

A text-book of dental pathology and therapeutics : for students and practitioners / by Henry H. Burchard ; revised by Otto E. Inglis.

Contributors

Burchard, Henry H.
Inglis, Otto Edward, 1864-
University of Glasgow. Library

Publication/Creation

London : Henry Kimpton, 1905.

Persistent URL

<https://wellcomecollection.org/works/dxzmm7h9>

Provider

University of Glasgow


License and attribution

This material has been provided by This material has been provided by The University of Glasgow Library. The original may be consulted at The University of Glasgow Library. where the originals may be consulted. Conditions of use: it is possible this item is protected by copyright and/or related rights. You are free to use this item in any way that is permitted by the copyright and related rights legislation that applies to your use. For other uses you need to obtain permission from the rights-holder(s).



Wellcome Collection
183 Euston Road
London NW1 2BE UK
T +44 (0)20 7611 8722
E library@wellcomecollection.org
<https://wellcomecollection.org>

Glasgow
University Library



Dent BL
Archives




30114011807321

Glasgow University Library

ALL ITEMS ARE ISSUED SUBJECT TO RECALL

GUL 96.18





STANDARD DENTISTRY WORKS.

New (2nd) Edition. Just Ready.

THE AMERICAN TEXT-BOOK OF PROSTHETIC DENTISTRY.

A Treatise on Prosthetic Dentistry for Students and Practitioners, by eminent American Authorities. Edited by CHARLES J. ESSIG, M.D., D.D.S., Professor of Mechanical Dentistry and Metallurgy, Department of Dentistry, University of Pennsylvania, Philadelphia. In one handsome octavo volume of 807 pages, with 1,089 engravings. Price 26s. net.

New (2nd) Edition. Just Ready.

THE AMERICAN TEXT-BOOK OF OPERATIVE DENTISTRY.

A Treatise on Operative Dentistry for Students and Practitioners by Eminent American Authorities. Edited by EDWARD C. KIRK, D.D.S., Professor of Clinical Dentistry, University of Pennsylvania, Department of Dentistry. In one handsome octavo volume of 857 pages, with 897 engravings. Price 26s. net.

Now Ready.

BURCHARD'S DENTAL PATHOLOGY AND THERAPEUTICS.

A Text-Book of Dental Pathology, Therapeutics and Pharmacology, for Students and Practitioners. By HENRY H. BURCHARD, M.D., D.D.S., late Special Lecturer on Dental Pathology and Therapeutics at the Philadelphia Dental College, Philadelphia. In one handsome octavo volume of 575 pages, with 371 engravings and 2 colored plates. Price 22s. net.

New (4th) Edition. Just Ready.

ESSIG'S DENTAL METALLURGY.

A Manual for the use of Dental Students and Practitioners. By CHARLES J. ESSIG, M.D., D.D.S., Professor of Mechanical Dentistry and Metallurgy in the Dental Department of the University of Pennsylvania. New (4th) edition, thoroughly revised by AUGUSTUS KORNIG, B.S., M.D., Demonstrator of Metallurgy in the Dental Department of the University of Pennsylvania. In one 12mo volume of 277 pages, with 43 engravings. Price 7s. 6d. net.

LONDON: HENRY KIMPTON, 13, FURNIVAL STREET, HOLBORN, E.C.

A TEXT-BOOK
OF
DENTAL PATHOLOGY

AND
THERAPEUTICS

FOR STUDENTS AND PRACTITIONERS

BY
HENRY H. BURCHARD

LATE SPECIAL LECTURER ON DENTAL PATHOLOGY AND THERAPEUTICS
AT THE PHILADELPHIA DENTAL COLLEGE

REVISED BY
OTTO E. INGLIS

PROFESSOR OF DENTAL PATHOLOGY AND THERAPEUTICS
AT THE PHILADELPHIA DENTAL COLLEGE

SECOND EDITION

ILLUSTRATED WITH 565 ENGRAVINGS AND 2 COLORED PLATES

LONDON:
HENRY KIMPTON
13 FURNIVAL ST., HOLBORN
E.C. 1
1905.

A TEXT-BOOK
OF
DENTAL PATHOLOGY
AND
THERAPEUTICS

FOR STUDENTS AND PRACTITIONERS

BY

HENRY H. BURCHARD, M.D., D.D.S.

LATE SPECIAL LECTURER ON DENTAL PATHOLOGY AND THERAPEUTICS IN THE PHILADELPHIA
DENTAL COLLEGE

REVISED BY


OTTO E. INGLIS, D.D.S.

PROFESSOR OF DENTAL PATHOLOGY AND THERAPEUTICS IN THE PHILADELPHIA
DENTAL COLLEGE

SECOND EDITION


ILLUSTRATED WITH 545 ENGRAVINGS AND A COLORED PLATE.

LONDON:
HENRY KIMPTON,
13 FURNIVAL ST., HOLBORN, E.C.
1905.



GLASGOW
UNIVERSITY
LIBRARY

THIS
VOLUME
IS AFFECTIONATELY DEDICATED
TO THE
MEMORY OF
J. FOSTER FLAGG, D.D.S.
AND
HENRY H. BURCHARD, M.D., D.D.S.
IN RECOGNITION OF THEIR UNSELFISH
EFFORTS FOR
PROFESSIONAL ADVANCEMENT






PREFACE TO SECOND EDITION.

IN revising this work the Editor has borne in mind the original motive of its author, namely, the production of a text-book which may serve as a useful basis of instruction upon a subject which students find difficult to comprehend from lectures alone. To this end, while the original plan and arrangement of chapters have been in the main adhered to, no hesitancy has been felt in revising the text, which, with the exception of certain portions, has been rewritten in order that new material might be inserted in its proper place and bearings. Where material has been drawn from the work of others full credit has been accorded. The section on pharmacology has been omitted, and in its stead the remedial agents referred to in the text have been completely indexed, so that their uses may be studied without difficulty.

The Editor desires here to express his thanks to the authors whose illustrations appear in the book and to the editors and publishers of the various dental journals and text-books from which they have been taken. In no instance has a request been denied.

In consideration of the fact that acknowledgment is not manifest in the text, the Editor would thank the S. S. White Dental Manufacturing Company, the Dental Manufacturing Company, Limited (London), P. Blakiston, Son & Company, William Wood & Company, and the J. B. Lippincott Company, for cuts from text-books published by them. Thanks are also due to Lea Brothers & Company, from whom the Editor has received the most generous aid and who have spared no pains to comply with every desire.

O. E. I.



PREFACE TO FIRST EDITION.

THIS volume is designed as a text-book of the principles and practice of dental medicine for the use of students, and as a reference work on applied special pathology and therapeutics for the use of dentists. Accepting the dictum of the advanced teachers of the day, the writer believes that an entirely rational system of dental medicine can have but one basis—namely, the same principles which underlie general medical and surgical practice. The book represents, therefore, an attempt at formulating, from data obtained from every available source, a system of dental pathology and therapeutics of which the several parts shall be in harmony with one another and also with the several collateral sciences involved. The impulse prompting the work was no desire to multiply books, but arose from a conviction expressed by many teachers, that such a volume is needed by students, practitioners, and teachers.


The extent and scope of references may be only partially seen in the numerous foot-note references, space limitations precluding any exhaustive bibliography.

It would be unjust, however, to omit this opportunity to credit two investigators without whose researches this volume would have been impossible: Professors G. V. Black and W. D. Miller, to whom frequent and specific references are made.

The immense development of modern dentistry has brought with it a more rational and convenient grouping of its subjects. The *American Text-books of Operative and Prosthetic Dentistry* have already won acceptance, each in its own field. They leave untouched a range of subjects which are naturally cognate, and hence are most advantageously taught in conjunction—namely, Dental Pathology, Therapeutics, and Pharmacology. The fitness of this grouping is manifest.

H. H. B.

APRIL, 1898.



ERRATA.

- Page 38, line 5, for "spirillæ," read "spirilla."
- " 115, line 14, for "ninth," read "twelfth."
- " 126, line 24, for "boundary wall, etc.," read "the follicular wall."
- " 227, line 12, for "bifurcated," read "trifurcated."
- " 284, line 21, read " $2\text{C}_6\text{H}_{10}\text{O}_5 + \text{H}_2\text{O} + \text{Ptyalin} = \text{C}_{12}\text{H}_{22}\text{O}_{11}$."
- " 366, line 7, read "both the pulp cells and the odontoblasts."
- " 369, line 13, for "Fig. 349," read "Fig. 355."
- " 417, Fig. 388, credit to Hopewell-Smith.
- " 569, line 25, for " $2\frac{1}{3}$," read " $21/3$."

CONTENTS.

SECTION I.

GENERAL PATHOLOGY.

CHAPTER I.

	PAGE
GENERAL PRINCIPLES	17

CHAPTER II.

CAUSES OF DISEASE, GENERAL AND LOCAL	26
--	----

CHAPTER III.

MICRO-ORGANISMS AS EXCITING CAUSES OF DISEASE	34
---	----

CHAPTER IV.

DISTURBANCES OF NUTRITION	50
-------------------------------------	----

CHAPTER V.

DISTURBANCES OF THE VASCULAR SYSTEM	71
---	----

SECTION II.

EMBRYOLOGY, ANATOMY, AND HISTOLOGY.

CHAPTER VI.

THE DEVELOPMENT, ANATOMY, AND HISTOLOGY OF THE JAWS AND TEETH .	107
---	-----

CHAPTER VII.

THE SURGICAL ANATOMY OF THE TEETH	156
---	-----

CHAPTER VIII.

DENTITION: ITS PROGRESS, VARIATIONS, AND ATTENDANT DISORDERS .	177
--	-----

CHAPTER IX.

MALFORMATIONS AND MALPOSITIONS OF THE TEETH :	206
---	-----

SECTION III.

AFFECTIONS OF THE ENAMEL AND DENTINE.

CHAPTER X.

	PAGE
ABRASIONS, EROSIONS, AND STAINS	247

CHAPTER XI.

STAINS OF THE ENAMEL AND DENTINE	269
--	-----

CHAPTER XII.

DENTAL CARIES: HISTORY; EXCITING AND PREDISPOSING CAUSES	277
--	-----

CHAPTER XIII.

DENTAL CARIES: PATHOLOGY, MORBID ANATOMY, AND CLINICAL HISTORY	292
--	-----

CHAPTER XIV.

DENTAL CARIES: DIAGNOSIS, SYMPTOMS, AND PROGNOSIS	323
---	-----

CHAPTER XV.

DENTAL CARIES: THERAPEUTICS AND PROPHYLAXIS	339
---	-----

SECTION IV.

DISEASES OF THE DENTAL PULP.

CHAPTER XVI.

CONSTRUCTIVE DISEASES	361
---------------------------------	-----

CHAPTER XVII.

DESTRUCTIVE DISEASES OF THE DENTAL PULP	382
---	-----

CHAPTER XVIII.

METHODS OF REMOVAL OF THE DENTAL PULP AND ROOT-CANAL FILLING	419
--	-----

CHAPTER XIX.

GANGRENE OF THE PULP	444
--------------------------------	-----

SECTION V.

DISEASES OF THE PERICEMENTUM.

CHAPTER XX.

SEPTIC APICAL PERICEMENTITIS (ACUTE)	PAGE 459
--	-------------

CHAPTER XXI.

CHRONIC SEPTIC, PURULENT, APICAL PERICEMENTITIS (CHRONIC APICAL ABSCESS)	476
---	-----

CHAPTER XXII.

NON-SEPTIC PERICEMENTITIS	499
-------------------------------------	-----

SECTION VI.

PERICEMENTAL DISEASES BEGINNING AT THE GUM
MARGIN.

CHAPTER XXIII.	523
------------------------	-----

CHAPTER XXIV.

SALIVARY AND SERUMAL CALCULUS	533
---	-----

CHAPTER XXV.

PYORRHŒA ALVEOLARIS	550
-------------------------------	-----

CHAPTER XXVI.

PERICEMENTAL ABSCESS	579
--------------------------------	-----

CHAPTER XXVII.

REFLEX DISORDERS OF DENTAL ORIGIN	590
---	-----

CHAPTER XXVIII.

INFECTION OF AND FROM THE MOUTH, AND STERILIZATION	602
--	-----



DENTAL PATHOLOGY AND THERAPEUTICS.

SECTION I.

GENERAL PATHOLOGY.

CHAPTER I.

GENERAL PRINCIPLES.

GENERAL pathology (*pathos*, disease, and *logos*, a discourse) is that branch of science which treats of the modifications in function and changes in structure occurring in disease. It embraces all pathological processes occurring in the human body, and as many of these occur in and about the teeth modified only by the peculiar anatomy of the parts, Dental Pathology may be said to be that branch of dentistry which treats of modifications in function and changes in structure occurring in the diseases of the teeth and associate parts.

This being true, it follows that the study of dental pathology must be preceded by a study of the general disease processes which affect the tissues of the body, and such of these as are applicable to the study are known as the General Principles.

The word Therapeutics is derived from the Greek *therapeuin*, to take care of, meaning the measures adopted to remedy or remove the changes induced by pathological processes.

The study of the pathology of a part begins with a study of its anatomy and histology, then naturally follows a study of its physiology and embryology. These form the basis from which degrees of abnormal function and altered structure may be judged by comparison with similar processes occurring in other parts of the body.

The body is composed of cells held together by intercellular substance. These cells are the essential functioning parts of the organism; each cell is composed of a small mass of protoplasm containing

in nearly all cases a nucleus, and has a form adapted to its environment and function. The exact chemical composition of protoplasm is unknown and efforts at analysis destroy its peculiar property as a substance exhibiting a sequence of phenomena called life. It is a viscid substance composed physically of a network containing a slightly more fluid substance.¹ Chemically it is 70 per cent. water containing a collection of proteids and differs as to these in the different classes of cells. Proteids are but imperfectly understood, but are known to consist essentially of carbon, hydrogen, oxygen, and nitrogen, combined with sulphur and other varying elements in enormous molecules approximately represented by the formula $C_{400}H_{310}O_{120}N_{50}S$.² The study of the properties of cell protoplasm may be made by observing *in situ* the action of living cells under normal conditions and when subjected to artificial stimuli, and by observing the action of free single cells such as an amœba under like conditions.

If a drop of water be taken from the sides or bottom of an aquarium, placed on a slide and covered with a cover-glass, and then placed under a microscope with, first, a $\frac{1}{4}$ " objective, there will be noted at some

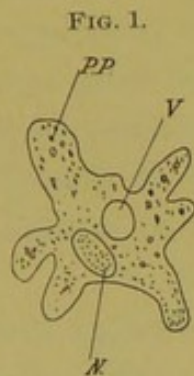


FIG. 1.
Changes of form in an amœba: PP, pseudopodia; V, vesicle; N, nucleus.

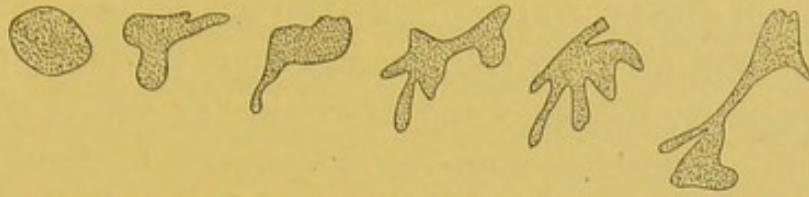
portion of the fluid a small transparent mass having the appearance of a colorless fragment of jelly; this is an amœba. The outline of the mass may have almost any form. At some portion there will be a defined and easily distinguished spot, the nucleus; at another point a vesicle is seen; the body of the amœba appears to contain numbers of fine granules. The nucleus appears more markedly granular than the body of the amœba. If kept under observation, the amœba will be seen to change its outlines; at one or more, and it may be in several places, projections like blunt arms or feet are seen to be extending from the amœba (Fig. 1). On account of their appearance they are called by the physiologist pseudopodia, from *pseudo*, false, and *pous*, a foot—false feet. These changes of form are much varied (Fig. 2). The cell has, therefore, the property of altering its form—*i. e.*, it has contractility. If the temperature of the slide be raised, the movements of the cell become more rapid, and if raised to a temperature of 55° C. the cell contracts in a round lump; it responds to stimuli, and has therefore the property of irritability.

¹ Kirke's Physiology.

² Schofield, Elementary Physiology.

When certain solid substances contained in the water come in contact with the amœba, the latter is seen to flow around and engulf

FIG. 2.



Amœboid movement of a white blood corpuscle of man; various phases of movement. (Klein.)

them; as is shown in Figs. 3 and 4, where the analogue of an amœba, a leukocyte, has taken in bacteria (phagocytosis). After a time the

FIG. 3.

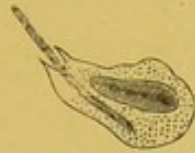

FIG. 4.

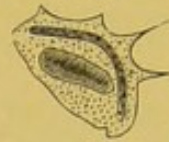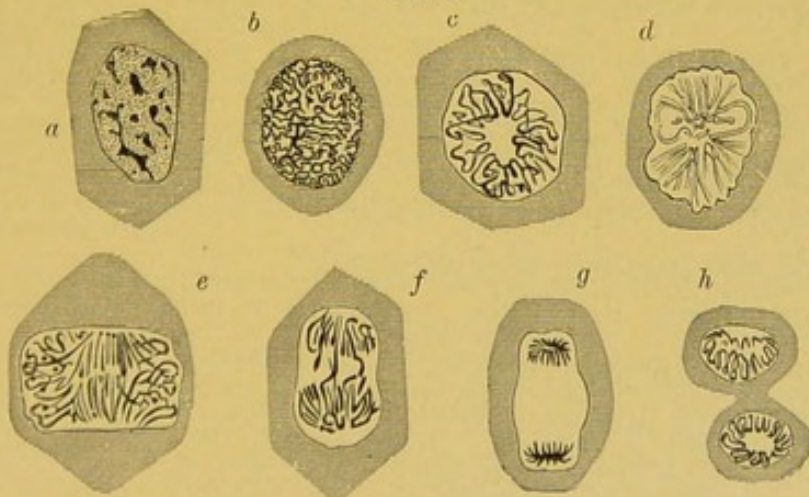


FIG. 3.—Leukocyte of a frog from the neighborhood of a piece of the lung of a mouse infected with anthrax, about forty-two hours after the piece of lung had been placed under the skin of the frog's back. The leukocyte is in the act of eating up an anthrax bacillus. (Brunton, after Metschnikoff.)

FIG. 4.—The same leukocyte a few minutes later, after it has completely enveloped the bacillus. (Brunton, after Metschnikoff.)

ingested body is found to have disappeared; it has been digested. Evidently the cell must produce a substance capable of dissolving

FIG. 5.



Forms assumed by a nucleus in dividing: *a*, resting nucleus; *b*, skein-form, open stage; *c*, wreath-form; *d*, aster, or star-form; *e*, equatorial stage of division; *f*, separation more advanced; *g* and *h*, star and wreath forms of daughter-nuclei. (Reduced from Flemming's drawings in the Arch. f. Mik. Anat.)

some foreign substances—*i. e.*, it has the function of secretion. More than this, the amœba does not take in substances indiscriminately; some it rejects.

If the observations are continued, it will be noticed that changes occur in the nucleus of the cell. A series of alterations in its figure are noted, as shown in Fig. 5. Two nuclei are formed, and soon the body of the cell divides and two cells appear—the amœba has reproduced itself. This primitive cell has, therefore, the properties of irritability, contractility, secretion and excretion (as will be seen in later studies), and reproduction; moreover, it responds to stimuli, as seen on warming the stage.

If the stage be cooled, the movements of the protoplasm are lessened, and when foreign substances come in contact with the cell it fails to encompass them—its irritability and contractility are lessened.

It is noted that some simple cells are attracted and stimulated by light; others are repelled by it.

If a mild induction (interrupted) current be passed through the water in which the amœba is,¹ the movements of the cells are checked; if a strong current be passed, the cell contracts sharply. If a galvanic (constant) current be passed, movement at first ceases, but pseudopodia are extruded toward the cathode and the cell crawls toward that pole.

The cell responds to mechanical stimuli, such as violent shaking, by contraction.²

If substances such as ether or chloroform are added to the fluid, the irritability of the cell is so lessened that it does not respond to stimuli.

If the supply of oxygen be cut off, or if carbon dioxide be admitted to the fluid, movement ceases and the cell remains contracted.

These examples serve to illustrate that protoplasm responds to stimuli of physical and chemical nature, and that its functions may be altered by substances which are brought in contact with it. Upon these facts depends the practice of therapeutics.

A living organism, it will be seen, has a certain degree of action and function. The general average of its action and function is spoken of as a condition of health. When, from any cause, the functions are raised or lowered from the general average, a condition of disease exists.

Stimulation. Certain agencies applied to the cell increase its activity; this is called stimulation. The movements of the cell become more rapid, food particles are taken in more rapidly and disappear more quickly; irritability, contractility, and secretion are increased.

¹ O. Hertwig, *The Cell*.

² *Ibid.*

The cell subdivides, or reproduces more quickly. Increase the stimulation, and the vital activity becomes fretful; in some cases cell division is incomplete—the nucleus divides, but not the cell body. Increase the stimulation beyond this degree, and the wearied cell ceases its movements—refuses to respond; is paralyzed by overwork.

Sedation. If the conditions be reversed; if, instead of applying a stimulus to the cell, an opposite influence be introduced, the phenomena are reversed.

If the temperature be reduced, the movements of the cell become sluggish; the body changes its form more slowly and less extensively—*i. e.*, contractility is lessened; particles taken into the cell remain apparently unchanged; irritability, secretion and excretion are lessened; and, furthermore, reproduction does not occur nearly so rapidly—that is, the cell in contact with sedative influences has all of its activities lessened.

There are two great classes of influences, then, which affect the vitality of cells: stimulation, which, if continued long enough, leads to death through overwork; and sedation, which, if continued, paralyzes all of the energies of the cell—it is starved to death.

Every cell has a range of resistance to these influences which tend to destroy it, which is fitly termed the resistance of vitality. Disease itself is some alteration in any one or more of these several cell-properties, of irritability, contractility, growth, secretion, maintenance, or reproduction. If any one of these properties is not exhibited, it is said that the cell is diseased.

If a brood of cells derived from one parent be examined, some will be seen to grow more rapidly than others, their movements are more rapid and they reproduce more quickly; others have sluggish functions and movements.

The cell lives its cycle and reproduces, and the parent is no more, the life being continued in the offspring.

The life and properties of this small mass of protoplasm represent in miniature the primitive functions and life of the highest animals.

The contractility is represented in the motive apparatus of the higher animals.

The reception, engulfing, and dissolving, or casting out, bodies with which the amœba is brought in contact correspond in the higher animals with the digestive apparatus and process and the excretory function.

The highly evolved irritability is represented in the nervous system of the higher animals.

The movements occurring in and about the vacuole are the progenitors of the circulatory apparatus and all of its adjunct organs.

If the irritability of a simple cell be increased or diminished, it corresponds with a disease of the nervous system, and so with the other functions.

Certain collections of cells are found in which one function is active, the others in abeyance; thus, large colonies of cells exist in which contractility is the dominant property noted; these are muscle cells. Others have but the property of irritability; these are nerve cells. Still others develop peculiar chemical functions, and become glandular or secretory cells. Such collections of cells are known as tissues. These special cell colonies or tissues are built together into defined masses for the performance of their specialized functions. In the development of these masses, means of holding and maintaining the cells in definite mass forms and provisions for their food supply and waste-removing apparatus are provided in what are called the connective tissues, binding the cells in definite forms and transmitting their vascular supply (food- and waste-carrier). When thus bound together the tissues are said to form organs.

While all tissues are capable of analysis into cells and intercellular substance, a more practical view may resolve the tissues into (1) functional cells; (2) a supporting intercellular substance; (3) intercellular spaces in which flows the lymph derived from the blood; (4) the channels of circulation and conductors of nervous impulses—*i. e.*, arteries, capillaries, veins, lymphatics, and nerves. The arteries bring to the tissues the blood freighted with oxygen and nutrient material. As it passes through the capillaries a portion of the blood plasma, under arterial pressure and osmotic force, passes into the intercellular spaces into contact with the cells. This exuded fluid is now called lymph.

Stated in general terms the food materials contained in arterial blood and furnished to the tissues by way of the lymph are: water, proteids, glucose, fats, inorganic salts, and oxygen. From this store the cells take what they require and within themselves they elaborate substances essential to their growth and maintenance as masses of functionating protoplasm, and as the protoplasm is of more complex composition than the majority of food elements, they are said to form from simple compounds substances of a higher degree of complexity (anabolism). From their substance they eject into the lymph stream such waste products as result from the breaking down of the previously formed protoplasm (catabolism). "There is reason to believe that

cell protoplasm as it becomes effete takes up oxygen and splits into a nitrogenous molecule, which is the first stage in the formation of urea and a non-nitrogenous molecule which forms fat."¹ In the process of healthy nutrition these products of the metabolism of the cells are still further elaborated and then removed.

The exact nature of the chemical changes occurring in cells is not known, and there is evidence that changes occur in the cell waste either in the blood or in various organs of the body. While then the bodily ejecta contain substances fairly constant in composition, they are held to represent elaborations of cell waste rather than actual cell ejecta. For example, urea is pretty certainly derived from muscular tissue, yet is nearly absent in muscle and is supposed to be synthesized from ammonium carbonate and water in the liver.² Lactic acid and ammonium carbonate have been experimentally shown to be probably combined into uric acid in the liver.³ The cell waste is carried by the lymph into the lymphatics connecting with the inter-cellular spaces. Thence it is delivered by way of the venous system to the circulation for further elaboration and elimination from the body. Any interference with such elaboration or elimination must of necessity result in a retention of waste products within the system.

Cell metabolism is a chemical change and is therefore accompanied by heat production. Energy is stored up in the cell as latent force capable of liberation under stimulus, which force is expressed in various forms of functional activity—*i. e.*, contractility in muscular tissue, irritability and mentality in nervous tissue, secretion in the various secretory glands, eliminative selection in the various excretory organs, etc. Cells after a period of activity undergo degenerative processes and are removed or reproduce by the process of mitosis (Fig. 5).

The life conditions of cells are necessarily those under which they best perform these functions without exhaustion, and are the following: 1. A proper food supply, including water and oxygen. 2. A proper temperature. 3. A proper removal of waste products. 4. Possibly a proper innervation. Any interference with these conditions, which may be termed the normal physiological conditions, results in a morbid process of physiology or *pathology* in its limited sense. With such interference *disease* may be said to begin. The definition of disease as an *alteration of nutrition* is therefore appropriate. For this reason the proximate exciting causes of disease are classed as

¹ Green, *Pathology and Morbid Anatomy*, ninth edition, p. 47.

² Schröder, *Kirke's Physiology*.

³ *Ibid.*

(1) abnormal food supply; (2) abnormal waste removal; (3) abnormal physical condition; (4) abnormal nerve supply.

The morbid physiology results in morbid products or in retained normal products and an altered cell function. When pronounced this is spoken of as Functional Disease, though it may be said to be in existence even if discomfort be not produced. Sooner or later an abnormal change in the histological characteristics of the cells or intercellular substance may occur which has been referred to as Morbid Histology.¹ As definite microscopic and often macroscopic appearances are associated with certain diseased conditions, these are referred to as the Morbid Anatomy of a Disease. The phenomena associated with a disease are called its Semeiology (*semeion*, a mark or sign) or Symptomatology, and are either described by the patient as sensations or pains of varied character or situation (Subjective Symptoms), or may be noted by normal or aided vision, by physical examination, or chemical analysis (Objective Symptoms). That which excites a disease or promotes the action of the excitation is called a Disease Cause. The study of disease causes is Etiology (*aetios*, a cause, and *logos*). It is noted that diseases having a fairly defined pathology and morbid anatomy have from their beginning to ending tolerably constant phenomena; they have each a natural history; this is called the Clinical History of a Disease.

The study of the origin and development of a disease together is known as its Pathogenesis (*pathos*, disease; *genesis*, birth). Through the study of the characteristic symptoms of diseases, as well as those common to several diseases, a particular disease may be distinguished. This is called Diagnosis (*dia*, a part; *gnosis* knowledge)—Direct Diagnosis when there is no question as to the symptoms, Differential Diagnosis when several diseases are possible and the characteristics of one are considered as more pronounced. Under certain circumstances a disease may be inferred to be present by excluding all other possible conditions (Diagnosis by Exclusion). In the course of a disease experience has shown that certain signs and symptoms are apt to be followed by good or ill results as the case may be. By these signs and symptoms it may be foretold with some degree of assurance what will be the probable outcome of the disease. The inference based upon these symptoms is known as the Prognosis (*pro*, before; *gnosis*, knowledge). The care of or treatment of a disease is its Therapeutics. This involves

¹ Green, Pathology and Morbid Anatomy.

a knowledge of remedies applicable, known as the *Materia Medica*. When applied upon the basis of a scientific study of the pathogenesis, clinical history, and prognosis of disease and a parallel knowledge of the physiological action of drugs and of other remedies, the treatment is known as Rational Therapeutics. When the treatment is based upon the known good effects of a remedy in a certain disease, and not upon its physiological action, it is known as Empirical Therapeutics.

The pathogenesis of a disease being known, intelligent efforts may be exerted for its prevention. The causes may be removed or neutralized before they have an opportunity to act; this is Prophylaxis. The science of prevention of disease upon the broad basis of a knowledge of and observance of laws of health is Hygiene.

It will be seen that a knowledge of special pathology can only be obtained from (1) a knowledge of pathology in general or at least of those principles of general pathology which underlie all disease processes; (2) a knowledge of the local anatomy and histology; (3) a knowledge of local embryology and physiology; (4) a study of local pathology and morbid anatomy. To this must be added a study of *materia medica* and special therapeutics.

CHAPTER II.

CAUSES OF DISEASE, GENERAL AND LOCAL.

A DISEASE cause may be defined as any influence of whatsoever nature which is capable of disturbing the nutritive balance of any portion of the body. The branch of study which deals with the causes of disease is called Etiology.

The causes of disease are classed as Exciting and Predisposing. These are each divisible into Extrinsic, originating from without, and Intrinsic, originating within the body.

EXCITING CAUSES OF DISEASE.

These are influences, either extrinsic or intrinsic, which are competent to suddenly or gradually interfere with the nutrition of the cells of a part or with the general nutrition of cells. These influences are very numerous, but may be grouped according to their action under a few convenient headings: 1. Abnormal Food Supply. 2. Abnormal Waste Removal. 3. Abnormal Physical Conditions. 4. Abnormal Nerve Supply.

These are termed the Proximate Exciting Causes, as their effects are immediately exerted upon the cells. Other causes may be back of these and are spoken of as Primary Causes—*e. g.*, tuberculosis of the lungs (primary) may cause insufficient oxygenation of the blood which constitutes an abnormal food supply (proximate).

Abnormal Food Supply. By abnormal food supply is meant an altered quantity or quality of nutritive elements delivered to the cells either of a part or of the entire body. The primary causes of this may exist as disturbances or faults in any of the food-elaborating organs, the lungs, the eliminating organs, or the oxygen carriers of the blood may exist in lessened numbers. In the first case the quality or quantity of nutritive material is impaired, in the second case oxygenation is insufficient, and in the third case material injurious to cells are retained in the body and are again presented as food to the cells, acting as poisons. Poisonous or even non-poisonous drugs, and the products

of bacterial action, whether absorbed from the intestines or from foci of infection, have all more or less deleterious action upon cell protoplasm, violent if entering the blood in quantity, chronic if entering continuously.

In anæmia the red corpuscles are reduced in number, hence less oxygen is carried to the tissues.

Faults in the circulatory apparatus interfering with the circulation generally cause an interference with general nutrition, while local disturbances of the circulation from any cause disturb the relations of the blood supply to the nutrition of a part. Thus the fresh blood supply may be excessive, as in the milder form of arterial hyperæmia, or deficient, as in venous hyperæmia and inflammation.

Abnormal Waste Removal. Abnormal waste removal is ordinarily included under the heading of abnormal food supply, and it is evident that retention of waste in the blood causes the presentation to cells of an abnormal food or poison. In local conditions such as venous hyperæmia and inflammation the stasis causing waste retention prevents the access of a fresh food supply as well. In kidney disease the substances ordinarily physiologically eliminated by the kidneys are retained in the blood and act as poisons to cell protoplasm generally.

Abnormal Physical Conditions. This class of disease causes includes all injuries due to any of the physical or chemical forces: Traumatic injuries, such as cuts, bruises, surgical openings, etc.: Mechanical causes, such as compressions, obstructions to ducts or the natural outlets of the body, faults in the circulatory mechanism, stoppages in the arteries or veins, abnormal temperature, burns, freezing, etc.: Irritations of various sorts, such as those due to mustard, arsenic, etc. Chemical causes, such as the action of acids or caustics, and the local effects of micro-organisms may all be classified under this heading. The disturbance is due to either a direct destruction of the life of the cells or an interference with the circulation in a part.

Abnormal Nerve Supply. It is known that division of, injury to, or disease of certain nerves causes trophic or nutritional changes in the part to which they are supplied. Whether the nutrition of the parts is controlled by special trophic nerve fibres has not been demonstrated. Halliburton,¹ in support of the trophic influence of nerves, instances that when the fifth nerve (sensory) is divided beyond the

¹ Kirke's Physiology.

Gasserian ganglion, ulceration of the cornea results; while if the seventh nerve (motor) be divided or paralyzed, the eyeball is equally exposed to irritants, yet does not ulcerate. He also instances that division of the vagi produces fatty degeneration of the heart.

While admitting the lack of anatomical proof, he regards the trophic influence of nerves upon parts to be unexplainable upon the ground taken by others, that all apparently trophic changes are due to disturbances of the vasomotor nerves controlling the calibre of vessels. According to these other observers degrees of dilatation are produced which modify the amount of blood delivered to a part and thus modify its nutrition.

Effects are produced upon nutrition by causes which can act only through the nervous system—*e. g.*, the effect of anxiety upon appetite and digestion. The interdependence of these classes of causes is almost self-evident; for example, constant suppuration at a focus of infection (abnormal physical condition) may induce a toxæmia (abnormal food supply) which may be responsible for kidney or other disease (abnormal physical condition), resulting in the retention of waste products in the blood (abnormal waste removal or food supply) which has a vicious result upon all metabolism, including that of the nervous system, inducing in turn an abnormal nerve supply and lessening resistance even in the tissues about the original focus of infection. Such a train of events is known as the establishment of a vicious circle.

PREDISPOSING CAUSES OF DISEASE.

A predisposing cause of disease is one which influences the cells or juices of the body or part in such a manner as to lessen the resistance to the action of the exciting causes of disease.

It must be considered that a predisposition or lessened resistance is in itself a condition of disease, not recognizable perhaps, yet a departure from the standard of the best health of an individual or part. For the most part predisposition is regarded in its relation to the extrinsic causes of disease, such as bacterial influences. Predisposition is either general or local.

General Predisposition.

This is either (1) a natural or inherent lack of resistance to infectious or non-infectious diseases, or (2) an acquired lack of resistance

to infectious or non-infectious diseases. The human race in general is naturally predisposed to many infectious diseases, such as tuberculosis, cholera, malaria, measles, smallpox, typhoid fever, scarlet fever, and syphilis.¹ When a person is exposed to the disease and contracts it he is said to be predisposed to it. If he does not contract it his system is immune either temporarily or permanently. (See Immunity.) This immunity is ordinarily operative when the individual is in the best state of health, and when a departure from this standard is brought about by any cause exciting infective causes may then act. This is acquired predisposition. Some individuals have a natural or congenital lessened resistance to external influences of a non-infectious character, such as heat or cold, mental effort or nervous irritations of a degree ordinarily borne by the great majority of individuals. This may also be acquired, as, for example, by extreme subjection to the above or other enervating causes. An inherited predisposition to such diseases as insanity, cancer, or gout may exist.

Some persons cannot bear certain kinds of food without illness or react strongly to small doses of drugs. This is called an idiosyncrasy and may be either congenital or acquired.

The predisposing causes capable of producing a lessened resistance may be grouped under a few headings.

Sex as an Intrinsic Predisposing Cause. In this connection the influence of sex upon predisposition to disease must be considered. While the general resistive power of the bodies of both sexes may be regarded as practically equal under similar conditions, yet the anatomical structures and physiology of each sex have an influence upon predisposition to certain diseases. Aside from the diseases peculiar to sex, on account of their peculiar organs, each sex exhibits predispositions to diseases which the other sex escapes; for many of these the habits of life furnish an explanation, for others an explanation is not available. For example, while women are predisposed to functional and emotional disturbances of the nervous system, such as hysteria, they are almost exempt from such structural nervous diseases as locomotor ataxia and general sclerosis. Males are much more subject to hæmophilia than women.

Age. During the first two years after birth the nervous system and the appendages of the alimentary canal are developing, and improper feeding, difficult teething, or other influences readily act as exciting causes of alimentary or nervous disturbances.

¹ Ziegler, General Pathology,

Later children are subject to acute infectious diseases, especially tuberculosis, diphtheria, and the eruptive fevers. At adolescence other predispositions occur, notably chlorosis in young girls. Later come the diseases of early maturity, such as typhoid fever, pulmonary tuberculosis, and to a degree dental caries.

In old age or middle life occur arterial and other degenerations and diseases consequent upon them or upon overstimulation of organs or tissues.

Temperament. Temperament is the peculiar congenital constitution of an individual imparting certain physical characteristics and certain natural tendencies.

There are four basal temperaments. The sanguine is that in which individuals are decidedly inclined to the blonde type with evidence of an abundance of the nutritive fluid, the blood—*i. e.*, the vascular system is said to dominate the other functions of the body. Such are predisposed to acute pulmonary and cardiac diseases and inflammatory disturbances of serious import. The mental characteristics of this temperament are hopefulness, cheerfulness, and solidity but floridity of mental endowments. The recuperative power is good. The bilious temperament is characterized by a decided inclination to the brunette type, with evidence of a domination of other functions by the liver. There is a tendency to hepatic and digestive derangements and despondency; at the same time there is possessed great physical and mental strength, together with a reliable recuperative power.

The nervous temperament is indicated by the smallness and delicacy of frame and the quickness of motion and perception, evidencing a domination by the nervous system to diseases of which such temperament predisposes.

The lymphatic temperament is indicated by bulk, pallor, and flaccidity of tissue, a colorlessness of temperament, indicating an inherent feebleness. There is a tendency to serious chronic conditions. This temperament is accompanied by poor recuperative force.

There are no individuals of pure basal temperament, so that the nearest approach is a dual temperament such as the bilio-sanguine, in which the characteristics of the sanguine predominate strongly modified by those of the bilious temperament. In like manner the sanguo-nervous, nervo-lymphatic, and other classes, twelve in number, are recognized as having typical representatives in each community. A third or ternary classification is possible—*e. g.*, sanguo-nervobilious. It will be seen that temperament has a distinct relation to

the vital resistance normally implanted in an individual, and therefore may to a certain extent be counted upon in a prognosis. Temperament is a predisposing cause probably only in so far as it introduces a natural general lack of resistance to disease, or irresistibly drives an individual into certain habits of life which may become the cause of a lessened resistance.

Heredity. Certain diseases exhibit a predisposition to descend from parent to child or from grandparent through the unaffected son or daughter to a grandchild (in the latter case it is called atavistic hereditary transmission).

The mode of transmission is in all probability the inheritance of a type of tissue, a tissue anatomy and physiology which permit the more ready action of the exciting causes of the disease. This tendency is called a diathesis—*e. g.*, hemorrhagic diathesis (*hæmophilia*), gouty diathesis, or tuberculous diathesis.

Existing Disease. The presence of one disease may weaken the resistance of a part or the organism so that another disease may the more readily become implanted—*e. g.*, measles accompanied by pneumonia.

Previous Disease. At a period subsequent to disease the same disease may recur or another disease may be implanted—*e. g.*, pneumonia predisposes a lung to a recurrence of pneumonia or tuberculosis may readily follow. Previous disease may confer immunity (which see).

Extrinsic Predisposing Causes of Disease. Under this head are included all those conditions of external origin which lessen the resistance of an individual to the action of exciting causes. Excessive heat is weakening; cold and damp, by chilling the surface of the body, cause hyperæmia of internal parts, and thus predispose to such diseases as pneumonia, rheumatism, etc. Fatigue, unhealthy, cramping or sedentary occupations, continued loss of sleep from any cause, evil habits, continued hunger, etc., are other examples of debilitating influences which may be partly intrinsic.

Local Predisposition.

Alterations in the normal physiology of a part are apt to occur through certain causes liable to act upon it. Apart from this fact a part may be predisposed, by nature apparently, to permit the growth of organisms which do not grow well in other tissues. Local depression of tissue vitality predisposes to the growth of organisms in the

tissue. Mild injury producing hyperæmia of a part or a local anæmia (ischæmia) thus predispose. More severe injury also may predispose, but the contrary effect has also been observed—*i. e.*, that severe injury excites a phagocytic reaction (a later stage of inflammation) which repels the bacterial invasion.

The structure of a part has also been shown to have an effect upon the life of organisms gaining access to its tissues. Thus the peritoneum resists or kills out pyogenic cocci more successfully than other soft parts or bones.¹

IMMUNITY.

Immunity is the opposite of predisposition and, like it, can be either natural or acquired. It signifies an insusceptibility to a disease. Natural immunity to a particular infectious disease can only be determined by repeated exposures, and may then fail at last owing to some systemic change. Immunity may be exhibited toward only one disease. In some persons disease appears to be influenced by sex, as, for example, males have a general immunity from goitre, females from Addison's disease. Immunity is influenced by age in certain diseases; for example, the diseases of childhood are rare in the elderly; they do occur, however. The degenerative diseases of old age are almost unknown in childhood. Race has its influence; the negro is almost immune to malaria and yellow fever, but particularly susceptible to smallpox and tuberculosis.

Immunity may be acquired in several ways: (1) by an individual having passed through an attack of a specific disease; (2) by inoculation with the attenuated living virus of the disease; (3) by inoculation only with the chemical products of the virus; (4) by the introduction of the serum of an animal inoculated with the chemical products of a virus—*i. e.*, by the introduction of an antitoxin. The last process is admirably summarized by Green for diphtheria as follows:

1. "A pure culture of the bacillus diphtheriæ (Loeffler) is made in a medium giving a toxin of greatest virulence.
2. "The organisms are removed by filtration through porcelain.
3. "The toxin thus obtained is injected into a horse in small quantities two or three times a week until no reaction follows. This period extends over from one to three months.

¹ Green, Pathology and Morbid Anatomy.

4. "Some of the blood is then withdrawn and the serum is separated, sterilized, and stored for subsequent use."

The subcutaneous injection of a small portion (about 20 c.c.) of this substance will render a person exposed to diphtheria immune for a period of about six weeks. If injected in the early stage of an attack it renders the system more capable of warding off the serious toxic effects of the toxalbumins produced by the germs.

In the case of smallpox the Saracens in the sixth century introduced the protection against the disease by introduction of a minute quantity of the virus from a smallpox pustule into the body of a healthy person. A mild attack ensued, which conferred immunity. Later, in 1798, Jenner introduced inoculation with the virus from a bovine—cowpox pustule. This practice of vaccination is still used to confer immunity to smallpox.

The nature and action of antitoxins are unknown. Ehrlich¹ theorizes that the body cells receive and neutralize the toxin at first presented to them, and that the cells under this stimulus form an excess of the neutralizing substance (self-formed antitoxin) which floats in the blood serum, and therein combines with fresh portions of toxin absorbed from the focus of infection. It is considered that a special antitoxin is formed for each form of toxin.

In the case of serum therapeutics as described for diphtheria, which represents the principle involved, the antitoxin is formed in the body of the horse instead of in the human body. The principle does not seem to be capable of application to all varieties of infection. In natural immunity there is a healthy liquor sanguinis which contains substances, probably of the nature of nuclein, which are germicidal for bacteria. These substances are collectively known as "alexins."

According to Emmerich and Löw a third body, an enzyme formed by the bacteria, may enter the blood and in sufficient concentration first agglutinates and then destroys the bacteria (bacteriolysis). The combinations of this enzyme with proteids are also considered to have bacteriolytic action. (See Chapter III.)

¹ Vaughan and Novy, Cellular Toxins.

CHAPTER III.

MICRO-ORGANISMS AS EXCITING CAUSES OF DISEASE.

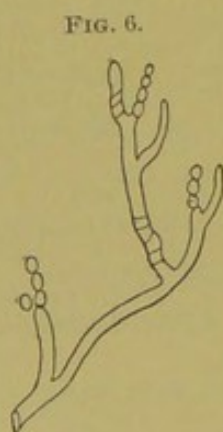
THE infectious and contagious diseases have for the most part been shown to be caused by low forms of vegetable organisms, while in a few diseases minute animal organisms (protozoa) are the causes.

The following table shows the position of the vegetable organisms in the scale of vegetable life and gives the lowest forms of animal life:

Vegetable kingdom	Phanerogams: plants reproducing by flowers and seeds.				
	Cryptogams, reproducing by spore formation or division.	Leafy cryptogams.		Lichens. Algæ. Fungi . . .	Hyphomycetes (mould fungi). Blastomycetes (bud fungi). Schizomycetes (fission fungi)
		Thallophytes, having no distinction between the leaf and stem.			
Animal kingdom	Lowest form .	Protozoa: single cells without circulatory or nervous systems		Sarcodinea. Flagellata. Sporozoa. Infusoria.	
	Higher forms .	Mycetozoa, fungi not certainly defined as animal or vegetable forms. ¹			
		Certain insect and worm forms are pathogenic.			

{ Cocci.
Bacilli.
Spirilla.

The fungi are divided into (1) schizomycetes, or fission fungi; (2) hyphomycetes, or mould fungi (Figs. 6 and 7); (3) blastomycetes, or bud fungi (or yeasts) (Figs. 8 and 9).



Trichophyton tonsurans. Diagrammatic. (Lehmann.)

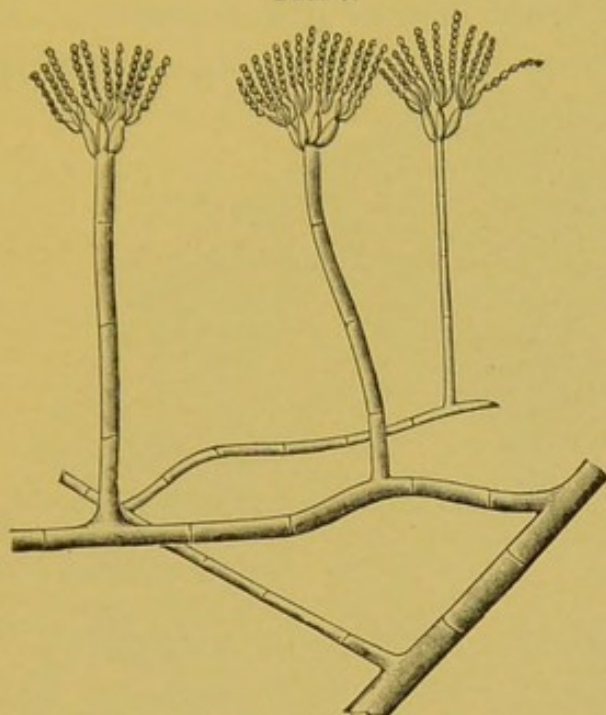
Being achlorophyllous, the fungi are unable to utilize the simple compounds, such as carbon dioxide and ammonia, as foods, and are therefore compelled to break down the complex organic compounds, for which purpose they are competent. All three classes of fungi have representatives which produce disease in the human body, but the schizomycetes furnish by far the greater number of infectious disease causes.

Of the protozoa four classes are known, though but few are pathogenic; these classes are (1) the sarcodinea (amœboid), which includes the amœba dysenteriae (Fig. 10); (2) the

¹ The terms mycetozoa and protozoa seem to be practically synonymous to pathologists, who use the term protozoa in the sense of mycetozoa as above defined.

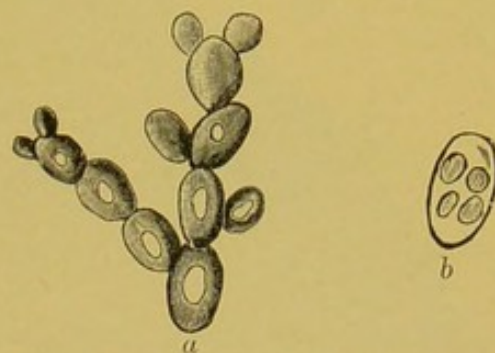
flagellata, non-amœboid but motile by means of flagella; (3) the sporozoa living within the bodies of other animals, a class which in-

FIG. 7.



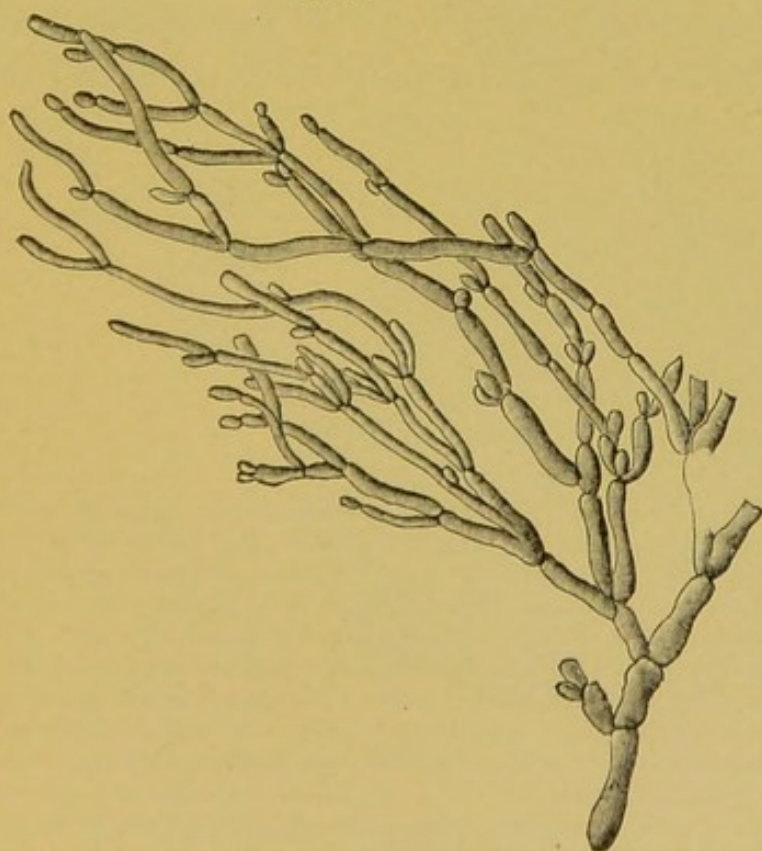
Penicillium with spores. (Lehmann.)

FIG. 8.



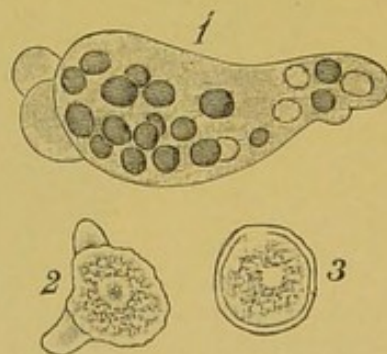
a, saccharomyces; b, cell with four spores. (Lehmann.)

FIG. 9.



Saccharomyces albicans. (After Grawitz, in Lehmann.)

FIG. 10.

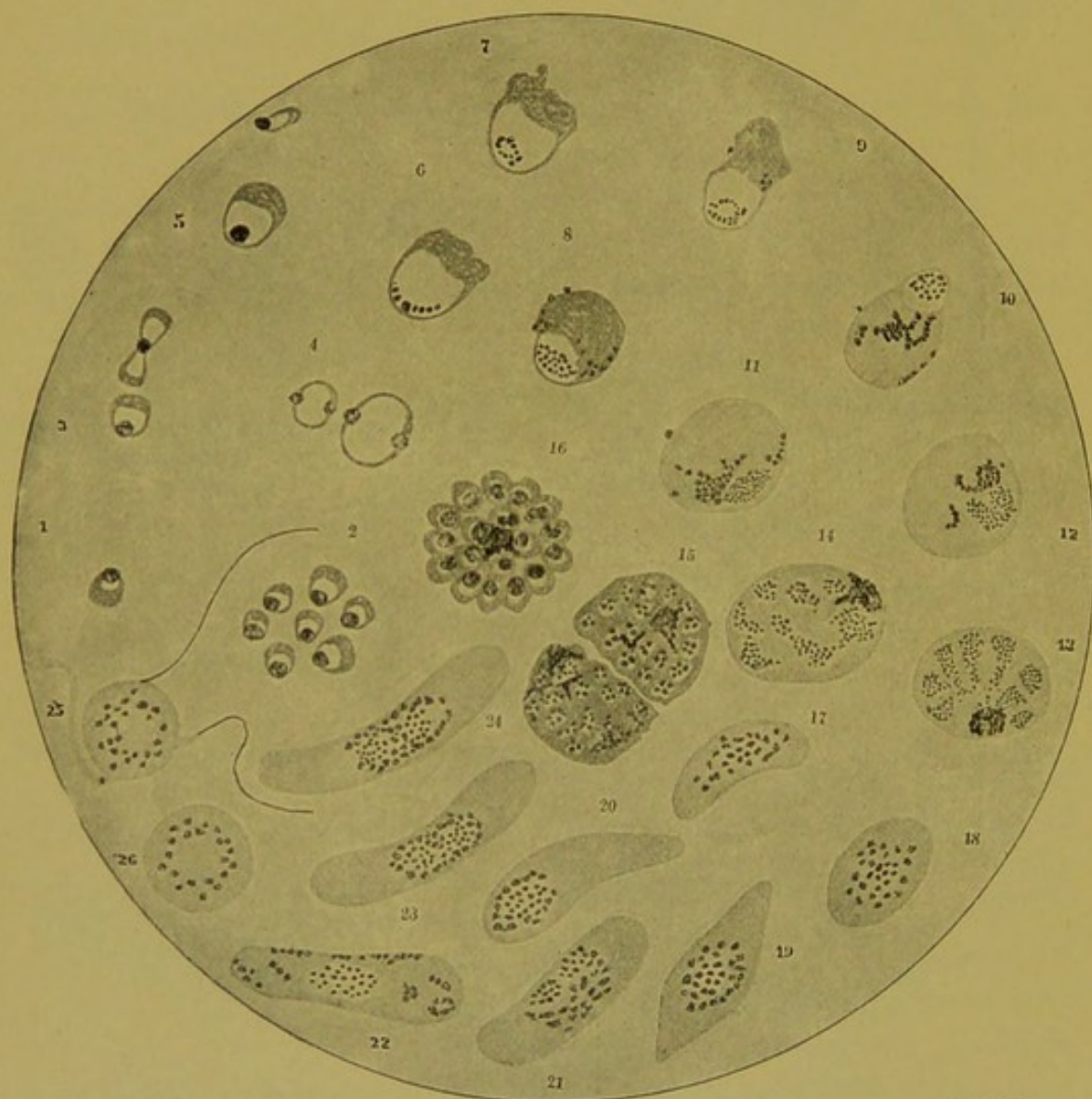


1, amœba from dysenteric stool, with vacuoles and enclosed red cells; 2, amœba from straw infusion; 3, the same encysted $\times 600$. (Künster.)

cludes the hæmosporidia, amœboid motile parasites living in the blood, and of which the hæmatozoön (plasmodium) malariae is an example (Fig. 11); (4) the infusoria.

The schizomycetes (Greek *schizo*, to split, and *mukes*, a fungus) are minute single-celled plants without nuclei, but possessed of a cell wall and cell protoplasm called mycoprotein. They have a size of about one

FIG. 11.

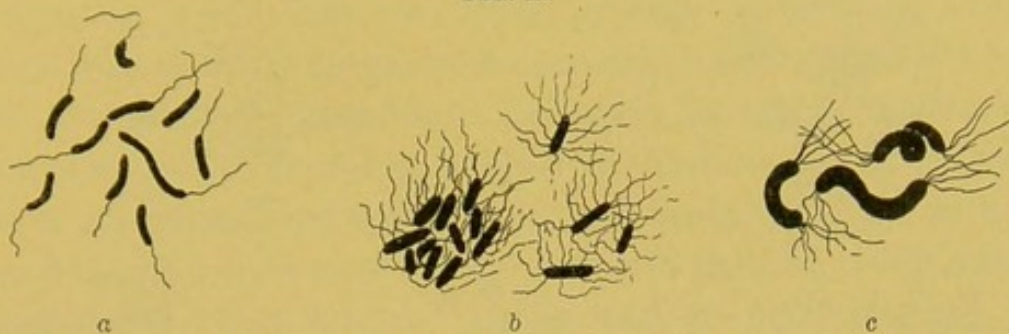


Cycles of estivo-autumnal parasite. 1. Very young form. 2. Infection of one cell with seven young parasites. (Drawn from a marrow smear.) 3. Triple infection; two parasites joined by single chromatin mass. 4. Double infection; peculiar rings with two chromatin grains at opposite poles. 5. Double infection; small ring adherent to cell. 6, 7. Signet-ring forms; subdivision of chromatin. 8, 9. Later ring forms, with subdivided chromatin and few pigment grains. 10-12. Full-grown forms with finely subdivided chromatin and gradual concentration of pigment. 13, 14. Stages of presegmenting forms, with concentrated eccentric pigment. 15. Double infection with separate presegmenting bodies. 16. Estivo-autumnal rosette. 17, 18. Young crescent and ovoid. 19. "Pulsating" crescent. 20-22. Various forms of crescents. 23. Two bows about single crescent. 24. Fully developed crescent; two masses of chromatin; achromatic substance; double wreaths of pigment. 25. Diagrammatic flagellating body. 26. Extracellular sterile body. (Schmaus and Ewing.)

micromillimetre ($1 \mu = \frac{1}{25000}$ inch) or less in their smallest diameter. Some of them possess flagella, hair-like processes, often very numerous, arising from the protoplasm rather than the wall, with which they lash

the fluid surrounding them, and by which means they effect locomotion (Fig. 12). Other bacteria again are non-motile. Entering the organic compounds, carbohydrates, hydrocarbons, and nitrogenous (albuminous) substances, they ferment or decompose them and extract from them substances necessary to their growth and subsequent reproduction.

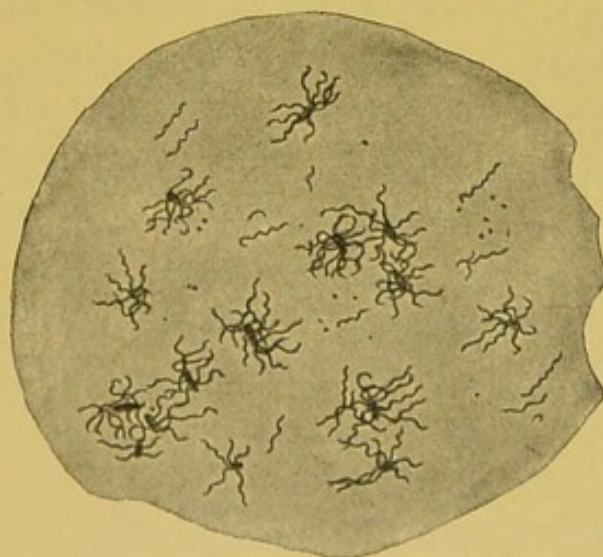
FIG. 12.



a, spiral forms with a flagellum at only one end; b, bacillus of typhoid fever with flagella given off from all sides; c, large spirals from stagnant water with wisps of flagella at their ends (*spirillum undula*). (Abbott.)

The substance in which they thus grow is called the medium or soil. The conditions under which this is accomplished are: (1) the fungi must have a proper vitality; (2) their food supply or soil must be suited to their growth and must be moist; (3) the temperature must be suitable; at or near 0° F. their development ceases, but they are not necessarily killed; at 160° F. maintained they usually die, but in some cases,

FIG. 13.

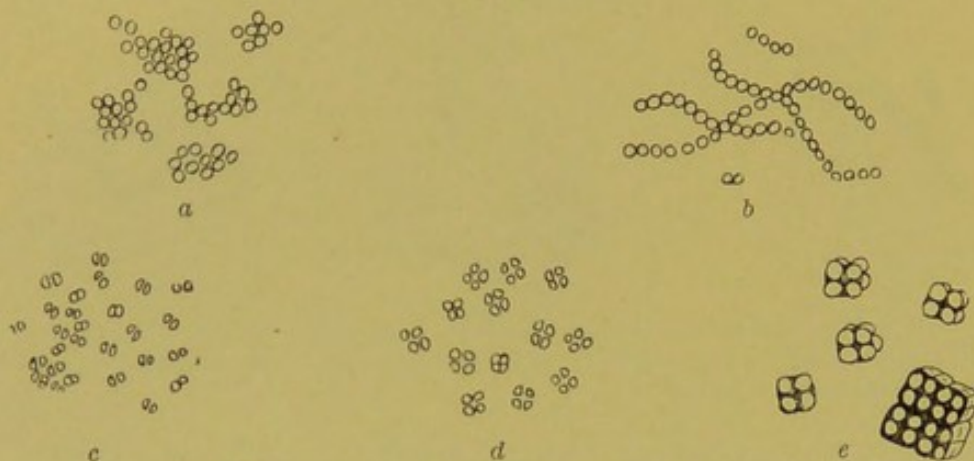


Typhoid bacilli—stained by Van Ermengem's method to show flagella.

as with the typhoid bacilli, they may live in the spore form at even 212° F. unless maintained for some time. (4) Their waste products must be removed or they die in them—*e. g.*, in lactic fermentation 0.75 of 1 per cent. of lactic acid destroys the germs. Morphologically the schizomycetes are grouped into several classes according to form.

1. Micrococci (*mikros*, and *kokkos*, a berry), including all of the spherical forms or those having equal or nearly equal diameters.
2. The bacilli (*bacillum*, a rod), or rod-like forms; one diameter being greater than the other.
3. The spirillæ (Greek *spira*, a coil), or the curved forms.

FIG. 14.

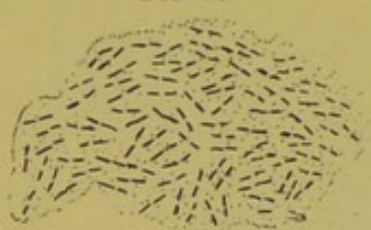

a, staphylococci; b, streptococci; c, diplococci; d, tetrads; e, sarcinæ. (Abbott.)

All of these groups may again be subdivided. The micrococci are subdivided according to their modes of grouping. Double cocci are called diplococci (*diplois*, double). If in division the cocci agglomerate

like a bunch of grapes they are called staphylococci (*staphyle*, a grape). If they arrange themselves in a chain they are called streptococci (*streptos*, a chain). If they divide in two directions and form a bunch of four cocci they are called tetrads. If in three directions they form sarcinæ. The bacilli are of many and varied forms and differ

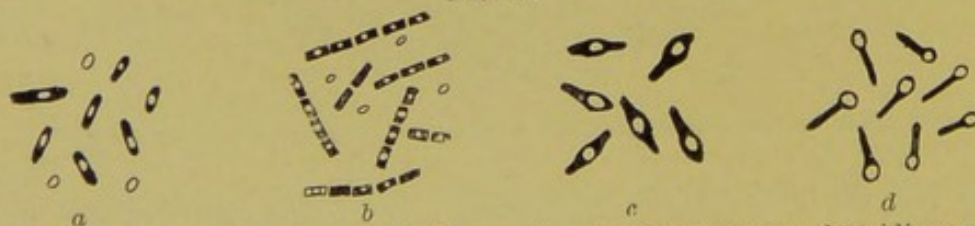
FIG. 15.



Zoöglœa of bacilli. (Abbott.)

as to their mode of grouping. During reproduction bacteria may excrete a material which unites them into a gelatinous mass called zoöglœa.

FIG. 16.




a, bacillus subtilis with spores; b, bacillus anthracis with spores; c, clostridium with spores; d, bacillus of tetanus with spores.

The bacilli in the course of reproduction may form long threads showing as a rule the traces of segmentation. Under certain condi-

tions the bacilli form glistening oval bodies within themselves. The body of the bacillus may disappear, leaving the spore only. These spores are very resistant to devitalizing agents. The bacilli forming spores are said to be in the resting stage. These spores under favorable conditions again form bacilli like their progenitors, but do not form other spores without this return to the bacillus form. A single cell forms as a rule but one spore. Under unfavorable conditions bacteria may undergo degeneration and take on abnormal or involution forms, and when the conditions are again favorable to development they may resume their typical forms.¹ While these form changes occur, bacteria are never permanently changed from one form to another.¹ Those bacteria which have several forms in their life cycle are termed pleomorphic. Those having but one form are monomorphic. Those bacteria which exist on living tissue are known as parasitic. They enter the body by way of open wounds or surfaces deprived of epithe-

FIG. 17.



a, spirillum of Asiatic cholera (comma bacillus); b, involution forms of this organism as seen in old cultures. (Abbott.)

lium or may lodge at certain points of the mucous surface of the lungs, skin openings, or alimentary canal. If not killed out they multiply in the natural juices of the part on which they locate and produce an infective inflammation. Toxic substances called toxins are generated, which are absorbed into the system and may act as poisons, producing toxæmia. The character of both the inflammation and the poisoning depends upon the particular bacterium or bacteria present. The bacteria may in certain cases be taken into the blood and, coming to rest at certain spots, the above-described process is repeated.

The bacillus anthracis divides in the blood stream,² and other organisms, such as the diplococcus pneumoniae and bacillus influenzae may exist in it. Many forms of organisms exhibit a preference for certain spots at which they find the conditions best suited to development—*e. g.*, the typhoid bacillus in the glands of the ileum, Peyer's patches; the anthrax bacillus in the lungs of animals; the diphtheria bacillus

¹ Abbott.² Green.

in the mucous surfaces of the pharynx and contiguous parts. Those parasitic bacteria which produce disease are called pathogenic, others are non-pathogenic.

The mouth offers a suitable habitat for many bacteria.

The bacteria which live on dead organic matter are called saprophytic (*sapros*, rotten, and *phuton*, a plant). They break up the dead animal and vegetable matter into simple compounds like carbon dioxide, ammonia, etc., which are utilized by the higher chlorophyllous plants. As animals are dependent upon plants for existence, their vast importance in the economy of nature is evident. Bacteria may often pass from a parasitic existence to a saprophytic one—a fact which is utilized in their study by bacteriologists, who prepare artificial media in which to cultivate them. These are called cultures, which by transference from one culture plate to another of like kind are said to be passed through generations. When by careful segregation one form of bacterium is separated from others present in a mixed culture and thereafter cultivated alone, it is called a pure culture. Bacteria may pass from a saprophytic to the parasitic form of existence. Bacteria which have this power of adaptation are called facultative. When without this power they are obligate bacteria.

According to Pasteur those which require oxygen in order to live are called aërobic. Those which cannot live in its presence are anaërobic. Those which live either way are facultative.

FERMENTATION.

Fermentation in the broadest acceptation of the term has been defined as the decomposition of substances possessing complex molecules under the influence of organized or unorganized ferments. The decompositions occur when organic substances are exposed to the action of bacteria or are subjected to the action of certain substances such as are found in the digestive fluids secreted into the alimentary canal.

According to Woodhead¹ the molecules of the fermented compound are separated from one another for a brief period and then allowed to combine and form simple and more stable compounds. The process is accompanied by heat due to chemical changes.

Ferments, then, are of two kinds: (1) organized ferments or living

¹ Bacteria and their Products.

bacteria which multiply at the expense of the substance which they are fermenting; (2) unorganized ferments or enzymes, nitrogenous bodies produced by living cells which have the power of producing chemical changes in organic substances. They thus affect many times their own weight of the particular organic substance being fermented without being themselves much affected, though eventually exhausted. Typical examples are ptyalin of the saliva, which changes starch to glucose, and pepsin of the gastric juice, which changes albumin to peptone. The unorganized ferments usually act by oxidizing, deoxidizing, or hydrating the substance modified.

About one-third of all pathogenic bacteria have been shown to possess such unorganized ferments.¹ It is probable that they produce their effects on organic substances by the aid of these ferments, which serve them as pepsin serves man. It is thought that in other cases the germs take up organic food, digest it, and excrete waste products in somewhat the same manner that the body cells nourish themselves. As a rule more than one species of bacterium infects a fermentable substance. The more active varieties predominate in the fermentation, but mixed fermentations may proceed. Some may die out, finding an unfavorable soil. After a time the predominating bacteria may die in the waste products accumulated about them, leaving the field clear for a second or third variety. In this way progressive decompositions may occur—*e. g.*, the alcoholic fermentation may be succeeded by the acetic, in which the alcohol is changed to acetic acid; as in cider-vinegar formation. The nature of the chemical changes produced in a fermentable substance depends upon the chemical nature of the latter and upon the nature of the fungus causing the fermentation.

Thus in an infusion of vegetable juices containing sugar a yeast fungus (one of the blastomycetes) will produce carbon dioxide gas and alcohol if the oxygen of the air be freely admitted, while if to a fresh portion of the same solution scrapings from carious dentine be added lactic acid will be formed and, as a rule, no gas. Moreover, the reaction will occur if oxygen be excluded.² In albuminous compounds an alkaline reaction and entirely different substances will be formed upon the addition of carious dentine.

The progressive decomposition of albuminous matter into simple compounds is effected by many bacteria through processes of oxidation, deoxidation, and hydration.

¹ Green, Pathology and Morbid Anatomy.

² Miller.

Peptones¹ are first formed, next alkaloid-like bodies called ptomaines; succeeding this such nitrogenous bases as leucin, tyrosin, and the amines (methyl, ethyl, and propylamine) are formed. Next fatty acids and such acids as butyric, lactic, and succinic acid appear. Next aromatic products such as indol, phenol, and cresol are formed, and the final decomposition is represented in the end products—carbon dioxide, CO₂; hydrogen sulphide, H₂S; ammonia, NH₃, and water, H₂O.¹ When bacteria produce decomposition of living animal tissue they effect this putrefaction as distinctly noted in certain cases of abscess.

Such products of bacterial action either produced in a living or a saprophytic medium as are capable of acting as poisons in the animal organism are called toxins. Some animal parasites also produce them. It is understood that they differ according to the fungus and the medium. If the toxin be proteid in nature it is termed a toxalbumin.

Some of the ptomaines are toxic; the greater number are not.

When the toxins alone are absorbed from a focus of infection the subject is poisoned—a condition called toxæmia, whether due to a toxic ptomaine, as in the case of Asiatic cholera, or to a toxalbumin, as in the case of diphtheria. Such toxæmia is commonly accompanied by more or less fever, according to the amount taken up. When the organisms enter the circulation and multiply in the blood, or at least move about and live in it to be carried to capillaries in which they can rest and multiply, the condition is termed a septicæmia.² In toxæmia and septicæmia the symptoms depend upon the nature of the organism and their products. Bacteria are found everywhere and exist upon the surface of the body, in its external cavities, and in the alimentary canal. Here under conditions of health there seem to be conditions favoring certain forms, which, when implanted, occupy the field and exclude, except temporarily, other forms to which the soil is not so well suited. These are known as the "normal flora."

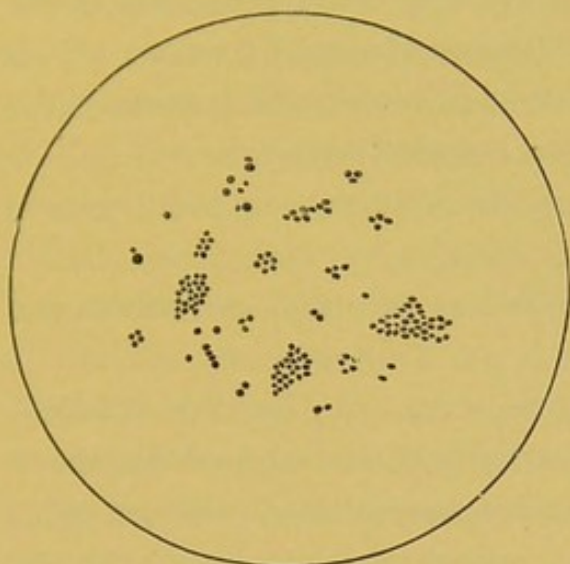
With certain changes occurring, other forms may become implanted. Pathogenic bacteria may exist in the healthy cavities and produce no ill results. Again, the soil may favor and disease begins. Certain bacteria have been found constantly present in relation with certain diseases—*e. g.*, the spirillum of Asiatic cholera with that disease. These are specific bacteria. Taken from individuals with the disease, they produce it in susceptible animals inoculated with them if circumstances favor their growth.

¹ Ziegler's General Pathology.

² Abbott.

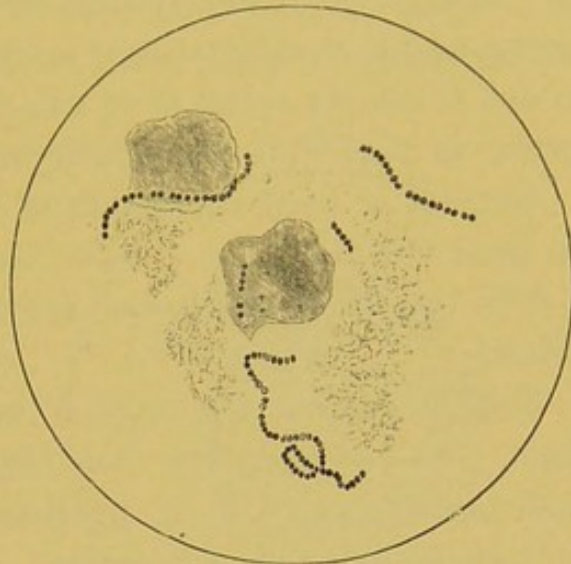
Bacteria spread in the tissue along the lines of least resistance. They may follow the cellular tissue or enter the lymphatics, or pass at once into the veins and be carried into the circulation. They may be strictly localized at the point of infection.

FIG. 18.



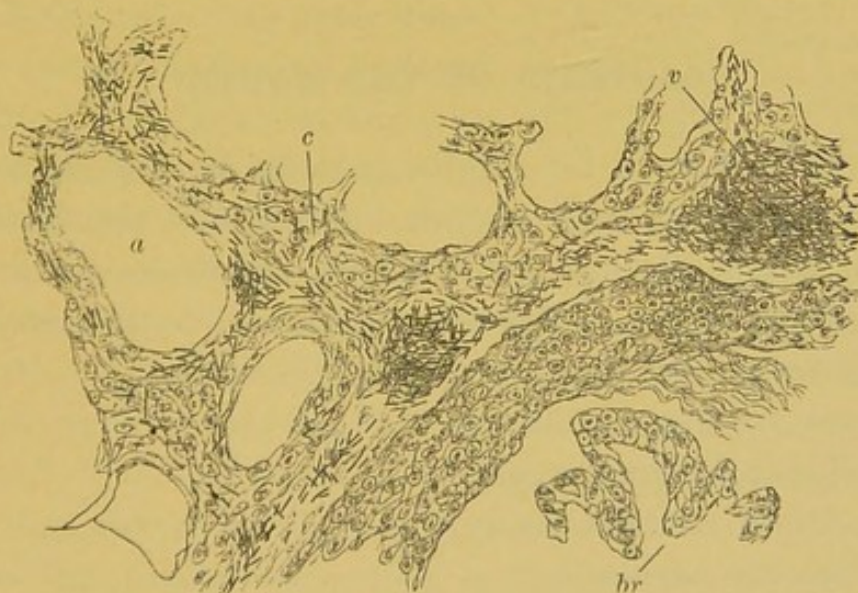
Staphylococcus pyogenes aureus. From a culture. $\times 1000$. (Green.)

FIG. 19.



Streptococcus pyogenes. From pus found in a pyæmic abscess. $\times 1000$. (Green.)

FIG. 20.



Mouse's lung; vessels plugged with bacilli anthracis. *a*, alveolus; *v*, vein full of bacilli; *c*, capillaries also full; *br*, bronchus. $\times 400$. (Horsley.)

Thus there may be a localized inflammation—*e. g.*, in simple abscess due to the *staphylococcus pyogenes aureus*; a diffuse inflammation, as in case of infection by the *streptococcus pyogenes*; or a metastatic inflammation, as in pyæmia, in which the germs (usually *S. pyogenes*) gain access to the blood from a local focus of infection and are carried to distant parts, in which they cause inflammation. To produce effect

germs in the blood must come to rest at some point, which may occur in the capillaries owing to their injury, in thrombi or emboli, or in case of entrance of bacteria into a leukocyte they may migrate into the connective tissue (Fig. 20).

It has been shown that pyogenic germs may exist in the blood without local effects, while again a local injury may cause the arrest of the germs and a secondary local inflammation or abscess be set up. This is due to simple arrest or to extravasation of blood, which permits the germs to pass from the vessels into the connective tissue.

General or local depression of tissue vitality acts as a predisponent to local infection.

The infections themselves are classified as primary, secondary, and mixed.

The primary is the original infection, say, *e. g.*, bacillus tuberculosis. The secondary is that implanted when the original disease is well under way—*e. g.*, *S. pyogenes aureus* upon tuberculosis; a third or tertiary infection is possible.¹

The original infection may be by mixed germs, more than one of which may multiply. Thus the *S. pyogenes aureus* and *diplococcus pneumoniae* may both be found in an abscess. This is mixed infection.

BACTERIA OF THE MOUTH.

In even the best cared for mouths bacteria are numerous and find the conditions suited to their growth. In unclean mouths containing food débris, dead epithelium, etc., their life conditions are much more favorable. According to Miller² there are a number of bacteria which almost invariably occur in every mouth. These are:

1. *Leptothrix innominata*.
2. *Bacillus buccalis maximus*.
3. *Leptothrix buccalis maxima*.
4. *Jodococcus vaginatus*.
5. *Spirillum sputigenum*.
6. *Spirochæte dentium* (denticola).

To this list Goadby³ has added:

Leptothrix racemosa of Vicentini, further described by Williams.⁴
Streptococcus brevis of Lingelsheim, and *Cladothrix buccalis* (provisionally added).

¹ Park, Surgery by American Authors.

³ Mycology of the Mouth, 1903.

² Micro-organisms of the Human Mouth.

⁴ Dental Cosmos, 1899. See Dental Caries.

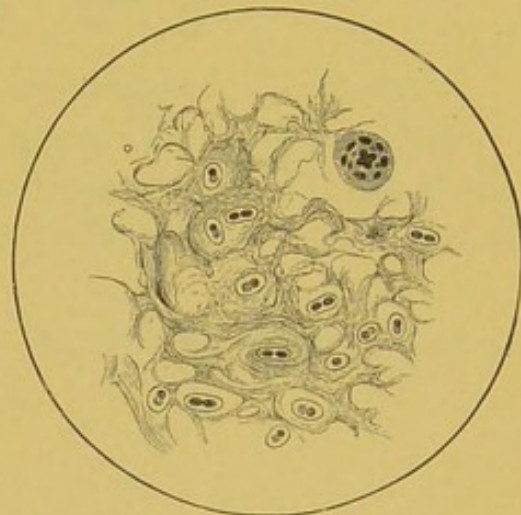
With the exception of *S. brevis* and perhaps *Cladothrix* and *B. buccalis maximus* these are uncultivable on laboratory media, are strictly obligate parasites. Of the last-named organism Goadby obtained biological characteristics of the pure culture, but did not establish its disease-producing power, if any.

Certain pathogenic organisms have been shown to be present in the mouths of healthy persons, such as bacteriological investigators; those nursing infectious diseases, such as diphtheria, scarlet fever, etc., and even in the mouths of healthy individuals apparently not exposed to any infection. In about 10 per cent. of all individuals examined at random Netter found *staphylococcus pyogenes aureus* (golden pus). *Staphylococcus pyogenes albus* was also found. The pneumococcus or diplococcus pneumoniae was found in the mouths of about 15 per cent. of healthy individuals. This organism has been found by Kirke to be apparently causative of pericemental abscess, and has been reported by Schreier¹ as found in 75 per cent. of cases of apical abscess examined. It has also been related with cases of osteomyelitis. The bacillus diphtheriae of Loeffler has been found in about 10 per cent. of mouths examined at random, and 33 per cent. of 600 children in a school examined during an epidemic of diphtheria were found to have the bacillus present in the mouth, while but about 2 per cent. developed the disease.² This latter fact shows the absolute necessity for a predisposition as well as an exciting cause

The bacillus tuberculosis exists in the mouths of many suffering from pulmonary tuberculosis, and exists also at times in the mouths of the healthy. Primary tubercular osteitis has been observed. The *saccharomyces albicans* may be present and at times produce thrush (Fig. 9).

The bacillus typhosus (typhoid) has been found in the healthy mouth, and at times has oral pathogenicity. Many other organisms have been isolated from the human mouth. Some of these have specific

FIG. 21.

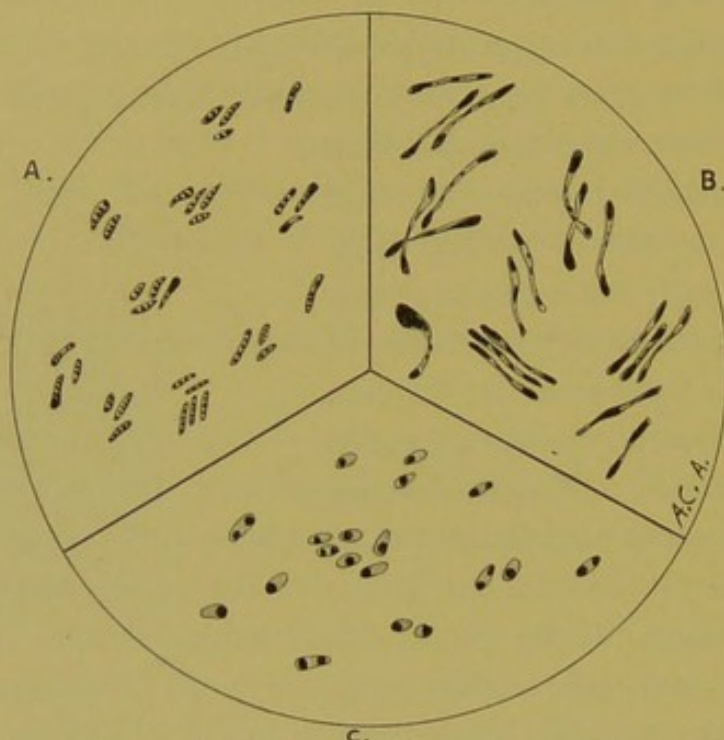


Diplococci pneumoniae entangled in the meshes of the fibrinous exudation. From a section of lung in the "red hepatization" stage of acute pneumonia. In the upper part of the field is a cell containing several cocci—possibly a phagocyte. $\times 1000$. (Green.)

¹ Dental Cosmos, 1893.² Goadby.

character, of others little is known. Some of the bacteria of the mouth possess the power, under certain conditions, of felting themselves in a gelatinous mass or film upon the surfaces of the teeth. Here if prop-

FIG. 22.



Bacillus diphtheriae. A. Its morphology on glycerin-agar-agar. B. Its morphology on Loeffler's blood serum. C. Its morphology on acid blood-serum mixture. (Abbott.)

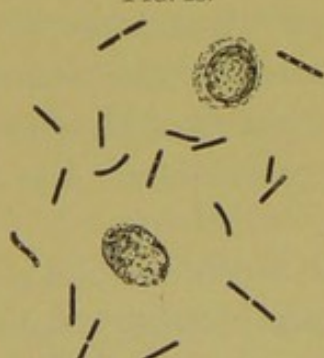
erly supplied with carbohydrate food some of them produce lactic acid and decalcify the teeth. Some have a later putrefactive action upon the organic matrix of the dentine. Goadby¹ gives an interesting classi-

fication of bacteria found in dental caries (which see). Some bacteria not yet isolated are the probable causes of pyorrhoea alveolaris.

The bacteria in the mouth probably are taken into the food and swallowed in great numbers. Many are doubtless killed by the gastric juice, which is a weak germicide; notwithstanding, some pyogenic cocci and some of the blastomycetes may develop in the stomach and produce disease. Many also may enter the intestines and either excite disease of spe-

cific character or produce abnormal intestinal fermentations the toxins of which may be absorbed. They may remain localized in the mouth and produce oral disease, dental caries, or pericemental diseases, etc.

FIG. 23.



Bacillus tuberculosis.
× 1000. (Green.)

¹ Mycology of the Mouth

The relation of an unclean mouth to effects upon the mouth and alimentary canal and air passages is, therefore, a direct one of an importance that renders exact studies in this direction of extreme value. Unfortunately the problem is but partially worked out. (See *Pyorrhoea Alveolaris*.)

THE RESISTANCE OF THE TISSUES TO INFECTION.


The resistance of the tissues to bacteria is to be considered from two main standpoints:

1. The prevention of the entrance of bacteria into the tissues.
2. The destruction of the bacteria after entrance into the tissues.

(1) The prevention of entrance. It has been shown that pathogenic bacteria may enter the mouth, alimentary canal, lungs, etc., but few develop.

The skin acts as a mechanical barrier, though its openings may at times harbor bacteria.

FIG. 24.



1, a spore which has penetrated the intestinal wall and entered the abdominal cavity, where four leukocytes have surrounded its end: *m*, the muscular layer of the intestine; *e*, epithelial layer; *s*, the serous layer. 2, a spore surrounded by leukocytes from the abdominal cavity of a *Daphne*. (Metchnikoff.)

The mucous membrane secretes mucus, which envelops bacteria and with it they are carried away. The healthy mucus also has apparently a devitalizing power for some bacteria, not for others. The acid gastric juice kills many and probably the intestinal juices also inhibit in large degree the action of such as have entered the alimentary canal. In all cases the agitation of the fluids of a part seems to act mechanically to prevent localization of bacteria.

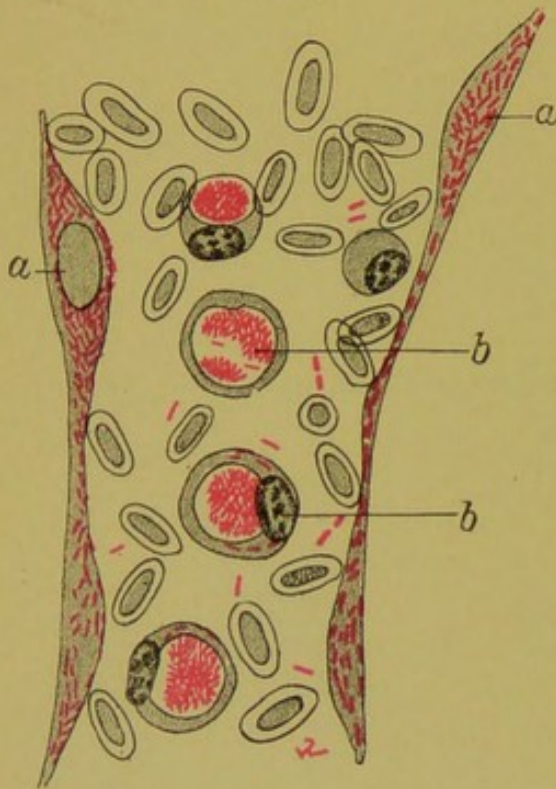
(2) The prevention of development in the tissues. Within the healthy tissues bacteria find several elements opposing their development.

It seems the consensus of opinion of pathologists that the blood serum contains a germicidal substance or substances probably of the nature of a nuclein and called by Buchner "alexin."

This belief is mainly based upon the demonstrations of Nuttall that

filtered blood serum possesses the power of producing the degeneration of bacteria. Buchner found that heating to 55° C. destroyed this property, a fact pointing to the albuminous nature of the alexins. After reviewing all the evidence Vaughan and Novy¹ conclude: "(1) the exact nature of the germicidal constituents of the blood or alexins is not known; (2) the alexins have their origin in the white blood cor-

FIG. 25.



Active phagocytosis. Endothelial cells enclosing the bacilli of swine septicæmia, from an hepatic vein of a pigeon: *a*, endothelial cells; *b*, leukocytes. (Metschnikoff.)

puscles; (3) disintegration of the white blood corpuscles liberates alexins; (4) it is probably true that alexins are also secreted by living leukocytes."

Metschnikoff, in 1884, demonstrated that the leukocytes take up bacteria within themselves and claimed that they thus destroy them. This process he termed phagocytosis (*phago*, I eat; *cytos*, a bud). It is now considered that this property, which is also possessed by the endothelial cells of the blood-vessels and by the fibroblasts, is but evidence of the nutritive function of simple cells occurring after the bacteria have been partially degenerated by the serum (Fig. 25). If the conclu-

sions of Vaughan and Novy be correct, that the alexins are furnished by the leukocytes, it would seem quite possible that the destruction of some of the bacteria may be produced within the leukocytes. Researches of Leber, Buchner, and others have shown that leukocytes may be attracted by certain bacterial products even in high dilution and by other chemical substances, such as mercury and copper salts. This is called positive chemotaxis. Other substances, such as methylamin, leucin, tyrosin, and urea, exhibit a repulsion—negative chemotaxis.

If the combined local forces be incompetent to kill out the infecting organisms the local infection spreads until limited or the patient

¹ Cellular Toxins, 1902.

dies, or a metastasis may occur, in which case the process is practically repeated in another locality.

The absorbed toxins may produce a toxæmia in either case; a reaction takes place upon the part of the body cells generally and new substances enter the blood, which are not necessarily fatal to the organisms themselves, but act as antidotes to their toxins, which they neutralize¹—*i. e.*, they are self-formed antitoxins. (See Immunity.) A third body may exist in the blood after infection, consisting of an enzyme produced by the bacteria, and which after reaching a certain degree of concentration may first agglutinate the bacteria in masses (agglutination) and later dissolve them (bacteriolysis). This action may occur either in old cultures out of the body or in the blood, etc., within the body.² The general name of nucleases has been proposed for these ferments.

Combining with certain normal albuminous bodies in the blood they produce combinations known as immune proteids, which retain the original bacteriolytic properties of the enzymes and in some cases have antitoxic properties as well.

Emmerich and Löw, who are responsible for the above formulations, claim that experimentally the enzyme of *Bacillus pyocyaneus* (pyocyanase) and its immune proteids (pyocyanase-immune proteids) are bacteriolytic for *B. pyocyaneus* and the bacteria of anthrax, typhoid, diphtheria, pest, and Asiatic cholera.³

The theory as demonstrated runs somewhat counter to that of Ehrlich's theory of antitoxin formation (see p. 33) and both are necessarily *sub judice*.

EXTERNAL ANTIBACTERIAL INFLUENCES.

Many chemical substances and physical forces prevent the growth and reproduction of bacteria without necessarily killing them; these are called antiseptics; a weak solution of boric acid is an example, agitation is another, dryness another. Other substances or forces kill the bacteria after an exposure to their influence for a sufficient length of time; these are germicides—*e. g.*, a 1:1000 solution of mercuric chloride in water, boiling water, or streaming steam; light for some bacteria. Other substances destroy both the bacteria and their products; these are disinfectants—*e. g.*, sodium dioxide or other substances liberating nascent oxygen.

¹ Ehrlich.

² Vaughan and Novy.

³ Ibid.

CHAPTER IV.

DISTURBANCES OF NUTRITION.

DISORDERS of nutrition are of three classes: (1) due to an excess of nutritive material; (2) due to a deficiency of nutritive material; (3) due to the presence in the blood of material which, instead of serving the purpose of metabolism, disturb it.

EXCESS OF NUTRITION. HYPERNUTRITION.

An excess of nutrition may be either general or local. In either case it is associated with an overfulness of the bloodvessels (hyperæmia). If the individual possess this general overfulness of vessels he is said to be plethoric. Sthenic plethora is such an overfulness associated with activity of the circulation and a consequent increase of the vital processes due to plentiful cell nutrition, and with an active repair of even excessive waste of cell protoplasm.

In asthenic plethora, on the contrary, the vessels are overful, but the circulation is sluggish; waste products are probably accumulated in the blood and the vital processes are sluggish in consequence. Instead of the rich color and active movements associated with sthenic plethora, the asthenic have a purplish appearance and the movements are more labored.

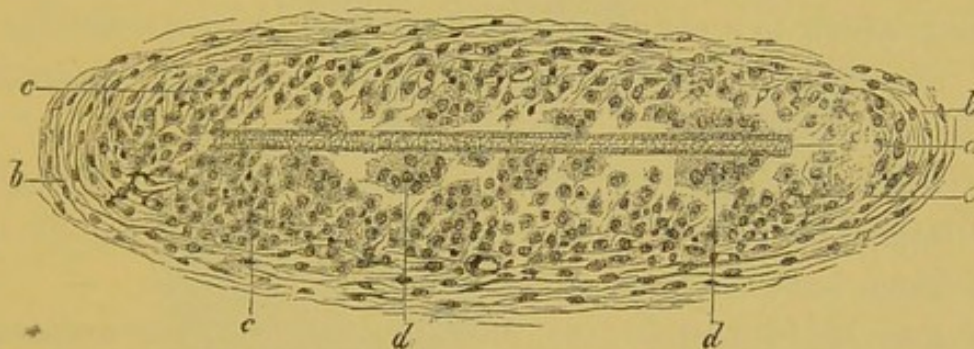
Local Hypernutrition. An increased stimulation of the nerves of a part invites more blood to it, which within certain limits increases the nutrition to the cells of the part. This results in increased irritability, contractility, and general functional activity of the functioning cells. If this be maintained the cells grow or multiply or both, and the part is enlarged and capable of an increased amount of work.

Stimulation beyond this point causes irritation or overstimulation of cells and the vital processes become fretful, incomplete chemical changes occur in the cells, and the functional activity is disordered. The cells are wearied and if the overstimulation be continued paralysis from overwork results.

Hypertrophy. Though strictly meaning an excess of nutrition, this term signifies an increase in size of a part due to an increase of

nutrition. The new-growth must be practically normal in structure. As a rule both the size (simple hypertrophy) and number of the cells (numerical hypertrophy or hyperplasia) are increased. The calibre of the bloodvessels is increased to comply with the stimulus to their controlling nerves—the vasomotors. Hypertrophy is frequently exhibited in tissues subjected to an unusual amount of work short of marked fatigue. An increase in its function occurs; its capacity for work becomes greater, and if the strong stimulus (mild irritation) implied be continued the cells increase in size and it may be in number, all three phases of the expenditure of an increase of vital energy being represented—functional, nutritive, and reproductive. If the heart be subjected to an increase in the strain ordinarily brought upon it an increase in the volume of the muscular fibres follows, causing hypertrophy of the walls. The same is true of the muscles of the gravid uterus,

FIG. 26.



Dog's hair encapsulated in subcutaneous tissue: *a*, hair; *b*, fibrous tissue; *c*, proliferating granulation tissue; *d*, giant cells. Preparation hardened in alcohol, stained with Bismark brown, and mounted in Canada balsam. $\times 66$. (Ziegler.)

in which the cells increase to many times their normal length. When one organ, as a kidney, takes up alone the work usually performed by two it increases in size (hypertrophies). This is called compensatory hypertrophy. It may occur in an organ which endeavors to supply the deficient function in another organ of different sort. Hypertrophy also occurs in many inflammatory conditions, and is due to the area of hyperæmia surrounding every focus of inflammation. Thus the epithelium about the edges of an ulcer may thicken or new bone may be formed about an area of inflamed bone tissue or periosteum. The bone tissue may become more compact, a condition termed sclerosis of bone, as it results in the formation of formed (intercellular) tissue at the expense of the cellular elements.

The removal of an accustomed resistance often produces an irritation resulting in mild hyperæmia and thickening or hypertrophy

results — *e. g.*, non-occlusion of teeth frequently produces hypercementosis.

A form of cellular hypertrophy appears to occur in certain leukocytes, resulting in the formation of a multinucleated cell or "giant cell."

Under irritation the nucleus subdivides, but the cell body fails of division, and instead of complete reproduction a large cell with many nuclei is formed (Fig. 26). These cells appear where tissue is to be removed, as in the case of aseptic foreign bodies or the roots of deciduous or even of permanent teeth. (See Resorption of Temporary Teeth.) An hypertrophy or excessive development may occur during intra-uterine life and is spoken of as congenital hypertrophy. A low grade of inflammation may lead to a numerical hypertrophy, as in the case of hypertrophy of the dental pulp (which see).

Cyst and Tumor Formation. A cyst is an enlargement containing a cavity which in turn contains liquid, gelatinous, or pultaceous material about which is a capsule condensed from the surrounding structures. The accumulation of the fluid or semifluid contents produces the enlargement of the part even if bony (Fig. 27).

They differ from tumors in being strictly localized, though they may be large, and in their generally benign character, though tumors may at times have a cystic character.

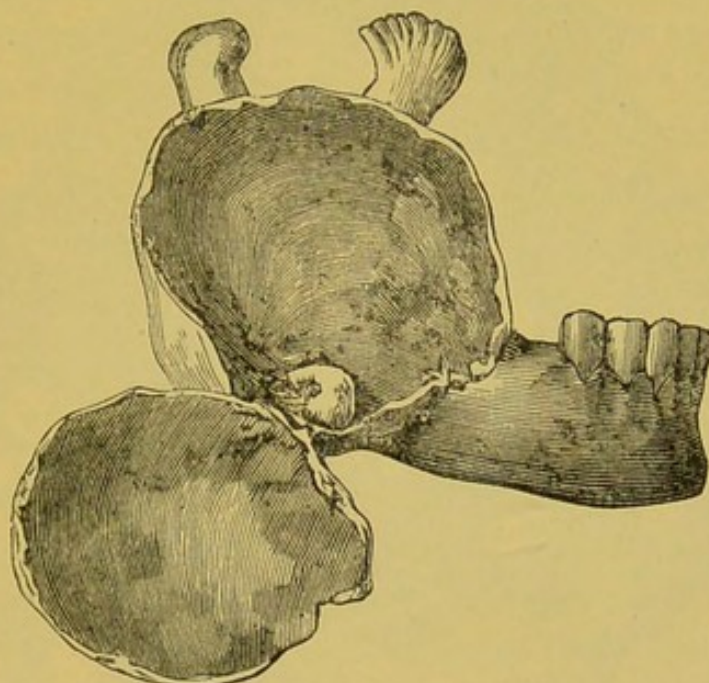
Cysts may be formed by the retention, secretion, or extravasation of fluid in several ways: (1) By the retention of normal secretion of a gland owing to the obstruction of its duct—*e. g.*, ranula. These are called retention cysts. (2) By abnormal secretion into ductless cavities—*e. g.*, bursæ (exudation cysts). (3) By the extravasation of blood into a ductless cavity (extravasation cyst). (4) Independently in tissue as a result of mucoid or fatty changes or liquefaction necrosis, the surrounding tissue becoming condensed into a capsule. (5) Independently as a collection of fluid in connective-tissue spaces, which enlarge and fill. The surrounding tissue condenses into a cyst wall. (6) Independently as a result of chronic irritation by foreign bodies, extravasated blood, or parasites, as in dentigerous cysts¹ (Fig. 27). Cysts may have but one cavity (simple cysts) or have numerous intercommunicating cavities known as loculi (compound or multilocular cysts). Forming within bony walls, these may be largely distended and the walls are usually thin. Dentigerous and other cysts are usually lined by epithelium peculiar to the part.

¹ Green.

Dermoid cysts are cystic tumors of widely varying sizes found in various parts, such as the ovary, neck, base of brain, orbit, etc. They contain fatty débris, and are lined with epithelium, outside of which is a corium with its papillæ, and outside of this subcutaneous adipose tissue. The whole is enclosed in a fibrous capsule of connective tissue. The epithelial lining may contain and develop the characteristically dermoid structures, hair, teeth, sebaceous and sweat glands¹ (Fig. 28).

Dermoid cysts are classed with the teratomata or monsters considered as partially developed fetal structures attached to the surviving foetus.

FIG. 27.



Cyst of the lower jaw, having its origin about an undeveloped tooth (Garretson.)

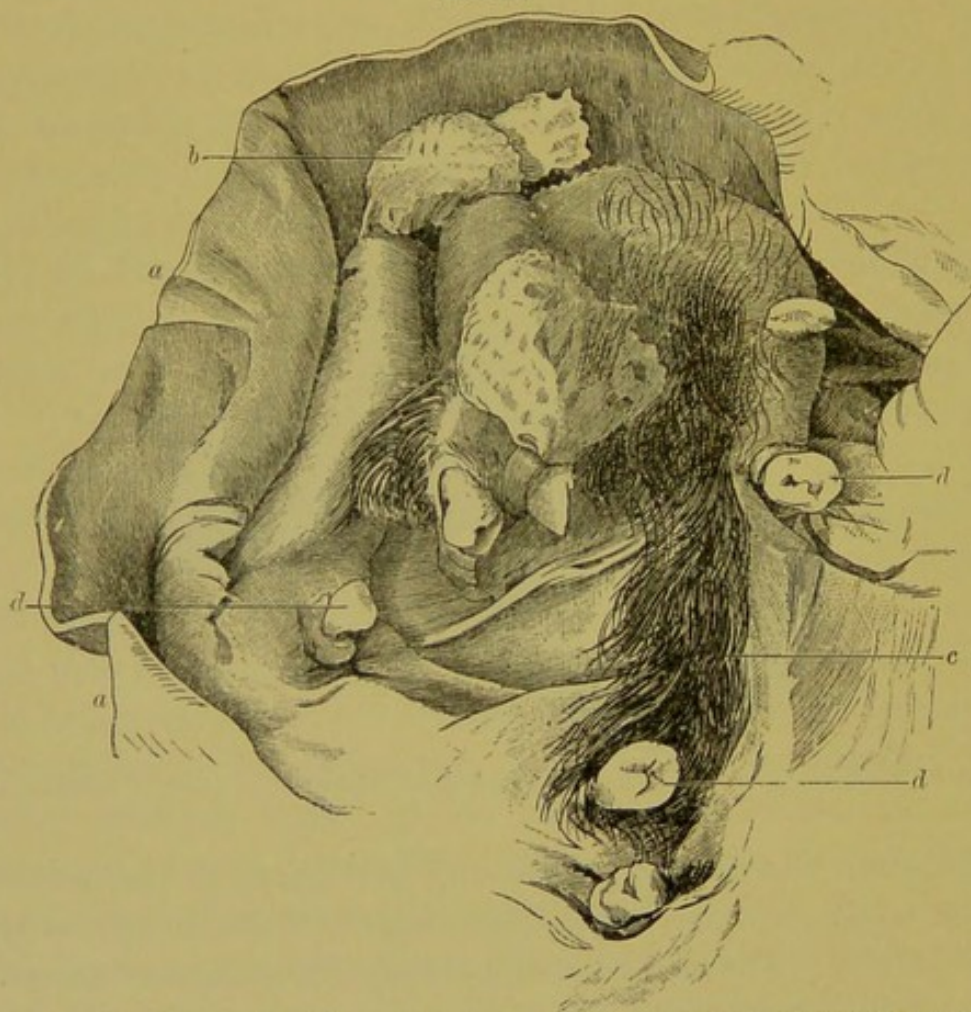
A tumor is a new-growth conforming to a degree to the normal histology of a part, but having no physiological function and no typical limit of growth. They are classed as benign or malignant accordingly as they are strictly localized and comparatively harmless or tend to sap vitality and to spread dangerously or to be transferred to other localities (metastasis).

The growth of a tumor is attended by a sapping of the vitality of a sufferer—the degree of the debility produced being apparently in direct ratio to the size and the rapidity of the growth. Besides the size and the rapidity of development of individual tumors, another element determines their malignancy, their position, and, furthermore, their occurrence in other parts, resulting in multiple tumor formation. A

tumor victim acquires a peculiar appearance—a cachexia, whose intensity and rapidity of advance are directly dependent upon the degree of malignancy.

Tumors introduce no new form of tissue element; they are reproductions of the cells of the tissues of the body. They may have the same cell formation as the tissue from which they spring, and are then called homologous tumors; or they may have a different histological structure from the tissue in which they are found, being then called

FIG. 28.



Portion of a wall of an ovarian dermoid cyst: *a*, wall of the cyst; *b*, projecting portion made up of fatty and cutaneous tissue; *c*, hairs; *d*, teeth. (Ziegler.)

heterologous tumors. For example, a bony tumor growing from bone would be homologous; a cartilaginous tumor growing from gland tissue would be heterologous.

Causes. The causes of tumor formation are unknown; it has been believed that their growth is due to parasites, especially the protozoa; this, however, has not been proved. A certain proportion of tumor formations, 7 to 14 per cent.,¹ appear to be caused by traumatic injury;

¹ Ziegler.

as, for example, in cases of mammary tumor, a history of a blow or fall may be at times obtained.

Long-continued, sluggish inflammation appears to be causative of tumor formation in an unknown percentage of cases. A chronic irritation of certain portions of the body, such as the junction between the mucous and skin surfaces of the lip, the sides of the tongue, etc., is a frequent antecedent to their formation. Ziegler gives a reasonable explanation of the origin of certain epithelial tumors in organs which are undergoing atrophy; for example, in advanced age the connective tissue of the body is undergoing atrophy and there is relaxation of its strata; the epithelium of the surface (or of glands), still possessed of its power of reproduction, proliferates and invades the connective tissue, producing cancer.

Tumor formation consists in the reproduction of the cells of one or more tissues, and in the growth thus formed bloodvessels are developed. Tumors do not contain nerves. Their blood supply, however, is generous, so that for long periods a superabundance of nutritive material is carried to them; but after a variable period, depending upon the type of growth, the nutritive supply becomes disordered and degenerations occur.

About the more slowly developing tumors a condensation of connective tissue occurs in many cases, forming a distinct limiting wall or capsule from which the tumor may be enucleated.

The two great classes of tumors, those of mesoblastic and those of epiblastic and hypoblastic origin, may be subdivided into orders according to their histological peculiarities.

CLASS ONE.¹

TUMORS OF MESOBLASTIC TISSUES.

Order One.

Tumors of mature connective tissue:

Bony tumors, or Osteoma.

Cartilaginous tumors, or Chondroma.

Fibrous tumors, or Fibroma.

Fatty tumors, or Lipoma.

Mucous tumors, or Myxoma.

Lymphoid-tissue tumors, or Lymphoma.

¹ Modified from Green's Pathology, p. 148.

Order Two.

Tumors of the embryonic connective tissues:

The fleshy tumors, or Sarcoma.

Order Three.

Tumors of the higher tissues:

Tumors of muscle, or Myoma.

Tumors of nerves, or Neuroma.

Tumors of bloodvessels, or Angioma.

Tumors of lymphatic vessels, or Lymphangioma.

CLASS TWO.

TUMORS OF EPIBLASTIC AND HYPOBLASTIC TISSUES.

Papilla of skin and of mucous membrane, or Papilloma.

Tumors of glandular tissue { Adenoma.
Carcinoma.

The tumors of epiblastic and hypoblastic type are sometimes called Epitheliomata, for epithelial tissue is their characteristic histological structure.

Malignant tumors are found in both of the great classes, mesoblastic and epiblastic and hypoblastic. Carcinoma represents the type of malignancy in the epithelial tumors. The sarcomata are the malignant tumors of the connective-tissue type.

Tumors are rarely composed of but one type of tissue; several types may be present, the tumor receiving its name from the tissue predominating. When the distinguishing feature of a tumor is two predominating tissues, the tumor is given a compound name; as, for example, when, in a sarcomatous growth, numerous large multinucleated cells characteristic of bone-marrow are found, it is called a myeloid sarcomatous tumor. When fibrous and sarcomatous tissues are distinguishing features the tumor is called a fibrosarcoma.

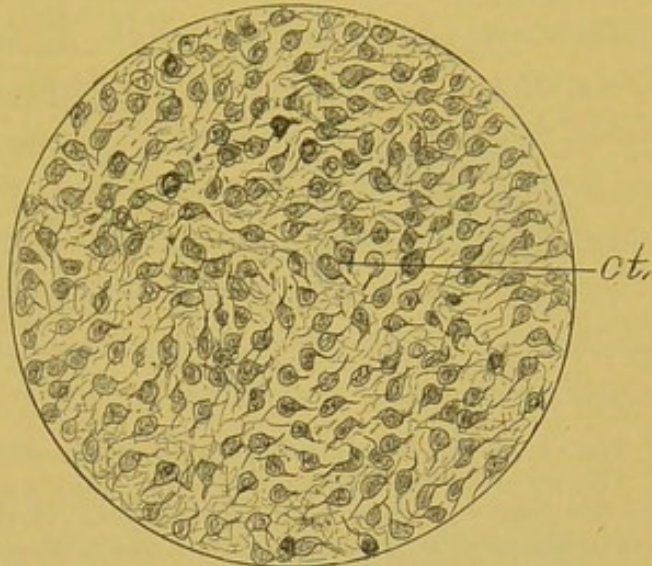
Since the malignancy of a tumor is due primarily to the size and the rapidity of its growth, it is clear why sarcomata are more malignant than fibromata, and why some forms of sarcoma are more malignant than others. To illustrate:

Begin observation at the indifferent stage of connective-tissue development, when connective-tissue cells have first divided, reproduced; the tissue produced, seen in granulation tissue and in the embryo, is at

the indifferent stage, as seen in section of the embryonic jaw (Fig. 29).


Mesoblastic cells at this early period are in an indifferent stage; some of the cells shown in the figure will form bloodvessels, others will become bone corpuscles, others will form fibrous and others muscular tissue. This structure has its analogue among tumors in a soft, fleshy, rapidly growing growth, called the round-celled sarcoma. As cells expend their vital energy in three ways (nutritive, functional, and reproductive activity), the embryonic cells of such a growth may expend their energy in nutrition (growth), and will then grow out of the indifferent stage into a more mature form of connective tissue, the ultimate form of one type being a fibre, an embryonic round cell undergoing a series of form changes from a small round cell to a long fibre (Fig. 30). The growth may cease at any stage of this form change, the tumor composed of such cell forms receiving a corresponding name. The embryonic connective-tissue tumors, as stated, are called sarcomas, the form of the cells composing them giving them a qualifying title.

FIG. 29.



Porcine embryo: *ct.*, embryonic connective tissue of mesoblast. $2\frac{1}{2}$ cm. \times 250.

FIG. 30.



In Fig. 30 are represented the stages of development of a connective-tissue fibre from a round cell. If growth cease at stage 1, and the cell energy thereafter expend itself in reproduction, a rapidly growing tumor composed of small round cells is formed—a small round-cell sarcoma, markedly malignant. If the cells expend a portion of energy in growth of cell size, a large-cell sarcoma is formed, less malignant than the former. If the cells expend a portion of their energy in forming intercellular substance, reproduction and malignancy are less active. So the spindle forms, 3 and 4, represent less rapid reproduction and

lesser malignancy than 1 and 2, although the form 4, which should be of less rapid reproduction than 3, because of more mature organization, is frequently more malignant, because less intercellular substance is formed, as shown in Figs. 31 and 32, the energy represented in that

FIG. 31.

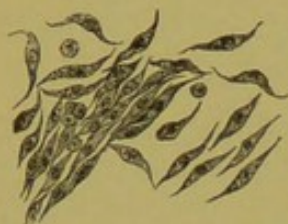

FIG. 32.

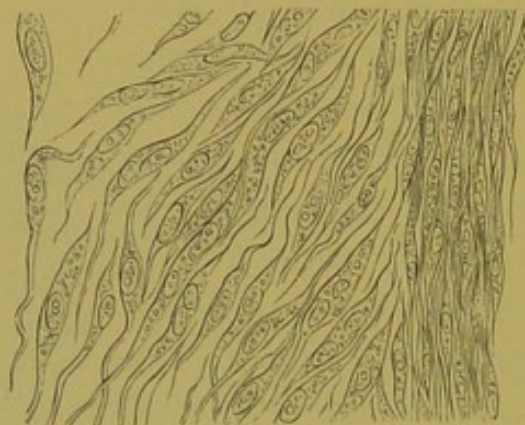
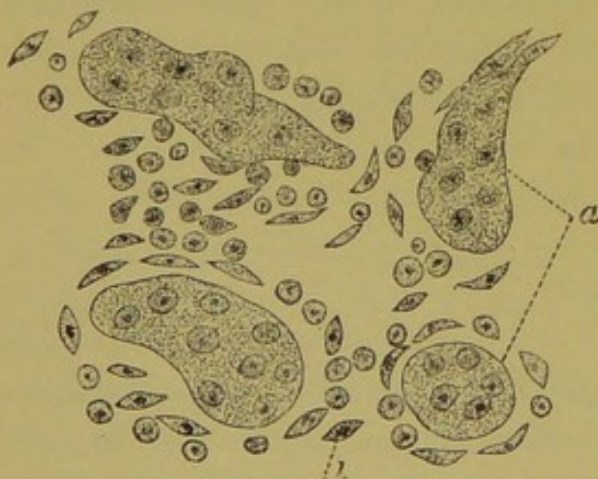
FIG. 31.—Small spindle-celled sarcoma (from a tumor of the leg). $\times 200$.

FIG. 32.—Large spindle-celled sarcoma. To the left the cells have been separated by teasing, so that their individual forms are apparent; to the right, they are in their natural state of apposition, such as would be seen in a thin section of the tumor. (Virchow.)

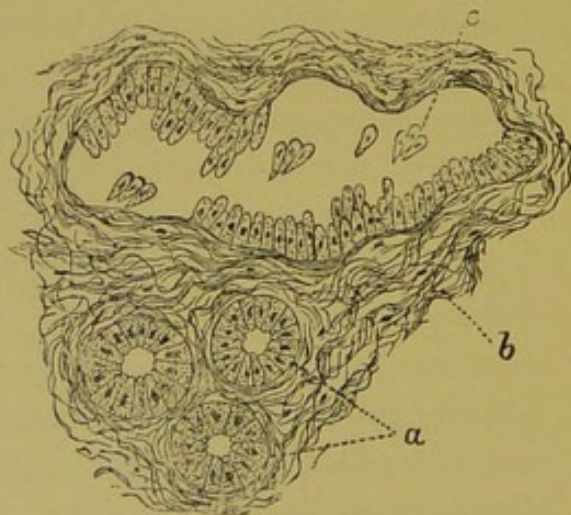
process being used up in reproduction. The nearer the approach to the mature form (6, Fig. 30), the slower the growth of the tumor, which, when composed of tissue of this type, loses its fleshy (sarcomatous) appearance and becomes fibrous, and is hence called a fibroma.

FIG. 33.



Myeloid epulis from lower jaw: *a*, multi-nucleated giant cells; *b*, oval cell. $\times 265$. (Pepper.)

FIG. 34.



Adenoma of the breast: *a*, group of glandular acini; *b*, fibrous stroma; *c*, cells broken away from their attachment. $\times 265$. (Pepper.)

When a sarcoma begins its growth from bone its histological character is frequently modified (Fig. 33). It contains large marrow cells which have undergone incomplete reproduction, forming giant multi-

nucleated cells; this is a common form of tumor emerging from the sockets of teeth. Some of the cells of a sarcomatous growth may go on to maturity, while others remain at some stage of their developmental career. Malignancy will be modified according to the amount of mature tissue formed.

Epithelial Tumors. Growths arising from epiblastic or hypoblastic tissues may be benign or malignant. What are called the adenomata may be taken as the type of the benign epithelioma; that is, comparatively benign. They present all of the characters of typical glandular tissue: numerous acini lined with epithelial cells and surrounded by connective tissue (Fig. 34). Tumors of this type may lose their comparative benignancy and become of the succeeding epithelial type.

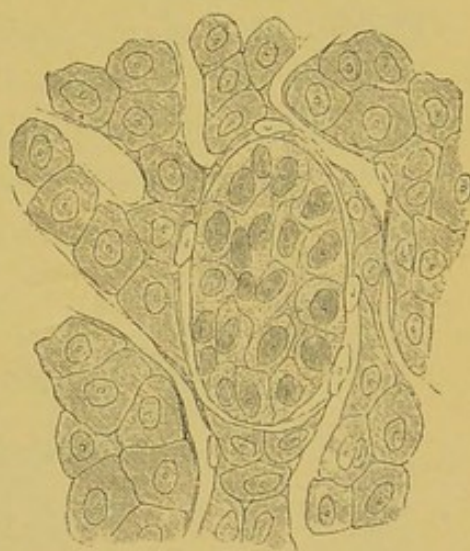
Carcinomata. These are growths arising from pre-existing epithelial tissue, which possess the characteristics of epithelium developing without the limitations of a basement membrane. Beginning upon a skin, or mucous surface, or in a gland, the reproduced epithelial cells are not sharply marked off from the connective tissue by a limiting membrane, but, gaining entrance to the alveoli of connective tissue, they proliferate there, find their way into lymphatic vessels and lymphatic glands, and reproduce epithelial growths in such places of lodgement, so that a tumor having its origin in one part may give rise to tumors in other parts of the body—metastasis (Fig. 35).

Like the connective-tissue tumors, types of carcinoma differ as to rapidity of growth in their original situation and in the degree of transference; these factors determine their malignancy. Tumors of the sarcoma group may also give rise to growths in other parts, the tumor cells being carried thence by lymphvessels or bloodvessels.

After a period, tumors frequently suffer such interference with their nutrition that degeneration occurs in them.

After removal, some varieties of tumors, both those which infiltrate surrounding tissues and those which are metastatic, show a tendency to recurrence; that is, removal does not effect a cure, and the tumor

FIG. 35.



Section through an aggregation of very young cancer cells, lodged like an embolus within a capillary of the liver. The parent growth was an adenocarcinoma of the stomach. Preparation stained with hæmatoxylin. $\times 300$. (Ziegler.)

may upon reappearance assume another and a more malignant character.

Epithelial tumors never become tumors of the connective-tissue type; and, *vice versa*, connective-tissue tumors cannot become epithelial tumors.

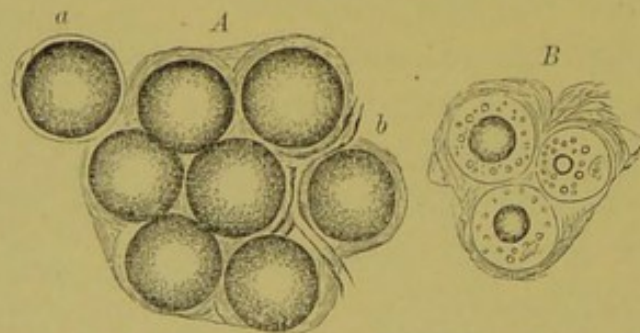
The distinction formed between epiblast and mesoblast in the embryo is maintained throughout life.

DEFICIENCY OF NUTRITION. HYPONUTRITION.

If the quantity or quality of the blood delivered to a part be deficient, the nutrition of the cells of the part is impaired. First, atony, a lessened activity of the vital processes of the part, occurs. Cell chemistry is disordered, less oxidation occurs, hence there is a lessened heat production.

The function of the cells is diminished: if secretory, its secretion is lessened; if muscular, the cell has a lessened contractility; the relations between nutrition and waste are disturbed; the part becomes physiologically wearied sooner than usual.

FIG. 36.



Adipose tissue. A, normal; B, atrophic, from a case of phthisis; a, a single fat-cell, with cell wall, nucleus, and drop of fat. $\times 300$. (Virchow.)

If the process cause interference with the development of an organ, so that it is much below normal in size, the condition is spoken of as aplasia or agenesis.

If the interference merely checks the growth of a developed organ, the condition is known as hypoplasia.

Atrophy. If the process of hyponutrition be marked, the waste in the part may exceed repair, and the part affected becomes diminished in size or atrophied. Atrophy may be general or local. In general atrophy there is a general loss of tissue due to an excessive waste or

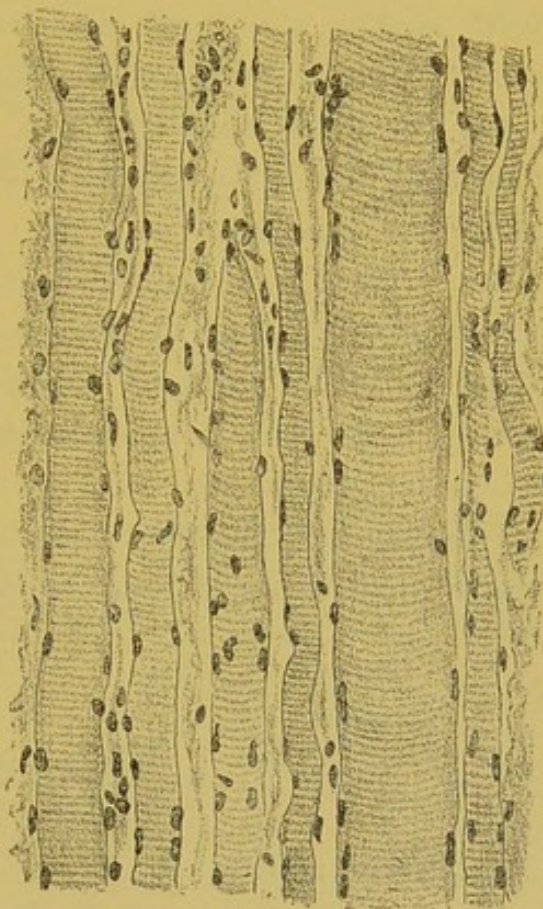
faulty assimilation of food by the tissues. There is a loss of bodily weight, due first to a loss of the fat, later to shrinkage in the tissue cells. The shrinkage in size of the tissue cells causes shrinkage of the entire organ. The cells may recover their size when the faulty waste or assimilation is corrected. During atrophy many cells are lost through the process of fatty degeneration and removed by the phagocytes (leukocytes), so that atrophy may, like hypertrophy, be both simple and numerical. An atrophied part is pale and shrunken, contains less fluid, and is tough and fibrous. At times the fibrous portion or connective tissue may increase as the cells diminish (sclerosis).

Causes. General atrophy is caused:¹ 1. By a deficient supply of food material delivered to the tissue cells. This may be due to a primary food deficiency or any interference with its preparation for absorption or with its proper absorption or circulation. 2. By excessive waste of the tissues generally, as in fevers, prolonged suppuration, etc. 3. By impaired vital activity of the cells themselves, as in senile conditions.

Local atrophy may be caused:

1. By a lessened circulation in a part due to obstruction of the arteries, veins, or capillaries. 2. By diminished functional activity or disuse of a part, as in the case of unused muscles or even bones. Certain organs are atrophied or resorbed as a part of the cycle of life—*e. g.*, the umbilical cord, the roots of deciduous teeth, the thymus gland, the mammary glands after the menopause. 3. The loss of nervous connection of a part with the nerve centres controlling it (trophoneurosis). 4. Excessive functional activity may cause atrophy by producing a degenerative condition due to overstimulation.

FIG. 37.



Muscle fibres in simple atrophy. (Schmaus.)

¹ Green.

MALNUTRITION.

By the term malnutrition is meant a more or less general disturbance of the metabolism of cells, as a result of the failure of one or more important organs to perform its full function, either of food supply or waste elimination. The fault may lie with disturbance of the nervous system controlling metabolism or with the stomach, lungs, liver, skin, kidney, blood, etc. The tissues are either deprived of normal food elements (tissue starvation) or are presented with waste products formed within the body and retained in the blood (auto-intoxication). The proteids of which the tissues are normally composed are not normally built up, and a general disease of the cellular elements of the body occurs. These lose their vital potential and capacity for resistance to other forms of exciting causes, such as bacteria. Whether a tangible disease condition or merely an alteration in nutrition not obvious to the individual, it may act as a predisposition to local bacterial action—*e. g.*, as in pyorrhœa alveolaris. When the malnutrition is accompanied by a local infection, the latter may, by the production of toxins which are absorbed, increase the malnutrition, which further aids the action of the exciting causes by acting as a predisponent, lessening resistance. This result is called a vicious circle. (See Pyorrhœa Alveolaris.)

DEGENERATION.

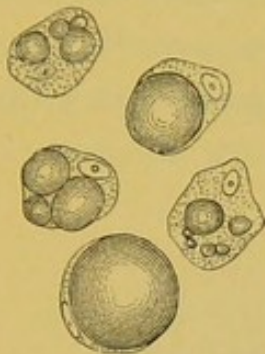
If cells have reached the limit of their life cycle or have been subjected to influences markedly disturbing their nutrition, the proteids of which they are composed are replaced by other substances formed from the cell proteids and accumulated at their expense. As a rule, the cells shrink in size and number, so that atrophy usually is associated with degeneration. This is a true degeneration, and is to be distinguished from an infiltration of foreign material into a cell, which material mechanically pushes aside the cell protoplasm—*e. g.*, fat-globules in liver cells (Fig. 38).

Fatty Degeneration. Fatty degeneration is a condition in which an accumulation of fat is found in the substance of cells as the result of partial decomposition of cell substance itself. The cell appears granular and fat-droplets appear within the substance of the protoplasm. These do not tend to coalesce, as in the case of fat infiltration.

"The larger the amount of cell albumin replaced by fat, the nearer is the whole cell to death." (Fig. 40).

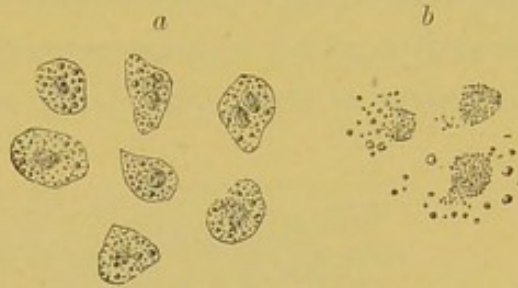Causes.—Depression of the vital activity of the cells is always the proximate cause. This may be induced (1) by an altered blood supply or a persistent diminution in the supply of oxygen to the cells; (2) by changes in the physical condition of the cells, or (3) by an expression of the natural limit of life of the cells. Of these causes, probably

FIG. 38.



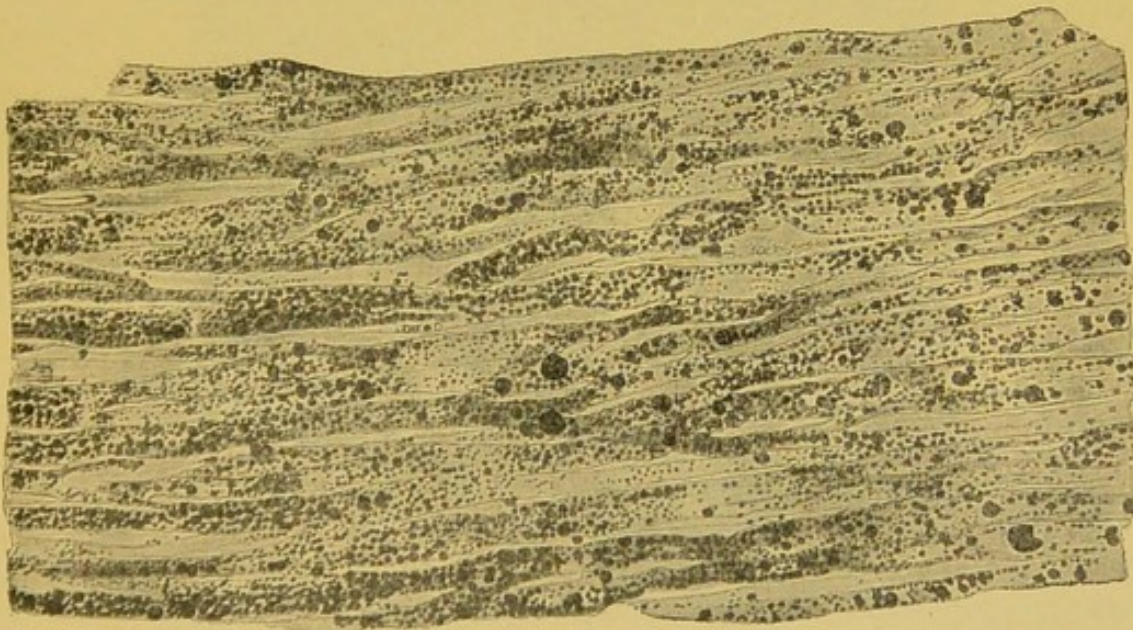
Liver cells in various stages of fatty accumulation. $\times 300$. (Rindfleisch.)

FIG. 39.



Fatty degeneration of cells: *a*, from a cancer; *b*, from the brain in chronic softening. $\times 200$. (Green.)

FIG. 40.



Fatty degeneration of the heart, from a case of pernicious anæmia. The protoplasm is replaced by globules of various sizes stained black by osmic acid. The outlines of the fibres are irregular owing to inequality in their distention. $\times 400$. (Green.)

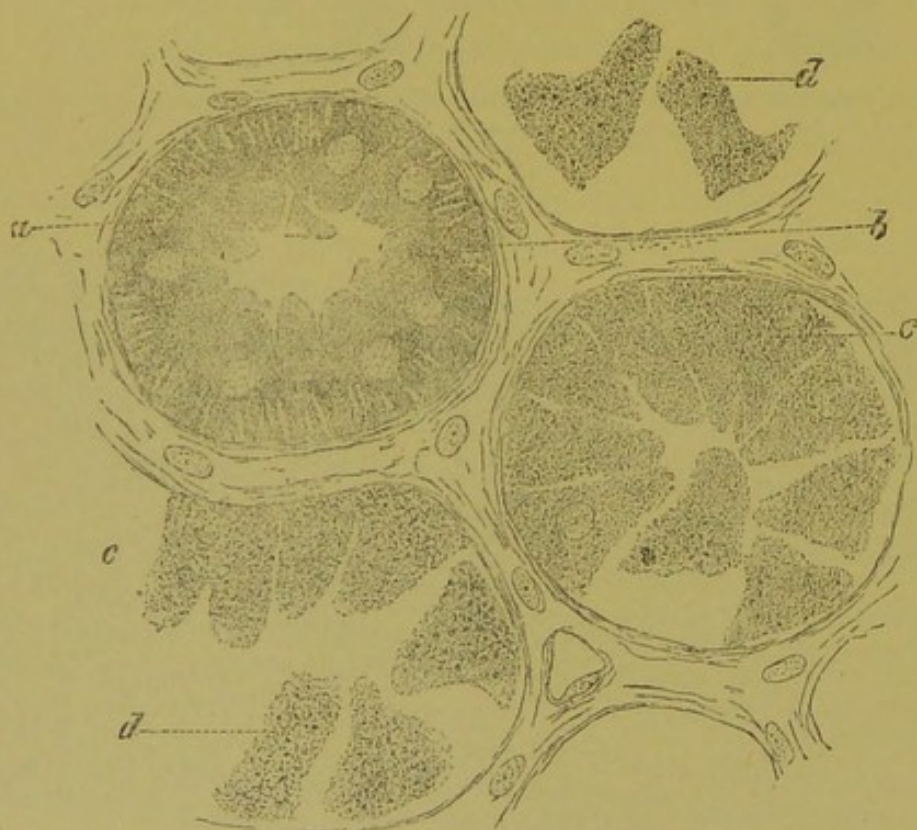
the insufficiency of oxygen supplied, as, for example, in anæmia or in inflammation, or the inability of the cell to appropriate oxygen seems to be the most important factor (Fig. 40). In inflammation the oxidation of cells is interfered with, and fatty degeneration of

¹ Green, Pathology and Morbid Anatomy.

cells occurs. In areas which have undergone fatty degeneration, a cheesy substance may be formed out of the degenerated elements existing in the part. The fluid is gradually absorbed and a mass composed of atrophied cells, fatty debris, and cholesterin crystals is left. This process is known as caseation. Encapsulation of the caseous mass by fibrous tissue may take place, or its liquefaction or its calcification may occur. Fatty degeneration may occur in many tissues, and the danger is proportionate to the importance of the tissue involved.

Cloudy Swelling (*Parenchymatous or Granular Degeneration*). Cloudy swelling is a change occurring in the parenchyma (essential cells) of a part as the result of the presence of toxic substances in the blood.

FIG. 41.



Cloudy swelling of kidney epithelium: a, normal epithelium; b, epithelium beginning to be cloudy; c, advanced degeneration; d, cast-off degenerated epithelial cells. From a preparation which had been treated with ammonium chromate. $\times 600$. (Ziegler.)

Causes. The toxins of the acute specific fevers and also phosphorus, arsenic, and the mineral acids act as causes.

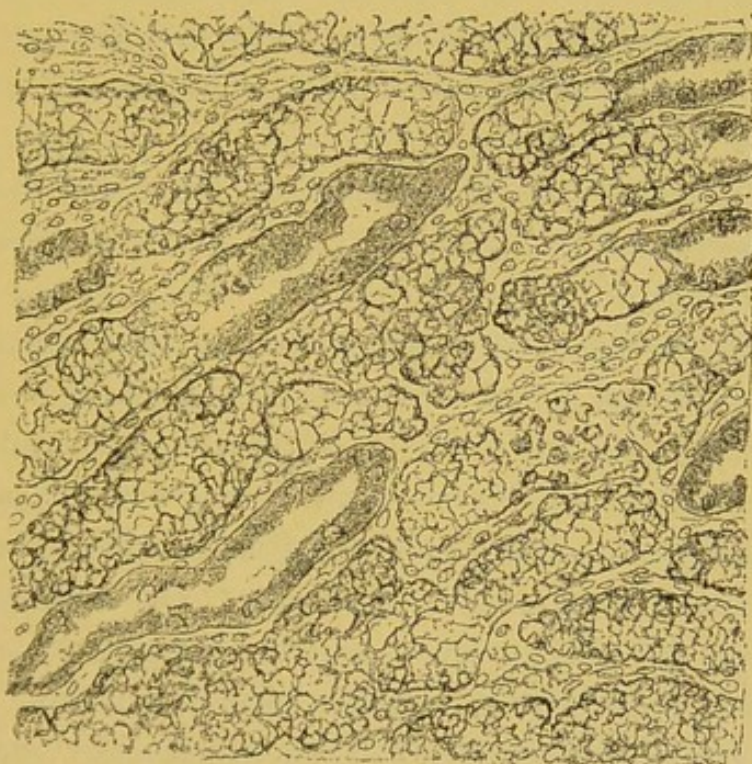Pathology. The cell absorbs fluid, swells, its contents become granular, and the histological structure is lost. In the early stages the change is albuminous; no fat is demonstrable; later, however, it appears, so that the change is regarded as a first stage in the produc-

tion of fatty degeneration, by which process many of the cells are lost, though the organ may recover if the patient withstands the original disease (Fig. 41).

Mucoid, Colloid, and Hyaline Degeneration. The albumin of cells may undergo other chemical changes than transformation into fatty substances; they may undergo mucoid, colloid, or hyaline transformation. The causes of the degeneration are not made out. The function of the part affected is destroyed.

Lardaceous Degeneration. This type of degeneration is known as amyloid, albuminous, or waxy. The formation of the material from which this condition derives its name is preceded by an unknown type

FIG. 42.



Calcareous infiltration of renal epithelia. From the edge of an old infarct; a few tubules still to be recognized. $\times 250$. (Schmaus and Ewing.)

of degeneration of the cells of the part affected. The degenerative processes appear to be the result of long-continued suppuration due usually to tubercular diseases. In the connective tissue about the degenerated cells a substance akin to albumin is deposited, which causes swelling and a pseudohypertrophy of the organ affected. The substance gives a reaction with iodine resembling that of starch; hence the name amyloid (*amylum*, starch). It may affect any organ of the body. It usually appears first in the connective tissue lying between the inner and middle coats of small arteries. The swelling caused by the infiltration markedly lessens the calibre of the vessels and diminishes

the nutritive supply of the parts supplied by the artery, which may lead to fatty degeneration and atrophy of the insufficiently nourished parts.

Calcareous Degeneration. In tissues which have undergone previous degeneration, calcium, sodium, or magnesium salts may be deposited as an infiltration from the blood plasma. The parts are thus petrified. The cells take no active part in the process.¹

It is believed, however, that the deposit of salts in the dying tissue is more than a mere precipitation, and that calcification results from a combination of the salts with an albuminous base and with fatty acids, such an affinity being favored by the degenerative changes. Ordinarily the carbonate and phosphate of calcium are the infiltrating salts, but in gout uric acid salts are deposited, owing to an excess of uric acid in the form of urates in the body fluids. A sluggish circulation in the part favors the deposition of the salts. The calcification may occur in both the cells and in the intercellular substance.² (See Calcific Degeneration of the Pulp.)

"The white fibrous tissue is the form of connective tissue usually affected, but concretions may occur in the connective tissue surrounding the bloodvessels."³

As a secondary process after degeneration, calcification of the middle coats of the arteries may occur, rendering them inelastic. This renders them incapable of regulating the blood supply to parts, and these suffer more or less nutritive disturbance, and, in some cases, actual death of the part (gangrene). Many forms of free calculi are formed in the body. These occur most frequently in ducts or cavities lined with epithelium—*e. g.*, the salivary ducts and the bladder.

"All free concretions have an organic basis or nucleus," with which is combined the calcium salts, oxalates, cholesterin, etc., making up the inorganic or crystallizable part of the combination. The organic part may consist of inspissated feces, as in enteroliths; mucus or mucin, as in the calculi upon the teeth; epithelial scales, mucus, etc., in the urinary passages.⁴

Calcareous degeneration is clearly to be distinguished from the normal calcification of the hard tissues, bone, enamel, dentine, and cementum. These are composed of calcoglobulin, in which calcium and magnesium salts are combined under the superintendence of certain living cells with albuminous bases derived probably from their own substance.

¹ Green, Pathology and Morbid Anatomy.

³ Ibid.

² Ziegler, General Pathology.

⁴ Ibid.

NECROSIS.

Necrosis (from *nekros*, dead) signifies death in mass of a part due to a profound disturbance in its nutritive supply or to a destruction of the vital activity of its cellular elements.

Causes. The conditions which bring about a cessation of vitality in the cells of tissues may, therefore, be grouped under two heads: 1. Interference with the supply of nutritive material. 2. Destruction of the vital activity of the cellular elements.

CLASS I. An interference with the nutritive supply of cells through obstruction in the arteries, capillaries, or veins is the usual cause.

1. *Obstruction of the Arteries.* If from any cause—surgical ligation of an artery, pressure upon it by effusion or new-growths, degeneration or affections of the arterial walls, the presence of an embolus or thrombus—the flow of blood to a part is arrested, the nutritive supply ceases and the cells dependent upon that vessel perish. If the part receive a collateral arterial supply, the cells may retain their vitality, although if this supply be inadequate they are in danger of degeneration and atrophy. This will explain the greater relative frequency of extensive necrosis of the lower jaw, as compared with necrosis affecting the upper jaw, the lower jaw being supplied mainly by one large arterial trunk, while in the upper jaw there is a freely anastomosing circulation.

2. *Obstruction of the Veins.* If the entire venous outlet of a part be obstructed, there is not that removal of waste products necessary to the life of cells; moreover, access of nutritive material is prevented and the parts die.

3. *Obstruction of the Capillaries.* Complete obstruction of the capillary supply to a part is followed necessarily by a cessation of nutrition in the part; consequently necrosis results. For example, when an inflammatory effusion occurs between the surface of a bone and the periosteum, the capillaries are torn from their attachment; and if the condition be prolonged, necrosis of the underlying bone results. When the effusion occurs outside the periosteum its pressure may cause occlusion of the capillaries of the part. The interference with the nutritive supply may be due to a lack of force with which the blood is propelled, owing to insufficient action of the heart. Necrosis is not infrequently due to the violence and continuance of the inflammatory process in a part. Coagulation of the blood in the capillaries of a part occludes the circulation and death results.

CLASS II. Destruction of the vital activities of cells may be caused by any of the physical forces or by the action of chemical agents, including among the latter the poisonous substances formed through the action of bacteria.

Injuries, blows, excessive heat or cold, the passage of powerful electric currents, are all influences which directly injure or permanently destroy vital activities of cells. The application of chemical agents which so act upon cell substance as to change its character produces necrosis.

While this is particularly true of such substances as powerful acids and alkalies, which immediately destroy cell integrity, it is also true of milder agents acting for longer periods. Certain poisons, particularly those of bacterial origin, paralyze the vital activities of cells and necrosis results.

The occurrence or non-occurrence or the liability to necrosis will largely depend upon the degree of vital energy of cells prior to the action of the active causes of necrosis. Parts debilitated from any cause are more liable to necrosis than those which have suffered no debility. A part chronically ill-nourished subjected to the causes producing degenerations is liable to suffer necrotic changes, for the several degenerations and atrophy, are but successive stages leading to necrosis.

When a tissue undergoes death as the result of the infliction of an injury the process is called necrosis *per se*, to distinguish it from the form of death which occurs in a descending scale, which process is called necrobiosis.

A necrosed part acts as an irritant to the tissues about it, inaugurating an inflammatory reaction which marks off the dead from the living parts. The dead part is sequestered, and hence is called a sequestrum.

Necrosis may be of several types, of which the following are the chief forms:

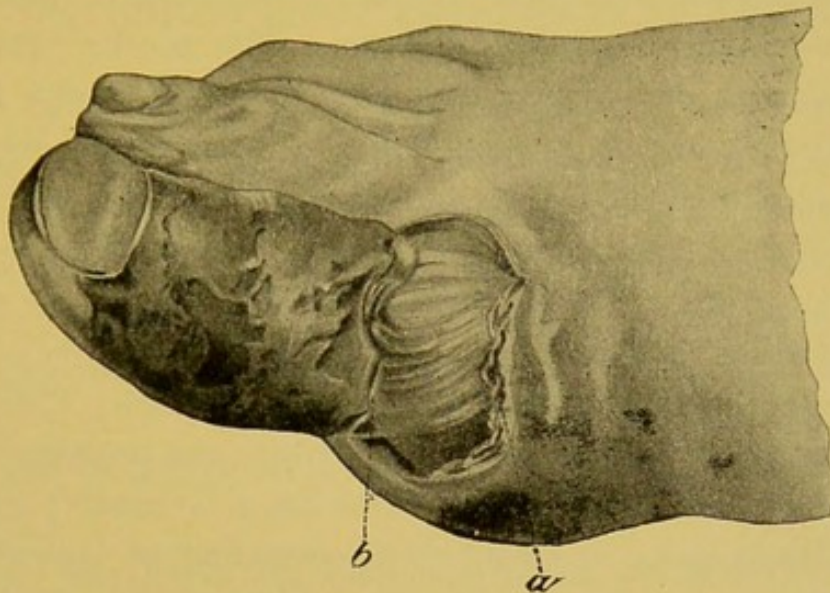
Coagulation Necrosis. When a dead tissue contains coagulable material and the necessary ferments the parts undergo coagulation. (See Coagulation.) The cells and parts about become solidified; the cells lose their nuclei and do not stain as usual. It occurs in suppuration.

Liquefaction Necrosis. When the necrosed parts are saturated with lymph the dead part breaks down and liquefies.

GANGRENE.

When death *en masse* of a part occurs as the result of an interference with its nutritive supply the process is termed gangrene.

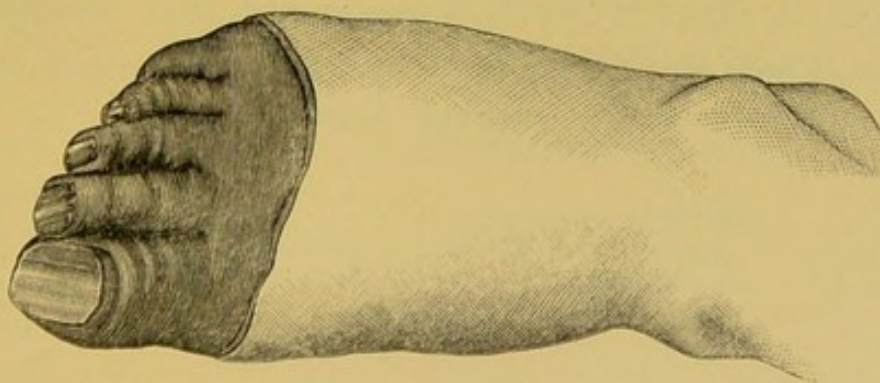
FIG. 43.



Senile gangrene of the great toe, from a case of arterial thrombosis. The toe is shrunk and its epidermis is being exfoliated. At the line of demarcation the skin has retracted (a) and the deeper parts are separating (b). (Green.)

Dry Gangrene. In parts which ordinarily contain but little fluid the obstruction of the artery may be associated with but little obstruction of the veins and lymphatics. Under such circumstances the dead part is drained of the little fluid it contains and a fresh access of fluid

FIG. 44.



Dry gangrene of the toes, caused by narrowing and closure of the arteries supplying these parts—arteriosclerosis. (Ziegler.)

is prevented. Exposure to the air aids a further loss of moisture by evaporation. The conditions are not favorable to the development of micro-organisms and the part changes from a pale appearance to a

dark, shrunken one. The process of gradual drying is also called mummification. (See Dry Gangrene of the Pulp.)

Moist Gangrene. Under opposite conditions—*i. e.*, a venous obstruction with a weak arterial supply—there is much venous engorgement and extravasation of blood into the tissues, which are stained red by the hæmoglobin from disintegrated red corpuscles. Abundant effusions also cause the part to be swollen. Death of tissue occurs from interference with nutrition. The moisture present favors the development of bacteria and they enter the tissue through the skin. Putrefaction with the evolution of malodorous gases, such as hydrogen sulphide (H_2S), hydrogen phosphide (PH_3), and ammonium sulphide ($NH_4)_2S$, causes the part to have an offensive odor.

If the gangrene be due to infective inflammation or the surrounding tissue be debilitated from any cause, the area of gangrene may spread—*i. e.*, invade the living tissue (spreading gangrene). This is probably due to the presence of bacteria, which irritate and progressively destroy the surrounding tissue. If the adjacent tissue be healthy and resistant, a line of demarcation is established, consisting of leukocytes, which dissolve all fibres or firm connections between the dead and living parts. Suppuration occurs at the line, and the dead portion is separated as a sphacelus or slough. Occurring in bone this is called a sequestrum. An ulcerated surface is left. The latter form is circumscribed gangrene. If gangrene be deep-seated and septic, suppuration occurs, which establishes one or more fistulæ upon the surface of the body or in one of its cavities. (See Moist Gangrene of the Pulp.) A sequestrum may be cast out through one of these. In the aged atheromatous or calcareous changes in the arteries produce a slow circulation in the extremities. A slight injury to a vessel wall may induce extensive thrombosis (which see). The result is gangrene of a part or all of an extremity known as senile gangrene (Fig. 43).

CHAPTER V.

DISTURBANCES OF THE VASCULAR SYSTEM.

A CERTAIN amount and quality of blood flows through the circulatory apparatus and is in close relation to processes of nutrition.

The amount of blood in the vessels may be increased (plethora). It may be decreased in quantity or its red corpuscles may be lessened in number (anæmia). The proportion of white corpuscles to red ones may be increased abnormally (leukæmia). The hæmoglobin of red corpuscles may be deficient (chlorosis). Locally the amount of blood in a part may be increased (hyperæmia or inflammation) or diminished (ischæmia).

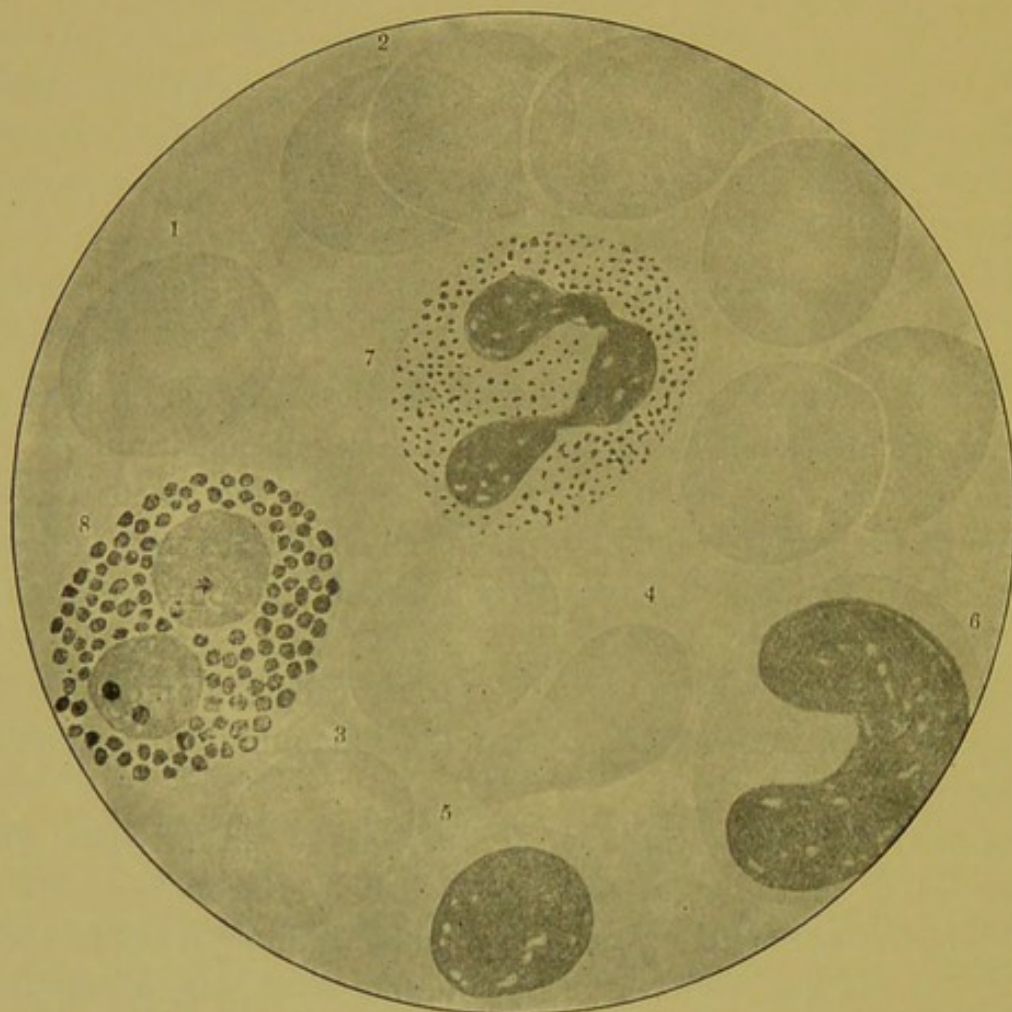Normally the blood contains floating in the plasma 5,000,000 red corpuscles or erythrocytes and from 5000 to 10,000 (1 to 500 red) white corpuscles or leukocytes to each cubic millimetre. (See Plate I., Fig 2.) A marked increase in the number of erythrocytes is termed polycythæmia; a marked decrease oligocythæmia. The temporary increase in number of white corpuscles is leukocytosis; a persistent increase leukocythæmia or leukæmia.

The blood corpuscles may be classified as follows:

				Fig. 45.	Plate I. Fig. 7.
Erythrocytes. Non-nucleated red corpuscles.	{	Normal to blood.	{	Normocytes (normal size),	1, 2, 3, 4. <i>a</i>
			{	Microcytes (small size).	
	Pathological indicators.	Macrocyte (large size).			
		Megalocyte (very large size).		. . . <i>i</i>	
		Poikilocyte (irregular form).	. . . <i>d e f g</i>		
Erythroblasts. Nucleated red corpuscles derived from red marrow of bones.	{	Pathological indicators.	{	Normoblasts (normal size) <i>k</i>
			Microblasts (small size) <i>l</i>	
			Megaloblasts (large size) <i>m n</i>	

				Fig. 45.	Plate I. Fig. 1
Leukocytes. White corpuscles.	{	Normal to blood.	{	Lymphocyte, small	. . . 22 % 5 <i>f</i>
			Lymphocyte, large	. . . 6 " 6 <i>e</i>	
			Polymorphonuclear neutrophiles	70 " 7 <i>a</i>	
			Polymorphonuclear eosinophiles	2 " 8 <i>b</i>	
	{	Pathological indicators.	{	Basophilic leukocytes or mast-cells.	
			Neutrophilic myelocytes from bone-marrow		
Eosinophilic myelocytes		 <i>d</i>		

FIG. 45.



Normal blood (triacid stain). 1. Normal red cell, flatly spread and evenly stained. 2. Normal rouleau. 3. Normal red cells varying slightly in size, thickly spread, showing central clear areas. 4. Normal red cell, of slightly altered shape. 5. Lymphocyte, medium size. 6. Large mononuclear leukocyte, incurved nucleus. 7. Polynuclear neutrophile leukocyte. 8. Eosinophile leukocyte. Separate nuclear lobes. (Schmaus and Ewing.)

ANÆMIA.

Anæmia is a condition in which the blood is lessened in quantity or partly deprived of its essential constituents—*i. e.*, red corpuscles and hæmoglobin—in consequence of which the tissues receive less oxygen and the general nutrition is impaired.

Acute traumatic anæmia occurs as a result of copious hemorrhage. The individual becomes temporarily pale and weak. The arterial pressure is lessened, the circulation slowed, and the pulse is frequent and small. Recovery is, as a rule, prompt, the water being first restored and later the corpuscles being regenerated.¹ Frequent hemorrhages cause the blood to become watery, and debility results from impaired nutrition. (See Plate I., Fig. 3.)

¹ Ziegler, General Pathology.



Fig. I

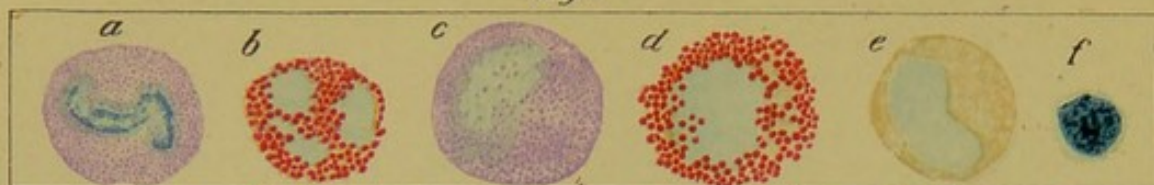


Fig. II.

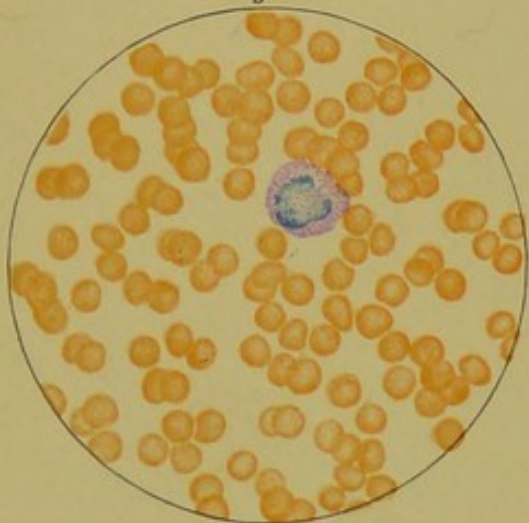


Fig. III

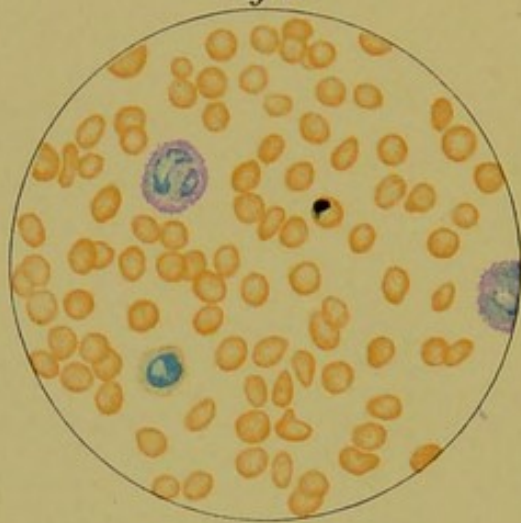


Fig. IV.

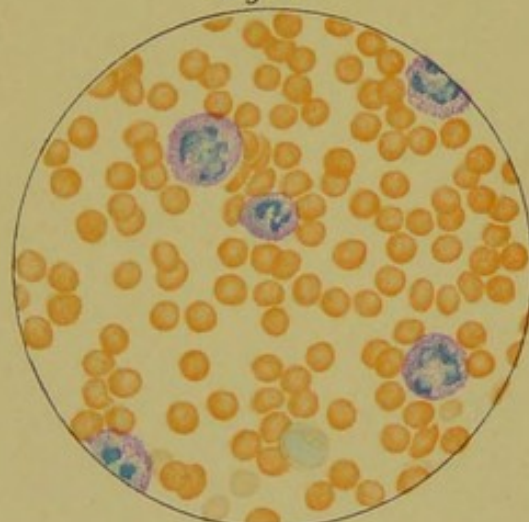


Fig. V.

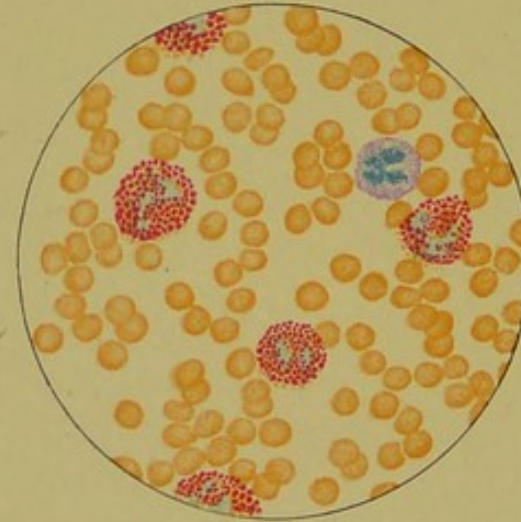


Fig. VI.

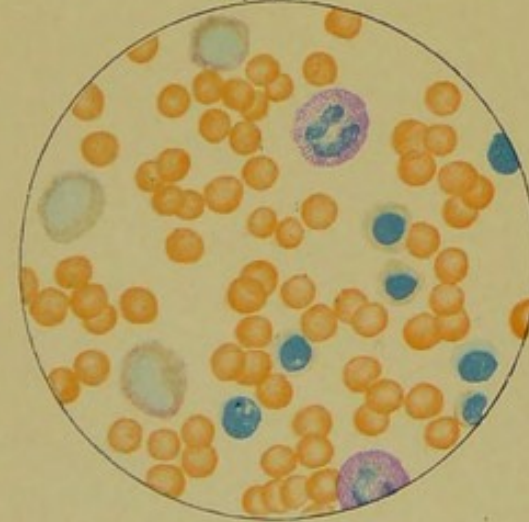


Fig. VII.

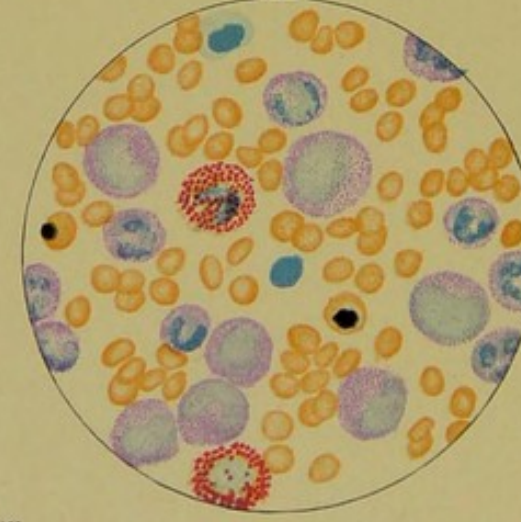



Fig. VIII.



BLOOD.

(Ehrlich triple stain.)

(Prepared by Dr. I. P. LYON.)

Fig. I. TYPES OF LEUCOCYTES.

a. Polymorphonuclear Neutrophile. b. Polymorphonuclear Eosinophile. c. Myelocyte (Neutrophilic). d. Eosinophilic Myelocyte. e. Large Lymphocyte (large Mononuclear). f. Small Lymphocyte (small Mononuclear).

Fig. II. NORMAL BLOOD.

Field contains one neutrophile. Reds are normal.

Fig. III. ANÆMIA, POST-OPERATIVE (secondary).

The reds are fewer than normal, and are deficient in hæmoglobin and somewhat irregular in form. One normoblast is seen in the field, and two neutrophiles and one small lymphocyte, showing a marked post-hæmorrhagic anæmia, with leucocytosis.

Fig. IV. LEUCOCYTOSIS, INFLAMMATORY.

The reds are normal. A marked leucocytosis is shown, with five neutrophiles and one small lymphocyte. This illustration may also serve the purpose of showing the leucocytosis of malignant tumor.

Fig. V. TRICHINOSIS.

A marked leucocytosis is shown, consisting of an eosinophilia.

Fig. VI. LYMPHATIC LEUKÆMIA.

Slight anæmia. A large relative and absolute increase of the lymphocytes (chiefly the small lymphocytes) is shown.

Fig. VII. SPLENO-MYELOGENOUS LEUKÆMIA.

The reds show a secondary anæmia. Two normoblasts are shown. The leucocytosis is massive. Twenty leucocytes are shown, consisting of nine neutrophiles, seven myelocytes, two small lymphocytes, one eosinophile (polymorphonuclear) and one eosinophilic myelocyte. Note the polymorphous condition of the leucocytes, *i.e.*, their variations from the typical in size and form.

Fig. VIII. VARIETIES OF RED CORPUSCLES.

a. Normal Red Corpuscle (normocyte). b, c. Anæmic Red Corpuscles. d-g. Poikilocytes. h. Microcyte. i. Megalocyte. j-n. Nucleated Red Corpuscles. j, k. Normoblasts. l. Microblast. m, n. Megaloblasts.



Symptomatic Anæmia. A diminution in the number of red corpuscles may occur as a result of protracted overwork, anxiety, study, or long-continued illness, such as a fever.

The number of red blood corpuscles may be reduced to one-half the normal amount, and there is a corresponding debility. The condition may disappear with appropriate removal of the cause.

Chlorosis. This is a form of anæmia occurring, for the most part, in girls and young women, and characterized by a great deficiency in the hæmoglobin of the red corpuscles without a corresponding reduction in the number of the red corpuscles. In the blood very small red corpuscles (microcytes) are seen; also a few very large ones (macrocytes), and some of irregular outline (poikilocytes).¹ The pathology is uncertain.

Being, as a rule, readily cured by a course of iron, it is inferred that the body is starved of iron, an essential constituent of hæmoglobin. It is often associated with gastric disturbances, constipation, defective hygiene, and irregular habits, which apparently have a causal relation. The skin and mucous membranes are pale and have a slightly greenish tinge.²

Leukocytosis. This is not a form of anæmia, but a temporary increase in the number of multinucleated leukocytes, apparently derived from the lymphoid structures of the body in response to some demand for leukocytes. Thus it occurs after a full meal, in the later months of pregnancy, in acute fevers, in tuberculosis, and in conditions accompanied by suppuration.³ Its presence during the course of surgical disease has been held to be diagnostic of pus formation⁴—*e. g.*, in abdominal surgery. (See Plate I., Fig. 4.)

Leukæmia. Leukæmia is a disease characterized by a considerable and permanent increase in the number of white corpuscles of the blood, by a diminution in the number of the red corpuscles, and by enlargement of some of the lymphatic organs. The proportion of one white to ten red corpuscles is common. The spleen may be hypertrophied (splenic leukæmia). The lymphatic glands may be hypertrophied (lymphatic leukæmia). In these cases the blood contains an excess of uninuclear leukocytes. When the marrow of bones is hypertrophied (myelogenic leukæmia) large mononuclear leukocytes with neutrophile granules are found (myelocytes).⁵ (See Plate I., Figs. 6 and 7.)

¹ Green, Pathology and Morbid Anatomy.

⁴ Cabot, Boston Medical and Surgical Journal.

² Ibid.

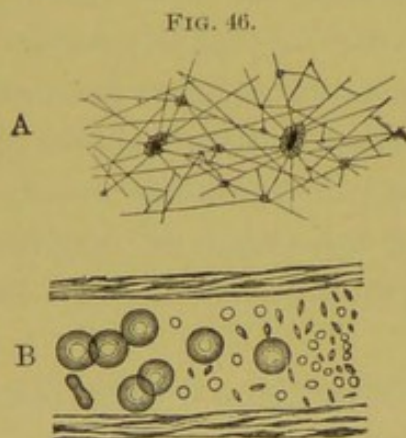
³ Ibid.

⁵ Ziegler, General Pathology.

Pernicious Anæmia. This is a comparatively rare but generally fatal disease, characterized chiefly by a great fall in the number of red corpuscles, those remaining being altered in form and size and showing evidences of degeneration. The total hæmoglobin is reduced, but the relative amount may be increased. Degeneration is shown by peculiarities of staining. Normal red corpuscles (normoblasts), nucleated red corpuscles (megaloblasts), large nucleated red corpuscles (gigantoblasts), microcytes, and poikilocytes are found. The blood platelets and leukocytes are somewhat diminished.¹ The oxygen-carrying power is markedly lessened and all tissues suffer from malnutrition. The power of coagulation of the blood is lessened. Marked fatty degeneration of the heart muscles is apt to occur.²

COAGULATION OF THE BLOOD.

The blood when drawn from the body or in contact with a wounded surface or injured vessel wall undergoes a process of solidification called coagulation. This is due to the splitting up of the fibrinogen ordinarily in solution in the blood into a globulin and fibrin. The



Fibrin filaments and blood tablets: *A*, network of fibrin, shown after washing away the corpuscles from a preparation of blood that has been allowed to clot; many of the filaments radiate from small clumps of blood tablets. *B* (from Osler), blood corpuscles and elementary particles or blood tablets within a small vein.

latter takes the form of a network in the open spaces of which the corpuscles are entangled (Fig. 46). The formation of fibrin is brought about by the activity of an unorganized ferment (fibrin ferment or thrombin) liberated by injured white corpuscles. For the production of this ferment calcium salts are necessary.³ Coagulation may occur in the living vessel, as a thrombus, or in the interstitial tissue, as in inflammation and infarction.

Thrombosis. The formation of thrombi or clots within the living vessel may occur in the heart arteries, veins, or capillaries. If the blood stream be somewhat retarded an increased number of white corpuscles and blood platelets occupy the peripheral zone and adhere to the vessel wall. If the vessel wall be injured the blood platelets become attached to it. With these platelets the white

¹ Green, Pathology and Morbid Anatomy.

³ Kirke's Physiology.

² Ibid.

corpuscles and sometimes the red become deposited. Fibrin forms and the corpuscles are included. The thrombus is red when red corpuscles are included in it; white when only white corpuscles are present. The causes of thrombosis are these: 1. A retardation of the blood current at some point from some cause. 2. Local changes

FIG. 47.

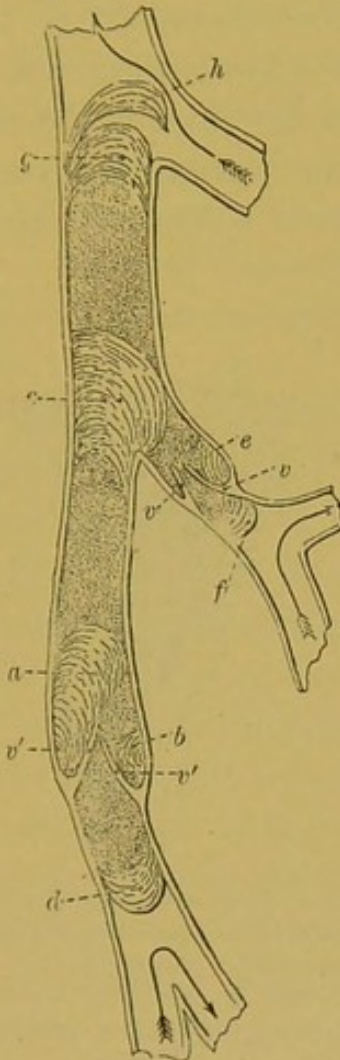
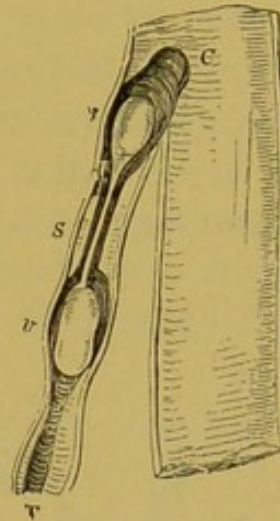


Diagram to show phenomena of venous thrombosis: *v, v'*, valves of veins; *a, b*, primary thrombus (white); *c, d, e, f, g*, secondary white thrombi connected with primary white thrombus by various red thrombi; *h*, piece of white thrombus becoming detached by blood current. (Green, modified from Thoma.)

FIG. 48.



A thrombus in the saphenous vein, showing the projection of the conical end of the thrombus into the femoral vessel: *S*, saphenous vein; *T*, thrombus; *C*, conical end projecting into femoral vein. At *v, v'*, opposite the valves, the thrombus is softened. (Virchow.)

in the walls of the vessels and probably pathological changes in the blood.¹

Older thrombi are firmer than those recently formed. Thrombi are also formed in the capillaries, a circumstance which favors the spontaneous cessation of hemorrhage. They may form in the vessels in inflammation. Remaining in the situations in which they were formed, they either undergo simple or puriform softening or are calcified or are resorbed and replaced by connective tissue. (See Regeneration.) The calcified varieties are called phleboliths in the veins; arterioliths in the arteries. In senile gangrene a thrombus may extend a great distance.

Embolism. Portions of the softened varieties of thrombi may become detached and float about in the blood; these are called emboli.

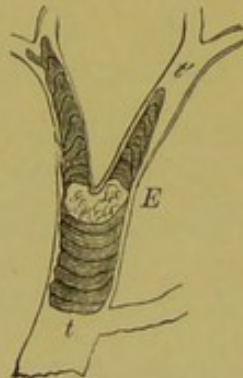¹ Ziegler, General Pathology.

Other foreign substances may act as emboli—*e. g.*, air or fat-globules.

If the thrombus be septic, as in the case of puriform softening, the emboli may lodge in small vessels and cause secondary septic disease processes, as, for example, in the cases of pyæmia accompanied by infarctions.

Infarction. When an embolus occludes a terminal artery, that is, an artery whose branches spread like those of a tree without anastomosis, the backward pressure from the vein upon the blood in the capillaries causes an extravasation of blood into the interstitial tissue of the wedge-shaped area, forming what is called a hemorrhagic infarct.

FIG. 49.



Embolus impacted at the bifurcation of a branch of the pulmonary artery, showing the formation of thrombi behind and in front of it, and the extension of these as far as the entrance of the next collateral vessels: *E*, embolus; *t*, *t'*, secondary thrombi. (Virchow.)

FIG. 50.

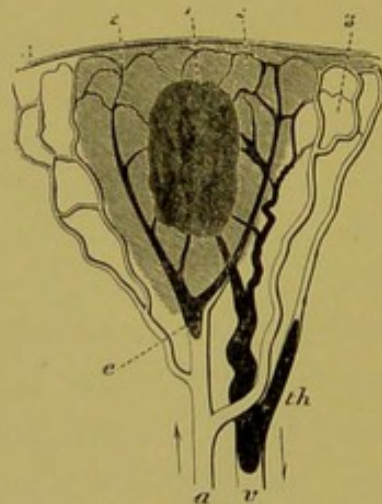


Diagram of a hemorrhagic infarct: *a*, artery obliterated by an embolus (*e*); *v*, vein filled with a secondary thrombus (*th*); 1, centre of infarct which is becoming disintegrated; 2, area of extravasation; 3, area of collateral hyperæmia. (O. Weber.)

A clot forms, degeneration of the clot occurs, and if aseptic it is absorbed and replaced by connective tissue (see Regeneration); if caused by a septic embolus, it may be involved in the resulting septic process—*e. g.*, in pyæmic metastatic abscess. Infarction has been held by Black to occur in the dental pulp. No demonstration has, however, been made.

Hemorrhagic Diathesis. This is a condition, largely hereditary, in which coagulation does not close wounds readily, and ordinarily trivial wounds may, in spite of surgical aid, induce death by hemorrhage. Hereditary hemorrhagic diathesis (*hæmophilia*) is usually transmitted through the female line to the male line—*i. e.*, from grandfather to grandson through the grandfather's daughter—and seven or more gen-

erations of hæmophilics have been recorded.¹ Males suffer more than females in the ratio of about 11 to 1.

According to Legg,² "It is of three degrees of severity:

"1. Characterized by external and internal bleedings of every kind and by joint affections.

"2. By spontaneous hemorrhages from mucous membranes, but no traumatic bleeding or ecchymoses, and no joint affections.

"3. A tendency simply to ecchymoses. The first is seen most frequently in men, the second in women; the third may appear in either sex."

The joint affections are due to hemorrhage and simulate rheumatic affections. Hæmophilics are apt to be thin-skinned, neurasthenic, and liable to sudden flushings and vasomotor disturbances.³ Blondes suffer more than brunettes.⁴

The injured part may bleed from the first or a normal clot may form and secondary hemorrhage or capillary oozing occur. Death may rapidly occur or the patient bleed to fainting or until almost dead and hemorrhage then cease. This may require any period, even weeks. The pathology of the condition is uncertain. Fillebrown⁵ reports a fatal case in which the arteries were excessively thin. Porter points out that the blood may clot in the receptacle, yet not in the small vessels of the wound, and infers that some hereditary deficiency exists which interferes with the action of the vasoconstrictors.

Hæmophilics usually manifest a history of bleeding before puberty, and hæmophilic infants have died from hemorrhage due to gum-lancing, circumcision, etc. The therapeutic measures indicated are local styptics, compresses, etc. Hæmostatics internally, dilute sulphuric acid, hydrastis canadensis, calcium chloride, and gelatin locally and by injection.⁶ Absolute quiet and the withholding of food for two days; the hunger to be relieved by small doses of opium and thirst by ice-water in small quantities.⁷ The acute anæmia induced requires treatment.

Individuals known to be hæmophilic should live a hygienic life and avoid all injuries, however slight, possible to avoid. If operation be unavoidable they should be treated with calcium chloride, gr. iij *ter die*, for not more than four days, as thereafter the coagulability of the blood is decreased.⁸

¹ Porter, International Dental Journal, 1900.

² Porter, loc. cit.

³ International Dental Journal, 1900.

⁴ Porter, loc. cit.

⁵ Musser, Medical Diagnosis.

⁶ Thompson, Practical Medicine.

⁷ Hare, Practical Therapeutics.

⁸ Hare, loc. cit.

LOCAL DISTURBANCES OF THE CIRCULATION.

The amount of blood in a part may be increased or diminished. The types of local disturbance of the circulation differ as to causes, phenomena, and effect, and as to the indicated treatment for each.

In health the bloodvessels are maintained at a proper calibre through the action of two sets of vasomotor nerve fibres:

1. The vasoconstrictors, which control the involuntary muscles of the vessel wall and which, when stimulated, cause contraction of the vessel.

2. The vasodilators, which, when stimulated, inhibit the muscular action and permit dilatation.

Arterial Hyperæmia. Arterial or active hyperæmia is a more or less prolonged increase in the amount of blood in the dilated arteries of a part. It expresses the reaction which occurs as the consequence of the presence of an irritant, the action of which lessens the arterial tension and permits dilatation with a consequent excess of blood.

Causes. The lessened arterial resistance is produced either by a stimulation of the vasodilator nerves or a sedation or paralysis of the vasoconstrictor nerves. Certain causes act to produce constriction of the vessels, but later the muscle cells of the walls are fatigued and dilatation results—*e. g.*, the reaction after the prolonged application of cold.

The removal or diminution of pressure, to which vessels have become accustomed, is also a cause of their dilatation; often sudden enough to cause bursting.

Irritants and mild injuries act upon the sensory nerves of a part, and by reflex action through the vasomotors (sympathetic system) produce hyperæmia of the part itself—*e. g.*, heat.

Irritation of sensory nerves may induce a reflex hyperæmia in other parts to which branches of the same nerve are distributed—*e. g.*, the peripheral hyperæmia of neuralgia, induced by irritation of a tooth pulp.

A similar effect may be produced in deep-seated organs to which other nerves are distributed—*e. g.*, hyperæmia of deep organs through the application of irritants to the skin over them or hyperæmia of the intestinal wall (tenth nerve) as the result of the stimulation of a pulp underlying an erupting tooth (fifth nerve).

Collateral hyperæmia is induced by the diminished flow of blood to other parts—*e. g.*, by the bandaging of parts or through the chilling of

the surface of the body. A part having a lessened resistance may become hyperæmic.

Compensatory hyperæmia may occur through the removal of one of a pair of organs; the other receives the excess of blood, sometimes becomes hypertrophied, and takes upon itself an increased amount of work. (See Hypertrophy.)

Arterial hyperæmia is produced as the first step in the process of inflammation. (See Inflammation.)

Pathology. The arteries are dilated; there is an increased flow of blood through them and also to them through their own nutritive arteries; the pressure in the veins rises as the veins are enlarged to accommodate the blood. As exudation sometimes does not increase markedly, the lymph pressure is not increased except in marked cases, in which some œdema may occur. The function of the part may be disturbed in the more marked cases. (For illustrations, see Chapter XVIII.)

Results. Continued arterial hyperæmia, as a rule, results in an increase of nutrition. The arteries may be permanently enlarged, their walls thickened, and the tissues about them hypertrophied in consequence of the increased capacity for work in the part. Hyperæsthesia of nerves and nervous tissue is often a result. In marked hyperæmia with function altered there is a tendency to the degenerations. (See Arterial Hyperæmia of the Pulp.)

Symptoms. These naturally would be and are increased redness, temperature, and sensibility; more or less throbbing, in some cases swelling and throbbing pain. The increased temperature is due to the increased oxidation.

Degrees of Hyperæmia. It is to be borne in mind that the hyperæmia may be of several grades, varying from a very mild exaltation of function and sensation to a distinctly pathological condition with altered function. The effects may be constructive in character or destructive, the former due to the increased nutrition, the latter to interference with it. (See Constructive and Destructive Diseases of the Pulp.)

Hyperæmia as a Local Predisposition. It is generally acknowledged that the presence of a local hyperæmia lessens the resistance of a part to the action of pathogenic bacteria—*e. g.*, hyperæmia of the lungs to diplococcus pneumoniæ.

Treatment. The principle underlying the treatment is to remove the cause and procure surgical rest. The symptoms, as a rule, then sub-

side promptly. It may be that the conditions require treatment irrespective of the cause, which may not be determined or be absent, the vessels being dilated as the effect of a previously acting cause. The effect aimed at is the reduction of the dilated vessels. This is attempted at times through the use of drugs; for example, ergot stimulates the vasoconstrictor system and lessens the calibre of all the vessels, including those affected. The antagonist of ergot, aconite, reduces the heart action by paralyzing the motor apparatus of the heart, thus reducing the arterial pressure.¹ Less blood is delivered to a part in a given time. Many cases of superficially seated hyperæmia are amenable to local treatment.

Local sedation of sensory nerves and contraction of vessels are produced by application of dry or wet cold (ice-bags, ice wrapped in muslin, cloths taken in succession from a block of ice, etc.); also by the application of sedative astringents, as the liquor plumbi subacetatis in the well-known formula of lead-water and laudanum—

R—Tincturæ opii,	fʒj;
Liq. plumbi subacetatis,	fʒj;
Aquæ,	Oj—M.;

in which to the astringent effect of the lead is added the sedative effect of the opium.

The principle of derivation is also employed. What is known as counterirritation is a common means of treatment. An irritant such as a mustard plaster or a blister or dry cup applied at a distance to the affected part induces a flow of blood to the point of application and lessens the amount of blood in the area of hyperæmia. The volume of the blood being in definite amount, if an excess exist in any part a deficiency will be found in other parts.

The hot pediluvium acts upon this principle by drawing a considerable excess of blood into the vessels of the lower extremities. This action is increased by adding a small quantity (two or three tablespoonfuls) of mustard to the hot water. It is suggested by Endelman that the water be at first only warm and the hot water added as the vessels relax.²

The volume of the blood may be actually reduced and a derivative hyperæmia of the sweat glands be produced by the use of diaphoretics. Cathartics lessen the blood volume and cause mild hyperæmia of the alimentary canal. Diuretics act in a similar way upon the kidneys.

¹ Biddle, *Materia Medica and Therapeutics*.

² Dental Cosmos, 1904.

In deep-seated hyperæmia counterirritation is valuable alone or conjoined with other forms of derivation.

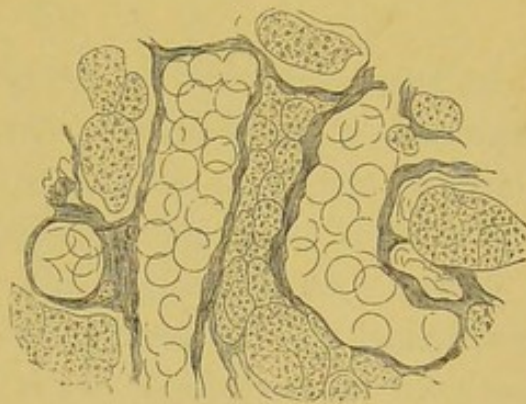
Venous Hyperæmia. Venous (mechanical or passive) hyperæmia is an excess of blood in a part beginning in the veins, which are dilated.

Causes. 1. Any mechanical interference with the passage of the blood through the veins on its way to the heart—*e. g.*, the action of bandages, tumors pressing on veins, thrombi in veins, etc.

2. Insufficiency of any of the mechanical forces aiding the propulsion of the blood through the veins—*e. g.*, diminished cardiac power or valvular insufficiency, obstructions, dilatations, or rigidity of arteries; insufficient muscular contraction upon or valvular incompetency in veins, or lessened or excessive thoracic aspiration, etc. The second class of causes produces a collection of blood in the veins and a consequent reduction of volume in the arterial system.

Pathology. The veins are dilated, the current is slowed, and the intravenous pressure is increased, in consequence of which watery (serous) exudations occur in the parts about them (œdema). For the same reason in marked cases diapedesis of red corpuscles may occur, and their hæmoglobin may be dissolved out. The blood in the parts not being sufficiently changed, and in some cases in a state of stasis, there is a lessened food supply and waste removal, and cell nutrition suffers accordingly. Vital processes are lessened, secretion is diminished, there is less oxidation, and hence less heat is produced and less work is done. Degeneration, atrophy, and in markedly continued cases necrosis may occur. Long-continued venous hyperæmia with great intravenous pressure may produce dropsies. The exudate of venous hyperæmia differs markedly from that of inflammation.¹

FIG. 51.



Venous hyperæmia of the liver. Two capillaries near central hepatic vein. Showing the thickening of the walls and the accumulation of red blood corpuscles within them. $\times 500$. (Green.)

Hyperæmic Exudate.

Poor in albumin.
Rarely coagulates in the tissue.
Contains few cells.
Low specific gravity.
Contains no peptone.

Inflammatory Exudate.

Rich in albumin.
Usually coagulates in the tissue.
Contains numerous cells.
High specific gravity.
Contains peptone (product of cell disintegration).

¹ Park's Surgery.

Treatment. The treatment consists of the removal of the mechanical obstruction to the return of the blood and mechanical support of the engorged vessels, with a view to recovery of the tone of their muscular walls. This latter is accomplished by means of elastic bandages or compresses, and in situations in which these cannot be used astringents may be employed. The part is elevated, when possible, to aid in the return of the blood to the heart. In certain circumstances, as in an engorged tooth pulp, actual depletion of the engorged part must be resorted to by blood-letting. (See Destructive Diseases of the Pulp.)

INFLAMMATION.

Inflammation may be defined as a series of hyperæmic changes expressive of the reaction of living tissue against an irritant, and characterized chiefly by an excessive diapedesis of white corpuscles and exudation of coagulable lymph from the bloodvessels.

Causes. Any irritant or injury capable of producing a lesion of the bloodvessel wall not involving its immediate death can produce inflammation. In case direct death is produced the inflammation, if any, occurs in the tissue contiguous to the dead part.

The causes of inflammation may be divided first into non-septic and septic or infective. The non-septic causes may be extrinsic or intrinsic. The extrinsic non-septic causes are: 1. Physical irritants, such as violence, mechanical irritation, pressure or traumatism, excessive heat or cold, and electrolytic action. 2. Chemical irritants—*e. g.*, the action of acids, caustics, etc. 3. Nervous or vital irritants—*e. g.*, rubefacients, epispastics, arsenic, etc. These act only on living tissue through the medium of the nerves.

An intrinsic non-septic cause may produce inflammation—*e. g.*, urates in tissue, mechanical strains upon tissue, temporary lack of blood in a vessel or central nervous disturbance, as in herpes from locomotor ataxia.

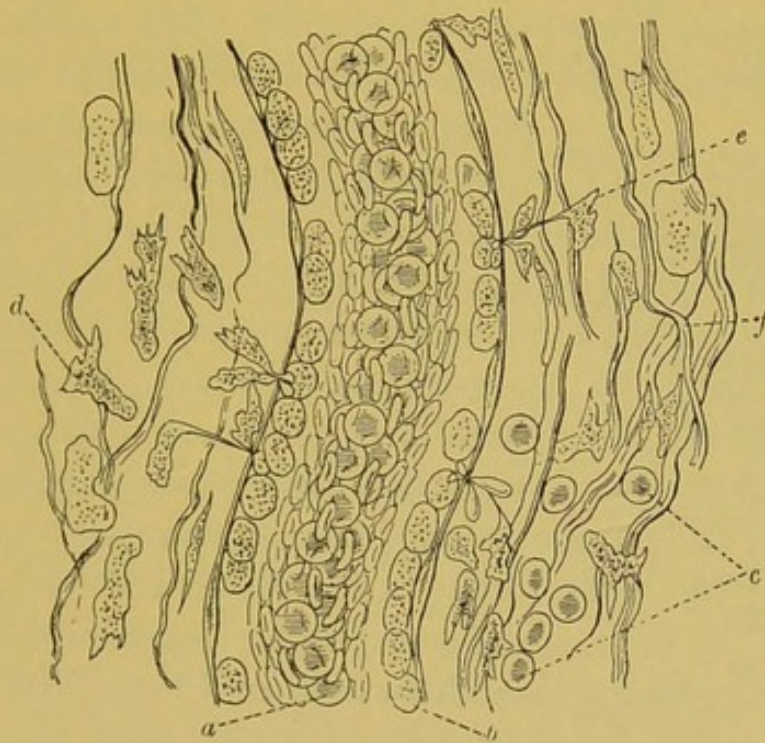
Non-septic causes, as a rule, produce only such mild inflammatory phenomena as are concerned in circumvallation of an irritant, absorption of it, and in repair or production of new tissue. No pus is produced unless pyogenic bacteria gain ingress. This class of inflammation is termed *simple inflammation*.

SEPTIC OR INFECTIVE CAUSES. These are fungi or their products, and the classes of inflammations produced are much more severe, con-

tinuous, and destructive in their nature, and are termed *infective inflammations*.

Pathology of Simple Inflammation. If to the web of a frog's foot tincture of capsicum be applied or if its mesentery be exposed to the air and either be examined under the microscope while the animal is living, it is noted that after a possible short period of contraction of the arterioles dilatation of arteries at once begins and is gradually followed by dilatation of the veins and capillaries. This continues to steadily increase for about twelve hours. During the first hour of this period the blood current is accelerated and arterial hyperæmia may thus be

FIG. 52.



Small vein in mesentery of dog, after exposure for half an hour and irrigation with salt solution: *a*, red corpuscles; *b*, leukocytes adhering to wall of vein; *c*, red corpuscles; *d*, leukocytes which have escaped from vessel; *e*, leukocyte in act of escaping; *f*, fibrous tissue. $\times 340$. Modified from Thoma. (Green.)

said to be the first stage of an inflammation. Following this acceleration the blood flow is increasingly retarded. The retardation is due to the action of the leukocytes, large numbers of the mononuclear and polymorphonuclear forms of which fall out of the central blood stream into the periaxial stream and collect along the walls of the small veins (Fig. 52, *b*). Several layers of leukocytes may thus form. Probably some peculiar attraction exists between the leukocytes and the wall of the vessel.

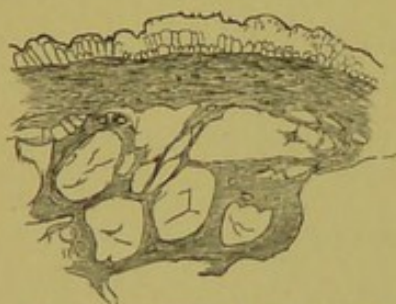This massing of leukocytes compels the red corpuscles to the centre of the stream (Fig. 52, *a*) and their passage is mechanically interfered with, and the further dilatation of the vessel becomes a process of

venous hyperæmia. The vessels are increased in size and length and become more tortuous. Pulsation is noted.

Coincident with retardation of the blood flow, the leukocytes are seen to work their way by an amœboid movement through the stomata of the veins and to some extent of the capillaries into the perivascular spaces—*i. e.*, into the adjoining tissue—in which they may move far from their point of escape and mass about the irritant if one be present. This process is called diapedesis (Fig. 52, *e*). At the same time a fluid rich in albumin, and thus capable of coagulation, escapes by the same route into the tissue (Fig. 53).

As the venous hyperæmia increases the flow of red corpuscles in the veins is increasingly retarded until stopped, when a to-and-fro motion (oscillation) begins. Some red corpuscles may escape into the tissue.

FIG. 53.



Inflammatory oedema of skin. The large spaces shown were filled with exuded fluid. $\times 2\frac{1}{2}$. (Boyd.)

Finally all motion ceases, diapedesis ceases, and stasis is complete. This blood may remain fluid in the vessel for several days (*i. e.*, without coagulation), and if the blood flow be re-established the separate red corpuscles are seen one by one to roll away from the general mass until all are in movement and stasis ceases (Thoma).

Coagulation (thrombosis) may, however, occur in the vessels involved in the stasis and the part be later removed through the process of resorption. (See Resorption of Clot.) With the inflammation fully established there are in the tissue the following abnormal elements:

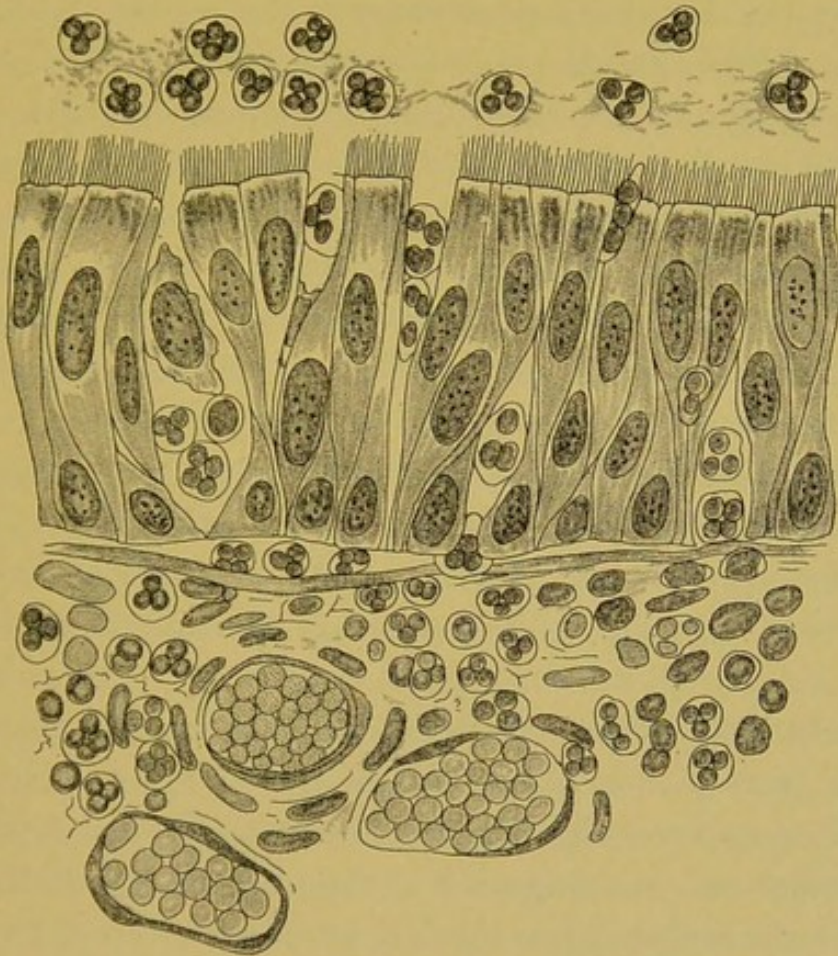
1. Leukocytes and some red corpuscles.
2. Coagulable lymph.
3. Later new embryonic cells which surround the leukocytes massed about the irritant. These are fibroblasts ready to form scar tissue—*i. e.*, they are the elements composing granulation tissue.

The disposition of these elements of inflammation is as follows: The leukocytes mass about the irritant, exert a certain amount of phagocytic activity, and may in turn be injured, liberating fibrin ferment, which, acting upon the fibrinogen of the lymph, produces fibrin, which in turn forms a coagulum. This coagulum blocks the lymphatic vessels leading from the part involved, thus causing a retention of fluid in the tissue.

In the later stages of non-infective inflammation the tissue cells undergo multiplication, forming cells larger and having more power

of amœboid movement and phagocytosis than the leukocytes. These become mingled with the leukocytes in the area of inflammation. They are fibroblasts from which all the connective tissues develop, and to the action of which regeneration is mainly due. Around and about the focus of inflammation the bloodvessels are in a condition of arterial hyperæmia and about this is an area of normal tissue. These areas shade off into each other. The phagocytes cause dissolution of coagula and dead aseptic tissue, and remove them. If the irritant be thus removable, it is eaten away. If the dead tissue be superficial, the con-

FIG. 54.



Acute bronchial catarrh: passage of leukocytes through the epithelium of the bronchus between the ciliated cells. $\times 700$. (Thoma.)

nection with the living tissue beneath is eaten through and the latter thrown off. If the superficial tissue have been previously removed, the wound is covered with the exudates and leukocytes, which dry into a scab, beneath which regeneration occurs. If inflammation occur in a mucous surface, the exudate and corpuscles escape from the submucous tissue between the epithelial cells as a catarrhal discharge (Fig. 54). If the inflammatory exudate be highly coagulable and coagulate, firm swelling is caused, apt to lead to organization of tissue, hence called fibrinous inflammation. If it be productive of hypertrophy,

it is called productive inflammation. If the exudate be watery, poor in albumin, and hence not readily coagulable, the inflammation is called serous inflammation.

Symptoms of Simple Inflammation. These are:

1. *Redness* due to the excess of blood in the vessels and in the tissue. In some cases the part may have a dusky hue. The color is deepest in the area of greatest stasis.

2. *Heat* due to the increased oxidation in the area of hyperæmia about the area of stasis. It has been shown that there is no increased heat in the area of stasis. In this area chemical action is lessened.

3. *Swelling* due to the excess of blood in the vessels, the exudates of leukocytes and fluid, and the multiplication of tissue cells. The hardness of a swelling is due to coagulation of the fluid exudate.

4. *Pain*; the result of the pressure of the effusion upon sensory nerve terminals; it is frequently throbbing in correspondence with the heart beat; the impulse causes temporarily increased pressure upon the nerve terminals. Gravitation also increases the pressure and pain in a dependent part—*e. g.*, in a hand or foot or in recumbency in case of pulpitis (which see).

5. *Impaired function* is an evident result of a disturbance involving such pathological phenomena as have been described.

There are no general disturbances in simple inflammation beyond a slight traumatic fever due to absorption of some aseptic material from the seat of inflammation—*e. g.*, fibrin ferment.¹

Infective Inflammation. If micro-organisms enter the tissue through a wound or puncture or an abraded surface, or if they locate upon predisposed or non-resistant mucous membrane, their multiplication causes irritation and inflammation of the tissue about them. This at first resembles a simple inflammation, but later becomes more severe, prolonged, and may spread into the surrounding tissue, or in some cases cause inflammation in another place in no way connected with it except by the blood or lymphatic channels (metastasis). Briefly, the process may be described as beginning with the entrance or location of the organisms and their multiplication. An injury of the vessel walls occurs and the phenomena, such as occur in simple inflammation, begin. There is arterial hyperæmia, later retardation of the blood current; diapedesis of leukocytes occurs, and a copious exudate of coagulable lymph is poured out into the intervascular tissue. By positive chemotaxis the leukocytes are attracted to the bacteria, surround

¹ Green's Pathology and Morbid Anatomy.

them, and apparently endeavor to limit their activity, or, perhaps, to digest them. If the bacteria be few in number and not too virulent, the phagocytes are successful and the phenomena of resolution occur. If, however, the contrary be the case, the leukocytes are overcome and the inflammation spreads. The central or most involved area dies. It is thus seen that there may be two terminations of an infective inflammation, resolution and necrosis.

Resolution. If the phagocytes destroy or wall up the bacteria, so that they die in their own products or are killed by the protective juices of the part (alexins), the lymphatics are unblocked, the circulation is re-established, the tissue that has died is removed by resorption and replaced by scar tissue if the loss be considerable. No evident pus nor externally evident necrosis is produced, and the part exhibits phenomena much like those of a simple inflammation. This is the only termination for a simple (non-infective) inflammation.

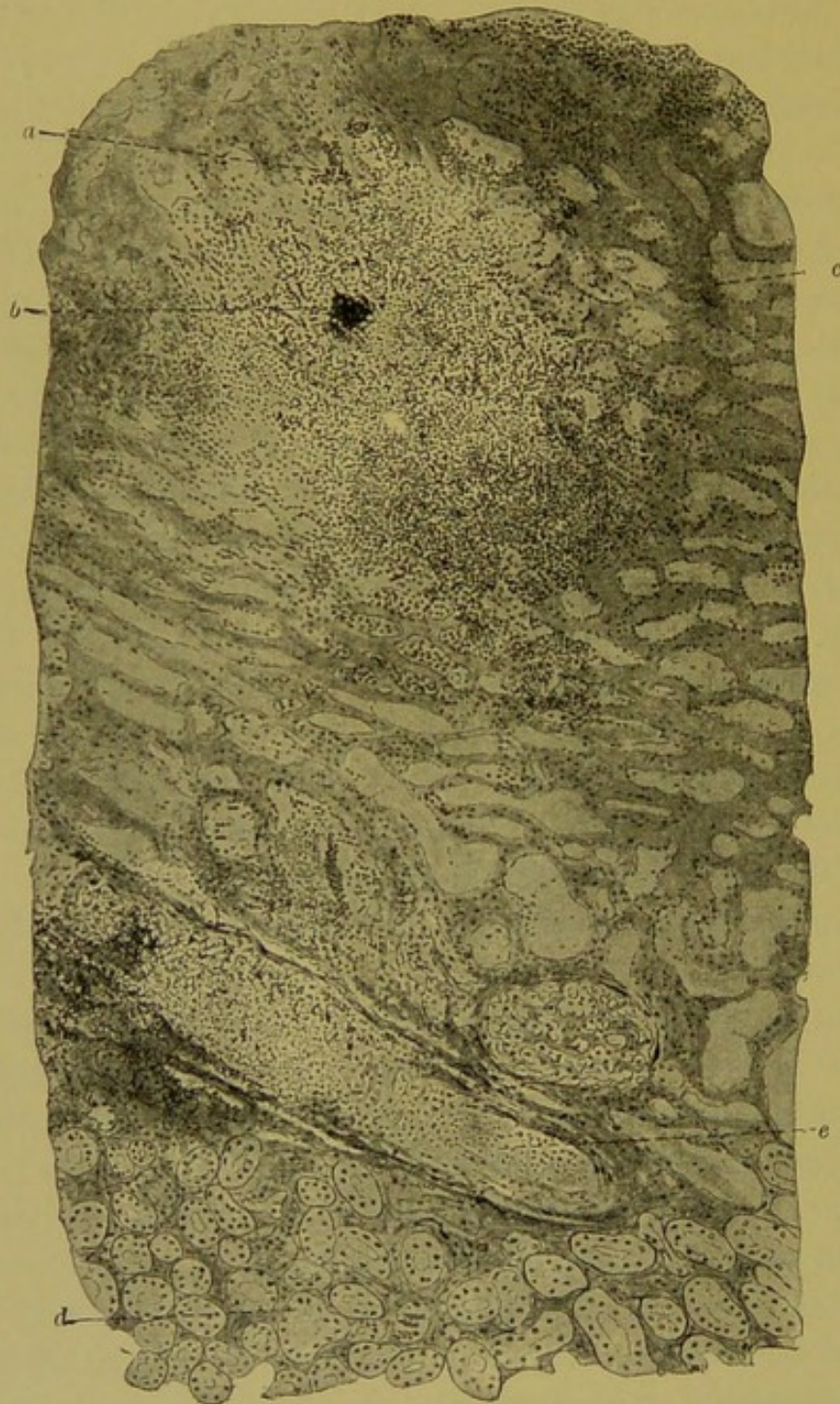Necrosis. Death of a part may result from infective inflammation, either with or without pus formation.

Suppuration. If the irritant in the tissue consist of pyogenic organisms, such as the staphylococcus pyogenes aureus or albus, the streptococcus pyogenes, the bacillus pyocyaneus, bacillus typhi abdominalis, diplococcus pneumoniae, or the gonococcus, pus will be formed, provided the germs be not killed out. The staphylococcus pyogenes aureus is most frequently the organism infecting wounds. It is practically universal.

Entering a part the bacteria distributed in the tissue act as irritants and excite the phenomena of inflammation as described. Some of the cocci are taken up by the fixed connective-tissue corpuscles, the leukocytes, and the endothelial cells of the capillaries, and some lie free in the tissue. The cocci multiply and the polymorphonuclear and eosinophile leukocytes increase in number by diapedesis and surround them. The original tissue cells, including those of the bloodvessels, undergo coagulation necrosis as the result of the action of bacterial ferments and do not take up staining reagents (Fig. 55). Coagulation of the exudates occurs. The leukocytes and tissue cells are in part degenerated into pus corpuscles by the action of the unorganized ferments of the bacteria—*i. e.*, their nuclei are fragmented and they undergo fatty degeneration. Some cocci die. The exudate is peptonized into a fluid which, together with the cocci, dead leukocytes, and tissue remnants, constitutes *pus*. About this pus is a circumvallating wall of living leukocytes, and about this again a zone of fibroblasts arranged about

new capillary loops (granulation tissue). The whole constitutes, when confined within tissue, an abscess. When upon a surface the granu-

FIG. 55.



Miliary abscess in a case of septic embolism of the kidney: *a*, leukocytes advancing toward and surrounding *b*, a mass of cocci, in whose neighborhood all trace of structure has disappeared; *c*, renal epithelium too damaged by bacterial products to take the stain; *d*, kidney tissue staining normally; *e*, vein from which leukocytes are making their way to the commencing abscess. $\times 100$. (Green.)

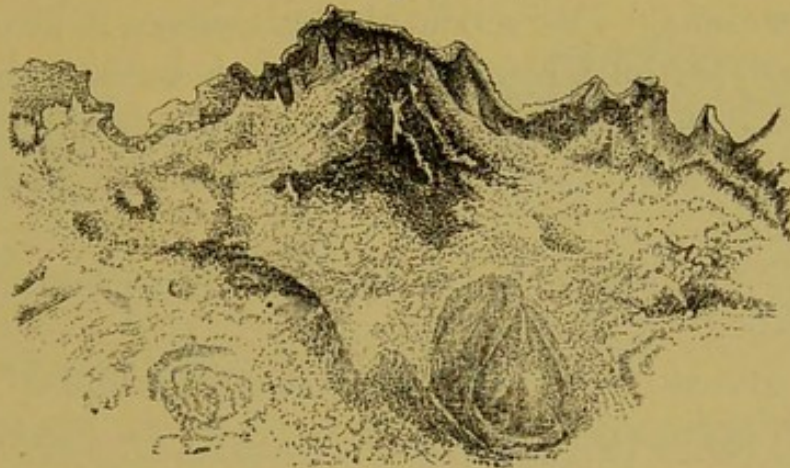
lation tissue is upon the under side only, and the whole constitutes a suppurating ulcer.

While the leukocytes may overcome the bacteria, the reverse is often

the case, and the pus cavity enlarges in the same manner as at first, by a new formation of coagulation necrosis, more circumvallation, further liquefaction of the coagulum, etc. The path offering the least vital or mechanical resistance is usually followed until the surface of the body or some internal cavity is reached. The last portion of tissue overlying the forming pus is tumefied and a soft, yellow spot appears. This is called *pointing*. The tissue is ruptured by the internal pressure and the pus escapes. The tract from the point to the abscess cavity is a *fistula*. As soon as this occurs granulation tissue springs up upon the sides of the abscess cavity and usually soon fills it with scar tissue. (See Regeneration.) If the cause continue to act, as, for example, in case of a portion of dead and septic bone beneath soft tissue, a gangrenous pulp in a tooth root or infected crypts of the abscess walls, the

FIG. 56.

a



An abscess in the skin. The horny layer has largely disappeared, and the Malpighian layer is pushed upward by the subjacent abscess (a). The mass of pus corpuscles is just breaking down to form a cavity, the walls of which are thickly infiltrated with similar cells. (Boyd.)

granulation tissue breaks down and the condition is one of ulceration or a chronic abscess with a fistula. If, in the course of abscess formation, bone be encountered by the pus, it may be and often is molecularly broken down into pus. (See Acute Apical Abscess.) It does not always happen that the pus finds escape either naturally or through surgical aid: the patient may die before this occurs, or the tissues around the seat of pus formation may form a boundary wall which the organisms fail to break down and thus die starved out. The abscess contents undergo changes resulting in caseation, or later the mass may calcify. (See p. 64.) The streptococci pyogenes may multiply laterally, following the subcutaneous cellular tissue, and produce violent spreading inflammation with but little pus formation—*e. g.*, some forms of apical abscess and erysipelas.

The products (toxins) from an abscess or infective inflammation may find their way into the blood and a general toxæmia result, or the organisms themselves may enter the blood and a general infection result (septicaemia).

There are various varieties of pus which have names describing the chief characteristics:

Creamy pus is the erroneously called laudable pus associated with an acute abscess or ulcer which progresses, as a rule, toward a cure. It is of a yellowish-white color, creamy consistency, and without odor.

Curdy pus contains flakes.

Ichorous pus is thin, odorous, and irritating.

Muco-pus is pus containing mucus.

Sero-pus is pus containing much serum.

Sanious pus contains blood.

Cause. The cause of suppuration is the development in tissues of pyogenic organisms. The action of these causes is favored by the presence in the part of a hyperæmia or simple inflammation, such as the injury introducing the organisms may cause. These as well as depraved or debilitated tissues favor the action of bacteria—*i. e.*, act as predispositions.

Symptoms. The symptoms of suppuration are both general and local.

LOCAL SYMPTOMS. The symptoms of inflammation occur, but usually much aggravated. The pain is often of a lancinating character, sudden darts often following comparative quiescence. On the other hand, the throbbing pain may be continuous and intense, especially when the pus is confined by bone or tense tissues, as in case of a felon or acute apical abscess. Recalling that around the pus area there is one of active inflammation, and about that hyperæmic, then normal tissue, one may judge of the degree of involvement of deeper parts by the appearance of the surface above them. Thus, for example, hyperæmia at the surface indicates inflammatory action directly beneath, while inflammation at the surface, together with hardness and tumefaction, shows a more involved condition of the tissue directly beneath it—*i. e.*, a more advanced state of inflammation or even of suppuration.

The softening of the apex of the swelling gives a feeling of lessened resistance, indicating pointing or pus at the surface. In large, superficial abscesses the sensation known as fluctuation may be obtained by placing one finger on one side of the swelling and gently tapping upon the other. Yellowness of the apex, together with softness, indicates

that the abscess is about to discharge its contents. A fistula upon the surface is indicative of a discharged abscess, and leads to a pus-forming area beneath (chronic abscess).

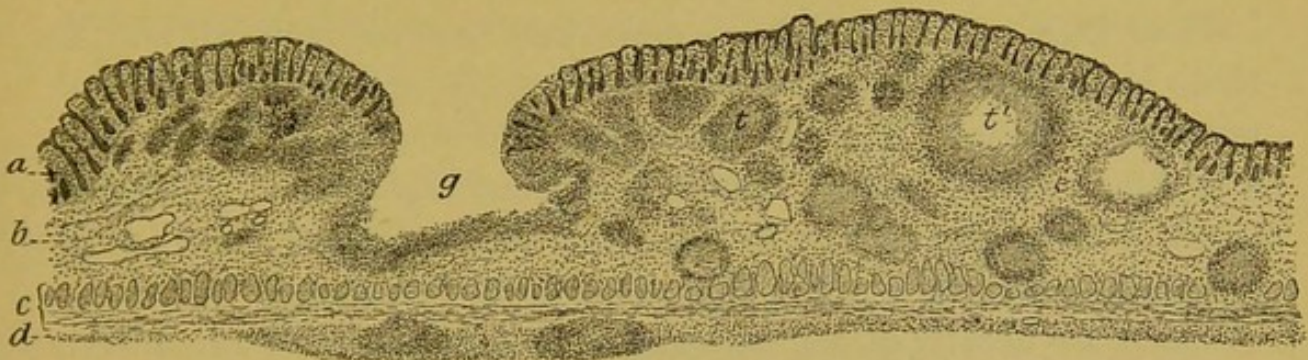
GENERAL SYMPTOMS. If toxæmia be produced, there may be chills, and, at the same time, fever as high as 104° F. A full, bounding pulse accompanies this, and there are other evidences of septic intoxication, which may become profound. (See Septic Intoxication.)

Leukocytosis after surgical disease is considered pathognomonic of suppuration.

Ulceration. The development of micro-organisms upon a free surface causes tissue degeneration and death, as described under abscess; in fact, an abscess is a confined ulcer.

Numerous forms of pathogenic organisms are capable of causing tissue degeneration and death of a mucous or skin surface. If infection

FIG. 57.



Tubercular ulcer of the intestine: *a*, mucosa; *b*, submucosa; *c*, muscularis; *g*, ulcer; *t*, tubercle in the mucosa; *t'*, focus caseating in the middle. $\times 12$.

take place through a hair follicle, or if organisms develop upon an abrasion, or in the epithelium in conditions of general or local debility, the epithelium is destroyed over an area, and in the subepithelial tissues the organisms multiply and cause tissue loss. If the organisms be pyogenic—and ulcerous surfaces are usually infected by these bodies—pus is formed. (Fig. 57.) Under some conditions, as in debilitated and neglected children, the ulcerous process may spread rapidly, as in the cheek in *cancrum oris*; or when specific bacilli, which excite much swelling and quick death of the tissues of the cheek, proliferate, causing the condition called *noma*.

Prognosis. Abscesses tend, as a rule, to spontaneous cure without marked systemic disturbance. If the pus discharge persist after evacuation of the abscess, persistence of the cause, or infection of the abscess walls through reinfection or by retention of bacteria in the crypts, is to be suspected. The occurrence of rigors (chills) and high

fever is a danger signal. A fluttering, weak pulse, and clammy extremities indicate profound septic intoxication, and are indications for local disinfection and systemic treatment.

Treatment of Inflammation. If the cause of inflammation be in evidence it must be removed; good examples of removable causes are a splinter in the flesh, a gangrenous tooth pulp, etc. Ordinarily the pus of an abscess or an ulcer contain the cause (organisms) within it; therefore the pus should be removed by opening the abscess, if its situation can be determined, after which the pus cavity is syringed out with antiseptics, which destroy the pus and the organisms. Hydrogen dioxide in 3 per cent. aqueous solution is commonly used; it is made more effective by the addition of mercuric chloride (1 : 1000).

In ulceration the pus and organisms are destroyed in a similar manner, though at times sloughing tissue requires removal by the curette, caustic agents, or by digesting agents, as caroid, papoid, brewers' yeast,¹ etc.

Dead bone acts as a septic irritant and requires removal, and at times an abscess will remain persistently infected, requiring surgical removal of tissue. The abscess or ulcer, if protected from further infection, usually heals by formation of granulation tissue. A deeply seated abscess may require to be packed with antiseptic gauze (nosophen), in order that it may granulate from the bottom out.

Ulcers are usually dusted with antiseptic powders, iodoform, aristol, or nosophen, which cause drying of the surface and prevent the access or action of organisms. Under certain circumstances the presence of suppuration is not certain, though phlegmonous (spreading) inflammation is somewhat pathognomonic of it. In such cases hot, moist applications, such as hot poultices, soften the surface above the abscess and determine its direction of discharge, thus limiting burrowing. Counterirritants applied directly above the inflamed area also hasten in such cases. The stimulation may aid resorption (destruction by phagocytosis) of the pus and resolution occur.² The vascular engorgement in an inflamed part may be reduced by local blood-letting.

Nancrede found, on dividing a vein upon the distal side of an area of inflammation, that after a brief period the flow of blood was established through the inflamed area. Local blood-letting by leeches (Gensmer) produced even more marked effects. Drugs which stimulate the vasoconstrictors (ergot), and those which paralyze the constrictors (aconite), lessen the blood pressure in the inflamed area; so

¹ Park's Surgery.

² Ibid.

that if administered in the early stages of inflammation they may modify its severity. If, on the contrary, they are administered after stasis occurs, they increase the stasis—ergot actively and aconite passively. If the flow of blood through the inflamed area be re-established by local blood-letting, then the arterial sedatives are distinctly useful in lessening the flow of blood to the part.

When, owing to vascular engorgement, throbbing pain is a prominent symptom, applications of cold are useful in lessening the calibre of vessels and in relieving pain. But if there be firm exudation and marked stasis, cold is a detriment. Heat then gives relief through inducing a more free flow of blood in the collateral circulation. Very hot applications act as do cold applications, by causing contraction of vessels, and may be used to abort an inflammation.

In certain situations, as in case of an inflamed tooth pulp, sedative applications, antiphlogistics, are required. Conjoined with local measures of reducing vascular engorgement, the use of counterirritants and general derivatives are indicated. (See Treatment of Hyperæmia.)

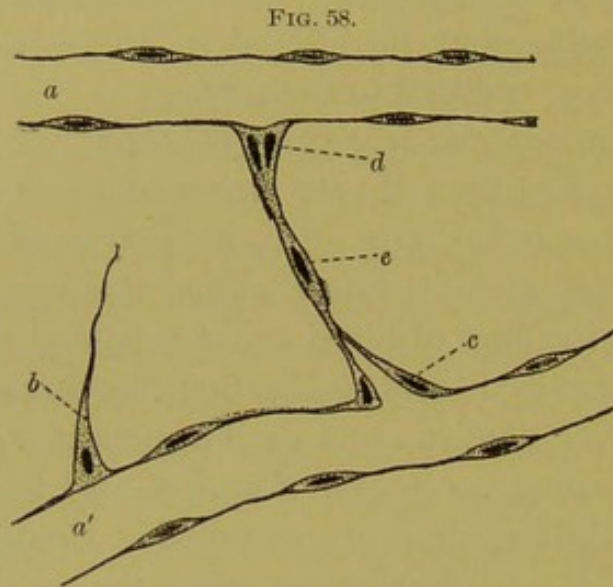
General sedatives are at times demanded for the relief of pain. Morphine used in small and continued doses not only relieves pain, but causes a contraction of small vessels. Other anodynes are also used in this connection.

REGENERATION OF TISSUES.

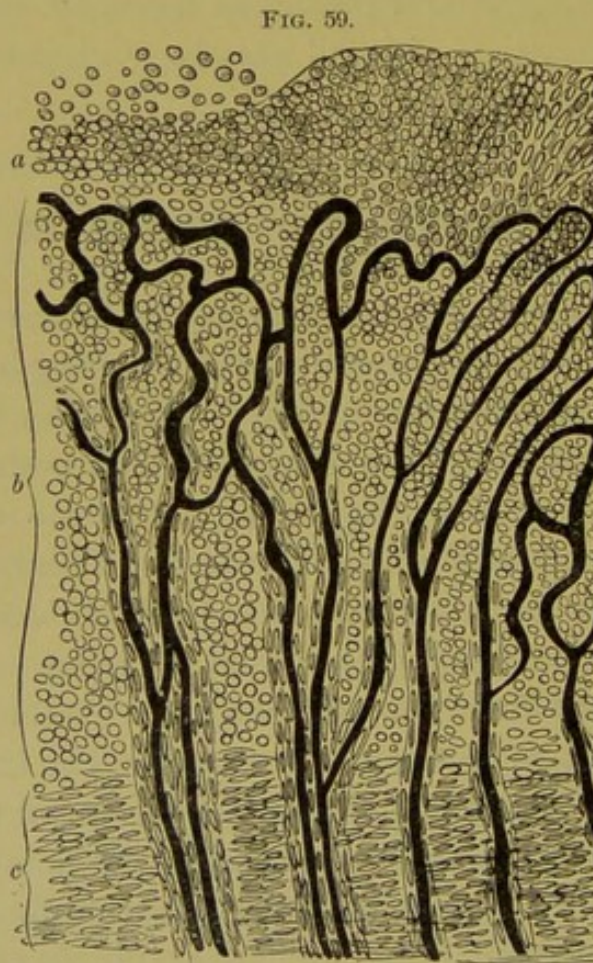
Connective tissues that have been lost by inflammatory process or operation are replaced by granulation tissue arising by mitotic division of cells of the connective-tissue group. The forms of healing are by first intention, second intention or granulation, healing under a scab, and healing under a clot. Epithelial tissues are replaced only by multiplication of epithelial cells. The forms of healing are practically alike by formation of granulation tissue, the form being simply a modification (of extent) of healing by second intention.

Healing by Second Intention. Shortly after evacuation of pus from an abscess the process of repair is instituted. The leukocytes come to the surface of the wound in great numbers; some of these may degenerate into pus cells. Immediately beneath the uninjured connective-tissue cells multiply, forming embryonic cells (fibroblasts); at the same time the endothelial cells of the capillaries multiply at points, throwing out solid-pointed projections or buds from the sides of the capillaries (Fig. 58, *b*). These lengthen and join buds from other capillaries

(Fig. 58, *c, d, e*). By mitosis the nuclei divide horizontally, lying side by side (Fig. 58, *d*). Later these separate into two cells, discovering a lumen into which blood enters from the parent capillary (Fig. 58, *a', c*).



Regeneration of capillary bloodvessels: *a*, normal capillaries; *b*, capillary process; *c*, new capillary appearing in divided process; *d*, process undergoing division; *e*, connecting cell in which no sign of division has yet appeared. Diagrammatic. (Green.)



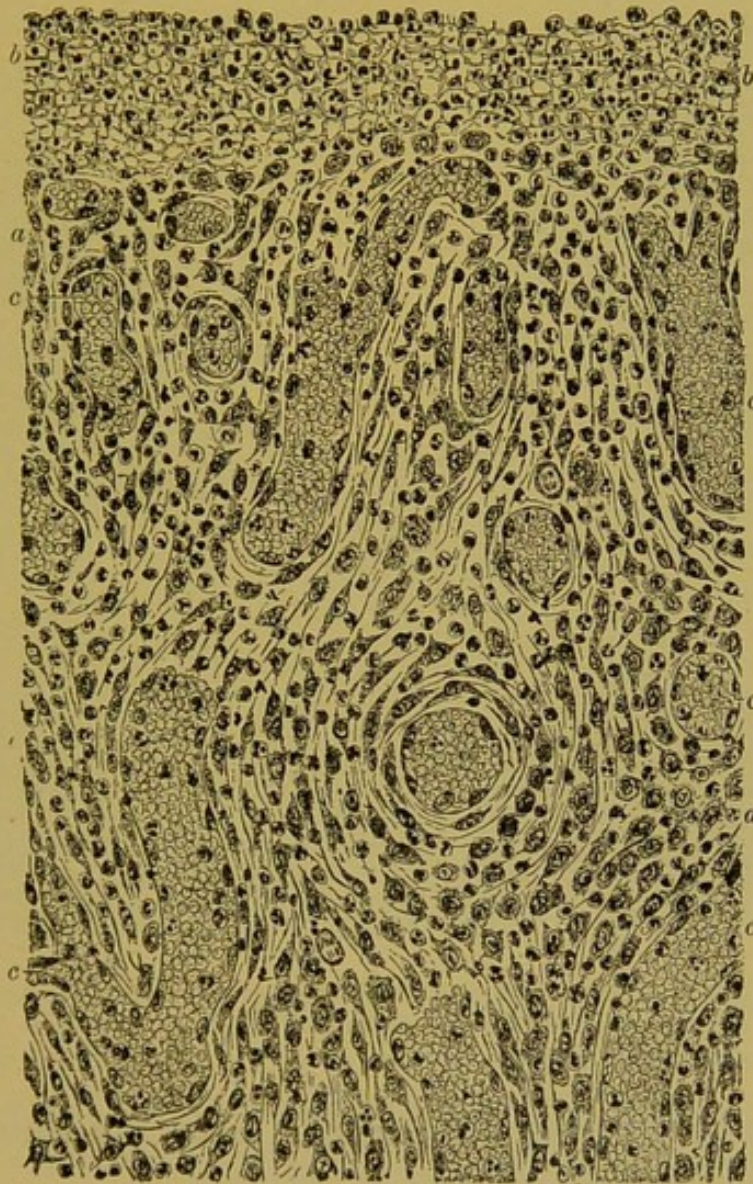
A granulating surface: *a*, layer of pus; *b*, granulation tissue with loops of bloodvessels; *c*, commencing development of the granulation tissue into a fibrillated structure. $\times 200$. Diagrammatic. (Rindfleisch.)

In this manner loops are formed, about which the fibroblasts are arranged (Figs. 59 and 60).

Together these form minute red elevations upon the surface of the abscess cavity or wound, called granulations. Repeated, the process gradually fills the abscess cavity.

Naturally, collapse of the walls or apposition of cut edges of a wound lessens the amount of granulation tissue necessary; hence, in the latter

FIG. 60.



Transverse section of granulation tissue from an open wound with fibropurulent deposit:
a, granulation tissue; b, fibropurulent deposit; c, bloodvessels. $\times 150$. (Ziegler.)

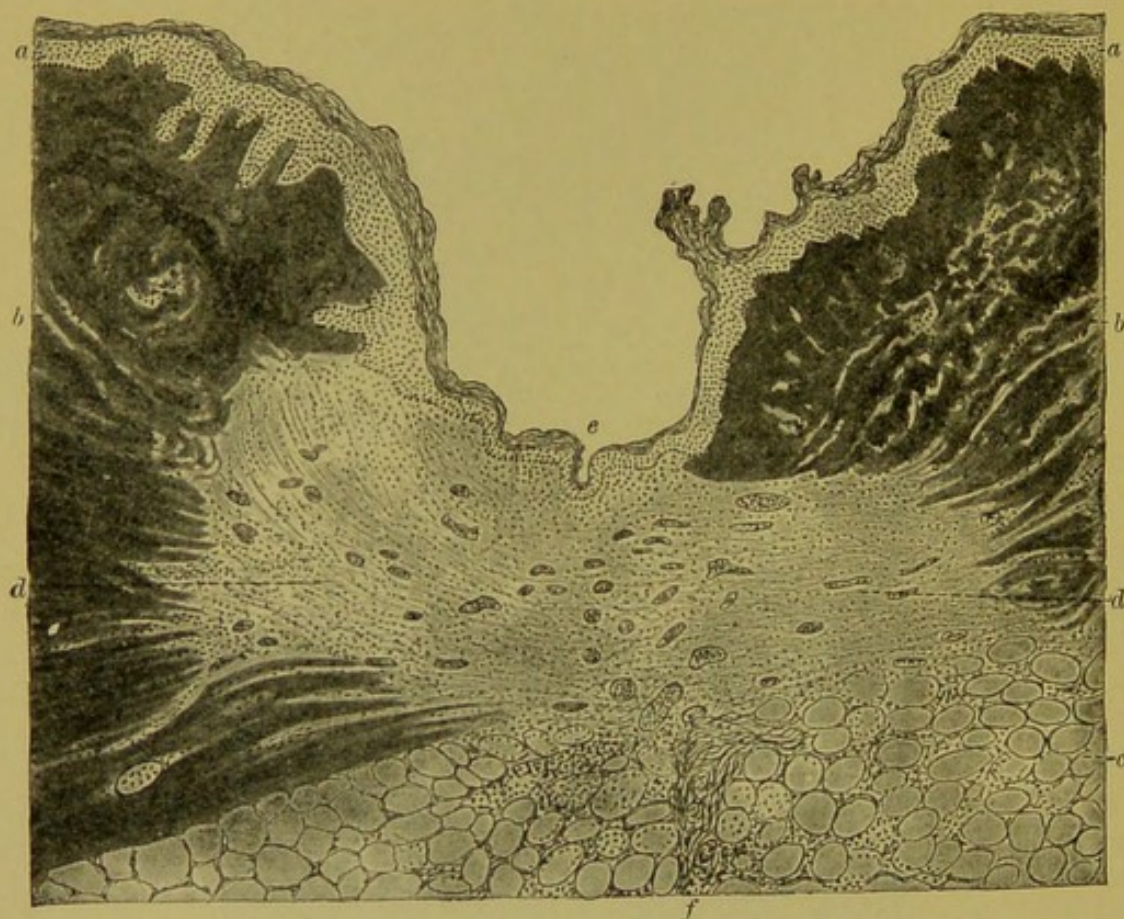
case, healing by first intention (with a minimum amount of granulation or scar tissue).

The wound having been filled up, epithelium grows from the sides and covers the granulations (Fig. 61, *e*). The granulation tissue, at first highly vascular, later contracts, and many vessels are obliterated so that it becomes whiter than normal tissue.

The indifferent embryonic cells may have the function of forming any of the connective tissues. If cartilage is to be formed, chondrification takes place about the specialized cells. If bone is to be formed, certain cells form islets, about which calcification proceeds. Nerves require a month or more to pierce the cicatricial tissue (Eichhorst).¹

In healing beneath a scab the exudation and leukocytes upon the surface of the wound dry into a scab beneath in which granulations

FIG. 61.



Laparotomy wound—sixteenth day: *a*, epithelium; *b*, corium; *c*, subcutaneous fat; *d*, vessels in scar tissue of corium; *e*, newly formed epithelial layer; *f*, vessels in subcutaneous scar tissue. $\times 40$. Modified from Ziegler. (Green.)

and an epithelial covering are formed. Later the scab falls off. If prematurely lost the granulations are exposed.

In healing under a clot the clot is invaded by leukocytes, which have a solvent action upon it. Granulation tissue forms upon all sides of it, grows into it, and, at the same time, removes it by resorption (Fig. 62). If the clot become septic, the granulations may become infected and break down.

Healing under a clot is the form commonly seen after tooth extraction.

In certain cases of abscess with contracted fistulæ or openings of

¹ Ziegler, General Pathology.

discharge, the orifice may close before the granulations have filled the pus cavity. If pus or an excess of exudate be now formed within the cavity, a second discharge may occur. To obviate this difficulty, abscesses are often packed with antiseptic gauze, so that healing may occur from the bottom of the cavity, while drainage is assured. In other cases the placing of a tent or drain tube in the fistula together with asepsis suffice for the attainment of the object.

INFLAMMATION OF BONE.

"Active inflammatory changes may occur in the periosteum, the medullary canal, the medullary spaces of the spongy bone, and the Haversian canals, the compact tissue and ground substance remaining passive."¹ The inflammation is termed periostitis, osteomyelitis, and osteitis, the terms referring to the point of location of the inflammation

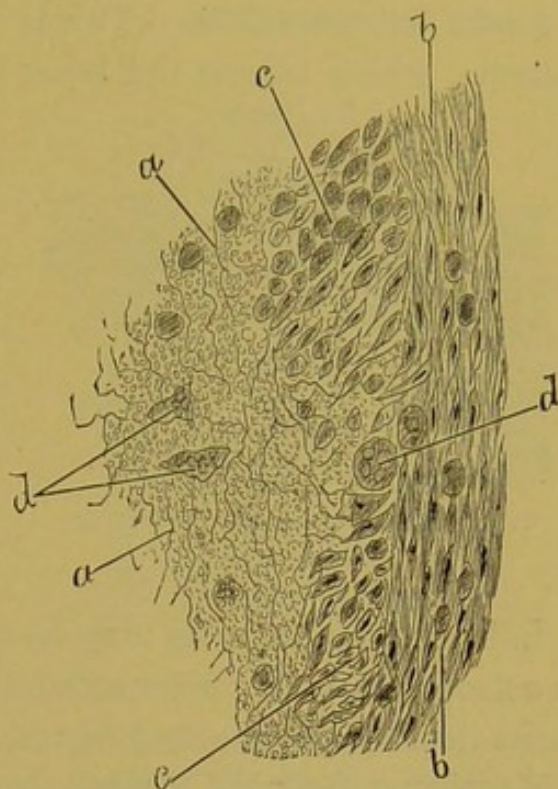
—*i. e.*, the periosteum, the medulla, and the spaces—the bone being involved in all cases.

Inflammation of bone may be non-infective or infective; the latter is usually due to pyogenic organisms—*i. e.*, suppuration occurs.

Proliferative Periostitis. This is a proliferation of cells of the deeper layers of the periosteum combined with emigrated leukocytes. A node is thus formed which may ossify.

Suppurative Periostitis. Pyogenic organisms may enter an injured periosteum or one weakened by previous disease (*e. g.*, by scarlet fever). The origin of the bacteria is by way of the blood, either directly or by way of the medulla (a secondary effect of osteomyelitis), or by way of the skin.

FIG. 62.



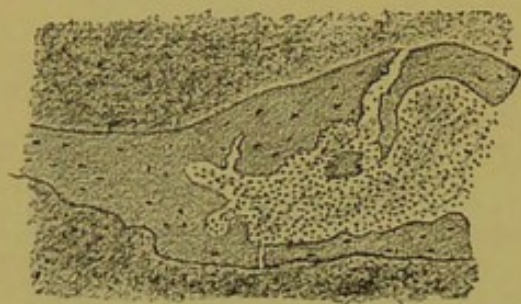
Absorption of blood clot. Section through the margin of a clot formed among the tissues by extravasation, showing the growth of granulations by which it is removed: *a, a*, portions of clot; *b, b*, original tissue; *c, c*, granulations springing from the original tissue and projecting into the clot; *d, d*, wandering cells or leukocytes that seem to have taken red blood disks into their interior. (Section cut in gum arabic and stained with hæmatoxylin.) $\times 350$. (Black.)

¹ Schmaus and Ewing, Pathology and Pathological Anatomy.

Pus forms beneath the periosteum, raises it, and destroys its connection with the bone. The vessels are stretched, damaged, and thrombosis occurs. Superficial necrosis of bone results, which may be total if other sources of blood supply are also cut off.

Acute Osteomyelitis. This is a suppuration occurring in the bone-marrow, which infects the bone proper, causes much thrombosis of vessels, coagulation necrosis of bone cells, and may rapidly cause much necrosis of medullary tissue. Occurring in large bones, much toxin is produced, which may rapidly cause death. The organisms and thrombi formed, becoming emboli, may rapidly lead to pyæmia.¹ Prompt surgical interference is called for.

FIG. 63.



Trabeculae of bone with perforating canals. $\times 50$.

Inflammation of bone may lead to its rarefaction (rarefying osteitis or osteoporosis), its condensation (condensing osteitis or osteosclerosis), or its death (necrosis and caries).

Rarefying Osteitis (Osteoporosis). In the rarefying process which occurs in chronic inflammation, granulation tissue is formed, which enters the Haversian canals and spaces of spongy bone and destroys (resorbs) the bone. They thus form new channels between the spaces—perforating canal resorption (Fig. 63). With suppuration (ulceration) added, the granulations break down, leaving the bone as a dead, spongy, or honeycombed mass. This is *caries of bone*. In the early stages the inflammation may cease, and the bone not only be restored, but condensed.

Condensing Osteitis (Osteosclerosis). In chronic inflammation, instead of rarefaction, the trabeculae of bone may increase in thickness, so that all spaces and Haversian canals become smaller. The bone becomes very compact, and if built up in excess of its original dimensions, constitutes the condition known as *exostosis*. Both condensing and rarefying osteitis occur about the alveolar process and the roots of teeth. (See Hypercementosis and Resorption.)

Necrosis of Bone. Necrosis of bone following rarefying osteitis is known as *caries*. It is a molecular death of bone. Subperiosteal death of bone occurs from infective periostitis, and is due to the compression

¹ Park's Surgery.

of vessels by the exudation and to thrombosis. Nutrition ceases; death results. The dead piece is demarked by a line of leukocytes (phagocytes), solution of continuity occurs at the line of union with the living

FIG. 64.

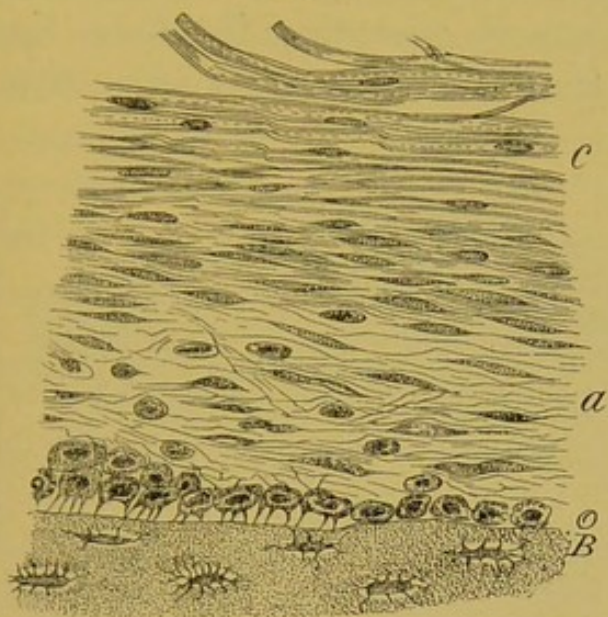
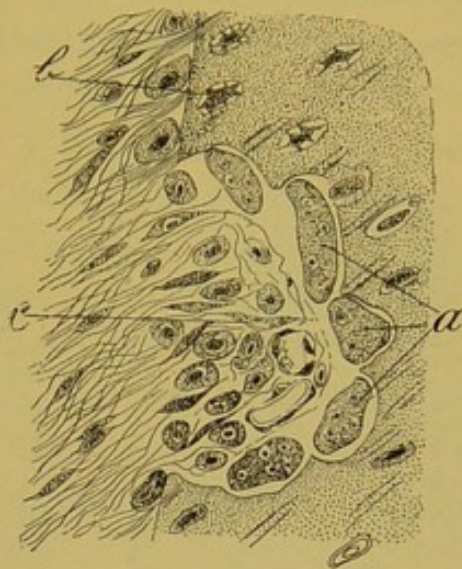


FIG. 65.

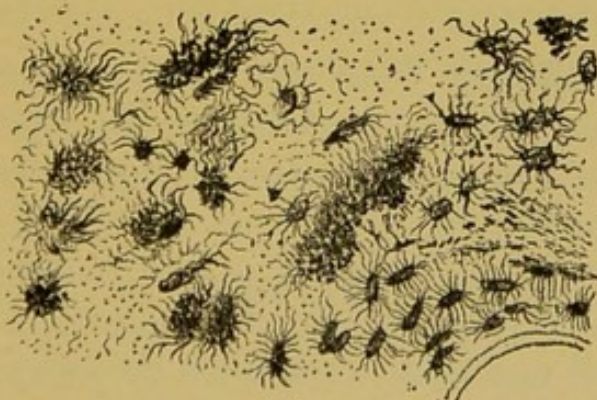

Section of bone and periosteum covering it: *B*, bone; *c*, outer fibrous layer; *a*, inner layer of white fibrous tissue; *O*, layer of osteoblasts, some of which reach the bone with their prolongations. (Black.)

Section of bone and periosteum covering it: *a*, osteoclasts, cells that absorb bone; *b*, surface of bone, showing fibres of periosteum penetrating it and a Howship lacuna. (Black.)

bone, and the piece is thrown out as a *sequestrum*. The solution is effected by granulation tissue as the rarefying process above cited. (See Gangrene.)

FIG. 66.



Lattice-work figures in haliteresis. (After v. Recklinghausen.)

Resorption of Bone. Under conditions of chronic inflammation bone is often removed by neighboring tissue in one of several ways.

Lacunar Resorption. In this form the bone is excavated by giant cells into bays called Howship's lacunæ, which may enlarge, or later

a reconstructive action may occur and osteoblasts may fill up the bays with bone.

Perforating Canal Resorption. This has been described under Caries of Bone. The canals connecting medullary spaces are enlarged by the granulation tissue formed in them (Fig. 63).

Halisteresis Ossium. In this form of resorption the bone first undergoes decalcification and the matrix is later removed (Fig. 66).

FIG. 67.

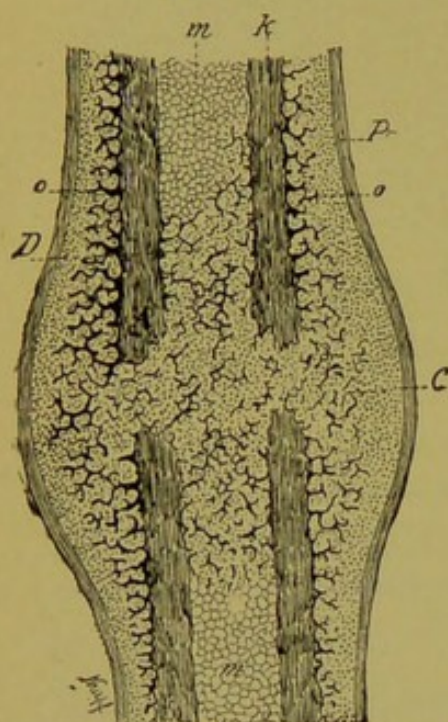


FIG. 68.

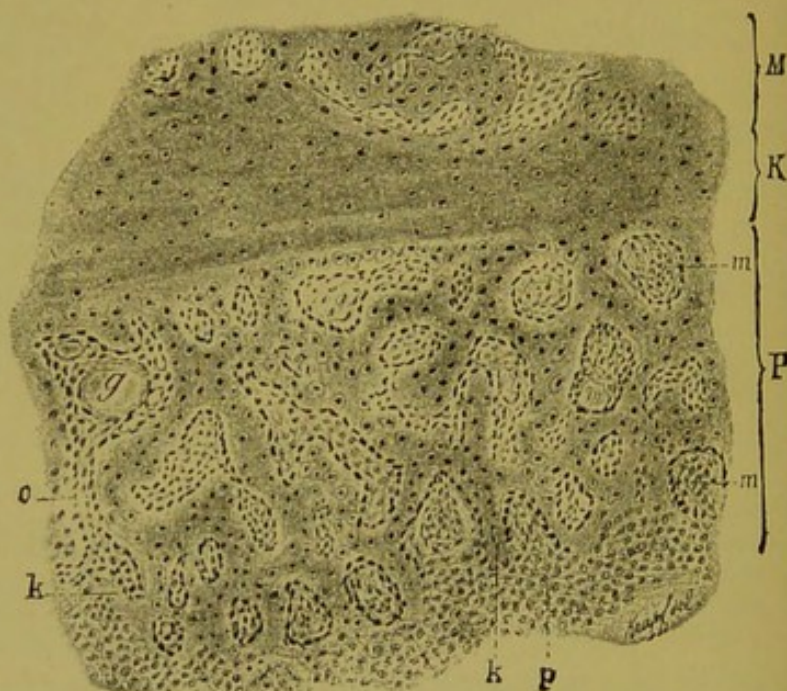


FIG. 67.—Diagram of healing fracture. From a guinea-pig, ten days after injury: *K*, ends of the bone; *m*, marrow; *c*, periosteal callus; *d*, medullary callus; *o*, osteoid tissue. $\times 6$.

FIG. 68.—The same preparation: *M*, myelogenous callus; *P*, periosteal callus; *K*, end of the bone; *k*, osteoid trabeculae; *o*, osteoblasts in rows; *p*, thickened periosteum. $\times 250$. (Schmaus and Ewing.)

Regeneration of Bone. Bone lost by suppuration is first replaced by provisional tissue of the connective-tissue type in which appear osteoblasts. Calcification then proceeds under superintendence of these (Figs. 67 and 68).

FEVER.

The term fever is applied to a condition the most prominent feature of which is an elevation of the bodily temperature above the normal, 37° C. To constitute a fever this rise in temperature must continue for some length of time.

Causes. Fevers are commonly caused by the presence in the circulatory fluids of substances which act as poisons upon, probably, the nerve centres controlling heat production. As a rule, the offending

substance is a poison generated in the body through the action of micro-organisms. The character and type of the fever are determined by the nature of the offending substances—*i. e.*, the variety of infection.

Classes. Fevers are divided into periodical or continued, according as to whether there is a periodical fall of temperature and a subsequent rise, or whether the fever continues practically unabated from the beginning to the termination of a disease. Fevers are classed in severity according to the maximum temperature and again according to their duration. A temperature of 100.5° to 101.3° F. is called slightly febrile; 101.3° to 103° F. moderate fever; 103° to 105° F. marked fever. A temperature above 106° F. is termed hyperpyrexia.

Symptoms. The most characteristic symptom of fever is the elevation of temperature; accompanying this there is an increased frequency of the pulse. In acute inflammatory diseases the pulse is full and bounding, the eyes injected, the bowels constipated, and the urine scanty, containing an excess of urea. On standing, the urine throws down a brick-dust deposit (urates). In fevers of a lower type, or in many fevers which begin as described, the high, bounding pulse is succeeded by a soft, quick pulse, and evidences of great debility. In fevers in which the temperature runs high there is commonly evidence of intoxication, more or less delirium, and reflex muscular action. With a persistent temperature and a pulse becoming softer and more frequent, there is increasing debility.

Pathology and Morbid Anatomy. In all cases of continued high temperature the fat of the body rapidly disappears and granular degeneration occurs in the muscles and viscera of the body. If the fever be long continued and of an adynamic type, this degeneration may become marked. Its occurrence in the muscles of the heart is common and is an element of danger. There are an increase in the amount of carbon dioxide formed and exhaled from the body, and an increased amount of oxygen inhaled. This, with the increase of urea, the product of the oxidation of nitrogenous tissues (muscles, glands, etc.), indicates that the oxidation of the tissues is largely increased; hence the elevation of temperature. As repair does not equal waste in fevers, the nutritive processes being profoundly disturbed, the essential elements of the tissues suffer from the increased oxidation and undergo degenerative changes.

Prognosis. The higher the temperature and the longer it continues, the greater drain there is upon the vital forces. As a rule, a temperature of 106° F. persisting more than twenty-four hours presages death. If

the vital forces flag and the heart action becomes weakened, and if there be evidence of profound intoxication, such as twitching of tendons, low, muttering delirium, and a clammy surface, the outlook is bad. Favorable signs are falling temperature, a clear eye, tongue losing its coating, free action of the bowels, free perspiration, free action of the kidneys, and a good vascular tension.

Treatment. In the light of present knowledge, efforts should first be made to discover the nature of the cause of the fever and to remove it, if possible. If not, attention should be directed to maintaining the vital forces until the body rids itself of the offending causes. As many fevers are self-limited in course and duration, this latter treatment becomes an important consideration. The temperature should be kept within safe limits by the administration of antipyretics, when the condition of the heart will permit their use, and also by cool sponging or cool baths. The action of the heart should be sustained by the administration of concentrated nutriment, and by stimulants when necessary. The bowels must be kept open.

In any form of fever there is no therapeutic measure comparable with the removal of the cause, provided this be discoverable, identified, and removable.

TOXÆMIA.

By toxæmia is meant a more or less general disturbance of the economy as the result of the presence in the blood of substances poisonous to a tissue or the tissues. The substance may be a normal constituent of the blood which has accumulated owing to faulty elimination—*e. g.*, urea—or be derived from the alimentary canal as the result of unusual fermentation therein. Such an effect is known as autointoxication. It may be due to the action of drugs of toxic character—*e. g.*, alcohol, or iodoform. This is drug toxæmia. Again, it may be due to the action of the products of bacteria, which products, absorbed from certain foci of infection, produce general effects, such as fever.

Septic Intoxication. By septic intoxication is meant the absorption into the blood of the products of bacterial activity, which products are produced at some focus or foci of infection as the result of tissue or tissue-juice decomposition. These bacterial products produce symptoms of general poisoning or intoxication, which are mild or severe, according to the character of the poisonous body produced. The organisms do not necessarily enter the blood, hence the blood is

not infectious if inoculated into another person (or experimental animal).

Two varieties of septic intoxication may be distinguished:

1. Intoxication by the products of the action of specific bacteria developing upon living tissue.

2. Intoxication by the action of bacteria upon non-vital materials (sapræmia).

The action of the bacilli of diphtheria, Asiatic cholera, and tetanus are examples of the first class. Their toxins are virulent, but the bacteria are confined to the pharynx, intestine, and the wound, respectively.

Sapræmia. The entrance of putrefactive or the pyogenic organisms into such material as a large blood clot or gangrenous area may, by putrefaction, cause the formation of large quantities of toxins. These, if absorbed, produce rapid and profound symptoms of intoxication. The symptoms vary according to the nature of the toxin and the quantity absorbed, but ordinarily occur in the following order: malaise, rigor, fever and its symptoms, nausea, vomiting, headache, diarrhœa, prostration, delirium in some cases, muscular weakness, clammy skin, feeble pulse, quick respiration, and in fatal cases coma and death. The symptoms are similar to those of septicæmia, but appear more rapidly—*i. e.*, septicæmia requires time to spread. There is a putrid wound which is the source of the toxic substance. The condition is usually complicated by septicæmia.

SEPTICÆMIA (GENERAL SEPTIC INFECTION).

By septicæmia is meant a condition in which the bacteria, usually one of the pyogenic varieties, gain entrance to the living tissues, enter the circulation, and are carried to inaccessible parts, where their development continues and from which point their toxins are absorbed (Fig. 69).

This process requiring more time than mere absorption of toxins, the symptoms are much more delayed than in sapræmia. The blood is highly infective in minute amount, as it contains bacteria.

Pathology. There is a septic wound in which incubation occurs for several days. The lymphatics leading from the part and the nearest lymphatic glands become inflamed. In pronounced cases the spleen is enlarged. There is marked leukocytosis.

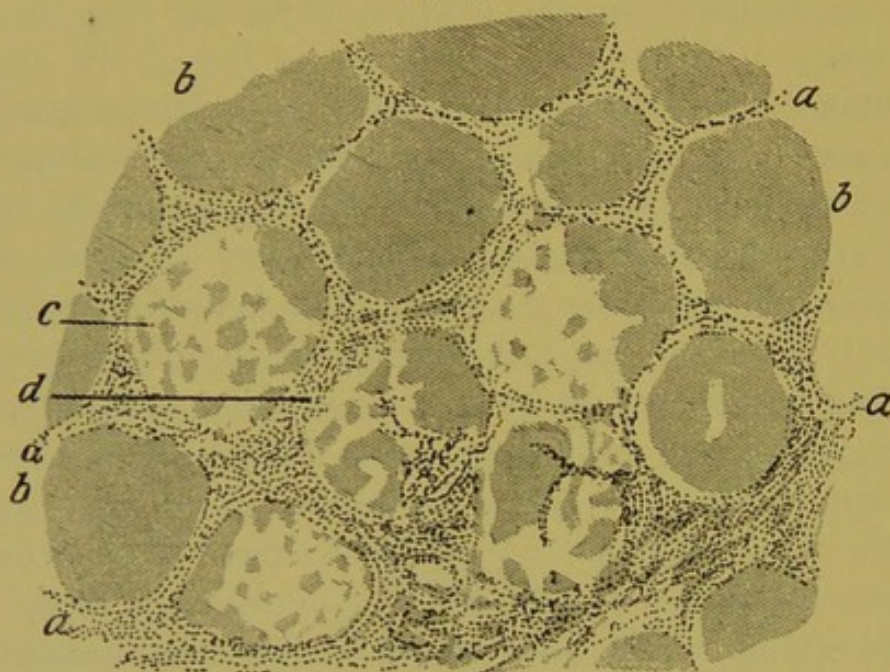
Examination made after death from the septic intoxication pro-

duced by both sapræmia and septicæmia exhibits fairly constantly enlargement of the spleen and disintegration of the red corpuscles, with staining of the intima of the vessels and heart. The lungs are congested. Death occurs through heart-failure.¹

Symptoms. These are similar to those of sapræmia, except that the periods of incubation about the body cause delays.

Treatment (for Sapræmia and Septicæmia). The treatment is both local and general. The local treatment involves the opening and dis-

FIG. 69.



Pectoral muscle beset with large numbers of the streptococcus pyogenes, from a case of phlegmonous inflammation of the subcutaneous and intermuscular connective tissue, due to cadaveric poisoning (the phlegmon of the wall of the chest developed two days after the finger was injured, and the intermediate lymph-vessels of the arm showed no evidences of being involved): *a*, perimysium internum full of streptococci; *b*, transversely cut muscular fibres, still intact; *c*, transversely cut muscular fibres which are beginning to degenerate; *d*, muscular fibres into which the cocci have penetrated. (Preparation treated with gentian violet and vesuvin, and mounted in Canada balsam. Magnified 350 diameters.) (Ziegler.)

infection of all wounds, even the extirpation of a part and of neighboring glands being sometimes necessary for removal of the cause. If possible, the part is immersed continuously in hot water, which may occasionally have mercuric chloride added to it.

An antiseptic salve, consisting of resorcin, 5 parts; ichthyol, 10 parts; unguentum hydrargyri, 40 parts; lanolin, 45 parts, is to be applied to the area of infection.

Credé's silver ointment may be applied to the unbroken skin for the systemic antiseptic effect of the silver.²

¹ Green, Pathology and Morbid Anatomy.

² Park's Surgery.

The general treatment consists in: 1. Clearing the alimentary canal by means of cathartics and maintaining its asepsis by means of mercuric chloride in small doses, salol, or other suitable antiseptic. 2. Supporting the heart action by means of alcohol and strychnine. 3. Supporting the strength by concentrated liquid nourishment, such as egg albumen, beef peptonoids, beef juice, peptonized milk,¹ to which diet fruit may be added.² 4. Reducing the temperature by means of cold sponge baths or quinine. 5. Maintaining the eliminative action of the kidneys until the system has rid itself of the toxins. For the more profound cases Park recommends the intravenous infusion, as an intravascular germicide, of from 500 c.c. to 1000 c.c. of a solution of Credé's soluble silver, 1 : 1000 of sterilized water at 105° F. The value of streptococcus antitoxin is still not proven.

PYÆMIA.

By pyæmia is meant a form of septicæmia or septic infection by pyogenic organisms, which, locating at favorable spots, as in the capillaries, multiply and produce numerous abscesses known as miliary or metastatic abscesses. From these foci toxins are absorbed, which produce a septic intoxication.

The organisms may enter the blood from some focus of suppuration as free cells or be taken up by leukocytes, or thrombosis may occur at the original focus of infection and portions of clot be carried in the blood as septic emboli to terminal arteries, where the results of septic infarction are set up. (See Infarction.)

Symptoms. The symptoms of pyæmia are, in general, those of septicæmia; their appearance is delayed from the date of the reception of an injury or the outbreak of the primary suppuration. The onset of pyæmia is usually by a chill or a succession of chills. Each fresh area of pus formation is believed to be announced by a chill and a rise of temperature. The temperature is subject to remissions, and sudden variations in its height are noted. The general symptoms are those of an adynamic fever. Local symptoms appear according to the point of lodgement of septic emboli. Pus centres may be found in the lungs, and cause symptoms of dyspnoea; collections frequently occur in joints, causing loss of mobility; eruptions appear on the skin, the swellings being apparent; typhoid symptoms become more pronounced, and an increasing debility ushers in a usually fatal ending. At times both septicæmia and pyæmia may become chronic.

¹ Thompson's Practical Medicine

² Park's Surgery.

Treatment. The treatment of pyæmia should be preventive. The carrying out of rigid antiseptic precautions has much lessened the frequency of pyæmia. If areas of infection are removable, they are removed no matter what extent of operation may be necessary. The general treatment is the same as in septicæmia, with much less hope of recovery.

A consideration of the infective surgical processes in connection with dental and oral diseases is of the utmost moment to the practitioner of dentistry. Nearly all of the diseases which the dentist is called upon to treat are infective from their inception. Moreover, the saliva, holding in suspension numerous forms of bacteria, both saprophytic and parasitic, and their waste, is a highly infective fluid.

It has been clearly demonstrated by the researches of Miller¹ that many forms of bacteria found in specific diseases, and found inhabiting the intestinal tract, are more or less constantly present in the human mouth, and that the pathway in many general infections is no doubt *via* the oral cavity. A wound made in the human mouth is necessarily an infected wound. In the vast majority of cases the body exercises its protective function in a phagocytosis,² which disposes of invading bacteria. In other cases it is beyond question that this protective provision fails and infection occurs.

THE EXANTHEMATA.

Certain acute specific diseases, such as rubeola, rotheln, scarlatina, varicella, and variola, are accompanied by skin eruptions generally distributed over the body, and which represent an infective dermatitis; indeed, the eruptions of many of these diseases are contagious to other individuals. Syphilis, a chronic specific disease, produces similar effects.

The special interest lying in the exanthemata is that occurring during the development of the teeth; the latter are often profoundly affected so that malformations, sometimes serious in character, occur in the teeth. It is to be recalled that teeth are dermoid structures, certainly in so far as the enamel is concerned. (See Malformations of the Teeth.) Again, after or during exanthematous diseases, notably scarlet fever, the oral tissues are much debilitated, so that abscesses about the teeth may produce much necrotic tissue.

¹ Micro-organisms of the Human Mouth.

² Hugenschmidt, Dental Cosmos, 1896.

SECTION II.

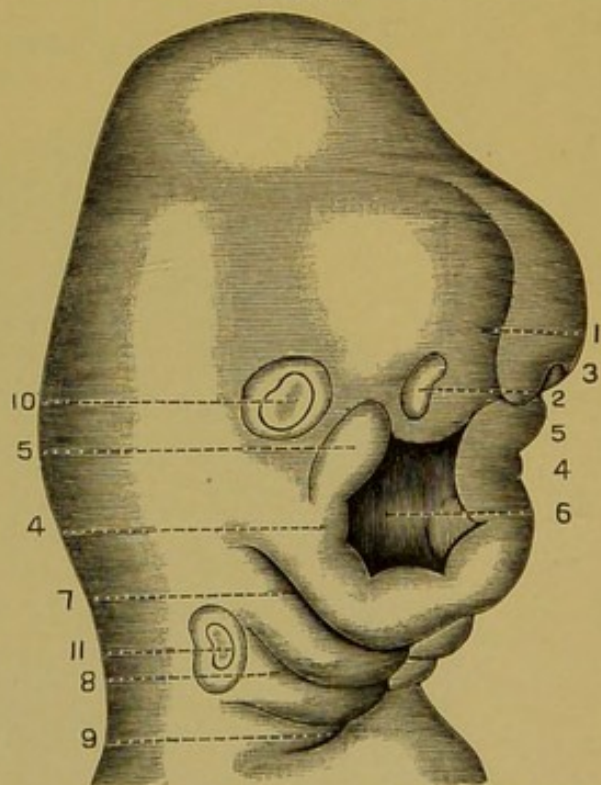
EMBRYOLOGY, ANATOMY, AND HISTOLOGY.

CHAPTER VI.

THE DEVELOPMENT, ANATOMY, AND HISTOLOGY OF THE JAWS AND TEETH.

As malformations of the parts about the mouth and of the teeth are dependent upon defective development of the same, it is incumbent that certain facts concerning their embryology should be stated. In like manner, as the processes of pathology are modified by the peculiar anatomy of the teeth and associated parts, it is necessary that a previous knowledge of these be acquired before the special dental pathology can be comprehended. The embryology of the mouth begins at a very early period—before the twelfth day the future mouth may be located (His, Fig. 71). The mouth and nasal cavity are circumscribed by parts which are developed by outgrowths from the head fold of the foetus. Those structures immediately concerned are the lateral tubercles arising from the frontal prominence (Fig. 71), which grow downward and fuse, forming the nose, the nasal septum, the intermaxillary bones, and anterior portion of the upper lip (Figs. 72 and 73). From the sides of the head fold at the level of the

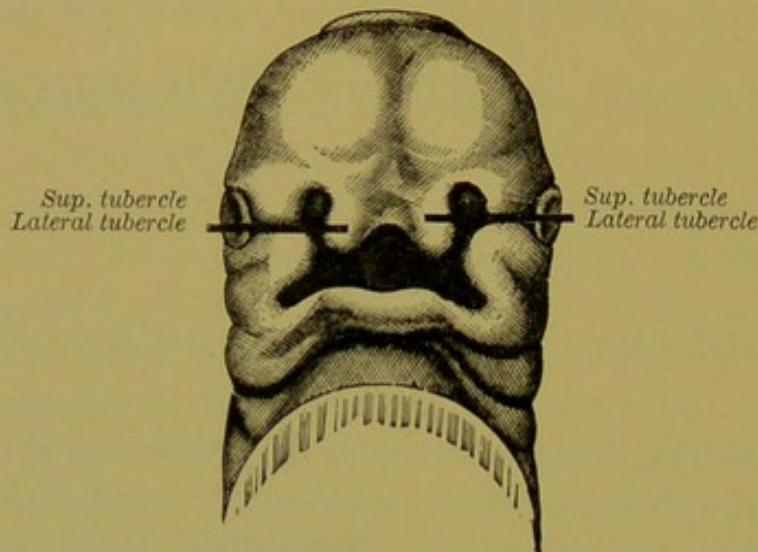
FIG. 70



Face of an embryo of twenty-five to twenty-eight days (magnified fifteen times): 1, frontal prominence; 2, 3, right and left olfactory fossae; 4, inferior maxillary tubercles, united in the middle line; 5, superior maxillary tubercles; 6, mouth or fauces; 7, second pharyngeal arch; 8, third; 9, fourth; 10, primitive ocular vesicle; 11, primitive auditory vesicle. (Gray.)

mouth and neck appear certain lateral protuberances, or pharyngeal arches. The first pharyngeal arches (Fig. 70, 4) divide into (1) the superior maxillary tubercles (Fig. 70, 5) and (2) the inferior maxillary

FIG. 71.



Head of an early human embryo, showing the disposition of the facial fissures and the superior and lateral tubercles. (His.)

FIG. 72.

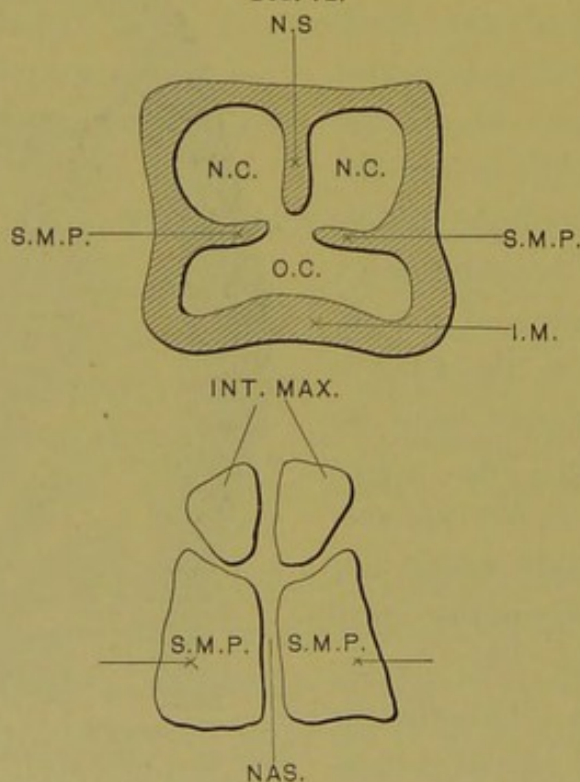
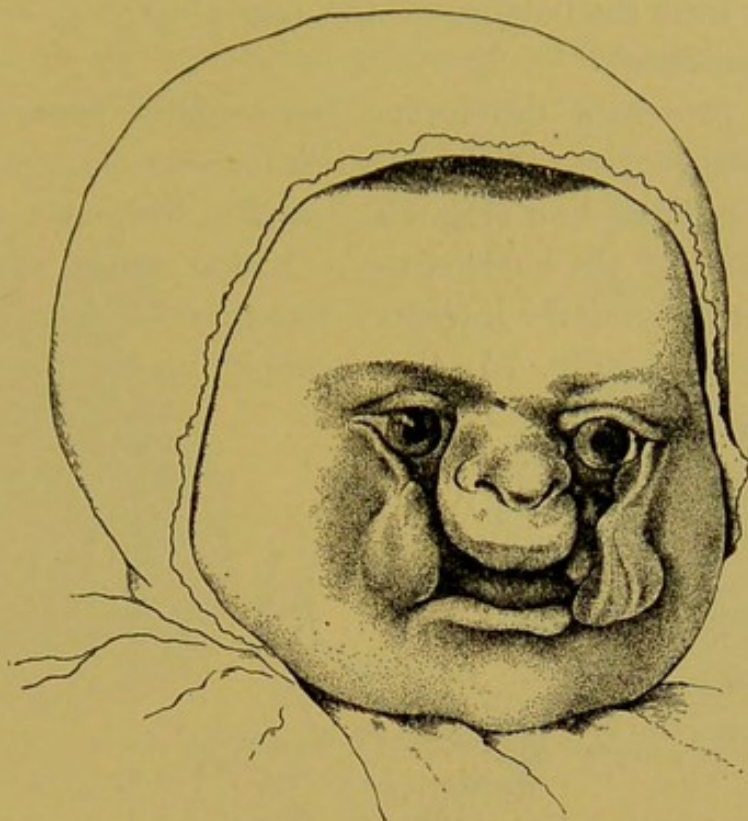

Diagram illustrating scheme of union of the processes. *N.S.*, lateral tubercles forming internal maxillary bones, *INT. MAX.*, and nasal septum. *S.M.P.*, superior maxillary processes forming palatal processes of superior maxillæ, *S.M.P.* *N.C.*, nasal cavity. *O.C.*, oral cavity. *I.M.*, inferior maxillary processes united.

tubercles (Fig. 70, 4, shown just beneath the oral cavity and united in the median line).

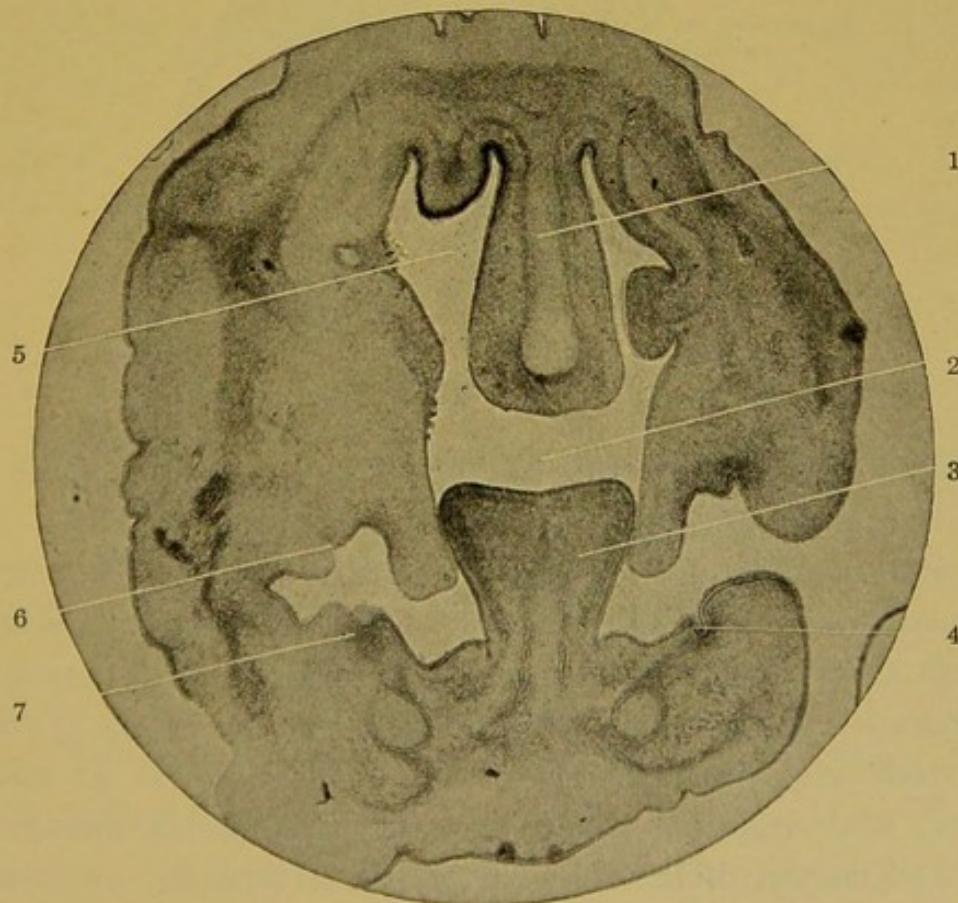
The superior maxillary tubercles develop the palate bones, the

FIG. 73.



Complete bilateral fissures (coloboma) of face. (Guersant.)

FIG. 74.

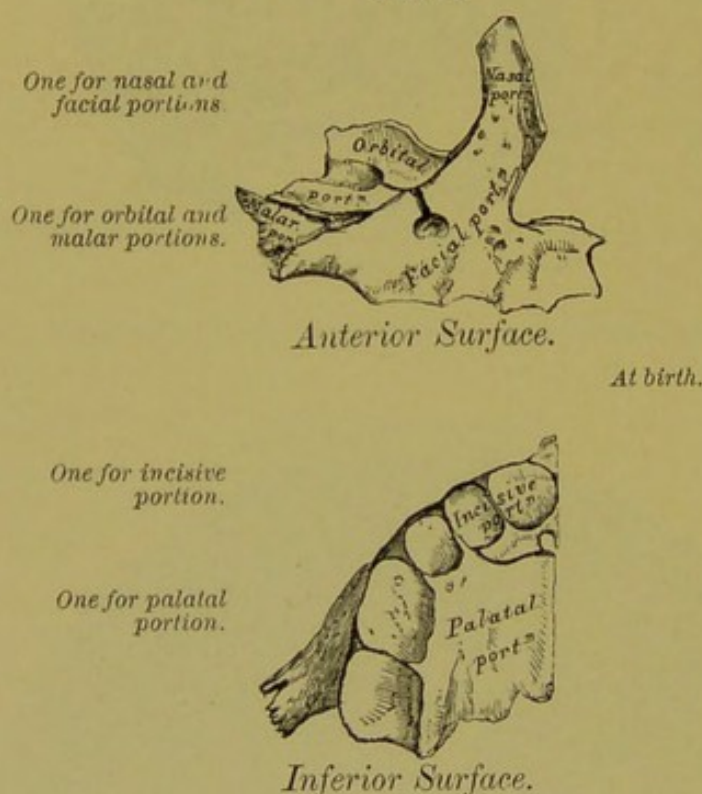


Vertical transverse section through head of human embryo, about the tenth week: 1, nasa cartilage; 2, buccal cavity; 3, tongue; 4, dental ridge, lower jaw; 5, nasal cavity; 6, denta ridge, upper jaw; 7, dental ridge, lower jaw. $\times 30$. (Bromell.)

superior maxillæ, and, with the aid of the lateral tubercles, the malar bones. They form the balance of the upper lip (Fig. 73). The arch itself forms the cheek.

Secondary processes developing horizontally toward each other form the palatal portions of the superior maxillæ and palate bones and unite at the median line (Fig. 72, *S.M.P.*), forming the vault of the mouth and floor of the nasal cavity. Union occurs with the lateral processes later forming the intermaxillary bones and bearing the germs of the incisor teeth (Fig. 75), thus completing the formation of the upper jaw and lip.

FIG. 75.



Development of the superior maxillary bone, by four centres.

The inferior maxillary tubercles grow forward and unite at the median line, developing the inferior jaw and lip.

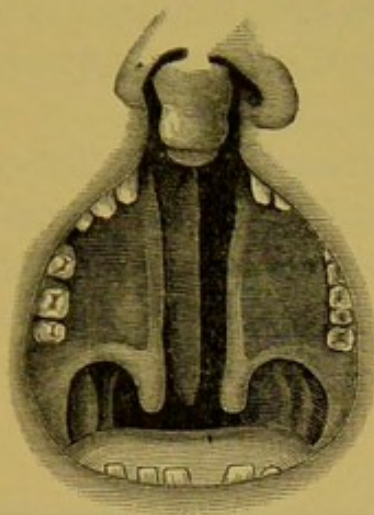
The structures of the floor of the mouth and neighboring structures are formed from the second, third, and fourth pharyngeal arches and a tubercle arising near the first pharyngeal arch. The fusions of the lateral portions of the upper maxillæ begin first anteriorly at about the eighth week and progress posteriorly until complete at about the eleventh. Malformations due to non-union, therefore, date from this period, and consist of the following typical varieties:

1. Non-union of lip and of maxilla and intermaxillary bone on one side (harelip, Figs. 76 and 80).

2. Non-union of lip and intermaxillary bone on both sides (double harelip, Fig. 73).

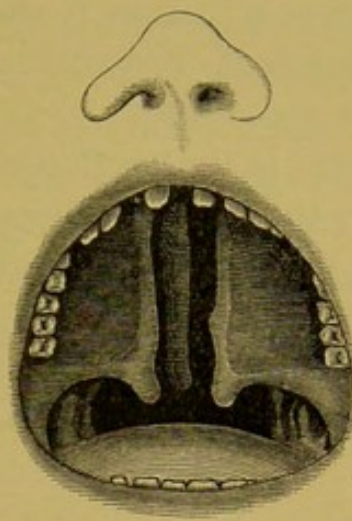
3. Non-union of all horizontal processes in the median line (cleft palate, Figs. 76 and 77).

FIG. 76.



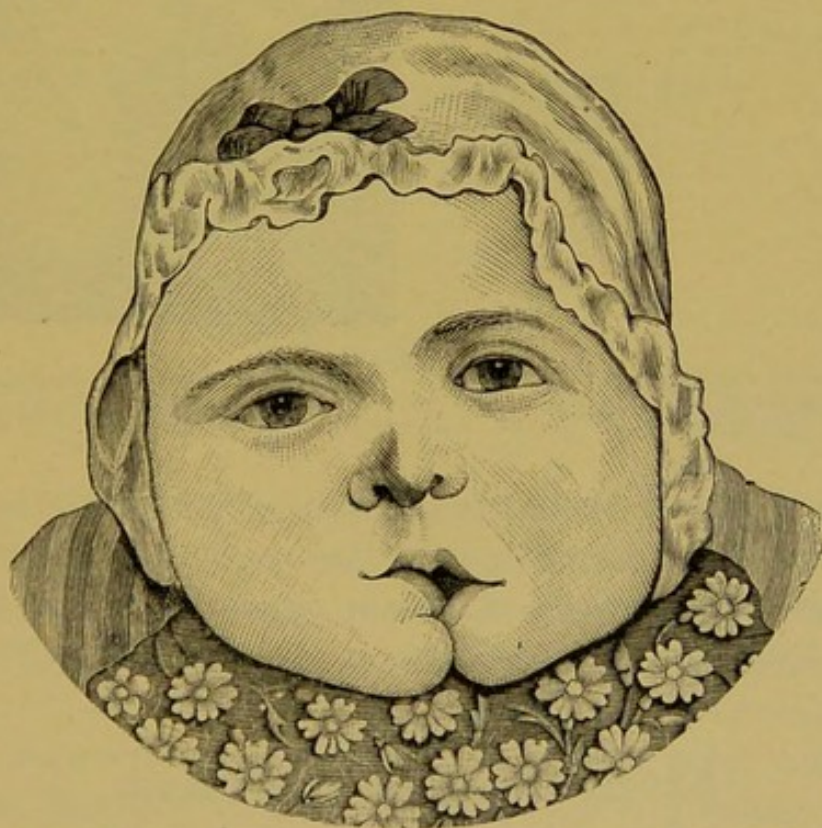Cleft of hard and soft palate: rudimentary intermaxillary bone placed in advance of lips. (Mason.)

FIG. 77.



Cleft of hard and soft palate. (Mason.)

FIG. 78.



Median fissure of the lower lip and chin. (Marshall, after Wöfler.)

4. Non-union of halves of soft palate (cleft velum).

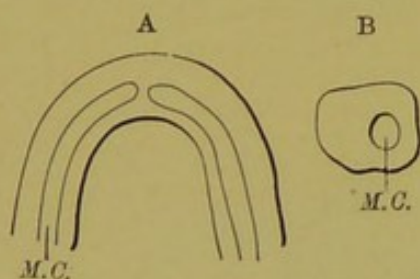
5. Non-union of halves of the uvula (bifid or cleft uvula).
Combinations of cleft velum and cleft palate or of cleft palate and single or double harelip may exist.

The failure of the inferior maxillary tubercles to unite is rare, but is occasionally seen (Fig. 78). The inferior maxillary tubercles develop a transitory support to the lower jaw known as Meckel's cartilage. The cartilages of the right and left side do not fuse together at the future symphysis (Hertwig). (Fig. 79.)

It acts as a support to the fetal jaw, undergoes atrophy at about the sixth month of gestation, and at birth but few fragments are found near the symphysis.

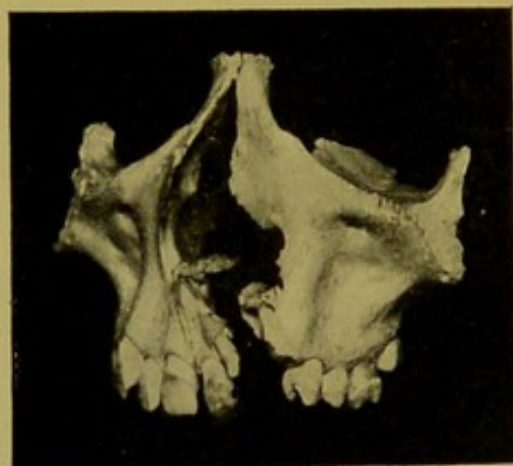
The end of the cartilage in the base of the inferior maxillary process becomes the future malleus (one of the bones of the middle ear). The portion of the cartilage running from the malleus to the formed bony lower jaw becomes transformed into the internal lateral ligament of the inferior maxilla (Hertwig).

FIG. 79.



Showing Meckel's cartilage (M.C.) in longitudinal and transverse section.

FIG. 80.



Osteology of harelip. (Museum of the Philadelphia Dental College.)

It is to be remembered that these processes are formed by the mesoblastic layer of the blastoderm and are covered by epithelial tissue springing from the epiblast. Both are concerned in the formation of the teeth. Epithelium is reflected over the face and oral cavity.

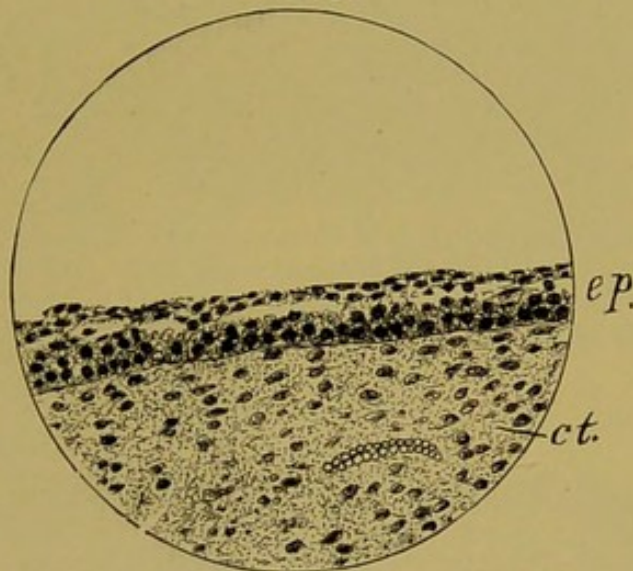
DEVELOPMENT OF THE TEETH.

The first evidences of tooth formation are seen at about the sixth week of gestation, at a period when the superior and inferior maxillary processes are but ill-defined masses of mesoblastic tissue surrounded on all sides by epiblastic tissue. Before the union of the processes which are to separate the nasal from the oral cavity and which form

the future palate is complete, the first evidences of tooth formation may be observed. It is to be borne in mind that during the entire period of tooth formation other formative changes are in operation, out of which arise all of the parts associated with the teeth.

A transverse section of the jaws at this period (Fig. 74) exhibits the following features: The oral cavity is as yet not separated from the nasal cavity by the palatal processes of the superior maxillæ. The tongue is seen as a pear-shaped body attached to the lower jaw. Over the summit of the lower jaw and tongue is reflected the epithelium of the developing mucous membrane, which is continuous with that of the cheeks and upper jaw, etc. Over the outside of the fetal head is reflected the epithelium of the developing skin. These epithelial structures are derived from the epiblastic layer of the blastoderm.

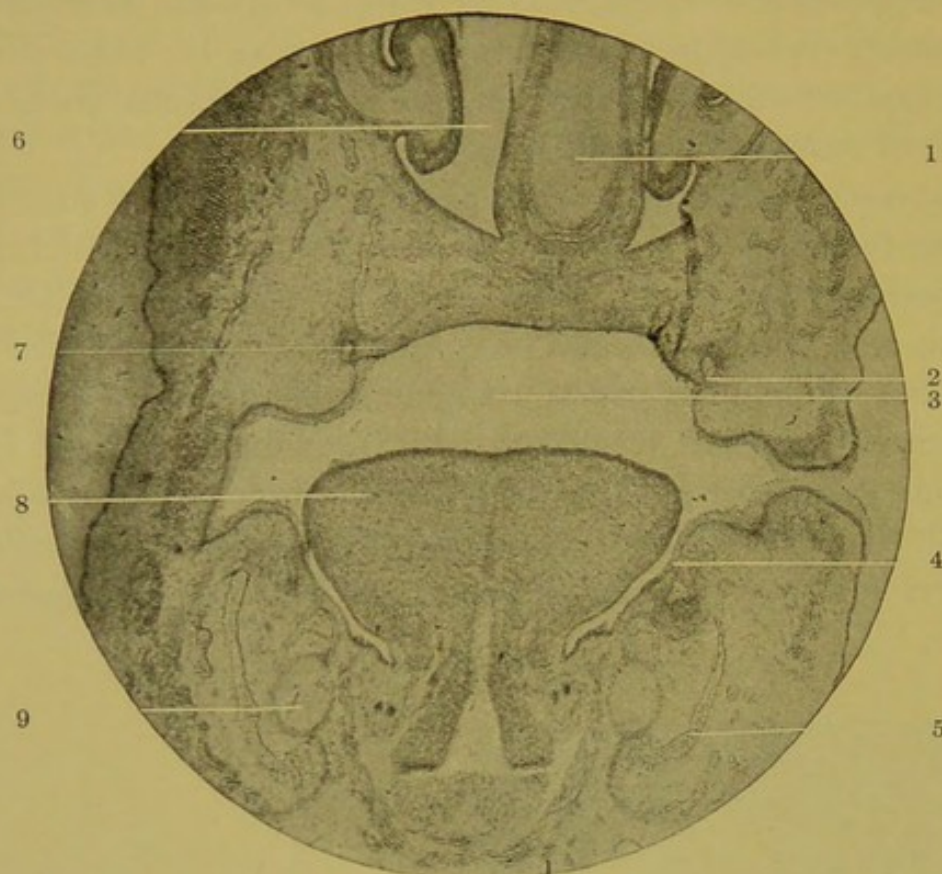
FIG. 81.



Porcine embryo: *ep*, epithelium, infant layer or stratum Malpighii; *ct*, embryonal connective tissue with large intercellular interspaces. $1\frac{1}{2}$ cm. \times 250. (Sudduth.)

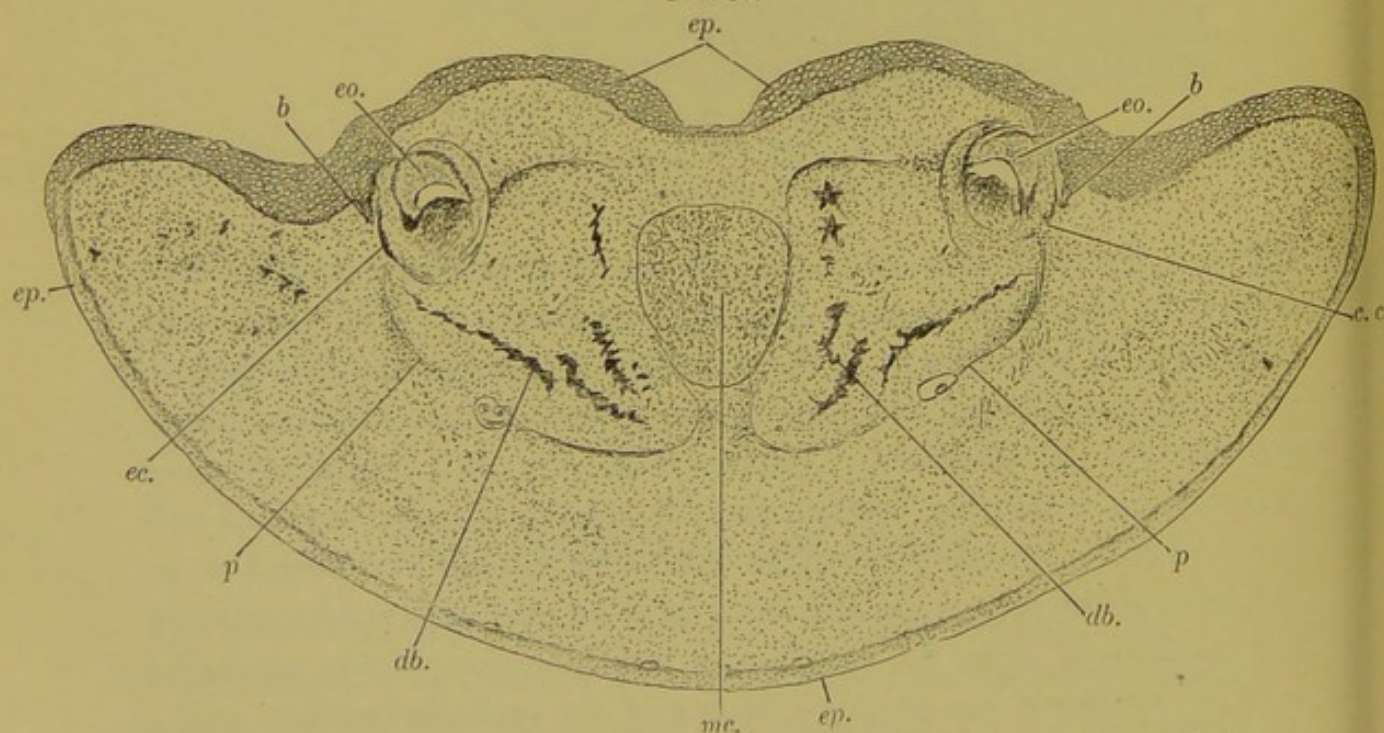
Between the epithelium of the mouth and that reflected over the face is seen at the sixth week a mass of indifferent or embryonic cells (Fig. 81). These arise from the mesoblastic layer of the blastoderm. Later in its substance are seen in the lower jaw two elliptical areas, the sections of Meckel's cartilage (Fig. 82, 9). Examined more minutely in transverse section there is seen at a point upward and outward from Meckel's cartilage and outward and downward from the sides of the tongue (in the lower jaw) on each side a thickening of the epithelium (Fig. 82, 4). Active multiplication of the epithelial cells at this point has caused a raising of the epithelial surface and a depression of the stratum Malpighii (Fig. 81, *ep*) into the mesoblastic tissue beneath (Fig. 83, *b*, and Fig. 85, *c*). This extends the entire length of the jaw (Fig. 84, *b*), and is most pronounced at the anterior

FIG. 82.



Vertical transverse section through head of human embryo, about twelfth week, showing the single buccal cavity transformed into the oral and nasal cavities: 1, cartilaginous septum of nose; 2, dental ridge; 3, oral cavity; 4, dental ridge; 5, anlage of lower jaw; 6, nasal cavity; 7, dental ridge; 8, tongue; 9, Meckel's cartilage. $\times 30$. (Bromell.) Compare with Fig. 74.

FIG. 83.

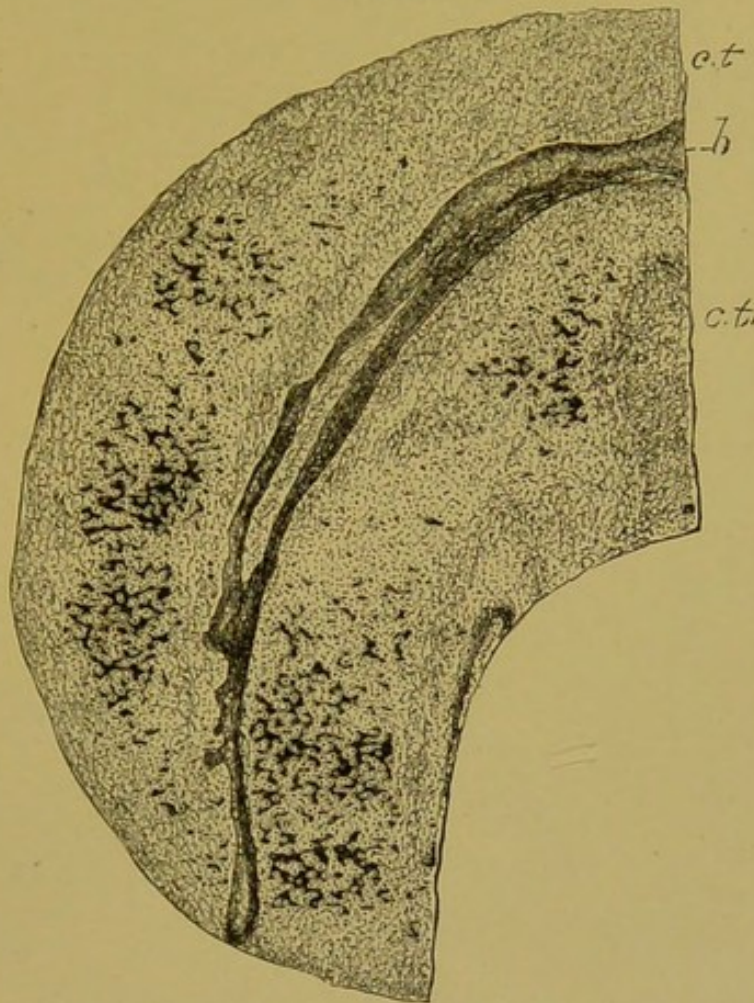

Vertical transverse section of jaw of porcine embryo, showing differentiation of periosteum: *p*, periosteum of either jaw; *ec.*, follicular wall, appearing as a continuation of the periosteum; *b*, band; *eo.*, enamel organs for premolars; *ep.*, epithelium; *db.*, developing bone; *mc.*, Meckel's cartilage. $5\frac{1}{2}$ cm. $\times 25$. (Sudduth.)

portion, thinning toward the posterior. The elevation is the dental ridge (Fig. 82, 4, 7). The depression was named by Goodsir the primitive dental groove, a name now obsolete. To the continuous horseshoe-shaped structure the name "band" has been applied (Fig. 84, *b*, and Fig. 85, *c*).

From the inner side of the band at regular intervals are given off in each jaw ten buds or dental cords, which are to form the enamel organs

FIG. 84.



Longitudinal transverse section of the inferior maxilla of a porcine embryo: *b*, band, solid at anterior portion, but divided posteriorly into band and lamina. 3 cm. \times 40. (Sudduth.)

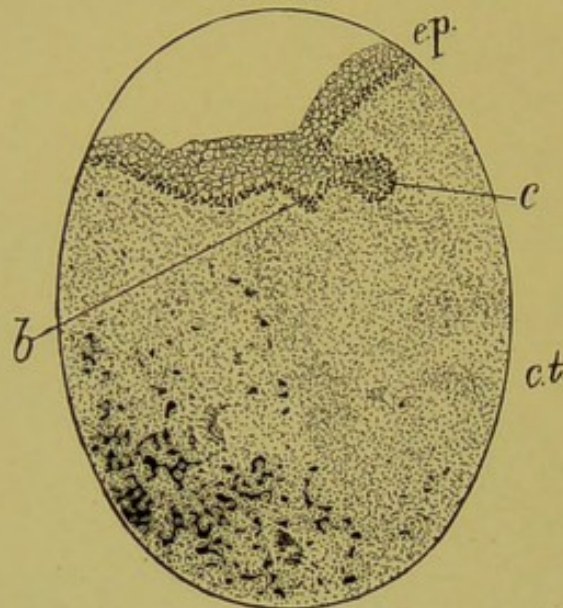
of the twenty deciduous teeth. The order of formation is: 1. Central incisor. 2. Lateral. 3. First molar. 4. Second molar. 5. Cuspid (Magitot). The cords grow down (down means here away from the epithelium, whether up or down) into the mesoblastic tissue.

A small sac is formed, somewhat constricted at the neck, and containing in its interior epithelial cells. This is the enamel organ in its first or saccular stage of development¹ (Fig. 86). Up to the ninth week epithelial cells are pushed into the interior of the enamel organ

¹ Andrews, American Text-book of Operative Dentistry.

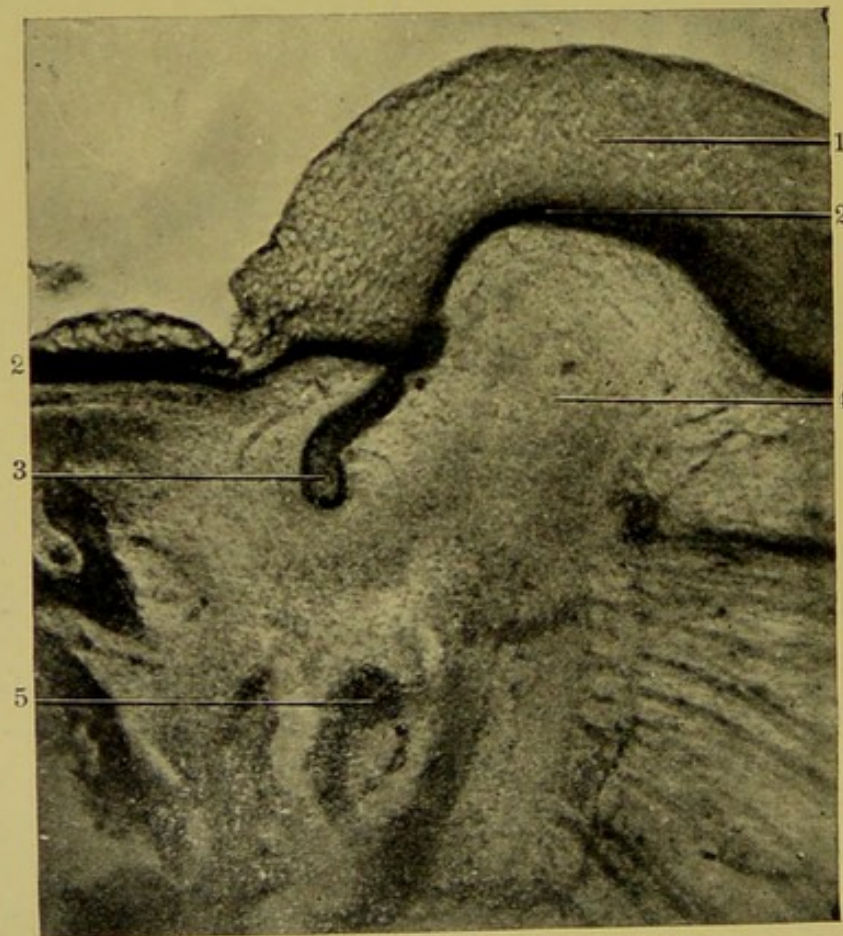by multiplication from the inner sides of its walls, which are composed of the rete Malpighii. An interiorward growth of cells corresponds with an upward growth upon the mucous membrane.

FIG. 85.



Vertical section through band from jaw of porcine embryo: *ep*, epithelium; *b*, band; *c*, cord; *ct*, connective tissue. $3\frac{1}{2}$ cm. \times 60. (Sudduth.)

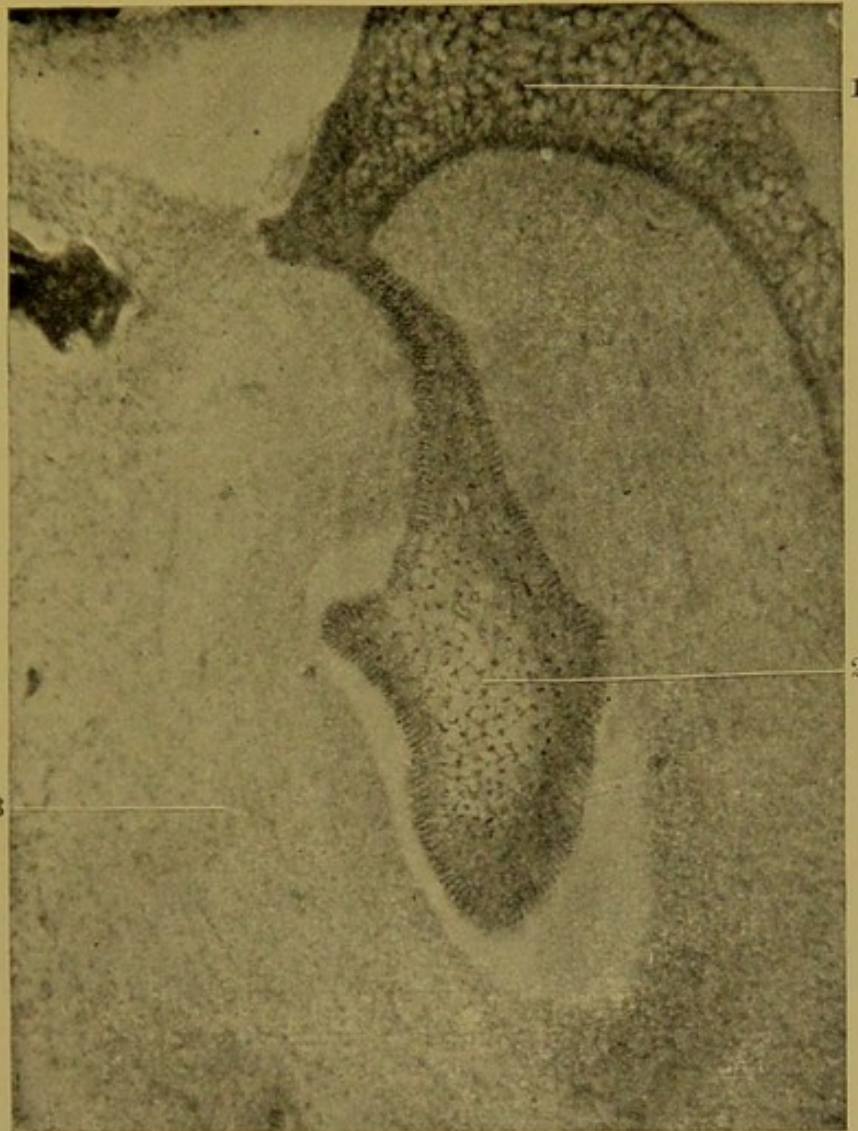
FIG. 86.



Section of jaw, embryo of pig, showing growth of enamel organ: 1, epithelium; 2, stratum Malpighii; 3, first stage in growth of enamel organ of temporary tooth; 4, embryonic connective tissue; 5, developing bone of jaw. (Andrews.)

By this means the enamel organ is enlarged at its lowest portion, while it coincidentally remains constricted at its attachment to the mucous membrane (Fig. 87). The enamel organ thus assumes a shape likened to a Florentine flask. This is the second stage in its saccular development and takes place from the ninth to the twelfth week (Magitot). At the same time the mesoblastic tissue condenses about

FIG. 87.



Section of jaw, embryo of pig, showing growth of enamel organ: 1, epithelium; 2, second stage in growth of enamel organ; 3, embryonic connective tissue. (Andrews.)

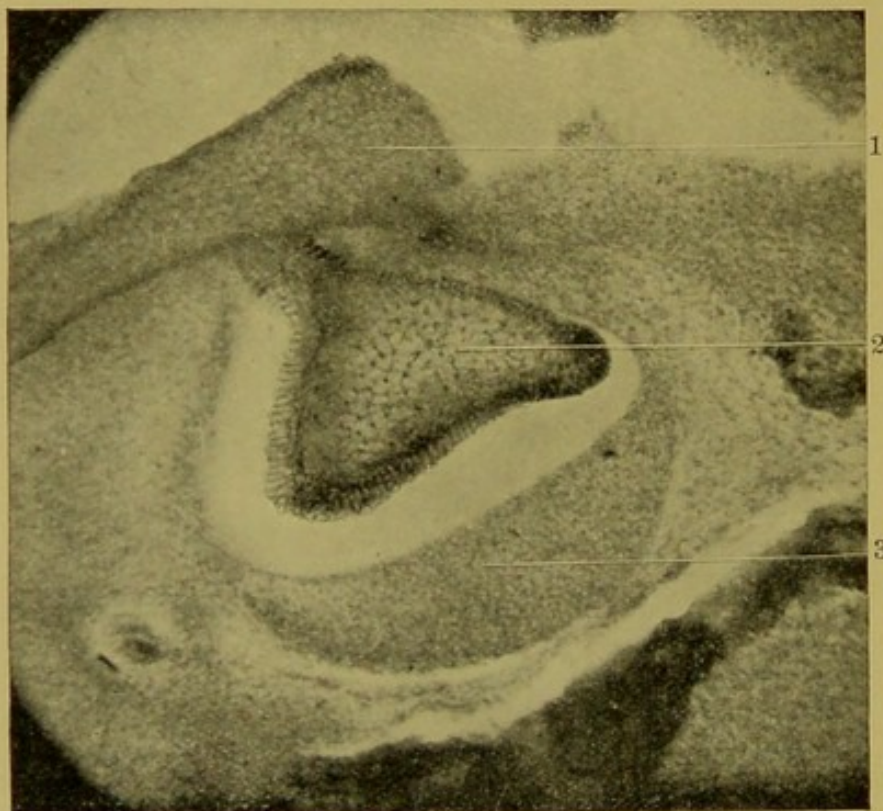
the lower part of the enamel organ, begins to flatten it (Fig. 88), and later invaginates it. The mesoblastic tissue directly beneath thus becomes a papilla, over which the enamel organ adapts itself.

From the twelfth to the sixteenth week the papilla enlarges and further invaginates the enamel organ, which is reflected over it (Fig. 89, *sr* and *dp*), and at the same time the mesoblastic cells surrounding both condense into a fibrous structure (the follicular wall), which

entirely surrounds the papilla and enamel organ, and is continuous with a developing fibrous structure reflected to form a periosteum for the outer surface of the bone of the jaw (Fig. 89, *c*, *ct*, and *p*). The follicular wall and its enclosures constitute the dental follicle. This is the follicular stage of tooth development. At points between the follicular wall and periosteum bone develops in islets, which later coalesce. This is the interstitial bone formation of Sudduth.

At the sixteenth week the cord of the enamel organ of the temporary tooth gives off from its side an epithelial bud and then parts from the

FIG. 88.



Section of jaw, embryo of pig, showing growth of enamel organ and zone of dentine-forming tissue: 1, epithelium; 2, enamel organ; 3, zone of dentine-forming tissue. (Andrews.¹)

enamel organ. This bud is to later develop the enamel organ of the permanent tooth (Fig. 89, *cp*).

From the twelfth to the sixteenth week internal changes occur in the enamel organ, dentinal papilla, and follicular wall, preparatory to their respective functions of enamel, dentine, and cementum deposition.

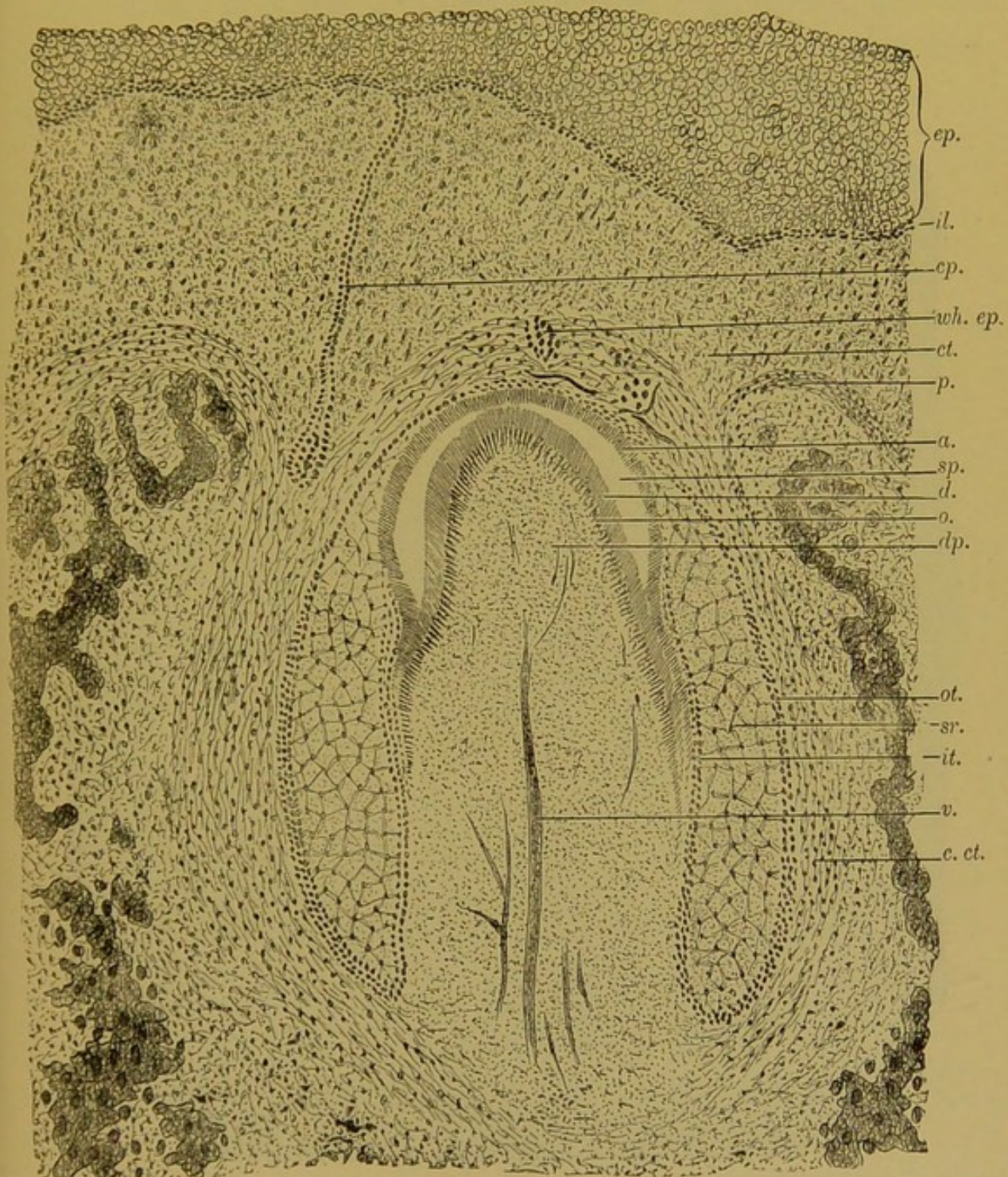
The developing enamel organ consists of an inner and outer Malpighian layer of cells with epithelial cells enclosed.

The nucleated cells of the Malpighian layer lying next to the

¹ American Text-book of Operative Dentistry.

papilla become columnar from mutual pressure and development, and are, apparently, defined at their ends by an inner and outer membrane (Fig. 90, *d*, *c*) and are now called ameloblasts (Fig. 90, *e*).

FIG. 89.

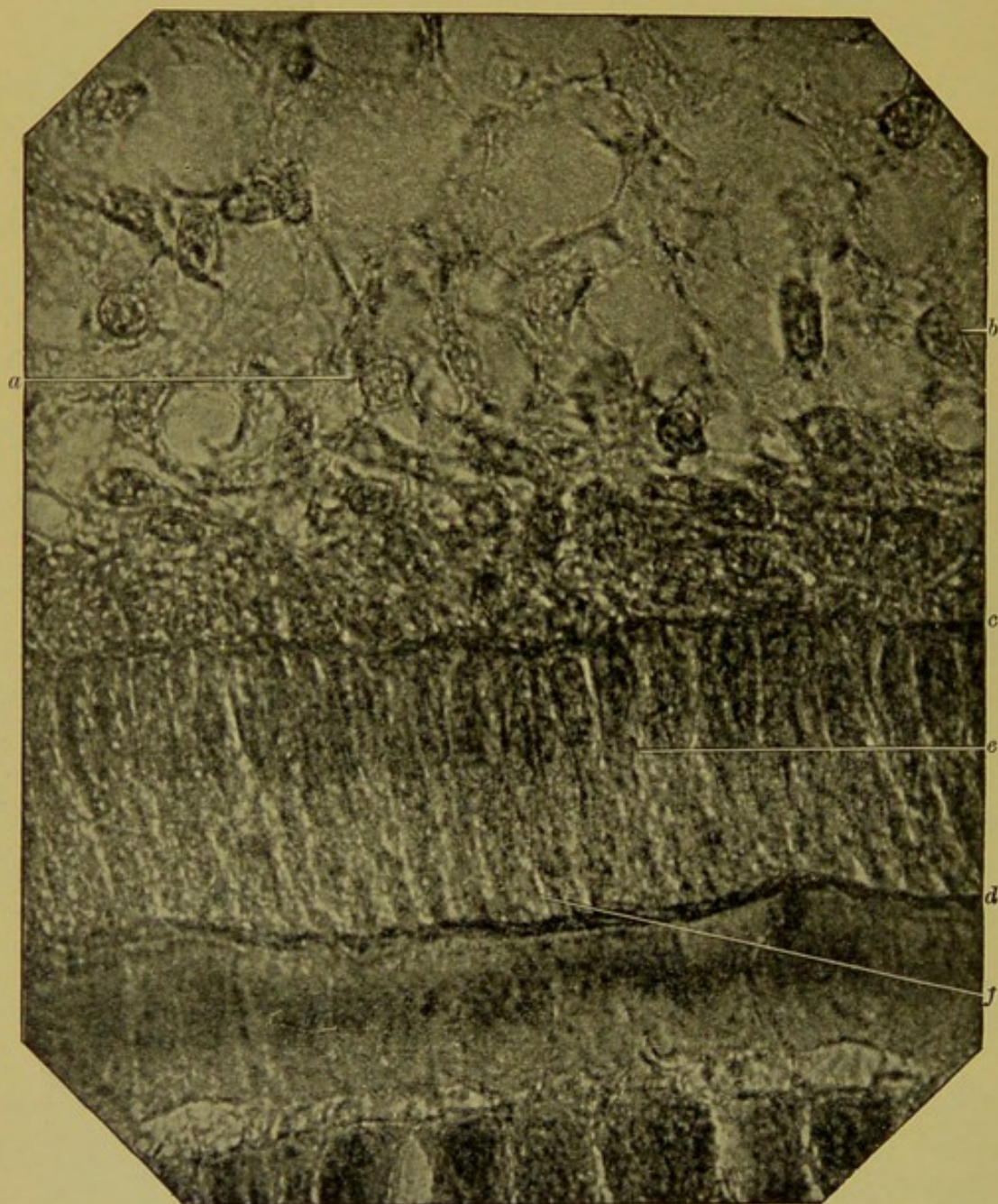


Vertical transverse section of jaw of porcine embryo, injected: *ep*, epithelium, with (*il*) infant layer; *a*, layer of ameloblasts; *o*, layer of odontoblasts; *cp*, cord for permanent tooth; *ot*, outer tunic; *it*, inner tunic; *sr*, stellate reticulum; *wh. ep.*, whorls of epithelium formed from outer tunic and stellate reticulum; *d*, dentine; *dp*, dentinal pulp; *v*, bloodvessels of pulp; *ct*, connective tissue; *c. ct.*, follicular wall; *p*, periosteum; *sp*, space. 10 cm. \times 60. (Sudduth.)

Their function is the deposition of enamel. Those epithelial cells lying next to them (interiorly) in the enamel organ become developed into a layer known as the stratum intermedium (Fig. 91, *b*), which

Williams has shown to have later in the rat a papilla-like structure and to stand in nutritive relation to the ameloblasts (Fig. 92). In the centre of the enamel organ lie nucleated cells made polygonal by mutual pressure. These cells constitute what is known as the stellate retic-

FIG. 90.



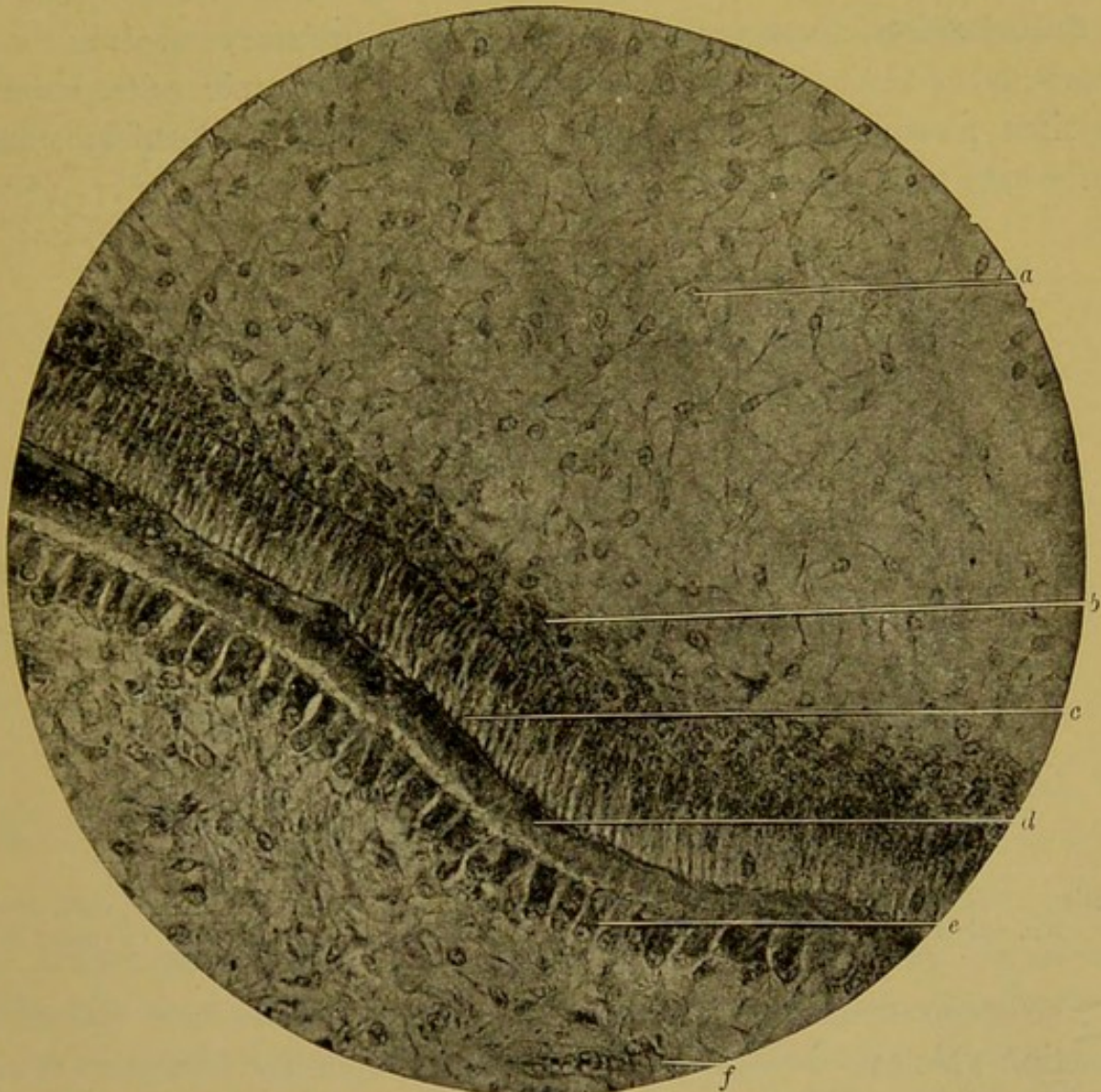
Section of developing tooth of an embryo calf: *a, b*, nuclei of reticulum of enamel organ, showing spongy character; *c*, outer ameloblastic membrane; *d*, inner ameloblastic membrane; *e, f*, enamel globules faintly showing nuclear network. $\times 1000$. (Williams.)

ulum (Fig. 89, *sr*; Fig. 90, *b*), and have been shown by Sudduth to disengage carbon dioxide when a weak hydrochloric acid is allowed to infiltrate beneath the cover-glass, thus showing the presence of calcium salts. Their function is supposed to be the fabrication of the

pabulum for the first deposition of enamel. They disappear before the entire thickness of the enamel is deposited.

Within the papilla changes also occur. Upon the surface next the enamel organ appear nucleated elongated cells called odontoblasts, the function of which is to deposit dentine (Fig. 89, *d*; Fig. 91, *e*). Connective-tissue cells, nerves, and bloodvessels also develop (Fig. 89, *v*; Fig. 91, *f*).

FIG. 91.



Section of developing tooth of an embryo calf: *a*, stellate reticulum of enamel organ; *b*, stratum intermedium; *c*, ameloblasts; *d*, dentine; *e*, odontoblasts; *f*, bloodvessel—corpuscles *in situ*. $\times 275$. (Williams.)


The follicular wall also develops and contains osteoblasts and other structures peculiar to itself, to be described when treating of the pericementum, which the follicular wall later practically becomes. Its function in tooth development is to deposit cementum, which, however, does not occur until the crown of the tooth is formed. While the structures which are to form the hard tissues of the teeth are in process of development there appear at different points in the mesoblastic

tissue, situated between the follicular wall and the periosteal fibres, certain cells about which calcification occurs. It is probable that these cells deposit the bone about pre-existing fibres. The calcification begins at what are termed islets which later coalesce.

With an understanding of the development of these three structures and of the formation of bone in islets, the student is prepared to grasp the facts connected with the development of the hard and soft tissues of the teeth.

Calcification. Analyses of the enamel, dentine, and cementum show them to be composed of a combination of inorganic salts, chiefly calcium phosphate and carbonate and magnesium phosphate, and carbonate with an organic basis.

FIG. 92.



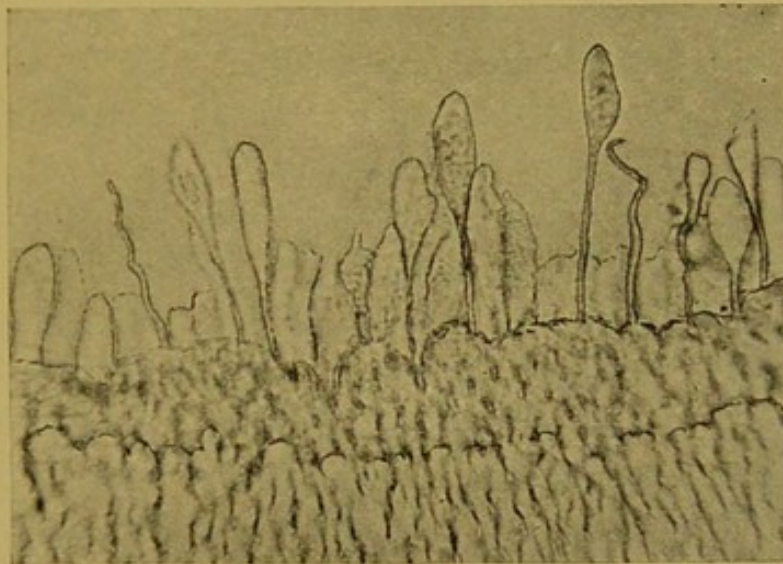
Section of incisor of rat: *a*, capillary loops torn out of secreting papillæ; *b*, secreting papillæ after removal of capillary loops; *c*, ameloblasts; *d*, enamel; *e*, dentine. $\times 80$. (Williams.)

The experiments of Harting, Rainey, and Ord have shown a reaction which no doubt has a direct bearing upon the formation of all calcified tissues. If to an albuminous solution a solution of a calcium salt be added, the calcium enters into chemical combination with the albumin, forming a substance indefinitely known as albuminate of calcium, and called by its discoverer calcoglobulin. If calcium carbonate be formed in a solution of albumin, the above combination occurs, making definite structural forms, minute laminated spheres, which are called calcospherites; these spheres coalesce and form laminated masses—*i. e.*, form in layers. When exposed to the action of dilute acids these spherites are more resistant than the crystallized salts; moreover, after the action of the acid the form of the spherite

remains. This chemical fact, the union of crystalloidal with colloidal substances, is, no doubt, of wide significance in general and special pathology, for it is extremely probable that the formation of all pathological concretions is an expression of some such reaction. The evidence is strong that calcium albuminate is the basis of all of the calcic tissues; but precisely where its formation occurs in enamel formation is unknown; presumably, it occurs or is completed in the enamel-forming cells, the ameloblasts.

It is to be remembered that the materials composing bone, enamel, dentine, and cementum, while of one family, differ as to the proportions of their constituents.

FIG. 93.



Section of growing tooth of calf at birth, showing fibrils, fibril cells, and odontoblasts; also the layer of calcoglobulin and the forming dentine. (Andrews.)

Dentinification. The first deposition of calcific material occurs with the dentine at about the seventeenth or eighteenth week (Magitot).

The odontoblasts upon the surface of the papilla are apparently of two kinds: (1) fibril cells which have the function of developing tubules, and (2) other odontoblasts apparently concerned in the development of intertubular substance.

The deposition of dentine has been variously described. Mummery has demonstrated that between the odontoblasts appears a delicate network of connective-tissue fibres derived from the connective-tissue cells of the pulp, which are in close relation to the odontoblasts. These fibres are surrounded by a protoplasmic fluid. Into the fluid the odontoblasts secrete calcospherites, small globular bodies capable of further calcification or of hardening *in situ*. These are pressed closely

against each other, largely obliterating the connective-tissue matrix. Andrews¹ terms this layer of unhardened calcospherites calcoglobulin (Fig. 93). This either hardens or is further calcified into formed dentine (Fig. 92, *e*). This process must also occur about the protoplasmic prolongations from the fibril cells which are left in the dentinal tubules as fibrillæ. As these fibrillæ have later the power under irritation of adding substance to the inner wall of the tubule (tubular calcification), it is probable that they are the real formers of the tubule wall. Additional evidence of the mode of deposition is afforded by observation of the points of arrested development in dentine—*i. e.*, interglobular spaces. These contain a partially calcified matrix material, and upon the borders of the defects are seen globular masses. The tubules run as independent formations through the matrix material. (See Interglobular Spaces.)

The first deposition of dentine occurs against the inner ameloblastic membrane and represents the future external portion of the dentine of the crown. The deposition occurs first at a point beneath the location of the future cusp or cusps, which are supplied by the enamel organ. The dentine of the root is formed first against the inner side of the follicular wall, which later supplies the cementum.

The first layer deposited, the odontoblasts and fibril cells recede, the latter leaving a protoplasmic prolongation in the dentinal tubule.

After an appreciable portion of the crown is formed the papilla is called the pulp, and continues to form dentine and to recede from the neighborhood of the ameloblasts, until the dentine of the root is formed (to be later described), when it practically ceases its formative function, unless pathologically excited, and persists as the dental pulp. In this latter stage its normal function is nutritive rather than formative (Figs. 96, 98, and 100).

Amelification. Shortly after the deposition of the first layers of dentine the ameloblasts deposit enamel upon the dentine.

Williams has shown that bubbles of carbon dioxide are developed simultaneously in the cells of the stellate reticulum, the stratum intermedium, and the ameloblasts, when a mineral acid is applied.

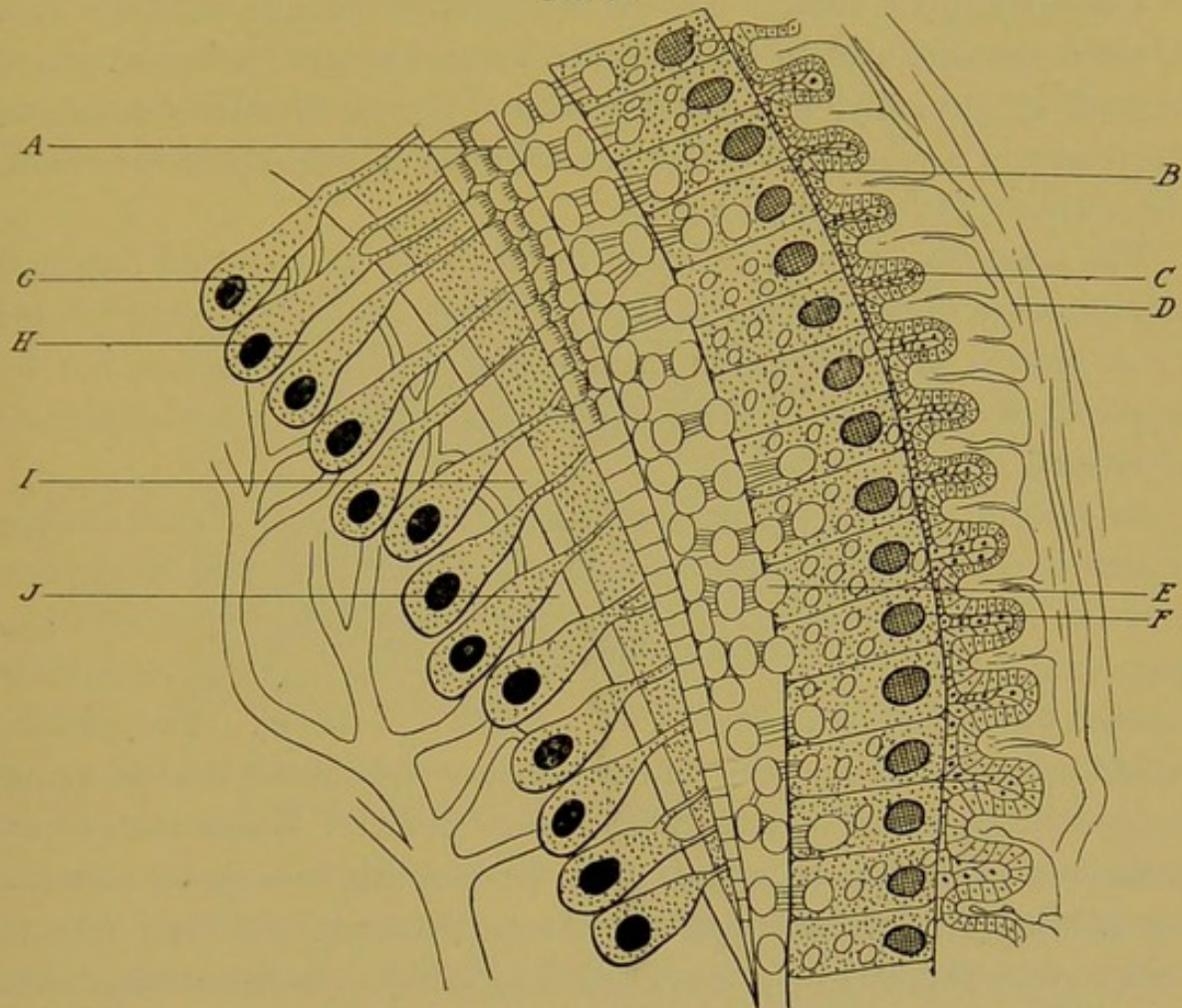
The inference, therefore, is that the stellate cells give up pabulum to the cells of the stratum intermedium, which elaborate it and pass it to the ameloblasts.

Within the ameloblasts are to be seen two classes of globular bodies which stain differently. The first class consists of one or more bodies

¹ American Text-book of Operative Dentistry.

of like size, which are only found at points between the nucleus and the end of the cell proximating the dentine (the proximal end), and are connected by strings of protoplasmic material. These are the enamel globules (calcospherites) inferred by Williams to arise by mitosis of the nucleus of the ameloblasts (Fig. 94, *E*). The second class of bodies are glistening droplets of various sizes, which coalesce, becoming larger as they approach the proximal end of the cell.

FIG. 94.



Mode of enamel deposition: *A*, formed enamel; *B*, ameloblasts; *C*, secreting papillae of stratum intermedium; *D*, bloodvessels in external fibrous coat and to secreting papillae; *E*, enamel globules with connecting plasmic strings; *F*, nuclei of ameloblasts; *G*, blood supply of odontoblastic layer; *H*, odontoblasts; *I*, unformed dentine; *J*, formed dentine. Semidiagrammatic. (Williams.)

Williams has found these droplets also in the stratum intermedium. This substance he named the interprismatic cement substance. The droplets and the globules are the materials from which the ameloblast constructs the enamel rod under its superintendence, and are both calcoglobulin. They differ, however, in that later the globules have a crystalline structure, while the cement substance is amorphous. The ameloblast extrudes first against the previously formed dentine a droplet of interprismatic cement substance, and into this it also deposits an

enamel globule; as these two substances are not in a hard condition when deposited, in order for it to become the mature enamel, some change must take place. Noyes¹ assumes the position that the ameloblasts remove any organic matter present in the calcoglobulin (globules and cement substance), depositing calcific matter in place of it.

It would be reasonable to infer this, as enamel contains little if any organic matter.

After the first layer of enamel is deposited more cement substance is extruded and a second globule is deposited directly atop the first. Mutual pressure causes the globules to assume an hexagonal shape viewed transversely, and also reduces the interprismatic cement substance to a minimum. The record of this process is to be seen in the sections of finished enamel.

The ameloblasts lie at an angle to the developing enamel rods and also preserve their integrity to the end; hence the rods are not formed by a process of calcification of the ameloblasts themselves, but by a process of deposition of calcified materials under the superintendence of enamel cells.

As soon as the first layers of enamel have formed, a notable change is seen to occur in the enamel organ; the stellate reticulum disappears over the forming enamel. The calcic material stored in its cells has been exhausted in forming the first layer of enamel; the succeeding enamel has a different source of formative material. The stellate reticulum atrophies and the outer boundary wall of the enamel organ comes into apposition with the stratum intermedium. Williams observed in the enamel organs of rodents (Fig. 92) that the cells of the stratum intermedium become arranged over loops of vessels from the follicular wall, so that papillæ are formed. He infers that a similar arrangement occurs in the enamel organ of man; and that the function of the papillary structure is the selection from the blood plasma of material to be passed into the ameloblasts and out of which enamel is formed.

Enamel and dentine formation proceed during the rest of fetal life and in advance upon the tips of the papilla or pulp, gradually extending down its sides. At birth the process is not complete, the crown dentine being but two-thirds formed and the enamel lacking the lustre of mature enamel.

Constant² points out that the proper lustre is not imparted before

¹ American Text-book of Operative Dentistry.

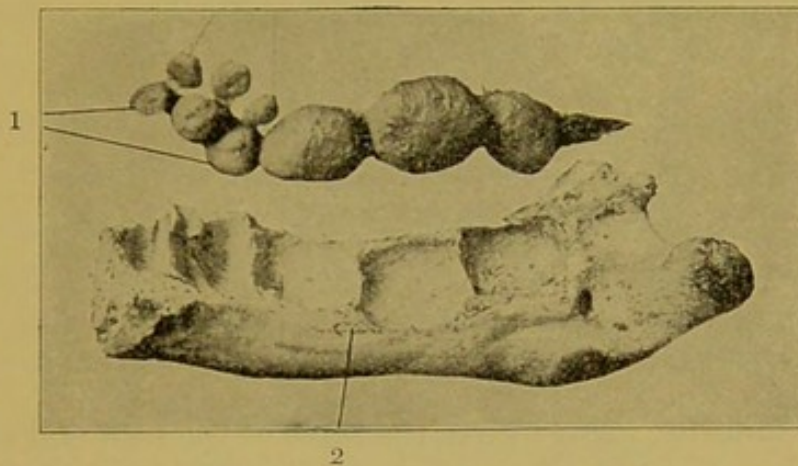
² International Dental Journal, June, 1903.

resorption of the roof of the crypt takes place—perhaps at five months after birth for the central incisors.

Upon the surface of the erupted tooth is found, after special treatment with dilute acids, a delicate membrane said by Kolliker to be $\frac{1}{20000}$ inch in thickness, known as Nasmyth's membrane. It is considered by Andrews¹ to be the remains of the ameloblasts which have undergone partial calcification.

Hopewell-Smith² dissents strongly from this view, and apparently demonstrates his position that it is an epithelial remnant of the enamel organ which may have a diameter of $\frac{1}{500}$ inch, and which consists of a translucent layer nearest the enamel, upon which is superimposed a layer containing epithelial cells.

FIG. 95.



1, tooth sacs of deciduous teeth turned out of crypts; 2, lingual surface of mandible. The interior of the crypts and septa shown. (Bromell.)

OSSIFICATION. During fetal life the bone develops in islets between the follicular walls and the periosteum. These islets coalesce for mutual support. Between the several follicular walls and over the outer edge of the dental follicle bone also develops, so that the jaw may be considered as a gutter of bone divided into cells by septa of bone and roofed over by the follicular wall and gum tissue (Figs. 95 and 96).

In these cells or crypts lie the dental follicles. The follicle wall is attached to the pulp only at its base, and between their other portions is a fluid.³ A transverse section of a crypt and its contents is shown in Fig. 96.

Cementification. Root Formation. The forming crown is gradually pushed by the forces bringing about eruption (which see) toward

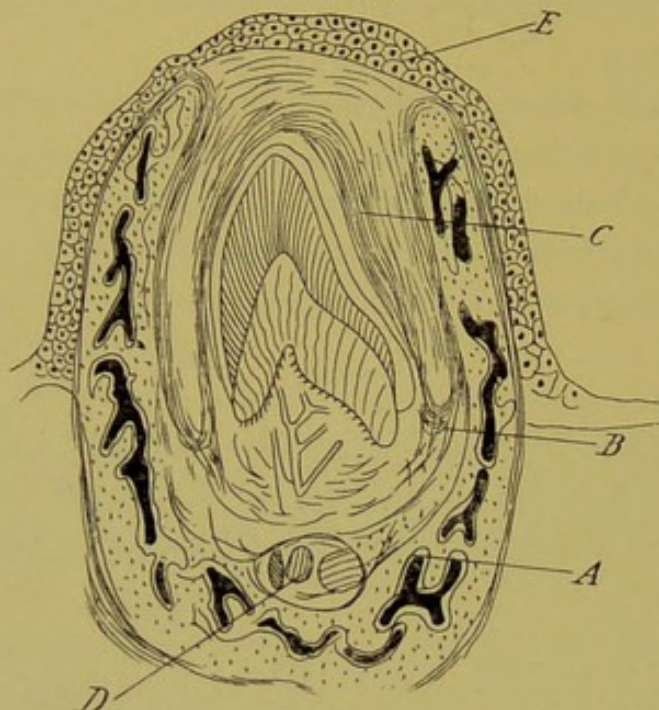
¹ American Text-book of Operative Dentistry.

² Histology and Patho-histology of the Teeth.

³ Constant.

the gum, and root formation begins after practical completion of the enamel. Fig. 98 shows that at six months after birth a portion of the roots of the anterior teeth is formed; at birth the crown was not completed. This much of root formation has, therefore, been completed

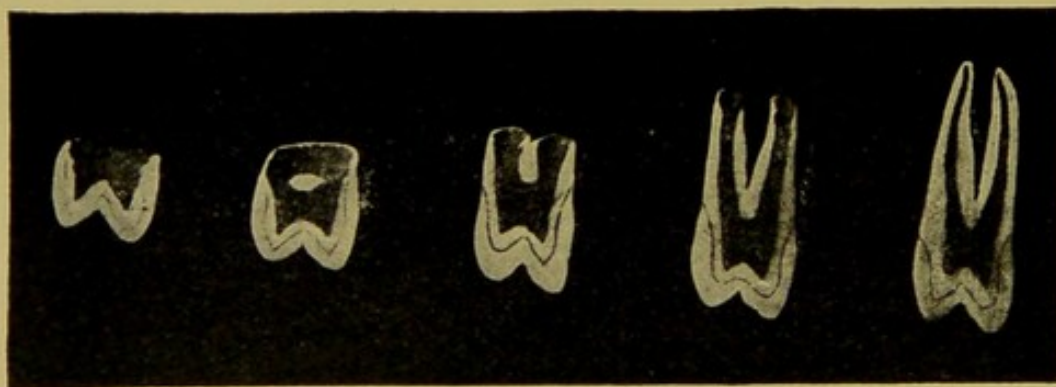
FIG. 96.



A, developing bone; *B*, tissue reflected from follicular wall and forming alveolar periosteum; *C*, follicular wall; *D*, vessels and nerves; *E*, epithelium of gum.

during the six months. After birth the state of the root end at eruption demonstrates a very large apical foramen occupied by a soft pulp filled with bloodvessels (Figs. 97, 100, and 101). At the exit

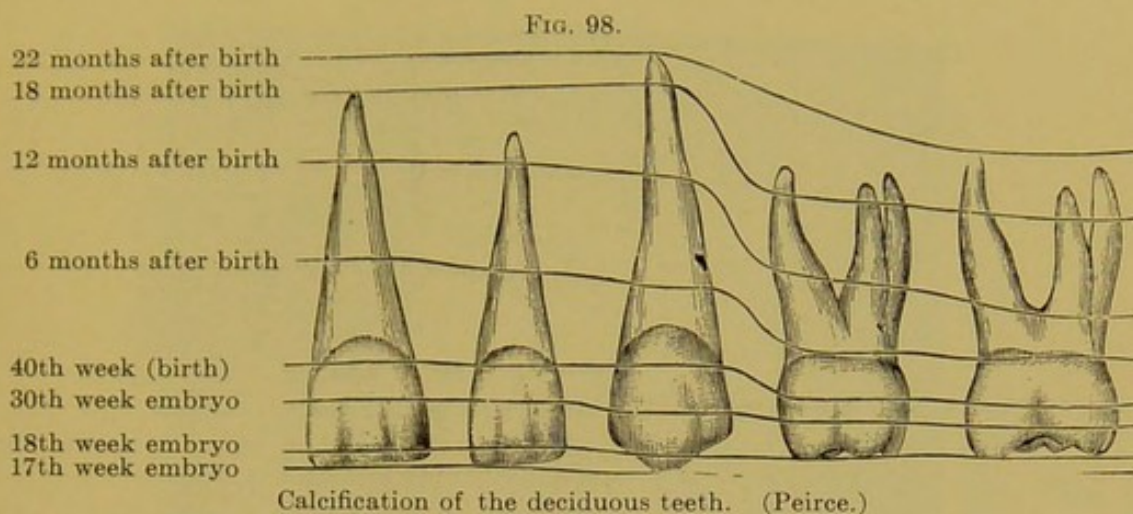
FIG. 97.



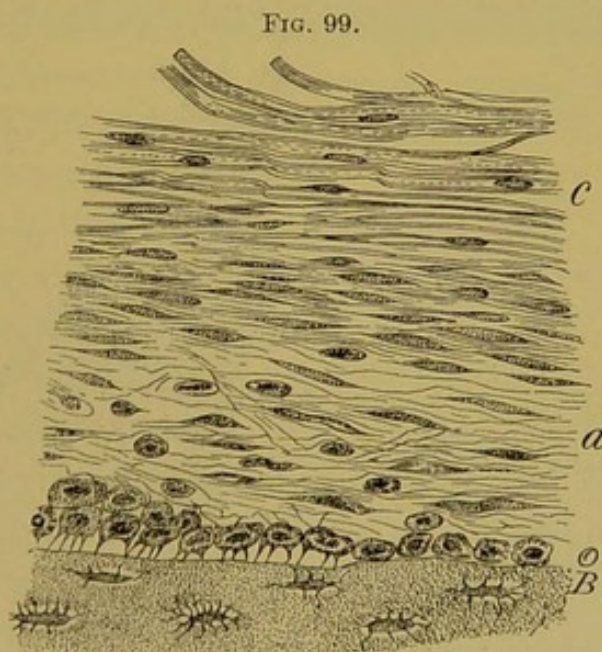
Pulp cavities of the superior first bicuspid, from the seventh to the twelfth year. (Bromell.)

from the root the pulp is attached to the follicular wall, which is reflected up the sides of the root (Figs. 96 and 100). Between these two cementification and dentinification are accomplished by a process analogous to enamel and dentine formation in the crown.

The pulp forms a layer of dentine extending beyond the enamel. On the inner surface of the follicular wall and between its fibres appear a row of osteoblasts, bone-forming cells which are here given the name of cementoblasts, and these deposit cementum (a modified bone) upon



the formed dentine. They contain glistening bodies which they extrude against the formed dentine and then retire. Some of them become included in the cementum by the deposition of cementum about them. They persist thus as bone corpuscles in lacunæ connected by canaliculi.



Section of bone and periosteum covering it: *B*, bone; *c*, outer fibrous layer; *a*, inner layer of white fibrous tissue; *O*, layer of osteoblasts, some of which reach the bone with their prolongations. (Black.)

The second layer of cementum is deposited upon the first and so on at increasing distances from the dentine. The pulp deposits dentine as in the crown, at increasing distances from the first-formed dentine and the cementum. As the crown rises through the gum and into place

in the arch, more root is built in the same manner until a type is reached. During this process the follicular wall becomes partly drawn up with the tooth, and the alveolar bone fills in about the root. The follicular wall is thus attenuated and, remaining attached to the cementum, is

FIG. 100.

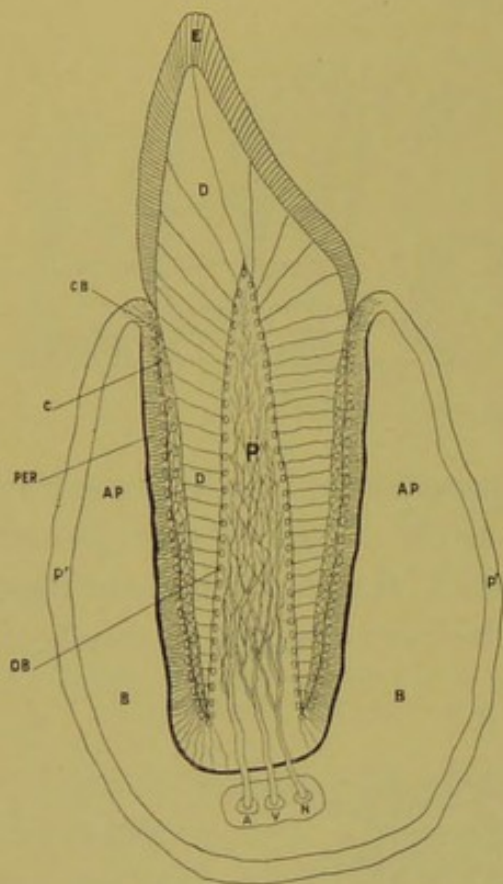
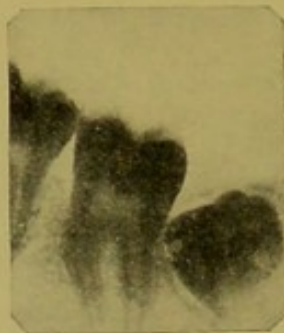

Diagram illustrating root development and condition of an incomplete root: *E*, enamel; *D*, dentine; *P*, pulp containing odontoblasts, *OB*; *AP*, alveolar process; *B*, bone; *C*, cementum; *P'*, periosteum of bone continuous with the pericementum; *PER*, pericementum containing cementoblasts, *CB*; *A*, *V*, *N*, arteries, veins, and nerves.

FIG. 101.



Condition of third molar at thirteen years of age.
(Skiagraph by Custer)

known as the pericementum (Fig. 100). There is some evidence that the pulp may assume root form in advance of calcification, ocular in the case shown in Fig. 102, inferential in cases of fusion by the roots. (See Malformations of the Teeth.)

In the development of multirooted teeth the follicular wall plays a part. The downward growth of the tooth pulp is counteracted at definite points by an upward development of the follicular wall. As a result the pulp is invaginated and is divided into two or more portions, which are to become the pulp filaments of the

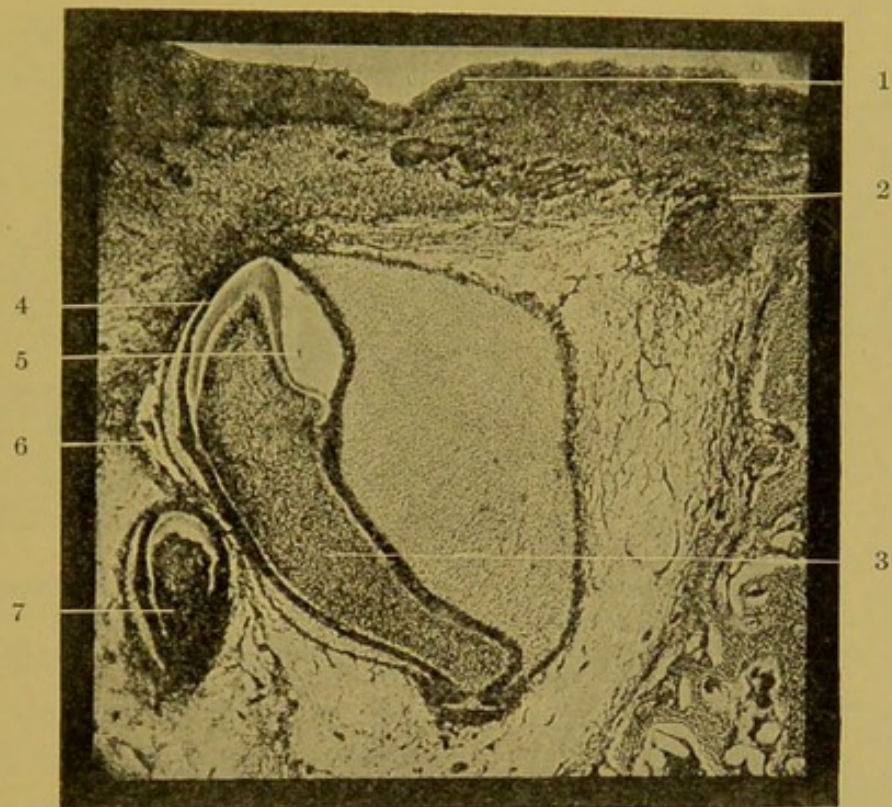
individual roots. Around each of these dentine and cementum are formed as in any single-rooted tooth, while the upgrowth of follicular wall develops the cementum of the bifurcation as well as the sides of the roots.

There is evidence that a lateral division of the pulp may occur in the same manner. The cementum so formed has been termed by Bromell interdental cementum (Fig. 103).

The Development of the Permanent Teeth. At the fifteenth week of fetal life the cords for the first permanent molars are given

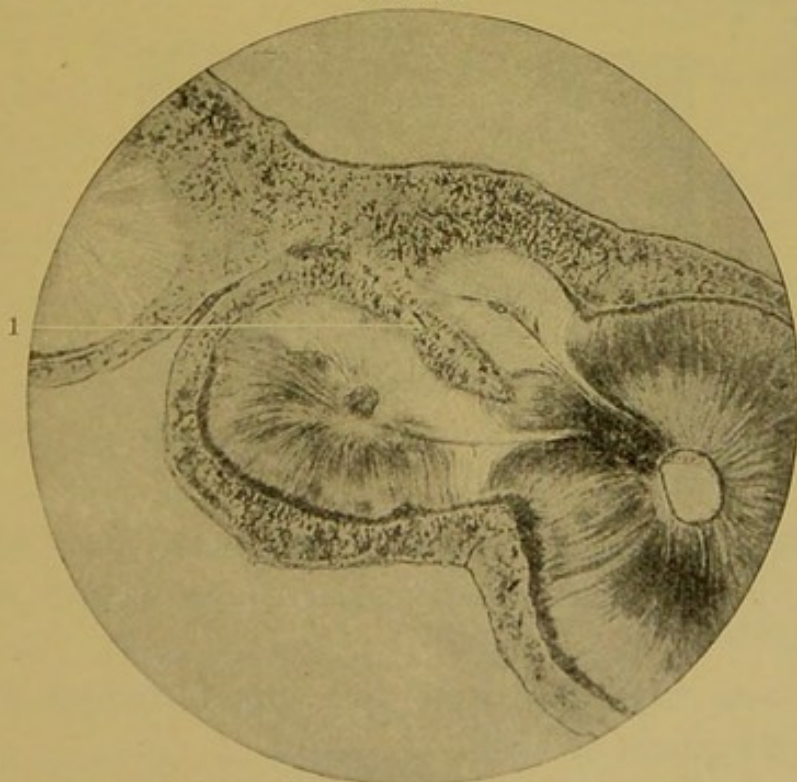
off from the epithelium of the mouth. Their development proceeds exactly as with the temporary teeth, and at the twenty-fifth week the cap of dentine appears (Magitot).

FIG. 102.



Development of deciduous incisor, from human foetus: 1, epithelium of jaw; 2, dental ridge; 3, dentine papilla; 4, calcified dentine; 5, enamel; 6, outer enamel epithelium; 7, germ for permanent incisor. (Geise.)

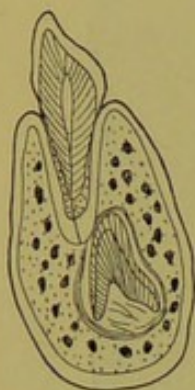FIG. 103.



Transverse section through fused roots of molar tooth, showing interdentinal cementum: 1, interdentinal cementum. $\times 30$. (Bromell.)

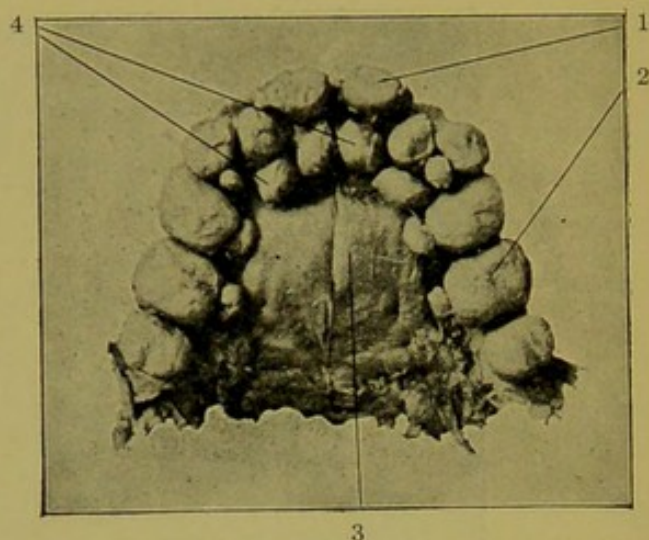
The cords for the permanent incisors, cuspids, and bicuspid are given off at the sixteenth week from the side of the cords of their temporary predecessors, and their follicles occupy a position at first

FIG. 104.



Showing the relation of permanent tooth follicle to the root of the temporary tooth.

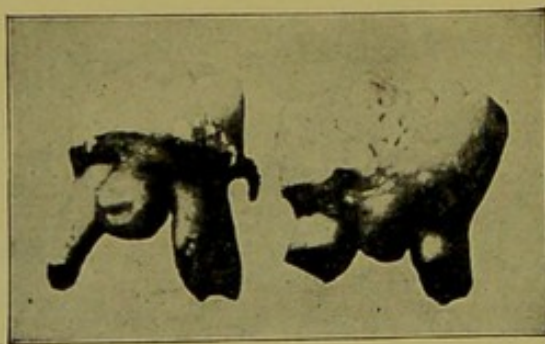
FIG. 105.



Tooth follicles for deciduous and permanent teeth, three months after birth: 1, 2, tooth sacs of deciduous teeth; 3, periosteum of hard palate; 4, tooth sacs of permanent teeth. (Bromell.)

lingual to the temporary follicle and later lingual to and above the root of the temporary tooth (Figs. 104 and 105), except in the case of the bicuspid, which lie in the bifurcations of the temporary molars at a later period (Fig. 106).

FIG. 106.



Deciduous molars with tooth sacs for permanent bicuspid attached to the gingival tissue. (Bromell.)

The process of crown and root development in the permanent teeth is the same as for the deciduous teeth, but proceeds much more slowly (Fig. 107).

It will be seen from the above data that forty-four teeth are in process of development at birth.

At three months after birth the cord for the second molar arises

from that of the first molar, and at three years of age the cord for the third molar arises from that of the second molar.¹

The temporary teeth are completely formed in a period averaging about three years (Fig. 96). The permanent teeth require from ten to seventeen years, as may be seen by reference to Fig. 107.

As the temporary teeth erupt, the germs of the permanent teeth become more deeply seated and are enclosed in crypts of bone at a point lingual to and above the roots of the temporary teeth. The bicusps lie between the roots of the temporary molars.

Later Development of the Maxillæ.

Parri passu with the development of the teeth, which require increased space for their accommodation, the jaws enlarge in all dimensions in correspondence with development in the other bones and tissues of the body. In common with these, resorptions and redepositions of tissue occur, so that the child's jaw is in all probability entirely removed and redeposited. In no other way can the change of position and size of the ramus be accounted for. The alveolar process is evidently resorbed and redeposited at least once (during second dentition), and but little of the lower infant jaw is left to be considered. The same process must occur about the maxillary sinus in the upper jaw to account

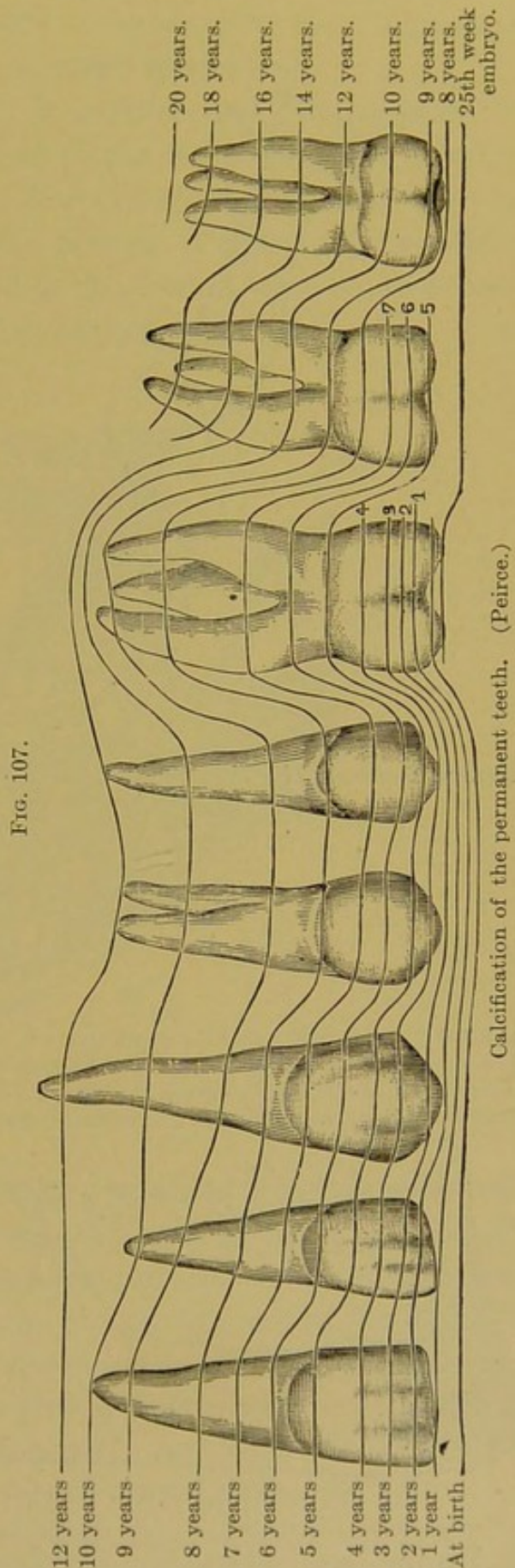
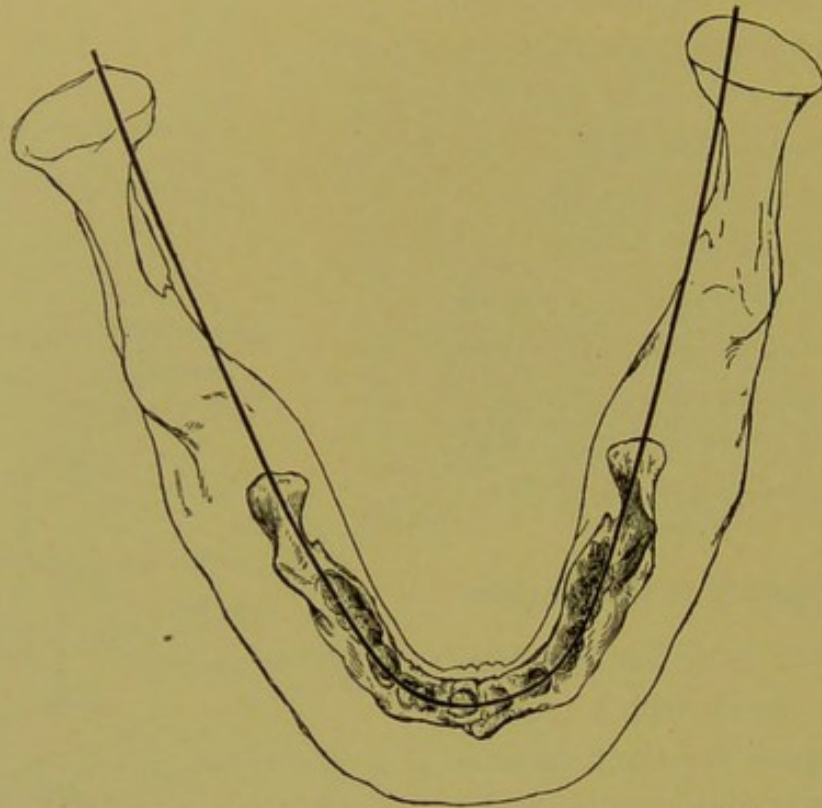


Fig. 107.

¹ Peirce, American System of Dentistry.

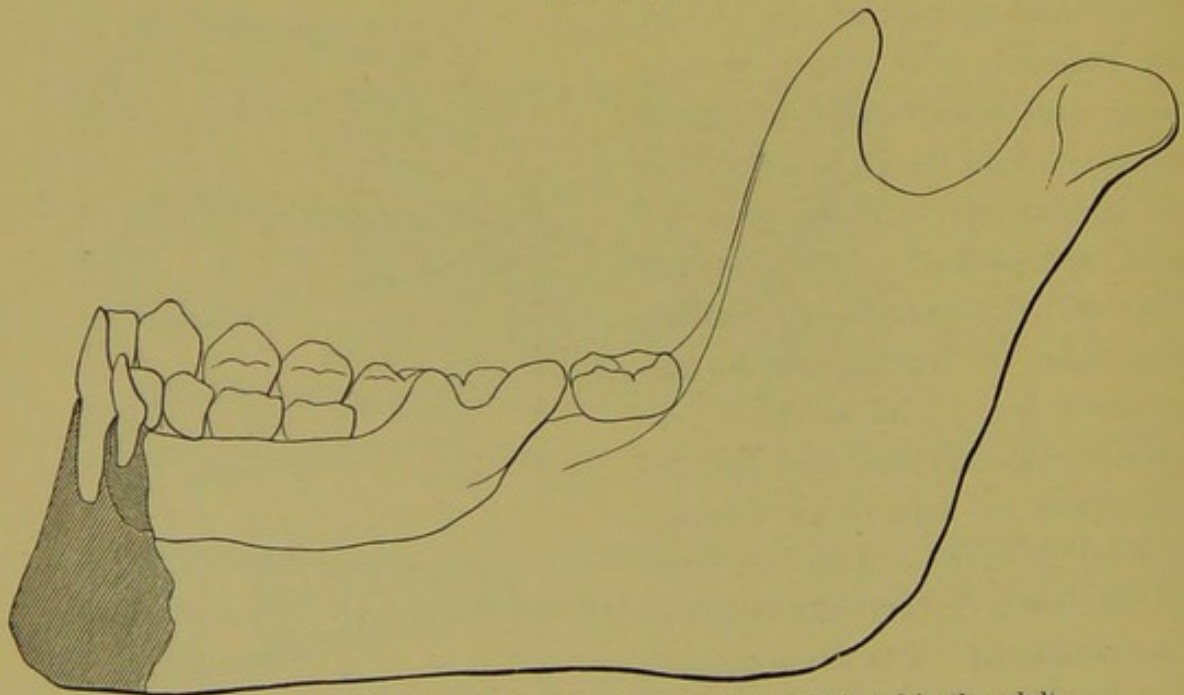
for its enlargement, and this with the enlargement of the various processes by probably the same process completes the development. Reference to Fig. 109 with Fig. 110 and Fig. 66 demonstrates this.

FIG. 108.



Representing a jaw of a nine months' foetus, superimposed on an adult's jaw, to show in what directions increase has taken place. (Tomes.)

FIG. 109.



Showing the relative sizes of jaws at the age of two years and in the adult.

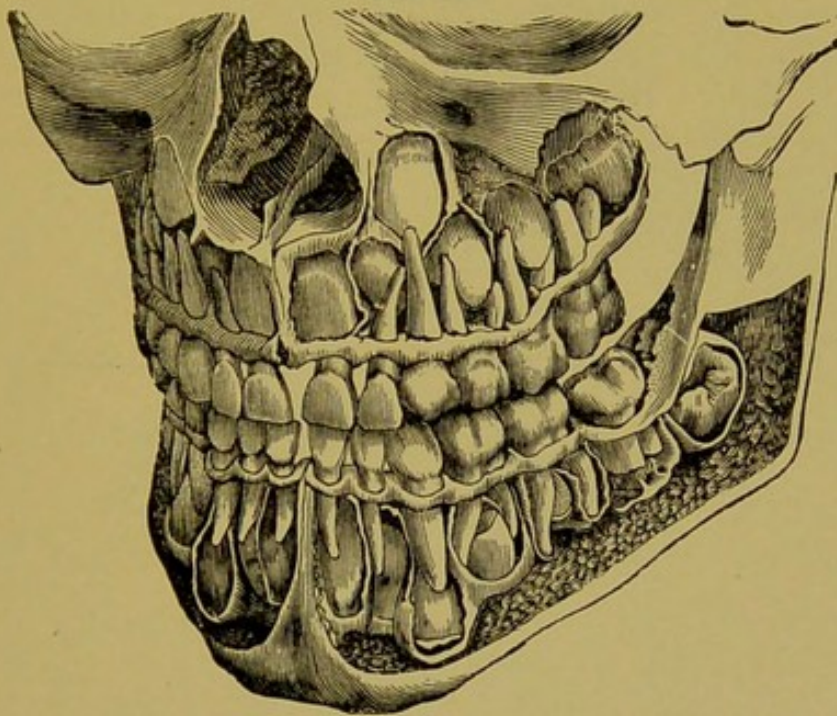
During development the alveolar process is widened and deepened, and the body of the bones enlarges in all directions.

Histology of the Mature Teeth.

For purposes of description, human teeth may be defined as hard bodies of definite form implanted in the maxillary bones and gums, attached thereto by membranes and subservient to the purposes of mastication, facial contour, and assistance in speech.

That portion of a mature tooth in position and not implanted is known as the crown, that implanted is the root; the point at which these join is the neck or cervix. The loosely constructed bone by which the roots are supported is the alveolar process, and the socket is known as the alveolus. The tooth is attached to the alveolar process by a tough, fibrous membrane, the pericementum (Fig. 111). The

FIG. 110.



View of the upper jaw of a child, aged about six and one-half years. The anterior teeth are slightly separated by the partially developed permanent teeth, lying behind or posterior to them, pushing forward to occupy a more anterior position. The equal height which the crowns of the deciduous originally occupied is also being disturbed by the advancing permanent teeth.

tooth may be said to be composed of three hard and three soft structures. These are: (1) the dentine, forming the bulk of the tooth; (2) the enamel, covering the dentine of the crown; (3) the cementum, covering the dentine of the root; (4) the pulp, occupying a central cavity in the crown and root dentine, known respectively as the pulp chamber and root canal; (5) the pericementum, covering the cementum and attaching it to the alveolar process; (6) Nasmyth's membrane, found on the enamel of newly erupted teeth and later mostly worn off.

For further description it may be stated that a periosteum covers the outside of the alveolar bone and body of the maxilla. Over this upon

the alveolar process lies submucous tissue, and upon this mucous membrane composed of a corium with its papillæ, covered in turn by epithelial cells. The gum tissue is projected somewhat over the

FIG. 111.

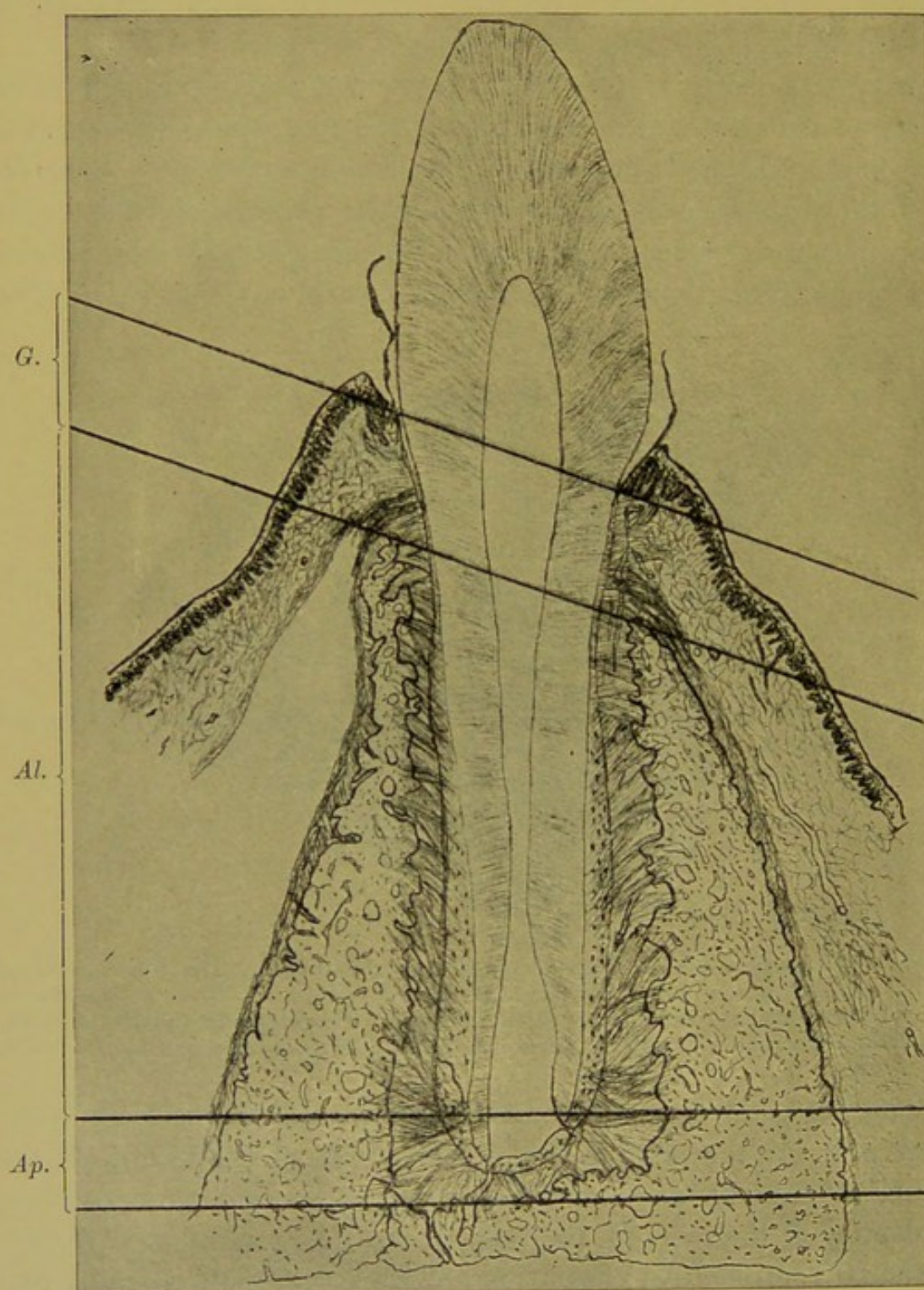


Diagram of the fibres of the periodontal membrane: *G.*, gingival portion; *Al.*, alveolar portion; *Ap.*, apical portion. From a photograph of a section from incisor of sheep. (Noyes.¹)

enamel, is known as the free gingival margin, and the slight free space between is known as the gingival space.

¹ American Text-book of Operative Dentistry.

Enamel. The enamel is a hard substance covering the crown of a tooth and lying directly upon the dentine, from which in the dried specimen it may readily be removed. It is thickest at the cusps and thinnest at the cervix of the tooth. It is composed chemically of calcium phosphate, some calcium and magnesium carbonate, and a small percentage of calcium fluoride, all combined probably with a minute quantity of organic matter and water of crystallization. As stated by Noyes, the scheme of enamel formation involves first the

FIG. 112.

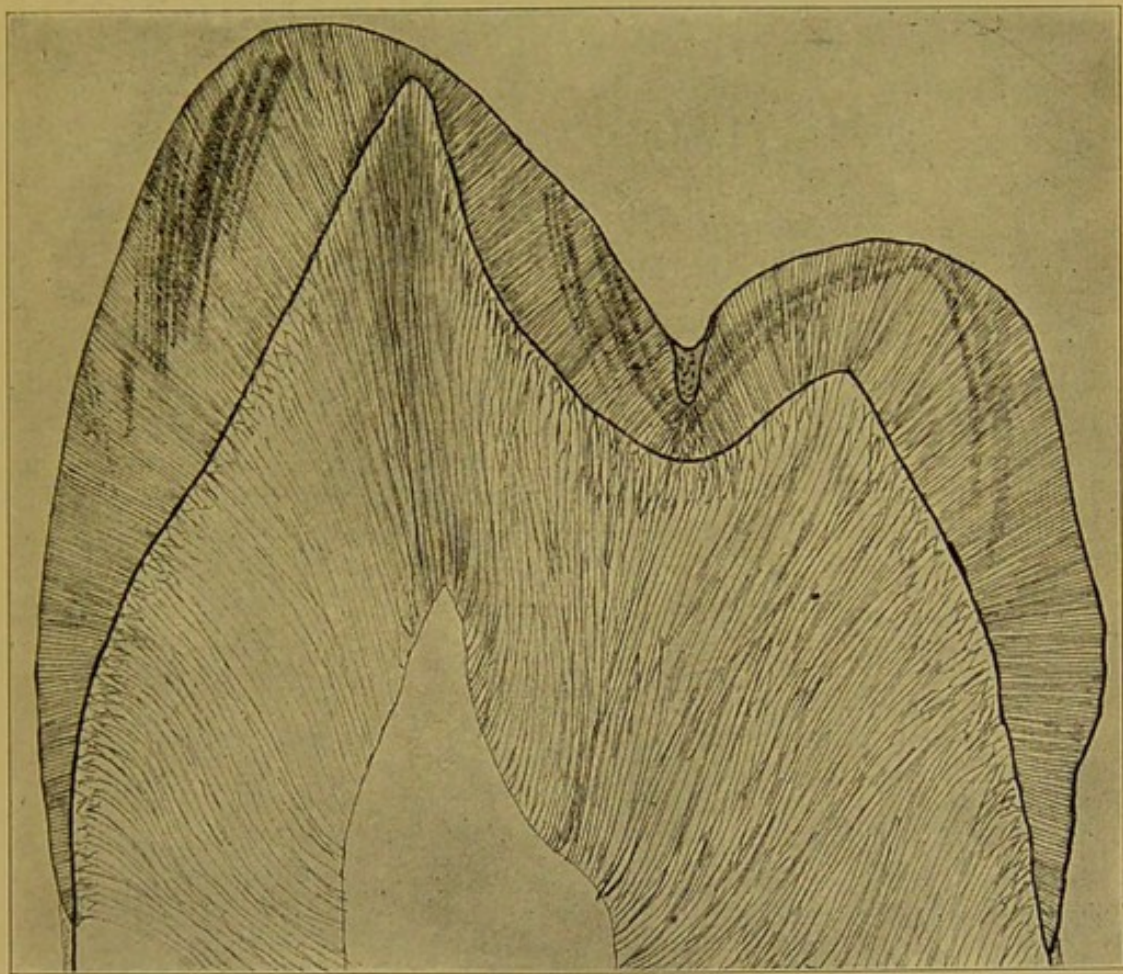



Diagram of enamel-rod directions, from a photograph of a buccolingual section of a superior bicuspid. (Noyes.)

deposition of calcoglobulin by the ameloblasts; later these cells remove all or nearly all organic matter, replacing it with inorganic salts. A longitudinal section of enamel shows it to be made up of rods of a wavy or even gnarled outline, radiating in the main from the dentine to the exterior of the crown. These rods subjected to force cleave apart longitudinally.

Microscopic examination shows the individual rods to be made up of globular bodies (enamel globules) set end to end like a string

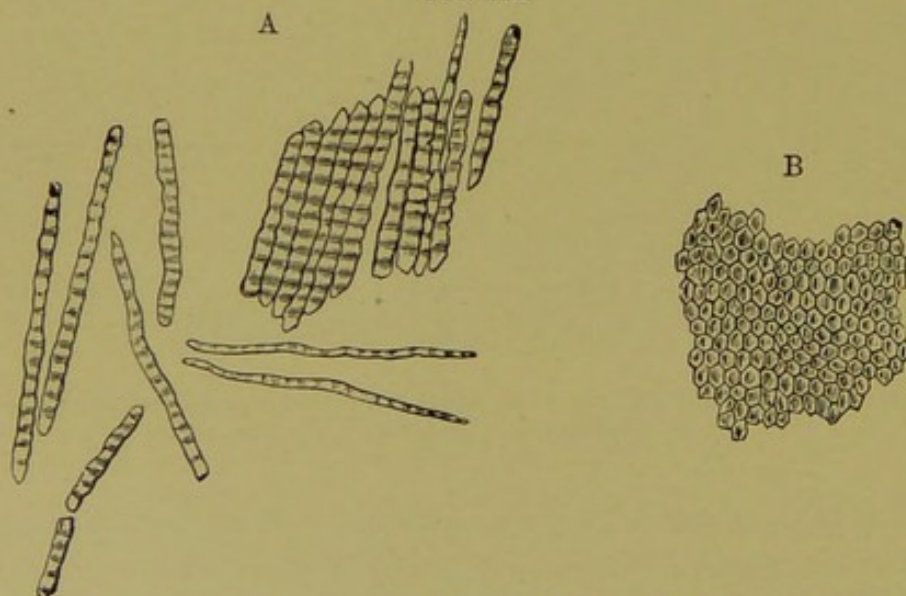
of beads. Between these globules is seen a cementing substance lying transversely to the axis of the rod, and between the rows of globules

FIG. 113.



Section of enamel of human tooth. Photographed with Zeiss apochromatic lens and Powell and Leland apochromatic condenser. The optical parts accurately centred and the focus "critical." The enamel rods are seen to be resolved into distinct sections (enamel globules), the cement substance often passing entirely between the sections. $\times 400$. (Williams.)

FIG. 114.



Enamel prisms: A, fragments and single fibres of the enamel isolated by the action of hydrochloric acid; B, surface of a small fragment of enamel, showing the hexagonal ends of the fibres. $\times 350$.

is more of the material known as interprismatic cement substance (Williams). (Fig. 113).

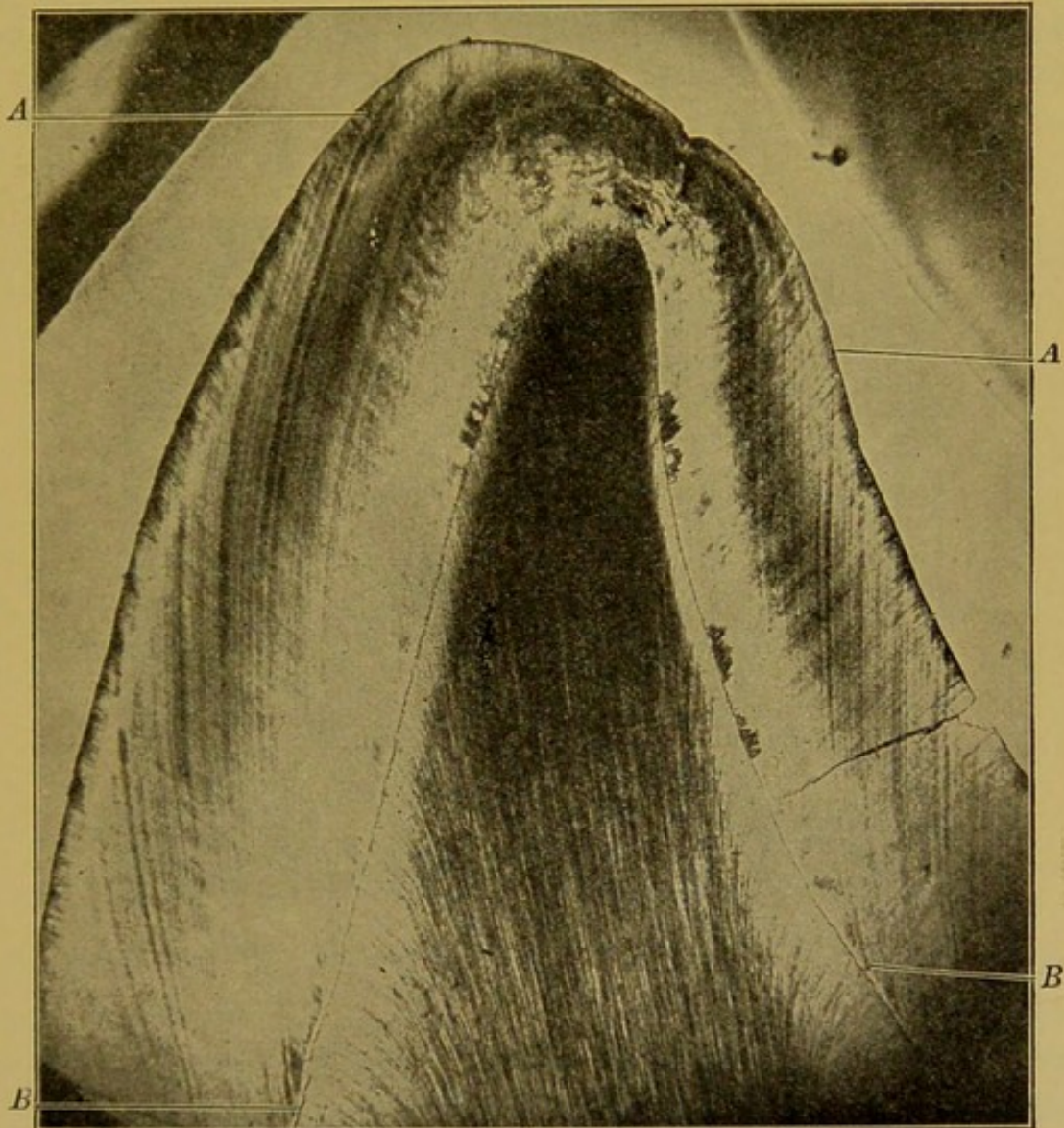
In transverse section the rods present an hexagonal appearance due

to mutual lateral pressure of their globules during development. Between the rods is seen interprismatic cement substance.

Recalling the embryology of enamel, this arrangement of enamel globules and interprismatic cement substance is seen to be the rational outcome of such a mode of deposition.

Section of an individual globule has been made by Mummery and shows a centrosome-like, crystalline arrangement of its molecules.¹

FIG. 115.



Incisor tip, showing stratification or incremental lines. Rods at *A* were fully formed at the time the rods at *B* were beginning to form. $\times 80$ (about). (Noyes.)

The interprismatic cement substance so far as known is amorphous. Both are originally calcoglobulin, but the cement substance is more soluble in dilute acids. These penetrate between the rods, assisting their cleavage and strongly marking the transverse interprismatic cement substance.

¹ Kirk, lecture before the Philadelphia Academy of Stomatology.

In the sulci of crowns the enamel rods may be separated—*i. e.*, not deposited in part owing to persistence of Nasmyth's membrane in that locality (Fig. 112).

The enamel of human teeth, and, indeed, that of animals, differs in the relative amount of cementing substance and the number of globules, and, again, in the regularity of the distribution of the two. In one specimen the globules may so predominate that the cementing substance shows in sections as fine lines; in others the globules may be small, rounded, and surrounded by a relatively large volume of cementing substance. Again, at different parts of the enamel rods both arrangements as to relative amounts of the two substances may be seen.

FIG. 116.

Enamel showing both striation and stratification. $\times 80$ (about). (Noyes.)

The enamel rods are crossed at an angle by transverse brown bands known as the striæ of Retzius, which are parallel with one another.

They are pigmentary markings representing periods of enamel increment, also termed developmental lines.

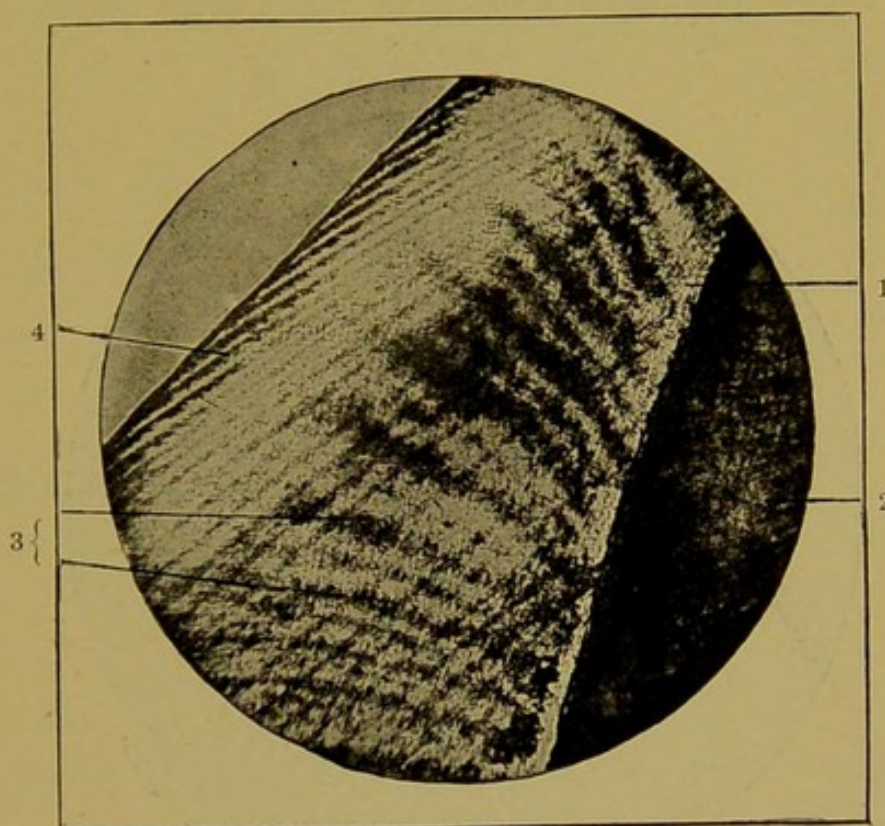
They are most abundant in the thickest portions of enamel, least so in the thinnest—*i. e.*, more or fewer incremental periods have been required for completion. Strata are also noted at times in addition to the striæ of Retzius.

Another set of cloud-like markings are seen by reflected light as stripes crossing both the rods and striæ of Retzius. These are

explained by Caush¹ as due to the presence of tubes between the enamel rods, as will be shortly described. They are the stripes or lines of Schreger in enamel (Fig. 117.) The enamel globules in the area are normal.

Williams was unable to make enamel take up staining reagents except at isolated spots, which he regarded as accidental. He occasionally found dentinal fibrillæ extending into the enamel (Fig. 185), but regarded the arrangement as a malformation. He concluded that enamel was without nutrient spaces. More recently Caush, by means of special technique, staining both by external application

FIG. 117.



Enamel and dentine, human tooth: 1, enamel; 2, dentine; 3, lines of Schreger in enamel; 4, brown striæ of Retzius. (Bromell, after Geise.)

and from the pulp chamber, has succeeded in showing the existence of tubular structures in the enamel ("enamel tube"), and which run from the dentine out and from the surface in. He found them also in the teeth of animals. Fibrillar connections were seen to enter the tubes next the dentine, which contained a material taking up stain, and, therefore, considered uncalcified. Caush, therefore, regards the enamel as endowed with nutrient spaces, by which he accounts for the staining of enamel by copper and other amalgams placed in cavities of decay. If his contention be true, it may explain several of the phenomena connected with the enamel.

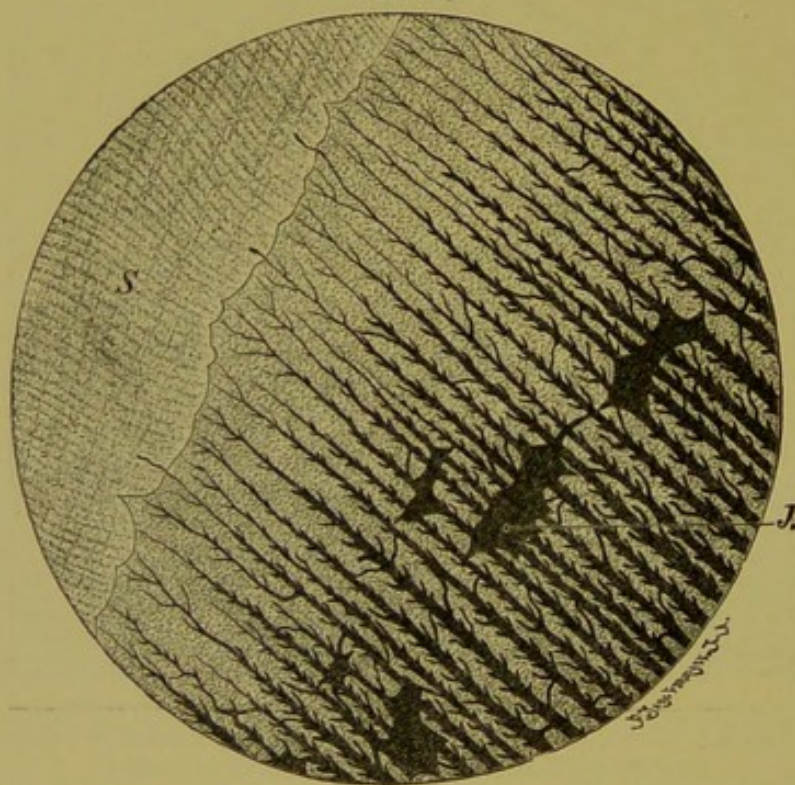
¹ International Dental Journal, June, 1904.

The color of implanted teeth sometimes changes to that of the other teeth. This cannot be due to a nutritive change under the influence of the pulp, as it is removed in such cases.

Physiologically the enamel is a protective covering for the dentine. It is insensitive—resistant to ordinary wear, practically impervious and highly resistant to acids generated in the mouth except when concentrated upon particular spots, as in caries or erosion.

Nasmyth's Membrane. This is a thin membrane $\frac{1}{500}$ inch or less in thickness found upon the enamel of newly erupted teeth, but later worn off by friction. It may be removed from the enamel for study by the use of a 10 per cent. solution of hydrochloric acid. It is regarded as the persistent remains of the enamel organ (Figs. 127 and 130).

FIG. 118.



Longitudinal ground-section through the crown of a cuspid of a man aged twenty-three years. Wet ground-section stained by Golgi's method: *J*, interglobular space; *S*, enamel. $\times 250$. (Röse.)

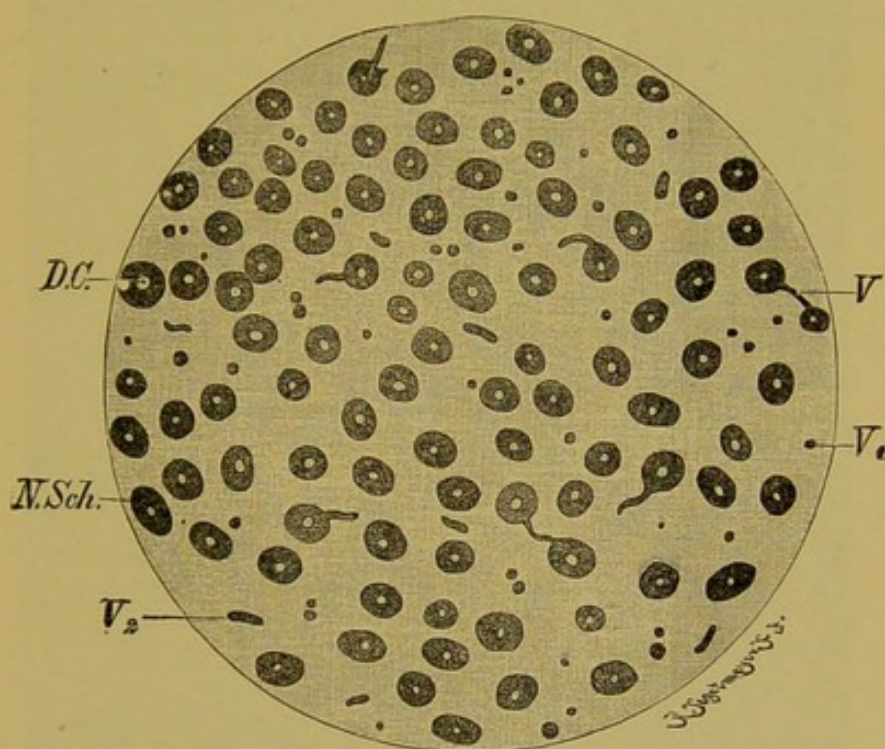
The Dentine. The dentine forms the great bulk of the hard tissues of the tooth and is bounded by the enamel, the cementum, and the pulp.

Its substance is seen upon section to be composed of tubules and their contents and intertubular or basis substance. There is from four to ten times as much basis substance as of tubules. The latter have an outside diameter of from $\frac{1}{22000}$ to $\frac{1}{5000}$ inch. The tubules pursue a curved course from the pulp cavity to the periphery of the dentine, where they divide dichotomously and may anastomose.

Those curves nearest the pulp are termed primary, those farther away secondary. In the crown they radiate from the pulp; in the root they lie at right angles to it and are less curved. They are seen upon transverse section to be round or oval in outline, and to have a central opening or lumen (Fig. 119).

Longitudinal sections show that this lumen contains a protoplasmic prolongation of a fibril cell from the row of odontoblasts upon the pulp surface (Fig. 120). This prolongation is called a Tomes fibre or fibrilla and extends the entire length of the tubule. The tubule wall surrounding it is known as the sheath of Neuman (Fig. 119, *N.Sch.*).

FIG. 119.



Transverse ground-section through the dental tubules of the first molar of a child aged seven years. *V*, Koch's and Golgi's methods combined. $\times 1200$. (Röse.)

The tubule walls are seen in both sections (Figs. 118 and 119) to have transverse processes connecting them. These stain like the tubule walls, but have not been shown to contain central fibres.

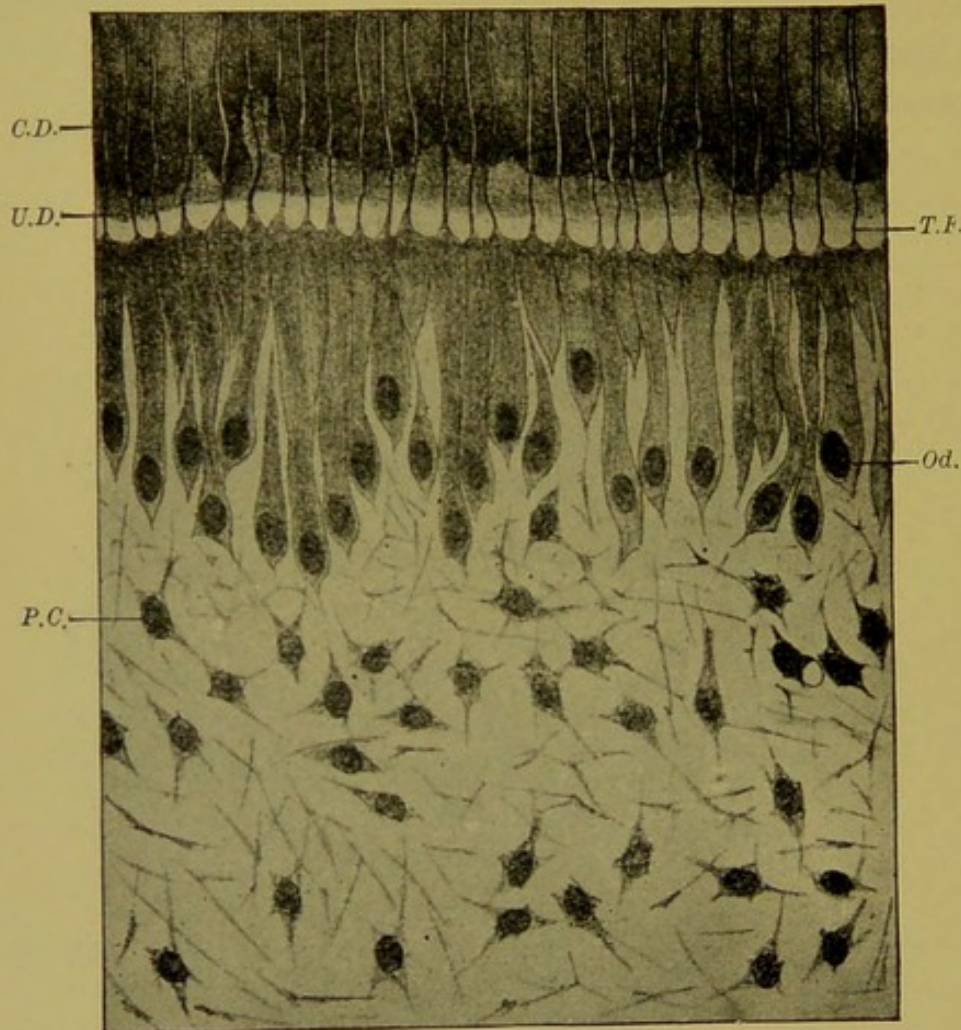
Tomes and Noyes call attention to the fact that these transverse tubules are scarce in the proximal (pulpal) ends of the tubules in the crown, but numerous in the distal ends of the crown tubules and throughout the length of the tubules in the root dentine.

Lines are observed in some specimens of dentine having a general parallelism to the pulp. They run at right angles to the axis of the tubule and are due to short bends in the length of many adjacent tubules, occurring on one general plane. They may be interpreted as due to changes of direction assumed by the odontoblasts in tubule

building at the particular period. Salter has termed them "incremental lines." They are known as the lines of Schreger in dentine.

It has been shown by Hart¹ that the basis substance of dentine is traversed by a fine network of fibres, a connective-tissue stroma in which the calcific process occurs (Fig. 121). Röse² regards these as the gelatin-yielding fibres of the dentine. The demonstration of

FIG. 120.



Section of pulp, showing the relations of the odontoblasts to the dentine; *Od.*, odontoblasts; *T.F.*, Tomes' fibres—odontoblastic processes; *U.D.*, uncalcified dentine; *C.D.*, calcified dentine; *P.C.*, pulp cells. $\times 800$. (Röse and Gysi.)

Mummery that a connective-tissue stroma is seen forming in advance of calcospherite deposition in dentine formation is worthy of attention as corroborative evidence. (See Dentinification.)

In the border-ground between dentine and enamel and dentine and cementum the dentine may present a different histological appearance from the general mass of the dentine. Instead of the orderly subdivision of the dentinal tubules, this portion of the dentine may be

¹ Dental Cosmos, 1891.

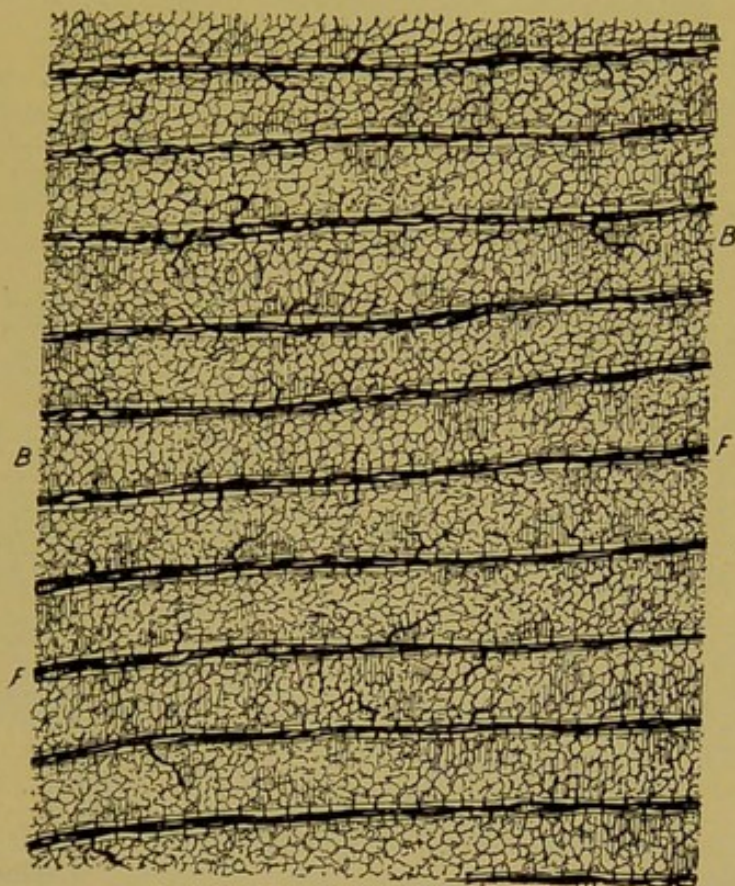
² Ibid., 1902.

occupied by irregular spaces—interglobular spaces in which the fibrillæ may expand. This particular layer of tissue was named by its discoverer, Sir John Tomes, the granular layer (Fig. 122, *J*). As he pointed out, the layer is much more marked beneath the cementum than beneath the enamel.

Interglobular spaces are also found in the body of the dentine. (See Fig. 118 and Malformations of the Teeth.)

Anatomically the dentine is the tissue composing the bulk of the tooth. It is a tissue receiving nourishment from the pulp *via* the

FIG. 121.



Main mass of dentine of a temporary tooth, stained with chloride of gold, decalcified with acetic acid: *F, F*, dentinal fibres, partly vacuolated; *B, B*, basis substance, traversed by a reticulum. $\times 1200$. (Hart.)

fibrillæ and through the same is capable of warning sensations and of some vital reaction to causes threatening its disintegration. Under stimulus the fibrillæ may produce sclerotic changes in the dentine (tubular calcification.)

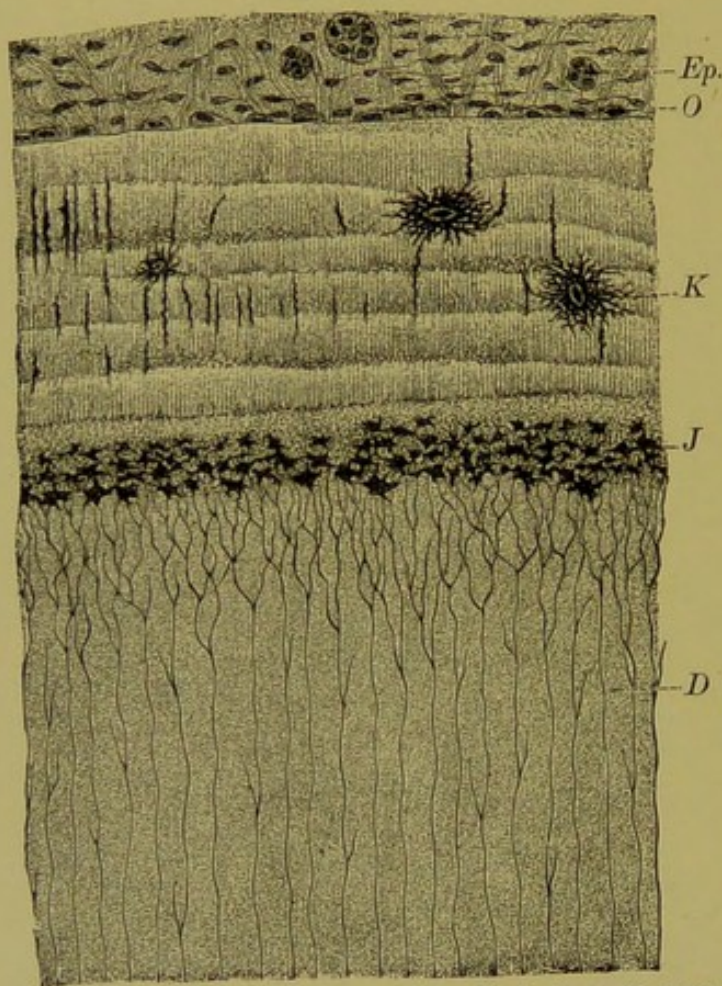
In a vital condition the fibrillæ and pulp preserve the translucency of the tooth.

The Pulp. The pulp is the highly developed remainder of the dentinal papilla.

It consists of a gelatinous matrix containing branched connective-

tissue cells, a type of tissue known as myxomatous (Fig. 119). This is traversed by bloodvessels and nerves which enter by way of the apical foramen and subdivide, breaking up finally into a closely interlacing plexus of non-medullated nerve fibres and a capillary network near the surface of the pulp (Figs. 123 and 124). Over the entire surface is arranged a layer of nucleated columnar cells. These are the odontoblasts.

FIG. 122.



Ground-section through the root of a human premolar: *D*, dentine; *K*, cement corpuscles; *O*, osteoblasts; *Ep*, pericemental glands of Black;¹ *J*, interglobular spaces. $\times 200$. (Röse.)

The latter send prolongations into and throughout the length of the tubules of the dentine. These are the Tomes fibres or fibrillæ.

One or more arteries enter the apical foramen or by several foramina, and several veins may emerge. The arteries subdivide in the central portion of the pulp and form a rich network of capillaries beneath the odontoblasts.

The arteries of the pulp soon lose almost entirely their muscular coat, and their external coat is reduced to an inconsiderable amount of fibrous connective tissue; the veins remain for an unusual distance

¹ The editor takes the liberty of altering the interpretation.

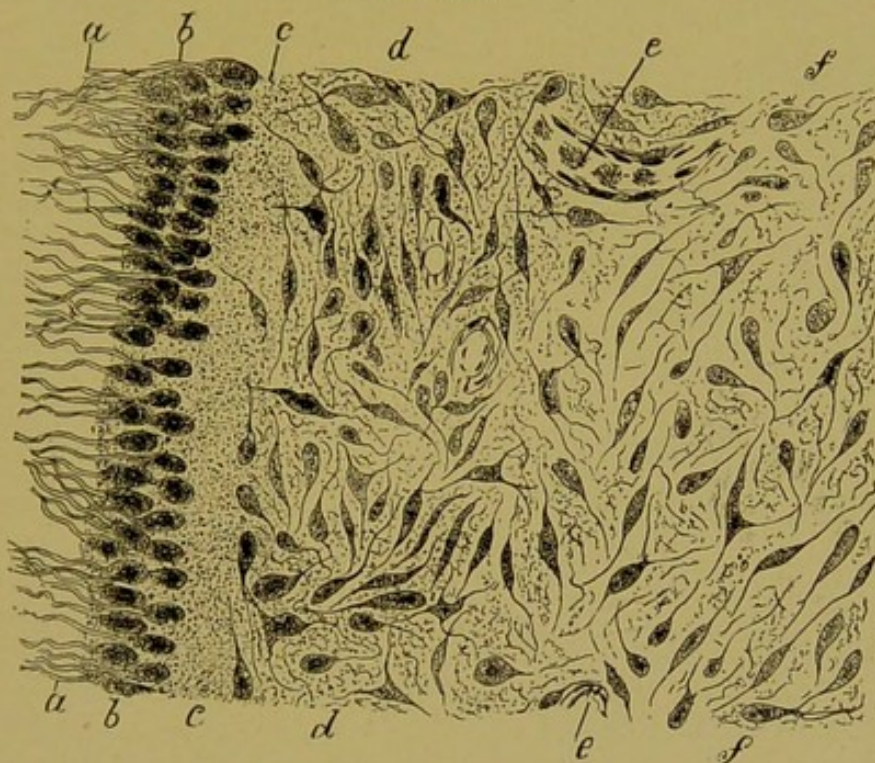
without a muscular coat. This histological datum has great clinical significance. (See Diseases of Pulp.)

The vascularity of the pulp decreases with age. "In young teeth there are a number of arterial trunks entering the apical foramen, which lessen in number as the passage lessens in size." (Black.)

The passage of arteries and veins through a constricted foramen has important consideration in connection with pulp diseases. (See Venous Hyperæmia of the Pulp.)

The nerves enter by several bundles and if medullated soon lose the medullary sheath. They are derived from the trigeminus and the sympathetic system.

FIG. 123.



Margin of dental pulp: *a, a*, dentinal fibrils, pulled out of the dentine; *b, b*, membrana eboris or layer of odontoblasts; *c, c*, transparent zone between the odontoblasts and the cells of the pulp proper; *d, d*, layer of cells closely packed together; *e, e*, bloodvessels; *f, f*, cells less closely placed toward the central portions of the pulp. Wales' immersion, $\frac{1}{10}$ -inch objective. (Black.)

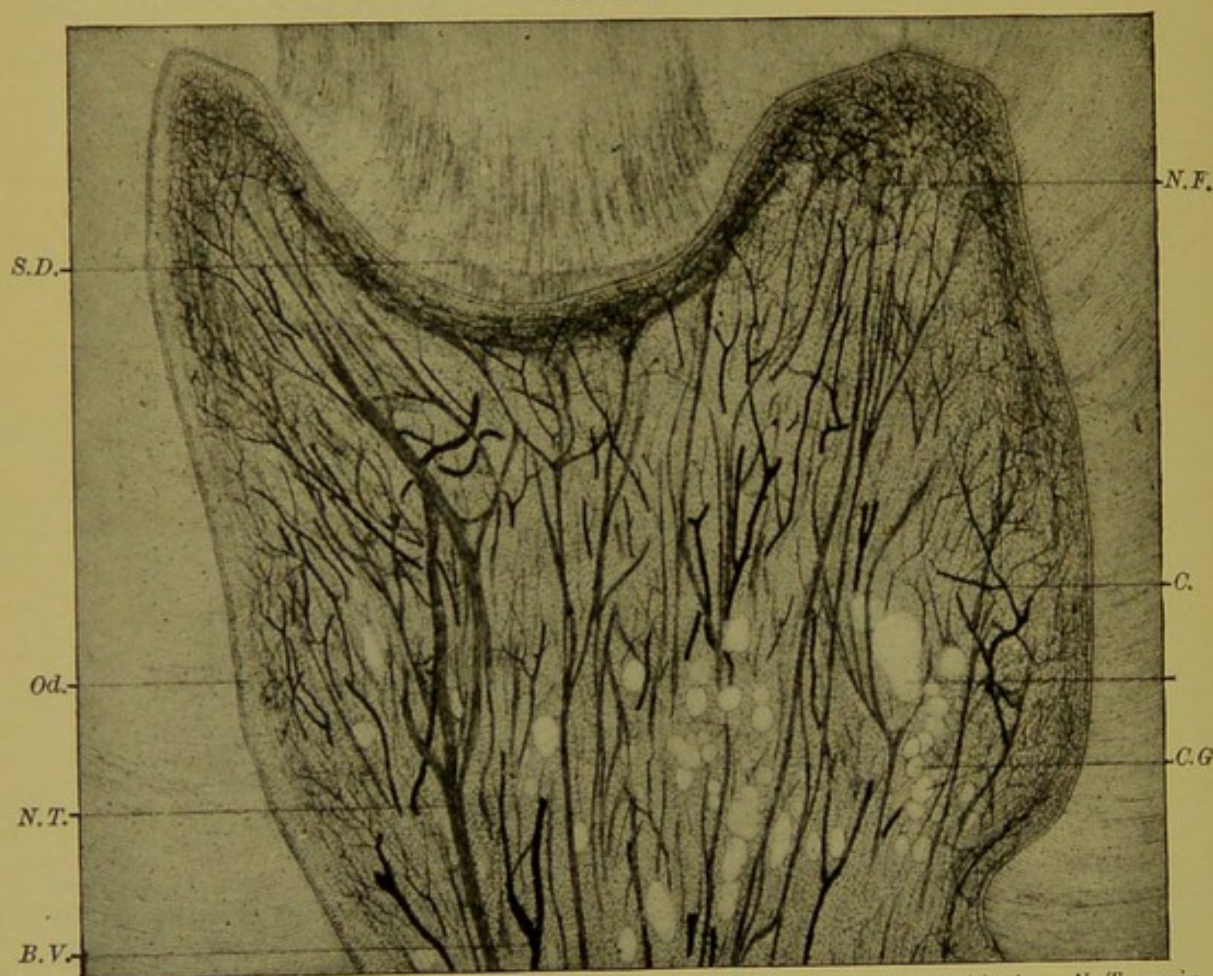
Those from the sympathetic are distributed to the bloodvessels as vasomotors; the others form a plexus in intimate relation with the odontoblasts. They have been found by Retzius to terminate in knob-like extremities between the odontoblasts in the mouse. These are probably sensory nerves.

No direct anatomical connection has been made out between the nerve fibres and the odontoblasts or the fibrillæ, although Robertson has claimed to have traced the long central fibre running from the odontoblasts into the pulp into nerve bundles and claims that they become axis cylinders. The phenomenon of sensitive and hyper-

sensitive dentine shows an evident physiological connection. The nerves of the pulp do not possess tactile sense. The pulp contains no demonstrable lymphatics, and if absent their office is probably performed by the veins, which in other parts may take up this function.¹ The pulp becomes more fibrous and less vascular with age.

During its health it preserves the translucency of the tooth through its relations with the fibrillæ, and under certain circumstances renews its formative activity and produces secondary dentine.

FIG. 124.



Section of a tooth-pulp: *B. V.*, main bloodvessels of pulp; *C.*, origin of capillaries; *N. T.*, main nerve trunk; *N. F.*, subdivisions of nerve into fibrillæ; *Od.*, odontoblastic layer; *S. D.*, secondary dentine; *C. G.*, masses of calcoglobulin. $\times 30$. (Röse and Gysi.)

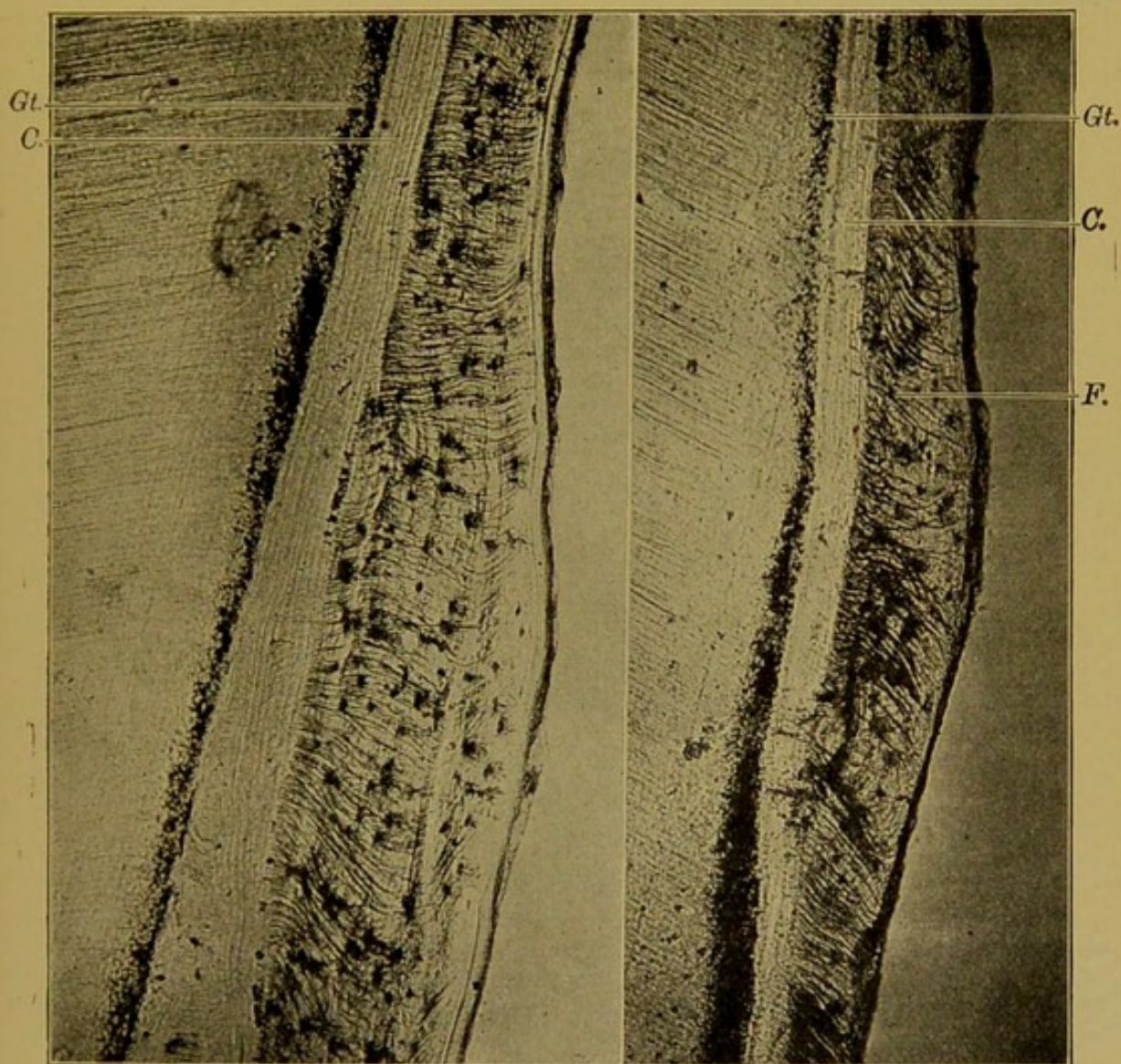
The forms of the pulp and the pulp cavities are shown in Chapter VII.

The Cementum. The cementum is a modified bone distributed over the root of the tooth. It meets the enamel edge to edge. In some cases it overlaps the enamel and in others is overlapped by it. (Choquet.)

¹ Green, Pathology and Morbid Anatomy.

It is thinnest at the cervix of the tooth, at which point the first layers are formed, and thickest at the apex and in the bifurcation of the roots. It is thicker in the aged. During development some of its formative cells, the osteoblasts, are caught in its substance, persisting in lacunæ with their canaliculi. This is true of thick lamellæ, not of thin ones, as of the cervix.

FIG. 125.

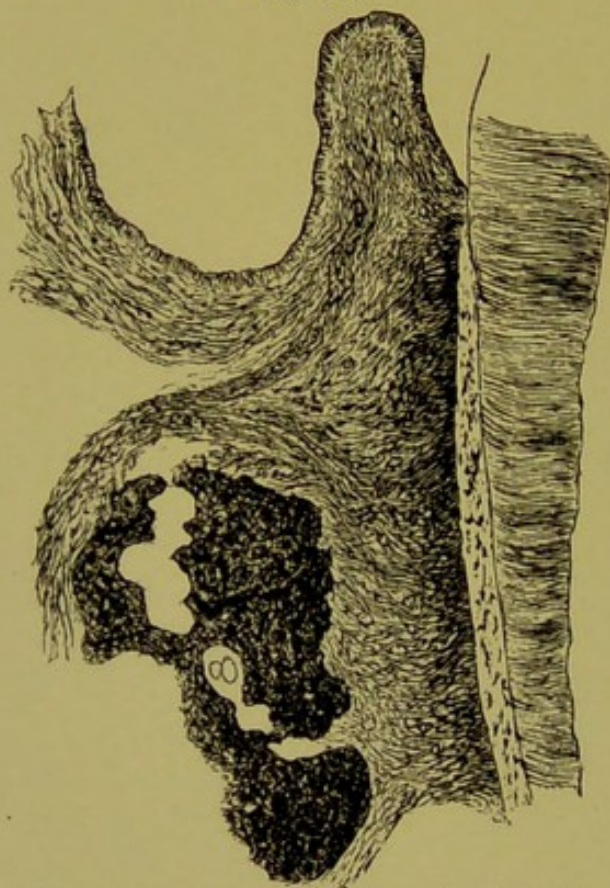

Two fields of cementum, showing penetrating fibres: *Gt.*, granular layer of Tomes; *C.*, cementum not showing fibres; *F.*, penetrating fibres. $\times 54$ (about). (Kirk.)

There is evidence of stratification, evidencing periods of increment (Figs. 122 and 125), and the remains of pericemental fibres which have undergone calcification are seen as numerous fine lines running at right angles to the axes of the strata. These lines represent old points of attachment of the pericemental fibres (Sharpey's fibres). In some cases the dentinal tubules of the root terminate in the cementum, but, as a rule, terminate in the granular layer of Tomes.

The physiological function of the cementum is to afford a means of attachment of the teeth to the maxillary bones through the medium of the pericemental fibres. In case of death of the pulp, and, therefore, of cessation of nutrition of the dentine, the vital relations of the cementum and alveolar process are thus maintained and the usefulness of the tooth assured. Whether the dentine can ever receive nourishment from the cementum after pulp death has never been scientifically shown.

FIG. 126.



Portion of the side of a root of a tooth, the gum and alveolodental membrane, and the edge of the bone of the alveolus. A band of fibres is seen passing over the surface of the alveolus and dividing, some passing upward into the gum, others passing more directly across to the cementum. Numerous orifices of vessels cut across transversely are seen between the tooth and the bone. (Black.)

The Pericementum. (*Syn. Peridental Membrane.*) The pericementum is the highly organized remains of the follicular wall. As the alveolar bone and cementum develop on either side of it, it forms also the periosteum lining the alveolus. It is, therefore, the means by which the teeth are retained in their sockets and a certain degree of motion permitted. If articulation by gomphosis be an admissible term, and it is adopted by anatomists, the pericementum subserves the office of a ligament not altogether unlike that found in the sutures of the cranial bones.

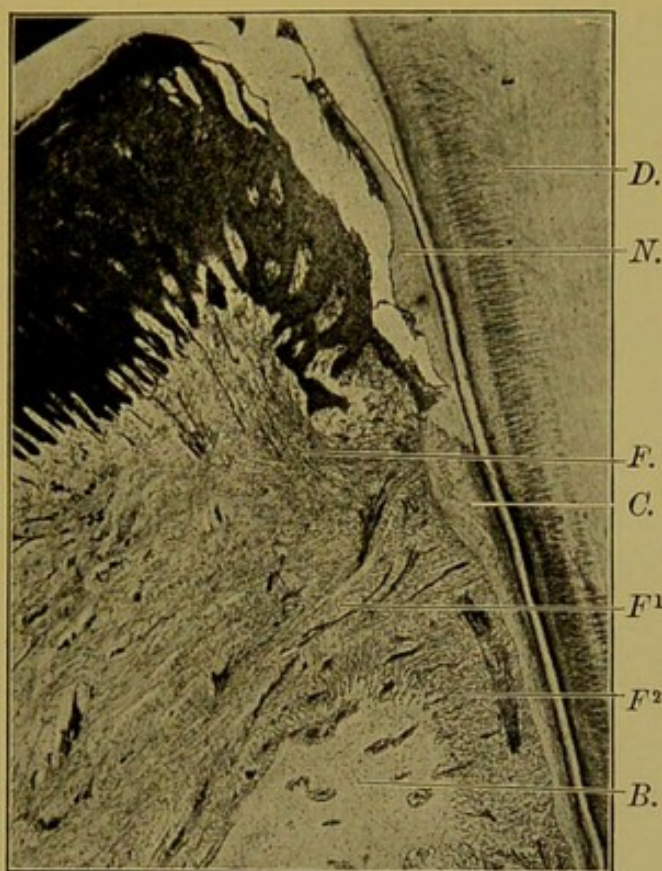
It is continuous with the periosteum on the outside of the alveolar process, as the sutural membrane is with the pericranial membrane.

Its outline study divides the pericementum into three portions—a gingival, an alveolar, and an apical portion.¹

It is composed largely of white fibrous tissue with interlaced blood-vessels, nerves, and glands. It also contains functional cells, fibroblasts, cementoblasts, osteoblasts, and osteoclasts.

The fibrous tissue is made up of principal fibres and indifferent fibres.²

FIG. 127.



Longitudinal section of the periodontal membrane in the gingival portion: *D*, dentine; *N*, Nasmyth's membrane; *C*, Cementum; *F*, fibres supporting the gingivus; *F*¹, fibres attached to the outer layer of the periosteum over the alveolar process; *F*², fibres attached to the bone at the rim of the alveolus; *B*, bone. $\times 30$ (about). (Noyes.)

The principal fibres are grouped for the most part in bands or bundles (Fig. 111).

In the alveolar portion these bundles run for the most part from the cementum to a higher point on the alveolar process. The attachment is secured by the penetration of the fibres into either structure. This secures to the tooth support against direct pressure into the socket and against rotary motion.

¹ Noyes, American Text-book of Operative Dentistry.

² Ibid.

At the apical portion the bands have a fan-like distribution. In the gingival portion the fibres are directed outward and slightly downward for attachment to the process, or outward and downward over the edge of the process to become continuous with the periosteal fibres, or outward and upward with the submucous gingival tissue to aid in the support of the gum margin. Some of the gingival fibres pass from the cementum of one tooth to that of the next.

The bloodvessels of the pericementum are derived from several sources: (1) from several vessels derived from a single trunk entering the apical space from the bone above; (2) from vessels entering the membrane through the Haversian canals of the alveolar process and anastomosing with branches from the descending arteries; (3) from the vessels of the outer periosteum, coming over the edge of the alveolar process.

There are comparatively few capillaries. The vessels lie mostly in the outer or alveolar half of the pericementum.

This disposition of the arterial blood supply ensures nutrition to the peridental membrane in case of loss of the apical tissue, as in case of apical abscess, and also ensures a collateral blood supply to the pulps in case of loss of main arterial trunks, as, for example, in operations upon the inferior dental canal.

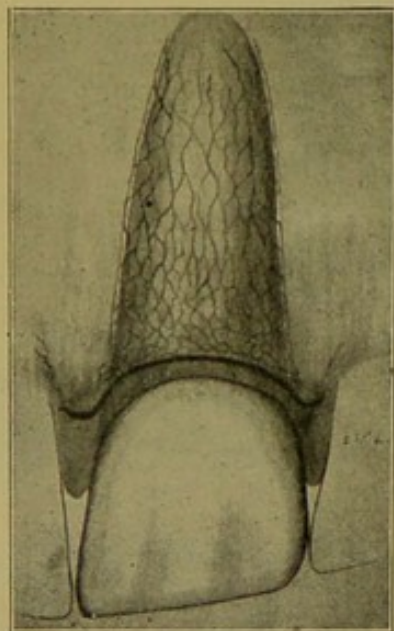


Diagram of glands of peridental membrane. (Black.)

The arteries thus furnishing blood to the teeth are, for the upper jaw: the anterior dental branch of the infraorbital, to the upper anterior teeth; the superior dental branch of the alveolar, to the upper bicuspid and molars and the bone about their root ends; the descending palatine and its anastomotic connection, the sphenopalatine, supplied to the palatine side of the upper alveolar process, etc.; the alveolar, supplied to the buccal side of the upper alveolar process.

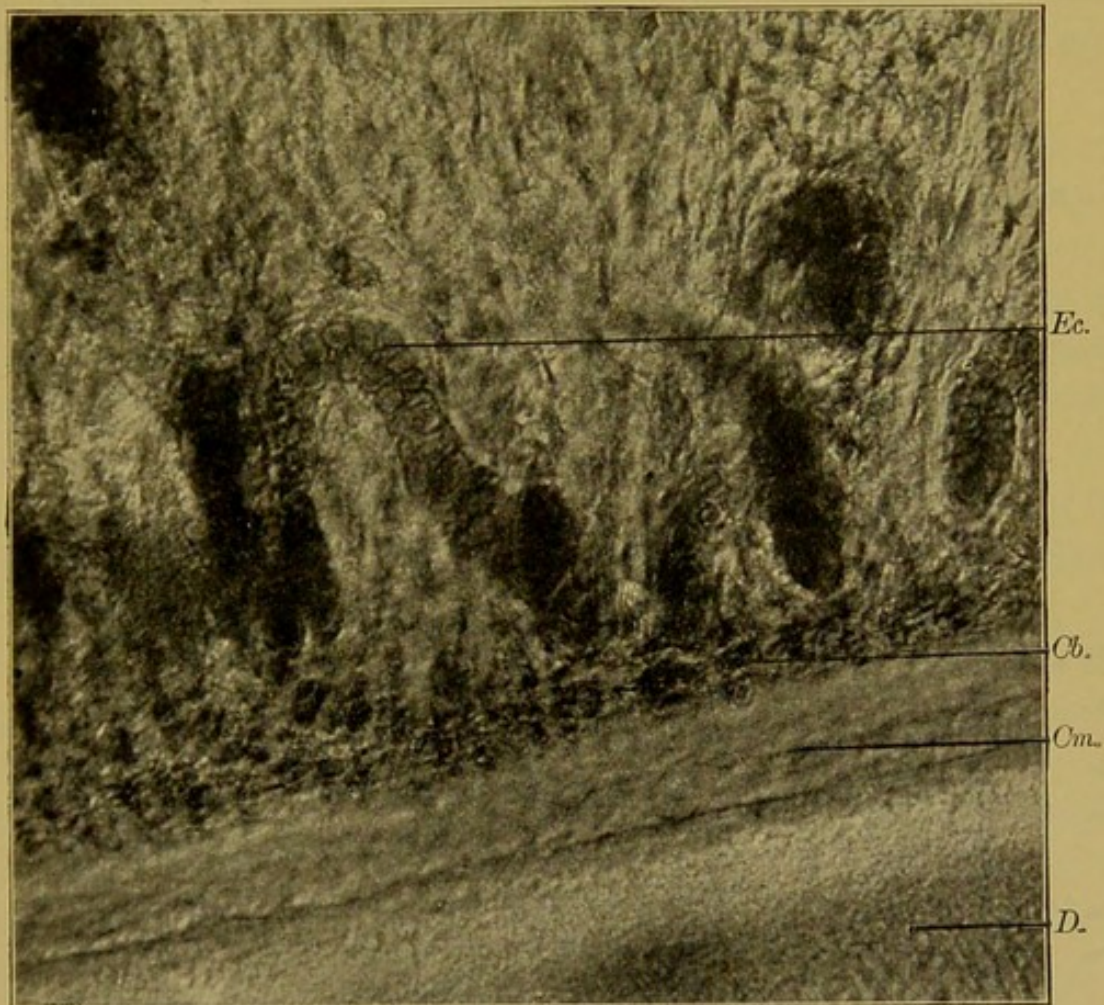
In the lower jaw the inferior dental artery and its incisor branch supply the apical tissues of the lower teeth from the inferior dental canal. Its mylohyoid branch supplies the gums and lingual periosteum of the lower alveolar process, the mental branch supplies the lower buccal process anteriorly, while a branch of the facial artery anastomoses

with the mental anteriorly, and the facial sends branches to the coverings of the buccal aspect of the lower jaw posteriorly.

The veins return the blood by similar channels.

The nerves of the pericementum enter by several trunks in the apical tissue and also enter from the alveolar wall and over the alveolar edge. While their distribution is not yet fully described, some of them possess the tactile sense, as touch upon the teeth is fully localized. They are derived from the fifth nerve and the sympathetic.

FIG. 129.

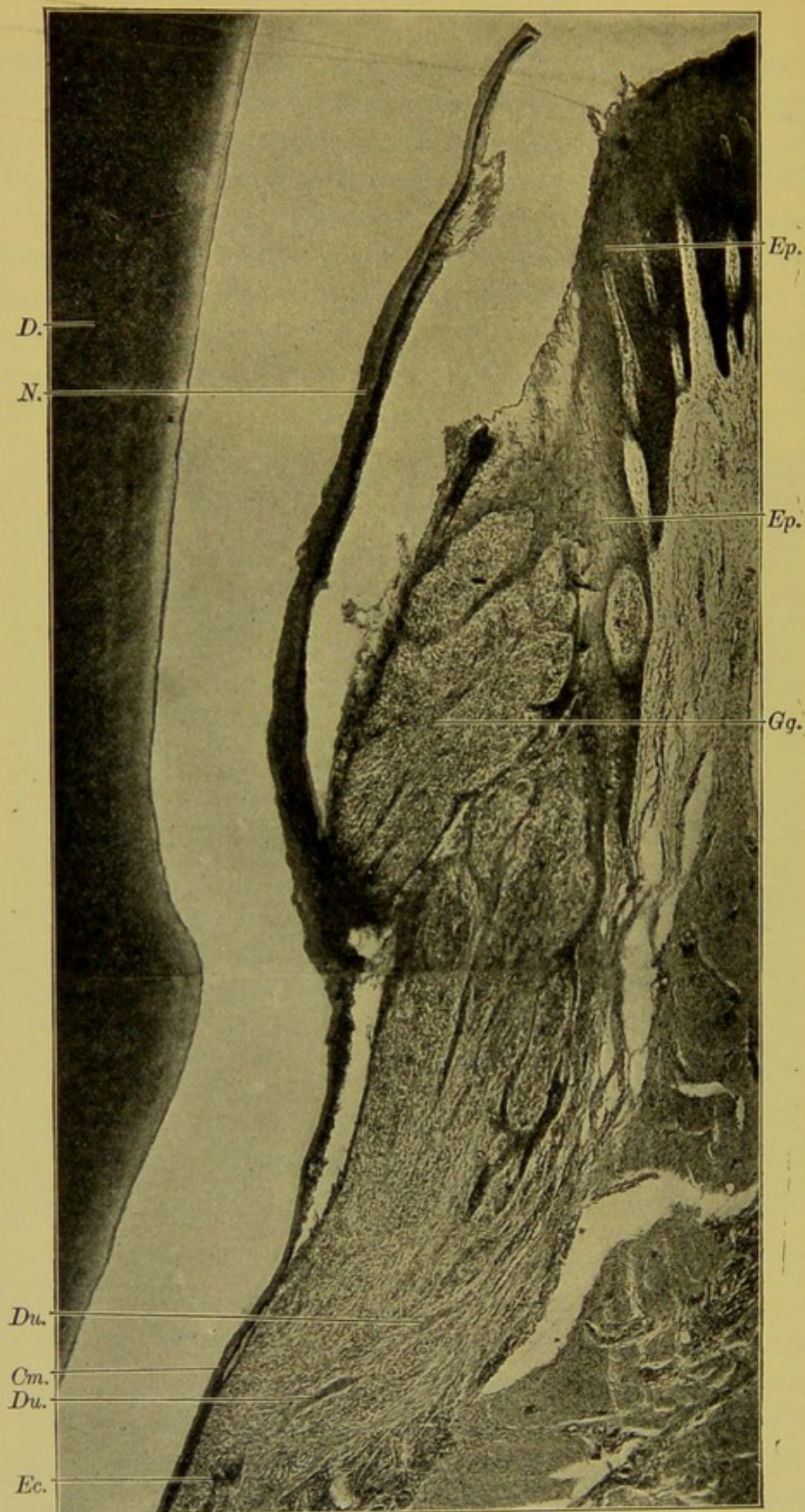


Epithelial structures: *Ec*, epithelial cord, apparently showing a lumen; *Cb*, cementoblasts; *Cm*, cementum; *D*, dentine. $\times 500$ (about). (Noyes.)

The Pericemental Glands. Black has described gland-like structures lying in the pericementum nearer the cementum than the alveolar wall. These are distributed over the root in a network, as shown in Fig. 128.

They are convoluted cords of epithelial cells invested with a delicate basement membrane and can be traced to the epithelium of the gingival space, but not to the surface.

Traces of a lumen have been seen, which if established as common



Longitudinal section: *Ep*, epithelium lining the gingival space: *Gg*, gingival gland, so-called; *D*, dentine; *N*, Nasmyth's membrane; *Du*, duct-like structure stretching away toward the gingivus from the epithelial cord, seen at *Ec*; *Cm*, cementum, separated from the dentine by decalcification. $\times 50$ (about). (Noyes.)

would constitute them as tubes. Their function is not definitely known, but it is presumptive that they are either secreting glands or lymphatics. The entrance of bacteria from the gingival space to deep portions of the pericementum, there to develop, may possibly be favored by their presence (Figs. 122 and 129).

Glands of Serres. At the deepest portion of the gingival space is found a gland-like body which has been given the above name. Its function is not known (Fig. 130, *Gg*).

The Cellular Elements. The fibroblasts are spindle-shaped cells destined to become mature fibres. They lie among the other fibres. The cementoblasts lie along the cementum and are the cementum builders. Osteoblasts are found engaged in bone construction along the alveolar wall. (See Figs. 64 and 65.)

Osteoclasts, large multinucleated cells, lie at points along the cementum of teeth and alveolar bone. Their office is the removal of bony tissue. They remove both the organic and inorganic material, and their effects are seen upon the cementum and dentine of the roots of teeth undergoing resorption, also upon resorbed alveolar process. The excavations in which they lie at work are called Howship's lacunæ.

Calcospherites are sometimes found within the substance of the pericemental membrane and may have some significance in relation to its diseases.

The pericementum in the young is comparatively large and vascular, and in the old becomes much attenuated, more fibrous, less vascular, and subject to degeneration.

Union of alveolar bone and cementum but rarely occurs, though a mechanical attachment by fibrous pericementum may occur. On the other hand, the union of the cementum of one tooth with that of another is not uncommon. (See Malformations of the Teeth.)

CHAPTER VII.

THE SURGICAL ANATOMY OF THE TEETH.

By the surgical anatomy of the teeth is meant the peculiar relation of the tissues of the teeth and of the parts immediately adjacent to diseases arising either within the teeth or in other parts.

THE TISSUES OF THE TEETH VIEWED SURGICALLY.

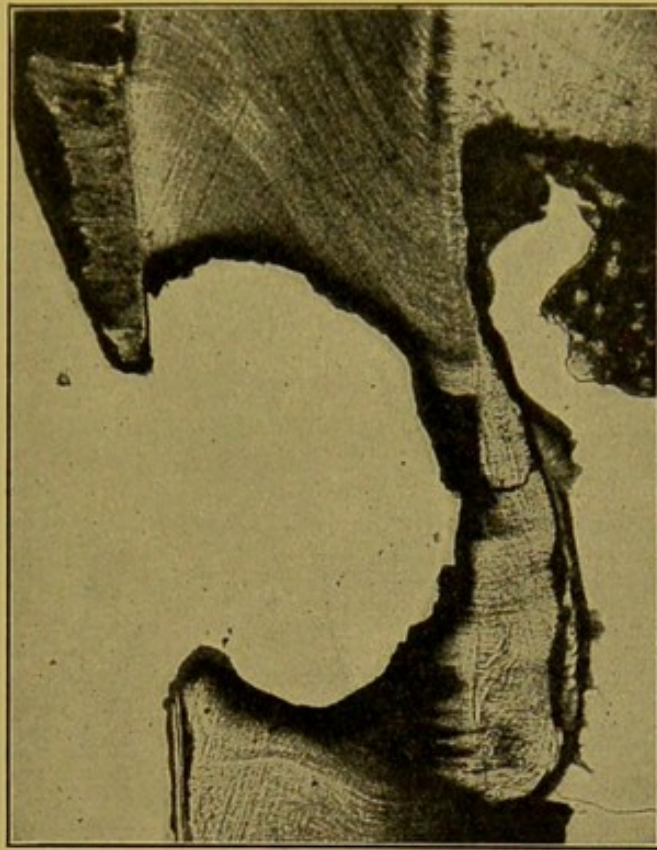
Nasmyth's Membrane. The enamel of the newly erupted tooth is covered by Nasmyth's membrane. This is soon worn off at points exposed to wear, persisting longest at the necks and in the fissures of the enamel, in which situations it may serve as a breeding ground for micro-organisms.

The Enamel. Enamel once formed is considered to have lost its source of nutrition with the atrophy of the ameloblasts into Nasmyth's membrane. If Caush be right, it is possible that it receives nutrition *via* the enamel tubes; otherwise, it is only a protective covering for the dentine. Its resistance to acids is insufficient to be effective if the action of the acid be concentrated upon it for a time, yet it is much more resistant in this respect than dentine. This, however, is probably because of its smoothness and homogeneity of structure.

"If two blocks of equal size, one of enamel and one of dentine, be subjected to stress, it is seen that the enamel block crushes at a much lower stress than that of dentine, the latter being elastic, the former inelastic; this appears to be true no matter in what axis the enamel is pressed upon; but if a layer of material such as a mat of soft gold be interposed between the enamel and the instrument pressing upon it, its resistance is much increased."¹ If sections of the crowns of teeth be made, it will be seen that there is a mechanical arrangement of the enamel elements and substances fitted to counteract the innate brittleness of the substance itself. First, the enamel surfaces are highly polished, so that there is a minimum of friction between opposing teeth; any increase of roughness or any jaggedness of enamel robs the teeth of this advantage. Secondly, it will be noticed that nearly

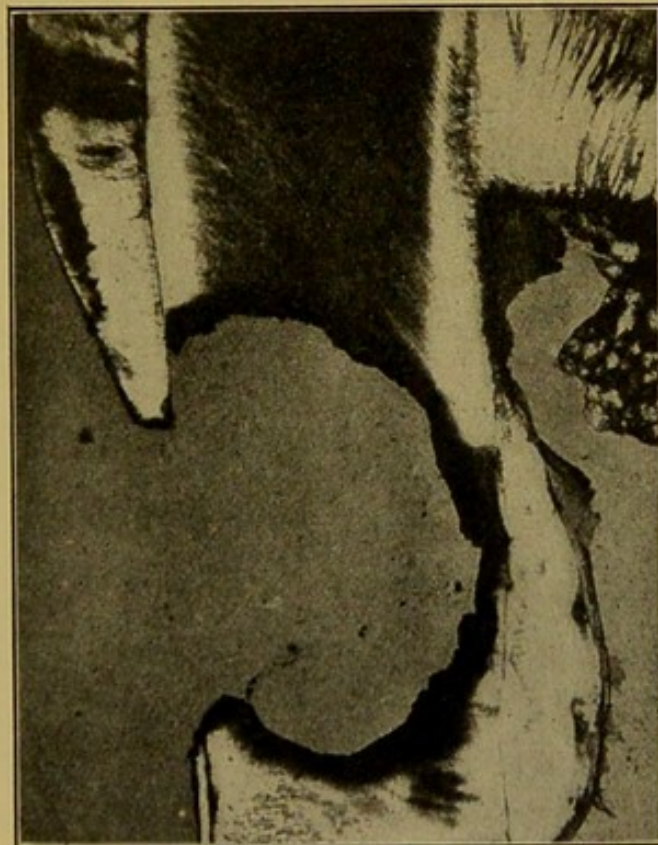
¹ Black.

FIG. 131.



Section showing carious cavity, secondary dentine, and pulp nodules by ordinary transmitted illumination. (Kirk.)

FIG. 132.



Same as Fig. 131, showing greater transparency of highly calcified structures by polarized light. (Kirk.)

all of the enamel surfaces which are brought into action during mastication receive mechanical support through an appropriate arrangement of enamel masses.

Its attachment to the dentine is greatest in vital teeth, owing probably to the integrity of the dentinal tissue at the point of attachment; nevertheless the attachment is considerable in even devitalized teeth.

The arrangement of the enamel rods is such as to afford the greatest possible resistance to stress.

The Dentine. Dentine is the second hardest tissue of the body. The texture of this tissue changes, as does that of the other connective tissues, with age. In the young or immature dentine there is a greater ratio of organic matter than in the dentine of a middle-aged person. The increase of calcium salts, the inorganic constituents, has been shown by Black not to be so great as was formerly believed. The average amount of calcium salts in teeth at the age of 11 years is found to be 62.26 per cent.; at 53 years the percentage is 64.56. The average specific gravity at 11 years is 1.066, and at 63 years 2.109. While in the main the increase of specific gravity corresponds with the increase of calcium salts, it is not constant. Between the ages of twenty and forty years there appears to be a cessation in the increase of calcium salts.


These facts show that increase of density is caused by deposition of dentinal substance rather than a mere increase of calcium salts. (See Transparency of Dentine.)

Dentine is an elastic substance: a cube of $\frac{8}{100}$ inch side under a stress of 150 pounds is compressed 4 per cent. of its thickness, resuming its form after removal of the pressure. Under a pressure of 238 pounds the cube is crushed. Clear and translucent dentine has a high crushing stress; in opaque specimens it is much lower. An increase in the percentage of calcium salts diminishes the elasticity of dentine; but the amount of crushing stress appears to be governed more by the condition of the organic matrix than by the percentage of calcium salts or the density. When the nutrition of the dentine is interfered with by secondary deposits, or destroyed through death of the dental pulp, the dentine appears to diminish in strength, as seen in the abraded teeth of elderly persons.

The average percentage of organic matter in dentine is 25.36; this diminishes as the density increases. Black believes that the condition of the organic matrix of the teeth has more to do with the strength of the teeth than have the density and specific gravity. The proportion

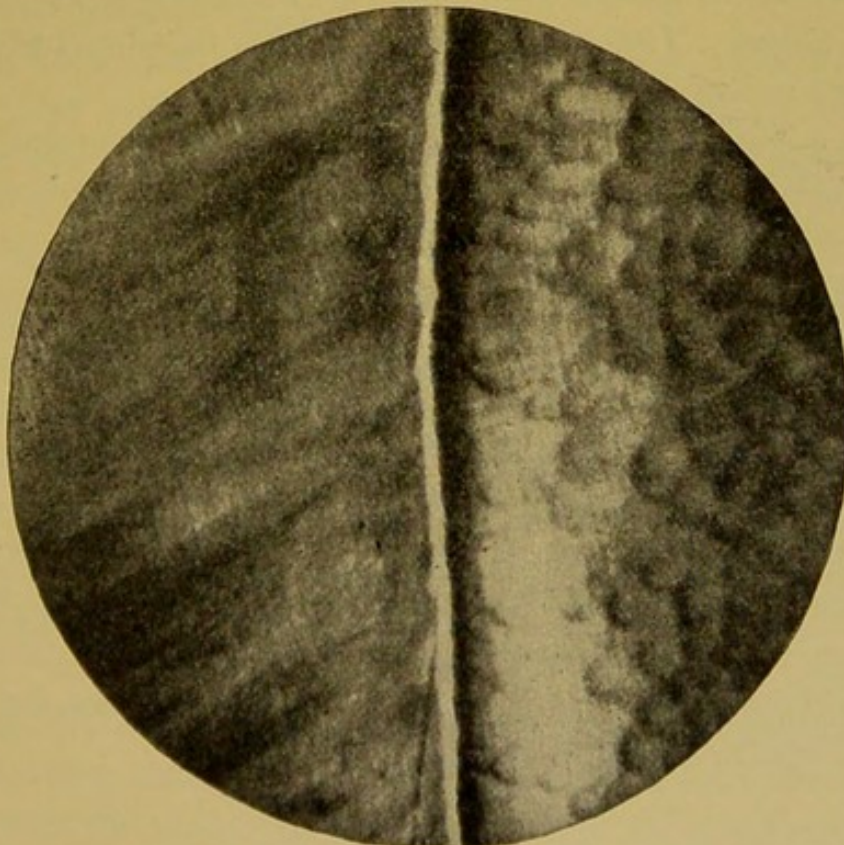
of organic matter, as pointed out by Miller, is not an exact measure of the hardness of the dentine, for many interglobular spaces and wide

FIG. 133.



Enamel and dentine of deciduous molar. (Kirk.)

FIG. 134.



Same as Fig. 133, photographed by polarized light. (Kirk.)

tubules may account for a high percentage of organic matter, and yet the dentine of the tooth be very dense.

Black's researches showed that there is a greater variation in the density and specific gravity of the individual teeth of a denture than is found in the general average density of many persons.

Investigations conducted by Kirk¹ with polarized light, to determine possible variations in the degree of density or calcification of the various structures composing the teeth, show that such variations exist, not only in different teeth, but in the same tooth and the same tissue of the tooth, and even within what are apparently normal tissues. The variations probably represent the nature and degree of calcification or possible alterations as the result of sclerotic change.

The dentine presents for consideration several structures of surgical interest:

1. The subenamel dentine.
2. The body of the dentine containing tubules and intertubular substance.
3. The protoplasmic material in the tubules.
4. Accidental malformations, such as interglobular spaces.
5. The pulp cavities.

That portion of dentine just beneath the enamel seems more subject to the action of the causes of caries than the more typical dentine, so that once access is gained to it the micro-organisms spread readily along this tissue. The decussations of the tubules, however, may assist in this process.

Sections of teeth which have been subjected to the prolonged action of dilute acids show that the dentine immediately surrounding the protoplasmic filaments from the odontoblasts is more resistant to the action of the acids than the formed material of the dentine. Noting this comparative insolubility, this portion of the dentine (Neumann's sheaths) has been accepted as a partially calcified tissue.

There seems to be no rational foundation for the contention of the Heitzmann school of histologists that the basis substance of dentine undergoes retrograde metamorphosis or return to the embryonic condition during dental caries, Miller having shown that the embryonal elements are in reality micro-organisms, or that resorption and redepositions occur during pregnancy. Black's analyses indicate that no such resorption and deposition occur.

¹ Dental Cosmos, May, 1903.

The dentinal fibril is the occupant of the lumen of the tubule. These tubules afford avenues by which the fungi of caries gain deep access to the dentine, and working from which sites they readily destroy the tubule wall and intertubular substances. During the process the fibrillæ have their function at first exalted and are then destroyed for a distance. The exaltation of function causes some vital manifestations capable of interpretation as a resistance to the progress of caries, abrasion, or erosion. (See Hypersensitivity of Dentine, Tubular Calcification, Secondary Dentine).

Interglobular spaces existing in the dentine contain an uncalcified material through which the tubules pass uninterruptedly. The fungi of caries obtaining access to them *via* the tubules, etc., multiply readily at the expense of their contents, the process of caries being thereby accelerated.

The uncovering of the dentine from any cause exposes its fibrillæ, which, being acted upon by external agencies, may become hyperæsthetic, producing the phenomenon of hypersensitive dentine.

The Pulp and the Pulp Cavities. The pulp occupies the pulp chamber of the crown, and one radicular portion runs into each root canal. It conforms in regularity to the outline of the pulp cavity or cavities and extends through the apical foramen or foramina, to be fused with the tissue of the apical space from which it derives its vascular and neural supply.

Beneath each cusp or incisal angle of the crown it has fine projections called cornua (horns), which render exposure by caries or excavation liable to first occur at that point. It is attached to the dentine by means of its odontoblastic prolongations—the fibrillæ. In a general way its form is a miniature of the external form of the tooth, but differences in relative length of cornua occur (Fig. 138).

The vascular network of the pulp is in close relation to the odontoblasts, and nerves have been traced to endings between them, though as yet no nerve fibrils ending in the odontoblasts have been discovered. The attenuation of the muscular coats of the vessels has a direct relation to the hyperæmic diseases of the pulp. The lack of tactile nerve endings in the pulp accounts for the reflected character of its pains.

The constriction of the pulp at the apex renders its arteries and veins liable to mutual compression during hyperæmia, and the relations of the pulp with the apical tissue render liable the involvement of one in disease of the other. The pulp decreases in size with age and under

stimulus of certain dental diseases in exact ratio with the diminution in size of the pulp cavity.

It also at times forms within itself hard bodies known in a general way as pulp nodules.

FIG. 135.

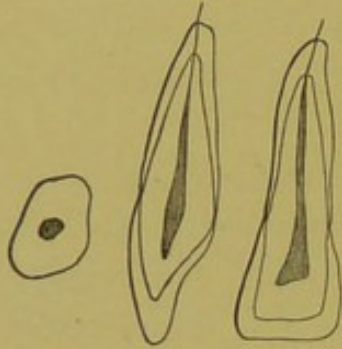


FIG. 136.

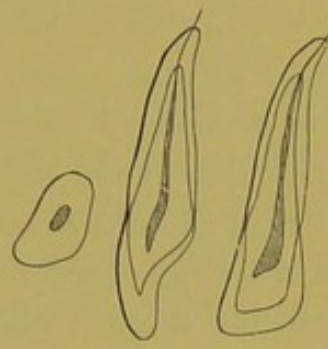


FIG. 137.

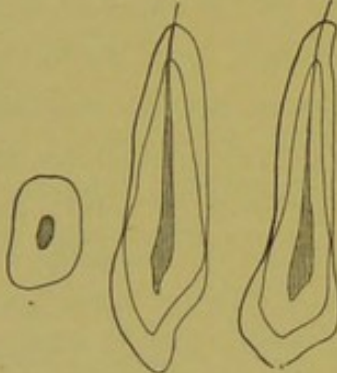


FIG. 138.

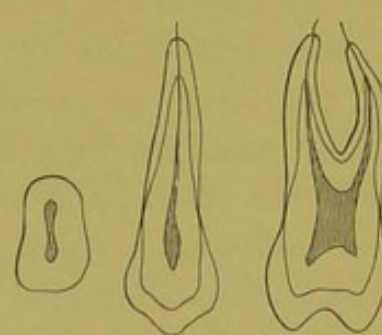


FIG. 139.

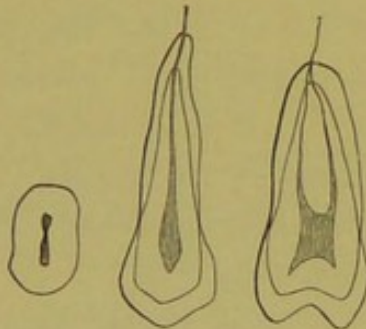


FIG. 140.

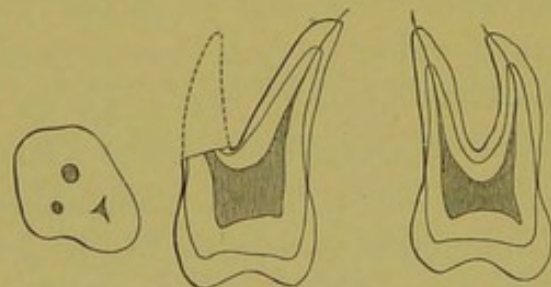


FIG. 141.

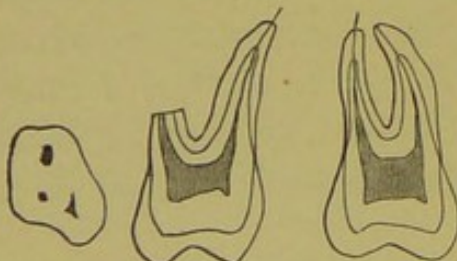
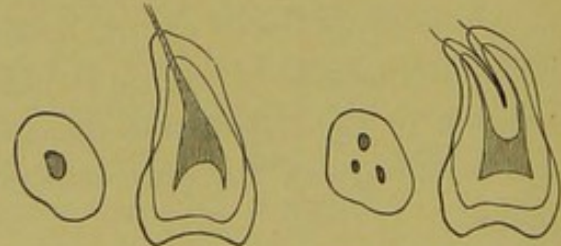


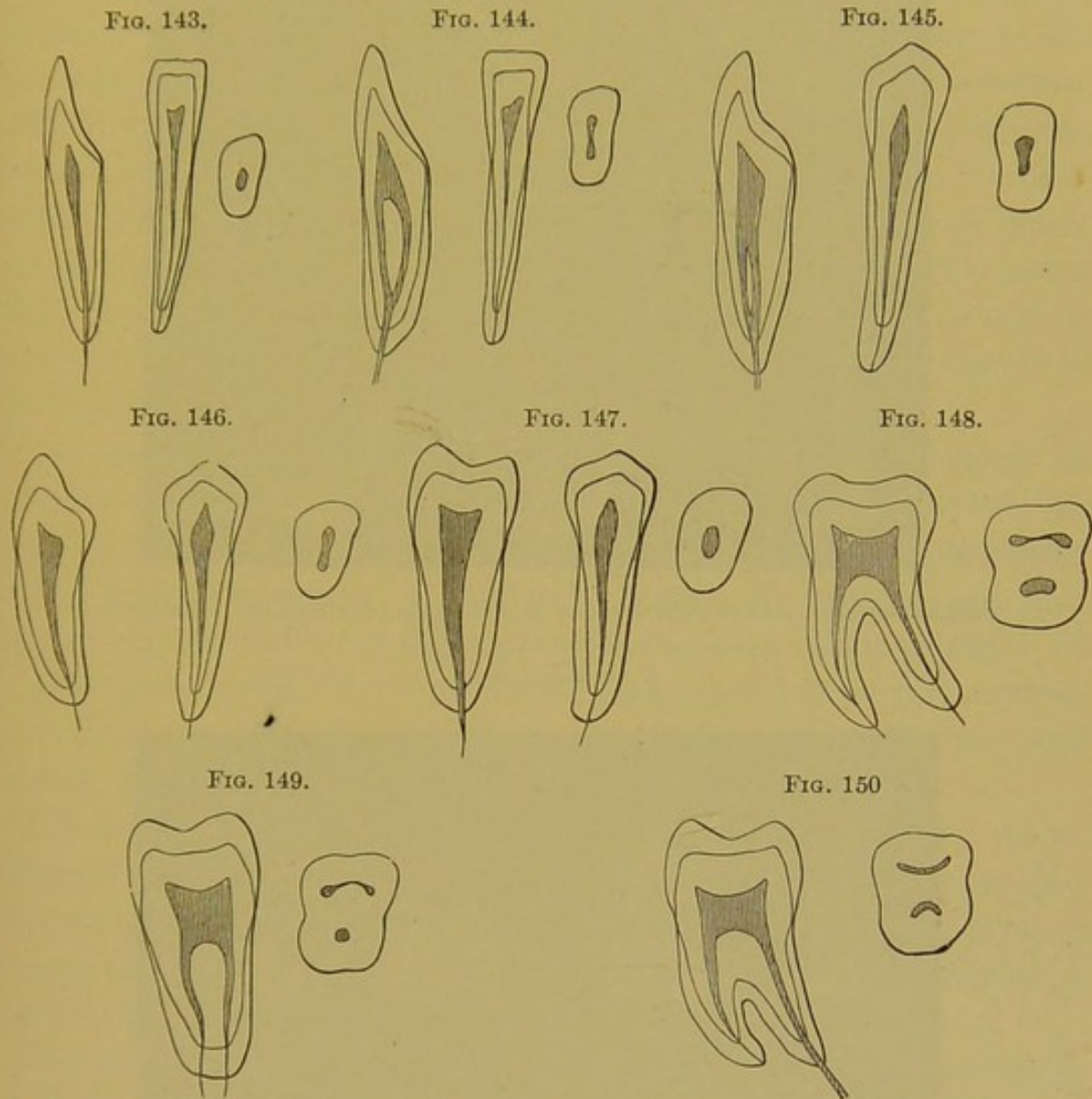
FIG. 142.



Longitudinal and transverse sections of upper teeth, showing shapes of pulp chambers and their positions.

The general forms of the pulp cavities may be studied in: (1) longitudinal and transverse sections of extracted teeth; (2) by direct and

tactile observation of such teeth in the mouth during the course of treatment; (3) by skiagraphs of teeth *in situ*, and (4) by the use of formalin gelatin injected into pulp canals of extracted teeth. After hardening the tooth is itself digested away, leaving the formalin gelatin as a cast of the canal interior (Figs. 151 and 152).




Longitudinal and transverse sections of lower teeth, showing shapes of pulp chambers and their positions.

The form and location of pulp cavities are of importance in considering the depth of possible excavation of cavities, the exposure of pulps by caries, the formation of secondary dentine, and the necessary treatment of pulps and of pulp canals in the therapeutics of diseases of the pulp and pericementum.

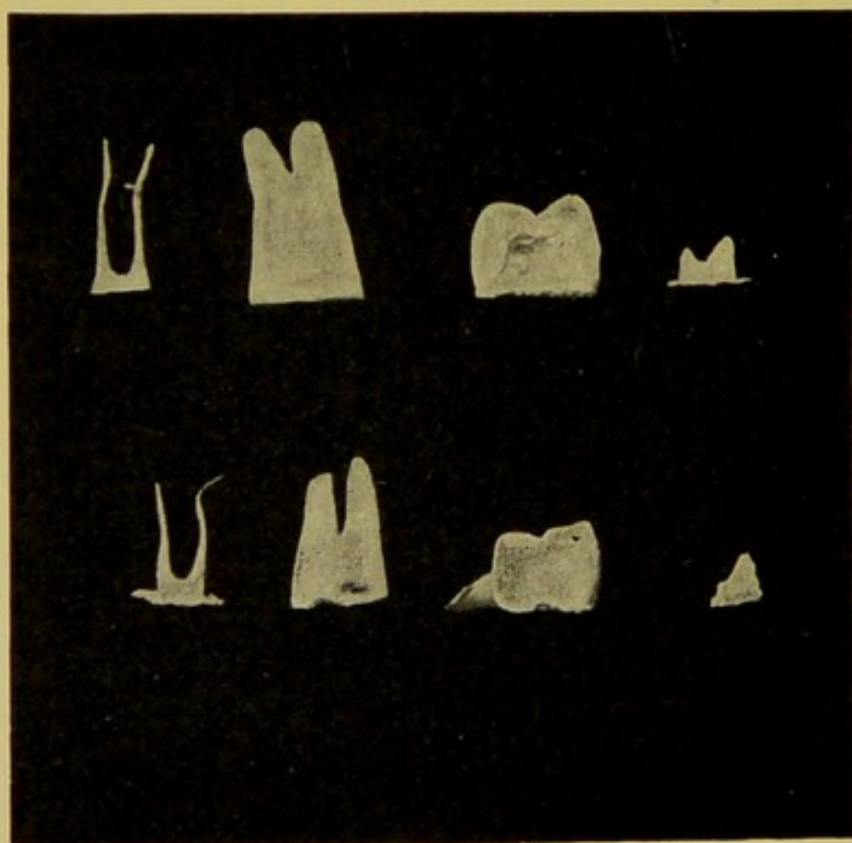
Cementum and Pericementum. At the apex of the root the pulp is continuous with the structures external to the tooth, viz., the pericementum.

FIG. 151.



Formalin-gelatin casts of pulp cavities, showing pulp irregularities. (Richards.)

FIG. 152.



Formalin-gelatin casts of pulp cavities compared with the teeth themselves. (Richards.)

The pericementum is the touch organ of the tooth, the nerves possessing the sense of location. The pericementum is the mutual periosteum of the cementum of the tooth and of the enclosing alveolar wall; reflected over the external alveolar wall this periosteum becomes continuous with the general maxillary periosteum. In addition, the pericementum is the ligament binding the tooth in its articular (the alveolar) walls. As a periosteum it is a source of nutrition to the cementum and to portions of the alveolar walls, so that interference with its vascular supply is followed by malnutrition of these tissues, the effects being governed by the extent of the interference. (See General Pathology). As a ligamentous tissue, its fibres, as shown by Black, have a peculiar arrangement. The bundles of fibrous connective tissue which pass from the alveolar walls to the cementum are oblique in their general direction, the fibres passing from a point nearer the margin of the alveolus to a deeper portion of the root.

The nerves of the pericementum are accustomed to a degree of pressure represented in the amount of force necessary to crush the particles of food; if subjected to a greater stress, they rebel. Similarly, if their functional activity is exalted in hyperæmic disturbances, they become cognizant of very slight pressure and react more strongly. It is to be remembered, however, that the teeth rarely receive direct stress, the movements of the teeth in mastication being more of a rotary and laterally moving character, than perpendicular.

The elasticity of the pericementum is to be regarded also as an adjuvant to the local circulation; by its movements the blood is pumped through the vessels of the part. This fact becomes important when it is recognized that in some dentures increasing age is accompanied by a lessening of the volume and elasticity of the pericementum.

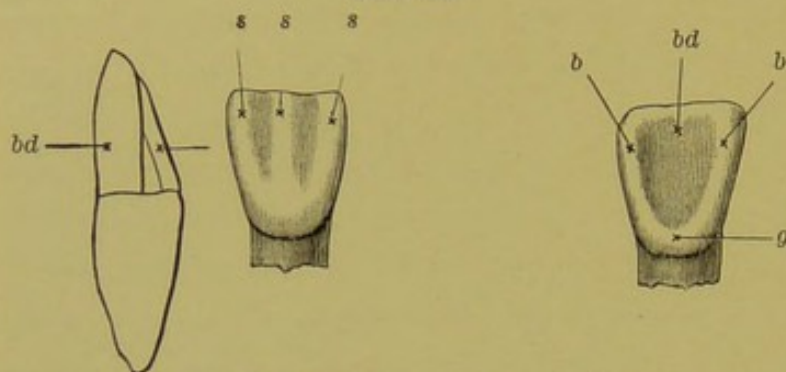
The power of recovery of the pericementum after injury appears to be very great. It will be observed that the pericementum has two sources of vascularity: one from the apical vessels, that from which the vascular supply of the pulp arises; the other, an anastomotic circulation from the alveolar walls, directly and indirectly from the general alveolar periosteum. When the apical vessel trunks have been obliterated as the result of disease the pericementum receives from the anastomotic circulation a blood supply practically sufficient.

The cementum maintains its vitality so long as the pericementum is intact; in the condition just mentioned it is evident that the apical portion of the cementum dies, or is at best very ill-nourished. The layer of cementoblasts (osteogenetic cells) retain their function so long

as the pericementum is intact, and under varied conditions exert their constructive function in an irregular manner. (See Hypercementosis.)

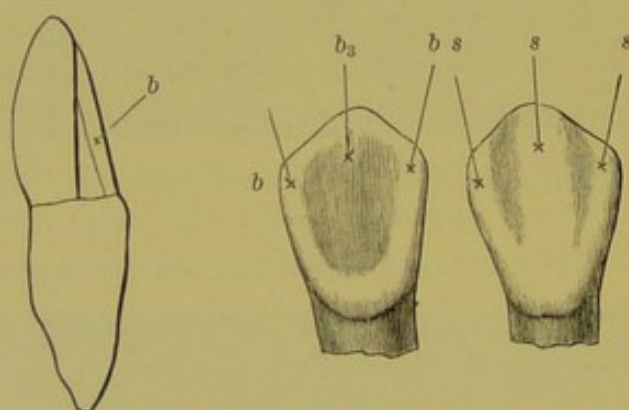
The Teeth as Mechanical Appliances. Architecturally the upper incisors and cuspids are protected against an outward strain from

FIG. 153.



Architectural structure of an incisor.

FIG. 154.



Architectural structure of a cuspid.

the antagonizing lower teeth, tending to break away the labial section of the teeth (Fig. 153, *bd*) by buttresses (Fig. 153, *b, b*) and a cervical girdle (Fig. 153, *g*), and are further fortified by labial stanchions (Figs. 153 and 154, *s s s*).

FIG. 155.

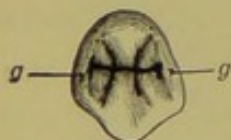

FIG. 156.

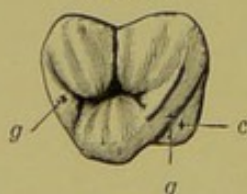
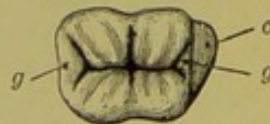

FIG. 157.



Architectural elements of bicuspid and molars.

The bicuspid and molars receiving the cusps of antagonizing teeth into their sulci, which are, architecturally speaking, points of weakness, have a tendency to split between the cusps, which are strengthened by girders (Figs. 155, 156 and 157, *g*).

Decay destroying any of these points weakens the teeth, but up to a certain point loss of tissue is not fatal to the integrity of the tooth, as shown by its behavior, both before and after filling for dental caries.

An excessive loss of dentine, however, is apt to be followed by fracture when an undue strain is applied. The dentine of devitalized teeth has less cohesion than vital dentine, but in otherwise sound teeth it is sufficient for ordinary use.

FIG. 158.

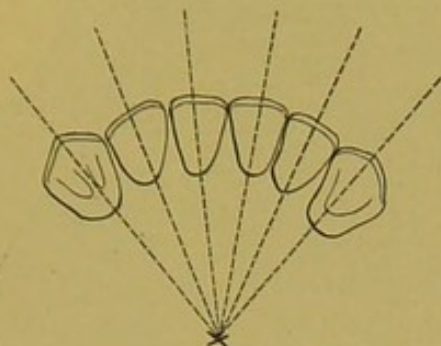
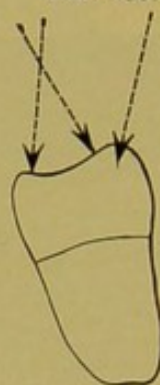

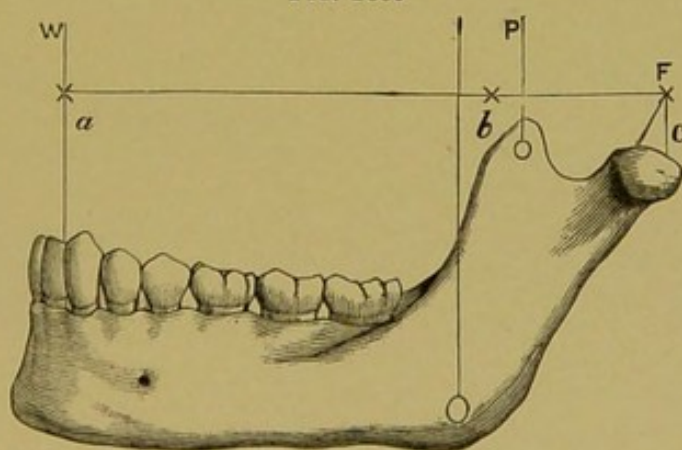
FIG. 159.



The rotary movements of the lower jaw bring about between the teeth a gliding movement of their articular surfaces rather than a direct impact, which, however, may be imparted in the effort to crush hard bodies.

In the lower anterior teeth labio lingual stress exerted by the upper teeth forces the teeth together laterally, affording mutual support (Fig. 158).

FIG. 160.



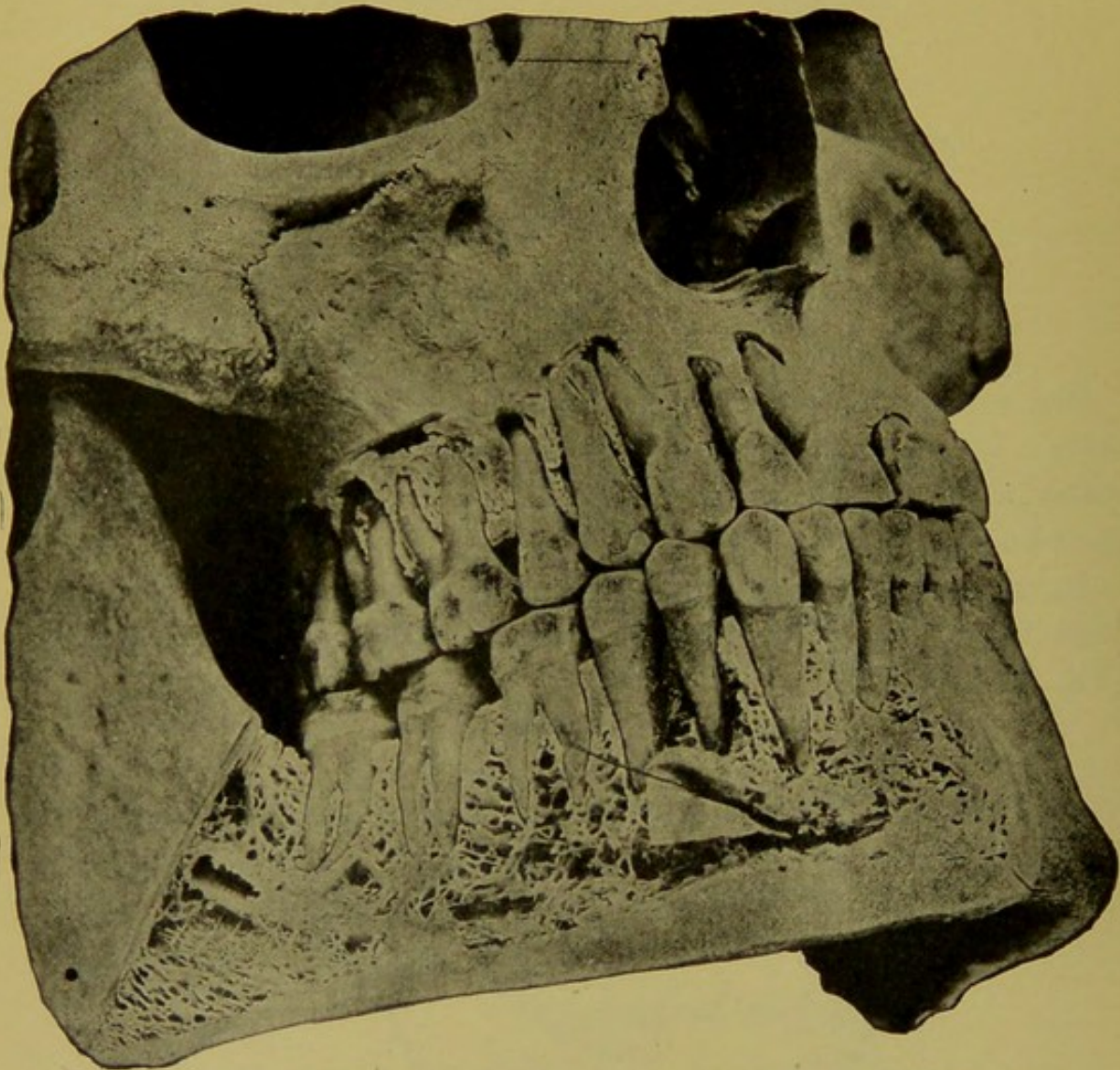
The lower jaw as a lever of the third class.

The upper anterior teeth enclosing the lower anterior teeth prevents outward displacement of the latter by the force of the tongue. The upper posterior teeth are inclined outward, the lower posterior teeth inward, an arrangement best suited to resist the mutual pressure exerted in mastication.

The enamel dentine and cementum, if exposed, are subject to the action of abrasion, erosion, and caries (which see).

The Alveolar Process. The alveolar process is that portion of bone which is continuous with the body of the maxilla, and is built up as a support to the teeth. In general it differs but little from the bone of the jaw, consisting internally of cancellated bone bounded by more dense bone externally. The surface of bone lining the alveoli is also

FIG. 161.



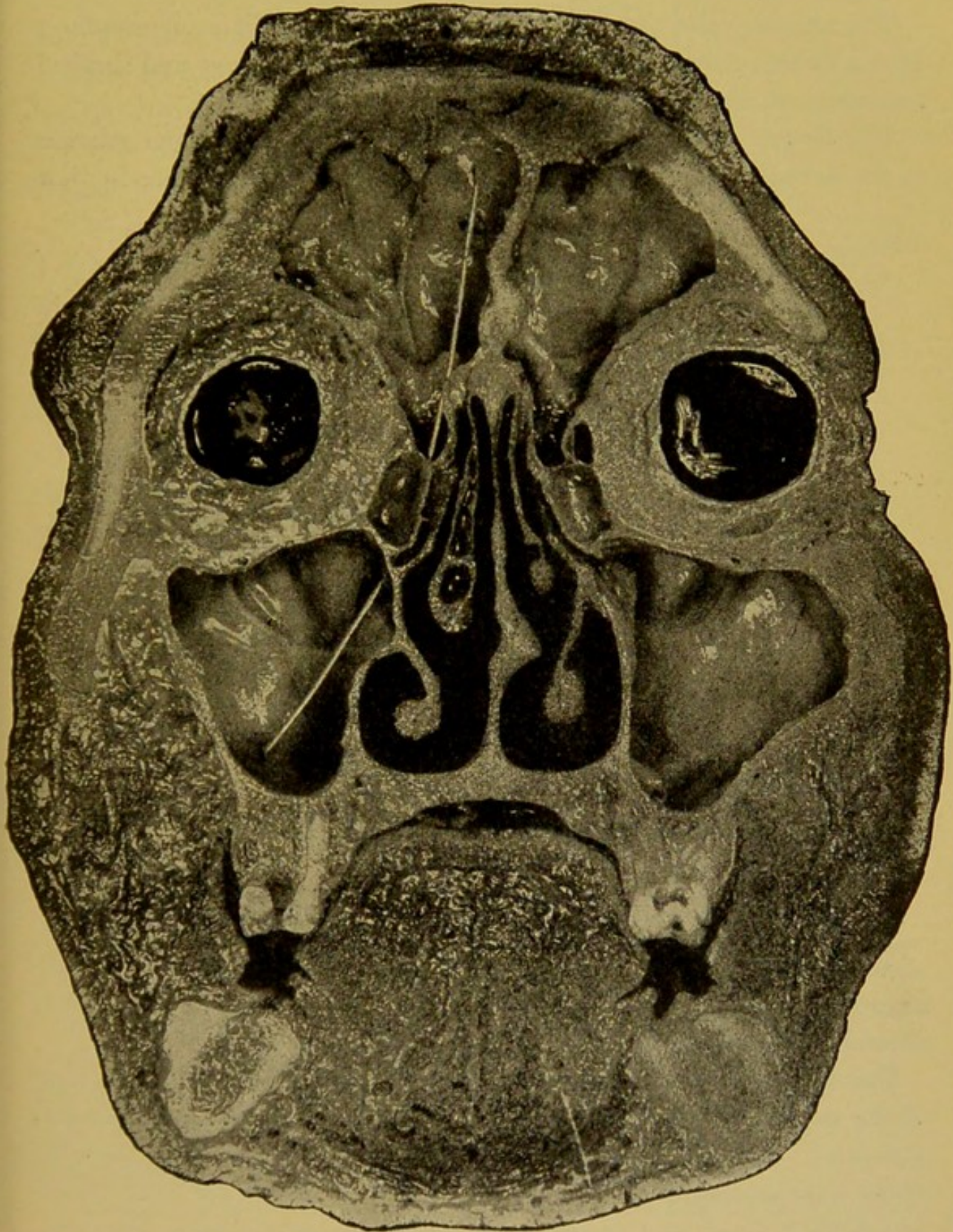
Showing the buccal surfaces of the crowns and roots in position. (Cryer.)

fairly dense, being, however, pierced by many spaces affording passage of vessels to the pericementum. The openings in the cancellated bone contain red bone-marrow. The walls of the alveoli afford attachment to the pericementum, which thus becomes its periosteum. The division of the pericementum into an alveolar and cemental membrane having different functions is not regarded favorably by Tomes, though claimed by some histologists.

The relations of the teeth and alveolar process are further shown by Figs. 162 and 168.

Under the action of chronic inflammation the cancellated bone

FIG. 162.



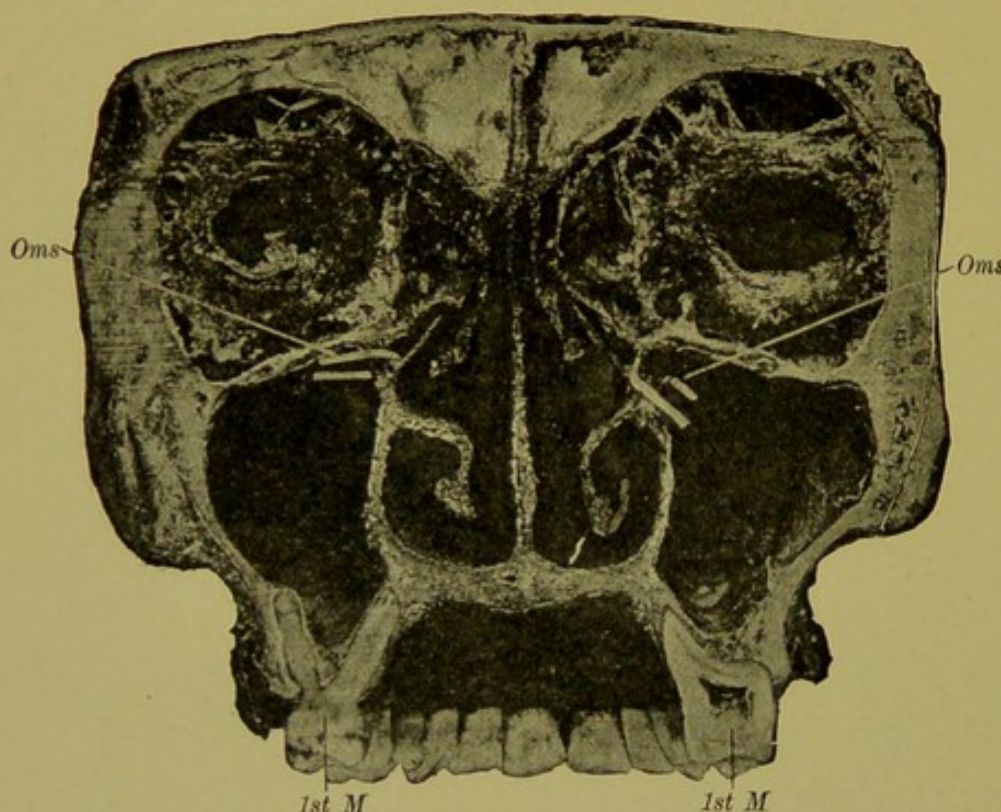
Vertical section of a frozen head, rear view. Shows relations of roots of molars and the maxillary sinus, and of the maxillary sinus with the frontal sinus. Wire passes from the latter through the infundibulum, the hiatus semilunaris, and the ostium maxillare, into the maxillary sinus, establishing a connection. (Cryer.)

may undergo a constructive change (condensing osteitis), and is more firmly bound to the cortical bone. Cryer has shown that this may prevent the forward movement of the cancellated bone and thus prevent the proper placement of teeth in the jaw. He regards this as a cause of impaction.

The anatomy and histology of the teeth and immediate surroundings have a direct relation to the consideration of the pathology and surgical treatment of diseases of the parts.

The length, size, number, and form of roots bear a direct relation to the security of implantation, a consideration of importance in view

FIG. 163.



Section of somewhat dried specimen: *Oms*, opening maxillary sinus; *1st M*, first molar. (Cryer.)

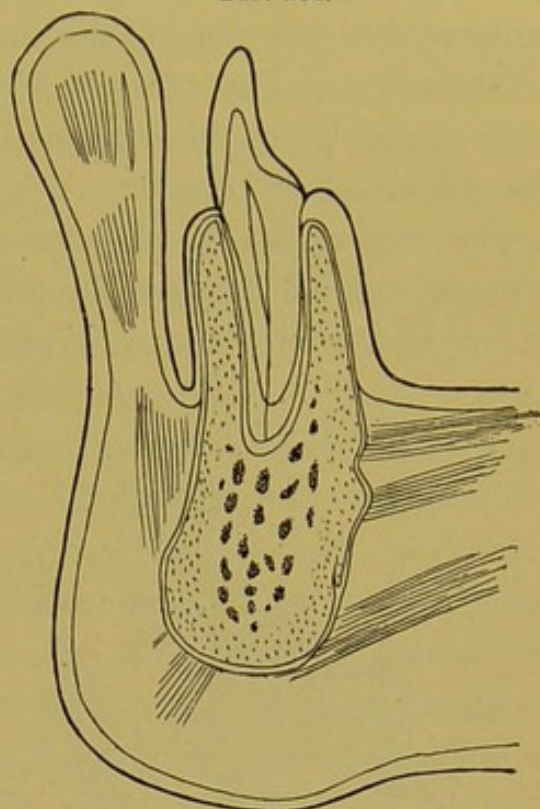
of the strains to be brought to bear upon prosthetic appliances, such as crowns, bridges or plates, or upon remaining natural teeth. In the determination of such conditions *x*-ray skiagraphs are valuable.

The Lower Denture. Reference to Fig. 164 will show the relation of the roots of the lower incisors and cuspids to the alveolar process and jaw. The apices of the roots lie at a point below the reflection of the mucous membrane. Labially the bone is thick over their apices and at their necks, and sometimes thin at the middle portion; lingually the bone is thickest over the apices. Apical abscesses tend to discharge labially, following a course from the apex to a point above the mucous

reflection. They sometimes discharge lingually. They may follow the cancellated bone and penetrate the cortical layer at the rim of the jaw and discharge through the soft tissues upon the chin. Again, penetrating the cortical bone labially, they may dissect away the periosteum of the bone and, reaching the rim of the jaw, discharge through the soft tissue upon the chin. (See Chronic Apical Abscess.)

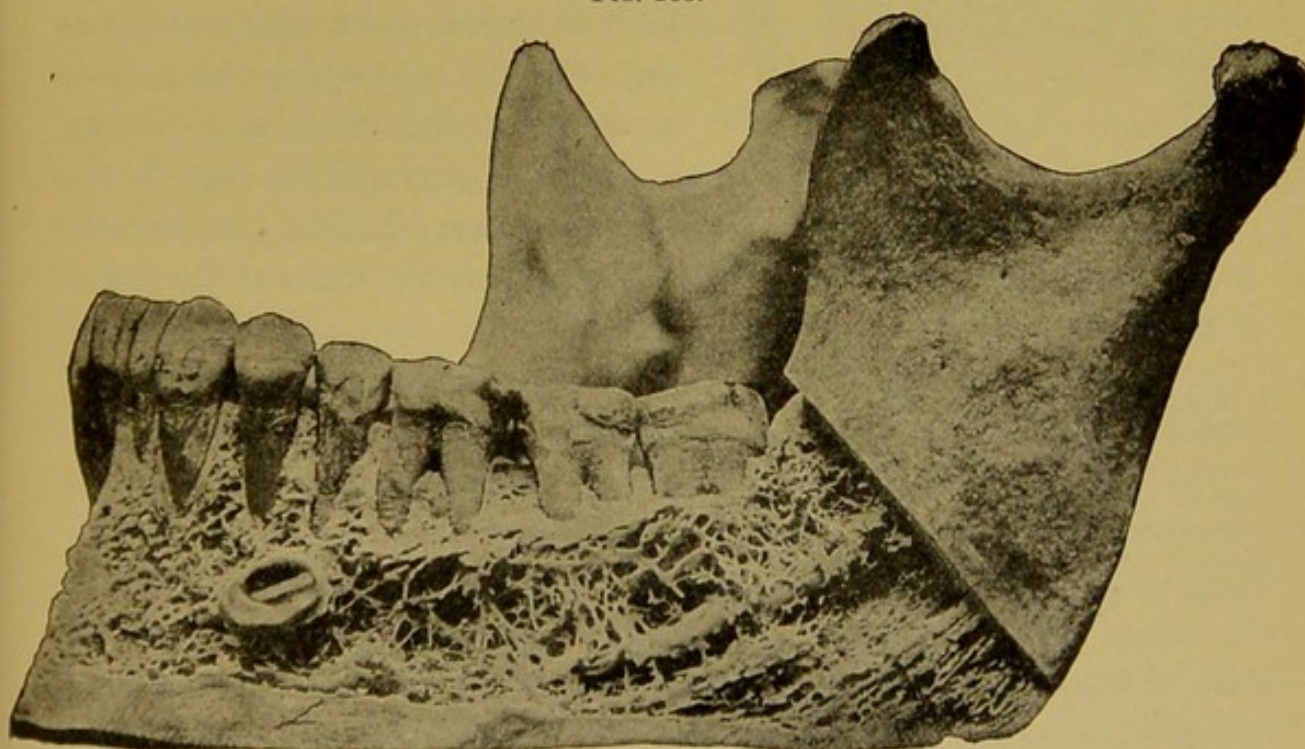
The bone overlying the roots of the lower bicuspid at their lingual aspects is sometimes relatively thin, as it forms the wall of the sublingual fossa. Upon the buccal face the cortical bone is in greater amount, although thin. The spaces between the first and second bicuspid usually mark a site immediately above the mental foramen, although the

FIG. 164.



A longitudinal section through a lower central incisor and its neighboring parts.

FIG. 165.



From the same jaw as Fig. 161, showing outline of inferior dental canal and the surrounding cancellated bone. (Cryer.)

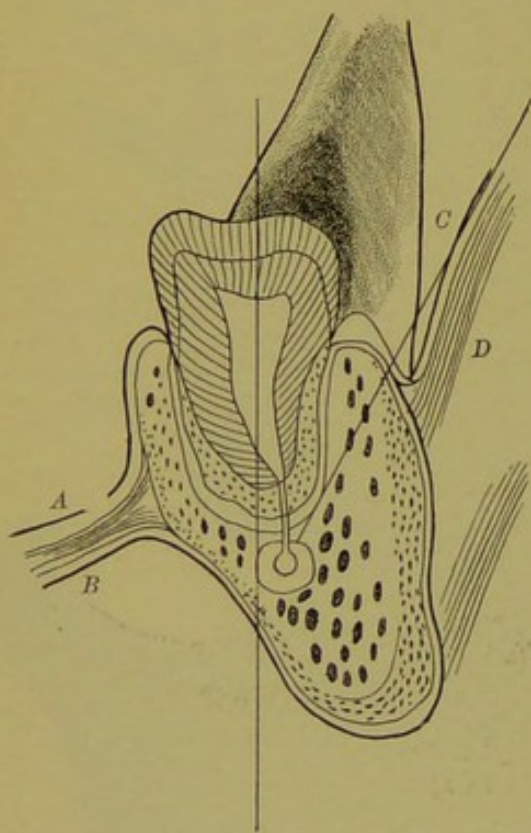
opening may be posterior, or in some cases anterior, to the position named (Fig. 165). If the roots of the bicuspid are abnormally

long, they may encroach upon the area of the foramen. This occurs most frequently with the root of the second bicuspid, affections of which tooth may cause diffused pain, apparently owing to the proximity of the root apex to the nerve trunk at the foramen.

Reference to Fig. 166 will show the relation of lower molars to the body of the bone, the alveolar process, the inferior dental canal, and the submaxillary triangle.

The root of the third lower molar may terminate at a point some distance behind the anterior pillar of the fauces. Upon the external or buccal face of the bone it will be seen that the position of the third

FIG. 166.



Showing the relations of the roots of the lower third molar with the cavities of the mouth and neck, and with the external bony wall: *A*, cavity of mouth separated from *B*, the cavity of the neck, by the mylohyoid muscles; *C*, base of coronoid process; *D*, muscles of the cheek.

molar is at times some distance posterior to the outer branch of the base of the coronoid process, the continuation of the external oblique line, so that a greater distance separates the roots of the second and third molars from the external surface of the bone than with any of the teeth of a denture. Abscess upon the roots of particularly the lower third molar, therefore, finds the path of least resistance as to pus exit, first, by destroying the pericementum of the tooth and finding exit at the gum margin, or, if the outer alveolar plate be not entirely walled in by the base of the coronoid process, through the alveolar process near the gum margin. An abscess may, by penetrating the lingual alveolar wall, open far back in the mouth, if the roots of the tooth are not deeper than the mylohyoid ridge; if the roots do pene-

trate beyond this ridge, it may open in the neck in the submaxillary triangle.

In some cases the roots of the second and third molars may immediately overlie the inferior dental canal, and the tissue intervening between the apices of the molar roots and the canal may consist of the very thin layer of perforated cortical bone which forms the roof of the canal.

In some cases a molar root may be so deeply embedded as to encroach upon the canal, lessening its lumen and causing more or less compression of the inferior dental vessels and nerves (Fig. 240). Pressure from such sources is, no doubt, the cause of obstinate maxillary neuralgias, which would be greatly exaggerated in disease conditions about the pericementum, accompanied by inflammation or even hyperæmia. In impacted third molars the pressure of some part of the tooth may cause great distortion of the course of the canal. The anatomical relations of the third lower molars are such that apical abscess upon them will have tardy vent, or else open in unusual situation.

The blood supply to the inferior maxilla through the inferior dental artery—large single trunks which traverse the bone longitudinally upon both sides—may be seriously impeded or checked by pressure upon the trunk as it enters or shortly after its entry to the canal, and thus necrosis of half the maxilla is a probable danger. In many cases, however, where the inferior dental vessels have been obliterated by operation upon one side necrosis does not occur, the anastomosis of the facial artery with the dental about the mental foramen continuing sufficient circulation to maintain vitality.

The Upper Denture. In the upper jaw the inner alveolar plate is thicker than the outer, particularly when the vault is low. In general terms, the higher the arch of the vault the thinner the inner alveolar plate. (Compare Figs. 162 and 163.)

The central incisor lies beneath the nasal cavity with its root end on a level with the lowest portion of the nasal spine. It is in somewhat close relation with the anterior palatine canal. The lateral incisor also underlies the nasal cavity at the ala nasi; its root end is one-eighth inch less implanted, though sometimes more deeply. The cuspid root lies with its apex implanted one-eighth inch deeper than that of the central. It is not under the antrum, but slightly anterior to it. In occasional instances it may underlie the lower anterior portion of the antrum.

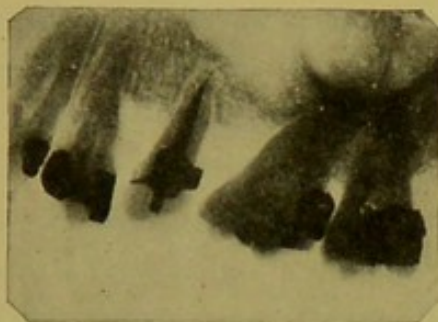
Any of the upper bicuspid or molars may underlie the antrum, but intimate association of the root apices with its floor is usual only with the second bicuspid and the molars (Fig. 167). The apices of the roots of the latter may, in abnormal skulls, lie directly in the antrum and be covered only by the periosteum and mucous membrane. In other cases the bone is thinly distributed over them.

The antrum enlarges with age,¹ and the resorption may produce the same effect.

¹ Cryer.

It is clear that alveolodental abscess may readily discharge in this situation into the sinus, or that fractures of the floor of the antrum may occur in extractions, either by crushing in or tearing out portions interlocked with roots. The elevation produced by the malar process

FIG. 167.

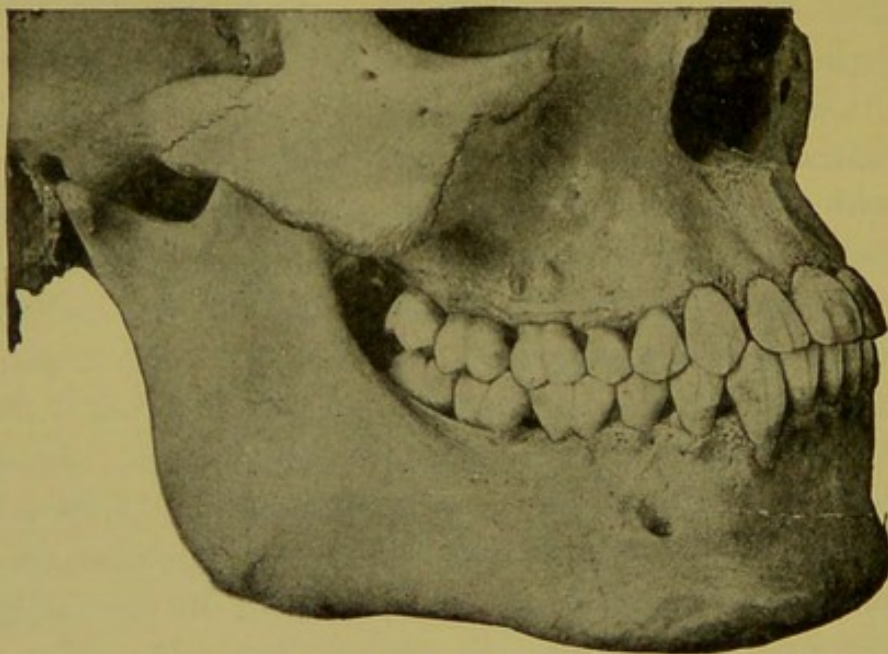


Outline of antrum. (Skiagraph by Custer.)

overlies the roots of the first molar. The roots of the upper third molar lie in the tuberosity of the upper maxilla and in close relation to the descending palatine artery. It has been pushed into the antrum in attempt at extraction, and its extraction has also resulted in fracture of this tuberosity, exposing the antrum.

It is pointed out by Cryer that the frontal sinuses may communicate with the maxillary sinus. Fig. 162 shows a wire passing from the left frontal sinus to the antrum *via* the infundibulum, hiatus semilunaris, and ostium maxillare. The possibility of relation of these sinuses in disease is plainly shown.

FIG. 168.



Front and side views of the teeth and jaws.

The Occlusion of the Teeth. Viewed in occlusion—that is, with all the teeth together and at rest—the teeth present the relation shown in Fig. 168, in which it may be seen that the occluded surfaces of the upper teeth describe a curve with the convexity slightly downward.

The lower teeth have the reverse curve.

The longer the cusps of the teeth—*i. e.*, the greater the overbite—the greater the curve of the arch will be.

The Articulation of the Teeth. The lower jaw is a lever of the third class, the fulcrum being the condyles, the weight the work done by the teeth, and the power applied at an intermediate point by the temporal muscles at the coronoid process, the masseter muscles at the ramus and angle of the jaw (Fig. 160). These produce the closing or occluding power of the jaw (occlusion). The internal pterygoid muscle attached at the inner surface of the angle draws the jaw sidewise to the side opposite that upon which the muscle is contracting. The two heads of the external pterygoid attached at the condyle project the jaw forward.

This combined action imparts to the lower jaw a forward, sidewise, and occluding movement which causes the teeth to glide over each other, the jaws being slightly opened as the articular surfaces of the molar cusps come into contact. This movement is called articulation.

Suppose Fig. 169 to represent an anterior view of an upper and lower right molar. As the lower jaw is thrust to the right the jaw slightly opens, the buccal cusp of the lower molar leaves its point of occlusion in the sulcus of the upper molar, and presents its articulating surface, *D*, to that of the buccal cusp of the upper molar, *A*. At the same time *F* glides over *C*. In the reverse motion the buccal cusp of the lower molar is returned to the sulcus, and then *E* glides over *B*, *C*, and *F*, meanwhile separating. In normally articulating molars *G* and *H* are unworn. In the bicuspid the articulation of *C* with *F* does not occur except to a very limited degree between the lower first molar and upper second bicuspid.

The lower incisors and cuspids articulate only upon their labio-incisal edges, while the upper incisors and cuspids articulate with their lingual surfaces and linguo-incisal edges, the articulation beginning at the linguo-incisal margin (with the jaws opened and lower jaw thrust forward) and gliding cervically as the jaw closes and recedes until the molars are in contact. In the lateral motion of the jaws some teeth are in articulation on both sides, and the cuspids on one side or the other are in contact. They seem, therefore, to act as guides in articulation.

FIG. 169.

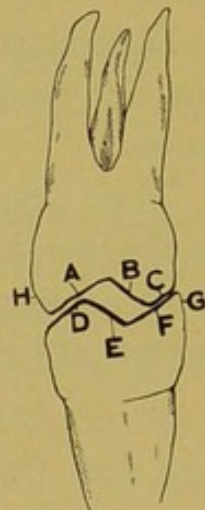


Diagram illustrating articulation.

The abnormal occlusion and articulation of the teeth are consequent upon the eruption of the teeth into irregular situations, or upon injudicious extractions, or upon diseases or habits leading them into abnormal relations with their antagonists. (See Abrasion, Malpositions, etc.)

Black¹ found by test that the force which the muscles of mastication of adults were capable of exerting was from 30 to 175 pounds on the incisors, and from 70 to 240 pounds on the molars. The figures represent the minimum and maximum total capacity found. The temporary molars averaged about 70 pounds. The amount of force required to crush foodstuffs by direct action ranges from 30 pounds for tender meats to 90 pounds for tough, fried meats; 100 pounds for hard candy, and 250 pounds for hard crusts.

Black states that many persons fail to exert the muscles to their full capacity owing to the debility of the pericementum of one or more teeth.

Diagnosis of Teeth. At a time when both temporary and permanent teeth are in the mouth they must often be carefully distinguished.

Their greater size and deeper color, as well as form and position in the mouth, characterize the permanent teeth. The temporary teeth have an abrupt shoulder of enamel at the cervix not present in the permanent teeth.

¹ Dental Cosmos, June, 1895.

CHAPTER VIII.

DENTITION: ITS PROGRESS, VARIATIONS, AND ATTENDANT DISORDERS.

THE process of teething, eruption, or dentition is comprised of that series of vital operations which causes the teeth to leave their crypts in the maxillæ, to pierce the gum, and to take their places in the dental arches. It is a continuation of the process of dental development and is accompanied and succeeded by root, alveolar, and maxillary developments, which are also to be considered in connection with it.

Physiologically dentition is divided into: (1) the first dentition or that of the temporary teeth; (2) the second dentition or that of the permanent teeth.

Examination of Fig. 96 will show the state of tooth development at a period shortly after birth (a central incisor being under consideration). The crypt is roofed over at birth by a membranous structure. During the period from then to perhaps six months after birth about one-third of the root will have been formed. (See Fig. 98.) The root end is widely open (unformed) and the margins are thin and sharp. A very vascular tissue occupies the space between the root and the bone and fills the interior of the root. Meanwhile the crown cusp has advanced from the situation shown in Fig. 96 to a point just beneath the mucous membrane, which is pressed up and stretched over the advancing tooth crown, presenting to oral view a tumefied condition more or less corresponding to the form of the crown. This is nicely shown in Fig. 170, *A* and *B*.

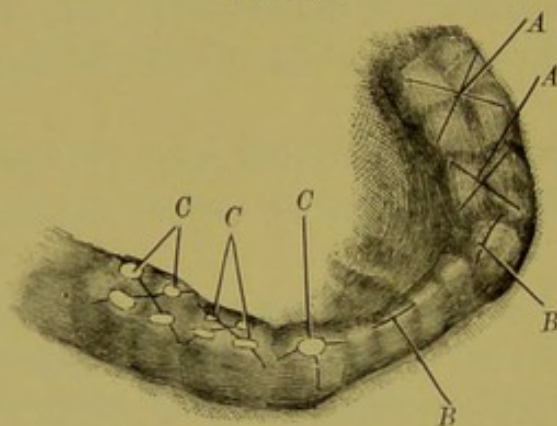
These anatomical data serve for the consideration of the causes and process of eruption.

Causes of Eruption. It is evident that there are forces which can bring about the elevation of a tooth crown from its bed in the crypt to its position in the mouth.

The consideration of these has caused the development of the following rational theories, as well as others now obsolete:

1. That crown elevation is due to the lengthening of the root—*i. e.*, as root tissue is formed by the pulp and follicular wall lying beneath and to the side of its edges, the tooth is mechanically pushed up, more root is formed, and a further extrusion occurs. It is to be noted that the root end occupies the same level, at all stages of eruption, in the developing jaw that was occupied by the cervical edge of the crown (Fig. 171). As no two bodies may occupy the same space at the same time, the root-forming pulp and follicular wall push the tooth up to gain room for more root formation. The pressure of the soft tissues against the root end is explained by Constant to be derived from the normal blood pressure.¹ That such an internal pressure exists is shown by the extrusion of ordinarily confined parts when released

FIG. 170.



Lines of incision in lancing: *A, A*, over the molars; *B, B*, over the cuspids and incisors before eruption; *C, C*, over the molars and cuspids after partial eruption.

from the accustomed pressure. A simple accident demonstrated this to the editor. While excavating with a large bur the softened dentine about a decayed pulp chamber, the cementum was widely removed from the pericemental tissue beneath which latter fortunately remained unbroken. It immediately protruded into the perforation. Constant also cites the extrusion of a tooth in pericementitis as an evidence of the influence of the blood pressure. Another evidence is the occasional rapid advance of a tooth after lancing of the gum.

2. The process of tooth development is a vital process, and that of eruption has been held also to be (Tomes). That cells concerned in development seem to have a predestined end or function cannot be denied; at the same time, throughout dental development, defined resistances to opposing forces seem to play a part in the moulding of

¹ International Dental Journal, June, 1903.

the soft and hard tissues—*e. g.*, the invagination of the enamel organ by the papilla.

3. Peirce¹ holds that the impact of blows upon the jaws causes the tooth to rise toward the gum. He explains the eruption of crowns without roots upon this theory.

4. Tomes explains the eruption of teeth, after development of the root, upon the theory that the closing in of the alveolar process or contraction of the alveolus upon the pericementum (follicular wall) causes the lifting up of the tooth. That such a closure occurs about the extruding roots of teeth left after the breaking away of the crowns is shown by examination of the sockets of such roots. An abnormally shallow alveolus closed by deposition of bone at its apex will be found

FIG. 171.

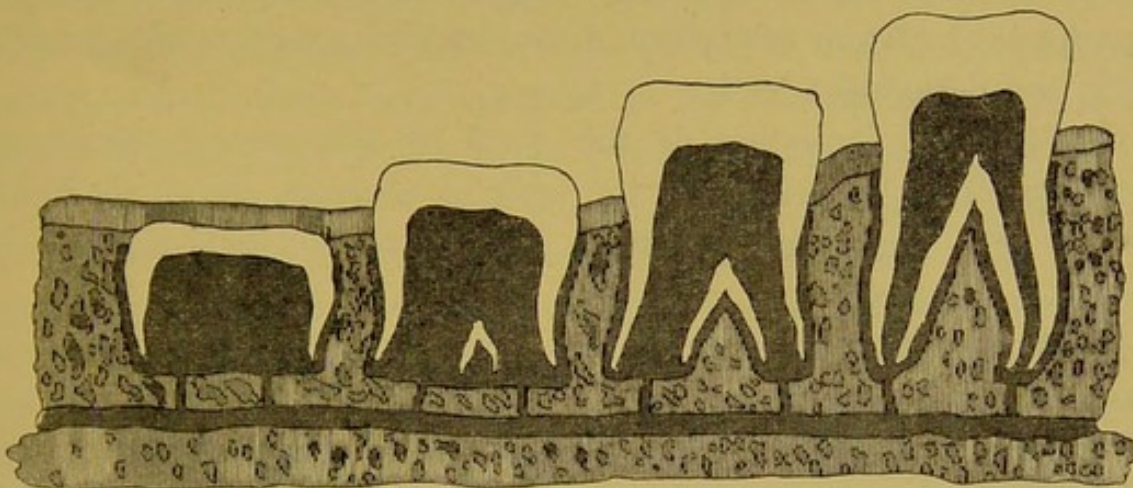


Diagram showing the upward movement of the crown during eruption and root development. (Constant.)

in cases of small apical portions of roots so extruded. Upon the whole Constant's theory of blood pressure seems the most satisfactory explanation of tooth elevation under any circumstances.

The Process of Dentition. At varying ages, according to the state of tooth development, the formed crown of the tooth advances and presses upon the follicular wall overlying it; this is resorbed, the overlying tissue is reached, and osteoclasts remove this as well as the upper edge of the wall of the crypt; the mucous membrane is pushed up and moulded over the crown, thereby causing a tumefaction.

The mucous membrane, at first normal in color, becomes slightly hyperæmic and then changes to an ischæmic condition and whitens

¹ American System of Dentistry.

cwing to the removal of the blood by the pressure of the underlying crown. Resorption from beneath causes a break in the continuity of the mucous membrane and the crown tip erupts into the mouth (Fig. 170, C).

The rate of resorption and crown advance are equalized in perfectly normal dentition.

The crown rises from the gum, is directed by the tongue and lip or cheek, and finally meets its antagonists of the opposite jaw. The interlocking of cusps and meeting of occlusal surfaces limit further movement of position.

Meanwhile root development proceeds and as it occurs the alveolar process is built about the pericementum, which has been drawn up from the follicular wall. By this means the roots are firmly implanted. The further development of the root proceeds until complete, and so remains until normal resorption of the temporary roots occurs, and for life in the permanent teeth.

The state of formation of the roots of temporary teeth at any given age may be judged by the table of averages shown by Peirce in Fig. 98. Being but averages, allowance for delays must be made.

Apart from the presence of the temporary teeth the process of eruption is identical in both sets of teeth.

Periods of Eruption. As a general rule, the eruption of the deciduous teeth may be said to begin about the seventh month after birth, and is completed somewhere about the twenty-fifth month. This rule, however, varies within wide limits; some children may be born with teeth erupted; again, the initiation of the process may not occur until the twelfth month or even later.

The incisor teeth are usually erupted in pairs, the molars and cuspids making their appearance in fours, the first molars in one group, the cuspids in another, and the second molars in a third group. The several groups require different lengths of time to complete their eruption, the time occupied in the eruption of the first molars being longer than that required for the eruption of the other groups. Between the appearance of additional groups of the teeth an interval elapses, no doubt a physiological provision, for, as will be shown later, the process of dentition is usually accompanied by evidences of more or less local disturbance, frequently by disturbances throughout the intestinal tract, and even reflex disorders of the central nervous system occur. It is

believed, therefore, that the period which elapses between the eruption of the dental groups permits the organism to recover from the effects of previous disturbance before the new source of irritation appears.

TABLE.¹

Group 1.	Lower central incisors.	Time of eruption, 7 months.	Duration of eruption, 1 to 10 days.	Interval, 2 to 3 months.
Group 2.	Upper central and lateral incisors.	Time of eruption, 9 months.	Duration of eruption, 4 to 6 weeks.	Interval, 2 months.
Group 3.	Lower lateral incisors.	Time of eruption, 12 months.		
Group 4.	First molars.	Time of eruption, 14 months.	Duration of eruption, 1 to 2 months.	Interval, 4 to 5 months.
Group 5.	Cuspids.	Time of eruption, 18 months.	Duration of eruption, 2 to 3 months.	Interval, 3 to 5 months.
Group 6.	Second molars.	Time of eruption, 26 months.	Duration of eruption, 3 to 5 months.	

In the above table it will be noted that the time of eruption of the lower lateral incisors is later than that of the eruption of the upper lateral incisors. The reverse course is frequently observed; indeed, it has usually been accepted as the rule of precedence in the United States. All tables as to periods of eruption give but the approximate times; while variations are extremely common. The ages given in this table are those at about which the several teeth may be expected to make their appearance. Stellwagen (the American editor of *Coleman*), in commenting upon this table, states that the periods of eruption in this country are from one-seventh or more earlier than the dates given. He suggests that the difference in food-habit may account for the differences in time.

Pari passu with the development and eruption of the teeth occur developmental changes in all of the glandular appendages of the alimentary canal; probably the alterations in their structure, and no doubt in their physiological chemistry, are accompanied by dental provision for the mechanical subdivision of foods of postinfantile character.

Symptoms of Eruption. Slight local disturbances are so common in even so-called normal first dentition as to be accepted as physiological. The resorption about the tip of the crown of the tooth implies a condition of mild non-septic inflammation at that point. In more marked cases there is evidence of some irritation cognizable to the infant; the gum is of a somewhat deeper color and its temperature is elevated. Relief is afforded by pressure, which temporarily reduces the hyperæmia, and the child is pleased to have its gums rubbed, to

¹ *Coleman's Dental Surgery.* (Stellwagen.)

bite upon its own or the nurse's fingers, upon rings or other objects. Still more marked is the soothing effect of biting upon cold substances such as ice, which, in addition to mechanically lessening the blood supply, causes contraction of the dilated vessels.

Slight reflex disturbances are evidenced by the stimulation of the salivary glands, which produces an increased flow of saliva.

Reflex disturbances of more severe character occur in pathological dentition, to be considered later.

PATHOLOGICAL FIRST DENTITION.

The local disturbances may be exaggerated beyond that degree accepted as physiological and may be accompanied by nervous, alimentary, pulmonary, or cutaneous disturbances. This is pathological dentition and may be of several grades of severity.

Causes and Pathology. The primary cause of pathological dentition may be stated as an inequality in the rate of gum resorption and crown advance. The advancing crown pressing upon the gum tissue causes irritation; the hyperæmia or mild aseptic inflammation, instead of remaining at a point favoring the development of giant cells and resorption, passes the physiological point and causes a disturbance of function. Inflammation, simple or even infective, may occur in the area.

Swelling of the gum occurs, which, being distributed in all directions, presses upon the crown, depressing it upon the pulp beneath the sharp root margins; at the same time the blood pressure of the pulp tends to press the tooth upward.

The sharp edges of the root must irritate the sensitive and delicate pulp tissue, which becomes hyperæmic and swollen and still more strongly urges the tooth upward. Two sources of disturbance now are possible: (1) the irritated gum tissue and (2) the irritated pulp tissue. Through the intimate sympathetic relations of the fifth cranial nerve, supplied to these parts, with the seventh, ninth, and tenth cranial nerves in the floor of the fourth ventricle of the brain, salivary, muscular, nervous, alimentary, and pulmonary disturbances become possible.

Any systemic disturbance—*e. g.*, smallpox, general debility, etc.—which lowers the nutritive function in the parts associated with the teeth may favor the production of local pathological phenomena.

Again, systemic disturbance readily produces a hyperæsthesia of the nervous system, favoring the production of nervous phenomena.

Pathological dentition may occur in the absence of an evident hyperæmic gum tissue. The tissue may be white, showing ischæmia from pressure, a binding down of the root end upon the pulp being proven by the subsidence of symptoms after lancing, and sometimes by the rapid, partial eruption of the tooth immediately after lancing.

Again, pathological phenomena have been noted where no superficial local disturbance was evident. In these cases the deeper tissues may exert a restraining influence upon the crown.

Symptoms. The symptoms of pathological dentition are both local and general.

LOCAL SYMPTOMS. The local symptoms are usually those of inflammation, red and swollen gum tissue at times assuming a dusky hue. The gums may be white, indicating their tense stretching over the crowns. Evidence of local irritability is given by the fact that the child resists the touching of the gums, seizes the breast or bottle nipple and immediately releases it.

The readiness with which the child will take cold substances, ice or ice-water, is notable and self-explainable. Alternate excessive flow of saliva and oral dryness is present. In the gum over the erupting tooth there may exist a vesicular enlargement containing fluid.¹

In the more marked cases of local disturbance evidences of bacterial infection of the mucous membrane of the mouth may make their appearance, such as ulcerative stomatitis. While, as a rule, the breaking down and ulceration of the tissue are confined to the parts overlying the erupting teeth, a general stomatitis or widely scattered patches of ulceration may make their appearance. The localized condition has been called *odontitis infantum*.

GENERAL SYMPTOMS. The general symptoms may be differentiated into mild and severe.

The mild symptoms are such as are attendant upon severe and painful inflammations about the face at almost any age; thus anorexia, fretfulness, anger, restlessness, sleeplessness, thirst, mild fever, and evident desire for the upright position occur. The pain is at times paroxysmal, but may become continuous.

These symptoms subside upon the eruption of the tooth or lancing, though erupting cuspids, bound by a ring of tense gum tissue or by

¹ *Tomes, System of Dental Surgery.*

adjoining teeth, may continue the irritation even when apparently erupted (Fig. 170, C).

The more severe general symptoms are such as are brought about by reflex neuroses.

The roots of the fifth cranial nerves supplied to the teeth are in intimate relation with the roots of the seventh, ninth, and tenth cranial nerves in the floor of the fourth ventricle, as well as with other cranial nerves. It may be argued upon *a priori* grounds that irritation of the peripheral ends of the fifth in the pulp tissue may therefore readily produce neurotic results in the brain, salivary glands, skin, lungs or larynx, intestinal canal, or muscles of the face or extremities.

Taking the intestinal canal as the most complicated example, we find the following data: The stomach and intestines are under the influence of the pneumogastric nerve, which sends to its muscular coats both stimulant and inhibitory fibres. Likewise, it sends vasomotor fibres to the intestines, division of which leads to inhibition of the muscular fibres of the vessels and leads to vasodilatation and a great increase of very watery succus entericus.¹

Intestinal Disturbances. That intestinal disturbances may arise independently of teething is self-evident. They are most liable to so occur during the very period during which teething may be supposed to act as a primary cause of intestinal troubles; hence differentiation becomes important.

That the conditions may be associated is also evident. As a rule, intestinal disturbances arise from improper feeding, the food acting as an indigestible irritant to the stomach and intestines. Fermentation due to bacteria ensues, and diarrhoea and colic are a natural result.

Musser² attributes these cases to development of the bacillus coli communis and bacterium lactis aëriiformis existing harmless in the normal intestine, but developing under the abnormal conditions.

This occurring in warm weather when the child suffers from intense heat has a very debilitating if not fatal result.

The condition may be viewed as an infective diarrhoea following a vasomotor disturbance of the intestinal walls set up by reflexes primarily caused by the indigestible food.

A similar train of circumstances may be caused by teething. Peripheral irritation of terminals of the fifth nerve in the pulp may, through the tenth nerve, cause a reflex vasomotor dilatation in the

¹ Halliburton, Kirke's Physiology, 1896, p. 684.

² Medical Diagnosis.

walls of the intestines—*i. e.*, hyperæmia, a condition which favors bacterial invasion. Intestinal digestion is disordered and an infection ordinarily resisted occurs.

Diarrhœa may follow. In either case alimentation is interfered with and the general nutrition suffers. The child is debilitated by lack of nutrition; moreover toxic substances are generated in the intestine which cause a toxæmia, to which many of the general symptoms may be attributed. The general debility also further interferes with the process of dentition.

Diagnosis. A diarrhœa due to improper feeding would not be preceded by symptoms of pathological dentition, would have a history of improper feeding, and possibly of unhygienic conditions, such as unsterilized milk or milk bottles, filthy surroundings, etc. There is a catarrhal diarrhœa accompanied by vomiting and further constant acid, watery stools. The stools may have a chopped-spinach character. There is colic due to collections of gas.

Such an infective diarrhœa may readily follow the reflex and debilitating effects of pathological dentition, as shown above.

White¹ has noted that a choleraic diarrhœa may accompany and be a sign of pathological dentition. Barrett² states that a diarrhœa due to dentition will probably be followed by constipation.

A symptomatic diarrhœa will, as a rule, be accompanied by signs of pathological dentition at points in the jaws at which teeth should be in process of eruption.

NERVOUS DISTURBANCES. Disorders referable to the central nervous system are the most alarming and are those indicating the higher grades of severity of irritation.

The milder forms of these are faint muscular twitchings and evidences of slight cerebral disturbance.

Either of these may be the result of poisons absorbed from the alimentary canal during the course of intestinal fermentation, but as cases of even convulsions have occurred without other cause than teething apparent and been relieved by lancing alone, the possibility of direct connection between teething and central nervous disturbance must be admitted.

A distressing symptom not easy to elicit on account of the age of the patient is headache. The child is sleepless, and cries without apparent cause; it becomes quiet, partially from exhaustion, and after a

¹ American System of Dentistry.

² Oral Pathology and Practice.

period again commences sobbing. The indication of central disturbance may at times be noted in the contracted pupils of the eyes and in throbbing arteries. The usual treatment, the administration of chloral hydrate and potassium bromide, with cold applications to the head, furnishes relief, which is frequently not complete without attention to the dental organs.

In the more severe and dangerous cases the evidences of disorder of the central nervous system become unmistakable. These appear as clonic convulsions or symptomatic eclampsia. While it is probable in many cases that reflex irritation from the process of dentition in itself is but a secondary cause of convulsions, yet evidence is sufficient to warrant its being regarded as a determining factor. In very many cases teething convulsions appear to indicate a neurotic family taint, and eclampsia may attend many disorders in children of this type, notably the mechanical and chemical irritation induced by the presence of large masses of indigestible food in the intestines.

So-called teething convulsions occur usually at a time when several teeth are in process of eruption. The onset of the convulsion is rarely, although apparently often, sudden. If the child be closely observed, it is noted that a period of cerebral disturbance—fretful crying, evidences of headache, sleeplessness, etc.—is followed by a period of dulness and somnolence, or the child may lie with eyes half-open. Twitching of one or more groups of muscles may be observed; the orbicularis oris and other muscles of the lips, and the muscles of the eye, notably the superior and internal recti, may contract spasmodically. A common muscular spasm ushering in convulsions is that of the adductor muscles of the thumb; the thumbs are drawn toward the palms of the hands. The adductor muscles of the feet contracting, the feet are drawn inward. This period may be ushered in by a sharp cry, the eyes roll upward with the lids half-open, and consciousness is lost. The symptoms may disappear, the child awakening dazed and fretful; or it may sink into sleep. Unless the source of irritation be removed, or active therapeutic measures be instituted, the eclampsia may return and in severe cases be the precursor of death.

Infantile paralysis of a group of muscles or even a single muscle has been recorded, lasting from a few days to months, appearing with dentition and disappearing after it. In some cases it persists for life.¹

¹ White, American System of Dentistry.

SKIN DISORDERS. It is so common as to be almost termed the rule to find that when there are intestinal symptoms there are eruptions observable on the skin. The mildest form of these is an herpetic eruption about the mouth; in other cases papular and vesicular eruptions are observed upon the skin of the body and limbs.

Occurring within the mouth infection may be added and ulcerative stomatitis may occur upon the gums, tongue, lips, or inside of the cheek.

PULMONARY SYMPTOMS. Pulmonary irritation may be expressed in laryngeal cough attending the eruption of teeth and disappearing thereafter.

Treatment of Pathological First Dentition. This may be divided into prophylactic and remedial. The prophylactic measures include care as to Pasteurization of milk or modified milk diet, sterilization of bottles, bottle nipples and rings, the prevention of the introduction of unclean fingers into the mouth of the child, and the antiseptic care of its mouth by frequent washings with a saturated solution of boric acid in water. This last may be applied to the mouth on a soft linen rag wrapped on the forefinger. These measures, together with the proper feeding, ventilation, and care as to clothing tend to prevent intestinal fermentation and to reduce the general irritability of the infant.

REMEDIAL MEASURES. To reduce local hyperæmia of the gum above an erupting tooth a common domestic measure is valuable, viz., a small block of ice is placed in a clean napkin, and confined in place by a knot; the infant places it in its mouth at pleasure if old enough, or the nurse permits the child to bite upon it. The mechanical effect of biting upon a hard substance has added to it a degree of cold which lessens the local vascular engorgement.

Any severe local irritation about erupting teeth should be relieved by thorough lancing of the gum. It is irrational that the child should be permitted to suffer from local irritation which may develop into more serious complications.

This operation is performed by dividing the gum lineally over the incisors and cuspids before eruption, crucially over the cuspids after eruption of the cusps only, crucially over the upper first molar, and with an X incision over the upper second and lower first and second molars (Fig. 170).

For severe cases Flagg advised the removal of a block of gum

from over a molar. A cut is made parallel with the lingual side of the crown, a second parallel with the buccal side, a third parallel with the mesal side. A tenaculum is thrust into the block of gum, which is drawn tense and then divided at the distal portion, preferably with a pair of curved gum scissors. Lacking these latter the bistoury may be used.

The cut over the upper incisors should, if possible, be made a little to the outside of the cutting edge, that for the lower to the inside, in order that their crowns may take a proper direction toward occlusion.

The instrument to be used is a sharp-pointed bistoury, as it penetrates well and permits a free draw cut. It is to be wrapped with tape or a strip of linen cloth until only a half-inch of the point is exposed. This precaution prevents accidental wounds. The child must be securely held by an assistant the least sympathetic available.

Flagg's method was to place the child upon its back across the lap of the assistant, who, in one position, places his left hand over the child's eyes, securing the head; his right hand secures the hands upon the abdomen, while the legs are held against his body by the right arm. The position may be exactly reversed. The feet should be placed toward the light for the upper jaw, the reverse for the lower jaw. In another position the child sits upon one thigh of the assistant, the back of the head resting upon the chest, and the hand of that side (usually the right) pressed upon the child's forehead to hold the head firmly. The other hand and forearm hold the child's arms and legs firmly.

The operator encloses the gum about the part to be cut with the thumb and forefinger of the left hand, so that the bistoury cannot slip and cut lip, cheek, or tongue. Incision over the erupting tooth should be made until the knife-blade is felt to touch the enamel surface. The operation of scarifying the gums, making merely a few scratches to relieve engorged vessels, is but temporizing with the condition; the cut should be of sufficient extent to entirely remove tension from above the tooth. The little finger of the right hand may rest upon the chin of the child as an additional guard.

If the child bite, a cork with a string attached for safety may be used as a prop.

More or less bleeding follows upon the operation, and, as a rule,

ceases spontaneously. A short period of bleeding is desirable, so that vascular engorgement may be reduced. Suckling the infant usually serves to check the bleeding; the tissues about the cut surfaces are compressed by tongue and lips during suckling, and bleeding ceases. In the event of the bleeding continuing the mouth should be carefully examined, and a piece of ice in a napkin may be given the child to suck. The child may swallow the blood and later regurgitate it. Obstinate bleeding may require the use of styptics, but these should be of a character to cause only coagulation of the blood, not the destruction of tissue. A little powdered tannin laid upon the cut acts promptly, as does also a small amount of powdered alum.

Death has occurred from hemorrhage due to lancing in cases of presumably hemorrhagic diathesis; so that inquiry as to family history would be a wise precaution. Obtaining such a history the gravity of the symptoms alone warrant the operation. In the absence of such a history the operation is to be held as trivial. (See *Hæmophilia*.)

The operation of lancing is warranted even when the gum may be likely to heal over the tooth by formation of cicatricial tissue, provided symptoms demand it.

TREATMENT OF STOMATITIS. Should general stomatitis, with or without stomatitis ulcerosa, make its appearance, the mouth is to be promptly and freely sprayed with a 3 per cent. solution of hydrogen dioxide, followed by a spray of potassic chlorate (gr. xx- ℥j), which usually affords prompt relief. Should the spots of ulceration not disappear promptly, the mouth and tissues about the ulcer are to be guarded by soft linen napkins; each ulcer is dried and touched with carbolic acid, full strength. The spraying is to be repeated at intervals of three hours during the waking period. This method of treatment is productive of decidedly better results than follow the use of the common formula of honey and borax.

TREATMENT OF SKIN ERUPTIONS. The eruptions which appear upon the skin during dentition may be a source of annoyance to the child by causing itching. As a rule, measures directed toward a regulation of the intestinal functions cause a disappearance of the skin affections. If the eruption be widespread and cause much itching, a wash of phenol-sodique diluted to one-third with water usually affords relief. If the surfaces be then dried and talc powder dusted over them the condition is much alleviated. About the mouth and over excoriated surfaces an ointment of zinc oxide is useful.

TREATMENT OF INTESTINAL SYMPTOMS. The fermentative material in the bowel, together with the great mass of bacteria present, should be removed by the use of a cathartic. It is indicated in both constipation and diarrhœa. Castor oil serves well and is readily taken by children. To lessen the irritation of the bowel laudanum and powdered acacia may be added.

The following formula may safely be used even at six months of age:

R —Tincturæ opii,	gtt. x.
Olei ricini,	fʒjss.
Pulveris acaciæ,	ʒij.
Saccharin,	gr. ij..
Aquæ cinnamomi,	q. s. ad fʒiij.—M.

Sig.—Shake the bottle, and give one teaspoonful each two hours if needed.

For an additional six months of age ten drops more of laudanum may be added to the general formula.

Following catharsis, antacid sedative astringents and intestinal antiseptics are indicated:

R —Salol,	ʒj.
Bismuthi subnit.,	ʒij.
Misturæ cretæ,	ad fʒiij.—M.

Sig.—One teaspoonful every four hours. (Biddle.)

Or,

R —Tincturæ opii,	gtt. xvj.
Bismuthi subnit.,	ʒij.
Misturæ cretæ,	ʒjss.
Syr. simp.,	ʒjss.—M.

Sig.—Shake well, and give in teaspoonful doses every four hours. (Barrett.)

The virtues of both formulæ may be obtained by including the laudanum (gtt. xii) with the salol formula.

Listerine in 10-drop doses, in water, every three hours, serves as an intestinal antiseptic.

The gums are, of course, to be lanced at the outset if the diarrhœa be due to pathological dentition. Following the intestinal antiseptics the general debility and possible intestinal toxæmia (see page 102) is to have careful attention, and the child's food is to be properly adjusted to its needs.¹

TREATMENT OF NERVOUS CONDITIONS. If nervous reflexes, great irritability or cerebral congestion appear, attention should be directed to the condition of the bowels and the teeth.

If constipation or diarrhœa exist a cathartic is given and the gums lanced. A cerebral sedative is to be prescribed.

¹ See works on diseases of children.

R—Chloral hydrat.,	gr. ij.
Sodii brom.,	gr. v.
Aquæ menthæ pip.,	fʒij.—M

Sig.—Per orem. One dose; enlarge formula for repetition as needed.

If convulsions be threatened, the clothing should be loosened and cool applications made to the head.

If the child be in convulsions, it should be immersed to the waist in water as hot as can be borne, to which has been added two table-spoonfuls of common mustard flour, and cool water poured over its head, when, as a rule, the symptoms promptly subside. Chloroform, which children endure well, may be administered.

After immersion a rectal injection of a drachm of glycerin or a glycerin suppository will usually cause a free stool. A cerebral sedative should be administered.

R—Chloral hydrat.,	gr. ij.
Sodii brom.,	gr. v.
Starch paste,	ʒij.—M.

Sig.—To be administered per rectum. (Atkinson.)

It is well also to administer a cathartic to unload the intestines of irritating substances possibly present.

After sleep, if appearances indicating dental irritation be observed, gum lancing is practised. It is wise that this operation be thus deferred, as convulsions may be precipitated by the act of lancing when the nervous system of the child is overexcited. The removal of intestinal irritants by a cathartic given *per orem* is also in order before lancing.

It has been repeatedly noted that where evidence of marked cerebro-spinal irritation is present, for which no probable source can be assigned and an examination of the gums shows no apparent local disturbance, yet if it be at a period when one or more teeth are in process of eruption, but are still covered or bound down by gum tissue, if gum lancing be practised relief is immediate and the lancing may even avert a threatened attack of eclampsia. It is presumed that these are cases of pulp irritation in which a failure of resorption of tissue in advance of the tooth crown has caused pressure upon the pulp forming the root end.

Constitutional States Modifying Dentition.

Children who are the victims of hereditary syphilis usually cut their teeth very early, the alveolar process being in many cases insufficient. Cases are recorded where children have been born with crowns of teeth visible upon the gum, there being no evidence of root formation, the crowns being loosely held to the gum by fibrous tissue. It is necessary

to remove these loose crowns to permit the infant to suckle. Children affected with rachitis have the process of eruption much delayed. It is seen, therefore, that the presence of loose crowns of teeth is a condition pointing to, though by no means diagnostic of, hereditary syphilis. Long-delayed eruption of teeth should prompt a search for further indications of rachitis. Particularly in children in whom a history of hereditary syphilis is obtainable the process of dentition may be accompanied by rapid and frequently widespread breaking down of the soft tissues over and about erupting teeth. Local measures of treatment seem to be of but little avail, except that antiseptic treatment undoubtedly prevents complications from extraneous infection.

In children classified indefinitely as strumous, which may mean the children of syphilitic or tuberculous parents, or those with no such history whose surroundings are of the most unhygienic kind, the process of dentition may not only have an untoward course, but phagedenic ulcerations may occur. It is usually in the degree of a child's debility, either inherited or acquired through improper care, that dentition assumes morbid features. The treatment of such cases must be directed to raising the health standard. As local therapeutics, no measures seem more effective than the sprays of hydrogen dioxide first; next, potassium chlorate, and, if conditions indicate it, sprays of dilute listerine, which is stimulant, antiseptic, and slightly astringent.

Infantile Scurvy. Cases are recorded in which the improper feeding of children has been followed by evidences of scorbutus. It occurs usually in bottle-fed babies confined to patent foods. The gums become tumid, and hemorrhagic extravasations occur in their substance; the periosteum is stripped from the margins of the alveolar walls, the soft tissues hanging in discolored, pendulous masses about and beyond the teeth if any be erupted.

The child is peevish, listless, and feeble. There is apparent pain in the limbs.¹

The treatment is largely systemic and consists of using fresh cows' milk modified to conform to human milk, and in the administration of fresh lemon-juice, preferably boiled, allowed to settle, and the supernatant fluid used.²

The mouth should be sprayed with antiseptics.

¹ Hare.

² Ibid.

THE SECOND DENTITION.

By reference to Fig. 110 it will be seen that at six and one-half years of age the twenty temporary teeth are still all in position, and that taking their places in the line of the arch are the four permanent first molars, the roots of which are still incomplete.

These molars do not replace any temporary teeth, but during the "change" support the jaws with the assistance of the temporary molars until the permanent incisors are fully erupted, and with the aid of the incisors until the bicuspid come into occlusion. Their office as jaw props and organs of mastication during the change is, therefore, very important. Of their later function more will be said farther on.

At six and one-half years the crowns of the permanent incisors lie in the relations shown with the temporary central roots resorbed and the lateral root partly so. Their crowns are practically complete, but the roots are unformed.

The cuspid crown lies well above the unresorbed temporary cuspid root, between the canine fossa and ala nasi. The roots of the first and second temporary molars a trifle resorbed upon the inner side embrace the formed crowns of the first and second bicuspid.

In their crypts back of the first molars lie the forming crowns of the second permanent molars. The third molars are not in evidence in the illustration, but their development is in progress.

It will be seen that the permanent central and lateral incisors replace the temporary central and lateral incisors, the permanent cuspid the temporary cuspid, and the first and second bicuspid the first and second temporary molars, respectively.

From this age to adult age as previously the jaw undergoes constant change, enlarges by constant resorptions and depositions of bone, and changes its contour to conform to the changes occurring throughout the body, and to accommodate the permanent teeth, which are in general terms larger and more numerous than the temporary teeth.

It may be said that the alveolar process built about the roots of temporary teeth and the roots of the temporary teeth are all resorbed during the replacement of the latter, and that when the crowns of the permanent teeth are fully erupted new alveolar process is built up about their roots. Any subsequent change in the position of the permanent teeth is accompanied by an alteration in the alveolar process, and after extraction the latter is resorbed, but upon an implan-

tation (which see) being done new process will form. Its dependence upon the teeth is, therefore, evident.

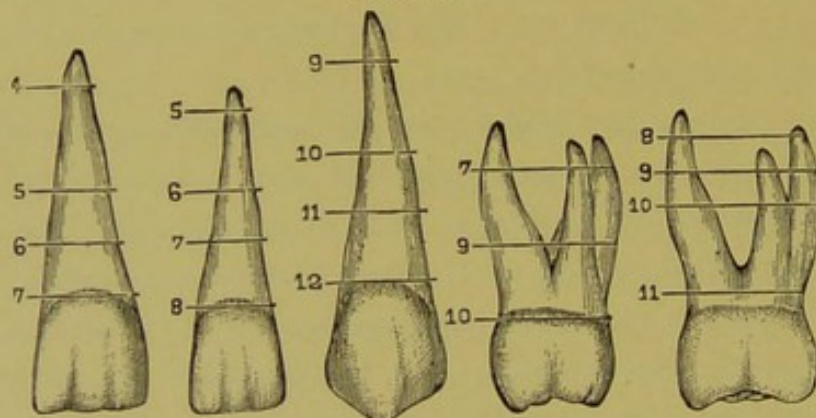
The following table gives the approximate ages for the eruption of the permanent teeth:

First molars	5½- 7 years.
Central incisors	7 - 8 "
Lateral incisors	8 - 9 "
First bicuspid	10 -11 "
Second bicuspid	11 -12 "
Cuspids	12 -14 "
Second molars	12 -15 "
Third molars	16 -20 "

and indefinitely beyond.

The Process of Resorption of the Temporary Roots. After completion of formation the roots of the temporary teeth remain in this state but a short time, as their successors are ready to advance to their places.

FIG. 172.



Decalcification of the deciduous teeth. The numbers indicate years. Compare with Fig. 98. (Peirce.)

Comparing the ages at which resorption begins with the ages at which it is complete (see Fig. 172), it will be noted that approximately three and a half years are required in all cases for the removal of the temporary roots.

At the time the permanent tooth begins its advance it lies in a bony crypt above and lingual to its predecessor, except in the case of the bicuspid, which lie between the roots of the temporary molars (Figs. 110 and 173).

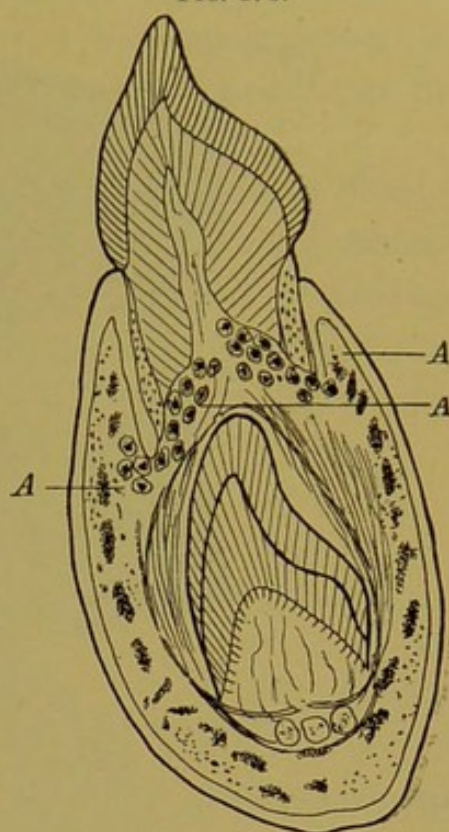
Each crypt has its own follicular wall enclosing a permanent tooth crown.

In the follicular wall overlying the crown appear large multinucleated cells the origin of which is unknown, but which by some are thought to be transformed osteoblasts, by others leukocytes (Figs. 173 and 174). The latter is the probable explanation, as analogous cells are found about tissues or foreign bodies about to undergo resorption

anywhere in the body. (See Resorption.) In the particular situation under consideration they are called odontoclasts. The tissue between the root and crown has by Tomes been given the name of the "resorbent organ" (Figs. 173, A, and 174). These giant cells have a solvent or digestive function not understood, but which is competent to remove both the organic and inorganic matter of cementum and dentine, and evidences of action upon enamel in other situations are not wanting. (See Resorption of Enamel.) That the solvent is acid is shown by the evidence of decalcification about the area of resorbed enamel of unerupted crowns of some permanent teeth.

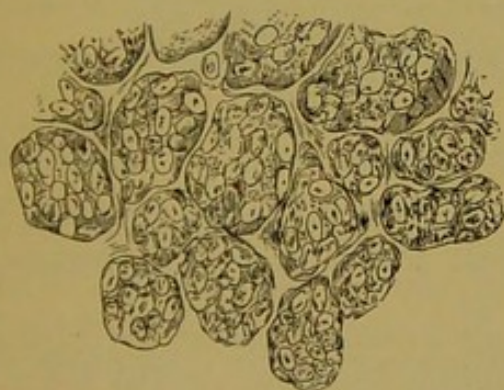
It is a curious fact that no evidence of decalcification of the permanent crown has been demonstrated to result from the proximity of the multinucleated cells in cases of physiological resorption of temporary roots. In all probability the enamel is protected by the presence of Nasmyth's membrane, which is resistant to acids. These cells are probably invited by irritation due to pressure of the advancing per-

FIG. 173.




Showing the relations of an erupting permanent tooth to its deciduous predecessor: A, A, A, odontoclasts.

FIG. 174.



The structure of the resorbent organ, showing multinucleated or giant cells (odontoclasts). (Tomes.)

FIG. 175.



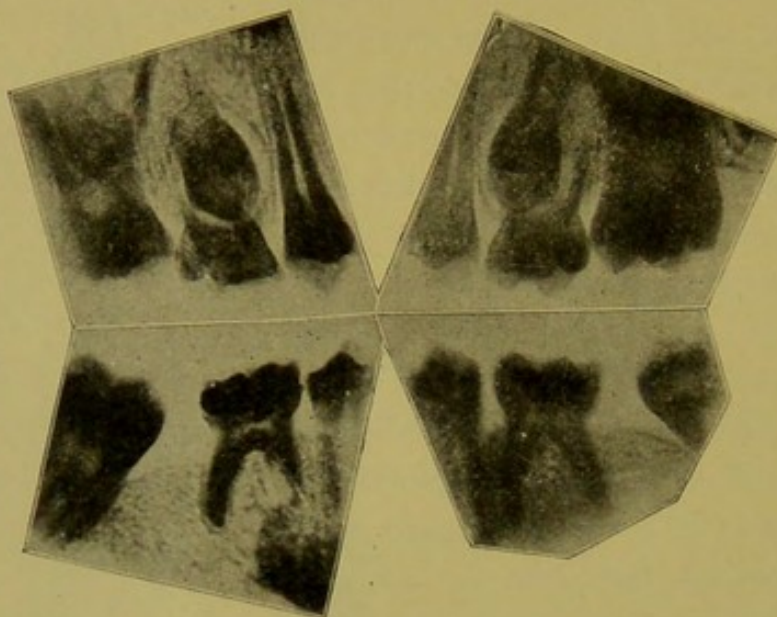
Imprisonment of second temporary molar; resorption of its roots, with absence of second bicuspid. (Skiagraph by Custer.)

manent tooth crown, as the resorption is almost always found at the point of approximation of the crown with the root, or, in other words, at the pressure point (Fig. 176).

Cases of resorption of temporary roots without the presence of a

permanent crown are, however, noted and explained by Tomes upon the ground that resorption is a vital act independent of the press-

FIG. 176.

Phases of resorption of temporary roots. (Skiagraphs by Price.¹)

ure exerted (Fig. 175). As resorption of permanent roots, however, has often occurred from pressure of the crown of another tooth and occurs at the pressure point in physiological resorption, localized irritation, even in the absence of a permanent crown, must be credited with a large influence in the process. It is to be remembered also that in the absence of the pressure resorption often does not occur—*e. g.*, when laterals are absent and the permanent cuspids erupt to the side of the deciduous cuspids (Fig. 179).

FIG. 177.

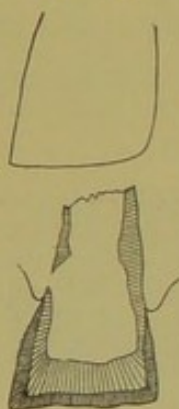

Diagram illustrating the relation of a resorbed temporary root and the permanent tooth, also the involvement of the pulp as a part of the resorbent organ. Resorption of the interior of crown of a temporary tooth.

According to Tomes redeposition of cementum occurs in previously resorbed areas upon temporary roots, a fact corresponding with effects noted in permanent roots. (See resorption of.)

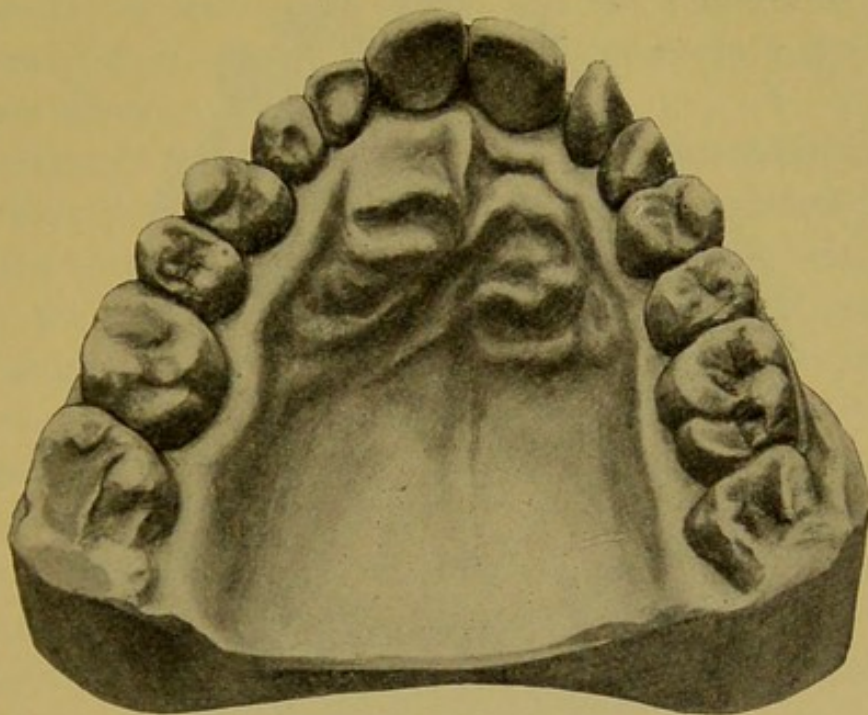
As the root of the temporary tooth disappears the pulp continuously fuses with the resorbent organ, so that when the crown alone remains the pulp is still vital (Fig. 173). At times it seems to take up the resorbent function and resorbs the crown dentine in some cases almost entirely. In one specimen a circumscribed portion of the cementum and of enamel were

¹ Items of Interest, 1901.

removed by it at the point of junction. This constituted practically a case of perforation by resorption (Fig. 177). At times bay-like excavations in the crown dentine occur. When the root resorption reaches the point shown in the central incisor in Fig. 110 the temporary tooth is loosened, moves about, and annoys the child, who may pick it out, or it is removed by extraction.

Formation of the Roots of Permanent Teeth. The extent of root development at any age is of great importance in view of canal therapeutics. Unformed roots present a mechanical difficulty of sealing the apex of the canal. The size of the pulp at the apical foramen of such teeth contraindicates the use of arsenic and even pressure anæsthesia is often unsuccessfully applied.

FIG. 178.



Absence of upper left lateral incisor, with permanent cuspid in its place; two temporary cuspids retained. Man, aged twenty-five years.

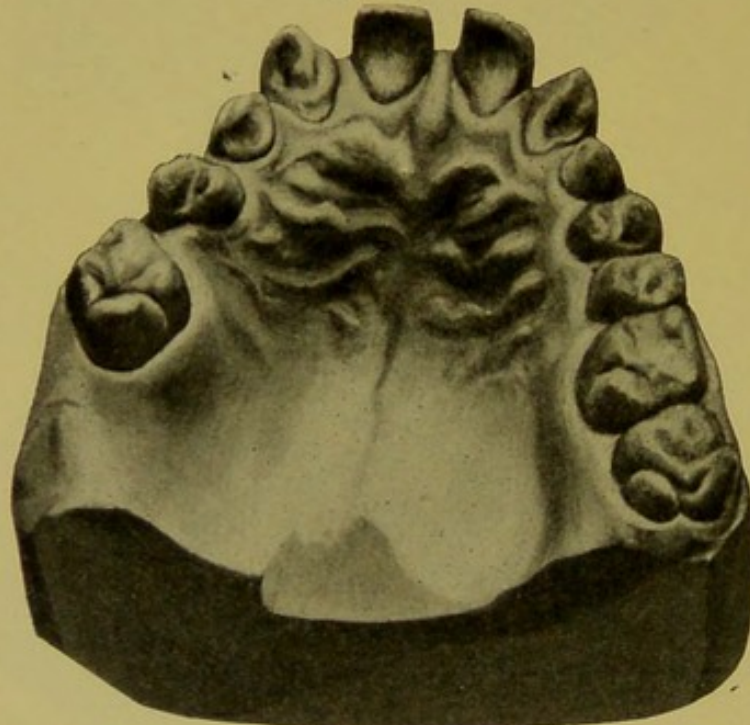The roots are developed in precisely the same manner as in the case of the temporary teeth, by the combined deposition from the follicle wall, which is drawn up on the root as a pericementum and from the papilla, which is drawn up as a pulp (Fig. 100).

The extent of development of any of the permanent teeth may be seen at a glance by reference to the valuable table of Peirce (Fig. 107). So graphically does this table give the desired information that explanation becomes unnecessary.

Irregularities of Second Dentition. Some temporary teeth may be retained long after adult age is reached. The teeth most subject to this are the cuspids and second temporary molars.

In the case of the cuspids, the permanent cuspid is delayed or takes an unusual direction, erupting lingually or labially, or at times being directed into the place normally occupied by the lateral incisors, which are wanting, or very rarely the cuspid erupts posteriorly to the first bicuspid. At about forty years of age the temporary cuspids may be lost by resorption of their roots, but until such time should be retained if usefully filling a space. If in interference with proper alignment or eruption of the permanent cuspid they should be extracted. Their late resorption is somewhat pathological in character and probably due to or incited by a partial resorption of the root end during the descent of the permanent cuspid.

FIG. 179.



Absence of upper lateral incisors and right bicuspid. Retention of temporary cuspids.
From an adult.

The late enforced loss of the temporary cuspid indicates the advisability of an implantation operation (Fig. 179).

The molars are retained as a rule because of an absence of permanent crowns to cause resorption, although this may occur without such pressure (Fig. 175). I have seen a case of an adult lady with eight deciduous molars in place. The question of the abnormal development or absence of permanent germs, or of the state of the roots of the temporary tooth may be settled by the *x*-rays (Figs. 175 and 176).

The question of extraction or retention depends upon the diagnosis. When retention of temporary molars and cuspids occurs, they are

apt to occupy an occlusal level lower than that of the permanent teeth (Fig. 175). They may not be in occlusion at all, as was the case with the eight molars just referred to. This proves the fact that the general occlusal level of the permanent teeth is farther from the margin of the alveolar process than in the case of the temporary teeth. The length of the permanent crowns accounts for this.

The maxillary and alveolar development which occurs during the years occupied by the "change" due to second dentition and the eruption of the second and third molars must also be borne in mind. The form of the lower jaw at the angle changes. The ramus becomes pronounced and the jaw lengthens from the ramus to the symphysis. Corresponding changes occur in the upper jaw. The antrum enlarges and the tuberosity becomes pronounced in correspondence with the development of the upper maxilla and the eruption of the teeth, in the consideration of which both predestination to a typical form and dynamic influences are to have weight.

Disorders of the Second Dentition. The devitalization of the pulp of a temporary tooth and proper canal filling delays but does not absolutely prevent resorption. Chronic abscesses upon such roots destroy the resorbent organ, but some pathological resorption may occur, as in case of permanent roots (which see). Pus has an alkaline reaction which may neutralize the acid solvent. As a rule such roots are mechanical obstructions to the permanent crowns, which are deflected to one side and caused to erupt irregularly; again, the temporary root may be bodily pushed aside, its apex pressed against the alveolar process and gum tissue, which are resorbed and the necrotic root end is seen extruded labially through the gum. Extraction is indicated.

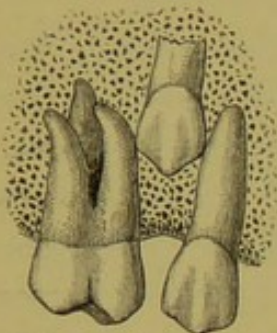
When temporary roots are not thus mechanically removed they are gradually extruded and decayed, or suppurative processes cause the resorption of the process about them.

Injudicious retention of temporary teeth may thus cause an irregularity. On the other hand, premature extraction by permitting the approximation of the previously erupted permanent teeth may have an equally bad effect upon an erupting tooth (Fig. 183).

In anticipation of physiological resorption of temporary roots, all temporary teeth should be carefully watched, cleansed, filled, and, if necessary, their roots treated so that a normal replacement by the permanent teeth may occur. If pronounced disease occurs just previous to the time for normal replacement, extraction is indicated.

It will be recalled that the teeth are an evolution of the dermoid system, which fact possesses pathological significance in certain acute and specific skin diseases. It is noted in some cases of the eruptive fevers of children, particularly when the child is much debilitated, that

FIG. 180.



Effects of the premature loss of a deciduous second molar.

after the cessation of the acute disease a necrotic affection of the jaw occurs, involving the alveolar bone and its contents. As many of these cases occur between the ages of three and seven years, the temporary teeth are still *in situ*; these, with the partially developed permanent teeth and the enclosing bone, may be exfoliated. The necrotic process may involve but one tooth, or may include all of the temporary teeth, their successors, and a large mass of bone.¹ The disease with which this necrosis is most frequently associated is scar-

let fever;² it is also found as a sequel of measles and smallpox. It will be observed that all of these diseases are forms of specific dermatitis, and the teeth as part of the dermoid system are affected. (See Chapter IX.) "The cases prior to exfoliation of the bone exhibit a stripping of the periosteum, apparently beginning about the necks of the teeth. A discharge of pus having a fetid odor is present, and the soft tissues may be raised from the bone for a variable extent;" that is, there is evidence of purulent periostitis. In the course of some weeks, six or eight, the necrotic bone and its contents exfoliate. Salter observes that the sequestra forming after severe scarlet fever are much more extensive than those which form as a sequel of measles.

The administration of mercurials has been credited with such a loss of teeth and process. I have been shown a sequestrum containing three teeth attributed to this cause. In these cases the parts should be kept as aseptic as possible by means of hydrogen dioxide and the compound tincture of capsicum and myrrh (enough to cloud a glass of water) used as a stimulant mouth wash.³ When loose the sequestrum should be removed. The parts heal by granulation if due attention be paid to the general physical welfare of the child.

Eruption of the Molars. The first permanent molars rarely produce more than slight rheumatic pains. The gum irritation may be relieved by an X incision, or at times by the application of phenol-sodique

¹ Salter, Dental Pathology.

³ Garretson, A System of Oral Surgery.

² Ibid.

and laudanum, equal parts, with the finger-tip. A little alcohol or dilute tincture of iodine serves almost equally well.

As some time may elapse between eruption and occlusion the first molars do not receive a proper friction. Associated frequently with carious temporary teeth, they are frequently decayed in their sulci and fissures; to prevent this it has been recommended that oxyphosphate of zinc be placed over these fissures without previous excavation.¹

The lower second molars may cause some irritation owing to an insufficient development of the jaw at the angle, leaving an inadequate accommodation for the crown. At about nine years of age the second molar occupies the angle of the jaw in much the same position as shown in Fig. 101 for the third molar. If held back a pathological condition equivalent to that occurring in the temporary teeth may result; reflexes producing heavy pains about the jaw or worse effects, such as epileptiform convulsions, may be produced.

Truman² has prevented a threatened second attack of this sort by deep incisions in the gum over the site of the crown. The presumption is that such treatment relieves the tension upon the pulp underlying the developing root.

The third molars frequently induce pathological conditions.

The upper third molar meeting in its descent the roots of the second molar may be united to it by hypercementosis—the condition of con-
crescence (which see); escaping this it may meet a dense palato-alveolar plate of bone at the tuberosity and be deflected buccally through the thinner buccal plate of bone, so that its occlusal face presents cheekward (Fig. 181). Here retained food collects about it and caries occurs, or a suppurative inflammation of the cheek or free gum margin may occur. For this condition sterilization, free incision of the gum margin, and subsequent asepsis maintained by antiseptic sprays will reduce the inflammation, which, however, is apt to recur at intervals. If the cheek be irritated or the position of the tooth permanently fixed, only traction of the tooth into a correct position, grinding away of the sharp cusps, or extraction will alleviate the condition. The extraction of such a tooth is little loss to the individual. The possibility of concrescence in such a case as shown in Fig. 181 must be considered when extraction is intended. Individual motion is diagnostic.

The pressure of an erupting third molar upon the second molar may cause neuralgic pains, and at times the teeth in general, as far

¹ L. Ashly Faught.

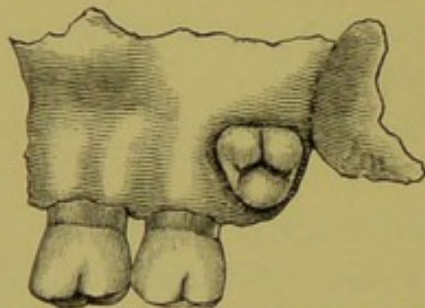
² International Dental Journal, 1899.

forward as the central incisor, may seem to loosen up and become tender to touch and again become comfortable and tight. These symptoms may be repeated apparently in consonance with the efforts at eruption.

Owing to insufficient development at the angle of the jaw it is almost the rule that the eruption of the third molar is attended with some degree of discomfort due to gum and bone irritation and possibly to pressure on the formative pulp (Fig. 182).

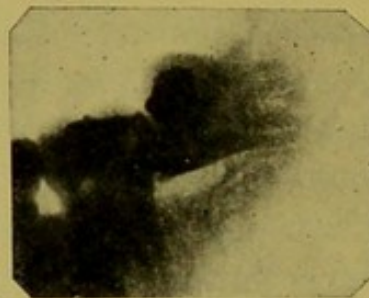For some months prior to eruption heavy, gnawing, rheumatic pains may be indefinitely located about the jaw and ear of the affected side. The muscles of mastication become stiff and may contract spasmodically, simulating trismus. These symptoms, if severe, may be relieved by deep X incisions in the gum; or, if mild, by the application of non-

FIG. 181.



Abnormal eruption of the upper third molar.

FIG. 182.



Partial eruption and impaction of third molar. (Skiagraph by Custer.)

discoloring rubefacients or sedatives to the outside of the face, over the affected parts. The massage of the parts affords some relief. Flagg¹ recommended the following:

R—Tinct. opii,
Tinct. aconiti,
Chloroformi, āā q. s.—M.

Sig.—To be rubbed on the outside of the face.

Or,

R—Aconitine, gr. j.
Cerat. simp., 5j.—M.

Sig.—To be well spatulated. To be distended with oil of cloves or campho-phenique and gently rubbed on the outside of the face, the mouth and eyes to be particularly avoided.

Or, when the aconitine fails to produce relief:

R—Veratrine, gr. xx.
Cerat. simp., 5j.—M.

Sig.—To be used in the same manner as the aconitine.

As the tooth advances the symptoms may become progressively severe. The gum may become inflamed, swollen, and be masticated

¹ Dental Cosmos.

upon, the oral pyogenic organisms produce infection, presumably finding an entrance at the point proximating the second molar. The patient suffers from the pain and inability to masticate and becomes nervous, irritable, and debilitated; the breath becomes fetid and the salivation excessive. The inflammation extends into the contiguous tissues, and pus may form, extending into them; all mastication is prevented, fever is present, and the patient prostrated; septicæmia and death may follow.¹

Results similar to these may occur when the crown is partly erupted, being covered at its distal portion by a curtain of gum which may be ulcerated upon its under surface.

In these latter cases the pus as a rule finds egress, but occasionally it burrows into the pocket between the tooth and contiguous tissue, causing much inflammation.

Treatment. The treatment depends upon the stage to which the inflammation has advanced.

If the patient be able to partly open the mouth the part may be sterilized by spraying it with a germicide such as a 1 : 2000 solution of mercuric chloride in hydrogen dioxide. Following this an injection of cocaine solution is made into the gum tissue or flap of tissue and the gum completely removed from over the face of the crown.

To accomplish this a deep linear cut is made with a sharp bistoury, extending from the distolingual to the mesolingual angle of the crown. A similar cut is made from the distobuccal to the mesobuccal angle. If not already free the gum is divided at its mesal contact with the distal surface of the second molar. The block is now penetrated by a tenaculum, drawn tense, and the final cut made at the distal border with decidedly curved gum scissors.

The hydrogen dioxide spray should be again applied to remove any possible pus germs present and should be repeated at intervals of about two hours. A neglect of this simple precaution cost the editor a week's personal discomfort and ability to masticate after the removal of a trifling and apparently non-inflamed flap of gum. A cold compress should be recommended for the angle of the jaw if deemed advisable. Magnesium sulphate as a derivative may be used with advantage.

If the patient be confined to his bed and unable to open the jaws a more difficult operation presents. The first object should be to reduce the intensity of the inflammatory symptoms. This is accomplished by the removal of the gum block as above if the mouth can

¹ Flagg, and occasional reports.

be opened sufficiently. Etherization may be resorted to, after oral sterilization, for the purpose. A jaw separator is introduced and operated until sufficient space is gained and the cuts made. If no more be possible at the first visit the lingual and buccal linear cuts should be made to ensure free blood-letting, which may be increased by syringing forcibly with luke-warm water, the position of the patient being such that gravity favors its flowing out of the mouth.

Cold compresses are to be placed over the angle of the jaw and magnesium sulphate and the hot pediluvium administered as derivatives. The antiseptic sprays are to be used as before directed.

If in addition local massage over the angle of the jaw be practised the swelling and muscular hardness usually disappear in a few days.

It is well to then remove the entire block of gum to prevent reinfection.

If the third molar be correctly placed its eruption as a rule proceeds uninterruptedly from this point, though it may never be entirely free from some degree of overlapping by the gum tissue. Pockets are thus formed which favor food retention, which, undergoing fermentation, may either cause ulceration of the soft parts or caries of the distal and distobuccal surfaces of the tooth.

More marked malposition may cause difficulty of eruption, necessitating the extraction of the third molar or even of the second molar.

In some cases it may be better to extract the upper third molar, as it will probably elongate in time.

A presentation of the occlusal face of the third molar to the distal surface of the second molar is the most common form of malposition.

If very deep seated the third molar may at times be diagnosed in this position by passing an explorer or thin right-angled blade down the distal surface of the second molar, or by means of a deep incision with a bistoury. Failing this or preferably replacing it, the *x*-rays are a very valuable means of diagnosis.

In this situation pathological resorption of the root of the second molar may result and irritation of its pulp be added as a complication. In this case the second molar must be extracted.

A more common form of presentation exhibits the distal surface of the crown above the gum and the mesoocclusal angle locked beneath the cervix of the second molar (Fig. 182). The third molar may be removed by an operation involving the surgical removal of a portion of the base of the coronoid process followed by extraction. The pulp of the third molar may be devitalized by arsenic applied and sealed in

a pit drilled in its distal surface. After death of a portion of the pulp the pit may be made to perforate the crown from side to side, and then a dentate fissure bur mounted in the right-angle handpiece may be used to saw off the occlusal half of the crown. In the space thus gained and between the second and third molars a wedge of seat-angle may be neatly fitted; its swelling causes mutual separation, which loosens the third molar somewhat by the process of resorption. It should now be quite readily extracted by appropriate movements.

Cryer recommends the removal of the occlusal section of the crown of the third molar by means of a carborundum disk, and the removal of the tooth by means of forceps or elevators.

The loss of a second molar may be for other reasons necessary, but such a loss in the last case described is equivalent to a loss of two teeth, as the third molar will be of little value.

CHAPTER IX.

MALFORMATIONS AND MALPOSITIONS OF THE TEETH.

ABNORMALITIES of the teeth are found associated with position, size, form, and structure. Aberrations in form, structure, and size are included under the head of malformations of the teeth; aberrations of position are discussed under the head of malpositions of the teeth. The particular section of dentistry relating to malpositions of the teeth is by general consent made a special department of operative dentistry, that of orthodontia; but many of the phases of the subject are of great pathological interest, although the therapeutic measures usually demanded are mechanical in character and clearly belong to the fields of operative and prosthetic dentistry.

Malformations of the teeth may be macroscopic or visible to the naked eye, or microscopic, requiring special preparation for observation under the microscope.

The causes of imperfectly formed enamel or teeth must be sought by study of the conditions preceding their development. That modifications of general nutrition must modify tooth development seems to be a safe proposition.

An ill-nourished child is apt to have at least poorly organized tooth material, while in one that has actually undergone an exanthematous disease the tooth form subsequently seen seems frequently to have been profoundly modified by the disease.

MICROSCOPIC MALFORMATIONS.


Microscopic or histological defects of the teeth may affect any of the dental tissues, enamel, dentine, cementum, pulp, or pericementum.

Enamel. Defects in enamel structure range from any degree of orderliness in the even distribution of globular bodies and cementing substance in the tissue to gross aberrations in formation. The finer variations of structure are not easily recognizable.

Theoretically perfect enamel should show in longitudinal section a series of squares of uniform size built into rods, the spaces between the squares and rods being marked by lines of cementing substance having

a refractive index slightly different from that of the squares. While such a structure is perhaps never found, it is difficult to draw a line where aberrations from such a standard become pathological. An arbitrary standard might be assumed as follows: regard any enamel as pathological where areas of it differ from its general substance to such an extent as to have a decidedly different refractive index. A typical form of abnormality is noted in what are known as white spots

FIG. 183.



Portion of a white spot in enamel, showing lack of interprismatic cement substance. $\times 2000$.
(Williams.)

of the enamel, areas in which an opaque surface exists instead of the normally translucent enamel.

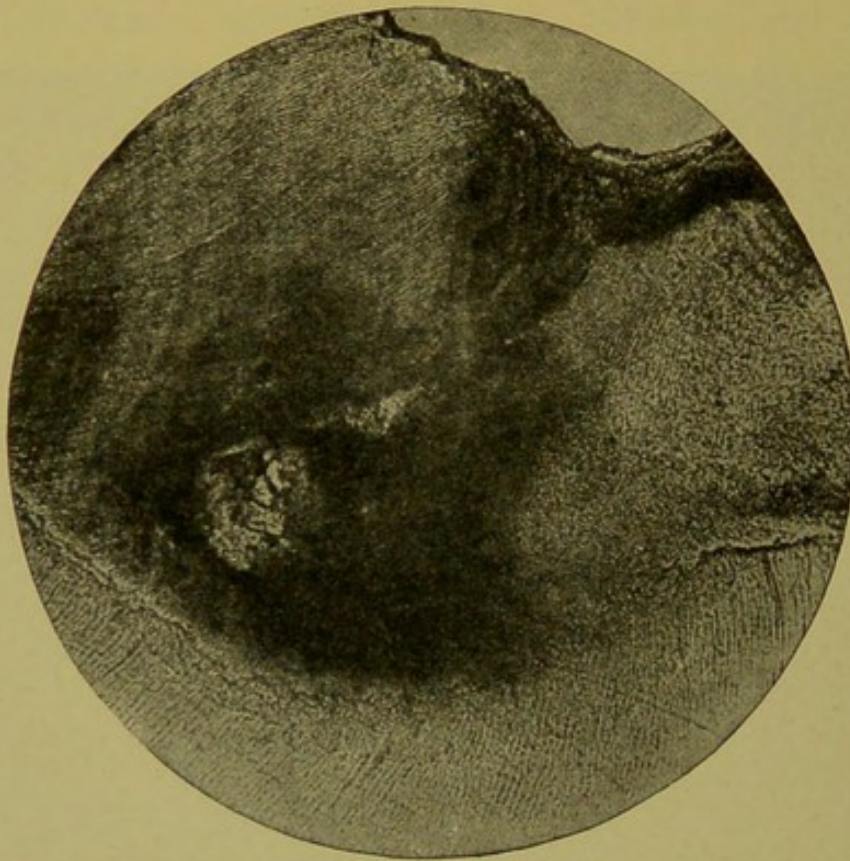
Opaque Spots in Enamel. White, brown, and corn-colored opaque areas of enamel are frequently seen surrounded by apparently normal enamel.

Examined without the aid of the microscope they are seen to present a surface as smooth as any enamel, but upon this surface being broken up with a bur a chalky, granular, whitish material containing at times

the yellowish pigment is seen sometimes occupying the entire thickness of the enamel.

Williams submitted the enamel at the borders of such spots to microscopic examination and compared it with enamel in the first stages of decay, finding in both a similar appearance characteristic of a lack of or a loss of interprismatic cement substance (Fig. 183; also Fig. 301).

FIG. 184.



Section through human cuspid, showing sulcus and appearance of tissue in its vicinity.
 × 75. (Specimen by Choquet, photo. by Williams.)

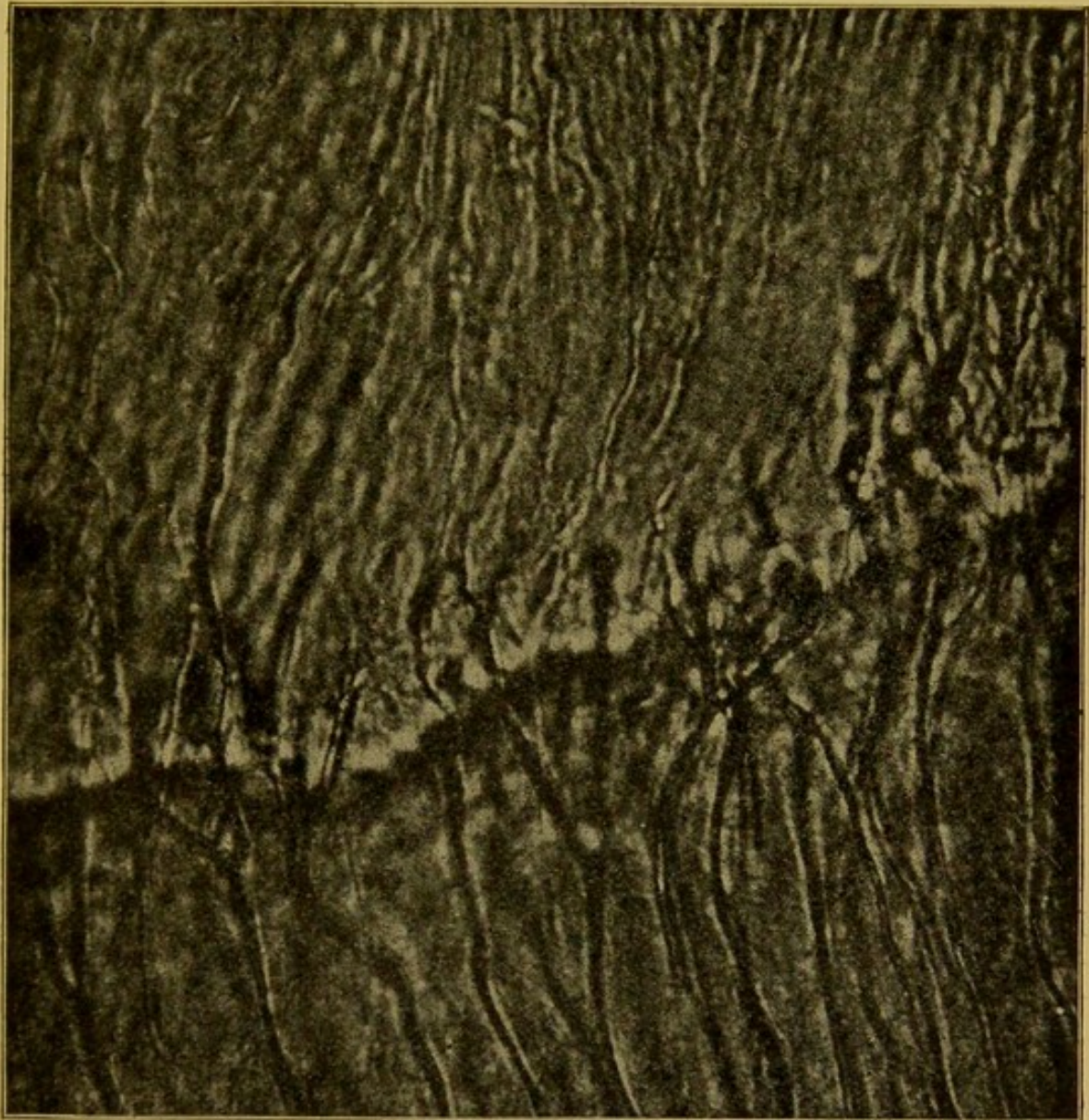
Upon the data derived from his investigations with the development of the enamel he concluded that these spots are due to a lack of such cement substance. This leaves as the probable substance in the spot unfused globules mingled with some pigment.

Enamel formation about the sulci of teeth is frequently faulty; owing to an imperfect union of the enamel segments forming the cusps of the teeth minute fissures exist in the enamel; these are most marked in the fissures of molars, as shown in Fig. 184. The enamel bounding these fissures has an irregular structure.

The dentinal fibrillæ may penetrate the substance of the enamel (Fig. 185), occupying defined channels in its substance; this is regarded by Williams as a developmental accident. He points out that

the organic filaments from the dentine become atrophied with the progress of enamel formation and canals remain. Caush¹ claims to have found this to be a normal condition of human enamel, and regards these as nutrient spaces. (See p. 141.) This condition, as also many other variations of structure found in the dental tissues

FIG. 185.



Section of human molar, showing dentinal fibrillæ penetrating enamel. $\times 600$. (Williams.)

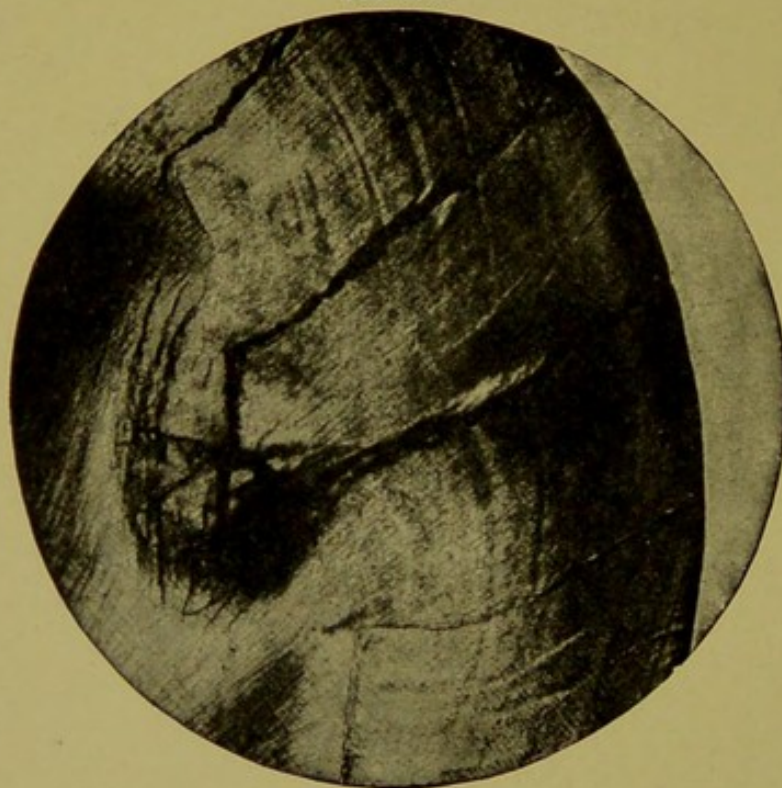
of man, are shown by Williams to have their normal prototypes in the dental tissues of lower animals; for example, the penetration of dentinal fibrillæ into enamel is a normal condition in the teeth of the kangaroo. Such conditions are not to be confounded with fissures of enamel where large lines of faulty calcification or non-calcification extend through the thickness of enamel. A portion of the enamel, as

¹ International Dental Journal, June, 1904.

shown by Fig. 186, may occupy an area normally occupied by dentine.

Enamel, even normal enamel, is not of uniform composition; were it so, it would exhibit, in addition to an orderly arrangement of its histological elements, a uniformity in color. So common are differences in this direction that the presence of pigment bands must be regarded as normal. It is the rule to find enamel traversed by deeply pigmented parallel bands (Fig. 115) which pass obliquely upward from the surface of the dentine to the surface of the enamel. These are termed the bands of Retzius (see Chapter VI.); they appear to mark the size of the enamel cap at successive periods of its growth.

FIG. 186.

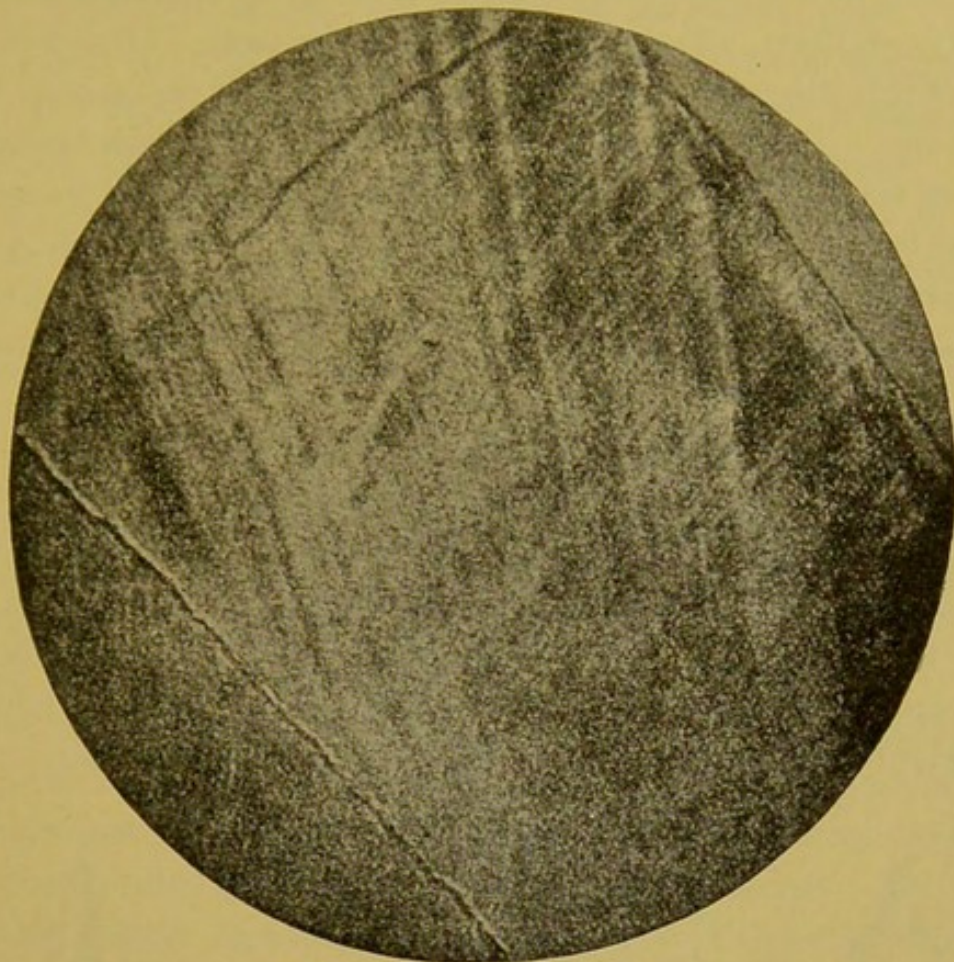


Section of human bicuspid, showing mass of very imperfectly calcified enamel projected into the dentine, with coarse fissures leading to the surface. $\times 75$. (Williams.)

Stratification and striation of the enamel, as shown by Williams, must be regarded as normal physiological records of the mode of enamel formation. Kirk has shown that normal enamel shows variations in density in the same teeth. (See p. 160.)

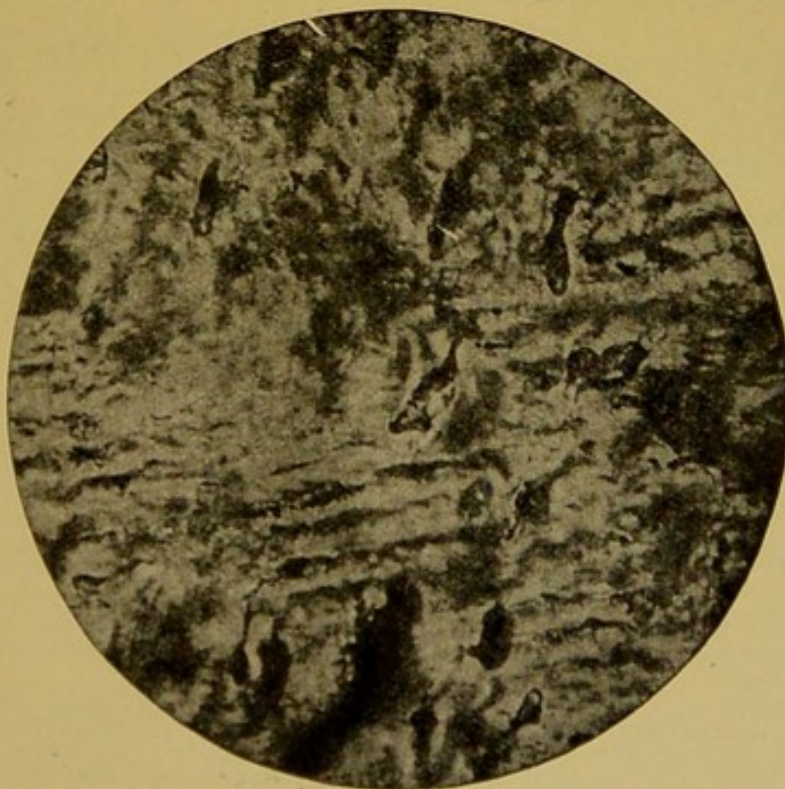
All of these histological defects represent variations of deposition, no doubt due to fluctuations of the nutritive processes of the child at the time of tooth formation. Histological records made in the enamel are not like those made in other tissues, for there is no certain provision through which such defects can be remedied at subsequent periods.

FIG. 187.



Section of human incisor, showing "bands of Retzius" and marked stratification of enamel. $\times 125$. (Williams.)

FIG. 188.

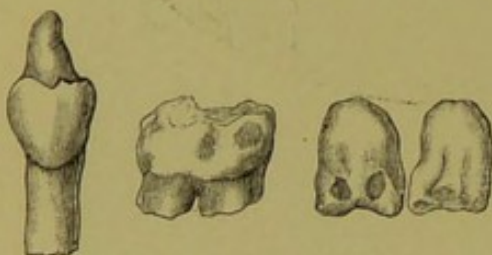

Section of enamel from syphilitic tooth, with appearances resembling the lacunæ of cementum. $\times 600$. (Williams.)

Profound nutritive disturbances, such as those attending hereditary syphilis in children, affect the structures of the teeth. One of the gross results of this disease is a common malformation of the general form of the incisors. The hard tissues of such teeth exhibit microscopic evidences of faulty histology; they are dull and opaque and traversed by irregular bands. Viewed in section the enamel of such teeth is seen to be almost structureless (Fig. 188). Williams found that the contents of the large, irregular spaces in this enamel did not respond to stains—*i. e.*, did not contain organic matter.

There is evidence that other forms of specific dermatitis—scarlet fever and measles—which occur at an early age may affect the formation of enamel. The defects attributed to the exanthemata are irregular pits upon the crowns of, particularly, the incisors (Fig. 189), though the cuspids and first molars also suffer. In some cases the crowns appear honey-combed. The condition is known as hypoplasia of the enamel and is evidently due to an effect upon the enamel organs.

FIG. 189.



Hypoplasia due to eruptive fevers.

FIG. 190.



With a history of a case, including the age of the child at the period of the disease, if examination be made of the positions of the defects, the age will serve as an indication as to whether there has been any connection between the eruptive fever and the dental malformation. For example, if enamel pits upon incisors have been caused by an eruptive fever between the ages of four and five, they should occupy about the half-way area of the crown-face; it is evident that the enamel being already formed about the cutting edge of the tooth, alterations of nutrition could not affect the already formed tissue. In cases where a causal association of enamel defects with the eruptive fever is made out with reasonable clearness, it is usual to find all of the crowns of the teeth which are in process of formation affected in a similar manner.

Cases are observed where there has been a formative crisis to the extent of having no enamel whatever formed over the occlusal section of the crown, its deposit on the remainder of the crown being quite normal (Fig. 190).

D. B. Freeman¹ records the case of an individual, aged twenty-six years, whose teeth anterior to the second molar were entirely devoid of enamel. The condition was hereditary; it appeared in both brothers and sisters, and could be traced back for three generations.

Hopewell-Smith² claims that teeth apparently devoid of enamel have, in all cases examined by him, had attenuated enamel upon them. This would also be classified as hypoplasia.

Black³ has described the teeth of a man, aged twenty-seven years, as having enamel of an opaque, paper-white appearance, as readily cut as a slate-pencil, and with dentine of ordinary consistence. The teeth presented little caries. He also described the temporary teeth of a child as all without trace of enamel, the dentine soft, bendable in any direction, with production of pain, and penetrable with a sharp explorer (agenesia of enamel).

Hopewell-Smith⁴ describes the enamel developed during rickets as faulty, and, in so far as limited observation could determine, contained numerous spaces probably filled with soft tissue. These spaces were in the first-formed portions of the specimens observed.

Dentine. Data regarding the finer phases of defective histological structure of the dentine are meagre. It has been observed that the dentinal tubuli of some teeth are much larger than in others of the same age, and, no doubt, future investigations with an improved technique directed toward a study of the exact mode of dentine formation will exhibit defects more certainly.

The chief histological defects noted in dentine are areas of faulty or non-calcification, called interglobular spaces. (See Chapter VI.) These are most common in the dentine immediately underlying its covering tissue, so common in the dentine under the cementum that this portion of dentine has been called the stratum granulosum, the granular layer of Tomes (Fig. 191). In the body of the dentine these spaces have a more irregular distribution (Fig. 118).

In wet ground sections (Röse) the dentinal filaments are seen to pursue an unbroken course through these areas. The contents of the interglobular spaces react to stains like the sheaths of Neumann; that is, they probably contain transitional tissue. These areas probably represent, as do defective spots of enamel, periods of depressed vitality, or of altered nutrition. In the light of present knowledge regarding the subject they are to be viewed as areas in which the calcific process

¹ See Guilford, *American System of Dentistry*, vol. iii.

² *Histology and Pathol. Histology of the Teeth*.

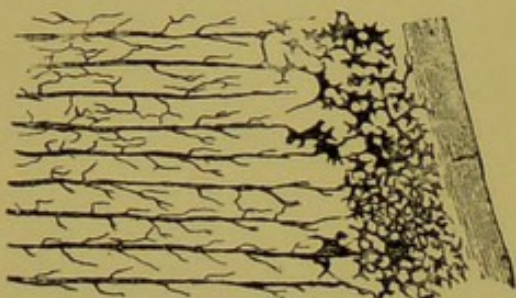
³ *Dental Cosmos*, June, 1898.

⁴ *Loc. cit.*

was faulty. The malformations noted in connection with the enamel of syphilitic teeth have their analogues in the dentine (Fig. 192).

Interglobular spaces afford some evidence of the formation of dentine by a deposition of globular bodies in a matrix of protoplasmic material. The continuation of the tubules through the mass of uncalcified contents is evidence of their independent formation by the fibril cells.

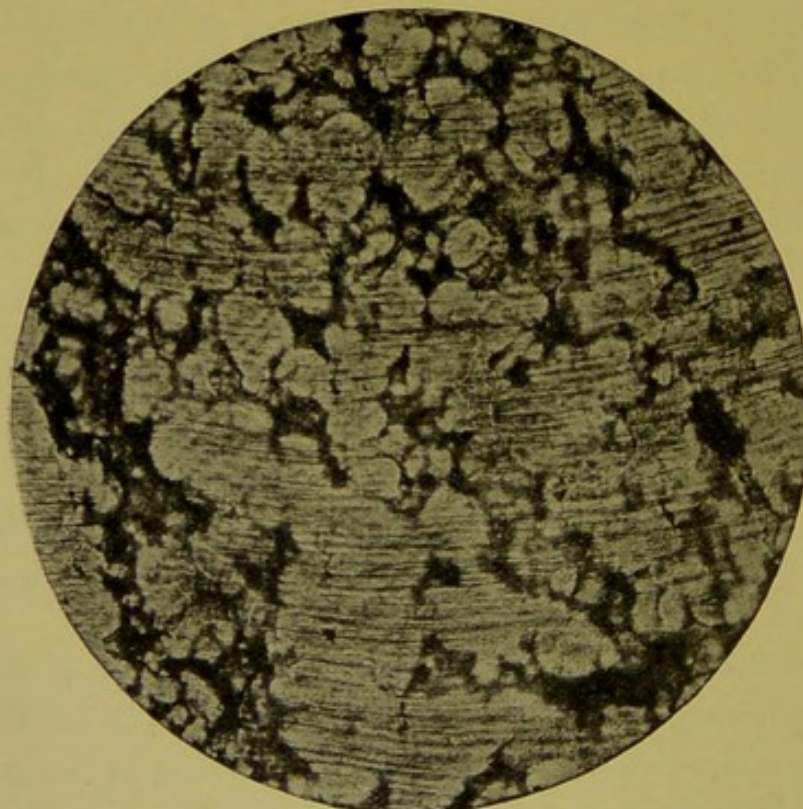
FIG. 191.



Dentinal tubuli terminating in the spaces of the granular layer. (Tomes.)

Histological malformations of the pulp have not been recorded, the normal histology of the organ not being made out with sufficient certainty to determine what appearances are to be regarded as abnormal. Grosser aberrations, such as those shown in Fig. 151, are made out.

FIG. 192.

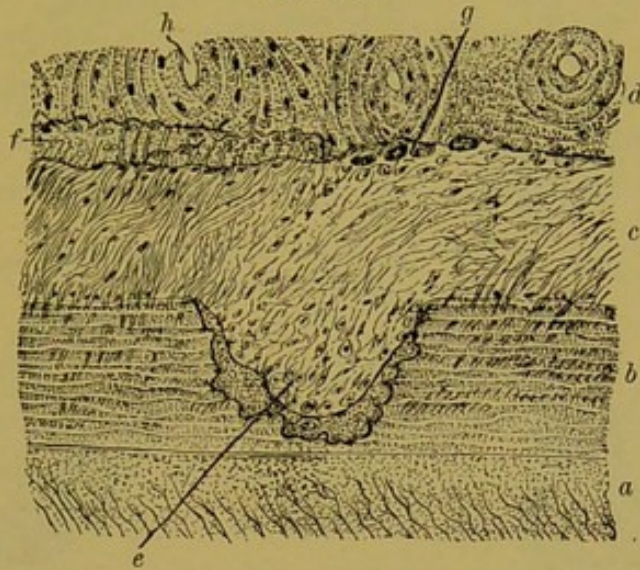


Section showing interglobular spaces in dentine of a syphilitic human tooth. (Williams.)

Cementum. As stated in Chapter VI., the pericementum contains numbers of multinucleated cells—odontoclasts; and their presence is not to be regarded as abnormal. The cementum of the roots of teeth may exhibit evidences of former action of these cells in excavations of

cementum which by a subsequent deposition of cementum have become filled. This gives an irregular course to the cement laminae (Fig. 191). These appearances are to be regarded as not necessarily pathological, for the following reason: for some time (years) subsequent to the eruption of the teeth developmental changes occur in the alveolar bones; depositions (subperiosteal) increasing their volume are accompanied by resorption of other portions of the bone, such a balance being kept between their processes that the teeth, although shifting their positions, are kept in normal occlusion.

FIG. 193.



Section of a bicuspid with its alveolus, showing a pit-like absorption upon the side of the root in which the redeposit of the cementum has begun: *a*, dentine; *b*, cementum; *c*, peridental membrane; *d*, bone forming the wall of the alveolus; *e*, absorbed area of cementum. It will be noticed that a new deposit of cementum has begun the filling of the area, and that the soft tissue in the area of absorption is of a cellular type. The bone also shows the effects of absorption in the cutting away of portions of the rings of the Haversian systems at *f*, while at *g* the presence of osteoclasts shows that absorption is in progress at that point. (Black.)

The cementum may be thickened by additional deposits as in hypercementosis, which is an excess of development classed as pathological.

A small excrescence may be found upon the cementum, and is known as a cemental nodule.

MACROSCOPIC MALFORMATIONS.

The teeth may vary from the normal either as regards size or external configuration.

Variations as to Size. It is patent to the most casual observer that the teeth vary as to size. Comparisons in this direction are made by an examination of the upper central incisors. Fig. 194 shows nearly

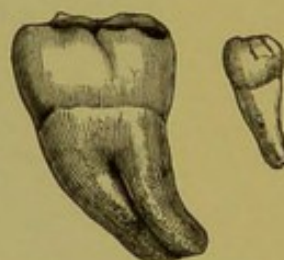
the extremes of observable sizes; Guilford¹ points out that excessively large central incisor crowns are usually supported by abnormally small conical roots. Marked giantism of the central incisors usually occurs in pairs, the other teeth being of normal size. On the other hand, dental giantism of less degree may involve all of the teeth of a denture. The molar teeth are occasionally of enormous size, the bicuspid rarely so, and the cuspids next in frequency to the molars as to the occurrence of giantism. Guilford observes that giantism of the cuspid crowns, unlike that of the central incisors, is usually accompanied by a corresponding size of root. He mentions the case of a cuspid measuring an inch and a half in length from tip to tip.

Dwarf Teeth. Deficiency in size is of more common occurrence than excessive size. It appears to occur more frequently with the upper third molars and upper lateral incisors than with any other teeth. Fig. 195 shows the extremes in size between two perfectly

FIG. 194.

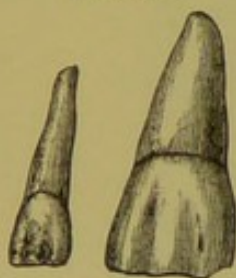

FIG. 195.



formed lower third molars. The stunting of these and of other teeth is, however, usually associated with such an aberration of outward form that most dwarf teeth must be considered as abnormal in form as well as in size.

Conical Teeth. The primitive tooth is composed of but a single cone. Human teeth have forms which are modified cones or combinations of cones. Return to a conical form is therefore denominated reversion to a primitive type.

A central incisor, or more frequently a lateral incisor, may have a conical crown, as shown in Fig. 196. The condition may be double.

Upper third molars frequently consist of but a single cone, diminutive in size; at times a crater-like crown is formed by a series of small cones about a central pit.

Pitted and Grooved Teeth. Nutritional disturbances, the exanthemata, and syphilis all seem to have a profound influence upon the form of teeth developing during the period of active disease. With

¹ American System of Dentistry, vol. iii.

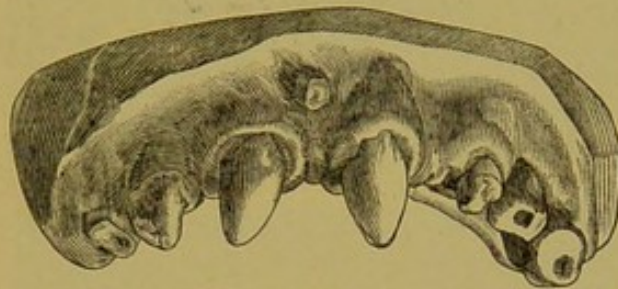
the passing of this period the development of the tooth may proceed in an orderly manner.

The malformations described under this heading may consist of a series of irregular grooves or pittings, the crowns having the general normal outlines

Of these malformations Figs. 197 and 202 are fairly typical.

Hutchinson Teeth. During the first few weeks after birth skin eruptions characteristic of hereditary syphilis are apt to occur in the

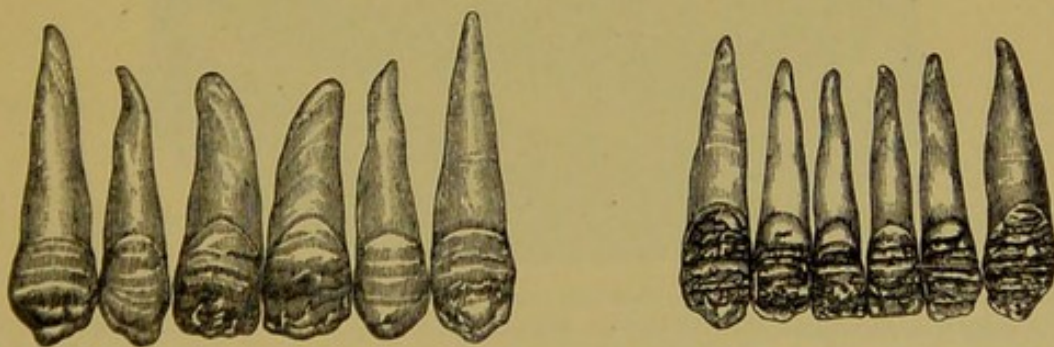
FIG. 196.



Tusk-like permanent central incisors, temporary teeth retained on either side.
Lady, aged twenty-five years.

contaminated child. At this period the enamel of the tips of the permanent incisors is undergoing development (see Fig. 107) and the effect of the eruption is to cause a defective development at this point. Instead of the normal angles and flattened curves of the labial surfaces the incisors may have a roughly rounded and stunted appearance. The incisal edge of the tooth is narrower than its neck. The enamel

FIG. 197.



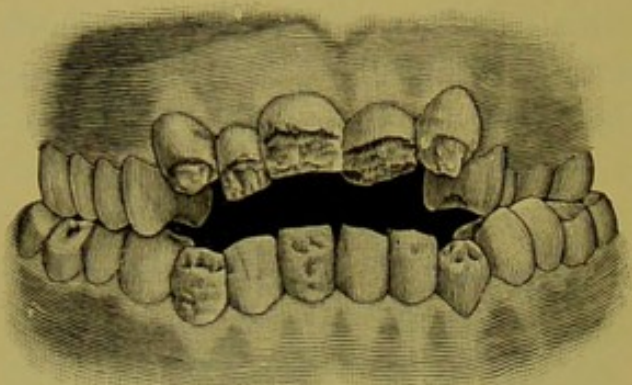
Showing the front teeth grooved from the alternation of perfectly and imperfectly developed portions of enamel. (Tomes.)

at this edge is irregularly and badly formed; but there is a semblance of the three enamel tubercles found normally. The middle tubercle being composed of defective enamel is soon lost by abrasion, causing the tooth to have a notched appearance (Figs. 199, 200, 201).

A lack of development of the anterior portion of the upper jaw has been noted in a number of cases clearly syphilitic (Fig. 199). It has

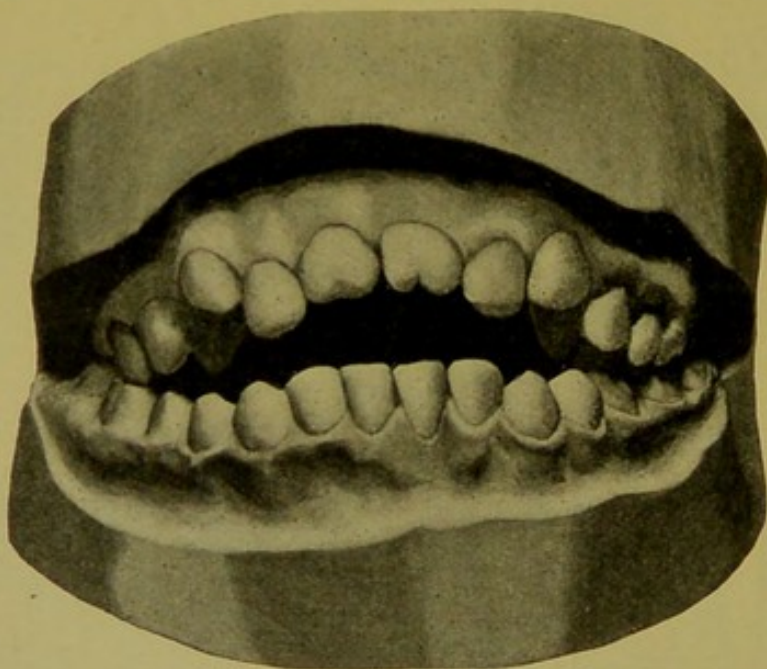
been noted that not all syphilitic children present these dental appearances; and again appearances *said* to be identical with them are observed in children *said* not to be syphilitic; nevertheless the presence

FIG. 198.



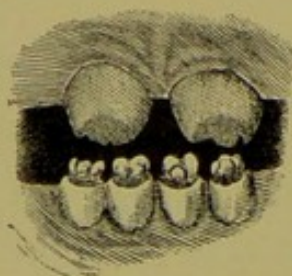
Malformations of incisal half of crowns, with cervical half perfect. Attributable to malnutritional processes rather than syphilis. (Model by W. A. Capon.)

FIG. 199.



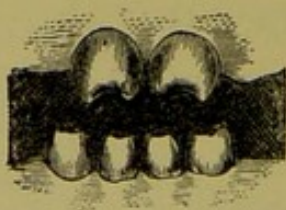
Hutchinson's teeth. Two upper centrals notched and contracted. Characteristically undeveloped upper jaw. From an hereditary syphilitic, aged twelve years.

FIG. 200.



Syphilitic teeth in upper and lower jaws as they appear when recently erupted.

FIG. 201.



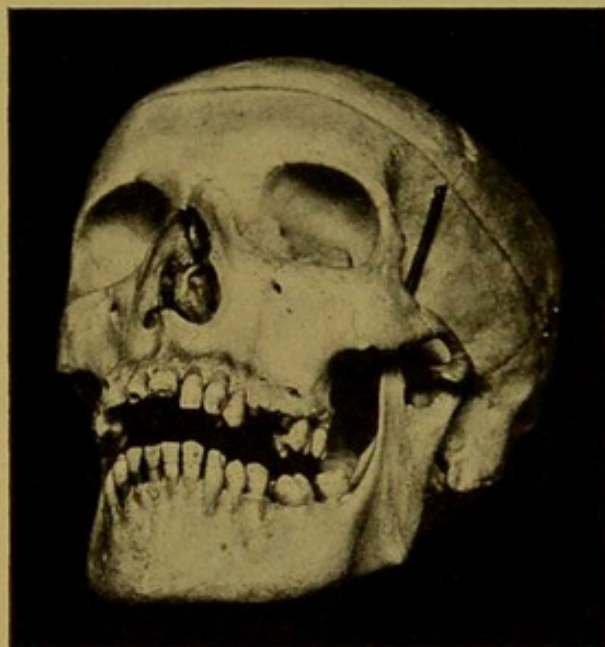
The teeth of hereditary syphilis at maturity.

of such teeth is usually regarded as a valuable diagnostic sign of hereditary syphilis. The existence of interstitial keratitis and of chronic catarrh of the middle ear in connection with Hutchinson's teeth are held to be diagnostic signs of hereditary syphilis (Hare).

Therapeutics based upon such a diagnosis are followed by better results as a rule than when the general indication is ignored. The boy from whose mouth a model (Fig. 199) was obtained had interstitial keratitis in the left eye, chronic nasal catarrh, and a somewhat flat development of the nasal bones.

Tomes favors and adduces evidence to support the contention of Hutchinson that honey-combed incisal edges of incisors and cuspids

FIG. 202.



Pitted and fringed teeth, some of them carious at the incisal edges. Specimen in museum of Philadelphia Dental College.

and occlusal surfaces of first molars are indicative of mercurials administered in early childhood.

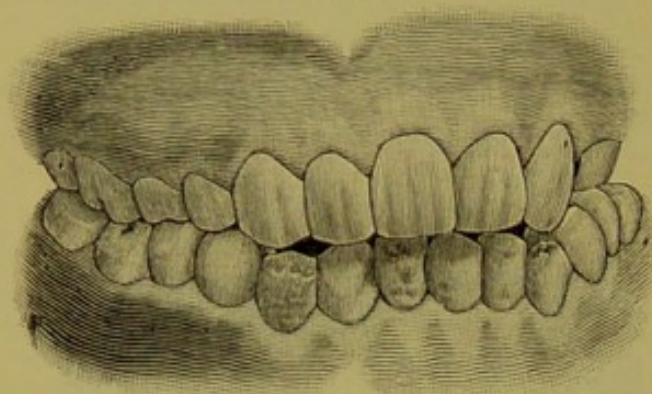
Pitted, grooved, or otherwise malformed teeth may decay sometimes so badly as to produce a black, slimy appearance almost loathsome to view. In other cases surprisingly little caries develops.

Treatment. If slightly pitted, gold or porcelain fillings may be introduced. In some cases grinding off the rough incisal edge is sufficient; in other cases the teeth may require to be drawn down after this procedure, or porcelain inlays may be used to restore the incisal edges. In the extremely disagreeable cases above mentioned some form of crowning must be resorted to. Fig. 203 exhibits a restoration of the case shown in Fig. 198.

Fusion of Teeth. Two or more teeth may be united during the process of development. The union may occur (1) by the crowns, (2) by the roots alone, and (3) by both crowns and roots.

Fused teeth united by the crowns alone have not been shown. The nearest approach to it is the case illustrated by Tomes, in which two central incisors have fused by union of the crown portions and one-

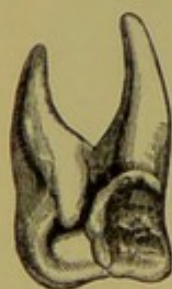FIG. 203.



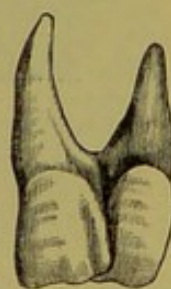
Same as Fig. 198, with Land jacket crowns placed over anterior teeth. (W. A. Capon.)

fifth of the root portions of the two teeth (Fig. 204). Such teeth would have dentine common to both crowns at the point of union, the enamel being reflected over the outside of the common dentinal mass according to the scheme shown in the diagram Fig. 208, *B*. The pulp may be common to the two teeth in the crown. Of course, the root pulps are separate.

FIG. 204.



Lingual view.



Labial view.

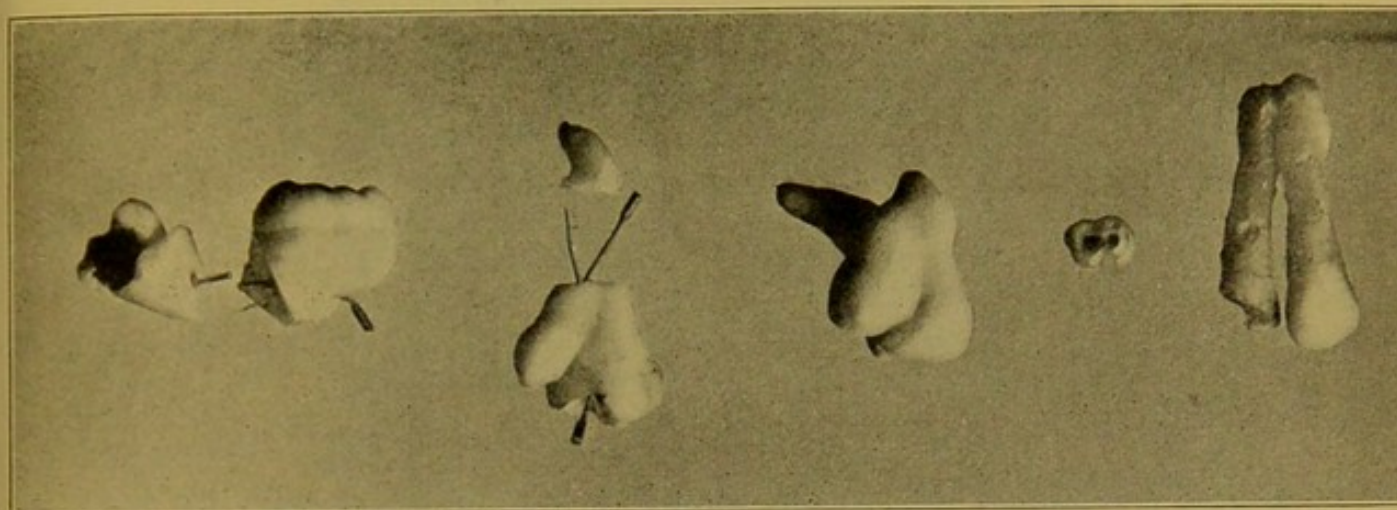
Fusion of two permanent upper central incisors by their crowns and a portion of the roots. (Tomes.)

The condition is a record of the fact that prior to dentinification the papillæ and enamel organs of the two teeth have coalesced at some point. This must have occurred at an early period, perhaps even during the descent of the buds into the jaw. When it is considered that the two central incisors are contained in two separate intermaxillary bones, the rarity of such a union and in such a manner may be appreciated. I have seen such a union between a right lower central and lateral

incisor in the mouth. Recession of the gum permitted a view of the cervical conformation.

Those teeth united by fusion of the roots have a common dentine at the point of union, with cementum reflected over that. The pulp is common to the two teeth at the point of fusion.

FIG. 205.



a

b

c

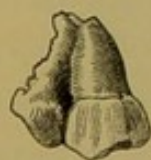d

e

a, fusion of two molars at the roots—two pulp cavities, one foramen; b, c, fusion of supernumerary teeth roots to buccal roots of upper molars, pulp canal common where probes cross; d, view of resorbed root end of two fused temporary teeth; e, concrescence by hypercementosis.

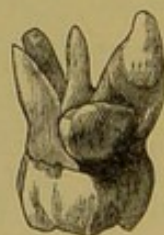In the specimen shown in Fig. 205 at *a* there is but one apical foramen. In that shown at *b* and *c* there is but one foramen for the two fused portions of pulp, though the other canals have their usual foramina. These cases evidence an accidental coalescence of pulps after much independent root formation. Fusion throughout both crowns and

FIG. 206.



Fusion of temporary teeth by their roots.

FIG. 207.



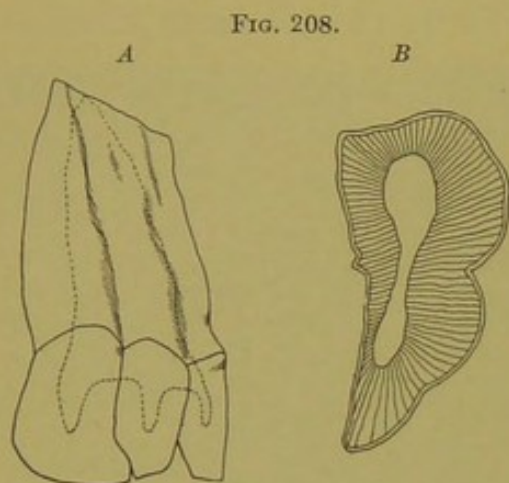
Fusion of a supernumerary tooth with an upper third molar.

roots have the same characteristics as the others combined in the one specimen. The diagrams (Fig. 208) show the scheme for the crown and root.

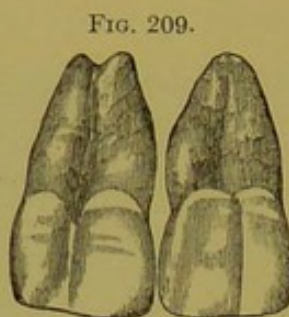Fig. 210 shows specimens of fusion in both the upper and lower jaws. It occurs also with the temporary teeth (Fig. 211). Fig.

208, *A*, shows a very rare condition, the fusion of the temporary central, lateral, and cuspid of one side (triple fusion).

Fusion is evidently an abnormality of development dependent upon coalescence of formative organs at some point, and is most likely to occur where the adjacent tooth follicles have least anatomical separation.



A, diagram of a case of triple fusion showing crowns with independent incisal edges and pulps, but otherwise fused into one crown with one pulp; *B*, transverse section of same, showing common pulp cavity and common dentine overlaid by enamel (or cementum). From a specimen.



Permanent central and lateral incisors of the upper jaw, united throughout the whole length of the teeth. (Tomes.)

ration from their fellows. The roots of fused temporary teeth are resorbed as usual (Fig. 205, *d*).

No particular treatment is required unless the mass in some way cause interference with function,

which is unusual. The teeth having a common pulp, no attempt should be made to divide them.

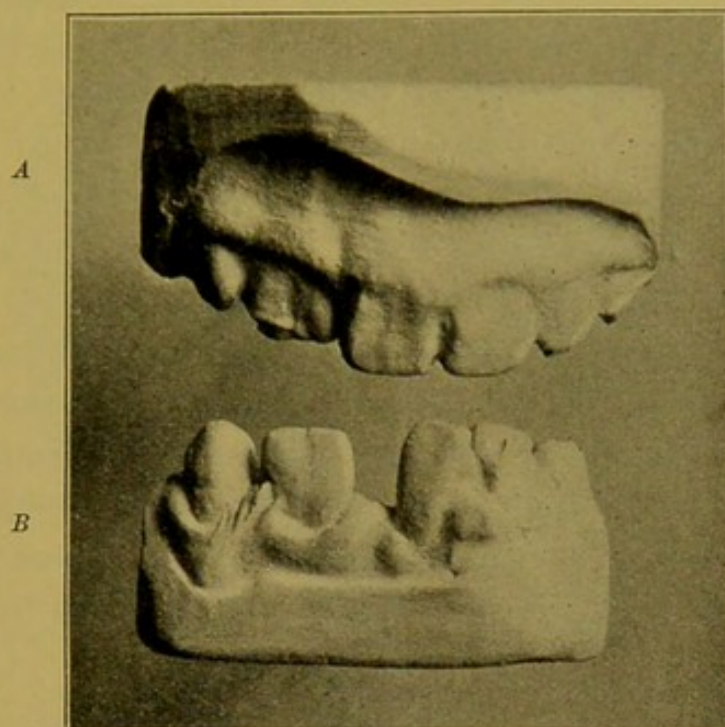
Fusions are most common between the anterior teeth of each set and between the second and third or third and fourth (supernumerary) permanent molars. It has not been noted in bicuspid, presumably because these teeth lie in the bifurcations of the temporary molars.

Concrescence of Teeth. Concrescence of teeth is their union after the tooth is formed; it is evident, therefore, that the union can only be caused by fusion of cementum. This means that during the formative and eruptive period or after eruption the bony partition between the teeth disappears, and that their pericementi become united, receding from the line of compression as cementum is deposited between and joining the roots. The united teeth show evidences of hypercementosis at points other than the point of union (Fig. 205, *a*, and Fig. 212).

In the eruption of the third molars, particularly the upper, temporary lack of space for the eruption of the crown may cause resorption of the bone covering the roots of the second molar, and fusion of the formative pericementum of the third molar with that of the second occurs; a deposition of cementum then binds the teeth together,

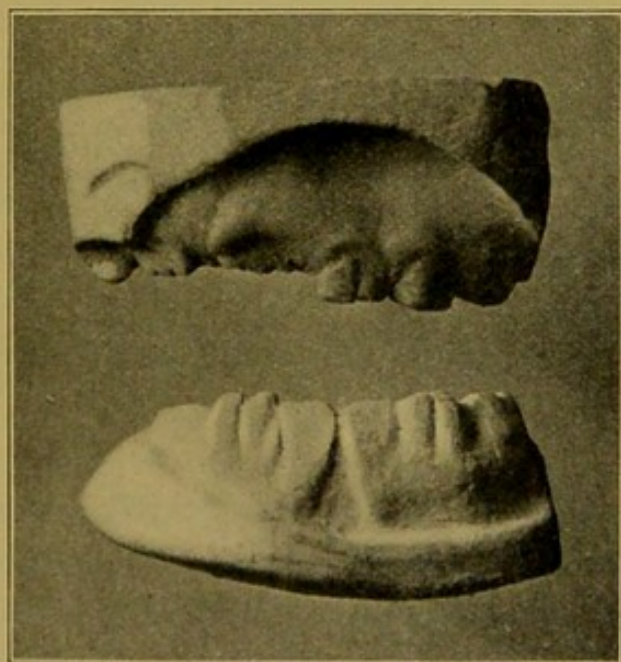
preventing the eruption of the third molar. The lower third molar rarely presents its roots to those of the second molar; the contrary presentation is the rule. The condition also occurs apart from the

FIG. 210.



A, Fusion of upper geminous, permanent laterals. B, Fusion of lower right permanent central and lateral incisors.

FIG. 211.

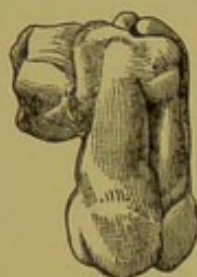

Fusion of upper temporary teeth. Double fusion of lower temporary lateral and cuspid.

eruptive process. Excessive hypercementosis upon the roots of individual teeth may finally result in their union (Fig. 205, *e*).

In at least one case, the crown of the upper third molar was partly erupted when concrescence occurred. Retained in this situation the crown decayed away, necessitating extraction; the second molar came away with it.

FIG. 212.



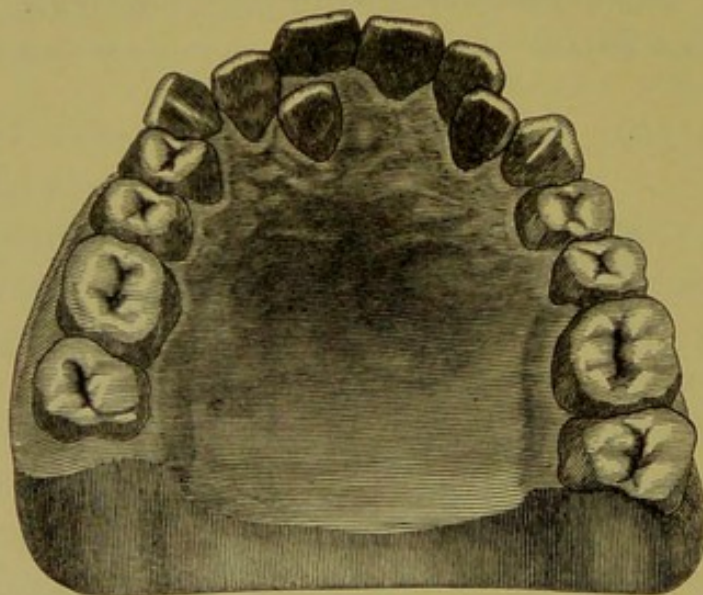
Concrescence. Third upper molar imprisoned between the roots of the second molar.

The only treatment required for concrescence is that indicated for hypercementosis (which see).

Gemination of Teeth. (Twin Teeth.) This term has been used by Tomes in the sense of union of teeth, but it is perhaps better used to designate supplemental teeth of the same class. In twin teeth the enamel organ of a permanent or temporary tooth is duplicated, in all probability, two buds arising from the cord or band as the case may be.

One of the teeth formed is, of course, a supernumerary tooth, but in some cases both are typical teeth (Fig. 213). The second germ may develop an atypical tooth or one but slightly abnormal in form. The geminous teeth may undergo fusion as seen in Fig. 210, A.

FIG. 213.



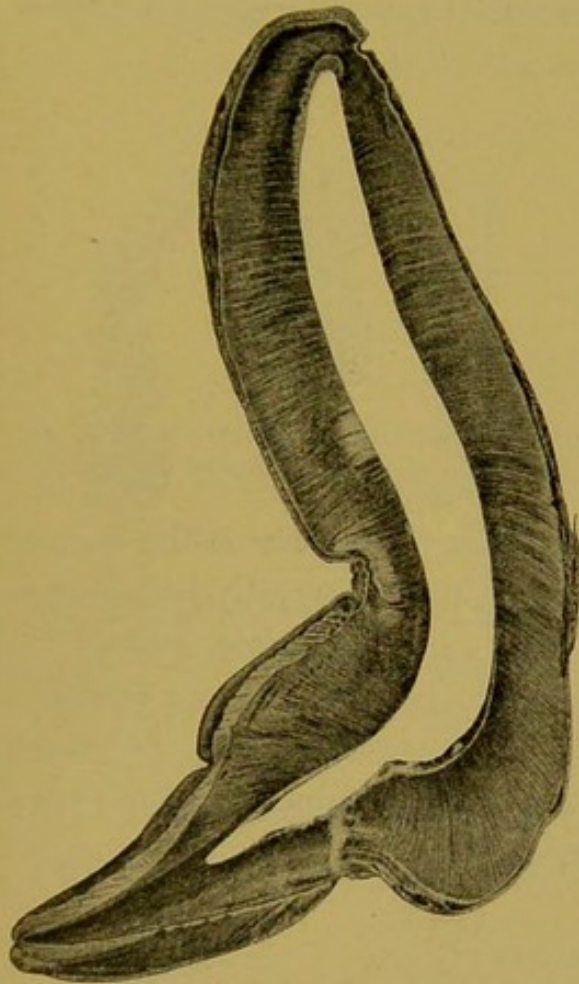
Double gemination of upper permanent lateral incisors.

Dilaceration and Flexion. By dilaceration is meant a displacement of a formed portion of a tooth in such a manner as to change its relative position to the soft parts engaged in its development, the development then being continued in the new relation.¹ The term "flexion" may be made to include cases of abnormal development in which the formative tissues, the enamel organ, or dentinal papilla

¹ Tomes.

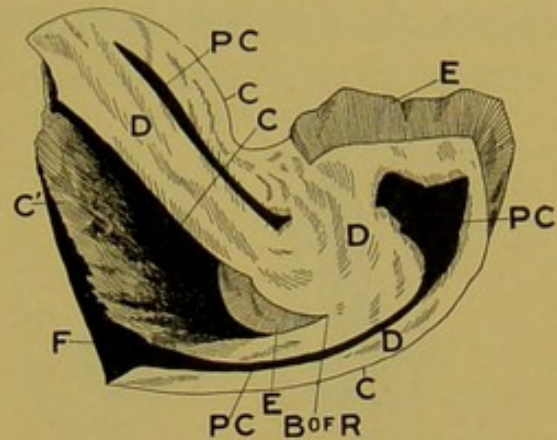
have had their relative positions altered by unknown forces. If, as an example of the first class, an accident to a temporary tooth occur, the force may displace the partially formed permanent crown. The balance of the crown may be formed in the new situation and be of

FIG. 214.



Dilaceration. Shows fold in the labial enamel and cervical dentine. (After von Wunschheim.)

FIG. 215.



Pulp hernia, flexion, and dilaceration, mesodistal section: *E*, enamel, distal section in the bifurcation of the roots; *D*, dentine; *C*, *C'*, cementum; *PC*, pulp cavity; *F*, large apical foramen; *B of R*, bifurcation of the roots.

fairly perfect or of imperfect structure. The same is true of the tissues of the root; Fig. 214 illustrates both conditions.¹ This is most likely to occur with the anterior teeth.

As an example of the second class, a portion of the enamel organ of a tooth may be displaced and in its new relations may form enamel in an unusual situation, as, for example, upon the side or neck of the root (see enamel nodule) or even in the bifurcation (Fig. 215). Again, it is conceivable that lack of space may cause deflection of a pulp engaged in root formation, a curved root being the result (Fig. 223).

Unusual Locations of Enamel. That during development the enamel organ or portions of it may assume an abnormal relation to the pulp is evidenced by odontomes. Apart from these there are evidences seen in teeth which show that portions of the enamel organ may become detached from the main organ and develop enamel in unusual situations. Thus columns of enamel may penetrate the body of the dentine.

¹ G. von Wunschheim, *Fracturen, Infraktionen und Knickungen der Zähne*.

A small nodule or cap of enamel overlying dentine, and itself overlapped at the edges by cementum, may be found upon the root of a molar, usually upon the side of an upper third molar at a point about one-eighth inch from the cervical margin of the crown enamel. A thin ridge of enamel sometimes, though not usually, seen connecting them indicates the nodule to have been formed by a detached portion of

FIG. 216.

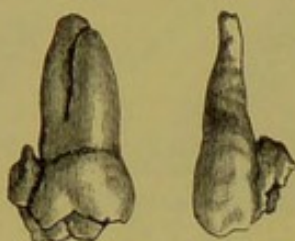
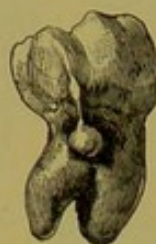Enamel excrescences.
(Salter.)

FIG. 217.

Lower molar with enamel nodule connected with
enamel of crown by a ridge of enamel.

the original enamel organ. This formation is known as an enamel nodule. It may occur upon a lower molar, though usually found upon the upper molars (Fig. 217). They may cause neuralgia (Ottofy).

A molar root may have a cap of enamel upon its apex, an evidence of extreme displacement. Sometimes an excrescence may be found upon the enamel (Fig. 216). Fig. 215 shows enamel formed in the bifurcation of the roots of a lower molar.

FIG. 218.

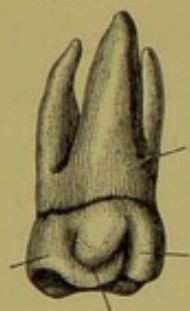


FIG. 219.

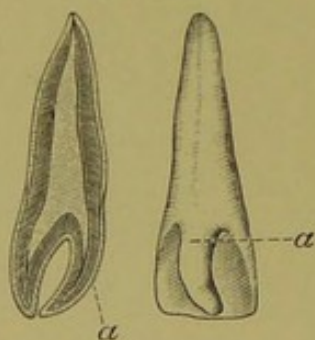


FIG. 220.

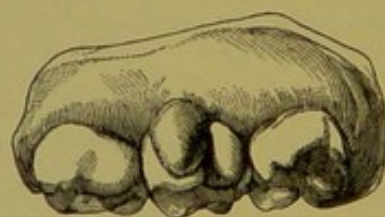


FIG. 218.—Upper molar with supplemental cusp on lingual side.

FIG. 219.—Showing unusual development of the cingule or basal talon on an incisor. (From case reported by W. H. Mitchell, *Dental Cosmos*, vol. xxxiv.)

FIG. 220.—Very large supplemental cusp on upper molar.

Supplemental Cusps. Occasionally a tooth has a greater number of cusps than usual. The most common form of this condition is a supplemental mass attached to the palatal side of the mesopalatine cone of the upper first molars (Fig. 218). It is more rarely the case that a cingule of this sort is noted upon the lower molars. The palatal tubercle, the prominence upon the cingule of an upper incisor, may

be of exaggerated size. In one case (Fig. 219) this development gave the appearance of a talon upon the tooth, a distinct cusp segment in itself.

Fig. 220 illustrates a marked supplemental cusp upon the buccal surface of a molar.

Malformations of Roots. Differences in regard to the size, arrangement, form, and number of the roots of teeth are the most common

FIG. 221.



Cuspids with long roots.

FIG. 222.



FIG. 223.

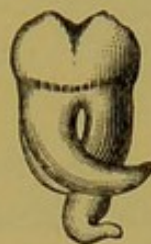
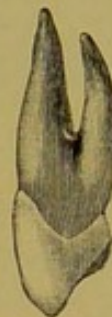
FIG. 224.



Curved roots. Upper cuspid with two roots.

of dental malformations. The roots of teeth may be abnormally long (Figs. 221 and 222) or abnormally short (Figs. 225 and 226).

The roots of cuspids may be bifurcated, particularly in the lower jaw (Fig. 224).

The upper bicuspid may have bifurcated roots, the extra root usually being on the buccal aspect. The upper second bicuspid may

FIG. 225.

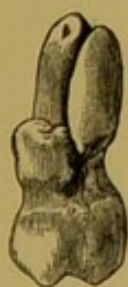

FIG. 226.



FIG. 227.

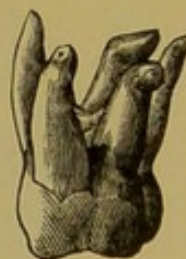

FIG. 225.—Short buccal root of a molar, otherwise properly developed.

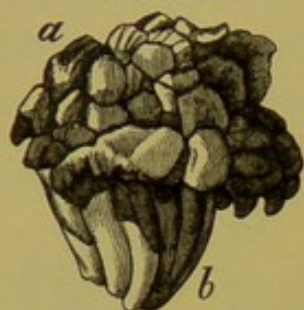FIG. 226.—Central incisor with short root.

FIG. 227.—Five-rooted upper third molar.

be bifurcated; upper molars may have more than three roots, the third molar often having four, five, or six, and in one case reported eight roots (Fig. 227). In some cases upper third molars have but one root with a single, large canal. In other cases the roots are fused so as to form apparently but one root, while the canal divisions may exist. Lower molars may have three or four distinct roots, but at times only one.

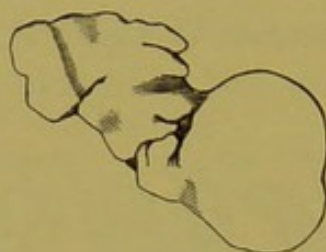Abnormalities of root form are of extreme frequency and are probably explained by the hypothesis of flexion of the root pulp, previous to the deposition of the curved portion of root tissue.

FIG. 228.



Odontoma. (Garretson.)

FIG. 229.

Results of hernia of a pulp.
(Salter.)

It is impossible to diagnose the forms of roots from the appearance of the crowns, but an *x*-ray skiagraph will determine their form with certainty.

FIG. 230.

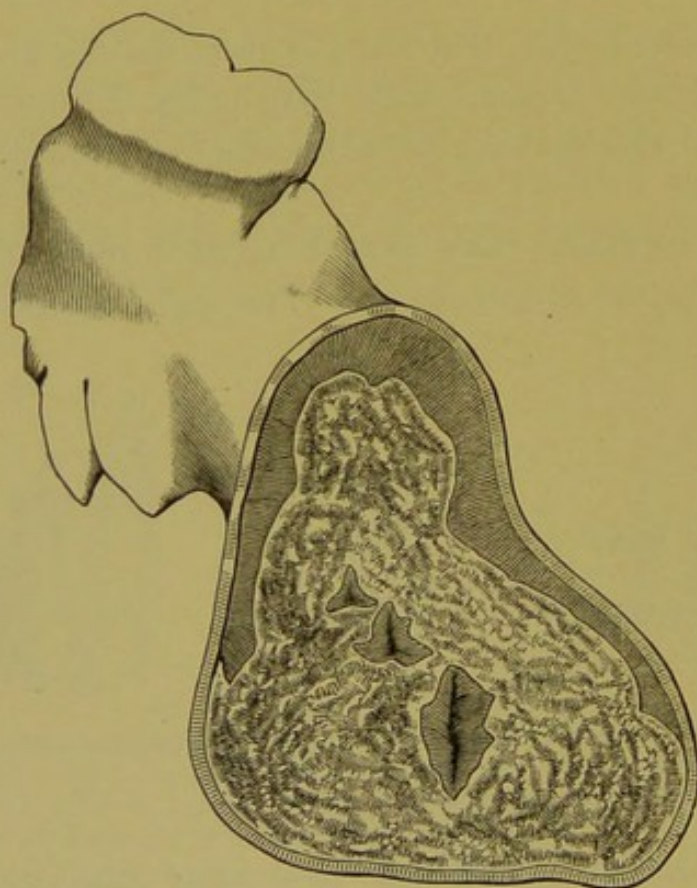


Fig. 229 magnified.

Odontomes. An odontoma is a growth composed of structures of which the teeth are composed, but the masses may be so arranged as to have no typical form or even resemblance to a tooth. They may appear in the arch or may remain embedded in the jaw, where they

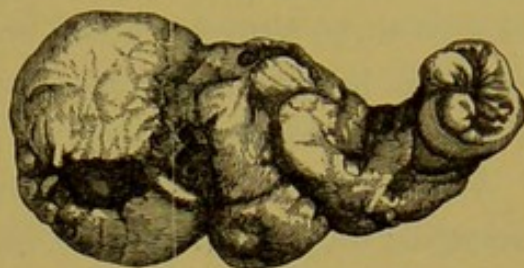may lie quiescent or may excite cyst formation (Fig. 27), or give rise to various morbid reactions.

It has been held by Broca that any of the formative organs of the tooth—enamel organ, dentinal papilla, or follicular wall—may undergo aberrant development and may thereafter deposit calcific tissue or not, as the case may be. If not, tumors not distinctly dental may form.

Figs. 229, 230, and 231 illustrate odontomes of simple and self-explainable nature. After completion of a crown and portion of the roots the pulp has suddenly enlarged far beyond its typical form, carrying with it the follicular wall. Ceasing to enlarge, deposition of dentine has taken place at the expense of the pulp.

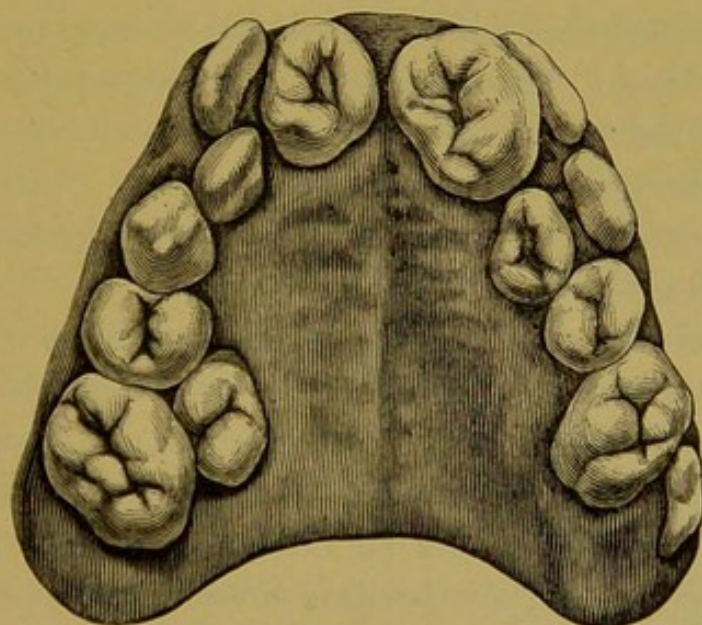
Over this dentine the follicular wall has deposited cementum. The whole forms what has been called a radicular odontome. The expansion of the pulp has been termed a pulp hernia. (See also Fig. 215.)

FIG. 231.



Results of pulp hernia. (Tomes.)

FIG. 232.



Extreme malposition of molar germs. (From model in Philadelphia Academy of Stomatology.)

The diagnosis of the presence of odontomes in cases of tumor formation is made either visually, by *x*-rays, or by incision and exploration. The treatment consists of their removal by surgical operation.

Fig. 232 illustrates a case which is probably merely a case of abnormal molar germs which, after misplacement in some manner, have developed in the incisal region and pushed aside the central incisors.

Anomalies of Number. Although the dental series of man normally consists of thirty-two members, cases are frequently observed in which the number is less than or in excess of that number.

Deficiency. It is observed with some frequency that the upper lateral incisors never make their appearance, a condition traceable to the influence of heredity in some of the instances. In an interesting case of three sisters, who all were without upper laterals, a son of one of them had them. Unfortunately the history as to the parents of the sisters was not certain, as they wore artificial teeth.

When the laterals are absent the permanent cuspid erupts and occupies the lateral incisor space, and thus sometimes fails to cause resorption of the root of the temporary cuspid, which persists in the cuspid space (Fig. 179). The lower laterals sometimes, but more rarely, fail to appear; are probably never formed. The third molar may never appear or appear as a peg-like tooth.

The cases of suppressed teeth next in point of frequency are those of the bicuspid teeth. If the corresponding teeth are all present in the dental arch, a well-founded suspicion of impaction of the missing tooth may be entertained.

An excessive growth of hair upon the face and body has also been associated in some cases with a deficiency in number and alteration in form of the teeth. In other cases no abnormality was noticeable.¹ In some cases the hair and other dermal structures may be normal and the teeth be quite deficient in number.

The extreme of suppressed formation is represented in a case described by Guilford.²

A patient over fifty years old had never erupted any teeth, temporary or permanent; the alveolar arches revealed no evidences of enclosed teeth, but had the appearance of typical edentulous jaws; the alveolar bone itself was but primitive. The case appeared to be sporadically hereditary, a grandparent and an uncle exhibiting a like condition. The cases are interesting also because of additional evidences of faulty evolution of dermoid structures. In the first case cited no sudoriparous glands appear to have formed, and there was but a faint growth of hair on the cranium, and none on the face and body. The uncle was hairless and edentulous from birth. Guilford found in other members of the family an absence of the full complement of teeth.

Excess. The possible occurrence of a condition in some respects the reverse of the preceding has been much written of and discussed

¹ Tomes.

² American System of Dentistry, vol. iii.

—*i. e.*, the occurrence of a complete third denture. There can be but one conclusion from an examination of all the evidence thus far presented, and that is that no clear and well-authenticated cases are made out. Isolated cases of the appearance of teeth subsequent to the loss of all of the second denture are not infrequent; and, so far as clear records can be obtained, are resolvable into cases of the eruption of supernumerary or impacted teeth. While these cases are, at least for the present, to be held as unproved in connection with elderly persons, a well-authenticated case of multiple dentition in a child is recorded by Catching.¹ Between the sixth and seventh month the eruption of one set of teeth was complete; within three months all of these had been lost. Between the eleventh and fifteenth months another period of dentition occurred, the teeth of this second denture being of such faulty structure as to crumble away quickly. At the age of two and one-half years a third dentition appeared, which caused the child such inconvenience that the teeth were extracted by the mother. At the age of eleven years a fourth series erupted, incomplete through the absence of six teeth. At the age of fifteen these teeth were sound and firm.

Fourth Molar. The molar series of man, particularly in the lower negroid races, may consist of four instead of three members. When the fourth molar appears in the white races it is usually as a stunted member, a conical or peg-like tooth, similar to that which occasionally replaces the third molar. There is rarely room posterior to the distal wall of the third molar for their eruption, so that they make their appearance in the region shown in the illustration. S. M. Hartman,² L.D.S., of Victoria, B. C., has furnished the model (Fig. 233) of a case in which the molar form of the fourth tooth is unusually well pronounced.

Supernumerary Teeth. Any teeth in excess of the normal thirty-two, although clearly cases of reversion of type in many instances,³ are included in the category of supernumerary teeth. Supernumerary teeth appear as simple unmodified cones, or as combinations of cones resembling the forms of teeth. The conical form is most common. Cases where these peg-like teeth appear around the third molars singly or in number are numerous. Their appearance in any situation is evidence that the normal number of dental cords has been

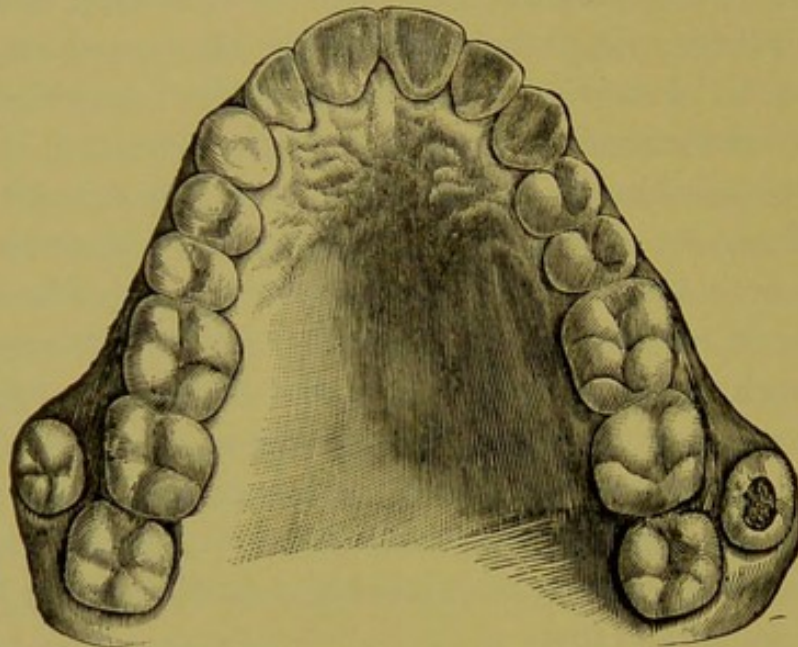
¹ Southern Dental Journal, October, 1886.

² Dental Cosmos, 1891.

³ A. H. Thompson, American System of Dentistry, vol. iii., and American Text-book of Operative Dentistry.

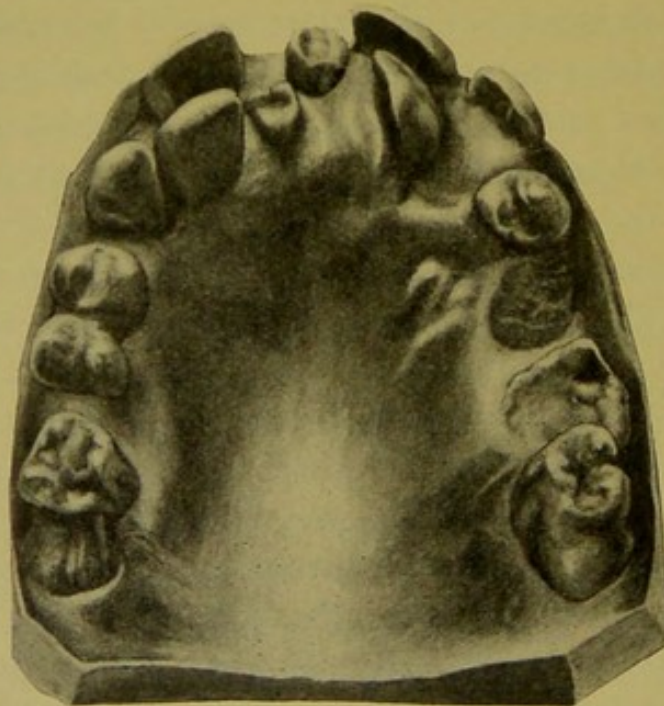exceeded. They are perhaps all to be regarded as cases of long reversion, not alone because they increase the number of the dental series, but because they have primitive forms, a modification of the forms found among the reptiles and fishes.

FIG. 233.



The fourth molar. (Hartman.)

FIG. 234.



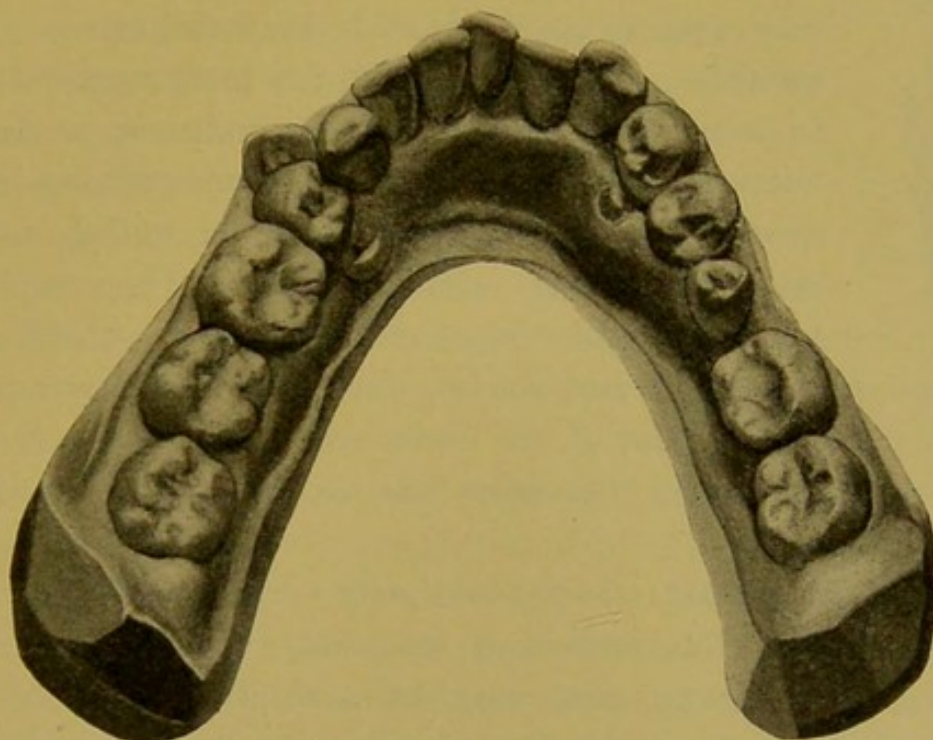
Two atypical upper supernumerary teeth displacing the incisors.

Guilford¹ divides supernumerary teeth into those having typical anatomical forms and those having the atypical forms.

¹ American System of Dentistry, vol. iii.

Supernumerary incisors having typical forms appear in either jaw. In the upper jaw supernumerary centrals and laterals both appear, the latter more frequently (Fig. 213). Supernumerary teeth may occupy any position relative to the dental arch, but are more frequently seen at its lingual side. The compound cone occasionally appears (Fig. 236). In addition to molars and incisors, supernumerary bicuspid are occasionally found (Fig. 235); supernumerary cuspids are very rare, but sometimes a brood of them exists, as many as seventeen fairly defined small teeth having been removed from a cyst in the location of the cuspid tooth.¹

FIG. 235.



Case of seven lower bicuspid, two supernumeraries in place and one erupting. This patient has two supernumerary upper central incisors displacing the centrals proper, yet closely resembling them.

Unless supernumerary teeth are a source of offence, either through their position or appearance, they need not be disturbed. If they are found to be so, they may be extracted.

Malpositions of the Teeth. A tooth is said to be in malposition when it is not in normal relation with the dental arch to which it belongs and to its antagonizing teeth of the opposing arch. Teeth are found in abnormal positions as the result of a variety of causes. Some of these operate prior to, during, or immediately after eruption; some long after the eruption of the teeth, and some because of non-eruption of teeth.

Malpositions which are remediable through the application of

¹ D. M. Clapp, *International Dental Journal*, 1900.

mechanical force applied by means of suitable apparatus belong to operative dentistry, as has been stated. They are fully treated of in works upon operative dentistry¹ and orthodontia,² so that their discussion in a treatise upon pathology might seem a work of supererogation; the plan of the book, however, demands their brief mention.

Malposed teeth may occupy any position relative to the dental arch, and any teeth of the dental series may be the offenders, although most commonly noted in connection with the incisors. So common is some degree of irregularity of the position of the lower incisors that its appearance is scarcely regarded as abnormal. The teeth may be

FIG. 236.



inside or outside the dental arch, or have their transverse axes at any angle with the arch line—*i. e.*, may be rotated in any manner. In the most aggravated cases an entire half denture may be malposed as regards its relations with the opposing or antagonizing half. Instead of having the upper teeth occluding outside the lower, they may occlude inside. They may occlude squarely without incisor overlapping. Both of these

abnormal conditions are, of course, due to lack of correspondence between the development of the lower and upper jaws. If one jaw has developed normally, the other has necessarily developed insufficiently or too much.

Causes of Malposition. Individual teeth become malposed at times through injudicious extraction of temporary teeth. The extraction of a second temporary molar may, for example, permit the approximation of the first permanent molar and the first bicuspid and the second bicuspid be thus compelled to either the buccal or the lingual side. Lack of space in the bicuspid region may compel these teeth to the lingual side, producing what is termed a saddle-shaped arch.

Such lack of space for the accommodation of teeth may thus be due to movement of the other teeth, to a lack of correspondence in the size of the teeth and jaw, or to arrested development of the jaw.

The injudicious retention of a temporary tooth root may cause the deflection of a permanent tooth.

If adenoids or nasal polypi exist the child may become a mouth breather, a habit which causes the muscles to compress the sides of the teeth and alveolar arches. As a result the arch is flattened on the sides and pointed anteriorly. The deformity is known as the V-shaped

¹ American Text-book of Operative Dentistry.

² Guilford, Angle, and others.

arch. Habits such as thumb or lip sucking are frequent causes of protrusion of the upper anterior teeth. Excessive or defective development of the upper or lower jaw, wholly or in part, produces a lack of correspondence in the two arches. Thus there may be inferior or superior protrusion or retrusion. It has been pointed out by Talbot that constitutional conditions are responsible for arrested or excessive developments of portions of the body.

If the first permanent molars be extracted before the bicuspid are erupted, the occlusion does not deepen normally. The lower incisors, erupting early, come to strike the uppers at their linguocervical portions, driving them forward (Fig. 237). To avoid this the first molars should be retained as props, even if only temporarily until the bicuspid are in position.

The first molars are the keystones of the arches and determine the extent of the formative process which shall occur in the alveolar bone posterior to them. They are also the teeth which, correctly placed or out of position, determine the occlusion of the teeth.¹

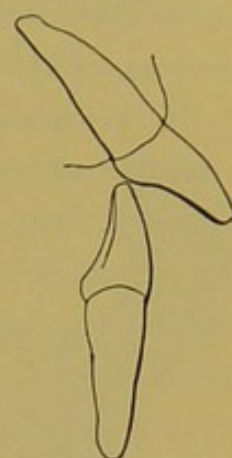If a temporary tooth be long retained it is sometimes raised to the occlusal level of the other teeth; again, it is sometimes left at its original level and occasionally imprisoned between other teeth. The x-ray should be used to determine the presence or absence of the permanent tooth germ or resorption of the temporary roots (Fig. 175).

If teeth erupt in malposition it is held as wise to correct as early as possible, in order to prevent further malposition of other teeth.

Impacted and Encysted Teeth. The extreme extent of dental malposition is reached when the permanent teeth do not erupt at all. Instead of presenting in the dental arch, they may be entirely embedded in the substance of the bone, either remaining there, with or without pathological manifestations, or erupting in some very unusual situation. In other cases a distinct cystic tumor forms about the enclosed tooth (Fig. 27).

Impacted Lower Third Molars. By far the most common dental impaction is that of the lower third molar. The extent of impaction varies from a partial eruption, or partial imprisonment of the tooth by its bony surroundings, to its entire imprisonment in any part of the ramus. Many of the more severe cases treated of under the head of

FIG. 237.



Effects of premature loss of permanent first molars.

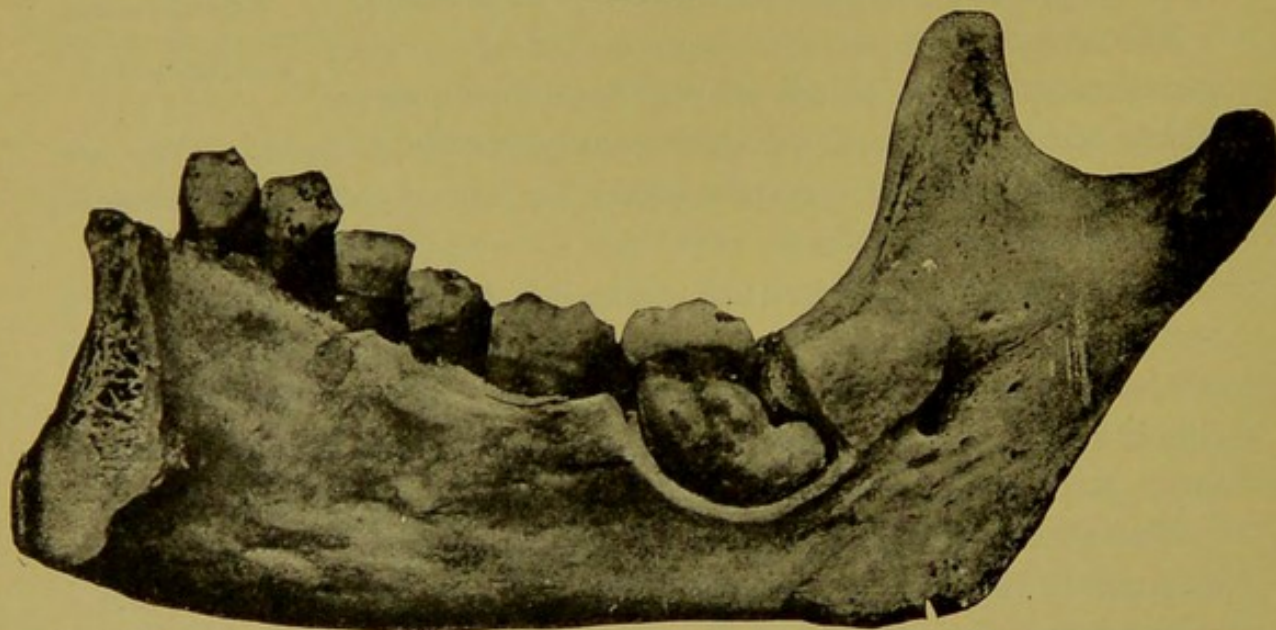
¹ Angle.

difficult eruption, if unrelieved, would be included in the category of impacted teeth.

In Fig. 238 is shown a lower third molar presenting the effects of a previous impaction. The irritation caused by the efforts of the tooth to disengage itself or to overcome the resistance to its eruption has caused an active formative reaction in the pericementum, resulting in a hypertrophy of the cementum.

If the distance between the posterior surface of the second molar and the columns of the coronoid process be very short, it is evident that upward eruption is impossible, so that the tooth may assume any direction of movement, the most common being forward, the axis of the tooth changing its position until the tooth may lie in a horizontal position or even become inverted.

FIG. 238.

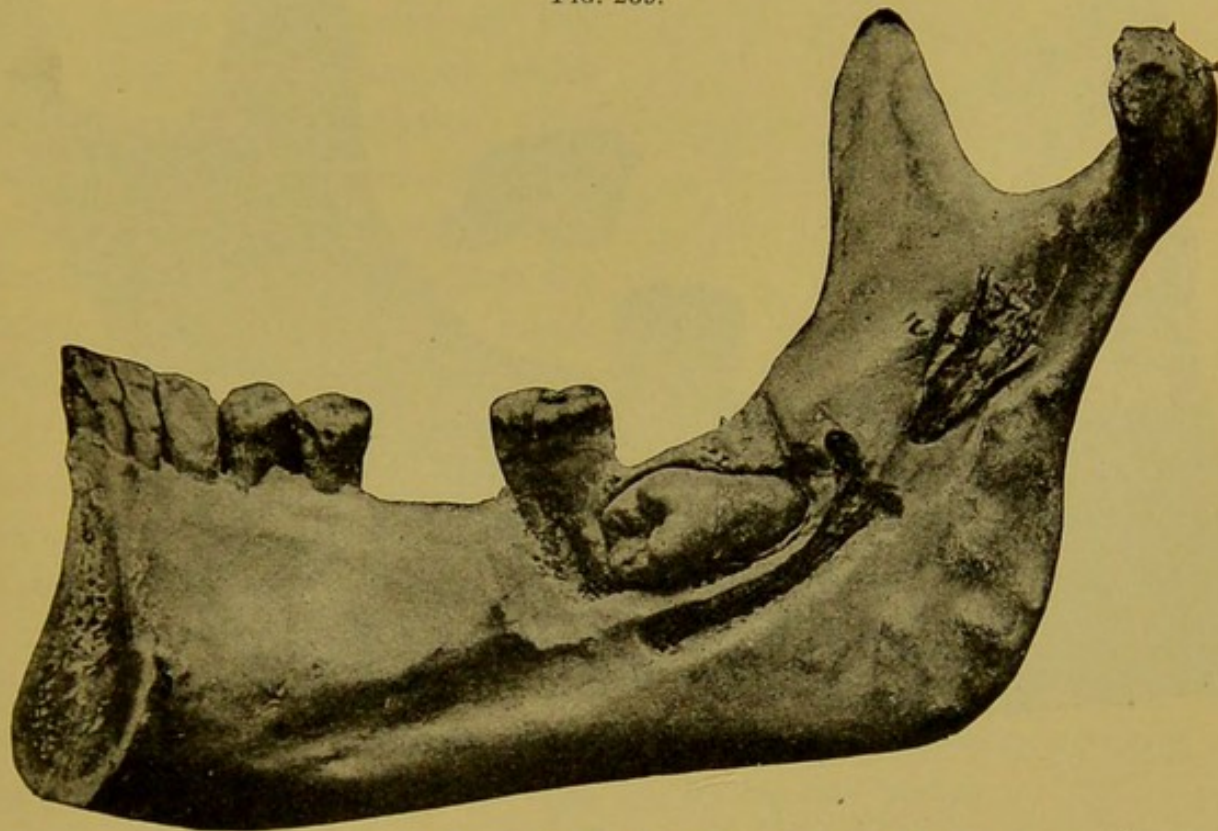


Right half of lower jaw, showing an impacted third molar. (Cryer.)

Fig. 239 is taken from the same jaw as Fig. 238, but shows the opposite side; the impaction is pronounced. Fig. 240 shows another case with different anatomical surroundings. In the first case there were evidences both in the tooth, in its bony surroundings, and in the external cortical bone, of the results of the irritation produced by the efforts at eruption. The cementum was thickened; the outer follicular wall, the tissue designed to form the alveolar periosteum, had exercised its formative osteogenetic function, and a capsule of bone had formed about the tooth; it lay in a bony chamber. The pressure exerted upon the distal wall of the second molar had resulted in a pressure resorption of its root until the pulp chamber was encroached

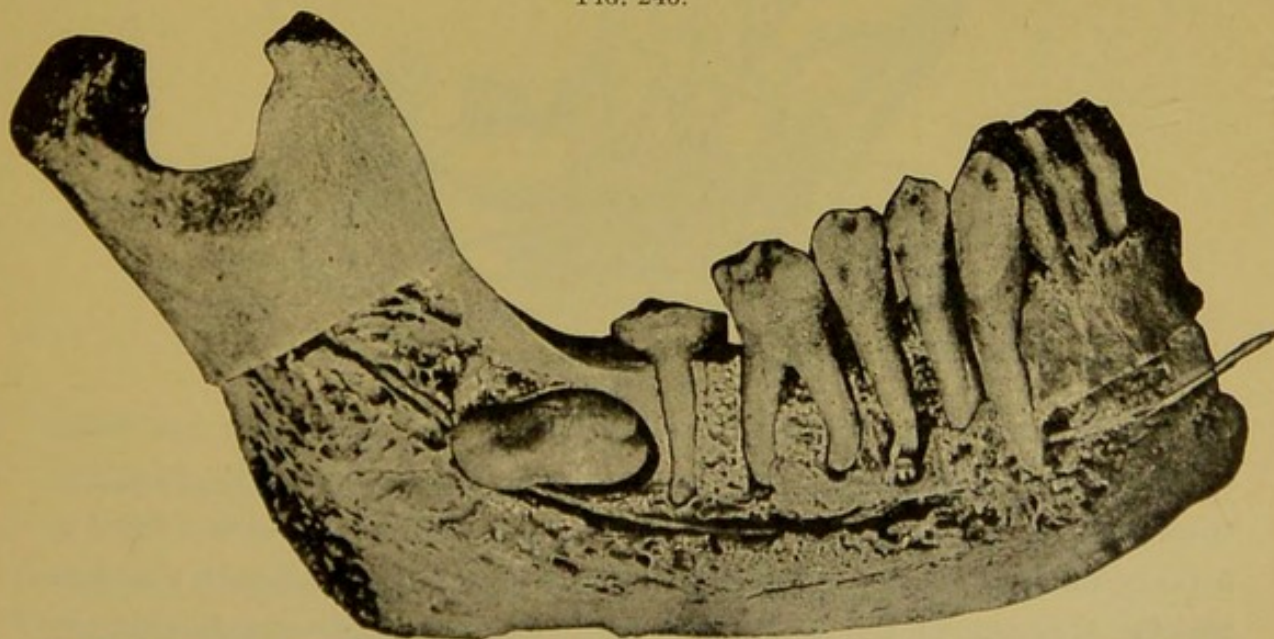
upon. In Fig. 240 the root development has caused impingement of the root apex upon the inferior dental canal. These were both post-mortem cases, and no records of their clinical histories were obtainable. The symptoms produced could only be surmised by the nature of the anatomical relations and the pathological evidences. There may have been a prolonged but mild periostitis, probably a continued pulp irritation; and in the last, neuralgia of any grade of severity.

FIG. 239.



Inner side of left half of same lower jaw. (Cryer.)

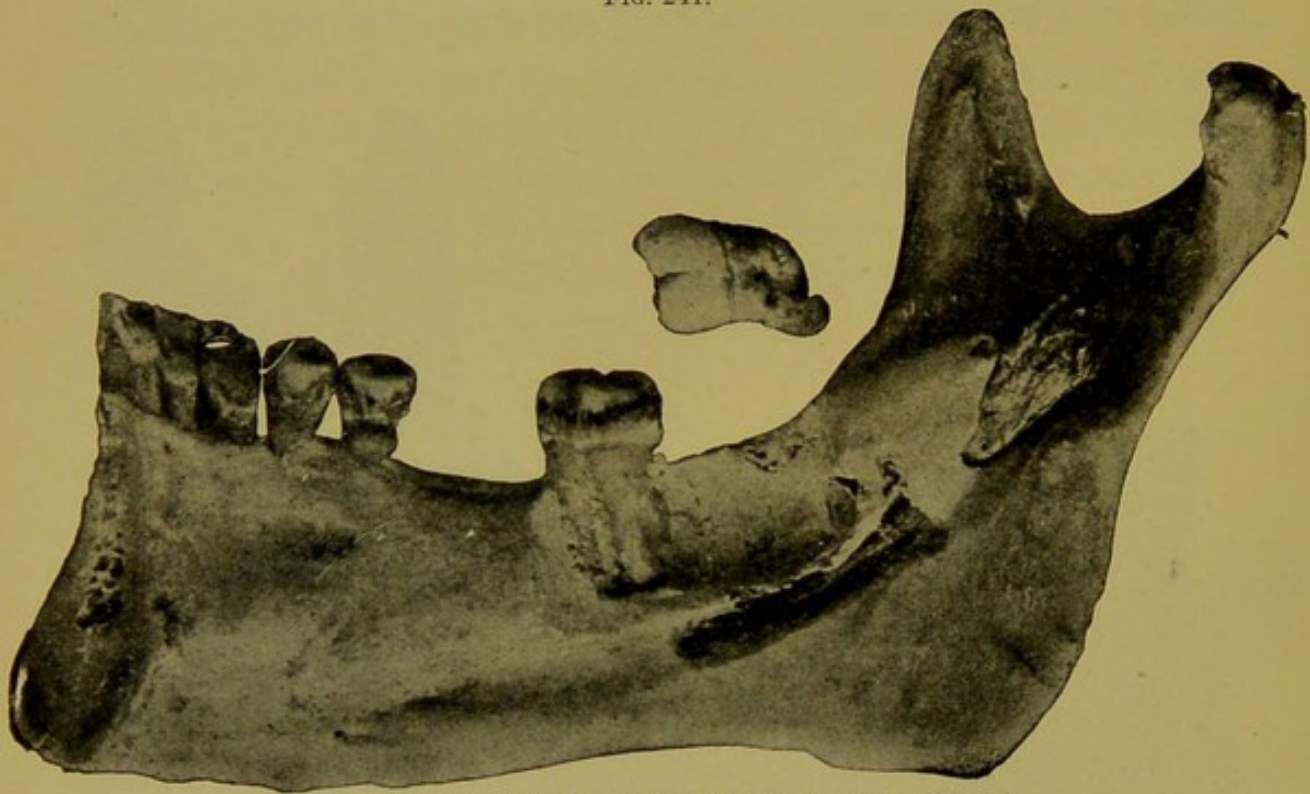
FIG. 240.



Impaction of lower third molar. Resorption of root of second molar and impingement of root upon inferior dental canal. (Cryer.)

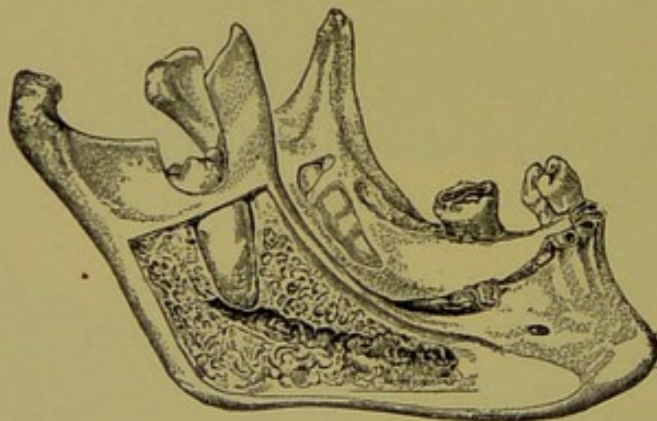
Judging from post-mortem records, cases of impacted third molars are more common than generally believed. Instead of remaining in the alveolar portion of the bone, the impacted tooth may come to occupy a cavity in some portion of the body or the ramus of the bone (Figs. 242 and 243). The positions of the teeth in such cases tend to

FIG. 241.



Same as shown in Fig. 239 with tooth removed. (Cryer.)

FIG. 242.



Wisdom teeth embedded in the rami of the lower jaw. (Tomes.)

confirm Tomes' theory of the development of the jaw. The jaw being lengthened, and the ramus developing through conjoined deposition and resorption of bone, the crown of the tooth appears to be either fixed in a bony nucleus and transported to some distant point in the developmental progress of the jaw, or to be irregularly shifted about during jaw growth. At later periods the pressure exercised by root formation

disturbs the relations of the tooth with its earlier surroundings. These efforts at eruption may at late periods cause the appearance of the tooth in odd situations. In the case shown in Fig. 244 the crown of the tooth made its way through the angle of the bone and through the muscles and skin. The opening in the skin healed upon extraction of the tooth.

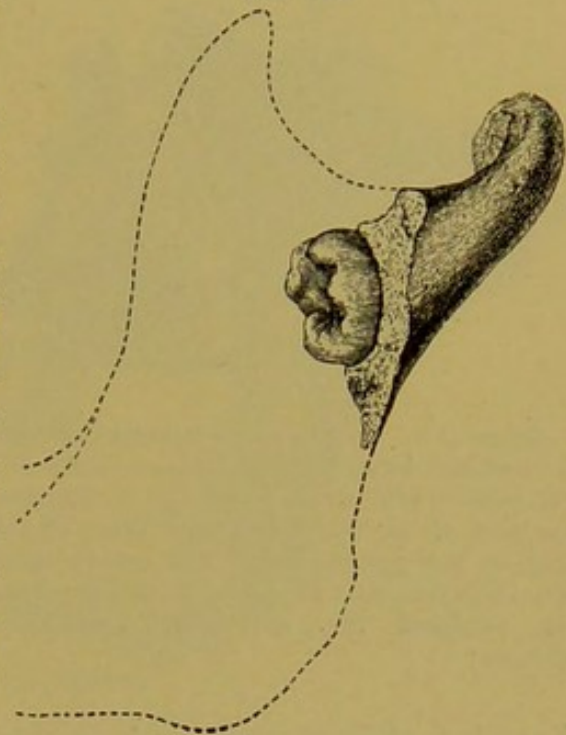
Impacted Upper Third Molars.

Some phases of impaction of this tooth have been spoken of under the head of difficult dentition. The most common is imprisonment of the tooth and its subsequent partial eruption in a horizontal position, the crown pointing toward the cheek (Fig. 245). The crown of this tooth may in rare cases be directed inward or backward, in the latter case being arrested by the pterygoid plates of the sphenoid bone.

In a case recorded by Tomes (Fig. 246) the extraction of the second molar revealed the third molar in a reversed position, its roots occupying the depression between the roots of the second molar.

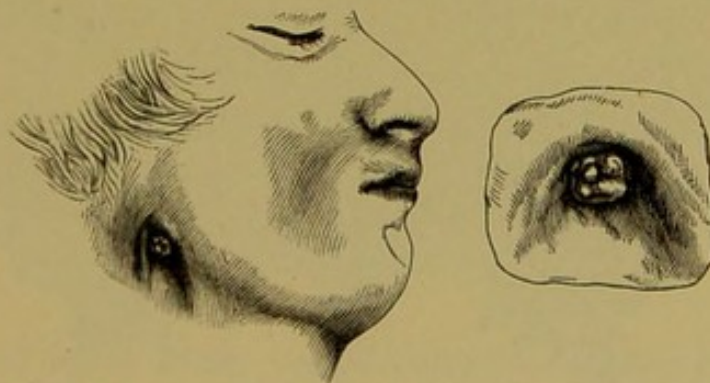
Impacted Cuspids. In point of frequency of impaction the upper cuspids stand next to the lower third molars. It will be recalled that

FIG. 243.



Wisdom tooth buried in the ramus.
(Tomes, after Marshall.)

FIG. 244.

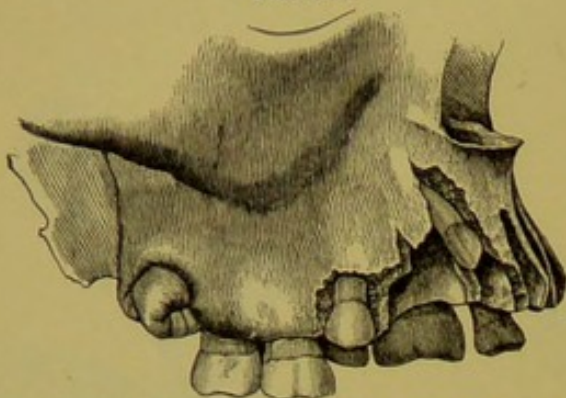


From a wax model in the museum of the London Odontological Society. (Tomes.)

the upper cuspids lie high up; the floors of their crypts, in which they lie *loosely*, are at a higher level than those of the adjoining teeth; they erupt at a much later period, and their crowns, as with the other

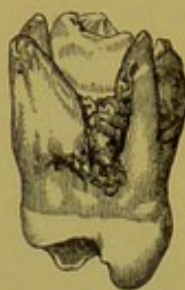anterior teeth, lie lingual to the roots of their predecessors. All of these are elements which might cause displacement of the developing cuspids. Should the advance of eruption not keep pace with the development of the alveolar bone, imprisonment is likely; again, the dense bone

FIG. 245.



Upper jaw, with the third molar directed forward, and impinging upon the second molar. The small tooth situated high up in the anterior part of the jaw was forced there by the spade of the grave-digger. The artist's accuracy in delineating all parts of the specimen has rendered this explanation necessary. (Tomes.)

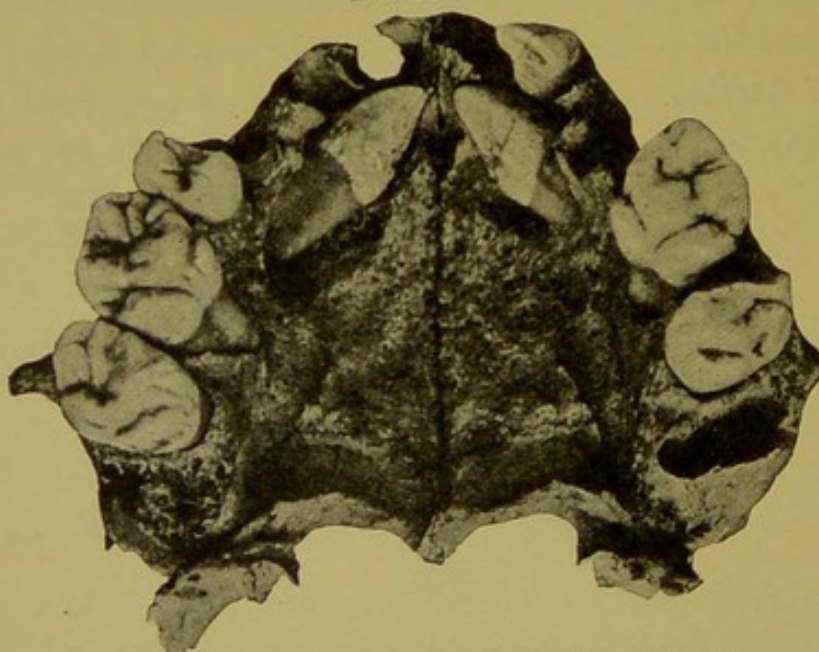
FIG. 246.



A second molar of the upper jaw, with the wisdom tooth inverted and embraced within the roots. (Tomes.)

immediately about the first bicuspid and lateral incisor may offer a deflecting resistance. Examining the texture of the bone about these parts, it is evident that the direction of least resistance to the advance of a much deflected crown is into the cancellated bone of the incisor portion of the alveolar

FIG. 247.

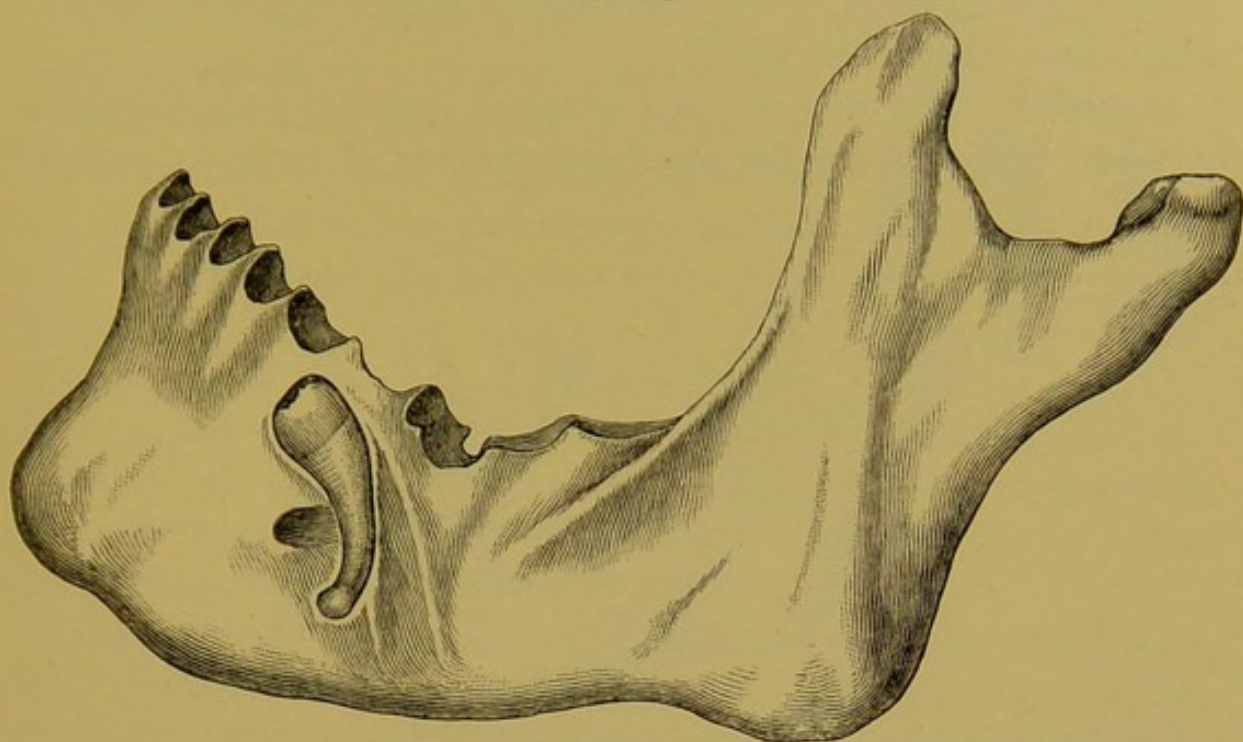


Abnormal jaw, showing impacted cuspids. (Cryer.)

process; hence it is most usual to find the crowns of these teeth lying with their cusps pointing forward (Fig. 247). Several recorded cases have the positions shown; one or both of the teeth may be impacted.

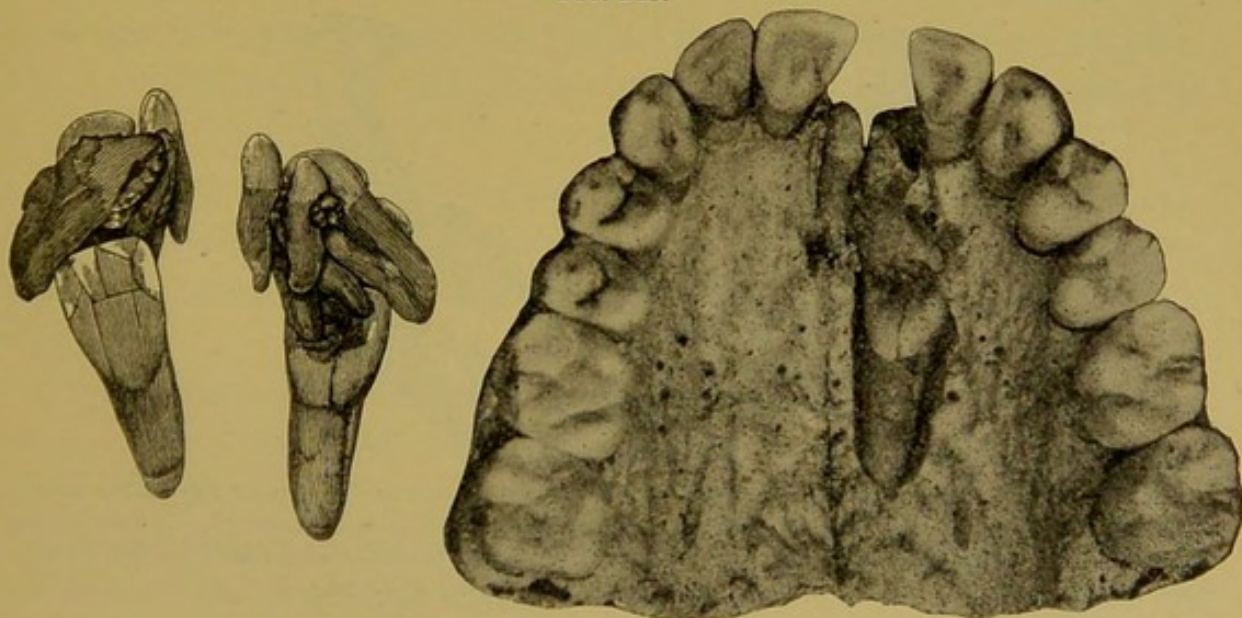
Cuspid teeth may erupt into the nasal cavity, appear in the canine fossa and present the crowns cheekwise or lie horizontally and above the roots of the bicuspid.

FIG. 248.



Impacted bicuspid. (Salter.)

FIG. 249.



Imprisoned central incisor. (Kirk and Cryer.)

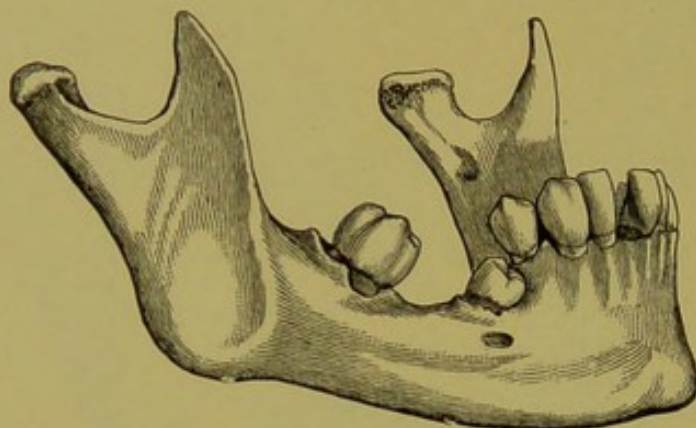
Impaction of Other Teeth. While impactions are most common in connection with the teeth named, any other teeth of a denture may be imprisoned. Fig. 248 shows an impacted bicuspid whose root development has been normal as regards its length, but whose curve has been modified by the resistance of surrounding tissues. Fig. 249 exhibits an imprisoned central incisor, whose retention was, no doubt,

determined and malposition caused by the development and presence of the brood of supernumerary teeth which surround its crown.

Upper incisor teeth have been seen inverted and their crowns erupted into the nasal cavity, where they have produced inflammation which later became infective.¹

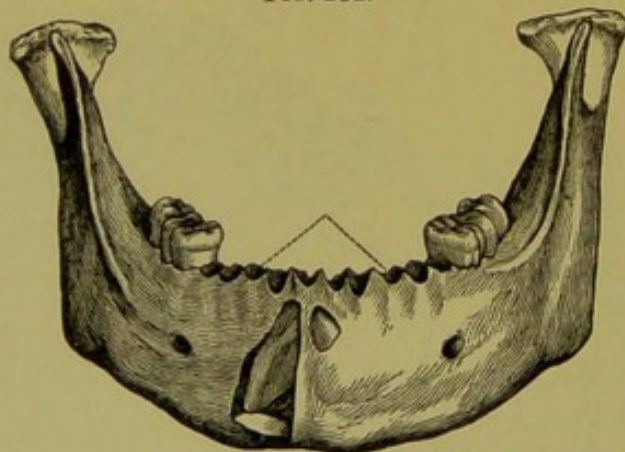
Symptoms. The most common symptom attendant upon impaction of teeth, judging from the obtainable records of cases, is trifacial

FIG. 250.



Lower maxilla, in which the right second bicuspid is placed obliquely, the root being directed backward. The crown, though exposed, does not rise above the level of the alveolar margin. (Tomes.)

FIG. 251.



Maxilla, in which the temporary cuspids (the sockets of which are shown by the dotted lines) were retained, and the permanent canines developed within the substance of the jaw. The bone has been removed on the one side to show the direction taken by the tooth, which has been twisted on its axis to the extent of a quarter of a turn. (Tomes.)

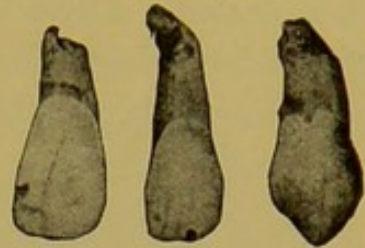neuralgia of any degree, caused by impingement of the malposed tooth upon nerve filaments or trunks. Cryer² records a case where a supra-maxillary neuralgia was traced to the presence of a central and lateral incisor, and a cuspid tooth in the anterior wall of the antrum; they were only discovered by an exploratory operation (Fig. 252). A cure of the neuralgia was effected by their removal.

¹ Jameson, *International Dental Journal*, 1899.

² *Dental Cosmos*, 1896.

Impacted third molars frequently give rise to heavy rheumatic pains about the side of the face and jaws, and no doubt in such cases as depicted in Fig. 240 would cause intractable and diffuse maxillary neuralgia. Salter¹ records a case of long standing and intractable neuralgia, exhibiting a constant painful area upon the scalp, and in which heat and tenderness were noticed over a swelling upon the hard palate. Immediate and permanent cessation of the neuralgia followed removal of the teeth.

FIG. 252.



Symptoms of maxillary periostitis—heavy, gnawing, and dull, throbbing pain, with more or less heat and engorgement of tissues—are noted as an accompaniment of impacted teeth. Such symptoms may herald the appearance of the tip of the tooth through its bony covering and gum.

Cases of maxillary abscess, in the absence of their usual cause (gangrenous pulp), may run a prolonged and painful course,² involving neighboring structures, and after free venting be found to have arisen about an impacted tooth.

Occasionally a circumscribed swelling is noted upon some aspect of a jaw, most frequently upon the palatal portion of the superior maxilla, which is attended by inflammatory symptoms, and an incision reveals an impacted tooth.

Quickly forming cysts of the jaw, upon receiving surgical treatment, may be found to contain the crown of an entire tooth, this evidently being the centre of irritation from which the cystic formation had its origin.

The pulps of other teeth have been devitalized by the strangulation due to the pressure of the crown of the impacted tooth upon the apical tissue.

The resorption of roots of other teeth has been produced by the pressure of the impacted tooth.

Hypercementosis and concrescence have also been produced by the descent of the tooth and has produced impaction. (See p. 222.)

In all these cases diagnostic features exist, though none are comparable to the *x*-rays.

Diagnosis. The first point of observance in cases of suspected tooth encystment is an examination of the dental arches. Are all of the permanent teeth in position? Given the absence of, particularly,

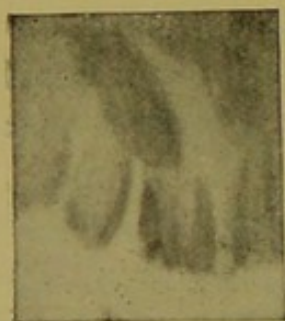¹ Dental Pathology.

² See Garretson's Oral Surgery and Salter's Dental Pathology.

a lower third molar from the dental arch, with a history of no eruption, and a persistent neuralgia, particularly if occasionally accompanied by or alternated with heavy rheumatic or what are known as bone pains, and finding no other evident cause of the neuralgia, an impacted tooth would be naturally diagnosed as the source of the disturbance. Impacted teeth which lie horizontally, or nearly so, along the palatal vault frequently cause a swelling. This, taken in conjunction with the absence of a tooth from the dental arch, points to a diagnosis of impaction.

In very many cases of impaction diagnosis has been a mere accident, discovery being made in the course of an exploratory surgical operation. Modern science solves with the *x*-ray the difficulties attendant upon the diagnosis of impacted teeth. B. H. Catching¹ was the first to practically apply this diagnostic test in this connection. The left upper central incisor of a female, aged nineteen years, became loosened, and an exploration through its pulp chamber revealed a hard body occupying a position part way up the root, which had undergone resorption to that point. The cuspid of the left side was absent from the arch. A skiagraph of the parts (Fig. 253) revealed the missing cuspid, whose crown had impinged upon and caused resorption of the root of the central incisor.

FIG. 253.



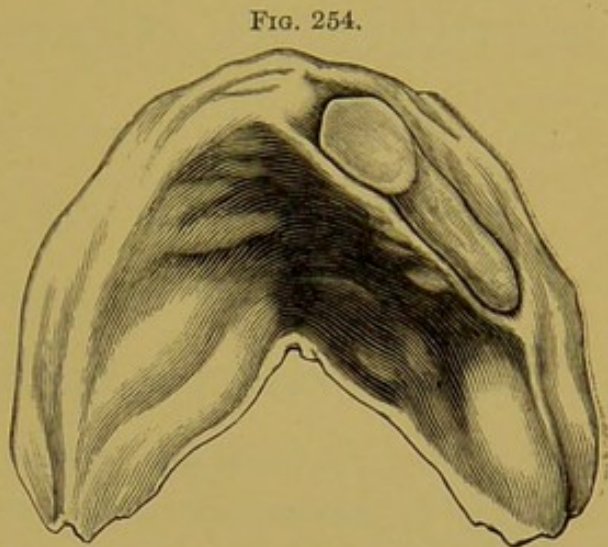
X-ray photograph, showing the malposed cuspid entirely embedded in the bone, and pressing upon the central.

Impacted teeth may become uncovered at some aspect late in life and the condition be discovered incidentally. Cases are recorded where the pressure of a plate has caused the resorption of tissues overlying an impacted tooth, thus revealing its presence. Fig. 254 illustrates a case where the presence of an impacted cuspid was revealed at the age of seventy years, through resorption of the alveolar bone and the gum tissue covering the tooth.

As the smooth feel of enamel is a diagnostic feature when instrumental examination is made, it is to be remembered that the enamel and dentine of an impacted tooth may undergo a true resorption with the characteristic Howship's lacunæ. When partly exposed to the oral fluid caries may occur. Both these conditions produce rough surfaces.

¹ Catching's Compend, 1896.

Treatment. The treatment of cases of impaction is the removal of the offending tooth. Whether or not this comes within the province of the dental operator depends upon the position of the tooth, and, incidentally, upon the usual range of practice of that particular practitioner. When the tooth is embedded deep in the substance of the jaw, access to it involves the etherization of the patient and the removal of the bone which obstructs the path of extraction; this may be an operation of some magnitude, and is usually done by a special surgical practitioner. When, however, it is evident that the obstructions to the removal of the tooth consist of the soft tissues and but a lamina of bone, the operation for removal is clearly within the province of the dental operator. For example, the presence of an impacted cuspid is determined lying horizontally along



Impacted cuspid revealed by resorption of the overlying tissues. (Burdach.)

the lateral aspect of the roof of the mouth. The parts may be injected with a cocaine or eucaine solution, and a curved cut made with a sharp bistoury through the soft tissues at the dental side of the swelling to the bone. The flap thus outlined is raised from the bone, the flap including the periosteum. A large, sharp bur is then employed to remove the covering bone. When the tooth is freely exposed it may be dislodged with forceps or elevator. The parts are then washed with a hydrogen-dioxide solution, dried, the flap pressed back into place, and steresol¹ painted over the parts.

¹ R—Purified gum lac.,	℥ix.
Purified gum benzoin,	℥ ¹ / ₃
Balsam of tolu,	℥ ¹ / ₃
Oil of cinnamon (Chinese),	℥ ¹ / ₅ .
Acid. carbolic.,	℥iij.
Saccharin,	℥ ¹ / ₅
Alcohol,	Oij.—M. (Berlioz.)

—Dental Cosmos, 1895.



SECTION III.

AFFECTIONS OF THE ENAMEL AND DENTINE.

CHAPTER X.

ABRASION, EROSION, AND STAINS.

MECHANICAL INJURY OF THE TEETH.

FORMED by the ameloblasts, later changed into Nasmyth's membrane, and borne upward with the crown during the process of eruption, enamel has no posteruptive source of nutritive supply from without.

Its only conjectural source of nutrition is therefore from the pulp *via* the dentinal tubuli. Of this there is no positive proof beyond that offered by Caush. (See p. 141.) Teeth do change in color with advancing age, but this is probably due to changes in the color of the dentine transmitted through enamel, which is normally almost or even quite transparent. Such a transparency may be seen at the incisal edges of thin incisors before these edges are worn down. Another proof of transmission of color through enamel is seen in caries; a bluish-black or white appearance is caused by the decayed mass or decalcified inner surface of the enamel.

Again, amalgam or gold, oxyphosphate or oxychloride, reflects its color through enamel, and in excavating the shadow of the excavator may be seen through thin walls. Enamel may be stained or whitened by decalcification due to causes acting externally. Extreme polishing may also cause a new character of light reflection simulating a change in color.

After implantation a tooth may somewhat change its color, but this evidently cannot be due to nutrition from the pulp, as this organ will have been removed before implantation.

It is generally regarded as a fact that while enamel may suffer mechanical and chemical injury it undergoes no constructive changes or retrograde metamorphosis. There is, however, a possibility that

a molecular change may occur as a result of time, environment, or impact of mastication.

The dentine and cementum contain about 28 and 30 per cent. of organic matter, respectively, and stain deeply and permanently with great readiness.

Possessed of living cells they also undergo changes in their structure under the influence of various stimuli, their substance being added to or reduced according to circumstances. They are also acted upon by mechanical and chemical agencies, if exposed to their influence.

ABRASION.

Abrasion is the mechanical wearing away of tooth substance.

Occurrence. It occurs most commonly upon the occlusal surfaces of teeth, but is also found upon the proximal surfaces, the labial cervix, and more rarely upon the lingual cervix alone. It is also seen in the temporary denture, especially in the molars.

Appearance. Purely abraded surfaces present a smooth, flat, or concaved, highly polished appearance. The surface may become stained or otherwise altered in color, or subsequent caries may remove its smooth surface.

Occlusal Abrasion. Occlusal wear is very common and occurs largely with men who chew tobacco; the contained silex, being gritty, acts as an abrasive. Such wear, due to the use of hard food or gritty substances, is seen in skulls of aboriginal man. Some degree of occlusal wear is accepted as normal to all teeth, the act of mastication producing marks or facets at the point of articulation of antagonizing teeth. A tip-to-tip variety of occlusion permits free lateral movement of the lower jaw and an herbivorous type of articulation causing abrasion. It is also frequent in those cases presenting the first degree of prognathism. In some of these cases the labial surfaces of the upper incisors and cuspids and the linguo-incisal margins of the lower incisors are worn. A single overlapped lower tooth may abrade an upper tooth in this manner.

The gritting of teeth during sleep is also a cause.

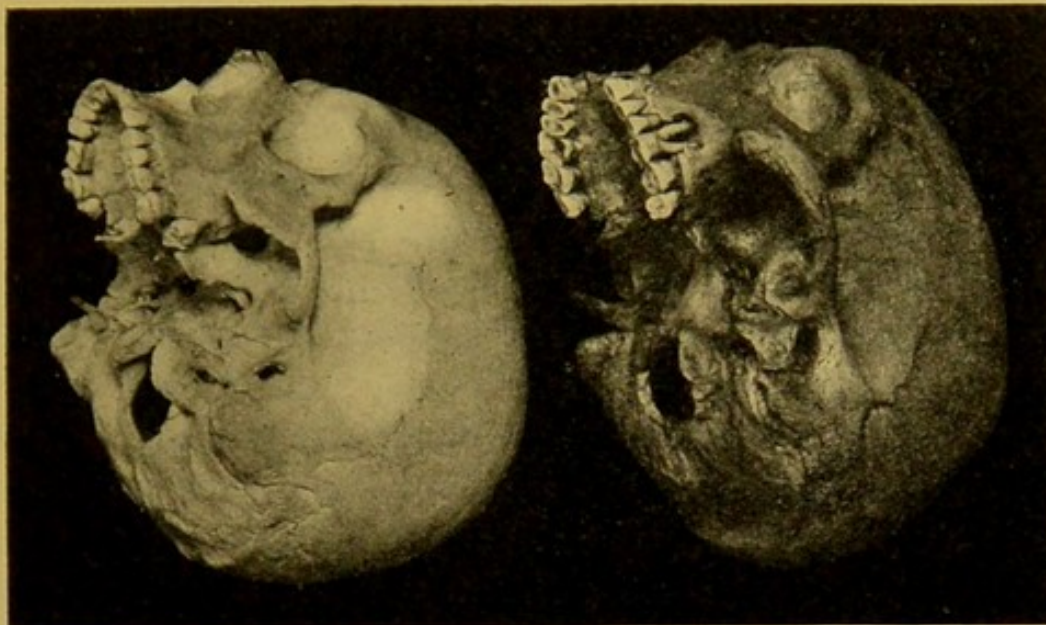
The undue loss of posterior occlusion and consequent overuse of the anterior teeth cause their abrasion after the manner shown in Figs. 261 and 274.

Where the abrasion occurs in a fairly regular manner four degrees of abrasion are classified (Figs. 255 and 256): (1) abrasion removing the cusps; (2) abrasion removing the occlusal third of the crown;

(3) abrasion removing the middle third of the crown; (4) abrasion extending to the gum line or beyond (Broca).

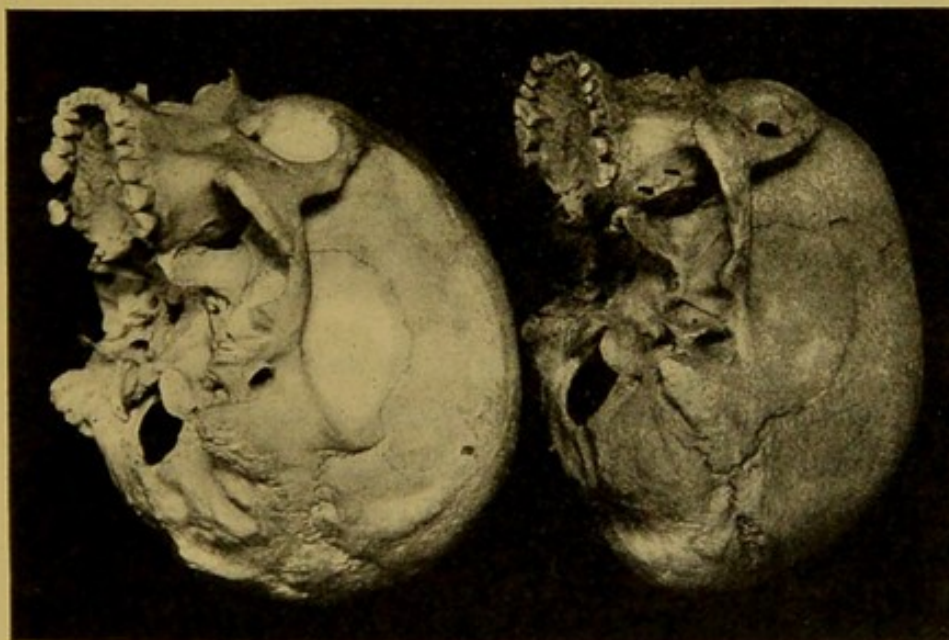
When there is a marked overbite occlusion, with a consequent lessening of the lateral movement of the mandible, the teeth do not

FIG. 255.



The first and second degrees of abrasion. Specimens from museum of Philadelphia Dental College.

FIG. 256.



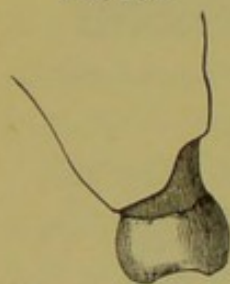
The third and fourth degrees of abrasion. Secondary dentine plainly visible. Specimens from museum of Philadelphia Dental College.

acquire flattened contact surfaces, but their cusps increase in sharpness and pointedness. This at times becomes exaggerated and produces an interlocking of cusps or rather worn surfaces which have very sharp edges.

In the first degree of abrasion the dentine is often hollowed out in advance of the enamel of the cusps, forming concave places in which berry seeds lodge and cause annoyance. These spots are at times hypersensitive.

Labial and Proximal Abrasions. Some forms of abrasion have been attributed to too vigorous use of tooth-brushes, particularly when gritty powders are employed. There is no doubt that mechanical abrasion about the necks of teeth is produced in this manner, the gum line receding beyond the enamel border, exposing the cementum: but a careful examination will reveal the cementum and next the underlying dentine to be affected; the enamel is not abraded. These tooth-brush abrasions are quite characteristic (Fig. 257). In well-kept dentures the gums are seen to have receded from their normal line, but exhibit no evidences of turgescence; the roots of the teeth, upper and lower, are exposed to a greater or less extent along their labial and buccal, but not along their lingual aspects; and they are excavated

FIG. 257.



to variable depths, upon the bicuspid and first molars more than upon the other teeth, as here the greatest force of brushing is received. The depressions have a normal dentine color, sometimes deepened in the mouths of non-smokers, and which in smokers may be periodically blackened by deposits of carbon. If caries supervene, the abraded areas lose their normal color, and may be readily indented by sharp instruments, which they resist before the advent of caries. The bicuspid and molars, particularly, may be grooved in such manner as to require restoration by fillings. The condition may closely simulate some forms of erosion.

A clasp may abrade a tooth, and, if food débris be retained on its inner side, caries may follow in the abraded area. The purely abraded surface will be polished. Slight proximal abrasion may be normal as a facet, due to the rubbing of one tooth upon another at the contact point. A marked example of this was seen in the lower jaw of a skull of a Maori.

The third lower molars are locked beneath the distal surface of the crowns of the second molars. Some form of bone loss occurred, producing looseness of the third molars. The individual motion of the teeth produced a deep abrasion of the enamel of the second molars upon the distal surface and an occlusoproximal abrasion of the third molars.

Extensive proximal abrasion may be due to extrusive elongation of a tooth in one or both jaws, causing a tooth to occlude with its antagonist with a glancing motion.

In this manner specimens are produced abraded from the occluso-proximal angle to nearly the apex of the root.

The festoon of a metal plate may rapidly cause abrasion of the lingual cervix of a tooth. The condition is, however, rare. In the editor's practice a case was seen in which several teeth were so affected in a few months by an ill-fitting metal plate. The festoon of a vulcanite plate has also produced such an abrasion.

Abrasion sometimes follows caries when the latter has become freely exposed to attrition. The softened surface wears away and the part assumes a polished appearance, but is discolored as the result of the stain due to the caries.

It is probable that a hyperacid condition of the saliva in connection with mechanical forces may be a cause of rapid abrasion. (See Erosion.)

Effects of Abrasion. These are external and internal, and most marked in the occlusal variety. The crown wears down until at times the gum is reached. In the process sharp edges of enamel are formed. These splinter off, leaving rough edges, or the enamel may fracture or split longitudinally, following the axis of the crown. Supported by dentine it does not further break away (Fig. 274).

Sharp enamel edges may irritate the tongue, producing ulcers of a sometimes chronic type which acquire indurated edges and simulate syphilitic sores or epithelioma. The causal relationship between sharp edges of the teeth and lingual epithelioma appears to be quite clear in some cases.

Sores which have given evidence of malignancy and been diagnosed as malignant growths have been cured by rounding and polishing sharp and irritating enamel edges of teeth.

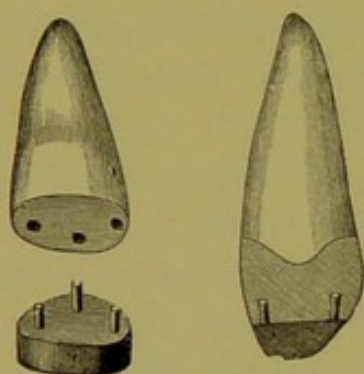
The continued stimulation of the ends of the dentinal fibrillæ, which are exposed in abrasion, causes them either to become hypersensitive or stimulates them to formative activity. Tubule material is built upon the inner walls of the tubule, obliterating their lumen. This is the so-called tubular consolidation or calcification (eburnation). Accompanying this secondary dentine is often formed. As a result, most commonly the pulp chamber of the crown is filled up with secondary dentine as the abrasion proceeds, and the crown may often be worn off until the cervix is reached while the pulp remains vital and covered

(Fig. 256). In some cases the abrasion closely approaches the pulp, which for some reason has failed to protect itself, and the phenomena of hyperæmia or even exposure and its results occur.

The causes and phenomena of abrasion of the temporary teeth are practically the same as in the case of adults, except, perhaps, that children are more subject to the action of rectal parasites, as *ascaris lumbricoides*, *tænia*, etc., or suffer from irritable bladder due to hyperacidity of the urine. These conditions commonly produce a reflex stimulation of the muscles of mastication, resulting in nocturnal gritting of the teeth.

Treatment of Abrasion. In the cases of cupped occlusal dentine, hard fillings of gold or preferably platinum gold are advisable.

FIG. 258.



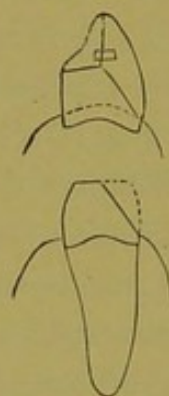Gold tip for abraded teeth with living pulps. (Evans.)

FIG. 259.



Gold tip for abraded teeth with pulps removed. (Evans.)

FIG. 260.



Porcelain-faced crowns for teeth with living pulps. (Evans.)

If nearly all teeth are present and the abrasion slight, bridge-work may be used to restore the full occlusion without attempt at restoration of the worn surfaces.

If the abrasion of the upper anterior teeth be deep the bite may be raised by appropriate posterior crowns or bridges, and solid platinum-gold fillings may be built upon the anterior teeth, either the uppers alone or upon both the upper and lower teeth. Anchorage may be obtained in the dentine or screws may be planted in the dentine between the enamel and pulp and the fillings be built about them. Instead of malleted fillings, tips of the gold-inlay type may be made (Figs. 258 and 259).

In other cases, after securing a proper opening of the bite and posterior occlusion, single porcelain-faced gold or platinum crowns may be made to cover each of the anterior teeth. For this purpose the crown is appropriately reduced to convenient form, but the pulps

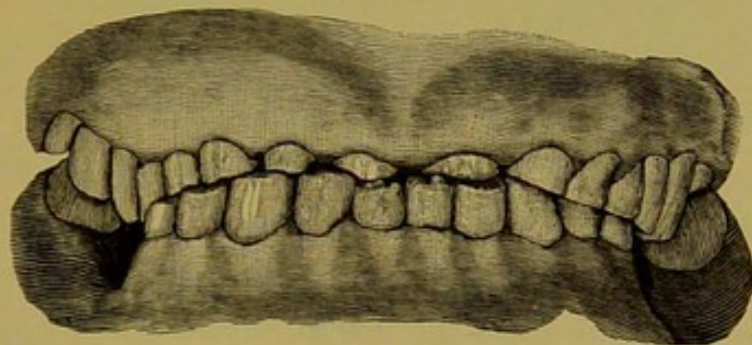
need not be destroyed. Fig. 260 represents the method outlined by Evans.¹

Land jacket crowns, consisting of a wedge-shaped platinum jacket with a porcelain facing attached by means of one of the numerous inlay bodies, may be used instead of the Evans crown. In some cases other forms of crowns may be indicated (Fig. 262).

There present at times cases of abrasion in which, aside from the wear, pyorrhetic conditions may be present, or where bridges cannot be properly inserted.

If this pertain to the upper jaw only, the lower denture may be restored to usefulness, the upper teeth extracted, and a full upper denture inserted; this permits the adjustment of the bite to any desired level. If the condition be transferred to the lower jaw and the anterior teeth be in good condition, a piece of the Griswold type may be fixed upon cuspid or bicuspid crowns.

FIG. 261.



Abrasion of anterior teeth, with loss of posterior occlusion. (W. A. Capon.)

It is to be remembered that in any case of opening of the bite the occlusion is to be restored throughout.

The bite must not be raised by means of partial plates which strike before the natural or crowned teeth, as they tend to embed themselves in the soft tissues and create inflammation.

If the bite be only slightly raised by plates this embedding will cause a return to the original condition.

In case of hypersensitivity, if the application of carbolic acid, deliquesced zinc chloride, Robinson's remedy, or silver nitrate be not effective, nitric, hydrochloric, or sulphuric acid must be applied and the resultant softened areas later filled.

If the abrasion be caused by tobacco its use should be stopped.

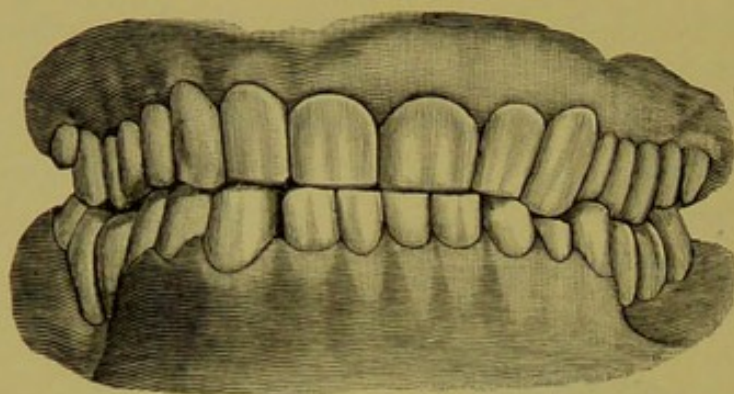
A difficult class of cases to treat is found in those highly nervous individuals who grit their teeth during sleep. It is probable and

¹ Crown and Bridge Work.

reasonable that this cause alone may serve to explain abrasions traceable to no other source. The cure of such cases as these could only be possible through the wearing at night of some modified form of interdental splint. The cases naturally indicate the medicinal use of a bromide before retiring, unless the causes can be discovered and removed.

If such gritting be present in children, the evidences of irritable bladder, due to hyperacidity of the urine or of rectal parasites, should

FIG. 262.



Same case as Fig. 261. Bite opened by bridge-work, posteriorly. Anterior teeth restored by means of Land jacket crowns. (W. A. Capon.)

be sought and treated. The urine may be rendered alkaline by the use of potassium salts and kept so by restriction to a largely vegetable diet. Belladonna may be used to reduce vesical irritability. Rectal parasites may be removed by the use of vermifuges or occasionally by rectal injections.

RESORPTION OF ENAMEL.

Definition. Resorption of enamel is the removal of enamel substance by soft tissue containing osteoclasts.

Occurrence. It occurs externally only in impacted teeth surrounded, at least in part, by irritated tissue, and internally very rarely after resorption of dentine by the pulp.¹

Pathology and Morbid Anatomy. Osteoclasts approximate the enamel as they do cementum, decalcify and resorb it. The dentine is next attacked. There result irregular excavations (Howship's lacunæ) and white or discolored areas of evident slight decalcification of the enamel. A deposition of bone into the area may occur.² The process is probably the result of a non-septic inflammation as in the case of root resorption. (See Interstitial Gingivitis.)

¹ Hopewell-Smith, *Histology and Pathohistology of the Teeth*.

² *Ibid.*

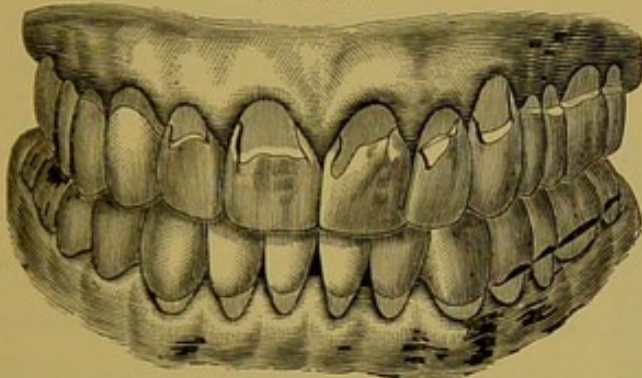
The enamel may be resorbed from its internal surface after the resorption of dentine by the pulp (see Chapter XVIII.), and, as shown by Woods,¹ may be filled in with adventitious material of a structure resembling cementum.

Treatment. Should the disease by chance occur upon a tooth which later has been drawn into place the area may be filled, otherwise it has only a pathological interest.

EROSION.

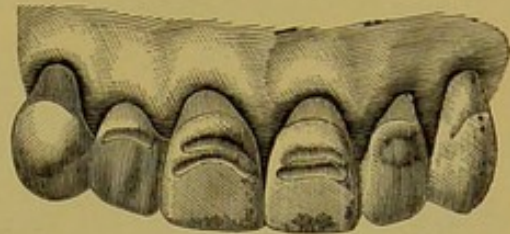Definition. Erosion of the teeth is a term applied to the chemical or chemicomechanical destruction of the hard tissues of the teeth in such a manner that broad, shallow, smooth excavations are made

FIG. 263.



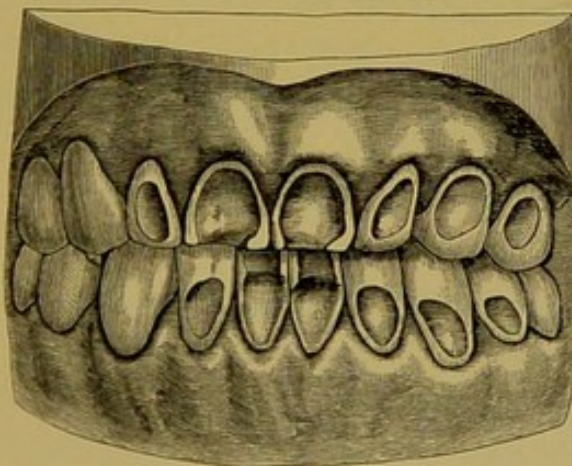
(Darby.)

FIG. 264.



(Darby.)

FIG. 265.



A case of erosion (drawn from the cast): B, silhouette from a perpendicular line through the left centrals, upper and lower, showing the loss of substance. (Black.)

in the enamel and dentine, and in situations in which dental caries and abrasion are least likely to occur.

The excavations occur upon surfaces where fermentative processes occur in least degree and where there is no marked attrition. Figs. 263, 264, and 265 illustrate the characteristic appearance of areas of erosion.

¹ Hopewell-Smith.

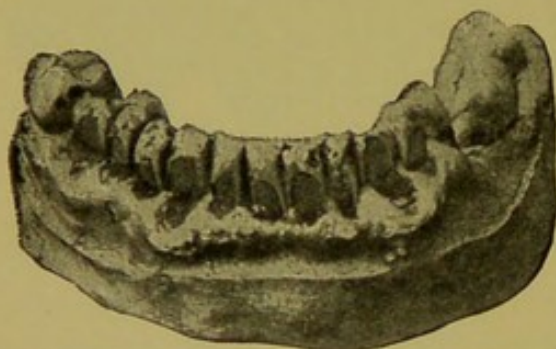
The labial faces of the anterior teeth are more frequently affected than those of any of the other teeth. These surfaces appear as though sections had been bodily cut out of them.

The enamel is affected to a greater extent than the dentine, forming shallow excavations in the teeth. When the destructive action lays bare the dentine, neither it nor the enamel presents any of the appearances of dental caries, the eroded surfaces being smooth and polished and of almost normal hardness.

The incisal edges of the anterior teeth are sometimes affected, being cupped out in a manner simulating abrasion, but it occurs at times in teeth which are distinctly not in occlusion.

Causes. Dental caries always presents *in situ* softened or decalcified dentine. Eroded areas sometimes later decay in part when the nature of the effects are seen to be distinct. The only other condition with which it may be confounded is abrasion.

FIG. 266.



Erosion of lower teeth in absence of use of tooth-brush. (Ivy.)

As individuals are seen with erosion who have never used a tooth-brush (Fig. 266), and it has been seen in animals,¹ it is evidently not caused by brushing, yet, as will be seen, some mechanical element may enter as a factor.

The abrasion of mastication evidently cannot cause it; even cases of marked occlusal abrasion may not be accompanied by erosion.

The field of inquiry is therefore narrowed to the lip. Lip friction alone is incompetent, as it occurs in every mouth, while erosion is comparatively rare.

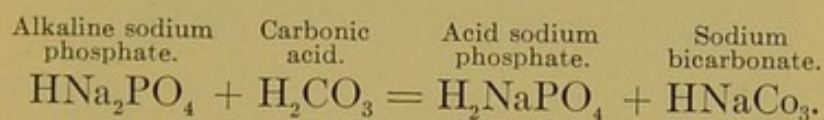
As only acid substances can dissolve the dental tissues in the mouth, the inquirer is driven to the conclusion first suggested by Truman that erosion is due to an altered secretion of the mucus-forming glands of the lip which lie in close relation to them. Truman found these to secrete an acid at night, while during the day the secretion might be alkaline. The disease appears to affect females more than males, appears usually after thirty years of age, and usually some history of gout, rheumatoid arthritis, or rheumatism can be obtained. Even when the existence of rheumatoid or gouty affections is denied by

¹ Tomes, Dental Surgery.

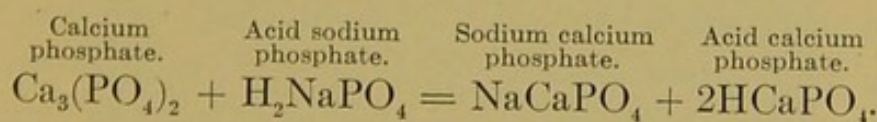
both patient and medical attendant, it is rare that the patient does not complain of some general disorder, the usual ones being neuralgia of long standing, marked anæmia, or perhaps neurasthenia. Be the condition what it may, the essential disease process is one which may be traced to the effects of suboxidation in the tissues.

"If the orbicularis oris muscles be dissected from the mucous membrane of the lip, the labial glands may be observed; they are more numerous near the centre than at the extremities of the lip"¹—*i. e.*, the greater number overlies the labial faces of the incisors toward the necks of these teeth. "These are small, racemose glands, their ducts lined with low granular epithelium; in the alveoli the cells are larger and columnar and stain less readily with carmine." "Their secretion is composed of water, mucin, and inorganic salts, sodium phosphate predominating, which gives the fluid its alkalinity under normal conditions. In conditions of irritation and consequent hyperæmia the secretion becomes increased in amount and acid in reaction (Kirk). The nature of the acid is not clearly known.

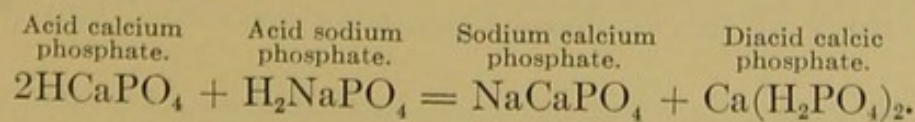
Brubaker has suggested the theory that the waste products of faulty metabolism, occurring in gout and kindred conditions, floating through the capillaries of the labial glands, produce irritation and the production of an excess of carbon dioxide. This exists in the cells of the gland as carbonic acid H_2CO_3 , and, combining with the alkaline salt sodium phosphate derived from the blood, the following reaction occurs:²



The acid sodium phosphate formed attacks the phosphate and carbonates of calcium composing the teeth in a double reaction after the manner shown in the following equations:



The acid calcium phosphate is further acted upon by additional molecules of the acid sodium phosphate (dihydrogen sodium phosphate) as follows:



¹ Brubaker, International Dental Journal, December, 1894.

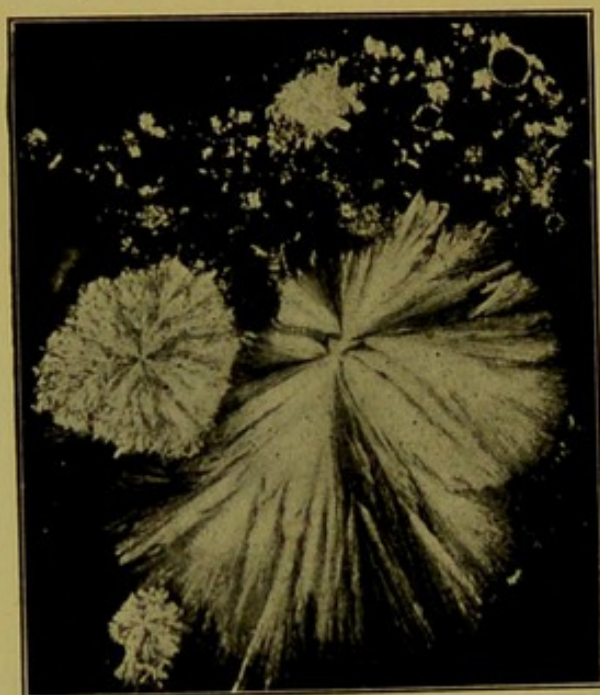
² Ibid,

The diacid calcic phosphate is freely soluble and doubtless washed away (Brubaker).

The reaction upon the tooth substance is but incompletely expressed, no disposition being made of the sodium calcium phosphate. It would seem that the reaction might well cease with the production of the sodium calcium phosphate and acid calcium phosphate.

Brubaker immersed a tooth for a week in a solution of acid sodium phosphate, subjecting it daily to toothbrush friction, and at the end of that time spots and grooves resembling erosion made their appearance.¹

FIG. 267.



Crystallization of salts from dialysate of saliva from erosion case, showing two typical forms. Large crystal is calcium lactate. (Kirk.)

In an article published in 1902, Kirk² describes polariscopic experiments made upon saliva from a patient afflicted with a general erosive wasting of the teeth. The saliva of the patient, who was a sufferer from inflammatory rheumatism and its associated migraine, etc., was dialyzed and the dialysate concentrated and found to contain lactic acid salts (calcium lactophosphate, calcium lactate, and magnesium lactophosphate). Kirk concluded that the case was one of erosion due to lactic acid (Fig. 267).


Kirk's study of the localized cases have convinced him that they

¹ It is to be understood that Brubaker advances this explanation hypothetically, not as an assured demonstration.

² Items of Interest.

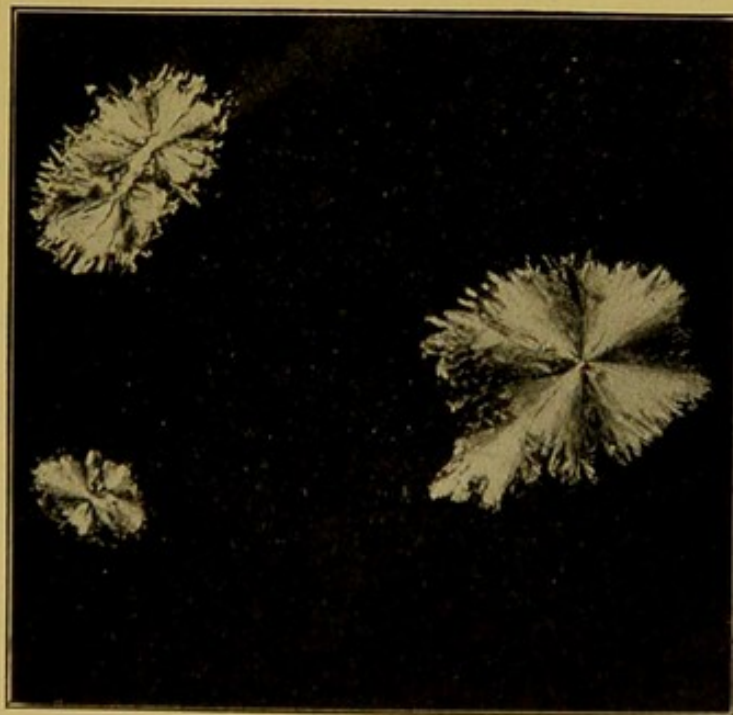
are produced by either acid sodium phosphate or acid calcium phosphate existing in an abnormal mucous exudate from the diseased labial glands.

FIG. 268.



Another field from the same specimen as Fig. 267, also showing two typical forms. Large crystal is calcium lactate. (Kirk.)

FIG. 269.



Crystallization from solution of a tooth in 1 per cent. lactic acid. Large crystal is calcium lactate. (Kirk.)

Regarding the production of these abnormal exudates, Kirk argues that in diseases of suboxidation the blood is loaded with carbonic

acid as a result of faulty metabolism. In the kidneys the mass action of the carbonic acid upon the sodium phosphate of the blood produces acid sodium phosphate which is eliminated in the urine, and sodium bicarbonate which is returned to the blood and maintains its alkalinity.¹

If the amount of carbonic acid produced be excessive as in gout, the labial glands also take up the action and produce acid sodium phosphate.

It is to be noted that the reaction in the kidney producing acid sodium phosphate is a normal one, this product being the acid salt of the urine and perspiration.

It is also to be remembered that in gout kidney elimination is faulty, so that the assumption of an eliminative function by the labial glands is not a surprising departure.

It is a point of importance that both the inorganic and organic matter of the dentine are removed. Experimentally, a 10 per cent. solution of acid sodium phosphate will do this rapidly. Kirk² stated that he was only once able to produce artificial erosion without roughness by the simple application of a solution of acid sodium phosphate.

Kirk has pointed out that the contents of the labial glands in cases of erosion gave an acid reaction—*i. e.*, reddened blue litmus paper—in all of the cases tested by him.

It appears to be almost self-evident that there must be some modifying factor causing the peculiar forms of the eroded areas, and that it must be an abrasive. In many of the cases where the erosions are in the form of transverse grooves there is no doubt that the action of the toothbrush upon the decalcified parts removes the latter; the areas of erosion may be oval, circular, or irregular patches; again, decalcification may appear to occur over the entire labial surfaces of teeth uniformly; however, erosions in grooves may occur upon the teeth of persons who do not use a toothbrush (Fig. 266). It is evident then that in these cases the mechanical factor must be sought in the muscular movements of the lips and tongue. The greatest effect of lip movement would be upon the entire labial faces of the central incisors, as the maximum force of contact of lips with teeth is at and near the median line, when the lips are alternately raised and depressed. The action of the tongue upon the labial faces of the teeth would be in a curved line passing across the labial and

¹ It will be seen that this is a modification of Brubaker's theory.

² Private communication.

buccal surfaces of the teeth, beginning at the occlusobuccal portions of the first molars, and having its highest point at the necks of the central incisors.

In the light of present knowledge, odd and isolated situations of areas of erosion can only be referred to localized gland affections, the glands overlying the spots of erosion being alone affected.

Black's experiments seem to show that the production of a current in the acid fluid used as a test medium will produce the erosive effects.

In some cases existing upon the sides of one or two teeth only, it would seem that there must exist an exudation into an exact area.

Again, certain erosions overhung by an irritated gum margin excite a suspicion that the gum itself may cause the acid exudate.

Other causes for erosion have been cited.

Guilford¹ mentions a case caused by shattuck eating. The pitting of grapes with the teeth has produced cases of peculiar erosion of the labial and lingual surfaces, and of the incisal edges of anterior teeth.

Tomes² instances cases of erosion caused by lemon and grape sucking.

Morbid Anatomy. The enamel is first affected as a minute facet, which deepens until a transverse groove or irregular area is formed. The cementum is often involved, and when reached the dentine is cupped out.

The erosion form shown in the lower jaw of Fig. 263 is the most common and, as a rule, slowest in progress. That form seen on the upper cuspids (Fig. 264) is also quite common.

At times the enamel is very irregularly removed, and at times sharp undercuts are formed. In other cases the acid action seems to have been distributed over the whole labial face (Fig. 265).

Ivy reports a case of erosion in a patient who had not used a toothbrush for fifteen years. The erosion was confined to the lower teeth (Fig. 266).

The other forms—labial and proximal grooves—also are seen.

The surfaces are highly polished, and the dentine hard, but has a peculiar horn-like feel to cutting instruments. The polish is retained after calcining.³

The dentine also often becomes more translucent, owing to tubular calcification. Much secondary dentine is often formed, filling the entire coronal pulp chamber. The erosion may proceed, exposing this secondary dentine, and when the groove form exists the grooving may

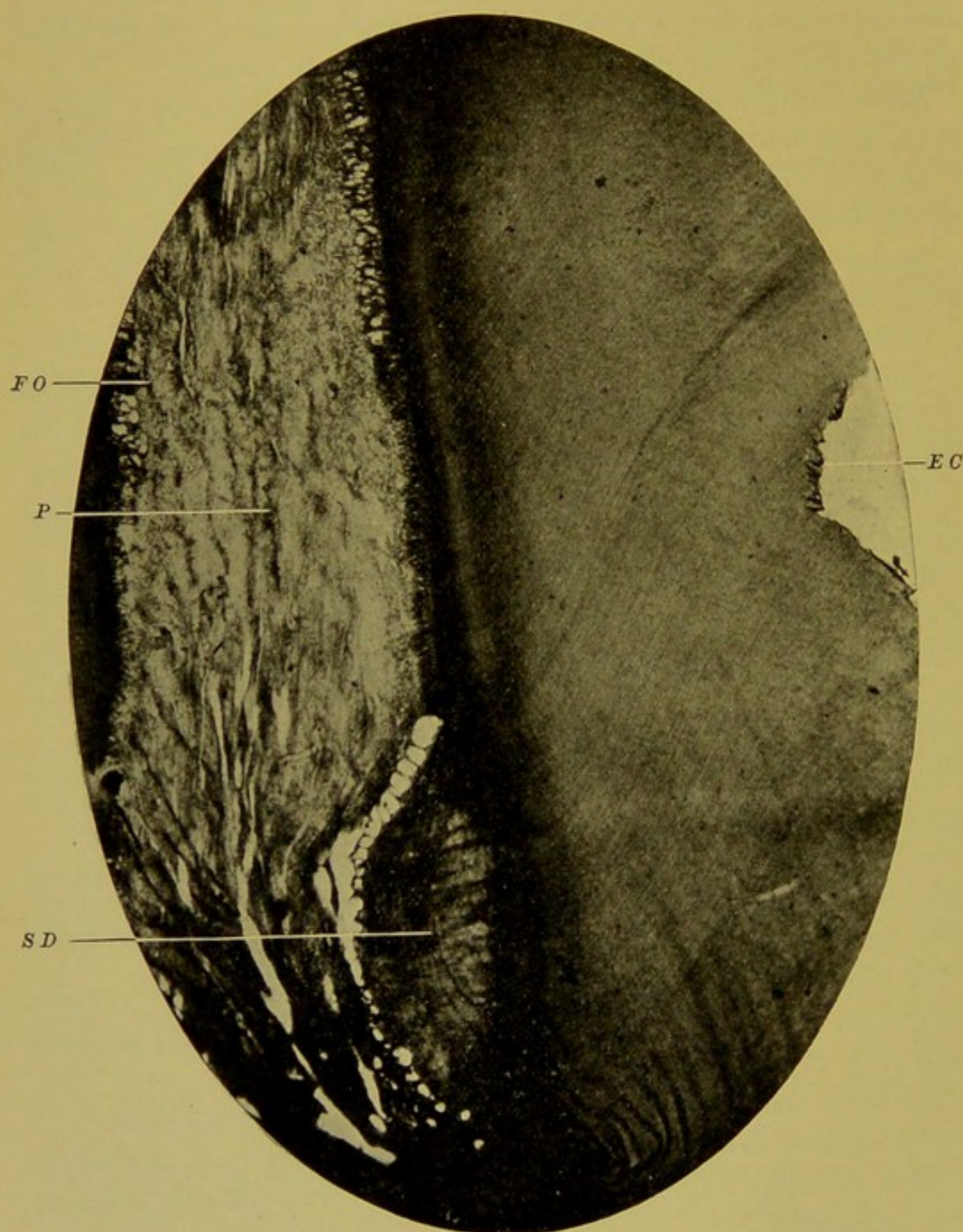
¹ Lectures.

² Dental Surgery.

³ Miller.

extend through it. The tooth is necessarily weakened and the crown may break off; such a result is, however, very rare. The pulp is very seldom exposed.

FIG. 270.



Sagittal section of human incisor prepared by Mr. Hopewell-Smith's process, and stained with hæmatoxylin: *EC*, erosion cavity, on surface of which can be seen Baume's clefts; *P*, pulp tissue undergoing degenerative changes; *FO*, atrophic odontoblasts; *SD*, secondary dentine. $\times 45$. (Hopewell-Smith.)

The editor has noted at times a peculiar grooving upon the dentine, consisting of a series of very fine lines. The lines are nearly parallel

and very close together. The inference is that these are due to friction from the brush, yet they may not be. Baume has pointed out the existence of clefts in the deepest portion of the erosion areas (Fig. 270).

The course of erosion may extend over a period of many years, and periods of erosion with periods of cessation intervening have been noted. This would indicate periods of general malnutrition.

Gold fillings placed when erosions are small are left as raised islands by the wasting of the tooth substance around them.

The acid stimulation of the dentinal fibrillæ may cause great hypersensitivity; as a rule, however, this is not marked.

The anterior teeth are sometimes shortened so that their occlusion is lost. Kirk's case was of this order. The shortening may be due to a solution of the incisal enamel and dentine imparting a wedge shape to the incisal edge, or a distinct cupping of the dentine may ensue. At times the carious process becomes implanted upon an eroded area, or at some part of it, usually the cervical portion. This indicates a temporary cessation of the erosion.

Diagnosis. The presence of the peculiar excavations, the hypersensitivity of dentine if any, and the acid character of the mucus from the follicles, as shown upon test with litmus paper made just after rising,¹ are diagnostic signs. The acid reaction is not marked during the day. The existence of erosion has become a valuable diagnostic sign for the general practitioner in his search for the nature of masked maladies from which patients frequently suffer. Obscure gout has been pointed out through dental indications alone, where the practitioner had before been baffled in his diagnosis.

Treatment. The treatment of erosion divides itself under two heads: prophylactic and restorative; the prophylactic is again divided into local and general treatment. The problem of eradicating the cause of the disorder lies in a correction of the morbid glandular secretion. It is evident that if the irritation and altered secretion of these glands be due to some systemic cause, a disease of suboxidation, notably an affection of the gout order, a cure of the local disturbance involves the cure of the underlying systemic cause.

The effect of an antigout regimen and antigout therapeutics upon the advance of the erosion has not been sufficiently tested or observed to furnish reliable data in this connection, but so far as tests have gone such treatment appears to lessen the formation of acid substances

¹ Truman.

by the labial glands. Brubaker has suggested the advisability of destroying these glands by means of the electrocautery, as a radical cure of the progress of erosion.

Next in importance to the prevention of acid formation is its neutralization. This implies the application of alkalis or the use of alkaline mouth-washes. The greatest production of acid occurring during the night, applications of adhesive masses of alkaline substances are made to the teeth at night. The principal of these is prepared chalk, calcium carbonate; it is rubbed over the labial faces of the teeth and between them, before retiring. It remains in sufficient amount to neutralize any acid substances coming in contact with it.

Excellent results as to the checking of the progress of the decalcification are obtained from the use of magnesium hydrate held in suspension in water, milk of magnesia. Kirk found that three hours after the use of a teaspoonful of the milk of magnesia the saliva maintained an alkaline reaction. It should be used at night as a wash, after cleansing the teeth, the residue to be left as an alkaline coating upon the teeth. The chalk and milk of magnesia may be mixed into a paste. If the preparation be disagreeable a few drops of oil of gaultheria or of rose may be added. If the patient care to take sufficient trouble, it is an excellent practice to dry the labial faces of the teeth each evening and paint them with a solution of amber in chloroform.

It has been suggested by Ottolengui¹ that in the earlier stages an impression and plaster model of the teeth be made for comparison at future dates, so that the progress of the erosion may be noted.

RESTORATIVE TREATMENT. If the eroded areas be excavated and filled the erosion may proceed about the edges of the fillings. It may, however, take some time for the erosion to become as deep as the original area.

If metal be used the margins must be extended to avoid this if possible. Metal is very unsightly in the locations peculiar to erosion, so that porcelain inlays which the locations favor are indicated. In their place gutta-percha or oxyphosphate fillings may be used, but must be constantly kept in a good condition of surface or they become unsightly.

The generally distributed erosions are only amenable to the prophylactic treatment (except by crowning when teeth are largely wasted away), and slight erosions are best treated in the same manner.

¹ Methods of Filling Teeth.

MECHANICAL INJURY OF THE TEETH.

It was pointed out on page 156 that the enamel is a material much more brittle and inelastic than the dentine, and, therefore, less capable of resisting a parting strain. Under ordinary circumstances, however, well-formed enamel distributed over sound dentine resists all the ordinary forces brought to bear upon it.

Under abnormal conditions, however, enamel appears to fracture readily in two directions: (1) along the line of the interprismatic cement substance between the prisms themselves; (2) along the line of cement substance between the globules. The possibility of reference of all cases into one or other class indicates that the cement substance is naturally a tissue relatively weak.

Dentine may apparently fracture in any plane.

Causes. The teeth may be mechanically injured by (1) the action of abrasion, which mechanically wears away the teeth; (2) by the application of undue force during mastication or by the improper use of cutting, filling, or extracting implements; (3) by blows of some sort delivered either directly upon the teeth or through forcible closure of the jaws, as the result of a shock or blow delivered upon the rim of the jaw.

Aside from blows or bites of sufficient force to break sound teeth, it is rare to find teeth fractured without a previously acquired weakness in the tooth itself. The causes of weakness are several.

During the course of abrasion the enamel is worn to a sharp edge which is readily fractured. Oblique splintering occurs in the line of cement substance between the globules. The enamel edges become ragged and further fracture is imminent. Thread biting produces a similar but localized condition (Fig. 274).

Caries by removing the natural support of the enamel renders this brittle material subject to fracture in ordinary use. The removal of dentine from both the mesal and distal sides of a crown by caries—*e. g.*, a bicuspid—renders the buccal or lingual section liable to fracture as the result of a strain delivered between the cusps and tending to wedge them apart. This accident is liable to occur in proportion to the lessening of the healthy dentine between the cavities or beneath the occlusal fissure. An upper incisor so decayed would naturally have its labial section fractured away, particularly its incisal half.

The exposure of the dentine of a devitalized tooth to the saliva seems to weaken it.

While these principles are correct it is surprising to what extent enamel undermined by caries may retain its integrity if properly supported by an adhesive oxyphosphate of zinc.

The packing of cohesive gold against frail enamel walls renders them liable to direct fracture, or if packed so as to permit leakage the wall is further weakened by lactic acid produced upon its under surface. Again, the improperly prepared cavity margin may be comminuted.

Gold does not support enamel walls so well as oxyphosphate. If built over comparatively frail walls in such a manner as to protect them from direct impact they stand fairly well.

Amalgam by its attendant leakage permits gradual weakening of frail enamel walls.

Johnson¹ explains fracture after filling, where the enamel walls were previously undermined but not fractured, upon the theory that previous to filling the pain attendant upon mastication brings about a temporary disuse of the diseased tooth. After filling comfort ensues, the patient again uses the tooth, and fracture occurs.

The fractures caused by blows present features of interest. An actual splitting off of one of the angular portions of a crown may occur, or a fracture may be seen resembling one sometimes seen in a pane of glass the result of a light blow from a stone.

In the latter case the cracks radiate from a central crushed spot, and may involve only the enamel. A large section of an incisor may be fractured away and include the labio-incisal third and all the lingual section of the crown and a small, obliquely fractured portion of the root.

Biting upon hard objects has caused the fracture of sound bicuspid and molars, the line extending mesodistally between the cusps, and in an upper tooth through the crown and between the roots. Thus, a molar or first bicuspid may be divided into two sections, each supported by a root or roots.

Fracture and repair of enamel after eruption is not, so far as I am aware, known. Cases of fracture and repair of dentine have occurred.

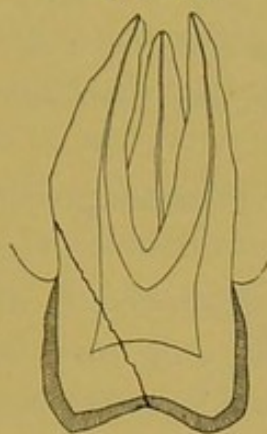
A case of such repair by adventitious (secondary) dentine has been recorded by Tames,² and Fig. 273 illustrates a fracture of the root well below the gum line. The root is girdled by the line of fracture, but the dentine has been repaired and the attachment is firm.

¹ Principles and Practice of Filling Teeth.

² A System of Dental Surgery.

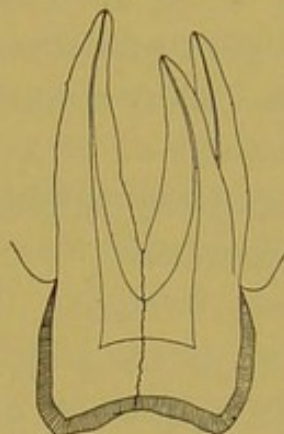
Longitudinal cracks in the enamel of otherwise fairly sound teeth occur, the line running from the labial edge of the gum to the incisal edge of an incisor (Fig. 274), or from the fissure of a bicuspid along the enamel to the summit of a cusp, or from the cervical margin of a proximal cavity to the gum margin.

FIG. 271.



Oblique fracture.

FIG. 272.



Fracture involving the bifurcation of the roots.

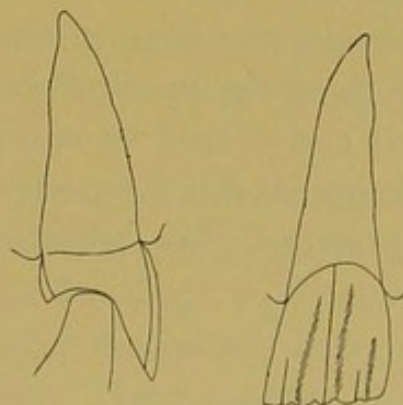
These lines probably indicate that force has been applied sufficient to cause a parting of the enamel cap without loss of continuity in the more elastic dentine. Dryness from mouth breathing may be a possible cause of cracks, and the contact of excessively hot or cold substances has been advanced as an hypothesis. In some cases the enamel

FIG. 273.



Root fracture and re-attachment by adventitious dentine. From a specimen.

FIG. 274.



Abrasion associated with fracture of the enamel.

cracks may be very numerous. These cracks take up stains, and at times in the preparation of cavities cause annoyance by centring the chisel and perpetuating a defect necessitating the removal of much tooth tissue or the risking of future caries.

Treatment. The treatment of fractures involves considerations purely operative, and depends upon the nature of the case. Roughened,

abraded enamel margins are best rounded with carborundum stones or coarse sandpaper disks, and should be polished. Sometimes a deep serration must be filled; corners are to be neatly rounded or restored to contour by fillings or inlays, or at times the entire incisal edge is to be ground away and the tooth drawn down and retained until firm.

In case of an uncompleted tooth root, and the pulp not quite exposed, a pure gold all-metal crown is to be adapted with or without grinding, according to the future requirements, and the root completion awaited.

If necessary the capping of the pulp may be attempted as well for the same purpose.

After root formation the pulp may be destroyed if desired. If conservation of the pulp be not possible the pulp may be prepared for removal by pressure anæsthesia or cocaine injection and the root filled. (See Root Fillings.)

Fractures involving the cementum demand either the removal of the loosened piece and the construction of a special crown retaining a portion of the natural crown as a base, or the removal of all of the natural crown and the mounting of a substitute upon the root, or the parts may be banded, or in case of molars an all-metal crown may be mounted. In some cases screws must be placed in the roots and the parts restored with amalgam. If the loosened portion be retained oxychloride of zinc or thin oxyphosphate is to be introduced into the joint after appropriate sterilization and before the gold crown is set. Should the pulp be vital at the time of fracture, it will become inflamed and should be removed by the pressure method if possible. To accomplish this the parts must be lashed together and an occlusal opening made. The requirements vary and must have due consideration.

CHAPTER XI.

STAINS OF THE ENAMEL AND DENTINE.

CERTAIN stains are found upon the surface of the enamel and sometimes penetrating its substance. The calculus sometimes located upon the enamel is not included in this consideration, though the calculus itself sometimes becomes stained. So far as they have been observed stains may be divided into those of metallic and non-metallic origin.

METALLIC STAINS.

Metallic stains are those which are caused by the direct deposition of minute particles of metal, inhaled by workers in the metals, in the organic collections upon the surfaces of the teeth or taken into the mouth in various solutions of drugs.

Copper. Miller found that "workers in copper, brass, or bronze all presented a green stain upon the upper teeth, showing every shade of green and bluish-green up to bluish-purple. The latter color predominated in rooms where phosphor-bronze was worked." Attention is called to the fact that "trumpeters very often show a discoloration of the teeth." Similar discolorations are sometimes noted in proximity to copper-amalgam fillings. The presence of copper was demonstrated in scrapings from some of the stained teeth, imparting a characteristic green color to a Bunsen flame.

Iron. "Workers in iron presented stains of a brownish color." As pointed out, "the green salts of iron under the conditions found in the mouth would become oxidized and brownish in color." The administration of iron salts, medicinally, is believed to produce black discolorations, iron sulphide being formed. "Iron deposits are usual in the border line between carious and normal dentine." It is usually believed that the brownish spots frequently seen in connection with incipient or arrested caries of the underlying enamel are due to the formation of iron salts.

Manganese. Manganese was found in the dark-colored deposits upon the teeth of herbivorous animals, but as yet not upon those of man. The investigator states "that alkaline saliva may be necessary to the production of these deposits."

Manganese stains may occur from the use of potassium permanganate, manganic oxide being formed.

Mercury. In cases of prolonged mercurial administration the deposits (black) upon the teeth may give the reaction for mercury. "If mercury and potassium iodide are given together, the green iodide of mercury might be present upon the teeth." It is probable in these cases that another discoloring substance may form. There is in mercurialism more or less gingivitis; the gums are swollen and spongy, bleeding readily. "More or less putrefactive decomposition of the albuminous matter present upon the teeth occurs, and hydrogen sulphide is formed. Reacting upon the oxyhæmoglobin of the blood, sulphomethæmoglobin is formed—greenish-red in concentrated, green in dilute solutions." Miller ascribes the discoloration found in conditions of gingivitis from various causes, with lack of hygienic care, to a probable reaction between hydrogen sulphide and oxyhæmoglobin.

Lead. Hirt (quoted by Miller) found in cases of lead-poisoning discolorations upon the teeth: dark brown at the necks, light brown on the crowns, with sometimes a trace of yellowish-green. Miller's tests (limited in number) showed no lead reaction from the dental deposits in lead-poisoning.

Nickel. Some of the salts of nickel are green. "Metallic nickel attacked by fluids of the mouth and mixtures of bread and saliva produce greenish salts. The entire root of a tooth containing a nickel retaining screw has been stained a uniform apple-green.

Silver. The dentine of pulpless teeth containing amalgam fillings is sometimes stained black, owing to the formation of silver sulphide.

The use of silver nitrate as a wash may cause the albuminate of silver to precipitate metallic silver upon the teeth. If a cavity be touched with silver nitrate and an amalgam filling be introduced the metallic silver will be instantly formed at any point where the silver nitrate and amalgam combine. If this be upon the enamel the latter will receive a somewhat lasting black stain.

The nitrate of silver applied to dentine causes the dentine to assume a light yellowish-green tinge, and the albuminate of silver is formed; later metallic silver is precipitated, the tissue becoming black.

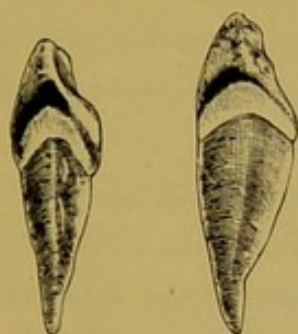
Gold. Gold stains may be formed during the bleaching of teeth containing gold fillings by the chlorine methods. The dentine becomes first pink, then violet or purple, then black.¹

¹ Kirk, American Text-book of Operative Dentistry.

NON-METALLIC STAINS.

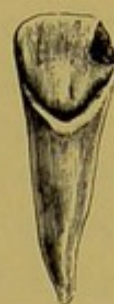Green Stain. This most common of green deposits upon enamel occurs upon both the temporary and the permanent teeth, particularly of young persons. The deposits usually have a crescentic form, are mainly upon the labial faces of the anterior teeth, and may be but a narrow line or may cover one-half the labial face. It is unusual for the deposit to extend far into the interproximal spaces, their tendency being to follow the edges of the proximal surfaces. While green stain undoubtedly does form upon adult teeth (Figs. 275 and 276) where clearly the enamel cuticle has long been absent, it is only very common upon young teeth where remnants of Nasmyth's membrane persist about their necks. The color of these deposits varies from light green to greenish-black.

FIG. 275.



Extension of green stain on the approximal surface of the incisors. (Miller.)

FIG. 276.



Extension of green stain on the lingual surface of incisors. (Miller.)

If an instrument be passed over the portion of enamel affected, more or less roughness of the surface is evident. If the deposits are subjected to friction with abrasives, they disappear slowly and the enamel beneath may be found roughened. This has led to the belief that these deposits cause decalcification of the enamel. It is found upon adult teeth that when an area of cervicolabial enamel has become roughened through slight decalcification a green stain is likely to form upon the rough surface if proper hygienic care be not exercised. It is also found that if the stain be removed by means of abrasives, the roughened enamel may be readily polished—*i. e.*, the decalcification is very superficial.

If cases be observed early enough in childhood, it will be noted that green stain is usually preceded by a lack of oral hygiene; collections of food debris are not removed from about the necks of the teeth, which implies that prior to the formation of green stain the affected

enamel surfaces have been subjected to the action of fermenting food débris—that is, to acids. These facts have led to an acceptance of the view that the roughness or decalcification has preceded the green deposits. “If teeth be placed in a 10 per cent. solution of hydrochloric acid, in from two to four minutes the enamel cuticle begins to loosen, and in from five to ten minutes is isolated. It is found that the entire stain comes away with the cuticle.”

Nature of the Coloring Matter. The coloring matter is found to be insoluble in water, glycerin, alcohol, ether, chloroform, and oil of turpentine. Mineral acids, hydrochloric, nitric, and nitrohydrochloric, act but slowly upon the coloring matter; even hydrochloric acid requires some hours to completely destroy it. Tincture of iodine, commonly believed to act as a solvent of green stain, was found to affect it but slightly. Both chlorine and nascent oxygen destroy the coloring matter rapidly, the cuticle being bleached in a few minutes by a 10 per cent. solution of hydrogen dioxide. Thick, dark-green deposits were incompletely bleached after eight hours' immersion in the 10 per cent. H_2O_2 solution, pointing to a lack of uniformity in the composition of the stain.

The belief that the green coloring matter is chlorophyll is contradicted by the fact that it is not soluble in ether.

Miller¹ regarded the association of the green discoloration with sulphomethæmoglobin, or some allied substance, as the most probable explanation, though he found a micrococcus in a deposit of green stain which produced a grayish-green color in glycerin agar.

Miller did not find any definite connection between a milk diet and green stain.

Goadby² has found *B. liquefaciens fluorescens motilis* present in several cases of green stain. It deposits in its culture medium a fluorescent blue-green pigment. Other mouth bacteria produce a greenish pigment—*e. g.*, *B. pyocyaneus* and *B. fluorescens non-liquefaciens*.³ The deposits of green stain are considered to be secondary to enamel decalcification rather than the cause of it, when found in connection with it.

In case of roughened enamel, green stain appears at times to have been taken into its substance, rendering removal without bleaching difficult.

Black Stain. A peculiar black stain occurs in the mouth of apparently healthy individuals, both men and women, and smokers and

¹ Dental Cosmos, 1894.

² Mycology of the Mouth.

³ Ibid.

non-smokers, and even with those who also neither drink tea nor coffee. It occupies the general position described for green stain, but may cover much of the surface of the teeth. It occurs in somewhat unclean mouths, though the teeth may have been regularly brushed. As a rule those teeth having the deposit are comparatively free from caries. Its etiology is not worked out, but it may be due to a formation of iron sulphide in place of sulphomethæmoglobin. It is very readily removed and does not, as a rule, affect the enamel. At times a superficial caries is found associated with it, and at some minute spot the enamel may be penetrated. Whether this cavity is a result of the action of the film is not certain.

Tobacco Stains. Smokers have characteristic black deposits upon both the teeth and calculus deposited upon them. The stain is most marked upon the lingual surfaces of the teeth, and a pipestem held well back in the mouth may cause a thick deposit upon some of the posterior teeth.

Tobacco juice itself stains exposed dentine and cementum, and enters cracks in the enamel, producing brown discolorations very difficult or impossible to remove.

Red Stain. A peculiar red stain occurs upon the necks of some teeth, but is not generally distributed. It is probably due to chromogenic bacteria, as it is only found in unclean surfaces.

According to Goadby,¹ *B. prodigiosus*, *B. rouge de Kiel*, *B. mesentericus ruber*, *B. roseus*, *sarcina roseus*, *micrococcus roseus*, and other micrococci produce a red pigment in at least some of their media.

Sarcina lutea and *sarcina aurantiaca* produce yellow and orange-colored pigment, respectively.² The exact relation of chromogenic bacteria to stains is not worked out.

DENTINE STAINS.

Exposed dentine may be stained as enamel is. In addition it may take up certain stains like tobacco.

Metallic fillings, such as amalgam, containing mercury, silver, copper, or cadmium metals which combine with sulphuretted hydrogen to form sulphides, may cause staining of dentine.

Metallic posts containing silver, copper, or nickel, or made of steel or iron wire, may produce sulphides in the same manner. The dentine

¹ Mycology of the Mouth.

² Ibid.

may also be stained pink by hæmoglobin entering the tubules during the progress of venous hyperæmia.

The dentine may also be stained by iron sulphide, formed during putrefaction of the pulp, by the action of hydrogen sulphide upon the iron contained in the hæmoglobin of the blood undergoing decomposition.

TREATMENT OF STAINS.

Enamel stains are best removed by mechanical means, after the removal of calculus from the teeth. (See Salivary Calculus.) For this purpose brush wheels and rubber cups charged with pumice and revolved in the dental engine are used to remove the accessible portions of the stains. Next a wood point, made by sharpening an orange-wood stick to a wedge-shape, is charged with the pumice and rubbed by hand over all the surfaces not reached by the brushes and cups. For the more inaccessible situations the point is to be mounted in a Cogswell or other carrier. A very fine linen tape, a German-silver strip, or floss silk charged with the pumice will remove the stains at the contact points.

The powdered pumice used is best mixed with glycerin to prevent the flying of the pumice during the rapid revolution of the wheels. Saturation of the stains with tincture of iodine renders them more visible and also brings to view the associated bacterial films upon the teeth.

Register recommends the use of 1 per cent. hydrogen dioxide to be forcibly sprayed upon the gums and deposits both before and after the use of tincture of iodine. The brush and pumice will then rapidly remove the stains and bacterial films upon the accessible portions of the teeth.

Tobacco stains in cementum need not be removed to their full depth.

Head¹ has suggested the removal of deep enamel stains and the deposits in irregular depressions, inaccessible to the stick, by the use of nascent oxygen derived from 25 per cent. ethereal pyrozone or a paste of sodium dioxide and water, made by dissolving the latter in distilled water at about 32° F. These are applied to the part on cotton, and nascent oxygen liberated with a hot burnisher. The face and gums are protected by the securely placed rubber-dam and by oiling the face.

The method is also applicable to the bleaching of obstinate stains of the dentine, especially near the cutting edges.

¹ Items of Interest, 1902.

If beneath green stains decalcification be discovered, the decalcified area should be removed, the enamel polished, and the patient urged to careful prophylaxis.

After the removal of calculus and stains from the teeth the mouth and teeth should be kept in as cleanly and aseptic a state as possible by the employment of correct prophylactic measures. Dental caries and pyorrhœa alveolaris are thus also largely prevented. (See Prophylaxis of Dental Caries and Pyorrhœa Alveolaris.)

The stains found in the dentine are also divisible into metallic and non-metallic. The former are best removed by transforming the insoluble metallic salt into a soluble one.

The most frequent and practicable course is to form soluble chlorides through the action of nascent chlorine. Copper, nickel, gold and iron stains should be subjected to the chlorine method of bleaching, followed by repeated washings with chlorine water, 50 per cent., and hot distilled water to remove the chloride formed.¹

Silver stains are converted into silver chloride by the chlorine method, or iodide by the use of tincture of iodine, and dissolved out by the use of sodium hyposulphite followed by hot distilled water.²

For mercurial stains Kirk recommends the use of aqueous, ammoniacal solution of hydrogen dioxide after the chlorine method, and a saturated solution of potassium iodide after the iodine method, in either case followed by washing with hot distilled water.

Manganese stain is removable by the use of 25 per cent. aqueous solution of hydrogen dioxide saturated with oxalic acid crystals and followed by washing with hot water.

The non-metallic dentine stains are removable by the use of nascent chlorine evolved from chlorinated lime by the reaction with dilute acetic acid or of nascent oxygen evolved from hydrogen dioxide or sodium dioxide.

In either case the color molecule is destroyed by the indirect or direct oxidizing effect.

The hydrogen dioxide may be used in the form of the 25 per cent. ethereal solution (25 per cent. pyrozone) applied for a time or sealed within the tooth for twenty-four hours, or the 25 per cent. aqueous solution may be driven into the tubuli by the aid of the cataphoric current.

Sodium dioxide should be employed in saturated solution in distilled water (made at about 32° F.). The dentine is first desiccated and

¹ Kirk.

² Ibid.

then saturated with the solution. Weak sulphuric acid (10 per cent.) is used to liberate the nascent oxygen. Kirk recommends a second application, omitting the use of the acid.

As with metallic stains, all the by-products should be washed out with hot distilled water.¹

¹ For a complete description of the bleaching process, see Kirk's article in American Text-book of Operative Dentistry.

CHAPTER XII.

DENTAL CARIES: HISTORY; EXCITING AND PREDISPOSING CAUSES.

Definition. Dental caries may be defined as a disease of a tooth characterized chiefly by the production of a localized cavity, concavity, or area containing decalcified tooth structure and due to a combined acid fermentation and liquefaction.

History. Examinations of crania show the disease to be certainly as old as semicivilization, and when more data are obtainable it will, no doubt, be found even older. The skull of a mummy in the British Museum, dating 2800 B.C., exhibits well-marked caries and other dental diseases. Caries appears in the teeth of the skulls of all peoples, no matter what their degree of civilization, provided their dietary included cooked starchy foods.

Causes. These may be divided into exciting and predisposing.

Prior to the investigations of Miller,¹ published in 1882, a vast amount of labor was expended in the effort to determine the cause of dental caries. The deductions made were partly speculative and partly based upon scientific investigations.

From 1754 to 1835 caries was regarded as an inflammation or gangrene of tooth structure; Boudett, Jourdain, Hunter, Fox, Bell, Fitch, and Koecker advancing one or the other theory.²

In 1835 Robertson,³ of Birmingham, England, advanced the opinion, based upon his observations, that it "is to chemical and not to inflammatory action that the destruction of the teeth must be attributed." The author points out forcibly the errors and fallacies of previous writers. He states that "Particles of food retained in fissures and imperfections of the teeth and in the spaces between the teeth undergo a process of decomposition and acquire the property of corroding, disuniting, and therefore destroying the earthy and animal substances of which the teeth are composed."

¹ International Dental Journal, 1884.

² For an interesting and exhaustive exposition of their views, see American System of Dentistry, Section on Dental Pathology, by Black.

³ A Practical Treatise on the Human Teeth, second edition, Philadelphia, 1839.

John Tomes, a little later, was the first to record microscopic examinations of carious dentine. He described the transparent zone lying between the carious and non-carious dentine, and observed and pointed out also the dentinal fibrillæ. He announced the very significant fact in relation to caries, that if blue litmus paper be applied to a carious cavity it is at once reddened, which furnishes evidence of the presence of an agent capable, if unresisted by the vitality of the dentine, of depriving the tissue of its earthy constituents, leaving the "gelatin to undergo a gradual decomposition favored by the heat and moisture of the mouth."

Tomes first established the essentially chemical character of some features of caries. The character of the acid and its localization were, however, not ascertained.

In 1867 Bridgman promulgated the theory that the crown of the tooth and the gum were of different electric potential, and that being bathed in the oral fluids the conditions of a battery were set up.

Acid substances were said to be set free at the positive pole (the crown) causing decalcification.

S. B. Palmer, in 1874, claimed that after filling recurrent caries was caused by the conditions of a battery being set up—*i. e.*, the difference of electric potential between the filling and dentine in the presence of saliva or of the fluid of the dentine as an electrolyte caused liberation of acids, producing decalcification of the tooth or disintegration of the filling—*e. g.*, oxyphosphate.

Miller, in 1881 and 1900,¹ experimentally examined these assumptions. He ground the enamel away from the crowns of freshly extracted teeth and filled cavities made in them with gold and gutta-percha. These he placed in separate flasks containing a physiological salt solution (0.75 per cent. table salt). This in the presence of electric currents should produce hydrochloric acid by liberation of hydrogen and chlorine, and decalcification should occur. After four years there was no decalcification.

Similarly filled teeth were suspended in dilute lactic acid. The decalcification was exactly similar to that in the unfilled pieces used as a control. Had electrolytic currents been generated between the metals and dentine the latter would have been acted upon more vigorously than in the unfilled pieces.

In 1868 Watt² advanced the theory that free sulphuric, nitric, and

¹ Dental Cosmos, April 1901.

² Chemical Essays, 1868.

hydrochloric acids were generated in the mouth during putrefaction processes and caused the different varieties of caries.

Magitot¹ pointed out that the essential phenomena of caries, as they were then understood, were the same in natural teeth mounted upon plates as in the natural organs *in situ*; proving that caries is intrinsically independent of the existence of vitality. By immersing teeth in solutions of sugar undergoing fermentative changes he found that decalcification occurred. Teeth immersed in solutions of sugar in which fermentation had been prevented by boiling the solution and sealing, or by additions of sufficient carbolic acid, remained unaffected.

Leber and Rottenstein, in 1867, first called attention to the probable causative association of bacteria with some phases of dental caries. By staining carious dentine with iodine the dilated dentinal tubules were shown to be filled with granular bodies, which they recognized as bacteria, identifying but one of the many forms of oral bacteria—the leptothrix. They deemed an initial exposure of dentine a necessary preliminary to the invasion and growth of the leptothrix, which in conditions of lessened resistance gained access to the tubules and in some undescribed manner caused their dilatation.

The question of the recognition of the presence of bacteria directly resolves itself into the subject of special staining. Prior to the work of Koch, presented in 1881, no means of isolating specific bacteria by special cultures and staining were known, and it is remarkable that in the same year the essential features of dental caries were first made out with some degree of clearness.

Miles and Underwood (World's Medical Congress, 1881) point out clearly and at length the different appearances produced by simple decalcification of dentine and those by dental caries. Speaking of Magitot's experiments, they say: "We assume that two factors have always been in operation: (1) the action of acids and (2) the action of germs. When caries occurs in mouths it is always under circumstances more favorable to the action of germs than to the action of acids." They believed that the acids necessary for the decalcification were excreted by the germs, which utilized the dentinal fibrillæ as a food supply.

It will be seen that the invasion and multiplication of organisms in the tubuli were held as the antecedent of the process of decalcification. The deductions of these gentlemen were drawn from data not derived from the methods of modern bacteriology—*i. e.*, special stains and

¹ Treatise on Dental Caries, Experimental and Therapeutical Investigations.

special cultures. Moreover, they were made before the physiological chemistry of bacteria was even partially understood.

In 1882 W. D. Miller, of Berlin, announced as the results of experiments conducted by him that he believed the first stage of dental caries to consist of a decalcification of the tissues of the teeth by acids which are for the greater part generated in the mouth by fermentation. This, it will be seen, is a position in agreement with that of Leber and Rottenstein, rather than with that of Miles and Underwood.

Miller's observations and experiments established the following basal facts in connection with dental caries:

1. That in all cases of dental caries micro-organisms may be seen under the microscope in the tubules of the carious dentine, and that bacteria exist in great numbers in the mouth.

2. That the invasion of the tubules is always preceded by decalcification of the dentine—*i. e.*, an area sometimes relatively large of decalcified dentine may be seen in advance of the organisms.

3. Analysis of the softened dentine proved that a large part of its lime salts were removed—*i. e.*, decalcification had occurred.

4. Test with litmus paper gave the acid reaction in nearly every case, so that the inference that decalcification was due to an acid was warrantable.

5. The food substances taken into the mouth are of all classes. Carbohydrates (sugars and starches), hydrocarbons (fats), and nitrogenous (albuminous) materials.

The carbohydrates are fermented with acid reaction by many mouth bacteria, commonly producing lactic acid; the albumins ferment with an alkaline reaction.

It was inferred from this and other experiments that caries was due to the acid fermentation of carbohydrates and not directly to the fermentation of albuminous substances.

6. That oral fermentation is the result of bacterial action his following fundamental experiments show:

- (a) A small tube was filled with a solution of starch and fastened to a molar tooth on retiring. The next morning the contents of the tube had a strong acid reaction. A tube of the starch solution with saliva added was incubated at blood temperature. After four or five hours the mixture became acid.

- (b) The mixture of starch and saliva was kept at 100° C. for a half-hour and incubated. It did not become acid—*i. e.*, the exposure to this temperature killed the ferment.

(c) The saliva was boiled for a half-hour and then added to the starch solution and the mixture incubated. No acid was produced—*i. e.*, the ferment existed in the saliva, not in the starch.

(d) The ptyalin of the saliva was destroyed by heating the mixture for twenty minutes at 67° C.; the incubated mixture still became acid—*i. e.*, ptyalin did not act as the acid-forming ferment, but the fermentation must have been caused by some other ferment not destroyed by exposure to this temperature.

(e) To the mixture of saliva and starch carbolic acid was added as an antiseptic. No acid was formed, but the ptyalin formed sugar.

(f) A number of tubes were each supplied with a small quantity of the saliva-starch solution and sterilized; a third of them were infected from the mouth, a third by carious dentine, and a third were left uninfected as controls. The infected tubes became acid; the controls did not.

(g) The first of a series of tubes containing sterilized saliva and starch solution was infected with carious dentine; when this became acid a fraction of a drop was carried from it to a second tube. After that became acid a third was infected from it and so on indefinitely.

Conclusion. Carious dentine contains a ferment or ferments capable of reproduction—*i. e.*, living organisms are present in it.

7. The nature of this living ferment was determined by infecting a culture medium with carious dentine taken from the deeper layers. The bacteria cultivated were distended into pure cultures by carrying through a series of cultures and examining microscopically during the process. The same morphological characteristics were exhibited in the last tube as shown by the germs in the deeper layers of carious dentine itself, and was identical with that of bacterium acidi lactici. These germs may be found in the sediment of a culture tube and consist of cocci and micrococci, either single or in chains. These cocci possess the power of forming lactic acid from glucose. The organism is a facultative anaërobe (Fig. 277).

8. A sound bicuspid was sawed into sections and an equal number of these sections placed in each of two test-tubes. Upon these was poured a 2 per cent. aqueous extract of beef (albuminous). To one tube a minute portion (0.2 per cent.) of cane-sugar was added. Both tubes were sterilized and after cooling infected with a pure culture of the germ obtained from the deeper layer of carious dentine. The sugar-containing solution became acid in a few hours; in a week the dentine was softened; in two weeks thin sections were completely

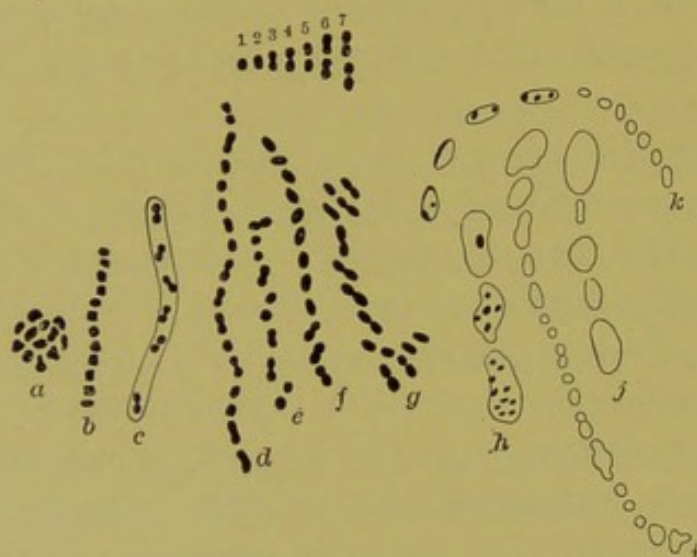
decalcified; in three weeks cavities were found in the dentine exactly similar to cavities formed in teeth in the mouth and presenting under the microscope other phenomena of caries to be described later.

A more prolonged fermentation resulted in the complete disintegration of the slabs of dentine, a proof of the fact that one organism may completely destroy dentine.

In the tube containing only the extract of beef no acid was produced, and no decalcification of the dentine occurred.

From these facts Miller argued that putrefaction does not initiate the process of dental caries, and may not be essential to the destruction of either the inorganic or organic dental elements.

FIG. 277.



9. That the acid produced was lactic acid Miller demonstrated as follows:

Starch and saliva were mixed and fermentation induced. This was then checked by sterilization with heat. A quantity of material being collected in this manner, the whole was concentrated by evaporation and tested with a solution of methyl violet, which would turn first blue and then green with an inorganic acid. Not so reacting, and not distilling off during the concentration, the acid present was pronounced a non-volatile organic acid. The concentrate was shaken with a quantity of ether, which dissolved the organic acid present. When the solution was clear it was filtered and the ether partially distilled off, when the partially concentrated solution was further concentrated over a water bath and then mixed with an excess of freshly prepared zinc oxide. The whole was boiled, water being added as needed, until the solution became neutral, when it was set aside to crystallize.

A drop placed upon a slide under the microscope showed the forms of crystals of zinc lactate (Fig. 278).

By testing the molecular weight of the washed and dried crystals it was determined clearly that the substance was zinc lactate.

In practically a similar manner lactic acid was obtained directly from carious dentine.

While Miller demonstrated the ability of one organism to produce all the essential phenomena of caries, including liquefaction of the dentine, he did not claim that only one or two organisms are involved in the process, but that "any germs possessing the power of producing acid fermentation of food may and do take part in the first stage of caries, and that all those possessing a peptonizing or digestive action upon albuminous substances may take part in the second stage; and that those possessing both properties may take part in both stages."¹

Out of eighteen mouth bacteria examined Miller found ten that produced lactic acid in sugar-containing solutions.²

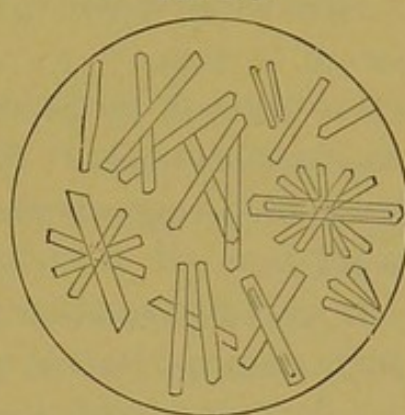
Hinkins and Acree,³ in experiments upon pure cultures of a number of oral bacteria in various artificial media, found lactic, butyric, valerianic, formic, carbonic, and hydrosulphuric acids as either principal or by-products of the fermentation.

It is quite clear from Miller's demonstrations that bacteria, or at least one bacterium, are the exciting causes of dental caries; and that for their function as such they require carbohydrate material as food.

Their action upon these substances has been studied. The carbohydrates introduced into the mouth as food are monosaccharids, diasaccharids, and polysaccharids. (1) The monosaccharids or glucoses have the general formula $C_6H_{12}O_6$ and are represented by dextrose and levulose, found in fruits, honey, and in some forms of so-called molasses candy, and galactose formed from lactose or milk sugar by hydrolysis. These ferment directly into lactic acid without formation of gas. $C_6H_{12}O_6 + \text{bacterial ferment} = 2C_3H_6O_3$.

A certain proportion of the glucose, etc., is appropriated by the bacteria as food. (2) Disaccharids or saccharoses have the general formula $C_{12}H_{22}O_{11}$. The principal one is saccharose found in sugar-

FIG. 278.



¹ Micro-organisms of the Human Mouth.

³ Dental Cosmos, 1901.

² Ibid.

cane, the sugar-beet, sugar-maple, and maize. This is inverted by the ferment of the bacteria into glucose and levulose through a process of hydration: $C_{12}H_{22}O_{11} + H_2O + B. \text{ ferment} = C_6H_{12}O_6 + C_6H_{12}O_6$.

Two other disaccharids enter the mouth or are formed therein: lactose and maltose, both $C_{12}H_{22}O_{11} + H_2O$.

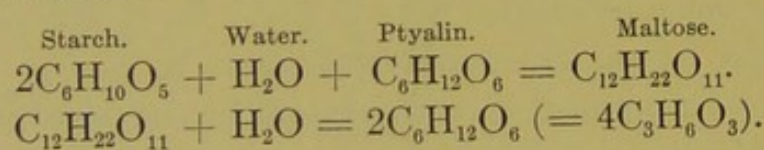
Lactose exists in milk and by hydrolysis is changed to galactose, $C_6H_{12}O_6$, and then ferments like other monosaccharids.

Maltose is an intermediate product in the formation of glucose from starch.

(3) Polysaccharids or amyloses with the general formula $(C_6H_{10}O_5)_n$. Starch, cellulose, glycogen and gum.

Starch was found by Miller not to undergo direct fermentation by mouth bacteria—*i. e.*, culture media containing starch but not sugar when infected by bacteria did not ferment into lactic acid unless ptyalin was present.¹ When saliva was used, however, the acid reaction occurred, owing to the formation of glucose through the action of ptyalin.

In oral fermentation starch is first changed to maltose by hydration; the maltose to glucose and levulose and these to lactic acid:



Miller has demonstrated that bacteria produce acid from starches and sugars in about equal proportions, provided the starches are cooked. The following synopsis of experiments² made with food mixed with saliva in definite quantities speaks for itself:

Material.	Duration of Experiment.	Acid Formed, in Units. ³
Bread, starch, potato, macaroni, rice, corn, and other cooked starches	12 and 30 hours.	20 to 25 and 42 to 110.
Raw starches, potato, spinach, etc.	" " "	0 " 0.
Cane-sugar and grape-sugar	" " "	17 to 20 and 37 to 41.
Meats, fish, eggs, etc.	" " "	0 or alkaline.

The table shows that albuminous materials and raw starches produce no acid and are not concerned in caries except in so far as meats, etc., act as culture media perpetuating bacteria which later may produce an acid reaction in carbohydrate materials.

That alkalies do not produce tooth disintegration in the mouth is

¹ American System of Dentistry, vol. i. pp. 805.

² Micro-organisms of the Human Mouth.

³ An acid unit equals the amount of acid necessary to neutralize 0.1 c.cm. of a 0.5 per cent. solution of potassium hydrate—*i. e.*, 0.5 c.cm. used equals five acid units.

shown by the fact that a tooth is not affected by alkaline solutions which are not strong enough to injure the soft parts.

The influence of carbohydrate diet in the production of caries is well shown by tables compiled by Mummery and quoted by Miller.¹ The races consuming a fish and meat diet almost exclusively—*e. g.*, the Esquimaux—are recorded as having about 3 per cent. of caries in skulls examined, while those using a mixed or vegetable diet have from 10 to 40 per cent. of caries. A most convincing example is that given by Miller² of two related tribes living on either side of the Andes in the Argentine Republic and Chili, respectively. The former, a cattle-breeding and meat-eating tribe, were practically free from caries, while the latter, living on mixed foods and consuming sugar, had 19 per cent. of caries.

While the mode of action of the causes of caries is properly to be considered under the pathology of the disease, it may be stated, as necessary to an understanding of the predisposing causes, that fungi existing in the food masses in the mouth, finding in the oral fluids conditions suited to such an action, form an exudate which may be spoken of as gelatinous and which attaches the bacteria to each other and to the surface of the enamel. In this situation carbohydrates are appropriated as food and lactic acid is produced *in situ* against the enamel rods and later against the walls of the dentinal tubules.

These "microbic plaques," as they have been termed by Black, are active only at spots sheltered from friction or neglected.

The Predisposing Causes of Caries. It is evident that the exciting causes of caries act only when the several factors of fungi, carbohydrates, and spots sheltered from friction are combined. These factors are so constantly present in the human mouth that caries is one of the most constantly encountered diseases at the present day. At the same time great differences are observed in different individuals as to the nature, extent, and rapidity of progress of caries. The extreme examples of this are, on the one hand, individuals who go through life with little or but ordinary care of the teeth, yet with practically no caries, and, on the other hand, those who only by constant care and dental service are able to check its ravages. These are evidently conditions of immunity or predisposition.

The causes of the predisposition to caries are local or general.

LOCAL PREDISPOSING CAUSES. So invariably does caries begin in sulci or pits upon proximal surfaces and unclean surfaces that

¹ Micro-organisms of the Human Mouth.

² Ibid.

faults of form, nature of approximation, and faulty position of the teeth must bear a relation to the difficulty of keeping the parts free from accumulations of bacteria and carbohydrates.

These local predisposing causes, as they are called, are simply conditions favoring the formation of the bacterial plaques upon the teeth.

Faults of Form. Deep pits or sulci in the occlusal surfaces of bicuspid or the occlusal or buccal surfaces of molars, or in the lingual surfaces of incisors, and occasionally cuspids or pits upon the cusps of bicuspid or molars, or in other unusual situations, are not subjected to a cleansing friction, and so permit bacteria to form plaques in these locations.

The nature of the proximal contact has to do with the inception of caries. Teeth are seen in which the proximal surfaces are well rounded and their buccal and lingual angles free from approximation. Such teeth are usually relatively narrow at their cervixes, so that these also recede well from the line of contact. A V-shaped space is formed which the gum festoon normally nearly fills. Such perfection of contour is also, as a rule, associated with a perfect organization of the enamel structure in virtue of which the surface is smooth.

While such teeth may decay proximally there is much less tendency to caries.

Opposed to this proximations exist of a broad nature. Broad proximations are very common and not infrequently are associated with a certain degree of enamel opacity and an unevenness of enamel surface plainly visible to the naked eye.

The fluid exuded by the gum is normally alkaline in character and probably neutralizes the products of acid fermentation. In view of this fact the first-mentioned form of contact evidently affords more of this immunizing principle. The carrying of cavity margins beneath the gum has been strongly indicated by experience as good practice and probably is explainable upon the same ground.

With the narrow approximations saliva is readily forced between the teeth and neutralizes the acids formed, or washes away soluble carbohydrates, the food for the bacteria. With the broad proximations such a result is less likely to occur.

Miller has found bacterial plaques upon both carious and non-carious teeth at the points of approximation, and claims that the carbohydrate masses are the agents most at fault. It is probable, however, that the plaques plus the carbohydrates are the determining factors.

A depressed proximal surface may decay, but frequently does not. An acquired fault of form requires notice.

Anatomically the gum covers the cementum and the enamel margin. When recession of the gum occurs, the cementum is left exposed and food débris accumulates at the angle formed by it with the gum. Owing to the cementum being less smooth than enamel microbial plaques readily collect, hence decay of the cementum frequently occurs. (See Figs. 286, 287, and 290.)

ARRANGEMENT AND POSITION OF THE TEETH. The overlapping of one tooth upon another creates a form of contact producing a tendency to decay at that point. Angle¹ claims to have observed a comparative freedom from caries of very irregular teeth.

The presence of a supernumerary third molar lying at the buccal side of the interdental space between the second and third upper molar or an inlocked bicuspid very frequently causes proximal caries at the contact points. The upper third and lower third molar frequently stand in bad relation to the cheek or the gum.

Food collects upon their buccal surfaces or they are not subjected to the friction of the toothbrush, and decalcification of a broad area of a buccal surface frequently results.

OTHER LOCAL PREDISPOSING CAUSES. Acids taken in excess into the mouth may act as predisponents by causing a roughness of the enamel, which invites the formation of the bacterial plaques. A course of tincture of ferric chloride has a bad reputation in this connection. In the cases observed by the editor the hydrochloric acid in the tincture seemed to have formed roughnesses between the teeth, and many large cavities of not unusual form were produced and evidently due to the carious process.

The acid vomitus of pregnancy and seasickness have an analogous effect. It is not likely, however, that during a transatlantic voyage large cavities can develop. The probable explanation of the presence of such cavities directly after the voyage is that they existed before the voyage was begun. (See Prophylaxis of Caries.)

Under conditions of oral irritation such as catarrhal stomatitis, or even the presence of many cavities of decay, a stringy, mucinous condition of the saliva may result. This may be due to a partial coagulation of the mucin by the acid present in the mouth, and the coagulum may entangle food masses and cause their adherence to the teeth.

¹ Dental Cosmos, 1903.

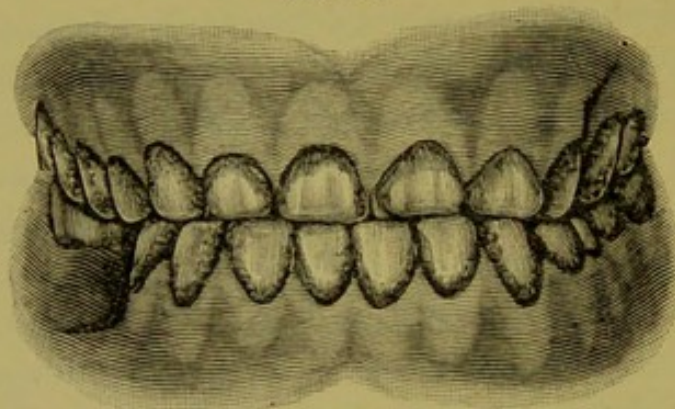
I have shown¹ that acid appears in a mouth within twenty minutes after a meal and after the mouth has been neutralized with sodium bicarbonate solution. It does not readily appear if the mouth has been thoroughly sterilized with potassium permanganate.

A lack of oral hygiene can hardly be considered a predisponent to caries, as it introduces the exciting cause, yet it favors the retention of food masses about teeth otherwise competent to care for themselves.

Insufficient mastication lessens the friction necessary to the cleanliness of the teeth and health of the gums.

It is possible that the secretion from the gum may in some cases be acid and favor the production of caries by decalcifying the enamel about the cervix (Fig. 279).

FIG. 279.



Caries of enamel about the cervices of many teeth, due to tenacious films collected upon them; at first probably neglected, later impossible to cleanse with brush alone. Model by W. A. Capon.

The structure of the enamel has no relation to the inception of caries. A roughness of the enamel surface may act as a favoring condition, and after inception of caries inferior structure and possibly the presence of Caush's tubes may permit more rapid disintegration. (See p. 141.) An interesting examination of 16,000 mouths made in Sweden by Forberg (Stockholm) and others by Röse in Baden and Thuringia seem to show that there is a relation between the color (structure) of teeth and the presence of caries, the following averages of all ages being observed: white teeth, 14.3 per cent. of caries; yellowish-white, 16.4 per cent.; yellow, 20.0 per cent.; grayish-blue, 24.3 per cent.

According to these observers,² in the regions in which the water was rich in calcium salts the individuals examined had the yellowish-white teeth.

¹ Dental Cosmos, 1899.

² Ibid., 1901.

GENERAL PREDISPOSING CAUSES. Some individuals seem to suffer much from caries, others in less degree. In either case periods of immunity or comparative immunity may be established and may be again followed by a period of susceptibility and a succeeding immunity.

Black¹ made analyses of so-called hard and soft teeth and deduced from them the opinion that the hardness and softness of teeth have nothing to do with the inception of caries.

Touching this point Black² instances the case of a man whose enamel had always been chalky and as easily cut as a slate-pencil, yet who had little caries of the teeth. That some teeth of apparently poor structure and defective form do not decay is also a fact of common observation.

These facts point to the conclusion that a period of caries is due either to a temporary lack of oral hygiene with a corresponding intensity in oral fermentation—*i. e.*, the exciting cause is active—or that it is due to some systemic condition which changes the constitution of the oral fluids, permitting the formation of the microbic plaques upon the teeth.

Black has shown that caries fungi are always present in the mouth, but do not always form the plaques. Cases also exist in which caries has begun during some period of susceptibility and a number of new cavities have been started. Later a period of immunity has followed and the cavities have not progressed.

So far as classed, systemic conditions influencing susceptibility and immunity may be placed under the four headings: Heredity, Prenatal and Postnatal Influences, Age, and Bodily Condition.

Heredity. The children of parents whose teeth decay readily seem to be subject to caries in marked degree. When one parent is immune the child may resemble one or the other in this respect.

Black³ records observations on certain families as showing a tendency to caries of certain teeth at a given age, or in certain positions upon the teeth—*e. g.*, occlusal pits. In certain cases the hereditary tendency persists throughout life.

Faults of form and position contributing to the inception of caries may be considered as direct inheritances or results of inherited disease or physical tendencies. The inherited tendency to caries may be due to an inherited general modification of cell physiology which permits the development of caries fungi and their plaques.

¹ Dental Cosmos, May, 1895.

² Ibid., June, 1898.

³ Ibid., 1899.

Prenatal and Postnatal Influences. It is quite possible that the systemic condition of the mother during gestation may profoundly modify the anatomicophysiological condition of the body cells of the child; nutritional processes may suffer and the postnatal tooth development proceed irregularly, structure being affected; moreover, the altered biochemical function of the cells may stand in close relation to the constitution of the oral fluids, and these in turn may favor the development of caries fungi. The same line of argument may be applied to bottle feeding of recently born infants, or to other conditions profoundly affecting general nutrition.

In an examination of school-children Th. Frick¹ (Zurich) found a much greater percentage of decay in children that had been bottle fed at between three and six months of age. He performed an experiment on a litter of six dogs, feeding three on cows' milk and bouillon; one of them died and the others had poorly developed teeth. The controls were normal.

Forberg and Röse² have shown that the individuals who drink water rich in calcium salts have a smaller percentage of caries than those drinking soft waters. Whether this effect is due to a better development of tooth structure or is a postdevelopmental effect is not stated. Degeneracy must be considered as a factor possibly influencing the body cells.

Age. That the age has an influence upon caries was noted by Flagg. He recorded the ages from five to eight, twelve to twenty, thirty to thirty-five, forty-five to fifty, sixty to sixty-five, and senility as periods of decay, while the intervening periods were intervals of comparative exemption.

Black has noted that caries is a disease of youth, most intense before adult age, at which time immunity is established, provided the teeth have been well and promptly filled and the mouth otherwise cared for. In view of this fact he aims at establishing this immunity by close attention to the teeth during youth.

He records fluctuations in susceptibility not unlike those recorded by Flagg, and also points out that some persons pass through the ordinary periods of susceptibility and first develop caries in middle age. In old age general recession of the gum is common, and in the conditions of debility associated with old age much caries of cementum occurs. So far as I have observed such cases it seems that the oral fermentation is more intense than at other periods, microbic

¹ Dental Cosmos, 1901.

² Ibid., 1899.

plaques form, and the tissue attacked is less resistant to decalcifying agents. Moreover, the patients are either unwilling or unable to keep the cementum cleansed.

Repeated examinations of the mouths of school-children show a deplorable amount of caries which may, perhaps, be attributable to several causes, such as the induction of a lessened systemic resistance due to confinement, study, etc., and also to the inhalation of vitiated air, which presumably also contains acid-producing bacteria. Moreover, bacteria of caries may be directly transmitted by kissing, common use of pencils, etc.

Michaels,¹ of Paris, has observed that "the saliva of adolescence contains a dextrinic principle (glycogen) susceptible of fermentation under the influence of ptyalin in the presence of earthy salts. Lactic acid is formed."

Bodily Condition. It is a matter of observation that such conditions as pregnancy, typhoid fever, anæmia, leukæmia, diabetes, dyspepsia, and debility are frequently accompanied by or followed by a development of cavities of decay, but whether the diseases themselves or a coincident lack of oral hygiene act to permit the formation of the gelatinous plaques has not clearly been made out. If oral and dental prophylaxis be practised during typhoid fever and convalescence therefrom, the production of cavities is much limited, but this does not prove anything. The same is true of pregnancy, which introduces an exciting cause (the vomitus), and of glycosuria, which introduces glucose. Black contends that periods of susceptibility are noted both in apparent good and ill health. That apparent health may really not be true health is a matter that must be considered.

Michaels² states that the constitution of the saliva changes with the establishment of various diatheses, and that a physiological saliva with the biochemical principles in a state of equilibrium is probably very rare. The exact findings of Michaels have not as yet satisfactorily explained the influence of the change in saliva upon the production of dental caries as commonly seen. He, however, states that the most active dental caries is found in the mouths of hypo-acid individuals.

That such a change may, however, favor or retard the growth of caries fungi, according to the nature of the change, is quite evident and may yet be shown to be the predisposing cause hinted at by Black.

¹ Sialosemeiology. See Dental Cosmos, 1900.

² Ibid, December, 1900.

CHAPTER XIII.

DENTAL CARIES: PATHOLOGY, MORBID ANATOMY, AND CLINICAL HISTORY.

PATHOLOGY AND MORBID ANATOMY.

It is a fact of common observation that caries begins only at spots protected from friction or uncleansed. These are in order of frequency: (1) pits, grooves, and fissures in the enamel; (2) proximal surfaces just above the contact points; (3) smooth surfaces which from any cause are habitually unclean; (4) necks of the teeth at or near the junction of the cementum and enamel (Black).

FIG. 280.

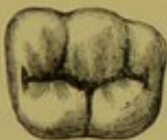

FIG. 281.

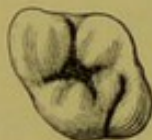

FIG. 282.



FIG. 283.

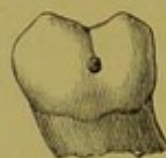


FIG. 284.

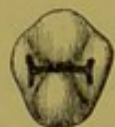

FIG. 285.

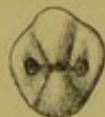

FIG. 286.

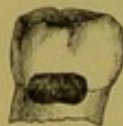

FIG. 287.

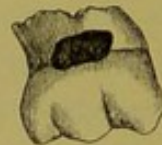

FIG. 288.

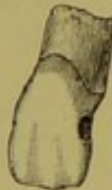

FIG. 289.

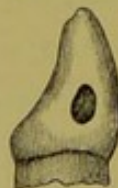

FIG. 290.



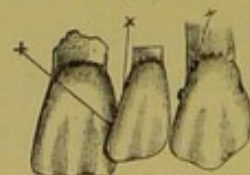
FIG. 291.

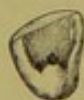

FIG. 292.

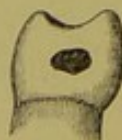


FIG. 293.



In these situations Williams has demonstrated the fact that the oral bacteria, protected from friction, attach themselves to the enamel, forming microbic plaques which are sufficiently adherent to permit their retention during the grinding of the specimen for microscopic examination. (See Figs. 294, 295, and 296.)

Black has stated¹ that "the formation of gelatinous plaques does not occur in every mouth, though the caries fungi do grow in all mouths, and that in the growth of the caries fungus on artificial media it may be made to produce a gelatinous material or grow without forming it by manipulation of the culture medium. The gelatinous plaque is a thin, transparent film, usually escaping observation, and is not the *materies alba* nor *sordes*."

FIG. 294.



Section of normal human enamel, showing thick, felt-like mass of micro-organisms slightly raised from the surface of the tissue by pressure of the cover-glass in mounting. $\times 350$. (Williams.)

Goadby² has succeeded in obtaining mucinous plaques upon sterilized teeth suspended in cultures of *staphylococcus viscosus* in non-carbohydrate media. He has found this organism upon the white decalcified surfaces of enamel in the mouth.³

In the plaques are bacteria of many kinds, including thread forms, and they form a thick, felt-like mass always present at spots of enamel undergoing decay. In these situations Williams⁴ has invariably found the *leptothrix racemosa* of Vicentini, a mould-like fungus. Its relation to caries is not, however, certain (Figs. 297 and 298).

¹ Dental Cosmos, September, 1899.

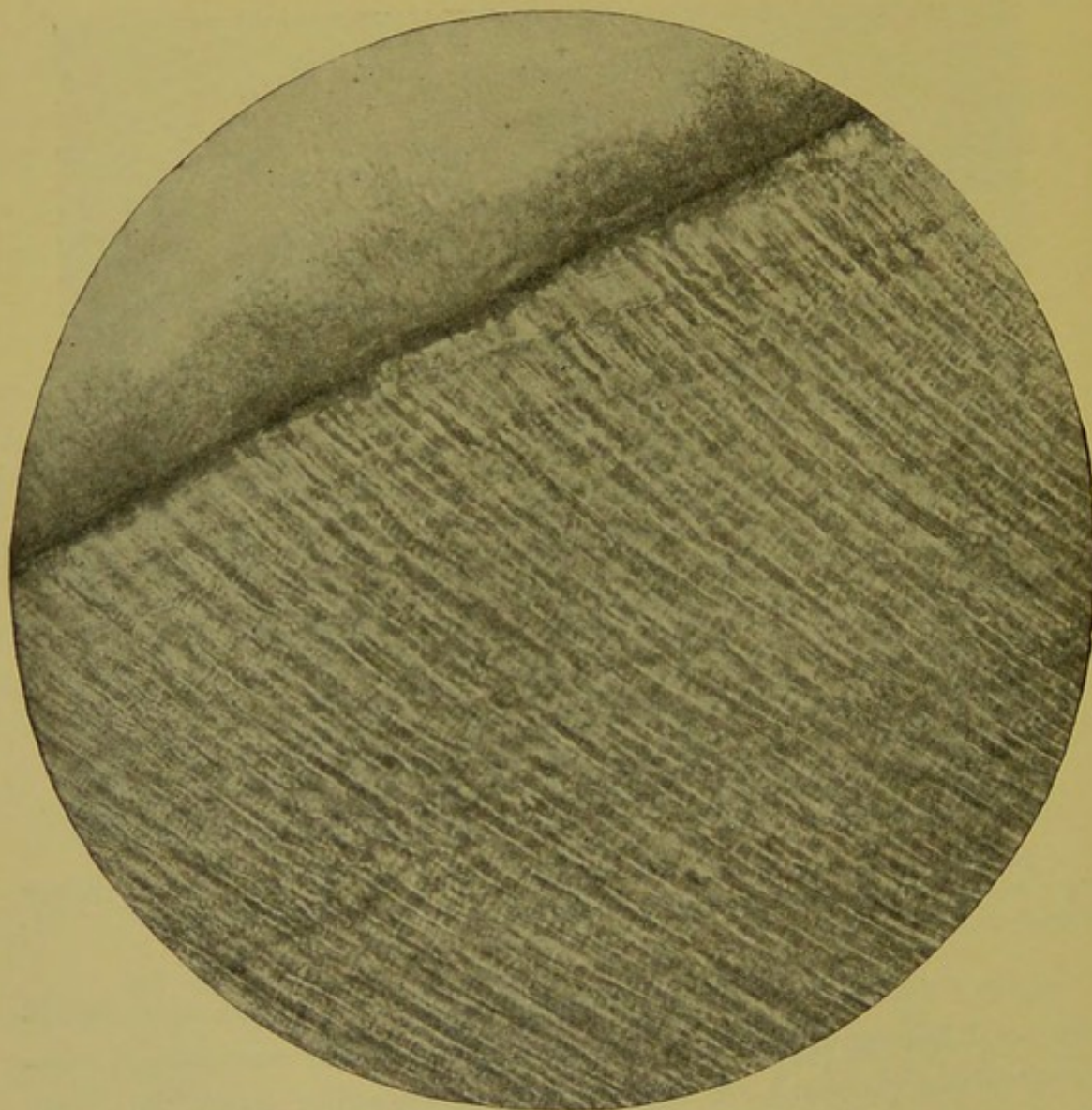
³ Ibid.

² Mycology of the Mouth.

⁴ Dental Cosmos, 1897.

The bacteria in the plaques require food and obtain it from the carbohydrate and albuminous materials which come in contact with them. From the carbohydrates lactic acid is produced as a waste product. (See Chapter XII.) Williams states that it is "highly improbable that the enamel is affected, except in rare and special instances, by any other acid than that which is being excreted by the bacteria at the very point at which they are attached to the enamel."

FIG. 295.

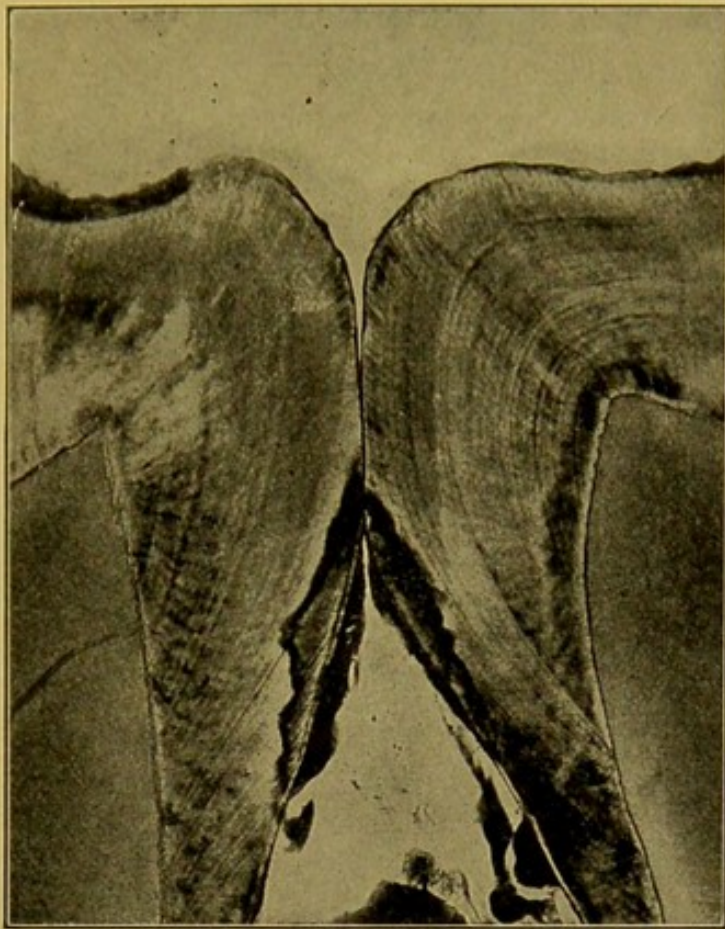


Micro-organisms of caries attached to enamel on approximal surface of tooth. (Williams.)

This thick, glutinous-like mass of fungi also prevents the excreted acid from being washed away, so that it exerts its full chemical power upon calcific tissue.

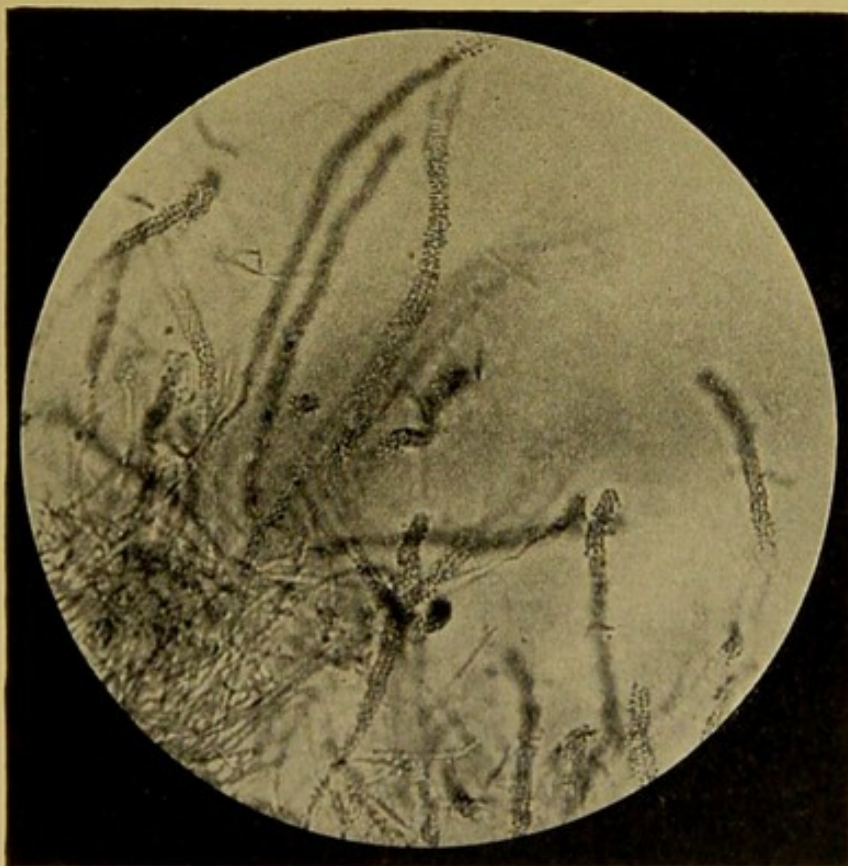
The lactic acid produced attacks the inorganic matter of the enamel, following first the interprismatic cement substance between the prisms, later dissolving the transverse cement substance between the globules.

FIG. 296.



Superficial approximal caries of enamel with films; also shows slight approximal abrasion. (Miller.)

FIG. 297



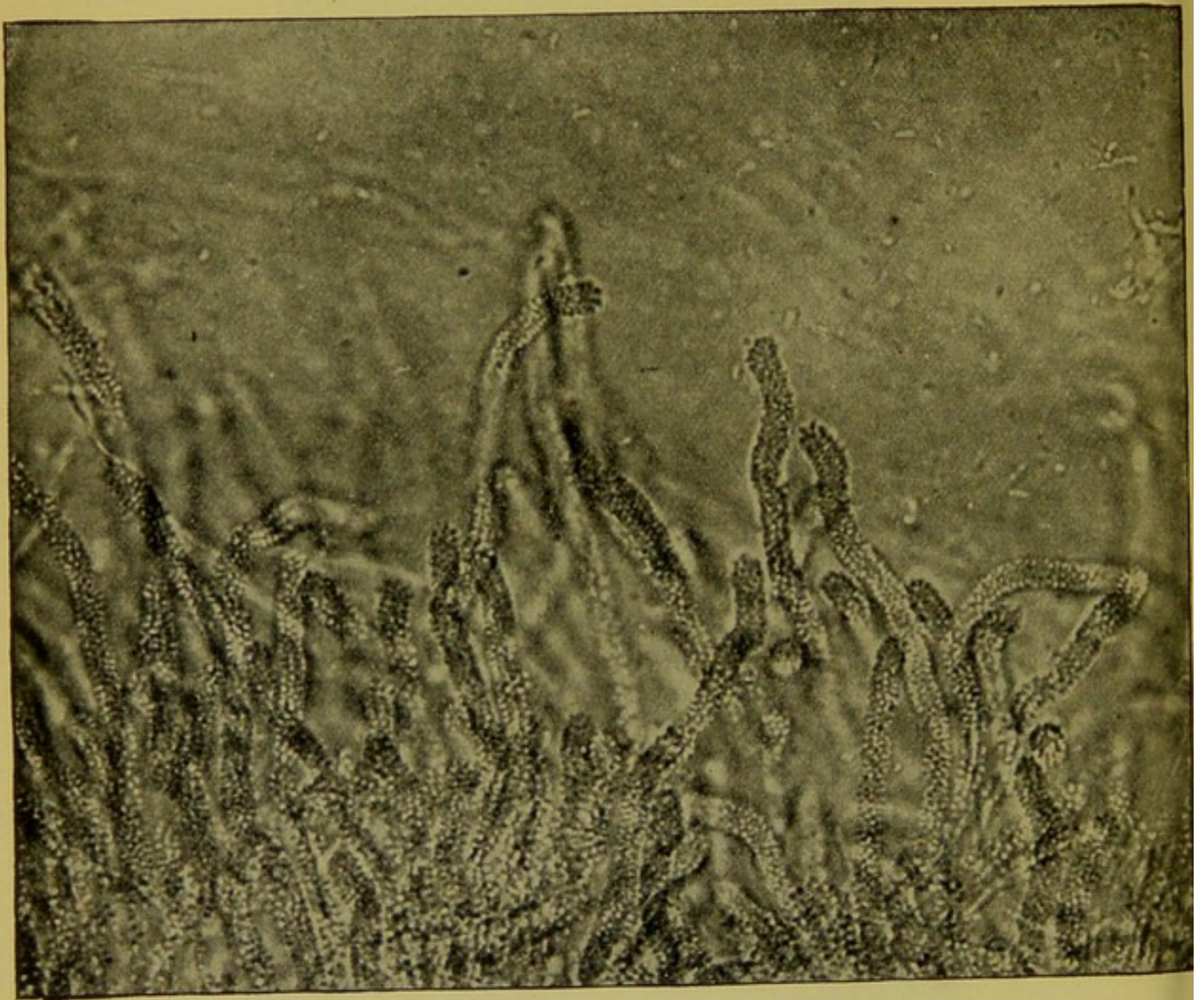
Budding of spores on the stems of leptothrix racemosa. (Williams.)

The effect is to produce an irregular, roughened surface of the enamel and to bring into view the structure of the rods (Fig. 301).

The gradual loss of cement substance unbinds the enamel globules, which are in turn dissolved and washed away, leaving a depression or cavity.

In the process of enamel dissolution the bacteria may enter the crevices formed by solution of the interprismatic cement substance and by repetition of the process gain access to the dentine (Fig. 304).

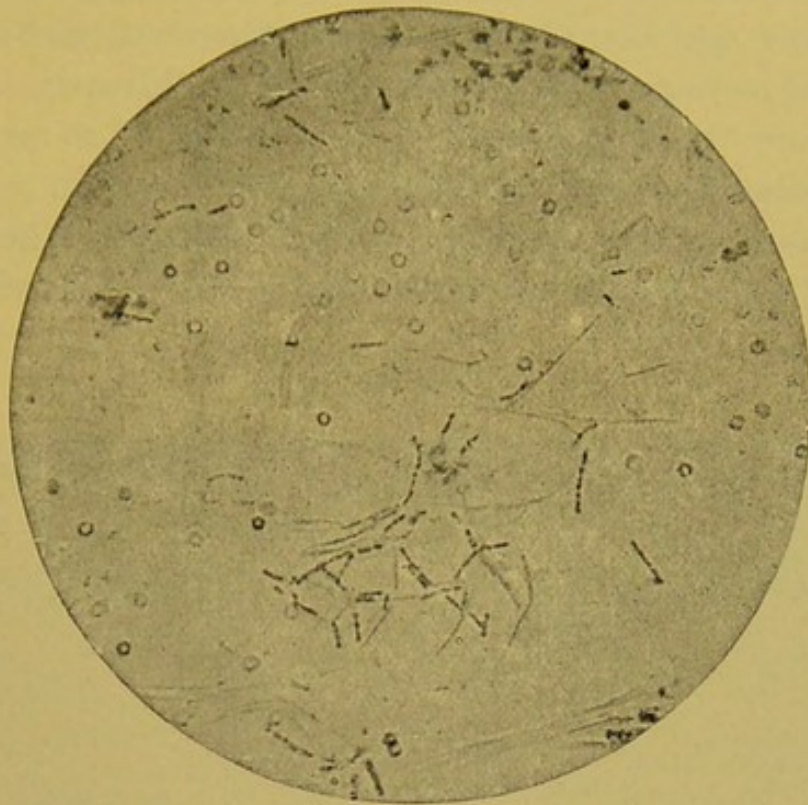FIG. 298.



Thick growth of *leptothrix racemosa* fructification heads from approximal surface of tooth, under high magnifying power. (Williams.)

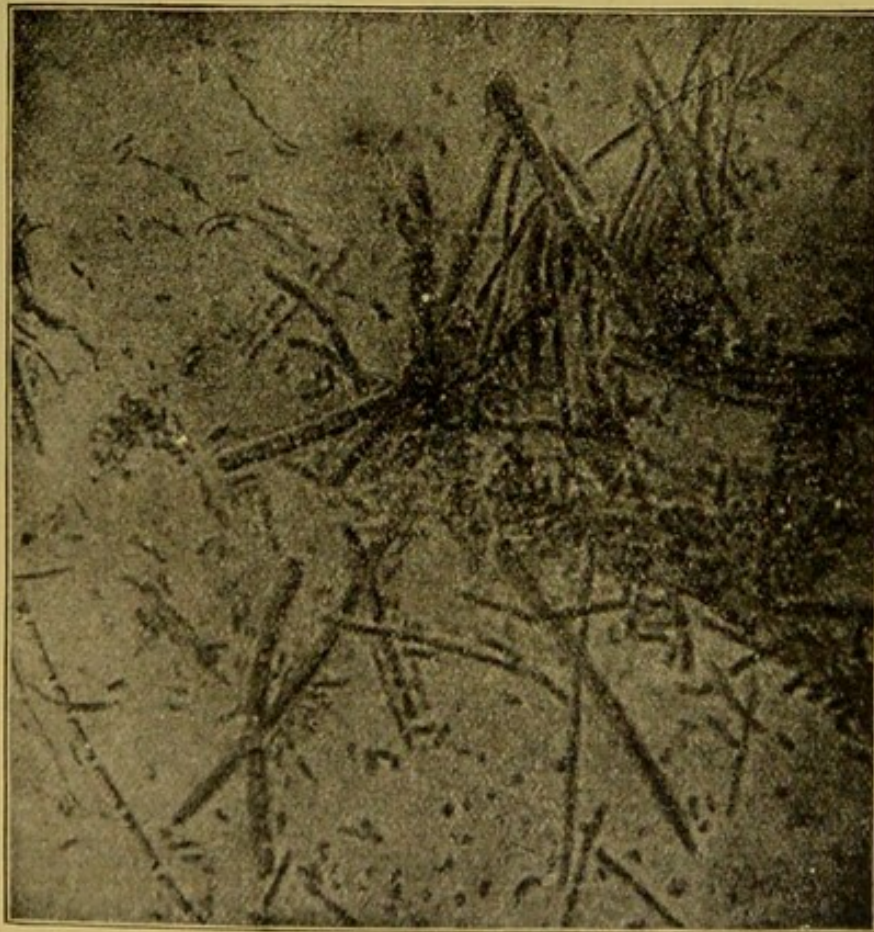The form of the enamel may be retained until and even after decalcification has reached the dentine. Clinically this is seen as a discolored spot, resisting the instrument until some force is used, when it rapidly breaks down.

FIG. 299.



A form of streptococcus found abundantly in mouths where very rapid decay of the teeth is in progress. $\times 750$. (Williams.)

FIG. 300.




Scrapings of micro-organisms from the approximal surface of a decaying tooth: shows the *leptothrix buccalis maxima* and the *bacillus buccalis maximus* of Miller. $\times 1500$. (Williams.)

It is also noted clinically and microscopically that the decalcification is deepest at a spot just above the point of contact, and less deep at points buccal or lingual, occlusal or cervical, to this spot, and still less at points more buccal or lingual—*i. e.*, it shades off to zero lingually, buccally, occlusally, and cervically (Figs. 296 and 305).

The dentine may in such cases be deeply affected. When the entire thickness of the enamel is penetrated and the dentine attacked, there is

FIG. 301.



Section through human enamel, showing first stages of caries—*i. e.*, solution of interprismatic cement substance. To be compared with Fig. 183. (Williams.)

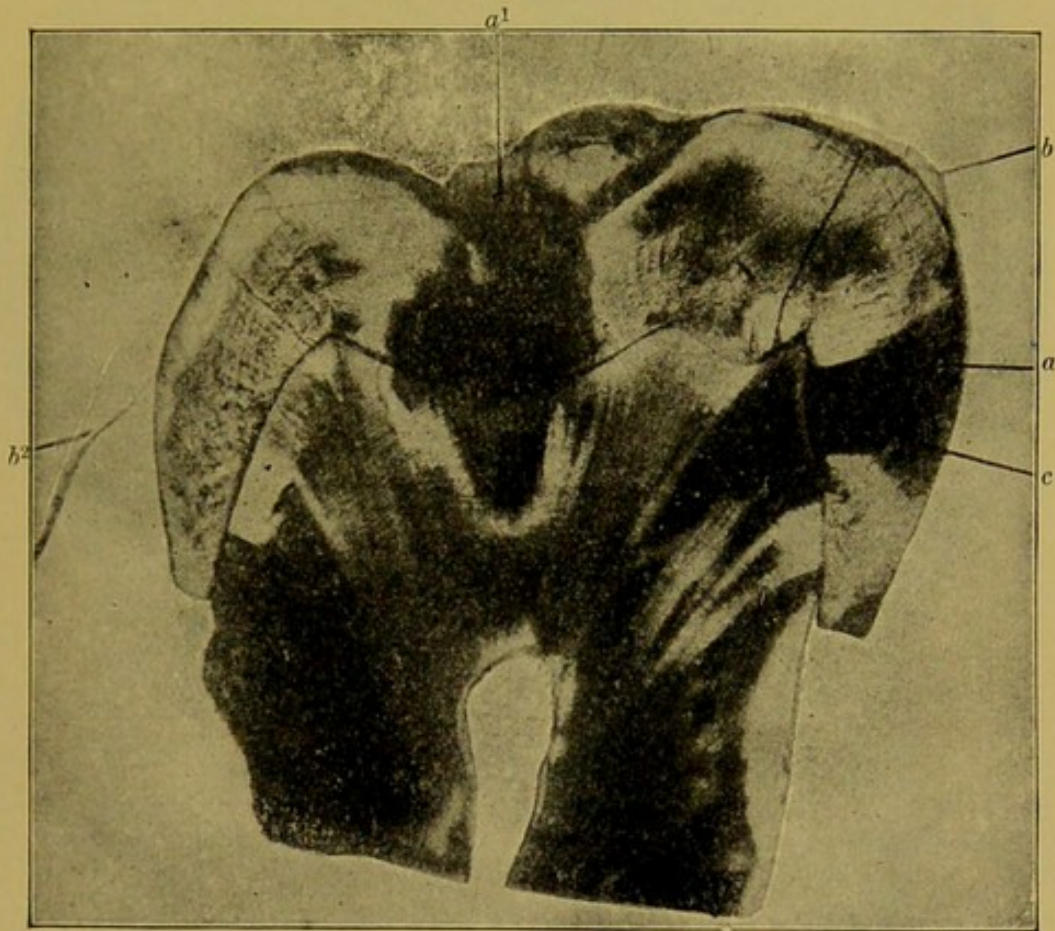
a change in the mode of progress of the decalcification, which proceeds along the line of union between the enamel and dentine, as well as directly into the dentine (Fig. 305); in this way the enamel is attacked from its dentinal side (Fig. 303). Bacteria growing in the spaces from which the interprismatic cement substance has disappeared cause detachment of masses of partially decalcified rods (Fig. 306).

In the ultimate breaking down of the enamel the rods first separate; the outlines of the several globules of which the rods are composed are

brought into plain view; next, the calcified plasmic strings noted in enamel formation become evident; and finally the bead-like masses upon these strings are left as the ultimate granular detritus of the enamel.

In cases of rapid enamel dissolution Williams found streptococci almost invariably present; and suggests tentatively that the variety of organisms may be the factor governing the rapidity of dissolution (Fig. 299).

FIG. 302.



Section of human bicuspid, showing commencement of caries: *a* and *a*¹, appearances caused in enamel and dentine by the acid of decay; *b* and *b*², shreds of a felt-like mass of bacteria raised from the surface of the enamel; *c*, a cavity. $\times 12$. (Williams.)

These are probably the streptococcus brevis of Goadby (micrococcus nexifer of Miller).

Williams found *S. pyogenes albus* and *aureus* and *sarcinea lutea* to be acid producers.

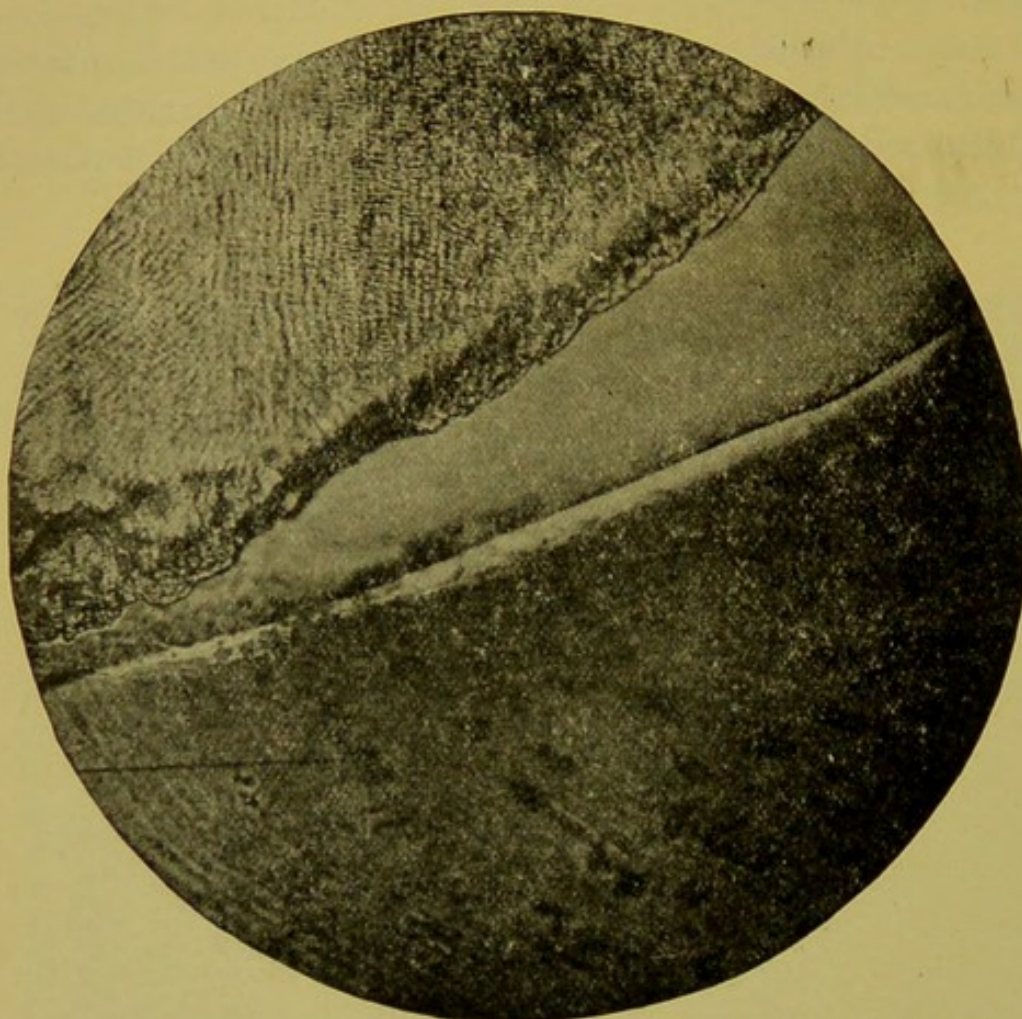
The large cocci and diplococci shown in Fig. 306 were always found in the secondary decay of enamel.

"In the direct caries of enamel the cavities are lined with leptothrix and thread-like forms" (Fig. 308).

"The leptothrix buccalis maxima and the bacillus buccalis maximus of Miller are nearly always found, the latter more sparingly" (Fig. 300).

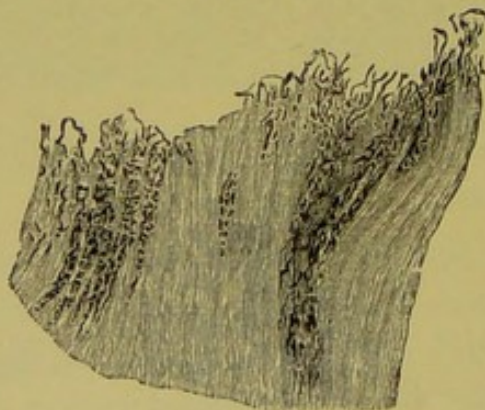
"Beneath the felt-like masses of thread forms and lying in contact with the decomposing enamel in direct decay, and also in deep cracks

FIG. 303.



Section of carious tooth, showing appearances of decay in enamel and dentine at the line of union of these tissues; the dark spots shown in the enamel and dentine are masses of micro-organisms. $\times 250$. (Williams.)

FIG. 304.



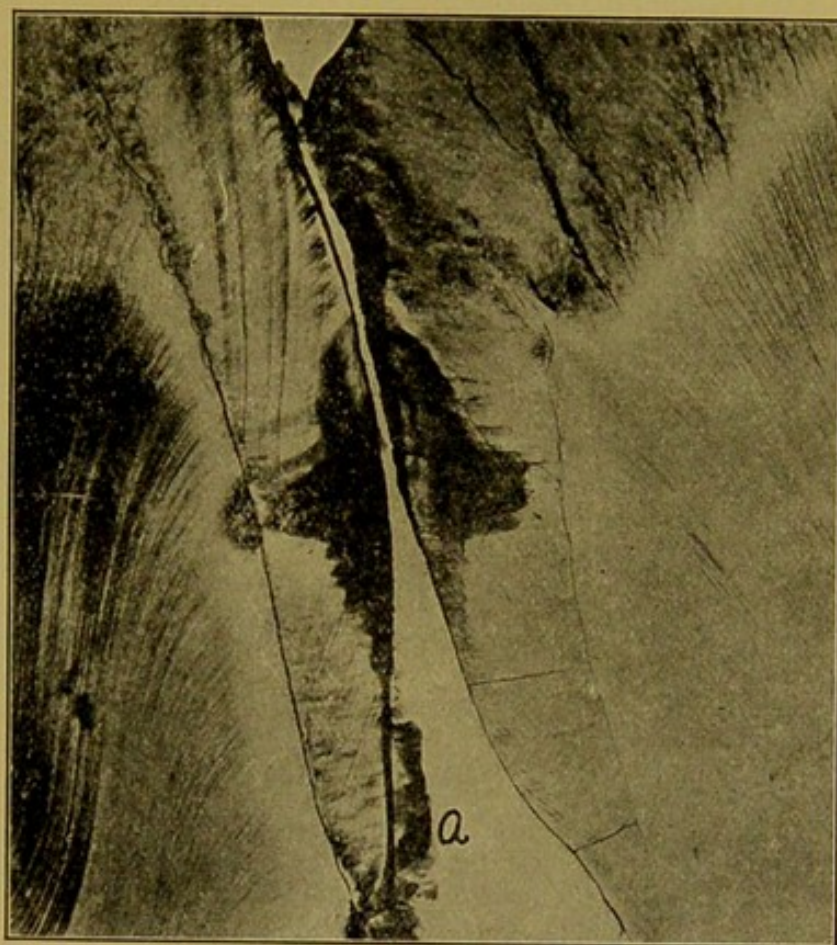
Penetration of bacilli between enamel prisms after solution of interprismatic cement substance. (Miller.)

and fissures in secondary decay, there is invariably found a short, thick bacillus, usually constricted in the centre."

Caries of Nasmyth's Membrane. Miller¹ demonstrated that the enamel cuticle may act as a breeding ground for many forms of bacteria which occupy it, forming a matrix which may retain minute particles of food, which in turn aid in acceleration of the progress of decay (Fig. 309).

Caries of Dentine. The bacteria after penetrating the substance of the enamel attack the dentine. This presents a different anatomical and chemical structure to be acted upon. Beneath the enamel the

FIG. 305.



Decalcification of enamel without loss of form: a, film. $\times 35$. (Miller.)

first layer of dentine is of a composition which permits the bacteria to rapidly spread laterally along this zone. They also enter the tubules of the dentine and penetrate by multiplication toward the pulp. A wedge-shaped area of decay is produced (Fig. 311).


In all cases decalcification precedes these invasions. At the periphery the tubules communicate freely by their lateral branches (Fig. 310), and the lateral spreading of the bacteria by multiplication is readily explained.

¹ Micro-organisms of the Human Mouth, 1890, and Dental Cosmos, 1900.

It is seen clinically in caries that a portion of the dentine is absolutely destroyed and removed, leaving within the tooth a "cavity of decay" bounded by dentine and enamel undergoing disintegration; beneath this lies dentine less affected, and beneath this sound dentine (Fig. 311). These phenomena require explanation.

The tubules of the decalcified dentine become packed for a distance with bacteria (Figs. 312 and 314). These probably act upon the organic

FIG. 306.

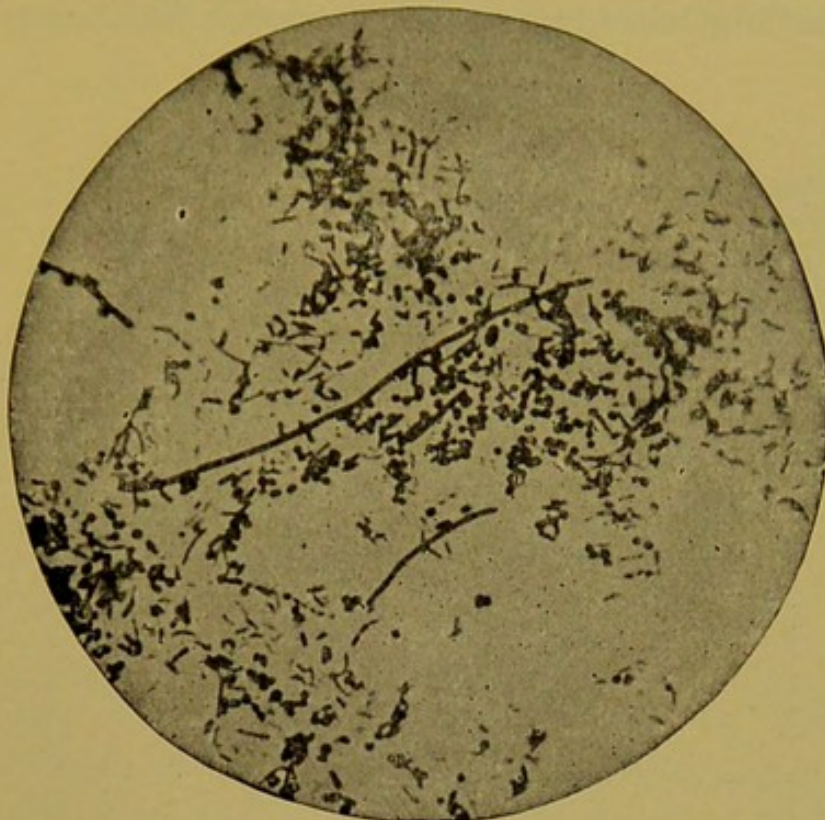


Cover-glass preparation from scrapings of white, opaque, decaying enamel: the cement substance between the rods is seen to be dissolved away, and the crevasses thus formed are filled with round and oval forms of micrococci and bacteria. Stained by the Gram method. $\times 450$. (Williams.)

matrix of the decalcified tubule walls. The internal pressure due to multiplication distends them so that the lumen is enlarged. At the same time the bacteria excrete a ferment or ferments which cause the wall at first to thicken. The dilatation and thickening together cause the compression of the decalcified intertubular substance, and the tubules

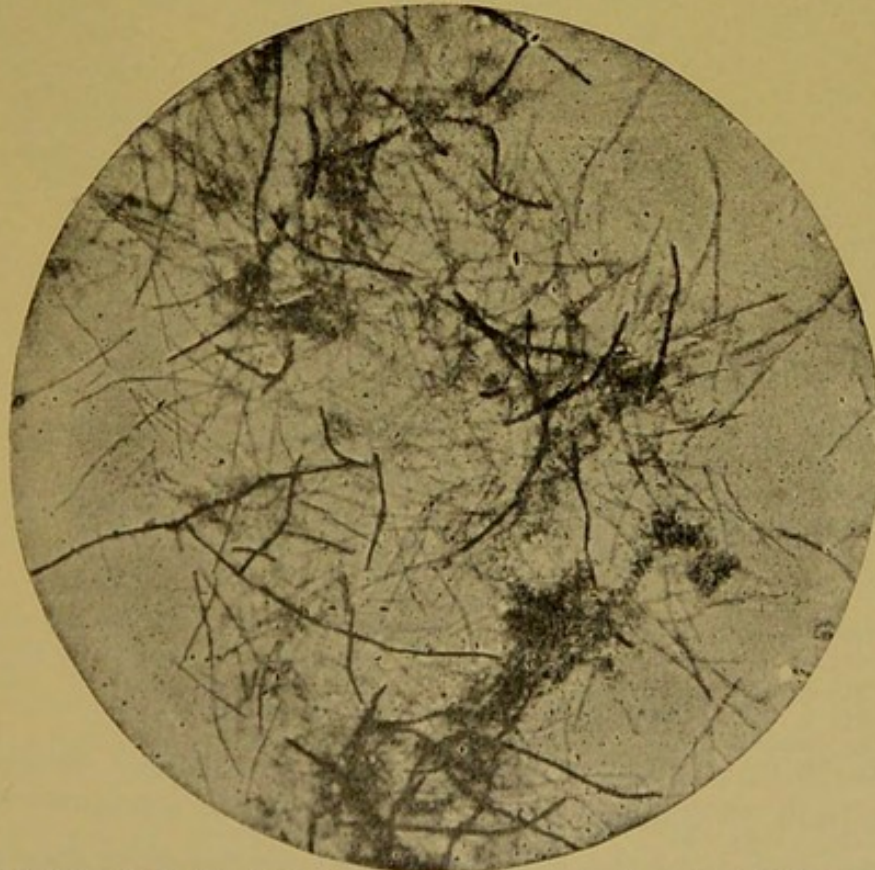
assume an hexagonal shape owing to the mutual pressure. The phenomenon is not a vital one, as it occurs in artificial caries (Miller). (Fig. 313.)

FIG. 307.



Various forms of micrococci and bacteria from decaying enamel. Photographed by Mr. Andrew Pringle from Williams' cover-glass preparation. $\times 1000$. (Williams.)

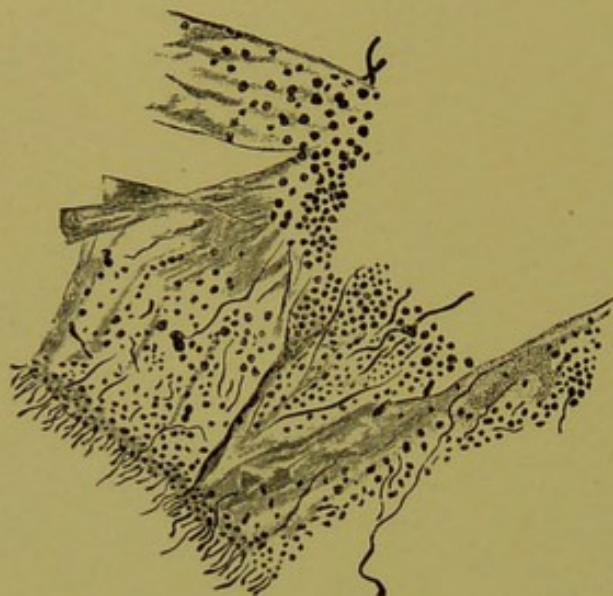FIG. 308.



Cover-glass preparation of scrapings from decay of enamel: shows leptothrix buccalis maxima and bacillus buccalis maximus of Miller. Stained by Gram method. $\times 850$. (Williams.)

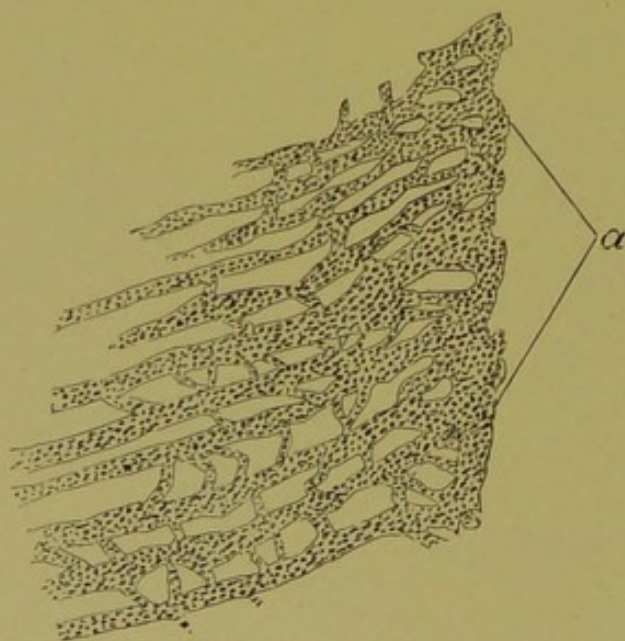
The bacterial ferment possesses a digestive or peptonizing power and begins to liquefy the inner surface of the tubule wall. As it does so the lumen is further increased and the bacteria fill the acquired space. Taking up carbohydrates lactic acid is produced, which combines with

FIG. 309.



Enamel cuticle permeated by bacteria. (1100 : 1.) (Miller.)

FIG. 310.



Carious dentine, stained with fuchsin to show micro-organisms. The section shows the condition of the tubules as filled with micro-organisms along the junction of the dentine with the enamel at *a*. The tubules are very much enlarged. ($\frac{1}{10}$ immersion objective.) (Black.)

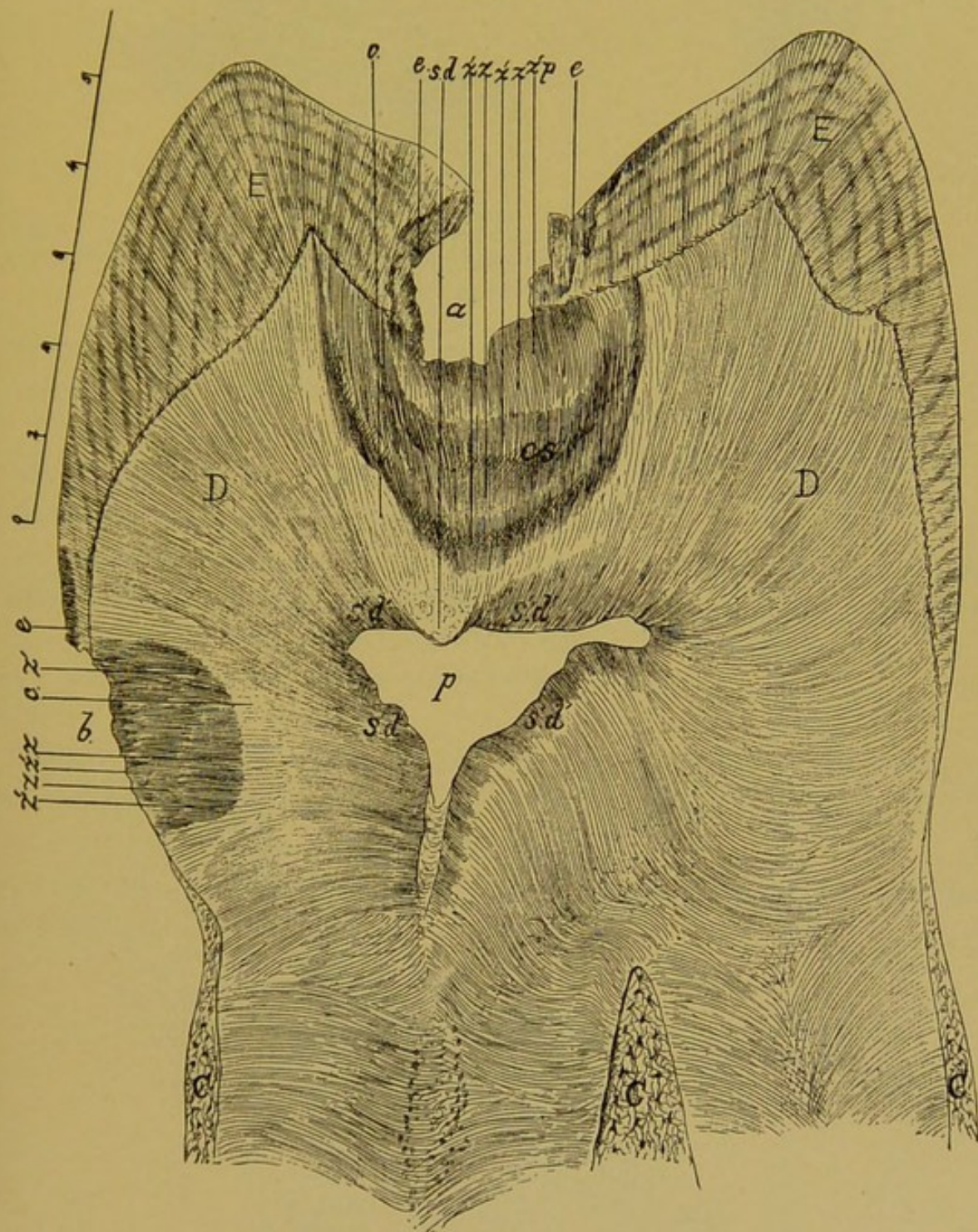
the calcium salts of deeper tubules and intertubular substance and prepares a path of decalcified tissue for bacterial advance (Fig. 314).

This combination of the acid with the calcium salts disposes of or neutralizes the acid, which, if accumulated to the strength of 0.75 per

cent., would cause the destruction of the bacteria (by their waste products). (Miller.) Calcium lactophosphate, calcium lactate, and magnesium lactophosphate are produced. (See p. 258.)

The bacterial ferments continue to digest the wall of the tubule

FIG. 311.



Longitudinal ground-section through the crown of an inferior molar of a negro: *E*, enamel; *D*, dentine; *C*, cement; *p*, pulp chamber; *a*, large decay, from the occlusal surface; *b*, small decay, from the mesal surface; *cs*, cone of septic invasion and discoloration; *e*, partially decalcified and discolored enamel around the carious cavity; *z*, dark cones; *z'*, clearer cones; *z'p*, oldest cones where putrefaction of the tooth cartilage begins; *c*, outer transparent zone, or zone of Tomes; *sd*, secondary dentine, caused by irritation; *sd'*, secondary dentine deposited by normal physiological process, recession of the pulp. This figure is drawn from a ground and polished section mounted in Canada balsam. (Gysi.)

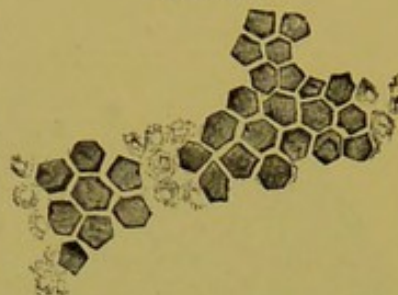
and a time arrives when they have penetrated its substance. The intertubular substance is then removed in like manner. The same process occurring in adjoining tubules as well, the entire dentinal

FIG. 312.



Carious dentine, showing invaded tubules and uninvaded but decalcified intertubular substance. (Miller.)

FIG. 313.

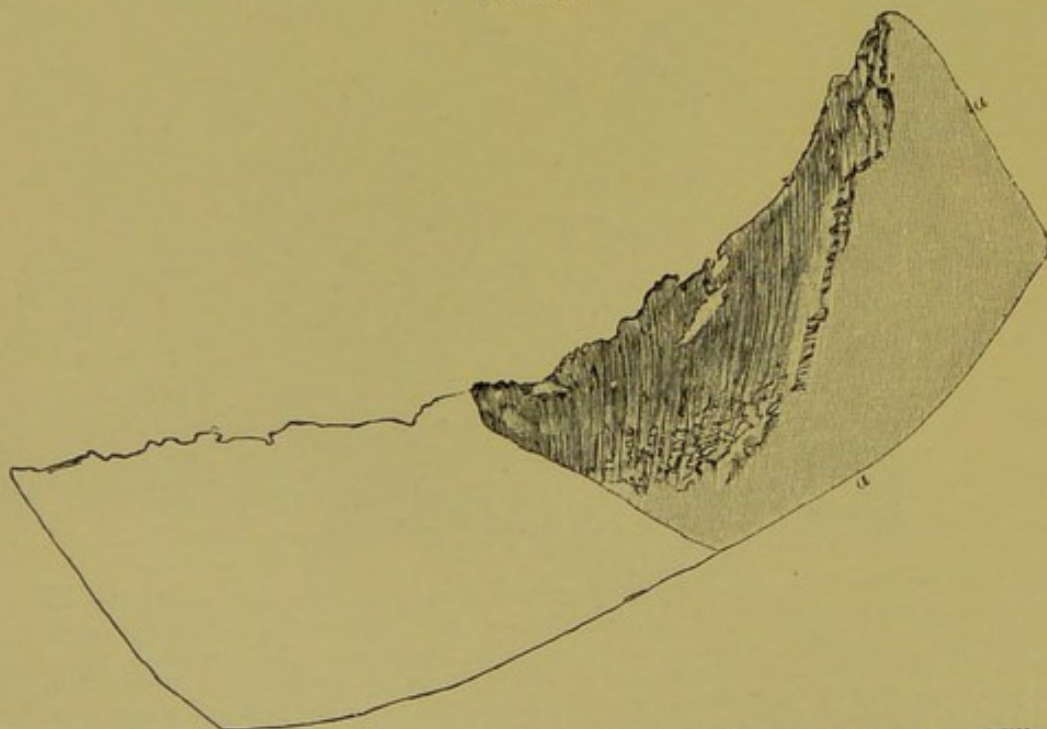


Cross-section of decayed dentine: the tubules through reciprocal pressure have assumed the shape of 5 and 6-sided prisms. (Miller.)

substance in the particular area at the cavity surface is destroyed—*i. e.*, liquefied and washed away (Fig. 311, *a*).

Occurring at a point beneath the general cavity surface, the bacteria in several adjoining tubules destroy their walls and the intervening intertubular substance, forming what Miller has called a "liquefaction

FIG. 314.

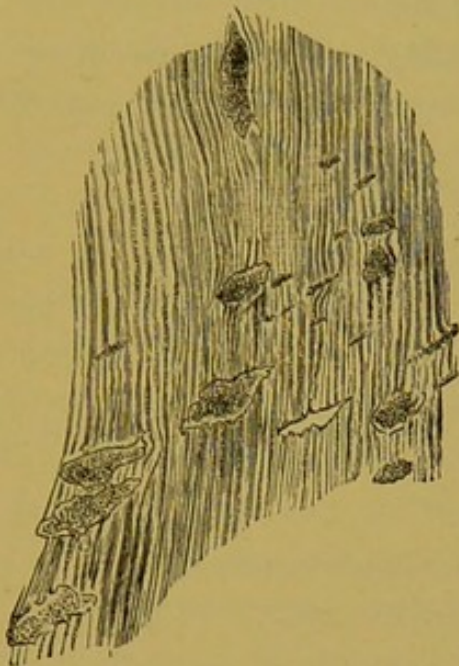


Section of decalcified dentine partly invaded by bacteria: *a*, uninvaded zone. (Miller.)

focus" (pl. foci). (Fig. 315.) This action proceeds until the enamel is undermined and the pulp is exposed.

As the enamel is undermined by the carious process the bacteria and their acids decalcify its inner surface, the process proceeding from within outward and termed "secondary caries" of enamel.

FIG. 315.

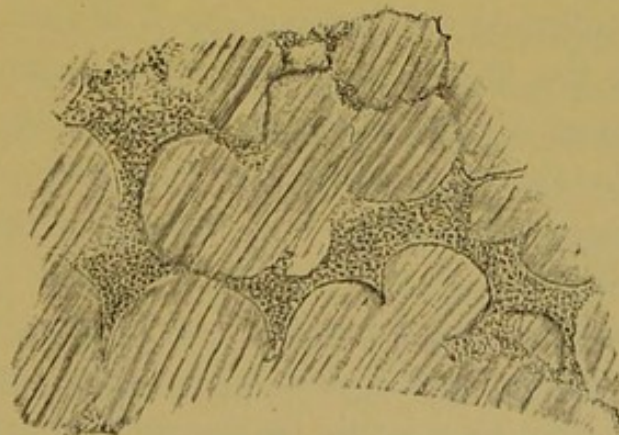


Liquefaction foci. (Miller.)

The enamel is thus weakened and at the same time deprived of dentinal support and breaks down under stress of mastication.

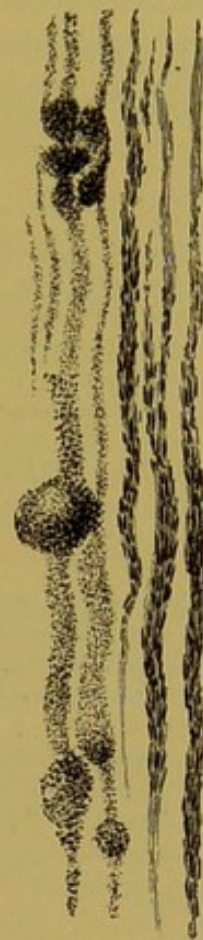Any interglobular spaces in the dentine being filled with transitional or uncalcified material like the tubule walls are rapidly invaded by the bacteria during their progress along the tubules (Fig. 317).

FIG. 317.



Interglobular spaces filled with bacteria. (Miller.)

FIG. 316.

Decayed dentine showing a mixed infection with cocci and bacilli. $\times 400$. (Miller.)

The character of the organisms in the tubules and the nature of the liquefaction seem to depend upon the particular germs present.

Miller has shown that in the deeper portions of tubules micrococci appear to predominate over the rod forms, which are also present; although one tubule may be filled with cocci and its neighbor with rod forms (Fig. 316). It is only in the more superficial layers that the thread forms are found in numbers.

Goadby¹ has done much interesting work in this direction and offers the following classification of bacteria found in decayed dentine:

BACTERIA OF DENTAL CARIES.

Acid-forming Bacteria.

Streptococcus brevis	.	.	.	}	Deep layers of carious dentine.
B. necrodentalis	.	.	.		
Staphylococcus albus	.	.	.		
Streptococcus brevis	.	.	.	}	Superficial layers of carious dentine.
Sarcina lutea	.	.	.		
Sarcina aurantiaca	.	.	.		
Sarcina alba (Eisenberg)	.	.	.		
Staphylococcus albus	.	.	.		
Staphylococcus aureus	.	.	.		

Bacteria which Liquefy Dentine (Decalcified).

None isolated as yet	.	.	.	}	Deep layers of carious dentine.
B. mesentericus ruber	.	.	.		
B. mesentericus vulgatus	.	.	.	}	Superficial layers of carious dentine.
B. mesentericus fuscus	.	.	.		
B. fervus	.	.	.		
B. gingivæ pyogenes	.	.	.		
B. liquefaciens fluorescens motilis	.	.	.		
B. subtilis	.	.	.		
Proteus Zenkeri	.	.	.		
B. plexiformis	.	.	.		

Goadby states that his experiments show that the bacteria which dissolve blood serum also digest decalcified dentine, while those which only liquefy gelatin do not digest decalcified dentine.

His experiments also indicate that of the bacteria found in the superficial layers of carious dentine some produce digestive enzymes, others acid fermentation, and others have both functions.

Choquet² has confirmed the observation of Miller, Vignal, Gallipe, and Goadby, that the deeper the portions of dentine examined the fewer species of fungi are found in the tubules, and explains it upon the ground that the anaerobic or facultative aerobic organisms in the outer layers advance into the deeper dentine because they are better suited to the conditions.

These exact findings are interesting as bearing out the general demonstrations of Miller; at the same time, Miller's experiment showing absolute dissolution by a single bacterium in pure culture is to be recalled.

¹ Mycology of the Mouth, and Dental Cosmos.

² Microbes of Dental Caries, Dental Cosmos, 1900.

Choquet¹ has shown that dental caries may proceed under fillings against sound dentine by the following experiment:

Artificial cavities were prepared in the incisors of a sheep. In these was securely sealed with cement a small particle of a gelatin culture of caries fungi applied on a sterilized platinum cap. Nine months later the dentine had become yellow, slightly decalcified, and the tubules penetrated by bacteria. This softened dentine was used to inoculate a portion of the medium originally used, and the species again cultivated.

Miller² estimated the relative loss of inorganic and organic matter in dentine during the process of caries by weighing and analyzing equal volumes of carious and sound dentine from the same teeth.

The carious dentine had lost about seven-ninths of its weight, twelve-thirteenths of its original calcium salts by decalcification, and two-fifths of its original organic matter by liquefaction of its substance.

Tube Casts. In the zone of decalcification in advance of bacterial invasion of the tubes are found rod-shaped bodies or shining granules, first described by J. Tomes. They occur in both natural and artificial caries, hence it must be inferred that their presence is not the result of a vital process.

The rods do not dissolve in organic acids, but dilute sulphuric acid quickly dissolves them. They are unaffected by alcohol or chloroform, a proof that they are not composed of fat. Miller regards them as probably calcic formations against the tubule wall as a cast of the wall, and which become loosened when enlargement of the tubule occurs. They have a tubular structure, are brittle, and may contain a central, thread-like filament which may possibly be the remains of a dentinal fibril. Bacteria may surround them, but do not enter them. The granules are probably broken rods.³ The data point toward a probability that the rods are composed of calcium lactate and calcium lactophosphate, the result of a combination of the lactic acid with the calcium salts of the dentine. The resultant salt is probably deposited as a tube cast, as suggested by Miller. Polariscopic experiments should be competent to settle the question.

The Transparent Zone. Around the zone of decalcified uninfected dentine appears a zone of dentine more transparent than the surround-

FIG. 318.



Tube casts.

¹ Microbes of Dental Caries, Dental Cosmos, 1900.

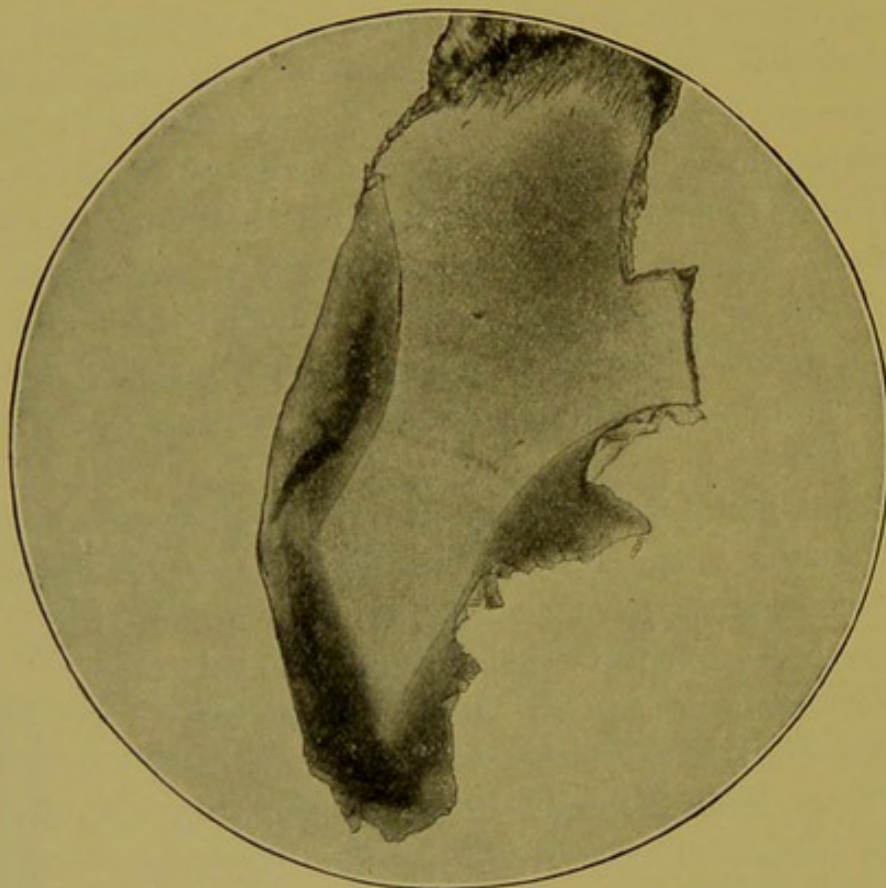
² Micro-organisms of the Human Mouth.

³ Miller

ing normal dentine. The zone extends from periphery to periphery around the cone of carious dentine (Fig. 311, *c*). The tubules in this area contain granular matter not seen in normal dentine nor in the dentine of dead teeth in the same situation.¹

Tomes and Magitot both regarded the transparency as an attempt made by nature to impede the progress of caries. Walkhoff regards it as due to a sclerotic action, the fibrillæ upon stimulation producing intercellular substance (tubule wall) at their own expense and primarily

FIG. 319.



Section from a lower incisor worn on a plate: extensive decay without increase of transparency.
× 15. (Miller.)

of their offshoots. Black regarded it as the earliest stage of decalcification. Miller advanced the following data:²

1. Transparency indicates increased homogeneity as opposed to the heterogeneity of normal dentine—*i. e.*, the coefficients of light refraction are brought nearer together.

2. It occurs in living dentine only and is not found in natural teeth mounted on plates and decayed in the mouth, nor in secondary caries of dentine from the pulp cavity to the periphery, and is, therefore, a result of vital action. (Compare Figs. 311 and 321 with Figs. 319 and 320.)

¹ Miller.

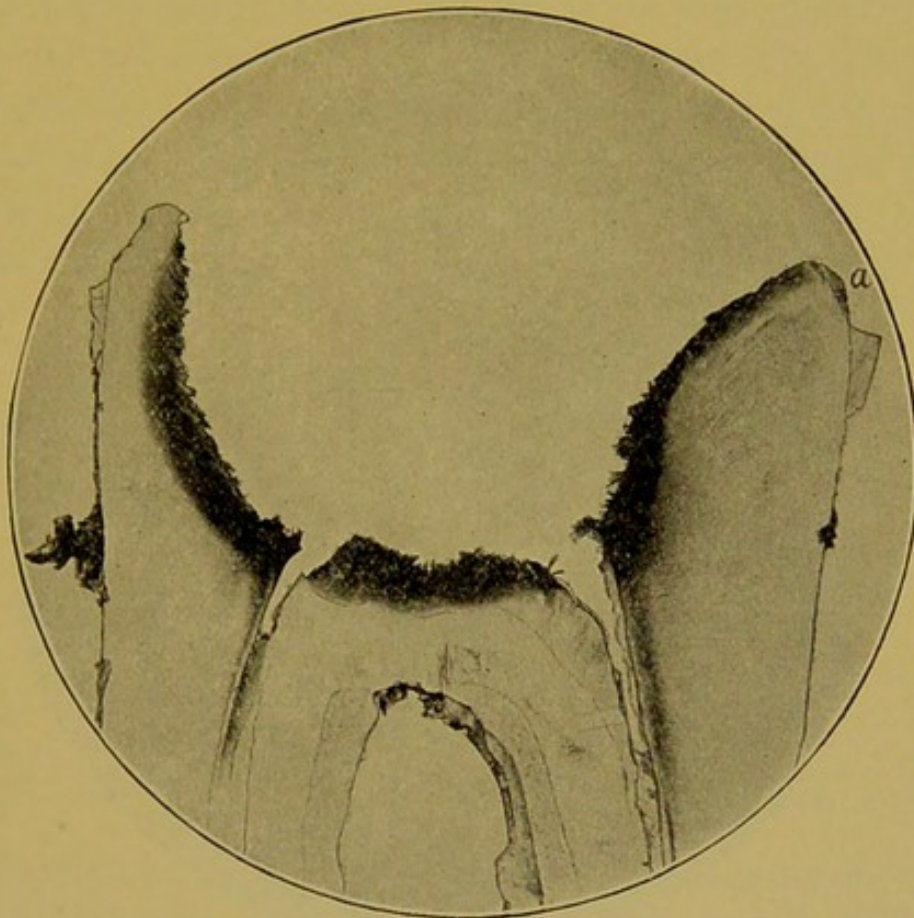
² Micro-organisms of the Human Mouth.

3. The tubules have their lumen lessened in diameter in the transparent areas, an agreement with the position of Walkhoff.

4. Secondary dentine may accompany the process in contiguity with the area; moreover, secondary dentine is translucent. It indicates a constructive excitation of the odontoblasts of which the dentinal fibrils are prolongations (Fig. 311, *Sd*).

5. Chemical analysis proved that no lime salts had been lost, and it was pointed out that a gain in the percentage of salts was unnecessary,

FIG. 320.



Secondary caries of dentine advancing from pulp chamber and therefore occurring after death of the pulp. Absence of transparency. $\times 15$. (Miller.)

as new dentine is necessarily composed of organic as well as inorganic matter, wherefore the analysis would not necessarily vary from that of normal dentine.

6. It is found in connection with abrasion of human teeth in which the activity of acid may possibly be an open question, and it also occurs in the worn teeth of dogs, the saliva of which is strongly alkaline.

Miller states that opacity may follow or be associated with transparency.¹

The natural conclusion is that the transparency is a form of tubular

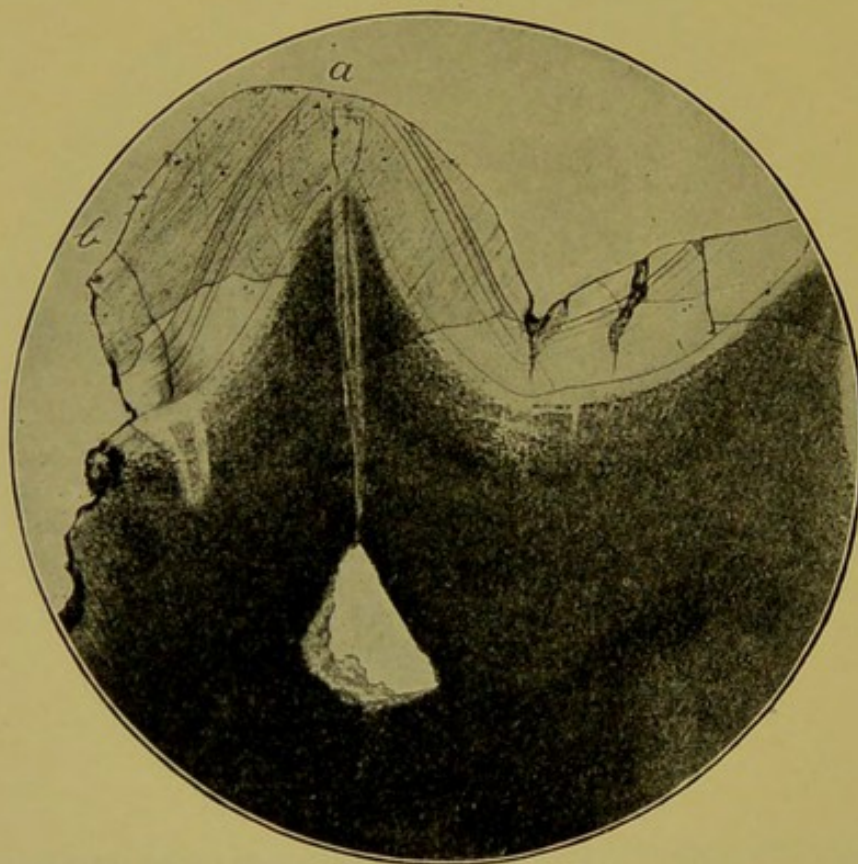
¹ Dental Cosmos, April, 1903.

calcification, and that it impedes the progress of caries; that it does not succeed, as a rule, is due to the overwhelming action of the bacteria.

In cavities from which the walls are broken away, freely exposing the carious dentine to mastication, the carious dentine and its contained bacteria may be removed by friction (Fig. 329).

In the transparent area the tubules become obliterated; a polished, discolored surface results resembling in degree an abraded surface. This process is called "eburnation" and is really tubular calcification (which see). In the same tooth a more sheltered border of this spot

FIG. 321.



Transparency resulting from cracks in the enamel at *a* and *b*. $\times 20$. (Miller.)

may be undergoing the carious process. Miller records cases of badly decayed teeth in which the process ceased spontaneously and the dentine became hard and smooth.

Pigmentation in Caries. Pigmentation occurs in caries possibly from extraneous substances entering the carious area, possibly from the substances formed during putrefaction.

The slower the progress of the decay the greater the discoloration. The colors vary from light yellow to reddish-brown, dark brown, and black.

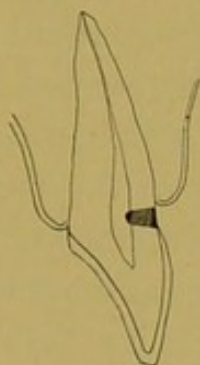
The color is, as a rule, darkest upon the outside of the carious

dentine, but the pigment may extend through large masses and be found staining dentine beneath the caries hard enough to leave *in situ*. As a rule this is not the case.

Black suggests the possible formation of sulphides. Miller has found iron almost constantly present in carious dentine. The discoloration of dentine does not seem to be necessarily due to the carious process, as it may be seen in areas of abrasion. In a specimen possessed by the editor a limited cervical caries caused a growth of secondary dentine and an area of tubular calcification. From the pulpal surface of the secondary dentine to the area of caries extends a sharply defined area which has a flesh-rose color (Fig. 322). Many areas of secondary dentine due to abrasion are stained a dark brown.

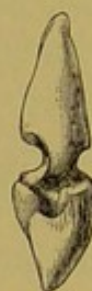Artificial caries produced in teeth placed in a mixture of bread and saliva and the mixture constantly renewed was white. If putrefaction was allowed to occur, discolorations ensued (Miller).

FIG. 322.



Cervical caries associated with secondary dentine. Area pigmented.

FIG. 323.



Caries of cementum and dentine completely encircling the tooth.

The discolorations of carious dentine may be due to the action of chromogenic bacteria. Miller isolated from the mouth an organism which he named *bacillus fuscans*, and "which, cultivated on the surface of nutritive agar-agar, in a few weeks imparts to the medium a yellowish-brown color, which gradually darkens and extends deeper into the substratum as the age of the culture increases."

It is significant that the three acid-forming organisms found by Goadby in the deep layers of carious dentine do not form pigment in their artificial media. (See p. 308.)

Caries of Cementum. Caries of cementum occurs when the gum has receded, exposing the cementum to the fluids of the mouth. As a rule a triangular depression exists bounded by the thickened gum margin, the cementum, and the enamel. This favors the collection of the bacterial plaques and caries follows. The gum may be much

receded, yet no caries occur. As a rule, however, recession and uncleanliness frequently assure its presence. Especially is this true in cases of general recession in aged or debilitated persons.

The path of bacterial invasion after decalcification is by way of Sharpey's fibres to the lacunæ and canaliculi; later the dentine is invaded as in the crown. Frequently the form of the cementum is largely retained while the decalcification is deep (Figs 322 and 323).

CLINICAL HISTORY OF CARIES.

The clinical history of dental caries records the observable phenomena associated with its inception, progress, and termination.

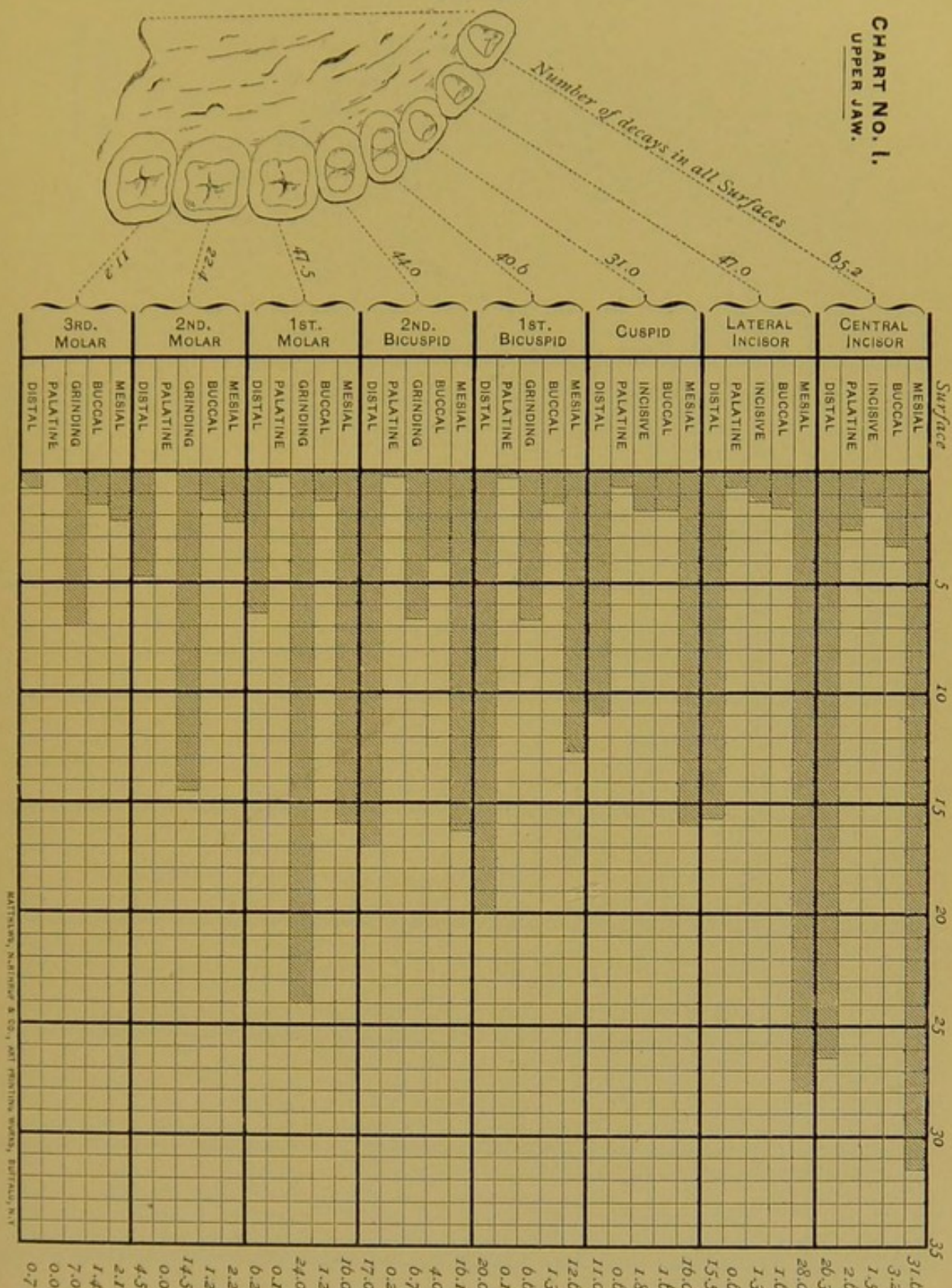
Inception of Caries. Caries begins, after the manner described in the pathology, at favoring spots. As a rule the occlusal fissures of the molar teeth are first decayed, the first molars being often carious in this situation before fully erupted. Uninformed parents usually consider this tooth a temporary one and frequently neglect it. It, moreover, has often seriously defective fissures which afford lodgement for gelatinous plaques, which seem to be readily formed because of the unhygienic state of the temporary teeth, which are frequently carious. Not infrequently a cavity is produced on the mesal surface of this tooth by a carious condition of the distal surface of the second temporary molar. In other mouths both teeth are affected alike, owing to the nature of the approximation. The relative liability of the various surfaces of the different teeth to caries may be averaged for a great number of persons, but tables drawn from clinical cases may have little application to one particular individual, as peculiarities of local predisposing causes and personal habits modify the inception. Nevertheless such tables are exceedingly interesting as showing a general relative liability.

Charts have been made by Black which explain themselves (Figs. 324 to 327). The figures given for the buccal surfaces of the third molars seem rather lower than those I would feel warranted in giving; certainly after adult age caries frequently occurs.

The lower anterior teeth are the last of all to be affected, and it is common to see the six lower anterior teeth free from caries years after all of the other teeth have been lost. This is attributable to the constant motion of the saliva, the presence of calculus, and to the mechanical effects of tongue movement, lip movement, and mastication.

In the temporary set the molars decay much more frequently than

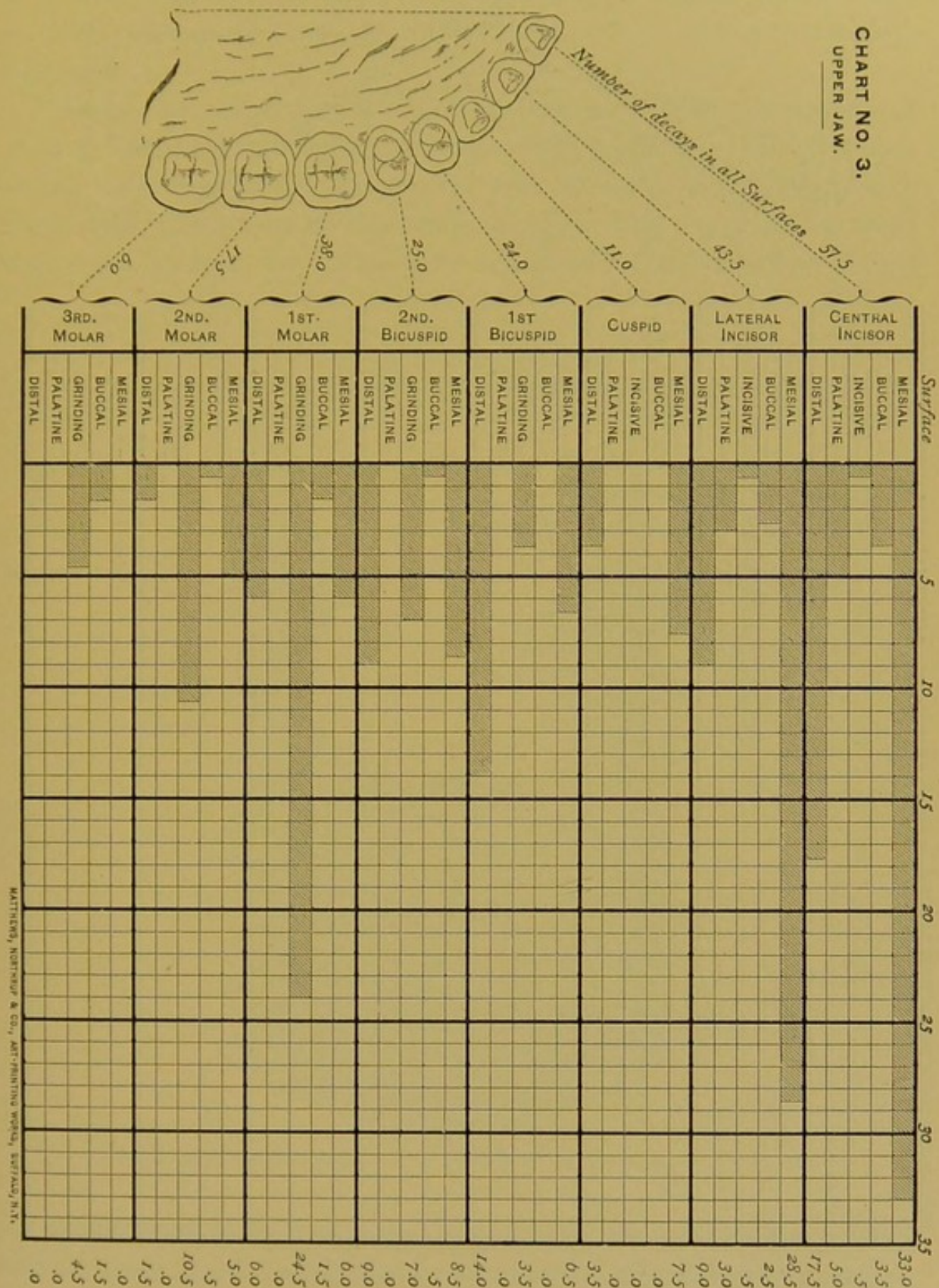
FIG. 324.

CHART NO. 1.
UPPER JAW.

DESCRIPTION OF CHARTS.

These charts represent the number of carious cavities observed in *one hundred persons*, and the position of these cavities on the individual surfaces of the teeth. There are five columns of squares devoted to each tooth of one side of the mouth, representing the five surfaces as shown on the left hand. The number of cavities in the surface represented is shown by the number of squares darkened, so that the effect of the diagram as a whole gives a striking picture of the frequency of decay in the individual surfaces of the several teeth. On the right the percentage, or the number per hundred persons, is given in figures calculated to the first decimal point. On the left the percentage of cavities in the individual teeth for all surfaces is given in the same

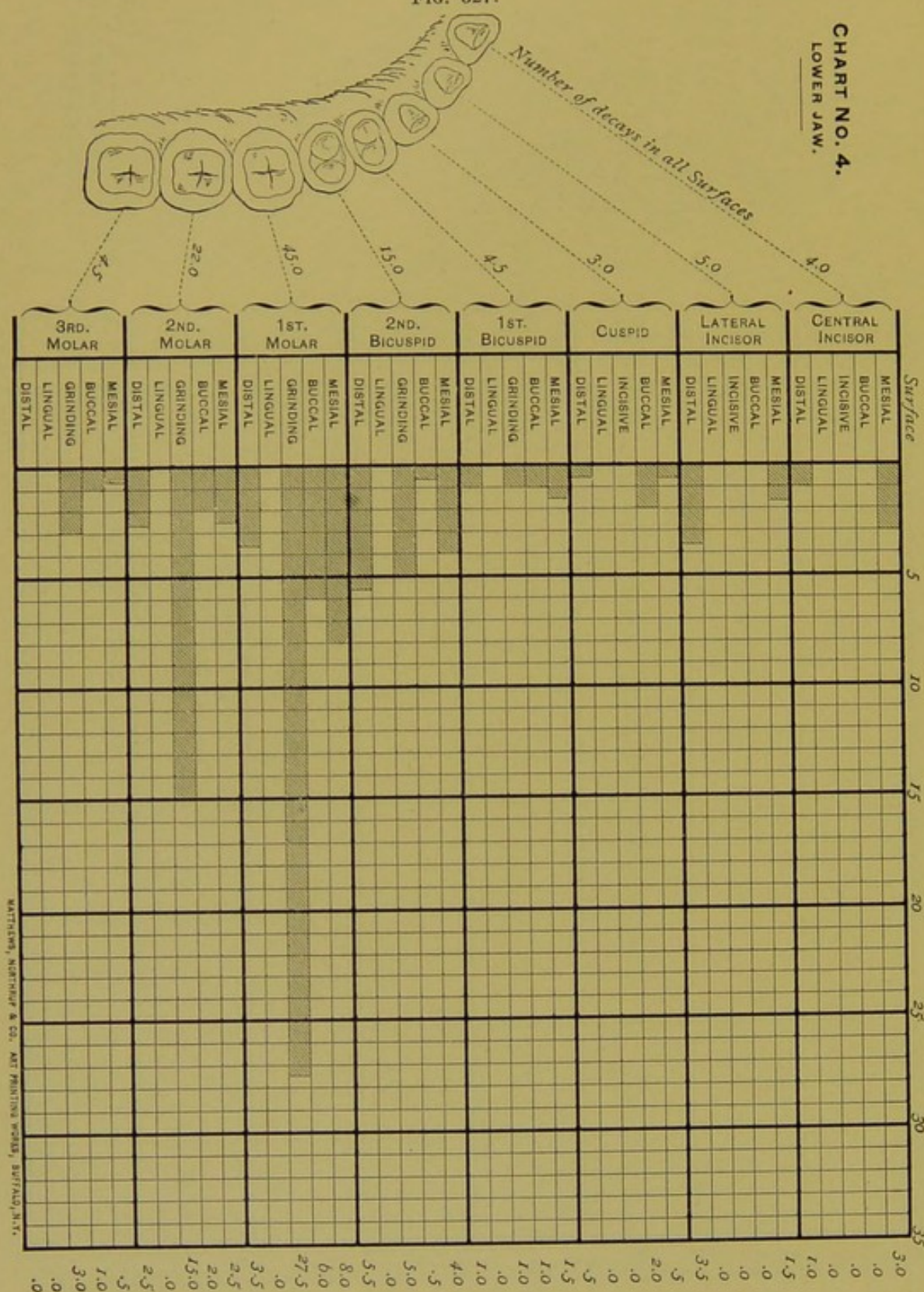
FIG. 326.

CHART NO. 3.
UPPER JAW.

the incisor teeth, partly because longer retained and partly because of the width of their approximations. The pulp is readily exposed because of its relatively larger size.

Proximal cavities in the anterior teeth are frequently more broad than deep and present problems of anchorage.

FIG. 327.

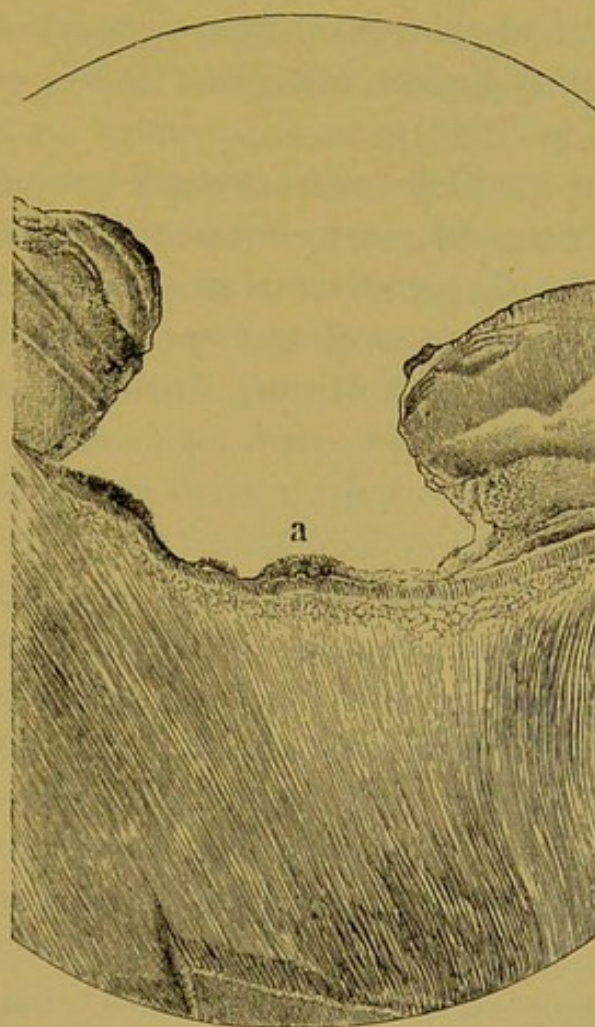
CHART NO. 4.
LOWER JAW.

Rapidity of Progress. The rapidity of progress of caries depends upon the intensity of the action of the exciting cause, the structure of the tooth, and the nature of the vital resistance offered. The exciting cause will act most intensely in mouths ill cared for and containing much carbohydrate debris, and these conditions being equal enamel

of poorer organization and presenting a greater degree of solubility, in teeth presenting broad approximations, will be the more rapidly destroyed.

Williams has expressed the opinion that, as a rule, the process of enamel destruction occupies a considerable period of time, a fact which may account for the general lack of caries in the temporary teeth until about four or five years of age. The decalcified enamel may retain its form for a time after dentine decalcification has begun.

FIG. 328.



Caries undermining enamel: *a*, masses of bacteria lining the cavity. $\times 50$. (Miller.)

An opaque spot, often discolored, is seen upon the tooth and is readily broken down by an instrument before dentine decalcification occurs. If the approximating tooth be extracted the carious process may cease, owing to the removal of the bacterial plaque or a lack of food supply (retention). This result may not follow if the dentine has been invaded before the extraction.

After enamel destruction at a limited area caries progresses along its inner side and penetrates the dentine. The enamel is undermined.

The extent of cavity orifice is no certain guide as to the depth of penetration.

Cases are frequently observed in which the only external evidence of caries in a molar or bicuspid is a white or bluish-black line marking the fissure, and yet the dentine may be deeply and widely penetrated (Fig. 329, *A*).

As a rule, however, as the cavity in the dentine enlarges the enamel at the orifice becomes disintegrated so that the orifice is enlarged and more food débris enters to accelerate the process (Fig. 328). A deep cavity may thus be formed before the patient is objectively or even subjectively aware of its existence. After a time the occlusal enamel boundary of the cavity breaks down and food is even more readily admitted.

It has been noted that if the enamel break away in such a manner as to expose the carious dentine to the friction of food masses which are not retained and to the access of saliva, the progress of the caries is delayed and in some cases ceases altogether. The process of eburnation is set up. (See Transparent Zone and Tubular Calcification). The

latter phenomenon, however, is rarely observable except in teeth of a high grade of organization (Fig. 329, *B*).

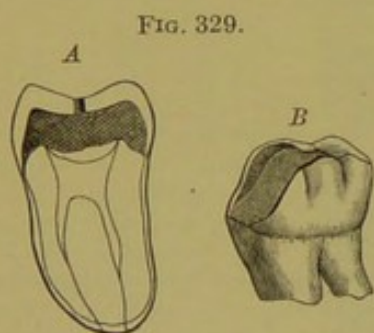


FIG. 329.

Caries may progress rapidly for a period, and then receive a check to its progress. Teeth previously free from the disease may suddenly fall victims to its rapid and widespread progress.

No doubt, in many of these cases there are removed from or added to the local oral conditions constitutional influences which deter or favor the local development of caries, producing bacteria.

The dentine of pulpless teeth is more rapidly invaded after enamel decalcification than that of vital teeth, owing to the absence of vital resistance. This condition does not necessarily apply to the enamel of pulpless teeth.

While caries appears at all ages from childhood to old age, its ravages are most pronounced and its progress most rapid during the period of adolescence and early maturity. Its effects are most marked between the ages of eight and twenty-five years. As a rule, a denture which remains for twenty-five years unaffected by caries remains unaffected or but slightly affected to an indefinite age. To be sure, this implies two conditions: first, that the active causes of caries have

been in but slight evidence; and, secondly, that the denture is of the highest order. The classes of denture which escape are perfectly formed and symmetrically arranged teeth, in the mouths of patients who lead sanitary lives, who masticate vigorously, and who escape other diseases.

Caries beginning at the junction of the cementum and enamel of the teeth has a somewhat different clinical history from that noted when its occurrence is in other situations. Its progress is subject to great variations. In any of the catarrhal conditions or atrophic conditions of the gum which lay bare the neck cementum, caries usually occurs. It occurs also as a process secondary to mechanical abrasion and erosion of the teeth. Teeth affected by erosion, however, as has been pointed out, are commonly exempt from dental caries.

The Terminations of Caries. After the pulp is exposed it sooner or later becomes inflamed and hypertrophies or dies. In the latter case putrefaction results, which for a time may exert a restraining influence upon decay, but not for a long time.

Masses of food freely enter the pulp cavity and caries proceeds in the dentine from within toward the periphery. This is "secondary caries" of dentine, and, occurring in dentine without vitality, no transparency results (Fig. 320). Notwithstanding, caries at this stage proceeds rather slowly, particularly if the crown be much broken down. The result of secondary caries is a hollowing out of the dentine of the root, and finally a decalcification of the cementum which may persist for some time as a thin, elastic wall. Finally this is destroyed either at the occlusal periphery or caries causes penetration to the pericemental tissue. This may occur laterally or through to the bifurcation of the roots. In either case it is called "perforation by caries." Into this perforation the pericemental tissue may become protruded by hypertrophy and the condition of fungous gum be established. Following the breaking down of the crown, the blood pressure in the pericementum begins an extrusive process, the pericementum becomes thickened, and the tooth is somewhat loosened.

Decay of the root face and breakage of the cemental margins proceed simultaneously with the extrusion until finally but a small discolored bit of the root end lies upon the surface of the gum, from which it is removed by some slight force or is extracted.

The entire process of caries in a tooth may thus extend over a period of from ten to twenty years.

At times the extrusive force pushes a root up sidewise, particularly

when the tooth has been tipped over before the loss of the crown. It may thus be retained in position and attached upon its under side for some time. The upper side may be polished by abrasion. The exposed end of a root undergoing extrusion is also sometimes made smooth by abrasion. A bit of root left *in situ* after breakage during extraction usually undergoes the same process of extrusion, but may not decay until it comes under oral influences. Usually a fistula leads to such a root, but very rarely the gum may heal over it.

Such a root may at any time become the source of apical abscess or of an intractable neuralgia.

CHAPTER XIV.

DENTAL CARIES: DIAGNOSIS, SYMPTOMS, AND PROGNOSIS.

HYPERSENSITIVE DENTINE AND ITS THERAPEUTICS.

Diagnosis of Dental Caries.

THE diagnosis of dental caries is made through both objective and subjective symptoms. The signs are the existence of cavities and of softened areas, directly visible or made evident through instrumental means. The symptoms are pains of several degrees of intensity. The nature and intensity of the pains furnish a guide to the depth of the carious invasion, and but an indirect indication of the location of the disease.


Diagnosis by Objective Symptoms. The presence of the markings of superficial decay, decalcified surfaces, or cavities may often be detected at a glance or be seen reflected in a mouth mirror. Opacity of enamel is usually due to its superficial decalcification or caries beneath it, though at times a malformation may exist. The discoloration or opacity about a fissure should excite suspicion of caries. In the routine examination for cavities, sharp, finely pointed explorers bent at various angles are to be passed over all the surfaces of the teeth. If the enamel at any point admit the point of the explorer, caries is usually present. Fissures are sometimes deceptive in this respect. A good rule is to adjudge the presence of caries when the point catches slightly as removed.

In the search for proximal caries great care is required, explorers with very short points being often necessary. Frequently a cavity may only be discoverable from one point of access. In the absence of evident cavities, some force should be applied to detect softened spots of enamel.

Unwaxed floss silk passed over carious surfaces indicates a rough surface by fraying. It may, however, at times pass readily over a cavity easily detected by instruments; so that it is not absolutely reliable as a test.

The strong light of an electric mouth lamp transmitted through the teeth exhibits a cavity as an opaque spot outlined upon a pinkish

FIG. 330.



Explorer for caries.
(Jack.¹)


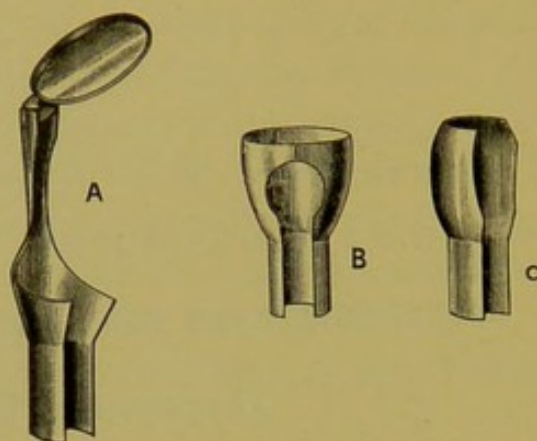


FIG. 331.



Dow electric lamp for mouth illumination with reflectors. Reflector *A* is jointed to vary the angle of reflection. Reflector *B* is for illumination of the fauces. Reflector *C* is for lateral illumination. (Jack.²)

background. It not only permits an easy diagnosis, but also affords evidence of the depth of penetration. Mechanical separators or wedges are at times necessary to press apart contiguous teeth sufficiently to admit exploring instruments.

The necks of the teeth should be examined with sharp points to note any softness of the tooth tissues. The margins, particularly the cervical and neighboring margins, of every filling should be explored to test the integrity of the junction of filling and tooth or any excess or deficiency of filling material.

The examination may be conducted by one of two systematic methods. In one method the occlusal faces of all the teeth are first examined in one survey, then the interproximal spaces, and, lastly, the buccal and lingual surfaces of the teeth. In the other method every portion of each tooth is examined, beginning with a central incisor or terminal molar, before passing to the adjoining tooth.

¹ American Text-book of Operative Dentistry.

² Ibid.

Diagnosis by Subjective Symptoms. Complaints by patients that salt, sweet, or acid substances taken into the mouth cause unlocalized or partly localized pain indicate exposed and hypersensitive dentine or pulp exposure. Such complaint is to have due consideration.

Pain produced upon mastication has either the same significance or is a symptom of pericemental irritation. Apart from its character as a symptom of caries, hypersensitive dentine is best treated of as a disease of the dentine consequent upon its exposure to abnormal conditions.

Prognosis of Caries.

If existing caries be promptly treated in youth and a proper systematic prophylaxis be employed, its recurrence during youth may be largely prevented. At about adult age a fair degree of immunity may be expected. In the absence of treatment or prophylaxis the exciting causes seem to become very active, and many teeth may be lost from caries or by reason of extraction for pulp and pericemental diseases. Extraction itself brings many evils in its train.

Even advanced caries may be checked by proper filling, and if then prophylaxis receive due attention the prognosis for the teeth is generally good; indeed, it seems as though but few conditions exist dependent upon caries alone which are not subject to correction by some of the means within the resources of the profession.

Hypersensitivity of Dentine.

The exposure of dentine to external agencies is so commonly followed by an increase in sensitivity that the condition requires description in itself. It is a general condition attendant upon abrasion, erosion, and caries, and has a therapeutics of its own.

The term sensitive dentine applied to this condition is a misnomer; all vital dentine is sensitive, and its degree of sensitivity differs markedly in individuals; it is only when hypersensitivity is observed that the condition becomes pathological.

Hypersensitivity of dentine may be defined as such a degree of sensitiveness of the dentinal fibrillæ as interferes with the comfortable excavation and shaping of a cavity of decay; or which, in the absence of dental ministrations, causes painful symptoms, as a rule reflected about neighboring parts.

Causes and Pathology. Normally the dentine is protected from external agencies by the enamel and in the early stages of gum recession by the cementum.

With the removal of these by caries, erosion, abrasion, or fracture, the terminal filaments of the dentinal fibrillæ become subjected to sudden variations of temperatures ranging from a little above 32° F., the temperature of ice-water, to 130° F., that of very hot foods or liquids.

These thermal stimuli at times give evidence of their effect by producing painful sensations. The pulp is stimulated through the odontoblasts and their relations with the terminals of sensory nerves in the pulp, and a degree of vascular overfulness occurs which may be denominated mild hyperæmia. The effect of these reactions is to cause the sensory functions of the pulp to become somewhat exalted, and it therefore becomes more responsive to the stimuli.

Apart from the effect of thermal changes, other substances act as irritants. The lactic acid and other bacterial products in the cavity of decay without doubt play a part in exalting the irritability of the fibrillæ. Salt, sweet, or acid substances introduced into the mouth are also evidently irritant, as active symptoms follow their application to hypersensitive dentine.

Mechanical abrasion or erosion may irritate the fibrillæ, or at least expose them to the action of other irritants. As a rule, however, the abraded or eroded surfaces are protected from hypersensitivity by the process of eburnation. (See Transparent Zone).

The scraping of necks of teeth with scalers sometimes induces exposure of dentine. Within cavities of decay the hypersensitivity is greatest, as a rule, at the dentinal periphery. That at this point the dichotomous endings of the tubules present a greater number of fibrils to the action of the irritant is quite evident.

In cervical hypersensitivity the cementum or enamel is removed by abrasion, erosion, or caries, and the fibrillæ are exposed. The presence of the granular layer of Tomes in this situation, and the possibility of this layer containing the expansions of the fibrillæ, are to be considered.

In certain cases the irritation excited by the touch of an instrument to dentine adjacent to enamel is carried to the pulp by anastomosing dentinal fibrillæ. This was proven by a few cases of which the following is an extreme one:

In a central incisor secondary dentine had filled a portion of the pulp cavity (Fig. 332, *SD*). Caries had subsequently removed the incisal portion of this secondary growth and also the dentine-containing fibrils leading from the pulp cavity to the middle of the incisal edge.

The application of an excavator to dentine in the incisal portion of the cavity (at *A*), the fibrillæ of which could have no direct relation with the pulp, produced flashes of pain. This was unmistakably of the character of hypersensitive dentine.

A professional friend claimed to feel sensitivity in a cervicolingual cavity of a molar in which the filaments had been destroyed by suppuration for one-third of the length of the canals.

If his contention was true, the sensation must have been conducted by way of the granular layer of Tomes to the level of the pulp and thence by the fibrillæ to its substance.

Spots of cervical hypersensitivity have been occasionally recorded as occurring in teeth the canals of which have been filled.

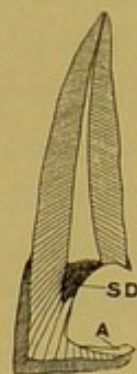
Head¹ records a case in which the dentine bounding the pulp canal remained hypersensitive for a year after the pulp was removed. In this connection the possibility of the presence of a vital pulp filament in the pulp canal, or of irritable apical tissue receiving the impact of liquid forced down upon it by a canal probe, or of a pericementum irritable to touch of any sort, must all have due differentiation. I have never seen a case of hypersensitivity of dentine in which some filament of pulp was not present in at least a part of the tooth.

Dentine cannot become inflamed, as leukocytes cannot enter the tubules; nevertheless the irritability of the fibrillæ, like that of other protoplasm, may be heightened. It has been noted that during excavation of a cavity the irritability is, as a rule, greatest at the surface of the dentine—*i. e.*, at the point at which irritants are present in greatest amount.

With hypersensitivity other functions are increased, and in conditions producing a constant stimulation a constructive change may occur and the fibrillæ form tubular substance at their own expense. (See Transparent Zone and Tubular Calcification).

That the hypersensitivity is, as a rule, a disease of the fibrils involved or of the fibrils and their odontoblasts is shown by the fact that occasionally of two cavities in the same tooth one will present a hypersensitivity and another none; again, one part of a cavity may be hypersensitive and the rest not so. In other cases perfectly normal

FIG. 332.



Indirect transmission of sensation in a case of hypersensitive dentine: *S D*, secondary dentine; *A*, point of hypersensitivity. (Diagrammatic.)

¹ Dental Cosmos, 1899.

dentine is hypersensitive, as noted when the attempt is made to reduce a sound tooth for bridge work.

There are two theories accounting for the transmission of the impulse which is translated by the patient as pain. (1) That a contraction of the whole cell, fibril and odontoblast, occurs, the sensory nerve endings being pressed upon in the act. (2) That a wave-like motion along the protoplasm is set up, causing excitation of the sensory nerves and due to the incompressibility of the water (Gysi).

The former is analogous to the contraction of a voluntary muscle cell under nerve impulse. The whole muscle cell contracts, though the nerve ending is supplied to only a portion of it.¹

This hypothesis fits the symptoms as excited by both mechanical and chemical irritants, while the latter theory does not.

Symptoms. A certain degree of uneasiness of undefined character may at times be noted in teeth containing cavities, but, as a rule, pain other than pulp pain is only felt upon the application of stimuli. In some cases the exposure of dentine about the necks of teeth may induce such an unbearable local pain or neuralgic condition as to positively demand relief.

The infiltration of acid, salt, or sweet substances into contact with a hypersensitive surface is followed by a wave of gnawing pain reflected usually along the course of contiguous nerve filaments. While not definitely localized owing to the fact that the pulp does not possess a tactile or localizing sense, the pain may usually be referred to a certain part of the mouth. The pressure of an instrument upon the dentine is attended by a flash of sharp pain, which continues for a time; but lessens if the contact be maintained. In this test the pain is localized in the affected tooth, the touch of the instrument being followed by a recognition of position by the tactile organ of the tooth, the pericementum.

Occasionally food forced by mastication against a hypersensitive surface, such as due to abrasion or caries in a crevice, will produce a sharp pain subsiding promptly.

Cavities dried for filling usually produce a steady pain, caused by dryness and relieved by an analgesic or by filling.

It is beyond doubt that individuals differ as to the degrees of normal dentinal sensitivity; the dentine of one person may be cut freely without evidence of marked pain; in another the touch of an instrument to the newly exposed dentine is productive of a paroxysm of pain. The

¹ Black, American System of Dentistry.

difference in degree of irritability is manifested in another manner: if a mild sedative—for example, oil of cloves—be applied to the hypersensitive dentine of one person, it may remove the distressing symptoms, but with others it may be necessary to employ the most extreme measures to reduce in any degree the hypersensitivity.

The general perceptivity of the individual seems to play a part, and even apparently normal dentine may be exquisitely hypersensitive. Again, pain produced in excavating may be due to the character of the manipulation, heavy continued burring producing heat; lighter touches may excavate equally well, but produce much less pain. The dullness of the excavator or bur has a similar effect.

Diagnosis. In the diagnosis the above characteristic symptoms are to be considered. The decisive test is made by pressing an instrument upon the suspected surface, when the characteristic pain is produced, subsiding upon or shortly after removal of the contact.

Upon the pulpal wall of deep cavities doubt may exist as to whether the pain is due to pulp irritation.

A suspected exposure may be differentiated by the localization of the pain upon touch to a point corresponding to the pulp horn or pulp body, or by the point catching in the exposure. Hypersensitive dentine will be more generally distributed. Pulp abnormality or approach may be detected by means of a drop of cool water or a blast of cool air from a syringe. (See Hyperæmia of the Pulp.)

Treatment. The methods of treatment which have been followed for the relief of hypersensitivity of dentine, and the induction of such a degree of analgesia as will permit the necessary cutting of dentine, may be divided into general and local.

GENERAL REMEDIES. The general remedies employed are those which abolish or lessen the perceptive function in the centres of the fifth pair of nerves, or which reduce hyperirritability of the nervous system. Either general anæsthesia or general anodynes are employed to lessen perception. The inhalation of a few whiffs of chloroform or ethylic ether lessens the perception of pain. Chloroform is avoided in this connection on account of its dangers when used in the sitting position. Slight etherization, the inhalation being carried only to the benumbing point, affords marked relief from the pain incidental to the cutting of hypersensitive dentine.

The administration of general anodynes, particularly the combination of morphia and atropia, has been found useful in this field:

R—Morphinæ sulph., gr. $\frac{1}{8}$.
 Atropinæ sulph., gr. $\frac{1}{150}$.

M. et ft. pil. No. 1.

Sig.—To be taken one-half hour before operation.

Flagg noted that blondes bear morphine sulphate better than brunettes; particularly are nervobilious and bilionervous patients idiosynceratically opposed to its use. For them he recommended morphine bimeconate solution in doses equivalent to one-eighth grain of the salt, to be taken one the evening before and the other before the operation.

Chloral in five-grain or ten-grain doses, administered in water before the operation, has a quieting effect upon the nervous system. Ambler¹ has suggested the use of from ten to twenty drops of fluid extract of piscidia erythrina, to be administered about ten minutes before operating. Drowsiness may be expected.

Hyoscyamine hydrobromate, $\frac{1}{60}$ grain, will be useful in those cases which are associated with muscular spasm or hysteria.

The coal-tar derivatives, phenacetin, acetanilid, and others, are occasionally efficient. The preparations known as antikamnia (said to be a combination of acetanilid, caffeine citrate, and sodium bicarbonate) and ammonol (acetanilid and ammonium carbonate, equal parts) are to be preferred in this connection. The dose of the latter two is ten grains, administered one-half hour before operation.

The induction of the hypnotic state belongs in the category of means acting upon the nerve centres.

LOCAL TREATMENT. The local treatment of hypersensitive dentine may be considered from two standpoints, according to whether a concavity containing it requires excavation, or whether the hypersensitive spots are not to be excavated after treatment.

TREATMENT IN CAVITIES OF DECAY. The remedies employed in the endeavor to reduce or abolish hypersensitivity in a cavity of decay at the time of operation are quite numerous; few are, however, always effective. They may be classed under two headings:

1. Those which temporarily benumb or anæsthetize the fibrillæ and prevent the transmission of sensation.
2. Those which chemically destroy the fibrillæ for a distance, thus preventing transmission of sensation.

REMEDIES WHICH BENUMB THE FIBRILLÆ. Chief among these for its universality of application is dryness. Dentine, which protests

¹ Dental Cosmos, 1901.

against even the touch of an instrument while wet, has its sensitivity so lessened after the application of a rubber-dam and drying that it may be cut freely, in many cases without the aid of medicinal agents. So well is this recognized that isolation and drying of teeth are regarded as a necessary preliminary to cavity preparation. The degree of insensitivity induced is in proportion to the dryness. The drying probably deprives the dentinal protoplasm of a portion of its water and inhibits the transmission of sensation.

A continuous blast of air passed from a compressed-air apparatus through a heated metal bulb and nozzle or through an electrically heated coil should be employed until the dentine is desiccated. This is evidenced by its extreme whiteness. Other forms of hot-air syringes may be substituted with less satisfaction.

The application of absolute alcohol assists the drying because of its affinity for water. Any pain produced by the dryness may be relieved by the application of a mixture of equal parts of carbolic acid and oil of cloves, or of gum camphor and carbolic acid (phenol-camphor), both of which have some anæsthetic effect.

An instrument known as the "dehydrator" causes absolute alcohol placed in a special chamber between the bulb of the hot-air syringe and the nozzle to be vaporized upon the hypersensitive dentine. The drying effect is thereby augmented and the dentine satisfactorily obtunded.

Some degree of dryness is, as a rule, a necessary preliminary to success with other applications.

Following dryness, the excavation should be done with sharp instruments and burs. The latter should only be lightly touched to the dentine and be revolved at high speed. Letting the bur occasionally run free cools it. The heat of friction is considerable and highly irritating.

Refrigeration by a spray of ether or ethyl or methyl chloride reduces the temperature of the fibrillæ and pulp, benumbing them. The rubber-dam should be applied to isolate the teeth operated upon. Ether is applied by means of an atomizer; the chlorides are contained in glass tubes conveniently capped. The cap being raised, the heat of the hand causes vaporization of the agent within the tube, which forces the liquid out of the orifice of the tube in a fine but forcible stream. The cavity should at first contain a pellet of cotton in order that the dentine may be gradually obtunded and painful response on the part of the pulp avoided.

"Vapocain" and "potassocain," proprietary agents which consist of a 15 per cent. solution of cocaine in ether, are applied to hypersensitive dentine upon the theory that the ether enters the tubules, carrying the cocaine into contact with the fibrillæ; the ether evaporates, leaving the cocaine in aqueous solution to benumb them. This requires several minutes. They are useful in the deeper cavities. Jack recommends that the cavity acidity be neutralized before their application.¹

A saturated solution of cocaine in water may be forced into the tubules by applying it on a pellet of amadou, placing over this soft vulcanite rubber and producing pressure with a burnisher. The pressure should be gradually applied. A gratifying degree of dentinal anæsthesia may often be obtained.

Adrenalin chloride solution 1 : 1000 plus chloretone² has been used in this manner with some effect.

A crystal of cocaine combined with an equal quantity of sodium chloride may be placed in the dried cavity and wet with water. After a few minutes the pain of cutting will be lessened. Some pain may occasionally be produced at first.

Cataphoresis (Greek *kata* down, and *phoreo*, I bear or bring) is, in technical parlance, the transference of substances from the anodal or positive pole of a battery toward the cathodal or negative pole, or in some cases the reverse.

Cataphoresis is to be distinguished from electrolysis, by which substances are decomposed and their elements carried from positive to negative or from negative to positive poles, according to their polarity. In cataphoresis a substance is carried unchanged from the positive toward the negative pole after the manner of granules in protoplasm acted upon by the same force. (See Chapter I.)

As applied to dentistry, a primary current from a battery arranged with the cells in series has the positive pole or conductor connected with a resistance or current controller capable of being so manipulated as to gradually reduce the resistance to the current a fraction of a volt at a time. This is usually a broken ring of graphite, to one end of which the incoming current is admitted by means of the conducting cord and travelling indicator; at the other end the current passes out by a similar cord, which in turn is attached to a milliampèremeter or instrument recording the quantity of current passing through the circuit. From this a cord leads to the positive electrode applied to the tooth cavity. To the face, neck, or wrist of the patient a moist

¹ American Text-book of Operative Dentistry.

² Parke, Davis & Co.

electrode (negative) is applied, which by its conducting cord leads the current back to the negative pole of the battery.

It will be seen that the current passes in turn from the positive pole of the battery to the resistance, to the recording instruments, to the patient (another resistance), to the battery, completing the circuit. These are said to be arranged in series.

In the use of the cataphoric apparatus the tooth is securely insulated by well-ligatured rubber-dam and cotton saturated with a solution of cocaine hydrochlorate or citrate of a strength of from 10 per cent. to a saturated solution is placed in the cavity. The platinum anode is wrapped with cotton, dipped in the solution, and inserted into contact with the cotton in the cavity. The controller is now so manipulated as to gradually cut out its resistance to the current and the high resistance of the dentine is gradually overcome.

The cocaine solution should be renewed as dryness occurs, as dryness increases the resistance. The cocaine is carried along the fibrillæ to the pulp by electric osmosis, and dentinal followed by pulpal anæsthesia results.

From eight to fifteen minutes or sometimes longer are required for dentinal anæsthesia, which loss of time is largely regained in the facility of operation.¹

Price² has shown that pulp anæsthesia is gained more readily by concentrating the action of the cocaine upon the pulpal wall by means of a small electrode. If general dentinal anæsthesia is required he prefers this method, as the pain receptivity of the pulp is abolished. A broader application anæsthetizes the dentine.

Woodward³ has shown that in the latter case the dentine in a cavity upon the opposite side of a tooth being operated upon may remain sensitive.

The pulp may be anæsthetized by this method for removal. In difficult conditions this is a very valuable means of therapeutics.

The pulp is not injuriously affected in ordinary applications, but occasionally a hyperæmia may arise, to obviate which the fibrillæ should be treated with carbolic acid.

In case absolute insensitivity is produced the anatomy of the pulp must carefully be considered, so that it be not exposed during the excavation of the cavity. Insulation of the pulp from thermal shock subsequent to filling is also to have consideration.

¹ Jack, American Text-book of Operative Dentistry.

² Dental Summary, April, 1903.

³ International Dental Journal, November, 1902.

Söderberg¹ has shown that painless excavation of cavities otherwise uncontrollable may be effected by the use of nervocidine, an alkaloid obtained by Dr. D. Dalma from the East Indian plant *gasu-basu*. Twenty-four hours are required for complete dentinal anæsthesia without pulp anæsthesia unless a second application be made.

The primary effect of nervocidine being irritating, Söderberg recommends the additional use of cocaine, both being mixed with zinc sulphate cement.

R—Gum arabic,	5j.
Zinc sulphate,	3ss.
Water,	f3j.—M.

Dissolve the zinc sulphate in the water, add the gum arabic, stir; let stand for twenty-four hours, strain.

R—Of above solution,	f5ij.
Nervocidine,	gr. x.
Cocaine hydrochlorate.	gr. x.—M.

To a portion of the latter solution add uncalcined zinc oxide to make a cement, which is placed in the dried cavity. Uncalcined zinc oxide added to the first formula makes zinc sulphate cement. After excavation the acidity of the nervocidine should be neutralized.

Recently hot water supplied by a tube leading from a coil heated by electricity and attached to the water supply-pipe of the fountain cuspidor has been recommended by Dr. A. F. Merriman, Jr., for the obtunding of hypersensitive dentine in cases in which dryness is not readily obtainable, nor immediately nor subsequently desirable.

It is claimed that satisfactory analgesia is obtained and that the mucous membrane of the mouth is not unduly uncomfortable, even when the heat is objectionable to the finger of the operator. The advantages of the method for excavation and grinding are obvious and most useful, particularly for trimming live teeth.

REMEDIES WHICH CHEMICALLY DESTROY FIBRILLÆ FOR A DISTANCE, PREVENTING TRANSMISSION OF SENSATION. Agents which chemically destroy the dentinal protoplasm form the most extensive group of dentinal obtundents. They include salts of metals, such as zinc chloride and silver nitrate; carbolic acid and its derivatives and like bodies; the cresols, etc.; mineral acids, notably sulphuric, chromic, and nitric; organic acids—trichloroacetic and lactic acids (full strength); alkalies—sodium and potassium hydrates and carbonates.

Zinc chloride, silver nitrate, and carbolic acid, all cause coagulation of the protoplasmic processes of the dentine. The mineral and organic

¹ Dental Cosmos, August, 1903.

acids chemically decompose both protoplasm and the calcified tissues. The concentrated alkalies mentioned chemically destroy protoplasm and bring about its quick dissolution. Like all active chemical substances, the extent of their action depends upon the freedom with which they are applied.

The application of any of these agents, as a rule, causes pain, the degree of suffering being usually in proportion to the depth of the cavity. For this reason the more powerful agents like zinc chloride and nitric acid are to be confined to cavities of moderate depth, while carbolic acid, especially in combination with the oil of cloves, may be used in the deeper ones.

Fused zinc chloride is used in its deliquesced form and is most active when some of the salt is still undissolved in the bottle. Its pain in suitable cavities is a full, bearable one, gradually increasing, sometimes in waves until a crisis is reached, when the pain gradually ceases. It has a double action, not only coagulating protoplasm, but combining with its water owing to its affinity for the latter. On account of this property its action may be limited by warm water.

An undue action of the zinc chloride is indicated by a throbbing pain; this indicates that the pulp has been irritated. When, as occasionally occurs, no pain is produced, no obtundent effect is obtained. If this occur often the drug is oversaturated with water.

Bogue has suggested that cocaine crystals be incorporated with the chloride of zinc as a means of alleviating the pain incident to the application.

Certain moderately deep cavities may be filled with oxychloride of zinc cement, the free zinc chloride acting as an obtundent. This requires a prolonged action and is only resorted to in cases which do not admit of immediate work, or in which procrastination is desirable.

A formula of wide renown is known as Robinson's remedy; this may be made in one of two ways:

R—Potassium hydrate
(or Sodium hydrate),
Carbolic acid,

āā.—M.

Reduce the gelatinous mass formed with alcohol.

Or,

R—Sodium hydrate (deliquesced),
Calvert's crystal carbolic acid,

āā.—M. (Huey.)

The liquid formed is spoiled when it effloresces upon the sides of the bottle neck.

The painfully caustic action of the sodium or potassium hydrate is modified by the carbolic acid.

The application is useful in the simpler cavities and about the undecayed but hypersensitive necks of teeth.

If this remedy or zinc chloride be required about the periphery of deep cavities the plan suggested by Jack,¹ of varnishing the cavity floor with chloro-percha as an impenetrable protective, is valuable.

A solution of gutta-percha in oil of eucalyptus will serve equally well for the purpose.

The combination of potassium carbonate with glycerin makes a water-extracting combination having but little coagulating power. For this reason it may be used in the deeper cavities, but not in cases of almost exposed pulp, as in such cases its application is painful.

R—Potassium carbonate, gr. xv.
Glycerin, f5j.

Mix in a mortar.

To be applied on a pellet of cotton. (Flagg.)

It may be used with effect even upon slightly moist dentine.

Not being escharotic to the gum, this remedy is exceedingly useful about the sensitive but undecayed necks of teeth, and may be freely applied after moderate drying of the parts.

If necessary the patient may be given the prescription and directed to apply by means of a clean tooth-pick, which should not be used a second time, as the mixture may be infected and spoiled.

Its pain simulates that of zinc chloride, but is less severe in its character.

A mixture of tannin and glycerin has a similar effect.

R—Tannin, 5j or 5ij.
Glycerin, f3j.

Mix in a warm mortar.

Carbolic acid in concentrated form may be applied to any cavity. Jenkins, of Dresden, has recommended that it be used hot; it is particularly useful for cavities containing masses of softened dentine.

Sodium bicarbonate is at times an efficacious remedy and may be freely applied to the moist cavity.

A 20 per cent. solution of ammonium carbonate, applied for five minutes or longer, is useful.²

The nitrate of silver powerfully coagulates fibrillar protoplasm, and is useful in posterior teeth well out of view and to which the rubber-dam cannot well be applied. It is also useful about undecayed hypersensitive necks of molar teeth. It discolors the dentine, metallic silver

¹ American Text-book of Operative Dentistry.

² Thiesing, Dental Cosmos, November, 1903.

being deposited. For this reason its use is ordinarily confined to posterior teeth, though in some obstinate cases of hypersensitive necks of lower incisors and cuspids it may be used.

The subsequent use of sodium chloride assists in partially removing the stains, argentic chloride being formed.

Register has suggested the use of iodine followed by ammonia for this purpose.

In shallow cavities and upon abraded surfaces nitric and chromic acid accurately applied in small quantity upon a gold probe is useful. Any softened dentine must later be removed and filled.

Aside from the treatment of hypersensitive dentine at the time of operation, analgesics may be introduced for their power of gradually lessening the hyperirritability of fibrillar protoplasm. If cotton wedges are introduced antiseptic analgesics, particularly oil of cloves and phenol-camphor, may be used on the cotton with advantage.

A partially prepared cavity may be moistened with oil of eucalyptus and temporarily filled with temporary stopping or gutta-percha.

A temporary filling made by mixing zinc oxide with Fletcher's carbolized resin or eugenol to a stiff paste will endure a week or more and reduce hypersensitivity.

R—Carbolic acid,
Colophony, $\bar{a}\bar{a}$ $\bar{x}\bar{j}$.
Chloroform, f3ss.—M. (Fletcher.)

The above may be applied on cotton for a day or two with advantage.

In cases in which devitalization is intended, arsenic may be used as an obtundent to effect a deeper placing of another portion as a devitalizing agent; twenty-four to forty-eight hours are required for this purpose. If left long enough it will devitalize the pulp even through a large mass of dentine.

There is no safety in short applications as a means of obtunding dentinal hypersensitivity. The pulp may die even after seeming excavation of all affected dentine.

Ninety per cent. of cavities may be comfortably excavated with sharp instruments by the aid of dryness and carbolic acid. A small percentage require the use of caustics, etc., while in a still smaller number cataphoresis is the only certain remedy.

During seasons in which acid fruits are consumed much hypersensitivity may be induced. This should always lead to examination for cavities of decay, but such may not exist or may be properly filled.

For hypersensitivity about undecayed necks of teeth, the mouth

should be kept in an alkaline condition by means of dilute phenol sodique or sodium bicarbonate, or, better, by the use of more lasting mild alkalies, such as chalk, or milk of magnesia, or a combination of the two.

The use of the potassium carbonate in glycerin is indicated and may be given to the patient for free use.

For hypersensitive incisal edges or occlusal surfaces Robinson's remedy may be dispensed.

At times zinc chloride, Robinson's remedy, and silver nitrate must be used by the operator. In very obstinate cases of cervical hypersensitivity Flagg has recommended the use of the electric cautery, the spots to be seared.

In a number of the localized cases fillings may be subsequently required unless rigid prophylaxis be practised. Acid mouth washes should be avoided.

CHAPTER XV.

DENTAL CARIES: THERAPEUTICS AND PROPHYLAXIS.

ACCORDING to the depth of invasion and variations in the therapeutics involved, caries may be divided into eight stages as follows:

1. Superficial caries, or that stage in which the enamel has been partially decalcified but the dentine not affected.
 2. Simple caries, in which the dentine has been affected slightly in such a manner as ordinarily to compel the formation of a cavity and its filling.
 3. Deep-seated caries, in which the complete excavation of the cavity renders pulp injury a possibility, but the pulp is not very dangerously approached.
 4. Almost exposed pulp. This is a refinement of the preceding stage, in which pulp exposure becomes an imminent danger during excavation of the cavity and special therapeutics are demanded.
 5. Exposed pulp, in which the actual exposure of the pulp by decay or by accident or intention during excavation renders its treatment necessary, or in which disease of the pulp compels canal treatment.
 6. Perforation by caries, in which after pulp death secondary caries of dentine and cementum has caused an opening into the pericemental tract.
 7. Loss of crown by caries.
 8. Loss of root by caries.
- Each of these stages of caries requires special consideration and a therapeutics adapted to each.

THERAPEUTICS OF SUPERFICIAL CARIES.

About cavity margins, beneath green stain, etc., and at points of proximal contact of teeth may frequently be seen areas of enamel decalcification, the enamel not being entirely penetrated (Fig. 296).

It is possible at times to remove the decalcified portion by means of carborundum strips, files, or disks. If the surface be highly polished by means of pumice and chalk and subsequent prophyl-

laxis be employed, the practice may be endorsed for the better grades of teeth, and particularly in the anterior part of the mouth. As a rule, however, the attempt to remove supposed superficial enamel caries demonstrates the fact that the enamel is deeply affected, and in all probability the dentine as well. The attempt to remove such caries upon proximal surfaces by files and stones results in tooth deformity, the exposure of dentine to the fluids of the mouth, and the destruction of the contact points, except, perhaps, when in the anterior teeth a lingual approach is made. It may be considered a safe rule to examine by means of the electric mouth lamp any cases of suspected superficial caries in order to determine the depth of enamel invasion.

The large majority of such cases, especially in the poorer grades of teeth, will be found to be of the class called here simple caries.

Upon the labial or buccal surfaces of anterior teeth a superficial decalcification may be found. This may be removed by abrasives, the surface highly polished, and the patient enjoined to use great care in prophylaxis. Any spots at which simple caries exists should be excavated and filled.

A superficial caries of cementum and dentine may exist. This may be removed, the dentine polished, and nitrate of silver applied if the surfaces be not exposed to view.

The superficial decay about cavity margins should either be disked off or the area included in the cavity, if diskings be judged capable of inducing recurrent caries.

THERAPEUTICS OF SIMPLE CARIES.

The cases cited above and all detectable cavities of very limited depth may be classed as cases of simple caries. The teeth should be wedged apart if this be needed for access, all decalcified enamel and dentine removed, the cavity properly extended and shaped, and, as a rule, a filling of gold inserted. All fissures about a cavity should be freely opened to their extremities and made a part of the general cavity.

At times, expediency—*i. e.*, the systemic condition of the patient, the character of the decay or of the surrounding tooth structure or economy—warrants the use of a good amalgam, or occasionally of gutta-percha, in suitable locations not exposed to attrition. Upon the labial surfaces of incisors porcelain inlays combine efficiency with æsthetics.

If a simple cavity prove inordinately sensitive, the more powerful

remedies may be used to reduce the hypersensitivity, and the cavity should be treated with carbolic acid before filling, particularly when gold is to be used in cervicolabial cavities of incisors. By this means the subsequent effect of thermal changes is lessened.

THERAPEUTICS OF DEEP-SEATED CARIES.

In this stage of caries there is usually, although by no means always, an easily discoverable cavity of size. After the removal of ragged and overhanging enamel margins, and of loose débris in the cavity, it is noted that the response to thermal impulse is painful and prompt. In washing such cavities, water at a temperature of about 100° F. should always be used; cold or very hot water being only employed in cavity irrigation to test the promptitude of response upon the part of the pulp.

In treating hypersensitivity of dentine the mineral acids are avoided, and if strong agents like zinc chloride are used, the cavity floor is to be varnished with chloro-percha or formo-percha, which are impermeable. If necessary, essential oils or a saturated solution of cocaine in glycerin, thymol in alcohol, or menthol in chloroform may be sealed in for twenty-four hours.

A mixture of cocaine with nervocidine may be useful, as indicated by Söderberg.

Cocaine cataphoresis is regarded as admissible in all stages of caries.

The removal of the softened dentine in these cases forms a cavity of such magnitude that proximity to the pulp is evident. The softening has proceeded for a distance beneath the enamel, so that when all softened dentine is cut away from beneath the enamel the latter tissue overhangs, unsupported, the general cavity. These overhanging walls are cut away until the region of normal enamel is reached, and then it may be that the walls still overhang the general cavity. It is usually not necessary nor advisable to remove this portion of enamel.

At the completion of excavation the pulpal wall of the cavity will be in close proximity to the pulp. A blast of cool air from a chip syringe may produce an immediate response upon the part of the pulp, vigorous in proportion to the thinness of its dentinal covering and its irritability.

In many cases non-conducting substances are required as intermediates between the pulpal wall and the metal filling. In many other cases the metal filling may be placed directly upon the dentine

without danger. In some cases a simple layer of non-conducting varnish, such as "cavitine," will be sufficient. In others zinc phosphate or gutta-percha must be added. The degree of the response to a blast of cool air will afford a guide to the nature of the intermediate required if any be deemed necessary. In no case should varnish or gutta-percha be allowed to remain in the portions of cavity that support the covering filling material and which is subjected to the force of mastication. The resilient nature of such substances will cause the loosening of the filling.

In some cases the undermined state of the enamel walls necessitates the use of an adhesive zinc phosphate as a means of support by replacing the lost dentine, and in such the pulpal wall may be covered and so protected from impact as well as from thermal changes.

The action of zinc phosphate upon dentinal fibrillæ and the pulp being a matter of some doubt, it is better that the pulpal wall be varnished before it is introduced. The varnish not only acts as an impervious coating, but also serves as an additional non-conductor. If made antiseptic it is still more useful.

After the cavity is prepared it is sterilized and dried as described in the next stage of caries, is coated with "cavitine" varnish, and Harvard zinc phosphate mixed stiff is packed into the undercuts and over the pulpal wall.

When set the enamel margins are freed of cement and the cement is excavated to the form required. In some cases cement can only be placed over the pulpal wall.

In deep-seated caries the extension of cavity margins in such a manner as to prevent recurrence of decay is demanded. Upon proximal surfaces the ideal conditions are an extension of buccal and lingual margins to a point which will permit a contoured metal filling to have its corresponding buccal and lingual margins well irrigated by the action of the toothbrush and food in mastication.

The cervical margin of the cavity and filling are best protected when overlapped by healthy gum tissue, and if possible should be so arranged. The cervical margin should always be extended beyond the contact point in such cases, whether carried beneath the gum or not. Incisal margins are to have similar consideration.

Firm proximal contact of fillings or filling and tooth are required to prevent packing of food into the interproximal space. This would both injure the gum and introduce the fermentable element in caries production. The point of contact should be neatly rounded so as to

cause as little contact as possible. This contact should be obtained even if the filling must be overcontoured at times.

An exception may at times be made where a space has previously naturally existed and the gum margin is healthy.

Teeth should never be joined by fillings alone. If necessary for the protection of the gum, both may be crowned and the crowns united by solder, or a staple may be placed in the pulp canals of the two teeth. About this a common filling may be built. (See *Pyorrhœa Alveolaris*.)

THERAPEUTICS OF ALMOST EXPOSED PULP.

In this stage of caries complaint is usually made that for some time pain has been produced by the presence in the mouth of cool or hot substances. Several classes of almost exposed pulps may be discovered after opening the cavity and removing the bulk of the decayed dentine. In the simplest class the pulpal wall may be found sound after removal of all decalcified dentine. This makes practically a case of deep-seated caries and is to be treated as such, the close approach to the pulp simply demanding additional precautions as to non-conduction, prevention of compression, and infection. The cavity is to be sterilized with 1 per cent. formaldehyde, 5 per cent. sodium dioxide solution, etc., and dried; over the pulpal wall "cavitine" with hydronaphthol added is painted and dried:

R—Hydronaphthol,	gr. ij.
Alcohol,	gtt. xx.—M.

Add to the half-ounce bottle of "cavitine."¹

A thin wafer of softened gutta-percha is to be laid over the pulpal wall in such manner as not to interfere with the introduction of cement. Harvard zinc phosphate mixed to a consistency just suited to the case may be pressed laterally into the undercuts and will spread nicely over the gutta-percha without pressure. Under no circumstances must the superstructures depend upon the gutta-percha base as a support, as the filling may loosen or the wall be broken.

The operation may be varied for cases of but limited retaining periphery by gently spreading the zinc phosphate over the varnish, or in some cases the gold and zinc phosphate or amalgam and zinc phosphate combination may be required.

In the use of gold and zinc phosphate a portion of crystal gold is

¹ "Cavitine," or "crystalline" of commerce, is composed of trinitrocellulose dissolved in subacetate of amyl.

gently tapped into a mass of soft cement placed over the varnish and the setting of the cement awaited. The gold is then condensed and more added.

With the amalgam and zinc phosphate combination, after placing the gutta-percha, soft cement is placed upon one cavity margin and a ball of previously prepared amalgam is laid upon it. Pressure upon the amalgam by means of a ball burnisher causes the cement to be spread over the cavity wall in advance of the amalgam. The margins are freed of amalgam and cement and the operation is completed with amalgam.

This, of course, refers to locations in which the latter is indicated. The cement in the combination increases the adhesion and prevents leakage and the discoloration of the walls by the amalgam. A trifle of aristol or hydronaphthol added to the cement (1 to 10) imparts to it an antiseptic character without impairing its integrity as a cement.

The second class of almost exposed pulp is that in which thorough excavation would cause exposure of the pulp.

If the dentine be of the disintegrated, boggy sort, it should be removed regardless of exposure; but if it be simply softened by decalcification and be quite firmly adherent to the cavity floor, and particularly if it be somewhat thickly distributed, the deeper layers may be left *in situ*, as a pulp covering.

In such cases all lateral walls should be thoroughly excavated and only a thin layer left over the pulp horns. While, without doubt, the tubules of decalcified dentine are liable to be invaded by bacteria, Miller has shown that frequently such dentine may exist without invasion.

The argument that such dentine contains poisonous products of bacteria deleterious to the pulp does not seem borne out by results in carefully handled cases.

That some of these protected pulps may die is a fact not to be disputed, but that many live in security is also true. Whether such dentine can be recalcified has not yet been scientifically shown, but certain cases treated with oxychloride of zinc have shown evidences of it, and Miller records cases of hardening of such caries even without treatment.

The treatment required by this dentine is first neutralization of the acid present; second, saturation with a permanent antiseptic; third, an antiseptic non-conductive covering.

After drying, a 5 per cent. solution of sodium dioxide or sodium

hydrate will accomplish the first requirements. The dentine is then thoroughly dried and saturated with cavatine varnish containing hydronaphthol or a solution of Canada balsam containing hydronaphthol, or thin chloro-percha containing aristol or iodoform, or the formaldehyde preparations known as "Formagen" and "Jodo-Formagen" may be spread over it, or oxychloride of zinc, the fluid of which has been diluted one-third with water, may be used as a covering.

Williams¹ suggests that the decalcified dentine be first saturated with absolute alcohol for one minute, then dried, then wet with oil of cloves for one minute, then again dried, after which the varnish, etc., is to be used.

Powdered sulphate of copper may be dusted over the floor of the cavity or used in solution to saturate the dentine, after which the dentine should be dried and encased in varnish.

The use of these preparations obviates the necessity of sealing temporary antiseptics in the cavity, as they are in themselves more or less permanently antiseptic. Over them asbestos paper or thin gutta-percha is placed and then zinc phosphate, made antiseptic with aristol or hydronaphthol, is packed, and if any doubt exist the cavity is temporarily sealed with gutta-percha or temporary stopping. When all doubt is at rest the metal filling may be placed.

In some cases of deep-seated caries in which gold filling is desirable, but in which linings are contraindicated, yet in which immediate filling with metal would involve such thorough excavation as to endanger pulp vitality either as the result of excavation or subsequent thermal shocks, oxychloride of zinc may be placed in the peripherally prepared cavities and over considerable masses of decalcified dentine. If allowed to remain for several months (three to six) the oxychloride stimulates the pulp to the formation of some secondary dentine and complete excavation to a sound basis may be made. There is also some evidence of hardening of the dentine. This method is open to the possible objection that secondary dentine is a source of future trouble, but the method has its advantages in badly decayed anterior teeth.² In very deep cavities the fluid of the oxychloride should be diluted one-third.

¹ Items of Interest, 1898.

² In some cases of this sort seen by the writer, and observed for from ten to sixteen years, the ill results of oxychloride of zinc claimed have not been observed. In one case, after sixteen years a lateral incisor crown broke off, and the pulp was found to have receded, but was otherwise apparently healthy. The question is one of the advisability of immediate devitalization, with its advantages and disadvantages in anterior teeth, or of a possible remote pulp death, etc.

In these cases porcelain inlays with their underlying cement should have due consideration as therapeutic means.

In deep and very deep-seated caries in situations in which discoloration is not of great moment the cavity may first be lined with copper amalgam for its antiseptic value. This is advanced toward setting by the use of a wafer of amalgam from which the mercury has been expressed. The filling material is then dished out so that the cavity margins are freed of it. The ordinary amalgam is then added to contour. Copper amalgam alone ordinarily becomes disintegrated and caries recurs. Occasionally it lasts well (especially Sullivan's).

Dobrzyniecki¹ (Budapest), in eight experimental cases upon microscopically sound-looking dentine, claims to have found the bacillus gangrenæ pulpæ vital after months of enclosure under sealed dressings of camphor, concentrated carbolic acid, or eucalyptus oil. All other organisms were devitalized. As Arkövy's² experiments showed the decided influence of carbolic acid over this organism, and as root-canal antiseptics are nearly always successful in cases of moist gangrene of the pulp (bacillus gangrenæ pulpæ Arkövy), the difficulty of destroying this germ by germicides left indefinitely in the cavity must be accepted with reservation.

THERAPEUTICS OF EXPOSED PULP.

The exposure of the pulp may be the direct result of caries; the removal of boggy, disintegrated dentine may produce it, or it may be the result of the removal of a last layer of decalcified dentine or of the careless or inadvertent perforation of sound dentine by instruments. Fracture or abrasion are occasionally responsible for exposure. Erosion rarely causes it.

Diagnosis. After excavation of the cavity, washing with tepid water, and drying, direct vision or a reflected image in the mouth-mirror may reveal the area of exposure as a round opening occupied by a pinkish or red body. If the exposure be large, pulsation of the red body may usually be observed. The exposure may be so slight as to be invisible, the depth of the cavity, however, indicating that exposure probably exists. Bleeding is a certain guide, but bleeding from the gum margin must be borne in mind. Truman advises in these cases that finely carded cotton be gently passed over the cavity walls,

¹ Söderberg upon Arkövy, Dental Cosmos, 1899.

² Ibid.

exposure being detected by the momentary pain produced when the fibres pass over the area of exposure.

As this test may fail in cases of known exposure it is not altogether reliable.

A finely pointed probe may be gently dragged over the pulpal wall and catches in the orifice of exposure, however small. A quick start upon the part of the patient is usually elicited. Flagg warned against requesting an affirmative nod by the patient, as this would cause injury to the pulp. Delicately used, this test is the most reliable in all classes of cases and is not painful.

It is to be remembered that disease may have caused a loss of a portion of a pulp horn; gentle exploration will detect the amount lost. Blood, or pus followed by blood, are evidences of exposure.

Excruciating pain following mastication, or pressure or suction exerted upon the cavity by means of the tongue, are subjective symptoms indicating a probable diagnosis of exposure.

Treatment. An exposed pulp is either to be capped or removed and the canals filled.

The concensus of opinion is that ordinarily all pulps should be removed, except those freshly exposed by removal of simply decalcified dentine and by accident. There is no certainty that pulps exposed by caries or practically so will live under capping materials, but the attempt may be made at times for special reasons.

Freshly exposed pulps may be capped or removed. Perhaps a good rule would confine capping to anterior teeth of the better grades in patients in good physical condition, and to pulps in teeth having incomplete roots. The improved methods of pulp removal and canal antisepsis warrant pulp destruction as a safer method than capping in most posterior teeth. Even in anterior teeth, pulp removal for anchorage purposes if needed is quite warrantable. The advantages of capping are maintenance of tooth translucency and the avoidance of canal work.

The disadvantages are: 1. Possible death of the pulp by hyperæmia due to conduction of thermal changes. 2. An overproduction of secondary dentine or the production of pulp nodules, the pulp becoming exhausted and death ensuing. Increased difficulty of canal treatment may result. 3. Disease of the pulp due to infection beneath the capping material. 4. The time required for assurance of success or failure.

The object sought in capping is the protection of the pulp from

infection and compression, as either is fatal to pulp vitality. This is best accomplished by placing against the pulp and in absolute contact with it an antiseptic paste beneath a metal cap, or an antiseptic cement having, when set, sufficient rigidity to permit other work to be done.

Prognosis is favorable for the cases selected as suggested.

Pulp Capping. The cap should be made of platinum or gold for anterior teeth. Tin, lead, or silver may be used posteriorly. After punching or trimming to shape it should be made concavo-convex by pressing it into soft wood by means of the rounded end of an instrument handle. A film of wax is placed on the convex side; a warmed, small burnisher is attached, and the cap is adjusted in proper position by trying in the cavity. It is then to be filled with the capping material (a little of the latter placed in any depression at the point of exposure in order to exclude air); then one side of the cap is laid upon the dentine and the other gradually brought down, and the edges of the cap firmly adapted to the dentine. This causes the paste to exude from beneath the cap. Any excess is gently removed with an excavator. A little "cavitine" varnish or chloro-percha is to be placed over the pulpal wall and cap and dried. A little soft cement is now placed over the varnish as a protection, and when set the filling is completed with gutta-percha or zinc phosphate cement, which is to be allowed to remain a year as a test of success.

These may be renewed as worn out if desirable, or a portion of the covering filling may be cut away and metal introduced. In case a plastic filling is desirable in any event, the operation is to be completed at the time of capping or at a subsequent sitting.

The materials used with success as pulp cappers are: 1. A mixture of oil of cloves and zinc oxide (equal parts of carbolic acid and oil of cloves may be used as the menstruum). Hubbuck's zinc oxide or cement powder may be used. This is mixed to a consistency which will flow yet set in time

2. Oxysulphate of zinc, the fluid of which is a saturated solution of zinc sulphate in water. The powder is uncalcined zinc oxide. This will make a thin, creamy paste which flows readily and sets quickly. A trifle of aristol, iodoform, or hydronaphthol may be added.

3. Plaster of Paris mixed with a 1 per cent. solution of formaldehyde in water will make an antiseptic, quick-setting paste.

4. "Formagen." This substance is said to have a mixture of eugenol and carbolic acid for the fluid, while the powder is of zinc

oxide, containing paraform, the solid form of formaldehyde. A cement is formed which sets quickly and must therefore be made very thin when placed in the cap. This material seems to have been somewhat successful as a capper even in exposures by caries, owing to its intense germicidal power. It is claimed that the formaldehyde penetrates the tissue of the pulp for a distance, yet permits its return to normality.

Results of Capping. If pain be initiated when the cap is placed and recur later, compression has occurred and the capping must be removed, the pulp quieted, and the capping renewed or the pulp removed. Though no sensation be produced at the time of operation a reaction to thermal changes may occur. If this gradually subside as counterirritants are used, a diagnosis of arterial hyperæmia (aseptic) is confirmed. If the reaction increase and heat become more irritating than cold, and if at the same time paroxysms of pain or reflex pain occur, the diagnosis is that of venous hyperæmia or infective inflammation, according to the character of the symptoms, and the pulp must be removed.

A pulp may remain quiescent for weeks or months and then unfavorable symptoms set in, or it may die without any apparent pain. It is probable that in the latter case some reflex pains have been felt, but not related with the tooth, in the mind of the patient.

In the successful cases, either the orifice of exposure is covered over by a deposit of secondary dentine, or the pulp remains perfectly quiescent beneath the capping material, without formation of deposit.

Even when a deposit occurs the pulp may die from the atrophy and degeneration attendant upon the formation of much secondary dentine, and when no deposit occurs infection following leakages about filling and capping materials may take place after years of apparent success.

While capping may be, and has been, successful in all grades of exposure, there is no certainty of success in the exposures by caries. The tentative treatment necessary offsets the labor of canal treatment.

THERAPEUTICS OF PERFORATION BY CARIES.

The progress of secondary caries about the pulp chamber hollows out the root until at least at one point the chamber wall is but a decalcified layer of cementum covered by decomposing dentine. At some point the pericemental tissue will be uncovered by excavation or by the carious process (Fig. 320). The crown will probably be hopelessly decayed.

Taking as an example a lower molar perforated at the bifurcation with the pericemental tissue hypertrophied into the opening (fungous gum), its treatment may be described as follows: The gum is first to be pressed out with cotton medicated with an antiseptic varnish. Fletcher's carbolized resin, or aristol in chloroform, or sandarac varnish plus orthoform will serve, or temporary stopping may be used.

If immediate work be desired the fungous gum may be saturated with trichloroacetic acid and cut away without bloodletting by means of a large, sharp, spoon excavator. Large, rose-head burs are used to free the cavity of all decay. The canals are opened and treated. If further treatment be desired, or be impossible until the perforation is disposed of, metal or wooden pegs are placed in the canals and a reasonably thin layer of copper amalgam is built about the pins and over the perforation. A slight movement of the pegs will permit their withdrawal, leaving openings in the amalgam through which the

FIG. 333.

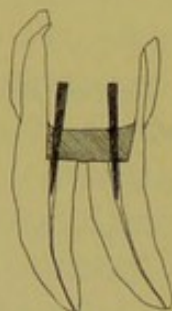
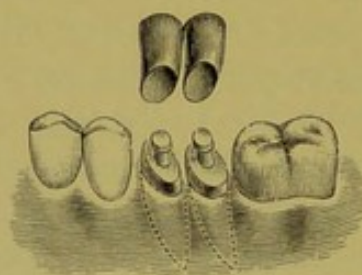


Diagram of treatment of perforation by decay.

FIG. 334.



Crowning of divided roots. (Evans.)

treatment may be conducted. The amalgam is then allowed to harden (Fig. 333).

After canal filling the canals may be further reamed for screws or pins, which are inserted and the operation completed with amalgam or zinc phosphate if the condition of the crown admit of it; or, if crowning be required, this is arranged for in the building up with amalgam.

A long perforation at a bifurcation may practically divide molar roots. This is to be made a complete division after treatment of the canals. Each section may be fitted with a pin and amalgam stump to which a gold barrel is fitted. The barrels are each given an occlusal face and soldered together (Fig. 334).

A smooth plaque of low-heat, white gutta-percha (not temporary stopping) makes an excellent covering for a perforation. It is made larger than the opening to be covered, pressed to place, and the edges

sealed with a hot burnisher. The covering filling will retain it in position.

In all cases judgment must be exercised and the attempt to conserve unsuitable cases avoided.

THERAPEUTICS OF LOSS OF CROWN BY CARIES.

If the portion of crown left after excavation be self-sustaining, but incapable of retaining a filling, pins or screws may be placed in the root canal or the pulp cavity may be enlarged and made retentive. A filling is then built about or into the anchorage so made. At times the remainder of a tooth crown will support a hollow metal crown.

When the carious crown has broken away or filling has become practically impossible or undesirable, the original beauty or useful form of the tooth may be approximately restored by means of one of the many forms of dowelled porcelain crowns, specially constructed gold and porcelain crowns, or all-gold, hollow-metal crowns.

If an anterior root be so hollowed out by caries as to be incapable of supporting a dowelled crown it may be extracted and the operation of transplantation performed, or, later, an implantation may be made.

In the former operation the existing alveolus is enlarged if necessary to accommodate a tooth; in the latter operation a new alveolus is created by means of appropriate trephines and reamers. The tooth is to be prepared as for replantation (which see).¹

If teeth have been lost by extraction, the spaces created may be filled by means of bridge-work or plates of various sorts.

By common consent crown and bridge work is considered a special department of dentistry.

CARIES OF THE TEMPORARY TEETH.

Caries of the temporary teeth differs but little from that of the permanent teeth. The pulp cavities are, however, relatively larger and the intensity of the carious process often causes rapid exposure of the pulp. Owing to the flat character of the approximations of the teeth there is often more proximal than occlusal caries and the cavities often have weak peripheries.

Children have a fear of dental offices, excited by unpleasant experiences or the talk of their elders, and they do not mention slight pain

¹ For methods of implantation see American Text-book of Operative Dentistry.

such as that excited by hypersensitive dentine. There is, however, abundant evidence that the dentine of the temporary teeth may be hypersensitive.

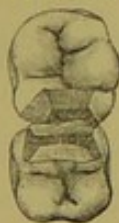In cavities of simple nature the fillings indicated for adults serve if the operations are well borne.

The shapes of the teeth, the restlessness and fear of the little patients, and the free flow of saliva indicate, for the most part, the use of plastic fillings, though the rubber-dam may often be readily used. In deep cavities not exposing the pulps the methods employed for adults, of varnishing or insulating with gutta-percha and the subsequent use of zinc phosphate as a lining under metal fillings, are indicated. Certain occlusal cavities having small orifices and large interiors are well, and often permanently, filled with pink gutta-percha.

If cavities are observed before pain has been complained of, and prompt and quickly subsiding response to applications of cold water is obtained, indicating a normal pulp, the cavity should be excavated, with more regard to removing the marginal caries than to thorough excavation, dried, and an application of a 20 per cent. solution of silver nitrate made for a few minutes, the cavity being subsequently filled.

In cases of adjoining approximal cavities there is a disposition for the affected teeth to press together and lessen the size of the dental arch. Bonwill advised as a practice, followed by uniformly good results in such cases, to cleanse the cavities (Fig. 335) and insert

FIG. 335.



Mode of preparing approximal cavities.

masses of pink gutta-percha base-plate. The constant biting upon the gutta-percha causes a separation of the teeth, which increases the size of the arch and affords additional space for permanent successors. He advised that before the gutta-percha masses are inserted small pieces of blotting-paper saturated with carbolic acid be laid against the dentinal walls and the gutta-percha be packed over them. The more efficient and per-

sistent antiseptic silver nitrate may be applied instead of the carbolic acid. Kirk advises that asbestos-felt be heated to destroy any organic matter present in it which might combine with the silver, and then be soaked in a saturated solution of silver nitrate, dried, and kept in dark bottles away from the light. Small pieces of the prepared felt may be used as described.

The silver nitrate method is particularly applicable to shallow

cavities in which excavation for filling is impracticable. The dentine surface is cleansed and dried, and the fused silver nitrate is rubbed upon the surface. This may be done after the method of Craven: a platinum wire is dipped into the powdered salt and held over a flame until the powder fuses into a button. By this means applications can be directly and accurately made.

Combination fillings of zinc phosphate and amalgam are of advantage in case of frail walls.

For the anterior teeth zinc phosphate and gutta-percha fillings are useful, and for the posterior ones Ames' oxyphosphate of copper serves a good purpose.

Caries is very liable to occur upon the proximal surfaces of the second temporary and first permanent molar. If the former be found largely decayed distally, the latter will usually be found decayed on the mesal surface.

Well-contoured fillings must be inserted in such a case. As a preventive measure during eruption of the first molar, the second temporary molar may be disked to the form shown in Fig. 336.

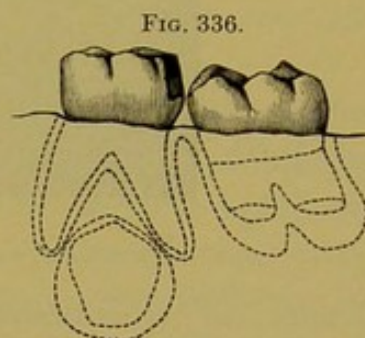


FIG. 336.
Impingement of permanent molar upon the distal wall of the temporary second molar.

If incipient or simple decay have occurred on the two teeth, or even the second molar alone, this form will be impossible.

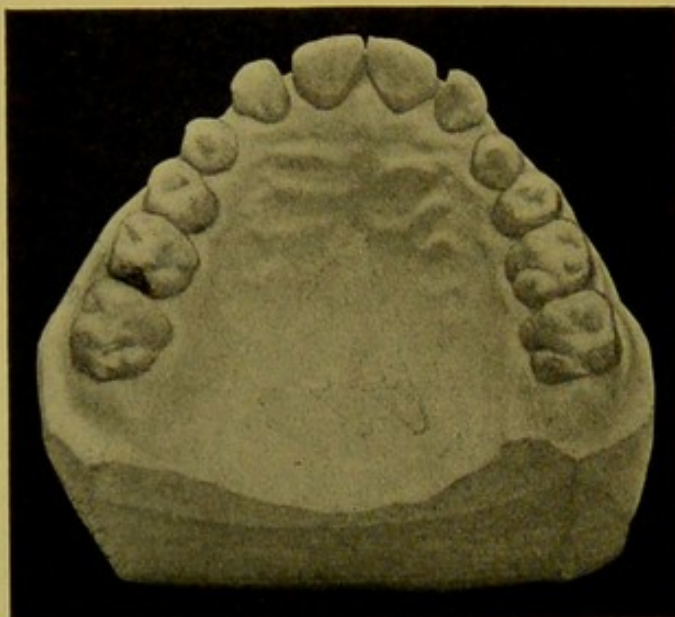It is then better to wedge the teeth apart and to make the disk separation (on the temporary tooth only) from the lingual or buccal side, or both, and to contour the filling even in exaggeration, so that a minimum of contact shall exist. Any surface of dentine exposed by the disking should be included in the cavity, or, if this be not possible, then it should be rubbed with silver nitrate (Fig. 337).

Such surfaces should be carefully observed at regular intervals; indeed, if prophylactic treatment can be regularly instituted early and before caries of the first permanent molar, much good will be done.

The pulp diseases resulting from caries of the temporary teeth will be considered with those of the permanent teeth. If the temporary teeth be so badly decayed as to be hopeless, as far as filling is concerned, they should be extracted. Occasionally the encircling of the teeth with pure gold bands cemented to place or filled in with amalgam is good practice.

The child should always be treated with kindness and truthfulness to establish faith, yet with sufficient firmness to command control.

FIG. 337.



Right upper temporary molar disked lingually and filled.

Under no circumstances should the child be given an excessive dread of dental operations, or be broken by nervous shock, as this attitude defeats the object sought.

RECURRENCE OF CARIES.

Passing over as disproved by Miller the theory of Palmer that caries recurs about fillings as the result of electric action, it may be stated as proven by scientific and clinical experience that it recurs because after teeth have been filled conditions exist which favor the collection of microbic plaques even more strongly than the original conditions, and that when recurrence has been prevented the work has been done in such a manner as to prevent such collections.

The specific defects which favor the formation of bacterial plaques may be epitomized as follows:

1. Lack of proximal contact (food wedging between teeth).
2. Roughness of the filling at an otherwise good proximal contact point which menaces the proximating tooth or the margin of the cavity.
3. Unremoved excess of filling material at margins, producing a ledge which collects food, etc. The edge of a crown may act in a similar manner.

4. Exposure of the cavity margin due to lack of covering by the filling material; whether not properly placed, flaked away, or due to fracture of margin during the filling process or subsequently thereto.

5. Exposure of the cavity margin due to shrinkage or shifting of the filling material.

6. Roughness of tooth surface, produced by polishing fillings with rough proximal trimmers, coarse grit strips, disks, or wheels. Exposure of dentine by overpolishing may be classed with the above.

7. Lack of extension of cavity margins to a point which brings them within the influence of ordinary prophylactic measures or forces.

8. Lack of hygiene of surfaces which tend to decay.

9. Solubility of the filling material, permitting the cavity wall to become exposed.

Treatment. The treatment of recurrent caries does not differ materially from that of primary caries.

Repairs to obliterate crevices, breaks, or new decays may at times be made, but so often is it the case that apparently slight recurrences are found after removal of the filling to involve the entire cavity wall, that the only sound recommendation applicable to all cases is that the filling be removed and the cavity reprepared and refilled. The exception exists when, after the new cavity of decay is all excavated, the adaptation of the filling is seen to be perfect. Decay at two or more points of recurrence, or general inferiority of the filling should condemn the entire piece of work.

PROPHYLAXIS OF CARIES.

If the factors of caries be removed from the mouth, caries cannot occur. That a clean tooth will not decay is a dictum many years established. That the caries fungi may be present in the mouth and be harmless, unless conditions favor the formation of gelatinous plaques upon the teeth, has been shown by Black and Williams.

These facts demonstrate that the sole requirement in the prevention of caries is the prevention of the formation of gelatinous plaques upon spots favoring their retention.

It has been shown by Williams that caries is a reasonably slow process; therefore, the removal of plaques at frequent intervals is sufficient for the prevention of caries.

In the absence of exact knowledge of the relation of general systemic conditions to the production of these plaques, it may be said that the

general health should, if possible, be maintained by the correction of any morbid body state, as, without doubt, perfect good health is a corrective of morbid oral secretions.

Apart from this, oral cleanliness is of great importance, not only for the health of the teeth, but of the gums, and indirectly of the stomach and intestines, which can but be affected by unhealthy oral conditions. Thus, while the general health may influence the mouth, the mouth may influence the general health.

It has been noted that caries is markedly lessened in well-kept dentures.

The first step in the prevention of caries is the removal of all possible causes of bacterial plaque formation. Cavities should be obliterated by means of exactly adapted, perfectly contoured, highly polished, insoluble (in so far as utilizable) fillings, the margins of which are extended into areas subjected to friction by ordinary means. Departures from this principle are to be made for well-judged reasons only. By these means centres of infection are removed and the problem is reduced to the care of the superficies of the teeth. Calculus should be thoroughly removed, the teeth highly polished and kept polished. This operation mechanically removes the plaques.

To prevent their return, daily cleansing of the teeth by the patient has always been practised, and a thorough cleansing once a month or oftener by the operator has been shown by D. D. Smith to be highly efficacious.

DAILY CLEANSING OF THE TEETH.

A well-made, stiff brush, having a lengthened tuft of bristles at its tip and its brushing surface serrated, is to be moistened and well charged with a good antiseptic tooth-powder or paste. It is to be grasped in the palm of the hand with the ball of the thumb placed upon the back of the handle, or exactly the reverse, according to the movement desired. The bristles are to be passed over the buccal and lingual surfaces of the teeth, from the gum toward the occlusal surfaces, by means of a dexterous, wiping motion imparted by a turn of the wrist. This cleanses the interproximal spaces so far as accessible to it. By a light to-and-fro motion the lingual and buccal crevices are freed of soft deposits which occur after each meal. Unless the gums be actually torn, this light friction is not injurious. Especial attention is to be paid to the buccal surfaces of third molars, which are often ignored even by conscientious patients.

The lingual surfaces of incisors are cleansed by means of the stiff tip of the brush. In cases of advanced recession of the gum about incisors, a brush with all the bristles except those of the tip cut away is advantageous. This is also useful for the lingual surfaces of bridge work. Occlusal surfaces are to be freely brushed.

A light brushing after each meal imparts to the mouth a pleasing sense of cleanliness which has a good moral effect upon the patient and removes from about the teeth much fermentable material.

The teeth should be thoroughly brushed upon retiring to remove any débris about the teeth, and the antiseptic and antacid treatment to be mentioned employed. This places the mouth in a fairly aseptic state for the night, during which the oral fluids are at rest and less interfere with fermentation or neutralize its products.

Before breakfast the mouth should again be treated to remove the bacteria developed during the night.

Once a week the patient should dip floss silk in the tooth-powder (or rub the powder over the interproximal spaces), carry it between the teeth and rub down the proximal surfaces, with the object of removing any bacterial collection upon these surfaces.

The floss silk should not be forced into the gum, as this will injure the gum margins and force infective material into it.

After cleansing the teeth an antiseptic should be held in the mouth for the space of two minutes, for the purpose of devitalizing bacteria present. For this purpose phenol-sodique in 25 per cent. solution in water (1 to 3) is as valuable as any agent, though many harmless preparations are sold for this purpose. Perhaps glycothymolin, being alkaline and antiseptic as well as agreeable, is to be preferred.

In a mouth especially prone to caries of the teeth it is well to use, once or twice a week, a disguised mercuric chloride wash 1:2000 for the space of two minutes. The object is to thoroughly devitalize oral organisms and promote the action of the milder and more agreeable antiseptics.

Finally, after the above treatment, Phillips' milk of magnesia (magnesium hydrate in suspension) should be taken in concentrated form into the mouth, rinsed about and drawn by suction between the teeth. The excess is to be expectorated and the residue left in the mouth. It is alkaline, slightly astringent, and is credited with some antiseptic property. These processes do not consume much time if the patient be systematic.

The periodical cleansing suggested by D. D. Smith involves the

monthly rubbing down of all surfaces accessible to a wedge-shaped wooden polishing point directed by a hand carrier. Powdered pumice is the abrasive suggested. The point is to be gently insinuated beneath the free gum margin for the purpose of effecting a cleanliness there, which shall prevent collections liable to produce pyorrhœa alveolaris.

This method may be supplemented by a careful rubbing down of contact points by means of floss silk charged with powdered pumice as an additional precaution against proximal caries.

The slight cleansing apparently required after a few visits is a strong argument in favor of these prophylactic cleansings.

Periodical examinations should be made at short intervals, preferably at the time of cleansing, for cavities of decay, roughness of filling margins, or accidents to the same. By these means the soil may be rendered unsuitable to the growth of caries fungi.

Some dentists pursue the policy of filling only the larger cavities existing in a mouth, the others being neglected until a subsequent period. Such a method is to be condemned as being a neglect of a plain duty and as tending to the propagation of caries in the mouth. The presence of cavities, calculus and pyorrhœa alveolaris in the mouth all tend to cause infection of the digestive tract, with production of inflammatory (catarrhal) disturbance, and to cause infection of parts in close association with the teeth as well.

Undoubted cases of septic intoxication and infection from decayed teeth and other oral conditions have been reported, the connection having been shown by their cure after removal of the local cause alone; in other cases the parts (as the stomach) having the secondary infection well implanted, have required special antiseptic treatment in addition to the removal of the primary exciting cause.¹ (See Systemic Effects of Pyorrhœa Alveolaris.)

The evils attendant upon sepsis are to be pointed out to patients, who have often a seeming indifference to conditions within the mouth which would alarm them if existing in any other part of the body.

PROPHYLAXIS IN SYSTEMIC DISEASE.


During a prolonged illness, seasickness, pregnancy, etc., the prophylactic care of the teeth should be rigidly enforced as a means of preventing decay of the teeth and sepsis of the mouth.

¹ Hunter, International Dental Journal, 1899. Abstract from Transactions of Odontological Society of Great Britain.

It has been shown that during pregnancy osteomalacia may occur and that it represents a demineralization of the bones of the mother. Whether or not this may influence caries of enamel is not certain, but there is no reason why the resistance of the fibrillæ of the dentine should not be lessened, or even that the dentine may not be to an extent demineralized, as positively claimed by some accurate observers (Black to the contrary). An excessive osteomalacia may be held to represent a deficiency of osteogenetic nutritive material for the child. This would lead to an inferior development of the child's teeth.

Any abnormal condition of the mother should be corrected, if possible, in order that her general nutrition and that of the child may not suffer.

Probably upon the congenital constitution of the child depends much of its future susceptibility or immunity to caries.



SECTION IV.

DISEASES OF THE DENTAL PULP.

CHAPTER XVI.

CONSTRUCTIVE DISEASES.

DISEASES of the dental pulp are both acute and chronic. According to the anatomical features, they may also be divided into constructive and destructive. The acute diseases are usually destructive; in the chronic, structural and constructive changes are commonly noted. Constructive diseases of the dental pulp are those attended by the formation of deposits of new masses of calcific substance. Destructive diseases are those which cause retrogressive and necrotic changes in the tissues of the pulp. The essential difference between the two classes of diseases is in the mode and character of the degeneration—the one is acute, the other chronic.

Pathologically there is no abrupt line of separation between those disorders usually termed diseases of the dental pulp and those which are described under the head of diseases of the live dentine. As soon as the dentine of the crown of a tooth is deprived of a portion of its normal protective covering, the enamel, either through chemical solution incident to the first phase of dental caries or from mechanical abrasion, the vital portions of the dentine are subjected to new and abnormal conditions. These vital portions being in reality prolongations of the peripheral cells of the pulp, it is evident that the morbid conditions engendered by their exposure are expressions of pulp disturbance, and we should expect to find reactionary effects upon the part of the pulp. Depending upon the severity of the irritation and the length or number of times sources of irritation have been in operation, evidences of functional and structural disorders in the body of the dental pulp are observed.

Post-mortem knowledge of structural diseases of the dental pulp is comparatively complete, but a parallel knowledge of the exact nature

of the causes producing definite and recognizable conditions, together with the symptoms which precede and accompany the several morbid states, is incomplete. In the absence of precise information as to the association between disease causes, their symptoms and effects, physiological and pathological, the practitioner bases his diagnosis of the anatomical condition of the pulp on symptoms which he is enabled to elicit by certain tests, and by the history furnished by the patient. The tests applied and histories obtained direct attention to the vascular system of the pulp as the primary cause of many, or most, of the conditions of the organ which are attended by paroxysmal and reflex pains. The reactions to tests occur both with and without exposure of the pulp to external sources of bacterial infection, although they are found in the vast majority of cases where bacterial invasion is a probability.

SYMPTOMATOLOGY OF THE PULP.

Writers upon dental pathology, during at least the past twenty-five years, have called attention to the fact that pain produced through the irritation of the dental pulp is rarely referred to its point of origin; that is, diseases of the pulp are, as a rule, characterized by reflected pains. G. V. Black has clearly set forth the causes and reason of this phenomenon. "The pulp of a tooth is not its tactile organ; that is, it does not possess the sense of location. The only stimulus to which it responds in its normal state, when encased in an unbroken chamber of dentine, which is perfectly sheathed with enamel, is applications of heat or cold. Far removed in its normal state from situations in which a tactile sense could perform any physiological function, such a sense would be useless. Organs in which the tactile sense is absent, and in which it would be perhaps superfluous, when the seat of disease have the pain incidental to the disease reflected to other parts; for example, in hip-joint disease, pain at the inner side of the knee is a diagnostic sign; in inflammations of the iris the pain is referred to the brow; pain at the orifice of the urethra is indicative of disease of the bladder, and so on. So with irritation of the dental pulp, the pain is indefinitely or vaguely located. In those cases where pain is referred to the tooth irritated, there are associated conditions which produce a response of the true tactile organ of the tooth, the pericementum."

The pathological conditions of the pulp are judged by the phenomena induced by applications of air or water of varying temperatures,

and by the presence of certain appearances of the tooth, which, taken with the symptoms and tests, lead to a fair inference of the disease present.

It was pointed out by Black¹ that if a healthy tooth be isolated by a double layer of rubber-dam, and a jet of water at a temperature of 40° F. be directed against the tooth, a paroxysm of pain is produced. A jet of hot water will also induce a similar pain, and if the patient's eyes be shielded no difference in the sensations is noted; that is, the pulp responds to thermal stimuli, hot or cold, indifferently. The organ is accustomed to variations of temperature between 60° and 105° to 110° F., and within this range, in a condition of health, takes no apparent cognizance of this degree of change.

With a decrease in the amount of dentine covering the pulp—*i. e.*, with the advance of caries—the reaction to thermal stimuli increases in promptness, until, when the pulp is nearly exposed, the response is immediate. Succeeding this is noted prompt response to lesser degrees of temperature change, until the pulp comes to respond immediately to water at a temperature of 70° F., or thereabout, and slightly over the bodily temperature, 102° F. Later, another feature makes its appearance; instead of a sharp contraction pain, applications of moderate thermal stimuli are followed by a heavy, throbbing pain. Later, similar pains occur in the absence of tangible external sources of irritation. In the ordinary sequence of events intense pain is later caused by hot applications, and cold applications afford relief.

The response to thermal stimuli may pursue the opposite course. The normally prompt response is followed by delays in reaction, until it is only after the continued application of cold to the exterior of a tooth that a paroxysm of pain is induced. In these cases there follows after a long time an increasing response to heat, as in the former instance, the reaction occurring only upon decided or prolonged heat stimuli. Following upon the period of increased response to heat, in both cases there comes a period of quiescence, in which there is no response whatever to applications of intense cold, even that produced by the evaporation of a spray of ethyl or methyl chloride—*i. e.*, the sensory function of the pulp is paralyzed.

These are the available subjective evidences of the anatomical condition of the pulp; while they indicate with a degree of accuracy, useful in clinical work, the alterations in the pulp, the exact relations between

¹ American System of Dentistry, vol. i.

the reactions and the morbid anatomy of the organ are not entirely clear. In the light of personal knowledge it is assumed that, in consequence of the loss of the normal protective covering of the pulp, its sensory and perhaps vasomotor nerve fibres become stimulated, overstimulated, irritated, then paralyzed by thermal stimuli in the progress of caries. The bloodvessels, which retained their tonus up to a certain point, suffer vasomotor irritation; next, paralysis leading to their dilatation and to the throbbing pain. Later, even change of posture is sufficient to cause distention of the paralyzed vessels, hence pain in resuming the reclining position. Stimulation by cold, until the later stages, causes a sharp, continuous pain, ascribed to the paroxysmal contraction of the vessels; although unquestionably specific, sensory-nerve reaction is involved. In the stages of paralysis heat causes further distention of the vessels, and, if adventitious gases be present, causes their expansion with pressure upon nerve filaments.

The decreasing and delayed response to thermal stimuli must be referred to two sources: first, an increase in the non-conducting covering of the pulp—*i. e.*, a lessening of the amount of the fluid contents of the dentinal tubuli and a thickening of the dentinal walls, which necessarily implies a recession of the pulp from its normal position; secondly, to degeneration of the sensory-nerve fibres themselves; and, thirdly, changes in the walls of or about the bloodvessels, which check vasomotor response and changes in the calibre of the vessels. These two classes of reactions still further emphasize the division of pulp diseases into two types, the acute and chronic; the first class of reaction is associated with the acute destructive diseases; the second, with the chronic constructive but degenerative conditions.

CONSTRUCTIVE DISEASES OF THE DENTAL PULP.

The constructive diseases of the dental pulp include all the secondary dentine formations, tubular calcification, the formation of pulp nodules, and calcareous degeneration of the pulp.

Tubular Calcification. Definition. By tubular calcification, or, to express the condition more accurately, tubular dentinification, are meant those changes that occur in the dentine which lead to an obliteration of the dentinal tubuli by constructive changes in the walls of the tubules.

Causes and Occurrence. The apparent cause is a mild degree of irritation, not passing the stage inducing constructive metamorphosis,

and apparently caused by heightened thermal sensitivity or direct irritation of the fibrillæ. It occurs in the course of mechanical abrasion and erosion of the teeth, under metallic fillings, and probably a modification of the process precedes the slow invasion of dental caries. It occurs in some degree as a normal vital change due to age, and is common in persons who are victims of the gouty or rheumatic diathesis.

Pathology. The fibrilla is lessened in diameter as the lumen of the tubule becomes smaller. There is sometimes an increased, but more often a lessened, sensitivity of the dentine.

Other phases of the condition are discussed under transparency of the dentine, to which the disease corresponds. (See p. 309.)

The altered dentine becomes translucent, acquiring a horn-like appearance.

Tubular calcification is, for the most part, to be regarded in the light of an effect due to a physiological process. In so far as the disease is confined to the dentine, it may be regarded as a physiological barrier erected against the progress of caries, erosion, or abrasion, threatening the invasion of the pulp. While it delays the disintegration of the tissue, it does not prevent it. In the cases due to age or the irritants produced by gout, it is probably a local expression of a general sclerotic change, the intercellular substance (tubule wall) being formed at the expense of the cellular (fibrilla). In senility the change in the dentine may cause the teeth to be almost transparent. It requires no treatment.

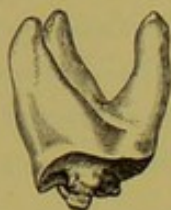Secondary Dentine. Definition. By secondary dentine is meant a deposit of dentine upon the wall of the pulp chamber, as the result of pulp stimulation after the pulp has enjoyed a physiological period of rest from dentine formation. It is always attached to the dentine.

Causes. The cause of formation of secondary dentine is a stimulation of the pulp to increased functional activity. This stimulus may be provided by any constant irritation of the dentinal fibrillæ, as, for example, when exposed at necks of teeth, upon abraded or eroded surfaces, or within cavities of decay. The presence of metallic fillings conductive of thermal changes may provide the necessary stimulus. Gold crowns upon ground-down crowns of vital teeth have a similar effect. The slightly irritative effects of oxychloride of zinc often produce much secondary dentine. A pulp capping may provide the stimulus and new dentine fill the orifice of exposure.

Absolute exposure without treatment has been recorded as productive of secondary dentine. In two cases described by Charles

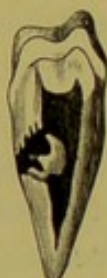Tomes, pulps widely exposed by fracture of crowns during extraction covered themselves completely in. The histological record as seen

FIG. 338.



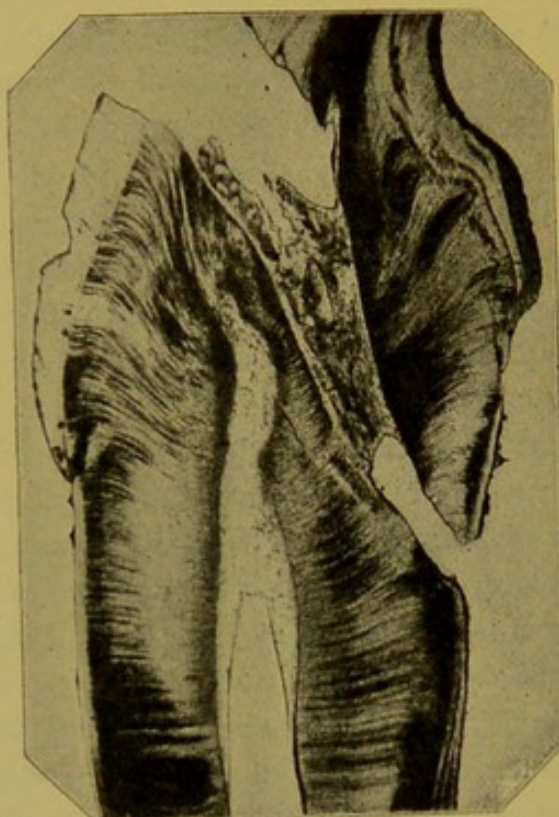
Secondary dentine formed after exposure of pulp by fracture during extraction. (Tomes.)

FIG. 340.



Bicuspid in which a formation of secondary dentine has failed to obviate perforation of the pulp cavity by resorption. (Tomes.)

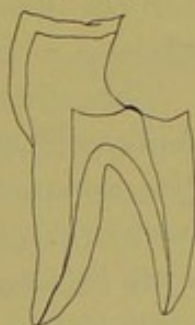FIG. 339.



Harding's case of united fracture. The uniting material is of coarse osseous structure with numerous lacunal spaces. (Tomes.)

in the photomicrograph demonstrated that a plastic exudation was first exuded, which later calcified as an amorphous mass.

FIG. 341.



Elastic layer of calcific material formed over an exposed pulp. From a case.

Next an irregular lamina was formed, and, lastly, dentine containing tubules. It is to be inferred that both the pulp and its odontoblasts may take part in the process (Fig. 338).

I have seen one case in which a wide exposure had been covered in sufficiently to enable me to gently indent the covering, which was convex, with a ball burnisher. Upon removal of the instrument it resumed its original shape owing to its elasticity. The periphery of the original exposure was clearly defined (Fig. 341).

Age seems to be a cause of general secondary dentine formation, but no doubt certain forms of irritation are introduced competent to produce the changes. At times reflex irritation

seems to be a competent cause, as in cases of partial abrasion the unworn teeth may be affected in equal degree with the worn ones.

Pathology and Morbid Anatomy. The formation is usually noted opposite to some area of injury and may be distinguished from normal dentine by its translucency, or sometimes by its color, which may be a light brown. The deposit may be of fairly regular or irregular distribution, and even tumors attached to the dentine have been described (Figs. 340 and 344).

FIG. 342.

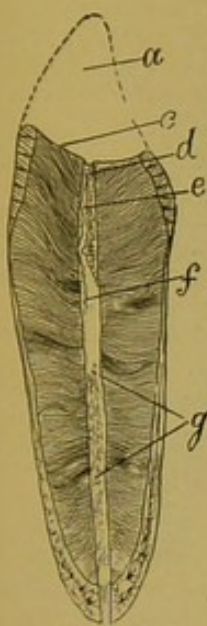


FIG. 343.

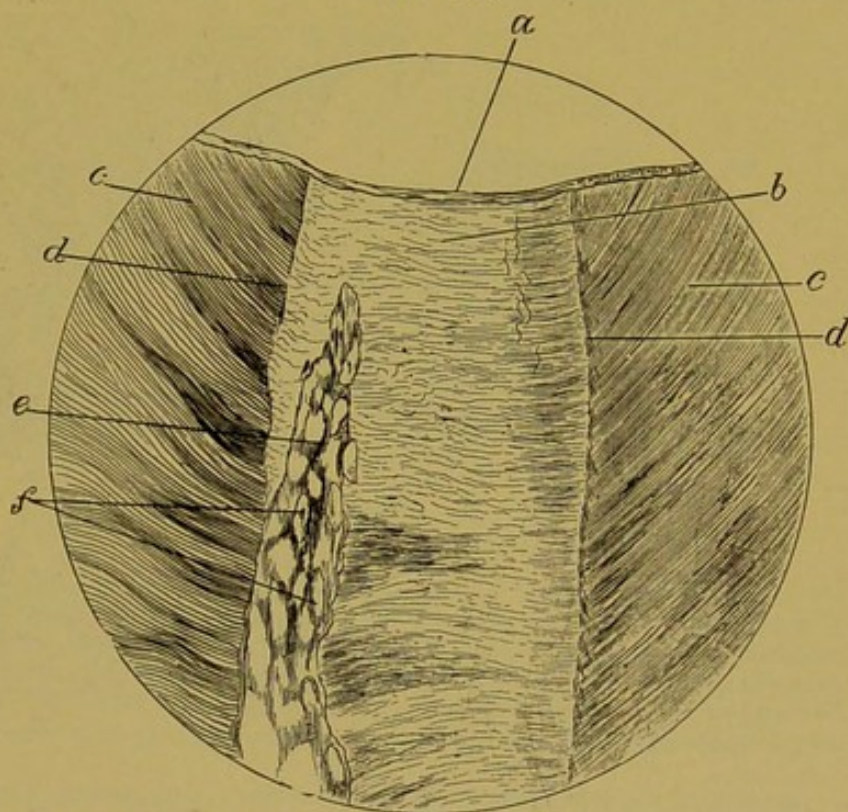


FIG. 342.—Secondary dentine filling the pulp chamber in a case of abrasion of a cuspid tooth: *a*, portion lost by abrasion; *c*, abraded surface; *d*, secondary dentine, filling a portion of the pulp chamber, and acting as a protection to the pulp; *e*, slender point of the pulp; irregular deposits are seen on the walls of the pulp chamber, as at *f*; *g*, cylindrical calcifications in the root portion of the pulp chamber.

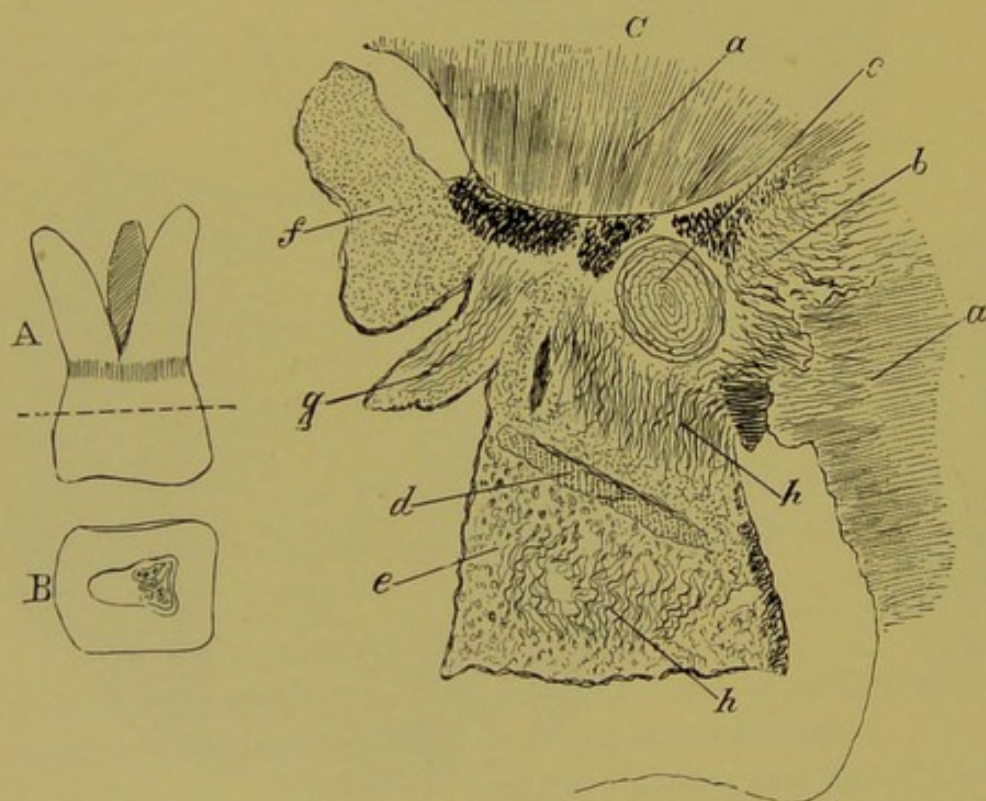
FIG. 343.—Secondary dentine from the same specimen as Fig. 342, magnified sufficiently to show the difference in primary and secondary tissue: *a*, abraded surface crown; *b*, secondary dentine; *c*, primary dentine; *d*, junction of primary with secondary dentine; *e*, remains of pulp tissue; *f*, small oval masses of calcific material. (Black.)

Black has shown that in the deposits against normal dentine the first-formed portion contains an almost normal number of tubules, but their direction is sharply changed. As the deposits become thicker, the tubules become fewer and finally the dentine becomes amorphous in character (Fig. 347).

Black relates these appearances with the gradual atrophy and disappearance of the odontoblasts.

Hopewell-Smith, treating of secondary dentine under the title of "Adventitious Dentine," mentions several varieties: (1) Fibrillar, or that containing tube-like markings finer and less regular than in normal dentine. This would correspond to that in Fig. 344, *h*. (2) Areolar, that containing interglobular spaces formed by the non-union of calcospherites. (3) Cellular, or that in which the connective-tissue cells of the pulp remain encapsuled in the calcifying matrix. (4) Laminar, in which laminated spherites appear (Fig. 344, *c*). (5) Hyaline,

FIG. 344.



Dentinal tumor within pulp chamber: *A*, diagram of the tooth, with dotted line showing the position of the section *B*. In *B* the pulp chamber is shown in section, nearly natural size, showing the tumor within. *C* is an illustration of the tissue of the tumor; *a, a*, the primary dentine; *b*, irregular tubules connecting the new growth with the primary dentine—most of these are very dark and irregular; *c*, a calcospherite included in the mass; *d*, apparently a bloodvessel calcified; *e*, calcified tissue; *f*, a finely granular mass; *g*, a spur of very transparent dentine. Dentinal tubules appear at *h, h*. (Black.)

having a granular or ground-glass-like appearance (the amorphous substance of Black). (Fig. 344, *f*.)

He regards the adventitious dentines as formed by pulp cells rather than by the odontoblasts.

In these cases the pulp deposits calcoglobulin against the dentine. Apparently in some of Black's cases the calcoglobulin was deposited about pre-existing fibrillæ which continued to persist in the new-

formation, while in 'Tomes' cases the pulps were compelled to calcify a plastic exudation as a sort of basis for the beginning of tubule formation. Black has shown that in abrasion the deposit is more regular than in caries, without doubt due to the fact that the thermal irritation in caries is more irregular than the irritation of the fibrillæ by abrasion.

The entire crown may be removed by abrasion and yet the pulp be protected. In some cases the protective action ceases and the pulp becomes closely approached or exposed (Fig. 256).

The mode of deposition upon the sides of the canal in abrasion, shown by Fig. 347, is quite characteristic.

FIG. 345.

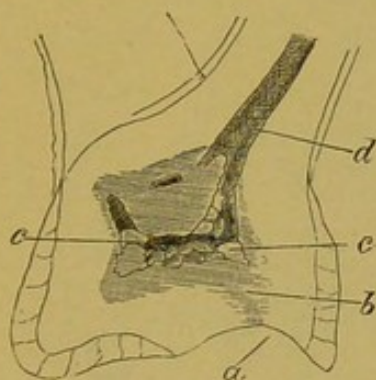


FIG. 345.—Illustration of the narrowing of the pulp chamber in a molar (superior) by the deposit of secondary dentine resulting from abrasion, showing the portions of the chamber in which the deposit usually occurs. The light-shaded portion (*b*) shows the original dimensions of the chamber, which, in this instance, seem to have been pretty large; *a*, a point of deep abrasion; *c, c*, remaining pulp chamber, which is mostly filled with irregular masses; *d*, one of the root canals. It will be observed that the narrowing of the root canal is within the original pulp chamber. (Black.)

FIG. 346.

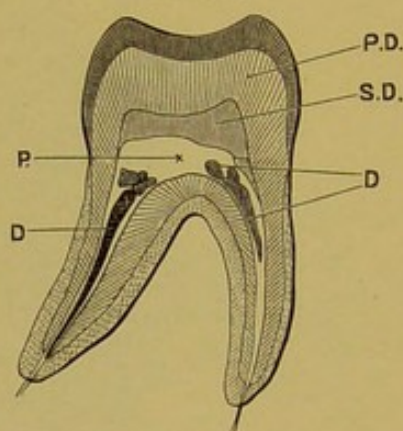


FIG. 346.—*P.D.*, primary dentine; *S.D.*, secondary dentine; *P*, pulp chamber; *D*, nodules.

Deposits in canals may occur, lessening their lumen and increasing the difficulty of canal exploration (Fig. 349).

"Secondary growths in cases of abrasion are not confined alone to the abraded teeth, but other teeth which have escaped wear may be affected in equal degree. In all of these cases there is direct evidence that the odontoblastic layer has been stimulated to increased activity and produced the regular secondary deposition."¹

Secondary dentine is often accompanied by other constructive changes in the pulp—*i. e.*, pulp nodules and calcareous degeneration (Figs. 346 and 352).

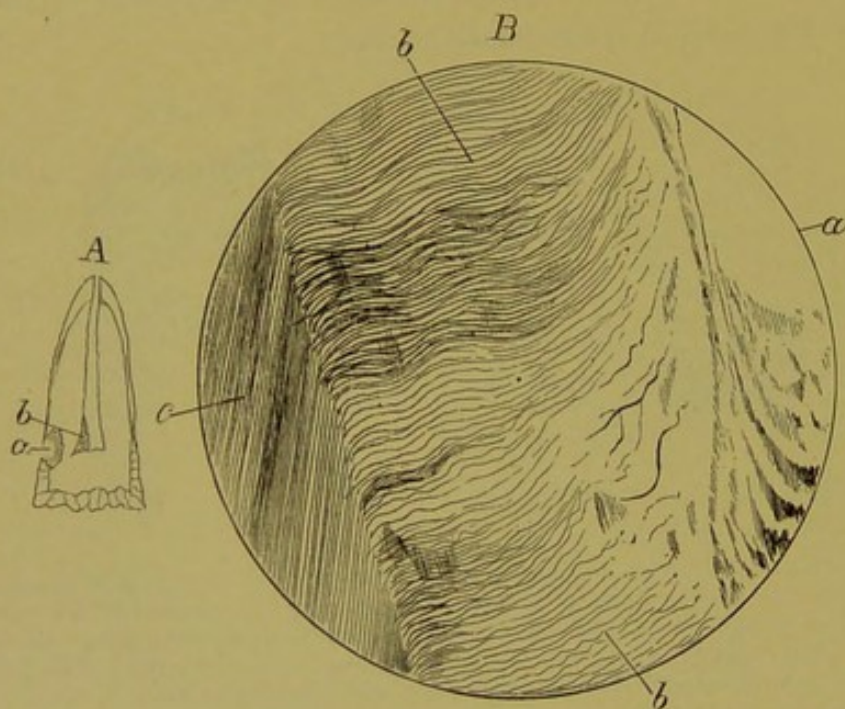
Miller has shown that dentine resorption by the pulp may be

¹ Black, American System of Dentistry, vol. i.

repaired by a new deposit of secondary dentine, which Hopewell-Smith has shown to be of the nature of cementum (Fig. 365).

Tomes¹ describes and illustrates a peculiar case of united fracture occurring in the practice of Mr. Harding. In an incisor an oblique fracture occurred which entirely separated the fractured segment, yet a plastic exudate from the pulp occurred which, when calcified, attached it to the fixed portion of the tooth. The new-formation did not resemble dentine (Fig. 339).

FIG. 347.



Calcification, or deposit of secondary dentine, resulting from caries of an incisor: *A*, diagram of section of incisor, showing caries at *a*, and secondary dentine at *b*. *B*, illustration magnified 200 diameters, to show the tissue of the secondary dentine: *a*, pulp chamber; *b*, secondary dentine; *c*, primary dentine. It will be noticed that the dentinal tubes in the secondary dentine gradually disappear, giving place to a clear calcification. (Black.)

Fig. 273 illustrates a case of repair of an incisor fractured at a point well up beneath the gum, a condition reasonably ensuring asepsis. A firm reattachment occurred. (See Fig. 266.)

Kirk² records a case of immediate replantation in early life, followed in old age by root resorption. The tooth when extracted contained secondary dentine which could only have formed as the result of a reattachment of the pulp.

W. H. Trueman³ reported that hypersensitive dentine was noted some years after a replantation under similar conditions.

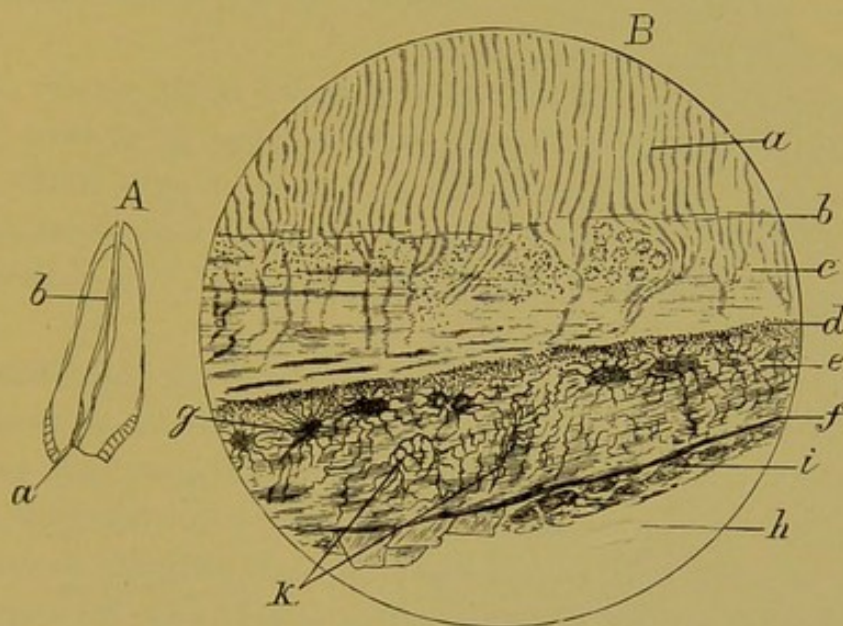
¹ Dental Surgery.

³ Ibid.

² Proceedings of the Academy of Stomatology, 1902.

Osteodentine. Tomes states that secondary dentinal deposits may assume the character of osteodentine, a form of dentine found in the teeth of some animals, in which the tissue presents combined characteristics of both bone and dentine. He cites the example also that elephants' tusks are frequently repaired with osteodentine after injury. The specimen illustrated (Fig. 348) was taken from a case in which the coronal portion of the pulp chamber was almost obliterated by a deposit of secondary dentine. Probably some of the pulp cells have taken on the characteristics of osteoblasts. Tissue resembling

FIG. 348.



Osteodentine: *A*, outline of incisor, showing a narrowing of the root canal at *b* by a deposit of osteodentine. *B*, illustration of the tissue: *a*, primary dentine; *b*, line of the beginning of a growth of secondary dentine; *c*, secondary dentine; *d*, layer of granular matter; *e*, osteodentine; this has the lacunæ at *g* and dentinal tubes at *k*; *f* seems to be the surface of the osseous deposit; *i*, irregular crystalline deposits; *h*, the pulp chamber. $\times 350$. (Black.)

cementum seems to be frequently found as a tissue of repair (Fig. 365).

Results of Secondary Dentine. The formation of large masses of secondary dentine unquestionably brings about a degenerative condition of the pulp which may become a cause of neuralgia. The pulp may die and, becoming infected, may produce pericemental irritation. In one case seen the secondary deposit in the pulp chamber had separated the canal filaments of the pulp of a multirooted tooth into independent pulps, one of which was dead and the others alive and undergoing degeneration. The specific symptoms were those of pericementitis—*i. e.*, elongation and tenderness to percussion.

In another case of a first upper bicuspid the lingual filament was

perfectly covered in and apparently vital. The buccal filament, likewise enclosed and isolated, contained an abscess within the pulp.

The symptoms complained of, however, were those of acute pericemental irritation, simulating incipient septic apical pericementitis (Fig. 375).

It has been shown by Hopewell-Smith that micro-organisms may enter the pulp by way of the spaces or tubes in adventitious dentine. In Burchard's case a molar containing a deep cavity filled with zinc phosphate gave vague pain, finally referred to the tooth, which responded only faintly to hot applications and not at all to cold ones. Secondary dentine was found complicated by calcareous degeneration—*i. e.*, a degenerated pulp was present.

In certain cases a deposit extends well into a canal, totally obliterating it for much of its length. Unless symptoms be present it may ordinarily be left. In such cases thermal tests for pulp vitality seem often inconclusive. The electric current should be a more satisfactory means of diagnosis, provided the dentine be moist. (See Dry Gangrene.)

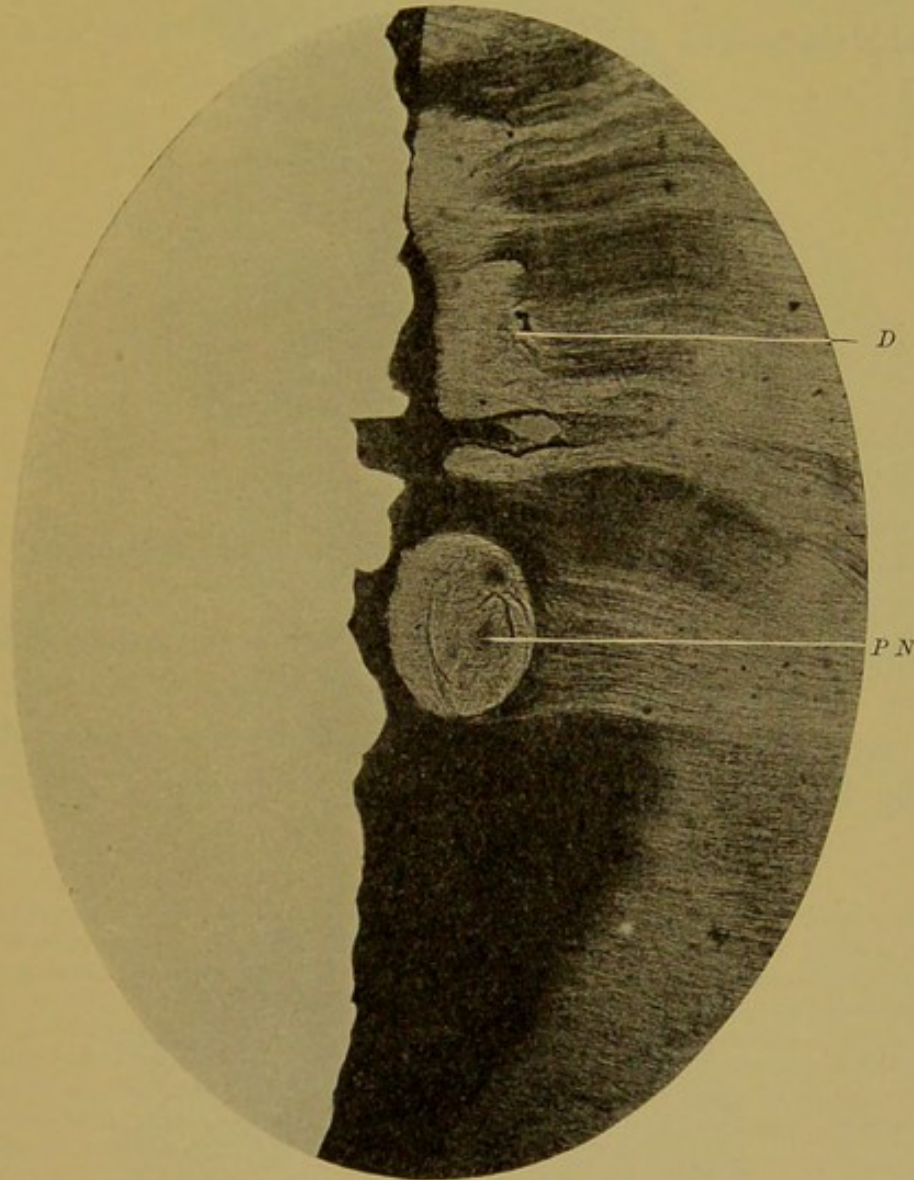
Treatment. Secondary dentine which has been regularly deposited, and particularly in the canals of anterior teeth, calls for no treatment. Should, however, great hypersensitivity of the dentine and pulp, or pulp disease, be evident or inferred from symptoms, the pulp should be removed. This may involve a search of some difficulty and necessitate the removal of much dentine. The canals may be much constricted, especially at that portion nearest the pulp chamber. The condition may be more or less complicated by the presence of pulp nodules or calcific degenerations in addition to the secondary dentine.

Pulp Nodules. Definition. Pulp nodules (pulp stones, nodular calcifications) are masses of more or less translucent, calcific material, apparently the result of secretion, having a fairly definite histological structure differing from that of dentine, and occupying a position within the pulp substance. They are rarely fused with the dentinal walls of the pulp chamber, and then are included by formation of secondary dentine.

Occurrence. While these growths may occupy the pulp chambers of teeth in which the pulp has been the seat of direct irritation, their occurrence is by no means confined to such teeth. They are found not only in teeth which have suffered abrasion, erosion, and slowly progressing caries, but, as pointed out by Black, they may, and frequently do, form in other teeth of the same denture which are not directly involved

in the irritation. This investigator notes that irritation of the pulp of one tooth of a denture very frequently causes a general hyperæsthesia of the pulps of all of the teeth. This is particularly notable in the type of persons classed as neuralgic. It is also common in persons of the gouty diathesis. It should be remarked that a general

FIG. 349.

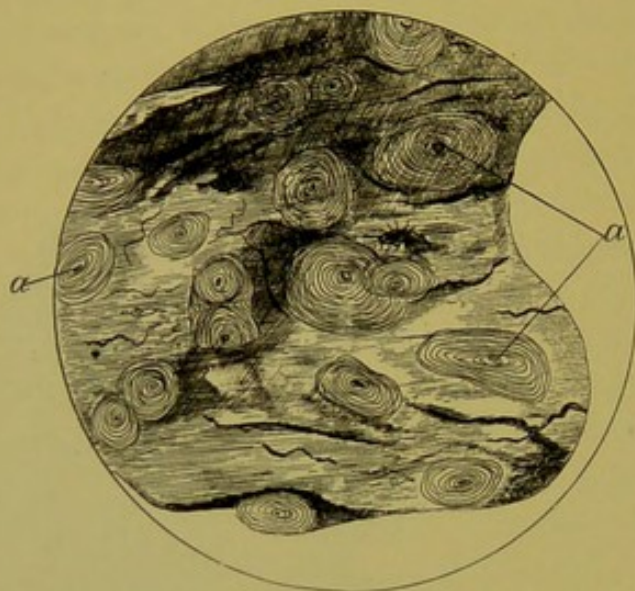


A pulp nodule fused to the parietes of a pulp cavity. Prepared by grinding. PN, pulp nodule; D, dentine of the tooth. $\times 15$. From section by J. F. Colyer. (Hopewell-Smith.)

pulp hyperæsthesia is frequently the precursor of an acute outbreak of gout in such persons. Nodules are found much more frequently in the teeth of middle-aged persons than in those of youth, although they may be present as early as the fifteenth year. They occur more frequently multiple than single. Some of the larger nodules are evidently formed by the coalescence of smaller ones.

Pathology and Morbid Anatomy. The structure of pulp nodules does not resemble that of dentine; they possess about the same degree of translucency and hardness. Outwardly they may assume almost any

FIG. 350.

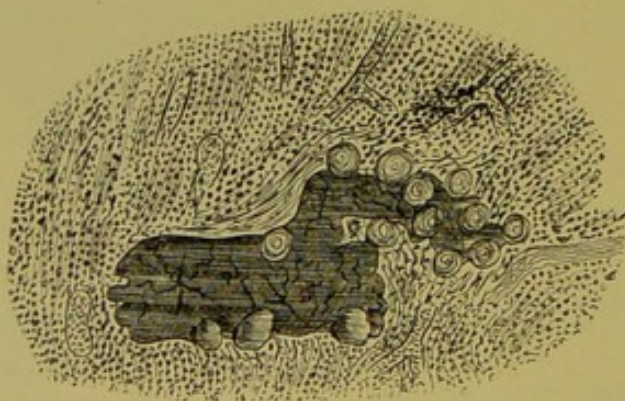


Section of a pulp nodule, showing many calcospherites, as pointed out by *a, a*. (Black.)

form; they range in size from minute bodies to a size sufficient to almost obliterate the pulp (Figs. 346 and 352).

A section of a nodule exhibits the presence of a number of concentrically laminated bodies, recognizable as hardened calcospherites.

FIG. 351.



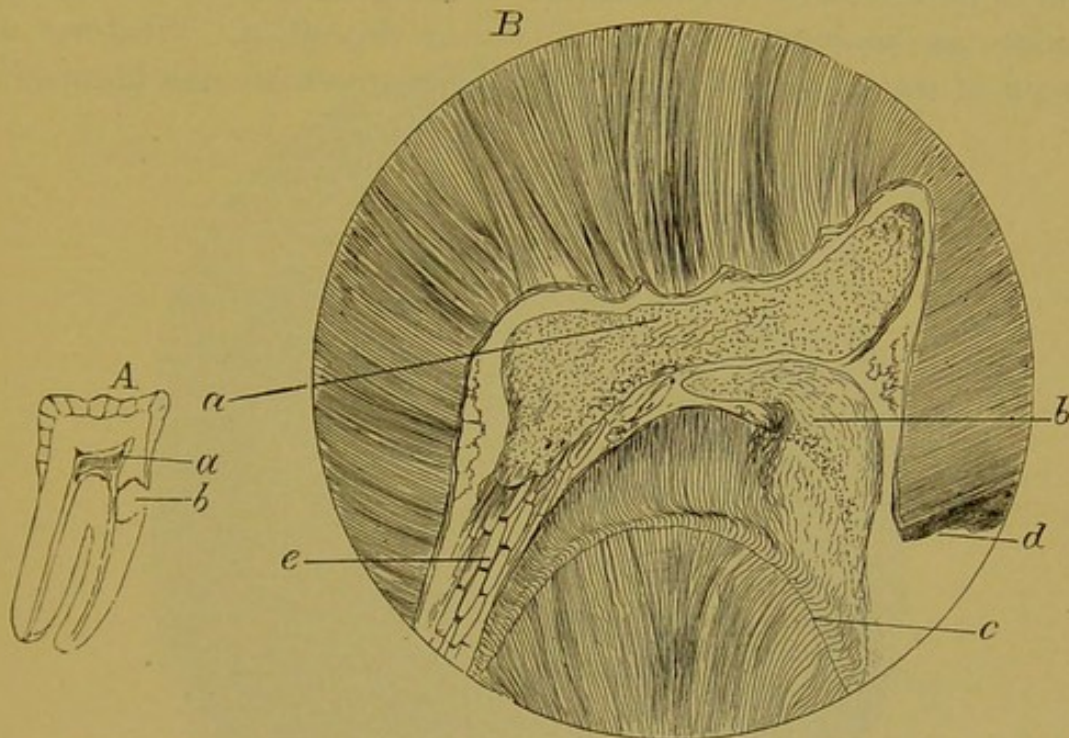
Deposit of calcoglobulin within the tissues of an inflamed pulp. (Black.)

Black found them to rarely make up any considerable portion of the bulk of the nodule. The remainder of the nodule is made up of structureless material which may contain a few fine tubes.

He also found deposits in the pulp which throw light upon the

possible origin of nodules in some cases, and to some extent upon the conditions under which they may be formed. In the pulp of a second molar of a girl aged fifteen, in which there had been decided subjective evidences of pulpitis recurring at intervals for a period of two months, he found a mass representing a pulp nodule in its soft state. "About one-half of the coronal portion of the pulp was involved in the inflammation; lying a little inside of the layer of odontoblasts were several masses similar to Fig. 351, having globular forms

FIG. 352.



Calcification of the dental pulp. At *A* is shown the outline of a lower molar with a cavity at *b*. The pulp chamber is much reduced in size and filled with calcific material, as shown in *B*. *a, a*, large granular mass of calcific material, which is very transparent but finely granular. A very few irregular lines are seen in the centre, which slightly resemble dentinal tubes; *b*, an erratic growth of irregularly formed and unusually transparent dentine; *c*, line of the growth of dentine from the floor of the pulp chamber: the growth from other directions is so perfectly regular as to leave no markings; *d*, margin of the cavity of decay; *e*, a bundle of cylindrical forms of calcific material extending down into the root canal. These extended to the apex of the root. (Black.)

in their mass or attached to their margins. The globular bodies present the laminated appearance of calcospherites." These masses may in all probability be interpreted as intermediate products in the formation of nodules; they have not yet become calcified.

A small nodule may be made up of laminated, structureless material, the laminae being arranged about a central nucleus, the nature of which is not clear, but may possibly be calcified dead cells (Fig. 353).

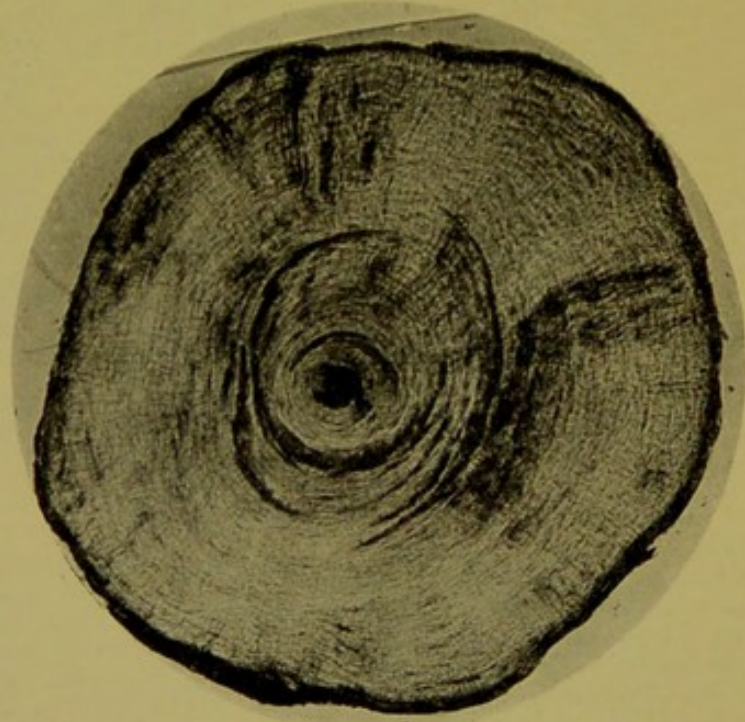
The conditions of calcification of nodules are not definitely known.

Hopewell-Smith considers that they are deposited by the pulp cells as a secretion about themselves, and that the cells are later obliterated or may persist *in situ* (Fig. 354). He also describes and illustrates a case of a nodule which had within it a pulp cavity containing pulp tissue.

Pulp nodules occur, as a rule, in the better grades of teeth which show constructive tendencies upon the part of the pulp.

It is possible that in these pulps the pulp cells under conditions of irritation secrete calcoglobulin, which in part is developed into spherites and in part remains without definite histological characteristics. The masses are probably calcified after their deposition. Whatever the origin of the masses—by cell secretion or otherwise—the histological

FIG. 353.



A pulp nodule isolated from the pulp. Shows its central nuclear formation and its concentric lamination. Prepared by grinding. $\times 50$. From collection of G. W. Watson (Hopewell-Smith.)

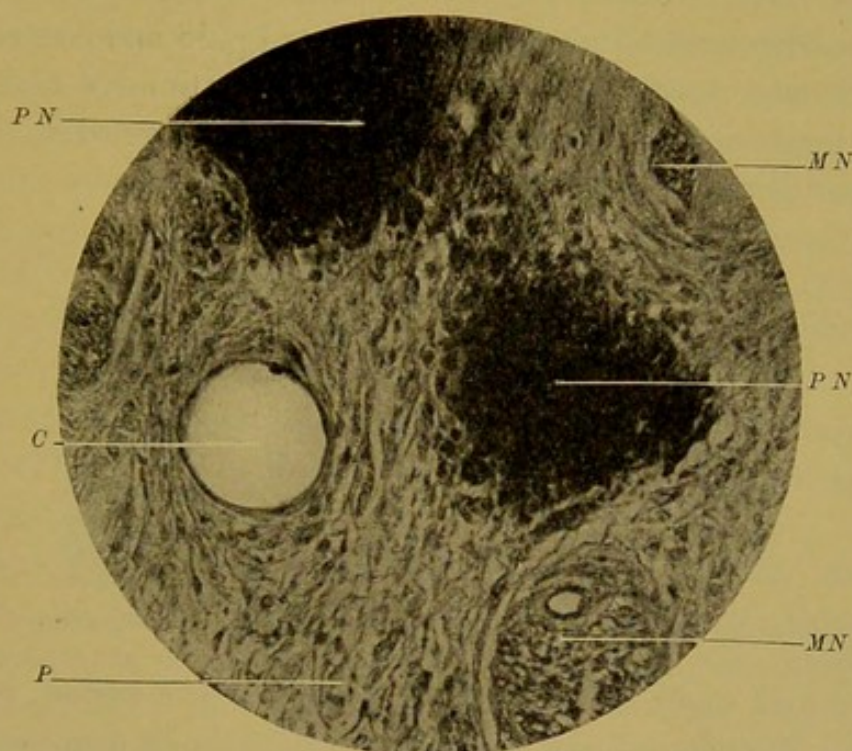
record indicates a gradual increase in the size of the deposit. Pressure upon the nerves results in irritation. Pulp nodules are usually found in the coronal portion of the pulp, but sometimes exist in the root portions, either free or embedded in secondary dentine. If they obstruct the lumen of the canal they cause interference with the circulation and nerve tissue and may produce great pain.

Symptoms. Multiple nodules may exist in a dental pulp and give rise to no evident symptoms whatever, as is shown by their presence

in extracted teeth, many of them free from caries, and in which there was no history of pain. On the contrary, the pulp of a tooth may be the seat of intractable pain without a depth of carious invasion which would lead to the inference of acute pulp disease; and relief only be secured through divitalization of the pulp, which upon examination may reveal a small pulp nodule.

The symptoms attendant upon the presence of nodules, so far as they can be made out, appear to be of two types—those associated with small and those with extensive deposits. Reflex pain is the common associate of both.

FIG. 354.



The formation of the pulp nodule. Prepared by Mr. Hopewell-Smith's process. *PN*, pulp nodules; *MN*, medullated nerve bundles; *P*, pulp tissue; *C*, capillary. $\times 230$. (Hopewell-Smith.)

SMALL DEPOSITS. While it is true that pulp nodules exist in apparently sound teeth without inducing pain, yet the pulps of teeth containing them become excessively hyperæsthetic under what are ordinarily mild sources of irritation. This is manifested, first, through the contents of the dentinal tubuli; the dentine becomes exquisitely sensitive, and cool water directed into a shallow cavity produces a paroxysmal and excruciatingly painful response from the pulp. In the absence of direct, extraneous irritation of the pulp, the dental symptoms may be absent, but a persistent neuralgia may be located at some distant point. Pain in the ear is a frequent symptom. Occasionally an obstinate scalp neuralgia, with the existence of a hyperæsthetic

spot, appears. Pain in the eye, with tenderness over the supra-orbital foramen, is also common. Guilford¹ has reported a case of *tic douloureux* of two years' standing, the result of pulp nodules. The pain may be recurrent or persistent. If, in the absence of a more probable explanation of the pain, a pulp nodule be suspected, and arsenical applications be made to devitalize the pulp, it is found that not only is intense pain caused, but examination after from forty-eight to seventy-two hours shows the pulp to be still vital and hypersensitive; and, in order to effect its destruction, repeated applications and large doses of arsenic must be used. Cocaine introduced by cataphoresis is also apt to be slow in action.

LARGE DEPOSITS. In extensive deposits of pulp nodules the dentine may be almost devoid of sensation, and applications of heat or cold, even in large cavities, may be followed by delayed and faint pulp response. Such cases, however, commonly give a history of reflex

FIG. 355.



FIG. 356.



Pulp nodules in the radicular and coronal portions of the canal. (Skiagraphs by Price.²)

neuralgia and vague dental pains extending over a period, it may be, of years. With some large deposit the pain may be exquisite.

Diagnosis. Their diagnosis by means of the *x*-ray is positive (Figs. 355 and 356), but their diagnosis by symptoms may only be inferential and confirmation be lacking until after devitalization of the pulp and the finding of the pulp nodules in its substance.

The tardy action of arsenic is also observed in the cases of large deposits, it being frequently necessary to devitalize the pulp piecemeal, and sometimes the arsenic will hardly be tolerated at all.

Treatment. Pulp inferred or shown by *x*-ray to contain nodules should be removed. If the cataphoric apparatus be at hand it may be used to benumb the pulp by cocaine; at least, sufficiently for the removal of the nodule. If desired, the remainder of the pulp may be anæsthetized by cataphoresis or cocaine pressure anæsthesia and

¹ Private communication.

² Items of Interest, 1901.

removed. The bloodletting attendant upon removal of the bulb of the pulp usually permits an arsenical application for devitalization of the remainder of the pulp to be painlessly made, but this is not always the case.

The same result may be attained by drilling open the pulp cavity while the patient is under the influence of nitrous oxide gas.

At times arsenic may be applied to the pulpal wall of the cavity, if one exist, or in a specially prepared pocket, without production of painful reaction.

After forty-eight hours a portion of dentine is to be removed and a stronger application made. When the pulp is closely approached, the arsenic is to be left a week or longer in position, when, as a rule, the nodule may be removed. Another application may then be left in position for a week or longer to ensure devitalization.

If, after devitalization, the nodule or calcific degeneration be found as a spicular deposit in the mouth of the canal, it may usually be removed by teasing it from side to side, first soaking the part with a sodium dioxide solution, or 50 per cent. sulphuric acid, which quickly destroys the organic matter of the pulp.

Pericemental reactions are quite apt to follow the removal of such pulps. This result is best obviated by awaiting the thorough death of the pulp filaments before attempting their removal.

If such reaction arise, sedatives, such as tincture of aconite plus cocaine, are to be applied on cotton as root-canal dressings, and counterirritants are to be applied to the gum. (See Aseptic Apical Pericementitis.)

Calcific Degeneration of the Pulp. By a calcific degeneration is meant the infiltration of inorganic matter derived from the lymph into tissue which is dead or undergoing degeneration. It occurs in any part of the body in which the necessary conditions are present. (See p. 66.)

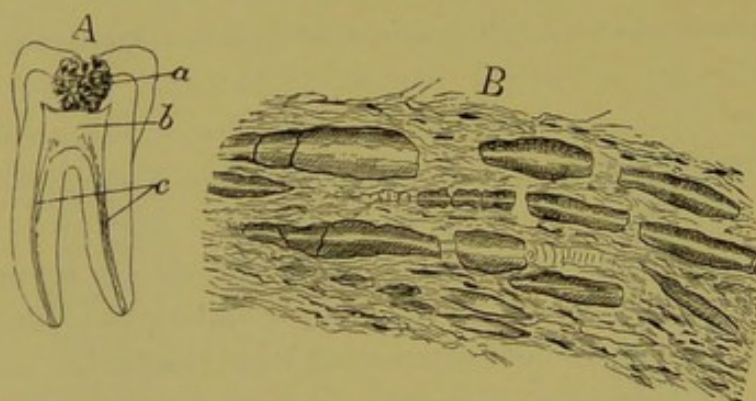
Causes and Pathology. The conditions apparently necessary for the production of calcific degeneration are those which occur in a semi-stagnant blood current. An acid reaction occurs owing to the presence of an excess of carbon dioxide. The albuminous matter of the tissue undergoes degenerative changes owing to the faulty nutritive supply and waste removal.

Probably some cells die. They or their constituents have some affinity for inorganic salts which are taken up from the lymph. Thus gradually the tissue becomes infiltrated.

Those causes which produce a sufficient degeneration of pulp tissue to induce the above process are: (1) the pulp exhaustion due to the formation of secondary dentine or pulp nodules; (2) continued hyperæmia or chronic inflammation in which venous hyperæmia plays a part.

Pathology and Morbid Anatomy. The calcic material, unlike the cases of nodular calcification, encloses the anatomical elements of a pulp in process of degeneration in a mass produced by deposition, not secretion. In the root portions of pulps in which fibrous elements have become pronounced the calcification may be tubular or cylindrical in character, the nature of the calcareous masses being apparently a deposition about and along the fibres (Fig. 357).

FIG. 357.



A, outline of a lower molar, with a large carious cavity at *a*; *b*, pulp chamber; the shaded portion, *c*, was occupied by cylindrical calcifications. B, cylindrical calcifications. $\times 100$. (Black.)

The pulps are, of course, living. There is a comparative absence of cellular elements in the pulp—*i. e.*, they have atrophied, degenerated, and been absorbed. Upon optical examination the masses are seen to be opaque, are brittle, and decidedly unlike pulp nodules in form.

Another evidence of the cellular degeneration is seen in the great ease with which such pulps are removed after devitalization, even the most minute apical portions freely coming away upon slightly catching a hook in the pulp.

The usual odontoblastic attachment to the dentine is not present. When extracted these pulps have a granular feel to the fingers, and when dry are quite stiff (Fig. 358).

Symptoms. Degenerations of the pulp, as a rule, present symptoms of reflex pain, vaguely referred to other parts. The response to hot applications is usually greater than that to cold ones, and both are

delayed—*i. e.*, five seconds or more may elapse before pain follows a severe test like the intensely cold spray of ethyl chloride or a hot burnisher or blast of hot air. At times with an open pulp chamber the symptoms of chronic pulp inflammation are obtained. There may be a painful reaction to arsenic applied to the pulp.

Diagnosis and Treatment. The *x*-ray should afford a positive diagnosis, but in its absence the diagnosis, apart from the inference from the symptoms, is a post-mortem one. In cases warranting the interference, in which there is a delayed response to intense thermal tests applied to a filling or a clean pulpal wall, the dentine over the pulp should be removed and the pulp devitalized. Upon removal of the pulp it may be found to contain one or more large or many granular masses.

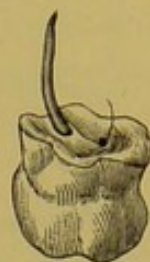Fig. 358 illustrates a case discovered upon fracture of a molar during the operation of extraction. In another case the pulp was slightly bendable when extracted, but after drying for a half-hour became at its apical end of needle-like sharpness and stiffness. It was filled with calcific granules.

The constructive diseases of the pulp are an evidence of an attempt upon the part of the pulp to protect itself; but with the exception, perhaps, of a very regularly deposited secondary dentine the effects react upon the pulp itself, causing its destruction. To what extent, therefore, secondary dentine is beneficial is an open question.

Evidences of constructive action upon the part of the pulp may occasionally be noted in the temporary teeth—*e. g.*, secondary dentine following deep abrasion.

There do not seem to be any observations as to the formation of nodules or calcific degenerations in the pulps of temporary teeth, but there is no good reason why they should not occur, particularly after abrasion. The pulp diseases of the temporary teeth are usually of an acutely destructive nature, which may account in some degree for the absence of reports touching this subject.

FIG. 358.



Lingual filament of pulp of an upper molar, broken in extraction. The rigidity of the filament was due to the presence of calcific granules.

CHAPTER XVII.

DESTRUCTIVE DISEASES OF THE DENTAL PULP.

THIS class of pulp diseases consist of those of an acute character, although chronic diseases may arise as sequelæ of the original conditions. They are essentially destructive in character and attended by prompt degeneration of the pulp tissues. The most important clinically are those having an evident association with disorders of the bloodvessels of the pulp.

HYPERÆMIA OF THE PULP.

Hyperæmia of the pulp is an excess of blood in the more or less dilated vessels of that organ. It is of two forms: active or arterial hyperæmia, and venous or passive hyperæmia or congestion. These two classes differ in their probable direct causations and in effects.

Active Hyperæmia of the Pulp. Definition. Active or arterial hyperæmia of the pulp is an excess of blood in the dilated arteries and capillaries of the pulp.

Causes. The most common cause of active hyperæmia of the pulp is a lessening of the non-conducting covering of the organ, enamel, and dentine, leading to an increased response and continued irritation of the pulp through thermal stimuli. A similar condition consists in the presence of large metallic fillings in close proximity to the pulp, through which abnormal thermal stimuli are received. Fillings through which prompt pulp response to thermal changes are felt are a direct menace to the continued health of the pulp. "The vigorous use of sandpaper disks in finishing large fillings may and does precipitate an attack of pulp hyperæmia." The loss of tooth substance mentioned may occur either through abrasion, erosion, fracture, or caries. The condition frequently occurs without direct exposure of the dental pulp, and at times when cavities are relatively shallow. Septic dentine beneath fillings acts as a cause by constantly irritating the dentinal fibrillæ.

Pulp hyperæmia may also be caused by injury to the apical tissue of a tooth containing a vital pulp. Acute malocclusion from any cause, a blow, or overmalleting, is competent to produce it. An

abscess upon an adjacent tooth may have its area of hyperæmia extend into the apical tissue of the tooth adjoining, thus producing hyperæmia of the pulp. An intense hyperæmia or inflammation in the pulp of one tooth may by reflex action produce hyperæmia with its characteristic response to hot and cold applications in another tooth. It may occur from the presence of a pulp nodule. An aphthous ulcer upon the gum over a tooth has produced arterial hyperæmia of the pulp by reflex action.

Apart from the hyperæmia occurring in inflammation and that due to septic dentine, it may be said that arterial and venous hyperæmia are mainly due to non-septic causes.

Symptoms. The symptoms of arterial hyperæmia vary according to the degree of vascular disturbance. So long as a quick, sharp pain is produced by contact with cold or hot substances, ceasing immediately, and only reappearing in response to direct stimuli, no serious vascular disturbance is inferred; but when paroxysms of sharp pain lasting from many minutes to hours follow upon an application of cold to a carious cavity, an unbroken enamel surface, a filling, or an area of erosion or abrasion, a disturbance of the vessels of the pulp is indicated.

The pains, in the absence of direct irritation are, as a rule, but vaguely located. During paroxysms it is of a lancinating character, and usually reflected to another part than the tooth affected—*e. g.*, a sound tooth at a distance, the gum between or above the teeth, the ear, the eye, the supra-orbital region, the infra-orbital region, the scalp, the chin, the arm, etc.

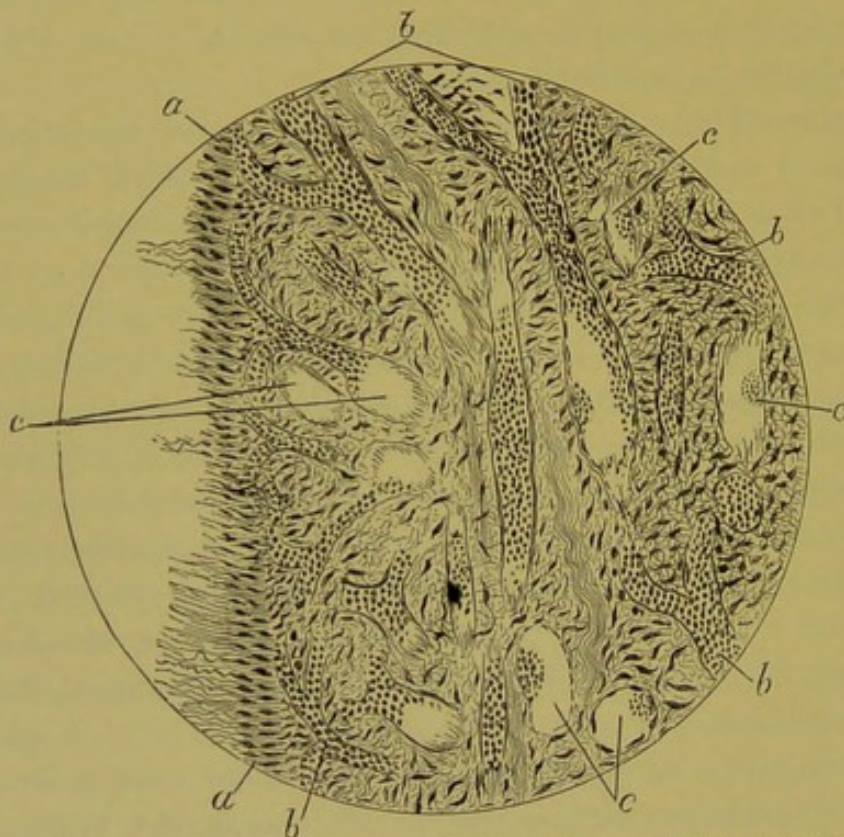
As a rule, when an upper tooth is affected the pain is located in the superior maxillary division of the fifth nerve; if a lower, in the inferior maxillary division. The pain varies in intensity from a vague uneasiness to an acute neuralgic attack, with tender spots over the emergence of the nerve tracks, at the supra-orbital and infra-orbital and mental foramina. The neuralgic pains are not always constant; they may disappear from the second or third division of the fifth nerve and appear in the first.

The proof of the direct connection between the pulp pain and the neuralgia may in some cases be clearly made out by the thermal test. When a jet of cool water is directed against the tooth whose pulp is affected, it may produce, in addition to a local pain, an aggravation of the neuralgic pains.

Pathology and Morbid Anatomy. The one distinctive and characteristic anatomical condition associated with active hyperæmia is an

irregular dilatation of the vessels of the pulp.¹ Fig. 359 represents a section of the pulp of a tooth extracted during a paroxysm of acute pain—"acute paroxysms of pain lasting for an hour or more were occasionally occurring in consequence of very trivial changes of temperature; the condition had existed for several weeks." In some cases of a similar character—*i. e.*, presenting the same symptoms, but extracted during an interval of quiet—nothing remarkable is pre-

FIG. 359.



Hyperæmia of the dental pulp, showing the injection of the vessels: *a, a*, membrana eboris, or layer of odontoblasts; *b, b, b, b*, vessels distended with blood; *c, c, c, c*, points from which the blood has fallen in handling the section. (Black.)

sented. The veins of the bulb may be abnormally large and contain more blood than usual, while the arteries will be almost or quite empty and the injection of the capillary system wanting; that is, the affected arteries have recovered their calibre, if not their tone. Black found the varicose enlargement of vessels so common (Fig. 360) as to be a characteristic. Salter² first called attention to the dilatation of veins into ampullæ, describing them in connection with ulceration of the pulp, as due to engorgement and overtension of the veins.

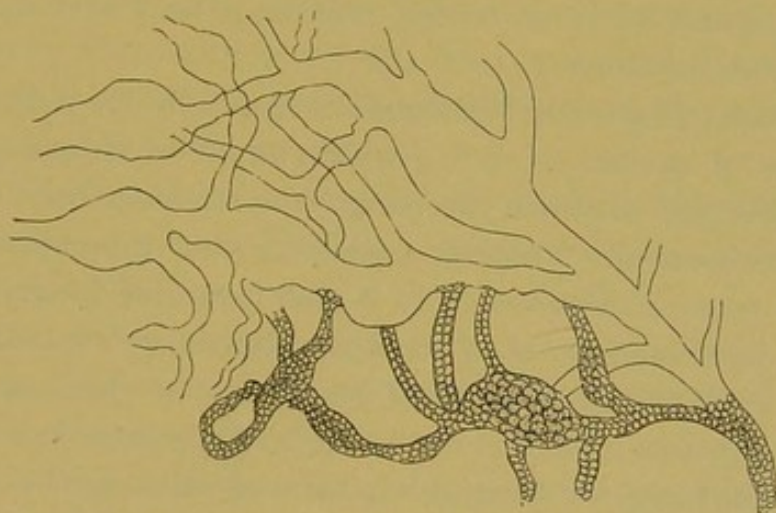
¹ Black, American System of Dentistry.

² Dental Pathology and Surgery.

The most rational explanation of the dilatation of the vessels is that it is an irregular paralysis of vessel walls—*i. e.*, of vasomotor nerves. Whether the more usual painful responses of the pulp to thermal stimuli are due to the stimulation of vasodilator fibres, which causes hyperæmia, is a matter of doubt; but the pathological conditions noted in pronounced hyperæmia signify a paralysis of vasoconstrictor fibres. Subjected to repeated overstimulation, they become inactive and the vessel walls yield to the pressure of the blood column. Black's researches indicate that the vessel walls may recover their tone and the vasoconstrictor nerves their functional activity after paralysis.

Diagnosis and Prognosis. Diagnosis of hyperæmia of the pulp is made through observance of a combination of signs and symptoms. The symptoms leading to its detection are paroxysms of pain induced

FIG. 360.



Dilated bloodvessels from the dental pulp in hyperæmia, from tooth extracted during a paroxysm of intense pain. (Black.)

by thermal stimuli, and a history of pain in the region in which this response is elicited. The signs of the condition in the order of their importance and frequency are carious cavities, the presence of large metallic fillings, deep erosions or abrasions, and, again, fractures exposing the dentine, or metallic crowns on teeth containing vital pulps.

It is to be remembered that arterial hyperæmia may be of several grades of severity, according to the vascular disturbance.

The diagnosis is made purely by differentiation. The causes acting and other possible pulp diseases must be fairly considered and excluded before a certain diagnosis can be made. As a rule, the absence of pulp exposure and the character of the response to thermal tests are the decisive phenomena.

The temperature of the water used in testing should not be lower than 60° F., and should be applied drop by drop. A normal pulp will rarely respond painfully to a few drops of water at the temperature named, flowed into a cavity; but a hyperæmic pulp will almost invariably respond vigorously. As a rule, a current of air from a chip blower is a test of sufficient severity.

In the absence of a carious cavity the source of the pain is to be sought in large fillings, testing each tooth by dropping cool water on the filling; in cases of erosion or abrasion the test is made upon the exposed dentine. The tooth which responds with a quick paroxysm of intense pain, passing away slowly, is diagnosed as the seat of pulp hyperæmia.

In making this test doubt may arise as to which of two adjoining teeth, similarly filled, is at fault. A small square of rubber-dam, with a single hole punched in its centre, may be passed over the tooth to be tested, thus isolating it.

The prognosis of arterial hyperæmia is favorable for pulp conservation in cases of cavities of decay which admit of cleansing without pulp exposure, and in which the paroxysms have not been too severe or too often repeated. Properly protected from thermal shocks the vessels may recover their tone. It is also favorable in cases of light blows or malocclusion if rest of the apical tissues be secured.

It would be favorable in cases of deep erosions which can be filled with non-conductors; but this condition is rarely seen in erosion. It is favorable in fractures without exposure if caps can be secured in place, but it is unfavorable in ordinary abrasions or in cases of sound teeth largely filled with gold, or in sound teeth the pulps of which are irritated without evident cause. In cases of actual exposure of the pulp it contraindicates attempts at conservation, except in the mildest varieties and most favorable circumstances, and then only when conservation is important.

Treatment. The therapeutic principles involved in the treatment of this condition are, the removal of the source of irritation and the securing of physiological rest; the latter can only be secured through the removal of the former. The treatment is directed toward immediate relief of the existing condition and the prevention of its recurrence. If a carious cavity exist it is to be freed from débris, and the grosser portions of the carious dentine are removed; the pulp, if unexposed, is to have the layer of softened dentine covering it left unremoved.

Sedative agents are imperatively called for; of those used the most effective being the oils of cloves or cinnamon, equal parts of oil of cloves and carbolic acid, equal parts of carbolic acid and camphor (phenol-camphor), a saturated solution of thymol in alcohol or of menthol in chloroform, or a combination of tincture of aconite with cocaine. These agents are all germicides as well as sedatives, and, therefore, sterilize the dentine of cavities in which they are sealed.

They are to be applied upon a pledget of cotton and carefully secured in place by means of temporary stopping, soft zinc phosphate, or facing amalgam. In from twenty-four to forty-eight hours the tooth is placed under the rubber-dam and excavated; its walls are varnished, and over the wall nearest the pulp a disk of softened gutta-percha is laid. Over this zinc-phosphate paste is flowed. "Formagen" or "Jodo-Formagen" may be used in place of the gutta-percha. It is usual to complete such fillings with zinc phosphate or gutta-percha, to remain for six months or a year. The conductivity of zinc phosphate is too high to be used as the sole material over pulps which have been the seat of pronounced hyperæmia.

If the pulp be exposed, it is probably the part of wisdom to remove it after sedation or immediately by cocaine; though if for any special reason capping be demanded, it may be done.

If desired the protective pocket-like coverings made for arsenical applications may be utilized for the reception of the sedative application. (See Coverings for Arsenic.)

It not infrequently happens that it becomes necessary to assist the pulp arteries to recover their tone by means of counterirritants applied to the gum over the apex of the root. This is especially true in cases of pulp capping. Dental tincture of iodine (a saturated solution of iodine in alcohol) is to be applied in spots to the gums, or a mixture of equal parts of tincture of iodine and tincture of aconite may be painted upon the gum. A mixture made of two parts of tincture of aconite and one part of chloroform is recommended by Jack,¹ to be applied to the cleansed and dried mucous membrane by means of a pad of cottonoid, one-half inch wide by three-fourths of an inch long. It should be held in place by the finger for fifteen seconds. Tincture of aconite upon cotton, placed in the rubber-cup applicator of a cataphoric apparatus and held against the gum for a half-minute, will produce a circumscribed area of irritation which may later lose its epidermis. This amount of irritation is valuable.

¹ American Text-book of Operative Dentistry.

In cases of abrasion or erosion carbolic acid is applied; an excavation having a retentive form is made, which is varnished and filled; or in abrasion the pulp may require removal. A tooth containing a large metallic filling must have the filling removed, and after reducing the hyperæmia a non-conducting layer must be placed between the pulp and the filling. The precaution should always be taken, when the pulps of teeth in which cavities have been prepared respond unduly to the temperature test, to cover the dentinal walls with a layer of non-conducting material. In the absence of this precaution the constant overstimulation of the pulp by thermal impulses conducted through the metallic filling, may at any time result in hyperæmia. If mild hyperæmia occur after filling with metal it ordinarily passes away after a few weeks. The fibrillæ at first rebel, then become tolerant.

In the cases due to apical irritation, not only must counterirritants be applied to the gum, but it may be necessary to cap one or two adjacent teeth in order to guard against the irritation of the apical tissue by overocclusion. (See Non-septic Apical Pericementitis.)

If the hyperæmia is of a gradual onset and due to an overoccluding filling or crown, this is, of course, to be reduced.

Idiopathic hyperæmia occasionally affects teeth in which there is no loss of enamel or dentine; and when this condition occurs, it leads to suspicion that the pulp is the seat of nodular deposits; though cases have occurred, particularly of lower incisors, in which none were found after devitalization. Some form of apical traumatism may also be looked for. Such teeth are to be dried, heavily varnished, and wedged upon both sides for twenty-four hours, until a gutta-percha cap can be fitted to them, completely enclosing the crown. The cap is to remain and to be renewed until the tooth responds normally to the temperature test.

If the pulps do not respond to this treatment they are to be devitalized. Counterirritants may also be used.

Such cases may be very obstinate and demand relief by devitalization of the pulp.

The test of success of remedial measures is the gradual reduction of response to slight variations in temperature—*i. e.*, the pulp gradually bears higher and lower temperatures until approximately a normal tolerance is established.

As shown by Jack this varies for hot applications from 152° F. to 118° F., and for cold ones from 74° F. to 32° F.

In order to determine the rate of tolerance normal to the individual,

he suggests that sound lower incisors be isolated by the rubber-dam and tested by throwing upon them first water at a temperature of 80° F. The temperature of the water is then gradually lowered or raised until slight pain is produced by the test. The point registered by the thermometer will be the normal limit of thermal tolerance for the particular test.

The data gained are useful in determining the progress of a case of hyperæmia.

A lack of success in the reduction of the arterial hyperæmia is evidence that the more severe condition of venous hyperæmia has supervened.

In the devitalization of hyperæmic pulps there is often painful reaction to any of the means employed. Sedatives should precede arsenical applications, and if at any time arsenic produce a painful hyperæmia or aggravate one previously existing, it must be removed and sedatives used before its renewal, or it may be applied at another portion of the tooth while sedatives are kept against the pulp.

It is evident that such a grade of vascular excitement as exists in cases of exposed dentine is quite capable of producing the constructive diseases of the pulp described as secondary dentine and pulp nodules. On the other hand, inflammation of the pulp has produced resorption of the walls of the pulp chamber.

Pulp Irritation from Electric Action. It is of quite common occurrence that galvanic electricity causes pulp irritation. The cataphoric current too long continued may induce a hyperirritability of the pulp amounting in some cases to evidence of hyperæmia, which may subside under proper treatment or eventuate in pulp death from venous hyperæmia. The occasional connection of a newly placed or bright amalgam filling with a gold filling, bridge, plate or clasp, through the medium of saliva or food (which amounts practically to the same thing), will, at times, produce painful galvanic shocks in a vital tooth. Dr. Franz Trauner¹ has reported that such pain has been felt in devitalized teeth. This is outside of the editor's experience and should not occur, as the electric current is a test for pulp vitality.

Treatment. With cataphoresis, the mischief being accomplished, the case must be treated as other arterial hyperæmias.

In the case of shocks from the presence of the two metals it may be ignored if slight and the filling new, as it will probably soon pass away. A well-set and brightly polished filling may be tarnished if

¹ See Dental Cosmos, 1903.

necessary by touching it with a 1 per cent. solution of silver nitrate; or, if good color be a necessity, the pulp of the tooth may be well insulated by means of a gutta-percha substratum, or the pulp may be devitalized. If the fillings be in adjoining teeth they should be contoured so as to touch if possible. If in the same tooth, the fillings should be connected by either amalgam or gold.

Painful shock is sometimes produced by the animal electricity discharged from the operator during dry, cold weather. It usually occurs when the finger is placed upon a metal filling or the plugger point is returned to a metal filling. Touching the metal part of the chair before approaching the patient will obviate this disagreeable contact.

Venous Hyperæmia of the Pulp. Definition. By venous hyperæmia of the pulp is meant a condition of the pulp in which the return of the blood in the pulp to the heart is mechanically prevented.

Causes, Pathology, and Morbid Anatomy. But two causes seem competent to produce such a venous hyperæmia. These are: (1) a pre-existent arterial hyperæmia; (2) thrombosis of vessels at the apex of the pulp canal.

In arterial hyperæmia the excess of blood is contained in enlarged capillaries and arterial trunks. The enlarged main trunks or trunk at the apex of the pulp *must* compress the veins, as the apex of the canal is unyielding. In proportion to the severity of the arterial hyperæmia, therefore, are the emergent veins unable to remove the blood collected in the capillaries and venules, which gradually enlarge into varicosities in consequence.

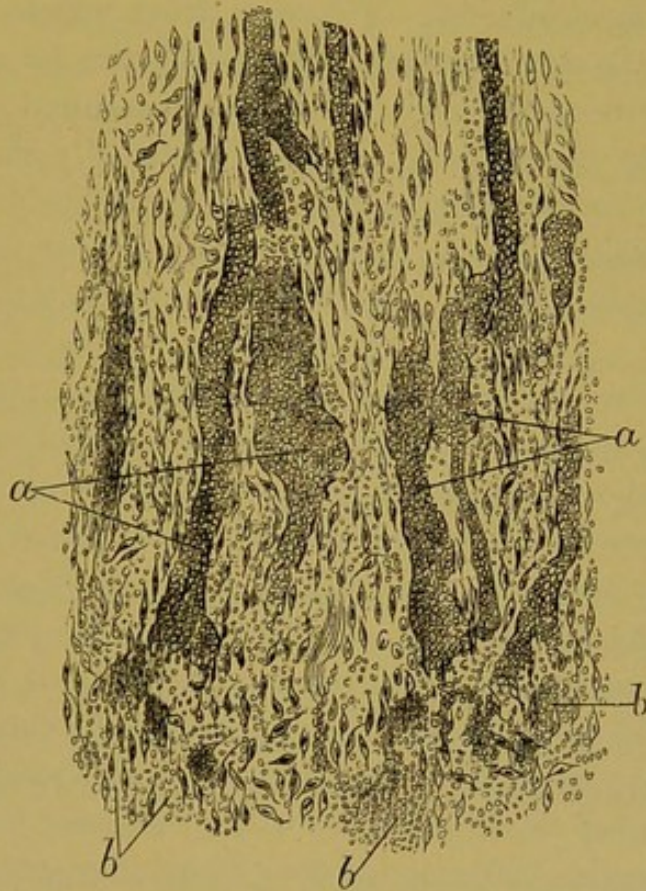
Black has shown that the diapedesis of red corpuscles, which is a characteristic result of the engorgement of the veins in venous hyperæmia (see p. 81), occurs in the pulp. Œdema, which usually accompanies venous hyperæmia in other situations, cannot well occur in the pulp because of its unyielding surroundings (Fig. 361).

It is possible, however, that fluid may exude into the perivascular spaces, compressing the cellular elements. Black has shown that deposits of lymph may thus occur in pulpitis. The intense congestion and distention of the vessel walls permit a free diapedesis of red corpuscles into the pulp tissue. These go through the stomata of the vessel wall. Disintegration of the red corpuscles may occur and the coloring matter of the corpuscles may be diffused through the dentine, giving it a pink discoloration technically known as suffusion. The infiltrated dentine may then become progressively discolored through

the characteristic changes of color noted in connection with gradually decomposing hæmoglobin—becoming brown or blue, and finally blue-black. Cases have occurred of coronal suffusion in which the pulp vitality has persisted. The vasomotor paralysis is extreme.

If a tooth receive a blow of sufficient severity, its pulp may die without much evidence of pulp pain. On the other hand, if the blow be less severe it may give evidence of an arterial hyperæmia, gradually increasing in severity.

FIG. 361.



Section of hyperæmic pulp, showing aneurysmal dilatation of the vessels, extravasations of blood, and red blood disks escaped apparently by diapedesis: *a, a*, dilated vessels; *b, b, b*, extravasated blood. Besides this, red blood disks are plentifully distributed everywhere in the neighborhood of the veins. The tooth was extracted during a paroxysm of pain. (Black.)

In the former case it is probable that the bruising of the apical tissue produces a condition of thrombosis at the apex which involves the pulp by shutting off both its afferent and efferent vessels. A stagnation results, and death from lack of nutrition occurs.

In the latter case the thrombosis has not occurred, but an arterial hyperæmia is set up by the irritation of the pulp nerves and may go on to venous hyperæmia.

It is quite probable that the death of the pulp in pulpitis is due to the associated venous hyperæmia.

Kirk¹ mentioned an interesting case of venous hyperæmia with intense suffusion of all the teeth as the result of hanging.

Symptoms. The symptoms of this condition, in the absence of definite data, can only be inferential. When the paroxysms of pain are continuous, instead of temporary—that is, when the pain, instead of temporarily subsiding, maintains a constant intensity for hours, and does not respond promptly to sedative therapeusis, and is accompanied by a sense of fulness rather than sharp agony, a condition of serious venous congestion is inferred. The case from which Fig. 361 was taken had been the seat of intense paroxysmal pain for some hours.

Prognosis. Perfect recovery from this condition is extremely doubtful, so that if the pulp be not intentionally devitalized and removed, it will undergo degenerative changes. The fact that pulps have remained alive for years, after having been the seat of marked congestion, scarcely warrants the attempt to save so seriously crippled an organ.

Treatment. The prognosis being doubtful, the pulp should be obtunded and devitalized. As the pulp pain does not ordinarily yield to sedatives it should be gently exposed if the excavation does not accomplish its exposure. An antiseptic is to be applied and by means of a very sharp puncture probe the pulp is to be delicately punctured. A free flow of blood follows, which relieves the vascular engorgement. When this is accomplished the cavity is to be syringed out with warm water and a pellet of cotton containing a saturated solution of menthol in chloroform may be sealed in the cavity, or simply retained by means of a second pellet of cotton saturated with inspissated tincture of benzoin or chloro-percha. After twenty-four hours an arsenical application may be made for the purpose of pulp devitalization, or the pulp may be removed by other means if tolerated.

The extreme paralysis of the vessel walls is occasionally shown by persistent hemorrhage after depletion, and which resists all effort at limitation. In some cases the intense pain may continue as well. The application to the pulp of a mixture of powdered thymol and dried alum, equal parts, taken up on a pellet of cotton moistened with a saturated solution of thymol in alcohol, has proved useful in some cases. Adrenalin chloride solution should be useful in this connection. A general anodyne may be required for relief of the pain.

¹ Private communication.

INFLAMMATION OF THE PULP (PULPITIS).

Definition. Pulpitis is the occurrence of the phenomena of inflammation within the pulp tissue. The characteristic diapedesis of leukocytes into the perivascular tissues must have occurred.

Causes. This morbid anatomy is usually found associated with diseases of the tooth crown or pericemental tissue which admit bacteria to the pulp. At the same time it is quite possible that a non-septic irritant, such, for example, as a partially absorbed extravasation of red corpuscles or undue pressure of a filling upon a thin lamina of healthy dentine overlying the pulp, or an escharotic applied to the pulp may induce the characteristic pathology of inflammation. (See inflammation, p. 83.)

According to the character of the cause, therefore, inflammation of the pulp may be divided into simple and infective. It may be that a simple inflammation may become an infective one owing to the association of bacteria—*e. g.*, the pressure of a foreign body may initiate the process and the inflamed pulp become a soil for the propagation of the bacteria present.

The causes of pulpitis may be grouped under three headings:

1. Mechanical or physical causes, which irritate by acting as foreign bodies.
2. Chemical causes, which act as irritants by either producing a chemical destruction of pulp tissue or by irritation without direct destruction. In the former case the dead tissue acts as a foreign body against which the pulp reacts in an effort to cause its exfoliation or absorption.
3. Parasitic or infective, which cause the phenomena of infective inflammation.

Pulpitis is classified, according to its extent, into partial and complete; according to its duration, into acute and chronic; according to its infective character, into purulent and non-purulent; and, again, according to the character of the degeneration which follows upon the inflammatory process. While pathologically these conditions may be clearly differentiated from one another, they may be reduced to more compact groupings according to their clinical significance. For example, acute pulpitis is frequently infective, partial, and purulent; chronic pulpitis is frequently non-infective, extensive, non-purulent, and indicative of secondary degenerations.

For the sake of convenience, pulpitis will receive a clinical division into acute and chronic.

Acute Pulpitis. By acute pulpitis is meant that form of inflammation of the pulp which runs an active and more or less violent course toward pulp death, and has associated with it acute paroxysms of pain.

Causes. The causes of acute pulpitis are direct and indirect, intrinsic and extrinsic; the vast majority of cases being due to extrinsic causes. The direct intrinsic causes are hemorrhagic extravasations accompanying venous congestion, pulp nodules, and injury of the vessels at the apex of the root. The direct extrinsic causes are, perhaps, invariably associated with bacterial invasion, a possible exception being the pressure of filling material upon a thin elastic lamina of softened dentine, covering the pulp. The dental pulp is intolerant of the slightest pressure, and rebels vigorously when subjected to compression. Irritating drugs may also act as irritants—*e. g.*, zinc chloride. It is not necessary¹ that the pulp should be exposed to permit bacterial infection, and direct or extensive bacterial invasion is probably not necessary for the production of pulpitis. The waste products, ptomains, etc., of bacteria, may find their way to the surface of the pulp *via* the dentinal tubuli, through a layer of softened dentine, and excite inflammation. It is extremely probable that infection of the pulp is an invariable consequence of its exposure; but as a pulp may be exposed without subjective evidences of hyperæmia or inflammation, it follows that infection does not necessarily imply inflammation, though the absence of acute symptoms may be accounted for by the escape of the effusions into the cavity of decay. The presence of a gross irritant, such as a mass of food débris, vegetable seeds, bread-crumbs, etc., in contact with the pulp will precipitate an acute inflammation in which bacterial relations must be taken into consideration.

“The severity of the inflammation does not appear to be proportionate to the number of bacteria present, and in a highly inflamed pulp we may be able to find but few bacteria. . . . The conclusion seems to be justified that the inflammation is due to the combined action of the bacteria and their products (acids, ptomains, etc.) with which the carious dentine becomes impregnated.”² Goadby has, however, shown that the streptococcus brevis and bacillus necrodentalis may pass through the tubules of even secondary dentine.

Pulpitis from injury of the vessels at the apex of the pulp must be mentioned. It may occur in consequence of blows, biting upon hard

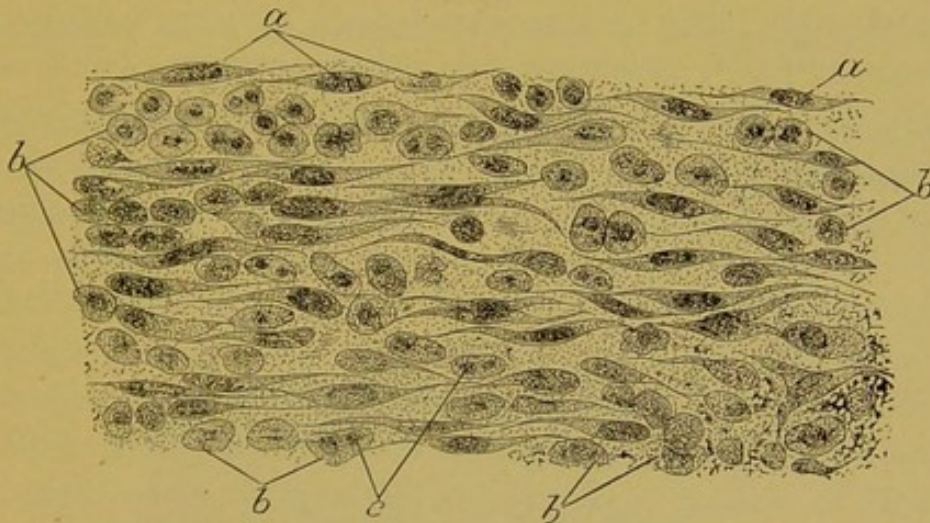
¹ Miller, Dental Cosmos, 1894.

² Ibid.

substances, too rapid wedging, the rapid movement of teeth in orthodontia, and the progressive loosening of teeth in pyorrhœa alveolaris. In these cases the pericementum is also affected and the teeth are tender upon percussion. Pain in the teeth upon assuming the recumbent position; dull, heavy uneasiness about the jaws, and inordinate response to thermal stimuli, particularly to heat, point to pulpitis. Bacteria from an abscess on an adjoining tooth or the pressure of an impacted tooth may also act as causes.

Morbid Anatomy and Pathology. In determining the existence of pulpitis, no matter what the symptoms which have presented or the condition as to exposure, etc., the microscopic examination of sections of the affected organ constitutes the only decisive test; if the changes characteristic of inflammation be absent, no matter what the symptoms,

FIG. 362.



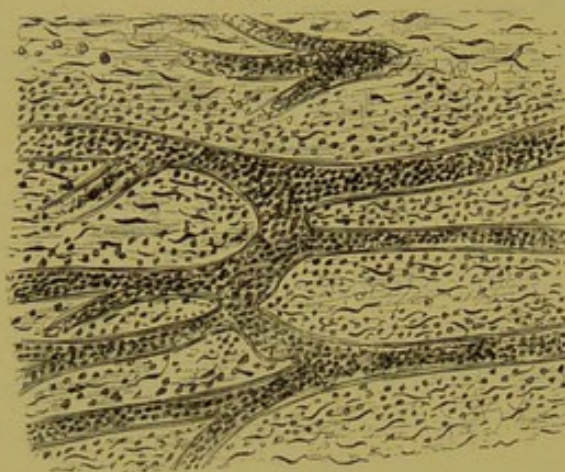
Inflammation of dental pulp: *a, a*, normal cells; *b, b, b, b*, inflammatory elements; *c*, cells in process of division ($\frac{1}{10}$ inch). (Black.)

pulpitis did not exist. The essential feature of the process is emigration of the white blood corpuscles from the small veins into the intercellular matrix of the pulp. At first the inflammatory elements (leukocytes) are scattered through the spaces between the pulp cells (Fig. 362); at a later stage the territory is occupied by round indifferent cells alone. The inflammation may be widespread, as shown in Fig. 363, or may be localized to some portion of the pulp, as one horn of a pulp; Black noted also inflammatory action occurring in small islands (Fig. 364).

Swelling of the pulp—exudation—cannot occur unless there be a break in the wall of the pulp-chamber through which additional space can be gained. Black has recorded that “he found *beneath* the layer of odontoblasts in the region of an exposure an unmistakable deposit

of inflammatory lymph. The case had a history of severe toothache for two days, two weeks previously. The pulp exhibited evidences of previous extravasations of blood from hyperæmia."

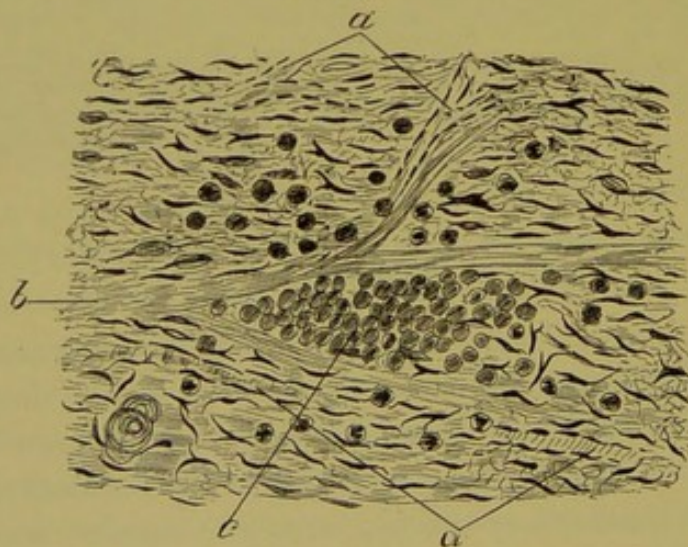
FIG. 363.



Section of dental pulp, showing the invasion of the inflammatory process along the course of the veins—the diapedesis of the white blood corpuscles.

There is evidence that the pulp may recover from attacks of inflammation, and that resolution occurs. In some cases, as shown under the head of calcareous degeneration, the tissues may become infiltrated

FIG. 364.



Minute inflammatory focus within the tissues of the pulp: *a, a*, arterial twigs; *b*, a nerve bundle; *c*, collection of leukocytes. (Black.)

with calcic material. In others, chronic degenerative changes—inflammatory degeneration—may supervene.

The cases thus far described have been given as non-infective, simply because their infective character has not been clearly made out, although it is very probable that they are infective.

Suppuration of the pulp is a common accompaniment of pulp inflammation; this being necessarily infective, will be described separately.

Gaskell¹ has reported a case where a central incisor entirely free from caries exhibited on its palatal aspect a pinkish tinge, which increased in depth until the enamel overlying crushed in, revealing the pulp of the tooth lying immediately beneath; there had been a resorption of a large mass of the dentine lying between the pulp and the enamel. The pulp was removed and the tooth filled. No history is given as to the condition of the root, whether resorption had occurred there or not. Shortly after, the adjoining central incisor exhibited a like pink coloration, which increased, leading to the inference that resorption was in progress in this tooth also. At the suggestion of E. C. Kirk the patient received continued doses of arsenic iodide and the compound syrup of the hypophosphites, in the hope of inducing a general and local constructive metamorphosis. This treatment was followed by a gradual disappearance of the pink coloration, an evidence of a redeposition of dentine. In the absence of histological data it is impossible to state just what was the nature of the repair tissue in this particular case, but Miller² has shown that the pulp may take up a resorptive function and remove dentine which may later be deposited as anomalous tissue. The new dentine does not contain tubules, but has the characteristics of cemental tissue³ (osteodentine), or even bone with Haversian systems⁴ (Fig. 365). This process has its analogue in the tusks of elephants and also in the production of Howship's lacunæ in the resorption of the cementum by the pericementum, these lacunæ later being filled up with cementum.

Symptoms. The early stage of inflammation is an arterial hyperæmia, and as the leukocytes collect in the venules a venous hyperæmia is established. No matter how far the area of stasis extend, beyond it will exist an area of arterial hyperæmia. Owing to the enclosing canal walls and constricted apex a general venous hyperæmia may be established which causes the death of the pulp.

In view of these facts it is not surprising that the symptoms of pulp inflammation take on somewhat the characteristics of both arterial and venous hyperæmia. The diapedesis of leukocytes and exudation

¹ Proceedings of the Academy of Stomatology, Philadelphia, 1895.

² Dental Cosmos, August, 1901.

³ Hopewell-Smith, Histology and Patho-histology of the Teeth.

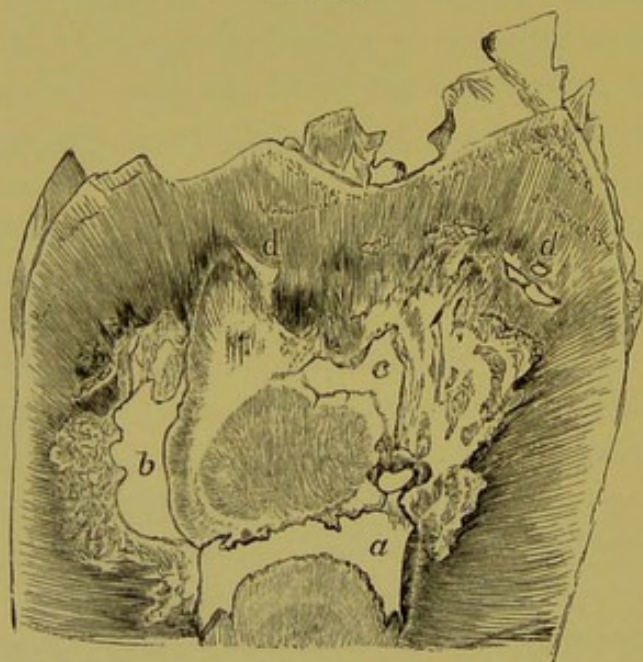
⁴ Salter, Dental Surgery and Pathology.

of fluid cause the phenomena of heavy boring pain and a feeling of internal pressure.

The pulp may be exposed and no symptoms be present. A sudden pressure of food or toothpick, suction upon the pulp or the contact of cold or hot, salt, sweet, or acid substances may excite an attack of throbbing or lancinating pain. This may be localized in the tooth or may be reflected to other teeth or the parts mentioned under hyperæmia.

The assumption of the recumbent position permits an increased flow of blood into the paretic vessels of the pulp and increased suffering results in correspondence with the law that inflamed parts are

FIG. 365.



Resorption of the walls of the pulp chamber and redeposition of new calcific matter : *a*, pulp chamber; *b*, *c*, *d*, portions of resorption areas not refilled and walled off by the new deposit-forming cavities occupied originally by the pulp tissue. (Miller.)

always more painful in the dependent position. (See Pathological First Dentition.) Indeed, recumbency is sufficient at times to induce a paroxysm in a comparatively quiet but inflamed pulp. Under a capping or filling pressing on the pulp or thin dentine the pain may begin as a slight pain and gradually increase in intensity, or it may respond as a sudden agony, beginning even some time after the operation. In the later stage of pulp inflammation the pain is of a heavy, boring, continuous character, the pericementum becomes somewhat hyperæmic, and the tooth responds to tapping. In case of a highly irritable pulp, however, the concussion of the pulp produced by tapping may readily cause pain.

In pulpitis the pulp responds both to heat and cold, but, as a rule, more to the former than to the latter.

Diagnosis. The diagnosis is largely inferential and made by observation of the symptoms and conditions existing. The pulp may be exposed or closely approached by caries, or the pulp may be approximated by a large filling. If there be a leak about the filling a septic fluid or actual decay beneath the filling may be the exciting cause. In the absence of evident causes such sepsis is always to have consideration, and, if necessary, the filling must be removed and tests applied. The more obscure causes, such as abscesses upon adjoining teeth, infection from the pericemental tract in the course of pyorrhœa, looseness of teeth or traumatisms, are to be carefully considered. If the tooth involved be uncertain, each tooth should be placed under rubber-dam and tested thoroughly.

Prognosis. The prognosis is always bad for the comfortable conservation of the pulp, and it should be removed and the canal filled.

Treatment. The treatment of pulpitis involves the reduction of the amount of blood in the vessels of the pulp, the sterilization of the infected area, and the relief from the pain. It is usual to excavate the cavity of decay thoroughly enough to remove from over the pulp decayed dentine which would prevent the action of remedies, or act as irritants *per se*. The cavity is then washed and one of the essential oils or phenol-camphor, saturated solutions of cocaine in glycerin, thymol in alcohol, or menthol in chloroform, or a mixture of acetate of morphine with oil of cloves or creosote is placed in it on cotton. During the half-hour succeeding the application the pulp should give some indication of relief. If it be somewhat decided, a portion of the remedy used should, if possible, be sealed in the cavity for twenty-four hours. The covering may be prepared first as for arsenic. (See Coverings for Arsenic.) If not possible to seal it in, it may be covered with cotton saturated with a varnish made by evaporating tincture of benzoin. This varnish hardens like sandarac varnish, but, unlike it, is not irritant.

If after the first half-hour no indication of relief has been obtained, it is well to expose the pulp and to relieve the engorged vessels by delicately puncturing it. (See Extirpation of Pulp.) After exposing the pulp it will perhaps exude a bead of pus, which makes the diagnosis one of pulp suppuration. After free bleeding, which may be encouraged by means of warm water, the sedatives will usually act. It may be necessary at times to employ general anæsthesia (nitrous

oxide gas) as a means to obtain free bloodletting. Everything being prepared, the patient is anæsthetized and the bulb of the pulp cut out, or in a single-rooted tooth the entire pulp may be taken out.

At times cocaine pressure anæsthesia is effective at least for the removal of the bulb of the inflamed pulp, and sometimes of the entire pulp.

In case of partial extirpation, not only is free bleeding induced, but the diseased pulp tissue is largely removed. When hemorrhage ceases arsenic may be applied. If the hemorrhage be obstinate the application of powdered thymol and dried alum may be used. (See Venous Hyperæmia.) When sedatives are used upon the pulp, counterirritants applied to the gum are aids of great value and are to be used as described under arterial hyperæmia. (See p. 387.)

Instead of these the principle of depletion may be employed. Deep cuts may be made with a sharp bistoury in the gum overlying the root apex. The anastomosis with the vessels of the apical tissue is expected to cause the cuts to act as openings made in veins leading from the inflamed pulp. According to Nancrede, depletion on the venous side of an inflamed area markedly reduces engorgement. In addition to these measures catharsis is a valuable means of derivation; a tablespoonful of sulphate of magnesia is to be dissolved in a goblet of water and taken internally.

If the pain be obdurate and its return feared, two one-eighth-grain sulphate of morphine tablets may be dispensed, preferably by the operator, to be taken only in case of severe pain and an hour apart. Acetanilid and phenacetin are also useful.

The following is a useful anodyne and antineuralgic prescription:

R—Phenacetin,	
Acetanilid,	<i>āā</i> gr. xxx.
Quinia sulph.,	gr. xv.—M.

Divide into six capsules.

Sig: One morning and evening.

Quiet of the pulp must be secured before an arsenical application is made or the latter merely increases the irritation instead of promptly devitalizing. Should such an irritation occur or be feared arsenic may be sealed in an opening made in another part of the tooth (a "pocket")¹ with a view to devitalizing the pulp through an avenue of healthy pulp tissue. At the same time the pulp may be quieted by applications made in the cavity of decay.

Instead of drilling a special pit the arsenic may be applied at a

¹ Flagg.

portion of healthy dentine in the cavity which is at some distance from the orifice of exposure; over the latter the analgesic may be placed.

SUPPURATION OF THE PULP.

Definition. By suppuration of the dental pulp is meant a formation of pus on its surface (ulceration) or in its substance (abscess). It occurs both as an acute and as a chronic affection.

Causes. The immediate cause of suppuration of the pulp is the ingress of pyogenic organisms to the pulp. As in inflammation of the pulp, while usually associated with direct exposure of the pulp, suppuration may occur in pulps covered by softened or even unsoftened dentine.

Arkövy¹ (Fig. 366) first observed infection of the pulp while still covered by a layer of unsoftened dentine.

Goadby has shown that micro-organisms may penetrate even secondary dentine, a condition not infrequently seen.

Miller states that sections of the overlying dentine in a case of suppuration of the pulp showed the same forms of bacteria as were found in the pulp itself.

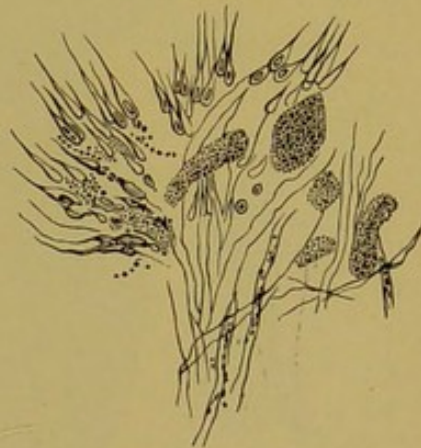Bacteria which have entered the body through wounds, etc., may be deposited in the pulp as well as in any other part of the body, wherever there may be a *locus minoris resistentiæ* at the time.

While bacteria may thus enter from the circulation, there is usually abundant opportunity for their entrance from the mouth.

Suppuration of the pulp is a not infrequent sequel of the capping of pulps which have given evidence of a previous hyperæmia or inflammation.

Morbid Anatomy and Pathology. Anatomically pulp suppuration, purulent or pyogenic pulpitis, is of two general varieties; one begins upon or close to the surface of an exposed pulp, and gradually destroys the organ through a process of progressive ulceration (Fig. 367); the second, that confined in the substance of the pulp, causes the gradual destruction of a part or all of the pulp through the formation of circumscribed abscesses (Fig. 368).

FIG. 366.

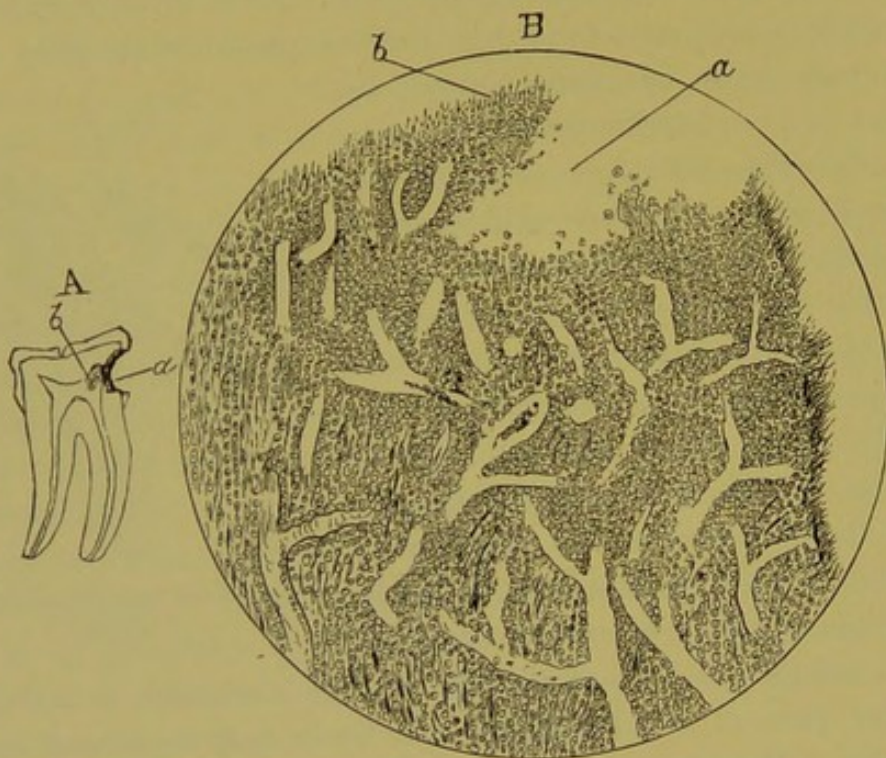


Invasion of pulp by micrococci.
(Arkövy.)

¹ Diagnostik der Zahnkrankheiten.

Ulceration of the Pulp. Of these two forms, ulceration is the more common. The capillaries (Fig. 367) are blocked with coagulated blood (they are left open in the illustration to clearly mark their position); the intercapillary meshwork is occupied by inflammatory exudation; the surface of the pulp is eroded, and covered with pus-corpuscles; the ulcerative process is undermining the layer of odontoblasts. The suppurative process penetrates the body of the pulp, following the direction of its veins and hollowing out the organ into

FIG. 367.



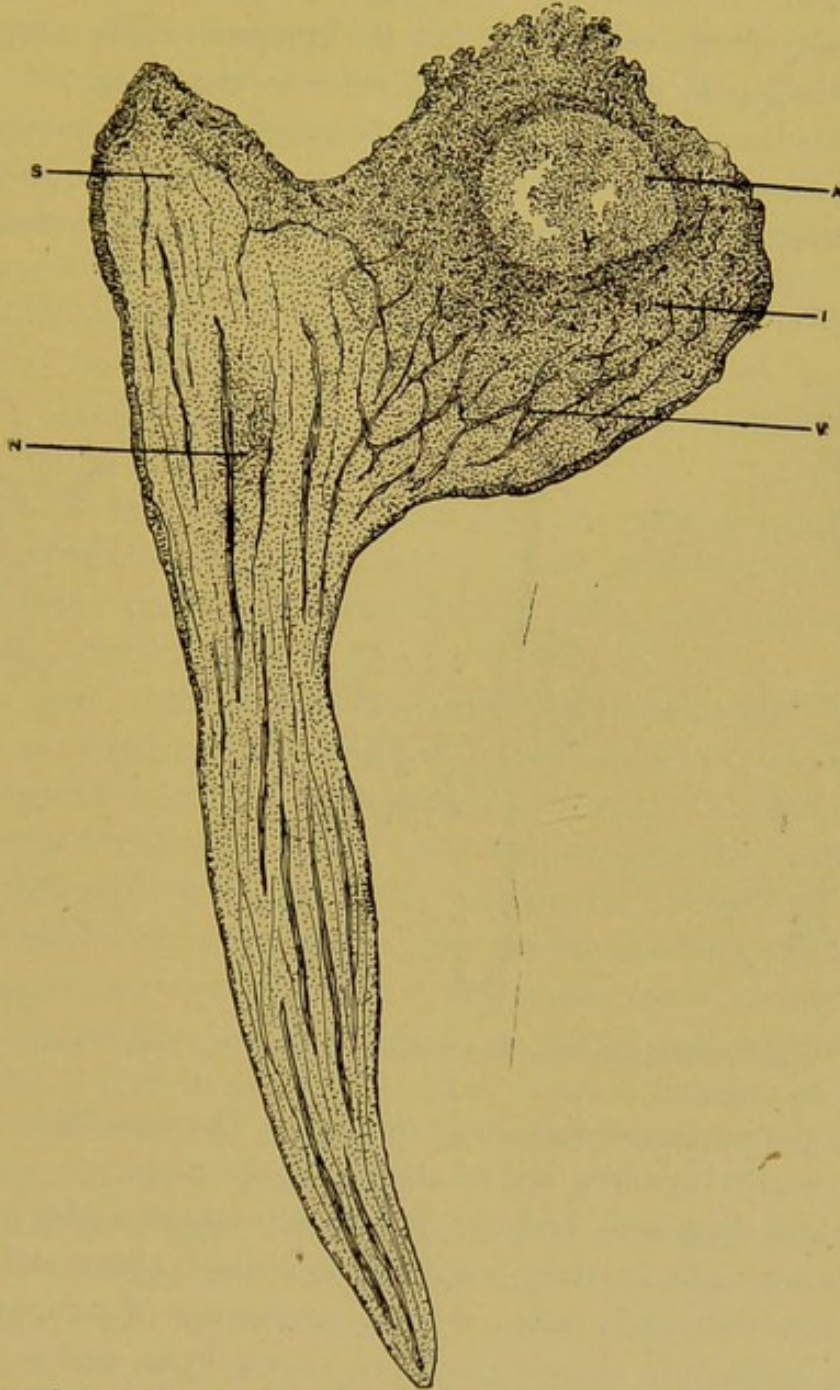
A, diagram of lower molar with caries at *a* which exposes the pulp; the darkened portion at *b* shows the extent of the inflammation; the rest of the organ was free from inflammatory change. B, illustration of the inflamed tissue, showing a part destroyed by suppuration at *a*; the odontoblasts are undermined at *b*; the bloodvessels which were filled with blood clot in the section are left blank here, that they may be more apparent. (Black.)

a deep cavern. Black regards the persistence of the layer of odontoblasts as indicating an inferior vitality, as it shows they are less susceptible of change of form than the other cells of the organ.

The process of ulceration may continue for weeks or months until the entire organ has been destroyed molecularly. The necrotic portions undergo putrefactive decomposition, probably passing through the same stages that any albuminous substance passes in its serial decomposition, into the end products—ammonia, carbon dioxide, hydrogen sulphide, and water.

"Very interesting and instructive results were obtained by examining material from different parts of the same tooth. In the case illustrated in Fig. 369 the pulp chamber at *a* was wide open and filled with

FIG. 368.



Acute suppurative pulpitis in the coronal portion: *I*, intensely inflamed horn; *A*, abscess; *V*, bloodvessels engorged with blood; *S*, superficially inflamed horn; *N*, nest of inflammation. $\times 10$. (Bödecker.)

food particles, which had a foul, half-putrid odor; at *b* the pulp was putrid and foul-smelling; at *c* there was a small abscess, filled with pure white pus, while the tissue between this point and the apex of the root was highly inflamed and bright red. Material from the pulp

chamber (Fig. 369, *a*) contained the forms shown in Fig. 370; material from point *b* those shown in Fig. 371, and from the point *c* those shown in Fig. 372. We perceive a gradual diminution of the large cocci, and the appearance of small, delicate cocci and diplococci" (Miller).¹

Symptoms. If the cavity of decay be open the pus and serous exudate may freely escape, so that the symptoms may not exceed a dull, gnawing pain which is usually reflex in character.

As a rule the response to cold will be much delayed or even absent. Intense pain may exist when the pus cannot find exit owing to food débris being massed in the pulp chamber, or owing to the presence

FIG. 369.

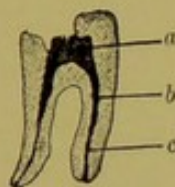


FIG. 370.

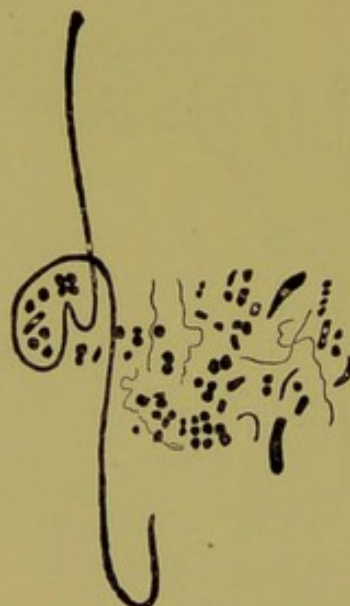

FIG. 371.

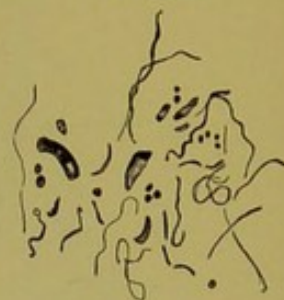

FIG. 372.

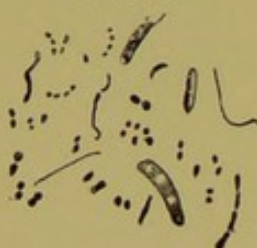
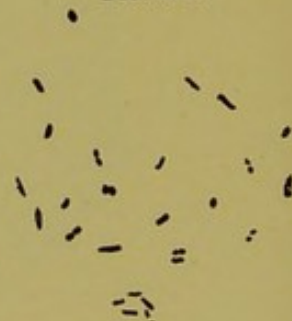
FIG. 373.



Micro-organisms found in cultures from gangrenous pulp. (Miller.)

of a filling or mass of secondary dentine. The case then resembles, and practically becomes, one of abscess of the pulp.

The chief diagnostic feature of pulp ulceration is the presence of the subacute inflammatory symptoms described above and the presence of a pulp partially removed by decomposition of its upper portion.

Thus, if the pulp chamber be open at one horn, and a probe may be passed into it for a short distance until it comes into contact with an irritable portion of pulp and when withdrawn have the odor of putrefaction, the diagnosis is clear—loss of pulp substance by putrefactive changes, presumably by suppuration. Many phases of this condition may be seen; thus in an extreme case one canal of a lower

¹ Dental Cosmos, 1894.

molar contained a highly irritable vital filament of pulp extending but one-quarter inch from the apical foramen; a second canal was entirely occupied by a perfectly vital but ulcerating filament; the third canal contained an entirely dead pulp. The bulb of the pulp had disappeared, doubtless by suppuration.

Treatment. The treatment of pulp ulceration in its early stages involves the opening of the orifice of exposure, the sterilization of the superficies of the pulp, and pulp removal.

Superficial sterilization may be accomplished by removing the pus or putrefactive material present by means of warm 3 per cent. hydrogen dioxide or a 50 per cent. solution of meditrina. The saturated solutions of thymol in alcohol or menthol in chloroform, or 2 per cent. formaldehyde may be sealed in position against the pulp for twenty-four hours as a sedative antiseptic. The application of arsenic may then be safely made.

In favorable cases the bulb of the pulp, or even the entire pulp, may be removed at the first or second sitting by means of cautiously applied cocaine pressure anæsthesia. In some cases, however, the patient will rebel.

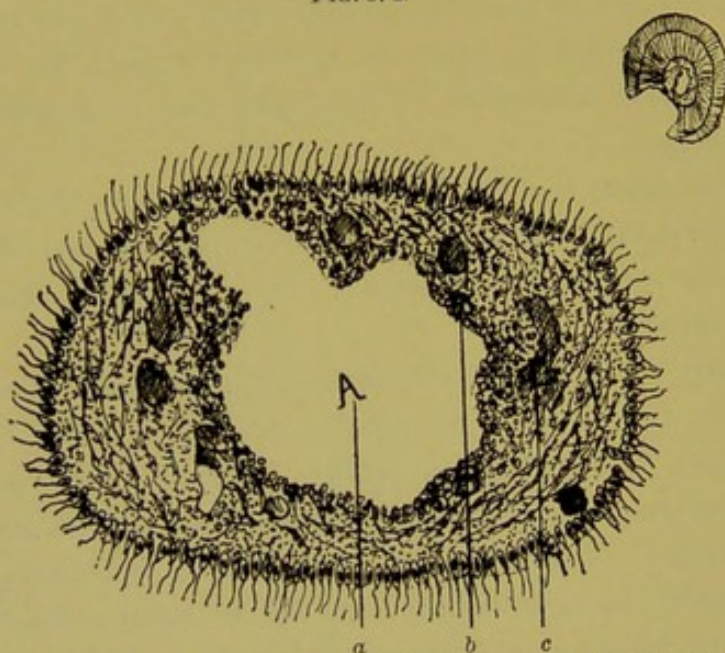
When a part of the canal filaments alone remain, after syringing to remove pus, the pressure anæsthesia may be resorted to. A long thread of spunk is cut from the sheet, saturated with carbolic acid or carbolic acid and cocaine, and gently packed into the canal against the pulp filament. Pressure with vulcanizable rubber is now produced and after a few minutes the pulp will be sterilized and anæsthetized sufficiently for removal. Puncturing is also useful at times (which see). Arsenic may be cautiously placed on cotton half-way up a canal against such a pulp filament. Another method consists of packing a thread of cotton dipped in carbolic acid tightly against the filament, in which thrombosis is thus induced.

Abscess of the Pulp. Abscess of the pulp is usually situated near the point of exposure of the organ. It may be confined to one horn of the pulp, or may involve nearly the entire substance of the pulp, the peripheral tissue of the pulp being unbroken. Abscess may exist at some distance beneath the surface of the pulp, and the latter be still covered with a layer of dentine. Burchard once uncovered the horn of a molar pulp which was covered by a lamina of hard dentine, and no fluid appeared; but upon passing a sharp probe into the *white* area of exposure for over one-eighth of an inch or more there was a free flow of pus which quickly filled the larger carious cavity. A pulp

removed entire from a tooth and which was yellowish-white in color and unbroken showed upon section its interior hollowed out into an enormous abscess cavity (Fig. 374). The bloodvessels were blocked; the peripheral tissues were unaltered; between the odontoblasts and the abscess cavity, the latter lined with pus corpuscles, evidences of inflammation were plenty. Black found that the odontoblasts retained their form after neighboring cells of the pulp had been destroyed.

Miller's¹ researches show a preponderance of cocci and micrococci in cases of enclosed abscess; cocci and diplococci were of constant occurrence. Many of the forms, both cocci and bacilli, were cultivable

FIG. 374.



Transverse section of inferior bicuspid pulp, one-half diagrammatic: a, abscess cavity; b, embryonic cells at the periphery of the abscess cavity; c, occluded bloodvessels. (Burchard.)

upon gelatin and agar-agar. Some of them, cocci and bacilli, brought about the liquefaction of gelatin; others did not. So that it must be inferred that infective inflammation and necrosis of the pulp may occur without suppuration. (See Gangrene of the Pulp.) In some instances streptococci were found. In the freely exposed pulps varieties of organisms were found which would render clear the possibility of a general infection by way of the dental pulp.

Symptoms. The usual symptoms are as follows: In a tooth containing an enormous filling, one in which the pulp has been exposed, or in a tooth having a large carious cavity, the patient gives a history of discomfort or decided pain, appearing at intervals, sometimes

¹ Dental Cosmos, 1894.

appearing and disappearing suddenly, the existing condition having been ushered in by dull, gnawing pain, which is usually not positively located, although it may be. The pain grows in intensity, and, in contradistinction to the pulp conditions previously described, pain is relieved instead of increased by applications of cold. It may be, however, that the prolonged contact of ice-water may induce a response. The response to heat is marked, so that a mouthful of hot coffee or even the warmth of the tongue may precipitate an attack of severe and continued pain. Pain produced upon passing from a warm to a cold atmosphere, and *vice versa*, is also symptomatic. If the pulp be freely exposed and pricked with a sharp instrument, a flow of pus follows in many cases, and the relief is almost immediate. In the earlier stages a period of throbbing pain may follow evacuation of the pus.

In other cases the response to heat may decrease until it is almost absent, and the case only be seen when evidences of the action of bacterial products upon the pericementum appear, which they usually do in the later stages of pulp suppuration, when the tooth becomes loose, extruded, and tender upon percussion.

The symptoms of pericemental disturbance may simulate those of incipient, acute, apical abscess, even though a quarter of an inch or more of apical pulp tissue exist in a vital though highly inflamed condition. Upon clinical evidence it is assumed that the inflammation of the pulp produces inflammation of the apical tissue (Fig. 375). In one case the gum and contiguous parts about an upper molar were swollen, apical abscess diagnosed, and a free flow of pus followed by blood obtained upon opening the crown. An examination made twenty-four hours later, after symptoms had subsided, demonstrated all three pulp filaments to be alive when a *post hoc* diagnosis of extensive abscess of the pulp was made. If untreated, symptoms of pulp and pericemental disturbance may disappear for weeks or months; but if the parts be not perfectly sterilized and reinfection prevented, it is only a question of time when septic pericementitis will arise.

Diagnosis. The most valuable diagnostic sign is the peculiar reaction to thermal stimuli—the decreasing, then absent response to cold, and the increasing reaction to applications of heat. This reaction, together with the continued gnawing and full sensation in the tooth, usually affords a diagnosis which is confirmed by evacuating pus from the pulp, which exudes usually as a minute bead followed by blood, though the reverse order may obtain.

In cases where several teeth are involved in the diagnosis, differentiation is made by isolation of each tooth by means of a small square of rubber-dam. The thermal test is then applied. The presence of a quantity of secondary dentine will confuse by causing dulness of response. In such case the electric test should be resorted to. (See Dry Gangrene.) In some cases secondary dentine will have formed

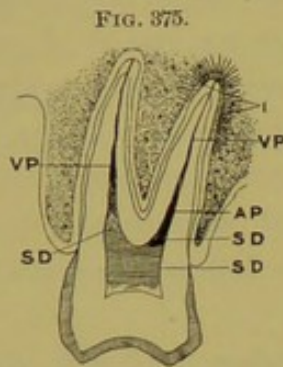


FIG. 375.
Abscess of the pulp after formation of a large amount of secondary dentine, dividing the pulp into two portions: *S D*, secondary dentine; *V P*, vital pulp; *A P*, abscess or confined pus; *I*, area of apical inflammation. (Diagrammatic.)

in the pulp cavity and the abscess may be found in one of the filaments while the other will be apparently healthy. Fig. 375 is a diagram of a number of cases seen in practice.

Prognosis. General experience regards ulceration and abscess of the pulp as precursors of the death of the organ. Usually this is by progressive suppuration. It is undoubtedly true, however, that attempts at circumvallation of the dead tissue are made in some cases (Fig. 376). The pus cells undergo degeneration and the abscess site may be the seat

of calcareous deposits. Even in these cases death is delayed, not averted. The remainder of the pulp undergoes atrophic changes, and commonly suppuration reappears.

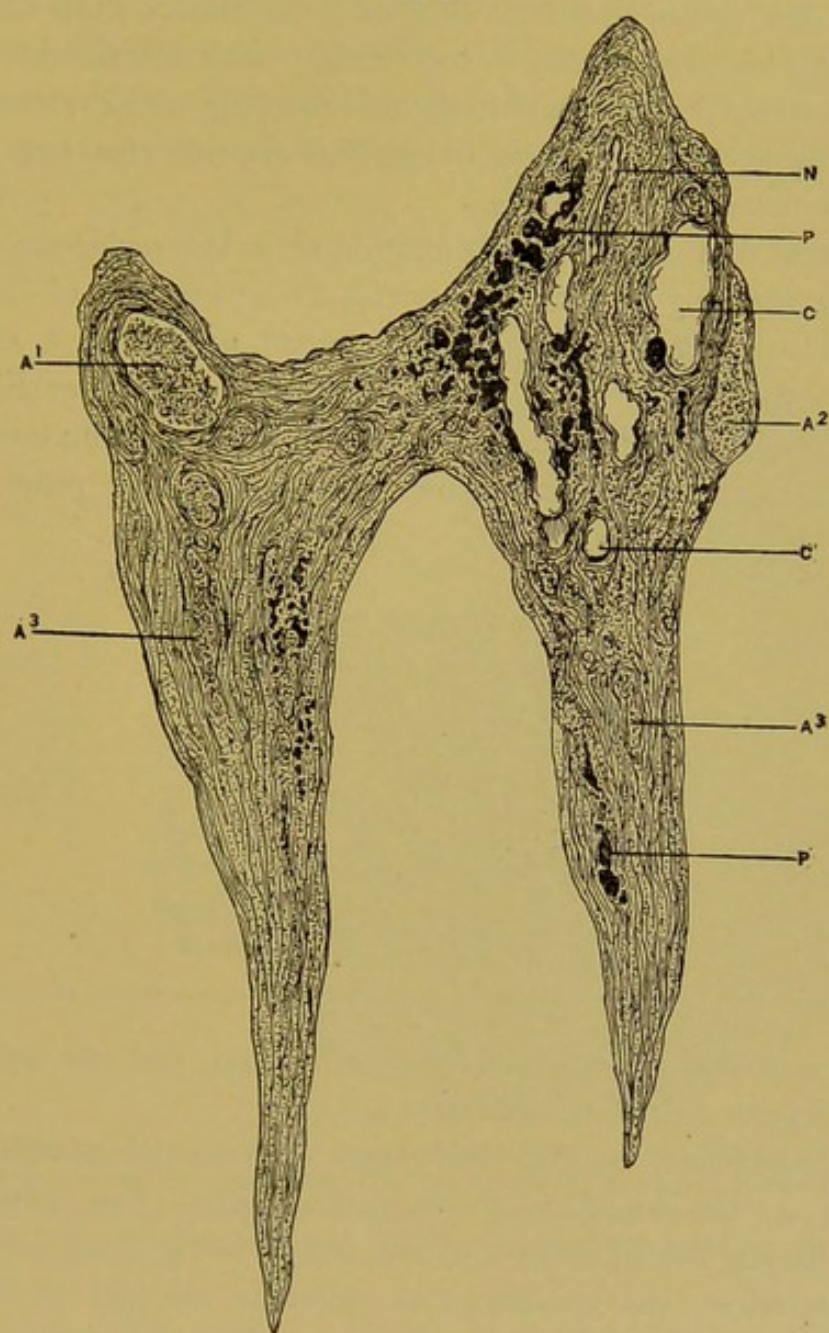
Treatment. The treatment of the case consists in relieving the existing pain, completing the devitalization of the pulp, and removing it in such a manner that no organisms or dead matter are carried beyond the apex of the root.

To secure relief, evacuation of the pus is imperatively necessary. The organ is freely exposed, exercising no pressure in gaining free access to it. If pus do not flow upon exposure of the surface of the pulp, a sharp, slender, sterilized probe is quickly passed into the substance of the pulp, when, if pus be present, it will usually escape freely through the opening thus made and be followed by blood.

If the pus formation be limited and circumscribed, throbbing pain may follow, which promptly quiets under an application of cocaine in glycerin. The application is not made until the pus flow ceases. A pellet of cotton wet with a 3 per cent. solution of formalin, or a saturated solution of thymol, is laid upon the pulp and the cavity is sealed for twenty-four hours (never longer), and then an arsenical application

is made. Should the exposed portion of the pulp be insensitive it is burred away until access is had to the vital portion, where the arsenic is to be applied. The pulp may otherwise be surgically removed.

FIG. 376.



Chronic suppurative pulpitis terminating in calcification of the pus and atrophy of the pulp. *A¹*, larger abscess, filled with calcified pus; *A²*, abscess at the periphery of the pulp; *A³*, *A³*, small longitudinal abscesses, all calcified; *N*, calcified nerve bundle; *C*, *C*, calcareous depositions in the fibrous pulp tissue; *P*, *P*, pigment clusters from previous hemorrhage. $\times 10$. (Bödecker.)

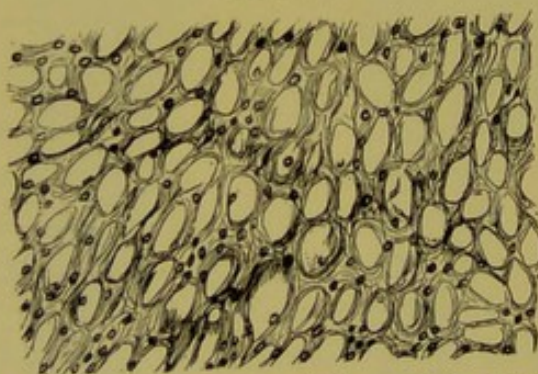
The rubber-dam need not necessarily be applied for the treatment preliminary to devitalization, but the pulp should be kept under the influence of antiseptics

CHRONIC INFLAMMATION OF THE PULP.

In cases in which the resistive force of the pulp is great and the causes of less violent nature or less violent in action, the inflammation may be of low grade and continue for some time. Pulp ulceration may pursue a chronic course, as has already been described. Abscess of the pulp may also become chronic, and the pulp may even encapsule the pus area and, the bacteria dying, the abscess area may become the seat of calcareous deposits.

Sclerosis of the Pulp. Inflammation of a low grade may persist in the pulp for long periods, giving rise to an increase of its fibrous tissue with atrophy of the cellular elements, producing a condition found in chronic interstitial inflammation in some other tissues—a sclerosis. Instead of the usual distribution of myxomatous tissue, bands and bundles of fibrous tissue appear. The pulp appears

FIG. 377.



Chronic inflammation of the pulp, areolation, and degeneration. (Black,)

shrunk and stiff, bloodvessels are contracted, and the nerve fibres have undergone partial or complete atrophy.

Black found that in the late stages of sclerotic atrophy areolæ developed in the bundles of connective tissue, the inflammatory elements having disappeared and the areolæ being occupied by fluid. Arkövy describes the condition as reticular atrophy of the pulp (Fig. 377).

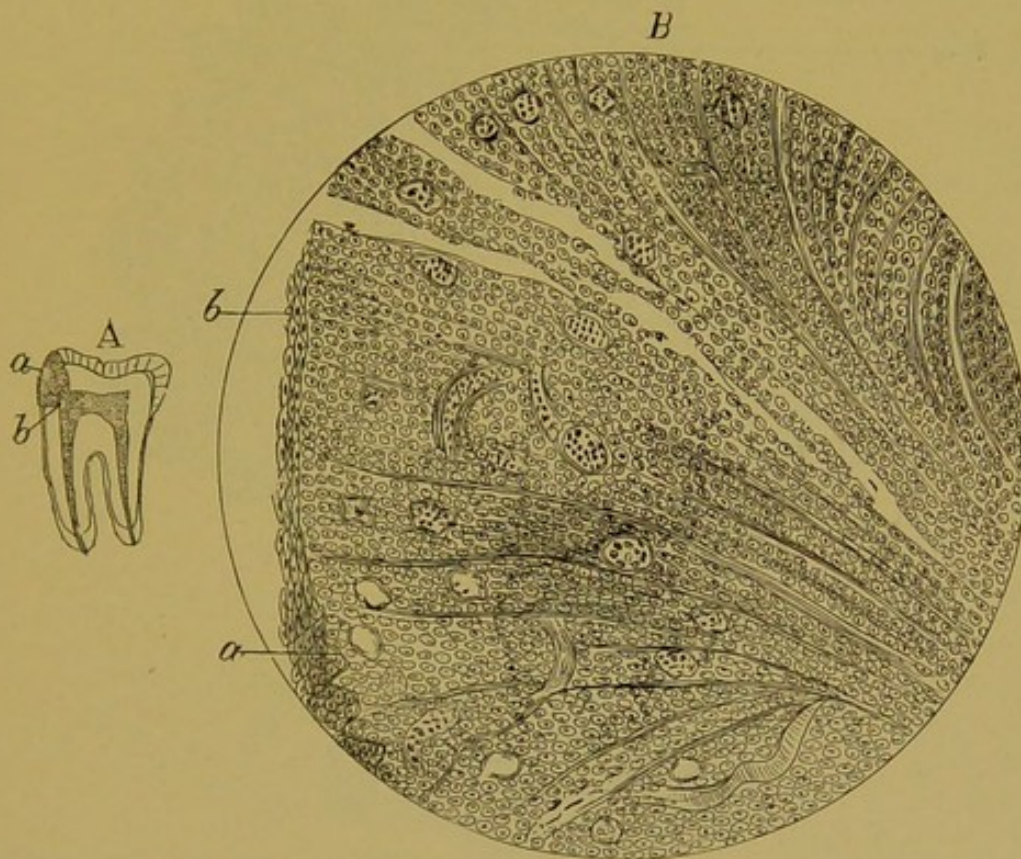
The condition would point, as suggested by Black, to venous hyperæmia as the cause of the œdema rather than inflammation; but the evidences of former chronic inflammation in the existence of the bundles of reticulated tissue show this to have been the essential condition. The observations of the same writer indicate that atrophy of the odontoblasts is a usual accompaniment of all of the chronic pulp affections.

Sclerotic and other chronic degenerations of the pulp usually present the history of one or more attacks of pulpitis in the past, with more or less continuous uneasiness extending over a long period. The response of the pulp to all tests becomes diminished and dull.

Treatment. Such pulps are to be devitalized and removed.

Chronic Hypertrophic Pulpitis. When the pulp is exposed over a wide area, long-continued chronic inflammation may lead to an enlargement of the organ with a protrusion of altered pulp mass

FIG. 378.



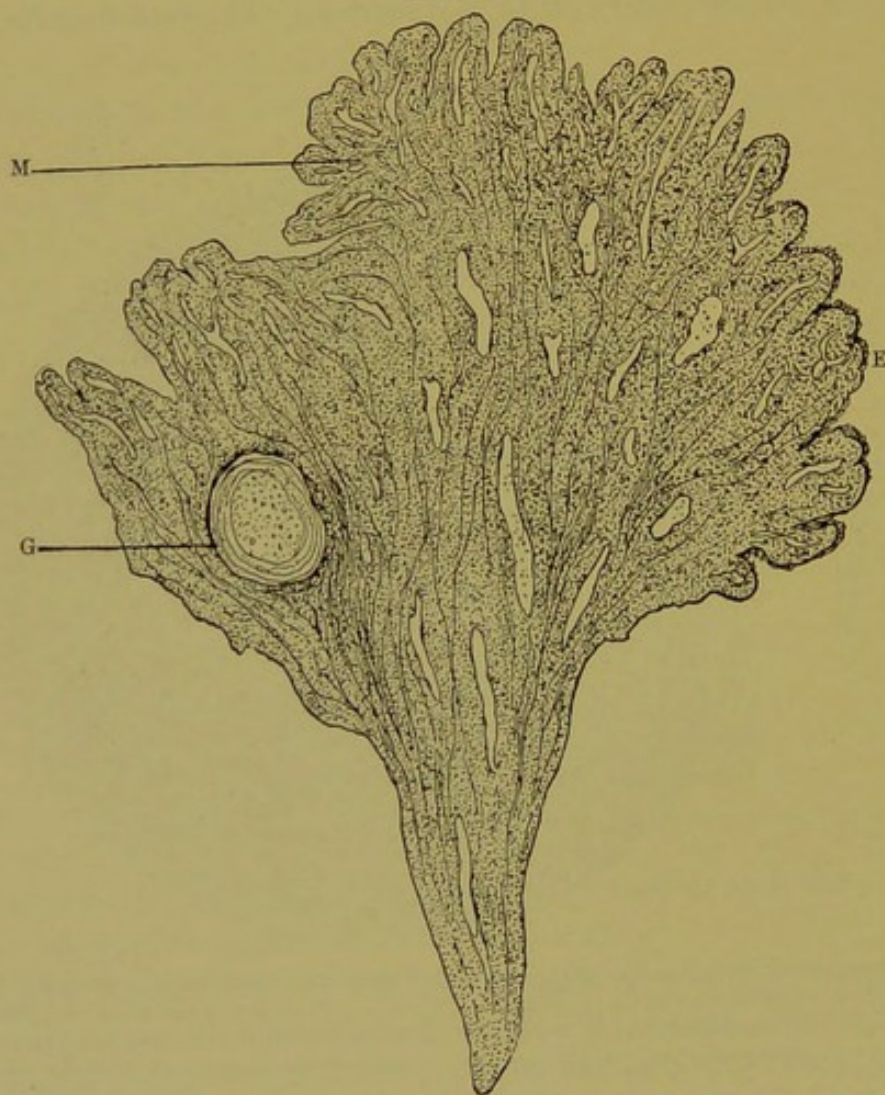
A, a first lower molar with a cavity at *a* completely filled by a hypertrophy of the pulp, which has grown out through the orifice, exposing the pulp at *b*. B, a field illustrating the tissue of the growth, which is composed almost entirely of granulation tissue of a very primitive type: *a*, a covering of epithelium presenting papillae; *b*, epithelium apparently without papillae. (Black.)

through the orifice of exposure, producing the condition known clinically as fungous pulp. When the growth extends beyond the boundaries of the orifice and then increases in bulk it forms a pedunculated mass to which the term polypus of the pulp has been applied.

Morbid Anatomy and Pathology. The growth has its origin in a chronic inflammation of the body of the pulp; the organ swells, and contact with the sharp edges of the orifice of exposure excites a continued irritation, leading to further proliferation of the cells of the

inflamed part, so that a large mass of embryonic tissue is formed (Fig. 378), termed by Black granulation tissue of a low type. As in the granulation tissue of repair, bloodvessels grow into this mass, so that it may bleed at a slight touch. Black noted in his case illustrated a covering of squamous epithelium upon the periphery of the growth, which might be interpreted as the transformation of

FIG. 379.



Hyperplastic myxomatous pulp, which filled a carious cavity: *M*, lobules made up of papillæ of a myxomatous structure, rich in capillary and venous bloodvessels; *G*, calcareous globule; *E*, epithelial cover of papillæ. $\times 10$. (Büdecker.)

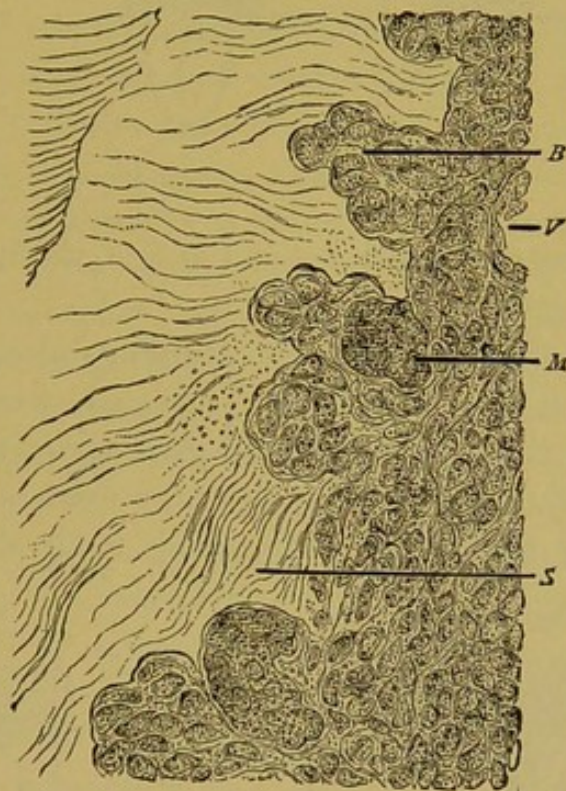
mesoblastic into epiblastic tissue, but the correct explanation beyond doubt is that advanced by the same author, that the epithelium is transplanted from the gums, and grows after the manner of a skin-graft. The growth does not contain nerves.

These growths may undergo further changes; higher organization of the granulation tissue occurs and fibrous tissue is formed; the cells may

undergo degenerations, first granular, then fatty, and suppuration and gangrene may occur. 'Tomes' records a case where calcification of a hypertrophied section of a pulp occurred; but as the case was due to traumatism (fracture of a tooth), different vital conditions existed from those in the cases under discussion. Actual calcification of the mass is scarcely possible, although calcareous degeneration may occur within the fungous mass (Fig. 379).

Resorption of the walls of the pulp chamber may occur as an accompaniment of chronic pulpitis. What appears to be an idiopathic

FIG. 380.



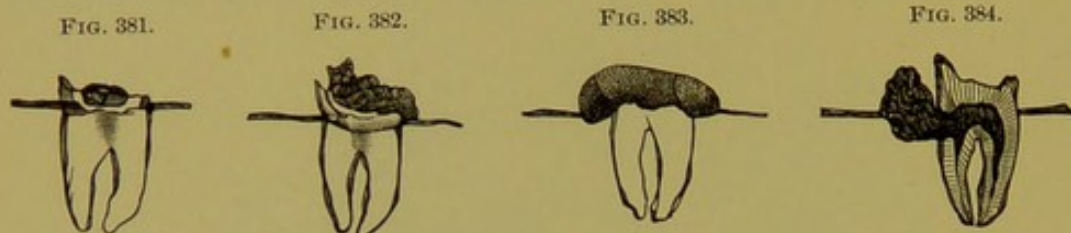
Acute pulpitis: *S*, secondary dentine; *B*, bay-like excavations filled with medullary or inflammatory corpuscles; *V*, transverse section of a blood vessel; *M*, multinuclear body. $\times 300$. (Bödecker.)

dentine resorption is described on page 397. Black records a case where, after pulp capping in a lower molar and the insertion of a large gold filling, the tooth was examined at the end of ten years; for two or three years the pulp had given evidences of irritability, and when the pulp was removed the pulp chamber was found enormously enlarged and opening into the pericementum between the roots of the teeth. Fig. 380 exhibits resorption of previously formed secondary dentine with the probable agency through which the resorption is brought

about. The area of resorption is invaded by numerous multinucleated cells, which are evidently performing the function of odontoclasts.

As shown by Miller, Hopewell-Smith, and others, a reconstructive change may occur and adventitious dentine be redeposited in the area of resorption (Fig. 365).

Symptoms. The symptoms of chronic pulp inflammations and degenerations are usually those of long-continued discomfort, with reflex pains, which rarely persist into the latest stages of degeneration.




Hypertrophy of pulps. (Garretson.)

The response to heat and cold, present at first, declines until the pulp scarcely reacts, and then but slowly.

No nerve fibres develop in the hypertrophic pulp tissue, so that the new-growth has no sensitivity in itself, although pressure upon it may cause sharp pain through the still vital pulp nerves themselves.

Four or five of these hypertrophies may exist in a mouth, filling whole cavities of decay, the surrounding tooth structure being in



Hypertrophy of the pericementum. (Garretson.)

Hypertrophy of the gum. (Garretson.)

various stages of disintegration. They seem to be comparatively insensitive to mastication (Fig. 382).

Hypertrophy of the pulp also may be associated with pulp ulceration, the growth arising from one canal of a tooth.

Regeneration of an extirpated pulp has been claimed, but I have never seen any cases that were not referable to the above form of hypertrophy or to a fungoid growth from the pericementum.

Diagnosis. The only condition with which hypertrophic pulp may be confounded is a pedunculated growth of gum tissue through a

cavity at the neck of a tooth beneath the gum margin (Fig. 385). It is important to differentiate between these conditions, because if an application of arsenical paste be made to a fungous gum, the destruction of tissue may extend into the sound pericementum. The physical appearances of the two are alike: they both bleed freely and have about the same degree of sensitivity.

Histological examination of this class of hypertrophy of the gums, conducted by Dr. Luigi Ancone,¹ of Italy, demonstrated that the growth is a simple exaggeration of the normal elements of the part.

If the tumor be central to the tooth tissue and the latter not decayed out to very thin walls, it may be at times laid aside by means of a blunt instrument and be seen to have its origin from an orifice of exposure (Fig. 381). It is then fairly inferred to be a pulp mass, especially if the tooth has never been operated upon. The diagnosis may be a doubtful one, in which case the rubber-dam is to be applied, the polypus frozen by means of a spray of ethyl or methyl chloride, and the mass removed with a sharp blade passed across its peduncle.

The source of the tumor may then be usually clearly seen. As an alternative proceeding the tissue may be thoroughly saturated with a strong solution of trichloroacetic acid and then ablated. If any further doubt exist the pulp is to be sterilized with hydrogen dioxide, etc., and a pellet of cotton saturated with oil of cloves, carbolic acid, or dental tincture of iodine is laid upon it, and over this temporary stopping is firmly packed. By this means the growth may be pressed away until it is seen to arise from either a pulp chamber or a perforation made by decay or accidental excavation into the pericemental tract.

Pressure anæsthesia may be resorted to partly as a diagnostic measure. In such case no danger exists beyond the possible forcing of cocaine into the gum tissue. Nervocidin should be useful in cases of doubt. The *x*-rays should afford a diagnosis.

Hemorrhage may be checked with adrenalin chloride 1 : 1000 solution, or 25 per cent. pyrozone or a saturated solution of silver nitrate.

Treatment. If the case be one of pulp hypertrophy, arsenic may be applied or pressure anæsthesia attempted for pulp removal.

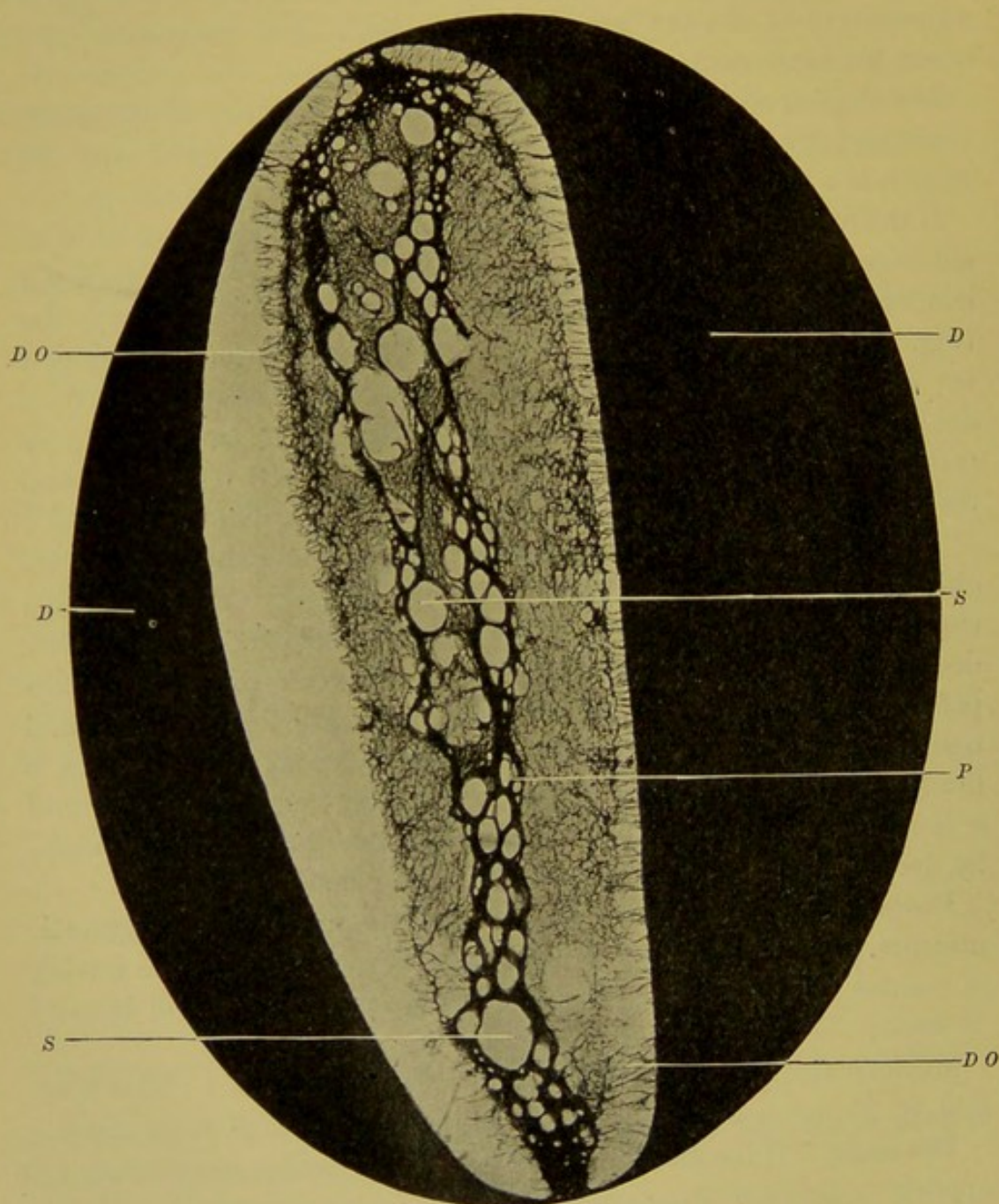
Crystals of iodine have been used with satisfaction in combination with pressure for pulp devitalization.

If a perforation exist it is to be treated by sealing the orifice with gutta-percha or copper amalgam if practicable. (See Therapeutics of Dental Caries.)

¹ Abstract from *L'Odontologia* by Dr. W. Dunn, in *International Dental Journal*, 1899.

Fibroid Degeneration of the Pulp. Apart from the degenerations due to inflammatory conditions, a form of degeneration occurs "as a

FIG. 387.



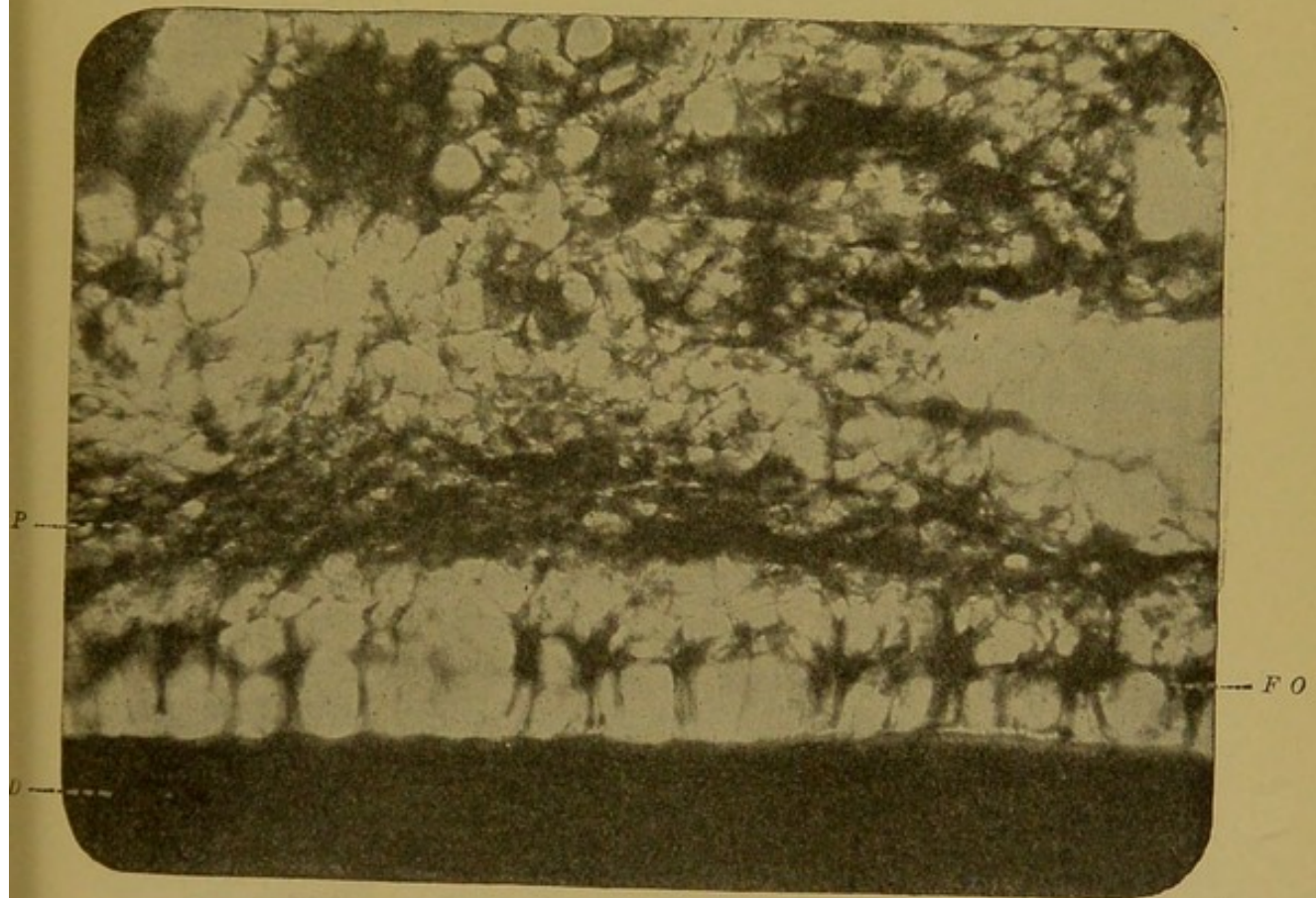
Horizontal section of fibroid degeneration of the pulp *in situ*. Prepared by Mr. Hopewell-Smith's process: *D*, deeply stained-dentine; *S*, large areolar spaces; *D O*, degenerate odontoblasts; *P*, fibroid tissue of pulp. $\times 45$. (Hopewell-Smith.)

natural old-age termination of the life of a healthy pulp," and similar to senile changes occurring in the pericementum. (See Fibroid Degeneration of Pericementum.) This change, first described by Hopewell-

Smith,¹ occurs in teeth of the aged in whose mouths simple alveolar resorption has occurred.

Morbid Anatomy. "The pulps are shrunken and may have left the wall of the pulp chamber. Many areolar spaces appear which may be arranged in chains. The odontoblasts are degenerated. The pulp stroma is very dense, has a clear, fibrous structure, becomes very marked in staining, and is highly differentiated from the surrounding

FIG. 388.



Fibroid degeneration of the pulp. *D*, dentine with tubules; *FO*, fibroid odontoblasts; *P*, atrophied pulp tissue.

tissue. The bloodvessels, nerves, cells, and connective tissue have all disappeared and their place is taken by a new, firm, fibrous structure devoid of cells, nuclei, or any regular arrangement of constituent parts.

"There is no calcification of the pulp and no obliteration of the dentinal tubules.

"The proximate cause and associate phenomena are not as yet clearly related."

¹ Histology and Patho-histology of the Teeth.

Fatty Degeneration of the Pulp. During the course of degeneration of the elements of the pulp fatty changes may occur as in other parts. The fatty changes occur in the walls of the arteries and sheaths of the nerves, and in the odontoblasts.¹

Practically all of the destructive pulp diseases (excepting sclerosis and fibrosis) occur in the pulps of the temporary teeth, and are to be treated in like manner except as to the use of arsenic, which, being accompanied by greater danger, should, for the most part, be replaced by nervocidin, pressure anæsthesia, or cantharides. This point is discussed at length in the chapter upon removal of the pulp.

If the tooth roots be largely resorbed the pulp may bear capping with a paste composed of oxide of zinc and eugenol, even when ulceration has occurred. The pulp may die under this capping, when the case is further treated as indicated. (See Chronic Apical Abscess.)

¹ Hopewell-Smith.

CHAPTER XVIII.

METHODS OF REMOVAL OF THE DENTAL PULP AND ROOT-CANAL FILLING.

THE removal of the dental pulp being a valued and in some cases the only method of curing certain pulp diseases, a consideration of the methods available is of importance.

1. Under the influence of a general anæsthetic, nitrous oxide or even ether, the pulp cavity may be opened and the pulp removed. The influence of nitrous oxide as ordinarily administered will be too evanescent to permit removal of root filaments of pulps of multirooted teeth. In these, therefore, the removal of the pulp bulb alone is, as a rule, accomplished. By this means the pulp is depleted and the engorgement of the pulp vessels reduced. The devitalization is completed with arsenic, or by cocaine pressure or nervocidin anæsthesia.

In single-rooted teeth the pulp chamber may be opened with a sharp bur and the pulp quickly removed with a barbed broach. Under the influence of ether the operation may be made complete in any tooth. It is seldom used for the purpose.

2. Sprays of rapidly vaporizable substances, such as ethyl or methyl chloride, directed against the exposed pulp, the tooth being isolated under rubber-dam, will, in some cases, render the pulp entirely insensitive, although, as a rule, they fail to entirely anæsthetize to the apical foramen. The method is painful and not applicable in many cases of highly irritable pulps.

3. Applications of even saturated solutions of cocaine being ineffective, it has been suggested to inject cocaine into the pulp: the surface of the pulp is benumbed by applications of strong solutions of cocaine, the needle of a hypodermic syringe containing a solution of cocaine hydrochlorate (from 4 per cent. to 10 per cent.) is quickly thrust into the pulp canal, and a drop of the solution forcibly injected; in a few seconds the pulp may be so benumbed that it can be removed.¹ This procedure, however, appears to fail as often as it succeeds. A strong solution of silver nitrate has been suggested by Dr. A. N. Gaylord as useful in place of the cocaine before applying the needle.

¹ Maxfield, Proceedings of the New Jersey State Dental Society, 1894.

4. Cocaine cataphoresis is usually effective, although in conditions of active hyperæmia and inflammation even the maximum current and saturated solutions of the alkaloid may fail to subdue the irritability of the pulp. In favorable cases about fifteen minutes are required for pulp anæsthesia.

5. A more reliable method of utilizing cocaine is in combination with pressure. The rubber-dam is applied. A small pellet of amadou (spunk) is wet with a saturated solution of cocaine hydrochlorate in water, alcohol, or chloroform, and then dipped in the finely powdered cocaine. It is then laid upon the pulp and a strip of soft, vulcanizable rubber is folded into the cavity until it fills it. A burnisher as large as convenient is then used to gently press the rubber in the direction of the pulp. A piece of amadou placed over the rubber will concentrate the force of the burnisher and prevent egress of the rubber. A slight pain will be produced, upon indication of which further pressure should cease for the time, but the advance made be maintained. In a half-minute pressure may be again renewed and, unless pain be produced, be increased until the full force of the wrist is exerted. The rubber and spunk are then removed, the pulp cavity opened, and the pulp lifted away with a broach. For multirooted teeth a more prolonged pressure is required than for the single-rooted. On account of possible non-removal of some portion of pulp tissue in fine roots it may be well to instill carbolic acid into the fine canals to prevent return of sensation. By this operation the pulp tissue is visibly compressed and in some cases ischæmia with its accompanying lessening of sensibility is produced; at the same time the cocaine is probably forced into the pulp tissue. In some cases the anæsthesia is satisfactory, while the pulp itself still bleeds readily, so that cocaine anæsthesia seems the most satisfactory explanation. The operation appears to fail in the teeth with very large foramina, though with the moderately large foramina it is, as a rule, successful. Some pulps rebel totally against the treatment, some require several applications, and some are not affected at all by the second application. The application sometimes stops acute pain and sometimes produces it in a fairly quiet pulp. In all these the conditions may seem favorable to the attempt. The effect seems most pronounced when the exposure is free and the pressure effected in a direct line with the pulp axis. For this reason a second application may be successful while the first may only permit a better exposure. The dentine may be anæsthetized by the method in order to gain an exposure in cases of sound teeth from which it is desired to remove

pulps by this method. In some cases it is necessary to close the buccal and lingual interdental openings by means of the thumb and forefinger in order to concentrate the force exerted upon the pulp. The force should be carefully applied in cases of frail walls. These are perhaps better cut away. In cases of ulcerated pulp filaments the above-described pressure may be modified. A thread of spunk may be saturated with carbolic acid or carbolic acid and cocaine and packed into contact with the pulp and the pressure with vulcanite rubber made. Some caution should be observed in the use of both cataphoresis and pressure anæsthesia after partial devitalization by the use of arsenic, as cases have been recorded of the carriage of the latter to the apical tissues by these means. The obvious indication is the thorough removal of all arsenic and dead tissue before applying either of the cocaine methods. Cases of the systemic action of cocaine *via* the pulp have been noted in this method. Some of these cases are due to syncope alone, as it has occurred when other materials have been used experimentally. Hemorrhage after the pulp extraction may be treated with adrenalin chloride, 1:1000, caustic pyrozone, zinc chloride, or other styptic.

6. Arkövy has recommended nervocidin for its anæsthetic action upon the pulp. A small quantity is placed upon a piece of spunk and applied to the pulp, which it anæsthetizes in from a few hours to a day, when the pulp may be painlessly removed in an ischæmic condition. Two applications are required in case of unexposed pulp: one to obtain a painless exposure.¹ It is not injurious to the gum.

7. A fully exposed pulp in a single-rooted tooth or single root of a multirooted tooth may be suddenly "knocked out" by means of a delicately pointed orange-wood stick or Portuguese tooth-pick. The point is dipped in carbolic acid, and suddenly and boldly driven into the pulp either by hand or mallet force. The method is not so agreeably delicate as pressure anæsthesia.

8. Darby uses with success in deciduous teeth a paste of about $\frac{1}{20}$ grain of cantharides in carbolic acid. The application must be very carefully sealed. Flagg² has mentioned a case of strangury in a man as the result of its use against a tooth pulp. While probably an idiosyncratic case, the effect is in correspondence with the known occasional effect of cantharides applied as a vesicant.

9. A vital remnant of pulp may be removed after instilling carbolic acid or a paste of carbolic acid and acetate of morphine into its sub-

¹ Söderberg, Dental Cosmos, 1901 and 1902.

² Private communication.


stance by means of a "puncture probe." This instrument may be made by filing down an old Donaldson cleanser to a fine point, which is further whetted on an oil stone. The sides of the probe are polished by folding a cuttle-fish disk upon itself, holding it between the thumb and forefinger of the left hand and drawing the probe through it. The pulp canal is flooded with the carbolic acid and gentle thrusts are made into the pulp until the probe is stopped at the apex. If it pass through, that must be judged by the sense of touch. At times a small end of pulp filament may be seared with a hot Evans' root drier which is quickly thrust into it. This does not necessarily give much pain.

10. A slow but effective method of disposing of these filaments, when hyperirritable or when patients are timid, consists in packing a cotton twist saturated with carbolic acid containing cocaine hydrochlorate in solution into contact with the pulp and then gently compressing the pulp. The cotton is to be left in position for a day or two, when, as a rule, the pulp may be removed.

11. Arsenious acid (arsenic trioxide) is, as a rule, prompt, certain, and complete in its action, and is applicable for devitalization in nearly all cases of pulps in mature teeth. It was introduced by Spooner for this purpose in 1836.

When a small quantity of pure powdered arsenic, or of a paste in which it is mixed with other ingredients, is applied to the pulp horn or the dentine, the pulp gradually dies progressively from the horn toward the apex. So universally is this the case that a short application almost invariably involves the necessity of a second application to the pulp or of a painful extirpation of the undeitalized portion of pulp.

Action of Arsenic upon the Pulp.—Arkövy¹ was the first to point out the details of the action of arsenic upon the dental tissues:

"1. As_2O_3 brought into contact with the tooth pulp acts in the following way: a certain degree of inflammatory hyperæmia, total or partial, depending upon the quantity of the agent applied, sets in; the bloodvessels become expanded, and here have a tendency to thrombosis. This latter effect may also be in connection with embolism of the capillaries, when the agent is quickly taken up into the bloodvessels. 

"2. As_2O_3 produces no coagulation of tissue whatever.

"3. It has a specific influence upon the blood corpuscles, combining with the hæmoglobin to form a compound of arsen-hæmoglobin, and

¹ Transactions of the International Medical Congress, London, 1881.

of this chemical process there seems to be evidence in the profuse yellowish tinge of the whole pulp tissue and in the discoloration of blood in several of the bloodvessels.

"4. In nearly every case it is taken up *in substantia* (in form of molecules) into the blood-ways; when there it produces, besides the above-mentioned changes, granular detritus of the contents and anæmic collapse—shrinkage, the latter effect being brought about nearly exclusively in cases where greater doses were used.

"5. The bulk of the pulp tissue—viz., connective-tissue fibres and odontoblasts—undergoes no change whatever; not so the connective-tissue cells, which increase three or four times their normal size.

"6. The special action of arsenic trioxide upon the nerve elements consists in the following: the neurilemma is only so far influenced that its nuclei are somewhat increased; a more essential change takes place in the axial part, where, after the application of more than one mgrm., granular destruction of myelin sets in, and the axis-cylinder commences here and there to disappear. A very surprising alteration may be seen in the notchy tumefaction of the axis-cylinder, described heretofore almost only in cases of central lesions.

"7. All these alterations occur in and among normal-looking tissue.

"8. The action of arsenic trioxide is macroscopically exhibited by a brownish-red tingeing of the whole or of certain parts of the pulp body, as well as of the neighboring dentine and the cementum, this latter in cases treated with greater doses—viz., two to five mgrms. This alteration is most expressed at the top of the crown pulp and at the apical one-fourth to one-third part. This circumstance may be considered as an external evidence of the devitalization being completely attained to."

In some cases the pinkish discoloration of the dentine may be marked; the broken-down corpuscles of the extravasated blood have their coloring matter taken up by the odontoblasts, and being distributed through their protoplasmic processes produce a condition technically known as suffusion. The same result may be an attendant upon injury to the vessels from other causes, from sudden thrombosis, as when teeth are moved too rapidly in regulating.

Miller's experiments¹ upon the tails of mice (made without and with rings at the root of the tail to simulate the surroundings of the apical vessels of a tooth; made without and with encasement of the tails in

¹ Dental Cosmos, 1894.

plaster of Paris to imitate the rigid surroundings of the dental pulp) showed that in the absence of the plaster encasement enormous œdema of the tail was produced and a sensory paralysis of the hind limbs; complete anæsthesia of the tail occurred in forty-eight hours. "The action of arsenic appeared somewhat accelerated when a glass ring was applied close to the root of the tail. In more than forty cases there was not one in which the action of the arsenic extended beyond the ring, and the action was not appreciably affected by enclosing the tails in plaster casts. The action of the arsenic is of a progressive nature, beginning at the point of application and extending gradually in each direction."

Flagg¹ devitalized ten pulps and removed them, cut off the portion of the bulb of each which had contact with the arsenic, and tested the ten pulps together by Reinchs' test. Arsenic was found, estimated at a one-hundred-thousandth part of a grain or one-millionth of a grain for each pulp. Allowing for possible mechanical introduction or contact of arsenic during extirpation, the quantity of arsenic introduced by the circulation must be very minute indeed.

Flagg argued that as the pulp subsequently putrefies it cannot have died as the result of arsenical poisoning alone.

The indication is that a minute quantity of arsenic is absorbed, exerts its peculiar chemical effects, which cause the pulp in part to become quickly filled with blood. Circulation in the part ceases and death of the part ensues. Arkövy's and Miller's experiments seem to show that the arsenic may be absorbed into part of the pulp beyond the original area of congestion, and this probably produces further stasis, which progresses apexward. It has been contended that arsenic may pass out through the apical foramen. For the roots with large foramina this has been shown to be true, as areas of devitalization of the apical and overlying gum tissue have been noted. In several apparently authentic cases the pericementum of a mature tooth has been said to be destroyed from the apex down and the tooth lost. I have never seen such a case resulting from the arsenical method alone in either clinical or private practice, though cases of marginal gum alveolar and pericemental death beginning as the result of leakage or application to perforations have been noted. It is probable that as stasis proceeds the apical portion of the pulp becomes involved in advance of arsenic absorption. Miller's experiments show that arsenic does not pass the point of constriction.

¹ Dental Cosmos, 1868.

Variations in the Action of Arsenic. In most cases of fully formed single-rooted teeth in young adults, an application of arsenical paste directly to the exposed pulp will be followed by the complete death of the organ in forty-eight hours. At the expiration of that time a sterilized broach may be passed almost to the apex of the root and the pulp removed *en masse* without pain. Pulps of molars require a longer time, often a week, before the filaments are dead. The finer filaments resist longer than the larger ones. If pulp nodules exist, the action of the arsenic may be delayed or in some cases be almost *nil*. In calcareous and other chronic pulp degenerations the action is also delayed. If arsenical applications are made over a layer of dentine, the same delay is noted, and is increased in very mature teeth. There is also a greater tendency to suffusion.

Some pulp, irrespective of the pulp condition, exhibits a peculiar idiosyncrasy in resisting the action of arsenic, requiring large doses and long applications before succumbing.

Forms in which Used. The following formulæ have been recommended. The analgesics included are intended to dilute the arsenic and quiet the pulp and thus both directly and indirectly modify the pain:

- | | |
|--|---------------------|
| 1. R—Acidi arsenosi, | |
| Morphinæ sulph., | ââ gr. x. |
| Acidi carbolicî, | q. s. ft. pasta.—M. |
| | (J. D. White.) |
| 2. R—Acidi arsenosi, | gr. x. |
| Morphinæ acetatis, | gr. xx. |
| Olei caryophylli, | q. s. ft. pasta.—M. |
| | (J. Foster Flagg.) |
| Creosote may be substituted for oil of cloves. | |
| 3. R—Acidi arsenosi, | gr. x. |
| Cocainæ hydroch., | gr. xx. |
| Olei cinnamomi, | q. s. ft. pasta.—M. |
| | (E. C. Kirk.) |

4. Any of the above may have the powdered ingredients mixed. The cotton pellet may be wet with an analgesic oil and then dipped into the powder.

5. Absorbent cotton cross cut with scissors to a fine lint may be dusted into any of the above pastes made thin by adding an extra portion of the menstruum. It is then dried and bottled for use.¹

As the ordinary pastes tend to separate into layers of arsenic, morphine, and menstruum if made thin, they should either be made into stiff pastes or spread over the bottom of a wide jar so that some arsenic may be scraped off the bottom at each application.

¹ J. Foster Flagg.

Miller suggests using thymol in connection with arsenic, it being both analgesic and antiseptic. He offers the following general rules as deductions from his observations:

"1. The rapidity and intensity of the action of arsenious acid depend, under certain circumstances, to a very considerable degree upon the substance or substances with which it is incorporated.

"2. Where there is but a small point of exposure, and in particular where extensive calcification has taken place in the pulp, escharotics should be avoided, since the coagulation of the tissue retards the absorption of the arsenic. This retardation is but slight where there is a broad surface of exposure. In stubborn cases, where applications of the ordinary paste fail to effect the devitalization, a paste consisting of arsenious acid in oil of cloves, glycerin, or salt solution should be employed, undiluted by any third constituent.

"3. Thymol is worthy of a trial as a substitute for morphine, on account of its anæsthetic and antiseptic properties.

"4. For devitalizing pulps of temporary teeth or remains of pulp tissue in root canals, arsenious acid, if employed at all, should be diluted with two or three parts of some other constituent (thymol, zinc oxide, morphine, iodoform)."

Cobalt was introduced by Robert Arthur as a devitalizing agent some forty years ago. Within recent years it has been employed, notably by the Herbst method (which see), to destroy pulps. The cobalt paste of Herbst was analyzed by E. C. Kirk and found to consist of *metallic* arsenic and cocaine hydrochlorate. Kirk suggests that free acids which cocaine salts may contain, or the chlorine from the chloride, may combine with the metallic arsenic and form soluble salts. Commercial cobalt will certainly devitalize the dental pulp, but it is in consequence of the arsenic contained in it.

Mode of Application. After sterilization of the cavity and pulp and drying, a minute pellet of cotton is to be rolled in the paste and placed in the desired location. As arsenic destroys gum tissue freely it should be used in minute quantity only and be accurately sealed in the cavity.

In purely occlusal cavities the application may be covered with a flat pellet of cotton containing an analgesic and over this temporary stopping or cement may be placed. In those cases in which the cervical wall approaches the gum the rubber-dam should be applied, the cavity dried, and temporary stopping packed against the cervical wall, allowing it to extend against the adjoining tooth. Other portions

are packed into the buccal and lingual walls. A pocket is thus formed into which arsenic may be safely placed and covered with a pellet of cotton containing an analgesic; over this may be placed a last pellet of temporary stopping which closes the opening. When one is expert the dam may at times be dispensed with.

If the packing of the temporary stopping upon the pulp be feared a small pellet of amadou may be laid over the exposure, and after the stopping is placed it may be removed.

The same principle may be employed with Flagg's "facing" amalgam or its equivalent (alloy—silver, 40 parts; tin, 55 parts; zinc, 5 parts plus mercury).

It may be used in desperate cases in which no great retaining periphery exists or where displacement by mastication is feared. In its use a pellet of spunk is laid upon the pulp and the cavity is practically filled with the soft amalgam. An excavator is then used to cut through to the spunk, which is carefully withdrawn. An opening is thus left into which the application and the extra cotton pellet saturated with the analgesic is placed. The opening is then dried and sealed with a portion of amalgam. This amalgam will retain its integrity for months, yet may be removed in a few minutes by dividing the filling into two portions.

When pulp removal is intended the application may be removed through the opening and a probe may be passed into the pulp to test the progress of the devitalization. If needed, a second application may be made or the tooth may be temporarily closed. In case the pulp be found partially dead it is better to allow more time for complete devitalization than to make a second application (Fig. 389).

Adhesive zinc phosphate may be flowed over an application if the cavity be accessible and gravity be not likely to interfere. The saliva may be admitted as soon as the cement begins to stiffen.

The chief objection to the placing of coverings *after* the application has been made is the danger of squeezing the arsenical paste, which causes capillary attraction to quickly carry the arsenic to the cervical gum tissue.

If redundant gum be within the cavity of decay it is to be carefully

FIG. 389.

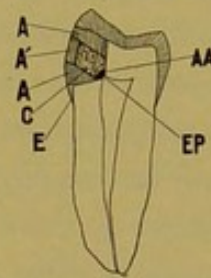


Diagram showing method of first making the covering for an arsenical or sedative application. (See text.) E P, exposed pulp; A A, arsenical application; C, sedative covering to same; A, amalgam placed before these applications; A', amalgam to seal them in; E, enamel.

saturated with trichloroacetic acid and cut away before attempting to make the arsenical preparation. It has been recommended that carbolic acid be always applied to the gum margin to kill it. It is argued that arsenic will not pass through dead tissue.¹ It is better, however, that no confusion of diagnosis occur. If, after an application is made, dead gum be found, it is to be presumed to have been caused by the arsenic and treated accordingly. If the coverings be made as suggested the danger of leakage is greatly lessened.

If the cavity be inaccessible, and the rubber-dam cannot be used to exclude fluids, and an arsenical application cannot be made with precision, or when arsenic applied directly is likely to cause pain, it is advisable to form a special cavity or "pocket"² for its reception. This should always be made when possible in a line of direct approach to a healthy pulp horn. The cavity is to be made as deep as possible without plunging into the pulp. A spear drill of narrow face is to be used. As a rule, in the conditions demanding extirpation of the pulp the dentine is insensitive or nearly so, so that the pulp may be almost exposed without pain. An exception to this, however, is found when pulp nodules exist, when the dentine may be exquisitely sensitive. In these cases two or more applications of the paste are required; as soon as the pulp can be exposed, a direct application of the paste is to be made. The cavity of decay is used as a receptacle for analgesics in these cases.

Cervical cavities not having a retentive form, and abraded teeth, offer difficulties, which are overcome by drilling a pocket for the reception of the paste.

In cases where there are pulp nodules, and where chronic degenerations of the pulp exist, the arsenic is removed at the end of the usual devitalizing period and free entrance is made to the pulp, cutting away all insensitive portions; if pulp nodules can be lifted away painlessly, they are removed, and a fresh application of arsenic is made, to remain again several days. In all of these cases, to effectually devitalize it may be necessary to apply a paste of arsenic trioxide in glycerin, or in one of the essential oils.

Before applying the arsenic to the pulp the latter is always to have been quieted and its superficies sterilized.

During the application all pressure is to be avoided or inflammation will be induced, which defeats the absorption of the arsenic and causes needless pain as well.

¹ Flagg

² Ibid.

If the pulp be much diseased at the point of exposure it is better to apply the arsenic to healthy dentine at another portion of the cavity, or in a pocket, and apply analgesics at the point of exposure.

Symptoms. A vast majority of pulps die with no more pain than the slight sensation of throbbing or fullness due to the gradual and rapid production of bulbar stasis. In these cases the absorption of the arsenic has been prompt and the irritative effects less than the paralyzant. In some cases the throbbing pain may be felt shortly after application and may pass away rapidly. In others the application must be removed and the pulp quieted before the end of the sitting. In others again the pain may begin several hours after application and either pass promptly into the sensation of heavy fulness or it may become paroxysmal. If endured for about two hours this, as a rule, gradually or suddenly ceases. If applied to healthy dentine in sound teeth the pain, if any, will be delayed, and if applied to sound dentine of teeth which have pulps elsewhere exposed, little pain is produced if the pulp be kept under the influence of an analgesic.

Not infrequently when the arsenic is applied to the dentine, whether for twenty-four hours or longer, the pain and suffusion of venous hyperæmia may occur.

In cases of secondary dentine or nodules pain may supervene, no matter whether the arsenic be applied to the dentine or the pulp. The amount of pain produced seems to depend more upon the condition of the pulp than upon other considerations. Vigorous, healthy, and diseased pulps are apt to respond to arsenic. It is assumed that absorption is incomplete.

Accidents with Arsenic. If a portion of an arsenical application escape from beneath its covering, it may destroy much or a little gum tissue, according to the amount which escapes.

The arsenic may attack the gum festoon, inducing in it stasis followed by necrosis. The gum assumes a purplish turgidity, which later changes to a dirty-yellow slough.

The bone is usually devitalized for a distance.

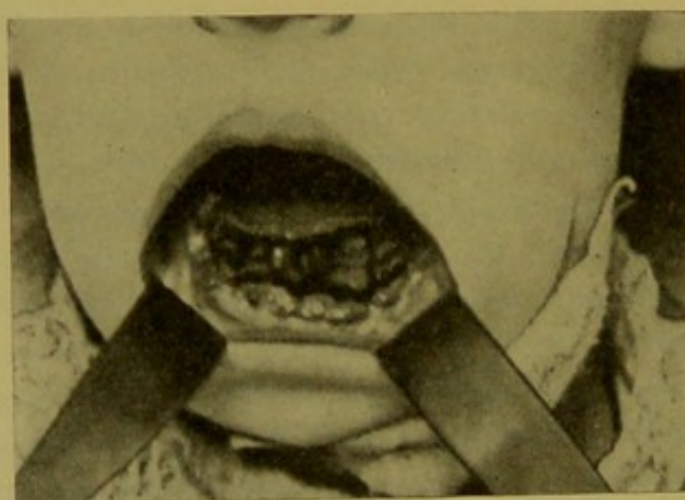
If the necrosis be self-limited, as is usually the case, a small sequestrum comes away after a few weeks.

In some cases the arsenic may follow the festoon of the gum of one or more teeth, causing disagreeable sloughs and ulcerations. It may follow the pericemental tract, kill the pericementum, and the tooth drops out. The alveolar process about one or several teeth may be devitalized and a sequestrum occur which includes the teeth. Certain

toothache nostrums are sold which contain arsenic. Dr. G. C. Chance¹ records a case of arsenical necrosis occurring from this source. Dr. J. E. Powers² records a case in which extensive necrosis occurred from the use of colored woollen yarn (as a cleanser of interdental spaces) which contained arsenic used in the dye.

From the infirmary of the Philadelphia Dental College was referred to the oral clinic a case of extensive coagulation necrosis, resulting from the rubbing of "toothache drops" upon the gum. Analysis showed the preparation used to contain arsenic. Collapse from blood poisoning being the immediate danger, the child was operated upon

FIG. 390.



Boenning's case of coagulation necrosis due to arsenic; shows exposed and blackened alveolar process.

by Prof. Boenning for drainage of the parts. During the recovery, the teeth from the right lower cuspid to the left lower second temporary molar, and the gums over the process, were lost, leaving a blackened alveolar process to be later removed surgically (Fig. 390).

Arsenic is liable to pass through the apical foramina of unformed or much resorbed roots. It may possibly pass through mature roots, when an application is placed high up in the canal, rarely when applied under normal conditions (as recorded by some), or, as occurred in one case, by the application being pushed through the apex. It may be forced through in the act of broaching, or through the subsequent use of the cataphoric current or pressure anæsthesia without the preliminary precaution of removing the arsenic.

¹ Proceedings of the Academy of Stomatology, Philadelphia, 1898.

² International Dental Journal, November, 1902.

Dr. J. C. Curry¹ exhibited to me a case of an upper central incisor which loosened about three days after pulp extraction and canal filling. The pulp was apparently vital at the apical end when extirpated. The crown and cervical half of the root were suffused, the apical half was normal in color, but the foramen was rather large. The gum showed no sign of sloughing, but the root was entirely denuded of pericementum. There was no hemorrhage or appearance of pus in the alveolus when the tooth was extracted with the fingers. * In most of the extensive cases of arsenical necrosis, the paste made of finely ground arsenic and creosote has been used.

In some cases arsenic has been applied to perforations made through the sides of roots under the impression that the vital tissue found was pulp tissue. In such case its necrotic effects will be noted upon the gum overlying the root apex or over the perforation, the tooth being loosened and extruded and may possibly be lost.

E. C. Kirk² has recorded several cases of loss of teeth from arsenical necrosis of the pericemental tissue following the use of mummifying paste to pulp stumps previously impregnated with arsenic. His theory is that the arsenic was liberated by the affinity of the ingredients of the mummifying paste for the proteid constituents of the pulp tissue.

Such dangers as these demand that extreme precautions be taken against the careless use of quantities of the agent. The rules laid down should be adhered to.

The only cure of the condition consists in the thorough removal of every particle of the arsenic. Any projecting masses of œdematous gum should be cut away, as they are dead and will slough at any rate, and a freer access to deep parts is had—the blood-flow may itself wash away the arsenic. The forcible washing should be prolonged and repeated. Dialyzed iron or tincture of iodine should be applied with a view to possible neutralization of the arsenic.

The editor, in a case of known application of arsenic to an obscure perforation, succeeded in causing regeneration of tissue by removing surgically the dead tissue and inviting regeneration.

It may, therefore, be that after minute portions of arsenic, forced through foramina, exert their full effect, the resulting dead tissue may be removed by resorption or even exfoliation; indeed, this result has been noted in which no other explanation seemed possible.

If the teeth are loosened and lost as the result of arsenical necrosis,

¹ Private communication, July 14, 1904; too late to make tests, which may be reported later.

² Dental Cosmos, October, 1903.

either beginning at the gum margin or at the apical space, the alveolus will exhibit a bare periphery and even some odor of putrefaction may be present. The alveolus should be sterilized and the walls burred away to a tissue capable of healthy granulation.

If suffusion occur, essential oils or phenol should be avoided in the subsequent treatment, as they tend to set the color by acting as a mordant (Kirk), rendering bleaching difficult. After the pulp is removed it is well to at once bleach by the use of 25 per cent. ethereal pyrozone, after which the canal may be filled.

REMOVAL OF THE PULP.

At the end of four or five days the dressing seals, and cotton containing the paste are removed, the cavity freely syringed with hydrogen dioxide, and the rubber-dam applied. Large, sterilized rose burs are used to open the pulp chamber freely and to remove *all* softened dentine.

The cavity is now to be given such form that pulp broaches may be passed directly and freely to the apex of each root. This rule is to be followed, no matter how much tooth substance is sacrificed to carry it into effect. As the future health of the tooth depends almost entirely upon the thoroughness with which each canal is cleansed, sterilized, and hermetically sealed at the apex, it is evident that the removal of crown tissue is a small evil compared with incomplete entrance to and cleansing of a canal.

A new and perfect pulp broach is dipped in carbolic acid and gently passed to the apex of the root; the teeth of the broach are turned away from the pulp until the instrument is fully inserted, when the broach is turned so that its teeth shall engage the entire length of the pulp, which may then usually be removed entire. The finest Donaldson cleanser may sometimes be used in this manner. Cotton may be wound on a fine Swiss broach and twisted into the pulp to engage it.

In multirooted teeth the largest canal may have its pulp removed as above indicated. As a rule, the smaller canals require enlargement.

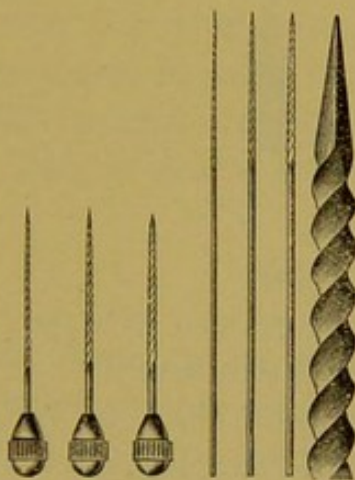
Gates-Glidden drills are passed into the mouths of canals, slightly enlarging them. Kerr or Downie broaches—a form of tapering twist drill—are then passed into the canals as far as they will go and turned, reaming the canal. As they are of fine temper and conform to the curve of the canal, they are comparatively safe. The small sizes are

used first, then the larger ones. They may be had for the straight and angle hand-pieces. Successive sizes of nicely tempered Swiss broaches may be used as canal reamers until larger instruments can be used. Of these the writer prefers the Downie reamers (Fig. 392).

Gates-Glidden drills may again be used or Donaldson cleansers may be employed to rasp the sides of the canal not touched by the Downie or Swiss broaches.

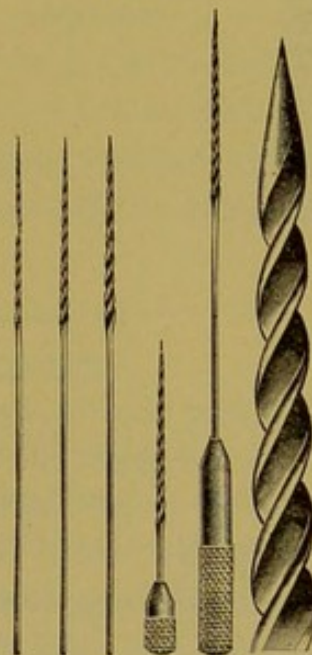
In place of drills the process of canal enlargement devised by Callahan¹ may be employed. The general cavity wall is varnished to prevent the action of the acid upon the dentine, and by means of a pair of Flagg's dressing pliers or a minim dropper a drop of sulphuric

FIG. 391.



Kerr root-canal reamers and broaches.

FIG. 392.



Downie root-canal reamers and broaches.

acid (50 per cent. solution) is deposited at the mouth of the canal to be operated upon. The finest size of Donaldson's canal cleanser is then passed into the canal as far as it will go, using a pumping movement to carry the acid farther into the canal and to scrape the canal walls softened by the action of the acid. The acid chemically destroys any organic matter—*i. e.*, pulp tissue—present, releases the calcium of the dentine from its combination, and forms calcium sulphate, which is mechanically removed by scrapers. The operation is continued until the apex of the root is reached. F. T. Hayes suggests the use of aqua regia as less injurious to broaches; lactic acid is also less injurious. When the cleanser will not enter readily it is well to

¹ Proceedings of the Ohio State Dental Society, 1894.

file away the barbs from an old cleanser and leave it roughened, and to use it for a time with the acid until the cleanser proper can be employed. Iridioplatinum or gold broaches may be used for this purpose.

In the canals of posterior teeth short cleansers are mounted in a chuck handle and the shank sharply bent at a right or obtuse angle.

FIG. 393.



FIG. 394.



FIG. 395.



FIG. 396.



Dr. Donaldson's pulp-canal cleansers.

If the cleanser bind in the canal it should be grasped with the thumb and forefinger and given a straight pull to relieve it.

The use of 5 per cent. formalin, tannin, or alum, to be specially applied about three days after the application of arsenic, has been suggested for the toughening of pulps. Their use necessitates a visit for their special application. They toughen the pulp, but this is of little advantage in the finer canals and not needed in the larger ones.

The point of importance is the removal from the pulp canal of all removable portions of pulp tissue, and an enlargement sufficient to admit a satisfactory root filling. It is an open question whether in multirrooted teeth this is ever complete, or whether it is necessary that it be made absolutely so, regardless of other dangers.

A perfectly safe rule for mechanical procedures is as follows: Use drills only when they advance readily into the root lumen; prefer Downie broaches and Donaldson cleansers under other circumstances. Advance no large reamers into delicate apical portions of roots, as a lateral perforation may be made. If a fine broach cannot be passed through the apical foramen, do not attempt its enlargement.

If doubt exist as to the presence of a portion of pulp in the apex of the root, papain paste may be placed in the canals for a few days to digest the remaining pulp tissue. (See Pulp Digestion.)

If the pulp be removed to the end of the root and the canal sealed to that point with a mechanically perfect and antiseptic root filling, it is improbable that any future trouble will arise; and *it is better that any such trouble should be subsequently treated than that immediate trouble should be set up by perforation.*

It has been recommended that all canals should be drilled or scraped to remove the organic matter attached to the periphery of the dentine. The Callahan method accomplishes this. Such organic matter may later undergo putrefaction and is well removed.

If the operations have been done under antiseptic precautions the root is ready for filling, unless irritation of the apical tissues be severe, in which case a sedative antiseptic—*e. g.*, menthol in chloroform—on cotton should be sealed in the canal. The gum should be painted with iodine as a counterirritant and the subsidence of the symptoms awaited. (See Aseptic Apical Pericementitis.)

THE ROOT-CANAL FILLING.

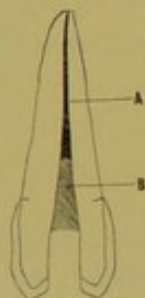The features to be possessed by a canal filling should be: first, it should be non-irritating; second, it should hermetically seal the canal; third, it should be unalterable in the conditions surrounding it. If possible, it should be continuously antiseptic, and be removable if subsequent conditions ever demand its removal.

These conditions may all be fulfilled in the well-opened roots by the use of temporary stopping, gutta-percha or wax, each made antiseptic by combining with it suitable ingredients. Each may be gently melted in a spoon held over a flame and a third of its bulk of aristol or iodoform incorporated with it. When partly cold it is moulded into cones suitable for introduction into the canal. This may be done on a glass slab by rolling with an ivory paper-cutter or spatula. When the canal is prepared and its walls thoroughly dried by means of hot air, a trifle of eucalyptol is introduced into the canal and all excess removed, or a little chloro-percha is introduced. The pointed section of a cone of temporary stopping or gutta-percha is attached by heat to a canal plugger and carried to the apex of the canal, where it is firmly yet gently compressed. Other sections are added until the canal is one-half or three-fourths filled. Over this is placed oxychloride.

of zinc or zinc phosphate made antiseptic by the addition of aristol while mixing. Whether the crown filling shall be introduced at the same sitting or not depends upon the general irritability of the tissues of the patient and the operator's convenience. As a rule, it is well to temporarily fill the crown cavity with base-plate gutta-percha¹ (Fig. 397), apply a good counterirritant to the gum over the apex, and permit the apical tissues to recover their normal tone. In a vast majority of cases this immediate root filling is accompanied by a successful issue, whether some apical irritation arise or not, and as a rule it does not.

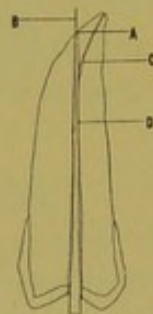
In case of an open foramen a long cone is rolled; this is tried in the canal and, passing through the foramen, will irritate the tissue. It is cut off a line at a time until it stops at the foramen without irritation. To allow for slipping of the cone a half-line more is removed. The

FIG. 397.



Root-canal filling: A, gutta-percha;
B, oxychloride of zinc.

FIG. 398.



A, perforation through side of apex; D, cone of gutta-percha passing through; B, portion to be cut off; C, portion of canal not treated.

apex of the canal is moistened with thick antiseptic chloro-percha and a quarter-inch of cone packed into the root canal, which it should exactly fit (Fig. 398). A bit of sterilized grafting sponge may be inserted beyond the apex and the canal then filled.

In the case of wax, yellow beeswax and aristol or wax and paraform are to be preferred to paraffin. The cone is thrust into a dry canal, packed cold for a distance, and then the point of a warmed Evans root drier is used to melt and pump it into the canal until the latter is partly filled, when oxychloride of zinc or antiseptic zinc phosphate is used to cover it.

In open canals thin oxychloride of zinc may be introduced. It is carried to place upon shreds of cotton. Some operators prefer to place a shred of cotton saturated with an antiseptic oil in the apex of the root canal. It has been claimed that the cotton is converted

¹ White base-plate gutta-percha may now be had.

into amyloid. I have conducted experiments to determine this point, and found that it can hardly be true for oxychloride of zinc, though true when cotton is placed in a chloride of zinc solution.

Good results are nevertheless obtained by the method, owing to the antiseptic property of the oxychloride of zinc. It is very difficult of removal and should, therefore, only be employed after temporarily dressing the canal with a sedative antiseptic, unless it be desired to take the risk of apical pericementitis which, in these cases, is a rare sequel.

Antiseptic chloro-percha—a solution of gutta-percha in chloroform with aristol or iodoform added—may be used on a twist of cotton as a filling in place of a cone. It is more difficult of removal than the cone, owing to the presence of the cotton fibres. Ottolengui recommends that a number of pieces of floss silk about an inch long be saturated with chloro-percha and dried. These are to be introduced into the previously placed chloro-percha and the end allowed to remain in the pulp chamber. If removal be necessary the floss may be engaged and removed. If a root can be drilled for a free opening the gutta-percha cone can largely be removed with the drill.

In the finer canals an antiseptic eucalyptol solution of gutta-percha is preferable to chloro-percha. Dr. J. C. Blair has introduced, under the name of "Forma-Percha," such a solution containing oil of cassia and paraform. Its uses as a root filling are identical with those of chloro-percha. Its removability lies in its weakness of cohesion after drying. For use it should be warmed into a creamy mass and used with cotton. Cotton saturated with wood creosote has been used for the finer canals, but cotton is an absorbent and after losing the creosote may take up deleterious matter unless mechanically antiseptic coverings are placed over it. If used it should be confined to the apical third of doubtful roots. With oxychloride of zinc, chloro-percha, or other impervious materials in its meshes cotton is probably a root filling of more permanency.¹

¹ When cotton is used as a root filling or a vehicle for non-absorbent substances it should be mounted on a delicate Swiss broach. The latter should have its hard temper drawn by annealing in a test-tube over a flame. The heat is applied at the shank, and the tube is to be moved over the flame so that a pigeon-blue color runs out to the tip of the blade. Such broaches are fit for reamers, and are of splendid temper. The tip should be removed with scissors, so that penetration of the cotton may be avoided. The wisp of cotton is to be laid upon the left forefinger, the broach laid upon it, the thumb closed down, and the broach twisted with the right thumb and forefinger, the left ones being then used to stroke the cone to symmetrical form. This requires some practice. As a swab this is always twisted to the right. As a dressing it is passed into the root, twisting to the right. When placed the broach is given two turns to the left, is slightly withdrawn and then pressed in again. This causes the cotton to be crimped upon itself. Raw cotton is preferable to absorbent when used for other purposes than as a root swab.

The secret of success in root-canal filling lies perhaps more with the prevention of infection from the mouth than with the character of the material placed in the apex of the root canal. Nevertheless, the prevention of ingress of fluids from the apical tissues seems to be necessary; at least, the entrance of such fluids invites earlier infection.

M. L. Rhein has recorded an opinion that recurrent sepsis may often arise by way of the circulation. The possibility of this is not to be denied, but my experience leads me to doubt its frequency as a cause. Opportunity for oral infection is usually sufficient.

Accidents Occurring during Canal Opening. During the mechanical enlargement of canals or during pulp removal portions of broaches or drills may be broken off in the canal. Their removal is at times difficult or practically impossible. If lying loosely in the canal a probe magnetized by rubbing upon a steel magnet or by contact with the field magnet of a dynamo will remove it. Flagg recommended a power magnet attached to a probe. The magnet is to be energized by an electric current.

Wrapping a Swiss broach with cotton, the fibres may at times be made to engage the barbs of a loose broach.

A Donaldson cleanser will also at times engage the barbs of the broken instrument.

The removing instrument is passed to one side of the instrument to be removed and pressed against it as withdrawn. The instrument is thus gradually jiggged out.

Moving the broach or drill back and forth while sulphuric acid or sodium dioxide solution is about it will sometimes loosen it.

If very deeply placed common salt may be packed over the broach, moistened, and sealed in in the hope of rusting it. Tincture of iodine will rapidly disintegrate steel placed in it, but repeated applications are necessary to produce the same effect in a canal.

Sulphuric or nitric acid or aqua regia or 25 per cent. pyrozone may be sealed in to effect its chemical solution. The tip of a fine Donaldson cleanser deeply seated in the apical third of a fine canal is practically irremovable. If the root has given no previous trouble, strong and persistent antiseptics, such as iodoform, are to be placed over it and the attempt to remove considered unwarrantable. The head of a Gates-Glidden drill is to be saturated with sodium dioxide or sulphuric acid and the attempt is made to jig the piece loose; failing this an attempt is to be made to pass through the opening between

the blades so that permanently antiseptic materials may be made to go beyond the drill, in which case its presence is harmless.

Dr. W. S. How has introduced the split and threaded cone socket shown in Fig. 400, which may be useful at times.

FIG. 399.



Improved Gates-Glidden nerve-canal drill for engine work.

In use the canal is enlarged after a direct opening has been made to it and the cone is introduced and rotated.


In all cases the forcing of bits of broaches into the apical tissues during efforts at removal is to be carefully avoided. If it occur, however, it will produce a chronic apical pericementitis if not excite a septic condition. The cure lies in amputation of the root apex, though at times levelling the broach with the root end through an external opening has been successful.

Perforations. A drill passed through the apical foramen enlarges it unduly. The condition simulates an imperfectly completed foramen and is treated as for that condition. (See p. 436.)

A Gates-Glidden drill may perforate a root near the apex by passing through the wall of the canal in a direct line with the canal, while the root end may be curved (Fig. 398).

A finely pointed root may be perforated laterally by the use of too large a drill or reamer. The part should be thoroughly sterilized and the hemorrhage checked by the use of adrenalin chloride 1 : 1000 plus chloretone,¹ and a carefully prepared gutta-percha point is to be adapted to the opening. If subsequent trouble arise amputation or extraction, perfect root filling, and replantation may be resorted to.

FIG. 400.



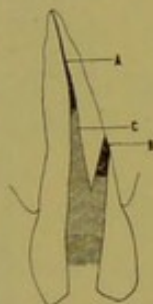
Split and threaded instrument for engaging the shank of a Gates-Glidden drill.

¹ Prepared by Parke, Davis & Co.

If the perforation be readily reached the inner walls should be bevelled and a smooth plaque of low-heat white gutta-percha should be adapted, its edges sealed, and zinc phosphate or oxychloride of zinc packed over it to secure it in place. Soft copper amalgam gently tapped to place and later hardened by the wafering process is valuable. In such cases the canal apex is filled as usual. With a difficult lateral perforation a bit of sterilized grafting sponge may be placed in the tissue beyond the perforation, and against this the gutta-percha or copper amalgam may be packed.¹

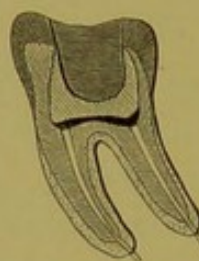
Partial Removal of Pulp. The Cobalt method of pulp treatment has been alluded to. Wm. Herbst, of Bremen, advanced the idea that if the bulbous portion of the pulp be devitalized by cobalt and removed,

FIG. 401.



Lateral perforation due to holding a bar at a wrong angle to the axis of the root: A, root canal subsequently filled with gutta-percha; B, perforation filled with a fitted cone of gutta-percha; C, oxychloride of zinc.

FIG. 402.



Herbst's method of preserving pulp stumps.

leaving the root portions, the latter will remain vital, if protected after a manner described by him. The bulbous portion of the pulp is cut away and the pulp chamber enlarged by means of large rose burs. Over the pulp stumps a cylinder of tin-foil is laid, and burnished to fit the floor of the pulp chamber, without pressure upon the pulp stumps (Fig. 402). Over this a filling is placed. Herbst claims that the pulp stumps will remain vital. Were this to be depended upon, it would be a marked saving of time and trouble, and would lessen the chances of pericementitis subsequent to pulp removal; but when it is known that the cobalt of Herbst is metallic arsenic, the ultimate death and decomposition of the pulp remnants seem almost inevitable, and in fact does occur. The method should not be employed.

¹ G. Brunton, Eng., Dental Cosmos, 1900.

MUMMIFICATION OF THE PULP.

Many experiments have been performed relative to leaving *in situ* portions of pulps and covering them with substances having for their object the chemical alteration of the pulp tissue, so that no pericementitis shall result from its putrefaction. The first effort in this direction is credited to Witzel (1874).

W. D. Miller,¹ after many experiments with various materials, has shown that none but the most powerful and penetrating antiseptics have value as permanent sterilizers. These are the cyanide, bichloride, and salicylate of mercury, sulphate of copper, and oil of cinnamon. Orthocresol, carbolic acid, trichlorphenol, and zinc chloride penetrate the pulp tissue rapidly, but are too diffusible, their effects disappearing in a few weeks.

He classifies salicylic acid, eugenol, camphophénique, hydro-naphthol, α -naphthol and β -naphthol, aceticotartrate of aluminum, and some essential oils, resorcin, thallin, sulphocarbolate of zinc, etc., as being of doubtful value.

Those nearly or quite worthless are iodoform, basic anilin coloring matters, borax, boric acid, dermatol, euophen, calcium chloride, hydrogen dioxide, sozoiodol salts, tincture of iodine, spirit of camphor, and naphthalin.

The preparation giving the best results consisted of mercuric chloride, 0.0075 gram; thymol, 0.0075 gram, in tablet form.

The pulp is devitalized; the crown portion and all the root portion readily accessible are removed; one of the tablets is placed in the pulp chamber, crushed by means of an amalgam plugger, and covered with gold-foil. The mercury salt tends to discolor the crown of the tooth, so that its employment should be restricted to the posterior teeth; indeed, the necessity for its use would be, as a rule, found with these teeth, being those from which it is most difficult to extract pulp remnants. Miller expresses faith in the power of oil of cinnamon to permanently sterilize pulp fragments.

Theodore Söderberg² recommended a paste composed as follows:

R—Alum exsic.,	
Thymol,	
Glycerol.,	$\bar{a}\bar{a}$ 5j.
Zinci oxid.,	q. s. to make a stiff paste.—M.

It is preferable to add the zinc oxide as needed or to make a small quantity of the paste frequently, as it gradually hardens. To the paste

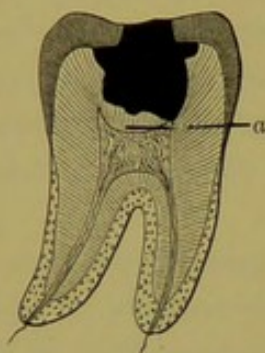
¹ Proceedings of Columbian Dental Congress, 1893.

² Dental Cosmos, November, 1895.

used a crystal of cocaine is added to prevent pain. Bennette (Eng.) has advised the use of paraform incorporated in the paste, for its well-known antiseptic and hardening effects. Greenbaum suggested the use of a drop of 40 per cent. formaldehyde solution to be incorporated with the paste.

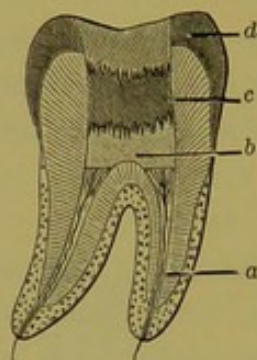
Söderberg reopened cases months after application of the paste to pulp stumps, and found them shrunken and with an odor of thymol about them.

FIG. 403.



a, caries exposing a horn of the pulp.

FIG. 404.



a, root portion of pulp; b, mummifying paste; c, zinc phosphate; d, gold or amalgam.

He applied the paste in the manner shown in Figs. 403 and 404. In 1900, Söderberg¹ reported the use of the paste in about nine hundred cases,² of which two hundred and twenty were test cases of from two to six years' standing. He claims that in no case did apical pericemental disturbance arise from the use of the paste as described.

This method has met with much opposition from prominent operators, who prefer the thorough cleansing and filling of the canals. No doubt the rational method of procedure is to cleanse the canals as well as possible and to use the paste against unremovable pulp stumps.

The best results were obtained when arsenic was applied for a limited time only in order that the arsenic should not penetrate too deeply. In view of Kirk's observations (p. 431) this would seem wise.

While the paste may effect mummification of entire canal filaments of pulp, leakage is always imminent about shrunken pulps, and the only safeguard is the antiseptic effect of the paste. This is much enhanced if the bulk of putrefiable material be replaced with the antiseptic paste used as a root filling. Many such root fillings have done good service for many years.

¹ Dental Cosmos.

² Items of Interest, 1898.

A certain percentage of failures would be no argument against the employment of the method when indicated, as no method is infallible in all circumstances, and particularly in those in which the method is indicated.

DIGESTION OF THE PULP.

Harlan has recommended the digestion of inaccessible pulp remnants with a vegetable ferment. The pulp chamber is dried and then moistened with a 1:300 solution of hydrochloric acid and packed with a paste composed as follows:

R—Papain,	gr. v.
Price's pure glycerin,	℥iv.
$\frac{1}{200}$ hydrochloric acid,	℥v.

Over this is placed a layer of blotting-paper soaked in liquid vaselin. The cavity is sealed with oxyphosphate of zinc or oxysulphate of zinc.

The paste should be freshly made in the above proportions, reduced to suit the quantity needed. The application requires a few days to reduce the pulp tissue to a jelly-like digested mass, which can readily be washed away. It is recommended that the papain be kept in a dark-glass bottle. It is harmless to living tissue which is not digested. Alcohols, tannin, lead, mercuric chloride, nitric acid, and salts of heavy metals are incompatibles.

Such pulp digestion is only a preliminary to root filling.

CHAPTER XIX.

GANGRENE OF THE PULP.

Definition. By gangrene of the pulp is meant its death through an interference with its nutrition. It may be partial, as when an abscess in the pulp or violent irritation causes the bulbar portion to die, the canal portions being found alive; or when only one canal portion is dead, the others being alive. Either dry or moist gangrene may occur.

Causes. It is probable that a constriction of apical root tissue (hypercementosis) about the pulp may so constrict it as to bring about its death. Sudden shocks, such as occur from thread, string, or cigar biting, or blows or rapid movement in regulating or wedging or non-fixation after regulation, may cause torsion or tension of the blood-vessels entering the apex of the pulp.

These influences may either cause pulp hyperæmia or strangulation of the apical bloodvessels, or possibly an area of apical thrombosis, cutting off the nutritive supply to the pulp. Septic or aseptic inflammation of the pulp may cause its total death. Death of pulp tissue due to arsenic produces results in nowise differing from gangrene, provided the pulp be left *in situ*.

DRY GANGRENE OF THE PULP.

Definition. By dry gangrene of the dental pulp is meant its death *in toto* and its subsequent transformation into a dry, shrivelled mass occupying the pulp chamber and canal.

Causes and Pathology. If the pulp die and remain under conditions which exclude bacteria from contact with it, the water of the pulp may be removed, leaving the organ as a tough, shrivelled mass (Fig. 405). The conditions most favorable seem to be: (1) pulp death from some aseptic cause; (2) constriction of the apical foramen; (3) the presence of secondary dentine over the bulbar portion of the pulp; (4) the capping of the pulp with zinc oxychloride or formagen paste; (5) the covering of pulp stumps with a paste containing a tannifying substance, such as alum, formaldehyde, or tannin.

The water necessary to putrefaction is abstracted, either naturally or chemically, and probably bacteria are at the same time excluded

either mechanically or because the chemical substances used have penetrated the pulp tissue, acting as antiseptics.

Symptoms. The tooth has a nearly normal color, but under reflected light is seen to have lost perfect translucency. There is no response to thermal or electric tests for pulp vitality. The dentine is insensitive to cutting instruments and the cuttings upon the bur have no odor. There is no odor or fluid in the pulp canal when this is entered, and the pulp is found as a tough, dry mass not unlike that seen in a dry extracted tooth which contained a vital pulp at the time of extraction. These cases are relatively rare.

Tests for Pulp Vitality. The diagnosis of pulp vitality or death being in practice almost daily required, the decisive tests are here indicated.

A tooth containing a vital pulp is translucent; that containing a dead one always opaque to transmitted light.

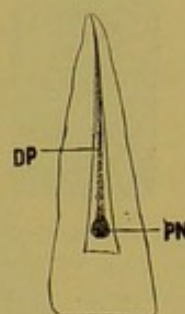
An electric mouth lamp with a mirror so arranged as to reflect the light upon the lingual surface of the tooth will supply the means for this test. In its absence strong sunlight may be reflected by means of a mouth mirror, but is not nearly so good a means as the electric light (Fig. 331).

If the tooth be isolated by means of rubber-dam and first cold water be thrown or later ethyl or methyl chloride be sprayed upon it or upon the filling contained in it, absence of response will indicate either pulp death or the formation of a quantity of secondary dentine. In the latter case the test must be renewed as the excavation proceeds.

A hot burnisher or hot gutta-percha applied to a filling or dentine, or very hot water thrown upon an isolated tooth should provoke at least a delayed response from a vital pulp.

Woodward has shown that if a few cells of a cataphoric apparatus are in action and the positive electrode be applied to the dentine or metal filling in a vital tooth, while the negative pole is at the cheek or wrist of the patient, a distinct sensation should be felt; while in case of a dead pulp there will be no response. A mild faradic current has also been used for the test. There may be no response through a metal filling, while such response may be obtained by packing wet cotton against the dentine after some drilling. The pos-

FIG. 405.



Dry gangrene of the pulp: PN, pulp nodule; DP, shrivelled pulp. (From a specimen of pulp extracted intact in this condition.)

sibility of contact of the filling with another in a vital tooth is to be remembered. Insulation with rubber-dam is indicated.

In doubtful cases, such as that shown in Fig. 406, the *x*-ray skiagraph is valuable, and indicates at least the removal of the filling for further diagnosis and treatment.

A strong odor of putrefaction may be obtained from bur cuttings in cases of moist gangrene only. This must be differentiated from the odor of decayed dentine, which usually also has an acid character.

FIG. 406.



Skiagraph of unfilled root canals with large mass of filling material built in over them. (Price.¹)

In case of partial death of the pulp not discoverable by the tests given above, a fine, sharp probe passed into contact with the pulp remnant will demonstrate its vitality.

Treatment. If septic matter be introduced a violent pericementitis may be lighted up; but if aseptic precautions be employed in opening the canal, and this be kept under the influence of a germicide, such as 5 per cent. formaldehyde or sodium dioxide, the root may be filled by the immediate method—*i. e.*, when opened and sterilized it is to be dried and then moistened with eucalyptol and the excess of this removed; previously prepared cones of temporary stopping are then packed into the root. The method of moistening the canal with Forma-Percha and then placing the cones, or the use of cotton, silk, or asbestos fibres saturated with Forma-Percha (see p. 435), has all the advantages of the temporary antiseptic filling with the added merit of permanency if the indications declare a success.

A temporary filling of pink base-plate gutta-percha is to be inserted in the crown cavity until all irritation, if any, subsides.

Slight aseptic apical irritation may be anticipated as a matter of precaution by the use of iodine as a counterirritant at the time of root filling. (See p. 387.) Such irritation is either mechanical or due to the chemical substances used.

MOIST GANGRENE OF THE PULP.

Definition. By moist gangrene of the pulp is meant death of pulp tissue *en masse* and its subsequent decomposition by the action of

¹ Items of Interest, 1901.

putrefactive agencies. As putrefactive decomposition is the essential feature in these cases, and that which gives the process its pathological significance, the causes, nature, effects, and treatment of putrefactive decomposition of the pulp are included under this sub-heading.

Causes. The causes of moist gangrene are such as may cause the death of the pulp and its subsequent decomposition by bacteria. Without bacteria moist gangrene cannot occur. Among these the bacillus gangrenæ pulpæ (Arkövy) figures prominently. Four types of cases are seen: (1) in teeth apparently sound; (2) in teeth filled, but the canals not treated—*i. e.*, death of the pulp has occurred after filling; (3) in teeth filled with canals partly filled; (4) in teeth having open cavities and canals.

In the first type of cases the bacteria may enter by way of the blood channels, but it is not improbable that slight cracks or histological defects in the enamel may admit to the dentinal tubules the necessary bacteria, or that they may gain entrance by way of the cementum and dentine at the neck of the tooth. (See Caush's tubes.)

A case presenting some analogy to these teeth is that of an egg with apparently perfect shell, but in which intense decomposition has occurred.

Many of these teeth do not develop abscesses even after the tooth has become dark in color. If the dentine be exposed as at the incisal edge the abscess may develop.

In the filled cases crevices about crown and root fillings may admit bacteria, which may pass through the tubules of even secondary dentine in some amount. On the other hand, it is irrational not to admit the possibility of an infection *via* the circulation.

In cases of obvious pulp infection beneath fillings—*e. g.*, suppuration of the pulp—the bacteria necessary are *in situ*.

In the open cases the infection obviously arises from the mouth.

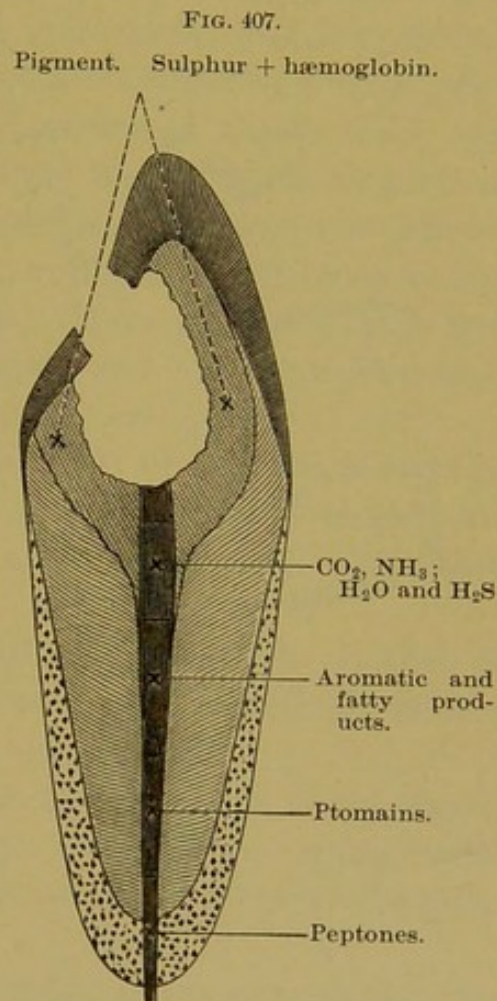


Diagram illustrating the more complete decomposition of the pulp at its coronal end.

Pathology and Morbid Anatomy. The pulp being wholly or partly dead from any cause whatever, saprophytic bacteria gain access to it and the serial decomposition it undergoes is in exact correspondence with that of moist gangrene or putrefaction in other localities.

FIG. 408.




FIG. 409.

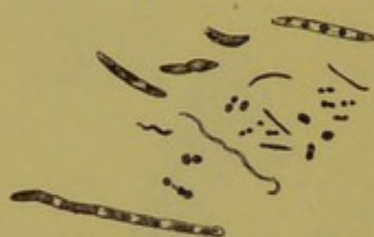

FIG. 410.

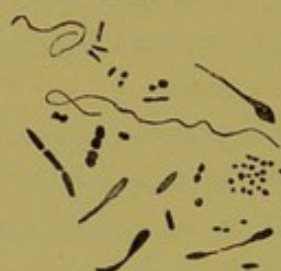

FIG. 411.

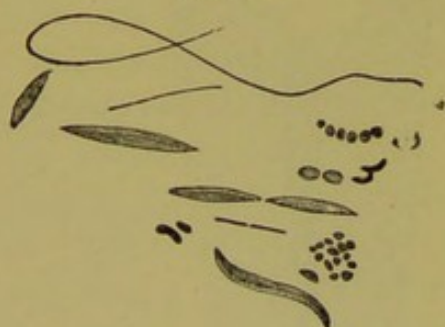

FIG. 412.

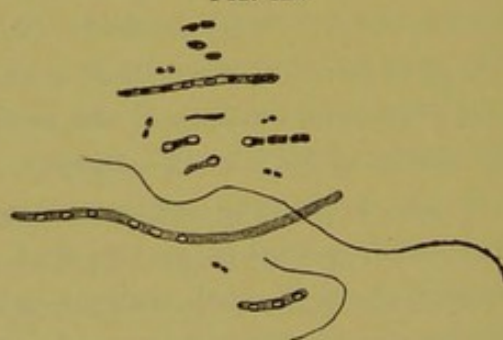


FIG. 413.




FIG. 414.

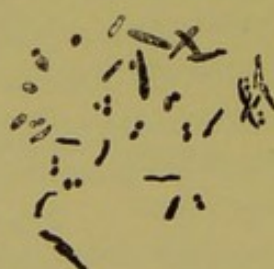
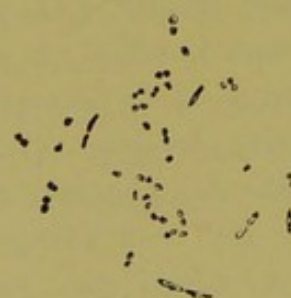
FIG. 415.



In this serial decomposition albuminous substances are first transformed into peptones and allied substances, some of them being very toxic. Compound ammonias, known as ptomains, or animal alkaloids, are probably next formed. Next the nitrogenous bases—leucin,

tyrosin, and the amins (methyl, ethyl, and propyl)—make their appearance, together with organic fatty acids. Next aromatic products, indol, phenol, cresol, etc., and finally hydrogen sulphide, ammonia, carbon dioxide, and water. By alternating processes of hydration, reduction, and oxidation, bodies of increasing simplicity of chemical composition are formed.¹

Miller² found in the deepest portions of the degenerating, putrefying pulps, where inflammation and suppuration were in progress, a preponderance of small cocci and diplococci, and proceeding toward the open pulp chamber an increasing number of large cocci, several forms of bacilli, vibrios, and other spirillæ, spirochætæ, and long thread forms (Figs. 408 to 415). Figs. 414 and 415 are from the same pulp; Fig. 415 was taken from the radicular portion of a pulp which was alive and suppurating; Fig. 414 was from the putrid crown portion. Miller found that bacteria of pulp putrefaction cultivated in gelatin, with and without the access of air, exhibited a difference in the poisonous properties of their products. Those developed with free access of air produced stronger reaction, and more extensive suppuration than those developed without the access of air.

Arkövy,³ in an examination of 43 cases of chronic apical abscess, pulp gangrene, etc., found the bacillus gangrenæ pulpæ present in 41; the *S. pyogenes aureus* in 15; *S. pyogenes albus* in 8; *S. pyogenes citreus* in 2; *S. pyogenes* in 10, and *B. pyocyaneus* in 4.

He found the bacillus gangrenæ pulpæ in mouths free of caries as well as in mouths containing carious teeth, and established the fact that it is pleomorphous (bacillus and coccus form).

He inoculated healthy pulps with this bacterium and found that in pure culture it produced total gangrene without suppuration; while mixed cultures, and even the mixed pleomorphic forms of the same bacillus, produced chronic pulpitis.

On gelatin cultures a putrid, cheese-like odor was perceptible. The germ is subject to the antiseptic effects of strong acids, alkalies, carbolic acid, and tincture of iodine, which explains in part the success of the treatment hereinafter mentioned.

Arkövy's demonstration seems a satisfactory explanation of cases of quiet death of pulps under fillings.

The hydrogen sulphide combines with the iron in the hæmoglobin of the red blood corpuscles, producing ferric sulphide which, entering

¹ Ziegler, General Pathology.

² Synopsis by Söderberg, Dental Cosmos, 1899.

³ Dental Cosmos, 1894.

the tubules, stains the dentine a slaty-gray or bluish-black color. Other derivatives of hæmoglobin may be responsible for the yellowish-brown discoloration often seen in cases in which bacteria have not reached the pulp until long after pulp death. The color is, therefore, not due to the presence of hydrogen sulphide.

Fig. 407 is a diagram illustrating these changes; it being assumed that the decomposition is most advanced at the crown portion of the pulp, owing to the entrance of bacteria at that point.

In the early stage of the process the gangrenous pulp resembles a yellowish mass of sloughing tissue, which can be easily removed. In the later stages it is more decomposed, and yields to the broach. In the final stages nothing but fluid, or even an almost dry canal, may be found. This last condition must not be confounded with dry gangrene. If fluid, or odor without fluid, be present the case is one of moist gangrene.

Symptoms. As a rule, the tooth presents at least an opacity upon transmission of light, but usually has the bluish or brownish discoloration mentioned, most marked at the cervical third of the crown and most noticeably upon the lingual side. There is an absence of response to thermal and electric tests. Occasionally the patient complains of a bad taste in the region of the tooth. This is due to slow leakage. The symptoms of septic apical pericementitis may be localized about the apex of the tooth, or at times the pain of incipient pericementitis may be reflected or a history of apical abscess may be obtained, confirmed by the presence of a fistula. Occasionally the patient complains of apical pain upon passing from a warm to a cold atmosphere and *vice versa*. Upon drilling out a filling the odor of putrefaction may be clearly noticed, even before the entrance of the canal. The odor of the bur cuttings is diagnostic in less pronounced cases. The malodorous gases may be present in quantity without acute symptoms of pericementitis.

It is presumptive that in some cases these gases gradually escape through the tubules and by way of leaks about the fillings, a fact which may act favorably by preventing accumulation and the formation of an apical abscess.

A confusing condition clinically is found where one half of a pulp has died and undergone decomposition, as in molars, the other half remaining vital, although the seat of infection and inflammatory action. So far may this condition go, that abscess, acute or chronic, may be present upon the root of one tooth long before the second

segment of the pulp has succumbed. The diagnosis of such cases is made by the light test, by obtaining the painful reaction to heat and perhaps to electricity, and usually some tenderness upon percussion upon some particular portion of the tooth; upon opening the tooth the peculiar condition described is found.

In one case of a lower molar with a fistula related with the distal root, I found the pulp apparently vital upon entering the pulp chamber with a bur at a point about midway between the horns. There was apparently a persistence or hypertrophy of the pulp bulb attached to the mesal filaments. The distal canal was found to contain only the fluid remains of a pulp filament.

In cases seen at the right time the bulbal half of a pulp may be gangrenous without positive putrefaction, while the apical half is still vital.

J. H. McQuillen¹ recorded a case of longitudinal fracture of a bicuspid tooth extending from the sulcus to the bifurcation of the roots, and which was apparently due to the expansion of the gases of decomposition. Poinso² records a similar case and states that several teeth containing decomposed pulps confined in a glass tube caused the latter to break.

Observations previous to that of McQuillen have recorded a sound, as of an explosion, to have occurred simultaneously with the fracture of the tooth. I have looked all my professional life for such a case, but have never been able to eliminate the possibility of fracture from ordinary causes.

Treatment. The general principle of treatment, in all cases presenting without symptoms of apical pericementitis, is the disinfection of canals, the removal of all decomposed and decomposing pulp tissue, prevention of infection of the pericementum, and hermetical sealing of the apex and body of the canal by means of appropriate root fillings.

In all cases the imminent danger and that to be guarded against is to avoid mechanically carrying a portion ever so minute of infective material past the apical foramen. This implies either great dexterity, or the use of a germicide which shall sterilize the pulp tissue before the attempt is made to remove it. Should any pass through, it must be sterilized by strong germicides passed after it.

There are three good methods of accomplishing the treatment of gangrenous pulps to be chosen from, according to the access obtainable

¹ Dental Cosmos, 1871.

² Ibid., 1901.

to the apices of canals. The first is an "immediate" method. The tooth is to be placed under rubber-dam and the crown sterilized, or the mouth is to be sterilized by the use of a germicidal mouth-wash—*e. g.*, a strong solution of potassium permanganate, meditrina, or a wash representing 1:2000 mercuric chloride, preferably in hydrogen dioxide.

The tooth is then to be carefully opened until all the canals can be readily entered. This, as a rule, implies a free opening from the occlusal surface in direct line with the canal, though a slight indirectness, if the entrance be free, is often admissible as conservative of tooth structure. The opening must admit of thorough work, even if the tooth be somewhat weakened. A finely pointed broach, made by filing down an old Donaldson cleanser, is moistened by drawing it through a drop of water. It is then drawn through dry sodium dioxide, several small portions of which have been placed upon a glass slab. The adherent material is carried to the canal, which may be left in a moist condition, and gently insinuated into it.

Reaction with the water produces sodium hydrate, which dissolves all organic matter, and hydrogen dioxide, which by a further reaction liberates nascent oxygen.¹ This first application may be carried as far as may be done without pressure. If the canals be constricted they may be slightly enlarged at their mouths with Gates-Glidden drills, etc. (See p. 432.) More sodium dioxide is then applied and after its action the canal may be partially freed of débris by means of a stream of water, and a fine Donaldson cleanser acting at the same time. The canals are partly dried and more sodium dioxide deeply inserted.

A small, short, Kerr or Downie broach, a form of tapering twist drill, is now used to enlarge the apical portion of the root, following which either the Callahan method of enlargement by sulphuric acid and the Donaldson cleanser (see p. 433), or enlargement by Gates-Glidden or Moray drills may follow as indicated. These latter should be avoided if the roots are curved.

¹ Schrier's alloy of metallic sodium and potassium (kalium-natrium) may be substituted, but with no distinct advantage, as by reaction with water an explosion occurs, an atom of the hydrogen of the water molecule taking fire while sodium and potassium hydrate (caustic sodium and potassium) are formed. Could the heat be produced within the canal there would be advantage, but it occurs only at the canal mouth or a short distance beyond. Sodium dioxide in the dry state should not come into contact with carbolic acid or essential oils, as an explosion may occur; when water is used the sodium dioxide is decomposed by it and the danger is removed. Instead of the sodium dioxide method a strong solution of potassium permanganate may be used. The discoloration may be removed by the use of a saturated solution of oxalic acid in 25 per cent. hydrogen dioxide. In certain cases it may be left without decolorizing.

A Swiss broach nicely tempered to a pigeon-blue color in a test-tube is useful for the reaming of fine roots.

If the apical foramen be open, or can be opened, the dilute sodium hydrate may be permitted to pass through into the apical tissue to destroy any putrid matter possibly forced through. Meditrina is less irritating. A good method is to apply sodium dioxide for five minutes, and then 25 per cent. ethereal pyrozone or meditrina for ten minutes. If the foramen be impossible of exploration several methods of sterilization are available:

1. The 25 per cent. ethereal solution of pyrozone may be placed in the canals on cotton, upon the theory that it will penetrate the slight portion of unexplored root canal and the tubules of the dentine as in bleaching. Its action will be favored by the slight amount of sodium dioxide previously used.

2. A zinc probe may be introduced into the canal and the positive pole of the cataphoric apparatus applied to it. Oxychloride of zinc is formed at the canal apex,¹ and penetrates to the soft tissues, sterilizing everything.

3. Nitrate of silver may be forced by cataphoresis into the canal, according to the method advocated by Bethel, confining the operation to posterior teeth because of the discoloration produced. The crown cavity is to have its walls covered with wax or varnish to prevent the passage of the silver nitrate into the crown dentine; the canal is pumped full of a silver-nitrate solution (25 per cent. to 75 per cent.), a pellet of cotton containing the same solution is wrapped around the positive electrode of a cataphoric apparatus, the current is applied, and the silver solution is driven into all of the tortuosities of the canal (Fig. 416). The silver combines with the contents of the dentinal tubuli, forming silver albuminate; nitric acid is formed at the positive pole (the electrode), giving an acid reaction to the canal contents; the acid is to be neutralized with ammonia. Unless a very high voltage be applied, the silver does not penetrate the dentine to any considerable depth, and it is not desired to have it do so. Credé's experiments indicate that metallic silver acts as an antiseptic by being oxidized by bacterial products, the argentic oxide being afterward transformed into antiseptic salts of silver by bacterial waste products, notably by lactic acid, silver lactate being formed.

Morton has suggested the driving of such antiseptics as mercuric

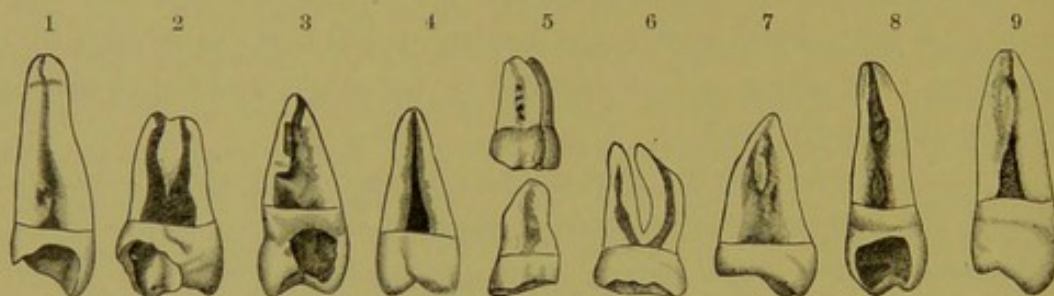
¹ Rhein, Items of Interest, 1897.

chloride in hydrogen dioxide into the tubuli and canal ends by the aid of the cataphoric current.

F. Milton Smith recommends that carbolic acid be forced into the apical tissue by the method used in pressure anæsthesia (see p. 420) as a germicidal agent after the canal is cleansed.

Dr. J. C. Blair introduced the method of vaporizing iodoform lodged in a special receptacle of a hot-air bulb. The vapor is driven by the air stream into the dried dentine. The method is successful, but the odor generated is exceedingly objectionable.

FIG. 416.



1. Operated on in the mouth with a 50 per cent. solution silver nitrate. Crown cavity protected from discoloration by a thin coating of melted wax.
2. Operated on in the mouth with a 75 per cent. solution silver nitrate. Crown cavity protected with wax.
3. Operated on in the mouth with 75 per cent. solution silver nitrate.
4. Shows perfect lining formed, and penetration of the silver nitrate into the dentinal tubuli.
5. Freshly extracted tooth operated on outside the mouth. The crown and roots were filled with decomposing material which was not removed, the electrode and nitrate being applied to the surface; still the nitrate permeated the canals. Exposed surfaces of both canals shown.
6. Operated on outside of mouth. Foramen on inside of root.
7. Shows penetration in flat root with constricted and branching root canal. Could not get broach more than one-eighth inch into canal.
8. Operated on outside of mouth for twelve minutes, attempting to force the silver nitrate through foramen of root.
9. Shows returning branch of canal that might easily be left unfilled. (Bethel.)

The same object may be attained by introducing a saturated solution of iodoform in alcohol after complete desiccation of the root dentine.¹

Complete carbonization of the contents of a canal by means of a suitable electrocautery or Evans root drier is a rapid and satisfactory method of sterilization.

The principle involved in immediate sterilization is the destruction of all septic matter within the canal and beyond the apex at the first sitting.

After the canal disinfection is accomplished by one or more of the various immediate means suggested, its walls should be desiccated

¹ Register.

and made absorbent by means of hot air, then moistened with eucalyptol or "Forma-Percha" and a root filling of temporary stopping or gutta-percha packed in. If aristol be added to these the effect is increased. Cotton and "Forma-Percha" make a readily removable filling suitable to cases in which some doubt exists. I have had excellent results in molars with this material. (See p. 437.)

A temporary filling of base-plate gutta-percha is then placed in the crown cavity as a test filling, or, in case of need, the filling may be inserted.

Any apical irritation may be attributed to the disinfectant and be treated by counterirritation or the counterirritant may be applied as a precaution at the time of operation. Refrigeration of the gum over the root by means of ethyl chloride is a valuable means of reducing inflammation in these cases. This traumatic irritation is often mistaken for acute septic pericementitis. Any irritation not too severe is to be considered as due to non-septic causes and treated accordingly. A few of these cases may, of course, result in failure owing to imperfection in the application of the method. The great majority of cases are successful.

As a precaution against possible infection of the apical space while cleansing the root some operators prefer to open the pulp chamber and seal therein a pellet of cotton containing a 10 per cent. solution of formaldehyde; twenty-four hours later the canal cleansing is undertaken. The formaldehyde gas expands at body temperature and penetrates the pulp tissue, sterilizing it.

Geranium-formol¹ may be substituted and has the following composition:

R—Formic aldehyde,	40 parts.
Essence of geranium (redistilled),	20 "
Alcohol, 80 degrees,	40 "

Phenol-camphor may be made by rubbing together in a mortar equal parts of gum camphor and crystal carbolic acid. An oily liquid is formed.

Endelman² modifies this as follows:

R—Formalin (40 per cent. aqueous formaldehyde solution),	℥x.
Oil of geranium,	ʒj.

If confidence in the suitability of immediate root filling in any case be lacking, the canal may after desiccation be dressed with cotton

¹ Dental Cosmos, 1904.

² André and de Marion, L'Odontologie. Abstract by International Dental Journal, 1901.

saturated with a diffusible antiseptic, such as 5 per cent. formaldehyde or geranium-formol, iodoform or hydronaphthol in alcohol, creosote, phenol-camphor, etc., and the cavity sealed for a few days. The oils of cassia and cloves are apt to cause discoloration of the dentine and should be avoided in anterior teeth. The supervention of acute septic pericementitis is an indication of failure. This may be denominated the "tentative" method.

The withdrawal of the cotton dressing in the tentative method should be done under aseptic precautions. There may be found no collection upon the cotton. In such case a fresh twist on a Swiss broach should be passed to the apex to determine its condition. If nothing be found the root may be dried and filled unless odor be present, when the root should be resterilized before filling or the dressing renewed.

Active hemorrhage may ensue or serum may ooze from the apical tissue. This may be checked with 25 per cent. pyrozone, adrenalin chloride 1:1000, or preferably deliquesced zinc chloride, and the root filled.

If a pus flow follow the removal of the temporary dressing and be but slight, the pyrozone or zinc chloride (or both) should be used and the root filled. The condition is one of apical abscess without fistula and is often amenable to immediate root filling. If, however, this be not considered advisable the temporary dressings may be renewed, though often without benefit. Sometimes a thick, glairy fluid will ooze from the apical tissue. This is coagulable lymph and the parts require treatment in the same manner as when a slight amount of pus is present. The principle involved in the departure to an immediate method of treatment is based upon the thorough sterilization of the apical tissue, the sealing of the canal to prevent infection from the mouth, and the exclusion of effusions from the apical tissue. This done, the apical tissue is expected to care for itself.

In order to prevent apical irritation in so far as possible, the gum is to be painted with ordinary tincture of iodine or spotted with the dental tincture of iodine, both lingually and buccally, as a counter-irritant.

R—Iodine, ʒiij.
 Alcohol, ʒj.
Shake frequently for a week or two. (Flagg.)

If infection of the apical tissue by any chance ensue, either as the result of the operation of canal cleansing or previous to operative

interference, the disease known as septic apical pericementitis is established.

Pericementitis following the opening of teeth containing gangrenous pulps has been explained upon the ground that the bacteria in the absence of free admission of oxygen have lost their virulence, which is restored when the air is admitted. It is quite likely that either this is true or that extraneous bacteria are introduced during the course of treatment.

In case of partial moist gangrene in which a portion of a filament is gangrenous and the balance of it vital, or in which one root filament is dead and the other vital, the treatment must be varied to suit the requirements. The dead portion is removed as described and the living portions treated as ulcerated pulps (which see, p. 405).

In a few cases the continuity of the canal has been lost because it has become involved in caries upon one side of the root. To remedy this if the root be still salvable the cavity should be excavated and then a tapering probe run through the tap in the crown and into the apical portion of the root canal. Around this an amalgam filling may be built. The probe is then withdrawn, leaving a canal in the amalgam through which later the canal may be treated and filled.

Moist Gangrene of Pulps of Temporary Teeth. The same considerations pertain to moist gangrene of the pulps of temporary teeth, but as the roots are resorbed to some extent or are to be resorbed, the root filling should be of such a character as to permit its resorption. Probably a combination of paraffin and aristol will best fulfil the indications.

If the roots be much resorbed it is better to use a material which will permit venting of the tooth if necessary. The canals and pulp chamber may be filled with a combination of vaselin and aristol and this covered by a filling. If trouble arise a spear drill is driven into the pulp cavity from a point near the cervix.

At an age when the permanent tooth will shortly thereafter erupt, extraction of the temporary tooth is often to be preferred to treatment.

Root-canal Work in Cases of Gangrenous Pulps Involving Future Consideration. In some cases of doubtful root sterilization or filling, and in which crowning by means of dowelled crowns is a necessity, provision may be made for future relief or treatment by the employment of one of two excellent methods of procedure:

1. Kirk has suggested that the post and band of a Richmond crown be painted while warm with a solution of gutta-percha in chloroform.

The solvent evaporates, leaving a coating of gutta-percha. The crown is then set with cement. By warming the crown with a hot crown-setting tool (How) or forceps, it may be removed with ease. The crown may be set with gutta-percha alone.

2. Girdwood (Edinburgh) has suggested root intubation, the tube being closed at the end with temporary stopping and then set with cement. Immediately thereafter the temporary stopping and soft cement are removed with Donaldson cleansers, leaving the root lumen free to the apical foramen or root filling. The tube and canal are then treated as a continuous root canal would be. The idea is also applied to a Richmond or all-porcelain crown, the tube being allowed to extend through the solder backing, to be later filled as desired.

SECTION V.

DISEASES OF THE PERICEMENTUM.

CHAPTER XX.

SEPTIC APICAL PERICEMENTITIS (ACUTE).

Classification. The dental periosteum and ligament, or the pericementum, is the seat of numerous nutritive and functional disturbances, which may be grouped, according to their causes, into septic and non-septic.

The term pericementitis has been indiscriminately applied to all affections of the pericementum, and in some cases erroneously, for in not all affections of this structure do the phenomena of inflammation appear. However, most of the acute and chronic degenerations are accompanied by evidences of inflammation.

Bödecker's division of the affections of the pericementum into purulent and non-purulent is misleading. Cases may be due to septic causes without pus formation; pus formation represents but one form of sepsis.

The most convenient clinical classification of these disorders is that offered by G. V. Black:¹ first, diseases of the pericementum beginning at the apex of the root; secondly, those beginning at the gum margin; thirdly, those beginning in some intermediate portion of the pericementum. These may again be divided, according to their causes, into septic and non-septic. Another clinical classification would be into localized and general disturbances—another into acute and chronic.

Evidences of Pericemental Disturbance. It was noted in the study of the diseases of the dental pulp that the diagnostic signs of pulp disturbance were exaggerated or diminished response to thermal stimuli; reflected instead of localized pains; and, except in rare cases

¹ American System of Dentistry, vol. i.

of advanced degeneration, no tenderness upon percussion. Disturbances of the pericementum are accompanied by entirely different symptoms which serve to distinguish between them and diseases of the pulp. They are, in general, tenderness upon percussion. As shown by Black,¹ the pericementum is the touch organ of the tooth, its tactile organ, through which a tooth locates force applied to the tooth. The pains of pericemental disturbance are, therefore, in the majority of cases, exactly localized, instead of not being localized as in the case of the pulp. A tooth tender upon percussion has its pericementum as the seat of disturbance. Most cases of pericemental diseases are accompanied by vascular reactions ranging from an increased blood flow or grades of hyperæmia to pronounced inflammation, and have the corresponding symptoms. The increased volume of the pericementum causes the protrusion and loosening of the tooth, heightened sensitivity being the accompaniment. As the vascular supply of the pericementum and that of the gum are in a degree collateral (see p. 152), evidences of vascular engorgement are seen in the gum overlying the affected tooth. Owing to the altered density of the parts surrounding the tooth root, percussion upon the tooth elicits a different sound from that observed in health—the sound is dull. The general symptoms of pericemental affections are, therefore, tenderness upon percussion and a dull percussion note, more or less protrusion and looseness of the tooth, and a deepening of the local gum color.

DISEASES OF THE PERICEMENTUM BEGINNING AT THE APEX.

Diseases of the pericementum beginning at the apex of the root are of two classes, septic and non-septic. The septic cases are almost invariably the sequel to diseases of the pulp, namely, suppuration and gangrene; or arise in consequence of infection through the canals of pulpless teeth. The non-septic cases are due to mechanical and chemical irritants, and in rare cases to undiscovered causes.

Acute Septic Apical Pericementitis—Acute Alveolodental Abscess. Definition. By septic apical pericementitis is meant an inflammation of the apical pericementum due to the entrance of septic organisms into the tissue lying in the apical space.

Causes. The most common causes of septic apical pericementitis are:

¹ American System of Dentistry, vol. i.

1. Septic organisms engaged in the putrefaction of a gangrenous pulp. The gases and toxic products evolved by the process also cause much irritation.

2. Pyogenic organisms engaged in the production of suppuration of the pulp.

3. Septic organisms introduced into the otherwise aseptic tissues of the apical space by means of instrumentation or other lack of aseptic precautions.

4. Infection of an apical space by an abscess arising in some contiguous part and extending in the direction of the apical space under consideration.

5. Septic infection from a pyorrhœa pocket located upon the side of the tooth in question, the deepest portion of which approximates the apical space.

6. Possible infection by way of the pericemental tract from the gum margin or by way of the circulation, which infection may cause a pericemental abscess located in the apical tissue.

The last two conditions would be septic apical pericementitis, but are to be considered separately as pericemental abscess. (See *Pyorrhœa Alveolaris*.) As a cause of apical abscess it is rare, but has been seen.

Apart from these causes infective inflammation of apical tissue does not seem to occur. It is to be remembered that a small portion of gangrenous pulp beneath a root-canal filling is equivalent to an entire gangrenous pulp as a cause of pericementitis. The vast majority of cases occur as a sequel to moist gangrene of the pulp, either before or after instrumentation or as a result of infection of the apical tissue by instruments either unsterilized or reinfected by contact with the oral fluids.

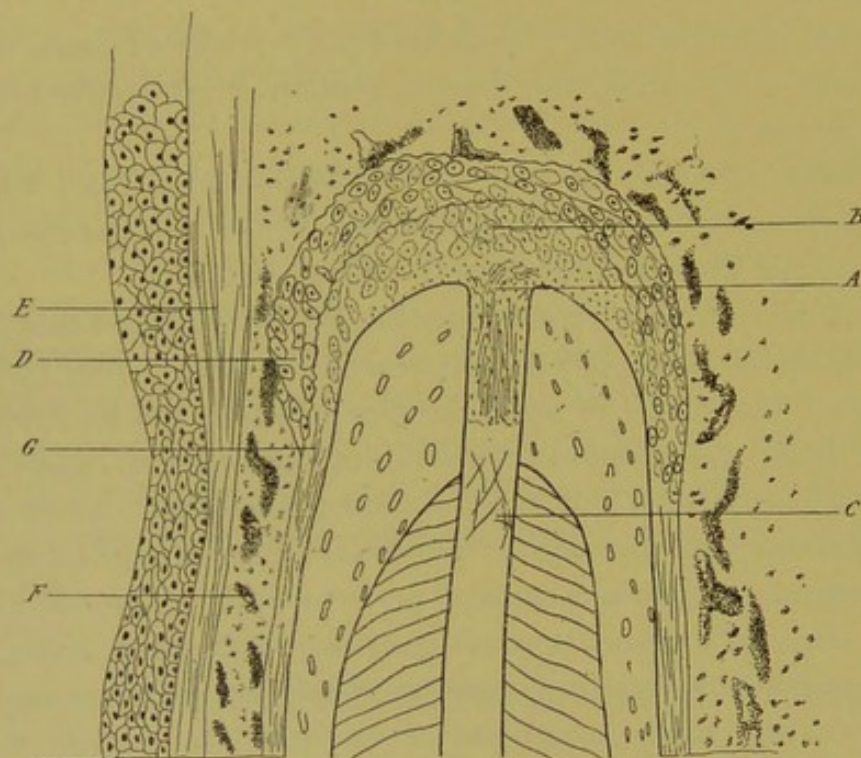
The organisms found in acute apical abscesses are those usually found in gangrenous and suppurating pulps and in a certain percentage of even healthy mouths. (See p. 45.) Schreier found the *diplococcus pneumoniae* in fifteen out of twenty cases examined. He also found *staphylococcus pyogenes albus* and *aureus*, and occasionally *streptococcus pyogenes*.

Arkövy found the *bacillus gangrenæ pulpæ* in a number of cases. (See p. 449.) These are virtually the same organisms that are found in the deeper portions of a suppurating or gangrenous pulp: this fact in itself is enough to show the continuity of infection from the pulp canal. It is a well-known clinical fact that acute outbreaks of septic apical pericementitis are most liable to occur under those conditions when

patients "take cold." Schreier points out that these atmospheric states produce a bodily condition which favors the development of the diplococcus pneumoniae, and finds in the association of these factors the reason why this diplococcus should be pathogenic in the dental condition.

Pathology, Morbid Anatomy, and Symptoms. THE INFLAMMATORY STAGE. As in abscess elsewhere there is first infection by pyogenic organisms which produce the phenomena of infective inflammation within the substance of the apical tissue, and in the later stages in the contiguous tissues.

FIG. 417.



Showing the morbid anatomy of septic apical pericementitis (acute): A, pus; B, area of dying leukocytes; C, septic matter in root canal; D, excavation of process (osteomyelitis); E, swollen periosteum and gum; F, alveolar bone; G, pericementum at edge of necrosis.

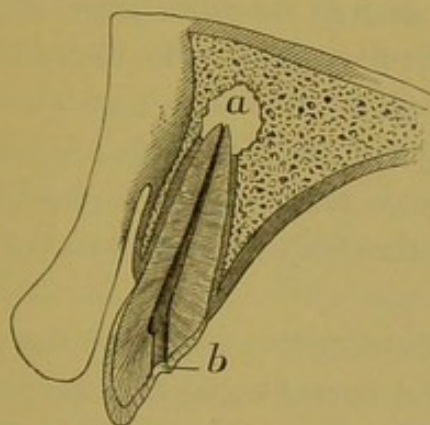
Following the infection, arterial hyperæmia is produced, sensation is exalted, and the tooth becomes tender upon percussion; but if forcibly pressed upon—*i. e.*, if the arteries be compressed—the hyperæmia is momentarily lessened and the pressure brings a sense of relief. At this stage the gum over the apex looks normal, but may respond to pressure.

Following the arterial hyperæmia the venous obstruction which ends in stasis is inaugurated, and diapedesis of leukocytes and fibrinous exudation into the intervascular tissue occurs. The fixed cells undergo proliferation.

As this condition of inflammation becomes established the pain due to pressure upon the sensory nerves becomes of a violent throbbing character, accompanied by a sense of fulness. The swelling of the tissue about the apex of the root, due to the excess of fluid, blood, leukocytes, and tissue cells, of necessity pushes the tooth from its socket, so that it feels and is longer than the other teeth. Moreover, as it is bitten upon the apical tissue is further irritated. The tooth is loosened and percussion induces pain and elicits the dull note which is diagnostic of the increase of bulk in the pericementum. The color of the gum over the root becomes deepened.

FIRST STAGE OF PUS FORMATION. The central area of the apical tissue—*i. e.*, that next the apical foramen—is broken down into pus,

FIG. 418.

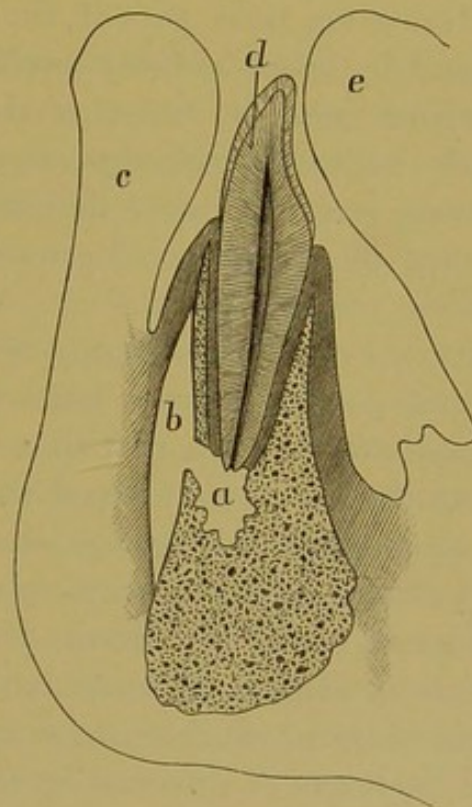


Acute abscess in second stage. Tooth opened at *b* for treatment, making a blind abscess. (Black.)

some of which enters the root canal (Fig. 417, *A*). As the area of pus formation widens, all of the apical tissue is liquefied (Figs. 418, *a*; 419, *a*).

SECOND STAGE OF PUS FORMATION. The bone cells become involved in the process and are destroyed (osteitis). The throbbing pain, the extrusion, looseness, and dulness to percussion, and the inflammation and œdema of the contiguous tissues are marked. The gum is widely inflamed, reddened, and swollen, but no demarcation of an abscess may be noted upon the gum at this stage. The membranes of the adjoining teeth become irritated and hyperæmic, and they may exhibit tenderness upon percussion (Fig. 418).

FIG. 419.



Acute alveolar abscess of a lower incisor, with pus cavity between the bone and the periosteum: *a*, pus cavity in the bone; *b*, pus between the periosteum and bone; *c*, lip; *d*, tooth; *e*, tongue. (Black.)

THIRD STAGE OF PUS FORMATION. The pus continues to form in all directions until the bone is perforated at some point—*i. e.*, usually through the labial alveolar plate—that being the thinnest and most readily perforated. The periosteum is now destroyed and the gum tissue directly involved as a boundary to the pus, which, collecting beneath it, raises it into a distinctly demarked tumefaction (Fig. 419, *b*). The pain becomes less acute owing to the binding resistance of the gum being less than that of the bone. At first the swelling is hard, and this represents a mass of gum tissue overlying pus; later it softens at its highest point, pus appears as a yellow spot beneath the mucous membrane. The mucous membrane bursts and a discharge of pus follows. The inflammation and tenderness then largely subside, but some degree of looseness and protrusion remains.

During the latter part of the second and in the third stage of pus formation, instead of the swelling extending but little beyond the overlying gum, the tissues of the lips, cheeks, or neck may be very much swollen and with upper teeth the eye of the affected side injected. In some cases the outer skin may become reddened and dusky, exhibiting the evidences of extension of the inflammatory process far from its original site.

While in the vast majority of cases the direction taken by the pus, and the point at which it finds exit, is the buccal or labial aspect, and immediately over the root apex of the affected tooth, or near it, these being the directions of least resistance, other anatomical conditions or histological peculiarities (see Chapter VII.) may make the direction of least resistance in some other path (Figs. 420–423).

Instead of the circumscribed suppuration described as the ordinary course of abscess formation about the apices of roots (septic apical pericementitis) which accompanies infection by the staphylococci, clinical evidences of infection by streptococci occasionally appear. The inflammatory process, instead of being circumscribed, is diffuse; the inflammation extends along the lines of the connective tissues and of the lymphatics; the connective tissues are swollen, the swelling extending to the tissues of the cheek, down the neck, and even to the shoulder—a phlegmonous inflammation. Instead of the comparatively free flow of pus which follows incision of the swelling in ordinary abscess, pus formation in streptococcus infection is seen, upon incision, to be limited and seropurulent. While in alveolar abscess of the ordinary types evidences of septic intoxication or poisoning are unusual, the lymphatics being blocked, as a rule, by the inflammatory exudation,

septic intoxication and poisoning are the rule in the erysipelatous cases, those probably due to streptococcus infection; bacterial poisons being taken up by the lymphatics find their way into the circulation.

The symptoms of the absorption of bacterial products from the circumscribed abscesses are: fever, often ushered in by a distinct chill. The pulse increases in volume and tension; it is full, hard, and frequent. The tongue is coated, the bowels constipated. The patient is also weakened and made irritable by pain and attendant loss of sleep and appetite.

In the streptococcal infection there is danger that these may change into the more profound symptoms of septicæmia—*i. e.*, a soft, frequent pulse, repeated chills, diarrhoea, clammy skin, general depression, and a disordered nervous system.

In multirooted teeth the inflammation and abscess frequently appear on only one root. If the case be seen early, before the active exudation period of the inflammation sets in, the symptoms may be clearly localized in one root, the tooth exhibiting tenderness upon pressure over the affected root, but not upon the opposite side.

After spontaneous discharge of the pus from an abscess, the condition remaining is that of an ulcerous surface (the abscess boundaries), which is being continuously infected from the putrescent pulp remnants. The conditions, it is seen, are not like those of ordinary abscess, where the infective material is largely discharged in the pus evacuation, and the cells bounding the abscess wall dispose of remaining bacteria, so that regeneration of tissue occurs. Spontaneous healing of an alveolar abscess is the exception; the embryonic tissue lining the abscess walls being continuously infected, degenerates and dies as fast as it forms, leaving a condition known as chronic alveolar abscess, or chronic purulent, apical, septic pericementitis.

Clinical History. The clinical history of acute alveolar abscess may be divided into three stages: first, that of initial inflammation and pus formation; secondly, the destruction of the alveolar process; thirdly, the passage of pus through the periosteum and mucous membrane. The second stage is usually the longest. The duration of the disease depends upon the readiness with which the tissues between the point of beginning pus formation and its exit yield. When the pulp chamber is open pus may find exit by this path, constituting the condition known as blind abscess—a misnomer, because a blind abscess is one without a point of discharge, without a fistula leading

to it; in the cases discharging *via* the canal, the latter may be considered a fistula (Fig. 418).

Acute abscesses usually run a short course, the inflammatory symptoms rarely being severe, and the tissue destruction limited (Fig. 418). Notably upon lower molars, and upon the palatal roots of upper molars, the density and thickness of bone overlying the roots may make paths of greatly increased resistance, so that the destruction of tissue proceeds along the line of the pericementum, the pus finding exit at the neck of the tooth. It is rare in cases of lower second molars and still more rare upon the third molars, that pus finds exit over the apex of the root, the dense bone of the external oblique line offering the greatest resistance (Fig. 420). Over any teeth the outer fibrous layers of the external periosteum may present

FIG. 420.

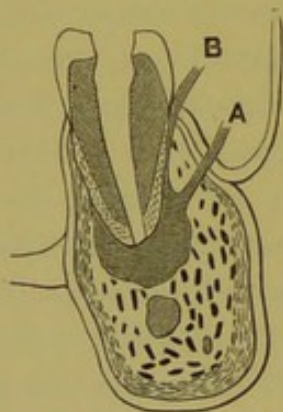


FIG. 421.

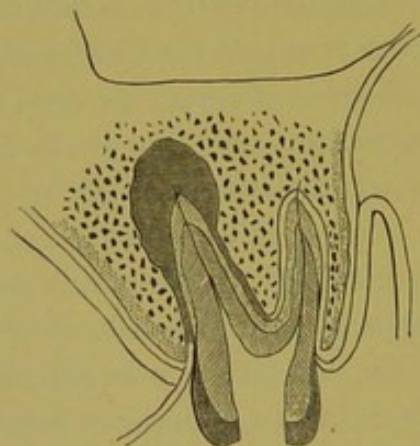


FIG. 420.—Abscess upon lower third molar, showing the usual paths of pus exit, *A* and *B*.
FIG. 421.—Abscess upon palatal root of an upper molar discharging at the neck of the tooth.

unusual resistance to the perforative advance of pus, so that when the fibres of attachment of the periosteum have been softened by the inflammation, and pus gains entrance between bone and periosteum, it may travel or burrow along the course of this membrane (Fig. 420), depriving the bone of its main nutritive source, so that limited necrosis threatens. The roots of the central incisors may lie unusually close to the floor of the nose, and be overlaid externally by an unusually resistant layer of bone; in these cases the path of least resistance may be in the direction of the floor of the nose, the abscess opening at that point (Fig. 422), or the pus may perforate the lingual alveolar plate and, raising the periosteum and mucous membrane, form a large swelling upon one side of the hard palate (Fig. 431).

The root apices of the posterior upper teeth, particularly of the first and second molars, may after the age of twenty-five or thirty be

encroached upon by the enlarging maxillary sinus, so that any or all of the roots of these teeth may be separated from the floor of the sinus by but a very thin lamina of bone; should abscess arise upon any of these roots, pus discharge into the antrum would necessarily follow. In these cases the acute symptoms may rapidly subside, but later symptoms of antral empyema may follow (Fig. 423).

Resort to the use of poultices upon the face, for the relief of the pain of abscess formation, may induce such a softening of the tissues over which they are applied that the passage of pus is invited toward the exterior; the abscess may thus open upon the face or neck, producing permanent, disfiguring scars (Fig. 447).

In patients who are in a cachectic condition, who have an evil heredity, or whose tissue resistance is markedly lessened in consequence

FIG. 422.

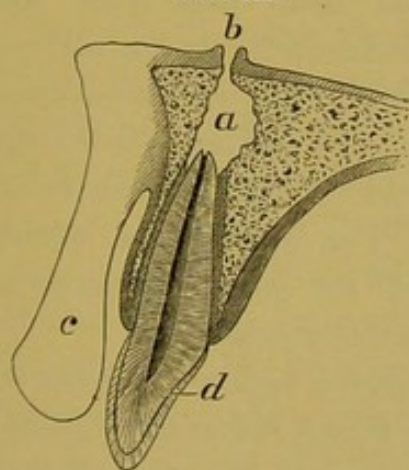


FIG. 423.

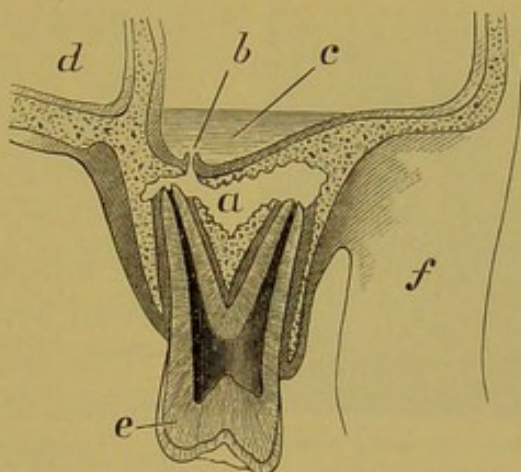


FIG. 422.—Alveolar abscess at the root of a superior incisor, discharging into the nose: *a*, large abscess cavity in the bone; *b*, mouth of fistula on the floor of nostril; *c*, lip; *d*, tooth. (Black.)

FIG. 423.—Alveolar abscess at the root of an upper molar discharging into the antrum of Highmore: *a*, abscess cavity in the bone; *b*, mouth of fistula on the floor of the antrum; *c*, pus in the antral cavity. (Black.)

of tuberculosis, or more frequently of syphilis, septic pericementitis may run a riotous course; the bone suffers extensively by direct action; the periosteum is undermined, is stripped from the bone over large areas, and breaks down readily; so that while in the healthy person alveolar abscess formation may run a direct course and find prompt outlet, in the syphilitic patient extensive pus infiltration, with necrosis, may occur. In cachectic persons lymphatic involvement is common; waste products of bacterial origin find their way into the lymphatics, and set up secondary irritative processes in the nearest lymphatic glands—lymphadenitis.

In persons whose oral hygiene is neglected the third stage of alveolar

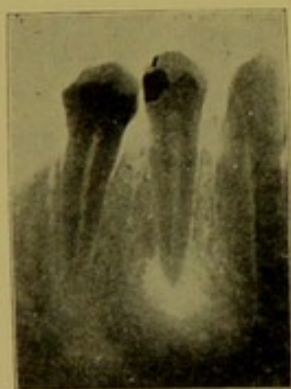abscess is frequently violent and the inflammatory process widespread.

Diagnosis. In incipient apical pericementitis the symptoms may consist of reflex pains, but, as a rule, are distinctly localized in the teeth affected, which are tender to the touch. The discoloration of the tooth crown and other evidences of moist gangrene are usually present unless the tooth has been previously partially treated, when the color may be good, but by transmitted light opacity is noted. In the pronounced cases the symptoms are as described.

After high inflammation has existed for twenty-four hours, pus is generally present in the apical tissue (Fig. 424).

Of two pulpless teeth surrounded by a zone of inflammation the most tender is the one affected, though both may be acting at once.

FIG. 424.



Diagnosis of apical abscess by x-rays. (Price.¹)

It is to be remembered that adjoining, otherwise normal, teeth may show some evidence of pericementitis, so that differentiation is necessary. The various stages of inflammation and pus formation are judged by the appearance of the gum or by the x-ray Fig. 424. The greater the swelling and injection of the gum, the more advanced is the pus formation.

The inflammatory action precedes the advance of pus, which furnishes a guide to the direction the pus is pursuing—viz., where the most intense coloration and the

greatest swelling appear will be the point at which the abscess will point or discharge. A sudden subsidence of inflammation without an immediately discoverable point of pus exit should lead to the suspicion that the discharge has taken place in an unusual situation.

An abscess originating about an impacted tooth, or one due to subperiosteal inflammation, must be differentiated.²

A pericemental abscess must also be considered. An acute abscess of the pulp in its most pronounced stage may simulate incipient or even pronounced acute apical pericementitis. (See p. 407.)

The last three conditions are usually associated with suspected teeth containing vital pulps, so that tests for pulp vitality are to be applied.

In certain cases of pulp gangrene part of the pulp only may be

¹ Items of Interest, 1901.

² Black, American System of Dentistry, vol. i.

dead—*e. g.*, the lingual filament of the pulp of an upper molar; while the balance may be vital (the buccal filaments). This fact may confuse the response to tests and is to be borne in mind.

Prognosis. In the majority of cases the prognosis of acute alveolar abscess, as to the future retention of the tooth, is favorable; and usually very favorable, if the case receive intelligent therapeutic aid. The future of the tooth depends upon the thoroughness with which sources of infection may be destroyed and permanently removed, and the completeness with which regeneration of tissue can be induced.

Treatment. In the initial inflammation and first stage of pus formation the treatment should be abortive. The cause of the inflammation should be removed, if possible, and the pus formed be removed or at least permitted to escape by way of the pulp canals. The promptness of relief from pain depends upon the thoroughness with which this is accomplished.

The pulp chamber should be opened to an extent which permits the free passage of broaches into the canal (Figs. 418 and 421).

If the cavity of decay be open the pulpal wall is to be perforated. If a filling be present, it is in part or entirely removed. If the enamel be entirely sound, or if subsequent treatment require a new opening in line with the pulp canals, it is at least in part made.

These openings are usually begun with a small, spear-pointed drill (No. 101 S. S. W. Catalog) revolving in a perfectly true hand-piece. The opening made is enlarged with successive sizes of sharp, round, dentate burs until of sufficient size.

According to the amount of tenderness, the tooth will require a counterpressure to that of the drill. If the entrance be made through the occlusal face of the tooth, or in a direction which would cause direct pressure on the apical pericementum, a ligature of linen thread with long ends may be placed around the tooth, and traction be made by drawing on the loose ends of the ligature.¹ Effective counterpressure against lateral entrance to the pulp chamber may be made by softening a small roll of modelling compound and moulding over the face of the affected tooth and several of those adjoining it, and permitting it to harden. This temporary splint is held in place by the index finger of the left hand. In case the inflammatory process is marked, it may be necessary to make a vent opening by the most direct path—*i. e.*, at the junction of enamel and cementum—directly into the chamber.

¹ J. Foster Flagg, Lectures on Dental Therapeutics.

As soon as entrance to the pulp chamber is effected, the cavity is syringed with a strong antiseptic; a 20 per cent. solution of meditrina answers well in this connection. Fine probes are passed and repassed into the opening to free the outlet, so that gases may escape and fresh portions of the antiseptic be worked into the cavity. The quickness with which relief is secured will depend upon the thoroughness with which the canals are entered and their putrid contents destroyed. A tedious class of cases are those in which a canal of a molar is unfilled or but partially filled. Unless entrance to and cleansing of the canal be accomplished, the inflammation will proceed until the pus finds external vent. An hour spent in gaining access to and cleansing such canals is well spent.

If entrance to the canals be free, repeated applications of sodium dioxide solutions should be made, pumped into the canals, and the cavity washed from time to time with meditrina or hydrogen dioxide. Near the end of the canal the meditrina is used alone with broaches, and finally by syringing. The canals are dried, and an anodyne antiseptic, such as phenol-camphor plus menthol, is pumped into the canals. If now provision for surgical rest of the irritated pericementum be made, relief is tolerably certain.

A moldine impression may be taken of a tooth at some distance; from this a fusible metal die is made, which is driven into soft lead for a counter-die. Between these is swaged a metal cap (German silver, 26 gauge, will do), to cover the occlusal and part of the buccal and lingual surface. This is attached to the dried tooth by means of zinc phosphate and allowed to remain a day or two. As a quickly made substitute, a strip of rubber-dam about three inches long and about seven-eighths inch wide is rolled into a pad of the width of the occlusal face of the tooth to be capped. Floss silk is then sewed through this in such a manner as to cause it to tie the pad over the tooth, the silk itself encircling the neck of the tooth.¹ This will ensure rest of the affected pericementum (Fig. 425).

A mixture of tincture of aconite and tincture of iodine or dental tincture of aconite should be then painted upon the gum over the tooth.² The inflammation usually subsides and almost disappears in a couple of days. The local measures should be supplemented in somewhat severe cases by the administration of a saline cathartic or


¹ Flagg.

² Dental tincture of aconite may be made by evaporating the official tincture to one-fourth its bulk. It should be used with great care, and be covered for a half-hour with a pad of cottonoid. The patient should be cautioned against swallowing the saliva during this time. (Flagg.)

the hot pediluvium as derivatives. Instead of catharsis the hot pediluvium and diaphoresis may be conjoined; 10 grains of Dover's powders in hot lemonade are to be taken after the pediluvium¹ and the patient well covered up in bed. These several measures are to be regarded as the abortive treatment of alveolar abscess; they apply to all cases if seen early enough, and will in the majority of cases prevent the disease of the pericementum passing the early inflammatory stages. In all cases the severity of the inflammatory process is lessened in proportion to the thoroughness with which the antiseptic measures are applied, provided that in the attempt at such application no septic matter be violently thrust through the apical foramen.

While this is true, marked relief is so often given in even severe cases by the simple opening of the pulp chamber by means of a spear drill, thus permitting the gases and pus to find vent, that in those cases in which tenderness of the tooth prevents thorough opening, or when patients are confined to bed by illness, such an opening may be made, either at the neck of the tooth or through a filling.

FIG. 425.



Rubber-dam guard for use in pericementitis: A, roll of dam threaded; B, guard fitted over tooth; tooth eliminated to show the manner in which the silk encircles it.

In the second stage of pus formation the abortive treatment may still be attempted. In some cases this is successful in at least reducing the acute pain which demoralizes the patient.

If the pain persist, the gum and bone overlying the apical space should be perforated in order to form an artificial fistula.

Black's method is a good one. A few drops of carbolic acid are placed on a glass slab and a deeply serrated plugger point is dipped into this, and the tiny drop adherent is laid upon the gum, which it eschars and, in part, anæsthetizes. The serrated point is used to scratch the escharred tissue; more carbolic acid is added and the process repeated until the bone is reached. A fresh drop is then placed and the bone perforated with a sharp chisel or a spear drill. The

¹ Endelman (*Dental Cosmos*, March, 1904) suggests the rational improvement of immersing the feet in warm water which is gradually made hotter, as bearable, until the vessels of the feet become well engorged.

location of the abscess may be determined by measuring the length of the root by the use of a Donaldson hook, over the shank of which a disk of rubber-dam has been passed as a guide.

The gum may be refrigerated with ethyl chloride or a little cocaine solution may be injected into it and a deep cut be made to the

bone, after which the perforation of the bone is made. After cocainizing the parts a Rollins tubular knife may be used to remove a circular section of gum tissue, after which a fine trephine or the drill may be employed to enter the apical space. The difficulty of determining the exact location of the abscess seat renders this operation of perforation almost impracticable in some cases. Under such circumstances the abortive treatment, both local and systemic, must be made as thorough

as possible, and if not successful the patient may be kept under the influence of morphine until such time as the pus formation has reached the third stage. This may be hastened by the use of a capsicum plaster applied to the gum. This may properly be denominated the *expectant* treatment, and, while perhaps unsurgical, presents at times no alternative but tooth extraction.

As a preventive of possible blood infection the following may be administered:

R—Hydrargyri bichloridi, gr. j.
Tinct. ferri chloridi, fʒj.—M.

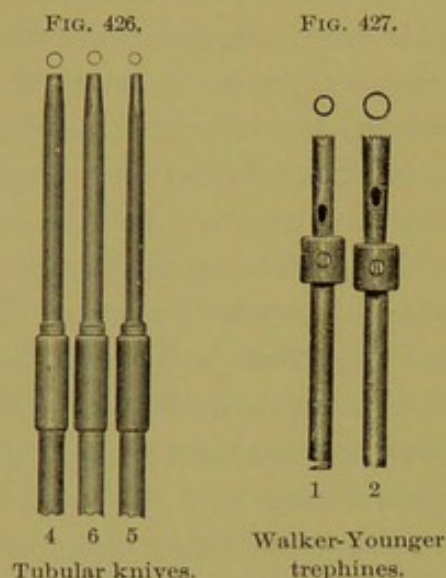
Sig.—Twenty drops in water four times a day.

In case the patient suffer marked physical debility owing to pain and intestinal disturbance, a stimulant tonic should be used after the use of the saline cathartic.

R—Saloli,
Quininæ sulphatis, āā gr. xxx.
M. et fiant capsulæ No. x.
Sig.—Take one capsule before each meal and on retiring.

This combination acts as tonic, antipyretic, and antiseptic. The following¹ is also suggested as analogous:

¹ Endelman, Dental Cosmos, 1904.



R —Quininæ sulphatis,	gr. xxx.
Acetanilid,	gr. xxiv.
Caffeinæ citratis,	gr. iij.
M. et fiant pil. No. xij.	
Sig.—One every hour.	

In the third stage the pus is in the tissues exterior to the alveolar process. A deep, free incision should be made in order to evacuate the abscess; a methyl chloride spray or a cocaine injection being used as an anæsthetic in those cases in which the pus is deep seated.

The abscess cavity is then to be syringed out with hamamelis (distillate) and afterward with hydrogen dioxide.

It has been recommended that at this time the root end be scraped or amputated as a means of ensuring the cure of the abscess. There can be no objection to the removal of shreds of necrotic tissue about the root apex, nor even to slight amputation if the operation be endurable. The great majority of these cases are, however, curable by correct root-canal treatment, and the inflammatory symptoms and conditions under which one operates seem to indicate that a better course is to introduce a drain of antiseptic gauze into the abscess cavity through the incision in order that the fistula shall not close externally. Upon the cheek should be placed compresses wet with an antiphlogistic.

R —Liquor plumbi subacetatis,	f℥iv.
Tinct. opii,	℥j.
Aquæ,	Oj.—M.

The root canals need not necessarily be opened at this time. In a day or two the intense inflammatory symptoms should have subsided. If, later, the treatment for chronic abscess be not successful, the abscess cavity may be packed open with antiseptic gauze and the root end amputated under conditions vastly more favorable to success. (See Treatment for Chronic Apical Abscess.)

Under no circumstances should hot poultices be applied to the outside of the face, as a discharge of pus in that direction will cause a disfiguring scar. If an abscess threaten to open externally the abscess should be opened by an incision made from a point within the mouth, and, after sterilization of the tract, a drainage tent of antiseptic gauze should be introduced nearly to the bottom of the pus cavity. This should be removed daily, the abscess cavity sterilized, and the tent renewed. An antiphlogistic compress should be applied to the face. The principal object sought is the mechanical apposition of the walls of the abscess cavity at the dependent or external portion, in order that these shall unite by granulation and that the fistula shall

in this manner become an ordinary one. The patient should lie in a position to counteract the natural effect of gravitation.

After lancing, the mouth should be kept well sterilized by frequent sprays or gargles of hydrogen dioxide, which may be diluted to one-third strength with water—*i. e.*, to a 1 per cent. solution.

If, in connection with the lower third molar, marked swelling be observed in the submaxillary triangle, free incision of the tissues of the floor of the mouth should be made at the angle of junction with the bone. The cut should be made close to the bone and toward it, but not too deep, lest the mylohyoid artery or nerve be injured.

The deep lancing of an abscess upon the hard palate may cause a cut to be made in the posterior palatine artery. External to the lower jaw the facial artery is to be considered.

It is ever to be borne in mind that so long as the source of infection remains pus formation continues, and so long as pus forms tissue destruction is in progress; furthermore, in proportion to the amount of tissue loss perfect recovery after alveolar abscess is delayed or imperfect.

While it is the clinical experience of nearly every operator that a tooth and adjacent structures may recover from inflammation which involves not only the first tooth attacked, but by an extension of the inflammatory process involves the general periosteum and neighboring teeth, provided the case receive prompt and decisive surgical treatment, yet the danger of necrosis and septicæmia in prolonged cases is always imminent. When the general periosteum is involved, as shown by extensive boggy swelling in the mouth, if several free incisions carried to the bone do not afford prompt relief, the tooth which is the centre of infection should be promptly extracted. If, in the continued course of the pericementitis, chills, followed by fever, a coated tongue, and much physical depression occur, a general infection is to be feared, and no time should be lost in sterilizing the mouth, extracting the tooth, and subjecting the socket to free spraying with antiseptics.

It has been a subject of controversy whether a tooth should be extracted while the abscess is forming. It has been claimed that the continuation of pus formation after extraction renders the state of the patient even worse than before extraction.

This occurrence is comparatively infrequently seen, and is, of course, due either to the retention of some pyogenic organisms beneath the clot which forms in the alveolus or the infection of the parts by extraneous organisms.

The retention of the tooth until a fistula forms would also confine the bacteria for the time.

In cases of extraction during the second stage of pus formation, the alveolus should be forcibly syringed for ten minutes with hydrogen dioxide, in every four ounces of which two grains of mercuric chloride has been dissolved. If thought desirable to repeat the syringing, a tent of antiseptic gauze may be gently carried to the apex of the alveolus and left. This tent may be removed to permit syringing, and should never be left long at any one time, as septic inflammation of the alveolar walls may occur.

In cases of this kind oral sterilization and derivative systemic medication are of importance. As soon as improvement is noted the tent should be removed, the alveolus sterilized as before, and a new clot induced by a curetting of the walls. The case should now proceed as any ordinary extraction.

In cachectic individuals acute abscesses may cause inflammation of the deeper tissues and of the periosteum as well, and extensive necrosis may occur.

Acute septic apical pericementitis may occur on a temporary tooth, most frequently a temporary molar. The symptoms and pathology are the same, except that the looser character of the alveolar structure seems to frequently permit the abscess to assume the chronic form before the dentist is consulted. Children often hide these conditions from their elders out of fear of the dentist. In strumous children the inflammation may be spreading and the lymphatic glands may be involved. There may also be some symptoms of septic intoxication evidenced by chills accompanied by fever, etc. These cases require an opening of the abscess, sterilization of the part, and attention to the systemic condition. If seen in the acute stage the treatment is the same as for the permanent teeth, unless the disease occur shortly before the date for eruption of the permanent successor, when the temporary tooth should be extracted. If treated, the canals should be filled with materials which can be resorbed by the tissues, such as paraffin or wax with aristol.

CHAPTER XXI.

CHRONIC SEPTIC, PURULENT, APICAL PERICEMENTITIS (CHRONIC APICAL ABSCESS).

By this title is meant a condition of apical pericementitis due to septic influences in which pus is continuously formed at the expense of the apical pericementum and contiguous tissues. It is the usual outcome of acute apical abscess, and is established as soon as the pus finds vent either through the gum as a natural result or through the root canal as the result of surgical interference or the opening of the canal by caries.

These two avenues of pus escape give the two clinical conditions of (1) chronic apical abscess discharging *via* the root canal; (2) chronic apical abscess with fistula.

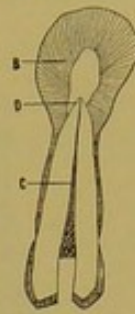
CHRONIC APICAL ABSCESS DISCHARGING VIA THE ROOT CANAL.

Pathology and Morbid Anatomy. FIRST GRADE. Upon abortion of an acute abscess in the first stage the pressure of pus upon the apical tissues is released and, as a rule, the walls of the abscess cavity throw out granulations which fill it. This tissue tends to organize into more or less healthy tissue (cicatricial tissue). The bacteria are killed out except at that part represented by immediate contact with the root foramen; at this point the tissues are infected and some molecular loss of tissue as pus may occur. A limited loss of granulation tissue by pus formation is compensated for by the formation of new granulations. The conditions are almost analogous to those existing in moist gangrene of the pulp and require analogous treatment.

SECOND GRADE. If the abortion of the abscess have only partly permitted the pus to drain, or the alveolar walls or crypts of the abscess wall remain infected, the pus will continue to form and escape in some degree *via* the canal. If the tooth now be extracted a small abscess sac will be found upon the root end. If opened this will be seen to be a mass of fibrous vascular tissue (inflamed pericemental apical tissue) having a central lumen connecting with the root canal (the abscess cavity).

THIRD GRADE. With partial vent to the pus formed, the abscess cavity of the second grade may enlarge, involve the bony walls of the alveolus, and the soft tissues then proliferate to such an extent that they finally organize into a large, fibrous, vascular sac attached to the tooth. This sac has the central pus cavity before described, which is connected with the pulp canal. It may be a half-inch or more in length (Fig. 428) and may be extracted with the tooth or may be left attached to the bone. It necessarily occupies in the latter a cavity of a size corresponding to its own bulk. As its inner walls are infected, extraction without its removal leaves an infected area which must be disinfected or a secondary acute abscess may result.

FIG. 428.



Chronic apical abscess, third grade: B, abscess sac containing a central pus cavity; D, apex of root; C, canal containing pus.

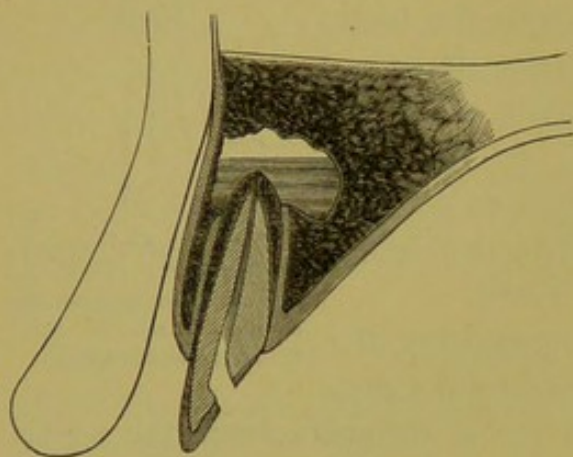
FOURTH GRADE. Instead of organizing the fibrovascular tissue may be liquefied into pus. The root apex becomes denuded for a distance about the apical foramen. Pus collects about the apex of the root and rests upon the bone owing to the influence of gravity. The bone is thus infected, inflamed, and further liquefied, while necessarily the abscess cavity enlarges. If a bistoury be thrust through the labial alveolar wall in such a case as shown in Fig. 429, but slight resistance will need to be overcome. In the lower jaw the tendency is to burrow into the cancellated tissue of the bone away from the tooth, so that destruction of the pericementum may not be very extensive. In the upper jaw the tendency is to spread along the pericementum and into the cancellated bone, so that the cavities of chronic abscess upon the upper anterior teeth particularly may cause extensive excavation in the palatal process of the superior maxillary bone (Fig. 431). The pus may burrow in irregular and circuitous directions, until it finds external vent.

In long-established cases deposits of pus calculi (serumal) may form upon the root end (Fig. 432). The cement corpuscles of the apical cementum may die and the root tissue itself become infected. In other cases resorption of the root end occurs. (See Resorption.)

Symptoms. In all of these cases the formations are gradual owing to the partial vent, and it may be that no pain beyond a slight gnawing or feeling of fulness or an occasional reflex pain may occur. If for any reason the vent become occluded, the pus formation becomes rapid and an acute abscess is set up, which may be painful or not,

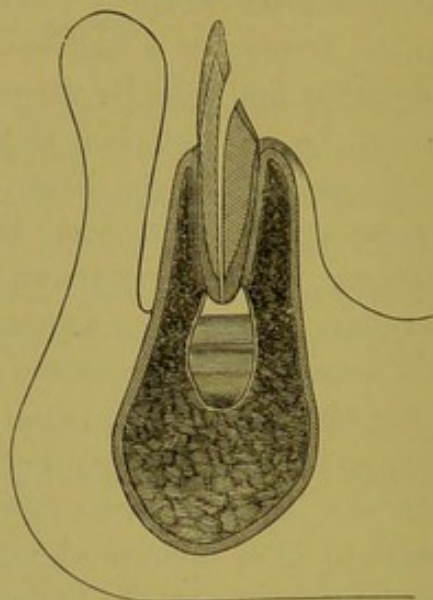
according to the amount of tension produced before discharge of the pus. Aside from this the gum color at the apex is somewhat deepened, the tooth is slightly loosened, and slightly tender to percussion. Signs of previous moist gangrene are in evidence.

FIG. 429.



Chronic blind abscess of upper incisor, showing tendency of pus to progressively destroy pericementum, owing to the influence of gravity.

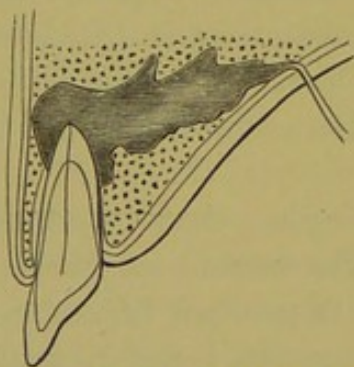
FIG. 430.



Chronic blind abscess upon lower tooth, showing tendency of pus to sink into the substance of the lower maxilla, owing to the influence of gravity.

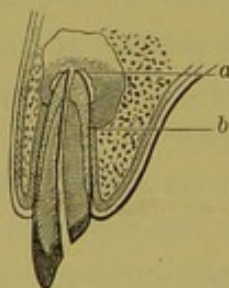
Diagnosis. The passage, without production of sensation, of an undue length of fine probe into a canal is evidence of destruction of apical tissue and a guide to its probable extent.

FIG. 431.



Chronic apical abscess discharging through the hard palate and threatening to discharge labially.

FIG. 432.



Chronic abscess, showing denudation of apex of root (a to b), with deposits of calculi (a) upon cementum.

An extensively inflamed gum tissue over the apex indicates a probable approach of pus formation to gum tissue. The presence of pus in the canal or upon several dry cottons introduced for absorbent

purposes is diagnostic. If pus be not seen, and the canal be thoroughly sterilized and dressed with an antiseptic, the supervention of an acute abscess affords evidence of the presence of an abscess sac or cavity. The *x*-ray affords a means of diagnosis (Fig. 424).

Prognosis. The prognosis is favorable to a cure in nearly all of these cases, provided thorough canal asepsis and filling can be attained and the abscess cavity can be drained and disinfected. In cases resisting this treatment, amputation of the root end or replantation will cure a certain percentage of cases. In all other cases extraction should be resorted to.

Treatment. The first and second grades of chronic alveolodental abscess discharging *via* the canal may be treated upon exactly the same principles which are involved in the treatment of moist gangrene of the pulp. The infection is considered as simply more deep seated, so that it is necessary to pass disinfectants into the abscess cavity with two objects in view: (1) to destroy the bacteria present; (2) to stimulate the tissues to granulative activity. To accomplish this the apical foramen must be opened. The canal should be sterilized with sodium dioxide and the foramen enlarged with a fine Donaldson cleanser, the canal having been flooded with meditrina or a 10 per cent. solution of zinc chloride in water as an antiseptic.

If necessary the root canal may be otherwise enlarged. (See p. 432.) If removable but otherwise permanent antiseptic root fillings be introduced (see p. 437) and counterirritants be applied to the gum, the chances are that in a great majority of the cases any resultant irritation will be of a passing character and symptomatic of an aseptic inflammation. In cases in which the canal cannot be explored even by the aid of the known means of enlargement, it is to be assumed that the end of the root is curved or the canal in some unknown way occluded, and it is well to employ Rhein's method of cataphorically producing zinc oxychloride *in situ*, or Bethel's nitrate of silver method (see p. 453), or 25 per cent. ethereal pyrozone or formaldehyde solution (5 to 20 per cent.) may be introduced on cotton for twenty-four hours. At the end of that time the root canal is to be opened under aseptic precautions and the canal examined for the presence of pus. No pus may be noted upon the cotton dressing, but if sterilization has failed the pus may later be found upon cotton introduced as an absorbent.

In these cases these or other dressings may be renewed every other day until pus formation ceases; some operators prefer to leave a

small vent in the temporary covering, used to act as a drain. This, however, is apt to prevent the concentration of the action of the medicament upon the apical tissue.

After sterilization of the abscess sac and the canal, whether this be accomplished immediately or by tentative dressings, the pulp canal may be filled with a removable antiseptic root filling (Forma-Percha, aristol and wax, paraform and wax, etc.) and a temporary cavity filling inserted. After a test of a week or two the cavity may be filled.

If, on the other hand, pus formation increase or be persistent, an artificial fistula must be established (see p. 471) and the case treated as a chronic apical abscess with fistula.

In the third and fourth grades the prognosis for treatment by way of the canal is not, as a rule, good. If, however, an artificial fistula be established the ease of treatment is greatly increased. The case is then treated as a chronic apical abscess with fistula.

In no case should hydrogen dioxide be forced in quantity into the pus occupying such an abscess cavity until the fistula has been made, and it is better even then that the bulk of it be washed out with warm water before applying the drug. A neglect of this precaution may bring about great pain, owing to the rapid reaction of the hydrogen dioxide with the pus present.

CHRONIC APICAL ABSCESS WITH FISTULA.

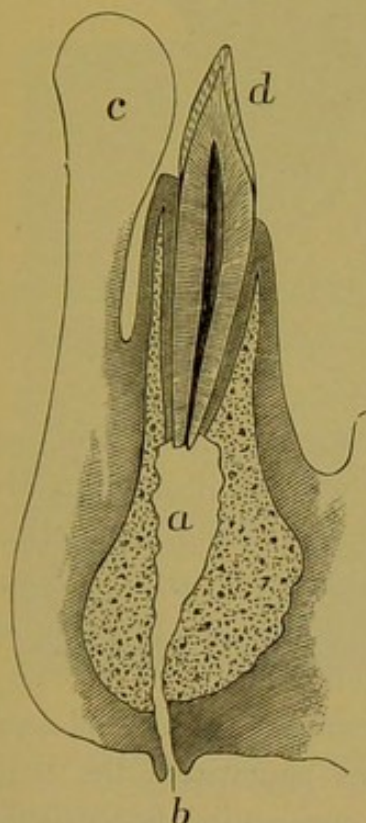
Morbid Anatomy and Pathology. This form of chronic abscess occurs as the result of the discharge of an acute abscess through the gum or other part to the surface of the body. (The interior of the mouth or other cavity exposed to contact with the air is considered external to the body proper.)

If the acute abscess has been severe or long continued the tissue destruction may be great, but, as a rule, granulation promptly sets in and the walls of the abscess cavity organize into cicatricial tissue. From the interior of this a canal (fistula) lined with cicatricial tissue leads to the surface, the pus being almost constantly formed at the expense of the granulation tissue which is as constantly renewed.

The fistulous opening, as a rule, appears as a small teat of inflamed tissue located in the majority of cases upon the buccal surface of the gum, about a quarter of an inch below the apex of the root and slightly distal to it—a position probably determined by the density of the

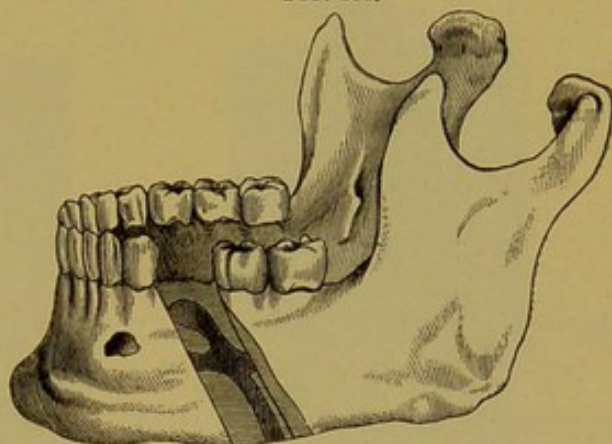
tissues surrounding the acute abscess. At times the only evidence of a fistula is a small spot of inflammation surrounding a minute opening from which pus exudes. The fistula is sometimes located upon the lingual surface of the gum. It may perforate the bone of the hard palate and open through the mucous membrane of the roof of the mouth (Fig. 431). Instead of finding exit by a direct path through the buccal or lingual alveolar plate and gum the pus may burrow along the length of the pericementum and discharge at the neck of the tooth. One-half or more of the lateral aspect of the pericementum

FIG. 433.



Chronic alveolar abscess of the root of the lower incisor, with abscess cavity passing through the body of the bone and discharging on the skin beneath the chin: *a*, very large abscess cavity; *b*, mouth of the fistula. (Black.)

FIG. 434.



Fistula passing down through the body of the lower maxilla. (Black.)

may remain vital, although involved in a chronic inflammation, the remainder being destroyed. Not infrequently the pus burrows along the surface of the bone and discharges at a point over an edentulous portion of the jaw. This is common to a lower bicuspid.

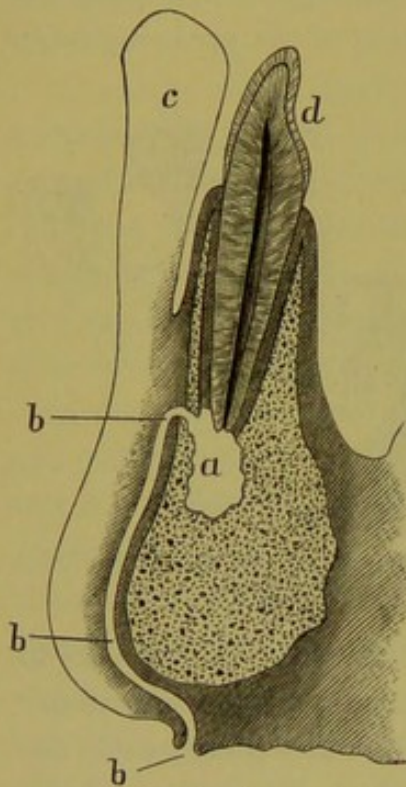
Where the apices of the roots of upper posterior teeth lie in very close proximity to the floor of the antrum, perforation of this floor may occur

before tissue destruction has proceeded far enough in other directions to afford escape to the pus (Fig. 423). Extensive pus accumulations may occur in the antrum in consequence. It may discharge into the nasal cavity, in connection with acute abscess; at such points the discharge may remain persistent. Sometimes the discharge occurs through the canal of the affected tooth; the condition then becomes one of blind abscess (Fig. 418). Upon a lower tooth, particularly the incisors, the pus may burrow downward through the

cancellated tissue of the bone and emerge at the base of the bone and open upon the face (Figs. 433 and 434).

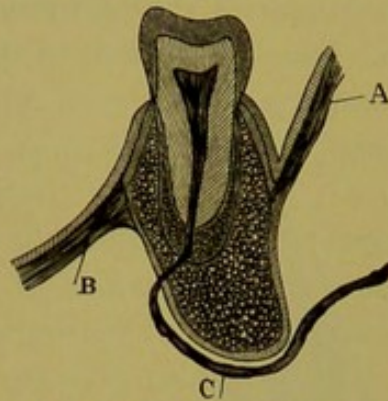
In other cases the pus may perforate the bone, and find passage along the submuscular tissue, opening upon the face or neck (Fig. 435). The apices of the roots of teeth lying beneath the line of insertion of the mylohyoid muscle may cause an abscess to open in the

FIG. 435.



Chronic alveolar abscess at the root of a lower incisor, with a fistula discharging on the face under the chin: *a*, abscess cavity in the bone; *b, b, b*, fistula following in the periosteum down to the lower margin of the body of the bone and discharging on the skin. (Black.)

FIG. 436.



Abscess with tortuous sinus, opening upon the face: *A*, tissue of cheek; *B*, floor of mouth; *C*, abscess tract.

neck cavity. Cryer records a case where an abscess opening upon the face immediately anterior to the line of the facial artery was traced to the root of a lower molar; the direction of the sinus is shown in Fig. 436. In a case having a similar anatomical association, the pus penetrated the bone lingually, was encapsuled beneath the internal pterygoid muscle, and appeared as a swelling at the inner aspect of the angle of the jaw. Occasionally the apices of the roots of lower molars are separated from the inferior dental canal by only a thin lamina of bone, so that discharge into this canal may occur with infiltration along the vessels and nerves in the canal (Fig. 240). While discharge into the nasal chamber is most frequently associated with abscess upon the central incisors, abscesses upon molars may discharge into the same cavity.

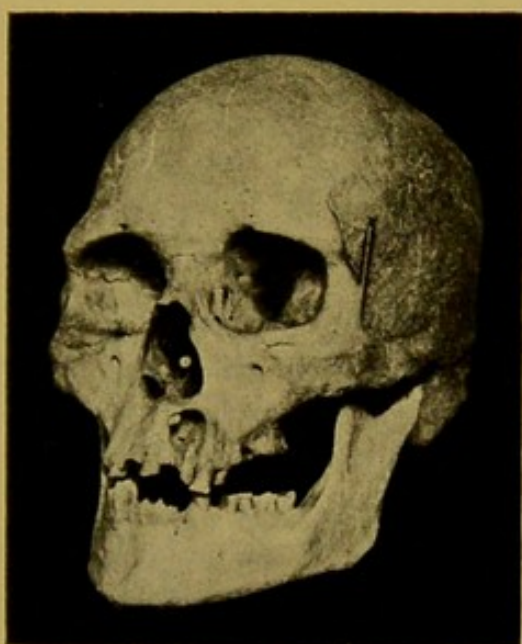
Cementum infection occurs as a sequence to death of the cement corpuscles from lack of nutrition. Pus calculi may also form on the roots in the long-continued cases. The granulation tissue springing

up about the parts has a resorbent action and the root ends are often resorbed, though this action is probably to an extent counteracted by the alkalinity of the pus. The formation of the latter may, however, be in abeyance at times.

The extent of tissue destruction varies considerably, but is usually greatest in dependent parts, gravity influencing the burrowing of the pus.

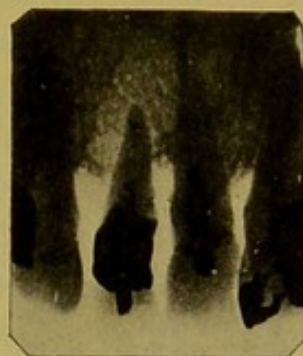Symptoms and Diagnosis. A fistula is seen upon the gum, visible as either a small teat of flesh (perhaps pedunculated), discharging pus,

FIG. 437.



Large abscess cavity in relation with a lateral incisor, complicated by an impacted supernumerary tooth beneath the nasal spine. (Philadelphia Dental College Museum.)

FIG. 438.



Apical abscess, rarefied area, showing light in the skiagraph. (By Custer.)

or as a tiny orifice in the gum surrounded by inflamed tissue, and from which pus may be squeezed (Fig. 422). As a rule, a soft, silver probe may be passed to the apex of a nearby root, whether possessing a crown or embedded in

the bone. In case of an external opening upon the face a similar procedure shows the trouble to lie with some tooth root. The *x*-ray will sometimes be valuable in determining the exact location of the abscess cavity.

Upon the teeth themselves but four conditions may cause a fistulous opening: (1) moist gangrene of the pulp or its equivalent apical infection; (2) septic perforations, apical or lateral; (3) a pericemental abscess (see Pericemental Abscess); (4) a secondary abscess associated with a pyorrhœa pocket. (See Pyorrhœa Alveolaris.)

Aside from these, the probe may lead to carious or necrosed bone, a cyst, an impacted tooth, or a subperiosteal abscess (maxillary periostitis).

In these cases the probe does not lead to the root. Carious bone will have a rotten feel to an excavator, necrosed bone will be exposed and firm, or the sequestrum will be in evidence as a movable body. There may also be several fistulæ and extensive inflammation of the tissue. A cyst will be a tumor with certain characteristics and an impacted tooth will usually impart the feel of smooth enamel to the instrument, though the enamel may at times be rough at certain points. An embedded root will be movable, and will present the dentine and its central opening, the pulp canal, as diagnostic features. Maxillary periostitis will, as a rule, have a history of traumatism, or the previous use of a probably infected hypodermic needle¹ associated with it. In all cases not clearly due to other than dental causes, evidence of the four dental conditions mentioned should be sought.

Treatment. In cases arising from sources not dental, surgical interference for the removal of the cause is necessary. This may require a minor or major operation, according to the case. In some cases radical operation may not be advisable.

In the purely dental cases the cause must also be removed. If due to pericemental abscess this is to be treated. If due to a septic perforation not yielding to treatment by way of the root canal the fistula may be enlarged, packed open with antiseptic cotton or gauze applied on successive days, and when the perforation is exposed it may be filled with amalgam. If properly done the fistula should heal. If this operation be impossible the root should be amputated at a point between the perforation and the crown. If the perforation be in the middle or cervical third of the root it may at times be treated from the root canal. If incurable the entire root must be amputated in case of a multirooted tooth. In case of a single-rooted tooth the tooth must be extracted, and if the conditions warrant the operation the root may be perfectly sterilized, properly filled, and then replanted after the associated abscess cavity has been surgically obliterated.


In the cases due to moist gangrene of the pulp the canals must be freely entered, the apical foramen opened with Donaldson or other cleansers, and the canals and abscess tract thoroughly sterilized.

The canals are sterilized with sodium dioxide freely used. The canal is flooded with 3 per cent. hydrogen dioxide and with a Swiss broach upon which cotton is wound; a plunging force is exerted upon the fluid in the canal. This tends to drive it into the abscess cavity

¹ Boenning, *Dental Cosmos*, 1902.

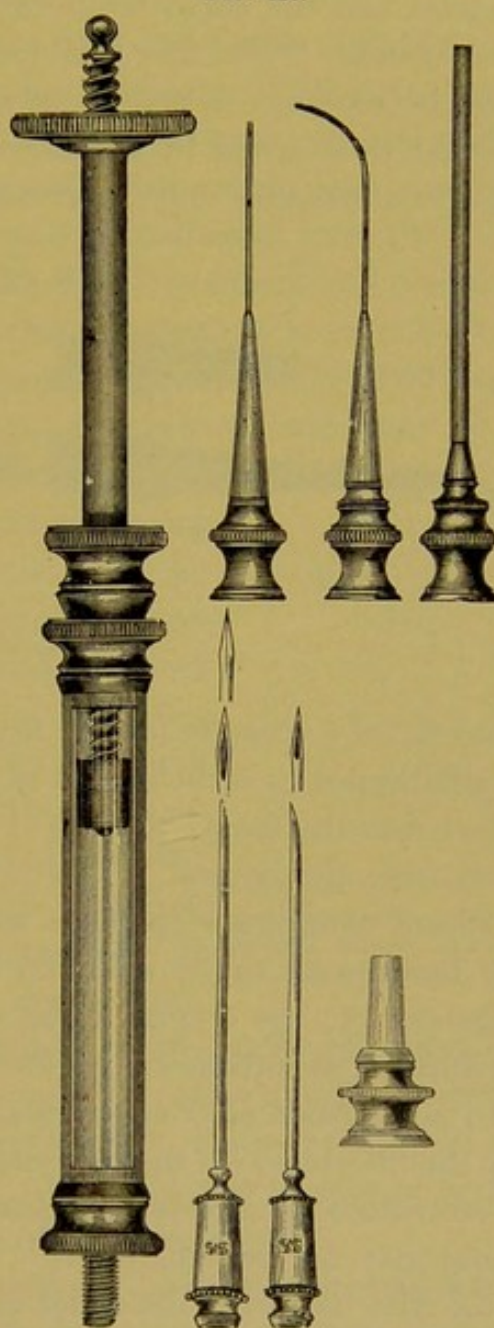
and out of the fistula, flushing and sterilizing the abscess tract. This is then repeated. If this simple procedure be not effective, a thread of cotton saturated with hydrogen dioxide should be placed in the canal. Pressure is then exerted with vulcanizable rubber, as in

FIG. 439.



Minim syringe.

FIG. 440.



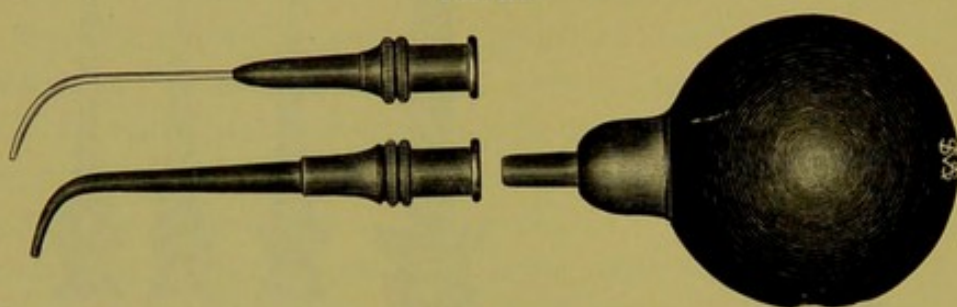
J. N. Farrar's alveolar-abscess syringe.

pressure anæsthesia. A third method consists of filling the crown cavity with gutta-percha or vulcanite rubber, forcing the nozzle of an abscess syringe through the mass, and driving down the piston of the syringe. In all these procedures except the initial sterilization the unaffected roots of multirooted teeth are to be avoided as far as

possible, as undue pressure may excite an abscess. The fistula will admit the nozzle of the syringe, which may be used to flush out the abscess tract with hydrogen dioxide.

All preliminary work having been done as well as possible, phenol-camphor, carbolic acid, or an essential oil is to be pumped into the abscess tract and the canal temporarily stopped with the same antiseptic on cotton. With this treatment the discharge of pus should cease and be replaced by serum; in a week or two the fistula should have healed if attached to treatable canals; for the difficult canals subjected to antiseptics only, more time may be required.

FIG. 441.



Bulb syringe.

In the case of a recently formed fistula or large abscess cavity, a bit of floss silk dipped in carbolic acid or a tent of antiseptic gauze should be packed into the fistula to keep it open, in order that the abscess may heal from the bottom. This is a surgical principle established for all ulcers with small openings which tend to heal over confined pus. If the abscess cavity does not heal, one of several causes may be assigned: (1) the crypts in the walls of the abscess cavity may require further disinfection; (2) the cotton in the canal may have absorbed pus formed after an interval of antiseptic influence and may keep up the infection; (3) the root end may be incrustated with calculus, or the cementum be infected, or dead bone may be present; (4) the root canal may not be explorable.

For the first condition the canal and abscess tract may be treated with 10 per cent. zinc chloride, or mercuric chloride may be added to hydrogen dioxide (1:500 or 1:1000) and the abscess cavity syringed out at intervals. For the second condition a non-absorbent dressing should be used, such as Forma-Percha, or the root apex may be permanently filled with gutta-percha. In the fine, unexplorable canals, 25 per cent. pyrozone may be used for twenty-four hours as though bleaching the root, or Rhein's or Bethel's cataphoric methods may be

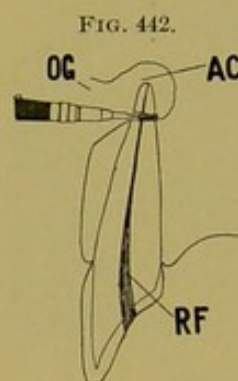
employed. In some cases abscesses require some weeks to heal, but eventually do so, particularly if the abscess be syringed out with an antiseptic every third day *via* the fistula.

Tissues about abscesses have an inherent tendency to regeneration; cases of long standing frequently healing promptly, sometimes though not often in twenty-four hours.¹

For the third class of cases the root and fistula should be syringed with aromatic or 25 per cent. sulphuric acid. The root apex should be sealed with gutta-percha and the abscess tract syringed once a week with the 25 per cent. sulphuric acid, the mouth and clothing being properly protected by using a pad of cottonoid over the fistula and needle to absorb the excess. This dissolves calculi and disinfects dead cementum. It also stimulates the soft parts to a granulative action. If necessary the patient should receive appropriate systemic treatment. In this way some old and somewhat obstinate cases may be induced to heal. If the abscess be incurable by the above method, or radical measures being considered better, the root end may be amputated. The fistula is enlarged and packed open with antiseptic gauze applied until the root end is fairly in view. After sterilization of the abscess cavity and local anæsthesia, a dentate fissure bur is laid upon one side of the root at the level of the healthy tissue, and carried laterally with a sawing motion until the root end is separated. It may readily be picked out. If the root can be correctly located before packing the fistula the part may be anæsthetized and a portion of gum may be cut away with a tubular knife or an incision may be made, after which a fissure or surgical bur may be used to cut away the root. Any necrosed bone may be removed in the same manner by the use of sterilized burs.

Necrosed root ends may occasionally be seen projecting through the gum and alveolar process which have been lost above them. They should be removed as above indicated.

Antiseptic gauze should be packed into the abscess cavity to stimulate granulation activity. The quantity of gauze should be gradually lessened until the cavity is nearly healed. It should thereafter be kept sterilized by means of hydrogen dioxide until the cavity has healed.



Amputation of root apex: OG, opening in the gum made by packing fistula; AC, abscess cavity; RF, root filling.

¹ Darby, Proceedings Academy of Stomatology, Philadelphia, 1899.

Stimulation by means of fused silver nitrate is at times necessary. Bone should gradually be deposited about the roots (Figs. 443, 444 and 445). Failure indicates some condition of sepsis; presumably the amputation has not included all septic root or the canal filling is defective.

A still more radical method of surgical treatment involves the extraction and replantation of the root. The mouth is sterilized and the tooth extracted, care being taken not to injure the enamel with the forceps. It is then placed in a 1:1000 solution of mercuric chloride at 120° F. The apex of the alveolus is in the mean time sterilized with hydrogen dioxide plus mercuric chloride and thoroughly curetted. Bleeding is checked with the same solution or adrenalin chloride, and a tampon of cotton saturated with a 20 per cent. solution of phenol-sodique is packed into the alveolus.

FIG. 443.

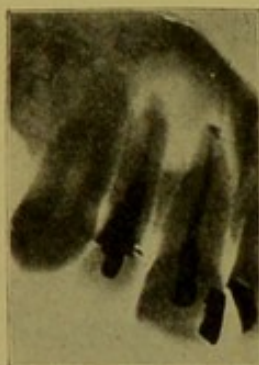

FIG. 444.

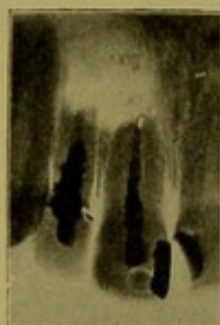

FIG. 445.

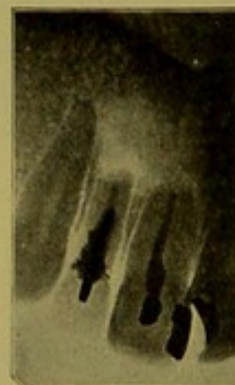

FIG. 443.—A skiagraph of apical abscess cavity about two root apices; incurable by ordinary means.

FIG. 444.—The same after root amputation.

FIG. 445.—The same thirty days later, showing a certain amount of new bone formation. (Price.)

Returning to the tooth the apex is cut off slightly beyond the denuded area and smoothed; the pulp canal is well opened from the apex, all débris removed from it, and it is then well sterilized with sodium dioxide or 25 per cent. pyrozone, or both. The canal is then dried and filled entirely with gutta-percha, or partly with gutta-percha, and the operation completed with gold, which is nicely smoothed. The root should be handled in an aseptic napkin or one wet with the antiseptic, and when ready should be returned to the sterilizing solution. All being ready the tampon is removed, the tooth replaced in its socket, and a previously prepared retaining appliance cemented to place. This should remain from three to six weeks and be replaced should indications demand it. If the tooth be valueless for replantation purposes, the operation of transplantation may be done either imme-

diately after extraction of the offending tooth or a few days later. The possibility of resorption of the root after plantations should have careful consideration, though it is not prohibitory.

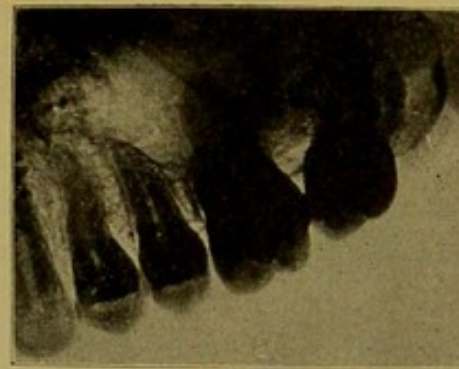Several cases of fistulous openings into the antrum have been noted by canal exploration in which no history of discomfort from antral empyema could be obtained. It was assumed that the root ends approximated the floor of the antrum, and that the abscesses were of simple chronic type. Such cases were treated upon the common principle of canal antisepsis, flushing the abscess tract with hydrogen dioxide, and filling the canals. The antral condition was explained to the patients, who were warned of possibilities, but such as yet have not been reported.

A chronic abscess may discharge into the maxillary sinus for a long period before being discovered, unless the pus-accumulation be extensive, when it escapes from the antrum into the cavity of the nose, discharging by one side. Smaller accumulations of pus find exit in the recumbent position, and attention is called to one antrum as the seat of affection by noting that in the morning pus appears at but one nostril. The discharges from purulent nasal catarrh appear upon both sides.

A more common history of antral empyema is the patient's complaint of dull, heavy pains and uneasiness over one side of the face, and an offensive odor, which may not be evident to the operator. High transillumination of the tissues about the mouth and through the cheek by means of the electric mouth-mirror may reveal an opacity on one or perhaps both sides, indicating the presence of fluid in the antrum. Examination of the posterior teeth will show one of them to be pulpless. If such a tooth be extracted, a profuse flow of pus may follow, and a probe may be passed through an alveolus directly into the antrum. It is to be remembered that antral empyema may occur from the influenza bacillus in the blood. It has been noted in connection with *la grippe*. The x-rays are valuable diagnostic means (Fig. 446).

Although extraction is the usual surgical relief, dental conservatism rebels against the immediate condemnation of the offending tooth.

FIG. 446.



Empyema of antrum due to abscess upon root of bicuspid tooth. (Radiograph by Price.)

Efforts at curing the antral condition through the pulp canal are well-nigh hopeless—the antrum is entered at some other point. The tooth is treated as any infecting root; is sterilized and filled. The most certain spot of entry to the antrum is about one-quarter inch above the buccal roots of the upper first molar. The part, or the patient, is anæsthetized, and the soft tissues incised or a section removed by means of a tubular knife; a drill or trephine at least one-eighth inch in diameter, driven rapidly, is passed upward, backward, and inward, piercing the thin shell of the antrum at this point. The nozzle of an atomizer, filled with a 3 per cent. solution of pyrozone, which has been rendered alkaline by sodium dioxide and warmed, is passed into the antrum and the cavity is freely sprayed. A probe is passed into the cavity and an exploration made to detect the presence of any dead bone, which, if found, must be removed, the cavity of entrance being enlarged to permit its removal. After operation the cavity is packed with nosophen or other gauze until granulation is stimulated, after which the cavity is sprayed about every other day with very dilute, warm Dobell's solution. (For further information see works on oral surgery.)

Unless much necrosis of bone occur cases of fistula, opening upon the face or neck, may be healed by the ordinary methods carried out with extraordinary care to accomplish the irrigation of the fistula. The scar formation is less than when extraction is practised for the removal of the cause. If the fistula be indolent the granulations may be stimulated by means of an injection of 10 per cent. silver nitrate solution. If the fistula obstinately refuse to heal the tooth should be extracted and necrosed bone, if any be present, surgically removed.

Flagg¹ suggested as a means of lessening scar formation that a seton be passed through the external fistula into the mouth, and that it be gradually drawn into the mouth as the external fistula heals, after which the tooth is to be extracted.

In fistulæ discharging upon the face the formation of scar tissue may bind the tissue of the cheek tight to the bone. When this occurs beneath the tip of the chin, the scar, after healing, usually resembles a dimple, and calls for no interference. The scar and binding down along the border of the inferior maxilla, or beneath the malar bone in the upper maxilla, may produce deformity calling for remedy (Figs. 447 and 448). Black's operation is to be performed to lessen the deformity, for its complete correction is not practicable. A finger

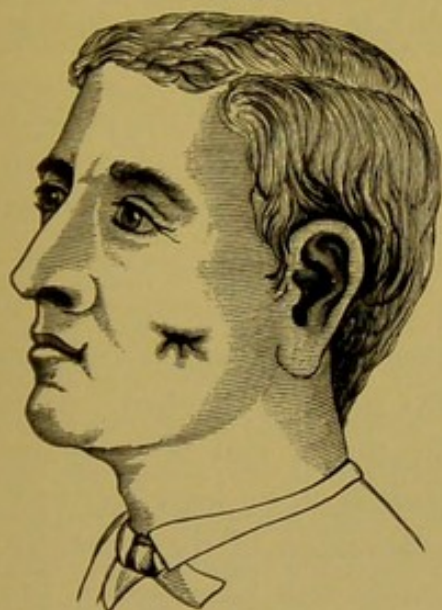¹ Lectures on Dental Therapeutics.

placed in the mouth draws the cheek away from the alveolar wall, when the exact position of the cord of attachment is discovered. A tenotome-knife is passed into the tissues, dividing the band of attachment; a long pin is passed through the most depressed portion of the scar, its centre, the long ends of the pin resting upon the face; strips of adhesive plaster laid upon the skin under the head and point of the pin will prevent the latter sinking into the soft tissues. The pin is retained for several days, until the cut in the mouth heals.

BONE INFECTION ASSOCIATED WITH DENTAL LESIONS.

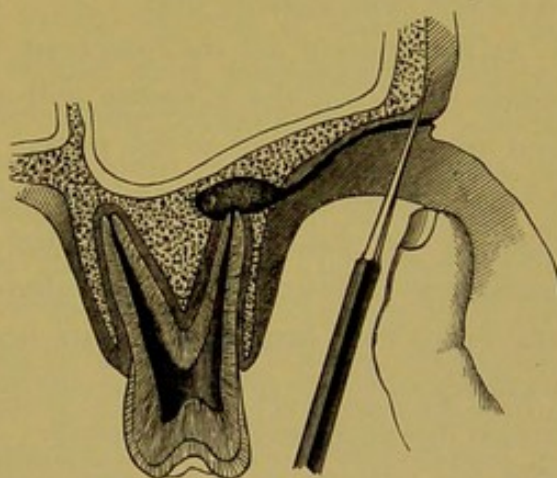
During the course of acute and chronic abscess the bone-marrow becomes inflamed by the pyogenic organisms and is broken down into pus. The condition may continue after extraction for apical abscess in the second stage. It may also occur from the bruising of

FIG. 447.



Scar caused by alveolar abscess discharging on the face. (Black.)

FIG. 448.



Operation for the remedy of scar on the face caused by alveolar abscess. (Black.)

the periosteal lining of the alveolus as the result of extraction of a hypercementosed root, or from a bruise induced by forcible use of forceps in the removal of deeply seated roots.

The walls of the alveolus become infected by pyogenic organisms, among which the *diplococcus pneumoniae* figures prominently. (See p. 98.)

The leaving of cotton tampons, placed as vehicles for pain-relieving agents, for an undue length of time also invites infection.

If during extraction the alveolar margins be lacerated, and espe-

cially if the bone be uncovered by clot, it also becomes infected. Ragged gum margins become gangrenous.

Symptoms. The symptoms are those of local inflammation without necessarily much swelling of contiguous tissues, such as occurs in acute abscess. If due to an acute abscess in the second stage, however, the symptoms of that condition may continue.

In the majority of cases the pain is of a deep, boring, continuous character. Reflex pains are also produced. Much debility is caused by the wearing character of the pain, the loss of sleep and appetite, and probably also because of absorption of toxins. The gum margins are perhaps sloughing; the bone may be exposed and exquisitely painful to touch, or it may be necrotic and insensitive superficially.

If the suppuration extend deeply into the bone the contiguous tissues are inflamed; in some cases widely so. Cases of general septicæmic or pyæmic infection from this source have been recorded.

Treatment. The mouth and, in so far as possible, the inflamed part must be sterilized. Probably mercuric chloride in hydrogen dioxide (1:1000) will answer best.

An injection of a 1 or 2 per cent. solution of cocaine into the healthy tissue overlying the alveolus will assist in alleviating the acute pain and partly anæsthetize the parts. All sloughing gum should be cut away. Exposed bone should be anæsthetized by strong cocaine solutions if painful to touch, or the patient should be anæsthetized if necessary. Whether acutely inflamed or necrotic, the bone should be cut away with large sterile burs until healthy tissue is reached. After washing out the débris and further sterilization a clot is to be induced by curetting if necessary. The mouth is to be kept sterilized and the patient is to be seen daily for a repetition of the curetting. In ordinary cases one or two local treatments will be effective, but the tonic, antiseptic, systemic medication recommended under the heading of acute apical abscess is advised.

If the infection be of aggravated character, precautions in the form of suitable systemic medication should be taken against a possible septicæmia.

If the patient be not willing, or unable, to bear this operation at the first visit because of the demoralization produced by the pain, an alternative proceeding may be adopted. A pellet of cotton wet with campho-phenique should be rolled in powdered orthoform and introduced into the socket after sterilization with the mercuric chloride solution.

The repetition of this after five to eight hours will afford marked relief. Later the radical operation may be performed. The introduction of cotton or gauze dressings into the alveoli for relief of pain immediately following extraction is to be done only with extreme care and for short periods only, as such dressings are apt to be left in place by patients, and, becoming septic, act as causes of sepsis of the alveolar process. While alveoli will fill with granulations in the absence of a clot filling them, such a clot seems to be the best protection against sepsis.

EXTENSIVE NECROSIS ASSOCIATED WITH CHRONIC ALVEOLODENTAL ABSCESS.

Every chronic alveolodental abscess carries with it the danger of bone complication. It has been shown that in bone infection the organisms are highly virulent. Fortunately in most cases the involvement is slight and the parts care for themselves when the cause is removed. In more aggravated cases, either caries or necrosis of the bone may follow. Pus is formed at the expense of the parts. In caries the pus escapes by several fistulæ, and examination leads to porous dead bone. In necrosis there is circumvallation of a portion or portions of bone, and finally one or more sequestra are loosened and later in part liquefied. The remainder gradually works out of the fistula as one large or numerous small pieces. The patient may be much debilitated. Surprising recoveries of extensively necrotic parts occur if the patient be brought into good physical condition and the parts are antiseptically treated, the thorough loosening of the sequestra being awaited. By this means teeth have been retained in place and covered with new tissue, which operation would have exposed or removed. The determination of the point at which operative interference is desirable must depend upon the particular case and the amount of deformity likely to result from the operation.

Honl and Bukovsky are credited with the successful treatment of bad chronic suppurations by means of local applications of pyocyaneo-protein. (See immune proteids.)

Jesensky¹ treated a case of six months' standing, incurable by ordinary antiseptic and systemic treatment, and obtained remarkable results.

Syphilitic intoxication may cause a necrosis of alveolar bone. The

¹ Dental Cosmos, 1901.

extent to which the teeth or oral infection act as active exciting causes depends upon the condition present.

SEPTIC APICAL PERICEMENTITIS COMPLICATED BY PERFORATION.

In the treatment of root canals the required mechanical work sometimes results in (1) the passage of the drill through the apical foramen, enlarging it; (2) through the side of the root, causing a perforation.

In the first variety the complication chiefly concerns the root filling, which is to be conducted after sterilization upon the same plan as for filling an unformed foramen. (See p. 436.)

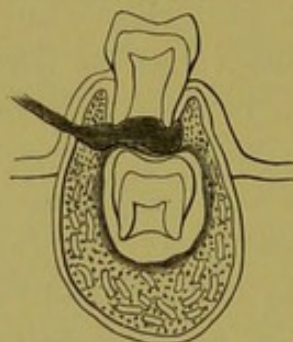
If a lateral perforation be made near the root apex, it may be filled after sterilization with a cone similarly applied, but made bevelled

FIG. 449.



Skiagraph of crowned curved root, with perforation and protruding root filling near apical foramen, with septic conditions, would require root amputation. (Price.¹)

FIG. 450.



Showing the relations of an abscess upon a temporary tooth, with the crown of a developing permanent tooth underlying it.

at the end or a bit of aseptic sponge may be introduced against the tissue for a base and be covered by oxychloride of zinc. If septic conditions persist the root end must be amputated, or the tooth extracted, prepared, and replanted. If made in the middle third of the root the canal must be sought for and treated as usual beyond the perforation, which is then separately treated with a gutta-percha cone, or a plaque of gutta-percha may be laid over the perforation and antiseptic cements or copper amalgam used to secure it in position (Fig. 401). Amputation or extraction and replantation may be resorted to. In a favorable case after canal exploration a tapering probe may be passed into the canal and copper amalgam gently tamped about it and against the perforation, the probe is then withdrawn, leaving a central canal which is later

¹ Items of Interest, 1901.

treated. Girdwood has reported good results from the use of copper amalgam which, in this connection, the writer can confirm.

Chronic Septic Pericementitis in the Temporary Teeth. Any of the chronic septic conditions described may occur upon the temporary teeth. The presence of resorption and of the permanent crown usually confines the inflammation to a point lower in the alveolar process than in the case of permanent teeth. The loose character of the structure causes the ulceration to occupy a larger area, and the parts in chronic inflammation look more angry, but are fairly well tolerated. The treatment is practically the same for the curable cases; the others should be extracted. The root canals when treated should be filled with absorbable materials such as paraffin or wax combined with aristol (Fig. 450).

Johnson¹ suggests that a eucalyptol solution of gutta-percha (see p. 437) be pumped into the canals and pressure exerted with temporary stopping until the solution appears at the fistula. The temporary stopping that does not interfere with filling integrity should be left.

Chronic Septic Apical Pericementitis (Non-purulent). Continued inflammation of a low grade (interstitial gingivitis), or what may in reality be continued atonic hyperæmia, may exist in the apical pericementum for long periods without pus formation.

Cause and Pathology. The cause consists of unremoved gangrenous pulp tissue, septic serous collections in canal apices or about imperfect root fillings, or septic material in the root tubuli.

Albuminous fluid may enter the canal *via* the apical foramen and, becoming infected, putrefaction ensues. The source of infection may possibly be the blood, but leaky crown and root fillings more probably permit bacteria to enter from the mouth. The more or less constant result of filling roots with cotton permeated with evanescent materials only is evidence of this. The cotton absorbs fluid either from about leaky fillings, too often placed in contact with it, or else from the apical tissues; infection readily occurs and a highly odorous cotton is removed because of the apical irritation. When the cotton is well placed and confined under tight sealing materials to the apical half of the root canal, this result is long delayed in many cases. Portions of gangrenous pulps remaining in canals may likewise become infected. Extra and untreated canals are frequently causes.

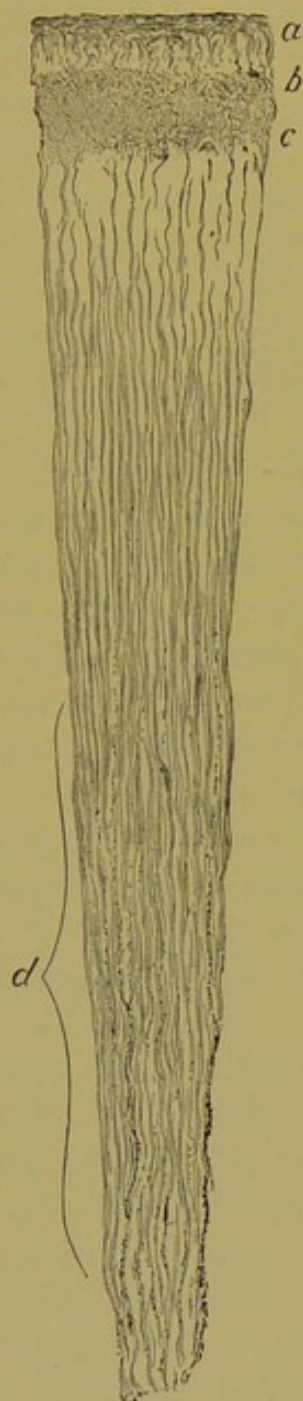Miller² has shown that root tubules are infected only for a short distance at their canal ends, so that infection from the pericementum

¹ Dental Cosmos, 1899.

² Ibid.

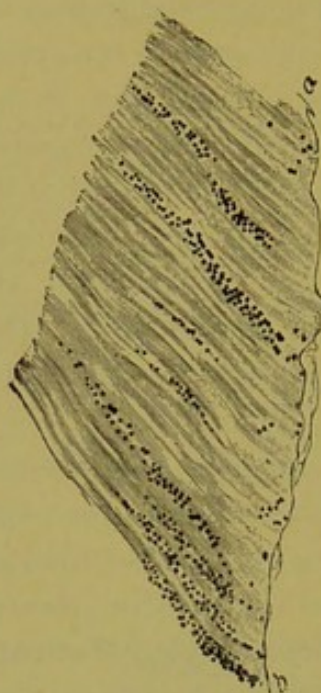
via the cementum and dentinal tubules is highly improbable (Fig. 452). The putrefaction produces gases and these exuding slowly pro-

FIG. 451.



Sector of a cross-section from a diseased root: *a*, cementum; *b*, stratum granulosum; *c*, very narrow and finely branched tubules. $\times 150$.

FIG. 452.



Dentine from the root of an abscessed tooth, showing the penetration of cocci to a depth of about $\frac{1}{10}$ mm. ($\frac{1}{250}$ in.); the side *a-b* bordered upon the canal. $\times 1000$. (Miller.)

duce the irritation. If pyogenic organisms be present, apical abscess may at any time supervene.

Symptoms. Subacute inflammation of apical tissue being present, the symptoms of this condition are tenderness upon decided pressure or upon percussion; the response may only be elicited by pressure or percussion in one direction. The tooth gives a dull note upon percussion and is usually looser than its neighbors. The red line of the gum extends farther toward the gum margin than normal—quite to it in some cases.

Some slight looseness may be noted and the patient is apt to avoid the tooth in mastication. In some cases acute reflex pains in other teeth may precede an outbreak of purulent pericementitis, a frequent

sequel to this condition. There are also evidences of previous devitalization of the pulp in opacity, lack of response to tests for vitality, etc. At times a history of previous canal treatment may be obtained or the evidences of an attempt at canal filling may be seen upon opening the tooth.

Diagnosis. The condition requires careful differentiation from (1) apical pericementitis due to traumatism or malocclusion; (2) pericemental abscess in the early stage; (3) abscess of the pulp in the later stages. In all these cases the pulp may be vital. Being itself only subsequent to death of the pulp, tests for vitality are made. (See p. 445.) If pulp death be indicated by the tests the pulp canal is explored and, if found, filled; a septic condition about or beyond the same is looked for.

Treatment. The condition being analogous to that of moist gangrene, the treatment is the same. Before it can be applied the root canals should be opened, and to accomplish this all root fillings involved require removal. If an extra canal be found after apparently conscientious work has been done, this should receive attention before removing root fillings.

The bulk of gutta-percha root fillings are best drilled out with Gates-Glidden drills revolved in the engine hand-piece. Where they extend beyond the reach of the finest drill the Downie broach may be used, or the Swiss broach may be used to drive eucalyptol into the gutta-percha to dissolve it.

All cement fillings are removed by a drill so far as can be safely done, dryness being a great aid in locating the cement in the canal. When the danger of perforation arises a stiff Swiss broach may be rubbed down to a drill edge and used as a tamp drill. Sulphuric acid in 50 per cent. solution or aqua ammonia aid by dissolving the cement.

The object sought for is an unfilled canal lumen which, when found, is readily recognized by the penetration with the broach.

There can be no assurance of safety until the apical tissue can be explored. The Dayton broach and fine Downie broach are useful in difficult cases, and if necessary a No. 1 Beutelrock drill may be used. When the apical foramen is open or further work is impossible without the danger of perforation, the canal treatment is conducted upon the lines laid down for gangrenous pulp. (See p. 453.)

If the pericementitis have been of long standing, the thickening of the membrane will have caused protrusion of the tooth. The tooth should be ground off at its point of occlusion until it occludes with

somewhat less force than its neighbors, the therapeutic principle in these cases being that of removing the source of irritation and procuring surgical rest. Indications of favorable results are found in the red gum line assuming its normal position, tenderness disappearing, and increased tightness of the tooth.

This affection is extremely common about the roots of pulpless teeth, and always signifies more or less enforced disuse of the teeth, and, if uncorrected, their ultimate loss.

This condition is sometimes associated with a chronic swelling, probably cystic in character, upon the gum simulating an acute abscess in local appearance, but the contiguous tissues are not involved. The swelling may have the size of a hazelnut. Upon treatment, acute apical abscess is apt to be lighted up; therefore, the sterilization by cataphoresis or by 25 per cent. pyrozone should be prolonged and the swelling should be promptly opened by a deep incision, thus establishing an artificial fistula. In one case of one year's standing, associated with a lower molar tooth which had a leaky gutta-percha crown and partial canal filling, extraction was advised for reasons other than canal treatment. The cyst then promptly developed as an acute abscess, which shifted its position toward the cheek and there discharged without production of scar.

CHAPTER XXII.

NON-SEPTIC PERICEMENTITIS.

VARIOUS grades of pericemental irritation, ranging from a mild arterial hyperæmia to actual inflammation, may be produced by non-septic causes.

The most satisfactory evidence that inflammation may be so caused is furnished by Talbot's experiments with the mercurialization of dogs. Beginning with healthy pericementi these were, after mercurialization of the animal, found to contain the round-celled infiltration characteristic of inflammation, and no bacteria could be found. Further evidence is given by the usual experimental study of inflammation with the mesentery of the frog. Simple irritation, even with antiseptic substances, produces the phenomena. Any of the causes which may produce inflammation may, if acting in more mild degree, produce arterial hyperæmia. If the action of the cause be violent and then discontinued, as in the case of a blow, the inflammation resulting is acute, but may pass into a chronic form; but if the cause continue to act it produces a chronic inflammation.

For purposes of description, non-septic pericementitis may be divided according to its character into traumatic and symptomatic, and according to its location into apical and general.

TRAUMATIC PERICEMENTITIS.

By traumatic pericementitis is meant a profound irritation of the pericementum, the result of mechanical violence applied externally to the tooth, or of instrumentation or chemical irritation of the pericementum through the root canal.

Causes. *Violence externally applied* Excessive force delivered directly upon the teeth, as in case of blows, falls, overmalleting in building fillings, the biting of nuts, thread, or other hard objects, or force indirectly delivered, as in case of blows received under the chin, bringing the teeth forcibly together, may all cause an acute pericementitis.

An excessive amount of filling on the occlusal surface of a tooth, a maloccluding crown or overfull fillings upon the proximal aspect,

maintaining a wedged condition cause overocclusion upon the tooth and an irritation of its pericementum.

The overstraining of the pericementum of a tooth as the result of overuse, as in cases where only a few teeth remain for mastication, or where pyorrhœa or calculus has caused resorption of the alveolar process and looseness of the teeth, or where artificial dentures are clasped to remaining teeth, or where bridges are supported upon insufficient piers, are frequent causes of non-septic pericementitis of a degenerative character. The presence of a rough flaring or a too deeply placed crown band beneath the gum margins, portions of cement used in cementation of crowns, or excess of filling material beneath the gum are all causes of marginal gingivitis with which pericementitis may be associated. With these marginal cases septic causes usually have to be considered as complications.

Too violent wedging is always followed by more or less pericementitis of the wedged teeth and their neighbors, more marked when elastic-rubber wedges are used.

In correcting irregularities of the teeth, if they be moved too rapidly, are not firmly directed during the operation, or subsequently not firmly maintained in position, pericementitis of a high grade is frequently excited.

VIOLENCE INTERNALLY APPLIED. If a wholly or partially vital pulp be torn from its apical connections, as in the use of pressure anæsthesia, an apical traumatic pericementitis may be set up. This is usually transient.

Excessive laceration of the apical tissue by means of barbed instruments; the inclusion of air or medicament under a root dressing or filling, the same exercising pressure upon the apical tissues; the mechanical irritation of a projecting root filling, pivot wire, broach or drill are all sufficient causes.

The undue enlargement of the apex of the root canal or the passage of a reamer through the lateral aspect of a root may excite inflammation, and the perfect filling of the opening may be exceedingly difficult, so that if the tissues are not infected at the time sepsis may later follow.

CHEMICAL IRRITATION. The application of arsenic to a perforation may excite inflammation and necrosis. (See p. 429.) The use of arsenic as a pulp devitalizer may cause a hyperæmia of the apical tissue, causing slight tooth extrusion which is aggravated by the malocclusion.

The undue use of escharotics, such as carbolic acid, sodium dioxide, zinc chloride, sulphuric acid, or mercuric chloride, in a pulp canal may excite an undesirable irritation. The limited irritation following their limited use is often more than offset by the advantages of the asepsis produced.

PROPHYLAXIS. Many of these causes are avoidable, and operators mindful of possible irritations should avoid the mechanical irritation of apical tissues, neutralize powerful acids or alkalies, use escharotics with caution, wedge teeth gradually, and after wedging either pack gutta-percha between the teeth to permit them to rest for a few days or fix them immovably with wooden wedges or steel separators during malleting.

During orthodontia, teeth should be moved steadily and, after alignment is secured, they should be firmly maintained in position until deposition of bone occurs.

Patients should be warned against the evil effects of thread biting and biting hard substances.

Pathology and Morbid Anatomy. Chemical substances applied in excess cause a destruction of tissue dependent upon the quantity used. Inflammation tending to the resorption of the dead tissue occurs. The pericementitis presumably persists in some degree until the foreign (dead) material is removed by natural processes.

In the case of protruding foreign bodies, such as root fillings, broaches, etc., there is a tendency of the inflammation to become subacute or chronic. The foreign body may to an extent become encysted, particularly in the case of a gutta-percha root filling. In other cases the continued vascular disturbance, if of mild degree, produces hypercementosis (see p. 505); in more severe cases resorption of the root occurs. (See p. 509.)

Cases due to perforation of the root and wounding of the pericementum, after the acute symptoms have passed, commonly assume an irritative and chronic type, the soft tissues included in the perforation being in a state analogous to an ulcer. Many of these cases become infected owing to the difficulty of completely sterilizing the apical portion of the canal which lies beyond them.

The pericementitis produced by pressure of included air, liquid, or plastic root filling upon the apical tissue is often severe. Upon removal of the root dressing or filling the engorgement is relieved by the gushing of blood through the root canal. The inflammation may, however, continue unless sedatives be applied to the apical tissue *via* the canal.

In cases due to traumatism, such as violent wedging, rapid movement in regulating, overmalleting, blows, biting of thread, ice, nuts, etc., the condition is surgically one of bruise.

The phenomena of active inflammation make their appearance to an extent governed by the degree of violence—exudation, swelling, redness, and pain; fibrinous and corpuscular exudations occur, and later a reorganization of tissue occurs, in some cases a degeneration, depending upon the completeness with which the indicated therapeutics is applied and upon the vitality of the patient.

Traumatic pericementitis in high degree in the young may be recovered from; but in the middle-aged and aged it may give rise to a series of degenerative changes which only end with the loss of the tooth.

In cases due to looseness of the teeth, of course, septic primary causes have to be considered, but the pericementitis may be quite as much mechanically as septically produced.

In all cases the extrusion caused by the inflammation adds another exciting cause of apical pericementitis—*i. e.*, malocclusion, which aggravates the condition.

Symptoms and Diagnosis. The amount of pericemental inflammation present is evidenced by the soreness and extrusion of the tooth and the degree of redness in the overlying gum tissue.

A history of violence may be obtained when it has occurred. Malocclusion may be detected by occlusion marks upon fillings or by means of carbon paper. The untoward results of canal operations may be inferred from a personal knowledge of the case or, perhaps, from the history. It is at times difficult to exclude septic, non-purulent, apical pericementitis as a cause, particularly if the case come from the hands of another practitioner. In doubtful cases the treatment for inferred traumatism may be employed, and if followed by good results a *post hoc* diagnosis of traumatic pericementitis may be made. The *x*-rays afford a means of determining extruding root fillings, broaches, etc.

Treatment. Foreign bodies protruding from the root apex must be removed if persistent symptoms demand it. This may require an artificial opening for its performance, or root amputation. Perforations should be carefully treated.

If evidence of pericementitis persist, the end of the root including the perforation should be amputated or the tooth may be extracted, the perforation and canal filled with gold or gutta-percha, and the tooth replanted under antiseptic precautions.

In all cases due to violence the treatment is that adapted to injury; first, surgical rest of the pericementum. This may be accomplished in two ways: either by preventing the tooth striking its antagonists or holding it so rigidly that it cannot move if it does meet them. As a preliminary measure the tooth is gently but firmly lashed to its neighbors by means of ligatures so that it is rigidly held. A swaged cap is either fitted to a neighboring tooth, or the antagonizing teeth are ground away until they fail to strike the injured tooth; the first method is to be preferred.

In cases involving several teeth, such as all of the incisors, two metallic plates are quickly swaged to cover the posterior teeth, and they are cemented in position.

When the apical tissues have been irritated by way of the canal, sedatives, such as strong tincture of aconite or menthol in chloroform or menthol-phenol¹ (menthol 3 parts, carbolic acid 1 part, melted together), should be applied on cotton to the apical tissue by way of the root canal. The addition of $\frac{1}{8}$ grain of cocaine hydrochlorate to one of the above sedatives will notably increase its action. It may either be rubbed into the fluid or preferably be taken up upon the point of the cotton twist introduced into the canal. All cases of traumatic pericementitis require the persistent use of counterirritants applied every other day to the overlying gum.

Systemic derivation is also useful in the acute cases. In even mild cases not due to violence the guarding of the extruded tooth against malocclusion is of advantage.

If the cause be some mechanical irritant at the gum margin this should be removed and the case treated as above described. Recognizing the possible influence of septic causes, oral antiseptics are to be used.

SYMPTOMATIC NON-SEPTIC PERICEMENTITIS.

By symptomatic non-septic pericementitis is meant an aseptic pericementitis occurring as the result of systemic conditions, or of the action of drugs taken internally.

If mercury be administered to patients in large doses for long periods, or in one or more massive doses, or if the patient have an idiosyncrasy to the action of this agent, an irritation of the salivary glands is excited, followed by looseness and soreness of the teeth and swelling of the gums; that is, a general pericementitis and maxillary

¹ Dr. Morgan Howe.

periostitis arise. Potassium iodide administered in this condition relieves the maxillary periostitis and pericementitis; but the same drug administered in health, or for conditions other than mercurial poisoning, also causes irritation of the pericementum. Pilocarpine has a similar effect, though in much less degree. All of these drugs are partially eliminated by the glandular appendages of the mouth, and during elimination apparently act as local irritants. Lead poisoning may have a similar action.

Patients who have a gouty heredity, or who are the subjects of active gout, frequently exhibit a tenderness of the entire pericementum of one or more or sometimes all of the teeth. This pericemental disturbance may be the precursor of an acute outbreak of gout in the metatarsophalangeal joint.

Scurvy—a very rare systemic disease—is attended by rapid degeneration of the pericementum of the teeth and of the alveolar tissues.

Syphilis is also attended by pericemental irritation. This, of course, is of septic origin.

Talbot's experiments on dogs show conclusively that a true pericementitis may be induced owing to the chemotactic properties of the mercury alone. (See Interstitial Gingivitis.)

In autointoxication by intestinal toxins or by leucomains in diseases involving general malnutrition, the irritants are probably in part eliminated by the gums, which are in turn irritated. (See Gouty Pericementitis.)

It has been shown by Loup that mercurial stomatitis may be cured by mercury used as an oral antiseptic; therefore, the logical conclusion is that oral organisms play a part in the production of the local effects of mercury; probably the mercury produces a local predisposition.

Treatment. The drug should be discontinued, the disease, if present, should be antagonized, and the local complications, if any, should be appropriately treated, antisepsis being always advisable.

Results of Chronic Non-septic Pericementitis. If at any point of the irritated pericementum a constructive grade of irritation be maintained the cemental tissue becomes hypertrophied (Fig. 454). If a more severe grade of irritation—*i. e.*, low-grade inflammation (interstitial gingivitis)—be present for a long time, the cementum and even the dentine of the root may be resorbed. Both of these results may go on concurrently at different points, or resorption may be followed by deposition of cementum if the conditions change (Fig. 455).

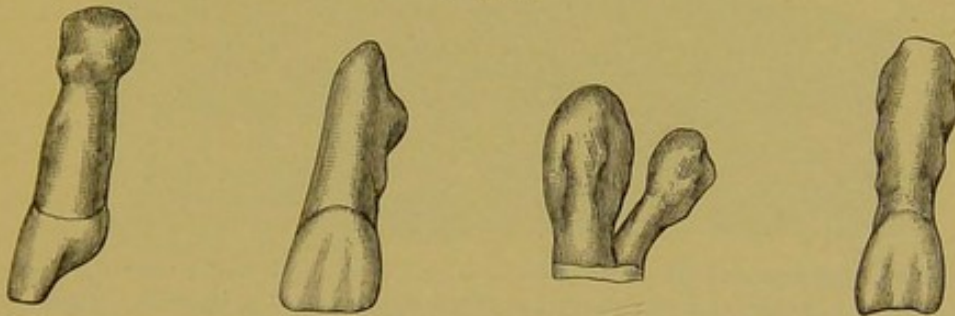
Chronic overuse or disuse of teeth result in degenerations of the pericementum through a process of interstitial gingivitis.

HYPERCEMENTOSIS (DENTAL EXOSTOSIS, EXCEMENTOSIS, HYPERPLASIA OF THE CEMENTUM).

Definition. By hypercementosis is meant a secondary deposit, or an increase of volume of the cementum of a tooth beyond the normal limit. It may be circumscribed or diffuse.

Causes. A mild or constructive degree of irritation is the proximate cause which may be excited by numerous primary causes, such as a projecting root filling, a projecting edge of crown filling, deposits of salivary calculus, the overlapping of a cavity margin by the gum, mal-occlusion, non-occlusion, the biting of hard objects such as nuts or thread, the overuse of certain teeth, the habitual tapping together of

FIG. 453.



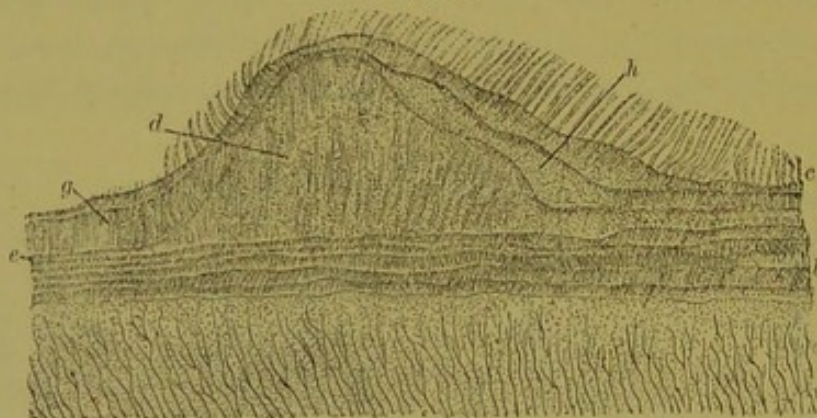
teeth, the habitual chewing of toothpicks, the gradual pressure of gas from dead pulps. The pressure of a tooth root against another root during eruption is a sufficient cause. (See Figs. 205 and 212.) The overcrowding of teeth in an arch has also caused this condition. Chronic alveolar abscess may cause it by inducing about itself at a distance an area of hyperæmia. Interstitial gingivitis is also a cause. It also seems at times to be induced after pulp devitalization from any cause. Hypercementosis is a possibility in any case of chronic pericemental irritation; it represents a degree of irritation rather than any one specific cause. It has been discussed by some writers under the heading of Constructive or Condensing Pericementitis.

Situation. Hypercementosis may be diffused over almost an entire root or several roots, or be localized as a distinct nodule at some lateral aspect, or exist as a circumscribed enlargement about the apex of a root, or at the neck of a root. It is always located where the cause (hyperæmia) has been produced (Fig. 453).

Flagg noted that 75 per cent. of cases of hypercementosis were found upon posterior teeth, and that the teeth were usually of the character termed dense—*i. e.*, the tissues of the individual were of recuperative type tending to produce constructive changes.

Pathology and Morbid Anatomy. For some time after eruption the cementum consists of but few lamellæ of deposit. It, however, reaches a maximum normal development at which it normally rests, as in the case of the physiological pulp cavity. As age progresses it is apt to be more thickly deposited at the expense of the pericementum, which becomes more attenuated. Whether this is due to irritants floating in the blood stream, or to the various local irritants above mentioned,

FIG. 454.



Hypertrophy of the cementum on the side of a root of a lower molar near the neck of the tooth of a man: *a*, dentine; *b*, cementum; *c*, fibres of peridental membrane; from *b* to *c* the cementum is normal and the incremental lines fairly regular, but at *d* one of the lamellæ is greatly thickened; at *e* this lamellæ is seen to be about equal in thickness with the others. The next two lamellæ are thin over the greatest prominence, but one is much thickened at *g*, and both at *h*. These latter seem to partially fill the valleys which were occasioned by the first irregular growth. From a lengthwise section. (Black.)

or to perfectly normal development is not clear except for certain definite cases.

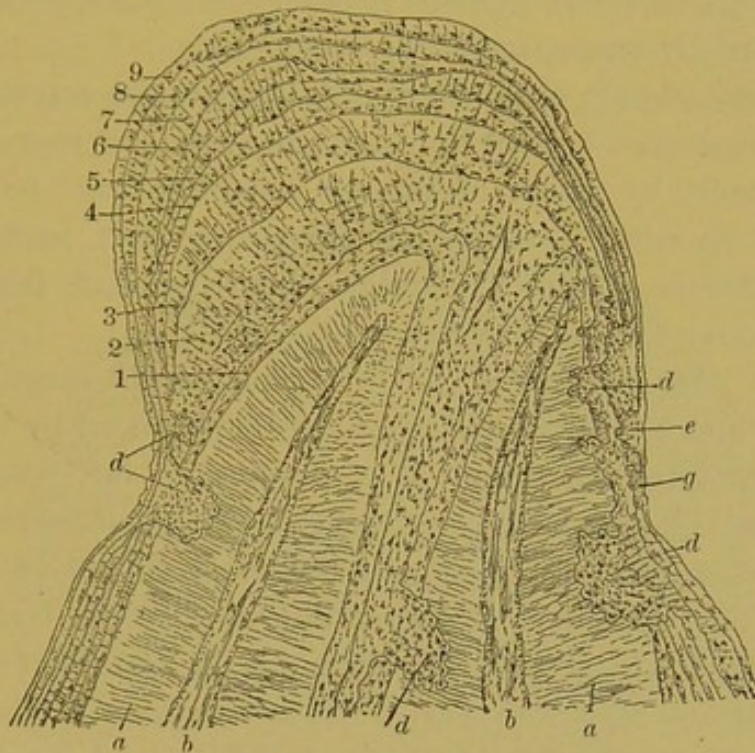
Nodular and irregular forms arising from the general surface are clearly of abnormal type.

Successive lamellæ are deposited; the pericementum recedes, causing resorption of the alveolar process. Union of the bone and cementum (ankylosis) very rarely occurs. A resorption of cementum and dentine may occur at some point owing to a different degree of irritation, and in the area a new deposition of cementum may occur (Fig. 455, *d*). In some cases distinct areas of hypercementosis and root resorption are seen in close proximity. Chronic apical abscess may produce a denudation of the root end, and at a short distance below an annular ridge of hypercementosis may occur. Areas of

hypercementosis may be translucent or decidedly opaque, and some times the two are combined, a mottled appearance being produced.

If the growth proximate another root the pericementum may resorb at the point of contact and a deposition of cementum occur which firmly unites the roots in a union called concrescence. (See p. 222.)

FIG. 455.



Apex of root of an upper bicuspid tooth with irregularly developed cementum: *a, a*, dentine; *b, b*, pulp canals. The lamellæ of cementum are marked 1, 2, 3, etc.; *d, d, d*, absorption areas that have been refilled with cementum. It will be seen that the apices of the roots were originally separate, but became fused with the deposit of the second lamella of cementum, and that in this the regular growth began and was most pronounced. It has continued through the subsequent lamellæ, but in less degree. It will also be noticed that the absorption areas, *d, d, d*, have proceeded from certain lamellæ. That between the roots has broken through the first lamellæ and penetrated the dentine, and has been filled with the deposit of a second lamella. Other of the absorptions have proceeded from lamellæ which can be readily made out. The small points, *e*, seem to have been filled with the deposit of the last layer of the cementum, while others have one, two, or more layers covering them. (Black.)

It has occurred that a root filling protruding through a perforation has caused a diffused exostosis of the alveolar process.¹ The hypertrophied process may be ivory-like in hardness.

Symptoms and Diagnosis. Many cases exist without active local symptoms. In no case is the color of the gum altered unless other disease than hyperæmia be acting as a cause. In some cases there are symptoms of hyperæmia expressed as a disposition to bite hard upon the particular tooth, or to grind upon it. A paroxysm of gnawing pain

¹ Garretson's Oral Clinic, 1884.

lasting for some hours, and recurring at intervals, is also somewhat characteristic. The gum may have slightly receded.

Neuralgia, functional blindness, functional deafness, epileptiform fits, paralysis, cardiac neuralgia, insanity, and other related conditions have been cured by the extraction of hypercementosed teeth.¹

The treatment of teeth presenting obstinate symptoms of pericementitis, apparently due to moist gangrene of the pulp, may at times be complicated by unsuspected hypercementosis.

In such cases, if pulp or pericemental complication cannot be determined, suspicion should point to hypercementosis and an *x*-ray examination be made, by which means the condition may be positively determined. As entire dentures have been extracted, tooth by tooth, in a vain endeavor to cure a neuralgia about the head, this means of diagnosis should not be overlooked.

Treatment. The treatment for hypercementosis may first be a conservative one if only slight annoyance be produced by it.

Counterirritation—correction of malocclusion, etc.—may be employed. The symptoms may disappear. If they do not, or they are severe when the patient applies, the tooth should be completely extracted. The operation of amputation of the root end might be safely tried for this condition, but there are no records of its employment as a means of cure. The bulbous condition of the root end may cause extraction to be difficult, and fracture of the root end may occur. Flagg recommended that in such a case a fissure drill be passed about the circumference of the root end to remove the bony obstruction to its passage out of the alveolus, after which it may be lifted away with tweezers. Cocaine may be used as an obtundent.

Extraction for hypercementosis may cause considerable bruising of the walls of the alveolus, followed by excruciating pain lasting often for days. The alveolus may refuse to granulate and a septic condition result. The pain has at times been relieved by the injection of a 2 per cent. solution of cocaine into the gum on either side of the alveolus, after which the surfaces of the alveolar walls should be sterilized and burred away until tissue capable of granulation is reached.

The alveolus should then be irrigated and a clot invited by causing a slight hemorrhage. (See p. 492.)

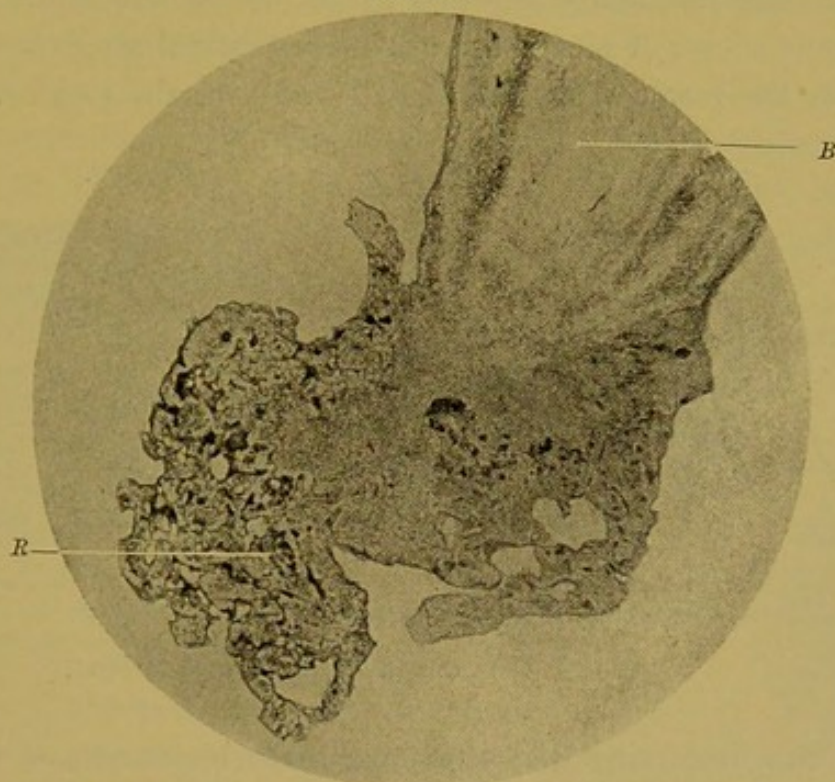
¹ Brubaker, American System of Dentistry.

(ANKYLOSIS) SYNOSTOSIS.

By this is meant the union of bone and cementum, a condition analogous to ankylosis of bone.

Hopewell-Smith¹ has described five cases, of which he offers the following explanation: (1) inflammation occurs and the membrane is changed into granulation tissue; (2) the cellular elements destroy portions of the bone and excavate the cementum; (3) the mass of granulation tissue is then ossified, joining the bone and cementum in a firm union.

FIG. 456.



Vertical section of a human tooth ankylosed to the jaw: *R*, root; *B*, bone of jaw. The absolute continuity of the two hard tissues is strikingly shown. From the collection of the late Storer Bennett.¹ (Hopewell-Smith.)

RESORPTION OF THE ROOTS OF PERMANENT TEETH.

By resorption of the roots of permanent teeth is meant the gradual removal of the cementum and dentine of permanent roots by phagocytic cells existing in the adjacent soft tissue (osteoclasts).

Causes. The proximate cause is probably in all cases a degree of irritation greater than that required to produce hypercementosis. Talbot's demonstrations upon interstitial gingivitis, a term meant to

¹ Histology and Pathohistology of the Teeth.

² Transactions of the Odontological Society of Great Britain.

include interstitial pericementitis, show that it is a frequent cause of both root and alveolar resorption. (See Interstitial Gingivitis.)

The disease has been discussed by other writers as a result of "Rarefying Pericementitis."

Chronic apical abscess seems to be a frequent cause. Although theoretically the alkaline pus formed should neutralize acid formation, the fact of resorption remains and is probably explained upon the ground that it is produced by the granulation tissue formed about the root apex during periods of lessened pus formation.

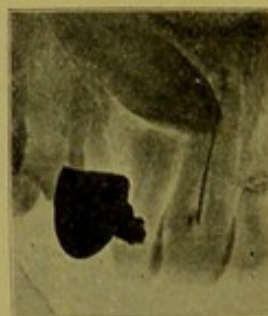Protruding root fillings or broaches are common causes (Fig. 457). Plantations are frequently followed by it. Looseness of a tooth with the resultant excess of movement excites interstitial gingivitis. Partial luxation as the result of a blow or fall produces the same result, the

FIG. 457.



Apical abscess and resorption, produced by a protruding broach.

FIG. 458.



Deciduous cuspid crowned, mistaken for permanent cuspid which lay in jaw and caused resorption of root of permanent lateral. (Skiagraph by Price.)

pericementum becoming thickened, the tooth loosened and extruded, and malocclusion, which is also a cause, being induced.

A toothpick broken off in the gum tissue has produced resorption at the neck of the root.

The descent of a supernumerary or impacted tooth upon a permanent root has caused resorption, exposing the pulp of the resorbed root, and producing pulp reactions. This may be quite extensive before violent symptoms occur (Fig. 458).

Calculus beneath the gum margin has produced resorption. In one case noted four lower incisors presented the characteristic bays at a point one-eighth inch below the gum line.

Some of the cases exhibit no tangible cause; the root resorbs apparently as the result of a peculiar reaction upon the part of the tissues of the individual, who may lose many teeth by this process—*i. e.*, a

dyscrasia exists. The teeth may be non-carious and the pulps vital. In some of these cases neurasthenia or a uric acid diathesis seems to have some association with the condition.

Pathology and Morbid Anatomy. Both resorption of cementum and its redeposition occur in teeth as physiological processes; at some aspect of the cementum the tissue becomes hollowed out, and later filled in by new cementum. Resorption of tissue throughout the body is accomplished by means of multinucleated cells (giant cells, osteoclasts). At some part to be physiologically resorbed these cells make their appearance in contact with the tissue to be removed, and it gradually disappears, the layer of multinucleated cells constantly occupying the excavated territory.

If a foreign (aseptic) body be introduced into living tissues, it becomes surrounded by these cells, which in some cases effect its removal; in others, failing to remove the foreign body, connective tissue forms about it and encysts it; encystment may occur after partial removal by giant cells.

The resorption may be of any extent, from a slight spicular roughness of the apex of the root to almost complete removal of the root.

Perforation of the root from side to side may occur, of course, involving the pulp canal and, if the pulp be alive, obscure reactions upon its part may occur.

An area of marked resorption may occur at a point just beneath the gum margin and upon any aspect of the tooth. In this situation it may simulate a cavity of decay beneath the gum. It occurs upon either vital or devitalized teeth and may expose the pulp or the root-canal filling (Fig. 459). After plantations peculiar resorptions over even the entire root may occur.

It is probable that in plantations the root is regarded as an aseptic foreign body; mild inflammation occurs, subsides, and giant multinucleated cells attack the tooth root and endeavor to remove it by solution; this they accomplish in part in spots; then a tolerance is established and connective tissue organizes about the roots; later more complete regeneration is represented in the formation of bone; a condition of bony fixation is established, evidenced by the clear-ringing note elicited upon tapping the planted tooth.

FIG. 459.

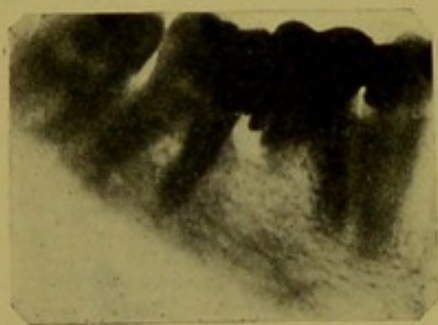


Idiopathic resorption of permanent root. The bay upon the side exposed the pulp and perforated the root as shown. Crater-like resorption about apical foramen. Pulp first devitalized on account of persistent pain and the tooth later extracted.

The inflammatory reaction and resorption is least when replantation is practised, but may at times be pronounced in even those cases. If the socket of a tooth extracted for resorption be examined, a mass of soft tissue will be found occupying the locations corresponding to the areas of resorption (Fig. 460). These soft masses correspond to granulation tissue. No acid reaction can be detected with litmus paper, but, nevertheless, it is probable that the cells producing resorption excrete an acid capable of dissolving the tissue.

There is some evidence of this in cases of enamel resorption occurring upon the crowns of impacted teeth which have never been in relation with the oral fluids, and about which there is no evidence of caries in the areas of dentine resorption also present. In the fortunate specimens of these cases a superficial decalcification of the enamel surface may be seen which can only occur as the result of acid action.

FIG. 460.



Resorption of distal root of a first molar.
(Skiagraph by Custer.)

FIG. 461.

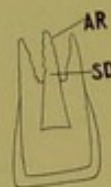

Diagram of a case of root resorption after secondary dentine had formed; SD, secondary dentine; AR, area undergoing resorption; peculiar central spire of secondary dentine. Specimen in possession of Dr. A. P. Fellows.

Symptoms and Diagnosis. The tooth may present symptoms of non-septic pericementitis, and may be loosened in advanced cases. In the early stages no looseness may be observed until a strain suddenly applied causes a luxation; thereafter the tooth progressively loosens.

The condition may be discovered by accident: evidences of mild pericementitis appear, and the pulp canal is opened to search for a cause. The pulp may be found alive; if alive, and it is killed, or if it is found dead, broaches pass suddenly into the mass of soft tissue underlying the root. The progressive loosening of the tooth, with its peculiar movement, is about the only constant symptom of the condition.

In cases of live pulp this organ may be hyperæmic, so that increased response to heat or cold is felt; this, taken in connection with the tenderness upon percussion which can usually be elicited, and with the peculiar loosening of the tooth, is a diagnostic guide.

Flagg¹ states that reflex neuralgias occur in this condition, but that the most constant indication noted by him was a sense of discomfort about the jaws, vaguely associated with some one tooth. The patient is convinced that if the tooth were removed relief would follow. In the absence of the loosening, which may not occur until the root is nearly gone, the resorption is most commonly discovered by entering the pulp canal and finding its length much shortened. In some cases the resorption may be found near the gum margin and simulating a cavity of decay, from which it may readily be diagnosed by its appearance when exposed by packing the gum away. Such cases appear to accompany a marginal gum resorption.

The *x*-ray should exhibit the condition with sufficient clearness to furnish an absolute diagnosis.

If a direct diagnosis can be made the tooth should be extracted, except in the cases near the gum margin, which may be filled usually with plastic fillings. If a diagnosis be not possible, probable causes of irritation should be sought for and removed and the non-septic pericementitis treated as indicated. (See p. 502.)

Failing a cure the tooth is to be removed, when a *post hoc* diagnosis may be made. In view of the availability of the *x*-rays this involves an unnecessary endurance and loss of time.

DEGENERATION OF THE PERICEMENTUM.

Strictly speaking, the overuse, abuse, and disuse of the teeth are causes which produce a general hyperæmia or inflammation of the pericementum (interstitial gingivitis). These either render it liable to the degenerations and resorptions which accompany continued hyperæmia or inflammation, or act as a predisposing cause to local infection by oral organisms, beginning their action at the gum margin, and sooner or later producing a purulent or non-purulent liquefaction of the gingival portion of the pericementum (pyorrhœa alveolaris).

In view of applied therapeutics it is well to consider these causes separately.

OVERUSE OF TEETH.

By overuse of a tooth is meant such a variety of occlusion that the tooth receives a greater stress than its neighbors, or than it is designed to bear. The stress may be received in the normal direction, but be excessive in amount. The most prominent cause of this condition is

¹ Lectures on Dental Therapeutics.

the loss of one or more other teeth, permitting undue stress to fall upon the neighboring teeth, or, in some cases, on far-distant teeth. Too prominent artificial crowns, particularly those of the all-gold type, cause a general increase of stress upon the pericementum. Enormous overfull contour fillings may establish a similar condition. When but few isolated teeth remain in one denture and have antagonists, the teeth are certain to be overworked. Isolated and other teeth, to which are attached clasps of artificial dentures, are in the majority of cases being constantly overstrained.

Pathology. Like any other functional part which is overworked, the pericementum is first stimulated, causing the vessels to dilate. Soon evidences of overwork appear in a passive dilatation of the pericemental vessels, and atonic hyperæmia is established. The condition passes into one of irritation and interstitial gingivitis; the tooth projects, and is loosened; the overlying gum deepens in color, and evidences of venous engorgement are common. The result of the condition is a softening and degeneration of the substance of the pericementum; the alveolar wall is involved in the degeneration, and it melts down—is resorbed to a greater or less extent. At any stage of the disturbance infection may occur, and the degeneration and destruction of the pericementum be hastened by suppuration or other secondary degenerations.

The symptoms, diagnosis, and clinical history are involved in the description. The prognosis is the inevitable loss of the tooth if the causes be not removed, in which event the prognosis is governed by the extent to which the degeneration has proceeded. (See Interstitial Gingivitis.)

Treatment. The treatment is the removal of the causes and procuring surgical rest until the injured pericementum has recovered. The insertion of carefully made artificial dentures is indicated in those cases of scattered natural teeth having spaces between them. The prosthetic appliance must not be attached to these teeth, nor in its movements should it bear against them. No attempt is made, however, to cause the artificial teeth to strike before the natural teeth in the hope of giving surgical rest to these organs. Such attempts always result in failure, as they cause injuries to the tissues upon which the plate and teeth rest, which are more severe than the pericemental disturbance.

Properly adjusted bridge-work frequently does good service in these cases, provided the overoccluding tooth or teeth be first dressed down

short of occlusion and are given a period of rest until the pericementum recovers. The bridge, if carefully planned, may be made to direct and control the stress received by the injured teeth.

Improperly occluding artificial crowns should have this fault corrected by removing the excess of material or by setting properly made crowns.

Overfull fillings should be reduced to correct proportions and shape.

Teeth which are being strained by clasps should have the latter removed. If necessary, a new appliance should be made on which clasps are either omitted or are properly designed for other teeth.

Surgical rest is the only hope of saving the tooth.

MALOCCLUSION OF THE TEETH.

Each tooth of a denture is not only designed to receive a definite amount of force, but to receive it in a particular direction or directions; any excess of this force, or alteration of its direction, is followed by abnormal stimulation of the pericementum and by its overstraining. (See Chapter VIII.) The effects following a general increase of stress have been considered under the previous heading. By malocclusion is here meant the constant reception of stress by the pericementum in directions to which it is quite unaccustomed, or are not in accordance with the anatomical design of the tooth. It is a peculiar form of overuse.

Causes. Original malpositions of the teeth may cause their faulty occlusion. The most prolific source of the condition is, however, altered occlusion due to those changes of position of the teeth which follow upon the loss of adjoining teeth.

Artificial crowns which do not occlude in correspondence with the other teeth are a common cause. Improperly formed fillings are another cause.

The shifting of positions of the teeth, in consequence of pathological changes occurring in or about the pericementum, cause the crowns of teeth to occlude improperly.

Pathology. The conditions established are those of overuse in a direction other than direct. A typical example of this condition is that of a lower second molar which has gradually tilted forward in consequence of the loss of the first molar; or a central incisor which has altered its position in consequence of secondary formations in or about

the pericementum, a common precursor of phagedenic pericementitis. Some portion of the tooth, an edge, which before did not occlude with an antagonizing tooth, is brought into occlusion; if the occlusion be not unduly forcible, no immediate degenerative changes are evident. If the occlusion be excessive, the pericementum is not uniformly affected, but the greatest stress is brought to bear upon some lateral aspect of the structure. It responds in the degree of the overwork, and degenerative changes occur which, if the active causes be not removed, gradually spread to other portions of the pericementum, and the phenomena noted in connection with overuse occur, but are not so general in distribution. The tooth becomes more movable in one or more directions—*i. e.*, is loosened; it may develop some degree of tenderness upon percussion, and the gum color toward the affected side deepens, although it may remain normal in other parts. As in the previous cases, infection may—indeed, is likely to—occur. In some cases the pericementum may degenerate and be destroyed about one root of a multirooted tooth, and remain about the other. It is to be remembered that a less degree of irritation may produce hypercementosis.

Diagnosis and Treatment. In all malposed teeth a careful examination should be made of their mode of occlusion. If the tooth exhibit tenderness and looseness, malocclusion is almost a certainty; it only remains to determine its direction.

The spots of faulty occlusion may be determined by placing a strip of carbon paper (articulating paper) over the tips of the antagonizing teeth and having the patient bite; the spots of contact should then be ground away until the tooth is slightly short of direct occlusion. Fresh strips of paper are used, and the jaws moved laterally, as in mastication, to note other points of contact; these should also be ground away.

Prognosis. If the condition be not corrected every time occasion requires, the degeneration progresses until the tooth is lost.

If marginal infection has occurred, purulent or non-purulent marginal pericemental liquefaction (*pyorrhœa alveolaris*) may have to be considered.

DISUSE OF TEETH.

Definition. By disuse of teeth is meant a degree of usage less than the amount, the forms, and structure of the teeth and contiguous parts fit them for. The disuse may be absolute or relative; teeth may not

occlude at all, owing to the loss of antagonists or to extremely irregular positions.

Partial Disuse. Causes and Pathology. If soft food be used instead of that requiring vigorous mastication, or if one tooth of a side be diseased so that that side of the mouth is unused in mastication, or if one of the antagonists of a tooth be lost, the pericementi of the teeth involved do not receive their proper amount of exercise and a degree of atony ensues.

This partial disuse has a more distinct relation to the health of the gum margin, which does not receive a normal amount of friction from mastication, and if this be not offset in part by the use of the tooth-brush, atony, followed by passive hyperæmia of the gum margin, ensues.

Infection and the formation of calculus increase the irritation to a marginal gum inflammation which is liable to run into a pyorrhœa alveolaris. This is the real significance of disuse as a cause.

Diagnosis and Prognosis. A diagnosis of disuse (relative) is usually made out by inquiring as to the food habit of individuals. It is excessively common in civilized communities, particularly among the well-to-do, and is of almost constant occurrence in gourmands.

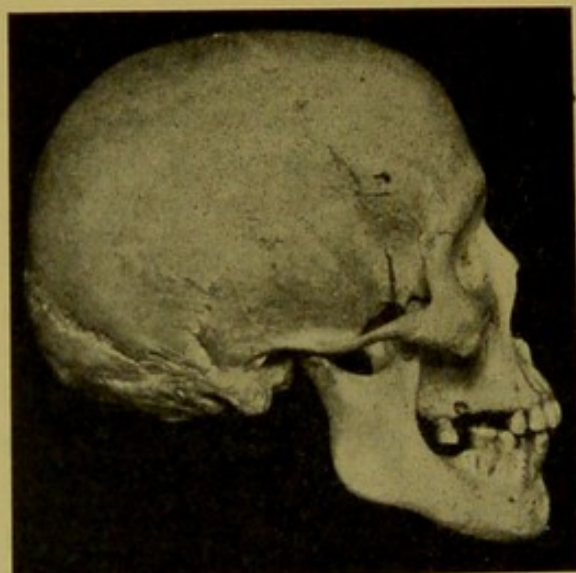
Treatment. Patients should have pointed out to them the results of insufficient mastication, together with the evils of faulty oral hygiene. Every effort should be made, by the use of constant prophylactic measures, to forestall the occurrence of pyorrhœa alveolaris. This and similar conditions are particularly to be feared in the degenerative periods of early and late middle age. It is between the ages of thirty and fifty years that ill-consequences are most to be feared from acquired debility of the pericementum.

Absolute Disuse. Teeth which perform no work directly in mastication, or indirectly by serving as abutments for a bridge-piece, may be said to be in a condition of absolute disuse.

Results. A tooth or root whose pericementum receives no stimulus becomes relatively a foreign body to the organism. It is a useless part, and the body attempts to cast it out. Perhaps these phases are insufficiently exact; however, a disused tooth is lost through a series of pathological changes. Teeth which perform no work may be retained in the mouths of young adults for long periods without marked changes occurring in their vital connections, but during the degenerative period of life they are usually lost with a degree of rapidity differing in individuals.

The pericemental condition of passive hyperæmia following upon relative disuse of the teeth has been described; the condition following upon absolute disuse differs in that the pericementum receives no exercise whatever. The clinical history of these cases is that of a progressive extrusion of the tooth; it projects beyond its fellows in increasing degree. The borders of the alveolar process recede, but usually to less extent than the tooth protrudes or is extruded. The tooth becomes progressively looser, until in its latest stages a portion, which may be one-half of its root length, is attached to the jaw through the medium of a mass of soft tissue alone; all true alveolar connection has disappeared. After extraction or complete extrusion, the root of

FIG. 462.



Absolute disuse and elongation of an upper and a lower molar; partial disuse of bicuspid; small abscess cavity in the bone about a root. (Philadelphia Dental College Museum.)

the tooth is seen to be devoid of pericementum except at the apex of the root. The alveolar process has undergone limited atrophy, although in some cases its outer walls may be thickened.

Pathology. The passive hyperæmia has apparently led to swelling and degeneration, with subsequent atrophy of the pericementum, and the normal atrophic changes which occur in the alveolar process have become hastened and quickened. These cases frequently become complicated by infections, when the tooth loosening becomes pronounced. The pulp vessels are cut off and the dead pulp tissue furnishes a soil for micro-organisms, whose poisons hasten degeneration of the tissues in the abnormal alveolus. Suppuration may occur—*i. e.*, abscess form. Through this process the jaws cast out crownless roots; in these the

local alveolar atrophy may be complete before there is any external evidence of it.

The danger of marginal infection is always great in these cases. Some degree of infection, no doubt, exists in all of them, which serves to explain the increased rapidity of the degenerations.

Prognosis. If teeth can be directly or indirectly brought into use, so that their pericementi receive exercise, the cases may recover, provided the atrophic changes are not very pronounced; in which event the atrophy proceeds, although more slowly. Teeth crowned or made abutments for bridges, after degenerative changes have become established—*i. e.*, when the normal pericementum has been replaced by a thickened mass of partially organized connective tissue—usually become progressively looser; the alveolar atrophy proceeds until all attachment is lost.

If this is utilized early, the teeth may be saved. The results are better if the teeth or roots be utilized before the age of thirty than at later ages.

Treatment. The treatment, as might be inferred from the foregoing statements, consists in bringing the teeth into use, if the degeneration have not proceeded too far. Later, extraction is inevitable. The operation, when determined upon, should not be delayed, for not only are bacterial growths invited about the loosened tooth, but the soft tissues are frequently increased in volume, and if extraction be delayed until complete local atrophy of the alveolar walls has taken place, a soft and spongy mass remains, which interferes with the comfortable wearing of prosthetic appliances in the future.

FIBROID DEGENERATION OF THE PERICEMENTUM.

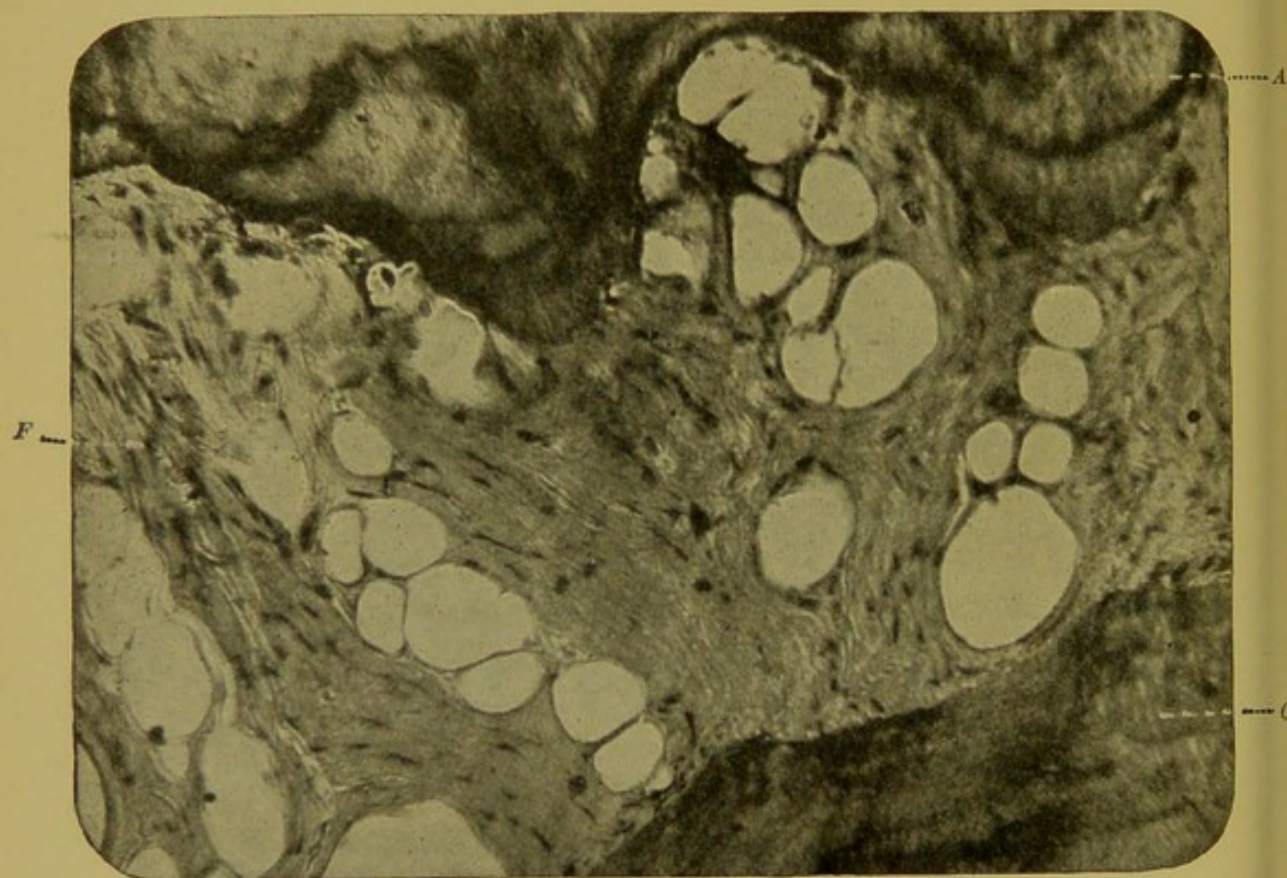
Fibroid degeneration of the pericementum is a senile atrophic change occurring in teeth, the pericementi of which have run a healthy life course, but finally have become subject to senile marantic constitutional changes of not clear nature. The condition thus first defined by Hopewell-Smith¹ is further described as found in that class of teeth of the aged which have resorbed alveolar margins and exposed cementum, but not necessarily subject to pyorrhœa alveolaris; though traumatic pericementitis may be present. In some cases the teeth may be firm.

¹ Dental Cosmos, 1904.

Pathohistology. The chief characteristics are an increase in size of the fibres of the pericementum, the loss of their nuclei, and their generally structureless character, and their arrangement in prominent bundles about large spaces (areolæ). (See Fig. 463.)

The fibres are firmly implanted in both bone and cementum. The cementum does not become hyperplastic (hypercementosed), but the bone becomes osteoporous and the Haversian canals contain a shrunken fibroid tissue resembling that in the pericementum (Fig. 464).

FIG. 463.



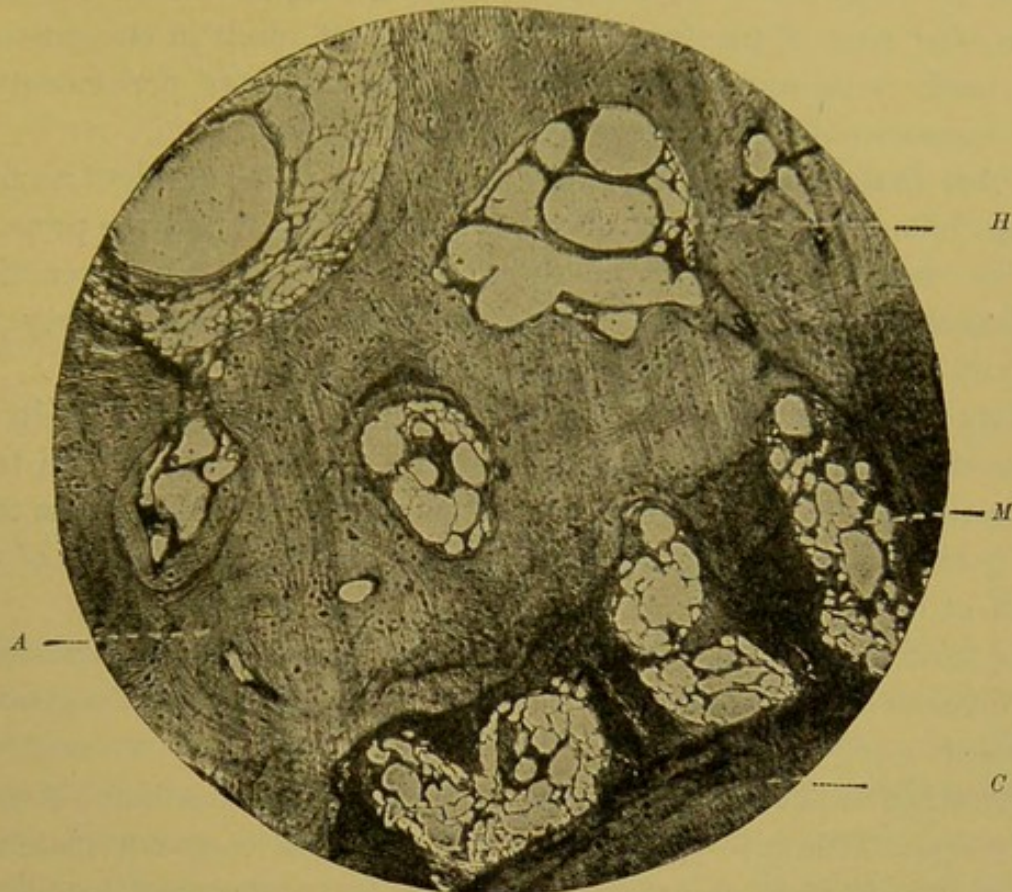
Fibroid degeneration of the pericementum: *C*, cementum; *A*, alveolus; *F*, fibres with decrepit nuclei. Transverse section. (Hopewell-Smith.)

The gum tissue in the vicinity also undergoes retrogressive changes in sympathy, becomes less vascular and more fibroid.

The condition may persist without inflammatory or suppurative changes, though it may act as a cause of obscure neuralgia or as a predisposing cause to pyorrhœa alveolaris.

Hopewell-Smith points out that the areolar spaces may admit micro-organisms to deep parts, thus predisposing to antral disease or possibly osteomyelitis.

FIG. 464.



Fibroid degeneration of the pericementum: *C*, cementum; *M*, degenerated pericementum; *A*, alveolus; *H*, enlarged (osteoporotic) Haversian canals. Transverse section. (Hopewell-Smith.)

ACCIDENTS TO TEETH.

Apart from fracture of the teeth by accidents, several interesting accidental conditions involving therapeutics require consideration.

Teeth Driven into Alveolar Process. Blows, falls, etc., have occasionally caused teeth to be driven forcibly into the jaw. The condition may be complicated by fracture, in which case the judgment of the operator must be exercised. If the tooth be not fractured it may be drawn down with forceps and ligated in place until firm. If evidence of pulp death be noted by subsequent test, or apical pericemental inflammation, the pulp should be removed.

Luxation or Partial Dislocation by Accident. Teeth may be partially knocked out and driven either lingually or buccally. The pulp connections will be ruptured, as a rule, but after asepsis of the parts by means of antiseptic sprays the teeth may be pressed into place, and if ligated or splinted may again become firm by deposition of bone about them. The pulps nearly always give evidence of death; so that the pulps should be replaced with canal fillings.

Occasionally evidences of reattachment of pulp have been recorded,¹ even after total displacement. If the accident result in elongation of the tooth with production of a chronically spongy pericementum, the operation of replantation should be performed.

Total Dislocation of Teeth by Accident. If the accident result in total displacement from the mouth the tooth or teeth may be prepared as for replantation (see p. 488), and under aseptic precautions replanted in their alveoli. If held by ligatures or splints they will usually become firm.

Attachment of Teeth. Two or more teeth may be attached by the intervening alveolar process, fracture of which may cause both teeth to be removed in extraction. In a few cases of loose deciduous teeth the gum has been sufficient attachment to cause the removal of two teeth at once.

In some cases the tough, fibrous nature of the pericementum causes the alveolar bone fractured by the leverage upon it to remain attached to the tooth.

Fracture of the Alveolar Process. Slight fractures of the alveolar plate are of little consequence as a rule. In some cases one plate may be fractured, and, unless removed with the tooth, may usually be pressed back into place. Reunion may be looked for if asepsis be maintained. Fractures of the alveolar process from blows, kicks, etc., upon the jaw may become septic and sequestra may form, necessitating removal of both bone and teeth. Such fractures should have immediate attention.

Hæmorrhage following Extraction. Even in the absence of hæmophilia postextraction hæmorrhage may be somewhat severe, and is well controlled by a little tannic acid or powdered alum upon a pellet of cotton, or nosophen gauze wet with phenol-sodique.

If necessary a linen compress should be placed over it and a Barton or Garretson bandage applied. The internal use of calcium chloride or other hæmostatic is indicated if the bleeding be continued.

¹ Kirk and W. Trueman.

SECTION VI.

PERICEMENTAL DISEASES BEGINNING AT THE GUM MARGIN.

CHAPTER XXIII.

NEARLY all the degenerations of the pericementum which begin at the gum margin are sooner or later accompanied by suppurative processes, which give a generic name to these conditions, viz., pyorrhœa alveolaris. Under this head dental writers have included several disease processes which should be clearly differentiated from one another. In general terms these diseases are characterized by an inflammation originating about the gum margin, and followed by a progressive degeneration and atrophy of the pericementum and of the alveolar walls. In the areas of pericemental atrophy and death progressive deposits of calculi take place, and infection of the disease territory by pyogenic organisms is the rule. Their characteristics, therefore, are loss of pericementum in any direction, forming pockets in which calculi deposit, and from which pus exudes or may be pressed. The primary cause of the atrophy, pericemental necrosis, calculi, and infection are so clearly associated with a primary affection of the gums about the necks of the teeth, that a critical examination of the causes, clinical history, and pathology of inflammation of the gum margin is a necessary preliminary to the study of the later degenerations.

GINGIVITIS.

By gingivitis is meant an inflammation of the gum. When distinctly confined to the gum margin it may be designated as marginal gingivitis. When the inflammation has reached the deeper connective tissues of the gum and pericementum it has been called interstitial gingivitis (Talbot).

MARGINAL GINGIVITIS.

Definition. By marginal gingivitis is meant an inflammation confined to the margins of the gums about the necks of the teeth.

Causes. The causes of marginal gingivitis are local and general, which may be subdivided into predisposing and exciting. Both local and general causes may be in action at the same time.

LOCAL CAUSES. Marginal gingivitis may be excited by the presence of food masses or unremoved collections about the necks of teeth, their fermentation liberating chemical products more or less irritating.

Miller¹ has shown that the materies alba about the necks of teeth may have either an alkaline or acid reaction and the gums be inflamed.

Bacterial plaques not unlike those producing dental caries have been shown by Miller² to be formed upon many surfaces of the teeth even when no ill results are notable. In practice staining the teeth with tincture of iodine will readily demonstrate the presence of such bacterial films. Under favoring circumstances these no doubt produce marginal gum irritation, a fact proven by the relief of such a condition by the mere continued cleansing of the teeth—*i. e.*, the removal of the plaques.

Talbot³ has demonstrated that a deep pocket may normally exist at the gum margin favoring the retention of food and other débris.

Mechanical causes produce direct irritation: these are deposits of salivary calculus resting upon the gum or beneath the gum margin; fillings projecting beyond cavity margin; gum overlying cavity margins; bruising of the gum margin by food crowded between teeth and removed by toothpicks; the fermentation of such crowded food; the mechanical action of toothpicks or floss silk improperly crowded upon the gum margin; projecting edges of artificial crowns or bits of cement used in their cementation; toothbrush bristles; fragments of toothpicks or oyster-shells, etc.; rings of rubber or of torn rubber-dam or ligatures left in position; improper contact of the edges of prosthetic plates or appliances about the necks of teeth; injuries inflicted by rubber-dam clamps, wedges, ligatures, etc.

The action of any of these causes may be complicated through the infection of the mechanically irritated part by oral bacteria. An excellent example occurred in the editor's practice. A perfect gum margin was irritated by the margins of a gutta-percha cap used as a

¹ Dental Cosmos, 1894.

² Ibid., 1902.

³ Interstitial gingivitis.

remedy for hyperæmia of the pulp. Pyogenic organisms produced a marginal suppuration which subsided upon removal of the cap.

Excessive smoking and the use of alcoholic liquors produce local irritative effects, resulting in catarrhal stomatitis and gingivitis.

Lack of exercise or brushing of the gums produces an atonic condition of the gum margin, predisposing to gingivitis of infective character. Too persistent brushing with stiff brushes may be equally injurious by causing marginal irritation.

GENERAL CAUSES. It is quite certain that in conditions of general faulty metabolism substances are generated in the system or are retained by reason of faulty elimination, and which, floating about in the blood stream, act as irritants to the pericementi and gum margins about the teeth.

Moreover, the pericemental glands seem to be eliminating organs which may become overstimulated and thus diseased.

In all general nutritional disorders parts peripheral to the circulation are most affected, become debilitated, and tend to a degenerative metamorphosis of cells.

Rhein found after repeated examinations of hospital patients that "marginal gingivitis was an accompaniment of typhoid fever, tuberculosis, malarial disorders, acute rheumatism, pleurisy, pericarditis, and syphilis, among the acute diseases. Of chronic nutritional diseases, it was commonly observed in cases of gout, diabetes, chronic rheumatism, several forms of nephritis, scurvy, chlorosis, anæmia, leukæmia, and pregnancy. Also in disorders of the central nervous system and following the administration of mercury, lead, and iodine."

Rhein states that the gingivitis produced by any of these diseases has distinctive features which may even serve as diagnostic signs as to the nature of the general malady.

Talbot's experiments in the mercurialization of dogs (see *Interstitial Gingivitis*) demonstrates that efforts upon the part of the pericementum to eliminate the bichloride of mercury result in a non-septic pericementitis, exhibiting in its morbid anatomy the characteristic round-celled infiltration of inflammation.

Black¹ has shown that a gingivitis produced by the systemic administration of potassium iodide may be proven to be caused by its elimination by the pericemental glands by test of the gingival secretion for the iodine reaction.

It is quite reasonable to suppose that irritative substances originating

¹ American System of Dentistry.

in the body and floating in the blood stream may act in like manner. This has been termed autointoxication.

Irritation resulting from the administration of mercury, lead, and iodine, or from toxic substances absorbed from the intestines, is, of course, extrinsic intoxication.

It has been claimed by Hunter, Herschell, Goadby, W. B. Keyes, D. D. Smith, and others, that the toxins formed by oral fermentations and the septic infection of the stomach, intestines, etc., arising from the mouth are competent to excite a train of systemic disturbances ending in a general malnutrition.

Certain accomplished cures of such states by constant oral prophylaxis lend plausibility if not certain proof to this argument. Still the malnutrition, whatever its cause, oral or otherwise, may become a predisposition by lessening the resistance of the soft parts about the teeth.

While it is evident that such causes are competent to produce a gingival irritation, it is probable that the marginal irritation is in large measure due to bacteria present in the mouth. Probably the mercurial or other irritation plays the part of a predisponent.

Loup¹ has shown that a mercurial stomatitis involving the gum margins may be relieved by the use of washes containing mercuric chloride—*i. e.*, the oral exciting cause—the infection—is removed by the use of a germicide.

A variety of marginal gingivitis exists under the name of stomatitis ulcerosa; the cause is clearly infective, but the exact bacterium has not yet been recognized. It tends to rapidly penetrate the pericemental tissue. The gum margin has a pasty, sloughing appearance. The ulceration is rapidly cured by a wash consisting of mercuric chloride in hydrogen dioxide (1:2000).

Pathology. The pathology of marginal gingivitis is that of an inflammation located in a peculiar situation—*i. e.*, in the marginal gum tissue—and tending to spread into the deeper interstitial tissues. (See Pathology of Interstitial Gingivitis.)

Symptoms. The symptoms of marginal gingivitis depend upon the cause. When mechanical causes are acting the gum presents an inflamed appearance; it is swollen, of a bright-red or purplish color, very sensitive to touch, and bleeds readily.

If a calculus rest against the gum the latter may present a raw, chronically inflamed surface in contact with it. A ragged, red, split

¹ Third International Dental Congress, Paris, 1900.

margin of gum is often associated with calculus upon the labial surfaces of lower incisors, cuspids, and bicuspid, and upper cuspids and bicuspid. At times the lingual surfaces of the lower incisors present such an appearance. If subgingival calculus be present the gum margin, if markedly affected, appears loosened and is of a flabby appearance and purplish in color. In some cases the gum margin appears thickened or hypertrophied.

A bloodshot appearance—*i. e.*, enlargement of terminal vessels—is often seen in gingivitis.

In cases due to unhygienic conditions—*i. e.*, food collections or vitiated secretions about the necks of teeth—a raw, red, outer surface of the gum margin is noted, particularly in young persons.

In stomatitis ulcerosa a yellow, pasty ulceration of the gum margins may occur. It is rodent in character, very painful, and may cause rapid loss of the pericementum and of the tooth. In gingivitis due to oral infection by the coccus of gonorrhœa an intense gingival inflammation with looseness of the teeth, pyorrhœa alveolaris, and profuse salivation may occur.¹

Rhein describes a serpentine line of inflammation as appearing a short distance above the margins of the gums in Bright's disease of the kidneys. He considers it pathognomonic of this disease.

Prognosis. If the case has run an acute course and is due to the action of mechanical causes plus infection, recovery is usually prompt upon the removal of the cause and sterilization of the injured part. In the chronic cases due to the more slowly acting mechanical and infective causes combined—*e. g.*, salivary calculus plus infection—much interstitial gingivitis may have occurred accompanied by pericemental and alveolar resorption. This constitutes a permanent loss. If the gum margin is in a state of atony or inflammation as the result of collections of bacteria, etc., upon the cervices of the teeth, their condition may be improved by frequent cleansings of the teeth.

The improvement of certain chronic malnutritional disorders may be hoped for if frequent prophylaxis be practised as a means of cause removal, and at the same time the accumulated waste products be eliminated from the body fluids by appropriate means. This may, in advanced cases, also involve the treatment of diseased organs.

The idea of systemic infection from the mouth is gaining such headway that it deserves increased prominence. Even should its influence be overestimated it will serve as a strong argument in present-

¹ Vines, *British Journal of Dental Sciences*, 1903, and *Dental Cosmos*, 1903.

ing the subject of oral prophylaxis to patients who unfortunately often require the education imparted by bitter experience in order to fully grasp its importance.

Treatment. The treatment of the condition consists in removing the source of irritation and restoring the normal circulation in the parts. If the source of the disorder be in some underlying constitutional condition, the symptoms may be ameliorated, although not entirely cured, by the correction of the general disorder.

Cases due to mechanical irritation are commonly confined to one or several teeth, rarely to an entire denture, except cases continued in consequence of deposits of scaly calculi beneath the gum margin. Foreign bodies, such as bristles and fragments of bone, should be removed. Projecting fillings or overhanging crown margins should be made flush with the general tooth surface. Salivary calculi should be removed.

Antiseptic mouth-washes should be employed frequently, no matter what the cause. If the gum tissue be soft and spongy, showing signs of venous hyperæmia, antiseptic, astringent mouth-washes should be freely used:

R —Zinc. chlorid.,	gr. x.
Aq. menth. pip.,	ʒj.—M.
Increase as desired.	

The above preparation, used in spray from an atomizer or as a wash several times a day, is an excellent local application, meeting both indications. Preparations containing carbolic acid and allied substances do not appear to act happily in these cases. Prescriptions containing eucalyptus and benzoic acid are to be preferred:

R —Acid. benzoic.,	3 parts.
Tinct. eucalypti,	15 "
Ol. menth. pip.,	1 "
Alcohol,	100 "
Saccharin,	2 " —M. (Miller.)

The above formula diluted one-half is agreeable and efficient.

An alkaline 1 per cent. salicylic acid wash is useful:

R —Sodii boratis,	ʒiss.
Acidi salicylici,	gr. xv.
Aquæ menthæ pip.,	fʒiij.—M.

The following is astringent and antiseptic:

R —Boroglycerini,	
Tinct. krameriæ,	
Tinct. calendulæ,	
Alcoholis,	aa fʒj.—M.

Sig.—One or two teaspoonfuls to a small glass of water.

Truman advises the use of hydronaphthol in an astringent vehicle as an effective germicide for use by a patient:

R—Hydronaphthol,	gr. x.
Glycerol,	f3j.
Alcohol,	f3j.
Aquæ destil.,	f3ij.—M. (Peirce.)

Sig.—Use as wash several times a day.

The following is a 5 per cent. formaldehyde solution which can be used as a mouth-wash, having astringent and antiseptic qualities. It is also useful in various strengths as a germicide for root-canals and instruments. A formula for quantity is given, which may be reduced in prescriptions:

	No. 1.	
R—Thymol,		5iss.
Menthol,		5ss.
Oil of eucalyptus,		
Oil of gaultheria,		
Oil of cassia,		
Oil of cloves,	āā	f5iss.
Alcohol,		f3ij.—M.
	No. 2.	
Formaldehyde, 40% sol.,		Oj.
Boric acid,		
Sodium borate,	āā	3iij.
Water,		Oij.—M.
	No. 3.	
Water to		gal. j.

Make up No. 1 first, and shake well. Place No. 2 in a gallon demi-john, and shake well; add No. 1 and shake again; add No. 3 and shake well. For dispensing this may be filtered; for ordinary use this is not necessary. For mouth use a teaspoonful is to be diluted in two ounces of water, making a 1:300 formaldehyde solution.

Equal parts of listerine and ordinary distillate of hamamelis is a useful combination. Glycothymolin is a very popular proprietary mouth-wash. All mouth-washes require an application of about two minutes' duration at least twice a day after cleansing the teeth in order to produce the best effects. As this is somewhat fatiguing to the oral muscles several applications may be made, one after the other, until the total is attained.

INTERSTITIAL GINGIVITIS.

Definition. Interstitial gingivitis may be defined as an inflammation characterized by the presence in the connective-tissue elements of the pericementum and gum tissue of an excessive number of leukocytes, attracted thither by a general or local irritation of the tissues mentioned.

Causes. The causes are those competent to produce marginal gingivitis, but their irritant action has passed beyond the gum margin into the deeper pericemental tissue, gum tissue, and alveolar process.

The causes seem to be divisible into local exciting (mechanical and infective) and systemic predisposing (drug action and autointoxication).

Pathology and Morbid Anatomy. The phenomena of inflammation are produced. The bloodvessels become overfull, diapedesis of leukocytes into the interstitial submucous gum tissue occurs, and the spaces are filled with inflammatory exudate. The papillæ become enlarged and the epithelial layer undergoes an increase in formation of cells (hyperplasia). The gum in consequence of these changes becomes swollen, its color deepened, and it bleeds readily.

If the process be advanced the infiltration extends through the alveolar process to the periosteum and gum tissue.

FIG. 465.

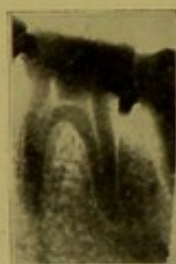

FIG. 466.



FIG. 467.



Resorptions of alveolar process due to interstitial gingivitis, caused by marginal irritation from excessive filling material. (Radiographs by Price.)

After a time the effects of continued low-grade inflammation are expressed in resorption of bone or cementum, or both, or hypertrophy of bone or cementum, or both, or the two processes may be in evidence at the same time.

If at any time pyogenic infection occur at the gum margin, the purulent phenomenon of pyorrhœa alveolaris is produced.

Following resorption of the alveolar process the teeth loosen, more irritation occurs, infection has a deeper action, calculi may form on the roots, and the teeth are finally lost.

Talbot describes several forms of bone resorption occurring in interstitial gingivitis:

(a) Lacunar resorption carried on by the osteoclasts normally lying upon the surface of the bone. Under irritation they increase in number and excavate irregular bays in the bone (Howship's lacunæ). These are then deepened and widened, destroying areas of bone. (See Fig. 65.)

(b) Perforating canal resorption beginning in the small canals normally perforating the trabeculae of bone in various directions and transmitting the bloodvessels from one medullary space or Haversian canal to another (Volkmann's canals). The osteoclasts widen these, necessarily reducing the substance of the trabeculae (Fig. 63).

(c) Halisteresis ossium, beginning with a decalcification of masses of the bone, the organic matrix being for a time undisturbed, but is later removed. This is a local expression of what may occur in other bones of the body in the condition known as osteomalacia (Fig. 66).

FIG. 468.

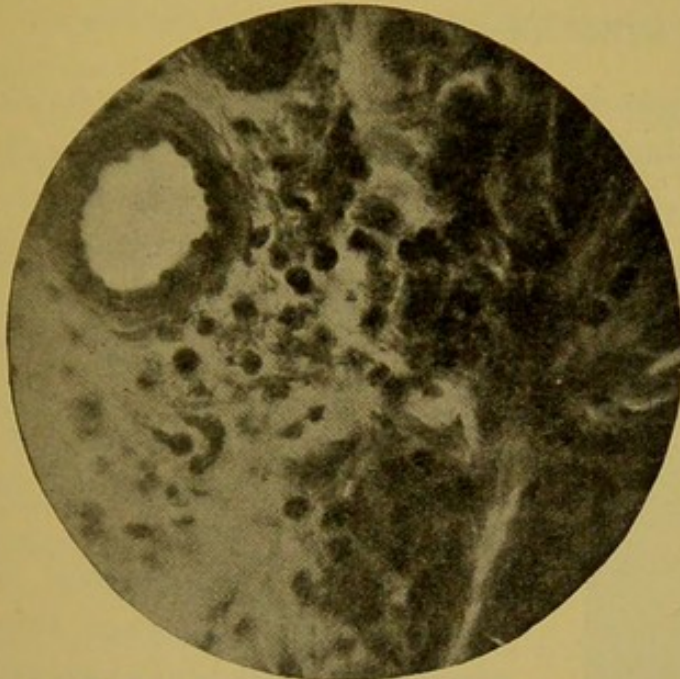


FIG. 469.

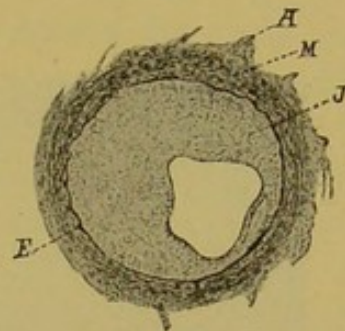


FIG. 468.—Longitudinal section of gingival border, showing round-cell inflammation, due to mercury, and extending to the inner coat of the bloodvessel, and also plasma mast-cells. From a dog. (Talbot.)

FIG. 469.—Endarteritis obliterans: *A*, adventitia; *E*, elastic tissue between middle coat and intima; *M*, muscular coat; *J*, thickened intima. (Talbot, after Kaufmann.)

According to Talbot premature resorption of the alveolar margins, either local or general, is due to this process, called by him alveolar osteomalacia, and occurs in pregnancy or senility, as a rule.

He states that the decalcified bones may be recalcified after confinement in pregnancy, but is never restored in senility.

A lesser degree of irritation may set the osteoblasts at work and cause the building up of the alveolar process, either as a restoration of resorbed bone or as an hypertrophy of either the alveolar process or the cementum of the root (hypercementosis).

Endarteritis obliterans is a thickening of the intima of an artery or capillary, due to chronic irritation and causing a lessening of the lumen of the vessel, even to the point of obliteration of the capillaries.

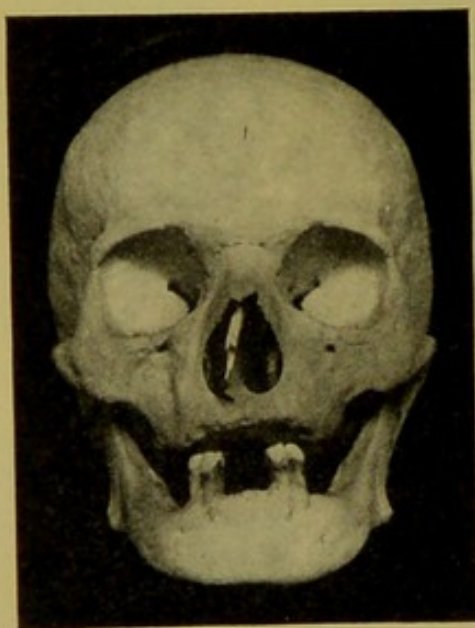
The blood flow is impeded and nutrition of cells impaired. Any cause of interstitial gingivitis may produce it; in all cases of chronic interstitial gingivitis the bloodvessels are so diseased¹ (Fig. 469).

Treatment. The treatment of interstitial gingivitis is either that of marginal gingivitis or pyorrhœa alveolaris. The description is introduced as an explanation of the deep action of causes producing marginal gingivitis, and of the manner in which marginal gingivitis leads to pyorrhœa alveolaris or other forms of pericemental and alveolar loss.

MARGINAL ATROPHY OF THE GUMS.

In advanced age there exists often a tendency of the gums to shrink evenly away from the enamel, exposing the cementum. Hopewell-

FIG. 470.



Recession of gum in senility; beginning decalcification of cementum; alveolar resorption after extraction. (Philadelphia Dental College Museum.)

Smith describes this as accompanied by fibroid degeneration of the pericementum, and regards the latter as a purely senile change.

It may be noted upon the buccal side only of a denture and be due to vigorous brushing.

It is also seen localized at cervices next to a space from which a tooth has been extracted. In one case the editor saw a slightly hypertrophied gum distinctly overlapping a cavity margin drawn back one-eighth inch within a month as the result of extraction of the adjoining root.

Apart from senile changes and possibly even including them these

effects seem to be the result of an overstimulation of the gums resulting in atrophy. It may be that collections upon the teeth are in some degree responsible. The gums have, for the most part, a healthy look, but are in a condition predisposed to pyorrhœa alveolaris.

There seems to be no treatment possible beyond careful removal of deposits of all kinds and the avoidance of excessive brushing of the gums.

¹ Talbot.

CHAPTER XXIV.

SALIVARY AND SERUMAL CALCULUS.

CALCULI are more or less hard concretions found in varying situations and composed of inorganic and organic matter combined in an unknown manner.

As related to the teeth, calculi arise from the following recognized sources:

1. Obviously from the saliva, and deposited in situations which clearly indicate its source (salivary or *ptyalogenic* calculus).

2. From the serum of the blood deposited at some point along the side of the root between the gum margin and the apex of the root, and called *serumal* calculus. Of this there are several varieties:

(a) That associated with a probable fermentation and an altered secretion from the gum margin, and known as *subgingival* calculus.

(b) That occurring in situations in which a chronic pus flow is found, whether apical or subgingival, and which may be called *pyogenic* calculus.

(c) That found upon the roots of teeth at a point to which saliva has no access and over which pus does not flow, and which is therefore deposited by the lymph derived from the blood, and to which the appellation *hæmatogenic* calculus (Peirce) is applicable.

These several names will be adhered to in further descriptions as having definite significance.

SALIVARY CALCULUS.

Definition. Salivary or *ptyalogenic* calculi are hard formations composed of calcium salts of the saliva which have been deposited or precipitated and combined in an unknown manner with organic substances, probably mucin or globulin.

OCCURRENCE. They are found upon the surfaces of the teeth, notably in situations opposite the mouths of the salivary glands, in the ducts of the muciparous salivary glands (sublingual and submaxillary), and upon artificial dentures. A photograph of a plate¹

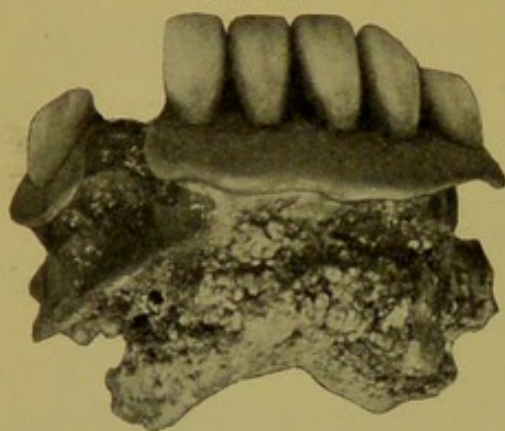
¹ Possession of Academy of Stomatology of Philadelphia.

containing an enormous mass of calculus, the result of seven years' accumulation, is shown in Fig. 471.

Varieties. Clinically two distinct varieties of salivary calculus are recognizable: (1) the soft, friable, whitish-yellow deposits found chiefly upon the buccal surfaces of the upper molars and upon the lingual surfaces of the lower anterior teeth; (2) dark-colored and hard deposits found more frequently in the latter situation, less frequently in the former.

Origin of Salivary Calculus. The origin of salivary calculus may be studied from several standpoints: (1) the formation of calculi in

FIG. 471.



Salivary calculus attached to a lower partial plate worn seven years without removal. Shows form of sublingual space. Practice of Dr. Ford, Toulouse, France. (Specimen in possession of Philadelphia Academy of Stomatology.)

other parts of the body; (2) an analysis of saliva and salivary calculi; (3) extra-oral experiments upon saliva with a view to the formation of salivary calculus extra-orally; (4) the changes observed clinically in salivary calculus during its deposition.

Ziegler¹ states that all free concretions have an organic basis or nucleus (inspissated feces, vegetable material, epithelial scales, mucus, etc.).

As to cholesterin gallstones he states that if the cholesterin be dissolved out by ether a yellowish, organic matrix remains, which retains the form of the stone and presents upon examination radiating spaces formerly occupied by the crystals. He describes the formation of the gallstone as an infiltration or incrustation of degenerated organic matter (epithelial scales, etc.) with cholesterin, bile-pigment, etc., to which, after a nucleus is formed, other portions are added in like manner.

Of urinary calculi he states that Ebstein has shown an organic substance albuminous in nature to be left after dissolving out the various salts.

In stratified calculi this stroma also shows stratification. Such a stroma may be seen after decalcification of a bit of salivary calculus.

Analysis of salivary calculus shows it to be composed of about 22 per cent. of water and organic matter as the portion removable by burning

¹ General Pathology.

the calculus, and about 78 per cent. inorganic matter as the portion removable by decalcification with acids.

Following are the analyses of salivary calculus by Stevenson and Schehevetskey, respectively:¹

	Soft tartar on molars.	Hard tartar on lower incisors.
Water and organic matter	21.48	17.51
Magnesium phosphate	1.31	1.31
Calcium phosphate with a little carbonate and trace of fluoride	77.21	81.18
	<hr/> 100.00	<hr/> 100.00
Water and organic matter	22.07	
Magnesium phosphate	1.07	
Calcium phosphate	67.18	
Calcium carbonate	8.13	
Calcium fluoride	1.55	
	<hr/> 100.00	

These observers are practically agreed upon the substances present in calculus as mainly calcium phosphate with some calcium carbonate, calcium fluoride, and magnesium phosphate combined with organic matter.

Talbot furnishes the following analysis of serual calculus by J. H. Salisbury:²

Water and organic matter	32.24
Magnesium phosphate	0.98
Calcium phosphate	63.08
Calcium carbonate	3.70
	<hr/> 100.00

According to Mitscherlich,³ parotid saliva contains globulin, but no mucin, and contains calcium carbonate; calcium phosphate being present in but minute amount. The submaxillary saliva contains a large amount of mucin, which gives to mixed saliva its viscid nature.

Analyses of submaxillary saliva and mixed saliva by Bidder and Schmidt gave the following results:

SUBMAXILLARY SALIVA.

Water	991.45	
Organic matter	2.89	
Inorganic matter {	Calcium chloride }	4.50
	Sodium chloride }	
	Calcium carbonate }	1.16
	Calcium phosphate }	
	Magnesium phosphate }	
		<hr/> 1000.00

¹ Talbot, Interstitial Gingivitis.

² Ibid.

³ Halliburton, Physiological and Pathological Chemistry.

MIXED SALIVA.

Water		995.16
Organic matter {	Epithelium	1.62
	Soluble organic matter	1.34
Inorganic matter {	Potassium sulphocyanide	0.06
	Sodium, calcium, and magnesium phosphate	0.98
	Sodium and potassium chloride	0.84
		<hr/> 1000.00

That an error of experiment or estimation exists in these analyses is shown by the fact that calcium carbonate is not mentioned as existing in mixed saliva, while it exists in submaxillary saliva; this is a physical impossibility.

It is presumptive, however, that calcium carbonate has not been specially estimated.

The blood contains about 0.8 per cent. of inorganic salts including those found in salivary calculi, and a certain percentage of them is also found in the blood corpuscles. They probably, therefore, exist in body cells in some proportion.

The salts are also taken into the body in the form of food. Their appearance in the various excretions and secretions of the body is to be regarded as in all probability an effort upon the part of the system to eliminate a superabundance of inorganic material from the body.

The ingestion of quantities of animal or vegetable food rich in phosphates or the excessive liberation of the phosphoric acid in malnutrition may produce an excessive elimination of these in the excretions and cause a tendency to the production of calculi about the body. This condition, known as phosphaturia, is observed in certain nervous diseases, rachitis, osteomalacia, leukæmia, gout, and rheumatism,¹ in which the phosphaturia is symptomatic of an excessive catabolism; also in intestinal disturbance resulting in imperfect assimilation of food.

Whether taken in as food or liberated during metabolism it is probable, as pointed out by Talbot, that if one excretory organ fail to perform its office in full degree another must take up its work. For this reason in any bodily condition affecting elimination, a superabundance of inorganic salts may appear in the blood and hence in the saliva, and probably in even the secretions from the gingival margins.

That the deposit of calculus is mainly dependent upon the superabundance of calcium salts in the saliva is evidenced by the fact that

¹ Thompson, Practical Medicine.

in young children but little calculus is deposited upon the teeth, though the oral fermentation is not lacking.

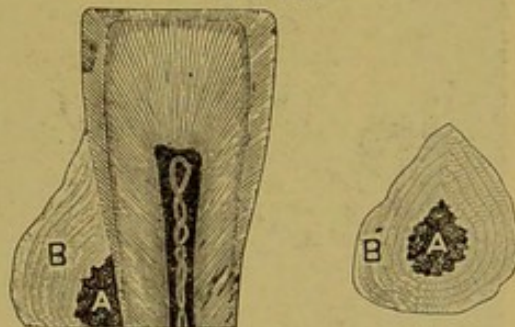
If a bit of calculus be dried and then burned at a red heat, the organic matter present will burn out, the calculus retaining its form. If a similar bit be subjected to a dilute acid (1 per cent. nitric), the inorganic matter will be removed, the calculus will float to the top of the liquid, and, after a time, remain as a light stroma of nearly the original form of the piece.

If a bit of calculus be transversely ground, it is seen under a low-power lens to present a laminated appearance—*i. e.*, it has been deposited in layers representing periods of activity. The under surface of the calculus shows a concentric formation. Beneath the mass a nidus of darker calculus may be found, and if section of extensive calculi be made the greenish deposits may be seen scattered through the mass. Black has noted the presence of urates in nearly all specimens examined by the murexid test. Foreign bodies are sometimes entangled in the mass. Peirce recorded a case in which a small clasp plate was securely fastened to the teeth, and the patient denied possession of such a substitute.

In some cases extensive salivary deposits are found associated with highly offensive odors—*i. e.*, putrefaction of the organic matter occurs as a part of the process—indeed, bacteria are constantly associated with the mass and may furnish their quota of the organic matter. Extraneous matters, such as tobacco-smoke or other pigments, cause discoloration of the mass. With data relative to the physical and chemical analysis of calculi, the mode of calculus formation may be studied. It will be noted that the necessary elements of calculus formation are supplied by the saliva and food débris—*i. e.*, an organic basis is furnished in which calcium salts may be entangled, precipitated, or chemically combined.

Mode of Calculus Formation. If a test-tube be filled with saliva and allowed to remain at rest for several days, a flocculent, light-yellow precipitate will be noted at the bottom of the tube. If the supernatant fluid be drawn off with a pipette and the precipitate be allowed to dry, it will be found possessed of the chief characteristics of calculus—

FIG. 472.



A, nidus; B, calculus.

hardness, friability, a light-yellow color, tenacity of adherence to objects with which it is in contact, and capability of analysis into organic matter and inorganic salts.

Various theories are held as to the mode of precipitation of the calculus upon the teeth:

1. The calcium salts are held in suspension by carbon dioxide. As the carbon dioxide escapes the calcium salts precipitate, but become combined with a certain percentage of the albuminous elements of the saliva—*i. e.*, globulin and mucin.

FIG. 473.

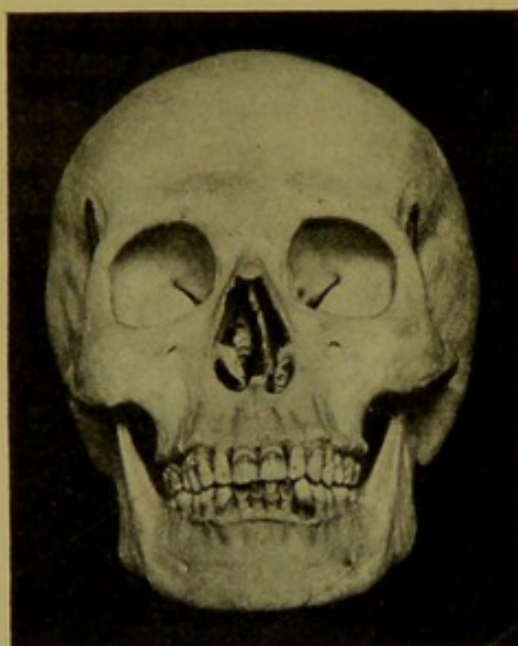


FIG. 474.

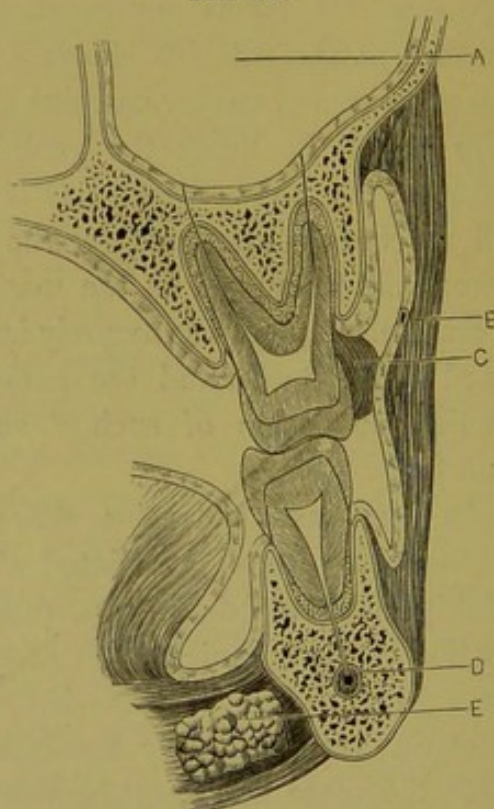


FIG. 473.—Unclean necks of teeth, salivary calculus, and green stain. (Philadelphia Dental College Museum.)

FIG. 474.—A, maxillary sinus; B, duct of Steno; C, parotid calculus; E, submaxillary gland.

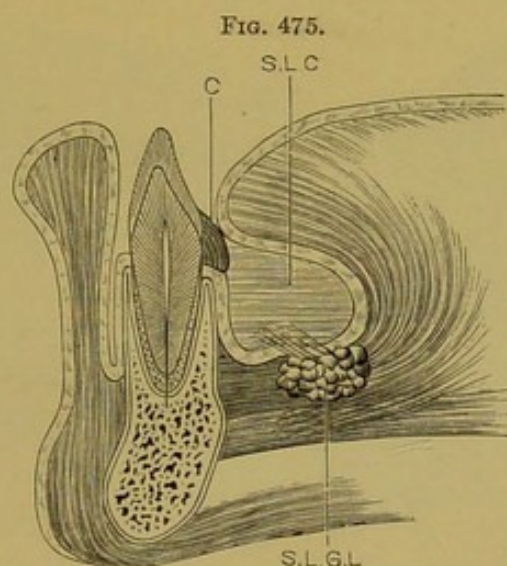
2. Burchard¹ observed that lactic acid, as well as acetic acid and mineral acids, has the property of coagulating mucin. If to a test-tube half filled with saliva a few drops or more of a 1 per cent. solution of lactic acid be added, a cloudiness will appear in the solution; shred-like coagula of mucin are formed, which slowly agglomerate and rise to the surface of the saliva. If the amount of acid be increased, the coagula form more promptly. If the coagulum be removed and dried it is found upon analysis to contain calcium salts.

¹ Dental Cosmos, 1895.

The combined precipitation of calcium salts, owing to escape of carbon dioxide and the coagulation of the mucin entangling them, is held responsible for the formation of the calculi.

3. It has been suggested that the carbon dioxide in the air expired from the lungs causes the precipitation of the calcium in the saliva. That this is an error is seen by reference to analyses of calculi, which would be largely composed of calcium carbonate were this the case; whereas they consist largely of calcium phosphate pre-existent in the saliva; moreover, such a theory fails to account for serumal calculi.

That rest or relative quiescence of the saliva is necessary for the formation of calculus is shown by the fact that it occurs at points which are ordinarily not subjected to agitation—*i. e.*, buccal surfaces of upper molars, lingual and labial surfaces of lower incisors.



C., calculus; S. L. C., sublingual cavity; S. L. G. L., sublingual gland.

Adhesive precipitations of newly formed and very soft calculus form in these latter situations in the course of twenty-four hours. If not removed by brushing they harden and thicken. An unused side of a denture often accumulates calculus in greater degree than the side used for mastication. This does not occur, however, if the brush be used properly and equally vigorously upon both sides.

Burchard has pointed out that irritations of various natures about the teeth and gums may by reflex action cause secretions of fluid, abnormal in quantity and quality, from both the salivary glands and the buccal parietes (glands and gum margins).

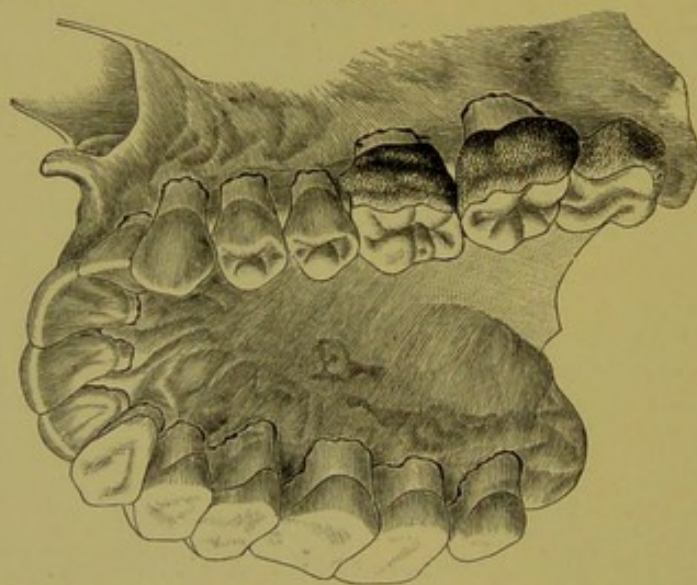
An increase of oral fermentation is commonly associated with an excess of calculus formation, but conditions of oral fermentation may be seen in which but little deposit occurs. The mouths of many children are examples of this.

Kirk has pointed out that there may occur a chemical combination between the organic and inorganic elements of the calculus somewhat analogous to that occurring between calcium salts, etc., and albuminoid materials in the formation of calcoglobulin. (See p. 122.)

Calculi harden with age. It is commonly noted that soft calculus may be readily removed with a brush. Calculus deposited upon lower teeth within a week or two after a thorough cleansing may be scraped away as a cheesy mass; after a much longer time it comes away as a hard scale. In very old deposits it may be exceedingly hard and quite firmly attached to the teeth.

These clinical observations lead to the deduction that an infiltration of calcium salts occurs in the dead organic stroma of the calculus

FIG. 476.



Right side, abrasion from overuse; left side, deposits due to stagnation.

analogous to that occurring in dead or degenerative tissue throughout the body (calcareous infiltration or degeneration). Another theory is suggested—*i. e.*, that a firmer chemical combination of the organic and inorganic elements of the calculus occurs (following the theory suggested by Kirk), density being thereby increased.

In the analyses furnished by Stevenson (p. 535) it will be seen that hardness is in part at least due to an increased proportion of inorganic elements.

Theoretically, subgingival calculi, pyogenic calculi, and hæmatogenic calculi formed within the unbroken pericementum may derive their organic material from the secretions or necrotic tissue of the part, and their inorganic material (largely phosphate of calcium, carbonate

of calcium, and sodium biurate) from the serum of the blood (serumal calculus). In the case of simple subgingival calculus the saliva may play a part by furnishing the necessary calcium salts as claimed by Peirce, but this does not seem to be absolutely proven, nor would it seem to be necessary; indeed, in certain cases of pyorrhœa pockets located about lower incisors in which salivary calculus might readily be deposited, and from which both salivary and serumal calculus has been thoroughly removed, the serumal calculus has again collected in quantity, while the salivary calculus has not been redeposited.

Pathological Effects of Salivary Calculus. In contact with the mucous membrane a salivary calculus excites first marginal gingivitis and later interstitial gingivitis and its effects. (See p. 530.) There is some-

FIG. 477.

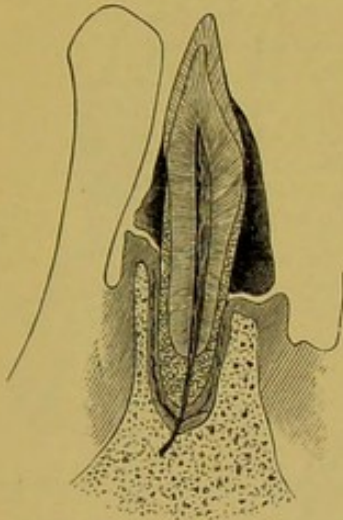


FIG. 478.

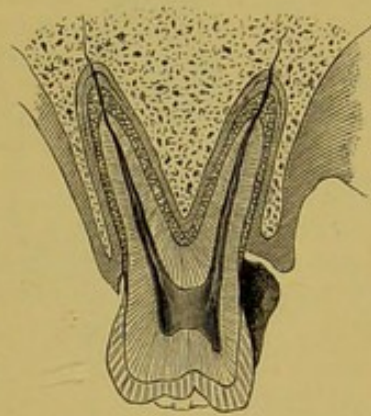


FIG. 477.—Section of a lower incisor, with a large deposit of salivary calculus impinging upon and causing inflammation of the gum. (Black.)

FIG. 478.—Section of an upper molar, with deposit of calculus on its buccal surface, causing inflammation and absorption of the gum and lower border of the periodontal membrane and alveolar wall. (Black.)

times in this stage the wavy, gnawing, uneasy sensation, associated with mild hyperæmia, and the pulp being reflexly irritated the teeth respond more readily to thermal stimuli. The gum margin is inflamed, and occasionally pyogenic organisms cause pus formation. The gum margin recedes and coincidently a resorption of the alveolar process is produced. More calculus is deposited and the process proceeds until much of the alveolar support is lost. Micro-organisms no doubt aid in the process.

The tooth is thus progressively loosened, moves about, and a resultant interstitial inflammation of the remaining pericementum occurs; as a result the membrane is thickened and the alveolar process partially

resorbed (Fig. 480). Increased looseness occurs until the tooth drops out unless mechanically held in place. As soon as the alveolar loss is considerable infection usually occurs and suppuration may be grafted upon the results of mechanical irritation.

The entire process may occupy but a year or two; in other cases the atrophy of the alveolar walls is very slow.

Prognosis. The prognosis of this condition depends upon the extent of alveolar atrophy. If the loss of support be not so extensive as to cause marked loosening of the tooth or teeth, the teeth may be retained for an indefinite period, if they be so attached to neighboring teeth as to render them firm. If left unsupported the pericementum is certain to

FIG. 479.

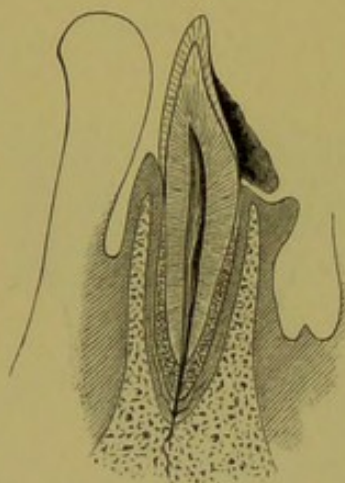


FIG. 480.

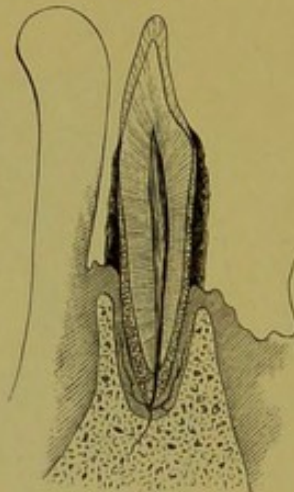

FIG. 479.—Sectional illustration of a heavy deposit of salivary calculus on a lower incisor, with partial destruction of the alveolus of the tooth. (Black.)

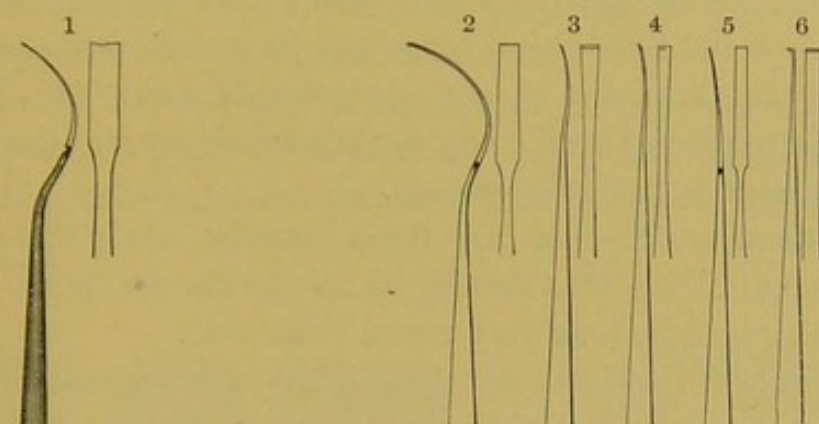
FIG. 480.—Sectional illustration of lower incisor with deposit of salivary calculus less heavy than that shown in Fig. 477, but with greater destruction of the alveolus. (Black.)

degenerate, owing to the increased mobility. The alveolar atrophy will continue, and probably infection of the degenerated pericementum occur. Redeposit is almost certain unless all morbid conditions are removed and extraordinary precautions be taken as regards cleanliness.

Treatment. The treatment may be divided under three heads: removal of deposits, correction of the effects of their presence, and prevention of their recurrence. The sole means of removing salivary calculi should be instrumental. It is frequently recommended that mineral or some of the organic acids be used to soften the deposits or facilitate their removal. Anyone, having seen a case in which a 5 per cent. solution of sulphuric acid had been used for this purpose, needs no further warning against the application. Acid solutions will

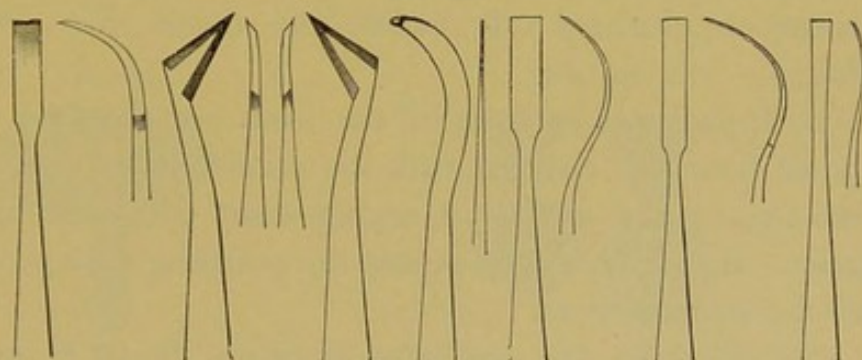
certainly soften the deposits, but at the same time inevitably cause a roughening of the enamel of the teeth by a solution of the calcium salts.

FIG. 481.




George H. Cushing's scalers. The forms and general character of these scalers are well shown. All the instruments except No. 6 are intended to be used with the push stroke. Nos. 1 and 2 are specially intended for application to the posterior surfaces of lower incisors; they are also admirably adapted for removing calculous deposits below the gum between molars and bicuspid, and from the posterior surfaces of the last molars. No. 2 can be passed quite to the extremity of most roots with less disturbance to the soft tissues than a thicker or more rigid instrument would cause. Nos. 3 and 4 are for removing deposits at and below the gum between the teeth, particularly the lower front teeth. They can also be easily used upon the sides of the roots of many teeth, being passed toward the apex of the root in a line nearly or quite parallel with that of the axes. No. 5 is intended to be passed between the lower front teeth at or near the gum and then directly upward, to remove the deposits on the proximal surfaces. No. 6 is a hoe, and is intended to be passed quite to the apex of the roots, where a hoe is desired.

FIG. 482.



Scalers.

FIG. 483.



Moose-hide wheels.

To be sure, the acid does affect the calculus more than it affects the enamel, but the roughened surfaces of the latter not only invite wide-

spread deposits of fermentable material, but render certain the more extensive accumulations of calculi in the future. After oral sterilization the gross deposits may be removed by means of large, sickle-shaped scalers and curved chisels, nearly all used with a draw cut (Fig. 482). The instruments should have sharp edges and be introduced beneath the deposits, so that the gum be not unnecessarily wounded. The scaling should be continued until every surface which can be cleansed by these instruments is perfectly smooth.

For the proximal surfaces of the lower anterior teeth the flat-bladed instruments (Fig. 481) should be used with the push cut. Younger's pyorrhœa scalers are very useful (Fig. 494).

For the removal of associated subgingival calculus not too deeply placed beneath the gum a No. 35 Darby-Perry excavator is of almost universal utility. It is used with the draw cut for the most part. A pair of them may be employed and made safe-sided by rounding one edge if desired to avoid injury of the gum margin. All of the calculi visible, and all that can be detected by their roughness, are thoroughly detached and scraped away by these instruments. The surfaces of the teeth are next cleansed with pumice made into a paste with glycerin to prevent spattering. The paste is applied to the surfaces of the teeth with rubber cups, or Robinson's brush wheels or cups, which are used to cleanse the labial, buccal, and such lingual faces of the teeth as they will reach (Figs. 484 to 490). The lingual surfaces of upper and lower incisors are cleansed with moose-hide wheels (Fig. 483) and wheel-brushes.

The approximal surfaces of the teeth are cleansed with fine linen tape or floss silk charged with the pumice paste. More inaccessible parts require the use of an orange-wood point mounted in a hand carrier. It is advisable to repeat the polishing with precipitated chalk and the same carriers.

After cleansing, the associated gingivitis should be reduced and the parts kept sterilized while healing by means of an antiseptic astringent mouth-wash.

The prescriptions given on page 528 answer admirably.

If desired the operation may be divided, the gross deposits and subgingival calculus being removed at the first sitting. After a few days' use of the mouth-wash the stains and bacterial plaques upon the teeth and any overlooked deposits may be removed. Tincture of iodine painted over the teeth brings the deeper stains of the collections into prominence.

Register states that a forcible spray of 1 per cent. hydrogen dioxide used after the application of tincture of iodine will soften the stains and render them more readily removable.

The smoother the surfaces of the teeth are made, the longer the redeposition of calculi will be delayed.

It is a wise measure to cleanse the teeth before any long series of operations is undertaken, and as a prophylactic measure in the combat with caries and pyorrhœa alveolaris the operation should be frequently

FIG. 484.



FIG. 485.

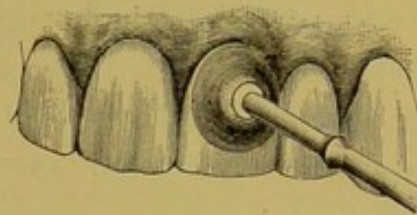


FIG. 486.



FIG. 487.

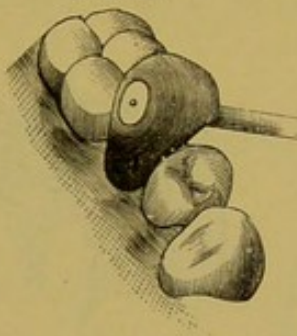


FIG. 488.

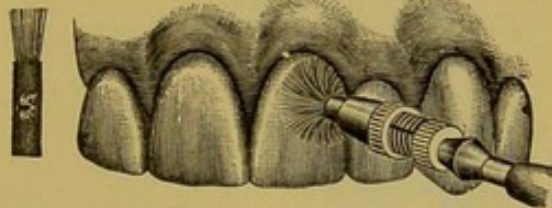
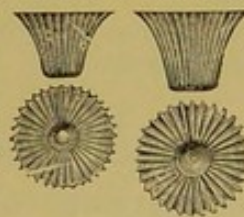


FIG. 489.



FIG. 490.



performed. Indeed, the teeth should be cleansed with pumice frequently so that it may not be necessary to remove actual salivary calculus, except in those cases in which it collects with abnormal rapidity. (See prophylaxis of caries and of pyorrhœa alveolaris.)

In cases of very rapid recurrence of salivary deposits, evidence of an associated systemic condition should be sought. In this direction sialosemeiology and urinalysis may develop data worthy of attention. The systemic condition, if recognizable, should receive appropriate treatment. Free water drinking is advisable.

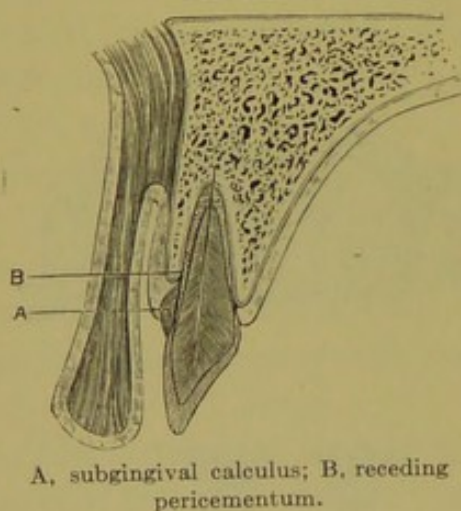
SUBGINGIVAL CALCULUS.

By subgingival calculus is meant that form of deposit which occurs beneath the free gum margin and between it and the tooth. The deposits consist of small scales or granules, usually quite smooth and much darker (olive green) than salivary calculi (Fig. 491).

Composition. They consist mainly of calcium phosphate combined with undetermined organic substances. (See p. 541.)

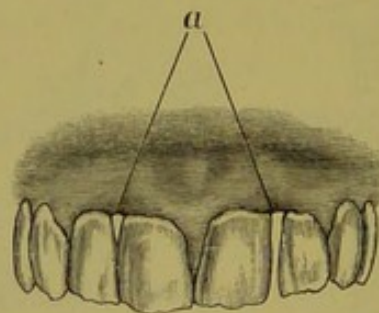
Cause and Pathology. It is probable that some degree of marginal gum irritation first occurs, though many cases of an apparently healthy gum with a scale of calculus beneath it are seen. Whether the irritation arises through fermentations about the unclean necks of the teeth or as the result of an effort upon the part of the gum margin to eliminate waste products from the system is not absolutely certain.

FIG. 491.



A, subgingival calculus; B, receding pericementum.

FIG. 492.



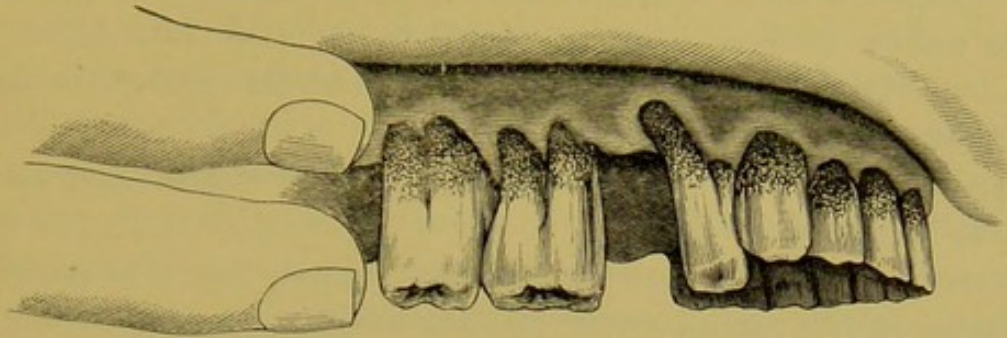
Resorption of the septum of bone and recession of the gum between the central and lateral incisors, caused by deposits of serumal calculus under the gingivæ. (Black.)

The theory most tenable is that uncleanness exists; fermentation of the mixed marginal collection and gum secretion occurs, the gum secretion containing calcium salts; these are precipitated with some organic matter, forming a calculus.

Talbot has shown that a natural pocket may exist at some aspect of the gingival space which is capable of harboring collections of foreign material. The normal gum margin closely approximates the tooth and has an apparent protective influence over the portion it covers. For some reason, such as a lack of normal friction or the presence of microbic plaques just above it, the gum may lose its normal tone and the calculus deposition be favored. Its secretion is also probably altered in quality.

Effects and Symptoms. The direct effects are exerted upon the gum margin. The mechanical irritation may cause the gum and alveolar process to undergo resorption, the calculus being exposed.

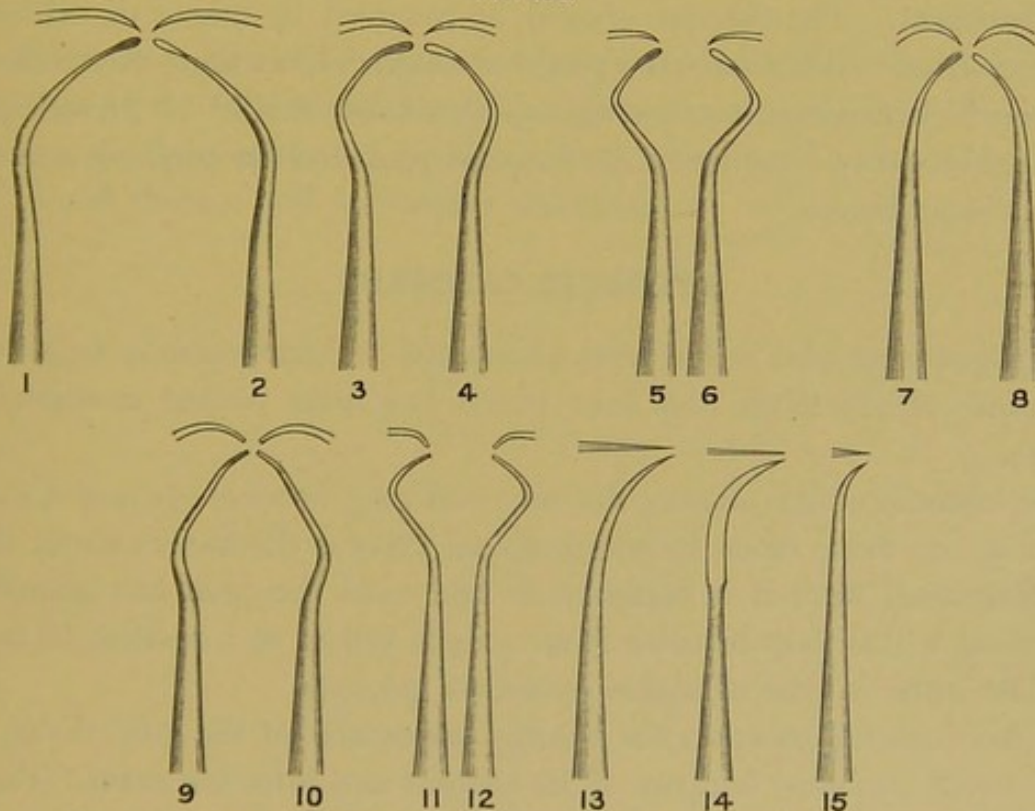
FIG. 493.



The alveoli irreparably destroyed by calcic inflammation. (Black.)

At times this resorption is accompanied by evident marginal inflammation, at others the gum margin has a normal color, but the resorbing portion is sharply defined by a fine line (or crease) from the normal

FIG. 494.



Younger's new set of pyorrhœa instruments. (Revised by Dr. Robert Good.)

gum tissue. In a more advanced stage this demarked portion appears sunken or atrophied and may have a sort of semihyaline redness characteristic of the inflammation. At times the gum margin appears

everted. If the deposit occur on only one side of a root the gum resorption may be confined to that side.

The lingual root of an upper molar is often exposed for a considerable portion of its length by successive deposits of calculi. The same is true in other situations, notably upon the labial surface of a lower incisor.

If the deposit be generally distributed about the neck of the tooth the resorption is more equalized.

In some cases the bifurcation of roots may be exposed and calculi deposit in that situation.

In some cases the gum margin becomes simply atonic or passively congested and is pushed away from the teeth by large masses of the calculus, which undergo lateral accretion. It appears as a flabby, thickened, loosened gum margin, which readily draws about the necks of the teeth if the calculus be removed.

Finally pyogenic infection may occur about the calculus and the symptoms of pyorrhœa alveolaris be implanted. When this is established, calculi may be deposited farther up the side of the root.

Treatment. The calculus should be removed by means of delicate scalers used with either the push or draw cut, as most convenient, after which astringent antiseptic mouth-washes should be prescribed. The subsequent frequency of removal and oral prophylaxis are of great importance.

PYOGENIC CALCULUS.

Pyogenic calculus is that form of serumal calculus which is deposited at parts of the tooth root over which pus more or less continually flows.

In chronic apical abscess the root end may become encrusted with it, and in those cases in which apical abscess discharges along the pericemental tract it is common to find over the area fine granular deposits which vary in color from a light yellow to a reddish-brown.

The same is true of active pyorrhœa pockets.

This calculus prevents the healthy apposition of the gum tissue to the roots, probably because of its irritant and infective nature (Figs. 432 and 495).

Treatment. All such calculi should be removed by whatever means possible, which may necessitate scraping the root end or its side, or even the amputation of the apical end of the root. In some cases aromatic sulphuric acid may dissolve it. (See p. 487.)

HÆMATOGENIC CALCULUS (Syn. Sanguinary Calculus).

This form of sérumal calculus occurs in the so-called gouty pericementitis, a form of pericemental abscess.

It may occur in the absence of apical abscess or a primary pyorrhœa alveolaris, and, therefore, at points not acted upon by saliva or pus; hence it must be deposited by the blood through the lymph.

Miller¹ has offered a satisfactory evidence of this in a description of a case of impacted cuspid well embedded in the bone, and not in any way exposed to either saliva or pus influence except that at a point over the cusp; the gum underwent suppuration for a short time. The crown had undergone resorption showing local irritation, and an olive-green calculus had formed upon the middle third of the root. Cases of pericemental abscess have been noted opening upon the gum face and presenting dark-green calculi upon the root in that situation. (See gouty pericementitis.)

Peirce found in such deposits a proportion of sodium urate as shown by the murexid test and the cases associated with goutiness of the patient.

While such deposits may not cause immediate irritation they may in time excite inflammation and necrosis of tissue resulting in a discharge of glairy material representative of the condition. This form of dental disease will be further discussed.

¹ Dental Cosmos, 1901.

CHAPTER XXV.

PYORRHŒA ALVEOLARIS.

WHILE the term pyorrhœa alveolaris implies but one symptom common to several distinct varieties of disease of the pericementum, that of a flow of pus from the alveolus, it is generally understood as a term descriptive of degenerative conditions which have some distinctive features; these are a progressive loosening of the teeth attended by a loss of the retentive structures, alveolar walls, and pericementum, the loosening of the teeth being in a majority of cases attended by a flow of pus from the margin of the affected alveolus, and by deposits of calculi upon the sides of the denuded roots. The disease ceases spontaneously with the loss of the teeth; the resorption, loss, or atrophy of the alveolar wall being arrested at any period of the disease, if the affected tooth be extracted.

Causes. The several clinical varieties of this disorder all seem to be associated with an obvious infection which in turn has found a favoring condition in a degenerative state of the pericementum or gum margin of one or more teeth. While this is probably true, investigations in this direction have proven negative in so far as the determination of a specific bacterium is concerned.

Galippe and Malassez, Miller, Black, Goadby, Younger, Cook, and others have all failed to definitely isolate such a specific bacterium. The closest approach to a demonstration yet made was the determination by Kirk of the presence of a pure culture of the diplococcus pneumoniae in a few cases of freshly opened pericemental abscesses (which see).

The investigations of Goadby, however, do not confirm this as a cause of pyorrhœa alveolaris in general, but rather point to the probability that the cause may be found among other oral bacteria, possibly thread forms or some of the blastomycetes.

Mr. Sydney Vines¹ reports a case of intense suppurative stomatitis and gingivitis with great salivation due to gonorrhœal infection by the medium of the hands and a toothpick in a patient suffering from gonorrhœal urethritis. The gonococcus was found in the mouth.

¹ British Journal of Dental Science, 1903.

This, of course, has no definite relation to ordinary pyorrhœa.

Curtis¹ believes obstinate cases of the disease to be either caused by or aggravated by tertiary syphilis. He bases his belief upon observations of fresh blood which, he states, upon the authority of Dr. Robert L. Watkins (New York City), contains syphilitic spores.

"Egg-skin" eschar is the oral pathognomonic sign.

The local infection in nearly all cases is of so mixed a type as to render it at present uncertain whether the liquefaction of the peridental membrane, etc., is due directly to the pyogenic organisms present in the pus formed or to other oral bacteria of uncultivable type which may irritate the process, after which pyogenic organisms may enter and form pus. The fact that pyorrhœa alveolaris is seldom found fully established before thirty years of age, but is common after that period, and that it occasionally occurs in youth or even in childhood in association with some pronounced systemic state or disease, strongly indicates a systemic factor in the more pronounced forms of the disease. It is probable that the various systemic diseases—*e. g.*, rachitis in childhood, Bright's disease, anæmia, or neurasthenia in adults, etc.—have a degenerative influence over the pericementum in one of two ways: 1. By introducing the factor of retention of normal or abnormal waste metabolic products within the body fluids which, presented as food to the pericemental cells, act as irritants (autointoxication).

2. Through a possible deprivation of the pericemental tissue of necessary nutritive material (tissue starvation)—*e. g.*, as in anæmia.

It is a well-known fact that peripheral nutrition is disturbed by systemic conditions—*e. g.*, the rapid falling out of quantities of the hair during periods of excessive drain upon the system, as, for example, during lactation.

At other periods no such result may be noted. The presumption is that a disturbed peripheral nutrition or circulation from any cause renders the part affected less resistant to the action of the micro-organisms.

The investigations of Michaels and Kirk upon the composition of saliva in various systemic states throws much light upon the possibility of the presence of the before-mentioned irritants in the blood fluid. Kirk² reports the finding of quantities of sodium oxalate in the urine of certain patients suffering from malnutrition and neurasthenia. These later followed by the appearance in the saliva and urine of calcium oxalate. These are, of course, derived from the blood. The

¹ Dental Cosmos, 1901.

² Ibid., July, 1903.

presence of sodium urates in the blood in gout is well established. Using these substances then as a foundation for argument, it is seen that no reason exists why these (and other waste products as well) should not float through the capillaries and lymph channels or even the glands of the pericementum, and produce irritation which may be followed by atrophic or hyperæmic changes in that tissue. These changes are well known to lead to degeneration, and degeneration lessens resistance. At this point the micro-organisms produce active effects which previously are resisted. In this connection the fibroid degeneration of the pericementum due to age, demonstrated by Hope-well-Smith, should have some consideration as a predisposing cause at the proper age.

It is not to be supposed that local causes are not competent to produce pericemental degenerations—*e. g.*, such causes as malocclusion, over-use, abuse, and disuse of teeth; the lack of friction necessary to maintain the normal tone of the gums; the excess of friction in some cases.

The presence of fermentable material about the necks of the teeth, particularly those of the narrow-necked variety, causing the precipitation of calculus, may all excite the degenerations following chronic irritation, and thus favor the development of the bacteria producing pyorrhœa.

It has been argued, notably by D. D. Smith, that if the teeth be frequently thoroughly cleansed of all deposits of all sorts the pyorrhetic conditions will be cured. The success which seems to attend the use of the *x*-rays and high-frequency electric current in this condition is also argument that the cause may be killed out by local treatment alone. It does not follow, however, that a cure by removal of a cause implies a lack of predisposition on the part of the tissues of a part or individual. The tendency in some cases to relapse unless the cause be continually removed is a proof of this fact.

It has been shown, on the other hand, that intelligent attention to systemic conditions has been followed by amelioration or in some cases even cure of the pyorrhœa when local treatment alone (apart from constant attention) has failed—*i. e.*, an increased resistance of the tissues to the bacteria present has been brought about by the systemic treatment.

The argument that pyorrhœa alveolaris is of purely local origin, because it disappears after the tooth is extracted, is no more sound than would be the argument that gout in the great toe is of local origin because it disappears with the amputation of the leg. Pyorrhœa is

a disease of the dento-alveolar joint (the pericementum), and extraction eliminates that joint.

It is also argued that the local infection is competent to produce not only the gingivitis, but also by the production of toxins, either in the oral cavity or at some point in the alimentary canal, to produce the systemic malnutrition.

When the long continuance of oral infection is considered, this view is entitled to great respect, but the general predisposition must again be a factor in the advance of the disease.

In brief it may be stated that the infectious nature of pyorrhœa alveolaris is becoming more established, albeit not yet fully scientifically proven, and that the causes require a local predisposition for their action. This local predisposition may be the outcome of local sources of irritation and degeneration alone or be produced by waste products floating in the blood stream, etc.

Clinically, fully established cases of pyorrhœa alveolaris may be divided into two classes: (1) cases associated with a primary gingivitis and with the formation of hard, scaly, dark, annular calculi beneath the gum margin (subgingival calculus), the pockets not usually extending far beyond the deposits; (2) cases beginning with a marginal gingivitis and apparently not dependent upon the association with calculus, though frequently complicated by it; (3) cases having an apparent origin at some point between the gingival margin and the apical tissue, the gingival margin at first being apparently intact.

It is probable that the nature of the infecting agent in these types are different or that in the event that they may be proven to have a similar origin the tissues react differently to them, either partially resisting them, forming calculus as a result of the irritation, or rapidly giving way to them, permitting a deep action.

In the absence of known causes the conditions may be divided according to their clinical expressions.

In the consideration a pus flow due to apical abscess, lateral abscess upon a perforation, or that due to obvious salivary calculus is excluded. (For these see under proper headings.)


PYORRHŒA ALVEOLARIS BEGINNING AS A MARGINAL GINGIVITIS AND ASSOCIATED WITH SUBGINGIVAL CALCULUS.

Causes. The causes of this condition are those predisposing and exciting causes of marginal gingivitis which have been described. (See p. 524.) Several local factors have to be considered in this

connection: (1) the marginal infection; (2) the irritative effects of any calculus that may be formed; (3) the deep infection by pyogenic organisms; (4) the modification of the progress of the disease by the attendant loosening of the teeth and death of the pulp.

Clinical History, Pathology, and Symptoms. There is usually an unclean condition of the teeth (Fig. 473); infection exists either in tenacious films of bacteria attached to the necks of the teeth and requiring reasonably close observation for their detection, or in masses of detritus readily noticeable. Subgingival calculus is obviously present.

FIG. 495.



Serumal calculus, showing stalactite-like formations. (Talbot.)

The gum margin may be atrophied and inflamed, or it may have a fairly normal appearance. When the gum margin is pressed upon, pus may be squeezed out in variable quantity.

It is assumed that the local infection brings about fermentation at a point beneath the gum margin, and that formation of subgingival calculus occurs, followed by pyogenic infection and pus formation.

The gum may now be resorbed and the calculi be exposed. In this manner the bifurcations of the roots may be uncovered and calculi be deposited in that situation. The resorption may only be confined to one side of a root and be the result of several successive depositions which may remain when the gum recedes, or which may be removed

and again be deposited (Fig. 493). In this way the side of the root may be exposed nearly to, and in some cases quite to, the apex. In such cases the pus pockets may not be deep and the pus formed may readily be washed away. Instead of this the pericementum may be progressively destroyed by suppuration and the gum margin remain practically intact. In these cases the pus flow is more abundant, a deep pocket is formed, extending a third or even two-thirds or more of the length of the root. It is common to find beads of calculus deposited along the side of the root and presumably of serumal origin. (See pyogenic calculus.)

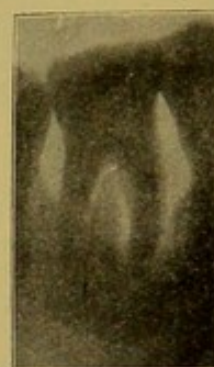These inflammatory disturbances necessarily involve an interstitial gingivitis or infiltration of leukocytes into the interstitial connective tissue of the gum. As pointed out by Talbot, resorption of various kinds and at times constructive changes accompany such an inflammation. (See interstitial gingivitis.) These results are noted in connection with this variety of pyorrhœa alveolaris. In the early stages of the disease the probe usually fails to discover uncovered alveolar bone, although it may do so. If not uncovered its loss is due to resorption; if, however, necrotic and bare alveolar bone be found it is undergoing a molecular necrosis under the influence of the pyogenic organisms.

In some cases the pericementum may be destroyed at the cervical third of the root, the alveolar process may be resorbed on its inner surface, and an accompanying constructive irritation may cause the deposition of bone upon the outer aspect of the alveolar process; the gum margin is also thickened by cell proliferation. The condition imparts the appearance of hypertrophy of the gum and gum margin (Fig. 497).

When about one-half or more of the root has been stripped of pericementum and deprived of alveolar support, looseness and extrusion of the tooth become marked. The teeth are nearly always looser than normal, even in the early stages.

The advance of the disease now becomes more rapid; the undue mobility and malocclusion of the tooth excite an inflammatory reaction beyond the directly infected part, so that soreness and looseness are further increased. Extraction at the later stages reveals a thickened apical pericementum as the sole attachment to the bone.

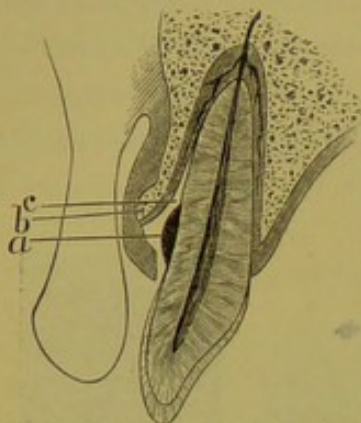
FIG. 496.



Pyorrhœa pockets. Mesial root of molar largely denuded. Treated by amputation. (Price.)

After the looseness of the tooth becomes marked, the pulp of the tooth undergoes hyperæmic changes, reacts to thermal stimuli, and is often killed by strangulation of its vascular supply. Pulp nodules often

FIG. 497.

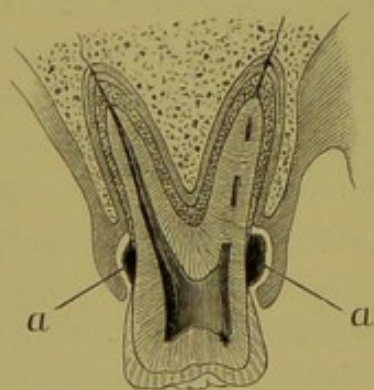


Section of an upper incisor, showing destruction of the periodontal membrane and eversion of the alveolar wall, with thickening of its border: *a*, serumal calculus; *b*, thickened border of the alveolar wall; *c*, pus cavity. (Black.)

are formed before its death. Infection of the dead pulp readily occurs, and septic apical pericementitis arises. The symptoms of the latter condition are modified, according to the facility with which the pus finds vent along the degenerating pericementum. The disease proceeds until the affected tooth or teeth are cast out, the alveolar walls and pericementum having entirely atrophied. The disease ceases with the loss of the affected teeth, leaving a flattened or absent alveolar ridge covered by a mass of more or less spongy gum tissue.

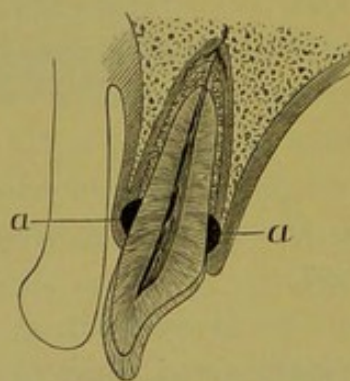
The duration of this disease may be months or years, and a number of teeth may be affected at once. A general subcatarrhal condition of the mouth usually attends the disease. The presence of pus often imparts to the breath a peculiar, sweetish fetid odor which may, however, be masked by an odor of putrefaction.

FIG. 498.



Section of an upper molar with its alveolus, etc., showing deposit of serumal calculus under the gingival borders: *a*, *a*, serumal calculus. (Black.)

FIG. 499.



Section of an upper incisor, showing at *a*, *a*, a deposit of serumal calculus within the free margin of the gum. (Black.)

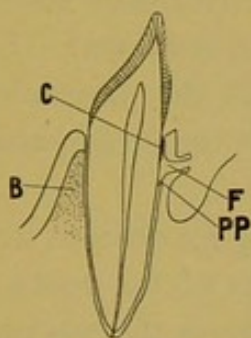
In a number of cases of deep pyorrhœa pockets an infection of the alveolar structure, or, at least, of the tissue remaining over the deepest portion of the pocket, may occur, and an abscess form which discharges by a fistula through the labial or lingual aspect of the gum.

It is to be regarded as an abscess secondary to a primary pyorrhœa alveolaris. The passage of a silver probe through the two sinuses at once will reveal this (Fig. 500).

In one case of pyorrhœa alveolaris of the variety under consideration the pocket existed upon the mesobuccal aspect of a right lower third molar. The second and first molars were absent. The pus dissected away the periosteum of the bone and formed a large abscess over the entire area of bone between the third molar and second bicuspid. After evacuation of the abscess, the probe was passed through it to the pyorrhœa pocket (Fig. 501).

While dental caries may occur with pyorrhœa alveolaris, it is usual to find the teeth of the most highly organized structure. The pulp tissue is usually increased in density, and there is a tendency to the constructive changes, secondary dentine, nodules, etc., and the inevitable degenerative changes following these diseases.

FIG. 500.



Gingival abscess secondary to pyorrhœa alveolaris. C, calculus in pyorrhœa pocket; F, fistula leading to pocket PP; B, bone on lingual side.

FIG. 501.

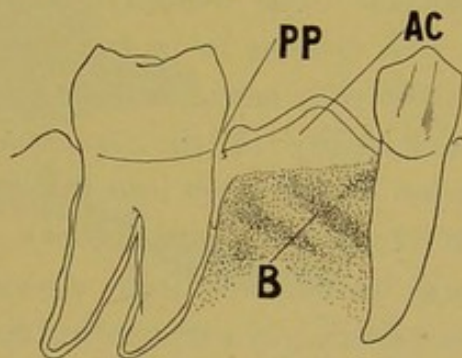


Diagram of abscess secondary to pyorrhœa alveolaris (see text). PP, pyorrhœa pocket; AC, cavity of secondary abscess; B, bone.

It has been contended that these pulps are responsible in a measure for the pyorrhetic condition, and it is possible that they may by reflex action influence the tissue nutrition of the pericementum and gum margin, though the contrary process is quite as probable. If the pulps be degenerated their removal aids the cure of the disease by diverting the blood they receive into the pericemental bloodvessels. This probably counterbalances the effects of the endarteritis obliterans. (See interstitial gingivitis.)

It is also true that calculus does not seem to form as readily upon a devitalized tooth as upon one containing a vital pulp; it does form at times, however.

Diagnosis. The diagnosis is easily made when the disease is established by observance of the phenomena just described. A persistent

gingivitis with an exaggeration of the space between the tooth and gum margin means, as a rule, a future pyorrhœa. The same is true of a receding gum margin constantly associated with an uncleanly tooth cervix. The causes of the condition are to be removed and the patient cautioned to seek frequent dental attention as a prophylactic measure.

Prophylaxis. As outlined above, the prevention of pyorrhœa alveolaris of the first class involves the removal of the local and, if possible, the systemic causes of the gingivitis, and the systematic cleansing of the teeth at short intervals. The daily use of the toothbrush and antiseptic powders and washes by the patient is also important.

D. D. Smith advises for this class of cases a thorough cleansing once a month, or at first even oftener. The cleansing is to be done with an orange-wood point, grasped in a Smith or Cogswell carrier and charged with pumice paste. The local sources of gum infection are thus continually removed and the gums stimulated by the mechanical irritation with the wood point.

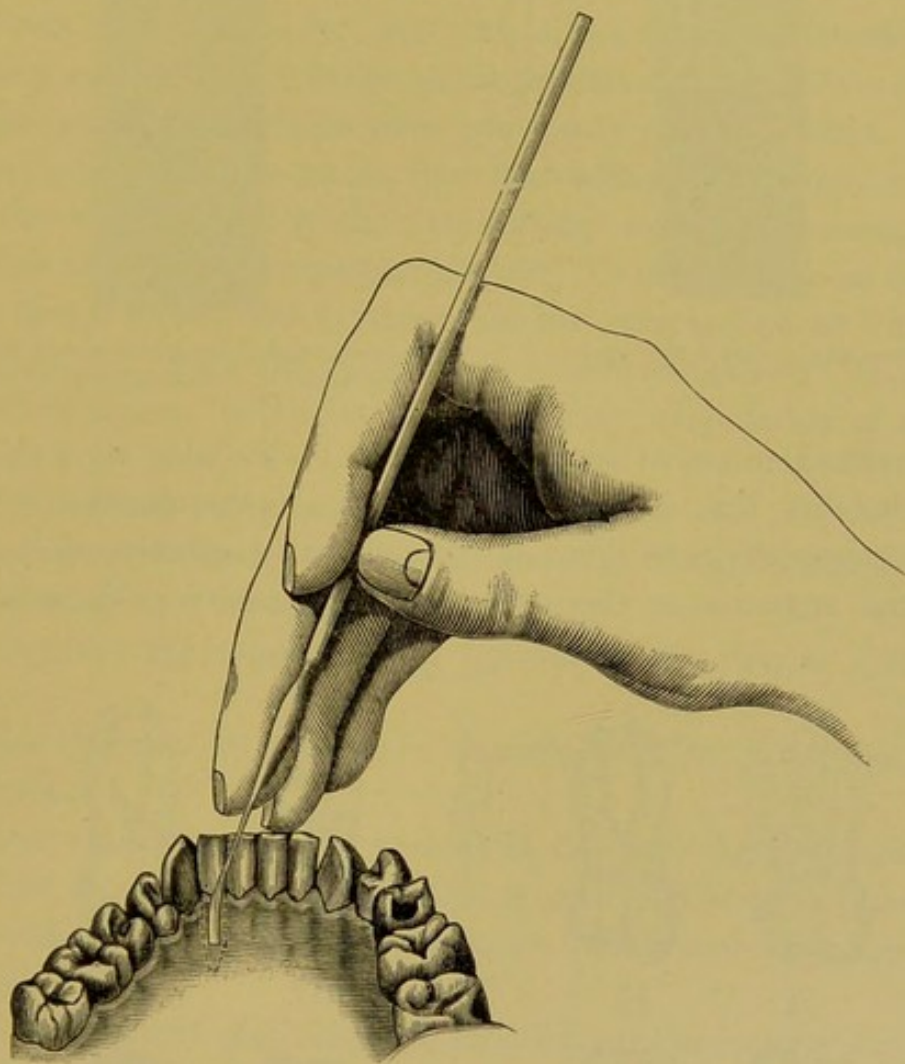
Treatment. The treatment of well-established pyorrhœa alveolaris of the first class is to be considered under three headings: (1) the removal of pus, calculus, and bacterial films; (2) the prevention of extreme mobility; (3) the medicinal treatment and the prophylaxis, or prevention of a relapse into the diseased condition.

THE REMOVAL OF THE CAUSES. Calculus being an obvious irritant it should be removed from crowns and all parts of the roots. To prevent infection of surrounding tissues and to remove the pus present the pockets are to be flushed out with hydrogen dioxide, which may be done by means of a syringe with fine nozzle or an atomizer operated by hand or preferably by compressed air. The forcible spray lifts away the gum margin and cleanses the pockets mechanically as well as chemically. The mouth is sterilized at the same time. If large quantities of supragingival calculus exist it is well to next remove the gross deposits and permit the patient to use an astringent, antiseptic mouth-wash for a few days or the operation may be proceeded with.

Following this, cotton containing 25 per cent. pyrozone or 10 per cent. trichloroacetic acid is to be packed into the gum pockets in order to superficially constrict the gum tissue, lessen the hemorrhage, and render more facile the removal of the subgingival calculi. The latter is accomplished with scalers of any suitable form. Those consisting of flat blades to be used with the push cut are best adapted to deep-seated calculi, while the more superficial deposits may be removed with small, draw-cutting excavators.

Fig. 502 illustrates the method of guarding against unnecessarily wounding the soft tissues. If the calculi be extraordinarily inaccessible the pockets may be enlarged by packing for ten or fifteen minutes with cotton tampons saturated with the 10 per cent. trichloracetic acid, which also softens the calculi, or salicylized cotton may be left in the pocket for a day (Black). In some cases cocaine injections or applications

FIG. 502.



Showing the manner of holding an instrument for detaching calcareous deposits when using the pushing motion. The third finger rests on the edges of the teeth, allowing freedom of the hand to make rapid and effectual movements in dislodging the calculi.

must be made to prevent excessive pain. After removal of the bulk of calculus with scalers, any fine granules or gummy collections may well be rubbed off with Rhein's or coarser proximal trimmers, and the roots should then be rubbed with aromatic sulphuric acid by the aid of an orange-wood point mounted in a hand carrier. This is to be immediately followed by a syringing with bicarbonate of soda; after this medicinal applications are made. (See later.) Good results are

obtained by the use of pumice with the stick. The scaling of each tooth is to be completed at one sitting, as repeated scalings interfere with the regenerative process.

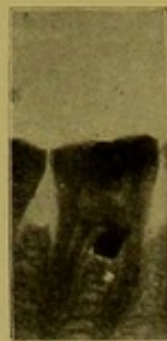The gum margins are not to be unnecessarily wounded, but very redundant granulations may be cut away. In cases of excessive loss

FIG. 503.



Pyorrhœa pocket in bifurcation.

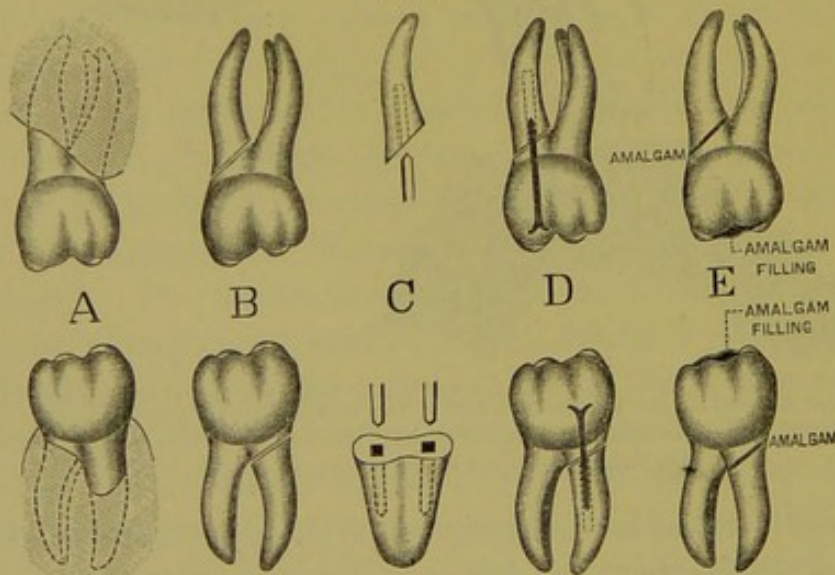
FIG. 504.



The same treated by scraping and filling with gutta-percha. (Radiographs by Price.)

of the pericementum of one root it is well to devitalize the pulp, as, in all probability, that organ will have been overstimulated and will be in a degenerative condition, and sometimes is actually infected. An abnormal response to thermal changes (ordinary cold) may occur

FIG. 505.



Heteroplasty following the amputation of natural roots. (Rheim.)

(hyperæmia or inflammation), or the pulp may fail to respond to extraordinary cold (ethyl chloride), indicating degeneration. It has been claimed by Rhein, Smith, and others, that if the pulp be devitalized the nutrition received by it will be diverted into the pericementum

to the benefit of the latter. Clinical experience seems to confirm this statement. The method also permits the use of pins placed in the root canal as part of an appliance fixing the teeth in position. W. A. Price recommends that an exposed pocket in the bifurcation be treated by scraping and filling the same with gutta-percha. If the pulp be devitalized the bifurcation may be opened for the purpose of successfully placing the gutta-percha, which is known to be well tolerated by the soft tissues (Figs. 503 and 504). In case of hopeless involvement of one root of a multirouted tooth the root may be amputated if the remaining roots will endure the strain put upon them. The canals of the roots retained must have been previously carefully filled.

Rhein¹ calls attention to the fact that collections are apt to occur about the surfaces left by the amputation, and that postextraction resorption of the alveolar process occurs. To obviate this he suggests the use of a porcelain root to replace the lost root, and about which the tissues contract firmly and remain in a healthy condition. This operation Rhein terms "heteroplasty following the amputation of natural roots."

Briefly outlined the process is as follows:

1. Prepare and fill the root canals as far as the pulp chamber; fill this with temporary stopping.
2. Amputate the necrosed root by means of a fissure drill, and remove.
3. Coat the root with a film of paraffin to allow for shrinkage of the porcelain.
4. Take an impression of one-half of the root (longitudinally) by embedding in plaster; make articulating grooves and pour plaster for an impression of the other half; separate and remove the root from the plaster.
5. Burnish matrix platinum into each half of the impression, stiffen with porcelain, and reburnish. Complete one side with porcelain as in inlay work, in the other fuse a platinum box formed over a square platinum pin (this pin should be left in the box until the packing of the porcelain about the box is complete).
6. Flatten the proximating sides of the halves; paint with thin, fresh body; press together and fuse.
7. Strip off all platinum and dress off all protruding points, coat the entire porcelain with a thin film of body, place in furnace in an upright position, and heat almost but not quite to a glaze.

¹ Dental Cosmos, September, 1900, and September, 1902.

8. Wash out socket of natural root with antiseptics and remove temporary stopping from the crown cavity; try porcelain root in place, and if right dry everything; fill the box with cement, return the root to place, and pass the pin through crown cavity and into the root box. Adjust root, leaving a slight space for an amalgam joint.

9. Pack the crown cavity and the joint with amalgam, and at a later sitting finish the same.

THE PREVENTION OF EXCESSIVE MOTION. The excessive movement of loosened teeth but increases the interstitial gingivitis in the remaining tissues. These demand rest. Any excessive occlusion due to the swelling of pericemental tissue may be compensated for by grinding the occluding surfaces. Such excessive occlusion and motion are readily detected during the act of occluding the teeth or by means of carbon paper. Slightly loosened teeth may be temporarily splinted with ligatures of wire or floss silk. To prevent the slipping of these

FIG. 506.

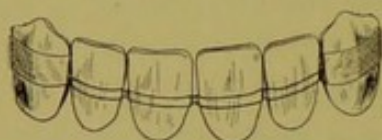

Diagram showing labial view of Mitchell's splint, with two bands and wiring.

FIG. 507.

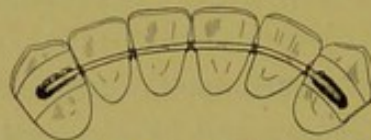


Diagram showing lingual view of Mitchell's splint, with two bands and bar.

toward the gum margin it has been suggested¹ that small buttons of Harvard or other adhesive zinc phosphate be placed upon the labial faces of the teeth while under the rubber-dam. The floss silk may be saturated with a solution of chemically pure celluloid in acetone (155 grs. to 500 grs.)² to render it impermeable and more lasting. The preparation after application is allowed to dry under the dam to a coagulum and then dismissed for twenty-four hours, when it may be polished. It lasts for several months. For certain cases Dr. Hugh Mitchell has suggested a bar of iridioplatinum wire adapted to the lingual surface of the teeth to be splinted, and soldered to simple gold bands to be attached with cement to two of the teeth adjoining the loose teeth. The other teeth are braced to the splint with fine wire, gold or platinum being preferred for anterior teeth.

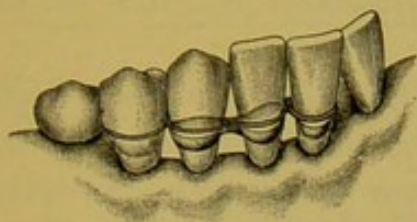
Such a splint may be quickly made and is very effective, all slipping of ligatures being prevented; moreover, the wire may be kept away from the necks of the teeth and the gums. After a reasonable period of immobility the attachment secured by treatment may be tested (Figs.

¹ Reitz.

² Kowarska's paste

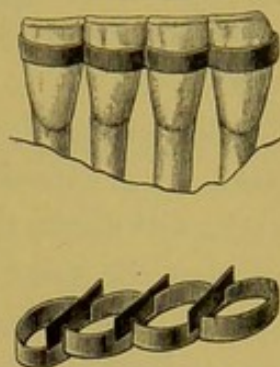
506 and 507). Very loose teeth which have lost much of their supporting alveolar process must be secured by permanent splints. The simplest of these is a series of rings soldered together or its equivalent, shown in Fig. 509. The teeth are firmly ligated at their necks with floss silk. A wire measure is taken of the entire circumference of the teeth to be

FIG. 508.



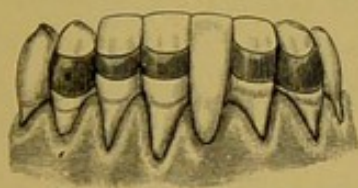
Temporary splint of silk floss or silver wire, 30-gauge (one turn only shown). Buttons of zinc phosphate. (Rhein.)

FIG. 509.



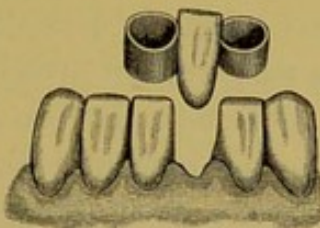
included, allowance being duly made for burnishing. A piece of thin platinum No. 34 gauge and one-eighth inch wide is cut to measure and a lap joint made and soldered. The ring is placed upon the teeth and moulded to their surfaces and to their interspaces. The thinnest separating saw is used to cut almost through the splint on both sides at one interspace. In this groove a straight piece of the platinum is

FIG. 510.



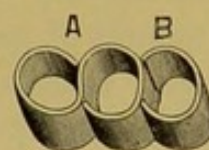
Five rings and included artificial tooth. (Evans.)

FIG. 511.



Two rings and included artificial tooth. (Evans.)

FIG. 512.



Method of making rings as in Fig. 510. (Evans.)

placed and the whole withdrawn from the teeth and the joints soldered. The process is repeated at another interspace and so on until the piece is complete. If the teeth are very tender a plaster impression of the tips of the teeth may be taken and the work done on a fusible metal model. If space be necessary the teeth may be slightly disked upon their proximal sides. If such spacing be not desirable the necessary room can usually be obtained at the median interspace, but one platinum septum is placed and the piece is to be

somewhat stiffened with solder at the indentations representing the interspaces.

Evans' method is readily comprehended by reference to Figs. 510, 511, and 512.

These splints are to be cemented with adhesive zinc phosphate so manipulated as to set quickly, and this is best done with the rubber-dam in place. Quick-setting Harvard cement is excellent.

The foregoing splints are too conspicuous for use in some cases.

A simple device introduced by Dr. L. C. Bryan¹ consists of a pure-gold band about one-eighth inch wide and nicely bevelled at its edges, and is adapted about the necks of the lower incisor teeth to be splinted in somewhat the same manner that the splint illustrated in Fig. 509 is adapted. Particular attention is paid to the interspaces in the endeavor to bring the labial and lingual sections together at that point. When ready the piece is sprung off, the rubber-dam is applied, zinc phosphate is placed within the band and upon the necks of the teeth at all points, and the band is put in place and burnished. Before the cement has set gold wire is to be passed around the interdental portions, tightly twisted, and the twisted end cut off to within one-eighth inch of the band, and the remainder bent back into the indentation in the band. Dr. Bryan recommended gold clamps in the place of wire, but these are difficult of adaptation.

Such a piece is to be placed only on those lower incisors about which salivary calculus promptly collects, and should be avoided in the mouths of patients who will not present frequently for prophylactic service. Confined to such cases they do good service and the cement does not readily wash away; indeed, a slight coating of calculus seems to protect the surface of it from solution. If the calculus be kept from the gum margin this does no harm.

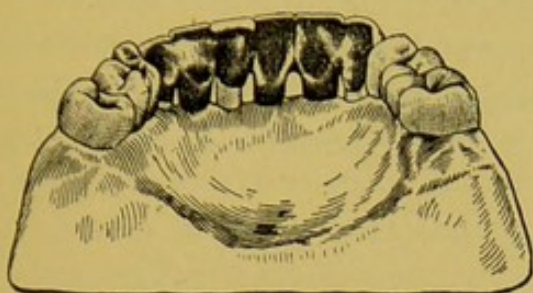
Several devices have been offered which require the devitalization of the pulps and filling of the root canals of the several teeth to be splinted.

D. D. Smith² suggests reduction of the lingual surfaces of the teeth and the fitting to them of thin metal backings, which, after adaptation to the teeth, are perforated and pins are thrust through for the root canals. After soldering each pin to its plate, readapting the latter and stiffening with solder, an impression is taken and the plates are united. The whole piece is cemented to place with the rubber-dam

¹ International Dental Journal, 1899.

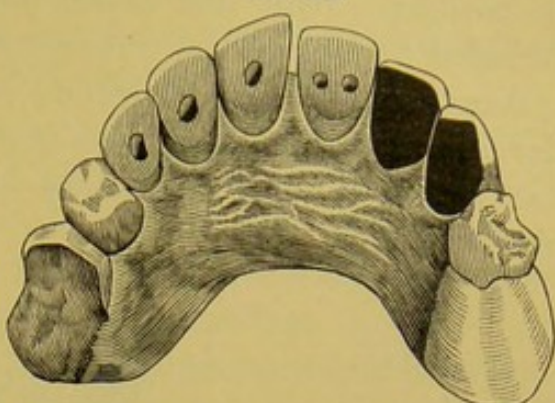
² Dental Digest, 1902.

FIG. 513.



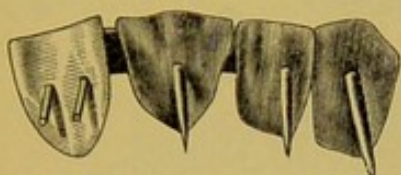
Splint for securing previously treated lower anterior teeth. (Ames, after Smith.)

FIG. 514.



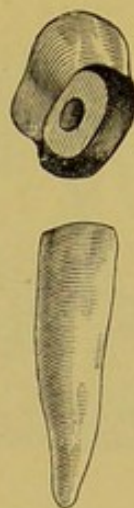Upper teeth prepared for splint. (Ames.)

FIG. 515.



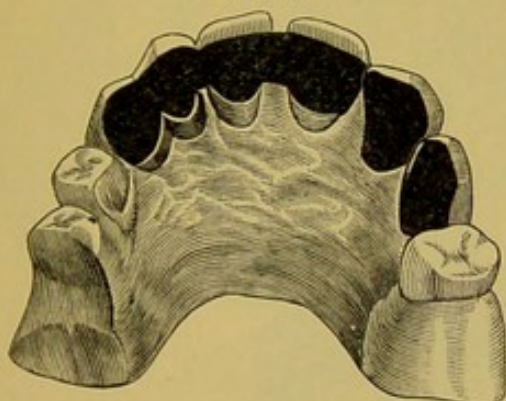
Splint for use in the case shown in Fig. 514.

FIG. 517.



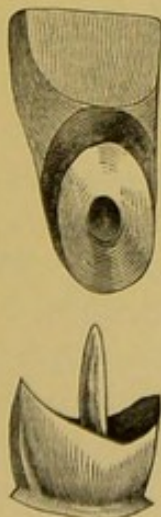
Root with cap fitted. (Ames.)

FIG. 516.



Same as Fig. 514. Splint in position.

FIG. 518.



Tooth with Richmond cap. (Ames.)

FIG. 519.

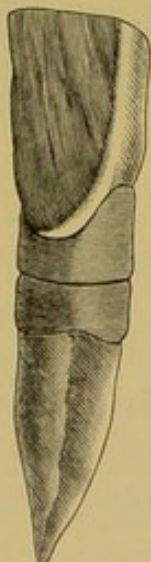
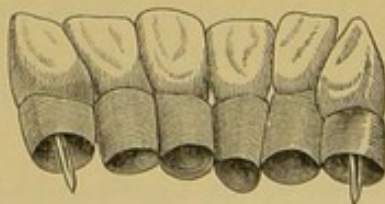


FIG. 520.

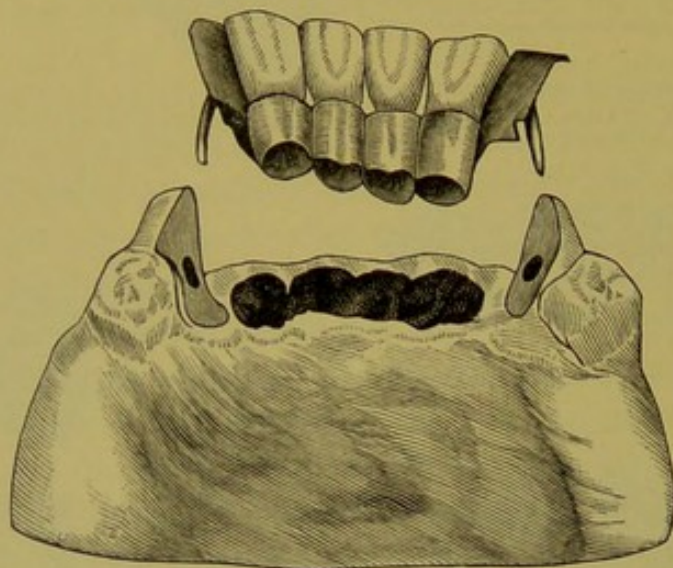


Splint for lower incisors. (See text.) (Ames.)

in position. With this device one or more artificial teeth may be included to replace lost incisors (Figs. 513, 514, 515, and 516).

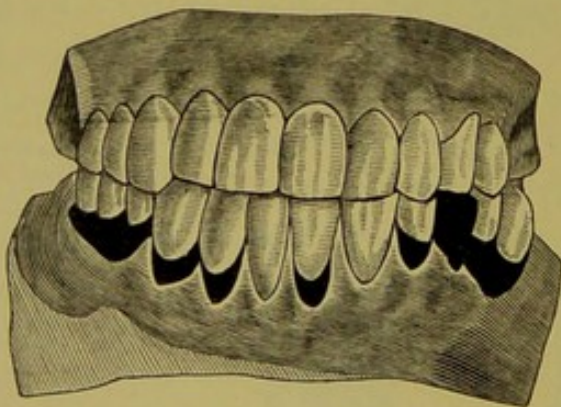
Ames¹ suggests that in certain cases of lower incisors the teeth be devitalized and amputation be performed at the neck of each. Each root is then trimmed and fitted with a gold Richmond cap without pin (Fig. 517).

FIG. 521.



Splint for lower incisors. (See text.) (Ames.)

FIG. 522.



Splint and double saddle bridge combined. Front view. (Ames.)

Each natural crown is slightly trimmed and fitted with a gold Richmond cap with a pin (Fig. 518). These two caps are united with wax, carried to the mouth and adjusted in position. Each is then carefully removed, the natural crown laid aside (in water), and the gold sections invested and soldered together (Fig. 519). The individual parts are readjusted in the mouth, an impression taken, an investment made,

¹ Dental Cosmos, 1903.

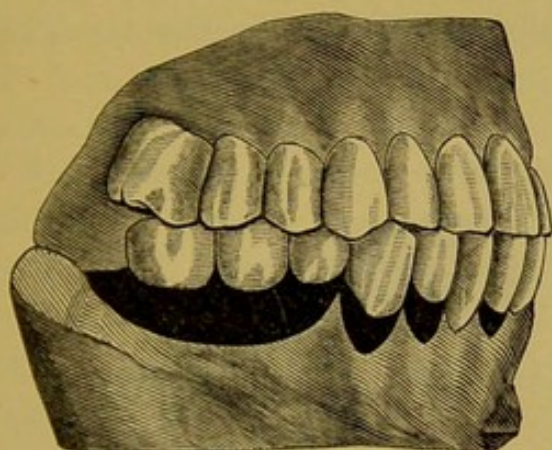
and all soldered together. The natural crowns are then fastened in their prepared sockets with cement and the piece is cemented to place. Pins may be placed in the roots if desired (Fig. 520).

If desired the piece may be further attached to the adjoining teeth by means of the lingual plate and pin (Fig. 521). The Ames device would be useful in cases in which proximal cervical caries exists.

It may be stated that three or four teeth fairly loose individually when united together may, as a whole, be quite firm.

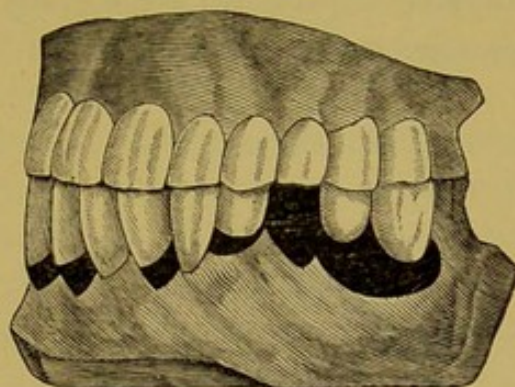
Ames further suggests that in case the pericemental attachment is hopelessly lost such teeth may be extracted, the roots amputated and prepared as for replantation, and then adjusted in the gold bridge, otherwise made as above described. These roots are to go in their

FIG. 523.



Right side of extension bridge, shown in
Fig. 522.

FIG. 524.



Left side of extension bridge, shown in
Fig. 522.

own sockets, and, being firmly fixed in position, the tissues settle about them.

Ames claims that the extension bridge shown in Figs. 522, 523, and 524 lasted five years and was in as good condition then as at the beginning. Fig. 522 gives the anterior view, Fig. 523 that of the right side, and Fig. 524 that of the left side.

Rhein offers the following: After pulp removal and root filling a transverse groove is cut in the lingual side of the central or loose teeth and a half-groove upon the mesolingual aspect of the pier teeth. A staple is formed of triangular iridioplatinum wire to fit into the root canals of the pier teeth. To this is soldered a pin for each of the central teeth. The face of the wire should approximately fit the bottom of the groove. Rhein suggests the following method of attachment: (1) fill the root with a paper point, place cement over that, and

fill the cervical margin of the cavity and its floor with gold; (2) drill through the gold to the paper point, remove it, and refit the retaining appliance; when ready set with zinc phosphate, avoiding excess; (3) when this is set cut away to the gold and complete the gold fillings.

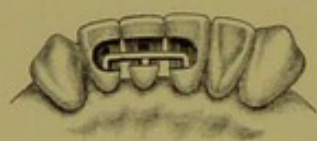A less elegant but still practical method would be to cover the pins with a good, color-keeping amalgam pressed into the excess of cement before it has set. The margins are then to be freed of cement and the operation completed with amalgam, which later should be polished.

Smith's, Rhein's, and Ames' devices permit the use of an artificial tooth if necessary. The same may be said for the device which consists of a series of gold rings (Evans').

For the molars and bicuspid Rhein's device is transferred to the occlusal surface (Fig. 526).

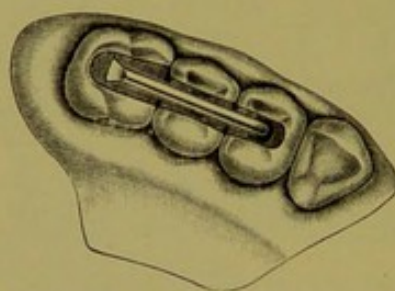
Short metal caps made for the incisal tips of lower incisor teeth adjoining a space will successfully hold a bridge tooth. The device is, however, rather conspicuous.

FIG. 525.



Permanent splint for cases of pyorrhœa alveolaris in upper or lower incisors. (Rhein.)

FIG. 526.



Permanent splint for cases of pyorrhœa alveolaris on molars and bicuspid.

For the molar and bicuspid teeth it seems good practice to adapt short crowns to the partially trimmed teeth and unite these with solder. A sort of bridge is thus made which causes the teeth to be firm even if all are originally loose. It is mainly this factor which renders bridge-work useful in pyorrhœa alveolaris upon isolated teeth.

The use of united barrel crowns reaching the gum margins is at times useful, but the configuration of exposed roots may render this impossible in some cases.

By the use of pure-gold bands, which may be stiffened occlusally with solder to gain strength, better adaptation at cervical portions may be obtained by hand burnishing after cementation of the piece.

All appliances cemented to the teeth and having a free margin are subject in some degree to a solution of the cement. These cases should

be seen frequently in any event for prophylactic purposes, when the condition of the appliance may be noted.

Extraction and bridge-work may be at once resorted to in some of the aggravated cases, though if the appliance be mechanically constructed teeth which may be extracted with the fingers may be firmly held in splints for years. While this is a fact, good judgment may demand the early removal of such teeth before an appliance is constructed.

If desired the bridge may be made so as to mount the natural teeth after their extraction, by constructing sockets of gold for the reception of the necks of the teeth somewhat after the manner employed in the Ames method. The sockets are then soldered to each other and to the bridge piers, after which the teeth are attached.

These sockets are to be made deep at first, and it is well to attach the teeth with gutta-percha in order that the row of sockets or a new row may be lowered to fit the gum if desirable. This will require the raising of the teeth to the occlusal level.

The Medicinal Treatment and Prophylaxis. The pockets after scaling should be forcibly syringed or sprayed with hydrogen dioxide to sterilize the pockets and remove particles of calculus, and then cauterized with either lactic acid, full strength (Younger); trichloroacetic acid, 25 or 50 per cent. strength (Kirk); or sulphuric acid, 25 per cent. strength (Truman). If the case be of local origin the application of tincture of iodine to the gums every other day and the judicious use of a well-made and hard brush (the "S. S. White 2½," "Prophylactic," "Sanitol," or Talbot's will serve) well charged with an antiseptic and astringent tooth-powder, will cause the gums to resorb to a healthy consistency.

Dr. A. B. Harrower has suggested the following formula for a powder which has in his own and my hands given good results as an astringent antiseptic:

R—Magnesium carbonate,	lb. j.
Cream of tartar,	lb. iss.
Red cinchona bark,	ʒij.
Calcined alum,	ʒj.
Oil peppermint,	fʒv.
Oil cinnamon,	fʒiiij.
Oil rose geranium,	fʒj.

All ingredients to be finely powdered. The oils to be added to the magnesium before thorough mixing of the powders. The whole is to be sifted through silk.

Saccharin may be added to the above as a sweetening agent. The powder when wet is almost neutral, and should do no harm in its limited use as a therapeutic agent.

Truman advocates the use of quinine sulphate to be packed in the pockets as a germicide, and as inhibitory of diapedesis of leukocytes.

Black has recommended the use of the 1-2-3 mixture, or phenol-camphor, to be put into the pockets every three days, and a few drops to be used on the toothbrush.

R—Oil of cinnamon,	1 part.
Carbolic acid,	2 parts.
Oil of gaultheria,	3 parts.

R—Gum camphor,	
Crystal carbolic acid,	āā q. s.
Mix in a mortar to an oily fluid.	

Argyrol, a compound of metallic silver, is less irritating than silver nitrate, and may be injected in 25 to 50 per cent. aqueous solution with marked benefit. The application may be made twice a week.

Regeneration in the pockets should not be disturbed, so that unless the pus flow be active one should wait until sufficient time has been afforded (about ten days) for granulations to form. If pus be then detected the pocket should be again treated thoroughly. Good results are obtained from the use of an astringent antiseptic wash used in forcible spray from an atomizer. This should be done daily by the patient. Stagnant fluids in the pockets are washed out and replaced by the antiseptic, thus inhibiting the bacterial growth in the pockets and the mouth.

The teeth should be cleansed after meals to prevent media for infection lodging about the interstices, after which the antiseptic spray will aid in destroying bacteria. The gums should be massaged daily by the thumb and forefinger of the patient. This strips the collections from about the gingival spaces and stimulates a healthy circulation.

If the good results of the application of the *x*-rays and high-frequency currents claimed by C. H. Parker,¹ W. A. Price, W. Guy, and others, shall be generally confirmed, it will be a great aid in the prompt reduction of this disease. It is also possible that radium rays, applied by radium-chloride-containing applicators, or radio-active solutions, may, in the near future, have a proven therapeutic value.

The question must be considered as yet *sub judice*. Good results have been obtained in some cases by extraction and replantation, after root preparation and sterilization of the tooth and alveolus. The alveolus may have to be deepened.

If the interstitial gingivitis underlying the case be of systemic origin, —*i. e.*, due to autointoxication from any disease, the alimentary canal,

¹ Dental Cosmos, December, 1903.

the pyorrhœa itself, or to drug action—these should have attention. The systemic disease should, if possible, be cured by correct medical attention. Pyorrhœa patients are of the hyperacid type (Michaels) and treatment should be directed toward elimination of waste products and the reduction of hyperacidity by the use of alkaline remedies. The bowels should be kept active and the skin pores open. Brisk exercise in the open air, if not specifically contraindicated by organic disease, is valuable in both directions. Warm baths followed by cold douches and vigorous rubbing stimulate the skin. Turkish baths followed by massage directed to stimulation of the eliminating organs are valuable unless contraindicated. Free drinking of pure water is necessary to the successful elimination of the waste products of the body. The water entering the blood increases the blood pressure and flushes the tissues and the kidneys, dissolving waste products. Water should be freely taken between or before meals in order that digestion be not interfered with, and if medicated with salts of lithium the alkalinizing effect and solvent action of lithium upon urates are obtained. Patients exhibiting an aversion to water drinking are more apt to take it when medicated than as a physiological necessity.

The prophylaxis of pyorrhœa alveolaris is all important, especially in the cases of systemic origin in which chronic disease or malnutrition may not be readily overcome owing to confirmed habit of life or advanced stage of disease. The local conditions existing even after a cure of pyorrhœa are such as to invite reinfection and the establishment of microbic plaques, which frequent cleansing of the teeth will remove. The system of monthly or, if necessary, more frequent cleansing advocated by D. D. Smith should be practised. Its good results are particularly manifest in this class of cases.

Recurrence of the condition is probable if the oral prophylaxis or systemic treatment be neglected. The simpler cases yield quite readily; the advanced ones, in which much of the alveolar process is lost, tax the patience of operator and patient alike, and are apt to end, sooner or later, in loss of the teeth affected.

This fact, however, should not prevent the retention of these teeth by every means at command during the period for which they may be made useful. If, however, any tooth prove an incurable source of pus formation it should be removed, otherwise the remaining teeth are continuously infected.

SYSTEMIC EFFECTS OF PYORRHŒA ALVEOLARIS.

It has been abundantly shown by Hunter and others that the pus of pyorrhœa and other intense oral sepsis is a source of systemic infection, producing effects ranging from gastritis to actual septic infection. The importance of this fact is not to be lost sight of, and patients are to be informed of the dangers of constant pus formation, as well as of the presence of other forms of sepsis about the mouth and teeth.

Goadby¹ reports the cure of a case of profound muscular weakness, mental depression, and insomnia after unavailing general medical treatment for neurasthenia, as following the extraction of teeth affected by pyorrhœa.

Hunter and Leith² have described cases of subacute and chronic catarrh of the stomach and phlegmonous gastritis due to the ordinary pyogenic cocci, such as are found in the mouth, and which the gastric juice of the stomach of the particular individual at least was not competent to kill. Considering the fact that an oral subacute catarrhal condition is established in pyorrhœa, the local transfer of the infection is not surprising.

D. D. Smith³ claims to have cured cases of confirmed nervous dyspepsia, nervous prostration, and other local and systemic conditions simply through constant dental prophylaxis.

PYORRHŒA ALVEOLARIS NOT DEPENDENT UPON CALCULUS FORMATION.

Phagedenic Pericementitis. By the term phagedenic pericementitis Black has distinguished a form of interstitial gingivitis, the chief characteristics of which are the more or less rapid destruction of a portion of the pericementum and the resorption of the alveolar process contiguous to the lost area; leaving a pocket extending from the gum margin which may be partly intact to a point deep in the alveolus, and from which much or little pus may exude. The disease may be considered under the heading of pyorrhœa alveolaris, beginning with a marginal gingivitis, but of aggravated type and especially virulent infection.

¹ International Dental Journal, July, 1902.

² Transactions Odontological Society of Great Britain, International Dental Journal, 1899.

³ Proceedings Philadelphia County Medical Society, 1903.

Whatever its cause the disease presents a peculiar rate and manner of progress which warrant a special description.

Causes. The causes of this condition seem to be clearly infective, the evidence of this being the fact that it yields only to operation for removal of infected tissue or infective material, and to the action of germicides. Without doubt systemic conditions favoring tissue debility may act as predisposing causes. A proportion of the cases begin with a marginal inflammation of acute form, sometimes associated with calculus formation and sometimes without it. In several cases observed some form of traumatism, such as violent and persistent wedging, blows, etc., or malocclusion, has preceded the development of the disease. The infection usually spreads from one tooth to another; in other cases one or two teeth may be the only ones affected.

Black failed to find any association of this condition with gout, rheumatism, or heredity, but considered the scrofulous diathesis and anæmia as general predisponents. He considers the deposition of calculus, if present, as favoring the action of the infecting fungus, and that the latter is peculiar and of virulent type, though the specific fungus was not established.

He views it as an oral fungus not subject to technical methods of cultivation and study as yet developed by bacteriologists. He regards the pericemental glands as the avenues by which infection travels from the gingival space into the deeper portions of the pericementum.

Pathology. The disease begins with a marginal infection which inflames the pericemental margin. The infection advances toward the apex of the root, either slowly or rapidly, and following often but one side of the root. The pericementum is liquefied, the alveolar process disappears by resorption, and a distinct pocket is formed. The gum may be partly resorbed from about the neck of the tooth, but need not be markedly destroyed.

Hyperostosis of the outer edge of the alveolar process may occur (Fig. 497), or the process may disappear at this point. When the inflammation of the pericementum is deeply established the tooth involved may shift its position laterally, carrying another tooth with it, and elongate far beyond its fellows, sometimes establishing malocclusion, but sometimes the teeth are not in occlusion at all. Black considers this due to the pressure produced by the swelling of the inflamed pericementum.

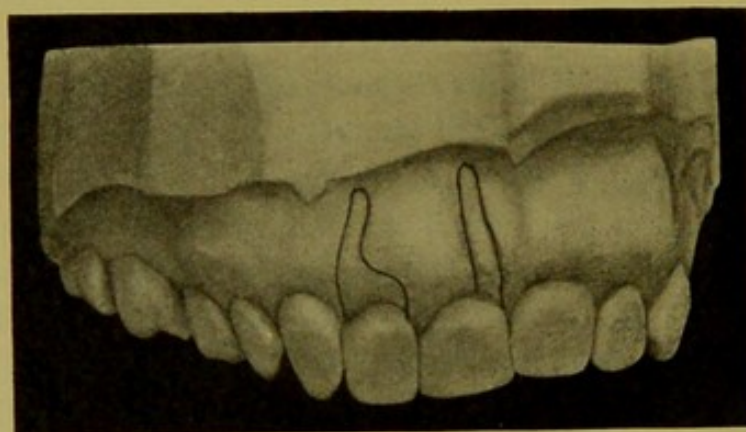
The advance of the disease toward the apex may be very rapid, the pericementum being destroyed even over the apex of the root, or

of one root, while the attachment upon the other side of the tooth may hold it in position.

Black regards the absence of decided mobility of the tooth, even though shortly after the tooth may drop out, as characteristic of this condition.

Examination of the area of the root involved usually demonstrates either calculi or a substance of viscous nature or both attached to its surface. Pus may exude in some quantity from the gum margin, but it may not be of great amount. Of course the pocket may afford ingress to the ordinary pyogenic organisms of the mouth, which may not be the primary cause of the disease, but merely implanted upon a favoring soil. The calculus present may be a deposit from this pus or from the serum exuded by the inflamed tissue.

FIG. 527.



Phagedenic pericementitis. Pockets as shown. Teeth were one-sixteenth inch longer, but have been shortened. Practically no calculus and but slight flow of thick, creamy pus. Gum prominent over affected teeth.

The advance of the case may be very slow and limited to the teeth originally involved. The following is an example:

Miss H., aged twenty-five years, presented with well-established pockets, extending one-half inch toward the apex, upon the mesal aspect of the root of the right upper central incisor and distal and distobuccal aspect of the right upper lateral incisor. There was a history of traumatism due to violent and persistent wedging with rubber at about the age of sixteen. The case was then of several years' standing and the two teeth elongated about one-eighth inch beyond their fellows (Fig. 527). The pockets were treated with some benefit and the teeth shortened for the cosmetic effect, but the patient left the city suddenly before recovery, and was not seen again for three years. At this second visit it was found that the pockets

were nearly the same as at first and no other teeth had become involved. Nor had the teeth further elongated.

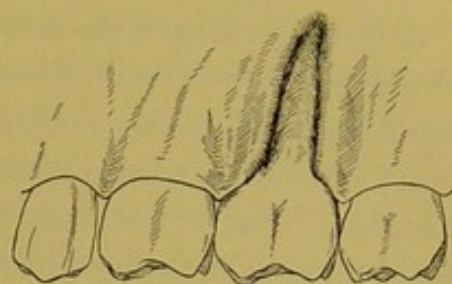
The destruction of the tissues may assume several forms. In certain mouths, especially in neurasthenic and anæmic patients, a viscous material may accumulate upon the necks of teeth or exposed roots; and the pericementum, bone, and gum may rapidly inflame and disappear, leaving the roots exposed to collect more of the material.

The resorption may occur as shown in Fig. 529, or the gum may be split and the destruction follow the length of the root on one side only until even the apex is reached (Fig. 528).

The tooth may be loose or firmly attached by the remainder of the pericementum.

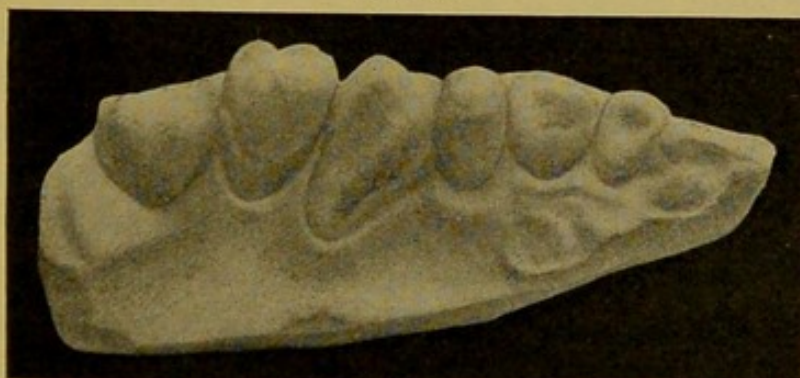Fig. 529 is a model of the lingual side of the right upper teeth undergoing the former process. The left upper posterior teeth and the lower incisors have also been lingually affected. There is but little calculus, but the viscous material is quite abundant, black stain is present, and dental caries is rife. The patient has been anæmic and neurasthenic

FIG. 528.



Destruction of pericementum, bone, and gum over buccal root of a molar.

FIG. 529.



Resorption of gum over palatal root of an upper molar, associated with but trifling deposit of calculus, but the root is covered with a viscid deposit. Age thirty-two years. Patient neurasthenic and of tuberculous diathesis.

for years, and one lower molar has been removed for resorption of the apices of the roots associated with looseness.

When pericemental destruction has involved the apical pericementum death of the pulp occurs, and infection of the necrosed pulp results; abscess forms and pus discharges *via* the pyorrhœa pocket.

When the disease attacks but one root of a molar, destruction of the pericementum around that root, death of half of the pulp, and abscess formation may result, and the other roots be unaffected; a portion of the pulp of the tooth may retain its vitality for some time, notwithstanding the apical abscess upon one root. In these cases pus discharge from about the root of a tooth may be continued.

A form of phagedenic pericementitis causing very rapid destruction of the pericementum and loss of the teeth without loss of alveolar wall has occasionally been noted. In one notable case two upper incisors came away three weeks after an ulceration appeared about their gum margins. The patient wore the teeth for several weeks *in situ*, and could remove and reinsert them at will. The alveolar walls were bare, but intact. There was but little pain. The sockets healed after removal of the teeth and the freshening of the bone. While perhaps classifiable under this heading, the clinical features of this case were entirely distinct from those of the phagedenic condition recognized as phagedenic pericementitis, and were more probably caused by the so-called stomatitis ulcerosa.

The acute gingival abscess sometimes noted in connection with pyorrhœa alveolaris, and secondary to it, may sometimes occur in connection with this condition (Fig. 500).

While the disease is usually first noted about a single tooth, it is rare that a lengthened period elapses before it makes its appearance about other teeth; usually an adjoining tooth or, it may be, on a distant one. This disease may make its appearance in the mouths of patients who take extraordinary care of the teeth, in mouths where the teeth are apparently entirely free from deposits, where the gum appears normal, and where the teeth are free from caries. It is of more frequent occurrence in dentures comparatively free from caries than in those where caries prevails or has prevailed.

Symptoms and Diagnosis. The disease being often of rapid onset, nothing may be noted until the patient complains of pain about the teeth, when the pocket may be found as described. A line of deepened color in the gum over the pocket may also be noted. The shifting of teeth points to the condition; otherwise the signs noted under the pathology are the distinguishing characteristics.

A differential diagnosis may have to be made between phagedenic pericementitis in its later stages and acute apical abscess or pericemental abscess.

Thermal or electric tests, or a history of response to thermal

changes, may indicate at least partial vitality of the pulp which may have undergone degeneration. Any excessive response not reduced by treatment of the pyorrhœal condition and any lack of response to decided thermal or electric tests indicate pulp inflammation or degeneration and a necessity for pulp devitalization.

Prognosis. The prognosis of this disease, so far as the teeth affected are concerned, is in general decidedly unfavorable. While it may be temporarily arrested in its earlier stages, its recurrence and ultimate loss of the affected teeth are the rule. It may attack but few teeth of a denture and progress until they are lost, the other teeth remaining unaffected. The common history, however, is that when the disease makes its appearance the denture is ultimately lost through it, although the period of loss may cover many years. Several years may elapse between the loss of one tooth and the affection of the second. Upper incisors and molars appear to suffer more frequently from the disease than any of the other teeth.

Treatment. It has been asserted¹ that if in the early stages—*i. e.*, that of tooth shifting—the pulp be removed and the canal filled, the impending degeneration and necrosis of the pericementum will be averted. The probable explanation is that the diversion of the blood stream of the pulp into the pericemental vessels enlarges them in compensation of a degree of endarteritis obliterans produced by the interstitial gingivitis. Possibly the extra nutrition thus obtained by the pericementum fortifies it against degenerative changes, and possibly even against the existing infection.

The treatment, as regards splinting of the teeth and sterilization of the pockets, is the same as in the first class. Black emphasizes two points of much importance in the next stage of treatment—*i. e.*, the removal of deposits—first, that the gum margin must not be unnecessarily injured; secondly, that vigorous scaling of the roots may be done without special regard to avoid cutting the tissues lining the pocket, instead of avoiding such injury, as in the first class of pyorrhœa. The pockets are freely syringed with hydrogen dioxide, or with a 1:500 solution of mercuric chloride in hydrogen dioxide. The alveolar edges are to be freely scraped with the scaling instruments, which should have slender stems and comparatively broad cutting-blades (Fig. 530). The use of cauterants, such as trichloroacetic and lactic acids, is more important than in the former type of disease. The same astringent antiseptic washes are to be prescribed. After removing all

¹ M. L. Rhein, D. D. Smith.

foreign material, including dead matter and sterilizing, correcting occlusion, and securing immobility, the astringent antiseptic wash is expected to draw the tissues tightly about the teeth and to prevent infection, so that a regenerative process can be established in the vital tissues of the former disease pocket.

In case the pockets are so deep or have such form that the alveolar margins cannot be well trimmed without overstretching or injuring the gingival edges, Black advises that gum flaps be raised, exposing the alveolar margins (Fig. 531). A semicircular incision is made and turned back, and bleeding checked. By means of sharp chisels the alveolar borders are freely scraped, the pockets are flushed with hydrogen dioxide, and the flap secured by a couple of stitches. Cocaine anæsthesia should precede this operation. The same writer advises, in cases where eversion of the alveolar margin has occurred, that the

FIG. 530.



Scalers (three times natural size).

FIG. 531.

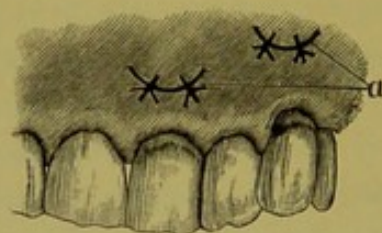


Illustration of the position and form of incision through the gum for exposing the root of the tooth and injured alveolar process: *a*, incision. (Black.)

process be exposed by cuts and broken down by three cuts made with a sharp chisel and mallet; the loosened segment of bone to be pressed firmly against the root. It is desired next that the entire pocket will fill with granulation tissue, and organization of the granulations take place, furnishing reattachment. That this occurs in some cases is undoubted. Black believes that a reproduction of alveolar margins also occurs in some cases. The hope of good results lies in keeping the parts aseptic after all foreign deposits and dead material have been removed.

For this purpose the case should be seen every few days while under treatment, so that the pockets may be injected with antiseptic substances, such as 1-2-3 mixture or phenol-camphor.

Particular attention should be paid to the prophylactic treatment.

CHAPTER XXVI.

PERICEMENTAL ABSCESS.

IN comparatively rare cases there begins in the lateral aspect of a pericementum a swelling which finally discharges its contents either at the gum margin or directly through the gum tissue.

The pulp of the tooth may be perfectly vital and the attachment at the gum margin at first at least practically unbroken. A deposit of calculus may or may not be formed in the area, and the discharge may consist of a glairy mucus or of purulent matter. Cases of this disease have been noted and described by Darby (1874), W. E. Walker (1895), D. D. Smith (1897), and Kirk¹ (1898).

Causes and Pathology. When seen as above described the condition occurs in the mouths of individuals predisposed to pyorrhœa alveolaris associated with general malnutrition²—*i. e.*, there is an interstitial gingivitis present in the area affected that may be predisposed to by an autointoxication, the result of a general malnutrition or intestinal toxæmia. The general association of malnutritional conditions with an excess of waste products in the blood leads to the just inference that such waste floating through the tissues acts as an irritant, lessening in time the vital energy of the cells of a part or of the body as a whole. For this reason gout and kindred diseases are considered at least predisposing causes of pericemental abscess and pyorrhœa alveolaris.

The frequent association of malnutritional conditions with an excess of uric acid in the blood in the form of its urates, and the demonstration by C. N. Peirce, in 1892, that such urates exist in the deposits upon the lateral aspect of the tooth affected, gave force to his claim that uric acid or the waste products associated with it are responsible for the concretions and the symptoms.

E. T. Darby (1880), W. J. Reese (1886), and J. S. Marshall (1891) pointed out the relation of gout with certain pericemental conditions.

Kirk's studies in pericemental abscess have demonstrated that in a few cases the diplococcus pneumoniæ may be found in pure culture in the abscess when first opened. The question still *sub judice* is: (1) whether the toxic waste products floating in the sluggish blood stream

¹ Dental Cosmos, 1898 and 1901.

² E. C. Kirk, Dental Cosmos, November, 1900.

of the affected portion of the pericementum cause interstitial gingivitis, and a necrotic area from which the degenerated tissue and coagulated lymph are expelled as the contents of a gouty abscess; or (2) whether the diplococcus pneumoniae or some other organism enters an area irritated by the waste products, etc., and excites the acute conditions—such organisms have two possible avenues of entrance to the diseased area: (a) *via* the general circulation; (b) from the gingival space *via* the pericemental glands of Black or the bloodvessels; or (3) whether the said organisms are alone capable of exciting the disease as a purely local phenomenon.

The association of gout with at least a proportion of the cases requires a consideration of its pathology, which will serve to illustrate the principle of autointoxication. (See also interstitial gingivitis.)

General Pathology. The conditions called gouty are held to be due to the retention in the circulating fluids of an excess of urates, a waste product of tissue and food metabolism; this excess of material acts as an irritant and inflammation-exciting agent in the tissues of the body, producing alterations of function and structure in many tissues and organs, but most palpably in the members of the connective-tissue group. The association of an excess of urates with gout was demonstrated by Garrod, who detected crystals of urates in the serum of blisters from gouty patients. The association became still more clear after an examination of the calculi of gout, which were found to contain urates. In gouty joint affections urates of sodium are found in the diseased areas, and they constitute the common tophus found in gouty patients.

Urates of sodium are also discharged in gouty abscesses through the skin, either in liquid or solid form, and with or without pus (Musser).

According to Musser¹ a number of these abscesses may discharge without impairment of the general health, or even with benefit to the system.

It is demonstrable that the deposition of crystals of sodium biurate in and about joints are the cause of acute but non-suppurative inflammations of those joints. The conditions necessary for deposition seem to be a sluggish circulation in the part which permits the urates to infiltrate into and crystallize in tissues somewhat degenerated by the sluggish circulation and consequent deficient oxidation. (See p. 66.)

In gouty patients there is a tendency to degenerative changes, probably induced in parts by the irritative effects of the urates before

¹ Medical Diagnosis.

deposition in quantity. There is first a tendency to sclerosis—*i. e.*, to the development of the connective tissues at the expense of the cellular elements peculiar to the parts.

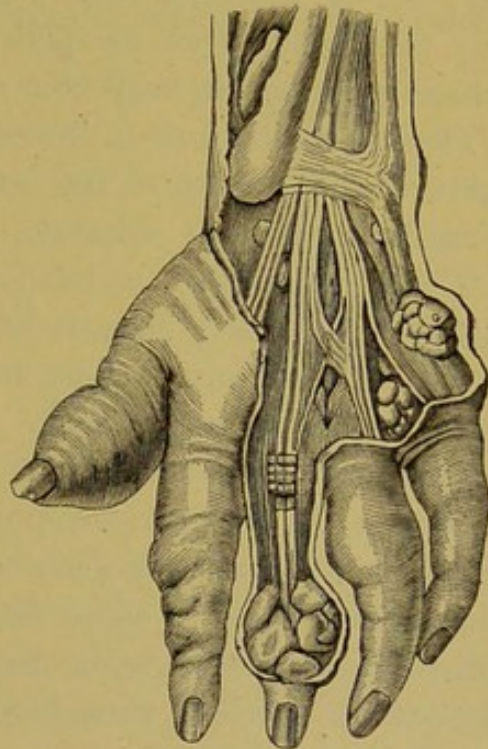
Gout, or uric acid poisoning, may exist as a chronic affection without acute outbreaks; deposits accumulate in small joints (tophi), as of the fingers, causing stiffness and deformity, as the joints are successively affected. An injury to a joint may determine the affection in that joint, and any joint may be affected (Flint). (Fig. 532.)

Gout may exist as an obscure affection without any of the joint affections noted. Tophi may deposit in tendons (Ziegler). Disorders of the stomach, liver, kidneys, heart, bloodvessels, and lungs may all attend chronic gout, and be caused by it. The evidence of connection of obscure conditions, such as headache, hebetude of mind, lassitude; digestive, circulatory, or respiratory troubles, with the gouty condition, may only be made manifest by their relief through antigout therapeutics.

All forms of gout are largely hereditary. The manifestation of the diathesis may skip one generation and appear in the next. Hereditary gout in the female may manifest itself as rheumatoid arthritis. In a proportion of cases no heredity can be traced, although the existence of gout in the individual is unmistakable. The deposits in gout are only readily detected when they exist as defined concretions. They may be present as fine crystals and escape detection.

The chief causes of a rise of uric acid in the blood are: (1) diseases or conditions in which oxidation of waste products is lessened—*e. g.*, anæmia, sedentary life or occupation; (2) a diet introducing albuminous or starchy and perhaps inorganic constituents in excess of the ability of the tissues to appropriate or oxidize the resulting products, or which disturb the alimentary and hepatic functions; (3) a lessened elimination of waste products, normal or otherwise, from the system.

FIG. 532.



Tophi of gout. (Ziegler.)

Heredity, age, and habits of life are all contributory to the above.

Special Pathology. The test of the soundness of the theory that there are distinctive gouty dental affections depends upon whether their causation, pathology, and symptoms are explainable by the phenomena of gout exhibited in other parts, and, again, by the effects of antigout therapeutics.

First, an examination of the teeth themselves. Upon section the enamel, dentine, and cementum of the teeth lost by this disease are found to be highly organized. The pulp chambers are frequently almost obliterated, even without external evidences of abrasion or erosion. Data relative to the condition of the pulp and pericementum are wanting, although from the degree of immobility of the teeth it may be inferred that the pericementum is markedly diminished in volume prior to the beginning of the disease.

These facts indicate an increase in the intercellular elements of the parts, at the expense of the essential cellular elements (sclerosis), as a result of a chronic irritation.

The articulation of the teeth with the maxillæ is by implantation in alveoli (gomphosis), relation being secured by the fibrous membrane—the pericementum. While not a joint in the ordinary sense, it may be practically viewed as such. There is no reason why under certain favoring conditions urates may not be deposited in the pericementum as well as in the metatarsophalangeal joint or in the joints of the fingers or the knee. Reference to Fig. 532 will demonstrate that the deposit may occur in white fibrous tissue, such as tendons (Ziegler). That the deposit of urate may be slight and masked by subsequent deposits of calcium phosphate does not imply more than that the peculiarity of the tissue may produce a peculiar deposit.

It is probable that the hyperæsthesia about the teeth, accompanied by a disposition to grind the teeth at night, and a disposition to shifting of positions of the teeth are explainable upon the ground of general irritation of the pericementum as the result of the presence in them of an excess of urates.

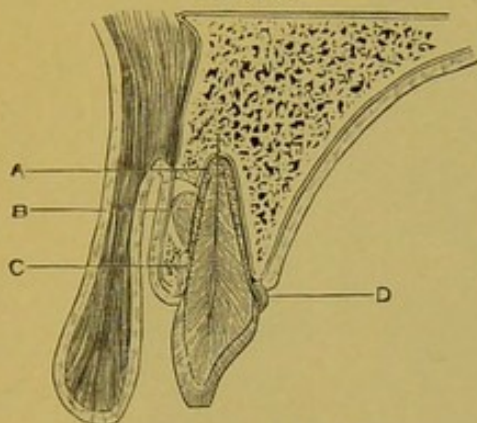
An outbreak of the acute form of gouty pericementitis upon some one tooth is explainable by the fact that an area of debility has been established upon the said tooth by some local cause, such as overuse, malocclusion, disuse, abuse, chance blows, etc. The sluggish circulation established in the area causes the deposition of urates to occur in the degenerative tissue of the area. (See calcareous degeneration.)

Inflammation of a chronic or acute nature is excited and pyogenic infection may or may not occur, either by way of the circulation or from the gum margin by way of the pericemental glands of Black.

Teeth have been extracted during this period, one of which exhibited these significant features: The apical pericementum was intact, as was also that portion toward the gingival margin; between the two was an area of denudation in which loosely attached to the root was a rough, irregular calculus (Burchard).

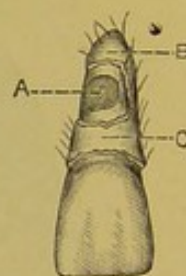Calculi scraped from the roots of such teeth exhibit in a varying degree a response to the murexid test, the test for urates (Peirce). The reaction may be very faint in some cases, being overshadowed by the calcium phosphate which makes up the bulk of these masses; in others it is pronounced—*i. e.*, urates make up a portion of the deposits.

FIG. 533.



A and C, vital pericementum; B, gouty calculus;
D, a subgingival calculus.

FIG. 534.



A, calculus in area of necrosis; B and
C, vital pericementum.

Black¹ by test found urates in nearly all concretions, salivary and serumal, about the teeth. While he claimed that this proved that urates have no causal relation to pyorrhoea, the findings seem rather to point to frequent presence of urates in the salivary and serumal excretions, which may really be a cause of irritation even when no obvious symptoms of gout are present.

Miller's demonstration of a calculus upon an unerupted tooth is to be recalled. (See p. 549.)

Other cases have occurred in which no calculus was present, but a small sac was found in the pericementum, either at the lateral aspect or in the bifurcation. This sac may contain a globule of pus (D. D. Smith).²

If a collection of fluid form and discharge the condition is known

¹ Dental Review, 1894.

² Dental Cosmos, 1897.

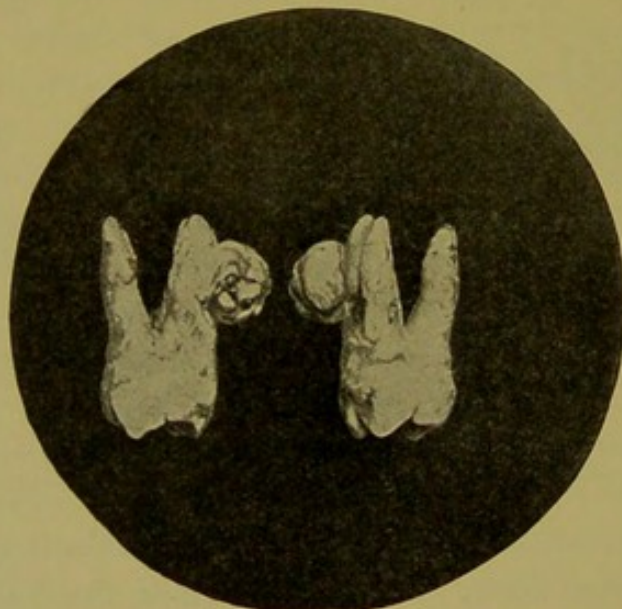
as a gouty abscess or, as more lately termed, a pericemental abscess. The fluid may consist of coagulated lymph or of pus. The discharge in the one case may be glairy, in the other purulent.

If the abscess be located near the gum margin it may follow the pericemental tract just as an apical abscess may do and discharge at the free margin. In this case the condition simulates a pyorrhœa pocket.

If the abscess begin near the apex it may find vent through the gum and thus produce a fistula simulating that of apical abscess (Fig. 536).

Morbid Anatomy. Aside from the state of the teeth which show evidences of a tendency to secondary dentine and nodule formation, it has been noted that the abscess is intrapericemental, not sub-

FIG. 535.



Two views of an intrapericemental abscess. Pulp vital. (Kirk.)

pericemental. Figs. 535 and 536 show the inflammatory swelling of the pericementum, the central abscess cavity, and the loss by resorption of the alveolar process may easily be calculated. The original chronic nature of the local irritation in this case is evidenced by the presence of hypercementosis.

In several of these cases, where the fistulæ have been of long standing, the editor has removed calculi (Fig. 537).

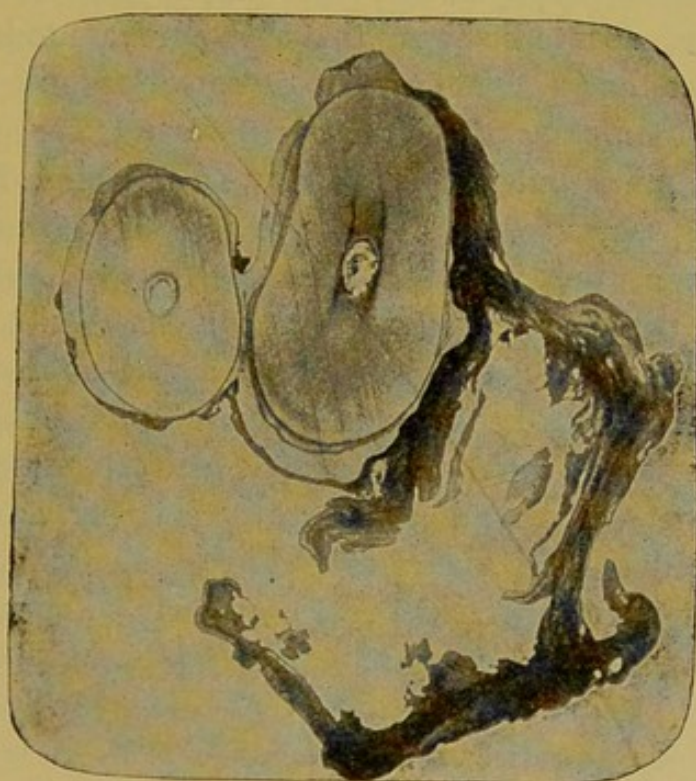
Symptoms. These have been largely foreshadowed in the discussion of the pathology. Upon some vital tooth there appears an uneasiness, at first not very painful, followed later by an inflammatory swelling which may produce acute pain and then discharge a glairy fluid or

purulent matter. There is an absence of the phlegmonous inflammatory involvement of contiguous tissues common in cases of acute apical abscess. The fistula may persist after the discharge and the case may first be seen in this condition.

D. D. Smith calls attention to the absence of marked pain upon tapping, and the production of a feeling of apprehension upon the part of the patient during the stages preceding the formation of the fistula.

In other cases the shifting of the tooth from its position is the first noticeable symptom, followed later by the pain, and later still by the discovery of a pocket alongside the tooth.

FIG. 536.



Transverse section through buccal roots and pericemental abscess shown in Fig. 535, showing intrapericemental abscess cavity with fistulous outlet and nearby areas of nodular hypercementosis. (Kirk.)

In other forms of gout urates exist in excess in the urine after anti-gout therapeutics is applied. The inference is that the local conditions are relieved by the solution of the urates in the focus of inflammation and by a general elimination of the excess from the blood. They re-enter the blood by way of the lymph stream and are eliminated by the kidneys.

While the pericemental irritation may involve many teeth, acute outbreaks are usually confined to but one or at most two teeth. The

disease subsequently attacks other teeth singly, although these may escape involvement for years.

It is but just to state that by some prominent practitioners the gouty symptoms are held to be due to a toxæmia primarily originating in the mouth—*i. e.*, either mouth toxins are formed from oral detritus by bacteria, which toxins enter the alimentary tract and are absorbed, or the bacteria enter the intestines and there form toxins which are absorbed.

It is held that these toxins are responsible for kidney disease and evidences of general malnutrition.

Before either of the explanations offered can be finally accepted, more corroborative evidence of the cure or failure of cure of systemic conditions by oral prophylaxis, as practised by D. D. Smith, must be forthcoming. It is to be hoped that such cures are to be so effected, as it will reduce the treatment of obscure conditions to a simplicity.

Diagnosis. In making the diagnosis the symptoms described are to be borne in mind, but the disease may be confounded with several diseases having somewhat similar symptoms. An acute apical abscess due to gangrenous pulp may be differentiated by obtaining evidences of pulp death, previous root-canal treatment, etc. There is also much greater pain upon percussion than in pericemental abscess.

If the apical abscess be in the third stage it may be differentiated if any doubt exist, by incision and subsequent exploration.

An acute lateral abscess due to a root perforation is more difficult of differential diagnosis, but after incision evidences of perforation may be sought externally, or the root canal may be opened. In these acute conditions the *x*-ray may render valuable aid. (See Fig. 449.) The pulp being found alive by any reliable test is evidence that the case is either one of pericemental abscess or of acute traumatic pericementitis. In a few cases of partial gangrene of the pulp the pulp may test as vital, yet really the symptoms be due to apical abscess.

Acute traumatic pericementitis usually has a history of traumatism and presents more pain upon tapping.

A form of pericemental abscess is sometimes found existing as a secondary process dependent upon a primary pyorrhœa of the first class. The pus burrows from the gum pocket into the gum tissue and excites an abscess which discharges upon the lateral aspect of the gum. The connection of the sinus at the gum margin with the fistula will demonstrate their relation. (Figs. 500 and 501.)

Again, a pericemental abscess may be caused by metastasis of

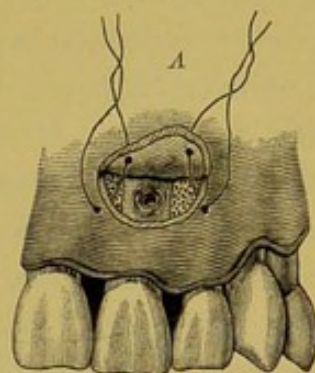
pyogenic organisms from an acute apical abscess—*e. g.*, an abscess in the bifurcation of the roots of a molar may have been caused by bacteria from an apical abscess; the presumption is that the bacteria have followed the pericemental tract, perhaps *via* the glands of Black or by way of the bloodvessels, and, finding a suitable location in the bifurcation, have there developed. Of course, in such a case the pulp of the tooth in question, or of that in an adjoining tooth, will be dead. Failing a positive differential diagnosis, the case should be treated upon general principles—*i. e.*, counterirritation, derivation, etc., and decisive developments awaited.

Prognosis. The prognosis of the disease depends largely upon the form in which it first exhibits itself, and also upon the length of time an increased amount of waste products has been present in the circulation. In all grades of the inflammation, except that attended by pus formation, the cure of the general condition is usually followed by a more or less prompt subsidence of the dental symptoms; although if a tooth be loose the condition may improve, but does not disappear. If pus form, as indicated by the unusual activity of the inflammatory symptoms, destruction of tissue, pericemental and alveolar, it will progress until it is given vent, no matter how active or effective in other particulars therapeutics may be. In these cases the tooth is usually lost sooner or later.

One or more teeth may be repeatedly attacked, and if the underlying cause be promptly removed they may partially recover.

Treatment. If the pericemental abscess discharge by way of the gum margin, infection from the oral cavity occurs and the pocket originally formed becomes deeper. The case simulates then a pyorrhœa alveolaris beginning at the gum margin. The treatment is then conducted accordingly. If the swelling occur upon the gum, at a point more or less midway upon the root, it should be opened under antiseptic precautions. An injection of cocaine solution should be made and a semicircular flap raised. The diseased area should be explored for calculus and, whether found or not found, the necrotic tissue should be curetted away. Next the pocket should be syringed out with mercuric chloride in hydrogen dioxide 1:1000 or meditrina. The flap is next stitched into place and the gum painted over with steresol. (See

FIG. 537.



A, calculus.

p. 245.) The mouth should be kept in an aseptic condition during the healing of the parts. Whether the exciting cause of this condition shall be finally shown to be bacterial or not, the predisposing cause in a general malnutrition or intestinal toxæmia should be sought for and, if possible, corrected.

In the elimination of the waste products which act as irritants the best results seem to be attained by measures directed to an increase of the general eliminative functions, the increase of tissue oxidation, and a restriction of diet. Such measures in general cause the elimination of existing waste products from the circulation and prevents the formation of an excess of new waste products.

The waste products in the system are dissolved by the copious ingestion of water. At the same time the blood pressure is raised and the kidneys stimulated to increased action (diuresis). A pure water is of as much value in gout as one containing lithium salts.¹ The amount consumed daily should be from five to eight pints, preferably to be taken between meals; as water taken at meals is apt to interfere with digestion. It may be necessary at times to prescribe salts of lithium with the water for the effect upon the mind of the patient who may have an aversion to water. E. C. Kirk has recommended the bitartrate of lithium, to be administered in 5-grain doses, three times daily in water. Talbot prefers thialion, a laxative salt of lithium. The use of Turkish or Russian baths, if not specifically contraindicated by acute or chronic disease, followed by massage of the liver and kidneys, is valuable for the stimulative effects upon these organs and upon the skin. During the perspiration induced by the bath many impurities are eliminated from the blood.

If constipation exist the bowels should be kept open by the use of laxatives. It tends to the production of an intestinal toxæmia.

Vigorous exercise in the open air, if not contraindicated by some organic disease, is valuable, as it increases the function of the eliminating organs and supplies to the tissues an abundance of oxygen for metabolism. All overwork, worry, loss of sleep, or other causes tending to neurasthenia should be carefully avoided. Anæmia should be corrected if possible, as it signifies a lessened oxidation. Disorders of the intestinal tract and its appendages, particularly hepatic disorders, also demand correction.

The diet should be of a character which will lessen the formation of urates. The amount of vegetable food, in proportion to animal, should

¹ Hare, *Practical Therapeutics*.

be increased, thus raising the alkalinity of the body fluids. Red meats, and white meats difficult of digestion, increase the formation of urates. Poultry and shell-fish in the dietary lessen their formation. The consumption of malt liquors notably increases it, and sweet wines, particularly champagnes (both sweet and dry), are poisonous to gouty patients. Spirituous liquors are also harmful, since they lessen tissue oxidation and produce gastric and hepatic disturbances which cause faulty metabolism.

Recognizing the predisposition which exists in gouty persons to active pericemental degenerations, the operator should guard against injuries to the pericementum, which might induce a weak articulation and precipitate gouty pericementitis. Such teeth should not be violently wedged; injury to the gum or gum margins, by the use of improper rubber-dam clamps, ligatures driven beneath margins, etc., may excite the first stages of a degeneration which will end only in the loss of the abused tooth.

CHAPTER XXVII.

REFLEX DISORDERS OF DENTAL ORIGIN.

RECOGNIZING pain as a condition produced through the overexcitation of sensory nerves, a reflex pain may be defined as a pain referred to some point other than that of its origin. Pain referred to the distribution of a sensory nerve may be due to overexcitation of any portion of the nerve in its terminal distribution, to diseases affecting any portion of the nerve trunk, or to disorders affecting the central termination of the nerve. Again, irritation of one sensory nerve may be referred to some other sensory nerve. The condition is called neuralgia.

As both the upper and the lower teeth and their surroundings receive their neural supply from branches of the fifth pair of cranial nerves, discussion of this subject is confined to causes operating within the distribution of that nerve.

As such general conditions as malaria, syphilis, and forms of anæmia operate to produce neuralgia which may be referred to the teeth, or the parts about them, only those cases will be regarded as dental which have undoubtedly a dental origin, as evidenced by disappearance of the neuralgia following cure of the exciting dental condition. It should be noted, however, that vague and sometimes severe pains referred to the teeth may entirely disappear after the cure of some constitutional disorder. For example, cases of periodically recurring dental pain have been entirely relieved through the administration of quinine and arsenic; the pains were clearly of malarial origin. Pain about the teeth in syphilitics has disappeared after the administration of iodides. Pain referred to the teeth in anæmic patients has disappeared after a long course of chalybeates.

Reflexes of dental origin are both motor and sensory, the latter far outweighing the former in importance. Motor reflexes may be noted in the quick spurt of saliva from the ducts of the salivary glands upon infliction of pain in the teeth, and by the spasmodic contraction of the muscles about the mouth when the pulp of a tooth is deliberately irritated. Twitching of the muscles about the face is a common accompaniment of trigeminal neuralgia.

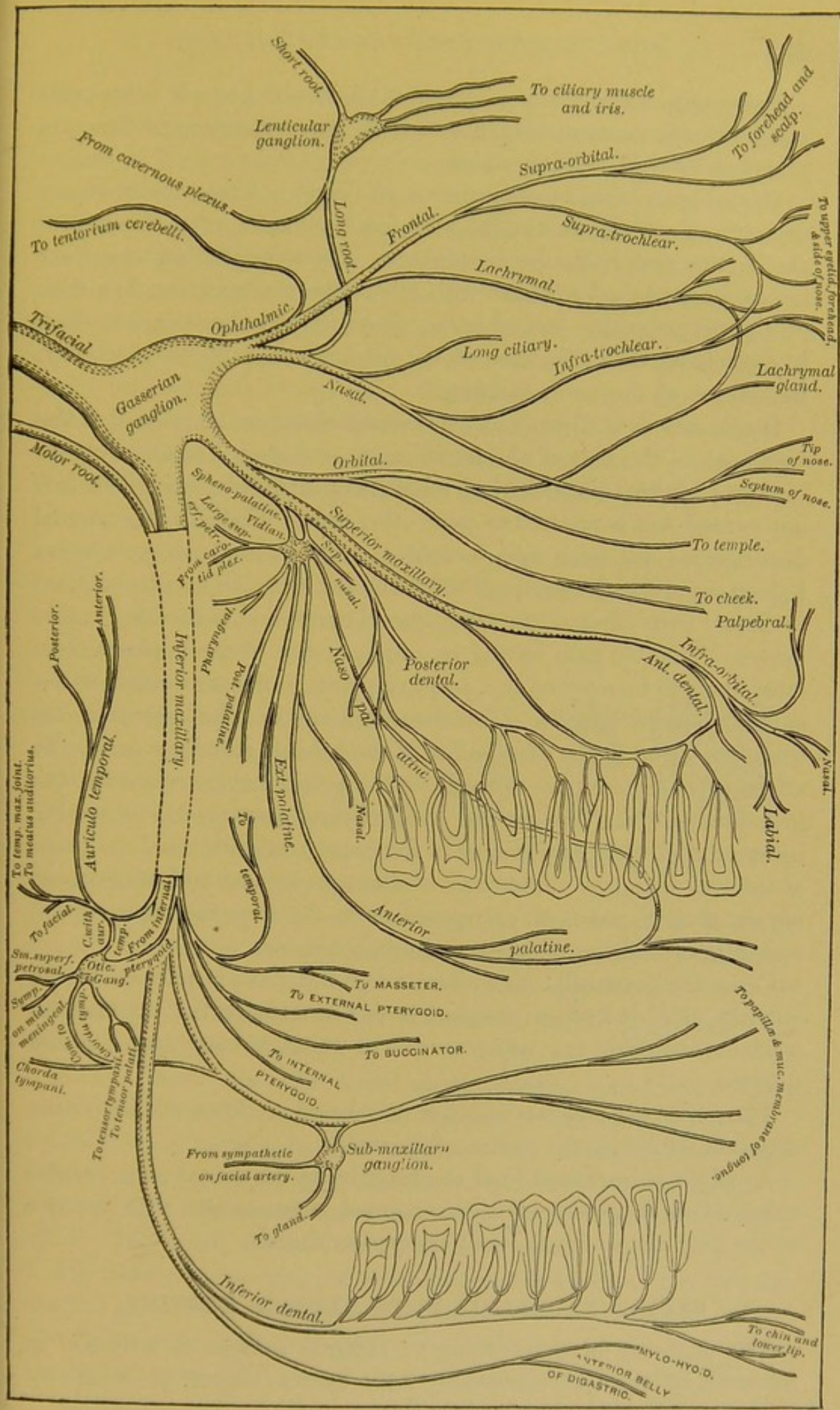


FIG. 538.—Plan of the fifth cranial nerve, showing the relationships of the dental nerves.
(After Flower.)

Before direct association of dental diseases with pains in other parts can be clearly demonstrated, a review of those conditions of the teeth attended by pain must be made.

Dental pain arises in consequence of disorder of the sensory structures; these are situated in the pulp, and are continuous throughout the dentine and in the pericementum. The roots of teeth may have unusual anatomical relations with other sensory structures than their own pericementum. Dental pains, therefore, may be discussed, first, in connection with affections of the dentine and pulp and, secondly, with those of the pericementum.

It was stated, in discussing the diseases of the dental pulp, that this organ is not the seat of the tactile sense and that, like other organs having a kindred physiological relationship, irritation excited in it is not located, but is referred to some other part. While all reflex dental disturbances are, as a rule, located in some part of the great nerve branch supplying the source of irritation, the irritation may be reflected to distant parts: first, of the same cranial nerve, and, secondly, to other nerves. That is, pain having its origin in one of the upper teeth is most likely to be referred to a point or points in the distribution of the superior maxillary nerve. Disturbances in or about the lower teeth are usually referred to the distribution of the inferior maxillary nerve. In affections of either upper or lower teeth the pain may be referred to the first division of the fifth nerve. In all of these cases, but most notably in connection with disturbances of the upper teeth, the usual symptom of trifacial neuralgia—tenderness of the supra-orbital and infra-orbital nerves at their points of emergence upon the face, the supra-orbital and infra-orbital foramina—is commonly present.

Cases are extremely rare where the reflex pain is referred to the opposite side; indeed, so unusual is this occurrence that its mention warrants suspicion that other sources of irritation exist upon the side referred to.

The extent of acuteness of reflex pain bears no direct relation to the apparent extent of the source of irritation.

As might be surmised from the function of the dental pulp, painful reflex dental disorders are more common in connection with diseases of the pulp than with those of the pericementum.

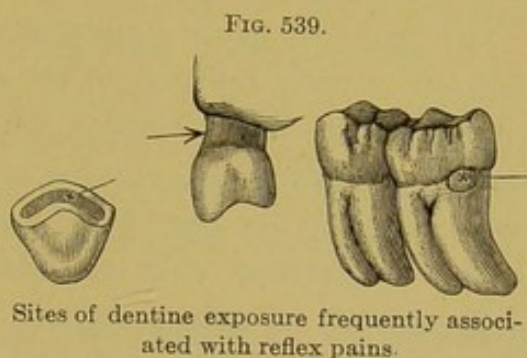
REFLEX NEURALGIA FROM EXPOSED DENTINE.

The exposure of the dentine to external sources of irritation is followed by reactions governed, first, by the degree of sensitivity

inherent in the protoplasm of the tissue; and, secondly, by the degree of hypersensitivity induced in it. Reflex disturbance due to these irritations is more common in the class of persons called "neuralgics" than in other persons. Like direct pulp pains, unless actual pressure be exerted upon the affected tissue, there is no localized pain. In the absence of deliberate irritation, the pain may be referred to any portion of the peripheral distribution of the fifth nerve upon the face; but if an acid liquid such as lemon-juice or vinegar, or sugars, be taken into the mouth, pain is excited, which is referred indefinitely to the teeth of one side, frequently of one jaw. Reflex pains due to this cause are much more likely to appear when there is but little loss of dentine.

When carious cavities have proceeded to any depth evidences of direct pulp disturbance are obtained through the increased response to thermal changes.

Reflex pains from exposed dentine appear most common in connection with exposures at the neck of the tooth and upon abraded areas. Obstinate and persistent neuralgia, positively referred to another nerve branch, may apparently owe its origin to so slight a cause as exposure at the neck of a tooth of a line of dentine (Fig. 539). The proof of the connection between the two is made clear by a disappearance of the neuralgia after the exposed dentine has been subjected to the action of powerful caustics, destroying the dentinal filaments to some depth. The connection between the two may be revealed only by accident; the contact of a toothpick, a dental instrument, or the finger-nail may induce a paroxysm of pain.



While in some cases the dental origin of reflex pain may be made clear by the induction of a painful response in the area of reflection, by irritating a tooth pulp, this reaction is not constant. The causal relation is only certain when the cure of localized dental disease is followed by a disappearance of the neuralgia without further treatment. This proof should be exacted in all cases.

The most common sources of neuralgic attacks about the face are diseases of the eyes and teeth. In general terms, diseases of the eye give rise to reflex pains referred to the distribution of the first branch of the fifth nerve; diseases of the teeth usually cause reflex pains in

either the superior or inferior maxillary divisions, according as the upper or lower teeth are affected. In all painful affections of these nerves attention should at once be directed to the organs named.

REFLEX NEURALGIAS FROM PULP DISEASES.

The disturbances require classification according to the distance between their source and their manifestations.

In the Fifth Pair of Nerves. Pain referred to a different spot or area than its origin is a characteristic of all pulp diseases. The extent of its reflection depends, first, upon the patient, as noted in connection with the reflex pains from exposed dentine; and, secondly, upon the variety of pulp disease. In neuralgic patients any variety of pulp disease may cause comparatively distant pains. But, as Black has pointed out,¹ the general rule is, that the more chronic and profound degenerative diseases of the pulp are much more liable to give rise to distant reflex pains than are acute pulp diseases.

The pains of acute hyperæmia and of acute inflammation of the pulp are usually referred to the region of the tooth affected, or to a corresponding nerve trunk. In conditions of venous hyperæmia, nodular calcifications, chronic inflammation, and, later, pulp degenerations, the pains may be of such character that their dental origin is only determined after persistent search. Particularly is this true of the growth of pulp nodules. The source of the reflex pains is all the more obscure from the fact that in these chronic degenerations direct dental symptoms may be entirely absent, and are only elicited upon the most searching examination and exhaustive tests.

There is no constancy in the location of the pain due to any of these causes; but tenderness of the eyeball upon pressure; persistent pain in the temporal and anterior auricular regions, particularly in connection with pulp diseases of the lower posterior teeth; in the ear itself, a common site of the reflex pain excited by chronic pulp inflammation and suppuration of that organ; behind the ear, back of the lower border of the mastoid processes, tender spots may develop; tenderness to pressure may appear at the supra-orbital and infra-orbital or mental foramen, and about the chin. In the same class of diseases the pains may frequently radiate as far as the shoulder. Many of these cases receive attention from the general practitioner, and the painful attacks recurring at irregular intervals are relieved by analgesic

¹ American System of Dentistry, vol. i.

remedies—phenacetin, acetanilid, exalgin, etc.—and no attention paid to a probable dental source of the disorder. It should be a routine practice to examine the teeth in cases presenting pains of the type and in the situations described. Immediate search should be made for teeth containing pulps in late degenerative stages. (See Symptoms of Diseases of the Pulp.) Acute diseases of the pulp, including suppuration and, notably, abscess of the pulp, usually have attention directed to the teeth through pain induced by thermal changes, so that their diagnosis is quickly made. Not so, however, with the chronic degenerative changes, except possibly of pulp nodules; for if the pulp is in the late stages of degeneration, it may require repeated applications of cold and heat to elicit a response from teeth which do not respond by tenderness upon percussion.

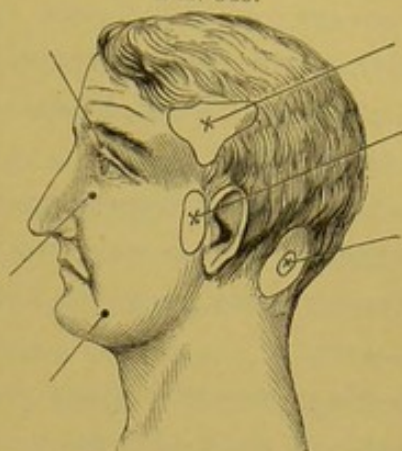
Failing to obtain evidence of pulp disorders, examination should be made for exposed and hypersensitive dentine. Then, examination of the pericemental reaction of each tooth should be made, and for any evidences about the teeth pointing to pericemental disturbance. (See later.)

Lauder Brunton¹ records that, in his own case, temporal neuralgia accompanied by tender eyeball was found due to exposed dentine upon the posterior cervical surface of a lower third molar (Fig. 522). The same writer² announces "that so frequently are headaches dependent upon decayed teeth that in all cases of headache the first thing I do is to carefully examine the teeth;" as should everyone else. Brunton explains the painful reaction upon the accepted hypothesis of the pathology of megrim, that it is due to spasmodic contraction of the peripheral end of an artery, with dilatation of the proximal portion. "Irritation in the tooth is reflected to the cervical sympathetic ganglia and causes spasmodic contraction of the arteries through irregular stimulation of the vasomotor nerves."

REFLEX PAINS FROM DISEASES OF THE PERICEMENTUM.

As a general rule, pericemental pains are located at the affected tooth; but in some of the disorders, particularly those in which either

FIG. 540.



Spots of tenderness in reflex neuralgias of dental origin.

¹ St. Bartholomew's Hosp. Rep., vol. xix. Reprinted in his Disorders of Digestion. ² Ibid.

hyperæmia or inflammation, acute or chronic, is not present, the teeth may not be tender upon percussion, and yet excite reflex pains in other parts, the proof of the connection being determined by a disappearance of the pain upon extraction of the tooth. The roots in such cases usually present either an hypertrophy of cementum or show that resorption of a portion—it may be a major portion—of the root has occurred.

In cases of hypercementosis it is assumed that the source of the irritation is pressure upon the nerves of the pericementum by the hypertrophic growth. Very widespread disorders may arise from this source.

Flagg records¹ many varieties of trifacial neuralgia; pains in remote parts of the body; grave functional disorders of the eye and ear; and motor disturbances—chorea, epilepsy, and paralysis—having a direct demonstrable connection with hypercementosis. Insanity has also been produced.

He mentions violent attacks of trifacial neuralgia as the most common reflex disturbance from this source; and next, long-continued pains in the ear or eye of the affected side. The existence of acute disease of these organs is usually diagnosed by the general practitioner. He states that oral and ocular disturbances, both functional and painful, are of gradually increasing severity.

In examining for a dental source of such pains, exposed dentine, pulp diseases, and inflammatory affections of the pericementum should be first excluded. In examinations by percussion a different response may be obtained from some one tooth than from the others. Hypercementosis of a particular tooth is indicated by finding the gum line slightly receded and the tooth attachment unusually firm; if, in addition, vague, heavy, dental pains have persisted at intervals over a long period, the diagnosis is probable. It is only certain when tapping upon the tooth brings on a paroxysm of neuralgia, or where a skiagraphic view actually exhibits the hypertrophic growth. The remedy is extraction. Any root fragment left unextracted may perpetuate the reflex disorder.

Painful affections referred to the neighboring region of the affected tooth, or diffused through the distribution of the corresponding nerve trunk, or to the eye or ear, may accompany the process of resorption of the roots of permanent teeth. Gillman² records a case where facial paralysis disappeared upon extraction of a tooth which had long been

¹ Dental Cosmos, 1878.

² Boston Medical and Surgical Journal, 1867.

the seat of disturbance and which, upon extraction, revealed resorption of its root. In these obscure cases the skiagraph if taken at once will be a great aid in the exclusion or diagnosis of pericemental and root abnormalities.

All of the acute or chronic, septic or non-septic, inflammations of the pericementum may give rise to reflex pains. In many of these cases the cause of the reflex irritation is due, perhaps, to sepsis, rather than to a pure neurotic connection. The most common causes of the reflex pains are found in that stage of pericemental irritation which antedates acute septic apical pericementitis, and which accompanies the chronic inflammations of the apical pericementum from any cause. In some of these cases reflex neuralgia may play a subordinate part to general infection from the focus of disease. The reflex nervous disorders consist in painful disturbances in the distribution of the fifth nerve and disorders of special senses, particularly that of hearing. Unless an exacerbation of the reflex disorder, or symptoms referable to that region, be induced by pressure or percussion on the tooth, a causal relationship is only made out by either relieving an existing dental disorder, an *x*-ray skiagraph, or extracting the teeth. The symptoms of septic intoxication and septicæmia must be carefully differentiated from reflex neuralgias in such cases: the latter are rare; the former probably more frequent than supposed in connection with septic dental diseases.

IMPACTED TEETH AS A CAUSE OF NEURALGIA.

Neuralgia of varying degrees of severity is a common accompaniment of impacted teeth. It is most frequently noted in connection with eruption of the lower third molars, not only because this tooth is the one most frequently impacted, but because of the anatomical relations of its roots with the inferior dental nerve.

In the milder forms of impaction, those in which eruption, though delayed, is subsequently completed, the pains are commonly localized and associated with but occasional attacks of rigidity of the masseter muscles. If, however, the crown present horizontally or nearly so, and its progress is arrested by impaction against the posterior wall of the lower molar, or if its progress be arrested by permanent imprisonment of the advancing crown between the posterior surface of the second molar and the base of the coronoid process, not only may intense local pains be induced, but severe reflex disturbances of both a sensory and motor character may occur. In some of these cases root formation is

completed, although the crown of the tooth does not advance, in which case compression of the inferior dental canal and its contents may occur and cause grave reflex disturbances. The local irritation about the root, due to root growth, may excite continued constructive action by the pericementum, and the hypertrophic growth in its turn may be the source of reflex neuralgias.

Complete imprisonment of the entire tooth has been found to be the exciting cause of facial neuralgias, for the cure of which extensive surgical operations have been performed.

Impacted cuspids and other teeth may excite no other symptoms than reflex neuralgia. The possible connection between an impacted tooth and neuralgia is made out after excluding other dental causes, when it may be observed that one or more of the permanent teeth are absent from the dental arch, at dates long after their normal time of eruption.

A condition equivalent to partial impaction, in which dental irritation may be the source of reflex neuralgia, is seen when the teeth are crowded—jammed into arches too small for their accommodation. During the period of eruption severe maxillary pains may recur at intervals.

PAIN REFERRED TO NERVOUS TRACTS OTHER THAN THE FIFTH.

The most common disturbance appearing in other cerebrospinal nerves than the fifth, due to dental diseases, is an affection of the eighth or auditory nerve. Cases of deafness have been recorded due to diseases of both pulp and pericementum, notably to hypercementosis. Deafness which has persisted for a long period has been markedly lessened by the extraction of teeth the seat of disease. Cases of suppurative otitis media have been regarded as having pathological association with septic diseases about the teeth, from the fact that the aural trouble subsided immediately after extraction of the diseased teeth.

Sensory disturbances of the eye, associated with dental diseases, have been alluded to; in addition to these, grave structural and functional diseases of the eye, traceable to dental causes, have been recorded, such as motor, sensory, and special sense disturbances, together with trophic disorders.¹ Among the latter may be mentioned corneal inflammation and ulceration and phlyctenular conjunctivitis. These are probably due in part to reflex trophic disturbances.

¹ See Brubaker, *American System of Dentistry*, vol. iii., for very full and detailed discussion of these subjects.

Irregular paralyses of the third, fourth, and sixth nerves of the affected side have been noted.

Amblyopia and functional blindness without retinal conditions to account for it have been found to arise from notably advanced degenerative changes in the dental pulp, sight returning to the eye after loss of a diseased tooth. De Witt¹ records a most instructive case where temporary blindness was associated with septic apical pericementitis, disappearing after evacuation of the abscess and reappearing when secondary inflammatory action arose in the pericementum. The ocular affection disappeared permanently and almost entirely with the loss of the tooth. The history of this case illustrates the important causal relationship of reflex disturbances with late pulp degenerations; for the blindness arose two months after some teeth were filled, and existed for twelve years before the septic apical pericementitis appeared.

A careful examination of these and all other reflex disturbances shows that pulp degenerations outnumber all other affections as causes. Many or most of the cases are recorded by general practitioners, who make no distinction between diseases of the pulp and those of the pericementum, but a reliable diagnosis of the conditions is made possible by the accompanying descriptions.

Cases of ovarian and uterine neuralgia and sciatica and cases of obstinate pains in the toes and fingers have been traced to dental irritation of some one of the varieties named; the proof of association being disappearance of the pain with loss of the tooth.

MOTOR DISTURBANCES FROM DENTAL DISEASES.

Motor disturbances due to dental irritation may occur as recurrent or persistent contraction or paralysis of muscles, together with more or less general chorea; in rare instances epilepsy and hystero-epilepsy. Twitching of muscles of the affected side of the face, ranging from slight affection of the occipitofrontalis or orbicularis palpebrarum to recurring spasm of the elevators and depressors of the lower lip, are far from uncommon phenomena attendant upon pulp diseases. In one case mentioned by Guilford² a pulp nodule was the cause of tic douloureux of two years' standing.

Contraction of the masseter muscle is a common accompaniment of retarded eruption of the lower third molar, which may be intensified until the condition is fitly termed trismus, in some cases of partial

¹ Quoted by Brunton, Disorders of Digestion.

² Private communication.

impaction of the teeth. Partial trismus has been found due to a general overcrowding of the dental arch.¹ Records of cases of torticollis, due to dental diseases, are also given by Brubaker.

Cases of facial paralysis, and cases of paralysis of one arm, of paraplegia and hemiplegia, and even of general paralysis, have been noted as disappearing after the extraction of diseased teeth. It is noteworthy that in these cases, as well as in several cases of tetanus recorded, the probability of an infection entered into the pathogenesis of the nervous diseases.

Stellwagen² records a case where symptoms of partial hemiplegia followed upon the operation of capping the pulps of two molar teeth; the symptoms disappeared promptly upon extraction of these teeth.

Cases of insanity arising from dental diseases have been recorded; they were both maniacal and melancholic. In several of them a restoration to a normal mental state followed promptly upon removal of the offending teeth. In some of these cases a pre-existing maxillary neuralgia directed attention to the teeth as possible sources of the nervous diseases.

DENTAL PAIN ARISING FROM OTHER THAN DENTAL SOURCES.

Conditions of pain the reverse of those discussed—*i. e.*, pain definitely or indefinitely located in teeth which exhibit no morbid conditions whatever—demand occasional attention at the hands of the dentist.

Chronic malarial poisoning, as stated in the beginning of this chapter, may give rise to periodical attacks of maxillary neuralgia. As in the gouty cases, the constitutional cause of the disturbance is made clear through the therapeusis most effective, *viz.*, the periodical recurrence of the pain leads to the inference of a malarial origin, and to the administration of quinine.

Syphilitic pains in the jaws have a pericemental character, and other evidences of syphilis are present which point to a diagnosis.

Pains in or about the teeth are occasional accompaniments of diseases of the brain or its vessels, and of diseases of the uterus, kidneys, and bladder.

Disease in any portion of the fifth cranial nerve may cause pain referred to the teeth.

¹ Brubaker.

² Private communication.

Dental pain during pregnancy, without any direct evidence of dental disease, is relatively common.

Disorders of the lower bowels, causing constipation, may give rise to pain referred to one or more teeth, the pain ceasing promptly upon the administration of an active evacuant.

Treatment of Facial Neuralgia. The cause should be sought for, and, if possible, removed. If due to diseases of the teeth these should be relieved; if due to eye disease this should receive attention. Should one not discover the cause, yet desire to afford a relief pending its discovery, the accepted remedies antipyrin, acetanilid, and phenacetin, combined with caffeine or the bromides, are useful.

R—Antipyrini (vel phenacetini vel acetanilidi),	5j.
Caffeinæ citratis,	gr. x.
Potassii bromidi,	5iij.—M.

Ft. in chart. No. x.

Sig.—One every thirty minutes until relieved. (Hare.)

If the patient be constipated the bowel should be freed of toxic substances by the use of castor oil, repeated as necessary.

In obstinate neuralgia and other painful affections with unremovable cause, the application of the *x*-rays has been urged by Morton as highly efficacious.

CHAPTER XXVIII.

INFECTIONS OF AND FROM THE MOUTH, AND STERILIZATION.

THE conditions found in the human mouth, as pointed out in Chapter III., are of a character which afford lodgement to, and opportunities for multiplication of, many forms of bacteria, both saprophytic and parasitic. The oral conditions are, however, not entirely constant, so that at different periods they may favor the development of some special bacterial forms more than others. The nature of these variations has not been made out, although their effects are indubitable. Again, the oral bacterial inhabitants are not constant as to species, for while there are many forms which appear to be invariable occupants of the oral cavity, many pathogenic forms are but accidental residents. Becoming resident, they may or may not develop according as they find in the mouth a suitable soil. The nature of what constitutes a suitable or unsuitable soil has not been determined, though in some cases extra-oral culture experiments furnish some indications.

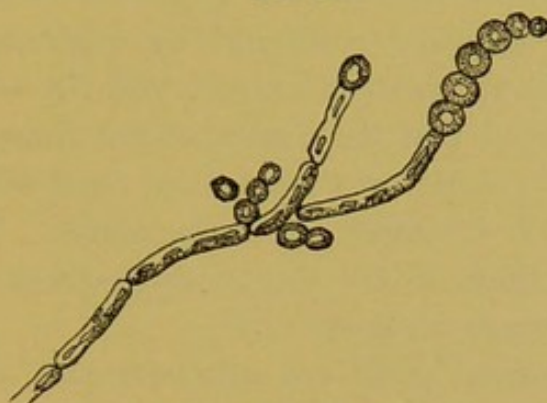
Bacterial growths, as causes of dental caries and diseases of the pulp and pericementum, have been discussed in connection with those several diseases. It was shown that the pyogenic cocci are almost constant inhabitants of the human mouth. There appeared also evidence that some of the reflex disorders of distant parts are directly traceable to septic processes about the teeth, and, in addition to these, suppurative diseases in other parts become curable after removal of a septic tooth; such conditions representing infection from a local dental infection, an important aspect of dental pathology.

The infections arising from the growth of mouth fungi are local and general. The phrase fungi is used in this connection, because other classes besides the fission fungi (schizomycetes) are pathogenic also. Both the thread fungi (hyphomycetes) and bud fungi (blastomycetes) may induce morbid conditions in the human mouth.

The notable fungus of the blastomycetes is the *saccharomyces albicans*; this organism, when classified by mycologists as a thread fungus, was known as the *oidium albicans* (Fig. 541). The growth of this organism illustrates forcibly the influence of soil on the growth of

fungi. It does not occur in the mouths of healthy, well-nourished, and clean children with good surroundings. It is a disease of childhood, particularly of nurslings, and its occurrence is almost always confined to bottle-fed babies whose feeding bottles are kept in an unclean condition. Debility of the oral tissues is established in consequence of the fermentations arising from the source just named,

FIG. 541.



Saccharomyces albicans, thrush fungus.
(Miller.)

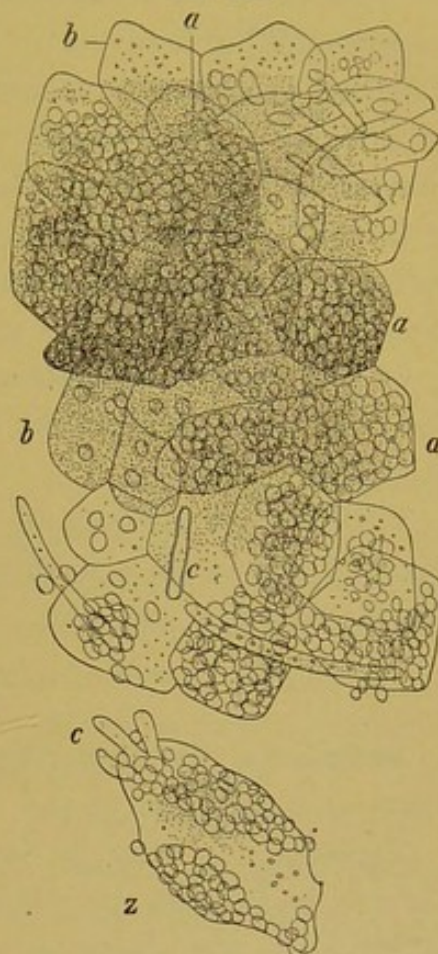
furnishing a favorable condition for the development of the *saccharomyces* (*oidium*) *albicans*. The condition produced is known as thrush. The infection may be carried from one child to another, and if the fungus be brought in contact with an abraded mucous surface of an adult it may develop.

The fungus burrows between the epithelial cells of the mucous membrane (Fig. 542), not beyond it. It first appears in small spots, which coalesce, until large patches of a membranous-like growth cover extensive surfaces, spreading by continuity to all of the mucous surfaces associated with the mouth.

As bud fungi flourish only in media of acid reaction, the use of alkaline washes is indicated in the treatment of this condition. Wiping the patches with dilute phenol-sodique is efficacious. Small spots may be cauterized.

The hyphomycetes, or thread fungi, although associated with diseases of the human skin, have not had any pathological significance attached to them as regards the mouth.

FIG. 542.



Pavement epithelium covered with
spores of the *oidium albicans*. (Ch.
Robin.)

INFECTIVE BACTERIA OF THE MOUTH.

Bacteria, being ever present, must always play a part in either originating, modifying, or associating with all oral diseases.

That the progressive decomposition of albuminous substances, always present in the mouth to a greater or less degree, by the action of saprophytic fungi, must give rise to derivatives of albumin, many of them toxic in effect, would be surmised even in the absence of experimental demonstration, a suspicion confirmed by experiment. Vulpian¹ produced septicæmia by vaccinating animals with the saliva of a healthy man. Griffin² showed that the parotid saliva (pure) is harmless. The saliva, if boiled, exerts no toxic action, from which it is clear that it derives its toxic substances from the mouth. The saliva of individuals differs at times in the degree of its poisonous action. In some diseases it becomes intensely toxic.

Of the many oral bacterial forms, some are cultivable and some are not; hence the specific effects of some are discovered, others are doubtful.

With regard to local affections, other than those described in the body of this book, a bacterial causation has been made out in some, but in others it has not.

STOMATITIS.

Definition. By stomatitis is meant a catarrhal inflammation of the mucous membrane of the mouth.

Varieties. It may be localized, as in marginal gingivitis, or be diffuse; and, again, be accompanied by localized tissue destructions—ulcerations; the character of the ulceration differs according to its probable causes.

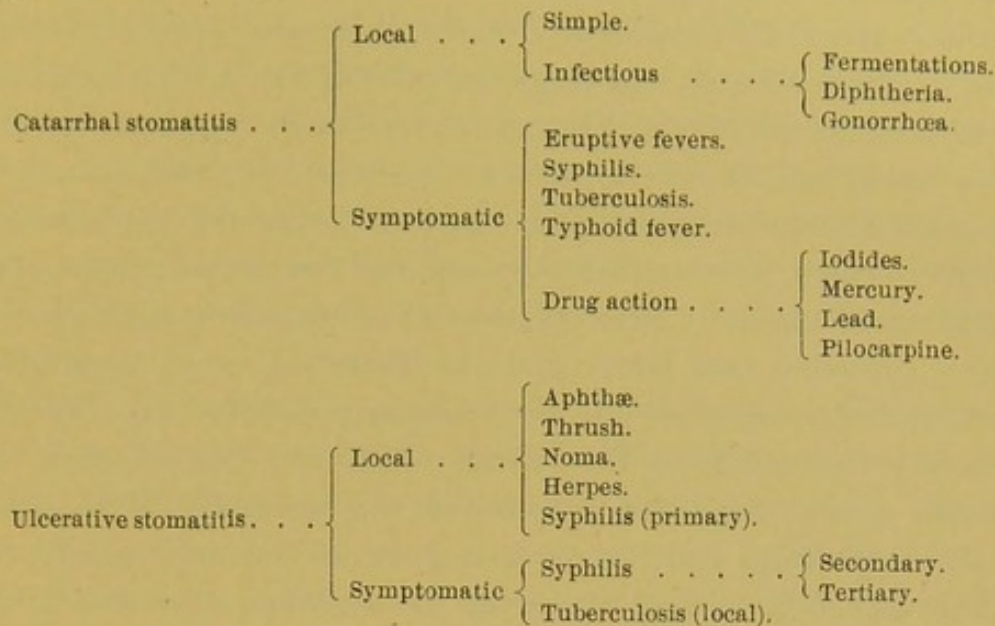
Occurrence. Most of these diseases belong to the period of childhood, although localized ulcerative stomatitis may appear in the adult.

Causes. The causes of stomatitis are so many and varied as to suggest a classification under heads according to assignable causes. While it is true that bacterial infection has not been shown to be a direct cause of all of these conditions, some degree of causal relationship is probable in all of them. The disease may, however, be included under two heads according as they are or are not localized, and necrotic. The less localized cases appear as a diffuse catarrhal affection, affect-

¹ Quoted by Miller.

² Ibid.

ing wide areas of the oral mucous membrane; the others appear as spots of localized tissue destruction attended by surrounding hyperæmia.



Simple Local Catarrhal Stomatitis. The general symptoms of catarrhal inflammation—heat and swelling, with deepened color of the mucous membrane, followed by increased secretion and exudation—attend several types of oral irritation, such as the irritation induced by erupting teeth, particularly of the deciduous teeth. Inflammation of any degree may follow the taking into the mouth of caustic chemical substances, such as caustic alkalies, mineral acids, carbolic acid, etc., which are occasionally taken by children. Other irritant drugs and very hot fluids may produce similar results. General catarrhal stomatitis is a frequent affection of confirmed smokers, and of drinkers of distilled liquors.

The cure of these conditions consists in the removal or neutralization of the cause, and the use of local sedatives and antiseptics to allay irritation and prevent infection. The most effective method of treating the inflammatory condition is by antiseptic sprays, such as diluted Dobell's solution, followed by sprays of strong solutions of potassium chlorate. If much pain exist, phenol-sodique is an admirable sedative antiseptic, used in 10–20 per cent. solution, as a spray.

Infective Local Catarrhal Stomatitis. This in some degree is a common, perhaps the necessary, antecedent condition to many of the ulcerative forms of stomatitis. It is probable that many of the cases of stomatitis found in infants, children, and adults are due to unusual fermentations occurring in the mouth. Children whose nursing bottles

are not kept clean; those who at a later age suffer from neglect of the teeth and from the effects of improper food; adults in whose mouths dental disease is widespread, and whose oral hygiene is very faulty; all exhibit abnormal conditions of the oral mucous membrane—more or less swelling, softness, and deepened color of the mucous membrane, a coated tongue, and offensive breath, with an increase of oral secretions.

The complexus of oral symptoms is commonly, and also by the general practitioner, regarded as symptomatic of gastric, intestinal, and hepatic disorders, as doubtless they are, but the causal relationship is in many cases probably the reverse of that implied in such opinions, for it is probable (see later) that the disturbances of digestion are fermentative in character, and the organisms causing them find their way to the stomach from the mouth, which was first affected. The treatment of this condition consists in the correction of its causes, their non-repetition, and the continued use of oral antiseptics.

While the point of first attack of the diphtheria bacillus is most marked about the soft palate and tonsils, the false membrane forming there and spreading to the pharynx, more or less general inflammation of the oral mucous membrane also occurs. The gonococcus may be lodged in some portion of the oral cavity and excite its specific effects upon contiguous mucous membranes.

Symptomatic Catarrhal Stomatitis. Stomatitis in its catarrhal form is usually associated with the early and later stages of the eruptive fevers, scarlet fever, smallpox, etc. In scarlet fever and smallpox evidences of direct infection of the mouth exist and the inflammatory reaction is pronounced.

Catarrhal stomatitis is one of the manifestations of secondary and tertiary syphilis, antedating the appearance of tissue necrosis (ulcerations).

More or less catarrhal stomatitis, confined, it may be, to the mucous membrane of the gums, is common in the mouths of phthisical patients; this condition exhibits no evidence of direct association of the local development of the bacillus of tuberculosis, because no tubercular ulcers may arise or threaten.

The stomatitis of typhoid fever may be regarded as an almost essential feature of the disease.

The effects of drug elimination by the oral tissues have been already discussed. (See Chapter XXIII.)

Ulcerative Stomatitis. It has been customary to describe ulcerative stomatitis as simple and infective; in all probability these ulcerations

are always infective. Like catarrhal stomatitis the ulcerative disease may have only a local significance or be indicative of some general disease.

Ulcerative Stomatitis of Local Significance. The more usual or infantile forms of these disorders are a sequel of catarrhal stomatitis, at least of an acquired debility of the oral tissues, and their primary cause is, therefore, the cause producing a condition of mucous membrane which permits the growth of infective organisms. One of these diseases, thrush, has already been described. The others, aphthæ, herpes labialis, and noma, are all probably due to the action of organisms.

Aphthæ. This affection is common in its isolated form, as the canker sore. In the catarrhal stomatitis of children, during or after dentition, multiple sores frequently make their appearance. The condition can best be studied when it appears as an isolated sore in the mouth of the adult. The most common situation of the sore is at the junction of two mucous surfaces, such as that of the gum with the lip or cheek, or that of the floor of the mouth with the gum or tongue. Redness diffused over a limited area, followed by a nodular hardening, occurs, during which local pain is annoying; the centre of the hardened area breaks, the epithelium disappearing, forming a raw surface, which quickly acquires a rough, yellowish-white coating which is easily removable. The sores are very painful.

The mouth is usually otherwise healthy, and there is an absence of associated throat and skin affections.

This condition follows so constantly upon the taking of very indigestible food, such as lobster, Welsh rarebits, etc., that acute indigestion must be regarded as having some causal relationship with it. It is also of frequent occurrence in the mouths of dyspeptics; that form of gastric disturbance attended by a deficiency of hydrochloric acid in the gastric juice appears to have a constant association with it, though it is probably caused by the *oidium albicans*.

The appearance of ulcerative stomatitis in children, together with its treatment, was discussed in the chapter on Dentition.

The general treatment of these ulcerations appearing in the mouths of children is the administration of a laxative, and the subsequent administration of listerine, gtt. x, every two hours. Locally the mucous membrane is to be sprayed with pyrozone, followed by sprays of strong solutions of potassium chlorate.

Localized aphthous patches in the adult are promptly relieved by

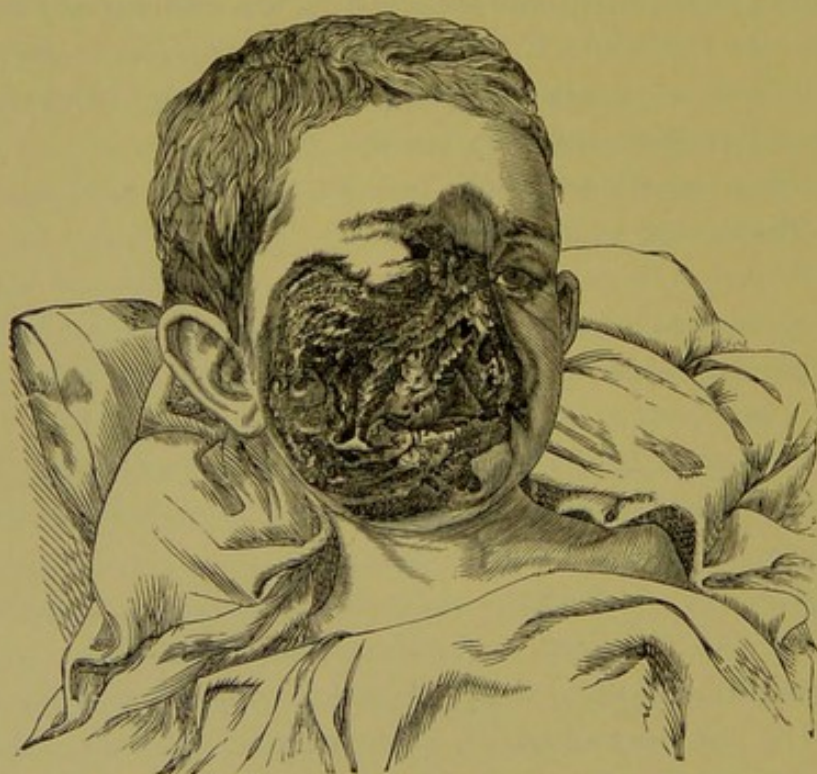the administration of calomel, gr. ij, at night, followed in the morning by a mild saline. The local sore is dried and touched with pure carbolic acid. The administration of alkalies before meals, and hydrochloric acid after meals, usually remedies the gastric condition, unless it be of long standing.

A variety of aphthous sore is called, from the anatomical situation of the ulcers, follicular stomatitis. Irritation and swelling of the mucous follicles in the palatal, buccal, and labial mucous membrane are accompanied by more or less localized inflammation; the follicles become ulcerous, the small ulcers having a uniform size. This condition quickly disappears under the treatment advised for ulcerative stomatitis. An indication of the bacterial origin of all of these disturbances is seen in the efficacy of antiseptics used in their treatment.

NOMA, CANCRUM ORIS, GANGRENE OF THE MOUTH.

In ill-fed, ill-nourished, and ill-kept cachectic children, the debilitation of the oral tissues may exceed the grades given, and a disease,

FIG. 543.



Noma. (J. Lewis Smith.)

probably bacterial in origin, may arise which leads to widespread necrosis of the cheeks and maxillæ. The condition is called gangrene

of the mouth, noma, or cancrum oris; the latter term has been applied to the less severe varieties.

This disease may make its appearance as an ulcer at the junction of cheek and gum; in other cases a severe stomatitis arises without a primary ulcer. A greater or less extent of the cheek acquires a board-like hardness, becoming livid; the overlying mucous membrane breaks, exhibiting a large slough. The necrosis extends toward cheek and jaw, destroying further tissue. The sloughs undergo putrefactive decomposition, emitting a stench. The destruction of tissue may be arrested, or may proceed, destroying in a few days the entire cheek and bony tissues. In the more severe cases the disease is almost invariably fatal, because the extent of the tissue destruction bears a constant relation to the underlying debility of the patient. It will be seen that the disease resembles malignant pustule or carbuncle in several of its features.

While no specific organism has been isolated as pathogenic of this condition, Schimmelbosch¹ found a bacillus (pure culture) upon the borders of the necrosis, which may prove pathogenic of noma.

These cases are purely medical; so that their full discussion is not warranted in these pages. The principle of treatment is to improve the general condition of the child, destroy the probable infection in the borders of the still vital tissue by cauterization, and promote sloughing of the necrosed tissue by the use of antiseptic applications.

Dr. L. Fisher (New York) reported a case upon the inside of the cheek, cured by applications of ichthyol in lanolin four times a day over the entire area.²

SYPHILITIC AFFECTIONS OF THE MOUTH.

The recognition of syphilitic lesions about the mouth is of vital importance to the dental operator, first, because by the recognition he may take steps to prevent the carriage of infection to innocent patients; and, secondly, that he may avoid inoculation of himself by the poison.

In the minds of many, syphilis is associated with the lower class of persons, who are confirmed *débauchés*. While it is undoubtedly true that its prevalence is most marked in this class of persons, it appears, and with horrible frequency, in persons who would be little suspected of having such infection. The operator is to be guided in his opinions and precautions in this matter, not by the social status of the patient, but by the nature of the morbid conditions existing.

¹ Miller, Dental Cosmos, September, 1891.

² Dental Cosmos, 1902.

Syphilis is usually divided into three stages, primary, secondary, and tertiary; to these may be added a fourth stage, viz., in patients who have been discharged as cured mild manifestations of disorders, particularly of the skin and mucous membranes, make their appearance from time to time, and disappear promptly upon the administration of iodides.

The first stage of syphilis—primary syphilis—consists in the formation of the primary sore or chancre, and the involvement of the nearest lymphatic glands. Secondary syphilis is attended by fever, eruptive inflammations of the skin, inflammation and superficial ulcerations of mucous structures. In tertiary syphilis destructive inflammation of the skin, mucous membranes, and connective tissue occurs, together with the formation of specific tumors—gummata.

Some difference of opinion exists among syphilographers as to the relative infective power of the secretions from the several lesions of syphilis. All are agreed, however, that the secretions from the secondary lesions observed in and about the mouth are highly infective. It is the part of prudence to regard all syphilitic lesions as infective. All these stages of syphilis may be seen in the human mouth. It is to be remembered that if the mucous membrane of the mouth be infected from a mucous patch (a secondary lesion), the acquired disease will appear, not as a mucous patch, but as a chancre. It is from mucous patches that infection is most to be feared.

Primary Syphilis of the Mouth. Causes. The primary lesion of syphilis, chancre, when found in the mouth is a consequence of direct infection from a syphilitic. The infection occurs from contact of the mucous surface of the mouth with a syphilitic lesion upon another person: it has been transmitted by kissing; it may occur from using a glass or cup previously used by a syphilitic, by smoking cigars or cigarettes which have been made by syphilitic cigarmakers, who have applied the tongue to the tobacco in attaching the wrapper. Any of the articles named, or the contact of any article which has been in contact with a syphilitic lesion, if brought in contact with an abraded mucous surface may cause infection.

The infection may be transferred from patient to operator if the fingers have any abraded surface, or if the surface is broken accidentally by an instrument. Infection may be transmitted from one patient to another by any instrument, appliance, or article used by a syphilitic being afterward used by an innocent person. Drinking glasses, mouth mirrors, exploring instruments, rubber-dam, rubber-dam clamps,

saliva-ejector tubes, lancets, forceps, or any other instruments may be the medium of communication. During and since the time of Hunter the use of teeth from syphilitic patients in plantation operations has been a clearly recognized medium of communication.

Appearances and Diagnosis. "The primary lesion of syphilis never makes its appearance before ten days after infection; the maximum period is about ninety days; the average is twenty-one days."¹

It usually appears as a single, elevated, hard papule. In cases of dental infection, most frequently about the lips, the papule loses its epithelial coating after some days. The induration surrounding the papular mass increases until the papule, which is now raw and in a process of ulceration, appears surrounded by a ring of cartilaginous hardness. This induration is the one distinguishing feature of the chancre, which is not painful. In about a week after the appearance of the primary sore, swelling of the submaxillary lymphatic glands is observed. In case the chancre appear upon the tongue, the subhyoid lymphatic glands are swollen.² Unless pyogenic infection have occurred the lymphatic involvement is not inflammatory, there being no pain present. In from three to four weeks the sore disappears, leaving no signs of its site in some cases; in others, some induration may persist.

The diagnosis of this condition is the important consideration, so far as the dental practitioner is concerned, its treatment being the province of the general surgeon.

The elevation of the sore, its *induration*, and, if obtainable, the time of inoculation, are diagnostic data. The sore is single, and there is hard, nodular, painless swelling of the neighboring lymphatics. A single ulcer of ulcerative stomatitis may in some degree simulate the appearance of a very small chancre. It may exhibit slight induration, but its irregular form, situation, painfulness, and the usual absence of lymphatic involvement, together with its prompt disappearance after sterilizing the mouth and cauterizing the ulcer, will differentiate the two sores. If the chancre be upon the tip or sides of the tongue, where it is subjected to irritation, it may become very large and bear a close resemblance to epithelioma of that organ.

It is a wise precaution to view all sores about the mouth as possibly infectious. All errors of diagnosis in this direction will be more than compensated for by the assurance of non-transference of infection.

Secondary Syphilis of the Mouth. The secondary manifestations of syphilis are observed in and about the mouth, no matter what the

¹ Gross, System of Surgery.

² Park, Surgery.

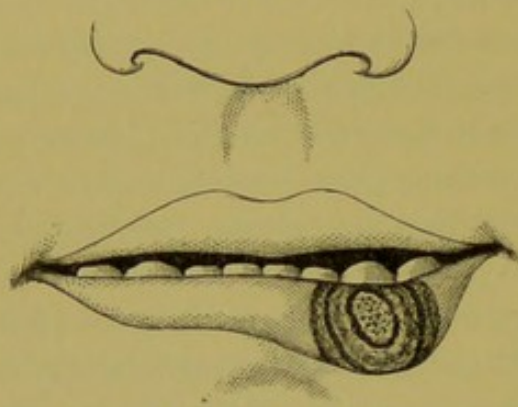
location of the primary lesion may have been; they are the result of a general, not a local, infection.

Secondary affections of the mucous tissues appear in from four to twelve weeks after the appearance of the primary lesion. Sore throat, due to inflammation of the mucous membrane of the pharynx and parts about, is almost constant; together with syphilitic hoarseness, due to the extension of the affection to the mucous membrane of the larynx.

The appearance of copper-colored areas upon some portion of the mucous membrane, on the tonsil, pharynx, soft palate, lips, or bucco-

labial surface, precedes the loss of epithelium over these surfaces, which soon occurs, forming the most virulently contagious lesion of syphilis, the mucous patch. The patches become covered with a grayish-white, pasty covering, resembling the ulcerations of non-specific stomatitis. So close is the resemblance that a differentiation can only be made at times by additional evidences of second-

FIG. 544.



Chancre of the lip.

ary syphilis. Single patches may coalesce, forming large, irregular areas covered by a grayish-white pellicle. These patches are rarely painful. Ulcerations having ragged, irregular outlines may appear at the sites of the original patches or in other situations, and exhibit a tendency to spread.

The diagnosis of the condition is determined by a discovery of other lesions of secondary syphilis; skin eruptions, falling out of the hair (alopecia), and the areas of copper-colored eruption upon the mucous membrane of the pharynx and soft palate.

Hugenschmidt¹ has observed among syphilitics, who presented no local lesions, the frequent nocturnal occurrence of indefinitely located dental pains, spreading to the palatal region.

Tertiary Syphilis of the Mouth. The syphilides of the secondary stage arise in, and are confined to, the mucous and dermal structures; those of the tertiary stage arise in the deep connective tissues, and are frequently associated with periosteum.

Tertiary lesions, as seen by the dentist, are usually in the form of ulcers of, first, the soft or hard palate, and of the tongue or lips. In

¹ Dental Cosmos, 1892.

the earlier stages hard, nodular formations may be noted as antecedents to the ulcerations. Chronic periostitis of the palatal processes may occur, leading to the formation of localized thickenings. In other cases, in the soft palate, upon the tongue, or in the hard palate, localized swellings may occur; the overlying mucous membrane breaks, establishing an ulcer, which may perforate the soft palate and destroy a portion of the palatal process, or form large ulcers on the tongue. These lesions appear in from two to five years after the secondary manifestations.

Although there is much doubt as to the degree of infectiveness of these tertiary lesions, precautions as to sterilization should be taken as with the primary and secondary lesions. A defined, ragged ulcer occupying the hard or soft palate, which has persisted for a long time, should always be viewed with suspicion, and a search be made for other evidences of syphilis.

These ulcerations appearing upon the side of the tongue may closely simulate epithelioma of that organ. The confusion is increased if, in consequence of the presence of jagged teeth, a continuous irritation is excited. Moreover, leukoplakia of the cheeks, a diagnostic sign of incipient epithelioma, frequently accompanies tertiary syphilis. In some cases an absolute diagnosis is only made by noting the disappearance of the local lesion following the administration of iodides, the specific treatment of tertiary syphilis.

The existence of tertiary syphilis is of great clinical importance to the dentist in that a condition of lessened resistance of tissues is established, and disease processes which in the healthy person are comparatively circumscribed, in the syphilitic run a riotous course. A septic pericementitis by extension may involve a wide area of periosteum, leading to extensive maxillary necrosis.

TUBERCULOSIS OF THE MOUTH.

The bacillus of tuberculosis, under favorable conditions, develops in the tissues of the mouth, producing its characteristic lesions. Finding a suitable soil, such as is furnished by the heredity which predisposes to phthisis pulmonalis, the bacillus may find entrance to the deeper tissues from the mucous membrane of the mouth and excite tuberculosis in the deep structures, the bone, etc. What part is played by local oral and dental lesions in tuberculosis of distant parts, by establishing pathways for the entrance of the bacilli into the circulation, is at present conjectural, but that such infections occur is very probable.

ACTINOMYCOSIS.

The condition produced by the development of the ray-fungus, the actinomycosis, in the lower jaw and cervical regions of cattle and swine—lump-jaw—is not unknown in human beings.

Miller¹ gives 203 cases reported in German medical literature between 1886 and 1891. In at least 120 of these cases the point of entrance of the fungus was found to be in the region of the mouth or throat. Actinomycosis threads have been repeatedly found in the saliva and in carious teeth, and notably in the tonsils. Whether the path of entrance to deeper structures is ever through carious teeth is undetermined, but certainly lesions or wounds about the mouth furnish an entrance.

GONORRHOEA.

Undoubted cases of oral infection by the gonococcus of Neisser have occurred. The oral mucous membrane and the gums may undergo intense suppuration. Fever and its accompaniments may be present. The mouth and eyes are very subject to secondary infection in an individual suffering from gonorrhœal urethritis. The toxins and the germs formed in the mouth may be swallowed.

GENERAL SEPTIC DISEASES OF DENTAL ORIGIN.

The effect of the existence of dental diseases upon the body at large, particularly as regards secondary infection, is a matter increasing in importance as the possibilities of their connection are made out. At present, the organisms of greatest demonstrable pathological interest are the pyogenic cocci. The almost constant presence of these organisms in the mouth, carried thence into the pharynx, posterior nares, larynx, lungs, and stomach, furnishes the reason for the pyogenic and phlegmonous inflammations which occur in these organs. The diplococcus of pneumonia, a frequent organism, but waits a favorable opportunity to establish high inflammations and fibrinous exudations in the lungs, and possibly in other structures.

The most important clinical associations of dental with general infections are diseases of the pericementum. The pulps of teeth, having no lymphatics, do not appear to take up and transmit the products of the action of septic organisms; but while the evidences

¹ Dental Cosmos, 1891.

of such absorption, involvement of the neighboring lymphatics, are not present, it must be remembered that the veins may transmit the poison, and, in addition, may perhaps convey organisms from a diseased but still vital pulp to distant parts. When, however, the pulp is dead and the pericementum is invaded, there is no doubt of general infection from this local source. More or less septic intoxication is a common attendant upon severe septic apical pericementitis, and septicæmia accompanied by inflammation of the neighboring lymphatic glands is of sufficient frequency to emphasize the need of the vigorous antiseptic treatment recommended in all of these cases.

Pyæmia is far more uncommon.¹ Pyogenic organisms, gaining access to the blood current from the local source of infection, establish suppuration in distant parts; in other parts of the bone, or in other bones (osteomyelitis), in the lungs, meninges, and substance of the brain. One case² has been reported where abscess of a toe, ear, and forearm ceased, and recovery took place after treatment and filling of septic root canals. Several cases are tabulated by the same author in which extensive necrosis and death resulted from pyæmic infection from septic pericementitis. Some of these cases recorded were associated with acute, some with chronic septic pericementitis.

In addition to the usual pyogenic cocci, Miller has isolated several forms of cocci, bacilli, and spirilla, forming products which, if injected into the circulation of animals, cause death from septicæmia in from hours to days. As many of these forms may be brought into relation with deep parts by the anatomical conditions created by pulp death, the possibilities of many types of infection *via* pulpless teeth are evident.

The possibilities of local as well as general infections through the conditions established in the several forms of pyorrhœa alveolaris should not be forgotten.

The pockets formed by the soft tissues overhanging lower third molars whose eruption is impeded invite the passage of septic organisms to deep parts. Local pyogenic infections are common in these cases.

DENTAL STERILIZATION.

It must ever be borne in mind that the dental operator constantly works in a field of infection, and unless extraordinary precautions be taken every instrument which touches this field—the fingers of the

¹ Miller, Dental Cosmos, 1891.

² Ibid.

operator, his mirrors, glasses, napkins, rubber-dam, rubber-dam clamps—becomes immediately infected as soon as it is brought in contact with the mouth of the patient. The likelihood of infection varies with the patient and the particular instruments; mouth-mirrors, rubber-dam clamps, scalers, and all instruments used in the treatment of pulp canals are likely to become more promptly and extensively infected than other instruments. Again, the forms of the instruments determine whether or not increased opportunity is given for the retention of infective material. The fingers of the operator may be the medium through which infective material is transferred from one patient to another. Infection may be carried from superficial areas of the mucous membrane of the mouth, from the enamel and the saliva, into deeper structures, where conditions are favorable for the development of sepsis.

The scheme for dental sterilization, therefore, includes the sterilization of the operator, instruments, apparatus, appliances, etc., used in operations, and the sterilization of the field of operation prior to operating.

The Operator. Extreme personal cleanliness upon the part of an operator is clearly the first step in asepsis. The best class of dentists are exceedingly neat as regards personal habits: daily bathing, care of the nails and of the skin, and immaculate linen form as much a part of the day's labor as dental operations *per se*. The virtues of soap and water, wherever they may be applied, are regarded as a very important item in preventing infection.

Linen which has been boiled prior to wearing may be regarded as safely sterile; so that the matter of personal sterilization relates to the hands, particularly to the finger-nails. The space under the nails is a favorable habitat for many organisms, notably the pyogenic cocci, the staphylococcus pyogenes aureus being commonly present in this situation.

It has always been advised that the finger-nails be trimmed short, and be made smooth to avoid mechanical injury to the soft tissues of the patient. Since the advent of aseptic and antiseptic surgery these precautions have an additional significance; nails kept short and smooth may be more readily cleansed than if long and ill-kept. The nails should be cut so that they nowhere project beyond the tips of the fingers. Their mechanical cleansing should be done with smooth instruments, not sharp knife-blades; the latter produce rough surfaces, which furnish spaces for lodgement of bacteria. There is but one

effective method of washing beneath the nails; it is that followed by the general surgeon: after dipping the soap in water as hot as can be borne by the hands, all of the finger-nails should be made to scrape the soap until the spaces under the nails are filled with soap. After this, coarse hand-brushes are used to scour every part of the hands with soap and water as hot as can be borne. Special nail-brushes are next used to scrub beneath the nails, driving out piecemeal the soap masses there. The general surgeon continues the scrubbing until the nails are scrupulously clean. The soap usually used is Castile, or soap made from palm oil, etc.; but antiseptic soaps, such as ethereal soaps, may be substituted with advantage.

Sterilization of the cleansed hands is ensured by immersing them for five minutes in antiseptic solutions, such as a 1:2000 solution of mercuric chloride. The hands should be sterilized after treating each patient; rubbing the hands with a paste of flour of mustard and water for three minutes and washing off with sterilized water is effective (Nancrede). If the patient dismissed have possessed an unusually septic mouth, or have been a syphilitic, for example, the time for hand cleansing and sterilization is to be prolonged; if syphilitic, every instrument used is transferred to separate vessels containing antiseptic solutions or boiled, and the hands are viewed as highly infected; they are scrubbed with mercuric chloride solutions to prevent personal infection or the carriage of infection. Chancres have from time to time appeared upon the fingers of dentists as well as physicians.

Sterilization of Apparatus. The scrupulous cleanliness of the operating chair, whose head-rest should receive frequent changes of boiled-linen coverings, metallic parts rubbed, and general covering cleansed; the cleansing, polishing, and sterilizing of cuspidores; the changing of paper coverings upon instrument tables, etc., are part of the general scheme of sterilization. The floor of the operating room also requires attention; instead of being covered with carpet, it is preferable to have it made of parquetry material or cement, over which rugs are laid, which may be removed from the room for cleansing, the floor proper being scrubbed.

Napkins used about the mouth are certain to become infected, so that their boiling should be prolonged at least fifteen minutes. For many operations it is preferable to substitute strips of muslin for linen napkins, which after being used may be thrown away.

If a hydraulic saliva ejector be used, the glass mouth-tubes should be changed for each person, a sterilized tube being substituted directly

before its use is required. A number of these tubes should be in use and may be sterilized after washing by placing them in a 50 per cent. solution of listerine or in 5 per cent. formaldehyde for a few hours. Tumblers and mouth-mirrors may be sterilized in like manner. The cloudiness of saliva tubes is produced by the formation of salivary calculus, and may be removed by the use of acidulated water.¹

At the close of each day a large cup should be filled with an antiseptic solution, which is to be drawn through the tubing of the ejector to keep it in a reasonably aseptic condition.

Rubber-dam may be sterilized by boiling water, but it is more safe and cleanly to use a new piece for each patient. It should be washed and then dusted with borated talcum powder. The possibilities of infection through this medium are great, particularly in syphilitic cases.

Sterilizing Instruments. The sterilizing of instruments comprises their mechanical cleansing and the use of germicides; boiling water, formaldehyde vapor, and antiseptic drugs are all employed for this purpose. The former, being the most convenient and certain sterilizing agent, is used wherever it cannot produce injury to instruments.

Nancrede² states that all pyogenic cocci, and even anthrax spores, are killed by boiling instruments for two minutes in a 1 per cent. solution of sodium carbonate, which also prevents rusting.

All instruments should be kept in a highly polished condition, being rubbed with crocus cloth at the end of each day's use. Excavators, explorers, and pulp-canal cleansers should be mechanically freed from visible foreign matter before boiling, by rubbing their points with a cocoa-fibre or wire brush. A fibre brush should be used to cleanse all excavating burs which have been in use. The brush should also be boiled daily and especially after an unusually infective case. It is good practice to permit it to lie in a 5 or 10 per cent. solution of formaldehyde.

Mouth-mirrors, of which there should be several, require special care. Their edges afford favorable lodging places for bacteria, and require careful sterilization. Miller³ found that the usual antiseptic solutions used cold acted as very imperfect sterilizers, but at the temperature of boiling their efficacy was markedly increased.

Extracting forceps require careful mechanical cleansing and prolonged boiling after each use, for perhaps more cases of infection,

¹ Thornton, Dental Review, 1903.

² Dental Cosmos, 1891.

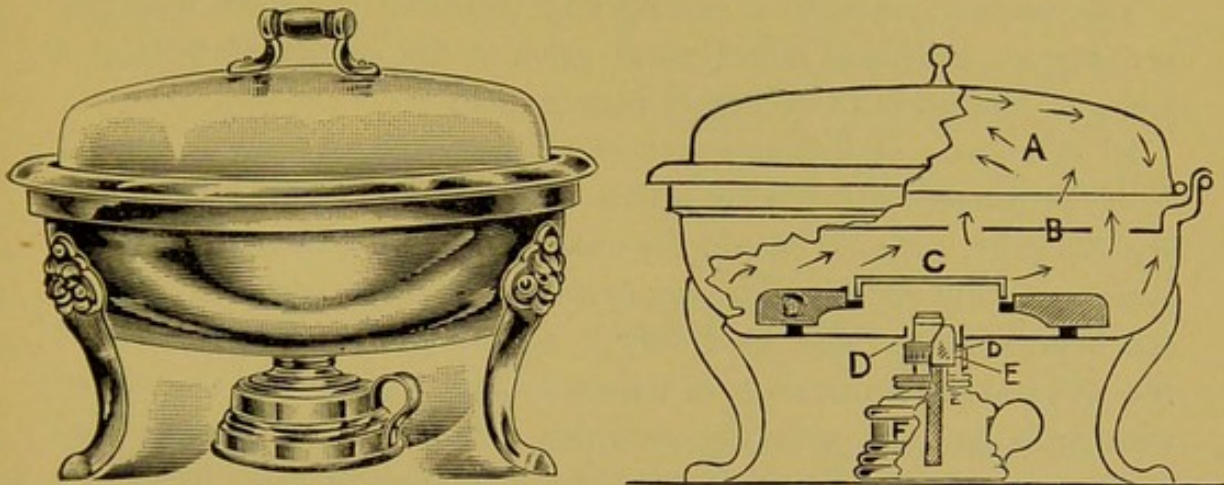
³ Park's Surgery by American Authors.

and of many kinds, have resulted from unclean forceps than from all other causes combined.

Instruments, such as hand-pieces which cannot be conveniently boiled, may be subjected for ten minutes to formaldehyde gas, developed in a Low or Schering apparatus.¹ If desired, all the instruments may be so sterilized. The entire instrument case may be disinfected by burning a Low lamp in one drawer of the dental cabinet for a half-hour at night. The drawers should be made communicating by small perforations at one or more points.

Sterilizing the Field of Operation. To ensure sterilization of the field of operation antiseptics should be used freely about the mouth

FIG. 545.



Low sterilizer: A, sterilizing chamber; B, perforated tray on which instruments to be sterilized are placed; C, glass dome and cast aluminium support, O, forming condensing chamber for removing all moisture from gas; D, formaldehyde burner; E, platinum cone, which generates the gas from Columbian spirit; F, lamp body. The course of the gas through the apparatus is indicated by the arrows.

prior to operating. The thoroughness of the sterilization will depend in great degree upon the personal habits of the patient. If by the systematic use of the agents and measures described under the prophylaxis of caries the patient's mouth be kept in a reasonably aseptic condition, sterilization of the oral cavity can be accomplished with sufficient readiness. The choice of antiseptic will depend in great degree upon the state of oral hygiene; in ill-kept mouths, with deposits of foreign materials about and between the teeth, on the gums and tongue, much more active and penetrating germicides will be required than if the parts are clean. The presence of putrefactive decomposition in the mouth, made evident by ill odors, amid which that of hydrogen sulphide may be detected, needs for its treatment the

¹ See American Text-book of Operative Dentistry.

immediate and free use of preparations from which nascent chlorine or nascent oxygen may be disengaged. No operation or even examination should be begun in such cases before a claret-colored solution of potassium permanganate, or a strong solution of hypochlorites (*meditrina* diluted), has been freely used by the patient. A better method is to forcibly spray the mouth with a 1 to 3 per cent. solution of hydrogen dioxide in order to force infective material from about the teeth. The other solutions may then be used. This spraying should be somewhat prolonged when the mucous membrane is likely to be injured. Many operators keep a stock of inexpensive toothbrushes for such cases, which are thrown away after the patient has used them, who is directed to scrub the teeth well with brush and the antiseptic solution.

The routine practice of scaling and polishing the teeth and prescribing an antiseptic mouth-wash prior to the commencement of a series of sittings is to be highly commended.

If ulcerations or inflammatory conditions exist, the sterilization is to be prolonged, using such agents as *meditrina*. If a suspicion of syphilis exist, not only should the mouth be freely washed with strong antiseptics, but special instruments should be used, preferably an old set, kept sterilized and used only in special cases. If the hands of the operator have abrasions or irritated spots, they should be covered with collodion, and after the operation should be carefully sterilized to prevent personal infection, of which a number of cases have been recorded.

A deep infection may usually be prevented during the treatment of pyorrhœa alveolaris and pulp gangrene by attention to the sterilization of the infected tract before beginning work upon the parts or during its progress. These methods have been indicated in the discussion of these subjects.

INDEX.

- A**BNORMAL food supply as disease
 cause, 24, 26
 nerve supply as disease cause, 27
 physical condition as disease cause, 27
 waste products, effects of, 27
 removal as disease cause, 24-27
- Abnormalities of teeth, 206
- Abrasion, 248
 appearance of, 248
 causes of, 248, 251
 cervical, 250
 by clasp, 250
 degrees of, 248
 eburnation in, 251
 effects of, 251
 epithelioma from sharp edges in, 251
 fracture after, 251
 hyperæmia in, 388
 hyperacidity of saliva in, 251
 of urine in, 252
 labial, 250
 occlusal, 248
 occurrence of, 248
 pathology of, 249
 by plate, 251
 proximal, 250
 pulp exposure from, 252
 rectal parasites in, 252
 secondary dentine in, 251
 sharp edges from, 249, 251
 treatment of, 252
- Abscess, acute, 88, 459
 apical, 463. *See* Pericementitis, septic.
 blind, 465, 476
 causes of, 81
 definition of, 88
 dental. *See* Pericementitis, septic.
 gouty, 579, 580, 584. *See* Pericemental abscess.
 maxillary, 243
 pathology of, 88
 pericemental, 579. *See* Pericemental abscess.
 pointing of, 89, 464
 of pulp, 405. *See* Pulp, abscess of.
 scars from treatment of, 490
 secondary to pyorrhœa alveolaris, 556, 576, 586
 with fistula, 89, 476, 480
- Accidents to teeth, 521. *See* Fracture.
- Acetanilid as anodyne, 330, 400, 601
 as antipyretic, 473
- Acidity of mouth, 337
- Acids. *See* modifying adjective—*e. g.*, lactic.
 effect upon teeth, 156, 251, 256, 294, 542
- Aconite, tincture of, as anodyne, 202, 387, 470
 dental, 470
 to reduce heart action, 80
- Actinomycosis of mouth, 614
- Adenoids as causes of irregularity of teeth, 234
- Adrenalin chloride, 332, 392, 415, 421, 456
- Agnesia, 60
 of enamel, 213
- Agglutination, 33, 49
- Alcohol as counterirritant, 201
 as drier, 331, 345
 as solvent, 245, 341, 387, 420, 528
 use of, internally, 105
- Alexins, 33, 47
- Alum, as astringent, 569
 as mummifier, 434, 441
 as styptic, 392, 400
- Alveolar necrosis, treatment of, 492
 process, 168
 dependence upon teeth, 193
 development of, 193
 enlargement of, 134
 hypertrophy of, 507, 531
 interstitial inflammation of, 530
 necrosis of, 429, 493, 555
 resorption of, 250, 530, 532, 555
 regeneration of, 578
 surgical anatomy of, 168
- Amadou, use of, 405, 420
- Amalgam facing, use of, 387, 427
- Amber, use of, 264
- Amelification, 124
- Ameloblasts, 118
- Ammonia, use of, 337
- Ammonium carbonate, use of, 336
- Ammonol, use of, 330
- Amœba dysenteriae, 35
 properties of, 18
 structure of, 18
- Amœboid movement, 18

- Amputation of roots in acute abscess, 473
 in chronic abscess, 484
 method of, 487
 in perforations, 494, 502
- Amyloid, 437
- Anabolism, 22
- Anæmia, 26, 71
 chlorotic, 73
 debility in, 72, 73
 degeneration of cells in, 74
 hæmoglobin in, 72
 influence on caries, 291
 on pyorrhœa alveolaris, 551, 573
 leukæmic, 73
 pernicious, 74
 symptomatic, 73
 traumatic, 72, 77
- Anæsthesia of pulp, 333
- Anæsthetics, general, 329
 local. *See* Cocaine.
- Anatomy, surgical, of teeth, 156
- Ankylosis of roots, 509
- Anomalies of teeth. *See* Malformations.
 of number, 230
- Antibacterial influences, 47, 49
- Antikamnia, use of, 330
- Antiphlogistics, use of, 473
- Antipyretics, use of, 102, 105, 472
- Antipyrin, use of, 601
- Antiseptics for blood, 104, 492
 for canals, 452
 for cavities, 344, 345
 for mouth, 357, 528, 569
 for pyorrhœa pocket, 569
- Antitoxins, 32, 49
- Antrum of Highmore, empyema of, 481, 489
 fistula in, 488
 relations of, 174, 467, 489
- Aphthæ, 607
- Aphthous ulcer, 607
- Aplasia, 60
- Aqua regia, use of, 433, 438
- Arch, V-shaped, 234
- Architecture of teeth, 166, 436
- Argyrol, use of, 570
- Aristol, use of, 92, 344, 348, 475
- Arsenic in cobalt, 440
 iodide, use of, 397
- Arsenical fibre, 425
- Arsenious acid, in abscess of pulp, 408
 accidents with, 429
 action of, idiosyncrasy as to, 425
 upon gum, 424, 429
 upon pulp, 422
 variations in, 425
 application of, mode of, 426
 of, second, 427
 coverings for, 426
 dangers of, 424, 427, 429
 forms in which used, 425
 in hypersensitive dentine, 337
 and mummifying paste, 431
- Arsenious acid, necrosis from, 429
 in nostrums, 430
 passage of, through foramen, 424, 430
 through perforation, 431
 pastes, separation of, 425
 pocket for, 400, 428
 poison from, 428
 in pulp nodules, 378
 in pulpitis, 400
 suffusion from, 423, 432
 symptoms from, 429
 in temporary teeth, 418, 426
 use of, 422
 rules for, 426
 in venous hyperæmia, 372
- Arterial hyperæmia, 78. *See* Hyperæmia.
- Arteries, calcification of, 66, 70
 obstruction of, 67
 sclerosis of, 69
- Articulating paper, use of, 516
- Asbestos, use of, 345, 352
- Astringents, use of, 80, 528, 569
- Atomizer, use of, 570
- Atony, 60
- Atrophy, causes of, 61
 general, 61
 local, 60
- Attachment of teeth, 522
- Autointoxication, 102, 526
- BACILLI, 38**
 Bacillus anthracis in blood, 39
 necrodentalis, 394
 pulpæ gangrenæ, 346, 450, 461
 tuberculosis, 45, 613
 typhosus, 45
- Bacteria, action of gastric juice on, 46
 in media, 41
 predisposition to, 28, 31, 44
 aërobic, 40
 anaërobic, 40
 in blood, 39
 classification of, 37, 38
 cultures of, 40
 degeneration of, 39
 facultative, 40
 fermentations produced by, 37, 41
 flagella of, 37
 in green stain, 272
 grouping of, 38
 intestinal infection by, 46, 602
 involution forms of, 39
 life conditions of, 37, 42
 mode of entrance to body, 39, 602
 monomorphic, 39
 of mouth, 44
 non-motile, 37
 non-pathogenic, 40
 normal flora, 42
 obligate, 40, 45
 oral infection by, 46, 602
 parasitic, 39

- Bacteria, pathogenic, 40
 pleomorphic, 39
 pyogenic, 43, 44, 202, 401, 406, 461
 resistance of part to, 32
 of tissues to, 32, 47, 614
 rest as factor in life of, 44
 saprophytic, 40
 size of, 36
 soil of, 39, 40, 41, 42
 specific, 42
 spores of, 38
 spreading of, in body, 43
 thermal death point of, 37
 toxic action of, 39
 unorganized ferments of, 41
 zoöglæa of, 38
 Bacteriolysis, 33, 49
 Band, dental, 115
 Bands, use of, 268
 Benzoic acid, use of, 528
 Benzoin, use of, 245, 392, 399
 Bicuspids, architecture of, 166
 eruption of, 194
 impaction of, 241
 surgical relations of, 173
 Bismuth, use of, 190
 Bite, opening of, 252
 Black stain, 272
 Black's mixture, use of, 570, 578
 Blastomycetes, 34
 pathogenic in mouth, 602
 Bleaching processes, 274, 431
 Blindness from dental disease, 508, 599
 Blisters, use of, 80
 Blood, bacillus anthracis in, 39
 bacteria in, 39
 bacterial enzymes in, 33
 bactericidal properties of, 33, 48
 calcium salts in, 536, 551
 clotting of, 74
 coagulability of altered, 77
 coagulation of, 74
 in capillaries, 68, 74
 ferments in, 74
 in inflammation, 84
 corpuseles in health and disease, 71
 erythroblasts of, 71
 erythrocytes of, 71
 germicidal power of, 48
 letting, 82, 92, 392, 399
 phagocytes of, 48, 72
 platelets of, 74
 supply to teeth, 152
 urates in, 552
 Bone, development of, in jaw, 122, 127
 formation of, 66
 infection in dental lesions, 491
 inflammation of, 97
 necrosis of, 98, 493
 regeneration of, 100, 488, 578
 suppuration of, 89
 Borax, use of, 189, 528
 Boroglycerin, use of, 528
 Bridge-work, use of, 253, 351, 514, 568
 Broaches, barbed, 432, 438
 broken in canals, 438
 Dayton, 497
 Downie, 432
 Kerr, 432
 pushed through apical foramen, 438
 Swiss, 432, 437, 438
 Bromide of potassium, use of, 601
 of sodium, use of, 161
 Brush, use of, 356, 569
 wheels, use of, 274, 544

CAFFEINE, use of, 473, 601
 Calcareous degeneration, 66
 of pulp. *See* Pulp.
 Calcification, 122
 after pus formation, 89
 of arteries, 66, 70
 of dentine, 123
 of teeth, 129, 133
 of thrombi, 74
 tubular, 251, 310, 320, 364
 Calcium chloride, use of, 77, 522
 Calcoglobulin, 122, 376
 Calcospherites, 122
 Calculi, origin of, 66
 Calculus, salivary, 533
 analyses of, 535
 in children, 537
 composition of, 534
 hardening of, 540
 mode of formation of, 537
 odor of, 537
 origin of, 534
 pathological effects of, 541
 pigmentation of, 537
 progress of, 542
 recurrence of, 533
 stratification of, 534
 treatment of, 542
 urates in, 537
 varieties of, 534
 serumal, 533
 analyses of, 535
 in apical abscess, 477, 482, 548
 hæmatogenic, 549
 mode of formation of, 540
 pyogenic, 477, 482, 548, 555
 in pyorrhœa alveolaris, 554
 subgingival, 546
 cause of, 546
 effects of, 547
 pathology of, 546
 symptoms of, 547
 treatment of, 548
 on unerupted tooth, 549, 583
 urates in, 583
 Calendula, use of, 528
 Callahan method of enlarging canals, 452
 Calomel, use of, 608
 Camphor, use of, 337, 399, 570
 Canada balsam, use of, 345
 Canals, pulp, accidents to, 438

- Canals, pulp, broken broaches in, 438
 cleansing of, 432
 continuity of, loss of, 457
 disinfection of, 452, 470
 enlargement of, 432, 452, 479
 filling of, 435
 lining with silver nitrate, 453
- Cancrum oris, 607
- Canker sore, 607
- Cantharides, danger of, 421
 use of, 421
- Capillaries, obstruction of, 67, 531
 thrombosis of, 74
- Capping of pulp, 347
- Capsicum and myrrh, use of, 200
 plaster, use of, 472
- Carbolic acid as anæsthetic, 405
 as antiseptic, 352, 432, 454, 486
 as caustic, 189, 415, 421, 422, 608
 as ingredient in formulæ, 245, 335, 337, 348, 425, 570
 as obtundent of hypersensitive dentine, 253, 336
 as sedative, 387
- Carcinomata, 59
- Caries, dental, acids of, 282, 283
 age as factor in, 290, 320
 alkalies in, 284
 almost exposed pulp in, 343
 arrangement of teeth in, 287
 bacteria of, 281, 292, 299, 308
 bodily condition as factor in, 291
 calcium salts produced in, 258, 305, 309
 causes of, 280
 exciting, 280
 general predisposing, 289
 local predisposing, 285
 theories of, 277
 Caush's tubes in, 288
 cavity production in, 302
 of cementum, 313
 changes of saliva influencing, 291
 clinical history of, 314
 cooked food as factor in, 284
 decalcification in, 294, 298, 301
 deep-seated, 339, 341
 defects of teeth in, 286
 destruction of dentine in, 301, 304
 Nasmyth's membrane in, 301
 diagnosis of, 322
 diet in, 285
 enlargement of tubules in, 302
 erosion and, 256
 exploration for, 323
 exposure of pulp in, 306, 346
 factors in, 283
 form of teeth in, 286
 healing of, 320
 heredity as factor in, 289
- Caries, dental, history of, 277
 hypersensitivity of dentine in, 325
 including the pulp canal, 457
 in interglobular spaces, 307
 leaving decalcified dentine in, 344
 liquefaction of dentine in, 304
 foci in, 306
 loss of crown by, 321, 351
 of root by, 321
 microbial plaques in, 289, 292
 Miller's experiments on, 280
 morbid anatomy of, 292
 neutralization of acid in, 304
 pathology of, 292
 pigmentation in, 312
 prenatal and postnatal influences in, 290
 prognosis of, 325
 prophylaxis of, 356
 rapidity of progress of, 318
 recurrence of, 354
 relative liability of teeth to, 316
 secondary, 307
 signs of, 322
 simple, treatment of, 339, 340
 situations in which found, 292
 stages of, 340
 structure of enamel in, 288, 289
 sugar and starches in, 283
 superficial treatment of, 339
 systemic disease as factor in, 291
 effects of, 358
 of temporary teeth, 351
 terminations of, 321
 therapeutics of, 340
 transparent zone in, 309
 tube casts in, 309
 undermining, 319
 variations in progress of, 320
- Cartilage of Meckel, 112
- Caseation, 64, 89
- Castor oil, use of, 190
- Catabolism, 22
- Cataphoresis, introduction of drugs by, for canal disinfection, 453, 479, 486
 dangers in, 429, 430
 for hypersensitive dentine, 332, 341
 irritation resulting from, 389
 for pulp removal, 378, 419
- Cathartics in dentition, 190, 191
 as derivatives, 80, 400, 470
- Cavitine, use of, 342, 343
- Cells, amoeboid movement of, 19
 degeneration of, 23, 62
 destruction of vitality of, 67, 68
 functions of, 19
 health of, 20
 hypertrophy of, 51

- Cells, infiltration of, 62
 malnutrition of, 62
 nutrition of, 19, 22
 interfered with, 62, 167
 reproduction of, 19
 sedation of, 21
 specialized, 22
 stimulation of, 20
 structure of, 17
- Cementification, 127
 tables of, 129, 133
- Cementum, 148
 caries of, 313
 death of, 482
 deposition of, 127
 hypertrophy of. *See* Hypercementosis.
 infection of, 482
 interdental, 130
 malformations of, 214, 222
 staining of, 248
 surgical anatomy of, 163
- Cervix, definition of, 135
- Chalk, use of, 190, 264, 338, 544
- Chancre of mouth, 611
- Chemical causes of disease, 27
- Chemotaxis, 48, 86
- Chloral hydrate, use of, 191, 330
- Chlorine, use of, 275
- Chloroform, use of, as analgesic, 202, 399, 405
 as counterirritant, 387
 as general anæsthetic, 329
 as ingredient in formulæ, 337, 405, 420
 as solvent, 264, 399, 405, 435
 in pulp-pressure anæsthesia, 420
- Chloro-percha, use of, 392, 435, 436, 458
 antiseptic, 437
- Chlorosis, 71, 73
- Chorea from hypercementosis, 596
- Chromic acid, use of, 337
- Cinchona bark, use of, 569
- Cingule, enlarged, 226
- Cinnamon, oil of, discoloration by, 456
 use of, as ingredient of formulæ, 245, 425, 529, 569, 570
 as sedative, 387
- Circulation, 22
 local disturbances of, 78
 vasomotor control of, 78
- Circumscribed gangrene, 70
- Clasps, abrasion by, 250
- Cleansing of teeth, 356
- Cleft palate, 111
- Cloves, oil of, use of, as antiseptic in cavity, 345, 387
 as canal antiseptic, 456
 in hypersensitive dentine, 337
 as ingredient of formulæ, 348, 425, 426, 529
 of pulp capper, 348
 as sedative, 387, 399, 415
- Coagulation of blood, 74
 in capillaries, 68, 74
 ferments in, 74
 in inflammation, 87
 necrosis, 68
- Cobalt, use of, 426, 440
- Cocaine, use of, anæsthesia by injection, 492, 508, 578, 587
 danger in, 421
 in hypersensitive dentine, 332, 341
 as ingredient, 425
 introduced by cataphoresis, 332, 378
 in pulp removal, 378, 387, 415, 419
 as pulp sedative, 399
- Cogswell carrier, use of, 274
- Cold as a test, 341, 363, 381, 386, 407, 445
 as a therapeutic agent, 80, 204, 473
- Colic in teething, 184
- Colloid degeneration, 65
- Colophony, use of, 337
- Combinations of filling materials, use of, 343, 352
- Compressed air, use of, 331
- Compresses, use of, 77, 203, 204, 473
- Concrescence of teeth, 222, 223, 243
- Concussion of pulp, 398
- Cone compound, 234
- Conical teeth, 216, 231, 234
- Constipation, effects of, 588
- Contractility, 18, 21, 23
 stimulation of, 20
- Convulsions, 186, 191, 201
- Copper amalgam, use of, 346, 415, 440, 494
 stains, 269, 273
 removal of, 275
 sulphate, use of, 345
- Cord, dental, 116
 for permanent tooth, 118
- Cork, use of, 189
- Corpuscles, blood, disintegration of, 390
 in health and disease, 71
 in thrombosis, 74
- Cotton, absorbent, use of, 425
 tampon, danger of, 491
 use of, with arsenic, 425
 as a devitalizing agent, 422
 in pulp removal, 432
 as a root dressing, 437
 filling, 437
 as a test, 346
- Cottonoid, use of, 387
- Cough in teething, 187
- Counterirritation, use of, 92, 93, 387, 400
- Counterpressure in pericementitis, 469
- Cows' milk, use of, 192
- Creosote, use of, 399, 437
- Crown, amputation of, 205, 351
 definition of, 135
 tool, use of, 458

- Crowning in doubtful cases, 457
 - use of, 219, 252, 268, 350, 353
- Crypts, dental, 127
- Cultures, bacterial, 40
- Cuspids, architecture of, 166
 - eruption of, 181, 194
 - impaction of, 239
 - retention of temporary, 198
 - supernumerary, 233
- Cusps, supplemental, 226
- Cysts, dentigerous, 52, 243
 - dermoid, 53
 - formation of, 52
 - varieties of, 52

DAYTON broach, use of, 497
 Deafness caused by dental disease, 508

- Decalcification of dentine, 301
 - of enamel, 271, 294
- Deficiency of teeth, 230
- Degeneration, 62
 - calcareous, 66, 379
 - calcific, of pulp, 379. *See* Pulp, calcific degeneration of.
 - of cells in anæmia, 74
 - colloid, 65
 - fatty, 62, 74
 - hyaline, 65
 - in inflammation, 87
 - lardaceous, 65
 - mucoid, 65
 - of pericementum, 513
 - of pulp, 372, 379
 - in venous hypercemia, 81
- Dehydrator, use of, 331
- Dental band, 115
 - caries, 277. *See* Caries, dental.
 - cord, 116
 - crypts, 127
 - follicles, 119, 127, 132
 - groove, 115
 - pathology, definition of, 17
 - study of, 25
 - ridge, 115
- Dentinal changes, 121
 - fibrillæ, 146
 - papilla, 117
 - tubules, 142
- Dentine, 142
 - basis substance of, 144
 - calcification of, 123
 - caries of, 301
 - changes with age in, 157
 - chemical composition of, 157
 - decalcification of, 301
 - decalcified, leaving of, 344, 386, 432
 - density of, 147
 - deposition of, 123
 - elasticity of, 147
 - exposed, reflex pains from, 328, 592
 - fibrillæ of, 142
 - granular layer of, 144

- Dentine, hypersensitive, arsenious acid in, 337
 - causes and pathology of, 325
- hypersensitivity of, 325
 - diagnosis of, 329
 - in erosion, 210
 - reflex neuralgia from, 592
 - symptoms of, 328
 - treatment of, 329
- interglobular spaces in, 145
- malformations of, 213
- physical properties of, 157
- recalcification of, in caries, 344
- repair of, 266, 397
- resorption of, 413
- Schreger's lines in, 144
- secondary, 309, 365
- suffusion of, 390, 392
- surgical anatomy of, 157
- staining of, 248, 273
- tubular calcification of, 364
- tubules of, 142
- Dentinification, 123
- Dentition, 177
 - at birth, 191
 - causes of eruption in, 178
 - constitutional states, modifying, 191
 - first, 177
 - hygiene of, 187
 - multiple, 231
 - pathological, first, 182
 - constitutional states producing, 191
 - death from, 187, 189
 - general symptoms of, 184
 - treatment of, 189
 - intestinal disturbances in, 184
 - lancing in, 187
 - hemorrhage after, 188
 - local symptoms of, 183
 - treatment of, 187
 - nervous disturbances in, 185
 - paralysis in, 187
 - pulmonary disturbance in, 187
 - reflexes in, 181, 183, 185
 - skin eruptions in, 187, 189
 - stomatitis in, 187, 189
 - systemic treatment of, 189
- second, 199
 - convulsions in, 201
 - death from, 203
 - eruption of molars in, 200, 201, 235
 - exanthemata, influence of, upon, 200
 - lancing in, 201
 - stomatitis in, 201, 203
 - symptoms of, 200
 - treatment of, 200, 203
 - x-rays in, 198
- periods of, 186, 194
- process of, 186, 194

- Dentition, second, 193
 disorders of, 199
 resorption of temporary roots in, 195
 symptoms of, 182
 Depletion, 82, 92, 392, 399, 400
 Derivation as therapeutic means, 80
 Development of face and jaws, 107
 of mouth, 107
 of permanent teeth, 130
 of temporary teeth, 112
 Devitalization of pulp, 419
 Devitalizing fibre, 425
 Diabetes, influence of, on caries, 291
 Diagnosis, 24
 differential, 24
 direct, 24
 by exclusion, 24
 Diapedesis, inhibition of, 569
 of leukocytes, 83, 393
 of red corpuscles, 81, 390
 Diaphoretics as derivatives, 80
 Diathesis, 31
 hemorrhagic, 31, 76
 pathology of, 77
 treatment of, 77
 Diet in dental caries, 285
 in pyorrhœa alveolaris, 588
 Digestion of pulp, 443
 Dilaceration of teeth, 224
 Dilatation of vessels, 79, 81, 83, 384, 390
 Disease, 23
 causes of, 24, 26
 exciting, 26
 predisposing, 28
 proximate, 23
 clinical history of, 24
 diagnosis of, 24
 etiology of, 24
 functional, 24
 immunity from, 29. *See* Immunity.
 mode of study of, 25
 morbid anatomy of, 24
 previous disease as predisponent to, 31
 prognosis of, 24
 semeiology of, 24
 therapeutics of, 25
 Disking of teeth, 205, 268, 353
 Dislocation of teeth, 521
 Disturbances of vascular system, 71
 Disuse of teeth, 516
 results of, 517
 Diuretics as derivatives, 80
 Dobell's solution, use of, 490
 Donaldson's cleansers, use of, 432, 434, 438
 Downie broaches, use of, 432, 452, 497
 Drawing down teeth, 268
 Drills, Beutelrock, use of, 497
 broken in canals, 438
 Gates-Glidden, 433, 452
 Dwarf teeth, 216
 EBURNATION, 251. *See* Transparency and Tubular calcification.
 Edentulous mouths, 230
 Electric mouth lamp, use of, 323, 445, 488
 Electricity in dental therapeutics. *See* Cataphoresis and x-ray.
 effects of, on amœba, 20
 as pulp irritant, 389
 as test, 408, 445
 Elimination of waste, 23
 Embolism, 75
 Embolus, 75
 septic, 44, 76
 Empyema of antrum of Highmore, 481, 489
 Enamel, 137
 abrasion of, 248
 absence of, 212
 agenesis of, 213
 brittleness of, 156, 265
 caries of, 244, 292. *See* Caries, dental.
 Caush's tubes in, 141
 chalk-like, 213
 chemical resistance of, 156
 decalcification of, 271
 dentinal processes in, 208
 deposition of, 124
 erosion of, 256
 excrescences, 226
 faulty, about sulci, 208
 feel of, in impaction, 244
 fracture of, 265
 globules, 125, 137, 139
 histology of, 137
 hyperplasia of, 212
 interprismatic cement substance of, 125, 138
 lines of cleavage in, 265
 malformations of, 207
 nodules, 225, 226
 opaque spots in, 207, 213
 organ, 117
 perfect, 206
 polariscopic appearance of, 159
 of pulpless teeth, strength of, 157
 resorption of, 254, 512
 rickety, 213
 rods, 137
 solubility of, 156
 staining of, 141, 247
 stratification of, 140, 210
 striæ of Retzius in, 210
 striation of, 210
 stripes of Schreger in, 141
 structure of, 137
 supplemental cusps of, 226
 surgical anatomy of, 156
 syphilitic, 212
 transparency of, 247
 unusual locations of, 225
 Encystment of teeth, 233, 235
 Endarteritis obliterans, 531
 Enzymes, bacterial, in blood, 33, 49

- Epiblast, products of, 60
 Epilepsy, 508, 596
 Epithelioma, 56, 59, 255
 Ergot, use of, 80
 Erosion, 255
 abrasive factors in, 260, 261
 acid fruits in, 261
 sodium phosphate in, 258
 agency of labial glands in, 260
 appearance of, 255
 Baume's clefts in, 263
 causes of, 256
 diagnosis of, 263
 eburnation in, 261
 experiments in, 258, 261
 fracture in, 262
 hypersensitivity of dentine in, 263
 lactic acid in, 258
 location of, 255
 morbid anatomy of, 261
 periods of, 263
 polariscope in, 258
 secondary dentine in, 261
 suboxidation in, 259
 systemic factor in, 259, 263
 treatment of, 263
 Eruption of teeth, 177. *See also* Denti-
 tion.
 causes of, 178
 difficult, 194
 of molars, 200, 235
 pathological, 182, 199
 periods of, 180
 process of, 180
 symptoms of, 182, 199
 theories of, 179
 Eruptive fevers, 106. *See* Exanthemata.
 Erythroblasts of blood, 71
 Erythrocytes of blood, 71
 Ether, use of, 329, 331, 419
 Ethyl chloride, use of, 331, 363, 415, 419,
 455, 472
 Eucalyptus, oil of, use of, 337, 528
 Evans' root drier, use of, 422, 436
 Exanthemata, effects of, on teeth, 106,
 212
 sequestrum from, 200
 Excess of teeth, 230
 Excretion, 23
 Exfoliation, 68
 Exostosis of alveolar process, 507, 555
 of tooth roots. *See* Hypercemen-
 tosis.
 Exploration for caries, 323
 for impaction, 244
 Exposure of pulp, 344, 365
 Extension for prevention of caries, 342
 Extraction of hypercementosed roots,
 508
 indications for, 191, 198, 204, 244,
 556, 571, 596
 Exudates of hyperæmia and inflamma-
 tion, 81, 390, 395
 Eye, diseases of, caused by dental dis-
 ease, 598
- F**ACE, development of, 107
 Faradic current, use of, 445
 Fatty degeneration, 62
 of pulp, 418
 Fermentation, 37, 40
 acetic, 41
 of albuminous compounds, 41, 402,
 448
 alcoholic, 41
 lactic, 41
 mixed, 41
 nature of products of, 41
 progressive, 41
 Ferments in coagulation of blood, 74
 organized, 40
 unorganized, 40
 Fever, 100
 oxidation in, 101
 Fibrillæ, dentinal, 146
 Fibrin, formation of, 74
 Fibroid degeneration of pericementum,
 519
 of pulp, 416
 Fibromata, 56
 Fibrosarcomata, 56
 Fistula in antrum of Highmore, 488
 artificial, making of, 471
 on face, 490
 in suppuration, 89
 Flagella, 34, 35, 36
 Fletcher's carbolized resin, use of, 337,
 350
 Flexion, 224
 Floss silk, use of, 274, 357, 358, 437
 Fluctuation in suppuration, 90
 Follicles, dental, 119, 127, 132
 Follicular wall, development of, 117,
 121
 Food supply, 23
 abnormal, 24, 26
 in anæmia, 27
 in circulatory changes, 27
 Foramen, large, treatment of, 436
 Formagen, use of, 345, 348, 387, 444
 in cavity sterilization, 343,
 405
 Formaldehyde, use of, in capping mate-
 rial, 348
 in mouth sterilization, 529
 as mummifying agent, 434, 444
 in canal sterilization,
 455
 in instrument steril-
 ization, 529, 618,
 619
 in pulp suppuration, 408
 Forma-Percha, use of, 437, 455
 Fractures of teeth, 265
 from pulp decomposition, 451
 repair of, 266, 397
 treatment of, 267
 Frontal sinuses, relations of, 174
 Functional disease, 24
 Fungi as exciting cause of disease, 34
 Fusion of teeth, 220

- Fusion of teeth by crowns, 220
by roots, 221
complete, 220
- G**ALVANIC shock of pulp, 390
- Gangrene, 69
circumscribed, 70
dry, 69
gases in, 70
moist, 70
of pulp, 444
dry, 444
moist, 446
senile, 69
sloughing in, 70
spreading, 70
- Gases in gangrene, 70, 446
- Gastric juice as germicide, 46
- Gates-Glidden drills, 433, 439, 497
broken in canals, 438
- Gaultheria, oil of, use of, 264, 529, 570
- Gauze, antiseptic, use of, 473, 475
- Gelatin, use of, 77
- Germination of teeth, 224
- Geranium-formol, use of, 455
- German-silver strips, 274
- Giant cell, 51
teeth, 216
- Gingival margin, 136
resorption of, 513
space, 136
- Gingivitis, interstitial, 529
causes, 530
endarteritis in, 531
pathology, 530, 555
resorption in, 530
treatment in, 532
marginal, 524
causes of, 524
pathology of, 526
prognosis of, 527
symptoms of, 526
treatment of, 528
- Glands, pericemental, 153
of Serres, 155
- Globules, enamel, 125
- Glycerin, use of, 191, 274, 336, 399, 426, 441, 443
- Glycosuria, influence on caries, 291
- Glyco-Thymolin, use of, 357, 529
- Gold stains, 270
removal of, 275
use of, 219, 252, 263, 266, 340, 343
- Gonorrhœa of mouth, 614
- Gout, pathology of, 580
- Gouty diathesis and erosion, 257, 260
- Granular layer of Tomes, 144, 213
- Granulation tissue, 88, 411, 481, 512
resorbent action of, 483
- Green stain, 271
causes of, 271
decalcification under, 271
removal of, 274
- Grinding, use of, 219, 267, 516
- Grippe in antral empyema, 489
- Griswold denture, use of, 253
- Gritting of teeth, 248, 253
- Groove, dental, 115
- Grooved teeth, 216, 217, 219
- Guarding in pericementitis, 470, 503
- Gum, atrophy of, 532
- Gummata of the mouth, 612
- Gums, action of arsenious acid on, 424, 429
hypertrophy of, 415, 427
inflammation of. *See* Gingivitis.
injury of, 342
lancing of, 187, 201
necrosis of, 492
removal of, 427
structure of, 135
ulceration of, 204
- Gutta-percha, use of, 264, 340, 342, 343, 345, 350, 352, 388, 436, 440, 455, 458, 485
as root filling, 435, 488
- H**ÆMOGLOBIN in anæmia, 72, 73
iron in, 73
solution of, 81
- Hæmophilia, 76, 189
treatment of, 77
- Hæmostatics, use of, 77
- Hair, relation to teeth, 230
- Halisteresis ossium, 99, 531
- Harelip, 110, 112
- Health, condition of, 20
- Heat, use of, as a germicide, 49
as a test, 341, 363, 381, 407, 445
as a therapeutic agent, 80, 334
- Hemorrhage, control of, 77, 392, 400, 415, 421, 456, 522
- Hemorrhagic diathesis, 31, 76
pathology of, 77
treatment of, 77
infarction, 76
- Herbst's method of treating pulps, 440
- Hernia of pulp, 225, 229
- Histology of teeth, 135
- Honeycombed teeth, 212
- Howship's lacunæ, 215, 244, 397, 530
- Hutchinson's teeth, 217
- Hyaline degeneration, 65
- Hydrastis Canadensis, use of, 77
- Hydrochloric acid, use of, 253, 443
- Hydrogen dioxide, various uses of, 92, 189, 203, 415, 452, 484, 545, 577. *See* Pyrozone.
use of, 245, 405
- Hydronephthol, use of, 343, 344, 345, 529
- Hygiene, definition of, 25
- Hyoscyamine, use of, 330
- Hyperæmia, 78, 81
arterial, 78
causes of, 79
collateral, 78
compensatory, 79

- Hyperæmia, arterial, degrees of, 79, 385
 enlargement of vessels in, 79, 384
 oxidation in, 27, 71, 79
 pathology of, 79
 of pericementum, 462
 as predisposition to infection, 79
 of pulp. *See* Pulp
 reflex, 78
 results of, 79
 symptoms of, 79
 treatment of, 79
 venous, 81
 causes of, 81
 exudate of, 81
 pathology of, 81
 of pericementum, 517
 of pulp, 390. *See* Pulp.
 treatment of, 82
- Hypercementosis, 243
 causes of, 505
 diagnosis of, 507
 neuralgia from, 596
 paralysis from, 508
 pathology of, 506
 results of, 444
 situation of, 505
 symptoms of, 507
 treatment of, 508
- Hypernutrition, general and local, 50
- Hyperplasia, 51
- Hyperpyrexia, 101
- Hypersensitive dentine, 325
 arsenious acid in, 337
 causes and pathology of, 325
 diagnosis of, 329
 in erosion, 263
 reflex neuralgia from, 592
 symptoms of, 328
 treatment of, 329
- Hypertrophy, 50
 of alveolar process, 507, 531
 of pulp, 411
- Hyphomycetes, 34
- Hypo-acidity, general, influence on caries, 291
- Hyponutrition, 60
- Hypophosphites, use of, 397
- Hypoplasia, 60
- I**CE, use of, 80, 187
- Ichthyol, use of, 609
- Idiosyncrasy, 29
- Immune proteids, 49
- Immunity, 29, 32
 acquired, 32
 to caries, 285
- Impaction of teeth, 235
 caries in, 244
 cause of, 240
 diagnosis of, 243
 exploration of, 244
 neuralgia from, 243, 597
- Impaction of teeth, results of, 243
 symptoms of, 242
 treatment of, 244
 under artificial denture, 244
- Implantation, change of color after, 247
- Incisors, eruption of, 181, 194
 impaction of, 241
- Infarct, hemorrhagic, 76
 of pulp, 76
- Infarction, 76
- Infection, mixed, 41, 44
 of mouth, 602
 primary, 44
 resistance of tissue to, 47
 after root filling, 438
 secondary, 44
- Infiltration of cells, 62
 fatty, 62
- Inflammation, 82
 areas of involvement in, 85
 blood supply in, 27
 of bone, 97
 catarrhal, 85
 causes of, 82
 chronic, 410
 coagulation in, 84
 degenerations in, 87
 diapedesis in, 84
 exudate of, 81
 fibrinous, 85
 infective, 82
 symptoms of, 90
 interstitial, 529
 of alveolar process, 530
 local predisposition to, 90
 oxidation in, 27, 86
 pathology of, 83
 phagocytosis in, 84
 productive, 85
 prognosis of, 90
 of pulp, 393
 recumbency in, 398
 regeneration after, 93
 resolution in, 85
 serous, 86
 simple, 82, 479
 symptoms of, 86
 suppuration in, 87
 symptoms of, 86, 90
 terminations of, 87
 treatment of, 90
 varieties of, 83
- Injury, mechanical, of teeth, 265
 causes of, 265
 repairs of, 266
 treatment of, 267
- Inlays, use of, 252, 264
- Innervation, 23
- Insanity from dental disease, 600
- Instillation method of removing pulp, 420, 421
- Interglobular spaces in dentine, 145
- Interprismatic cement substance, 125
- Interstitial gingivitis. *See* Gingivitis
- Intoxication, septic, 102

Intubation of root, use of, 458
 Iodine, use of, as aid in cleansing teeth, 337, 544
 as counterirritant, 201, 387, 435, 470
 in pyorrhœa alveolaris, 569
 as solvent of steel, 438
 Iodoform, use of, 92, 345, 348, 426, 454
 Iridio-platinum, use of, 433
 Iron, chloride of, use of, 472
 stains, 269
 Irritability, 18, 21, 23
 stimulation of, 20
 Ischæmia, 71

JAWS, development of, 108
 surgical anatomy of, 170
 Jodo-Formagen, use of, 345
 Joining of teeth, 343

KARYOKINESIS of cells, 19
 Kerr broaches, use of, 432, 452
 Kidneys, faulty elimination by, 27
 Knife, tubular, use of, 472
 Knocking out pulp, 421
 Krameria, use of, 528

LABIAL abrasion, 250
 glands, 257
 secretion of, 257
 Lac, gum, use of, 245
 Lactic acid, use of, 433, 569, 577
 Lacunar resorption, 99, 397, 530
 Lancing of gum, 188, 201, 203
 Lanolin, use of, 609
 Lardaceous degeneration, 65, 66
 Lateral incisors, absence of, 230
 Laudanum, use of, 201
 Laxatives, use of, 588, 607
 Lead stains, 270
 use of, 80, 473
 -water and laudanum, 80, 473
 Lemon-juice, use of, 192
 Leukæmia, 71, 73
 influence of, on caries, 291
 Leukocytes in blood, 71
 amœboid movement of, 2
 phagocytic action of, 19, 21, 48, 84, 87
 Leukocythæmia, 71
 Leukocytosis, 71, 73
 normal and pathological, 71
 Lining cavity, 345
 Liquefaction foci, 306
 necrosis, 68
 Listerine, use of, 190, 529, 607
 Lithium salts, use of, 588
 Luxation of teeth, 521
 Lymphatic infection in abscess, 89, 467

MAGNESIUM carbonate, use of, 569
 Magnesia, milk of, use of, 264, 338, 357,
 sulphate of, 203, 400
 Malaria, hæmatozoön of, 35
 Malformations of cementum, 214
 of enamel, 206
 dentine, 213
 of roots, 227
 of teeth, 206
 Malignant tumors, 56
 Malnutrition, 60, 62
 Malocclusion of teeth, 515
 Malpositions of teeth, 233
 causes of, 234
 Manganese stains, 269
 Mastication, force of muscles of, 176
 Maxillæ, development of, 133
 Maxillary periostitis, 243, 474, 483
 abscess, 243, 483
 Mechanical causes of disease, 27
 injury of teeth, 265. *See* Injury.
 Meckel, cartilage of, 112
 atrophy of, 112
 Meditrina, use of, 405, 453, 470, 587
 Membrane, Nasmyth's, 142
 pericemental. *See* Pericementum.
 Menthol, use of, 341, 387, 392, 399, 405, 435, 529
 Mercury, bichloride, action of, 503
 effects of, 200, 503
 stains of, 270
 use of, 49, 105, 92, 203, 357, 441, 453, 472, 486, 492, 577, 587
 Mesoblast, products of, 60
 Metabolism, 22, 23
 Metallic stains, 269, 273
 Metastasis, 43
 of tumors, 59
 Microbic plaques, 292
 Micrococci, 38
 classification of, 38
 Micro-organisms as exciting causes of disease, 34
 Mitosis of cells, 19
 Molars, eruption of, 181, 194
 first, importance of, 235
 fourth, 231
 impaction of, 235
 Monomorphic bacteria, 39
 Moose-hide wheels, use of, 543
 Morphine, use of, 93, 330, 399, 400, 421, 425, 426
 Motor disturbances of dental origin, 599
 Mouth, acidity of, 337
 actinomycosis of, 614
 bacteria of, 44
 chancere of, 611
 development of, 107
 gonorrhœa of, 550, 614
 gummata of, 612
 infections of and from, 602
 prop, use of, 189, 204
 sterilization of, 452, 474

- Mouth, syphilis of, 609
 sterilization in, 620
 syphilitic affections of, 609
 tuberculosis of, 613
 washes, antiseptic, 338, 528
- Mucin, coagulation of, by lactic acid, 538
- Mucoid degeneration, 65
- Mucous patches, 612
- Multinucleated cells, 51
- Multiple dentition, 231
- Mummification of pulp, 441
- Mummifying paste, 441
 reaction with arsenic, 431
- Murexid test for urates, 583
- Muscles, stiffness of, in dentition, 202
- Mustard, use of, 80, 191
- Mycetozoa, 34
- Myrrh, use of, 200
- N**ASMYTH'S membrane, 127, 142
 caries of, 301
- Necrobiosis, 68
- Necrosis, 67
 alveolar, treatment of, 492
 of alveolar process, 429, 493, 555
 of bone, 98, 429, 493
 from arsenic, 429
 from arsenious acid, 429
 causes of, 67
 coagulation, 68
 in eruptive fevers, 106, 209
 in inflammation, 87, 97
 liability to, 68
 liquefaction, 68
 types of, 68
- Nerve, fifth cranial, plan of, 571
 terminals of, in pericementum, 153
 in pulp, 147, 326, 328
- Nerves, trophic, 27
 vasomotor, 28, 78
 of pulp, 385
- Nervocidin, use of, 334, 341, 415, 421
- Nervous disorders of teething, 185
 disturbances from dental disease.
 See Reflexes.
- system, influence on disease, 28
- Neuman, sheath of, 143
- Neuralgia about teeth from various
 sources, 596
 caused by impaction, 243, 597
 of dental origin, 590
 from hyperæmia of pulp, 383
 from hypercementosis, 508, 596
 from hypersensitive dentine, 328, 592
 from inflammation of pulp, 398, 400
 from moist gangrene of pulp, 496
 from pericemental disease, 595
 from pulp disease, 594
 nodules, 376, 378
 reflex, from hypersensitive dentine, 592
 from root resorption, 513
- Neuralgia, treatment of, 60/
 from use of arsenic, 429
- Neuroses, reflex. *See* Reflex pains.
- Nickel stains, 270
- Nitric acid, use of, 253, 337, 438
- Nitrous oxide, use of, 400, 419
- Nodules, cemental, 215
 enamel, 226
 pulp. *See* Pulp nodules.
 effect of arsenic in cases of, 378
- Noma, 91, 608
- Non-conductors, use of, 341
- Nucleases, 49
- Nuclein, 33
- Nucleus, division of, 20
- Number, anomalies of, 230
- Nutrition, alteration of, 23
 of cells, 22
 disturbances of, 50
 excess of, 50
 deficiency of, 60
 impaired, 67, 72
- O**BTUNDENTS of hypersensitive dentine, 329, 330
 of pulp pain, 387, 399, 405, 408
- Occlusal abrasion, 248
- Occlusion, loss of, 248, 515
 of teeth, 167, 175
- Odontitis infantum, 183
- Odontoblasts, 146, 194
 appearance of, 121, 123, 144, 146
 arrangement of, 121, 123, 146
 atrophy of, 367
 development of, 121
 effect of stimulation of, 162, 251, 261, 310, 364, 365
 function of, 123
 relations of, with nerve terminals, 147, 328
 with Tomes' fibres, 146
- Odontoclasts, 194, 214
- Odontomes, 228
- Oedema, 81, 84, 390
- Oidium albicans, 603
- Oils. *See* qualifying terms, *e. g.*, Cloves, oil of.
- Oligocythæmia, 71
- Opium, use of, 77, 80, 190, 202, 473
- Orange wood, use of, 274, 421, 559
- Organs, nature of, 22
- Orthoform, use of, 492
- Ossification, 127
- Osteitis, 98
- Osteodentine, 371, 397
- Osteomalacia, 531
- Osteomyelitis, 98, 491
- Osteoporosis, 98
- Osteosclerosis, 98
- Ovary, pain in, from dental disease, 599
- Overuse of teeth, 513
 pathology of, 514
 treatment of, 514
- Oxalic acid, use of, 452

- Oxidation of cells, 20-26
 increased, 51
 in fever, 101
 heat due to, 23, 86
 in hyperæmia, 79, 81
 in inflammation, 86
 lessened, 60
 Oxygen, nascent, 452
 importance of, to tissues, 20, 22, 63, 81
- PALATE**, cleft, 111
 Papain, use of, 443
 Papilla, dentinal, 117
 changes in, 121
 Paraffin, use of, 436, 475
 Paraform, use of, 349, 436
 Paralysis from dental disease, 599
 from hypercementosis, 508
 of vessels, 392
 Parasitic bacteria, 39
 Paste, arsenical, 425
 Kowarska's, 562
 mummifying, 441
 Patches, mucous, 612
 Pathogenic bacteria, 40, 42
 Pediluvium, hot, 93, 470
 as a derivative, 80, 204
 Penicillium, 35
 Peppermint, use of, 528, 569
 Perforating canal resorption, 100
 Perforation by caries, 349, 415
 treatment of, 349
 by drill, 415, 435
 treatment of, 436
 exostosis following, 507
 by resorption, 511
 Pericemental abscess, 461, 468, 483, 579
 causes of, 579
 diagnosis of, 586
 general pathology of, 580
 morbid anatomy of, 584
 prognosis of, 587
 special pathology of, 582
 symptoms of, 584
 treatment of, 587
 glands, 153
 Pericementitis, 459
 acute septic apical, 460
 causes of, 460
 clinical history of, 465
 complicated by perforation, 494
 confluence of cachexia in, 467
 diagnosis of, 468
 direction taken by pus in, 464
 extraction in, 474
 necrosis in, 475, 493
 pathology of, 462
 prognosis of, 469
 septic intoxication in, 465
 Pericementitis, acute septic apical, stages of pus formation in, 463
 streptococcal infection in, 465
 symptoms of, 459, 462
 treatment of, 469
 systemic, 472
 use of poultices in, 467
 aseptic. *See* Pericementitis, non-septic.
 chronic septic apical, with blind abscess, 498
 with fistula, 480
 destruction of tissue in, 477
 diagnosis of, 483
 direction of pus in, 481
 discharging externally, 490
 healing of, 480
 pathology of, 480
 symptoms of, 483
 in temporary teeth, 495
 treatment of, 484
 without fistula, 476
 diagnosis of, 478
 prognosis of, 479
 symptoms of, 477
 treatment of, 479
 non-purulent, 495
 causes of, 495
 diagnosis of, 497
 pathology of, 495
 treatment of, 497
 gouty. *See* Pericemental abscess.
 mercurial, 503
 non-septic, chronic, 504
 results of, 504
 symptomatic, 503
 traumatic, 499
 causes of, 499
 diagnosis of, 502
 pathology of, 501
 prognosis of, 502
 prophylaxis of, 501
 symptoms of, 502
 treatment of, 502
- Pericementum**, 150
 apical irritation of, 407
 as avenue to deep infection, 520
 bloodvessels of, 152
 degeneration of, 513, 516, 517
 fibroid, 519
 diseases of, 459
 beginning at apex, 460
 classification of, 459
 epithelium in, 153
 evidence of disturbance of, 459
 fibres of, 151
 fibroid degeneration of, 519
 functions of, 151

- Pericementum, hyperæmia of, arterial, 462
 venous, of, 517
 infection of, 456, 461
 inflammation of. *See* Pericementitis.
 as a ligament, 150, 165
 nerves of, 153
 origin of, 130
 overuse of, 514
 structures in, 152, 155
 surgical anatomy of, 163
 thickening of, 497
- Periostitis accompanying apical abscess, 467, 474, 483
 forms of, 97
 maxillary, 243
- Permanent tooth, development of, 130
 eruption of, 194
 origin of, 118
- Phagedenic pericementitis, 572
- Phagocytosis, 19, 21, 48, 84, 87
- Phenacetin, use of, 330, 400, 601
- Phenol-camphor (campho-phenique), 455
 as canal disinfectant, 455
 disinfectant in pyorrhœa pockets, 570, 578
 formula for, 570
 in hypersensitive dentine, 337
 as obtundent of pain in tissues, 492
 in pulp diseases, 387, 399
 -sodique, use of, 189, 200, 357
- Phosphaturia, 536
- Physical condition, abnormal, 24, 27
 as disease causes, 27
- Pigmentation in caries, 312
- Pilocarpine, action of, 504
- Piscidia erythrina, use of, 330
- Pitted teeth, 216, 219
 treatment of, 219
- Plantations, result of, 511
- Plants, classification of, 34
- Plaques, microbic, 292
- Plaster of Paris, use of, 348
- Plates, use of, 253, 351
- Pleomorphic bacteria, 39
- Plethora, 50, 71
- Pocket for arsenic, 427
- Pointing, 89, 90
- Poisons, effect on protoplasm, 26
- Polycythæmia, 71
- Polypi as causes, 234
- Porcelain, use of, 219, 340, 560
- Potassium bromide, use of, 601
 carbonate, use of, 336
 chlorate, use of, 189
 hydrate, use of, 335, 452
 iodide, action of, 504
 permanganate, use of, 452
- Potassocain, use of, 332
- Poultices, use of, 467, 473
- Powder, tooth, use of, 357, 569
- Predisposition to action of bacteria, 28, 31, 44, 45, 79
- Pregnancy, influence of, on alveolar resorption, 531
 on caries, 291
 causing reflexes to teeth, 601
- Pressure anæsthesia, dangers of, 421, 430
 use of, 400, 405, 415, 419, 420
- Previous disease as predisposing cause, 31
- Probe, magnetized, use of, 438
 use of, 347, 392, 483
- Process, alveolar, 168
 dependent upon teeth, 193
 enlargement of, 134
 surgical anatomy of, 168
- Prophylaxis of caries, 355
 in pyorrhœa alveolaris, 558, 569
 in systemic disease, 358
- Proteids, composition of, 18
 immune, 49
- Protoplasm, effect of poisons upon, 27
 of retained waste upon, 27
 physiology of, 21
 structures of, 18
- Protozoa, 34
- Pseudopodia, 18
 of amœba, 18
- Ptomaines, toxic and non-toxic, 42
- Pulp, 145
 abscess of, 372, 405
 arsenious acid in, 408
 diagnosis of, 407
 pathology of, 405
 pericemental irritation in, 407
 prognosis of, 408
 symptoms of, 406
 treatment of, 408
 absence of lymphatics in, 148
 action of arsenious acid on, 422
 almost exposed, 343
 atrophy of, 367, 371
 calcific degeneration of, 379, 396
 causes of, 379
 pathology of, 379
 symptoms of, 380
 canals, cleansing of, 432
 capping, 268, 347, 348, 365, 387
 cavities, shapes of, 162
 concussion of, 398
 death of, tests for, 445
 degeneration of, 372, 379
 fatty, 417, 418
 fibroid, 416
 devitalization of, 388, 419
 in impaction, 243
 digestion, 435, 443
 diseases of, 361
 constructive, 364
 destructive, 382
 symptomatology of, 362
 in temporary teeth, 418
 electric irritation of, 389
 exposure of, 344, 346, 365
 diagnosis of, 346
 therapeutics of, 346
 treatment of, 347

- Pulp, fractures of teeth from decomposition of, 451
 fungoid, 411
 galvanic shock of, 390
 gangrene of, 444
 dry, 444
 treatment of, 446
 moist, 446
 causes of, 447
 discoloration from, 449
 doubtful cases of, 457
 pathology of, 448
 symptoms of, 450
 treatment of, 451
 hernia, 225, 229
 hyperæmia of, arterial, 382
 causes of, 382
 degrees of, 385
 diagnosis of, 385
 idiopathic, 388
 pathology of, 384
 prognosis of, 385
 symptoms of, 383
 treatment of, 386
 venous, 390
 causes of, 390
 pathology of, 390
 prognosis of, 392
 symptoms of, 392
 treatment of, 392
 hypertrophy of, 411
 infarction, 76
 inflammation of, 393
 acute, 394
 causes of, 393
 chronic, 410
 hypertrophic, 411
 diagnosis of, 414
 epithelium of, 412
 nerves in, 412
 pathology of, 411
 resorption of dentine in, 413
 treatment of, 415
 pathology of, 395
 resolution in, 396
 resorption of dentine in, 397
 diagnosis of, 399
 prognosis of, 399
 symptoms of, 397
 treatment of, 399
 mummification, 434, 441
 nodules, 372
 deposition of, 375
 diagnosis of, 378
 occurrence of, 372
 pathology of, 374
 symptoms of, 376
 treatment of, 378
 osteodentine in, 371
 partial death of, 450
 extirpation of, 440
 puncturing of, 392
 removal of, 432
 methods of preparation for, 419
- Pulp, sclerosis of, 410
 treatment of, 411
 sterilization of, 399, 405
 suppuration of, 401
 causes of, 401
 pathology of, 401
 surgical anatomy of, 161
 ulceration of, 402, 457
 hypertrophy in, 414
 pathology of, 402
 phases of, 404
 symptoms of, 404
 treatment of, 405
 vessels and nerves of, 146
 vitality of, tests for, 445
 Pulpitis, 393. *See* Pulp.
 arsenious acid in, 400
 chronic hypertrophic, 411. *See* Pulp.
 Pumice, use of, 274, 358, 545
 Puncture probe, 422
 Puncturing of pulp, use of, 392, 399, 405, 407, 408
 Pus, 87
 burrowing of, 464, 481
 calcification after, 89
 caseation of, 89
 causes of, 43
 pointing of, 89
 varieties of, 90
 Putrefaction, 41, 402
 of pulp, 448
 Pyæmia, 43, 76, 105
 of dental origin, 203, 465, 492, 615
 Pyocyaneo-protein, use of, 493
 Pyogenic bacteria, 43. *See* also the suppurative diseases.
 Pyorrhœa alveolaris, 550
 beginning as a gingivitis, 553
 bridge-work in, 568
 catarrh of mouth in, 556
 causes of, 550, 573
 clinical division of cases of, 553
 history of, 554
 dental caries associated with, 557
 diagnosis of, 557, 576
 factors in, 553
 gingival abscess secondary to, 556
 heteroplasty after amputation for, 560
 infection in, 550
 local origin of, 552
 odor in, 556
 pathology of, 554, 573
 phagedenic, prognosis of, 577
 treatment of, 577
 varieties of, 572
 prevention of mobility in, 562
 prophylaxis of, 558, 569, 571, 578
 syphilis in, 550
 systemic effects of, 572, 586
 splints for, 562

- Pyorrhœa alveolaris, symptoms of, 554, 576
 treatment of, 558, 577
 medicinal, 569 588
- Pyrozone, 25 per cent., 274, 415, 421, 438, 453, 456, 479, 486, 558
- Q**UININE, use of, 400, 472, 473, 569
- R**ACHITIS, effect of, upon dentition, 192
 upon enamel, 213
- Radiographs. *See* x-rays, use of.
- Red stains, 273
- Reflex action, 78
 hyperæmia, 78
 neuralgia from hypersensitive dentine, 592
 pain, 362, 371, 377, 383
 dental, 590
 from diseases of the pericementum, 595
 from exposed dentine, 592, 595
 facial, origin of, 593, 598
 from general diseases, 590
 hypothesis, explanatory of, 595
 location of, 593, 594
 from pulp diseases, 594
 referred to teeth, 600
 to tracts not supplied by fifth nerve, 598
 treatment of, 601
- Reflexes, motor, of dental origin, 599
- Refrigeration, use of, 331
- Regeneration, 93. *See also* Granulation tissue.
 forms of, 93-96
- Removal of pulp, 419. *See* Pulp.
- Replantation of teeth, 488, 494, 502
- Reproduction of cells, 19
- Resorbent organ, 195
- Resorption, 96
 of alveolar process, 243
 of bone, 96, 530
 of dentine, 413
 of enamel, 255
 by halisteresis ossium, 99, 531
 lacunar, 99, 530
 perforating canal, 99, 530
 of permanent roots, 509
 causes of, 509
 diagnosis of, 512
 idiopathic, 511
 pathology of, 511
 symptoms of, 512
 treatment of, 513
 by pulp, 196, 397
 of roots in impaction, 243
 of temporary teeth, 194
- Rest, employment of, 77
 surgical, use of, 79, 470, 503
- Retention of temporary teeth, 198
- Retzius, striæ of, 140
- Ridge, dental, 115
- Robinson's remedy, use of, 253 335, 338
- Root, amputation of, 473, 484, 487
 ankylosis of, 509
 apex, amputation of. *See* Amputation.
 definition of, 135
 disinfection, 452, 470
 drier, use of, 422, 436, 454
 filling, 435, 452, 455, 480
 absorbable, 475
 immediate, 452
 infection after, 438
 removable, 436, 455
 removal of, 497
 in temporary teeth, 475, 495
 tentative, 456, 479
 formation of, 127
 of permanent, 197
 table of, 129
 incomplete, 268
 intubation, 458
 long and short, 227
 malformations of, 227
 multi, formation of, 228
 perforation. *See* Perforation.
 resorption of, paralysis from, 596
 of temporary, 194
 failure of, 230
- Rose geranium, oil of, use of, 569
 oil of, use of, 264
- Rubber cups, use of, 274, 544
 -dam, use of, 386, 387, 426, 470
 vulcanite, use of, 405, 420, 421, 485
- S**ACCHARIN, use of, 245, 528
- Saccharomyces, 35
- Sacs, tooth, 127
- Salicylic acid, use of, 528
- Saliva, analysis of, 535
 changes in composition of, 291, 545
 551
 hyperacidity of, in abrasion, 251
- Salivary calculus, 533
 analyses of, 535
 in children, 537
 composition of, 534
 hardening of, 540
 mode of formation of, 537
 occurrence of, 533
 odor of, 537
 origin of, 534
 pathological effects of, 541
 pigmentation of, 537
 progress of, 542
 stratification of, 534
 treatment of, 542
 urates in, 537
 varieties of, 534
- Salol, use of, 105, 190, 472
- Salve, antiseptic, 104
- Sapræmia, 103
- Saprophytic bacteria, 40

- Sarcomata, 56
 Sealers for calculi, 543, 547, 578
 Scar on face, operation for, 490
 Schizomycetes, 34, 36
 Schreger, lines of, in dentine, 144
 in enamel, 141
 Schrier's alloy, use of, 452
 Sciatica from dental disease, 599
 Sclerosis of bone, 98
 of pulp, 410. *See* Pulp.
 Screws, use of, 252, 268, 351
 Scurvy, infantile, 192
 Secondary caries, 307
 dentine, 309, 364
 in abrasion, 251, 369
 causes of, 364
 in erosion, 261
 as obstacle, 371, 408
 pathology of, 367
 results of, 371, 381
 Secretion, 19
 stimulation of, 20, 23
 Sedation as a means of treatment, 80, 387
 Sedative effect on cells, 21
 Semeiology of disease, 24
 Senile gangrene, 69-70
 Senility, effect of, upon caries, 290
 upon gums, 532
 upon pericementum, 519
 Septic disease of dental origin, 614
 infection, 103, 105
 intoxication, 102, 358, 492
 Septicæmia, 90, 103, 358, 492
 prevention of, 472
 Sequestrum, 68
 from exanthemata, 200
 from mercury, 200
 Serres, glands of, 155
 Serum, blood, germicidal properties of, 47
 therapeutics, 33
 Sharpey's fibres, 149
 in cementum, 149
 Sheaths of Neumann in dentine, 143
 Shock, galvanic, 390
 nervous, 354
 Sialosemeiology as diagnostic, 545, 551
 Silk floss, use of, 357, 358
 Silver, Credé's soluble, 105
 nitrate, use of, 336, 352, 415, 453, 479, 488
 ointment, 104
 Sizes of teeth, 215
 Skin eruptions in teething, 187, 189
 Sloughing, 70
 Sodium bicarbonate, use of, 336, 559
 borate, use of, 529. *See* Borax.
 bromide, use of, 191
 chloride, use of, 438
 dioxide, action of, 452
 use of, 49, 343, 379, 438, 484
 hydrate, use of, 335, 344
 and potassium, alloy of, 452
 Specific bacteria, 42
 Sphacelus, 70
 Spirilla, 38
 Splints, use of, 254
 Sponge graft, 436, 440
 Spores of bacteria, 39
 Spunk, use of, 405, 420, 427
 Stains, amalgam, 273
 black, 272
 bleaching of, 274, 275
 cadmium, 273
 copper, 269, 273
 of dentine, 273
 gold, 270
 green, 271
 iron, 269, 273
 lead, 270
 manganese, 269, 273
 mercury, 270
 metallic, 269, 273, 275
 nickel, 270, 273
 non-metallic, 271, 275
 red, 273
 silver, 270, 273
 of suffusion, 274, 390, 392
 tobacco, 272
 treatment of, 274
 Starch paste, use of, 191
 Starches as factors in dental caries, 284
 Stasis in inflammation, 84
 Stellate reticulum, 120
 Steresol varnish, use of, 245, 587
 Sterilization of cavity, 343
 dental, 615
 of dental apparatus, 617
 of field of operation, 619
 of hands, 616
 of rubber-dam, 618
 Stimulation, effect on cells, 20
 Stomach, effect of caries upon, 358
 Stomatitis, 604
 catarrhal, 605, 606
 causes of, 604
 infective, 605
 simple, 605
 symptomatic, 606
 in teething, 183, 189, 192
 ulcerative, 526, 527, 606
 varieties of, 604
 Strata in enamel, 140
 Stratum granulosum, 144
 intermedium, 119
 Streptococcus antitoxin, use of, 105
 Striæ of Retzius, 140
 Strips, German-silver, use of, 274
 Structural disease, 24
 Struma, effect of, upon dentition, 192
 Strychnine, use of, 105
 Styptics, use of, 77, 392, 400, 415, 421
 Subgingival calculus. *See* Calculus.
 Suboxidation, diseases of, 259, 525, 580
 Suffusion of teeth, 390, 392, 423, 428
 treatment of, 432
 Sugars as factors in dental caries, 284
 Sulphomethæmoglobin in green stain, 272

- Sulphuric acid, use of, 77, 253, 276, 379
 433, 438, 497, 559, 569
 Supernumerary teeth, 231
 Suppression of teeth, 230
 Suppuration, 87
 of bone, 97
 causes of, 90
 leukocytosis in, 73
 of pulp. *See* Pulp.
 septicæmia from, 90
 spreading, 89
 symptoms of, 90
 treatment of. *See* Suppurative diseases.
 by pyocyaneo-protein, 493
 Swab, root, 437
 Swelling, cloudy, 64
 as symptom. *See* Inflammation.
 Swiss broaches, use of, 432, 437, 438, 453, 497
 Symptomatic anæmia, 73
 Syphilis, 106, 609
 diagnosis of, 611
 effects of, 106, 191, 212, 216, 217
 upon dentition, 192
 upon teeth, 106, 504
 hereditary, signs of, 219
 of mouth, 610
 sterilization in, 620
 personal infection by, 617, 620
 primary, 610
 reflex pains from, 600
 secondary, 611
 tertiary, 612
 Syphilitic teeth, 212, 217
 Syringe, abscess, 485
- T**ALC, use of, 189
 Tannin, use of, 336, 434, 444
 Tape, use of, 274
 Tartar, cream of, use of, 569
 Teeth, abrasion of, 248
 anomalies of number of, 230
 architecture of, 166
 articulation of, 175
 attachment to bone, 151. *See* Ankylosis.
 blood supply to, 152
 caries of, 278
 concrescence of, 222
 conical, 216
 development of, 106, 112
 diagnosis of, 176
 diseases of pericementi of, 459
 pulp of, 361
 dwarfed, 216
 encystment of, 235
 erosion of, 255
 eruption of, 177. *See* Dentition.
 permanent, 193
 exanthematous, 212
 fusion of, 220
 gemination of, 224
 giantism of, 216
 histology of, 135
 Hutchinson, 217
 impaction of, 235
 influence of feeding upon, 290, 359
 injury of, 265
 inspection of, 235
 malformations of, 206
 of roots of, 227
 malocclusion of, 515
 malposition of, 233
 as mechanical appliances, 166
 occlusion of, 174
 pitted and grooved, 216, 217
 relations of, 156
 stains on, 270
 surgical anatomy of, 156
 transparency of, 309
 variation in size of, 216
 Teething, 29. *See* Eruption and Dentition.
 Temperature, effect of, on cells, 21, 23
 Temporary teeth, caries of, 351
 eruption of, 181
 moist gangrene of pulps of, 457
 pulp capping in, 418
 diseases of, 418
 retention of, 198, 235
 Teratomata, 53
 Thallophytes, 34
 Thermal changes, effects of, 326, 341
 363, 365, 377, 381, 383, 407
 tolerance, rate of, 388
 tests for pulp vitality, 445
 Thirst, treatment of, 77
 Thrombosis, 74, 75
 in pulp, 391, 405
 Thrombus, 74
 hardening of, 75
 septic, 44, 76
 Thrush fungus, development of, 602
 Thumb sucking, 235
 Thymol, use of, 341, 387, 392, 399, 400, 405, 408, 426, 441, 529
 Tic douloureux from pulp nodules, 378, 599
 Tissues, 22
 analysis of, 22
 granulation of, 88
 nutrition of, 22
 resistance to bacteria, 47
 Tobacco in abrasion, 248, 253
 stains, 250, 273, 274
 Toes, pain in, from dental disease, 599
 Tolu, use of, 245
 Tomes, granular layer of, 144
 Tonics, use of, 472
 Toxæmia, 42, 46, 90, 91, 102,
 drug, 102
 intestinal, 102
 Toxins, 32, 39, 42, 49, 90
 Transparent zone, 309
 Transplantation of teeth, 488
 use of, 351
 Traumatic anæmia, 72, 77

Traumatic pericementitis. [*See* Pericementitis, non-septic.
 Trepine, use of, 471
 Trichloracetic acid, use of, 350, 415, 428, 558, 569, 577
 Trismus from dental disease, 599
 muscular, in dentition, 202
 Trophic nerves, 27
 Tube casts, 309
 Tuberculosis, effects of, upon dentition, 192
 of mouth, 613
 Tubular calcification, 364
 Tubules of dentine, 142
 calcification of, 309, 364
 of enamel, 141
 Tumors, carcinomatous, 59
 classes of, 55
 definition of, 53
 formation of, 53
 malignant, 56
 sarcomatous, 56
 Turkish baths, use of, 588
 Twin teeth, 224

ULCER, aphthous, 607
 caused by jagged teeth, 251, 613
 definition of, 88
 syphilitic, 612
 Ulceration, 89, 91
 of pulp, 402. *See* Pulp.
 Urates in blood, 580
 in connective tissue, 581, 582
 deposition of, conditions of, 581
 in deposits on teeth, 583
 elimination of, 585
 in joints, 580
 Urea, origin of, 23
 Uric acid, origin of, 23, 581
 Urinalysis as diagnostic, 545, 551
 Urine, hyperacidity of, in abrasion, 252
 Uterus, pain in, from dental disease, 599
 Uvula, cleft, 111


VACCINATION, 33
 Vapocain, use of, 332
 Varnish, amber, use of, 264
 benzoin, 399
 in cavities, 342, 345, 399
 steresol, 245, 587
 Vascular system, disturbances of, 71
 nerves controlling, 78
 Vasomotor nerves, 78
 Vein, obstruction of, 67
 thrombosis in, 74
 Velum palati, cleft, 111
 Venous hyperæmia, 81
 arsenious acid in, 372

Venous hyperæmia, degeneration in, 81
 exudate of, 81
 of pulp, 390
 treatment of, 81
 Veratrine, use of, 202
 Vessels, dilatation of, 79, 81, 83, 384, 390, 392
 paralysis of, 392
 Vicious circle, 28, 62
 Vulcanite rubber, use of, 405

WASH, mouth, antiseptic, 528
 Waste elimination, 23
 products, eliminative treatment of, 571, 588
 retained, effect of, 27
 synthesis of, 23
 removal, 23
 abnormal, 24, 27
 Water, boiling, as germicide, 518
 distilled, use of, 276
 as a therapeutic agent, 570, 588
 Wax as root filling, 435, 436, 475
 Wounds, healing of, 93-96

X-RAY, use of, in diagnosis of condition of pulp, 415, 446
 of hypercementosis, 508
 of impaction, 244
 of odontomes, 229
 of perforations, 415, 494
 of pulp nodules, 378
 in pyorrhœa alveolaris, 570
 of resorptions, 195, 196, 513
 in treatment of neuralgia, 601
 of pyorrhœa alveolaris, 555, 560, 570

ZINC chloride, as astringent, 528
 effect of, upon cotton, 437
 use of, 253, 334, 341, 421, 486
 oxide, use of, 348, 426, 441
 oxychloride, in canal filling, 435, 436, 437, 440
 as cause of gangrene, 444
 of secondary dentine, 365
 in deep decay, 345
 in fractures, 268
 hydrated, use of, 345
 oxyphosphate in canal filling, 436
 in deep-seated caries, 342, 343, 348
 in erosion, 264
 in fractured teeth, 268
 in hyperæmia of pulp, 387
 as support to enamel, 266
 oxysulphate, use of, 334, 348
 Zoöglœa of bacteria, 38



Telegraphic Address : "HIRSCHFELD, LONDON."
Telephone No. : 2757 Central.

SPRING, 1904.

HENRY KIMPTON'S

Catalogue of

Standard

Medical Publications

Mr. HENRY KIMPTON is always prepared to undertake the Publication of Medical and Scientific Works, upon the most advantageous terms. He has exceptional facilities for disposing of same both at home and in the Colonies, as well as America.

HENRY KIMPTON,
13, FURNIVAL STREET, HOLBORN,
LONDON, E.C.

LIST OF BOOKS.

AMERICAN SYSTEM OF PRACTICAL Medicine.

In contributions by Eminent Clinicians. Edited by ALFRED LEE LOOMIS, M.D., LL.D., late Professor of Pathology and Practical Medicine in the New York University, and WILLIAM GILMAN THOMPSON, M.D., Professor of Materia Medica, Therapeutics, and Clinical Medicine in the New York University. In four handsome imperial octavo volumes, containing from 900 to 1000 pages each, fully illustrated in Colours and in Black. In Roxburgh Binding, Gilt tops. Price per volume, £1 5s. net.

Vol. I.—Infectious Diseases.

Vol. II.—Diseases of the Respiratory and Circulatory Systems, and of the Blood, Kidneys, Bladder, and Prostate Gland.

Vol. III.—Diseases of the Digestive System, of the Liver, Spleen, Pancreas, Thyroid, and other Glands. Addison's Disease, Drug Habits, Infectious Diseases Common to Man and Animals.

Vol. IV.—Diseases of the Nervous System and of the Muscles. Gout, Rheumatism, Diabetes, and Rachitis. Diseases of Doubtful Origin, Isolation, etc.

"In the style and substance of its contributions, as well as in the handsome manner in which the work has been produced, it leaves nothing to be desired. . . . The work is, indeed, one of a high class, and will be all the more welcome as the selection of writers has evidently been made with great judiciousness, so that their contributions represent fully the high position which American medicine may well claim to have attained."—*Lancet*.

"This System of Medicine will prove one of the most important contributions of the kind ever made to medical literature."—*Scottish Medical and Surgical Journal*.

"It is impossible to speak in detail of the twenty-eight articles contained in this, the first volume, but there can be no question as to their value, and we warmly recommend the first instalment of a work which bids fair to do honour to the fair name of America in the world of medicine."—*British Medical Journal*.

American Text-Books of Dentistry.

IN CONTRIBUTIONS BY EMINENT AUTHORITIES.

PROSTHETIC DENTISTRY.

Edited by CHARLES J. ESSIG, M.D., D.D.S., Professor of Mechanical Dentistry and Metallurgy, Department of Dentistry, University of Pennsylvania, Philadelphia. In one royal octavo volume of 817 pages, with 1089 Engravings. New (Second) Edition. Thoroughly Revised and greatly Enlarged. Cloth, Gilt top. Price 26s. net.

"The tendency of Essig's book will be to raise the standard of mechanical dentistry, not merely in name, but in fact. No one can rise from the reading of the pages here presented without a feeling of increased respect for the basis of his profession—prosthetic dentistry. No more thorough production will be found either in this country or in any country where dentistry is understood as a part of civilization."—*The International Dental Journal*.

"This work is very much the best in its line in our literature. It is written and edited by masters in their art. It is up-to-date in every particular. It is a practical course on prosthetics which any student can take up during or after college."—*Dominion Dental Journal*.

OPERATIVE DENTISTRY. Edited by Edward

C. KIRK, D.D.S., Professor of Clinical Dentistry, Department of Dentistry, University of Pennsylvania. In one royal octavo volume of 857 pages, with 897 Engravings. New (Second) Edition. Thoroughly Revised and greatly Enlarged. Cloth, Gilt top. Price 26s. net.

A TEXT-BOOK OF DENTAL PATHOLOGY AND THERAPEUTICS, -including Pharmacology; being a Treatise on the Principles and

Practice of Dental Medicine for Students and Practitioners. By HENRY H. BURCHARD, M.D., D.D.S., Special Lecturer on Dental Pathology and Therapeutics in the Philadelphia Dental College. In one royal octavo volume of 587 pages, with 388 Engravings and 2 Coloured Plates. Cloth, Gilt top. Price 22s. net.

DENTAL METALLURGY: A Manual for the Use of Dental Students and Practitioners.

By CHARLES J. ESSIG, M.D., D.D.S., Professor of Mechanical Dentistry and Metallurgy in the Dental Department of the University of Pennsylvania. New (Fourth) Edition, thoroughly revised by AUGUSTUS KOENIG, B.S., M.D., Demonstrator of Metallurgy in the Dental Department of the University of Pennsylvania. In one 12mo volume of 286 pages, with 43 Engravings. Cloth, Gilt top. Price 7s. 6d. net.

To meet the needs of all concerned—students, teachers, and dentists—the work has been subjected to a most searching revision. As now issued, it is believed to be complete as a laboratory guide, a practical working manual and a book of instruction. No effort has been spared to make it represent the latest and best knowledge with scientific accuracy, directness, and simplicity.

BACON.—A Manual of Otology. By GORHAM

BACON, A.B., M.D., Professor of Otology in Cornell University Medical College, New York; Aural Surgeon, New York Eye and Ear Infirmary. With an Introductory Chapter by CLARENCE JOHN BLAKE, M.D., Professor of Otology in Harvard University. 422 pages, with 114 Illustrations and 3 Coloured Plates. New (Second) Edition, thoroughly Revised and greatly Enlarged. Cloth, 10s. 6d. net.

"The avowed object of the author of this book is to meet the demands of the student by giving him a short and compact treatise on the subject, and at the same time to afford him a book of easy reference.

"The manual before us, as it gives a clear and concise account of the present-day knowledge of the subject of Otology, is one to be commended to the notice of students, and to those practitioners who have not had the opportunity of practical instruction in the diagnosis and treatment of aural affections."—*Journal of Laryngology*.

BALLENGER and WIPPERN.—A Text-Book of Diseases of the Eye, Ear, Nose, and Throat.

By W. L. BALLENGER, M.D., Assistant Professor of Otology, Rhinology and Laryngology in the College of Physicians and Surgeons, Chicago, and A. G. WIPPERN, M.D., Professor of Ophthalmology and Otology, Chicago, Eye, Ear, Throat, Nose College, Chicago. In one handsome small octavo volume of 525 pages, with 148 Illustrations and 6 Coloured Plates. Cloth, 10s. net.

"The information given is good, and there are many practical suggestions which are of distinct value."—*Lancet*.

BIDIE.—Laboratory Analysis of Water, Milk, Bread, etc. By GEORGE BIDIE, F.R.C.S., Edin., Surgeon-Captain, Indian Medical Service (Madras), Medical Officer, 4th Infantry, Hyderabad Contingent, Civil Surgeon and Superintendent of Jail Ellichpur, etc. Crown octavo. Price 2s. net.

BIGELOW and MASSEY.—International System of Electro-Therapeutics. For the use of Students, General Practitioners, and Specialists. By EMINENT AUTHORITIES. Edited by HORATIO R. BIGELOW, M.D., Fellow of the American Electro-Therapeutic Association, etc., and G. BETTON MASSEY, M.D., Physician to the Gynaecological Department of Howard Hospital, etc. Assisted by 38 Eminent Specialists in Europe and America as Associate Editors. Second Edition. Thoroughly Revised, Rearranged, and greatly Improved, including an entirely new Section on the X-rays. Fully Illustrated with many Fine Engravings. Complete in one royal octavo volume of 1160 pages. Roxburgh binding. Gilt top. Price 25s. net.

"... The book has been brought into line with our present knowledge of electro-therapeutics."—*British Medical Journal*.

BROWN.—Elements of Alkaloidal Aetiology. Introductory to the Study of Auto-Intoxication in Disease. By A. M. BROWN, M.D. Crown 8vo, 86 pages. Price 2s. 6d. net.

"... The whole subject of Auto-Intoxication is one which merits much more attention from the profession than it has already received, and Dr. Brown in this little work treats of it clearly and interestingly."—*Scottish Medical and Surgical Journal*.

CIECHANOWSKI.—Anatomical Researches on the so-called "Prostatic Hypertrophy" and Allied Processes in the Bladder and Kidneys.

By STANISLAUS CIECHANOWSKI, Assistant Professor of Pathological Anatomy, University of Krakaw. Authorized Translation. Edited by Robert Holmes Greene, M.A., M.D., Genito-Urinary Surgeon to French Hospital, etc., etc. Octavo, 175 pages. Cloth. Price 5s net.

COLBECK.—Diseases of the Heart. A Clinical

Text-Book for the use of Students and Practitioners of Medicine. By EDMUND HENRY COLBECK, B.A., M.D. (Cantab.), M.R.C.P. (London), D.P.H. (Cantab.), Physician to Out-Patients at the City of London Hospital for Diseases of the Chest, Victoria Park, E., late House Physician at St. Mary's Hospital, etc., etc. In one demy octavo volume of 355 pages, with frontispiece and 43 Engravings. Handsomely bound in Half Leather, Gilt top. Price 12s. net.

"... Particularly useful to the busy practitioner of medicine. . . . We consider that Dr. Colbeck has produced a work of more intrinsic value than some more pretentious volumes."—*Lancet*.

"... A work which we can cordially commend as a well-arranged, well-written, and trustworthy text-book, suitable alike as a work of reference to the busy practitioner and to the advanced student."—*British Medical Journal*.

"Written by one who is evidently a master of his subject, this work will be invaluable both to the student . . . and also to the medical man desirous of refreshing his knowledge. . . . It is lucid, well illustrated, and carefully explained. . . . We congratulate the author on having compiled such a reliable and worthy manual, which we cannot praise too highly."—*Quarterly Medical Journal*.

COLBECK and CHAPLIN.—The Science and Art of Prescribing.

By E. H. COLBECK, B.A., M.D. (Cantab.), M.R.C.P. (Lond.), D.P.H. (Cantab.), Physician to Out-Patients at the City of London Hospital for Diseases of the Chest, Victoria Park, E.; Physician to the Metropolitan Dispensary, etc., etc.; and ARNOLD CHAPLIN, B.A., M.D. (Cantab.), M.R.C.P. (Lond.), Physician to Out-Patients at the City of London Hospital for Diseases of the Chest, Victoria Park, E.; Physician to Out-Patients at the East London Hospital for Children, etc., etc. In one 12mo volume of 192 pages, Handsomely bound in Full Leather, Gilt edges. Price 5s. net.

"Can be thoroughly recommended."—*Medical Review*.

"This little volume should prove invaluable."—*London Hospital Gazette*.

"Will be cordially welcomed both by students and practitioners."—*British Medical Journal*.

"The book is full of useful information and excellent formulæ . . . is sure to be perused by many."—*Canada Lancet*.

"Is a very good little book."—*Lancet*.

COAKLEY.—A Manual of Diseases of the Nose, Throat, Naso-Pharynx and Trachea.

For the use of Students and Practitioners. By CORNELIUS G. COAKLEY, M.D., Clinical Professor of Laryngology in the University and Bellevue Hospital Medical College, New York. In one small octavo volume of 536 pages, with 92 Engravings and 2 Coloured Plates. Cloth, price 12s. net.

"The excellent way in which the entire field has been covered. . . . The work is a convenient and inexpensive guide to the entire field of diseases of the nose and throat, which may be recommended as a complete and trustworthy summary of the subject."—*Medical News*.

"So clear and concise that the perusal of the work is a pleasure."—*Practitioner*.

COLLINS.—A Text-Book of Medical Diagnosis.

By C. P. COLLINS, M.D., Attending Physician to St. Luke's Hospital, New York. In one handsome small octavo volume of about 350 pages. In Preparation.

COLLINS and ROCKWELL.—Physiology.

By H. D. COLLINS, M.D., Assistant Demonstrator of Anatomy, and W. H. ROCKWELL, JR., A.B., M.D., Assistant Demonstrator of Anatomy, College of Physicians and Surgeons, New York. Small octavo, 323 pages. Illustrated, with 153 Engravings. Bound in Cloth. Price 7s. 6d. net.

"As a collection of facts it would be hard to beat, but the reading of these is facilitated by the plentiful use of illustrations. DECIDEDLY GOOD. We can recommend the manual as a book of revision to those going up for examination,"—*Glasgow Medical Journal*.

CREDÉ and LEOPOLD.—A Short Guide to the Examination of Lying-in Women.

By Prof. CREDÉ, late Director of the Lying-in Hospital at Leipzig; and Prof. LEOPOLD, Director of the Lying-in Hospital at Dresden. Translated by WILLIAM H. WILSON, M.A., M.B. (Oxon.), Radcliffe Travelling Fellow. Illustrated with woodcuts. Small octavo. Limp Cloth. Price 1s. 6d. net.

CORLETT.—A Treatise on the Acute, Infectious Exanthemata.—Variola, Rubeola, including Scarlatina, Rubella, Varicella and Vaccinia, with Especial Reference to Diagnosis and Treatment. By WILLIAM

THOMAS CORLETT, M.D., L.R.C.P. (London); Professor of Dermatology and Syphilology in Western Reserve University; Physician for Diseases of the Skin to Lakeside Hospital; Consulting Dermatologist to Charity Hospital, St. Alexis Hospital, and the City Hospital, Cleveland; Member of the American Dermatological Association and the Dermatological Society of Great Britain and Ireland. New edition in preparation.

"We can heartily congratulate the author. . . . We can thoroughly recommend this work."—*British Medical Journal*.

"Not only as a work of reference, but as one which affords pleasant and interesting reading, we commend Dr. Corlett's treatise."—*Lancet*.

CROCKETT.—A Text-Book of Diseases of Women. By MONTGOMERY A. CROCKETT.

A.B., M.D., Adjunct Professor of Obstetrics and Clinical Gynecology, Medical Department, University of Buffalo, New York. In one handsome small octavo volume of 368 pages, with 107 illustrations. Cloth, 7s. 6d. net.

"Nothing of importance has been overlooked. . . . The teaching is up-to-date, and the most important operations are clearly described."—*Glasgow Medical Journal*.

"The book is well and clearly written, and gives a sound and well-balanced view of the subject . . . will doubtless be appreciated by a large circle of readers."—*Practitioner*.

DALTON.—Gleet and Chronic Diseases of the Urethra and Prostate. By GERALD

DALTON, M.S.A. (Lond.), F.R.S.L.; Member of the British Medical Association; Member West London Medico-Chirurgical Society; Hon. Sec. Assoc. Physicians and Surgeons; late Assistant-Surgeon, St. Francis Hospital and Lecturer to Nursing Staff; Assistant to Skin Department, Charing Cross Hospital; etc., etc. Crown 8vo, 48 pages. Limp Cloth. Price 1s. net.

DALTON.—The Aix-la-Chapelle Treatment.

By GERALD DALTON, M.S.A. (Lond.), F.R.S.L., Member British Medical Association, etc., etc. Demy octavo. Price 6d. net.

DAVIS.—Qualitative Chemical Analysis and Analytical Charts for Pharmaceutical and Chemical Students. By FREDERICK DAVIS,

Member of the Society of Public Analysts, Member of the Society of Chemical Industry, Member of the Pharmaceutical Society, etc. Demy octavo. Cloth. Price 3s. net.

DEUTSCH.—Medical German: a Manual designed

to aid Physicians in their Intercourse with German patients, and in reading medical works and publications in the German language. By SOLOMON DEUTSCH, M.A., Ph.D. Fifth Edition, small octavo, 346 pages. Cloth. Price 10s. net.

DEWAR.—Indigestion and Diet. By JOHN

DEWAR, L.R.C.P., L.R.C.S. (Edin.), etc. Second Edition. Crown octavo. Cloth. Price 1s. 6d. net.

DONDERS.—Refraction: An Essay on the Nature

and the Consequences of Anomalies of Refraction. By F. C. DONDERS, M.D., late Professor of Physiology and Ophthalmology in the University of Utrecht. Authorised Translation. Revised and Edited by CHARLES A. OLIVER, A.M., M.D., one of the Attending Surgeons to the Wills Eye Hospital; one of the Ophthalmic Surgeons to the Philadelphia Hospital, etc. With a very handsome Portrait of the Author and a series of Explanatory Diagrams. Octavo. Price 6s. net.

"... Nothing but the highest praise can be given to the work itself, which will for years to come continue to reflect the highest honour on the great man who wrote it."—*British Medical Journal*.

DRUIFF.—Refraction: A Simple and Concise

Treatise on Practical Sight-Testing. By GUY E. DRUIFF. In one very handsome royal octavo volume of 312 pages. Illustrated with 135 Cuts and Diagrams. Cloth. Price 10s. 6d. net.

DUDLEY.—Diseases of Women: A Treatise on

the Principles and Practice of Gynæcology for Students and Practitioners. By E. C. DUDLEY, M.D., Professor of Gynæcology in the Chicago Medical College. Third Edition, Revised and Enlarged, in one very handsome octavo volume of 762 pages, with 474 Engravings, of which 60 are Coloured, and 22 full-page Plates in Colours and Monochrome. Cloth, 21s. net.

"We know of no work on gynæcology better written or more suitable for the needs of the student and the general practitioner. The methods of treatment advised are practical and in accord with the accepted views of the profession. The illustrations are attractive and helpful."—*Medical Standard*.

"Thorough, and based on the author's wide clinical experience. The book is well bound, clearly printed, and provided with a large number of diagrammatic illustrations, which, with the numerous tables on differential diagnosis, should tend to assist its readers in their comprehension of the text."—*Glasgow Medical Journal*.

DUTTON.—Indigestion clearly Explained, Treated,

and Dieted, with Special Remarks on Corpulency and Gout. By THOMAS DUTTON, M.D. (Univ., Durh.), M.R.C.P. (Edin.), etc. Fifth Edition, Revised and Enlarged. Crown octavo, 224 pages. Cloth. Price 3s.

"Full of sound good sense and wise saws."—*British Medical Journal*.

"Well written and concise little book and herein is its chief merit."—*Hospital Gazette*.

"Is a sensibly-written, interesting little work."—*Provincial Medical Journal*.

DUTTON.—Food and Drink Rationally Discussed. By THOMAS DUTTON, M.D. Durh.,

M.R.C.P. (Edin.), etc. Third Edition. Crown octavo. Cloth. Price 2s.

"It is an invaluable treatise on dietetics."—*Court Circular*.

DUTTON.—Domestic Hygiene. By THOMAS

DUTTON, M.D. (Durh.), M.R.C.P. (Edin.), etc. Crown octavo. Cloth. Price 2s.

"So full and complete are its teachings that it is really a *multum in parvo* of the subject."—*Health Messenger*.

"A great deal of useful and practical information is given in a practical form."—*Health Record*.

DUTTON.—Rearing and Feeding of Children (a Practical Mother's Guide). By THOMAS

DUTTON, M.D. (Durh.), M.R.C.P. (Edin.), etc. Second Edition. Crown octavo. Cloth. Price 2s.

DUTTON.—Sea-Sickness: Cause, Treatment, and

Prevention; VOYAGING FOR HEALTH; HEALTH RESORTS. A Concise Practical Treatise, by THOMAS DUTTON, M.D. (Durh.), M.R.C.P. (Edin.), etc. Fourth Edition. Crown octavo. Cloth, 2s. Paper, 1s.

"Dr. Dutton has had very considerable experience, hence his remarks on Sea-Sickness are very valuable."—*Provincial Medical Journal*.

"Full of useful suggestions not found in textbooks, either of surgery or medicine."—*Pharmaceutical Journal*.

"Contains much useful and original information of much value to those who traverse the seas in ships."—*Hospital Gazette*.

ECKLEY.—Regional Anatomy of the Head and Neck. A Manual for Dental Students and

Practitioners. By WILLIAM T. ECKLEY, M.D., Professor of Anatomy, and CORINNE B. ECKLEY, M.D., Demonstrator of Anatomy in the College of Physicians and Surgeons, Chicago, and in the Medical and Dental Departments of the University of Illinois, etc.

In one handsome octavo volume of 240 pages, with 36 Engravings in the text and 20 full-page Plates in Black and Colours. Cloth, 12s. 6d. net.

"A most useful book for the student and practitioner."—*Lancet*.

EVANS.—A Text-Book of Obstetrics. By DAVID

J. EVANS, M.D., Demonstrator of Obstetrics, McGill University, Faculty of Medicine, Montreal. In one handsome small octavo volume of 409 pages, with 148 Illustrations. Cloth. 7s. 6d. net.

"This is a clearly written and nicely published little work on Obstetrics, on which the author must, on the whole, be congratulated.

"... We are sure the book will be appreciated by Students."—*Dublin Journal of Medical Science*.

"We can thoroughly recommend this small text-book to both students and practitioners."—*Glasgow Medical Journal*.

EWING.—Clinical Pathology of the Blood: A

Treatise on the General Principles and Special Applications of Hematology. By JAMES EWING, A.M., M.D. Professor of Pathology in Cornell University Medical College, New York City. Second Edition, Revised and Enlarged. In one very handsome octavo volume of 496 pages, Illustrated with 43 Engravings and 18 Coloured Plates drawn by the Author. Cloth. Price 21s. net.

"To any one engaging in such researches (and every practitioner must engage in them more or less) the work of Dr. Ewing will be found invaluable. The book will be found a mine of information, and,

indeed, will prove indispensable to any one investigating blood changes in disease."—*Dublin Journal of Medical Science*.

"As a thoroughly sound and philosophical treatise on hæmatology, free from prejudice and exaggeration, the book may be strongly recommended alike to the beginner and the advanced student."—*Practitioner*.

"Of the sterling merits of the book we have already spoken, and its perusal may be most heartily commended."—*British Medical Journal*.

GALLAUDET.—A Text-Book of Surgery. By

BERN B. GALLAUDET, M.D., Demonstrator of Anatomy, and Clinical Lecturer on Surgery, College of Physicians and Surgeons, New York. In one handsome small octavo volume of about 400 pages, with many Illustrations. In Preparation.

GAYLORD and ASCHOFF.—The Principles of Pathological Histology. By HARVEY R.

GAYLORD, M.D., Professor of Surgical Pathology in the University of Buffalo, N.Y., and LUDWIG ASCHOFF, M.D., Professor and First Assistant in the Pathological Institute of the University of Göttingen, Germany, with an Introductory Note by WILLIAM H. WELCH, M.D., Professor of Pathology in Johns Hopkins University, Baltimore.

A Combined Atlas and Treatise upon Disease-Structure, giving the best methods for microscopical tissue diagnosis, the actual appearance of each abnormal condition, and its clinical significance. It applies science directly to practice. The most accurately and elaborately illustrated work extant on its subject. Quarto, 354 pages, with 81 Engravings in the text, and 40 full-page Plates of Helio-Types and Coloured Lithographs, containing about 200 figures. Handsomely bound in half morocco. 31s. 6d. net.

GERRISH.—A Text-Book of Anatomy. Edited

by FREDERIC H. GERRISH, M.D., Professor of Anatomy in the Medical School of Maine at Bowdoin College. New Second Edition, Revised and Enlarged. In one magnificent imperial octavo volume of 944 pages, with 1003 Engravings in Black and Colours. Handsomely bound in cloth. Price 32s. net.

In this magnificent work no effort or expense has been spared to combine an authoritative text with the most successful anatomical pictures which have yet appeared in the world.

The Editor has secured the co-operation of the Professors of Anatomy in leading medical colleges, and with them has prepared a text conspicuous for its completeness, simplicity, unity, and judicious selection of such anatomical facts as bear on physiology, surgery, and internal medicine in the most comprehensive sense of those terms. The authors have endeavoured to make a book which shall stand in the place of a living teacher to the student, and which shall be of actual service to the practitioner in his clinical work, emphasising the most important details, clarifying obscurities, helping most in the parts most difficult to learn, and illustrating everything by all available methods.

Pictorially, "Gerrish's Text-Book of Anatomy" marks a great advance beyond even the elaborately illustrated works hitherto procurable, the series of engravings being far more extensive both in number and in the use of colours. They have been drawn so large that every detail is distinct, and a particular advantage has been achieved by engraving the names of the parts directly upon them, whereby the nomenclature, positions, and relations of the various structures are impressed on the memory at a glance, and the great difficulties inseparable from reference letters and lines are avoided.

By a new and ingenious arrangement this one volume serves as a

complete Atlas of Anatomy, a dissecting guide, and a thorough treatise on systematic, descriptive, and applied anatomy.

Special interest will attach to the novel pictorial method of showing the origin, contour, and insertion of muscles, to the complete series of Röntgen-ray engravings, the normal living skeleton in relation to the soft parts, and to an equally important series of surface landmark photographs and annexed diagrams.

" . . . We can recommend the work very cordially to practitioners and others whose desideratum is a richly illustrated text-book, reliable in its information, and easily handled."—*Glasgow Medical Journal*.

"There can be no doubt that the work will meet with a wide and well-deserved recognition, and the editors are to be congratulated on its production."—*Quarterly Medical Journal*.

GRANDIN and JARMAN.—Practical Obstetrics.

Pregnancy, Labour, the Puerperal State, and Obstetric Surgery. A Text-Book for Physicians and Students. By **EGBERT H. GRANDIN**, M.D., Consulting Obstetric Surgeon to the New York Maternity Hospital, Consulting Gynecologist to the French Hospital, etc.; with the collaboration of **GEORGE W. JARMAN**, M.D., Obstetric Surgeon to the New York Maternity Hospital, Gynecologist to the Cancer Hospital, etc. New (Third) Edition, Thoroughly Revised. In one handsome octavo volume of 500 pages, with 52 full-page Photogravure Plates taken from Nature, besides many other cuts in the text, the whole forming the most Modern and Complete Work on the Science and Art of Obstetrics. Cloth. Price 18s. net.

GRAYSON.—The Diseases of the Nose, Throat, and Ear. By **CHARLES PREVOST GRAYSON**,

M.A., M.D., Lecturer on Laryngology and Rhinology in the Medical Department of the University of Pennsylvania; Physician-in-Charge of the Department for Diseases of the Nose and Throat in the Hospital of the University of Pennsylvania; Laryngologist and Otologist to the Philadelphia Hospital. Illustrated with 129 Engravings and 8 Plates in Colours and Monochrome. Octavo, 540 pages. Cloth. Price 18s. net.

GRINDON.—Diseases of the Skin. By **JOSEPH**

GRINDON, Ph.B., M.D., Professor of Clinical Dermatology and Syphilis, Washington University; Dermatologist to the O'Fallon Dispensary, St. Louis Mullanphy Hospital, St. Luke's Hospital, and the Missouri Baptist Sanitarium; formerly Physician to the Small-pox Hospital, St. Louis; Member of the American Dermatological Association; Ex-President of the St. Louis Medical Society and of the Association of City Hospital Alumni, St. Louis. In one small octavo volume of 378 pages, illustrated with 39 Engravings and a coloured Frontispiece. Handsomely bound in extra Cloth. Price 7s. 6d. net.

HANSELL and REBER.—A Practical Handbook on the Muscular Anomalies of the Eye. By

HOWARD F. HANSELL, A.M., M.D., Clinical Professor of Ophthalmology, Jefferson Medical College; Professor of Diseases of the Eye, Philadelphia Polyclinic and College for Graduates in Medicine, etc., etc.; and **WENDELL REBER**, M.D., Instructor in Ophthalmology, Philadelphia Polyclinic and College for Graduates in Medicine, etc., etc. With 28 Illustrations and one Plate. 182 pages. Price 6s. net.

"This little book, whose modest aim is to serve as a guide to 'beginners in ophthalmic work,' will, we think, be read with interest even by

surgeons of experience . . . based on much clinical observation, and is marked by a soberness of judgment which has not always been conspicuous in works dealing with this subject. The methods of diagnosis are clearly described, and the lines of treatment—general, optical, and operative—are fully and temperately discussed. . . . We think the book is a good one, and likely to be helpful to students—more helpful, possibly, in some respects than Maddox's work on the same subject, inasmuch as it deals rather with patients in the flesh than with problems in physiological optics."—*Ophthalmic Review*.

HARDAWAY.—A Clinical Manual of Skin Diseases: With Special Reference to Diagnosis

and Treatment; for the use of Students and General Practitioners. By W. A. HARDAWAY, A.M., M.D., Professor of Diseases of the Skin and Syphilis in the Missouri Medical College, St. Louis; Physician for Diseases of the Skin to the Martha Parsons Hospital for Children and to St. John's Hospital; Ex-President of the American Dermatological Association. Second Edition, Revised and Enlarged. In one small octavo volume of 557 pages, with 42 Engravings and 2 Plates. Cloth. Price 10s. 6d. net.

"Can be recommended as a trustworthy guide."—*British Medical Journal*.

HARE.—Practical Diagnosis. The use of

Symptoms in the Diagnosis of Disease. By HOBART AMORY HARE, M.D., Professor of Therapeutics and Materia Medica in the Jefferson Medical College of Philadelphia, etc. New (Fifth) Edition, Revised and Enlarged. In one octavo volume of 698 pages, with 236 Engravings and 25 full-page Coloured Plates. Cloth. 21s. net.

"Dr. Hare is to be congratulated on having written a most stimulating and suggestive book."—*Lancet*.

"Handsome and beautifully illustrated. . . . The matter is worthy of the illustrations, and greater praise cannot be given to it. It is made very readily accessible by a very full index, which fills more than forty pages."—*Quarterly Medical Journal*.

"We congratulate the author on a book that has been of value to a very varied class of readers, both students and practitioners."—*Practitioner*.

HARE.—A Text-Book of Practical Therapeutics:

With Especial Reference to the Application of Remedial Measures to Disease and their Employment upon a Rational Basis. By HOBART AMORY HARE, M.D., Professor of Therapeutics and Materia Medica in the Jefferson Medical College of Philadelphia. With special chapters by Drs. G. E. DE SCHWEINITZ, EDWARD MARTIN, and BARTON C. HIRST. New (Ninth) Edition, thoroughly Revised and greatly Re-written. In one octavo volume of 858 pages, with 105 Engravings and 4 Coloured Plates. Price 21s. net.

The demand for nine editions of Professor Hare's Practical Therapeutics in twelve years, proves its accepted position as a standard work for both students and practitioners, whose needs it equally answers. The author has faithfully revised it at each opportunity, so that it is always up-to-date, and is so recognised. The latest revision has increased the volume by about 60 pages, and nearly 100 Illustrations, including a coloured plate, have been added.

Reviews of former editions:—

"We can thoroughly recommend this book to practitioners and students."—*Lancet*.

"We strongly recommend the book as a useful aid to the practical work of the profession."—*Scottish Medical and Surgical Journal*.

"The work can be strongly recommended to English practitioners, to whom, perhaps, it is not so well known as it undoubtedly deserves to be."—*Quarterly Medical Journal*.

HARE.—The Medical Complications, Accidents, and Sequelæ of Typhoid or Enteric Fever.

By HOBART AMORY HARE, M.D., B.Sc., Professor of Therapeutics in Jefferson Medical College of Philadelphia, Physician to the Jefferson Medical College Hospital, Laureate of the Medical Society of London, of the Royal Academy in Belgium. With a special chapter on the mental disturbances following Typhoid Fever, by F. X. DERCUM, M.D., Clinical Professor of Diseases of the Nervous System in the Jefferson Medical College. New Edition in preparation.

" . . . In his work, Dr. Amory Hare has given to the literature of Typhoid Fever a valuable contribution, and has added to the reputation of the great American School of Medicine."—*Dublin Journal of Medical Science*.

HARRINGTON.—A Manual of Practical Hygiene

for Students, Physicians, and Medical Officers. By CHARLES HARRINGTON, M.D., Assistant Professor of Hygiene in the Medical School of Harvard University. In one very handsome octavo volume of 729 pages, illustrated with 12 Plates and 105 Engravings. Cloth. Price 21s. net.

" . . . This work is one of the best of its kind ever published."—*Dublin Journal of Medical Science*.

" . . . We may say that the book is very agreeable reading, and that the execution of the illustrations is, as a whole, excellent."—*Practitioner*.

" . . . The chapters on foods . . . are well done. . . . The book is nicely printed and got up."—*Sanitary Record and Journal*.

HAYDEN.—A Manual of Venereal Diseases. By

JAMES R. HAYDEN, M.D., Chief of Venereal Clinic and Instructor in Venereal and Genito-Urinary Diseases, College of Physicians and Surgeons, New York. Third edition. In one crown octavo volume of 50 pages, with 60 Engravings. Cloth. Price 7s. 6d. net.

" . . . Clearly and judiciously dealt with."—*British Medical Journal*.

HEMMETER.—Diseases of the Stomach. Their

special Pathology, Diagnosis, and Treatment, with sections on Anatomy, Physiology, Analysis of Stomach contents, Dietetics, Surgery of the Stomach, etc. In three parts. By JOHN C. HEMMETER, M.B., M.D., Ph.D., Clinical Professor of Medicine at the Baltimore Medical College, Consultant to the Maryland General Hospital, etc. With many original illustrations, a number of which are in Colours, and a Lithograph Frontispiece. New Edition in preparation.

"Dr. Hemmeter's Treatise comprises a thorough survey of the whole subject of disease of the stomach, and nothing is omitted which is material to its full comprehension. . . . We part from Dr. Hemmeter's work with the sense that it embodies the best knowledge of the time, that it is a book which is of inestimable value as a work of reference, and that it will well repay the most careful study which can be given to it. The index is remarkably complete."—*Lancet*.

HUTCHINSON.—Syphilis. By JONATHAN

HUTCHINSON, F.R.S., LL.D., Consulting Surgeon to the London Hospital, and to the Royal London Ophthalmic Hospital, Vice-President of the Royal College of Surgeons. With eight Chromo-lithographs. In one small octavo volume of 544 pages, handsomely bound in half leather. Price 9s. net.

HUNTINGTON.—The Anatomy of the Human Peritoneum and Abdominal Cavity considered from the standpoint of Development and Comparative Anatomy. By

GEORGE S. HUNTINGTON, M.D., Professor of Anatomy in the College of Physicians and Surgeons, Columbia University, New York City. In one handsome quarto volume of 590 pages, including 300 full-page plates in colours and monochrome, containing 582 figures. De Luxe Edition. Gilt top. 42s. net.

This comprehensive and authoritative work will appeal to an unusually wide constituency of readers. Dr. Huntington has approached the subject in the light thrown upon it by embryology and comparative anatomy, thereby clarifying the hitherto difficult and complicated morphological problems presented by these regions.

The book is unique in its marvellous wealth of illustrations, amounting practically to an atlas, with full explanatory text. These illustrations are for the most part taken from preparations in the Morphological Museum of Columbia University, and wherever practicable, direct photographic reproductions of the actual preparations are given.

HYDE and MONTGOMERY.—A Practical Treatise on Diseases of the Skin. For the

use of Students and Practitioners. By J. NEVINS HYDE, A.M., M.D., Professor of Dermatology and Venereal Diseases in Rush Medical College, Chicago, and FRANK HUGH MONTGOMERY, M.D., Assistant Professor of Skin, Genito-Urinary and Venereal Diseases, Rush Medical College, Chicago, etc. New (Sixth) and thoroughly Revised Edition. In one octavo volume of 831 pages, with 107 Engravings and 27 full-page Plates in Colours and Monochrome. Cloth. Price 25s. net.

"The authors of this text-book should feel satisfied with the success of their work, as they find it necessary to produce their fifth edition two years only after the publication of the fourth. The treatise is certainly at present ONE OF THE STANDARD TEXT-BOOKS OF DERMATOLOGY, and gives a good account of the subject from the point of view of its teachers in English-speaking countries. It is very noticeable on reading the text-books published in the United States, how closely the ideas and methods coincide in both Transatlantic and British schools. . . . In our opinion, this work has distinctly risen in the scale of English text-books as the result of its careful revision, and we have no hesitation in recommending it as a thoroughly reliable guide to Dermatology."—*British Journal of Dermatology*.

"From every point of view we can cordially recommend the book to our readers."—*Dublin Journal of Medical Science*.

"To its enterprising publisher, this must be one of the most satisfactory works he has issued. Appearing first in 1883, and reaching a second edition five years afterwards, it appeared in its present guise (fifth edition) at the close of 1899, a volume which every one concerned in its production may well contemplate with a sense of gratification.

"This admirable work is a valuable addition to any medical practitioner's literary capital."—*Glasgow Medical Journal*.

JACKSON.—The Ready Reference Handbook of Diseases of the Skin. By GEORGE

THOMAS JACKSON, M.D., Professor of Dermatology in the Woman's Medical College of the New York Infirmary, and in the Medical Department of the University of Vermont; Chief of Clinic and Instructor in

Dermatology, College of Physicians and Surgeons, New York, etc., etc. Fourth Edition, Revised and Enlarged, 642 pages, with 80 Illustrations and 3 Coloured Plates. Octavo. Price 12s. 6d. net.

"EVEN THOSE WHO ARE CONVERSANT WITH THE LITERATURE OF DERMATOLOGY WILL BE LIKELY TO LEARN SOMETHING FROM THIS ADMIRABLE LITTLE WORK."—*Lancet*.

"... The very best of the short treatises on the subject which have been published. ... In every way excellent, and it is a pleasure to recommend it to those desirous of having at hand an accurate and concise presentation of the subject on Dermatology."—*New York Medical Journal*.

"... Has earned a permanent position in Dermatological literature. ... Dr. Jackson has now made for his work a well-defined place. The present edition of the ready reference hand-book is certainly one of the best of the smaller treatises of Dermatology."—*Practitioner*.

JEWETT.—The Principles and Practice of Obstetrics. By Eminent Authors. Edited by

CHARLES JEWETT, M.D., Professor of Obstetrics in the Long Island College Hospital, Brooklyn, Fellow of the British Gynecological Society, etc. New (Third) Edition in preparation.

"... Of a high-class order. There are no fewer than nineteen contributors to this volume, and we may say that each has done his part well. ... This is full and trustworthy, and its value is enhanced by several fine engravings, both plain and in colour, as well as several beautifully-coloured plates, which are really works of art. ... In a book by so many contributors, it is not often that one finds all the articles of such order of merit. We have had great pleasure in reading it. It is excellently got up in every way. Dr. Jewett has done his work well, and with his collaborateurs has produced a work on Obstetrics which we can with every confidence recommend to the student and practitioner as a reliable guide to them in their difficulties."—*Glasgow Medical Journal*.

JEWETT.—Essentials of Obstetrics. By

CHARLES JEWETT, A.M., M.D., Sc.D., Professor of Obstetrics and Gynecology in the Long Island College Hospital and Obstetrician and Gynecologist to the Hospital; Fellow of the British Gynecological Society, etc. Assisted by HAROLD F. JEWETT, M.D. New (Second) and Revised Edition, in one octavo volume of 386 pages, Illustrated with 80 Woodcuts and 5 full-page Plates in Colours. Cloth. Price 10s. 6d. net.

"... is a good example of its kind and is accurate and trustworthy."—*Lancet*.

"It is a simple, easy, clear setting forth of what the student ought to know. ... It will be a welcome friend to many a student. Its teaching is very good. ... The book is a good one."—*British Medical Journal*.

"The book is essentially a practical one."—*Journal of Obstetrics and Gynecology*.

"We can heartily recommend the work."—*British Gynecological Journal*.

"It is a clearly written and succinct account of the essentials of Obstetrics."—*Dublin Journal of Medical Science*.

KEHR.—Introduction to the Differential Diagnosis of the Separate Forms of Gallstone Disease.

Based upon his own experience gained in 433 Laparotomies for Gallstones. By Professor HANS KEHR of Halberstadt. Authorised Translation. By WILLIAM WOTKINS SEYMOUR, A.B., Yale, M.D., Harvard. Formerly Professor of Gynæcology in the University of Vermont; Fellow of the American Association of Obstetricians and Gynæcologists; Surgeon to the Samaritan Hospital, Troy, New York. With an Introduction by Professor KEHR. In one small octavo volume of 370 pages. Cloth. Price 9s. net.

" . . . It is a pleasure to have the subject dealt with in a manner both masterly and masterful by a surgeon of such wide experience as Professor Kehr, and we feel sure that this volume will be welcomed by surgeons in this country."—*Glasgow Medical Journal*.

KIMPTON'S POCKET MEDICAL FORMULARY.

Containing Seventeen Hundred Prescriptions representing the latest and most approved methods of administering remedial agents. By E. QUIN THORNTON, M.D., Demonstrator of Therapeutics, Pharmacy, and Materia Medica in the Jefferson Medical College, Philadelphia. In one wallet-shaped volume, strongly bound in leather, with pocket and pencil. Price 7s. 6d. net.

KING.—A Manual of Obstetrics. By A. F. A.

KING, M.D., Professor of Obstetrics and Diseases of Women in the Medical Department of the Columbian University, Washington, D.C., and in the University of Vermont, etc. Ninth Edition, Revised and Enlarged. In one demy octavo volume of 630 pages, with 275 Illustrations. Cloth. 12s. 6d. net.

"Prof. King's Manual is now so well known that the appearance of the Sixth Edition calls only for a congratulatory note from the reviewer. A large number of additional illustrations have been introduced into the work, which is quite worthy of the high place it has attained in the undergraduate mind."—*Edinburgh Medical Journal*.

"The book is undoubtedly the best manual of obstetrics extant in English."—*The Philadelphia Polyclinic*.

"We welcome this new edition, which gives a very excellent résumé of the main facts of obstetrical theory and practice, and is likely to prove as fully popular as its predecessors."—*British Gynæcological Journal*.

KOCHER.—Text-Book of Operative Surgery.

By Dr. THEODOR KOCHER, Professor of Surgery and Director of the Surgical Clinic in the University of Bern. Authorised Translation from the fourth German Edition, by HAROLD J. STILES, M.B., F.R.C.S., Edin., Surgeon to the Royal Edinburgh Hospital for Sick Children; late Assistant Surgeon, Edinburgh Royal Infirmary; Examiner in Anatomy, Royal College of Surgeons, Edinburgh. Second English Edition. In one very handsome super royal octavo volume, with 255 magnificent illustrations, many of which are colored. Cloth. Price 20s. net.

KOPLIK.—The Diseases of Infancy and Childhood.

Designed for the use of Students and Practitioners of Medicine. By HENRY KOPLIK, M.D., Attending Physician to the Mount Sinai Hospital; Formerly Attending Physician to the Good Samaritan Dispensary, New York; Ex-President of the American Pediatric Society; Member of the Association of American

Physicians, and of the New York Academy of Medicine. In one handsome octavo volume of 675 pages, Illustrated with 169 Engravings and 30 full-page plates in colours and monochrome. Cloth. Price 21s. net.

"This new text-book on the diseases of infancy and childhood will be read with considerable interest in this country where Dr. Henry Koplik's name is so well known. . . . This book must be regarded in every sense as a complete and up-to-date treatise of the diseases of children."—*Lancet*.

LIKES.—A Text-Book of Genito-Urinary and Venereal Diseases. By SYLVAN H. LIKES,

M.D., Demonstrator of Pathology and Genito-Urinary Surgery at the College of Physicians and Surgeons, Baltimore. In one handsome small octavo volume of about 350 pages, with many illustrations. In Preparation.

LINN.—The Health Resorts of Europe.—A

Medical and Popular Guide to the Mineral Springs, Climatic, Mountain and Seaside Health Resorts, Milk, Whey, Grape, Earth, Mud, Sand, and Air Cures of Europe. By Dr. THOMAS LINN, of Paris and Nice. With Appendices : (a) British and Foreign Hydropathic Establishments, Sanatoria, Private Cliniques, etc. ; (b) The British Balneological and Climatological Society ; (c) The Continental Anglo-American Medical Society ; (d) The American Dental Society of Europe, etc. ; (e) Homes for the Treatment of Alcoholism, the Morphium Habit, etc. In one crown octavo volume of 328 pages. Price 2s. 6d. net.

McGRATH.—Surgical Anatomy and Operative Surgery. For Students and Practitioners. By

JOHN J. McGRATH, M.D., Professor of Surgical Anatomy and Operative Surgery at the New York Post-Graduate Medical School, Visiting Surgeon to the Harlem Hospital, etc. Royal octavo. 560 pages. 227 illustrations, including 18 full-page Plates in Colors and Half-tones. Bound in extra cloth. Price 18s. net.

MAISCH.—A Manual of Organic Materia Medica :

Being a Guide to Materia Medica of the Vegetable and Animal Kingdoms. For the use of Students, Druggists, Pharmacists and Physicians. By JOHN M. MAISCH, Phar.D., Professor of Materia Medica and Botany of the Philadelphia College of Pharmacy. New (Seventh) Edition, thoroughly revised in accordance with the new (1898) Edition British Pharmacopœia, by H. C. C. MAISCH, Ph.G. In one very handsome small octavo volume of 523 pages, with 285 Engravings. Cloth. 10s. 6d. net.

"For the past seventeen years this work has been a favourite text-book with American and English Students, and the influence it has exerted has been very marked, the system of classification adopted in it having proved to be the most convenient in practice. . . . It must be acknowledged that the book remains the only fairly complete work of its kind. . . . Its price is moderate, the paper and printing are excellent, and the pharmaceutical student who does not procure a copy of the book is making a grievous mistake."—*Pharmaceutical Journal*.

MALSBARY.—Practice of Medicine. By

GEORGE E. MALSBARY, M.D., Assistant to the Chair of Theory and Practice of Medicine, Medical College of Ohio, Cincinnati. 404 pages, Illustrated with 45 Engravings. Price 7s. 6d. net.

"Accurate and up-to-date. Students preparing for examination will find a handy *résumé*."—*Scottish Medical and Surgical J1*.

"Worthy of recognition and success. The author possesses the art of clear statement and careful arrangement."—*Physician and Surgeon*.

MARTIN and ROCKWELL. — A Text-Book of Chemistry and Physics. By WALTON

MARTIN, M.D., Assistant Demonstrator of Anatomy, and WILLIAM H. ROCKWELL, JR., A.B., M.D., Assistant Demonstrator of Anatomy, College of Physicians and Surgeons, New York. In one handsome small octavo volume of 366 pages, with 137 Illustrations. Cloth. 7s. 6d. net.

MONELL.—The Treatment of Disease by Electric Currents. A Hand-Book of Plain

Instructions for the General Practitioner. By S. H. MONELL, M.D., Founder and Chief Instructor of the Brooklyn Post-Graduate School of Clinical Electro-Therapeutics and Roentgen Photography; Fellow of the New York Academy of Medicine; etc., etc. Third Edition. Royal octavo. 1,100 pages. 437 Illustrations. Cloth. Price 30s. net.

"... There is much good matter in it."—*British Medical Journal*.

MONELL.—Elements of Correct Technique.

Clinics from the New York School of Special Electro-Therapeutics. By S. H. MONELL, M.D. Third Edition. Octavo. 320 pages. Cloth. Price 12s. 6d. net.

MUSSER.—A Practical Treatise on Medical Diagnosis. For the use of Students and

Practitioners. By JOHN H. MUSSER, M.D., Professor of Clinical Medicine, University of Pennsylvania, Philadelphia. New Edition in preparation.

"Dr. Musser may be congratulated upon the outcome of his labours. A most valuable text-book is the result, containing a vast amount of information set forth in a manner to which no exception can be taken.

... BY A CAREFUL PERUSAL OF THESE PAGES A STUDENT MAY HOPE TO BECOME A VERITABLE SHERLOCK HOLMES IN THE DEDUCTION TO BE ARRIVED AT BY MERE OBSERVATION OF A PATIENT. The Illustrations are beautifully produced, and add to the value of a trustworthy and instructive manual."—*Lancet*.

NICHOLS and VALE.—A Text-Book of Histology and Pathology. By JOHN B. NICHOLS,

M.D., Demonstrator of Histology, Medical Department, Columbian University, and F. P. VALE, M.D., Assistant in Pathology, Medical Department, University of Georgetown, Washington, D.C. In one handsome small octavo volume of 458 pages, amply Illustrated. Cloth. 7s. 6d. net.

"There are few who will not pick up much useful knowledge from its perusal."—*Dublin Journal of Medical Science*.

"Correctly and carefully drawn up."—*Practitioner*.

OHLEMANN.—Ocular Therapeutics for Physicians and Students. By F. W. MAX

OHLEMANN, M.D. (Minden, Germany). Late Assistant Physician in the Ophthalmological Clinical Institute of the Royal Prussian University of Berlin, etc. Translated and Edited by CHARLES A. OLIVER, A.M., M.D., one of the Attending Surgeons to the Wills Eye Hospital, one of the Ophthalmic Surgeons to the Philadelphia Hospital, etc. 274 pages. Cloth. Price 7s. 6d. net.

"Its aim is to give in an easily accessible form the prescriptions most in favour with various ophthalmic surgeons, chiefly, of course, those of Germany. The book is divided into two portions, the first or general part dealing with the various forms in which treatment is applied, and

the various classes of drugs, while in the second, or special, part, different diseases form the different headings, and for each the appropriate remedies are suggested. There is a very copious cross-reference index of drugs, of diseases, and of authors, which reflects credit upon the pains expended on its arrangement and carrying out."—*Ophthalmic Review*.

PARK.—Bacteriology in Medicine and Surgery:

A Manual for Practitioners, Health Officers, and Students. By WILLIAM H. PARK, M.D., Associate Professor of Bacteriology and Hygiene in the University and Bellevue Hospital Medical College, New York. In one small octavo volume of 688 pages, with 73 Engravings and 2 Coloured Plates. Cloth. 10s. 6d. net.

"In this book of over 600 pages, Dr. Park covers the whole ground of bacteriology, with special reference to such parts of the subject as are likely to be of practical utility to physicians, surgeons, and medical officers of health, and, after a pretty careful reading, we can aver that his work has been carefully and conscientiously performed, and that the volume does really deserve a place on the book-shelves of those for whose use it is intended. . . . Highly practical information—the fruits of an extremely wide experience. "We know of no English work in which the entire subject of diphtheria is dealt with in so full and detailed a manner as it is in this book of Dr. Park. Very full of valuable practical hints is also his chapter on typhoid. . . . Extremely concise and valuable."—*Dublin Journal of Medical Science*.

"It may safely be recommended to all whom it may concern, as an unusually full and complete guide to the medical aspects of bacteriology."—*Lancet*.

PARK.—A Treatise on Surgery. By Eminent

Authors. Edited by ROSWELL PARK, M.D., Professor of Surgery and Clinical Surgery, Medical Department, University of Buffalo, Buffalo. In one magnificent royal octavo volume of 1261 pages, with 625 Engravings and 37 full-page Plates in Colours and Monochrome. Handsomely bound in half-morocco. Gilt top. Price 25s. net.

"We can unreservedly commend them as exceedingly well done by men thoroughly conversant with what they were writing about. We can only speak in terms of the highest of praise; paper, printing, coloured plates, illustrations in the text, and binding, are all of the best, and one wonders how the book can be turned out at the exceedingly moderate price at which it is issued."—*Glasgow Medical Journal*.

"The work is an admirable treatise on surgery."—*Edinburgh Medical Journal*.

POSEY.—A Treatise on Diseases of the Eye.

For Students and Practitioners. By Various Authors. Edited by WILLIAM CAMPBELL POSEY, B.A., M.D., Professor of Ophthalmology in the Philadelphia Polyclinic; Surgeon to the Wills Eye Hospital; Ophthalmic Surgeon to the Howard and Epileptic Hospitals; Member of the American Ophthalmological Society. In one octavo volume of 702 pages, illustrated with 358 Engravings and 19 Plates in Colours and Monochrome. Cloth. Price 21s. net.

"Amongst the contributors we are glad to see the names of Mr. W. T. Holmes Spicer, who has undertaken the important chapter on Diseases of the Retina, Optic Nerve, and the Cerebral origin of that nerve, and of Mr. E. Treacher Collins, by whom the chapter on Glaucoma has been written. . . . In conclusion, we consider that amongst the many treatises on Ophthalmology that have been recently published, Dr. Posey's Diseases of the Eye will occupy a distinguished place and may be regarded as an authoritative and altogether trustworthy exposition of the present condition of Ophthalmology in the English language."—*Lancet*.

POSEY and WRIGHT. — A Treatise on Diseases of the Eye, Nose, Throat, and Ear. For

Students and Practitioners. By Various Authors. Edited by WILLIAM CAMPBELL POSEY, B.A., M.D., Professor of Ophthalmology in the Philadelphia Polyclinic, etc., etc., and JONATHAN WRIGHT, M.D., Attending Laryngologist to King's County Hospital; Laryngologist to the Brooklyn Eye and Ear Hospital, etc., etc. In two very handsome octavo volumes of 1238 pages, illustrated with 650 engravings and 35 plates in colours and monochrome. Cloth. Price 32s net.

For Review see Posey's Diseases of the Eye.

POTTS.—A Text-Book of Nervous and Mental Diseases. By CHARLES S. POTTS, M.D.,

Instructor in Electro-Therapeutics and Nervous Diseases in the University of Pennsylvania, Philadelphia. In one handsome small octavo volume of 442 pages, with 88 Illustrations. Cloth. 7s. 6d. net.

"This is a well-known book; it is very suitable for students who desire to pay special attention to neurology. . . . Even qualified practitioners might find that some of their wants are met by this volume."—*Glasgow Medical Journal*.

"Dr. Potts has written a book which is pleasant to read, very helpfully illustrated, and which will be useful both to student and practitioner."—*Practitioner*.

PRICE-BROWN.—Diseases of the Nose and Throat. By J. PRICE-BROWN, M.B.,

L.R.C.P.E., Member of the College of Physicians and Surgeons of Ontario; Laryngologist to the Toronto Western Hospital; Laryngologist to the Protestant Orphans' Home; Fellow of the American Laryngological, Rhinological, and Otological Society; Member of the British Medical Association, the Pan-American Medical Congress, the Canadian Medical Association, the Ontario Medical Association, etc., etc. In one handsome octavo volume of 470 pages, Illustrated with 159 Engravings, including 6 full-page Colour Plates and 9 Colour Cuts in the text, many of them original. Cloth. Price 16s. net.

"Dr. Price-Brown's book is one which will be of special value to those in general practice . . . will prove a useful book of reference to busy practitioners."—*Lancet*.

PRITCHARD.—The Physiological Nursery Chart and Nursery Emergency Chart. By ERIC

PRITCHARD, M.A., M.D. (Oxon.), M.R.C.P. (Lond.). Second Edition, Revised and Enlarged. Price 1s. net.

PRITCHARD.—The Physiological Feeding of Infants. A Practical Handbook to Infant

Feeding. By ERIC PRITCHARD, M.A., M.D. (Oxon.), M.R.C.P. (Lond.). Second Edition, greatly Enlarged and entirely Re-written. Demy octavo. Cloth. Price 3s. 6d. net.

PROGRESSIVE MEDICINE: A Quarterly Digest of Advances, Discoveries, and Improvements in the Medical and Surgical Sciences.

General Editor, HOBART AMORY HARE, M.D. From its commencement in March, 1899, to December, 1902. 16 vols. Royal octavo. Cloth. Gilt top. Price £6 6s. net, or single volumes, price 10s. 6d. net each.

"The name of Dr. H. A. Hare is so well and favourably known to the

readers of the *Practitioner* that a sympathetic welcome is sure to await his latest editorial work. In this he proposes to treat the progress of medicine in a novel method. Instead of summing it up in a year-book at the conclusion of the year, he proposes to issue a volume quarterly, different departments being treated every three months. This work of Dr. Hare's will not only receive a *succes d'estime* from his own reputation. The names of his contributors are also earnest of good work, for they include those of many coming men on both sides of the Atlantic. The list is long and excellently selected, and is exactly what a record of progress should be—well-selected, well-arranged, and practically helpful. . . . We feel sure that the work will gain a leading place amongst the numerous digests of progress. The volume is of convenient size, and the large type adds to the pleasure of perusal."—*Practitioner*.

PROUST and BALLEET.—The Treatment of Neurasthenia. By A. PROUST, Professor

à la Faculté de Médecine de Paris, etc., and GILBERT BALLEET, Professor agrégé à la Faculté de Médecine de Paris, etc. Authorised Translation from the French. By PETER CAMPBELL SMITH, L.R.C.P.E., L.R.C.S.E., L.F.P.S. (Glas.). In one very handsome 12mo volume of 227 pages. Cloth. Price 5s. net.

" . . . This little Book is a really excellent translation of a work by Prof. A. Proust and Prof. Gilbert Ballet. . . . The treatment which is recommended in the pages of this little book is essentially common sense in character, and may be summed in the following words: Good Moral and Physical Hygiene, a well-considered dietary and encouragement by suggestion."—*Lancet*.

" . . . The work may be commended to the notice of practitioners desirous of guidance in the recognition and treatment of a very difficult class of cases. The subject is admirably treated, and the advice given is sound. We may add that the work is clearly printed, and attractively turned out."—*Medical Press*.

" . . . It is an eminently practical little work."—*Medical News*.

PURDY.—Practical Uranalysis and Urinary Diagnosis: A Manual for the use of Physicians,

Surgeons and Students. By CHARLES W. PURDY, LL.D., M.D., Queen's University, Fellow of the Royal College of Physicians and Surgeons, Kingston; Professor of Clinical Medicine at the Chicago Post-Graduate Medical School. Fifth Revised and Enlarged Edition, with numerous Illustrations, including Photo-engravings and Coloured Plates. Cloth. Price 10s. 6d. net.

ROBINSON.—Baldness and Greyness: Their Etiology, Pathology and Treatment. By

TOM ROBINSON, M.D. New (Fourth) and Revised Edition. In one crown octavo volume of 133 pages. Cloth, Gilt. Price 2s. 6d. net.

" . . . Very practical. . . . We will conclude this short notice by expressing the wish, as we confidently feel the hope, that this fourth edition will continue to maintain the popularity of its predecessors."—*Dublin Journal of Medical Science*.

ROBINSON.—Lectures on Acne, Acne Rosacea, Lichen, and Prurigo. By TOM ROBINSON,

M.D. Crown octavo. Cloth. Price 2s. 6d. net.

ROBINSON.—Lecture on Worry. By TOM

ROBINSON, M.D. Second Edition. Price 6d. net.

ROBINSON.—The Power of the Will. By TOM ROBINSON, M.D. Second Edition. Price 6d. net.

ROCKWELL.—Anatomy. A Manual for Students and Practitioners. By WILLIAM H. ROCKWELL, JR., M.D., formerly Assistant Demonstrator of Anatomy in the College of Physicians and Surgeons, Columbia University, New York. In one handsome small octavo volume of 620 pages, illustrated with 70 Engravings. Cloth. Price 10s. net.

SAUNDERS' POCKET MEDICAL FORMULARY. By WM. POWELL, M.D., attending Physician to the Mercer House for Invalid Women at Atlantic City. Containing 1850 Formulæ, selected from several hundred of the best known authorities. Forming a handsome and convenient pocket companion of nearly 300 printed pages, with blank leaves for additions; with an Appendix containing Posological Table, Formulæ and Doses for Hypodermic Medication, Poisons and their Antidotes, Diameters of the Female Pelvis and Foetal Head. Obstetrical Table, Diet List for Various Diseases, Materials and Drugs used in Antiseptic Surgery, Treatment of Asphyxia from Drowning, Surgical Remembrancer, Tables of Incompatibles, Eruptive Fevers, Weights and Measures, etc. Sixth Edition, Revised and Greatly Enlarged. Handsomely bound in morocco, with side index, wallet and flap. Price 7s. 6d. net.

A concise, clear, and correct record of the many hundreds of famous formulæ which are found scattered through the works of the most eminent physicians and surgeons of the world. The work is helpful to the student and practitioner alike, as through it they become acquainted with numerous formulæ which are not found in text-books, but have been collected from among the rising generation of the profession, college professors, and hospital physicians and surgeons.

"This volume contains a collection of prescriptions arranged under the head of various diseases which they are designed to benefit. The diseases are classified in Alphabetical order, and the volume is supplied with a thumb-nail index, which renders consultation the more easy. The prescriptions given appear to have been selected with judgment from a large number of sources, and this hand-book will doubtless often be useful in indicating how an unfamiliar drug may best be prescribed. It will also be of use sometimes in suggesting new lines of treatment, for there is no doubt that we are all rather disposed to fall into habits in the matter of drug prescribing."—*British Medical Journal*.

SCHMAUS.—A Text-Book of Pathology and Pathological Anatomy. By Dr. HANS SCHMAUS, Extraordinary Professor and First Assistant in the Pathological Institute, Munich. Translated from the Sixth German Edition by A. E. THAYER, M.D., Instructor in Pathology in the Cornell University Medical College, New York. Edited, with Additions, by JAMES EWING, M.D., Professor of Pathology in the Cornell University Medical College, New York. In one very handsome octavo volume of 602 pages, illustrated with 351 Engravings, including 35 coloured inset Plates. Cloth. Price 21s. net.

"... Supplies a much-felt want."—*British Medical Journal*.

"... Can be confidently recommended."—*Practitioner*.

SCHRENCK-NOTZING.—Therapeutic Suggestion in Psychopathia Sexualis (Pathological Manifestations of the Sexual Sense): With

Especial Reference to Contrary Sexual Instinct. By Dr. von SCHRENCK-NOTZING

of Munich. Authorised translation from the German. By CHARLES GILBERT CHADDUCK, M.D., Professor of Diseases of the Nervous System, Marion-Sims College of Medicine; Member of the American Medico-Psychological Association, etc., etc. In one octavo volume of 340 pages. Cloth, gilt top. Price 12s. net.

(SOLD ONLY TO PHYSICIANS AND LAWYERS.)

SCHLEIF.—A Text-Book of Materia Medica, Therapeutics, Prescription Writing, Medical Latin and Medical Pharmacy. By WILLIAM

SCHLEIF, Ph.G., M.D., Instructor in Pharmacy in the University of Pennsylvania, Philadelphia. In one handsome small octavo volume of 352 pages. Cloth. 7s. 6d. net.

"... Very carefully and accurately done, and it is a book that might well be used by students."—*British Medical Journal*.

SIMON.—A Manual of Clinical Diagnosis by Microscopical and Chemical Methods. For

Students, Hospital Physicians, and Practitioners. By CHARLES E. SIMON, M.D., late Assistant Resident Physician, Johns Hopkins Hospital, Baltimore. New (Third) and Revised Edition. In one very handsome octavo volume of 563 pages, with 138 Engravings and 18 full-page Coloured Plates. Cloth. Price 18s. net.

"... Covering practically the same ground as the well-known work of Professor von Jaksch, the book contains in some sections even more information than does that volume. We have, after a careful review of the contents of the book, no hesitation in commending it as one of the best and most compendious manuals for the clinical laboratory that has appeared."—*Lancet*.

"The volume is most appropriately illustrated both by coloured plates and by woodcuts in the text. We heartily welcome the appearance of the work, which we feel sure will find a permanent place in the working literature of the profession, and will adequately supply a well-recognised deficiency."—*British Medical Journal*.

STIMSON.—A Practical Treatise on Fractures and Dislocations. By LEWIS A. STIMSON,

B.A., M.D., Professor of Surgery in the New York University, etc., etc. New (Third) Edition. Thoroughly Revised and Greatly Enlarged. With 336 Illustrations and 32 Plates in Monotint. 846 pages, royal octavo, Roxburgh binding. Price 25s. net.

"On a general survey of the work before us, we are struck with the evidences on every page of patient research and accurate observation. The work of another transatlantic author has long been the standard work of reference on fractures and dislocations, namely, that of Dr. Frank Hamilton, and it is no small praise to say (as we can honestly do) that not only is Dr. Stimson's book worthy to be placed alongside of Hamilton's, but that it is destined largely to supersede it, as representing conclusions based on wider and more recent work. . . . The book is clearly printed and handsomely bound, and in every respect worthily upholds the credit of our transatlantic brethren."—*Glasgow Medical Journal*.

"This edition unquestionably represents the most authoritative teaching, and is now probably the most trustworthy work on the subject in the language."—*British Medical Journal*.

STOKES.—Sterility in Men and Allied Functional Disorders. By F. W. STOKES, M.R.C.S. (Eng.), L.R.C.P.I. Crown octavo. Cloth. Price 5s. net.

STOKES.—Chronic Diseases of the Urethra and Prostate, with especial reference to their Treatment by Irrigation. By F. W. STOKES, M.R.C.S. (Eng.), L.R.C.P.I. Second Edition. Crown octavo. Limp Cloth. Price 1s. net.

TAYLOR.—A Practical Treatise on Sexual Disorders in the Male and Female. By ROBERT W. TAYLOR, A.M., M.D., Clinical Professor of Venereal Diseases, College of Physicians and Surgeons, New York. New (Second) and Revised Edition. In one octavo volume of 433 pages, with 91 Engravings and 13 Coloured Plates. Handsomely bound in Cloth. Price 16s. net.

Prompt appreciation of this, the ablest, most scientific, and most practical work ever prepared on its important subject resulted in the exhaustion of the first edition in a year. The eminent author has thoroughly revised it for this new edition, and has enlarged it particularly in the section on female sexual disorders. Those who own the first edition, as well as the large number who were unable to procure it on account of its early exhaustion, will be interested in possessing a volume whose popularity ensures finding the latest and best information within its covers.

TAYLOR.—A Practical Treatise on Genito-Urinary and Venereal Diseases and Syphilis. By ROBERT W. TAYLOR, A.M., M.D., Clinical Professor of Venereal Diseases in the College of Physicians and Surgeons, New York. New (Second) Edition, thoroughly revised. In one very handsome octavo volume of 720 pages, with 135 Engravings and 27 Coloured Plates. Roxburgh binding, 25s. net.

The eminent author has utilised the opportunity offered by the demand for a new edition of his book to produce what is practically a new work. He has at once broadened his field by including an entirely new department, namely, GENITO-URINARY DISEASES, and at the same time reduced the size of his volume to most convenient limits by omitting discussions of many questions which the previous edition settled definitely and finally. This new edition is therefore more direct and practical than ever, and in this single volume alone the student, practitioner, or specialist will find this entire range of cognate subjects handled by an authority of the highest standing. The rich series of illustrations has been revised as carefully as the text, and no less than twenty new full-page coloured plates have been added.

"We consider that this new edition can be confidently recommended as complete and trustworthy."—*Lancet*.

"The work is one of great merit, and deservedly occupies the front rank in works of this class."—*Practitioner*.

"In this volume we have a most readable exposition of the subject. . . . The practitioner and student need only to read the book to find that the author has succeeded in accomplishing his aim."—*Glasgow Medical Journal*.

TAYLOR and WELLS.—Manual of the Diseases of Children.

By JOHN MADISON TAYLOR, A.M., M.D., Professor of Diseases of Children, Philadelphia Polyclinic, Assistant Physician to the Children's Hospital and to the Orthopedic Hospital, Neurologist to the Howard Hospital, Consulting Physician to the Elwyn and to the Vineland Training Schools for Feeble-minded Children, etc.; and WILLIAM H. WELLS, M.D., Adjunct Professor of Obstetrics and Diseases of Infancy in the Philadelphia Polyclinic, Instructor in Obstetrics in the Jefferson Medical College of Philadelphia, Fellow of the College of Physicians of Philadelphia, Member of the Philadelphia Pediatric Society, etc., etc. New (Second) Edition, thoroughly Revised and Enlarged. In one handsome volume of 866 pages, with numerous Illustrations. Roxburgh binding, gilt top. Price 2rs. net.

"We heartily congratulate the authors on their work. Although containing little that is novel, it is so well arranged, clearly written, and devoid of padding as to form one of the best books for the use of the student and the practitioner."—*Lancet*.

"... Can be most confidently recommended as a most reliable text-book for the student and young practitioner. A due sense of proportion prevails throughout, and the descriptions are clear, accurate, and concise. The illustrations add greatly to the value of the volume."—*Glasgow Medical Journal*.

THOMPSON.—A Text-Book of Practical Medicine.

For Students and Practitioners. By W. GILMAN THOMPSON, M.D., Professor of Medicine in Cornell University Medical College, New York. In one very handsome octavo volume of 1012 pages, with 79 Illustrations. Cloth. Price 21s. net.

This completely new work by one of the foremost American physicians and teachers is assured of wide acceptance as a text-book for students and as a guide for practitioners. Professor Thompson has presented the entire range of practical medicine, including the latest advances in pathology, diagnosis and therapeutics, in a single volume of convenient size. He has laid especial stress upon treatment as the main object, and his recommendations will be found sufficiently full and detailed for application in all diseases, their varying stages, complications, etc.

"Unusually detailed and complete."—*Lancet*.

TUTTLE.—Diseases of Children.

By GEORGE M. TUTTLE, M.D., Attending Physician to St. Luke's Hospital, Martha Parson's Hospital for Children, and Bethesda Foundling Hospital, St. Louis, Mo. New edition in preparation.

"... The work is excellent, and we have in this volume an attractive addition to this series of pocket text-books."—*New York Medical Journal*.

"... It cannot but prove acceptable to many students of medicine."—*Glasgow Medical Journal*.

WHITE and HUMPHREY.—Pharmacopædia:

A Commentary on the British Pharmacopœia. By EDMUND WHITE, B.Sc. (Lond.), F.I.C., Pharmaceutist to St. Thomas's Hospital; and JOHN HUMPHREY. One volume crown 4to. 710 pages. With 46 full-page Plates. Red Cloth, Gilt, with Marbled Edges. Price 14s net, or interleaved with white paper for notes. Price 17s. 6d. net.

"The book meets a 'distinct want.'"—*Lancet*.

"Students, physicians, and pharmacists will find it profitable to have the book."—*Amer. Journal of Pharmacy*.

"We feel sure that 'Pharmacopædia' will become one of the best-known English works on pharmacy in the widest sense."—*Chemist and Druggist*.

"Can be welcomed as one of the most valuable contributions to pharmaceutical literature that has appeared for many years."—*Australasian Journal of Pharmacy*.

"Of these commentaries we cannot speak too highly."—*Medical Press*.

"We can confidently recommend the work."—*Chemist's Assistant*.

"Useful alike to the student and practising pharmacist."—*British and Colonial Druggist*.

"Should be in the hands of every medical and pharmaceutical student."—*Practitioner*.

WHITEHEAD.—The Anatomy of the Brain. A

Text-Book for Medical Students. By RICHARD H. WHITEHEAD, M.D., Professor of Anatomy in the University of North Carolina. In one royal octavo volume of 102 pages. With 41 Engravings. Cloth. Price 5s. net.

WHITMAN.—A Treatise on Orthopædic Surgery.

For General Practitioners, Specialists and Students. By ROYAL WHITMAN, M.D., M.R.C.S., Adjunct Professor of Orthopædic Surgery in the New York Polyclinic, Instructor in Orthopædic Surgery in the College of Physicians and Surgeons, and Chief of Orthopædic Department in Vanderbilt Clinic, New York. In one very handsome octavo volume of 642 pages. With 447 Illustrations, mostly Original. Cloth. Price 25s. net.

"This portly octavo of xii and 650 pages is one of the handsomest professional text-books with which we are acquainted. The binding is in the best taste of chaste simplicity; the paper is superb; the type is artistically formed and exquisitely clear; the illustrations are profusely scattered throughout the text, are admirably adapted to its elucidation, and are executed with the most enjoyable clearness. Take it all in all, we have not seen the equal of this volume on the special subject of which its author is so thorough a master and so brilliant an exponent. Slips are very rare in the very splendid volume before us, which we cordially recommend to the best attention of our surgical readers."—*Dublin Journal Medical Science*.

"The author is to be congratulated on the production of such a handsome and useful work on the subject, and we are sure that it will be found of use to both the general practitioner and the surgeon."—*Glasgow Medical Journal*.

WOOLSEY.—Applied Surgical Anatomy.

REGIONALLY PRESENTED. For the Use of Students and Practitioners of Medicine and Surgery. By GEORGE WOOLSEY, B.A., M.D., Professor of Anatomy and Clinical Surgery in the Cornell University Medical College, etc., etc. In One Octavo Volume of 511 pages, with 125 Illustrations, including 59 full-page plates in colours and monochrome. Cloth. Price 21s. net.

ZAPFFE.—Bacteriology; A Manual for Students

and Practitioners. By FRED. C. ZAPFFE, M.D., Professor of Pathology and Bacteriology in the Illinois Medical College; Professor of Histology in the Department of Medicine and in the School of Dentistry of the University of Illinois, Chicago. In one crown octavo volume of 350 pages, illustrated with 146 engravings and 7 coloured plates. Cloth. Price 7s. 6d. net.

KIMPTON'S

Essential Series of Compends

ARRANGED IN QUESTION AND ANSWER FORM.

Essentials of Physiology.—By H. A. HARE, M.D., Prof. Therapeutics in Jefferson Med. College, Philadelphia. Numerous Illustrations. Fourth Edition, revised and enlarged, containing a series of handsome Plate Illustrations taken from the celebrated "Icomes Nervorum Capitis" of Arnold. 192 pages. Cloth, 4s. net.

Essentials of Diagnosis.—By SOLOMAN SOLIS COHEN, M.D., Prof. of Clin. Med. in the Philadelphia Polyclinic; and AUGUSTUS A. ESHNER, M.D., Instructor in Clin. Med. in Jefferson Med. Coll. Second Edition, revised and enlarged. 419 pages. 60 Illustrations, some of which are coloured, and a Frontispiece. Cloth, 6s. net.

Essentials of Obstetrics.—By EASTERLY ASHTON, M.D., Obstetrician to Philadelphia Hospital. 75 Illustrations. Fourth Edition, thoroughly revised and enlarged: 256 pages. Cloth, 4s. net.

Essentials of Gynecology.—By EDWIN B. CRAGIN, M.D., Gynecologist to Roosevelt Hospital, New York. 200 pages. 62 fine illustrations. Fourth Edition, revised. Cloth, 4s. net.

Essentials of Diseases of the Skin, including the Syphilodermata.—By HENRY W. STELWAGON, M.D., Ph.D., Lect. on Dermatology in Jefferson Med. Coll. Fourth Edition, revised and enlarged, with 72 Letterpress Cuts and 15 Half-Tone Illustrations. 276 pages. Cloth, 4s. net.

***Essentials of Histology.**—By LOUIS LEROY, M.D., Professor of Histology and Pathology, Vanderbilt University, Nashville, Tennessee. 255 pages, with 72 Illustrations. Cloth, 4s. net.

Essentials of Refraction and Diseases of the Eye.—By EDWARD JACKSON, A.M., M.D., Prof. Dis. of Eye in the Philadelphia Polyclinic. Third Edition, revised and enlarged. 261 pages, with 82 Illustrations. Cloth, 4s. net.

Essentials of Diseases of the Nose and Throat.—By E. BALDWIN GLEASON, M.D., Surg. to Nose, Throat, and Ear Dept., Northern Dispensary, Philadelphia. Third Edition, revised and enlarged. 241 pages, with 112 Illustrations. Cloth, 4s. net.

Essentials of Genito-Urinary and Venereal Diseases: A Manual for Students and Practitioners.—By CHARLES H. CHETWOOD, M.D., Visiting Surgeon, Denilt Dispensary, Depart. of Surgery and Genito-Urinary Diseases, New York. 178 pages. Illustrated. Cloth. Price 4s. net.

Essentials of Diseases of Children.—By WILLIAM M. POWELL, M.D., Third Edition. 222 pages. Cloth, 4s. net.

Essentials of Medical Electricity.—By D. D. STEWART, M.D., Chief of Neurological Clinic in the Jefferson Med. Coll.; and E. S. LAWRENCE, M.D. New Edition in preparation.

Essentials of Practice of Medicine.—By HENRY MORRIS, M.D., late Demonstrator, Jefferson Med. Coll., Philadelphia. Numerous Illustrations and a Coloured Frontispiece. New Revised Edition in preparation.

Essentials of Surgery.—By EDWARD MARTIN, A.M., M.D., Clin. Prof. of Genito-Urinary Diseases, Instructor in Operative Surgery, and Lecturer on Minor Surgery, Univ. of Pennsylvania. Illustrated. New Edition in preparation.

Essentials of Pathology.—By F. J. KALTEYER, M.D. In preparation.

***Essentials of Forensic Medicine, Toxicology, and Hygiene.**—By C. E. ARMAND SEMPLE, B.A., M.B., Physician to the Bloomsbury Dispensary, etc. 196 pages, 130 Illustrations. Cloth, 4s. 6d. net.

Essentials of Bacteriology.—By M. V. BALL, M.D., Bacteriologist to St. Agnes' Hospital, Philadelphia. New Edition in preparation.

Essentials of Nervous Diseases and Insanity.—By JOHN C. SHAW, M.D., Clin. Prof. of the Dis. of the Mind and Nervous System, Long Island Coll. Hosp., Med. School. 48 Original Illustrations. New Edition in preparation.

Essentials of Diseases of the Ear.—By E. B. GLEASON, S.B., M.D., Clin. Prof. of Otology, Philadelphia Med. Coll. Second Edition, revised and enlarged. 206 pages, fully Illustrated. Cloth, 4s. net.

Essentials of Anatomy.—By FRED J. BROCKWAY, M.D., Assistant Demonstrator of Anatomy, Coll. of Phys. and Surg., New York; and A. O'MALLEY, M.D., Instructor in Surg., New York Polyclinic. Second Edition, with full-page Plates. 376 pages. Cloth, 6s. net.

Those marked * are not in question and answer form.

SUBJECT INDEX.

					PAGE
ALKALOIDS.					
Brown's Alkaloidal Ætiology.	2s. 6d. net	4
ANALYSIS.					
Bidie's Laboratory Analysis.	2s. net	4
Davis' Qualitative Chemical Analysis.	3s. net	6
Purdy's Practical Uranalysis.	10s. 6d. net	20
ANATOMY.					
Brockway and O'Malley's Anatomy.	6s. net	27
Eckley's Regional Anatomy of the Head and Neck.	12s. 6d. net	8
Gerrish's Text-book of Anatomy.	32s. net	9
Huntingdon's Anatomy of the Human Peritoneum.	42s. net	13
McGrath's Surgical Anatomy.	18s. net	16
Rockwell's Anatomy.	10s. net	21
Schmaus' Pathological Anatomy.	21s. net	21
Whitehead's Anatomy of the Brain.	5s. net	25
Woolsey's Surgical Anatomy.	21s. net	25
BACTERIOLOGY.					
Ball's Essentials of Bacteriology.	4s. net	27
Bidie's Laboratory Analysis.	2s. net	4
Park's Bacteriology.	10s. 6d. net	18
Zapffe's Bacteriology.	7s. 6d. net	25
BLOOD.					
Ewing's Clinical Pathology of the Blood.	21s. net	8
BRAIN.					
Whitehead's Anatomy of the Brain.	5s. net	25
CHEMISTRY.					
Davis' Qualitative Chemical Analysis.	3s. net	5
Martin and Rockwell's Chemistry and Physics.	7s. 6d. net	17
CHILDREN.					
Dutton's Rearing and Feeding of Children.	2s.	8
Koplik's Diseases of Infancy and Childhood.	21s. net	15
Powell's Essentials of Diseases of Children.	4s. net	27
Pritchard's Physiological Feeding of Infants.	3s. 6d. net	19
Taylor and Wells' Diseases of Children.	Second edition.	21s. net	24
Tuttle's Diseases of Children.	24
CLIMATOLOGY.					
Dutton's Sea-Sickness, Health Resorts, etc.	1s. and 2s.	8
Linn's Health Resorts of Europe.	2s. 6d. net	16
DENTISTRY.					
Burchard's Dental Pathology and Therapeutics.	22s. net	3
Eckley's Regional Anatomy of the Head and Neck.	Price 12s. 6d. net	8
Essig's Dental Metallurgy.	Fourth edition.	7s. 6d. net	3
Essig's Prosthetic Dentistry.	Second edition.	26s. net	2
Kirk's Operative Dentistry.	Second edition.	26s. net	3
DIAGNOSIS.					
Cohen and Eshner's Essentials of Diagnosis.	Second edition.	6s. net	26
Collins' Medical Diagnosis	5
Hare's Practical Diagnosis.	Fifth edition.	21s. net	11
Musser's Medical Diagnosis.	17
Purdy's Urinary Diagnosis.	10s. 6d. net	20
Simon's Clinical Diagnosis.	Third edition.	18s. net	22
DIETETICS.					
Bidie's Laboratory Analysis of Water, Milk, etc.	2s. net	4
Dewar's Indigestion and Diet.	1s. 6d. net	7
Dutton's Indigestion.	3s.	7
Dutton's Food and Drink.	2s.	7
Pritchard's Physiological Feeding of Infants.	3s. 6d. net	19

SUBJECT INDEX.

29

	PAGE
ELECTRICITY.	
Bigelow and Massey's Electro-Therapeutics. 25s. net	4
Monell's Treatment of Disease by Electric Currents. 30s. net	15
Monell's Elements of Correct Technique. 12s. 6d. net	15
Stewart and Lawrence's Medical Electricity	28
FEVER.	
Corlett's Acute, Infectious Exanthemata	6
Hare's Typhoid Fever	12
FORENSIC MEDICINE.	
Schrenck-Notzing's Therapeutic Suggestion in Psychopathia Sexualis. 12s. net	21
Semple's Essentials of Forensic Medicine. 4s. 6d. net	27
FRACTURES.	
Stimson's Fractures and Dislocations. Third edition. 25s. net ..	22
GALL STONE DISEASE.	
Kehr's Diagnosis of Gall Stone Disease. 9s. net	15
GENITO-URINARY DISEASES.	
Chetwood's Essentials of Genito-Urinary Diseases. 4s. net ..	27
Likes' Genito-Urinary Diseases	16
Taylor's Genito-Urinary Diseases. 25s. net	23
GERMAN.	
Deutsch's Medical German. 10s. net	6
GYNECOLOGY.	
Cragin's Essentials of Gynecology. Fourth edition. 4s. net ..	26
Crockett's Gynecology. 7s. 6d. net	6
Dudley's Diseases of Women. Third edition. 21s. net	7
HAIR.	
Robinson's Baldness and Greyness. Fourth edition. 2s. 6d. net ..	20
HEART.	
Colbeck's Heart. 12s. net	4
HISTOLOGY.	
Gaylord and Aschoff's Pathological Histology. 31s. 6d. net ..	9
Leroy's Essentials of Histology. 4s. net	26
Nichols and Vale's Histology. 7s. 6d. net	17
HYGIENE.	
Dutton's Domestic Hygiene. 2s.	8
Harrington's Hygiene. 21s. net	12
INSANITY.	
Potts' Nervous and Mental Diseases. 7s. 6d. net	19
Shaw's Essentials of Insanity. 4s. net	27
LARYNGOLOGY.	
Ballenger and Wippenn's Diseases of the Nose and Throat. 10s. net ..	3
Coakley's Nose and Throat. 12s. net	5
Gleason's Essentials of the Nose and Throat. 4s. net	26
Grayson's Diseases of the Nose, Throat, and Ear. 18s. net	10
Posey and Wright's Diseases of Nose, Throat, etc., 2 vols. 32s. net ..	19
Price-Brown's Diseases of the Nose and Throat. 16s. net	19
MATERIA MEDICA.	
Maisch's Materia Medica. 10s. 6d. net	17
Schleif's Materia Medica. 7s. 6d. net	21

	PAGE
MEDICINE.	
Hare's Progressive Medicine. £6 6s. net, or 10s. 6d. per volume ..	19
Loomis and Thompson's System of Medicine. 4 vols. £5 net ..	2
Malsbary's Practice of Medicine. 7s. 6d. net ..	16
Morris' Essentials of Practice of Medicine ..	17
Thompson's Practical Medicine. 21s. net ..	25
NERVOUS SYSTEM.	
Potts' Nervous Diseases. 7s. 6d. net ..	19
Proust and Ballet's Neurasthenia 5s. net ..	20
Robinson's Worry. 6d. net ..	20
Robinson's Power of the Will. 6d. net ..	21
Shaw's Essentials of Nervous Diseases. 4s. net ..	27
NEURASTHENIA.	
Proust and Ballet's Treatment of Neurasthenia. 5s. net ..	20
NURSING.	
Pritchard's Physiological Nursery Chart. 1s. net ..	19
OBSTETRICS.	
Ashton's Essentials of Obstetrics. 4s. net ..	26
Credé and Leopold's Examination of Lying-in Women. 1s. 6d. net ..	5
Evans' Obstetrics. 7s. 6d. net ..	8
Grandin and Jarman's Obstetrics. Third edition. 18s. net ..	10
Jewett's Essentials of Obstetrics. 10s. 6d. net ..	14
Jewett's Practice of Obstetrics. ..	14
King's Obstetrics. Ninth edition. 12s. 6d. net ..	15
OPHTHALMOLOGY.	
Ballenger and Wipperfurth's Eye, Ear, Nose and Throat. 10s. net ..	3
Donders' Anomalies of Refraction. 6s. net ..	7
Druiff's Refraction. 10s. 6d. net ..	7
Hansell and Reber's Muscular Anomalies of the Eye. 6s. net ..	10
Jackson's Essentials of the Eye. 4s. net ..	26
Ohlemann's Ocular Therapeutics. 7s. 6d. net ..	17
Posey's Diseases of the Eye. 21s. net ..	18
ORTHOPÆDICS.	
Whitman's Orthopædic Surgery. 25s. net ..	25
OTOLOGY.	
Bacon's Diseases of the Ear. Second edition. 10s. 6d. net ..	3
Ballenger and Wipperfurth's Ear, etc. 10s. net ..	3
Gleason's Essentials of the Ear. 4s. net ..	28
Grayson's Nose, Throat, and Ear. 18s. net ..	28
Posey and Wright's Diseases of the Ear, etc. 2 vols. 32s. net ..	17
PATHOLOGY.	
Burchard's Dental Pathology 22s. net ..	3
Ewing's Clinical Pathology of the Blood. 21s. net ..	8
Gaylord and Aschoff's Pathological Histology. 31s. 6d. net ..	10
Kalteyer's Essentials of Pathology ..	27
Nichols and Vale's Pathology and Histology. 7s. 6d. net ..	17
Schmaus' Pathology. 21s. net ..	21
PERITONEUM.	
Huntingdon's Human Peritoneum and Abdominal Cavity. 42s. net ..	13
PHARMACY.	
Schleif's Pharmacy, etc. 7s. 6d. net ..	22
White and Humphrey's Pharmacopædia. 14s. net, and 17s. 6d. net ..	24
PHYSICS.	
Martin and Rockwell's Physics and Chemistry. 7s. 6d. net ..	17
PHYSIOLOGY.	
Collins and Rockwell's Physiology. 7s. 6d. net ..	5
Hare's Essentials of Physiology. Fourth edition. 4s. net ..	26
Pritchard's Physiological Feeding. 3s. 6d. net ..	19
Pritchard's Physiological Nursery Chart. 1s. net ..	19

SUBJECT INDEX.

31

	PAGE
PRESCRIPTIONS.	
Colbeck and Chaplin's Science and Art of Prescribing. 5s. net ..	5
Kimpton's Pocket Medical Formulary. 7s. 6d. net ..	15
Powell's Pocket Medical Formulary. 7s. 6d. net ..	21
Schleif's Prescription Writing. 7s. 6d. net ..	22
PROSTATE.	
Ciechanowski's Prostatic Hypertrophy. 5s. net ..	4
Stokes' Diseases of the Urethra and Prostate. 1s. net ..	23
SEA-SICKNESS.	
Dutton's Sea-Sickness. 1s. and 2s. ..	8
SEXUAL DISORDERS.	
Taylor's Sexual Disorders in the Male and Female. Second edition. 16s. net ..	23
SKIN DISEASES.	
Grindon's Dermatology. 7s. 6d. net ..	10
Hardaway's Manual of Skin Diseases. 10s. 6d. net ..	11
Hyde and Montgomery's Diseases of the Skin. Sixth Edition. 25s. net ..	13
Jackson's Handbook of Diseases of the Skin. Fourth edition. 12s. 6d. net ..	13
Robinson's Baldness and Greyness. 2s. 6d. net ..	21
Robinson's Acne. 2s. 6d. net ..	21
Stelwagon's Essentials of the Skin. Fourth edition. 4s. net ..	26
STERILITY.	
Stokes' Sterility. 5s. net ..	23
STOMACH.	
Hemmeter's Diseases of the Stomach. ..	12
SURGERY.	
Gallaudet's Surgery. ..	9
Kocher's Operative Surgery. 20s. net ..	15
Martin's Essentials of Surgery ..	27
McGrath's Operative Surgery. 18s. net ..	16
Park's Surgery. Price 25s. net ..	18
Stimson's Fractures and Dislocations. 25s. net ..	22
Whitman's Orthopædic Surgery. 25s. net ..	25
Woolsey's Applied Surgical Anatomy. 21s. net ..	25
SYPHILIS.	
Dalton's Aix-le-Chapelle Treatment. 6d. net ..	6
Hutchinson's Syphilis. 9s. net ..	12
Taylor's Syphilis. Second edition. 25s. net ..	23
THERAPEUTICS.	
Bigelow and Massey's Electro-Therapeutics. 25s. net ..	4
Burchard's Dental Therapeutics. 22s. net ..	3
Hare's Practical Therapeutics. Ninth edition. 21s. net ..	11
Ohlemann's Ocular Therapeutics. 7s. 6d. net ..	17
Schleif's Therapeutics, etc. 7s. 6d. net ..	22
URANALYSIS.	
Purdy's Uranalysis and Urinary Diagnosis. Fifth edition. 10s. 6d. net ..	20
VENEREAL DISEASES.	
Chetwood's Essentials of Genito-Urinary and Venereal Diseases. 4s. net ..	27
Hayden's Venereal Diseases. 7s. 6d. net ..	12
Likes' Genito-Urinary and Venereal Diseases. ..	16
Taylor's Genito-Urinary and Venereal Diseases. Second edition. 25s. net ..	23
WILL.	
Robinson's Power of the Will. 6d. net ..	21
WORRY.	
Robinson's Worry. 6d. net ..	20

KIMPTON'S SERIES OF MODERN TEXT BOOKS

A completely new set of manuals covering the entire domain
of the Medical Sciences, authoritatively, concisely, with
large type, and handsomely bound in red cloth.

In sixteen small octavo volumes, each containing from 350 to 650 pages, amply
illustrated.

Written by teachers of their respective subjects in leading medical colleges.

EDITED BY BERN. B. GALLAUDET, M.D.,

Of the College of Physicians and Surgeons, New York.

Students will find in this series an unrivalled set of concise text-books, covering an entire medical course, thoroughly up to date, easy to read and quick to refer to by reason of the special system of paragraph headings and catch words.

Practitioners desiring to inform themselves on any branch will find it covered satisfactorily in this new series.

The set of sixteen volumes constitutes a library of modern medicine for all readers, a maximum of information and convenience at a minimum expense. They are beautifully bound and an ornament in any bookcase. Their exceedingly low price is only rendered possible by the certainty of a phenomenal sale.

VOLUMES NOW READY.

Materia Medica.—By WM. SCHLEIF, Ph.G., M.D. Price 7s. 6d. net.

Physiology.—By H. D. COLLINS, M.D., and W. H. ROCKWELL, Jr., A.B., M.D. Price 7s. 6d. net.

Practice of Medicine.—By GEORGE E. MALSARY, M.D. Price 7s. 6d. net.

Gynecology.—By MONTGOMERY A. CROCKETT, A.B., M.D. Price 7s. 6d. net.

Histology and Pathology.—By JOHN B. NICHOLS, M.D., and F. P. VALE, M.D. Price 7s. 6d. net.

Anatomy.—By W. H. ROCKWELL, Jr., M.D. Price 10s. net.

Dermatology.—By JOSEPH GRINDON, M.D. Price 7s. 6d. net.

Nervous and Mental Diseases.—By CHARLES S. POTTS, M.D. Price 7s. 6d. net.

Diseases of the Eye, Ear, Nose, and Throat.—By W. L. BALLINGER, M.D., and A. G. WIPPERN, M.D. Price 10s. net.

Obstetrics.—By DAVID J. EVANS, M.D. Price 7s. 6d. net.

Chemistry & Physics.—By WALTON MARTIN, M.D., and WILLIAM H. ROCKWELL, Jr., A.B., M.D. Price 7s. 6d. net.

Diseases of Children.—By GEORGE M. TUTTLE, M.D. Price 7s. 6d. net.

Bacteriology.—By FRED. C. ZAPFFE, M.D. Price 7s. 6d. net.

Volumes in Press for Early Publication.

Surgery.—By BERN. B. GALLAUDET, M.D.

Diagnosis.—By C. P. COLLINS, M.D.

Genito-Urinary and Venereal Diseases.—By SYLVAN H. LIKES, M.D.

HENRY KIMPTON, 13, FURNIVAL STREET, HOLBORN, LONDON, E.C.



GLASGOW
UNIVERSITY
LIBRARY

