

The pathological histology of bronchial affections, pneumonia and fibroid pneumonia : an original investigation / by A.G. Auld.

Contributors

Auld, Alexander Gunn.
Bristol Medico-Chirurgical Society. Library
University of Bristol. Library

Publication/Creation

London : J. & A. Churchill, 1891.

Persistent URL

<https://wellcomecollection.org/works/hzfeyjr2>

Provider

Special Collections of the University of Bristol Library

License and attribution


This material has been provided by This material has been provided by University of Bristol Library. The original may be consulted at University of Bristol Library. where the originals may be consulted.

This work has been identified as being free of known restrictions under copyright law, including all related and neighbouring rights and is being made available under the Creative Commons, Public Domain Mark.

You can copy, modify, distribute and perform the work, even for commercial purposes, without asking permission.




Wellcome Collection
183 Euston Road
London NW1 2BE UK
T +44 (0)20 7611 8722
E library@wellcomecollection.org
<https://wellcomecollection.org>



D3076

I6c





THE LIBRARY OF THE
Bristol Medico-Chirurgical Society.

Dec. 9th 1891

Store 579600

SHELF
D.A.





THE
PATHOLOGICAL HISTOLOGY
OF
BRONCHIAL AFFECTIONS, PNEUMONIA
AND
FIBROID PNEUMONIA

AN ORIGINAL INVESTIGATION

BY
A. G. AULD,
M.D.


WITH ILLUSTRATIONS

LONDON
J. & A. CHURCHILL
11, NEW BURLINGTON STREET

1891



EDINBURGH :
E. SYMON, PRINTER, 8 ST. JAMES SQUARE.



TO

SIR ANDREW CLARK, BART.,

M.D., LL.D. (ABERD.), LL.D. (EDIN.), LL.D. (CANTAB.), F.R.S., &c.

PRESIDENT OF THE ROYAL COLLEGE OF PHYSICIANS

THIS VOLUME IS AFFECTIONATELY

Dedicated

BY HIS FORMER PUPIL

THE AUTHOR.



Digitized by the Internet Archive
in 2015

<https://archive.org/details/b21446969>

P R E F A C E.

THE greater part of this research consists of a series of papers published within the past two years, which I have carefully revised and considerably expanded. The Chapters on Bronchial Affections were published in the *Glasgow Medical Journal*, with the exception of that on Chronic Bronchitis which has been entirely re-written; the section on Fibroid Pneumonia appeared in a more condensed form as a series of three articles in *The Lancet*. The Chapter comprising the Normal Histology of the Lung and Broncho-Pneumonia, and likewise that on Acute Pneumonia are published now for the first time. All the work has been done in the pathology rooms of the Western Infirmary of Glasgow.

The pathological histology of Bronchial Affections has notoriously suffered neglect at the hands of pathologists, and it is hoped the following contribution will to some extent supply a felt want. With respect to Pneumonia and Fibroid Pneumonia, the case is different. Both Acute Pneumonia and Broncho-Pneumonia have been described by many, but, as I am forced to conclude, in a manner not altogether in conformity with fact, nor yet with just regard to variations in type. On the other hand, the dis-

ease to which I have applied the term "Fibroid Pneumonia" is new, and I have endeavoured to develop the subject as faithfully as possible. No doubt much yet remains to be done ere the scope of this disease be accurately determined, and its claims to recognition be fully appreciated.

My thanks are due to Dr. J. Coats, the Pathologist to the Infirmary, who has cheerfully granted me many facilities for carrying on my work; they are also heartily offered to the various Physicians who have permitted me to make use of the clinical records of the cases.

GLASGOW,
November 28th, 1891.

CONTENTS.

PART I.

BRONCHIAL AFFECTIONS.

CHAPTER I.

	PAGE.
NORMAL HISTOLOGY OF THE BRONCHI - - - - -	1

CHAPTER II.

ACUTE BRONCHITIS - - - - -	19
----------------------------	----

CHAPTER III.

CHRONIC BRONCHITIS - - - - -	40
------------------------------	----

CHAPTER IV.

BRONCHIECTASIS - - - - -	58
--------------------------	----

CHAPTER V.

BRONCHIAL ASTHMA - - - - -	78
----------------------------	----

PART II.

PNEUMONIA AND FIBROID PNEUMONIA.

CHAPTER VI.

NORMAL HISTOLOGY OF THE LUNG—BRONCHO-PNEUMONIA—	
CATARRHAL PNEUMONIA - - - - -	98

CHAPTER VII.

ACUTE PNEUMONIA - - - - -	118
---------------------------	-----

CHAPTER VIII.

FIBROID PNEUMONIA - - - - -	146
-----------------------------	-----

CHAPTER IX.

FIBROID PNEUMONIA (<i>Continued</i>) - - - - -	175
--	-----

INDEX - - - - -	203
-----------------	-----

LIST OF ILLUSTRATIONS.

FIG.	PAGE.
1. EPITHELIAL CELLS FROM THE HUMAN BRONCHUS - - -	3
2. EPITHELIAL CELL-FORMS OF ACUTE BRONCHITIS - - -	31
3. ACINI OF MUCOUS GLANDS IN ACUTE BRONCHITIS - - -	33
4. PECULIAR AND RARE EPITHELIAL LESION OF THE BRONCHI -	45
5. SKETCH OF BRONCHIAL WALL SHEWING FORMATION OF BRIDGE	63
6. WALL OF BRONCHUS SHEWING ABERRANT GROWTH OF SMOOTH MUSCLE - - - - - - - - - -	65
7. SECTION OF BRONCHUS SHEWING SQUAMOUS EPITHELIUM AND "DUCT-FORMATION" - - - - - - - - -	71
8. I.—EXUDATION CELLS OF PNEUMONIA.	
II.—CHANGES IN PROTOPLASM AND NUCLEUS OF CELL IN STAGE OF RESOLUTION - - - - - - - - -	
	126
9. FIBROID PNEUMONIA (<i>Low Power Drawing</i>) - - - -	160
10. FIBROID PNEUMONIA (<i>High Power Drawing</i>) - - - -	161
11. FIBROID PNEUMONIA (<i>High Power Drawing</i>) - - - -	195

PART I.—BRONCHIAL AFFECTIONS.

CHAPTER I.

NORMAL HISTOLOGY OF THE BRONCHI.

OWING to the difference of opinion which exists among histologists as to the precise structure of certain constituents of the mucous membrane of the human bronchus, and keeping in view the fact that these same constituents are most importantly involved in all pathological conditions of the membrane, it becomes necessary to discuss in detail the normal anatomy of the bronchus, more particularly with reference to disputed points, and thus pave the way for the better appreciation of morbid processes.

The bronchial tubes anatomically considered, may be conveniently regarded in two great divisions. The first comprises all bronchi above half a line in diameter or thereabouts; the latter, all those below this to the commencement of the alveolar ducts. Both sets are provided with an epithelium, an inner connective tissue layer, a circular muscular layer, and an outer fibrous tissue layer or adventitia, but to the first set alone pertain a compound (or stratified) epithelial layer, a well marked basement membrane, hyaline cartilages, and mucous glands. It will thus be seen that no organ of the body contains such a variety of structural elements as these larger sized bronchial tubes.

Further, be it observed that the adventitia of this group is continuous with that of the accompanying blood-vessels, and the interlobular septa, whilst that of the smallest bronchi is continuous with, and passes insensibly into, the supporting structure of the alveolar walls. In respect of their blood supply, it would seem from the careful injections of Waters * that the bronchial arteries supply the whole of the structures of the bronchial tubes, the coats of the blood-vessels, the nerves and lymphatics, and the areolar tissue of the lungs, but not the air sacs, which derive their nutrition from the pulmonary plexus. The bronchial arteries form two plexuses in the air tubes, one which supplies the muscles and deeper structures, the other, the branches of which are very minute, the mucous membrane. Further, these injections seem to leave no doubt that the branches of these two plexuses, as well as the vessels which supply the other structures mentioned, all terminate in the *pulmonary veins*. No direct communication exists between the bronchial and pulmonary arteries. As regards the bronchial veins, according to the same authority there are no *venæ comites* to the bronchial artery within the lung. "The so-called deep bronchial veins do not accompany the bronchial arteries within the lungs, and do not return any portion of the blood which is supplied to the bronchial tubes, but they are simply vessels which return the blood from the structures situated about the root of the lung." In the smallest bronchi there is no doubt but that a very free anastomosis exists betwixt their vessels and these of the dependent lobules.

Take now a medium sized bronchus. On examining a transverse section, the mucous membrane will be seen to have a somewhat sinuous outline, and its epithelial margin interrupted at intervals by the trumpet-shaped orifices of

* *On Diseases of the Chest*, art. *Anatomy of the Lung*.

the ducts of the mucous glands, whilst lying above the epithelial cilia is a more or less fine coating of mucus. It is best and most convenient to examine the various structures from within outwards. Beginning, therefore, with the *epithelium*, it is easy to distinguish at least four different kinds of cells—a columnar ciliated cell, a goblet or chalice cell, a more or less spindle-shaped or ovoid cell, and a rounded or cuboidal cell lying underneath, all resting above a clear, apparently homogeneous basement membrane.

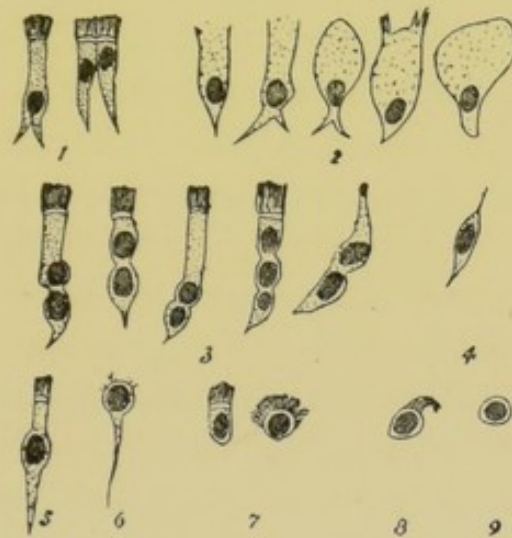


FIG. 1.—EPITHELIAL CELLS FROM THE HUMAN BRONCHUS.

1, 5, various forms of columnar cells. 2, goblet cells. 4, transitional cell. 9, cell from Debove's layer. (Nos. 3, 6, 7 and 8 are found in acute bronchitis, *vide.*) ($\times 200$.)

into which some of the rounded cells of Debove's layer sometimes appear to be slightly imbedded. With regard to the goblet cell, it is usually seen to taper to a narrow rounded extremity, and in this respect presents a striking contrast to its appearance generally in inflammatory conditions. It contains a nucleus which has become displaced downwards into a somewhat triangular area above its attached extremity. These goblet cells are exceedingly prominent in this situation in the cat, sometimes attaining a great size and almost perfectly globular, or even of greater breadth than

length, in which case it is often difficult to demonstrate a nucleus. Owing to the difficulty in obtaining perfectly fresh specimens from the human subject, in order to study the ciliated columnar and the spindle cells, recourse must be had to the lower animals, and of all the mammalia that I have examined, the rabbit is most suitable. Here the ciliated cells are seen to be of diverse shapes. When contiguous with a goblet cell it is sharply triangular, with a long pointed process, the ciliated margin representing its base, and its nucleus which is also more or less triangular, is often quite close to the free margin. The cell in fact has sunk from compression at the expense of the intra-cellular substance, and the intra-cellular network being thus rendered closer, causes the cell body to stain more deeply than the fully extended columnar cell. The ciliated cells not so compressed, when traced downwards usually exhibit two processes as fork-like projections from each side of the cell body directed towards the mucosa, the intervening space being occupied by a spheroidal basal cell. In some of these largest columnar cells I have observed two and even three nuclei one behind the other, a phenomenon which Valentin and Biermer have observed in the case of man. This seems to be especially the case in cells about to become goblet cells, and while as yet the most external cilia are undetached in the process of transformation into the goblet cell, a pale rounded nucleus may sometimes be observed high up apparently in the cell protoplasm, in addition to the more deeply stained nucleus at its base. Further, in some of the ciliated cells a large oblong nucleus may be perceived in the centre of the cell body apparently undergoing division by karyomitosis. With regard to the wall of the columnar cell, in silvered preparations it has the appearance (and this when quite isolated from its surroundings) of a chain of granules easily seen with a magnifying power of 700

diameters, a phenomenon which is not apparent in the cells of Debove's layer.

The basal layer of cells, already referred to, has quite the appearance of an endothelium in longitudinal sections, and was hence described by Debove * as a subepithelial endothelium. It is a single layer in the normal condition, though similar cells are invariably found here and there superimposed, and even existing for some distance up amongst the columnar cells. It has been considered by some—*e.g.*, Recklinghausen, Pagenstecher, Biesiadecki—that some of these cells are migratory lymph corpuscles, but this seems, in the normal condition at least, to be very doubtful.

Now whilst there can be little question as to the characters and nature of the cells already referred to, it yet remains to be seen whether the same can be said respecting certain of the spindle-shaped or pyriform cells which are invariably found amongst the columnar cells. It is asserted by Klein, † in a somewhat emphatic manner, that there exist amongst the columnar cells true fixed connective tissue cells, and that these cells lie in spaces that form canals extending from the free surface of the epithelium downwards to the corium, where they communicate with the interfascicular lymph spaces, in which lie the connective tissue cells of the mucosa. And this eminent observer affirms that such cells (to which he has given the name of pseudo-stomatous cells) exist normally in all epithelia, and have a similar connection with the endothelial cells of serous membranes. Klein characterises these cells as being more or less branched, being drawn out into at least two processes, one directed towards the mucosa and the other towards the free surface, the appearance being quite different from that of mere inter-

* *Comptes Rendus*, Décembre, 1872.

† *Anatomy of the Lymphatic System*, vol. ii., p. 26 ; see also his *Atlas of Histology*.

cellular cement substance. Further, they possess a small body, which is more opaque than that of the epithelial cell, and containing a small nucleus, which becomes more deeply stained by hæmatoxylin than the nucleus of an epithelial cell; and lastly, they are in connection with connective tissue corpuscles in the mucosa—all which, “prove them to be inter-epithelial connective tissue cells.” He further maintains that these cells and spaces form the only channel of communication betwixt the free surface and the mucosa, whereby fluid or formed material can pass either outwards or inwards, notwithstanding that epithelial cells in connection with connective tissue cells have been described by Billroth, Heidenhain, Huxley, and others. Hence Klein would have us believe that the epithelial layer is a compound structure containing a mesoblastic derivative. This theory might indeed appear to receive some support from an experiment of Sikorsky’s,* which consisted in introducing a watery solution of carminate of ammonium into the air passages of cats and dogs during life, when it was found that the ordinary columnar cells remained unstained, but that peculiar cells—on superficial aspect resembling columnar cells—took up the carmine readily, whence it had penetrated by vertical canals into the lymphatic system of the mucosa. Arnold,† also, by reversing the order of this experiment, found that indigo sulphate of sodium, injected at high pressure into the blood-vessels passed through the lymphatics into the cement substance of the epithelial cells.

Now in examining the tracheal epithelium of the rabbit, it will be found that there exist amongst the columnar cells at least three well marked varieties of ovoid cells. First there will be observed (what is especially well marked in the cat) a pyriform cell whose body is a little larger than

* *Centralblatt f. Med. Wiss.*, 1870, No. 52.

† *Virchow's Archiv*, vol. 66.

one of the basal cells and whose process is in connection with one of these latter cells; secondly, a somewhat thin spindle-shaped cell with a central globular nucleus, and having a long process directed downwards, and it may be one or two fine processes directed upwards; and thirdly, a slender somewhat columnar cell, bulging towards its base, and drawn out here into one, but more usually two processes, and having a minute process from each side of its free extremity, or without these latter processes, but presenting a fine striation of its blunted point, and containing in its bulging basal part a small perfectly globular deeply staining nucleus. By a Zeiss $\frac{1}{18}$ th inch oil-immersion lens, I have further occasionally detected minute branchlets from the thickest part of its body, which becomes lost in the cement substance of the adjacent cells. There can be no doubt whatever that this cell corresponds to the pseudo-stomatous cell described by Klein. But I must dissent from the view that it is a connective tissue cell. On the other hand I believe it to be merely a *growing* columnar cell, of which those previously described were the antecedents, which in turn were derived by division of the deeper or Debove's layer of cells—in short, that these cells demonstrate the process of epithelial regeneration. In support of this statement, it may be pointed out that the striation and processes described as occasionally detected at the free surface of the most advanced of these, no doubt represent the commencing formation of cilia, whilst, as regards the staining, it cannot be admitted that the connective tissue corpuscle stains with hæmatoxylin more deeply than an epithelial cell. That this particular epithelial cell stains more deeply than those in its vicinity is due to the fact of its being an actively growing cell, and the same holds good with respect to the actively growing cells derived from connective tissue corpuscles.

In order still further to bring out the true nature of this

cell, I tried the effect of silvering. First, I put pieces of fresh trachea into the silver solution, but found that while the superficial part of the epithelium was sufficiently stained, the silver had not thoroughly penetrated to the deeper layers. Silvering sections previously frozen is not attended with very satisfactory results. I accordingly employed the tracheæ of freshly killed rabbits and cats as follows:—After exposure I placed a ligature tightly round the tube at its bifurcation, and then injected into it by the cut extremity, and whilst almost at blood heat, a quarter per cent. solution of nitrate of silver, applying a graduated pressure until after the space of two or three minutes the tracheal wall was ruptured. By this method I obtained some exceedingly beautiful sections. The silver had everywhere penetrated the cement substance, and had passed into the mucosa, just as the carmine in the experiment of Sikorsky. Now if as Klein asserts, inter-epithelial connective tissue cells and spaces exist, they could not fail to appear characteristically in specimens so treated. I obtained, however, wholly negative evidence of such spaces, not only so (and this in the very thinnest sections which could possibly be cut by the freezing microtome), but the peculiar cells referred to were outlined by the silver in precisely the same manner as the rest of the epithelial cells, and were indeed themselves to a certain extent stained, as contrasted with the clear intracellular substance of the ciliated columnar cells. I therefore conclude that the cell described by Klein as a pseudo-stomatous connective tissue cell is in reality but a growing epithelial cell, and that no such connective tissue medium exists or is required for the purpose of the absorption and transmission of substances to or from the mucosa.

The surface epithelium is continued for some distance along the ducts of the *mucous glands*, but the columnar cells soon lose their cilia, become more stunted, and ultimately

give place rather abruptly to a single layer of spheroidal cells. The mucous glands are found in abundance in the mucous membrane and adventitia, extending between the cartilages. It is noticeable that they are relatively larger and more numerous in the child than in the adult. In none of my sections of mammalian bronchi other than human, have I observed these glands in the adventitia. But their absence in this situation in animals seems made up for by their great abundance in the submucosa. In the cat for instance they may often extend here as a continuous layer for more than a third of the whole circumference of the tube, at least in the trachea. They are also abundant in the sheep. With regard to the alveolar cells, they are always found to vary in the same gland. Whilst some are semi-transparent and columnar, others are granular and spheroidal, according as they were actively secreting or not before death. In the former case, the nucleus is always displaced quite close up to the membrana propria and has generally a flattened appearance. If the cell however is simply *enlarging* for the purpose of secreting, the nucleus is some distance from the membrane and is spherical. And just as in the columnar cells of the surface layer, so also in the secreting gland cell, in this transitional stage, two or more nuclei may be often seen, one behind the other. Yet another cell has to be considered in the mucous glands; these are the crescents of Gianuzzi, which are by no means infrequently observed in this situation. Without going at length into the controversial views regarding these bodies, from what occurs in inflammatory states I am rather inclined to accept the opinion of Heidenhain, Boll, and Lavdowski, that these represent young germinal cells and yet there is much to be urged in favour of the view of Ewald, Ranvier, Ebner, and others, as to these cells representing exhausted shrunken

secreting cells, the shrinking being mainly brought about by the pressure of the swollen adjacent secreting cells, just as has been pointed out in the case of many of the columnar ciliated cells on the free surface of the mucosa. Lying in the centre of the alveoli round cells are sometimes to be observed. The basement membrane of the gland consists, according to Schwalbe, Ebner, and others, of branched flattened cells from which fine filaments proceed into the cement substance betwixt the gland cells. I find that this filament, which is said to exist in connection with the secreting cells of all glands, is exceedingly marked in those of the intestine of the pig, being easily seen there with a magnifying power of 700 diameters, and here indeed would likewise appear to be some confirmation of the statement of Watney,* that these processes may be accompanied by cellular bodies of the connective tissue beneath.

Pertaining to the epithelia there yet remain to be considered the *mucous corpuscles*, which are to be found amongst the mucus coating the surface. Reference has been made to the presence of round cells amongst the surface epithelial cells, resembling those of Debove's layer, and naturally it might be presumed that these cells are passing out to appear as mucous corpuscles. That such is the case normally is however by no means clear. On the other hand, I have drawn attention to the occasional presence in the largest of the ciliated cells, and that apparently before they become converted into goblet cells, of several nuclei in a row, and although hitherto undescribed, there is a strong presumptive evidence that at a certain stage the outermost of these nuclei acquire a cell-body and pass out as mucous corpuscles. Indeed Hamilton† has described a not dissimilar process in some of the transitional spindle-shaped cells. By

* *Philosophical Transactions*, 1876.

† *Pathology of Bronchitis*, pp. 20, 21.

division of the nucleus, the outermost pointed part of the cell is cast off and discharged as a mucous corpuscle, the remaining portion continuing to grow. In the mucous glands, however, which furnish some of the mucous corpuscles, no such transitional cells occur, and the corpuscles, derived from them must be held to be produced in the manner I have described.

Next to the epithelium comes the consideration of an interesting and important structure, which, in pathological conditions of the mucosa, has been the theme of considerable discussion—the *basement membrane*. In the trachea and main bronchi it is normally only about $\cdot005''$ in diameter (Kölliker). It forms the outer boundary of the corium, with which it is inseparably united. Its thickness diminishes *pari passu* with that of the bronchi, becoming exceedingly attenuated in the smaller tubes, and quite imperceptible in their smallest ramifications. *This membrane occurs only in the human subject.* It is no doubt true that a faint resemblance to such exists in the bronchi of certain mammals, *e.g.*, pig, rabbit, but in these instances it is not a specialised structure, it is simply an outer boundary of ordinary connective tissue, and it is observable that in these cases, in the bronchi namely of lower animals, the basal layer of cells presents a greater degree of coherency than is the case in man. Owing to its thinness and delicacy the basement membrane is but little fitted for examination in the normal state, but in inflammatory conditions it swells greatly from oedema, becoming exceedingly prominent and measuring nearly $\cdot15''$ in diameter, and is then well fitted for examination in certain respects. Care must be taken that the cut sections are perfectly perpendicular to the axis of the tube, else deceptive appearances arise from parts of the membrane not being seen at the same level. Without any further treatment it appears under a high power to be perfectly

homogeneous, with the exception of fine vertical canals which appear as whitish lines extending from the connective tissue beneath up to the epithelium. These are the lymph-canalliculi, first observed in this particular situation, I believe by Rindfleisch and described by him in his *Pathological Anatomy* as pores, and since much insisted on by Klein in connection with his so-called pseudo-stomatous cells. These canals are connected with a lymph space in the corium in which a connective tissue corpuscle lies, and by a Zeiss oil-immersion lens I have observed in stained sections a fine streak extending from this cell through the canal up to the epithelium. It is stated by Schäfer in Quain's *Anatomy* that processes are also directed downwards from the epithelial cells. This is apparently given on the authority of Klein. I have never been able to obtain the very slightest evidence of such processes. The process mentioned by Schäfer must on the other hand be held to refer to that already described, which passes into the epithelial cement substance just as has been seen to exist in mucous and other glands.

Now as to the structure and homologies of this membrane, it is very commonly asserted to be a homogeneous somewhat elastic layer. Further than this Kölliker* declines to go, but thinks it possible that it may belong genetically to the cells which it supports. Hamilton states most positively that it is absolutely homogeneous and remains so after silvering, and curiously enough he seems to have even overlooked altogether the canaliculi referred to, as he remarks that "there are no interspaces visible in it."† Klein advances the proposition, which he (I believe by mistake) attributes to Debove, that it is in reality an endothelial membrane—"the subepithelial endothelium of Debove," which description as has been mentioned was applied by

* *Microscop. Anat.*, p. 59. † *Ibid.*, p. 36.

Debove to the basal layer of epithelial cells. Klein further states that that portion of the basement membrane lining the trachea is a homogenous non-nucleated elastic layer, while that lining the bronchi is an endothelium. This is utterly erroneous. The membrane has precisely the same structure throughout. It is quite true that little or nothing can be made of it by silvering or by the gold method. All my efforts in this respect ended in failure, owing no doubt to the difficulty in obtaining fresh sections, for which alone in fact silvering is of any use. Maceration in $\frac{1}{10}$ th per cent. solution of common salt as recommended by Schweigger-Seidel also gives unsatisfactory results. I find however that by prolonged immersion in an *alcoholic* solution of picric acid, this so-called homogenous membrane is in reality composed of excessively fine longitudinally disposed fibrils. And if previous to maceration the sections be stained in Bismarck brown there will occasionally be observed small fusiform nuclei and granules imbedded in it, more especially in the young subject,—a phenomenon which caused some of the older writers, *e.g.*, Cornelius Black, to regard it as a “germinal membrane.” There can thus be little doubt that this is a connective tissue structure of a special kind, being intermediate betwixt ordinary connective tissue and elastic tissue, but more nearly allied to the latter. That it is not endothelial in character is proved by the disposition of its fibres and by its elastic properties, resisting as it does the action of strong acetic acid and prolonged maceration in liquor potassii. As to its homologies it is probably to be classed with the anterior elastic lamina of the cornea which is structurally much the same (Kölliker indeed having stated that he has detected nuclei in it) and which likewise is only to be well seen in the human subject. The capsule of the lens, the membrane of Reissner, and the hyaloid membrane appear also to correspond to this structure, and pro-

bably also the subendothelial layer described by Bizzozero* and Salvioli occurring under serous membranes, which however in my limited observations of the same, seems to have more of a fenestrated character than these structures. Stirling† has drawn attention to a probably homologous structure in the stomach of the cat existing as a clear line above the muscularis and beneath a thin subepithelial connective tissue layer, occupying in fact a position somewhat analogous to that of Henle's elastic lamina in arteries. I find that this layer in the cat's stomach (which does not exist in the human subject) is likewise resolvable into fibrils, but it is penetrated by numerous cells and fibres, and in this respect, but in this respect only, differs from the bronchial basement membrane. It seems improbable however as some have asserted, that Descemet's membrane pertains to this division being more of a true elastic tissue, and staining yellow with picrocarmine whilst these other structures stain a deep red. Nor can the basement membrane of glandular elements such as that in the intestinal tract, be classed in this group, being probably cellular in origin, and more akin to the membrana reticularis and the tectorial membrane. Authors indeed usually describe the membranæ propriæ of the ducts of the mucous glands as a continuation of the bronchial basement membrane just as in the intestine the basement membrane covering the villi is continuous with, and structurally identical with, that of the crypts of Lieberkühn. It is no doubt true that the bronchial basement membrane passes insensibly into the membrana propria of the gland duct, but it soon disappears, giving place to the true membrana propria which may be advantageously studied in certain animals—*e.g.*, the sheep, wherein no trace of a bronchial basement membrane exists.

* *Centralblatt f. Med. Weis.*, 1874, No. 14.

† *Atlas of Histology*.

The *inner connective tissue layer* consists first of all of an inner reticulated highly vascular strand immediately subjacent to the basement membrane. Inside of this are numerous elastic fibres, very pronounced in some animals—*e.g.*, the pig. More especially in young subjects and in animals, strands of connective tissue proper may be seen passing at intervals through the elastic layer and becoming continuous with bundles of wavy fibrous tissue beneath. Outside the inner fibrous coat is an annular layer of unstriated muscular fibres, which is a prominent feature of even the smallest bronchi. In the trachea the special disposition of the elastic and muscular tissues must be noted.

The *cartilages* extend through all bronchi which contain mucous glands. It is noticeable that, whilst the cells in the perichondrium are flattened and lie parallel to the surface of the cartilages, the oval cells of the interior lie across the long axis. Also, the perichondrium is seen to be continuous with the connective tissue of the submucosa, which latter tissue passes between the free ends of the cartilages to join the adventitia. The adventitia or external coat consists of bundles of white fibrous tissue mingled with a certain proportion of elastic tissue, the latter being especially prominent in the smaller bronchi. The minute structure of hyaline cartilage has been carefully studied by Thin,* and his results throw a strong light on morbid processes. By a special method of preparation which consists in immersing pieces of fresh hyaline cartilage in a solution of caustic potash at a temperature of 105°—107° F., Thin has discovered that its substance is composed of parallel bands having approximately the diameter of a human red blood corpuscle. The ordinary cartilage cells intercept these bands at intervals. By maceration in sealed aqueous humour or blood serum, these

* *Quarterly Journal of Micros. Science*, No. 16, N. S.

bands or laminae become resolved into bundles of fibrillae, which are in every way similar to the primary bundles of ordinary connective tissue. Hence the structure of hyaline cartilage resembles that of the cornea. And just as by the silver method, epithelial layers have been demonstrated in the substance of the cornea by Bubnoff, Heitzmann, and others, so in cartilage, layers of epithelial-like flat cells may be found. The protoplasmic communications which are said to exist between the cartilage cells are supposed by Thin to represent a system of communicating spaces formed by the apposition of two layers being incomplete, and this he also thinks the true explanation of Recklinghausen's *saftkanälchen* in the cornea. The cartilage cells are analagous to the stellate cells of the cornea and of connective tissue generally, and in sections soaked in a solution of logwood and alum and subsequently treated with acetic acid, when the protoplasm has shrunk round the nucleus in the centre, fine glistening fibres can be seen to enter the ground substance.

The *lymphatics* of the bronchi are numerous and important. According to Klein they take origin in the mucosa as a network of fine capillaries, and are connected with larger vessels with valves situated in the submucosa and adventitia. In this latter situation they form a network, the individual vessels having for the most part a course parallel to the long axis of the bronchus. These peribronchial lymphatics are most numerous in that part of the adventitia next to the branch of the pulmonary artery, anastomosing there with the perivascular lymphatics, which latter also anastomose with those of the alveolar septa. Klein also states, what on careful examination may be verified, that in the mucosa proper the lymphatic arrangement is more that of a lymph-canalicular system, consisting of lacunæ and anastomosing canals containing branching corpuscles; whereas

in the adventitia the arrangement is that of elongated or rhombic spaces, connected by short canals, and these lacunæ are lined with corpuscles resembling an endothelium, being unbranched. In any case, the corpuscles, be they branched or unbranched, are continuous with the endothelium lining the lymphatic vessel in their vicinity. In young subjects particularly, the corpuscles lining the bundles may be occasionally observed to contain two nuclei. Besides these fixed corpuscles, whose nuclei appear spindle-shaped when seen on edge, there may be seen in the mucosa occasional large granular unbranched cells, containing a relatively large nucleus which contains in its interior granules which stain deeply with nuclear staining reagents—the plasma cells of Waldeyer. The origin, functions, and behaviour in disease of these cells are as yet unknown.

In connection with the bronchial lymphatics are numerous *lymphadenoid bodies*. They are most usually observed in the medium sized bronchi, and are situated in the walls of lymphatic vessels, both in the mucosa and adventitia. They are frequently found near the ducts of mucous glands, which they may even envelop. They consist of a delicate fibrillated reticulum, supporting capillaries, and more or less crowded with lymph corpuscles. My observations of these bodies in man would lead me to conclude that they are less cellular than the corresponding structures in the cat and guinea-pig, whilst on the other hand, they are more cellular containing less reticulum, than those in the rabbit. Burdon Sanderson observes that in the adventitia they usually occupy a position near the artery. In morbid processes they are often useful as indicators of lymphatic vessels.

The *nerves* of the bronchi have not been satisfactorily traced. They are derived from the pneumogastric and the sympathetic system. I have observed large gangliated trunks containing medullated and non-medullated fibres,

running in the adventitia, accompanied by one or more small branches of the bronchial artery. Stirling* has discovered a large number of ganglia in the course of the nerves lying outside the posterior muscular wall of the trachea.

* *Histology*, p. 59.

CHAPTER II.

ACUTE BRONCHITIS.

HAVING examined in some detail the normal structure of the bronchi, and, as I trust, cleared up to some extent certain difficult and disputed points pertaining thereto, I shall now endeavour to represent the remarkable series of events developed in these organs in acute bronchitis, the progressive events, namely, which constitute the rise, progress, and issues of a catarrhal inflammation of the bronchial tubes. It is the more encouraging to attempt to do so when it is found that in what has been written on this subject, unquestionably the descriptions of the more minute changes have been either inadequately or inaccurately expressed, more especially in connection with the various epithelial elements and the basement membrane. It is surely unnecessary to insist on the importance of a correct appreciation of the morbid anatomy and pathogenesis of a disease having such a great and such a calamitous frequency in this and other countries.

By bronchitis, as already mentioned, is understood a catarrhal inflammation of the bronchial tubes, howsoever induced. When such inflammation is slight, transient, and limited to the mucous membrane, it is usually spoken of as "catarrh" or "congestion." Though acute bronchitis may set in with varying degrees of severity, according to the nature of the irritant which induces it and the resisting power of the organism, yet there is no essential difference in the phenomena so induced other than in the rapidity of

of their development.* At the same time inflammation must not be confounded with the mere mechanical congestion following such diseases as interfere with the normal circulation in the lungs, or with the hypostatic congestion immediately preceding death in many cases. In such conditions the mucous epithelium is always desquamated, owing to the œdematous state of the tissues underneath. Yet passive hyperæmia or congestion, long enough continued, may give rise to many of the appearances of a genuine inflammation, and no doubt may occasionally pass into such. It is doubtful whether *post-mortem* changes can effect desquamation of the bronchial epithelium as Biermer supposed, the evidence is against such a possibility. Bronchitis is spoken of as "idiopathic" or primary, and "secondary," and with reference to the catarrhal secretion, the terms mucous, serous, muco-purulent, purulent, &c., have been applied. These latter terms indicate in a rather loose manner the particular stages of the affection and are clinical adaptations. The term *idiopathic* is rather misleading—it has no really intelligible signification, and had therefore better be abandoned. However, whether primary or secondary there can be little doubt but that in the majority of cases a *poison* of some sort gains access to, and is distributed in, the blood-vessels and lymphatics of the mucosa. It may be inhaled from without or it may be carried by the lymphatics or the blood-stream from centres of infection within, either in the form of schizomycetes or as ptomaines, or it may exist *in loco* as part of a general infection of the system,

* As bearing on this, it must not be supposed that the condition known as plastic or croupous bronchitis, rare in man, but easily induced experimentally in animals, is necessarily a severe form of inflammation. In fact, as a rule, the very opposite is the case, and there is by no means, that total destruction or coagulation-necrosis involving the epithelium, which Weigert rather ingeniously propounded to be indirectly the cause of the deposition of fibrin, by the consequent death of the white blood corpuscles—a view which, in the light of the facts, seems hardly sufficient.

or lastly, it is probable enough that it may be developed *de novo* by local conditions of faulty metabolism. The various exanthemata are fruitful sources of bronchitis. In these cases, as likewise in diphtheria, influenza, and whooping-cough, multitudes of micro-organisms have been demonstrated in the walls of the bronchi by Buhl, Eberth, Wyss, and others. In this group of cases the inflammatory process is liable to become developed in the finer bronchi, as a result no doubt of the direct application there of the specific virus. E. F. Grün recently described a peculiar bacillus which he invariably found in the sputum of catarrhal bronchitis, and which he succeeded in cultivating on nutrient media.* In ordinary uncomplicated bronchitis, in adults at least, the inflammation is generally limited to the trachea and larger and middle sized bronchi and termed tracheo-bronchitis; in children the affection very frequently involves the finest bronchi when *as a necessary consequence* more or less catarrhal pneumonia is set up. It might be surmised that the inflammation in the latter case had spread from the larger to the smaller tubes by mere contiguity. This may be possible enough in some cases, but in the majority specific agencies are at work.

Although ordinary acute bronchitis in all its stages may, as to its morbid anatomy, with ease be studied in the human subject, yet a large number of experimental investigations have been carried out—chiefly by Continental workers. And bearing in mind the structural difference betwixt the bronchi of man and those of the lower animals, by which I mainly refer to the presence in the former of the basement membrane, these experiments are not so much to be relied upon as illustrating the progressive development of the general process. Rather are they valuable as aids to the

* *The Lancet*, vol. i. 1891, p. 1424.

study of the changes in individual elements. Again, many of these artificially induced inflammations partake of the fibrinous variety. This seems to depend on the nature, degree of dilution, and length of time of the agent employed. Thus, as regards the irritant, the inhalation of hot steam (Heidenhain), or the injection into the bronchi of solution of ammonia (Reitz), or of perchloride of iron (Sommerbrodt), are followed by a fibrinous bronchitis; while the injection of mercury (Cruveilhier), of vermilion or Berlin blue (Schottelius), or of a three per cent. solution of chromic acid (Socoloff), gives rise to the catarrhal form. So far as I have observed, the results of experiment serve to render clear certain of the more obscure phenomena observed in the human subject. But at any rate, with or without experiments, it is necessary to examine a large variety of cases, so as to obtain specimens illustrative of the morbid process in all its stages. And in the preparation of the specimens much care is needed. After hardening the tissues for a few months they should be subjected to the process of embedding—either in celloidin or in paraffin. This preserves with the greatest possible accuracy the relative positions of the elements, and the risk of injury in cutting the sections is reduced to a minimum.

I need not here describe the *macroscopic* appearances of catarrhal inflammation of the bronchi, as these no doubt are sufficiently familiar to every one. What then it may be asked is the very first indication in the bronchus of the commencement of the morbid process? Such may readily enough be imagined but it is not so easy as usually to permit of demonstration in man. Finding that the experiments referred to had exclusive reference to the more advanced changes, I was witness of the following simple one:—Tracheotomy was performed in a rabbit, and into the trachea a few drops of emulsion of oil of turpentine were

injected. In about twenty minutes the animal was killed and the trachea and lungs excised. Microscopically, the blood-vessels ramifying in the mucosa were found to be immensely distended, and there were frequent hæmorrhages. *The epithelium showed no change whatever.* The vascular engorgement was confined to the mucosa, it was not apparent to the adventitia (which usually contains a quantity of fat in most animals). From this it is apparent that bronchitis commences with engorgement of the vessels in the inner connective tissue layer, causing redness, tumefaction, and that irritating sensation experienced at the commencement of a catarrh. There seems to be little or no secretion of mucus at this stage; the mucous membrane feels hot and dry subjectively. Very soon however the exudation of corpuscular and fluid elements from the blood becomes energetic. The leucocytes tend to accumulate immediately underneath the basement membrane, and in the vicinity of the glands. As the transudation of fluid continues, the connective tissue interspaces become *more apparent*, the basement membrane becomes *highly œdematous*, and its straight and Y shaped canals become *distended*. This distension is similar to that described by Stricker as occurring in the plasma canals of the cornea in inflammation. Coincidentally with these changes, the epithelial cells of the surface *swell*, and many ciliated cells *rapidly undergo transformation into goblet cells*. This is effected as follows:—The cilia are entirely or partially thrown off,* the nucleus gets displaced to the extreme base, the meshes of the intracellular network widen, while the cell substance increases in amount, and undergoes a mucous metamorphosis. The orifice

* It is stated by Klein that the first thing in the process of transformation into the goblet cell is loss of the cilia. This may no doubt be true normally but owing to the rapidity of the process in inflammation, it is usual to find a few cilia towards the edges of the cell. See 2 in Fig. 2.

of the cell then generally *dilates*, the intracellular network *breaks up*, when the mucus issues forth and immediately becomes cloudy, though it is clear before its escape. In this way large quantities of mucus are generated by the surface epithelial cells alone, while at the same time it wells out in abundance from the ducts of the mucous glands. The gland cells are seen to be excessively active, but as yet do not present any marked abnormal changes. Hitherto let it be noted that no proliferation or desquamation of any of the epithelial cells has taken place, and should the inflammation proceed no further, should *restitutio ad integrum* be now brought about, the pathological phenomena enunciated sufficiently well represent what might be termed a slight "congestion" or "catarrh" of the bronchi. On the other hand, it must be remembered that in severe inflammations the above changes take place rapidly—probably within two hours. What constitutes a catarrh slight is essentially the slowly progressive course of the limited pathological events.

As the inflammation proceeds (and in ordinary cases after about twenty-four hours) the *proliferation* and *desquamation* of the epithelium commence. First of all, *many of the columnar ciliated cells exhibit two or more nuclei, and they divide into as many separate cells*, the outermost of which occasionally still preserve their cilia. (Fig. 2). So far as I am aware, such a transformation of the columnar cells has either been ignored or denied hitherto. Hamilton,* for instance, who speaks with most authority on this subject, states that "the columnar epithelium is shed at a very early stage in the attack, and takes no part whatever in the afterchanges which ensue. It does not proliferate, there is no endogenous division of its nuclei, and it seems to behave very much in the same way

* *Pathology of Bronchitis*, pp. 28, 29.

as the *formed* layer of epidermis does in inflammatory affections of the skin." He regards the columnar ciliated cells as the fully and finally developed forms, and naturally proliferative changes are not to be expected in them. Flemming* also states that he has never observed karyomitosis in a fully formed ciliated columnar cell. I repeat however, that there can be no doubt whatever as to the division of these cells, some of which are represented in Fig. 2. They must be diligently searched for in cases dying early, and they are not to be found in cases of mere mechanical hyperæmia. Another phenomenon in connection with some of these dividing cells is the presence within them of vacuoles. The appearance is highly suggestive of one of the nuclei having escaped, forming what is termed a free nucleus. Virchow was the first to observe these vacuoles in cells which he termed brood-capsules, and he further imagined that the vacuoles were first developed, and in them daughter cells originated by a *generatio æquivoca* of the nucleus. I need hardly say that this view is long since given up. In many of the lower vertebrates—*e.g.*, frog, evidence of the division of ciliated epithelial cells in certain parts has been obtained by several, and Cornil and Ranvier† have described such in the artificially inflamed trachea of the rabbit, the karyokinetic figures of which have been recently demonstrated by Cox.‡ I have examined the results of an inflammation produced in the bronchi of the rabbit by the method they recommend viz., the hypodermic injection of an ethereal solution of cantharidin, and I find that the *entire* cylindrical epithelium breaks up into round cells at a very early stage. In treating of the normal histology of the epithelia, I pointed out how

* *Studien über Regeneration der Gewebe*, p. 96.

† *Path. Anat.*, vol. ii., p. 10.

‡ Ziegler's *Beiträge z. Path. Anat.*, Band. v. 1889.

frequently in this mammal bi- and tri-nucleated ciliated cylinders were to be seen, and hence these results are precisely what one would expect. In the human subject however, bi-nucleated columnar cells are rarely if ever seen normally, never, according to Baumgarten, and this, together with their comparative infrequency in most cases of bronchitis at all advanced, no doubt accounts for the supposition that they cannot exist. The only objection which could be urged against them is, that the supposed nuclei were simply pus corpuscles coming from the mucosa which had penetrated into the cell. That there is such a possibility in the general sense can not be doubted, after the investigations of Volkmann and Steudener* on this subject. In this particular case however the contention is useless, for the fission of the cell-protoplasm is apparently taking place, and more than this, as yet no lymph-corpuscles have passed through the basement membrane. As these changes proceed in the columnar cells they soon begin to be loosened from each other and to be desquamated. Their desquamation is effected by two distinct agencies. First of all the epithelial cement substance gets dissolved by the serous exudation from beneath, and secondly, the rounded cells of Debove's layer proliferate and give rise to round cells resembling pus cells which push out the superimposed cylinders by their mere accumulation (No. 9, Fig. 2). Vast numbers of these round cells are rapidly produced, carrying outwards the columnar cells in some places in the smaller bronchi to nearly the centre of the lumen of the tube. Socoloff† has well depicted this appearance in his experimental investigation, and not inaptly likens these cellular accumulations to hills, on the tops of which the cylindrical cells lie. Not a few of the latter cells, however, lie scattered here and there

* *Centralblatt. f. Med. Wiss.*, 1868, p. 267.

† Virchow's *Archiv*, vol. 68.

in the exudation (No. 1), and a few spindle-shaped or transitional cells are likewise to be detected (No. 4). Another occasional factor in the raising and pushing outwards of the cells, is the mucus derived from the glands, which as it issues from the duct may sometimes be observed to have insinuated itself under the epithelial layer in the immediate vicinity, dissecting out the cells.

Now it may indeed be asked whether the catarrhal products just described—the various epithelial cells namely, all embedded in a tough mucus—are not associated with others derived from the mucosa, whether in fact many of the cells of the catarrhal secretion are not lymph corpuscles which have passed out through the basement membrane. Let us see therefore what at this period is taking place in the deeper structures. It will be found that the loose tissue of the mucosa has become raised at intervals, chiefly opposite the interspaces of the cartilages, and hence the mucous membrane is irregularly thrown into folds. Both here and in the submucosa the cellular infiltration, and distension of the blood-vessels are considerable, and rows of lymph corpuscles or leucocytes may sometimes be observed between the muscular fasciculi. The adventitia however shows no change further than that of oedema. A good deal of inflammatory action is noticeable in and around the nerve ganglia. The numerous capillaries which ramify in the connective tissue framework of the ganglion are engorged, and this no doubt causes irritation of the ganglion cells by pressure, and likewise leads to nutritive disturbances. Hence it may be conjectured that this condition of the ganglia stands in a causal relationship to the spasmodic attacks which so frequently supervene in this disease. This supposition has been denied by some—*e.g.*, Wintrich, Traube, Weber—who have propounded theories of their own, while others again have connected

this spasm element with the presence in the inflammatory secretion of Leyden's or Charcot's crystals. On the other hand there are those who regard the ganglia as chiefly concerned with the regulation of the mucous discharge, and thus look upon the excessive secretion of that element as the reflex expression of their irritation. The congestion and pressure exerted on the different fibres of the vagus give rise to the cough, and Kohts* of Strassburg states that there is a particularly sensitive area of the mucous membrane just at the bifurcation of the trachea, and this no doubt serves to explain in many instances the aggravation of the cough in the recumbent posture, by the gravitation to this area of irritating products. Now, at this particular stage of the affection, with these features in the wall of the bronchus, do we find cellular elements (which, without reference to their origin, I may term lymph corpuscles), escaping from the tissue underneath the basement membrane on to the free surface? Again referring to Hamilton I must quote his strongly worded and reiterated negation of such a process. "I have never," he remarks, "seen any evidence in acute bronchitis that the catarrhal cells are lymph corpuscles which have escaped on the surface, the basement membrane seeming to form an impenetrable barrier to their exit. I do not believe that such diapedesis takes place, and even in chronic bronchitis, where this structure becomes much attenuated, I have never seen any direct and clear evidence that they pass through it." He further seems to regard the inability he attributes to the lymph corpuscles as matter for regret, because owing to the block which ensues later on, the corpuscles become forced back and ultimately wander into the adventitious tissues, and excite serious and often irrecoverable damage therein.

* Virchow's *Archiv*, vol. 66.

Now in a cursorily conducted examination, this statement of Hamilton appears easy of refutation. It looks as though breaches of the basement membrane were frequent, and the evidence of corpuscles escaping through it, clear. Careful examination has convinced me that these appearances are mainly deceptive. Again and again have I thought the cells to be escaping, only to find that the phenomena were illusory. For the mere fact of cells lying above or beneath the membrane, or of a hæmorrhage into it, proves nothing; and in like manner the existence of cells in the lumen resembling pus corpuscles proves nothing, for these cells might have come from the mucous glands, and moreover, the proliferated epithelial cells are hardly if at all distinguishable as to their nuclei from those of pus corpuscles. Nevertheless I have frequently been enabled to demonstrate the various stages in the actual translation of the lymph corpuscle through the membrane. The appearance is quite characteristic, and once seen leaves no doubt whatsoever. The following then is the *mode in which the lymph corpuscle passes through the basement membrane*:—It first shoots out a process, easily seen passing along one of the now distended canaliculi already referred to. Situated in this fashion I cannot liken it better than to a *comma* with its body beneath and its tapering process curving upwards. It next follows up the process and gets moulded into an oval shape—its extreme length being now just the breadth of the membrane. A similar oval form of lymph cells is seen in inflammation of the cornea, as they squeeze themselves through the lymph canaliculi of von Recklinghausen, and Axel Key* has, I believe, described a similar appearance in the ducts of Bellini. The next step is that the corpuscle gathers itself together near the epithelial margin of the membrane, having now a process

* *Hygeia*, vol. 30.

directed the opposite way, and very soon afterwards it emerges as a round cell on the free surface. In this way, by the third, or at most the fourth day, the catarrhal discharge contains a considerable number of cells derived from the mucosa, whilst the various forms of epithelial cells first discharged, now present further very curious and instructive changes.

Let us examine these cell forms. First with regard to the columnar cells, it is apparent that they are undergoing a retrograde metamorphosis. Some are undergoing fatty, and others mucoid, degeneration. Hence it is that ciliated columnar cells are comparatively infrequent in the expectoration of bronchitis. They die and become dissolved early, before the expulsive efforts have been sufficient to dislodge the tough stringy mass which clings to the surface of the tubes. The goblet cells are desquamated only to perish quickly. Various forms of these after they are shed, are depicted in Fig. 2. The bi- and tri-nucleated columnar cells have already been referred to. I have also depicted rounded and short oblong ciliated cells (7), and the peculiar cell No. 6, having a round body and a long process, all which I have observed but very rarely. Similar forms have been noted in the artificial bronchitis of animals. Discussion has centred most round the spherical ciliated cell. I have only observed it in cases wherein the dividing columnar cells existed, and hence can have no dubiety whatever as to their origin by such division. My acquaintance with this cell dates prior to my perusal of Socoloff's experimental researches, wherein an exactly similar body is described and depicted, as well as the cell No. 6. The round ciliated cell has also been noticed by Rindfleisch,* by Ranvier,† by von Brücke,‡ and by E. Neumann.§ It exhibits amœboid

* Virchow's *Archiv*, vol. 21. † *Traité Technique d'Histologie*, p. 243.

‡ *Vorlesung über Physiologie*, I., p. 445. § *Med. Centralblatt.*, 1876, p. 417.

movements when recent, and behaves generally as a white blood cell. It is noticeable, however, as Neumann points out, that the cilia are only complete round a portion of the periphery, so far as I have noticed, about three-quarters of its extent. Occasionally also the cilia converge to a point (as in No. 8), an appearance which Neumann describes as "resembling the point of a small paint brush." The production of these cells by endogenous division of the nuclei of the columnar cells I take as proved, and this is the view maintained by Rindfleisch, Ranvier, and Neumann.

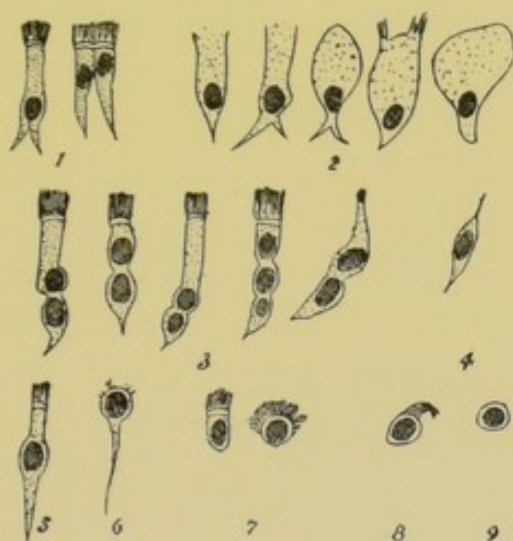


FIG. 2.—EPITHELIAL CELL-FORMS OF ACUTE BRONCHITIS.
($\times 200$).

Socoloff* however has advanced a new theory for their formation. He points out that in the catarrhal secretion of the artificially inflamed mucosa of the dog, ciliated cells may be seen having a round body and a long pointed process, corresponding to No. 6, but with the addition of cilia. He regards this cell to have assumed such a form in virtue of a certain contractile peculiarity, by the further exercise of which the process gets absorbed, and hence the round ciliated cell. In this he is supported by von Brücke. Socoloff has also observed multi-nucleated cylin-

* *Ibid.*

dricul cells in the exudation, but these he regards as formed by the penetration into the epithelial cells of pus corpuscles, and he further states that he has observed *red* blood cells in the interior of these epithelial cells—which is rather remarkable if correct. An objection to Socoloff's theory is, that the cilia of the desquamated cells are usually the first to disappear, while the process is last, and is it at all likely that the columnar cell can have passed through all the stages referred to, and either absorb or lose its process, and yet the cilia remain intact and adherent? Then it may be retorted, how is the round cell, No. 6, with the tail or process to be explained? I have obtained conclusive evidence that in some cases at least this body is nothing other than *the nucleus and process of a ciliated columnar cell* (No. 5), the former having retained around it a small quantity of the cell protoplasm, the jagged edge of which might give rise to the fancy that degenerate remains of cilia were still adherent.

If the phenomena hitherto described in the mucosa and epithelial layers are striking and significant, it will be found that the ducts and acini of the mucous glands have become the theatres of active changes not a whit less remarkable. On examining the duct it will be found that its lining epithelium is proliferating in a luxuriant fashion, and not infrequently as a result of this, a complete block takes place. To such a degree may the pressure thus occasioned on its walls attain, that occasionally a saccular dilatation ensues, leading in severe cases to solution of continuity of the *membrana propria*, and giving rise to the appearance of a small diffuse abscess. The appearances in the alveoli are generally very diverse in the same gland, and at first are very perplexing. Finding the descriptions of the gland changes conflicting and quite unsatisfactory, I endeavoured as carefully as possible to trace the course of events *seriatim*.

The first and earliest inflammatory change in the secreting cells is, that they become more *cloudy* and *enlarge* until the lumen is almost entirely occupied by them, when they are of a more or less *conical* shape. The nucleus also *doubles in size*, and *moves forward* to near the centre of the cell protoplasm. The acinus at this stage is represented in No 1 (Fig. 3). It will be noticed that some of the cells are bi-nucleated, and an endothelial-like layer rests above the membrana propria. A new phase is then entered on. Many of the cells divide and give rise to catarrhal cells, some of which are seen lying free in the centre of the acinus, and

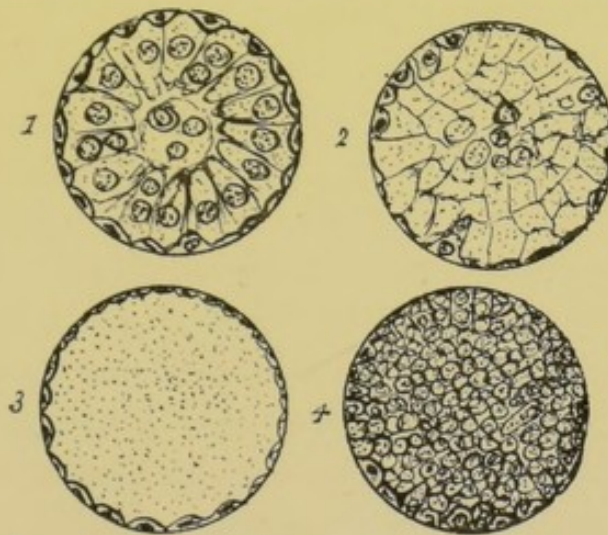


FIG. 3.—ACINI OF MUCOUS GLANDS IN ACUTE BRONCHITIS ($\times 120$).*

all of them, whether dividing or not, soon become distended with mucus. They then present an appearance as in No. 2. No nuclei are visible, and only the outlines of the cell are to be seen. Owing to their mutual distension, they seem to have assumed diverse shapes, while the acinus becomes considerably enlarged from the pressure thus exerted. Very soon all the cells burst, they become confluent, and a transparent or hyaline-looking, though somewhat finely granular mass is all that can be made out in the acinus—represented in No. 3. That this is mucus is easily

* The outlines of the cells have unfortunately been indistinctly drawn.

proved by the addition of acetic acid, when a dense precipitation of mucin is produced. Now is this swelling of the glands and tension of mucus to be regarded as solely due to the inflammatory process, as most authors assert? Partly no doubt, but it seems to me highly probable that it is due to a mechanical cause as well, by which I mean the stoppage in the duct already referred to. The mucus is unable to escape, and hence possibly enough, the bursting of the cells, hyaline appearance, and distension of the acini. That such is the case receives support from what occurs next. As the mucous plug in the duct dissolves, the acini assume quite a different appearance. The pent up mucus escapes, and round or oval granular catarrhal cells take its place. They are evidently derived by germination of the lining endothelium-like cells mentioned, for these latter can now be seen to enlarge and exhibit nuclear fission. The inflammatory stimulus seems too great to allow of these cells developing into fully formed secreting cells: they are kept proliferating, and thus it will be seen that in this respect they exhibit the exact counterpart of what takes place in Debove's layer of the surface epithelial cells. Hence also, we find in this process strong support to the Heidenhain-Pflüger theory, that these proliferating cells, and crescents of Gianuzzi are not merely shrunk exhausted secreting cells. Again, in some cases of severe bronchitis the fully formed secreting cells seem to be desquamated at an early period, when young darkly granular nucleated bodies may be seen partly or entirely lining the membrana propria. Up till the time of this catarrhal proliferation, it is quite certain that no leucocytes have penetrated into the alveoli from the stroma, as they have been seen to penetrate the basement membrane to reach the surface. This is in great part owing to the opposing pressure exerted by the distended vesicles. In severe cases of bronchitis, however, with the

increasing accumulation of cellular bodies in the stroma, and with no such barrier to oppose them, they frequently effect a passage through the membrana propria, and become mixed up with the proliferated epithelial elements, giving the acinus the appearance represented in No. 4. It may be described as nothing else than a small abscess, and should the inflammation be very prolonged or become chronic, several acini may unite to form a purulent mass.

About the fourth day in the course of the bronchitis, a new and highly interesting phenomenon develops in the connective tissue of the mucosa and submucosa. Hitherto, as we have seen, the infiltration of leucocytes and the serous exudation have been the only marked features in this structure. But now the fixed tissue-cells begin to show signs of activity. They undergo a remarkable metamorphosis. The stellate corpuscles in the lymph spaces *swell*, becoming unduly prominent and granular and get *desquamated from their bundles*. They then *lose their processes*, probably by their being retracted into the body of the cell. The cell greatly increases in size, its oval nucleus *enlarges* and becomes darkly granular from chromatic change. The nucleus now divides, and the cells containing such divided nuclei assume various shapes, that most general being of a more or less irregularly oblong type. The cell may now divide, or it may present a still further endogenous increase of its nuclei, which may be seen to be of various sizes. One of two things may then occur. The protoplasm may break up into as many separate cells as its contained nuclei, or, it may dissolve, and the nuclei be set free. The appearance of these cells does not favour the supposition that leucocytes have penetrated into them, indeed the very fact of their attaining such large dimensions is of itself a proof to the contrary. Nor is this process confined to the connective tissue corpuscles proper. If one of

the lymphatic vessels in the vicinity be picked out, and this is generally easy in the adventitia of bronchi containing some pigment, and by the further presence of the lymphoid bodies—which form diverticula of their walls, and will also contain a certain amount of pigment granules—if the lymphatic vessel be examined, it will be found that the endothelial cells lining it present pretty much the same characters as the corpuscles lying in the spaces. That is to say, they have become prominent, bulging from the vessel wall, and some of them containing two nuclei. In fact the accumulation within the lymphatic vessels of the morbid cells has set up inflammatory changes in their walls, extending along the same until their termination in the lymphatic glands at the root of the lung, which in turn are markedly enlarged, contain an excessive quantity of lymph corpuscles, and exhibit cells in their connective tissue trabeculae undergoing nuclear division.

The outcome of this cellular multiplication in the mucosa and submucosa is, that long rows of cells are disposed between the fibrous tissue bundles. The lymph spaces between the bundles become confluent, and hence the tissue become dissected out by these cellular infiltrations. Similar appearances, though to less extent, are to be found in the muscular layer. The cells are also to be seen passing in transverse rows between the cartilages (which in turn show, however, no marked changes), and if the inflammation is exceptionally severe, it is not very long until the connective tissue cells in the adventitia also divide and multiply. These, together with the leucocytes, likewise forms rows, dissecting out the wavy bundles of the tissue, which in their turn, are laden with round and fissiparous cells. It would seem as though this process, when once begun in the adventitia, proceeded in a very active fashion, and the adventitia soon comes to have the appearance of a broad

peribronchial cellular zone, which contrasts strongly with the contiguous unchanged adventitia of the vessels. There could, in fact, be no more striking example of the production of a vast array of pus cells in inflammation from the fixed tissue cells, than that here afforded, in this sparsely vascular peribronchial fibrous tissue. How Cohnheim can assume such an attitude of opposition to this, is inexplicable. He appears to have been rendered blindly enthusiastic by his observations connected with the blood-vessels in the inflammatory process. In his *Lectures on Pathology*,* he states that "a new production of pus corpuscles from fixed tissue cells has not so far been demonstrated. . . . If we disregard such (regenerative) processes, which, after all, are to a certain extent accidental concomitants of inflammation, the prospect of proving the occurrence of progressive cellular changes, directly induced by the inflammatory irritant, appears doubtful enough." In my humble opinion, it requires neither a Virchow nor a Stricker to demonstrate the contrary of at least the first of these propositions. It can be plainly enough seen by any one caring to do so. We may therefore regard the entire bronchial wall at the height of an acute inflammation, as more or less infiltrated with cells derived in the various modes stated. It is of course difficult to draw the line here betwixt the different species of inflammation. In the milder forms, no doubt recovery ensues before any cellular infiltration of the adventitia supervenes, and on the other hand in the suppurative or putrid forms of bronchitis caused by septic micro-organisms, not only is the bronchial wall throughout infiltrated with cells, but the cartilages, glands, &c., are entirely destroyed, until little other than a mass of cells is ultimately to be seen. In some cases of suppurative bronchitis a peculiar duct-like formation of epithelial cells may

* Vol. i., pp. 290, 291.

be found persisting in the wall—a phenomenon which will be more fully discussed on a future page (see Fig. 7). In these severe processes, the basement membrane is ulcerated away. It is possible however that the basement membrane may take an active part in the process. In the chapter on Normal Histology, it was stated that fusiform nuclei were sometimes rendered visible in the substance of the membrane. There is strong probability that these nuclei germinate, and in this way contribute to the gradual disintegration of the membrane. Socoloff, in his experimental investigations, describes a layer of proliferating spindle-shaped cells existing immediately underneath the epithelial layers, which he affirms to be the changed membrana propria, and I have seen a less marked layer of spindle cells in this situation in the artificially inflamed bronchus of the rabbit. That the nuclei of the basement membrane in man undergo fission is thus borne out by analogy.

But in ordinary bronchitis, the basement membrane remains intact throughout, though permitting the passage of a greater or less number of leucocytes. Schottelius* has obtained most conclusive evidence of the degree of emigration of the lymph cells by the blowing in of vermilion dust into the trachea of dogs. The coloured particles were only absorbed by the protoplasm of the lymph cells, the epithelial cells remaining passive, and hence their relative proportion in the exudation could easily be distinguished. By the continual discharge of these cells the catarrhal mass in the lumen undergoes changes. The discharge of mucus abates, and the expectorated matter is highly purulent, and often tends to agglomerate into masses—*sputa cocta* of authors. The disease having now attained its height, in favourable cases begins to recede. The inflammatory cells partly undergo fatty disintegration, and are partly—and

* Virchow's *Archiv*, vol. 73.

no doubt chiefly—carried off by the lymphatics. In the experiment referred to, the lymphatics, and likewise the bronchial glands, were choked ultimately with vermillion-laden cells. The epithelial activity ceases, and new cells are formed in the manner I formerly described, any gaps being filled up by the peripheral extension of the existing cells, just as is seen taking place in healing wounds of the surface of the body.

CHAPTER III.

CHRONIC BRONCHITIS.

THE term chronic bronchitis is generally applied to cases of what is popularly known as "winter cough." But from a pathological point of view, the term has a wider significance. For what may be designated a chronic bronchitis is associated with almost all chronic affections of the lungs. Yet this bronchitis manifests itself by lesions of remarkable diversity, frequently inappreciable to the naked eye. On the other hand, there are oedematous conditions of the bronchi, such as that associated with heart disease, which are not truly inflammatory, but which, on account of the cough and expectoration are nevertheless referred to as cases of bronchitis. They are no more cases of chronic bronchitis than brown induration of the lung is chronic pneumonia or cyanotic induration of the kidney is chronic Bright's disease. The bronchi in cases of heart disease or in coal miner's lung do not present *post mortem* the characteristic features of chronic bronchial inflammations. In fact if the disease be not exceptionally advanced, the various structural elements of such bronchi are, with the exception of the epithelium, in a fairly normal condition, and there is usually an entire absence of new nuclear tissue development. The central lesion is the excessive dilatation, often varicose, of the blood vessels throughout the whole bronchial wall, but especially in the adventitia. The capillaries of

the mucosa become developed into tortuous channels of considerable dimensions. Owing to the abundance of serous discharge thus produced, the surface epithelium is unable to subsist in a normal condition. No sooner have new cells begun to develop than they are desquamated by some exacerbation of the disease, so that *post mortem* the round cells of Debove's layer with groups of spindle cells are usually all that is present. The basement membrane is however, as might be expected, always intact and is also very thick from persistent cedema. The mucous glands, partly from the sodden and catarrhal condition entailed, but chiefly from the pressure of the dilated vessels, become considerably wasted in advanced and extreme cases. It will in fact be seen that this affection is analagous to nutmeg liver, both in respect of its proximate cause and the *modus operandi* of that cause. And in the one just as in the other the dilated vessels and atrophied parenchyma are accompanied as a rule by but slight alteration of the connective tissue, though it occasionally happens that a leucocytal infiltration has occurred to a greater or less extent.

In cases of carbonaceous deposit, Dr. Hamilton * correctly notes that the pigment is never found internal to the adventitia, and further, that the deposit of pigment is so excessive round the branches of the pulmonary artery as to cause their compression and occasionally their obliteration. The result of this will be "a serious interference with the blood circulation, inducing an cedematous state of the bronchial mucous membrane." Careful examination will undoubtedly reveal narrowing of the pulmonary vessels, apparently from this cause. It has been urged by Dr. Coats† that compression of the pulmonary *arteries*

* *Op. Cit.*, p. 67.

† *Glas. Med. Jour.*, May, 1890.

could not be followed by congestion and œdema. However, there can be little doubt but that the pulmonary veins are affected equally with the arteries, and according to the careful injections of Waters,* a very free communication exists between the bronchial vessels and the pulmonary veins—in fact, according to that observer, almost the whole of the blood of the bronchial arteries is poured into the latter.

The naked eye appearances of lungs, the seat of chronic bronchitis—the emphysema, local depressions, frothy serosity on section, &c.,—have been so frequently described and are so well known, that further allusion to the subject is here unnecessary. It may be remarked however, with regard to the bronchi themselves, that they are generally full of purulent secretion, their walls thick and injected, and on squeezing out the retained pus, fibrous striation or delicate rugæ are visible through the transparent basement membrane. In other cases, fibrous septa, bands or bridges are stretched over the wall, and occasionally small recesses or diverticula are found in it. In emphysematous parts, the bronchial walls are dilated and thin, devoid of injection and usually also of purulent secretion.

It is perfectly certain that chronic bronchitis never exists except in association with very marked changes both in the interstitial tissues and parenchyma of the lung. These changes are unequally distributed over one or both lungs, and not infrequently the bronchitic affection is circumscribed. In the latter case, the middle third of the right lung is a favourite site. When bronchitis has become fairly chronic, its “cure” can only be accomplished by the supervention of fibroid changes.

Reference has been made to a bronchitis induced by a strong irritant, and characterised by a more or less rapid

* See page 2.

destruction of the bronchial structures, and their replacement by purulent infiltration. Betwixt this and what may be described as chronic catarrh, all grades of the inflammatory process are to be found, each being characterised by lesions peculiar to itself.

In what follows, the lesions of genuine chronic bronchitis will be considered. The affection may, as is most common, arise insidiously, or it may be set up by an acute attack or by a succession of such. It may be regarded as presenting two stages: the stage of hypertrophy and the stage of atrophy.

STAGE OF HYPERTROPHY.—After an acute inflammation has run its course, it not infrequently happens that more or less irritation of the tissues persists, their blood supply continues abnormally abundant, and there is continued extrusion of leucocytes and lymph from the vessels. The whole part or organ becomes enlarged. To this enlargement a true hypertrophy usually succeeds from new formation of connective, muscular, and other tissues. In the more usual varieties of this inflammatory thickening of the bronchus, it will be found that the surface epithelium is always intact, and the ciliated cells are if anything larger than normal. Numbers of round cells are to be seen amongst the cylindrical cells, derived partly from the deepest epithelial cells by fission, and partly from the mucosa. The bronchial channel is wholly occupied by these cells imbedded in mucus, the ciliated cells always remaining attached to the basement membrane, intermingled with a goodly proportion of goblet cells. The basement membrane is always thick, homogeneous and entire. The inner connective tissue layer is extremely infiltrated with cells and likewise very vascular. The distension of this layer by leucocytes seems to hinder the formation of new tissue which is seen to be progressing in the deeper parts and in the coats of the

vessels. The inter-muscular and submucous connective tissues are likewise unduly cellular and hypertrophied, while the glands exhibit a distension of their acini from muco-serous exudation. But little change is found in the cartilages or in the adventitious fibrous tissue at an early stage of the affection—not indeed until inflammatory changes are concomitantly set up in the fibrous septa of the lung.

In some cases there is a very striking hyperplasia of the constituent tissues, especially the epithelial (Fig. 4). There is a very luxuriant growth of the lining epithelium, the cells being greatly increased, both in number and in size. The outermost cells are columnar and ciliated, and there are also many goblet and spindle-shaped cells. The cilia, instead of standing straight out are frequently *curved in one direction*, and sometimes they *converge to a point*. They are also as a rule of excessive length. It is very improbable that such cilia are capable during life of exercising the normal vibratile movement. Beneath these cells are several rows of round cells, which also exist in numbers, sometimes in excessive number, amongst the cylindrical ones. Tracing the epithelium along the ducts of the mucous glands, it will be found to retain its ciliated character to a much greater extent than normally. These ducts also are considerably multiplied and present great and frequently cystic dilatation (D). The ciliated columnar cells lining the principal channels attain their greatest development in the cystic dilatations, where they are associated with mucus-secreting goblet cells. These dilatations seem to be of the nature of retention cysts, and they do not show any intra-cystic papillary growths, such as are found in certain gastric polypi and in uterine cystoma. Yet more remarkable is the hyperplasia of the acini. They present no increase in size, rather indeed the reverse, but they are vastly multiplied and may be seen sprouting throughout the entire bronchial wall to the most

remote parts of the adventitia—(in the illustration they are represented rather under their relative size). Further, in lungs presenting this peculiarity, thin walled ectatic bronchi in emphysematous parts are richly clad with epithelial cells,

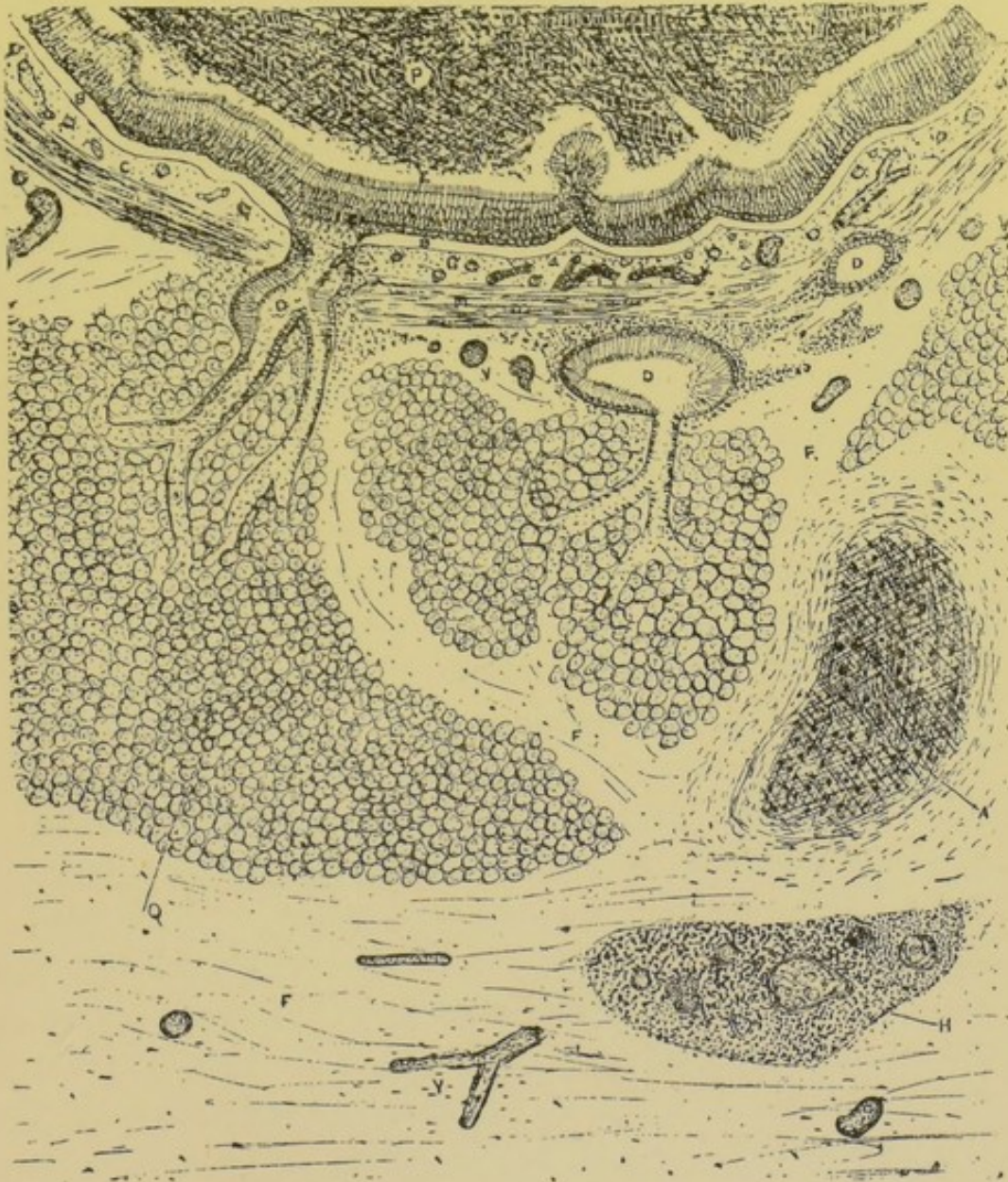


FIG. 4.—PECULIAR AND RARE EPITHELIAL LESION OF THE BRONCHI.

P, purulent mass in lumen; E, epithelium; B, basement membrane; C, inner connective tissue layer; M, muscularis; D, ducts of mucous glands; Q, gland acini; A, cartilage; F, dense fibrous tissue; H, embryonic cellular mass replacing gland tissue; V, blood-vessels. ($\times 25$).

although their other elements are almost entirely wasted away—a discrepancy which never obtains in ordinary cases. As I have been unable to find any mention of this bronchial lesion in pathological literature, and being fully convinced of its singularity and importance, it becomes necessary to discuss the matter from various points of view.

Friedländer * in his experimental researches on foreign-body pneumonia, found that after three weeks a formation of epithelial clusters and canals had taken place inside and around the bronchial walls—a process which likewise occurs in the analagous affection in man, but on a more extensive scale. These cells were polygonal, with rounded nuclei, and their connection with the surface epithelium could be traced. The epithelial formation occurred in the case of dogs in bronchi of the third and fourth orders, which normally contain no glands. Prochownick, working under Friedländer, observed a similar formation in certain phthisical lungs which he was unable to explain. It was also to be seen in chronic interstitial pneumonia in children and in granulation-tissue bronchial walls in adults, and in these instances, as in the experiments, this “atypical epithelial growth” occurred in bronchi which were destitute of glands and had likewise invaded the adjacent alveolar walls. After deciding that the atypical epithelial growth is not truly cancerous, nor yet is an infiltration into the lymphatics, Friedländer concludes that it “comes out from the superficial epithelium of the bronchi.” Now the peculiar formation here described by Friedländer is indeed a form of atypical epithelial growth, but it does not correspond to the above-described bronchial lesion. That Friedländer’s views as to its nature are to a great extent erroneous is certain, and the true explanation of the appearances he observed will be found on a future page. At the same time his descrip-

* *Ueber Epithelwucherung und Krebs* 1877, and Virchow’s *Archiv*, vol. 68.

tion is worthy of consideration in this place, as showing a very singular epithelial abnormality in the bronchi as the result of excessive stimulation.

In 1889 W. H. Cox* described an atypical epithelial growth which he had experimentally induced in the dog and rabbit. He induced a prolonged bronchitis in these animals and found after three days that a system of canals or cavities had formed in the bronchial wall, lined with cylindrical epithelium, and after ten days the appearance "gave quite the impression of a gland tissue." The cells showed frequent karyokinesis, which however was wanting after twenty-one days. Cox affirms this formation to be identical with that described by Friedländer.

According to my observations, atypical epithelial growth occurs in the bronchus in more forms than one; there are at least three forms under which it is found. These varieties are respectively akin to certain epithelial abnormalities occurring in other parts of the body, and further, it is not unlikely that under certain circumstances and when of long duration, certain of these anomalous growths have a tendency to assume the characters of epithelial cancer.

As regards the particular variety here under consideration, it may be inquired whether the lesion can indeed be regarded as a mere inflammatory hyperplasia. That it is not so, seems evident from the epithelial luxuriance in non-inflamed parts, as also from the fact of their being in the thickened bronchi an actual infiltration of new gland tissue, as is found to be characteristic of adenoma. Again, it differs from the glandular hyperplasia found in inflammatory mucous membranes in general, such as occurs most typically in the stomach, for in such the epithelial development is subsidiary to the new growth of fibrous tissue. In some cases however, of long standing

* Zeigler's *Beiträge zur Path. Anat.*, Band v. 1889.

hyperplasia of the gastric mucous membrane, the glandular structures in connection with the papillomatous outgrowths have been to a certain extent newformed, and have hence been designated by some—as by Cornil and Ranvier—cylindrical-celled adenomata. Others again, whether the glands are actually new formed or whether the glandular increase is in the form of an intracystic papillary growth, would consistently deny the term adenoma as applicable to such cases. Herein lies the difficulty. Wherein does an adenoma differ from a glandular hyperplasia? Not in being circumscribed, for tubular adenoma of the liver is not circumscribed. Nor are there, in view of the present contradictory definitions of the term adenoma, well marked differences in the arrangement of the tubes or acini, or in the characters of the contained epithelium. But when as in the present case, the glandular development is associated with productive changes in the other component tissues of the organ, and when further, the new gland tissue secretes a fluid resembling the normal, then it may justly be regarded as outside the category of the adenomata. Consequently, as the epithelial lesion in the present instance fails to conform to inflammatory hyperplasia on the one hand, and to adenoma on the other, it falls to be classed as what, for want of a better name, may be termed an atypical epithelial growth. It is conceivable that in certain cases, and probably those presenting individual peculiarities, the effect of persistent irritation of a special kind, would be to develop an abnormal and disproportionate growth of the epithelial structures; and here I record my belief that the irritation referred to will be found to be caused by a specific micro-organism.

In certain chronic diseases of the larynx, the glands of its membrane become much hypertrophied, a condition which

may be associated with a similar hypertrophy of the pharyngeal glands, when the affection has received the name of *glandular angina*. This hypertrophy of the glands sometimes causes distinct elevations on the membrane.

In the mucous glands of the bile ducts a somewhat similar development has been observed by Raynaud in a remarkable case to which Goodhart refers in his *resumé* of diseases of the liver in the New Sydenham Society's *Atlas*. Reference may also be made to the peculiar lesion described by Fairlie Clark as *ichthyosis linguae*.* It consists in a slowly spreading, diffuse, painless growth of the epithelium of the tongue and inside of the mouth. I o doubt the papillæ are also enlarged, but the epithelial development seems to be the main factor. From the accumulation of the effete cells the surface of the tongue assumes a patchy whiteness. Mr. Clarke ascribes the lesion to inflammatory irritation, and affirms that after existing for some years, it tends to assume the characters of epithelioma. The justification of placing this disease alongside the epithelial lesion of the bronchi may be doubted, but it at anyrate cannot be denied that in respect of causation and eccentric mode of growth, they are curiously alike.

It has been mentioned that the cystic dilatations of the enlarged mucous ducts are of the nature of retention cysts. They probably owe their origin to two causes. One of these is the inspissated secretion which blocks many of the tubes, and which is never wholly relieved. Another is the progressive new formation of connective tissue around them, by which it is not improbable that some of the ducts are at points snared, and may ultimately be cut off from their communication with the surface. As regards the acini, they are filled with a mucous fluid, and their

* *Brit. Med. Journal*, 1874, vol. i, p. 346.

lining epithelium is indistinct, swollen, and more or less desquamated.

The minute changes which are observed in the muscular and cartilaginous tissues in the hypertrophic stage of chronic bronchitis may now be considered. In the case of the muscles there are good grounds for believing in a veritable increase of the nuclei from inflammatory irritation—an increase similar to that described by Klein* as occurring in the arterioles of the kidney in cases of glomerulonephritis. Many authorities have had considerable difficulty in coming to a conclusion with respect to the regeneration and multiplication of non-striated muscle cells. Nor is the matter yet near settlement. This much however I am enabled to contribute to the subject. In cases of excessive inflammatory irritation arising from infection with sanious products, I have obtained unequivocal evidence of the participation to a very extensive degree of the muscular coat of the affected blood-vessels in the obliterative thickening. The staff-shaped nuclei were actively proliferating and extending in strings from the muscularis across the intima and mingling with the nuclear new formation derived from the latter. Thus in bronchitis a true thickening from nuclear division is highly probable, but at the same time it is undoubted that the inter-muscular connective tissue elements have become increased, causing the entire coat to appear abnormally compact, and sooner or later producing atrophy of the specific elements.

Of course it might be alleged that the muscular hypertrophy was the result of increased function. This may be so, but if, as undoubtedly happens, the cartilage cells proliferate under similar circumstances, is there any reason why the muscular cells should not respond in the same manner? There is reason to believe that hypertrophy of

* *Trans. Path. Soc.* vol. 28.

unstriated muscle has been only too frequently ascribed to excess of function to the exclusion of inflammatory irritation, and in owning the latter cause of an hypertrophy, smooth muscle may be said to differ from the striated variety.

With respect to the cartilages, in the commoner cases of chronic bronchitis it cannot be demonstrated in a satisfactory manner that they partake of hyperplastic changes, but in others, and notably in such as present the atypical epithelial growth described, these changes are very marked. In young subjects especially, are such to be found. In these cases the cells of the perichondrium are seen to be very active, and there is reason to believe that a true increase of the cartilage takes place. The cartilage cells themselves present very diverse appearances, not only in different subjects, but in different bronchi of the same subject. Sometimes the capsules have *disappeared*, and the ground substance becomes invisible from a *vast aggregation of small semi-transparent round cells*. This, as Redfern* long ago showed, is due to inflammatory stimulation. At first the cells divide, and two, three, or four of such divided cells are to be found within the capsule. This corresponds with the statement of Fischer† in a recent investigation on this subject. The cells then escape from the capsules and the latter disappear. This having taken place, the cartilage does not recover itself, it proceeds steadily to total disorganisation. It is stated by Cornil and Ranvier and others that the cells of articular hyaline cartilage, after undergoing division from inflammatory irritation, may develop new capsules around them. In destructive bronchitic processes, there is no appearance of new capsules forming. After division of the cells, the ground substance assumes a cloudy

* *Abnormal Nutrition in Articular Cartilages*, Edinburgh, 1850.

† Zeigler's *Beitrag z. Path. Anat.*, Band. v. 1889.

appearance, and necrotic changes soon set in. There are however other cases in which no such cell-division is seen to occur from the beginning to the end of the process.

The thickening of the bronchial wall is also in so small measure due to the distended blood-vessels, and to leucocytal infiltration, with more or less development of inflammatory connective tissue. Chronic endarteritis is invariably found in the larger vessels. Cox* in his experiments found this well marked on the 13th day, and he also observed mitosis in the endothelial cells of the capillaries. Very rarely a certain degree of *Stenosis* of the bronchi has been observed in connection with this inflammatory thickening, without any other complication. Wilks† has described cases of this sort.

STAGE OF ATROPHY.—After the hypertrophic condition of the inflamed bronchus has existed for some time, it gives place to a slowly progressive fibroid atrophy. There are two varieties of bronchial atrophy, viz.:—the inflammatory and the non-inflammatory. The latter will be considered in treating of bronchiectasis. The first, or that which is characterised by induration of the entire bronchial wall, is the invariable issue of chronic bronchitis. Does the induration which is ultimately caused by chronic venous congestion of the bronchi, originate in the same manner as that produced by chronic inflammation, viz.—from nuclear division, and fibre development therefrom? It is difficult often to decide to what extent cell development has taken place, but there can be little question that in some cases (as notably in cyanotic induration of the kidney) a considerable *shrinking* of the connective tissue has taken place, causing it to assume a more dense appearance, and as such to occupy the place of the wasted specific elements. In certain degenerations of the brain and cord, such a shrink-

* *Loc. Cit.*

† *Guy's Hospital Reports*, 1863.

ing of the neuroglia is highly probable, though many assert that in such cases the cells of the neuroglia divide and become fibrillated. But it is probable that the thickening of the connective tissue in cases of chronic venous congestion has a more substantial origin. By the persistent soaking of the tissue with lymph its corpuscles and fibres will become unquestionably *swelled*, and along with this swelling it is more than likely that the cells also *secrete* new tissue, as in such cases the capsules of the cartilage cells are indubitably much thickened. Not infrequently, however, there are intercurrent inflammatory attacks which gradually lead to new formation of tissue. The bronchial walls in the secondary or congestive variety of chronic bronchitis, if they escape inflammatory cell-infiltration, will therefore be found to have ultimately assumed this indurated condition.

But in the inflammatory form, the new fibrous tissue continues to be formed whilst the hyperplastic activity of the specific structures is on the wane. The columnar epithelium subsists with difficulty; the embryonic cells seem to lose the power of developing into ciliated cells, they become spindle-shaped and as such may frequently be seen in considerable luxuriance lining the wall. The basement membrane persists for a long time, until in fact almost all the other elements have disappeared. The muscularis frequently undergoes fatty degeneration, but in other cases seems to undergo a fibroid transformation. It is a curious circumstance that the muscular coat can withstand destructive processes acting with great energy, better than either the elastic, glandular or cartilaginous tissues, whereas in slow chronic disease it is one of the first structures to disappear. As regards the cartilages, they undergo various changes. If the cells have retained their capsules, the latter become much thickened, while the cells undergo a granulo-fatty degeneration. It

will be found, as has been truly remarked by Paget,* that it is the nuclei of these cells which first show this fatty degeneration—a peculiarity which seems confined to cartilaginous tissue. The thickened condition of the capsules has likewise been noted by the same distinguished observer. Necrosis of these cartilages ultimately ensues. This results from a purulent infiltration of the perichondrium. At first a granulation tissue eats away the perichondrium and subsequently the cartilage itself in an irregular manner. New fibrous tissue develops in the wake of this granulation tissue. This is in agreement with the description of Fitz† who remarks that the cartilages undergo atrophy from the ingrowth of a granulation-tissue proceeding from the perichondrium, while he states that the ground substance is passive, and the part played by the cartilage cells is questionable, but he thinks they are active at first. Rindfleisch and Orth express themselves somewhat similarly. Fischer‡ could not find evidences of activity in the cells themselves, he notes the cloudy state of the ground substance, and the forcing in of fibrovascular and cellular tissue, causing the reduction of the cartilage plates to small islands, until ultimately they disappear. Hamilton's description is much the same, a cellular deposit taking the place of the perichondrium, and sometimes loops of vessels projecting inwards, causing the gradual absorption of the cartilage.§

Cornil and Ranvier, Zeigler and others speak of ossification of the cartilages in chronic bronchitis. An infiltration with lime salts is sometimes found, but a true bony metaplasia I do not believe to occur.

The most common degenerative process however which I have noted overtaking the cartilages is neither necrosis and

* *Surgical Pathology*, 3rd edit., p. 80.

† *Virchow's Archiv*, vol. 51, p. 123.

‡ *Loc. Cit.*

§ *Loc. Cit.* p. 58.

absorption by peripherally encroaching fibrous tissue, nor yet calcareous infiltration, but what may be described as *genuine fibrous transformation*. It applies especially to such cartilages as have escaped much cellular infiltration of the perichondrium. This fibrous transformation is a true degeneration, and has nothing in common with a metaplasia into fibro-cartilage. Neither is it an ingrowth from the perichondrium, but consists in the development of fine glistening fibres throughout the ground substance. The cartilage cells seem to blend with the fibrillated tissue, until soon they are no longer recognisable. The new tissue has generally a radiating appearance, and ultimately nothing is left of the original cartilage, its place being entirely occupied by fibroid tissue. In the light of Thin's researches, which have already been discussed, the phenomenon is not difficult of explanation. Thin having demonstrated that the ultimate structural unit of hyaline cartilage is a connective tissue fibril, it is evident that the appearance here described is due to the accession of coarse indurative changes which end in the production of a scarlike tissue.

In the case of the glands, a fibro cellular growth derived chiefly from the perivascular tissues and from the perichondrium invades the stroma, dissociating the individual acini and causing their disappearance from pressure. The new growth seems to come out in stems and traverses the gland like a branching tree. At the same time the nuclei of the struma germinate. Also, in many cases, a number of acini coalesce into a mass after the manner of the acini in the adenomatous stage of rodent ulcer; such a mass sometimes becomes encapsulated, the wall being lined by nuclei, whose only distinguishing feature from the tissue nuclei consists in a more intense reaction with staining media. Sometimes the membrana propria which underlies the alveolar cells undergoes thickening, and in these cir-

cumstances the gland resists the compression of the new growth longer.

This atrophy of the glandular tissues, when it occurs unequally, largely accounts for the local depressions of the walls which are frequently found in this stage of the disease. But in some cases this is aided by an actual disintegration of the connective tissue itself. This is brought about by widening of its interspaces and shrinking of its nuclei. The bundles thus separated have a hyaline or vitreous appearance, and may be so brittle as at many points to shew a broken edge. (Refer to Bronchiectasis.)

In the most extreme cases, when these atrophic and indurative changes have advanced to completion, the bronchial wall is represented by a fibroid and irregular tissue which is bound up with, and cannot be demarcated from, the fibrous tissue which in such cases has invariably formed to a greater or less extent in the connective tissue framework of the lung.

But the ultimate result of bronchitis is not invariably fibroid atrophy. Frequently the chronic indurative progress of the disease is intercepted by acute exacerbations. The effect of such is to cause an infiltration of cells throughout the bronchial wall, derived chiefly from the vessels. In the ordinary form of chronic bronchitis, *i.e.*, when unaccompanied by chronic pneumonia—there is new granulation tissue formed. The mucosa present cellular protuberances like papillary growths. These cells however are of low vitality, so that in many parts the bronchial wall is abscess-like. The basement membrane is seen to persist in places, but where the cellular infiltration is dense, it has disappeared. It has in fact disappeared from ulceration. This corresponds with the observations of Birch-Hirschfeld,* and others. Spindle-shaped epithelial cells will invariably be

* *Path Anat.* 1885.

found to line those portions of the basement membrane which have escaped destruction. All cases of chronic bronchitis which have attained this stage will present a degree of bronchiectasis, and some authors have affirmed that it is the stagnant bronchial secretion which secondarily induces the inflammatory changes. Thus Trojanowsky* affirms that the epithelium is normal so long as there is no decomposition of the catarrhal secretion and Grainger Stewart† still more explicitly remarks that "it is to the changes in the tubes that I should refer the changes in the membrane, not to a morbid action originating in itself. In the earlier stages the membrane is unaltered, but as secretion accumulates it becomes granular and opaque; further accumulation and decomposition of the retained material produces of course greater irritation, the villous condition and ulceration." That the retention of decomposing secretions has a considerable influence over the changes is rendered likely from the increasing difficulty with which the wall reacts to staining reagents the nearer it approaches the locality of these retained secretions. The villous outgrowths are however slight and unimportant in the ordinary forms of chronic bronchitis; it is as a feature of bronchiectasis occurring usually with severe and specific pulmonary inflammations that they assume interest and importance. These and other remarkable inflammatory lesions of the bronchi associated with bronchiectasis will next be considered.

* *Inaugural Dissertation*, Dorpat, 1864.

† *Edin. Med. Journal*, vol. xiii.

CHAPTER IV.

BRONCHIECTASIS.

FIRST, the *lesions* pertaining to bronchiectasis will be considered. These are divisible into two classes, the atrophic and the inflammatory.

Atrophic lesions are invariably found in the dilated bronchi of emphysematous parts, when they partake of the nature of the pulmonary degeneration. But it is possible for a bronchus to be forcibly distended without undergoing degenerative changes and remain so for a considerable time. It has been affirmed by Biermer that such bronchi may subsequently become hypertrophied. The thin-walled bronchi which have undergone fusiform and saccular dilations will not unfrequently be found lined with cylindrical epithelium. If however the wall be much atrophied, and especially the muscular layer, at most, spindle-shaped cells will be found. It cannot be too strongly stated that the basement membrane always persists, and notwithstanding the stretching to which it has been subjected, it nevertheless presents little diminution in thickness. In some cases the muscular coat will be found of almost normal thickness, although the glands and cartilages are exceedingly wasted. Frequently however the bronchial tissues consist merely of the basement membrane and a thin layer of fibrous tissue. This severe form of atrophy is evidently induced by obliteration of the blood-vessels, and consequent granular and fatty degenera-

tion of the specific elements, just as occurs in the surrounding alveolar walls. Without the occurrence of emphysema however, an equal tenuity of the bronchial walls may result from their infiltration and partial destruction by tubercle.

These wasted bronchi may present either a tolerably even contour or else numerous plications giving in transverse section the appearance of a multilocular crypt.

In other cases, and not necessarily connected with emphysema, a peculiar and unequal atrophy gradually proceeds. In connection with the wasting of the glandular structures in chronic bronchitis, it was mentioned that when this took place in an irregular manner, it contributed in no small measure to the local depressions which not infrequently are found in an advanced stage of the disease. In addition to this, the elastic and connective tissue elements appeared to be crumbling down in places. But without causing such marked depressions, it is undoubted that a similar process will by gradual extension, involve tracts of the deeper parts of the wall, giving rise to the peculiar bridge-like formation which has been described by Dr. Grainger Stewart.* "In this lesion," he remarks, "the atrophy advances in a very remarkable manner, particular portions of the wall wasting and others retaining their natural volume; the latter parts form bands or ridges elevated above the surrounding mucous membrane. As the atrophy of the neighbouring parts advances, these become more and more prominent, drawing gradually closer till they resemble a mesentery connecting the unatrophied band with the bronchial wall. At length, apparently by gradual absorption, the mesentery-like membrane disappears and the band is left as a bridge stretching across the dilated tube." I have observed in one case appearances which seemed to justify this description

* *Loc. Cit.*

to the full. There was no *active* inflammatory process to be detected, but there were indications, such as the thickened intima of the vessels, that such had existed in the past. Dr. Stewart however believes, that this lesion owns no inflammatory origin, that it is on the other hand, a primary degenerative process, probably of constitutional origin.

I now turn to the consideration of certain inflammatory lesions of ectatic bronchi, which either accompany or flow from lesions of the lung. The majority of these have been hitherto undescribed. Allusion may first be made to that accompanying chronic pneumonia, under which name may be included, for present purposes, the various forms of indurated lung, excluding the tubercular. As in the ordinary form of bronchitis, the tissues primarily involved are those of the mucosa, and very specially the epithelium, so in chronic pneumonia exactly the reverse occurs. Herein the peribronchial fibrous tissue is the principal seat of the disease, the innermost structures being affected secondarily and to a less extent. It is a fact, though not generally known, that in many cases of acute pneumonia which are met with on the *post-mortem* table, the nuclei of the fixed cells of the fibrous framework of the lung and the pleural matrix, show division and multiplication. When the pneumonia becomes chronic, this cellular multiplication leads to tissue formation. In the case of the bronchi, a peribronchitis is set up which connects itself with the similar changes in the coarser septa and perilobular membranes, but does not extend inward to the mucosa, for the same reason that the pigment in deeply pigmented lungs never passes inwards from the peribronchial fibrous tissue, however dense its infiltration there may be. The changes in the mucosa are in fact due to the congestion which occurs secondarily within it, and likewise to the irritating or corrosive effect of the

transuding serum, just as inflammatory changes are seen to occur in the skin, when serum trickles over it for some time. Sooner or later however, the bronchus becomes fibroid throughout, and presents that irregular and frequently angular dilatation which is so characteristic of the cirrhotic lung of Corrigan. The walls of such bronchi do not as a rule become the seat of more extensive changes.

But when the induration follows in the wake of tubercular infiltration, the corresponding bronchial lesions partake of a different character, for in such cases the fibroid changes are associated with the virulent irritation of the tubercular virus. In bronchiectatic fibro-tubercular lungs, the condition of the bronchial walls varies in accordance with that of the surrounding lung territory. If the latter be consolidated from tubercular inflammation and infiltration, the bronchi will, as a rule, show thickened and infiltrated walls; on the other hand, if a district of lung shows atrophic or emphysematous change, the enclosed bronchi will be thin-walled and ectatic. The remarkable histological features which the bronchial walls may present in such lungs will be the better appreciated by making particular reference to a case in which they occurred most typically. It is that of a young man, aged 22, who had been troubled with bronchitis for several winters, and nine months before death the bronchial affection became much worse and was attended by blood-streaked sputum. Phthisis set in, and latterly kidney disease, and evidences of wide-spread tuberculosis. The *post-mortem* report states that "the left lung is firmly adherent throughout. At its apex is a large irregular cavity which has generally a smooth lining; elsewhere in this lung there are a few smaller cavities, some of them at least having bronchiectatic characters. There is no appearance of recent caseous infiltration or of recent softening. The lower lobe of this lung is uniformly beset with grey nodules.

The right lung is firmly adherent at the apex and posteriorly; less firmly in front, where there are some remains of fibrinous exudation. There is a large cavity at the apex with a distinct lining, and in all other regions of the lung there are numerous cavities having the characters of bronchiectatic cavities, and often showing ampullar dilatations. In some of the cavities the mucous membrane is partially retained. In this lung, besides, there are numerous tubercular nodules, many of them caseating." Now, from this description it will be seen that the cavities are divisible into two classes, the one class consisting of healed tubercular excavations, the other of bronchiectases. Of the latter some plainly showed their bronchial origin to the naked eye, in many of which were numerous prominences, and bands or bridges of a fibrous consistence. But others, and these the majority, gave no naked-eye indication of a bronchial nature. They were simply irregular channels and caverns tunnelled out in the dense pulmonary ground tissue, always partially, and sometimes totally obscured by inspissated contents. The channels generally intercommunicated, and a few ended blindly. First, I shall describe the bronchi showing the prominences and bridges, and the mode of their formation, which differed *in toto* from that described by Dr. Grainger Stewart. In general, the various structures of the wall were fairly well preserved, the cartilages especially, but the adventitia was wasted and the surrounding pulmonary tissue was collapsed and full of caseating tubercles. The deeper structures of the bronchial wall stained well, but towards the surface the tissues showed considerable resistance. The prominences of the mucosa and the bridge-like bands were chiefly composed of a granulation tissue (Fig. 5). Of at least the majority of them, it was evident that they did not result from wasting of parts of the wall; it was evident that in this case the excessive growth of granulation tissue

was the main factor in their production. And how were the bridge-like septa passing from point to point in the wall produced? Clearly in one way only. Two papillary granulation-tissue outgrowths, springing from points considerably apart, proceeded to grow towards each other, and *when their summits met, organic union took place by the vessels of the granulation tissue piercing the basement membrane.*

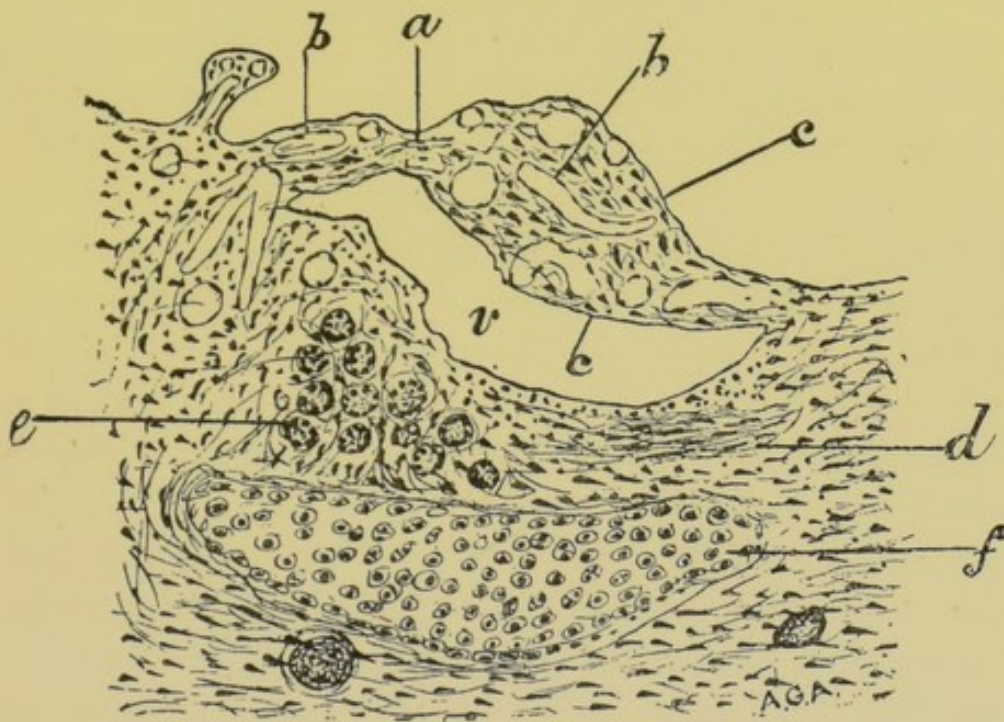


Fig. 5.—SKETCH OF BRONCHIAL WALL SHOWING FORMATION OF BRIDGE.

a, Place of junction of granulation tissue outgrowths, a slender capillary blood-vessel is seen passing across; *b*, vessels of the granulation tissue (to the left a small outgrowth is seen); *c*, basement membrane, which also lines the viaduct, *v*; *d*, remains of the muscularis; *e*, gland undergoing atrophy, the stroma invaded by fibroblasts; *f*, cartilage ($\times 75$).

Usually one of the outgrowths outstripped the other, and not infrequently there was only one large outgrowth which had attached itself to an elevated part of the wall. That the bridges were formed in this manner is, in my opinion, irrefragably demonstrated by the fact of the basement membrane lining the viaduct formed by the bridge, which

in size, would usually allow the passage of a probe; and though failing to observe the actual process of union in the present case, it was not many days until I had an opportunity of examining the lungs from another case, in which the finest possible demonstration of this union was to be had. So far as I can find, this mode of formation of the bridges has not been hitherto described. Cornil and Ranvier* figure a dilated bronchus, showing papillary outgrowths, and an enclosed cavity, but they make no mention of this process.

Next as to the structure of the walls of the channels and caverns, which to the unaided eye had no bronchial features. In the case of the channels it consisted of a very thick belt of new formed tissue, which streamed out in greater or lesser rays along the coarser septa, the perilobular membranes and alveolar walls. The innermost portion of the wall, and that for about a third of its entire thickness, was exclusively cellular, at some points taking the form of thin, close-set papillary processes (Fig. 6). It resembled the superficial part of a pyogenic membrane. The cells had the characters of degenerated granulation cells, being large and granular, yet opaque and with ill-defined nuclei, which condition was most probably due to the retention of decomposing secretion. The alveoli surrounding the wall, for the greater part of its circumference, were filled with inflammatory products of various kinds. Some contained large proliferated epithelial cells, mingled with leucocytes and ill-formed fibrin; others were filled with blood; others were packed with cells resembling those characteristic of the purulent infiltration of pneumonia; while the contents of not a few gave a homogeneous appearance, apparently from necrotic change. Here and there amongst the alveoli were caseating tubercles. For a small part of its circum-

* *Manual Path. Hist.* (Bronchiectasis).

ference the wall was bounded by fairly crepitant lung tissue. Now the question arises—Is the bronchial origin of the wall susceptible of histological proof? No clue could be obtained from the inner cellular layer, but in many parts

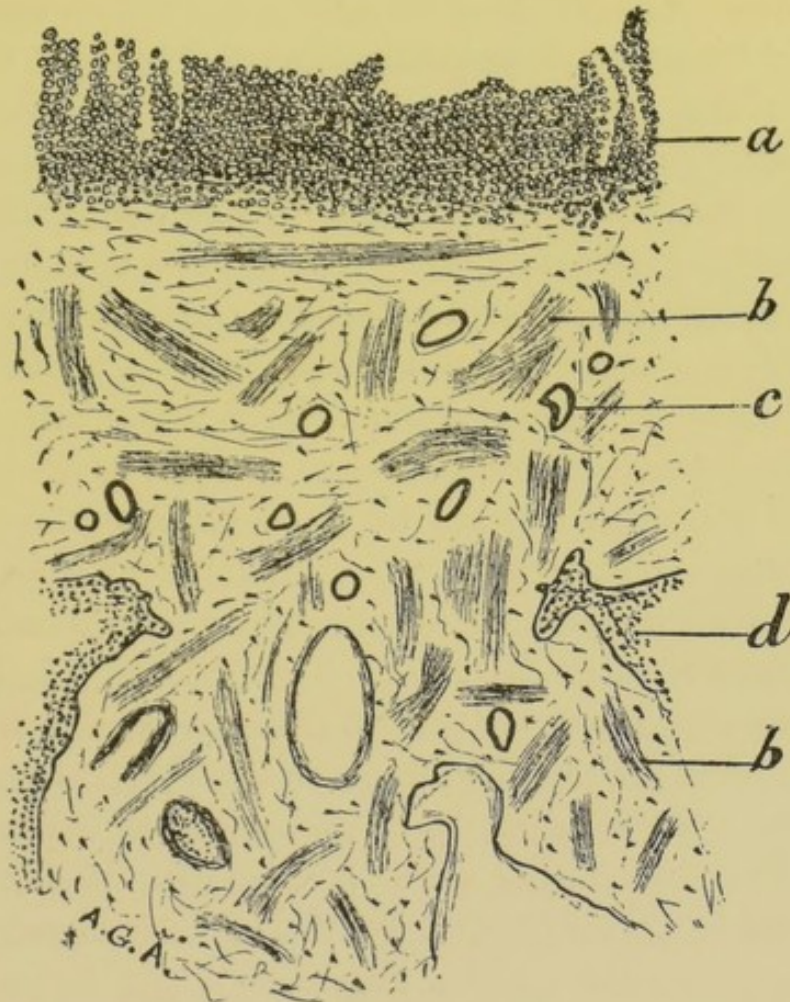


FIG. 6.—WALL OF BRONCHUS, SHOWING ABERRANT GROWTH OF SMOOTH MUSCLE.

a, Granulation-like cells forming innermost layer ; *b*, smooth muscle in the midst of the connective tissue ; *c*, thickened vessel ; *d*, cellular space in wall (× 75).

the deeper fibrous part showed a very remarkable structure. It was in great part composed of *irregularly disposed and interlacing bundles of smooth muscle*, which likewise had invaded the radiating bands (Fig. 6.) The aberrant muscular fibres, in their disposition to the fibrous variety,

caused the tissue to assume somewhat of a leio-myomatous appearance. That these were in reality muscular fibres and not a peculiar fibrous formation was evident not only from the appearance of their nuclei, but also from the effect produced by picro-carmin. They gave the characteristic mahogany-red reaction which contrasted strongly with the surrounding pink fibrous tissue. It must therefore be admitted that this formation supplied the histological proof of these thick walls being transformed bronchi, and if it be admitted, it presents nevertheless a problem both in respect of its remote causation and its immediate derivation. It is not such a muscular development as could possibly have arisen from exaltation of function; it seems rather to be due to a peculiar irritation, and so to resemble the atypical epithelial growth referred to in connection with chronic bronchitis. Here again we have to confront the problem of the relation which such a muscular growth bears to the true muscle tumour. As to its immediate derivation, difficulties no less great present themselves. Do the fibres spring from pre-existing fibres, or are they derived from connective tissue corpuscles? As bearing on this, mention may be made of the growth of smooth muscle fibres observed by Arnold* and by Wolf† in inflamed pleura and in pericardium, which they state to be derived from connective tissue corpuscles. A similar statement is made by E. Neumann,‡ and Ziegler remarks that "it appears certain that cells having at least the structure and appearance of non-striated muscle cells are developed from connective tissue corpuscles," though he adds that "no proof has been given that they have corresponding physiological qualities." Bardeleben affirms that he has traced the development of smooth muscle fibres between the

* Virchow's *Archiv*, vol. xxxix.

† Quoted by Arnold.

‡ *Arch. d. Heilkunde*, x.

cells quite independently of the nuclei. Reference may also be made to the alleged muscular development in brown induration of the lungs. In this affection, Delafield* has affirmed that the alveolar walls derive their thickness from the development within them of smooth muscle, and from my own observations, I can at any rate vouch for the presence of staff-shaped nuclei.

In favour of the view that the aberrant fibres are derived from pre-existing ones, is the fact that the muscular layer of the bronchus is exceedingly persistent in even the most destructive processes, as in suppurative bronchitis, being indeed about the last structure to disappear. And a still stronger argument consists in the fact that the walls of the caverns, which have been referred to, did not show any such structure, though in all other respects they were similar to the walls of the channels. Outside of the considerations already adduced in favour of transformed bronchi, I may mention that somewhat similar appearances to those described are to be found in the Fallopian tubes in chronic salpingitis. This is well shown in the excellent plates of Wyder,† the innermost part of the tube being composed of granulation cells, generally showing a papillary arrangement, outside of which is a great hyperplasia of the muscular tissue.

In the portions of the lungs in which the disease was least advanced, the tissue was fairly crepitant, but was strewn with tubercle. The bronchi were ectatic, often showing the moniliform arrangement, and their walls were smooth and membranous, though at points ulcerated from tubercular infiltration. The basement membrane invariably persisted, generally also remains of the muscularis, and outside this was a thin connective tissue layer. Occasionally atrophic glands and cartilages were visible.

* *Studies in Path. Anat.* vol. i.

† See *The Lancet*, 17th January, 1891.

I shall next refer to certain very peculiar inflammatory lesions of the bronchi, as they occurred in a lung whose base was the seat of two gangrenous cavities communicating with one or more bronchi, and with the pleura. The whole lower lobe was bronchiectatic. From the nature of the bronchiectatic lesions I inferred that an old bronchial affection preceded the development of the gangrenous cavity, and on turning to the clinical history there was evidence of this. The patient, a man aged 50, had been troubled with cough and expectoration for six or seven months, and had signs of extensive disease in the right lung. The sputum latterly became highly offensive, but no tubercle bacilli were found in it. The gangrenous cavities were thus later developments, for had the lung become secondarily infected from this source, a virulent form of broncho-pneumonia would have been set up—an insufflation pneumonia—causing a rapid destruction of the tissue. In the present case, the bronchi, to the naked eye, could be classed in two principal groups. In the one, they were greatly injected, thick-walled, irregularly dilated, full of inspissated pus, and the surrounding pulmonary tissue was consolidated. The other group consisted of comparatively thin-walled, much dilated bronchi, having a white lining membrane. Microscopically, the members of the first group were found to be excessively cellular, and a new fibro-cellular tissue had destroyed and replaced all the component structures, with the exception of some muscular remains. In a few cases less advanced, wasting glands and cartilages were noticeable. The mucosa presented a most fantastic appearance. It had sprouted up into a papillary granulation-tissue, resembling a range of high mountains. It was here that the union by their summits of these papillæ were so well seen. The vessels of the papillæ were excessively abundant. Their walls actually formed the surface of the tissue, and strange to say, numbers

of epithelial cells were attached to them ; at no part could any trace of the basement membrane be detected. This persistence of the epithelium over the granulation tissue is a very instructive fact. It was not altogether normal epithelium, it consisted almost entirely of spindle-shaped cells, but a few were ciliated. As regards the joining of the papillæ, in some places it was evident that over the arch formed by the union of two adjacent summits, a second union had taken place by still longer papillæ arising externally to the bases of the first. This was proved by the fact of both the enclosed cavities being lined or partially lined by epithelial cells. (Refer to Fig. 5).

But still more remarkable were the characteristics of the second group. Their walls were of about average thickness, but were composed of a fibro-cellular tissue, almost wholly cellular at its surface, most fibrous at its periphery. The surrounding pulmonary tissue was atrophous and emphysematous. There were no papillary growths in this case, the surface being quite even, but *the normal epithelial layer was replaced by a compound squamous epithelium, resembling that of the skin.* (Fig. 7). The deepest cells were short columnar or polygonal, and there seemed to be no basement membrane. Several rows of short polygonal cells existed above these, and in some places club-shaped or pyriform cells existed, like those seen in the bladder. As the cells neared the surface they became typically squamous, but there was no satisfactory evidence of horny change, nor yet in the deeper layers of the existence of prickle-cells, and again, beneath the epithelium the connective tissue was not thrown into papillæ. Not only were the surface cells squamous, but cavities existed in the bronchial wall, like old dilated gland-ducts, whose walls showed a similar lining. This epithelial metamorphosis in the bronchi has been described by at least two observers. It was observed

by Raap in 1850, who described the epithelial squames as larger than those of the buccal mucous membrane; and by Fischer* of Vienna, in 1887, in a case of chronic inflammatory irritation. A similar transformation of the columnar epithelium of the urethra has been described and figured by Posner.† The same observer has described what he terms a dermoid transformation of certain parts of the uterus, vagina, and larynx, and Marchand, and lately Cabot,‡ have observed dermoid changes of the mucous membrane of the bladder, which the former regards as derived by ingrowth of the epithelium of the skin; and it seems certain that in cases of perineal wounds this ingrowth may occur. Consequently, such cases are not to be classed in the present category, and the same may in all probability hold good for the epithelial metamorphosis in the larynx first described by Fœrster, the *pachydermia laryngis* of Virchow,§ which consists in a dermoid or cornified state of the squamous epithelium of the larynx, but not of the ciliated columnar, which caused the last named distinguished pathologist to conclude that the latter variety was insusceptible of such a change. Again, in the instances of the bladder and larynx, the presence of connective tissue papillæ rendered complete the dermoid character of the transformation. Lastly, it may be observed that in cases of prolonged acute pneumonia the alveoli usually become lined by two or more rows of squamous cells, but whether this is an exact analagous process may be doubted, as in this case these cells divide and are constantly being cast off, when they take a rounded form. In all the cases referred to, except those wherein extension from the skin

* Ziegler's *Beitrage z. Path Anat.*, 1889.

† Virchow's *Archiv*, 1889.

‡ *International Journal*, February, 1891.

§ *Berlin. Klin. Wochen*, August, 1887.

could be shown, this change was ascribed to inflammatory irritation. In the case of the bronchi, it might naturally be imagined that the membrane when subjected to peculiarly offensive irritation would protect itself in this way, yet I cannot help believing that deeper causes are at work.

Although in the two classes of bronchi described, the characters of the innermost layers differed widely, yet the deeper fibrous part of the walls in both varieties was the

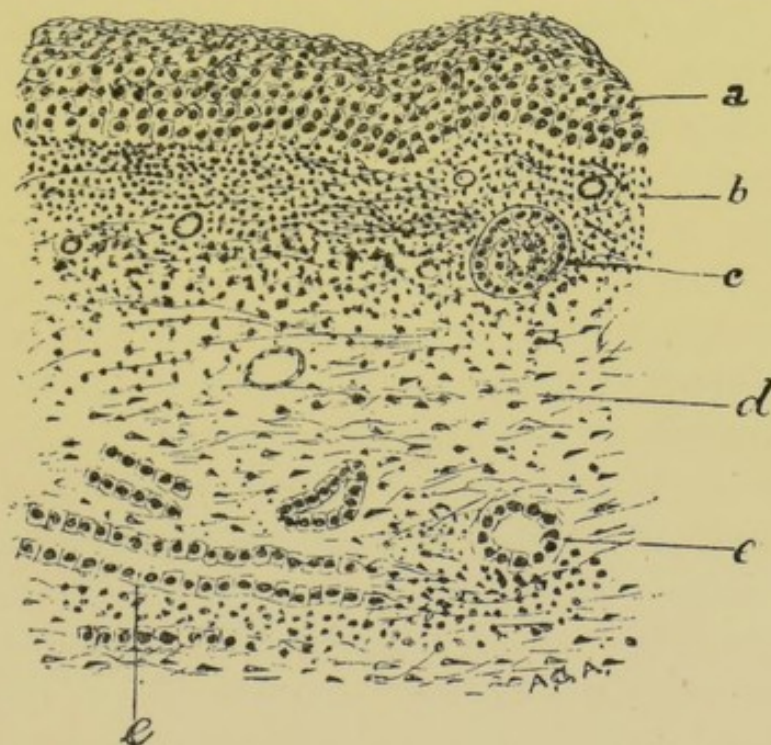


FIG. 7—SECTION OF BRONCHUS SHOWING SQUAMOUS EPITHELIUM AND "DUCT FORMATION."

a, squamous epithelial layer ; *b*, mucosa, infiltrated with leucocytes ; *c*, space in wall nearly filled with cells resembling those of surface ; *d*, fibrous tissue, showing fibroblasts ; *e*, "duct-like" formation ($\times 75$).

seat of a peculiar formation which has incidentally been referred to in the chapter on acute bronchitis. It consisted in *a number of duct-like spaces, lined by square or short columnar deeply staining epithelial cells*. Rather were the cells to be regarded as composed of a large nucleus and a delicate periplast. They rested on the general tissue,

without any intervening *membrana propria*. They chiefly occurred in double longitudinal rows, but not infrequently in circles, in ellipses, or in somewhat irregular shapes, and when in rows, they vanished insensibly into the surrounding fibro-cellular tissue. Both in the character of the nuclei, and in the disposition in rows in the tissue without any *membrana propria*, these formations presented generally a striking resemblance to the new bile ducts of hepatic cirrhosis. There seems to me to be not the slightest doubt but that they represent the remains of the mucous glands, in fact there is abundant histological proof of this. The reason of the adjustment of the cells in rows is to be sought in the compressing of several acini by the growing connective tissue around, and which in its growth tends to a longitudinal arrangement of its fibres. At the same time, in many sections there were strong grounds for believing that some of the spaces lined by the cells were extra-glandular, being spaces left in the course of the granulation tissue metamorphosis, into which the epithelial cells had budded, and hence we must regard this also as a form of atypical epithelial growth. It is in fact the atypical epithelial growth of Friedländer which has already been described. Being unable to account for it otherwise, Friedländer regarded it an ingrowth of the surface epithelium. It is needless to say that this is erroneous, and further it implies a carcinomatous nature seeing that normally the bronchial epithelium does not dip inwards as that of the skin does. Again, Friedländer's assertion that the growth occurs in glandless bronchi is to be explained by the budding or skinning process described. Why in such cases the young gland cells or nuclei should persist amongst the granulation tissue is a problem, and it is not unlikely that it is a problem which is bound up with that of the metamorphosis of the surface epithelium. But elsewhere in

granulation tissue growth involving epithelium, a similar peculiarity prevails. For instance, in *lupus vulgaris* an active epithelial growth is seen extending in lines and clusters amongst the granulation tissue which not infrequently has been mistaken for carcinoma, and likewise in chronic eczema a somewhat similar growth occurs.

From another point of view, may not this duct-like formation serve a good purpose by throwing some light on what takes place in what is more particularly described as biliary or hypertrophic cirrhosis of the liver? Do we not herein find support to the view which denies any actual new growth of ducts? By those however, who believe with Wickham Legge, Hamilton, Kiernan and others, that the cirrhotic tissue is actually formed by the hepatic cells, it might be objected that the analogy is unfair. It is not so unfair as it seems to be, and as a matter of fact, Professor Hamilton, has described the new bile ducts as representing the remains of the liver parenchyma.

The existence of these remarkable lesions will in great measure clear up a long recognised difficulty, viz.:—as to the distinction between a bronchiectatic cavity and a tubercular excavation. A dilated bronchus can simulate a healed tubercular cavity when the destruction of the bronchial wall has proceeded apace until all its characteristic structures are destroyed. But in most of the bronchiectases, some clue will be obtained proving the nature of the case. It may be muscular fibres, or it may be the duct-like formation described, but in most cases, and invariably in the thin-walled saccular bronchiectases there is one sure and abiding sign, and that is the presence of the basement membrane. I do not attach great importance to epithelial-like cells lining a pulmonary cavity—there is just a suspicion whether many of the spindle-shaped cells so seen are not leucocytes which have moored themselves to the surface;

but as regards those of evidently epithelial origin their presence proves nothing, for epithelial cells can creep over a false membrane. It is certain, as was previously mentioned, that they can exist over granulation-tissue without any intervening basement membrane, but that they can also *extend* over such a surface is pretty conclusively proved by what has been described in connection with the duct-like formations. Again, by an ingenious experiment, this was well demonstrated by Zielonko,* who placed the folded cornea of a frog into the cavity of the lymphatic sac of another frog, when it was found that the false membrane formed round the foreign body became lined by epithelium similar to that of the cornea. However, the presence of the basement membrane puts an end to all doubt. In some of the older writings, it is evident that this structure was either overlooked or else its importance under-estimated, and hence we find Gairdner,† in 1850, declare "that almost all the so-called bronchial dilatations, and all of those presenting the abrupt sacculated character are in fact the result of ulcerative excavations of the lung communicating with the bronchi"—a theory which has since received adequate refutation on general and comparative grounds, and whose complete demolition has been accomplished by improved histological methods. If then the various histological tests which have been mentioned fail, the presumption is that we have to deal with a healed cavity. This presumption is strengthened if the lining membrane be pyogenic in character. Ewart,‡ in his excellent Gulstonian lectures on pulmonary cavities, describes their walls as consisting of three layers. Innermost is a false membrane, possessing pyogenic characters and resembling the wall of the medullary

* Described by Charcot—see *Med. Press and Circ.* vol. i. 1879.

† *Monthly Journal of Medical Science.*

‡ *The Lancet*, vol. i. 1882.

cavity of bone, in that it sheds its waste products internally, and acquires thickness from without. Next this is a fibro-vascular layer, superficially smooth, and in uninterrupted continuity with the surface of the bronchial tube which opens into the cavity. External to this is a purely fibrous layer. The epithelium and limiting membrane may be seen to stretch over the infundibular bronchial opening. As regards the source of the new tissue forming the walls of such cavities, Ewart regards it as derived by germination of the nuclei pertaining to the adventitia of the intercepted bronchi. To this opinion I take no objection, but see no reason to exclude the alveolar walls from participating in the process.

Lastly, a few considerations may be offered concerning the *origin* of bronchiectasis; and as elaborate investigations on this subject have been made by many of the ablest observers, I shall occupy no space by going over ground already well trodden. If the writings of Barth, Biermer, Corrigan, Greenhow, Williams, and others, be consulted, it will be found that there is a general consensus of opinion in favour of bronchiectasis being caused either by the normal or an exaggerated pressure of air acting on bronchi whose walls have been damaged by inflammatory or atrophic processes, or else caused by a stretching of the walls by the fibrous tissue bands in cirrhotic lungs—the pleura by virtue of its adhesions acting as a fixed point. Of course the accumulation of secretion is also recognised as a factor in many cases. Allusion has already been made to Dr. Grainger Stewart's explanation of the bridges formed in bronchiectasis, but this observer further affirms that true bronchiectasis is a disease *per se*, and is not to be confounded with bronchiectatic conditions which are either associated with or dependent upon pulmonary affections, such as those occurring in bronchitis, in lung induration, and in stricture

of the bronchi. The true bronchiectasis he regards as due to a primary atrophy of the wall, of constitutional origin, which causes it to yield, just as an aneurysm is formed. Owing to accumulation of secretion, inflammation is subsequently induced, causing villous outgrowths and so forth. Now I do not presume to say either yea or nay as regards the truth of this theory, but may remark that it must indeed be a difficult matter to determine whether in a case at all advanced, the bronchiectasis had begun in this fashion, or whether it was preceded by inflammatory changes. But I have never seen atrophic changes in the air tubes, unaccompanied by similar changes in the pulmonary tissue which did not give evidence of preceding inflammation: and on the other hand, I have never observed non-inflammatory atrophic bronchi which were unaccompanied by atrophous or emphysematous lung tissue. It seems to me that in general too much stress has been laid on the local changes and on the air pressure, and too little account taken of the influence of the changes in the pulmonary tissue. This seems the more certain when it is considered that most true bronchiectases are usually of the moniliform type, and the pressure of air theory is inadequate to account for this. Furthermore, in many such moniliform dilatations the muscular layer is normal, or at least fairly preserved. But *by placing the collapsed and atrophous lung tissue in the foreground*, it is intelligible how in such cases the bronchial wall will expand to fill up the vacancy, just as in acquired capillary ectasis moniliform dilatations are in this manner formed, as for instance in cavernous angioma of the liver. This applies, however, only to a certain class of cases; in others, the degenerative change in the wall is the main factor, and such may consequently be compared to true aneurysms. In support of the extra-bronchial causation maintained, it is interesting to note that

Cohnheim* recognised cases of bronchiectasis in which the dilatation occurred in advance of the *absolute occlusion* of the bronchus, evidently not by accumulation of secretion as a hydro- or pyo-nephrosis is formed, as he remarks that "the destruction of the alveoli preceded the dilatation of the bronchi." Here then is a bronchiectasis altogether apart from the pressure of the air. That bronchiectasis may arise therefore after the manner here suggested is I think justifiable both on theoretical and anatomical grounds.

* *Lects. on Gen. Path.*, vol. iii. p. 1015.

CHAPTER V.

BRONCHIAL ASTHMA.

IN those who are the subjects of acute or chronic bronchitis, attacks of spasmodic breathing not infrequently supervene. Many of these attacks are referable to conditions existent in the bronchi alone, when they resemble those of ordinary or idiopathic asthma, as likewise those occurring in hay fever. To all such cases, when the dyspnœa is obviously the outcome of an obstruction situated in the bronchial tubes, the term bronchial asthma may be fitly applied. And in connection with the histological investigation of bronchitis, the pathological histology of bronchial asthma is a most appropriate theme for discussion. For this subject is much beset with theories, is begirt and indeed beclouded with laborious and conflicting speculations, culled from the domain of analogy, from the domain of symptomatology, and from the domain of therapeutics. The prospect therefore of approaching it from the histological standpoint, seems to me all the more needful and hopeful. Indeed it is highly probable that many of the conflicting statements as to the proximate cause of the asthmatic paroxysm are in no small measure due to the neglect of applying the criteria legitimately available from the histological manifestations of the bronchi, both in health and in inflammatory conditions.

Broadly speaking, there are at the present time two dominant theories as to the nature of the mechanical impediment in the air tubes. The first and oldest, which

originated with Laennec, is, that the bronchial muscles and especially those in the smaller bronchi, contract spasmodically at certain points, and continue in a condition of tonic spasm for a longer or shorter period. This theory has found its chief advocates in Bergson, Biermer, Hyde Salter, and Williams. The other theory is that which attributes the bronchial constriction to a "fluxionary hyperæmia," or a sudden congestive swelling of the mucosa from vasomotor paresis. It is chiefly associated with the names of Weber, Traube, Villemin, Störck, and (more recently) Sir Andrew Clark. At the same time these statements are liable to certain modifications. Some authors, and notably Biermer, and also Trousseau, while recognising bronchial spasm as the prime element, nevertheless regard a hyperæmic condition of the bronchial membrane as an accompaniment of much importance, and *vice versa* there are those—*e.g.*, Sir Andrew Clark, who regard a fluxionary hyperæmia of the mucosa, with the production of more or less mucus or of a fibrinous exudation, as occasionally exciting an accessory, though slight and unessential, spasm of the bronchi. Whether in addition to these alleged causal agencies, there exists in some cases more or less spasm of the diaphragm, as insisted on by Wintrich and Bamberger, may be probable enough, but this factor does not much concern us here.

One of the most prominent objects in the bronchial tubes is a layer of circularly disposed muscle by which they are completely invested to their terminations in the infundibula. It lies immediately subjacent to the mucosa proper or tunica propria, which is in all bronchi a structure of great tenuity. In the middle and smaller sized tubes it is so exceedingly attenuated that the muscular coat at many points appears almost to touch the basement membrane. This tunica propria is composed of an interlacing web of elastic fibres, along with connective tissue fibres and cells, supporting

a network of vascular and lymph capillaries. Beyond the muscular layer, situated between it and the cartilage plates, is the somewhat loose fibrous tissue constituting the submucosa, wherein lie the blood-vessels and many of the glands. It is of variable thickness, but generally speaking, it is about equal to that of the mucosa proper and muscular layer combined. As the tubes decrease in size, the tissues composing the submucosa and adventitia merge into each other, until in the glandless bronchi the outermost part of the wall is entirely composed of but a thin layer of fibro-elastic tissue of about equal thickness with the muscular tunic. It is apparent then, that the bronchial tubes are structures endowed with a high degree of elasticity, being quite as extensile as the lung alveoli, and equally capable of expanding during inspiration and of relaxing during expiration, while the additional presence in them of a muscular tissue makes it likewise apparent that they possess a mechanical power and function over and above that of the pulmonary alveoli.

What is this power and this function? First of all it may be remarked that after the demonstration by Reisseissen, and subsequently by Kölliker, of the muscular fibre-cells of the bronchi—a demonstration or observation which being at all times so easy, it is difficult to see why many should have dignified with the name of a *discovery*—it was not very long until Williams in his well known experiments, and following him Longet and Paul Bert, demonstrated their contractile power. In like manner, it is not easy to see why this demonstration should be termed (as it generally is) a discovery. It would indeed be a discovery did any one succeed in showing that a muscular structure in any part of the body was *incapable* of contracting. Contractility is a *sine qua non* of all muscular tissue, striped or unstriped. To imagine or suppose for a moment that the muscle cells

of the bronchi were incapable of contracting until proved experimentally to do so, is absurd. The value of experiments does not consist in merely showing that the bronchial muscles are capable of contracting, but by showing how, by what means, and to what extent, they do so. In the experiments of Williams* it was clearly shown that contractions could be induced in bronchi of all sizes on the application of mechanical, chemical, and electrical stimuli. It was however the middle sized bronchi which responded most, complete closure of the lumen being occasionally observed. Apparently these contractions took place immediately on the application of the stimulus, but not until after the lapse of a minute or two if the lungs were previously inflated. These results were obtained in the lungs of various animals after death, but the effect of stimulating the vagus was as yet negative. Subsequently Longet† and Volkmann‡ produced a constriction of the bronchi by irritation of the vagus, but quite recently Roy§ and Graham Brown, by a delicate and ingenious method of experiment applied to the curarised dog, obtained a highly valuable and more complete series of results. They found that stimulation of one vagus with an induced current caused a powerful contraction of the bronchi of both lungs. If one vagus was cut, stimulation of its peripheral end with an induced current of the same strength caused a much more powerful contraction of the bronchi of both lungs, the tubes appearing to close almost completely, while stimulation of its central end caused a considerably less powerful contraction. On the other hand, section of one vagus caused a marked expansion of the bronchi of the corresponding lung, preceded by a slight temporary con-

* *Path. and Diag. of Dis. of the Chest.* London, 1840.

† *Traité d' Anatom. et de Physiol. du Syst. Nerv.* vol. ii.

‡ *Handwörterb. d. Physiol.*, vol. ii. (Wagner).

§ *Transactions of the Physiological Society*, vol. vi., appendix, p. 21.

striction due to the stimulus of the section, and in non-curarised animals, narcotised with ether, stimulation of the central end of one cut vagus, the other being uncut, caused a powerful expansion of the bronchi, while stimulation of the peripheral end caused first contraction and then expansion. In these animals expansion also followed stimulation of one uncut nerve, the other being cut. From these results the authors conclude that the vagi contain constricting and expanding (or inhibitory) fibres, "the difference in the effect of the stimulation of the uncut nerve and the peripheral end of the cut nerve being explained by the inhibiting action of centripetal fibres on the upper centre or centres." It seems therefore to be conclusively proved that cerebro-spinal centres exist, the stimulation of which, direct or reflex, causes through the medium of the vagus, either contractions or relaxations of the bronchial muscles.

With respect to the normal functions of these muscles, Dr. Gairdner* attributed what he terms a deobstruent function to the bronchial tubes. By this he implies that the bronchi, and especially the smaller bronchi, by slow vermicular or peristaltic contractions, impel outwards the pulmonary mucus. That such a movement takes place is probable, more especially in those of the bronchioles whose epithelium is devoid of cilia. And as vermicular contractions take place in the efferent ducts of all other organs which possess them, it would be strange indeed did the bronchi present an exception. Moreover, in the experiments of Roy and G. Brown, it was concluded that there was "reason to believe that the bronchial contractions are occasionally vermicular or rhythmic." Still the effect of such must be but slight, and it is more probable that the

* *Monthly Jour. of Med. Science*, 1850, p. 39; and *Brit. and For. Med.-Chir. Rev.*, 1853, p. 476.

mucus is chiefly moved forward by the "expiratory blast of air" as MacVail has in an able manner sought to prove.* Another very obvious function of the bronchial muscles is the regulation of the calibre of the tubes in the varying conditions of pressure and relaxation to which they are subjected, to limit temporary and to prevent permanent over-distension, and to counteract the narrowing of the lumen which would necessarily result from a weak or paralytic condition of the pulmonary vesicles. In inflammatory and other conditions entailing much cough this regulating function is clearly indicated.

Having considered the muscular capabilities of the bronchi, it behoves us now to inquire with respect to a point which has not hitherto met with much attention, but which in my opinion has a most important bearing on the theory of bronchial asthma, and that is—the relative thickness of the bronchial walls. I have made, by means of the camera lucida, a series of measurements of the walls in the larger and smaller bronchi, carefully comparing their thickness with the diameter of the lumen at the respective points.

Ere estimating the diameter of the bronchial lumen it must of course be remembered that the healthy lungs present themselves *post-mortem* considerably collapsed. The surface of the bronchus appears considerably undulated by this collapse. I believe however that we possess a simple and efficient means of obtaining the natural dimensions of the bronchi and air cells in sections submitted for examination. This consists in applying a certain amount of pressure to the cover glass. One can easily judge from appearances of the pressure requisite to bring about the mean natural distention. I find then that in all the membranous bronchi, or those below have a line in diameter, the diameter of the

* *Brit. Med. Journal*, Nov. 15, 1884.

wall is on an average one-seventh that of the lumen. In the larger bronchi, making allowance for variation in the location of the cartilages, it seems that the diameter of that part of the wall comprising the mucosa and submucosa is also about one-seventh the diameter of the lumen at the corresponding point. So that the thickness of the entire wall in bronchi half a line in diameter is not more than the $\frac{1}{168}$ th part of an inch, and the entire vascular part of the wall in bronchi of a line and a half in diameter (or a good middle-sized bronchus) is only $\frac{1}{36}$ th of an inch in thickness.

Turning now to another portion of the respiratory tract—the Schneiderian membrane—let us compare it structurally with the bronchial membrane. It is well known that great stress has been laid, in more recent years especially, on the connection between nasal disease and asthma. Since Voltolini twenty years ago pointed out that nasal polypi were frequently associated with, and apparently also causal of, asthmatic attacks, the subject has been taken up to such an extent by nasal specialists and others, that it is now I imagine, pretty well worn out—and seems indeed to have been considerably overdone.* However, with regard to the pituitary membrane, the important and essential region concerned with the stenotic catarrhal phenomena, associated or not with asthmatic attacks, is of course that over the inferior turbinated bone. Now what is the structure of the mucosa here? Under the epithelium and basement membrane is a thin strand of very cellular though compact connective tissue. Abutting on this strand, and extending right down to the periosteum, is the thick layer of erectile tissue first described by Kohlrausch and Kölliker, and afterwards with great exactness by Voltolini.† It consists of a

* See Discussion (Med. Soc. Lond.) *The Lancet*, vol. ii., 1890, p. 1101.

† *Die Rhinoskopie und Pharyngoskopie.*

framework composed of fibro-cellular and elastic tissue, enclosing large venous sinuses. Mucous and serous glands also lie embedded in parts of the tissue. Voltolini states that its entire thickness is one-sixth of an inch, while that of the sub-epithelial strand is, according to my measurement, not more than $\frac{1}{80}$ th of an inch. There is of course no muscular layer. Now with these facts before us, does it not seem as though those asthma theorists who assert that the Schneiderian and bronchial mucosæ greatly resemble each other, must be drawing pretty largely on imagination?

According to the Weberan theory the asthmatic paroxysm is fully explained by the supposition of a sudden tumefaction of the bronchial mucous membrane throughout the whole or the greater part of its extent. This tumefaction is brought about by acute dilatation of its blood-vessels from nervous influences. It is, so to speak, the first stage of a universal acute catarrh. But it is something more. "The paroxysms begin," says Sir A. Clark,* "by a more or less diffused hyperæmic swelling of the bronchial mucous membrane, and are continued by the development at various parts thereon of circumscribed congestive swellings which come and go with greater or less rapidity, resembling the skin in urticaria." Others have described the bronchial lesion as herpetic, eczematous and erysipelatous in character. The frequent association of coryza and asthma, and the phenomena of hay fever in which the asthma often alternates with the nasal symptoms, are strongly adduced in favour of this theory. Others have pointed out that the retrocession of cutaneous eruptions is not infrequently simultaneous with the accession of asthmatic attacks. It is also urged that a reflex vascular turgescence is the natural outcome of irritation of the bronchial surface, and as a

* *International Journal of the Medical Sciences*, January, 1886.

matter of fact, Professor Störck observed by means of the laryngoscope an intensely congested state of the trachea and part of the right bronchus during the attack. The urticarial or herpetiform swellings being duly developed, they are soon followed by an exudation on the free surface of the membrane. The swellings, according to Clark, become at first coated with a viscid mucus, the vibration of which gives rise to the sibili and rhonchi, "râles vibrants," "at the end they subside, and moist take the place of dry râles." The truth is, that the proposition enunciated by Clark, the substance of which is given in the above extracts, is pretty much the revival of the old theory of Beau, that asthma is simply a bronchial catarrh having a peculiar highly viscid sputum, the dislodgement of which into the larger tubes terminates the attack. Leyden* and Curschmann† have described in cases of asthma a fibrinous exudation contained spiral and other filaments, and the spindle-shaped, octahedral, and rhombic crystals described by the former, likewise termed Charcot's crystals. Leyden suggested that these sharp-pointed crystals might irritate the terminal fibres of the vagus and so induce spasm. A recent writer, Berkart,‡ contends that asthma is nothing less than a severe form of fibrinous bronchitis. Of course it is sufficiently recognised by all, that cases of fibrinous bronchitis with the expectoration of casts are attended with great and very often intense dyspnœa, but to attribute such a physical basis to cases of what are regarded as genuine *asthma nervosum* is certainly rather startling.

Now with regard to this intumescence of the bronchi, with the production of more or less mucus or fibrin, there can be no doubt but that it presents itself in rather an

* Virchow's *Archiv*, vol. lv., p. 324.

† *Deutsch, Arch. f. Klin. Med.*, vol. xxxii.

‡ *On Bronchial Asthma*, London, 1890.

alluring aspect for our acceptance. And that such an intumescence, together with an exudation of mucus, actually takes place in all cases of asthma cannot admit of a doubt. But the point is this:—Is the asthmatic paroxysm adequately explained by these phenomena? I venture to say that it is not, and that instead of the catarrhal phenomena being the cause, they are but the necessary complications of the attacks.

To begin with, it cannot be conceded that a fluxionary hyperæmia of the bronchi has anything like the stenotic effect which is attributed to it. To argue that an analogous condition of the nasal mucosa produces more or less stenosis there, is quite inadmissible. It is unjust, it is grotesquely inappropriate to compare the distension with blood of the thick cavernous tissue over the inferior concha and the consequent occlusion of the slit-like meatus, to a vascular fulness of the bronchial wall. It is only necessary to call to memory the relative dimensions of the bronchial walls and their intimate structure to see that this is so. Imagine an orange cut in two equal parts. Looking at one of the cut surfaces, imagine the rind to represent the bronchial wall and the area of the pulp to represent the lumen. Now could there possibly exist such a dilatation of the vessels of the wall, with the addition if you choose, of a serous exudation into its plasma spaces, as would very markedly diminish the area of the lumen, as would diminish it to the extent requisite for the production of urgent dyspnœa? It is perfectly evident that a consideration of the tenuity of the walls of the smaller bronchi is sufficient to dispel the assumption that a stenotic narrowing could possibly be produced by the greatest possible degree of congestive swelling compatible with their integrity. Nor is it necessary to appeal to imagination. For on examination it is found that conditions of œdema or of acute inflammation of the

bronchi have not a conspicuous effect on their capacity, have in fact no more effect than similar conditions of the alveolar walls have on the capacity of the alveoli.*

The intumescence of the bronchi being obviously insufficient to account for the dyspnœa, there is yet the exudation to be reckoned with. The production of the mucus implies a congestion of some duration. In discussing acute inflammation of the bronchi, it was seen that a period of vascular fullness, with absence of all secretion, preceded the outflow of the mucus. The sudden nature of the asthmatic attack is inconsistent with the gradual outflow of the mucus. No doubt if it were possible for mucus to be suddenly generated in great quantities in a sufficiently large number of bronchi, more or less dyspnœa would ensue. But it is notorious that some of the most distressing paroxysms of asthma are terminated by little more than a teaspoonful of mucus. When this is compared with the immense quantities often expectorated in ordinary bronchitis, without the existence of dyspnœa, it is clear that the mucus theory must be given up. As to the existence of a fibrinous exudation forming casts of the smallest bronchi, this, as has been stated, is a view which has lately been championed in a rather fantastic manner by Dr. Berkart. The writer admits that the existence of the croupous exudation *in loco* is of itself insufficient to produce the dyspnœa, "for the sputum is often very small at the end of the paroxysm, and again, there is nothing like the exudation in capillary bronchitis." There are no symptoms of dyspnœa whatever whilst the exudation is forming. "The exudation is harmless at its place of origin, its presence does not betray itself even by

* It must not be supposed that a comparison is here intended to be drawn between the bronchial and alveolar walls in engorged states. But in the case of the alveoli, as a matter of fact their capillaries are capable of very great distention, and by their projection into the air cavities may narrow the latter to a very considerable, though by no means serious, degree.

cough." Gradually however, the exudation shrinks and is rendered movable, and passes up to the main bronchus or else the trachea. The moment the plug arrives here the paroxysm begins, and ceases only with the dislodgment of of offending body. "*All the symptoms of the asthmatic paroxysm become intelligible by this obstacle,*" says the ingenuous author! It may, indeed, be inquired why the plug made its way so easily through the smaller bronchi, and on coming to the larger branches was unable to proceed any farther, even with the aid of cough? But this extraordinary theory carries with it its own condemnation. For it is evident that the dyspnœa caused by an obstruction in the trachea or main bronchus would be of the inspiratory type the antithesis of that occurring in bronchial asthma.

Having failed to obtain in these doctrines on the causation of asthma, sufficient evidence of a physical condition able to withstand the tests with which pathological histology supplies us, it becomes our endeavour to seek the fulfilment of such a condition in the capabilities of the bronchial muscles. And judging from the results of experiments already detailed, I think there can be little doubt but that any unbiassed observer will admit that a spasmodic constriction of the bronchial muscles is not only possible, but so far as our knowledge at present goes, is the only legitimate explanation of the chief phase of the asthmatic paroxysm. True, a great many cannot entertain the idea of a bronchial spasm. It is to them a perfectly unwarrantable supposition, and many and ingenious are the arguments which have been employed against it. On the anatomico-physiological side it has in particular been urged by Clark* that the bronchial muscles are unable to contract so quickly and completely as is supposed; that the bronchial

* *Ibid.*

contraction is slow, persistent, and progressive, and hereby opposed to the sudden shiftings heard on auscultation; that the alleged spasms are most common where the circular muscles are least abundant, the spasm stopping short at the terminal bronchi and earlier inter-alveolar passages, where the muscles, it is affirmed, are most numerous (*i.e.*, thickest); and lastly, that the full inflation of the lungs is incompatible with such a contraction of the bronchi, which are on the contrary straitened. To these ingenious arguments there is, in the first place, confrontation of the fact that the exact amount of speed and completeness with which, in the living body, the bronchial or other involuntary muscles are capable of contracting, together with the possible duration of such contraction, are as yet unsolved physiological problems. According to M'Kendrick, the period of latent stimulation is longer than that of striped muscles and the contraction lasts for a lengthened period, is one single contraction of greater or less duration. Nothing definite is known regarding the conditions of fatigue.* It is no doubt quite true, as has already been mentioned, that the normal contractions of the bronchi, like those of the intestine, are "slow, persistent, and progressive;" but, is *abnormal* contraction of unstriped muscle likewise to conform to this type? Is such the character of the contraction in ileus, in singultus, or in urethral stricture? And further than this, in the experiments of both Williams and Roy the contractions obtained seemed sufficiently quick and complete to satisfy the requirements of the asthmatic attack. Next as to the plea that the alleged spasms are absent in the inter-alveolar passages, where the muscles are asserted to be most abundant—now, granting as much, is there not Sir A. Clark's own contention that the alveolar distention is too much for the bronchial constriction, and surely this

* *Text-book of Physiology*, vol. I., pp. 435, 436.

distensile force is exerted to the maximum on the inter-alveolar passages which are on all sides surrounded by the pulmonary alveoli? As to the subsistence of the pulmonary inflation with the contracted bronchi (leaving out of account the inter-alveolar passages), their mutual compatibility has been so well expounded by Biermer* that it is unnecessary to do other than briefly refer to his work. The assertion by Wintrich, Bamberger, and Lehmann, and repeated by Clark, that in tonic bronchial spasm the chest should be collapsed, the diaphragm elevated, and the intercostal spaces sucked in, is met by Biermer with the statement that these conditions imply a spasm of the *lung*, in which both alveoli and bronchi are reduced to a smaller volume. In spasm of the bronchi alone, on the other hand, "the antagonists of the bronchial muscles, which are to be sought among the inspiratory muscles, will exert themselves and draw the air through the narrowed bronchioles into the alveoli, while the air will be slowly and imperfectly expelled in expiration in spite of the additional force called into requisition. The alveoli, in consequence of insufficient exit for the air, would be acutely inflated, and so the diaphragm depressed."

No doubt much of the opposition to the theory of bronchial spasm is owing to the circumstance that its advocates were too exclusive, and did not offer a sufficient explanation of the catarrhal element, which in some cases, and especially in those of long duration, is certainly very marked. It may indeed well be asked how this element is to be explained, as likewise the alternation between nasal catarrh, cutaneous rashes, and bronchial asthma? First as regards the catarrhal symptoms, Gairdner has advanced a view which in the light of his theory of the bronchial

* *On Bronchial Asthma*. New Sydenham Soc., 1876. Translation by Dr. Joseph Coats, p. 177.

movements is no doubt logical and plausible, and which, if it does not satisfy the demands of the case, is nevertheless not altogether to be lost sight of. As previously stated, this physician attributed to the bronchial tubes a deobstruent function by means of a slow and vermicular contraction of their muscular fibres. In bronchial asthma this function is deranged or suspended, and hence an accumulation of mucus results. "It is obvious," he observes, "that accumulation must accompany the derangement of that action, just as constipation is the invariable concomitant of the analogous derangement of colic or ileus. In both cases the paroxysm cases when normal action is restored, and in general there is in both a copious discharge of the previously retained excretions." * Now when asthmatic attacks complicate acute or chronic bronchitis, it is perfectly evident that such an accumulation of mucus is taking place, the copious expectoration of which signalises the close of the attack. In cases however of so-called idiopathic asthma, wherein the patient remains well, or nearly well, in the intervals, it is certain that there is not merely an accumulation, but likewise an abnormal secretion of mucus, as also of serum, during the attack, because in health the mucus secreted is not of sufficient amount to cause even the slight expectoration with which such attacks terminate. I think that on a little consideration, the *rationale* of this phenomenon will be plain. The spasmodic contractions of the bronchial muscles do not of course involve continuous areas of the tubes, they are sphincter-like in character, just as though ligatures were applied around the tubes at certain points. Such sphincter-like constrictions, by dragging and jamming together the tissues of the wall, would have the effect of seriously impeding the local circulation. The venous channels in particular in such constrictions would be

* *Ibid.*, p. 39, *et seq.*

narrowed, and some of them temporarily closed. Hence a mechanical congestion would arise and extend along the tube, causing hypersecretion of mucus and a serous exudation. On the relaxation of the spasm, the circulation would soon be re-established and the catarrh would speedily abate. At the same time it is manifest that the frequent repetition of such congestive attacks would ultimately set up a chronic catarrh of the membrane, as is in fact found to be the invariable concomitant of old-standing asthma.

The existence of sputa containing Charcot-Leyden crystals and Leyden's or Curshmann's spirals is well known to be by no means pathognomonic of asthma, as many observers have found them in the sputa of the several varieties of bronchitis and also in pneumonia. And as the precise mode of formation of these bodies is not yet ascertained, it is quite unwarrantable to place them in a causal relationship to attacks of asthma. Although this may be so, their importance as an integral factor of the bronchial exudation in its bearings on the phenomena of bronchitic asthma is not to be overlooked. The viscid and adhesive mucus with which the spirals and crystals are herein generally associated, is, together with the underlying congestion, doubtless a fruitful source of the dry râles, notwithstanding that some have laid stress on the almost exclusive production by these râles by bronchial spasms. This is the position recently taken up by Dr. T. R. Fraser * after witnessing the influence of the nitrites on the adventitious sounds in bronchitis. Fraser found, as others had previously indicated, that after the administration of nitrite of amyl or nitroglycerine, the sibili and rhonchi were either lessened or removed for a time. Thereupon he concluded "that the cause of these sounds cannot be intumescence by congestion

* *The International Journal of the Medical Sciences*, February, 1888

of blood-vessels, or other results of inflammation, otherwise nitrites would increase rather than lessen or suspend the sounds. Adhesive mucus cannot frequently be a cause, otherwise nitrites would not in so large a proportion of the observations have succeeded in producing complete silence. . . . The only explanation of the results of the observations that can reasonably be adopted, seems to be that in bronchitis the rhonchi and sibili are frequently produced by contractions of the bronchial muscles, that dyspnœa is produced by the impeded movement of air caused by the constrictions resulting from these contractions, and that both are removed by nitrites, because nitrites reduce the spasmodic contractions of the bronchial muscles." Now as regards these conclusions, it may be observed that though probably correct in the main, there is unquestionably a certain degree of risk in endeavouring to settle a pathological problem from the supposed action of a drug, and especially a drug having such powers as the nitrite of amyl. After perusing Fraser's results, I tried the effect of the inhalation of nitrite of amyl in several cases of unilateral nasal stenosis from congestion of the membrane, and found that after the lapse of a few seconds, when the face began to flush, *the nostril always became more pervious to air*. Now this seems to throw doubt on Dr. Fraser's argument to the effect that nitrites would increase the sounds if caused or partly caused by intumescence. Might not the *general* dilatation and fulness of the vessels caused by the nitrite have the effect of relieving the *local* dilatation which we may imagine incapable of augmentation by the drug? Without going any farther into this matter, it may be repeated that in the dyspnœa of bronchitis, the sonorous and sibilant râles are in all probability the frequent outcome of deposits of adhesive mucus over congested districts, as also of contractions of the bronchial muscles.

The objection that the bronchial muscles are incapable of contraction for such a length of time as the symptoms frequently last, must be stated fairly. Although the possible duration of the contraction of unstriated muscle is as yet unknown, it is by no means to be assumed that the sphincter-like contractions are constant. On the other hand, there is the strongest auscultatory proof that the spasms are frequently and speedily shifting. That the sudden shiftings are caused by the "rapid coming and going of circumscribed congestive swellings, resembling the skin in urticaria," is but a skilful hypothesis, whose premises have already been rejected on histological grounds, unless indeed a variety of congestive swelling of the bronchial mucosa exists, which has not as yet revealed itself *post-mortem*. Lastly, as to the interchanges of nasal catarrh, skin rashes, and asthma, it will suffice to notice the connection between nasal disease and asthma, more especially with reference to hay fever. There is a substantive disease of the interior of the nose, naso-pharynx, conjunctivæ, &c. It subsides more or less for a time, and asthmatic symptoms arise. Now I do not deny the existence of a substantive disease in the bronchial tubes. There is unquestionably a severe hyperæmia of the membrane, accompanied by more or less catarrh. This hyperæmia may attack the bronchi, in the first instance, by a natural extension along the passages. But I submit that this is insufficient to cause the asthma, on grounds already stated. The asthma in this case we may imagine to be induced by the action of an irritant peculiar to the disease on the terminal fibres of the vagus in the bronchial muscles. On the other hand, the spasmodic phenomena may precede and induce the hyperæmia, on the principles already enunciated. Here the irritation may pass from the nasal mucosa, by Meckel's ganglion along the Vidian nerve, and by its sympathetic branch to the carotid plexus, which

is connected to the posterior pulmonary plexus of the pneumogastric. The reflex asthma hereby set agoing would in due time set up catarrhal symptoms vicarious of the nasal disease.

PART II.



PNEUMONIA AND FIBROID
PNEUMONIA.

CHAPTER VI.

NORMAL HISTOLOGY OF THE LUNG. BRONCHOPNEUMONIA.
CATARRHAL PNEUMONIA.

THE histology of the lung, as compared with that of the bronchi, is very simple. The whole lung may be said to be represented in a single alveolus. The minute structure of the alveolar wall has been thoroughly investigated by so many eminent observers that little or nothing further remains to be done. I purpose therefore to discuss briefly the nature and significance of certain of the pulmonary elements in the light of my own investigations.

If pieces of the lung of an adult be hardened in Müller's fluid and afterwards in alcohol, the cut sections will show under the microscope the capillary network of blood-vessels filled with the natural injection of the blood. Müller's fluid preserves the blood in the capillaries perfectly, and thereby renders their examination so easy, as to put entirely in the shade the results obtainable by the most carefully conducted artificial injections. To see the capillary network spread over the alveolar wall, these sections should not be made too thin. In stained sections there will be seen scattered through the intercapillary spaces, and it may be, also overlapping the capillaries, variously shaped nuclei. These are the connective tissue corpuscles of the alveolar wall, and when the latter is seen in profile, the corpuscles are found to be fixed in its substance.

Rarely by this mode of preparation is the epithelial

lining adequately to be seen. This is partly owing to the slender attachment of the epithelial plates left after making the section, which causes many of them to fall off, and partly to the extreme thinness and transparency of this layer and the scarcity of its nuclei. But the epithelium may be studied in the lungs of children, and best of all, in the lung of the kitten.

In the case of the pulmonary, as of the bronchial epithelium, the existence of connective tissue pseudo-stomatous cells interposed between the placoids has been affirmed by Klein.* It is curious how Klein can maintain this so strongly after figuring, as he does, actual stomata in the angles between the placoids. These stomata are frequently surrounded by several smaller granular and apparently germinating cells as is seen on the surface of the pleura, peritoneum and other serous membranes. Buhl, Rindfleisch, and others maintained the truly stomatous disposition of these germinal groups in the lung. Now on what does Klein ground his statement? Chiefly on the existence of such pseudo-stomata in the bronchial epithelium—a view which I have already shown to be utterly false. But more than this, he declares that “the connective tissue cell plates are found actually penetrating into the alveolar cavities.” Now if this be so, considering the minute nature of the openings existing between the epithelial cells to admit of the passage of the plates of these connective tissue cells, how in such circumstances can pigment-bearing lymph cells pass from the alveolar cavity into the lymphatic vessels? Klein himself seems to have recognised this difficulty, for he remarks that “under certain circumstances the pseudo-stomatous canals may be dilated so that even formed particles may find their way from the alveolar cavities into the lymphatic system of the alveolar walls.”

* *Op. Cit.*

If then, is it necessary that the canals into which the connective tissue cell plates have fixed themselves, require to be dilated before formed material can pass through, what is the necessity of these plates in this situation? They are only a hindrance and a bar to absorption, and that absorption can be carried on without them is certain, as direct communication is admitted to exist by all observers, Klein included, between the pleural lymphatic vessels and endothelial surface.

I cannot admit however that the cell figured by Hamilton as corresponding to the pseudo-stomatous cell of Klein is at all justifiable.* The granular spindle-shaped cell which on profile are seen attached to the wall, are *entirely* superficial and their epithelial nature cannot be mistaken. Klein never represented the *nucleus* of the pseudo-stomatous cell as being superficial, as Hamilton indicates, but merely a part of the cell plate.

Closely applied as they are, to the tissues of the alveolar wall, the epithelial plates have necessarily an intimate connection with the underlying connective-tissue cells, and the existence or non-existence of pseudo-stomata is after all but unimportant. There can be no question but that lymph cells pass very readily between the epithelial plates into the lymphatic spaces. Nothnagel found that if blood was sucked into the lung of a rabbit, corpuscles could be found in the interstitial connective tissue in the space of three and a half minutes. Normally there are lymph cells wandering free in the alveolar cavities, acting as scavengers. They are well seen in the lungs of guinea-pigs, containing black particles.

What is the function of the pulmonary epithelium? It is somewhat remarkable that physiologists in describing the gaseous interchanges which take place in the lung

* *Loc. Cit.*, p. 105.

regard the epithelium and capillary wall as constituting a passive membrane, acting a mere mechanical part in these vital proceedings. It is not many years since a similar *rôle* was assigned to the epithelium covering the glomerular tuft in the secretion of urine. The view of Heidenhain, Cohnheim, and others with regard to the truly glandular function of this epithelium may now be said to be universally adopted. That the pulmonary epithelium has escaped due recognition I am convinced. And as to the part played by it in the respiratory act, it at anyrate cannot be doubted but that it prevents the escape of anything of a fluid nature from the pulmonary capillaries, whose walls are of excessive delicacy. Judging from analogy, it is impossible to see, except on this hypothesis, why serum should not escape abundantly into the alveolar cavities. In addition to this preventive function, it may be assumed that the alveolar epithelium takes a vital participation in the distribution of the gases to and from the blood.

The *lymphatics* of the lungs have been carefully studied by Wywodzoff,* Sikorsky,† and Klein.‡ These observers are agreed that the rootlets of the lymphatic system begin as a plexus of anastomosing canals and spaces in the alveolar walls. Without special methods of preparation, the branching processes of the connective tissue cells lying in the lymph spaces can be made out. It is said by Pierret and Renaut that each alveolus of the lung in the ox is surrounded by a large lymph space such as occurs in the salivary glands. In Man, several canaliculi take origin from a lacuna; they then course in all directions through the wall. There seems to be quite an unnecessary amount of description as to the course and varying currents of the lymphatics of the lung. If pigmented lungs be carefully examined the course of the lymphatic current stands simply thus:—

* *Wiener Med. Jahrb.*, Band xii. † *Op. Cit.* ‡ *Op. Cit.*

From the alveolar walls, the lymph flows into the corresponding perilobular membranes and thence into the larger septa containing the principal vascular branches. It can be seen that it is chiefly along the *sides* of these septa that the pigment travels. All the septa converge to the root of the lung. The deep layer of the pleura in like manner may be regarded as equivalent to the interlobular septa, and thence the current flows by the pulmonary ligaments to the root of the lung. Where the alveoli are in contiguity with the adventitious structures, their lymphatics communicate directly with the lymphatic vessels of these structures, the lymph forming a common stream with that of the bronchi and blood vessels. It may here be remarked that a very free capillary anastomosis may likewise be seen to exist between the alveolar *blood* vessels and those of the interlobular septa and larger areolar trunks. Hence inflammatory affections of the pulmonary substance necessarily involve to a greater or less extent the fibrous framework of the lung and *vice versa*. This is found as a matter of fact, and it is undoubted that distinctions of far too pronounced a character have hitherto been formulated. If in bronchitis inflammatory action extends to the peribronchial and perivascular tissues, it will of a certainty affect a strand of the pulmonary substance, just as in pleurisy a similar strand is found to be involved. This anastomosis must therefore be kept constantly in view in the study of pulmonary affections.

The question as to whether *muscular fibres* exist in the alveolar walls may now be regarded as well nigh settled. The observation of Moleschott has been partially confirmed, that is to say, it is demonstrable that muscle cells exist in those alveoli which surround the larger alveolar ducts. It is questionable however whether such exist in those of the terminal ducts and infundibula, though in certain morbid

conditions the muscle nuclei seem to have invaded these alveoli also.

That *communications* existed between adjacent alveoli by means of openings in their walls was affirmed by Köllicker. The statement has not been unchallenged, but morbid anatomy confirms Köllicker's observation. In acute pneumonia, strings of fibrin are frequently found passing through slits in the alveolar walls, which cannot be confounded with the larger orifices communicating with the alveolar ducts.

Lastly, the difference in character betwixt the pulmonary epithelium in childhood and that in adult life must be carefully kept in view. If the foetal lung be examined, channels and spaces lined by polygonal epithelium will be observed. Before breathing takes place, the alveolar epithelium resembles in all respects that lining the bronchioles. When breathing occurs the cells become flattened out with each inspiration, shrinking more or less with expiration. This phenomenon may be observed in the case of the pleural endothelium by artificially inflating the lung of the guinea pig (Klein). As age advances, the alveolar placoids are permanently distended, exceedingly thin, and entirely destitute of any granular appearance. In childhood not only are these cells somewhat granular in character, but the small germinal cells, or "intercalary cells" of Küttner, are relatively more numerous. In cases of atelectasis from pleural effusion in the adult, I have observed the epithelial plates revert somewhat to the infantile type.

BRONCHO-PNEUMONIA. CATARRHAL PNEUMONIA.

Some authors are inclined to discard the old term "catarrhal pneumonia," but it is difficult to see for what reason. Irritants giving rise to this form of pneumonia

do not all enter the lungs by the bronchi. Some enter from the pleural cavity and others by the pulmonary artery. Hence, there is a broncho-pneumonia and a catarrhal pneumonia, which may and usually do possess similar anatomical features—features which though presenting more or less variation according to the nature of the irritant, nevertheless are at all times sufficiently well demarcated from those which characterise acute lobar or fibrinous pneumonia.

It will suffice here to consider broncho-pneumonia: the changes in the lung herein being typical of all catarrhal pneumonias, but no neoplasm, such as tubercle, can be considered in connexion with the disease.

This affection, which commences as what is usually termed a "capillary bronchitis," has received great attention and been described in a very extensive manner by Barthez and Rilliet, Balzer, Cornil and Ranvier, Wyss and many others. I shall not therefore go over the ground which has been so well utilised by these authors; I shall do no more than refer in an incidental manner to certain of their observations, in so far as they bear on the original remarks which follow. These are necessarily of a limited character, for in a purely histological investigation, it is impossible to discuss the numerous and frequently obscure proximate causes of this intricate affection, or its diversiform associated pathology, or the numerous lesions which follow in its train, always dangerous, usually permanent and often fatal.

It sometimes happens that capillary bronchitis succeeds to tracheo-bronchitis. The latter affection abates and the inflammatory process seizes on the finer bronchi. Or without such an apparent sequence, without any wave of inflammation springing from the greater branches of the bronchial tree and steadily advancing towards the smaller, a capillary bronchitis may arise and proceed variously.

Sometimes the contents of a pulmonary cavity are suddenly sucked into the finer bronchi. Various forms of cocci, bacilli, as well as vibriones are discovered in such cases. At the very beginning of the process the channel of the minute bronchus becomes well nigh filled with cellular products. These consist of epithelial and lymph cells. In some cases, the columnar epithelium divides, and forms round cells, as is seen in the experimental bronchitis of animals. These are the most acute cases. In subacute varieties, or those due to milder irritants, this layer persists, and gets raised frequently from its attachment to the mucosa in the form of a palisade of cells, but permits the passage outwards of leucocytes, which lie in vast numbers over its surface. The bronchial wall shows at this stage a considerable infiltration of leucocytes, a uniform infiltration which extends along the walls of the contiguous alveoli, but as yet, the fixed cellular elements of neither bronchial nor alveolar walls have shown signs of division. This process has not existed long in the bronchioles until the alveolar ducts become invaded and *a great swelling and vascular distension of the alveolar walls takes place*. When irritants are injected into the lungs of certain mammals there is observed *post mortem* in this stage, a swelling of the alveolar walls so great as almost to obliterate the alveolar cavity. The capillaries are stretched both longitudinally and transversely to at any rate double their normal dimensions. They are seen projecting inwards in loops, and occasionally a leucocyte may be seen bulging from between the endothelial cells constituting their walls. The exuding serum soaks and thereby swells the alveolar tissues, whilst it loosens and ultimately completely detaches the epithelial plates. Changes exactly similar likewise occur in the connective tissue which limits the lobule. With these phenomena the very earliest stage of the affection is ended.

As the inflammation proceeds, the exodus of lymph cells into the lumen of the bronchiole becomes very great, is indeed quite disproportionate to what takes place in the larger bronchi at the corresponding stage. This is in great part to be attributed to the absence in the finer bronchi of a well marked basement membrane. If, as Hamilton imagines, the presence of this structure is the main hindrance to complete recovery from ordinary bronchitis, by preventing the outflow of the inflammatory cells (a view which is undoubtedly erroneous), it would seem as though its absence in capillary bronchitis were equally deplorable. Indeed the wonder is that suffocation from choking of the tubes with pus is not more frequent than it is, and were it the case that larger areas of the lungs became involved than usually happens, a fatal issue would quickly supervene. To this excessive exudation of leucocytes, there is soon to be added the embryonic cells of the actively germinating tissue cells. It is not long until the bronchial channel is completely filled by cellular elements, whilst the bronchial wall suffers throughout its entire extent such a lymph-cell infiltration as almost totally obscures its proper structural elements. What is taking place in the alveoli of the lobule? The alveolar cavity will be found usually to contain a fibrinous exudation, which in the majority of cases cannot be distinguished from that of acute pneumonia—that is to say, the alveolar cavity is filled with fibrin, which adheres closely to the alveolar walls and contains a variable quantity of epithelial cells, leucocytes and red blood cells in its meshes. In some cases, the entire lobule or groups of lobules become the seat of this fibrinous exudation; in other cases, it is the more central alveoli of the lobule which are thus affected, those outside containing desquamated epithelium and lymph cells. The epithelial cells are in acute cases never very abundant; they are frequently

binucleated, and contain pigment granules. Their mode of germination has been aptly compared to that of the endothelial cells of inflamed omentum.* In slow inflammatory processes, these epithelial cells are almost the sole occupants of the alveoli, they then attain large dimensions, and are sometimes multi-nucleated and vesicular, but in acute processes they do not attain much growth, indeed it is frequently difficult to distinguish them from turgid lymph cells. Hence the contradictory conclusions at which investigators have arrived, such as those of Friedländer and Dreschfeld. As a matter of fact, I find that in *acute* broncho-pneumonia the lymph cells greatly supersede the epithelial. Most authors following the example set by Charcot and A. Clark, have regarded broncho-pneumonia as essentially an *epithelial* pneumonia—a pneumonia in which the epithelium is *primarily* affected and the connective tissue of the alveolar walls *secondarily*. In cases of *chronic* broncho-pneumonia there may be truth in this view, at anyrate with respect to a certain class of cases, but in regard to the acute disease, it is erroneous. What then is the grand distinction betwixt acute broncho-pneumonia and acute lobar pneumonia? As has been seen, there normally exists in the former a fibrinous exudation which is indistinguishable from that so characteristic of the latter. *But in the case of acute broncho-pneumonia, the fixed connective tissue cells of the alveolar walls invariably germinate and give rise to a great crowd of young cells which soon fill up the alveolar cavities. No such germination occurs in the vast majority of cases of ordinary pneumonia; when it does occur, it is exceptional and gives rise to grave consequences.* It is not the swelling and infiltration of the alveolar walls, nor the presence of fibrin, nor of desquamated epithelium: all of

* For complete account of the epithelial changes, see Hamilton—the *Pathology of Bronchitis*, &c.

which in either of these diseases may be less or more found—it is not these to which any diagnostic value can be ascribed, they are but extrinsic features; the sole anatomical distinction consists in the germination of the connective tissue corpuscles in the one and not in the other. This opinion I have formed after prolonged examination of a large number of examples of both affections, and am convinced that no other view respecting the anatomical distinction will be able to hold its ground.

It is well thus early to arrive at a clear understanding with regard to this matter. It suffices to remove a number of difficulties which continually come cropping forth in the study of acute pulmonary inflammations. This landmark, once surely established, enables us to proceed more easily on our way.

As the exudation, whether cellular or fibrinous, fills up the alveoli, their walls get gradually compressed, and hence the blood is to a certain extent diminished in their vessels. Sooner or later the pressure thus exercised causes the wall to assume pretty much its normal dimensions. Those vesicles which originally contained fibrin usually at this period shew a lymph-cell infiltration, which has gradually replaced the fibrin; in other cases the fibrin persists. Sometimes blood is mingled in large quantity with the original fibrin, or the vesicles may be almost entirely filled with blood. In either case lymph-cells take their place. Examine the lobule at this stage from without, outwards. The central bronchiole is acutely distended from the great cellular accumulation in the lumen. It may be difficult to distinguish where this cellular accumulation ends and the bronchial wall begins. But in many cases, and especially in the young subject, the curious phenomenon is to be observed of the perfect preservation of the columnar epithelium. Balzer* has described and figured this appearance. It

* *Dict. de Med. et de Chirurg. Pratiques*, vol. xxvii.

looks very remarkable, the circlet of columnar epithelial cells in the midst of a purulent mass. It is apparent that the pus cells are passing from the deeper parts between the columnar cells, and that the latter are detached from their connexion with the bronchial wall. The latter circumstance may account for their non-proliferation. It is possible that they may become detached early by lymph-cells, and though maintaining therecoherence one to another, are thus rendered passive. In other cases, it may be that they throw off young cells by fission, but continue to maintain their normal dimensions. Some who have observed this preservation of the columnar epithelium imagine that a purulent mass has either gravitated, or been inspired into, an otherwise healthy bronchus. While not denying the likelihood of this in certain cases, the state of the bronchial wall is sufficient to disprove it in most. The slender wall of the tube is seen to be densely infiltrated with cellular elements. At first some elastic and muscular fibres and small blood vessels may be seen, but soon these disappear almost entirely and more or less circularly arranged cellular rows remain. Immediately surrounding the bronchus are several layers of flattened or elongated alveoli (the result of the bronchial distension), which are filled with fibrin or cells according to the peculiarities or stage of the affection. Outside these are normally shaped alveoli filled with lymph cells, and if the affection has not proceeded very far, an external zone of alveoli shewing congestion and epithelial proliferation will be seen. These layers constitute the *Zones of Balzer*. If the alveolar walls throughout the lobule be carefully examined, their fixed corpuscles will be observed in a state of great activity, giving rise to cells resembling leucocytes, containing relatively large nuclei. Some authors, *e.g.*, Béhier, Buhl, Fauvel, supposed that the alveolar contents merely gravitated from the bronchi, and that no genuine inflammation took

place in the lung. Even if aspiration from the bronchi be granted, the inspired products would excite inflammation. Moreover, it is evident that the inflammatory process has no such limited signification. I would look on the inflammation as extending by the bronchi into the lung from continuity of surface, a *superficial* extension, and likewise as extending from the peribronchial fibrous tissue through and through the lung substance, a *deep* extension. So prone is the inflammation to proceed by the latter method, that even in large bronchi whose vascular supply is independent of the contiguous alveoli, when the inflammatory process extends to the adventitia, proliferated epithelial cells will frequently be observed in a limited number of air vesicles in the immediate vicinity. In connexion with this gradual involvement of the lobule, it may be inquired whether *collapse* of the lobule is at any time to be observed. It may be remarked that collapse from acute broncho-pneumonia has been greatly misapplied. No doubt a good deal depends on what is meant by collapse, whether the collapse be a genuine one from abstraction of air, or whether the collapse be merely apparent, from consolidation of certain areas contrasting with undue inflation of surrounding parts. A theory more ingenious than demonstrable has been advanced by Gairdner to account for lobular collapse when it occurs. This is to the effect that a plug of mucus moves up and down the air tube with inspiration and expiration respectively, prohibiting the ingress of air to the alveoli, but permitting its egress until the lobule is completely evacuated. To this view there are some fatal objections. In the first place, a plug of mucus cannot travel backwards and forwards on a surface formed by an adhesive secretion, as a ball does in a smooth metal groove. In the second place, suppose such a plug to be actually carried by inspiration to the furthest point it can

travel. The act of inspiration causes a considerable distension of the bronchus. The plug would thus be carried to a bronchus, the lumen of which in the respiratory pause is actually smaller in diameter than the diameter of the plug. Now, the amount of air beyond the plug is not nearly equal to that by which it was driven in, because a portion of the latter air is distributed to other small branches in advance of the original position of the plug. Hence, how could the expiratory air brought to bear on the plug suffice to expel it, when the recoil of the bronchial wall is at the same time fixing it firmly in position? In view of these considerations this "ball valve" theory seems to fall to the ground. The truth is that lobular collapse is a much simpler affair. If a bronchiole be ligatured or stopped up entirely by a foreign body, the dependent alveoli soon become collapsed. This results from the absorption by the blood of their contained air. It is not necessary for the air to be driven out at all. According to Lichtheim,* the blood first absorbs the oxygen, then the carbonic acid, and lastly the nitrogen. The part thus rendered airless speedily however becomes cedematous and swollen, and may attain greater relative bulk than the corresponding healthy parts of the lung, and hence the previously collapsed part becomes in reality an expanded part. Rindfleisch† describes in a graphic manner the *modus operandi* of this transformation.

But in acute broncho-pneumonia, it is rare to find pure lobular collapse. Any collapse which may occur is speedily removed by the cellular exudation. When this exudation is completed throughout the lobule, the zones of Balzer are no longer demarcatable. Examining at this period the perilobular membrane, it will be found greatly swollen and

* *Arch. f. Expr. Path.* vol. x.

† *Path. Hist.*, vol. ii., p. 23.

infiltrated. The infiltration is sometimes almost wholly fibrinous. It may resemble in all respects that seen in pleuro-pneumonia of the ox. In other cases, the infiltration is chiefly cellular. Examining these cells by high powers, many of them look like endothelial cells, sometimes binucleated. They are rather large, round cells with clear protoplasm. Some of these are derived from the endothelium lining the lymphatic vessels which are so abundant in this structure. But close inspection will reveal that the majority are derivatives of the connective tissue corpuscles. Stain carefully hardened sections in lithium-carmin and logwood and mount in Canada balsam. The large branching connective tissue cells will be seen containing large divided nuclei, which give rise to young cells considerably larger than leucocytes. As a rule, more or less fibrin is associated with these cells. Latterly, and in severe cases, the infiltration becomes dense and even purulent. Precisely similar changes are seen in the deeper layer of the pleura bounding the affected lobules. In like manner the sheaths of the smaller pulmonary blood-vessels are irregularly thickened by a densely aggregated mass of cells. The tunica intima is also thickened by strata of new cells and the muscle nuclei may show proliferative changes. The cellular infiltration in the perivascular sheath results from the gradual filling up and distension of the large lymphatic vessels therein. A somewhat similar lesion is described by Klein* as occurring in the artificial tuberculosis of guinea pigs under the term "perivascular or endolymphangeal cords." They originate, according to Klein, "by the distension of the lymphatics with plasma and lymph corpuscles, then a number of fibres in connection with the endothelial wall extend amongst the lymphoid cells in the lumen and likewise outwards into the surrounding interalveolar tissue.

* *Lymphatics of the Lung.*

Thus the lymphatics are transformed into cords of adenoid tissue." These cord-like granulations do not undergo caseation after the manner of catarrhal-pneumonic blocks. The blood-vessels whose external coats become invaded by this change, shew germination of their endothelium, giving rise to rows of cells in the intima and stenosis of the vessels, also infiltration of the middle coat with lymphoid cells, causing an appearance of lamination, which lymphoid cells Klein affirms to proceed from the perivascular cords—"an active growth of the tissue of the cord into the wall of the vessel." It is difficult to conclude however to what extent these appearances are associated with the actual formation of tubercle. In any case, it is difficult to see how the fibres in these cords have arisen; no mention of the process is made by Klein. In cases of broncho-pneumonia I have not seen such fibres, although a network of fibrin is common enough, and sometimes fibrin is likewise to be seen in the interior of the vessels.

When, as is frequently the case in children after measles, &c., a number of foci of lobular pneumonia coalesce, large tracts or even an entire lobe may become homogeneously hepatised (pseudo-lobar variety of Damaschino). In such cases there is frequently an incongruous mixture of fibrinous and cellular hepatisation. That is to say, irregular areas in which fibrin predominates are in juxtaposition with others in which the alveoli are packed with lymph cells. In these cases, the interlobular septa are greatly thickened from a granulo-fibrinous infiltration. So far as I have observed, the fibrin in the alveoli is flaky and homogeneous rather than fibrillated. It resembles an ordinary albuminous coagulum. Fibrin forms with difficulty in the presence of living epithelium. In the child the alveolar epithelium is more granular in character than that of the adult; this may have something to do with the comparative rarity of

fibrinous pneumonia in early life. The pneumonia of childhood is principally of the "catarrhal" variety. Buhl had a theory to the effect that fibrinous coagulation on a mucous surface was effected by a certain transformation of the epithelium. This view was further elaborated by Weigert, who attributed to the living epithelium the property of maintaining alive the white blood-corpuscles. In the case of diphtheria, for instance, coagulation-necrosis of the mucous epithelium occurs; this causes death of the white blood corpuscles and hence on Cohnheim's theory a fibrinous coagulum. Virchow held that fibrinous exudations were under certain circumstances interchangeable with those whose characteristic ingredient is a substance allied to mucin.* Mucin is relatively abundant throughout the body in early life, and without doubt a fluid holding mucin in suspension is present in the pulmonary alveoli in the cases under consideration. Putting these views together therefore, it may be conjectured how the abundance and vitality of the epithelium, together with the formation of a mucoid fluid, might modify or even prevent the formation of fibrin, in at least a large number of cases.

Sometimes an inflammation primarily attacks considerable areas of lung, and resolution takes place, but a bronchitis remains. Such a bronchitis may be aptly termed a *pneumono-bronchitis*. It may proceed as a broncho-pneumonia in the manner already described. Hence a broncho-pneumonia may arise out of a pneumono-bronchitis. (Refer to Fox—*Atlas of the Pathological Histology of the Lung*—article *Catarrhal Pneumonia*.)

We have now to consider the final stage of non-specific broncho-pneumonia. We have to deal with one lobule or with several. The cellular accumulation in the cavity of the bronchus, in the bronchial wall and in the alveolar

* *Spec. Path. u Therap. and Archiv.* vol. iv., p. 310.

cavities undergoes further changes. If the irritant which has caused the pneumonia be exceedingly virulent, such as the fluid from a gangrenous cavity, or decomposed food or foreign matter which has gained access to the bronchi, *suppuration* is liable to supervene. The bronchial wall and a zone of pulmonary substance blend together into a suppurating focus. This may ultimately lead to a cavity, constituting in all probability the "vacuoles" described by Barthez and Rilliet, Vulpian and others. Death usually occurs, but around such cavities a *reactive inflammation* may set in. First a fibrinous exudation forms round the circumference of the cavity. Then new tissue rapidly forms both in the alveolar walls and throughout this exudation. I have observed this new formation take place in a very intense and rapid manner, involving the intercepted bronchi and blood-vessels until their walls were converted into dense fibrous tissue. This new formed zone of tissue forms a wall to the cavity, and if circumstances be favourable, the cavity will contract and become quiescent until ultimately it is represented by a cicatrix. Such cases become usually the seat of a chronic form of broncho-pneumonia, in which the alveolar walls undergo thickening and their cavities become filled with large epithelial cells.

In other cases the broncho-pneumonic foci undergo *caseous necrosis*. Some affirm that this of necessity implies tuberculosis. Such however is by no means the case. In non-specific cases of broncho-pneumonia the following changes may unquestionably occur. After the cellular infiltration of the alveoli has ceased, more or less circular areas varying in size from a millet seed to a pea, or even larger and diffuse, and to the naked eye looking like tubercles or groups of tubercles, may be found in greater or less abundance. Under the microscope, it will be found that each of

these areas consists of a dense aggregation of cells, but at first the individual alveoli composing the mass can be made out, from the presence of a few elastic fibres and a capillary blood-vessel encircling the wall of each. In older masses, only a few of the alveoli can be thus distinguished at various points, the others having completely merged together, no blood-vessels or elastic fibrils being now visible. Gradually, all traces of the alveolar walls disappear from all but the periphery of the mass. There remains a densely packed amassment of cellular elements of a somewhat angular shape, and reacting less to staining reagents. The central area of such masses then becomes somewhat homogeneous and granulo-fatty, a condition which soon replaces the entire cellular accumulation. It is therefore the cutting off, or rather the obliteration by pressure, of the blood-vessels which precedes the necrotic transformation. In view of these changes it seems unwarrantable to attach specificality to caseation. All forms of caseation are in fact conditions of coagulative necrosis, whether occurring in tubercle, in inflammatory exudations or in embolic infarctions. Why then does not the grey hepatisation of pneumonia undergo caseation? Because the patient dies ere the process can take place. This occurs as a rule, but there is likewise a very evident physical reason. In lobar pneumonia, a whole lobe is uniformly affected with grey hepatisation, and this lobe is likewise uniformly infiltrated with fluid. A section through it is followed by a considerable fluid exudation. It is necessary for the occurrence of caseation that this fluid be abstracted. In lobar hepatisation this cannot be effected, but in the case of lobular pneumonia, the healthy lung tissue surrounding the condensed areas readily absorbs the serum which is compressed out.*

* Some authors have affirmed that lobar pneumonia may terminate in partial caseation.

As to the termination of acute broncho-pneumonia by resolution I know nothing. It is only when the disease is confined to a portion of the lung that recovery ensues, and even then it is doubtful if the affected area ever recovers perfectly its original healthy character. The disease known as chronic broncho-pneumonia usually originates as a subacute or chronic process, it does not often arise as a typical acute attack. When acute catarrhal pneumonia is described as presenting an abundance of large epithelial cells in the alveoli, with proliferating epithelium projecting from the walls, it is in reality subacute, and it is this variety which gives rise to the chronic form. At the same time, an acute broncho-pneumonia even when it terminates in suppuration or caseation, will, if a fatal issue be averted, induce around the primary foci, a greater or less extent of catarrhal pneumonia as already alluded to. The subsequent history of broncho-pneumonia is as a rule bound up with that of tubercle.

CHAPTER VII.

ACUTE PNEUMONIA.

THIS disease, which has been the wonder no less than the study of physicians in all ages, presents problems widely different from such as have hitherto been considered. Fortunately however, its pathological histology presents, in its typical aspects, a series of phenomena, clear and marvellously instructive, and which shed a flood of light over the true nature of the affection, dispelling meagre and limited notions which have held and still hold sway amongst many respecting its compass and domain. While as yet these histological features had escaped narrow observation, and no distinguishing marks were drawn betwixt them and those of other diseases, and when in addition the etiology, associations, and therapy of the disease only served to increase the mystery attached to it, is it any wonder that the pendulum of scientific opinion should have oscillated, at one time indicating the constitutional, and at another, the local nature of the disease? Nor has the progress of bacteriology been sufficient to unravel the difficulties attaching to its origin and nature. But I think it will be admitted, when the pathological histology of the affection is justly considered, that there is herein found one of the best indications as to the real significance of the malady. The histological study will best be begun by setting forth the true anatomical lesions of the typical disease. It will be found that the following description differs somewhat from the commonly accepted statements.

COURSE OF TYPICAL PNEUMONIA ENDING IN RECOVERY.

The disease is divisible into three and only three stages viz.:—Congestion, Hepatisation, Resolution.

I. STAGE OF CONGESTION.—Acute pneumonia commences in the same manner as has already been described in the case of broncho-pneumonia, namely, by an acute distension of the pulmonary capillaries and concomitant swelling of the alveolar walls. Stokes* affirms the existence of a separate stage of arterial injection, in which the tissue is drier than normal. It is quite unwarrantable to emphasise in this manner the initial injection which is common to all inflammations. Stokes himself admits he has observed it in phthisis and other affections. Again, the congested parts of lung adjacent to "red" hepatisation must not *post-mortem* be always regarded as representing the first stage. These may represent the hypostatic congestion incidental to the moribund condition. If pneumonic sputum be injected into the lung of an animal, and a *post-mortem* examination be made in from eight to twelve hours, this initial congestion will be seen at its height. Not only are the alveolar capillaries greatly distended, but likewise those of the interlobular septa, bronchi, and pleura. From the vessels there oozes into the alveolar cavity a *fluid rich in sodium chloride and fibrinogen*. A few leucocytes, and generally, though by no means invariably, a considerable quantity of red blood discs pass out with this fluid, while simultaneously many of the epithelial plates are loosened and detached, and many of the granular cells surrounding the stomata *germinate* and are *floatated out in the exudation*. In this way the alveolar cavity is *filled to overflowing*, and the exudation continuing, the exudate is *displaced into the bronchial tubes*. A similar exudation takes place into the

* *Diseases of the Chest*, pp. 310, 311.

interlobular connective tissues, pleura and bronchial and vascular adventitious tissues—a circumstance generally overlooked by those who have described the morbid anatomy of this disease. At a certain period, and corresponding in all probability with the death of the epithelium which is mixed up with the alveolar contents, the exudation from the wall *ceases*, and this signalises the end of the entire phenomena constituting the first stage of the affection.

II. STAGE OF HEPATISATION.—The remarkable peculiarity of this stage is, that the alveolar walls *take no part whatever in it*. It consists in the coagulative necrosis of the exudation in the alveolar cavities, interior of the bronchi, and also of the exudation, more or less limited, which is effused into the lymphatics of the interlobular septa, bronchial and vascular adventitia and pleura. Taking the case of the alveoli, the first phenomenon observable is the production of threads of fibrin stretching right across their area and attached by their extremities to the alveolar walls. Soon the entire mass coagulates, presenting a meshwork of thick threads of well formed somewhat granular fibrin, coalescing with the protoplasm of the contained epithelium, and adhering with considerable firmness to the alveolar walls. It is curious how Stokes and certain other physicians could have declared hepatisation sometimes to accrue without any intervening stage of congestion and effusion. How could hepatisation take place unless there was an exudation to coagulate? The alveolar contents having thus coagulated may be regarded as *dead* and any further changes they undergo are solely those of degeneration. The coagulation necrosis thus brought about, may according to Wooldridge* be accomplished by substances contained in the plasma itself without the intervention of corpuscular elements. Certain

* *Proc. Roy. Soc.*, Ap. 8, 1886.

appearances, which cannot here be discussed, have led me to believe that Wooldridge's theory has yet to be overturned. But, on the accepted view, the dissolution of the white corpuscles is by no means necessary here, since the same observer has shown conclusively that the *stromata* of the *red* corpuscles will induce coagulation in plasma.* The hæmoglobin has nothing to do with the process. Lister has recently expressed himself to the effect that "the walls of the capillaries have acted for the time being like ordinary solid matter, and that as a consequence of this behaviour of the capillaries the corpuscles have given up to the liquor sanguinis (to use Schmidt's language) the necessary fibrinoplastic substance, and if the exuded liquor coagulates we cannot doubt that the plasma which remains in the capillaries also coagulated."† At the commencement of hepatisation, the hæmoglobin is present in considerable quantity, and hence the term *red* hepatisation, although the lung at this stage is not as red as in that of congestion. It is not scientific to insist on distinguishing betwixt "red" and "grey" hepatisation, any more than between "red" and "yellow" softening of brain, as can easily be shewn. For as the hæmoglobin gets dissolved out and disappears, the fibrinous mass shews but little alteration, in fact, a certain degree of "greyness" is not inconsistent with the perfect preservation of the fibrin. An examination of the alveolar walls in this stage will be attended with chiefly negative results. The blood-vessels are somewhat prominent, and the epithelial layer seems broken, but the tissues of the wall are normal and their corpuscles shew no change. Epithelial cells of diverse forms and containing sometimes two or more nuclei may be perceived both clinging to the alveolar wall and throughout the fibrin. These forms are depicted in the

* *Practitioner*, 1886, p. 187.

† *The Lancet*, May 16, 1891.

accompanying illustration (p. 126), and may now be briefly discussed.

First as regards the leucocytes (1), some are seen with a single large nucleus, others with two well formed nuclei, and there is a third class in which the nucleus is tripartite—the true pus nucleus. There seems to me to be very strong grounds for believing those of the second class to present true proliferation. I have seen both nuclei large and considerably apart, and that these cells are capable of division after extravasation has been regarded as probable by several observers.

The leucocytes cannot readily be confounded with cells of epithelial origin (2), which are of considerable size, paler both in respect of protoplasm and nuclei, and frequently show prolongations continuous with cords of fibrin. The most common form of these is the mono- or bi-nucleated cell, rarely they contain three or more nuclei; sometimes a curious bulging exists, the significance of which is not very apparent. An interesting and tolerably common transformation of the protoplasm of the cells given rise to a vesicular appearance (3), the nature of which has received varied interpretations. It is the “myelin-degenerated” cell of Buhl. Sometimes, it looks as though the protoplasm had fallen asunder and a clear space was left, or as though a nucleus had escaped, leaving a vacuole. But in the majority of cases, the nucleus and what remains of the protoplasm are pushed to one side of the cell, which consequently bulges a little there, giving the genuine appearance of a normal fat-cell. Hence it is evident that a fluid occupies the remainder of such cells, and I think there can be little doubt but that this fluid is mucoid. If it is not, what else can it be? In disease the alveolar epithelium reverts somewhat to its original nature, and there can be no doubt but that in intra-uterine life, the epithelium covering the

bronchi in nowise differs from that destined for the respiratory functions proper. Both are in fact mucous epithelia. Again, in other situations, in which similar changes occur, as for instance in the case of acute arthritis, similar mucoid globes are found in the epithelial cells originally lining the synovial membrane, associated with fatty cells and masses of actual mucus, all embedded in a fibrinous exudation. It is therefore to be concluded that these cells in fact represent the goblet cells found in acute bronchitis and like them result from mucoid degeneration of the original protoplasm. A few epithelial cells are in a state of granular degeneration, and show their nucleus but faintly, and some others may be seen of an oval or peg-top shape with long drawn-out processes (4).

The lung thus hepatised becomes gradually paler, as already pointed out, and after a few days commences to loose the somewhat passive state it has remained in during the period of hepatisation. This indicates the commencement of the final stage, or that of resolution.

III. STAGE OF RESOLUTION.—This stage is ushered in (crisis) by the pale intra-alveolar granulations becoming *loosened* from the alveolar walls. This is accomplished by the serum which exudes slowly after the inflammation has subsided, owing to the denudation of the capillaries of their lining epithelium. It is not to be imagined that the fibrinous network dissolves of its own accord. It is doubtful also whether it undergoes a softening comparable to that of a blood clot, for the latter, as in the case of a cardiac thrombus, begins to soften in the central parts, and the process is essentially one of fatty degeneration. In the case of pneumonia it is a muco-fatty transformation. Rindfleisch decided that the fibrin underwent a mucous metamorphosis, but this is a somewhat strong statement. Now what occurs

in the alveolar walls and contents by which resolution is effected? A serous fluid, as has been said, is permitted to escape from the vessels and it is highly probable that a *ferment* of some sort is generated between this fluid and the fibrino-cellular exudation, which causes the latter to undergo the following changes. First the fibrin *breaks down into a granular mass*; then the protoplasm of the contained cells becomes *granular* and *fatty*, and the nuclei *break up into fragments* (see Fig. 8, II). Similarly the mucin-holding cells *burst*, and the whole mass is resolved into a granulo-fatty emulsified *débris* into which not a few leucocytes from the alveolar walls begin to penetrate. This liquefaction releases the walls from the pressure to which they were subjected; a reaction of relaxation sets in, their vessels become highly charged with blood, and the whole lung becomes quickened anew. The epithelium begins to reform, and *absorption* of the liquefied mass now takes place, sometimes with great rapidity. Air is gradually permitted to enter, and the new epithelium is not slow in accommodating itself to the respiratory process. The respiratory act greatly assists the absorption of the liquefied products, as the elastic recoil of the walls serves to pump on the blood and lymph. Unquestionably absorption takes place chiefly into the blood direct, and when this has rapidly occurred, delirium with albuminuria is apt to supervene from the poisoned blood. Expectoration contributes little or nothing to the removal of the *débris*, as Rindfleisch and other authors have supposed. In respect also of the behaviour of the epithelium during and after absorption, the statements by Cornil and Ranvier, and Rindfleisch, require considerable modification. These authors have regarded the alveolar epithelium as undergoing a "catarrhal desquamation" during the period of resolution. According to Cornil and Ranvier, two or more layers of spindle-shaped epithelial

cells line the alveoli, and apparently shew proliferative changes. "This layer of tumefied epithelium is always observed in slow inflammation of the lung, and at the period of decline of acute inflammation."* But it can hardly be supposed that the epithelial changes which have been correctly described as occurring in cases of delayed resolution, can exist either in degree or kind during the process of absorption. So also Rindfleisch, who, in describing his third stage, or that of "yellow hepatisation," remarks that "the whole internal surface is lined with several layers of epithelial elements which are abundantly intermingled with lymph corpuscles. Here in fact we have the signs of a true catarrhal inflammation."† Now to maintain that a lobar pneumonia *terminates* by a catarrhal pneumonia, as Rindfleisch, Buhl, and not a few others have imagined, is a pure travesty of the whole subject of inflammation. The truth is, that as the new epithelium accommodates itself to the alveolar wall, it throws off waste products. As breathing becomes gradually possible, many of the new formed cells are unnecessary and cast away. Nature has provided them just as she provides a large number of spermatozoa for one ovum. Again, if a "catarrhal desquamation" was going on, how could absorption of the pneumonic products *simultaneously* be effected? The two processes are mutually opposed, and I can admit no such desquamation as would interfere with absorption, as occurs in cases of protracted resolution.

The disease having now passed through its last stage, in favourable cases the lung is not long in recovering its wonted strength, and the rapidity of the whole process coupled with such an apparently grave involvement of the whole organ have led some pathologists to believe that the

* *Man. Path. Hist.* vol. ii. part i. p. 109 (Translation).

† *Path. Anat.*, art. Lobar Pneumonia.

affection is not a true inflammation at all, that it is but a high degree of "congestion,"* or represents the effect of a sudden rise of the blood pressure in the lung.†

If acute pneumonia be truly represented by the above description, it may indeed be inquired how it comes about that the disease is often established a week or longer ere resolution occurs? The answer to this is, that in such cases the disease invades the lung progressively, and as a new area becomes involved, the hepatised part resolves (resolution by lysis). Furthermore, many cases of pneumonia, not conforming to the above standard, are capable of resolution. Such will shortly be considered. The course

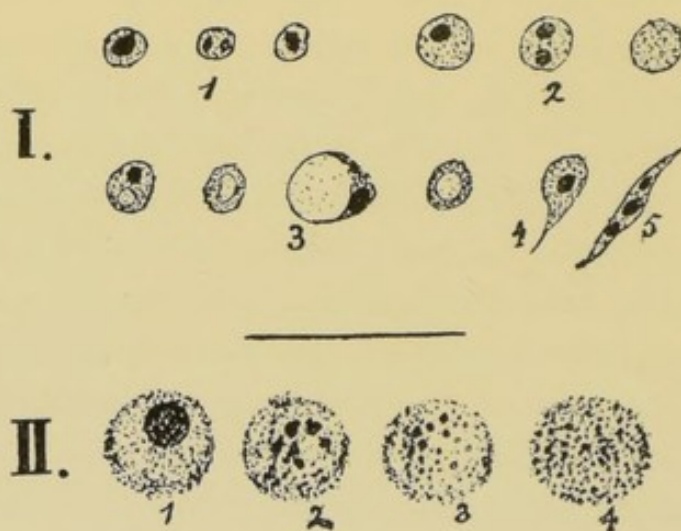


FIG. 8.

I.—EXUDATION CELLS OF PNEUMONIA ($\times 300$).

II.—CHANGES IN PROTOPLASM AND NUCLEUS OF CELL IN
STAGE OF RESOLUTION ($\times 650$).

of the disease which I have described as typical is proved by (1) the examination of lungs from young previously healthy adults, in which areas undergoing resolution existed in juxtaposition to those in which the fibrinous exudation was complete; (2) the minute histological examination of

* Sir A. Clark (*Proc. Med. Soc.* 1885, p. 103).

† Hamilton, *Op. Cit.* p. 110.

the alveolar walls in such cases as compared with those in cases of grey hepatisation or purulent infiltration. In addition to these anatomical tests, the history, physical signs, and sputum of typical pneumonia, attest the disease to consist of the three stages as above described, and it is quite unwarrantable to add a fourth stage of grey or purulent hepatisation to cases in this category.

Some considerations respecting the nature of this—the resolving form of classical pneumonia—will be offered, and then grey or purulent hepatisation will be considered and the various modifications which pneumonia may present, in its earlier stages, course, and issues.

Now, in our inquiry into the anatomical details throughout the three stages of the affection, little reference was made to the fixed corpuscles of the alveolar walls. And this for the simple reason that these corpuscles showed no departure from the normal. The statement therefore made in treating of broncho-pneumonia cannot be too strongly insisted on again here. That is, the only but at the same time, momentous difference which exists anatomically between broncho- or catarrhal pneumonia and acute classical pneumonia is, that the tissue cells germinate and multiply in the former, but show no changes whatever in the latter. Similar epithelial forms, leucocytes and fibrin may in both varieties exist, these are superficial, and afford no criterion as to the nature of the disease, it is to the connective tissue corpuscles alone that the real difference is to be referred.

This leads to the question of the true nature of the changes which characterise acute pneumonia ending in resolution. First, consider hæmorrhagic infarction of the lung. A recent infarction exhibits the air cells filled with an exudation consisting of blood, a fibrinous network, epithelial cells and a few leucocytes. The walls of these air cells are compressed by the exudation, but otherwise show

no departure from the normal. The walls of the alveoli at the edges of the infarction are however turgid with blood and swollen. The large amount of blood in the alveoli relatively to the cells and fibrin is that which characterises the infarcted portion. Next, take the case of diphtheritic inflammation of the lung. The air cells are filled with granular fibrin, lymph cells, and some red blood-corpuscles, while the epithelium has broken up into an amorphous granular mass. The walls are infiltrated with lymph cells having bright nuclei, derived from the blood-vessels and from proliferation of the connective tissue corpuscles. In diphtheritic inflammation, the corpuscular elements are the chief ingredients of the exudation, while the alveolar walls in addition show tissue changes. Now to which of these varieties does acute pneumonia most nearly approximate? Undoubtedly to hæmorrhagic infarction. The only anatomical difference between the two is, that in pneumonia the fibrin is more abundant and the epithelial forms more varied. Hæmorrhagic infarction truly represents a great increase in the blood pressure in the pulmonary capillaries, and if events prove favourable, it clears up much as pneumonia does. But the great deposition of fibrin in pneumonia implies something more than mere increase of blood pressure; it implies an alteration in the pulmonary capillaries brought about by an inflammatory irritant. And in the case of diphtheritic inflammation, the irritant is one of excessive violence.*

Now when the superficial character of the inflammation in pneumonia is considered, as evidenced by the limitation of the anatomical changes almost exclusively to the

* Dr. Hamilton has brought forward the extraordinary and preposterous theory that not only is acute pneumonia the result of mere increase of the blood pressure in the lungs, suddenly applied, but that laryngeal croup, pleurisy, &c., are brought about solely from the same cause.—*Op. Cit.*, p. 111.

extravasation of the constituents of the blood—when this is considered alongside the excessive gravity frequently of the constitutional symptoms, and likewise the vast extent of the lungs involved, then it becomes convincingly manifest that the local changes utterly fail to be ranked as causative of the malady. In the whole range of pathology there is no such extraordinary phenomenon as a vastly extended acute congestion of an organ commencing *per se* giving rise to such grave constitutional disturbances, and frequently disappearing suddenly, without the development of the deeper local inflammatory changes. To affirm that the disease termed acute pneumonia is a local pulmonary inflammation is just as unwarrantable as to affirm that acute rheumatism is a local inflammation of the joints. Acute pneumonia and acute rheumatism are in certain respects perfect parallels. Both are due to specific constitutional irritants or organisms, causing the general symptoms of a fever, and having each its own special sites for locally manifesting itself, the one selecting principally the lung, the other the joints and endocardium. And in respect of these local lesions, in either case they exhibit a marked difference from inflammations proper originating in the same parts. As acute pneumonic inflammation of the lung differs from broncho- or catarrhal-pneumonia, so does acute rheumatic inflammation of a joint differ from acute synovitis. The inflammation attending the specific diseases is a quickly induced, superficial, generalised inflammatory engorgement, not involving the tissue corpuscles proper, not engaged in a deadly warfare with the vital structures, but the messenger of an overburdened constitution, seeking an outlet for its load—a messenger whose departure is generally as signal and as sudden and complete as its invasion.

But how does the irritant in pneumonia primarily act? Here we are led to think of engorged and hepatised or

semi-hepatised lungs, occurring in the course of diseases which greatly weaken the cardiac impulse, leading to hypostatic engorgement, or such as follow on shock communicated to the lung, as witness that produced by direct violence to the chest wall. In the latter class, a pneumonic condition of lung is set up which may partake of the characters of ordinary hepatisation, due to a greater or less degree of vasomotor paralysis of the pulmonary blood-vessels. Now in the case of true pneumonia, it cannot be doubted that the circulation of the pneumonic virus in the pulmonary capillaries causes them to assume a condition not far removed from the above, except in point of intensity. The virus expends itself on the capillary walls, and does not cause a reaction of the cellular elements. It looks as though Nature merely wished to obtain an egress for the impurities flooding the circulation, and having obtained this, sought no more. This leads us to believe that venesection is naturally indicated for the relief or cure of the disease.

Thus it is seen how the inflammation is of so superficial a character; it is an inflammatory congestion, or but the expression of the earliest stages of inflammation, and differs from true primary inflammation which goes on to tissue proliferation. There is indeed strong evidence that in some cases of pneumonic fever, the lung is not hepatised at all, and certain observers have held that the disease may in fact avoid the lung altogether.*

It has very naturally been urged that pneumonia is characterised by concomitant pleuritis, and sometimes pericarditis and even peritonitis. True; and does not this the more certainly prove the general character of the disease? If pneumonia were a local disease, there is no

* Sir A. Clark has advanced in connection with a remarkable case of relapsing pneumonia, very able arguments for the spurious nature of the pneumonic inflammation. *Loc. Cit.*

reason to see why peritonitis or pericarditis should arise. This granted, it is next to be inquired whether a concomitant pericarditis or peritonitis shows the inflammation to be any more real or deep. By no means. For, in the first place the outflow of lymph on the pericardium or peritoneum does not imply that deeper changes have as yet ensued, and secondly, in cases where the pericarditis progresses and a fatal issue ensues, it will be found that the fixed corpuscles of the alveolar walls have partaken likewise of reactive changes. But the latter (which shew that the inflammation has become thoroughly developed), are not directly originated by the acute disease, they are in fact originated by an antecedent weakness or a cachectic state of the body. The stimulus of the pneumonic virus has been sufficient to develop this latent disease-energy, as is not infrequent in the case of habitual drunkards. In this way true inflammatory changes—and changes of a very intense character—may be aroused in certain cases of pneumonia.

Experiments made on animals with cultures of the several cocci found in pneumonia have led to very varied results. It is a curious fact that subcutaneous injection of the organisms of Fränkel, Friedländer, and others, never causes acute pneumonia. The animal dies of septicæmia without any structural alterations in the lungs. When these organisms are injected into the pleural cavity or lung, they cause an inflammation, but it is difficult to decide whether this corresponds to the acute pneumonia of Man. The rusty sputum of pneumonia injected subcutaneously causes death of a rabbit within eighteen hours from septicæmia. I have had the opportunity of examining the bodies of rabbits into whose lungs pneumonic sputum had been injected. I shall describe a typical case. The animal died twenty hours after the injection into the right pleural cavity. On opening the thorax a quantity of serous fluid escaped. The mediastinum

was coated with milk-white lymph, which adhered strongly to the pericardium. Both pleuræ were coated with soft lymph, and the pericardial sac and right pleural cavity contained large quantities of fluid lymph. The right lung was throughout enlarged, dark red, and almost solid to the feel. The left lung was small and pale. The peritoneal cavity contained a large quantity of flaky lymph. Sections made from the right lung shewed the apparent hepatisation to consist in great part, of an extraordinary swelling of the alveolar walls. The distension of their blood-vessels was so great and their tissues so engorged that at some points the alveolar cavities were almost totally obliterated from these factors alone. In general however, the alveolar cavities contained in their greatly diminished space an exudation consisting of leucocytes, desquamated and variously swollen epithelial cells, and red blood cells. There was no conclusive evidence of fibrin in the great majority of the vesicles, but in a few, fine filaments of fibrin were occasionally seen. The epithelium of the kidney was universally broken up into a molecular fatty mass. The tubes were filled with these epithelial masses undergoing acute fatty degeneration. In the case of the liver the hepatic cells were the seat of a granulo-fatty change which caused occasional obscuration of their nuclei, but the fat globules did not exist in such abundance as in the cells of the kidney. From these appearances can it be concluded that the acute pneumonia of Man was transferred to the animal? Now, very recently, what promises to be a definite answer to this question, and a good deal more besides, has been afforded by certain remarkable experiments conducted by Drs. G. and F. Klemperer of Berlin.* These observers have announced that they have rendered animals immune against pneumonic septicæmia by the subcutaneous injection of any nutrient

* *Berlin. Klin. Wochen*, August 24 and 31, 1891.

medium in which the pneumococcus has been cultivated; that the injection of the serum of animals enjoying immunity cures pneumonic septicæmia; and that the serum from pneumonic patients after the crisis, cures pneumonia in rabbits. These results are to be hopefully regarded, and pending further observations, any comment thereon may be suspended.

Still, the observations of Weichselbaum, Gamaleia, Netter and Klein, go to shew that as yet no particular organism can be assigned as the exciting cause of the disease. Weichselbaum * gives four different kinds of organisms as causative of pneumonia; of these the diplococcus pneumoniæ (Fränkel) was of most frequent occurrence, but it was met with also in lobular and patchy pneumonias, and in some secondary pneumonias. The results of inoculations were diverse. He concludes that these organisms cause pneumonia, but "the separation of pneumonias into croupous and non-croupous, lobar and lobular, has an anatomical, but no etiological significance." It is difficult to accept these statements, considering all the facts. I have observed the lance-shaped coccus in chronic pneumonia (see Fibroid Pneumonia), and it is affirmed to exist normally in the buccal secretion of man. Consequently it is regarded by many as an accident and not a cause of the disease.

In Man the lesions which accompany pneumonia are such as are met with in the acute specific fevers, that is to say the so called "parenchymatous" degeneration of organs. There is cloudy swelling of the renal epithelium, and of the hepatic epithelium, causing obscuration more or less of the nuclei; enlargement and softening of the spleen; and occasionally waxy degeneration of the muscles, including the myocardium. The special complications of pneumonia

* *Wein. Med. Wochen.*, Nos. 37, 40, & 41, 1886 (*Edin. Med. Jour.*, xxxiii., part I).

—such as pleuritis, meningitis, peri- and endo-carditis, peritonitis, nephritis—are usually ascribed to the action of the pneumono-cocci in these parts. It is doubtful whether these organisms (presuming them to be the cause of the inflammation) will attack parts previously healthy—the evidence is against this, as for instance in the case of endocarditis it has been found that an old lesion existed in the case of the valves attacked. Leucocytes and fibrin deposited round such lesions have been found by Lancereaux and Netter to contain numbers of pneumococci. Netter* obtained identical appearances in animals by wounding the cardiac valves prior to the inoculation of the pneumonic virus into the subcutaneous tissues. In other cases again, the meningitis or endocarditis is not associated with pneumococci, but with the accidental introduction of pus organisms. The same observers have found histologically, the streptococcus pyogenes of Rossbach in some cases, and absence of the pneumonia coccus.

CORPUSCULAR OR “GREY” HEPATISATION.

From these observations respecting the histology and pathology of typical acute pneumonia, I pass on to the consideration of “grey” or corpuscular hepatisation, and the various modifications which pneumonia may present in its beginnings and in its endings. In this inquiry, the key to the whole situation is to be found in the nature of the ground on which the disease is implanted, or in other words, in the blood and tissues of the individual. And here it may be remarked that there is at the present day a tendency—and a deplorable tendency—to minimise, overlook, or even altogether set at nought the distinctions which pathologists have in the past endeavoured to establish with respect to “inflammatory lymph.” No doubt there was a tendency

* *Arch. d. Physiol.*, Aug. 15, 1886.

amongst many to carry these distinctions too far, and draw too sharp a boundary betwixt the fibrinous and the corpuscular or croupous varieties, in respect of their transformations. Thus Rokitansky* distinguished four different kinds of fibrin. There was the fibrin obtainable from the dead bodies of healthy individuals, and fibrin more than usually adhesive, consisting of a basement membrane invested with delicate wavy fibrils and nuclei. These two forms were plastic or organisable fibrins, and corresponded to the *fibrin* crasis. In contrast with these he described a fibrin, opaque, yellow, and consisting of a granular stratified membrane, in which were a vast number of cells, and another form having somewhat similar characters, but in which the cellular element was excessive and partook of the nature of pus. Such were non-organisable, and always disintegrated; they corresponded to the *croupous* crasis. Paget,† who follows closely in the path of Rokitansky, recognises two forms of inflammatory lymph, the fibrinous and the corpuscular. Sometimes these forms exist in combination and a *mixed* variety results. It was the character of the blood which chiefly determined the character of the inflammatory lymph. This Paget admirably demonstrates by the effects of blistering. He carefully examined the materials contained in blisters raised by cantharidin applied to the skin of thirty patients in St. Bartholomew's Hospital. "In cases of purely local disease in patients otherwise sound, the lymph thus obtained formed an almost unmixed coagulum, in which when the fluid was pressed out, the fibrin was firm, elastic, and apparently filamentous. In cases at the opposite end of the scale, such as these of advanced phthisis, a minimum of fibrin was concealed by crowds of corpuscles imbedded in it. Between these were

* *Path. Anat.*, vol. i., pp. 94, 95.

† *Lectures on Surgical Pathology*, Lect. xiv.

numerous intermediate conditions. . . . The highest health is marked by an exudation containing the most perfect and unmixed fibrin, the lowest by the production of the most abundant corpuscles, and their nearest approach *even in the early state** to the characters of pus cells." Similar forms of lymph are described by Clark, who has minutely studied this subject, but to the fibrinous and croupous varieties he adds a third, namely the proliferative, which is especially concerned in tissue formation.†

Now the exudations observed after blistering are strictly comparable to the exudations of pneumonia. The pneumonia already described is characterised by a well formed fibrin containing relatively few corpuscles, but in diseased, aged, and intemperate individuals, the pneumonic exudation partakes more of the corpuscular nature. And these corpuscles, *at the commencement*, while as yet the red hepatitis exists, exhibit frequently the true pus nuclei. Such cases, unless the disease be very limited, it may safely be assumed, invariably terminate fatally. On the other hand, it not infrequently happens that cases in which the exudation was originally of the most perfect type, present, owing to the failure of normal resolution, a hepatitis composed of corpuscular lymph. This corresponds to the "grey hepatitis" or "purulent infiltration" of authors, but which I prefer to designate as "corpuscular" hepatitis. In these cases, instead of the normal liquefaction and absorption of the exuded products, cellular elements continue to crowd into the alveolar cavities, pushing their way into and gradually disintegrating the fibrinous network. These cells are chiefly composed of leucocytes, but a goodly number are derived from active germination of the alveolar epithelium. The alveoli may be seen lined with variously

* The italics are mine.

† *Lumleian Lectures, The Lancet*, vol. i., 1885, p. 601.

sized spindle-shaped cells, containing one, two, and sometimes three nuclei, and which, as they divide give rise to round cells, much resembling leucocytes (see Fig. 8, I., No. 5). Authors usually describe all these cells erroneously as leucocytes. Now if these elements do not early assume the characters of typical pus cells, that is to say, if they preserve their nuclei entire until the commencement of fatty degeneration of their protoplasm, and if further, the alveolar walls continue normal, neither showing division nor disintegration of their nuclei, nor yet serious interference with their blood circulation then there can be no question but that recovery of the lung may ensue. This is affected by the lymphoid elements undergoing fatty degeneration with disintegration of their nuclei. This disintegration is not to be regarded as simply equivalent to the formation of pus-nuclei. It seems to be a different process, for the nucleus seems to get shattered into a number of fragments, some of them angular, and this without the intervention of the tri-lobate form (see Fig. 8, II.) A certain amount of mucus mixes with these fatty cells, and the resulting mass is in no way different from that seen in normal resolution, except perhaps in its containing a greater percentage of fat. *Post mortem* such lungs have a characteristic slippery or greasy feeling. Absorption takes place more slowly in these cases, corresponding with the greater protraction of the resolution, which is commonly delayed till after the first week.

DESTRUCTION OF THE LUNG.

It has been remarked that many pneumonic lungs shew at an early stage of the affection cells resembling true pus cells amidst the fibrin, usually in considerable quantity. Such cases are very prone to terminate in destruction of the lung. Again, cases presenting corpuscular hepatitis at

a late stage may likewise terminate thus. But in all cases, however they may commence, or by whatever characters their exudate may be called, there is but one process by which ultimately the lung is destroyed. This is not correctly termed "purulent infiltration," for the process is not one in which ordinary pus is formed. How then is destruction of the lung effected? Now, as we have seen, the process of resolution, in its higher or lower degrees, is essentially the same. It consists in the granular disintegration of the fibrin and fatty degeneration of the cells with disintegration of their nuclei. *In destruction of the lung, the alveolar contents present similar changes, but in addition the alveolar walls themselves participate in the process.* This is the kernel of the whole matter. The walls seem unable to absorb the liquefied mass. Whether it be from a corrosive or poisonous action thus engendered from without, or from failure of vitality from within, or both combined, the result is that the walls perish, and they shew precisely similar changes to those occurring in the exudation. For a considerable period, and even while destructive changes have begun, spindle-shaped cells seem to be germinating on the alveolar walls. They are apparently epithelial. The connective tissue corpuscles seem to break up, without shewing evidences of previous nuclear division. Their nuclei are seen in the form of broken fragments studding the tissues of the wall, mingled with granular matter. The elastic fibres become pale, brittle, and at many points denuded of cells; occasionally, they break down and mingle with the surrounding *débris*. Thus, briefly reviewing pneumonia from its beginning to its endings, the process is seen to be simply one of degree. The exudation, however different at first, sooner or later assumes the same condition. It is a secondary factor of the process. It depends on the state of the blood and the tissues generally, whether this exuda-

tion will be liquefied and removed early, or after it has received an accession of "corpuscular lymph," or whether it be incapable of removal, when the blood and tissues perish with it.

VARIETIES OF PNEUMONIA.

Histological variations from the type of true pneumonia are of considerable frequency. In many such cases, the pneumonia is genuine and primary, but antecedent bodily conditions modify its expression. Some authors, and notably Sturges and Coupland, contend that all cases of pneumonic hepatisation which are not characterised during life by the distinct and definite course of "that form which the prevailing nomenclature describes as 'acute sthenic exudative pneumonia,'" must be excluded from the category of true pneumonias. "All we maintain now is that hyperæmia or hepatisation or both, are sometimes the consequences of pre-existing disease, and sometimes they are the expression of the disease itself. In other phrase, there is a disease—pneumonia—of which the most prominent local manifestation is hyperæmia and hepatisation; and there is besides, the anatomical condition of hyperæmia or of hepatisation, apt to supervene in the course of many diseases, and notably connected with the many causes which tend mechanically or otherwise to embarrass the pulmonary circulation." Of the causes giving rise to the latter condition are cerebral diseases, alcoholism and privation, renal disease, pythogenic organisms, pregnancy, and heart disease. Now while admitting that much truth is contained in these remarks, it cannot but be seen that too much stress has been laid on "sthenicity" as a feature of pneumonia. The existence of pleurisy and pericarditis is by no means pathognomonic of this "sthenic" variety, as these authors seem to imply elsewhere; and further, there are abundant

facts in proof of the view that it is not the nature of the irritant but the constitution of the individual which determines the violence of an inflammation. Thus take the familiar example of the effects of the sting of the honey bee. In some individuals, the poison causes great swelling and redness, and constitutional irritation, the effects are "sthenic"; in others again, those of lymphatic temperament, no effects whatever, beyond the initial pain, ensue. This clearly demonstrates that no hard and fast line can be drawn in the case of pneumonia between the sthenic and asthenic forms. It is difficult, if not impossible to tell whether the pulmonary hepatisation in some cases is owing to general or to mechanical conditions. The anatomical appearances alone may afford but little indication. At the same time, there are of course cases not a few, in which it is evident that the hepatisation is not that of lobar pneumonia but is composed of confluent areas of bronchopneumonia, or it may in fact partake of the patchy character of the latter disease.

Cases have been observed in which the pneumonic exudation has been *corpuscular from the outset* without any intermediate deposition of fibrin. Dr. Da Costa* has alluded to this as "yellow hepatisation." He remarks that he had "seen specimens of grey hepatisation, where the lung was firm, yellow and granular, and under the microscope nucleated cells of varying shapes, and no transition from red hepatisation anywhere to be seen." I cannot agree with this observer however when he classes this "yellow hepatisation" as a distinct form of hepatisation from that usually described as "grey." As a matter of fact Da Costa admits this exudation to be "allied to the corpuscular variety of lymph and may break up into pus or fatty

* *American Journal of the Medical Sciences*, October, 1855.

molecules." Dr. Thomas J. Raven* described a case of what he terms "acute purulent conversation of the lung." It set in with pain and rigor, and soon a white viscid mucus was expectorated. The left lung was dull for three fourths of its extent. Death occurred in a week, and five sixths of the left lung was gorged with pus. The extreme apex was crepitant and there was no intermediate red hepatitis; the right lung was normal. This purulent form of pneumonia was frequently met with by Ranvier during the siege of Paris, and is evidently due to excessive poverty in the quality of the blood. In contradistinction to this variety, there is a form, which has been termed the *massive pneumonia of Grancher*,† in which the fibrin is excessive, and fills the bronchi, and contains but few corpuscles. According to Delafield,‡ it is a sign of severe constitutional symptoms. In other cases, *blood* is excessively abundant in the alveoli. It is probable that this is due to a congenital weakness of the blood vessels—a sort of haemorrhagic diathesis; this has been termed the *haemorrhagic form of Schützenberger*. In another way this haemorrhagic exudation may be set up by *embolism occurring after pneumonia*. I have known this occur in a case of pneumonia complicating valvular disease of the heart, in which latterly infarctions occurred in the spleen, kidney, and lower lobe of the hepatised lung. This lobe presented a very curious appearance. The blood had compressed the fibrin, and formed a layer round it; tree-like casts of fibrin were suspended in the extravasated blood.

A special variety of pneumonia has been recognised by some in which the fluidity or serosity of the exudation is a principal feature—the *pneumonia serosa* of Wunderlich and Schützenberger. It is chiefly confined to old persons,

* *Practitioner*, vol. xxxv., p. 94.

† *Gaz. Med. de Paris*, December, 1877. ‡ *Studies in Path. Anat.*, vol. i.

and consists essentially in the admixture or serous fluid with a low form of corpuscular lymph.

Buhl and others have described an *epithelial* form of acute pneumonia in which the exudation, instead of being fibrinous, consists in a conglomeration of epithelial cells. I have never seen it and do not believe in its existence, except as catarrhal pneumonia. In this connection, it may be added that Da Costa* has erroneously described the "red" hepatisation stage of pneumonia as being due to abundance of epithelial forms within the alveoli.

There is to be found in some cases of pneumonia, at a very early stage of the affection, an unusual degree of infiltration of the lymphatics of the framework of the lung with fibrin. This may exist to such an extent that the adventitious coats of the bronchi and blood-vessels, the alveolar septa, and generally also the pleural matrix, are totally obscured. The interstitial connective tissue seems to be the chief seat of the disease, and it looks as though the irritant has gained access from the pleural cavity, and extended along the interlobular channels. It is unlikely that it could travel from the root of the lung, as this is contrary to the lymph stream. Most probably however, it is inhaled. Such cases may present a striking resemblance to the pleuro-pneumonia of cattle. Without presenting a suppurating character, this interstitial pneumonia may be associated with a fibrinous pneumonia of the lung substance. The fibrin is however not abundant in the air vesicles; proliferated epithelial cells and leucocytes are in greater abundance. I have compared such cases with the pleuro-pneumonic lungs of oxen and can detect no difference in the lesions. I have been unable to confirm the statement of Fleming (Diseases of the Ox) that "the pulmonary cells contain serum and

* *Loc. Cit.*

very rarely fibrin"; as a matter of fact I have observed a greater abundance of fibrin in such cases in the Ox than in the corresponding disease in Man. J. H. Steel (Diseases of the Ox) quotes Yeo as describing the origin of the disease in a "chronic ulcerative bronchiolitis" leading to peribronchitis and infiltration of lymphatics. The morbid process thus spreads by the broncho-vascular lymph channels to the root of lung; also by the pleura, which is affected by the subjacent lymphatics. I cannot entertain the idea of a "chronic ulcerative bronchiolitis" as applicable to these cases. Howsoever originated, the condition tends to issue in suppuration, and then forms the disease known as *dissecting* pneumonia. It may possibly issue in induration. In Man, death usually occurs early, and the interlobular septa are seen to be four or five times thicker than normal.*

UNUSUAL TERMINATIONS OF PNEUMONIA.

It has very rarely been observed, after the resolution of pneumonia has been regularly accomplished, that sudden symptoms of great gravity supervene, referable to *acute œdema* of the organ. The cause of this remarkable œdema may in all probability be sought in the onset of a paralytic condition of the left ventricle of the heart, owing to the action of the poisonous products absorbed into the blood. This I throw out as a suggestion. Regarding the terminations of pneumonia in *abscess* and in *gangrene* I have nothing specially to remark. There is a high probability that when genuine abscesses are found after pneumonia, they are not a direct result of the pneumonia, but are secondarily induced from further proliferative changes in the alveolar walls, to which allusion will shortly be made.

* Since this was written I have found some exhaustive papers on pleuropneumonia of the ox by Sims Woodhead in *The Journal of Comparative Pathology and Therapeutics*, vol. i., 1888, pp. 33, 123, 339, to which the reader is referred.

Of an alleged termination in *caseation* I know nothing. But there is a condition, and it is one which demands just and careful consideration, which is sometimes described by the phrase "*delayed resolution*." That is to say, the symptoms of the disease subside, but over a greater or less area of lung, dulness, râles, and deficient breathing persist, and may persist for months, and yet the lung may ultimately clear up and resume its normal functions. Now this is a very remarkable state of affairs, and it is one moreover which has been very inadequately understood. Some have regarded it as due to the accession of "fibroid" changes in the lung; others, as the result of changes outside the lung altogether, to pleural effusion namely. It is no doubt possible that a localised pleural effusion may be confounded with this lesion, but as to the persistence of the pulmonary consolidation, there is little room for doubt. It is also difficult to decide why destructive changes should not more readily ensue in such cases. Charcot* gives the case of a woman who died 35 days after the pneumonia set in, with signs of persistent hepatisation. The alveoli contained mucous masses, white globules, epithelial cells, and free fatty granules, and there was slight thickening of the walls. Delafield† remarks that "the stage of grey hepatisation may remain for weeks without any attempt at resolution. *Post mortem* the lung is firm, dry, and white, and the air cells are quite filled with fibrin, pus, and epithelium. This is the nearest approach to caseation seen in lobar pneumonia." Henoch‡ states that delayed resolution is frequent in the case of infantile pneumonia. I have very carefully examined lungs microscopically in which resolution was protracted, and am in essential agreement with the above quoted authors. The alveolar cavities con-

* *De la Pneumonie Chronique*, Paris 1860.

† *Loc. Cit.*

‡ *Lectures on Diseases of Children*, (New Sydenham Society.)

tain a variable quantity of granular fibrin and round cells, but their principal contents are epithelial cells. The alveolar walls are seen to be lined by one or two rows of spindle-shaped proliferating epithelial cells; and there is at first *absence of interstitial new growth*. The lesion is emphatically an epithelial one, and as such may be compared to the epithelial lesion of the glomeruli which unquestionably follows certain cases of acute glomerulo-nephritis, as is evidenced by albumin in the urine. Such cases ultimately recover. In the case of the lung, the condition is during life liable to be mistaken for phthisis pulmonalis, and it is not unlikely that some cases of phthisis are in fact in this manner set up, by portions of this consolidation breaking down. In other cases, and when the disease is very limited, the part may gradually lose vitality and cicatricial changes ensue, converting the damaged portion of lung into a fibrous mass. In course of time, the lung tissue surrounding the mass becomes emphysematous, and the fibroid area becomes so buried in this emphysematous tissue as to be no longer recognisable by auscultation and percussion. Here, such cases may terminate in either of these three ways—in recovery in phthisis, or in gradual limitation of the area of the lesion, and its ultimate fibrous transformation.

Now a very decided line must be drawn bewixt these “delayed resolution” terminations of pneumonia, and that which is characterised by the development of *nuclear tissue-changes throughout the alveolar walls, and adventitious framework of the lung*. While the fibrinous exudation is forming or has already formed, it occasionally, though at the same time rarely, happens that concomitant changes are taking place in the connective tissue corpuscles of the alveolar walls, the issue of which is in induration of the lung. It is to the consideration of this particular form of induration that the concluding portion of this investigation will be devoted.

CHAPTER VIII.

FIBROID PNEUMONIA.

Introduction.

UNDER the term "fibroid pneumonia" I now propose to describe a chronic inflammatory disease of the lung, which hitherto cannot be said to have been adequately recognised in respect of its mode of origin, anatomical features, limitations, and essential nature. In a stage more or less advanced, it has no doubt been comprehended under the "grey induration" of Addison, the pulmonary cirrhosis of Corrigan, the fibroid phthisis of Clark, and the chronic pneumonia of Grisolle. But fibroid lesions of the lung arise, and develop in various and widely different ways. It is due to the fact that all these fibroid lesions may at a late stage of their progress exhibit both to the naked eye and under the microscope features not at all dissimilar, that it has become customary to apply indiscriminately the terms chronic pneumonia, chronic interstitial pneumonia, chronic bronchopneumonia, &c., to all such cases. This confusion having arisen, it becomes necessary to adopt a distinguishing term for that special fibroid affection of the lung now to be considered. The name I adopted when I first described this disease on its true and more comprehensive basis was "fibroid pneumonia."*

* *The Lancet*, vol. I., 1861, pp. 1308, 1371: previously printed as "Chronic Lobar Pneumonia," in vol. I. 1890, p. 792.

few French writers had some time ago described chronic broncho-pneumonia, it nevertheless has remained in abeyance, has not been adopted in other countries, and consequently may be fitly applied to the affection now to be described, for which indeed, as will shortly be seen, no term could be more appropriate or more truly expressive.

First of all a few observations may be made concerning the ordinary chronic interstitial pneumonia of authors. This affection, howsoever arising, whether from inflammatory processes, more or less acute, or from inhaled impurities, is typically represented in the cirrhotic lung of Corrigan. This shrunken, pigmented, tough lung, on section appearing chiefly to consist of an aggregated mass of dilated bronchi and blood-vessels united by more or less fibrous tissue, is too well known to require further description. Broadly speaking, this cirrhotic lung assumes its ultimate form from the progressive growth and contraction of new fibrous tissue developed in the framework of the lung,—in the peribronchial and perivascular tissues, interlobular septa and pleural matrix, rather than in the alveolar walls. In only a few cases is the thickening of the alveolar walls to be regarded as coincident in time with the thickening of these adventitious structures. Such cases of chronic catarrhal pneumonia generally present a nodular form of cirrhosis, with occasional diffuse induration. This is the “epithelial cirrhosis” of Charcot, so called by this illustrious observer on account of the abundant epithelial forms found in the diminished air cavities, and further because, as he supposed the epithelium was affected chiefly and in the first instance, “the lesions which it undergoes communicating themselves secondarily to the subjacent tissues.” This form of interstitial pneumonia Charcot regards as identical in kind with contracted granular kidney and cirrhosis of the liver, chiefly on account of the epithelial manifestations. In the lung,

the epithelium lining the air cells reverts to the foetal type, and in the liver "the ranges of hepatic cells of a single column are replaced successively by cubic epithelial cells resembling those which exist in the normal state in the interlobular canals, while at the same time the cellular column, or rather the series of cubic cells which hereafter represent it, diminishes in diameter and forms round it a connective tissue embryonic layer of greater or less thickness which separates it from the vessels with which it was previously in immediate contact." As regards the kidney, "at a given period of the process, the granular glandular epithelium of the convoluted tubes is replaced by a cuboid epithelium resembling morphologically the cylindrical cells of the collecting tubes." *

But this lobular form of cirrhosis is always associated with, and most commonly preceded by, indurative changes of a very pronounced character extending from the pleura along the inter-lobular septa and sheaths of the blood-vessels and bronchi. In a large number of cases, the process has begun in the pleura, originating either as a simple pleurisy or pleurisy with bronchitis, and ultimately bringing about the condition known as chronic pleurogenous interlobular pneumonia. Here we have the indurative process progressing from the pleura along the adventitious tissues and ultimately to the alveolar walls. This must be distinctly kept in view as the true order of progression, a progression which has been described with remarkable lucidity by Clark. "Whilst fibre development," he remarks, "has been thus proceeding towards the costal pleura, it has been also advancing into the substance of the lung. The proliferating exudation steals along the inter-lobular fissures, consolidating the peripheral alveoli of the lobules, seizes upon the peribronchial and

* *Maladies du Poumon*, 1888.

perivascular connective tissues, enters the lobules of their roots, and travels along the terminal air passages, blood-vessels and lymphatics into the alveoli."* Again, while the pleural thickening is very great, the process has begun as a peribronchitis, and extending along the areolar tissue seizes on the pleura, and gradually involves the interlobular septa throughout their whole extent, the bronchioles and ultimately the alveolar walls. In yet other cases "the induration extends from the fibrous tissue and lymphatic glands at the root of the lung and proceeds radially along the peribronchial structures."†

Thus it is seen that the cirrhotic lung of Corrigan may arise in at least three different ways. It may begin by lobular broncho-pneumonic indurations with secondary or concomitant induration of the fibrous framework of the lung; or by chronic indurative pleuritis extending by the interlobular channels and peribronchial and perivascular tissues into the pulmonary substance; or lastly by a peribronchitis or inflammation of the areolar tissues at the root of the lung, travelling by the septa to the alveolar walls. But the lung of Corrigan ultimately assumes such a condition as renders it difficult or impossible to tell from the anatomical features in which of the three ways it arose. And unless certain complications arise which will hereafter be alluded to, the alveolar walls, in places where they are still recognisable, are found to be greatly thickened, sometimes showing nodular projections, and the interior of the alveolus to be filled with various epithelial forms in a greater or less degree of degeneration. Further, in the majority of these cases either at the beginning or towards the end of their development, tubercles will be formed, taking on sometimes a caseous and sometimes a fibroid

* Lumlein Lectures, *The Lancet*, vol. I., 1885, p. 602.

† Ziegler, *Path Anat.*, art. 581.

metamorphosis, hence the name so frequently applied to the affection—fibroid phthisis. It may be remarked that Sir A. Clark holds that in many cases at least, a caseous degeneration or metamorphosis overcomes the fibroid tissue in spots and patches at an advanced stage of the disease—a degeneration which has its roots in the constitution of the individual, or it may be, which is hastened by neglect. This caseous metamorphosis he holds to be frequently independent of tubercle, and to proceed to ulcerative destruction of the lung, which at no time is associated with that neoplasm—a “non-bacillary phthisis.” To this view, I at present see no objection.

Hitherto I have made no reference to acute pneumonia as a precursor of induration of the lung. It is and has been generally recognised that ordinary fibrinous pneumonia may issue in simple cirrhosis. According to Ziegler at anyrate, this may be brought about in one way by the lung failing to expand after the resolution and absorption of the exudation, the wall becoming adherent and undergoing a certain amount of thickening. This process is analagous to the “cirrhosis of collapse” described by the same author. Now, it is difficult to see how such a cirrhosis could occur. For in acute pneumonia, the lung is not *collapsed* after the resolution and absorption of the exudation, it is generally considered to be rather expanded. But Ziegler affirms this collapse to be due to persistent obstruction of the bronchi or to compression from without. Again, it may be remarked, if there be persistent obstruction of the bronchi, how could absorption and resolution have taken place? On the other hand, if there be compression from pleural exudation, then the disease is pleurisy and not pneumonia. Consequently, such a form of cirrhosis cannot be admitted as occurring after genuine acute pneumonia, except indirectly as a result of pleurisy.

That acute pneumonia may issue in induration has been held, and the process described, by Andral, Biermer, Broussais, Charcot, Durand-Fardel, Jurgensen, Marchand, Rokitansky, and many others. Such a sequence has however been accounted rare, and even altogether denied by some, as for instance Buhl and Wilks. I shall endeavour to shew however that the general belief is the correct one, and will describe the minute histological features of the fibroid lung so induced. This form of indurated lung commences in a manner totally different from any of the modes already described. This was particularly recognised by Charcot,* who under the term "chronic lobar pneumonia" described what he considered to be the true course of the disease. There could be no objection taken to this term, provided the lesion it represented originated solely from an acute lobar pneumonia. This is the signification it bears, but as will hereafter be shewn, a precisely similar induration of the lung arises and proceeds as a totally independent affection, having no connection at any time with an ordinary acute pneumonia, but which is characterised by an induration following in the immediate wake of a slowly progressing or creeping fibrinous pneumonia of a special kind. To this affection, therefore, whether beginning independently or succeeding to an acute pneumonia, I apply the term "fibroid pneumonia." We may speak of the first variety as "primary fibroid pneumonia," and of the latter as "secondary fibroid pneumonia." The secondary form will first be considered.

SECONDARY FIBROID PNEUMONIA.

It has already been remarked, when treating of acute pneumonia, that in certain cases wherein the disease was of considerable duration, interstitial changes could be detected, consisting in nuclear division and multiplication of

* *De la Pneumonic Chronique*, Paris 1860.

the fixed connective tissue corpuscles in the adventitious structures, pleural matrix and alveolar walls. I instituted observations on a large number of red and grey hepatised lungs with the view of testing whether such interstitial changes could be discovered as occurring in undoubted acute pneumonia, just as similar changes are now well known to occur in cases of genuine acute nephritis. It seemed to me that this discovery finally disposed of the objections which have been urged by Dr. Wilks in particular, against the possibility of a chronic pneumonia succeeding to an acute. Here is what Dr. Wilks said in 1879:—"If under any circumstances whatever of an inflammatory attack in the chest, under whatever name that attack may be called, there result localised dulness with absence of breath sound, and perhaps distant tubular breathing, an empyema may be safely suspected. . . . If it have been thought from the nature of the attack that the inflammation was confined to the lung alone, and yet after some time, when all other symptoms have ceased, there remain a localised dulness with absence of breath sound, it implies that a pleurisy had accompanied or succeeded the pneumonia, and as a result, a local empyema is present. Under all circumstances with a history of an inflammatory attack the result and conclusion are the same." That the physical signs did not result from changes in the lung was further borne out. "I could not imagine," he continues, "what this half-recovered lung was like, or what the results of an acute pneumonia could be, since I had no knowledge of such condition in the *post mortem* room. The slight undetected pleurisy which accompanied the pneumonia continues to progress and the physical signs observed are due to fluid compressing the lung rather than the lung itself being consolidated." Quite recently Dr. Wilks has expressed himself somewhat differently as follows:—

"Whilst working in the *post mortem* room I failed to get good proof of a chronic pneumonic condition succeeding to an acute, and the clinical facts were better explained by other causes. But a few cases for clinical considerations made me *believe* in the possibility of such a sequence, and which I was also bound to admit on the authority of good observers." A little further on he remarks "I have no doubt whatever that what I was taught was in the main wrong, that is—that chronic diseases succeeded to the acute. What I really know is, that these chronic diseases are different in kind, they are chronic in their nature from the very first day they start." * Now it is well known that a great proportion of the cases of acute pneumonia met with are not of the so-called idiopathic or acute sthenic type. Sturges and Coupland † give a classification of all the cases of pneumonia occurring in St. George's Hospital for a period of twenty years. "The result of this labour led to the conclusion that all the fatal cases of so-called pneumonia occurring in this series of years fell naturally, in view of their clinical histories, into four classes. The *first* and largest class would comprise patients who died of tedious and exhausting diseases of whatever kind, such as the constant drain of an abscess, or the gradual extension of large areas of ulceration, as from bed sores; or, generally, where lingering was unusually prolonged and prostration extreme. A *second* class would consist of the subjects of a specific fever, or of some definite affection of a secreting organ and conspicuously renal disease and the poison of typhus. In some of these cases the lung affection gave rise to clinical symptoms resembling idiopathic pneumonia, with which indeed it would claim sometimes a near alliance. In a *third* class hepatisation would seem due mainly to mechanical

* Epistolatory communication to the Author.

† *Pneumonia*. London, 1890.

causes such for example as would arise from defective power of the heart; from obstacles opposed to the circulation owing to some valvular imperfection; from the altered constitution of the blood itself; or from any combination of these states. *Fourthly*, hepatisation was met with in that form which the prevailing nomenclature describes as 'acute sthenic exudative pneumonia.' It was then invariably associated with pleurisy and sometimes with pericarditis; then and only then, it ran a definite course, other organs besides the lung being sometimes involved." In this classification it seems to me that the fourth or idiopathic variety has been too strongly marked off from other cases which although not conforming to that variety in all respects, nevertheless cannot be regarded as secondary to abscesses, renal disease, fevers and mechanical causes. Every Pathologist must be familiar with such cases. How can it be said that one case is more idiopathic than another? If pneumonia be, as is commonly believed, a specific fever, caused by a specific organism, is it not just as likely to attack those who are the subjects of disease as the subjects of health? But because, forsooth, renal degeneration, or heart disease is found *post mortem* with the hepatised lungs, it is said not to be genuine pneumonia. It has not existed in a "sthenic" form, and sometimes parts of the lung, have shewn further changes not observed in such sthenic cases. I have already shewn that an inflammatory irritant which is injected into the system may in one individual produce "sthenic" symptoms and in another produce no symptoms whatever. But John Hunter long ago explained that persons in good bodily health reacted more strongly to, and had a worse chance of recovery from, a sudden illness than those who were the subjects of some chronic disease. "Thus if a man in perfect health gets a very bad compound fracture in the leg or has his leg taken

off, he stands a much worse chance of recovery than one who has been accustomed to local disease. * * * Health brooks disease ill, and full health is often above par; persons in full health are too often at the full stretch of action and cannot bear an increase, especially when diseased; it is a new impression on the constitution, and till it be in some degree accustomed to local disease, it is less able to bear such as are violent," &c.* In this light we judge that those who have chronic diseases react less violently, though not necessarily less fatally, to acute pneumonia than those attacked in health, but there is no reason whatever to deny that the disease in both cases is not one and the same. Further, the presence of previous chronic diseases modifies the pneumonia not only in respect of its acute manifestations but likewise in respect of its consequences. It is quite possible however, that cases of "sthenic" pneumonia occurring in previously healthy persons never issue in induration; most of the recorded cases, including my own, have a history of previously existing chronic disease, either in the chest or elsewhere.

Considerable difference exists in the descriptions of the mode of origin and development of the anatomical lesions which characterise the induration arising from acute pneumonia. With regard to the general process, however, it is commonly held that the stage of hepatisation is unduly prolonged and takes to itself new activities, resulting in the development of fibrous tissue which gradually involves a greater or lesser extent of the lung, inclusive of its various specialised structures, *pari passu* with which change is a darkening of the transforming organ, until it assumes the distinctive iron-grey hue defined by Addison and Audral. It cannot be said, however, that the more minute evolutionary phases of the inflammatory new growth have been at

* *Works.* Vol. III., pp. 281-2.

all adequately comprehended, chiefly owing to the circumstance that death in a very early stage is a comparatively rare event, whilst the later anatomical appearances are such as in great measure obscure and obliterate the very earliest manifestations. The course of the histological changes, will, as I think, be truly represented in the following cases:—

CASE 1.—Mrs. R——, aged 34, was admitted to the Glasgow Royal Infirmary under Dr. Gemmell, Nov. 24th, 1889, with the symptoms of acute pneumonia. In 1887 the patient had acute rheumatism, which left a slight systolic murmur. Ten days previously to admission, she had rigors and severe diarrhœa came on. Temperature on admission 103° ; respirations 60, pulse 120. Sputum viscid, frothy and slightly rusty. Herpes labialis; diarrhœa very troublesome. The left lung was dull on percussion from the apex to the cardiac dulness. There was feeble and tubular respiratory murmur accompanied by moist râles. Posteriorly there were similar signs with abundant bubbling râles. On the 25th the temperature was morning 100.2° , evening 103° ; on the 26th, morning 100.6° , evening 103° ; on the 27th, morning 102° , evening 101° . On this day the diarrhœa subsided. The dulness over the left apex continued absolute, and there was much delirium. The pericardium now became implicated. The expectoration was still viscid, but not copious, and had changed to a lemon-yellow colour. Nevertheless, it gave the usual blood reaction with the guaiacum test, and a questionable reaction to the tests for bile pigments. There was the usual diminution of chlorides in the urine. On the 28th the temperatures were, morning, 100° , evening, 100.6° ; and on the 29th, morning 100.2° , evening, 98.8° . Death occurred on the 30th, six days after admission to the hospital, and sixteen days from the initial rigor. *Summary of the post mortem examination by Dr*

Steven:—The apex of left lung was found to be densely consolidated and moderately adherent. The consolidation extended over the whole lung. On section, the upper lobe presented typical grey hepatisation, while the lower lobe approached more to the characters of red hepatisation. The right lung was normal. There was acute generalised pericarditis.

From pieces of the grey hepatised upper lobe provided me by Dr. Steven, I cut numerous sections, mounted some in Farrant's solution and others in Canada balsam, stained the former in logwood, and the latter first in lithium carmine and then in logwood. It was evident in cutting the sections that the tissue had not the characteristic friability of ordinary grey hepatisation. It was tougher, and lacked the tendency to fall to pieces which characterises the latter. Under the microscope, the appearances were very striking. The alveolar walls were throughout pervaded with large bright kidney-shaped, oval, and spindle-formed nuclei. The youngest of these were rounded, almost occupied the entire cell-protoplasm and took on an intense stain. The walls were normal in respect of the blood vessels, but the epithelial lining was altered. In some places it was shed as a garland into the alveolar cavity; elsewhere, epithelial cells and plates were detached in greater or less abundance. All of the alveolar cavities were occupied by a fibrinous exudation, and in this exudation were scattered nuclei resembling those pervading the alveolar walls. In a few of the alveoli the nuclei were more conspicuously spindle-shaped, and a stalk of new fibrous tissue had united the fibrinous mass to the alveolar wall. Where the stalk entered the exudation its fibres expanded fanlike into it for a short distance, in advance of which were a number of the bright nuclei described. In fact, there was here to be seen the very commencement of the *organisation of the fibrinous exuda-*

tion. Examination of the interlobular septa and connective tissues of the bronchi and blood vessels, shewed the connective tissue cells therein to be likewise partaking of a germinal change, which had not as yet advanced to the stage of new tissue formation. These were the minute changes to be perceived in the greater part of the hepatised lung; at the same time, sections made from certain portions did not shew these phenomena, but on the other hand exhibited the characters of ordinary grey hepatisation. This latter circumstance is probably to be accounted for on the supposition that these parts had been involved latest, when the constitution was more exhausted, and when the organising process, which in fact is to be herein regarded as a healing one, was less prone to be initiated. In this case then, we have a demonstration of how the indurated lung arises; in the next case, a further development of this process will be illustrated.

CASE 2.—Daniel M——, aged 50, ship's caulker, had suffered from cough and expectoration for eight winters. He was admitted to the Glasgow Western Infirmary, January 11th, 1889, under Dr. M'Vail. He was then very weak, had abundant expectoration, not bloody, and temperature of about 103°. There was dulness over the right lung, and sonorous râles were audible over both. There was a distinct trace of albumen in the urine. The temperature remained about 103° till January 15th. It then rapidly sank to the normal and continued so till death on January 18th. *Post-mortem examination by Dr. Coats:*—There was slight œdema of the lower limbs. On opening the thorax, the heart was found to be enlarged, chiefly the right ventricle, weighing 19½ oz. No valvular disease, but the auriculo-ventricular orifices were dilated, the left admitting four fingers, the right, six. There were several globular thrombi at the apex of the right ventricle, one of them softened in

the centre; the muscular fibres of this ventricle were pale, but not obviously fatty. The right lung was firmly adherent, and for about two-thirds of its extent, excluding the extreme apex and base, it presented consolidation of a dark-grey colour, was considerably shrunk in this part and firmly adherent to the pleura. The upper lobe was slightly œdematous. The lung weighed 38 oz. The left lung was something voluminous, but not otherwise remarkable, it weighed 28 oz., and was non-adherent. There was marked hyperæmia of the liver, kidneys, and spleen."

Submitting the right lung to further careful examination, I found the pleura to be somewhat irregularly thickened, and at the root of the lung it united with the peribronchial and perivascular areolar tissues to form dense bands and membranes. The consolidated part had a zone of vesicular emphysema at its apical and basal boundaries, and the bronchi leading to it were puckered and in a state of chronic catarrh. It was smooth on section, though in the more recently affected parts a distinctly reddish somewhat granular appearance was noticeable—a circumstance which Sutton *, Oulmont †, and Leyden ‡ have observed. On close inspection the cut surface shewed a fine mottling, being a network of whitish lines on a darkish ground, and was intersected at intervals by comparatively thin white bands passing in from the pleura. No tubercles, abscesses, or cavities of any sort were anywhere discernable. Under the microscope, it presented remarkable characters. Almost all the alveoli were in whole or in part occupied by globular or pyriform masses of highly vascular fibro-cellular tissue, usually quite fibrous at their immediate periphery, and either sessile or attached by one or more fibro-vascular pedicles to the walls (Fig. 9). Not a few of those masses

* *Med. Chir. Trans.*, 1865, p. 294.

† *Progrès Méd.*, 1877, p. 584.

‡ *Berlin Klin. Wochen.*, 1870.

were individually distinct, but the majority were connected to each other by fibrous bands crossing over the walls, while others yet again coalesced to form more or less extensive fibro-cellular tracts. What of the alveolar space they had left free at their margins was occupied by degenerating epithelial cells and leucocytes, and at certain points the alve-

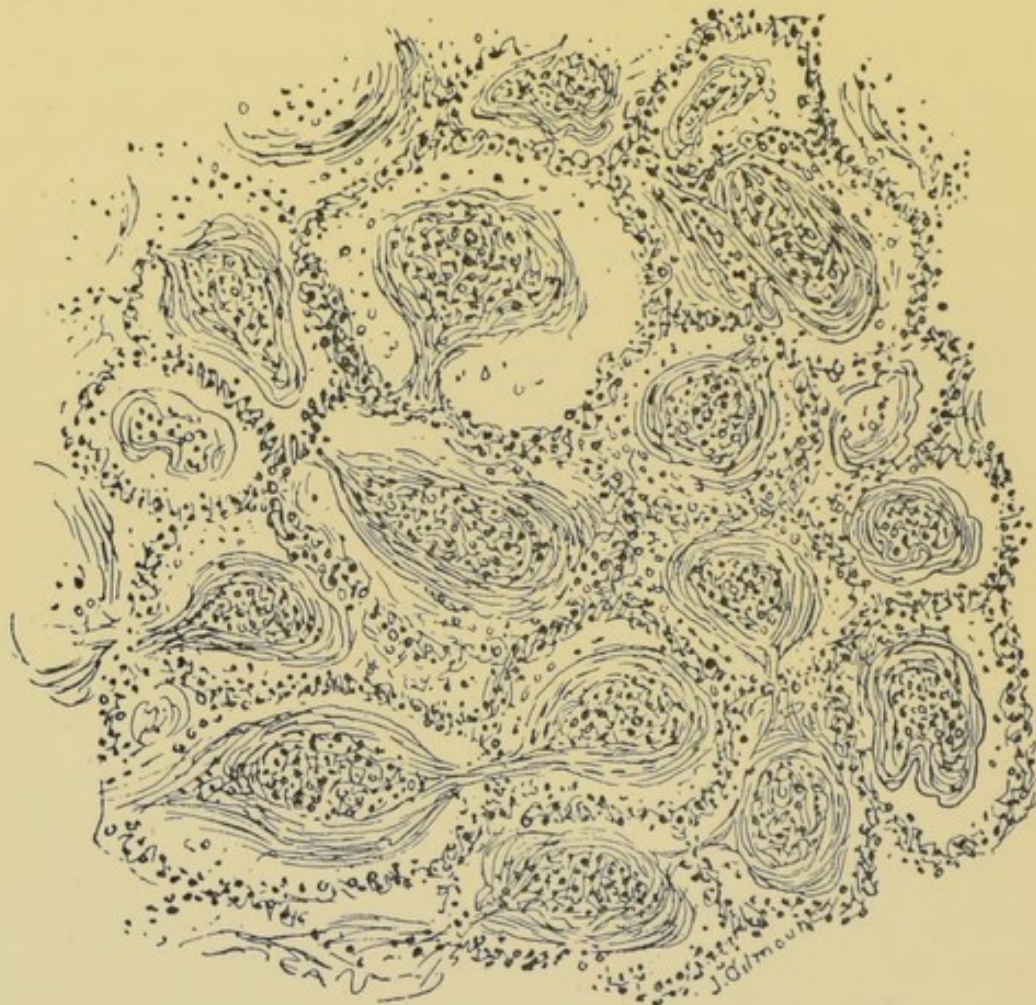

FIG. 9.—FIBROID PNEUMONIA. (Low Power Drawing.)

olar contents consisted solely of such cells mingled with pigmented corpuscles and amorphous matter. The alveolar walls were wonderfully intact throughout, the elastic fibres being easily demonstrated by suitable reagents, such as liquor potassii, but they were exceedingly vascular, and were more or less unevenly infiltrated and thickened by round and fusi-

form fibrous tissue elements, as were also the interlobular septa, the lymphatics, and the interior of the blood vessels. Sections of the granular-looking parts above-mentioned exhibited a few alveoli occupied by a fibrinous exudation, in which degenerated leucocytes were unduly frequent, being

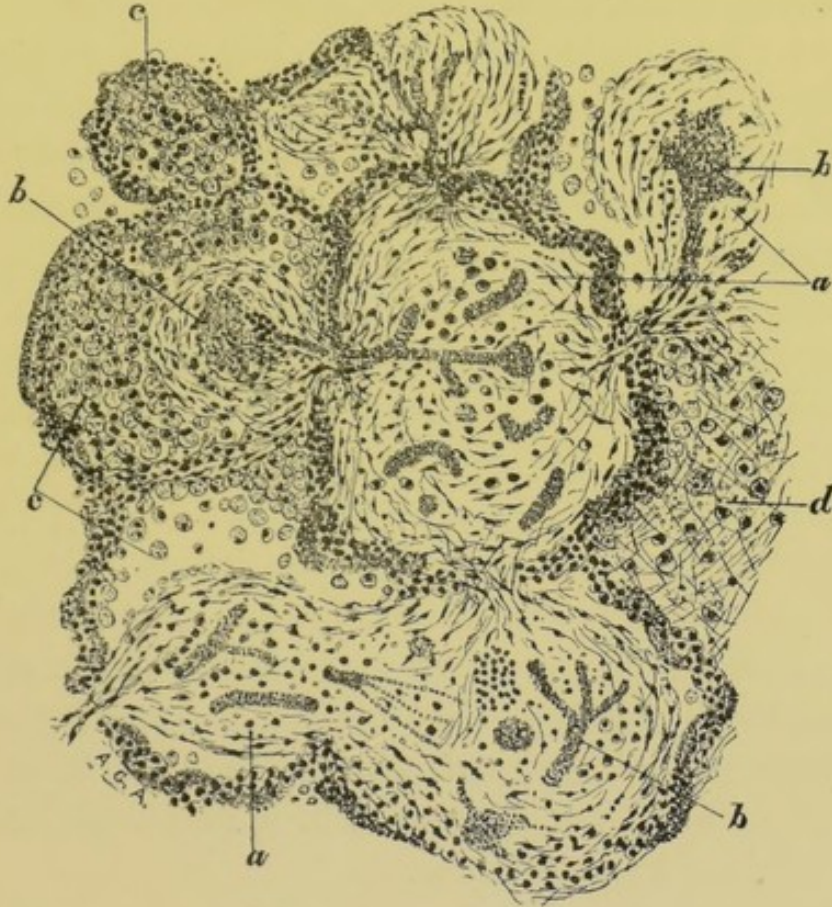


FIG. 10.—FIBROID PNEUMONIA.

a, Masses of connective tissue developed within the alveoli; in some places fusion with the alveolar walls has taken place; *b*, blood-vessels of the new tissue; in two alveoli considerable extravasation is seen; *c*, desquamated and fatty epithelium mingled with some leucocytes and red blood cells; *d*, alveolus filled with a fibrinous exudation ($\times 120$, considerably reduced).

occasionally aggregated in clumps, and in which, further, were interspersed delicate proliferated epithelial cells, some of which possessed two nuclei; which the remaining alveoli, with their walls, contained numbers of young deeply stain-

ing fibroblastic cells and leucocytes, and murally-disposed epithelial cells. Although not present in this case, it is usual to find in fatal cases at this early stage of the disease one or more cavities in the midst of the consolidated tissue, not infrequently taking on a gangrenous character.

In the first case, the organisation of the fibrinous exudation was just beginning; in this case, it is seen to be completed. A good idea of the completed process is given in the accompanying drawings. How differently this form of fibroid lung originates as compared with the cirrhotic lung of Corrigan? Herein, instead of the induration travelling by the bronchial adventitia, and interlobular septa, either from the pleura, root of the lung or larger bronchial tubes, it originates within the alveoli by a remarkable process; the adventitious tissues being thickened usually after the intra-alveolar process is completed. This form of induration is also unique in respect of the absence of bronchiectasis, tubercles, and retraction of the chest wall. No doubt at a very advanced stage, owing to the inevitable shrinking of the new tissue, a certain degree of bronchiectasis may be brought about, but this never approaches in extent that found in other forms of indurated lung.

It is remarkable that the organisation of the fibrinous exudation should give rise to these polypoid-like masses. Why does the organic connection to the alveolar wall not subsist all round the alveolus? Instead of this a process of fibrous tissue, containing one or more blood-vessels, is generally all that at first forms the bond of union. It is evident (and this is apparent from the microscopical examination of Case 1,) that the fibrinous mass previous to its transformation is considerably *loosened* from the greater part of the circumference of the wall. It seems to cling to a portion of the wall, and it is not improbable that the con-

tinued germination of the epithelial cells has to do with this: the mass being pushed aside by the accumulation of these cells, just as in a remarkable case of acute pneumonia formerly described, *blood* had loosened and compressed a fibrinous mould. These and other minute changes in the organising process, with the subsequent development of the same, form a remarkable series of events, hitherto undescribed, and will be considered in full after the narration of the third and concluding case. Nevertheless, the fact of acute pneumonia assuming by this process the chronic state has been apprehended by a considerable number of observers. The first, and in some respects the most accurate description, is that of Rokitansky.* “The red inflammatory product,” he observes, “becomes grey and compact and indurated. The air cells contract over the granulations, coalesce with them round their circumference and become obliterated, their tissue being changed into a cellulo-fibrous structure in which from the similarity of organisation, the granulations are most probably merged. This condition may exist for a long time, and is always followed by cachexia, and especially by dropsical symptoms, and it often proves fatal.” Rokitansky held that the induration might be gradually resolved, or else merge into obliteration of the air-cells and atrophy of the tissue. The curative process was “analagous to the resolution in pneumonia—an exhalation of serous fluid takes place from the inner wall of the air-cells and acts as a menstruum which gradually corrodes and absorbs the indurated granulations, rendering the pulmonary cells again permeable to air.” We cannot of course, at this day admit such a resolution, but as will hereafter be seen, Rokitansky’s opinion as to the disappearance of the indurated granulations is to a great extent true, though the process is very different. Charcot†

* *Path. Anat.*† *Op. cit.*

regarded the development of a chronic pneumonia from an acute to proceed in one or other of two methods. After the subsidence of the acute attack, the physical signs persisted and induration ran a chronic course; or else there were recurrences of acute attacks over the same area, leading ultimately to induration. The characters of this induration after a few months were thickening of the alveolar walls and polypoid vegetations of fibrous tissue in the alveoli. There were no bronchial dilations. Cavities were sometimes found, of a non-tuberculous character. Charcot distinguished cases in which dulness persisted for a time, but ultimately cleared up, as a special group. The anatomical features in such cases, when death occurs from intercurrent disease, have already been discussed. (See Acute Pneumonia.) Barth * remarks that chronic pneumonia may come on after one or several attacks. "The alveolar exudation acts as a foreign body to which the walls react by embryonic proliferation. Microscopically one sees polypi of fibrous tissue. There is cough with tenaceous mucus and bronchitis, then hecticcy. Late development of tuberculosis in such lungs in hospitals,"—which he is careful to maintain as "accidental, through the tubercle bacillus attacking the ground injured by the pneumonia." Marchand † discusses the subject at some length, and lays much stress on the intra-alveolar growth. He maintains the sequence from acute pneumonia, as Virchow and Orth had hinted at first, but as already mentioned Rokitansky was probably the first to do so. Marchiafava travels much on the same lines as Marchand. Eppinger ‡ and Woronicher § also give cases. In England

* *Dict. des Sci. Med.*, Art. *Pneumonia*.

† Virchow's *Archiv.*, vol. LXXXII.

‡ *Sitz. Bericht KK. Acad. Wiss. zu Wien*, vol. LII., 1868.

§ *Prager Vierteljahrschrift*, vol. CXXV., 1875.

Goodhart, Coupland, Sutton, and Green have described cases. Under the title "Acute Interstitial Pneumonia," Goodhart* describes this form of indurated lung as occurring in a young man who died on the twelfth day after admission to Guy's Hospital for the acute disease. In this case the indurated lung contained a cavity two and a-half inches in diameter opening into the pleura. Coupland† succinctly describes a case in which after a cough recurring for ten winters, pneumonia supervened, death occurring on thirteenth day after admission to the hospital. For a full account of the case, reference should be made to the work on Pneumonia by this authority and Dr. Sturges, where it is accompanied by a very striking illustration. In this case, chronic Bright's disease existed, and chest symptoms had been prominent for a good time prior to admission to hospital, which makes it questionable if the case can be admitted as an example of secondary fibroid pneumonia. Sutton,‡ in his paper on "Fibroid Degeneration of the Lung," has appended a drawing of the intra-alveolar growth from a subject aged 26, who died in the third week after the development of acute symptoms. "The air cells in some parts were filled with a fine fibre-like tissue which had a definite and mostly a linear arrangement." So impressed was Dr. Sutton with the appearances that he inclines to view the process rather as "an acute fibroid transformation" than as the result of inflammation alone, though how this transformation is effected is a problem not very easy of comprehension; indeed it cannot now be regarded as a possible pathological process. The cases above referred to I have adduced as examples of what is here termed secondary fibroid pneumonia. It is a

* *Trans. Path. Soc.*, vol. XXV., p. 33.

† *Trans. Path. Soc.*, vol. XXX., 1879.

‡ *Med. Chir. Trans.*, p. 294, *et seq.*, 1865.

difficult matter to decide whether all of them presented a genuine lobar pneumonia, previous to the process of organisation, but on the eminent authority quoted—I have not given the clinical details of Charcot's and Marchand's cases which bear out what I say—there can be little doubt of it in most of them. In all, organisation of the intra-alveolar exudation had taken place, and it now remains to be seen what are the subsequent changes in such cases. This is the point of real difficulty and real importance in the history of these cases: the ignorance of which has led to universal error in the conception and interpretation of the anatomical evolution of this variety of cirrhotic lung. Towards the elucidation of this point, the following case will be submitted, and deductions made therefrom.

CASE 3.—James L——, aged 62, ship carpenter, was admitted to Glasgow Western Infirmary, Dec. 27, 1881, under Dr. Gairdner. The summary of his illness is, that on admission he was suffering from pneumonia of the upper lobe of the right lung which had been preceded by a bad cold. The symptoms partook of a typhoid character, with extreme debility and dry roasted tongue. Chlorides were very deficient in the urine, and the expectoration was rust-coloured. Temperature 104.2° . The respiratory murmur was highly tubular at the apex, and the percussion over the upper lobe was dull and tympanitic, but no râle was discovered in front. Scanty muco-purulent crepitation behind, and latterly in front. Temperature declined gradually to 101.2° (pseudo crisis), but with a second rise to 103.6° , and then a quite gradual decline to very slightly over the normal—about 99.4° . Pulse 116 with the highest temperature, gradually declining to 82, afterwards 104, 80 90. Respirations steady about 26-34. Gradual invasion of lower lobe during resolution in upper. Con-

tinued debility without new symptoms and very slight and insignificant fever. Chlorides continued scanty and albumin was present in the urine from January 7th, with specific gravity 1019-1021; before the albuminuria the s. g. was 1015. The physical signs persisted, especially in the lower lobe. Death occurred suddenly from semi-asphyxia on February 5th, forty days after admission. *Post-mortem examination.*—The body was much emaciated. The heart was normal in size, weighing $9\frac{1}{4}$ oz. Occasional opaque patches were seen on the valves and one of the aortic curtains shewed a slight warty projection. The left lung was moderately adherent posteriorly, its tissue was highly œdematous, and the lower lobe presented considerable condensation, frequently of lobular character, and grey in colour, occasionally yellowish. The right lung adhered very firmly at the apex and posteriorly. The lung was *bulky*, solid, and entirely non-crepitant, except anteriorly at the apex. On section it presented a marked iron-grey colour, with a very smooth cut surface, having none of the granular appearance of ordinary hepatisation. In this condensed portion, the bronchial tubes were somewhat cylindrically dilated, without the formation of definite cavities. The spleen was normal. The left kidney was small, weighing $3\frac{1}{2}$ oz., capsule somewhat adherent, and the surface granular; cortex extremely thin. Cysts were frequent, some of considerable size. [There is no mention in the report, of the right kidney]. The liver presented nothing of special note.

Half of the right lung is preserved in the Infirmary Museum. There is abundant growth of fibrous tissue in the framework of the lung, corresponding to the thickened pleura, but this has caused no diminution in the bulk of the organ. In the cirrhotic lung of Corrigan, an equivalent amount of new connective tissue round the bronchi and

vessels and in the septa and pleura would have exceedingly diminished its bulk. Here it was evident that the pulmonary substance was filled up by new fibrous tissue whereby such shrinking was obviated. Pieces of the other half of the lung were likewise preserved in spirit, and of these I made a minute microscopical examination. The alveoli were much thickened by a richly-nucleated actively-growing tissue, and many of the air cells were likewise filled by globular masses of this tissue, which however, had a much more extensive attachment to the walls than those described in the last case. There were no pedicles joining them, it was a more or less extensive base of tissue. In some tracts, such a new growth had occurred as to render the alveolar walls indistinguishable: all the structures had merged into a mass of fibrous tissue which streamed into the thickened bronchial and vascular sheaths. But a great many of the air cells which were apparent—probably I should say about half of them—were not occupied by fibrous tissue. Their contracted cavities contained desquamated epithelial cells undergoing fatty degeneration, many of them pigmented; large granular nucleated and non-nucleated corpuscles; smaller granular nucleated corpuscles and free nuclei; hyaline irregular plates with occasional attached nuclei; pale hyaline nucleated spindles, and pieces of decayed tissue and amorphous detritus. Not that each alveolar cavity contained all these elements, but each contained several of them, with the exception of a few cavities which seemed to be entirely filled with epithelial cells, and whose walls also were clad with cuboidal epithelium.

Now, it will be seen that this form of fibroid lung corresponds pretty closely with the usual description of authors. It is the chronic interstitial pneumonia of Wilson Fox, consecutive to the acute disease. Fox and others have

regarded the lesion to consist essentially in thickening of the alveolar walls, whilst noting also the epithelial contents of the air cells, but some as Thierfelder and Ackermann,* Heschl,† Marchand,‡ and Ziegler,§ have also noted a certain amount of intra-alveolar growth. Now, the question arises:—Does this usually described lung with its thickened alveolar walls differ in its earliest stages from Cases 1 and 2? Does it indeed exhibit a general organisation of the fibrinous exudation, or is the thickening of the walls the only marked feature from the commencement,—the intra-alveolar growths found, being but localised overgrowths of the wall occurring at a stage more or less advanced? The fact is, that the latter has been the general belief; it has been supposed that the few cases recorded showing the early intra-alveolar formation have been more or less of curiosities, and hence we find Coupland|| remarking that “organisation of the alveolar products as distinguished from growth into the alveolus is not sufficiently recognised.” But I shall now endeavour to shew beyond cavil that there is no such distinction, that, on the other hand, there is but one mode of origin in such cases—the late appearances being perfectly intelligible in the light of well recognised processes governing such pathological new growths, as will be borne out by a critical examination of the various corpuscular and other elements already described as existing in many of the alveolar cavities.

In the first case, while as yet the organising cells were only beginning to appear in the alveolar contents, the colour of the lung was grey, because no new blood-vessels had been formed. In the second case, the colour of the lung

* *Deutsch. Arch. f. Klin. Med.*, 1872, vol. x.

† *Prager Vierteljahrsch.*, 1856, vol. ii.

‡ *Loc. Cit.*

§ *Path. Anat.*, vol. iii.

|| *Trans. Path. Soc.*, vol. xxv.

was reddish, because blood-vessels had formed in considerable abundance in the organised masses. These vessels are connected to those in the walls from which they spring by slender branches passing through the pedicles. The more slender and the fewer these pedicles, the more easily cut off would be the blood supply to the fibrous masses. Now, as the fibrous tissue increases in the walls, becomes more dense and contracts, the blood-vessels, as in all such circumstances, gradually disappear. It follows as a matter of course that the branch or branches supplied to the intra-alveolar tissue are sooner or later obliterated. In this way many of these masses die and disintegrate, and the products of their disintegration are in fact subsequently found, as in Case 3. It is only such of the original masses as have a more or less extensive attachment to the walls at first, that survive and become inseparably bound up with the fate of the alveolar walls themselves. But there is yet another destructive process at work. In many of the new-formed tissue masses, *hæmorrhages* of comparatively great extent occur (refer to Fig. 10). The young inflammatory blood-vessels are very delicate, and anything which causes an unusual rise of pressure in the lung, as an intercurrent exacerbation, will lead to the rupture of many of them. Such hæmorrhages block the circulation, they are in fact analagous to infarctions and may be succeeded by the death of the part. Lastly, it is not improbable that in some cases *thrombosis* may occur in the efferent vessel. Thus as time goes on, these processes continue at work and the lung ultimately assumes the condition described in Case 3. The nucleated spindles and amorphous detritus therein found, result from the breaking down of the fibrous masses, and it is a singular corroborative fact that occasionally pedicles are seen jutting out solitary from the walls. The larger granular corpuscles are partly epithelial, and

are partly derived from formative cells. Many authors describe them all as epithelial, but I am satisfied that such is not the case. This is shewn from the great dimensions assumed by some of them, and the abundance of their nuclei, in one such I counted as many as nine. In carefully prepared sections, their course from the alveolar walls can plainly be traced. They grow in the air cells for a time on what nourishment they can pick up, but soon die, becoming fatty and transformed into Gluge's corpuscles. The epithelial cells on the other hand usually contain pigment granules, and may likewise be seen adherent to the walls. The epithelial origin of the hyaline plates is self-evident. The fact of many of the air cells containing only epithelial cells is due to the absorption by granule-carrying cells of the disintegrated masses, whilst the epithelium lining the alveolar wall lives and proliferates. To these histological circumstances little need be added in support of the sequence maintained. But it may be observed first, that in all the recorded cases wherein death occurred very early, organisation has been noted, whilst in all those not presenting much organisation, the disease had existed for long. Secondly, in localised fibrinous exudations, occurring in connection with slowly advancing fibroid changes, similar organisation occurs. This will be referred to subsequently. Thirdly, on what other hypothesis can the existence of the fibrous masses filling the air cells in the advanced cases be explained? Fibrous tissue cannot grow in this fashion into a cavity; it is essential that there be a previous exudation of fibrinous lymph, affording a pabulum for the new formed cells while as yet the vessels are unformed. And lastly, if the exudation be not organised to begin with what becomes of it? It is not absorbed at first, else the lung would recover; it is being infiltrated with fibroblastic elements, and just as surely as these elements grow and

organise in the alveolar walls, so surely will they do so in their contents. In fact, some have supposed that it is these contents which, acting as a foreign body, incite in the first instance the cellular proliferation in the walls.

I shall now summarise the entire series of histological changes. When the germinal nuclei are first observed in the exudation, it seems as though they must have actually been shed with it; it is difficult frequently to conceive how they could have traversed it. Yet there is no course open but to believe they have pushed their way in. In some cases, leucocytes are shed in greater or less abundance, but these soon die, and the formative cells with their large bright nuclei persist. The question as to organisation from leucocytes must now be regarded as definitely closed. The theory was upheld chiefly by Ziegler and Cohnheim, but the former authority has now abandoned it. Heschl regarded the capillary nuclei as the source of the new tissue, whilst Woronicher ascribed it to the alveolar epithelium. Some authors, *e.g.*, Green, Wilks, Ziegler, speak of the new tissue as growing out from the wall like a "bud." This is incorrect. The young fibroblasts stream into the fibrinous exudation, nourish themselves on it, and generally, but not always, tend to assume the spindle form first towards the periphery of the mass. As the cells continue to invade the fibrin, new vessels spring from those points of the wall corresponding to the insertions of the pedicles referred to, rapidly grow, and unite with others from neighbouring alveoli to form rich pervading plexuses. The central part of the intra-alveolar new tissue remains cellular longest. But from being huddled together at first, these cells soon form into closely packed circular or longitudinal rows, their protoplasm becomes clearer and yet more granular, elongates into fibrillated spindles which become more or less dove-tailed into each other, their

adherent nuclei gradually fading, until ultimately the majority of them will no longer react to staining reagents. The intra-alveolar masses of now fully organised tissue are many of them isolated, but a great many are connected by processes of fibrous tissue of variable thickness crossing over the walls, and not infrequently several of them coalesce. The alveolar space left over at their circumference is occupied by desquamated epithelium, with more or less leucocytes and sometimes red blood discs. Meanwhile, the new fibrous growth actively proceeds in the alveolar walls, and in all the pulmonary structures included in the affected portion of the lung, causing progressive thickening with diminishing vascularity. Many of the intra-alveolar organised masses now disintegrate, die, and disappear after the manner stated. After a time the nuclear activity ceases, the lung in whole or in part has become welded into a dense fibrous mass, generally undiminished in size, and shewing but slight bronchiectasis. If life be prolonged beyond this period, parts of the lung break down from caseous necrosis or peribronchial ulcerations, giving rise to a more or less active form of phthisis.

Such, then, I conceive to be the true anatomical sequence of this variety of fibroid pneumonia. As chronic broncho-pneumonia has been compared by Charcot to chronic granular kidney, so secondary fibroid pneumonia may be likened to the chronic renal lesion which succeeds to acute nephritis. This comparison will be gone into in detail after the primary variety of fibroid pneumonia has been described.

Minor Forms of Secondary Fibroid Pneumonia.—Under whatever circumstances a fibrinous exudation of a more or less limited extent occurs in the alveoli, fibroid transformation is liable to ensue. Thus broncho-pneumonia is frequently of a fibrinous character; tubercular infiltrations

become surrounded by fibrinous exudations, and in the course of chronic catarrhal pneumonia, localised acute fibrinous pneumonia is apt under certain circumstances to arise. In all such cases, this exuded fibrin may become organised, and if from such areas alone sections be examined microscopically, it might be concluded that the disease was fibroid pneumonia. This precaution is specially needed in cases of chronic broncho-pneumonia. I have seen such cases after running a chronic course for years, develop acute symptoms for some weeks before death, and *post-mortem* it was found that these symptoms indicated the breaking down of parts of the diseased lung into cavities. Around these cavities, acute inflammation is set up, and from the nature of the process going on in the alveolar walls the exudation into the alveoli in these areas soon becomes organised. Again I have observed induration of a fibrinous exudation which had occurred in a lobular form around inhaled secretions of a decomposing or gangrenous character. A more important and more generalised pneumonia arising in this manner is that described by Sir William Gull * as "destructive pneumonia," which succeeds to the bronchial paralysis caused by compression of the structures at the root of the lung. It corresponds to the "foreign-body pneumonia" of Friedländer. Saundby † has reported a case of indurated lung which had succeeded to a pneumonia at any-rate associated with symptoms of compression, to which more particular allusion will hereafter be made. These minor and accidental fibroid-pneumonic lesions are therefore to be kept in view in the investigation of this disease.

* *Guy's Hosp. Reps.*, 1879. See also papers by Irvine, *The Lancet*, vol. i., 1879.

† *Birm. Med. Rev.*, 1885, p. 25.

CHAPTER IX.

FIBROID PNEUMONIA (*Continued*).

PRIMARY FIBROID PNEUMONIA.

THAT acute pneumonia assumes a fibroid character, which fibroid changes are so intimately bound up with the acute manifestations as to fully warrant the application of the term "fibroid pneumonia," has, as I think, received full and final vindication. But, as has been incidentally alluded to, a similar fibroid lesion of the lung exists which owns no origin in an acute pneumonia. It begins insidiously, steals its course through the lung, frequently from apex to base, preserves a greater or less uniformity throughout, in respect of its superficial manifestations, and commonly proves fatal after some weeks or months. It is a disease which is extremely liable to be diagnosed as acute phthisis. Examination of the sputum however reveals the absence of bacilli, and *post-mortem* one is surprised to find the affected lung or lungs frequently large and more or less uniformly solid, possibly without a single breakdown, and not a solitary tubercle to be discovered either here or elsewhere in the body.

It is only within recent years that this affection has begun to be recognised, and unsettled and conflicting are the opinions which have emanated from its investigators as to its mode of origin, affinities, and consequences. The disease for instance which Heitler, Wagner, and some others have described as "parenchymatous pneumonia," or

"primary interstitial pneumonia" includes cases of this affection, as also cases of subacute indurative bronchopneumonia, or what may be termed fibroid phthisis. This parenchymatous pneumonia is by these observers asserted to be constantly an independent disease, never succeeding to an acute pneumonia, a *bona fide* affection. They go further than this, and declare that an ordinary acute pneumonia never issues in chronic interstitial pneumonia. In their opinion parenchymatous pneumonia fits in with the disease which Buhl describes as genuine desquamative pneumonia, and which likewise he affirmed to have no origin in an acute pneumonia. Now, the disease which is here termed primary fibroid pneumonia has considerably narrower limits than this parenchymatous pneumonia. With Buhl, Eppinger, Wagner, Heitler, Talma, and some others, I therefore join issue in respect of the following propositions. First, I hold that the lesions which characterise the primary form of indurative pneumonia are to be found consecutive to certain cases of genuine acute pneumonia, and secondly, that the disease is of more limited scope than these observers have assigned to it. I shall shew moreover, wherein consist the fallacies by which these observers have been misled.

In the year 1872 Dr. Ludwig Buhl described an affection of the lungs for which he invented the designation "genuine desquamative pneumonia" to distinguish it from the condition, or rather combination of heterogeneous conditions to which he applied the term "consecutive desquamative pneumonia." The genuine desquamative pneumonia had in his opinion characteristics which sharply distinguish it as an independent affection of the lungs. He held it to be like Bright's disease, myocarditis, or liver atrophy, the localised expression of a general disease. For its investigation, there was generally a period of from four

to six weeks. The disease was lobar in distribution. It might be confined to one lobe, and then commonly the upper one; in other cases the whole lung might be involved, or both lungs. Its course was usually from above downwards, but in a very acute case "all parts seemed to be seized with one stroke." It could be distinguished clinically from phthisis and ordinary pneumonia by the abundant desquamated pulmonary epithelium to be discovered in the sputum, hence the name applied to it. *Post mortem*, the affected lung or lobe was increased both in volume and in weight. Its surface was smooth or else covered with fibrous adhesions. Its elasticity was destroyed. On section it contained little or no air, was diffusely consolidated and had a granular appearance. This granularity differed from that of croupous pneumonia in which the fibrinous plugs filling the alveoli could be pressed out, inasmuch as the granulations were caused by a "remarkable swelling and infiltration which is bound up with the throughout thick and indurated inter-alveolar parts." The longer the disease had lasted the darker did the lung appear, until it became slate grey or even black. Also "while the infiltration, as we have said, appears fast bound to the tissue, there is a spare quantity of gelatinous flux obtainable on scraping the cut surface, which is bloody and turbid from innumerable cell elements." This flux differed from that of the consecutive desquamative pneumonia, which only shows a serous exudation. *The exudation of genuine desquamative pneumonia is of a plastic and productive character.* Microscopically, fatty and frequently pigmented epithelium was to be found in the air cells and bronchioles. These epithelial cells were suspended in a gelatinous albuminous fluid. In the most recently affected parts, there was a more bloody exudation. Latterly the alveolar epithelium consists of cells which in addition had assumed the "myelin" degeneration—*i.e.* hav-

ing the appearance of clear drops in their interior. (Refer to Acute Pneumonia). Behind all these phenomena was a plastic activity consisting in a new growth of fibrous tissue. The disease ended as cirrhosis of the lung, or else as caseous phthisis. The issue in cirrhosis Buhl thus states—"The plastic exudation shows itself as (1) proliferation of the alveolar epithelium and (2) of the connective tissue cells. In cirrhosis, the latter issue comes to the front, so far that the epithelial alterations fall out of consideration." Now, although these morbid appearances described by Buhl have been as a rule interpreted by succeeding pathologists in a manner contrary to his conception of their significance, namely, that they merely indicated the chronic catarrhal pneumonia of Niemeyer, nevertheless, reading between the lines, it becomes manifest that Buhl has at anyrate *included* in his description cases of the disease here named primary fibroid pneumonia, as will shortly be seen. This becomes the more certain when it is considered how short was the duration which he ascribed to some cases, and in which *post mortem*, tubercle was awanting.

Pretty much in accord with the essential features of the disease described by Buhl, cases have from time to time been recorded by subsequent Continental observers. The papers of Dr. M. Heitler of Vienna in 1884 and 1886* embody most of the work done on this subject. Under the title "parenchymatous or primary interstitial pneumonia"—the first of these terms being a suggestion of Buhl's—Heitler reviewed the subject and gave a detailed account of five cases observed by himself. With Buhl, Eppinger, Wagner, and others, and in opposition to Oppolzer, Jurgensen, and Eichorst, he contended that the disease he described was "a primary affection of the lung parenchyma, independent of any other affection of the lung or other organs." At the

* *Wien. Med. Wochen*, 1884 and 1886.

same time he did not deny the possibility of it succeeding to an acute attack, but of such he had no experience, while the observations of others had not satisfactorily shewn it. Heitler remarks, as I think with some justice, that the doctrine of induration succeeding to acute croupous* pneumonia has proved a hindrance to the conception of a primary indurative pneumonia. Buhl on the other hand, had also hindered it by bringing his genuine desquamative pneumonia into a genetic relationship to tuberculosis of the lung. The cases observed by Heitler were subacute or chronic. The duration of the disease was—in two cases, one month and twenty days; in one case, two months and eight days; in one, six months and four days; and in one, nine months and nineteen days. In the sub-acute cases, the temperature as a rule ranged from 38° to 39° C. (about 101° F.) and the respirations numbered 30 to 50 per minute. Dropsy of the extremities was a constant symptom, even with healthy kidneys. These cases ran a course not unlike acute phthisis. The disease began more or less suddenly with pain, cough, and much dyspnœa. Expectoration was entirely absent in one of the cases, in three it was abundant and purulent, and in another it soon became foetid. Sanguineous frothy sputum had also been observed at the beginning, which according to Eppinger, was derived from the new intra-alveolar capillaries. Dulness was found over a considerable extent of one or both lungs, associated with mucous *râles*, and latterly signs of cavities were occasionally developed. The disease attacked sound individuals and also those suffering from previous disease. The ages were 22, 26, 31, 37, and 62. Slight retraction of the affected lung was seen in some cases. *Post mortem* the lung was greyish, tough, smooth on section, and marbled with pig-

* It is a pity the Germans have got into the habit of using this stupid word.

mentation. Walnut-sized cavities were not uncommon. The pleura was more or less thickened from new growth of tissue. Histologically, the appearances differed according to the stage of the disease. In the most recent parts, the alveoli were infiltrated with a cellular exudation, as were also the peribronchial and perivascular tissues. Some of the alveoli contained variously sized nucleated cells, epithelial and other; others contained a fibrinous exudation enclosing red blood cells and proliferated epithelium. If the process was more advanced, the alveoli were thickened by the growth of fibro-cellular tissue, and "the alveoli almost completely filled by an outgrowth from their walls. The wall and contents formed an interdependent mass and showed the same construction." In some spots a finely granular mass and large nucleated epithelial cells were seen in the alveoli. There was no bronchiectasis. Tubercle is described as present in one case, it was limited and a late accident of the disease. Heitler holds the affection essentially to consist in "a diffuse inflammation of the entire connective of the lung, with further consecutive alterations of the lung parenchyma." He goes at length into the question of the disease succeeding to acute pneumonia as represented by the cases of Marchand, Marchiafava, and Ziegler. Dürr had also given two cases of acute pneumonia in children, in which indurative changes ensued. In Heitler's opinion, the evidence decidedly goes against this sequence, but there are also probabilities in its favour. Again, the disease had certainly no origin in a chronic catarrh of the air-passages, there being no history of cough, and when first observed, there was infiltration of the lung. It was likewise clear that the process did not come from the pleura. The disease threw light on gangrene of the lung—gangrenous cavities had been observed in one or two cases.

Heitler has included cases in which pretty extensive

tuberculosis was present. In one such, microscopically examined by Dr. Zemann, the left lung was the seat of tubercular infiltrations undergoing fibroid changes, and around these masses was a fibrino-cellular exudation. In the other lung a cavity, the size of a hen's egg, existed in the posterior inferior part of the upper lobe, and in the surrounding parts were smaller ones filled with dark sanious matter, and irregularly bounded by villous tissue. Outside of these again were purulent foci the size of a pea. The rest of this lobe showed the characteristic fibroid changes already described. Now, it is very doubtful indeed whether such a case as this can be described as a primary fibroid pneumonia, it is most likely that the pneumonic process was induced by the tuberculosis, because in the clinical history it is stated that the disease began with pain in the *left* side, and cough. Nor has Heitler sufficiently distinguished this form of pneumonia from chronic catarrhal pneumonia, in which areas of indurating fibrinous exudation, of a lobular or more or less circumscribed character not infrequently present themselves. So also Talma, who describes a case wherein there was thickening of alveoli and septa, but without any fibrinous exudation, the alveoli being filled with epithelium, and tubercles also present. Such belong to quite a different category.

In English medical literature we find a condition described by Wilks* which seems to me to represent this affection very truly. Speaking of chronic pneumonia he remarks, "As distinct from the more ordinary pneumonic changes seen by a cell production in the alveoli, and *even from the more chronic forms of a similar character* (the italics are mine), there is a condition tending to induration of the tissues where a production of fibrin or fibro-plastic material swallows up and envelops the whole respiratory portions

* *Pathological Anatomy* (Wilks and Moxon), p. 335.

of the lung. The term "interstitial" is scarcely correct, as it might imply a process limited to changes in the interlobular connective tissue, whereas the process of which we speak commences *in the alveoli and their walls*. A portion of lung is seen to have entirely lost its spongy character and becomes hard, dense, and fibrous. The microscope shows a fibro-nucleated material occupying nearly the whole of the pulmonary structures, although within the alveoli there may also be found cells and nuclei. It is a question whether the new product has its origin in the fibrillation of a cell formation or whether it does not spring up entirely in the walls of the alveoli and blood-vessels, and proceed slowly after the manner of a growth." Dr. Wilks affirms that such lungs may become interspersed with cheesy masses, and sometimes the tissue ulcerates and cavities are formed. Now it seems to me that this eminent observer has herein indicated with remarkable fidelity the disease under discussion.

Isolated cases are also to be found which may with tolerable certainty be placed in the category of primary fibroid pneumonia. From the accounts given it is frequently difficult to decide to what extent the disease succeeded to an attack of acute pneumonia. In some cases, chest symptoms had been prominent for some weeks, then an exacerbation took place, when the patient was admitted to hospital, and pneumonia was said to be present, but in how far this pneumonia was a genuine acute attack, it is difficult to say. Such cases have been reported by Sutton, Coupland, Kidd, and Harris. The following cases however seem fairly representative:—

A good many years ago Dr. John Popham* published a case entitled "Chronic Pneumonia" which seemed to him to possess features of an unusual character. The patient, a woman, aged 44, was admitted to Cork Union Hospital.

* *Dublin Journ. of Med. Sci.*, Vol. X., p. 321.

April 14th, 1848, suffering from cough and dyspnoea. She had been ill for six or seven weeks, daily becoming worse. Dulness existed from the clavicle to the mamma over the right lung. Cough was constant, expectoration was thin, viscid, and blood streaked. Pulse, 100—120. (The temperature is not recorded). The signs and symptoms pointed to tubercular disease. Under the clavicle there was subsequently diagnosed either a cavity or a dilated bronchus. She died June 3rd, six weeks after admission to the hospital. *Post mortem* examination revealed the upper part of the left lung to be hepatised, and containing two or three small abscesses holding pus. The rest of this lung was loaded with bloody serum, and there were no adhesions. The right lung was firmly adherent, of fleshy consistence, and somewhat shrunken. It was slate grey in colour. The upper lobe contained a cavity containing two ounces of genuine pus. There was no tubercle. The pericardium contained some yellow serum. "It differed from Corrigan's cirrhosis in which dilated bronchi is a principal feature, and again by the presence of an abscess."

It seems to me unquestionable that this is a typical case of primary fibroid pneumonia. The appearances in the left lung point to recently developed pneumonic exudation, while the older lesion in the right lung represents the fibroid alteration of that exudation. The blood-streaked sputum lends additional confirmation to this view.

Osler*, in a 100 *post mortem* examinations of cases of pneumonia found fibroid induration in one. It was the case of a man, aged 58, who had pain in the side and cough, five days before admission. Temperature, 101° F.; pulse, 106; respirations, 26; expectoration not bloody. Physical signs of pneumonia over right lower mammary, infra-axillary, scapular and infra-scapular regions. During the

* *Montreal General Hospital Reports*, Philadelphia, 1885.

first ten days there was no progress; temperature ranged from 99° to 103° F.; pulse, 100; defective resonance over the same areas as on admission, with a few *râles*. Scanty muco-purulent expectoration, not bloody. Death occurred the 27th day after admission. *Post mortem* examination: "The right lung was uniformly solid, greyish in colour, with recent pleuritic exudation, and the surface on section bathed with serous fluid. On carefully inspecting the cut surface, three features called for attention. In the first place, in certain regions the air cells could be seen with their fibrinous plugs of a very opaque white character, undergoing fatty change. This state existed in very considerable areas. Secondly, there were small localised areas densely infiltrated with pus, and breaking down into definite abscesses. The largest of these was the size of a marble. And thirdly, in several areas of the lung were spots which had a very translucent aspect, firm, smooth, homogeneous, not granular, and had the look of recent connective tissue. In these areas a fibroid change was going on in the lung, the alveolar walls were thickened, and the fibrinous plugs filling the air cells were undergoing transformation into a new growth of connective tissue." This is evidently a subacute case in which the fibroid change occurred only to a limited extent. This circumstance may be due to the fact that death occurred early, and further, the lung shewed signs of breakdown when the indurative process may have lost its vitality.

Saundby* relates a remarkable case of a man aged 39, who had been suffering from a cough for eight weeks previously to admission to hospital. The patient was getting thinner and weaker, and had been a heavy drinker. The temperature was 101° F.; respirations, 24; and pulse, 120. The left lung was dull to percussion throughout, there was

* *Birmingham Med. Rev.*, 1885, p. 25.

no retraction of the chest wall. Three weeks after admission, severe hæmoptysis occurred, and death took place the following day. *Post-mortem*, the left lung was found to be adherent throughout, and the pleura greatly thickened. It weighed 41 oz. It was smooth on section, of a pale grey colour and traversed by connective tissue bands. Dotted over the cut surface were small yellow spots surrounding minute bronchi. The lower lobe was greatly collapsed and the bronchi dilated and thickened. The right lung shewed congestion and œdema. There was an aneurysm of the aorta at the junction of the arch with the descending aorta, the size of a duck's egg, which had caused erosion of the bodies of the 4th and 5th dorsal vertebrae. It contained a little loose black clot and on its upper and anterior wall was a black sloughy hole as large as a shilling which opened into the left bronchus where this crosses the arch. Microscopically there were great tracts of new connective tissue in which were many dilated vessels full of clot. The inter-alveolar stroma was much swollen and infiltrated with leucocytes. "The alveoli themselves were small and generally filled, some with remains of hæmorrhagic exudation, some with desquamated epithelium, and others, perhaps the majority, with a myxomatous connective tissue formed of interlacing stellate cells. The clot and epithelium underwent fatty changes, while the round cells became organised." Dr. Saundby remarks that this was a case of chronic lobar pneumonia, not preceded by an acute attack, but chronic from the beginning. He asks the question, whether aneurysm played a part in producing the pneumonia by pressure on the vessels and bronchi at the root of the lung, causing congestion and the insufflation of the bronchial secretions into the alveoli, and so giving rise to the destructive form of pneumonia, described by Sir William Gull. The bronchiectasis in the lower lobe Saundby regards as

compensatory. "As the lung tissue shrinks, either the wall of the chest falls in or else the cavities in the lung dilate." In this case, there was no retraction of chest wall, and so dilatation of the bronchi occurred.

The cases of destructive pneumonia given by Sir W. Gull are all of them of a much more violent character than that here described by Saundby. In Gull's cases, the pulmonary tissue sloughed, preceded by red and grey hepatisation. Consequently, I am not prepared to place Saundby's case outside the category of primary fibroid pneumonias. At the same time, it is open to question. It may be permitted to remain a good example of the disease in many respects, but with a halo of doubt about it.

Dr. T. Harris* gives a lengthy and good account of a "case of chronic lobar pneumonia of the lower left lobe with subsequent interstitial pneumonia of both upper and lower lobe." This is a somewhat ambiguous description. The case was that of a man aged 65 "who according to his own account had an acute inflammation of the lung fifteen months before admission, ever since which he had been troubled with cough and expectoration." Clinically the case resembled chronic pleurisy with retraction. Dulness existed over the left lung except in the infra-clavicular region where the percussion note was slightly tympanitic; breath sounds absent over all the dull region. Sputum was profuse, thick, and tenaceous, not bloody; temperature normal, pulse 60. *Post-mortem* examination showed, besides the lung affection, recent adhesions between heart and pericardium, dilatation of right side of heart, thrombi in left femoral and subclavian veins, infarcts in the spleen and commencing cirrhosis of the liver. The left lung was retracted and very adherent. The *lower* lobe on section was uniformly solid and smooth, and intersected by white

* *Journal of Anat. and Physiol.*, 1881, p. 502.

fibrous tracts. The bronchi were contracted. There were large tracts of red and grey hepatisation alongside the fibroid induration. The *upper* lobe presented a totally different appearance. It was very much diminished in size, and its cut surface consisted of firm slate-coloured fibrous masses separated by irregular cavities filled with detritus; it had much more the appearance of the lung in Corrigan's cirrhosis, and its bronchi were dilated. The pleura throughout was $\frac{1}{4}$ inch thick. Microscopically, the lower lobe showed in many places patches of typical croupous pneumonia, the alveoli still filled with fibrin, small cells and a few red blood corpuscles; the inter-alveolar tissue being infiltrated with young embryonic elements, and thickened. In other parts the alveoli were occupied by fibrous tissue "which seemed to have its origin from within the alveoli, and transitional stages were seen which showed the correctness of the view, for between the stage of croupous exudation and that of complete organisation, a gradual change from one to the other could be observed, different parts showing the various stages of the process of the transformation of the inflammatory products within the alveoli into fibrous tissue. This intra-alveolar tissue contained capillaries which in some places seemed directly to proceed from the capillaries in the alveolar wall. In other parts, the alveolar arrangement had completely disappeared and was replaced by a more or less fully formed fibrous tissue with round cellular elements which took the staining well." In addition this lobe contained a considerable quantity of recent tubercles, which "from their position there can be no doubt were of later date than the pneumonia and were implanted on the fully formed organisation." The upper lobe shewed different features. "It was a typical specimen of chronic interstitial pneumonia, and differed from the lower lobe in the absence of intra-alveolar exudation, in the

presence of large masses of pigment, in the presence of dilated bronchi, and in the presence of a peculiar epithelium in some of the lung alveoli." Dr. Harris draws the conclusion "that we had here first a pneumonia or pleuro-pneumonia of the lower lobe, and that afterwards both lobes became affected with an interstitial fibrous growth and a gradual chronic thickening and infiltration of the pleura." Again, he remarks that "the patient's history gives evidence of an acute febrile attack sixteen months before death, and the examination of the lung shews large tracts yet in a state of red and grey hepatisation.

It is perfectly evident that Dr. Harris's deductions are erroneous. In the first place how could a *red* hepatisation exist for sixteen months? It might as well be asserted that an ecchymosis from a bruise could retain its original colour for a like period. Again, even if it were possible for a fibrinous exudation to remain so long, how is it that it was not invaded by the fibrous growth going on around it? The fibrinous exudation in this case had occurred within a week or so of the patient's death. Granting the patient's statement to be correct, that an acute inflammation occurred long previously, it is evident that it must have been the upper lobe which was affected, as the oldest changes were found in it, and these changes point to a pleurisy leading to pleurogenous interstitial pneumonia, rather than to a lobar pneumonia. On the other hand, the lower lobe was evidently the seat of a more or less recent fibrinous pneumonia undergoing fibroid changes. The presence of tubercles is suspicious, but let the view of Dr. Harris be accepted that they were "implanted on the fully formed organisation."

In the last place I refer to a paper by Dr. Percy Kidd,* entitled "Subacute Indurative Pneumonia." Here Dr.

* *The Lancet*, Vol. I., 1890, p. 740.

Kidd has noted the work of Heitler and one or two others, and adduces two cases in support of their contention that this form of pneumonia is not a sequel of the acute form. The first of these cases is that of a man aged 44, who had suffered for years from some bronchial irritation. He had drank pretty freely. Three months previous to admission to hospital he was seized with chills, weakness, and cough. Since then he had been ailing with feelings of soreness in the chest, expectoration, shortness of breath, and night sweats. On admission his temperature was 103° ; pulse, 126; and respirations, 30. Right lung was dull, and sonorous rhonchi and râles could be heard in both lungs. Sputum abundant, not rusty. During the first twelve days the temperature varied from 102° to 101° ; pulse, 130; respirations, 40-60. Four days before death temperature fell to normal, and continued between that and 101° . Albumin now appeared in the urine. *Post-mortem*, the right lung was throughout solid, with two small cavities at the apex. Microscopically, the indurated lung presented the typical characters of fibroid pneumonia, as detailed in the previous chapter. On the whole I think it must be admitted that Dr. Kidd's contention is correct, that this case was of a chronic nature from the first—a good example of primary fibroid pneumonia. The same, however, cannot be said with respect to his second case. It need not be detailed here, suffice it to say that it is a typical example of chronic broncho-pneumonia. In one lung the lobular condensations were evidently produced from the insufflation of putrid fluid from the cavity in the opposite lung.

I have introduced the above somewhat lengthy extracts preparatory to a detailed account of the following cases which are illustrative of this affection. The clinical notes I have obtained through the kindness of those physicians under whose charge they were.

CASE 1. Alex. C——, age 40, grocer, of very temperate habits, enjoyed good health till three weeks before admission to the Western Infirmary (under Dr. Finlayson). According to his own statement, he had inflammation of the left lung ten years ago, from which he made a good recovery. The present illness came on with cough and spit. The latter was yellowish, sometimes white, not bloody. He was growing worse, and on admission to the hospital, he noticed a streak of blood in the expectoration. He was thin and wasted and a hectic flush was seen at times. Temperature on admission 103° , next day it was 101° in the morning, 103° in the evening, falling to 101° in the evening after two days; it continued at that degree pretty uniformly for a week, when it ranged from the normal to 101° ; pulse, 120; respirations, 26. Sputum yellow, purulent, and had a disagreeable odour. No perspirations or swelling of the legs. No albumin in the urine. Slight curving of nails and clubbing of fingers. The expiration at the apices was prolonged, and mucous râles were heard in both bases. His condition rapidly became worse and signs of extensive consolidation developed in both lungs, chiefly in the lower lobes. The diagnosis was acute phthisis. Expectoration continued considerably abundant till death, which occurred after three weeks, making in all a period of about six weeks during which the disease ran its course. *Post mortem examination by Dr. Coats*:—Heart flabbly, right ventricle being somewhat dilated and its walls thin, external fat abundant. Mitral orifice admits four fingers, the tricuspid, six. Valvular structures present nothing beyond opaque patches. Left lung is somewhat firmly adherent posteriorly and in the lower parts. It weighs 25 oz. The entire lower lobe is condensed and its bronchial tubes are occupied by a thick yellow pus and are generally somewhat dilated. Condensation homogeneous and presents a slate grey colour. In the

lower part of the upper lobe the bronchi are also occupied by muco-pus and the lung tissue is condensed, but with the appearance more of an ordinary hepatitis, the cut surface being granular, but with considerable grey mottling. The rest of the upper lobe is crepitant though cedematous. The right lung is almost precisely similar to the left. It weighs 35 oz. Yellow pus in the bronchi, which is thick, tenaceous and pultaceous. The larynx and trachea present nothing remarkable. Spleen enlarged, soft, and weighs $18\frac{1}{4}$ oz. The other organs are healthy. No tubercle in the lungs or any part of the body.

After hardening pieces from all parts of both lungs in Müller's fluid and afterwards in alcohol, I mounted and examined a large number of sections. The left base contained areas of dense connective tissue, formed by the fusion of intra-alveolar masses with the fibrous walls of the alveoli. The entire remaining condensation in both lungs had the following characters:—In some areas, the alveoli were filled with fibrin and large epithelial cells. Occasionally the fibrin was replaced by a gelatinous exudation resembling frog's spawn. Encroaching on these areas and occupying much the greater extent of the consolidated parts, was the characteristic induration of the intra-alveolar exudation—globular pedunculated masses of fibrous tissue, very vascular and shewing frequent extravasations (see Fig. 11). The alveolar walls were also somewhat thickened by the nuclear growth. White and red blood cells and proliferated epithelium, the latter in considerable abundance, occupied such space of the alveoli as was unoccupied by the fibrous tissue, and side by side with the tissue-containing alveoli were not a few which were exclusively occupied by the former products. Neither the pleura nor interlobular septa shewed any thickening, but the sheaths of the smaller blood-vessels participated in the

new growth. The bronchial mucous membrane was crowded with lymph cells, and its surface stripped of its epithelial layer, but at rare intervals a few ciliated columnar cells derived from this source were to be found in an alveolar cavity. In many places it seemed as though the plastic pus in the bronchi resulted from the infiltration with leucocytes of fibrinous plugs, and Dr. R. Buchanan on examining this pus found a capsulated organism in every respect resembling the *diplococcus pneumoniæ* of Fränkel. In the deeper parts of the bronchial walls the peculiar epithelial formation, described under "Bronchiectasis" as "duct-like formation" was to be seen. Both the muscular and inner coats of the pulmonary artery were thickened.

This is a very striking and probably unique case. The patient was in the prime of life, and had been a healthy and temperate man. It is apparent that the base of the left lung was the seat of the disease to begin with; it is not improbable that some permanent damage had been inflicted on this part by the inflammatory attack ten years previously. Still as the patient enjoyed good health and had no cough in the interval, it is difficult to connect the older lesion (presuming it to exist), with the present illness. There certainly can be question as to the entire absence of acute pneumonia; the disease crept on gradually through the lungs.

CASE 2.—John M——, aged 63, shoemaker, was admitted to the Western Infirmary under Dr. Coats, suffering from cough, dyspnœa, and swelling of the feet and legs. Family history showed chest complaints as the cause of death in his mother and only brother and sister. Patient had suffered for years from more or less breathlessness, which however was never so bad as to disable him from work. Swelling of the feet was first noticed six months ago. A bad cold was contracted four months ago, getting worse and

patient was confined to bed three weeks before admission. The temperature was 96° — 98° ; pulse soft and easily obliterated, surface of body cold and general condition very feeble. Face wasted and sallow; tongue dry and brown, and lips and gums covered with sordes. Œdema of the limbs and slight œdema of the trunk. Slight cough with little or no expectoration. Percussion normal above, dull over bases; respiratory murmur feeble and accompanied by crackling and bubbling râles. Cardiac dulness and sounds normal. Great breathlessness persisted. Urine albuminous, with hyaline casts and leucocytes. Death took place the second day after admission. *Post mortem* examination: The lower limbs were the seat of considerable œdema. The heart showed considerable enlargement from dilatation of the ventricles. The mitral orifice admitted four fingers; the tricuspid, eight. At the extreme apex of the left ventricle was a large white thrombus, above it were two smaller ones. A similar thrombus existed in the apex of the right ventricle. In both ventricles, the muscular walls were very thin at the apex, being at one point of the left ventricle only $\frac{1}{8}$ th of an inch thick; the thin part being partially filled up by the subpericardial fat. The valvular structures were normal. The left lung was adherent at the extreme apex. It was highly œdematous, with partial condensation. It weighed 27 oz. At the extreme apex beneath the adhesions a dark pigmented cicatrix existed, with cretaceous matter in the midst. The right lung showed more extensive and firmer adhesions. It also showed in the upper lobe cicatrices with cretaceous matter and a small ragged cavity. Otherwise the lung was condensed and œdematous. It weighed $33\frac{1}{2}$ oz. There was no appearance of active or recent tubercular consolidation. The aorta presented recent athromatous patches without much thickening. The left kidney was consider-

ably shrunken, the capsule being firmly adherent and the surface granular, but the cortex not greatly diminished in thickness. Liver of about normal size and its surface highly granular. Spleen rather soft, and weighed $5\frac{1}{2}$ oz. The femoral arteries were considerably dilated and showed considerable patches of atheroma.

The condensation of the lungs was chiefly of the lower lobes; in the case of the right, almost the entire lobe was consolidated. There was no bronchiectasis or shrinking of the organs. Under the microscope the consolidation presented features in all respects similar to those of the first case. The fibrous masses in the alveoli were however herein more dense and homogeneous: less vascular and not a few had the appearance of the sclerosed glomeruli of contracted kidney. Large, swollen, frequently binucleated epithelial cells were in considerable abundance. Many of the alveoli also contained a fibrinous exudation, more or less hæmorrhagic. The alveolar walls were scarcely at all thickened, neither were the interlobular septa. The bronchial mucous membrane was perfectly normal, but some columnar cells were in this case also to be found in a few of the air cells, although it is just possible that this was brought about artificially in cutting the sections. A very marked feature, and one of considerable interest from another point of view, was the extreme atrophy of the muscular coat of the bronchial and pulmonary arteries. Sometimes the muscle existed only as a series of dots along the walls of the smaller vessels, in the midst of a fibroid tissue, and was well brought out in mahogany red by picrocarmine in a light-pink ground.*

* This phenomenon conclusively shows that the observations of Gull and Sutton on the muscular coat of the arteries in Bright's disease were in some cases at anyrate perfectly correct; but which some have been unwilling to concede. Also, I am aware that Klein affirms the muscular coat of the pulmonary artery to be normally interrupted.

When this patient was first seen, he was in a dying state, and the temperature was low. It is not to be inferred from this that the temperature was not previously higher. The dyspnœa from which he had suffered for some years is no

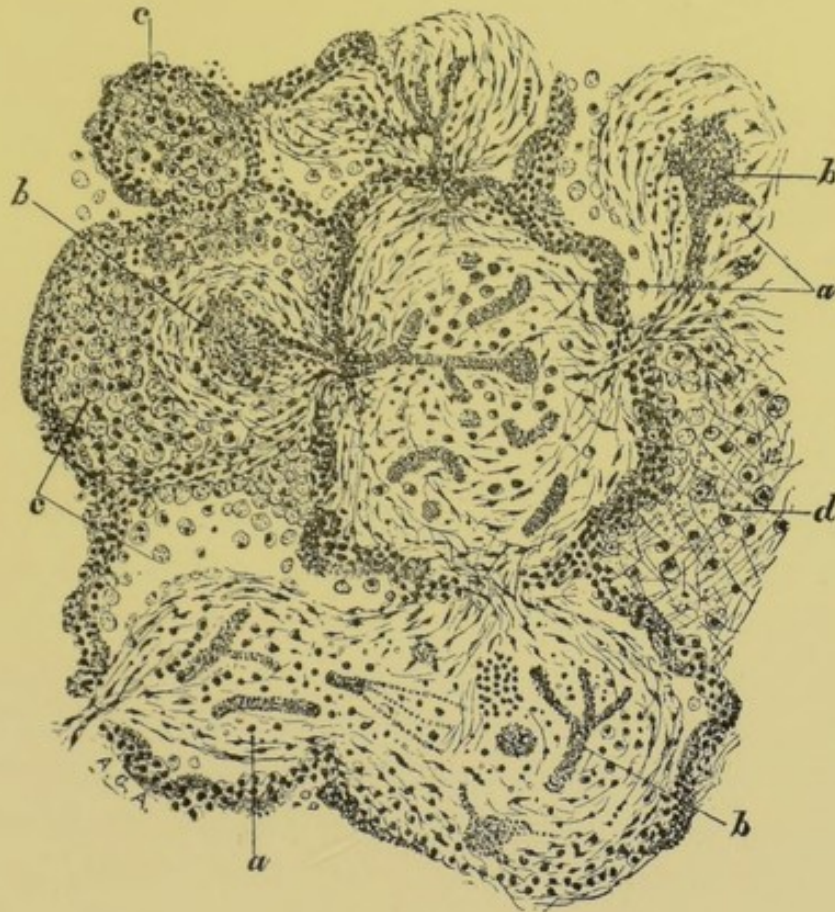


FIG. 11.—FIBROID PNEUMONIA.

a, Masses of connective tissue developed within the alveoli ; in some places fusion with the alveolar walls has taken place : *b*, blood-vessels of the new tissue ; in two alveoli considerable extravasation is seen ; *c*, desquamated and fatty epithelium mingled with some leucocytes and red blood cells ; *d*, alveolus filled with a fibrinous exudation ($\times 120$, considerably reduced).

doubt to be connected with the chronic renal disease, and the state of the heart. The history points to a bad cold received three months prior to his appearance at the hospital, as the cause of the fresh pulmonary trouble. It is apparent that a pneumonic affection of an insidious

character established itself, taking on fibroid changes. The total absence of disease in the bronchi is noteworthy as compared with the last case, as is also the existence of older fibroid changes in other organs of the body.

From the consideration of these cases, together with the indications afforded by those previously alluded to, it is plain—(1) that there is a pneumonic lobar affection of the lungs, insidious in its origin and subacute or chronic in its course, characterised essentially by induration of a creeping fibrinous exudation, and by interstitial changes, and accompanied by proliferation and fatty degeneration of the alveolar epithelium, and it may be also, of the bronchial epithelium: (2) that anatomically the disease commences in a manner absolutely identical to chronic pneumonia succeeding to an acute attack. In the earlier stage at all events, the morbid anatomy of the disease has such distinct and unequivocal features as to give the affection an assured position, and to permanently exclude the possibility of confounding it with any other chronic affection of the lungs. And inasmuch as this disease, whether preceded by an acute pneumonia or being chronic from the first, has as its leading feature the development of a nuclear fibrous tissue in, with, and about, a pneumonic exudation, it is most fitly termed “fibroid pneumonia.”

An excellent comparison can be drawn between this affection and parenchymatous nephritis. It is well recognised that the latter disease, often termed “large white kidney”—may succeed to an acute nephritis or may be chronic and insidious from the beginning. In any case, it has different features to, and is much sooner fatal than, the true granular kidney, which latter Charcot compared anatomically to chronic broncho-pneumonia. Howsoever arising, parenchymatous nephritis is characterised both by interstitial fibrous growth, and by desquamation and fatty

degeneration of epithelium. Moreover, there seem good grounds for recognising a special group in which the interstitial changes are specially marked in the glomeruli, and in respect of which the comparison with fibroid pneumonia can be drawn remarkably close. There can be no question that the capillaries of the glomeruli bear to the glomerular cavities a relationship almost identically similar to that which the pulmonary capillaries bear to the alveolar cavities, and further, it is remarkable that the epithelial lining of both capsule and tuft, but especially of the former, approximates in character very closely to the pulmonary epithelium. Now when glomerulo-nephritis has lasted for some time, when it has become subacute or chronic (and this is by no means confined to scarlatinal cases), a great many of the glomerular cavities are seen to be filled or partially filled with a new growth of connective tissue—a tissue obviously developed between the capsule and the tuft. With Cornil I hold this as certain, notwithstanding the opposition of Ziegler and others. Further, I have obtained good evidence that in some cases at least, this fibrous tissue is produced by the invasion of a fibrinous exudation in the periglomerular space, by fibroblasts proceeding from the intercapillary connective tissue.

Not only in minute anatomy, but likewise in respect of duration, the comparison holds, some cases running their course quickly, others remaining chronic for a longer or shorter time.

Again the kidney supplies a complete answer to one of the most formidable objections which has yet been urged against the possibility of a fibroid pneumonia succeeding to an acute, and which is supposed to establish the constant independence of the chronic affection. It is well known that there are many cases of acute pneumonia in which, after the crisis or pseudo-crisis, dulness, deficient breathing

and râles persist for months, and yet the lung ultimately recovers itself. Wagner* especially lays stress on this as distinguishing the chronic issue of a genuine pneumonia, in opposition to induration. But the same thing is found in connexion with acute nephritis. It is common to have albuminuria and dropsy persisting more or less for months after an acute attack, but with ultimate recovery. In this case, as in that of the lung the morbid condition must be regarded as due to the persistence of *epithelial* as apart from interstitial changes. As a matter of fact, in pulmonary cases of this sort I have already described abundant proliferated epithelial cells as existing amidst a granular material in the lung alveoli, the walls of which are found to be lined with spindle shaped epithelial cells, containing two and three nuclei (see under Acute Pneumonia).

Now it has already been remarked that under the term "parenchymatous pneumonia," certain writers have included cases which have not the definite characters enunciated above. Cases in fact of subacute or chronic broncho-pneumonia, sometimes associated with tuberculosis more or less extensive, have been adduced as examples of the disease. At the same time it is no doubt true that at an advanced stage of fibroid pneumonia, tubercle may become engrafted as an accident of the disease. There can be no question whatever that the term "parenchymatous pneumonia" has been applied to a variety of destructive lesions of the lung associated with and dependent upon necrotic excavations, gangrenous cavities, lobular pneumonias and secondary fibroid indurations. Hence the term having no definite signification is objectionable, and had better be discontinued. I shall give one or two illustrative cases bearing out the truth of this remark.

The first of these is that of a woman, aged 41, who has

* *Loc. Cit.*

been subject to cough for years, but became seriously ill three weeks before her death, from exacerbation of the pulmonary symptoms—the sputum being profuse and attended with slight hæmoptysis. Dulness existed over the left lung almost throughout and over the right base, and loud crepitations were heard in both lungs. There was much dyspnœa, and when first seen (the day before she died) the face, arms, and upper part of the trunk were livid. Temperature 99.8° , respirations 44, and pulse 100. *Post mortem*:—The body was extremely obese, and with slight œdema of the feet and ankles. The left lung was firmly adherent at the apex and posteriorly. A large irregular cavity existed in the apex, the walls of which were in a sloughing condition. In the lower part of this upper lobe were a number of small gangrenous-looking cavities, containing a large quantity of purulent and sloughy material. Round these cavities the pulmonary tissue was condensed. In the lower lobe of this lung were frequent focal condensations, occasionally of a diffuse character. There was also some emphysematous tissue. The right lung chiefly showed a considerable degree of hyperæmia. Heart was voluminous, soft, both ventricles dilated, and the right in addition showed considerable hypertrophy. The liver presented “nutmeg” characters and the kidneys were hyperæmic. Under the microscope the alveolar walls generally through the left lung were much thickened by interstitial new growth, the alveolar cavities being contracted and containing the characteristic epithelial cells. But around the cavities in the upper lobe and in the condensed lobules of the lower lobe, the alveolar cavities were to a large extent filled with recently effused fibrine which was rapidly becoming organised, and in certain areas the organisation was complete. Hence if a limited microscopical examination were made, it might be concluded that the

case was one of fibroid pneumonia. The anatomical disclosures clearly show that this was a case of chronic broncho-pneumonia (as is evident from the thickened septa and alveolar walls); that towards the termination of the disease, parts of the lung broke down, and circumscribed areas surrounding such ulcerations had become the seat of a fibrinous exudation which underwent fibroid metamorphosis. The lobular condensations in the lower lobe are most probably to be regarded as produced by the insufflation of the sanious contents of the cavities. This case I have given in some detail to emphasise the fact already adverted to, in treating of the secondary variety of fibroid pneumonia, that limited secondary indurations of the lung are not at all uncommon, and are apt to mislead, if the history of the case, the naked eye features and general morbid anatomy of the affected lung be overlooked.

A lung, the seat of bronchiectasis and cavities—possibly gangrenous—and presenting lobular and partially diffuse consolidation, is not to be regarded as an example of fibroid pneumonia. In nine cases out of ten such, the consolidation is secondary, and when diffuse, results from the confluence of several lobular patches. The following case illustrates this:—A man, aged 59, from whom no history was obtainable, was admitted to the hospital in a state of great exhaustion, with a temperature of 102.2° , very oppressed breathing and profuse purulent and very offensive expectoration. He died shortly after admission. *Post mortem*, both lungs were consolidated throughout the greater part of their extent. The consolidation was lobular, but at intervals was diffuse. It had generally a remarkable appearance, like a number of tubercular consolidations. Two gangrenous cavities communicating with dilated bronchi were found in the base of the left lung, while the right had a cavity in the apex and

another with ulcerated walls resulting from a dilated bronchus at its base. Microscopical examination of the condensed lobules shewed their central area to be reduced to an abscess, surrounding which was a dense exudation, partly purulent and partly fibrinous, and at many points new fibrous tissue was growing in the alveolar walls and throughout the fibrinous exudation. It is very evident that an irritant of unusual violence—the gangrenous secretion namely—had invaded the lobules, partially destroying them, and setting up a reactive inflammation towards their periphery. Heitler describes a case which seems to be of this nature, and which, if even in the beginning was a “parenchymatous pneumonia” leading to cavities, is demarcated off clearly enough from primary fibroid pneumonia.

Here I bring to an end my observations on this disease. Regarding its further progress and terminations, it is beyond the scope of my present work to enter. Suffice it to say, that when the disease becomes very chronic, it doubtless partakes of the characters of “fibroid phthisis.”

The affection has been adequately established from the standpoint of pathological histology, and it remains that it receive due clinical recognition. There are clear indications not a few, both positive and negative, on which a diagnosis might be based, though in some cases this may doubtless prove a difficult and perplexing, yet by no means insuperable task.



INDEX.

- ABERRANT growth of smooth muscle
 in bronchial wall, 65
 Abscess of the lung, 143
 Absorption of exudation in pneumonia, 124
 Acini of mucous glands, hyperplasia
 of, 44
 contents, 49
 Acute bronchitis, 19
 causes, 20, 21
 artificial, 22
 commencement, 22, 23
 varieties, 37
 Acute interstitial pneumonia, 142
 ,, phthisis, 175
 ,, pneumonia, 118
 ,, purulent conversion of the
 lung, 140
 ,, Edema of the lung, 143
 ,, rheumatism, 129
 Adenoid tissue, cords of, 112
 Adenoma, 47
 tubular of liver, 48
 Adventitia of bronchi, 15
 in acute bronchitis, 36
 Air pressure in bronchi, 75, *et. seq.*
 Angioma of liver, 76
 Arteritis obliterans, 50
 Arthritis, exudation cells of, 123
 Artificial bronchitis, 22
 Asthma, bronchial, 78
Asthma nervosum, 86
 Atelectasis, 103
 Atrophous lung in relation to bronchiectasis, 76
 Atrophy, stage of, in chronic bronchitis, 52
 Atypical epithelial growth, 46, 47, 48, 72

 BACILLUS in bronchial sputum, 21
 pneumoniae, 131, 132
 "Ball-valve" theory, 111.
 Basement membrane of bronchus, 11
 in acute bronchitis, 28, 29, 38, 56
 in chronic bronchitis, 41, 43, 56

 Basement membrane of bronchus,
 in bronchiectasis, 73, 74
 Bile ducts, glands of, 49
 new, of cirrhosis, 72, 73
 Blood pressure in acute pneumonia,
 126, 128
 Blood vessels of the bronchi, 2
 dilatation, 40
 of lung, 102
 Bridges in the bronchi, 42, 59, 62
 Bronchi, divisions, 1
 functions, 80
 measurement, 83
 Bronchial arteries, 2
 veins, 2
 results of compression, 41
 Bronchial asthma, 78
 Bronchial walls in emphysema, 42, 45
 Bronchiectasis, 58
 atrophic form, 58, 76
 inflammatory lesions, 60
 and pulmonary cavities, 73
 in fibroid lung, 162, 200
 Broncho-pneumonia, 103
 chronic, 115, 117
 Brown induration of the lung, 40, 67

 CAPILLARIES of lung, 102
 Capillary bronchitis, 104
 Cardiac thrombi, 123
 Cartilages of the bronchi, 15
 in chronic bronchitis, 51, 53, 54, 55
 Caseation in broncho-pneumonia, 115
 in reference to acute pneumonia, 116, 143
 in fibroid lung, 149
 Cases of fibroid pneumonia, 163, *et seq*
 primary form, 182, *et seq*
 Catarrh in asthma, 91, 92
 Catarrhal desquamation in acute pneumonia, 124, 125

- Catarrhal secretion, decomposition of, 57
 Cavities, pulmonary, 73 74, 75
 Cerebral centres for asthma, 82
 Channels and caverns in lung, 64
 Charcot's crystals in asthma, 86, 93
 Chronic bronchitis, 40
 „ disease and pneumonia, 164, 155
 „ interstitial pneumonia, 46, 168, 176
 „ lobar pneumonia, 151
 „ pneumonia, 146, 147, 168
 "Chronic ulcerative bronchiolitis," 143
 Ciliated epithelium of the bronchi 3, 4
 Circumscribed bronchitis, 42
 Cirrhosis after acute pneumonia, 150 of collapse, 150
 Classification of pneumonia, 153
 Coagulation-necrosis of epithelium, 114
 of pneumonic exudation, 120
 Coal miner's lung, 40
 Cocci in capillary bronchitis, 104
 Collapse, lobular, in broncho-pneumonia, 110
 Columnar epithelium of bronchi, 3
 Communications between pulmonary alveoli, 103
 Comparison between kidney diseases and varieties of fibroid pneumonia, 196 *et. seq.*
 Congestion, stage of, in pneumonia, 119
 Conclusions respecting fibroid pneumonia, 196
 Connective tissue cells, 5
 of bronchi in inflammation, 35
 in relation to muscle, 66
 Connective tissue of bronchial wall, atrophy of, 56
 "Consecutive desquamative pneumonia," 176
 Contraction of the bronchi, 80, 81, 89, 90, 91, 95,
 Corpuscular or grey hepatisation, 134, from outset, 140
 Corrigan's cirrhosis, 61, 146, 147, 149, 162
 Coryza and asthma, 85, 95
 Cough, 28
 Course of fibroid pneumonia, 172, of typical acute pneumonia, 119
 Crases, fibrin and croupous, 135
 Croupous bronchitis, 20
 "Cure" of chronic bronchitis, 42
 Cyanotic induration, 52, 53
 of the kidney, 40, 52
 Cylindrical-celled adenomata, 48
 Cystic dilatation of mucous ducts, 44, 49
 Cystoma of uterus, 44
 DEBOVE'S layer of cells, 5
 Delayed resolution in pneumonia, 143
 "Deobstruent function" of the bronchi, 82, 92
 Destruction of the lung, 137
 "Destructive pneumonia," 174
 Diaphragm, spasm of, 79
 Diphtheritic inflammation of the lung, 128
Diplococcus pneumoniae, 133
 Dissecting pneumonia, 143
 Ducts of bronchial mucous glands in acute bronchitis, 22, 34
 in chronic do. 49
 "Duct-like formation" of epithelium, 37, 71, 72, 192
 Dyspnoea, 87, 88, 94
 ECTASIS, capillary, 76
 Empyema, 152
 Endocarditis in pneumonia, 134
 "Endolymphargal cords," 112
 Epithelial cells on false membranes, 74
 Epithelial cirrhosis of the lung, 147
 Epithelial metamorphosis in the bronchi, 70
 "Epithelial" pneumonia, 107, 142
 Epithelium of bronchi, 3
 of rabbit's bronchus, 4
 regeneration, 7
 in acute bronchitis, 20, 24, *et seq.*, 30, 31
 in chronic do. 43, 44, 53
 in broncho-pneumonia, 105
 in acute pneumonia, 119, 122, 143
 "Expiratory blast of air," 83
 Exudations after blistering, 135
 of pneumonia, 136
 FIBRIN, homogeneous in broncho-pneumonia, 113
 Fibrinous exudation, in asthma, 86, 88
 in chronic broncho-pneumonia, 174

- Fibrous changes in pneumonia, 145
 Fibroid phthisis, 146, 149, 201
 Fibroid pneumonia, 146, (continued)
 175
 and parenchymatous nephritis,
 196
 cases, 163, 182
 Fibroid transformation of muscle, 53
 of cartilage, 55
 "Fluxionary hyperaemia" theory of
 asthma, 79, 85
 "Foreign-body pneumonia," 46
 Functions of the bronchial muscles,
 82
- GANGRENE of the lung, 143
 Gases, interchange of, in lung, 101
 Gastric polypi, 44, 47
 "Genuine desquamative pneumonia"
 176
 Genuine fibrous transformation of
 cartilage, 54
 Gianuzzi, crescents of, 9, 34
 Glands (*see* mucous glands)
Glandular angina, 49
 Goblet cells, 3, 23
 Grey hepatisation, 134
 "Grey induration," 146
- HAEMORRHAGIC infarction of the
 lung, 127
 Haemorrhagic variety of pneumonia,
 41
 from embolism, 141
 Hay fever, 78, 85
 Heart disease, bronchi in, 40
 Hepatisation, stage of, in pneumonia,
 120
 Hyperplasia, and adenoma, 47
 Hypertrophic stage of chronic bron-
 chitis, 43
 Hypostatic congestion, 20, 119
- ICHTHYOSIS linguae, 49
 Idiopathic pneumonia, 154
 Immunity from pneumonia, 132
 Induration, from acute pneumonia,
 155
 microscopical characters, 157,
 159
 of the lung, 146
 forms, 148, 149, 150
 Infantile pneumonia, 144
 Inflammation of pneumonia super-
 ficial, 129
- Inner connective tissue layer of
 bronchus 15
 in chronic bronchitis, 43
 Interstitial changes in lung, 145, 150,
 152
 Intra-alveolar growth of fibrous
 tissue, 157 *et seq.*, 169, 191
 Insufflation-pneumonia, 68
- LARYNX, hypertrophied glands, 48
 dermoid transformation of epith-
 elium, 70
 Lesions accompanying pneumonia,
 133
 Liquefaction of exudation of pneu-
 monia, 124
 Lobular cirrhosis of the lung, 147, 148
 Lobule, changes in broncho-pneu-
 monia 106
 Lung, atrophous, a cause of bron-
 chietasis, 76
 spasm of, 91
 inflation in asthma, 90, 91
 Lymph corpuscles, 5, 27, 28, 29
 infiltrating bronchial wall, 37
 Lymphadenoid bodies, 17
 Lymphatics of the bronchi, 16
 of the lung, 99
 infiltration with fibrin, 142
 Lymphatic vessels in acute bronchi-
 tis, 35
 glands of lung in *do.*, 36
- MECHANICAL hepatisation of lung,
 139
 Meningitis in pneumonia, 134
 Minor forms of secondary fibroid
 pneumonia, 173
 Mucin and fibrin, 114
 Mucoid degeneration, 30, 122, 123
 Mucous corpuscles, 10
 Mucous glands of the bronchi, 8
 in acute bronchitis, 32
 in chronic *do.* 44, 55
 in bronchiectasis, 59, 72
 Mucus, in bronchitis, 24
 expulsion of, 82
 in asthma, 86, 87, 88
 Muscles of the bronchi, in acute
 bronchitis, 27
 in chronic *do.*, 50, 53
 in bronchiectasis, 65
 Muscular fibres in lung alveoli, 102
- NASAL disease and asthma, 84, 87

- Nasal stenosis, 94
 catarrh, 95, 96
 Nature of bronchiectasis, 75
 of pneumonia, 127, 138
 Nerve ganglia in bronchitis, 27
 Nerves of the bronchi, 17
 Nitrites in bronchial spasm, 93
 "Non-bacillary phthisis," 150
 Normal histology of the bronchi, 1
 of the lung, 98
 Nutmeg liver, 41
- OCCLUSION of the bronchi, 77
 Edema of the bronchi, 87
 of alveoli, 88
 acute of lung, 143
 Origin of bronchiectasis, 75
 Organisms of pneumonia, 131, 157
 Ovoid cells in bronchus, 6
- PACHYDERMIA laryngis, 70
 Papillary growths on mucosa, 56, 63, 69
 Parenchymatous degeneration of organs in pneumonia, 133
 Parenchymatous nephritis and fibroid pneumonia, 196
 "Parenchymatous pneumonia," 175, 176, 178, 198
 tuberculosis in, 181
 Peribronchitis, 36, 149
 Pericarditis in pneumonia, 130, 131, 134
 Perichondrium of bronchial cartilages in bronchitis, 54
 Perilobular membrane, 111, 112
 Peritonitis in pneumonia, 130, 131
 Pharyngeal glands, hypertrophy, 48
 Phthisis pulmonalis, 145
 after fibroid pneumonia, 172, 201
 Pigment-bearing cells of the lung, 99
 Pigmented lungs, 41
 Placoids of lung, 99, 103
 Pleural changes in broncho-pneumonia, 112
 Pleurisy in acute pneumonia, 130
 after pneumonia, 150, 152
 Pleurogenous inter-lobular pneumonia, 148
 Pleuro-pneumonia of Ox, 112, 142
 Pneumonia serosa, 141
 Pneumococci, 131, 132, 134
 Pneumono-bronchitis, 114
 Polypi of nose, 84
 Primary fibroid pneumonia, 175
 Pseudo-lobar hepatisation, 113
 "Pseudo-stomatous" cells, 5, 6, 7, 8, 99, 100
 Pulmonary arteries, 2, 41
 in broncho-pneumonia, 112
 veins, 2, 41
 Pulmonary cavities, 73, 74, 104
 Purulent conversion of the lung, 140
 "Purulent infiltration," 138
 Putrid bronchitis, 37
 Pyogenic membrane, 74
- RALES in asthma, 86, 93
 Reactive inflammation round pulmonary abscess, 115
 Red hepatisation, 121
 Regeneration of bronchial epithelium, 7
 Resolution stage of pneumonia, 123
 duration, 126
 Rhonchi and sibili in asthma, 94
- SCHNEIDERIAN membrane and asthma, 84, 85
 Secondary fibroid pneumonia, 151
 Serous membranes, 5, 14
 Shock communicated to the lung, 130
 Singultus, 90
 Spasm of bronchi, 91, 95
 theory of asthma, 79
 Spirals, Charschmann's, 86, 93
 Spindle-shaped cells of bronchi, 5
Sputa Cocta, 38
 Stomata of lung alveoli, 99
Streptococcus pyogenes in pneumonia, 134
 "Subacute indurative pneumonia," 188
 Subepithelial endothelium of Debove, 5
 Suppurative bronchitis, 37, 67
 Suppuration in broncho-pneumonia, 115
- TAILED cell in acute bronchitis, 31, 32
 Termination of acute pneumonia, 125
 Tests, histological in bronchiectasis, 73
 Tracheo-bronchitis, 21

- Tubercle in indurated lung, 140
Typical acute pneumonia, 119
- UNUSUAL terminations of pneumonia, 143
- VACUOLES, 25, 115
Vagus, stimulation and section of, 81, 82
Varieties of pneumonia, 139
Venesection in pneumonia, 130
- Vermicular contractions of the bronchi, 82
- WEBERAN theory of asthma, 85
" Winter cough," 40
- "YELLOW hepatisation " of the lung, 125, 140
- ZONES of Balzer, 109

