

Nasal obstruction : the diagnosis of the various conditions causing it, and their treatment / by W. J. Walsham.

Contributors

Walsham, William Johnson, 1847-1903.
Bristol Medico-Chirurgical Society. Library
University of Bristol. Library

Publication/Creation

London : Ballière, Tindall and Cox, 1898.

Persistent URL

<https://wellcomecollection.org/works/phuyy8hq>

Provider

Special Collections of the University of Bristol Library

License and attribution

This material has been provided by This material has been provided by University of Bristol Library. The original may be consulted at University of Bristol Library. where the originals may be consulted.

This work has been identified as being free of known restrictions under copyright law, including all related and neighbouring rights and is being made available under the Creative Commons, Public Domain Mark.

You can copy, modify, distribute and perform the work, even for commercial purposes, without asking permission.



Wellcome Collection
183 Euston Road
London NW1 2BE UK
T +44 (0)20 7611 8722
E library@wellcomecollection.org
<https://wellcomecollection.org>

NASAL OBSTRUCTION

WALSHAM


1305
UNIVERSITY OF BRISTOL.

Medical Library.


PRESENTED BY

THE BRISTOL
MEDICO-CHIRURGICAL SOCIETY.
224





NASAL OBSTRUCTION.



with the Author's Consent


NASAL OBSTRUCTION:

The Diagnosis of the Various Conditions
Causing it, and their Treatment.

BY

W. J. WALSHAM, M.B., C.M. ABERD., F.R.C.S. ENG.,

SENIOR ASSISTANT SURGEON, LECTURER ON SURGERY, AND SURGEON-IN-CHARGE OF
THE ORTHOPEDIC DEPARTMENT, ST. BARTHOLOMEW'S HOSPITAL; CONSULTING
SURGEON METROPOLITAN HOSPITAL, BROMLEY COTTAGE HOSPITAL, AND
HOSPITAL FOR HIP DISEASES, SEVENOAKS; MEMBER OF THE COURT
OF EXAMINERS ROYAL COLLEGE OF SURGEONS, ETC., ETC.



LONDON:
BAILLIÈRE, TINDALL AND COX,
20 & 21, KING WILLIAM STREET, STRAND.
[PARIS AND MADRID.]

1898.

[All rights reserved.]



PREFACE.

MANY excellent works on Nasal Surgery have been published in recent years, but I know of none in which the diagnosis of the conditions that may give rise to nasal obstruction has been treated on the lines I have here attempted to lay down, namely, by working from the known to the unknown—in other words, by working from the known conditions of the parts, such as redness, hardness, swelling, etc., to the unknown disease of which they are signs and symptoms, instead of first describing the disease, and then discussing how it may be diagnosed from similar affections. It is the method I have constantly employed as a teacher of general surgery, and it seemed to me that it would be especially useful if applied to the diagnosis of nasal disease, a department of practice to which students and general practitioners have not hitherto given much attention.

It has so happened that in consequence of having done some work on injuries of the nose, whilst I was in charge of the Throat Department of the Metropolitan Hospital, now twenty years ago, I have since, through the kindness of old pupils and professional friends, had a very considerable experience in the treatment of all forms of nasal disease. The result of this experience is embodied in the present work. But whilst drawing chiefly on my own observations, I have at the same time consulted

the literature of the subject, and have to acknowledge the help I have received from the works of Zuckerkandl, Bosworth, Burnett, Cohen, Mackenzie, De Havilland Hall, Ball and McBride, and from articles too numerous to mention in the *Journal of Laryngology and Rhinology*, the *Centralblatt für Laryngologie und Rhinologie*, and the "Transactions of the American Laryngological Association."

I am much indebted to my friend and colleague, Mr. W. Ernest Miles, for the valuable assistance he has given me in preparing the book for press and in reading the proof sheets. I have also to thank Messrs. Arnold and Sons, Messrs. Meyer and Meltzer, and Mr. Schall, for permitting me to make use of several illustrations from their surgical catalogues.

W. J. WALSHAM.

77, HARLEY STREET,
December, 1897.

CONTENTS.

	PAGE
PREFACE	V
CHAPTER I. THE SYMPTOMS, SIGNS, AND EFFECTS OF NASAL OBSTRUCTION	1
„ II. THE CONDITIONS THAT MAY GIVE RISE TO NASAL OBSTRUCTION	10
„ III. METHOD OF EXAMINING FOR NASAL OBSTRUCTION	14
„ IV. GENERAL DIAGNOSIS	26
„ V. DIAGNOSIS OF SEPTAL CAUSES OF OBSTRUCTION	31
„ VI. DIAGNOSIS OF TURBINAL CAUSES OF OBSTRUCTION	63
„ VII. DIAGNOSIS OF CAUSES OF OBSTRUCTION DISTINCT FROM THE SEPTUM AND TURBINALS	90
„ VIII. DIAGNOSIS OF GENERAL SWELLINGS OF THE NASAL MUCOUS MEMBRANE	110
„ IX. DIAGNOSIS OF OBSTRUCTION WHEN SEATED AT POSTERIOR NARES OR IN NASO-PHARYNX OR PHARYNX	125
„ X. DIAGNOSIS OF OBSTRUCTION NOT DEPENDING UPON ANY LOCALIZED OR GENERAL SWELLING	151
„ XI. DIAGNOSIS OF OBSTRUCTION DEPENDING ON OCCLUSION OF THE ANTERIOR NARES	153
„ XII. TREATMENT OF THE FUNCTIONAL CAUSES OF NASAL OBSTRUCTION	156
„ XIII. TREATMENT OF THE INFLAMMATORY CONDITIONS CAUSING NASAL OBSTRUCTION	163

	PAGE
CHAPTER XIV. TREATMENT OF SPURS, DEFLECTIONS, AND HÆMATOMATA OF THE SEPTUM	171
„ XV. TREATMENT OF FOREIGN BODIES AND RHINOLITHS .	181
„ XVI. TREATMENT OF TUBERCLE, LUPUS, SYPHILIS, DIPHTHERIA, RHINOSCLEROMA, GLANDERS, AND LEPROSY IN THE NOSE	184
„ XVII. TREATMENT OF INTRANASAL NEW GROWTHS .	192
„ XVIII. TREATMENT OF ADHESIONS BETWEEN THE SEPTUM AND TURBINALS AND OF OCCLUSION OF THE ANTERIOR AND POSTERIOR NARES	204
„ XIX. TREATMENT OF NASO-PHARYNGEAL CAUSES OF NASAL OBSTRUCTION : STENOSIS OF THE NASO-PHARYNX, TUMOURS OF THE SOFT PALATE, RETROPHARYNGEAL ABSCESS AND TUMOURS, ADENOID VEGETATIONS, AND NASO-PHARYNGEAL GROWTHS OR POLYPI .	208
„ XX. TREATMENT OF VARIOUS AFFECTIONS OF THE ACCESSORY SINUSES THAT MAY BE PRESENT IN NASAL OBSTRUCTION.	237

NASAL OBSTRUCTION.

CHAPTER I.

THE SYMPTOMS, SIGNS, AND EFFECTS OF NASAL OBSTRUCTION.

IN many cases the signs of nasal obstruction are so obvious that they can hardly be overlooked; the patient is unable to breathe through one or both nostrils, and it is for this reason that he applies for relief. In other instances, however, he may not be aware that there is obstruction in the nose or naso-pharynx, and the symptoms he complains of have, to him, no apparent connection with the nose; thus, he may seek advice for symptoms referable to the throat, deafness, or it may be for asthma or spasmodic cough. It may be useful, therefore, before entering into the diagnosis of the various conditions that may cause nasal obstruction, to consider the symptoms and signs attending nasal obstruction generally, and the effects to which such obstruction may give rise.

The chief symptoms of nasal obstruction are :

- a.* Inability to breathe freely through the nose ;
- b.* An alteration in the voice ;
- c.* A characteristic facial expression ; and
- d.* The presence of a discharge from the nose,
or at the back of the throat.

These symptoms, which, of course, may be variously modified according to the nature, seat, duration and amount of obstruction and general condition of the surrounding cavities, will first be con-

sidered somewhat in detail; subsequently, other symptoms and effects of the obstruction that may occasionally or less frequently be present will be discussed.

(a) **Inability to breathe freely through the Nose.**—This symptom may be permanent, or temporary and intermittent, or, though always present to some extent, worse at times. The difficulty in breathing may be confined to one side or may affect both sides simultaneously; or at one time one nostril may be obstructed, the other free, whilst at another time, perhaps within a few hours or quite suddenly, the nostril previously obstructed may become free, and the free one blocked. The feeling of obstruction may be worse at night or in wet weather, or it may come on or be increased by entering or leaving a hot room. As the result of this inability to breathe freely, the patient complains that he is constantly trying to clear his nose by blowing it; that he is continually 'sniffing' or 'snuffing'; that his tongue, mouth, and back of the throat get dry, and that he often wakes up in the night with a dry tongue, and has constantly a dry tongue in the morning. Snoring in consequence of mouth-breathing during sleep is complained of by the friends, and an unpleasant and peculiar sound is often produced during eating and drinking. At times the patient's sleep is disturbed, or he has suffocative attacks from the tongue lolling back during inspiration and pressing down the epiglottis. In infants, sucking is difficult, and in marked cases of obstruction may be rendered impossible on account of spasmodic attacks of dyspnoea.

(b) **Alteration in the Voice.**—The voice may always be said to be altered in character, but the alteration varies in kind as well as in degree according to the situation and the amount of the obstruction. In slight cases, beyond some thickness or some slurring of certain consonants, there may be no marked change; in other instances the alteration is so pronounced as to be pathognomonic of the affection. When the obstruction is anterior, the voice has the so-called nasal twang—the tone that may be produced by closing the anterior nares with the finger and thumb, familiar as the 'punchinello squeak,' but in a modified form. When the obstruction is posterior, there is a lack of resonance: the voice has a dead character, as has been expressed by Meyer. The patient speaks as if he had a cold in the head, and certain consonants are altered—thus the *m*, *n*, and *ng* sounds are converted respectively into *b*, *d*, and *gg*; *man* is sounded like *bad*, *sing* becomes *sigg*. The singing voice is also, to some extent, affected: the lower registers, and perhaps

the middle, may be perfect, but in the upper registers the tone is muffled. To sum up, in anterior obstruction the nasal consonants can be pronounced, but the resonance is increased; in posterior obstruction they cannot be pronounced, but are altered as stated above.

(c) **Facial Expression.**—When the obstruction is at all marked, the facial expression is characteristic, though it varies somewhat, according to the exact seat of the obstruction. The most noticeable feature, perhaps, is the half-open mouth, and consequent drawing backwards and downwards of the naso-labial fold, so common in children with obstruction in the naso-pharynx. The lower jaw is dropped, and looks narrow; hence, the face has a long appearance. The upper lip, which is often swollen and thick, is slightly turned up, so that it appears short and everted, and exposes to view the upper incisor teeth. The nose, when there has been long-continued mouth-breathing, looks pinched, the anterior nares narrowed, and the alæ nasi flattened more or less against the septum.

In long-standing cases, moreover, the bridge of the nose may appear broadened or slightly depressed, whilst, when the obstruction is due chiefly to swelling of the middle turbinal body, the tip of the nose, together with the upper lip, may be slightly raised, so as to give the anterior nares a somewhat forward direction. The cheeks, as the result of the sharpening of the nose, may have a prominent look, or they may appear flattened. This flattening may be due in part to the broadening and depression of the root of the nose, and in part, perhaps, to defective development of the maxillary sinuses, consequent upon the disuse depending on the diminished flow of air through the nose. The distance between the eyes may be apparently increased owing to the broadening of the nose, whilst their external angles in long-standing cases may be drawn somewhat downwards.

Altogether, the half-open mouth, the dropped jaw, the elongated look of the face, and the general lack of attention, due to the deafness which is so often present, especially in children with adenoids, give a peculiar expression of vacancy. In those cases in which there is some defective mental activity, following on the inefficient aeration of the blood and general malnutrition, this vacant expression is still more marked.

A vein at the root of the nose—the *transverse nasal*—that joins the two angular veins is very apt to become enlarged in obstruction at the posterior part of the nose. In adenoid vegetations, the condition

in which it is perhaps most often met with, this symptom is ascribed by Dr. Scanes Spicer, who first called attention to it, to obstruction to the free return of blood through the veins that pass from the nose by the sphenopalatine foramen to the pterygoid plexus.

(d) **Discharge from the Nostrils or from the Posterior Nares into the Throat.**—There may be no discharge whatever, or only at times. When present, it may be continuous or intermittent, or it may be increased or diminished by altering the position of the head, by changes of temperature, or by variations in the hygrometric conditions of the atmosphere. A professional friend of mine complained that the discharge, which in his case was thin and watery, was always increased, so as to become a continual dripping, when he lowered his head to auscult a chest.

The discharge may be abundant, necessitating the use of many handkerchiefs during the day, or so slight as at times to be almost imperceptible. In character it also varies greatly. It may be thin and watery, glairy, viscid, mucoid, or muco-purulent, or even pure, creamy, canary-yellow pus. Again, it may be blood-stained, or accompanied by bloody serum, clots of blood, or pure blood. At times it becomes inspissated from the loss of water, and forms greenish-yellow or dark-coloured crusts which may be expelled on blowing the nose, or come away in masses on spraying or syringing. The discharge may be sweet or offensive, or only offensive at certain times, or although always tainted the odour may be so slight as to be almost imperceptible. The patient may or may not be able himself to detect any unpleasantness, or, conversely, may complain of a disagreeable smell when none is perceptible to others. The odour of the discharge when present is often a clue to the disease; thus, the sickly smell attending necrosis is distinct from that in empyema of the antrum, and from that due to decomposition beneath adherent crusts. The discharge may come entirely from the anterior nares on one or both sides, or only from the nasopharynx, in which case it appears running down the back of the pharynx; or it may escape in both directions together, though perhaps in larger quantities in the one than in the other.

The following symptoms may also be present:

Swelling or Redness of the External Nose.—In obstruction from syphilis there is frequently some swelling over the nasal bones, due to

periostitis or gummata; and in some forms of rhinitis the skin of the nose may present a dull blush of redness on one or other side, or anteriorly just below the bridge. In the so-called strumous rhinitis of children, the *alæ nasi* and vestibule are often thickened and red, or eczematous, whilst the upper lip may be similarly affected by the irritation of the discharge flowing over it.

Snoring is a marked symptom in all forms of nasal obstruction, and is commonly attributed to relaxation of the soft palate, or to weakening of the supports of the palate. Fraenkel, however, believes it to be due to the epiglottis falling over the entrance to the larynx as the result of the dropping of the lower jaw and consequent lolling back of the tongue. The fact that the snoring of deep chloroform anæsthesia, which is no doubt due to lolling back of the tongue and falling of the epiglottis, is relieved by pushing up the jaw as well as by drawing the tongue out of the mouth, certainly lends some support to this view.

Nightmare and distressing dreams are often complained of, especially when, in connection with obstruction from adenoids, the tonsils are also enlarged. This symptom may be due to inefficient aeration of the blood, and may be caused, like snoring, by the dropping of the lower jaw, and consequent falling back of the tongue and epiglottis.

Headache is not an uncommon symptom, especially in the obstruction due to hypertrophic rhinitis, and to a less extent in that due to adenoid growths in the naso-pharynx. The explanation of this symptom is not very clear. It has been attributed to inefficient aeration of the blood, and to some alteration in the vascular interchange between the nose and base of the anterior fossa of the skull.

Vertigo is sometimes complained of in nasal obstruction, and has been attributed to reflex irritation of the fifth nerve, and to vascular disturbance at the base of the brain, accounted for by the free vascular communications between the nose and anterior fossa of the skull established by the anterior and posterior ethmoidal vessels.

Aprosexia, or the inability to concentrate the mind on any individual subject, is certainly of common occurrence in some forms of nasal obstruction. It is especially noticeable in children with adenoid growths. The marked improvement in their ability to learn and in their progress at school or college after the obstruction has been removed is familiar to all who have seen many of these cases.

Defective development is undoubtedly one of the most marked effects when the obstruction, such as that due to adenoid growths,

occurs in young people. Its dependence upon the obstruction is rendered more evident by the rapid growth that so frequently takes place after the obstruction has been removed.

Night-sweats are an occasional symptom, and are probably caused by the general failure of nutrition and disturbed sleep resulting from the prolonged stenosis. Moreover, children with adenoids are often tuberculous, and the sweating at night is then, no doubt, dependent more on the tubercular condition than on the nasal obstruction.

Pallor, which is so frequent a symptom of nasal obstruction, and is especially common in children with post-nasal growths, may in these cases be accounted for by a deficiency of oxyhæmoglobin in the blood, since Curtis,* who has worked at this subject, has shown by the spectroscope that, after the removal of the obstruction, the amount of oxyhæmoglobin undergoes a constant increase.

Constant and oft-recurring catarrh of the pharynx, larynx, trachea, and bronchi appear in some cases to be dependent upon nasal obstruction. These conditions certainly often cease after the nasal trouble has been removed. Dry catarrh of the pharynx—pharyngitis sicca, as it is often called—is especially a symptom of obstruction in the upper and middle portions of the nasal chambers.

Restlessness, twitchings, and even convulsions in young patients, especially infants, are sometimes met with, apparently as the result of an obstructive lesion in the nose or naso-pharynx.†

Sneezing, especially when first rising from bed, is a familiar symptom, and is, perhaps, most common in obstruction depending upon turbinal turgescence. I have known cases where patients have sneezed as often as two or three hundred times a day, the desire being quite uncontrollable. The removal of the turgescence of the turbinal was effective in relieving this distressing symptom.

Loss of Smell and Taste.—Loss of smell is, as might be imagined, often found to occur in nasal obstruction, especially in that due to polypi, or hypertrophy of the middle turbinal, *i.e.*, in conditions which interfere with the passage of odoriferous particles to the upper portions of the nasal chambers, in which the sense of smell is located. Taste is less often interfered with than smell, in that the free passage of air from the pharynx to the superior turbinal, which lies at the back of the nose and which may be said to be a taste organ, is seldom continuously impeded.

* *International Journal of Surgery*, February, 1890, p. 96.

† Spicer, 'Throat and Nose Affections in Children.'

Sensation of a movable body in the nose is sometimes complained of when a polypus is the cause of the obstruction. Thus, such a growth may be felt to sway forwards and backwards in the nose, causing a flapping sensation, or the feeling as if there were a valve present that opened or shut during expiration or inspiration, as the case may be.

Over and above the symptoms of nasal obstruction already described, there are others which may be looked upon rather as effects than as symptoms proper of the obstruction, inasmuch as they may be said to have symptoms of their own. Some of these are undoubtedly the result of the nasal lesion; others are probably only indirectly, or in part, referable to it, and although they are amenable to nasal treatment to the extent that they may be temporarily benefited by the removal of the obstruction to free nasal respiration, they cannot, in the true sense of the word, be said to be cured by it. Other so-called effects probably have little or nothing to do with the nasal lesion.

Deafness.—This is a very frequent accompaniment of nasal obstruction, especially of the obstruction caused by adenoid vegetations in the vault of the pharynx. The following signs point to deafness being of nasal origin: The deafness has come on insidiously—there may at first have been some difficulty in hearing general conversation, and the hearing varies with the state of the weather and with the general condition of health. There may have been tinnitus, at first intermittent, later persistent. The patient feels as if the ears were stuffed with cotton-wool, or he has a tightness in the head, or perhaps giddiness. Even if very deaf, he may hear quite well in a noise, as in a railway-carriage or cab. The membrana tympani may appear normal, more often opaque; it is not congested but is often markedly retracted, at times atrophied or calcified. The tuning-fork is heard louder in the affected ear, and the Eustachian tube, on politzerisation, etc., is found to be obstructed. In short, the deafness is such as depends upon catarrh of the middle ear.

Although it is quite clear that nasal obstruction may give rise to deafness, opinions differ as to the way in which this is brought about. It has been attributed to the catarrhal process causing swelling, thickening and obstruction of the Eustachian tube, thus giving rise to mechanical obstruction to the free entrance of air into the middle ear. We seldom, however, detect with the rhinoscopic mirror any

congestion, swelling or redness, or other signs of catarrh about the Eustachian orifice. Hence it would appear that the mere spread of the catarrh is not a common cause of the middle-ear trouble. It has therefore been ascribed to defective pressure in the air current behind the obstruction in the nose, and hence defective pressure or rarefaction of the air in the Eustachian tube and cavity of the tympanum. This defective condition is believed to set up, when long-continued, congestion and catarrh of the lining membrane of the middle ear.

Naso-pharyngeal or Post-nasal Catarrh.—When air passes naturally through the nose it becomes saturated with moisture prior to entering the naso-pharynx. When, however, nasal obstruction exists, such saturation cannot take place, and the inspired air reaches the naso-pharynx in a dry state, and consequently absorbs moisture from the secretion of that region, which hence becomes thickened, inspissated, and ropy, and adherent to the back wall of the pharynx and soft palate. Here it gives rise to tickling and irritative cough, and the patient has to hawk and scrape his throat to remove it. This trouble is especially noticeable in the morning, since during sleep the mucus accumulates in considerable quantities. It is often for this symptom that patients with nasal obstruction apply for relief.

Spasmodic Cough and Asthma.—Much difference of opinion exists as to what relationship, if any, there may be between obstruction in the nose and attacks of so-called spasmodic cough and asthma. By some the cough is regarded as a reflex symptom dependent upon the irritation of the so-called reflex centre on the inferior turbinal body. By others it is looked upon merely as the result of the dryness attending continual mouth-breathing, causing irritation of the larynx and trachea. In other instances it would appear to depend upon extension of the catarrhal inflammation to the air-passages. With regard to asthma, it is probable that the nasal trouble, when present, is only one factor in its production, a neurosis playing a more important part. This is a subject, however, which cannot obviously be here discussed, and I must content myself with saying that although I have seen many cases of asthma markedly relieved—indeed, apparently cured for a time—on the establishment of free nasal respiration, so far as I know the asthmatic attacks have ultimately, sooner or later, recurred, although it may have been in a milder degree.

Elongation of the uvula in some forms of obstruction, especially in the later stages of hypertrophic rhinitis, is often seen. It would appear to depend upon a relaxation of the mucous membrane due to the faucial irritation and consequent hawking and coughing required to clear the throat of the accumulated mucus about the palate and fauces.

Aphonia, or loss of voice, has been attributed in some cases to nasal obstruction. In some of the cases* reported nothing was found in the larynx, and no benefit followed local faradization; but removal of the obstruction was followed by relief of the symptom. How much the neurotic temperament entered into these cases is of course a question.

Deformity of the Chest.—When the nasal obstruction is associated with rickets, the softened ribs not infrequently yield to the atmospheric pressure, the chest becoming pigeon-breasted, and exhibiting the depressions or grooves so well known as occurring in rickets when there has been obstruction to free respiration from any cause.

Hypochondriasis and melancholia are occasional symptoms. The former is perhaps more common than the latter.

Salivation.—A continual flow of saliva believed to depend upon nasal obstruction has been reported by Bosworth and E. Fraenkel. The flow in Bosworth's cases was continuous, and gave rise to much annoyance from the constant expectoration it necessitated.

Eye Affections.—Amongst the eye troubles that depend upon obstructive lesions in the nose, or have been believed to depend upon such lesions, are epiphora, lachrymation, conjunctivitis, photophobia, ocular or orbital neuralgia, asthenopia and glaucoma. Epiphora from direct obstruction of the nasal duct is not so very uncommon in certain forms of deflection of the septum and turbinal disease.

Hernia.—Nasal obstruction is said to be an exciting cause of hernia, but can only be taken to be so in the sense that hernia may be produced by the constant coughing and hawking—recognised factors of hernia—employed by patients in order to free the nose.

Stammering and stuttering,† **nocturnal eneuresis, epilepsy, chorea, dyspepsia, gastralgia, palpitation of the heart, and muscular rheumatism,**‡ have also been attributed in some cases to nasal obstruction, but with how much reason is a question that cannot here be discussed.

* Schaeffer, 'Monats. f. Ohrenheilkunde,' 1886, p. 11.

† Matheson, *British Medical Journal*, 1888, vol. vii., p. 487.

‡ Moldenhauer, 'Die Krankheiten der Nasenhöhle,' 1886, p. 176.

CHAPTER II.

THE CONDITIONS THAT MAY GIVE RISE TO NASAL OBSTRUCTION.

THE conditions that may give rise to nasal obstruction are very numerous. Thus, the obstruction may be due to some congenital malformation of the nose or naso-pharynx; to swelling, turgescence, or hypertrophy of the mucous membrane; to an alteration in the bony framework of the nasal fossæ; to a new growth, either innocent or malignant, in the interior of the nose or in the naso-pharynx, or invading the nasal cavities from some of the neighbouring sinuses; or to some general disease, such as tubercle or syphilis, with local manifestations in the nasal chambers or naso-pharynx.

The causes of nasal obstruction may be conveniently classified under the following heads:

1. The intranasal, or those depending on some primary condition in the nose itself.
2. The extranasal, or those depending on some condition external to the nose.

The intranasal may be subdivided into the local and the general.

1. The local causes are such as are due to lesions localized to the septum, turbinals, or other parts of the nasal chambers; to accidental conditions, as the presence of a foreign body or rhinolith; and to adhesions between the turbinals and septum.
2. The general intranasal causes are such as depend on a general swelling of the mucous membrane due to catarrh or to such affections as syphilis, tubercle, rhinoscleroma, etc.

The extranasal causes may be subdivided into the following classes :

1. Occlusion of the anterior nares, due to congenital malformation, or cicatricial contraction following an injury or such diseases as syphilis or lupus.
2. Occlusion of the posterior nares, which may also be the result of congenital malformation or of cicatricial contraction.
3. Obstruction in the naso-pharynx, due to adenoid vegetations, polypi, or growths; enlargement of the faucial tonsils; adhesion of the palate to the post-pharyngeal wall; tumours of the soft palate, meningocele and encephalocele.
4. Obstruction caused by extension of growths from neighbouring cavities, as the antrum, or the ethmoidal or frontal sinuses.

TABULAR VIEW OF CONDITIONS CAUSING NASAL OBSTRUCTION.

A. Intranasal.

I.—Local.

(a) *Septal.*

1. Spur and erection of tubercle.
2. Deviation and deflection.
3. Dislocation of columnar cartilage.
4. Hæmatoma.
5. Enchondroma and osteoma.
6. Papilloma.
7. Vascular and erectile tumours.
8. Myxoma (polypus).
9. Sarcoma and carcinoma.
10. Inflammation and abscess.
11. Necrosis.
12. Local contagious ulcer (soft chancre).
13. Primary syphilitic sore (hard chancre).
14. Gumma and periostitis.
15. Tubercle.
16. Lupus.
17. Rhinoscleroma.
18. Glanders.
19. Actinomycosis.

(b) Turbinal.

1. Erection or turgescence.
2. Hypertrophy (local and general).
3. Varix.
4. Myxoma (polypus).
5. Papilloma.
6. Vascular and erectile tumours.
7. Sarcoma and carcinoma.
8. Necrosis.
9. Tubercle.
10. Gumma.
11. Lupus.
12. Rhinoscleroma.
13. Actinomycosis.

(c) Accidental.

1. Foreign body.
2. Rhinolith.
3. Adhesion of turbinal to septum.
4. Larvæ, maggots, etc.

II.—General.

1. Hypertrophic rhinitis or catarrh.
2. Syphilis.
3. Tubercle.
4. Lupus.
5. Rhinoscleroma.
6. Actinomycosis.
7. Glanders.
8. Diphtheria.
9. Congenital smallness.

B. Extranasal.**I.—Occlusion of Anterior Nares.**

1. *Congenital malformation.*
2. *Cicatricial contraction, due to*
 - (a) Injury and burn.
 - (b) Syphilis.
 - (c) Tubercle.
 - (d) Lupus.

II.—Occlusion of Posterior Nares.

1. *Congenital malformation.*

2. *Cicatricial contraction*, due to

- (a) Syphilis.
- (b) Tubercle.
- (c) Lupus.

III.—Obstruction in the Naso-pharynx.

1. Adenoid vegetations.
2. Hypertrophy of pharyngeal tonsil.
3. Growth from the vault (nasopharyngeal polypus).
4. Retro-pharyngeal abscess.
5. Adhesion of soft palate to pharyngeal wall.
6. Retro-pharyngeal adenoma.
7. Retro-pharyngeal sarcoma.
8. Enlargement of the tonsils (adenoma).
9. Tumours of the soft palate.
10. Meningocele and encephalocele.
11. Growth from sphenoidal sinuses.
12. Enchondroma of Eustachian tube.

IV.—Obstruction due to Extension of Growths from Neighbouring Cavities.

1. Fibrous, osseous, sarcomatous, and carcinomatous tumours of the antrum.
2. New growths from the ethmoidal, sphenoidal, and frontal sinuses.

CHAPTER III.

METHOD OF EXAMINING FOR NASAL OBSTRUCTION.

HAVING come to the conclusion, from the history of the case and a review of the symptoms, that nasal obstruction is probably present, the only way of making an exact diagnosis is by a thorough examination of the nose and naso-pharynx, and it may be of the antrum and other of the accessory cavities. Merely to look in the nose by turning up its tip, or by everting its ala, or to insert a speculum in a cursory manner, is useless. To make a complete examination of the nose investigate each case systematically as follows :

- a.* Test the breathing-power through each nostril.
- b.* Ascertain the condition of the external nose, the ala, vestibule, and columella in a good natural light.
- c.* Examine the interior of the nose from the front with a suitable speculum aided by an efficient artificial light.
- d.* Supplement the examination with the speculum, if necessary, by exploration with the nasal probe.
- e.* Explore the naso-pharynx and posterior nares with the rhinoscope from behind the soft palate.
- f.* Further explore under some circumstances the condition of the naso-pharynx and posterior nares with the index-finger.
- g.* Lastly, examine the antrum and other accessory sinuses by transillumination, etc.

a. **Estimation of the Amount of Breathing-power through the Nostrils.**—The breathing power can be readily tested by the patient breathing alternately through first one and then the other nostril, with the opposite nostril closed. There is a right and a wrong way of doing this. If the thumb or finger merely presses on the side of the ala, the septum may be slightly driven over beyond the middle line, and less air may pass through the nostril being tested than would

otherwise be the case. The ball of the thumb should be applied to the anterior nares in an upward direction, without making any lateral pressure, and thus without causing the septum to encroach at all upon the opposite side. The patient should then be directed not only to expire but to inspire through the side being tested. Expiration may be free, or comparatively speaking free, whilst inspiration through the nose may be hardly possible.

During this procedure, it should be noted if the ala during inspiration is abnormally retracted. A good test of freedom of the passage is to hold a match near the nose in the course of the stream of expired air, and ask the patient with his mouth closed to blow it out; and during inspiration to note if the flame is drawn towards the nose. The full free sound of air passing through a patent nostril is very different from the shrill hissing sound produced by air driven through a partially-obstructed one.

b. Examination of the Exterior of the Nose, the Ala, the Vestibule, and the Columella with Natural Light.—First inspect the exterior of the nose, noting any abnormal redness or swelling, depression of the bridge or cartilages, or deflection of the bones or lateral cartilages to one or the other side. Further note whether there is any eczema or excoriation about the anterior nares or upper lip, or evident flow of discharge over the lip, or thickening of the lip. Examine the anterior nares, observing whether they are contracted, or regularly formed, or reddened, or in other way abnormal. Next, with the patient's head raised, gently lift the tip of the nose and the ala with the thumb, in order to examine the columella, the front of the septum, the inner surface of the ala, the vestibule, and the fore part generally of the nasal chamber. This preliminary examination is best made in front of a window in a good natural light.

c. Examination of the Nose from the Front with the Speculum (Anterior Rhinoscopy).—The patient should be comfortably seated, as for examination of the larynx, and a good light be thrown on to the nose from the ordinary head-mirror. The light I employ myself at home is a fifty-candle-power electric lamp. In my out-patient room at St. Bartholomew's Hospital on sunny days I use reflected sunlight; when this is not available, an Argand burner, mounted on the well-known Mackenzie's rack-movement stand. The speculum, of which Duplay's (Fig. 1) is perhaps the best, should now be introduced into the nose, with the blades closed. With all gentleness they should be next opened by the screw arrangement, taking care not to unduly stretch

the ala, or entangle any of the vibrissæ between the blades. The speculum should not be passed too far in, as this only gives pain, and no better view is obtained. It is needless to say that the speculum should always be clean and bright, and in cold weather slightly warmed before being used. The light should next be directed up the speculum, and if the condition of the parts is obscured by the presence of discharge or of crusts, these must be removed before proceeding with the examination. This can usually be done by mopping out the cavity by a small pellet of moist cotton-wool, twisted on the end of a nasal probe, or held by the nasal forceps, the mucous membrane having previously been sprayed with a 10 per cent. solution of cocaine, if abnormally sensitive. If, however, the crusts are adherent, they may have to be removed by spraying or syringing the nostril with a weak alkaline solution. The examination should be made systematically; it is not sufficient to merely introduce the

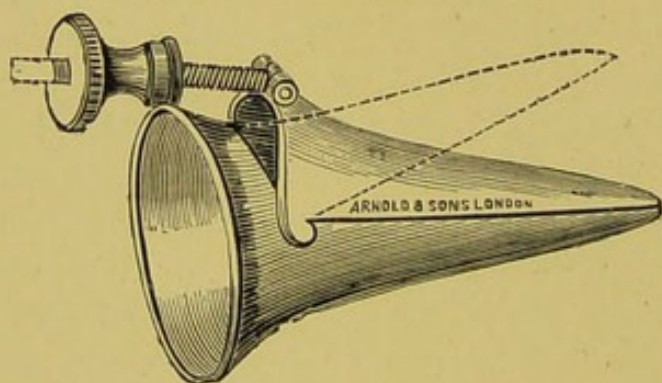


FIG. 1.—DUPLAY'S SPECULUM.

speculum, and look at the parts with the head in that position in which it happens to be at the time. The head should be well thrown back in order to gain a view of the middle turbinal body and upper portion of the nasal chambers; then held straight for the purpose of ascertaining the condition of the inferior turbinal body and corresponding portion of the septum. Next, the chin should be depressed that the floor of the fossa may be inspected, and the patency of the inferior meatus ascertained. Finally, the head should be rotated slightly to and from the light, the better to see the lateral boundaries of each nasal chamber. The examination of the floor of the inferior meatus is of some importance, as, although the patient may be able to breathe fairly well through both nostrils, the inferior meatus may still be more or less blocked, and the stream of air consequently compelled to pass through the upper channels, instead of flowing as

it should normally do over the Eustachian orifice. If the passage is fairly large and moderately straight and the light good, the posterior wall of the pharynx and the Eustachian cushion can be seen. On asking the patient to swallow, the rising of the palatal cushion, and at times, though more rarely, the movement of the salpingo-pharyngeal and salpingo-palatine folds, may be observed. When the movements of the palatal cushion can be thus distinguished, the fact that there is no obstruction in the inferior meatus is definitely established. As the passage, however, is frequently narrow, or not quite straight, and the inferior turbinal body irregularly formed, the converse does not hold good.

It must not be forgotten that the rising of the palatal cushion may be simulated during deglutition by the lifting up by the palate of a small polypus or other growth attached to the posterior end of the inferior turbinal, or of a drop of mucus at the back of the meatus. A polypus, however, will be seen to sway to and fro during respiration, and can be further distinguished by the use of a probe and posterior rhinoscopy; whilst a drop of mucus will be dispersed by forcibly blowing the nose.

d. Examination with the Nasal Probe.—The nasal probe should be blunt-pointed, bent to the proper nasal angle, not too fine, and fixed on a suitable handle. If the probe is too fine and has not a bulbous end it may readily be passed through the mucous membrane covering the turbinal bodies, and, impinging on the delicate osseous tissue beneath, make it appear that bone is exposed, or carious, or necrosed, when such is not the case. The probe is of use in detecting necrosed bone, foreign bodies, and rhinoliths, in determining the seat and attachments of polypi or other new growths, in testing the reflex irritability of the mucous membrane, etc.

e. Examination of the Naso-pharynx and Posterior Nares (Posterior Rhinoscopy).—Having completed the examination of the nose from the front, the naso-pharynx should be next examined by the rhinoscope from behind the soft palate. With the head straight, the mouth widely open, and the tongue, if necessary, held down with the tongue-depressor, the light should be thrown on to the posterior wall of the pharynx, the rhinoscope, with the mirror warmed, passed behind the soft palate, and the mirror raised to the necessary angle by pressing on the lever or trigger on the handle. The back of the mirror should be either firmly but gently placed against the posterior wall of the naso-pharynx, or else not allowed to come into contact

with it. By slightly altering the angle between the mirror and the stem by acting on the lever on the handle, and by slightly turning the mirror from side to side, the septum, the posterior nares, the pharyngeal vault, the orifice of the Eustachian tube, and the upper surface of the soft palate, can be successively examined. Posterior rhinoscopy is always, however, to say the least, a troublesome procedure, and in some instances, owing to the proximity of the soft palate to the post-pharyngeal wall, a good view of the posterior nares cannot be obtained. When the parts are exceedingly sensitive, they should be sprayed or painted with a 10 per cent. solution of cocaine. At times the difficulty of obtaining a view depends upon the patient's inability either to depress the tongue by his own effort, or allow it to be depressed by the surgeon. As soon as the tongue is sufficiently depressed to permit of the mirror being passed, uncontrollable movements of the levatores palati, whereby the soft palate is drawn backwards and upwards, ensue, and may end, if the examination is persisted in, in actual vomiting. Notwithstanding this, a momentary view, with patience and perseverance, may generally be obtained. When the difficulty arises from want of room between the soft palate and post-pharyngeal wall in consequence of the soft palate being drawn upwards and backwards by the levator muscles whenever an attempt is made to pass the rhinoscope behind it, sufficient space may sometimes be gained by directing the patient to breathe through the nose, to hold his breath before the mirror is introduced, or to pronounce a nasal sound, as 'hang.' These procedures are intended to relax the muscles of the palate, and allow it to hang down in a flaccid condition. More often than not, however, the patient declares that he is unable to breathe through the nose with the mouth open, and these manœuvres are of no avail. Sufficient room may be sometimes obtained by the patient depressing his chin. The rays from the lamp must then be directed slightly downwards, whilst the surgeon, with his head on a lower level, throws the light reflected from his mirror upwards. I have succeeded in making a satisfactory examination in this way when other methods have failed. Room for the mirror may also be obtained in some cases by drawing the palate forwards by one of the many forms of palate-hook; but if with patience and perseverance the employment of the above means are not successful, I have generally found hooks and like contrivances of little avail.

Tying the palate forwards with delicate rubber tubing is some-

times successful. I still consider the best way of doing this is by the method I described in the *Lancet* for July 8, 1883. A thin rubber tube is passed along the floor of the nose, previously sprayed with cocaine, till it appears in the pharynx below the palate. It is then seized by forceps, and deftly drawn through the mouth and tied to the other end across the upper lip. The opposite side of the palate is then tied up in the same way. If the manipulation is neatly done, it causes very little inconvenience to the patient, and a good view of the parts is usually obtained. Even with this method, however, I have in a few cases failed to get a satisfactory inspection.

The reasons why posterior rhinoscopy in some patients, in spite of

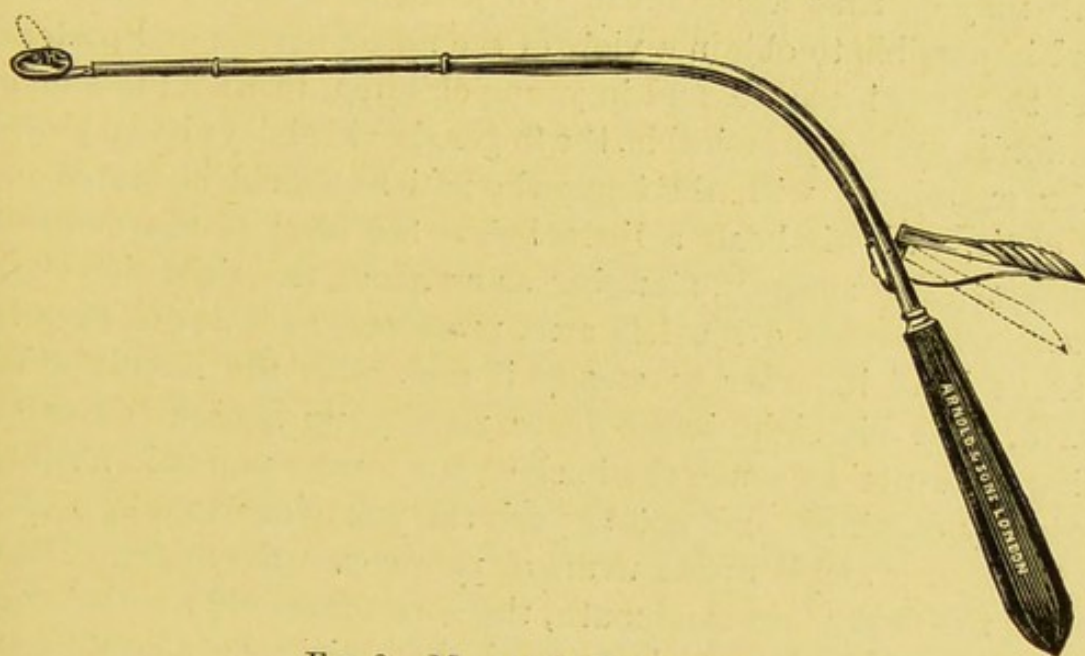


FIG. 2.—MICHAEL'S RHINOSCOPE.

every effort, cannot be made are that the hard palate extends so far backwards that there is not room between it and the posterior wall of the pharynx for the mirror to be passed; or that the soft palate is so thick and deep that it encroaches upon the naso-pharyngeal space to such an extent as likewise to preclude the passage of the mirror. Enlargement of the tonsils or of the uvula may interfere with a satisfactory examination. If the tonsils are so large as to meet, the mirror cannot be passed.

The rhinoscope I employ is that known as Michael's (Fig. 2). The lever on the shank near the handle when pressed upon alters the inclination of the mirror, which is fixed to the stem by a hinge, to any angle that is desired.

f. Examination of the Naso-pharynx with the Finger.—In many cases the examination will not be complete unless the finger is passed behind the soft palate in order to determine the condition of the posterior nares and naso-pharynx. Such an examination is especially desirable should a polypus or other morbid growth have been detected by the rhinoscopic examination of the naso-pharynx, as in this way the extent and attachments of the growth can be more accurately ascertained. Where a large growth occupies the naso-pharynx and is pressing the soft palate forwards into the mouth, there may not be room for the introduction of the finger. A probe suitably bent, and passed between the growth and the walls of the cavity, may then be substituted, and some idea of the attachments may be thus ascertained. In patients in whom it has been found impossible to obtain a view of the naso-pharynx and posterior nares by the rhinoscope, and in young children, in whom this manipulation is seldom practicable, the finger should always be employed.

For examining with the finger the patient should be seated on a low chair, with his head a little below the level of the surgeon's shoulder. The surgeon, standing as a rule on the right side of the patient, should place his left arm, protected by a towel, over the patient's head in order to steady it and, with the mouth widely opened, pass his right index-finger rapidly up behind the palate, taking care not to touch the back of the tongue unless it has been previously cocained, and not to push the palate or uvula in front of the finger or crumple up the uvula or palate over the finger. Before passing the finger into the mouth, the surgeon should see that there is no false-tooth-plate or loose tooth that might be displaced and forced down the pharynx; and the patient should be asked not to seize the surgeon's hand whilst his finger is behind the palate, since in this way the palate may be torn by the finger, or the surgeon's knuckle be grazed by a sharp tooth in the lower jaw. It is well for the patient to take a firm hold of the seat of a chair, or, in the case of a child, to have its hands held by a friend.

The examination with the finger should be done systematically, and not in a mere perfunctory or haphazard manner. The finger, having been passed behind the palate, should first be rapidly swept over the right Eustachian tube, then carried forward into the right choana, and the posterior end of the inferior turbinal body examined. It should next be passed over the septum into the left choana, thence to the left Eustachian orifice, and finally

carried from left to right over the vault and back of the pharynx, investigating the condition of the adenoid tissue in that situation and the pharyngeal tonsil. With a little practice a systematic examination may be made in a few seconds; it should always be done as quickly as possible, as it necessarily causes the patient considerable annoyance.

g. Examination of the Antrum and other Accessory Sinuses.—Nasal obstruction may occur in the case of new growths invading the nose from the accessory sinuses, especially the antrum. It may also occur in diseases, other than new growths, of these cavities. A short account, therefore, is here added of the method of examining the accessory sinuses.

The ANTRUM may be suspected to be affected if there is some prominence of the cheek, protrusion of the eyeball, and depression of the hard palate. In the earlier stages of a new growth arising in the antrum and invading the nose, and especially in the case of polypi of the antrum, there may be neither prominence of the cheek, protrusion of the eye, nor depression of the palate, although the inner and more delicate wall of the antrum may have yielded and allowed the growth to more or less obstruct the corresponding nasal passage. In such cases, and in empyema, in which also there may be no external sign, the condition of the antrum may be investigated as follows:

(a) *By comparing the Percussion Note of the Two Cheeks.*—In an antrum containing a growth or fluid, the percussion note is often distinctly duller on the affected side.

(b) *By passing the Finger between the Cheek and the Anterior Wall of the Antrum.*—Some slight bulging, yielding, eggshell-like crackling, or distinct softening of the wall in the neighbourhood of the canine fossa, may be felt in the case of certain new growths, cysts, etc.

(c) *By inspecting the Teeth, Alveoli, and Gums.*—The discovery of a carious tooth or stump, of pain on percussing a tooth, of a fungating granulation from an alveolus, or of a discharging or fungating sinus in the gum, will point to antral mischief. A discharging alveolus or sinus should be probed, and any fungous granulation examined microscopically.

(d) *By Succussion.*—A stethoscope is applied over the front wall of the antrum, and the patient's head shaken. A splashing sound may sometimes be detected if the antrum contains fluid.

(e) *By Catheterization of the Antral Ostium.*—The mucous membrane of the nose having been cocained, the antral cannula, which resembles the Eustachian catheter but is somewhat shorter, should be passed along the middle meatus into the hiatus semilunaris, and an endeavour then made to find the ostium. It is only in a certain proportion of cases that the catheter can be introduced into the antrum. If the surgeon is successful in passing the instrument, the condition of the antrum may be investigated by syringing through the catheter a boracic solution or peroxide of hydrogen. If the antrum is healthy the boracic solution will return through the nose

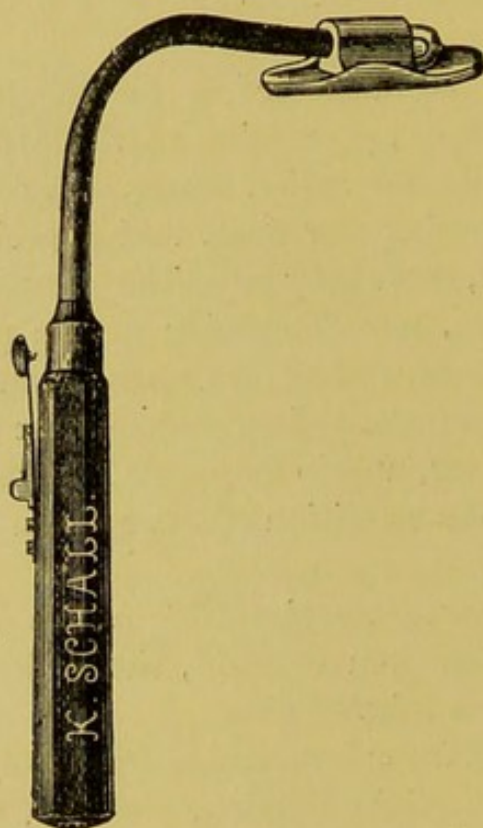


FIG. 3.—ELECTRIC LAMP FOR TRANSILLUMINATION OF THE FACE.

clear; if it contains pus a purulent fluid will escape. If it contains a new growth it will probably be found impossible to force any of the fluid in. On injecting peroxide of hydrogen the nose may become filled with froth if pus is present.

(f) *By Transillumination.*—For this the electric lamp (Fig. 3), manufactured for the purpose, is necessary. The lamp is placed in the mouth, the mouth closed, the room darkened, and the circuit completed. Should the antrum contain a growth or fluid, that side of the cheek will light up less brilliantly than the sound side, or an umbra will be noticed below the eye or at some other spot. The

tongue is protected from the lamp by the vulcanite tongue-depressor fixed to the stem of the instrument below the lamp. To obtain a satisfactory examination, the room should be quite dark, and a lamp requiring 11 volts and 1.6 ampères should be employed.

(g) *By Puncture of the Antrum.*—The antrum may be punctured through the canine fossa, through a tooth socket, or through the inferior meatus of the nose. The best of these methods for the purpose of exploration is that through the inferior meatus, as it can be done in a few minutes without general anæsthesia, and, if the inferior meatus is well cocained, causes no pain. A fine steel trocar and cannula (Fig. 4) is passed about an inch and a quarter into the nose, and the point pressed on the inner wall of the antrum, below the anterior third of the inferior turbinal body. The trocar and cannula must be held very obliquely, the tip of the nose being well drawn over to the opposite side, so as to gain the proper direction. A sharp push is now given to the trocar, and it will enter the antrum.




FIG. 4.—LICHTWITZ'S TROCAR AND CANNULA FOR EXPLORING THE ANTRUM.

On withdrawing the trocar and placing in the proximal end of the cannula the nozzle of an antral syringe filled with boracic solution, the fluid will pass out through the nose, clear if the antrum is free, or mixed with pus if it contains pus; but nothing will probably flow if the cavity is filled with a new growth. Indeed, in this case it will probably be found that the fluid from the antral syringe cannot be passed in. On withdrawing the cannula, a few drops of blood, or perhaps nothing at all, will be found in its end. Moreover, the end of the cannula in the one case will be felt to move freely in a cavity; in the other it will be evidently fixed in a solid substance. In polypi of the antrum, the cannula may not be felt to be fixed, and some fluid may escape through the nose in consequence either of its being injected between the polypi, or of the polypi being broken down by the point of the trocar. Another method of investigating the interior of the antrum through the puncture is to fit an aspirating syringe into the end of the cannula and apply suction. Pus may escape if the antrum contains pus, or merely blood if it contains a new growth. Again, by injecting air by the syringe, frothy pus, if pus is present, may enter the middle meatus through the natural antral ostium.

The FRONTAL SINUSES may be suspected to be affected if, in conjunction with the nasal obstruction, there is a prominence in the region of the frontal eminences, a fulness of the eyebrow, depression of the upper eyelid, bulging at the inner angle of the orbit, broadening of the root of the nose, protrusion of the eyeball downwards and forwards, diplopia, or impaired sight. The patient, moreover, will probably complain of pain of a dull or neuralgic character in the neighbourhood of the sinuses, or in the course of the supra-orbital or supra-trochlear nerves.

The condition of the sinuses may be investigated as follows :

(a) *By Irrigation per Vias Naturales through the Infundibulum.*—The nose having been filled with a warm, weak boracic solution and the head well depressed between the knees, the fluid may be felt by the patient in some cases to enter the frontal sinuses, and may return clear or mixed with pus, according to the condition of the sinuses.

(b) *By Catheterization of the Infundibulum.*—A slender catheter, suitably bent at about an inch from its point to an angle of 125° , is passed into the middle meatus between the middle turbinal and outer wall of the nose. By gently depressing the handle and manipulating the point in an upward and forward direction, it may be felt to pass into the infundibulum. Frequently the anterior end of the middle turbinal must be excised before the infundibulum can be entered. A warm, weak boracic solution may now be injected into the frontal sinuses, and will return mixed with pus if there is empyema, or clear if the sinuses are healthy. It will be impossible to inject any fluid into the sinuses if they contain a growth. The test is not conclusive, in that the infundibulum is common to the anterior ethmoidal cells and frontal sinuses.

(c) *By Exploration through the Anterior Wall.*—A vertical incision having been made in the middle line, from the nasion for about two inches upwards, and the frontal bone bared in the usual way, a trephine is applied with its pin at a spot exactly in the middle line and on a level with the upper margin of the orbits. The crown of bone having been removed, the lining membrane of the front wall of both sinuses is exposed. By cutting through this membrane the interior of the sinuses can now be investigated.

The ANTERIOR ETHMOIDAL SINUSES may be suspected as the primary seat of the affection if there is a bulging at the inner angle of the orbit, epiphora, protrusion of the eyeball downwards and outwards, disturbance of the muscular control of the eyeball, diplopia, or failing

vision or actual loss of sight. The patient will probably have deep-seated pain in the nose or orbit.

The condition of the ethmoidal cells may be investigated as follows:

(a) *By Transillumination of the Face.*—This is done as described under *Antrum*. If there is pus or a growth in the ethmoidal cells some opacity may be observed. Too much reliance, however, must not be placed on this test.

(b) *By Exploring the Sinuses through the Nose.*—The anterior ethmoidal sinuses may be catheterized through the infundibulum, as described under *Frontal Sinuses*, or they may be opened and explored by means of careful curetting or the use of small drills. The anterior end of the middle turbinal will probably require removal before a satisfactory examination can be made.

(c) *By Exploring through an Incision at the Inner Angle of the Orbit.*—The anterior ethmoidal sinuses may be opened by a suitable incision through the soft tissue at the inner angle of the orbit, and cutting away of the subjacent bone forming the outer wall of the sinuses.

The SPHENOIDAL and POSTERIOR ETHMOIDAL SINUSES may be suspected to be the seat of the trouble if there is, in addition to signs of nasal obstruction, ptosis, protrusion of the eyeball, strabismus or complete paralysis of the ocular muscles, impaired vision, or loss of sight.

The condition of the sphenoidal sinuses may be investigated:

(a) *By Exploration with a slender Catheter through the Nose.*—A long, slender catheter, to which a syringe can be attached, is passed horizontally between the middle and inferior turbinal bodies, using the upper border of the middle turbinal body as a guide. When the catheter has reached the back of the nose, a slight depression of the handle is said to cause the point to enter the sphenoidal sinus through the natural opening.

The sphenoidal and posterior ethmoidal sinuses may also be investigated:

(a) *By Curetting or Drilling the Walls of the Sinuses through the Nose or Naso-pharynx.*—These sinuses may be opened by attacking their walls with drills or sharp spoons either through the nose or from behind the palate. It need hardly be said that these methods of investigation are attended with very considerable risk of perforation of the base of the skull, and should be only undertaken by those thoroughly conversant with intra-nasal surgery.

CHAPTER IV.

GENERAL DIAGNOSIS.

SOME clue as to the nature of the obstruction will probably have been obtained from the history of the case and from the patient's replies to the questions that have already been put to him. An exact diagnosis, however, can only be made by inspecting the nasal chambers and naso-pharynx, and in some cases the accessory sinuses, in the way described in Chapter III., p. 14.

Should the obstruction depend upon some malformation or other condition resulting in occlusion, either partial or complete, of the anterior nares, this will of course be evident on looking at the nose. The differential diagnosis of the various conditions that may give rise to such occlusions will be considered at section 219. On the discovery of occlusion of the anterior nares, it should not, however, be taken for granted that such is the sole cause of the obstruction until the naso-pharynx and the posterior nares have been thoroughly explored and made out to be healthy. Even then, in addition to the occlusion of the anterior nares, some obstruction may exist in the nasal cavities themselves, the presence of which it may not be possible to detect until a clear view of the interior of the nasal chambers has been obtained by a preliminary removal or amelioration of the obstructive lesion in front.

Supposing that there is no occlusion at the anterior nares, proceed to ascertain whether the obstruction is unilateral or bilateral. This is readily done by desiring the patient to breathe through one nostril while the other is stopped by compression (see Chapter III., p. 14). By this means also the fact of one nasal chamber being more obstructed than the other will be determined. If one nasal cavity is obstructed, attention may be given to that one first, but on no account should the other be allowed to escape examination.

In the case of a young or unruly child it may be impossible to

make the examination necessary to discover the cause of the obstruction without placing it under the influence of an anæsthetic. This should never be neglected if the obstruction is attended with a unilateral, purulent, and offensive discharge, as with such symptoms a foreign body is probably present.

If nothing abnormal is discovered by anterior rhinoscopy, begin below at section 1. If something abnormal is found, pass on to section 4.

NOTHING ABNORMAL IS DISCOVERED BY ANTERIOR RHINOSCOPY.

§ 1. On looking into the nostril nothing abnormal is discovered, and upon inspecting the opposite one a similar normal state is apparent.

Under these circumstances the obstruction is probably situated in the naso-pharynx, or about the posterior nares, *i.e.*, beyond an anterior view; or it may be that the obstruction complained of is the result of *temporary erection of the turbinals*, so common in chronic catarrhal rhinitis, these bodies being, at the time of inspection, in a collapsed or normal state. Or, again, it may be that the obstruction is due to *collapse of the ala nasi* during inspection.

If, therefore, no apparent cause of obstruction is discovered on examining the nasal chambers from the front, proceed, after reading sections 2 and 3, to the examination of the posterior nares and naso-pharynx, as set forth in section 170, Chapter IX.

Before doing this, however, with the speculum *in situ*, and the head slightly depressed in order to expose the inferior meatus and floor of the nose, ask the patient to swallow. If the palatal cushion is seen to rise and the salpingo-pharyngeal fold to move, it is pretty certain that there is no obstruction in the inferior meatus, except such as may be caused by intermittent erection of the inferior turbinal. If the passage is small and not quite straight, however, it may be impossible to see the palatal cushion at all, and consequently, if these movements are not observed, their absence must not be taken as evidence of obstruction.

Caution.—Do not forget that the rising of the palatal cushion may be simulated by the movement of a small growth, or drop of mucus far back during deglutition or respiration (see Chapter III., p. 17).

§ 2. Nothing abnormal is seen on anterior inspection, but the patient complains that the obstruction comes on suddenly, and often

as suddenly ceases; that it is sometimes on one side, sometimes on the other; that it perhaps occurs only at nights, or on entering or leaving a hot room; that the obstruction is accompanied by a watery discharge; and that, as a consequence of the obstruction, he is compelled to breathe through the mouth, which hence becomes dry. *The trouble is probably due to turbinal erection.*

With symptoms such as the above given, the obstruction is no doubt due to turbinal erection, but, of course, a certain diagnosis cannot be made unless the erected turbinal is actually seen. The patient should be asked, therefore, if possible, to present himself for examination when the obstruction is present. A further account of turbinal erection and its differential diagnosis will be found at section 70, under the head of 'Turbinal Erection.'

§ 3. Nothing abnormal (beyond, perhaps, such a slight erection of the turbinal, or bulging of the septum, as is evidently insufficient to account for the obstruction) is noted in the affected cavity. Inspiration is more affected than expiration; expiration may possibly be free. On slightly withdrawing the speculum, or on inspecting without the speculum, the upper part of the ala is seen during inspiration to fall into contact with the septum, whilst externally the fossa immediately above the ala is noticed to recede abnormally during inspiration. On gently holding the ala away from the septum with a probe, the patient can inspire as freely as he expires. He can also breathe freely with the speculum *in situ*, but the obstruction to inspiration returns when the speculum is withdrawn. *The obstruction is due to collapse of the ala nasi.*

This condition, in my experience, is not uncommon, and was first described by Mr. Roughton. The patient is unable to inspire freely, in consequence of the ala half an inch or so above the anterior naris falling, during inspiration, into contact with the septum, and thus forming a kind of valve. There is often in these cases some slight deflection of the lower end of the septum, and moderate erection of the inferior turbinal, either or both of which conditions may increase the discomfort. Indeed, when these conditions are relieved, the breathing may be improved, but, as a rule, the obstruction cannot thus be completely overcome. I have called the condition collapse of the ala, but it is rather a falling-in of the tissues at the junction of the ala with the lateral cartilages, and is due, I imagine, to atrophy of the tissues, and, perhaps, wasting of the dilator muscles. The nose in the cases I have observed is

usually contracted and thin, and the tissues especially wasted in the fossa above the ala, the fossa itself being more than usually marked.

In some of these patients there has been a previous injury to the nose, driving it slightly to the opposite side; but in others there has been no history of injury of any kind. The trouble appears to come on about thirty years of age—at least, I have not met with it in younger patients. It is clear, therefore, that it is not a congenital deformity. This condition must not be confounded with the slight retraction of the fossa above the ala so often observed in serious obstruction from other causes.

SOMETHING ABNORMAL IS DISCOVERED BY ANTERIOR RHINOSCOPY.

§ 4. On looking into the nostril something abnormal is discovered.

If the abnormality has the appearance of a localized swelling, whether in connection with the septum or with the turbinals, or apparently distinct from each, or consists in a general swelling of the nasal mucous membrane, commence below at section 5; if otherwise, pass on to section 215, Chapter X.

§ 5. In many cases it will at once be evident that the obstruction is due to a polypus or group of polypi, the bluish-gray, semi-transparent, gelatinous appearance of a polypus, when once seen, being so characteristic that it can scarcely be mistaken for anything else, except, perhaps, a pure nasal cystoma. Under these circumstances turn to section 117, where the differential diagnosis of polypi is fully considered. On the other hand, if the obstructing lesion has not the ordinary appearance of a polypus begin below at section 6.

Caution.—It should be borne in mind that other conditions that may give rise to obstruction, may co-exist with polypi, such, for instance, as a deflection of the septum, a spur of the septum, or some obstructive lesion located in the naso-pharynx. Accordingly, should any other abnormal condition be found to co-exist with a polypus, its nature must be investigated as set forth in section 6. Similarly, the posterior nares and the naso-pharynx should be subjected to examination as indicated at section 170. Moreover, after the polypus has been removed, some further abnormality may be discoverable in the interior of the nose, the diagnosis of which may also be proceeded with as in section 6.

§ 6. The abnormal swelling or prominence that has been dis-

covered has not the well-known gelatinous, grayish appearance of the ordinary mucous polypus, but is evidently connected with the septum, with the inferior or middle turbinal body, or is quite as evidently, so far as can be thus seen, separate and distinct from each; begin at section 8, *Evident Swellings of the Septum*, or at section 66, *Evident Swellings of the Turbinals*, or at section 115, *Swellings, apparently distinct from both the Septum and Turbinals*. Again, the swelling may involve the nasal mucous membrane generally, affecting both the septum and turbinals; then turn to section 147, *General Swellings of the Nasal Chamber*.

If, however, it is not clear whether the swelling, or what looks like a swelling, is septal, turbinal, or distinct from each, begin below at section 7.

Method of determining whether a Swelling is Septal, or Turbinal, or Distinct from each.

§ 7. Spray into the nostril, or introduce upon a pledget of cotton-wool, a 20 per cent. solution of cocaine, and then examine with the nasal probe. If the probe can be passed between the septum and the swelling, it will be evident that the swelling is not septal; in like manner it can be determined that the swelling is not turbinal, by passing the probe between it and the turbinals. In some cases it will be impossible to determine the origin and connection of the swelling; then begin at section 115, and further investigate by examining the naso-pharynx and posterior nares, as given in section 170.

CHAPTER V.

GENERAL DIAGNOSIS—Continued.

THE OBSTRUCTION IS EVIDENTLY OF SEPTAL ORIGIN.

§ 8. **The swelling, or what looks like a swelling, is discovered to be septal.** It may be due to :

a. Functional derangement: Erection of the cavernous tissue over the tubercle of septum.

b. Hypertrophy of normally existing structures: Spur or ridge.

c. Congenital deformity: Deviated septum; displacement of columnar cartilage; nævus.

d. Traumatism: Hæmatoma; displacement of columnar cartilage; deflection of bony or cartilaginous septum.

e. Inflammation: Localized septic inflammation; acute or chronic abscess; local contagious ulcer (soft chancre).

f. General constitutional disease: Primary syphilitic sore (hard chancre); gumma.

g. Bacillary infection: Glanders, (*a*) acute, (*b*) chronic; tuberculous granuloma; lupus; rhinoscleroma.

h. New growth: (*a*) Innocent—osteoma, enchondroma, fibroma, myxoma, angioma, papilloma; (*b*) malignant—carcinoma, sarcoma.

Caution.—In any of these instances there may be concomitant swelling of the middle and inferior turbinal bodies; whilst further back (if the swelling of the septum or, if present, the concomitant swelling of the turbinals is not too great to allow of inspection of the chamber beyond) some other swelling may be seen. Because some form of swelling of the septum is discovered, it must not therefore be concluded that this is necessarily the cause of the obstruction. It may be only a partial cause, or may have little or nothing to do with it. Thus, in the case of a nasal spur, the spur may be little more than a slight increase of the normal tubercle of the septum,

and the obstruction, should nothing else be seen anteriorly, may depend upon such a condition as intermittent turbinal erection, or upon some affection so situated as to be beyond the reach of anterior rhinoscopy. Accordingly, these contingencies must be borne in mind, and the cause of obstruction not be attributed wholly to a slight septal swelling until a thorough investigation has been made of the parts beyond with a view to excluding the possible existence of other, and perhaps more important, obstructive lesions.

If not already done, the opposite nostril should be examined, so as to determine whether the swelling is unilateral or involves both sides of the septum.

If the swelling or prominence is unilateral, it may be (a) erection of the tubercle, (b) a spur or ridge, (c) a nævus, (d) a deviation of the septum, (e) a dislocation of the columnar cartilage, (f) a new growth, (g) a gumma, or possibly (h) a blood tumour, or (i) an abscess.

If bilateral, it may be (a) erection of the tubercle, (b) a hæmatoma, (c) an abscess, (d) a gumma, (e) an S-shaped deflection of the septum, (f) a second spur or ridge, (g) glanders.

Caution.—In the case of a tumour, the septum may be bulged over to the opposite side to a greater or lesser extent, and so make it appear as if the swelling was bilateral; but this condition can usually be recognised with a little careful observation.

Having discovered a swelling, or what looks like a swelling, the next point to observe is whether or not it is accompanied by signs of acute inflammation. If the swelling is accompanied by signs of acute inflammation, it may be due to (a) an acute abscess, (b) a septic inflammation, (c) a suppurating hæmatoma, (d) a suppurating gumma, or (e) glanders; then begin below at section 9. If there are no acute inflammatory signs pass on to section 20.

ACUTE INFLAMMATORY SWELLINGS OF THE SEPTUM.

§ 9. The swelling is accompanied by redness, heat, and pain with probably some concomitant swelling of the exterior of the nose and of the upper lip, and possibly of the cheek and lower eyelid. The swelling may be due to (a) abscess, (b) septic inflammation, (c) inflammation of a hæmatoma, (d) breaking down of a gumma, or (e) glanders. If there is no ulceration, begin below at section 10. If there is ulceration, pass on to section 15.

§ 10. **There is no Ulceration.**—The swelling may be (a) an abscess, (b) a septic inflammation, (c) an inflamed hæmatoma, or (d) a breaking-down gumma.

§ 11. The swelling has probably come on rapidly after an injury to the nose. Both nostrils may be occluded, and the swelling perhaps protrudes at the anterior nares. The mucous membrane is reddened and œdematous. The swelling itself feels hot, is tender to the touch, and its formation has been attended by throbbing pain and some fever. Fluctuation can be detected through the septum from side to side. *It is probably an acute abscess.*

As a rule, in acute abscess there is considerable swelling of the nose and upper lip, the skin of which is reddened and perhaps œdematous, the œdema in some instances extending to the eyelid on one or both sides. Pain and tenderness on pressure in these parts is also noticed. In addition to the local signs, there is generally some sharp constitutional disturbance—the temperature is raised one or two degrees, the pulse increased in frequency, and an attack of shivering or a distinct rigor supervenes as pus is formed.

The history of some injury to the nose, the throbbing character of the pain, the evident signs of inflammation, the rapidity with which the swelling has taken place, together with the presence of fluctuation in the part, will serve for establishing a correct diagnosis.

An acute abscess, however, may be mistaken for an attack of facial erysipelas, a suppurating gumma, suppuration following the septic infection of an abrasion, or a suppurating hæmatoma. Each of these, with the exception of erysipelas, is to all intents and purposes an abscess, and presents similar clinical signs. An exact differential diagnosis, therefore, is not important, except, of course, in the case of a gumma, when it will be necessary to recognise the cause of the abscess for appropriate treatment. (See section 13.)

Acute nasal abscess should be easily distinguished from acute erysipelas of the face by the facts that in the latter any swelling in the nostril, if present at all, will be less marked, that there is usually extensive œdema of the eyelids, that the inflammatory zone is definitely separated from the healthy integument by a sharply defined line of demarcation, that the cuticle is often raised into blebs, and that the constitutional disturbance is more severe.

§ 12. The swelling presents the characters given above in section 11, but the patient states that it came on immediately after a severe injury of the nose, and that it was at first unaccompanied by any

of the signs of acute inflammation which are now present. *It is probably a hæmatoma that has become inflamed, and is now suppurating.* (See 'Hæmatoma,' section 40.)

§ 13. The swelling presents signs similar to those given in section 11, but less acute, and the patient states that he has had no injury to the nose, and that the swelling started as a hard mass, which only of late has become soft and shown inflammatory signs. There are probably lesions of other parts of the nose, or elsewhere, pointing to syphilis, and a history of that affection is obtained. *The swelling is probably an inflamed and suppurating gumma.* (See 'Gumma,' sections 33, 39, 55, and 60.)

§ 14. The swelling is unilateral, prominent, red, angry-looking, and brawny, and perhaps a pustule is present on the most prominent part. There is probably some œdema of the surrounding tissues, and the part feels hot, is tender to pressure, and there is throbbing pain, but no fluctuation. *It is probably a septic inflammation, due to plucking out a hair from the nostril, or to the infection of a scratch or abrasion by septic material.*

These septic inflammations are exceedingly common, and are usually situated upon the anterior and front part of the septum, close to the junction of the skin and mucous membrane, by reason of the frequency with which this part suffers abrasion from scratching with the finger-nail. They are also common just within the vestibule on the inner surface of the ala.

§ 15. **There is Ulceration.**—In addition to the inflammatory signs, the mucous membrane covering the swelling is ulcerated. It may be (1) ulceration accompanying a septic inflammation; (2) destruction of the mucous membrane following a neglected abscess; (3) a local contagious ulcer (soft chancre); or (4) glanders.

§ 16. A small ulcer in the centre of a brawny swelling is observed on the septum near its anterior margin. The ulcer is quite superficial, the destruction of tissue being limited to the mucous membrane. The margin of the ulcer is irregular and inflamed. The surface is covered by a yellow discharge. The surrounding mucous membrane is intensely inflamed and œdematous, and there may be some swelling of the external nose and upper lip, and perhaps œdema of the eyelid. The patient has complained of throbbing pain in the part, and the swelling is extremely painful to the touch. *It is ulceration following septic inflammation.*

Ulceration supervening upon septic inflammation is frequently

met with, and is the later stage of the septic pustule caused by septic inoculation of an abrasion. The history of the case—that there was a slight abrasion of the part, or that a hair had been recently plucked out; that there was first noticed a small pimple, which became painful and tender, later brawny, and afterwards developed into a pustule, finally breaking and discharging a small quantity of pus; and that during the progress of the case the attendant œdema of the part and surrounding tissues became more pronounced, will readily explain the nature of the swelling.

§ 17. An ulcer is seen having an uneven and ragged outline, and apparent absence of floor. The base is slightly indurated or brawny, and the surrounding mucous membrane is inflamed and œdematous. A thick yellow discharge, perhaps tinged with blood, escapes from the ulcer when the base is pressed upon, and a probe, when passed into the ulcer, is found to enter a cavity of some size, and its point can be felt beneath the mucous membrane in the opposite nostril, which is probably occluded by considerable swelling. *The ulcer is due to a neglected abscess.*

This is the natural termination of an abscess that has not been subjected to surgical treatment. The mucous membrane covering the abscess gradually becomes inflamed and thinned, and finally gives way, leaving an irregular ragged-looking opening on the surface. The history of the case—that a swelling first appeared in one nostril, and later in the opposite one; that, as it increased in size it became hot and tender to the touch and attended by throbbing pain; and that finally there was a sudden discharge of a quantity of pus from the nostril in which the ulcer is situated—together with the fact that a probe passes through the ulcerated opening into a cavity beneath, will be sufficient to establish the diagnosis.

An abscess of the septum is perhaps most commonly the result of an injury to the nose, as a fracture of the septum, and may be preceded by a hæmatoma. Should there be a history of an injury, therefore, followed by sudden swelling and obstruction in the nose, and later by inflammation, and, on the bursting of the swelling, by an escape of breaking down blood and pus, the ulcer is probably due to suppuration of an inflamed hæmatoma.

§ 18. The ulcer is situated upon the anterior portion of the septum, close to the mucó-cutaneous junction. The edges are somewhat undermined, sharp-cut, and slightly everted. The surface is irregular, and covered by granulations in places, which impart to it a worm-eaten

appearance. Where the granulations are wanting the surface is covered by tough, adherent portions of tissue, having a grayish colour. The discharge is thick and purulent, and offensive in smell. The surrounding mucous membrane is inflamed and œdematous. The base may be very slightly indurated; but such induration as exists is not definitely circumscribed, but gradually fades into the surrounding tissue. *It is probably a local contagious ulcer of the septum (soft chancre).*

This form of ulcer is very rarely met with in the nose, but may occur in a patient suffering from a local contagious ulcer on the penis or vulva, who has inadvertently conveyed the virus to the nose by means of the finger-nail. The diagnosis may not be easy, and will have to be made from a primary syphilitic sore, ulceration due to breaking down of septic inflammation, and ulcerating actinomycosis. The history of the case—that it began as an inflammatory pimple, surrounded by a zone of acute inflammation; that the pimple speedily became a pustule, which broke and discharged pus; that the ulceration has extended more or less rapidly, and has shown no tendency to cicatrize; and that it made its appearance during the existence of a similar ulcerative condition of the glans penis or vulva, will throw some light upon the nature of its cause. Should there be evidence of auto-inoculation of the parts coming into contact with the ulcer, such, for instance, as the opposite wall of the nasal cavity, and should the submaxillary glands be enlarged and tender, and perhaps tending towards suppuration, a further confirmation of the suspicion aroused will be obtained.

§ 19. One or more ulcers are seen on the front part of the septum, close to the muco-cutaneous junction, surrounded by a zone of intense inflammatory congestion, with perhaps inflammatory nodules and pustules in the near vicinity. The ulcers are ill-conditioned and phagedænic, and are stated to have started as nodules, which quickly broke down into ulcers. The ulceration is said to be rapidly progressing, shows evidence of destruction of deeper structures, and is attended by œdema and swelling, and perhaps ulceration, of the external nose. There is a thin, glairy, or it may be a thick, sanious, and fœtid, discharge from the nose, and the patient states that the appearance of the ulceration was preceded by malaise, headache, high fever, shivering, great prostration, and pains in the muscles and joints. *It is probably acute glanders.*

Acute glanders is rare, and its progress is so rapid that it is still

more rare to meet with the nodules or ulcers confined to the septum. The diagnosis of the condition is often obscure. The acuteness of the disease, the rapidity with which the nodules break down into ulcers, the unhealthy, phagedænic character of the ulceration, and the great destruction of tissue resulting therefrom, all point to an acute infective process suggestive of glanders. If the patient's occupation is that of a coachman, hostler, or veterinary surgeon, and especially if it be known that he has been brought into contact with a glandered horse, and if in the later stages of the disease a pustular eruption which closely resembles that of small-pox appears upon the face and in the neighbourhood of the joints, the suspicion will be increased. An accurate diagnosis, however, can perhaps in such an early stage only be arrived at by making bacteriological cultures from the discharge. Microscopical examination would then show the presence or absence of the *Bacillus mallei*, which is now known to be productive of the disease.

THE SWELLING IS NOT ATTENDED BY SIGNS OF ACUTE INFLAMMATION.

§ 20. *If there are no signs of acute inflammation*, such as are alluded to in section 9, the swelling may be one of the following: (1) a simple spur or ridge; (2) erection of the tubercle; (3) a nævus; (4) a deviation of the septum; (5) a dislocation of the columnar cartilage; (6) a hæmatoma; (7) a gumma; (8) a chronic abscess; (9) rhinoscleroma; or (10) a new growth.

Of these, it should be borne in mind, a nævus and rhinoscleroma are very rare.

If there is no ulceration attending the swelling, begin below at section 21. *If ulceration is present*, pass on to section 58.

THERE IS NO ULCERATION.

§ 21. If on looking into the opposite nostril a concavity is seen corresponding to the swelling, the swelling is probably the convexity of a deviated or deflected septum: begin at once at section 22; otherwise pass on to section 25.

§ 22. **A concavity corresponding to the swelling is seen in the opposite nostril.**

§ 23. The swelling is smooth, perhaps irregular on the surface, gradually shelving into the rest of the septum, and hard or cartilaginous to the touch. The mucous membrane covering it is healthy,

or perhaps paler than natural. It may yield slightly to pressure. On looking into the opposite nostril, a concavity is seen corresponding to the situation of the swelling on the other side. *The swelling is the convexity of a deviated septum.*

The swelling or prominence caused by a septal deflection, though usually smooth, may have a crumpled and irregular surface, and the mucous membrane covering it is generally natural-looking, but may be somewhat thickened. That lining the corresponding concavity in the opposite nostril is also natural. If a probe is introduced into each nostril, only a thin plate of tissue may be found to intervene, showing that the swelling in the occluded nostril is entirely due to the septal deformity, or there may be a heaping up of cartilage or bone on the convex side forming a spur-like projection. In most cases of deflected septum, especially when the result of an injury, there is usually some degree of deformity of the external nose, such as lateral displacement of the cartilages or nasal bones, or a depression of the cartilages at their junction with the nasal bones.

Having discovered that the obstruction is caused by a deviation of the septum, the next point to determine is its resiliency and thickness; whether it is cartilaginous or bony, or both; whether it involves the maxillary crest; and whether the deviation is simple or S-shaped, since all these points have a practical bearing on treatment.

§ 24. A small red prominence, or it may be a smooth ridge covered by healthy or thinned mucous membrane, is seen just within the anterior nares on the anterior end of the septum. The ridge is made more prominent on bending the tip of the nose to the opposite side. In the opposite nostril there is a slight concavity corresponding to the prominence. *It is a dislocation of the anterior end of the septum from the columnar cartilage.*

A dislocation of the anterior end of the septum is common, and is often associated with some deflection of the end of the nose to the opposite side. It is met with both idiopathically or as a result of an injury. At times it is the prominent end of the septum which produces the obstructing swelling, this prominent end then having the appearance of a sharp ridge which is made more prominent by pressing the end of the nose upwards and to the opposite side. The swelling in this case has a yellowish or pearly-white colour, in consequence of the cartilage shining through the thinned mucous membrane. At other times the columnar cartilage itself, rather than the septum, may be said to be the part displaced. The anterior

naris then appears deformed, and a reddish-looking swelling is seen projecting from the columella at the entrance to the naris, and blocking, more or less, the passage on its inner side. Beneath this swelling the end of the septum can be felt.

§ 25. No concavity corresponding to the swelling is seen on looking into the opposite nostril.

If the swelling has the appearance of being merely a ridge or prominence of the septum itself, and is of a cartilaginous or bony consistency and covered with healthy mucous membrane, it is probably a simple spur or ridge, or possibly a commencing enchondroma or osteoma; begin below at section 26. If the obstructive lesion appears to depend upon a more or less circumscribed swollen or infiltrated condition of the mucous membrane, rather than upon a distinct tumour or outgrowth, it is probably an erection over the tubercle of the septum, a nævus, early lupus, a syphilitic lesion, or early rhinoscleroma; begin at section 28. Again, if the swelling has the form of a distinct tumour or outgrowth, it is probably a chronic abscess, a hæmatoma, a gumma, a papilloma, an angioma, a tuberculoma, a sarcoma, a carcinoma, a fibroma, an enchondroma, or an osteoma; pass on to section 35.

§ 26. The swelling has the appearance of being merely a ridge or prominence of the septum itself, is of a cartilaginous or bony consistency, and covered with healthy mucous membrane. Begin below at section 27.

§ 27. The swelling is angular or ridge-like, smooth on the surface, regular or irregular in outline, abrupt or shelving off gradually to the rest of the septum, firm on touching with the probe, and covered with healthy mucous membrane the colour of which is natural or, it may be, paler than that of other parts of the nasal cavity. *It is probably a simple spur or ridge.*

These spurs may be composed entirely of cartilage, or partly of cartilage and partly of bone, or in some instances wholly of bone. They are frequently met with, but should not be considered pathological, or call for treatment, unless they are of some size, and are clearly producing obstruction. They may be situated almost anywhere on the anterior half or two-thirds of the septum, but are rarely met with further back. A common position is along the junction of the septal cartilage with the vomer, when they are generally both cartilaginous and osseous in structure.

They may take the form of a rounded eminence, or be more or less pyramidal, with the apex perhaps touching the inferior turbinal body. Or they may occur as irregular projections extending towards the floor of the inferior meatus with their lower part curved hook-like below their point of attachment, so that a probe can be passed beneath them. When arising at the junction of the cartilaginous and osseous septum they may take the form of a smooth or irregular ridge extending backwards along the chondro-osseous suture. At times they extend downwards, involving the maxillary crest, thus narrowing the inferior meatus. Spurs are frequently associated with deviations of the septum. In many of these cases, when the result of traumatism, I believe the spur is often little more than callus that has been thrown out to unite a fractured septum. A spur is sometimes adherent by its apex to the inferior turbinated body, and may then be productive of serious obstruction. A similar spur may exist at the same time in the opposite nostril, or in the opposite nostril a concavity may be met with corresponding to the position of the spur, which is then practically a thickening on the convex part of a deflected septum.

§ 28. The obstructive lesion appears to depend upon a more or less circumscribed swollen or infiltrated condition of the mucous membrane, rather than upon a distinct tumour or outgrowth:—the swelling may be due to erection of the mucous membrane over the tubercle of the septum, a nævus, early lupus, a syphilitic lesion, or early rhinoscleroma. If the surface of the mucous membrane is intact, and the swelling disappears either on the application of cocaine, or on pressure, it is probably either erection of the tubercle, or a nævus: begin at section 29; otherwise, pass on to section 31.

§ 29. The swelling is situated about the region of the tubercle of the septum; it is smooth, slightly prominent, and shelves off gradually into the rest of the septum. The mucous membrane covering it is probably slightly redder than normal. The swelling dimples when touched with a probe, and disappears when sprayed or painted with a 20 per cent. solution of cocaine. *The swelling is due to erection or turgescence of the erectile tissue in the mucous membrane covering the tubercle of the septum.*

This condition is frequently met with in conjunction with turbinal erection and in chronic catarrhal rhinitis. The behaviour of the swelling on probing and on painting with cocaine should serve for its diagnosis.

§ 30. The swelling is uniform, slightly raised, probably situated near the anterior end of the septum, of a pinkish-blue or purplish colour, smooth on the surface, and traversed by numerous tortuous venules. It disappears momentarily on pressure, does not pulsate or bleed when touched, and is stated to have existed since birth. *It is a nævus of the septum.*

A nævus of the septum is rare. The congenital history, disappearance on pressure, absence of pulsation and of inflammation, and the slow growth, should render the diagnosis fairly easy. Other capillary or venous nævi will probably be met with in various parts of the body, especially about the face. I have seen such a venous nævus of the upper lip continuous with a nævus on the septum. This form of nævus must be distinguished from the arterial nævus or pulsating angioma, which occurs as a circumscribed pulsating tumour, is attended with alarming hæmorrhage, and readily bleeds when touched (see section 45).

§ 31. The mucous membrane covering the triangular cartilage of the septum, or thereabouts, is considerably thickened and infiltrated, and is covered by pale red granulations having a nodular character, each nodule varying in size from a millet-seed to a split pea. Some of the nodules may have lost their firm, nodular feel, and be of softer consistence than the rest, and also of a different colour, being of a light brown rather than a pale red. One or more of them, on closer examination, may be seen to be covered by a crust composed of flat and broad scales of a brownish hue. There is no history of epistaxis, but slight bleeding may occur on forcibly removing the scales. There is probably a scanty serous or mucous discharge. *It is lupus in its early stage.*

Lupus in its early stage is very rarely seen in the nose, probably because it does not give rise to symptoms that urge the patient to seek relief. The nodules speedily break down and ulcerate; when they become softer and change colour they are in the transitional stage.

The diagnosis, especially from *syphilis*, is not easy, but if the patient is watched, the breaking down of the nodules to form ulcers, the formation of the characteristic scales, the chronicity of the disease, and its non-yielding to anti-syphilitic remedies, will help us. If lupus exists on the face or external parts of the nose, the diagnosis will be easier, especially if it can be traced on to the mucous membrane of the septum. In most of the cases that I have seen, such a

continuity of the disease has existed. From *sarcoma* and *carcinoma*, the slow growth of *lupus*, the absence of bleeding, and, if necessary, the examination of a small portion of the swelling microscopically, taken with the characters above given, will serve to distinguish it. For the differential diagnosis of *lupus* and *tubercle*, see § 60.

§ 32. One or more grayish-white, slightly-raised patches, surrounded by a red areola, are seen on the anterior part of the septum and perhaps on both sides, and are accompanied by a muco-purulent discharge. Similar patches, or superficial ulcers, are probably present at the corners of the mouth, on the inner surface of the lips and cheeks, or about the tonsils and fauces. *The patches are probably mucous tubercles.*

On inquiry it will most likely be found that the patient has lately had syphilis, and secondary lesions, such as skin eruptions, mucous patches on the inner surface of the lips and cheeks, on the sides of the tongue, on the fauces and tonsils or back of the pharynx, and condylomata about the anus, etc., will probably be discovered.

At times a mucous patch in the nose may assume the form of a distinct tumour of lobulated appearance.* A slight erosion on the apex of a spur on the septum may simulate a mucous patch, but the cleansing of the part with a pellet of cotton-wool will reveal the nature of the case.

§ 33. The mucous membrane covering the septum is swollen and studded with one or more irregular or rounded nodule-like projections of a somewhat darker red colour than the rest of the mucous membrane. One or more of the nodules may have a softer consistency than the rest. On the external surface of the nose, and on other parts of the face, there is a well-marked tubercular syphilitic eruption. *It is a tubercular syphilide (superficial gummata) of the septum.*

As far as I know, this condition is only met with in conjunction with the so-called tubercular syphilis of the exterior of the nose or upper lip, and an extension of the lesion can be traced from without on to the septum. If allowed to run their course, the nodules break down into superficial ulcers, the condition in which the affection is more often met with. Before ulceration has occurred it is difficult to distinguish a tubercular syphilide of the septum from early *lupus*. The characteristic appearance of the rash on the face, the history of syphilis, and the effects of anti-syphilitic remedies, are then the chief points to depend upon in the diagnosis.

* Lacoarret, French Society of Laryngology and Otology, May, 1892.

§ 34. The swelling is hard to the touch, almost of bony consistence, and slightly raised from the level of the surrounding tissues. The surface is flat, smooth, shiny, and perhaps the natural colour of the mucous membrane, though more probably of a brownish-red hue. When pressed upon by the probe, tenderness is elicited, but there is no actual pain in the part, or sign of inflammation or ulceration, and the surrounding mucous membrane is of healthy appearance. The margin of the growth is probably rounded, and ends abruptly. *It is probably rhinoscleroma confined to the septum.*

In this disease there is usually some implication of the skin of the external nose, especially of the alæ, the patient complaining of a sense of stiffness and immobility in the part. There is also a great tendency for the growth to extend, and to spread backwards into the naso-pharynx, and it has been known to invade the mouth. The larynx, too, is often affected. The diagnosis may be difficult in the early stages and whilst the septum alone is affected, but later it becomes easy, since the disease, when well advanced, is unlike any other. The slow progress of the disease, its tendency to increase by direct continuity of tissue, its liability to involve the posterior nares and larynx, the absence of all pain and inflammatory phenomena, and especially the fact that the growth is hard and shows no tendency towards ulcerating or breaking down, are points that are characteristic of rhinoscleroma.

§ 35. **The swelling has the appearance of a distinct tumour or out-growth.**

If the swelling is soft, or only moderately firm, begin below at section 36; if it is firm or hard, *i.e.*, almost or quite of cartilaginous or bony consistency, pass on to section 52.

§ 36. **The swelling is soft or only moderately firm.** If the swelling is broad-based, rounded, smooth, and evidently situated beneath the mucous membrane, the surface of which is intact, it is probably a *chronic abscess*, a *hæmatoma*, a *softening gumma*, or possibly a *soft sarcoma*; begin below at section 37. If, on the other hand, the tumour is circumscribed or pedunculated, and apparently grows from the mucous membrane, it may be a *papilloma*, an *angioma*, a *tuberculoma*, a *sarcoma*, or a *carcinoma*; pass on to section 42.

§ 37. **The swelling is broad-based, rounded, smooth, and evidently situated beneath the mucous membrane.** It is probably a chronic abscess, hæmatoma, or softening gumma, possibly a soft sarcoma.

§ 38. The swelling is uniform, smooth, situated just within the

nostril, and there is probably a similar swelling on the opposite side. The mucous membrane covering the swelling is of a pale pink, or perhaps of a yellowish-pink colour. The swelling does not pit on pressure, but is soft and semi-fluctuating, or distinctly fluctuating, and fluctuation may perhaps be obtained from one side of the septum to the other. There is no sign of acute inflammation, and no history of any recent injury to the nose; but the patient may have lately suffered from typhoid fever, or some similar debilitating disease. *The swelling is probably a chronic abscess.*

A chronic abscess is not very common. Morell Mackenzie states that he only met with one in the course of his practice. I have met with several in the general surgical work of the out-patient room. Their cause was not very evident. They are said often to follow some debilitating disease, as typhoid, etc.; sometimes they appear to be tubercular in origin. They are also said to be due to syphilis; but this statement, I imagine, refers to a breaking-down gumma. They at times lead to perforation of the septum.

A chronic abscess may have to be diagnosed from (1) a breaking-down gumma; (2) a hæmatoma; (3) a soft sarcoma; (4) a deflected septum; (5) an enlarged inferior turbinal; and (6) a foreign body or rhinolith.

From an *enlarged turbinal* there should be no difficulty in distinguishing a chronic abscess of the septum if ordinary care is taken to make out whether the swelling is septal or turbinal (see section 7).

The fact that there is an absence of a concavity in the opposite nostril corresponding to the prominence on the obstructed side will at once exclude the existence of a *deflection of the septum*.

From a *breaking-down gumma*, a *soft sarcoma*, or a *hæmatoma*, it may be impossible to make a diagnosis without puncture with a grooved needle. The following considerations, however, will be of assistance:

The non-existence of similar swellings in the same or opposite cavity, or upon the nasal or cranial bones, the absence of syphilitic manifestations in other parts of the body and of a history of that disease, taken with the facts that the swelling has remained unchanged for some considerable time, and that pus escapes on puncture with a grooved needle, should serve to distinguish a chronic abscess from a *gumma*.

The history that the swelling is not increasing rapidly in size, and has not been attended with repeated attacks of epistaxis, and

the facts that the swelling fluctuates, is not friable, does not bleed on sponging or probing, that the mucous membrane covering it is normal or merely thinned, and that pus and not pure blood escapes on puncture, will usually set aside the question of a *soft sarcoma*. When, however, the mucous membrane covering a soft sarcoma is intact, and the growth is so soft that it gives a sense of semi-fluctuation, puncture or an exploratory incision will be the only way of settling the diagnosis.

The absence of any history of an injury to the nose, or of signs of ecchymosis, together with the gradual development of the swelling, should dispose of a *hematoma*. With a moderate amount of care there should be no possibility of confounding a chronic abscess with a *rhinolith* or *foreign body*.

§ 39. The swelling is prominent, smooth on the surface, rounded or perhaps irregular, and occludes more or less completely the inspection of the chamber posterior to it. The mucous membrane covering it is of a dull red or purplish colour, and is perhaps slightly eroded where in contact with the turbinal. The swelling is soft, or semi-fluctuating more or less all over, or may be harder in places, and probably extends to the floor, or to the roof of the nose, or in both directions. A similar swelling may be discovered over the turbinals or the exterior of the nasal bones, in the roof of the mouth, possibly on the forehead or on some of the cranial bones, whilst in the substance of the lip or in the ala of the nose hard, or, it may be, semi-fluctuating swellings may be found. *The swelling is probably a softening gumma.*

A gumma situated on the septum is said to be usually unaccompanied by the deep boring nocturnal pains so characteristic of gummata affecting the bones in other situations. In my personal experience of gummata of the septum, which has been fairly considerable, there has usually been nocturnal pain; but then, in the majority of cases I have seen there have been concomitant gummata in the floor of the nose, on the turbinals, or on the buccal surface of the hard palate, and it has been difficult to obtain from the class of patients who attend in the out-patients' room the exact seat of the pain. Anyhow, the pain has certainly not been severe. At times on looking at the palate a perforation will be found as the result of necrosis of the bone, consequent on the breaking down of a gumma of the hard palate. When perforation of the palate has occurred, it will nearly always, as far as my experience goes, be found that

the gumma of the septum has broken down, and ulcerated through the mucous membrane of the nose at some spot, and although no ulceration may be visible in the swelling on the septum, the existence of a perforation may be demonstrated by a probe passed through the hole in the palate, entering the nasal chambers on one, or possibly on both sides. Necrosed bone under these circumstances will nearly always be felt with the probe. The existence of a swelling of the septum, such as described with perforation of the palate, may be taken as almost pathognomonic of a softening gumma.

In the majority of cases I have seen in the out-patient room of gummata of the septum, there have been other gummatous swellings in various stages in the near region of the nose, or on some part of the cranium or face. Thus, perhaps, most frequently there have been thickenings and induration over the nasal bones, or gummata on the frontal bone; in several cases, gummata in the upper lip, or in the ala of the nose.

The swellings of the septum which may simulate a softening gumma are: a chronic abscess, a hæmatoma, or a soft sarcoma. The probable multiplicity of the swellings, their varying consistence in different parts, the absence of a recent injury to the nose or of ecchymosis of the surrounding tissues, coupled with the gradual and progressive development of the tumour, will enable the distinction to be made from a hæmatoma. From a *chronic abscess* the diagnosis may be attended with difficulty, though the fact that the softening began in the centre of the swelling while the periphery still remained firm and indurated, the probable existence of more than one swelling, and the detection of other undoubted signs of syphilis in various parts of the body, should clear up any doubt that may exist on the point. The slower and more gradual development of the tumour, the concomitant signs of syphilis, the action of anti-syphilitic remedies, the absence of spontaneous bleeding and friability of structure, or, when the mucous membrane is intact, the presence on puncture of fluid of a purulent nature in the softer parts, would exclude the possibility of *soft sarcoma*.

§ 40. The swelling, which is situated just within the nostril, or perhaps protrudes at the anterior naris, is globular, uniform, broad-based, smooth on the surface, and more or less obstructs the passage, probably touching the inferior turbinal. A similar swelling probably exists on the opposite side. The mucous membrane covering it is of a bluish-purple colour, and the rest of the mucous membrane may

have a similar tinge. The swelling is soft, dimples on being touched with a probe, does not bleed, is not painful or tender on pressure, and probably fluctuates through on placing a finger on each side of the septum. There is no œdema or signs of inflammation. The patient states that the swelling came on suddenly after a blow or fall upon the nose, or was first noticed on the subsidence of the more external swelling that followed the injury. *It is probably a hæmatoma.*

A puncture with a grooved needle will settle the diagnosis. A blood tumour is not so very uncommon after injuries to the nose, more especially fractures of the septum. The above characters should serve to distinguish a hæmatoma from the following affections, for which it may be mistaken, namely: a chronic abscess, a deflected septum, an enlarged turbinal, a gumma, or a soft sarcoma.

A *chronic abscess*, as a rule, forms slowly; the mucous membrane, instead of being bluish-purple, is pale pink, or even of a yellowish tinge, from the pus showing through it, and there is probably some cause for an abscess discoverable, such as an attack of typhoid fever.

Gummata are usually multiple, and there is no history of a sudden onset of the swelling, nor of a recent injury followed by ecchymosis; but there is probably a history of syphilis, and other manifestations of that disease.

A *soft sarcoma* is usually of rapid growth, attended by frequent hæmorrhages, and is of semi-solid rather than of fluctuating consistency. Puncture also of the mass fails to elicit the presence of broken-down blood, and is followed by the escape of pure blood.

In *deflected septum* there will be in the unaffected nostril a concavity corresponding to the convex swelling, and the swelling will be hard in consistence, and fluctuation will be absent.

In *enlargements of the turbinal*, the fact that a probe can be passed between the swelling and the septum should be sufficient to show that the swelling is not connected with the septum.

§ 41. The swelling is broad-based, smooth, soft, elastic or semi-fluctuant, and the mucous membrane covering it, though its surface is intact, may be of a purplish-pink or bluish-gray colour and highly vascular, and readily bleeds when touched. The patient, who is probably young, says that the obstruction has increased very rapidly, but without pain. There may have been attacks of epistaxis. On puncture arterial blood escapes. *It is probably a soft (round celled) sarcoma.*

It is rare to meet with a soft sarcoma in so early a stage, and in

the form above described. Soft sarcomata, perhaps, more often appear as distinct tumours, apparently growing from the mucous membrane, and not, as here, covered by it. In consequence of their rapid growth, moreover, they are nearly always when met with already ulcerated and fungating, filling more or less the whole nostril, so that their septal origin cannot be readily made out. (See Chapter VII.)

A sarcoma in the form and early stage above described must be distinguished from a chronic abscess, a hæmatoma, and a softening gumma. The absence of any cause for the swelling and of any concomitant signs or history of syphilis, and the rapid growth, and tendency to bleed, should excite suspicion of malignant disease; the escape of only pure blood on puncture and a microscopical examination should clear up any remaining doubt.

§ 42. **The swelling is circumscribed or pedunculated, and apparently grows from the mucous membrane.** It is probably (1) a papilloma, (2) an angioma, (3) an arterial nævus, (4) a tuberculous granuloma, (5) a sarcoma, or (6) a carcinoma. If the swelling readily bleeds when touched, and has been attended with profuse attacks of epistaxis, it is probably a sarcoma, a carcinoma, an angioma, or a pulsating angioma; begin below at section 43. If, on the other hand, although the swelling may perhaps bleed when touched, and there may have occasionally been slight bleeding, there have not been profuse attacks of epistaxis, pass on to section 49.

§ 43. **The swelling readily bleeds when touched, and has been attended by frequent attacks of profuse epistaxis.** Inquire as to its duration and rate of growth. If it is of slow growth, begin at section 44; if of rapid growth, pass on to section 46.

The swelling is of slow growth.

§ 44. The growth is found to arise from the fore-part of the septum, opposite to the anterior extremity of the inferior turbinal body (Kesselbach's area). It is broadly pedunculated, possibly bilobed, moves freely during nasal respiration, is of a red or bluish colour, smooth on the surface, soft and elastic to the touch, and bleeds readily when probed. There is no pulsation. Its growth is said to have been slow, and the only inconveniences are the obstruction to respiration it produces, and the frequent hæmorrhages. The mucous membrane around is natural-looking. *It is an angioma of the septum.*

Pure angiomata of the septum are very rare. Out of 7,429 cases examined at the Massachusetts Hospital, only one example of this kind of tumour is recorded. Most of the cases reported by authors were found upon microscopical examination to consist of myxomatous tissue containing numerous bloodvessels, but these must not be classified as true angiomata. Others were found to contain sarcomatous elements. Roe reports a case of true angioma which subsequently underwent sarcomatous degeneration. Microscopical examination can alone decide whether a tumour of this nature is a pure angioma, in which case the growth will be found to be composed of large vascular sinuses, with more or less round cells interspersed in the connective-tissue elements.

§ 45. The swelling is circumscribed, globular, sessile, dark red, readily bleeds when touched, pulsates synchronously with the heart, and is attended with frequent and alarming bleedings. It is probably situated on the anterior end of the septum, in the region of Kesselbach's area. *It is a pulsating angioma or arterial nævus.*

These growths are exceedingly rare. The fact that they pulsate, taken with the other signs above given, should make their diagnosis fairly easy.

The swelling is of rapid growth.

§ 46. The obstructing swelling is sessile, or it may be pedunculated, soft and spongy, perhaps friable, smooth or corrugated on the surface, of a purplish-pink or bluish-gray hue, highly vascular, and readily bleeds when touched with the probe. There are no similar swellings visible in the same or in the opposite nostril. The patient says the obstruction has increased very rapidly, but has not been attended with much if any pain. He is probably young, and shows no signs of syphilis, and states that he has not suffered from that disease but that he has had several attacks of epistaxis. On puncture, arterial blood escapes. *It is probably a soft (round celled) sarcoma of the septum.*

It is rare to meet with soft sarcomata in so early a stage. They grow so rapidly, and at first are attended with such slight symptoms, that as a rule the growth has already become ulcerated and may have given rise to some bulging or external deformity before advice is sought. The appearance of a sarcoma when ulcerated is given at section 64.

A soft sarcoma in an early stage, such as above described, may be mistaken for an early gumma, a chronic abscess, an irritated mucous

polypus, or a soft carcinoma. There should be no difficulty in diagnosing it from a deflected septum or from a cartilaginous or osseous tumour, in that the sarcoma bleeds and is soft, whilst the other swellings are hard and are not attended with hæmorrhage. Apart from its salient features of rapid growth, repeated bleedings, and escape of blood only on puncture, the absence of any evidence of syphilis in the nose or elsewhere and of a history of that disease, should help to distinguish a sarcoma from a *gumma*, and the absence of fluctuation or of any determining cause from a *chronic abscess*; whilst an *irritated mucous polypus* can be drawn down and then be recognised by its characteristic gelatinous appearance. From a *fibroma* or *carcinoma*, it may be impossible to distinguish a sarcoma without a microscopical examination of a small portion of the growth. The hard or spindle-celled sarcoma is described at section 57.

§ 47. The tumour is moderately firm to the touch, irregular on the surface, of a mottled, bluish-red colour, and readily bleeds when probed. It is adherent to the underlying structures, and the immediate surrounding mucous membrane is thickened and indurated. It is said to be of rapid growth, and to have been attended by hæmorrhages and perhaps by a sero-sanguinolent discharge. *It is probably spheroidal-celled carcinoma of the septum.*

A primary carcinomatous tumour of the septum is very rare, and when presenting the above signs is probably of the spheroidal-celled type, having originated in the glands of the mucous membrane. The squamous variety generally ulcerates early, and when seen has usually the appearance of the carcinomatous ulcer. The age of the patient, the rapid growth of the tumour, and the fact that it is fixed to the underlying structures, will materially help us in arriving at a correct conclusion. Should there be enlargement of the neighbouring lymphatic glands, this suspicion will be confirmed. In this very early stage of the growth, however, the glands would probably not be affected. Indeed, enlargement of the glands in intra-nasal growths is the exception rather than the rule. Too much weight should not be therefore placed upon the presence or absence of glandular enlargement.

§ 48. The growth is small, hard, irregular, wart-like, sessile or, it may be, pedunculated, and bleeds readily when touched; the base is hard and infiltrated. The neighbouring lymphatic glands may or may not be enlarged. The patient is probably old, or past middle

life. The obstruction has only been observed a short time, there is perhaps a sero-sanguinolent discharge, and there may have been one or more attacks of epistaxis. *It is probably a squamous-celled carcinoma (epithelioma) of the septum.*

It is exceptional to meet with a squamous-celled carcinoma (epithelioma) of the septum in this condition, since ulceration, as in epitheliomata in other situations, commonly occurs early, and spreads commensurately with the invasion of the surrounding tissues. For an account of an ulcerating epithelioma, refer to section 65, where its diagnosis from the other forms of ulcerating growths which it then simulates is discussed. Early glandular enlargement is said not to be common.

When an epithelioma assumes, as it sometimes does, the pedunculated form, it may very closely resemble a papilloma. Indeed, it may occasionally begin as a papilloma (see section 51).

§ 49. The swelling, though it may perhaps bleed when touched, and though there may have occasionally been slight bleedings, has not been attended by profuse attacks of epistaxis.

§ 50. The swelling is situated upon the anterior portion of the septum. It is irregular in shape, and has a reddish colour. It is soft and friable, very vascular, and bleeds freely when touched. There is no thickening of the surrounding mucous membrane, but there may be an oval ulcer in the near vicinity. *It is probably a tuberculous granuloma of the septum.*

It is exceedingly rare to meet with tuberculous disease of the septum in a form such as is above described—that is, localized and at the same time productive of sufficient swelling to cause obstruction. In this stage a tuberculous granuloma may be simulated by simple erection of the mucous membrane over the tubercle of the septum, a nævus of the septum, a papilloma, and an early malignant growth.

An erection of the mucous membrane over the tubercle of the septum will dimple on probing, and disappear under the influence of a 20 per cent. solution of cocaine.

A nævus of the septum will disappear on pressure, and the mucous membrane covering it will be seen traversed by dilated and tortuous venules, and will probably be known to have existed since birth. Moreover, it does not bleed when touched.

A papilloma, which a tuberculous granuloma may sometimes resemble, is usually much larger, less flattened, more wart-like, has a less rounded shape, and does not readily bleed.

In an early *malignant growth* the symptoms and signs may be so similar that the diagnosis cannot be made with any degree of certainty without watching the patient for some time, or by making a microscopical examination of a portion of the growth, or by cultivation of the *Bacillus tuberculosis*. The points that may help us will then be other evidence of tubercle in the nose, as, for instance, a small tuberculous ulcer in the near neighbourhood of the granuloma or upon the turbinals; or evidence of tubercle past or present in other regions of the body, such as the larynx, lungs, or testicle; the discovery of tuberculous glands in the neck, or the characteristic scars of former suppurating glands in that region or in the neighbourhood of joints, or in the groin or elsewhere. The family history, as well as the personal history of the patient, will influence the formation of an opinion. For the differential diagnosis of *tubercle* and *lupus* see section 61.

§ 51. The growth, which is probably situated at or near the mucocutaneous junction, is pedunculated or sessile, and freely movable. Its surface is irregular, and may present a typical wart-like, or cauliflower or mulberry appearance. Its colour is slightly paler than the surrounding mucous membrane, and a few small bloodvessels may be seen traversing its substance. The surrounding mucous membrane is healthy, and there is no infiltration at the attached part. It is said to have grown slowly. *It is a papilloma.*

Papillomata are not often met with in the nasal cavities, and when they do occur are more commonly situated on the inferior turbinal or inner surface of the ala than on the septum. They may exist singly or in numbers, and are most often pedunculated, though they may be sessile. Their growth is slow, and even when large enough to completely block the anterior naris they seldom give rise to any external deformity. Occasionally they bleed, but this is probably due to some abrasion of their surface rather than rupture of a bloodvessel in them. When near the anterior naris they are generally firm and distinctly wart-like; when further back in the nasal cavity they are soft, mulberry-like, or villous-looking. The appearance of these tumours when they assume the wart-like form is sufficiently characteristic to make their diagnosis easy, but when of soft consistence, sessile, or mulberry-like, they may be mistaken for a sarcoma, a papillary angioma, a tuberculous granuloma, or a carcinoma. The slow growth, absence of severe attacks of hæmorrhage and the non-induration of the pedicle or base, taken with the

characters of the growth above given, will usually establish the diagnosis. They may undergo carcinomatous degeneration; their pedicles therefore should be examined for evidence of infiltration and induration.

§ 52. The swelling is firm or hard, *i.e.*, almost or quite of cartilaginous or bony consistence. It may be an enchondroma, an osteoma, a fibroma, a hard or spindle-celled sarcoma, or an early gumma.

§ 53. The swelling is circumscribed, and attached by a broad base, probably about the junction of the septal with the alar cartilage. The surface is irregular and nodulated. It feels hard, resistant, and somewhat elastic to the touch. The mucous membrane is healthy in appearance, and freely movable over the tumour, but is paler than natural, imparting to the swelling a yellowish-pink colour. A needle is able to penetrate into its substance. It is not painful, and the patient says it has grown very slowly. There may or may not be some bulging of the nose on the affected side. On examining the opposite nostril, the septum is found to be natural, but perhaps pushed over if the growth is large. There is probably a muco-purulent discharge, which may be offensive if prevented from escaping by the size of the growth. There have been no attacks of epistaxis. *It is an enchondroma of the septum.*

Enchondromata are rarely met with on the septum. They vary in size from a pea to a walnut, or larger. As they grow slowly, they may exist for years without giving rise to symptoms that call for relief. When of large size they cause obstruction to nasal respiration, and may give rise to external deformity. They may be recognised by their nodular appearance, immobility, and their peculiar density. They have to be diagnosed from a hard fibroma, osteoma, and deflected septum.

From a *fibroma* the diagnosis is not always easy, and may be impossible until a microscopical examination of the tumour has been made. An *osteoma* is harder to the touch, and does not impart a sense of elasticity to the probe. Moreover, a needle cannot penetrate its substance, as in the case of enchondroma. An examination of the opposite nostril to ascertain the condition of the septum will help us to avoid mistaking an enchondroma for a *deflected septum*.

§ 54. The swelling on the septum is circumscribed, and attached by a broad base. The mucous membrane covering it is not adherent, and is of natural colour. When touched with the probe, the tumour

feels hard and inelastic. A needle, when introduced, is unable to penetrate its substance, and after piercing the mucous membrane is felt to grate upon the surface of bone. The surrounding tissues are not infiltrated or thickened, there are no signs of inflammation, and no tenderness is complained of. *It is an osteoma of the septum.*

A distinction must be made between an osteoma and an exostosis, or spur. Bony growths which simulate physiological protrusions are to be considered as exostoses, or spurs—such, for instance, as an hypertrophied normal tubercle of the septum; whereas bony tumours, which originate independently of, and in nowise resemble, such physiological structures, must be classed as true osteomata.

Osteomata are not common, and when met with occur chiefly in young people. They vary in size, but may attain large dimensions. They are composed sometimes of cancellous bone, but more often are of compact texture. As a rule they cause no inconvenience, but when sufficiently large to obstruct nasal respiration they call for surgical interference. When of long standing, they may ulcerate and necrose, giving rise to a highly offensive discharge, which soon attracts the patient's attention.

The hardness and inelasticity of the growth, the healthiness of the mucous membrane covering it, and the fact that a needle is unable to penetrate its substance but grates upon its surface, serve to distinguish this form of tumour from an enchondroma or fibroma, with which it may be confounded. An examination of the opposite nostril, to ascertain the condition of the septum, will also render the diagnosis from a deflected septum certain.

§ 55. The swelling is prominent, smooth, rounded, and perhaps touches the turbinals, thus occluding the posterior part of the nasal chambers from view; the mucous membrane covering it is of the normal tint, or perhaps slightly lighter in colour than the rest of the mucous membrane, and the swelling feels hard, semi-elastic, or perhaps even cartilaginous to the touch, and is not tender on pressure. The patient may or may not complain of pain. On inspecting the opposite nostril a similar swelling of the septum may be seen, but there is no concavity corresponding to the swelling on the affected side. Similar swelling on the turbinals, floor, or roof of the nose, as far as these parts can be inspected, may be discovered either in the affected or the opposite nostril, and a hard, smooth, rounded swelling may be present over one or other of the nasal bones externally, or in the roof of the mouth, or on the skull, or on one of the long

bones. *The swelling is probably a syphilitic gumma in its early stages.*

Where, in conjunction with a swelling of the septum having the characters above mentioned, there are similar swellings in the nasal chambers, with perhaps a hard swelling or swellings over the nasal bones or on the hard palate, the probabilities of the septal tumour being a gumma are great. If in addition concomitant signs of late (tertiary) syphilis are discovered in other parts of the body, the diagnosis will be almost certain, and the effect of a few doses of iodide of potassium will probably remove the last remaining doubt. It may happen, however, that there may be no concomitant signs of syphilis, and no history obtainable of that disease. The characteristic nocturnal pain, moreover, may be absent if the gumma is confined to the septum. The diagnosis may be then very difficult to make.

The swellings with which an early gumma may be confounded are: a deflection of the septum; a hæmatoma; a chronic abscess; a cartilaginous tumour; or a hard sarcoma.

From a *deflected septum* it may be distinguished by the absence of a corresponding concavity in the opposite nostril; from a *chronic abscess*, by its firm, solid feel, and by the absence of fluctuation and of pus when the swelling is punctured. Its smooth, regular surface, the sense of elasticity imparted to the finger, and its progressive alteration in size and shape, will enable the diagnosis to be made from a *cartilaginous tumour*, while the distinction from a *sarcoma* will rest upon the non-occurrence of spontaneous and repeated epistaxis, or of bleeding when the swelling is touched, upon the probable existence of similar swellings in the same or opposite cavity, or in other parts of the body, upon the microscopical examination, and upon the effect of anti-syphilitic treatment.

§ 56. The swelling is broad-based or pedunculated, and is said to be slowly increasing in size. The mucous membrane covering it is healthy in appearance, though it may be redder and more vascular than natural. The surface of the swelling is smooth, firm, and solid to the touch, and is quite free from pain and tenderness. The surrounding tissues are neither indurated nor infiltrated. There is bleeding on probing, and attacks of hæmorrhage have occurred. *It is probably a fibroma.*

Fibromata of the septum are very rare. Their firm consistency and slow growth will serve to distinguish them from the sarcomata, but in a doubtful case a microscopical examination should be made.

§ 57. A firm, hard, broad-based swelling, probably about the size and shape of half a small walnut, is seen on the septum. It is of a pale or pinkish-red colour, and covered by apparently healthy or slightly hyperæmic mucous membrane, and may bleed when touched. There have probably been attacks of hæmorrhage from time to time, and in the intervals a watery or slightly blood-stained, and perhaps offensive, discharge. The obstruction is said to have come on comparatively slowly. On looking into the opposite nostril no concavity corresponding to the swelling is seen, but the septum may be pushed over to that side, or may be perforated by the growth. *It is probably a hard (spindle-celled) sarcoma.*

Spindle-celled sarcomata of the septum often contain a considerable amount of fibrous tissue, and, unlike the round-celled sarcomata, are firm and hard, at times almost of fibrous, or even of cartilaginous consistency, and instead of growing rapidly, increase so slowly that they may exist for months or even some years, and may not recur after removal. A hard sarcoma may be confounded with an enchondroma, fibroma, carcinoma, or an early gumma in its hard stage. The cartilaginous consistency of an *enchondroma* on puncture and its extremely slow growth, the probable existence of concomitant signs of syphilis and the effects of anti-syphilitic remedies in a *gumma*, and the absence of spontaneous bleedings, or of bleedings when probed or punctured with a grooved needle in both, will generally serve to distinguish these growths from a hard sarcoma. A *fibroma* and *carcinoma*, like a sarcoma, are characterized by bleeding; on the other hand, in a hard sarcoma, this indication of malignancy is not always present; hence a microscopical examination will be necessary to settle the diagnosis.

THERE IS ULCERATION, BUT NO SIGN OF ACUTE INFLAMMATION.

§ 58. If there is ulceration as well as swelling, the affection is probably (1) a primary syphilitic sore; (2) tuberculous ulceration; (3) tertiary syphilitic ulceration due to breaking-down of a gumma; (4) lupus; (5) ulcerating sarcoma; (6) ulcerating carcinoma.

If the obstruction has been attended by profuse attacks of epistaxis, pass on to section 63, otherwise begin below at section 59.

The obstruction has not been attended by profuse epistaxis.

§ 59. There is an ulcerated swelling upon the anterior part of the septum close to the muco-cutaneous junction. The surface is

granular in appearance, and the granulations are exuberant, and bleed readily when touched with a probe. The margins are ill defined, and continuous with the surface of the ulcer. The base is hard, indurated, and of almost cartilaginous consistence. The ulcer is single, and although its surface is in contact with the opposite wall of the nasal chamber, there is no evidence of infection of that part. In addition to these local phenomena, the patient has perhaps a sallow, earthy look, and his temperature is slightly raised. Moreover, the submaxillary glands on the side affected are enlarged and indurated. *It is probably a primary syphilitic ulcer of the septum (hard chancre).*

Examples of primary syphilitic lesion occurring in the nose are exceedingly rare. When a chancre is met with in this locality, its usual seat is upon the anterior part of the septum, since this is more liable than any other to abrasions caused by the finger-nail. The diagnosis of a primary syphilitic sore on the septum is not easy—at any rate, in its early stage. Should, however, a single ulcer be discerned in the situation above mentioned, having a peculiarly hard base, and a surface covered with exuberant granulations which bleed readily when touched; should the submaxillary glands be enlarged and hard, the temperature be raised, and the well-known syphilitic cachexia be present, primary syphilis may be suspected. If, in addition, there is a history that the patient has exposed himself to syphilitic infection, and that the ulcer appeared recently and has been slowly progressing, and, above all, if a secondary rash is discovered upon the surface of the body generally, and the ulcer rapidly heals under a mercurial course, any doubt as to the nature of the disease will be at an end.

A diagnosis, however, may have to be made from tuberculous and malignant ulceration. From *Tuberculous Ulceration*.—The ulcer is not clearly defined, its edges are not undermined, there is no evidence of caseation, and there is probably no evidence of tuberculous disease of the larynx or lungs, or of present or past tuberculous lesions in the neck or other parts of the body, lesions which almost always exist with nasal tuberculosis. From *Malignant Ulceration*.—The ulcer does not increase rapidly in size, it does not bleed spontaneously, and there is no tendency to fungation. Moreover, the submaxillary glands are affected early in primary syphilis, and do not attain any great size, whereas the opposite holds good in malignant disease.

§ 60. After the purulent, offensive, and perhaps blood-stained discharge, and the dark yellowish-green or blackish-brown crusts have been removed, a foul, deeply-excavated ulcer, surrounded by swollen and congested mucous membrane, is discovered on the septum. The ulcer is irregularly circular or oval in shape, its edges are ragged and overhanging, and its floor is covered by a tough, adherent, yellowish slough, having the appearance of wet wash-leather. It is encircled by a bright, shining red areola. Similar ulcers probably exist in other parts of the same or opposite nasal cavity. On probing, necrosed bone will probably be felt, and the point of the probe may pass into the opposite nostril, showing a perforation of the septum. *It is a deep tertiary ulcer due to breaking down of a gumma.*

Deep tertiary syphilitic ulceration, although it may be confined to the septum, may occur in other parts of the nasal cavity at the same time. It is preceded by a deep gummatous infiltration, which, if untreated, slowly softens and finally breaks down, frequently leading to perforation of the septum, destruction of the cartilage, and necrosis of the bone. A sequestrum will often be detected in the bottom of the ulcer with the probe, and pent up beyond the swelling a caseous mass of inspissated mucus will often come away on syringing. The ulceration does not spread beyond the limit of the gummatous infiltration, but as this may extend to the inner surface of the nasal bones and lateral cartilages or floor of the nasal fossa, a sinking of the bridge of the nose, and retraction of the soft tissues or perforation of the palate, is not uncommon. Gummata in their early, softening or ulcerating stage may also be met with on the exterior of the nasal bones, the ala of the nose and the upper lip, or on the forehead or scalp, whilst at the same time there may be other manifestations of past or present syphilitic lesions in various parts of the body. The appearance of a gumma of the septum and the differential diagnosis in the early and in the softening stage is given at section 55 and sections 13 and 39 respectively. The appearance of the ulceration *per se* is so characteristic when the disease has reached this stage that it can hardly be mistaken, much less so should it be accompanied by the concomitant syphilitic lesions above mentioned. Its differential diagnosis from tubercular, lupoid, and malignant ulceration, with which it might possibly be confounded, is given below. As the ulcers begin to heal exuberant granulations extend from their edges over their surface, whilst the edges may at

times become œdematous, and assume the form of myxomatous polypi.

§ 61. A slightly raised, reddish-brown, granular-looking swelling is seen upon the anterior part of the septum at or about the position of the triangular cartilage. The swelling is covered with flat and broad scales of a brownish colour, which, when removed, reveal the presence of one or more small round or irregular-shaped ulcers. The mucous membrane in the vicinity of the ulcers is thickened, and studded with pale red granulations of a nodular character, varying in size from a millet-seed to a split pea, one or more of which may be found to be on the point of breaking down and covered by similar crusts. The crusts are readily detachable, and when removed a thin watery discharge escapes from beneath them, but there is next to no bleeding. The discharge is usually sweet, but if pent up becomes offensive. A probe sinks easily into the swelling, showing it to be soft and friable, and detects deep destruction of tissue, or, it may be, perforation of the septum; but if such exists, no signs of necrosis are present. *It is lupus of the septum.*

Lupus of the nasal septum may exist by itself, but more commonly is co-existent with lupus of the face. When confined to the septum alone, the diagnosis is rendered more difficult, but the fact that the disease occurs in young people, that it runs a slow course, that it is progressive and tends towards ulceration, that the ulceration spreads in one direction and tends to cicatrize in another, and that when perforation exists there is no necrosis, should help us in arriving at a correct conclusion. The peculiar character of the crusts may be said to be almost pathognomonic of the disease. When the septum is only secondarily invaded by an extension of the disease from the ala of the nose or lip, there is no difficulty in recognising the nature of the case.

Lupus may have to be distinguished from syphilitic, tuberculous, and malignant ulceration.

In syphilitic ulceration the destruction of the deeper tissues is rapid, and there are always signs of necrosis. The ulcer is deeply excavated and surrounded by a bright, shining areola, whilst its edges are irregular, ragged and overhanging. There are no nodules to be found in the adjacent mucous membrane. There may be a history of syphilis, and other evidences of that disease are probably present, such as scarring of the pharyngeal mucous membrane, perforation of the palate, and gummous infiltration of various parts.

In tuberculous ulceration the ulcer is irregularly rounded in shape, and the margins are level with the surrounding mucous membrane. There is usually a single ulcer. The discharge consists at first of a grayish mucus, but later may become thick and purulent. There are no characteristic brownish crusts, there is no areola, but there are signs of tuberculosis elsewhere, such as in the lungs and larynx, glands of the neck, etc.

In malignant ulceration the extension is rapid, and the ulcer is sinuous in outline, its edges are indurated and everted, and its floor is irregular, fungating and covered by a sanious discharge. There have probably been attacks of profuse epistaxis. Enlargement of the submaxillary glands may be present, and a microscopical examination of a portion of the growing edge will show its sarcomatous or carcinomatous nature.

§ 62. There is a single ulcer, or, it may be, several ulcers, probably near the anterior margin of the septum. The ulcer is irregularly rounded or oval in shape. Its floor is whitish or yellowish-gray in colour, and its surface, which may be covered by caseating nodules or crusts, is level with that of the general mucous membrane, which appears healthy. There is a mucoid, or it may be offensive and slightly blood-stained, discharge. The base of the ulcer is not indurated, and there is no bright shining areola. There is little or no pain. The patient has probably similar ulcers in the pharynx or larynx, or shows evidence of tubercular disease in the neck, the lungs, or elsewhere. *It is probably tuberculous ulceration.*

As a rule, there is only a single ulcer to be seen, and that is generally situated upon the anterior part of the septum, close to the muco-cutaneous junction. From this locality, however, the ulcerative process may spread to the floor of the nose, and to the turbinal bodies. The ulceration is progressive, and shows no tendency to cicatrize, a feature which may help to distinguish it from lupus.

It should be remembered that tuberculous disease of the nasal passages may take the form of a new growth, in which case it exhibits the characters of a typical infective granuloma (see § 50). The swelling then varies in size, from a millet-seed to a filbert-nut, is irregular in outline, reddish in colour, highly vascular, soft and friable, bleeds readily, and is predisposed to superficial ulceration.

This form of tuberculous disease of the nose is difficult to diagnose in the early stages unless recourse be had to microscopical examination, when the existence of miliary tubercles and Koch's bacillus

may be demonstrated. Both the ulcerative and neoplastic forms may be present in the same individual.

The differential diagnosis of tubercle, lupus, syphilis, and malignant disease is discussed in section 61. Evidence of tuberculosis in the lungs, and the microscopical demonstration of miliary tubercles and the tubercle bacillus, are points which serve to clear up a doubtful diagnosis. (See also sections 50 and 59.)

§ 63. **The obstruction has been attended with frequent attacks of epistaxis.** It is probably an ulcerating sarcoma or carcinoma.

§ 64. The ulcerated surface of the swelling, which is of a dusky-red or bluish-gray colour, is extensive and irregular in shape. The margins of the ulcer are ill-defined and below the general level of the ulcerated surface, which presents the appearance of a fungating grumous mass, covered by a sanious discharge. The tumour is soft and friable, and bleeds readily on touching with the probe. The growth is probably broad-based, and adherent to the underlying septum, which may bulge into the opposite nostril, or may be perforated. The discharge from the nose is copious, sanious, and very offensive, and attacks of profuse bleeding are stated to have occurred from time to time. The obstruction has most likely come on very rapidly. *It is probably an ulcerating sarcoma.*

Sarcomata, when arising from the septum, are prone to ulcerate, but before doing so the growth, as a rule, has increased so much in size as to block the whole nasal cavity, and so preclude its septal origin from being made out; moreover, there is often considerable external deformity of the nose already present before the patient seeks relief. The diagnosis under these circumstances has to be made, not only from nasal growths, but from growths invading the nose from the surrounding cavities (Chapter VII.). Should ulceration occur before the growth has attained such a size as to obscure its septal origin, the general features of the ulceration, the pre-existence of a rapidly-growing tumour, and the frequency of the bleeding from the nose, all point to the malignant nature of the disease; but a microscopical examination of a piece of the tumour may be necessary to determine whether it is a sarcoma or carcinoma.

Caution.—It must not be forgotten that a hard or spindle-celled sarcoma may grow comparatively slowly, and may not be attended by hæmorrhages. (See section 57.)

§ 65. The ulcerated surface of the swelling is irregular in shape, and of sinuous outline. The margins are thickened, indurated,

and everted. The base is indurated and adherent to the underlying structures. The floor is devoid of granulation tissue, and is covered by epithelial débris and a thick, sanious, and foetid discharge. The ulcerated surface when touched with a probe bleeds readily, and there is a history of spontaneous bleeding. The submaxillary glands may or may not be enlarged and indurated. The patient's general health is feeble, and he says he is losing flesh. *It is probably an ulcerating carcinoma.*

Such an ulcerating carcinoma will probably be of the squamous-celled variety, the spheroidal-celled type usually being of such rapid growth that it practically fills the nasal cavities, and so obscures its septal origin before ulceration takes place. The diagnosis, when ulcerating, between the squamous-celled and spheroidal-celled types of carcinoma, and, indeed, between these and the sarcomatous growths, without a microscopical examination, is in most cases practically impossible. The fact that the sarcomata are more common in the young, and the squamous-celled carcinomata in the old, might be suggestive of its true nature. For the differential diagnosis between the malignant ulcerations and those due to syphilis or tubercle, refer to section 61.

CHAPTER VI.

GENERAL DIAGNOSIS—Continued.

THE OBSTRUCTION IS EVIDENTLY OF TURBINAL ORIGIN.

§ 66. The swelling is discovered to be connected with the inferior or middle turbinal body, or with both turbinal bodies. It may be due to :

a. Functional disturbance : Erection of the cavernous tissue in the inferior or middle turbinal body.

b. Hypertrophy of normally existing structures : Varix.

c. Congenital deformity : Spur or ridge.

d. Traumatism : Necrosis.

e. Inflammation : Hypertrophic rhinitis ; local contagious ulcer (soft chancre) ; necrosis.

f. General constitutional disease : Gumma ; syphilitic necrosis.

g. Bacillary infection : Tuberculous granuloma ; tuberculous ulceration ; lupus ; rhinoscleroma.

h. New growth : (*a*) Innocent—osteoma, enchondroma, fibroma, myxoma, angioma, papilloma ; (*b*) malignant—sarcoma, carcinoma ; (*c*) cysts.

Caution.—In any of the above affections of the turbinals some concomitant affection of the septum may be present ; if such is the case, its nature should be investigated as set forth at section 8. Further, should some obstructive lesion connected with the turbinals be discovered, it must not be concluded that this is necessarily the sole cause of the obstruction ; thus, an erection of the turbinals may depend upon adenoid vegetation in the vault of the pharynx, these growths being the real cause of the trouble ; or, again, an enlargement of the middle turbinal or a polypus on that body may be associated with chronic purulent catarrh of one of the accessory

sinuses. The naso-pharynx should therefore always be examined, and in some cases the accessory sinuses also.

Having discovered that the obstructive swelling is connected with the inferior or middle turbinal body, or with both, the next point to determine is whether ulceration is or is not present. In many cases this will be quite easy. In other cases, however, in consequence of the turbinals being covered with a purulent or muco-purulent discharge, or obscured by crusts, the parts must be cleansed as described at p. 16 before this point can be settled. Any loss of surface or the reverse will then show whether ulceration is or is not present.

If there is no ulceration, begin below at section 67. If there is ulceration, pass on to section 99.

THERE IS NO ULCERATION.

§ 67. If the swelling appears to involve the **whole** of the inferior or middle turbinal body, or both, *i.e.*, as much as can be seen of either of these bodies by anterior rhinoscopy, it is probably turbinal erection, turbinal varix, hypertrophic rhinitis, a gummosus infiltration, or possibly rhinoscleroma; proceed with the diagnosis at section 68. If, on the other hand, the swelling appears to involve only a **part** of the inferior or middle turbinal body, or has the appearance of a distinct tumour or outgrowth from one of the turbinals, it may be hypertrophy of the anterior end of the inferior or middle turbinal body, a localized gumma, a mucous polypus or group of polypi, a papilloma, an angioma, a nævus, a tuberculous granuloma, a fibroma, an enchondroma, a cyst, a sarcoma, or a carcinoma; pass on to section 77.

General Swellings of the Turbinals.

§ 68. The swelling appears to involve the **whole** of the middle or inferior turbinal body, or both, *i.e.*, as much as can be seen of these bodies by anterior rhinoscopy. If the swollen turbinal retains its normal contour, begin below at section 69. If it has lost its normal contour, pass on to section 73.

§ 69. The inferior or the middle turbinal body, or both, present a **general swollen appearance**, but retain more or less their normal contour, and the investing mucous membrane is intact.

The swelling is probably due to turbinal erection, turbinal varix, or hypertrophic rhinitis.

Caution.—Either erection or hypertrophy of the turbinals, especially of the middle turbinal, may be due to some condition such as obstruction in the naso-pharynx, as from the presence of adenoid vegetations or a naso-pharyngeal polypus; or it may be that the enlargement is associated with some chronic purulent catarrh of one of the accessory sinuses, as the antrum of Highmore, the frontal sinuses, or the ethmoidal sinuses. The condition of the naso-pharynx, therefore, should be investigated as set forth at Chapter IX., to exclude the presence of obstruction there; whilst should a discharge of yellow, canary-coloured pus be seen in the depths of the nasal chamber, especially if the discharge is unilateral, before pronouncing the case one merely of turbinal erection or hypertrophy the condition of the accessory sinuses should be investigated in the way given at page 21, and at section 111.

In deflections of the septum the inferior turbinal body on the side corresponding to the concavity is generally greatly enlarged. If, therefore, the cavity in which the swollen turbinal is seen appears preternaturally roomy, inspect the opposite nasal chamber in order to ascertain whether the septum presents a convexity on that side. If it does, turn to section 22.

§ 70. The inferior turbinal, and perhaps the middle turbinal, appears generally swollen, but retains more or less its normal shape. The investing mucous membrane may be normal, or slightly redder than normal, or possibly paler. On touching the swelling with a probe, it does not bleed, but dimples as though it contained fluid, the indentation being at once effaced when the pressure is removed. When sprayed with a 10 or 20 per cent. solution of cocaine or eucaine, the swelling gradually disappears, and a complete cessation of the obstruction is experienced. The patient perhaps complains that he is troubled at times with a watery discharge from the nose, with fits of sneezing or spasmodic cough, or it may be that he suffers from asthmatic attacks or hay-fever. *It is probably turbinal erection.*

By turbinal erection is here meant the simple engorgement of the cavernous tissue found in the inferior and middle turbinal bodies, without any hypertrophy of the mucous membrane or underlying connective tissue. It probably depends upon some vaso-motor disturbance, and is hence sometimes called *vaso-motor rhinitis*. It must be distinguished from hypertrophic rhinitis, in which there is always some superadded vascular turgescence, and from turbinal

varix, in which the blood-spaces of the cavernous tissue appear to have undergone some permanent dilatation. Simple erection is characterized by the complete disappearance of the swelling under the influence of cocaine, whereas in the two other affections there is at most merely a slight shrinking as the vessels are depleted. Erection of the turbinal is of course a physiological function, and must only be considered pathological when it becomes excessive and gives rise to obstructive symptoms. It is commonly found in the condition known as hay-fever, and is frequently present in spasmodic asthma. In those affections, however, there are other factors at work, such as the neurotic state of the patient, and some atmospheric conditions peculiarly obnoxious to the individual. When the erection is long continued, and is productive of chronic obstruction, it may lead, like hypertrophic rhinitis, to naso-pharyngeal catarrh, catarrhal deafness, and other effects mentioned in Chapter I.

Perhaps the most distinctive feature of turbinal erection is the intermittent character of the obstruction. Thus, whilst at one period of the day the obstruction may be complete, at another period the nasal breathing may be quite free. Sometimes it is one nostril that is blocked, sometimes the other, the change from side to side being often quite sudden. Frequently the obstruction is brought on by lying down, ingestion of hot food or drink, entering or leaving a hot room, or the sudden exposure to a draught of cold air. When it occurs during recumbency, the side on which the patient is lying is usually the one that becomes blocked. The erection is often productive of a watery discharge, sometimes so abundant as to soak several handkerchiefs in quick succession. Occasionally the discharge is muco-purulent. At times the erection is so acute that it simulates a severe cold in the head, and is accompanied by sneezing and coryza, headache, or facial neuralgia, and is productive of great distress. In such cases I have found, on posterior rhinoscopy, the choanæ completely occluded by the swollen posterior ends of the turbinal bodies.

Turbinal erection may be mistaken for turbinal varix, hypertrophic rhinitis, a polypus or other new growth, or a deflected septum. From a *deflected septum* there should be no difficulty in distinguishing it, inasmuch as the one swelling affects the inner wall of the nasal fossa, the other the outer. Moreover, in the case of deflected septum the characteristic concavity is seen on looking into the opposite nostril. From a *polypus* or other *new growth*, an erected turbinal

may be diagnosed by the fact that it retains the general outline of the normal turbinal body, whereas the neoplasm has the form of a distinct tumour or outgrowth. From *hypertrophic rhinitis*, which turbinal erection much resembles, the latter may be distinguished by its dimpling when touched, and by its disappearance under the influence of cocaine. Indeed, disappearance under cocaine is characteristic of turbinal erection, and the effect of this agent upon it should be sufficient to differentiate it from any other affection. From *turbinal varix* mere erection may be diagnosed by the swelling in the former having a bluish-red, congested appearance, and by the fact that though, like erection, it dimples when touched with a probe, it does not disappear completely under cocaine.

§ 71. The inferior turbinal body is generally swollen, and of a dull red or purple colour. The swelling readily yields to the probe, but does not disappear or shrink to any extent under the influence of cocaine. In addition to the obstruction, the patient complains of a slimy, sanguinolent discharge, occasional attacks of epistaxis, and, it may be, of parosmia, or of trouble about the fauces or palate. On posterior rhinoscopy, a purplish mass is seen projecting at the posterior nares, and on examination with the finger a sharply-circumscribed, soft, resilient swelling is felt on the affected side, free all round except at the situation of the posterior end of the inferior turbinal body. *It is probably turbinal varix.*

Turbinal varix may occur on one or on both sides. When the swelling is excessive, nothing may be seen on looking into the nostril from the front but a purplish-red mass, more or less completely blocking the passage. It may then be mistaken for a deflected septum, erection of the turbinal, or a new growth. The introduction of a probe between the septum and the swelling will show that it is not connected with the septum at all; its non-disappearance under cocaine will distinguish it from mere erection; while its general outline, which is that of the anterior end of the turbinal body, and the facts that it dimples on being probed, that it does not change its position on forcible respiration, and that it presents the characters above stated when examined posteriorly, should serve to distinguish it from a polypus or other new growth.*

§ 72. The turbinal bodies appear generally swollen and redder than natural. The middle turbinal is probably almost in contact

* A good description of turbinal varix by Wyatt Wingrave will be found in the *Journal of Laryngology* for 1894, p. 1789.

with the septum, and the anterior end of the inferior turbinal may be so much enlarged as to preclude a view of the chamber beyond. The inferior turbinal has a reddish-gray colour, and its surface is probably rugose. The middle turbinal may be of a brighter red, and is smooth and shining. The swelling does not completely disappear under the influence of cocaine, and the mucous membrane feels thick and velvety when touched with the probe. On posterior rhinoscopy, the enlarged turbinals appear as whitish masses projecting at the choanæ (*grub-worm hypertrophy*). The patient may complain of a muco-purulent discharge, or of a discharge running down the back of his throat, especially on first waking in the morning, and of inability to clear his throat without much hawking and coughing. He perhaps also suffers from deafness or from frontal headache and impairment of the sense of smell. *It is probably hypertrophic rhinitis.*

Hypertrophic rhinitis appears frequently to be the result of oft-repeated colds, especially when there exists some obstructive lesion in the nose such as septal spurs or deflections, and is productive of nasopharyngeal catarrh, Eustachian catarrh, catarrhal deafness, and possibly remoter troubles in the larynx and trachea. Like simple erection, it may be attended by spasmodic cough, asthma, hay-fever, and other affections. It is frequently on account of deafness and throat-trouble that advice is sought. As a result of the obstruction, erythematous patches or acne on the exterior of the nose is not of uncommon occurrence. On examining posteriorly, the swollen turbinals appear as whitish masses projecting through the choanæ, and have been compared to large white grub-worms; whilst the inferior turbinals may have a corrugated, mammillated, or papillomatous appearance.

The differential diagnosis of hypertrophic rhinitis, turbinal erection and turbinal varix is discussed at section 70.

§ 73. The swollen turbinal or turbinals have lost their normal contour.

The swelling is probably a gumma; it may be rhinoscleroma.

§ 74. The inferior turbinal, perhaps the middle also, is swollen, rounded and prominent, and feels hard, or even cartilaginous, to the probe. The mucous membrane covering it is normal, or slightly paler than the rest of the mucous membrane. There is no discharge, but the patient complains of boring pain, which is worse

at night. There may be a similar swelling on the septum, on the floor of the nose, on the exterior of the nasal bones, or on one of the cranial bones or bones of the extremities. *It is probably a gumma in an early stage.*

§ 75. The swollen turbinal is prominent and regularly rounded, and the mucous membrane covering it is of a dusky-red colour. The swelling probably extends to the floor of the nose, and may touch the septum so as to exclude a view of the posterior portion of the nasal cavity. It is soft and fluctuating, and there is probably a mucopurulent discharge. There may be a similar swelling on the septum, and perhaps in the opposite nostril, and hard or softening swellings on the exterior of the nasal bones, on the cranial bones, or in other situations. The patient complains of boring pain, especially at night, both in the nose and in the other swellings, if such exist. *It is probably a softening gumma.*

A gumma confined to one or other turbinal is very rarely met with, more especially in the earlier stages. When a gumma occurs on one or other of the turbinals, it is usually associated with gummatous infiltration of the nasal mucous membrane generally, and especially that covering the septum, and it has as a rule reached the ulcerating stage before it comes under observation. For the appearance presented by an ulcerating gumma, see sections 60 and 103.

In the earlier stages, before ulceration has occurred, it may be impossible to make a diagnosis from the intranasal appearances of the swelling alone. Whilst hard in consistency, a gumma may be mistaken for the hypertrophy of rhinitis, for actinomycosis or for a firm growth. When it begins to soften and the mucous membrane assumes a dusky-red colour, it still more resembles hypertrophic rhinitis, for which or for a tuberculoma or a soft sarcoma it may now be mistaken. In *hypertrophic rhinitis*, however, the swelling retains the normal contour of the turbinal body, whereas in a gumma it is more generally rounded, shelving off into the mucous membrane above and below, the appearance being rather that of a smooth, rounded protrusion of the outer wall of the nasal cavity than of a swollen turbinal. Too much reliance, however, must not be placed on these intranasal signs. The nightly boring pains will point strongly to syphilis, and a careful search should be made for other evidences of that affection. Full doses of iodide of potassium will probably clear up any doubt. In *early actinomycosis*, which a multiple gummous infiltration may closely resemble, iodide of potassium will not be of

much help, since both may disappear under its use. The gross appearances, moreover, are so similar that a distinction can hardly be made from these alone. The microscope therefore must be employed. In a *new growth* of the turbinal, such as a fibroma, a fibro-sarcoma, or possibly an enchondroma (the only neoplasms likely to be mistaken for a gumma in its hard and early stages), the swelling will probably be localized to one portion of the turbinal from which it would stand out new-growth-like, and there will be an absence of the nocturnal boring pain and other evidences of syphilis; whilst under the influence of antisyphilitic remedies the growth will either remain stationary or show a steady increase. In a *tuberculoma* the swelling is soft and friable, and readily bleeds when touched, and there are probably other signs of tuberculosis, such as a tuberculous ulcer of the septum, tubercle in the lungs or larynx, large glands in the neck, etc. In a *soft sarcoma* (the growth for which a gumma might be mistaken in its softening stage), the presence of a sanious discharge, the frequent attacks of hæmorrhage, the soft, friable consistency of the swelling, the readiness with which it bleeds when touched, and its rapid increase in spite of antisyphilitic remedies, will usually be sufficient to establish a diagnosis. The microscopical examination of a small portion of the growth will probably clear up any doubt.

§ 76. The swelling of the turbinal is very hard, almost of bony consistence; its surface is uniform, smooth, shiny, and of a brownish-red hue. The margin of the growth is definitely circumscribed and rounded. There is no thickening or induration of the surrounding mucous membrane, and there are no signs of inflammation. Some degree of tenderness is elicited on pressure, but the patient does not complain of pain. There is most likely a fœtid discharge. *It is probably rhinoscleroma of the turbinals.*

This disease, which is very rare in this country, may be limited to certain parts of the nose, such as the inferior turbinal, but more often affects other parts as well, such as the septum, floor and integument of the organ, and is generally bilateral. It shows a tendency to progress slowly and steadily, and is especially liable to extend backwards towards the pharynx, and may even involve the larynx. The diagnosis of the condition is easy; the almost stony hardness of the swelling, the slow progress of the disease, its tendency to increase by direct continuity of tissue, its liability to involve the posterior nares and larynx, the absence of all pain and inflammatory pheno-

mena, and especially the fact that the growth displays no tendency to break down and ulcerate, serve to distinguish this disease from any other, except perhaps keloid. Should any doubt exist, a small piece of the growth should be removed for microscopical examination, as the demonstration of the rhinoscleroma bacillus is the most accurate means of establishing the diagnosis.

Localized Swellings of the Turbinals.

§ 77. The swelling appears to involve only a **part** of the inferior or middle turbinal body, or has the appearance of a **distinct tumour** or **outgrowth** from one of the turbinal bodies. It is probably hypertrophy of the anterior end of the inferior or middle turbinal, a mucous polypus or group of polypi, a papilloma, possibly a nævus, an angioma, a tuberculous granuloma, a fibroma, an enchondroma, an osteoma, a cyst, a sarcoma, or a carcinoma.

If the swelling has the appearance of a localized enlargement of part of the inferior or middle turbinal, it may be hypertrophy of the anterior end of the inferior or middle turbinal, or a syphilitic gumma; begin below at section 78. If, on the other hand, the swelling has the appearance of a distinct tumour growing from one or other of the turbinals, it is probably a papilloma, a mucous polypus or group of polypi, a cyst, a tuberculous granuloma, an angioma, a fibroma, an osteoma, a sarcoma, or a carcinoma; pass on to section 86.

§ 78. The swelling has the appearance of a localized enlargement of **part of one or other of the turbinals**.

§ 79. A hard, irregular spur or ridge-like projection is seen on the inferior turbinal. The mucous membrane covering it is normal, perhaps slightly paler than normal. It does not disappear under the influence of cocaine, and has a bony consistency when touched with a probe. It is productive, beyond slight obstruction, of no inconvenience. *It is a spur or ridge.*

Such a condition of the inferior turbinal is sometimes met with, and is practically nothing more than a slight irregular enlargement of the bone, though it is sometimes spoken of as an exostosis. It can hardly be mistaken for any morbid condition.

§ 80. The anterior end of the inferior turbinal is swollen, smooth on the surface, or irregular, lobulated, papillomatous, or raspberry-like. The mucous membrane is redder than normal, but may be paler. The swelling does not wholly disappear under cocaine, but

dimples somewhat when touched with a probe. *It is hypertrophy of the anterior end of the inferior turbinal body.*

Hypertrophy of the anterior end of the inferior turbinal is not so very uncommon, and, as a rule, is practically nothing more than a local intensification of the general hypertrophy of hypertrophic rhinitis. The anterior and posterior ends of the inferior turbinal are especially prone to enlargement in this affection, probably on account of there being more erectile tissue in these situations.

Hypertrophy of the anterior end of the inferior turbinal might be mistaken for a polypus, a papilloma, or a malignant growth. An *ordinary myxomatous polypus* has usually a gelatinous, bluish-gray, semi-translucent appearance, and is, moreover, usually pedunculated, and rarely arises from the inferior turbinal, especially its anterior end. A *papilloma* is distinctly circumscribed, lobulated, and warty or raspberry-like, and is either pedunculated or, if sessile, springs from the turbinal as a distinct tumour having a narrow base. A *malignant growth* will probably display the usual character of malignancy, viz., bleeding and more or less rapid growth.

§ 81. The anterior end of the middle turbinal appears greatly enlarged, perhaps blocking up the middle meatus. It is either glazed and smooth, or spongy-looking, or even lobulated. It is redder than natural, probably of a bright pink colour. The slit that normally exists between the middle turbinal and the septum is effaced, and the swollen body may not only touch the septum, but may perhaps be in contact with the inferior turbinal. *It is hypertrophy of the anterior end of the middle turbinal body.*

Hypertrophy of the anterior end of the middle turbinal may be associated with empyema of the antrum, or of the frontal or ethmoidal sinuses, and there is then, as a rule, the escape of a pale yellow, canary-coloured pus from beneath the swelling—that is, from between it and the inferior turbinal. If pus is seen in this situation, therefore, turn to section 111.

Hypertrophy of the middle turbinal body, especially when the hypertrophied tissue presses against the septum, is often accompanied by pain of a neuralgic character over the eyes and in the forehead, and is said to give rise to mental hebetude, defective memory, melancholia, and even epilepsy; in not a few instances it has been attended by vomiting. The pressure exerted by the hypertrophied tissue upon the circulation within the nose is apt to cause obstruction to the return of blood from the capillaries and minute veins of

the skin, thus producing erythema and acne of the nose and face. The hypertrophy may also lead to dry catarrh of the naso-pharynx and pharynx (*pharyngitis sicca*); hence it is often for throat trouble rather than for nasal obstruction that patients seek relief. Irritation and consequent congestion of the turbinal mucous membrane, caused by repeated attacks of coryza, or the constant inhalation of an atmosphere charged with irritating particles, such as dust, fluff from cotton-wool, etc., is said to be the principal exciting cause.

Hypertrophy of the anterior end of the middle turbinal may be mistaken for a polypus or a malignant growth. A *polypus* has usually a characteristic gelatinous, bluish-gray appearance and is pedunculated, and then cannot well be mistaken; at times, however, polypi in this situation are of a pale pink colour, and sessile, and it may be impossible to say whether the growth should be called a polypus or a myxomatous hypertrophy of the turbinal. A *malignant growth* may very closely resemble an hypertrophied condition of the anterior end of the middle turbinal; and it may only be by watching the patient for signs of malignancy (hæmorrhages, sanious discharge, comparatively rapid growth) that the distinction can be drawn.

§ 82. A hard, firm swelling is seen on the inferior or middle turbinal. It is covered by healthy mucous membrane, has a smooth surface, a rounded outline, and is attended by severe nocturnal boring pains. *It is probably a localized gumma.* See section 74.

§ 83. A soft, prominent, rounded swelling is discovered on the inferior or middle turbinal. It has a smooth surface, regular outline, and is covered by dusky-red or bluish-red mucous membrane. It does not bleed when touched and has not been attended by attacks of epistaxis; but there may be a muco-purulent discharge, and there has been nocturnal pain. *It is probably a localized gumma in the softening stage.* See section 75.

§ 86. The swelling has the appearance of a distinct tumour or outgrowth from one of the turbinals.

Enquire if there have or have not been attacks of profuse epistaxis. If the growth has not been attended with frequent hæmorrhages, begin at section 87; otherwise pass on to section 92.

§ 87. The growth has not been attended with hæmorrhages.

The growth is probably a mucous polypus or group of polypi, a papilloma, a fibroma, or a cyst.

§ 88. Attached to the middle turbinal, or it may be to the inferior turbinal, are seen one or more globular, glistening, bluish-gray, gelatinous-looking sessile bodies varying in size from a pea to a nut. There is a slight mucous or muco-purulent discharge, but there have been no attacks of epistaxis. *It is probably a mucous polypus or group of polypi; it may be a mucous cyst.*

There is no method, as far as I know, of distinguishing clinically between a mucous polypus and a mucous cyst: their appearances are identical. But few cases of mucous cysts have been reported. I have met with only one myself. It exactly resembled a polypus growing from the middle turbinal, and it was not until it burst, whilst the snare was round it, that its true nature was discovered. It had thin walls, and contained a glairy mucoid fluid.

A single mucous polypus attached to the middle turbinal body, and accompanied by a discharge of pure canary-coloured pus escaping from beneath the middle turbinal is almost pathognomonic of chronic purulent catarrh of the antrum or of the ethmoid cells. When such is present, therefore, the condition of the antrum and ethmoidal cells should be investigated (see section 111). The differential diagnosis of mucous polypi is given at sections 117, 120, 121.

§ 89. A small hard, palish-gray, wart-like, sessile swelling is seen on the anterior end of the inferior turbinal body. It is firm to the touch, does not bleed when probed, and, beyond some slight obstruction, gives rise to no inconvenience. One or more similar wart-like little swellings may be present just within the nostril on the ala, septum, or floor of the fossa. *It is a hard papilloma.*

A hard or wart-like papilloma is exceedingly rare upon the turbinal bodies. In this situation papillomata are usually soft and raspberry-like (see section 90). In a case described by Fletcher Ingals,* both varieties were met with on the inferior turbinal. The hard exactly resembled ordinary integumental warts, except that they were somewhat lighter in colour, and fresh ones were developed from time to time on the inferior turbinal, on the septum, and on other parts of the nasal fossa.

§ 90. A distinct outgrowth somewhat resembling a raspberry or mulberry is noticed on the anterior or middle portion of the inferior turbinal body. It is of a pinkish-red colour, lobulated or villous looking, and is sessile, and attached by a narrow base, or perhaps pedunculated. It is of soft consistency, there is no

* E. Fletcher Ingals, *Trans. Amer. Laryng. Assoc.*, 1889, p. 64.

induration about its base, and the surrounding mucous membrane is healthy. In addition to symptoms referable to the obstruction the patient may complain of a slight increase in the normal secretion. *It is a soft papilloma.*

Nasal papillomata occur in at least two forms—the hard and the soft. The hard, which are commonly situated just above the muco-cutaneous junction, either on the ala or the anterior portion of the septum or floor of the nose, and rarely on the anterior end of the inferior turbinal body, resemble ordinary warts as seen on the skin. The soft varieties occur deeper in the nasal cavity, and have a villous or raspberry- or mulberry-like appearance. Their growth is very slow, and they do not as a rule give rise to hæmorrhages, although occasionally slight hæmorrhages are said to occur. They bleed freely on removal unless excised with the snare. These papillomata are rare, and must be distinguished from the papilloma-like hypertrophies frequently met with on the anterior and posterior end of the inferior and middle turbinal bodies (see section 80). The true papilloma is a distinct outgrowth; the papillomatous hypertrophy, merely an irregular mammillated or lobulated enlargement of the end of the turbinal. As a rule, true papillomata are usually sessile, and do not attain a large size, but in rare instances they have been found completely blocking up the nasal chamber. Their consistency, however, being soft, they do not usually give rise to any external deformity. The appearance of both the hard and the soft variety is so characteristic that they can hardly be mistaken for any other growth, except, perhaps, for the papillary form of epithelioma. The slow growth, the absence of induration at the base, the non-occurrence of severe attacks of epistaxis, the age of the patient, and the microscopical appearance of an excised portion of the growth, are the points which would then help in the diagnosis. The papillary form of epithelioma is, moreover, exceedingly rare in the nose.

§ 91. The swelling is situated upon the inferior, or possibly the middle, turbinal body. It is of an irregular rounded outline, and has an uneven, granular, or tubercular surface, and a grayish, grayish-yellow, or reddish colour, and is most likely covered by greenish-yellow crusts. It is soft, very vascular, and bleeds freely when touched, but is not attended by profuse attacks of epistaxis. When probed, it is found to be friable. The surrounding mucous membrane is probably not thickened, and is of natural appearance.

There may be a similar swelling, or one or more oval ulcers on the septum. The patient most likely complains of a muco-purulent discharge, which is more or less offensive in odour, and of his nose becoming blocked with greenish-yellow foetid crusts. He has probably no pain. *It is a tuberculous granuloma.*

Tuberculous disease of the turbinal bodies is not very common, and when it does occur, there is nearly always some tuberculous ulceration of the septum, palate, or fauces. The growth itself presents all the characters of an infective granuloma, and shows a great tendency to ulcerate superficially. The ulcerative and neoplastic forms may coexist side by side. Tuberculosis of the nose generally runs a chronic course, and, as a rule, does not lead to any external deformity, though occasionally, when the disease is very extensive, and the cartilaginous septum has been destroyed, some retraction of the soft parts of the nose (*saddle nose*) may occur. In some cases nasal tuberculosis appears to have been preceded by lupus of the face, the affection of the mucous membrane having the clinical characters of tubercle rather than those of lupus. Microscopically it is questionable whether a distinction can be drawn between these affections. Implication of the nasal duct and lachrymal canals and conjunctiva in the tuberculous process is an occasional complication. In several cases there have been chronic eczema, lupus, or tuberculosis of the skin of the face. Tubercle of the nose is most common between the ages of 10 and 40.* The diagnosis of a tuberculoma rests chiefly upon the general constitutional condition of the patient and the discovery of tuberculous lesions in other parts of the nose, especially the septum. Extensive disease of the lungs is almost always present in cases of nasal tuberculosis, but cases occur in which evidence of tuberculosis of the lungs or of other organs is entirely wanting. The differential diagnosis of a tuberculous granuloma and an *early gumma* is given at section 75. A *sarcoma* and a *carcinoma* may be distinguished by their rapid growth and attendant hæmorrhages; a sarcoma, moreover, has a smooth surface and a purplish-red colour; a carcinoma disintegrates more rapidly, and both return very quickly after removal. The discovery of the tubercle bacillus in the discharge or of the bacillus and giant cells in a portion of the growth will point to the nature of the disease, but their absence must not be taken as conclusive.

* Herzog, *American Journal of Medical Sciences*, 1893.

§ 92. There have been frequent attacks of hæmorrhage.

If the growth has been slow, begin at section 93 ; if rapid, at section 96.

The growth has been slow.

§ 93. There is a small growth situated upon the inferior or middle turbinal body, probably close to its anterior extremity. It is attached by a broad base, the margins of the growth gradually shelving into the surrounding tissue. The growth is somewhat rounded, more or less irregular on the surface, red or bluish in colour, soft and elastic, easily indented with the probe, readily bleeds when touched, and gives a distinct sensation of fluctuation. Pulsation may perhaps be detected. There is some muco-purulent discharge from the nose, and a history of copious and oft-repeated hæmorrhages. The growth is said to have existed for a long time. *It is an angioma.*

True angiomata are very rarely met with in the nasal cavities, there being but few authentic cases on record. Others that have been thus described were found microscopically to be either highly vascular myxomata or fibromata, and in some instances nothing more than simple varices. Angiomata may occur on any part of the nasal mucous membrane, but their chief seats are the middle and inferior turbinals and the septum. The diagnosis is as a rule easy, the general vascular appearance of the tumour being sufficiently characteristic. In conducting the examination, the probe must be used with great gentleness and care, lest the growth be lacerated. Should such an accident happen, profuse hæmorrhage would follow and might not readily be controlled. These growths increase in size very slowly, and show no tendency to recur after removal. The repeated attacks of hæmorrhage to which they give rise bring them under notice, but in other respects they occasion no discomfort to the patient, except when of sufficient size to interfere with free nasal respiration. The general health, however, may suffer when the hæmorrhages have been frequent. The slow growth, smooth surface, absence of tendency to ulceration, the slow, continuous bleeding on puncture, and, when present, the pulsation, are signs that serve to distinguish an angioma from a malignant growth, the neoplasm, for which it is most likely to be mistaken. Moreover, angiomata are exceedingly rare. The firm consistency of a fibroma or fibro-angioma, and the absence of spontaneous bleeding in a polypus and papilloma, should alone be sufficient to exclude these growths.

§ 94. A small growth with a broad base is discovered springing from the middle, or perhaps the inferior, turbinal. It is of a pale or pinkish-red colour, covered by apparently normal or slightly hyperæmic mucous membrane, and is moderately firm to the touch. There have been frequent hæmorrhages, and a continuous watery, slightly blood-stained discharge. *It is probably a spindle-celled sarcoma.*

In the nose, as in other situations, sarcomata vary in their consistence and rate of growth according to their structure. Thus, the small spindle-celled sarcomata here, as elsewhere, have generally a firm consistency, and grow comparatively slowly; that is, they may exist for some years before they end fatally, either from hæmorrhage, from involving the brain, or from becoming disseminated. The middle and upper turbinal bodies and the septum appear to be their favourite seats. Such a firm sarcoma, whilst still so small that its origin from the middle or inferior turbinal can be distinctly made out, might be mistaken for *hypertrophy of the middle turbinal*, which it then much resembles, or possibly for a *fibroma*, an *enchondroma*, an *osteoma*, a *carcinoma*, or a *localized gumma* in its hard or early stage. The diagnosis will rest on the following considerations: a gumma, a fibroma, an enchondroma, or an osteoma occurring in the form of a small tumour which can be localized to the middle or inferior turbinal body must be exceedingly rare; indeed, I do not know that such a condition has ever been observed.* A *gumma* would almost certainly be attended with some other evidences of syphilis, and would yield to iodide of potassium. An *enchondroma* and an *osteoma* would be distinguished by their cartilaginous and osseous consistency respectively. An *hypertrophic middle turbinal* does not steadily increase in size, and none of the above bleed readily when touched, nor are they attended with a blood-stained discharge or with frequent attacks of epistaxis. A *fibroma* and a *carcinoma*, like a sarcoma, are attended with the same hæmorrhagic tendency and blood-stained discharge; but a fibroma, although it steadily increases in size, does not grow as rapidly as a sarcoma, and a carcinoma has perhaps a tendency to ulcerate earlier, and would grow more rapidly than the hard form of sarcoma. The above characters, however, would scarcely be sufficient

* A small pedunculated fibroid tumour is reported by Dr. Knight (New York Acad. of Medicine, December 26, 1894), as growing from the inferior turbinal. Whether this was a fibroma is not quite clear from the description.

to distinguish these growths from one another, so the removal of a small portion for microscopical examination would therefore probably be necessary.

§ 95. A firm, hard, broadly-pedunculated growth is seen on the inferior or middle turbinal. It is covered by vascular mucous membrane having a pink or bluish-red colour, and bleeds readily when touched. The growth has been very slow, but there have been attacks of epistaxis, and most likely some discharge. *It is probably a fibroma.*

The slow growth, firm consistence, and absence of pain, are perhaps the chief diagnostic signs. The probable presence of a distinct though broad peduncle, and the fact that fibromata are more common in youth than in advanced life, are also points to be taken into consideration; but a microscopical examination will generally be required to substantiate the diagnosis.

The growth has been rapid.

§ 96. A small, prominent, rounded tumour, probably about the size of an ordinary marble, is seen growing from the middle or inferior turbinal body, and, although it may be in contact with the septum, is shown by the probe to be unattached to that structure. The growth has a broad base, or, if pedunculated, the peduncle is probably thick. It has a smooth surface, a bluish-gray or dark red colour, and is soft in consistency. The mucous membrane covering it is intact, but highly vascular, and bleeds both spontaneously and when touched with the probe. There is no especial thickening or induration of the mucous membrane about the base of the growth, and that covering the rest of the nasal fossa appears normal. The septum may be slightly bulged into the opposite nasal cavity. If the growth is punctured, say with an exploring-needle, no diminution in size takes place, and no glairy mucus escapes, but free bleeding follows. The patient complains that the obstruction has come on very rapidly and is fast increasing, that he has had several attacks of epistaxis, and that there is a serous discharge, which is generally blood-stained and offensive. *It is probably a soft round-celled sarcoma.*

The soft or round-celled sarcomata have an especial predilection for the upper turbinal bodies. They may also grow from the inferior turbinal and from the septum. When growing from the middle turbinal, they are sometimes found to be associated with ordinary mucous polypi either in the same or the opposite nostril. It is always

well, therefore, after having removed mucous polypi, to make sure that a sarcoma is not present.

Whether mucous polypi are capable of undergoing sarcomatous degeneration has not been accurately determined, but there are cases on record which seem to show that after removal mucous polypi may be followed by sarcomata. I once removed a sarcoma myself from a patient who had previously had ordinary mucous polypi extracted by a surgeon of repute, and whose diagnosis was not to be questioned.

Soft sarcomata in the nose, as in other situations, are frequently mixed growths, and according to the microscopical structure are called myxo-sarcomata, lympho-sarcomata, adeno-sarcomata, fibro-sarcomata, etc. These differences, however, are at present indistinguishable by clinical methods.

A soft sarcoma may be mistaken for a softening gumma, a soft papilloma, an angioma, an hypertrophied middle turbinal, a soft variety of carcinoma and a tuberculoma. A *softening gumma* would probably be associated with similar swellings either in the same or in the opposite nostril, or on the exterior of the nose, or elsewhere, and further evidence of past or present syphilis, or a history of that affection, would also be probably forthcoming. Full doses of iodide of potassium would settle the question. A *soft papilloma* has a lobulated raspberry- or mulberry-like appearance, and, though it may at times be attended with slight hæmorrhages, does not give rise to the frequent and severe attacks so common in sarcoma. An *angioma*, like a sarcoma, is soft, bluish-red in colour, and bleeds both spontaneously and when touched. It, however, is of slow growth, and may perhaps pulsate, and is not usually accompanied by an offensive sanious discharge. An angioma, moreover, is very rare. An *hypertrophied middle turbinal* may greatly resemble a sarcoma in appearance, but it has no tendency to bleed when touched; it does not give rise to frequent hæmorrhages, nor does it grow rapidly. A *carcinoma* can hardly be distinguished from a sarcoma without the aid of microscopical examination, but its tendency to early ulceration, its irregular uneven surface, the induration about its base, and its occurrence at a more advanced age than that at which a sarcoma is usually met with, are points that may be of some service. A *tuberculoma* is of slower growth, and though, like a sarcoma, it may bleed when touched, it is not attended by frequent hæmorrhages. There will probably be

signs of tubercle in other parts of the body, and giant cells or Koch's bacillus may be discovered by the microscope or by cultivation.

§ 97. The swelling is circumscribed, irregular on the surface, warty in appearance, and is firmly fixed to the underlying turbinal. The surrounding mucous membrane is healthy, but near the growth is thickened and indurated. There have probably been attacks of hæmorrhage, and in the intervals a thin sanious discharge. *It is probably a squamous-celled carcinoma.*

A squamous-celled carcinoma (epithelioma) of one or other of the turbinals is very rare; even when it occurs it is seldom seen in the early or pre-ulcerative stage, and could then hardly be diagnosed by its gross characters alone from a sarcoma or other form of carcinoma.

§ 98. A distinctly circumscribed tumour is seen on the inferior or middle turbinal body, to which it is firmly attached by a broad base. It has a pale pink colour, an irregular, coarsely-granulated, or nodulated surface, and readily bleeds. There may or may not have been any pain, but bleeding has occurred from time to time, and in the intervals there has been a watery or blood-stained discharge. *It is probably a spheroidal-celled carcinoma.*

A spheroidal-celled carcinoma may be mixed with adenoid or myxomatous elements, and is then called an adeno-carcinoma or myxo-carcinoma respectively; but these are differences of no import, and can only be determined by the microscope. Looked at broadly, the squamous-celled variety, which is the most common form of intranasal carcinoma, is more wart-like in appearance, ulcerates sooner, and is most often met with after middle life; whereas the spheroidal-celled carcinoma bears a greater resemblance to a sarcoma, having usually a broader base and a somewhat smoother surface. They may be harder or softer, according to the amount of fibrous, myxomatous or adenomatous elements they contain, and may hence vary slightly in their malignancy.

THERE IS ULCERATION.

§ 99. Ulceration may be simulated by purulent or muco-purulent discharge clinging to the turbinals, or by dried crusts adhering to their surface. Before pronouncing ulceration to be present, there-

fore, this source of fallacy must be excluded by thoroughly cleansing the nasal chambers in the way described at p. 16.

If ulceration is discovered, the affection may be necrosis of the inferior or middle turbinal bone, deep syphilitic ulceration due to the breaking-down of a gumma, lupus, tuberculous ulceration, a sarcoma, a carcinoma, a soft chancre, or actinomycosis. If the obstruction has been attended by attacks of profuse epistaxis, pass on to section 107. If the obstruction has not been accompanied by profuse bleeding, begin at once at section 100.

The obstruction has not been attended by attacks of profuse epistaxis.

§ 100. The obstruction is probably due to necrosis of the inferior or middle turbinal bone, to deep syphilitic ulceration following the breaking down of a gumma, to lupus, to tubercle, or possibly to a local contagious ulcer (soft chancre).

§ 101. The inferior turbinal appears enlarged and generally swollen. There is a purulent, foul-smelling discharge, and the mucous membrane at one spot is œdematous, perhaps polypus-like. At the centre of the œdematous tissue an ulcerated aperture may be seen, or may be discovered with the probe. The probe on passing through this touches bare bone. *It is necrosis of the inferior turbinal bone.*

Necrosis of the inferior turbinal is, perhaps, generally the result of the breaking-down of a syphilitic gumma of the muco-periosteum covering the bone. It may, however, be the result of ulceration following the irritation of a foreign body or rhinolith, or of an injury. I have seen it occur in at least two cases where there was no discoverable cause. In both these cases the whole bone was necrosed, and came away *en masse* on making traction on it with the ordinary nasal forceps.

§ 102. The middle turbinal appears swollen, red and œdematous, and covered by a purulent discharge. On passing a probe, bare bone is felt. *It is necrosis of the middle turbinal.*

Necrosis of the middle turbinal may occur as the result of the breaking-down of a syphilitic gumma, or of injury such as may be caused by the impaction of a foreign body, or by a rhinolith. A form of necrosis of the middle turbinal has also been described under the names of 'necrosing ethmoiditis' or 'osteitis granulosa,' in which, on passing a fine probe without a bulbous end through the œdematous and swollen mucous membrane, bare bone is felt. It should be

remembered that a fine probe may very readily be passed through the delicate tissues covering the middle turbinal, and, coming upon the fragile, spongy bone, may make it appear as if the bone was exposed or necrosed when such is not the case.

§ 103. After the offensive, purulent, and perhaps blood-stained discharge and dirty yellowish-green or blackish crusts have been removed, an irregular, foul, deeply-excavated ulcer, with ragged, overhanging edges, is discovered on one or on both of the turbinals. The surrounding mucous membrane is swollen and congested, forming a bright, shining, red areola immediately encircling the ulcer. The base of the ulcer is covered by an adherent, dirty yellowish slough, something like wet wash-leather, and when probed dead bone will probably be detected. The patient says that he has suffered from dull boring pain, especially at night, and perhaps admits having had syphilis, of which affection other evidences, past or present, may be discovered in various parts of the body. *It is deep syphilitic ulceration due to the breaking-down of a gumma.*

An ulcerating gumma, though it may in some instances be confined to one of the turbinals, nearly always at the same time involves the floor of the nose, and probably the septum as well. The ulceration is accompanied with a discharge, which is usually foetid from the decomposition of the breaking-down syphiloma. If the bone is necrosed, as it generally is, especially if the disease has been allowed to remain unchecked, the discharge will be excessively foul, and characteristic of necrosing bone, and a sequestrum will probably be detected. For the differential diagnosis of syphilitic, tuberculous, lupoid, and malignant ulceration, see section 61. For the appearances of a gumma of the turbinals in the early and softening stages, before suppuration has occurred, see sections 74 and 75.

§ 104. Several ulcerated patches are seen upon the surface of the swollen turbinals. These are irregular in shape, quite distinct from each other, and covered by crusts composed of flat and broad scales of a brownish colour. The removal of these crusts is attended with little or no bleeding, but a thin, watery discharge may escape from beneath them. The exposed surface of the ulcer is then seen to be covered with grayish or whitish tenacious mucus. The tissue composing the floor of the ulcer is very soft and friable, and can be easily penetrated by the probe to some depth, but no necrosed bone is detected. The mucous membrane near and between the ulcers is of healthy appearance, but scattered on its surface small pale red

granulations, having a nodular character and varying in size from a millet-seed to a split pea, may be seen, and one or more of these may be soft and friable, and have lost their nodular character. *It is probably lupus of the turbinals.*

Lupus of the turbinals very rarely, if ever, exists without evidence of the disease on the septum. In fact, the disease, when it occurs primarily in the nose, usually starts on or near the triangular cartilage of the septum, and is well advanced by the time the turbinals are implicated. Accordingly, if lupus of the turbinal is suspected, the septum should be carefully examined. (Sections 31 and 61.) In some cases lupus starts primarily in the nares, but more often invades the interior of the nose by direct extension from the neighbouring integument. Should well-marked lupus of the face exist, the diagnosis of the nasal disease is usually easy; but when the latter occurs independently, much difficulty in arriving at a correct conclusion may be experienced. Still, the facts that the disease occurs in young subjects of impaired constitution; that it runs a slow but progressive course; that it tends towards ulceration; that the ulcers are covered by broad brownish crusts; and that the disease usually first appears on the septum, and later spreads to the turbinals, should help us to a correct diagnosis.

The differential diagnosis of lupus, syphilis and tubercle is discussed at sections 31 and 61.

§ 105. An ulcer, or perhaps several ulcers, of an irregular rounded or oval shape, are seen on the inferior or middle turbinal body. The ulcer, which is covered by greenish-yellow crusts or by a mucoid or muco-purulent, offensive and slightly blood-stained discharge, has a grayish or yellowish-gray surface, from which here and there pinkish granulations or nodular, caseous-like masses protrude. The edges of the ulcer are soft, not indurated, but may be slightly elevated, and miliary tubercles may be seen in them. The surface of the ulcer is on a level with the swollen mucous membrane, which otherwise appears healthy, or perhaps slightly paler than normal. There is no areola around the ulcer. A soft, grayish, granular, strawberry-like mass may be seen in the neighbourhood of the ulcer or on the septum. The patient complains of little or no pain, but says that the nose gets stopped from time to time by yellowish-green crusts. There may have been one or more attacks of profuse bleeding. *It is probably tuberculous ulceration.*

Tuberculous ulceration, especially confined to the turbinals, is not

common in the nose. It more often starts on the septum, and then spreads to other parts, showing little tendency either to cicatrize, or, on the other hand, to extend deeply and lead to necrosis of the underlying bone. Occasionally the cartilaginous septum is destroyed, and the soft parts of the nose may fall in.

Although the above signs will make it appear probable that the case is one of tuberculous ulceration, a diagnosis can hardly be made with certainty without taking into consideration the history and general condition of the patient. Thus, there will probably be signs of tuberculous disease in other portions of the respiratory tract, as the larynx or lungs; or a history of hæmoptysis or of former lung trouble, or evidence of past or present tubercle in the glands of the neck or elsewhere, and perhaps a family history of tubercle.

A diagnosis will have to be made from syphilitic, lupoid and malignant ulcerations. See section 61.

In addition to the gross characters given above, the salient features of tubercular ulceration may be said to be, on the one hand, the absence of the shining red areola of syphilis, the absence of any tendency to cicatrize, the absence of necrosis, and the absence of nocturnal boring pain; and, on the other, the presence of past or present tubercle in the respiratory tract or in other parts of the body. If the tubercle bacillus or giant cells are discovered in a scraping taken from the ulcer or in the discharge, this will go far to substantiate the diagnosis; but the non-discovery of the bacillus or of giant cells is not sufficient to exclude tubercle.

§ 106. An ulcer is situated upon the inferior turbinal body, close to its anterior extremity. It is more or less oval in shape; its edges are slightly undermined; its surface is irregular and covered here and there by granulations, which give it a peculiar worm-eaten appearance. In those parts where granulations are absent, small pieces of tough adherent tissue may be seen. The surrounding mucous membrane is intensely inflamed and œdematous, and a purulent, offensive discharge escapes from the nose. On examining the septum at a point corresponding to the ulcer on the turbinal, an ulcer having similar appearances is found. There is probably enlargement of the submaxillary glands on the affected side. *It is probably a local contagious ulcer (soft chancre).*

When a local contagious ulcer is met with on the inferior turbinal, it is always secondary to one on the septum, and is the result of auto-inoculation. When two ulcers having identical characteristics are

met with, one on the inferior turbinal and the other on the septum, and exactly opposite one another, the venereal source of the disease must be suspected. The coexistence of a similar ulcer on the glans penis or vulva, and the presence of a suppurating bubo in the groin, will confirm the diagnosis.

§ 107. The obstruction has been attended with attacks of profuse epistaxis.

§ 108. The obstruction is probably due to a sarcoma or carcinoma.

§ 109. A distinct outgrowth, with an irregular, fungating and ulcerated surface, is seen springing from the inferior or middle turbinal body. It has a bluish-red or maroon colour, is of soft and friable consistency, is covered by a muco-purulent or blood-stained and offensive discharge, and readily bleeds when touched with the probe. The obstruction is said to have come on recently, and to have increased with great rapidity. There may have been several attacks of epistaxis, and there is a history of an offensive blood-stained, muco-purulent discharge. The opposite nostril is found healthy, or perhaps encroached upon by the septum, which has been pushed over or perforated by the growth. *It is an ulcerating sarcoma.*

It is only in the early stages, and whilst small, that the origin of an intranasal sarcoma can be accurately determined. As a rule, when the patient comes under observation, the mass has already filled the nasal cavity, and perhaps projects, both at the anterior and posterior nares. The diagnosis of a sarcoma before ulceration has occurred is given in sections 94 and 96.

When ulcerating, a sarcoma may be mistaken for a carcinoma, an ulcerating gumma, or tuberculous disease. The rapid growth, frequent attacks of epistaxis, the blood-stained discharge, and the absence of any evidence of syphilis or of tubercle, will usually serve for the diagnosis.

A sarcoma of the spindle-celled variety may at times grow slowly, and may have a firm consistency. Ulceration, however, will probably not then occur till the growth has attained such a size as to obscure its turbinal origin (see section 126).

§ 110. A distinct growth with an irregularly ulcerated surface is discovered on the inferior or middle turbinal body. The edges of the ulcer are sinuous, thickened and everted, the surface grayish or

grumous-looking, and the base indurated and firmly adherent to the underlying bone. The mucous membrane around is healthy. The patient most likely complains of a blood-stained, offensive, serous discharge, and of frequent attacks of epistaxis. *It is probably an ulcerating carcinoma.*

It is very uncommon to meet with an ulcerating carcinoma which has not attained such dimensions as to obscure its turbinal origin. As a rule, before ulceration occurs, the growth has blocked the passage, and nothing can be seen but a fungating mass occluding the nostril. Should a small ulcerating carcinoma be met with, the turbinal origin of which is evident, it will probably belong to the squamous-celled (epithelial) variety, since ulceration in this occurs early, and is often commensurate with the growth of the tumour. For the diagnosis of ulcerating carcinoma, see also section 65.

A. YELLOW DISCHARGE IS SEEN ISSUING FROM BETWEEN THE MIDDLE AND INFERIOR TURBINAL BODIES.

§ 111. If the hypertrophy of the middle turbinal body or the small polypus on that body discovered at sections 81 and 88, is associated with the escape of pale yellow, canary-coloured pus from between the middle and inferior turbinal, and no ulceration is present, there is probably a purulent collection in the antrum, frontal sinuses, or anterior ethmoid cells. If the discharge is unilateral, this is still more probable. A unilateral purulent discharge, however, may not only be due to empyema of one of the accessory sinuses, but may also occur in connection with a foreign body or rhinolith, with syphilitic ulceration, or with a new growth. The absence of a foreign substance, of ulceration, or of a distinct tumour, will exclude these affections as a cause of the discharge.

§ 112. The pus is seen, after the nasal cavity has been mopped out with a pellet of cotton-wool, to come from between the middle and inferior turbinal bodies, and the flow is probably increased on the patient depressing his head between his knees, or on his lying on the opposite side. On pressing with a probe at the spot whence the pus is issuing, the flow is also increased, and a peculiar foetid odour, if not already present, may now be detected. The patient says that the discharge of pus varies in amount from time to time, and is most abundant in the morning; or he may state that the odour is intermittent, or is more marked when a fresh flow of pus takes place after an interval of partial or complete cessation, or that the smell remains

even when the flow temporarily ceases. One or more teeth on the affected side are possibly carious, or may have been stopped, and pain or tenderness may be present on percussing one or more of them. On transillumination the cheek of the affected side may not light up equally with the opposite cheek, or a shadow may be noticed beneath the eye. *It is probably chronic empyema of the antrum.*

At times the pus, instead of flowing anteriorly, may pass into the naso-pharynx. When both antra are affected, pus will escape into both nostrils, and the signs will be similar on both sides. This chronic empyema, in which the ostium remains patent so as to allow of pus flowing into the nose, must be distinguished from the suppuration in the antrum in which the pus is prevented from escaping. In the latter condition there will be bulging of the walls of the antrum, and, if the condition is acute, severe pain, swelling and œdema of the cheek, and œdema of the eyelid.

Although the above signs point strongly to the presence of pus in the antrum, they are not conclusive. The pus may perhaps come from the frontal or ethmoidal sinuses; hence, a certain diagnosis can only be made by actually detecting pus in the antrum. In some instances this may be done by the introduction of a suitably curved cannula into the natural ostium (see Chapter III., p. 22). In other cases it will be necessary to effect an artificial entrance, as described at p. 23. In doubtful cases, before resorting to exploration, peroxide of hydrogen (1 to 12) may be injected into the antrum by passing a hypodermic syringe, with a long cannula bent within a quarter of an inch from its distal end to a right angle, into the hiatus semilunaris. If pus is present, the nose becomes filled with a white foam, and the patient may complain of a sense of fulness in the cheek and of slight pain in the teeth.*

§ 113. The pus, as in section 112, is seen to come from between the middle and inferior turbinal bodies. The flow is probably not increased on depressing the head, on lying on the opposite side, or on pressing with a probe in the region of the antral ostium, but may perhaps be encouraged by throwing back the head. It is probably not intermittent, and there may be little or no odour. The patient complains of a feeling of fulness, or of neuralgic pain in the region of the frontal sinuses, and there may be tenderness, and perhaps dulness, in that region. There is no evidence of pus in the antrum. *It is possibly empyema of the frontal sinuses.*

* Moreau Brown, *New York Med. Journ.*, vol. lii., p. 64.

Should there be a perceptible swelling in the region of the sinuses, or about the root of the nose, with displacement downwards of the eyeball or the formation of an abscess as shown by redness, swelling and œdema, the diagnosis will be rendered more certain. When, however, the above grosser signs are absent, it may be impossible to make the diagnosis without exploring in one of the ways mentioned in Chapter III., p. 25.

§ 114. An escape of pus from between the middle and inferior turbinal is seen as in section 112, but the discharge is continuous, and is probably increased by the patient throwing back his head, though not by depressing it or lying on the opposite side. The eye is perhaps slightly protruded, and there may be some fulness at the inner angle of the orbit, pain deeply seated at the back of the eye, and perhaps diplopia or other disturbance of vision. The antra probably light up equally on the two sides, and, if explored, are found not to contain pus. There may be some slight opacity on transillumination about the inner angle of the orbit. *It is probably empyema of the anterior ethmoidal cells.*

Empyema of the anterior ethmoidal cells is much less common than empyema of the antrum, but is said to be more often met with than empyema of the frontal cells. It may co-exist with empyema of the antrum; and before any gross sign has occurred, as protrusion of the eyeball or swelling about the angle of the orbit, a diagnosis may only be arrived at by excluding an empyema of the antrum by the actual exploration of that cavity, or by laying open the ethmoidal cells by curetting through the nasal fossa. Such a method of investigation as the latter, it need hardly be said, should only be undertaken with the greatest care, lest the base of the skull or wall of the orbit be perforated.

CHAPTER VII.

GENERAL DIAGNOSIS—Continued.

THE OBSTRUCTING MASS IS DISTINCT, OR APPARENTLY DISTINCT, FROM BOTH THE SEPTUM AND THE TURBINALS.

§ 115. On looking into the nose, a swelling or obstructing mass is seen, more or less blocking up the passage, and apparently distinct from both the septum and the turbinals. The swelling or mass may be independent of both septum and turbinals; or it may arise from the turbinals, perhaps from the septum, but the point of attachment is so high up, or so far back in the nasal chambers, or so obscured by the swelling itself, that it is impossible to say whether the growth or obstructing mass has or has not any connection with either of these structures, or indeed, in some cases, with any other part of the nasal cavity.

Thus, the swelling may be a foreign body or rhinolith, which is, of course, distinct from both turbinals and septum; or a large mucous polypus or other form of new growth springing from one of the turbinals, or possibly from the septum; or the intranasal portion of a new growth arising in the naso-pharynx or in one of the accessory cavities, and only secondarily encroaching upon the nose. Having therefore discovered, on making an anterior examination, that a large swelling, apparently independent of the septum and turbinals, is present, not only should the appearances it presents from the front be considered, but an examination should be made of the naso-pharynx and posterior nares, and of the accessory sinuses as well, should there be some external deformity of the nose or cheek, or of the frontal or orbital region, or other sign of any of these cavities being affected (see p. 17 *et seq.*).

If there is no external deformity, and nothing is felt in the naso-pharynx, *i.e.*, if there is no evidence of the naso-pharynx or of the antrum or other of the accessory cavities being either the primary

seat of the growth or secondarily involved by it, begin below at section 116; if there is some external deformity of the nose, cheek, etc., or if the swelling is felt in the naso-pharynx, pass on to section 135.

THERE IS NO EXTERNAL DEFORMITY, AND NOTHING IS
FELT IN THE NASO-PHARYNX.

§ 116. There is no external deformity, save perhaps some slight widening of the nose, or slight bulging of one or other of the nasal bones or cartilages. The globe of the eye is not prominent, the cheek does not bulge, the face lights up equally on both sides, the roof of the mouth is not depressed, and nothing is seen with the rhinoscope or felt with the finger behind the palate, except perhaps a tumour just within or slightly projecting through the choana, but evidently not attached to the roof of the naso-pharynx. The swelling is probably a new growth arising within the nose, or possibly a foreign body or rhinolith.

If the swelling presents the well-known characters of the common polypus, *i.e.*, if it is glistening, semi-transparent, bluish-gray, and gelatinous-looking, begin below at section 117. If it has not these characters, pass on to section 118.

The swelling presents a glistening, semi-translucent, bluish-gray,
gelatinous appearance.

§ 117. The swelling presents the well-known appearance of an ordinary mucous polypus. It is bluish-gray in colour, soft and gelatinous in consistency, moves on respiration, and occludes more or less completely any view of the cavity beyond. The patient complains of a glairy, mucoid, or muco-purulent discharge, and of the obstruction, if not complete, being worse in damp or wet weather. *The swelling is either an ordinary mucous polypus (myxoma) or a mucoid cyst.*

A distinction between a mucous polypus and mucoid cyst can hardly be made without puncture, when, if the swelling is a cyst, a mucoid fluid will escape and the swelling collapse; on the other hand, if it is a polypus, beyond the escape, perhaps, of a little fluid, it will not be materially altered.

On the removal of such a large mucous polypus, smaller polypi will generally be discovered attached to the middle turbinal body, or to some other part of the nasal chamber. These polypi, which are

by far the most common of the new growths met with in the nasal cavities, are known as mucous or gelatinous polypi, and have a myxomatous, fibro-myxomatous, or adeno-myxomatous structure. They are usually soft and gelatinoid in consistency, but vary in firmness according as they are composed of a greater or less amount of fibrous tissue. At times they contain mucoid cysts. They are usually of a pyriform or globular shape and pedunculated, but sometimes sessile. They vary in size from a small pea to a grape, or may even be larger, and exist singly or in large numbers. Generally both nasal chambers are affected, but the polypi may be confined to one. They can easily be swayed by a probe, and are sometimes observed to move to and fro during respiration, forcible expiration driving them further forward in the nasal chambers. They are semi-translucent and gelatinous-looking, and bluish-gray in colour; but when they descend towards the anterior nares, where they may be exposed to irritation, as by the finger or handkerchief, they are apt to assume a reddish-pink, or purplish hue (see section 120), and a more opaque appearance. They are usually smooth, but occasionally definitely lobulated, and their surface is often seen to be traversed by a few delicate bloodvessels. On cutting into them, a variable quantity of clear, colourless fluid escapes. When very numerous, or when they have been allowed to attain a large size, one may project at the anterior nares, or extend backwards into the naso-pharynx, and even hang down below the soft palate. In the museum of St. Bartholomew's Hospital is a specimen of such a polypus, which reached to the level of the epiglottis, and in the same museum another specimen removed from a woman who was accustomed from time to time to excise with scissors portions of the growth which hung below the soft palate, as it attained inconvenient dimensions. Very large polypi may at times in young subjects cause some expansion of the nose or bulging of the nasal cartilages, but as a rule they lead to no external deformity. They rarely give rise to any hæmorrhage, and have never been known to escape through the nostril spontaneously.

The symptoms of nasal polypi are at first trivial, and often vague; indeed, polypi may be present without the patient being aware of their existence. After a certain time a thin, watery discharge, which is usually continuous and has a tendency to increase in quantity, is perhaps the chief complaint, the patient regarding it as the result of a chronic or a neglected cold. Later he may experience a feeling of

fulness and weight in the nose or forehead and difficulty of breathing through one or other or both nostrils, and is continually sniffing in his endeavours to free the passage. These symptoms are usually worse in wet weather, and may increase till the patient is quite unable to breathe through the nose. The voice may now assume a nasal character, and, if the polypi are far back, so as to obstruct the posterior nares, there will be the characteristic inability to pronounce the *m* and *n* sounds; whilst should the obstruction become complete, mouth-breathing will be necessitated, with the accompanying phenomena of snoring, dry tongue and throat, and the facial expression peculiar to nasal obstruction (see p. 5). The sense of smell sooner or later becomes impaired, and may be completely lost, whilst the sense of taste is more or less interfered with. Some deafness, too, is not infrequent.

Uncontrollable attacks of sneezing and irritative cough, believed by some authors to be of a reflex character, are not uncommon in connection with polypi, whilst asthma, headache, trigeminal neuralgia, and vertigo may be present. Epilepsy is also said to have resulted. Epistaxis very rarely occurs, its absence serving to distinguish gelatinous polypi from fibromata or fibro-angiomata and malignant growths, in which bleeding is almost a constant symptom. Sometimes, though not often, there may be epiphora from the blocking of the nasal duct. The exact attachment of these polypi is often difficult to ascertain. They perhaps most frequently spring from the mucous membrane covering the superior and middle turbinal bones, and from that lining the superior and middle meatus. Occasionally they spring from the mucous membrane of the inferior meatus, and may in some instances, though rarely, be attached to the inferior turbinal body. Still more rarely they arise from the roof of the nasal cavity, from the lining membrane of the ethmoidal cells, and even from that of the frontal sinuses, whence they project through the infundibulum into the nose. The mucous membrane of the septum has been stated to be totally exempt from these growths, but, from the researches of Zuckerkandl and others, it undoubtedly in some cases is their primary source. Lastly, the antrum may be the starting-point of mucous polypi, whence they make their way in the course of time through the ostium into the middle meatus. In my experience, the most common seat is the middle turbinal body, around the anterior end of which they often form a fringe. It may be difficult, however, or well-nigh impossible, to locate the exact

attachment of the pedicles of these growths on the living subject, and opportunities for post-mortem examination are rare.

The swelling or obstructing mass has not the well-known glistening, bluish-gray appearance of the ordinary gelatinous polypus.

§ 118. The swelling obstructing the passage has not the well-known appearance of the ordinary polypus. It may be: (1) A gelatinous polypus, the surface of which has been irritated; (2) a gelatinous polypus in which blood has been extravasated; (3) a fibroma; (4) a sarcoma; (5) a carcinoma; (6) an enchondroma; (7) an osteoma; (8) a rhinolith or foreign body; or possibly (9) a mass of maggots developed from ova deposited in the nose by a fly. It might also possibly be (10) a papilloma or (11) an angioma, but these growths very seldom, if ever, attain such a size as to obscure their origin; their diagnosis is, therefore, discussed under 'Septal and Turbinal Swellings' (Chapters V. and VI.).

Determine by means of the probe the consistency of the obstructing mass, and if a good view is not obtainable on account of the presence of discharge, mop out the cavity as described at p. 16. If the swelling or obstructing mass is soft or firm, but not of cartilaginous or stony hardness, begin below at section 119. If, on the other hand, it is hard, *i.e.*, of cartilaginous, calcareous, bony, or metallic consistency, pass on to section 132.

The swelling or obstructing mass is soft or firm, but not of cartilaginous or bony consistency.

§ 119. The swelling or obstructing mass is either soft or firm, but not of cartilaginous or stony hardness. It may be: (1) A gelatinous polypus, the surface of which has been irritated; (2) a gelatinous polypus into which blood has been extravasated; (3) a fibroma; (4) a sarcoma; (5) a carcinoma; (6) a foreign body or rhinolith embedded in a mass of granulation tissue; or possibly (7) a papilloma, or (8) a collection of maggots developed from ova deposited in the nose by a fly.

§ 120. The swelling is of a pinkish-red or purplish colour, smooth on the surface, and globular or pyriform in shape. Its end is low down in the nasal passage; perhaps it projects at the anterior nares. There is no history of attacks of epistaxis, and it does not readily bleed when touched. On forcing the growth aside with a probe, or on gently pulling it down with the nasal forceps, the parts previously not visible are seen to present the ordinary glistening, semi-

translucent appearance of the gelatinous polypus. *It is a mucous polypus, the exposed surface of which has become altered from irritation, as with the handkerchief or finger.*

Such an alteration of the surface of an ordinary polypus is far from uncommon when the growth has been subjected to irritation. I have seen it produced by continual attempts to free the nose by pushing the growth up with the finger, or by forcing it aside with a hairpin. The surface thus irritated loses its gelatinous appearance, and becomes somewhat hard or leathery and of a pinkish-red or purplish colour, and at times blotched with darker red or blue, the result of minute hæmorrhages. When in this state, if care is not taken to examine the deeper and non-irritated portions of the growth, a polypus may easily be mistaken for a fibroma, a sarcoma, or a carcinoma.

The absence of attacks of epistaxis, of bleeding on probing, of external deformity, and of any growth in the naso-pharynx, beyond, perhaps, a gelatinous polypus projecting through the corresponding choana, together with a possible history that nasal polypi have been removed on former occasions and that the patient has from time to time irritated the growth with his finger or in some other way, should lead the surgeon to expect an ordinary nasal polypus, rather than a fibrous or malignant growth. If the growth can be drawn down or pushed aside, the characteristic appearance of the non-irritated portion will settle any remaining doubt as to its nature. Too much stress, however, should not be laid on the fact that gelatinous polypi have been removed on former occasions; for, although such a history would point to the present growth being a recurrence, it must not be forgotten that sometimes after the removal of ordinary gelatinous polypi sarcomata have occurred, but whether as the result of sarcomatous degeneration of the formerly innocent growth, or as the result of irritation produced by rough-and-ready methods of evulsion is a question which cannot here be discussed.

§ 121. The swelling is quite black or bluish-black, soft to the touch, globular in shape, and smooth on the surface. *It may be a gelatinous polypus into which hæmorrhage has taken place, or a melanotic sarcoma.*

§ 122. If the swelling has grown slowly, has not been attended with attacks of epistaxis, and does not bleed when touched, and ordinary polypi have been removed on former occasions or are discovered in the opposite nostril or on posterior rhinoscopy, it is probably an

ordinary polypus into which hæmorrhage has occurred. If, on the other hand, the swelling has only been detected a few weeks or months, has grown rapidly, has been attended with epistaxis, and bleeds on probing, it is probably a *melanotic sarcoma*.

Without a microscopic examination of a portion of the growth it may at times be impossible to diagnose a primary melanotic sarcoma in its early stage from a polypus into which hæmorrhage has taken place. The fearfully rapid growth of the sarcoma, however, the early dissemination, and the progressive emaciation, will soon clear up all doubts. In the case of secondary melanosis of the nose, the existence of black tumours in other parts of the body, and the rapid emaciation, will be distinctive. Secondary melanosis in the nose, however, is very rare.

§ 123. The swelling has a pinkish-red or bluish-red colour; the exposed surface is smooth and regular, or slightly lobulated and granular-looking, or it may be ulcerated. When the growth is pushed aside or gently pulled down, it presents the same characters as the exposed part. There is a discharge, which is probably offensive, escaping from the anterior nares; there have been frequent attacks of epistaxis, and the growth readily bleeds when touched. *It may be either a fibroma or a malignant growth.*

Caution.—In either case the growth may have originated in the nose, or in the naso-pharynx, or in the antrum, or in one or other of the accessory sinuses; but if it has had an extranasal origin, it will probably either be felt in the naso-pharynx or will have already led to external deformity (see section 135).

§ 124. The growth, which has the characters given above in section 123, has existed for a long period—many months or years—and is firm, smooth and glistening, and covered by healthy or slightly hyperæmic mucous membrane. *It is probably an intranasal fibroma.*

Fibromata originating in the nose itself are rare. They much more frequently arise from the vault of the naso-pharynx or from the roof of the choana, and then secondarily involve the nose (section 146). When starting in the nose, they may spring from the septum, from the roof, or from the turbinal bones, or probably from other situations. They grow slowly, and at first merely give rise to symptoms referable to the obstruction which they cause. Later they are attended with frequent epistaxis and more or less pain, and as they increase in size gradually expand the nose, producing the external deformity known as frog-face. As the nose

becomes blocked, the secretions are retained, and, undergoing decomposition, give rise to an offensive discharge, which is, in consequence of the great tendency to hæmorrhage, often blood-stained.

An intranasal fibroma may have to be diagnosed from an intranasal sarcoma, carcinoma, enchondroma, and osteoma, and from like tumours invading the nose from the accessory cavities or naso-pharynx.

From *malignant growths*, with which they are perhaps most likely to be confounded, the firm consistency of the fibromata and their slow growth are the chief points to be relied upon in the diagnosis. It must not be forgotten, however, that the spindle-celled sarcomata may have a firm consistency, and grow comparatively slowly. A microscopical examination, therefore, will be necessary to make the diagnosis certain.

From the *enchondromata and osteomata*, the fact that the fibromata, though hard, are not of cartilaginous or bony hardness, will serve to distinguish them. The former tumours, moreover, are not attended with hæmorrhage, and are exceedingly rare.

From *fibromata and other growths* invading the nose from the accessory cavities and naso-pharynx, an intranasal fibroma may be distinguished by the absence of external deformity and the freedom of the naso-pharynx. Later, when an intranasal fibroma has attained a large size, and has invaded or displaced the surrounding parts, it becomes very difficult to determine, in a given case, whether the fibroma is primarily intranasal or merely secondary. The method of then attempting a diagnosis is discussed at section 135.

§ 125. The growth is of a soft or only moderately firm consistency; its surface is smooth, irregular, flocculent, ulcerated, or cauliflower-like. It is probably a *sarcoma* or a *carcinoma*, possibly a *papilloma*. It may be a *foreign body* or a *rhinolith*, which has become, in consequence of irritation and inflammation, embedded in granulation tissue derived from the mucous membrane of the nasal chambers. In the last case the probe will detect the foreign body or rhinolith as a hard or calcareous mass beneath the soft granulation tissue* (see section 134). The soft mass may also possibly be a collection of maggots, in which case one would probably crawl out in

* There are several instances related in the literature of nasal disease in which a foreign body or rhinolith has been thus mistaken for a sarcoma. This mistake should not occur if the precaution is taken of using a probe.

cleansing the nose of the foul discharge while a view of the obstructing mass is being obtained.

§ 126. The growth is moderately firm, of a bluish-red colour, smooth on the surface, perhaps slightly lobulated, and covered by vascular mucous membrane. It bleeds when touched with a probe, and has probably been attended with epistaxis and an offensive muco-serous, and perhaps blood-stained, discharge, but with little or no pain. The symptoms of obstruction may have existed for many months, perhaps for one or two years. *It is probably an intranasal hard (spindle-celled) sarcoma.*

Pain is sometimes said to be a characteristic feature of sarcomatous and other malignant growths. It is not a constant symptom, however, especially in the early stages. When pain has been present, it would appear in most cases to have been due to the growth having attained such a size that it has compressed the surrounding tissues. The absence of pain must certainly not be regarded as a contra-indication of malignancy.

Hard or spindle-celled sarcomata in the nose are rare. As in other situations, they may contain varying amounts of fibrous tissue, gland tissue, myxomatous elements, cartilage, or even bone, and are then known as fibro-sarcomata, adeno-sarcomata, myxo-sarcomata, etc. These varieties, however, can hardly be distinguished clinically. Broadly, it may be said that the more fibrous elements a sarcoma contains, the slower the growth, the firmer the consistency, and the less tendency there is towards bleeding, and towards recurrence after removal. The hard sarcomata usually grow from the septum or from the turbinal bones, but may originate from other parts. The diagnosis of these tumours whilst they are still so small that their origin can be made out is given at sections 57 and 94. They may then be mistaken for an early gumma, but when they have attained a size sufficient to block the nose, such a mistake is hardly likely to occur.

The hard or spindle-celled sarcoma, especially when it contains much fibrous tissue (fibro-sarcoma), resembles in some respects a fibroma or fibro-angioma, in that it may grow comparatively slowly and may have a firm fibrous consistency. Both are characterized by hæmorrhages, and are more common in youth, although they may be met with in adult life and even in advanced age. It may be impossible to decide between them, or between a sarcoma and carcinoma, without a microscopical examination.

§ 127. The growth is soft, flocculent, or friable, of a bluish-gray or pinkish-gray colour, and probably ulcerated; it bleeds profusely on being touched, and is attended with a sanious, foul-smelling discharge and with severe attacks of epistaxis. The signs of obstruction have only existed a short time, and the growth has increased rapidly, but probably without much or any pain. It is an *intra-nasal soft (round-celled) sarcoma*.

The soft or round-celled sarcomata, as a rule, grow rapidly, and are especially liable to be attended with profuse epistaxis. Like the spindle-celled growths, they are rare, and may contain varying amounts of fibrous tissue, gland tissue, etc.; but they are then seldom as firm in consistency and as slow of growth as the latter neoplasms. A soft sarcoma very closely resembles, in its clinical characters, a spheroidal-celled carcinoma, and it is only by the microscope that the distinction can be made.

The favourite seats of round-celled sarcomata are the middle turbinal body and the septum. Whilst sufficiently small for their origin to be made out, these tumours may be mistaken for a softening gumma, an hypertrophied middle turbinal, etc. Their differential diagnosis is given at sections 46 and 96.

§ 128. The growth is soft or moderately firm, smooth or nodulated, irregular, warty, or cauliflower-like, perhaps ulcerated, of a pinkish mottled-gray colour, and accompanied by a sanious, foul-smelling discharge. There may have been little or no pain. *It is probably an intranasal carcinoma*.

Though carcinoma is of rare occurrence in the nose, all forms have been met with, the squamous-celled (epithelioma) the most frequently. Like the sarcomata, carcinomata in the nose may contain adenomatous or myxomatous elements, and are then known as adeno-carcinomata or myxo-carcinomata. The squamous-celled carcinoma (epithelioma), as in other situations, is more common after middle life, and is prone to early ulceration, the ulceration being commensurate with the increase in size of the growth. Glandular enlargement does not appear to be common in intranasal carcinoma—that is, as long as the growth is confined to the nasal cavities.

The characteristics which, from a clinical point of view, serve to distinguish carcinomatous from sarcomatous growths depend largely upon the particular kind of sarcoma present. When a sarcoma belongs to the typical embryonic class of tumours, the

round-celled type, the growth is much more rapid, its consistence is softer and more friable, and attacks of epistaxis are more frequent than in those sarcomata which tend to simulate the more highly-developed connective-tissue tumours, and are composed of the spindle-celled elements, such as the fibro-sarcomata or osteo-sarcomata. When of the latter variety, they present signs in common with the hard carcinomatous or even pure fibromatous growths, and accordingly the distinction between them is rendered extremely difficult, unless recourse be had to microscopical examination.

§ 129. A reddish granular-looking mass, which bleeds freely when touched with the probe, is seen blocking the nasal cavity, and is attended with a purulent or muco-purulent discharge. On passing the probe into the mass, a calcareous substance is detected. *It is a rhinolith that has become covered with granulation tissue.*

For the differential diagnosis of rhinoliths, see section 134.

§ 130. The swelling presents a typical wart-like or cauliflower- or mulberry-like appearance. Its surface is irregular, lobulated, pale pink or pinkish-gray in colour, and moderately soft to the touch. It does not readily bleed when probed, is said to have grown slowly, and has not been attended with severe attacks of epistaxis. *It is probably a papilloma.*

It is rare for a papilloma to attain such a size that its connections cannot be made out. As a rule, these growths are sufficiently small when attention is first directed to them for their septal or turbinal origin to be distinctly seen, or to be seen on pressing the growth to one or other side with the probe. Their appearance also is, as a rule, characteristic. A few specimens, however, have been met with in which the growth was so large as not only to completely block the affected nostril, but also to cause some bulging of the lateral cartilages, and in appearance was so altered as to simulate more or less closely a malignant growth. The slow progress, absence of hæmorrhage, and the microscopical appearances, would in such a case be the chief points to rely on.

For the differential diagnosis of papillomata see sections 61, 89, and 90.

§ 131. The obstructing mass is found filling the inferior meatus, perhaps the middle meatus as well; and on removing with a pledget of cotton-wool the thick sero-purulent secretion with which it is covered is seen to be composed of whitish, glistening bodies which move about. If one of these can be seized with a nasal

forceps and extracted, it is found to be a living grub or maggot. The case is one of *nasal myiasis*.

The obstruction is generally unilateral, and the external nose is swollen and œdematous. The mucous membrane lining the anterior nares is intensely injected, and a sero-purulent discharge issues from the affected nostril. The face and eyelids are often œdematous, and the patient may complain of great pain of a neuralgic character over the root of the nose and in the supra-orbital region, and of a sense of formication in the nose itself.

The following account of nasal myiasis has been kindly written by my friend Mr. W. Ernest Miles, who has had frequent opportunities of observing this disease, during some years' residence in the West Indies :

' Nasal myiasis, or the presence of maggots in the nasal cavity, is almost unknown in England or Europe, though a few isolated instances of the condition have been recorded from time to time. In tropical climates, such as the East and West Indies, Mexico, South America, and some of the Southern States of North America, the disease is not uncommonly met with. The maggots result from the deposit in the nose of the eggs of the ordinary blue-bottle fly, *Comptosia macellaria*, which, as a rule, enters during sleep, though it has been known to do so when the patient has been awake. It is said that those suffering from nasal discharge are especially liable to be attacked, probably owing to the fly being attracted by the nasal secretion which accumulates at the openings of the nostrils during sleep. In the same way the fly is attracted by the discharge from any open sore, such as a varicose ulcer of the leg, when, if eggs are deposited, maggots appear in the wound and the leg is said to be fly-blown. This fly-blown condition of neglected sores is of very common occurrence in the West Indies. So soon as the fly has deposited its eggs in the nasal cavity, it takes its departure and is seldom itself seen. About three or four days after the deposit has taken place the nasal mucous membrane becomes extremely irritable, and symptoms of a severe coryza set in. For this reason the natives of the West Indies hold coryza in great dread, and attribute all forms of it to the presence of maggots. Later on the patient complains of a sense of formication in the nasal cavity, which symptom occasions great distress, and is always indicative of myiasis, since it is due to the maggots crawling about in the interior of the nose. Severe fits of sneezing then supervene, during which one or more

maggots may be expelled. Considerable swelling and œdema of the nasal mucous membrane then takes place, and stenosis to a greater or lesser extent results. The œdema in some instances extends to the soft palate, which is then found to block up the naso-pharynx. The eyelids and face also become œdematous, and occasionally small rounded swellings occur at or about the root of the nose, which eventually burst, allowing the escape of maggots. I recollect seeing a case of myasis in which, when the patient inhaled tobacco smoke through the nose, several maggots escaped from a small opening situated just below the inner canthus of the eye. The presence of maggots in the nares not only causes intense inflammation of the nasal mucous membrane, but eventually leads to ulceration and destruction of the cartilaginous and bony framework. Fatal septic meningitis has been known to result from destruction of the bony roof of the nasal cavity. The pain occasioned by the presence of maggots, usually referred to the root of the nose and over the frontal sinuses, is of the most distressing kind, and has in some instances caused maniacal outbursts. These cases, unless relieved, usually end in septicæmia, coma, and death.'

The growth is of cartilaginous or stony hardness.

§ 132. The growth is of cartilaginous, calcareous, bony or metallic consistency. It may be an intranasal enchondroma or osteoma, a hard foreign body, or a rhinolith.

§ 133. The swelling is of cartilaginous or bony consistency, and firmly fixed, and the mucous membrane covering it is normal or paler than normal. *It may be either a cartilaginous or a bony tumour, the size of which obscures its origin.*

In such a case, however, there would probably be some external deformity of the nose or cheek, or else the growth would be of such dimensions as to enable its attachments to the septum or to the turbinates, from which, if intranasal, it probably springs, to be detected. If invading the nose from without, the deformity of the cheek, nasal bones or frontal bone would probably be quite obvious and indicate its origin (see sections 135, 136, and 138).

A cartilaginous may be distinguished from an osseous growth by the fact that, though both are hard, in the cartilaginous some resilience may be detected, and a needle can be made to penetrate its substance. Both are of extremely slow growth, and may exist for years without giving rise to any inconvenience, save such as may be caused by the obstruction to nasal respiration. They may be dis-

tinguished from a fibroma and a malignant growth by the absence of attacks of hæmorrhage and of hæmorrhage on probing.

§ 134. The swelling is probably situated just within the nose, or in the inferior meatus. It is confined to one side. There may or may not be movement obtained on touching it with the probe, and a metallic ring may perhaps be elicited when the body is struck. It is accompanied with a unilateral, purulent, fœtid, and perhaps blood-stained, discharge. The patient is probably a child, or is perhaps insane. *It is most likely a foreign body or rhinolith.*

If the patient is a child, the obstructing mass is probably a foreign body; and although there may be no history of the introduction of such, in all cases in which a child is brought with a unilateral obstruction and a unilateral, purulent, and perhaps blood-stained, discharge, the chances of a foreign body being present are great, and a thorough examination should be insisted upon, under chloroform if the child is unruly. In any case it may be necessary to thoroughly cleanse the parts by spraying or syringing with a weak alkaline lotion, and then with cocaine, before a satisfactory inspection is possible.

A foreign body may remain unsuspected in the nose for years, the discharge being attributed to catarrh or rhinitis. It may have been pushed up the nose by the child when quite young, and have been forgotten, or he may be frightened to confess to its introduction, or it may have been introduced by some other child in play or from malice. Or the foreign body may have entered the nose from behind the palate during a fit of coughing or vomiting, or it may have been introduced by the patient himself whilst insane. Buttons, beads, fruit-stones, and such-like are the most common; but almost every kind of small foreign body—even a tooth—has at times been discovered in the nose.

A rhinolith, or nose-stone, is a concretion formed by the deposit of earthy salts on a portion of inspissated mucus, a small blood-clot, or, more often, upon some foreign body introduced from without, or in one of the ways above described. Hence a rhinolith has usually a nucleus, but a few cases have been reported in which none whatever was discovered. The earthy salts, which are deposited in successive layers, consist chiefly of the carbonates and phosphates of lime and magnesia, their cohesion being maintained by a variable amount of cementing organic material.

Rhinoliths may attain a very large size—a case has been reported

in which one weighed as much as an ounce and a half. In colour they may be white or grayish-white, yellowish-green or brown, or even black. In consistency they vary from a soft crumbling mass to one of ivory hardness. They are most often found in the inferior meatus, or between the inferior turbinal body and the septum, but they may occur in any part of the nasal fossa. Nearly always they are single, and confined to one side. Whilst small they may be movable; but as they increase in size they usually become fixed, and, as the result of the irritation they set up, may become surrounded by a mass of soft vascular, readily-bleeding granulation tissue, derived from the mucous membrane. The nasal fossa in which they are contained is slowly dilated, the septum bulged to the opposite side, perhaps perforated, the turbinal bodies are atrophied, and the nose is expanded. They have been known to penetrate the ala and protrude on the external surface of the nose. They are more common in women than in men. Over and above the symptoms of nasal obstruction to which they give rise, a purulent or muco-purulent, and perhaps foetid, discharge is present, the discharge being usually unilateral, unless the septum has been perforated, when it may be bilateral. Pain at first may be absent, but later there may be pain of a neuralgic character radiating over the forehead and eyes; there may also be some irritation of the conjunctiva, perhaps epiphora from the rhinolith obstructing the nasal duct, and deafness as in other forms of obstruction.

If care is not taken to use the probe, a rhinolith may be mistaken for a polypus or malignant new growth, especially should it become embedded in vascular granulation tissue. It may also be mistaken, when perforation of the septum or external deformity has occurred, for syphilitic or other form of necrosis of the bones. From all of these, however, a rhinolith may be distinguished by the characteristic sensation detected on using the probe.

THERE IS SOME EXTERNAL DEFORMITY OF THE NOSE, CHEEK, ETC., OR THE GROWTH IS FELT IN THE NASOPHARYNX.

§ 135. There is some external deformity of the nose, cheek, etc., or the growth is felt in the naso-pharynx; the swelling may be a fibroma or fibro-angioma, a sarcoma, a carcinoma, an enchondroma, or an osteoma, that has arisen in the nose, and secondarily involved the naso-pharynx or one of the accessory cavities, or, more probably,

a similar growth that has arisen in the naso-pharynx, or in one of the accessory cavities, and secondarily involved the nose. It might possibly be a large rhinolith. If the growth is of large size, or has produced extensive external deformity, and at the same time is felt as a large mass in the naso-pharynx, it may be quite impossible to say, from the physical examination, where it took its origin. Thus a large fibroma or fibro-angioma of the naso-pharynx may so compress the superior maxilla as to come to occupy the situation of the antrum, the inner wall of that cavity being forced into contact with the outer wall.* The history of the case may then be of some help, as, for instance, when the patient is sure that the disease started as a swelling in the cheek, and apparently in connection, say, with a carious tooth or fang; but it cannot be entirely relied upon, since the symptoms in the early stages of either may be so similar that the patient may be quite unable to exactly locate the starting-point. Whilst the growth is small or of moderate dimensions, however, its origin may be made out with a fair amount of certainty. Thus, if there is external deformity, whether the growth is or is not felt in the naso-pharynx, begin below at section 136; if there is no external deformity, but the growth is felt in the naso-pharynx, pass on to section 146.

There is some external deformity, and the growth may or may not be felt in the naso-pharynx.

§ 136. The deformity may be confined to a broadening of the nose or slight bulging of the nasal bones or cartilages on one or other side. Such, though comparatively rare, is quite compatible with the growth being merely a mass of intranasal gelatinous polypi, or a large rhinolith, or even a papilloma.† It is always a suspicious symptom, however, since it is much more common in fibromata and in malignant growths in the nose. If this is the only deformity, and nothing is felt in the naso-pharynx, the growth, whatever its nature, is probably of intranasal origin (see section 116, *et seq.*). If, again, a hard fixed mass is felt in the naso-pharynx, the growth probably began here, and is now involving the nose (see Chapter IX.).

§ 137. If, however, the cheek is bulged, or, on passing the finger between the upper lip and superior maxilla, the anterior wall of the antrum is felt more prominent than on the opposite side, and

* Two specimens in the museum of St. Bartholomew's Hospital well illustrate this point.

† See Mr. Logan Turner's case, *Trans. Laryng. Society*, 1896.

perhaps crackles under the finger, or is soft in places; if the eyeball is protruded, the hard palate depressed, and nothing is felt in the naso-pharynx, the growth probably springs from the antrum. Further, if on transillumination the antrum on the affected side does not light up equally with the opposite side, the probability of the growth arising in that cavity is rendered almost certain. *The growth will most likely then be a fibroma, a sarcoma, or an epithelial carcinoma; or possibly an enchondroma, an ossifying sarcoma, or an osteoma;* begin at section 139.

§ 138. If, again, none of the signs of antral mischief are present, but there is a swelling in the region of the frontal sinuses or about the internal angle of the orbit or root of the nose, a fulness of the eyebrow, a depression of the eyelid, a protrusion of the eyeball downwards and forwards, epiphora, diplopia, impaired sight, loss of muscular control of the globe, and pain in the forehead or deeply seated in the orbit, and if at the same time nothing is felt in the naso-pharynx, the *growth seen in the nose* has probably originated in the *frontal sinuses or ethmoidal cells*, and is most likely of a sarcomatous or carcinomatous nature. Pass on to section 145.

If, from the signs mentioned in sections 137 and 138, the antrum, or the frontal or ethmoidal sinuses appear to be the starting-point, and the growth is also felt in the naso-pharynx, but not attached to its walls, the chances are that the growth has made its way backwards into the naso-pharynx as well as forwards, but has not arisen in that cavity. If, however, a huge mass is felt blocking up the naso-pharynx, to the walls of which it is firmly fixed, the probabilities are then in favour of the growth having commenced in this situation and secondarily involved the nose and its accessory cavities.

§ 139. **The growth in the nose is attended with the signs of antral disease given in section 137;** it may be a fibroma, a sarcoma, a carcinoma, an enchondroma, or osteoma, beginning in the antrum, and secondarily involving the nose. If the intranasal portion of the growth is soft or firm, begin at section 140; if of cartilaginous or bony hardness, pass on to section 143.

The intranasal portion of the growth is soft or firm, not hard.

§ 140. The growth has been slow; the patient is probably young; the teeth are sound; there are no glands to be felt; the swelling in the nose is firm, irregularly rounded or lobulated, glistening, smooth, and pinkish-red in colour; does not dimple on probing; and has been

attended by attacks of epistaxis, and of late by some pain. *It is probably a fibroma or fibro-angioma invading the nose from the antrum.*

For the differential diagnoses of fibroma and fibro-angioma, see section 124.

§ 141. The growth has been rapid or moderately rapid; the patient is probably young; the teeth are sound; the intranasal swelling is soft, friable, of a bluish-gray colour, yields to the probe, bleeds readily, has been attended by profuse attacks of hæmorrhage, and is accompanied by a sanious discharge. *It is probably a sarcoma invading the nose from the antrum.*

The growth may be also felt protruding at the choana, should it spread in a backward as well as a forward direction.

All forms of sarcoma may have their starting-point in the antrum, and secondarily invade the nose. The soft, round-celled variety is especially malignant, and may recur after the complete removal of the upper jaw within a few weeks or months. The myeloid is much less malignant, and after complete removal may not recur for several years, or, indeed, not at all.

§ 142. The intranasal growth has formed rapidly, it is moderately soft, perhaps firm, irregular, grumous, cauliflower- or liver-like, bluish-red, and is accompanied by a sero-sanious and offensive discharge. There is possibly an ulcerated aperture in or around the socket of a decayed fang, from which a sero-purulent discharge escapes into the mouth. The glands in the neck are perhaps enlarged. The patient is middle-aged or advanced in life. *It is probably a carcinoma that has arisen in the antrum and made its way into the nose.*

A carcinoma of the antrum may be of the spheroidal- or squamous-celled type. The latter is far from uncommon. It often begins about a carious fang or stump, and then makes its way into the antrum, and later into the nose. In this *creeping form of epithelioma*, as it is sometimes called, there is generally a discharging sinus in the gum from which a sero-purulent, and perhaps blood-stained, discharge escapes, and from which a fungating, readily-bleeding granulation may protrude. On passing a probe, the sinus is found to lead into the antrum, the cavity of which is filled with a friable growth, and bare or carious bone may be struck.

This form of carcinoma may be readily mistaken for an inflammatory condition attended with caries or necrosis. The age of the

patient, the character of the discharge from the sinus, the gross and microscopical appearance of the granulations at the entrance of the sinus, the detection of a sequestrum, and the presence or absence of enlarged submaxillary glands, will help the diagnosis, but certainty is only attainable by an exploratory incision into the antrum.

The intranasal portion of the growth is of cartilaginous or bony hardness.

§ 143. The intranasal portion of the growth is hard, of cartilaginous consistency, covered by healthy mucous membrane which does not bleed when touched, and there have been no attacks of epistaxis. Its progress has been very slow. *It is probably an enchondroma beginning in the antrum, and secondarily involving the nose.*

Enchondromata arising in the antrum are rare. They more frequently arise in the nose itself or in the naso-pharynx, and then secondarily involve the nose and antrum as they increase in size. The slow growth, the absence of hæmorrhage, and the cartilaginous consistency, which allows them to be punctured with a needle, should distinguish enchondromata from fibromata and osteomata, and from malignant disease.

§ 144. The intranasal portion of the growth is of bony consistency, is probably covered by healthy mucous membrane, does not bleed when touched, and is probably not accompanied by attacks of hæmorrhage. *It is either an osteoma or an ossifying sarcoma, beginning in the antrum, and secondarily involving the nose.*

It would be next to impossible, from the physical appearances of the intranasal growth, to distinguish an osteoma from an ossifying sarcoma. The rate of growth, presence or absence of hæmorrhage, and microscopical examination of a piece of the growing edge, are the points that will help the surgeon in forming an opinion.

Any of the above growths springing from the antrum may finally cause absorption of the walls of the cavity, and ultimately protrude on the cheek, invade the orbit or mouth, or extend backwards into the naso-pharynx or sphenomaxillary fossa.

§ 145. **The growth in the nose is attended with the signs of frontal or ethmoidal mischief given at section 138.** *It is probably a sarcoma or carcinoma that has arisen in the frontal or ethmoidal cells, and secondarily made its way into the nose.*

For the diagnosis of the sarcomatous or carcinomatous nature of the intranasal growth, see section 126, *et seq.*

There is no external deformity, but the growth is felt in the naso-pharynx.

§ 146. So far it has been assumed that the growth discovered on anterior examination cannot be seen or felt in the naso-pharynx, or that it can merely be seen or felt projecting at or just through the choana, but clearly not springing from the walls of that cavity. If, however, the growth is found on posterior rhinoscopy and on examination with the finger behind the palate to arise from the roof or walls of the naso-pharynx or upper margin of the choana, the intranasal portion will probably be merely an extension of the naso-pharyngeal, since it is exceedingly rare, if not unknown, for an intranasal growth to form secondary attachments to the naso-pharynx. If, therefore, the growth is found to be arising in this cavity, turn to the section on *Naso-pharyngeal causes of obstruction* (Chapter IX.).

It must not be forgotten, however, that a naso-pharyngeal growth, when it has existed for a long period, may encroach so much upon the nasal cavities that it may lead to considerable external deformity, pushing forward and separating the maxillary and nasal bones, and then giving rise to the peculiar appearance known as frog-face.

CHAPTER VIII.

GENERAL DIAGNOSIS—Continued.

THE SWELLING OF THE NASAL MUCOUS MEMBRANE IS GENERAL; *i.e.*, IT INVOLVES AS FAR AS CAN BE SEEN MORE OR LESS OF THE SEPTUM, TURBINALS, AND REST OF THE CAVITY.

§ 147. The obstruction is due to a general swelling of the mucous membrane of the nasal chambers. It may be acute catarrh, hypertrophic rhinitis, purulent rhinitis, fibrinous rhinitis, caseous rhinitis, specific rhinitis, the rhinitis of inherited syphilis, gummatous infiltration, tuberculous disease, lupus, glanders, leprosy, rhinoscleroma, or nasal diphtheria (primary or secondary). If the obstruction is accompanied by acute febrile symptoms, it may be due to acute catarrh, specific rhinitis, nasal diphtheria or glanders; pass on to section 165, otherwise begin below at section 148.

The obstruction is not accompanied by acute febrile symptoms.

§ 148. If there are no acute febrile symptoms attending the obstruction, it is probably due to hypertrophic rhinitis, fibrinous rhinitis, caseous rhinitis, the rhinitis of inherited syphilis, purulent rhinitis, a general gummatous infiltration of the mucous membrane, tuberculous disease, lupus, rhinoscleroma or leprosy. Determine whether ulceration is or is not present in the way set forth at p. 16.*

* In infants and young children it may be difficult or impossible to obtain an examination of the nose sufficiently satisfactory to determine whether there is or is not any ulceration of the mucous membrane. When, therefore, a satisfactory examination cannot be obtained, the presence or absence of ulceration may be judged of to some extent by the character of the discharge. A purulent and offensive discharge, mixed with blood and portions of black necrotic tissues, will make it probable that ulceration is taking place, especially if the discharge is bilateral. A purulent, offensive and blood-stained discharge, however, it should never be forgotten, may be due to a foreign body. In nearly every case of a unilateral discharge with these characters in young children, it is therefore advisable to exclude the presence of a foreign body by examination under an anæsthetic.

If there is no ulceration, begin at once at section 149 ; if there is ulceration, pass on to section 159.

There is no ulceration.

§ 149. If no ulceration is discovered, the swelling is probably due to hypertrophic rhinitis, to purulent rhinitis, to fibrinous rhinitis, to caseous rhinitis, to rhinitis of inherited syphilis, to a general gummatous infiltration of the mucous membrane at an early stage, to early leprosy, or to rhinoscleroma.

§ 150. On inspecting the nasal cavities, the mucous membrane is found swollen and slightly congested. The swelling is general, but the shape of the natural inequalities of the cavity is retained, so that the turbinals appear larger than normal, and perhaps come into contact with the septum or with each other. The mucous membrane is thick and velvety, and slightly redder than normal ; that over the middle turbinal may be of a bright pink colour. The inferior turbinal may be slightly rugose, the middle turbinal smooth and shining. Both are coated with a small amount of semi-transparent mucus, which is quite odourless, and does not form crusts. The thickened mucous membrane feels soft to the probe, and any indentation made is immediately effaced on removal of the pressure. If sprayed with cocaine the swelling, especially that over the inferior turbinal and tubercle of the septum, shrinks, but does not completely disappear, and its colour becomes paler. A deflection or spur of the septum is very likely present. On posterior examination, the enlarged turbinals are seen as whitish masses projecting at the choanæ. The patient complains of a continual watery, or it may be muco-purulent, discharge, of constant colds in the head, or of mucus or phlegm running down the back of the throat, which he is continually endeavouring to rid himself of by coughing and hawking. It may be for the throat trouble, or for spasmodic cough, asthma, hay-fever, or deafness, that he seeks advice. *It is hypertrophic rhinitis.*

Hypertrophic rhinitis has already been fully discussed under swellings of the turbinals (see sections 72 and 70).

§ 151. The nasal mucous membrane is slightly swollen and congested, and covered by a yellowish purulent discharge ; but no foreign body, growth, ulceration, or crusts, are discoverable, nor is there any pain, foetor, deafness, or alteration of the voice. The discharge, which is quite sweet, is not influenced by varying the

position of the patient's head, and is not found after cleansing the nose to come especially from between the middle and the inferior turbinal body. There may be a few scabs about the anterior nares, and an eczematous, or thickened condition of the upper lip. Both nasal cavities are affected, but the obstruction to nasal respiration is not great. The patient is probably a child. *It is purulent rhinitis.*

Purulent rhinitis is common in weakly, ill-fed children, of the so-called strumous diathesis, whose digestion is faulty and whose general health is below par; but it may be met with in children in robust health. It also occurs in infants from contact with leucorrhœal or gonorrhœal discharge in the mother, and occasionally in adults as the result of auto-infection, or otherwise, with gonorrhœal discharge. In children the condition may be associated with adenoid growths in the naso-pharynx, with enlarged tonsils and bronchial troubles. A purulent discharge may also occur as the result of the exanthemata (see specific rhinitis, section 166). Simple purulent rhinitis in children, if unchecked, is said by some authorities to end in atrophic rhinitis. I have not myself seen it do so.

Purulent rhinitis may have to be diagnosed from syphilitic ulceration, necrosis, tuberculous ulceration, a foreign body, a new growth, and empyema of the accessory sinuses, in all of which there may be a purulent discharge. The absence of ulceration will dispose of *syphilis*, *tubercle* and *necrosis*, and the absence of any localized swelling of a *foreign body* or *new growth*. In *empyema of the accessory sinuses*, the discharge, which then consists of pure, creamy, yellow pus, is usually unilateral, and can be seen to flow from between the middle and inferior turbinal body after the nasal cavity has been cleansed; whereas in purulent rhinitis the discharge is bilateral, does not flow from any special spot, and is not affected by alteration in the position of the patient's head. The swelling of the nasal mucous membrane, moreover, is general, not localized, as it commonly is in empyema. Further, simple purulent rhinitis, *per se*, is an affection of childhood; empyema of the accessory sinuses one of adult life.

§ 152. The patient is an infant, probably about four to six weeks of age. The parents complain that the child is continually snuffling, as if it had a cold in the head, and that it has a watery or mucopurulent discharge from the nose, which dries into crusts about the nares, and causes some excoriation of the upper lip. The infant

manifests the usual signs of nasal obstruction, and there are probably evidences of congenital syphilis in various parts of the body. The mucous membrane, if it can be seen, appears reddened and slightly swollen, and bathed in a watery or muco-purulent discharge, whilst here and there a mucous patch may possibly be detected. *It is the coryza of congenital syphilis.*

The history of syphilis in one or other of the parents, a history of miscarriages, and the well-known signs of congenital syphilis, which, if not present when the infant is first seen, will probably soon manifest themselves, will distinguish this form of coryza from simple acute coryza and from purulent rhinitis. The simple purulent rhinitis of children does not manifest itself, as a rule, till the child is three or four years of age, and that due to contact with gonorrhœal or leucorrhœal discharge during delivery occurs immediately after birth, whereas the coryza of congenital syphilis usually appears when the child is from four to six weeks old. A simple acute coryza, moreover, will usually cease in a few days, whereas the syphilitic form, if not treated, generally progresses, and is followed by gummatous deposits, ulceration accompanied with a foetid, blood-stained discharge, destruction of the septum, and characteristic falling in of the bridge of the nose.

§ 153. The nasal cavities are obstructed by false membranes of a grayish-white colour and fibrinous consistency, adhering to the swollen and reddened mucous membrane, especially that covering the septum and turbinal bones. The false membrane adheres more or less firmly, and leaves a bleeding surface when forcibly removed, or it may come away easily without any bleeding. Portions or shreds are expelled by the patient from time to time along with a muco-gelatinous, or perhaps muco-purulent, discharge, which may be slightly foetid. Cocaine does not cause a shrinking of the swelling; no membrane is discovered on the fauces; the glands in the neck are not enlarged, and no constitutional symptoms are present. The patient is most likely a child. *It is probably fibrinous rhinitis; it may be primary diphtheritic rhinitis.*

Fibrinous rhinitis, which has been variously called croupous rhinitis and membraneous or pseudo-membraneous rhinitis, is rare. It has been most often observed in childhood, but may occur in adults. It usually begins without apparent cause as an ordinary cold in the head, and may be ushered in by headache and slight fever, which, however, quickly subside. The mucous discharge

becomes more abundant, and nasal respiration is more or less completely obstructed; shreds or casts of the false membrane are now expelled from the nose, and are seen adhering to the mucous membrane on rhinoscopic examination. The temperature may be slightly raised for the first few days, but after that remains normal; the pulse is not increased in frequency; the glands in the neck do not enlarge; the urine is not albuminous, and the disease, after lasting about a fortnight or so, gradually subsides, and is not followed by paralysis. The affection is sporadic, and is not contagious. On bacteriological examination, the Klebs-Loeffler bacillus is not found; but the *Staphylococcus pyogenes aureus*, or a staphylococcus resembling this organism, may be present. The infant's sucking may be rendered very difficult, and severe symptoms may ensue.

By some observers fibrinous rhinitis is believed to be merely a mild form of nasal diphtheria, since in some supposed cases of the affection the Klebs-Loeffler bacillus has been discovered in the membrane, paralyses resembling post-diphtheritic have followed, and other members of the household have become affected. It is probable that these particular cases were mild forms of nasal diphtheria. So far, however, the evidence would seem to be in favour of fibrinous rhinitis being a benign disease distinct from diphtheria. The diagnosis from mild cases of primary nasal diphtheria is, however, at times very difficult. The points to be chiefly relied on, are the absence of constitutional symptoms, of glandular enlargement, of albumin in the urine, and of paralytic sequelæ, and last, but not least, the negative result of a microscopical and bacteriological examination of a portion of the suspected membrane.

§ 154. The mucous membrane is slightly reddened and swollen, whilst in one or more situations masses of yellow, caseous, and possibly slightly foetid material are seen blocking the passage. There is no ulceration discoverable. *It is caseous rhinitis.*

Caseous rhinitis, or cholesteatomatous rhinitis, as it is sometimes called, is by some believed to be merely the result of the necrobiosis of mucous polypi. Massei attributes it to the presence of the *Streptothrix albus* in a nose in which there is much purulent secretion, with obstruction to its outflow. I have met with it when no signs of polypi, or the remains of polypi, could be discovered, and where, beyond the general swollen and reddened condition of the mucous membrane, and the presence of the caseous masses, no

further pathological condition, so far as I could make out, existed. It is said by some to be of strumous origin, and to lead to caries or necrosis of the bone. Probably different affections have been described under this term.

§ 155. The mucous membrane over the turbinals, septum, and floor of the nose, is generally swollen, so as to occlude a view of the deeper parts of the nasal cavities. The swelling is moderately hard, and the mucous membrane is natural in colour, or perhaps slightly paler than natural. The patient complains of dull, boring, nocturnal pains, and it may be of some mucous or muco-purulent discharge. There are probably concomitant signs of syphilis in other parts of the body, and a history of that disease may be obtained. *It is most likely a gummatous infiltration in an early stage.*

Gummata may affect any part of the nasal cavity, and though more common in certain situations, as on the septum or the turbinals, may occur as a general gummatous infiltration of the mucous membrane. When such extensive deposits exist, there are usually other well-marked syphilitic lesions present in the vicinity, as in the hard or soft palate, or pharynx, over the nasal bones, or in the alæ of the nose or upper lip; or characteristic signs of past syphilis may be met with in the throat, tongue, or elsewhere. I have seen a case, however, where the only other sign of syphilis was a soft node on the cranium, and of this neither the patient nor his doctor was aware. The characteristic boring pain so common at nights is more marked the higher the gummata are situated in the nasal fossa.

A general gummatous infiltration is liable to be mistaken for hypertrophic rhinitis. The solid character of the swelling in gummatous infiltration, the absence of shrinking when sprayed with cocaine, the nightly pains, and the general appearance of the swelling as given above and in the sections on gummata of the septum and turbinals (sections 39, 55, 75, 82, and 83), are the chief points to be attended to in the diagnosis.

§ 156. There is a general tumefaction of the nasal chambers, the swellings over the septum and inferior turbinal perhaps being in contact and more or less completely occluding the cavity beyond. Whilst the greater part of the swollen tissue is hard and firm, at one or more spots an elastic or semi-fluctuating condition is discovered with the probe, and here the mucous membrane is congested, and of a dull red or purplish colour. Boring pains are

complained of at night, and there is probably much pain and tenderness on pressure, and a mucous or muco-purulent discharge. Other evidences of syphilis are most likely present. *It is gummatous infiltration in a later or breaking-down stage.*

Gummata at this stage might be mistaken for suppurating actinomycosis. The fact that signs of syphilis are present in other parts, together with the general configuration of the tumefaction, which would probably be better defined in actinomycosis, would help the diagnosis, whilst the examination of a drop of pus drawn from the softened parts by a grooved needle would reveal the presence or absence of the minute yellowish granules characteristic of actinomycosis. The latter disease, moreover, must be exceedingly rare in the nose, if, indeed, it has hitherto been recognised in that cavity. For the differential diagnosis of gummata in the early and breaking-down stage, from a hæmatoma, a chronic abscess, a sarcoma, rhinoscleroma, etc., see sections 39, 55, 60, 74, and 75.

§ 157. The lumen of one or both nasal cavities is greatly diminished, the mucous membrane covering the septum, inferior turbinal, and probably as much of the floor of the nose as can be seen, being swollen and thickened. On further examination this swollen and thickened condition of the part is found to be due to the formation of smooth, hard, dense, plate-like, or nodular masses of tissue beneath the mucous membrane, which in these situations has a brownish-red colour. The margins of the plates and nodules are sharply circumscribed and rounded. The lower part of the nose is probably broadened, and rendered markedly rigid and unyielding by the formation of similar dense masses of tissue in the alæ, columella and contiguous part of the upper lip, or in one of these situations a dense, hard, prominent swelling, over which the skin appears shining, smooth, or perhaps a little dusky, may have formed. There is no sign of acute inflammation, and probably no ulceration; but there may be some cracks or fissures about the margin of the nostrils. There may or may not be a mucous discharge, and this if present may possibly be foetid. There is no pain, but the parts are slightly tender to the touch. On posterior rhinoscopy the choanæ may be found narrowed, or they may be occluded by the swelling. The mouth or pharynx may possibly be similarly affected by a dense, stony infiltration of the mucous membrane. The disease is said by the patient to be steadily advancing, and to be unattended by pain. *It is rhinoscleroma.*

This disease, which has been most frequently met with in Eastern Austria, in Russia, and in Central America, is exceedingly rare in this country. It most frequently begins in the interior of the nose, spreading by continuity of tissue forwards to the anterior nares and upper lip, and at times backwards into the naso-pharynx and pharynx. Occasionally it begins in the upper lip, and it may possibly do so in any part of the respiratory tract, and secondarily involve the nose, or the nose may escape altogether. It is exceedingly slow in its course, and when it begins in the nose may at first be confined to either the septum or turbinals (see sections 34 and 76). As the disease progresses, the whole interior of the nose becomes more or less involved, the alæ become thickened and of stony hardness, and the nose appears broadened and ultimately may become of immense size. In some cases a distinct tumour-like formation of ivory hardness may occur on one or other side of the nose. Rhinoscleroma does not undergo inflammatory or retrogressive changes, though in some instances superficial abrasions or ulcerations of the mucous membrane have been observed.

When the disease is fully established, it is so unlike any other by reason of its rigidity, hardness, slow growth, continuous progress, and absence of ulceration and of pain, that it cannot well be mistaken. In the early stages a distinction may have to be made from a *gumma*, from a *malignant growth*, and from *keloid*. *Rhinoscleroma* may be diagnosed from a *gumma* by its stony hardness, its resistance to anti-syphilitic remedies, its steady progress, its much slower development, and by the absence of ulceration; or, if some superficial abrasion is present, by such abrasion not being sharp cut at the edges, and not deep, while its floor is impenetrable to the probe. The abrasion has, moreover, no characteristic areola as has the ulcer of syphilis. A *gumma* in its early stage may be hard, indeed almost cartilaginous, but it has not the stony rigidity of rhinoscleroma. When, as has in some cases occurred, a separate mass of rhinoscleroma is present in the upper lip and also in the pharynx, the resemblance to syphilis is great, but the rigidity of the neighbouring parts will then usually serve to distinguish it. From a *hard fibroma* or *fibro-sarcoma*, with which it could hardly be mistaken except in quite the early stage, rhinoscleroma may be distinguished by the absence of bleeding and its slow growth; but cases have occurred in which it was only by the discovery of the rhinoscleroma bacillus that a distinction could be drawn. From *keloid*, the

diagnosis of rhinoscleroma may be made by the continuous though slow progress of rhinoscleroma, by the stony hardness and rigidity of the infiltrated tissues, by the absence of any cause for keloid, and by the discovery of the rhinoscleroma bacillus.

§ 158. The mucous membrane is thickened, somewhat indurated, of a dark-red colour, and perhaps bleeds when touched with a probe. Here and there are small nodules, which are firmer and harder than the rest of the mucous membrane, and have a purplish hue. There is well-marked obstruction to nasal respiration on one or both sides, and there have probably been attacks of hæmorrhage. The face is most likely disfigured, the skin is thickened, coarse-looking, and congested, and numerous nodules are perhaps studded over the surface, especially on the forehead. The nose is flattened and broadened, the lips are everted and thickened, and the lobes of the ears may be enlarged and nodular. *It is leprosy, with early manifestations in the nose.*

There is ulceration.

§ 159. If ulceration is discovered, the obstruction may depend upon inherited syphilis, deep syphilitic ulceration, tuberculous ulceration, lupous ulceration, or leprous ulceration.

§ 160. The patient, an infant, has a purulent, slightly blood-stained foetid discharge from the nostrils, mixed with crusts and portions of necrotic tissue. It has the usual signs of nasal obstruction; the bridge of the nose is probably slightly depressed, and characteristic signs of inherited syphilis are present in various parts of the body. If the interior of the nose can be seen, ulceration will be detected, and if a probe is introduced, the septum may be found perforated, or necrosed bone may be felt. The parents probably state that the trouble began at about four to six weeks of age with a watery or mucoid discharge, and snuffling respiration. *It is deep gummatous ulceration due to inherited syphilis.*

The irritation of the crusts, which are liable to be retained, and the obstruction they then cause to the free escape of the discharge, may lead to serious nerve symptoms suspicious of cerebral syphilis, such as epileptiform convulsions, coma, etc.

The characteristic signs of inherited syphilis, the history of syphilis in one or other of the parents, the age of the child, together with the character of the discharge and commencing nasal deformity, should as a rule be sufficient for the diagnosis of this from any other affection.

§ 161. After the nasal cavities have been cleared of the foul purulent discharge and offensive blackish crusts, which are probably found blocking the passage, extensive ulceration, involving the septum, turbinals and floor of the nose, is discovered. The ulcers are deeply excavated and irregular in outline, the edges are ragged and overhanging or in places punched-out-looking, and the bases covered by tough adherent yellow sloughs and in places by dried pus and blood which form blackish crusts. The surrounding mucous membrane is swollen, and forms a bright shining red areola to the ulcer. On probing, dead bone may be detected, and the septum or palate, or both, may be found perforated. The patient perhaps says that particles of dead bone have from time to time come away in the purulent offensive discharge, and that till recently he suffered from boring pains especially at night. *It is deep syphilitic ulceration due to the breaking down of gummata.*

The diagnosis of the tertiary syphilitic ulcer is generally easy, the gross appearances being quite characteristic. But should there be any difficulty, then the history of syphilis having been contracted some years back, the presence of undoubted syphilitic lesions in other parts of the body, the fact that the ulceration was preceded by obstruction in the nose attended by boring pain with nocturnal exacerbations, the cessation of the pain as soon as the ulceration appeared, together with the presence of necrosis and perhaps increasing deformity of the external nose, will be of service in distinguishing this form from tuberculous, lupoid, or malignant ulcerations.

A further account of deep syphilitic ulceration is given in the sections on ulceration of the septum and turbinals (sections 60 and 103), and the differential diagnosis is there discussed. The signs and diagnosis of general gummatous infiltration in the early and softening stages is given at sections 155 and 156.

§ 162. On clearing the nose from the adherent yellowish-green crusts, which are probably found more or less blocking the passage, several small ulcerated patches are seen upon the nasal mucous membrane, and are especially well marked upon the septum and inferior turbinal, but exist also upon the floor of the cavity. The ulcers are for the most part distinct from one another, but in some places have coalesced, forming large irregular patches. The smaller ulcers are round or oval in outline, the edges raised, ragged-looking, and undermined. The floor is somewhat excavated, grayish-yellow

in colour, and covered in part by yellowish caseating masses, which are very friable. The secretion is mucoid or puriform, slightly sanious, and rather offensive. The contiguous mucous membrane is healthy-looking, but may be slightly congested; there is no scarring in the vicinity of the ulcers, showing that there is no attempt at repair. There is no tenderness to the touch, and the patient does not complain of pain. *It is tuberculous ulceration.*

As tuberculous ulceration is more often limited to the septum or to the turbinals, the differential diagnosis of this form of ulceration from syphilitic, lupoid, and malignant ulceration is given at sections 61 and 105.

§ 163. The mucous membrane of the nasal cavities on one or both sides is covered with crusts, which may almost completely block up the passage. The crusts consist of flat, broad scales, having a brown colour. On removing the crusts, little or no bleeding takes place, and a thin, watery discharge, perhaps having an offensive odour, escapes, while the underlying swollen mucous membrane appears as a granular mass with an irregular ulcerated surface. The tissue composing the floor of the ulcer is soft and friable, and easily penetrated by a probe, which, though it may pass to some depth, causes neither much pain nor bleeding, and does not detect dead bone. There are no signs of acute inflammation, and no oedema of the parts. The ulceration is best marked on the septum, and perforation of that structure may exist, as evidenced by the probe passing through it, or by its point being felt under the mucous membrane in the opposite nostril. *It is lupous ulceration of the nasal cavity.*

When lupus has invaded the nasal cavity, extensive lupous ulceration is almost always present on the face and external nose. Under these circumstances the diagnosis is not difficult. When, however, the disease is confined entirely to the nasal cavity, the differential diagnosis between it and tuberculous, syphilitic and malignant ulceration cannot always be positively made except by the aid of microscopical examination (see section 61). The facts, however, that the ulcers are covered by the characteristic brown scales, that there is but little or no bleeding or pain, that the disease occurs in young people, that it runs a slow and chronic course, that it is progressive, and tends towards deep ulceration and destruction of tissue, that it is not arrested by anti-syphilitic remedies, and that, though it may lead to perforation of the bony or cartilaginous

septum, no necrosis is found to exist, will materially aid the diagnosis.

§ 164. There is extensive ulceration in the nasal cavities. The ulcers are irregular in shape; their floor is covered with particles of necrotic tissue, and there is no indication of healthy repair. From the surface of the ulcer a foul-smelling discharge issues. When probed, dead bone may be detected, and bleeding readily takes place. The surrounding mucous membrane is thickened and congested. There is probably some external deformity of the nose owing to the destruction of the bony framework. The face is disfigured, being covered by tubercular nodules and ulcerative patches; the nose, lips, and ears are especially thickened and nodular. *It is ulcerative tubercular leprosy of the nose.*

Leprosy occasionally attacks the pituitary membrane, but not nearly so frequently as it does the mucous membrane of the pharynx and larynx. Amongst the numerous cases of tubercular leprosy that my friend Mr. Miles had an opportunity of seeing at the Leper Asylum in Trinidad, he can recollect only three instances in which the disease affected the nasal cavities. In all three well-marked ulceration was present, and in one the ulcerative process had almost entirely demolished the external nose, the destruction of the bony framework having been very extensive. In these cases the general signs of leprosy in other parts of the body were especially well marked, nearly the whole of the skin surface being covered by foul, ill-conditioned ulcers. The diagnosis of the condition is extremely easy, since the signs of leprosy are always present in the face and other parts of the body; indeed, no one who has seen a good example of tubercular leprosy could mistake it for anything else. The detection of the *Bacillus lepræ* would of course be corroborative evidence.

The obstruction is accompanied by acute febrile symptoms.

§ 165. If the obstruction is accompanied by febrile symptoms, it may depend upon acute catarrh, specific rhinitis, nasal diphtheria (primary or secondary), or glanders.

A patient with acute catarrh, or cold in the head, would hardly consult the surgeon for nasal obstruction, and further, as the signs of that condition are known to all, it need not be further considered here.

§ 166. The mucous membrane is generally swollen and congested,

and covered by a muco-purulent or purulent discharge. The patient is suffering from one of the exanthemata. *It is specific rhinitis.*

Rhinitis accompanied by a muco-purulent or purulent discharge is common during the exanthemata. The fact that the patient is suffering from one of these fevers is sufficient for the diagnosis. In small-pox the mucous membrane of the nose may be affected by the pustular eruption, and in scarlet fever it may slough in places, leading to necrosis of the cartilages or bones.

§ 167. The mucous membrane is reddened and swollen, and covered by an adherent grayish-white false membrane, portions of which may come away from time to time with the watery and slightly purulent or muco-purulent discharge that escapes from the nostrils. The membrane can be removed with the forceps in large flakes, or as a complete cast of the nasal cavity, leaving the mucous surface raw and bleeding. The submaxillary and cervical glands are enlarged, and tender on pressure. The urine probably contains albumin, and the Klebs-Loeffler bacillus is detected in the membrane. *It is primary nasal diphtheria.*

Primary nasal diphtheria is not often met with, and as the disease is at times attended by little or no constitutional disturbance, it may readily be mistaken for fibrinous rhinitis. Indeed, some observers do not admit a distinction. The first symptom noticed is usually more or less nasal obstruction, with consequent noisy breathing and restlessness at night. Enlargement of the submaxillary and posterior cervical glands occurs very early in the course of the disease, and post-diphtheritic paralyses frequently follow.

Primary nasal diphtheria shows little tendency to spread to the naso-pharynx, pharynx, or larynx, but is confined to the nasal cavity throughout its course.

The presence of false membrane in the nasal cavity in a person who has been exposed to the laryngeal form of the disease should at once arouse suspicion of diphtheria; and if a bacteriological culture made from a portion of the removed membrane shows the presence of the Klebs-Loeffler bacillus, no further doubt can exist. If on examining the larynx and naso-pharynx no similar membrane is detected, the probability that the case in question is one of primary nasal diphtheria rather than secondary is great. It should be borne in mind also that, though persons suffering from primary nasal diphtheria rarely or never suffer from the laryngeal form of the disease, yet other members of the household may do so.

Should this be the case, the diphtheritic nature of the affection under consideration would be confirmed. The diagnosis of primary nasal diphtheria from fibrinous rhinitis is discussed at section 153.

§ 168. The mucous membrane is red and swollen, and lined by an adherent false membrane of an ashen-gray colour. There is a discharge from the nostril, which is dark in colour, and rather offensive. The submaxillary and posterior cervical glands are enlarged and tender, especially those situated at the angle of the jaw. A similar ashen-gray membrane lining the soft palate and fauces is seen, and there is some difficulty in laryngeal respiration. The patient is suffering from severe constitutional disturbance, has a peculiar earthy look, and his temperature is raised. *It is secondary nasal diphtheria.*

Secondary nasal diphtheria, due to an extension of the membrane from the larynx and naso-pharynx to the nasal cavities, is always serious, as it indicates great virulence of the disease. When the nasal cavity is attacked, the discharge at first is watery in consistence, and slight in quantity; but it speedily becomes purulent, more plentiful, darker in colour, and offensive in smell. Bleeding from the nose, sometimes profuse and difficult to arrest, then follows, and the discharge assumes a tarry character, and is extremely foul. Such a condition indicates the supervention of sepsis, and a general pyæmic condition may follow. In some cases the nose and adjoining parts become swollen and œdematous, and the false membrane may extend up the lachrymal duct and form on the conjunctiva.

§ 169. The mucous membrane of the nasal cavity is intensely inflamed, swollen, painful, tender, and œdematous, and a glairy or thick yellowish, and perhaps blood-stained and offensive, discharge flows from the nose. Such mucous membrane as can be seen is found to be the seat of extensive, ill-conditioned, phagedænic ulceration. Similar ulceration involves the margins of the nostrils, upper lip, and perhaps the cheeks. The exterior of the nose is swollen and œdematous. There is high fever, great prostration, and pains in the muscles and joints. On the face and in the neighbourhood of the joints a papular and pustular eruption may be seen closely resembling that of small-pox. Multiple abscesses may also be found in various parts of the body. *It is glanders in an advanced stage.*

When glanders invades the whole nasal cavity, the disease is already far advanced, and will speedily terminate fatally. The

ulceration rapidly extends to the external nose and face, and assumes a chancroidal character. The discharge becomes thicker, sanious, and foetid. Multiple abscesses occur in different parts of the body, indicating the onset of a general pyæmia. The formation of each abscess is marked by a distinct rigor and profuse sweating. Diarrhœa and vomiting then set in, and the patient passes into a typhoid condition, coma and death then closing the scene. The diagnosis of glanders, when it affects the whole nasal cavity, is not attended with much difficulty; the intensity of the inflammation, the rapidity with which ulceration of a foul nature follows, the general prostration of the patient, the high temperature, the pains in the muscles and joints, and the appearance of the variolous eruption on the face and in the neighbourhood of the joints, all point to an acute infective inflammatory disease of great virulency. If to the above signs a knowledge of the previous history of the patient is added, that his occupation brings him into contact with horses, or that he had been in attendance upon an animal that was known to be glandered, the suspicion that the case is one of acute glanders will be strengthened. A bacteriological examination of the discharges, and the discovery of the *Bacillus mallei*, would, of course, remove all doubt as to the nature of the disease.

CHAPTER IX.

GENERAL DIAGNOSIS—Continued.

THE OBSTRUCTION IS AT THE POSTERIOR NARES, OR IN THE NASO-PHARYNX OR PHARYNX.

§ 170. Having previously examined the interior of the nose from the front, whether a cause for the obstruction has or has not been found, the posterior nares and naso-pharynx should be examined with the rhinoscope, and in some cases with the finger also in the way described at p. 17 *et seq.*

If, on looking into the mouth, with the tongue depressed, there is clearly nothing capable of producing nasal obstruction to be seen in the soft palate, fauces, back of the pharynx and tonsils, save perhaps some enlargement of the last-mentioned structures, proceed to the examination of the naso-pharynx as set forth at section 193. If, however, the passage from the mouth into the naso-pharynx is not free, in consequence of some affection of the soft palate, fauces, back of pharynx or tonsils, or of a tumour blocking up the passage, begin below at section 171 before proceeding with the examination of the naso-pharynx and choana.

The obstruction is due to some affection of the soft palate, fauces, back of the pharynx or tonsil, or to a growth blocking up the naso-pharynx and projecting below the soft palate.

§ 171. Some unnatural condition, evidently obstructing the free passage of air through the naso-pharynx, is noted in the soft palate, fauces, back of the pharynx, or tonsils. The conditions capable of producing such obstruction are: (1) Adhesions between the soft palate, fauces, and back wall of the pharynx, the result of cicatricial contraction; (2) acute and chronic retro-pharyngeal abscesses; (3) new growths in the posterior pharyngeal wall; (4) inflammatory

conditions, new growths and gummata of the soft palate; (5) inflammatory enlargement and new growths of the tonsils. If the obstruction is due to adhesions between the soft palate and walls of the pharynx, begin at section 172; if due to protrusion of the posterior pharyngeal wall, pass on to section 174; if due to a swelling of the soft palate, turn to section 181; if due to tonsillar enlargement, turn to section 186.

The entrance to the naso-pharynx may also be obstructed by a new growth blocking up the passage, and unconnected, as far as can be seen, with any of the above-named structures. This may arise from the vault of the naso-pharynx, or from the nose, whence it has made its way through the choanæ; begin at section 191.

§ 172. *The obstruction is due to adhesion between the soft palate and wall of the pharynx.*

§ 173. The posterior pillars of the fauces, with the soft palate, are drawn towards the back of the pharynx, to which they are adherent, leaving only a small aperture leading into the naso-pharynx: *It is stenosis of the naso-pharynx.*

This condition is usually the result of former ulceration, the soft palate being drawn by the posterior pillars of the fauces during cicatricial contraction into contact with the posterior pharyngeal wall. The aperture left varies in size, according to the severity and extent of the ulceration. It may admit the passage of a finger, or may be so small as barely to allow the introduction of a probe. The aperture may be centrally placed, or it may be on one side of the middle line when the ulceration has been more extensive on that side. The condition is rare, but it so happens that I have met with four or five cases. It is generally due to syphilitic ulceration—it was so in my patients; but it is said to have occurred as the result of tubercle. A similar state of the parts has been described as the result of congenital malformation. In the cases that have come under my observation there were other syphilitic manifestations in the nose, and in various parts of the body.

§ 174. *The obstruction is due to a protrusion of the post-pharyngeal wall.*

§ 175. The posterior wall of the pharynx is bulged forwards so as to be in contact, or nearly in contact, with the soft palate, which may itself be pushed forwards into the mouth by the swelling. The

protrusion may be due to an acute retro-pharyngeal abscess, a chronic retro-pharyngeal abscess, or a retro-pharyngeal growth.

§ 176. The swelling, which has come on rapidly, is soft and fluctuating, and the mucous membrane covering it is red and congested. There is more or less œdema of the neighbouring parts, and perhaps some external swelling about the angle of the jaw on one or both sides. The formation of the swelling has been attended with pain, some difficulty in swallowing, and sharp constitutional disturbance; thus, the temperature is high, the pulse rapid, the tongue furred, and there may have been shivering or a distinct rigor. *It is an acute retro-pharyngeal abscess.*

An acute retro-pharyngeal abscess is not very common. It is generally unilateral, and may extend upwards towards the base of the skull, when it more especially interferes with nasal respiration, or downwards towards the œsophagus, when dyspnœa, dysphagia, stiffness of the neck, and some alteration in the voice, are the most prominent symptoms. The patient snores when asleep, and throws his head backwards in order to obtain more room for the passage of air to the larynx. When the inflammation is very acute, the mouth can only be opened with difficulty, and there is often profuse salivation. A puncture with a grooved needle will clear up any doubt, should such exist.

§ 177. The swelling has come on slowly; it is soft and fluctuating, and the mucous membrane covering it is natural, or perhaps slightly congested. There is little or no collateral œdema, but probably a swelling about the angle of the jaw. *It is most likely a chronic retro-pharyngeal abscess.*

A chronic retro-pharyngeal abscess is perhaps most frequently the result of caries of the cervical vertebræ. Under these circumstances there will be signs of cervical spinal mischief, such as pain and tenderness on percussing the cervical vertebræ, on pressing on the head, on bending the head forwards, on rotation of the head, and on turning the neck from side to side and on bending it laterally. The patient holds his head stiffly, perhaps supporting his chin with his hands, and, when the upper vertebræ are the seat of the disease, complains of pain in the course of the suboccipital or great occipital nerve. The spine of the axis may appear more prominent than natural, and the head on a plane anterior to the normal.

A chronic retro-pharyngeal abscess may attain a very large size, and may even extend, if untreated, into the posterior mediastinum.

Fluctuation may then at times be detected between the external swelling at the angle of the jaw and the swelling in the pharynx.

Whilst small, a chronic retro-pharyngeal abscess may be mistaken for a retro-pharyngeal new growth or softening gumma. From a *retro-pharyngeal sarcoma*, which a chronic abscess in its earlier stages may greatly resemble, since in both there is a soft, prominent, rounded swelling of the posterior pharyngeal wall covered by healthy mucous membrane, a chronic abscess may be generally distinguished by the presence of fluctuation, and by signs of cervical caries, should it depend upon that affection, and by the absence of enlarged glands in the neck. But a soft sarcoma may give to the touch a sensation much resembling fluctuation, and an abscess may depend on causes other than caries, so that puncture with a grooved needle may be necessary to settle the diagnosis. A *retro-pharyngeal innocent growth*, such as an adenoma, fibroma, lipoma, or enchondroma, may usually be distinguished from a chronic abscess by the more limited character of the swelling, the presence of some irregularity in contour, the absence of fluctuation, the firm consistency in the case of a fibroma or enchondroma, and the absence of signs of cervical caries or other cause for an abscess; but in the case of the fatty tumour a puncture may have to be made to settle the point. A *softening gumma* may be distinguished from a retro-pharyngeal abscess by the more circumscribed condition of the swelling, by the fact that it is soft in places and hard in others, by the mucous membrane covering it being of a dull red colour, by the history of the case, the probable presence of other syphilitic lesions, and the effects of iodide of potassium.

§ 178. The posterior wall of the pharynx projects as a smooth, or perhaps slightly irregular, rounded prominence into the naso-pharynx and pharynx. The swelling is soft, though not distinctly fluctuating, and is fixed to the vertebræ behind. The mucous membrane covering it is healthy, possibly adherent; there is no collateral œdema or other sign of inflammation. The swelling has come on rapidly, and is increasing in size. *It is probably a retro-pharyngeal sarcoma.*

A retro-pharyngeal sarcoma is not so very uncommon, and in its earlier stages may simulate very closely a chronic retro-pharyngeal abscess, especially when the growth is of the soft, round-celled variety. It might also be mistaken for a gumma or an innocent new growth. For the differential diagnosis of these retro-pharyngeal swellings, see sections 177 and 179. It may be necessary to punc-

ture the growth, or to make an exploratory incision, before its exact nature can be determined. If it is a sarcoma, blood will probably escape on puncture.

§ 179. The posterior pharyngeal wall is bulged forwards in the form of a distinctly-circumscribed, irregularly-rounded, prominent tumour. The mucous membrane is healthy, and the formation of the tumour has been slow and probably painless. There is no collateral œdema or other inflammatory sign, and the swelling itself is soft, but not fluctuating, or it may be hard and of fibrous or cartilaginous consistency. *It is probably an innocent retro-pharyngeal new growth.*

Perhaps the most common of the retro-pharyngeal growths is the adenoma, but fibromata, enchondromata, osteomata, and lipomata have been met with in this situation. *Fibromata, enchondromata, and osteomata* may be distinguished by their firmness and cartilaginous or bony consistency as the case may be; by their very slow growth, and by their fixidity to the vertebral column. An *adenoma* is moderately firm but elastic, fairly movable, and the mucous membrane covering it is not adherent. A *lipoma* is soft, but not fluctuant, and, like an adenoma, movable on the vertebræ behind. On puncture a fibrous and cartilaginous growth will be found to be of firm consistency; an osteoma, impenetrable to the needle. In none of these growths will pus escape, and thus they may be distinguished from a chronic abscess. In a sarcoma blood will flow through the exploring needle. In the other growths a drop or two of blood may escape, or the puncture may be dry.

§ 180. The swelling of the post-pharyngeal wall is irregularly rounded, probably hard in places, soft in others, and covered by a dull red congested mucous membrane. Similar swellings may be seen in the palate or fauces, and possibly a deeply-excavated foul ulcer on another part of the pharyngeal wall. *It is probably a breaking-down syphilitic gumma.*

An isolated gumma of the post-pharyngeal wall in its early or pre-ulcerative stage may be very difficult to diagnose, unless other evidences of syphilis are present or a history of that disease is obtainable. The effect of iodide of potassium on the swelling will then be the chief diagnostic point. Usually, however, there are concomitant signs of syphilis, and when the ulcerative stage has been reached the gross appearances are so characteristic that a mistake is not likely to be made.

§ 181. *The obstruction is due to a swelling of the soft palate.*

§ 182. The swelling may be due to acute inflammation, to abscess, to diphtheria, to a gumma, or to an innocent or malignant tumour. If the swelling is attended with acute febrile symptoms, it will probably depend on acute inflammation such as that so commonly met with in acute tonsillitis, or it may be due to diphtheria. Acute inflammatory conditions, although they may cause some nasal obstruction, are not further discussed here, since it would be for the affection of the throat, and not for the symptom of impeded nasal respiration, that the surgeon would be consulted. If the swelling is unattended by acute febrile symptoms, the swelling may be a gumma, or an innocent or malignant new growth; begin below at section 183.

In the case of a gumma or new growth, the amount of obstruction to nasal respiration will depend to a great extent upon the situation of the swelling in the soft palate; the more the swelling projects in an upward and backward direction towards the choanæ, the greater the obstruction, whilst if the growth merely involves the anterior or lower part of the soft palate there may be none. It is only, therefore, such growths as are likely to impede the free passage of air through the nose that will be considered, no attempt being made to diagnose the many small growths and cysts which may arise from the lower surface or free margin of the soft palate, but which in no way interfere with normal respiration.

Tumours of the soft palate are more often situated on one side than in the middle line, hence the nasal obstruction caused by them is usually unilateral.

§ 183. A globular, rounded, or ovoid tumour is seen in the soft palate, probably on one or other side of the middle line. It is smooth, or perhaps slightly nodular, elastic, soft or firm, freely movable, non-adherent, and does not encroach on the fauces and tonsil. The mucous membrane covering it is non-adherent and normal in appearance, or perhaps slightly wrinkled or thinned. There is no glandular enlargement at the angle of the jaw; there has been no pain, and the growth has been very slow. *It is probably an innocent tumour—the so-called adenoma. It may possibly be an encapsuled sarcoma.*

These so-called adenomata of the soft palate vary in structure, but have this in common—that they are distinctly encapsuled, are

perfectly innocent, grow very slowly, and easily shell out when an incision is made through the mucous membrane covering them. I have removed several with great ease in this way. They sometimes give rise to marked nasal obstruction, especially when they project posteriorly. In a few cases the obstruction on one side has been complete. As a rule they are readily distinguished from the sarcomata by their slow growth, mobility, non-encroachment on the fauces and tonsil, and absence of glandular enlargement; but at times a sarcoma in the palate is distinctly encapsuled, and resembles most closely an innocent growth, even to the point of shelling out easily when an incision is made through the mucous membrane over it. A microscopical examination is then, perhaps, the only way of drawing a distinction.

§ 184. A globular, rounded, or irregular and perhaps lobulated, tumour is seen in the soft palate. It is probably firmly fixed to the palate, probably extends outwards and backwards towards the tonsil, and its margins are ill-defined. It is soft and semi-fluctuant, or perhaps merely elastic, or even firm. The mucous membrane covering it is adherent, and either natural in appearance or possibly dark and mottled. There is probably an enlarged gland about the angle of the jaw. The growth, though perhaps painless, has most likely been rapid. *It is a sarcoma or spheroidal-celled carcinoma.*

Sarcomata and spheroidal-celled carcinomata of the soft palate, like innocent tumours in that situation, may at times cause nasal obstruction when they encroach upon the naso-pharynx, and especially when they protrude upwards and backwards towards one or other choana. They are less often met with than innocent growths, and, before removal, may at times be quite indistinguishable from such. As a rule, however, they will be recognised by their rapid growth, their fixidity, their ill-defined outline, their extension towards the fauces and tonsil, the adhesion of the mucous membrane to them, the enlargement of the glands at the angle of the jaw, and their occurrence at an age older than that at which innocent growths are commonly met with.

A malignant growth may also be mistaken for a gumma or for an abscess, both of which it may, when soft and semi-fluctuating, closely resemble. A consideration of the signs above given, the effect of anti-syphilitic remedies, the absence of other evidence of syphilis, past or present, and of a history of that disease, the progress of the case, and puncture with an exploring needle, will clear up the doubt.

A squamous-celled carcinoma (epithelioma) may also occur in the palate, but is then perhaps usually an extension of a carcinoma of the tonsils, fauces, or tongue. In this form, ulceration as a rule proceeds commensurately with the growth of the tumour, and it is rare, as far as I know, for it to give rise to much, if any, nasal obstruction. Under any circumstances it would hardly be for the nasal trouble that the patient would seek relief.

§ 185. A smooth, ill-defined, more or less rounded swelling is seen in the soft palate. It may be hard in places, soft and semi-fluctuant in others; the mucous membrane covering it is of a dusky red colour, swollen and œdematous. A similar swelling or swellings may be present in the hard palate, or in the posterior wall of the pharynx, or in other parts of the body, and the nose when viewed anteriorly may be found obstructed on one or both sides by the presence of a swelling on the septum or turbinals or in both situations which has already been made out by anterior examination to be gummatous. There are, most likely, other evidences of past or present syphilitic lesions, and a history of syphilis may be forthcoming. *It is a gumma of the soft palate.*

Gummata in this situation do not, as a rule, cause nasal obstruction, unless they involve the upper and back part of the soft palate and the contiguous portion of the floor of one or both nasal fossæ. As in other situations, if untreated, they at length break down, giving rise to the characteristic tertiary syphilitic ulceration of the palate so familiar to all. In the early stages a gumma might be confounded with a new growth. The more circumscribed character of the latter, the history of the case, the duration of the swelling, the absence of all œdema, and of other syphilitic lesions, and the negative effects of anti-syphilitic remedies, will usually settle the diagnosis.

§ 186. *The obstruction is due to a swollen condition of the tonsils.*

§ 187. A swollen condition of the tonsils may be due to acute inflammatory causes, to chronic hypertrophy, or to a new growth, innocent or malignant. As the nasal obstruction in the acute inflammatory affections is merely a secondary phenomenon, their differential diagnosis is not discussed.

§ 188. The tonsils are more or less enlarged, perhaps almost blocking up the fauces. Their contour is generally rounded, or it may be irregular. The mucous membrane is natural, or perhaps

slightly paler than normal, and the mouths of the follicles appear preternaturally large. *It is chronic hypertrophy.*

Chronic hypertrophy of the tonsils is generally associated, invariably as far as I have observed, with adenoid growths in the vault of the pharynx. An examination of that cavity should therefore always be made when chronic enlargement of the tonsils is present.

§ 189. One or other tonsil is swollen, smooth, prominent, soft and elastic, or moderately firm, to the touch, and the mucous membrane covering it is natural in appearance. There is no infiltration of surrounding parts, the tonsil is not fixed to the underlying structures, and the tissues around are not infiltrated. There is no glandular enlargement and no pain. *It is probably an innocent tumour of the tonsil.*

§ 190. One or other tonsil is swollen, prominent, smooth or irregular, perhaps ulcerated. It is firmly fixed; the surrounding tissues are probably infiltrated. The induration or ulceration may extend to the side of the tongue, fauces, or palate; the glands at the angle of the jaw are probably enlarged and indurated. The growth has been rapid. *It is probably a malignant growth of the tonsil.*

The differential diagnosis of the innocent from the malignant tumours of the tonsil is not discussed, as when the growth is sufficiently large to cause nasal obstruction, this latter will be clearly secondary to the more important throat trouble, which will have been previously dealt with.

§ 191. *A distinct growth, free all round, is seen projecting below the palate.*

§ 192. A growth is seen projecting below the soft palate, and free all round. It may be a gelatinous polypus, or other intranasal growth that has extended into the naso-pharynx, or a fibroma, fibro-angioma, or malignant growth arising from the pharyngeal vault. Investigate its nature as set forth at section 194.

Nothing capable of producing nasal obstruction is seen in the soft palate, fauces, back of pharynx, or tonsils.

§ 193. If nothing abnormal is seen in the soft palate, fauces, back of the pharynx or tonsils, proceed at once to examine the naso-pharynx and posterior nares as described at page 17, *et seq.*; if with the rhinoscope and finger nothing capable of causing nasal obstruction is detected, the obstruction must depend upon something in

the interior of the nose, and will probably have been already discovered on anterior inspection. Or if nothing has been found in the interior of the nose, the obstruction is probably due to intermittent turbinal erection or collapse of the *alæ*; turn to sections 2 and 3. If, however, something abnormal is seen in the naso-pharynx, begin betow at section 194; if in the choana, begin at section 202; if in both situations, investigate the condition as set out in both sections respectively.

Something abnormal is discovered in the naso-pharynx proper.

§ 194. The swelling detected by the rhinoscope or finger may be adenoid vegetations, a gelatinous nasal polypus or other intranasal growth which has protruded through one or other choana, a fibromyxoma of the naso-pharynx, a fibroma or fibro-angioma springing from the roof of the naso-pharynx, a sarcoma or a carcinoma of the naso-pharynx, or possibly a meningocele or encephalocele, or an enchondroma.

If the swelling is found to fill the whole or greater part of the naso-pharynx, the choanæ cannot, of course, be seen, and all that can then be determined by the rhinoscope is the colour and general appearance of the occluding mass. Under these circumstances the finger or probe should be passed behind the palate to determine the consistency, and if possible the attachments, of the swelling.

§ 195. On viewing the naso-pharynx with the mirror, a rounded mammillated mass of tissue is seen occupying the vault of the cavity, and more or less obscuring the upper part of the septum nasi and superior margin of the choanæ. The mass, which is symmetrical, is of a pinkish-red colour, irregularly lobulated, and most prominent in the region of the pharyngeal tonsil, but smaller mammillated masses of tissue may be traced into Rosenmüller's fossæ, and detected about the orifice of the Eustachian tubes. On introducing the finger, a soft irregularly lobulated mass is felt occupying the vault and posterior wall of the naso-pharynx. A muco-purulent discharge is probably seen trickling down the posterior wall of the pharynx, and the tonsils are perhaps enlarged. On anterior inspection some hypertrophic rhinitis, with hypertrophy or erection of the turbinals, is very likely found to be present. The facial expression and tone of voice characteristic of nasal obstruction (see pp. 2, 3) are particularly well marked. The patient is most likely a child, and the parents state that it snores at night, that the mouth is constantly

half open, that it is always taking cold, and is either deaf to a greater or less extent on one or both sides, or has suffered from transient attacks of deafness. *It is adenoid vegetation in the naso-pharynx.*

Adenoid vegetations are exceedingly common, and are the most frequent cause of nasal obstruction in children. They consist of hypertrophy of the adenoid or lymphoid tissue so abundant in the vault of the naso-pharynx. The hypertrophy may be limited to the lymphoid tissue, forming the so-called pharyngeal tonsil, or may affect that in Rosenmüller's fossa or about the orifice of the Eustachian tube as well. A chronic hypertrophy of the faucial tonsil is often present at the same time.

Adenoid vegetations are most common in childhood. If left alone, they generally undergo atrophy and disappear after the age of puberty, or, in consequence of the enlargement of the naso-pharynx which takes place at about that time, they cease to give trouble or are overlooked. In the meantime, however, irreparable deafness may have been produced, the characteristic expression have become confirmed, the voice have been permanently affected, and mental and bodily growth stunted. Sometimes these growths persist into adult life, and have been met with above the age of fifty. They appear to vary in size from time to time, since several cases have been reported in which they have been discovered by one observer, whilst a few weeks afterwards they could not be detected by another, whilst later, again, they have been as undeniably present. I myself have had no experience of their complete disappearance, though there would seem, arguing from the analogous case of chronic enlargement of the tonsils, no reason why their almost complete disappearance should not take place. They undoubtedly vary as the result of change from a dry to a damp climate, or the reverse. The turbinal bodies are often found hypertrophied or erected, the posterior wall of the pharynx granular, and the glands in the neck enlarged.

They frequently occur in various members of the same family. The signs of nasal obstruction are as a rule well marked, but the half-open mouth, the dropped jaw, the elongated face, the contracted and pinched nares, the vacant expression, the dead tone of voice, the snoring at night, and transient attacks of deafness, are especially characteristic of this affection. These symptoms alone are often sufficient to diagnose the presence of adenoid growths; but a rhinoscopic or digital examination should always be made to confirm the

diagnosis. Without such they might be mistaken for a new growth in the pharynx. The latter will be recognised by its firm, circumscribed character, if a thorough digital examination can be made. Adenoid vegetations, however, may be present, together with a fibroma or sarcoma of the naso-pharynx. I once met with such a case myself. The child presented all the well-marked signs of adenoid growths, was very intractable, and a rhinoscopic examination could not be made. On passing the finger behind the palate, my hand was seized before the finger reached the vault. Having, however, felt some adenoids, and the signs of that affection being so well marked, I did not insist on further examination; and on placing the patient under an anæsthetic for the removal of the adenoids, I at once discovered a small naso-pharyngeal sarcoma in the vault of the cavity in addition to a fair crop of adenoids. In this case there was glandular enlargement in the neck, but this did not, I confess, suggest the presence of a malignant growth, since tubercular glandular enlargement is so often met with, particularly in children with adenoids.

There is still another condition which may be mistaken for adenoids if a rhinoscopic or a digital examination is not made, namely, congenital narrowing of the nasal cavities. In this condition the nasal cavities and choanæ, frequently the naso-pharynx and pharynx, are so deficient in size that they do not suffice for nasal respiration, and all the well-known signs attending adenoid vegetations are well marked, especially the 'adenoid face.' On examining posteriorly, however, no adenoids are encountered, and the pharyngeal tonsil is perhaps found to be unusually small. In these cases the head is generally microcephalic, the facial angle diminished, the chin receding, the arch of the palate high, the face narrow, and the mental, and perhaps physical, development arrested.

§ 196. The swelling resembles an ordinary nasal polypus. It is gelatinous and semi-translucent in appearance, of a bluish-gray or pinkish-gray colour, of soft consistency, and globular or pyriform in shape. It is freely movable, and can be traced by the finger to the upper margin of the posterior nares, or into one or other of the choanæ. There is no history of attacks of hæmorrhage, and it does not bleed when examined with the finger. *It is a myxomatous polypus that has arisen from the margin of the choana or has extended into the naso-pharynx from the nose.*

These so-called naso-pharyngeal polypi resemble ordinary nasal

polypi, and spring, like them, from the mucous membrane. In the mirror they present either the well-known appearance of those growths, or they may be of a pale pink or even reddish colour. They have a myxomatous or fibro-myxomatous structure, and may arise either from the margin of the choana, when they may be said to be true naso-pharyngeal polypi (myxomata or fibro-myxomata), or from within the choana from the posterior part of the middle turbinal, or from the superior turbinal body, or other part of the nasal chambers, and are then practically nasal polypi making their way into the naso-pharynx. Growths arising from the margin of the choana (naso-pharyngeal polypi proper) as they increase in size may either extend into the pharynx in the form of globular or pear-shaped masses attached by a more or less broad peduncle to their seat of origin, or they may extend forwards into the nose as well as backwards into the pharynx. When they extend into the naso-pharynx they may attain a large size, more or less blocking up the whole of that cavity. At times such polypi may be brought into view by the patient raising his palate, or they may project below the palate, and even encroach on the back of the tongue or entrance of the larynx.* When they spread forward into the nose, unless the nasal cavities are unnaturally narrow, or slightly twisted, or a view of the back part is obstructed by some condition previously discussed, they can be seen from the front. Indeed, I have met with several cases where, the naso-pharyngeal origin not having been recognised, the surgeon had attempted to remove the polypus from the front, with the result that merely small portions were detached, the chief mass of course remaining and continuing to grow. On seizing the polypus, however, with forceps passed behind the palate, the whole growth, with the nasal prolongations, came easily away, freeing the nose at one sitting.

The amount of fibrous tissue polypi contain varies according to the origin of the tumour. Those arising well within the choana, from the succulent Schneiderian mucous membrane, have the least, and the most closely approach in their characters the ordinary nasal polypus; whilst those that spring further back from the mucous membrane covering the posterior part of the body of the sphenoid bone and the adjacent basilar process of the occipital, where the mucous membrane becomes of a firmer consistency and blended

* Specimens illustrating these points are contained in the museum of St. Bartholomew's Hospital.

with the fibrous periosteum, contain more fibrous elements, and tend to pass by insensible degrees into true fibrous tumours. These growths increase somewhat rapidly in size as long as there is ample room for their development, but they do not, as a rule, give rise to any facial deformity, cause absorption of bone, or form secondary attachments, though when the nose is much encroached upon there may be some widening of the bridge, as is the case in ordinary nasal polypi when they have been neglected and allowed to grow very large.

Naso-pharyngeal polypi may attain considerable size without giving rise to symptoms. At times, however, there may be a feeling of drowsiness or headache, a sense of stuffiness in one or other nostril, increased, as in the ordinary nasal polypus, in damp or wet weather, or some amount of post-nasal catarrh; or muco-purulent or mucous discharge may escape from the nostrils anteriorly. As the obstruction advances, the characteristic post-nasal tone of voice becomes well marked (page 2), and is an important sign when the polypus is seen from the front in showing that there is also posterior obstruction, and consequently that the polypus seen in the nose has possibly its origin in the naso-pharynx. Pedunculated polypi may only cause obstruction during expiration. During inspiration they may flap back into the naso-pharynx in a valvular manner, allowing the air to pass freely. In consequence, too, of the polypus either pressing upon, or obstructing, or otherwise leading to catarrh of the Eustachian tube, some deafness may be present, but I have not myself found this a common accompaniment of the mucous polypus. When the tumour rests upon the velum palati, certain reflex neuroses may manifest themselves, such, for instance, as spasmodic asthma and bronchial cough. Epistaxis is rarely occasioned by these growths, probably by reason of their scanty blood-supply.

The diagnosis of the true naso-pharyngeal polypus is, as a rule, easy. The rounded appearance of the growth in the naso-pharynx, its more or less soft consistency, its undeniable mobility, the fact that it arises from the margin of the choana or from within the nose, the absence of a history of recurrent epistaxis, and the non-existence of facial deformity, all serve to distinguish it from the far more serious, and fortunately less common, fibroma or fibro-angioma.

It has been said that unilateral obstruction points to the growth being a myxoma or fibro-myxoma; bilateral obstruction, to its being a fibroma or fibro-angioma, in that a myxomatous polypus usually

arises within one or other of the choanae, whereas a fibrous growth arises from the vault of the naso-pharynx. This is no doubt a point in the diagnosis, but it is one that cannot entirely be depended upon, since a fibrous growth (frequently as far as my observation has gone) may spring from one or other side of the vault of the naso-pharynx, and thus cause unilateral obstruction, whilst a myxoma, when it has attained a large size, although at first it only obstructed one choana, may then obstruct both.

The diagnosis may also have to be made from an ordinary nasal mucous polypus which has escaped into the naso-pharynx through the choana. In the latter case no attachment to the margin of the choana will be made out, and there will in all probability be evidence of the presence of mucous polypi in one or both nasal cavities. When, however, as sometimes happens, the true naso-pharyngeal polypus has encroached on the nasal cavities, it becomes practically the same thing as a nasal polypus encroaching upon the naso-pharynx. A distinction can then hardly be drawn before the removal of the growth.

§ 197. On inspecting the vault of the naso-pharynx, an irregularly rounded growth is seen apparently springing from the roof of the cavity. It has a pale pink, dark red, or purplish colour, and feels firm and resistant or elastic to the touch. It may be slightly movable in the lateral direction, but it is for the most part firmly fixed to the vault of the naso-pharynx. The mucous membrane covering the tumour is exceedingly vascular, and bleeds freely on examination with the finger. There is a history of repeated attacks of epistaxis, and probably of pain and discharge. The patient says that the nasal obstruction has existed for some time, and is slowly getting worse. *It is a naso-pharyngeal fibroma (fibro-angioma) or a fibro-sarcoma.*

These tumours, which are commonly spoken of as naso-pharyngeal fibromata or polypi, occur as firm, dense, pedunculated, or sessile growths, usually springing from the fibrous tissue of the mucoperiosteum covering the basilar process of the occipital bone or body of the sphenoid. Some of these growths have been reported to be pure fibromata, but in the majority of cases they contain, amongst the fibrous tissue, spindle cells and round cells, and are then practically fibro-sarcomata. The recurrence or non-recurrence after removal probably depends upon the presence or absence of these sarcomatous elements. Before removal, and, indeed, after removal,

except by a microscopic examination, it is impossible to say whether they are pure fibromata or fibro-sarcomata. Whether composed of fibrous tissue, or of an intermixture of fibrous tissue and sarcomatous elements, they nearly always contain numerous large thin-walled bloodvessels, which in parts are so numerous that they form a cavernous structure, and give the growth on section a spongy appearance at these spots: hence the name fibro-angiomata, which is sometimes applied to them. It is from these vessels that the alarming hæmorrhage occurs should the growth be cut into during removal. The mucous membrane covering these tumours is also highly vascular, and its vessels are liable on very slight provocation to give way, thus explaining the severe hæmorrhages which so frequently occur, and which constitute the most prominent symptom. It is this vascular mucous membrane which, according to its degree of vascularity, gives them during life a pink, dark red, or purplish colour. The growths are smooth and regular in outline, at times lobed, and dense and fibrous in consistency. At first they are usually confined to one or other side of the naso-pharynx, and, if observed in the early state by means of the rhinoscope, are generally found to be situated just behind and above the corresponding choana. At times they are distinctly pedunculated, although perhaps more often their base of attachment is broad in comparison to the rest of the growth, and they may then be practically regarded as sessile. In several specimens of pedunculated growth in St. Bartholomew's Hospital Museum the peduncle is short, and measures as much as an inch or more in diameter. Though commonly connected with the periosteum covering the basilar process of the occipital bone or body of the sphenoid, in rarer instances they have been observed springing from the lateral wall of the pharynx, the posterior wall of the pharynx, and the internal pterygoid process of the sphenoid. As they increase in size, they soon lose the polypoid shape they may have had during the earlier period of their growth, and become irregularly lobed, and more or less moulded to the shape of the cavities into which they extend, where, moreover, they may form secondary attachments. If allowed to run their course, they may spread forwards into the nose, at first, as a rule, entering the posterior nares on the side corresponding to that on which they originate, and subsequently the opposite nasal chamber. From the nose they may invade the orbit, causing protrusion of the eyeball, or they may fill the antrum, and produce a bulging of the cheek. The widening of the nose,

and protrusion and separation of the upper maxillæ to which they often give rise, produces a characteristic deformity known as frog-face. Sooner or later they become visible on inspecting the anterior nares, or they may even protrude externally through the nostril. At other times they grow principally in a downward direction, blocking up the naso-pharynx and causing the palate to bulge forwards into the mouth, or they may project below the velum, and have been known to almost fill the cavity of the mouth. In one patient under my care the isthmus faucium was blocked up by the growth, and swallowing was almost impossible. Again, they may in other instances pass into the spheno-maxillary fossa through the spheno-palatine foramen, and thence make their way upwards through the spheno-maxillary fissure into the orbit, or outwards through the pterygo-maxillary fissure into the temporal fossa or into the zygomatic fossa. Not infrequently they cause absorption of the bones forming the base of the skull, distend the sphenoidal sinuses, and make their way into the interior of the cranium.

The rate of growth in the pure fibromata is very slow. They have been known to exist for upwards of fourteen years. Where the growth has been said to be rapid, it is probable either that they have existed for a longer time and have not been observed, since while small they give rise to very few symptoms, or that they contain sarcomatous elements. They are common in the young, though they may occur at any age; they are also more common in males than in females. They are said to atrophy as age advances; occasionally they have been known to slough away or to undergo cartilaginous and calcareous degeneration. After removal, recurrence is said to be frequent, but it is probable that where recurrence has been noted the tumour either contained sarcomatous elements or was not completely removed.

Some years ago I collected all the published cases to which I had access, for the purpose of ascertaining if possible whether the pure fibromata did or did not recur after removal. The investigation, however, was disappointing. In the greater number an accurate microscopical account was not made, and in most of those that were reported to be pure fibromata, sufficient time had not elapsed at the time of publication for obtaining the desired data. In none of the cases, however, described as pure fibromata was a recurrence reported, even, in some, after a lapse of several years; whilst

amongst the cases given as fibro-sarcomata recurrence within a few months or years was common, if not the rule.

The symptoms of these growths are at first very insidious; a feeling of slight stuffiness in one nostril, or perhaps a slight discharge, may be the only trouble, the patient regarding it merely as a chronic cold. In some cases the first symptom has been an attack of epistaxis. Pain has in some instances been present, especially when the growth has had a fibro-sarcomatous structure. It has been of a dull, aching character at the back of the nose, or of a neuralgic character in various branches of the fifth nerve. It is sometimes continuous, and gives the patient no respite by day, and deprives him of sleep at night. In some cases it has been intermittent; in other cases there has been absolutely none. The nasal obstruction, as the growth increases in size, becomes very marked, the patient being quite unable to breathe through the nose. The obstruction, unlike that due to a mucous polypus in the naso-pharynx, does not vary with the weather, and there is not, when the obstruction is only partial, the same variation in the power to inspire and to expire, that is often noticed in the former growths. The fibromata and fibro-sarcomata being usually attached by a broad base, or at any rate a stout peduncle, the valve-like flapping back which may occur in the fibro-myxomata, and so allow of freer inspiration than of expiration, is hardly possible in the firmer growths. There is usually a glairy or muco-purulent discharge, generally from one nostril, or at times from both. The hæmorrhage is often severe, as much as six or eight ounces of blood being lost at a time. In a patient at St. Bartholomew's, a pint of freshly-swallowed blood was vomited from the stomach, in addition to that which was lost directly through the nose and mouth. The bleeding is seldom continuous, but breaks out spontaneously at intervals, which commonly grow less as the tumour increases. It is induced on very slight provocation, and is generally sharp after examination of the growth with the finger behind the palate. The blood usually escapes from the nostril on the side occupied by the growth, coming also at the same time from the mouth. When, however, the affected nostril is completely blocked, it may escape from the other nostril or through the mouth, or, being swallowed and afterwards vomited in large quantities, and in an altered condition from the action of the gastric juice, may simulate bleeding from the stomach. In these cases it will nearly always be found, however, that there have been previous attacks of bleeding

from the nose, and on inspecting the fauces fresh blood will usually be observed flowing down the back of the throat. Further, the rhinoscope will show the naso-pharynx to be occupied by clots. In a patient in St. Bartholomew's hospital, the bleeding occurred chiefly during eating, and was probably caused by venous engorgement due to the obstruction of the veins by the muscles of mastication.

§ 198. The vault of the naso-pharynx is found occupied by an irregularly rounded, moderately firm, or it may be soft, or even pultaceous, mass of a pale pink, cream, or purplish-red colour. The growth is most likely firmly adherent to the subjacent parts, and is sessile, broad-based, or possibly broadly pedunculated. The mucous membrane covering it is adherent, or may have given way, leaving an irregular, raw, ulcerated surface. A watery, acrid, or it may be offensive muco-purulent discharge escapes into the naso-pharynx, or possibly through one or both nostrils, and on examination with the finger or with the probe, bleeding takes place. Nasal obstruction on one or both sides is probably well marked. The soft palate may be pushed forwards by the growth. On examining from the front, the growth may perhaps be seen in one or both nostrils; there may also be some facial deformity. The submaxillary glands, and even the cervical chain, are probably enlarged. The patient has a cachectic look, and says he is losing flesh rapidly, and that he has suffered from profuse attacks of bleeding from time to time and from a discharge which may have been blood-stained between the intervals of the bleeding. *It is a naso-pharyngeal sarcoma.*

Naso-pharyngeal sarcomata usually spring from the basilar process of the occipital bone, and from the body of the sphenoid. As they increase in size they extend downwards along the walls of the naso-pharynx, and forwards through the choanæ into one or both nasal chambers, whence they may ultimately protrude at the anterior nares, invade the antrum, sphenomaxillary fossa, and the orbit. In their downward growth into the pharynx they protrude the soft palate into the mouth, and may appear as a large mass, almost completely blocking up the fauces, thus rendering deglutition difficult, and embarrassing respiration. At times they extend upwards, eating away the basilar process, or they may invade the sphenoidal cells, and in either case enter the cranial cavity. Sooner or later the submaxillary and the cervical glands become enlarged, and

the sarcoma disseminated through the internal organs of the body. All varieties of sarcoma have been met with in the naso-pharynx, the round-celled variety here, as in other situations, running a rapid course, especially when it occurs in young subjects. The spindle-celled variety, especially when mixed with much fibrous tissue, remains localized to the naso-pharynx for longer periods, and has already been described with the fibromata, from which it is practically indistinguishable.

Perhaps the earliest signs are hæmorrhage from the nose, increasing obstruction, usually on one side, and the presence of an acrid, slightly offensive discharge, whilst nothing can be seen on anterior rhinoscopy. In its earlier stages, therefore, a sarcoma resembles a naso-pharyngeal fibroma or fibro-angioma, and it may be practically impossible at this period to diagnose one from the other. The rapid growth of the round-celled sarcoma, and the slow though steady progress of the fibro-sarcoma and its hard and firm consistency, will soon enable a distinction to be drawn, whilst later the implication of the glands, the character of the discharge, which is rarely offensive in fibromata, and the emaciation of the patient, will render the diagnosis still more certain.

When a sarcoma has attained a large size, can be seen from the front, and has invaded the antrum or the orbit, it may be impossible to determine its primary origin, *i.e.*, whether it started in the naso-pharynx and secondarily involved the nose and the accessory cavities, or whether it began in the nose and secondarily involved the naso-pharynx. As a rule, however, if a large mass is found in the naso-pharynx blocking up that cavity, and extending downwards into the pharynx and forwards into the mouth, the probabilities are strongly in favour of its extra-nasal origin. Early involvement of the glands will also point to its naso-pharyngeal origin, since glandular enlargement is not common in intranasal growths.

§ 199. The growth in the naso-pharynx is circumscribed, rounded, and hard to the touch. The mucous membrane covering the tumour is adherent, and that in its neighbourhood is indurated and thickened; moreover, the growth itself is fixed to underlying structures. The submaxillary lymphatic glands are enlarged, and indurated on one or both sides. There is a history of recurrent epistaxis, and an unpleasant discharge, which is sometimes tinged with blood. The patient is past middle age, and says that he has been losing flesh rapidly. *It is a naso-pharyngeal carcinoma.*

The carcinomata met with in the naso-pharynx are usually of the spheroidal-celled type; they increase rapidly in size, and run a very malignant course, infiltrating surrounding structures, and infecting lymphatic glands early. The symptoms attending the disease differ in no material respect from those of a sarcoma, and therefore it is difficult to say whether a given tumour belongs to the sarcomata or carcinomata, until a portion has been examined microscopically. These carcinomata may arise from any part of the naso-pharynx, their starting-point being probably the mucous glands that are so abundant in this region. As a rule, they are found attached to the basilar process of the occipital bone.

§ 200. The naso-pharynx is found to be occupied by a rounded swelling, which is smooth on the surface, and has a bluish-gray tint. When examined with the finger, it feels soft and elastic; when pressed upon from below upwards it diminishes in size, and if the pressure is continued, cerebral symptoms of compression may supervene. The swelling is found to become larger and more tense when the patient makes a strong expiratory effort. A probe can be passed readily between it and the walls of the naso-pharynx. The seat of attachment is at the roof of the cavity. When punctured with a grooved needle, a clear, limpid fluid escapes freely, and in some quantity. This fluid, when collected, is found to be of low specific gravity (1006), slightly alkaline in reaction, and to contain a trace of albumin and a slight trace of a material which reduces copper oxide. *It is a naso-pharyngeal meningocele.*

Meningoceles have in rare instances been met with in the naso-pharynx, and are always of congenital origin, though attention may not be drawn to them for years. As in other regions of the skull, they may be associated with hydrocephalus. When observed in the naso-pharynx, they are liable to be mistaken for an ordinary mucous polypus which has protruded from the nose into the naso-pharynx or has originated in that cavity, and which, moreover, they very closely resemble. A nasal mucous polypus, even when extending into the naso-pharynx, can always be made out to arise from the nasal cavity, and there are almost always present smaller growths of like nature in the cavities themselves. A mucous polypus of the naso-pharynx will be felt to arise from one side of the middle line from the margin or region of the choana, while a meningocele would be centrally placed. The soft fluctuant feel of the meningocele, and absence of hæmorrhage, will be sufficient to

distinguish it from a fibroma or other firm growth. If in doubt, the diagnosis should be cleared up by resorting to puncture with a grooved needle, when the nature of the escaped fluid would be indicative of its origin. Great care should be observed, however, in doing this, lest in the case of a meningocele the use of a septic needle might be followed by fatal meningitis. Of course, if on examining the swelling with the finger cerebral symptoms supervened, any doubt as to the nature of the case would be at an end, and a puncture would not then be made.

§ 201. The growth in the naso-pharynx is irregularly rounded, and nodular in contour. It feels hard and resistant to the touch, and is quite immobile. A probe can be passed between the growth and the posterior and lateral walls of the pharynx, but anteriorly prolongations of the growth may pass into the choanæ. The seat of attachment is apparently the roof of the naso-pharynx. The mucous membrane covering the tumour is healthy in appearance and of a pinkish or pale yellowish hue; when touched with a probe no bleeding occurs. Though the growth feels very hard, its substance can be penetrated by an exploring needle if it can be reached. There is a history of gradually increasing bilateral stenosis, but none of recurrent epistaxis. The growth can probably be seen on anterior inspection (see sections 52 and 133). There may be facial deformity, such as flattening of the bridge of the nose, and exophthalmos. *It may be a naso-pharyngeal chondroma.*

Chondromata of the naso-pharynx are of exceedingly rare occurrence, there being but few well-authenticated cases on record. They may arise from the basilar process of the occipital bone, the posterior wall of the pharynx, the floor of the nose, and the septum. Their growth is slow, and they show no tendency to recur after removal. When of small size they give rise to no appreciable symptoms, but as they extend they occlude the posterior nares, invade the nose, and so cause obstruction to nasal respiration. When the nasal cavities are encroached upon, facial deformity will manifest itself. The clinical course of a chondroma in this situation closely resembles a fibro-angioma, but can be distinguished therefrom by the slower rate of growth, the denser and harder feel, by the absence of recurrent attacks of epistaxis, and by the fact that no bleeding takes place when the growth is examined with the finger or touched with the probe.

Something abnormal is discovered at or within the choanæ.

§ 202. If, on rhinoscopical and digital examination, aided by a probe passed from the front, the choana on one or both sides, is found absent or greatly diminished in size, begin below at section 203; otherwise pass on to section 204.

The normal aperture of the posterior nares is absent or greatly narrowed on one or both sides.

§ 203. In place of the normal aperture of the choana on one or both sides, the mucous membrane of the vault is found to be continuous with that of the palate, leaving either a smooth surface or a blind depression. With the finger, the bridge across the spot where the normal choana should be is felt to be of bony or membranous consistency; and a probe passed along the nose cannot be made to enter the naso-pharynx and strike the finger. On anterior rhinoscopy the nasal cavities appear normal, or the septum may be slightly bulged to one side, or the inferior turbinal body may be enlarged. The patient has been unable to breathe through one or both sides of the nose since birth, and has been troubled by an abnormal mucous secretion, is perhaps deaf, and may partially or completely have lost the sense of smell. *It is congenital occlusion of the posterior nares.*

A number of cases of this rare condition have of late been reported. The occlusion may be due to a mere narrowing of one choana, the lateral margins being in contact. Or it may depend upon a bony or membranous partition stretching across from the septum to the lateral wall, thus shutting off the nose from the naso-pharynx on one or on both sides. The partition has at times consisted partly of membrane, partly of bone. In very rare instances the occlusion has been only partial, a bony bridge stretching across the aperture, about its middle, and leaving a free passage above and below—a condition which, if not clearly seen, may be diagnosed by passing two probes, one above and one below the bony bridge. This condition may be simulated by an incurving of the inferior turbinal so that it comes into contact with the septum.

Occlusion of the posterior nares is generally a congenital condition, but it has been attributed to inherited syphilis, and to adhesions following acquired syphilis. Great narrowing or complete occlusion may also occur in rhinoscleroma and in gummatous infiltration, when the gumma extends to the muco-periosteum cover-

ing the posterior end of the septum or the posterior end of one of the turbinals.

The apertures of the posterior nares are normal, but a swelling is seen just within, or bulging more or less through one or both of them.

§ 204. The swelling may be a myxomatous polypus protruding from the nose, an enlargement of the posterior end of the inferior or middle turbinal body, a growth from the posterior end of the inferior or middle turbinal body, œdema of the posterior margin of the septum, or an intranasal growth other than a gelatinous polypus invading the naso-pharynx. If the portion of the growth that can be seen is evidently distinct from both the septum and turbinal bodies, begin at section 205. If it is clearly connected either with one of the turbinal bodies or with the septum, pass on to section 208. It may not always be easy to determine whether the protruding growth is connected with the septum or with one of the turbinals, or is distinct from each. Some evidence may be afforded by spraying the parts with cocaine, when the swelling, if due to an enlargement of the turbinal, will shrink. The passage of a probe will also help to make the connections of the swelling clear. If this is insufficient, more may be learnt by examining with the finger, if necessary under an anæsthetic.

The swelling is evidently distinct from the septum and the turbinals.

§ 205. The swelling is of a bluish-gray or pinkish-gray colour, gelatinous-looking, globular, and appears just within, or bulging more or less through, the choanæ on one or other side. There have been no attacks of epistaxis; polypi may possibly be seen in the interior of the nose on anterior inspection. *It is a myxomatous polypus.*

§ 206. The swelling has a dark red or purplish colour, an irregularly-lobulated shape, an uneven, coarsely-granular, or ulcerated surface, and a soft and friable consistency, and probably bleeds when examined by the finger. It can most likely be seen in the nasal cavity on anterior inspection, or there may possibly be considerable external deformity of the nose or cheek. The obstruction is said to have come on rather rapidly, and to have been preceded by a sanious, and perhaps foetid, muco-purulent discharge, and attacks of hæmorrhage from time to time. *It is probably a malignant growth arising in the nose or in the antrum, and invading the naso-pharynx.*

The method of determining the origin and nature of such a growth is described at sections 116 and 136.

§ 207. The swelling has a yellowish, grayish, pinkish-red or perhaps purplish colour, a more or less regular outline, a smooth surface, and a firm, cartilaginous, or osseous consistency. *It is probably a fibroma, a fibro-sarcoma, an enchondroma or an osteoma invading the naso-pharynx from the nose or antrum.*

The method of determining the origin and nature of such growths is discussed at sections 116 and 136. All are rare.

The swelling is evidently connected with the inferior or middle turbinal body, or with the septum.

§ 208. The swelling is evidently connected with the inferior turbinal. It is pinkish-gray in colour, smooth on the surface, dimples on touching with the probe, and disappears under the influence of cocaine. The patient complains that the obstruction is intermittent, and, when present, is perhaps attended with excessive muco-purulent secretion. *It is erection of the posterior end of the inferior turbinal.*

Erection of the posterior end of the inferior turbinal is generally associated with some erection of the rest of the body, a condition that will be seen on inspecting the nose from the front (see section 70).

§ 209. The posterior end of the middle or inferior turbinal projects as a smooth, grayish-white, soft and resilient swelling, but does not disappear completely on spraying with cocaine. A hypertrophied state of the mucous membrane, especially of that over the inferior turbinal, is seen on anterior inspection. *It is hypertrophy of the posterior end of the middle or inferior turbinal body.*

§ 210. The swelling is of a reddish or purplish-red colour, mammillated on the surface, and globular in shape, looking somewhat like a ripe raspberry. It does not get less when sprayed with cocaine. *It is papillomatous hypertrophy of the posterior end of the inferior turbinal.*

§ 211. The posterior end of the inferior turbinal, on one or both sides, projects at the choanæ as a sharply-circumscribed purplish-red mass having a soft, resilient consistency. It does not completely disappear under the influence of cocaine. A similar condition of the inferior turbinal is seen on anterior inspection. *It is turbinal varix.*

For a further account of this condition see section 71.

§ 212. One or more small glistening, semi-transparent, gelatinous-looking bodies are seen attached to the posterior end of the inferior or middle turbinal body. Myxomatous polypi have probably been removed from the nose, or may be seen on anterior inspection. *The condition is due to small mucous polypi arising from the posterior end of the middle or inferior turbinal body.*

§ 213. A distinctly-circumscribed growth of a pinkish-red or purplish colour is seen attached to the inferior or middle turbinal body. It is either sessile or pedunculated, smooth on the surface, and hard and resistant to the touch. *It is probably a fibroma.*

§ 214. The posterior margin of the septum is obscured by a swelling of the mucous membrane on one or both sides. It is pale pink or red, oval in shape, and soft and resilient on palpation. *It is œdema of the posterior end of the septum.*

CHAPTER X.

GENERAL DIAGNOSIS—Continued.

THE OBSTRUCTION DOES NOT DEPEND UPON ANY LOCALIZED OR GENERAL SWELLING.

§ 215. On anterior rhinoscopy, something abnormal is discovered, but this abnormality is evidently not of the nature of a localized swelling or tumour, or mere deviation of the septum, nor is there any general swelling of the mucous membrane. The obstruction may depend upon an adhesion between the inferior turbinal body and the septum, or upon a congenital narrowing of the nasal chambers.

§ 216. On looking into the nostril, the inferior turbinal body is seen at one spot to be in contact with the septum, which may itself be more or less deflected to that side. On spraying with cocaine or eucaine, the turbinal at the affected spot still remains in contact with the septum, and on passing a probe is found to be firmly adherent to it. *It is an adhesion of the inferior turbinal to the septum.*

Adhesions between the inferior turbinal body and the septum are not uncommon. They may be the result of operations on the septum, cauterization of the turbinal, or they may follow syphilitic or other lesions of the nose in which there has been an abrasion of the contiguous surfaces, or at any rate of the surface of the septum or turbinal. At times there may be more than one such adhesion in the same nasal chamber. In like manner, the middle turbinal may be adherent to the septum; or the middle and inferior turbinal may adhere to each other; or the inferior turbinal may be adherent to the floor of the nasal cavity.

§ 217. On looking into the nostril, the inferior turbinal, at its lower part, is continuous with the septum, forming a kind of ridge across the floor of the nose, which considerably diminishes the

breathing-space. *It is the result of adhesion and contraction of the mucous membrane between the septum and turbinal.*

I have several times met with this condition as the result of ulceration, and after operations on the septum or turbinal bodies. It is due to the raw surfaces becoming adherent, and to the surfaces being drawn further and further together as cicatrization occurs. It differs from the bridge-like adhesions above described, in that there is no space below the adhesion.

§ 218. Both nasal chambers appear preternaturally narrow, but otherwise normal. The patient presents well-marked signs of nasal obstruction, especially the so-called 'adenoid face'; the nose is prominent, laterally flattened, and the alæ nasi compressed. The head is small, the facial angle diminished, the chin recedes. On inspecting the mouth, the hard palate is seen to be highly arched, the fauces narrow, and the space between the soft palate and back of the pharynx exceedingly restricted, the posterior pillars of the fauces having a high attachment to the pharynx. The naso-pharynx is small, the choanæ narrow, and the pharyngeal tonsil is probably of less size than normal. The patient is perhaps deficient in mental power, and his physical development is stunted. *The obstruction is due to congenital narrowing of the nasal tract.*

This condition very closely resembles that met with in adenoid growths, with which, if a rhinoscopic and digital examination is not made, it may readily be confounded.

CHAPTER XI.

GENERAL DIAGNOSIS—Continued.

THE OBSTRUCTION IS DUE TO PARTIAL OR COMPLETE OCCLUSION OF THE ANTERIOR NARES.

§ 219. Occlusion of the anterior nares may be due to a congenital malformation, or to cicatrization following an injury, a burn, syphilis, tubercle, or lupus.

§ 220. The external nose is well formed and natural-looking, but the patient is unable to breathe when the mouth is closed. On examination, the nostrils are found to be closed, and a probe cannot be introduced into them. The obstruction is due either to the ala of the nostril being fixed to the columna nasi, or to a definite membrane, or even bony plate, stretching between the septum and side-wall of the nose, and thus leaving a blind cul-de-sac. The membrane, if it exists, is probably semi-transparent, and a few small bloodvessels may be seen on its surface. During forced expiration it is bulged forwards, and it recedes during inspiration. If due to bone, the obstruction will be felt to be of osseous hardness. *It is congenital atresia of the anterior nares.*

The occlusion of the anterior nares, when met with, is generally total, but in some cases it is partial. The occluding membrane may be situated at the margin of the nostril, or at a point higher up, the passage into the nostril being found in such cases to terminate abruptly, at a varying depth, in a blind cul-de-sac. The occlusion may exist on one side only. When both sides are occluded, the condition is one of gravity, because the infant is quite unable to perform the act of sucking. In a very few cases the occluding septum has consisted of bone.

§ 221. The aperture to the nostril, on one or both sides, is more or less narrowed, reducing the lumen to a mere slit or irregularly rounded opening. There is probably extensive scarring of the upper

lip, or perhaps of one side of the lower half of the face. *The occlusion is probably the result of cicatrization following a burn, or of some injury of the external nose and contiguous portion of the face.*

The history of the case will here be all that is necessary to determine the cause of the cicatricial contraction.

§ 222. The nostrils, on one or both sides, are more or less closed by an irregular, raised, smooth, flattened, hard, reddish mass, which probably extends to the neighbouring portion of the upper lip or side of the face. There is a history of a burn, or perhaps some other injury of the affected part. *It is keloid.*

The appearance of keloid is so distinctive that occlusion from this condition could hardly be mistaken for any other.

§ 223. There is well-marked deformity of the external nose. The bridge is probably sunken and flattened. The tip of the organ is tilted backwards and upwards, so that the nostrils look forwards. The apertures of the nostrils are altered in shape, being rounded instead of oval, and their lumen is considerably diminished in size. The margins of the nostrils are cicatricial. When a probe is passed, the septum is probably found to be perforated. There may or may not be perforation of the hard palate. There is a history of the patient having had syphilis, and signs of that disease in other parts may be discernible. *It is occlusion of the anterior nares due to syphilis.*

§ 224. There is well-marked deformity of the external nose. The tip is drawn downwards and towards the upper lip. The nostrils are narrowed from side to side, and rendered slit-like in lumen, or they may be circular in shape and their lumen so diminished as barely to admit a probe. The bridge of the nose is natural, and there is no depression or falling in. The margins of the nostrils are extensively scarred, and feel firm and resistant. The columna nasi is shortened, and likewise cicatricial-looking. The adjacent skin of the face is probably the seat of extensive scarring. There may or may not be active ulceration having the characters of that of lupus in the neighbourhood of the scar. The interior of the nose cannot be inspected on account of the narrowing of the nostrils, and when the mouth is closed there is marked hindrance to nasal respiration. *It is occlusion of the anterior nares, due to old lupous ulceration.*

The history of the case, viz., that the occlusion was preceded by ulceration, that the ulceration began in youth, that the ulcerated

surface had been scraped or touched with the cautery before it healed, and lastly, that the ulceration had been pronounced to be lupoid in character, will probably settle the diagnosis.

§ 225. The anterior nares on one or both sides is considerably narrowed, and the ala, columella and contiguous portion of the upper lip are hard, rigid and infiltrated, rendering the parts unyielding and of stony hardness. *It is probably rhinoscleroma.*

For a further account of rhinoscleroma, see section 157.

CHAPTER XII.

TREATMENT OF NASAL OBSTRUCTION.

TREATMENT OF TURBINAL ERECTION—TURBINAL VARIX— ERECTION OF THE TUBERCLE OF THE SEPTUM—ŒDEMA OF THE POSTERIOR END OF THE SEPTUM.

ERECTION or turgescence of the vascular tissue in the inferior turbinal body, and in the mucous membrane over the tubercle of the septum and elsewhere, is a physiological act, and only calls for treatment when excessive and productive of obstruction to free nasal respiration or other of the troubles mentioned under the head of Diagnosis.

In the first place, the cause of the erection, such as adenoid vegetations in the naso-pharynx or spurs or deflection of the septum, should be sought and, if present, removed, and such circumstances as appear to bring on an attack as much as possible avoided. The general health, when below par, should receive attention, and any constitutional dyscrasia that may be present be appropriately treated. The patient should be careful not to catch cold, be warmly clad with woollen underwear, should take a cold bath daily and plenty of outdoor exercise, and avoid a stuffy and close atmosphere or the sudden change from a heated room to cold night air. Residence in a dry, bracing climate is usually beneficial.

Locally, in slight cases of short duration, simple sprays are sometimes of service when, beyond a neglected cold, there appears to be no special cause present for the trouble. The use of a spray with a watery base, although somewhat out of fashion, is nevertheless in slight cases often very beneficial. I have found the well-known alkaline lotion, consisting of bicarbonate, biborate and chloride of sodium, with glycerine and water, one of the best, and have frequently cured the excessive erection by its use. When there is much watery discharge, an astringent, such as sulphate or sulphocarbonate of zinc, may be added.

Of sprays with an oily base, which often prove less irritating than the watery, and which should be substituted if the latter is not speedily effectual, paroleine or fluid vaseline are perhaps the best. Menthol or eucalyptol, which are soluble in the paroleine, may be often advantageously added. The oily sprays are used with the numerous ointment atomizers, one of the best of which is the cheap and simple 'perfection atomizer' of Ellis and Goltermann (Fig. 5).

If, however, the condition of turbinal erection has existed for any length of time, there is nothing in my experience so efficient as

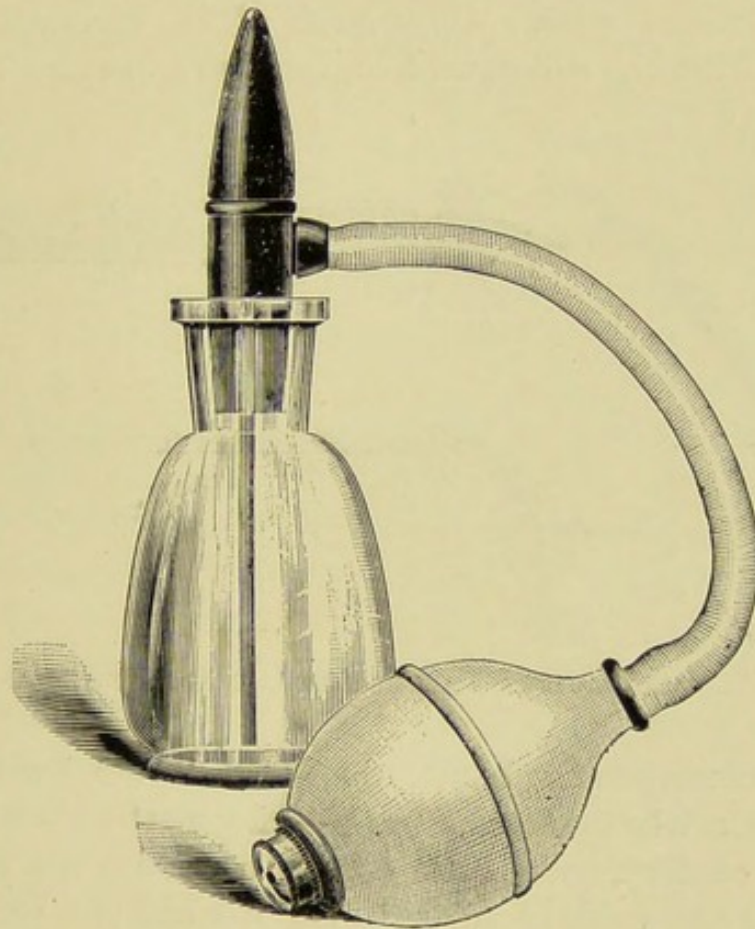


FIG. 5.—ELLIS AND GOLTERMANN'S SPRAY APPARATUS.

touching the turbinal in a few places with the galvano-cautery. When this is done under cocaine or eucaine, it causes no pain either at the time or subsequently, and no after-treatment of any kind is, as a rule, necessary. I usually introduce a small pellet of cotton-wool, soaked in a 10 per cent. solution of cocaine to which a 1 per cent. solution of resorcin has been added, and, as soon as the turbinal has been rendered insensitive to touch, stab the tissue with the galvano-cautery point in four or five situations, or else draw the

cautery knife (Fig. 6) horizontally along the turbinal two or three times, so as to produce linear scarifications. The aim of the cautery is to cause contraction of the tissues, and to tie them down to the bone beneath. I do not believe in severely cauterizing for this condition, much less in producing such sloughing as may lead to necrosis of the subjacent bone.

Erection, as already stated, is, no doubt, a physiological act, and serves the purpose of warming the air before it reaches the pharynx and lungs. By merely stabbing the body with the cautery point, or lightly scarifying it as described above, its erectile function is not seriously interfered with. Only some of the cavernous spaces are destroyed, whilst the subsequent contraction and tying down of the

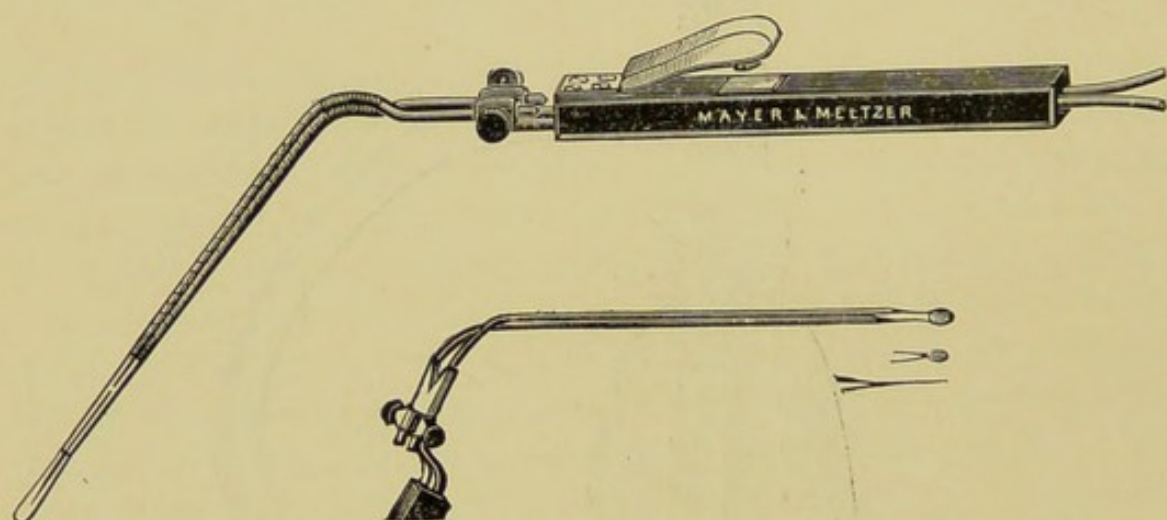


FIG. 6.—GALVANO-CAUTERY HANDLE AND CAUTERY KNIVES AND POINT.

mucous membrane to the bone reduces the turbinal within bounds, and prevents it, when erected, from blocking up the passage. In employing the cautery, some little care is necessary not to touch the septum with the cautery point, lest a troublesome adhesion form between it and the turbinal. Specula with an ivory plate, which can be placed against the septum so as to protect it from the cautery, have been devised by Goodwillie and others; but if ordinary care and skill are used, they are not necessary.

My own plan is to place the cautery point or knife firmly against the turbinal before touching the button and thus heating the end, and, in withdrawing it, to keep it well towards the outer wall of the cavity, so as not to touch the septum. An excess of heat should also be guarded against, as otherwise the mucous membrane covering the septum may be scorched, and subsequently, through the loss

of its superficial epithelial layers, may contract adhesion by its rawed surface to the turbinal. If after puncture the cautery point is allowed to cool before it is withdrawn from the tissues, it is liable to stick to them, and forcibly dragging it away may cause bleeding. The contact button, therefore, should be kept pressed home till the point is free of the tissues. Should the cautery be found to stick, from the neglect of this little precaution, it should be reheated and then withdrawn. In using the cautery, the battery or transformer should be regulated so that only the requisite amount of heat of the platinum point or knife may be produced on completing the circuit. Before placing the cautery point in the nose, it is advisable, therefore, by making contact, to test the maximum heat that can be obtained. The degrees of heat short of this can, of course, be regulated by the length of time the button is kept pressed down. The nose should be also gently dried with a pledget of cotton-wool, for should there be much moisture in the cavity the steam generated by the heat of the cautery might by scalding the septum denude it of epithelium, and so possibly lead to an adhesion.

On completing the cauterization, I usually smear the burnt tissues over with vaseline, or spray them with paroleine or olive-oil. One sitting in slight cases may be all that is necessary, but two or three may be required. When the erection is confined to the anterior end, this part only need be touched. When the whole body is affected, the whole of it may require the cautery treatment, though usually the reduction of the erection will be accomplished by cauterizing the anterior half or two-thirds. It is better, therefore, at the first sitting to cauterize only the anterior half or two-thirds. This may often be sufficient to give relief. If it does not do so, the posterior half or remaining third may be cauterized in a similar manner subsequently, but not, as a rule, till the effects of the first cauterization have completely cleared up—that is, not until a week to three weeks have elapsed, according to the extent and depth to which the tissues have been burned. Another advantage of limiting the cauterization at the first sitting is that, by reducing the size of the anterior part of the body, a better view and more room are obtained for dealing with the posterior part, and consequently there is less likelihood of an adhesion.

As far as I know, no untoward symptoms of any kind follow cauterization of the anterior half or two-thirds when it is skilfully

and cautiously performed as above described. In my own experience I have met with none, although I have employed the method many hundreds of times. Cauterization, however, of the posterior end of the inferior turbinal cannot be said to be attended with the same absence of complications. Eustachian and middle-ear trouble, septicæmia, and other serious sequelæ, are known to have occurred. Although it has hitherto been my good fortune not to have had any experience of such mishaps, I always avoid interference with the posterior end of the inferior turbinal as much as possible. Seeing that in many cases the cauterization of the anterior half, or at most two-thirds, may be sufficient to relieve the patient of his trouble, without interference with the posterior end, I have invariably tried what anterior cauterization would effect before resorting to the more risky procedure of posterior cauterization.

It is recommended by many that, both before and after cauterization, antiseptic sprays or lotions should be vigorously employed. As a general surgeon, I would yield to no one in my belief in the value of asepsis and antisepsis in surgery, and I am equally convinced of their importance in the case of the nose, but I do not think this end is attained by the use of so-called antiseptic sprays and lotions—indeed, in my experience the employment of such has only done harm. As a rule, I advise no after-treatment. No pain is felt, and the patient is allowed to pursue his usual daily occupation. There may, perhaps, be more or less discharge for a week or so, the discharge occasionally being a little blood-stained. Often, however, there is practically none. The amount will, of course, depend upon the depth and extent of the cauterization. When this has been severe, the discharge may be abundant, and the nostril on the cauterized side may be obstructed from inflammatory swelling for a few days; but any such vigorous cauterization as to cause this is hardly called for. Should there be excessive secretion and swelling, a simple cleansing spray may be used two or three times a day to clear the nostril.

Some, in place of the cautery, employ chromic acid, but its after-effects are often very painful when the influence of cocaine has passed off; and I can myself see no advantage in its use over the cautery when the latter is applied as here advised. When, however, the cautery apparatus is not at hand, chromic acid may be substituted for it.

A crystal of chromic acid is placed on the chromic acid introducer (Fig. 7), the latter carried through the speculum, and the point, with a crystal upon it, pressed upon the turbinal at the spot where the cauterization is wished to be made.

Some surgeons* use the chromic acid partly deliquesced, or made into a paste with glycerine, and then apply it on the end of a small cotton probe, carefully mopping the part dry afterwards; but there appears no special advantage in this method. Other surgeons, again, advise acetic acid, nitric acid, or lactic acid. I have had no experience of any of these in the treatment of turbinal erection.

Dr. Delavan treats the erection by introducing a small knife or needle deeply into the turbinal tissue, and then makes a sweep with the point through the submucous tissue, and withdraws the knife without enlarging the puncture. He claims for this method that it reduces the volume of the turbinal without destroying the mucosa.

I have never found it necessary to remove the whole, or even part,



FIG. 7.—CHROMIC ACID INTRODUCER.

of the turbinal body for simple erection; but for the somewhat similar condition, described by Mr. Wyatt Wingrave as turbinal varix, the ablation of the anterior or posterior end, or even of the whole of the turbinal, is in some extreme cases advised.

In many cases in which the turbinal erection has been associated with asthmatic attacks, irritative cough, laryngeal congestion or irritation, hay fever, and other so-called reflex troubles, the reduction of the erection has been of great benefit; but I know of very few in which, sooner or later, there has not been a recurrence of these troubles, necessitating a second, or even third, application. Relief, however, in some of my cases has lasted for two or three years.

Erection of the vascular tissue about the tubercle of the septum seldom calls for local treatment, the reduction in size of the turbinal alone sufficing to relieve the obstruction. If treatment is required, it should not be undertaken at the same time as the turbinal trouble

* Hobbs, *Journal of Laryngology*, 1891, p. 446.

is dealt with, as it would be almost sure to lead to an adhesion. Personally I have never found it necessary to do anything locally for this condition.

Edema of the posterior end of the septum is, in my experience, a very rare condition. Touching with the galvano-cautery appears to be the best treatment when no apparent cause is present to account for it.

CHAPTER XIII.

TREATMENT OF THE INFLAMMATORY CONDITIONS CAUSING NASAL OBSTRUCTION.

TREATMENT OF THE VARIOUS FORMS OF RHINITIS GIVING RISE TO NASAL OBSTRUCTION—HYPERTROPHIC RHINITIS, PURULENT RHINITIS, CASEOUS RHINITIS, AND FIBRINOUS RHINITIS.

TREATMENT OF HYPERTROPHIC RHINITIS.

IN the treatment of this sometimes very troublesome affection, the cause, if apparent, should, if possible, be first removed. Thus, should the rhinitis appear to depend upon adenoid vegetations in the nasopharynx, these should be extirpated; should the nasal septum be deflected sufficiently to obstruct free breathing through one or other nasal chamber, this condition should be remedied in the way discussed at p. 171; should there apparently be obstruction from a spur of the septum or a dislocation of the columnar cartilage, the one should be excised, the other corrected. Again, where the rhinitis seems to be due to some deleterious occupation, or to some defect in personal hygiene or the hygienic environment, these conditions should, if possible, be ameliorated. The affection will then often give no further trouble, the mucous membrane gradually returning to the normal, as is the case in inflammation in other situations.

The cause, however, is not always discoverable, or if found is not always remediable. Under these circumstances, and in those where the hypertrophy does not disappear on the removal of the primary trouble, topical measures must be undertaken for its relief.

In the early stages, before any marked hypertrophy of the turbinals exists, the application of cleansing sprays, followed by weak astringent sprays, will often suffice to cure the affection. I have found nothing better at this stage than the ordinary alkaline spray known as Dobell's, but without the carbolic acid. In many cases this alone

has been sufficient, but at times the addition of some astringent has been found necessary.

There are some who condemn the use of any form of spray having a watery base, and in many cases sprays with an oily base are no doubt attended with better results. I cannot, however, agree that watery sprays should never be used, since I have over and over again obtained the best effects from them.

Where there is much and uniform hypertrophy of the turbinals, nothing, in my experience, equals the application of the galvano-cautery. I prefer it greatly to chromic acid, though this latter agent is praised most highly by some excellent rhinologists. The galvano-cautery should be used as described under turbinal erection at p. 158, the destruction of tissue being as limited as is possible commensurate with success. Extensive destruction, with exposure of the bone, is to my mind wholly to be condemned. One or two linear scarifications or deep punctures are often sufficient, and this is all that should be done, at least at first.

Puncture has the advantage that the cautery point can be carried beneath the mucous membrane parallel with the bone, and the hypertrophied tissue thus destroyed without injury to the mucous surface, save at the spot of puncture. A too extensive submucous scarification, however, should be avoided, since it is liable to be followed by abscess or necrosis of the bone.

In warty hypertrophy of the anterior end of the inferior turbinal, the hypertrophied part may be removed (*anterior turbinectomy*) by the galvano-cautery snare, cutting or punch forceps, chisel, etc. As a rule, I have found no difficulty in engaging the hypertrophied tissue in the embrace of the cautery snare. Should the loop, however, be found to slip, a hare-lip pin may be first introduced obliquely through the hypertrophied portion at the line at which removal is desired, and the loop of the cautery wire passed over the end of the pin or pins; or a groove may be cut with scissors for the reception of the loop. This little operation of removing the anterior end of the inferior turbinal is attended with little or no hæmorrhage, and as a rule suffices for freeing the passage. As only a small amount of tissue is excised, the physiological function of the body is not lost as it is to a greater or less extent after complete turbinectomy. Where the bone itself is enlarged—a very rare condition—the anterior portion may be removed by cutting forceps or punch.

After removal of the anterior end of the inferior turbinal body, I

simply spray the cut surface with paroleine, or smear it with an aseptic vaseline, and find that healing takes place when the wound is thus treated without the inconvenience to the patient attending the use of a plug. Should there be any unusual amount of hæmorrhage, a plug should then of course be inserted.

For the removal of posterior hypertrophies (*posterior turbinectomy*) Jarvis's (Fig. 22) or some other suitable snare may be employed. The galvano-cautery, if used in this region, is attended with some little risk of injury to the Eustachian tube, and Carmalt Jones's spokeshave is apt to be followed by considerable, if not profuse and dangerous, hæmorrhage. When Jarvis's snare is used, it should be worked very slowly to prevent hæmorrhage, and if any difficulty is experienced in engaging the hypertrophied tissue in the loop, the patient had better be anæsthetized and the loop adjusted by the finger behind the palate; or a groove may be cut anteriorly with scissors by directing the points upwards and backwards, whilst a lodgment posteriorly may be made by the aid of the spokeshave.

Unless the posterior end of the inferior turbinal is the only portion of the body hypertrophied—a condition which is certainly exceptional—it is better to deal with the anterior hypertrophy first, since the removal of the anterior end is practically unattended with any risk. The larger vessels of the body which are derived from the arteries entering the nose through the spheno-palatine foramen are situated posteriorly; consequently, there is little or no hæmorrhage, and the risk of direct injury to the Eustachian tube, or of secondary involvement of this structure in inflammatory and septic processes, is avoided. Moreover, after excision of the anterior end it will, in many instances, be found that, in consequence of the removal of a cause of the negative pressure, the erection and enlargement of the posterior end will disappear, and further operative procedure will be unnecessary.

I have seldom had to remove the whole of the inferior turbinal body (*complete turbinectomy*); indeed, the cases in which I have done so could be counted on the fingers of one hand. When such has appeared necessary, I have generally contented myself with the ablation of the hypertrophied tissue rather than remove the whole bone. If complete turbinectomy is deemed advisable, it may be done with the director and scissors, with Carmalt Jones's spokeshave, or with Stipanitis's chisel.

For this operation it is better to have the patient under ether or

chloroform, though many perform it under local anæsthesia or under nitrous oxide gas. If the director and scissors are used, the director is first passed under the inferior turbinal, the probe end of the scissors slid along the director, and the mucous membrane and bone cut through. The advantage of this method is that as little or as much of the body can be removed as is considered necessary for the restoration of the patency of the nasal cavity, and the operation is done with precision.

If the spokeshave (Fig. 8) is used, it should be passed along the inferior meatus, and the ring knife fixed well behind the projecting

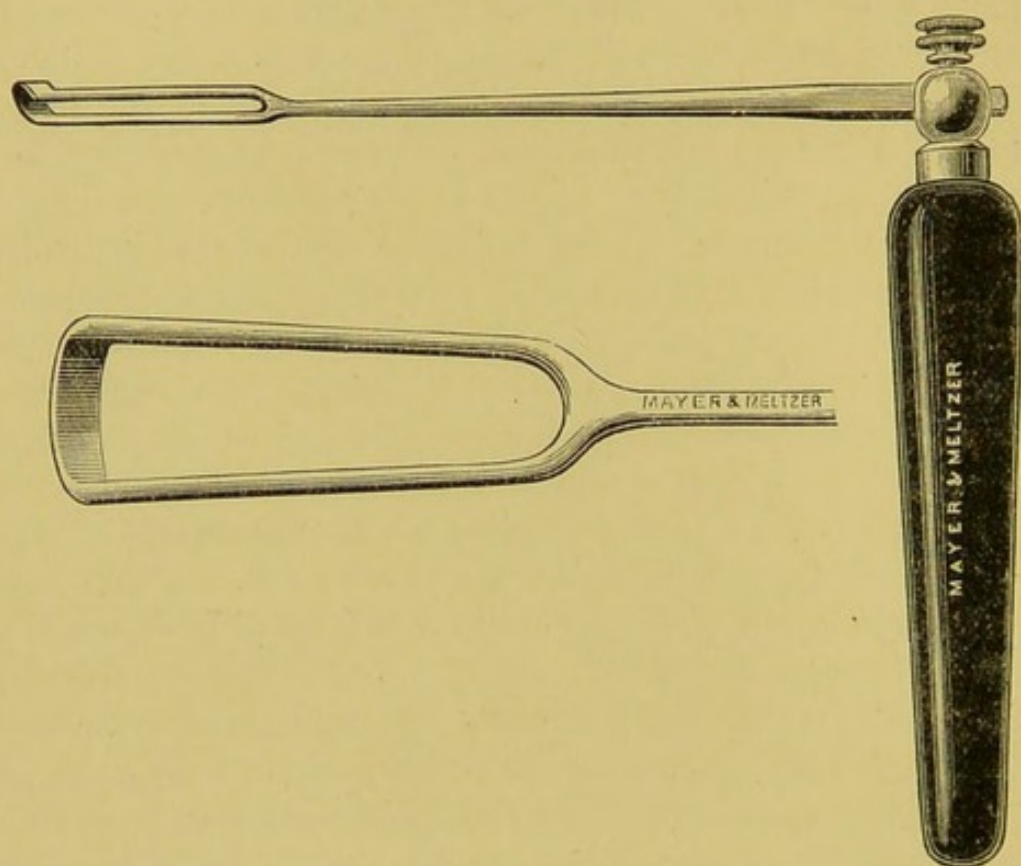


FIG. 8.—JONES'S SPOKESHAVE.

posterior end of the inferior turbinal, and then by a sharp pull made to cut its way forward through the bone. The hæmorrhage, which may be profuse, is readily controlled by plugging with iodoform gauze. The operation seems to me somewhat rough and ready—though it is spoken of by its advocates as one of precision—and to be attended with some risk of laying open the cavity of the antrum. It has been followed by secondary hæmorrhage.

Dr. Stipanitis removes the bone with a chisel under cocaine. The chisel is applied to the anterior end, and with the aid of a mallet made to cut its way through the bone and overlying tissue. He

claims that by this method he can remove as little or as much of the body as appears at the time desirable to restore the patency of the cavity. He thinks that healing after this method is more rapid than after any other.

After complete turbinectomy there is said to be some danger of septic trouble; this, however, is rare, as, in my experience, it is after any intranasal operation. Indeed, although I have performed a large number of what may be called major intranasal operations, none have hitherto been followed by any septic sequelæ. The most rigid precautions are always taken to work with absolutely aseptic instruments and hands; but the nose having been shown to be practically an aseptic cavity, I never employ antiseptics in the form of washes or douches before operating, and having taken care not to introduce any septic material from without, I leave the cavity after the operation rigorously alone. When this is done, an aseptic blood-clot forms, and no better antiseptic dressing or protective for the injured tissue can be found.

I attribute the absence of secondary hæmorrhage and septic troubles, which it has been my good fortune to experience, in very great measure to this abstention from syringing, douching, plugging, etc., and the consequent non-disturbance of the absolute rest so essential for aseptic repair. Although hæmorrhage may be sharp, as it usually is, in the severer operations, I seldom employ plugging of any kind, as it almost invariably stops, although there may be some slight oozing from the nostrils for some hours, as soon as the operation is over. Should a plug be necessary, strips of iodoform gauze should be introduced with a director and left in for some hours, or until the bleeding has ceased. They should then be very gently removed, so as not to start the hæmorrhage afresh.

The great objection to complete turbinectomy, to my mind, is the risk that there appears to be of making the passage too wide, and thus exposing the patient to dryness of the mucous membrane of the pharynx and larynx, and to crust formation. Patients, no doubt, for a time experience great relief from the restoration of the patency of the passage; but quite a number of cases have now been reported in which some months after the operation this dryness of the throat has occurred, and in two or three cases the voice has in consequence been so affected that the patients, who were preparing for the profession of singing, had to relinquish their studies.

The advocates of tubinectomy affirm that after complete removal

some regeneration of the inferior turbinal is often met with. It is difficult to understand how any regeneration of the complex tissues forming the inferior turbinal body can occur. I imagine what happens is, that in tearing out the body flaps of tissue remain attached to the general mucous surface, and it is these remnants, after healing has taken place, that have been assumed to be newly-formed turbinal tissue.

TREATMENT OF PURULENT RHINITIS IN CHILDREN.

The general health of the child should receive careful attention, any digestive disturbance being corrected by appropriate remedies, and cod-liver oil and the syrup of the phosphate of iron and lime, or the syrup of the iodide of iron, prescribed, and persevered in for some months. The syrup of the iodide of iron I have found of special service combined with the oil. If cod-liver oil cannot be borne, then the syrup of the iodide of iron alone, or combined with small doses of maltine, may be used as a substitute.

Locally the nose should be kept cleansed by alkaline or weak antiseptic sprays, such as Dobell's solution, boric acid or corrosive sublimate lotions, or lotions containing Listerine, and subsequently astringed by such preparations as the sulpho-carbolate of zinc; or the nose may be sprayed with menthol and eucalyptol (10 per cent.) in paroline or olive-oil, or be dusted with iodoform, iodol or boracic acid. The cleansing sprays should be used frequently, say every four hours.

Perseverance in this method of treatment will generally be successful, but it may be many months before the discharge quite ceases. Should it not yield to these remedies, it will probably be found that it depends upon some condition, such as the presence of a foreign body, that has been overlooked at the first examination, and a more thorough investigation should be made.

TREATMENT OF CASEOUS RHINITIS.

The caseous masses should be thoroughly removed by swabbing out the affected part of the nasal cavity with pellets of moist cotton-wool. The more solid masses may be removed with the nasal forceps. I have myself found this quite easy, but if it does not suffice, the masses may be removed by spraying or syringing. The portions thus detached may be blown out by the patient. I have not found it necessary to employ the insufflation of air, as recommended

by Wagner. After the nose has been cleansed, antiseptic sprays should be persevered in for some months, and any cause that can be discovered for the condition of course, if possible, removed.

TREATMENT OF FIBRINOUS RHINITIS.

As stated under section 153, this affection is regarded by many as nothing more than a mild degree of nasal diphtheria. It is advisable, therefore, to at once isolate the case, and examine the membrane and discharge bacteriologically and microscopically for the Klebs-Loeffler bacillus. If this is found, and until the examination has been made, the case should be treated as one of nasal diphtheria. If the specific bacillus is not discovered, it will be still well, in the present state of our knowledge, to keep the patient isolated. Iron should be given internally, and the muco-purulent discharge and membrane carefully swabbed away, and the mucous surface touched with a lotion of persulphite of iron, or with tincture of iron, twice or three times a day, the application of a 4 per cent. solution of cocaine being used before the iron is applied to prevent pain and to reduce the blood-supply and stenosis. Insufflation of iodoform after removal of the membrane, or the installation of iodoform emulsion, is highly recommended. After the membrane ceases to form, the nose may be sprayed with cleansing alkaline or astringent lotions till the discharge has completely ceased.

TREATMENT OF THE ACUTE INFLAMMATORY CAUSES OF NASAL OBSTRUCTION (EXCLUDING ACUTE RHINITIS OR COLD IN THE HEAD)—SEPTIC INFLAMMATION—ACUTE ABSCESS.

TREATMENT OF SEPTIC INFLAMMATION.

The small septic pimples on the anterior end of the septum or the inner surface of the ala, often so painful and troublesome, are best left entirely alone. They should not be squeezed or punctured unless matter forms, when a small incision under cocaine should be made. The application of a little vaseline over the swelling, and a hot boracic poultice to the nose at night, will generally give great relief. The patient should be warned not to irritate the part in any way with the finger or otherwise, since it may lead to serious extension of the inflammation and to septic troubles, as septic thrombosis of the facial or some of the intranasal veins, and general blood-poisoning.

TREATMENT OF ABSCESS OF SEPTUM.

The parts having been anæsthetized with cocaine, and thoroughly cleansed with carbolic lotion (1 in 20), a free incision in a vertical direction should be made into the most prominent part of the swelling on one or both sides of the septum, according to whether the abscess is unilateral or bilateral. On the evacuation of the pus, a small twist of iodoform gauze should be inserted between the edges of the wound to prevent premature closing; or a small piece of rubber drain-tube or a few strands of horsehair may be placed in the abscess cavity for a few days. It is advised by some to pass a strip of gauze through the septum if this is perforated, and bring it out through both incisions. When the abscess is the result of acute inflammation and attended with much swelling of the nose, a hot boracic poultice should be placed over the nose and changed every three or four hours. In the chronic forms an ordinary antiseptic dressing of iodoform, cyanide or sal alembroth gauze may be applied and secured by an ordinary nasal bandage. An acute abscess, as rule, heals in a few days if the incision has been free and an efficient drain established. Should the incision not have been made sufficiently free, or show a tendency to close, it should be enlarged with a probe, or the abscess again incised. When the abscess has supervened upon the breaking down of a hæmatoma, the cavity after it has been opened may with advantage be scraped out with a small Volkmann's spoon, and syringed with carbolic lotion (1 in 20). It will generally be found that the cartilaginous septum has been perforated. As the abscess cavity contracts, however, the perforation usually becomes closed by the soft tissues, and no trouble follows.

CHAPTER XIV.

TREATMENT OF SPURS, DEFLECTIONS AND HÆMATOMATA OF THE SEPTUM.

TREATMENT OF SPURS AND DEFLECTIONS OF THE SEPTUM.

THERE are few nasal septa that are perfectly straight, or that do not present some spur or prominence projecting into one or both nostrils. It is only when such deviations or spurs are sufficient to cause palpable obstruction or the symptoms or effects mentioned below, that surgical interference is necessary or justifiable.

Spurs should be removed (1) when they impede free breathing through the nose; (2) when they appear to be the cause of reflex irritation; (3) when they are the seat of ulceration or other trouble, as hæmorrhage; and (4) when they present at the anterior nares, and cause some deformity of the nostril.

Small spurs of the cartilaginous septum are best shaved off with a sharp, strong, narrow-bladed probe-pointed scalpel. This may be done in adults, and in children unless unruly, under cocaine or eucaine. The parts should be thoroughly anæsthetized with a 20 per cent. solution of cocaine or 5 per cent. solution of eucaine, and sufficient of the spur then shaved off, together with the overlying mucous membrane, to permit free passage of air through the nostril. Care should of course be taken, when the spur is combined with a deviation, not to injure the mucous membrane of the opposite side. I have found this little operation attended with no after-trouble or inconvenience. I remove the plug, if one has been thought necessary, as soon as the hæmorrhage has ceased, or in a day or two, and then employ no after-treatment of any kind except spraying the nostril night and morning for a few days with paroleine. For some forms of spur the little gouge (Fig. 9) invented by Delie* may be employed.

* *Journal of Laryngology*, vol. xi., p. 207.

This instrument is provided with lateral guides to prevent perforation. It is placed upon the spur, and then made to cut its way through from before backwards. If any bone is met with, a blow or two with the mallet will carry it through unless the spur is very dense.

In those cases in which the spur is partly cartilaginous and partly bony, I first cut through the cartilaginous portion of the spur down to the bone, and then complete the removal of the bony portion by



FIG. 9.—DELIE'S CHISEL.

means of Bosworth's nasal saw (Fig. 10). Where the bony projection is small, the operation may be done under cocaine, but where it is of some size, or consists of an enlargement or deflection of the maxillary crest, I prefer to have the patient under the influence of a general anæsthetic, as a more thorough and satisfactory removal can then be made. Two saws are useful: one with the teeth on the upper edge, the other with the teeth on the lower edge. The saw is first applied to the lower part of the spur

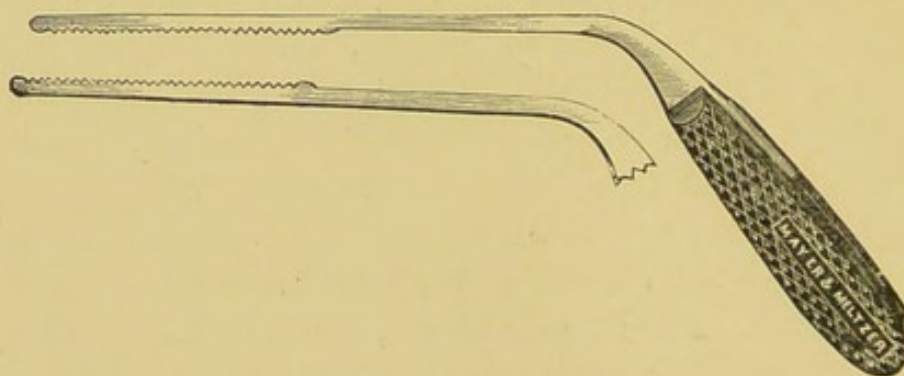


FIG. 10.—BOSWORTH'S NASAL SAWS.

where this is sufficiently overhanging to permit of the saw being placed below it. When half cut through, the saw with the teeth on the lower edge is next placed above the spur, and the section completed by cutting from above downwards.

Some authorities, as Dr. Moure, strongly recommend bi-polar *electrolysis* for the destruction of spurs, thickenings and deviations of the septum. It is contended that the passage can thus be restored at one sitting without pain and without hæmorrhage,

and, if care is taken, without perforation. Moure, who is a special advocate of this method, uses steel needles, as being stronger, less expensive, and more easily made to penetrate than platinum. Each needle is insulated by being covered with indiarubber. The negative needle is plunged into the centre of the spur, the positive pole placed above. The strength of the current should vary, according to the size and hardness of the growth, from eighteen to twenty-five milliamperes, and its application should last from ten to fifteen minutes. The needles are connected with an electric battery of at least thirty couples, provided with an ampèremeter and an immersion rheostat. Moure advises that the opposite fossa be watched through a speculum for any escape of gas from this side, 'which would indicate that the electrolysis is being carried beyond the point wished.'

I have had no experience of electrolysis myself, having found the cutting method satisfactory in every way. Some of those who have tried electrolysis speak of it as tedious and as painful both at the time of its application and, in some cases, for many days subsequently. They have also found it liable to produce perforation. Moreover, the manipulation is troublesome, requiring special skill and training.

The *galvano-cautery* is highly recommended by some for destroying spurs and thickenings in deviated septa. If care is not taken in its use, it is apt to lead to adhesions.

The *dental drill*, worked by the hand or electric motor, has its advocates for the removal of spurs, or deviations with thickening of the cartilage. It leaves an uneven surface, and it may cause irregular perforations of the cartilage or bone, or make for itself pockets under the mucous membrane—conditions that expose to septic trouble. I have heard of cases in which septicæmia occurred after its use, but I must confess I have never employed it myself.

Very slight cases of deviation of the *cartilaginous septum* may be corrected by the use of a nasal plug, but cases that may be benefited in this way hardly call for any treatment at all. For severer degrees of simple deflection of the cartilaginous septum I have found shaving off a thin slice on the convex side give, on the whole, the best results; but when the deflection is extreme, the removal of a slice of the cartilage is not, as a rule, sufficient to clear the passage. For such it is generally necessary, in addition, to forcibly straighten or fracture the septum with Adams' forceps, or the author's modification of

these instruments (Fig. 11). In these severe degrees it will generally be found that there is some deviation of the bony septum or of the maxillary crest. When this is so, a portion of the bone may be advantageously removed with the saw, and the remains of the crest then forcibly bent over to the opposite side by fracturing the bone with the forceps. After the removal of the cartilaginous part and the correction of any deviation of the maxillary crest, it will often be found that the anterior edge of the bony septum forms a prominent ridge. This may be seized with Adams' forceps, fractured, and forced into place. After such an operation the septum may be maintained in position by placing in the previously obstructed nostril a portion of indiarubber drain-tube, which should be retained for a few days to a week. If the tube, however, sets up much irritation, and produces a rise of temperature, a smaller tube or plug may be substituted for it, or all mechanical support in the nostril may be dispensed with till healing has ensued.




FIG. 11.—AUTHOR'S MODIFICATION OF ADAMS' FORCEPS.

The shanks are bowed so as not to crush the columella.

The correction of the S-shaped and crumpled septum is often attended with much difficulty. As a rule, perhaps, it is best to remove with the knife or saw, or with the two combined, the projecting portion from either nostril, and then, if necessary, break up the septum with Adams' forceps and fix it, corrected, in the middle line by a piece of rubber tube in each nostril, or by one of the various forms of retentive apparatus that have been invented for the purpose. I prefer, myself, the rubber tube to any of these.

One of the most difficult forms of deviation to deal with is a simple vertical deflection without thickening of any kind. In this form the cartilage can be readily forced into position, but, in consequence of its resiliency, it at once resumes its faulty position. Unless the deviation is very slight, shaving off a portion is not sufficient to render the passage patent, and if more than the thinnest slice is removed a perforation will result. For such, some form of incision, preferably a crucial one, should be made through the cartilage, and the four segments thus produced fractured at their bases with nasal

forceps, and forced into the middle line. They must be then held in position with a piece of rubber tube, plug, or other apparatus, till consolidation has occurred. At times it may be necessary to remove one or more of the apices of the little segments to obtain the best result. Considerable care is required in performing this operation, lest the mucous membrane on the concave side be injured, and sloughing, followed by perforation, result. It is also necessary, in the after-treatment, for the prevention of this mishap, to avoid too much pressure by the tube or plug. For this operation I myself employ general anæsthesia.

There are many other methods of correcting deflected septa, but the above-mentioned are those which, as the result of a very considerable experience in this department of surgery, I have found the most effective.

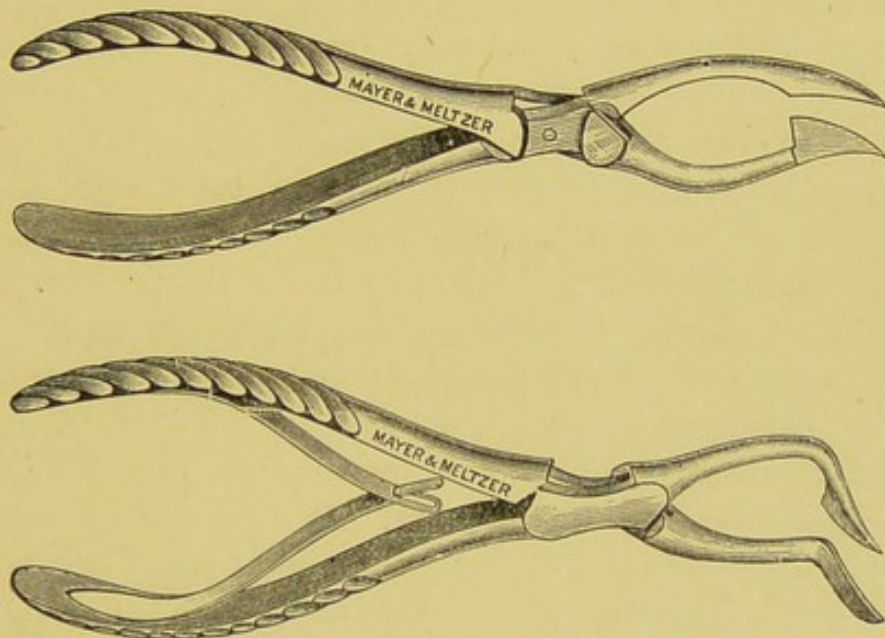


FIG. 12.—ASCH'S FORCEPS OR KNIFE-SCISSORS.

Asch* cuts the septum at the point of greatest deflection with a pair of knife-scissors, making a crucial incision, then bends the segments forcibly into place. His forceps, or knife-scissors (Fig. 12), consists of a blunt concave blade and of a cutting convex one, sufficiently far apart, when the instrument is closed, not to cut the columella. He introduces the blunt blade into the obstructed nostril, the cutting blade into the opposite one, then divides the septum parallel with the upper wall. A second cut is then made, as near to a right angle with the first as the conformation of the nose will allow.

* *New York Medical Journal*, December 20, 1890, and *Journal of Laryngology*, February, 1895.

A finger is next introduced into the obstructed nostril, and the four triangular flaps of cartilage fractured at their bases and forced into place. The septum is further straightened by Adams' or other forceps, and a splint placed in the nose for a few days, till the parts are consolidated.

For simple vertical deviations without thickening, Botey, Petersen, Cholewa, Chatellier, and others, recommend horizontal and vertical incisions through the cartilage and the subsequent removal of a portion of cartilage. Botey's* method of subperichondrial resection of a portion of the septal cartilage is briefly as follows: Under a 20 per cent. solution of cocaine he makes a horizontal incision along the junction of the cartilaginous septum with the floor of the nasal fossa and on the concave side, sparing the mucous membrane on the convex side. He then makes three deep vertical incisions through the mucous membrane, perichondrium, and cartilage from the vault to the floor of the fossa—one over the greatest concavity, one in front, and one behind, avoiding penetration of the mucous membrane of the opposite side. He next bares the cartilage to a sufficient extent, resects a portion, and forces the septum back into place. He employs specially constructed bistouries, the cutting edges of which are very limited, so as to avoid penetration of the septum.

Dislocation of the columnar cartilage is perhaps best treated by dissecting up a little flap of mucous membrane, shaving off the prominent projecting cartilaginous end of the septum, and then trimming away any mucous membrane that may appear redundant. No suturing of the flap is necessary. It falls readily back into its place on the completion of the operation, and healing occurs in a few days. In some instances it is better to remove the mucous membrane as well as the projecting cartilage, especially when the mucous membrane covering the projection is so thinned that it is next to useless to try and save the flap.

Blaudin, Rupprecht, Roser, and others, have employed an instrument something like a ticket-punch, with which they deliberately perforate the septum; one blade is placed in one nostril, one blade in the other, and then the piece of septum cut out. This does not remove the deviation, but simply allows the air to pass from the wider cavity and escape into the nostril on the obstructed side; a ridge of deflected septum, is apt to be left behind the perforation, and the size of the affected chamber remain unaltered.

* *Journal of Laryngology*, vol. viii., p. 318.

In cases of deflection associated with deviation or depressions of the bones, or of the cartilages, further measures are necessary to correct the external deformity.

Where the cartilages are deflected after the septal deviation has been corrected, the lateral cartilages should be forced into line with the bones, or, better, beyond the normal straight line, as they are only too apt to spring back when the pressure is removed. The correction may be made by the author's modification of Adams' forceps, aided by the fingers. After the cartilages have been straightened, they should be held in position by some form of nose-truss, securely held by an elastic band round the head, by the spectacle-frame apparatus, or by the author's poroplastic cap (Fig. 13) or nasal mask. The treatment, however, in these cases is not very satisfactory,

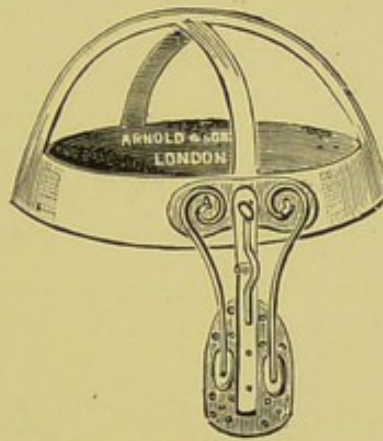

FIG. 13.—POROPLASTIC CAP WITH NASAL TRUSS.

since there is always a tendency for displacement of the cartilage to occur.

In many cases, whilst the cartilages are deflected to the one side, the nasal bones are driven in the opposite direction. In such the bones should be thoroughly loosened and replaced in the middle line, the cartilages driven in the opposite direction. Except in recent cases, great force is required to replace the bones. For this purpose, I had made, some years ago, an extra strong forceps (Fig. 14), with the blades so shaped that when one is introduced into the nostril and the other placed on the bone on the outside, a firm hold of the corresponding nasal bone is secured, but the soft parts are not inordinately crushed, since the blades, when the forceps are closed, are not quite in contact. Fig. 15 represents the forceps *in situ*. They are made in three sizes, and the blades are shaped to the configuration of the nasal bones. With their aid I have invariably succeeded

in replacing the bones, even after the displacement has existed many years. The surgeon should not be satisfied until the bones are felt to be quite loose beneath the fingers and thumb applied on either side of the bridge of the nose. They should then be further manipulated by the fingers into good position, and thus fixed, either by pad and strapping or by the nose-truss. If they remain in the rectified position no apparatus is necessary, but under these circumstances the patient must be carefully watched for the

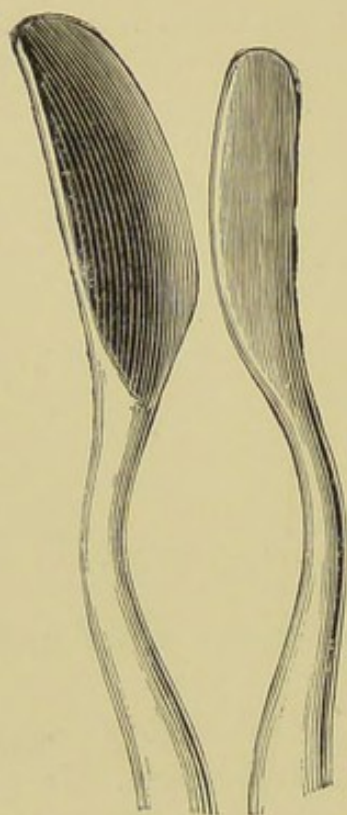


FIG. 14.—AUTHOR'S FORCEPS FOR CORRECTING DEVIATED NASAL BONES.

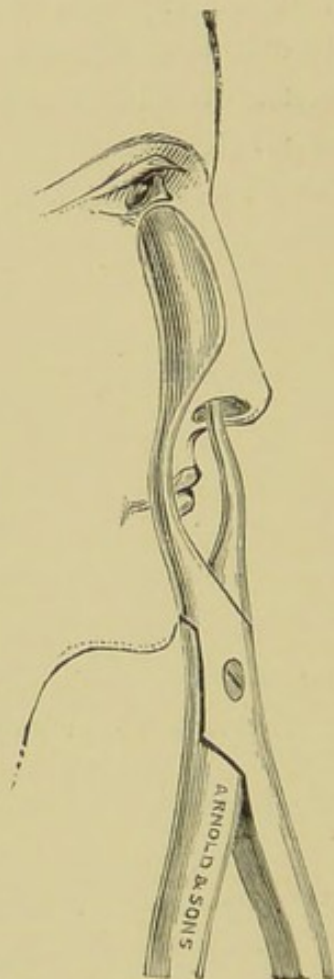


FIG. 15.—AUTHOR'S FORCEPS IN SITU.

first twenty-four hours, and especially when he is recovering from the anæsthetic, lest he again displace the bones with his hand. In twenty-four to forty-eight hours I have usually found the bones firmly fixed in the corrected position. In using the forceps, the skin should be protected by a few layers of antiseptic gauze placed beneath the blade. Should it give way during the manipulation, the little wound may be closed with collodion. I have seen no inconvenience, or, indeed, any perceptible scar, result from such a wound.

There is always very considerable bruising, followed by more or less swelling of the parts, but this rapidly subsides. The hæmorrhage, too, is often profuse for a few minutes. It is essential, therefore, to have a gag in the mouth, plenty of throat sponges in readiness, and to take care that the patient is not too deeply under the anæsthetic. I never use sprays or lotions by way of after-treatment, and have seldom found any plugging of the nostril for the purpose of restraining the hæmorrhage necessary. Where the deflection of the septum has been corrected at the same time, the rubber drain-tube will be found useful for a few days.

Depression of the cartilages at their junction with the nasal bones is exceedingly difficult to overcome, and in some cases is, I believe, beyond the help of surgery. Such cases are especially troublesome when the nasal processes of the superior maxillary bones have been separated, the nasal bones themselves depressed, and the nose in consequence widened out. For such something may be done by forcible reposition of the bones combined with an osteotomy of the nasal process of the superior maxilla, and in suitable cases by subcutaneous suture of the depressed cartilages, or wiring of the cartilages to the nasal bones. In several instances I have obtained some improvement by the method of subcutaneous suture. The material I have employed has been kangaroo-tail tendon or silk, of course rendered thoroughly aseptic. The needle, threaded with the suture, is passed through the skin and depressed cartilages from one side of the nose to the other, care being taken not to penetrate the mucous membrane. It is then re-introduced through the puncture in the skin, through which it has just emerged, passed beneath the skin parallel to the bridge of the nose, and brought out through the skin half an inch lower down. It is then again introduced at the last-made puncture, carried across the nose through the cartilages in the same manner as above, brought out through the skin on the opposite side, and then carried up between the skin and the cartilage as far as the first puncture, where it meets the distal end. The suture is now drawn tight and tied, the ends cut off, and the knot made to slip through the puncture, beneath the skin. In this way the cartilages are drawn together by the square loop of suture, and the depression to a greater or less extent is obliterated, the broadened bridge of the nose at the same time being made more or less sharp. The four little punctures are next closed by collodion, and the ligature remains buried subcutaneously.

Fixation of the depressed cartilage to the nasal bones may be done through a short incision in the middle line; the skin is raised each side of the incision, the bones drilled obliquely, and the cartilages perforated by the needle, first passed through the holes in the bones. A half-curved needle should be used, and care taken not to penetrate the mucous membrane. The skin incision should be closed with fine horsehair sutures, and sealed with collodion.

Another method of raising depressed cartilages is by the use of the silver or gold bridge; but I confess that I have not found this method satisfactory, nor does the method of Chaput,* of inserting a metal bridge in the tissues, appear to have met with much success. I have employed many forms of truss inserted in the nostrils for holding the depressed cartilages after replacement in position, but I cannot say that any of them have proved of much, if of any, service.

TREATMENT OF HÆMATOMA OF THE SEPTUM.

A hæmatoma of the septum is, in my experience, generally completely absorbed if left alone; but there is no objection to the application of cold evaporating lotions, or to an aseptic incision to let out the blood if the hæmatoma is large and obstructs both sides of the nose sufficiently to completely stop nasal respiration. Should suppuration supervene, a free incision on each side of the septum and insertion of a twist of iodoform gauze or small rubber or horsehair drain, and the application over the nose of a hot boracic poultice for a few days will be expedient. In old hæmatomata that have supplicated, it is well, after opening, to scrape out the cavity with a small curette or sharp spoon.

* *Medical Week*, January 4, 1895.

CHAPTER XV.

TREATMENT OF FOREIGN BODIES, RHINOLITHS, AND MAGGOTS IN THE NOSE.

TREATMENT OF FOREIGN BODIES AND RHINOLITHS.

IN adults the foreign substance can, as a rule, be removed under the influence of cocaine. In infants and in young or unruly children general anæsthesia will often be necessary; but before placing the child under an anæsthetic an attempt may be made to expel the foreign body by one of the inflation or pneumatic methods, but on no account by the nasal douche. The passage of a stream of water up the unobstructed nostril for the purpose of expelling the foreign body from the obstructed one is attended with great risk of setting up middle-ear disease, in consequence of the water, whilst under pressure, entering the Eustachian tube. In the inflation methods described by Slaton,* a stream of air is suddenly forced up the sound nostril by means of a rubber tube, to which a nozzle, large enough to close the nostril, is fixed, either by a Politzer's bag or by the surgeon's mouth. Or the sound nostril, as recommended by Dodd,† is simply closed by the finger, while the surgeon blows with his mouth into the mouth of the child. If the foreign body is not expelled in one of these simple ways, the child had better be put under an anæsthetic, and the foreign body extracted by forceps, bent probe, or wire snare.

The patient, if an adult, should be placed in a good light, and the nostril having been cleansed by spraying or gentle syringing, or by swabbing out by moistened cotton-wool, a 20 per cent. solution of cocaine should be thoroughly applied. This not only subdues the pain, but, by reducing the swelling of the mucous membrane, facilitates the extraction. Having thus well defined the situation and

* *New York Medical Journal*, 1891, vol. xxxix., p. 93.

† *Lancet*, 1888, vol. ii., p. 899.

character of the foreign body, if it is of moderate dimensions an attempt may be made to move it with nasal or dressing forceps, care being taken not to force it further into the recesses of the nose. If it cannot be grasped in this way, it may sometimes be removed by insinuating a suitably bent probe behind it, or it may be levered out by the aid of a flattened director, or with one of the extractors or spoons which have been invented for the purpose. Sometimes it may be possible to pass the loop of a snare over the mass; but this operation requires great delicacy of manipulation and the exercise of considerable patience, the surface of the mass being often so covered with mucus that it is difficult to prevent the wire loop from slipping.

Some advise that an attempt should be made to push the foreign body forwards by passing a curved probe from the pharynx, the point of the probe being guided by the aid of the rhinoscope or finger behind the palate.

Sajous* passes two loops of wire, one above and one below the foreign body, through the nose into the pharynx, draws them into the mouth, ties the two loops together by a piece of bandage, and pulls back the two loops through the nose; the piece of bandage will then bring the foreign body out in front of it.

When the foreign body is far back, it may at times be pushed into the naso-pharynx; but there is some risk in this method, though perhaps not much, of the body entering the larynx. In exceptional cases, when the body has been of large size and could not be broken up, it has become necessary to perform Rouge's, Dieffenbach's, or Syme's operation.

A rhinolith, if it cannot be extracted on account of its size, may be crushed with forceps, drill, or small lithotrite, and removed piecemeal. A useful forceps for this purpose is one in which the blades can be taken apart, like midwifery forceps; one blade can then often be insinuated above or to one side of the rhinolith, and the other below or to the other side; the forceps is then locked, and the stone crushed.

TREATMENT OF MAGGOTS IN THE NOSE—NASAL MYIASIS.

For the following account of the treatment of nasal myiasis I am indebted to my friend Mr. Miles, who had considerable experience of the affection whilst he was residing in the West Indies.

* *Centralblatt für Laryngologie und Rhinologie*, vol. iii., p. 166.

'The chief aim is the destruction of the maggots, after which they can be readily expelled by forced expiration through the nose. The popular remedy in the West Indies is the inhalation of the steam of an infusion of tobacco. This, though efficacious in most instances, has been known to fail. The best method of destroying the maggots is to make the patient inhale the vapour of chloroform. This was first introduced by Dauzat of Mexico, and has since then superseded all other remedies. The inhalation of the chloroform vapour should be continued until the patient has become anæsthetized, when a thorough exploration of the nasal cavity can be made. Should the vapour alone be insufficient for the destruction of the maggots, the nares may be syringed out with a solution consisting of equal parts of chloroform and water, or the chloroform may be used pure. This is now the routine practice in the West Indies, and no accident has been reported as resulting from its use. Since the washing out with either the chloroform or a mixture of it and water causes intense pain, the process should not be commenced until the patient is fully anæsthetized. As soon as all the maggots have been expelled or removed, the nasal cavities should be syringed several times with a mild antiseptic solution, such as boracic acid or corrosive sublimate (1 in 2,000). The after-treatment consists in irrigating the nasal chambers with an antiseptic douche several times daily until all discharge has ceased, and any ulceration that may have existed has healed.'

In some instances the maggots have been said to have found their way into the frontal sinuses through the infundibulum. When this is suspected to have taken place on account of severe and constant pain referred to the region of the sinuses, the sinus must be trephined, and any maggots, if present, removed. Should the maggots also be suspected to have entered the antrum, this cavity must be explored. Even after the complete riddance of all maggots, recovery may be delayed considerably by the presence of extensive ulceration, and even necrosis, conditions which must be treated upon ordinary lines, any pieces of dead bone being removed so soon as they have become sufficiently separated. When abscesses have formed on the face, they must be opened and their interior scraped. Sometimes these do not heal completely, but remain as sinuses leading from the exterior into the nasal cavities; in such instances some plastic operation is generally necessary to effect a cure.

CHAPTER XVI.

TREATMENT OF TUBERCLE, LUPUS, SYPHILIS, DIPHTHERIA, RHINOSCLEROMA, GLANDERS, AND LEPROSY, IN THE NOSE.

TREATMENT OF TUBERCLE IN THE NOSE.

THE treatment of tubercle in the nose, as elsewhere, should be local and general. The local treatment will vary according to the nature and situation of the lesion, *i.e.*, whether the tubercle is of the neoplastic or ulcerative form; whether it is confined to the septum or one of the turbinals, or is more or less general; and whether the disease is localized to the nose or affects more or less of the respiratory tract as well. When the disease is entirely local, operative treatment should at once be resorted to. If, on the other hand, it is extensive, involving more or less the whole cavity, and there are, perhaps, signs of tubercle in the larynx and lungs, any local operative treatment is hardly justifiable, and all that should be done is to keep the nose cleansed by antiseptic and astringent lotions frequently used with the spray apparatus or syringe, and then dusted with iodoform, or iodol, or with morphine in the form of Ferrier's snuff if there is much pain.

When the disease is localized and of the ulcerative variety, if the ulcer is small and confined to the septum or one of the turbinals the edges and base should be well scraped with a suitably bent Volkman's spoon, and then thoroughly cauterized with the galvano-cautery, any small neoplastic formations around being at the same time curetted or scraped away and their bases also destroyed by the galvano-cautery. When the ulcer is deep, the affected portion of the septum may be cut completely away, care being taken to remove a good margin of healthy tissue with the diseased. When the ulcerative process is more extensive, thorough curetting of the affected surface may be made, or lactic acid freely applied.

A distinct tuberculous granuloma confined to the septum or to one

of the turbinals should be removed under local anæsthesia, either with the galvano-cautery loop or with the cold wire snare, and the base of attachment then well cauterized with the galvano-cautery point or with some caustic, as lactic, trichloracetic or chromic acid. If the cauterization is made with the galvano-cautery, nothing in the way of after-treatment is required beyond smearing the burnt surface over with vaseline, or spraying it with paroleine, and subsequently keeping the nasal cavity cleansed by the use of a simple alkaline spray. The patient should be carefully watched for some months to make sure that the whole of the tubercle has been destroyed, and that no fresh focus has formed.

When the tuberculous granuloma, in place of forming a distinct growth, is more or less diffused, it may be destroyed by the galvano-cautery, or, better, scraped or curetted away by the sharp spoon, and the base then cauterized with the galvano-cautery, or with lactic, chromic or trichloracetic acid. When it involves a large extent of the inferior turbinal, this body should be completely removed, or the anterior or posterior end only excised if the tuberculous infiltration is confined to one or other of these parts. Should the tubercle involve merely the anterior end of the middle turbinal, this portion of the body should be amputated; but when the whole of the middle turbinal is affected, cautious curetting or scraping, or the safer procedure of cauterizing with lactic or other acid, is the most that can be done. It should be borne in mind that a general infection of the system with tubercle bacilli is a possible, though perhaps remote, contingency after partial operations for tuberculous disease. Hence, a thorough removal should be practised when possible. I would not, however, go the length of some authors, and say a complete operation or none, for I have seen the most marked relief follow partial removal when complete extirpation was out of the question, and I know of no case in which dissemination has occurred. To ensure a thorough eradication, should the general condition of the patient permit, one of the numerous operations devised for the purpose of exposing the interior of the nasal cavities may first be performed; but it is only in rare cases that this can be done with safety, as it is extremely uncommon to meet with extensive tuberculous disease of the nares unattended by manifestations of the disease in other parts.

In a case under my care, in which the septum was widely involved, I laid the nose open through an incision in the middle line, reaching from the glabella to the tip, turned back the soft tissues on the left

side together with the corresponding nasal bone, and cut away that part of the septum which was involved in the tuberculous process with a good margin of healthy tissue. The nasal bone and soft parts were then replaced and accurately sutured, leaving hardly any appreciable scar. Up to the present time there has been no recurrence. On several former occasions the growth had been extirpated by the intranasal method, and the patient was sent to me under the impression that the disease was a sarcoma.

When the intra-nasal disease appears to be secondary to, or merely a part of, a general tuberculosis of the respiratory tract, it becomes a question as to how far it is justifiable to subject the patient to any local treatment beyond cleansing the nasal cavities with alkaline sprays, and keeping the ulcerative surfaces dusted with iodoform or the like. If the general tuberculosis is extensive, and the patient is clearly rapidly succumbing to the disease in the lungs or larynx, no operative treatment in the nose can be expected to be of any service, and all that should be attempted is to keep the parts cleansed and comfortable in the way above indicated. The application of a 5 per cent. solution of menthol in paroleine will often soothe if there is much irritability, or morphia in the form of Ferrier's snuff may be insufflated if there is much pain.

At times, in spite of treatment, the tuberculous process in the nose spreads with great rapidity. I have known it destroy the whole organ in less than three months from the time the patient came under observation.

The general treatment of the disease is of the greatest importance. A nourishing and digestible diet should be selected, and, if possible, the patient should be sent to reside in an appropriate climate. Long sea-voyages are of especial benefit. When change of residence is impossible, the patient should be directed to keep out in the open air as much as practicable, and, above all, to avoid sitting in hot, stuffy rooms, and in a vitiated atmosphere. Cod-liver-oil and the more readily assimilable preparations of iron are indispensable adjuncts in the constitutional treatment.

TREATMENT OF LUPUS IN THE NOSE.

In the treatment of lupus in the nose, as in other situations, the chief factor, perhaps, in success is the thorough eradication not only of the main mass of lupoid tissue, but also of the small secondary foci that are nearly always found around. Where the lupus has

been extensive and has involved the ala and columella, my own plan has been to remove as thoroughly as possible the main mass under general anæsthesia, and then to attack any lupoid tubercles that have possibly been missed or appeared after the main operation, and before they have attained any size, under local anæsthesia. For the removal of the main mass I have myself always employed Volkmann's spoons, or Grünwald's curettes (Fig. 16). The spoons should be of different sizes, and should have their stems bent at different angles, to facilitate the scraping and allow of the various recesses of the nose being the better got at. Minute spoons are very useful, in that the small portions of lupoid tissue can be picked out which would escape larger instruments. After the lupus has been removed with the spoon, the parts should be thoroughly cauterized with solid nitrate of silver, chloride of zinc, lactic acid, or the

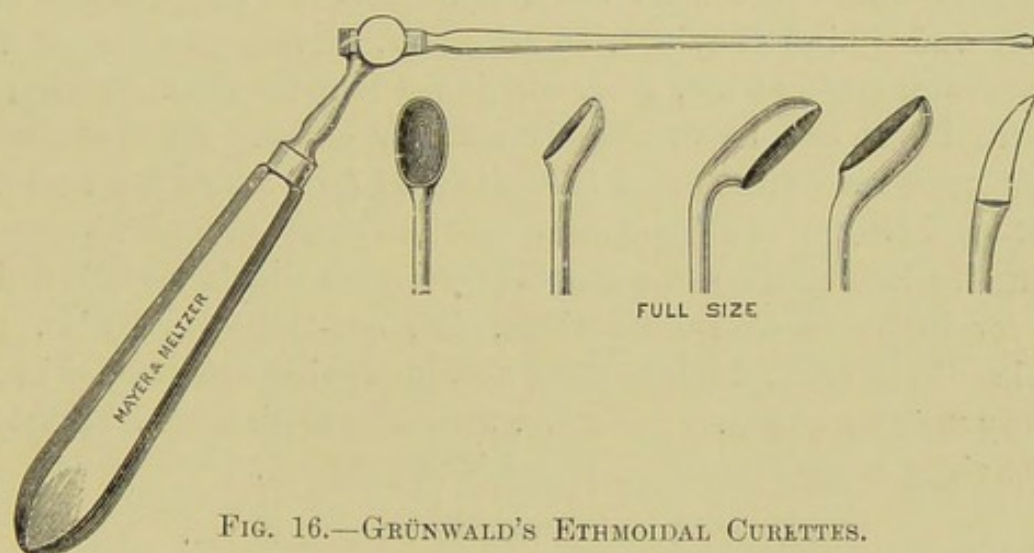


FIG. 16.—GRÜNWALD'S ETHMOIDAL CURETTES.

actual cautery. I myself prefer solid nitrate of silver, with the stick cut to a fine point, so that it can be insinuated into the small recesses left untouched by the scraping. If the cautery is used, the galvano-cautery or the fine point of the Assilini cautery will be found most convenient. I prefer scraping to excision of the ala or columella, as advised by some, since, after the most severe scraping, astonishingly little deformity remains, even although at the end of the operation it seems that a large portion of the ala, columella and tip of the nose had been removed. For the extirpation of any small nodules which may show themselves subsequent to the main operation, picking out the minute masses with a very small Volkmann's spoon, and then thoroughly cauterizing the surrounding tissues by inserting the fine point of the galvano-cautery into the

little pits that are left, is attended with the best success. These secondary operations may be done under local anæsthesia, either by a solution of cocaine and resorcin, 20 and 10 per cent. respectively, or by eucaine, or by the injection of a tabloid of morphia (gr. $\frac{1}{40}$), cocaine (gr. $\frac{1}{10}$), and carbolic acid (gr. 1), dissolved in 100 minims of water, or, when the nodule is situated just outside the ala, by chloride of ethyl. For lupus beginning in or confined to the nasal cavity, a condition which is exceedingly rare, scraping may also be employed, followed by the application of the galvano-cautery; or, better, the cautery may be used alone, as the steps of the operation are then less obscured by bleeding. In dealing with cases of lupus, the point which has most strongly impressed me is the desirability, after the main mass of the lupus has been destroyed, of searching for and extirpating all secondary foci around, and of attacking any such foci which may occur after the main operation immediately they appear, and whilst they are, so to speak, almost microscopical in size. When this is done, I am convinced that the great majority of cases of lupus can be ultimately soundly cured. Dundas Grant* recommends an ointment of salicylic acid (grs. xx ad ʒi), and Mil-ligant† swabbing with a 4 per cent. solution of pyoktannin.

Constitutionally the same general treatment should be followed as that for lupus in other situations, *i.e.*, cod-liver-oil, tonics, and arsenic. Whilst employing these, and improving the general health in every way by change of climate, attention to diet, etc., it must not be lost sight of that local treatment is paramount.

TREATMENT OF SYPHILIS IN THE NOSE.

Syphilitic disease of the nose must, of course, be treated constitutionally as well as locally.

In those rare cases in which a primary syphilitic sore of the nose is suspected, it is well to defer constitutional treatment until the diagnosis has been assured. This can only be done either by confrontation or by the subsequent development of secondary manifestations. This is important, because the early exhibition of mercury always retards the appearance of secondary symptoms, and, indeed, may prevent them altogether; and since a considerable element of doubt in the diagnosis surrounds every case of primary sore in the nose, it would be unwise to retard the corroborative evidence of secondary manifestations.

* *Journal of Laryngology*, vol. viii., p. 817.

† *Ibid.*, vol. viii., p. 502.

In addition to strict attention to general constitutional treatment, the adoption of local measures is of course of importance. Cleansing and antiseptic washes should be freely used by means of a syringe or in the form of a spray, in order to get rid of all accumulated secretions and dried crusts, and thus relieve the patient to a great extent of the horrible odour that is generally present, and allow of the application of local remedies. For the purpose of cleansing, warm vaseline is advised by some, but I have found nothing better than Dobell's solution.

When the crusts have been removed, all necrotic tissue should be thoroughly scraped away with a Volkmann's spoon, and any sequestra that are present should be extracted as soon as they are loose. The extremely foul odour emitted in syphilitic disease of the nasal cavity is to a great extent due to the presence of necrosed bone, and this will continue until the sequestra are removed, although it can be greatly palliated by keeping the parts cleansed and subsequently insufflated with iodoform. Should the sequestrum be too large to come away, an attempt may be made to divide it or break it up; or, if this is found to be impracticable, Rouge's operation may be undertaken to gain the necessary room. No attempt should be made to extract the sequestrum until it is loose, especially when situated in the region of the roof of the nasal cavities, since the forcible removal in this situation may involve the interior of the cranium, lacerate the dura, and set up a septic meningitis.

TREATMENT OF THE NASAL LESION IN DIPHTHERIA.

For the general treatment of diphtheria a work on medicine must be consulted. All that need be said here is that the nasal chambers must be kept thoroughly cleansed by antiseptics, the false membrane being removed from time to time by syringing and swabbing, and any larger or adherent masses extracted with the forceps. The raw surface must then be sprayed with lactic acid, or painted with the tincture of the perchloride of iron several times a day. A weak solution of cocaine or eucaine may be employed to prevent pain during the application of the astringents or caustics; but it should be used cautiously, seeing the liability there is to syncope in diphtheria. Insufflations of iodoform, or the injection of iodoform and glycerine emulsion, may also be found of service.

On the cessation of the formation of membrane, antiseptic and astringent sprays may be used till the discharge ceases.

TREATMENT OF RHINOSCLEROMA.

This disease is particularly unamenable to treatment, all efforts, both surgical and therapeutical, having generally proved futile. When the obstructing growths have been removed by the knife, recurrence has, as a rule, speedily taken place, and their destruction by cauterizing agents has generally been productive of but temporary relief. If met with in an early stage, however, free excision with the knife should certainly be practised, and even when the morbid process has made considerable progress excision, if the whole disease can be removed, should be attempted. Thus Peace,* in a case in which the nose and upper jaw were extensively involved, the nasal fossæ being completely blocked and the antrum and ethmoidal sinuses invaded by the growth, removed the whole of the upper lip, the external nose, the nasal process of the superior maxilla, and the turbinal bodies, and cleared out the antrum and ethmoidal sinuses with the curette. Such an operation must, of course, leave very considerable deformity, but much can be done to hide this by a well-planned plastic operation, after the whole disease is removed and cicatrization is complete.

Where the disease has extended to the pharynx or further, and is too extensive to admit of any operation, all that can be done is to endeavour to restore as far as possible the patency of the nasal fossæ, either by burning away some of the obstructing tissue with the galvano-cautery or by cautiously clearing the passage with the knife or curette. Attempts to dilate the passages by means of laminaria tents are productive of so much pain that even with the aid of cocaine it cannot be borne. Electrolysis has also been employed for destroying some of the obstructing tissue, but it does not appear to have been attended with much success, nor have a sufficient number of cases been treated by its means to allow of an opinion being formed of its value.

Attempts to destroy the parasite have been made by injecting subcutaneously into the affected tissue carbolic acid and salicylic acid, and with this aim in view Pawlowsky† has employed a glycerine extract of the rhinoscleroma bacillus. The carbolic acid injections in some cases appear to have had an undoubted effect in diminishing the progress of the growth, but in other cases they have not had

* *Bull. de l'Acad. de Médecine*, October 22, 1895, and *Journal of Laryngology*, February, 1896.

† *Deutsch. med. Wochen.*, xiii., xiv., 1894.

any. In no case has a cure resulted. The injection of the rhinoscleroma extract seems to hold out more hope of success. Pawlowsky obtained after the injections both a local and general reaction. The nose became reddened and swollen and the temperature raised. After fifteen injections the plates were found softened and inflamed, and the growth made no further progress for one year—the length of time the patient had been under treatment when the report was made.

Doutrelepont has recorded a case in which a perfect recovery followed the application of a 1 per cent. ointment of perchloride of mercury, but it is not beyond dispute that the case was one of syphilis and not of rhinoscleroma.

TREATMENT OF THE NASAL LESION IN GLANDERS.

The treatment of acute glanders is hopeless, but in some instances, in the chronic form of the disease, recovery, though very rarely, has taken place after a long lapse of time. Up to the present no specific remedy has been discovered, though it is impossible to foretell what sero-therapy may produce in the future. So far, all that can be done is to relieve symptoms as they arise, and to adopt a general tonic and stimulating plan of treatment. The nasal chambers should be irrigated frequently with warm antiseptic solutions such as tincture of iodine, 1 drachm to the pint; biniodide of mercury, 1 in 2,000; or carbolic acid, 1 in 40, so as to wash away all discharges and crusts, and to keep the nasal chambers cleansed. It has been recommended that the infected surfaces should be scraped or curetted, and afterwards cauterized by a paste of chloride of zinc, in the proportion of 1 to 10.

Glanders being a highly infectious disease, prophylaxis is of the utmost importance. The patient should be carefully isolated, and those in attendance upon him should be instructed in antisepticizing their hands and any instruments, sponges, towels, etc., that may be used for the purpose of treatment.

TREATMENT OF THE NASAL LESION IN LEPROSY.

In the early stages, beyond keeping the nose cleansed with alkaline sprays or washes, in the few cases I have seen, nothing further seemed required. In the later stages, when ulceration has occurred, the vigorous use of antiseptics, and, should respiration become much obstructed, the destruction of the leprous tubercles with the galvano-cautery or caustics, may give the patient some relief.

CHAPTER XVII.

TREATMENT OF INTRANASAL NEW GROWTHS.

TREATMENT OF INNOCENT NEW GROWTHS—MYXOMATA OR MUCOUS POLYPI, ADENOMATA, CYSTS, PAPILLOMATA, NÆVI, ANGIOMATA, FIBROMATA, ENCHONDROMATA, AND OSTEOMATA.

THE TREATMENT OF NASAL POLYPI—MYXOMATA AND ADENOMATA.

NASAL POLYPI may be removed under either local or general anæsthesia. In all ordinary cases local anæsthesia will suffice, but this method may, and generally does, necessitate several sittings, whereas under general anæsthesia a complete clearance can usually be made at a single operation, though often at the expense of tearing away healthy mucous membrane and perhaps more or less of the turbinal bones. General anæsthesia may be advantageously employed (1) when the polypi are very numerous, or (2) when situated far back and not easily got at from the front; (3) when the patient is very intolerant of manipulation, or has become tired of the many sittings sometimes required when local anæsthesia is used; and (4) when some other operation, as the rectification of a deviated septum, is needed at the same time. The great objection to removal under general anæsthesia is that it is impossible to see and define what is being done, and consequently that there is the risk on the one hand of missing some of the polypi, and on the other—especially as the forceps have to be used—of unnecessarily tearing away portions of the mucous membrane or fragments or even the whole of one of the turbinal bones. It is a method that should never be employed save under the above-mentioned exceptional circumstances.

Local anæsthesia may be produced by a 4 to 20 per cent. solution of cocaine, or a 5 per cent. solution of eucaine, the lotion being sprayed into the nostril or, better, applied on a pellet of cotton-wool which is placed in the upper part of the nasal cavity to allow the fluid to flow

downwards. It is well to gently rub it on the mucous membrane about the base or stalk of the polypus. A good application is a solution made from a compressed tabloid consisting of $\frac{1}{10}$ of a grain of cocaine, $\frac{1}{40}$ of a grain of morphia, and 1 grain of carbolic acid, the tabloid being dissolved in 100 minims of water. In this way a much smaller quantity of cocaine is used than in the ordinary solution, and toxic effects are less likely to ensue. When a patient is very susceptible to cocaine, or even to eucaine, a 20 per cent. solution of saccharin may be substituted. The saccharin will give complete anæsthesia, but its effect passes off sooner than that of cocaine or eucaine, whereas with the cocaine, or with cocaine and morphia, the anæsthesia will last for fully twenty minutes. When anæsthesia has been obtained, the polypi may be removed with the *galvano-cautery snare*, the *cold wire snare*, or with the *forceps*. Of these methods I personally much prefer the galvano-cautery. The forceps I never employ, except when the patient is under general anæsthesia. The advantages of the galvano-cautery are: (1) That there is less bleeding, and consequently the field of view is not obscured; (2) the base of the growth is more thoroughly destroyed, and therefore the polypus is less liable to recur; (3) it is easier to cut through the base with the hot wire than with the cold. Some surgeons, however, prefer the cold snare, in that they affirm the development of heat in the nose may do harm. When, however, the cautery is properly used, such an objection falls to the ground, since the wire should be merely heated to a dull red; and when the polypus has been deftly snared, the loop to be heated is very small; moreover, the application of what little heat is employed is practically only momentary. I have used the galvano-cautery myself many hundreds of times, and have never seen it productive of any harm. Further, it has been maintained that the galvano-cautery is responsible for the loss of smell which sometimes occurs in patients the subjects of nasal polypi. I do not admit this to be a fact. I have inquired into the point, and found that the loss of smell has occurred quite as frequently in patients who have had no operation performed, or have had their polypi removed by the cold snare or forceps, as in those on whom the galvano-cautery has been used. Indeed, in the cases of anosmia I have personally met with, the loss of smell occurred before the galvano-cautery was used; and I know of no case where the sense of smell was present before the cauterization, and lost afterwards.

Removal with the Galvano-Cautery.—A good light is absolutely essential. The nasal mucous membrane having been rendered insensitive in one of the ways already described, the cautery snare should be introduced through the speculum previously passed, and the largest and most projecting polypus secured. The loop should be of such a size that it will pass freely over the base of the polypus, but not so large that, when the wire is tightened, the whole of the loop cannot be drawn within the cannula. When the polypus hangs down, with the stalk in a vertical position, a cannula with the two tubes placed horizontally should be used, so that the lumen of the loop looks upwards. Whereas, when the polypus projects outwards

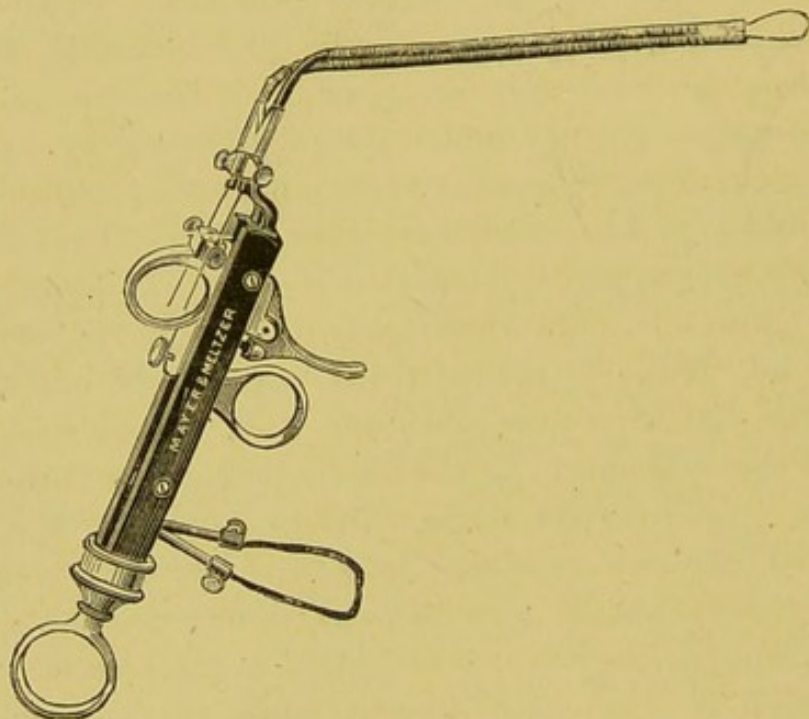


FIG. 17.—GALVANO-CAUTERY HANDLE FOR SNARE.

or inwards into the nasal space, and the pedicle has a horizontal direction, it will be found more easy to snare the growth by using a cannula with the tubes placed vertically, so that the lumen of the loop looks laterally. By paying attention to this little point, the facility with which the polypus can be snared will be much increased. Having gently manipulated the wire loop round the polypus, and slipped it as near the root of the growth as it will go, the wire should be tightened by drawing, with the index-finger, the ring on the upper part of the handle back towards the hinder end. Whilst this is being done, the cannula should be held steadily *in situ*, or slightly pressed further into the nose. If it is ever so slightly with-

drawn, the loop is apt to slip more or less over the body of the polypus, which, when the wire is heated, may then be merely cut in half, instead of being completely removed. When the wire has been drawn home in the above-mentioned way, and the base of the polypus has been firmly gripped, the trigger should be pressed by the fourth finger. The current will then pass through the wire, and the polypus will be detached. No traction should be made while the current is in action. On withdrawing the instrument, the polypus will come away sticking to the loop of wire. Small polypi will often come away without the necessity of heating the wire at all, the stalk being simply cut through as the wire is tightened. If the manipulation has been neatly carried out, there will be little or no hæmorrhage. The stump of the growth may now, if necessary, be further destroyed by applying the flat of the cautery knife (Fig. 6, p. 158) to it for a moment or two. This should always be done if the polypus has not been cut off flush with the mucous membrane, *i.e.*, if any stalk, or, in the case of a sessile growth, a portion, has been left. When any considerable portion remains owing to the loop having slipped or it having been found impossible to pass the wire satisfactorily round the polypus, a second snaring had better be made. This, as a rule, will be found more satisfactory than an attempt to burn down a large remaining mass of polypus. If, in consequence of having cut through the peduncle or base of the polypus too quickly, or in consequence of having made traction on the loop whilst the current is flowing, hæmorrhage should ensue, the nasal fossa should be gently sponged out with a cotton-wool pellet or two on the end of a probe or in the crocodile forceps (Fig. 18); and the bleeding-spot having been thus defined, it should be touched with the galvano-cautery point, when the hæmorrhage will at once cease. The next most prominent polypus should be then snared, and the extraction continued until the effect of the cocaine begins to pass off. It is better then to terminate the sitting. If more cocaine is applied, there is always the risk of toxic trouble coming on. One cavity is, as a rule, sufficient to deal with at a sitting.

When a fringe of small sessile polypi are attached to the middle turbinal body, the loop may often, with advantage, be made to include several at a time, or a portion of the middle turbinal body itself may also be snared and removed, together with the small polypi growing from it. Polypi far back may occasion some difficulty in extraction. They may often be brought better into view by asking

the patient to close his mouth and opposite nostril, and breathe forcibly through the obstructed one. At other times they may be drawn forwards with the nasal forceps (Fig. 18), or by Lange's hook (Fig. 19), and the snare in this way be passed over them; or, in dealing with polypi about the choana, after the situation of the

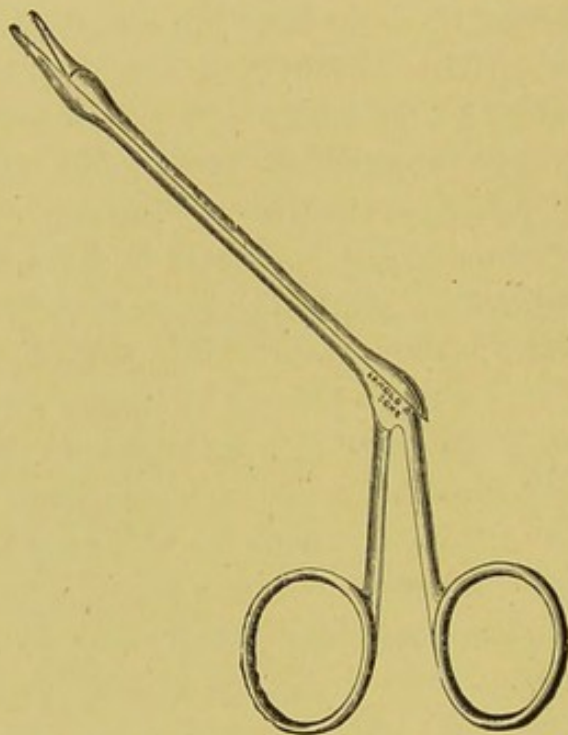


FIG. 18.—CROCODILE NASAL FORCEPS.

growth has been accurately ascertained by posterior rhinoscopy, the loop may be slid along the septum, and then, when it has reached the naso-pharynx, be deftly manipulated over the polypus.

Some recommend (McBride) that a pledget of lint or wool should be drawn from the pharynx through the nose by a string previously passed through the anterior nares, so as to protrude the polypus in front of it. This method—first advocated, I believe, by Voltolini,



FIG. 19.—LANGE'S POLYPUS HOOK.

who employed a sponge attached to a string—is useful in some cases in forcibly clearing the nose, with the patient under general anaesthesia.

Removal with the Cold Snare.—Several cold snares are in use, as, for instance, Mackenzie's (Fig. 20), Macdonald's (Fig. 21), Jarvis's

(Fig. 22). The method of manipulating the loop over the polypus is similar to that described under removal with the galvano-cautery. When the polypus has been seized, the loop is tightened and the growth then cut off. The tightening up of the loop should not be done too quickly, lest the bloodvessels in the pedicle be merely divided instead of being crushed. Some few minutes should be allowed for the process if a bloodless operation is aimed at, and the snaring should be gently executed, since clumsy attempts may result in extensive laceration of the nasal mucous membrane, and so occasion copious bleeding.

Removal with Forceps.—This method is exceedingly rough-and-ready, and even with the parts cocained gives rise to considerable

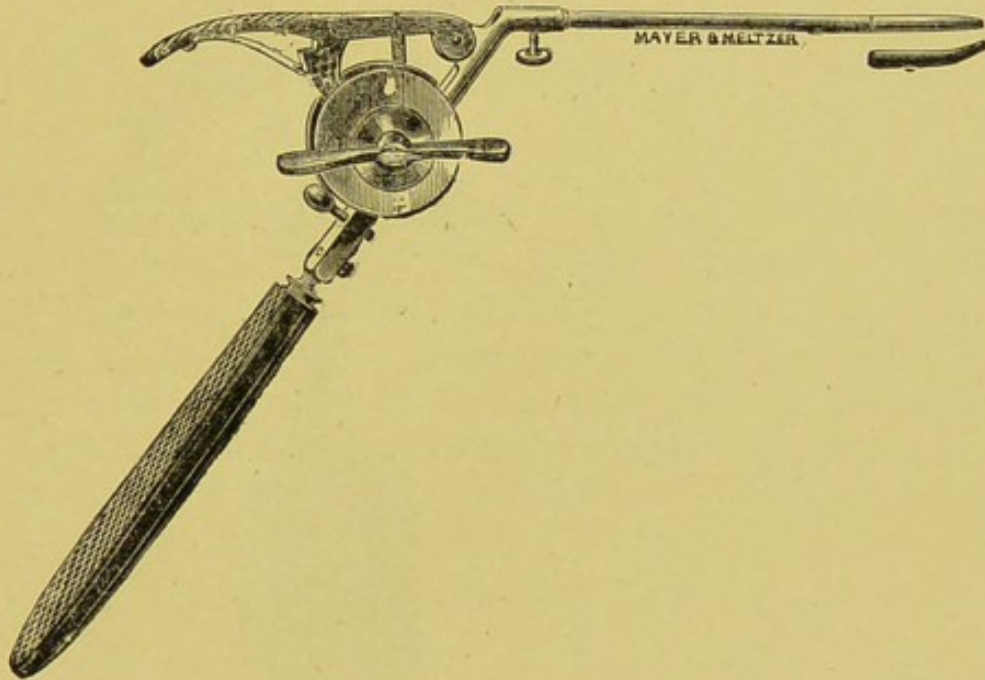


FIG. 20.—MACKENZIE'S COLD WIRE POLYPUS SNARE.

pain, and is always attended with smart hæmorrhage. It should never be employed save under exceptional circumstances, as, for instance, should it be found impossible to completely empty the cavity with the galvano-cautery or snare, or should the polypi be too numerous to be dealt with at one sitting with the snare and it is essential for the patient that they should be removed at once. In the latter case the operation should be done under general anæsthesia.

The polypus forceps (Fig. 23) are introduced, and growth after growth seized and twisted off. The surgeon's finger, if small, and the nostril is sufficiently wide, may be passed into the nasal cavity,

and will considerably aid the manipulation with the forceps. Even in skilful hands much damage may be done with the forceps. Portions of healthy mucous membrane and fragments of the turbinal bones, and at times the whole of the inferior turbinal or large portions of the middle turbinal, may be brought away with the polypus. Further, the bones so exposed may undergo necrosis, and finally come away

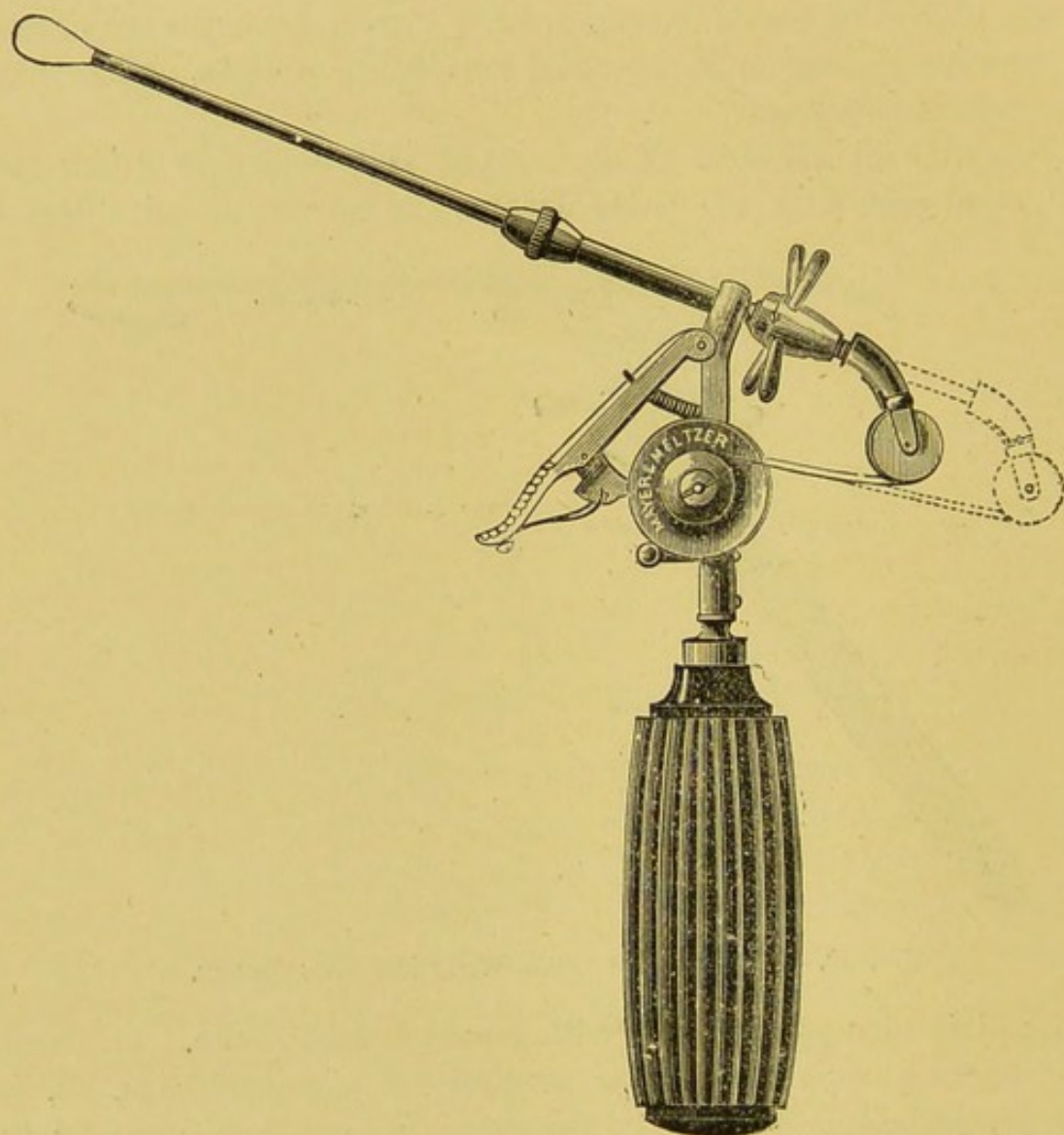


FIG. 21.—MACDONALD'S COLD WIRE POLYPUS SNARE.

as sequestra. When the polypus is far back, it may be seized by forceps introduced behind the palate; or the finger may be passed behind the palate, and thus guide the polypus into the grasp of the forceps. If the forceps are used, it is advisable to subsequently cauterize the base of the growth with the galvano-cautery under local anæsthesia, with the aid of the speculum and a good light.

After removal of polypi, in whatever way done, should there be any hæmorrhage it can usually be arrested by the insufflation of tanno-gallic acid. A plug, except a light plug of cotton-wool inserted just within the nostril to soak up any slight oozing of blood that may occur, is seldom, if ever, necessary unless the patient has been subjected to very rough usage. Tanno-gallic acid in the form of a

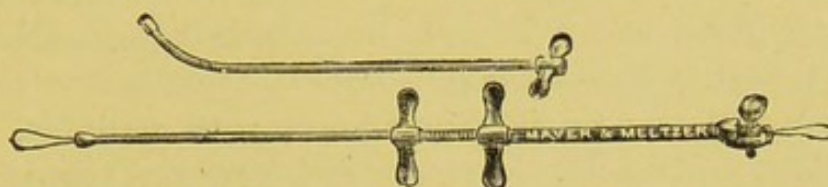


FIG. 22.—JARVIS'S SNARE.

snuff is said, moreover, to prevent a recurrence ; but I cannot say that I have ever found it exercise any influence in this way.

TREATMENT OF PAPILLOMATA.

The small wart-like papillomata found on the anterior end of the septum and inferior turbinal body, or on the inner surface of the ala, may be safely snipped off with curved scissors, or scooped out with a sharp spoon, and the base, should there be any tendency to bleed, touched with the galvano-cautery or with a stick of nitrate of silver. The larger wart-like growths and the soft, vascular, villous-like papillomata found on the turbinal bodies should be removed with the galvano-cautery or cold wire snare. The large wart-like papillomata sometimes met with filling the nasal cavity may give some

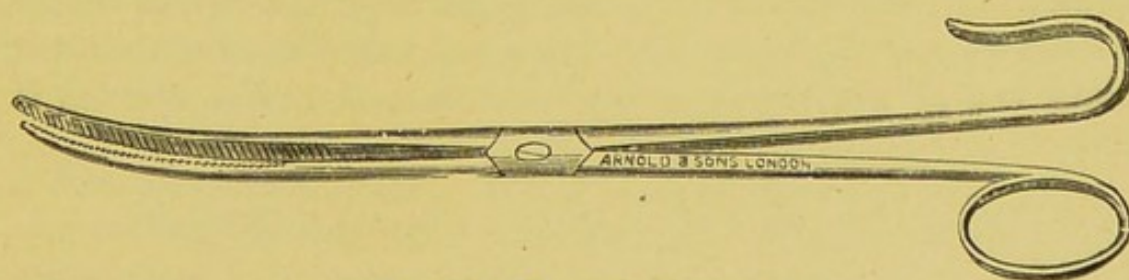


FIG. 23.—POLYPUS FORCEPS.

trouble in passing the loop of the snare, but with care and perseverance the loop can generally be placed around the pedicle. Where the pedicle is at all thick, the snare should be worked slowly, or, if the galvano-cautery is used, only a dull red heat applied. If removed too quickly, troublesome hæmorrhage may follow. Should this be the case, the bleeding-spot may be touched with the cautery at a

dull red heat, or the cavity may be plugged with iodoform gauze. If a bleeding vessel within reach is seen, it should, of course, if practicable, be seized with artery forceps, and an attempt be made to secure it with a ligature, or the forceps may be allowed to remain on for some hours, and then be very gently removed. Astringents like perchloride of iron should not be employed if it can possibly be avoided, since they tend to produce troublesome sloughs, and in the end may not prove effective. On the separation of the sloughs, moreover, secondary hæmorrhage is liable to occur. Some authors prefer to destroy the warty papillomata with chromic, carbolic, nitric, or glacial acetic acid. I have myself, however, always removed them with the scissors, snare, or spoon. Some speak well of electrolysis, but it is a difficult method to apply, and, to say the least, is uncertain in its action. I imagine no surgeon would resort to it, except, perhaps, when the growth was very large, and it was found impossible to pass the loop of the snare over it. After the removal of a papilloma, it is well to cauterize the base with the galvano-cautery or chromic acid, to prevent a recurrence. This is particularly necessary if any pedicle has been left. Where, however, a small growth has been well rooted out from the underlying mucous membrane with the curved scissors or sharp spoon, I have not found it necessary.

Multiple warty growths appear very liable to return. In a case under the care of Dr. Ingals, in which, after destruction with chromic acid, a continual recurrence was met with, he used the tincture of *thuja occidentalis* twice daily, applied on cotton-wool for twenty minutes. He thinks the *thuja* had some influence, but, as chromic acid was used at the same time, it is questionable whether the benefit should not be attributed to the chromic acid rather than to the *thuja*.

TREATMENT OF VASCULAR AND ERECTILE GROWTHS.

Capillary nævi may be treated by touching them with fuming nitric acid or ethylate of sodium. Care should be taken to limit the action of the acid to the nævus, and to avoid touching the opposite wall of the cavity, for fear of an adhesion taking place. The acid is best applied on the end of a delicate spiculum of wood, such as the end of a match, since when used in this way it is much more under control than when applied on the end of a glass rod or glass brush. It is better to touch too lightly than to do too much at each sitting, since sloughing and hæmorrhage,

if the acid is too vigorously applied, may ensue. If too much acid has been used, the excess should be neutralized by the application of a lotion of bicarbonate of soda.

Venous nævi in the nose are best treated by electrolysis, the same care in applying the needles and in regulating the strength of the current being required as in the destruction of nævi by electrolysis in other situations.

In the treatment of the *pure angiomata* and *vascular growths*, much gentleness is necessary to prevent hæmorrhage, since fatal results have followed their excision. The best way of treating them is to cut through their base very slowly with the cold wire snare or with the galvano-cautery. In a case under the care of Dr. Jarvis, three hours were consumed in cutting through the pedicle with his cold wire snare. There was but very slight hæmorrhage. The cautery should be used only at a dull red heat. When the pedicle is thin, the cautery is apt to cut through too fast, and hæmorrhage follow. The great difficulty in the treatment of these growths is that they are apt to begin to bleed as soon as they are touched, the blood then obscuring the steps of the necessary manipulation for applying the loop of the snare. All forms of injection used with the intention of producing a clot are highly dangerous, and should not be employed.

TREATMENT OF NASAL CYSTS.

Perhaps the commonest form of nasal cyst is that due to softening of an ordinary myxomatous or adenomatous polypus. These may be removed by the galvano-cautery or cold wire snare in the same way as an ordinary nasal polypus; indeed, in the few cases of these cysts I have myself met with, I believed I was dealing with a nasal polypus, till the cyst collapsed during the process of dividing the pedicle with the snare. The whole cyst-wall then came away.

For the cysts occasionally found at the anterior end of the inferior turbinal and in connection with the middle turbinal, a free incision, evacuation of contents, and cauterization of the interior, is usually sufficient, but when large a portion of the wall should be cut away.

In the case of the so-called cyst produced by expansion of the ethmoid cells, or of the tissue of the middle turbinal, a portion of the bony wall should be removed.

TREATMENT OF FIBROMATA, ENCHONDROMATA AND OSTEOMATA.

These growths, when small, may be readily snared, or cut or sawn through at the base, or chipped away by the cutting forceps. The purely cartilaginous growths may be shaved off with a strong narrow-bladed knife. Small exostoses of the turbinals, which are practically little more than irregular outgrowths of the turbinal bones, may be snipped off quite easily with the cutting turbinal forceps.

For fibrous, cartilaginous and osseous tumours of larger size, some preliminary operation for thoroughly exposing them will generally be necessary, the surgeon, of course, choosing the one that would seem likely to afford the best view. Where the growth has its origin in the antrum, partial or complete excision of the upper maxilla will probably be required, or, should it spring from the roof of the nasopharynx, a preliminary exposure similar to that employed in the removal of a naso-pharyngeal fibroma or sarcoma.

TREATMENT OF MALIGNANT INTRANASAL GROWTHS—
SARCOMATA AND CARCINOMATA.

When possible, the exact attachment of the growth, and whether it is pedunculated or broad-based, should be made out. Pedunculated growths, if small and their peduncle is in an accessible situation, may with fair safety be removed by the snare; but when of any size their extirpation by intranasal methods is so liable to be attended with hæmorrhage, and so difficult to accomplish, that it is better to make a preliminary exposure. This for the pedunculated growths need not be a severe operation; turning up the ala through an incision at its junction with the lip and cheek, or splitting the nose along the middle line and turning outward the ala with the lateral cartilage, will often suffice (see Chapter XIX.); but for sessile and broadly-pedunculated growths a more serious exposure is generally necessary, and must be determined in each individual case by the size, situation, and attachment of the neoplasm. Thus not only will it be found necessary in some cases to split the nose along the dorsum and reflect the ala outwards, but also to detach the corresponding nasal bone and turn it outwards as well. In this way a very excellent exposure of the septum and fair room for manipulation may be obtained, and but little deformity left on replacing the parts. The various methods of exposure are given in detail under the treatment of naso-pharyngeal tumours (Chapter XIX.).

Having exposed the growth, the wire of the cold or galvano-

cautery snare may be passed round it and the base slowly severed. If much of the growth has been left behind, this may be then cut away, if practicable, with the aid of curved scissors or knife, care being taken to remove a good margin of healthy tissue; where it is not feasible to use the knife or scissors, the remains may be thoroughly scraped away with a Volkmann's spoon, and the tissues around further destroyed by the actual or Assilini cautery at a dull red heat. After a radical extirpation in this way, as long as six years or more (Masson's case)* has elapsed without any recurrence. The hæmorrhage attending removal may be sharp, or even profuse. It is therefore well to plug the posterior nares, and to be provided with a good gag, plenty of sponges on holders, and efficient assistants.

Where the growth has invaded the nose from the antrum, a lesser or greater portion, or even the whole, of the superior maxilla may have to be removed; where the growth is very large and extensively implicates the surrounding tissues, or where the glands of the neck are much involved, or where there is evidence of dissemination through internal organs or in other regions of the body, surgical interference is, of course, unjustifiable. In such cases, however, the surgeon may be called upon to combat the profuse and alarming hæmorrhages which may from time to time occur. Antipyrin applied as a powder or as a solution (10 per cent.) is highly spoken of as a hæmostatic in such cases, as is also chloride of zinc. Electrolysis, with the positive pole in the nose, has been found of great service by some. Hazeline, both locally and internally, has often a marked effect. Plugging, if possible, should be avoided, since not only is it most irksome to the patient, but is too apt to be followed by fresh bleeding when the plug is removed. The galvano-cautery is also a useful method in some cases. If called to a patient *in extremis*, the nose should be plugged with iodoform gauze—or with strips of lint if the gauze is not to hand—or with lint soaked in perchloride of iron, the carotids in the meantime being compressed, the head lowered, and a pint to a pint and a half of hot saline solution injected into the rectum, or, if the apparatus is in readiness, two or three pints of hot saline solution infused into the veins.

The risks attending the removal of intranasal growths are profuse hæmorrhage, entrance of blood into the larynx, septic meningitis when the ethmoid is much involved, and erysipelas.

* *Journal of Laryngology*, 1890, p. 240. The growth had twice recurred after the intranasal method.

CHAPTER XVIII.

TREATMENT OF ADHESIONS BETWEEN THE SEPTUM AND TURBINALS, OCCLUSION OF THE ANTERIOR AND POSTERIOR NARES, AND COLLAPSE OF THE ALA.

TREATMENT OF ADHESIONS BETWEEN THE SEPTUM AND THE TURBINALS.

ADHESION between the septum and the inferior turbinal, perhaps the most common form of adhesion met with in the nose, is an exceedingly troublesome condition to deal with. The adhesion, as a rule, is readily cut through, but, notwithstanding the use of plugs, bougies, or plates, as quickly re-forms so soon as the agents used for separating the parts are dispensed with. The irritation, moreover, set up by such attempts to keep the parts separated generally leads to a further denudation of the epithelium, and a still denser adhesion is the result.

Perhaps the most satisfactory way of dealing with this form of adhesion is, first, to cut it through close to the septum, either with a tenotome or, better, with the nasal scissors (Fig. 24), hooked knife, or saw, and then with the sliding chisel (Fig. 25) or nasal punch (Fig. 26) to cut the cicatricial tissue or bone on the turbinal side away, together with a fair-sized portion of the turbinal body itself. If sufficient of the turbinal is not removed, the granulations which spring up from the wound will come into contact with the septum, and an adhesion will re-form. During healing, and until cicatrization is complete, the patient should be watched, and any exuberance of the granulations repressed by touching them with a probe coated with nitrate of silver, or with the blade of the cautery knife.

As a rule, it will be found better not to employ any form of plug or other agent for keeping the parts separated, for the reason above stated. If, however, the hæmorrhage, which is usually sharp, does not cease in a few minutes, as it generally does, a small plug of iodo-

form gauze covered with sterilized vaseline may be firmly applied to the raw surface for a few hours.

The other forms of adhesion between the inferior turbinal and

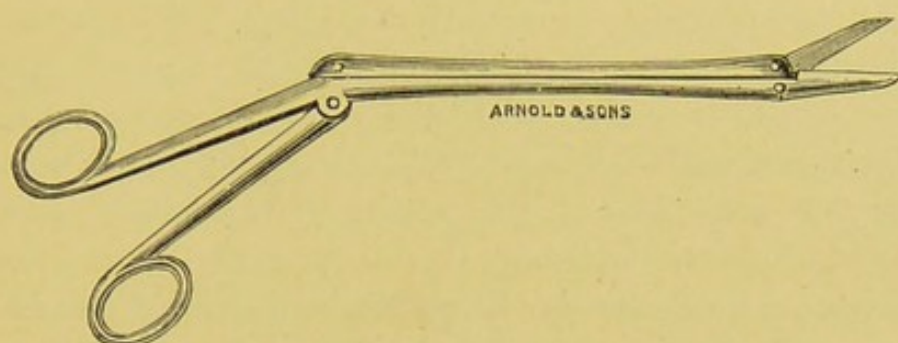


FIG. 24.—AUTHOR'S NASAL SCISSORS.

middle turbinal or floor of the nose, which, however, are exceedingly rare, may be treated on similar lines. The adhesion of the middle turbinal to the septum, so far as I know, cannot be remedied.

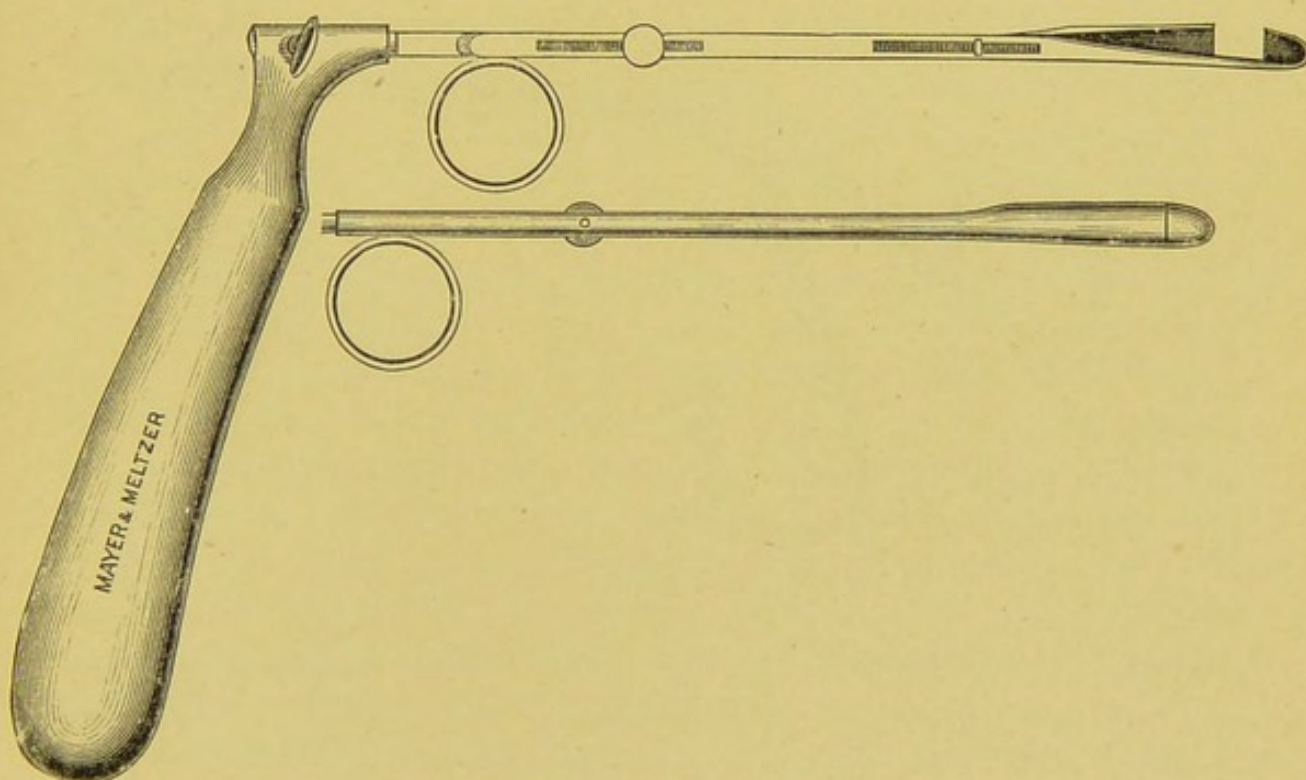


FIG. 25.—KRAUSE'S SLIDING CHISEL.

Should the adhesion, however, be productive of any trouble, the anterior end of the middle turbinal, between which and the septum the adhesion commonly occurs, may be amputated.

TREATMENT OF OCCLUSION OF THE ANTERIOR NARES.

No definite lines can be laid down for the treatment of these cases. When the result of congenital malformation, a well-planned plastic operation may do much to remedy the defect. When the occlusion is the result of cicatrization following syphilis, lupus, or tubercle, no operation should be undertaken till all active manifestations of the disease have ceased for at least twelve months; then a plastic operation, varying according to the nature of the lesion, may often be undertaken with advantage. In many cases, however, little or nothing can be done beyond attempts at dilatation, or, at any rate, the prevention of further contraction by the use of plugs, bougies, or tents, or the wearing of a properly-shaped silver or vulcanite tube.

TREATMENT OF OCCLUSION OF THE POSTERIOR NARES.

In congenital cases, the occluding tissue, if found to be membranous, may be divided in a vertical direction, and the communi-

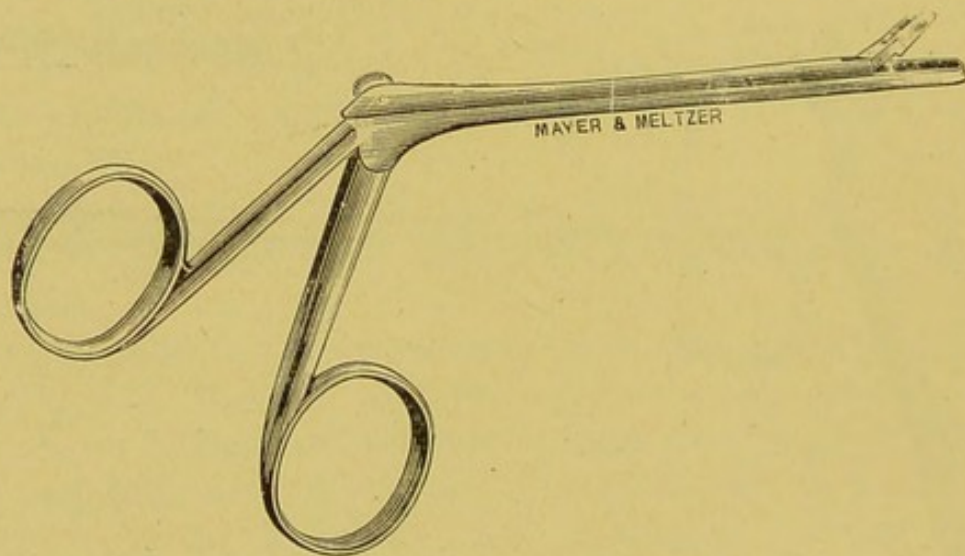


FIG. 26.—GRÜNWARD'S NASAL PUNCH.

cation between the nose and naso-pharynx thus formed kept patent by the introduction of an indiarubber drain-tube, or by the daily passage of a bougie till cicatrization is complete. Where the partition is bony, it may be cut through either with the nasal saw or with the nasal drill. If the saw is used, a passage for its blade must first be made with the drill, unless the partition is partly membranous, when room can, of course, be made for the saw with a knife. The saw should first be applied parallel to, and close to, the septum, and then a second cut made parallel to the first, and a

quarter of an inch or so from the septum, according to the age of the patient.

In young children the operation is, perhaps, best done with the drill, two or three vertical holes sufficing. In older patients, angular processes left by the drill and saw may be trimmed off with a fine nasal chisel. General anæsthesia is usually required, since the manipulation will be much facilitated by the aid of the finger passed behind the soft palate. In adults, in addition to vertical incisions, two cross-cuts with the saw above and below will probably be found necessary.

Where a mere bony bridge exists, this is readily cut through with the saw, two cuts being made on either side, and the intervening bony portion removed. In cicatricial cases, probably all that can be done is to divide the thickened tissues vertically with the knife or galvano-cautery, trusting to plugs or the passage of bougies for preventing recontraction, which, however, will only too probably occur.

TREATMENT OF OBSTRUCTION DUE TO COLLAPSE OF THE ALA.

Where, in conjunction with the collapse of the ala, there is some deviation of the septum or enlargement of the turbinal body, a slight shaving should be taken off the septum, and the size of the turbinal reduced by appropriate means. If this is not enough, an attempt may be made to prevent the ala collapsing during inspiration by a vulcanite or metal ring or plate, but such are difficult to fit and adjust. I have seldom found patients persevere with them for any length of time. In one case that came under my notice some years ago, the insertion of a tiny plug of cotton-wool just within the nostril, in the little fossa at the angle of junction of the ala and septum, was found quite sufficient to prevent the ala falling into contact with the septum, and gave complete relief. After various contrivances had been used, with more or less complete failure, the patient fell back on his plug of cotton-wool.

Massage of the dilator muscles has, in a few cases, been of some service, but what I believe would give the greatest relief, though I have not hitherto been allowed to do it, would be the removal of a tiny elliptical portion of the tissues along the line of junction of the ala with the cheek. It is, of course, assumed that any cause of obstruction in the nose or the naso-pharynx has been excluded.

CHAPTER XIX.

TREATMENT OF THE NASO-PHARYNGEAL CAUSES OF NASAL OBSTRUCTION.

STENOSIS OF THE NASO-PHARYNX, TUMOURS OF THE SOFT PALATE, RETROPHARYNGEAL ABSCESS, RETRO-PHARYNGEAL TUMOURS, ADENOID VEGETATIONS, AND NASO-PHARYNGEAL POLYPI.

TREATMENT OF STENOSIS OF THE NASO-PHARYNX.

THE treatment of this condition is very unsatisfactory ; for not only is it very difficult to establish a communication between the nasopharynx and the mid-pharynx when the stenosis is complete, or to enlarge the opening when one exists, but even if this is accomplished, the patient's condition may not be very much improved, since, although nasal respiration may to a greater or less extent be restored, it is often only at the expense of the passage of food and drink through the aperture into the nose.

Where no aperture exists, an attempt may be made, if it is thought desirable, to form a communication between the upper and mid-pharynx, by cautiously dividing the cicatricial tissue in the middle line, and then endeavouring to prevent recontraction by the use of a plug, tent, or suitably bent tube.

The operation, as a rule, is best done under an anæsthetic, as the surgeon will be considerably helped by the introduction of his index-finger, if sufficiently small, through the nose. If found practicable, it is advisable to take off a semi-elliptical slice from the tissues on each side of the central incision, and, if the tissues are not too rigid, to endeavour to bring the mucous membrane on the pharyngeal and nasal surfaces into contact, so that the newly-formed aperture has a mucous lining. The probabilities are that this will be found impossible, but an attempt in a suitable case should, nevertheless, be made, and may at times be accomplished by cutting a V-shaped

groove, with the base corresponding to the raw surface, in the tissues surrounding the aperture. The flaps thus made should be then brought together by one or two horsehair or fine fishing-gut sutures.

If an aperture is already present, and it is desired to enlarge it, a similar semi-elliptical removal of the tissues surrounding the aperture may be made, and the mucous surfaces, if possible, brought together in the same way; or the existing aperture may be enlarged, by making an incision either in a backward or forward direction according to the situation of the existing hole. An endeavour to prevent recontraction should then be made, either by the use of a plug, tent, or tube, or by the formation, if practicable, of some form of mucous flap to cover in the raw surface.

These cases are, fortunately, however, few and far between, and two exactly similar conditions are seldom met with. The surgeon will have, therefore, to exercise his ingenuity in each individual case; but some operation on the lines above laid down will serve as a general guide if it is thought feasible to attempt to rectify the condition. The risk of the passage of food into the nose if too large an opening is established should not be forgotten, but something can be done to obviate this trouble by the patient wearing a suitable plug or plate whilst taking his meals.

TREATMENT OF NEW GROWTHS IN THE PALATE.

Only such growths as may give rise to nasal obstruction here receive attention. Our consideration, therefore, is practically limited to the adenomata and sarcomata.

Adenomata of the palate may be readily exposed by a free incision through the overlying mucous membrane and capsule of the growth. They can then, as a rule, be enucleated with the greatest facility. In the cases I have thus treated, there has been but little hæmorrhage, and the mucous membrane, after the removal of the tumour, has rapidly contracted, the edges of the wound falling well together and requiring no sutures. The application of sutures in this situation only exposes to the risk of an abscess and septic absorption, and is in my experience quite unnecessary.

Sarcomata, in many instances, will shell out like the adenomata. Indeed, before removal, it may be quite impossible to distinguish some forms of sarcoma—for instance, the small spindle-celled—from adenoma. Infiltrating sarcomata and carcinomata may be excised with the knife in the early stage, but, as a rule, by the time

that they have given rise to nasal obstruction, they have so extensively involved the surrounding tissues that operative interference is unjustifiable.

TREATMENT OF RETROPHARYNGEAL ABSCESS.

The pus, as soon as it is discovered, should be let out through a free incision. Much discussion has arisen, and some difference of opinion exists, as to whether the incision should be made through the mouth, or externally through the neck. In simple abscesses, as, for instance, those depending upon trauma or localized retropharyngeal inflammation, where the abscess is pointing through the retropharyngeal wall, and where the mouth can be fairly widely opened, I have no hesitation in recommending a free incision through the retropharyngeal wall. It is the incision I have employed myself, and with the most satisfactory results, healing without further complication of any kind having taken place in a few days. On the other hand, where there is considerable swelling about the angle of the jaw, where the retropharyngeal swelling is but a part of a phlegmonous inflammation of the cellular tissue of the neck, and where the mouth cannot be sufficiently widely opened to obtain a good view of the back of the pharynx and easy access for the necessary manipulation, an incision through the neck is probably the better course. In all cases where the abscess depends upon caries of the cervical vertebræ, or tuberculous trouble in the deep cervical glands, or is but a part of a phlegmonous inflammation of the cellular tissue of the neck, the incision should certainly be made externally. When it is decided to open the abscess through the mouth, precautions should be taken to prevent the gush of pus entering the larynx, especially if the patient is under general anæsthesia, since several fatalities have thus occurred. The method I have myself pursued has been to first puncture the abscess with a long, and fairly large-sized trocar and cannula, and thus direct the first gush of pus well out of the mouth, and then subsequently convert the puncture into a free vertical incision with an ordinary scalpel. If this method is adopted, the patient may be safely placed in the recumbent position, with the shoulders slightly raised and the head thrown back. The mouth should be widely opened with a gag, the tongue well depressed in order to thoroughly expose the parts. Only very light anæsthesia should be employed. Immediately the incision has been made, the patient's head should be turned to one side, that the pus may run

into the cavity of the cheek, whence it may be freely mopped away by sponges on holders. Some surgeons, to prevent the pus entering the larynx, open these abscesses with the head in the hanging position. Scraping or curetting the cavity is advised by some, but it is certainly not necessary unless the abscess is of tuberculous origin, since ordinary cases, I have found, if left entirely alone, as a rule, readily and quickly heal. The mouth and throat may be kept cleansed with weak Condyl's lotion, and for the first twelve hours or so food and drink withheld. Where the abscess has been naso-pharyngeal rather than pharyngeal, and the soft palate has been pushed forward, so that the abscess could not be reached below it, I have made the incision through the soft palate itself, and can speak favourably of the method. In opening these abscesses through the neck, the incision should be made over the most prominent part of the swelling, if such exists, and the dissection carried cautiously down towards the abscess. When the abscess depends upon cervical caries, the cavity should be scraped out, irrigated, and either closed or, perhaps better, save under exceptional circumstances, drained by means of a fair-sized tube. The strictest antiseptic precautions should be employed throughout. If any carious bone is felt with the finger, it should be, as far as is prudent, scraped away; a sequestrum, if discovered and found loose, should of course be removed.

TREATMENT OF RETROPHARYNGEAL TUMOURS.

Innocent retropharyngeal tumours may be readily enucleated after a vertical incision has been made over them through the mucous membrane and their capsule. The wound left heals quite rapidly, and requires neither sutures nor drain. It should be kept cleansed for the first few days by antiseptic gargles and washes. It may be well also for the patient to abstain from taking food or liquids by the mouth for twelve to twenty-four hours after the removal of the growth, if the wound left is of any size.

Malignant retropharyngeal growths may, when encapsuled, as is sometimes the case in the fibro-sarcomata, shell out, like the innocent growths. The infiltrating varieties, however, can only be effectually dealt with by free incision with the knife, and then only when small and localized. Removal with the galvano-cautery snare is only practicable when the growth is pedunculated, or, if sessile, has a narrow base. But for such I myself prefer the more surgical procedure of excision with the knife. Where the growth is situated high in the

naso-pharynx, a preliminary exposure is desirable, and this can best be accomplished by splitting the soft palate in the middle line, and holding the flaps apart by silk threads. If more room is required, part of the hard palate may be readily chiselled away. After removal of the growth, the palate should be united by suture in a manner similar to that employed for the cure of cleft palate.

TREATMENT OF ADENOID VEGETATIONS.

Seeing that adenoid vegetations are little more than a hypertrophy of the lymphoid tissue normally existent in the naso-pharynx, it naturally follows that the amount of growths discovered may vary from a little more than what may be considered the normal condition, to large masses, more or less completely blocking up the choanæ. It has been found by experience, moreover, that the symptoms and effects to which adenoids may give rise do not necessarily depend upon the amount of the growths. Thus, although very little growth is present, there may be well-marked deafness, chronic catarrh, or oft-recurring colds, whereas the naso-pharynx may be literally stuffed with the vegetations, and yet, beyond mouth-breathing, the symptoms may be but slight. The mere amount of the growths is not, therefore, the chief consideration in advising as to the desirability of an operation.

Where the amount is excessive, and the nasal obstruction is extreme, there can, I imagine, be little doubt as to the propriety of their removal, any more than there is in the case of the faucial tonsils when these are greatly enlarged. If they are allowed to remain, not only is the child exposed to the supervention, sooner or later, of middle-ear trouble and catarrhal conditions of the nose and upper respiratory passages, but, as a direct result of impeded nasal respiration, they may be followed by alteration of the voice, adenoid expression of face, mental hebetude, aprosexia, stunted physical development, round shoulders, ill development of the chest, etc., and they may further dispose the patient, through the defective aeration of the blood, to tuberculous phthisis.

When the amount of growth is slight, perhaps little more than an enlargement of the pharyngeal tonsil, the question of operation will depend in great part upon the symptoms that may at the time be present. If the child is already deaf, or has had transient attacks of deafness, chronic colds, etc., I have no hesitation in strongly advising operation, however little growth may be discovered. On the other hand, if there has been no deafness or other well-

marked symptom, they may be left for a while, the patient in the meantime being given cod-liver-oil and the syrupus ferri iodidi and removed, if possible, to a dry, bracing climate. In this way the growths may atrophy and disappear without giving rise to any serious trouble. On the other hand, if, in spite of such treatment, they should increase, and the symptoms become marked, their immediate removal is imperative. Nor must it be forgotten that, although adenoids may disappear, and more frequently, perhaps, than is admitted by some, or cease to give trouble after the age of puberty, there is always a danger of their persisting into young adult life, and of the symptoms, at first slight, becoming pronounced. They may even at times be found in adults of mature or advanced age. In the cases of this kind that I have met with there has been more or less permanent deafness.

In deciding on the propriety of an operation, moreover, it should not be forgotten that, like the faucial tonsils, adenoid growths may vary in size from time to time, and this may possibly be the explanation of those cases in which deafness is present although the growths are found small in amount. Hence, if well-marked symptoms recur at intervals, it must not be concluded that, because little growth is detected at the time of examination, the cause of the trouble has not its origin in the naso-pharynx; whilst, again, it should be borne in mind that the symptoms characteristic of adenoids may depend upon congenital narrowing of the nasal chambers, a condition which, when the adenoids are small in amount, should of course be excluded before an operation is undertaken.

To sum up: The chief indications, perhaps, for the removal of adenoids may be said to be—(1) well-marked signs of nasal obstruction, such as mouth-breathing, adenoid expression of countenance, alteration of voice; (2) deafness or oft-recurring attacks of deafness, the result of middle-ear disease; (3) continually recurring head-colds or nasal, laryngeal or bronchial catarrh; (4) paroxysmal attacks of sneezing, hay-fever, laryngismus, or spasmodic asthma; (5) defective physical and mental development; (6) chronic tuberculous enlargement of the cervical glands.

In addition to the above, there are other conditions which are said to have been benefited by the removal of adenoid vegetations, such as nocturnal enuresis, stammering, chorea, epilepsy, and rickets.

There are many methods of removing adenoid vegetations. Some advise that the naso-pharynx should be merely scraped with the

finger-nail, or with the finger armed with the thimble-scraper; others employ various modifications of Löwenberg's forceps, others some variety of Gottstein's scraper, others some form of Meyer's ring knife, and others, again, a combination of these methods and instruments. Destruction by caustics or by the galvano-cautery are methods which are now obsolete.

Almost all surgeons, save under exceptional circumstances, operate under general anæsthesia. Removal under local anæsthesia at several sittings had formerly the support of some eminent surgeons and specialists, but the advantages of general over local anæsthesia for these cases are now so universally recognised that they need not be here discussed. The only cases in which I have employed local anæsthesia have been those in which the parents or the physician in charge would not allow the child to take a general anæsthetic. The anæsthetics generally used are gas alone; gas and ether; gas, ether and chloroform; and chloroform alone. The last appears to be attended with special danger in these cases, and should be avoided if possible. Gas is too transitory in its effects to allow of the operation being thorough and complete. The best and least objectionable is a combination of gas and ether, the patient being first placed under the gas, and then the ether slowly given till the patient is well under its influence, and, though not deeply anæsthetized, has sufficient ether in his blood to keep up the anæsthesia for a considerable time.

If sensibility begins to return before the operation is completed, as it may do when the tonsils as well as the adenoids have to be removed, light anæsthesia may be continued with chloroform administered through a tube by Junker's apparatus. The anæsthesia should never be deep; the laryngeal reflexes should not be abolished, and the pupils should be kept in a state of pin-point contraction.

With regard to the position of the patient during operation, much has been written. Some employ the sitting position; *i.e.*, the patient is anæsthetized sitting in a chair. All the anæsthetists I have spoken to on this subject consider that this position is attended with considerable risk. I have had no experience of it myself. Others place the patient in Roser's position, *i.e.*, with the head hanging back over the end of the table. The advantages claimed for this latter are that the blood cannot enter the larynx but runs into the nasopharynx, and that it is very convenient for the operator. The objections to it are that it causes congestion and increased hæmorrhage,

and that the blood in the naso-pharynx prevents the growths from being well defined and hence thoroughly removed. Others prefer the patient in the recumbent position, with the head and shoulders slightly raised; but there is then some danger of blood entering the larynx should the anæsthesia be pushed to the extent of inhibition of the laryngeal reflexes. I have always employed the recumbent position myself, with the shoulders raised, but with the head

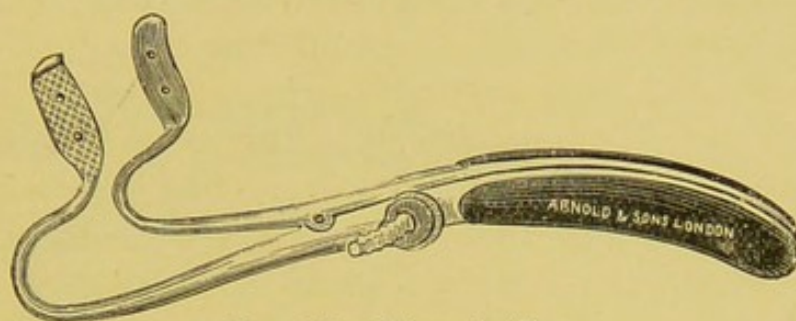


FIG. 27.—MASON'S GAG.

slightly depressed over a small pillow and turned towards the operator, or turned that way from time to time during the operation, so that the blood may run into the cheek, whence it can be continually sponged away. The advantages of this position are that the naso-pharynx is kept clear of blood, and at the same time there is little risk of blood entering the larynx.

The following operation is the one I have invariably practised

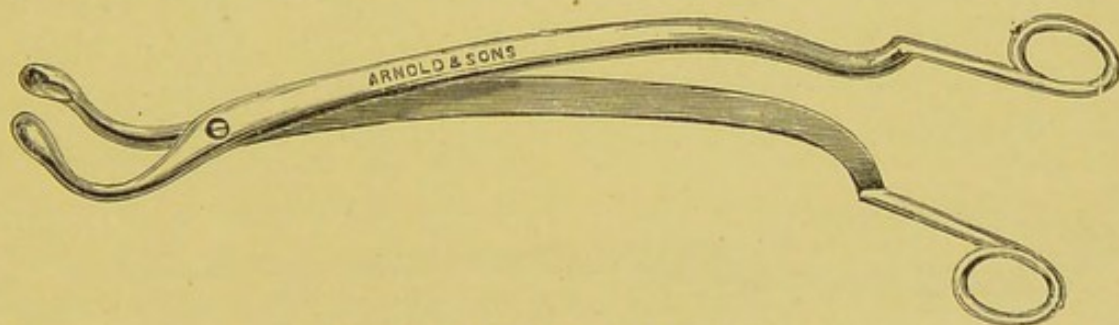


FIG. 28.—LÖWENBERG'S FORCEPS.

since the subject of adenoids was brought to our notice by Meyer. I have found it satisfactory in every way.

The patient having been brought well under the influence of the ether, the surgeon, standing on the patient's right side, introduces a good gag (I prefer Mason's, Fig. 27) into the mouth, and, placing it between the teeth of the left side, intrusts it to the assistant, or, better, to the anæsthetist, who has thus control of the lower jaw, and can manipulate it as the exigencies of the anæsthesia may require.

The mouth being widely opened, the tonsils, if enlarged, are first removed with the guillotine or tonsillotome, and a few moments allowed for the hæmorrhage to cease, the throat being kept well sponged during the interval. The right forefinger is now introduced into the naso-pharynx, and the circumference of the cavity well scraped with the nail, thus removing some of the smaller growths and carrying the larger towards Luschka's tonsil. Löwenberg's forceps (Fig. 28), or some one of the modifications of them (Fig. 29), are

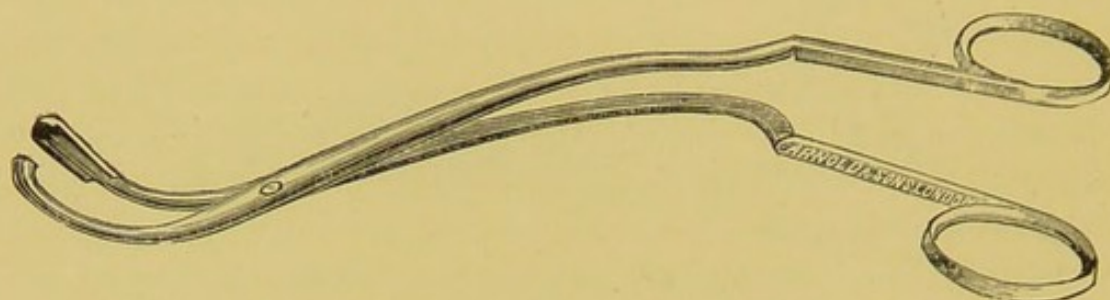


FIG. 29.—AUTHOR'S MODIFICATION OF LÖWENBERG'S FORCEPS.

The cutting blades are prolonged.

next passed behind the palate, care being taken to avoid grasping the uvula, and a mass of vegetations seized and brought away with the forceps, which are then shaken in a small bowl of water to free the blades of the growths. In this way the forceps are rapidly introduced, withdrawn, and cleansed, five or six times, bringing away the larger masses of the growth. In using the forceps, care should be taken not to seize or lacerate the lips of the Eustachian tube—a mishap that may be easily avoided by keeping the forceps in the middle line—and not to lay hold of and punch a piece out of the septum.



FIG. 30.—MEYER'S RING KNIFE.

The fore-finger is now again passed into the naso-pharynx, and the situation of any large vegetations that may have escaped having been defined, they are removed with the forceps. Meyer's ring knife (Fig. 30) is next slid along the inferior meatus of one side, and any vegetations situated in Rosenmüller's fossa and about the orifice of the Eustachian tube are carefully scraped away, the knife being guided by the finger behind the palate. The opposite side is treated in the same way. Some one of the many modifications of Gottstein's

scraper (Fig. 31) is next passed from below the palate into the naso-pharynx, and the base of the ring having been placed on the roof of the cavity just behind the choanæ, the scraper is drawn firmly over the roof and posterior wall of the naso-pharynx, thus removing any growth that may have escaped the forceps. Lastly, the finger-nail is swept round the upper margin of the choanæ, and the small fringe-like growths in this situation scraped away. The finger, before its withdrawal, is also carried round the circumference of the cavity, and especially through Rosenmüller's fossa, to make sure that the operation has been thoroughly and effectually performed, any small growths that may have been missed being removed by the nail. During the operation the head is turned from time to time to the right side, so that blood may run into the cavity of the cheek, whence it is sponged away. On the completion of the operation, the gag is kept in for a few minutes, until consciousness has partly returned, when the patient usually vomits some of the blood that he has swallowed, or he does so on being moved back to bed. The surgeon should therefore be in




FIG. 31.—GOTTSTEIN'S SCRAPER.

readiness for this, to prevent an unnecessary soiling of the room and bed. When the naso-pharynx has been thoroughly cleared of the vegetations in this way, I have never known any recurrence to take place. The operation here described, however, cannot be done under gas and in a few minutes, as some advise. At least ten minutes is required if the tonsils have also to be removed.

Should the first effects of ether begin to wear off towards the end of the operation, the patient is kept quiet by a few whiffs of chloroform given through Junker's tube. Unless the pharynx is completely cleared, there is a risk of the operation being required a second time. Where the naso-pharynx has been rapidly scraped with the patient under gas by other surgeons and throat specialists, I have had occasion to repeat it, bringing large masses of growths away. One patient on whom I operated, removing a large crop of vegetations, had had his throat twice scraped previously in the rapid manner, which I venture to affirm is quite inefficient if firm and large growths are present, and except in very slight cases in which it is questionable whether any operation is called for at all.

The hæmorrhage is often very free, but invariably ceases at the conclusion of the operation if no injudicious attempts are made to stop it by syringing the nose or throat with cold water, ice-water, etc. I never do anything myself but place the patient back in bed, darken the room, and allow him to sleep off the effects of the anæsthetic. Vomiting of blood from the stomach often continues at intervals from six to twelve hours, and during this period it is better to give the patient nothing save an occasional teaspoonful of hot water, or a small piece of ice to suck. No after-treatment in the way of syringing, etc., of any kind is employed beyond keeping the patient in bed in a warm room and out of a draught for the first two days and confined to the house for another two or three days. When this precaution is taken, very little risk is run of middle-ear or other trouble. I am inclined to believe that when middle-ear trouble occurs, it is in great part due to the employment of antiseptic syringing and douchings, and neglect to keep the patient in an equable temperature for a few days. If the instruments, hands and sponges are perfectly clean and aseptic, no septic material is introduced at the time of operation, and if the surgeon is then content to leave the parts absolutely alone, an aseptic blood-clot seals up the raw surface and aseptic healing ensues. In making this statement, I of course exclude lacerations of the lips of the Eustachian tube, penetration of the mucous membrane, bruising of the septum, and other injuries that may be inflicted by a clumsy or careless use of the forceps. Such a laceration of the Eustachian tube may not only lead to suppuration in the middle ear, but may cause permanent deafness through its complete closure from cicatricial contraction.

After the removal of adenoids, careful after-treatment is necessary to correct the habit of mouth-breathing. At times it may be of advantage to tie up the lower jaw at night-time with a four-tailed bandage. Should any erection or hypertrophy of the turbinals remain, they may be touched with the galvano-cautery in the way described at p. 158.

TREATMENT OF NASO-PHARYNGEAL TUMOURS.

In undertaking the treatment of a naso-pharyngeal tumour, the most important point for consideration is, 'Can the growth be removed through the natural passages, or ought a preliminary exposure to be made, in order that it may be rendered accessible, and so extirpated with efficiency and safety?' Thus, some growths, as the

myxomata, springing from about the choana and protruding into or filling the naso-pharynx, may be removed by merely seizing them with forceps from behind the soft palate and then wrenching them away, or by a snare passed around the pedicle of the growth either through the nasal cavities or from behind the palate. On the other hand, such growths as the fibro-angiomata springing from the roof of the naso-pharynx cannot thus be safely dealt with. They must be first exposed by a preliminary operation. The mere wrenching of them away with forceps passed behind the soft palate, without first obtaining a good view of their connections, is a highly dangerous procedure; for not only does it subject the patient to the risk of severe and perhaps fatal hæmorrhage, the source of which cannot be seen so that it may be controlled, but, as these tumours sometimes invade the interior of the cranium, portions of the cerebral membranes or brain may thus be dragged away. The operations for dealing with a naso-pharyngeal growth, therefore, may be considered under the heads of (1) operations for the removal of the growth, and (2) preliminary operations for exposing it.

1. *Operations for the Removal of Naso-Pharyngeal Growths without Preliminary Exposure.*

These are: (a) Avulsion with forceps passed behind the soft palate; (b) snaring with the cold wire *écraseur*; (c) snaring with the galvano-cautery loop; (d) enucleation with the blunt raspatory; (e) destruction by electrolysis; and (f) injection with chemicals.

Certain tumours, as the myxomatous, which spring from the mucous membrane, just within or about the choana, and then, as they enlarge, encroach upon, and even fill, the naso-pharyngeal space, are best removed by avulsion with the forceps passed behind the soft palate; but they may also be removed by the cold or galvano-cautery snare passed through the nose and directed round the growth with the finger behind the palate. Small fibromata and fibro-angiomata when pedunculated and the peduncle is fairly slender may also be extirpated in this way; but even for such, evulsion and snaring is not likely to prove a radical measure, except the base of the growth is at the same time, or subsequently, destroyed by thoroughly cauterizing with the post-nasal galvano-cautery. For larger growths of this character, especially when sessile and attached by a broad peduncle, or when secondary attachments have been formed, evulsion or snaring without a preliminary exposure is not to be re-

commended. Avulsion is not only unlikely to be effectual in completely extirpating the growth, but is also attended with considerable danger. The chances of a thorough removal are very small, and even if destruction with the post-nasal galvano-cautery (Fig. 32) of the portion that remains is subsequently attempted, a complete eradication is very unlikely. So much of the growth is generally left behind that its destruction with the galvano-cautery becomes a serious matter, and one of considerable difficulty. The dangers attending avulsion are excessive hæmorrhage and injury to the meninges or brain should the growth, as has at times happened, have invaded the interior of the cranium. Where the base of the growth contains much cavernous tissue, the hæmorrhage attending a partial removal may be most alarming, the blood literally pouring from the large and thin-walled vessels or blood-spaces in an uncontrollable stream. When, therefore, the base is very broad, or the growth has encroached upon the neighbouring cavities and formed secondary attachments to the



FIG. 32.—POST-NASAL GALVANO-CAUTERY.

surrounding parts, as, also, when it has attained a very large size, some one of the preliminary operations described later, at p. 225, must be performed for the purpose of obtaining a good exposure of the growth before any effectual attempt can be made to extirpate it by forceps, by the cold or galvano-cautery loop, or by other means. Rapid enucleation with a blunt raspatory, after the growth has been satisfactorily exposed, has answered in my hands for thoroughly extirpating the tumour. In some cases, where the growth has been of a very large size, and where the patient has been so run down by excessive and oft-recurring hæmorrhages as to be unable to undergo a serious preliminary operation, the growth has been successfully destroyed by electrolysis, or the injection of chemicals, or at least so reduced in size as to allow of its safe removal either with or without a preliminary exposure. I have had no personal experience of electrolysis or injections in the treatment of these growths; but some very successful cases have been reported, and the methods appear well worth a trial under circumstances such as those stated above.

(a) **Avulsion with the Forceps.**—This method is, in my opinion, the best way of dealing with myxomatous growths in the naso-pharynx. It is also employed by some surgeons for the removal of pedunculated and small fibromata and fibro-angiomata; but, for the reasons already given, it is not to be recommended in the treatment of such. Avulsion may be done either with or without an anæsthetic. When no anæsthetic is used, the patient is placed in a low chair, with his head thrown well back and steadied by an assistant. The mouth being widely opened, the surgeon passes a forceps, with the blades curved at right angles to the stem, behind the soft palate, seizes the growth firmly as near its peduncle as possible, and with a rotatory and dragging movement forcibly twists it off at its stalk. Generally some forward ramifications which have made their way into the nasal chamber on one or other side will come away with the main globular or pear-shaped mass of the tumour, and nasal respiration is at once completely restored.

There has been very little hæmorrhage, practically none, in the ten or twelve cases I have treated in this manner. An anæsthetic, either local or general, is quite unnecessary, but the palate and base of the tongue, if very irritable, may be painted with cocaine. If, however, on account of nervousness on the part of the patient, or for other reasons, a general anæsthetic is employed, the mouth must be held widely open by a suitable gag.

Local anæsthesia, as with cocaine, is hardly applicable if the growth is of any size, and especially if it has invaded either nasal chamber, since the anæsthetic cannot be applied to the attached spot, and pain is only felt at the moment that the stalk is wrenched through, and then in itself is very slight. In smaller growths, as, for instance, those merely projecting through the choanæ, where it may be difficult to seize them without a preliminary introduction of the finger once or more behind the palate, it is better to spray the naso-pharynx and the nasal cavity on the affected side with cocaine, or, better still, to place the patient under general anæsthesia, since removal of these small growths is often attended with considerable trouble and somewhat prolonged manipulation. With the patient, too, under general anæsthesia, the forceps or finger can be passed along the nose to detach the pedicle, if it is found, as sometimes happens, that the growth cannot be seized with the curved forceps behind the palate. Moreover, should nasal polypi be also present, these can be taken away at the same sitting.

(b) **Removal with the Cold Wire Snare, or Ecraseur.**—This method is preferred by some surgeons for the removal of myxomatous growths to avulsion with the forceps. It is also employed by some for the extirpation of fibromata and fibro-angiomata, when small and pedunculated, and in some cases is an efficient method of dealing with a growth after a preliminary exposure has been obtained. The objections to its use in the removal of fibromata and sarcomata without preliminary exposure have already been discussed (p. 219).

The operation may be performed either with or without general anæsthesia. When the growth is small and pedunculated, the naso-pharynx roomy and tolerant of instrumentation, the nasal passage sufficiently wide and well formed to allow of the passage of the stem of the snare, and the growth projects backwards and downwards so that the wire loop can be easily manipulated over it by the help of the rhinoscopic mirror, local anæsthesia will be found sufficient. If, however, the reverse of these conditions obtains, and if the finger has to be passed behind the palate to guide the loop over the growth, so much annoyance and irritation is produced that I now, if unable to guide the wire loop with the rhinoscope, always place the patient under a general anæsthetic.

If it is determined to remove the polypus without general anæsthesia, the nasal chambers on the affected side, and the naso-pharynx, should be well sprayed with a 20 per cent. solution of cocaine. It is also well to spray the soft palate and fauces. The snare with the wire loop bent to an angle suitable to the direction of the growth, moulded to the proper shape, and made of a sufficient size for slipping readily over the polypus, is introduced through a speculum into the nostril on the affected side, and gently slid along the floor of the nose close to the septum till it reaches the naso-pharynx. With the aid of the rhinoscopic mirror introduced behind the palate with the left hand, the wire loop is manipulated over the base of the growth. This part of the procedure is a delicate one, and, even with a practised hand, is often attended with difficulty. The growth having been encircled, the loop is next tightened by working the handle, button, wheel, or ring of the snare, according to the kind of instrument used. As soon as the loop has been drawn sufficiently tight to prevent its slipping, the further tightening is done very slowly, so as gradually to tear through, to crush as it were, the tissues and thus prevent hæmorrhage. When the polypus is severed from its attachment, it either drops into the naso-

pharynx and thence into the pharynx, whence it is expelled by the patient, or it is seized by the forceps behind the palate and thus withdrawn. As soon as any hæmorrhage that may occur has ceased, the attachment should be examined with the rhinoscope, and if any portion of the growth is seen to remain, it should be destroyed by the post-nasal galvano-cautery passed behind the palate and pressed firmly upon the stump of the growth. This method cannot be employed where the parts are exceedingly intolerant of manipulation even under cocaine, where the patient is exceptionally susceptible to its influence, and where the space between the soft palate and posterior wall of the pharynx is unusually small.

If a general anæsthetic is employed, after the patient has been brought under its influence, the mouth should be widely opened with a gag, and the snare with the loop prepared in the way above described passed along the nose into the naso-pharynx. The finger is next introduced behind the soft palate, and the loop manipulated over the growth. Whilst the surgeon ensures with his finger that the loop is well pushed around the base of the growth, an assistant should gradually draw it tight by working the mechanism at the end of the stem. The base of the growth should be now slowly severed. Before the separation is completed, a curved forceps should be passed behind the soft palate, and the growth seized, so that it may not fall into the pharynx, and either be swallowed or obstruct or enter the larynx. No traction, however, should be made on the tumour with the forceps till the separation with the snare is completed.

When a preliminary exposure has been made, the wire loop can of course be directed over the growth by the aid of the eye as well as by the finger. If the exposure has been obtained by one of the operations of splitting the palate, the loop may be passed either through the nose or through the mouth; if by one of the anterior operations on the nose or by removing or resecting the superior maxilla, the loop may be passed either through the nose or through the wound according as the one or the other method is found the more convenient.

(c) **Removal with the Galvano-Cautery Snare.**—This method only differs from the preceding in that the wire loop is capable of being heated by the electric current. It can also be employed either with or without general anæsthesia. The manipulation up to the point at which the wire loop is tightened round the base of the growth is

practically the same. Then, instead of tearing slowly through by gradually tightening the wire, the button or lever on the cautery handle is pressed down, the connection with the battery or transformer established, and the wire loop around the base of the growth becomes hot and burns through the growth. A dull red heat only should be employed, lest the peduncle be too quickly severed and hæmorrhage ensue.

(*d*) **Enucleation with a Blunt Raspatory.**—This method is only applicable to those cases in which preliminary exposure has been obtained. The raspatory is then inserted between the growth and the bone, and by a rapid sweep of the hand the neoplasm is separated from its bed. The method is especially applicable to sessile tumours with broad bases. The hæmorrhage is profuse for a moment or two, and a reliable assistant should be at hand to keep the throat clear. But as soon as the enucleation is complete it can be readily arrested by a firm plug of gauze. The great advantage this method of enucleation possesses is that the whole growth is got rid of, the bone being left bare, whereas when the forceps, snare, or cautery-loop is employed, a portion of the growth is apt to remain behind.

(*e*) **Destruction by Electrolysis.**—Destruction by electrolysis appears to be a useful method of dealing with fibromata, fibro-angiomata, and some forms of sarcomata, when the growth is of large size, and a preliminary operation for its exposure, in consequence of the patient having been greatly reduced in strength by frequent hæmorrhages, cannot be undertaken with safety. It necessitates many sittings; as many as a hundred and thirty were required in one case, the treatment extending over a year. In another case the treatment extended over two years. The operation may be performed without an anæsthetic when it is thought that anæsthesia would be attended by risk. The electrolysis needles, which had better be of steel, especially if the growth is of a very hard consistency, should be inserted into the most prominent parts of the tumour beneath the soft palate, and the operation proceeded with as in electrolysis for tumours in other situations. The growth is said to gradually shrink and atrophy. The treatment may be continued until the tumour has completely disappeared; or, after it has been reduced to reasonable dimensions, it may be removed by one of the methods before described.

(*f*) **Destruction by Chemicals.**—This is an unscientific method,

and one which is seldom employed at the present day. Indeed, to the surgical mind it appears to have little or nothing to recommend it. The chemicals that have been chiefly employed are strong solutions of perchloride of iron or chloride of zinc, injected by means of a small subcutaneous syringe into the substance of the growth. In the case of fibro-angiomata, I should imagine that the injection of perchloride of iron would be attended with a danger of producing clots in the cavernous blood-spaces, as it is in the case of nævi and vascular growths in other situations, and that fatal embolism might ensue, as it has done after the injection of nævi. A further objection to the injection method is the sloughing that is set up in the growth and the consequent danger of septic absorption, to say nothing of the foul odour to which the patient is subjected during the process of separation.

2. *Preliminary Operations for exposing Naso-Pharyngeal Growths and the Interior of the Nose.*

The preliminary operations for obtaining a good exposure of a naso-pharyngeal or intranasal growth, when too large for simple removal, or when electrolysis is considered unsuitable or has failed, may be divided into :

a. Operations in which the exposure is made from behind through the mouth ;

b. Operations in which the exposure is made from the front through the nose ; and

c. Operations in which the exposure is made by the resection or partial or complete removal of the superior maxillary bone.

(a) **Preliminary Operations for exposing the Growth through the Mouth.**—The following operations, amongst others, have been practised for obtaining exposure of the growth through the mouth : Division of the soft palate (Manne's operation) ; division of the soft palate, and removal of part of the hard palate (Nélaton's operation) ; buttonholing the soft palate (Maisonneuve's and Dieffenbach's operation) ; division of the pillars of the fauces (Levret's and Jobert's operation).

The conditions calling for a preliminary exposure of the growth have already been mentioned at p. 220. Assuming that such is considered necessary, and that the best method of exposure would be obtained through the mouth, I strongly hold that the surgeon should in the first place completely split the soft palate in the middle line, and

then, if more room is required, cut away, after separating the mucoperiosteum, sufficient of the posterior part of the hard palate to gain a thorough view. If a preliminary operation on the palate is required, I am convinced that it is better to obtain a thorough and complete view of the parts in the above-mentioned way, than a limited exposure, as by merely buttonholing the soft palate, trephining the hard, or by other minor methods. If the growth is capable of being removed by such a limited exposure, I am sure it could equally well be removed *per vias naturales*, without any preliminary operation at all. I have had, during the last twenty years, a somewhat considerable experience in the extirpation of naso-pharyngeal growths exposed by the palate method, and can speak in high terms of the procedure. The operation I have myself performed, which is a modification of Nélaton's, will be first described.

Exposure of the Growth by the Division of the Soft Palate and cutting away of the Posterior Part of the Hard (Method practised by the Author).—The patient having been anæsthetized by gas and ether, the narcosis is continued by Junker's apparatus, the delivery-tube being placed in the mouth, or the vapour conveyed through the shank of the gag. The mouth having been widely opened by a good gag (I usually employ Mason's or Coleman's, Fig. 27), the uvula is seized on one side by the surgeon, with a long-nibbed palate forceps, and the assistant having seized it in like manner on the opposite side, the surgeon divides the uvula and soft palate in the middle line with a sharp palate knife fixed on a long handle. The knife should be probe-pointed, lest the growth be pricked, and so give rise to embarrassing hæmorrhage. If the division of the palate is made in the middle line, there will be practically no bleeding. A fairly stout silk ligature is now passed through each portion of the divided soft palate about the level of the base of the uvula by means of a nævus needle. The needle having been withdrawn, the ligature is formed into a loop by tying together the two ends. The loop of ligature on either side is now given into the charge of an assistant, whose duty it is to thus keep the two halves of the palate well held apart. If the tumour is now sufficiently exposed, it may be removed in one or other of the ways described at p. 219. If still more exposure is required, the incision is continued forward in the middle line of the hard palate for half an inch to an inch or more, according to the space required. The mucoperiosteum having thus been divided down to the bone, a curved

scissors is passed between the two portions of the divided soft palate at its junction with the hard, and the reflection of the mucous membrane from the floor of the nose on to the soft palate cut through. With the aid of a raspatory, or of an aneurysm needle with a short curve, the muco-periosteum is now separated to a sufficient extent from the bones forming the hard palate. One or more sutures are passed through the flaps of muco-periosteum on either side, in order to hold them apart. The bone may be removed with a mallet and chisel, or with a small Hey's or Adams' osteotomy saw, aided in either case by the parrot-bill forceps. It is better to remove the hard palate piece by piece, than to take away a large portion at once, as no more of the bone should be cut away than is necessary to give a sufficient and thorough exposure. The tumour having been removed in one of the ways described in the former section, and the base thoroughly destroyed, the muco-periosteum is united by suture in the ordinary way; but the soft palate, unless the surgeon is more than satisfied that he has completely destroyed the base of the growth, had better be left ununited for the time being, say for three or six months, or until it is evident that there is no tendency for the growth to return. The edges of the soft palate may then be refreshed and the cleft closed.

*Manne's Operation.**—The soft palate is divided in the middle line, commencing at the tip of the uvula and terminating at the point where the soft palate is attached to the hard.

Nélaton's Operation.†—The soft palate, together with the uvula, is split along the middle line in its entire extent, the incision extending from the tip of the uvula to the centre of the posterior border of the hard palate. The incision is then carried forwards along the middle line of the hard palate to within a short distance of the incisor teeth, the muco-periosteum being divided down to the bone. From the anterior extremity of this incision, another is made at right angles on either side, extending in an outward direction for the space of about $1\frac{1}{2}$ centimetres. These two latter make with the first a T incision, the cross-bar of the T being placed anteriorly. With the elevator or raspatory, the muco-periosteum covering the inferior surface of the hard palate is stripped up as far as is possible. In order to reflect the muco-periosteum completely, a bistoury must

* 'Dissertation Curieuse, au Sujet d'un Polype Extraordinaire,' Avignon, 1717 (quoted by Bosworth, 'Diseases of Throat and Nose,' vol. i., p. 621).

† *Gazette des Hôpitaux*, 1849, vol. i., p. 128.

be passed along the posterior border of the hard palate, from within outwards, on both sides, dividing the mucous membrane where it passes from the floor of the nasal cavity on to the upper surface of the velum palati. The hard palate having been thus thoroughly exposed and bared of its muco-periosteum, a transverse incision is made through the bone immediately behind the anterior alveolar border, extending for a distance of one centimetre on either side of the middle line. From each extremity of this transverse incision, another is made, passing directly backwards, until the posterior border is reached and divided. The piece of bone included between these three incisions is then removed, its attachment to the vomer along the middle line having first been divided. In removing the piece of bone, great care is taken to preserve, so far as is possible, the muco-periosteum lining its superior surface.

Dieffenbach's and Maisonneuve's Operations.—These surgeons, instead of splitting the soft palate as in Manne's operation, merely carried their incision from the hard palate to the base of the uvula, 'buttonholing the soft palate,' as it is called. By leaving the free edge of the velum intact, they considered that subsequent union is expedited, in that there is less tension on the parts.

*Jobert's Operation.**—This surgeon also divided the soft palate vertically, in order to obtain a view of the interior of the nares, but carried the incision on one side of the uvula. He maintained that by so doing he obtained as large an opening as if he had made the incision through the middle line, and that the length of the incision was much smaller.

(b) **Preliminary Operations for exposing the Growth through the Nose.**—The operations for exposing the growth through the nose may be divided into :

1. Operations which have for their aim the obtaining of more room by fully laying bare the bony aperture of the nose ; and

2. Operations which have for their object the enlargement of the bony aperture and consequent more complete exposure of the nasal chambers, by the temporary removal of some portion of the bone forming the margin of the aperture.

1. *Operations for exposing the Bony Apertures of the Nasal Chambers.*—The following will be described : (a) Turning up the cartilaginous portion of the nose with the upper lip (*Rouge's operation*). (b) Dividing the upper lip in the middle line, continuing

* *Gazette des Hôpitaux*, 1858, p. 337.

the incision into the nostril of the affected side, and turning that portion of the lip with the corresponding ala of the nose outwards (*Syme's operation*). (c) Turning the soft parts of the nose outwards (*Furneaux Jordan's operation*). (d) Splitting the cartilaginous portion of the nose in the middle line, and turning the ala of the affected side outwards (*Roser's minor operation*).

The first-mentioned operation (*Rouge's*) possesses the great advantage that it leaves no external scar. The scar in the second and third operations is but little marked, since it follows the ridge on the upper lip and the line of junction of the lip and nose. The scar in the fourth is more serious, being in the middle line of the nose. At the same time, it does not cause much deformity if union by the first intention is obtained.

Other things being equal, *Rouge's operation*, in that it leaves no scar, and, at the same time, gives an equally good exposure, is the one that should be chosen.

(a) *Rouge's Operation of turning the Nose with the Upper Lip upwards*.^{*}—This operation consists in exposing the nasal chambers by turning up the upper lip with the cartilaginous portion of the nose. The patient having been brought well under the influence of gas and ether in the ordinary way, the anæsthesia is continued with chloroform by means of a Junker's apparatus, with the tube passed into the mouth. A good gag should be introduced between the teeth, for the purpose of opening the jaws when necessary, as a considerable amount of blood is apt to pass into the pharynx through the incision in the lip, and through the posterior nares. Sponges on sponge-holders should be in readiness for sponging out the mouth and pharynx as required. The upper lip, having been clamped near the corners of the mouth with Smith's hare-lip clamps, or seized on one side with the surgeon's finger and thumb of the left hand, and on the other side in like manner with the assistant's, is turned well upwards, so as to expose the reflection of the mucous membrane from the lip to the gums. An incision is now made through the line of reflection of mucous membrane, extending from the first pre-molar tooth on one side to the corresponding tooth on the other. The soft tissues intervening between the mouth and the nasal cavities are next rapidly divided, and the base of the cartilaginous septum detached with a bistoury from the anterior nasal spine. When this has been done, sufficient space will

^{*} *Bull. Soc. Med. de la Suisse Rom.*, Lausanne, 1868, vii., p. 265.

have been gained to admit the introduction of the finger; but if a thorough exposure of the bony aperture is required, the septum must be further detached from the maxillary crest by the scissors, as must also the lateral cartilages from the maxillary bones. The nose, with the upper lip, can now be turned upwards towards the forehead, fully displaying the bony entrance to the nasal chambers. The growth having been removed in the way described on p. 202, the nose and lip should be replaced, the base of the divided septum being brought into accurate contact with the maxillary crest and spine. No suture is necessary, and union of the divided parts usually takes place in a few days.

In the few cases in which I have performed the operation, there was no subsequent swelling of the lip, and practically no constitutional disturbance. In connection with this operation, it may be mentioned that Dupuytren,* in 1830, proposed turning the soft parts of the nose upwards, for the purpose of exposing the orifice of the nasal chambers, by an incision through the soft tissues around the alæ and base of the nose.

(b) *Syme's Operation of turning the Upper Lip of One Side, with the Corresponding Ala of the Nose, outwards.*†—An incision is made through the upper lip, a little to one side of the middle line, continued into the nostril, and the lip with the corresponding ala turned outwards and upwards on to the cheek. A good exposure is thus obtained of the bony aperture on the affected side.

(c) *Furneaux Jordan's Method of turning the Soft Parts of the Nose on to the Opposite Cheek.*—An incision is made through the upper lip in the middle line, continued between the lip and the ala, and then up the side of the nose at its junction with the cheek. The septum is now cut through, and the cartilaginous nose turned over on to the opposite side of the face. This is a useful operation when the nasal cavity is much dilated, and leaves very little scar.

(d) *Roser's Minor Operation of splitting the Cartilaginous Portion of the Nose in the Middle Line, and turning One or Other Ala outwards.*‡—An incision is made in the middle line of the nose, from the lip to the nasal bones, through the cartilage a little to one side of the septum, and the ala turned outwards. A view of the bony aperture on the affected side is thus gained, but the scar is

* *Journal de la Clinique*, 1830, tom. ii.

† *Edinburgh Medical and Surgical Journal*, vol. xxxvii., p. 322.

‡ 'Dictionnaire Encyclopédique des Sciences Médicales,' series ii., tom. xiii., p. 131.

more noticeable than when the ala and lip are reflected by Syme's method, and less space is obtained.

2. *Operations for enlarging the Bony Aperture of the Nasal Chambers.*—Among the operations having for their object the enlargement of the nasal aperture are the following: (a) Splitting the whole nose in the middle line, and turning the parts outwards to either side (*Roser's operation*). (b) Turning the nose upwards (*Lawrence's operation*). (c) Turning the nose downwards (*Ollier's operation*). (d) Turning the nose outwards on the cheek (*Chas-saignac's operation*).

Each of these operations may be said to involve distinct principles, namely: splitting the nose in the middle line, and turning each half out; turning the nose up; turning it down; and turning it outwards to one or other side. Beside these operations, there are many others, which, however, can only be looked upon as modifications of one or other of the above methods, and appear to possess little or nothing to especially recommend them.

(a) *Roser's Operation of splitting the Nose in the Middle Line, and turning the Cartilaginous Portions, with the Nasal Bone, the Nasal Process of the Superior Maxilla and the Lachrymal Bone of the Affected Side outwards on the Cheek.**—An incision is made along the middle line of the nose, commencing at the tip and extending upwards to the root of the nose, and the nasal bone, lachrymal and nasal process of the superior maxilla resected outwards upon the cheek of the side affected.

This operation is a revival of an old one practised by Celsus, who thus expresses himself: 'Narem incidendam esse ab uno parte ad os, ut et conspici locus possit, et facilius candens ferramentum admovari.'

(b) *Lawrence's Operation of turning the Nose upwards on to the Forehead.†*—In this operation the nasal cavity is exposed by turning a flap, consisting of the soft parts of the nose, together with the nasal bones and nasal processes of the superior maxillæ, upwards. An incision is commenced in the groove between the nose and the cheek at a point opposite the lachrymal sac, *i.e.*, immediately below the tendo oculi, and continued downwards as far as the lower extremity of the ala nasi. The knife is then carried transversely

* 'Dictionnaire Encyclopédique des Sciences Médicales,' series ii., tom. xiii., p. 131.

† *Medical Times and Gazette*, 1862, vol. ii., p. 491.

across, in the naso-labial groove, to the junction of the ala and lip on the opposite side, and finally carried upwards along the groove between the nose and cheek to a point corresponding to that from which the first incision started. The nasal bones, together with the nasal processes of the superior maxillæ, are next divided with cutting pliers. The septum is now dealt with in like manner. The flap thus mapped out, containing the above structures, is now turned upwards, and thus a good view is obtained of the deeper parts of the nasal cavity. At the end of the operation for removing the growth, the nose is replaced, and carefully fixed *in situ* with horsehair sutures, the line of incision being then sealed with collodion.

(c) *Ollier's Operation of turning the Nose downwards.**—An incision is commenced on one side at a point external to, and on a level with, the junction of the ala with the cheek, and carried upwards and inwards to a point corresponding with the position of the nasion. From the latter point another incision is made downwards and outwards on the opposite side, terminating at a spot corresponding to the starting-point of the first incision. This having been done, the bony structures are divided along the line of incision on both sides, and, the septum having been divided from above downwards, the nose is turned down, and the nasal cavities exposed to view. After the growth has been removed as described at p. 202, the nose is replaced *in situ*, fixed with horsehair sutures, and the line of wound sealed with collodion.

(d) *Chassaignac's Operation of turning the Nose outwards on to One or Other Cheek.†*—An incision is made across the nasion, and continued on one side downwards along the line of junction of the nose and cheek to the ala, and then between the nose and lip. The nasal walls are then drilled to allow of the insertion of a chain saw with which the nasal bones and the upper part of the nasal process of the superior maxilla are divided from before backwards along the line of the incision across the nasion. The nasal process of the superior maxilla is now further divided along the incision between the nose and the cheek. The septum having been cut through, the nasal process of the superior maxilla of the opposite side is next divided with bone forceps, care being taken not to injure the skin and soft tissues, since it is through these that the nose, when replaced, will obtain its vascular supply. The whole nose is now turned outwards on to the opposite

* *Bull. de la Société de Chirurgie*, 1866, p. 264.

† Chassaignac, '*Traité des Opérations Chirurgiques*,' tom. ii., p. 448.

cheek, and on the completion of the operation is carefully replaced and fixed in accurate apposition by horsehair sutures.

The following operation is a mere modification of the above, and appears to have no special advantage, in that it affords only a limited exposure of the growth.

*Langenbeck's Operation of turning a Piece of the Nasal Bone upwards.**—This operation consists in making an opening through the upper part of the nose. An incision is made through the soft parts by introducing the knife at a point corresponding to the situation of the nasion. From this it is carried downwards and outwards on the cheek of one side, terminating at a spot just external to the ala nasi. The soft parts anterior to this incision are then dissected forwards and upwards, and the nasal bone brought into view. The intranasal suture is now found and disrupted, and the nasal process of the superior maxilla cut off with pliers flush with the body of that bone. The bony flap thus obtained is turned upwards, its connection with the frontal bone being maintained by the periosteum, which must be preserved intact. After the nasal growth has been removed, the bony flap is replaced, and the soft structures united by a few points of suture.

(c) **Operations for completely exposing the Growth by the Partial or Complete Removal of the Superior Maxillary Bone.**—When the growth is too extensive to permit of a thorough exposure by means of one of the preliminary operations already described, this object may, in some cases, still be attained by the complete or partial removal of the superior maxilla, or, stopping short of this, by the temporary resection of the bone and its replacement after the extirpation of the growth by the methods of Langenbeck or Huguier, or by the separation of the maxillæ by the method of Annandale. The removal of the superior maxilla, either complete or partial, need not be here described, since the steps of the operation are so well known. The resection and subsequent replacement of the bone, as practised by Langenbeck and Huguier, may be done as follows :

Langenbeck's Osteoplastic Operation.†—In this operation the superior maxilla is turned in, as on a hinge, and replaced after the removal of the growth. Various incisions through the soft tissues and bones have been adopted by different surgeons since Langenbeck described his method. A semilunar incision is made from the ala of

* *Deutsche Klinik*, No. 48, 1859.

† *Ibid.*, 1861, p. 281.

the nose to the middle of the malar bone, with its convexity downwards, and a second semilunar incision from the nasion along the margin of the orbit to the termination of the first. The soft tissues are not dissected up. The masseter is next severed from the malar bone, the finger introduced through the pterygo-maxillary fissure into the spheno-maxillary fossa, and thence through the spheno-palatine foramen into the nose. This can hardly be done, however, unless these parts have been pressed aside and dilated by the growth. A narrow-bladed saw is inserted along the palmar surface of the finger, and the superior maxilla cut through from behind forwards. The upper jaw is next divided along the margin of the orbit, and the bone levered forwards and inwards, turning on the nasal process of the frontal bone. This operation and similar operations that I have seen have been accompanied with such serious hæmorrhages that I cannot recommend them. They also require a long time for their performance, and when the exposure has been obtained, there then remains the serious hæmorrhage which attends the removal of the growth itself to be contended with, and a still further expenditure of time in replacing and fixing the parts.

*Huguier's Operation.**—An incision is made transversely at the junction of the hard and soft palate, commencing at the middle line and extending outwards on the affected side. In this way a button-hole opening is made on one side of the soft palate at its attached border. A stout piece of silk is introduced through the nasal cavity of the affected side, and made to pass through the opening already made in the soft palate; the free ends of this ligature are then tied together. An incision is now made from the oral commissure on the affected side, horizontally backwards through the whole thickness of the cheek, as far as the anterior border of the masseter muscle. Another incision is then made, beginning in the groove between the cheek and the nose at a point opposite to the infra-orbital foramen, whence it descends along the groove as far as the ala nasi. At this point the incision is carried inwards towards the middle line until the columna nasi is reached, and then, turning downwards along the middle of the philtrum, is carried through the margin of the upper lip. The triangular flap thus marked out is carefully dissected up and held out of the way. The central incisor is now extracted, and the alveolus divided by means of bone forceps. A flat-bladed saw is introduced into the

* *Gazette des Hôpitaux*, 1861, p. 337.

nostril, and the whole hard palate is divided. The finger is now passed backwards on the external aspect of the superior maxilla beneath the malar process and the zygomatic arch, until the tuberosity of the superior maxilla is felt and recognised, when the pterygoid plate of the sphenoid abutting on this can be divided by bone forceps. The maxilla is then divided horizontally immediately below the malar process. In dividing the hard palate, the muco-periosteum lining its buccal surface should not be injured. The piece of bone thus mapped out can be turned downwards, its connection with the rest of the palate being maintained by the intact muco-periosteum. It is held out of the way by means of the silk which was passed in the initial stage of the operation. When the nares have been cleared of the growths for which the operation was undertaken, the resected bone can be replaced and kept in position by wire sutures. The bleeding during the operation is said to be trifling, the facial artery being divided and ligatured in two places. There would appear to be some danger of the portion of bone thus exposed necrosing.

*Annandale's Operation of dividing the Hard Palate and Alveolar Margin of the Jaw through Rouge's Incision, and forcibly separating the Upper Jaw.**—The operation consists in first exposing the anterior nares by freely dividing the mucous membrane connecting the upper lip and upper jaw, according to the plan of Rouge, and then dividing the bony septum of the nose along its attachment to the jaw, incising the soft parts along the middle line of the hard palate, and sawing through the alveolar margin of the upper jaw and through the entire hard palate along the same line. The soft palate may or may not require division in its middle line, according to the size and attachments of the growth. The jaws are forcibly separated, and the fingers, or the periosteal scraper or other similar instrument, are introduced through the gap with the view of freeing the secondary connection of the growth from surrounding parts. When the tumour has been removed, the jaws are brought together again, and secured by one wire suture through the alveolar margin of the bone, and two or more horsehair sutures through the soft parts of the palate wound.

The Choice of a Preliminary Exposure.—Different opinions, as may be well understood, are held on this subject. I can only express my own. For small intranasal growths situated anteriorly, too large, however, to be dealt with *per vias naturales*, either Rouge's opera-

* *Lancet*, January 26 1889.

tion or Syme's is to be preferred, or, when the growth is on the septum and extends some distance back, Roser's. For naso-pharyngeal growths confined to the pharynx, I have no hesitation in recommending the modification of Nélaton's operation described at p. 226. For larger growths involving the antrum, and for naso-pharyngeal growths invading the nose and spheno-maxillary fossa, partial or complete resection of the superior maxilla is necessary. The various methods of turning in or out of the superior maxilla, hinge-like, and its subsequent replacement, are so tedious in their performance, and attended with so much hæmorrhage, that the still further hæmorrhage which must necessarily accompany the enucleation or other method of removing the growth, may just turn the scale, and the patient succumb to syncope or shock within a few hours, if not, fortunately for the surgeon, actually on the operating-table.

CHAPTER XX.

TREATMENT OF CERTAIN AFFECTIONS OF THE ACCESSORY SINUSES THAT MAY BE PRESENT IN CASES OF NASAL OBSTRUCTION.

EMPHYEMA AND TUMOURS OF THE ANTRUM, AND EMPYEMA OF THE FRONTAL, ETHMOIDAL AND SPHENOIDAL SINUSES.

TREATMENT OF CHRONIC EMPYEMA OF THE ANTRUM.

THE treatment of chronic empyema or latent empyema, as it has been called, has of recent years been very freely discussed, but widely different opinions still exist as to the best method of dealing with the condition. All, I think it may be said, are agreed that if no treatment is undertaken suppuration will, as a rule, continue indefinitely, although Garel* has met with two cases in which spontaneous recovery occurred. I have had under my own care several cases in which the disease had existed for upwards of five years. Garel mentions a case in which it had lasted from fifteen to seventeen years. There is a consensus of opinion as to the propriety of irrigating or washing out the cavity, but whilst some are in favour of simple irrigation through the natural ostium, others advocate an artificial opening with irrigation and drainage either through the internal or nasal wall or through the socket of a tooth or alveolar process or through the canine fossa. Some advise that the cavity should be merely washed out and drained, and would never curette, whilst others prefer a large opening with a free scraping or curetting of the mucous membrane.

The conclusions that I myself have arrived at are, that all of these various methods are useful and applicable to certain cases, but that no one method is applicable to all. When the natural ostium is patent and of fairly large size, the corresponding nasal cavity roomy, the

* *Journal of Laryngology and Rhinology*, 1894, p. 528.

middle turbinal of such a shape and size as to readily permit of the ostium being entered, and the patient is sufficiently tolerant of intranasal manipulation, and of such intelligence and manual dexterity as to be able to learn to do the necessary irrigating process for himself, I admit that irrigation through the ostium may first be tried. Given, however, the reverse of all this, irrigation and drainage through an artificial opening is, I venture to think, desirable, and is the method I have almost invariably used.

When the suppuration is dependent upon the irritation of a tooth-fang, when the mucous membrane is much thickened, granular, or polypoid, or the cavity is filled with polypoid masses, I do not see how the condition is to be remedied without an artificial opening. My own practice has been, in such cases, either to make an entrance through the lower part of the canine fossa or alveolar process, or the socket of a tooth, or, when a large opening has been necessary, through the canine fossa. When a small opening has sufficed, and the teeth have been sound, I have opened through the lower part of the canine fossa or the alveolar process; where a tooth has been absent, through the empty alveolus; or when a tooth has been carious, through the alveolus after the decayed tooth or stump had been removed. In ordinary cases the puncture has been small, merely sufficient to admit of a tube the size of a small hydrocele cannula.

Where a thickened, granular, or polypoid condition of the mucous membrane has existed, or necrosed bone has had to be removed, an opening through the canine fossa, sufficiently large to admit the passage of the index-finger, has been employed. Where a small tube has been used, irrigations with a 10 per cent. solution of boracic acid have been made, the fluid being allowed to run out through the natural ostium, and thence to escape through the nose. The fluid has been injected either by the ball-apparatus, Higginson's syringe, or by a syphon irrigator. The irrigation is at first performed night and morning, and then, as the suppuration decreases, once daily, and subsequently at less frequent intervals, as the escaping fluid gradually becomes clear and inodorous. When suppuration has continued for some weeks, or longer, an astringent lotion of sulphate of zinc (grs. i.-ii. to $\bar{3}$ i.), sulpho-carbolate of zinc (grs. i.-ii. to $\bar{3}$ i.), or nitrate of silver (grs. x. to $\bar{3}$ i.), has been substituted for the boracic lotion. Koschier has obtained good results with a spray of nitrate of silver (3 to 10 per cent.). In the majority of cases that have come

under my notice, success has attended this treatment. In the intervals between the irrigations, the opening into the antrum is kept patent by the silver spiral antrum-tube. At first this may be attached, by a thread run through it, to the cheek by a small piece of strapping, but, as a rule, patients experience no difficulty in keeping the tube *in situ*, and find that the thread attachment is unnecessary.

The irrigation and the removal and replacement of the spiral tube can be easily mastered by the patients, and after a few days they are able to undertake the whole of the manipulation and washing themselves. The tube and irrigation should not be dispensed with till the suppuration has completely ceased. It may be necessary to continue to wash out the antrum for many months, or even longer; indeed, I have met with a few cases where the suppuration had gone on for years, in spite of careful treatment by competent surgeons. In one or two instances the continued suppuration has appeared to me to have been the result of wearing the tube too long. On its removal, the wound rapidly closed, and no further trouble was experienced.

In order to judge when the irrigation should cease, and the tube be discontinued, the patient should be directed to leave off the injection for, say, a week, when, if at the end of that time the fluid injected flows out from the nose clear, or nearly so, the spiral tube should not be reinserted, and the wound should be allowed to heal. If, in spite of irrigation and the use of various antiseptic and astringent lotions, suppuration continues, the aperture may be enlarged, the probe or finger introduced, and the condition of the lining membrane thoroughly investigated. The surgeon, however, should not be in too great haste to do this, since perseverance with irrigation, even after months have elapsed, will often succeed. Nor should he forget that the continuance of the suppuration may be due to the irritation from the tube. If, on opening the antrum, the mucous membrane is found thickened or polypoid in character, it should be thoroughly scraped or curetted, and the cavity insufflated with iodoform or the like. If a fang of a tooth is found exposed, or a sequestrum or carious bone is discovered, the offending agent should be removed. Some surgeons, in obstinate cases, recommend a counter-opening, to ensure a more efficient drain.

Irrigation of the antrum through the natural ostium, and the various methods by making an artificial opening, may now be described.

1. **Irrigation by the Natural Ostium.**—This method is strongly advised by Garel, Weil, Roth, and Koschier, amongst others. The antral cannula should be passed into the middle meatus, beneath the middle turbinal body, and, its point being directed towards the outer wall of the meatus, an attempt should be made to introduce it into the antral cavity. In many cases, owing to the shape and disposition of the middle turbinal body, it will be found difficult or quite impossible to gain an entrance. The anterior end of the middle turbinal body, or sufficient of the outer edge (Weil), may then be removed, if under these circumstances it is thought desirable to persevere in this method, and a further attempt made. It should not be forgotten, however, that in some cases the natural entrance is too small to admit the cannula, or it may be completely occluded.

Garel* succeeded in reaching the natural orifice twenty-eight times in forty-four cases, and in twenty-two of these the irrigation was successful. He maintains that, if suppuration resists irrigation by the natural orifice, it will be found equally rebellious to irrigation through an opening in the most dependent part of the cavity.

Weil, who is also an advocate for treatment by the natural orifice, strongly recommends removal of the anterior end of the middle turbinal, or the outer edge of that body, when the ostium cannot otherwise be found.

After the cannula has been introduced into the antrum, the irrigation of the cavity may be performed by attaching a ball-apparatus, syringe, or syphon-tube to the cannula. The success obtained by this method has varied considerably in the hands of those who have practised it. Some have found it pre-eminently successful, and obtained cessation of the suppuration on an average in eight or nine days (Garel), and even in some instances after only three or four days. Others have found it unsatisfactory, and affirm that it is impossible to completely clear the cavity of the antrum without an artificial opening. It has also been urged that it is difficult or impossible to teach the family practitioner or patient to pass the cannula; but Garel, Weil, and Stoerk affirm that they have had no trouble in doing this when a fair-sized opening exists, and a cannula of suitable shape and calibre is employed.

2. **Perforation and Irrigation through the Inferior Meatus.**—This method has the support of Garel, Krause, and Dundas Grant, amongst others. It may be done as follows: A long steel trocar and

* *Journal of Laryngology and Rhinology*, 1894, p. 531.

cannula (Fig. 4, p. 23), with the trocar slightly withdrawn into the end of the cannula, is passed into the inferior meatus of the nose, beneath the inferior turbinal body, and the end of the cannula pressed firmly on the outer wall of the nose, just behind the opening of the nasal duct, *i.e.*, about an inch and a quarter along the meatus. The cannula should be made to impinge on the wall of the antrum, as little obliquely as the conformation of the nose will allow, by drawing the end of the nose well over to the opposite side. The trocar should now be protruded from the end of the cannula, and with a sharp thrust, in a direction upwards, outwards, and backwards, made to enter the antral cavity. The bone at the moment of perforation is felt to crunch, and the instrument to slip on. The trocar is next withdrawn, and the cannula can be felt to move freely in the antrum and come against the alveolar wall. The ball-apparatus or antral syringe is now fixed to the cannula and irrigation proceeded with. If the trocar and cannula is held too obliquely, it is apt to glide beneath the mucous membrane on the bone, instead of perforating the antral wall. The little operation can be performed without pain under cocaine. I have found it useful as an aid to diagnosis. The chief objection to it as a means of irrigating the cavity is the difficulty of finding the opening from time to time and of keeping the opening patent. It is certainly more difficult, however, to teach the patient to do the necessary manipulation himself, than when the opening is made through the canine fossa or tooth alveolus. The opening on the next syringing may be found by searching along the nasal wall with the cannula, through which a blunt style has been passed, and it is advised, to facilitate the finding of the opening, that the anterior extremity of the inferior turbinal be excised by punch forceps, turbinal scissors, or the snare. Dundas Grant recommends the method in all cases arising from intranasal causes, and in all cases in which there is neither absence nor disease of a tooth.* He would further give it a trial as an adjunct to the alveolar method, when this is unsuccessful, before making a large opening through the canine fossa. Other advantages claimed for it, none of which, however, to my mind, seem very convincing, are: (1) that the inner wall of the antrum is thinner than the outer, and therefore more easily penetrated; (2) that irrigation through the meatus is less annoying to the patient than irrigation in other situations; (3) that an obturator is not necessary to prevent the food

* Dundas Grant, *Journal of Laryngology and Rhinology*, 1894, p. 798.

entering the antrum during meals; (4) that pus does not escape into the mouth; (5) that a sound tooth need not be sacrificed; and (6) that the operation can be done under local anæsthesia. On the other hand, it should be borne in mind that the inner wall of the antrum, in the region of the meatus, is sometimes so thick that it cannot be perforated by so fragile an instrument as Krause's trocar and cannula, held, as it must necessarily be, at an angle of much disadvantage to the plane of the bone,* whereas with the powerful antral perforator, employed for puncturing through the canine fossa, an entrance can be easily effected, however thick the bone. Moreover, the perforation, when made through the inferior meatus, is not at the most dependent situation in the antrum. Further, it is a question whether nasal irrigation is less annoying to the patient, and an obturator is certainly not necessary to prevent food entering the antrum when a small perforation is made through the canine fossa or an alveolus. The sacrifice of a tooth only applies when the intranasal method is compared with a perforation through an



FIG. 33.—SCREW-STOP ANTRAL PERFORATOR.

alveolus in which the tooth is sound, and not with the canine fossa method.

3. Perforation through the Canine Fossa.—This method is the one I have myself employed where the teeth are sound. The operation is best performed under general anæsthesia, but it can, if necessary, be done under gas, or even under the influence of cocaine. The situation of the canine fossa having been defined, the upper lip on the affected side is slightly everted and raised, and a short incision made with the knife in a vertical direction through the mucous membrane and underlying soft tissues, down to the bone. A triangular-bladed antrum perforator is next placed in the incision over the lower part of the canine fossa, and with a few turns of the wrist thrust into the antrum in a direction backwards, upwards, and very slightly inwards. In the hands of a careful operator, an ordinary triangular-bladed bone perforator may be safely used, but

* Garel failed in three instances to effect an entrance by this route into the antrum.

if the surgeon has any fear of the instrument at the moment of perforation penetrating too deeply, and injuring the floor of the orbit or inner wall of the cavity, he may employ a perforator with the screw-stop plate (Fig. 33). Care should also be taken not to thrust the instrument between the tissues and the bone, or to drive it deeply into the alveolar process, and so not into the antrum at all. To avoid such a mishap, the surgeon would do well to refresh his memory by looking up the exact relations of the part in the skull. On the removal of the perforator, the silver fountain cannula should be passed through the hole into the antrum, and the irrigation commenced as soon as the patient has sufficiently recovered from the anæsthetic to allow of his sitting up and depressing the head over a bowl. As soon as the fluid that escapes by the natural ostium through the nose runs clear, and has lost its offensive smell, the cannula is removed, and the spiral silver-wire tube introduced and left in the aperture. The enlarged head on the lower end of the tube will prevent the tube slipping into the cavity of the antrum, whilst the spiral twist prevents it from being extruded. To prevent any accident, it is safer for the first day or two, especially during sleep, to secure the tube to the cheek by a thin silk thread and a piece of sticking-plaster.

The chief advantages of this method over puncture through an alveolus are: that a sound tooth is not sacrificed, and that, should a larger opening into the antrum become necessary, the puncture can be very readily increased in size. An opening through the canine fossa may not, perhaps, be at the most dependent spot, but if it is made as here advised, quite at the lower margin of the canine fossa, *i.e.*, partly through the alveolar process, as well as through the outer wall of the antrum, it certainly leaves very little to be desired in this respect.

Scanes Spicer recommends a large opening through the canine fossa, large enough to admit the finger. He makes a crucial incision through the soft tissues, reflects the flaps with a raspatory, and then cuts away with a mallet and chisel the front wall of the antrum, taking care to remove the bone to the level of the floor of the antrum, thus forming a groove along the alveolar process. He then cures the mucous membrane, passes in his finger, and perforates the inner wall by Krause's cannula through the inferior meatus, making one or two large openings in this situation between the antrum and nose. The cavity is well irrigated with boracic lotion,

and packed with creolin gauze. He employs no drainage-tube, and aims at keeping the openings patent.

4. **Puncture through the Alveolus of a Tooth.**—This method is advocated, amongst others, by Lermoyez,* Chiari, and Hajek†. Puncture through an alveolus should be done under general anæsthesia. If a tooth is absent, gas will suffice. If the teeth are sound, the first premolar should be extracted. The antral perforator is then placed in the socket, and forced by a rotatory movement of the wrist through the apex of the socket into the antrum. The fountain cannula is introduced, and the irrigation proceeded with as soon as the patient has recovered from the anæsthetic. A spiral wire tube may be placed in the alveolus in the intervals between the irrigation. If the suppuration does not soon cease, a tube may be fitted to a dental plate, to which also an artificial tooth is fixed.

The points in favour of the alveolar method are: (1) A tooth is at times, often it is believed by some, at the bottom of the trouble, and the removal of this, when the cause of the mischief, is the first step in the treatment. (2) The opening is in the most dependent position. (3) The patient can very readily learn to irrigate through this opening. Against the method, apart from the sacrifice of a tooth when the teeth are sound, it is contended that the tooth-socket selected may not lead into the antrum, the socket being in front, so that the perforator passes out of the apex of the socket, between the bone and the soft tissues of the gum, or into the nasal cavity. If the mistake is not discovered, the connective tissue is inflated on passing the cannula and attempting to irrigate.

Such a connection of the tooth-sockets only exists when the antrum is very contracted at its lower part, a condition that may be diagnosed, as pointed out by Hajek, by the outer wall of the inferior meatus being extraordinarily concave. When this is observed, Hajek advises that no attempt should be made to enter the antrum through a tooth-socket.

Further, the socket may be very small, and its walls very thick. The last objection, however, has little weight, for with the patient under general anæsthesia no competent surgeon would be likely to fail to effect an entrance.

* *Journal of Laryngology and Rhinology*, 1894, p. 743.

† *Ibid.*, vol. x., p. 40.

TREATMENT OF ANTRAL GROWTHS ENCROACHING ON THE NOSE AND CAUSING OBSTRUCTION.

Innocent growths in the antrum that have encroached on the nose but are otherwise localized to that cavity, may be enucleated by turning back a flap of the cheek sufficiently far to expose the front wall and then cutting away enough of the bone to allow of complete removal with the raspatory and forceps, or in some instances it may be sufficient merely to turn up the upper lip, with the ala of the nose, and attack the growth through the wall of the antrum thus exposed.

If it is thought desirable to reflect a flap of the cheek, an incision should be made through the upper lip in the middle line, carried along the junction of the ala of the nose with the lip, and then along the line between the nose and the cheek to half an inch or so below the inner canthus of the eyelids. All bleeding vessels having been tied, the flap composed of the upper lip and cheek should be dissected up from the bone sufficiently far outwards to obtain a good exposure of the front wall of the antrum. The ala of the nose should next be detached from the bone and turned inwards. Sufficient of the front wall of the antrum should now be cut away with saw, chisel and forceps to thoroughly expose the growth, which, together with the intranasal portion, may then be enucleated, or torn away with forceps from its bed in the antrum. Where the growth is of larger size, it may be necessary to remove part of the nasal process of the superior maxilla, with more or less of the alveolar and palate processes. At the end of the operation the parts should be accurately united by horsehair or fine silkworm-gut sutures, the wound painted with iodoformized collodion, and lightly covered with an antiseptic dressing. If there is much oozing, a plug of iodoform gauze may be placed in the cavity of the antrum, and its end brought out beneath the upper lip, or, if there is no bleeding, a rubber drain-tube may be substituted for the plug.

Where it is considered that a sufficient exposure can be obtained by merely turning up the upper lip with the ala of the nose, an incision should be made through the upper lip in the middle line, and carried into the nostril. The mucous membrane of the mouth, along the line of junction of the lip and gum, is next divided down to the bone, the ala of the nose severed from its osseous connections, and, together with the lip, drawn upwards and outwards.

The front wall of the antrum and more or less of the lower part of the nasal processes of the superior maxilla, as may be required, are next cut away, and the antral portion of the growth, together with that encroaching on the nose, enucleated with a blunt raspatory or torn away with forceps.

For malignant growths of the antrum invading the nose, resection of the whole or part of the superior maxilla should be performed, provided it is decided that the whole disease can be got away, and there are no sufficient contra-indications to operative procedure. For a description of these operations the reader is referred to a work on general surgery.

TREATMENT OF EMPYEMA OF THE FRONTAL SINUSES.

In some instances the frontal sinuses may be irrigated effectually through the infundibulum by depressing the head. This method was first brought to my notice by a professional friend who succeeded in curing himself in this way, and illustrated the method to me on himself. The nose is filled with fluid, the nostrils closed, the head well



FIG. 34.—FRONTAL SINUS CANNULA.

depressed between the knees, and the fluid is felt to enter the sinuses, whence it returns mixed with pus when the head is raised. Few patients, however, I imagine, will have the fortitude and perseverance to cure themselves in this manner. In the first place, any polypus or granulations about the anterior end of the middle turbinal body should be removed; when this has been done, or the anterior end of the middle turbinal has been amputated, the suppuration in the sinuses may cease spontaneously. If it does not, a cautious attempt may be made to wash out the sinuses through the infundibulum (see p. 24) with the aid of the frontal sinus cannula (Fig. 34). When this cannot be passed, the removal of the anterior end of the middle turbinal may permit of its accomplishment; but absolutely no force should be used, since the operation is attended with considerable danger of perforating the base of the cranium. Thus, in a case of Mermod's, although every care was taken, the cannula entered the anterior fossa of the skull in front of the cribriform plate, and the patient died of septic meningitis. If not successful in passing the

frontal sinus cannula, or if injections through the cannula fail, an external opening must be made, and the sinuses drained either through the external wound or, better, through a passage made from the sinuses into the nose. Any attempt to force a passage into the sinuses *from* the nose is attended with the gravest risk, and should never be undertaken.

Trephining the Frontal Sinuses.—The skin having been rendered aseptic, and the patient placed under an anæsthetic, an incision is made in the middle line in a vertical direction from the nasion for about two inches upwards. Or, if only one frontal sinus is believed to be affected, a curved incision may be made through, or a little below, the inner third of the corresponding eyebrow, so as to avoid as much as possible an external scar. The frontal bone having been exposed, the pericranium is separated by a raspator, and the pin of the half-inch trephine applied at a spot exactly in the middle line, on a level with the upper margin of the orbits, or over the affected sinus if only one is to be opened, and the crown of bone taken away. Or the front wall may be removed with mallet and chisel. The lining membrane of the sinus, which now presents, being incised, the cavity of the sinus is exposed; this should be syringed out with an antiseptic lotion, and, if the mucous surface is villous and polypoid, scraped, curetted, or cauterized with chloride of zinc (20 per cent.). The sinuses may now be drained by a tube passing through the wound externally; or, better, a probe may be passed from the sinuses down the infundibulum into the nose, and, if the passage is sufficiently wide, a rubber drainage-tube may be introduced along the course of the probe, and brought into the nasal cavity, the upper end of the tube being left just within the sinus. If the passage from the sinus into the nose is too small to admit the probe, it may be carefully enlarged with a small rose-headed drill; or, if the passage has become obliterated, a new passage may be formed by cautiously boring with a perforator or rose-headed drill from the sinus into the nose in the direction which the natural passage normally takes. The external wound may now be accurately closed and dressed antiseptically, and the tube which serves as a drain removed at the end of from ten to twenty days, or earlier if it sets up much irritation. Some difference of opinion exists as to the propriety of leaving the tube in the passage from the sinus to the nose. The consensus of opinion is perhaps in favour of so doing.

If the tube is allowed to remain, the sinuses should be irrigated

through it once or twice daily with a weak antiseptic lotion, and an ethereal solution of iodoform thrown in after each injection. If no tube is employed, and the external wound is closed, the irrigation and injection of iodoform should be made with the frontal sinus cannula. The antiseptic solution employed for irrigating the sinuses should be weak—for instance, boracic lotion (gr. x. to ʒi.), or salt solution (ʒi. to Oi.)—since it has been stated that strong antiseptics, as perchloride of mercury, even when used as weak as 1 in 10,000, have caused necrosis of the thin, delicate layers of bone surrounding the passage. It is a question, however, to my mind, whether such necrosis was not the result of the manipulation in passing the tube, or of enlarging the old or making a new passage, rather than the effect of the antiseptics.

Some authorities, after the sinuses have been trephined, advise the complete removal of the whole mucous lining.

Trephining the frontal sinuses, when intranasal medication is not successful, and there are some surgeons who think that it is quite impracticable to cure frontal empyema by washing out through the infundibulum, should not be too long delayed, since there is a danger of septic trouble extending to the orbit. Thus, in a case under the care of Mr. Spencer, in which trephining had been delayed, septic inflammation of the eye had been set up, with loss of acute vision.

TREATMENT OF SUPPURATION IN THE ETHMOIDAL SINUSES.

Suppuration in the ethmoidal sinuses is a difficult and troublesome affection to treat, and if curetting and drilling in the upper regions of the nose has to be undertaken, considerable risk is run of septic meningitis. In the first place, the anterior end, or other portion of the middle turbinal body, should be removed with any polypi or hypertrophied tissue that may be obstructing the middle meatus, and this may be successful in staying the suppuration. The outer walls of the ethmoidal sinuses are then brought into view, and any openings through which pus is seen to be escaping may be cautiously enlarged by suitably-shaped cutting hooks or curettes. The nasal drill is a dangerous instrument for the purpose, since it may readily cause perforation of the roof or outer wall of the nasal fossa, and lead respectively to septic meningitis or to septic cellulitis of the orbital connective tissue. After the cells have been freely opened in the above-mentioned way, they should be kept well cleansed by

weak antiseptic sprays, or by irrigation with weak antiseptic solutions, and then insufflated with iodoform. Any rough curetting, or, indeed, curetting at all, of their lining membrane is attended with considerable risk, and should only be undertaken, if at all, by those conversant with intranasal surgery. Any necrosed bone in the region of the roof of the nose should be allowed to separate and come away spontaneously.

When suppuration has extended through the outer wall of the nasal fossa, and a swelling or abscess presents at the inner margin of the orbit, an external opening should be made, the incision being so planned as to correspond with the most prominent part of the swelling, and, of course, so as to avoid injury to important anatomical structures in the vicinity. When an external opening has been established, the sinuses should be kept irrigated with a weak antiseptic solution passed in at the external opening, and allowed to escape through the nose, and then insufflated with iodoform or the like.

TREATMENT OF SUPPURATION IN THE SPHENOIDAL SINUSES.

If the suppuration does not yield to sprays or syringing applied intranasally, or through a sphenoidal cannula introduced if practicable into the sphenoidal cells as described at p. 25, Hajek's hook may be passed through the natural opening, or through an opening made with a long straight trocar passed obliquely backwards and upwards between the middle turbinal and the septum, and the anterior wall of the sinuses chipped and broken away, sufficiently to allow of free drainage. Some surgeons, however, recommend that the inferior walls of the sinus should be attacked with Grünwald's special forceps from the pharynx. Such a procedure is more difficult in that bent instruments have to be used, and the inferior wall is thicker than the anterior. It is also attended with more risk of perforating the base of the skull.

The natural opening is difficult to find, owing to its being hidden from view and varying in position. Moreover, the mucous membrane lining the olfactory slit is often swollen and thickened in sphenoidal disease. On the other hand, the natural opening, as the result of the suppuration, may be dilated, and thus facilitate in some measure the passage of the cannula. When an instrument cannot be easily passed through the olfactory slit, a portion of the middle turbinal may be excised. When a sufficiently large opening has been made into the sinuses to ensure free drainage, they can be readily washed out

with weak antiseptics through the nose, or they may be syringed out with Lichtwitz's cannula.

It need hardly be said that operations in such dangerous regions as the sphenoidal sinuses and ethmoidal cells are attended with a good deal of risk, and require the utmost caution and skill in their performance. They should not be undertaken except by those who are conversant with intranasal manipulation.

INDEX.

- ABSCESS, retro-pharyngeal, 127
 treatment of, 210
 of septum, 33-44
 treatment of, 170
 Accessory sinuses, empyema of, 87
 treatment of, 237
 examination of, 21
 Adams' forceps, 174
 Adenoid vegetations, 135
 treatment of, 212
 Adenoma, nasal, 92
 treatment of, 194
 of palate, 130
 treatment of, 209
 Adhesion of pharyngeal walls to palate,
 126
 treatment of, 208
 of turbinal to septum, 151
 treatment of, 204
 Ala nasi, collapse of, 28
 treatment of, 207
 Angioma of septum, 48
 treatment of, 200
 of turbinal, 77
 Annandale's operation, 235
 Anterior nares, atresia of, 153
 keloid of, 154
 occlusion of, 153
 treatment of, 206
 Antral growths, 105
 treatment of, 245
 ostium, catheterization of, 22
 perforator, 242
 Antrum, affections of, 21, 105
 empyema of, 88
 treatment of, 237
 examination of, 21
 exploration of, 23
 irrigation of, 239
 puncture of, 23, 240, 242, 244
 transillumination of, 22
 Aphonia in nasal obstruction, 9
 Aproxia a sign of nasal obstruction, 5
 Asch's forceps, 175
 treatment of deflected septum, 175
 Asthma in nasal obstruction, 8
 Atresia of anterior nares, 153
 BLAUDIN'S punch, 176
 Bosworth's nasal saw, 172
 Botey's method of cutting septum, 176
 Bronchial catarrh in nasal obstruction, 6
 CANNULA, Lichtwitz's, 23
 Capillary nævi, 41
 treatment of, 200
 Carcinoma, intranasal, 99
 invading nose from antrum, 107
 naso-pharyngeal, 144
 treatment of, 218
 of palate, 131
 treatment of, 209
 of septum, 50, 62
 of turbinal, 81, 87
 treatment of, 202
 Carmalt Jones' spokeshave, 165
 Cartilages, nasal, depression of, 38
 treatment of, 179
 Cartilaginous septum, deviation of, 38
 treatment of, 173
 Caseous rhinitis, 114
 treatment of, 168
 Catheterization of antral ostium, 22
 of infundibulum, 24
 Causes of nasal obstruction, 10
 Cauterization of turbinals, 158
 Cautery knife, 158
 Chancre of septum, 57
 turbinal, 85
 Chassaignac's operation, 231
 Chest, deformity of, in nasal obstruction,
 9
 Chromic acid introducer, 161
 Cold snare, 196
 Collapse of ala nasi, 28
 treatment of, 207

- Columna nasi, dislocation of, 38
 treatment of, 176
 Congenital narrowing of nasal tract, 152
 Congenital occlusion of anterior nares, 153
 treatment of, 206
 of posterior nares, 147
 treatment of, 206
 Coryza, syphilitic, 113
 Crocodile forceps, 196
 Curettes, Grünwald's, 187
 Cysts, nasal, 74, 91
 treatment of, 201

 DEAFNESS in nasal obstruction, 7
 Defective development in nasal obstruction, 5
 Deflection of septum, 38
 treatment of, 173
 Delie's chisel, 172
 Depression of nasal cartilage, 38
 treatment of, 179
 Dieffenbach's operation, 228
 Diphtheria, nasal, 113, 122, 123
 treatment of, 189
 Discharge from nostril a sign of nasal obstruction, 4
 Dislocation of anterior end of septum, 38
 treatment of, 176
 Dodd's method of expelling foreign bodies from nose, 181
 Duplay's speculum, 16

 EFFECTS of nasal obstruction, 7
 Electric lamp for transillumination of face, 22
 Electrolysis, 173, 224
 Empyema of antrum, 88
 treatment of, 237
 ethmoidal cells, 89
 treatment of, 248
 frontal sinuses, 88
 treatment of, 246
 sphenoidal cells, 25
 treatment of, 249
 Enchondroma invading nose from antrum, 108
 naso-pharynx, 149
 of septum, 53
 treatment of, 202
 Epithelioma of septum, 51
 turbinal, 81
 Erectile growths, 48, 77
 treatment of, 200
 Erection of tubercle of septum, 40
 treatment of, 161
 of turbinals, 65
 treatment of, 156
 Ethmoidal cells, empyema of, 89
 treatment of, 248
 exploration of, 24
 Ethmoiditis, necrosing, 82
 External deformity of nose, 105

 FACE, trans-illumination of, 25
 Facial expression in nasal obstruction, 3
 Fibrinous rhinitis, 113
 treatment of, 169
 Fibro-angioma of naso-pharynx, 139
 treatment of, 218
 Fibroma of naso-pharynx, 139, 149
 treatment of, 218
 intranasal, 96
 treatment of, 202
 invading nose from antrum, 107
 of posterior end of turbinal, 150
 of septum, 55
 of turbinal, 79
 Fibro-sarcoma of naso-pharynx, 139, 149
 treatment of, 218
 Forceps, crocodile, 196
 Lowenberg's, 215
 Author's modification of, 216
 polypus, 199
 Foreign body in nose, 103
 treatment of, 181
 Frontal sinuses, empyema of, 88
 treatment of, 246
 exploration of, 24
 trephining of, 247
 cannula, 246
 Functional causes of nasal obstruction, 156
 Furneaux Jordan's operation, 230

 GAG, Mason's, 215
 Galvano-cautery, application of, 159
 handle, 158, 194
 post-nasal, 220
 removal of polypi with, 194
 snaring with, 223
 General diagnosis of nasal obstruction, 26
 Glanders, 36, 123
 treatment of, 191
 Gottstein's scraper, 217
 Grubworm hypertrophy, 68
 Grünwald's curettes, 187
 nasal punch, 206
 Gumma of palate, 132
 of septum, 34, 42, 45, 55
 of turbinal, 69, 73, 83
 retro-pharyngeal, 129
 Gummatus infiltration, general, 115, 119

 HEMATOMA of septum, 33, 47
 treatment of, 180

- Hajek's hook, 249
 Hard palate, division of, 255
 Headache in nasal obstruction, 5
 Hernia an effect of nasal obstruction, 9
 Hook-knife, 205
 Huguier's operation, 234
 Hypertrophic rhinitis, 68, 111
 treatment of, 163
 Hypertrophy of tonsils, 132
 of turbinals, 72
 treatment of, 163
 Hypochondriasis in nasal obstruction, 9

 INFUNDIBULUM, catheterization of, 24
 Irrigation of antrum, 239
 of ethmoidal sinuses, 249
 of frontal sinuses, 24, 246
 of sphenoidal sinuses, 249

 JARVIS'S snare, 199
 Jobert's operation, 228

 KELOID of anterior nares, 154

 LANGE'S hook, 97
 Langenbeck's operation, 233
 Laryngeal catarrh in nasal obstruction, 6
 Leprosy, nasal, 118
 treatment of, 191
 Lichtwitz's trocar and cannula, 23
 Loss of smell in nasal obstruction, 6
 of taste in nasal obstruction, 6
 Lupus of anterior nares, 154
 of septum, 41, 59
 of turbinal, 84
 treatment of, 186

 MACDONALD'S polypus snare, 197
 Mackenzie's polypus snare, 97
 Maggots in nose, 101
 treatment of, 182
 Maisonneuve's operation, 228
 Major's hook knife, 205
 Malignant growths of palate, 131
 of naso-pharynx, 143
 of septum, 47, 49-51, 56, 61
 of turbinals, 78, 79, 81, 86, 87
 intranasal growths, 95, 96, 98, 99
 treatment of, 202
 Mason's gag, 215
 Melancholia in nasal obstruction, 9
 Melanotic sarcoma, 95
 Meningocele, naso-pharyngeal, 145
 Meyer's ring knife, 216
 Mucous tubercles of septum, 42
 Myasis, nasal, 101
 treatment of, 182
 Myxomata, nasal, 91
 treatment of, 192

 NÆVUS of septum, 41
 treatment of, 200
 Nares, anterior, occlusion of, 153
 treatment of, 206
 posterior, occlusion of, 147
 treatment of, 206
 Nasal bones, deviation of, 38
 treatment of, 177
 cartilages, depression of, 38
 treatment of, 179
 cysts, 74, 91
 treatment of, 201
 diphtheria, 113, 122, 123
 treatment of, 189
 obstruction, causes of, 10
 effects of, 7
 general diagnosis of, 27
 method of examining in, 14
 signs of, 1
 myasis, 101
 treatment of, 182
 polypi, 74, 91, 148, 150
 treatment of, 192
 probe, 17
 punch, 176, 206
 saws, 172
 scissors, 205
 truss, 177
 Naso-pharyngeal carcinoma, 144
 catarrh, 8
 fibroma, 139
 fibro-angioma, 139
 fibro-sarcoma, 139
 growths, 135
 treatment of, 218
 meningocele, 145
 polypus, 136
 sarcoma, 143
 tumours, 136
 treatment of, 218
 Naso-pharynx, examination of, 20
 obstruction of, 124
 stenosis of, 126
 treatment of, 208
 Necrosing ethmoiditis, 82
 Necrosis of turbinal, 82
 Nélaton's operation, 227
 Nightmare in nasal obstruction, 5
 Night-sweats in nasal obstruction, 6
 Nose, examination with finger, 20
 probe, 17
 rhinoscope, 17
 speculum, 15

 OCCLUSION of anterior nares, 153
 treatment of, 206
 of posterior nares, 147
 treatment of, 206
 Œdema, posterior end of septum, 150, 162

- Ollier's operation, 232
 Otitis granulosa, 83
 Osteoma, intranasal, 102
 invading nose from antrum, 108
 of septum, 54
 treatment of, 201
- PALATE, adenoma of, 130
 treatment of, 209
 carcinoma of, 131
 treatment of, 209
 gumma of, 132, 133
 new growth in, 130
 treatment of, 209
 operation on, 226, 255
 sarcoma of, 131
 treatment of, 209
 tumours of, 131
 treatment of, 209
- Pallor in nasal obstruction, 6
 Papillomatous hypertrophy of inferior turbinal, 149
 treatment of, 165
 Papilloma, intranasal, 100
 of septum, 52
 of turbinal, 74, 75
 treatment of, 199
 Pharyngeal catarrh in nasal obstruction, 6
 Pharynx, obstructive lesion of, 125
 Polypus, 74, 91, 148, 150
 irritated, 95
 hæmorrhage into, 96
 of turbinal, 74, 150
 naso-pharyngeal, 136
 treatment of, 218
 in posterior nares, 148
 treatment of, 192
 forceps, 199
 hooks, 196
 snare, 197-99
 Posterior ethmoidal sinuses, exploration of, 25
 nares, obstruction of, 125
 occlusion of, 147
 treatment of, 206
 Posterior rhinoscopy, 17
 turbineotomy, 165
 Post-nasal galvano-cautery, 220
 growths, 135
 treatment of, 212
 Preliminary exposure operations, 225, 228
 choice of, 235
 Punch, nasal, 176, 206
 Puncture of antrum, 23
 through alveolus, 244
 canine fossa, 242
 inferior meatus, 240
- Purulent rhinitis, 111
 treatment of, 167
- REDNESS of external nose a sign of nasal obstruction, 4
 Retropharyngeal abscess, 127
 treatment of, 210
 growths, 129
 treatment of, 211
 gumma, 129
 sarcoma, 128
 treatment of, 211
 tumours, 129
 treatment of, 211
- Rhinitis, caseous, 114
 treatment of, 168
 diphtheritic, 113, 122, 123
 treatment of, 189
 fibrinous, 113
 treatment of, 169
 hypertrophic, 111
 treatment of, 163
 purulent, 112
 treatment of, 167
 specific, 122
 vaso-motor, 65
- Rhinolith, 100, 103
 treatment of, 181
- Rhinoscleroma, 43, 70, 116, 155
 treatment of, 190
- Rhinoscope, 19
 Rhinoscopy, anterior, 15
 posterior, 17
- Ring knife, 216
 Roser's operation, 230, 231
 Rouge's operation, 228
 Roughton's band, 28
- Salivation in nasal obstruction, 9
 SAJOUS' method of expelling foreign bodies from nose, 182
 Sarcoma, intranasal, 98, 99
 invading nose from antrum, 107
 retropharyngeal, 128
 treatment of, 211
 of palate, 131
 treatment of, 209
 of septum, 47, 49, 56, 61
 of turbinal, 78, 79, 86
 treatment of, 202
- Septal swellings, general diagnosis of, 30
 Septum, abscess of, 34, 44
 treatment of, 170
 adhesion of, to turbinal, 204
 angioma of, 48
 carcinoma of, 50, 51
 chancre of, 36, 57
 deviations of, 38
 treatment of, 171

- Septum, dislocation of, 38
 treatment of, 176
 enchondroma of, 53
 erection of tubercle of, 40
 erysipelas of, 33
 fibroma of, 55
 gumma of, 34, 42, 45, 55, 58
 hæmatoma of, 33, 47
 treatment of, 180
 lupus of, 41, 59
 mucous tubercles of, 42
 nævus of, 41
 œdema of posterior end of, 162
 osteoma of, 54
 papilloma of, 52
 rhinoscleroma of, 43
 sarcoma of, 47, 49, 56, 61
 septic inflammation of, 34
 treatment of, 169
 spur of, 39
 treatment of, 171
 tertiary ulcer of, 58
 tubercular syphilide of, 42
 tuberculous granuloma of, 51
 tuberculous ulcer of, 60
 ulceration of, 34
- Signs of nasal obstruction, 1
- Slaton's method of expelling foreign bodies from nose, 181
- Smell, loss of, in nasal obstruction, 6
- Snares, polypus, 197, 198, 199
- Sneezing in nasal obstruction, 6
- Snoring a sign of nasal obstruction, 5
- Soft palate, division of, 226
- Spasmodic cough in nasal obstruction, 7
- Specific rhinitis, 122
- Speculum, Duplay's, 16
- Sphenoidal sinuses, empyema of, 25
 treatment of, 249
 exploration of, 25
- Spokeshave, 166
- Spray apparatus, 157
- Spur of septum, 39
 treatment of, 171
 of turbinal, 71
- Stenosis of naso-pharynx, 126
 treatment of, 208
- Stippanitis's chisel, 165
- Swellings distinct from turbinal and septum, 90
 septal, 31
 turbinal, 63
- Syme's operation, 230
- Syphilis, congenital, 113
 primary, 57
 secondary, 42
 tertiary, 34, 42, 45, 55, 58, 69, 73, 83, 115, 118, 119, 129, 132
 treatment of, 188
- Syphilitic coryza, 113
- Syphilitic gummata, 34, 42, 45, 55, 69, 73, 115, 129, 132
- Syphilitic stenosis of anterior nares, 153
 treatment of, 206
 of naso-pharynx, 126
 treatment of, 208
 of posterior nares, 147
 treatment of, 206
- Syphilitic ulceration, 57, 58, 83, 118, 119, 129
- TASTE, loss of, in nasal obstruction, 6
- Tonsil, hypertrophy of, 133
 tumours of, 133
- Tracheal catarrh in nasal obstruction, 6
- Transillumination of antrum, 23
 of face, 25
- Transverse nasal vein, enlargement of, 3
- Trocar, Lichtwitz's, 23
- Tubercle of septum, erection of, 40
- Tuberculosis of septum, 51
- Tuberculosis of turbinal, 85
- Tubercular leprosy, 121
 treatment of, 191
- Tuberculous granuloma of turbinal, 76
- Tuberculous ulceration, general, 120
 of septum, 60
 of turbinal, 84
- Turbinal, adhesion of, to septum, 151
 treatment of, 204
 angioma of, 77
 carcinoma of, 81, 87
 chancre of, 85
 cauterization of, 158
 erection of, 65
 diagnosis of, 28
 treatment of, 156
 fibroma of, 79
 gumma of, 69, 73, 83
 lupus of, 84
 mucous cyst of, 74
 necrosis of, 82
 papilloma of, 74, 75
 polypus of, 74, 150
 rhinoscleroma of, 70
 sarcoma of, 78, 79, 86
 spur of, 71
 tubercle of, 76, 85
 warty hypertrophy of, 68
 treatment of, 164
- Turbinal swellings, general diagnosis of, 62
- Turbinal varix, 67, 149
 treatment of, 161
- ULCER, septic, of septum, 34

Ulceration, syphilitic, 57, 58, 83, 118,
119, 129
treatment of, 188
Uvula, elongation of, in nasal obstruction 9,

VARIX of posterior end of turbinal, 149
Vascular growths, 41, 48, 77
treatment of, 200

Vaso-motor rhinitis, 65

Venous nævi, 41,
treatment of, 201

Voice, alteration of, in nasal obstruction, 2

WARTY degeneration of inferior turbinal,
68
treatment of, 164

THE END.

