

Skiagraphic atlas showing the development of the bones of the wrist and hand : for the use of students and others / by John Poland.

Contributors

Poland, John, 1855-1937.
Bristol Medico-Chirurgical Society. Library
University of Bristol. Library

Publication/Creation

London : Smith, Elder, & Co. ..., 1898.

Persistent URL

<https://wellcomecollection.org/works/hwfskjxp>

Provider

Special Collections of the University of Bristol Library

License and attribution

This material has been provided by This material has been provided by University of Bristol Library. The original may be consulted at University of Bristol Library. where the originals may be consulted.

This work has been identified as being free of known restrictions under copyright law, including all related and neighbouring rights and is being made available under the Creative Commons, Public Domain Mark.

You can copy, modify, distribute and perform the work, even for commercial purposes, without asking permission.



Wellcome Collection
183 Euston Road
London NW1 2BE UK
T +44 (0)20 7611 8722
E library@wellcomecollection.org
<https://wellcomecollection.org>

SKIAGRAPHIC
ATLAS

POLAND

F2p1

The Library of the
Bristol Medico-Chirurgical Society.

November 1st 1898.


Stone 579155

SHELF

D.A.

J. LAW & SON
4, Wellington Square
Bristol





SKIAGRAPHIC ATLAS

By the same Author.


A PRACTICAL TREATISE ON
TRAUMATIC SEPARATION OF THE EPIPHYSES

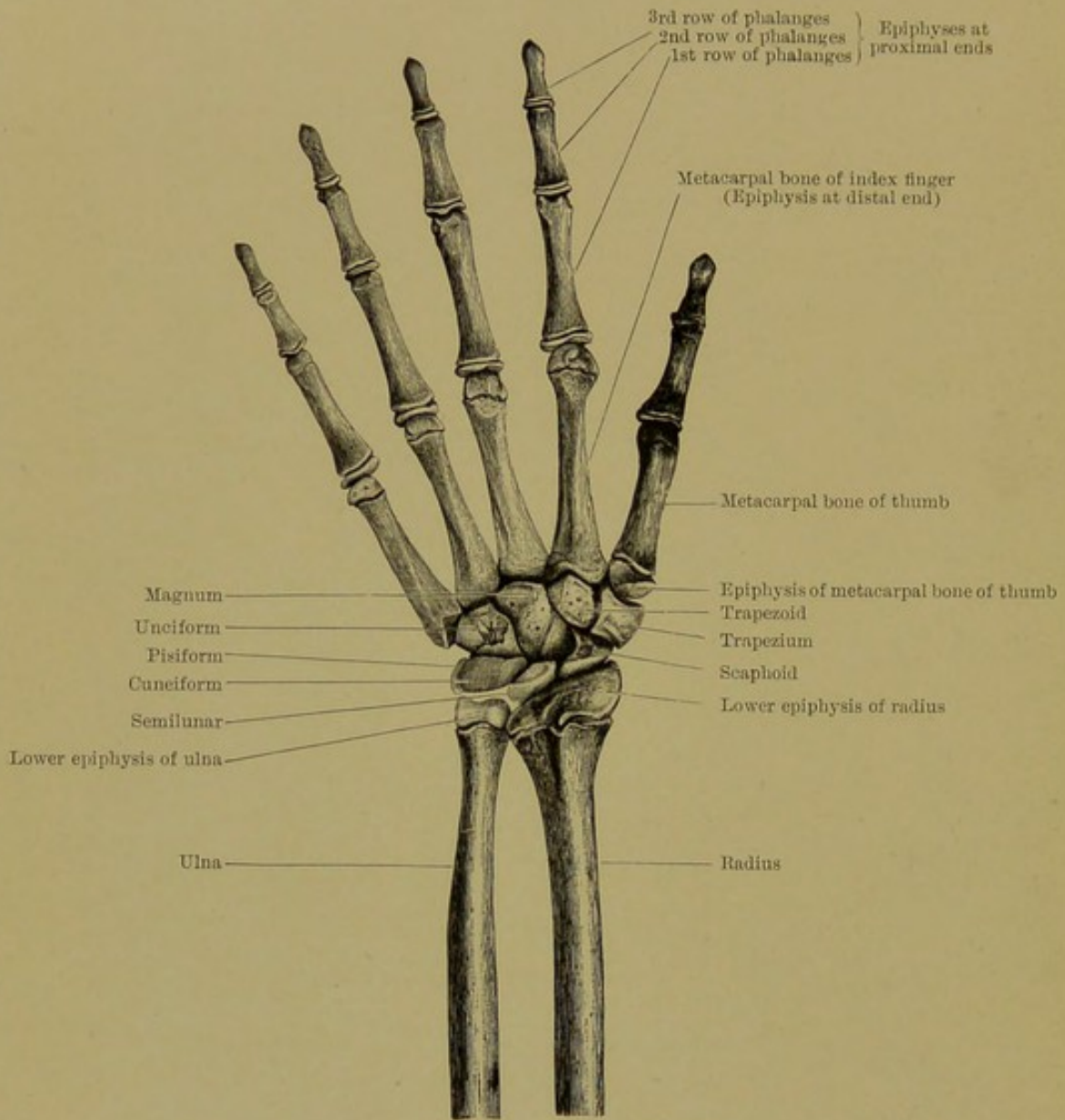
*Including the Anatomy of the Epiphyses, the Pathological
Anatomy, Symptoms, Treatment, and Results of
Traumatic Separations.*

926 pages, with numerous original Woodcuts, and
AN IMPORTANT SERIES OF SKIAGRAMS.

Royal 8vo. 52s. 6d.

London: SMITH, ELDER, & CO., 15 Waterloo Place.





BONES OF THE LEFT WRIST AND HAND AT FIFTEEN AND A HALF YEARS OF AGE. DORSAL ASPECT. (HALF NATURAL SIZE.)

SKIAGRAPHIC ATLAS

SHOWING

THE DEVELOPMENT

OF THE

BONES OF THE WRIST AND HAND

FOR THE USE OF STUDENTS AND OTHERS

BY

JOHN POLAND, F.R.C.S.

LONDON

SMITH, ELDER, & CO., 15 WATERLOO PLACE

1898

[All rights reserved]

UNIVERSITY
OF BRISTOL
MEDICINE

PREFACE


IT has been suggested that I should publish, in the form of an Atlas, the series of Skiagrams showing the ossification of the bones of the hand and wrist contained in my work on traumatic separation of the epiphyses.

The kindness of my friend, Mr. William Webster, to whom I am indebted for the whole series, with one exception, has enabled me to do this.

To the practical worker in the Röntgen ray process, as well as to anatomists and students, the advantages of such an Atlas are obvious, and it is hoped that in the near future all the bones of the body may be thus portrayed.


It will at once be noticed that the evolution of ossification differs very considerably from that hitherto described. I have, therefore, thought it advisable to reprint the anatomical description of the bones from my work.

JOHN POLAND.



ILLUSTRATIONS

BONES OF THE HAND AND WRIST AT FIFTEEN AND A HALF YEARS	<i>Frontispiece</i>
FEMALE INFANT AGED TWELVE MONTHS	<i>To face p. 8</i>
CHILD AGED TWO YEARS	10
CHILD AGED THREE YEARS	12
MALE CHILD AGED FOUR AND A HALF YEARS	14
CHILD AGED FIVE YEARS (SECOND CHILD OF PARENTS)	16
CHILD AGED FIVE YEARS (THIRTEENTH CHILD OF PARENTS)	16
MALE CHILD AGED SIX YEARS	18
MALE CHILD AGED SEVEN YEARS	20
MALE CHILD AGED EIGHT YEARS	22
BOY AGED EIGHT YEARS AND FIVE MONTHS	22
MALE CHILD AGED NINE YEARS	24
BOY AGED TEN YEARS	26
BOY AGED ELEVEN YEARS	28
BOY AGED TWELVE YEARS	30
BOY AGED THIRTEEN YEARS	32
BOY AGED FOURTEEN YEARS	34
BOY AGED FIFTEEN YEARS	36
BOY AGED SIXTEEN YEARS	38
BOY AGED SEVENTEEN YEARS	40



GENERAL DESCRIPTION OF THE BONES OF THE HAND AND WRIST

ANATOMY OF THE LOWER END OF THE RADIUS

THE nucleus of the shaft of the radius appears about the eighth week of intrauterine life, and invades the whole shaft at the time of birth. The lower end of the diaphysis is now slightly convex. Towards the end of the second year the osseous nucleus of the lower epiphysis of the radius appears above the scaphoid facet. Sometimes two granules appear, which rapidly blend together and form a plate projecting towards the borders of the epiphysis. This becomes much thicker towards the outer part, where it extends from about the sixth year to form the styloid process. By the tenth year the styloid process and lower epiphysis are almost entirely invaded by the osseous centre. Between the fourteenth and fifteenth years the external, middle, and internal thecal tubercles begin to project and extend upwards from the posterior aspect of the epiphysis.

The fully developed epiphysis is of an irregular quadrilateral shape, concave at the articular surface, which is formed into an outer triangular facet for the scaphoid and an inner quadrate facet for the semi-lunar bone. Its upper mammillated surface is also slightly concave, but more flattened than most of the epiphysial surfaces of the epiphyses, and accurately fits the quadrilateral convex end of the diaphysis.

Upwards it is limited in front by the anterior epiphysary crest, and between this crest and the border of the scaphoid facet is a rough area—of a triangular shape for the attachment of the anterior ligament of the wrist-joint, and somewhat bevelled off to permit of flexion of the scaphoid.

On the inner side it forms the whole of the sigmoid cavity or sinus lunatus, which is transversely concave, coated with cartilage for the convex articular head of the ulna.

The lower margin of this is separated from the inferior articular surface by a thin edge, to which is attached the thin base of the triangular fibro-cartilage of the wrist-joint.

The anterior epiphysary crest ends at the outer side towards the base of the styloid process in a sharp tubercle, which is the lower end of the pronator crest on the diaphysis, and which limits the attachment of the lower and outer part of the pronator quadratus. Posterior to this is a shallow groove divided into two for the tendons of the extensor ossis metacarpi pollicis and the extensor primi internodii pollicis.

Behind the groove is a ridge, the external thecal tubercle, passing downwards to the apex of the styloid process. To the lower end of the pronator crest, and to the surface of bone running backwards to this ridge, the supinator longus is inserted. Posterior to the external thecal tubercle is another broad, shallow groove, divided into two by a slight ridge, for the transmission of the tendons of the extensor carpi radialis longior and extensor carpi radialis brevior. Still more internal to this on the posterior surface of the epiphysis is the prominent middle thecal tubercle, on the inner side of which is a deep oblique, narrow groove for the extensor secundi internodii pollicis. This prominent ridge, therefore, forms a good guide to the epiphysal line on this aspect of the bone, the line running across the bone an eighth of an inch below the posterior end of the ridge. The inner ridge of this groove is the less prominent internal thecal tubercle. Between this and the posterior extremity of the sigmoid surface is the wide groove for the tendons of the extensor indicis and the extensor communis digitorum (see frontispiece).

The epiphysis, as seen at the seventeenth to eighteenth year of age, is 3 centimetres 2 millimetres in width from side to side and 2 centimetres in width antero-posteriorly; 8 millimetres in thickness about its centre. Its anterior lip is 6 millimetres in depth about the middle, and the posterior lip 10 millimetres at the same point; in the centre it is 5 millimetres thick vertically. On the outer side from the epiphysal line of cartilage to the apex of the styloid process it measures 2 centimetres. At its ulnar border, the sigmoid cavity, it is 6 millimetres thick vertically.

At fourteen years of age the vertical measurements are from epiphysal cartilage, outer side, to apex of styloid process, 7 millimetres; ulnar border, $4\frac{1}{2}$ millimetres; anterior lip, 6 millimetres; posterior lip, 9 millimetres, each about the middle.

This epiphysis is not united to the shaft till the nineteenth or twentieth year. Union takes place first towards the middle of the epiphysis—its thinnest part.

M. Voillemier has quoted instances in which the conjugal cartilage still persisted in subjects aged twenty-four and twenty-five years.

De Paoli gives the following table of measurements of the lower epiphysis of the radius and ulna at different ages :

Age	RADIUS			Breadth	ULNA	
	Height				Height	Breadth
	Styloid Process	About the middle	Internal edge			
Before birth . . .	5 mm.	4 mm.	3 mm.	10	6.5	6
Twenty months . . .	8 "	5 "	4 "	12	7	11
Two years	4 "	4 "	3.5 "	12	6	—
Four years	8 "	5 "	3 "	21	5	13
	12 "	6 "	3 "	22	6	14
Five years	11 "	5 "	3 "	24	5	14
Six years	12 "	5.5 "	4 "	22	5	12
Seven years	7 "	3.5 "	4 "	16	5	—
Nine years	13 "	6 "	5 "	—	5	—
	11 "	5 "	4 "	—	5	—
	14 "	6 "	4 "	23	6	14
Ten years	14 "	5 "	4 "	21	8	13
Fourteen years	15 "	7 "	6 "	26	8	—
Fifteen years	16 "	7 "	6 "	29	8	—
Sixteen years	15 "	5 "	4 "	29	8	16
Seventeen years	17 "	7 "	5 "	27	8	12
Nineteen years	16 "	8 "	5 "	28	7	15

ANATOMY OF THE LOWER END OF THE ULNA

At birth the lower end of the shaft of the ulna is completely ossified. Its distal extremity is flat, and on a level with that of the radius.

Up to three years the lower end of the shaft keeps its cylindrical form, and it is the lower epiphysis which chiefly gives the shape to this end of the bone.

About the fourth, fifth, or sixth year the chief nuclei of the carpal extremity appear towards the centre of the head and base of the styloid process. These lie close together, and soon blend, forming an osseous plate which extends downwards on the inner side into the styloid process. This process is formed principally from this centre, but an additional centre is sometimes seen at the summit, appearing about the twelfth year, and joining the rest of the osseous epiphysis three or four years later.

Béclard described two centres, one for the articular end and the other for the styloid process, appearing soon after birth.

The fully formed epiphysis comprises the whole of the articular surface of the head on the outer (for the radius) as well as the inferior aspect towards the inarticular fibro-cartilage, and also the styloid process projecting downwards on the inner side, which is grooved behind for the tendon of the extensor carpi ulnaris. Its upper aspect is concave and mammillated, and fits the corresponding convexity of the diaphysis.

The level of the epiphysial line of the lower end of the ulna is very slightly above the level of that of the radius, about $1\frac{1}{2}$ millimetres. The cartilaginous disc is 12 millimetres above (vertically) the apex of the styloid process in the fully formed epiphysis, and 7 millimetres at fourteen years of age. On the inner side or head it is 8 millimetres above (vertically) the lower articular surface, and at fourteen years of age 5 millimetres. Where the head joins the styloid process on the outer side the thickness (vertically) of the mature epiphysis is only 5 millimetres, at fourteen years 3 millimetres.

The head of the ulna is covered by the synovial membrane of the inferior radio-ulnar articulation, and rotates within the sigmoid cavity of the radius and on the surface of the triangular fibro-cartilage.

This epiphysis is held to the lower epiphysis of the radius in front and behind by the anterior and posterior inferior radio-ulnar ligaments, and also by means of the triangular fibro-cartilage, which is attached by its apex to the root of the styloid process, and by its thin base to the lunar margin of the radius. To the carpus it is held by the numerous anterior and posterior fibres of the capsular ligament of the wrist.

The apex of the styloid process affords attachment to the internal lateral ligament of the wrist.

This epiphysis joins the shaft at twenty years of age, often a little earlier or later.

ANATOMY OF THE BONES OF THE CARPUS

At birth all the bones of the carpus are entirely cartilaginous.

There is usually a single nucleus of ossification for each bone, which appears in the magnum towards the end of the first year, in the unciform at about the second year, in the cuneiform at the third year, in the semilunar at the fourth year, in the trapezium at the fifth year, in the scaphoid at the sixth, in the trapezoid at the eighth year, and in the pisiform at twelve years of age.

The scaphoid sometimes commences ossification with a second nucleus close to the first, and the unciform occasionally has an

independent centre for its hook-like palmar process. Serrès describes a second centre for the semilunar also.

There are no epiphyses to these bones.

An occasional ossicle, the centrale, is sometimes seen on the dorsal aspect of the carpus situated between the scaphoid, trapezoid and magnum.

ANATOMY OF THE METACARPAL BONE OF THE THUMB

The centre of the shaft appears at the eighth or ninth week of intrauterine life; the whole shaft is well ossified at the time of birth.

The epiphysis of the metacarpal bone of the thumb is developed like one of the phalanges, the epiphysis being situated at its proximal end. In the four inner or true metacarpals the epiphysis is placed at the lower extremity. Both morphologically and developmentally this bone should be regarded as a phalanx.

The epiphysis, hitherto cartilaginous, in all the metacarpal bones begins to ossify about the third year, and unites with the shaft about the twentieth year.

Traces of a distal epiphysis in the metacarpal bone of the thumb are usually to be seen, and in some instances a distinct epiphysis (as in the seal and some other animals) is visible at the age of seven or eight years.

The nutrient artery of this bone is situated on the ulnar aspect, and runs downwards.

To the margin of this proximal epiphysis is attached the capsular ligament of the carpo-metacarpal joint, which is stronger behind and on the outer side than in front.

The epiphysis is at fourteen years of age 5 millimetres thick vertically at the posterior border, and 4 millimetres anteriorly. In width, laterally, 11 millimetres. The epiphysis is at eighteen years of age $6\frac{1}{2}$ millimetres thick vertically at the posterior border, and 7 millimetres anteriorly; in width, 18 millimetres.

ANATOMY OF THE FOUR INNER OR TRUE METACARPAL BONES

Ossification of the shafts begins about the eighth week of intrauterine life, and is well advanced at the time of birth.

In the four inner or true metacarpal bones the epiphysis is developed at the distal extremity. The osseous nucleus appears

about the centre of the cartilaginous end from two and a half to five years of age, commencing in that of the index finger.

The epiphysis unites with the shaft about the twentieth year. The proximal end in each metacarpal bone is formed by the shaft.

In the metacarpal bone of the index finger the nutrient artery runs upwards on the ulnar side; in the three other metacarpal bones it runs upwards on the radial side.

There are frequently traces of a proximal epiphysis to be seen in the metacarpal bone of the index finger.

The fully formed epiphysis forms the whole of the condyloid head, and has the lateral ligaments attached to the tubercles and hollows on each lateral aspect.

The length of the epiphysis of the index finger vertically from the epiphysial line is 9 millimetres posteriorly and 7 millimetres anteriorly. Width from side to side at fourteen years, 10 millimetres; at eighteen years 12 millimetres. Width antero-posteriorly at fourteen years, 12 millimetres; at eighteen years, 15 millimetres.

The third metacarpal bone occasionally has an accessory centre for its prominent styloid projection on the outer side of its dorsal aspect.

ANATOMY OF THE PHALANGES OF THE DIGITS

Ossification of the shafts commences about the ninth week of intrauterine life, and extensively invades the shaft at the time of birth.

In all three rows of phalanges of the fingers, and in the two rows of the thumb, the epiphysis is placed at the proximal end. The lower ends are developed from the shafts.

There is commonly one osseous centre, but M. Serrès describes two centres appearing in the middle of the cartilaginous epiphysis side by side, which rapidly unite and form one osseous plate.

The same writer states that three centres are sometimes seen in the epiphysis of the first phalanx of the thumb.

Ossification takes place successively from the first phalanges to the second, and lastly in the third; in the first row from the third to the fourth year, and in the second and third row from the fourth to the fifth year.

The epiphysis of the terminal phalanx of the little finger is frequently absent.

The epiphyses unite to their respective shafts about the nineteenth year.

The nutrient canal runs upwards in each phalanx.

It should be noted that the unguis phalanges of the fingers commence the ossification of their shafts before birth at the distal end instead of in the middle like all the other long bones.

The proximity of the sheath of the flexor tendons on the palmar aspect of the epiphyses of the digital phalanges should be remembered.

The flat, disc-like epiphyses (of the first row) are in depth, vertically, at fourteen years, at the sides 4 millimetres, posteriorly 2 millimetres, anteriorly 3 millimetres. At eighteen years the epiphyses measure, at the sides 6 millimetres, posteriorly $2\frac{1}{2}$ millimetres, anteriorly $4\frac{1}{2}$ millimetres. In width across, laterally, at fourteen years 13 millimetres, at eighteen years 17 millimetres.

OSSIFICATION OF THE BONES OF THE WRIST AND HAND AS DISPLAYED BY THE RÖNTGEN RAY PROCESS

FIRST YEAR. FIRST CHILD OF PARENTS

Lower end of ulna.—There are no traces of calcareous material yet visible in the cartilaginous lower epiphysis, while the diaphysis is rounded, slightly curved with convexity inwards, and its end is flat and almost exactly on a level with that of the diaphysis of the radius.

Lower end of radius.—Although many works on anatomy describe the commencement of ossification of the cartilaginous lower epiphysis as late as the second, or even the fifth year, yet the osseous nucleus above the scaphoid facet is here seen to be of an oval shape and already of a considerable size. The end of the diaphysis is slightly convex, and the bone itself is thick, and has much the appearance of the fully shaped lower end of the bone.

Carpus.—Ossification of the *magnum* having commenced at the eighth month, is now well advanced—the nucleus at this period being of an oval shape. The nucleus of the *unciform* is of a rounded shape in the centre of the cartilaginous bone. None of the other bones of the carpus have as yet any point of ossification.

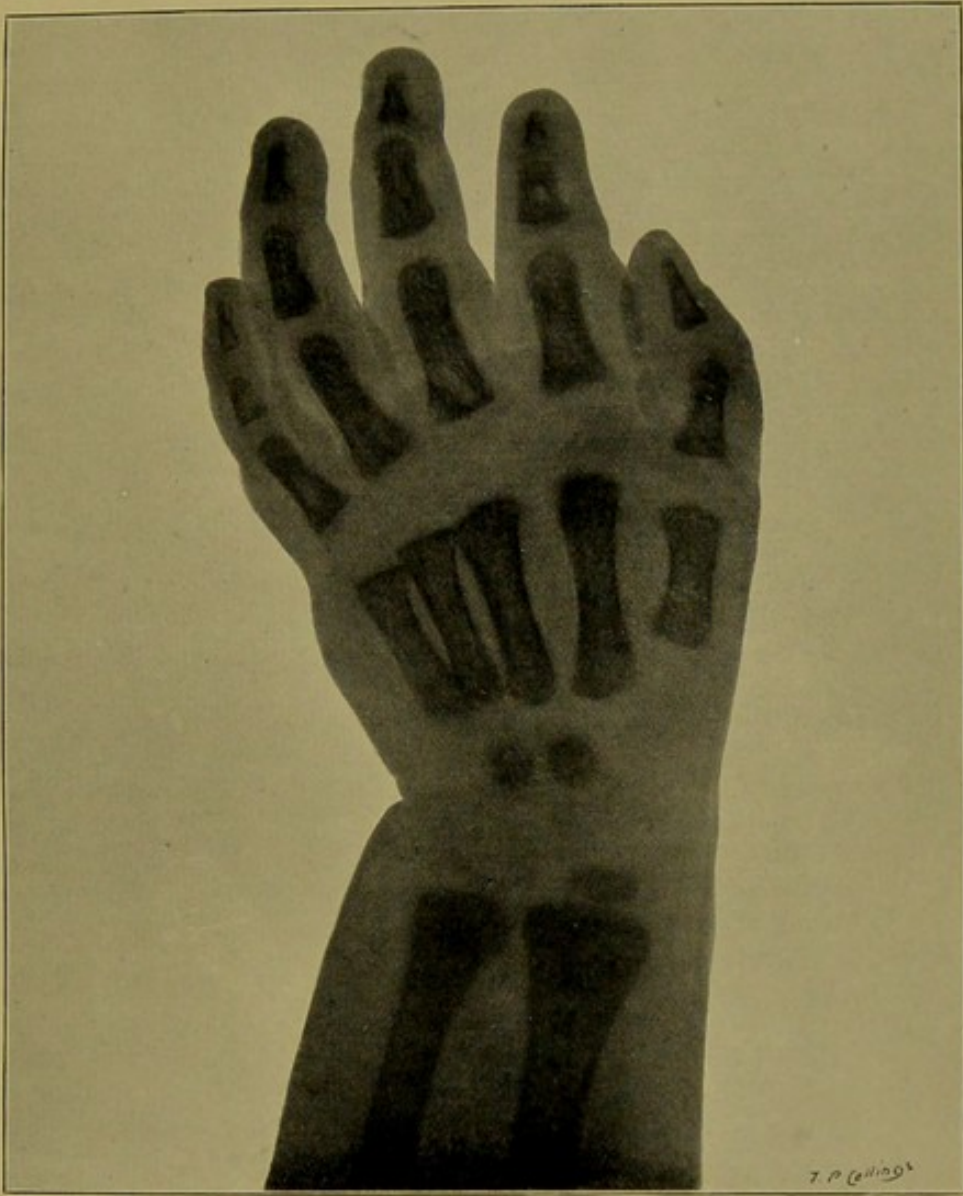Metacarpal bone of thumb.—Ossification of the diaphysis, which commenced at the eighth or ninth week before birth, is now complete. The centre for the epiphysis at the proximal extremity has not yet appeared.

Four inner metacarpal bones.—Ossification of the shafts is very extensive. Distal epiphyses entirely cartilaginous.

Phalanges of fingers. First row.—Ossification of shafts very extensive. Proximal epiphyses entirely cartilaginous.

Middle or second row.—Ossification of shafts very extensive. Proximal epiphyses entirely cartilaginous.

Ungual or terminal phalanges.—Ossification of shafts, which commenced at the distal extremity instead of middle of shafts, as the first and second row, is now complete. Proximal epiphyses entirely cartilaginous.




FEMALE INFANT AGED TWELVE MONTHS.

MR. T. P. COLLINGS'S GRANDCHILD. FIRST CHILD OF PARENTS.

'Snap-shot' exposure.

Taken by Mr. WM. WEBSTER.





SECOND YEAR. THIRD CHILD

In some respects the bones in this instance are more ossified than in the following skiagram of a child aged three years, eighth child of parents.

Lower end of radius.—The nucleus of the epiphysis is elongated transversely and thickens at the outer end.

Carpus—Cuneiform shows rounded centre of ossification about its centre. It is absent in the next skiagram of third year (eighth child) and in the skiagram of fifth year (thirteenth child).

Metacarpal bone of thumb.—A trace of calcareous deposit can already be seen in the proximal epiphysis.

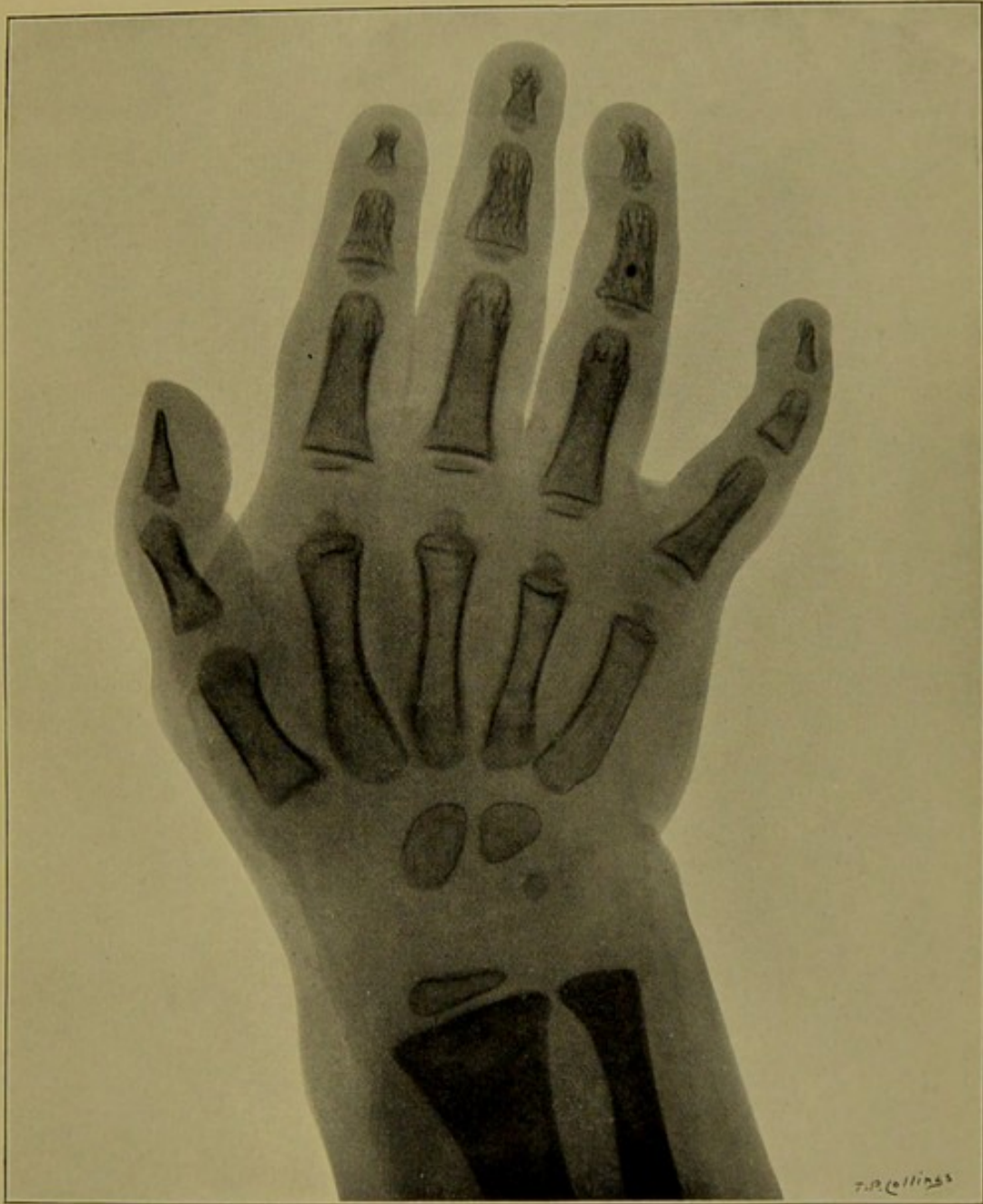
Four inner metacarpal bones.—The nucleus of the epiphysis or head at the lower end of each metacarpal bone is now visible, generally commencing in the index finger first.

First phalanx of thumb.—This is the first of the phalanges of the hand to commence ossification of its epiphysis.


Phalanges of fingers. First row.—Ossification has commenced in all the four fingers, that of the index finger is most advanced.


Middle or second row.—Ossification is seen commencing in the proximal epiphysis of each of the four fingers.

Ungual or terminal phalanges.—There are traces of ossification in the epiphyses of the thumb and first three fingers.



CHILD AGED TWO YEARS. THIRD CHILD.
Ossification in some respects more advanced than in the following skiagram.
Taken by Mr. WM. WEBSTER.





THIRD YEAR. EIGHTH CHILD

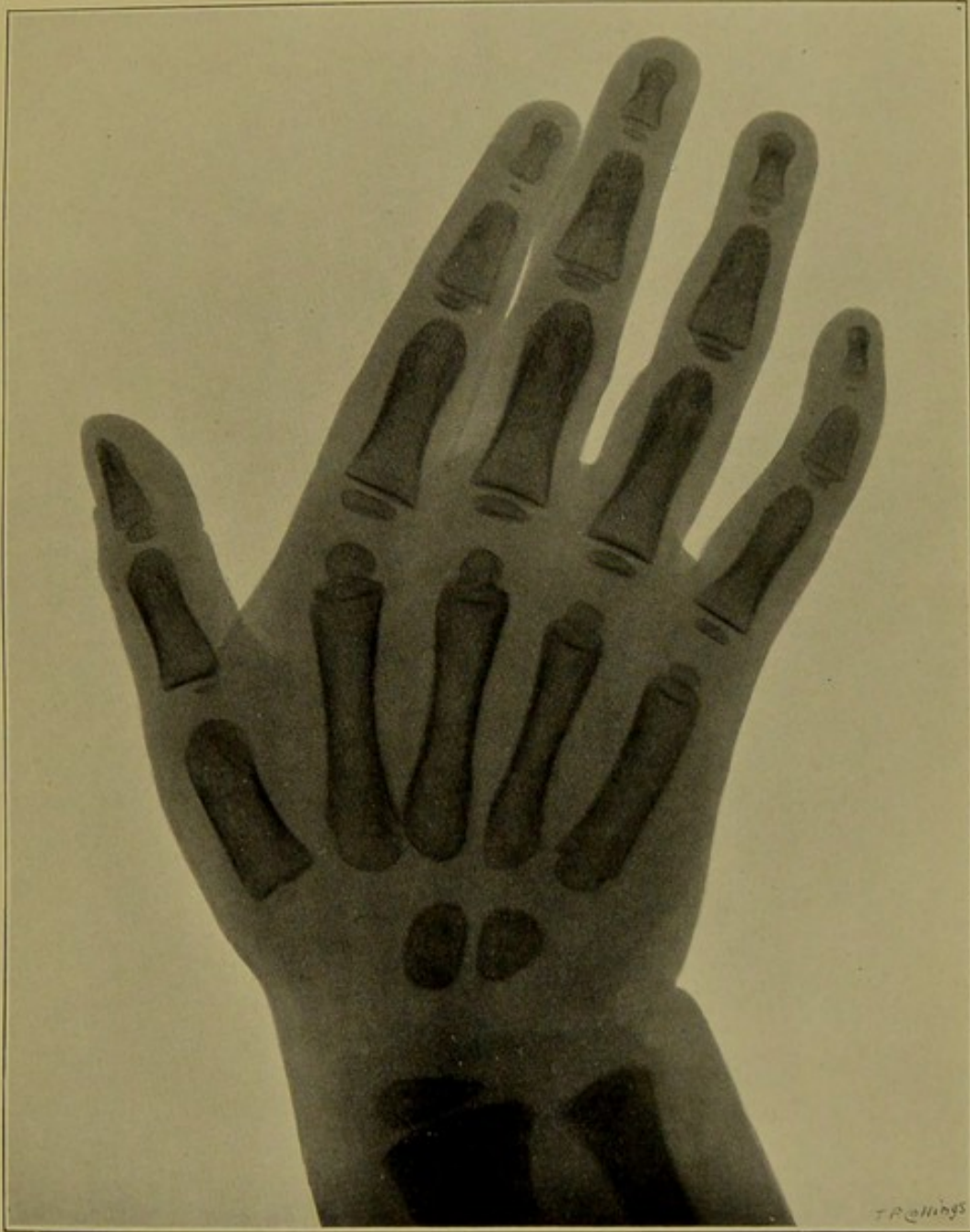Carpus.—Centres of ossification for the magnum and unciform only are seen in this instance.

Metacarpal bone of thumb.—The centre of ossification of the epiphysis is distinct, and of an oval shape.


Four inner metacarpal bones.—The nucleus of each epiphysis of head assumes a rounded shape.

Phalanges of fingers. First row and middle or second row.—Ossification of the epiphyses of the two rows advances.

Ungual or terminal phalanges.—Ossification of the epiphyses extends in the case of each bone—most developed in that of the middle finger.



CHILD AGED THREE YEARS. EIGHTH CHILD.
Taken by Mr. WM. WEBSTER.





FOUR AND A HALF YEARS

Lower end of ulna.—The centre of ossification of epiphysis has not appeared. Diaphysial end appears to be on a higher level than in the preceding instances.

Lower end of radius.—Diaphysis well developed—shape that of fully formed bone; if its end were concave instead of convex it might be mistaken for the entire bone, and it shows that the epiphysis contributes very little to the shape of the bone. Its extremity as just stated is below that of the ulna.

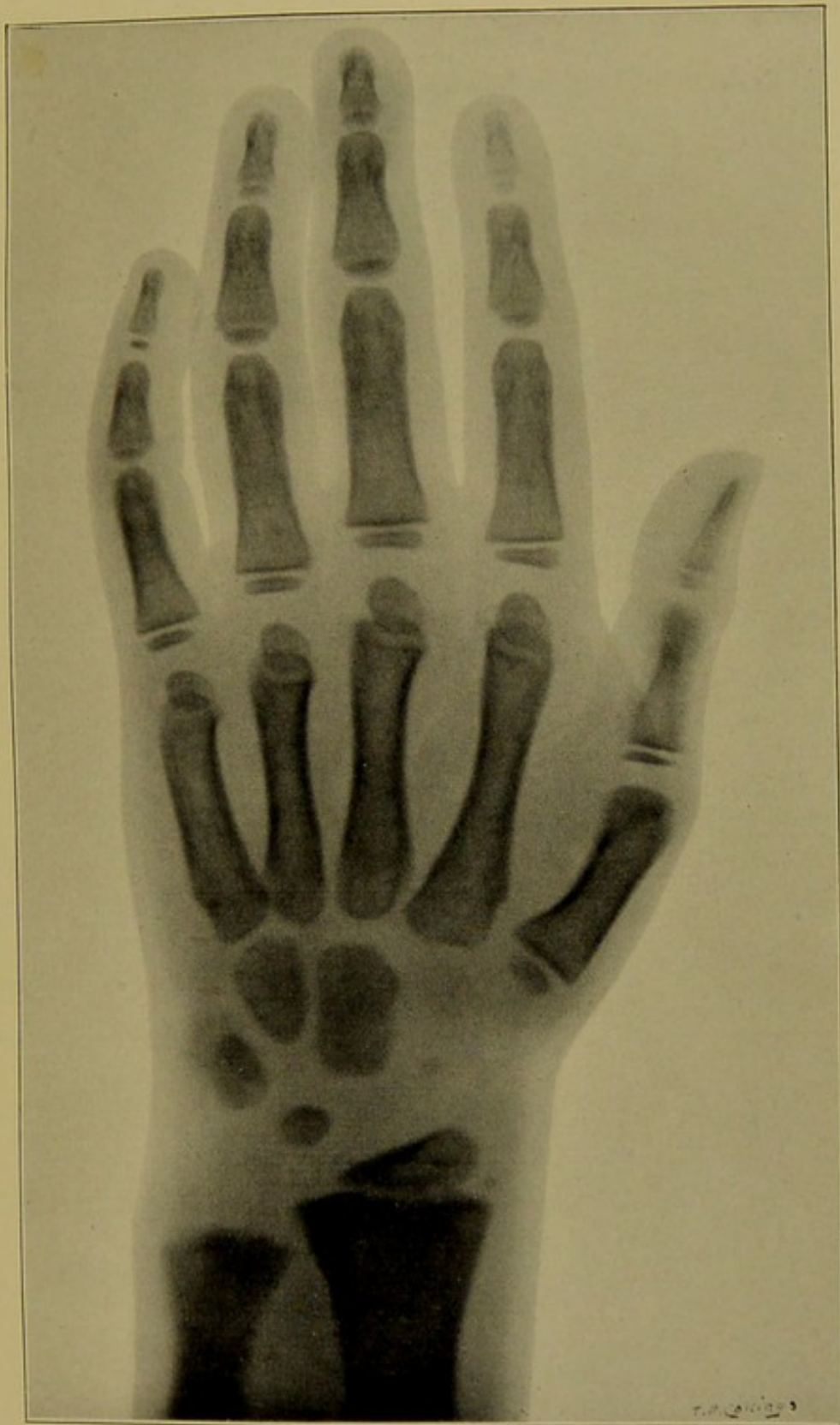The nucleus of epiphysis thickens considerably towards its outer side. It is sixteen millimetres transversely.

Carpus.—Ossification of *magnum* and *unciform* assumes the normal shape of the bones. Granules of ossification in *trapezium* and *trapezoid* are faintly visible.

The nucleus of *cuneiform* begins to assume the normal shape of bone, that of the *semilunar* is of a rounded form.

Metacarpal bone of thumb.—The centre for the proximal epiphysis is now of oval shape, and six by three millimetres in size.

Four inner metacarpal bones.—The nucleus of each epiphysis of head assumes the more mature form of this end.



MALE CHILD AGED FOUR AND A HALF YEARS.

½ second exposure.

Taken by Mr. WM. WEBSTER.





FIFTH YEAR. SECOND CHILD AND THIRTEENTH CHILD

In the second skiagram the ossification of the bones in a thirteenth child of parents is not so advanced as in the one aged five years, second child.

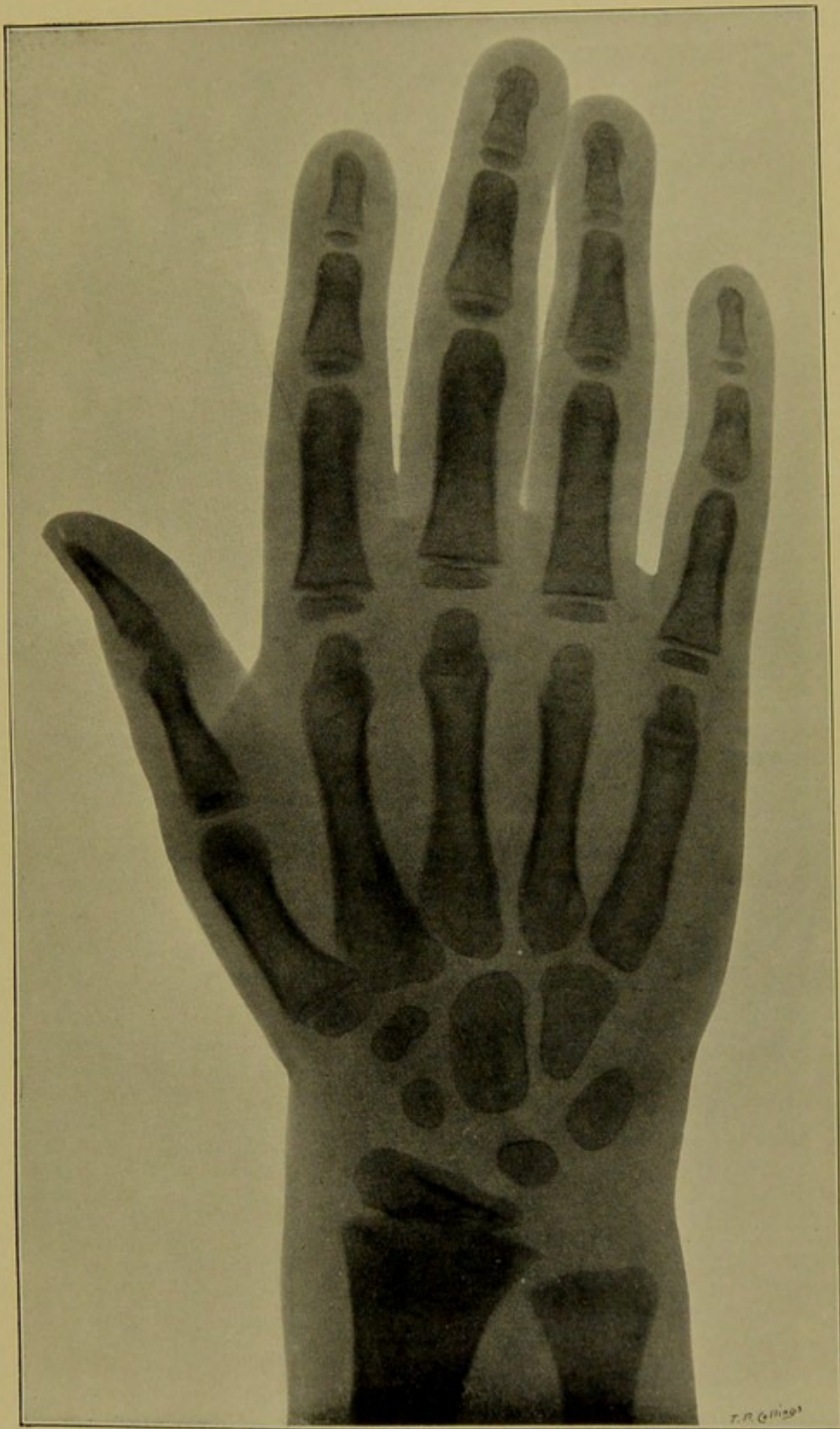
Lower end of ulna.—The centre of ossification of the epiphysis has not appeared.

Lower end of radius.—In size the nucleus of the epiphysis is twenty-three millimetres transversely.

Carpus.—The nucleus of the *unciform* assumes shape of bone and the centres of ossification of the *scaphoid* and *trapezium* and *trapezoid* are very distinct in the case of the second child of parents, but the shadows of the two latter are joined, probably on account of the somewhat oblique direction of the rays. In the case of the thirteenth child of parents only the centres for the *magnum* and *unciform* are visible.

Metacarpal bone of thumb.—The epiphysis rather more developed in the case of the second than in that of the thirteenth child.

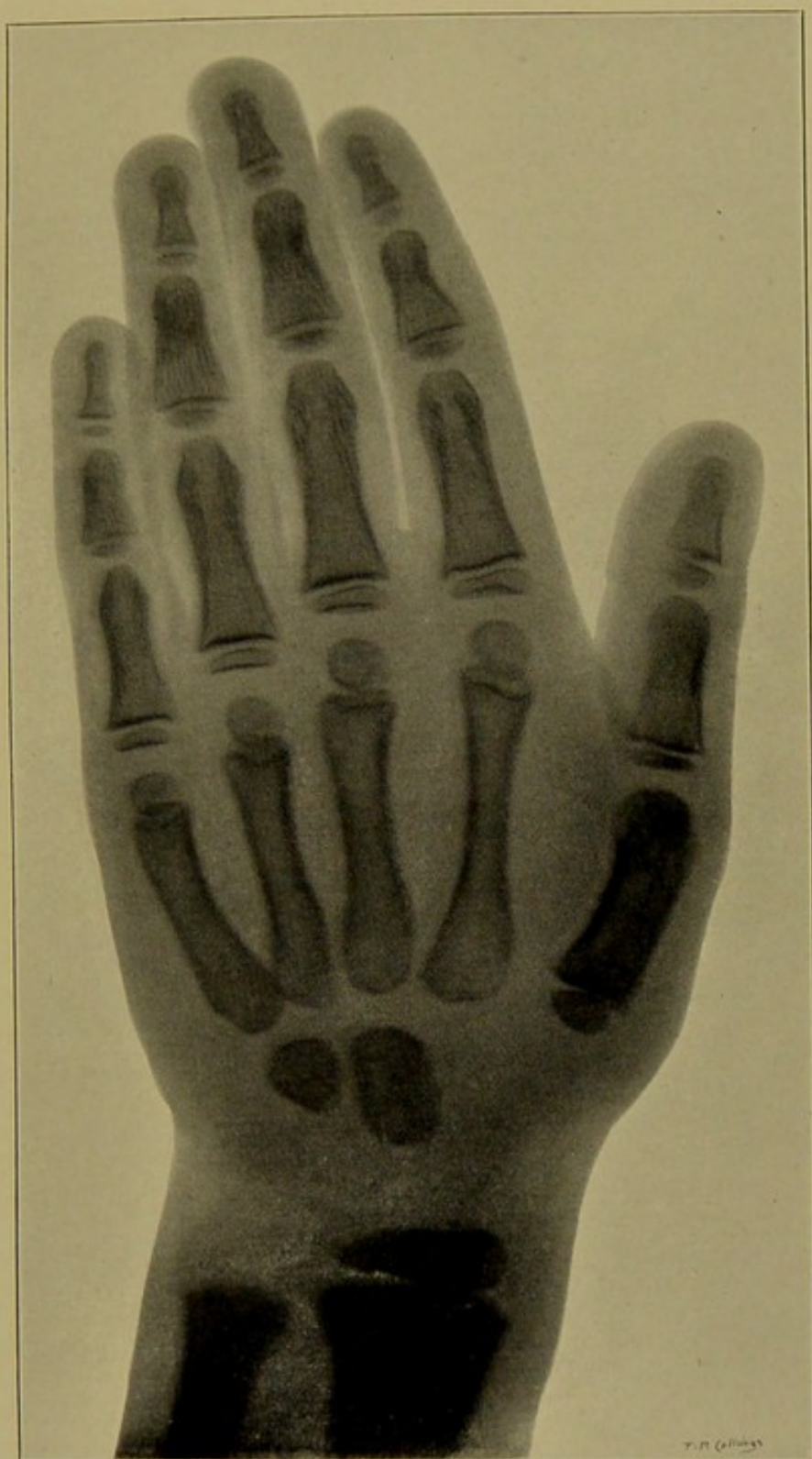
Four inner metacarpal bones.—The epiphyses rather more developed in the case of the second than in that of the thirteenth child.



CHILD AGED FIVE YEARS. SECOND CHILD OF PARENTS.


Taken by Mr. Wm. WEBSTER.





CHILD AGED FIVE YEARS. THIRTEENTH CHILD OF PARENTS.
Ossification not so advanced as in the following skiagram of a child of same age (second child),
and in some respects no further advanced than in skiagram of child of three years.

Taken by Mr. Wm. WEBSTER.

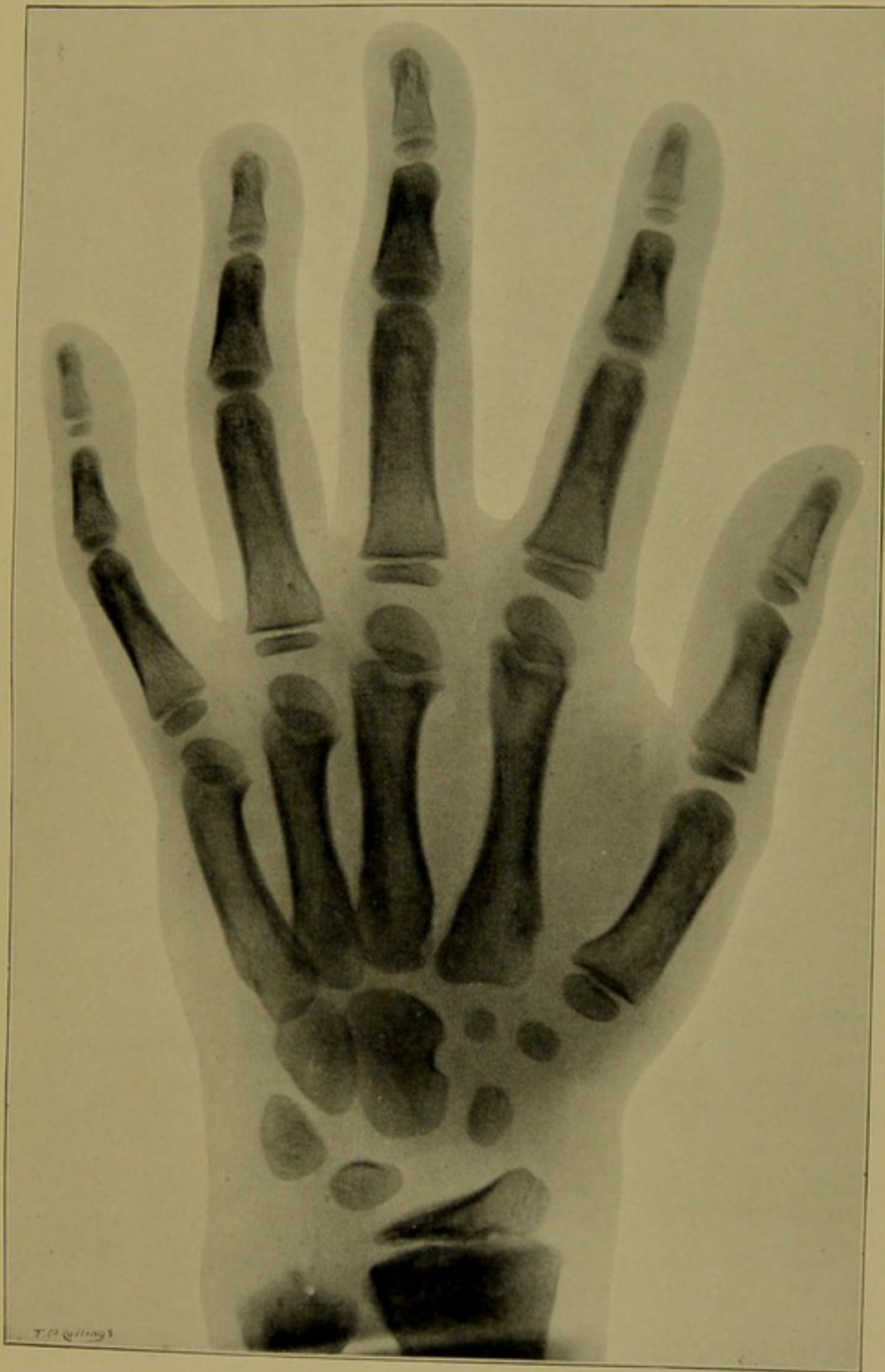



SIXTH YEAR

Lower end of ulna.—Ossification of epiphysis commences in the middle of the cartilaginous head.

Carpus.—In this instance the shadow of the nucleus of the trapezoid is away from that of the trapezium.



$\frac{1}{4}$ second exposure.

MALE CHILD AGED SIX YEARS.

Taken by Mr. WM. WEBSTER.

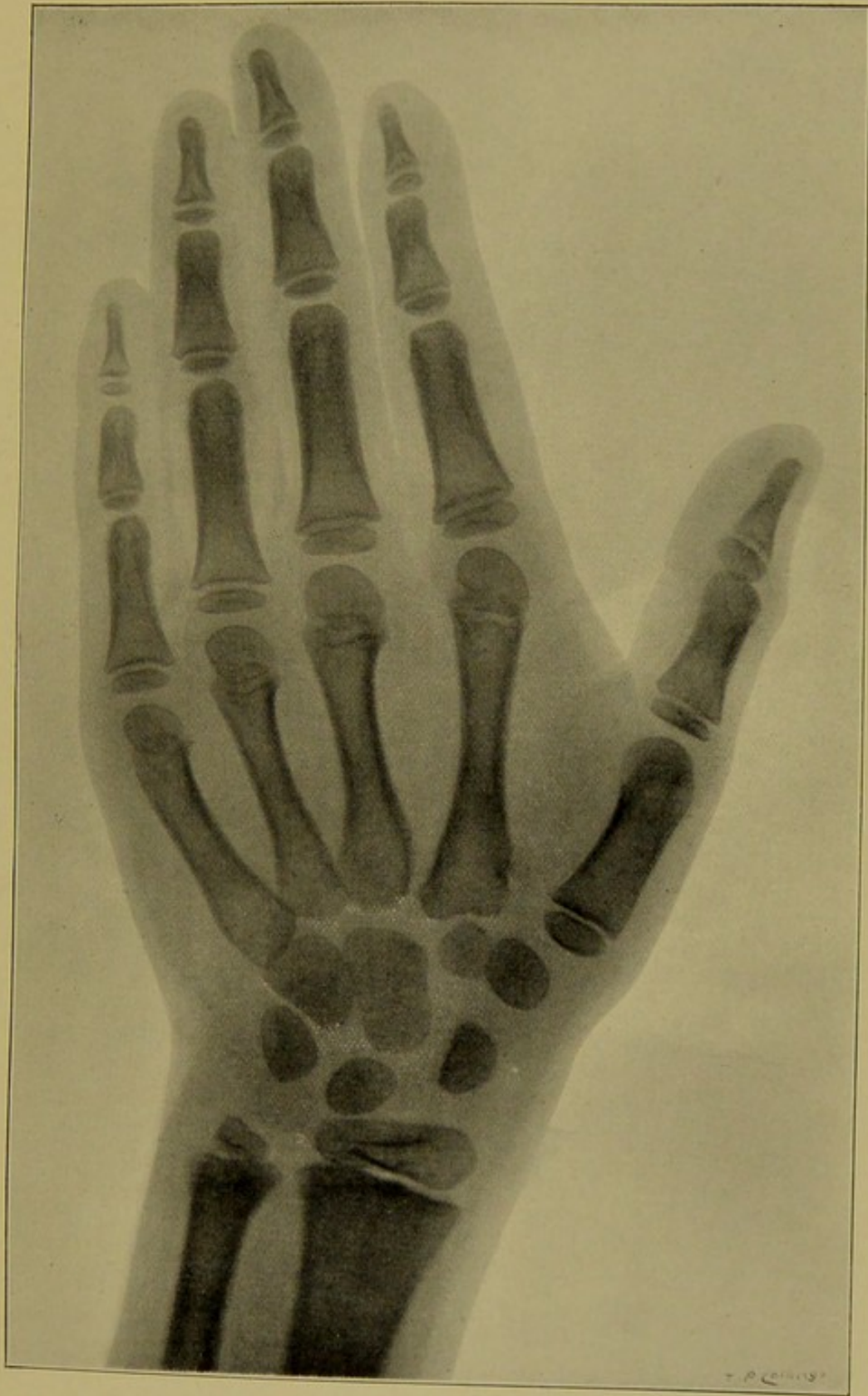


SEVENTH YEAR

Lower end of ulna.—The centre of ossification of the epiphysis is well developed, and already extends into the styloid process.

Lower end of radius.—The nucleus of epiphysis has made marked progress, and is two centimetres in its largest diameter, and is thickest towards its outer part, where it will form the styloid process, but this is as yet not ossified.

Carpus.—The centre of ossification of the *trapezoid* above the metacarpal bone of index finger is now very much enlarged.



MALE CHILD AGED SEVEN YEARS.

$\frac{1}{2}$ second exposure.

Taken by Mr. WM. WEBSTER.



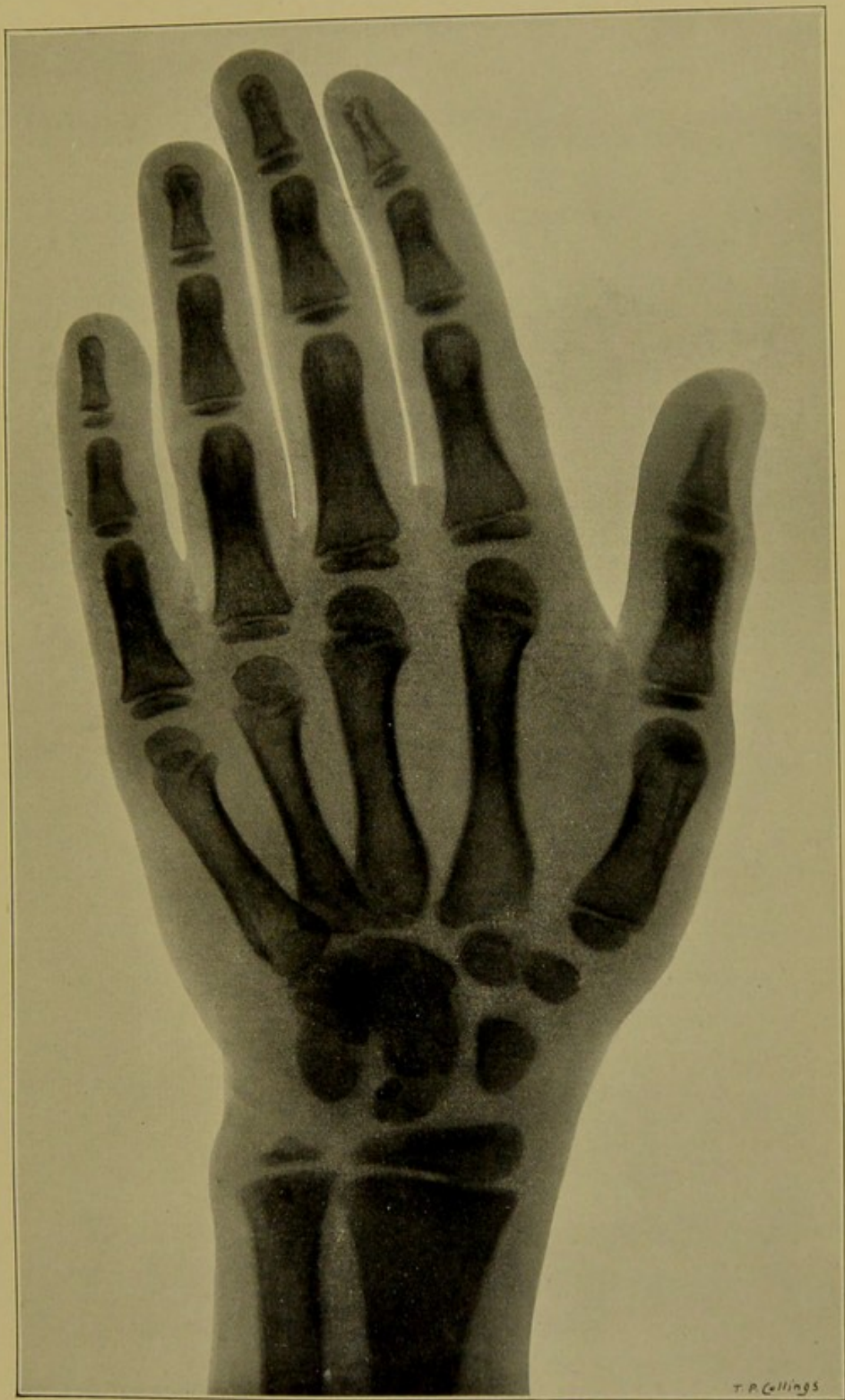

EIGHTH YEAR, AND EIGHT YEARS AND FIVE MONTHS

Note the difference in relation of cuneiform to the epiphyses of the radius and ulna during adduction of the hand in the child of eight years.

Phalanges.—Nucleus of epiphyses of the three rows assuming shape of mature discs.


Nucleus of first phalanx of index finger measures six millimetres transversely

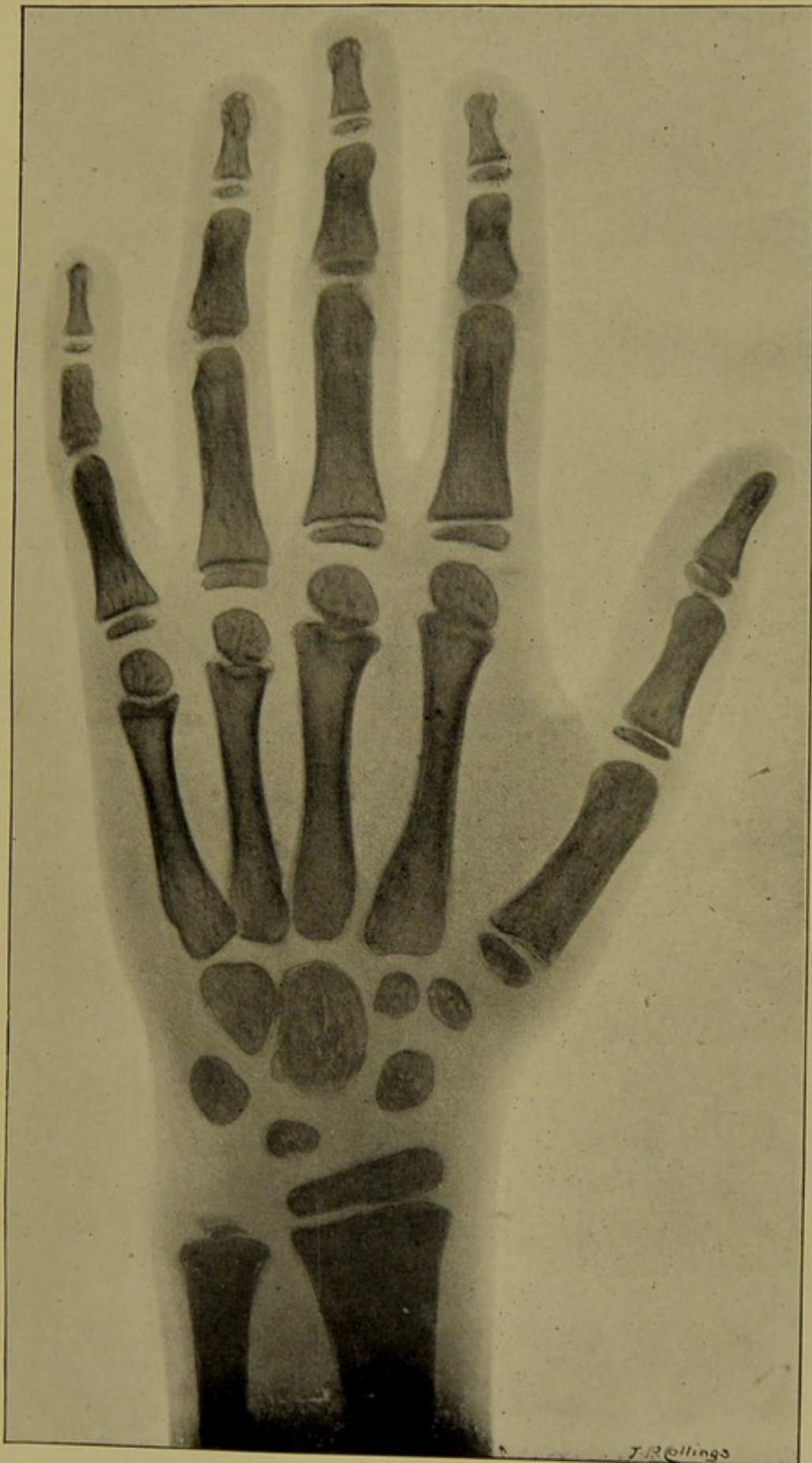

1 second exposure.


MALE CHILD AGED EIGHT YEARS.

Taken by Mr. Wm. WEBSTER.





AUTHOR'S SON (R. D. P.), AGED EIGHT YEARS AND FIVE MONTHS.
Skigram of Hand taken in April 1896 by Mr. C. SWINTON.

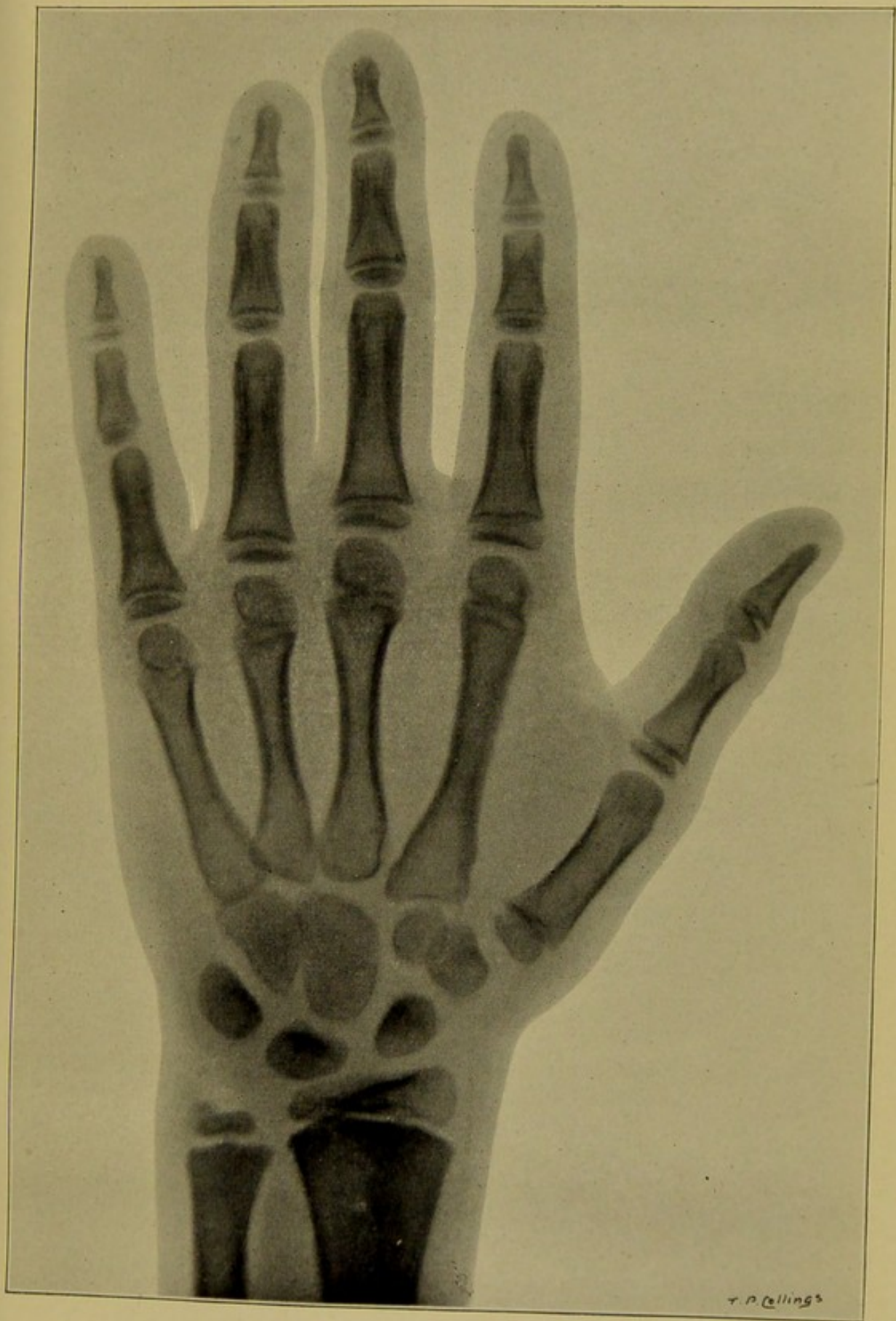




NINTH YEAR

Lower end of radius.—The ossification of the epiphysis has progressed so that the lower concave articular surface for the scaphoid and semilunar begins to form.

Carpus.—A faint shadow of the hook-like process of the unciform bone is noticeable.



1 second exposure.

MALE CHILD AGED NINE YEARS.

Taken by Mr. WM. WEBSTER.

f

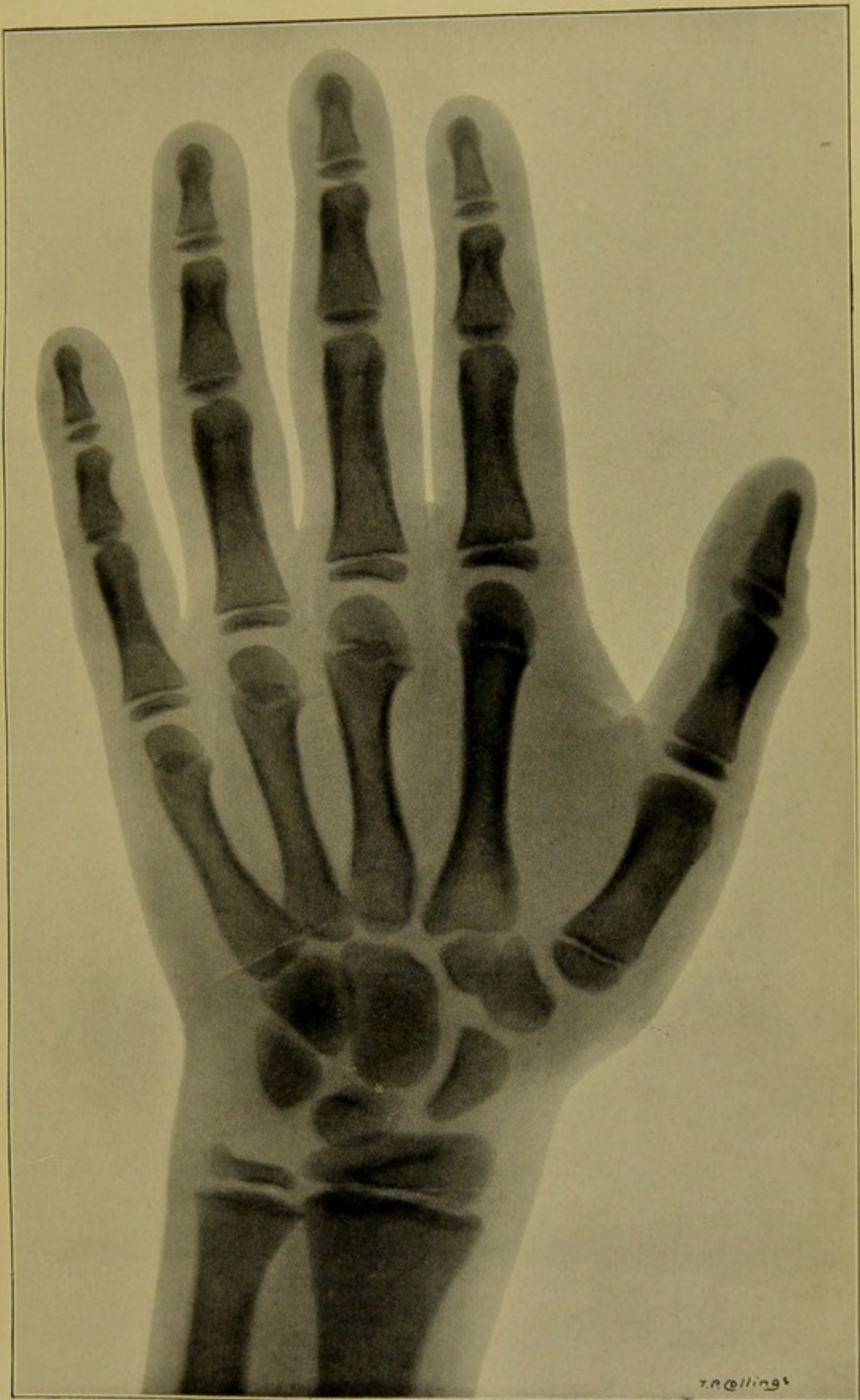




TENTH YEAR

The shadows of the compact layers and medullary spaces of the shafts of the metacarpal bones and phalanges are well differentiated


The ossification of the epiphyses of the long bones begins to assume the shape of the fully developed epiphyses.




1 second exposure.

BOY AGED TEN YEARS.

Taken by Mr. WM. WEBSTER.

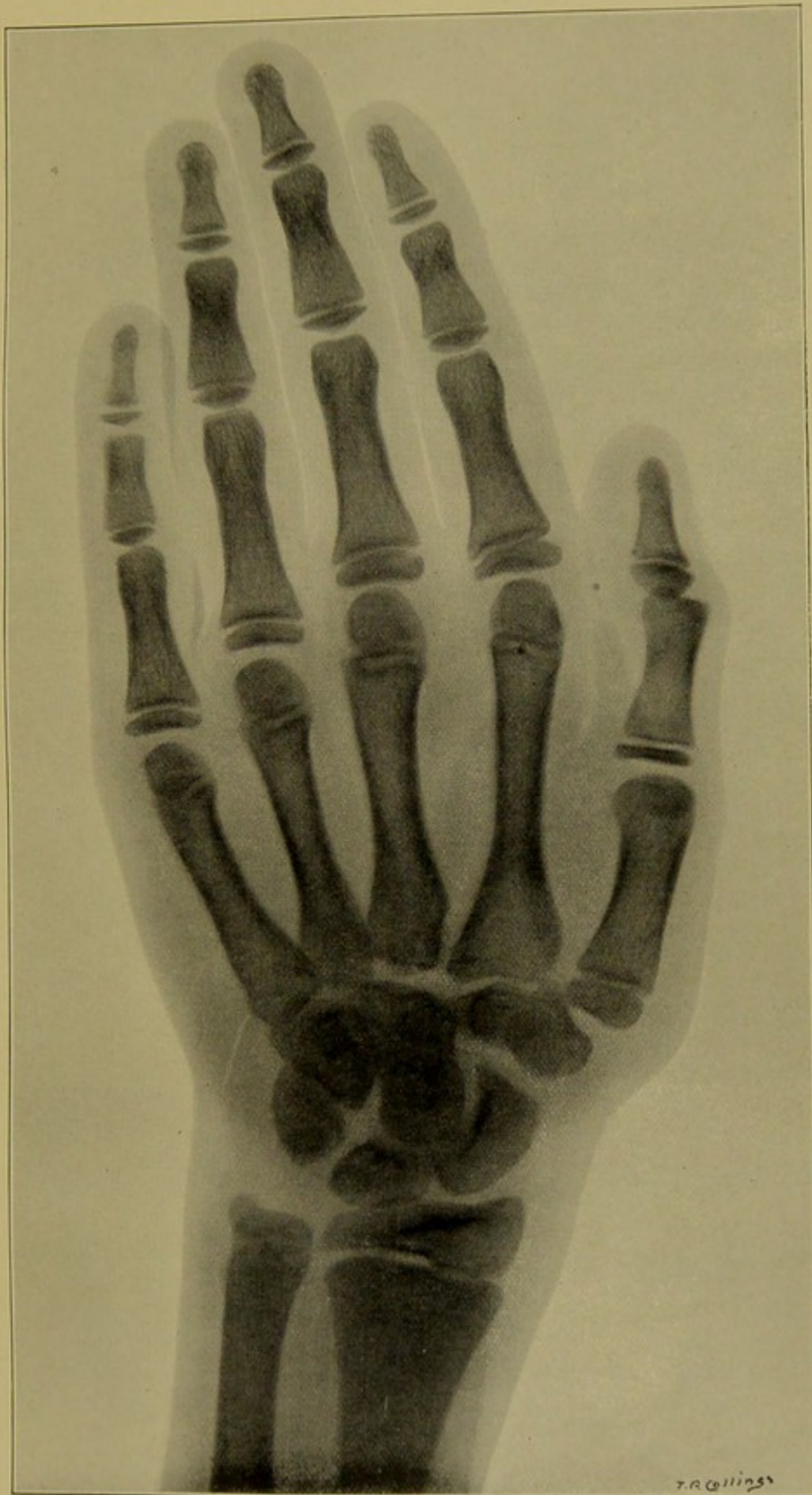




ELEVENTH YEAR

Lower end of ulna.—The styloid process of the epiphysis very distinct. None of the skiagrams examined by author show an accessory centre for the apex of this process, which is sometimes described by anatomists.

Lower end of radius.—Ossification of the epiphysis has now extended downwards into the styloid process.



1 second exposure.

BOY AGED ELEVEN YEARS.

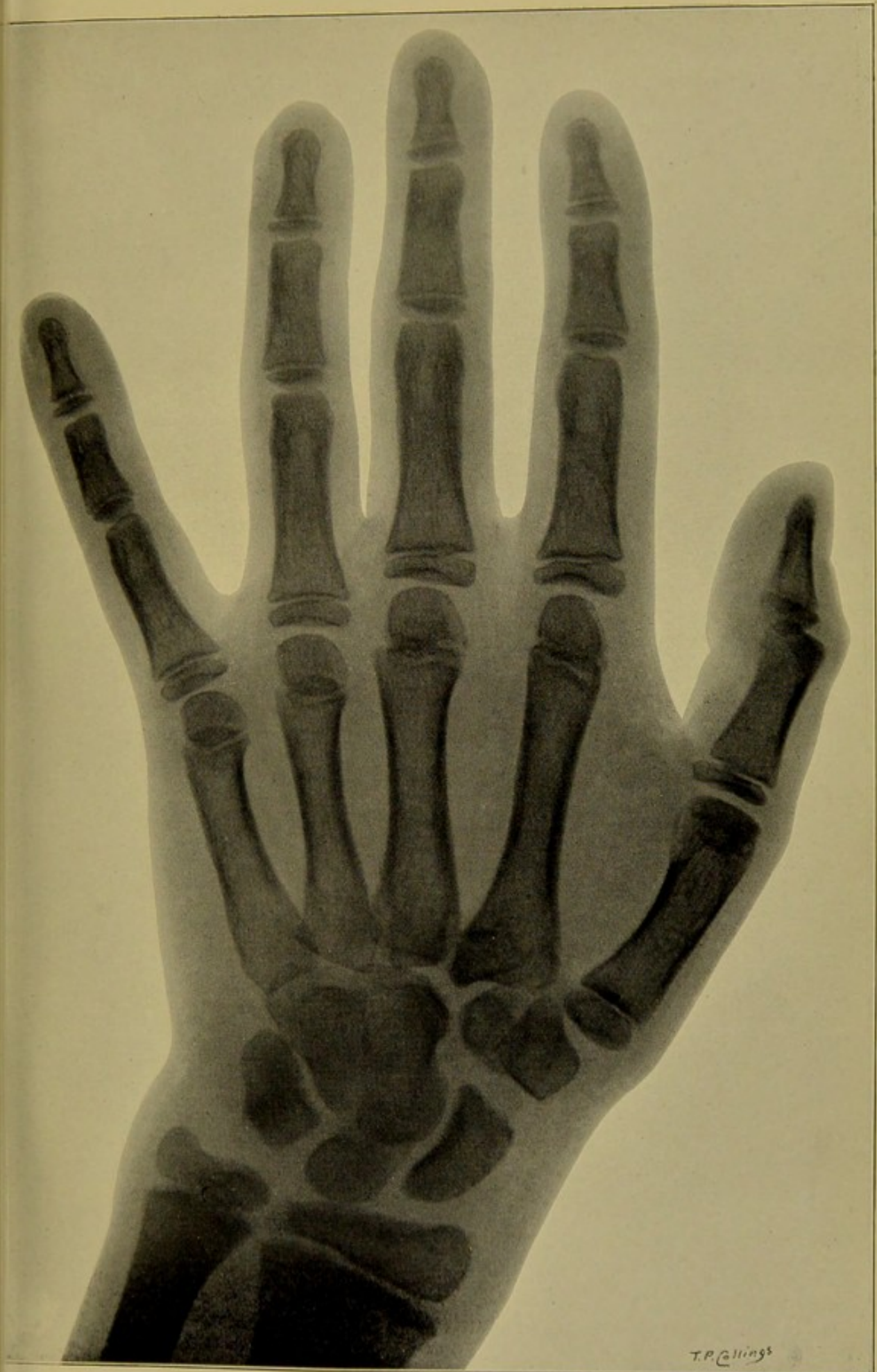Taken by Mr. WM. WEBSTER.





TWELFTH YEAR

Shadows much the same as during the eleventh year, but all commence to take the natural outline of mature bones.




T.P. Collins

1 second exposure.

BOY AGED TWELVE YEARS.

Taken by Mr. WM. WEBSTER.





THIRTEENTH YEAR

Lower end of ulna.—Ossification of styloid process progressing.

Lower end of radius.—Ossification of styloid process progressing.

Carpus.—Ossification of all the carpal bones now complete. The shape of the fully developed bones clearly defined.

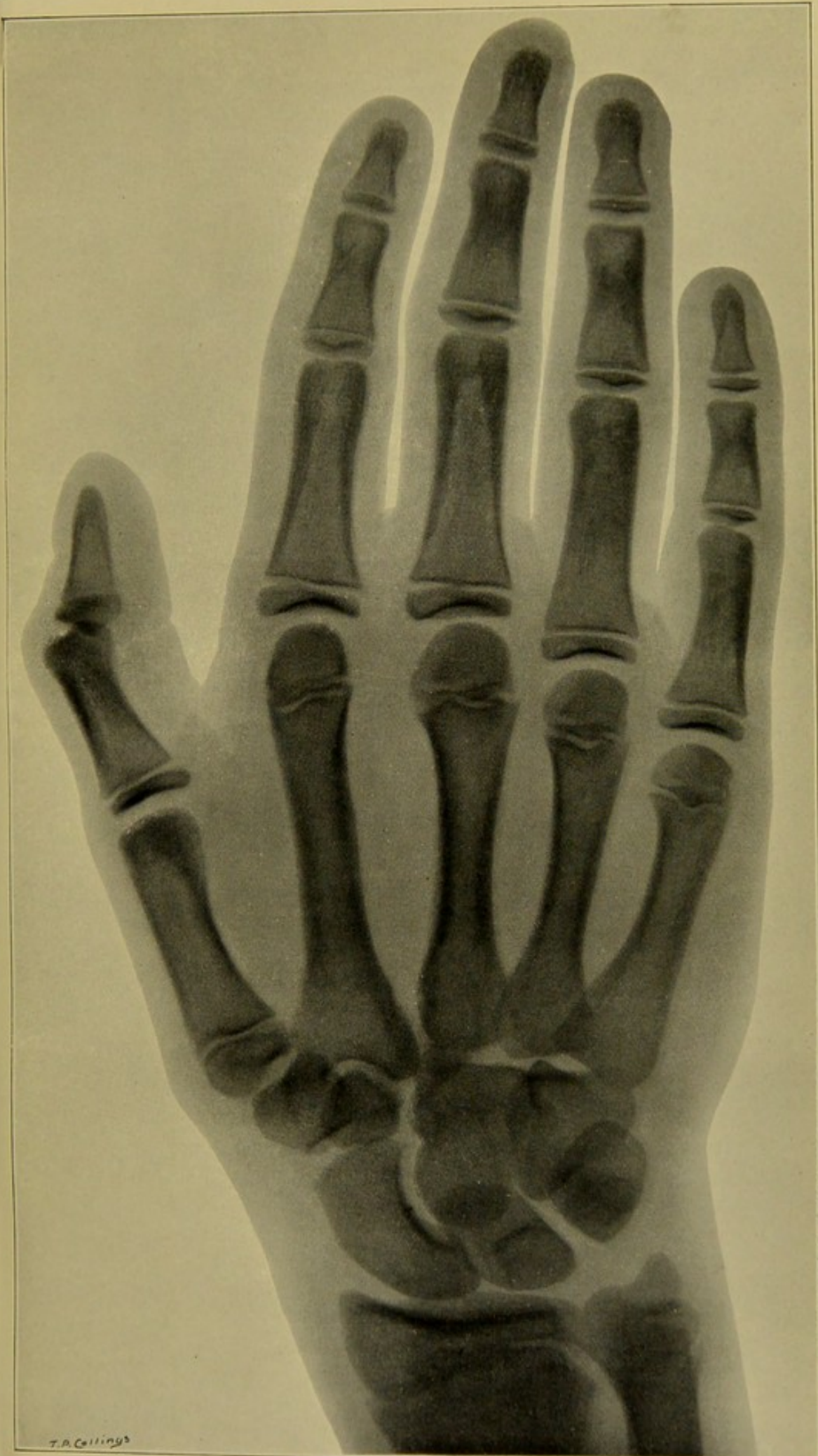
The hook-like process on the palmar aspect of the unciform now very distinct.

The shadow of the pisiform bone is noticeable.

Phalanges.—The medullary cavities of the shafts of the bones of the three rows are well developed.

First row.—The concave articular surface of the epiphyses very distinct.

Second and unequal rows.—The saddle shaped articular surface of the epiphyses is well marked.



T. A. Collins³

3 seconds exposure.

BOY AGED THIRTEEN YEARS.

Taken by Mr. WM. WEBSTER.

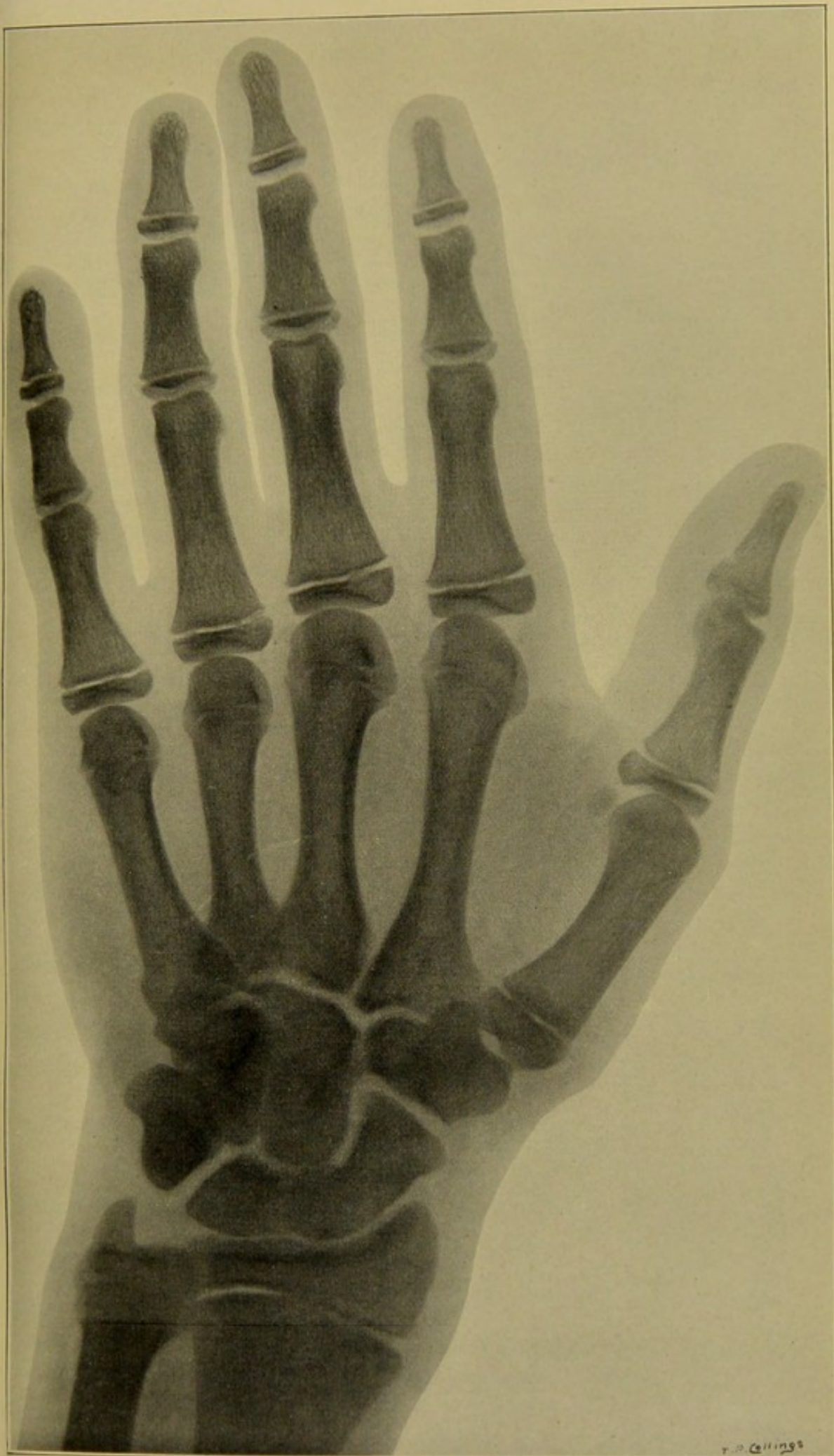


FOURTEENTH YEAR

Lower ends of radius and ulna.—The epiphyses of the radius and ulna are now almost completely ossified. The styloid processes are very distinct.

Ossification of the epiphyses of the bones of the metacarpus and phalanges of fingers and thumb is almost complete.

Metacarpal bone of thumb.—The sesamoid bones in the Flexor Brevis Pollicis tendons are seen on the palmar aspect of the metacarpo-phalangeal articulation of the thumb.





T. P. Collins

2 seconds exposure.

BOY AGED FOURTEEN YEARS.

Taken by Mr. Wm. WEBSTER.





FIFTEENTH YEAR

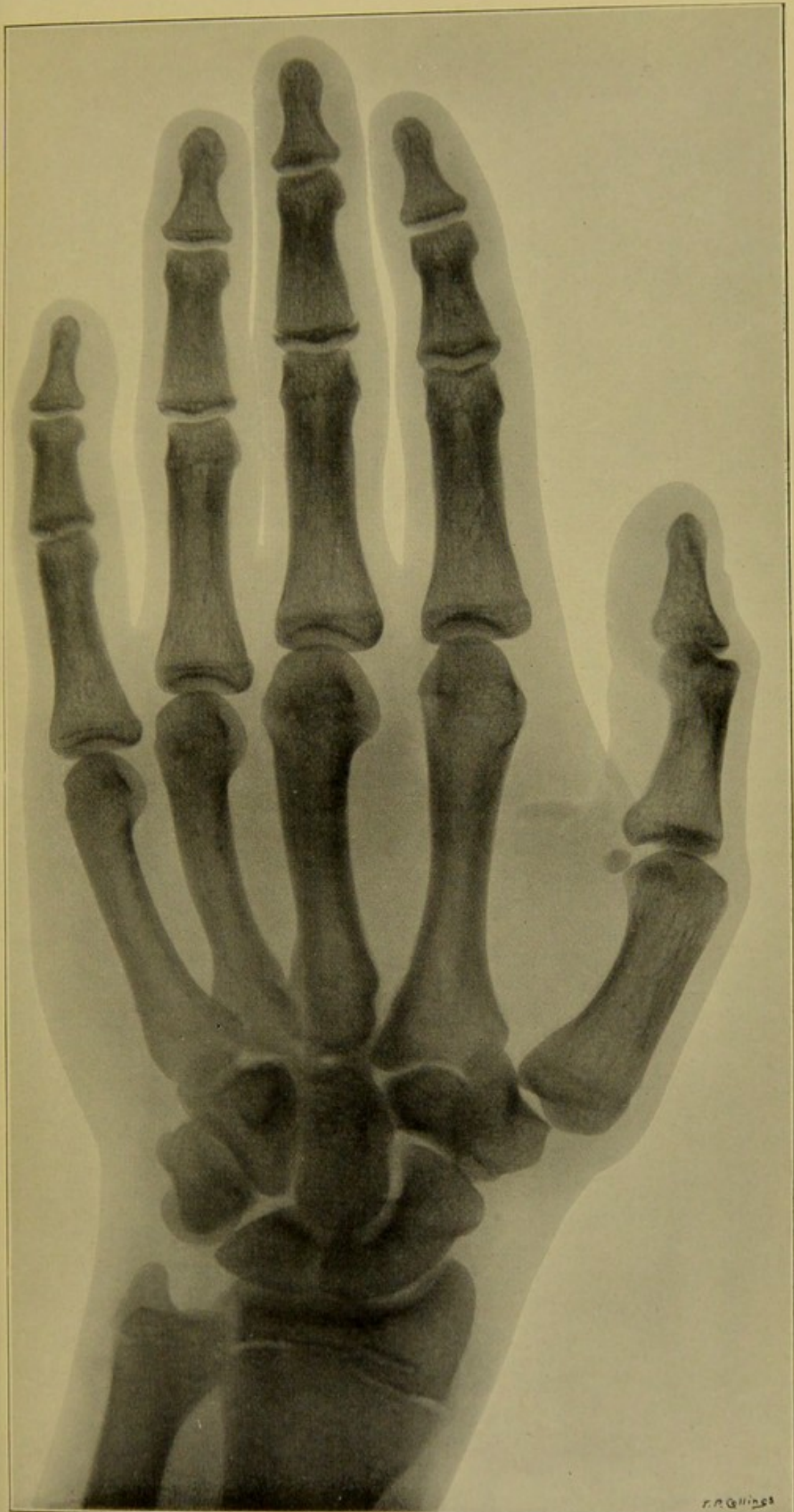Metacarpal bone and phalanges of thumb.—The epiphyses in this instance, as in the next skiagram, are completely ossified to the shaft. Their junction is traceable as a dark line.

Four inner metacarpal bones.—As in the next skiagram the epiphyses of the heads completely synostosed to shafts.

Phalanges. First row.—Epiphyses completely synostosed to shafts.

Middle or second row.—All epiphyses except that of middle finger synostosed to shafts.

Ungual phalanges.—All epiphyses completely synostosed to shafts.




r. n. Collins

3 seconds exposure.

BOY AGED FIFTEEN YEARS.

Taken by Mr. WM. WEBSTER.

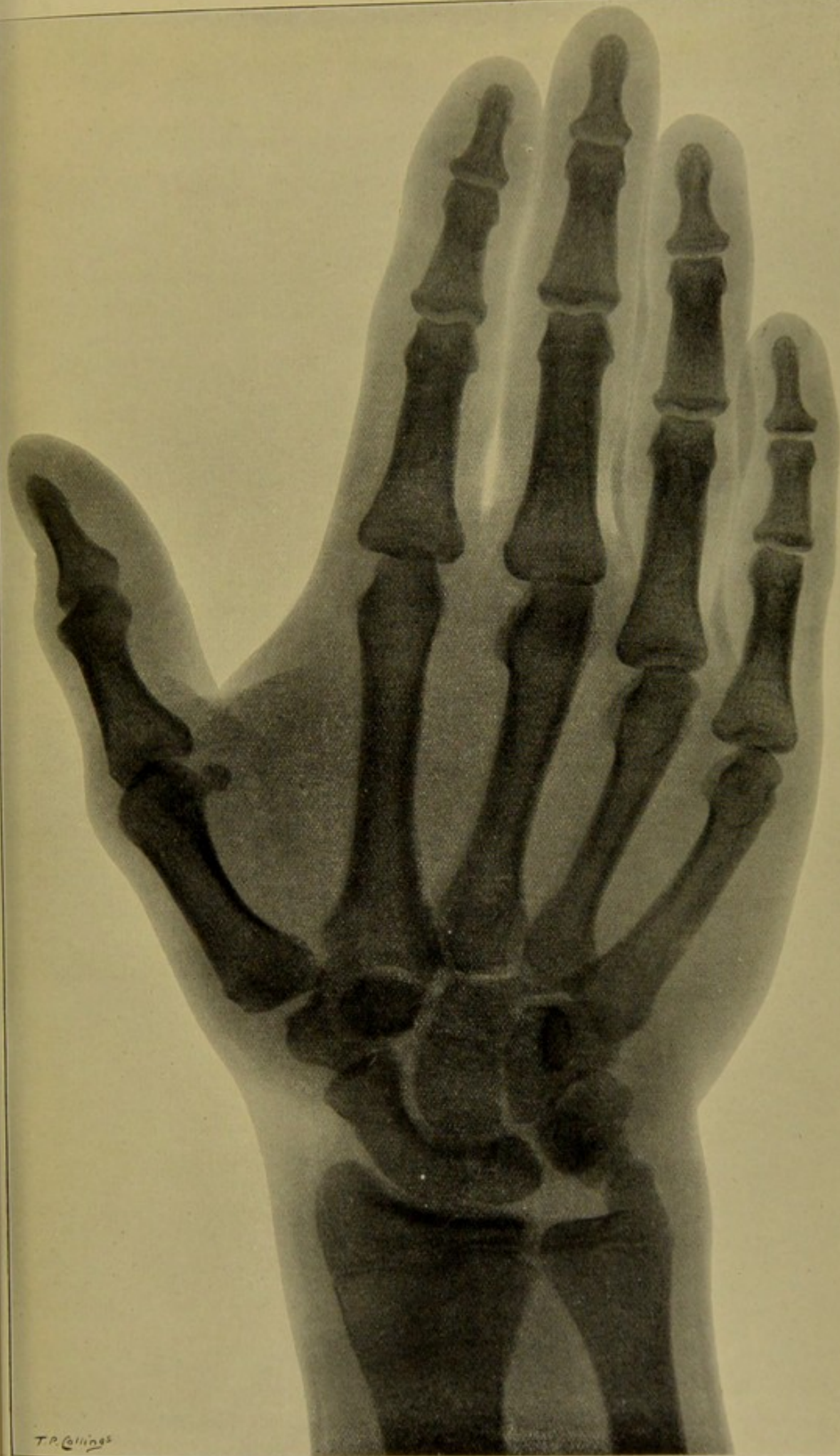




SIXTEENTH YEAR. SIXTH CHILD (BOY)


Lower epiphyses of radius and ulna.—In this instance the carpal epiphyses are almost synostosed with the shafts.

As in the previous skiagram, the epiphyses of the metacarpal bones and phalanges of fingers and thumb have also joined to the shafts.



T.P. Collings

BOY AGED SIXTEEN YEARS. MR. T. P. COLLINGS'S YOUNGEST SON (SIXTH CHILD).
4 seconds exposure. Taken by Mr. WM. WEBSTER.

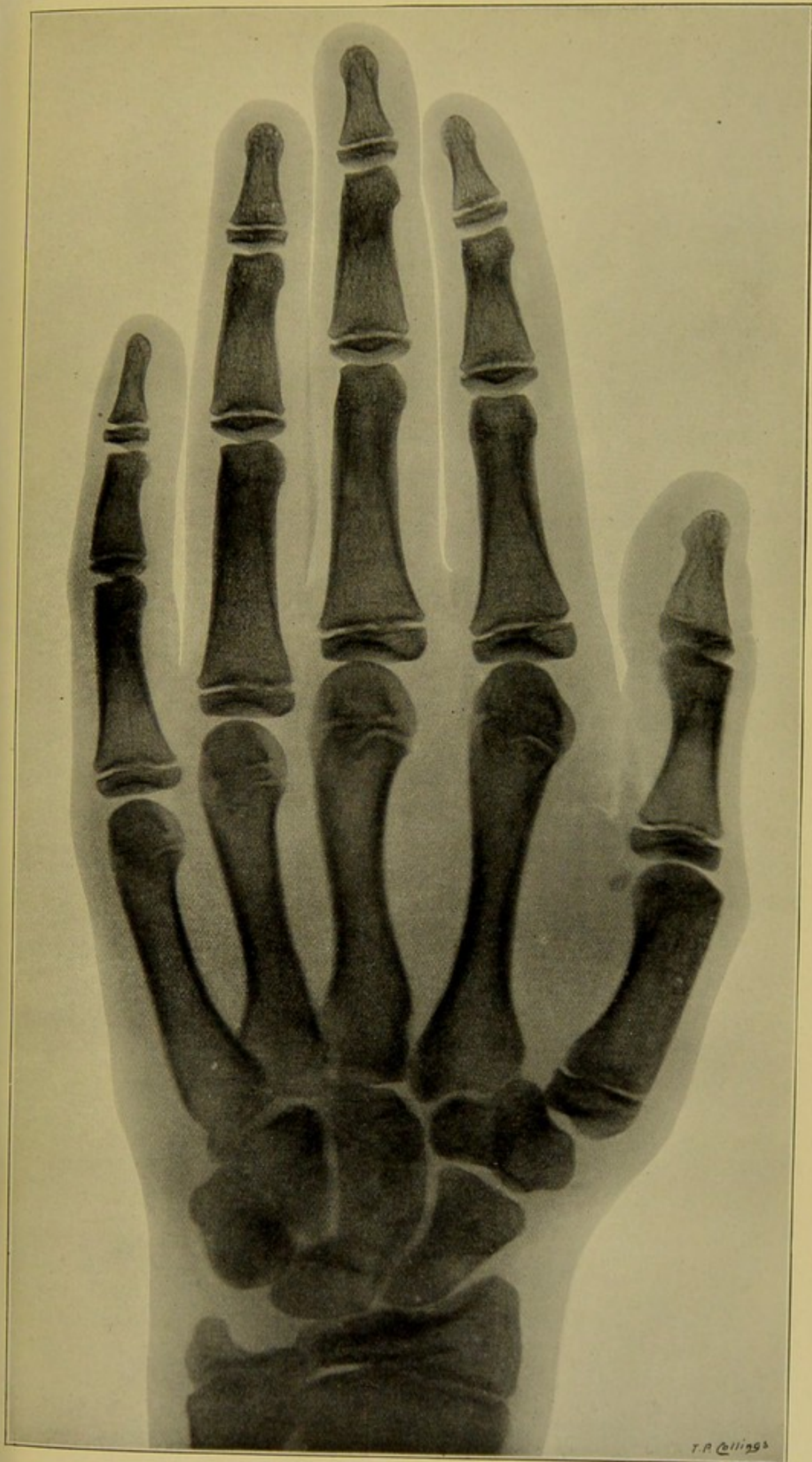




SEVENTEENTH YEAR

In this instance the epiphyses of the metacarpal bones and phalanges of fingers and thumb, though fully developed, have not, as in the two preceding skiagrams, joined their respective shafts.

Lower end of radius.—The thecal processes on the dorsal aspect of the epiphysis are not visible. The epiphysis is preparing to join with shaft, which it does two years later.



T. R. Collins

1 second exposure.

BOY AGED SEVENTEEN YEARS.

Taken by Mr. WM. WEBSTER.

