

The Gross and minute anatomy of the central nervous system / by H. C. Gordinier.

Contributors

Gordinier, Hermon C.
Watson-Williams, E.
University of Bristol. Library

Publication/Creation

London : Rebman, 1900.

Persistent URL

<https://wellcomecollection.org/works/akgq2wyz>

Provider

Special Collections of the University of Bristol Library

License and attribution

This material has been provided by This material has been provided by University of Bristol Library. The original may be consulted at University of Bristol Library. where the originals may be consulted.

Conditions of use: it is possible this item is protected by copyright and/or related rights. You are free to use this item in any way that is permitted by the copyright and related rights legislation that applies to your use. For other uses you need to obtain permission from the rights-holder(s).



Wellcome Collection
183 Euston Road
London NW1 2BE UK
T +44 (0)20 7611 8722
E library@wellcomecollection.org
<https://wellcomecollection.org>

ANATOMY OF THE

CENTRAL NERVOUS SYSTEM

GORDINI

store 57690⁴

UNIVERSITY OF BRISTOL.

Medical Library.

PRESENTED BY

Mr E. Watson-Williams

May 1939

151345904 0










Digitized by the Internet Archive
in 2015


<https://archive.org/details/b21445606>











THE GROSS AND MINUTE
ANATOMY OF THE CENTRAL
NERVOUS SYSTEM

GORDINIER



THE GROSS AND MINUTE ANATOMY OF THE CENTRAL NERVOUS SYSTEM

BY

H. C. GORDINIER, A.M., M.D.

PROFESSOR OF PHYSIOLOGY AND OF THE ANATOMY OF THE NERVOUS SYSTEM IN THE
ALBANY MEDICAL COLLEGE; MEMBER AMERICAN NEUROLOGICAL ASSOCIATION



With 48 full-page Plates and 213 Illustrations

A NUMBER OF WHICH ARE PRINTED IN COLORS AND THE MAJORITY OF
WHICH ARE ORIGINAL


LONDON
REBMAN, LIMITED
129, SHAFTSBURY AVENUE, W. C.

1900

THE GROSS AND MINUTE
ANATOMY OF THE CENTRAL
NERVOUS SYSTEM

BY
WILLIAM D. HALL, M.D.

LECTURE DEMONSTRATOR IN ANATOMY, UNIVERSITY OF CHICAGO
AND
ASSISTANT PROFESSOR OF ANATOMY, UNIVERSITY OF CHICAGO



LONDON:
H. K. LEWIS, LTD.
10, BEDFORD SQUARE, W. 1
1909

39232


TO

Professor M. Allen Starr,

IN GRATEFUL ACKNOWLEDGMENT OF MANY KINDNESSES,

THIS BOOK IS SINCERELY DEDICATED BY

ONE OF HIS FORMER PUPILS.



PREFACE.


The absence of a complete work in English on the Anatomy of the Central Nervous System has convinced the author of the necessity for the preparation of a systematic text-book which shall present this most difficult subject in a concise but comprehensive manner—a book that will meet the needs of medical students and at the same time be of service to the clinician in associating symptoms of nervous diseases with anatomic facts. This work consists essentially of the lectures which the author has been accustomed to deliver to his students, amplified, rearranged, and illustrated with many cuts, both original and borrowed. The writer desires to acknowledge his indebtedness to the magnificent works of Cajal, Edinger, Flatau, Déjerine, His, Jakob, Koelliker, Lenhossek, Quain, Retzius, Starr, Van Gehuchten, Wernicke, and others.

It is a pleasurable duty to testify to the help in this work from the interest of many pupils and from the investigations set on foot by the intelligent questions of many of those young seekers after truth in successive years. With the earnest hope that the author's labors will be helpful to some, and may perhaps clear up some obscure questions here and there, this work is submitted to the students of medicine.

The writer owes a debt of gratitude to his former students, Drs. James T. McKenna and Edgar R. Stillman, for assistance rendered in the preparation of this work, and to Mr. E. N. Reed for assistance in reading proof-sheets; to Wait H. Stillman and Joseph McKay, of Troy, N. Y., for the preparation of photographs and microphotographs, and to Dr. Thomas W. Salmon for the execution of several of the original drawings.

HERMON C. GORDINIER.

TROY, N. Y., *June 2, 1899.*



CONTENTS.

CHAPTER I.

	PAGE
THE HISTOLOGIC ELEMENTS OF THE NERVOUS SYSTEM,	17
Histology of the Nerve-cell,	17
Forms or Varieties of Nerve-cells,	24
Purkinje Cell,	25
The Basket Cell of the Cerebellum,	28
Pyramidal Cells of the Cortex,	28
Cell-processes and Nerve-fibers,	30
The Axis-cylinder,	31
Nerve-fibers,	31
Non-medullated Fibers,	35
The Peripheral Nerve Terminations,	37
The Terminations of Sensory Nerves,	38
The End Bulbs of Krause,	40
The Tactile Menisques,	42
The Corpuscles of Golgi,	43
The Muscle Spindle,	43
The Terminations of the Motor Nerves,	45
Neurone or Neurodendron,	47
The Neuraxone or Axone,	49
The Neuroglia,	52
Blood-vessels and Lymphatics,	58
The Tunica Adventitia,	58
Tunica Media,	59
Tunica Intima,	59
Veins,	60
Capillaries,	60
Lymphatics,	61
The Adventitial Lymph-space,	63
Pericellular Lymph-spaces,	63

CHAPTER II.

SPINAL CORD,	64
The Nerve-cells of the Cord,	76
The Course of Fibers in the Sensory Tracts of the Cord,	95
The Course of the Fibers of the Dorsal Funiculi or Posterior Columns,	97
The Column of Goll,	99
The Columns of Burdach,	99
The Cornu Commissural and Septomarginal Descending Tracts,	100
The Cornu Commissural Tract,	101
The Septomarginal Tract,	102
Gowers' Anterolateral Ascending Tract—Fasciculus Ventrolateralis Superficialis,	103
The Anterolateral Descending Tract of Marchi and Lowenthal,	104
The Olivary Tract of Bechterew,	105
A Long Sensory Tract in the Gray Matter (Ciaglinski),	106
Lissauer's Tract,	106
Anterior Ground Bundles,	107
The Ground Bundles of the Lateral Columns, or the Lateral Limiting Layers,	107
The Spinal Nerves,	108
Spinal Ganglia,	109
The Anterior or Motor Nerve-roots,	112

SPINAL CORD (*Continued*)—

	PAGE
The Posterior or Sensory Nerve-roots,	113
The Appearances of Transverse Sections of the Cord at Different Levels,	114
Neuroglia of the Spinal Cord,	117
The Subpial Neuroglia Layer, the Rindenschicht of the Germans,	119
Posterior Horns,	122
The Substantia Gelatinosa Rolandi,	122
The Region of the Central Canal,	122
The Blood-supply of the Spinal Cord,	122
Veins of Spinal Cord,	124

CHAPTER III.

THE MEDULLA OBLONGATA OR BULB,	125
The Fourth Ventricle,	131
A Transverse Section of the Medulla at the Level of the First Cervical Nerve,	137
A Section at the Level of the Motor Crossway,	140
The Raphe,	146
The Formatio Reticularis,	146
Connections of the Hypoglossal Nuclei,	152
The Vagus and Glossopharyngeal Nerves,	155
The Olivary Bodies,	159
The Central Tegmental Tracts of Bechterew and Flechsig,	163
Section through the Middle of the Olivary Bodies,	163
A Transverse Section of the Medulla near its Junction with the Pons,	166
The Abducens Nerve,	166
The Facial Nerve,	168
Connections of the Facial Nerve,	171
The Auditory Nerve,	171
The Cochlear Nerve,	171
The Vestibular Nerve,	172
Connections of the Auditory Nerve,	175
The Superior Olivary Body,	176
Connections of the Vestibular Nerve,	176
With the Cerebellum,	176
With the Lateral Fillet,	177
With the Internal or Mesial Fillet,	177
With the Nuclei of the Sixth Nerve,	177
With the Olivary Body and the Lateral Column of the Same Side,	177
The Pons Varolii,	178
A Transverse Section of the Pons,	179
The Nuclei of Origin of the Trigeminal Nerve,	182
The Cerebral Connections of the Trigeminal Nerve,	185

CHAPTER IV.

THE CEREBELLUM OR EPENCEPHALON,	186
The Vermis or Worm,	188
Superior Surface,	188
Inferior Surface,	189
Lobules of the Superior or Dorsal Surface of the Cerebellar Hemisphere,	190
Lobules of the Inferior Surface of the Cerebellar Hemisphere,	190
Minute Anatomy of the Cerebellum,	193
The Cortex of the Cerebellum,	198
The Cells of Purkinje,	200
The Cerebellar Peduncles,	202
The Middle Peduncles,	203
The Inferior Cerebellar Peduncles, or Corpora Restiformia,	203

CHAPTER V.

THE REGION OF THE MID-BRAIN,	210
The Corpora Quadrigemina,	210
Minute Anatomy,	212
The Cerebral Peduncles,	220
The Mesial Fillet, or Lemniscus,	223
The Superior Cerebellar Peduncles,	229

THE REGION OF THE MID-BRAIN (<i>Continued</i>)—	PAGE
The Superior Longitudinal Bundle,	230
The Motor Oculi, or Third Pair of Cranial Nerves,	235
The Connections of the Oculomotor Nucleus,	238
The Fourth Pair of Cranial Nerves,	240
The Superior or Accessory Nucleus of the Fifth or Trigeminal Nerve,	240

CHAPTER VI.

REGION OF THE THIRD VENTRICLE,	234
The Third Ventricle,	244
The Pineal Gland, or Conarium,	246
The Posterior Commissure,	248
The Optic Thalami,	248
The Ganglion Habenulæ,	257
Connections of the Optic Thalamus,	258
The Subthalamie Region, or Stratum Intermedium,	259
The Red or Tegmental Nucleus of Stilling,	261
The Connections of the Red Nucleus,	262
The Substantia Nigra (Locus Niger; Intercallatum of Spitzka),	263
Retina,	263
The Layer of Optic Nerve-fibers,	264
The Layer of Ganglionic Cells,	264
The Inner Molecular Layer,	265
The Inner Nuclear Layer,	265
The Outer or External Molecular Layer,	266
The Outer Nuclear Layer,	266
The Layer of Rods and Cones,	266
The Pigment-Layer,	267
The Course of the Optic Nerves and Tracts,	268
The Connections of the Optic Tracts,	273
The Optic Chiasm,	274
The Pituitary Body,	276
The Tuber Cinereum,	279
The Infundibulum,	279

CHAPTER VII.

THE MEMBRANES OF THE BRAIN,	280
Dura Mater,	280
Processes of the Cerebral Dura Mater,	281
The Falx Cerebri, or Processus Falciformis Major,	281
The Tentorium Cerebelli,	281
The Falx Cerebelli, or Processus Falciformis Minor,	282
The Arachnoid Membrane,	284
Subarachnoid Spaces,	285
The Pacchionian Glands, or the Arachnoid Villi,	287
The Pia Mater,	288
The Velum Interpositum and Choroid Plexuses,	288
The Tela Choroidea Inferior and Choroid Plexuses of the Fourth Ventricle,	291
Choroid Plexuses of the Fourth Ventricle,	291

CHAPTER VIII.

FORE-BRAIN OR PROSENCEPHALON,	293
Fissures,	294
The Fissures of the External Surface of Each Hemisphere,	294
The Longitudinal Fissure,	294
The Transverse Fissure,	294
The Fissure of Sylvius,	298
The Fissure of Rolando,	299
The Parieto-occipital Fissure,	299
The Intraparietal or Interparietal Fissure,	300
The Calcarine Fissure,	300
The Collateral Fissure,	300
The Callosomarginal Fissure,	303

FORE-BRAIN OR PROSENCEPHALON (<i>Continued</i>)—	PAGE
The Convolutions, Gyri, or Lobules,	303
The Frontal Lobe,	303
The Parietal Lobe,	306
The Ascending Parietal or Posterior Central Gyrus,	306
The Superior Parietal Convolution,	307
The Inferior Parietal Convolution,	308
The Occipital Lobe,	308
The Occipital Convolutions,	309
The Insula, or Island of Reil,	310
The Temporosphenoid Lobe,	313
The First or Superior Temporal Convolution,	313
The Second or Middle Temporal Convolution,	314
The Third or Inferior Temporal Convolution,	314
Convolutions of the Mesial Surface,	315
The Marginal Convolution,	315
The Gyrus Fornicatus,	316
The Quadrate Lobe, or Precuneus,	316
The Cuneus,	316
The Lingual Lobule,	316
The Limbic or Falciform Lobe,	317
The Gyrus Hippocampus, or Subiculum Cornu Ammonis,	317
The Dentate Gyrus, or Fascia Dentata,	318
The Base of the Cerebral Hemispheres,	318
The Inferior Longitudinal Fissure,	319
The Olfactory Bulb,	319
The Olfactory Tract,	319
The Corpus Callosum,	319
The Anterior Perforated Spaces,	320
The Sylvian Fissure,	320
The Optic Chiasm or Decussation,	320
The Interpeduncular Space,	323
The Tuber Cinereum,	323
The Infundibulum,	323
The Pituitary Body, or Hypophysis Cerebri,	323
The Corpora Albicantia or Mammillaria,	324
Posterior Perforated Space,	324
The Crura Cerebri, or Peduncles of the Cerebrum,	325
Olfactory Lobe, Bulb, Nerves, and Tracts,	326
The Olfactory Nerves,	326
Olfactory Bulb: Its Minute Anatomy,	328
The Outer Layer, or Layer of Olfactory Nerve-fibers,	328
The Layer of Olfactory Glomeruli; the Stratum Glomerulorum,	329
The Molecular Layer, or Stratum Gelatinosum,	330
The Layer of Central Nerve-fibers,	332
The Olfactory Tracts,	332
The Trigonum Olfactorium and Space of Broca,	335
The Anterior Commissure,	336

CHAPTER IX.

HISTOLOGY OF THE CEREBRAL CORTEX, TOGETHER WITH THE MINUTE ANATOMY OF THE CENTRUM OVALE,	338
The Histology of the Cerebral Cortex,	338
Layers of Cortical Cells and Fibers,	343
Superficial, Molecular, or Outer Cortical Layer,	343
Layer of Small Pyramidal Cells,	345
Layer of Large Pyramidal Cells,	346
Layer of Polymorphous Cells,	350
The Anatomy of the Cornu Ammonis, or Hippocampus Major, and the Gyrus Dentatus,	350
Gyrus or Fascia Dentata,	359
The Centrum Ovale,	362
The Association Fibers,	364
Fibræ Arcuatæ Propriæ,	364

HISTOLOGY OF THE CEREBRAL CORTEX, TOGETHER WITH THE MINUTE ANATOMY OF THE CENTRUM OVALE (<i>Continued</i>)—	PAGE
The Cingulum, or Bundle of the Gyrus Fornicatus,	364
The Fasciculus Arcuatus,	364
The Fasciculus Uncinatus,	368
The Superior Longitudinal Fasciculus, or Fasciculus Arcuatus of Burdach,	368
The Inferior Longitudinal Bundle,	368
Fasciculus Occipitofrontalis (Forel and Onufrowicz),	369
The Perpendicular Fasciculus of Wernicke,	370
The Projection System of Fibers,	373

CHAPTER X.

GENERAL ANATOMY OF THE INTERIOR OF THE CEREBRAL HEMISPHERE,	387
Corpus Callosum,	387
The Lateral Ventricles,	393
Eminentia Collateralis,	394
The Corpora Striata,	398
The Lenticular Loop, or Ansa Lenticularis,	402
The Tractus Striothalamicus (Edinger),	403
The Tænia Semicircularis,	404
The Internal Capsule,	407
The Fornix,	413
The Septum Lucidum,	414
The Fifth Ventricle,	414

CHAPTER XI.

THE BLOOD-VESSELS OF THE BRAIN,	416
Carotid Arteries,	418
The Anterior Cerebral Arteries,	421
The Middle Cerebral or Sylvian Artery,	422
The Central or Ganglionic Branches of the Middle Cerebral,	423
Posterior Communicating Artery,	424
The Anterior Choroid Artery,	424
The Vertebral Arteries,	425
The Basilar Artery,	425
The Posterior Cerebral Arteries,	425
The Circle of Willis,	428
Blood-vessels of the Cerebellum,	430
Arterial Supply to the Pons Varolii and Medulla Oblongata,	432
The Venous Systems of the Brain,	435
Characteristics of the Veins and the Venous Circulation,	435
The Cerebral Veins,	435
The Superficial Veins,	436
The Deep Cerebral Veins,	440
Veins of the Cerebellum,	440
The Venous Sinuses,	442
The Emissary Veins,	447

CHAPTER XII.

CEREBRAL LOCALIZATION,	448
The Cortical Centers for General Sensations,	454
The Centers of Vision,	457
Retinal Representation in the Occipital Cortex,	462
Color-vision,	462
The Auditory Centers,	462
The Centers for Language,	465
The Center for the Reception of Heard Words,	466
The Center for the Reception of Memories of the Appearance of Objects Seen and for the Appearance of Words as Written or Printed,	469
The Center for the Reception of the Appearance of Objects Gained through the Sense of Touch,	470
The Motor Speech-center, or Center for the Reception of the Muscular Memories Necessary to Produce Speech,	471
The Cortical Center for Writing,	475
Sensory Center for Writing,	479

CEREBRAL LOCALIZATION (<i>Continued</i>)—	PAGE
The Centers which Preside over the Higher Intellectual Faculties,	480
The Cortical Center for the Special Sense of Taste,	482
The Cortical Center for the Special Sense of Smell,	483
The Localization of Lesions in the Centrum Ovale,	484
Lesions of the Centrum Semiovale beneath the Motor Area,	485
Centrum Ovale of the Temporal Lobe,	486
Localization of Lesions in the Centrum Ovale of the Parietal Lobe,	486
Centrum Semiovale of the Occipital Lobe,	487
Lesions of the Corpus Callosum,	487
Localization of Lesions of the Internal Capsule,	488
Basal Ganglia,	488
Localization of Lesions of the Corpora Quadrigemina,	488
Localization of Lesions in the Crura Cerebri,	489
Localization of Lesions in the Pons Varolii,	490
Localization of Cerebellar Lesions,	493
Lesions of the Middle Lobe, or Worm,	493
Lesions of the Cerebellar Hemisphere,	494
Lesions of the Middle Cerebellar Peduncle,	495
Localization of Lesions in the Medulla Oblongata,	496
Localization of Spinal-cord Lesions,	499
The Divisions of the Cerebral Cortex According to Flechsig,	506

CHAPTER XIII.

THE EMBRYOLOGY OF THE CENTRAL NERVOUS SYSTEM,	508
The Development of the Spinal Cord,	513
Development of the Medulla Oblongata,	525
Cerebellum and Pons,	528
Corpora Quadrigemina, Crura Cerebri, and Aqueduct of Sylvius,	530
The Third Cerebral Vesicle (Second Primitive Vesicle), Mesencephalon, or Mid-brain,	530
Optic Thalami, Infundibulum, Pituitary Body, Pineal Gland, Corpora Mammillaria, and Optic Chiasm,	531
Development of the Cerebral Hemispheres,	539
Development of the Commissural System of the Cerebral Hemispheres,	543
The Evolution of the Fissures of the Cerebral Hemisphere,	545
The Callosomarginal Fissure,	545
The Fissure of Rolando,	545
The Precentral Sulcus or Fissure,	546
The Fissures or Sulci of the Island of Reil,	546
The Various Fissures of the Frontal, Parietal, Temporal, and Occipital Lobes,	546
Development of the Cranial Nerves,	547
Development of the Olfactory Lobe,	550
Development of the Retina and Optic Nerves,	552
The Retina,	556
The Optic Nerve,	557


CHAPTER XIV.

TECHNIC OF THE MACROSCOPIC AND MICROSCOPIC EXAMINATION OF THE BRAIN AND SPINAL CORD,	559
Virchow's Method,	560
Pitres' Method,	561
The Removal of the Spinal Cord,	563
Differential Stains for the Various Elements of the Nervous System,	563
Staining of Nerve-cells after the Method of Nissl,	564
To Stain Nerve-cells with Thionin,	564
Method of Bevan Lewis,	565
Modification of Kronthal's Method,	565
Golgi's Method for Staining Nerve-cells and Their Processes,	566
Golgi's Rapid Method,	566
Golgi's Slow Method,	566
Berkley's Method of Impregnation,	566

CONTENTS.

xv

TECHNIC OF THE MACROSCOPIC AND MICROSCOPIC EXAMINATION OF THE BRAIN AND SPINAL CORD (<i>Continued</i>)—		PAGE
Cox's Modification of the Golgi Sublimate Method,		567
Weigert's Method of Staining the Myelin Sheaths,		568
Marchi's Method,		569
Neuroglia Stains,		569
Differential Stains for Neuroglia Fibers.—Method of Mallory, . . .		569
Mallory's Phosphotungstic-acid Hematoxylin Method for		
Staining Neuroglia,		570
Stains for Axis-cylinder Processes,		571
Neutral Carmin,		571
Nigrosin,		571
Van Gieson's Method,		571
Stains for End Organs, Terminations of Nerves, and Collateral Branches, .		572
Method of Gerlach,		572
Method of Freud,		572
Method of S. Ramón y Cajal,		572
Ehrlich's Vital Methylene-blue Method (Modified by SemiMeyer), .		573
General Stains,		573
Hematoxylin,		573
INDEX,		575



ILLUSTRATIONS.

FIG.	PAGE
1. A Group of Multipolar Nerve-cells from an Anterior Horn of the Spinal Cord. Showing Nissl granules and pigment (<i>Colored</i>),	19
2. Multipolar Nerve-cells from the Spinal Cord of an Ox. Stained with methylene-blue and showing striation of cell-bodies and their processes (<i>Colored</i>),	21
3. A Ganglion Cell from an Anterior Horn of the Spinal Cord of an Ox. Showing the arrangement of the Nissl granules and the ramification of the dendrites (<i>Colored</i>),	22
4. Section of Posterior Spinal Ganglion of Embryo Chick. Illustrating bipolar cells. (<i>After Van Gehuchten</i>),	24
5. Microphotograph of a Group of Multipolar Nerve-cells from the Anterior Horn of the Human Spinal Cord. Stained with the Cox-Golgi method,	25
6. Microphotograph showing Purkinje Cell,	26
7. A Frontal Section through an Olfactory Bulb of a Six-weeks'-old Cat. Showing layer of granular cells. (<i>After Koelliker</i>),	27
8. Microphotograph of Small Pyramidal Cells,	28
9. Microphotograph of Large Pyramidal Cells,	29
10. A Group of Large Pyramidal Cells from the Motor Area of the Human Brain. Stained after the method of Bevan Lewis,	30
11. Nerve-fibers from the Muscle of a Frog Injected with Methylene-blue. Showing the dark stained axis-cylinders, the nodes of Ranvier, and the separation of the terminal axones into several primitive fibrillæ. (<i>After Koelliker</i>),	32
12. Medullated Nerve-fibers Blackened by Osmic Acid. (<i>Landois and Stirling</i>),	33
13. Medullated Nerve-fibers (with Osmic Acid). (<i>Landois and Stirling</i>),	33
14. A Bundle of Nerve-fibers Stained with Nitrate of Silver. Showing the outlines of epithelial cells of the perineurium. (<i>After Ranvier</i>),	34
15. Remak's Fiber from Vagus of Dog. (<i>Landois and Stirling</i>),	36
16. Transverse Section of a Nerve (Median). (<i>Landois and Stirling</i>),	37
17. Termination of Sensory Nerves in Stratified Squamous Epithelium. Golgi Stain. (<i>After Retzius</i>),	38
18. Vertical Section of the Skin of the Palm of the Hand. (<i>Landois and Stirling</i>),	38
19. Wagner's Touch Corpuscle from the Palm, Treated with Gold Chlorid. (<i>Landois and Stirling</i>),	38
20. Cylindric End Bulbs from the Conjunctiva of the Calf. (<i>Merkel</i>),	39
21. End Bulb of the Human Conjunctiva, Treated with a Mixture of Acetic and Osmic Acids. (<i>W. Krause</i>),	40
22. Articular Corpuscle from Phalangeal Joint in Man. (<i>W. Krause</i>),	40
23. A Microphotograph of Two Pacinian Corpuscles from the Mesentery of a Cat,	41
24. Tactile Menisque from the Nose of a Guinea-pig. (<i>Ranvier</i>),	42
25. Organ of Golgi from the Human Tendo Achillis, Chlorid of Gold Preparation. (<i>After Ciaccio</i>),	43
26. Muscular Fibers with Motorial End Plates. (<i>Landois and Stirling</i>),	45
27. Motor Terminations in a Lizard, Stained by Methylene-blue. (<i>Landois and Stirling</i>) (<i>Colored</i>),	46
28. A Large Cell of the Second Type of Golgi from the Granular Layer of the Cerebellum. (<i>After Koelliker</i>) (<i>Colored</i>),	51
29. Three Cajal Cells from the Cortex of the Gyrus Fornicatus of a Dog. (<i>After Koelliker</i>),	52
30. Motor and Sensory Neurones. (<i>Jakob's Atlas</i>) (<i>Colored</i>),	53
31. Microphotograph of Neuroglia Cells. Showing the relation they bear to the capillary blood vessels. Stained after the Cox-Golgi method,	55
32. Three Neuroglia Cells (Astrocytes). Showing the relation the neuroglia processes bear to the cell-body. (<i>After Weigert</i>) (<i>Colored</i>),	57

FIG.	PAGE
33. Neuroglia Cells from the Cerebral Cortex of a Dog's Brain. Showing their connection with blood-vessels. (<i>After Koelliker</i>),	59
34. A Capillary Blood-vessel from the Gray Matter of the Spinal Cord of an Ox. Stained with methylene-blue and magnified 400 diameters (<i>Colored</i>),	61
35. A Camera Lucida Drawing of a Part of the Gray Matter of the Anterior Horn. Showing pericellular and perivascular lymph channels (<i>Colored</i>),	62
36. View from Behind of the Lower End of the Spinal Cord with the Cauda Equina and Dural Sheath. (<i>Allen Thomson</i>),	66
37. Photograph of Human Spinal Cord,	67
38. Diagram Showing the Relative Size and Form of Different Segments of the Coccygeal, Sacral, Lumbar, Dorsal, and Cervical Cord. (<i>After Gowers</i>),	70
39. A Transverse Section of the Human Spinal Cord through the Mid-lumbar Region to Show its General Topography. Weigert's stain,	71
40. Transverse Section of the Human Spinal Cord at the Level of the Eighth Dorsal Vertebra. $\times 10$. (<i>Landois and Stirling</i>),	73
41. Section of the Isthmus of the Lumbar Cord. Showing the central canal in the middle, surrounded by the substantia gelatinosa centralis. (<i>After E. A. Schäfer, from Quain</i>),	75
42. A Group of Multipolar Nerve-cells from an Anterior Horn of the Spinal Cord. Showing Nissl granules and pigment (<i>Colored</i>),	77
43. Section of the Lumbar Cord of an Adult. Showing the anteromedian and posterolateral groups of cells (<i>Colored</i>),	79
44. Camera Lucida Drawing of a part of an Anterior Horn with Adjacent White Matter of the Lateral Column. Showing nerve-fibers coming from that column and coursing between and around the motor nerve-cells. Stained after method of Weigert-Pal,	80
45. Diagram of a Transverse Section of the Spinal Cord. (<i>After Starr</i>),	81
46. Microphotograph of Transverse Section of Cord. Showing nerve-fibers cut across,	85
47. Microphotograph of a Partial Transverse Section of the White Matter of the Spinal Cord of an Ox,	87
48. Schematic Representation of the Situation of the Various Tracts of Fibers in the Spinal Cord,	88
49. Diagram Indicating the Course of the Motor and Sensory Fibers of the Spinal Cord and Medulla (<i>Colored</i>),	93
50. Posterior Cornu and Column at the Last Dorsal Segment. (<i>After Gowers</i>),	97
51. Longitudinal Section of the Cord in the Cervical Region of a Sheep's Embryo, Twenty-two Centimeters long. Showing the division of the posterior nerve-fibers after entering the cord. (<i>Landois and Stirling</i>),	98
52. Lateral Column of a New-born Rabbit,	98
53. Transverse Section of the Spinal Cord at the Level of the First Sacral Segment. (<i>After Alexander Bruce</i>),	101
54. Course and Termination of Gowers' Tract. (<i>According to Hoche</i>),	103
55. Transverse Section through a Posterior Spinal Ganglion. Stained after the method of Weigert,	109
56. A Group of Cells from a Human Posterior Spinal Ganglion. Stained after the method of Nissl,	110
57. Schematic Representation to Show the Origin and Relations of the Anterior and Posterior Spinal Nerve-roots,	111
58. A Section through the Spinal Cord of a New-born Mouse. Showing reflex collaterals from posterior nerve-roots terminating about the nerve-cells of the anterior horn. (<i>After Lenhossek</i>),	113
59. Diagram Showing the Relative Size and Form of Different Segments of the Coccygeal, Sacral, Lumbar, Dorsal, and Cervical Cord. (<i>After Gowers</i>),	115
60. Transverse Section through a Sacral Segment of the Spinal Cord. Weigert preparation,	116
61. A Section through the Spinal Cord of a Human Fetus, Twenty-three Centimeters in Length. Showing the central canal with its substantia gelatinosa centralis and ependymal cells. (<i>After Lenhossek</i>),	118
62. Transverse Section of the Spinal Cord of a Human Embryo, Fourteen Centimeters in Length. Illustrating the distribution of neuroglia. (<i>After Lenhossek</i>),	119
63. A Transverse Section through a Segment of the Dorsal Cord, to Show the General Arrangement of Neuroglia. Nigrosin stain (<i>Colored</i>),	120
64. A Camera Lucida Drawing of a Field of the Lateral Column of Figure 63. Nigrosin stain (<i>Colored</i>),	121
65. Scheme to Show the Course and Distribution of the Terminal Branches of the Arterial Plexus of the Pia Mater. (<i>After Van Gehuchten</i>),	123

FIG.	PAGE
66. View from Before of the Medulla Oblongata, Pons Varolii, Crura Cerebri, and Other Central Portions of the Encephalon (Natural size). (<i>Allen Thomson</i>).—(<i>From Quain's "Anatomy"</i>),	127
67. View of the Medulla Oblongata, Pons Varolii, Crura Cerebri, and Central Parts of the Encephalon from the Right Side. (<i>Quain's "Anatomy."</i>)—(<i>Allen Thomson</i>),	129
68. Posterior and Lateral View of the Medulla Oblongata, Fourth Ventricle, and Mesencephalon (Natural size). (<i>E. A. S.</i>)—(<i>From Quain's "Anatomy"</i>),	133
69. Transverse Section through the Medulla Oblongata at the Beginning of the Motor Decussation. (<i>After Koelliker</i>),	137
70. Diagram of the Structure of the Medulla Oblongata. (<i>From Gowers' "Diseases of the Nervous System"</i>),	138
71. Transverse Section of the Medulla Oblongata through the Motor Decussation. (<i>After Henle</i>),	141
72. Transverse Section of the Medulla at the Beginning of Hypoglossal Nerves. The pyramidal or motor decussation is complete. (<i>After Henle</i>),	142
73. Section of the Medulla Oblongata at About the Middle of the Olivary Body. (<i>After Schwalbe</i>).—(<i>From Quain's "Anatomy"</i>),	143
74. Section of Medulla Oblongata at Level of Sensory Crossway. Weigert-Pal preparation,	145
75. Diagram Indicating the Course of the Motor and Sensory Fibers of the Spinal Cord and Medulla (<i>Colored</i>),	147
76. Section Through Formatio Reticularis of the Medulla Oblongata. Method of Weigert-Pal,	150
77. Microphotograph from a Seven-months' Human Fetus of Section of Formatio Reticularis Grisea. The cells with their decussating axones are seen,	151
78. Transverse Section through the Hypoglossal Nucleus. Method of Weigert-Pal (<i>Colored</i>),	153
79. Medulla Oblongata from a Human Embryo of Eight Months. (<i>After Koelliker</i>),	156
80. Transverse Section through the Medulla of a Mouse at the Level of the Commissural Nucleus. (<i>After Ramón y Cajal</i>),	157
81. Microphotograph Showing Multipolar Cells of Inferior Olivary Body,	159
82. Hemisection of Medulla to Show Olivary Body. Method of Weigert-Pal,	161
83. The Cerebello-olivary Tract. (<i>After Edinger</i>),	165
84. Transverse Section through the Pons Varolii. Illustrating the origin of the sixth and seventh cranial nerves,	167
85. Lateral View of the Medulla Oblongata with the Schematic Representation of the Nuclei and the Intramedullary Course of the Cranial Nerves. (<i>From Jakob's Atlas</i>) (<i>Colored</i>),	169
86. Transverse Section through the Distal Part of the Pons of an Eight-months' Human Embryo. (<i>After Koelliker</i>),	172
87. Microphotograph Showing Cells of Ventral Auditory Nucleus. Method of Golgi,	173
88. Dorsal Part of a Transverse Section of the Medulla Oblongata from a Human Embryo of Six Months. (<i>After Koelliker</i>),	174
89. Transverse Section through Upper Part of Pons Varolii. Method of Weigert-Pal,	178
90. Transverse Section through the Pons, in the Region of the Crossing of the Fourth Nerve in the Dorsal Medullary Velum. (<i>After Koelliker</i>),	181
91. Lateral Sagittal Section through the Pons and Cerebellum of a Fetal Mouse. (<i>After Ramón y Cajal</i>),	183
92. Section through Medulla of a Human Fetus of Seven Months. Showing axones and collaterals of the trigeminal nerve entering the enlarged caput posterioris,	184
93. Figure Showing the Three Pairs of Cerebellar Peduncles. (<i>After Hirschfeld and Leveillé, from Sappey</i>),	187
94. Superior Surface of the Cerebellum,	191
95. Inferior Surface of the Cerebellum,	191
96. Microphotograph of Cerebellar Cortex. Showing the molecular and granular layers and the arrangement of the arbor vitæ,	193
97. Section through Cerebellum to Show the Dentate Nuclei and White Matter of the Hemispheres,	195
98. Microphotograph of a Section through the Corpus Dentatum of the Human Cerebellum. Containing three large (multipolar) polygonal cells. Method of Berkley,	195
99. Microphotograph Showing Basket Cells and Fibers Surrounding the Bodies of Two Purkinje Cells (Human Cerebellum). Cox-Golgi method,	197
100. Granular Cells of the Inner Layer, with Ascending Neuraxones branching T-shaped to Form the Horizontal Fibers of the Molecular Layer. (<i>After Van Gehuchten</i>),	198
101. Microphotograph Showing the Moss-like Fibers of the Cerebellum. Cox-Golgi Method,	199

FIG.	PAGE
102. Microphotograph of Purkinje Cell,	201
103. Scheme of the Fibers Passing to and from the Cerebellum,	205
104. Schematic Representation of the Different Constituents of the Cortical Gray Matter of the Cerebellum. (<i>After Van Gehuchten</i>),	208
105. Lateral view of Mesencephalon, Pons, and Medulla. (<i>Gegenbauer</i>),	211
106. Metencephalon, Mesencephalon, and Thalamencephalon, from the Dorsal Surface. (<i>After Obersteiner</i>),	212
107. Microphotograph of a Transverse Section through the Corpora Quadrigemina of a Sheep. Showing layer of superficial cells. Method of Berkley,	213
108. A Characteristic Cell from the Third (Gray) Layer of the Optic Lobe of an Eighteen day-old Chicken. Golgi's method. (<i>After Koelliker</i>),	215
109. Schematic Representation of the Essential Histologic Elements of the Optic Lobe of a Bird. Showing the probable route taken by visual impressions to reach the cerebral (occipital) cortex. (<i>After Koelliker</i>) (<i>Colored</i>),	217
110. Transverse Section through the Corpora Quadrigemina from an Eight-months' Human Fetus. (<i>After Koelliker</i>),	219
111. Transverse Section through the Mid-brain of an Adult. Weigert's method,	221
112. Diagram of Section of the Crus. (<i>Modified from Wernicke, from Gowers</i>),	222
113. Diagram Indicating the Course of the Motor and Sensory Fibers of the Spinal Cord and Medulla (<i>Colored</i>),	225
114. Transverse Section through the Spinal End of the Posterior Corpora Quadrigemina of a Cat. Weigert preparation. (<i>After Koelliker</i>),	227
115. Horizontal Section through the Cerebellum,	229
116. Microphotograph through the Red Nuclei of the Mid-brain of a Young Sheep. Showing decussation of the fibers of the superior cerebellar peduncles. Method of Golgi,	231
117. Microphotograph of a Section through the Red or Tegmental Nucleus of a Young Sheep. Showing seven of its characteristic cells. Golgi method,	231
118. Course and Termination of Gowers' Tract. (<i>According to Hoche</i>),	234
119. Microphotograph through the Nucleus of Origin of the Motor Oculi Nerve. Showing the multipolar cells of this nucleus. Golgi preparation,	236
120. A Camera Lucida Drawing through the Nuclei of Origin of the Third or Motor Oculi Nerves. Showing the location of the nuclei and their cells, together with the descending axones from those cells which go to form the nerve-roots (<i>Colored</i>),	237
121. Diagram of the Groups of Cells Forming the Nuclei of the Third and Fourth Cranial Nerves. (<i>After Perlia, from Quain</i>),	238
122. Transverse Section through the Mid-brain at the Level of the Posterior Corpora Quadrigemina. Weigert preparation,	239
123. Schematic Representation of the Origin of the Trigeminal Nerve. (<i>After Edinger</i>),	241
124. Horizontal Section through the Cerebral Hemispheres to Show the Region of the Third Ventricle,	245
125. Section through the Superior Part of One of the Superior Corpora Quadrigemina and the Adjacent Part of the Optic Thalamus. (<i>After Meynert.</i>)—(<i>From Quain's "Anatomy"</i>),	250
126. Frontal Section through Basal Ganglia to Show the Nuclei of the Optic Thalamus. (<i>After von Monakow.</i>)—(<i>From Starr's "Atlas"</i>),	151
127. Microphotograph through Optic Thalamus Showing Busch Cells. Golgi method,	252
128. Microphotograph through Optic Thalamus Showing Stellate Cells. Method of Golgi,	255
129. Microphotograph through Optic Thalamus with a Single Large Polygonal Cell. Method of Berkley,	255
130. A Perpendicular Section through the Brain of a Rabbit Lateral to the Corpus Mamillare. (<i>After Koelliker</i>),	257
131. Section of Corpora Quadrigemina. Showing cells of red nucleus. Cox-Golgi method,	261
132. Diagrammatic Section of the Human Retina. (<i>Schultze.</i>)—(<i>After Quain</i>),	264
133. Section through the Retina of a Mammal to Show Layer of Horizontal Cells of the External Molecular Layer and the Spongioblasts of the Internal Molecular Layer. (<i>After Ramón y Cajal</i>),	265
134. The Essential Elements in the Retina of a Dog. (<i>After Van Gehuchten</i>),	267
135. The Origin and Relation of the Optic Tract. (<i>G. D. Thane.</i>)—(<i>From Quain</i>),	268
136. Microphotograph through Optic Thalamus of a Sheep. Showing fibers from optic nerve terminating about stellate cells. Method of Berkley,	269
137. Diagram of the Corpora Quadrigemina Anterior,	271
138. Horizontal Section through the Optic Chiasm of a Child. (<i>After Koelliker</i>),	274
139. Frontal Section through the Interbrain. (<i>After Koelliker</i>),	275

FIG.	PAGE
140. Sagittal Section of the Pituitary Body and Infundibulum with Adjoining Part of Third Ventricle. (<i>Schwalbe, from Quain</i>),	277
141. Examples of Some of the Various Forms of Pyramidal Cells Found in the Ventral Part of the Posterior Lobe of the Pituitary Body. (<i>After Berkley</i>),	278
142. Medisection of Brain, Showing Important Sinuses,	282
143. Section of the Posterior and Lower Parts of the Brain within the Skull to Exhibit the Subarachnoid Space and Its Relation to the Ventricles. (<i>After Key and Retzius</i>).—(<i>From Quain</i>),	286
144. Coronal Section through the Great Longitudinal Fissure, Showing the Meninges. (<i>Key and Retzius</i>),	287
145. Vertical Section of the Cortex Cerebri and its Membranes. $\times 2\frac{1}{2}$. (<i>After Landois and Stirling</i>),	289
146. View of the Upper Surface of the Velum Interpositum, Choroid Plexuses, and Corpora Striata. (<i>From Sappey, after Vicq d'Azyr</i>),	290
147. Photograph of the Superior Surface of the Cerebrum,	295
148. Photograph of the External Surface of the Brain,	297
149. Photograph of the Median Surface of the Brain,	301
150. Vertical Section through Frontal Lobe,	301
151. Diagrammatic Representation of the Lobes of the Cerebrum,	305
152. Frontal Section through Parietal, Temporal, and Occipital Lobes, Together with the Cerebellum,	307
153. Photograph of the Superior Surface of the Cerebrum,	311
154. Longitudinal Section through Cerebral Hemisphere to show the Centrum Semiovale of the Frontal, Parietal, Occipital, and Temporal Lobes,	313
155. Convolutions of the Mesial Surface of the Cerebrum,	315
156. Section through Left Gyrus Hippocampus. Showing the formation of the hippocampus major. Method of Weigert-Pal,	317
157. Photograph of the Base of the Human Brain,	321
158. Olfactory Lobe of the Human Brain. (<i>His</i>).—(<i>After Quain</i>),	327
159. A Schematic Representation of the Principal Elements of the Olfactory Bulb of a Mammal. (<i>Van Gehuchten</i>),	329
160. Mitral Cells from a Mouse Twenty-four Days Old. (<i>After Koelliker</i>),	331
161. A Frontal Section through an Olfactory Bulb of a Six-weeks'-old Cat. Showing layer of granular cells. (<i>After Koelliker</i>),	333
162. Sections of Cerebral Convolutions. (<i>After Baillarger, from Quain</i>),	339
163. A Scheme of the Distribution of the Nerve-fibers of the Cerebral Cortex. According to the views of Meynert, Obersteiner, Edinger, and Dejerine. (<i>After Dejerine</i>),	340
164. A Scheme Showing the Development of our Knowledge of the Different Cell-layers of the Human Cerebral Cortex from the Time of Vicq d'Azyr, in 1790, to the time of Cajal, in 1890. (<i>After Dejerine</i>) (<i>Colored</i>),	341
165. A Cajal Cell in Course of Development from Section of Ascending Frontal Gyrus of a Human Fetus at Eight Months. (<i>After Retzius</i>),	344
166. Microphotograph of Small Pyramidal Cells,	345
167. Microphotograph of Large Pyramidal Cells,	347
168. Cells with Ascending Axones from the Cortex of the Gyrus Fornicatus of a Six-days'-old Mouse. (<i>After Koelliker</i>),	348
169. Microphotograph of Polygonal Cell of the Fourth Layer of the Cerebral Cortex of a Mouse's Brain,	349
170. Diagram of the Cells of the Cerebral Cortex. (<i>After Starr</i>),	351
171. Section through Left Gyrus Hippocampus. Showing the formation of the hippocampus major. Method of Weigert-Pal,	353
172. Microphotograph of a Frontal Section through the Brain of a Mouse. Showing the peculiar involution of the gyrus hippocampus as it forms the cornu ammonis,	354
173. Microphotograph of Cornu Ammonis of a Dog's Brain. Showing contour and formation of cornu ammonis,	355
174. Microphotograph of Cornu Ammonis of a Rat's Brain. Showing three large pyramidal cells,	357
175. Microphotograph through Cornu Ammonis. Showing the deep part of the superficial layer, or stratum lacunosum,	358
176. Microphotograph of Section through Cornu Ammonis and Gyrus Dentatus (Rat's Brain). Showing a group of small pyramidal cells of the gyrus dentatus,	360
177. Microphotograph of Small Pyramidal Cells of the Gyrus Dentatus and their Axones, Forming the Moss-like Fibers,	361
178. Horizontal Section of the Cerebrum above the Corpus Callosum to Show the Centrum Ovale. (<i>After Van Gehuchten</i>),	363

FIG.	PAGE
179. Cortex of Human Brain. Showing the nerve-fiber systems and plexuses. Weigert's and Golgi's method combined. (<i>After Andriezen, from Starr's "Atlas"</i>), . . .	365
180. Diagram of the Association-fibers of the Cerebral Hemisphere. (<i>E. A. S., after Meynert, from Quain</i>), . . .	367
181. Semidiagrammatic Representation to Show the Fasciculus Occipitofrontalis, the Tænia Semicircularis, and the Fasciculus Uncinatus. (<i>After Dejerine</i>), . . .	369
182. A Scheme to Show the Origin and Termination of the Fibers of the Corpus Callosum. (<i>After Van Gehuchten</i>), . . .	370
183. Microphotograph Showing the Radiation of the Fibers Composing the Corona Radiata of a Rat's Brain. Method of Golgi.	372
184. Diagrammatic Arrangement of the Projection Tracts Connecting the Cerebral Cortex with the Lower Nerve-centers. (<i>After Starr</i>), . . .	374
185. Diagram to Show the Relative Position of the Several Motor Tracts in Their Course from the Cortex to the Crus. (<i>After Gowers</i>), . . .	375
186. Diagram of the Course of the Motor Tract as Shown in a Diagrammatic Horizontal Section through the Cerebral Hemisphere, Pons, and Medulla. (<i>After Gowers</i>), . . .	377
187. Diagram Indicating the Course of the Motor and Sensory Fibers of the Spinal Cord and Medulla (<i>Colored</i>), . . .	379
188. Diagram of the Course of the Pyramidal or Motor Tract of the Right Hemisphere. (<i>After Gowers</i>), . . .	381
189. (<i>After Sachs</i>). I. Sensory Tract. II. Horizontal Section of Cord. III. Relation of Motor Tract to Nuclei of Cranial Nerves. (<i>After Flatau</i>) (<i>Colored</i>), . . .	383
190. Horizontal Section of Cerebrum above the Corpus Callosum to Show the Centrum Ovale. (<i>After Van Gehuchten</i>), . . .	388
191. Portion of a Median Section of the Brain, . . .	389
192. View of the Corpus Callosum from Above. (<i>From Sappey, after Foville, from Quain</i>), . . .	390
193. Photograph of Horizontal Section through Cerebrum to Show Lateral Ventricles, . . .	391
194. View from Above and the Side of the Whole Left Lateral Ventricle. Natural size. (<i>E. A. S. and G. D. T., from Quain</i>), . . .	395
195. Two Views of a Plaster Cast of the Cavities of the Cerebral Ventricles. (<i>After Welcker, from Quain</i>), . . .	397
196. Photograph of a Section through the Frontal and Tip of Temporal Lobes, . . .	398
197. Photograph of Sagittal (Longitudinal) Section through a Cerebral Hemisphere, . . .	400
198. Microphotograph of Large Rectangular Cells of Corpora Striata. Golgi method. (<i>After Starr</i>), . . .	401
199. Diagram of a Section through the Crus, etc., in Front of the Corpora Quadrigemina. (<i>Modified from Wernicke</i>), . . .	402
200. Scheme Showing the Tractus Striothalamicus. (<i>After Edinger</i>), . . .	404
201. Photograph of a Longitudinal Section through a Cerebral Hemisphere to Show the Ganglia of the Hemisphere, . . .	405
202. Photograph of a Horizontal Section Through a Cerebral Hemisphere to Show Relations of Internal Capsule, . . .	409
203. Horizontal Section through the Right Hemisphere of a Man. (<i>After von Monakow</i>) (<i>Colored</i>), . . .	411
204. Distribution of Arteries in the Cerebral Cortex. (<i>After Duret</i>), . . .	417
205. The Arteries of the Base of the Cerebrum. (<i>G. D. T., after Duret, and from Nature, from Quain</i>) (<i>Colored</i>), . . .	419
206. Cortical Distribution of the Middle Cerebral Artery (Diagrammatic). (<i>G. D. T., after Charcot, from Quain</i>) (<i>Colored</i>), . . .	422
207. Diagram of the Blood-supply to the Central Ganglia by the Lenticulostriate Arteries, External (<i>E</i>) and Internal (<i>I</i>). (<i>After Duret</i>), . . .	423
208. Diagram Showing the Areas of Cortical Distribution of the Anterior, Middle, and Posterior Cerebral Arteries Respectively. (<i>E. A. S., from Quain</i>), . . .	426, 427
209. Arteries of the Anterior Surface of the Pons and Medulla. (<i>After Duret</i>), . . .	429
210. Arteries of the Posterior Surface of the Medulla. (<i>After Duret</i>), . . .	430
211. Anterior and Posterior Median Arteries of the Pons and Medulla. (<i>After Duret</i>), . . .	433
212. Diagram to Show Plan of Distribution of the Arteries of the Medulla. (<i>After Duret</i>), . . .	434
213. Superficial Veins of the Base of the Brain. (<i>After Testut</i>), . . .	436
214. Superficial Veins of the Internal Surface of the Left Hemisphere. (<i>After Testut</i>), . . .	437
215. Superficial Veins of the External Surface of the Left Hemisphere. (<i>After Testut</i>), . . .	438
216. Veins of Galen, or the Deep Cerebral Veins. (<i>After Van Gehuchten</i>), . . .	439
217. Diagram Showing Communications Existing between the Lateral and Cavernous Sinuses and the External Veins, indicated in Figure by *. (<i>After Leube</i>)—(<i>From Loomis and Thompson, "Practice of Medicine"</i>), . . .	441

FIG.	PAGE
219. Plan Showing the Relative Position of the Structures in the Right Cavernous Sinus, Viewed from Behind. (<i>After Gray</i>),	446
218. Medisection of Brain, Showing Important Sinuses,	444
220. Diagram of the Motor Areas on the Outer Surface of a Monkey's Brain. (<i>Horsley and Schäfer, from Landois and Stirling</i>),	449
221. Diagram of the Motor Areas on the Marginal Convolution of a Monkey's Brain. (<i>Horsley and Schäfer, from Landois and Stirling</i>),	450
222. A Drawing of the Left Cerebral Hemisphere (Human) (<i>Colored</i>),	451
223. A Drawing of the Right Cerebral Hemisphere (Human) (<i>Colored</i>),	452
224. Position of the Arm-center. (<i>After Gowers</i>),	453
225. Position of the Center for the Face and Tongue. (<i>After Gowers</i>),	453
226. Cortical Visual Centers on the Outer Surface of the Hemisphere. (<i>After Gowers</i>),	458
227. Inner Aspect of the Right Hemisphere. (<i>After Gowers</i>),	458
228. Diagram of Course of Optic Nerve-fibers from the Cortex to the Retina. (<i>After Sahli, Modified and Extended, from Tyson</i>),	459
229. Situation of Lesions Causing Word-deafness Only. (<i>From Starr</i>),	467
230. Situation of Lesions Causing Word-blindness Only. (<i>From Starr</i>),	469
231. Situations of Lesions Causing Aphasia. (<i>After Starr, from Tyson</i>),	472
232. Diagram Showing Location of Tumor which Produced Complete Agraphia (Author's Case),	475
233. View from Before of the Medulla Oblongata, Pons Varolii, Crura Cerebri, and Other Central Portions of the Encephalon (Natural size). (<i>Allen Thomson</i>)—(<i>From Quain's "Anatomy"</i>),	491
234A. Diagram of Skin Areas Corresponding to Definite Spinal Segments. (<i>From Tyson, after Starr</i>),	497
234B. Diagram of Skin Areas Corresponding to Different Spinal Segments. (<i>From Tyson, after Starr</i>),	498
235. Diagram (Framed from an Original Investigation) Showing the Relation of the Vertebral Spines to Their Bodies and to the Origin of the Several Nerve-roots. (<i>After Gowers</i>),	500
236. Diagram of Lesions Showing Brown-Séquard's Paralysis. (<i>After Starr, from Tyson</i>),	503
237. Schema Showing Chief Symptoms in Left Unilateral Lesion of the Dorsal Cord. (<i>After Erb, from Tyson</i>),	503
238. Sections Showing Stages in the Conversion of the Medullary Groove into the Neural Canal. (<i>E. A. S., from Quain</i>),	509
239. Longitudinal Section of Head of a Four-and-a-half-day Chick. (<i>After Von Mihalkovics, from Edinger</i>),	511
240. Fore-part of the Embryo Viewed from the Dorsal Side. (<i>After Koelliker, from Quain</i>),	514
241. Myelospongium from Spinal Cord of Three-and-half-weeks' Human Embryo. (<i>His, from Quain</i>),	515
242. Inner Ends of Spongioblasts with Germinal Cells between Them. (<i>His, from Quain</i>),	515
243. Inner Ends of Spongioblasts. (<i>His, from Quain</i>),	515
244. Three Neuroblasts, Each with a Nerve-fiber Process Growing out Beyond the Basement Membrane of the Embryonic Spinal Cord. (<i>His, from Quain</i>),	515
245. Ependymal Fiber of Marrow of a Seven-days'-old Embryo of a Chicken. (<i>After Golgi</i>),	517
246. Lower End of the Spinal Cord of a Human Embryo of Three Months. (<i>From Minot</i>),	518
247. Section of Spinal Cord of Four Weeks' Human Embryo. (<i>His, from Quain</i>),	519
248. Transverse Section of the Cervical Part of the Spinal Cord of a Human Embryo of Six Weeks. (<i>After Koelliker, from Quain</i>),	519
249. Transverse Section of the Spinal Cord from the Upper Dorsal Region of a Human Embryo of Six Weeks. (<i>After His, from Minot</i>),	521
250. Sections across the Region of the Calamus Scriptorius of the Brain. (<i>His, from Quain</i>),	523
251. Sections across the Fourth Ventricle of a Somewhat Older Embryo. (<i>His, from Quain</i>),	523
252. Sections across the Lower Half of the Fourth Ventricle of a still Older Embryo. (<i>His, from Quain</i>),	523
253. Transverse Section of the Medulla Oblongata of His' Embryo Ru. (<i>After W. His, from Minot</i>),	526
254. Transverse Section of the Medulla Oblongata of His' Embryo Mr. (<i>After W. His, from Minot</i>),	527

FIG.	PAGE
255. Median Section through the Brain of a Two-and-a-half-months' Fetus. (<i>His, from Quain</i>),	529
256. Fetal Brain of the Third Month. (<i>His, from Quain</i>),	531
257. Transverse Sections through the Brain of a Sheep's Embryo of 2.7 Centimeters in Length. (<i>After Koelliker, from Quain</i>),	533
258. Brain of a Chick Embryo, Fourth Day. (<i>After Duval, from Minot</i>),	535
259. Three Sections through the Fore-brain of a Four-and-a-half-weeks' Embryo. (<i>His, from Quain</i>),	537
260. The Surface of the Fetal Brain at Six Months. (<i>R. Wagner, from Quain</i>),	540
261. Brain of a Human Embryo of about Three Months (According to Marchand, four months). (<i>After F. Marchand, from Minot</i>),	541
262. Fetal Brain of the Beginning of the Eighth Month. (<i>Mihalkovics, from Quain</i>),	544
263. Sections across the Hind-brain of a Human Embryo, 10 mm. Long. (<i>His, from Quain</i>),	548
264. Section from the Same Embryo at the Exit of the Facial Nerve. (<i>His, from Quain</i>),	549
265. Cranial Nerves of a Human Embryo, 10.2 mm. Long. (<i>His, from Quain</i>),	550
266A. Brain of Chick of Second Day, viewed from below, to show the formation of the optic vesicles by outgrowth of the side of the fore-brain, and at the same time by the folding over of the enlarged part, the production of a grooving or cupping of the vesicles. (<i>His, from Quain</i> .) B. Brain of Human Embryo of Three Weeks. Showing the primary optic vesicles as outgrowths from the fore-brain. (<i>His, from Quain</i>),	553
267. Side View of Anterior Part of Brain of More Advanced Human Embryo. Showing the primary optic vesicle folded and tucked. (<i>His, from Quain</i>),	553
268. Side View of the Same Part of the Brain in a still more Advanced Embryo, the Eye Having Been Cut Away. (<i>His, from Quain</i>),	553
269. Rabbit Embryo of Ten and One-half Days; Section of the Lens Anlage. (<i>From Minot</i>),	555
270. Vertical Section of the Eye of a Chick Embryo of the Third Day. (<i>From Minot</i>),	555
271. Rabbit Embryo of Thirteen Days; Section of the Eye. (<i>From Minot</i>),	556

INTRODUCTION.

That the comprehension of the normal and abnormal activities of an organ must be based upon an understanding of its structure is a truth as old as Galen, and certainly there can be no doubt that a knowledge of the anatomy of the nervous system is absolutely essential to a clear understanding of its diseases. While teachers of the diseases of other organs have usually been content to refer their students to the general anatomic course for details of the anatomy of those organs, teachers of the diseases of the nervous system have almost universally included, both in their text-books and in their lectures, a more or less complete account of the anatomy of the brain and spinal cord; not alone because the symptoms of nervous diseases can only be explained by constant reference to the anatomy of the nervous organs, but also because in the general anatomic course the finer details of the peculiarly complex anatomy of the nervous system are neither sufficiently described nor demonstrated.

With one or two exceptions the text-books on nervous diseases continue to present, along with the pathology, more or less of the anatomy of the nervous system; but many of the teachers of this subject have of late years confined themselves rather strictly to its pathology, and have not attempted to combine with this, within the limits of a single course of lectures, the large mass of facts and theories in regard to the anatomy of the central nervous organs which has increased so rapidly during the past few decads. In a well-arranged college course students should have acquired and digested this anatomic knowledge before commencing the study of nervous diseases.

It is most desirable, it seems to me, that this change which

has partially taken place in the medical colleges should occur also in the text-books, so that these last may devote their entire space to pathology, as their title implies, and not be burdened by a necessarily somewhat cursory description of the anatomy of the central nervous organs, the importance of which is so great that every student of neurology should possess a book devoted exclusively to its harmonious and complete exposition. There seems, therefore, to be room for an English work which shall present the anatomy of the central nervous organs systematically and thoroughly; which shall begin with the simplest elements and proceed to their most complex combination in these intricate organs without getting beyond the grasp of the undergraduate student, and yet shall be complete enough to satisfy the demands of the neurologist.

Since the separation in the teaching of the anatomy and of the pathology of the nervous system took place in the Albany Medical College, Doctor Gordinier has been in full charge of the instruction in the anatomic part of the subject, and this book is the fruit of years of teaching, and, therefore, should, and I believe does, possess the two characteristics so desirable in teaching—clearness of style and profuseness of illustration.

HENRY HUN.

ALBANY, *June 6, 1899.*

THE
GROSS AND MINUTE ANATOMY
OF THE
CENTRAL NERVOUS SYSTEM.

CHAPTER I.

THE HISTOLOGIC ELEMENTS OF THE NERVOUS
SYSTEM.

The histologic elements comprise nerve-cells, nerve-fibers, and end organs, neuroglia tissue, blood- and lymphatic vessels, and lymph-spaces.

HISTOLOGY OF THE NERVE-CELL.

The nerve-cell—known also under the various names of nerve vesicle, corpuscle, or ganglion cell—is the beginning of a nerve unit, or neurone.

This unit, or neurone, consists of a cell-body with its various protoplasmic branches, one of which becomes a central or peripheral nerve.

The nerve-cell is a granular protoplasmic body containing a large, usually centrally placed, clear nucleus, in which lie one or more nucleoli. The nucleus is surrounded by a delicate membrane, and consists of a network which, because of its affinity for staining with different reagents, is called chromoplasm, and of a more fluid material in the meshes of the network called karyoplasm. Many of the cells in the sympathetic system contain two or more nuclei. During life the nucleolus is

usually angular, provided with processes, and capable of motion. After death the nucleolus is highly refractive, and assumes a spheric form. The cells of the central nervous system have no enveloping membrane or capsule, but many of the cells of the peripheral sympathetic ganglia, and the ganglia of the posterior spinal nerve-roots, have membranous envelopes continuous with the sheaths of the nerves.

If a nerve-cell is stained after the method of Nissl,—*i. e.*, with methylene-blue or magenta red,—and is examined with a high power of the microscope ($\frac{1}{12}$ oil immersion), the protoplasm surrounding the nucleus will be seen to consist of a stainable and an unstainable portion. The stainable portion, which stains very intensely, is composed of a number of granular bodies separated from one another by parts of the clear unstainable portion, which appears as a matrix in which these granular bodies rest. Each Nissl body consists of a number of very fine chromatic granules, held together by a very delicate coagulable achromatic substance of unknown nature. These bodies are somewhat irregular, and differ as to size and shape: some are oval or round, others assume the form of a wedge or spindle, while others are rod-like. The nucleus is frequently covered at each end or pole by granular masses of like nature, called nuclear caps. These granular bodies are often called the granules of Nissl, because this observer discovered a very unique method of staining them, by means of which they can easily be recognized and studied. They have the appearance of being arranged somewhat concentrically in layers, starting from the center and growing more numerous as they approach the periphery. They are called protoplasmic or chromophyllic granules, because of their affinity for the basic anilin dyes.*

Nissl, from the study of the relation that the nerve-cell body bears to its nucleus, has divided nerve-cells into two chief groups. The first group comprises the somatochrome nerve-cells, or those cells whose protoplasm completely surrounds the

* These chromophyllic bodies also exist in the dendritic or protoplasmic processes of the cell, where they are lengthened and appear rod-like, presenting a faint longitudinal striation. The axone, or axis-cylinder, and the adjacent portion of the cell-body from which the axone springs, called the axone hillock, is entirely free from these granules.





FIG. 1.—A GROUP OF MULTIPOLAR NERVE-CELLS FROM AN ANTERIOR HORN OF THE SPINAL CORD. Showing Nissl granules and pigment.



nucleus, and has a definite arrangement, thus giving most prominence to the cell-body. Most of the nerve-cells of the central nervous system belong to this group. The cells may have their chromophyllic particles arranged in a network, when they are termed arkyochrome nerve-cells; or they may be arranged in

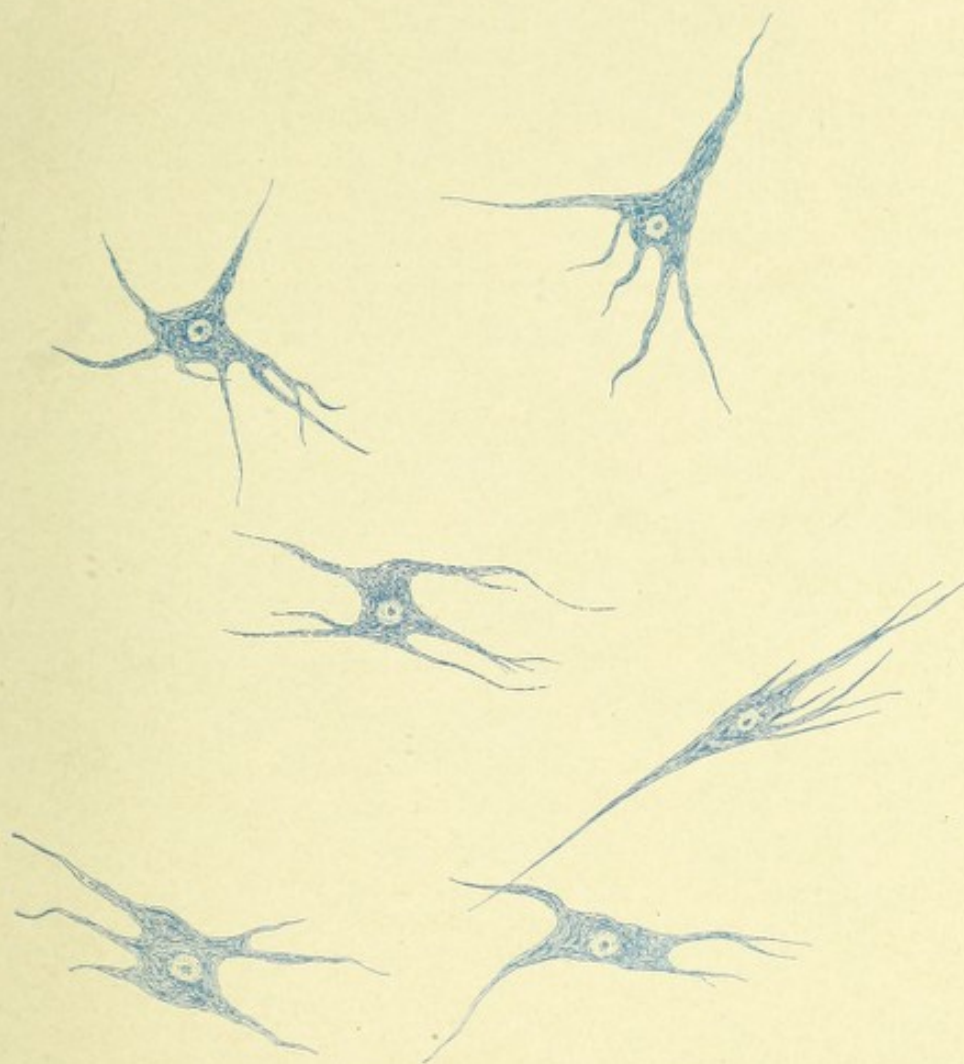


FIG. 2.—MULTIPOLAR NERVE-CELLS FROM THE SPINAL CORD OF AN OX. Stained with methylene-blue and showing striation of cell-bodies and their processes.

striæ which have the same direction, appearing as if continuous with one another, producing a fibrillated arrangement to the cell-body, the so-called stichochrome nerve-cells; or the chromophyllic particles of the cell-body, may present a combination of both the striated and network-like arrangements, when they are called arkyostichochrome nerve-cells; or, lastly, the chromo-

phyllic particles of the cell-body may consist of fine granules and have a definite arrangement; these are the gyrochrome nerve-cells.

The second group consists of nerve-cells in which the cell-body has no distinct form, the nucleus being the most prominent part of the cell. This condition of the cell is probably due to a lack of chromophyllic particles and to an increase of the unstainable portion. In this group there are two varieties: the cytochrome, or those nerve-cells whose bodies are very small in comparison to their nuclei, which are about the size of an ordi-

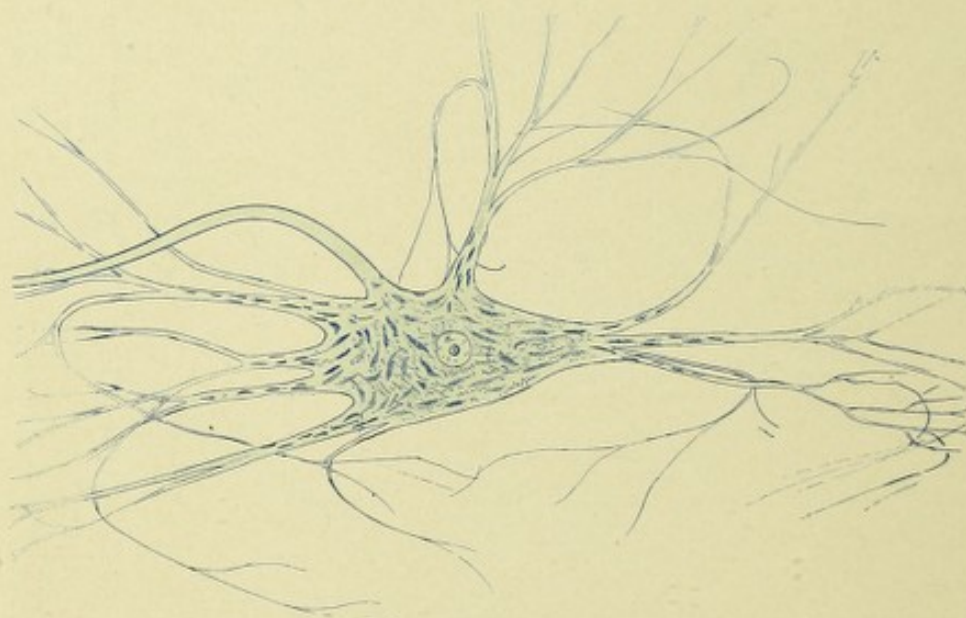


FIG. 3.—A GANGLION CELL FROM AN ANTERIOR HORN OF THE SPINAL CORD OF AN OX. Showing the arrangement of the Nissl granules and the ramification of the dendrites.

nary white blood-corpuscle; and the karyochrome, or those nerve-cells whose bodies are very small, but their nuclei equal in size the nuclei of ordinary nerve-cells.

It may be of interest to state that when structural alterations occur in nerve-cells, these changes are at first shown in the chromophyllic bodies and appear as alterations of form, size, position, and behavior toward staining reagents. Lenhossek*

* Von Lenhossek has designated these granular Nissl bodies tigroid, from the Greek *τιγρῶ-ειδής*, spotted, from the spotted appearance they give to the cell.

states that in no other cells of the body do granules exist having the foregoing characteristics.

Benda does not support this statement of Lenhossek. He says that similar bodies exist in gland-cells, liver-cells, cells of the pancreas, and in the cells of some sarcomatous tumors.

In nearly all of the cells of the spinal cord and in many of the cortical brain-cells, particularly the large ganglion cells of the latter, exist granular masses of yellowish pigment. These masses of pigment are frequently found close to the giving off of the axis-cylinder, and sometimes extend into that process and rarely into some of the dendritic branches of the cell. This pigment, although apparently consisting of small granules, must differ chemically from the chromophyllic bodies of the cell, because it does not ordinarily take any staining reagent which stains the protoplasmic granules. When, however, structural alterations in the cell occur, the pigment is increased in amount and will stain a deep black with osmic acid.

Max Schultze, about thirty years ago, discovered that each axis-cylinder of a nerve-cell was made up of a number of longitudinal fibrillæ, which were continuous with the fibrillæ that exist in the nerve-cell and in its protoplasmic branches. This observation of Schultze has been entirely ignored, until verified by the recent histologic studies of Becker, Flemming, Benda, Marinesco, Dogiel, Nissl, and Lugaro. These observers have found that in the unstainable portion of the cell-body exist numbers of fine fibrillæ, which extend into and terminate in the ultimate ramifications of the dendritic processes and are continuous with the fibrillæ of the axis-cylinder.*

* Gowers' theory of the conduction of nervous impulses is based upon the recent conception of the neurone and upon the histologic construction of nerve-cells and fibers as described long ago by Alexander Schultze and recently confirmed by Becker, Flemming, Marinesco, and Dogiel. He believes that the fibrillæ, which have their origin in the terminal ramifications of the dendrites and which pass uninterruptedly through the cell, conduct nerve impulses through that body, the impulses having come from the surrounding collaterals or axones, through the matrix or ground substance in which the cell and its dendrites rest. According to this theory the nerve impulses are merely in transit, the cell taking no part in their production. Whether or not the matrix in which the cell-body and dendrites rest, and in which the terminations of collaterals and axones occur, simply transfers impulses from nerve terminals to the fibrils in the dendrites of the cell, or whether it has anything to do with the excitation of nerve impulses, is still an open question. The only function assigned to the cell is trophic in character, the nutrition of the cell processes being dependent on the cell-body, this nutritional influence probably coming from the nucleus of the cell.

FORMS OR VARIETIES OF NERVE-CELLS.

The bipolar cells are found in the ganglia of the sympathetic system, in the posterior spinal ganglia, and ganglia of the sensory cranial nerves in embryonic life, and in the molecular layer of the cerebral cortex. They are spindle or pyriform in shape, and have a single fine axone springing from each pole.

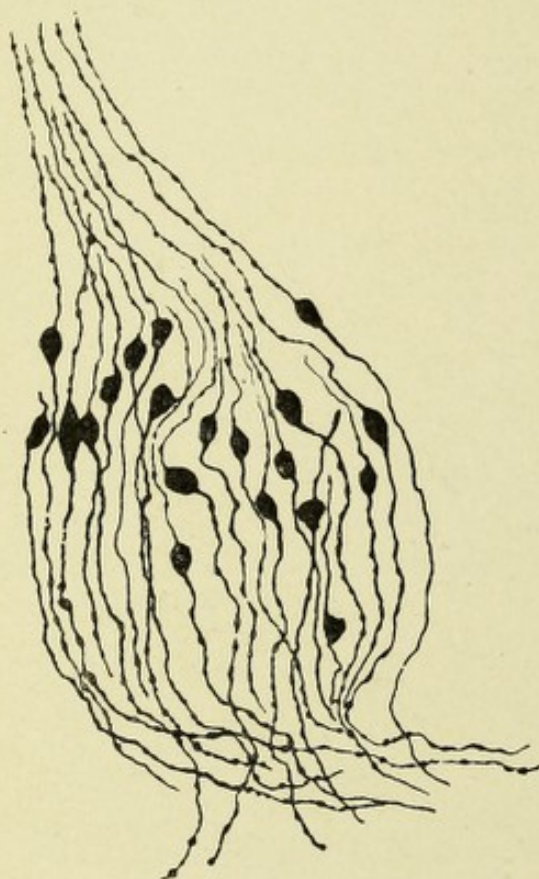


FIG. 4.—SECTION OF POSTERIOR SPINAL GANGLION OF EMBRYO CHICK. Illustrating bipolar cells.—(After Van Gehuchten.)

The *multipolar nerve-cells* are very irregular masses of protoplasm having a variety of shapes: stellate, angular, pyramidal, caudate, polygonal, and the like. They are the largest of all the cells of the nervous system, varying in diameter from eight to one hundred and twenty μ , the largest being about sixteen times the size of a red blood-corpuscle. They possess a large, clear nucleus with a nucleolus, and they usually contain masses of yellowish pigment. They give off from various angles of the cell-body numerous fine, tubular protoplasmic processes or dendrites, which divide and subdivide like the branches of a tree. They are found

throughout the entire nervous system, but predominate in the following localities—viz., in the anterior horns of the spinal cord, in the medulla oblongata, in the cortex cerebri, basal ganglia, and in the peripheral ganglia of the sympathetic.

There exist other forms of nerve-cells, probably transitional in character, among which may be mentioned the so-called granular cells, which form a distinct variety in many situations; as for

example: the cells of the substantia gelatinosa Rolandi of the posterior horns of the spinal cord, in the retina, olfactory bulb (the character of the small cells which compose the granular layer of the olfactory bulb is still much in dispute; Cajal believes them to be nerve-cells, while Van Gehuchten and Koelliker think they are neuroglia), and in the cerebellum, where they form a distinct layer. Their protoplasm is scant, and their processes are very difficult to discern with the ordinary methods of staining. They are probably bipolar cells.

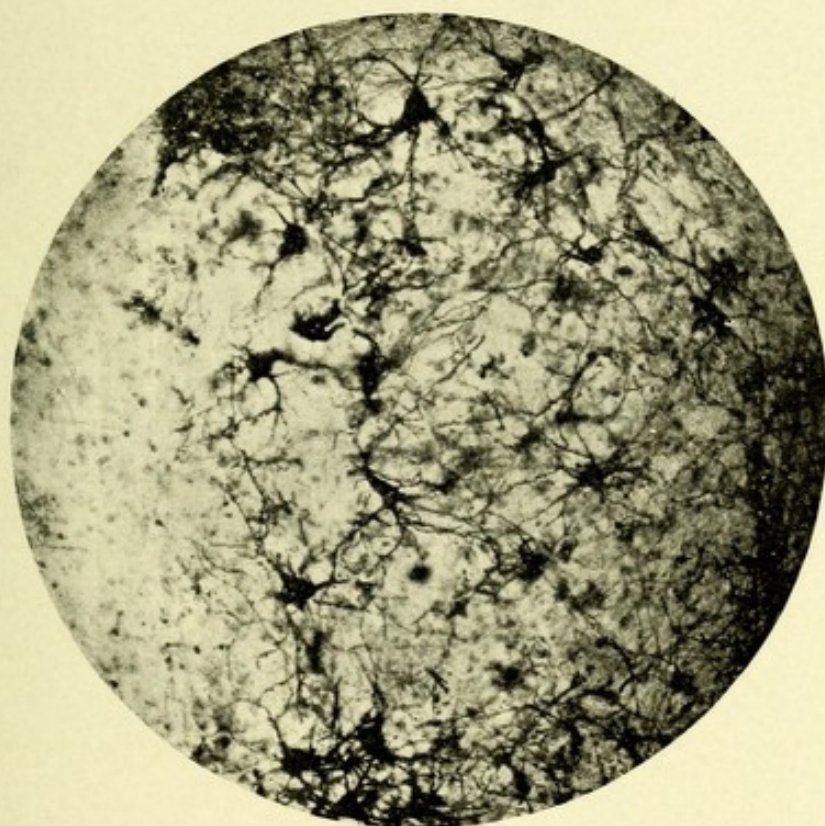


FIG. 5.—MICROPHOTOGRAPH OF A GROUP OF MULTIPOLAR NERVE-CELLS FROM THE ANTERIOR HORN OF THE HUMAN SPINAL CORD. Stained with the Cox-Golgi method.

PURKINJE CELL.

Another characteristic form of nerve-cell is the so-called Purkinje cell, found in the cortex of the cerebellum, where they form a distinct layer. They are quite regular in outline, somewhat flattened, and distinctly flask-shaped. They are from thirty to seventy μ in their longest diameter, and contain a large, spheric nucleus, "ten to fifteen μ in diameter," with a distinct

nucleolus. They are situated in the cortex of the cerebellum, between the external or molecular layer and the internal or granular layer. From their basal surface proceeds a distinct slender axis-cylinder process of great length, which continues downward through the granular layer into the medullary portion or white matter, where it becomes a medullated nerve-fiber. In its course it gives off collaterals which curve upward and ter-

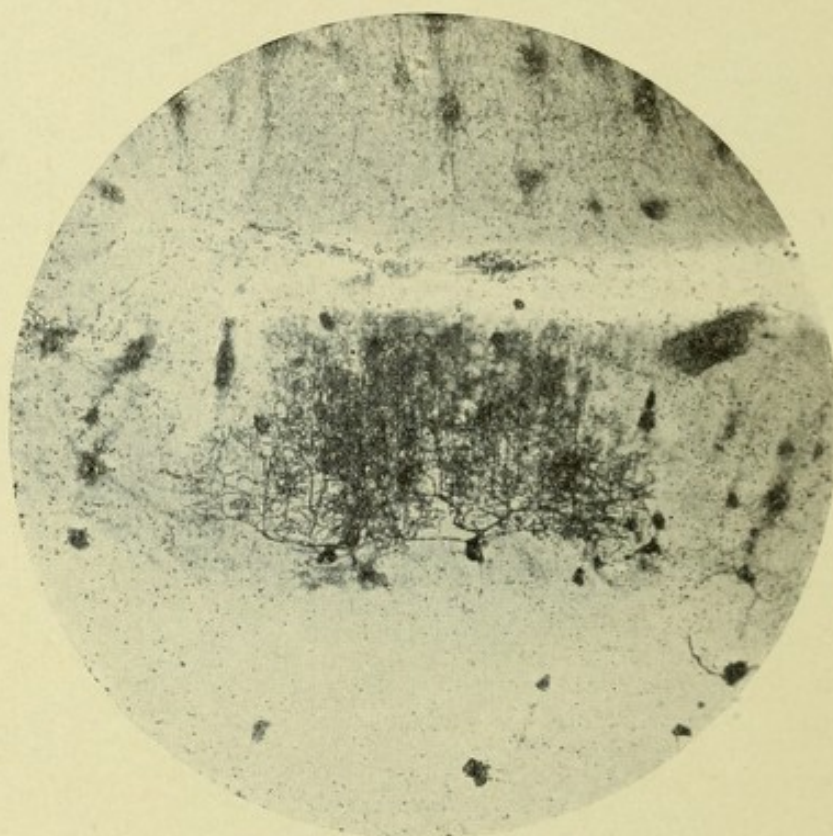


FIG. 6.—MICROPHOTOGRAPH SHOWING PURKINJE CELL.

minate in the external or molecular layer. From the opposite or cortical end of the cell-body spring two processes, or dendrites, or a single process which soon divides into two, and this dichotomous division continues until an enormous tree-like mass of fibers is produced, which covers a considerable extent of surface and is always distinct from the branching processes of other cells.

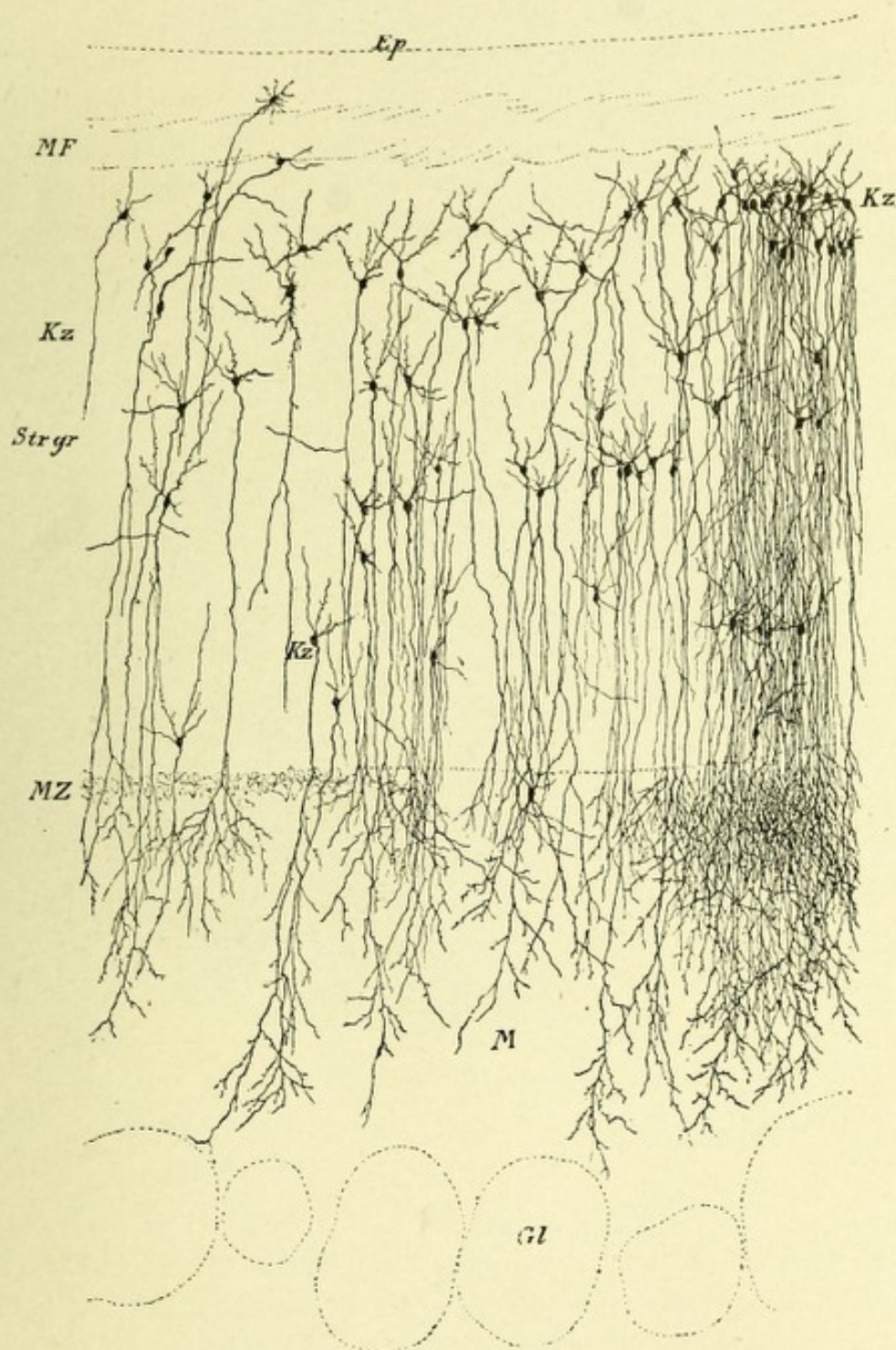


FIG. 7.—A FRONTAL SECTION THROUGH AN OLFACTORY BULB OF A SIX-WEEKS'-OLD CAT.
Showing layer of granular cells.—(After Koelliker.)

Ep. Ependyma. *Gl.* Glomerule. *Kz.* Layer of granular cells. *M.* Molecular layer. *MF.* Layer of medullated fibers. *MZ.* Layer of mitral cells. *Str. gr.* Granular zone (stratum granulosum).

THE BASKET CELL OF THE CEREBELLUM.

This is a cell peculiar to the cerebellar cortex, the axone or nerve process of which has a horizontal course, and continually gives off descending collateral branches which terminate in brushes of fibrils about the bodies of the Purkinje cells, giving them the appearance of resting in a basket of fine fibrils.

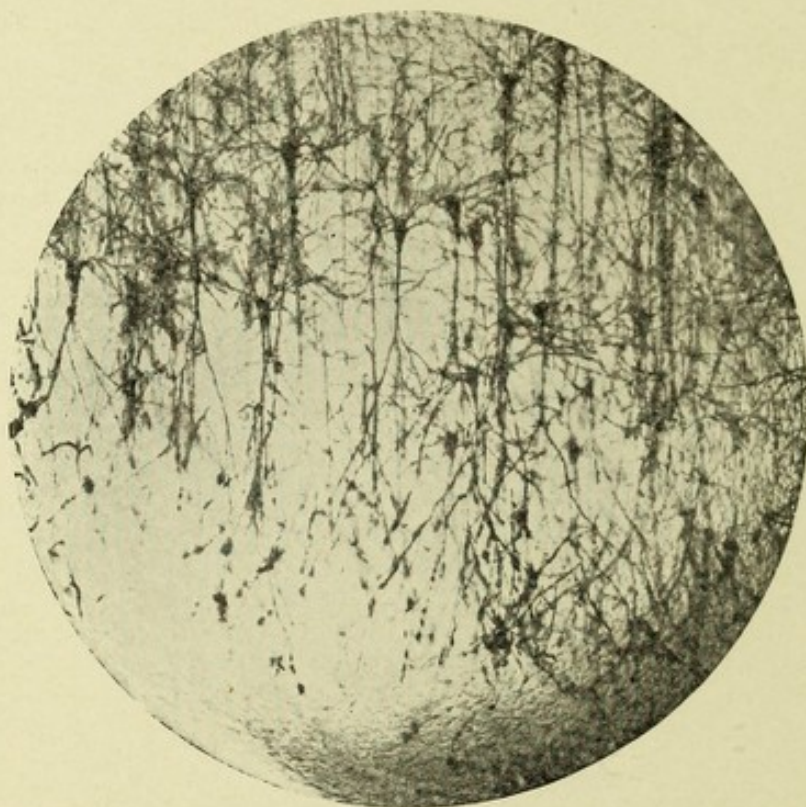


FIG. 8.—MICROPHOTOGRAPH OF SMALL PYRAMIDAL CELLS.

PYRAMIDAL CELLS OF THE CORTEX.

The pyramidal cells of the cerebral cortex are so numerous and of such anatomic and physiologic importance that they may well be described separately. They properly belong to the multipolar variety of cells, are triangular or pyramidal in shape, and possess a fine apical dendrite or process which gradually tapers as it extends toward the superficial layer of the cortex. Many of these apical processes bifurcate close to their cortical ending. Delicate protoplasmic processes or dendrites project

from all parts of the cell-body, while from each corner of the base springs a dendrite which extends obliquely to the plane of the vertical fibers of the cortex, and divides into numerous irregular branching filaments, all of which are studded in their course by minute protoplasmic offshoots, the so-called gemmules or buds. These buds or gemmules are minute in diameter where they join the dendritic branch, grow larger, and terminate in a beaded extremity. They are also found on the apical branches of the cell. They probably serve to convey nerve

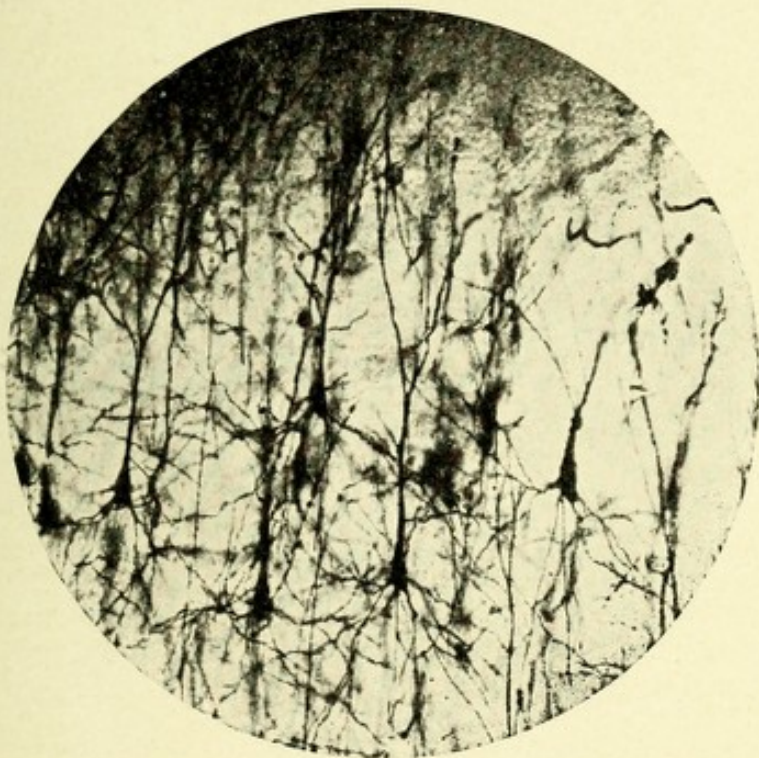

FIG. 9.—MICROPHOTOGRAPH OF LARGE PYRAMIDAL CELLS.

impulses from one dendrite to another, or receive impulses from the intracortical end-apparatus (Berkley). The axis-cylinder process generally springs from the middle of the basal portion of the cell-body, passes vertically downward, is usually of great length, smooth, less in diameter than the dendrites, and gives off at right angles collateral branches. Each cell contains an oval nucleus with well-defined nucleolus, and varies from eight to twelve μ in diameter. The larger ones are called the giant pyramidal cells (Betz), and are probably motor in function. Some of these

cells, according to Bevan Lewis, measure thirty to ninety-six μ in length and twelve to forty-five μ in breadth. This variety of cell nearly always contains an abundance of yellowish pigment.

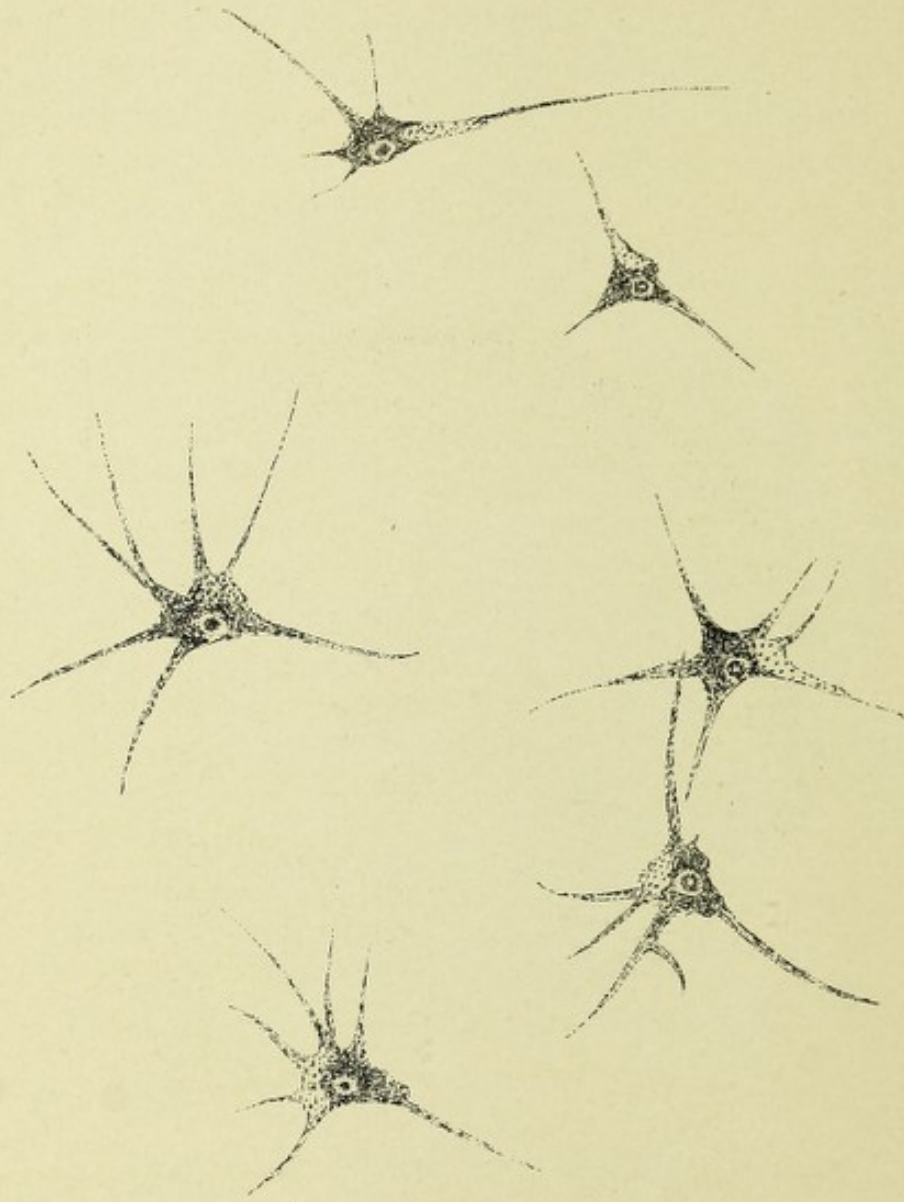


FIG. 10.—A GROUP OF LARGE PYRAMIDAL CELLS FROM THE MOTOR AREA OF THE HUMAN BRAIN. Stained after the method of Bevan Lewis.

CELL PROCESSES AND NERVE-FIBERS.

The protoplasmic body of the cell gives off from projections on its surface a number of processes which branch out, tree-like, in all directions and divide into filaments of extreme fine-

ness. Some of them are very long, while others are short and thick. These branches, or dendrites, as they are termed, do not anastomose with one another or with adjacent or distant cell branches, but may influence other dendrites or nerve processes by near approximation or slight contact.

By connecting with blood-vessels and lymphatics, they may serve a nutritional function (Golgi). Most observers, however, believe that they have a nervous function, collecting nerve impulses from nerve-cell processes and conveying them to their own cell-body.

The Axis-cylinder.—The most important process of the cell is the axis-cylinder process, known also under the name of neuraxone, axone, or nervous process. Along this process travel nervous impulses to or from the cell-body. It is, therefore, the conducting medium for nervous impulses originating from the periphery and passing centrally, or vice versa. This process is always single except from the cells in the uppermost cortical layer of the cerebrum and in the cells of the spinal and sympathetic ganglia and ganglia of the sensory cranial nerves. The cells of the posterior spinal ganglia in man have been incorrectly described by many authors as belonging to the bipolar type. This description is true inasmuch as it applies to the lower vertebrates. In man, however, this bipolar type is seen only in fetal life. As development goes on, the two axones either become fused in their entirety, forming one axone, which branches T-shaped, or, what seems more probable, there is an unequal development of the cell-body to form a protoplasmic pedicle from which the branching axone takes its origin. The axone starts as a delicate single strand of protoplasm, variable in length, which frequently gives off a few lateral branches (collaterals). In most cases it receives, soon after leaving the cell-body, a layer of myelin, and becomes a medullated nerve-fiber.

NERVE-FIBERS.

There are two chief forms of nerve-fibers, the white and the gray—the medullated and the non-medullated.

The white or the medullated nerve-fibers form the white sub-

stance of the cerebrospinal system and the greater part of the peripheral nerves, and give to them their characteristic microscopic and macroscopic appearance. Each fiber consists of a central portion or core,—the axis-cylinder of Purkinje, which is

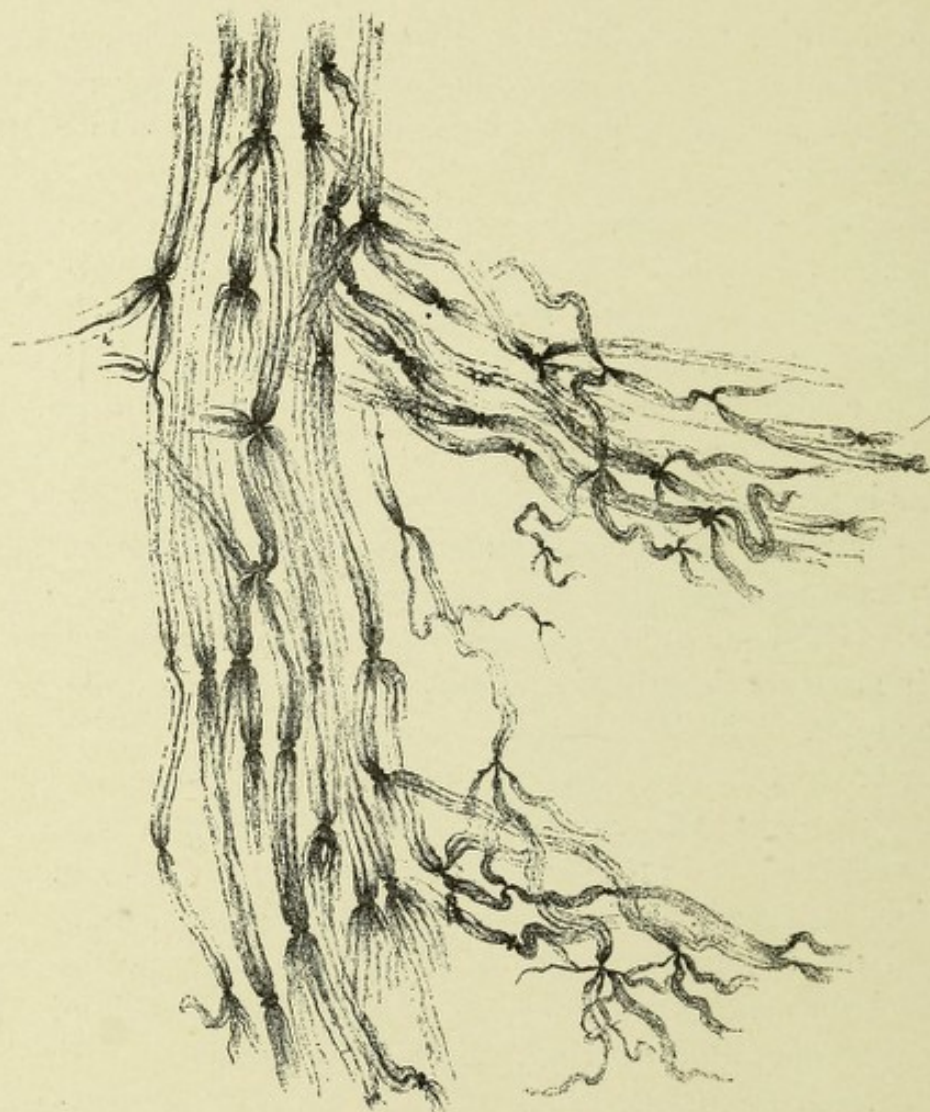

FIG. II.—NERVE-FIBERS FROM THE MUSCLE OF A FROG INJECTED WITH METHYLENE-BLUE. Showing the dark stained axis-cylinders, the nodes of Ranvier, and the separation of the terminal axones into several primitive fibrillæ.—(After Koelliker.)

the essential part of the nerve and conducts nervous impulses. This axis-cylinder is longitudinally striated, due to the fact that it consists of a number of exceedingly fine fibrillæ, which are arranged longitudinally and are held together by a very deli-

cate stroma or network called by Koelliker "neuroplasm," and by Waldeyer "axioplasm." At the termination of a nerve-fiber the axis-cylinder often separates into a number of terminal filaments, which are termed the primitive fibrillæ of Max Schultze (Fig. 11).^{*} Near the nodes of Ranvier it is not uncommon to find transverse markings in the axis-cylinder. These are the so-called lines of Frohmann. Each axis-cylinder

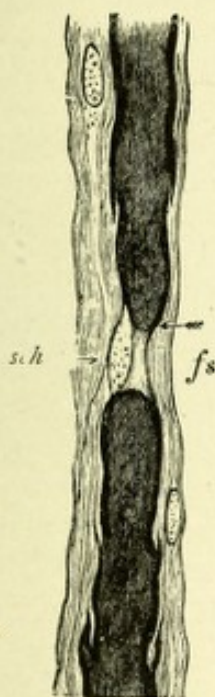


FIG. 12.—MEDULLATED NERVE-FIBERS BLACKENED BY OSMIC ACID.—(*Landois and Stirling.*)

fs. Ranvier's node. *sch.* Schwann's sheath.

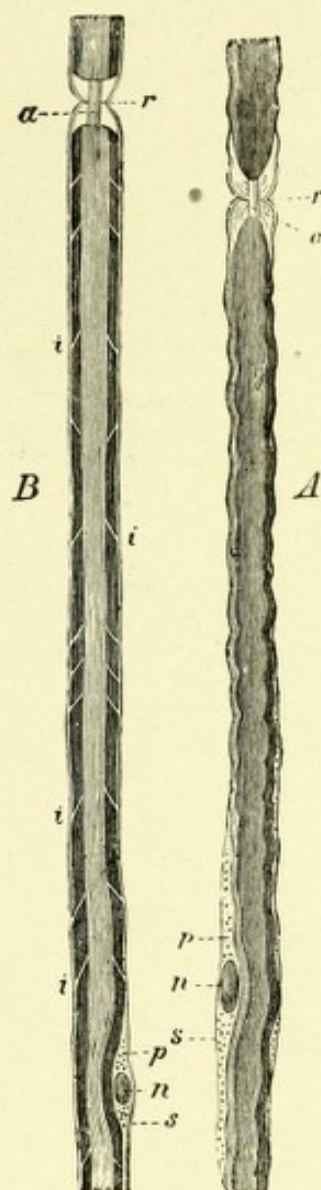


FIG. 13.—MEDULLATED NERVE-FIBERS (WITH OSMIC ACID).—(*Landois and Stirling.*)

a. Axis-cylinder. *s.* Sheath of Schwann. *n.* Nucleus. *p, p.* Granular substance at the poles of the nucleus. *r, r.* Ranvier's nodes, where the medullary sheath is interrupted and the axis-cylinder appears. *i, i.* Incisures of Schmidt.

is the prolonged axone of a nerve-cell, and remains uninter-

^{*} The fibrils composing the axone consist of a conducting medium called by Hansen "hyaloplasm," and a granular material called "spongioplasm." Gowers calls the terminal filaments of the axis-cylinder "axites."

rupted throughout its course. It is surrounded by a delicate sheath composed of a substance similar to horny material, hence called neurokeratin. This sheath is called the axilemma. Surrounding the axis-cylinder is a layer of semifluid fatty material which stains deep black with osmic acid, called myelin; or, from its discoverer, the white substance of Schwann. The myelin

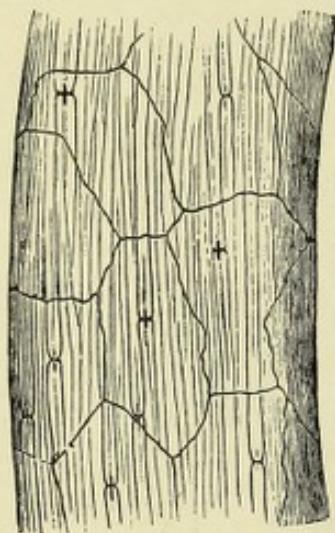


FIG. 14.—A BUNDLE OF NERVE-FIBERS STAINED WITH NITRATE OF SILVER. —(After Ranvier.)

Showing the outlines of epithelial cells of the perineurium. The dark crosses of Frohmann on the nerve-fibers at the nodes of Ranvier are due to the staining of the axis-cylinder and of a band of intercellular substance which encircles the axis-cylinder at the node.

has an inner and an outer layer of neurokeratin, with an intervening network of the same material, in the meshes of which exist the droplets of semifluid myelin. Owing to its peculiarity of refraction the myelin gives to the nerve-fiber as seen with transmitted light its double contour (Figs. 12 and 13).

The myelin, or white substance of Schwann, apart from giving to the nerve-fiber its contour, is a protective to the axis-cylinder, and possibly may act as a non-conducting medium to prevent nerve impulses from being deflected from their intended course. It does not form a continuous envelop for the axis-cylinder, but at rather regular intervals it is interrupted, leaving gaps or constrictions called Ranvier's nodes. The nerve segment between two nodes is called an interannular or internodal segment. The internodes are united within the sheath of Schwann by the constricting bands of Ranvier, a sort of annular ring formed of an albuminous-like material. This

material stains readily with silver nitrate, which agent also stains the axis-cylinder at the nodes, producing the so-called crosses of Frohmann (Fig. 14). Each internodal segment contains just below its middle an oval-shaped nucleus situated beneath the covering of the myelin or neurilemma in a depression of the myelin. The nodes of Ranvier are supposed to subserve a nutritive function, permitting the passage of blood

plasma into the axis-cylinder. Certain incisures can be seen in the myelin which extend obliquely across it. These are named, from their discoverers, the incisures of Schmidt or Lantermann. By many, and particularly Koelliker, they are considered as artifacts, the latter observer never having found them in living nerves.

It has been shown that the layer of myelin which surrounds most of the nerve-fibers of the central nervous system appears for the various tracts at different periods of fetal development. Flechsig has shown that fibers which have the same function develop simultaneously, and in the direction in which they conduct impulses.

Surrounding the myelin, or white substance of Schwann, is a closely investing, delicate, almost structureless membrane, called the neurilemma, primitive or tubular sheath of Schwann. This sheath is continuous and uninterrupted throughout, although it presents constrictions which correspond to the nodes of Ranvier, which dip down almost to the axis-cylinder. Some medullated fibers lack this sheath of Schwann, or neurilemma, being simply inclosed in myelin; as, for example, the white fibers of the brain and columns of the spinal cord. The size of medullated fibers varies very much, this being due mainly to the amount of myelin surrounding them, although the axis-cylinders also vary in diameter. The diameter of the axis-cylinder depends somewhat upon the cell from which it springs and upon the length of its course, the large cells usually giving off nervous processes of greater diameter and length than those from smaller cells. The medullated nerves vary from 2 to 2.5 μ , or $\frac{1}{1200}$ to $\frac{1}{1500}$ of an inch, in diameter.

Non-medullated Fibers.—These fibers occur chiefly in the sympathetic system, and are sometimes called sympathetic or Remak's fibers. These non-medullated fibers differ in form. First, simple nerve strands presenting globose swellings are found, occurring near the termination of nerve-fibers, being formed by the splitting-up of their axis-cylinder processes—as, for example, the optic nerve layer of the retina, the ramifications of the olfactory nerves, and as is often seen among the fibers of the spinal cord and brain. Secondly, as naked axis-cylinders,

which are primitive fibers held together by a cement substance—as, for example, the axis-cylinder processes of many nerve-cells. Thirdly, axis-cylinders surrounded by a very delicate sheath,

which corresponds to the neurilemma or Schwann's sheath of medullated nerves. These fibers bear the name of Remak, their discoverer, and are commonly described as the non-medullated fibers of the sympathetic system, or the fibers of Remak (Fig. 15). They contain nuclei situated at intervals in each fiber lying between the axis-cylinder and neurilemma, and are faintly striated.

This form is found in the sympathetic system and in some of the cranial nerves. All nerves of the embryo up to a certain period of development are also of this kind.

The size of the non-medullated fibers varies, these being in general about half the size of the medullated fibers; but some—as, for example, those of the olfactory bulb—are many times the size of the medullated fibers.

The nerve-fibers are joined into fasciculi or bundles by a connective-tissue sheath. These bundles are in turn united to other bundles, to form a peripheral nerve. The sheath which unites and covers the nerve bundles or fasciculi is called the epineurium (Fig. 16). It serves to convey to the nerve bundles blood-vessels, lymphatics, and nerves. The connective-tissue sheath which encircles each individual bundle or fasciculus is covered by epithelium, and from its position is called the perineurium. The delicate sheath which is

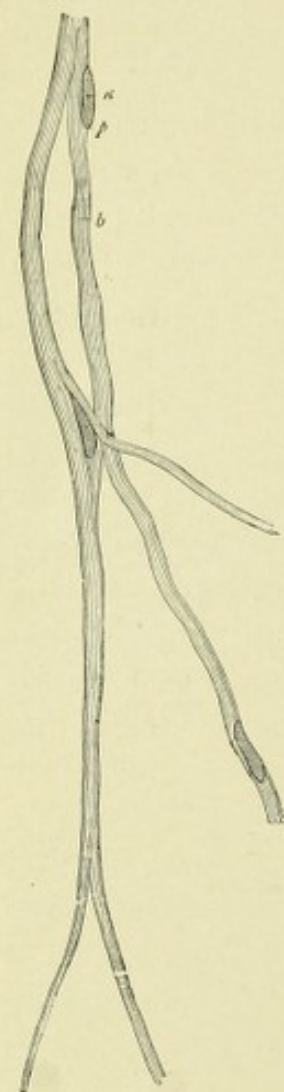

FIG. 15.—REMAK'S FIBER FROM VAGUS OF DOG.—(*Landois and Stirling.*)

b. Fibrils. *n.* Nucleus.
p. Protoplasm surrounding it.

between the fibers of each single fasciculus is termed the endoneurium. It serves to give support to the nerves and blood-vessels, and communicates by channels with the lymphatics of the perineurium. The nerve trunks themselves are supplied by

nerve-fibers which extend through the epineurium, terminating in end bulbs. These are the nerves of the nerve, or the *nervi nervorum*.

The nerve centers of the cerebrospinal axis are supported by connective-tissue envelopes, connective tissue about the blood-vessels, and, most important of all, a neuroglia tissue matrix.

THE PERIPHERAL NERVE TERMINATIONS.

The peripheral nerves, which contain mixed motor and sensory

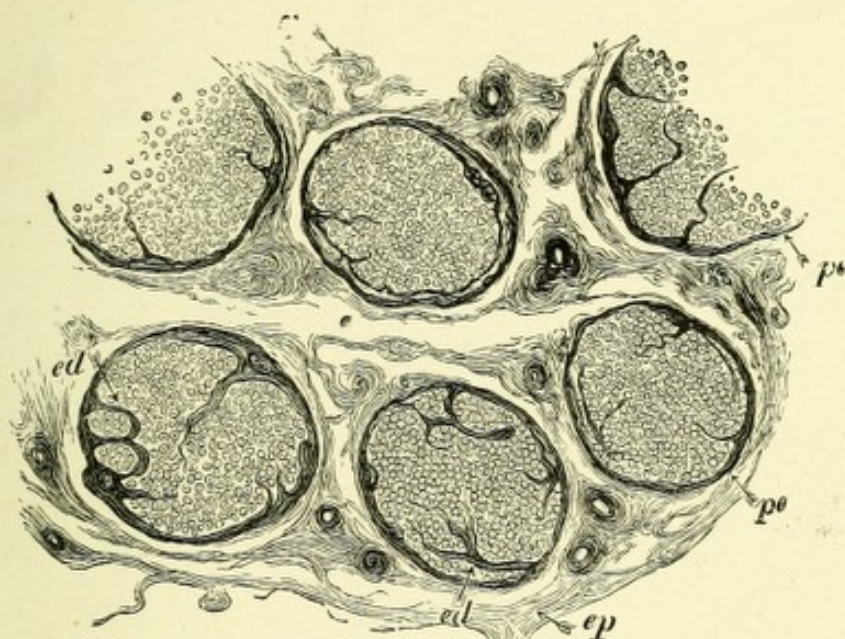


FIG. 16.—TRANSVERSE SECTION OF A NERVE (MEDIAN).—(*Landois and Stirling.*)

ep. Epineurium. *pe.* Perineurium. *ed.* Endoneurium.

fibers, terminate in one of three ways. First, in interepithelial arborizations; second, in specialized end organs or tactile corpuscles; and third, in the motorial end plates. The first two methods of termination belong to the sensory nerves only, while the last method belongs to the sensorimotor nerves of the voluntary muscles. There are six chief forms of specialized end organs—namely, the tactile corpuscles of Meissner and Wagner, the end bulbs of Krause, the Pacinian or Vater's corpuscles, the tactile menisques, the corpuscles of Golgi, and the so-called muscle spindles.

THE TERMINATIONS OF SENSORY NERVES.

First, the interepithelial arborizations. This is the usual mode of ending for a large number of sensory nerves. They termi-

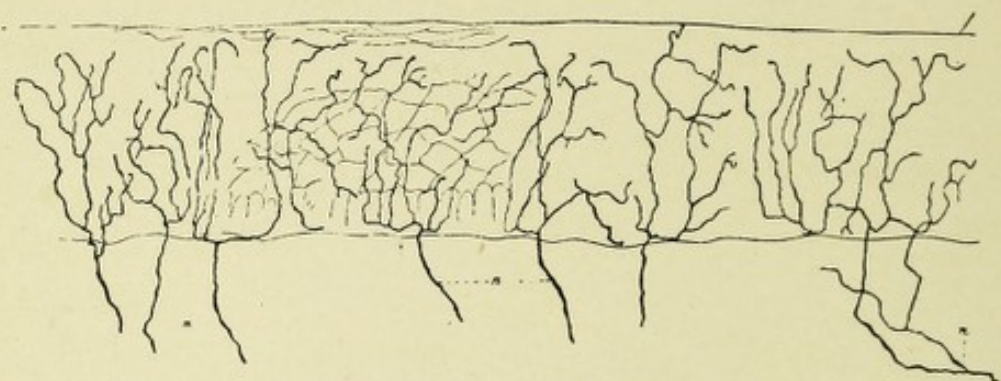


FIG. 17.—TERMINATION OF SENSORY NERVES IN STRATIFIED SQUAMOUS EPITHELIUM. GOLGI STAIN.—(After Retzius.)

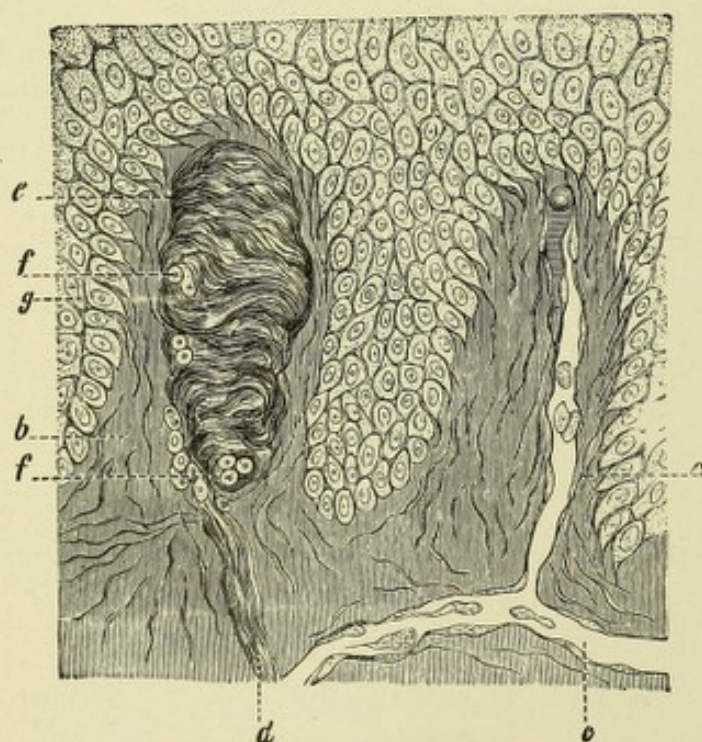


FIG. 18.—VERTICAL SECTION OF THE SKIN OF THE PALM OF THE HAND.—(Landois and Stirling.)

a. Blood-vessels. *b.* Papilla of the cutis vera. *c.* Capillary. *d.* Nerve-fiber passing to a touch corpuscle. *f.* Nerve-fiber divided transversely. *e.* Wagner's touch corpuscle. *g.* Cells of the Malpighian layer of the skin.

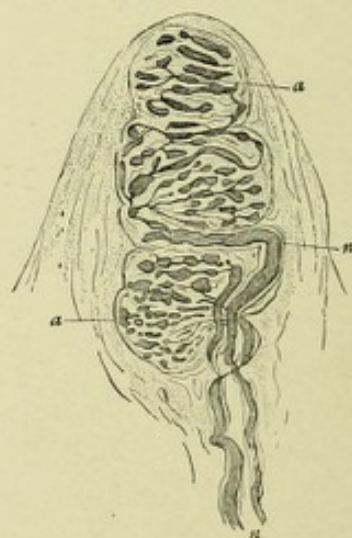


FIG. 19.—WAGNER'S TOUCH CORPUSCLE FROM THE PALM, TREATED WITH GOLD CHLORID.—(Landois and Stirling.)

n. Nerve-fibers. *a, a.* Groups of glomeruli.

nate in the skin and mucous membranes, as well as in the hair bulbs, the teeth, the tendons of muscles, and many of the glands of the body. As the nerve-fiber approaches the surface of the skin or the mucous membrane it loses its myelin and neurilemma. The naked axis-cylinder then repeatedly divides, forming a ramified plexus of fine fibrils, which terminate by passing among the epithelial cells of the skin and mucous membrane (Fig. 17).

Secondly, the tactile corpuscles of Meissner and Wagner. These touch corpuscles are most numerous where the sense of touch is best developed,—that is, in the palms of the hands and

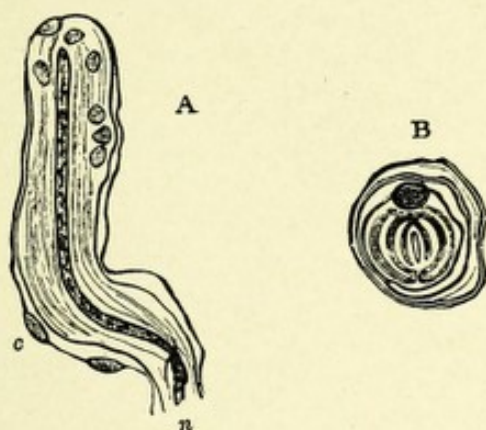


FIG. 20.—CYLINDRIC END BULBS FROM THE CONJUNCTIVA OF THE CALF.—(*Merkel*.)

A. Longitudinal section. B. Transverse section. *n*. Entering nerve-fiber. *c*. Nucleated capsule.

soles of the feet, especially in the ends of the fingers and toes,—more sparingly in the tip of the tongue, skin, and lips, back of the hands and feet, skin of the nipples, and in the conjunctiva. They are oval or elliptic in shape, about seventy μ or $\frac{1}{800}$ of an inch in length, and thirty μ or $\frac{1}{800}$ of an inch in thickness (Figs. 17 and 18). They are composed of connective tissue consisting of a capsule which sends numerous trabeculæ into its interior, which serve to support the nerve-fibers in their spiral or convoluted course. Several medullated nerve-fibers pass to the base of each capsule and surround it in a spiral manner; they then enter the capsule and pursue a spiral course, supported by the trabeculæ, and terminate in globular enlargements close to the capsule.

THE END BULBS OF KRAUSE.

These are very small cylindric or oval-shaped corpuscles, and are slightly bent near their base. They are from 0.075 to 0.14 mm. in diameter. They consist of a nucleated connective-tissue capsule, in the interior of which is a core of soft protoplasm containing numerous polyhedral cells, in which rests the naked axis-cylinder, the myelin being lost when the latter enters the base of the capsule (Figs. 20, 21, and 22). The neurilemma continues

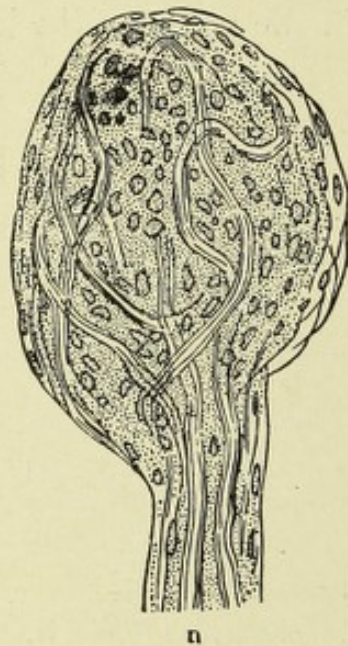


FIG. 21.—END BULB OF THE HUMAN CONJUNCTIVA, TREATED WITH A MIXTURE OF ACETIC AND OSMIC ACIDS.—(*W. Krause.*)

n. Two medullated nerve-fibers entering corpuscle.

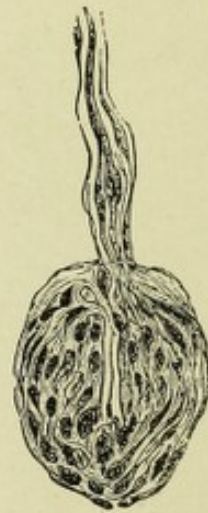

FIG. 22.—ARTICULAR CORPUSCLE FROM PHALANGEAL JOINT IN MAN.—(*W. Krause.*)

inward with the axis-cylinder, and forms a lining to the capsule and a covering for the central protoplasmic core. The axis-cylinder usually terminates near the extremity of the capsule in an elongated globular expansion. Rarely the nerve-fiber separates into two or three parts which become twisted before terminating. These corpuscles are found in the mucous membranes of the mouth, lips, nose, and conjunctiva, in the papillæ of the tongue, in the mucous membrane of the glans penis and vagina, and in the synovial membranes of the joints of the fingers, in which latter place they are often called articular end bulbs.

The Pacinian or Vater's corpuscles are irregularly oval-shaped bodies situated on some of the cerebrospinal and sympathetic nerves, and are from $\frac{1}{20}$ to $\frac{1}{10}$ of an inch in length and from $\frac{1}{25}$ to $\frac{1}{20}$ of an inch in breadth. Each corpuscle incloses the termi-

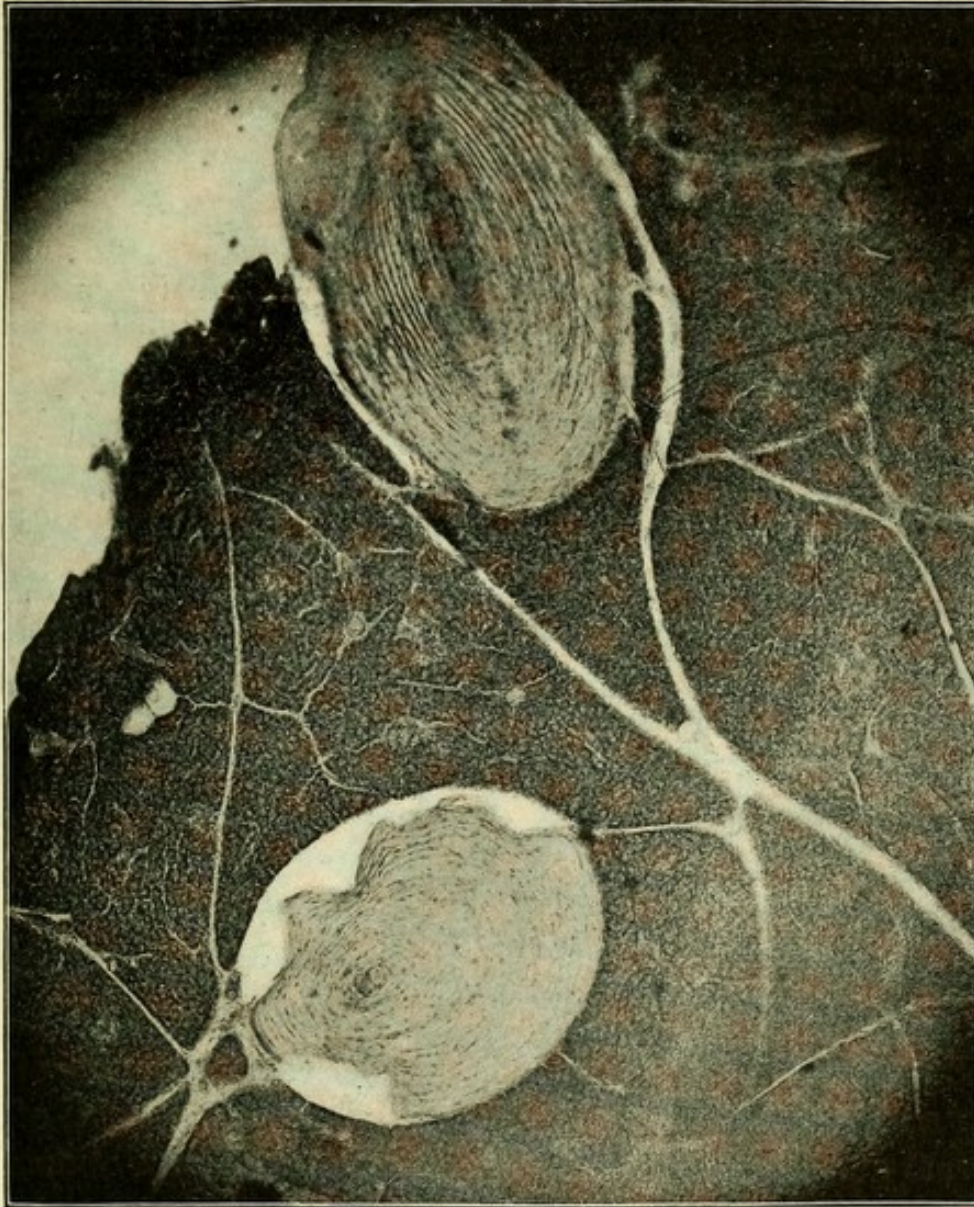


FIG. 23.—A MICROPHOTOGRAPH OF TWO PACINIAN CORPUSCLES FROM THE MESENTERY OF A CAT.

nation of a single nerve-fiber, which, with its connective-tissue sheath and blood-vessel, forms a pedicle by which the corpuscle is attached to the main nerve. These bodies consist of a laminated connective-tissue capsule composed of from forty to fifty tunics or lamellæ. Each tunic decreases in thickness from with-

out inward, and the several tunics are arranged similarly to the coats of an onion. Each lamella consists of white connective-tissue fibers arranged transversely, and of elastic fibers which pass in a variety of ways. The lamellæ are lined with endothelial cells, and are slightly separated from one another by a transparent fluid, probably lymph (Fig. 23). In the central part or axis of each corpuscle is the core, made of a soft material (protoplasm), through which passes the prolongation of the nerve-fiber. A single medullated nerve-fiber passes into each corpuscle, the sheath of Schwann uniting with the capsule. The myelin is lost and the naked axis-cylinder proceeds through the soft central core, to terminate near the extremity of the capsule in a varicosity. Sometimes the fiber forks, each division terminating in

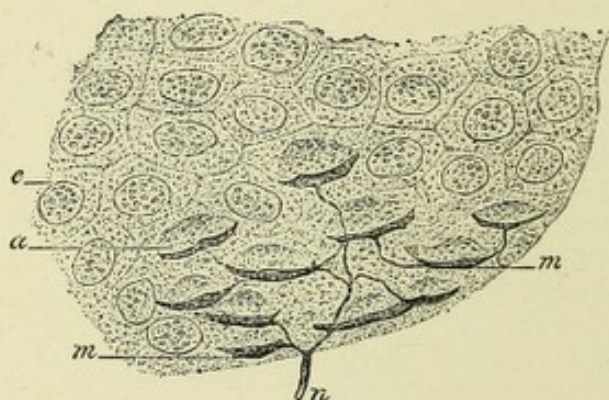


FIG. 24.—TACTILE MENISQUE FROM THE NOSE OF A GUINEA-PIG.—(*Ranvier.*)

n. Nerve-fiber. *a.* Tactile cells. *m.* Tactile discs. *e.* Epithelial cells.

an oval expansion. These corpuscles are found in the subcutaneous tissue on the nerves of the fingers and toes in the neighborhood of joints, on the intercostal nerves, the nerves of the arms and of the neck, on those of the nipples, on those of the external genitalia of both sexes, on the nerves of the abdominal sympathetic, and particularly on the nerves of the mesentery. They are very abundant on the nerves of the mesentery of the cat, where they are often so large that they may be seen with the naked eye.

THE TACTILE MENISQUES.

Another form of termination of the sensory nerve-fibers is that of the tactile menisques of Ranvier (Fig. 24). They occur

in both the superficial and deep layers of the skin, and consist of plexuses of nerve-fibers which form arborizations whose branches become flattened, resembling leaves in shape.

THE CORPUSCLES OF GOLGI.

A special form of muscle nerve-ending has been described by Golgi and Rollett, and occurs in tendons, particularly near the point of junction of the tendon with the muscle. At that point the bundles of fibers composing the tendon become somewhat enlarged, and medullated nerve-fibers, after losing their myelin, penetrate the fibers composing the tendon. They then, as naked

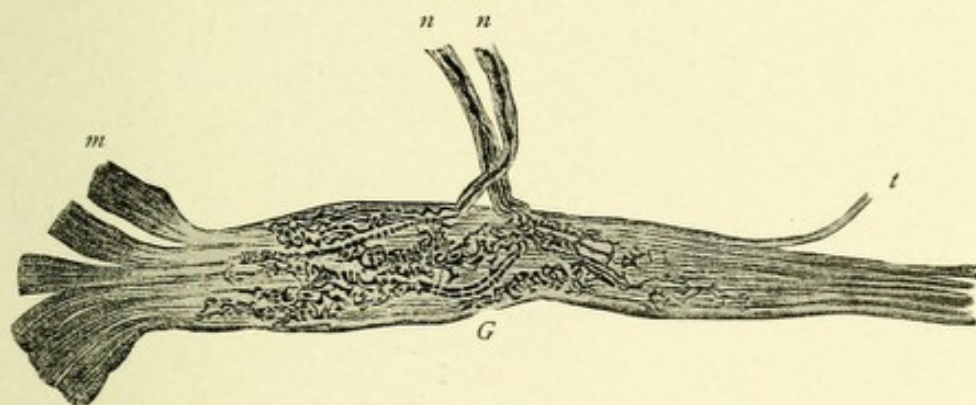


FIG. 25.—ORGAN OF GOLGI FROM THE HUMAN TENDO ACHILLIS, CHLORID OF GOLD PREPARATION.—(After Ciaccio.)

m. Muscular fibers. *t.* Tendon muscles. *G.* Golgi's organ. *n.* Nerve-fibers.

axis-cylinders, break up into a number of fibrils, which form terminal arborizations, somewhat spindle shaped. This enlargement of the fibers of the tendon, with the terminal arborizations, forms the so-called corpuscles of Golgi (Fig. 25).

THE MUSCLE SPINDLE.

These bodies have been found in nearly all the skeletal muscles, but are especially abundant in the biceps of the arms and in the small muscles of the hands. They are found more abundantly in the belly of the muscle than in the tendon, and are

most easy of demonstration in atrophied muscles. They do not occur or else are very uncommon in the muscles of the eye, the diaphragm, and intrinsic muscles of the tongue. They vary from 2 to 4 mm. in length and 0.15 to 0.4 mm. in breadth. These bodies, as their name implies, are spindle shaped. They are often found lying parallel to the nerve which supplies them; frequently two spindles will be found in the same plane, lying end to end.

The muscle spindle consists of muscle-fibers, nerves and their endings, a connective-tissue sheath, blood-vessels, and lymphatics.

One or more muscle-fibers, somewhat diminished in size, enter either the distal or proximal pole of the muscle spindle and pass toward the center of the spindle, where they usually divide into several smaller fibers; they then begin to lose their transverse markings, and become nucleated, the nuclei completely filling the muscle-fiber. These nuclei exist for a short distance in the muscle-fiber at the equatorial region of the spindle, after which the fiber again becomes striated. Each spindle is usually supplied by two nerves, one of which enters the spindle at the distal or proximal end, and one entering the spindle at its central part. The nerve-fiber which enters the spindle at its center is the larger, and probably terminates about the nuclei of the muscle-fiber. The other nerve-fiber forms a plexus of fibrils beneath or in the sheath of the spindle, or else terminates in bulbous extremities. The nerve sheaths blend with those of the muscle spindle on entering the latter.

The sheath of the spindle consists of several laminæ, which have, on cross-section, the appearance of an onion. At the center of the spindle there are from eight to ten laminæ, but at the poles they become less in number and blend with the sheaths of the muscle. The sheath of the spindle sends many septa into the interior of the spindle, which pass between the muscle-fibers and nerves. The blood-vessels of the spindle usually enter and leave at the opening for the central nerve. A lymphatic space exists in the center of each spindle, occupying about its middle third. The function of the muscle spindle is not positively known, but from the situation and important

nerve connection, it is supposed to be concerned in the production and conveyance of muscle-sense impressions.

THE TERMINATIONS OF THE MOTOR NERVES.

The motor nerves terminate both in voluntary and involuntary muscles. In the former the nerves are all medullated and have their origin in the cerebrospinal system, while in the latter they are non-medullated and belong to the sympathetic system. The motor nerves to the voluntary muscles terminate chiefly in special expansions which have received the various names of motor nerve plates or organs, motor sprays, or fields of inner-

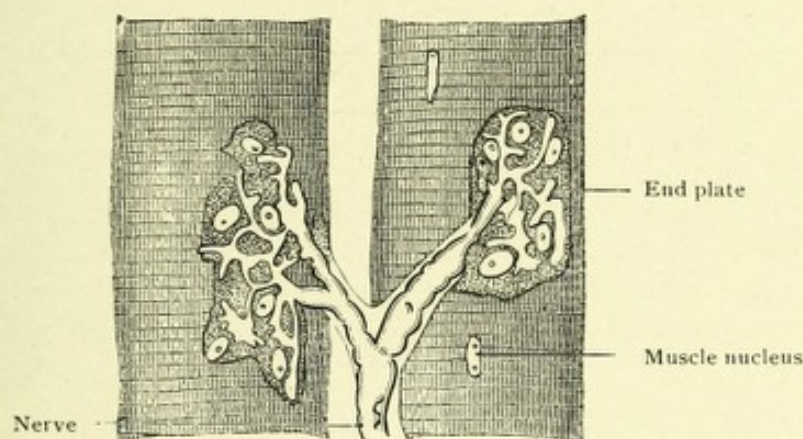


FIG. 26.—MUSCULAR-FIBERS WITH MOTORIAL END PLATES.—(*Landois and Stirling.*)

vations of Kuhne, or the eminences of Doyère. These end organs or plates are located beneath the sarcolemma of the primitive muscle-fibers, and are continuous with their sarcous substance. They are flattened or slightly elevated masses of granular protoplasm having an irregularly spheric or oblong shape, and contain cells with investing envelopes and clear oval nuclei and nucleoli.

In mammals each individual muscle-fiber usually has but one end organ and receives but one nerve-fiber. If the muscle-fiber be especially long, more than one nerve-fiber may enter it. In reptiles, however, two or more end organs are frequently found in a single muscle-fiber. Each motor nerve-fiber as it passes into the muscle repeatedly divides at the nodes of Ranvier

into a number of branches, the courses of which are both ascending and descending. These in turn give off a number of fine forked branchlets, each of which pursues mostly an oblique or transverse course between the muscle-fibers, forming an intramuscular nerve plexus. Each primitive nerve fibril still medullated passes to a muscle-fiber, having divided just before reaching it. As it enters the fiber it loses its myelin, and the neurilemma sheath becomes continuous with the sarcolemma of the muscle-fiber. The naked axis-cylinder then passes beneath the sarcolemma resting upon the motorial end plate, when it divides into two or three primary branches, which further subdivide into a

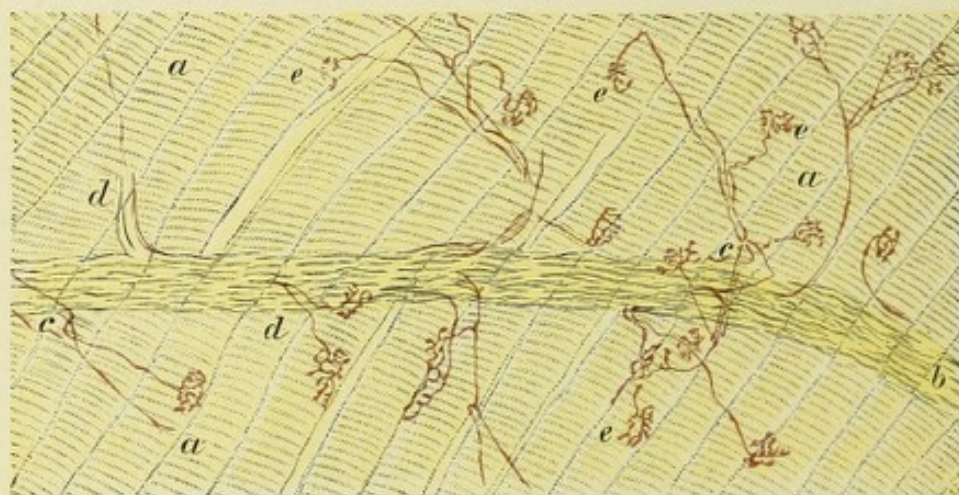


FIG. 27.—MOTOR TERMINATIONS IN A LIZARD, STAINED BY METHYLENE-BLUE.—(*Landois and Stirling.*)

a. Muscular fibers. *b.* A nerve trunk which splits up into small branches, *c*, containing a few medullated fibers, *d*. The medullated fibers, *d*, end in motorial end plates, *e*.

number of ultimate flat twigs expanding at their ends into minute bulbs. The nerve termination is then a distinct arborization, each branchlet retaining its individuality and not anastomosing, the whole figure resting upon the motorial end plate, which in turn is continuous with the sarcous element of the muscle-fiber. It is probable that the contractile wave of the muscle has its point of origin in the motorial end plate.

The motor nerves for the non-striated or involuntary muscles are non-medullated, and come mostly from the sympathetic system. Near their termini they ramify and form close networks or plexuses of fibers. In the angles formed by the cross-

ing of the fine fibrils composing these plexuses ganglion cells are found. From these ganglionic plexuses fibrillæ arise which pass between the muscle-fibers and continue parallel with them. They frequently bifurcate in their course, each division giving off small branches which terminate in varicose or bulbous extremities opposite the nuclei of the muscle-cells, without passing into them. According to Arnold and others, however, these terminal fibrillæ pass into the muscle-cells and end in their nuclei.

NEURONE OR NEURODENDRON.

The nervous system is known to consist of a great number of anatomic units variously arranged, which, after the development of their protoplasmic processes, remain absolutely independent bodies. These anatomic units have been designated neurones, or nerve units, by Waldeyer, and neurodendrons, or nerve trees, by Koelliker. They are the essential elements of nervous tissue and possess peculiar physiologic, chemic, psychic, and trophic properties.

The neurone, or nerve unit, is made up of three parts: the nerve-cell body, the protoplasmic processes of Deiter, or, as they are now called after His dendrites, with their terminal ramifications, and lastly, the so-called axis-cylinder process, axone, or neuraxone, with its collateral branches and terminal end brushes (telodendrons).

The neurones are arranged in certain localities in distinct groups—viz., in the cortex of the brain and cerebellum they exist in several thin layers; in the medulla oblongata or bulb and spinal cord they occur in vertical columns; in the central ganglia they are arranged in distinct masses. In many locations they occur singly or in slight groups.

The neurone, then, is a unit, an individual entity, consisting of cell-body, dendritic processes, neuraxone, collaterals, and terminal arborizations.

The cell-bodies, or neurocytes, present a variety of forms, the most generally distributed one being the irregular, large or small multipolar form. The form of cells have been sufficiently discussed, page 25.

The dendrites, or the protoplasmic processes which arise from the irregularities of the surface of the cell-body, branch in various directions, dividing and subdividing like the branches of a tree, not anastomosing with one another or with adjacent or distant dendritic processes of other cells. They are variable in length, some branches being quite long, whereas others are very short. Their thickness also varies, some of the short branches being rather thick, while the longer branches are quite thin. They frequently present along their course varicose-like swellings.*

They are variable as to number, some cells possessing but one or two dendrites, while others possess from five to seven. If the finer dendritic processes be observed with a moderately high power of the microscope, say with a $\frac{1}{4}$ or $\frac{1}{8}$ of an inch objective, there will be seen numerous minute protoplasmic buds jutting from their sides. They are somewhat club-shaped and are very minute in diameter, close to the parent stem, but become longer and larger to end in bead-like extremities. These lateral buds have been termed *gemmules*. They are very abundant on the dendritic branches of the cortical cells of the cerebrum or of the Purkinje cells of the cerebellar cortex. Owing to the fact that these lateral buds have until very recently been observed only in specimens stained after the method of Golgi, they have been considered by some authors as artifacts, but Ramon y Cajal has shown that they may be beautifully demonstrated in specimens stained by the intravital method of Ehrlich.

The function of the dendrites is not positively known, and much of our knowledge is as yet hypothetical. They probably convey nerve impulses to the cell-body from which they spring, influencing nerve terminations or filaments and other dendrites by contiguity of surface or possibly by contact through the *gemmules*. From the extent of surface occupied by the dendrites and their ramifications one would believe that they may serve a nutritional function, aiding the nutrition of the cells of which they are a part.

The belief of Golgi that they were connected with the blood-

* These tuber-like or varicose swellings that are seen on the dendrites of specimens prepared after the method of Golgi are due to local collections of chromophyllic granules (Lenthossek).

vessels, and that the nutritive plasma was carried by them to the cell-body has been disproven by various observers.

Lenhossek states that after carefully examining many Golgi sections he failed to find any connection between the dendrites and the blood-vessels. He further showed that they were developed long before the blood-vessels. He believes that they absorb nutritive plasma from all parts of their surface, the plasma coming from the lymph-spaces which surround the dendrites, which spaces exist in great abundance throughout the central nervous system. There is probably a much greater circulation and absorption of nutritive plasma in the gray than in the white matter, because of the abundant blood supply from the enormous number of capillaries and the liberal lymphatic distribution about the blood-vessels, nerve-cells, and processes in the former. Berkley states that in the cerebral cortex the dendrites are surrounded by a mass of nerve-fibers which give off at frequent intervals collaterals which divide and subdivide, ending in little bulbs, which constitute the intracortical end apparatus of these nerve-fibers. These little bulbar endings come into close approximation with the globular endings of the gemmules, and he states that it is exceedingly probable that the nervous impulses pass from cell to cell, or those impulses arising from the periphery and passing brainward, pass across from the bulbous endings of the nerve-fibers to the gemmules and through the dendrites to the cell-bodies, thus exciting the cells into activity. Berkley also states that in many diseased conditions—"intoxications"—these lateral buds are the first part of the neurone to become affected; and he believes that the early symptoms of dementia paralytica may be explained by their destruction and consequent loss of function as conductors of nervous impulses.

THE NEURAXONE OR AXONE.

The most important of the protoplasmic processes is the one which in most cases is destined to become, after receiving a covering of myelin, a medullated nerve-fiber. This process is the so-called axis-cylinder process, neuraxone, or simply axone. The neuraxones are smooth throughout, and are usu-

ally variable as to the length of their course, some having a short course, while the course of others is very long. They are of extreme fineness, and give off, at varying distances, side branches called collaterals (paraxonen). These collaterals may be seen issuing nearly at right angles from many of the nerve-fibers composing the columns of the spinal cord or the medulla. The collaterals frequently branch, and these in turn give off delicate branches, all of which end in fine brushes of fibers or arborizations about the dendrites of nerve-cells. The collaterals are usually finer than the neuraxones from which they issue, and often become medullated. The nerve-fibers, which are simply medullated axis-cylinders, frequently divide toward the end of their course into two or three branches, each one retaining its individuality.

Both the axis-cylinder process, or axone, and its collaterals (paraxonen) terminate or end about nerve-cells in brush-like expansions or tree-like arborizations, each little branchlet either ending free or in a minute bulbous expansion. These terminals are termed the telodendrons. As a rule, to which there are but few exceptions, the neurones throughout the cerebrospinal system possess but one neuraxone, the exceptions being found in the cells of the posterior spinal ganglia, which often possess two axones, one passing centrally, dividing T-shaped in the spinal cord, one division passing vertically upward, the other downward, each giving off at right angles numerous collaterals which enter the gray matter of the cord. The other, a peripheral axone, passes peripherally to terminate in a sensory end organ. The cells of the ganglia connected with the sensory cranial nerves have somewhat similar connections, possessing two axones, one central and one peripheral.

The Cajal cells in the outer or molecular layer of the cerebral cortex are known to possess two or more axones. They form a distinct type of neurone (Fig. 29).

Some of the cells of the visceral sympathetic ganglia have many axones or axis-cylinder processes.

Neurones may be classified into three chief types: (1) Those whose axones are very long, giving off collaterals, but retaining their individuality. They pass directly into the white matter

and become medullated nerve-fibers, ending in near or distant parts of the nervous system, or in peripheral end organs. Because the cells of the anterior horns of the spinal cord, whose functions are known to be motor, all possess so long a neuraxone Golgi termed this first type of neurone "motor." We know positively, however, that long axones are possessed not only by motor neurones, but by sensory ones as well—as, for example, the neurones of the multipolar cells of the ves-

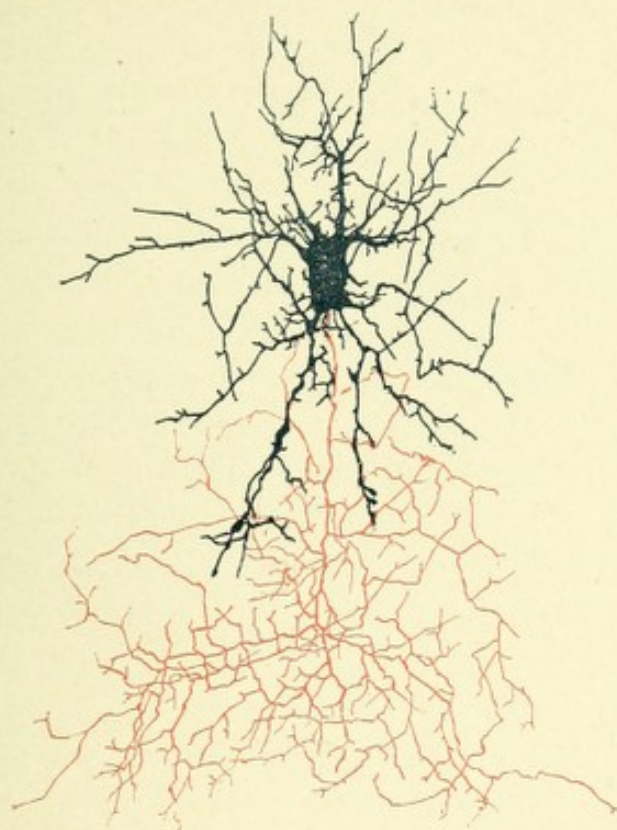

FIG. 28.—A LARGE CELL OF THE SECOND TYPE OF GOLGI FROM THE GRANULAR LAYER OF THE CEREBELLUM.—(After Koelliker.)

icular column of Clarke, which pass across through the white matter of the cord and become vertical in the direct cerebellar tract, thence passing upward to terminate in the cerebellum. Another example of long axones may be mentioned, the ascending branches of the posterior nerve-roots, many of which continue throughout the whole length of the posterior columns and terminate in the medulla about the cells of the nuclei of the posterior columns.

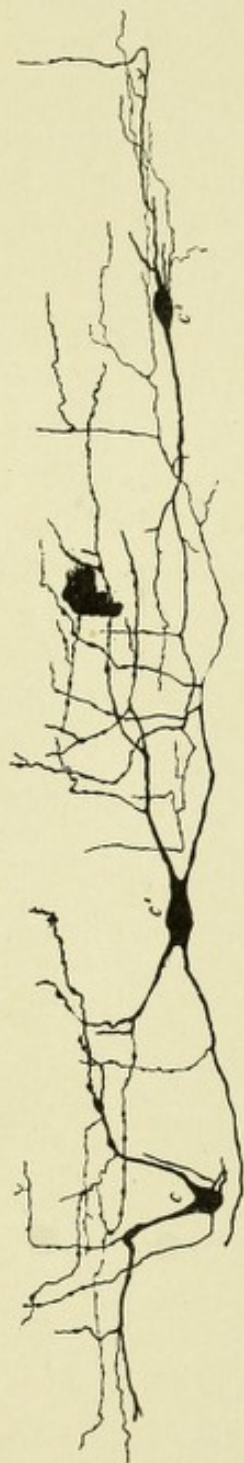


FIG. 29.—THREE CAJAL CELLS FROM THE CORTEX OF THE GYRUS FORNICATUS OF A DOG.—(After Koelliker.)

In the neurones of the second type, or second type of Golgi, the neuraxones, after a short course, break up into innumerable fine filaments which form networks, thus losing their individuality. Because of their abundance in the gray matter adjacent to the posterior horns, which is presumably sensory in function, Golgi concluded that this type of neurones was also sensory in character. It may be stated here that the axones of this second type of neurone rarely, if ever, leave the gray matter, and their function is that of association. Cajal denies their sensory character and states that cells with short axones are distributed throughout the central nervous system (Fig. 28).

The third type of neurones are those which have been recently described by Ramon y' Cajal, and hence are often called the Cajal cells. They have only been found in the molecular or outer layer of the cortex. They consist of small cells, which are variable as to shape, the spindle shape being the type. The axones from these cells have a horizontal course and are constantly giving off ascending collaterals which terminate in the outermost part of the molecular layer in minute bulbous expansions (Fig. 29).

Neurones are also divided according to their functions into three general classes: motor, sensory, and associative.

THE NEUROGLIA.

This is the name applied to the tissue which forms the supporting framework of the central nervous system. So closely does it resemble connective tissue in appearance

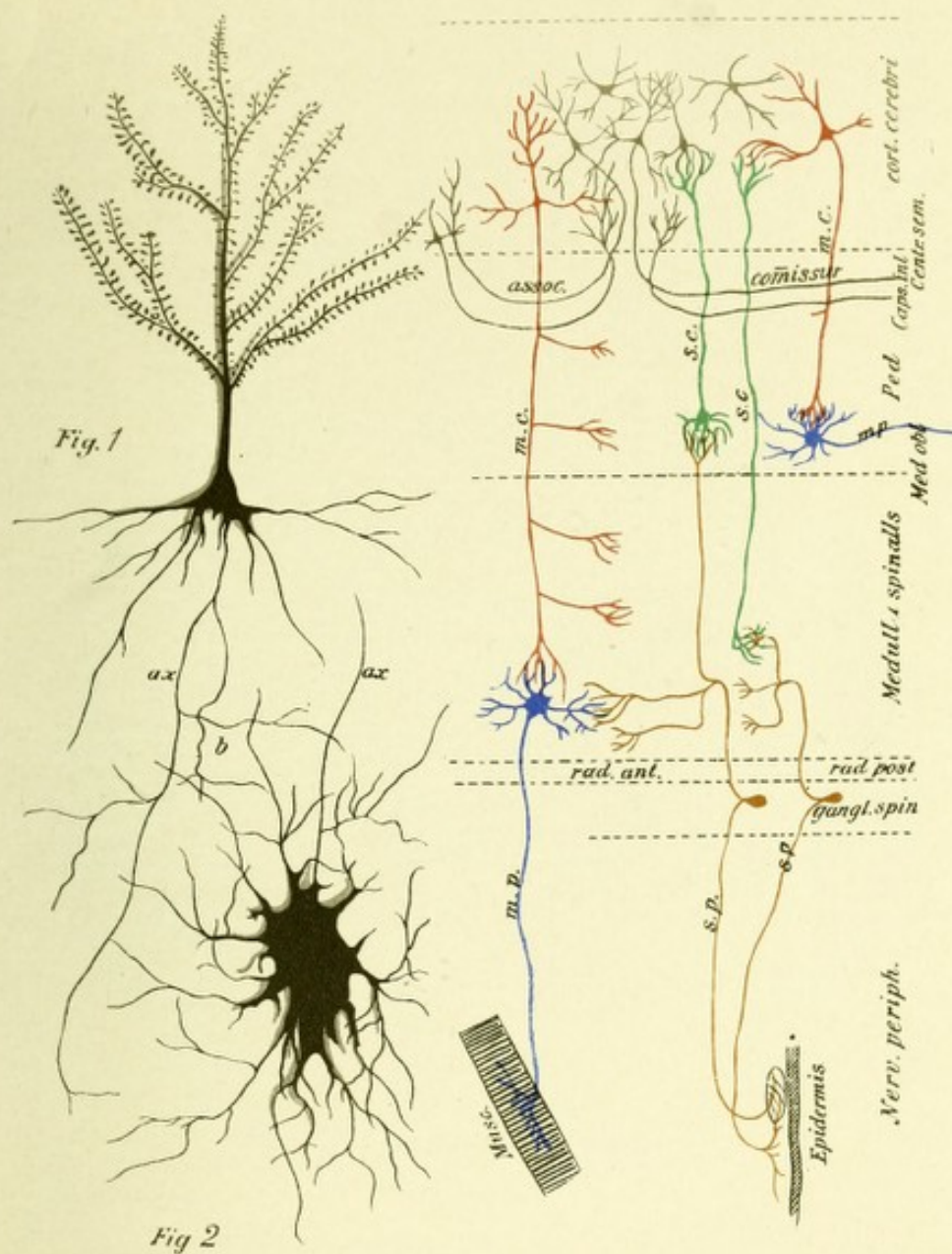



Fig 3

FIG. 30.—MOTOR AND SENSORY NEURONES.—(*Jacob's Atlas.*)

- Fig. 1.—A large motor or pyramidal cell from the cortex of the cerebrum, with its apical tree-like branching protoplasmic processes or dendrites possessing numerous lateral buds or gemmules. This cell possesses a single long slender basal process, *ax*, or axone (axis-cylinder process), which gives off at right angles collateral branches, *b*. This cell with its processes forms a central motor neurone.
- Fig. 2.—Represents a single motor or ganglionic cell from an anterior horn of the spinal cord, with its numerous dendrites and a single axone, *ax*, which axone terminates in a motor end plate, the whole forming a peripheral motor neurone.
- Fig. 3.—Indicates schematically the relationship between the cortical and peripheral motor neurones and between the peripheral and central sensory neurones.



and function that, until within a recent period, it was considered by most anatomists identical to that tissue. Virchow, however, as far back as 1846, discovered its true nature from the histologic study of sections of the brain beneath the ependyma of the ventricles. He discovered a structureless membrane which he believed differed from true nerve-cells and fibers and was perfectly satisfied that this tissue, which in 1853

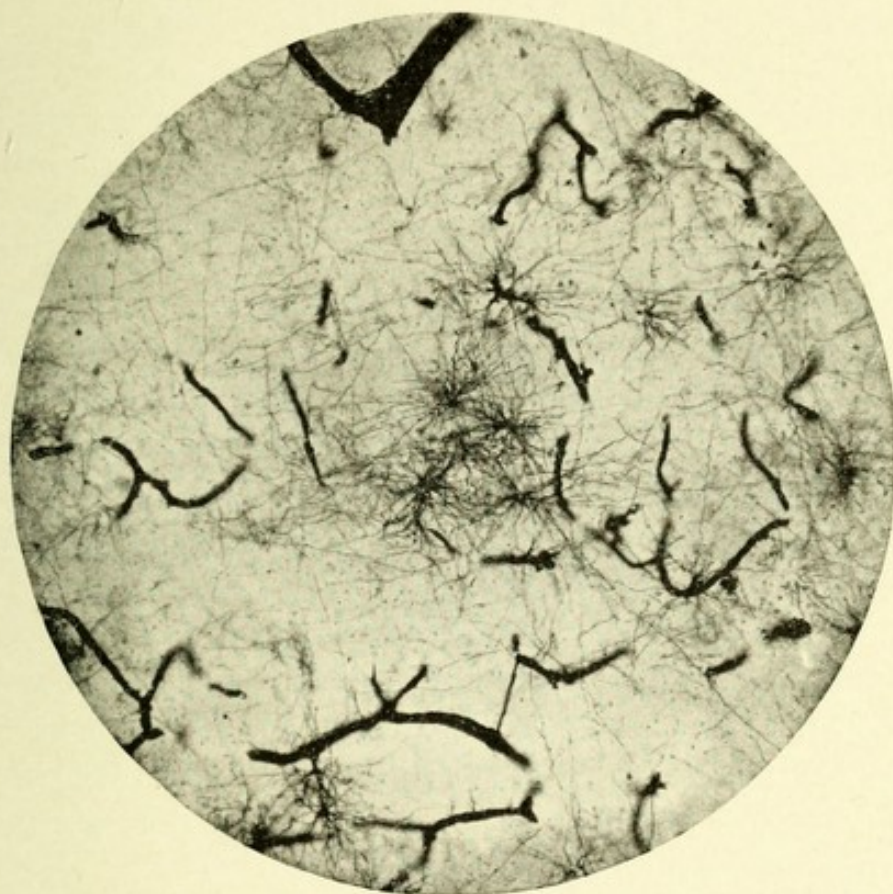


FIG. 31.—MICROPHOTOGRAPH OF NEUROGLIA CELLS. Showing the relation they bear to the capillary blood-vessels. Stained after the Cox-Golgi method.

he named neuroglia, differed decidedly from connective tissue. He also observed that neuroglia tissue did not occur in the peripheral nerves, and that the blood-vessels of the nervous system were surrounded by it. Owing to the embryologic researches of His and the histologic studies of Golgi, Ramon y'-Cajal, Beneke, Weigert, and Mallory, and the publication by the last two authors of their selective methods of staining, we are enabled to understand more accurately than ever before the

origin and histologic structure of neuroglia tissue. This tissue, which is epiblastic in origin, is composed of cells and their processes, which cells bear the various names of spider cells of Deiter, glia cells, neuroglia cells, and stellate cells or astrocytes. They are of two chief forms—large and small spheric. The cell-body is somewhat irregular in outline, is composed of protoplasm and contains a nucleus large in size and spheric in shape. These cells vary from six to thirteen μ in diameter. The large spheric cells contain granular chromatin, while the chromatin in the small spheric cells appears as a dark homogeneous mass. By another classification the cells are divided according as their processes are long or short. In the former—*i. e.*, those having long processes—delicate filaments are given off in a radiating manner from all parts of the cell-body; these processes are very fine, of uniform thickness, and occasionally bifurcate near their extremities, usually, however, remaining entire to their ends. They do not anastomose with each other, have no varicosities, and are solid and smooth throughout. A few of these cells have brush-like processes springing from one or both ends. The neuroglia cells with long processes exist mostly in the white matter.

In the cells of the second form, those with short processes, the filaments are not so long, are more irregular, and somewhat thicker than are those of the first form. These cells are found with but few exceptions in the gray matter, and resemble very closely some of the small forms of multipolar nerve-cells, from which they are with difficulty differentiated. The fibers vary in size from those of extreme fineness to those of fifteen μ in thickness. The latter fibers are only found where pathologic changes produce complete or incomplete destruction of nervous tissue, when they are in reality hypertrophied.

It is a remarkable fact that when degeneration changes occur in the central nervous system, the place of the destroyed tissue becomes in large part occupied by an increase of neuroglia tissue. It should be remembered that while neuroglia tissue resembles very closely connective tissue in function, it differs decidedly from it in development, the former being epiblastic while the latter is mesoblastic in origin.

In discussing the question as to the relation of the processes to the neuroglia cells, Weigert states that while in embryonic life they are parts of the cell, later the processes are lost to the cell-bodies, and the latter exist free in the network of neuroglia fibers. He bases his conclusions on the facts that the fibers are no longer of the same chemic composition as the protoplasm of the cell-bodies, and that the fibers react to his recent differential stain unlike protoplasm. He also believes that the

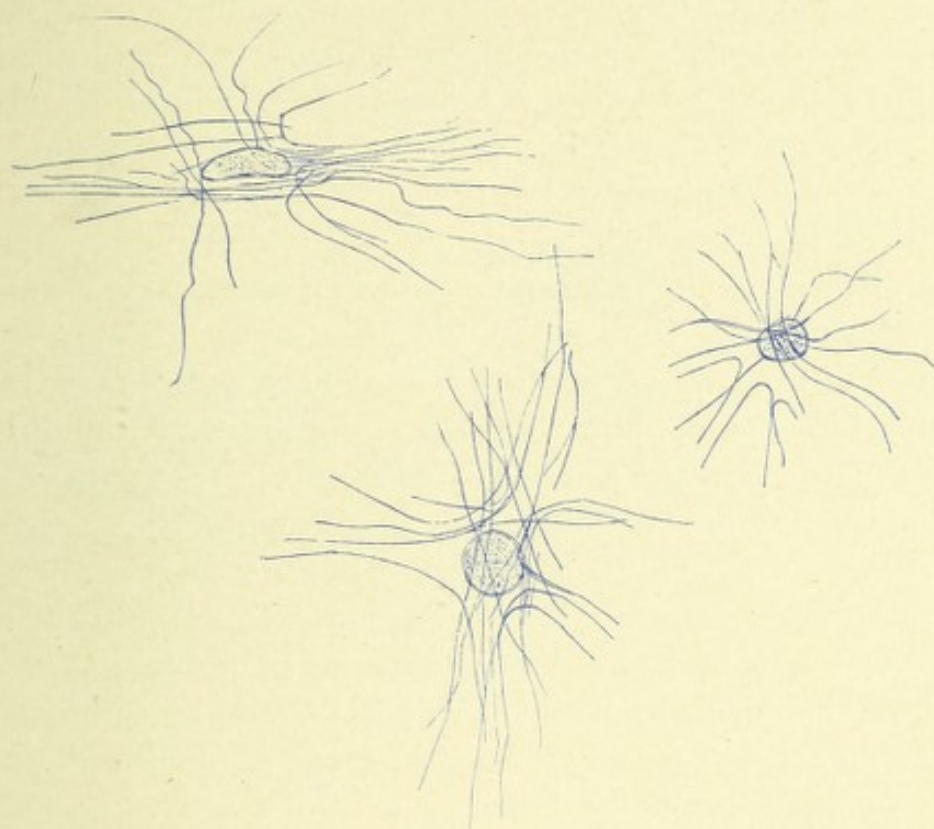


FIG. 32.—THREE NEUROGLIA CELLS (ASTROCYTES). Showing the relation the neuroglia processes bear to the cell-body.—(After Weigert.)

neuroglia cells and fibers, while epiblastic in development, differ decidedly from the true nervous tissue, his reasons being that neuroglia tissue proliferates when the nervous system becomes diseased, and that with his new neuroglia stain, true nervous tissue remains unstained, while neuroglia tissue stains blue. In gliomatous tumors, which are made up almost entirely of neuroglia fibers and cells, it is quite common to find in certain parts of the growth neuroglia cells with processes lying in

a meshwork of differentiated fibers, while in other localities neuroglia cells, with processes radiating from all surfaces of the cell-body, or else coming from either pole, may be observed.

BLOOD-VESSELS AND LYMPHATICS.

The blood-vessels of the central nervous system differ somewhat from those in the other parts of the body; it will therefore be necessary to give a brief description of them here.

The arteries of the brain and cord, like similar vessels elsewhere in the body, possess three distinct coats, but the inner coat is subdivided so that the larger arteries may be said to possess four coats—viz., an outer coat, or tunica adventitia; a middle or muscular coat, the tunica media; and an inner coat, the tunica intima, which is further subdivided into two layers, an outer or elastic lamina, the membrana fenestra, and an inner or endothelial layer.

The Tunica Adventitia.—The tunica adventitia of the larger arteries is composed of connective tissue continuous with the pia mater. In the smaller arteries this adventitial coat consists of a delicate membranous investment, lightly striated, containing connective-tissue cells, stellate or fusiform in shape, and possessing round or oval-shaped nuclei. This coat is frequently pigmented and often contains fat granules. While this outer coat is loosely applied to the middle coat, or tunica media, there exists between them a distinct space filled with lymph, which presents ampullar dilatations in the angles formed by the branching of vessels. This space is termed the adventitial lymph-space, or Virchow-Robin space. If sections of hardened brain-tissue are examined microscopically, distinct spaces will be found outside of the adventitial coat, which are so much larger than the diameter of the vessels that they form distinct channels in which the vessels rest; these are the perivascular lymph canals or spaces of His. They possess no endothelial lining. These channels communicate with the epicerebral space located between the outer surface of the cortex and the pia mater.

All the vessels of the central nervous system have a strong

protective coat of neuroglia tissue, which may have the function of preventing injury to the brain tissue from too great arterial pressure.

Tunica Media.—The tunica media consists of smooth, non-striated muscle-fibers arranged transversely to the long axis of the vessel, thus placing the spindle muscle-cells at right angles to the vessel wall, the muscle nuclei and those of the endothe-

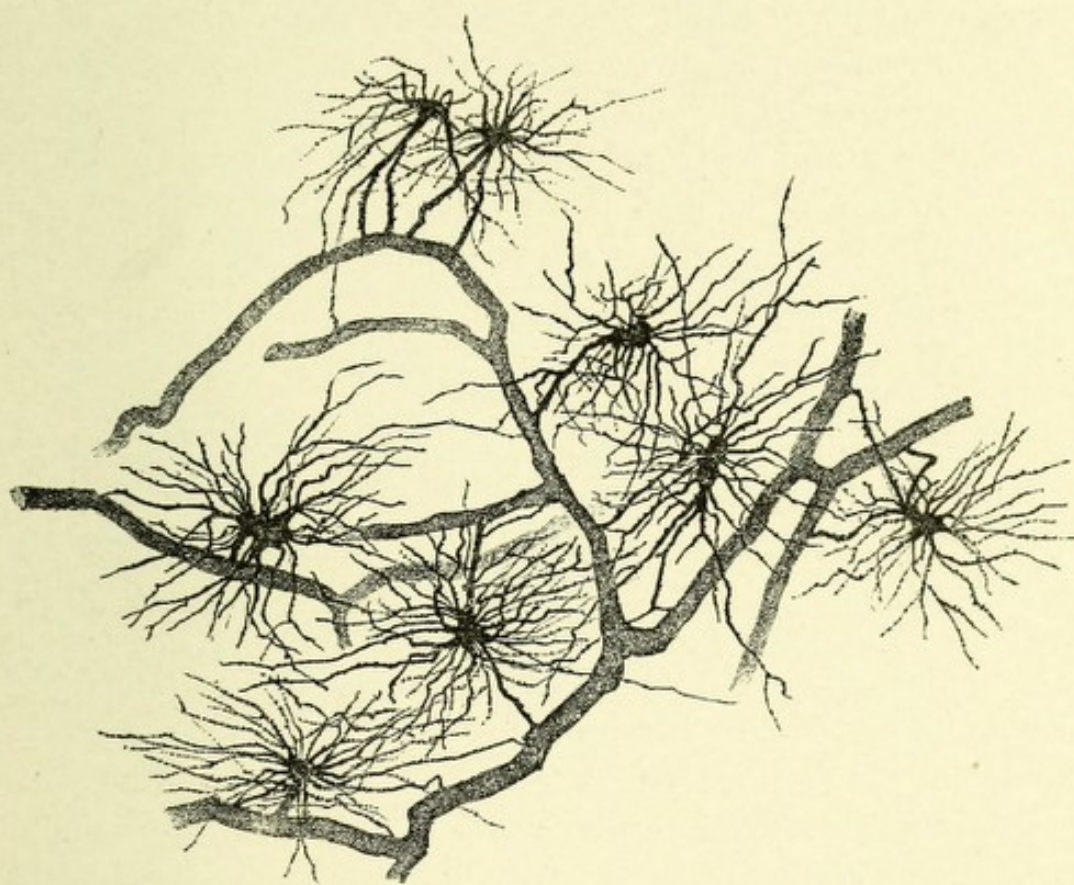


FIG. 33.—NEUROGLIA CELLS FROM THE CEREBRAL CORTEX OF A DOG'S BRAIN. Showing their connection with blood-vessels.—(After Koelliker.)

lium of the inner coat appearing to cross one another. In the small cerebral vessels this tunic differs from vessels of a corresponding size among the systemic arteries in that it contains a single layer of circularly arranged muscle-fibers.

Tunica Intima.—The tunica intima consists of an inner or endothelial layer, which is merely a tube of squamous endothelial cells united at their margins by cementine and possessing oval nuclei, which are arranged longitudinally, having

their longest diameter in the direction of the vessel's length. The outer or elastic layer is a delicate elastic membrane which, for the smaller arteries, has no definite structure. It gives to the larger arteries an appearance of longitudinal striation. The presence of this layer in the smaller arteries is doubted by many histologists.

VEINS.

The veins have three coats similar to those of the arteries. The tunica media, however, differs from that of the arteries in that it consists wholly of connective tissue, being devoid of muscle-fibers, and is, in the smaller vessels, destitute of elastic fibers. In consequence of these changes in the media the caliber of the veins is larger, the vessel wall thinner and more lax. They contain no valves.

CAPILLARIES.

The capillaries of the cerebrospinal system are exceedingly minute, some of them being smaller than the average diameter of a red blood-corpuscle. They vary from four to eight μ in diameter (about $\frac{1}{6000}$ of an inch). It is possible that various hardening reagents narrow the diameter of the capillaries, and that in the living state they are not so small, their lumen permitting the passage of the red cells. It is, however, perfectly possible for the red corpuscles, owing to their elasticity, to circulate through capillaries whose diameter is less than the diameter of the corpuscles. The capillaries may be distinguished microscopically by the disappearance of the muscular coat and the continuation of a vessel as a simple tube consisting only of an endothelial lining and having a slight adventitial sheath. The former is a continuation of the endothelium of the smaller arteries, and consists of elongated fusiform cells, which stain beautifully with silver nitrate, with oval nuclei; the nuclei are well stained with a saturated solution of methylene-blue. The slight adventitial layer is the remains of the tunica adventitia of the larger vessels, and its presence is indicated by a few round or oval nuclei, with a few nucleated connective-tissue cells arranged in a longitudinal manner outside of the endothelial layer.

LYMPHATICS.

The lymphatics of the central nervous system are confined to certain spaces about the blood-vessels and nerve-cells and to channels which appear as if tunneled out of the nervous substance. True lymphatic vessels or lymph-glands have never been discovered within the cranial cavity or in the spinal canal.

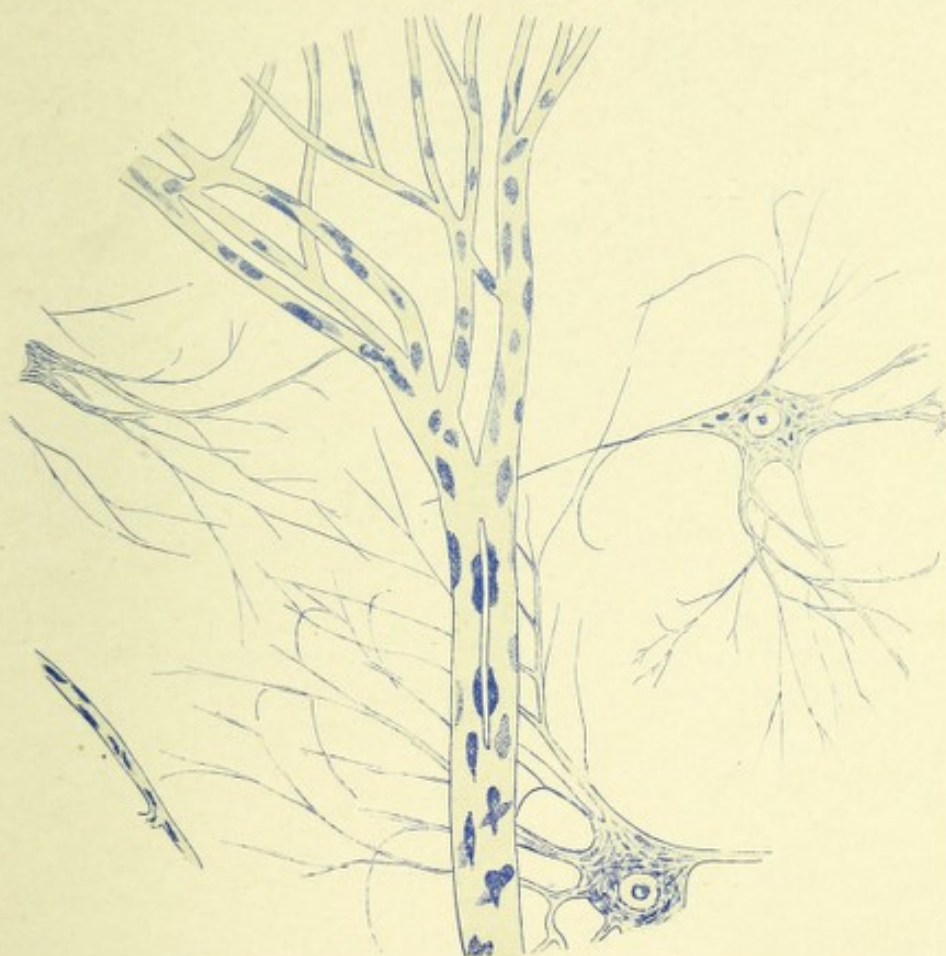

FIG. 34.—A CAPILLARY BLOOD-VESSEL FROM THE GRAY MATTER OF THE SPINAL CORD OF AN OX. Stained with methylene-blue and magnified 400 diameters.

The lymph-spaces, which are very abundant throughout the nervous system, communicate at the surface of the brain and cord with the subarachnoid space. This latter space in the brain communicates, according to Key and Retzius, with the venous sinuses by means of the Pacchionian bodies, which bodies may be considered as outlets for the subarachnoid (cerebrospinal) fluid. The

spinal and cranial nerves, as they pass out through their respective foramina, receive prolongations in the form of tubular sheaths from the dura, pia, and arachnoid membranes. The spaces between these sheaths are lymphatic in nature and communicate with the subdural and subarachnoid spaces. These perineural spaces are considered by many observers as outlets for the sub-

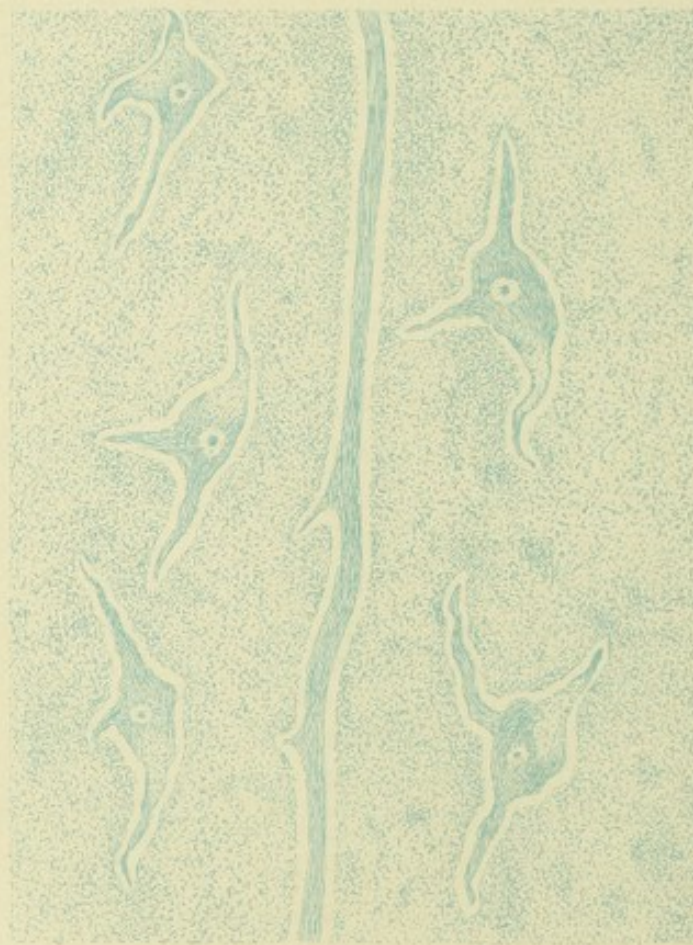

FIG. 35.—A CAMERA LUCIDA DRAWING OF A PART OF THE GRAY MATTER OF THE ANTERIOR HORN. Showing pericellular and perivascular lymph channels.

arachnoid fluid. This seems proven for the optic nerve and for some of the spinal nerves. The sheaths that surround the optic nerve remain distinct from one another, so that the perineural spaces may be injected through the subdural and subarachnoid cavities. William Browning has proven that the perineural spaces about the lumbar and sacral nerves may be injected through the subarachnoid cavity in lower animals at all

ages, but in man only during fetal life, as the spaces become obliterated shortly after birth. Hence these spaces may be considered as outlets for the subarachnoid fluid in the lower animals, but in the human body only during the intra-uterine life.

THE ADVENTITIAL LYMPH-SPACE.

In describing the histology of the blood-vessels of the nervous system mention was made of a space which exists between the tunica media and tunica adventitia; this space is very narrow, save in the angle formed by the branching of the vessel where it presents ampullar dilatations. These spaces are continued around the smaller arteries and capillaries throughout the central nervous system. Those of the brain pass out of the cranial cavity with the carotid and vertebral arteries and terminate in the deep cervical glands.

In addition to the adventitial lymph-spaces, small channels exist in which the small blood-vessels and capillaries rest; they appear as if tunneled out of the nervous tissue, and are called the perivascular lymph-canals of His. They do not possess a lining membrane; the adventitial sheath of the blood-vessel, however, is closely applied to the walls of the canal. In the walls of these channels exists a matrix of neuroglia, processes of which pass across each space and become connected with the adventitial sheath of the contained vessel. Whether these neuroglia processes aid in the absorption of lymph is as yet unknown.

PERICELLULAR LYMPH-SPACES.

Surrounding the nerve-cells of the cerebrospinal nervous system exist numerous oval, round, or polygonal-shaped spaces, which in hardened specimens at least are much greater in diameter than are the nerve-cells which rest within them. These pericellular spaces are continuous with the adventitial lymph-spaces into which they drain.

CHAPTER II.

SPINAL CORD.

The spinal cord, or medulla spinalis, is located in the vertebral canal, and is enveloped by three membranes—viz., the outer, or dura mater; the middle, or arachnoidean membrane; and the inner, or pia mater. These membranes protect the cord and give support to its nutrient vessels. The dura (so called from the Latin *durus*, hard) is a strong fibrous membrane continuous with the dura of the brain. It surrounds the cord and the plexus of nerves called the cauda equina in a loose, sac-like manner, and is separated from the bony canal of the vertebræ by loose areolar tissue and by a plexus of veins—the vertebral plexus. This space between the bone and the dura is called the epidural space. The dura is attached above to the circumference of the foramen magnum, and below to the third sacral vertebra, from which it extends as a fibrous cord to the periosteum of the coccyx. Double openings exist opposite the intervertebral foramina for the transmission of the spinal nerves; processes of this membrane surrounding these nerves at their exit forming tubular sheaths. The dura of the cord differs from that of the brain in several respects—*i. e.*, it does not form the periosteum of the vertebral canal; it sends no processes into the median fissures of the cord; nor does it separate into lamina for the formation of venous sinuses. The dura consists of dense bundles of connective tissue intermingled with elastic fibers; in the spaces between the fibers exist flattened connective-tissue corpuscles. The inner surface of the dura is lined with endothelium, and is abundantly supplied with nerves and blood-vessels. The small connective-tissue spaces serve for the lymph supply to the membrane.

The spinal arachnoid, from the Greek *ἀράχνη*, spider's web, is a loose, delicate membrane, seen on removing the dura. It is connected with the membrane beneath, the pia, by many delicate connective-tissue bands lined with endothelium, and separated by a congeries of spaces differing in size. These spaces are filled with cerebrospinal fluid, and together receive the name of the subarachnoid space. The arachnoid is devoid of nerves and has a very slight blood supply. It consists of very delicate connective-tissue fibers, which interlace with one another and are lined with delicate pavement epithelium.

It is rather loosely attached to the under surface of the dura mater, there existing between the two membranes a space called the subdural space, though in some situations the attachment is so close that no such space exists.

A space above referred to of much greater size exists beneath this membrane, between it and the pia mater, called the subarachnoid space. This space is divided on each side by a fibrous septum, the ligamentum denticulatum, into an anterior and a posterior subarachnoid space, continuous with the corresponding subarachnoid spaces of the brain and communicating with the general ventricular cavities of the brain by means of several small openings in the pia mater of the medulla oblongata. These subarachnoidal spaces contain an abundant serous secretion, the cerebrospinal fluid, and may be regarded as lymphatic reservoirs.

The pia mater (from the Latin *pia*, tender, *mater*, mother) closely invests the cord, forming its connective-tissue sheath or neurilemma. So closely adherent is it to the cord that it can not ordinarily be removed without lacerating the cord. It gives off tubular prolongations upon the spinal nerves. The pia at the lower end of the cord becomes contracted, and enters into the formation of the filum terminale and blends with the dura mater at the third sacral vertebra. The pia consists of an outer and an inner layer, the outer layer supporting the blood-vessels, the inner layer being much less vascular and composed of circularly arranged connective-tissue fibers. The ventral septum, a process of pia mater, passes into the anterior median fissure conveying blood-vessels to the cord.

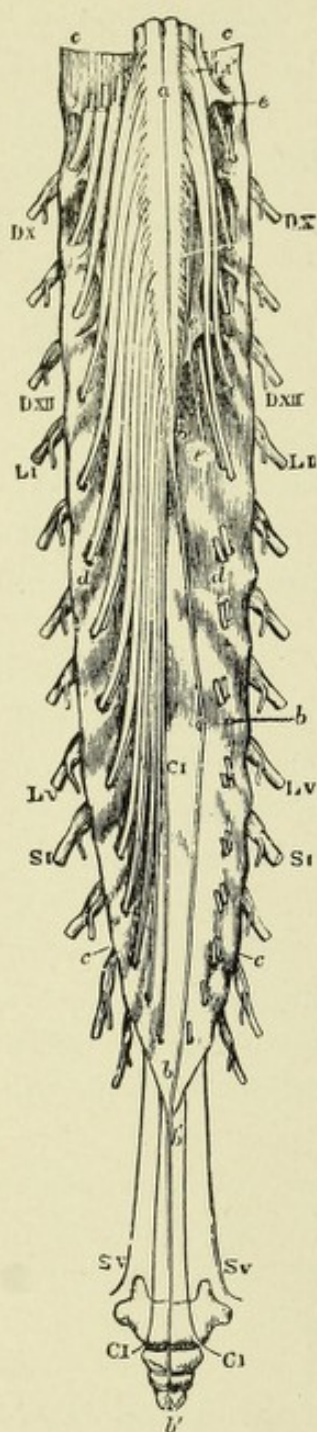


FIG. 36.

The ligamentum denticulatum, or dentate ligament, is a fibrous band located on each side of the spinal cord and separating the anterior from the posterior roots of the spinal nerves. It also serves to separate the general subarachnoid cavity into two compartments, anterior and posterior. It is composed of triangular dentations, twenty or more in number, whose inner broader portions are connected with the pia, the outer being connected with dura mater (Fig. 37); below it becomes continuous with the filum terminale. Its function is to support the cord in the fluid in which it lies.

The spinal cord, located in the vertebral canal and surrounded by its membranes, extends from the upper border of the atlas to the body of the first or second lumbar vertebra. It varies in length from sixteen to eighteen inches, about forty-five centimeters. Its weight is about fifty grams— $1\frac{1}{2}$ ounces. Above, it is continuous with

FIG. 36.—VIEW FROM BEHIND OF THE LOWER END OF THE SPINAL CORD WITH THE CAUDA EQUINA AND DURAL SHEATH.—(Allen Thomson.)

The sheath has been opened from behind and stretched toward the sides; on the left side all the roots of the nerves are entire; on the right side both roots of the first and second lumbar nerves are entire, while the rest have been divided close to the place of their passage through the sheath. The bones of the coccyx are sketched in their natural relative position to show the place of the filum terminale and the lowest nerves.

a. Placed on the posterior median fissure at the middle of the lumbar enlargement of the cord. *b, b.* The terminal filament, drawn slightly aside by a hook at its middle, and descending within the dural sheath. *b', b'.* Its prolongation beyond the sheath and upon the back of the coccygeal bones. *c.* The dural sheath. *d.* Double foramina in this for the separate passage for the ventral and dorsal (anterior and posterior) roots of each of the nerves. *e.* Ligamentum denticulatum. DX and DXII. The tenth and twelfth thoracic (dorsal) nerves. L1 and L5. The first and fifth lumbar nerves. S1 and S5. The first and fifth sacral nerves. C1. The coccygeal nerve.

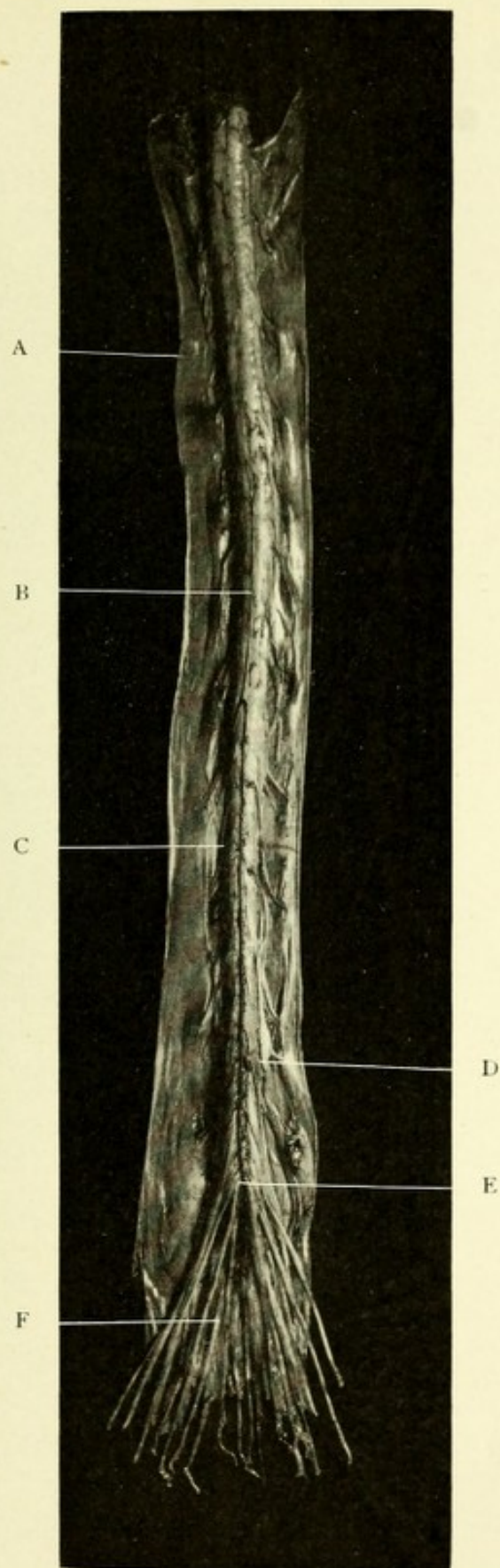


FIG. 37.—PHOTOGRAPH OF HUMAN SPINAL CORD.

A. Dura mater. B. Anterior spinal artery. C. Arachnoid. D. Ligamentum denticulatum.
E. Filum terminale. F. Cauda equina.



the medulla oblongata, or bulb, which is an enlarged upward extension of it, and below it terminates in a very slender process, the *filum terminale* or central ligament of the cord. The *filum terminale* at its upper part contains a few spheric cells which lie near the central canal. These pale nucleated cells are from 11 to 13 μ in diameter. In addition, one may observe the processes from the cells which encircle the central canal, the so-called *ependymal cells*. Surrounding the *filum terminale* is a leash of nerves made up of the descending lumbar and sacral nerves, called, from its resemblance to a horse's tail, the *cauda equina*.

An enlarged central canal extends through about half of the extent of the *filum terminale*; below, the latter terminates in a slender thread-like process of *pia mater* containing the end of the anterior spinal artery and vein; this process perforates the *dura mater*, which lends to it a sheath and becomes blended with the periosteum of the sacral canal or the back of the coccyx.

The spinal cord is cylindric, somewhat flattened on its anterior and posterior surfaces, rounded from side to side. It presents two enlargements: the cervical or brachial enlargement, the larger one, extending from the third cervical to the first or second dorsal vertebra, and the lumbar enlargement, extending from the spinous processes of the ninth or tenth dorsal to the first lumbar vertebra. That portion of the cord between the two enlargements is known as the dorsal cord; it gives origin to the intercostal nerves. These enlargements of the cord are due to the fact that at these points the nerves of the extremities—in the cervical region those of the upper limbs, in the lumbar region those of the lower limbs—unite with the cord. Below the lumbar enlargement the cord tapers in the form of a cone,—the *conus medullaris*,—the apex of which gives off the slender filament, the *filum terminale*. The embryonic cord completely fills the vertebral canal, but after the third month, because of the more rapid growth of the vertebral canal and of the sacral and lumbar nerves, the cord appears to recede from below, reaching only to the first or second lumbar vertebra. The cord may be considered as being made up of a number of segments superimposed one upon the other, each segment corresponding to the entrance and exit of a pair of spinal nerves. Thus, we speak of



cervical, dorsal, lumbar, or sacral segments. The different segments of which the cord consists are continuous with one another, there being no lines of division or constrictions to indicate their separation.* The nerve-roots leave the segments

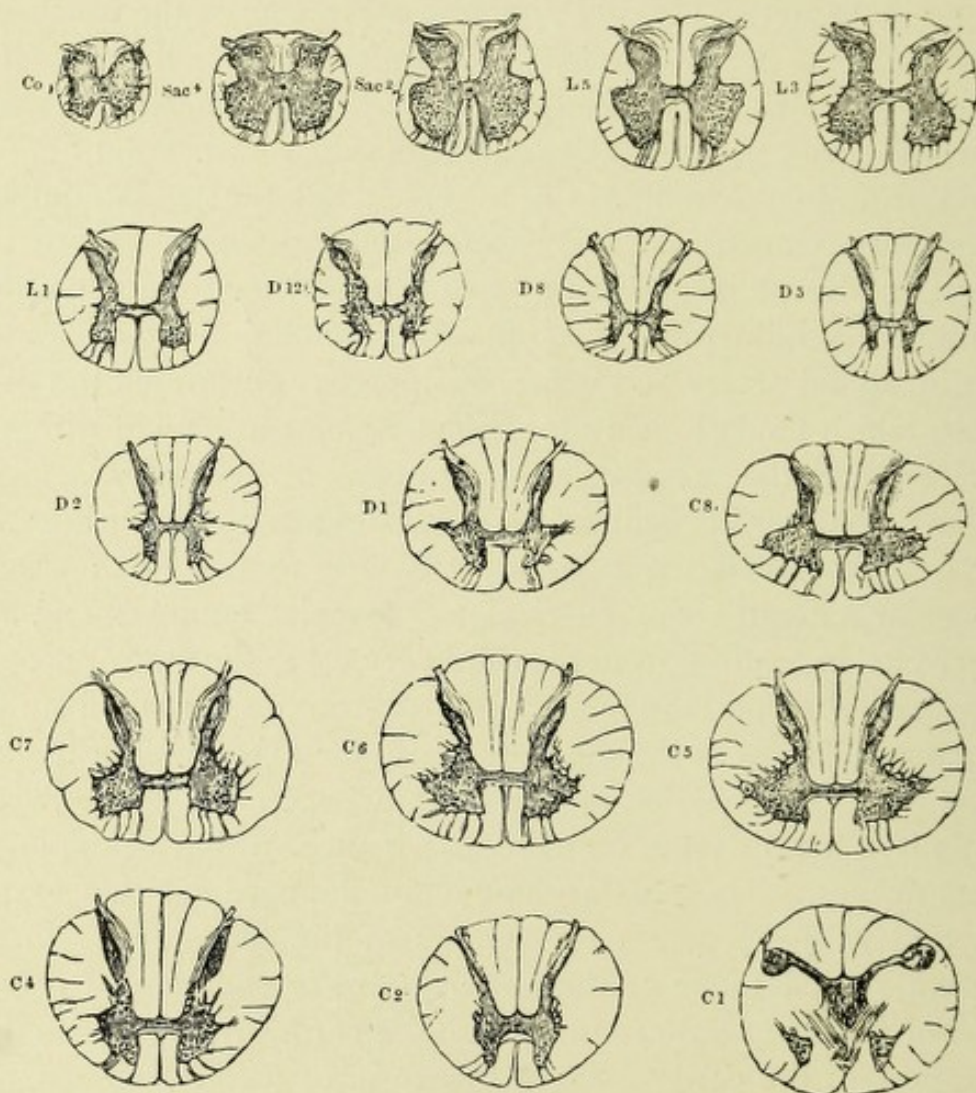


FIG. 38.—DIAGRAM SHOWING THE RELATIVE SIZE AND FORM OF DIFFERENT SEGMENTS OF THE COCCYGEAL, SACRAL, LUMBAR, DORSAL, AND CERVICAL CORD.—(After Gowers.)

in a horizontal direction ; they consist of an anterior pair, which are motor in function, and of a posterior pair, which are sensory. On the posterior nerve-roots of both sides may be observed a

* The transition of the spinal cord into the medulla is a very gradual one, there being no sharp line of demarcation. The anatomic division line which is usually accepted is the exit of the first cervical nerve, which passes out between the occipital bone and atlas.

small oval ganglion—the posterior spinal ganglion. Although the nerve-roots emerge from the cord in a horizontal direction, they soon become oblique, and gradually almost vertical, in their direction.

The cord, on tranverse section, is nearly circular, slightly flattened from before backward, and varies in size and shape according to the region from which the section is made. It is largest in the cervical and lumbar regions and smallest in the dorsal and sacral regions. It consists of two distinct parts: an

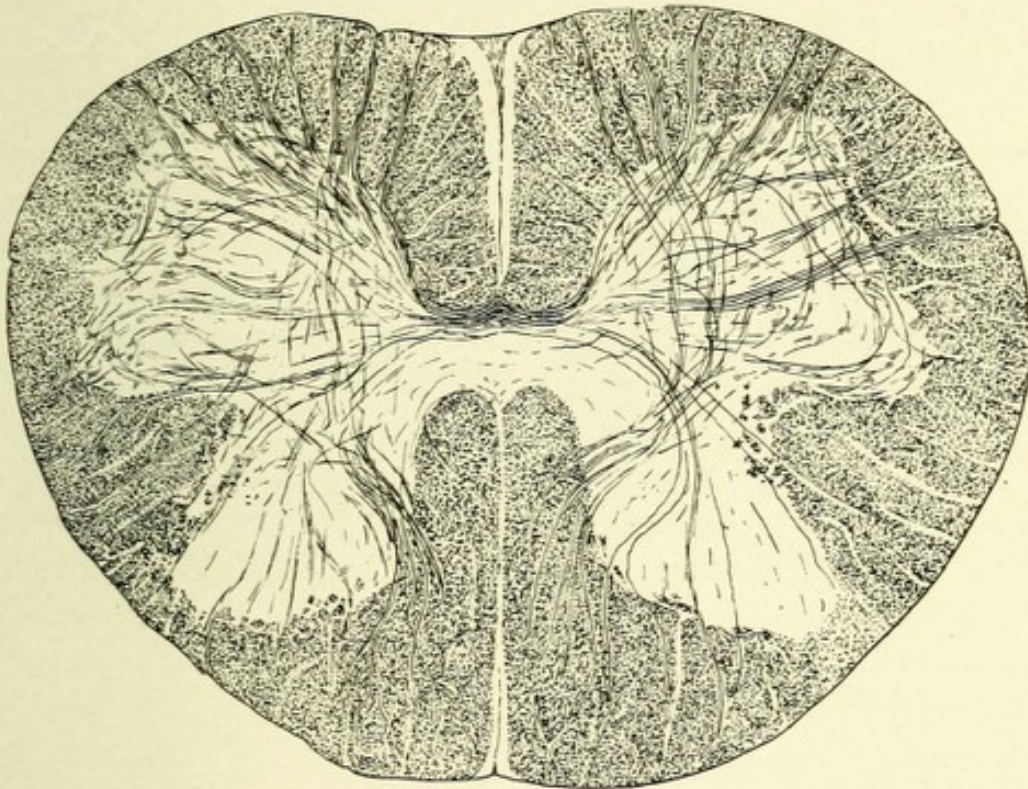


FIG. 39.—A TRANSVERSE SECTION OF THE HUMAN SPINAL CORD THROUGH THE MID-LUMBAR REGION TO SHOW ITS GENERAL TOPOGRAPHY. Weigert's stain.

inner part, or gray matter, shaped somewhat like the letter H, consisting of symmetric halves united by two bands of nervous matter, the commissures; and an outer part of white matter, which almost completely surrounds the gray. The white matter is incompletely divided into halves by an anterior longitudinal, or ventral, and a posterior longitudinal, or dorsal, fissure. The ventral one is shorter and much broader than the dorsal, and has extending centrally into it a process of pia mater, the ventral septum, which conducts blood-vessels to the cord. This anterior

fissure extends backward, and has for its posterior boundary the anterior or white commissure. The posterior or dorsal fissure is a mere landmark, there being no actual fissure present, this landmark being occupied not by a process of pia mater, but by a process of neuroglia tissue carrying with it blood-vessels. Each half of the cord is further subdivided by a posterolateral groove, made by the entrance of the posterior nerve-roots, and by an anterolateral slit, due to the outward passage of the anterior nerve-roots. Between the posterolateral groove and the posterior fissure, in the cervical region, exists a slight fissure, called the postero-intermediate fissure.

The gray matter consists of a spongy and a gelatinous portion. The former includes the anterior and posterior horns, and consists of a network of nerve-fibers and neuroglia tissue, among which exists a large number of nerve-cells; the latter surrounds the heads of the posterior horns and forms a layer around the central canal. The gray matter is completely surrounded by the white matter, save at the apex of the posterior horns. It is divided into three somewhat irregular extensions, or cornua,—anterior, lateral, and posterior,—and an intermediate portion, or body. The anterior extensions or horns form the larger part of the gray matter; in general they are shorter, much broader, and more irregular than are the posterior horns, and do not reach the ventral periphery of the cord. They contain, particularly in the cervical and lumbar regions, large collections of multipolar nerve-cells, variously grouped. The lateral horns exist throughout the cervical and upper dorsal regions as well as in the sacral cord. In the cervical region, near the base of the lateral and anterior horns, is found a special collection of multipolar cells, whose neuraxones form the root-fibers of the spinal accessory nerve on each side.

The posterior horns are, in general, longer and much narrower than are the anterior. They taper almost to a point near the dorsal periphery of the cord, and are enabled to reach the surface by a dipping-in of small processes of neuroglia tissue. They diverge slightly, this divergence being most marked in the cervical region. Each horn is divided into a narrow part, or neck, "cervix cornu," and an expanded part, or head, "caput

cornu." Near the tip of the head of each posterior horn exists a layer of semitransparent glassy material, which forms a cap to the cornu, and is called the substantia gelatinosa of Rolando. It extends throughout the entire cord and into the medulla, where it becomes markedly increased in amount, contains a large number of nerve-cells, and forms one of the end stations

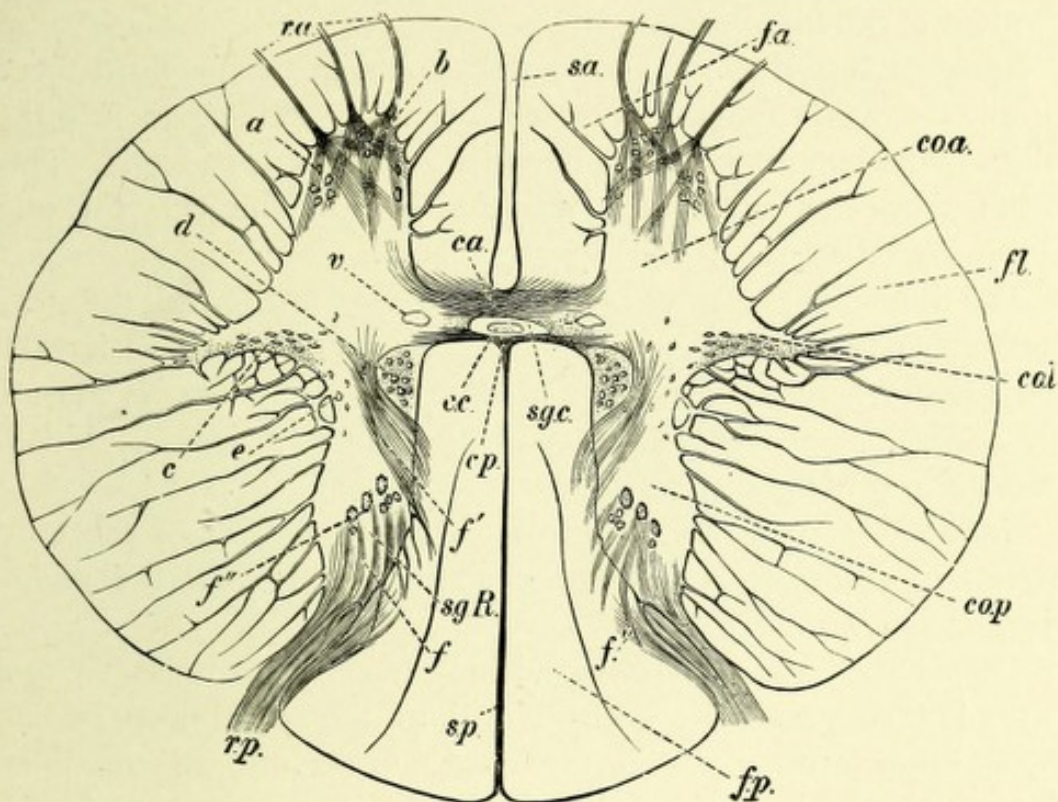


FIG. 40.—TRANSVERSE SECTION OF THE HUMAN SPINAL CORD AT THE LEVEL OF THE EIGHTH DORSAL VERTEBRA. $\times 10$.—(Landois and Stirling.)

s.a. Anterior longitudinal fissure. *s.p.* Septum posterium. *c.a.* Anterior commissure. *s.g.c.* Substantia gelatinosa centralis. *c.c.* Central canal. *c.p.* Posterior commissure. *v.* Vein. *coa.* Anterior horn. *col.* Lateral horn, and behind it the processus reticularis. *cop.* Posterior horn. *a.* Anterolateral. *b.* Anteromedian group of ganglionic cells. *c.* Cells of the lateral horn. *d.* Cells of Clarke's column. *e.* Solitary cells of the posterior horn. *r.a.* Anterior root. *r.p.* Posterior root, with *f* its bundle of fibers. *f'*. Postero-internal bundle. *f''*. Longitudinal fibers of the posterior cornu. *s.g.R.* Gelatinous substance of Rolando. *f.a.* Anterior column. *f.l.* Lateral column. *f.p.* Posterior column.

for the sensory division of the fifth or trigeminal nerve. This substantia gelatinosa Rolandi was formerly believed to be composed simply of a rich network of neuroglia fibers and cells, but it has been shown by the recent researches of Weigert that this substance is poor in neuroglia tissue. It contains numerous

small multipolar nerve-cells, whose neuraxones pass into the adjoining part of the lateral columns. Koelliker has shown that many collaterals from the posterior nerve-roots pass through the substantia gelatinosa on their way toward the anterior cornu, while others terminate about the cells existing in the posterior cornu. From the caput cornu they taper in the way described above, reaching the surface of the cord, and are called the "apices cornuum posteriores."

Between the bases of each anterior and posterior horn there is an extension of the intermediate gray substance into the white matter in the form of a dense interlacement of fibers. This is the processus reticularis, well marked in the cervical and upper dorsal regions.

The intermediate gray substance, or that portion of the gray matter between the anterior and posterior cornua, often termed the middle zone, consists of a network of neuroglia tissue, nerve-fibers, isolated nerve-cells and their processes, blood-vessels, and lymphatics.

Connecting the gray matter of the lateral halves of the cord exist two commissures—the anterior, or white, and the posterior, or gray.

The central canal is situated in the gray commissure and extends throughout the entire length of the spinal cord, ending in the filum terminale. As the cord merges into the medulla, the canal trends backward, and finally opens into the fourth ventricle. In the conus medullaris it is more dorsally located, becomes widened, and forms the ventriculus terminalis of Krause. In transverse sections it appears oval or circular, and is surrounded by neuroglia tissue—the substantia gelatinosa centralis of Stilling. It is lined with cylindric epithelium, which in the embryonic cord bear cilia. The epithelial cells have basal processes which are continuous with the neuroglia tissue upon which they rest. This canal is the remains of the neural or epiblastic canal of the embryo. In the adult it is filled with disintegrated products of the lining epithelium, the epithelial cells having lost their cilia.

The anterior or white commissure forms the floor of the anterior median fissure. It is composed of obliquely decussat-

ing medullated nerve-fibers, neuraxones from the intrinsic cells of the gray matter, which cross over and enter the anterior and anterolateral areas of the opposite side of the cord. It contains, in addition, neuraxones from the median cell groups of the anterior horns, and, lastly, collateral branches from the fibers of the direct pyramidal tracts which cross and probably end about the motor cells of the opposite side. According to Bechterew, fibers pass from the ventral part of each lateral column, via the anterior commissure, to the ventral column of the opposite side.

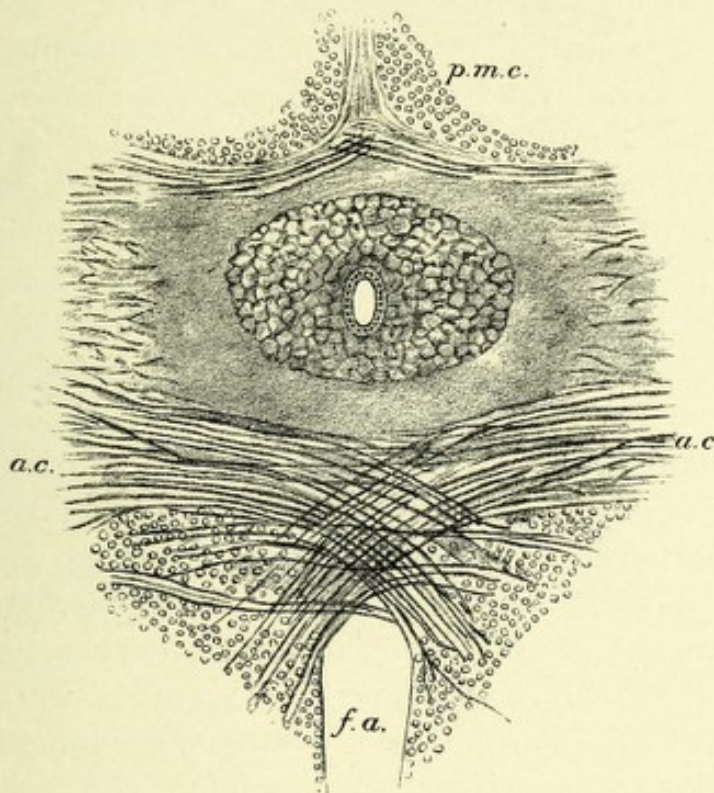


FIG. 41.—SECTION OF THE ISTHMUS OF THE LUMBAR CORD. Showing the central canal in the middle, surrounded by the substantia gelatinosa centralis.—(After E. A. Schafer, from Quain.)

f. a. Anterior median fissure. *p. m. c.* Posterior white column. *a. c.* Anterior white commissure.

The posterior or gray commissure contains the central canal and connects the posterior horns. It is made up of medullated nerve-fibers, which run transversely or obliquely. Between the fibers exists a large amount of neuroglia tissue, which gives to it its gray color. The fibers of the posterior commissure represent collateral branches of the posterior nerve-roots, which cross over to the opposite side. It also contains neuraxones from cells existing in the posterior horns, which pass over to the opposite side.

THE NERVE-CELLS OF THE CORD.

In the gray matter of the cord there exists a variety of forms of multipolar nerve-cells. They may, in general, be divided into two classes, corresponding to the types of Golgi—viz., those cells whose neuraxones, although giving off collaterals, retain their individuality and are usually of great length. These belong to Golgi's first type of cells; those whose neuraxones are short, soon divide and subdivide into fine ramifications, and do not leave the gray matter—Golgi's second type of cells.

Another classification, more in accordance with their supposed functions, is as follows: (1) The motor, ganglionic, or trophic cells; (2) the intrinsic cells; and (3) the reflex cells.

The motor cells differ from the others in size, being the largest cells of the cerebrospinal axis. They are irregular in form, and possess a very large number of offshoots, or dendrites, which branch repeatedly. They are located in the anterior cornua, throughout the whole extent of the spinal cord, and their neuraxones form the anterior nerve-roots. These cells, with their neuraxones and dendrites and the motorial end plates, form the peripheral motor neurones, or neurones of the first order.

Two important groups of motor cells are found most marked in the cervical and lumbar enlargements, but extending throughout the entire extent of the cord—viz., an anteromedian and posterolateral group (Fig. 43). The researches of Kaiser have thrown considerable light upon the exact anatomic grouping of the cells in the anterior cornua of the cervical region. The following four groups have been described by him: First, a group just anterior to the origin of the lateral horns and extending into those horns. This group extends downward as far as the sixth cervical segment. It is called the accessory nucleus, and gives origin to the spinal accessory, or eleventh pair of cranial nerves. Secondly, a group of cells on either side exists at the exit of the first cervical nerve, and on the internal surface of the anterior horn near its base. This group continues upward into the medulla, and there gives origin on each side to the hypoglossal or twelfth pair of cranial nerves. A third group is known as the middle or mesial group, and is located in the middle of the base of the





FIG. 42.—A GROUP OF MULTIPOLAR NERVE-CELLS FROM AN ANTERIOR HORN OF THE SPINAL CORD. Showing Nissl granules and pigment.



anterior horn of each side. This cell group extends throughout the entire cord. It is particularly well marked in quadrupeds whose dorsal muscles are well developed, and therefore has been termed by Kaiser the nucleus for the back muscles. The fourth group is found along the lateral periphery of the anterior horn, having a vertical extent from the fourth cervical to the upper part of the second dorsal segment. This is the area from which the nerves of the brachial plexus are derived. This group has been called by Kaiser the cell group for the upper extremity.

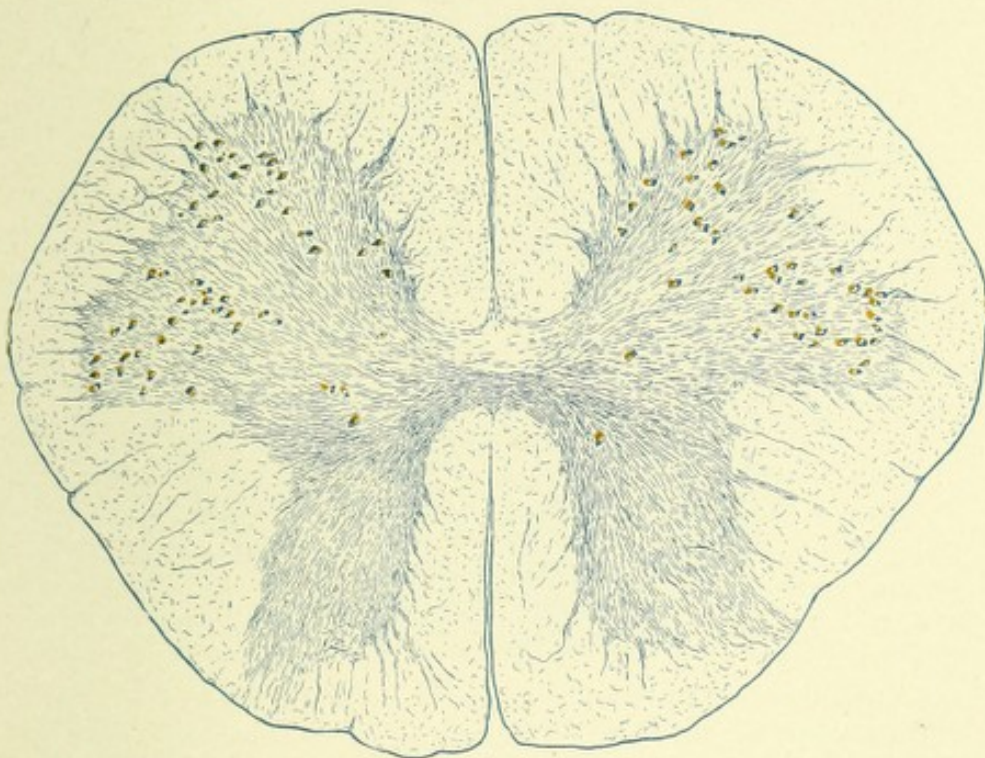


FIG. 43.—SECTION OF THE LUMBAR CORD OF AN ADULT. Showing the anteromedian and posterolateral groups of cells.

All these cells are motor in function, innervating the muscles to which the anterior nerve-roots are destined. They also have a very important bearing upon the nutrition of the anterior nerve-roots and the muscles which those nerves innervate. Any acute pathologic change in the cells is followed by motor paralysis, partial or complete, degeneration of the motor nerve-fibers, and rapid wasting of the muscles to which they are distributed. They are, therefore, trophic as well as motor in function. These cells are functionally grouped, according to certain definite movements associating groups of muscles.



The intrinsic cells are found distributed throughout that part of the gray matter located between the anterior and posterior cornua, the so-called middle zone. The neuraxones of the intrinsic cells pass into the white columns of the same and opposite sides, as long and short fibers, where they divide T-shaped, one branch passing upward, the other downward. The long fibers are doubtless sensory. The short fibers are probably associative in function, passing upward and downward in the white columns of the

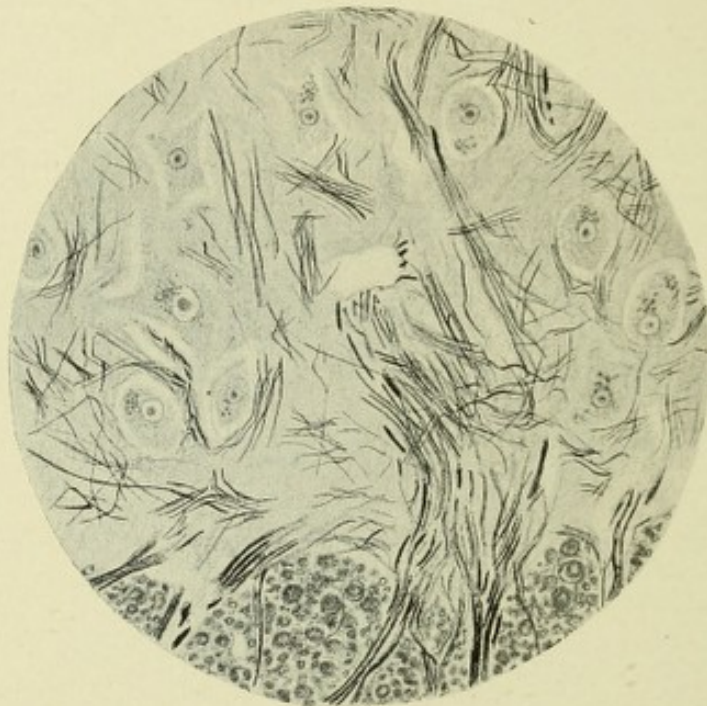

FIG. 44.—CAMERA LUCIDA DRAWING OF A PART OF AN ANTERIOR HORN WITH ADJACENT WHITE MATTER OF THE LATERAL COLUMN. Showing nerve-fibers coming from that column and coursing between and around the motor nerve-cells. Stained after method of Weigert-Pal.

cord, giving off collaterals which reenter the cord at higher and lower levels, ending in brush-like expansions about the intrinsic cells of those levels. A group of intrinsic cells exists near the base of each anterior horn, the neuraxones of which pass obliquely across the gray and white matter, becoming vertical near the periphery of the opposite side of the cord, forming the antero-lateral ascending tract of Gowers. This tract is probably sensory in function, transmitting to the brain impulses of pain and temperature. A second group of these cells is located at the

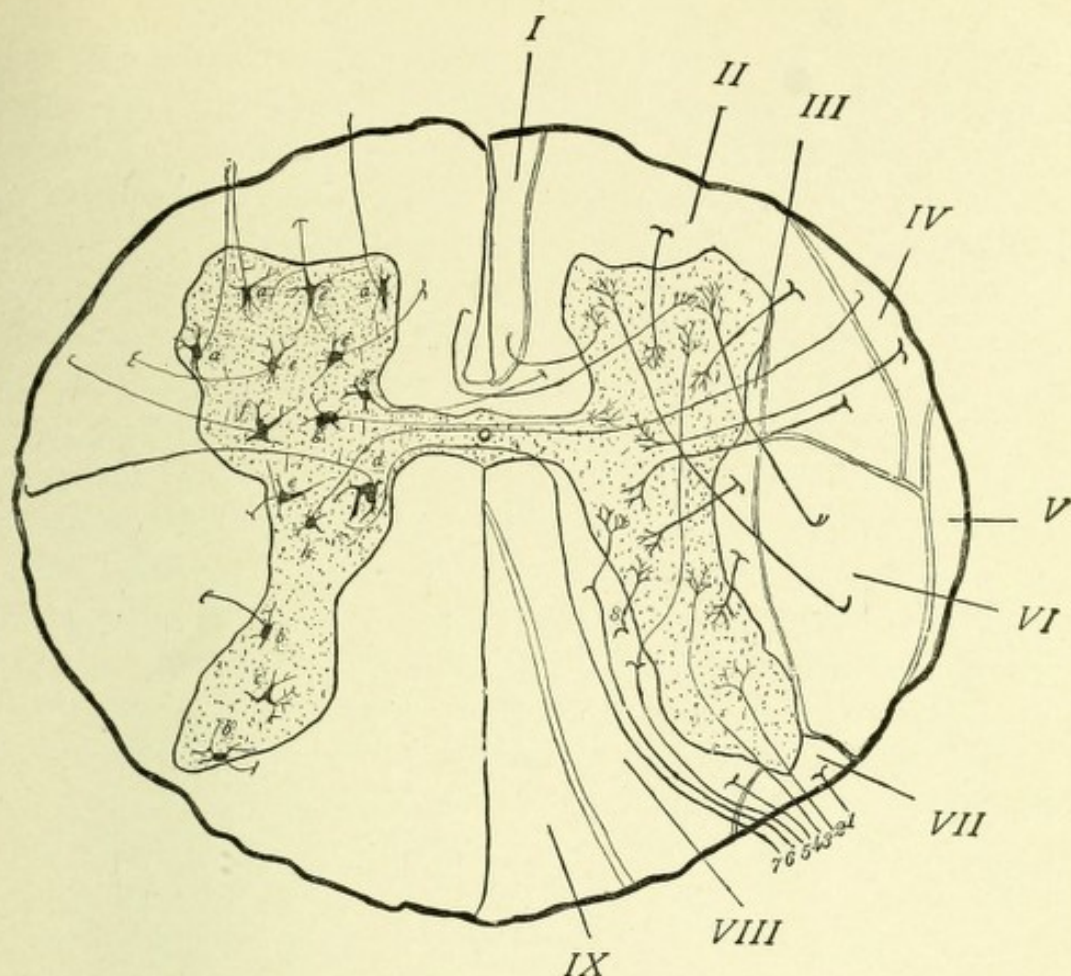


FIG. 45.—DIAGRAM OF A TRANSVERSE SECTION OF THE SPINAL CORD.—(After Starr.)

On the right side the columns of the cord are shown, and the fibers entering the gray matter from these columns. I. Anterior median column. II. Anterolateral column. III. Lateral limiting layer. IV. Ascending anterolateral tract of Gowers. V. Direct cerebellar column. VI. Crossed pyramidal column. VII. Lissauer's column. VIII. Column of Burdach. IX. Column of Goll.

The posterior nerve-roots are shown on the right side of the diagram, and their various methods of termination in the gray matter: 1. Fiber entering Lissauer's tract. 2. Fiber entering posterior horn. 3. Fiber terminating deep within posterior horn. 4. Fiber entering column of Burdach. 5. Fiber passing to root zone of column of Burdach, and sending the collateral fiber to the anterior horn. 6. Fiber entering root zone, and sending collateral to the Clarke column of cells. 7. Fiber entering root zone and passing by way of the gray commissure to the opposite side of the cord.

On the left side the various cells of the gray matter are shown: *a*. Motor cells, with motor nerve-roots passing out of the cord. *b*. Intrinsic cells of the posterior horns; the one on the margin is a "border-cell"; the other lies deep within the horn; they send neuraxones into the posterior and lateral columns respectively. *c*. Intrinsic cell of the posterior horn; Golgi's second type. *d*. Cell of the column of Clarke, with its axone passing to the direct cerebellar column. *e*. Intrinsic cells of the intermediate gray matter, with their axones passing into the anterolateral column. *f*. Intrinsic cell in median gray matter, with its axone passing to Gowers' tract. *g*. Commissural cells in the median gray matter, their axones passing to the opposite side of the cord. *h*. Sensory cell sending its axone to opposite column of Gowers.



base of the posterior horn, near its inner side, close to the posterior commissure. They are of large size, multipolar, and sensory in function. Spread about them exist the end brushes of collaterals and axones from the posterior nerve-roots, which conduct impressions of equilibrium from the trunk muscles to these cells. From this group of cells neuraxones pass horizontally across the gray and white matter of the same side, becoming vertical along the periphery of the cord, where they form the direct cerebellar tract, or column of Flechsig. They extend from the third lumbar to the seventh cervical nerve. This entire group of cells forms the vesicular column of Lochart Clarke. Cells of a like character exist in the same location throughout the sacral region, and have been termed the sacral nucleus of Stilling. Among the intrinsic cells may be mentioned a group of cells on each side located near the median surface of the base of the anterior horns—the so-called commissural cells. They possess axones which have both a short and long course, those of short course passing in curves through the anterior commissure into the opposite anterior cornu, where each axone terminates by breaking up into two or three fine filaments. They probably associate in function the two anterior cornua. The axones having a long course pass via the anterior commissure through the gray matter into the anterolateral area of the cord. They may conduct sensory impressions to the opposite side of the cord. The remaining cells belong to the second type of Golgi; they are small, spheric or triangular, and exist mostly in the posterior horns. Their axones are short and do not leave the gray matter; they divide dichotomously, breaking up into a network of fine filaments. They may possibly serve a reflex function.

The white matter of the cord surrounds the gray matter on all sides except where the posterior horns reach the dorsal periphery of the cord. Macroscopically, it consists of a homogeneous white mass, which, when examined with a low power of the microscope, resolves itself into masses of cut-off, medullated nerve-fibers arranged vertically. These nerve-fibers differ very much as to size, and have no neurilemma or sheath of Schwann. Between the nerve-fibers exists neuroglia tissue and many fine collaterals. A mantle of neuroglia, the subpial neuroglia

layer, surrounds the periphery of the cord. The neuroglia gives support to the nerve-fibers and to the numerous blood-vessels which are given off from all portions of the periphery and ramify toward the center of the cord.

The fibers are variable in size, usually corresponding in diameter to the length of the tracts to which they belong.

The white substance is divided anatomically into three primary columns for each side—an anterior or ventral, a lateral, and a posterior or dorsal. The anterior column lies between the anterior cornua and ventral nerve-roots. The lateral columns are between the exit of the anterior and posterior nerve-roots. The posterior columns are situated between the posterior cornua and nerve-roots, being separated from each other by the dorsal median septum. They are subdivided by the intermediate neuroglia septum into two smaller columns—an inner or median one, adjacent to the posterior median fissure, called the column of Goll, and an outer or external one, located between the septum and the posterior horn, called the column of Burdach or the posterior root zone. It is to be noted that this intermediate septum is only well marked in the cervical region, but the columns are distinct throughout the cord. These various columns are further subdivided into a number of tracts or fasciculi of nerve-fibers, long and short, whose anatomic and physiologic relations have been made known by pathologic and embryologic research. The fibers which compose these tracts spring from four different sources: First, from the posterior nerve-roots and spinal ganglia, having a centripetal course; second, fibers from the motor area of the brain, centrifugal in their course; third, fibers which pass into the white matter of the cord from the intrinsic cells of the gray matter, which form long and short tracts, the long tracts being doubtless sensory in character, while the short tracts are supposed to associate different levels of the gray matter; and fourth, fibers having a descending course: the neuraxones from the Purkinje cells of the cerebellar cortex.

We have thus found that the white matter which appeared to the naked eye as a homogeneous mass may be resolved into vertical fibers grouped into tracts whose course may be long or

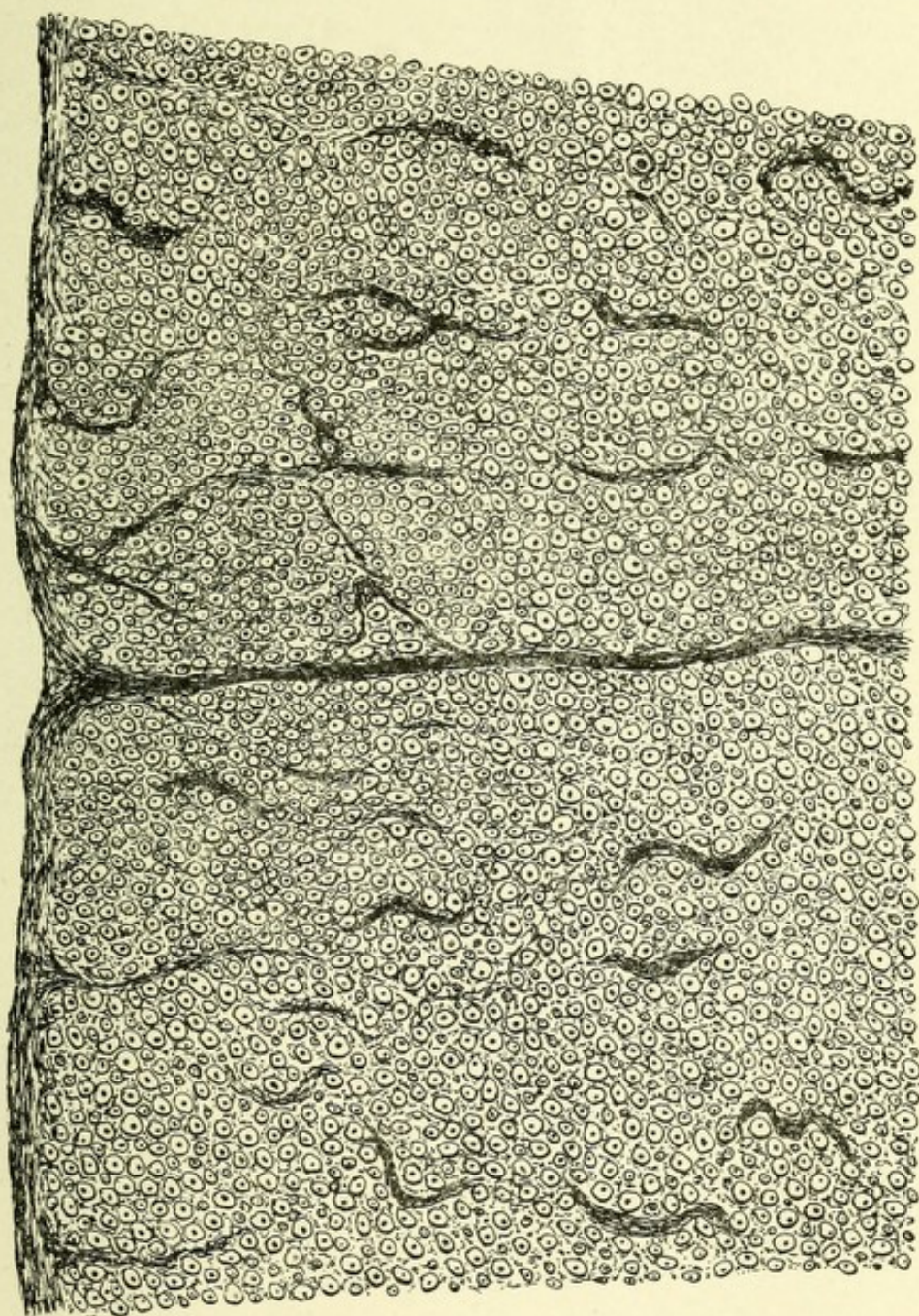



FIG. 46.—MICROPHOTOGRAPH OF TRANSVERSE SECTION OF CORD. Showing nerve-fibers cut across.



short. Our knowledge in regard to the exact location of the different systems of these tracts has been greatly aided by the study of secondary degeneration, the result of experimental or pathologic destruction of partial or total transverse sections of the cord. This study was undertaken by Turck, who investigated the after-effects of such sections of the cord. He found that when the cord was completely destroyed transversely by a

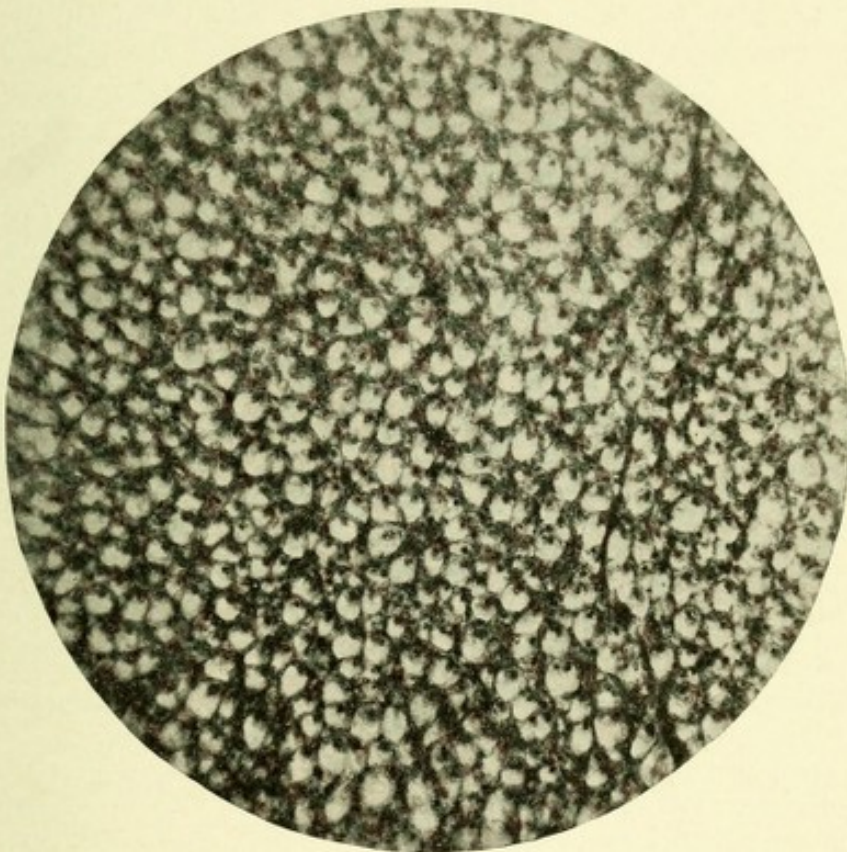


FIG. 47.—MICROPHOTOGRAPH OF A PARTIAL TRANSVERSE SECTION OF THE WHITE MATTER OF THE SPINAL CORD OF AN OX.

lesion,—such as transverse myelitis, hemorrhage, or the like,—certain definite tracts or systems of fibers degenerate upward or centripetally, while others degenerate downward or centrifugally. The study of secondary degeneration was long ago carried out by Waller, who showed that if a nerve were severed from its mother cell, it would degenerate throughout its whole extent, the degeneration usually being in the direction in which the nerve-fiber conducted impulses. For example, if an anterior

nerve-root be severed from its connection with its trophic cell in the anterior horn of the spinal cord, that nerve degenerates peripherally to its termination in the muscle which it innervates, the muscle sharing in the resulting atrophy. Also on section of a posterior or sensory root, ventrad to its ganglion, which contains its trophic cell, that nerve degenerates centrally or in the direction in which it conducts impulses. On the contrary,

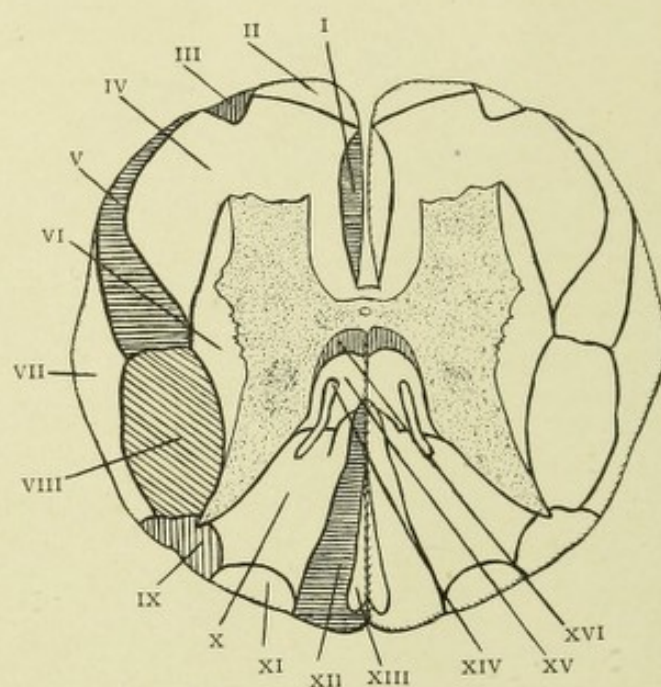


FIG. 48.—SCHEMATIC REPRESENTATION OF THE SITUATION OF THE VARIOUS TRACTS OF FIBERS IN THE SPINAL CORD.

- I. Direct pyramidal tract. II. Descending tract of Marchi and Lowenthal. III. Olivary or triangular tract. IV. Anterolateral ground bundles of fibers. V. Anterolateral ascending tract of Gowers. VI. Lateral limiting layer. VII. Direct cerebellar tract. VIII. Crossed pyramidal tract. IX. Lissauer's tract. X. Middle root zone. XI. Posterior root zone. XII. Postero-internal or column of Goll. XIII. Septomarginal tract. XIV. Comma tract of Schultze. XV. Anterior root zone. XVI. Cornu commissural tract.

if a section be made dorsal to the ganglion, the nerve degenerates peripherally throughout its whole extent in a direction opposite to that in which impulses are conducted. A careful study has shown that the following tracts in the spinal cord undergo secondary degeneration—viz., the direct and crossed motor tracts, the tracts of the columns of Burdach and Goll, the direct cerebellar, the anterolateral ascending tract of Gowers, and the descending tract of Marchi and Lowenthal. It is in-

teresting to note that the embryologic studies of Flechsig, Bechterew, Edinger, and Kahler have confirmed the separate existence of these tracts and have proved that other tracts also are found in the cord. Flechsig has shown that the different tracts of the white matter receive their myelin at certain definite periods of embryonic development. In early embryonic life that part of the cord which afterward consists of white matter is composed entirely of naked axis-cylinders, which gives to a section a dark gray appearance. Later, as the tracts become medullated, they can easily be distinguished by the white appearance which each tract assumes. By this method, the following tracts or systems of fibers have been differentiated—viz., the ground bundles of the anterior columns, ground bundles of the posterior columns, the anterolateral mixed zones, the lateral limiting layers, the columns of Goll, the direct cerebellar tracts, the direct and crossed pyramidal tracts, the anterolateral ascending tracts of Gowers.*

In order to render clearer the anatomic relations of the separate tracts, it will be necessary to accurately describe the relative positions of these tracts as seen on transverse section.

The *anterior or direct pyramidal tracts or columns of Turck* form narrow columns of nerve-fibers bordering on each side of the anterior median fissure. These tracts extend downward in the cord, gradually decreasing in size, and usually terminate at the mid-dorsal region. In rare instances, when a larger percentage than normal of the motor-fibers take this direct course,

* 1. The ground bundles of the anterior columns receive their myelin when the fetus is from 30 to 32 cm. long. About the sixth month.

2. The ground bundles of the posterior columns, when the fetus is 25 cm. in length. About the fifth month.

3. The anterolateral mixed zone, when the fetus is 25 to 35 cm. long. Fifth to seventh month.

4. Lateral limiting layer, when the fetus is 32 cm. long. About the sixth month.

5. The fasciculi of the columns of Goll receive their myelin when the embryo is between six and seven months old.

6. The direct cerebellar tracts receive their white substance about the seventh month of fetal life.

7. The fibers of the direct and crossed pyramidal tracts become enveloped in myelin at about the ninth month.

8. The anterolateral ascending tracts of Gowers become medullated at the eighth month of embryonic life.

they continue downward as far as the lumbar or sacral region, and extend from the white commissure to the periphery of the cord, causing slight bulgings on each side of the anterior median fissure. On the other hand, when the columns contain less than the normal number of fibers, they terminate about the middle of the cervical region.

The *anterior ground bundles of Flechsig* comprise all that part of the anterior columns outside of the direct pyramidal tracts. They extend throughout the entire length of the cord, and consist chiefly of fibers having a short course, which fibers doubtless connect different levels of the anterior cornua.

The *anterolateral mixed zone*, one on each side, is bounded on its inner side by the gray matter; externally, by Gowers' tract and the crossed pyramidal tract. The posterior portions of these columns bordering upon the intermediate gray matter and the posterior horns are called the lateral limiting layers. This zone is composed of association fibers which probably connect different levels of the gray matter.

The *anterolateral ascending tracts of Gowers* occupy rather long, narrow, crescentic areas along the anterolateral periphery of the cord in front of the direct cerebellar and crossed pyramidal tracts, and are found throughout the cord as low down as the lumbar enlargement.

The *anterolateral descending tracts of Marchi and Lowenthal* comprise a small area in Gowers' column of each side, close to the periphery of the cord. These areas were discovered by Marchi and Lowenthal. They have been found to extend throughout nearly the entire length of the cord.

The *direct cerebellar tract*,—also called the column of Flechsig,—one for each side, exists along the periphery of the lateral column, posterior to the tract of Gowers and external to the crossed pyramidal tract. In the upper cervical region its posterior part is separated from the periphery of the cord by the crossed pyramidal tract. It originates as low down as the first lumbar nerve, and has its greatest size where the cells of Lockhart Clarke, whose neuraxones form the greater portion of this tract, are best developed—namely, in the dorsal region.

The *crossed motor or pyramidal tracts*—the fasciculi cerebro-

spinalis lateralis—occupy a large area in the posterior part of the lateral columns of each side. They extend throughout the entire length of the cord, some of their fibers terminating in the conus medullaris. Through the greater part of the cervical and dorsal regions these tracts are separated from the periphery of the cord by the cerebellar tracts. In the upper cervical and lower dorsal regions, owing to a movement ventrad of the direct cerebellar tracts, the motor tracts are permitted to reach the periphery of the cord, which position they retain throughout the lumbar region. Their posterior surfaces are in contact with the posterior horns; their anterior portion, with the tracts of Gowers and the lateral limiting layers.

The posterior columns contain two chief systems of fibers or tracts, which extend throughout the cord, being separated from each other in the dorsal and cervical regions by a process of neuroglia called the intermediate septum. On each side the outer area, which borders on the posterior horn, is called the column of Burdach, posterior ground bundle of Flechsig, or the posterior root zone of Charcot. The inner fasciculus or bundle of fibers, which borders upon the posterior median fissure, is called the column of Goll, or postero-internal column.

The origin and partial course of the fibers which compose the various tracts of the cord will be described in the order of their relative importance from a clinical and physiologic standpoint.

The Crossed and Direct Pyramidal Tracts.—The motor fibers of the cord which are located in the direct and crossed pyramidal tracts arise from the motor areas of the brain, and represent the neuraxones of the large pyramidal cells, which are abundantly found in the third layer of the cortex. Their course from the cerebral cortex to the medulla will be described later. When they reach the medulla they occupy a large area on each side of the anterior median fissure, and at the first or second cervical nerves large bundles of fibers or axones, representing about eighty per cent. of the whole number, pass obliquely across to the opposite side, entering the posterior part of the lateral column of the cord; hence the name "crossed pyramidal tract." These crossed fibers become vertical and extend downward, gradually decreasing in size until they reach

their termination, at the level of the third or fourth sacral nerve, a small number of fibers continuing downward to terminate in the *filum terminale*. The neuraxones which do not cross, representing about twenty per cent. of the motor fibers, pass downward in the area of the cord adjacent to the anterior median fissure on the same side; hence they are called the direct or uncrossed pyramidal tract. They usually cease about the level of the mid-dorsal region. The motor neuraxones, like most of the long fibers of the columns of the cord, give off at different levels side branches or collaterals which leave the parent stem at right angles. The axones, with the collaterals composing the crossed pyramidal tract of each side, pass forward and inward, entering the gray matter, where they break up about the motor nerve-cells into innumerable fine filaments or arborizations.

The neuraxones and collaterals of the direct pyramidal tract end, according to Lenhossek, in fine brush-like expansions about the motor nerve-cells of the anterior horn of the same side. On the contrary, undoubted clinical and experimental evidence is at hand to prove that the greater portion of fibers cross over through the anterior commissure to end about the motor cells existing in the opposite anterior cornu. Most of the fibers of the direct pyramidal tract seem destined to the arm; hence the relation of the arm is almost exclusively with the cerebral hemisphere of the opposite side.* The fibers of the motor tracts, direct and crossed, conduct impulses of voluntary motion from the motor areas of the brain to the muscles. If the fibers of the motor tract be destroyed by severing their connection with the cells of the motor area of the brain, there will result a motor paralysis of the opposite side of the body and a descending degeneration from the point of lesion throughout the entire extent of the tract. In the cord the degenerated areas will be the direct pyramidal tract of the same, and the crossed pyramidal tract of the opposite side. This degeneration is complete, involving the termination of the axones and collaterals

* W. H. B. Stoddart has proven by experimental division of an anterior pyramid in a number of dogs that nearly all the fibers of the direct pyramidal tract ultimately cross to the opposite side of the cord.

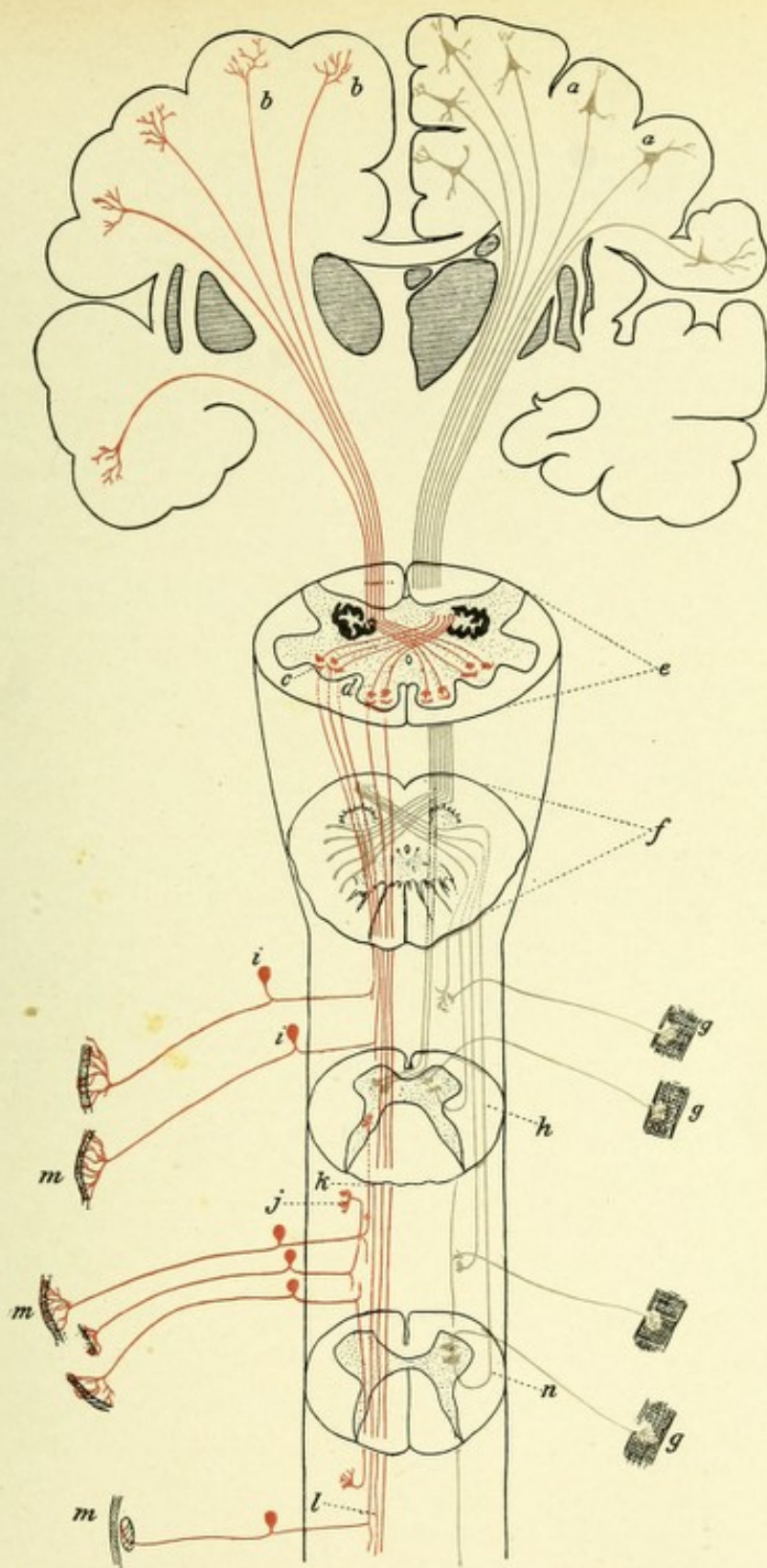



FIG. 49.—DIAGRAM INDICATING THE COURSE OF THE MOTOR AND SENSORY FIBERS OF THE SPINAL CORD AND MEDULLA.

a, a. Motor cells of the cerebral cortex. *b, b.* Arborizations of the fibers of the sensory tract in the cerebral cortex. *c.* Nucleus of the column of Burdach, showing terminal arborizations of the long sensory fibers of the cord. *d.* Nucleus of the column of Goll, showing terminal arborizations of the long sensory fibers of the cord. *e.* Section of the medulla, showing sensory decussation. *f.* Section of medulla, showing motor or pyramidal decussation. *g, g.* Motorial end plates. *h.* Section through the cervical region of the cord, showing termination in the anterior horn of the motor fibers of the direct pyramidal tract after they have crossed in the anterior commissure; also fiber of crossed pyramidal tract ending about anterior horn cell of same side. *i, i.* Posterior spinal ganglia. *j, k.* Sensory fibers of short course. *l.* Sensory fibers of long course, terminating in medulla. *m, m, m.* Sensory end organs. *n.* Section through lumbar cord.



about the nerve-cells of the anterior cornua, and is due to the loss of trophic or nutritional influence which results from the severance of the nerve-fibers from their mother cells in the motor areas of the cortex. The peripheral portion of the tract, on the contrary, remains normal, because its nutrition is dependent upon the motor cells of the anterior cornu, whose neuraxones form the peripheral portion of the tract.*

THE COURSE OF FIBERS IN THE SENSORY TRACTS OF THE CORD.

The sensory portion of the cord may be divided into four chief areas for each side—that is, the direct cerebellar tracts, the columns of Burdach and Goll, and Gowers' anterolateral ascending tracts.

The *direct cerebellar tract*, or the fasciculus cerebellospinalis, owes its origin to neuraxones from the cells of the vesicular column of Clarke.† These cells, which are multipolar, exist at the base of the posterior horn near its inner side, and form a distinct column, vertical in extent from the seventh cervical to the third lumbar segment. It should be noticed, however, that Stilling has called attention to a number of cells in a corresponding portion of the cord in the upper cervical and lower lumbar regions, which cells probably perform a similar function, so that in reality the column may be said to extend throughout the cord. From this column of cells numerous neuraxones pass rather obliquely across the white matter of the lateral column, reaching the circumference of the cord, dorsad to Gowers' tract,

* In many of the lower animals—*i. e.*, in the dog, cat, rabbit, etc.—there is an apparent total decussation of the motor fibers, the latter, after decussating, occupying the posterior part of the lateral columns. The experiments of Marchi, Moeli, Lowenthal, and Sherrington seem to have established the fact that about twenty-five per cent. of the fibers which were formerly believed to decussate in the medulla to form a part of the crossed pyramidal tract do not, but trend backward to pass downward in the posterior part of the lateral columns of the same side and terminate about the nerve-cells of the anterior cornu of that side. This view is supported clinically by the fact that in many hemiplegias there is also present a paresis of the side of the lesion involving particularly the lower extremity.

† According to Tooth, the fibers of the direct cerebellar tracts come directly from the posterior nerve-roots.

where they bifurcate, the long branches passing upward, the short branches downward. (See Fig. 50.)

The long branches continue upward and pass by way of the restiform body to end about the cells in the cortex of the superior vermis of the cerebellum of the same and opposite sides.* No collaterals from the axones of the central portion of this tract have been discovered. No axones from the cells of Clarke's column pass into the posterior columns. The peripheral portion of this tract consists of fibers and collaterals from the posterior nerve-roots of the same side which pass through the white matter of the postero-external column and then enter the base of the posterior horn to end in brush-like expansions about the cells of Clarke and Stilling. These fibers probably serve to conduct sensations of equilibrium to the cells of Clarke and Stilling, whence they are further conveyed via the direct cerebellar tract to the cerebellum.

The direct cerebellar tract receives its myelin at the seventh month of fetal life. Experimental division of the cord in the lower animals has shown that the long branches of the axones of this tract degenerate in an ascending or centripetal direction, which degeneration ends in the worm of the cerebellum. The short branches of the axones of this tract degenerate downward for a short distance. Their function is unknown. The trophic influence of the central portion of this tract comes from the cells of Clarke and Stilling. The peripheral portion as well, according to Edinger, receives its trophic influence from the same source.

This statement of Edinger is merely hypothetic. It is more probable that the peripheral portion of this tract consists of collaterals from the posterior nerve-roots, which roots consist of the central axones of the cells of the posterior spinal ganglia.

* According to Alexander Bruce, the direct cerebellar tract, after entering the middle portion of the restiform body, ascends in front of the nucleus dentatus of the cerebellum, at the upper margin of which it passes backward along the convex margin of the superior cerebellar peduncle, immediately after that structure has emerged from the hilum of the dentate nucleus. At the posterior margin of the peduncle the direct cerebellar tract bends inward toward the superior worm, terminating on both sides of the central, monticulate, and lingual lobules. A majority of the fibers terminate in the same side of these lobules, but a considerable number cross over to the same-named lobules of the opposite side via the ventral cerebellar commissure of Stilling.

THE COURSE OF THE FIBERS OF THE DORSAL FUNICULI OR POSTERIOR COLUMNS.

As before mentioned, the posterior columns are separated into two divisions: an inner portion, or column of Goll, or funiculus gracilis; and an outer one, the column of Burdach, wedge-shaped column, posterior root zone, or the funiculus cuneatus. Throughout the cervical and part of the dorsal regions these

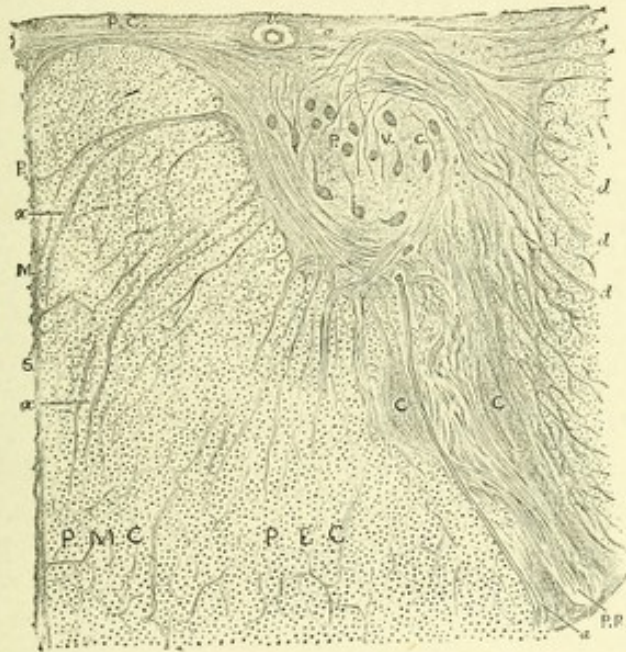

FIG. 50.—POSTERIOR CORNU AND COLUMN AT THE LAST DORSAL SEGMENT.—(After Gowers.)

P. M. C. Posteromedian column. P. E. C. Postero-external column. P. M. S. Posterior median septum. P. C. Posterior commissure. v. Commissure vein. P. V. C. Posterior vesicular column. C. C. Caput cornu. P. R. Posterior root. a. An artery. d, d, d. Adjacent to a strip of the lateral column, indicate the tracts of fibers passing from the vicinity and interior of the posterior vesicular column along the septa of the lateral column, to form the direct cerebellar tract. x, x. Tracts of fibers passing from the neck of the horn, near the posterior vesicular column, to the postmedian column.

columns are separated by the postero-intermediate septum. That these columns are distinct from each other and contain separate systems of fibers seems proved by two facts: first, that the separate systems of fibers receive their myelin at different periods of embryonic life; secondly, from the study of the pathologic appearances of secondary degenerations in this area.

In the lumbar and sacral regions it is not possible to separate the component fibers of the posterior columns into a postero-

internal, or column of Goll, and a postero-external, or column of Burdach. This is owing to two facts: first, the long fibers which arise from the lower spinal ganglia have not reached the position which they occupy in the dorsal region adjacent to the posteromedian septum; second, a number of short and long fibers exist in both regions which do not take their origin from the spinal ganglia, but originate from the intrinsic cells of the gray matter of the cord.

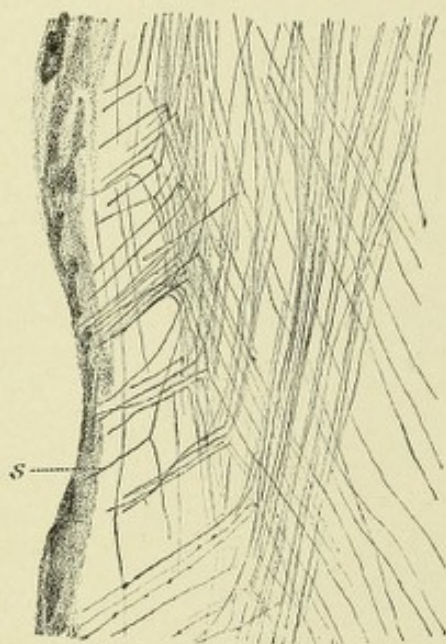


FIG. 51.—LONGITUDINAL SECTION OF THE CORD IN THE CERVICAL REGION OF A SHEEP'S EMBRYO, 22 cm. long. Showing the division of the posterior nerve-fibers after entering the cord.—(*Landois and Stirling.*)

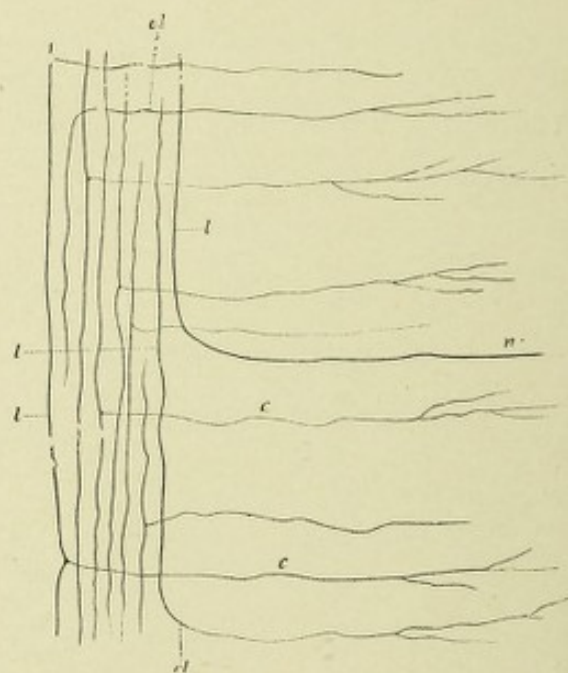


FIG. 52.—LATERAL COLUMN OF A NEW-BORN RABBIT.

c. Collateral fibers. *el.* Bending rounding of the longitudinal fibers to end in the gray matter. *n.* Axis-cylinder process of a nerve-cell bending in among the longitudinal fibers of the white column. *l, l, l.* Longitudinal fibers of different lengths.

With the exception of fibers which come from the intrinsic cells at the base of the posterior horns,—which form in the lumbar and sacral regions two distinct tracts, the cornu commissural and septomarginal,—the fibers of which these columns are composed are derived from the posterior nerve-roots, which represent the central neuraxones of the cells of the posterior spinal ganglia. The posterior nerve-roots enter the posterior columns just outside of the posterior horns, in the region of the sub-

stantia gelatinosa Rolandi, where they bifurcate, both divisions having a vertical course, one upward, the other downward. Both give off collaterals nearly at right angles, which enter the gray matter and break up into fine filaments about the intrinsic nerve-cells, or the motor cells of the anterior cornua.

The branches which continue downward after pursuing a short course enter the gray matter in curves and end about the nerve-cells of the posterior horns. The branches which continue upward may be divided into those having a short and those having a long course. The former pass upward a variable distance, and finally pass into the posterior horns, to end about the cells in the gray matter. Those of long course pass upward, and when they reach the medulla they curve slightly forward and end in free arborizations about the cells of the nucleus cuneatus, or nucleus of the column of Burdach, and nucleus gracilis, or nucleus of the column of Goll.

The Column of Goll.—These columns, also termed the postero-internal columns, consist of long fibers only of the posterior nerve-roots from the various levels of the sacral, lumbar, and dorsal regions of the cord, which fibers end in the medulla, about the cells of the nucleus gracilis, or nucleus of the column of Goll, of the same side. These fibers probably have the function of conducting impressions from the sensory muscle nerves.

The Columns of Burdach.—These columns contain fibers of short and long course, with their collaterals. The fibers bifurcate, one division passing downward, the other upward. Most of the fibers whose course is downward are said by Schultze, Flatau, and Lenhossek to occupy a comma-shaped area in the ventral and median portion of this column, known as the comma-shaped bundle of Schultze.* Hoche has shown that the fibers of the comma-shaped bundle pass in curves into the gray matter of the cord. In addition, the median portion of this column, in the

* The comma-shaped bundle, or tract of Schultze, was formerly believed to have but a short course and to consist entirely of the short descending axones from the posterior nerve-roots. Hoche has followed descending degeneration of this tract through ten spinal segments, and believes the tract to have a long course. Zapfer believes the fibers of this tract to come from cells in the gray matter (endogenous fibers), and also from the posterior nerve-roots (exogenous fibers). Gombault, Philipe, and Tooth believe that this tract consists of fibers coming only from cells of the dorsal part of the gray matter.

cervical region contains long branches, which pass upward and end in arborizations about the cells of the nucleus of the column of Burdach. The posterior portion of this column, or posterior root zone, which borders on the posterior horn, contains fibers with collaterals from the posterior roots, which, after a short course, enter the posterior horns. Many fibers from the column of Burdach pass into the column of Goll, as is shown by the study of secondary degeneration.*

The majority of the fibers from both of these columns depend for their nutrition upon the cells of the posterior spinal ganglia. The fibers degenerate in the direction in which they pass. The fibers which degenerate downward occupy three areas: first, the comma-shaped area in Burdach's column; second, the area of the septomarginal tract; and third, the area of the cornu commissural tract. A complete transverse section of the nerves composing the cauda equina results in a complete degeneration of the root-fibers that enter into the formation of the posterior columns at the point where the cauda equina merges into the cord. Just above this area where new fibers enter, the degenerated area now occupies the entire column of Goll, with a portion only of Burdach's column. Higher up the cord this degenerated area is confined to the column of Goll, and passes upward to terminate about the cells of the nucleus of that column in the medulla.

THE CORNU COMMISSURAL AND SEPTOMARGINAL DESCENDING TRACTS.

That the fibers of which both of these tracts are composed have their origin from the intrinsic cells of the posterior part of the gray matter of the cord seems proved from the fact that they are not found degenerated when the posterior nerve-roots

* Flechsig and Bechterew, on embryologic grounds, have divided the fibers of which the columns of Burdach are composed into three root zones—an anterior, a middle, and a posterior. The anterior root zone lies between the posterior commissure, base of posterior horn, and posterior median fissure. The middle root zone lies between the anterior and posterior root zones, being bounded on the inner side by Goll's column, and on the outer side by the posterior horn. The posterior root zone occupies the dorsal part of Burdach's column, and rests against the dorsal periphery of the cord.

are experimentally divided, or when they are atrophied, the result of disease. In locomotor ataxia, a disease which is now universally regarded as due to sclerosis of the posterior nerve-roots, the fibers of these two tracts remain undegenerated, and are in striking contrast to the degenerated fibers in the posterior column from the posterior nerve-roots. The fibers of these two fasciculi degenerate downward when the diseased process destroys the intrinsic cells existing in the posterior part of the gray matter of the cord, such degeneration having been observed by Hoche in two cases of compression myelitis. Other observers have found them degenerated in cases of syringo-

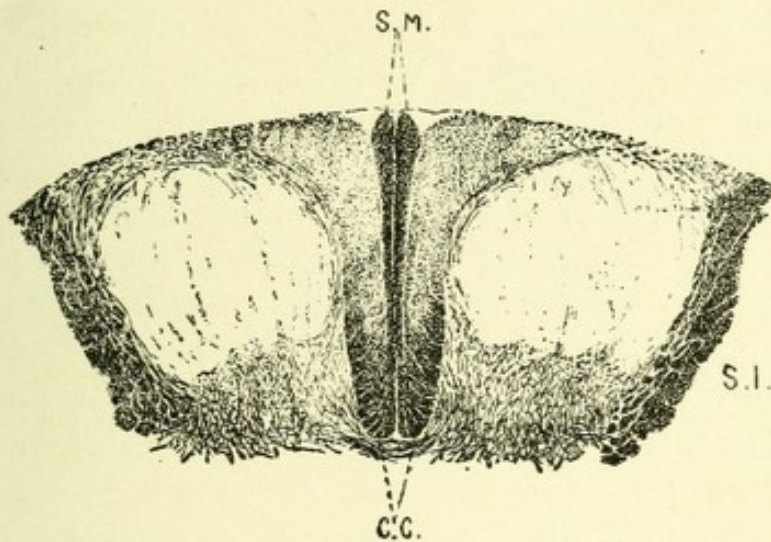


FIG. 53.—TRANSVERSE SECTION OF THE SPINAL CORD AT THE LEVEL OF THE FIRST SACRAL SEGMENT.—(After Alexander Bruce.)
S. M. Septomarginal tract. C. C. Cornu commissural tract.

myelia, which is a gliosis affecting at first the gray matter surrounding the central canal and then gradually extending in all directions from that point (Fig. 53).

The Cornu Commissural Tract.—This tract lies in the anterior part of the posterior column, adjacent to the posterior commissure, posterior cornu, and the posterior median septum. It attains its greatest size in the lower lumbar region, and diminishes in size both above and below this level. This tract extends throughout the lumbar and sacral regions of the cord, originating as high as the eleventh dorsal segment and terminating at the fifth sacral segment.

The Septomarginal Tract.—This tract, as its name denotes, is located along the margin of the posterior median septum. It attains its greatest size in the sacral and lumbar regions. It consists of a narrow strip of fibers located alongside the median septum, extending in the sacral region as far forward as the cornu commissural tract, with which its fibers commingle, and reaching backward to the periphery of the cord, where it expands into an oval-shaped area. At the level of the fifth lumbar segment this tract is much reduced in size, extending ventrally to about one-half the length of the septum, and being entirely distinct from the cornu commissural tract. Above this level it rapidly diminishes in size, until at the level of the third lumbar segment it occupies a slight triangular field bordering on the posterior part of the septum and the adjoining part of the periphery of the cord. At the level of the twelfth dorsal segment it is entirely displaced from its position along the septum, and comes to occupy a small area along the dorsolateral periphery of the posterior column. Hoche has proved that this tract may originate as high as the lowest cervical segment, and that its fibers continue downward into the filum terminale.

In the cervical region, owing to the fact that the nerves coming from the lower extremity occupy the column of Goll and those of the upper extremity are confined to Burdach's column, a section of the cervical nerves at this level produces an ascending degeneration, confined to Burdach's column, which degeneration passes upward, terminating about the cells of the nucleus of this column in the medulla. Thus, the study of secondary degeneration proves that the entering posterior nerve-roots are located close to the posterior horns, and that the fibers which enter the cord at higher levels displace inward, toward the column of Goll, those that have entered below, so that in the cervical region the fibers from the lower extremities occupy almost entirely the columns of Goll, while most of those from the arms are located in the columns of Burdach.

GOWERS' ANTEROLATERAL ASCENDING TRACT—FASCICULUS VENTROLATERALIS SUPERFICIALIS.

This tract consists of neuraxones from the intrinsic cells of the intermediate gray matter, and from cells at the base of the anterior horns. This origin has been positively proved by the experiments of Mott, who found that when the posterior nerve-roots only were severed Gowers' tract remained undegenerated, but, on the other hand, when the intermediate gray matter was injured or destroyed, this tract was found degenerated throughout its entire extent. The axones from these intrinsic

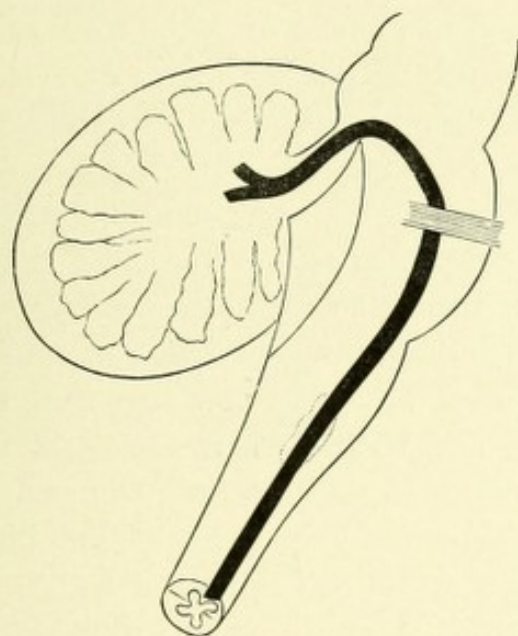


FIG. 54.—COURSE AND TERMINATION OF GOWERS' TRACT.—(*According to Hoche.*)

cells doubtless decussate in the anterior commissure of the cord, and pass obliquely across the white matter of the anterolateral area of the cord, where they occupy a broadly comma-shaped area, situated midway between the periphery and gray matter, in front of the direct cerebellar and crossed pyramidal tracts, and extending as far forward as the anterior nerve-roots, being separated from the periphery of the cord by the anterolateral descending tract of Marchi and Lowenthal. This tract increases in size from below upward, and passes into the anterolateral field of the formatio reticularis of the medulla oblongata, in which

region some of the fibers may be connected with the cells of the lateral nucleus. This bundle then continues onward through the medulla and pons as far as the root of the trigeminal nerve, beyond which point its course is in much dispute. According to Hoche,* the terminal course of Gowers' tract is as follows: At the level of the upper half of the olivary body the direct cerebellar tract turns backward into the restiform body, while Gowers' tract continues upward through the medulla and pons to the region of the trigeminal or fifth nerve, around which nerve it curves, and passes into the cerebellum by means of the velum medullare anticum and superior cerebellar peduncle.

Mott, however, after studying the course of Gowers' tract in monkeys, believes it to consist of two afferent bundles—axones from the gray matter of the cord: one, the ventral cerebellar tract, occupying the most peripheral part of this area, which, on reaching the pons, forms a loop over the fifth nerve to join the superior cerebellar peduncle, and then descends on its posterior aspect to the middle lobe or vermis of the cerebellum. The remaining bundle, which he terms the crossed afferent tract of Gowers and Edinger, continues upward through the cord, the medulla, and the pons, beyond which it lies outside of the lateral fillet or lemniscus, and terminates in the corpora quadrigemina, some fibers continuing to the optic thalamus.

Bechterew has shown that the constituent fibers of this tract receive their myelin at the eighth fetal month.

The function of this tract, according to Gowers, is to conduct sensations of pain and temperature, and the very interesting case recently reported by Henry Hun is confirmatory of the same fact.†

THE ANTEROLATERAL DESCENDING CEREBELLAR TRACT OF MARCHI AND LOWENTHAL.

This tract of fibers, discovered by Lowenthal, is located ventrad

* Hoche's case is the only one in man in which Gowers' tract has been completely traced. See original article in "Archives für Psychiatrie und Nervenkrankheiten," 1896, p. 510.

† "New York Medical Journal" for April 17, May 1 and 8, 1897: "Analgesia, Thermic Anesthesia and Ataxia."

to the crossed pyramidal tract, and extends along the anterolateral periphery of the cord as far forward as the anterior median fissure, some of its fibers being commingled with those of Gowers' tract. That this tract is distinct from the motor tracts seems proved by the fact that it has never been found degenerated after disease or ablation of the motor area of the brain. While the exact position of the anterolateral descending tract in the cord is well known, the source and distribution of its component fibers still remains in much doubt. The experiments of Marchi and Biedl seem to prove that the fibers of this tract have their origin in the cerebellum. Marchi found that, after hemi-extirpation of the cerebellum, a secondary descending degeneration occurred in the spinal cord, the degenerated area corresponding exactly to the known anatomic position of this tract. Biedl also found, on experimental division of the restiform body, a similar degeneration, thus confirming the earlier experiments of Marchi. Ferrier, Turner, and Risien Russel, on the contrary, found the anterolateral descending tract degenerated after destruction of Deiter's nucleus, the cerebellum and restiform body being intact. According to Risien Russel, this tract of fibers occupies a position in the formatio reticularis between the descending root of the fifth nerve and the raphe; the fibers pass downward between the inferior olivary body and the lateral nucleus, occupying the anterolateral periphery of the cord as far forward as the anterior median fissure. The anterolateral descending tract extends throughout the cord, but decreases in size from above downward. The fibers of which it is composed may enter the anterior horns at different levels, to terminate about their nerve-cells.

THE OLIVARY TRACT OF BECHTEREW.

The olivary fasciculus, or the triangular bundle of Helweg, appears on transverse section as a small triangular area of fibers located in the ventral part of the anterolateral portion of the spinal cord, with its base resting against the periphery of the cord. The most lateral fibers of the anterior nerve-roots frequently pass through this triangular area. At the beginning

of the motor decussation the olivary tract becomes spread out and loses its triangular shape. Just above the motor crossway the fibers of this tract occupy an oblong field along the ventral periphery of the medulla, adjacent to the anterior pyramid. At the beginning of the inferior olivary body the tract becomes much reduced in size, and again assumes a triangular form, the base of which caps the inferior part of the olive. At a higher level the tract appears to have joined the olivary body. It is possible, as suggested by Bechterew, that the fibers of which this tract is composed are axones from cells of the olivary body. The fibers of this tract, according to Bechterew, become medullated after birth, hence they are entirely distinct from the motor tracts or from the ground bundles of fibers. Because the fibers of the olivary tract become medullated at about the same time as those of the central tegmental tract of the medulla, Bechterew believes that both tracts form a functionally continuous system of fibers.

A LONG SENSORY TRACT IN THE GRAY MATTER (CIAGLINSKI).

In connection with the sensory tracts of the cord, mention may be made of a long sensory tract of fibers in the gray matter of the cord, discovered in 1896 by Adam Ciaglinski. This tract of fibers is somewhat pyramidal in shape on transverse section, and is located, according to Ciaglinski, in the gray commissure between the ventral border of the posterior columns and the central canal. It has been traced from the lumbar cord to the cervical enlargement. Ciaglinski believes its fibers to come from the posterior nerve-roots, and thinks that it may conduct sensations of pain and temperature. Further clinical and experimental evidence must be at hand before any positive statements regarding this tract can be made.

LISSAUER'S TRACT.

This comprises an area which surrounds the tip of the posterior horns, extending in part into the lateral column and in part into the column of Burdach. It is composed more particularly of

fibers from the lateral division of the posterior nerve-roots. These fibers soon divide, passing up and down and giving off collaterals, which, with the axones, enter the posterior horns and finally terminate in brush-like expansions about the cells existing in those horns.

ANTERIOR GROUND BUNDLES.

The anterior ground bundles occupy all of the anterior columns of each side save the direct pyramidal tract, the fibers of Gowers' tract, and those of Marchi and Lowenthal. They are collections of fibers which extend throughout the entire length of the cord, and consist of neuraxones from the intrinsic cells of the gray matter which lie near the base of the anterior horns. These neuraxones mostly cross in the anterior white commissure, although some fibers of the same side enter the anterior ground bundle of that side. After entering these columns the axones branch T-shaped, one branch passing upward, the other downward, both branches having only a short course. They give off collaterals at right angles. The branches, with their collaterals, reenter the gray matter at higher and lower levels, and end in brush-like expansions among the motor and intrinsic cells of the anterior cornua.

At the point of the motor crossing in the medulla, part of the fibers of the ground bundles are pressed backward into the posterior part of the *formatio reticularis*, where they continue upward as a distinct bundle of nerve-fibers on each side of the raphe, and from this point on are called the posterior longitudinal bundles.

One of the functions of this system of fibers is to associate different levels of the anterior cornua, thus bringing into harmony the action of the motor-cells of various levels.

THE GROUND BUNDLES OF THE LATERAL COLUMNS, OR THE LATERAL LIMITING LAYERS.

These bundles of fibers occupy areas adjacent to the gray matter of the cord between the anterior nerve-roots and base of

the posterior horns of each side. They are composed of neuraxones from the intrinsic cells of the intermediate gray matter of the same and opposite sides. The axones pass into the white matter and bifurcate, passing, after a short course, upward and downward; with their collaterals, reenter the gray matter at higher and lower levels, where they divide into fine filaments about the intrinsic nerve-cells. These bundles are traversed by many fibers from the cells of the gray matter passing across the lateral columns, and also by fibers entering the gray matter from the crossed pyramidal tract. They may serve to associate different levels of the gray matter. Experimental evidence seems to prove that the fibers of the ventral portion of the lateral limiting layer associate different levels of the anterior cornu of the same side, while the fibers of the dorsal portion probably associate different levels of the posterior cornu of the same side.

THE SPINAL NERVES.

There are thirty-three pairs of spinal nerves in man, each pair corresponding to a spinal segment.* According to the region from which they issue, they are termed cervical, dorsal, lumbar, sacral, and coccygeal nerves, there being eight cervical, twelve dorsal, five lumbar, five sacral, and three coccygeal nerves. These nerves—each possessing an anterior and a posterior root—emerge from the cord at regular intervals. The anterior roots, which leave the cord, arise from the multipolar cells of the anterior horns and pass out through the anterolateral columns of the cord. The posterior roots, which enter the cord, have their point of entrance at the posterolateral sulci.

These nerve-roots are made up of filaments,—from five to ten in number for each root,—the posterior roots having their filaments associated into two bundles. The posterior sensory roots are of greater size than the anterior or motor roots, and have connected with them the posterior spinal ganglia.

* Most anatomists only enumerate thirty-one pairs of spinal nerves; this is owing to the fact that the two lowest pairs of coccygeal nerves are rudimentary, and hence without special function.

SPINAL GANGLIA.

The spinal ganglia are in general located in the epidural space, just in front of or within the intervertebral foramina. The ganglia connected with the sacral nerves, however, are contained within the subdural space of the spinal canal. The spinal ganglia are oval, usually bilobate, the lobes corresponding to the two bundles of filaments into which each sensory nerve-root is divided. Each ganglia is made up of a large number of cells, chiefly unipolar, spheric, or slightly pyriform in shape, and between 60 to 80 μ

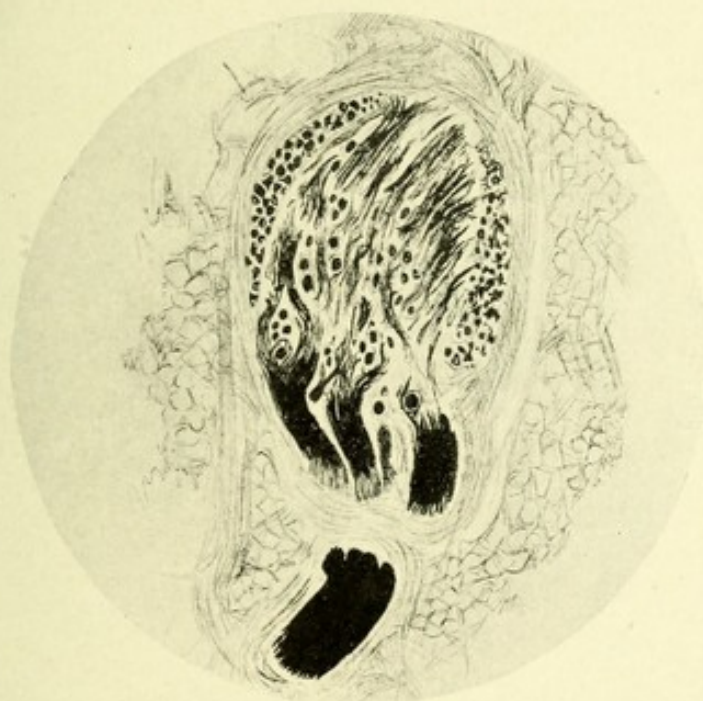

FIG. 55.—TRANSVERSE SECTION THROUGH A POSTERIOR SPINAL GANGLION. Stained after the method of Weigert.

in diameter; great variations in size occur, the largest being as much as 170 μ in diameter, and the smallest as low as 25 μ in diameter (Figs. 55 and 56).

Each cell is surrounded by a distinct connective-tissue capsule, which is continuous with Henle's sheath of the corresponding axis-cylinder, and is lined with a layer of epithelium. Beneath this capsule, surrounding the protoplasm of the cell, exists a small, clear, homogeneous, unstainable space devoid of granules. This seems to indicate that the protoplasm does not entirely

occupy the capsule; at least Lenhossek says that this clear space is not an artifact, due to the shrinking of the protoplasm during the process of hardening. The protoplasm is made up chiefly of chromophyllic granules. These granules are very fine throughout the body of the cell, but around the periphery there exists a layer of much coarser granules. The construction of the matrix in which these granules are embedded is still in dispute. By some it is considered to be composed of a number

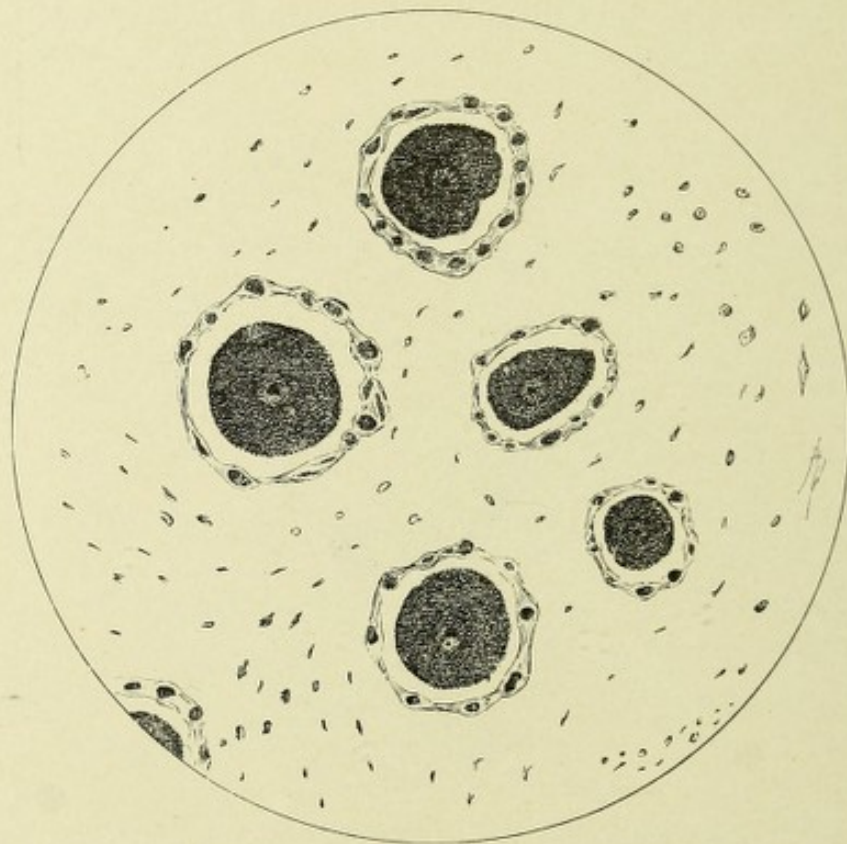


FIG. 56.—A GROUP OF CELLS FROM A HUMAN POSTERIOR SPINAL GANGLION. Stained after the method of Nissl.

of fine fibrillæ, continuous with the fibrillæ composing the axones, while others assert that no such fibrillæ exist. These latter believe that the matrix is simply a homogeneous ground substance in which the granules are embedded. Most of the cells of the posterior spinal ganglia are very deeply pigmented, the pigmentation being limited to the protoplasm, and occurs most often near the point of exit of the axone.

These cells contain a large spheric nucleus, surrounded by

a distant nuclear membrane. It is centrally located, contains a small nucleolus, and is made up of very fine granules. By far the greater number of these cells are monopolar, and hence give off but one axone. This axone, at a short distance from the cell-body, bifurcates T-shaped, one branch passing peripherally to terminate in a sensory end organ, while the

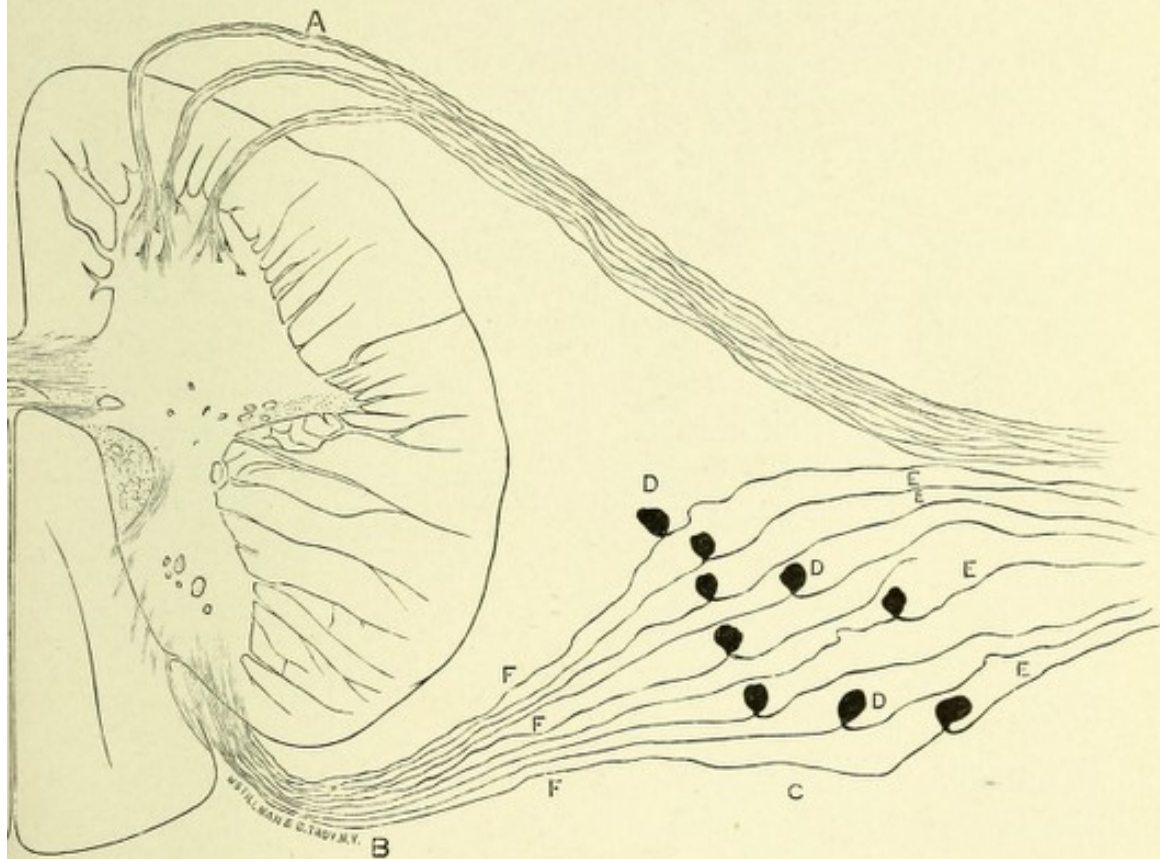


FIG. 57.—SCHEMATIC REPRESENTATION TO SHOW THE ORIGIN AND RELATIONS OF THE ANTERIOR AND POSTERIOR SPINAL NERVE-ROOTS.

A. Anterior or motor nerve-roots. B. Posterior or sensory nerve-roots. D. Posterior spinal ganglia. F. Central, E, peripheral, axones of the posterior spinal ganglia.

other continues centrally to arborize about nerve-cells in the spinal cord or medulla oblongata.

A few of these cells are bipolar, giving off two axones, one from each pole, one of which is peripheral as above and the other central. According to Dogiel, there exists in the posterior spinal ganglia numerous small cells which he calls spinal ganglion cells of the second type. These cells might be very properly termed the intrinsic cells of the posterior spinal ganglia. The

chief axone of each cell terminates, after losing its myelin sheath, in an arborization about and within the capsule of a chief spinal ganglion cell, forming an extra- and intra-capsular network. Dogiel further asserts that these intrinsic cells are in turn surrounded by the termination of sympathetic nerve-fibers.

The function of these posterior spinal ganglia is doubtless trophic, since on section of the nerve-roots posterior to their ganglia the fibers degenerate to their peripheral destination, while if they are divided anterior to their ganglia, there is an ascending degeneration of the fibers which continues as far as they extend, the short fibers to the posterior horns, the long fibers to their nuclei in the medulla. According to Edinger, the sensory fibers, carrying impressions of equilibrium to the cells of Clarke and Stilling, are dependent on these cells for their nutrition and not upon the cells of the spinal ganglion, merely passing between them in their course. The anterior and posterior nerve-roots become continuous in the intervertebral foramina, and continue peripherally as mixed nerves, having both motor and sensory functions. (See Fig. 57.)

THE ANTERIOR OR MOTOR NERVE-ROOTS.

The anterior nerve-roots, which consist of both coarse and fine fibers and are distributed to the voluntary muscles,* are the neuraxones of the motor cells of the anterior cornua of the spinal cord. The multipolar cells of large size give off axones which are greater in diameter than are those from the multipolar cells of smaller size. There are three distinct bundles of these axones, which form the anterior nerve-roots: first, a lateral bundle, coming from the lateral cell group; second, a median bundle, arising from the median cell group; and lastly, an inner bundle, springing from the anterior cell group.

These axones give off a few collaterals, the termination of which remains unknown. The anterior nerve-roots pass out of the anterolateral area of the cord in curves, and take mostly a

* According to Gaskell and Mott, the fine fibers join the sympathetic system and are distributed to the involuntary muscles of the internal organs.

downward direction. The curvature of the anterior nerve-roots gradually increases from above downward, so that while in the cervical region they are given off almost at right angles, with exception of the first cervical nerve, which ascends slightly, to pass between the atlas and occipital bone. In the dorsal region they

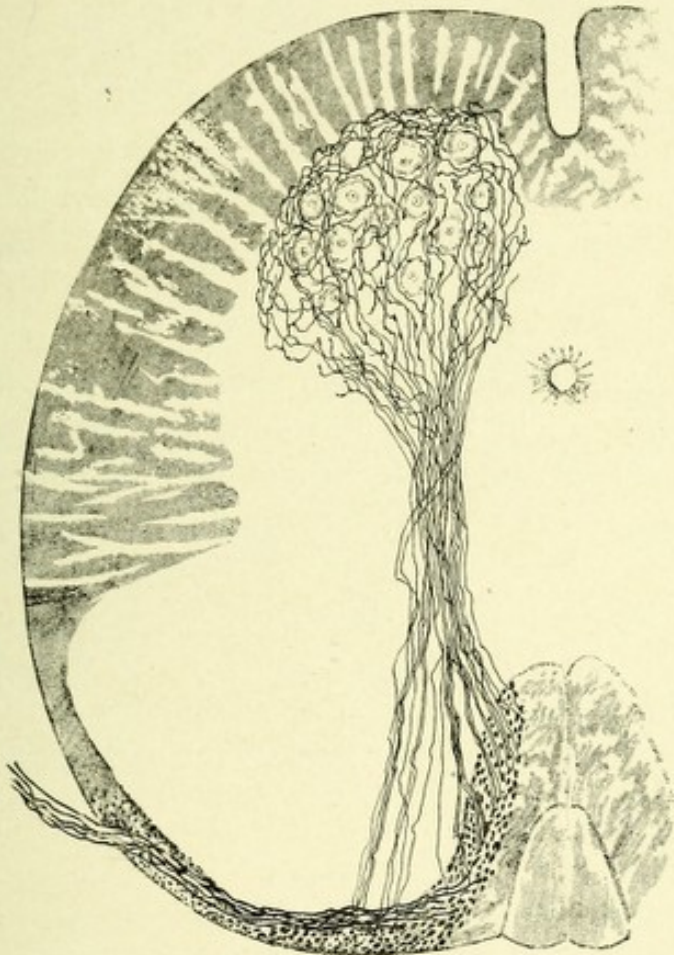


FIG. 58.—A SECTION THROUGH THE SPINAL CORD OF A NEW-BORN MOUSE. Showing reflex collaterals from posterior nerve-roots terminating about the nerve-cells of the anterior horn.—(After Lenhossek.)

are oblique, and in the lumbar and sacral regions their course is almost vertical.

THE POSTERIOR OR SENSORY NERVE-ROOTS.

These roots, on entering the cord, are arranged into two bundles—a lateral and a mesial. The former is composed of fibers of small size, which, near the tip of the posterior horn,

enter the substantia gelatinosa, become vertical, and form the boundary zone or column of Lissauer. The mesial bundle consists of fibers, some of which pass into the column of Burdach, while others pass through that column into the column of Goll. All these root-fibers bifurcate on entering the cord, one process passing upward, the other downward. Both divisions are constantly giving off collaterals at varying distances. Many of the fibers having a downward course unite to form a comma-shaped fasciculus or tract in the median portion of Burdach's column.

Those fibers which pass upward, with the exception of those which reenter the gray matter (see posterior column), end about the cells of the nuclei of the columns of Burdach and Goll in the medulla. The collaterals from these longitudinal fibers all pass into the gray matter, and may, in general, be divided into three sets: First, collaterals which pass across the intermediate gray matter to end in brush-like expansions about the motor nerve-cells of the same side; these are called sensorimotor or reflex collaterals; second, collaterals which end in arborizations about the cells of Clarke and Stilling and the intrinsic cells of the gray matter; these collaterals come largely from the middle region of Burdach's column; third, collaterals which pass across in the posterior or gray commissure and end among cells in the fine network of fibers of the substantia gelatinosa of the posterior horn of the opposite side.* (See Figs. 45 and 59.)

THE APPEARANCES OF TRANSVERSE SECTIONS OF THE CORD AT DIFFERENT LEVELS.

In the sacral region there is a preponderance of gray matter, there being only a thin layer of white matter, the most of which exists in the posterior columns. In general, the anterior and

* According to Morat and Bonne, there are present in the posterior nerve-roots a few centrifugal elements. They proved this fact by observing that, on stimulation of the peripheral end of a severed posterior nerve-root, there occurred vasomotor phenomena in the area of distribution of the nerve. They also found that, on section of the posterior nerve-roots of the last lumbar and first sacral segments central to the ganglia, on the central side of the section the great majority of the fibers degenerated, while a few remained normal. In the peripheral end, on the contrary, most of the fibers remained normal, while a few degenerated, thus proving that a few fibers degenerated downward and receive their nutrition higher up in the cord or in the brain stem. These facts remain to be corroborated by future observations.

posterior horns resemble each other in size and thickness. The lateral horns are well marked. The commissure is very broad.

The *conus terminalis* on transection resembles closely similar sections of the lower sacral part of the cord, the gray matter

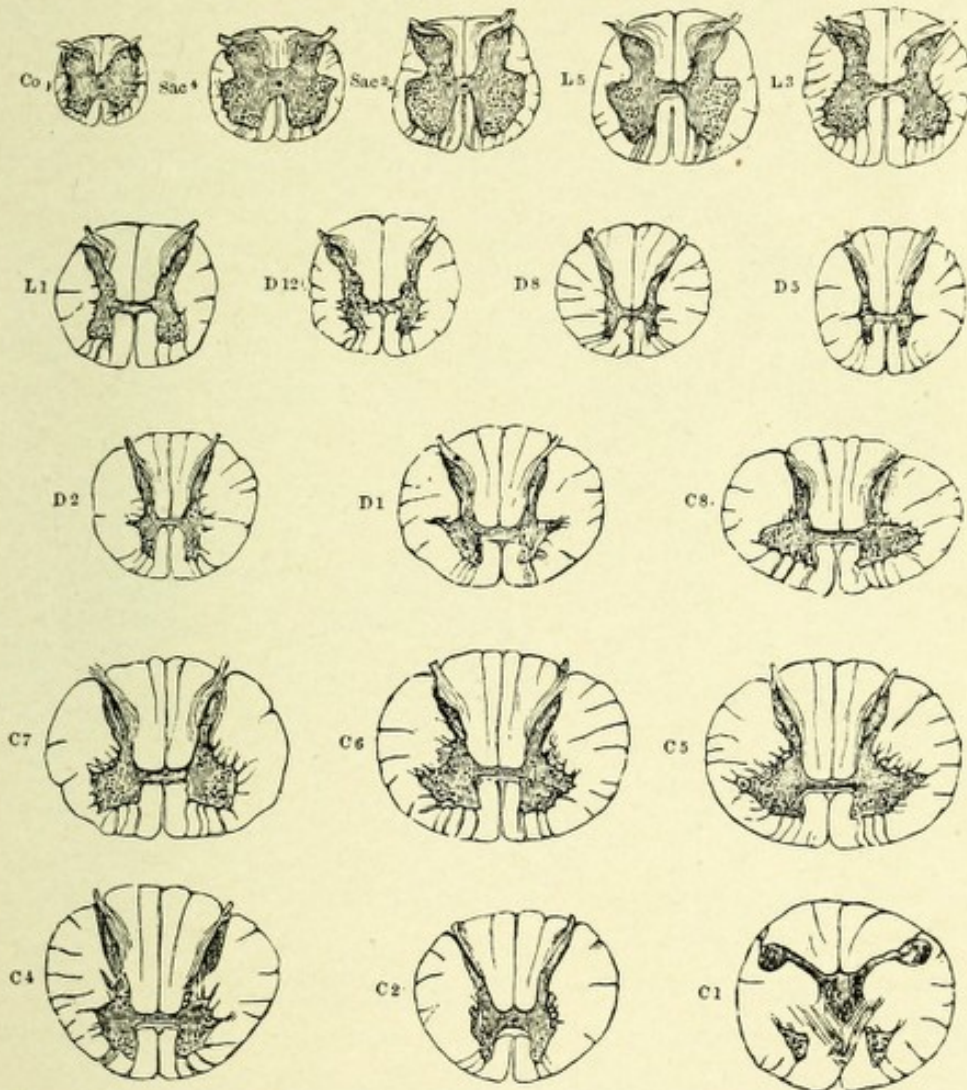


FIG. 59.—DIAGRAM SHOWING THE RELATIVE SIZE AND FORM OF DIFFERENT SEGMENTS OF THE COCCYGEAL, SACRAL, LUMBAR, DORSAL, AND CERVICAL CORD.—(After Gowers.)

preponderating, while the white matter consists of a very thin margin, most evident in the lateral columns.

In the lumbar region the outline of the cord is circular, the anterior horns are much broader and thicker than the posterior. There exist in the anterior horns well-defined groups of motor nerve-cells, which give exit to a large number of motor nerves

which are distributed to the lower extremities. The lateral horns are distinct only in the lower segments. The white matter preponderates, owing to the great number of nerve-fibers received from the lower extremities.

In the dorsal or thoracic region the gray matter consists of two narrow crescentic bodies united by means of a band of gray

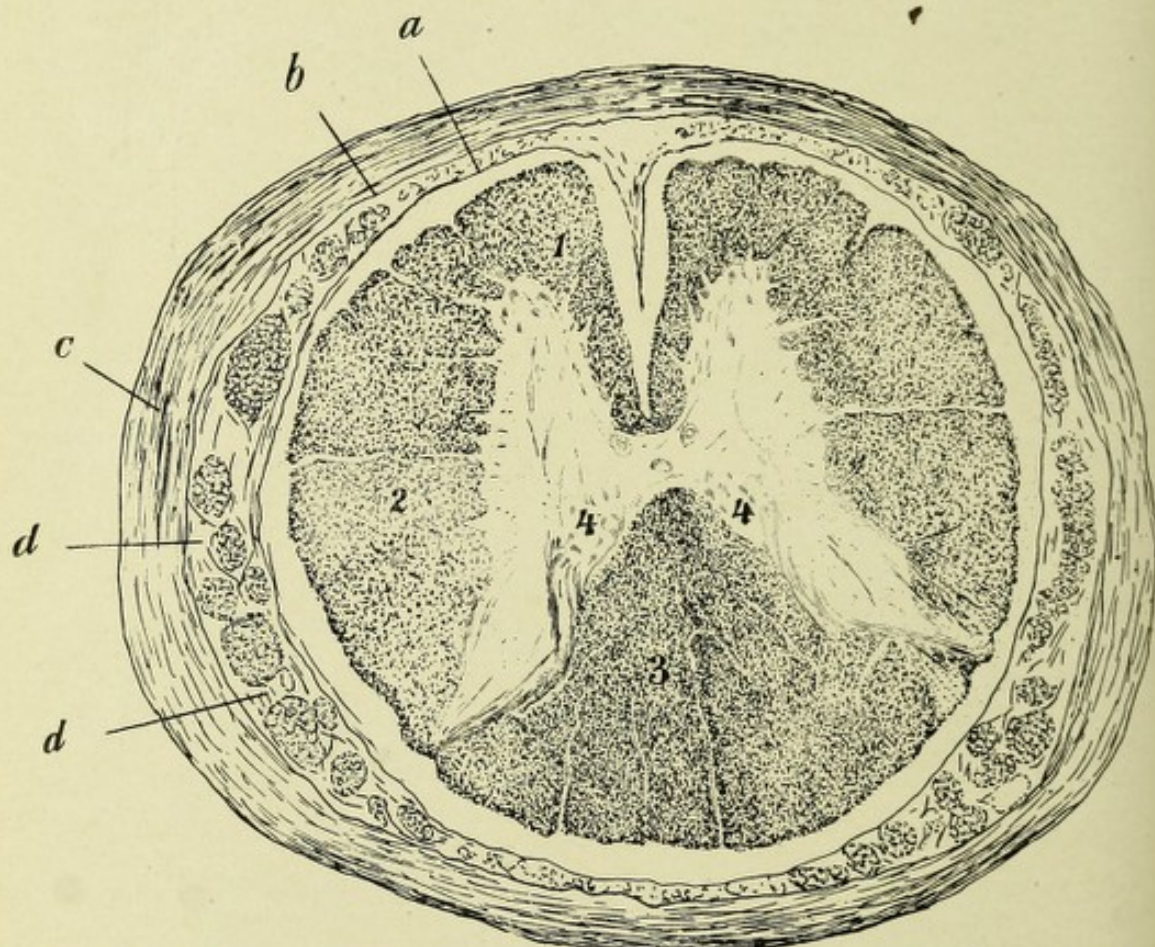


FIG. 60.—TRANSVERSE SECTION THROUGH A SACRAL SEGMENT OF THE SPINAL CORD.
Weigert preparation.

a. Pia mater. *b.* Arachnoid. *c.* Dura mater. *d, d.* Severed descending nerve-roots. 1. Anterior column. 2. Lateral column. 3. Posterior column. 4, 4. Cell groups of Stilling.

and white matter—the commissures. The lateral horns are well seen only in the upper segments. The anterior and posterior horns are about equal in thickness, but the anterior horn is much shorter, and contains, in this region, very few ganglionic cells. In the upper part, at the base of the posterior horn, is the group of the cells of Clarke. The great amount of white matter is the striking feature of transverse sections of this

region. In the upper part is found the beginning of the postero-intermediate septum, which is the dividing-line between the columns of Goll and Burdach.

In the cervical region there is a general increase in the size of the cord, which affects the gray as well as the white matter. This is due to the fact that this region receives the fibers from the upper extremities as well as the long and short tracts from below. The cord is flattened anteroposteriorly, hence loses its cylindric form. The lateral horns are very prominent, and in the upper segment exists a cell-group at the base of these horns, which group gives origin to the spinal accessory or eleventh pair of cranial nerves. The processus reticularis is prominent on the outer side of the gray matter between the anterior and posterior horns. The anterior horns are short and broad and appear of large size, which is due somewhat to the lateral extension of gray matter forming the lateral horns. The posterior horns are long and slender and gently diverge, the divergence increasing as the segments gradually approach the medulla. At the same time the central canal trends backward and assumes a somewhat flattened appearance. The nerve-roots leave the cord at nearly right angles.

NEUROGLIA OF THE SPINAL CORD.

The neuroglia of the cord, as elsewhere throughout the central nervous system, consists of large numbers of neuroglia cells (astrocytes) with their processes, which latter pass between the nerve-fibers and cells and around the blood-vessels, forming a supporting framework, ground substance, or stroma, in which the elements of the cord are embedded. In addition to the neuroglia cells described under head of histologic elements, there occurs lining the central canal of the cord, as well as the ventricles of the brain, a supporting framework similar in function to neuroglia tissue, but made up of the so-called ependymal cells and processes. In the cord during embryonic life these cells are oval or fusiform in shape, and are arranged around the central canal in a radiating manner. They possess two processes, one short and thick, extending to the cavity of the central

canal, then being prolonged into its lumen as a very fine ciliated process; the other, or peripheral process, extends transversely through the gray and white matter, to end just beneath the pia in a club-shaped enlargement. As this process nears the pia it frequently divides into two or more branches, which end as

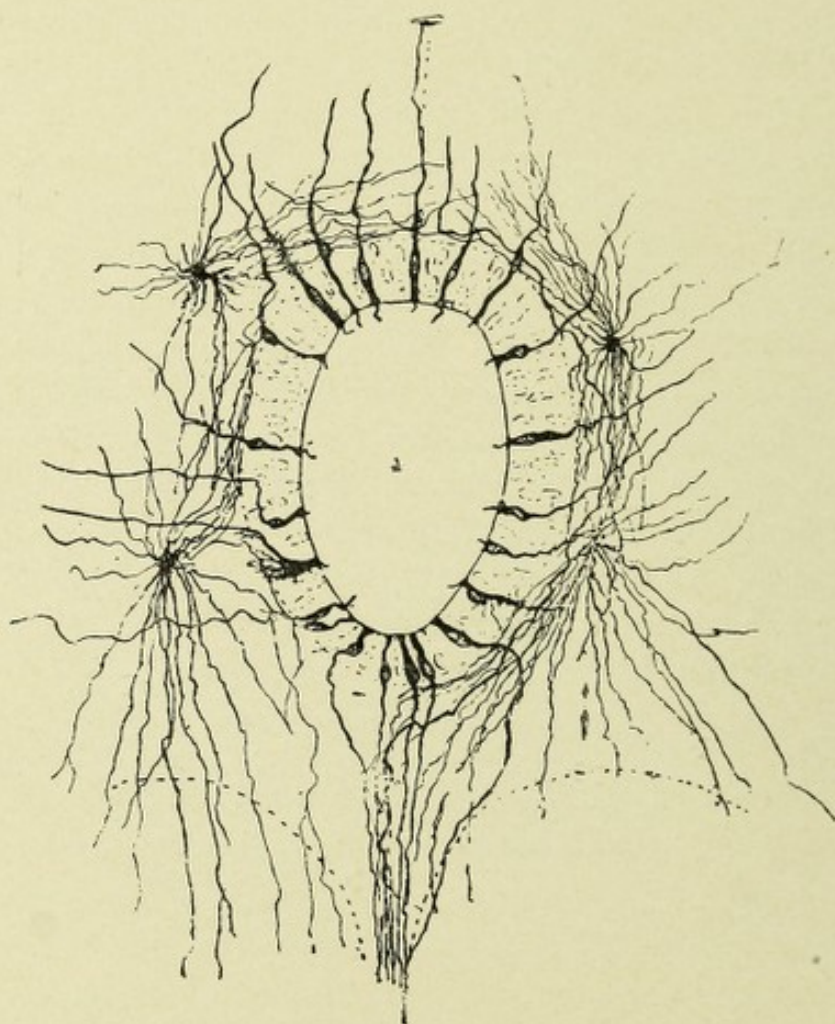


FIG. 61.—A SECTION THROUGH THE SPINAL CORD OF A HUMAN FETUS, 23 CM. IN LENGTH. Showing the central canal with its substantia gelatinosa centralis and ependymal cells.—*(After Lenhossek.)*

above described. As age advances this typical arrangement of the ependymal cells becomes lost by atrophy of its processes and the probable transformation of the ependymal cells into adult neuroglia cells.

In the following locations the neuroglia of the cord is much increased in amount: (1) Around the entire periphery of the

cord, where it forms a distinct mantle; (2) in the anterior horns; and (3) in the region of the central canal.

THE SUBPIAL NEUROGLIA LAYER, THE RINDENSCHICHT OF THE GERMANS.

This layer consists of a thick, closely-meshed network of neuroglia fibers, having interspersed among them large num-

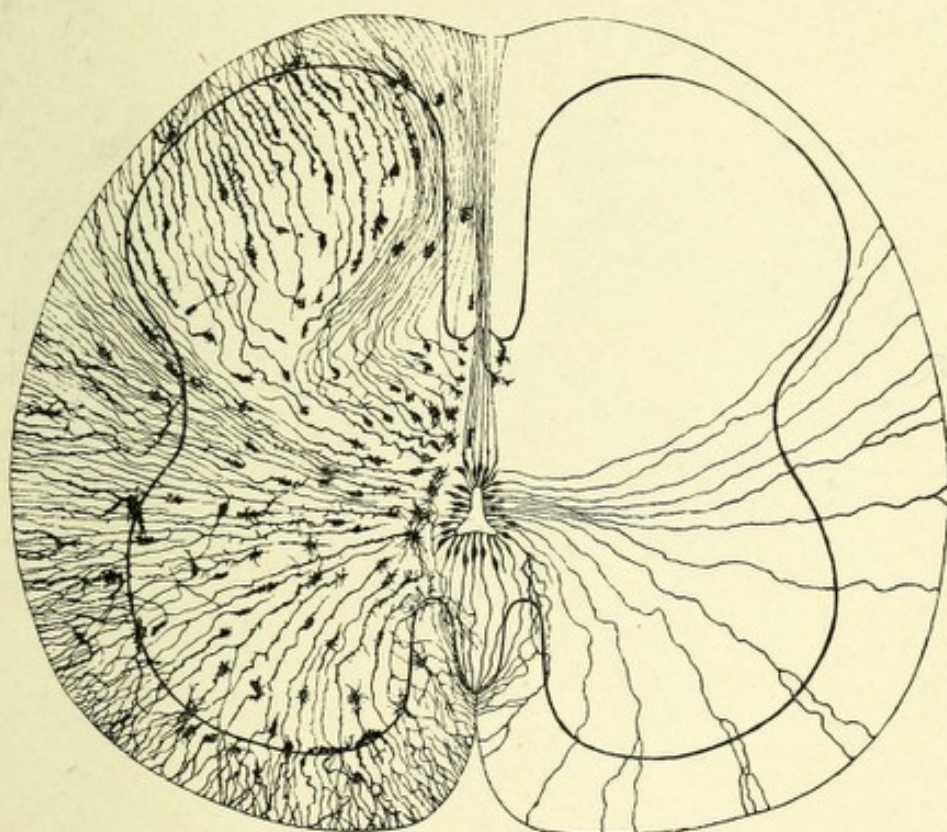


FIG. 62.—TRANSVERSE SECTION OF THE SPINAL CORD OF A HUMAN EMBRYO, 14 CM. IN LENGTH. Illustrating the distribution of neuroglia. On the right are seen the ependymal cells. On the left, the neuroglia cells.—(After Lenhossek.)

bers of neuroglia cells. It forms a covering or mantle for the cord, which varies in thickness from 0.01 to 0.06 mm. This layer is entirely distinct from the pia mater. It is thickest in the region about the anterior and posterior nerve-roots, and gives off fine parallel coursing bundles of fibers, which accompany the nerve-roots for a short distance. It is also quite thick at the entrance of the posterior median fissure, where a process, the posterior median septum, extends into that fissure

and serves to divide the posterior columns into symmetric halves, and conducts blood-vessels into the cord. A distinct process of neuroglia exists in the cervical region, the posterior intermediate septum, which separates the columns of Goll and Burdach from each other. The cells of this layer all possess long fibers, and are stellate in shape. The subpial neuroglia

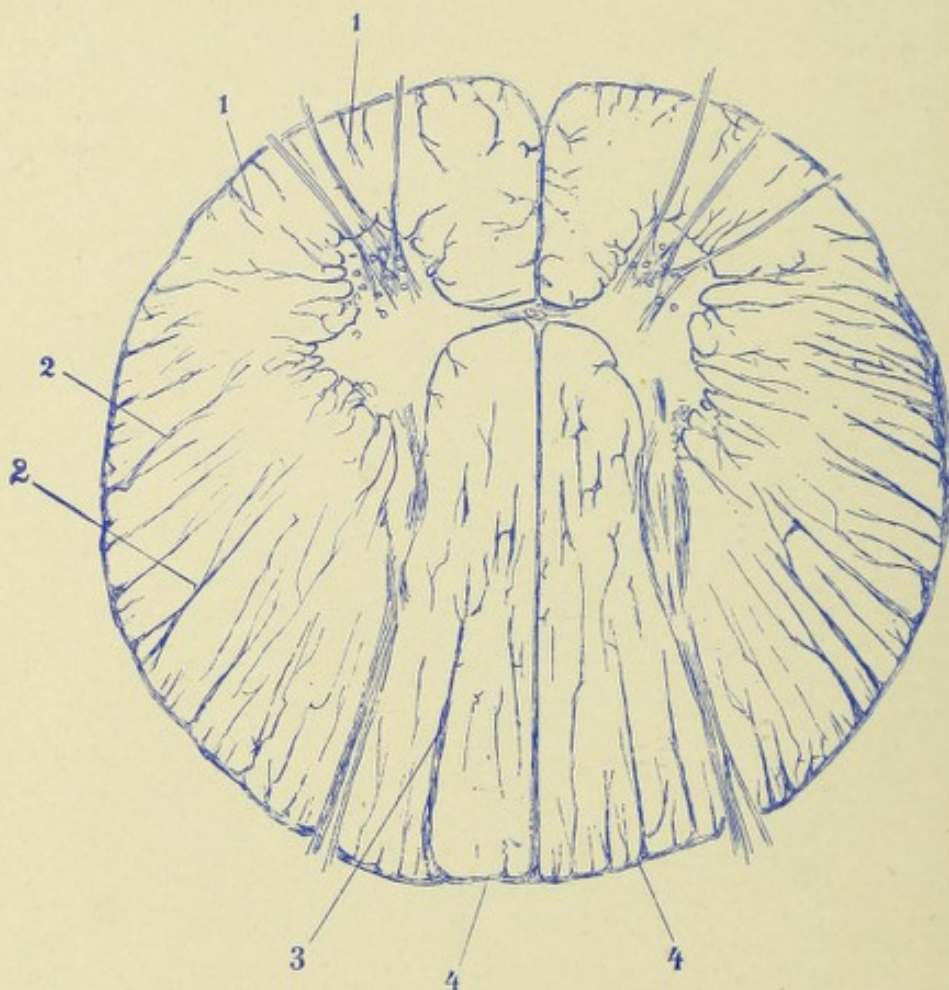


FIG. 63.—A TRANSVERSE SECTION THROUGH A SEGMENT OF THE DORSAL CORD TO SHOW THE GENERAL ARRANGEMENT OF NEUROGLIA. Nigrosin stain.
1, 1, 2, 2. Short and long neuroglia septa. 3. Postero-intermediate septum. 4, 4. Subpial neuroglia layer.

layer sends into the white matter of the cord numerous processes having a radial course, the glia septa, which accompany the blood-vessels; these processes surround the vessels and form for them canal-like channels. The neuroglia of the white matter of the cord consists only of cells with long processes. The fibers of the white matter, apart from being separated by

the glia septa into many bundles, are separated from one another by a delicate cribriform framework of neuroglia, so arranged that each individual nerve-fiber is surrounded by a neuroglia process. In the posterior columns this neuroglia framework is much increased in amount. No ordinary connective tissue exists in the cord save that which forms the adventitia of the blood-vessels, and the pia process extending into the anterior median fissure.

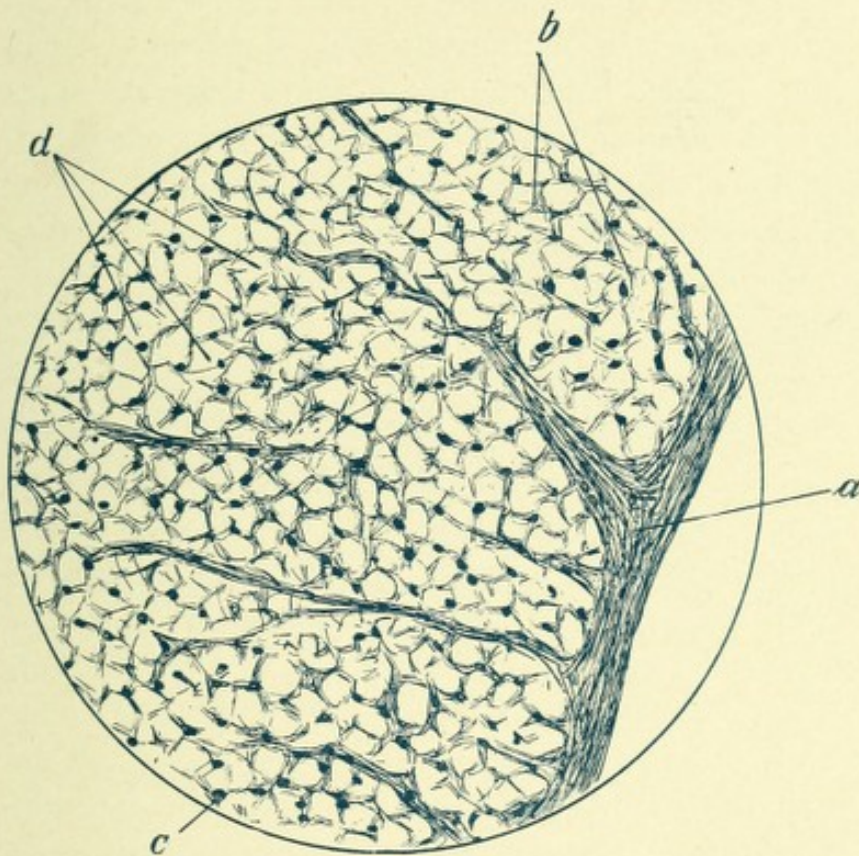


FIG. 64.—A CAMERA LUCIDA DRAWING OF A FIELD OF THE LATERAL COLUMN OF FIGURE 63. Nigrosin stain.

a. Subpial neuroglia layer with septa. *b.* Cribriform framework of neuroglia. *d.* Severed nerve tubes. *c.* Stellate neuroglia cells.

The neuroglia of the gray matter differs from that of the white matter in containing both varieties of cell. The antero-lateral horns contain an abundance of neuroglia cells and fibers, and according to Lenhossek, the cells with short processes predominate. These horns possess a rich network of very fine neuroglia fibers, in addition to coarse fibers which have a horizontal course, and are arranged in bundles which become nar-

rowed as they pass out with the anterior nerve-roots, while the central ends spread out in the interior of the cornua.

Posterior Horns.—The tip of the posterior horn and Lissauer's columns contain a rich plexus of neuroglia fibers, while the substantia spongiosa is very much less rich in neuroglia.

The Substantia Gelatinosa Rolandi.—This region of the posterior horn, contrary to the usually accepted opinion, is, according to Weigert, very poor in neuroglia, the few neuroglia fibers being found there having a radial arrangement.

The **region of the central canal** is rich in neuroglia cells and fibers. These are chiefly arranged in the form of a circular network just beneath and around the central canal. In front and behind the central canal the fibers display a commissural-like arrangement; laterally they are continuous with the fibers of the anterior horns (Fig. 61).

THE BLOOD SUPPLY OF THE SPINAL CORD.

The arteries which nourish the cord are the following: First, lateral spinal branches from the subclavian, from the thoracic intercostals of the aorta, from the lumbar, and from the internal iliac arteries. Second, the anterior and posterior spinal branches of the vertebrals. The anterior are two in number, and arise from the vertebrals a little below their junction to form the basilar, and at the level of the foramen magnum they unite into one vessel, the anterior median artery, which extends downward, throughout the entire length of the cord, receiving branches of reinforcement from the lateral spinal arteries. This vessel lies in the pia mater, which it supplies, and it also gives off branches to the substance of the cord.

The posterior spinal arteries, two in number, usually arise from the vertebrals at the sides of the medulla and pass backward to the dorsal portion of the medulla, where they take a descending course behind the line of attachment of the posterior nerve-roots, extending downward to the cauda equina.* These ves-

* The posterior spinal arteries occasionally have their origin from the posterior inferior cerebellar arteries (Duret).

sels receive reinforcements from the lateral spinal arteries through the intervertebral foramina. The lateral spinal arteries after entering the cord are designated root arteries. They pierce the dura mater, and send branches to the anterior and posterior nerve-roots. The anterior root arteries, of which there are about eight, are about twice as large as the posterior root arteries, but only one-half as numerous. The more minute arterial divisions which supply the substance of the cord may

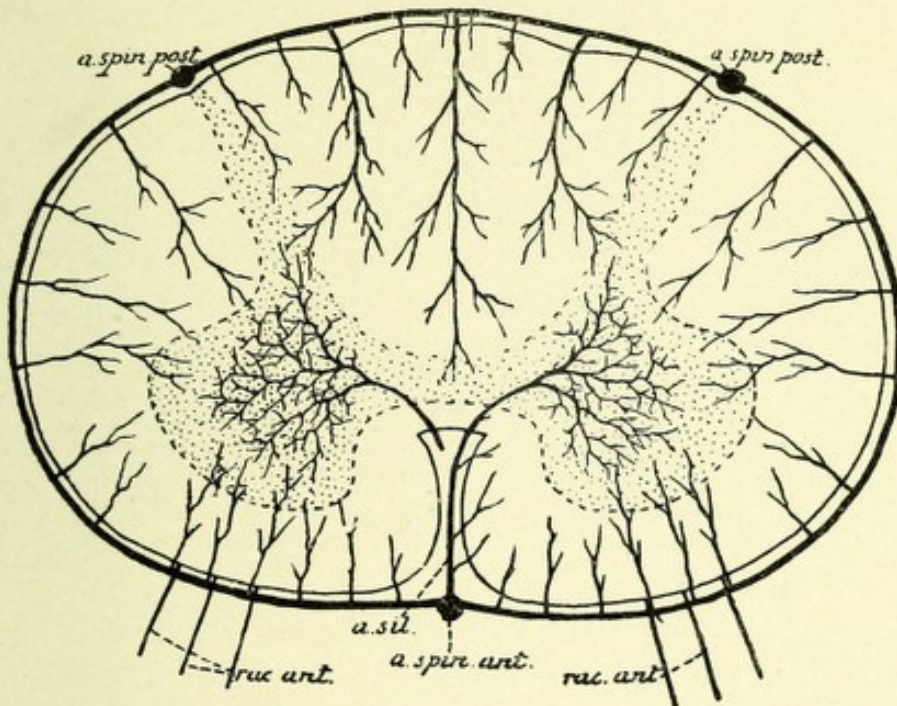


FIG. 65.—SCHEME TO SHOW THE COURSE AND DISTRIBUTION OF THE TERMINAL BRANCHES OF THE ARTERIAL PLEXUS OF THE PIA MATER.—(After Van Gehuchten.)

a. spin. post. Posterior spinal arteries. *a. spin. ant.* Anterior spinal arteries. *a. sil.* Anterior median fissure. *rac. ant.* Anterior root arteries.

be divided into two sets: first, a centrifugal set, which is composed of a series of arterioles, about 250 in number, which come from the anterior spinal artery into the anterior median fissure, penetrating the anterior commissure, then dividing into a right and a left branch, which soon subdivide into smaller arteries and capillaries for the central part of the gray matter. Ascending and descending branches are given off for anastomosis with the corresponding vessels at different levels. The centripetal set have a radial arrangement, coming in from all

parts of the periphery. They consist of short and long branches, the short branches supplying the outer portion of the white matter of the cord, the long branches penetrating the gray matter and supplying the parts not supplied by the centrifugal vessels. The posterior horns, as well as the adjacent white matter and cells of Clarke, are supplied by a small median artery, the inter-funiculate, which passes between the posterior columns of each side to the posterior commissure and then divides, entering the before-mentioned regions. The posterior fissural artery passes ventrally through the posterior median fissure to supply the columns of Goll.

VEINS OF SPINAL CORD.

These have no valves. They issue from the interior of the cord alongside of the anterior and posterior nerve-roots—hence they are often called root-veins. Of these, there are from forty to fifty in number—twenty-five to thirty anterior, the remainder posterior. They pass into the pia mater, where they form plexuses which cover the entire surface of the cord, emerging chiefly from the anterior and posterior median fissures, where they join the anterior and posterior longitudinal median veins. Near the base of the skull two or three small branches are formed, which communicate with the vertebral veins and then terminate in the inferior cerebellar veins, or in the inferior petrosal sinuses.

CHAPTER III.

THE MEDULLA OBLONGATA, OR BULB.

The medulla oblongata extends from the lower border of the transverse fibers of the pons Varolii above to the foramen magnum below, and gradually decreases in size from above downward. It is somewhat rhomboid in shape, and is continuous below with the spinal cord. Its anterior surface rests in the basilar groove of the occipital bone, while its posterior surface is continuous above with that of the pons Varolii, and lies between the hemispheres of the cerebellum, in a fossa called the vallecule, or little valley. Issuing from it are the lower six pairs of cranial nerves.

The medulla is divided into symmetric halves by the extension upward of the anterior and posterior median fissures of the cord. The anterior median fissure contains a fold of pia mater, and continues upward to just below the pons, where it ends in a small fossa, the foramen cæcum. It is interrupted below by the motor or pyramidal decussation. The posterior fissure is a deep but narrow fissure, and continues upward to about the middle of the medulla, where, owing to the divergence of the posterior columns, it becomes lost on the floor of the fourth ventricle.

The medulla may be divided into anterior, lateral, and posterior columns, which are continuations upward of the corresponding columns of the spinal cord. The columns, together with special deposits of nervous matter peculiar to the medulla, give to it its outward configuration. The anterior columns, or, more properly, the anterior pyramids of the medulla, lie between the anterior median fissure and the exit of the hypoglossal or twelfth pair of cranial nerves below, and the exit of the sixth pair above. The exact line of division between the anterior

pyramids and the lateral columns is the ventrolateral groove, which is the direct continuation upward of the line of emergence of the anterior nerve-roots of the spinal cord. The anterior columns of the cord are continued upward into the medulla in the same relative position on each side of the anterior median fissure. They form only a small number of the fibers present at or above the motor or pyramidal crossing.

In the spinal cord were noted two distinct divisions of the motor or pyramidal tracts, one coming down in the anterior column, adjacent to the anterior median fissure, known as the direct pyramidal or motor tract; the other, much greater in size, occupying a large area in the posterior part of the lateral column of the cord, known as the crossed pyramidal or motor tract because of having crossed in the medulla. These two bundles, direct and crossed motor tracts, form the anterior columns or pyramids of the medulla.

The lateral columns, or lateral areas of the medulla, lie between the exit of the hypoglossal nerves or the ventrolateral grooves in front and the exit of the spinal accessory, pneumogastric, and glossopharyngeal nerves behind, which nerves issue from the dorsolateral grooves, which are the continuation upward of like-named grooves existing in the cord. The olivary bodies are embedded in the upper part of the lateral area. The lateral columns are continuations upward of the corresponding columns of the cord, but the latter are not preserved as such in their entirety, owing to the fact that the fibers of the crossed pyramidal tracts leave their position to form the motor decussation, and the direct cerebellar tracts or columns of Flechsig gradually trend backward and unite with the restiform bodies to pass into the cerebellum.

The posterior area of the medulla is a continuation upward of the posterior columns of the spinal cord, which have gradually increased in size from below upward. This area is subdivided by a neuroglia process—the postero-intermediate septum—into the inner or column of Goll, and the outer or column of Burdach, which in turn are separated from the lateral area of the medulla by the dorsolateral groove. The former passes upward, the fibers of which it is composed ending about a collection of ganglionic

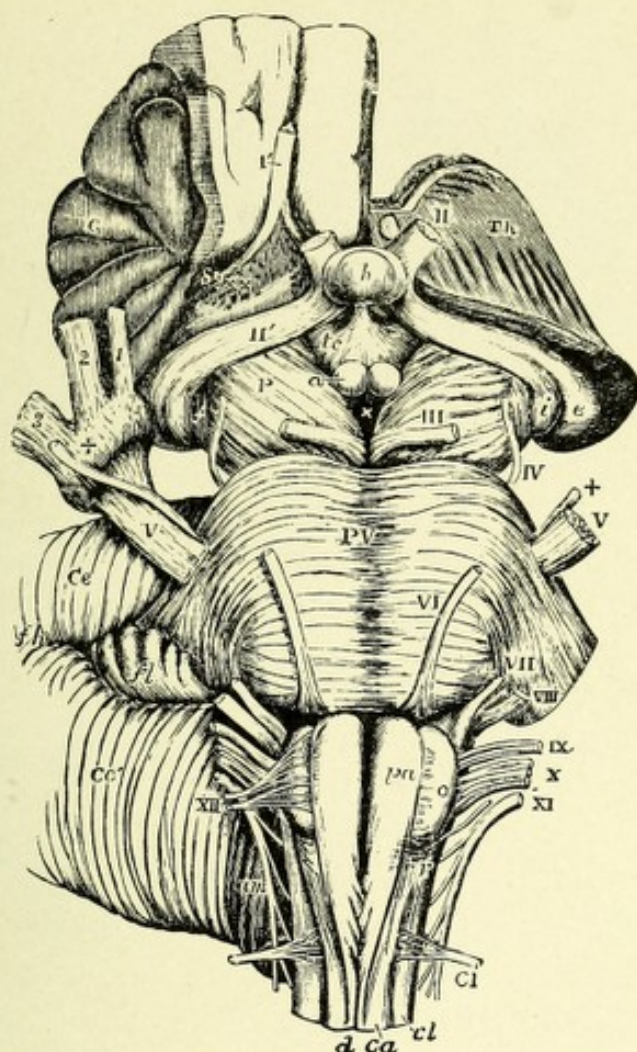



FIG. 66.—VIEW FROM BEFORE OF THE MEDULLA OBLONGATA, PONS VAROLII, CRURA CEREBRI, AND OTHER CENTRAL PORTIONS OF THE ENCEPHALON (Natural size).—(Allen Thomson.)—(From Quain's "Anatomy.")

On the right side the convolutions of the central lobe, or island of Reil, have been left, together with a small part of the anterior cerebral convolutions; on the left side these have been removed by an incision carried between the thalamus opticus and the cerebral hemisphere.

I'. The olfactory tract cut short and lying in its groove. II. The left optic nerve in front of the commissure. II'. The right optic tract. *Th.* The cut surface of the left thalamus opticus. *C.* The central lobe or island of Reil. *Sy.* Fissure of Sylvius. $\times \times$. Anterior perforated space. *e.* The external corpus geniculatum. *i.* The internal corpus geniculatum. *h.* The hypophysis cerebri or pituitary body. *tc.* Tuber cinereum with the infundibulum. *a.* One of the corpora albicantia. *P.* The cerebral peduncle or crus. III. Close to the left oculomotor nerve. \times . The posterior perforated space.

The following letters and numbers refer to parts in connection with the medulla oblongata and pons. *PV.* Pons Varolii. *V.* The greater root of the fifth nerve. $+$. The lesser or motor root. *VI.* The sixth nerve. *VII.* The facial. *VIII.* The auditory nerve. *XI.* The glossopharyngeal. *X.* The pneumogastric nerve. *XI.* The spinal accessory nerve. *XIII.* The hypoglossal nerve. *CI.* The suboccipital or first cervical nerve. *pa.* Pyramid. *o.* Olive. *d.* Anterior median fissure of the spinal cord, above which the decussation of the pyramids is represented. *ca.* Anterior column of cord. *r.* Lateral tract of bulb continuous with *cl*, the lateral column of the spinal cord.



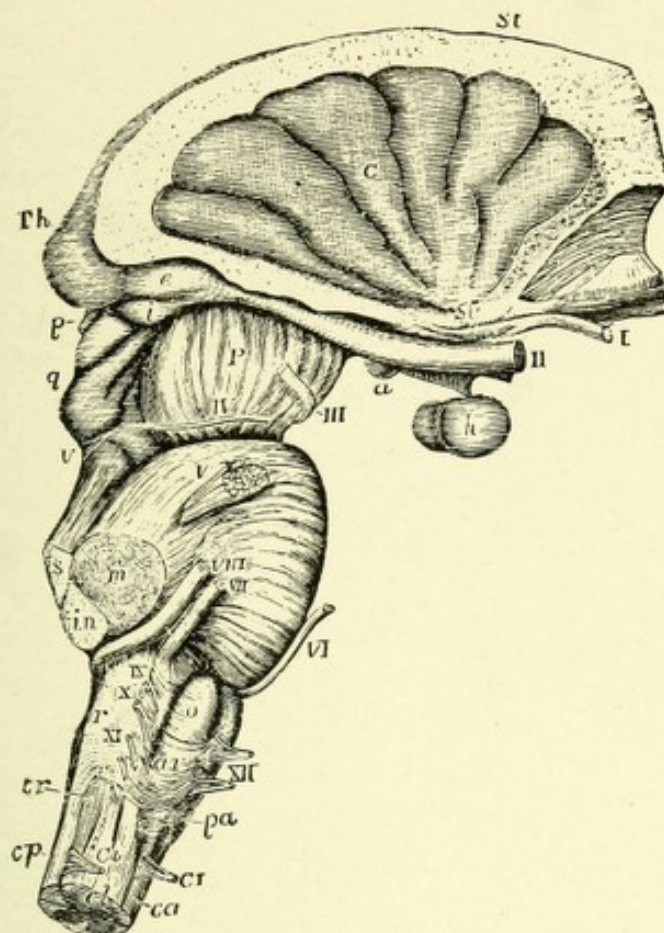


FIG. 67.—VIEW OF THE MEDULLA OBLONGATA, PONS VAROLII, CRURA CEREbRI, AND CENTRAL PARTS OF THE ENCEPHALON FROM THE RIGHT SIDE.—(Allen Thomson.)—
(From Quain's "Anatomy.")

The corpus striatum and thalamus opticus have been preserved in connection with the central lobe and crura cerebri, while the remainder of the cerebrum has been removed.

St. Upper surface of the corpus striatum. Th. Back part of the thalamus opticus (pulvinar). C. Placed on the middle of the five or six convolutions constituting the central lobe or island of Reil, the cerebral substance being removed from its circumference. Sy. Fissure of Sylvius, from which these convolutions radiate, and in which are seen the white striæ of the olfactory tract. I. The olfactory tract divided and hanging down from the groove in the convolution which lodges it. II. Optic nerves a little way in front of the commissure. a. Right corpus albicans with the tuber cinereum and infundibulum in front of it. h. Hypophysis or pituitary body. e. External, and i, internal, corpus geniculatum at the back part of the optic tract. P. Peduncle or crus of the cerebrum. III. Right oculomotor nerve. p. Pineal gland. q. Corpora quadrigemina. IV. Trochlear nerve rising from v, the valve of Vieussens.

The following numbers and letters refer chiefly to parts in connection with the medulla oblongata and pons. V. Placed on the pons Varolii above the right nervus trigeminus. s. The superior, m, the middle, and in, the inferior peduncle of the cerebellum cut short. VI. The sixth nerve. VII. Facial nerve. VIII. Auditory nerve. IX. The glossopharyngeal nerve. X. Placed opposite to the cut end of the pneumogastric nerve. XI. The uppermost fibers of the spinal accessory nerve. XII. The hypoglossal nerve. pa. Pyramid. o. Olive. ar. Arciform fibers. r. Restiform body. tr. Tubercle of Rolando. ca. Anterior, cp, posterior, and cl, lateral columns of the spinal cord. CI, Ci. Anterior and posterior roots of the first cervical nerve.





nerve-cells, which form, on the posterior aspect of the medulla, a distinct prominence, known as the nucleus of the column of Goll, or the nucleus gracilis. This collection of nerve-cells at the lower part of the fourth ventricle on each side is called the clava, or key, from its shape. These clavæ diverge and, with the restiform bodies, assist in forming the postero-lateral boundary of the fourth ventricle. The fibers of the outer column, or column of Burdach, end about a collection of nerve-cells, located lateral to the nucleus gracilis, which collection is called the nucleus cuneatus, or wedge. Both these nuclei are inseparably blended above. The columns of Goll and Burdach, with their end nuclei, are sometimes called the posterior pyramids. Just external to the nucleus cuneatus, and between it and the exit of the spinal accessory nerves, exists an eminence on each side, due to a marked increase of the substantia gelatinosa, capping the posterior horn, called the tubercle of Rolando.

The restiform bodies (from the Latin *restis*, a rope) are the largest prominences of the medulla, seeming, from the appearances of transverse sections at the lower part of the medulla, to occupy the upward extension of the posterior and a large part of the lateral columns, from both of which they receive many fibers. They diverge, assisting in the formation of the lateral boundaries of the fourth ventricle, and pass into the cerebellar hemispheres as the inferior cerebellar peduncles.

THE FOURTH VENTRICLE.

The fourth ventricle is the space located between the posterior surfaces of the pons Varolii and medulla oblongata in front and the cerebellum behind. Into this space the central canal of the spinal cord broadens out, and the space may be regarded as an expansion of that canal. It is rhomboid in shape, and has for its floor the posterior surfaces of the medulla and pons, and for its roof, which is somewhat arched, the superior and inferior medullary vela, together with a process of pia mater, the tela choroidea inferior, for the lower part. The superior medullary velum, or, as it is sometimes termed, the

valve of Vieussens, is a lamina of white matter from the middle lobe or worm of the cerebellum which arches across from one superior cerebellar peduncle to the other. The inferior medullary velum is likewise a process of white matter coming from the same source. The process of pia mater above referred to is a reflection of that membrane from the under surface of the inferior medullary velum to supply the interval left by the latter. This process of pia mater is lined by a layer of epithelium which is continuous below, and at its sides, with that lining the cavity of the ventricle, and is perforated along its median line by an opening, the foramen of Magendie, which connects this cavity with the subarachnoid space surrounding the spinal cord. This opening is just above the point where the central canal opens into the fourth ventricle. Before this epithelial layer mentioned above reaches the lateral boundaries of the ventricle it is somewhat thickened by an accession of white matter, this thickening starting at the inner margin toward the apex of the clava, coursing along the lateral boundary of the ventricle, crossing the restiform body, and ending at the exit of the vagus and glossopharyngeal nerves; it is called the tenia, or ligula. Just above the calamus scriptorius, at the apex of the ventricle, and occupying the interval between the clavæ, there is another thickening of white matter, called the obex. The widest part of the ventricle extends on each side between the cerebellum and medulla, forming the lateral recesses, the lower boundary of each being the ligula. The superior border of this ventricle is formed on each side by the superior cerebellar peduncles, coming from the region of the corpora quadrigemina above, and passing downward and diverging in their course to the cerebellum.

The inferior borders are formed by the diverging posterior columns of the medulla and the restiform bodies. The fourth ventricle at its upper angle communicates with the space above—the third ventricle—by means of a narrow passage known as the Sylvian aqueduct. This passage is nearly two cm., or about three-fourths of an inch, in length; on transverse section near the medulla it is T-shaped, becoming oval in the middle of its course, and triangular as it opens into the third ventricle. It is lined with

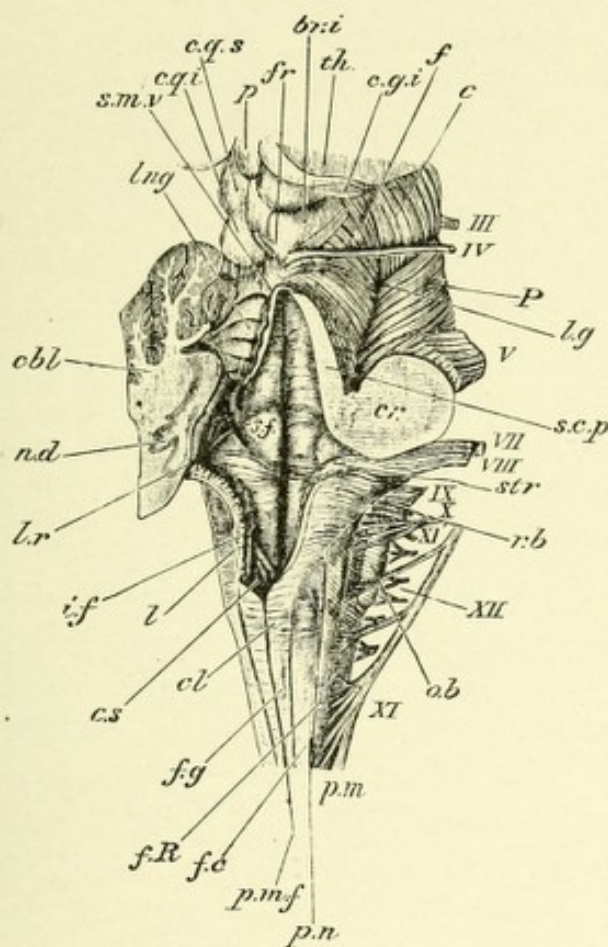



FIG. 68.—POSTERIOR AND LATERAL VIEW OF THE MEDULLA OBLONGATA. FOURTH VENTRICLE AND MESENCEPHALON (Natural size).—(E.A.S.)—(From Quain's "Anatomy.")

The cerebellum and inferior medullary velum, and the right half of the superior medullary velum, have been cut away so as to expose the fourth ventricle.

p.n. Line of the posterior roots of the spinal nerves. *p.m.f.* Posterior median fissure. *f.g.* Funiculus gracilis. *cl.* Its clava. *f.c.* Funiculus cuneatus. *f.R.* Funiculus of Rolando. *r.b.* Restiform body. *c.s.* Lower end of the fourth ventricle (calamus scriptorius). *l.* Section of the lingula or tenia; part of the choroid plexus is seen beneath it. *l.r.* Lateral recess of the ventricle. *str.* Striæ acusticæ. *i.f.* Inferior (posterior) fovea. *s.f.* Superior (anterior) fovea; between it and the median sulcus is the funiculus teres. *cbl.* Cut surface of the left cerebellar hemisphere. *n.d.* Central gray matter (nucleus dentatus) seen as a wavy line. *s.m.v.* Superior (anterior) medullary velum. *lng.* Lingula. *s.c.p.* Superior cerebellar peduncle cut longitudinally. *cr.* Combined section of the three cerebellar peduncles (the limits of each are not marked). *c.q.s., c.q.i.* Corpora quadrigemina (superior and inferior). *fr.* Frænulum veli. *f.* Fibers of the fillet seen on the surface of the tegmentum. *c.* Crusta. *lg.* Lateral groove. *c.g.i.* Corpus geniculatum internum. *th.* Posterior part of thalamus. *p.* Pineal body. The Roman numbers indicate the corresponding cranial nerves.



columnar ciliated epithelium, the basal surfaces of which cells are probably connected by radiating processes with the underlying neuroglia cells. The floor of the ventricle has, in general, the shape of two triangles placed base to base; it is lined with ciliated epithelium—the ependyma (Greek *ἐπὶ ἐνδύμα*, a close-fitting garment)—resting upon an underlying neuroglia matrix, and is continuous with the lining of the aqueduct of Sylvius. At the apex of the upper triangle is the opening of the Sylvian aqueduct. Just below, in the median line, begins a fissure (the median) which extends downward nearly to the apex of the lower triangle, to terminate in an opening—the ventricle of Arantius. On each side of this fissure is seen a longitudinal eminence which extends throughout the entire length of the ventricle. It is more prominent above, and becomes gradually indistinct below. These eminences consist of a few nerve-fibers, together with the bases of the anterior horns of gray matter, which have come to the surface of the ventricle after the spinal canal has opened into it. They are made up of a large number of multipolar cells, whose axones form the root-fibers of the hypoglossal nerves below and the abducens or sixth pair of cranial nerves above. These eminences have received the name of fasciculi or funiculi teretes. The white fibers of which each fasciculus is composed are the ascending part of the facial nerve and some fibers of the *formatio reticularis*.

At about its widest point the floor of the ventricle is crossed by several white streaks, called, from their relation to the auditory nerve, the *striæ acousticæ*. Just outside of the median groove, and above these *striæ*, is a small fossa on each side—the *fovea superior*; while below these *striæ* is a small triangular depression,—the *fovea inferior*,—the base of which is divided into two grooves, the inner one of which passes to the lower inferior angle of the ventricle, the outer one passing obliquely downward to the lateral border of the same. Between these two grooves exists another triangle, much darker than the adjoining gray matter, called the *ala cinerea* (ash-colored wing), the apex of which is depressed, but its lower portion is distinctly prominent, and is termed the *eminentia cinerea*. This eminence contains the sensory end nuclei for the pneumogastric and

glossopharyngeal nerves. At the lower portion of the floor of the ventricle, where the posterior columns begin to diverge, a small triangular space is formed, at the lower end of which is the ventricle of Arantius. This space is called the *calamus scriptorius*, "writing-pen," from its resemblance to a pen. This resemblance is further heightened by the median groove.

The following cranial nerves have their points of exit from the medulla, given in the order in which they leave, starting from above. The sixth pair, called the abducens, issue from the junction of the pons and medulla between the anterior pyramids and the olivary bodies, coming from the upper end of the ventrolateral groove, and cross the anterior surface of the pons near its middle.

The seventh, or facial, and the eighth, or auditory, nerves emerge at the periphery of the medulla near its junction with the pons, from a depression between the olivary and restiform bodies, the former being within and above the latter.

The roots of the ninth, or glossopharyngeal, and the tenth, or pneumogastric, nerves have their points of exit on each side external to the olivary bodies in a groove—the dorsolateral—located between the lateral column and restiform body, which corresponds to the dorsolateral groove of the spinal cord. The upper five or six filaments belong to the glossopharyngeal, while the lower ones, twelve to fifteen, belong to the pneumogastric.

The eleventh pair, or spinal accessory nerves, which consist of several distinct strands of nerve-fibers coming from the medulla and the cervical part of the spinal cord as low down as the fifth or sixth cervical segment, pass out dorsal to the olivary bodies from the dorsolateral groove in the same plane as the pneumogastric and glossopharyngeal nerves.

The twelfth pair, or hypoglossal nerves, consist of a dozen or more fine root-fibers which have their point of emergence in a groove—the ventrolateral—located between the anterior pyramids and the olivary bodies. (See Fig. 66, p. 127.)

While, in reality, the medulla oblongata is an upward continuation of the spinal cord, it differs essentially from the cord in its shape, owing to the development of new gray matter, to the

widening of the spinal canal into the fourth ventricle, and to the changed position of the various tracts proceeding from the cord.

A TRANSVERSE SECTION OF THE MEDULLA AT THE LEVEL OF THE FIRST CERVICAL NERVE.

The transition of the cervical part of the spinal cord into the medulla is a very gradual one. A section at this level differs from a section in the upper cervical region only in the following particulars: The posterior horns are much lengthened and narrowed, and present at their ends, or capita, globular enlarge-

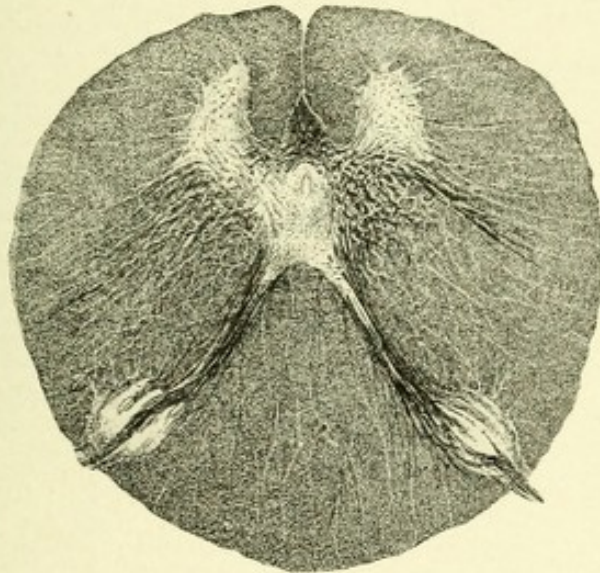


FIG. 69.—TRANSVERSE SECTION THROUGH THE MEDULLA OBLONGATA AT THE BEGINNING OF THE MOTOR DECUSSATION.—(After Koelliker.)

ments which are due to a marked increase of the substantia gelatinosa of Rolando. The caput, with its substantia gelatinosa, produces on each side an external prominence—the tubercle of Rolando. It is composed of a rich network of neuroglia fibers, among which exists a number of large and small cells, probably sensory in function. It is permeated by a number of fine fibers, which are located external to it, near the periphery of the medulla, and which appear on cross-section as a crescentic bundle of longitudinal fibers that occupy the same relative position until they reach the middle of the pons, where they emerge, forming the so-called ascending, but in fact descending, root of

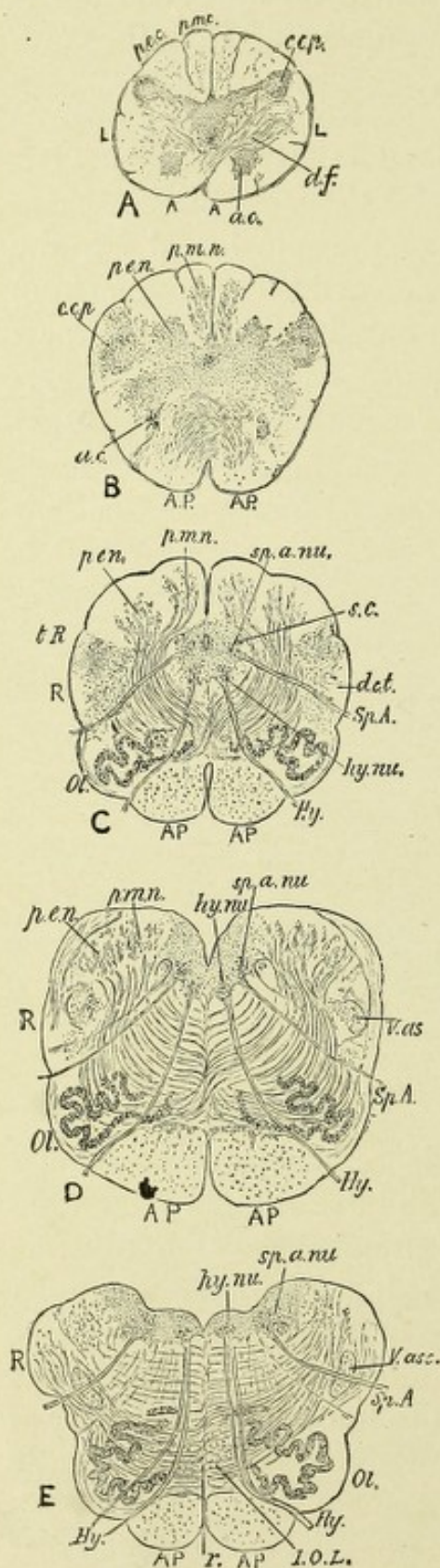


FIG. 70.

the fifth or trigeminal nerve. These fibers, with their collaterals, are the central axones of the cells of the Gasserian ganglion of each side. These axones consist of two sets: those having a long course, and those having a short course. The former, with their collaterals, end in brush-like expansions about the small sensory cells existing in the head of the posterior horns, which may be considered as the end nuclei for the axones. From the cells of the posterior horns new axones start out, and after crossing in the raphe, they pass into the fillet or lemniscus of the opposite side and continue brainward, forming the central sensory tract of the trigeminal nerve. The axones of short course, with their collaterals, probably subserve a reflex function, and end about the motor nuclei of the trigeminal, facial, glossopharyngeal, and possibly of the pneumo-

FIG. 70.—DIAGRAMS OF THE STRUCTURE OF THE MEDULLA OBLONGATA.—(From Gower's "Diseases of the Nervous System.")

A. Lower, and B, upper, part of decussation of the pyramids. C. At the lowest of the olivary bodies. D. At the apex. E. At the middle of the calamus scriptorius. A. Anterior. L. Lateral column of cord. A.P. Ant. pyramid. R. Restiform body. a.c. Ant. cornu. t.R. Tubercle of Rolando. c.c.p. Caput cornu posterioris. d.c.t. Direct cerebellar tract. Hy. Hypoglossal nerve. hy.nu. Its nucleus. Ol. Olivary body. p.m.c. Post. med. col. p.e.c. Post. ext. col. p.m.n. Post. med. nucleus. p.e.n. Post. ext. nucleus. Sp.A. Spinal accessory nerve; sp.a.nu. Its nucleus. s.c. Slender column. V.as. Ascending root of the fifth nerve.

gastric nerves. The cells of the Gasserian ganglia may be regarded as the centers of origin of the sensory portion of the fifth pair of cranial nerves. They are analogous to the posterior spinal ganglia, and contain cells which give off peripheral and central axones. The central axones bifurcate on reaching the pons Varolii, one branch passing slightly upward, to enter the enlarged termination of the head of the posterior horn, the other downward. These latter fibers—*i. e.*, those having a downward course—form the crescentic bundles before mentioned, and occupy an area outside of the head of the posterior horn on each side. Former anatomists termed this bundle of fibers the ascending root of the fifth pair, but recent investigation has shown, as above, that in reality the fibers have a downward course.

The posterior horns diverge, trending forward and outward, thus producing a broadening out of the gray matter. At this level the lateral horns have attained their greatest size, and project outward into the lateral area, producing distinct, somewhat triangular, masses of gray matter. At their base, and near their ventral portion, exists a collection of multipolar nerve-cells which form a distinct column on each side. These columns have a considerable vertical extent, and their axones form the root-fibers of the spinal accessory or eleventh pair of cranial nerves.*

Koelliker believes that this group of cells, whose axones form the spinal portion of the eleventh pair of cranial nerves, really belongs to the base of the anterior horns. There is a marked

* **The Spinal Accessory or Eleventh Pair of Cranial Nerves.**—The eleventh or spinal accessory nerve of each side consists of two portions, the spinal and the (accessorius vagi) bulbar accessory. The accessorius vagi, or bulbar accessory portion of this nerve, takes its origin from the most inferior part of the nucleus ambiguus, or the combined motor nucleus for the pneumogastric and glossopharyngeal nerves. The axones from the cells of this nucleus pass outward through the lateral field of the medulla ventral to the crescentic bundle of trigeminal (descending) nerve-fibers, forming four or five fasciculi of fibers which emerge from the dorsolateral groove of the medulla in the same plane with the pneumogastric and glossopharyngeal nerves. These fasciculi now unite with the spinal portion of this nerve, and, after passing through the jugular foramen, separate from the spinal portion and join the trunk ganglion of the pneumogastric nerve, and are distributed mainly with the pharyngeal and superior laryngeal branches of that nerve.

The spinal portion of this nerve on each side takes its origin from a group of nerve-cells existing at the junction of the lateral with the anterior horns. This column of cells extends from the level of the fifth to the first cervical nerve. The axones from the cells of this nucleus

growth of the processus reticularis at the side of the gray matter, ventral to the posterior horns, this growth, together with the forward movement of the posterior horns, crowding the lateral horns nearer to the anterior horns.

A SECTION AT THE LEVEL OF THE MOTOR CROSSWAY.

At this level, as the name implies, can be seen the lowermost decussation of the medulla, known as the motor or pyramidal decussation. Throughout the spinal cord, in the posterior part of the lateral columns, exist the crossed motor or pyramidal tracts. As the cord gradually passes into the medulla, the fibers of these tracts, from each side, leave their positions in the lateral columns, pass obliquely through the gray matter of the medulla, decussate with the corresponding fibers of the opposite side, and unite anteriorly with the direct or uncrossed motor or pyramidal tracts, forming a large, broadly triangular field of longitudinal fibers on the ventral aspect of the medulla, known as the anterior pyramids. These fibers continue brainward as the motor tracts, to end in the motor area of the cerebral cortex. Thus, if we trace upward the left motor tract of the cord, it crosses over in the motor crossway and unites with the direct pyramidal tract of the right side, forming in the medulla the right pyramid, the fibers of which pass, as we shall see later, to the right motor area of the brain. A destruction of this tract, either at its beginning in the brain or at any point above the motor crossing, produces a paralysis of the left side of the body,

pass outward through the lateral column, between the posterior nerve-roots and the ligamentum denticulatum, emerging from the cord in the dorsolateral groove. They form a series of nerve-filaments extending from the fifth to the first cervical nerve. The filaments now unite to form a round bundle of fibers, which pass brainward and enter the cranial cavity through the foramen magnum. Here they are joined by the accessory or bulbar portion. They then turn outward to enter the middle compartment of the jugular foramen, in common with the pneumogastric, being separated from the latter nerve by a fold of the arachnoid. At their exit through the jugular foramen they pass downward, backward, and outward between the occipital artery and internal jugular vein. They then descend behind the digastric and stylohyoid muscles and, piercing the sternomastoid muscle, pass obliquely across the posterior triangle of the neck, terminating deep within the trapezius muscle. In their course they give off several branches to the sternomastoid, and join in that muscle the second cervical nerve. In the posterior triangle they are joined by the third and fourth cervical nerves to form the subtrapezial plexus for the supply of the trapezius muscle.

and the tract itself undergoes a secondary descending degeneration throughout its entire extent. In order to avoid confusion, the motor tract has been traced from below upward, while in reality its actual course and conduction of impulses is downward—*i. e.*, from the brain to the cord. It may be stated here that while most of the fibers actually decussate in the motor crossway, it has been proved by several observers that the

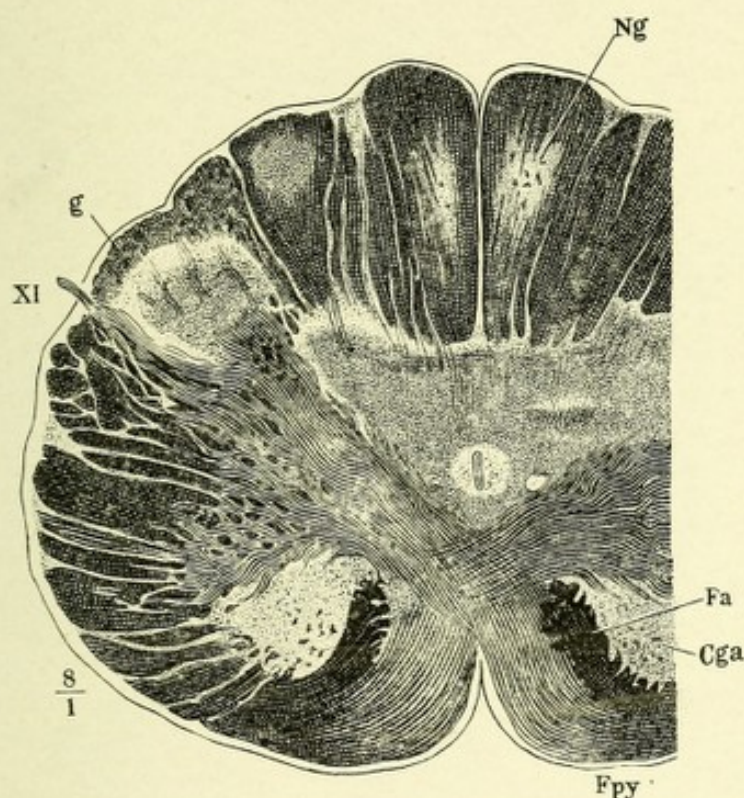


FIG. 71.—TRANSVERSE SECTION OF THE MEDULLA OBLONGATA THROUGH THE MOTOR DECUSSATION.—(After Henle.)

Fpy. Anterior pyramid. Cga. Anterior horn. Fa. Remains of the anterior column. Ng. Nucleus gracilis. g. Substantia gelatinosa. XI. Spinal accessory nerve.

decussation is not complete; that in many instances a minority of the fibers do not decussate, but pass downward in the lateral column of the same side. This explains an interesting fact long observed: that in some cases of hemiplegia the unaffected side, especially the leg, is distinctly weaker than normal, and presents exaggeration of the deep reflexes; this clinical fact seems to prove that the decussation is incomplete and that a number of fibers pass down the cord on the same side as the lesion.

Owing to the motor decussation, a part of each anterior horn becomes completely severed from its connection with the rest of the gray matter and is gradually pushed outward and backward, and comes to occupy a small space a little ventrad to the head of the posterior horn. The anterior horns continue upward in this same relative position to the pons, where they gradually become lost. The bases of the horns remain with the

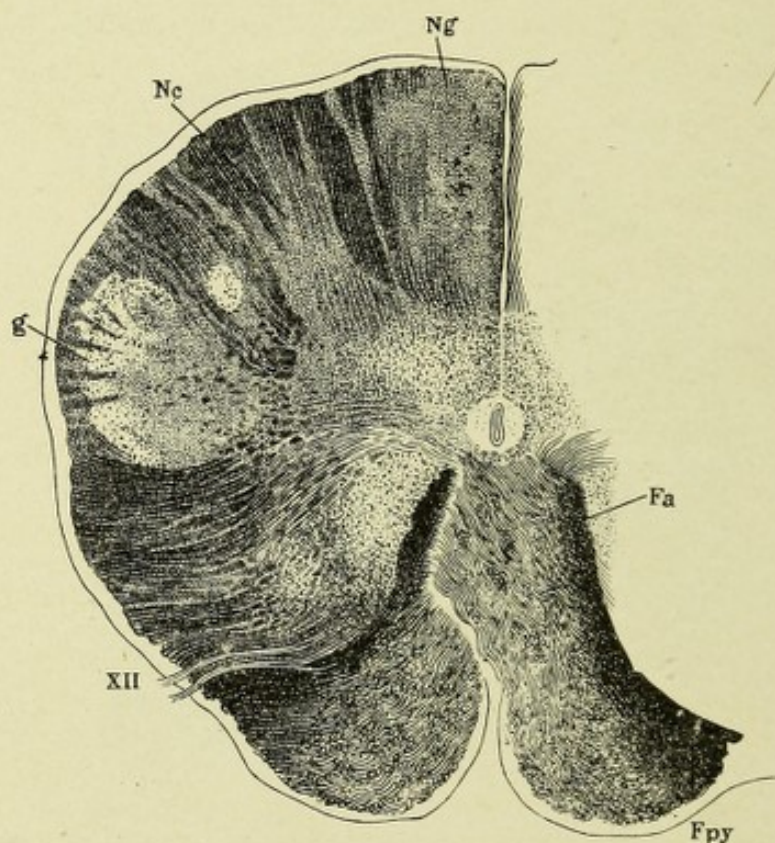


FIG. 72.—TRANSVERSE SECTION OF THE MEDULLA AT THE BEGINNING OF HYPOGLOSSAL NERVES. The pyramidal or motor decussation is complete.—(After Henle.)

Ng. Nucleus gracilis. Nc. Nucleus cuneatus. g. Substantia gelatinosa of posterior horn. XII. Hypoglossal nerve-roots. Fpy. Anterior pyramid. Fa. Remains of anterior column.

multipolar nerve-cells connected with the gray matter, and owing to the spreading out of the latter, they come to lie dorso-lateral to the central canal. The neuraxones of these multipolar cells form the root-fibers of the hypoglossal or twelfth pair of cranial nerves. The space left in each lateral area of the medulla, owing to the loss of fibers resulting from the motor decussation, is in part filled by the interposition of the lower-

most part of a new mass of gray matter,—the olivary body,—and in part by the posterior horn, which has trended forward.

In sections just above the motor decussation a distinct collection or group of nerve-cells exists, one on each side, which are located in the middle of the lateral area, adjacent to the gray matter. They are termed the nuclei of the lateral columns, or

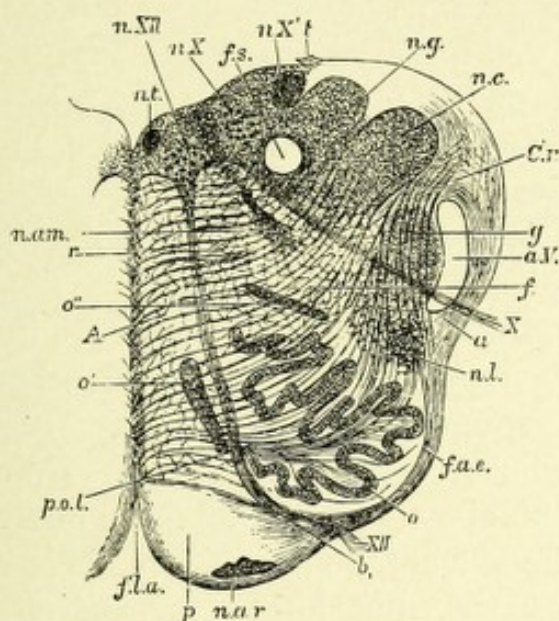


FIG. 73.—SECTION OF THE MEDULLA OBLONGATA AT ABOUT THE MIDDLE OF THE OLIVARY BODY.—(After Schwalbe.)—(From Quain's "Anatomy.")

f.l.a. Anterior median fissure. *n.ar.* Nucleus arciformis. *p.* Pyramid. *XII.* Bundle of hypoglossal nerve emerging from the surface; at *b* it is seen coursing between the pyramid and the olivary nucleus, *o.* *f.a.e.* External arciform fibers. *n.l.* Nucleus lateralis. *a.* Arciform fibers passing toward restiform body partly through the substantia gelatinosa, *g.*, partly superficial to the ascending root of the fifth nerve, *a.V.* *X.* Bundle of vagus root, emerging. *f.r.* Formatio reticularis. *C.r.* Corpus restiforme, beginning to be formed, chiefly by arciform fibers, superficial and deep. *n.c.* Nucleus cuneatus. *n.g.* Nucleus gracilis. *t.* Attachment of the ligula. *f.s.* Funiculus solitarius. *n.X.*, *n.X'.* Two parts of the vagus nucleus. *n.XII.* Hypoglossal nucleus. *n.t.* Nucleus of the funiculus teres. *n.am.* Nucleus ambiguus. *r.* Raphe. *A.* Continuation of anterior column of cord. *o'.*, *o''.* Accessory olivary nuclei. *p.o.l.* Pedunculus olivæ.

the lateral nuclei. These collections of nerve-cells are composed in part of cell groups from the anterior horns, with the addition of special deposits of nerve-cells found in this area. The direct cerebellar tracts, or columns of Flechsig, occupy the same relative position in the lateral periphery of the medulla as in the spinal cord, being situated in front of the crescentic bundle of

fibers, the descending root of the fifth nerve. Here also the posterior columns continue to diverge, the central canal and gray matter broaden out, and, after trending backward, the canal opens into the fourth ventricle, thus exposing the central gray matter of the medulla as part of the floor of that ventricle. Most of the fibers of the posterior columns have ended in their respective nuclei—namely, in an inner, club-shaped mass next to the median line, the nucleus of the column of Goll, or nucleus gracilis, and an outer broad swelling, the nucleus of the column of Burdach, or nucleus cuneatus. Both gray masses contain multipolar nerve-cells, about which the fibers of the columns, or funiculi graciles and cuneati, end. From the cells of these two nuclei new axones stream out, forming bundles of curved fibers,—the so-called internal arcuate fibers,—which pass anteriorly through the gray matter, decussate in the raphe with those coming from the opposite side, and become located just posterior to the anterior pyramids, between the olivary bodies, whence they assume a longitudinal course. Edinger has proved by embryologic studies that many of these fibers surround and pass through the olivary bodies without becoming connected with their nerve-cells, and locate themselves in the above-described area. To these bundles of fibers of each side the name mesial fillet or lemniscus has been given, and the decussation has been called the sensory decussation, or the posterior pyramidal decussation, and from its position between the olivary bodies it is often called the interolivary decussation. This system of fibers—the fillet or lemniscus—forms a long tract, which terminates in the sensory area of the cerebral cortex.

The higher the sections of the medulla, the smaller the posterior nuclei become, because nearly all their fibers are lost in the arciform fibers of the fillet, their place being gradually usurped by the appearance of the broad rope-like bands,—the restiform bodies, or the inferior cerebellar peduncles,—which at this level have attained considerable size.

The head of each posterior horn is severed from its narrow cervix by the internal arcuate fibers and by fibers of the lateral area passing into the *formatio reticularis*. The cervix is finally lost in this latter structure.

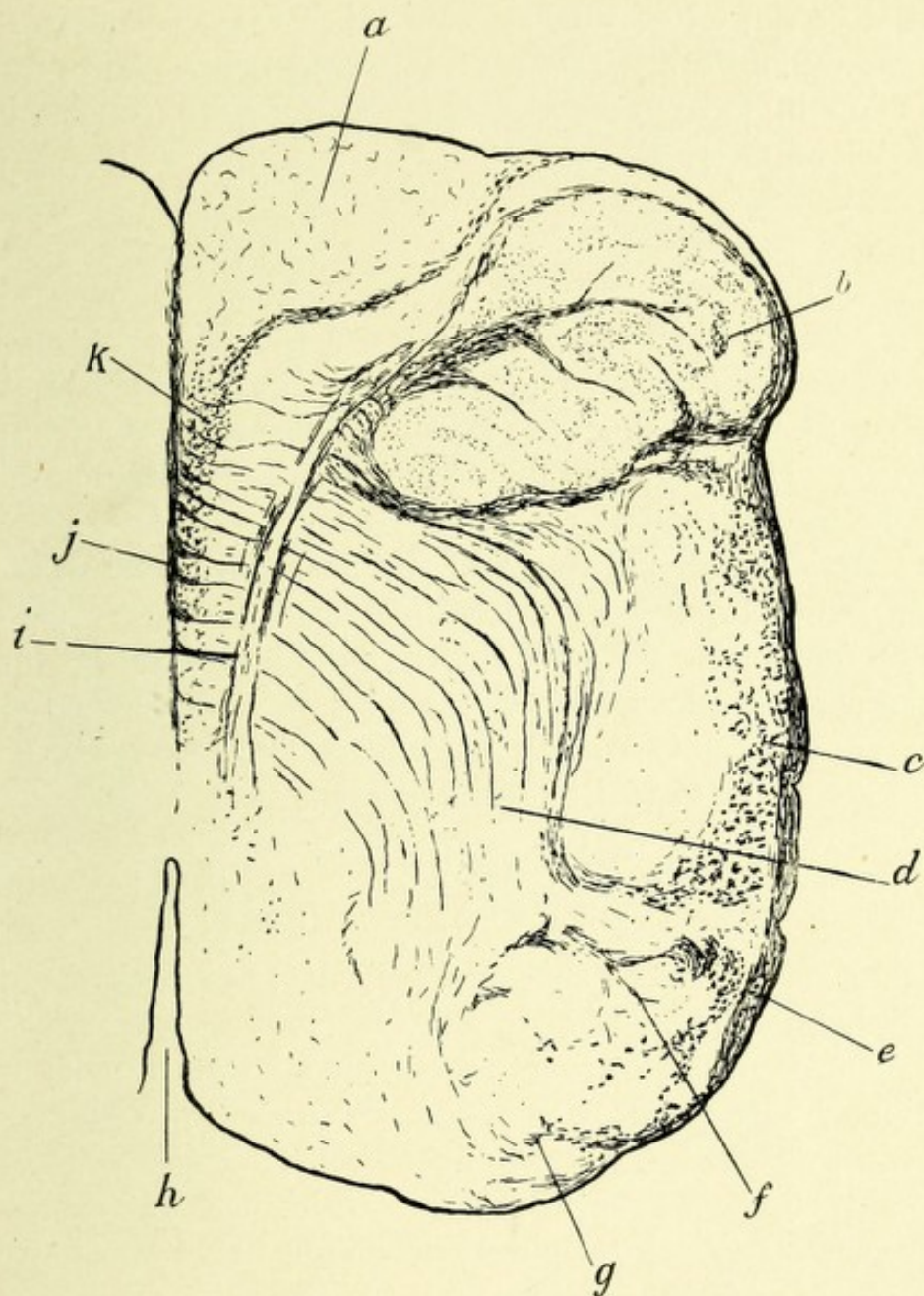


FIG. 74.—SECTION OF MEDULLA OBLONGATA AT LEVEL OF SENSORY CROSSWAY.
Weigert-Pal preparation.

- a.* Anterior pyramid or motor tract. *b.* Inferior olivary body. *c.* Restiform body or inferior cerebellar peduncle. *d.* Internal arcuate fibers from nuclei of columns of Burdach and Goll passing ventrally to decussate between the olivary bodies (sensory decussation). *e.* Postero-external arcuate fibers. *f.* Nucleus of column of Burdach. *g.* Nucleus of column of Goll. *h.* Fourth ventricle. *i.* Hypoglossal nerve-roots. *j.* Raphe. *k.* Interolivary bundle, median fillet, or lemniscus.

Owing to these two decussations, the fibers of the ground bundles of the anterior columns are displaced dorsally, so that in cross-sections a little farther brainward they come to occupy a position in the posterior part of the *formatio reticularis* on each side of the raphe.

THE RAPHE.

The raphe, or median septum, is the middle line of the medulla seen on transverse section. It extends from the bottom of the anterior fissure to the gray matter of the floor of the fourth ventricle. Here the various fine nerve-fibers decussate with their fellows of the opposite side. They consist largely of the fibers coming from the nuclei of the posterior columns, known as the internal arcuate fibers, with a small number of external arcuate fibers from the same source and fibers from the various cranial nerve nuclei. Scattered among the various decussating fibers of the raphe exist a number of multipolar nerve-cells belonging to the *formatio reticularis alba*.

THE FORMATIO RETICULARIS.

As its name implies, this is a reticulated meshwork of horizontal, longitudinal, and oblique fibers, crossing one another at various angles and having interspersed between them many multipolar nerve-cells, which cells collectively are called the *nucleus reticularis tegmenti* (Bechterew). These cells of the *formatio reticularis* are doubtless in part intrinsic and associative in character, combining the various complex acts which are performed by the *medulla oblongata*.

This formation lies between the olivary bodies and the nuclei of the posterior columns, and is bounded laterally by the direct cerebellar tracts. The area is subdivided into two regions, a lateral and a mesial. The former borders on the direct cerebellar tract of the medulla, and contains a large number of ganglionic cells derived in part from the remains of the anterior horns. This lateral region is called the *formatio reticularis grisea*. The mesial area is located between the raphe and the hypoglossal

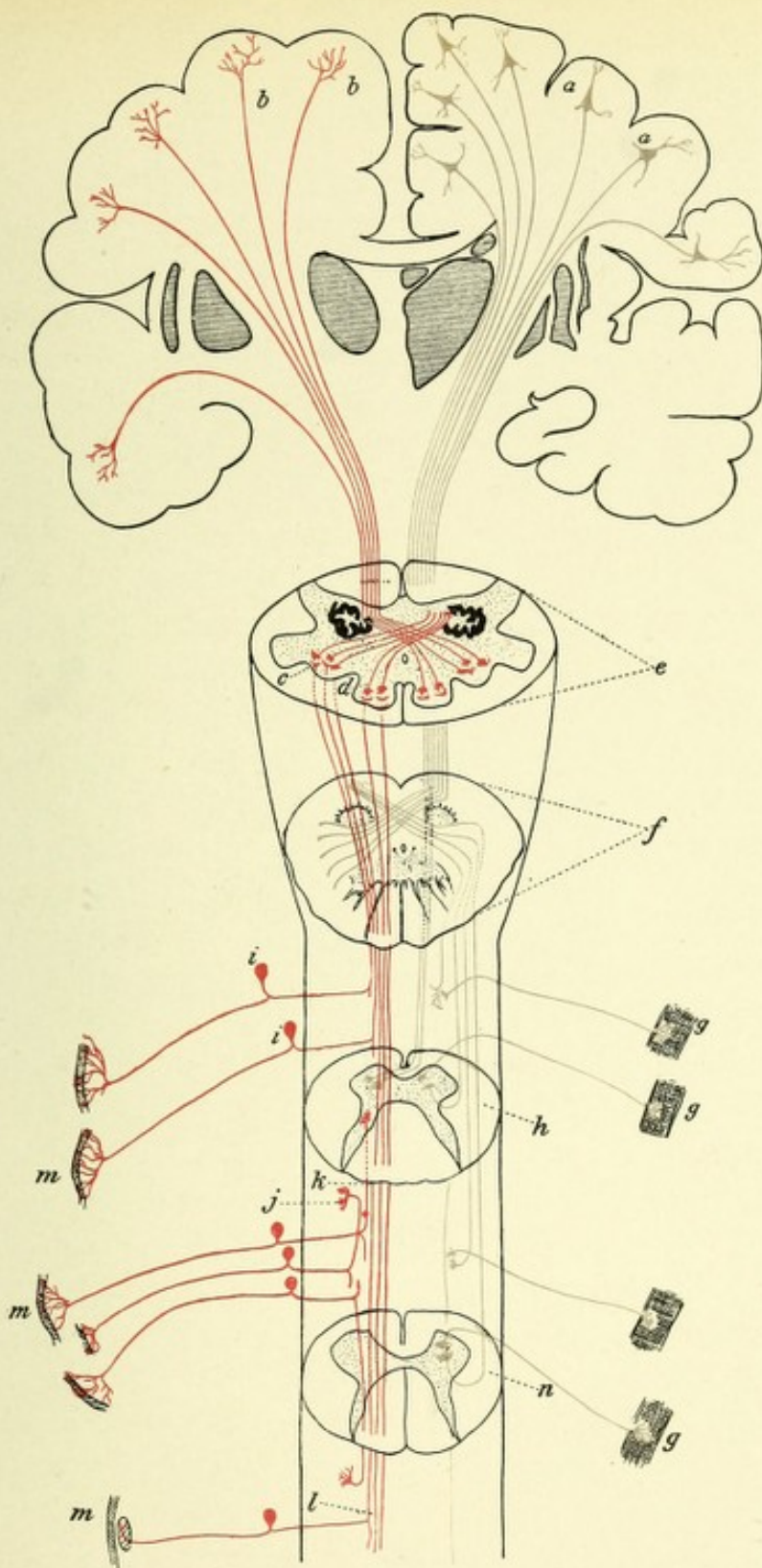


FIG. 75.—DIAGRAM INDICATING THE COURSE OF THE MOTOR AND SENSORY FIBERS OF THE SPINAL CORD AND MEDULLA.

a, a. Motor cells of the cerebral cortex. *b, b.* Arborizations of the fibers of the sensory tract in the cerebral cortex. *c.* Nucleus of the column of Burdach, showing terminal arborizations of the long sensory fibers of the cord. *d.* Nucleus of the column of Goll, showing terminal arborizations of the long sensory fibers of the cord. *e.* Section of the medulla, showing sensory decussation. *f.* Section of medulla, showing motor or pyramidal decussation. *g, g.* Motorial end plates. *h.* Section through the cervical region of the cord, showing termination in the anterior horn of the motor fibers of the direct pyramidal tract after they have crossed in the anterior commissure; also fiber of crossed pyramidal tract ending about anterior horn cell of same side. *i, i.* Posterior spinal ganglia. *j, k.* Sensory fibers of short course. *l.* Sensory fibers of long course, terminating in medulla. *m, m, m.* Sensory end organs. *n.* Section through lumbar cord.



nerve-roots, and because it is composed mainly of nerve-fibers, with only a few cells, this area is called the *formatio reticularis alba*.

The fibers of the *formatio reticularis* are arranged as follows: First, the horizontal fibers belonging to the fillet or lemniscus. Second, those fibers which have come from the anterior ground bundles of the spinal cord and have trended backward to form the posterior longitudinal bundles, and which appear on transverse section as two distinct bundles of nerve-fibers, more or less triangular in shape, on each side of the raphe, just below the floor of the ventricle, and continue to occupy the same relative position beneath the aqueduct of Sylvius until they reach the neighborhood of the nucleus of the oculomotor or third pair of cranial nerves, beneath the anterior corpora quadrigemina. In their course they give off collaterals to the nuclei of several of the cranial nerves, especially those concerned in the movement of the eyeballs. Some of the fibers of the posterior longitudinal bundles end in arborizations about the cells of the *formatio reticularis grisea* from the upper part of the pons Varolii to the anterior corpora quadrigemina. These collections of cells in the *formatio reticularis* of each side have been called by Koelliker the *nucleus magnocellularis diffusus*. Third, fibers from the remains of the lateral columns which pass into this area. These in part probably consist of the fibers of the ground bundles of the lateral columns. These fibers are connected with the cells of the *nucleus reticularis tegmenti*, and continue brainward to the region of the posterior corpora quadrigemina. Fourth, it is positive that Gowers' anterolateral ascending tract, which is located lateral and slightly dorsal to the olivary body, passes into the *formatio reticularis grisea*, and thence upward to the pons, where, according to Hoche, it joins the superior cerebellar peduncle and passes to the cerebellum. Lastly, are found the before-mentioned internal arcuate fibers, together with the axones and collaterals from some of the cranial nerves and those from the cells of the *nucleus reticularis tegmenti*. The cells of the *formatio reticularis* are rather large multipolar cells possessing long, thick, branching dendritic processes with strong axis-cylinders, which pursue different courses. Their common course is inward to the raphe, where they decus-

sate and pass into the ventral or dorsal parts of the formatio reticularis. After a short course they become longitudinal and give off numerous collaterals, which often bifurcate, one branch

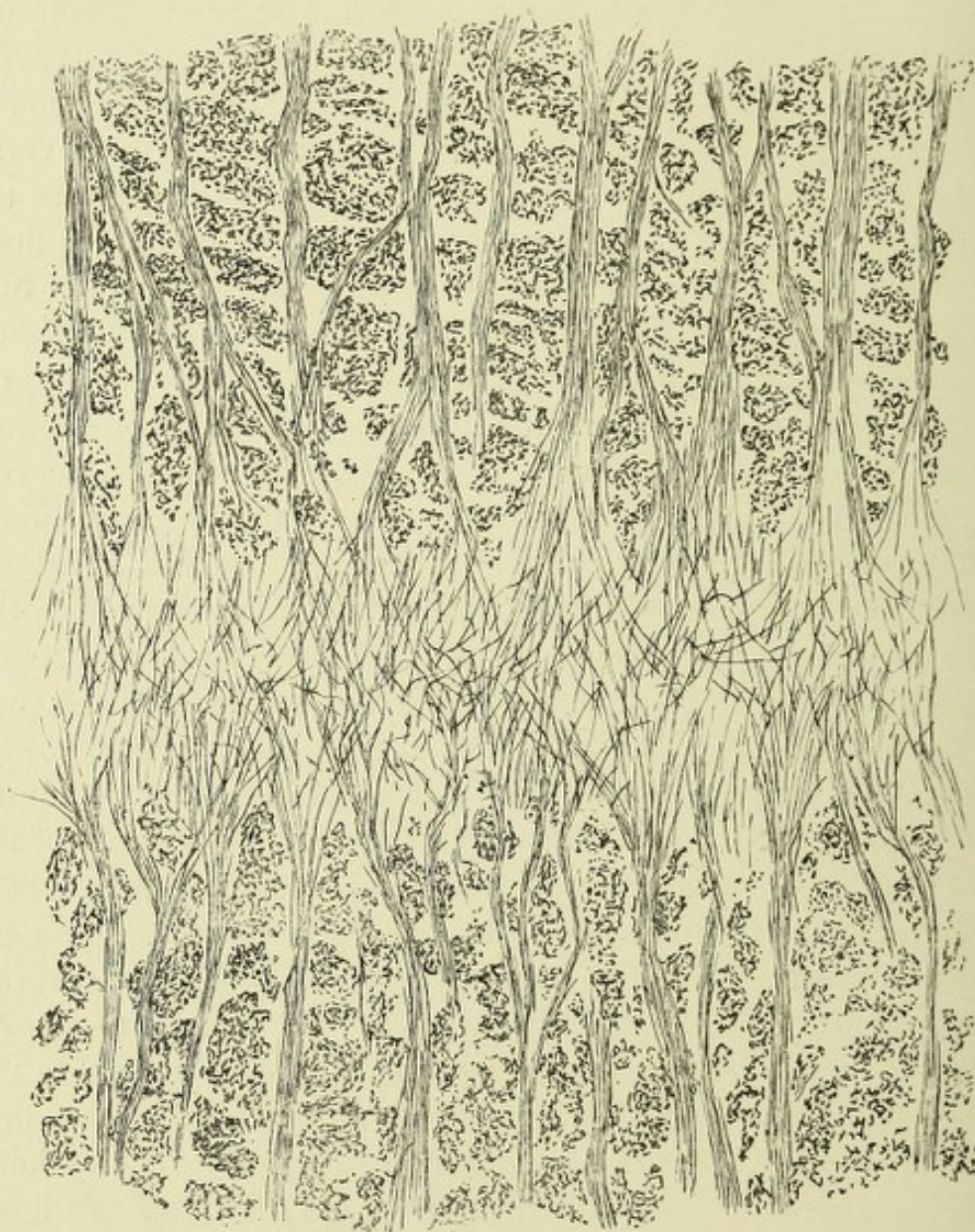


FIG. 76.—SECTION THROUGH FORMATIO RETICULARIS OF THE MEDULLA OBLONGATA.
Method of Weigert-Pal.

passing upward, the other downward, both branches probably ending by arborizing about the cells of the formatio reticularis at higher and lower levels.

Sections at this level—that is, at the sensory decussation—show

the interposition of several of the cranial nerve nuclei—namely, the twelfth, or hypoglossal, the ninth, or glossopharyngeal, and the tenth, or pneumogastric.

The nuclei of origin of the twelfth pair are found on each side of the median line, beneath the floor of the fourth ventricle and close to the aforesaid spinal canal, and consist of large groups of multipolar nerve-cells, which vary from 25 to 70 μ in diameter. Their protoplasmic processes, or dendrites, are very numerous, and pursue a rather long course. According to

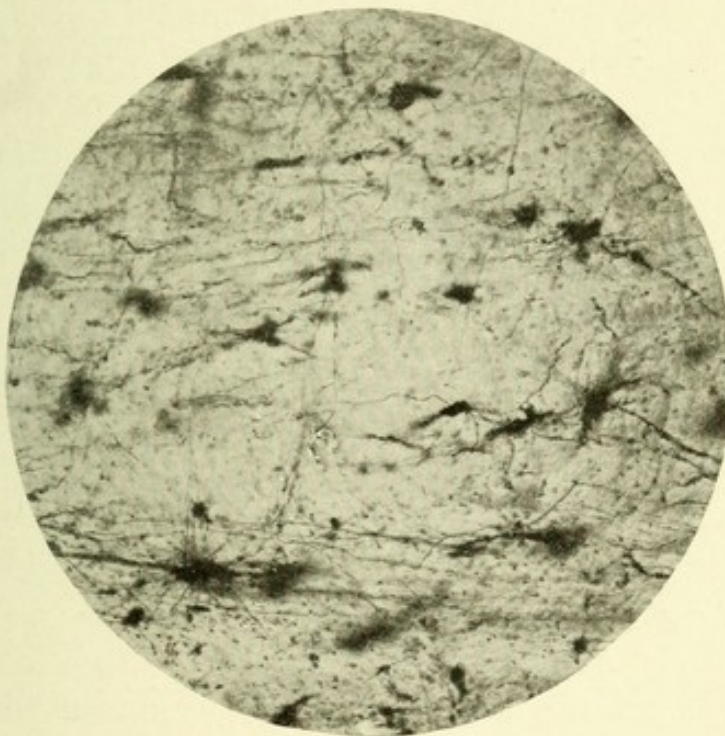


FIG. 77.—MICROPHOTOGRAPH FROM A SEVEN-MONTHS' HUMAN FETUS OF SECTION OF FORMATIO RETICULARIS GRISEA. The cells with their decussating axones are seen.

Van Gehuchten, many of the dendrites cross the median line and ramify about the hypoglossal nerve-cells of the opposite side, forming a protoplasmic commissure. The axis-cylinder processes pass in slight curves ventrally, and emerge from the medulla, between the olivary bodies and the pyramids, in the anterolateral groove. Some of the axones, however, frequently pass through the mesial portion of the olivary bodies and between the fibers of the anterior pyramids, having their point of exit in a slight sulcus on the ventral aspect of the pyramid of

each side. These axis-cylinders, or root-fibers, from the hypoglossal nuclei form a sharp boundary-line between the formatio reticularis alba and grisea. The group of cells from which these nerve-fibers arise corresponds to the cells which, in the spinal cord, are located at the base of the anterior horns. But owing to the previously described changes, they first occupy a position ventrolateral to the spinal canal, and when the canal opens into the fourth ventricle, they come to lie on the floor of the ventricle, on each side of the median line. This group of nerve-cells, on transverse section, occupies a somewhat triangular field, just beneath the ependyma of the fourth ventricle on each side of the raphe (Fig. 78).

Ventral to the chief nucleus of the hypoglossal nerve exists, in the formatio reticularis, slight groups of small multipolar nerve-cells, which surround the root-fibers of the hypoglossal nerve. These collections of cells form the *hypoglossal nucleus of Roller*.

It is highly improbable, at least in man, that the axones from these small cells take any share in the formation of the root-fibers of the hypoglossal nerve.

CONNECTIONS OF THE HYPOGLOSSAL NUCLEI.


Surrounding this nucleus, and passing between its nerve-cells, exist large numbers of very fine, and also coarse, medullated nerve-fibers, which fibers give to this nucleus the appearance of a stratum zonale.

These fibers arborize about the nerve-cells of the hypoglossal nucleus, and probably form the means of connection of this nucleus with the rest of the nervous system. Their source is as follows:

1. Fibers from the motor tract (central motor tract of the hypoglossal nerve), which occupy the middle part of the motor tract and, becoming longitudinal at the level of this nucleus, pass diagonally, and crossing in the raphé, terminate about the hypoglossal nerve-cells of the opposite side.
2. Fibers enter this nucleus from the posterior longitudinal bundle.

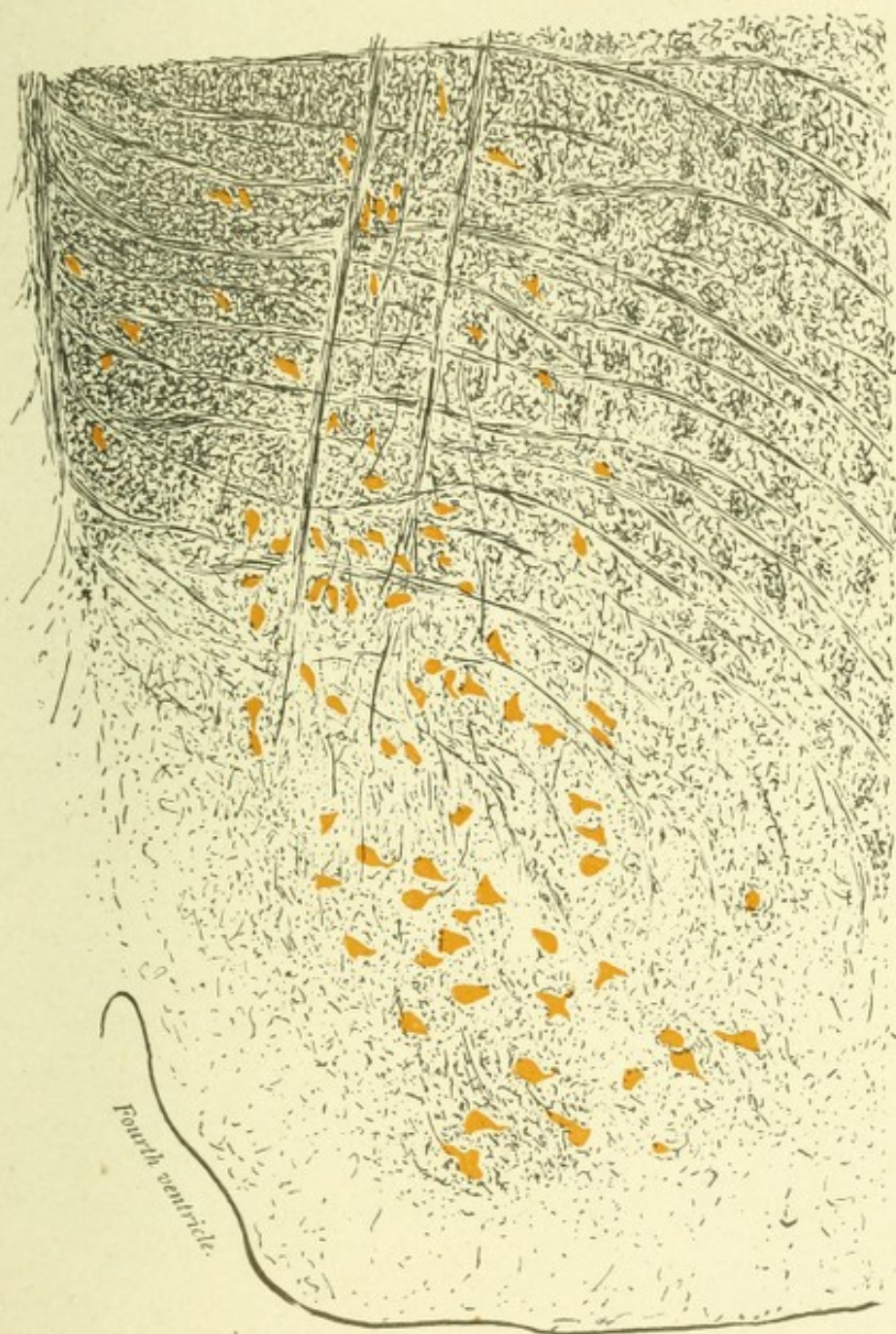

FIG. 78.—TRANSVERSE SECTION THROUGH THE HYPOGLOSSAL NUCLEUS. Method of Weigert-Pal.



3. Collaterals from the sensory end nuclei of the vagus, glossopharyngeal, and trigeminal nerves terminate about the cells of this nucleus.

4. Large numbers of radial coursing fibers, which appear to come from the olivary bodies, but may in part be motor fibers from the pyramidal tract, enter this nucleus (Koelliker).

5. The hypoglossal nuclei are united with each other by commissural fibers which cross in the raphe.

THE VAGUS AND GLOSSOPHARYNGEAL NERVES.

The vagus and glossopharyngeal are mixed motor and sensory nerves, and are connected in the medulla through three nuclei. The motor nerve-root of each of these nerves consists of the axones from the cells of the nucleus ambiguus. The combined sensory nerve-roots represent the axones from the monopolar cells of the jugular and petrosal ganglia. The sensory axones, on entering the medulla, do not immediately bifurcate, but pass dorsally between the descending trigeminal roots, to terminate after bifurcating among the cells of two distinct gray masses located in the dorsal part of the medulla. On approaching their end nuclei, they give off collaterals which, with their axones, arborize about the cells existing in those nuclei. There are thus two sensory end nuclei, among the cells of which these sensory nerve filaments terminate. The first of these is the so-called sensory nucleus of origin, and is located dorsolateral to the nucleus of origin of the hypoglossal nerve, producing on each side of the floor of the fourth ventricle the gray prominence, the *ala cinerea*, or *trigonum vagi*, which extends upward to the fovea inferior. These nuclei, one for each side, are composed of small spindle- or club-shaped cells about 30 to 40 μ long and 12 to 20 μ wide. The cell groups of these nuclei correspond in the spinal cord to cells which exist at the base of the posterior horns. The cells of the upper portion of these nuclei are connected with the sensory axones of the glossopharyngeal nerves, while the cells of the lower part of them are in relation with the axones of the pneumogastric nerves. The second end nucleus consists of axones, collaterals, and nerve-cells, and is called the vertical nucleus of Ramón y Cajal, the

fasciculus solitarius of Lenhossek, or the combined descending root of the vagus and glossopharyngeal nerves; also called the respiratory bundle (Meynert, Gierke, Krause). This combined descending root of the vagus and glossopharyngeal nerve is

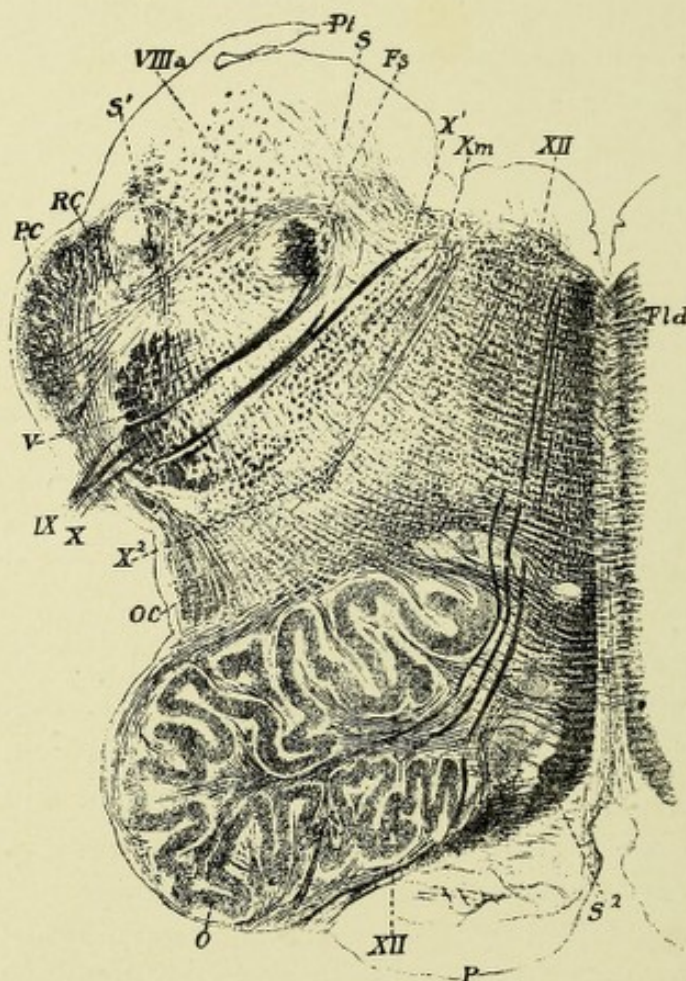


FIG. 79.—MEDULLA OBLONGATA FROM A HUMAN EMBRYO OF EIGHT MONTHS.—(After Koelliker.)

P. Anterior pyramid whose fibers are not medullated. *O.* Olivary and accessory olivary bodies. *OC.* Cerebello-olivary tract. *PC.* Cerebellar peduncle. *Pt.* Ponticulus or ligulae. *IX, X.* Glossopharyngeal and pneumogastric nerve-roots. *X¹.* Combined sensory end nuclei for vagus and glossopharyngeal nerves. *F₃.* Fasciculus solitarius with descending fibers. *Xᵐ.* Motor root-fibers of vagus and glossopharyngeal. *X².* Nucleus ambiguus. *V.* Descending sensory trigeminal nerve. *VIIIₐ.* Descending vestibular tract. *Fld.* Posterior longitudinal bundle. *S.* Median. *S¹.* Lateral fillet or lemniscus. *S².* Interolivary bundle. *RC.* Direct cerebellar tract. *XII.* Hypoglossal nucleus and root-fibers.

located in the formatio reticularis on each side, a little ventrolateral to the first sensory end nucleus. It extends brainward nearly as high as the superior end of the inferior olivary body,

and as far spinalward, according to Krause and Cajal, as the eighth cervical nerve, there being located near the base of each posterior horn. It has its greatest size just above the calamus scriptorius, and gradually decreases in size from above downward, and trends backward and inward. According to Koelliker, the fasciculi become lost among the fibers of the funiculi cuneati, but Cajal states that farther below they again become prominent

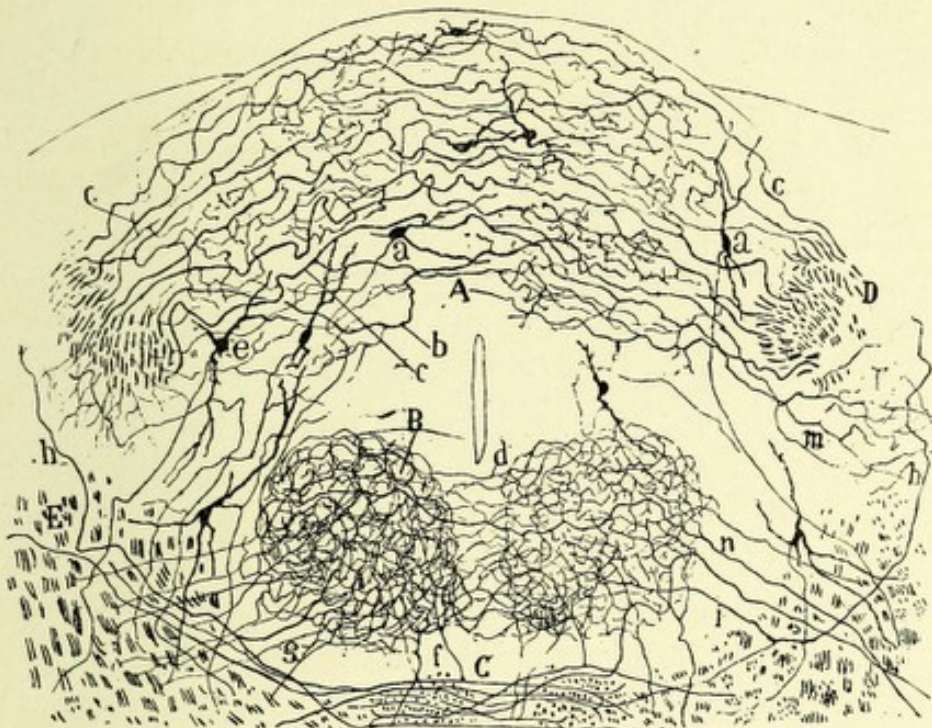


FIG. 80.—TRANSVERSE SECTION THROUGH THE MEDULLA OF A MOUSE AT THE LEVEL OF THE COMMISSURAL NUCLEUS.—(After Ramón y Cajal.)

- A. Commissural nucleus. B. Nucleus of the hypoglossal. C. Crossing of the fibers of median fillet or lemniscus. D. Transverse section of solitary fasciculus. a. Cells of the commissural nucleus. b, c. End fibers of the pneumogastric and glossopharyngeal. d. Decussation of collaterals from the hypoglossal nerve-cells. g, f. Sensory collaterals terminating about the cells of the hypoglossal nucleus.

near the base of the posterior horns. These fasciculi, one for each side, consist of fine axones, collaterals, and end brushes, with, in several places, deposits of gray matter, which gray matter is usually located mesial to the nerve bundles. In their upward course the fasciculi solitarii, deep beneath the ependyma of the fourth ventricle, approach the raphe, and the gray masses unite into an oval, somewhat saddle-shaped nucleus—the

commissural nucleus of Cajal. According to this observer, the fibers of the solitary bundles lie in the lateral portion of this nucleus. About three-quarters of them pass the middle line, decussate with their fellows, and then arborize about the cells existing in the opposite side of this nucleus. The cells of this nucleus are small, oval, spindle, or angular, having very fine neuraxones, which pass anteriorly across the raphe, forming bundles of fibers which enter the lemniscus or fillet, which is probably the central sensory tract for these nerves. This respiratory bundle may associate, through collaterals, the nuclei controlling the various respiratory muscles (Figs. 79 and 80).

The Motor Nucleus of the Vagus and Glossopharyngeal Nerves.—The motor root-fibers of the vagus and glossopharyngeal nerves are the axones from collections of multipolar cells located in the posterolateral portion of the formatio reticularis of each side deep beneath the floor of the fourth ventricle and mesial to the detached posterior horns. These cells form on each side a distinct nucleus, somewhat pear-shaped, which is prolonged upward to near the superior end of the inferior olive and downward to the beginning of the sensory crossway. It has received the name of nucleus ambiguus. The axones of the cells from the upper portion of this nucleus go to form the motor root-fibers of the glossopharyngeal, while those of the lower portion form the root-fibers of the pneumogastric and accessory portion of the spinal accessory nerve. About the cells of this nucleus exist fine end brushes, probably in part collaterals, from the descending root of the trigeminal nerve, thus establishing a connection between the fifth nerve and the motor division of the vagus and glossopharyngeal nerves. Collaterals also from the formatio reticularis grisea arborize about the cells of this nucleus. No collaterals have as yet been discovered connecting the sensory nerve filaments of the vagus and glossopharyngeal with their motor nerve-cells, although it is highly probable that such a connection exists. The axones from the cells of these nuclei pass dorsally to a point near the sensory end nuclei; then they form distinct curves and pass anterolaterally through the formatio reticularis and alongside of the sensory fibers from their respective ganglia. In

their course they give off a few collaterals, which decussate in the raphe with their fellows of the opposite side.

THE OLIVARY BODIES.

The olivary bodies, one on each side, are embedded in the lateral part of the medulla just behind the anterior pyramids, from which they are separated by the emerging hypoglossal nerve-roots. Posteriorly, they are separated from the restiform bodies by the dorsolateral groove for the exit of the spinal

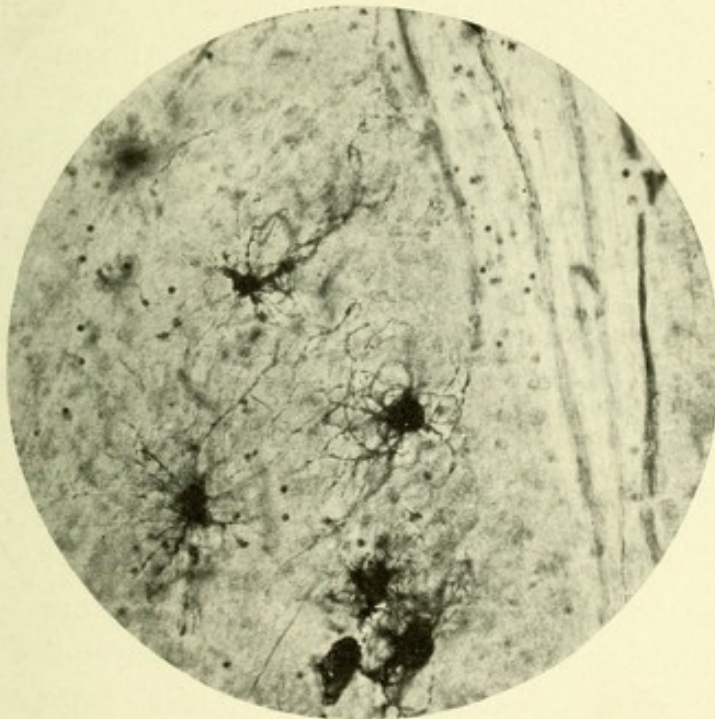


FIG. 81.—MICROPHOTOGRAPH SHOWING MULTIPOLAR CELLS OF INFERIOR OLIVARY BODY.

accessory, pneumogastric, and glossopharyngeal nerves. A short, deep, transverse groove exists between these bodies and the pons Varolii above. The olivary bodies produce externally two large, oval-shaped elevations, with their long axes arranged longitudinally. Numerous fibers may be seen passing across them to join the restiform bodies. They are about 16 or 17 mm. long, and consist of a mass of white, medullated nerve-fibers, surrounded by a capsule of gray matter which presents a wavy, sinuous outline. This capsule is closed at

either end, but presents on its median surface an opening—the hilum. On transverse section the capsulê may be seen to consist of two blades or laminae: an anterior or ventral, and a posterior or dorsal. The anterior blade is shorter and its direction almost transverse, while the dorsal or posterior lamina is longer, and has an oblique direction, backward and inward. The laminae are perforated on all sides by bundles of fine, medullated nerve-fibers; part of these fibers are rearranged within, pass out of the hilum, decussating in the raphe, and end in arborizations about the nerve-cells of the opposite olivary body. This bundle of fibers on each side forms a system,—the *cerebello-olivary tract*,—which will soon be described. The remaining fibers, *fibriae arcuatae*, simply pass through the olivary bodies entering the *formatio reticularis grisea*; while those which pass through the anterior or ventral lamina probably are external arcuate fibers. Microscopically, the olivary bodies are composed of a neuroglia network, in the meshes of which exist a great many small multipolar cells, which are roundish or pear-shaped, contain a yellowish pigment, and are from 18 to 26 μ in diameter. Each cell has from three to five dendrites, and a long, fine neuraxone, the destination of which is unknown, although Koelliker believes that it passes into the lateral columns, and ends about the motor cells of the cord. Cajal states that some of these neuraxones become transverse, cross the median line, pass through the opposite olivary body, and enter the white matter, while others pass out of the olivary body without decussating and are lost among the anterior external arcuate fibers. These bodies, in addition, contain a vast number of fine nerve-fibers, which end in brush-like expansions about the cells. They are probably arborizations from the neuraxones of the cells of Purkinje, from which, according to Koelliker, the *cerebello-olivary tract* arises (Fig. 82).

In addition to the olivary bodies, two other gray masses exist, having about the same histologic construction, which, because of their proximity to the former, are called accessory olivary bodies. They are divisible into a median or inner accessory olivary body and a dorsal or posterior accessory olivary body on each side. The inner one is located in the lemniscus, just dorsal to

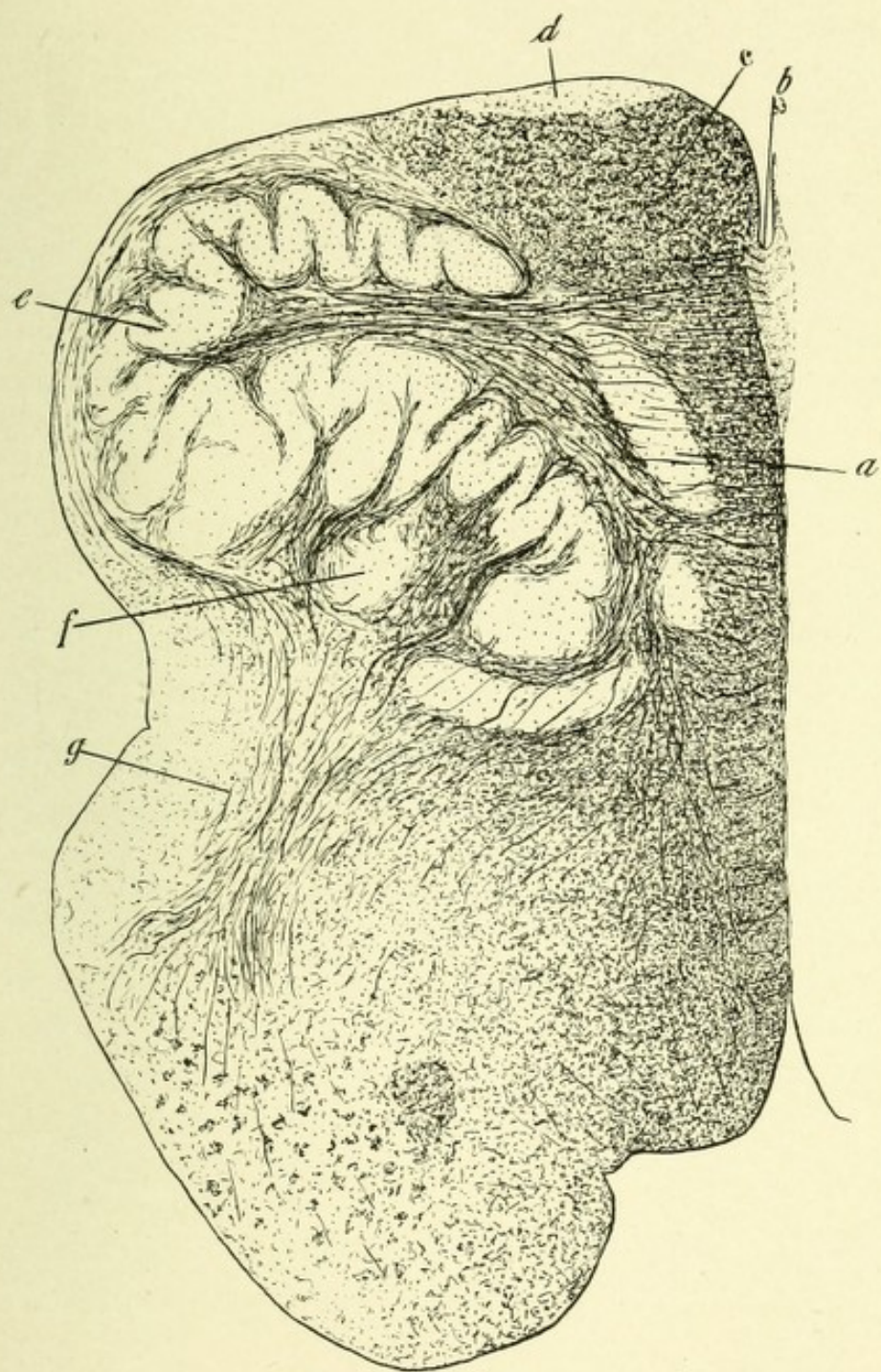



FIG. 82.—HEMISECTION OF MEDULLA TO SHOW OLIVARY BODY. Method of Weigert-Pal.
a. Median accessory olivary body. *b.* Anterior median fissure. *c.* Anterior pyramid. *d.* Nucleus arciformis. *e.* Olivary body. *f.* Dorsal accessory olivary body, which also includes gray mass at the extremity of the dorsal lamina of olivary body. *g.* Cerebello-olivary tract.



the pyramids and ventrolateral to the anterior lamina of the olivary body. Because of their relation to the anterior pyramids, they are sometimes called the pyramidal nuclei. The dorsal or posterior accessory body is found just dorsal to the inner portion of the posterior blade of the olivary body of each side. These accessory bodies are traversed by the internal arcuate fibers; usually, however, the root-fibers of the hypoglossal nerves pass between them and the main olivary bodies. In the ventral part of each pyramid among the external arcuate fibers exists a triangular-shaped mass of gray matter called the nucleus arciformis.

THE CENTRAL TEGMENTAL TRACT OF BECHTEREW AND FLECHSIG.

The central tegmental tract consists of a small bundle of fibers, which probably take their origin from the olivary body of the same side. This bundle is located in the *formatio reticularis*, dorsal to the olivary body, which position it retains until it reaches the level of the lower border of the pons Varolii, where it becomes located dorsal to the corpus trapezoides in the space between the superior olivary body and the lemniscus; at a higher level in the pons it occupies a position in the central part of the tegmentum, hence its name. Still higher up, this bundle of fibers passes between the crossing fibers of the superior cerebellar peduncle, and then takes a position lateral to the posterior longitudinal bundle, and terminates, according to Bechterew, in the region of the third ventricle. Flechsig states, however, that the fibers of this tract continue brainward and end in the globus pallidus of the lenticular nucleus. Helweg asserts that the fibers of this tract pass in part into the lenticular loop and in part into the posterior commissure.*

SECTION THROUGH THE MIDDLE OF THE OLIVARY BODIES.

Here the motor and sensory decussations are completed; the restiform bodies occupy the lateral periphery of the section, and

* It is probable that the olivary tract of Bechterew or the triangular bundle of Helweg and the central tegmental tract form a functionally continuous bundle of fibers which connect the spinal cord and olivary body with the mid-brain.

have attained considerable size. The gray matter is broadened; the anterior and posterior horns still exist, severed from their connection with the gray matter. The olivary bodies, with their accessory nuclei, are seen with their wealth of cells and fibers.

At this level exists another system or tract, consisting of fibers which decussate in the raphe and pass into the opposite olivary body; it is known as the *cerebello-olivary tract*. Take, for example, the right *cerebello-olivary tract*: Its fibers come, according to Koelliker, from the cells of Purkinje, in the cerebellar cortex of the same side, and pass downward in the lateral portion of the restiform body until they reach the medulla, when they move inward, and occupy the middle portion of the restiform body; they then pass to the neighborhood of the right olivary body in curves, "arcuate fibers," where they spread out and almost completely surround that body; they then pass through its laminae into its interior, where the fibers are rearranged, forming a compact bundle, which passes out at the hilum; the fibers decussating with their fellows of the opposite side, entering the hilum of the opposite olivary body, and ending in arborizations about the cells of that body.* The axones of the cells of the olivary bodies then pass outward into the lateral column, where they curve downward and inward to terminate about the motor cells in the anterior cornu of the left side.

The fibers which compose this tract degenerate downward. This fact has been proved by experimental destruction of a cerebellar hemisphere of a young animal, when there followed complete atrophy of this tract and of the opposite olivary body. The same condition has been observed in man after extensive disease of a cerebellar hemisphere.

The restiform bodies, which at this level have attained a large size, are composed of the following systems of fibers:

First, the direct cerebellar tract, which has passed backward into the restiform body of the same side; it terminates in the cortex of the superior worm of the cerebellum.

* Bechterew, on the contrary, believes that the majority of the fibers of this tract come from the cells in the corpus dentatum, only a few coming from the cerebellar cortex.

Second, a few fibers pass from the cells of the nuclei *graciles et cuneati* around the outer posterior surface of the medulla, reaching the restiform body of the same side. They are called the postero-external arcuate fibers.

Third, fibers from the nuclei of the posterior columns, which are continuations of the interolivary tracts. After decussating, they pass around the external surface of the opposite anterior pyramid and olivary body and join the restiform body of the opposite side. These are the antero-external arcuate fibers.

The posterior external arcuate fibers come from the posterior

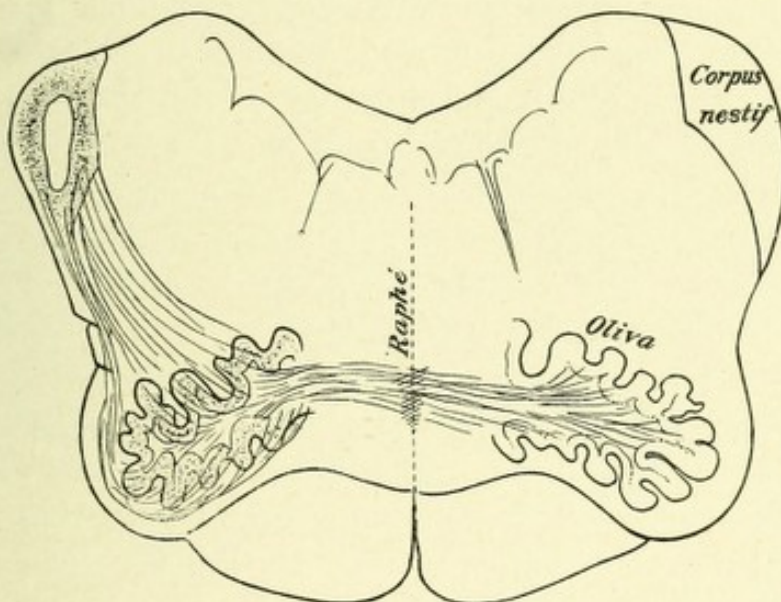


FIG. 83.—THE CEREBELLO-OLIVARY TRACT.—(After Edinger.)

nuclei of the same side, while the anterior external arcuate fibers come from the posterior nuclei of the opposite side.

The majority of these fibers pass to the cortex of the superior worm of the cerebellum. A few probably go to the corpus dentatum.

Fourth, fibers pass to the restiform body from the lateral nucleus of the same side.

Fifth, the descending tracts of Marchi and Lowenthal. They may have their origin in the cerebellar cortex and pass downward into the restiform bodies; thence into the anterolateral areas of the cord. They probably end in the median gray matter of the cord.

Sixth, the direct sensory cerebellar tract passes into the restiform body and thence to the cerebellar cortex, thus establishing a connection between the nucleus vestibularis of the auditory nerve and the cerebellar hemisphere.

Seventh, the large bundle of fibers of the cerebello-olivary tracts already described.

A TRANSVERSE SECTION OF THE MEDULLA NEAR ITS JUNCTION WITH THE PONS.

The restiform bodies here are very large, and are gradually passing into the cerebellum. The olivary bodies are greatly diminished in size. The crescentic bundles of fibers of the fifth pair of nerves may be seen internal to the restiform bodies. Dorsal and slightly medianward to the restiform body, lying between it and the dorsal nucleus of the auditory nerve, exists on each side an oblong area of longitudinal fibers, known as the *acusticocerebellar* or the *direct sensory cerebellar tract*. This tract extends downward as far as the posterior columns of the cord, and contains fibers which connect the cells of Deiter's nucleus with the cerebellar cortex. According to Edinger, this tract comes from the cerebellum, and is, in reality, the fasciculus solitarius, or the combined descending vagoglossopharyngeal root. Koelliker believes that it is connected with the sensory nuclei of the trigeminal, vagus, and glossopharyngeal nerves and terminates in the posterior columns.*

Three nerve nuclei occur in this region—namely, the sixth or abducens, the seventh or facial, and the eighth or auditory.

The **abducens** or sixth pair of cranial nerves represent the axones from a collection of multipolar nerve-cells, 40 to 50 μ in diameter, located just beneath the floor of the fourth ventricle, external to the posterior longitudinal bundles and below the *striae acousticae*. The nucleus of each side is inclosed in the loop of the facial nerve. According to Obersteiner, the root-fibers of this nerve receive an accession of fibers from the opposite nucleus, they having crossed in the raphe. The root-fibers

* Ferrier and Turner believe the direct sensory cerebellar tract to be an efferent bundle of fibers from the middle lobe of the cerebellum to Deiter's nucleus.

then pass anteriorly through the gray and white matter, and emerge in a depression existing at the junction of the pons with the medulla, just external to the fibers of the anterior pyramid. The innermost fibers of this nerve frequently pierce the anterior pyramid; the nerve is then directed upward and forward upon the anterior surface of the pons Varolii.

The nuclei of the abducens are connected with the posterior longitudinal bundles by fibers which, it is believed, pass to the

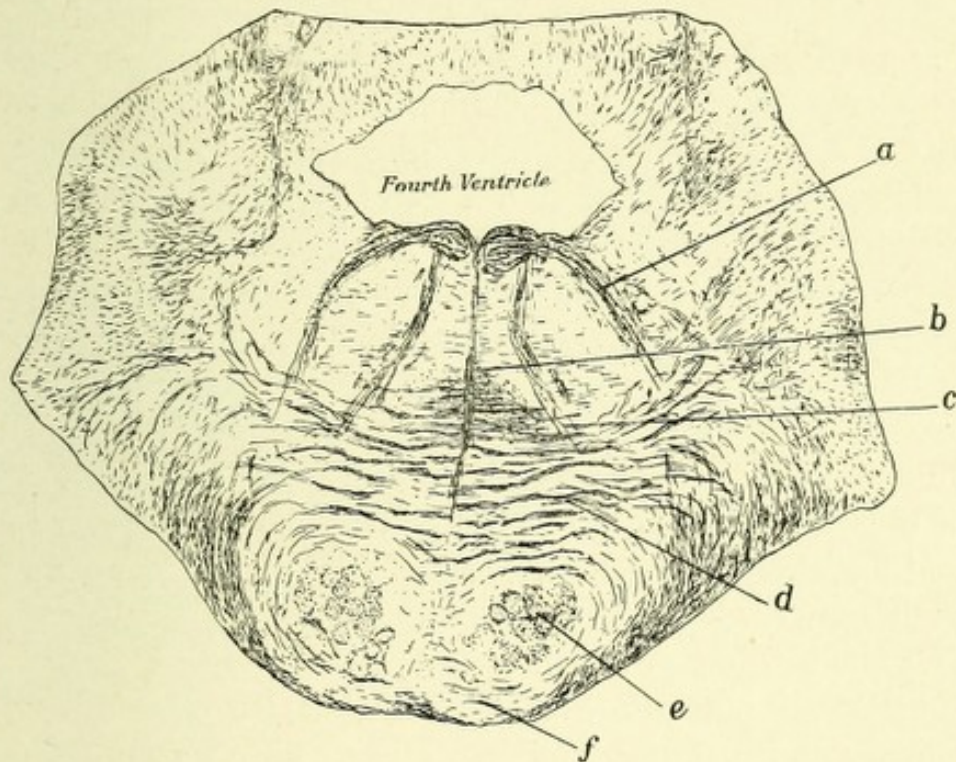


FIG. 84.—TRANSVERSE SECTION THROUGH THE PONS VAROLII. Illustrating the origin of the sixth and seventh cranial nerves.

The nucleus of the seventh is not shown, but its fibers can be seen, *a*, arching over the nucleus of the sixth nerve. *b*. Raphe. *c*. Fibers of the abducens nerve. *d*. Deep transverse pontine fibers. *e*. Pyramidal tract. *f*. Superficial transverse pontine fibers.

opposite oculomotor nucleus, thus permitting the associative movements of the eyeballs. These nuclei are also connected by fibers with the superior olivary bodies. (See p. 176.) These bodies are in relation with fibers from the auditory nuclei, and owing to the connection of these latter nuclei with the cerebellum, there is established an association between the motor nerves of the eyes, the auditory nerves, and the cerebellar cortex. This

association may be of great service in enabling us to judge of our position in space.

The **facial nerve** is a mixed motor and sensory nerve, consisting of a large motor and a small sensory root. The sensory root comes from the cells of the geniculate ganglion, and is called the nerve of Wrisberg, while the motor root represents the axones from a nucleus in the pons at its junction with the medulla. The motor nucleus is located deep in the lateral portion of the formatio reticularis, is about four millimeters long, and presents on transverse section a roundish or slightly oblong form. It consists of a group of large, mostly pigmented, multipolar nerve-cells, which are surrounded by a fine meshwork of fibers. This nucleus is probably the upward continuation of the nucleus ambiguus, which at a lower level gave origin to the motor fibers of the vagus and glossopharyngeal nerves. Some authors claim this nucleus to be the upward continuation of part of the cell group of the severed anterior horn. The axones from the cells of this nucleus pass at first dorsomedially to reach the floor of the fourth ventricle, where they form a distinct elevation—the *eminentia teres*, or the *tuberculum nervi facialis*. At this point the fibers are located just external to the posterior longitudinal bundle; they then make a sudden bend and pass ventrolaterally between the facial nucleus and the sensory trigeminal nerve-roots to their point of emergence—the upper end of the medulla at its junction with the pons, in a depression between the olivary and restiform bodies. Inclosed in the loop or genu formed by the two curves of this nerve is the nucleus of the sixth or abducens nerve. Just as the fibers of the facial are about to become horizontal beneath the ependyma of the fourth ventricle they give off collaterals, which cross the median line and end about the cells of the facial nucleus of the opposite side. It is a well-known fact that in facial paralysis the result of a central lesion, the lower branches only are affected, and the *orbicularis palpebrarum* and *frontalis* muscles remain normal; it is possible, as suggested by Mendel, that those muscles are supplied with fibers that join the facial through the motor oculi nerve. They probably pass in the posterior longitudinal bundle and join the facial at its genu. The nerve of Wrisberg, or the sensory

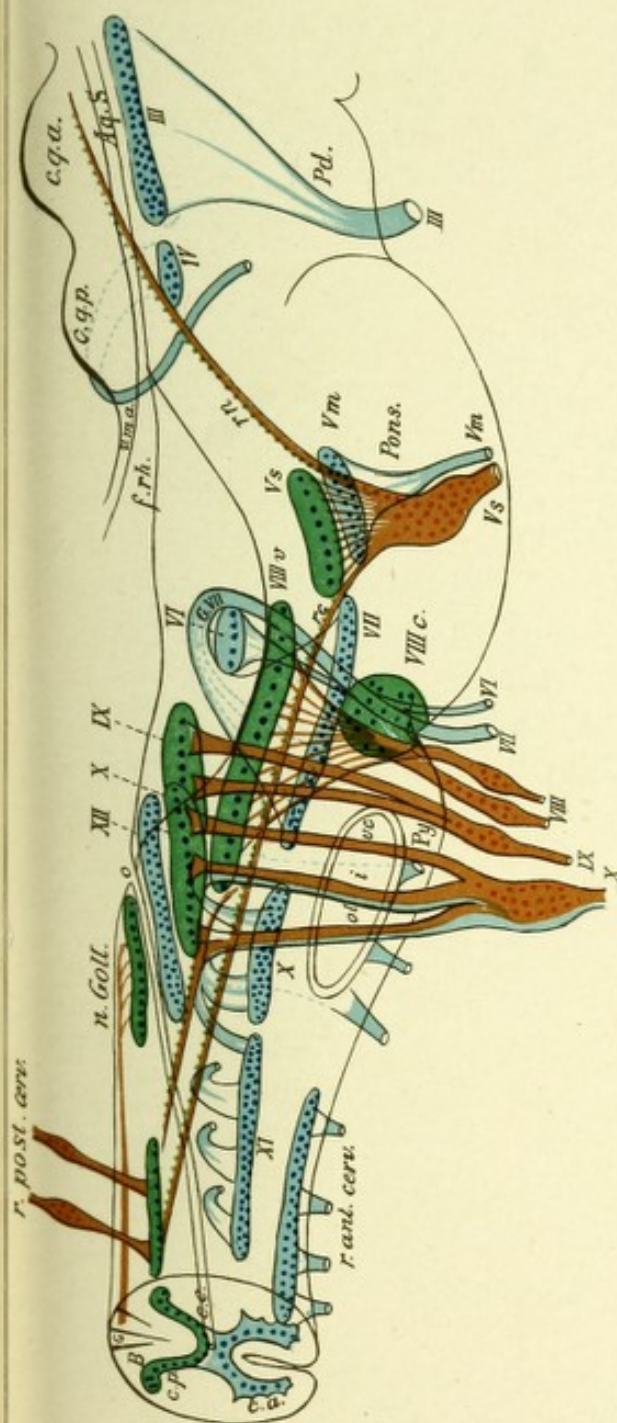


FIG. 85.—LATERAL VIEW OF THE MEDULLA OBLONGATA WITH THE SCHEMATIC REPRESENTATION OF THE NUCLEI AND THE INTRAMEDULLARY COURSE OF THE CRANIAL NERVES.—(From *Jakob's Atlas*.)

The uppermost nerve is the motor oculi (*III*). Its nucleus, of long extent and consisting of several parts, lies in the central gray matter of the ventricle beneath the aqueduct of Sylvius. Behind it lies the nucleus of the trochlear nerve; the nerve (*IV*) passes dorsally as one of the cranial nerves out behind the posterior quadrigeminal bodies, decussates with its fellow of the other side, and then passes to the base.

The trigeminus (*V*) arises in two portions: the anterior motorial (*V_m*) arises from the motor (*V*) nucleus, to it is joined the probably motorial nasal descending root (*rn*), which arises laterally from the aqueduct (here represented as sensory root). The posterior sensory (*V_s*) originates from the Gasserian ganglion and separates in the pons in three portions: one portion ends in the sensory vagus nucleus; a second portion passes as the caudal ascending root (*rc*) through the medulla as far as the first cervical segment, where it ends by degrees; a third portion passes to the cerebellum. The facial (*VII*) arises from its extensive and deeply situated nucleus in the medulla, gathers itself together to the knee of the facial, passes around the abducens nucleus (*VI*) with an outward curvature, and finally emerges beneath it. The course of the abducens is simple. The auditory (*VIII*) ends as the cochlear nerve (*VIII_c*) in the ventral nucleus, and as vestibular nerve (*VIII_v*) in the dorsal nucleus and its environs; one portion passes as descending root of the *VIII*, a short distance farther toward the spinal cord (not represented). The sensory glossopharyngeal-vagus fibers come out from the petrosal and jugular ganglia and end in the sensory *IX* and *X* nuclei in the posterior end of the calamus scriptorius (*X*, green); a portion passes as descending root of the *X* some distance toward the spinal cord (solitary fascicle). The motor fibers arise in part from the nucleus ambiguus (*X*, blue), and in part from the spinal accessory nucleus.

The hypoglossal (*XII*) nucleus lies in the caudal dorsal segment of the medulla and sends its fibers out through the medulla laterally to the pyramids. The nucleus of the spinal accessory (*XI*) reaches far down in the upper cervical cord and its fibers pass out through the lateral columns. *r. p.* Posterior, upper cervical root from the spinal ganglia. *r. a.* Anterior upper cervical roots.



division of the facial, represents the axone from the cells of the geniculate ganglion (P. Martin). These axones possess both a peripheral and a central division; the central division passes into the medulla to the region of the fasciculus solitarius or the combined descending vagus and glossopharyngeal roots. The peripheral fibers join the facial, and, according to Duval, are probably those which go to form the chorda tympani nerve, and are concerned with the special sense of taste.

CONNECTIONS OF THE FACIAL NERVE.

The facial nuclei are connected with the motor tracts by collaterals which pass from these tracts dorsally, decussate in the raphe near the bottom of the ventral fissure, and then course dorsolaterally to end about the cells of the facial nuclei.

The facial nerve is also connected with the sensory trigeminal nerve by four or five bundles of fibers, which are collaterals from the descending trigeminal nerve-roots.

This nucleus is indirectly connected with the cochlear division of the auditory nerve by fibers from the corpus trapezoides and superior olivary body.

THE AUDITORY NERVE.

The auditory nerve, or the nerve of the special sense of hearing, possesses two roots, which differ both in their anatomic relation and physiologic functions. The first, which is called the cochlear nerve, presides over the function of hearing; the second root, or vestibular nerve, is concerned in the maintenance of equilibrium. The cochlear nerve is also termed the lateral, posterior, or dorsal root; the vestibular, the ventral, anterior, or mesial root.

The **cochlear nerve** represents the axones from the cells of the spiral ganglion located in the bony wall of the cochlea which forms the anterior part of the labyrinth. The peripheral axones from the cells of this ganglion end about the ciliated cells of the organ of Corti in the cochlear duct. The central axones as they exist in the internal auditory meatus



resemble in their position the posterior root of a spinal nerve. The cochlear nerve in its centripetal course then enters the lowermost part of the pons, external or lateral to the restiform body, and, without decussating, terminates in an end nucleus—the ventral acoustic nucleus.

The **vestibular nerve** represents the axones from a swelling or ganglion in the auditory meatus called the vestibular ganglion, or the *intumescentia gangliformis* of Scarpa. The per-

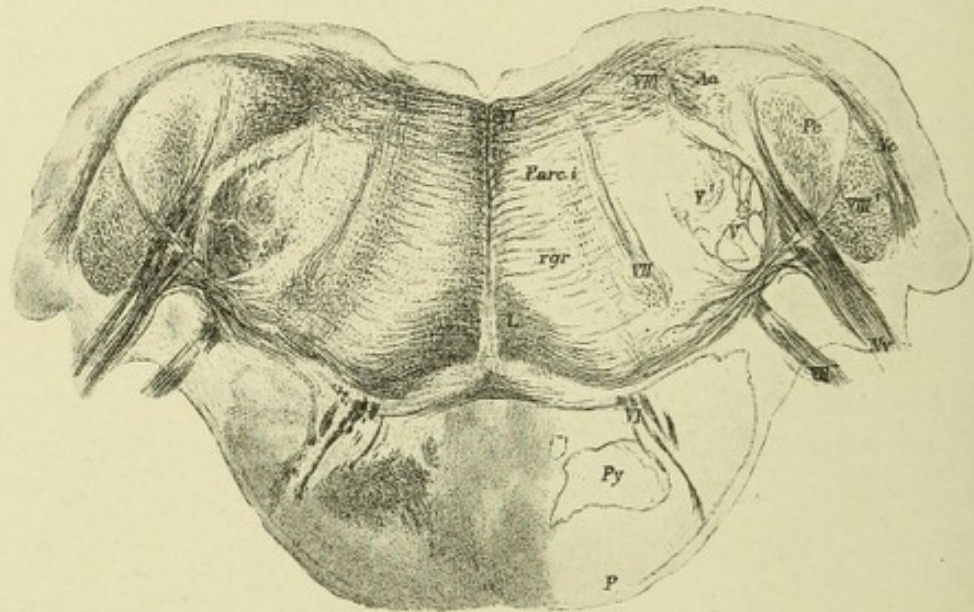


FIG. 86.—TRANSVERSE SECTION THROUGH THE DISTAL PART OF THE PONS OF AN EIGHT-MONTHS' HUMAN EMBRYO.—(After Koelliker.)

P. Superficial pontine fibers (non-medullated). *Py.* Anterior pyramid. *VIII*¹. Ventral auditory nucleus from which the medullated fibers of the corpus trapezoides arise. *VIII*². Dorsal auditory nucleus. *Nv.* Nervus vestibuli. *VII*². Emerging facial nerve-roots. *VII.* Nucleus of the facial nerve. *VI.* Abducens nerve. *L.* Lemniscus. *Fl.* Posterior longitudinal bundle. *Arc.i.* Internal arcuate fibers. *Nc.* Cochlear nerve. *Pc.* Cerebellar peduncle. *Aa.* Descending auditory root. *rgr.* Substantia reticularis grisea. *V.* Descending trigeminal nerve-roots. *V*¹. End nucleus of trigeminal nerve.

ipheral axones are distributed to the fusiform cells of the semicircular canals. The central axones of the vestibular nerve take a course internal to the ventral acoustic nucleus and restiform body, being located between the latter and the sensory bundle of the fifth nerve. In their course dorsally they bifurcate, the branches, with their collaterals, ending about the cells of Deiter's nucleus and the chief auditory nucleus. The cells of both spiral and vestibular ganglia are bipolar.

Both divisions of the auditory nerve are connected in the medulla and pons with three end nuclei: first, the anterior, ventral, or lateral acoustic nucleus; second, the dorsomesial, or chief auditory nucleus; and third, the dorsolateral, or nucleus of Deiter. The anterior nucleus is an oval collection of nerve-cells wedged in between the cerebellum in front and the restiform body behind. It produces on the outer surface of the medulla

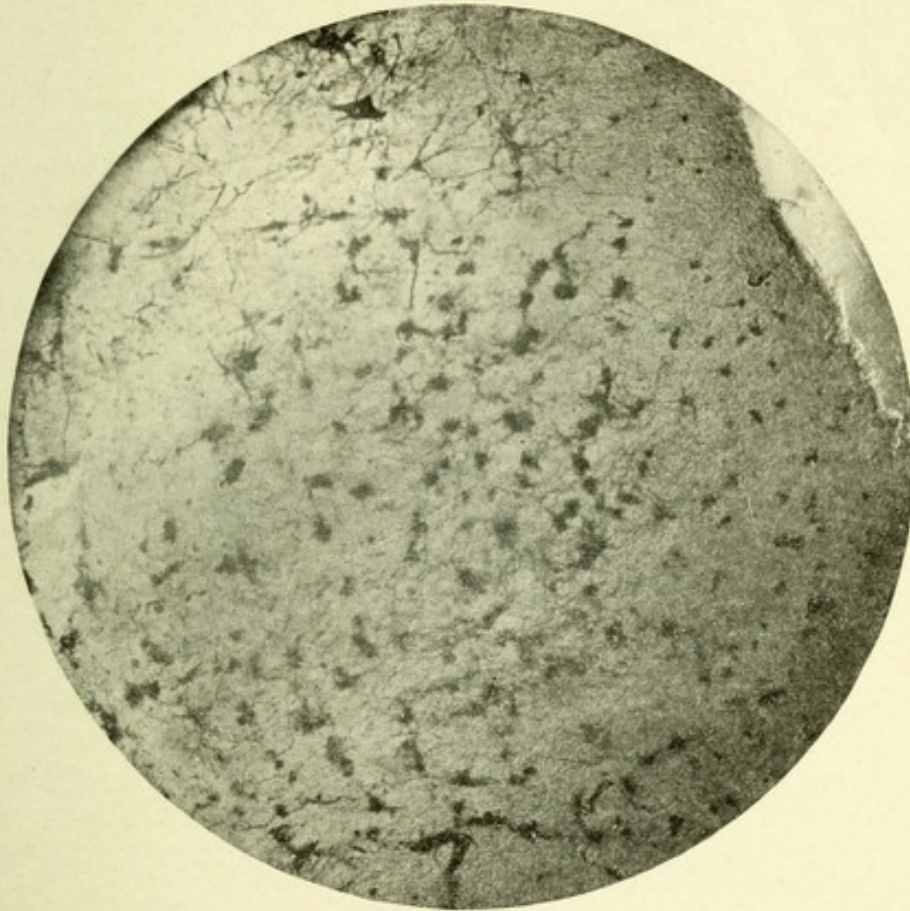


FIG. 87.—MICROPHOTOGRAPH SHOWING CELLS OF VENTRAL AUDITORY NUCLEUS. Method of Golgi.

an enlargement known as the tuberculum acousticum. The anteroposterior diameter of this nucleus is about three millimeters, and its transverse about two millimeters. It consists in man of two portions—dorsal and ventral. The ventral portion, often called the nucleus accessorius, consists of many rather small, roundish cells, 25 to 35 μ in size, which resemble closely those of the posterior spinal ganglia. They are surrounded by a great number of fine nerve terminals. The

dorsal portion, or tuberculum acousticum, which is located between the cerebellum and the pons, consists of two forms of cells—small, round ones, and large, somewhat cylindric-shaped cells; these are fewer in number than those of the anterior portion. The dorsomesial, or chief nucleus of the auditory, or nucleus vestibularis, occupies a large triangular area just beneath the floor of the fourth ventricle, external to the combined sensory

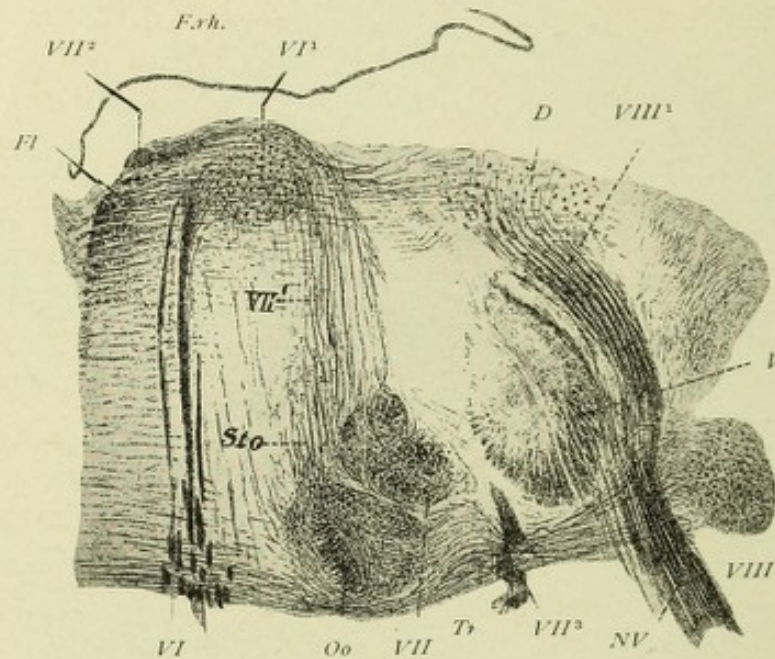


FIG. 88.—DORSAL PART OF A TRANSVERSE SECTION OF THE MEDULLA OBLONGATA FROM A HUMAN EMBRYO OF SIX MONTHS.—(After Koelliker.)

Fl. Posterior longitudinal bundle. *VI.* Abducens nerve. *VI¹.* Nucleus of abducens. *VII.* Facial nucleus. *VII¹.* Ascending axones from cells of facial nucleus. *VII².* Knee of facial nerve. *VII³.* Emerging facial fibers. *Tr.* Corpus trapezoides. *Oo.* Superior olivary body. *Nv.* Vestibular nerve. *VIII.* Ventral auditory nucleus. *VIII¹.* Descending vestibular root. *D.* Nucleus of Deiter. *V.* Sensory trigeminal nerve-root. *F.rh.* Fovea of the fourth ventricle.

nucleus of the vagus and glossopharyngeal nerves and postero-internal to the restiform body. This nucleus consists mainly of small multipolar nerve-cells, about 20 μ in diameter. The dorsolateral, or large-celled nucleus of Deiter, is located posterior to the restiform body and dorsolateral to the chief auditory nucleus, embedded in the field of fibers which form the direct sensory cerebellar tract. This nucleus may easily be distinguished from the former nucleus by the large size of its cells,

which are multipolar, and are from 40 to 100 μ in diameter. It increases in size from below upward. At the point where the fibers of the restiform body pass into the cerebellum it is more dorsally located, and has its greatest size. This part of the nucleus is called the nucleus of Bechterew, or nucleus vestibularis of Flechsig.

The fine fibers of which the cochlear nerve is composed are related to the cells of both divisions of the ventral or lateral auditory nucleus. On entering the nucleus they divide Y-shape, one division passing upward, the other downward, each division giving off several collaterals; these divisions, with their collaterals, further subdivide into fine plexuses about the cells of this nucleus. The rather coarse fibers of the vestibular nerve pass dorsolaterally through the medulla, internal to the ventral auditory nucleus and restiform body, and when they approach their end nuclei, the chief auditory nucleus, and the nucleus of Deiter, they divide Y-shaped, giving off at the same time numerous collaterals, one division passing brainward, the other spinalward. The former ends about the cells of these two end nuclei, while the latter branches, forming the so-called descending division of the vestibular nerve. These latter fibers, with their collaterals, end in fine end brushes about a group of cells which continue downward on both sides as far as the cuneate nuclei. Some of the cells of this group are large, while others are small. Monakow and Koelliker believe these cell groups to be a continuation downward of the nuclei of Deiter. They may be considered as the descending nuclei of the vestibular nerves.

Connections of the Auditory Nerve.—The axones from the cells of the accessory division of the ventral auditory nucleus proceed toward the raphe, producing transverse bundles of fibers which are located just posterior to the anterior pyramids called the corpora trapezoidea. Among the fibers of each corpus trapezoideum exist numbers of large, spindle-shaped, multipolar nerve-cells, whose axones pass anteriorly, and then bend at an angle and assist in the formation of the corpus trapezoideum by forming transverse fibers. The fibers pass in part into the superior olivary body of the same side, while the remainder decussate in the raphe and pass to the superior olivary body of the opposite side.

THE SUPERIOR OLIVARY BODIES.

These are cylindric masses of gray matter, consisting of neuroglia fibers, fine nerve terminations, and numerous pear- or spindle-shaped cells, which possess a single axis-cylinder and numerous dendritic branches. These cells begin at about the level where the nuclei of the facial nerves are first observed, and are located anterior and slightly internal to them. They are surrounded by the fibers of the corpora trapezoidea, which fibers end about their nerve-cells. A few axones of the cells of the superior olivary bodies pass dorsally to end about the nuclei of the abducens nerve. The majority of the axones of the superior olivary bodies pass dorsolaterally, decussate in the raphe, and form the lateral fillet of the opposite side. This fact seems to be proved by the experiment of Baginski, which showed that after the destruction of the cochlea in a young animal there followed an atrophy of the ventral auditory nucleus, the corpus trapezoideum, the superior olivary body, all of the same side, and of the lateral fillet of the opposite side. Most of the axones from the cells of the tuberculum acusticum and a few from the nucleus accessorius pass around the restiform body of each side, then proceed just beneath the ependyma of the ventricle, where they are known as the striæ acusticæ, until they approach the raphe; they then pass ventrolaterally, decussate in the raphe, and enter the lateral fillet of the opposite side. A few fibers do not decussate, but go to the fillet of the same side. Monakow found that the destruction of the lateral fillet close to the corpus quadrigeminum was followed by an atrophy of the striæ acusticæ of the opposite side. The nucleus of the lateral fillet or lemniscus is the upward continuation of the cells of the superior olive of each side. This group of cells continues from the upper end of the superior olive to near the point where the fillet fibers join the posterior corpus quadrigeminum.

CONNECTIONS OF THE VESTIBULAR NERVE.

1. *With the Cerebellum.*—The nucleus of Deiter is connected with the cerebellum, first, by a large bundle of fibers—the acous-

tico-cerebellar tract; also called the direct sensory cerebellar tract (Edinger). Much doubt still exists in regard to the source of the fibers of which this tract is composed. Some observers (Russel, Ferrier, and Turner) believe it to be an efferent tract connecting the middle lobe of the cerebellum with Deiter's nucleus, while Koelliker believes, from embryologic study, that the tract consists chiefly of axones from the cells of Deiter's nucleus, a few coming from the cells of the chief auditory nucleus. The fibers passing into the middle portion of the restiform body and proceeding to the region of the roof nuclei of the cerebellum, between which nuclei they decussate with their fellows from the opposite side, to end in the opposite roof nucleus.

2. *With the Lateral Fillet.*—The second connection is by fibers from the nuclei of Deiter and the chief nuclei, which course ventrolaterally into the formatio reticularis, cross over in the raphe, and pass to the dorsal surfaces of the superior olivary bodies, where they assist in the formation of the lateral fillet of each side.

3. *With the Internal or Mesial Fillet.*—The third connection is by axones proceeding from the cells of Deiter's nucleus and coursing ventromesially between the root-fibers of the vestibular branch and the mesial nerve, and turn upward, probably entering the internal fillet or lemniscus.

4. *With the Nuclei of the Sixth Nerve.*—The fourth connection is formed by fibers from both end nuclei of the vestibular nerve to the abducens nuclei.

5. *With the Olivary Body and the Lateral Column of the Same Side.*—The fifth connection is by the descending vestibular olivary tract and the descending vestibular spinal tract (Van Gieson). The vestibular olivary tract passes ventromesially through the lateral field of the formatio reticularis and ends in the olivary body of the same side. The descending vestibular spinal tract passes through the periphery of the lateral field of the formatio reticularis and descends in the lateral column of the spinal cord. Its ultimate distribution is unknown.

THE PONS VAROLII.

The pons lies between the brain stem, or crura cerebri, above, the medulla below, and the cerebellum behind. It serves to connect the cerebrum with the cerebellum and the cerebellar hemispheres with each other by means of broad, transverse bundles of fibers. It permits most of the long tracts of the

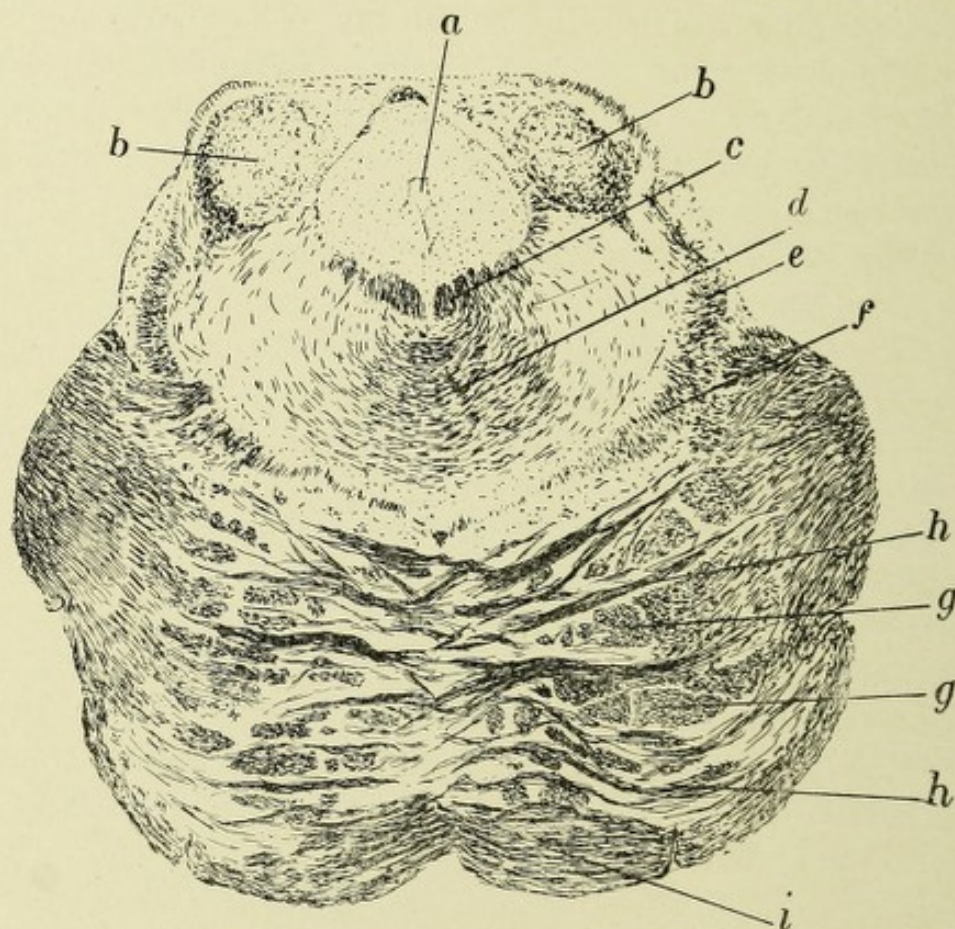


FIG. 89.—TRANSVERSE SECTION THROUGH UPPER PART OF PONS VAROLII. Method of Weigert-Pal.

- a.* Aqueduct of Sylvius. *b.* Posterior corpus quadrigeminum. *c.* Posterior longitudinal bundle. *d.* Beginning decussation of superior cerebellar peduncles. *e.* Lateral fillet or lemniscus. *f.* Median fillet or lemniscus. *h, h.* Deep transverse pontine fibers. *g, g.* Fasciculi of pyramidal tract. *i.* Superficial transverse pontine fibers.

medulla to continue brainward without any special change of relative position. It contains a few special gray deposits, whose cells give origin to the auditory, facial, abducens, and trigeminal nerves. The auditory and facial nerves come out lateral to the abducens at the junction of the pons with the medulla. The abducens comes out at the junction of the pons with the

medulla, close to the median surface of the pons in the upper end of the ventrolateral groove. The fifth pair, or trigeminal nerves, emerge from the lateral part of the ventral surface of the pons, just above its central portion. The anterior surface of the pons is convex, and rests in the sphenobasilar groove. This surface is contracted laterally, owing to the convergence of the broad bundles of transversely arranged fibers, which fibers form a commissural-like arch between the hemispheres of the cerebellum. The above fibers form the middle peduncles of the cerebellum. They are divided into a superficial and a deep set by the passage through them of the anterior pyramids, or great motor tracts. Along the middle of the ventral surface, running from before backward, is a groove in which the basilar artery rests. The dorsal surface forms the upper half of the floor of the fourth ventricle. Its middle part is somewhat flattened, while its sides are elevated, due to two broad bands of white fibers,—the superior peduncles of the cerebellum,—which have come from the neighborhood of the corpora quadrigemina. They form the upper and outer boundary of the fourth ventricle, which at this point is gradually narrowing into the aqueduct of Sylvius, which serves to connect the fourth ventricle with the ventricle above, or the third ventricle. The superior portion of the pons arches over the crura cerebri.

A TRANSVERSE SECTION OF THE PONS.

The pyramids, which occupy a position anteriorly, are no longer free, as they were in the medulla, being concealed between the superficial and deep transverse fibers, but they still remain as two distinct bundles of fibers, while above the middle of the pons they are separated into a number of fasciculi. Between the transverse fibers of the pons exists, on each side, a large number of small, multipolar nerve-cells, forming groups called the nucleus pontis. According to Cajal, the fibers of the corticocerebellar tracts end in brush-like expansions about these cells, and are further continued by the axones of these cells, which pass as transverse fibers to the cortex of the cerebellum. Koelliker believes that many of these transverse fibers conduct impulses centrifugally, and are the axones from the cells of Purkinje, which end in

arborizations about the cells of the nuclei pontis of the same and opposite side. Posterior to the transverse fibers is the *formatio reticularis*, which is an upward continuation of the same formation in the medulla; and, as in the medulla, it contains two fields—an inner and an outer. The former is located between the nerve-roots of the sixth pair of cranial nerves, they continuing anteriorly, as do the hypoglossal nerves. From the scanty supply of nerve-cells and consequent lack of color, this area is called the *formatio reticularis alba*. The outer field is located between the nerve-roots of the sixth and seventh pairs of cranial nerves. As it is rich in nerve-cells, it is called the *formatio reticularis grisea*. The raphe exists in the pons as in the medulla, but extends anteriorly only to its transverse fibers. In the *formatio reticularis* exist cell groups, continuations of like groups in the medulla, for the origin of the facial, abducens, and in part of the trigeminal nerves, and just posterior to the pyramids are the tracts of fibers—the *corpora trapezoidea*—already described.

In the anterior part of the *formatio reticularis*, surrounded by these fibers, exist the superior olivary bodies. The two divisions of the fillet or lemniscus occupy a large part of the anterolateral field of the *formatio reticularis*, the lateral fillet being located along the outer periphery and meeting the mesial fillet, which is located dorsal to the deep transverse fibers of the pons, at almost a right angle. Thus the fillet is seen to occupy a large part of the anterolateral region of the tegmentum, as the space occupied by the *formatio reticularis* is called. The fillet is divided into two distinct bundles of fibers,—a mesial fillet and a lateral fillet,—the anatomic and physiologic relations of which are entirely distinct. The mesial fillet represents the combined axones from the cells of the nuclei *cuneati et gracilis* and from the cells of the sensory end nuclei of all the cranial nerves of the opposite side except the auditory, the axones having decussated in the raphe. Some of the axones and collaterals of the mesial fillet that have come from the nucleus *cuneatus* end about the cells of the *formatio reticularis* of the pons and those of the anterior and posterior corpus *quadrigenum*; other fibers pass to the lenticular nucleus of the same and of the opposite side, while many reach the parietal lobe of the brain through the posterior

division of the internal capsule. The fibers from the nucleus gracilis and end nuclei of the sensory cranial nerves end in the ventral part of the optic thalamus (Monakow). From the cells of the optic thalamus axones pass through the posterior limb of the internal capsule and radiate toward the parietal lobe.

The lateral fillet or lemniscus is the central auditory tract,

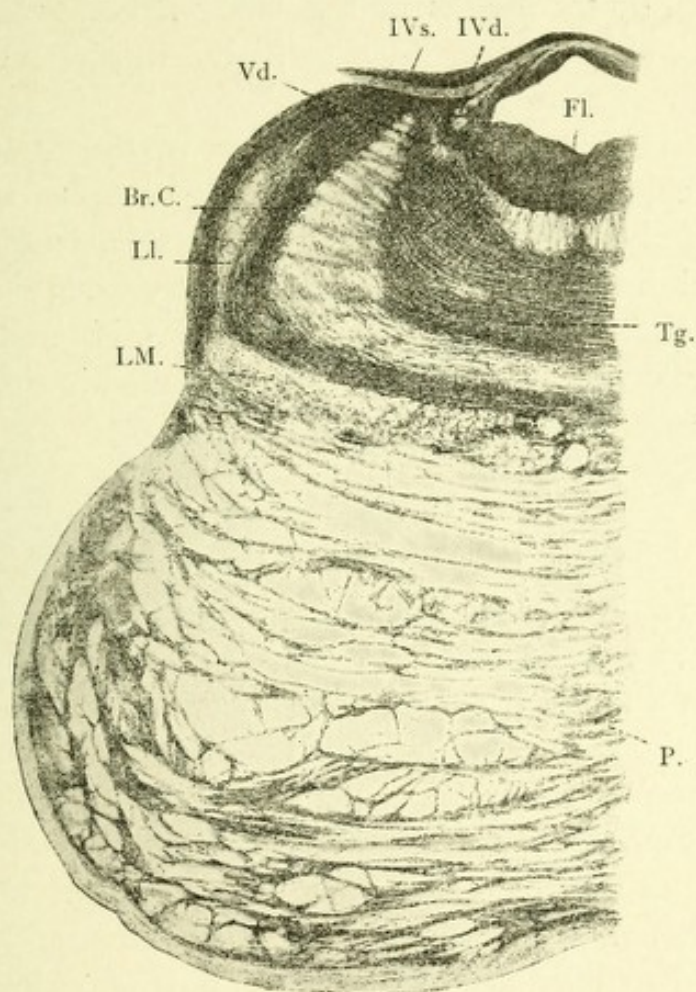


FIG. 90.—TRANSVERSE SECTION THROUGH THE PONS, IN THE REGION OF THE CROSSING OF THE FOURTH NERVE IN THE DORSAL MEDULLARY VELUM.—(After Koelliker.)

Br.C. Superior cerebellar peduncles. Vd. Descending cerebral root of fifth nerve. IVd. Fourth nerve of right side. Fl. Posterior longitudinal bundle. Tg. Tegmentum or substantia reticularis. LM. Median lemniscus or fillet. Ll. Lateral lemniscus or fillet. P. Pyramidal fibers between the superficial and deep transverse pons fibers.

being composed of axones from the end nuclei of the auditory nerve and the superior olivary body; it then passes to the posterior corpus quadrigeminum, and thence, by means of its brachium posterioris, through the extreme posterior part of the posterior limb of the internal capsule, and radiates, via the corona radiata, to the first and second temporosphenoid gyri.

On each side of the median line in the posterior part of the reticular formation is the triangular area of longitudinal fibers—the posterior longitudinal bundles. Beneath the ependyma of the fourth ventricle, and lateral to these bundles, exist a number of highly pigmented nerve-cells, called the substantia ferruginea. Just external to the posterior longitudinal bundle of fibers, in the loop formed by the bends of the facial nerve, is a collection of large multipolar nerve-cells, which give origin to the abducens or sixth pair of cranial nerves.

Slightly dorsolateral to the nucleus of the abducens is the dorsal or chief auditory nucleus, which occupies a large field. External and a little dorsal to this nucleus is the nucleus of Deiter and Bechterew, which has already been described. In front, and at the side of Deiter's nucleus, is the large bundle of fibers of the restiform body, or the inferior cerebellar peduncle.

THE NUCLEI OF ORIGIN OF THE TRIGEMINAL NERVE.

This nerve has two roots on each side—an anterior or motor, the smaller, and a posterior, the sensory. Both roots appear at the side of the pons, just above its middle. The motor root consists of the axones from the cells of the motor nucleus of this nerve in the pons. The sensory root is made up of the axones of the monopolar cells of the Gasserian ganglion, which is located in a fossa near the apex of the petrous portion of the temporal bone. The axones of these monopolar cells each divide into two divisions, one of which passes peripherally, forming the great sensory nerve of the face, while the other passes centrally, entering the pons, where it bifurcates, one division passing slightly upward, the other downward, both giving off very fine collaterals. The former, those which pass upward, enter the enlarged termination of the substantia gelatinosa of the posterior horn, ending about the small nerve-cells therein contained, and thus this termination may be considered as the end nucleus of this set of fibers. The latter, the descending branches (spinal portion of this nerve), pass downward as far as the beginning of the motor crossway or the upper level of the first cervical segment. They form crescentic bundles, one for each

side, which are located just external and slightly lateral to the substantia gelatinosa of the posterior horns, occupying about the same relative position to the heads of the posterior horns as do the tracts of Lissauer in the spinal cord. These bundles of fibers gradually diminish in size from above downward. In their course they give off, nearly at right angles, a large number of fine collaterals. The main branches, with many of their col-

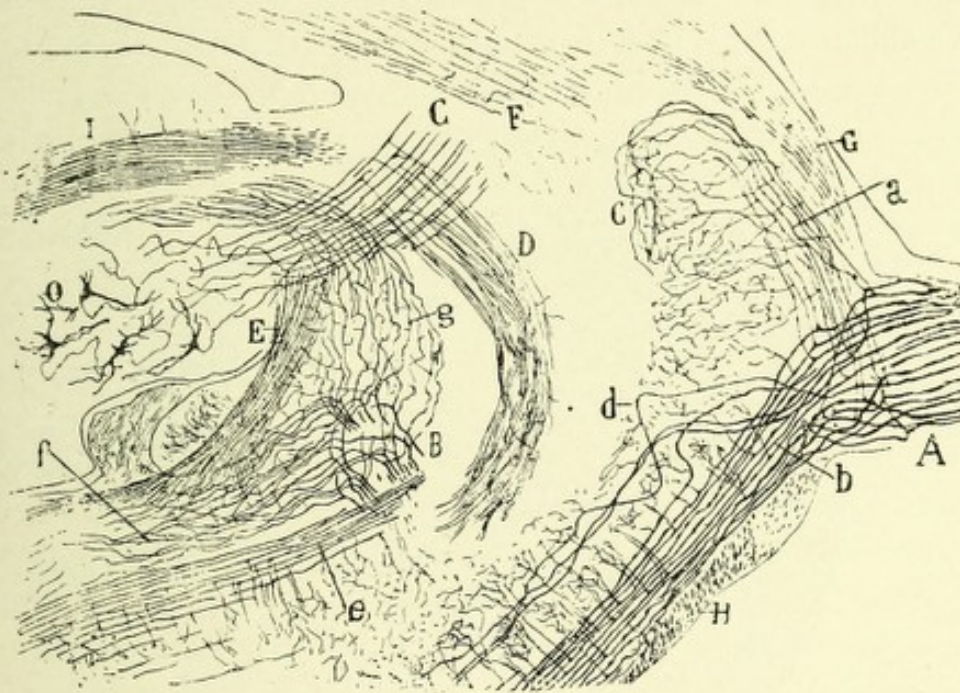


FIG. 91.—LATERAL SAGITTAL SECTION THROUGH THE PONS AND CEREBELLUM OF A FETAL MOUSE.—(After Ramón y Cajal.)

- A. Sensory root of the fifth nerve divided into (a) ascending and (b) descending branches. C. Terminal ramifications of the ascending branch. d. Root-fibers passing downward. e. Posterior part of the descending sensory root. B. Bifurcation of the vestibular nerve, whose ascending branch (g) goes to the cerebellum, and whose descending branch (f) goes to the medulla. G. Superior cerebellar peduncle. D. Descending cerebellar fibers. E. Corpus restiforme (inferior cerebellar peduncle). F. Lateral fillet or lemniscus. H. Corpus trapezoides. O. Corpus dentatum.

laterals, end in fine, brush-like expansions about the multipolar nerve-cells existing in the substantia gelatinosa of the posterior horns, which latter may be considered as continuous end nuclei for these descending branches, hence explaining the reason for the statement above, that these bundles gradually diminish in size from above downward. Other collaterals from the descend-

ing branches, probably comprising all the remainder, presumably reflex in function, end in fine arborizations about the cells of the motor nuclei of the hypoglossal, facial, and trigeminal nerves. The axones from the cells of the sensory end nuclei of the trigeminal nerves pass in curves (internal arcuate fibers), decussate in the raphe, and pass as longitudinal fibers into the mesial fillet or lemniscus of each side, thus forming the central sensory tracts of these nerves. These longitudinal fibers give off in their course collaterals, which end about the large multipolar nerve-cells of the *formatio reticularis*.

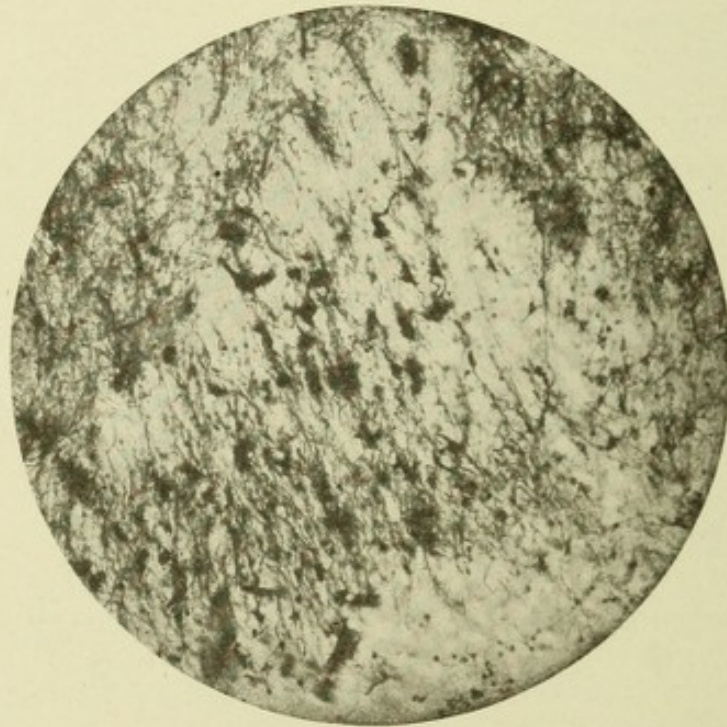


FIG. 92.—MICROPHOTOGRAPH OF A SECTION THROUGH THE MEDULLA OF A HUMAN FETUS OF SEVEN MONTHS.

Showing axones and collaterals of the trigeminal nerve entering the enlarged *caput posterioris*.

The **motor root**, also called the *nervus masticatorius*, because it innervates the muscles of mastication, comes chiefly from the motor nucleus in the pons, but it receives an accession of fibers from a nucleus which is located beneath and lateral to the aqueduct of Sylvius.

The chief motor nucleus of each side is a collection of multipolar nerve-cells located slightly backward and a little external to the sensory end nucleus in the pons, and also slightly dorsal

to the nucleus of the facial, of which it is probably an upward termination. The axones of these cells pass ventrolaterally, and issue from the side of the pons as a small bundle of fibers, just ventral to the sensory root, the two roots being separated from each other by a small bundle of transverse pontine fibers. A few axones from the cells of the median part of this nucleus pass dorsally in curves across the median line or raphe, and unite with the motor roots of the opposite side; hence each motor root receives a small number of fibers from the nucleus of the opposite side.

The *accessory nucleus*, the cells of which give origin to the descending trigeminal or cerebral root-fibers, consists of a collection of large, somewhat spheric or pear-shaped cells, which are probably multipolar in character, although it is usual to describe them as unipolar nerve-cells. No dendrites can be discovered coming from these cells after they have been stained with silver nitrate. In carmin-stained specimens, however, dendrites can usually be seen. They are located deep beneath, and lateral to, the aqueduct of Sylvius, extending as far brainward as the corpus quadrigeminum. The cells of this nucleus give off single thick axis-cylinders, which course downward until they reach the neighborhood of the chief motor nucleus, where they branch, one branch ending in a plexus of fibers about a motor cell of the chief nucleus (Lugaro, Ramón y Cajal), the other branch joining the root-fibers from the same nucleus.

The Cerebral Connections of the Trigeminal Nerve.—

The sensory end nucleus of the trigeminal nerve is connected with the opposite sensorimotor area by means of axones which leave this nucleus and cross in the raphe to pass brainward in the mesial fillet of the opposite side.

The motor area for the masticatory muscles, which is located probably in the lower part of the ascending frontal gyrus, is related with the motor nucleus of the opposite side by fibers which leave this area and join the pyramidal tract. According to some observers, fibers from the sensory trigeminal roots pass dorsolaterally, enter the lateral part of the restiform body, where they commingle with fibers of the direct sensory cerebellar tract, and pass to the cerebellum. This cerebellar connection of the trigeminal nerve is denied by Bechterew.

CHAPTER IV.

THE CEREBELLUM OR EPENCEPHALON.

The cerebellum, or little brain, is located in the inferior occipital fossa. Above it are the occipital lobes, separated from it by a strong process of dura mater—the tentorium cerebelli. In form the cerebellum is irregularly oval or oblong, its greatest diameter, 7.5 to 10 cm. (three to four inches), being from side to side. It measures 5 to 5½ cm. (2 to 2¼ inches) antero-posteriorly. Its greatest thickness is at its ventral portion, where it is about five cm., or two inches. Toward the periphery of the hemispheres it becomes quite thin, being at the periphery only about one cm., or five lines, in thickness. Its average weight in the adult is about 170 gm., or 5½ ounces. In the infant it is much smaller in proportion to the entire encephalon than in the adult. It is composed of two hemispheres, joined by a middle portion or lobe, which, from its shape and from the appearance given to it by numerous transverse ridges upon it, is called the worm, vermis, or vermiform process. This division into hemispheres is much more apparent on the under surface, owing to a broad, shallow depression or sulcus,—the vallecule, or little valley,—which, running anteroposteriorly, separates them. The vallecule lodges the posterior part of the medulla oblongata, and from it projects the inferior part of the middle lobe or worm, called the inferior vermiform process. The latter forms, in a general way, the roof of the fourth ventricle, and lies behind and below the corpora quadrigemina. The cerebellum has on its anterior and posterior surfaces deep depressions,—the anterior and posterior incised notches,—which are continuous with the vallecule. In the anterior notch, which is broader, rests the posterior corpora quadrigemina, while the posterior notch, which is shallower, contains the falx cerebelli. The bottom of these

notches is formed by the worm, while the sides are composed of the cerebellar hemispheres. The cerebellum is divided into an upper and a lower surface by a great horizontal fissure, which begins at its anterior margin and extends circumferentially to the median line behind.

The upper surface is convex at its middle portion and gradually slopes toward its periphery. It consists of two hemispheres connected by a convex median lobe, the superior vermis

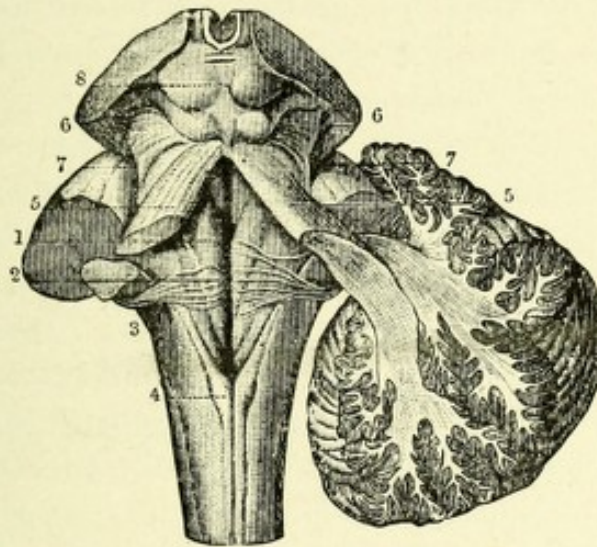


FIG. 93.—FIGURE SHOWING THE THREE PAIRS OF CEREBELLAR PEDUNCLES.—(After Hirschfeld and Leveillé, from Sappey.)

On the left side the three cerebellar peduncles have been cut short; on the right side the hemisphere has been cut obliquely to show its connection with the superior and inferior peduncles. 1. Median groove of the fourth ventricle. 2. The same groove at the place where the auditory striæ emerge from it to cross the floor of the ventricle. 3. Inferior or restiform body. 4. Funiculus gracilis. 5, 5. Superior peduncle.

On the right side the dissection shows the superior and inferior peduncles crossing each other as they pass into the white center of the cerebellum. 7, 7. Lateral grooves of the crura cerebri. 8. Corpora quadrigemina.

or worm. The latter is of great physiologic importance, since its experimental removal in lower animals and pathologic changes in it in man, such as a tumor, hemorrhage, injuries, etc., produce disturbances of coordinated movements and difficulty in the maintenance of equilibrium. This proves that this central portion or worm is principally concerned in the adjustment of coordinated movements and the maintenance of equilibrium.

The cerebellum is connected with the remainder of the cerebro-

spinal axis by three large bundles of nerve-fibers—the superior, middle, and inferior cerebellar peduncles. The superior peduncles (*processus ad cerebrum*) appear to come from the region just beneath the *corpora quadrigemina*, where they decussate, extending from one cerebral hemisphere to the opposite cerebellar hemisphere. In their course they run outward and backward, and before entering the cerebellum they diverge, forming the lateral boundaries of the upper half of the fourth ventricle, and are united by the valve of Vieussens, or the superior medullary velum. They then appear to pass into the nucleus dentatum of the cerebellum of each side. The superior cerebellar peduncles connect the cerebellum with the cerebrum.*

The middle peduncles (*processus ad pontem*) consist of the before-mentioned superficial and deep sets of transverse fibers, some of which pass from the pons to the cerebellar cortex and some from the cerebellar cortex to the pons, forming the great transverse commissure of the cerebellum. These are located external and anterior to the superior peduncles.

The inferior peduncles (*corpora restiformia*; *processus ad medullam*) serve to connect the medulla and the spinal cord to the cerebellum by means of long tracts of fibers. As they pass upward and backward on their way to the cerebellum they diverge, and assist in forming the lateral boundaries of the lower part of the fourth ventricle. They end chiefly in the cortex of the superior worm of the cerebellum.

THE VERMIS, OR WORM.

SUPERIOR SURFACE.

This surface presents a transversely ridged appearance, and has, from before backward, the following lobules: First, the *lingula* is most anterior, between the superior peduncles of the cerebellum, resting upon the superior medullary velum. It consists of a tongue-shaped process composed of four or five transverse *laminae*, which latter are prolonged over the superior peduncles,

* While the course of the superior cerebellar peduncles appears to extend as above described, yet most of the fibers have been proved to have an opposite course—*i. e.*, from the *corpus dentatum* toward the cerebrum.

and are called the *frænulum lingulæ*. Its basal part is continuous with the *lobus centralis*. Next is the *lobus centralis*, which is just back of the *lingula*, being separated from it by an interlobular fissure, the *precentral*; it is in front of the *culmen*, which overlaps it. This lobule, with the *lingula*, forms the bottom of the anterior incised notch. The next lobule is the *monticulus cerebelli*, which forms the greater part of the convexity of the worm, its anterior portion being called the *culmen*, or height, the posterior part, the *declive*. The *monticulus* is separated from the central lobe by the *postcentral fissure*. The *culmen* must be lifted in order to expose the central lobe, and the *declive*, when raised, exposes a lobule just posterior to it, the *folium cacuminis*, which is a small lobule next in size to the *lingula*, and continuous laterally with the posterior superior or semilunar lobes.

THE INFERIOR SURFACE.

This surface, from before backward, presents the following lobules: First, the *nodulus*, which bears the same relation to the inferior vermiform process as does the *lingula* to the superior. It occupies the anterior extremity of the *vermis*, and is composed of a few transverse *laminæ* separated by slight fissures. It is the smallest lobule of the inferior worm. The lateral part of the inferior medullary velum is continued on each side of the nodule as a thin white band which serves to connect the *nodulus* with the *flocculus*.

Second, the *uvula*, located just dorsal to the *nodulus*, forms the greater part of this surface of the worm. It increases in size from before backward, and attains its greatest size close to the *pyramid*; it is separated from the hemispheres by a deep fissure,—the *sulcus valleculæ*,—and is connected with the *amygdalæ*, or tonsils, which exist on each side, by a corrugated grayish ridge, the furrowed band, which crosses the *sulcus valleculæ*. Its surface is marked by three or four transverse intra-lobular fissures.

Third, the *pyramid*. The posterior portion of the inferior worm is called the *pyramid*. It is a large, conic projection

consisting of three or four transverse laminae, separated by fissures; the sulcus valliculae separating it from the hemispheres. It is connected with the digastric lobule by a narrow ridge of gray matter at the bottom of the sulcus valliculae; from the inferior surface of the pyramid, extending anteriorly over the superior surface, is a process called the tuber valvulae. The right and left sulci valliculae are the deep anteroposterior grooves on the inferior surface of the cerebellum which separate the inferior worm from the cerebellar hemispheres.

LOBULES OF THE SUPERIOR OR DORSAL SURFACE OF THE CEREBELLAR HEMISPHERE.

First, the lobulus quadratus, or square lobe, is located on each side of the monticulus.

Second, the posterior superior semilunar lobe occupies the posterolateral part of the dorsal surface. It is connected with its fellow of the opposite side by the folium cacuminis.

LOBULES OF THE INFERIOR SURFACE OF THE CEREBELLAR HEMISPHERE.

First, the flocculus, situated on each side of the nodulus below the middle peduncles and posterior to the sensory nuclei of the pneumogastric nerves.

Second, the amygdalum, or tonsil, is located on each side of the uvula. It is connected with the uvula and projects into the fourth ventricle.

Third, the cuneate or digastric lobule is a large, somewhat wedge-shaped or triangular area, located just external to the amygdalum and pyramid, being attached to the latter by a grayish ridge crossing the bottom of the sulcus valliculae. Its laminae are curved, with their concavity forward and inward. It is separated from the tonsil on each side by a fissure in front of the pyramid, called the prepyramidal fissure. The tonsil when removed leaves a hollow depression on the mesial surface of this lobule, which, because of its resemblance to a bird's nest, is called the nidus avis.

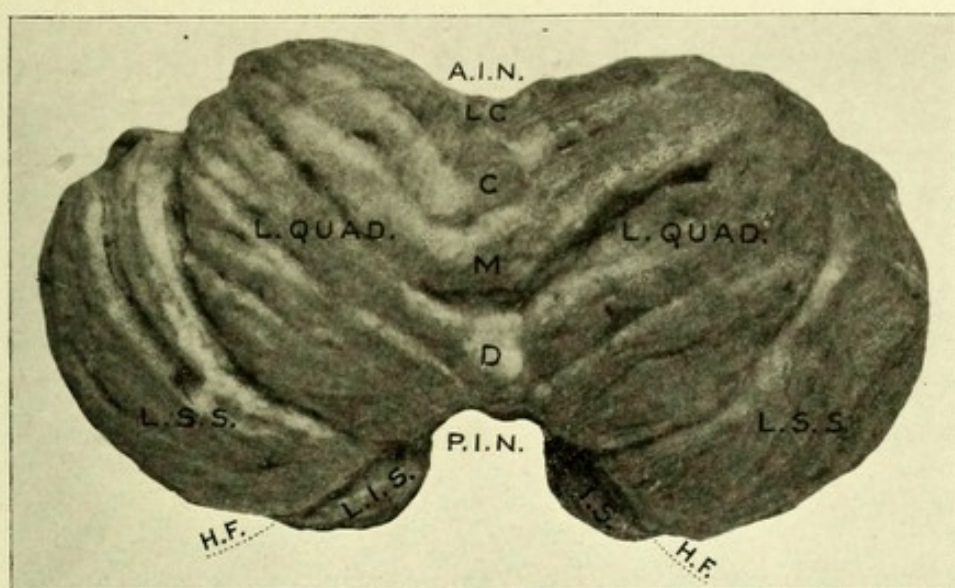


FIG. 94.—SUPERIOR SURFACE OF THE CEREBELLUM.

A.I.N. Anterior incised notch. L.C. Central lobe. C. Culmen. M. Monticulus. D. Declive. P.I.N. Posterior incised notch. L.I.S. Inferior semilunar lobe. H.F. Great horizontal fissure. L.S.S. Superior semilunar lobe. L. Quad. Quadrate lobe.

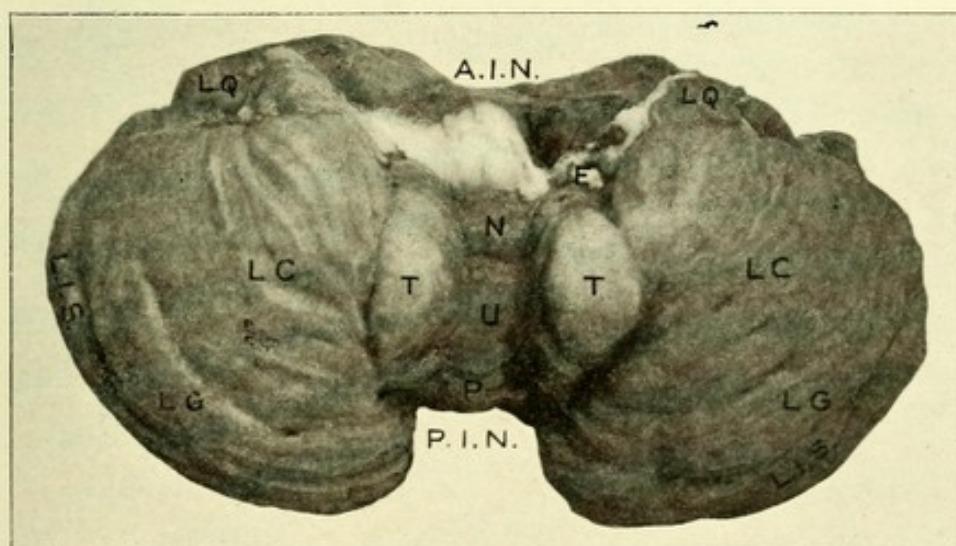



FIG. 95.—INFERIOR SURFACE OF THE CEREBELLUM.

A.I.N. Anterior incised notch. F. Flocculus. L.Q. Lobus quadratus. N. Nodulus. U. Uvula. P. Pyramid. P.I.N. Posterior incised notch. T. Tonsil. L.C. Lobus cuneatus. L.G. Lobus gracilis. L.I.S. Lobus inferioris semilunaris.



Fourth, the lobus gracilis, or slender lobe, is just external to the cuneate lobe, around the periphery of which lobe it extends. It is also connected with the pyramid. It has along its periphery the inferior semilunar lobule.

MINUTE ANATOMY OF THE CEREBELLUM.

The cerebellum consists of gray and white matter, the former surrounding the latter and forming its cortex. The gray matter

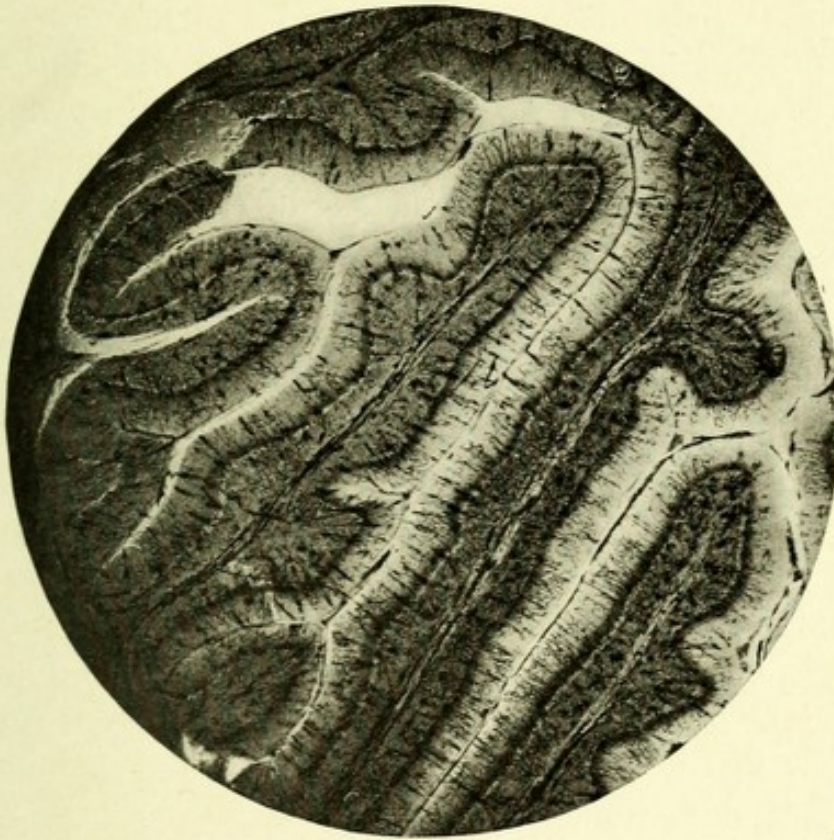


FIG. 96.—MICROPHOTOGRAPH OF CEREBELLAR CORTEX. Showing the molecular and granular layers and the arrangement of the arbor vitæ.

consists of foliated laminæ, each one of which has a central core of white matter, and is formed of secondary and tertiary folia, which arrangement gives to sections of the cerebellum the characteristic arbor vitæ appearance. The gray matter dips into the various fissures and sulci, and is thus spread over a large extent of surface, which surface is nearly as great as that covered by the cortex of the cerebrum. The white matter is more abundant

in the hemispheres than in the vermis. In the former it is irregular in contour and is somewhat oblong. In the latter it is scant and arranged in a quadrangular shape; hence the name *corpus trapezoideus*. From the central white stem of the vermis a thin extension of white matter passes out which bridges across the superior peduncles and forms the roof of the upper part of the fourth ventricle, upon which the lingula rests. This extension is the before-mentioned superior medullary velum, or valve of Vieussens. Below, a similar process of white matter extends from the cerebellum and forms, with a process of pia mater, the *tela choroidea inferior*, the roof of the lower part of the fourth ventricle, and is called the inferior medullary velum. The white matter consists of medullated nerve-fibers, which form short and long tracts, which will be described later. Deep in the central part of the white matter of each hemisphere and reaching below, nearly to the fourth ventricle, is embedded a nucleus—the *corpus dentatum*, or *ciliare*. Each dentate body consists of a convoluted, sinuous bag of gray matter, having a dorsal and a ventral lamina, with an opening or hilum on its ventral and mesial surface. It contains a rich plexus of nerve-fibers with a large number of multipolar nerve-cells in their meshes.* These cells vary from 30 to 40 μ in diameter, and possess numerous dendritic processes which come off chiefly from the inner portion of the cell-body. The neuraxones from these cells, after giving off within the corpus dentatum one or two collaterals, pass out of the hilum into the superior cerebellar peduncles, of which they form the great bulk. The dentate bodies resemble very closely the inferior olivary bodies. This resemblance is heightened by the fact that three smaller nuclei lie close to each—namely, the *roof nucleus* of Stilling, or *tegmental nucleus*, the *nucleus emboliformis*, and the *nucleus globosus*. The roof or tegmental nucleus belongs properly to the worm. It is about 10 mm. long, and is an oblong mass of gray matter on each side of the middle line, just above the ependyma of the fourth ventricle, from which it is separated by a thin

* It is probable that many of the fibers which form the network within the corpora dentata are the terminations of the axones coming from the cells of the nuclei rubri.

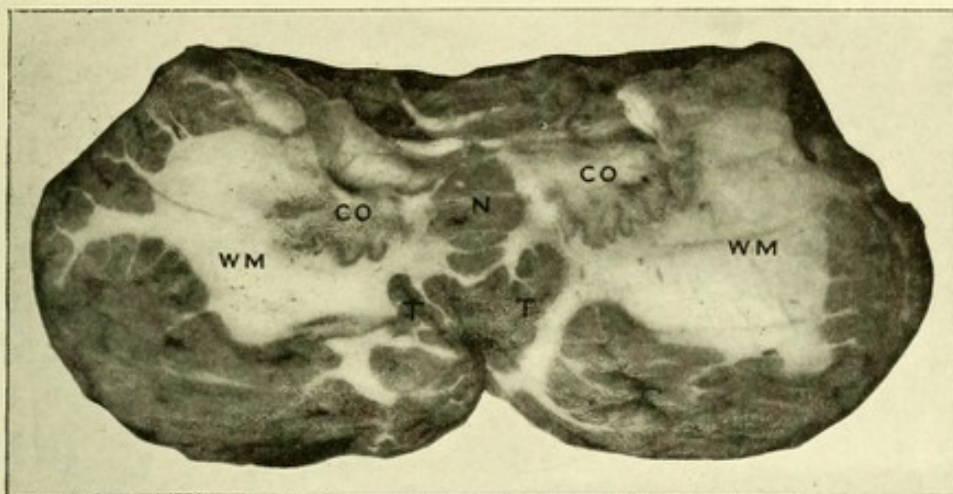


FIG. 97.—SECTION THROUGH CEREbellum TO SHOW THE DENTATE NUCLEI AND WHITE MATTER OF THE HEMISPHERES.

C.O. Dentate nucleus. N. Nodule. T. Tonsil. W.M. White matter of cerebellar hemisphere.

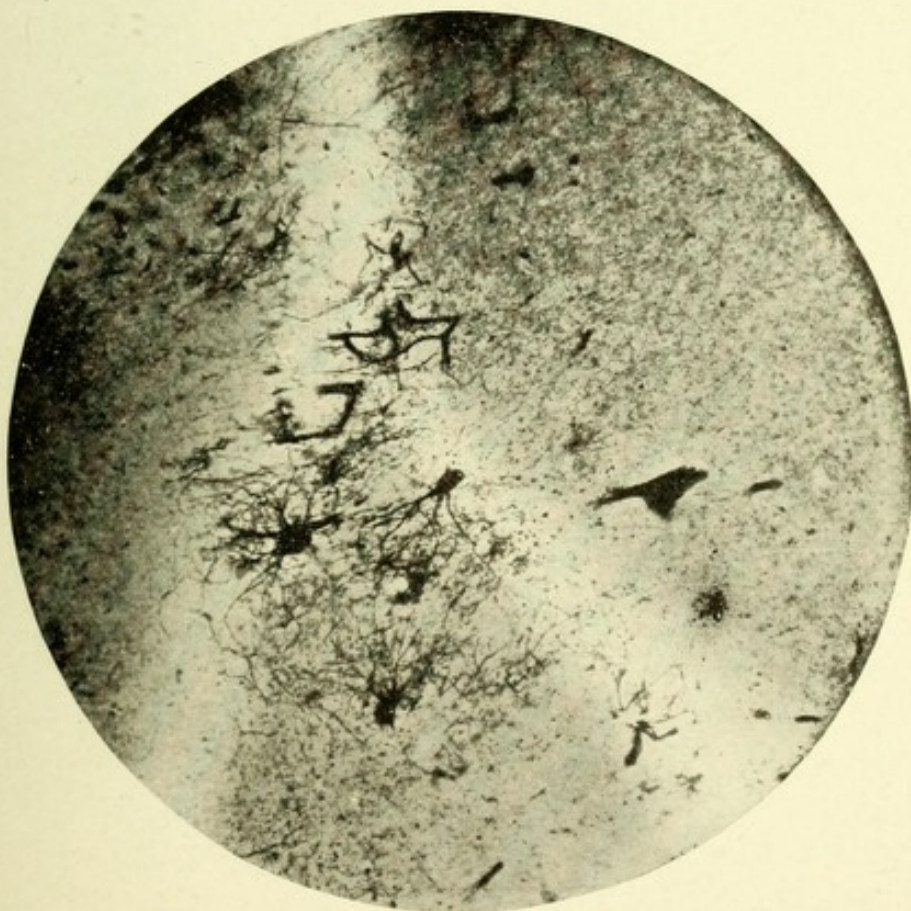



FIG. 98.—MICROPHOTOGRAPH OF A SECTION THROUGH THE CORPUS DENTATUM OF THE HUMAN CEREbellum. Containing three large (multipolar) polygonal cells. Method of Berkley.



layer of white matter. The nucleus emboliformis is a small, clavate mass of gray matter located mesial to the hilum of the dentate body. Beneath and on the inner side of this nucleus is the nucleus globosus. The fibers which surround the dentate bodies are called extracapsular or extraciliary fibers. From the intricate network of these fibers, resembling the hairs of wool, the term fleece is applied to this portion. These fibers doubtless come from the cerebellar cortex, being the axis-cylin-

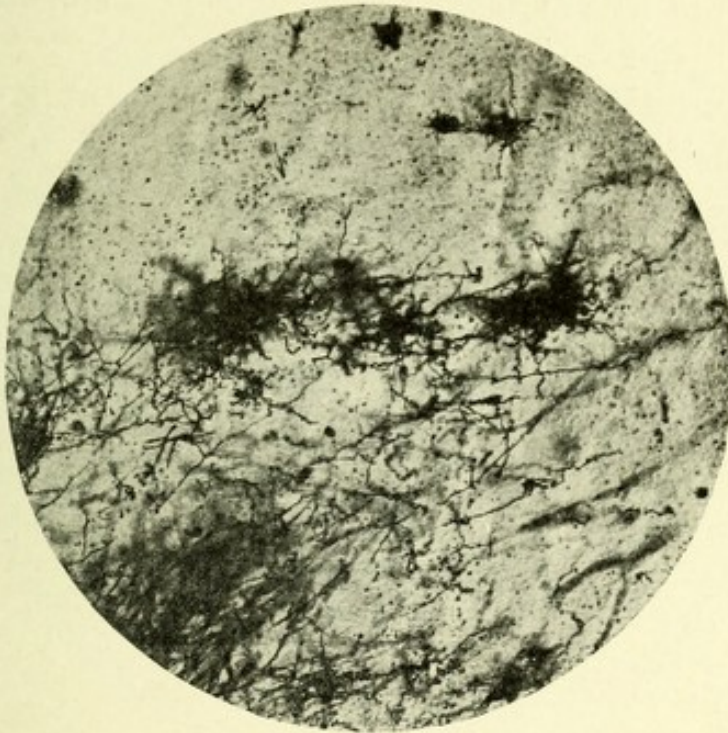


FIG. 99.—MICROPHOTOGRAPH SHOWING BASKET CELLS AND FIBERS SURROUNDING THE BODIES OF TWO PURKINJE CELLS (HUMAN CEREBELLUM). Cox-Golgi method.

ders of the cells of Purkinje. Some of them pierce the dentate body of each side and issue at the hilum, assisting in the formation of the superior peduncles, while most of them surround the dentate bodies and are probably those descending fibers which go to form the so-called cerebello-olivary tracts, and tracts of Marchi and Lowenthal, of the corpora restiformia. Others doubtless pass as pontine fibers, assisting in the formation of the middle peduncles.



THE CORTEX OF THE CEREBELLUM.

The cerebellar cortex is divided into two distinct layers, between which are the characteristic cells of the cerebellum, the cells of Purkinje. The first or outer layer is termed the molecular layer, and the other the internal granular or, from its appearance, the rust-colored layer. The molecular layer contains two chief forms of cells—outer, small, stellate cells, and inner, basket cells, or “Korbzellen” of the Germans. The stellate cells are small, multipolar cells, 10 or 15 μ in diameter, each

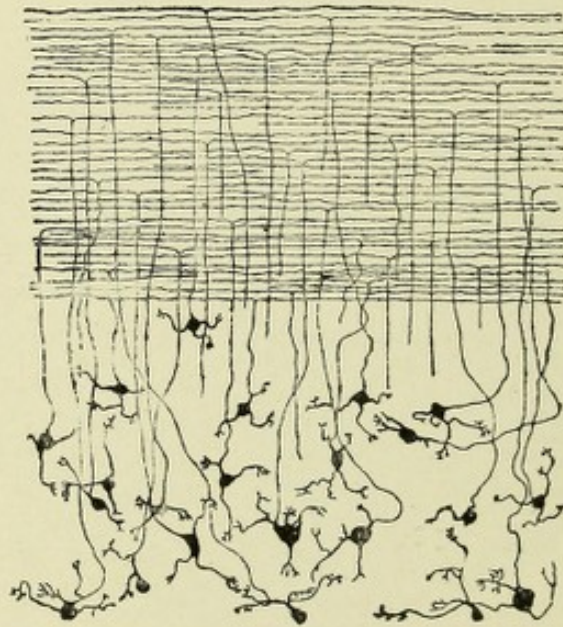


FIG. 100.—GRANULAR CELLS OF THE INNER LAYER, WITH ASCENDING NEURAXONES BRANCHING T-SHAPED TO FORM THE HORIZONTAL FIBERS OF THE MOLECULAR LAYER.
—(After Van Gehuchten.)

possessing several short dendrites which repeatedly ramify, many of them assuming a horizontal course. Their axis-cylinders, or neuraxones, are delicate processes of considerable length, and possess several collateral branches. The axones pass vertically, entering the upper part of the molecular layer, forming there an intricate maze of fibers. Their final destination has not been traced. The basket cells, which are the innermost of the molecular layer, are slightly larger than the stellate cells, being from 11 to 20 μ in diameter, and multipolar in form. Each cell possesses several dendrites which ramify in the innermost part of

the molecular layer, and a long, thick neuraxone. It is of interest to note that these axones start from the cell-bodies as very fine, horizontal processes which increase in size until they become two, three, or even four times their original thickness. Each neuraxone passes out horizontally from the cell-body and gives off, at varying distances, numerous branching collaterals, which pass vertically downward until they reach close to the

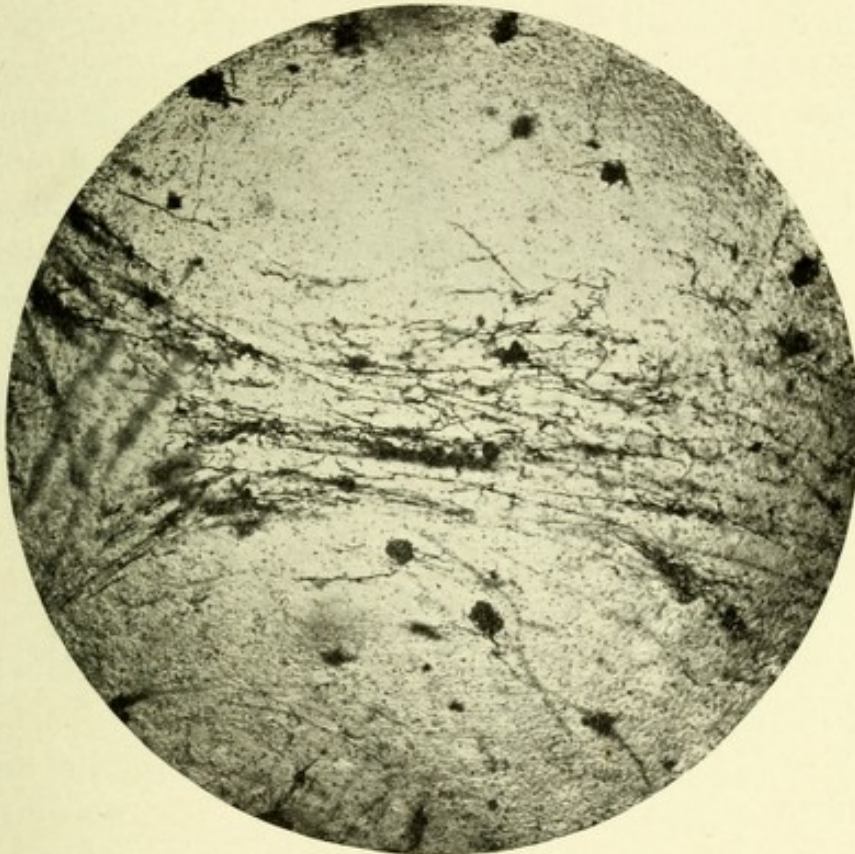


FIG. 101.—MICROPHOTOGRAPH SHOWING THE MOSS-LIKE FIBERS OF THE CEREBELLUM.
Cox-Golgi method.

bodies of the Purkinje cells, where the fibers end in tuft-like expansions, forming a basket-like network about each Purkinje cell; hence their name, "basket cells" (Fig. 99).

The inner or rust-colored layer is made up of a large number of closely arranged, granular, multipolar cells, each possessing a large nucleus and nucleolus. They are from 5 to 10 μ in diameter, and give off a large number of branching, dendritic processes and fine neuraxones, which often start from one of the short, dendritic processes. These neuraxones, according to

Ramón y Cajal, pass into the molecular layer, where they divide in a T-shaped manner, there forming horizontal fibers. It is thought by Cajal that these branches end about the dendritic processes of the cells of Purkinje. In addition to the before-mentioned cells, there exist large, multipolar cells, which belong to the second type of Golgi—that is, possessing short, stout, dendritic branches which occupy parts of the lower molecular and upper granular layers. The axis-cylinders of these cells repeatedly ramify in the granular layer, forming fine interlacements. It is not known whether or not they are connected with fibers of the underlying white matter. Cajal describes a large number of centripetal fibers which, on entering the granular and molecular layers, branch and show in their course, at their points of branching and at their terminations, irregular, moss-like thickenings. This appearance occurs mainly in the fibers of the granular layer. He believes that they conduct impulses to the granular cells of this layer. He describes other centripetal fibers entering the molecular layer, there branching tree-like, among the dendritic ramifications of the cells of Purkinje (Fig. 102).

THE CELLS OF PURKINJE.

These cells exist between the two previously-described layers, and are the characteristic cells of the cerebellum. They are of great physiologic importance because of their supposed function, which is to originate impulses which serve to coordinate the muscles of the body, and thus maintain equilibrium. They are oval, roundish, or flask-shaped bodies, 35 to 70 μ in diameter, possessing a nucleus and nucleolus. From their cortical surface are given off at first horizontal or oblique, stout, protoplasmic processes, one or two in number, which soon send out, nearly at right angles, many radiating processes, each branching like a tree, and further subdividing into many smaller branches. These dendrites are covered with minute, club-like protuberances—the gemmules, or buds. From its resemblance to a tree, this ramification bears the name arborization. These dendrites almost entirely occupy the molecular layer, each dendrite ending in a free extremity, which often curves upon itself near the

margin of the cortex. The Purkinje cells possess very long, delicate axis-cylinders, which pass through the granular layer, enter the white matter, and form the chief cortical system of fibers. In their course they give off numerous collaterals, which pass upward through the granular layer, enter the molecular layer, and, according to Cajal, come into contact with the dendritic processes of these cells. He believes, by this connection of collaterals and dendrites, the simultaneous action

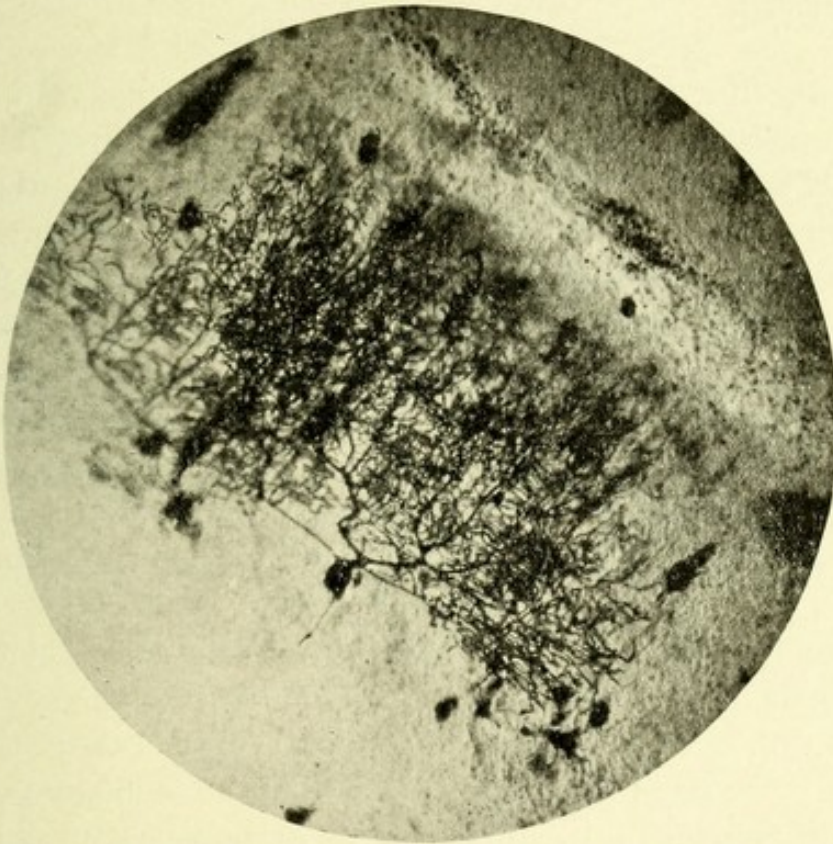


FIG. 102.—MICROPHOTOGRAPH OF PURKINJE CELL.

of many of these cells of Purkinje is secured. It is interesting to note that the axis-cylinders of these cells are developed much earlier than the dendritic processes.

The fibers of the cerebellum comprise the short and the long. The former, or association fibers, are delicate bundles of fibers lying just beneath the cortex, serving to unite adjacent areas of the same hemisphere. The long or projection fibers consist of two sets—centrifugal and centripetal. The former represent

the axones from the cells of Purkinje and the cells of the nuclei dentata. The centripetal fibers are those which proceed to the cerebellum from the various parts of the cerebrospinal axis. The projection fibers as a whole are the before-mentioned peduncular system of fibers, which serve to bring the cerebellum into relation with all the other parts of the central nervous system. There are three cerebellar peduncles—superior, middle, and inferior.

THE CEREBELLAR PEDUNCLES.

The superior peduncles, also called the brachia conjunctiva, consist of bundles of nerve-fibers which have their chief origin in the cells of the dentate bodies, and are the before-mentioned intraciliary fibers. They receive in addition fibers from the cells of Purkinje. They then pass from the cerebellum brainward to the region of the posterior corpora quadrigemina, beneath which is located on each side the nucleus ruber, or red nucleus, of the tegmentum. Below and close to each nucleus the majority of the fibers of each peduncle decussate with their fellows of the opposite side and pass to the opposite nucleus, ending about its nerve-cells. A few fibers, however, do not decussate, but pass to the nucleus ruber of the same side. Thus each corpus dentatum is connected with both nuclei rubri, but chiefly with the nucleus of the opposite side. Gudden, Forel, and Marchi have shown, by the study of secondary degeneration, that the fibers of these peduncles pass chiefly to the cells in the posterior part of the nuclei rubri. Many of them, however, pass antero-laterally, and end in the ventral part of the optic thalami. From the cells of each thalamus new neuraxones pass out through the posterior part of the internal capsule, and radiate toward the cerebral cortex, to terminate probably in the cortex of the parietal and central convolutions, thus establishing a connection between the cerebellar hemisphere of one side and the opposite cerebral hemisphere. The superior peduncles contain, in addition to these ascending fibers, some which degenerate downward, and these latter are probably the axones from the cells of the nuclei rubri. They pass to the corpora dentata, and end about the cells therein contained.

THE MIDDLE PEDUNCLES.

The fibers which form the middle peduncles consist in part of the axones from the cells of Purkinje, which pass from the cerebellar cortex in a transverse manner, ending about the cells of the nuclei pontis, some of the same, others of the opposite side. Other fibers from the same source end in a similar manner about the cells of the formatio reticularis of both sides, thus, according to Bechterew, establishing a connection between the cerebellum and the remains of the anterolateral ground-bundles of fibers, which also pass into the formatio reticularis. The remaining fibers of the middle peduncles come chiefly from the cells of the nuclei pontis, being their axis-cylinders, and, after decussating in the raphe, pass to the cortex of the opposite cerebellar hemisphere.

These peduncles establish a connection chiefly between the frontal, temporal, and occipital lobes of each side and the opposite cerebellar hemisphere, owing to the fact that fibers from these lobes end about the cells of the nucleus pontis of the same side, and the axones of these latter cells pass to the opposite cerebellar hemisphere, forming continuous paths of conduction—the so-called frontocerebellar and temporo-occipital cerebellar tracts.

THE INFERIOR CEREBELLAR PEDUNCLES, OR CORPORA RESTIFORMIA.

These contain fasciculi of fibers which come from several sources. Those which have been most thoroughly studied are the following :

First, the direct cerebellar tracts, or columns of Flechsig, whose fibers are the neuraxones from the cells of Clarke and Stilling, and have their greatest development in the upper lumbar and lower dorsal segments; they proceed upward along the posterolateral periphery of the cord, and on reaching the medulla, gradually trend backward into the corpora restiformia; they then pass medianward to the corpora dentata, and terminate, according to Bechterew and von Monakow, without decussation, in the cortex of the superior worm.

Second, two small bundles of fibers pass to the cerebellum from the nuclei of the columns of Goll and Burdach. The first, or the posterior external arcuate fibers, pass around the posterior periphery of the cord, and reach the restiform body of the same side. The second bundle, which comes from the nuclei of the posterior columns, after crossing in the raphe (interolivary fibers), passes around the periphery of the anterior pyramids and olivary bodies and joins the restiform body of the opposite side. These are the anterior external arcuate fibers. According to Bechterew, these fibers pass lateral to the corpora dentata and end in the cortex of the superior worm.

Third, fibers pass to the corpus restiforme from the lateral nucleus of the medulla of the same side. They pass to the superior worm.

Fourth, the descending cerebellar tracts of Marchi and Lowenthal, which probably have their origin in the cerebellar cortex, and are the axones from the cells of Purkinje. They degenerate

FIG. 103.—SCHEME OF THE FIBERS PASSING TO AND FROM THE CEREBELLUM.

The fibers of the superior peduncles are indicated by Roman numerals, the middle peduncles by letters, and the inferior peduncles by Arabic numerals. For convenience, both ends of the fibers are marked.

Inferior Cerebellar Peduncle.—1. Direct cerebellar tract. 2. Anterolateral descending tract of Lowenthal and Marchi. 3. Fiber from posterior nerve-root decussating in anterior commissure and ending about a cell of origin of Gowers' tract. 4. Postero-external arcuate fibers passing from the nucleus gracilis and cuneatus of the same side via the restiform body to the cerebellar cortex. 5. Internal arcuate fibers from the nucleus gracilis and cuneatus of the opposite side, decussating in the raphe, and passing around the opposite anterior pyramid to join the restiform body opposite to their origin. 6. Cerebello-olivary tract passing from the cerebellar cortex to the opposite olivary body, whence the tract is continued downward by axones from the cells of the olivary body in the lateral column to terminate about the cells of the spinal cord at various levels. 7. The vestibulocerebellar tract passing from the auditory nucleus to the cortex of the superior worm.

Middle Cerebellar Peduncle.—A, B. Fibers from cells of Purkinje passing to the formatio reticularis of the same and opposite sides. C. Fiber from nucleus pontis passing to cerebellar cortex of opposite side. D, E. Fibers from cells of Purkinje to nucleus pontis of same and opposite sides.

Superior Cerebellar Peduncles.—I. Fiber from corpus dentatum passing to optic thalamus of same side. II, IV. Fibers from corpus dentatum passing to red nucleus of the same and opposite sides. III, V. Fiber from red nucleus passing to corpus dentatum. VI. Fiber from red nucleus to optic thalamus. VII. Fiber of Gowers' tract passing through formatio reticularis, arching over the root of the fifth nerve, and reaching the superior cerebellar peduncle, passing the corpus dentatum of the same side and sending a collateral branch to the cerebellar cortex.

TH. Optic thalamus; CRUS, crus cerebri; PONS, pons Varolii; MED, medulla oblongata; S. C., spinal cord.

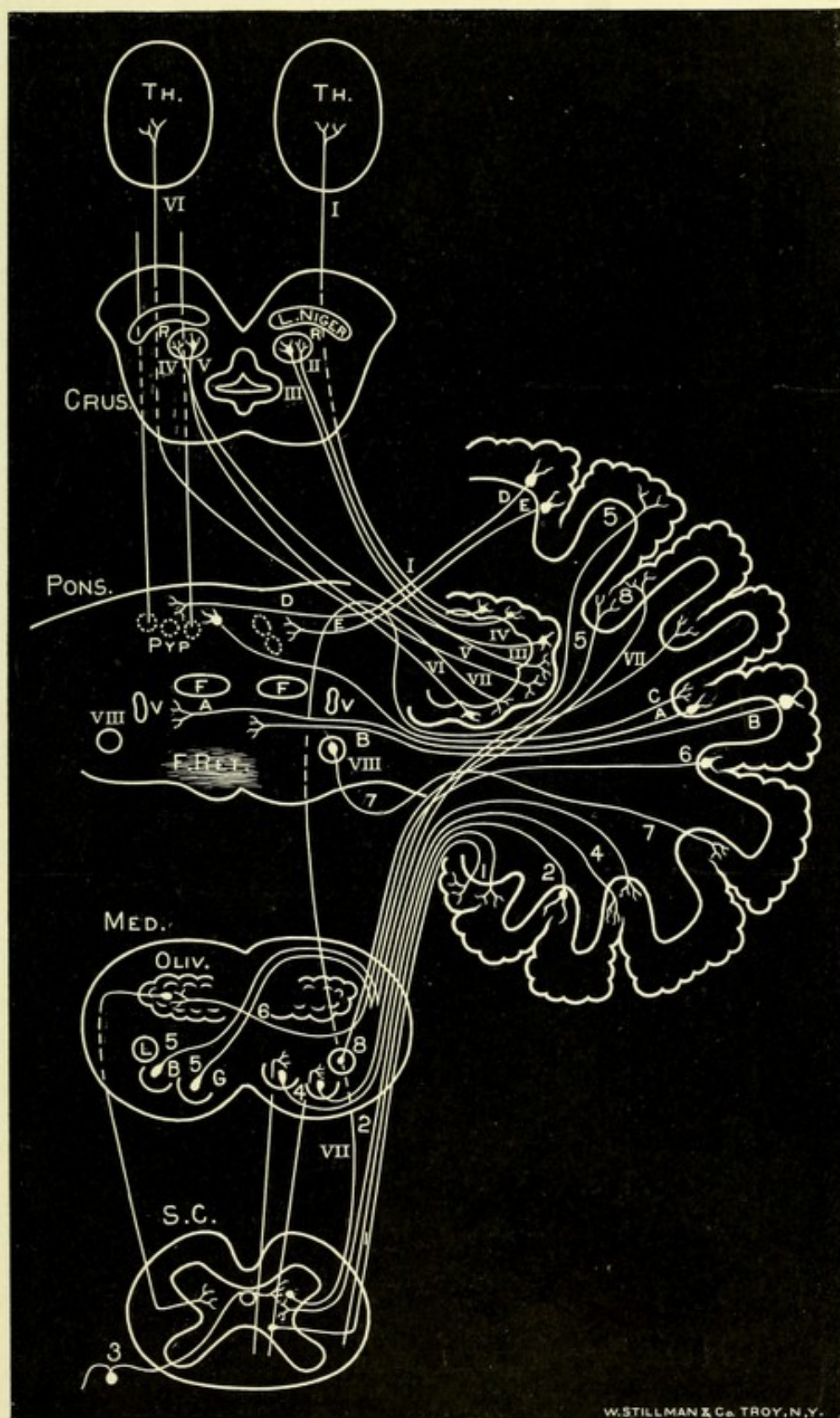


FIG. 103.—SCHEME OF THE FIBERS PASSING TO AND FROM THE CEREBELLUM.



downward and have been traced into the anterolateral area of the cord, they probably end in the median gray matter.

Fifth, the direct sensory cerebellar tract—better called the acousticocerebellar tract—joins the restiform body and proceeds, after decussating, to the opposite roof or tegmental nucleus and nucleus globosus. This tract conveys centripetal axones from Deiters' nucleus, thus establishing a connection between the nucleus vestibularis of the auditory nerve and the cerebellar hemisphere of the opposite side. This tract also contains descending fibers, axones of the cells of Purkinje, which, according to Koelliker, end about the cells of the nuclei of the posterior columns, and probably give fibers and collaterals to Deiters' nucleus and the nucleus of the trigeminal, pneumogastric, and glossopharyngeal nerves.*

Sixth, the large tract of centrifugal or efferent fibers, known as the cerebello-olivary tract, whose fibers are the axones of the cells of Purkinje of the same side, and, after having decussated in the raphe, end about the cells of the opposite olivary body.†

In addition to the previously-mentioned peduncular system of fibers, the cerebellar hemispheres are connected by means of two commissures which exist in the worm—an anterior and a posterior. The anterior commissure of Stilling is ventral to the roof nucleus, being separated from the latter by a narrow band of fibers. A fasciculus from this commissure passes between the roof nuclei, there decussating, and then, taking a direct downward course, is continuous upon each side with the vertical and horizontal branches of the arbor vitæ. According to Obersteiner, a fasciculus from this commissure passes between the roof nuclei, there decussating, and then assuming a sagittal

* According to J. S. Risien Russel, the direct sensory cerebellar tract of Edinger is a structure entirely separate and distinct from the restiform body, and ought to be so regarded. Anatomically they stand out clearly and distinctly as two definite structures, having little if any resemblance, and having connections totally distinct from each other. Embryologically it has been found that the fibers of the direct sensory cerebellar tract receive their myelin at a different period to the fibers of the restiform body.

† According to von Bechterew, each restiform body, or inferior cerebellar peduncle, contains a tract of centripetal or afferent fibers, which originate from cells in the opposite olivary body and terminate chiefly in the corpus dentatum, a few fibers passing to the cerebellar cortex. Koelliker states that no such afferent cerebello-olivary tract exists, the olivary fibers being the axones of the cells of Purkinje from the opposite side.



course. The posterior commissure is located ventral to the fibers of the corpora dentata and is continuous on each side with branches of the arbor vitæ.

A system of short fibers of association connect the different cerebellar folia; they are located just beneath the cortex, and are called, from their general arrangement, the garland-like fasciculi.

The fibers of the before-mentioned systems may be divided,

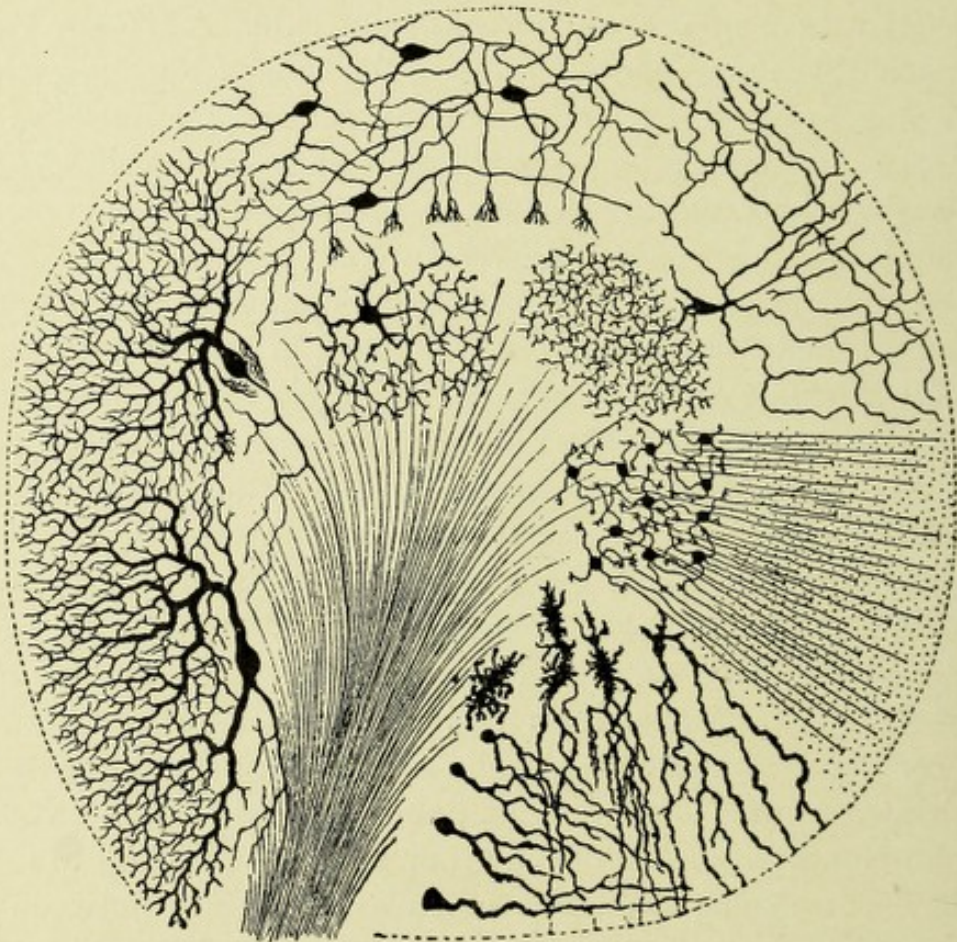


FIG. 104.—SCHEMATIC REPRESENTATION OF THE DIFFERENT CONSTITUENTS OF THE CORTICAL GRAY MATTER OF THE CEREBELLUM.—(After Van Gehuchten.)

according to the manner in which impressions are conducted, into two sets—those which conduct impressions peripherally, and, secondly, those which conduct them centrally. The former fibers, with the exception of those which pass out of the dentate bodies, are the axones from the cells of Purkinje. The latter terminate, according to Cajal, in two ways—first, as moss-like fibers, so called because, on entering the granular and molecular layers,

they show, in their course, at their points of branching and at their terminations, irregular, moss-like thickenings. These fibers terminate mostly about the cells of the granular layer; a few, however, end in the molecular layer. The second set of fibers enter the molecular layer and terminate in arborizations about the dendritic ramifications of the cells of Purkinje. According to Koelliker, however, these last-described fibers do not terminate about the cells of Purkinje, but about the basket cells and possibly about the small, stellate cells of the outer molecular layer. In the previous description of the cortex of the cerebellum, it was described as consisting of two layers—a molecular and a granular. However, as in the cerebral cortex, we find in the cerebellum five distinct layers of cortical cells: First, the small, stellate cells; second, the large cells with basket terminations; third, the Purkinje cells; fourth, the small, granular cells; and, lastly, the large, granular cells, or those of the second type of Golgi. All of these cells, save those of the third layer, are possibly concerned in the reception and conveyance of centripetal sensory impulses to the cells of Purkinje. The latter are supposedly concerned in the orderly arrangement of such impulses, and in originating impulses of coordination for the maintenance of equilibrium. This connection between the cells of Purkinje and the other sets of cells may be thus explained. The axones of the small granular cells form horizontal branches which terminate about the dendrites of the cells of Purkinje, after receiving the mosslike terminals. The collaterals of the basket cells terminate in the tuft-like expansions in the same way, only about the cell-bodies. The small, stellate cells, owing to their connection with centripetal fibers, presumably influence these cells in the same manner. The collaterals from the axones of Purkinje's cells pass upward, and probably associate the functions of many Purkinje cells. The action of the large, granular cells is thought to be associate, but their function is not definitely known.

CHAPTER V.

THE REGION OF THE MID-BRAIN.

From the middle cerebral vesicle are developed the parts which afterward form the mid-brain, or mesencephalon. In adult life the cavity of the middle cerebral vesicle has become extremely narrowed, leaving only a mere channel or passage of communication between the third ventricle or cavity of the primitive fore-brain and the fourth ventricle or cavity of the hind-brain. This canal, owing to this fact, is often called the *iter a tertio ad quartum ventriculum*, or the aqueduct of Sylvius, and in reality forms the ventricle of the mid-brain. It is about two centimeters (nine lines) long, is lined by ciliated, columnar epithelium, which is surrounded by a thick layer of gray matter, continuous with that of the fourth ventricle. On transverse section near the fourth ventricle, the aqueduct is T-shaped, becomes shield-shaped until near the third ventricle, when it becomes triangular. Just beneath the posterior commissure it expands into the third ventricle. This region of the mid-brain is a means of connection between the pons, medulla, and cerebellum below, and the inter-brain, or thalamencephalon, and the cerebral hemispheres above. This region includes the corpora quadrigemina, the crura cerebri, the Sylvian aqueduct, and adjoining gray matter which contains the nuclei of origin of the third and fourth and the descending root of the fifth pair of cranial nerves.

THE CORPORA QUADRIGEMINA.

The corpora quadrigemina are four rounded eminences which are developed from the dorsal wall or roof of the mid-brain. They are separated by two grooves, a median longitudinal and

a transverse, the latter separating them into a ventral or superior pair and a dorsal or inferior pair. The former groove, in conjunction with the transverse, separates them from one another. They are located just behind the optic thalami, third ventricle, and posterior commissure, and beneath the posterior extremity of the corpus callosum. They are above the crura cerebri, and rest upon the lamina quadrigemina, beneath which is the aqueduct of Sylvius. The anterior or superior pair, much the larger, are termed the nates; the dorsal or inferior pair, the testes. They have, extending from the external surface

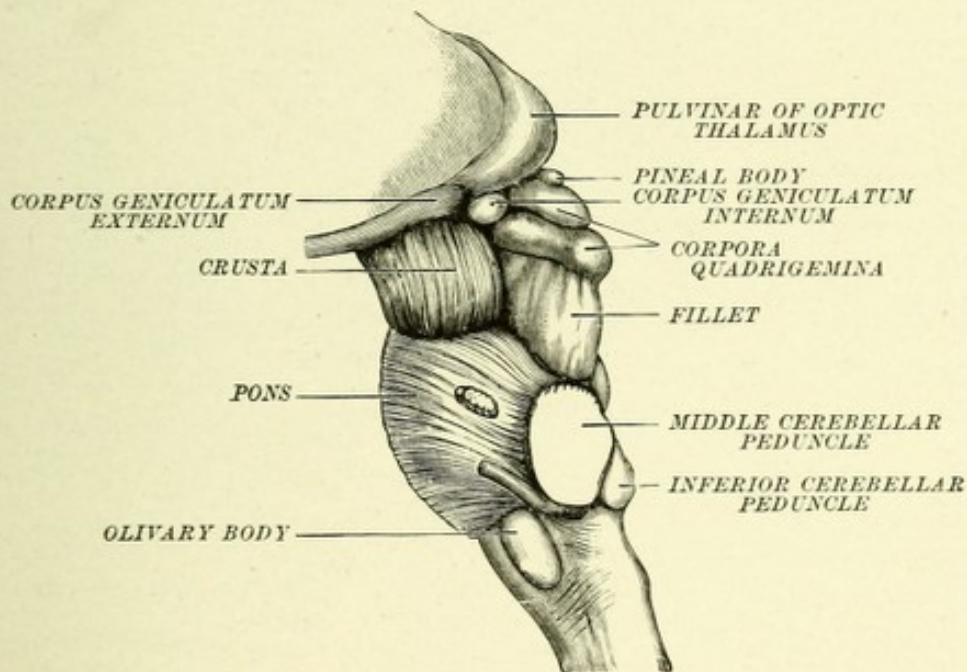


FIG. 105.—LATERAL VIEW OF MESENCEPHALON, PONS, AND MEDULLA.—(*Gegenbauer.*)

of each side, large bundles of fibers, termed their brachia, or arms, which are separated by a groove into an anterior pair, continuous with the anterior corpora quadrigemina, and a posterior pair, continuous with the posterior corpora. The brachium coming from the side of each anterior corpus passes outward under cover of the pulvinar of the optic thalamus, and between it and the internal geniculate body, to enter the external geniculate body and the optic tract, of which it is in great part a prolongation. The posterior brachia are very short and divide into two fasciculi, one of which joins the internal geniculate body

and the other disappears beneath that body and probably passes through the posterior limb of the internal capsule, and thence to the cortex of the temporosphenoid lobe.

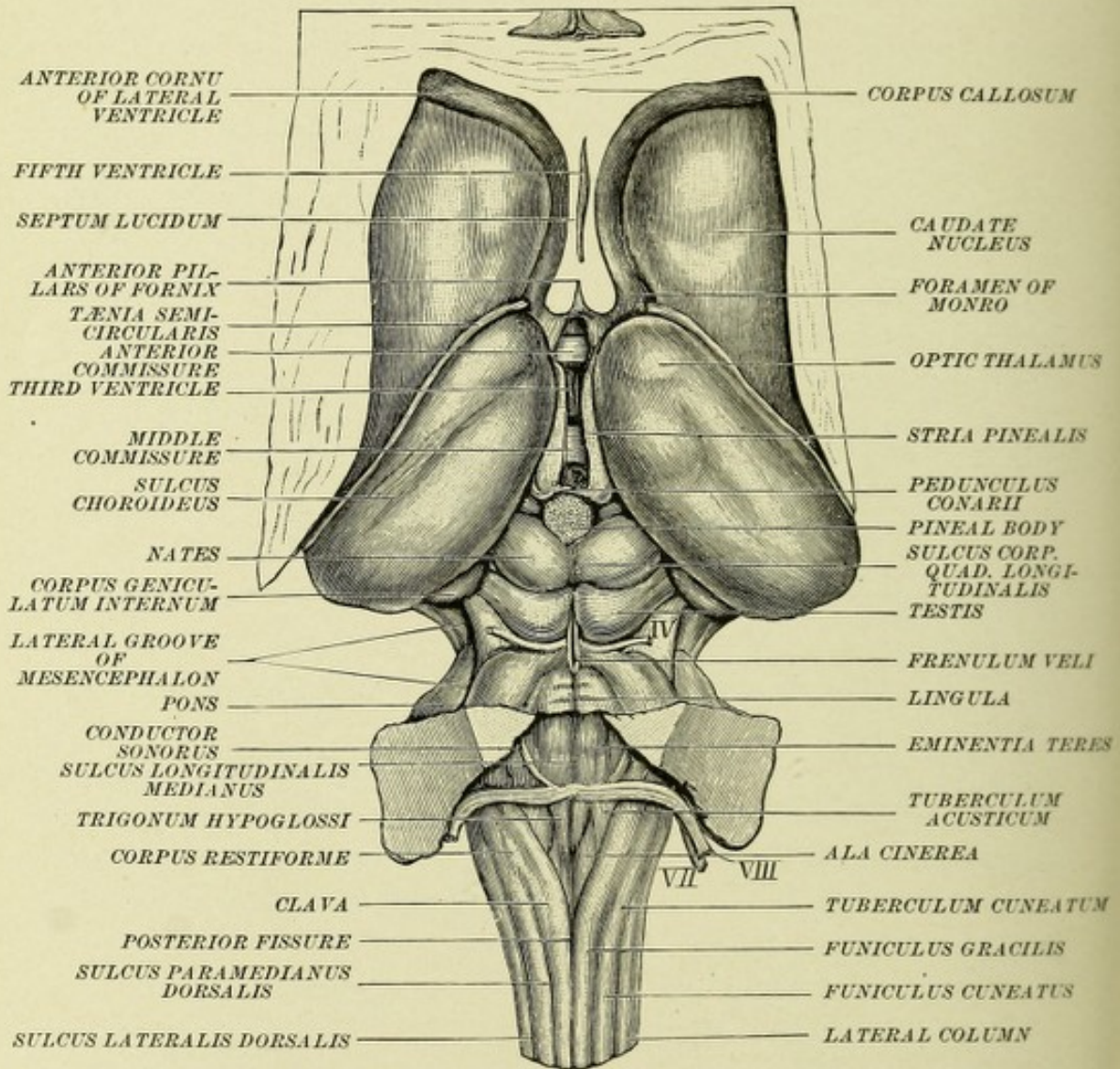


FIG. 106.—METENCEPHALON, MESENCEPHALON, AND THALAMENCEPHALON, FROM THE DORSAL SURFACE.—(After Obersteiner.)

MINUTE ANATOMY.

If a transverse section be made through the anterior or superior corpora quadrigemina of any mammal, the naked eye will discern that the gray and the white matter composing them are arranged in successive layers. If the section then be observed

with a low power of the microscope, six distinct layers can be recognized—viz. :

First, a narrow, outer layer, consisting of neuroglia cells and fibers, the cells being of the stellate variety.

Second, a superficial layer of medullated nerve-fibers, forming a stratum zonale, they being composed almost entirely of fibers from the optic tract, which are the axones from the multipolar cells of the retina, they arborize about the dendrites of the cells of the underlying third layer.

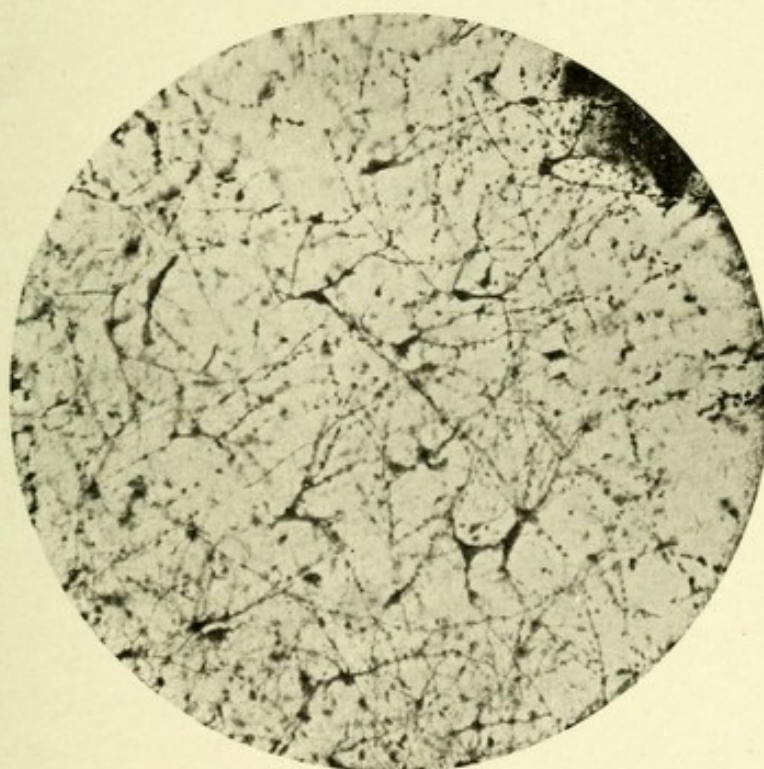


FIG. 107.—MICROPHOTOGRAPH OF A TRANSVERSE SECTION THROUGH THE CORPORA QUADRIGEMINA OF A SHEEP. Showing layer of superficial cells. Method of Berkley.

Third, a superficial layer of gray matter, consisting of an outer, lighter-colored portion of optic fibers and an inner, dark portion about which these fibers end. There are two chief forms of cells in this superficial gray layer—an outer layer of spindle-cells, and an inner layer of small, polygonal cells. Some of the former resemble the small, pyramidal cells of the second layer of the cerebral cortex. In the sheep these cells frequently give off four dendrites, two basal and two apical, the

former being short, seldom branching, and are finer than the latter. The apical dendrites continue upward until they reach the layer of superficial, medullated fibers, where they frequently bifurcate, ending free or in a roundish swelling. Many of them have but one apical dendrite, which is thick and forks after a short course, each branch proceeding to the superficial layer and ending free.

All these dendrites possess tuberos excrescences, which give a peculiar, beaded appearance to the layer. Their axones are difficult to follow, owing to the tangle of fibers occurring in this layer. Most of them come from the base of the cell-body, while some are given off from the main apical dendrite. They course forward and outward toward the optic fibers. The small, triangular or polygonal cells possess from two to four dendrites, which come off from angles of the cell-body. These branches are moderately thick, pursue mostly an oblique or a horizontal course, branch frequently at a distance from the cell-body, and terminate in free ends about cells of a like nature. Starr states that the axones of these cells enter the optic tract and pass to the occipital cortex.

The fourth layer consists of inner medullated nerve-fibers, which have a longitudinal course, and enter both the superficial and deep layers of gray matter. This layer contains axones from the cells of the outer gray layer, passing to the occipital cortex, to end about the pyramidal cells there, and axones passing in an opposite direction from the occipital cortex to the outer gray layer previously described (von Monakow).

The fifth or deep layer of gray matter contains a number of large, multipolar, triangular and polygonal cells, resembling closely the cells of the anterior cornua of the spinal cord, possessing from two to six very stout and long dendrites, which become attenuated in their course, branch frequently, and terminate free in a Y-shaped end. The axones come off usually from the base of the cell, or from one of the main dendrites, and have a mesial or dorsal course toward the fillet. Some of them probably pass to the red nucleus and to the nucleus of the oculomotor nerves.

The sixth layer consists of the central gray matter sur-

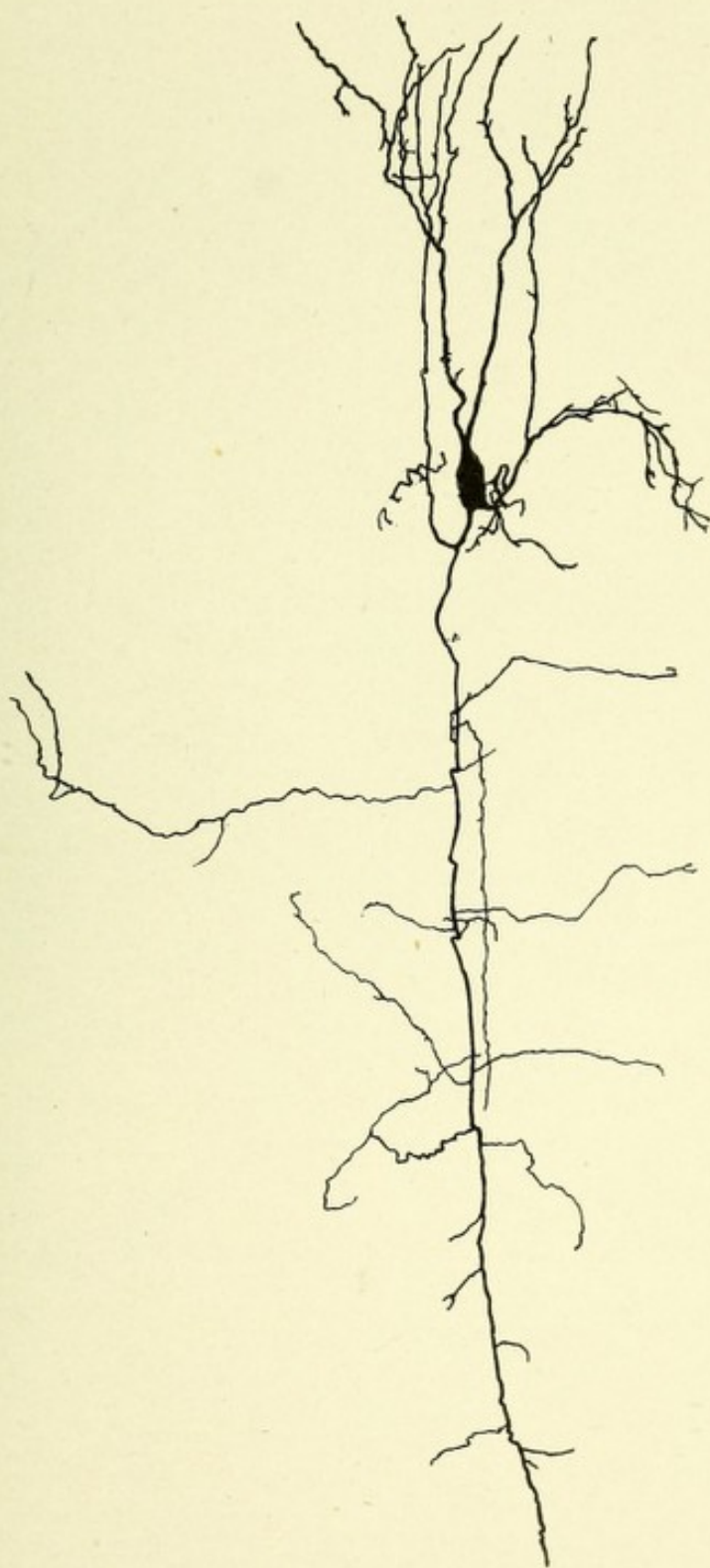



FIG. 108.—A CHARACTERISTIC CELL FROM THE THIRD (GRAY) LAYER OF THE OPTIC LOBE OF AN EIGHTEEN-DAY-OLD CHICKEN. Golgi's method.—(*After Koelliker.*)

N. The neuraxone from the cell-body with its numerous collaterals.



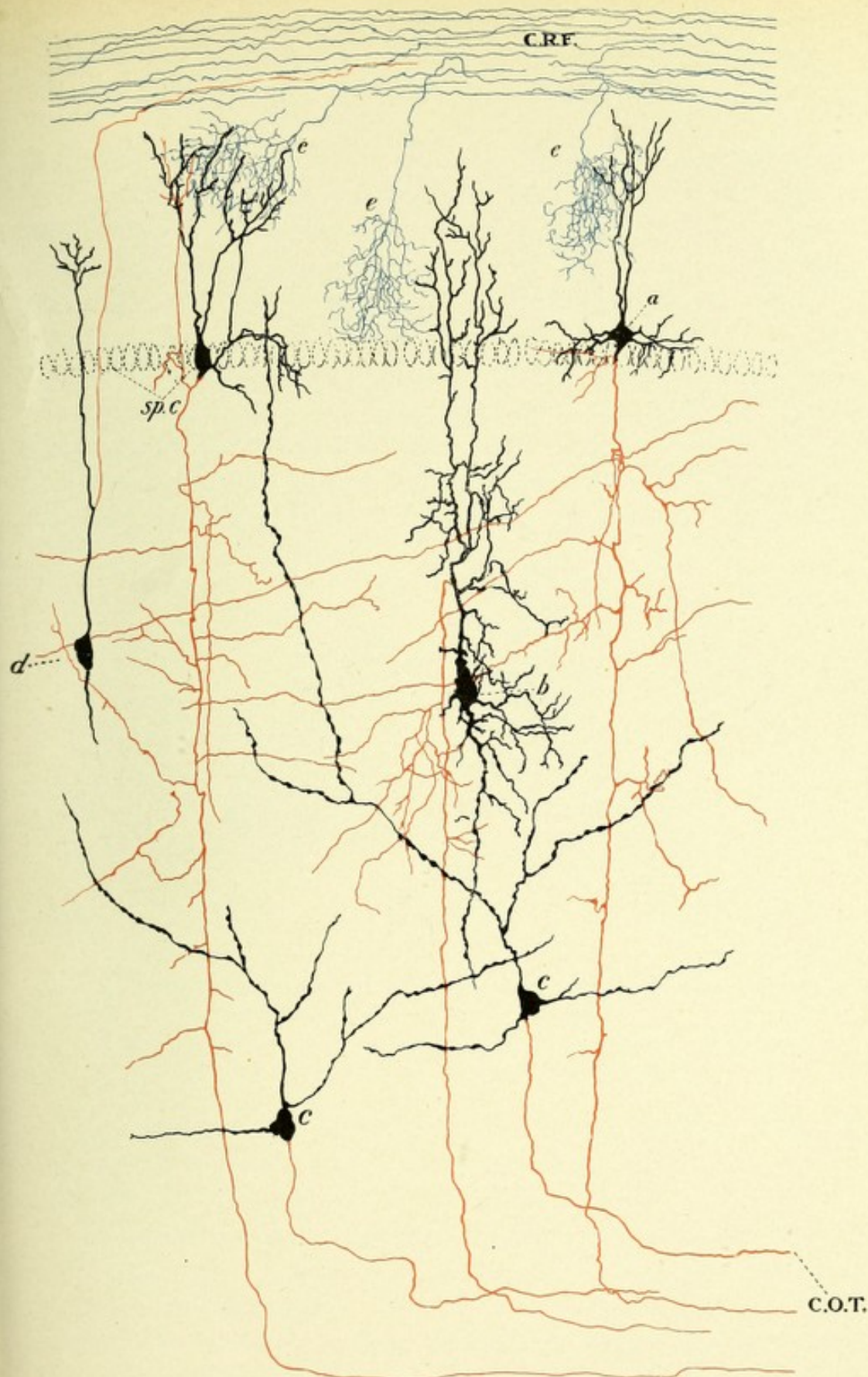



FIG. 109.—SCHEMATIC REPRESENTATION OF THE ESSENTIAL HISTOLOGIC ELEMENTS OF THE OPTIC LOBE OF A BIRD. Showing the probable route taken by visual impressions to reach the cerebral (occipital) cortex.—(After Koelliker.)

C.R.F. Centripetal retinal fibers with terminal arborizations, *e, e, e.* *a* and *sp.c.* Spindle-shaped cells of the second layer with descending axones. *b.* Pyramidal-shaped cell of the third layer with a descending axone coming from the chief apical dendrite. *c, c.* Triangular-shaped cells also with descending axones. The axones from the above-named cells form C.O.T., or the cerebral optic tract. *d.* Spindle-shaped cell of third layer whose axone ascends and forms a centrifugal optic fiber which probably terminates in the retina.



rounding the aqueduct of Sylvius. It is from two to three millimeters thick, and is composed of a homogeneous mass of neuroglia tissue, chiefly made up of spheric or slightly oblong neuroglia cells, with innumerable long, slender processes radiating from all parts of the cell-body. Embedded in this neuroglia mass exists a number of small and large multipolar nerve-cells, the small cells, triangular in shape, being scattered throughout the inner portion of the neuroglia layer, and each possessing four to eight dendrites and a fine long neuraxone, whose course is ventrolateral or mesial. The collaterals from these axones form the arch-like fibers of this layer. The large cells belong

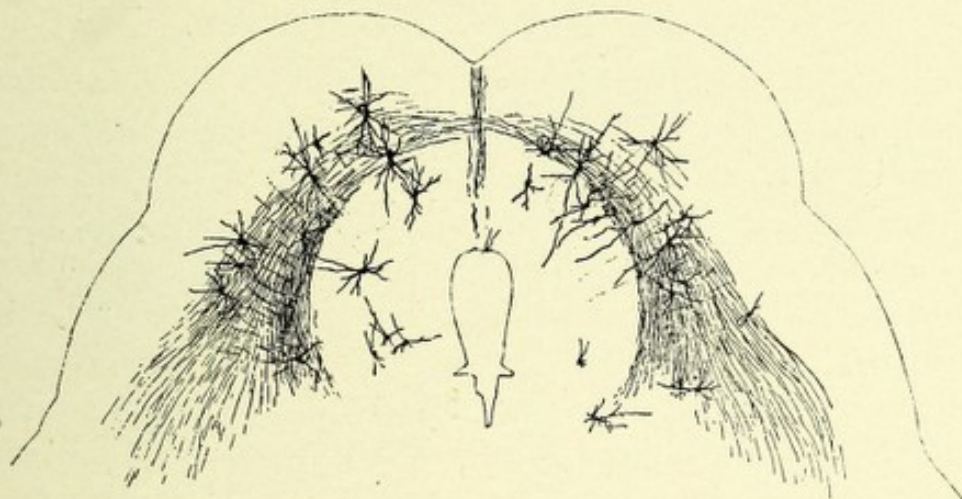


FIG. 110.—TRANSVERSE SECTION THROUGH THE CORPORA QUADRIGEMINA FROM AN EIGHT-MONTHS' HUMAN FETUS.—(After Koelliker.)

In the region of the aqueduct of Sylvius and between the arching fibers are to be seen the characteristic multipolar cells of the gray matter of this region.

to the nuclei of origin of the third, fourth, and upper or descending root of the fifth nerve. They are located ventral to and on each side of the aqueduct of Sylvius (Fig. 110).

The posterior quadrigeminal bodies possess small (15 to 20 μ) and large (30 to 50 μ) multipolar nerve-cells, similar to those which exist in the anterior corpora quadrigemina. The course of their axones is dorsal, mesial, or lateral, and they probably enter the lateral fillet or lemniscus or the posterior brachia. The cells of the posterior corpora quadrigemina are connected with the auditory apparatus by means of the lateral fillet, the fibers of which end in part about these cells, and in part about

the cells of the lateral tegmental nucleus. From these cells new axones start out and, entering the posterior brachium, radiate, after passing through the extreme posterior end of the internal capsule, through the centrum ovale, terminating about the cells of the first and second temporosphenoid lobes. The axones of the cortical cells of the temporosphenoid lobe pass centrifugally via the posterior brachium, and end about the cells of the posterior corpora quadrigemina, thus forming a double connection between these bodies and the cortex of the temporosphenoid lobe.

THE CEREBRAL PEDUNCLES.

These peduncles, or crura cerebri, consist chiefly of longitudinal tracts or fasciculi of fibers which have both a centrifugal and a centripetal course. They serve to connect the cerebral cortex and basal ganglia with the pons, medulla, cerebellum, and the spinal cord. Each peduncle is separated into a ventral convex portion, called the crusta, or "Fuss" (German), and a dorsal, slightly concave portion, the tegmentum, by the crescentic gray area of dark pigmented nerve-cells, the substantia nigra, which area extends from the upper margin of the pons Varolii to the posterior border of the corpora mammillaria, and reaches the surface on both the inner and outer sides of the peduncle. On its inner side is a groove, the sulcus oculomotorius, through which passes the third nerve. On the outer side another groove exists—the sulcus lateralis.

The ventral portion or crusta, also called pes pedunculi, consists of the following systems of longitudinal fibers: First, the motor or pyramidal tract; second, a tract connecting the temporal and occipital lobes with the pons, and thence with the opposite cerebellar hemisphere; third, the frontocerebellar tract; fourth, a fasciculus of fibers located above the pyramidal tract, between it and the substantia nigra; fifth, a small bundle of fibers on the inner side of the crusta, joining the fillet.

First, the *pyramidal or motor tract* of each side forms in the medulla the anterior pyramids, which, on reaching the inferior

border of the pons, separate into distinct bundles which lie between the superficial and deep transverse pontine fibers. On emerging from the superior border of the pons they are again collected into two bundles, which occupy the middle two-fifths of each crus. They then course upward until they reach the internal capsule, where they form the anterior two-thirds of the posterior limb of the internal capsule, and radiate to the region about the fissure of Rolando, known as the motor area of the cerebral cortex. The reason for tracing the course of the motor

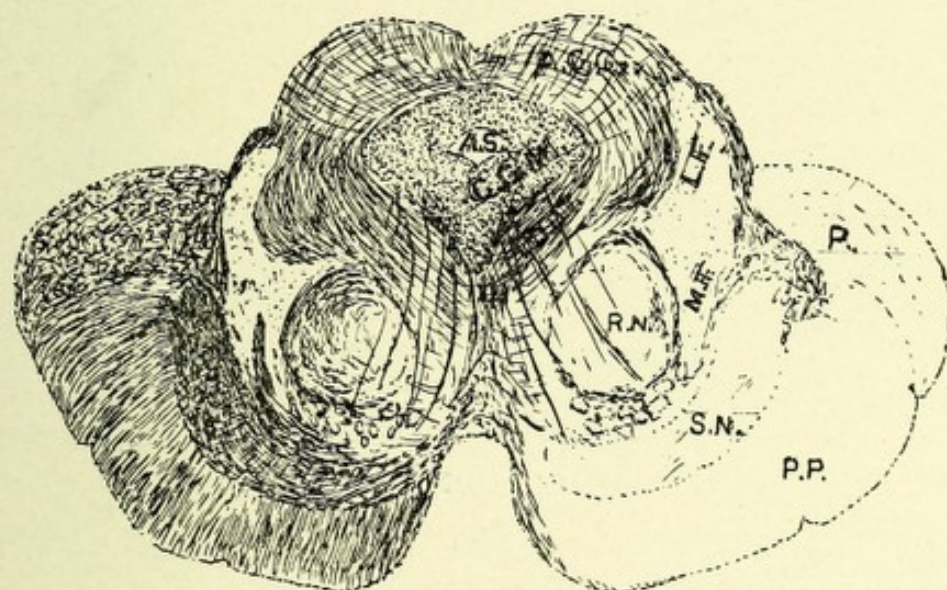


FIG. III.—TRANSVERSE SECTION THROUGH THE MID-BRAIN OF AN ADULT. Weigert's method.

A.C.Q. Anterior corpus quadrigeminum. A.S. Aqueduct of Sylvius. C.G.M. Central gray matter. F.D.O.T. Fountain-like decussation of tegmentum (Meynert's). L.F. Lateral fillet or lemniscus. M.F. Mesial fillet or lemniscus. III. Root-fibers of the third (oculomotor) nerves. R.N. Red or tegmental nucleus. P. Pulvinar of optic thalamus. S.N. Substantia nigra. P.P. Pes pedunculi or cerebral peduncles.

tract in a direction opposite to the development and conduction of its component fibers is given on page 141, section *Medulla Oblongata*.

The second is *a tract which connects the occipital and temporal lobes* with both cerebellar hemispheres, but chiefly with the one of the opposite side. The fibers of this tract proceed from the pyramidal cells of the cortex of the occipital and temporal lobes. The tract passes beneath the lenticular nucleus, and between its posterior extremity and the external geniculate body, and forms a

fasciculus which continues downward in the outer side of the crusta, occupying about one-fifth of its bulk. It extends into the pons, where the individual fibers arborize about the cells of the nucleus pontis, which nucleus continues this tract, by way of the middle cerebellar peduncle, to both cerebellar hemispheres, but chiefly to that of the opposite side.

Third, the *frontocerebellar tract* occupies rather more than the inner fifth of the crusta. The fibers of this tract come from the prefrontal lobe, and pass between the lenticular and caudate nuclei, occupying a large part of the anterior limb of the

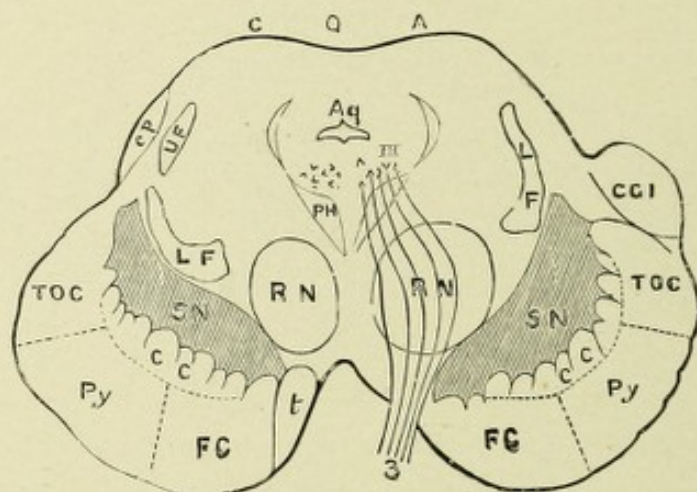


FIG. 112.—DIAGRAM OF SECTION OF THE CRUS.—(Modified from Wernicke, from Gowers.)

L F, U F. Upper and lower fillet. C Q A. Anterior corpora quadrigemina. Aq. Aqueduct. III. Nucleus of third nerve (3). P H. Posterior horizontal fibers. c p. Brachium of the posterior corpora quadrigemina. R N. Red nucleus. S N. Substantia nigra. C G I. Internal geniculate body. T O C. Temporo-occipital cerebellar fibers. P y. Pyramidal fibers. F C. Frontocerebellar fibers. C C. Caudate cerebellar fibers. t. Inner fibers of crusta to tegmentum.

internal capsule, and course downward on the inner side of the pyramidal tract, ending in the ventral portion of the pons Varolii about the nerve-cells of the nucleus pontis of the same side. The cells of the nucleus pontis of each side are joined by fibers from the cortex of both cerebellar hemispheres, chiefly, however, with the cerebellar hemisphere of the opposite side. The fibers are the axones of the cells of Purkinje of the same and the opposite side, the latter fibers having crossed in the raphe, thus establishing a connection between the frontal lobe of one side and both cerebellar hemispheres, but chiefly with the cerebellar hemisphere of the opposite side.

Fourth, *a rather broad but thin layer of fibers*, which in the crusta is located above the pyramidal tract, and between it and the substantia nigra. This bundle of fibers, according to Flechsig, arises from the cells of the corpus striatum, and continues downward through the crusta to the cells of the nucleus pontis. These latter cells may continue this tract by their axones to the cortex of the same and opposite cerebellar hemisphere, establishing a cross-connection between the corpus striatum of one side and the cerebellar hemisphere of the same and the opposite side.

Fifth, *the small bundle of fibers which occupies the most mesial portion of the crusta* is said to join the fillet. According to Spitzka, this bundle of fibers contains the central sensory tracts for the cranial nerves.

The tegmentum or dorsal part of the crura cerebri is continuous anteriorly with the tegmental region beneath the optic thalami, and below with the tegmental region of the pons and medulla. It contains longitudinal tracts of fibers,—continuations of tracts proceeding upward from the medulla, cerebellum, and pons,—in addition to several fasciculi of arched fibers, having among them several scattered collections of gray matter. The tegmentum is divided into a right and a left half by the upward continuation of the raphe, at which point the various decussations take place. The following longitudinal tracts of fibers are to be found in the tegmentum: First, the mesial fillet, or mesial lemniscus; second, the lateral fillet, or lateral lemniscus; third, the superior cerebellar peduncles; fourth, the superior longitudinal bundles; fifth, the remaining longitudinal tracts of the formatio reticularis. It will be proper at this point to trace these various systems of fibers not only through the tegmentum of each crus, but to their termination, either in the basal ganglia or in the cerebral cortex (Figs. 111 and 112).

THE MESIAL FILLET, OR LEMNISCUS.

This is a continuation brainward of the axones of the cells of the nucleus gracilis and nucleus cuneatus. In describing the course of the long tracts of fibers in the posterior columns of the cord, it was found that they terminated about the cells of

the previously-mentioned nuclei, and that most of the axones of these cells on each side passed ventromesially as internal arcuate fibers to decussate in the raphe between the olivary bodies, forming the so-called interolivary or superior sensory decussation. They then continue their course just back of the anterior pyramid of the opposite side in the same relative position through the pons, occupying the ventral portion of the *formatio reticularis*. On transverse section, each mesial fillet forms an oblong area on both sides of the raphe, just dorsal to the deep, transverse, pontine fibers. In the crus it occupies the ventral portion of the tegmentum, and becomes continuous laterally with the lateral fillet, or lateral lemniscus, which here occupies a somewhat triangular area in the outer side of the tegmentum, the two thus forming a sickel or crescentic mass of fibers. On its course brainward the mesial fillet receives an accession of fibers from the anterolateral columns and from the cells of the various end nuclei of the sensory cranial nerves of the opposite side, save the auditory, forming for those nerves central, sensory tracts. The mesial fillet gives off both axones and collaterals to the cells of both the median and lateral fields of the *formatio reticularis*.

The mesial fillet then continues brainward in the tegmentum of the crus to the subthalamie region, where, according to Bechterew, the fibers from the cells of the nucleus gracilis, and those from the nucleus cuneatus, pursue different courses. Some fibers from the cuneate nucleus pass to the anterior corpus quadrigeminum, giving off on their way a few fibers and collaterals to the nucleus of the lateral fillet, or lemniscus. The main bundle, however, continues upward to the outer side of Luy's body, to form two fasciculi, one joining the lenticular loop and the other Meynert's commissure.

The first of these fasciculi passes to the globus pallidus of the lenticular nucleus of the same side, while the remaining fasciculus passes to the lenticular nucleus of the opposite side by way of Meynert's commissure. The fibers of both fasciculi end about the intrinsic cells of these nuclei, whence new axones start out and radiate to the cortex of the central and parietal convolutions, thus establishing a connection between the nucleus cuneatus

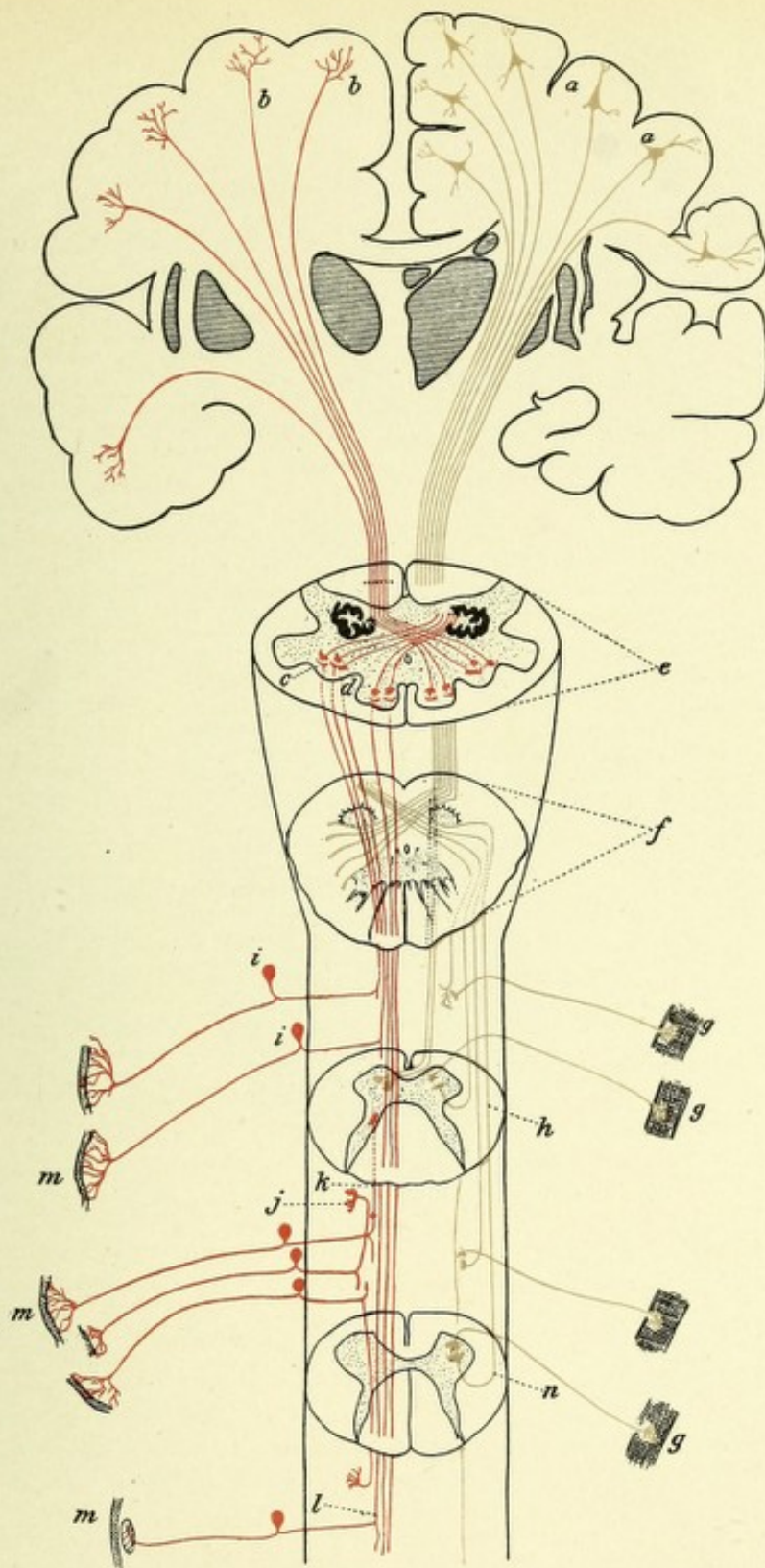



FIG. 113.—DIAGRAM INDICATING THE COURSE OF THE MOTOR AND SENSORY FIBERS OF THE SPINAL CORD AND MEDULLA.

a, a. Motor cells of the cerebral cortex. *b, b.* Arborizations of the fibers of the sensory tract in the cerebral cortex. *c.* Nucleus of the column of Burdach, showing terminal arborizations of the long sensory fibers of the cord. *d.* Nucleus of the column of Goll, showing terminal arborizations of the long sensory fibers of the cord. *e.* Section of the medulla, showing sensory decussation. *f.* Section of medulla, showing motor or pyramidal decussation. *g, g.* Motorial end plates. *h.* Section through the cervical region of the cord, showing termination in the anterior horn of the motor fibers of the direct pyramidal tract after they have crossed in the anterior commissure; also fiber of crossed pyramidal tract ending about anterior horn cell of same side. *i, i.* Posterior spinal ganglia. *j, k.* Sensory fibers of short course. *l.* Sensory fibers of long course, terminating in medulla. *m, m, m.* Sensory end organs. *n.* Section through lumbar cord.



and the cortex of the central and parietal lobes. The portion of the fillet whose fibers are the axones of the cells of the nucleus gracilis course mesially to the fibers from the nucleus cuneatus, and give off collaterals which join the anterior corpus quadrigeminum, ending probably about the cells of the fifth layer. The main bundle of fibers continues forward to end, according to von Mon-

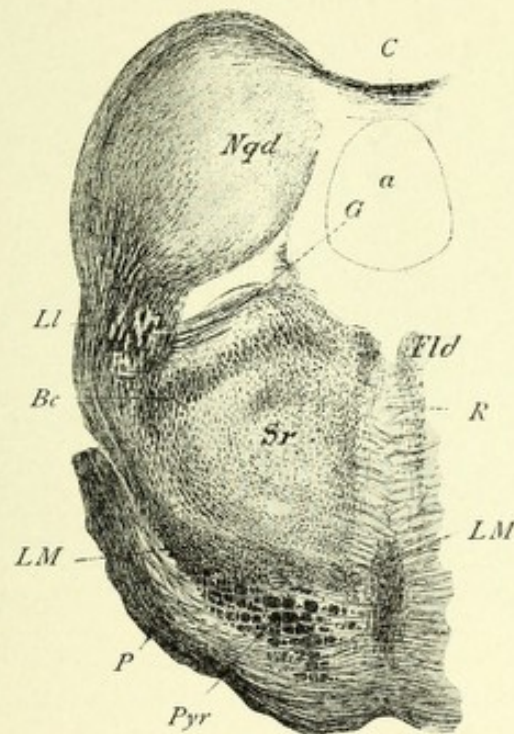


FIG. 114.—TRANSVERSE SECTION THROUGH THE SPINAL END OF THE POSTERIOR CORPORA QUADRIGEMINA OF A CAT. Weigert preparation.—(After Koelliker.)

Bc. Brachium conjunctivum (superior cerebellar peduncle). *C.* Commissure. *Fld.* Posterior longitudinal bundle. *G.* Fibers from lateral fillet passing medianward as fibræ arcuatæ. *Ll.* Fibers of the lateral fillet or lemniscus terminating about the cells of the posterior corpus quadrigeminum. *LM, LM.* Median fillet or lemniscus. *Nqd.* Nucleus of the posterior corpus quadrigeminum. *P.* Superficial pons fibers. *Pyr.* Pyramidal bundles of fibers. *R.* Raphe. *Sr.* Substantia reticularis. *A.* Aqueduct of Sylvius.

akow, Schlesinger, and Mott, about the cells of the ventral nucleus of the optic thalamus, where, by means of the axones from the cells of this nucleus, this tract, now called the cortical fillet, is further continued through the posterior division of the internal capsule, and through the centrum semiovale, to terminate in the region of the central convolutions, chiefly the post-central and parietal gyri. The mesial fillet contains a tract of

fibers which have been found to degenerate downward after lesions of the central ganglia, especially after destruction of the optic thalamus; this degeneration extends downward toward the nuclei of the posterior columns* (Figs. 111, 112, and 113).

The lateral fillet, or lateral lemniscus, is the chief central auditory tract. It forms an area somewhat triangular on the outer side of the pons. It is composed, first, of axones from the cells of the ventral auditory nucleus, chiefly of the opposite side; second, axones from the cells of the ventral auditory nucleus, passing dorsally around the restiform body and beneath the ependyma of the fourth ventricle (*striæ acousticæ*), decussating with their fellows in the raphe, and proceeding ventrolaterally to join the lateral fillet of the opposite side, a few fibers passing without decussating into the lateral fillet of the same side; third, axones from the cells of the superior olivary body, which, after decussating in the raphe, pass to the opposite lateral fillet, a few fibers passing to the lateral fillet of the same side; fourth, axones from the cells of the nucleus of the lateral fillet; fifth, fibers joining the lateral fillet in the region of the corpora quadrigemina, which come from the ventral tegmental decussation. The lateral fillet occupies, in the ventrolateral part of the tegmentum of the crus, a triangular area which is continuous on the inner side with the mesial fillet. It continues brainward in the same position until it reaches the region of the posterior corpus quadrigeminum, where most of the fibers terminate about its cells, while some terminate about the cells of the internal geniculate body and posterior nucleus of the optic thalamus. According to Koeliker, some of the fibers terminate also about the cells of the upper portion of the lateral nucleus of the lemniscus. A small bundle of fibers from the lateral fillet ends about the cells of the anterior corpus quadrigeminum, some axones of which are connected with the nuclei of the third and fourth nerves, and whose cells are also connected with the terminal fibers of the optic nerve. This connection may serve a common reflex purpose, by means of which movements of the eyeballs may be excited, owing to auditory or optic impressions.

* Such cases have been recorded by Bruce, Campbell, Jacob, and Mahaim.

From the cells of the posterior corpora quadrigemina, internal geniculate body, and posterior nucleus of the optic thalamus, axones pass out by way of the posterior arm, or brachium, through the extreme posterior end of the internal capsule, and thence radiate through the centrum semiovale to the pyramidal cells of the superior and middle temporosphenoid lobes.

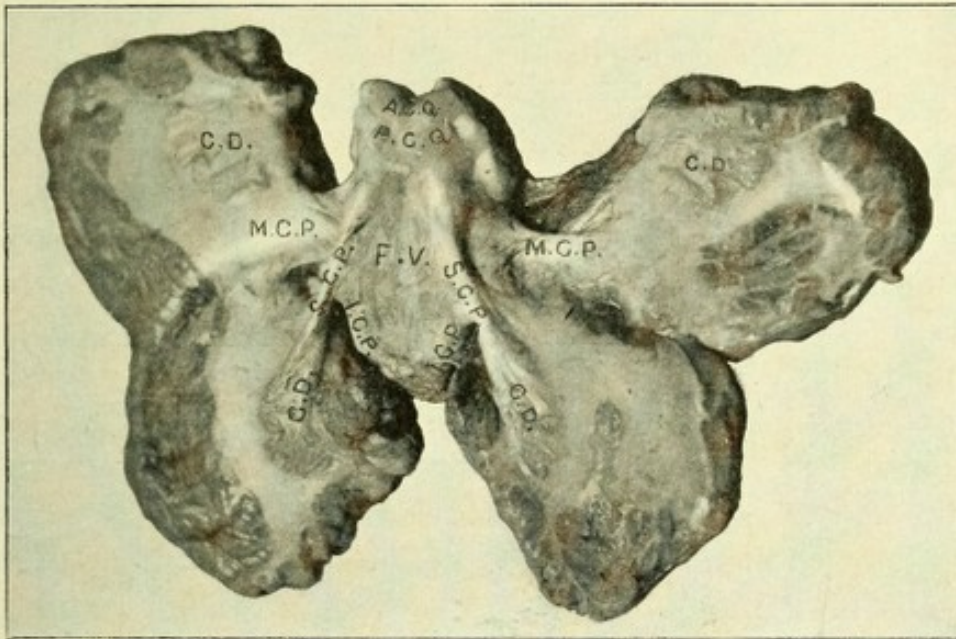


FIG. 115.—HORIZONTAL SECTION THROUGH THE CEREBELLUM.

A.C.Q. Anterior corpora quadrigemina. P.C.Q. Posterior corpora quadrigemina. C.D. Corpus dentatum. M.C.P. Middle cerebellar peduncle. S.C.P. Superior cerebellar peduncle. I.C.P. Inferior cerebellar peduncle. F.V. Fourth ventricle.

THE SUPERIOR CEREBELLAR PEDUNCLES.

The centripetal fibers, of which each peduncle is composed, have their chief origin from the cells of the dentate nucleus of the cerebellum. A few centripetal fibers join the peduncles from the cortex of the worm, being the axis-cylinders from the cells of Purkinje. These peduncles make two compact bundles, one on each side of the upper part of the fourth ventricle, forming its outer boundaries, and having between them the superior medullary velum. In their course brainward they converge and become located in the roof of the fourth ventricle and on each side of the aqueduct of Sylvius, where they form two long

bundles of fibers, crescentic on transverse section, which occupy a large part of the dorsolateral periphery of the tegmentum. As they approach the region of the posterior corpora quadrigemina they are more ventrally located, just posterior to the red or tegmental nuclei; the greater part of the fibers of each bundle decussate with their fellows of the opposite side, and terminate about the cells of the posterior portion of the nucleus ruber of the opposite side. A number of fibers do not decussate, but pass to the nucleus ruber of the same side. Some of the fibers of the superior cerebellar peduncles pass through the nuclei rubri into the optic thalami, where they terminate. Many fibers, probably axones from the cells of the nucleus ruber, continue onward to end about the ventral portion of the optic thalamus, from the cells of which new fibers start out to pass through the posterior portion of the internal capsule, and thence radiate to the region of the central gyri and parietal lobe. Some of these fibers may terminate in the lenticular nucleus. Some anatomists do not agree with this description of the cortical termination of this tract. There is also included in each superior cerebellar peduncle a centrifugal tract of fibers, which arises from the cells of the opposite red nucleus, and probably terminates among the cells of the dentate nucleus of the cerebellum.

THE SUPERIOR LONGITUDINAL BUNDLE.

Each bundle appears on cross-section as a somewhat triangular-shaped area of longitudinal fibers, located on one side of the raphe beneath the gray matter of the fourth ventricle and that of the aqueduct of Sylvius. Each bundle extends upward to a collection of cells in the central gray matter of the third ventricle, at the beginning of the aqueduct of Sylvius and ventral to the oculomotor nucleus. This is Edinger's nucleus, or the nucleus of the posterior longitudinal bundle, where, according to Cajal, a large part of the fibers terminate, the rest continuing onward to end in the optic thalamus. Inferiorly, they are continuous with the fibers of the anterior ground bundles of the spinal cord, being, in reality, their upward extensions. In the medulla, owing to the motor and sensory decussations and the interposi-

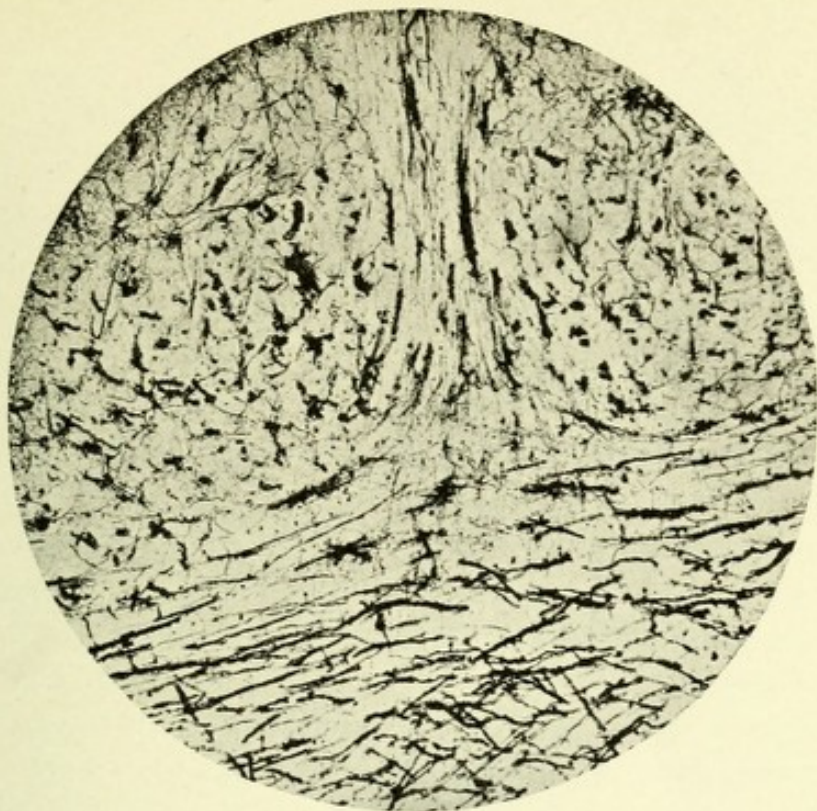

FIG. 116.—MICROPHOTOGRAPH THROUGH THE RED NUCLEI OF THE MID-BRAIN OF A YOUNG SHEEP. Showing decussation of the fibers of the superior cerebellar peduncles. Method of Golgi.

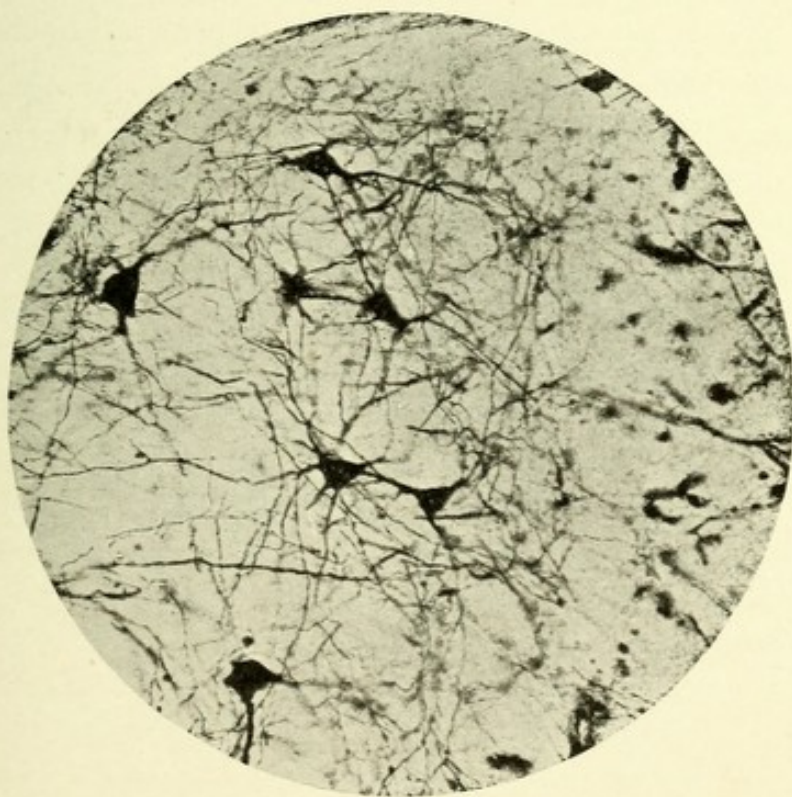



FIG. 117.—MICROPHOTOGRAPH OF A SECTION THROUGH THE RED OR TEGMENTAL NUCLEUS OF A YOUNG SHEEP. Showing seven of its characteristic cells. Golgi method.



tion of many fibers and cells, these ground bundles become displaced dorsally, and come to occupy a position on each side of the raphe, in the dorsal part of the *formatio reticularis*. In their course the posterior longitudinal bundles of fibers give off collaterals to the motor nerves concerned in the movements of the eyeballs (III, IV, and VI), and probably to all the motor cranial nerves. These collaterals pass in the raphe to the nuclei of the opposite side, although a few pass to the nuclei of the same side. It is probable that collaterals and axones from these bundles also terminate about the cells of the *substantia reticularis grisea*. According to Cajal, the posterior longitudinal bundle of fibers receives accessions of fibers from the auditory nucleus of Deiter, which have an ascending course and give off numerous collaterals to the motor nerves of the eyeballs, and, secondly, from the sensory trigeminal nuclei, and from the cells of the *formatio reticularis alba*.

Despite much clinical and experimental research, doubt still exists with regard to the exact course and termination of the two remaining tracts of the *formatio reticularis*—namely, the anterolateral ascending tract of Gowers and Bechterew and the lateral ground bundle of fibers. The former, which occupies, in the cord, a triangular or broadly comma-shaped area along its anterolateral periphery, ventral to the direct cerebellar and cross-pyramidal tracts, ascends to the medulla, where, according to Gowers and Bechterew, the fibers may be, in part or totally, intercepted by the cells of the lateral nucleus, and the tract is further continued, by means of the axones from these latter cells, which enter the lateral field of the *formatio reticularis*, occupying a position in the medulla dorsolateral to the lower olivary body, and continuing in the same relative position through the pons and brain-stem, to pass with the fibers of the mesial fillet through the posterior division of the internal capsule, and radiating through the *centrum ovale*, to terminate in the cortex of the parietal lobe. On the other hand, the studies of Auerbach, Löwenthal, and Patrick on lower animals, and of Hoche in man, would seem to prove that this tract, after reaching the pons, passes into the cerebellum.

In the description of Gowers' tract, contained in the section



on the spinal cord, the termination of the tract was given according to the latest view advanced by Hoche. From a clinical standpoint, however, this description seems inadequate, because lesions of the parietal cortex have been followed by a loss of sensation of temperature and pain. Therefore, if we must assume that Gowers' tract conducts such sensations, a part at least of the fibers must be in relation with the parietal lobe, a connection which Hoche's case does not take into account. It would seem that the view of Mott must be the more correct one, since he has shown that a part of the fibers of this tract

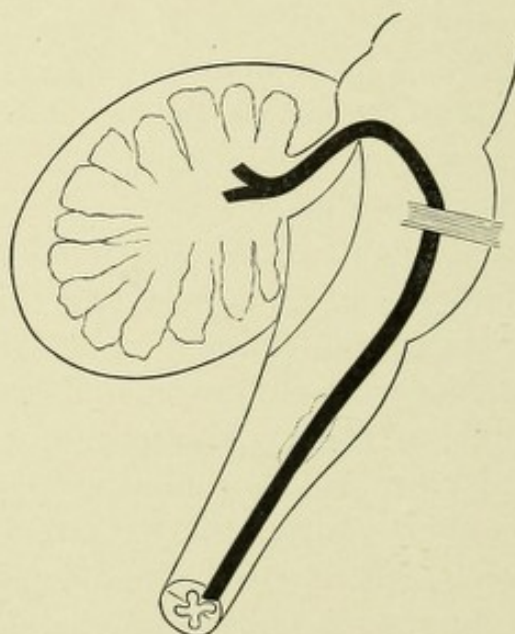


FIG. 118.—COURSE AND TERMINATION OF GOWERS' TRACT.—(*According to Hoche.*)

(crossed afferent tract of Gowers and Edinger) terminates in the optic thalamus, which we know is in connection with the parietal lobe.

The ground bundles of the lateral columns enter the formatio reticularis of each side, chiefly the lateral portions. Many of the fibers end about the collections of cells therein (nucleus reticularis tegmenti). The remainder, according to Bechterew, continue brainward to the region of the posterior corpus quadrigeminum, where the fibers end in a special collection of nerve-cells for each side in the central part of the formatio reticularis, named by Bechterew the superior central nucleus. The remain-

ing tracts of fibers, of short course, are probably the axones of the cells of the *formatio reticularis*, whose chief function is to connect the different levels of the medulla, pons, and brain-stem. In Golgi specimens it will be found that most of the axones, after a short course, decussate in the raphe, then fork, one division passing upward, the other downward, and they probably arborize about cells of a like character at higher and lower levels. Some of the axones do not decussate, but after a short course bifurcate in the same manner.

THE MOTOR OCULI, OR THIRD PAIR OF CRANIAL NERVES.

This is the common motor nerve of the eyeball and innervates all the external muscles of the eye save the superior oblique and external rectus. It also supplies the sphincter pupillæ and the ciliary muscle, through its connection with the ciliary ganglion. The origin of this nerve, on each side, is from a nucleus situated between the anterior corpora quadrigemina and beneath the floor of the ventral portion of the aqueduct of Sylvius, just outside of or lateral to the raphe. It extends ventrally as far as the posterior portion of the third ventricle and dorsally to beneath the middle of the posterior corpus quadrigeminum, where it becomes continuous with the nucleus of origin of the trochlearis or patheticus nerve, this latter nucleus being simply the posterior continuation of the former. The oculomotor nucleus is composed of large and small multipolar nerve-cells, containing a yellowish pigment and arranged on each side into an anterior, posterior, and median group. The anterior group is located in the wall of the posterior part of the third ventricle, and consists of a group of small, multipolar nerve-cells whose axones pass dorsally. Posterior to this group exists the main part of this nucleus, called the posterior group, the axones of the median cells of which pass inward, decussate with their fellows of the opposite side, and join the opposite oculomotor nerve, while the axones of the other cells of this group pass out on the same side without decussation. The median cell-group is just beneath the aqueduct of Sylvius and between the main divisions

of the two posterior groups, and its axones pass on each side toward the oculomotor nerve-roots of that side. Just anterior to the median cell group exists on each side two nuclei, united anteriorly and forming an imperfect, crescent-shaped mass. The cells of this group are small, and are embedded in a dense tangle of fibers. It is not at present known whether this nucleus on each side is connected with the nucleus of the oculomotor nerve or whether it is independent. It was discovered by Edinger and Westphal, and receives the joint names of both.

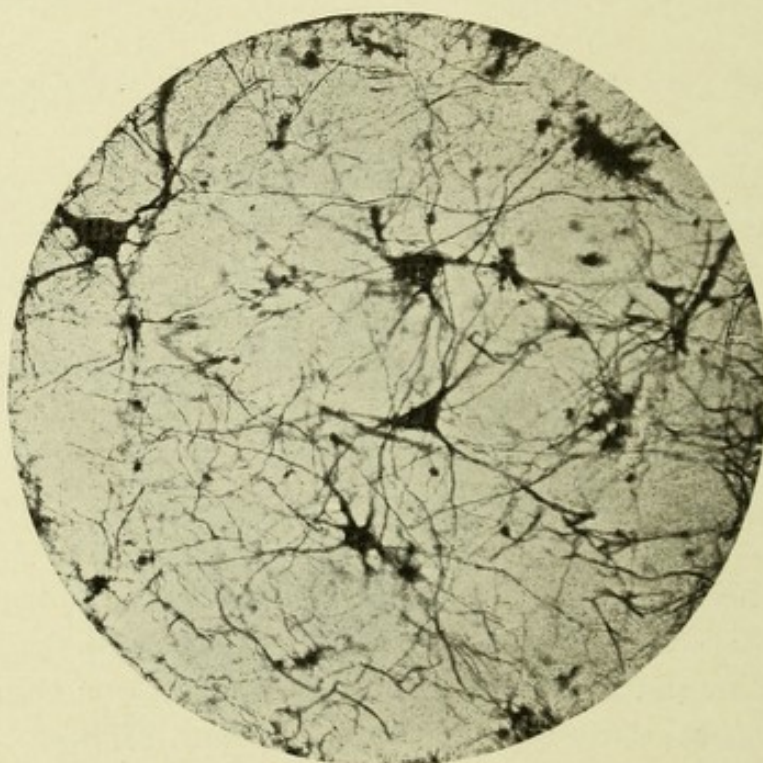


FIG. 119.—MICROPHOTOGRAPH THROUGH THE NUCLEUS OF ORIGIN OF THE MOTOR OCULI NERVE. Showing the multipolar cells of this nucleus. Golgi preparation.

The experiments of Hensen and Voelkers on dogs, and the clinical observations of Pick, Kahler, Oppenheim, Starr, and others, lend support to the theory that the oculomotor nucleus consists of a series of centers arranged from before backward, which are presumably as follows, in order from before backward: First, a group of cells concerned in accommodation; second, those presiding over the reflex action of the iris to light; then cells for the innervation of the following muscles—internal rectus, superior rectus, levator palpebræ superioris, inferior rectus,

inferior oblique, and superior oblique, the latter muscle being supplied by the patheticus, or fourth nerve.

The axones from these various cell groups pass ventrally through the tegmentum, some between and others through the mesial portion of the red nuclei, to reach the base of the brain,

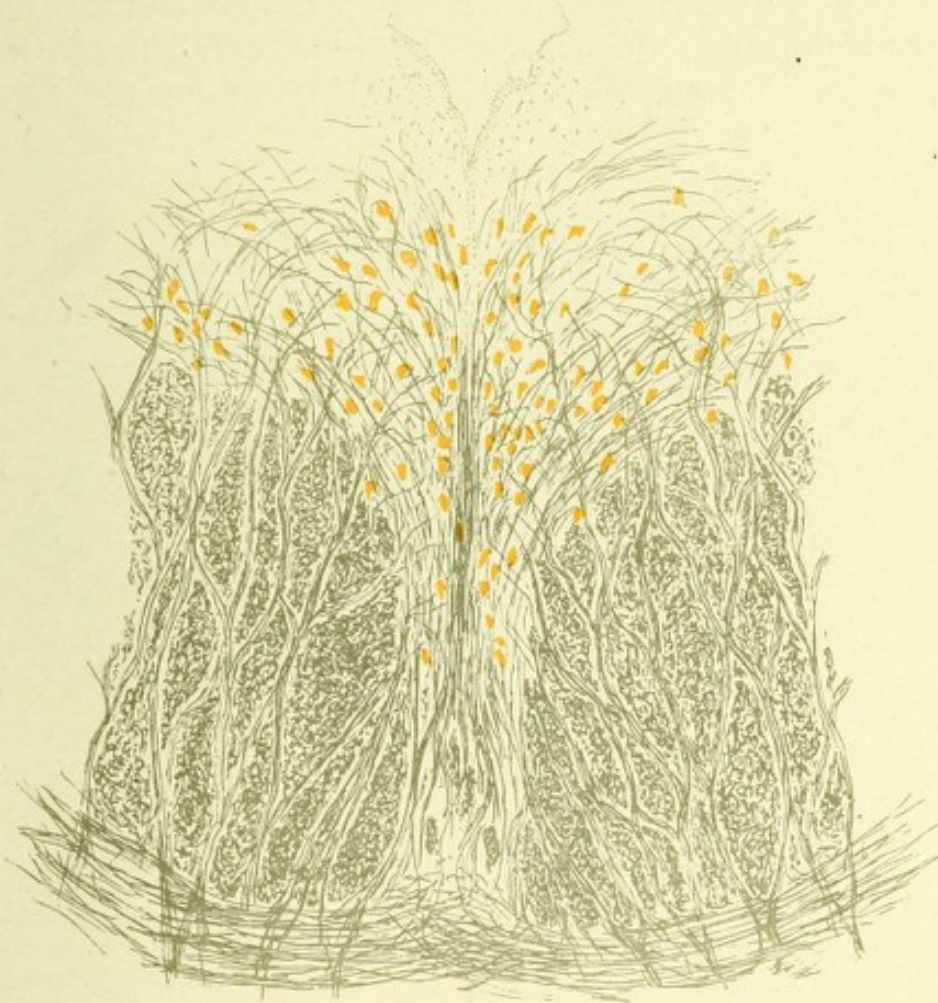

FIG. 120.—A CAMERA LUCIDA DRAWING THROUGH THE NUCLEI OF ORIGIN OF THE THIRD OR MOTOR OCULI NERVES. Showing the location of the nuclei and their cells, together with the descending axones from those cells which go to form the nerve-roots.

where they emerge from a groove—the sulcus oculomotorius—as two thick, roundish nerves, which become located in the interpeduncular space close to the inner side of each peduncle and just above the pons Varolii. They then pass between the superior cerebellar peduncle and posterior cerebral artery, forward to the outer side of the posterior clinoid process, just anterior to

which they pierce the dura mater, forming the outer boundary of the cavernous sinus, and continuing forward they enter the sphenoid fissures, where each nerve divides into two bundles, a superior and an inferior, which enter the orbit between the heads of the external rectus muscle. The superior bundle passes over the optic nerve to supply the superior rectus and levator palpebræ superioris muscles. The inferior bundle divides into three parts—one for the internal rectus, one for the inferior rectus, and the third, the longest, for the superior

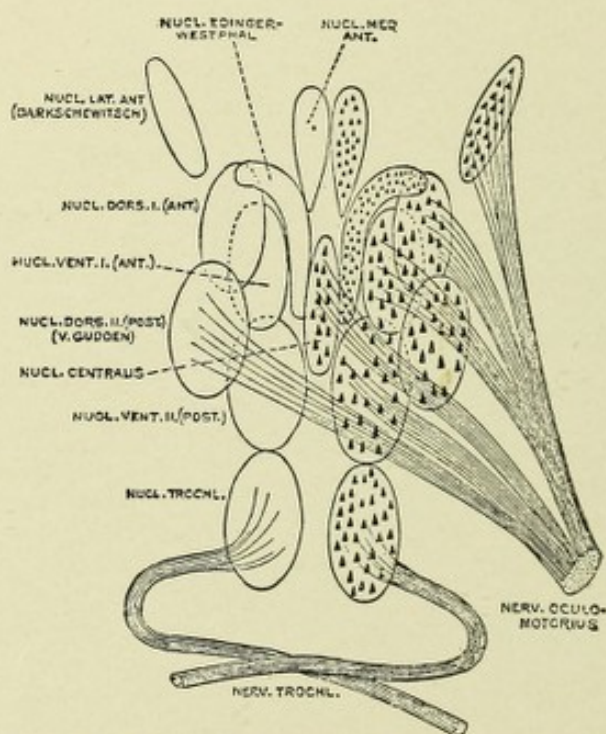


FIG. 121.—DIAGRAM OF THE GROUPS OF CELLS FORMING THE NUCLEI OF THE THIRD AND FOURTH CRANIAL NERVES.—(After *Perlia* from *Quain*.)

oblique. This latter branch is also connected with the ciliary ganglion, and contains fibers for the ciliary muscle and sphincter of the pupil.

THE CONNECTIONS OF THE OCULOMOTOR NUCLEUS.

First, with the motor or pyramidal tract, by collaterals which, after decussating, arborize about the cells of the nucleus of the third nerve of the opposite side; second, with the posterior longitudinal bundle. This bundle is chiefly connected with the oculo-

motor nucleus of the opposite side, although a few fibers pass to the nucleus of the same side. We may here recall the fact that the posterior longitudinal bundle is also connected with the nuclei of the fourth and sixth nerves. Owing to the latter connection, the conjugate or associative movements of the eyeballs may take place; thus, if both eyes are turned to the right, the right eye turns to the right by virtue of a contraction of the right external muscle, innervated by the right abducens or sixth nerve, while the left eye deviates to the right owing to a contraction of

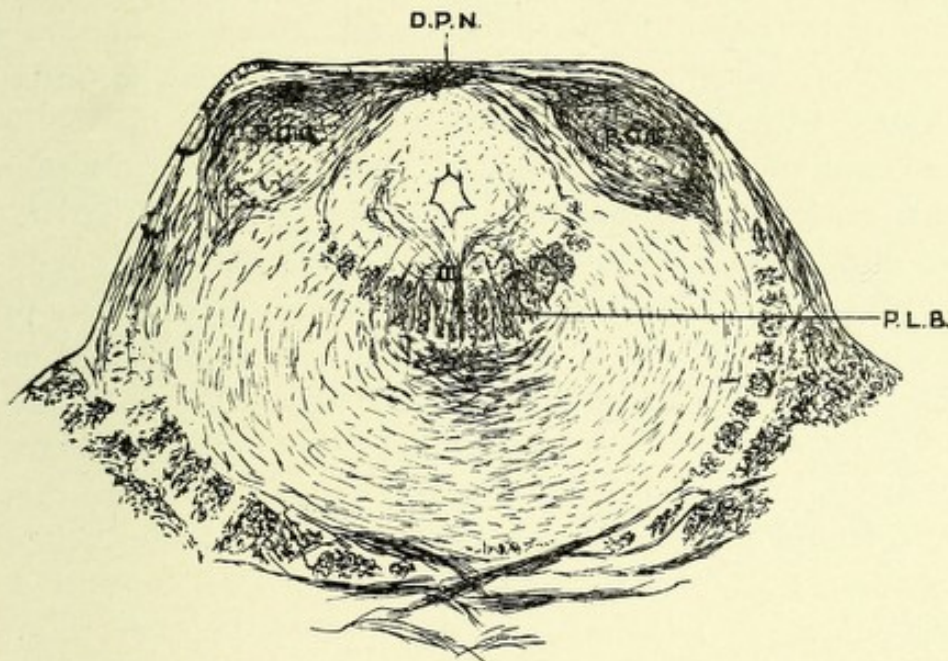


FIG. 122.—TRANSVERSE SECTION THROUGH THE MID-BRAIN AT THE LEVEL OF THE POSTERIOR CORPORA QUADRIGEMINA. Weigert preparation.

D.P.N. Decussation of the patheticus or fourth pair of cranial nerves. P.C.N. Posterior corpora quadrigemina. P.L.B. Posterior longitudinal bundle, showing its relation to the root fibers of the third nerve.

the left internal rectus, innervated by the left motor oculi nerve; hence, both eyes are moved conjointly to the right by the activity of the two chief motor nerves of the eye, associated through the posterior longitudinal bundle. The third connection is with the optic tract, possibly through cells in the anterior corpus quadrigeminum, whose axones and collaterals arborize about the cells of this nucleus (Koelliker). According to Darschewitsch, however, this connection is made by a small bundle of fibers leaving the mesial portion of the optic tract to pierce the optic thalamus

and to reach the oculomotor nucleus through the posterior commissure. This connection completes the reflex arc, by means of which the pupillary reflexes are subserved.

THE FOURTH PAIR OF CRANIAL NERVES.

This pair, called on each side the *patheticus*, or *trochlearis*, arises from a collection of medium-sized (40 to 50 μ) multipolar nerve-cells located beneath the anterior part of the inferior or posterior corpus quadrigeminum, in the ventral gray matter of the aqueduct of Sylvius, and internal to the descending root of the fifth nerve. This group of cells is continuous anteriorly with the oculomotor nucleus, and is in reality the dorsal continuation of that nucleus. The axones from the cells of this nucleus pass downward toward the pons Varolii, then curve dorsally around the lower part of the Sylvian aqueduct to enter the superior medullary velum, there to completely decussate with their fellows of the opposite side. The two nerves emerge just below the inferior quadrigeminal bodies, and, passing downward across the superior peduncles of the cerebellum, wind around the outer side of each crus cerebri, where they are to be seen. Each nerve then pierces the dura mater behind the posterior clinoid process, and runs forward in the wall of the cavernous sinus lying against the ophthalmic nerve, and then, crossing the third nerve obliquely, enters the sphenoid fissure and ramifies on the superior oblique muscle (Figs. 121 and 122).

THE SUPERIOR OR ACCESSORY NUCLEUS OF THE FIFTH OR TRIGEMINAL NERVE.

This nucleus* consists of a collection of multipolar cells slightly crescent-shaped, located in the central gray matter, at the lateral border of the aqueduct of Sylvius, and beneath the posterior corpus quadrigeminum. A few cells of this nucleus frequently extend forward as far as the beginning of the ante-

*The cells of the superior or accessory trigeminal nucleus are believed to be multipolar by Koelliker and Obersteiner, while Ramón y Cajal, Lugaro, and Golgi think they are without dendrites, and are pear-shaped, unipolar cells.

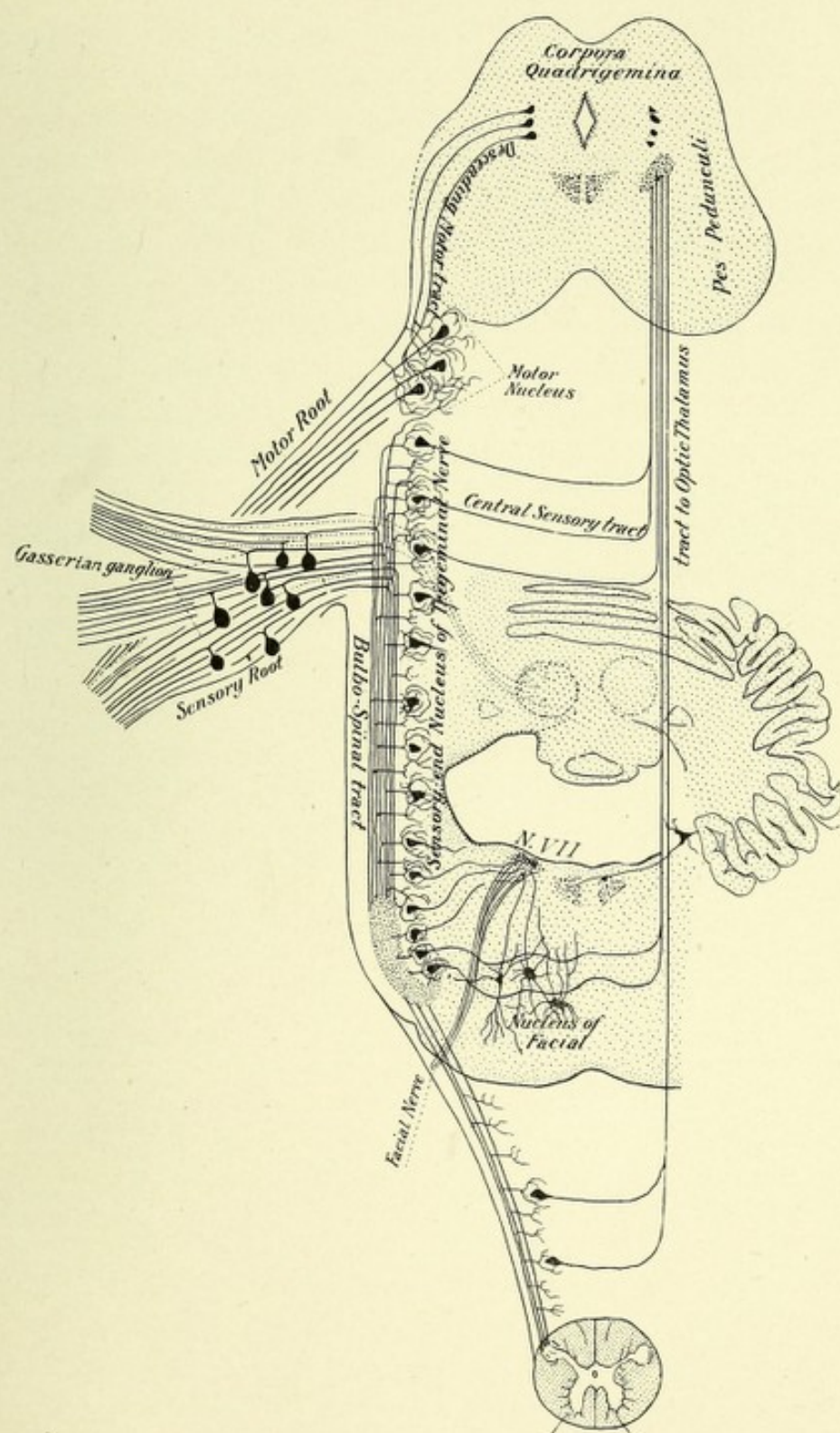



FIG. 123.—SCHEMATIC REPRESENTATION OF THE ORIGIN OF THE TRIGEMINAL NERVE.—
(After Edinger.)



rior corpus quadrigeminum. The nucleus probably extends caudad to the anterior extremity of the fourth ventricle, where it is continuous on each side with the darkly pigmented cells of the substantia ferruginea, which are grouped on each side of the ventricle, lateral to the posterior longitudinal bundles and beneath the ependyma, and are covered by a bluish-gray area,—the locus cœruleus,—through which this dark group of cells may be seen. This group may be considered as part of the nucleus, since Mendel found them wasted in a case of progressive facial atrophy where the fibers of the trigeminal nerve of that side were degenerated. The axones from the cells of the accessory trigeminal nucleus join the portiomotor or motor division of the fifth nerve; they are probably motor in function, although Merkel believes they may have a trophic function, while Huguenin thinks they have a vasomotor function.



CHAPTER VI.

REGION OF THE THIRD VENTRICLE.

From the primary cerebral vesicle is developed the 'tween brain, called also interbrain, or thalamencephalon; this includes the third ventricle, pineal body or gland, optic thalami, optic tracts, infundibulum and pituitary body, middle and posterior commissures, posterior perforated spaces, corpora albicantia or mammillaria, tuber cinereum, and lamina cinerea. This region is between the secondary fore-brain (cerebral hemispheres and contained ganglia) anteriorly and superiorly and the mid-brain, consisting of the corpora quadrigemina and crura cerebri, posteriorly and inferiorly. It is connected anterolaterally with the cerebral hemispheres, and they rest upon its superior surface with only pia mater intervening. Posteriorly it is connected with the corpora quadrigemina.

THE THIRD VENTRICLE.

This ventricle is the remains of the primary cerebral vesicle. It is a deep but narrow cavity, placed between the optic thalami and extending to the base of the brain. Above it exists the fornix and corpus callosum. It has for its roof the velum interpositum lined with epithelium, from which are suspended the choroid plexuses for this ventricle. Its floor is composed of the parts which exist in the interpeduncular space, which are, from before backward, the lamina cinerea, tuber cinereum, infundibulum, corpora albicantia, posterior perforated space, and part of the tegmentum. Its lateral boundary is, in reality, the surrounding central gray matter, although anatomists generally state that this boundary is the optic thalamus. The optic thalami lie very close to each other just anterior to

the middle part of the ventricle, and are connected by a transverse bundle of fibers—the middle or soft commissure. This commissure is the result of the union of the mesial surfaces of the thalami, which occurs at about the fifth month of fetal life.

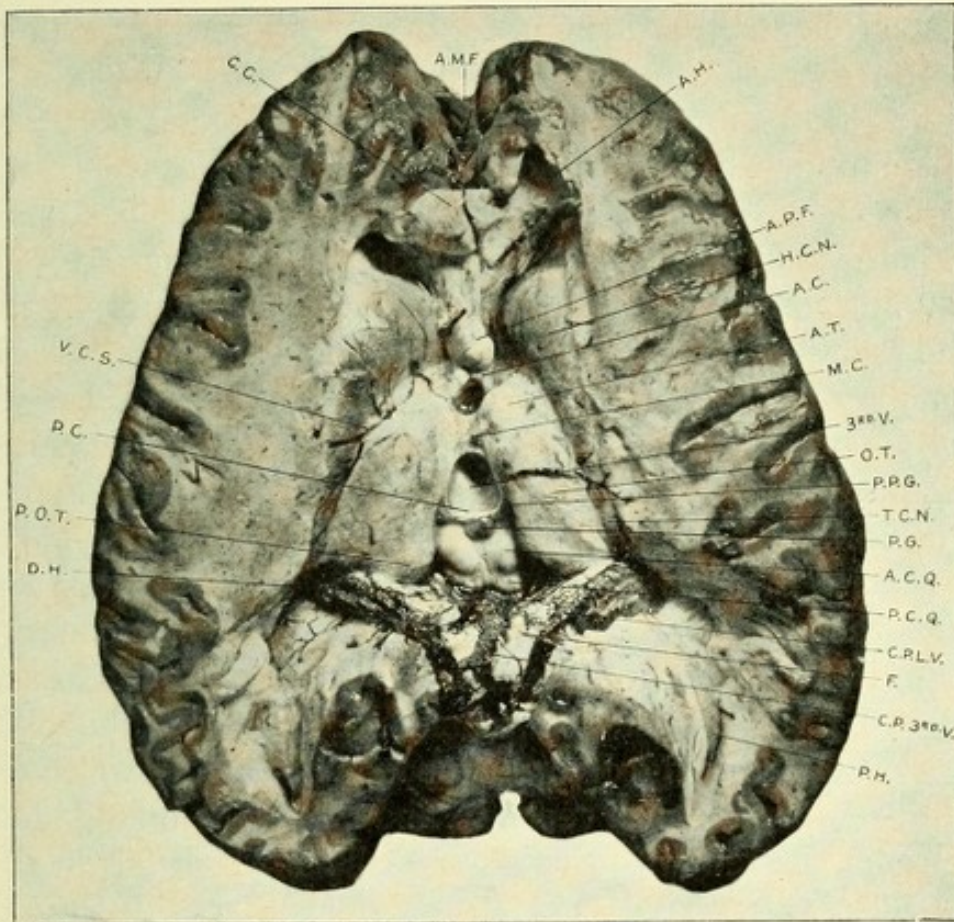


FIG. 124.—HORIZONTAL SECTION THROUGH THE CEREBRAL HEMISPHERES TO SHOW THE REGION OF THE THIRD VENTRICLE.

A.M.F. Anterior median fissure. A.H. Anterior horn of lateral ventricle. A.P.F. Anterior pillar of fornix. H.C.N. Head of caudate nucleus. A.C. Anterior commissure. M.C. Middle or soft commissure. 3rd.V. Third ventricle. O.T. Optic thalamus. P.P.G. Peduncle of pineal gland. T.C.N. Tail of caudate nucleus. P.G. Pineal gland. A.C.Q. Anterior corpora quadrigemina. P.C.Q. Posterior corpora quadrigemina. C.P.L.V. Choroid plexus of lateral ventricle. F. Fornix. C.P.3rd.V. Choroid plexus of third ventricle. P.H. Posterior horn. D.H. Descending horn. P.O.T. Pulvinar of optic thalamus. P.C. Posterior commissure. V.C.S. Vena corpora striati. C.C. Corpus callosum.

It is frequently absent, and is so soft that, unless great care be used in removing or manipulating the brain, it will be torn.

The anterior part of the floor of the ventricle is separated from its lateral walls by the prominent anterior pillars or columns of the fornix, which are lined at this point by the central gray matter of

the ventricle. Just anterior to the fornix passes the anterior commissure; between the anterior pillars of the fornix and the ventral part of each optic thalamus exists an aperture which leads into the lateral ventricle on each side. This is the foramen of *Monro*, which is the only means of connection between the third and lateral ventricles. The peduncles of the pineal gland run along on each side of the superior part of the margin of the lateral walls of the ventricle. This cavity is limited posteriorly by the entrance or opening of the aqueduct of *Sylvius*, by the posterior commissure, and by a reflection of epithelium from the upper surface of the pineal gland upon the under surface of the *velum interpositum*. The cavity of the ventricle is more shallow behind than in front. The deep anterior portion of it passes to a conic termination, which lies above the optic commissure, called the optic recess; behind this recess is another depression, the *infundibulum*, which leads to the pituitary body or *hypophysis cerebri*. At the posterior extremity of the cavity, above the entrance of the *Sylvian aqueduct*, is a depression which extends backward to the stalk of the pineal gland, or *conarium*. The third ventricle has four openings—viz., those of the foramen of *Monro*, one on each side, communicating with the lateral ventricles, the opening of the aqueduct of *Sylvius*, which communicates with the fourth ventricle, and that of the *infundibulum*. This cavity is lined with ciliated epithelium, which fills in all its inequalities, is reflected over the mesial surfaces of the optic thalami and upon the *velum interpositum* and choroid plexuses. The epithelium rests upon a thin layer of ependymal tissue, beneath which is the central gray matter, which is continuous with that lining the aqueduct of *Sylvius*—a prolongation of the gray matter of the fourth ventricle. It extends upon the mesial surfaces of the optic thalami and rests posteriorly upon the *tegmentum*. In front and below, it comes to the surface as the posterior perforated space and *tuber cinereum*.

THE PINEAL GLAND, OR CONARIUM.

The pineal gland, also termed *epiphysis cerebri*, receives its name because of its supposed resemblance to a fir-cone, the

Latin term *pinus* being the generic name for a class of the cone-bearing trees. It is a small, reddish-gray body about the size of a bean, but conic in form. It is dorsal to the posterior commissure, with which it is connected, and lies a little ventral to and between the superior or anterior corpora quadrigemina. It is retained in place by a duplicature of pia mater from the under surface of the velum interpositum. It is, according to Schwalbe, twelve millimeters in its anteroposterior, eight in its transverse, and four in its vertical diameter. It is connected with the rest of the cerebrum by a broad, flat bundle of white fibers, which bundle is separated by the pineal recess into a dorsal, or superior, and ventral, or inferior, lamina. The upper or dorsal lamina (pedunculus conarii) sends a bundle of fibers to the right and left into each optic thalamus. This lamina is also continuous on each side with the trigonum habenulæ, and its anterior portion continues forward as the peduncle of the pineal gland, along the margin of the third ventricle, and passes into the ganglion habenulæ. The lower or ventral lamina passes into the posterior commissure. These fibers are derived probably from the optic tract, and pass into the opposite oculomotor nucleus. The pineal gland is covered by pia mater, which sends into its interior a number of vascular connective-tissue processes, which divide the gland into a number of spheric or tubular spaces called follicles, which latter are lined with epithelium similar to that of the lymph-glands. These follicles are filled with calcareous granules composed of the phosphates and carbonates of the alkaline earths, which granules bear the name of the *acervulus cerebri*, or brain-sand. The gland is a hollow outgrowth of the medullary wall of the roof of the primary fore-brain vesicle, which latter afterward forms the third ventricle. The gland becomes separated from the ventricular cavity, after which numerous small processes bud out from its inner walls and coalesce, forming its crypts. Cajal has shown that nerve-fibers and cells are found in this gland. These nerve-fibers belong to the sympathetic system, and accompany the large vessels into the gland; they then leave the vessels, pass between the follicles, and repeatedly branch and unite with each other, forming an interstitial plexus; they end

free in varicose-like arborizations or club-shaped thickenings. The nerve-cells lie between the follicles ; they are small spheroid or irregular-shaped cells, with two to four dendrites, which vary as to length, some being rather short, while others are moderately long. They terminate with thickened free extremities.

THE POSTERIOR COMMISSURE.

This is a fasciculus of medullated fibers, mostly transverse, which overlies the entrance of the aqueduct of Sylvius into the third ventricle. It is located in the posterior wall of the latter cavity. The pineal gland is just above and slightly dorsal to it. A part of the fibers of the ventral portion of this commissure originate in the ganglia subthalami, deep in the inter-brain on each side of the raphe. These fibers proceed dorsally to reach the region just back of the corpora quadrigemina, where they decussate with their fellows of the opposite side and pass into the tegmental region of that side, close to the posterior longitudinal bundle, possibly being associated with that bundle. They then continue downward to the medulla. Darkschewitch asserts that the median fibers of this bundle pass into the nucleus of the oculomotor nerve, and that the dorsal bundle of the commissure passes into the corona radiata of the hemisphere connecting it with the opposite superior corpus quadrigeminum. According to Meynert, most of the fibers of this commissure are continuations of the fibers of the fillet, which, after decussating, pass through the optic thalamus into the corona radiata of the opposite side.

THE OPTIC THALAMI.

These are two large, oblong masses, chiefly of gray matter, appearing to be wedged in between the corpora striata and to rest upon the crura cerebri. Their superior or dorsal surfaces are covered by a thin mantle of white fibers—the stratum zonale. They are developed from the lateral walls of the inter-brain. On the outer side of each thalamus is the posterior limb of the internal capsule. Their internal surfaces form, with the

central gray matter, the outer boundaries or walls of the third ventricle. A small part of each thalamus assists in forming the floor of the lateral ventricle. Above exists the fornix, separated from the optic thalamus by the velum interpositum. Each optic thalamus has four distinct surfaces—superior or dorsal, inferior or ventral, internal or mesial, and external or lateral. The superior surface is separated from the nucleus caudatus by a groove, which contains the vena corpora striata and a fasciculus of fibers—the *tænia cornea* or *semicircularis*, or the *stria terminalis*. This surface is divided by a slight longitudinal depression corresponding to the thickness of the fornix, which lies above it, called the *sulcus choroideus*, dividing it into a mesial and a lateral portion. The lateral portion of this depression is found in the floor of the body of the lateral ventricle, and is covered with epithelium common to the lateral ventricle. Anteriorly this portion grows into a distinct prominence, called the *anterior tubercle*. The surface internal or mesial to the sulcus is covered by the velum interpositum. It is separated from the inner or mesial surface by the peduncles of the pineal gland. At the posterior and inner part of this area exists a large and important prominence—the *pulvinar*. It overlaps the brachia of the corpora quadrigemina. Between the pulvinar and the beginning of the peduncle of the pineal gland on each side exists a depressed area of gray matter, called the *trigonum habenulæ*. Ventral to the trigonum exists a small, club-shaped swelling—the *ganglion habenula*.

The internal or mesial surface of each thalamus is almost flat, and forms the outer boundary of the third ventricle. It is covered by the ventricular epithelium, which rests upon a very thin layer of ependyma, which gives to the surface a pale-gray color. It is united with its fellow of the opposite side by the middle or soft commissure. The external and lateral surface forms the inner boundary of the posterior limb of the internal capsule. This limb of the capsule separates the thalamus from the lenticular nucleus. This area extends from the anterior extremity of the thalamus backward to the pulvinar, and is called the *lateral nucleus*. Both extremities are somewhat rounded; the posterior extremity is composed almost entirely of the prominence called the pulvinar,

which latter is made up principally of gray matter—and is connected both with the optic tract and occipital lobe; on the posterior and inferior surfaces of the pulvinar exist two elevations of gray matter—the internal and external geniculate bodies. The internal geniculate body is an oval elevation, located on the inferior and inner side of the pulvinar between the brachia of the corpora quadrigemina. Below and external to it, and continuous ante-

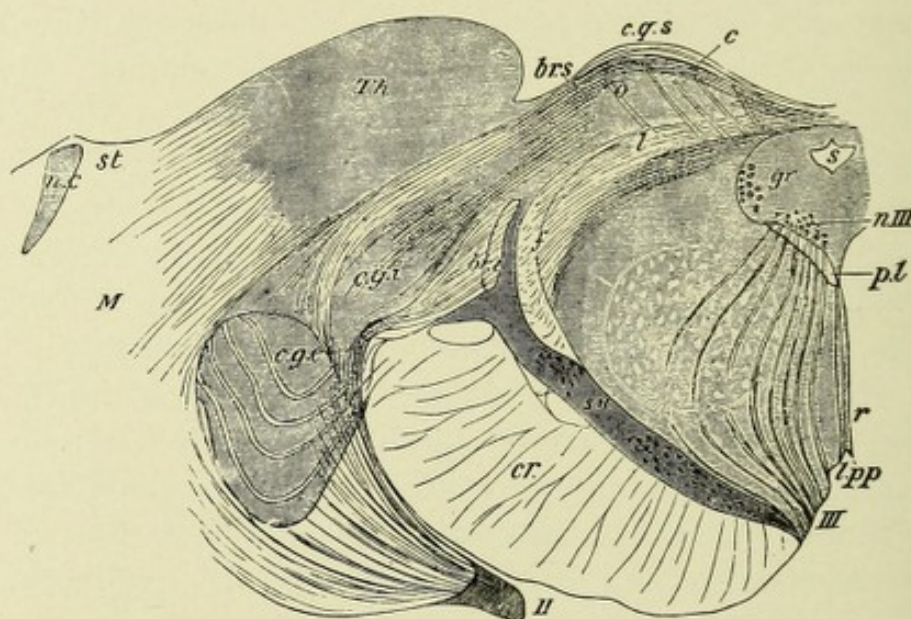


FIG. 125.—SECTION THROUGH THE SUPERIOR PART OF ONE OF THE SUPERIOR CORPORA QUADRIGEMINA AND THE ADJACENT PART OF THE OPTIC THALAMUS.—(After Meynert.)—(From Quain's "Anatomy.")

- s. Aqueduct of Sylvius. gr. Gray matter of the aqueduct. c.g.s. Quadrigenal eminence, consisting of: l. Stratum lemnisci. o. Stratum opticum. c. Stratum cinereum. Th. Thalamus (pulvinar). c.g.i., c.g.e. Internal and external geniculate bodies. br.s., br.i. Superior and inferior brachia. f. Upper fillet. p.l. Posterior longitudinal bundle. r. Raphe. III. Third nerve; n.III; its nucleus. l.p.p. Posterior perforated space. s.n. Substantia nigra. Above this is the tegmentum with its nucleus, the latter being indicated by the circular area. cr. Crusta. II. Optic tract. M. Medullary center of the hemisphere. n.c. nucleus caudatus. st. Stria terminalis.

riorly with the optic tract, is a small, club-shaped body, about the size of a bean, called the external or lateral geniculate body.

The internal geniculate body is covered with a layer of white fibers, and contains a number of small, multipolar nerve-cells, each from 20 to 25 μ in diameter, and is connected on each side with the auditory tract.

The external or lateral geniculate body is of a yellowish-gray

color,—owing to the preponderance of gray matter,—contains multipolar nerve-cells of from 30 to 40 μ in diameter, possessing many dendrites radiating from all parts of the cell-body. This body receives fibers from the optic tract, axones from the multipolar cells of the retina.

Both these bodies are connected with the corpora quadrigemina, the internal being connected with the posterior or inferior

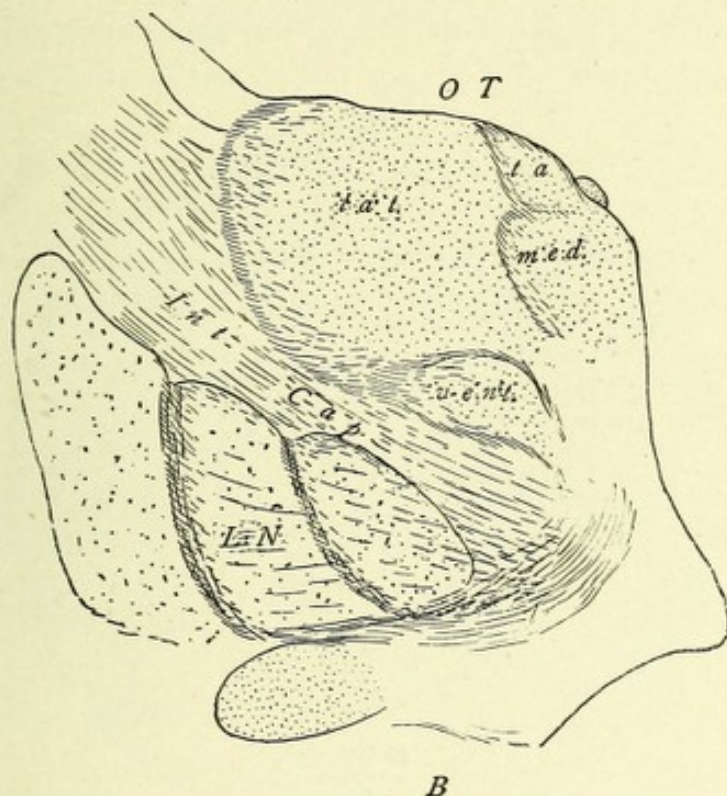


FIG. 126.—FRONTAL SECTION THROUGH BASAL GANGLIA TO SHOW THE NUCLEI OF THE OPTIC THALAMUS.—(After von Monakow.)—(From Starr's "Atlas.")

B. Section at junction of middle and anterior two-thirds of the thalamus. OT. Optic thalamus. lat. Lateral nucleus. med. Median nucleus. vent. Ventral nucleus. ta. Anterior nucleus. Int. Cap. Internal capsule. L.N. Lenticular nucleus. l. Lenticular loop.

corpus quadrigeminum and the external with the anterior or superior corpus quadrigeminum.

The optic thalami have a double connection with all parts of the cerebral cortex: first, by bundles of fibers from the different nuclei of the thalami (von Monakow), called the projection fibers of these bodies; and, secondly, by axones from the pyramidal cells of all parts of the cortex. In a general way, according to von Monakow, the thalami are anatomically related with the cere-

bral cortex, as follows: The anterior and mesial portions of the thalami are in relation with the frontal lobes; the lateral area or ganglion with the parietal lobe; the ventral ganglion with the operculum; the posterior ganglion, corpus geniculatum externum, and pulvinar with the gyri of the occipital lobe; the corpus geniculatum internum and posterior ganglion with the temporal lobe. This projection system of fibers passes through the internal capsule in bundles, which have been termed *laminæ medullares*, or peduncles of the optic thalamus. They divide

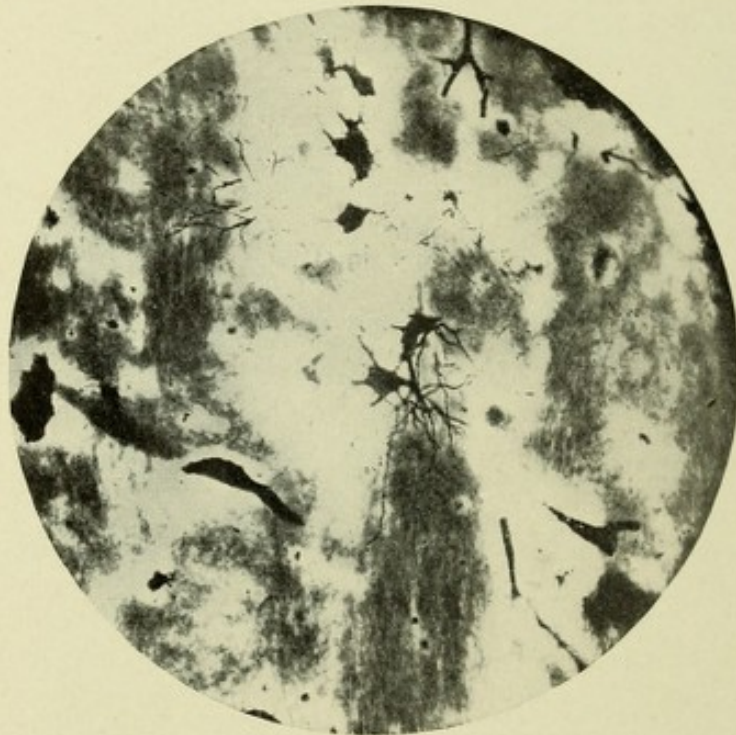

FIG. 127.—MICROPHOTOGRAPH THROUGH OPTIC THALAMUS SHOWING BUSCH CELLS.
Golgi method.

each thalamus, according to von Monakow, into the following nuclei: the anterior or tuberculum anterius, the median, the lateral, the ventral, the posterior, and the pulvinar. The geniculate bodies and the ganglion habenulæ are so closely associated with the optic thalamus that they will be described with that body.

The anterior nucleus, or tuberculum anterius, is the prominence on the anterior portion of the dorsal surface of the thalamus, lateral to its sulcus choroideus. It is surrounded on all sides by the white substance, and its free surface is covered

by the fibers called the stratum zonale. Some axones from the cells of this nucleus pass downward to the base of the brain, ending in the corpus albicans or mammillare, forming the bundle of Vicq d'Azyr or fasciculus thalamomammillaris, thus establishing a connection between the optic thalamus, the gyrus hippocampus, uncinate gyrus, and cornu ammonis. The cells of this latter region give origin to the fornix fibers, which end in the corpus mammillare. Von Monakow found in several cases where these regions were diseased an atrophy of the fimbria, of the anterior pillar of the fornix, and of the corpus mammillare of the same side.

The median nucleus is posterior and inferior to the anterior nucleus. It has been divided by von Monakow into a median and a lateral portion. It extends backward to the trigonum habenulæ. External to it is the lateral nucleus, while below and adjacent is the ventral nucleus. It is connected with the island of Reil and the second and third frontal gyri. The lateral nucleus occupies the entire lateral surface of the thalamus, resting against the internal capsule. It is the largest of the nuclei, and extends from the anterior extremity of the thalamus posteriorly to the pulvinar. It receives from the cerebral cortex numerous fibers, which come from the region of the central convolutions.

The ventral nucleus is located beneath the median and lateral nuclei, and occupies the entire ventral surface of the thalamus. It lies close to the lower portion of the internal capsule. According to von Monakow, the anterior portion of this nucleus is in relation anatomically with the frontal lobe, the remainder being in relation with the parts of the cerebral cortex about the fissure of Sylvius—viz., the operculum, central gyri, and the supra-marginal gyrus.

The posterior nucleus is located beneath the pulvinar and between the geniculate bodies; it is in anatomic relation with that part of the cortex located between the occipital and temporal lobes.

The pulvinar, which occupies the posterior portion of the optic thalamus, has been described on page 249. It is in relation with the optic tract and occipital lobe.

The nuclei of the optic thalamus contain three distinct forms

of nerve-cells: first, stellate, or "Strahlencellen"; second, the cells with brush-like processes ("Buschzellen" of Koelliker); third, the polygonal cells, first described by Starr.

The first variety exists throughout the optic thalamus, but is principally found in the lateral and median nuclei. They have been called by Starr stellate, and are identical with the cells described by Koelliker as the Strahlencellen. They are spindle, spheric, or triangular in shape, 35 to 50 μ in diameter, and give off from four to ten dendrites, which, with their many branching processes, radiate in all directions from the cell-body—hence their name. A few of the dendrites are very long, but the majority are short. They seldom possess granules, and their branches do not form brushes of fibers. The axone comes off from the cell-body and gives off a few collaterals. Its course can be traced a short distance only. It is probable, however, as suggested by Starr, that many of the axones from these cells pass into the internal capsule.

The Buschzellen, or the cells whose dendritic processes are arranged in brush-like expansions, were discovered by Koelliker. They are round, spindle, or triangular-shaped cells, from 25 to 40 μ in diameter, with six to eight dendrites, each of which repeatedly divides into a brush of very fine fibrils. Koelliker has shown that in preparations after the Golgi method the main stem of each dendrite is granular, and stains deep black, while the brush of fine fibrils takes the stain less readily, and is lighter in color. The axones of these cells resemble those of the first variety. These cells are located in the dorsal half of the optic thalamus, also in the corpus geniculatum lateralis of each side and in the gray matter about the third ventricle.

The polygonal cells occur only—according to Starr, who discovered them—in the ventral or anterior nucleus of the thalamus. They are large cells, from 50 to 60 μ in diameter, polygonal in shape, and give off from the cell-body a number of very long, slender dendrites studded with gemmules. The course of the dendrites is tortuous, but they do not possess as many branches as do those from the stellate cells. The axone comes from the body of the cell, gives off a few collaterals, and, according to Starr, has no uniform direction.

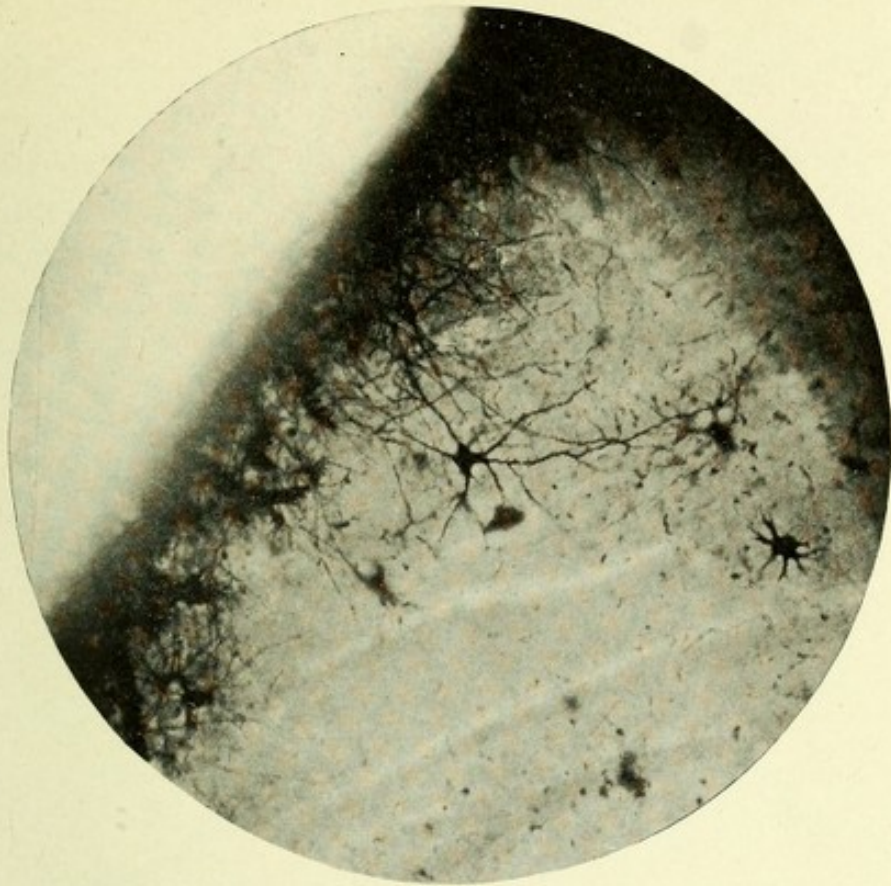


FIG. 128.—MICROPHOTOGRAPH THROUGH OPTIC THALAMUS SHOWING STELLATE CELLS.
Method of Golgi.

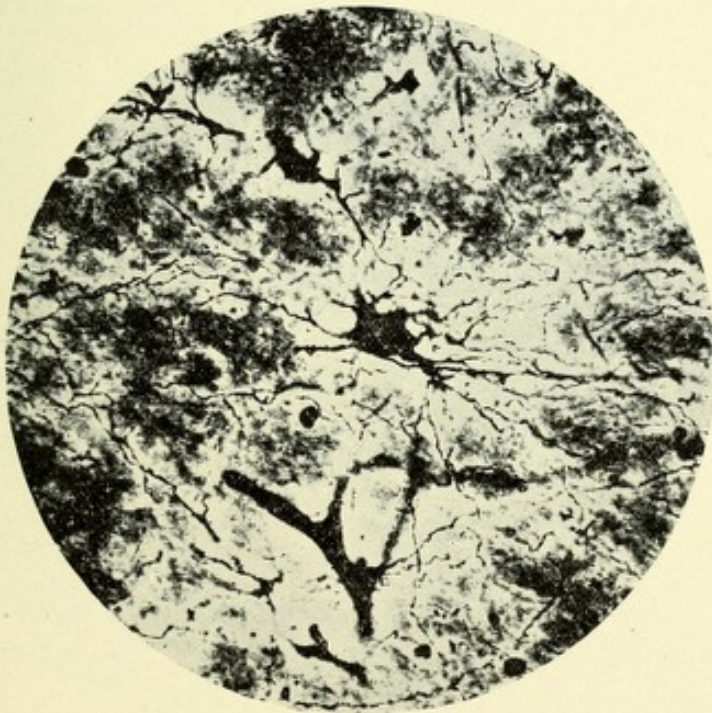

FIG. 129.—MICROPHOTOGRAPH THROUGH OPTIC THALAMUS WITH A SINGLE LARGE
POLYGONAL CELL. Method of Berkley.



THE GANGLION HABENULÆ.

This is a small swelling on the anterior portion of the mesial surface of the optic thalamus. It is united with its fellow of the opposite side by a commissural band—the dorsal thalamic commissure. From the cells of this ganglion a few fibers pass backward to the pineal gland (Starr). It receives fibers from

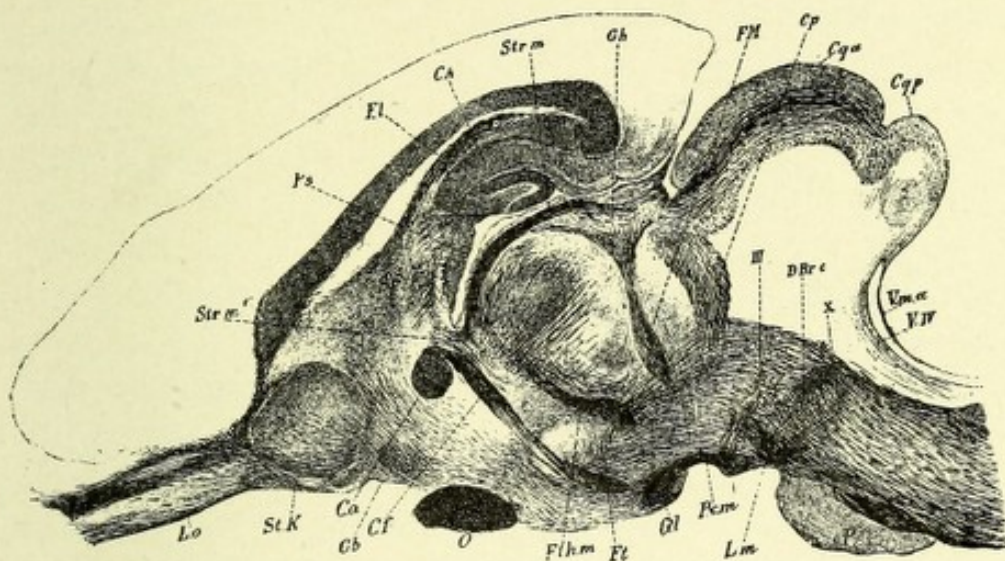


FIG. 130.—A PERPENDICULAR SECTION THROUGH THE BRAIN OF A RABBIT LATERAL TO THE CORPUS MAMMILLARE.—(After Koelliker.)

CA. Cornu ammonis. Cf. Columna fornicis. Cp. Commissura posterior. Cqa, Cqp. Corpora quadrigemina. D Br c. Decussation of the superior cerebellar peduncles. Fl. Fornix. FM. Fasciculus retroflexus (Meynert). Ft. Fasciculus tegmenti. Fthm. Fasciculus thalamomammillaris (Vicq d'Azyr). Gb. Basal ganglion. Gh. Ganglion habenulæ. Gl. Lateral ganglion of corpus mammillare. Lm. Median lemniscus or fillet. Lo. Lobus olfactorius. O. Optic tract. P. Pons. Pcm. Pedunculus corporis mammillaris. Ps. Psalterium. Sp. Septum pellucidum. St K. Head of caudate nucleus. Str m. Stria medullaris. Str m'. Connection of the same with the columna fornicis. Vm a. Anterior medullary velum. V iv. Fourth ventricle. III. Oculomotor nerve-roots. X. Radiation of the fibers of the peduncle of the corpus mammillare.

the peduncles of that gland. The cells of this ganglion give off axones which form a bundle of fibers—the fasciculus retroflexus, or Meynert's bundle.* This fasciculus of fibers passes downward through the tegmentum, between the red nucleus and posterior longitudinal bundle, giving off, according to Meynert,

* After destruction of the ganglion habenulæ, the fasciculus retroflexus of Meynert degenerates to its termination in the interpeduncular ganglion.

a few fibers to that nucleus ; then the main bundle bends nearly at a right angle, and proceeds downward into the tegmentum of the pons and medulla.* According to Forel, Gudden, and Edinger, however, this bundle of fibers curves through the tegmentum, between the red nucleus and posterior longitudinal bundle, and ends, after decussating with its fellow, among a collection of nerve-cells existing in the back part of the posterior perforated space between the crura cerebri, called the interpeduncular ganglion (Fig. 130).

CONNECTIONS OF THE OPTIC THALAMUS.

First, each thalamus has a double connection with all parts of the cerebral cortex, both by axones from the cells of the various nuclei of which it is composed (projection system of the thalamus) and by axones from the pyramidal cells of all parts of the cerebral cortex. Second, it is connected with the primary or first division of the optic tract by fibers (axones of the ganglionic cell layer of the retina) which end about the cells of the pulvinar and external geniculate body. Third, it has a double connection with the occipital lobe by axones from the cells of the pulvinar (optic radiation), which end about the pyramidal cells of the cortex of the occipital lobe, and by axones from the pyramidal cells of that lobe, which end about the cells of the pulvinar. Fourth, the anterior nucleus of each thalamus is connected with the corpus albicans by the fasciculus thalamo-mammillaris, or bundle of Vicq d'Azyr, bringing this nucleus into anatomic relation, through the fornix fibers, with the hippocampal and uncinatæ gyri. Fifth, the fibers of the lenticular loop end chiefly in the optic thalamus, and connect the lenticular nucleus (putamen chiefly) with the optic thalamus. Sixth, the cells of the ganglion habenulæ give rise to fibers which form the fasciculus retroflexus of Meynert. This connects the thalamus with the interpeduncular ganglia. Seventh,

* It is very probable that the fibers of the fasciculus retroflexus terminate in arborizations about the cells existing in the interpeduncular ganglion, and that the descending part of the tract which descends in the tegmentum to the pons and medulla is the axones from the interpeduncular ganglion cells.

von Monakow has shown that the chief part of the median fillet or lemniscus (interolivary bundle from the nuclei of Goll and Burdach) ends about the cells of the ventral and lateral nuclei of the thalamus, and that axones from these latter cells pass through the posterior part of the internal capsule and radiate toward the parietal lobe, forming the cortical fillet or lemniscus. Eighth, the thalamus is connected with fibers which originate from the cells of the nucleus ruber and fibers from the superior cerebellar peduncles; this establishes a connection between the optic thalamus and the opposite cerebellar hemisphere. Ninth, each optic thalamus is connected with the caudate nucleus by a fasciculus of fibers—the stria thalamica.

THE SUBTHALAMIC REGION, OR STRATUM INTERMEDIUM.

This is a region on each side located beneath the optic thalamus, above the peduncles of the cerebrum, and internal to the posterior portion of the internal capsule. This region contains an intricate maze of nerve-fibers,—the zona incerta,—which come from the lenticular nucleus, the internal capsule, and the optic thalamus on their way to the ganglia located in this region, which ganglia appear wedged in between the extreme posterior limb of the internal capsule and the inferior portion of the optic thalamus. These ganglia are the nucleus ruber, or tegmental nucleus; the subthalamic nucleus, or Luys' body; and the substantia nigra, or locus niger. The red nucleus appears, on transverse section, as a spheric shaped body located beneath the inner portion of the optic thalamus, internal to Luys' body and above and slightly internal to the substantia nigra. The subthalamic nucleus, **Luys' body**, is a lenticular gray mass resting above and a little internal to the crusta; it is external to the red nucleus and between the inferior border of the thalamus and the substantia nigra. The substantia nigra is located just above the crus cerebri, and continues into the peduncle of the brain, there forming an intermediate stratum, which serves to separate the peduncle into a ventral portion, or crusta, and a dorsal portion, or tegmentum.

The nucleus hypothalamicus, subthalamicum, or Luys' body, is of a dark brownish color, lenticular in form, and spindle-shaped on transverse section. It is, according to Koelliker, 9 to 10 mm. in its transverse, 3 to 5 mm. in its dorsoventral, diameter. It is inclosed, save at its mesial surface, by a capsule of fine medullated nerve-fibers, consisting of a ventral and a dorsal lamina. The nucleus proper consists of fine medullated nerve-fibers, having in their meshes a number of angular or spindle-shaped cells containing much granular pigment and possessing many protoplasmic processes. This body is very rich in capillary blood-vessels. According to Stilling and Koelliker, some of the fibers from the optic tract (perforating fibers), after having passed through the crus cerebri, end among the nerve-cells of this body. It is quite probable that these fibers belong either to Gudden's or Meynert's commissure, and are not an essential part of the optic tract. This statement seems proved by an observation of von Monakow, in one of whose cases there was complete degeneration of the entire optic tract while Luys' body remained absolutely normal. According to this observer, many of the axones from the cells of Luys' body pass through the crus cerebri and enter the corpus striatum, to end chiefly about the cells of the outer division of the lenticular nucleus or putamen, thus establishing a connection between this body and the lenticular nucleus. A commissure exists between the subthalamic nuclei, or Luys' bodies, consisting of nerve-fibers from two sources: First, fibers which originate in the subthalamic nucleus of one side, which probably pass, after decussating, into the subthalamic nucleus of the opposite side; second, a bundle of fibers, first described by Forel, existing in the tegmentum, lateral to the red nucleus. This bundle, according to Forel, consists of two fasciculi—a ventral and a dorsal. The ventral fasciculus (bundle H² of Forel) consists of fibers which probably originate in the corpus mammillare of the same side and then course upward and along the lateral border of Luys' body, into which some of the fibers enter, while the majority pass through the crista into the internal capsule. The fibers of the dorsal fasciculus (bundle H' of Forel) pass into the basal part of the optic thalamus.

THE RED OR TEGMENTAL NUCLEUS OF STILLING.

This has received its name because of the reddish appearance it presents in sections of fresh brain, this color being due to its great vascularity. On transverse section it appears round, while in sagittal sections it has an elongated oval appearance. The root-fibers of the third nerves pass vertically

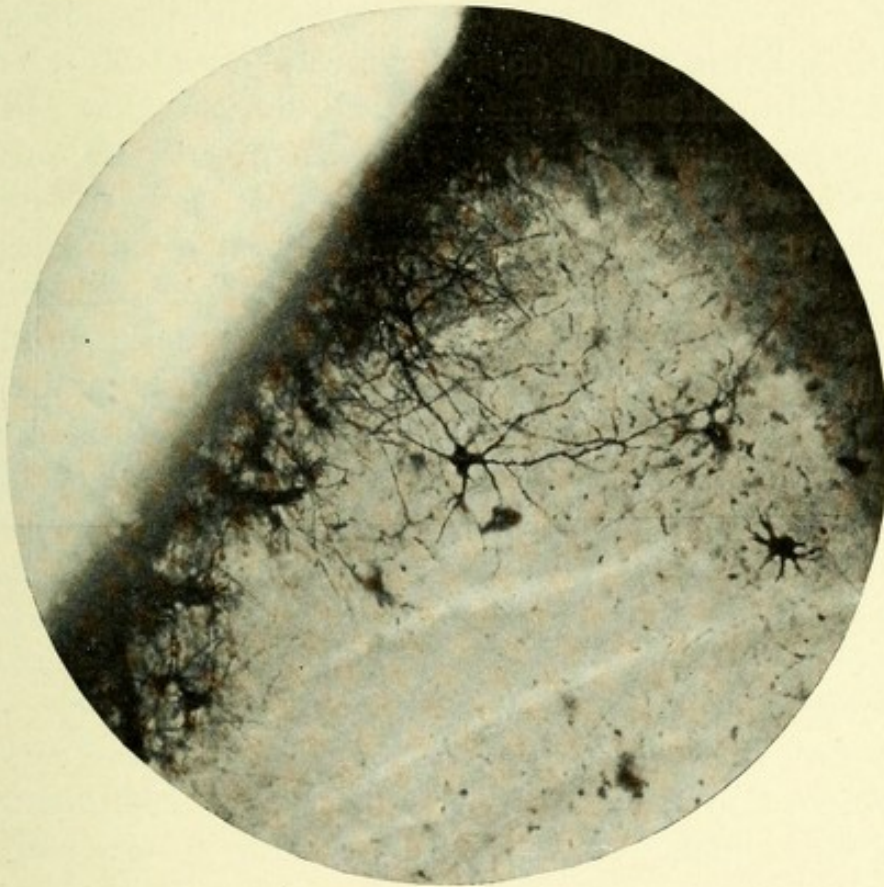


FIG. 131.—SECTION OF CORPORA QUADRIGEMINA. Showing cells of red nucleus.
Cox-Golgi method.

through the inner portion of these nuclei, which are located deep beneath and on each side of the aqueduct of Sylvius, above the substantia nigra and below the inner portion of the thalami. These nuclei are surrounded by a large number of medullated nerve-fibers, which form for them a sort of mantle, and come chiefly from the cerebellar peduncles. Each red nucleus is seen to be composed microscopically of a very thick tangle or plexus of nerve-fibers and collaterals, having inter-

persed among them a number of triangular multipolar nerve-cells, which often attain a very great size—20 to 70 μ in diameter. In the sheep these cells are possessed of from two to six, rarely more, very strong dendritic processes of great length. They frequently fork, and are only slightly beaded, terminating free or in a bulbous expansion. The axones usually come off from the body of the cells, although occasionally they may be seen to arise from the base of one of the primary dendritic trunks. They give off a few collaterals, which pursue a course dorsolaterally toward the dorsal tegmental decussation.

The Connections of the Red Nucleus.—First, with the superior cerebellar peduncles. The experiments of Forel and Gudden prove that a large number of fibers from the superior cerebellar peduncle of one side end about the cells located in the posterior portion of the nucleus ruber of the opposite side. Forel made a section of the right superior cerebellar peduncle of a rabbit, and found resulting, a complete atrophy of the fibers of the peduncle beyond its decussation and a corresponding atrophy of the posterior portion of the nucleus ruber. Gudden's experiment differed from the above only in that he removed the entire left cerebellar hemisphere. When the rabbit matured, a complete atrophy was found of the left superior cerebellar peduncle and posterior portion of the right nucleus ruber. Mahaim has proved that the axones from the cells of the middle and anterior portion of the nucleus ruber pass, after decussating, into the opposite cerebellar peduncle, and thence to the cerebellum. This nucleus, according to Cajal, receives collaterals from the descending tegmental bundle, which bundle is composed of axones from a group of multipolar cells located in the lateral portion of the superior layer of the anterior corpus quadrigeminum. They descend in curves, decussate in the middle line, and form the dorsal or fountain-like decussation of the tegmentum (Meynert). They then continue downward on the inner side of the lateral fillet. A few collaterals and axones from Gudden's commissure pass in and arborize about this nucleus. It is connected also by fibers with the optic thalamus and lenticular nucleus, the latter fibers passing through the internal capsule.

THE SUBSTANTIA NIGRA (LOCUS NIGER; INTERCALLATUM OF SPITZKA).

If a transverse section through the cerebral peduncles is made at any point beyond the ventral border of the pons, a dark-gray mass of increasing size, having an irregular crescentic outline, will be seen. It is rather thicker on its inner than on its outer border, and consists of fine nerve-fibers and numerous multipolar nerve-cells of a spindle shape containing granules of dark pigment; hence its name. This mass serves to divide each peduncle into a ventral and a dorsal portion. The former, which makes up about one-third of the bulk of each peduncle, receives the name *crusta*; the dorsal part, occupying the remaining two-thirds, is called the *tegmentum*.

RETINA.

In order fully to appreciate the relation between the integral parts of the retina and the optic paths, and the course taken by light impressions, it will be needful to precede the description of the optic nerves and tracts by a brief description of the histologic formation of the retina. The retina is developed embryologically from the ventral wall of the optic cup by a multiplication of its cells. It is, therefore, an outward expansion or growth of the wall of the primary forebrain. On vertical section the retina consists, microscopically, according to Schultze, of eight distinct layers, which are, from within outward, as follows:

1. The layer of the optic nerve-fibers.
2. The layer of ganglionic nerve-cells.
3. The inner molecular layer.
4. The inner nuclear layer.
5. The outer molecular layer.
6. The outer nuclear layer.
7. The layer of rods and cones.
8. The pigment layer.

The retina is bounded on its inner side by a very delicate membrane—the *membrana limitans interna*. A similar mem-

brane exists, lying between the outer nuclear layer and the layer of rods and cones—the external limiting membrane.

1. *The Layer of Optic Nerve-fibers.*—This layer consists of a large number of nerve-fibers, mostly axones from the ganglionic cells of the layer above, and whose course is centripetal,

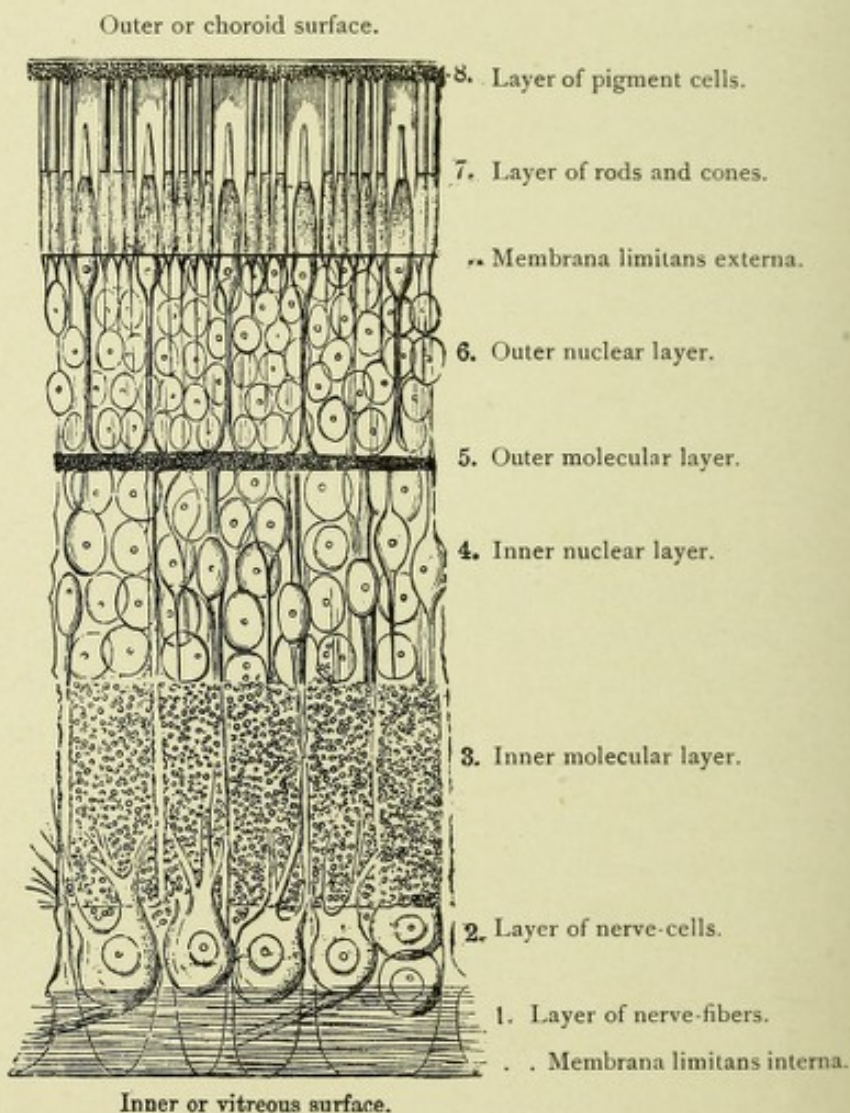


FIG. 132.—DIAGRAMMATIC SECTION OF THE HUMAN RETINA.—(Schultze.)—(After Quain.)

forming a large part of the fibers of the optic nerve. Some of the fibers of this layer course (centrifugally) through the ganglionic cell layer, and terminate either in the inner molecular layer or in the fourth or inner nuclear layer, among the bipolar cells.

2. *The Layer of Ganglionic Cells.*—The ganglionic cell layer

is located just external to the layer of optic nerve-fibers. It consists, save in the region of the macula, of a single stratum of multipolar nerve-cells. Each cell has a single axis-cylinder process, or axone, whose course is central, and these axones, with others, proceed inward to form most of the fibers of the optic nerve. The peripheral process or dendrite becomes branched, and terminates in the inner molecular layer, there

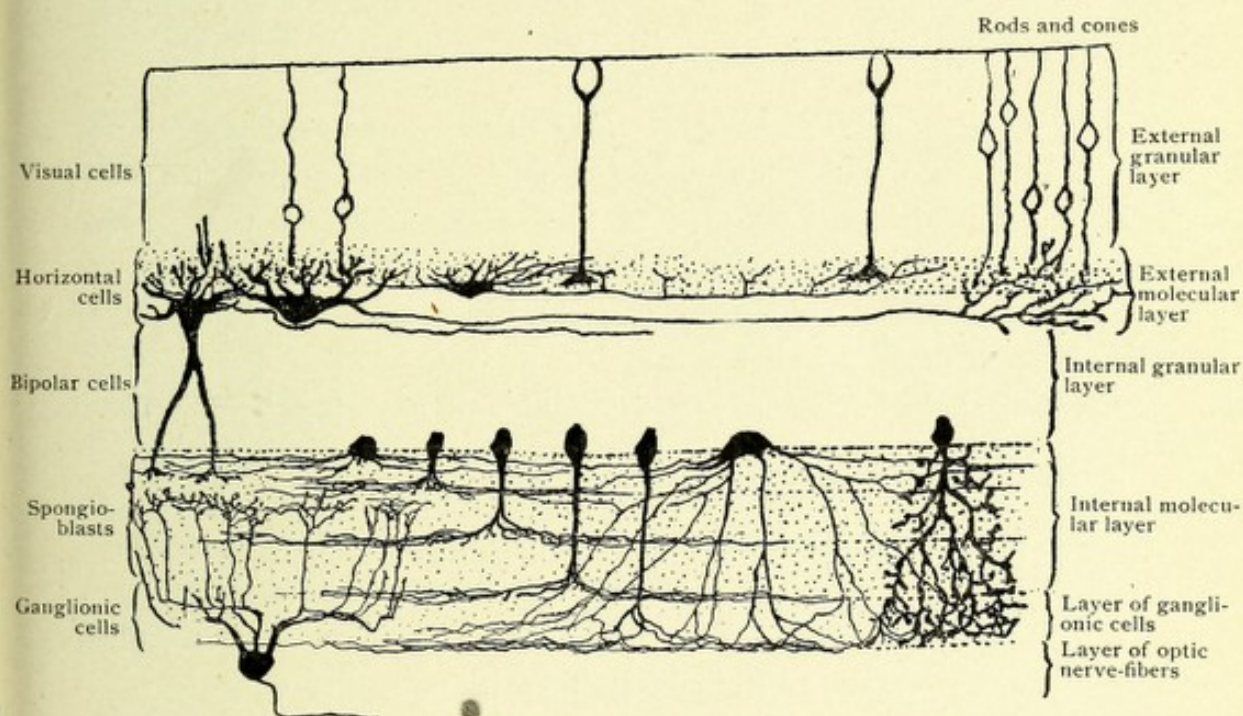


FIG. 133.—SECTION THROUGH THE RETINA OF A MAMMAL TO SHOW LAYER OF HORIZONTAL CELLS OF THE EXTERNAL MOLECULAR LAYER AND THE SPONGIOBLASTS OF THE INTERNAL MOLECULAR LAYER.—(After Ramón y Cajal.)

commingling with the central processes of the bipolar cells of the inner nuclear layer.

3. *The Inner Molecular Layer.*—This layer consists chiefly of the dendrites of the ganglionic cells of the second layer, together with the arborizations of the central processes of the bipolar cells of the inner nuclear layer. This layer contains, in addition, a number of cells which resemble young neuroglia cells (spongioblasts), but which, according to Ramón y Cajal, are nerve-cells. Owing to the inability to find axis-cylinder processes, he calls them amacrine cells.

4. *The inner nuclear layer* is made up mainly of round or

oval-shaped cells, each with two processes—a central and a peripheral. The peripheral process or axone, which is exceedingly fine, courses inward to the inner molecular layer, where it terminates in an arborization about a dendritic process of a ganglionic cell. The peripheral process or dendrite of these bipolar cells is quite thick, and continues outward into the outer molecular layer, where it breaks up into several fine branches, producing an arborization which comes in contact with an arborization from a central process or axone of a visual cell existing in the outer nuclear layer.

5. *The outer or external molecular layer* is not nearly so thick as the inner molecular layer, and consists almost entirely of the arborizations of the axones of the visual cells of the outer nuclear layer, together with the termination of the dendrites of the bipolar cells of the inner nuclear layer and the horizontal cells.*

6. *The Outer Nuclear Layer.*—This is the layer of visual cells (Van Gehuchten). These cells are oval or round in shape, and are bipolar. Their central processes or axones proceed inward, and terminate, either in arborizations or in enlarged or thickened extremities, in the outer molecular layer about the dendrites of the bipolar cells of the inner nuclear layer. The peripheral processes of these cells are the rods and cones of the retina, which may be likened to the dendrites of other nerve-cells. The axones of the visual cells whose dendrites form the rods, end in slight thickenings or in clubbed extremities, while the axones of the cells whose dendrites form the cones terminate in arborizations.

7. *The Layer of Rods and Cones.*—The rods and cones are the peripheral processes or dendrites of the visual cells; they are arranged in a palisade-like manner throughout the whole extent of the retina, between the external limiting membrane and the pigment layer. The rods are much more numerous than the cones, and are cylindric in form. The cones are conic

* These horizontal cells, according to Van Gehuchten, are found in the external molecular layer. Their protoplasmic processes (dendrites) are in relation with the axones of the visual cells, while their axis-cylinders pass horizontally through the molecular layer to end in fine ramifications about the axones of visual cells at variable distances.

in shape, and are shorter and broader than the rods. Both the rods and cones are divisible into outer and inner segments. In the case of the rods, this division is at about the middle of its length, while in the cones it is at the junction of the tapering point with the expanded part. The outer segments of the rods are cylindric, and are transversely and longitudinally striated; they terminate in the pigment or outer layer. The outer segments of the rods are supposed to occasion the purplish-red

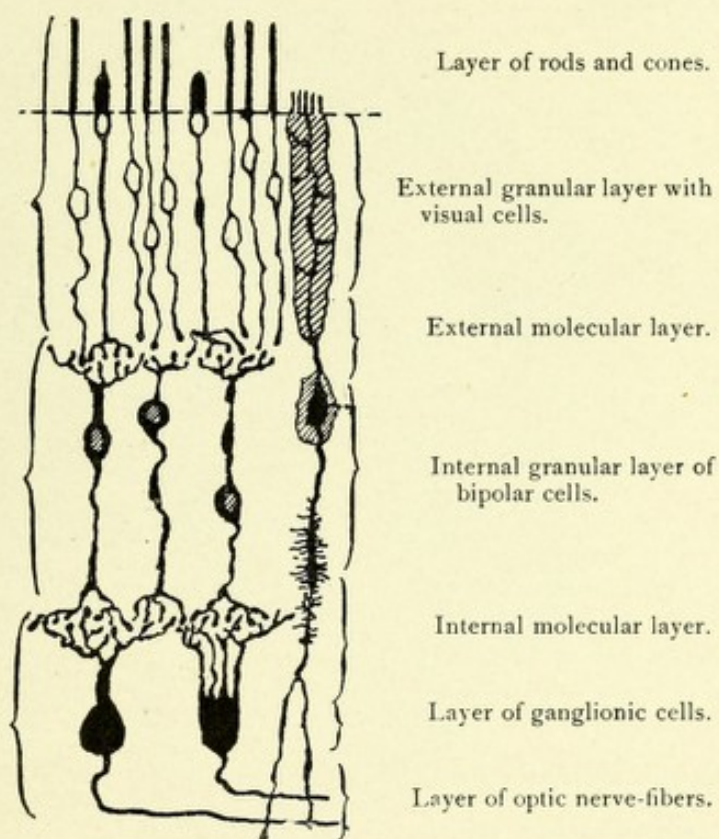


FIG. 134.—THE ESSENTIAL ELEMENTS IN THE RETINA OF A DOG.—(After Van Gehuchten.)

color of the retina. The outer segments of the cones are spindle-shaped, and taper to a blunt point, which also ends in the pigment layer; they are only striated transversely. The inner segments of both the rods and cones are continuous, through the membrana limitans externa, with the peripheral processes of the visual cells.

8. *The Pigment Layer of the Retina.*—This, the outer layer of the retina, is composed of a single layer of hexagonal cells

separated by a distinct amount of intercellular substance. The outer surface of these cells is slightly convex, and is in contact with the inner layer of the choroid. Their inner surface rests against the layer of rods and cones with which these cells come in contact, either by sending out slight protoplasmic processes, which pass between the rods and cones, or by contact with the inner surface of their cell-body. Each of these cells possesses an outer clear zone containing an unpigmented nucleus, and an inner zone filled with dark pigment granules (Figs. 132, 133, and 134).

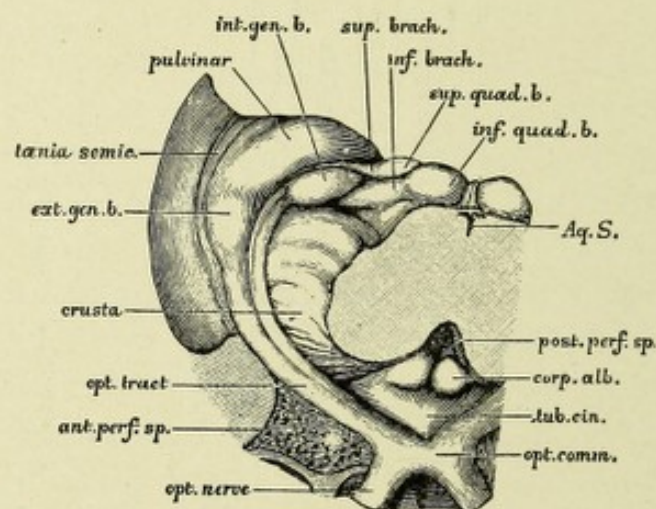


FIG. 135.—THE ORIGIN AND RELATION OF THE OPTIC TRACT.—(*G. D. Thane.*)—
(*From Quain.*)

The parts are viewed from below the mid-brain, having been divided transversely immediately above the pons, and the pons, cerebellum, and medulla oblongata are removed.

THE COURSE OF THE OPTIC NERVES AND TRACTS.

The optic nerve is protected by a strong outer sheath of dura mater, which is continuous with the sclerotic coat of the eyeball. A process of pia mater closely invests the nerve internally, and between the two exists the arachnoid membrane, the outer surface of which is adherent to the dura. The space between the arachnoid communicates with the general sub-arachnoid space. The individual nerve-fibers of which the optic nerve consists are not surrounded by a sheath of Schwann.

Each optic nerve contains an enormous number of nerve-fibers (400,000 to 450,000 Salzer), which may be divisible into centripetal and centrifugal tracts of fibers. The cen-

tripetal fibers of the optic nerve are the central processes or axones of the multipolar or ganglionic cells of the second layer of the retina. The peripheral processes or dendrites of these cells, as we have seen, arborize about the axones of the bipolar cells of the retina; the dendrites of these latter cells terminate about the axones of the visual cells, whose peripheral processes are the rods and cones. There is thus established a conducting medium through the retina continuous

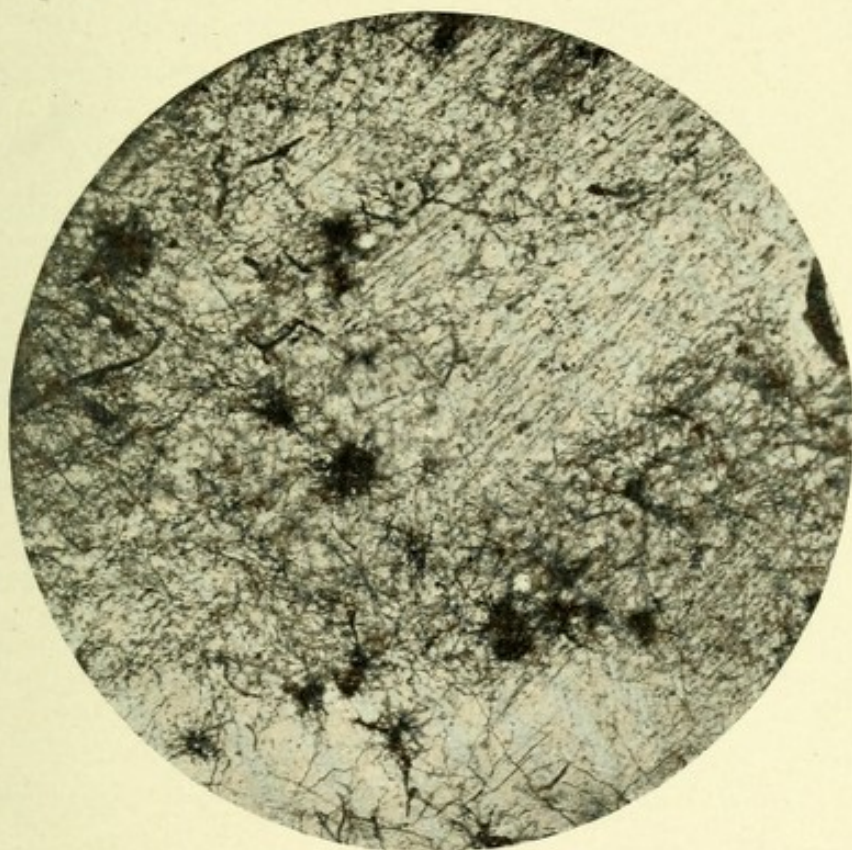


FIG. 136.—MICROPHOTOGRAPH THROUGH OPTIC THALAMUS OF A SHEEP. Showing fibers from optic nerve terminating about stellate cells. Method of Berkley.

with the optic nerve; each optic nerve then passes backward and slightly inward through the optic foramen to the region immediately in front of the tuber cinereum, where it unites with its fellow to form the optic commissure or chiasm. The greater part of the fibers of each nerve decussate with those of the opposite side to join the opposite optic tract, but the remainder continue backward in the lateral portion of the chiasm without decussating, passing into the optic tract of the same side. The

crossed fibers come from the cells of the nasal half of each retina, while the uncrossed come from the cells of the temporal half of each retina.

Each optic nerve contains a fasciculus of fibers which take their origin from the region of the macula of the retina and pass into the optic tract of the same and opposite sides. The fibers of this fasciculus which pass into the optic tract of the same side probably come from the temporal side of the macula, while those that decussate and pass into the optic tract of the opposite side doubtless come from the nasal side of the macula. This bundle of fibers is triangular on transection, and occupies, at first, the inferior portion of the optic nerve; as the nerve passes through the optic foramen, it becomes more centrally located; just before reaching the optic chiasm it occupies the dorsomesial part of the nerve. In the optic tract it is again centrally placed. Each optic tract, then, contains the fibers from the nasal half of the retina of the opposite eye and from the temporal half of the retina of the same eye. The optic tract then continues backward under the cover of the temporal lobe, passing around the crus cerebri, where it is separated by a groove into two distinct fasciculi or bundles—a lateral or external, and a mesial or internal. The mesial or internal fasciculus is not concerned with vision, but is connected with the internal geniculate body and posterior corpus quadrigeminum,

FIG. 137.—DIAGRAM OF THE CORPORA QUADRIGEMINA ANTERIOR, *CQA*, SHOWING THEIR CONNECTIONS.—(After M. A. Starr.)

On the right of the figure the superficial and deep masses of gray matter are shown. *pulv.* Pulvinar of the optic thalamus. *pn.* Posterior nucleus of the optic thalamus lying between the corpus geniculatum externum, *cge*, and the corpus geniculatum internum, *cgi*. *IC.* Internal capsule. *F.* Fillet. *R.N.* Red nucleus of tegmentum. *P.E.D.* Peduncle of cerebrum. *sn.* Substantia nigra. *OT.* Optic tract. *X.* Optic chiasm. *II.* Optic nerve. 1, 2. Fibers from retina to pulvinar of optic thalamus (1, centripetal) (2, centrifugal). 7 and 8. Fibers between the optic thalamus and occipital cortex. 3 and 4. Fibers between the retina and the corpus geniculatum externum. 9 and 10. Corresponding fibers to occipital lobe. 5 and 6. Fibers between the retina and corpus quadrigeminum anterior. 11 and 12. Corresponding fibers to the occipital cortex. 13. Cell of the superficial gray matter of the *CQA* sending fiber to the nucleus of the third nerve, 16. 14. Cell of the deep gray matter of *CQA* sending fiber to third nerve nucleus. 15. Cell of the deep gray matter of *CQA* sending fiber to fillet. 17. Fiber from the red nucleus terminating about 14. 18. Fiber from fillet terminating about 13. *OL.* Occipital lobe of the brain, with its cortex, containing both cells and terminal brushes of the visual tract.

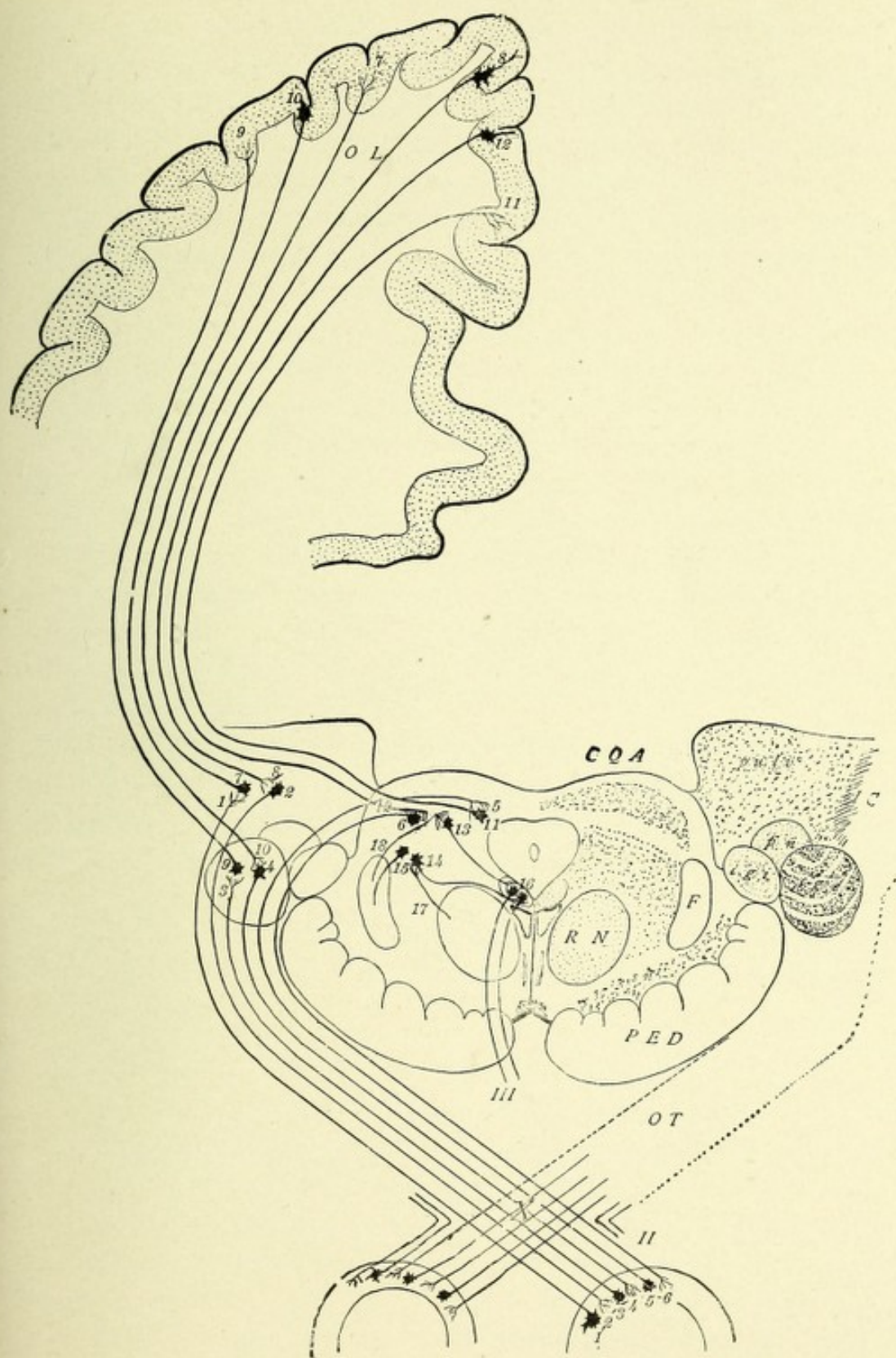



FIG. 137.—DIAGRAM OF THE CORPORA QUADRIGEMINA ANTERIOR.



and is a part of Gudden's commissure. The lateral bundle is the true optic tract, and passes into the primary optic ganglia, which are the external geniculate body, the pulvinar of the optic thalamus, and the anterior or superior corpus quadrigeminum, entering the latter by way of its arm or brachium. The fibers of the optic tract terminate in fine end brushes about the nerve-cells of the superficial and deep layers of the lateral or external geniculate body.* In the optic thalamus they terminate chiefly about the nerve-cells of the posterior portion (pulvinar). In the anterior corpus quadrigeminum they form the superficial layer of white fibers, terminating free or in brush-like expansions about its nerve-cells. From the cells of the primary optic ganglia new axones arise which issue from the outer side of the thalamus and pass through the extreme posterior end of the internal capsule; they then curve backward around the posterior horn of the lateral ventricle and radiate through the centrum semiovale (optic radiation of Gratiolet) to the cortex of the occipital lobe, ending chiefly in the cuneus and the parts adjacent to the calcarine fissure.

The centrifugal fibers of the first division of the optic nerve come from the cells of the primary optic ganglia and pass to the retina. The centrifugal fibers for the second division of the optic tract are the axones of the pyramidal cells of the occipital cortex. They end about the cells of the primary optic ganglia. There is thus established a continuous centrifugal fasciculus of fibers for the optic tract from the occipital cortex to the retina (von Monakow).

THE CONNECTIONS OF THE OPTIC TRACT.

Although the exact path of connection between this tract and the nuclei of the motor nerves of the eye is not definitely known, it is probable that it may be through the axone of the cells of the anterior corpus quadrigeminum on each side, which, proceeding downward, join the posterior longitudinal bundle, and thus reach the region of the nuclei of the third, fourth, and sixth

* The external geniculate bodies receive exclusively the fibers coming from the macula lutea.

nerves. According to Koelliker, the axones from these cells pass directly or by their collaterals to the central gray matter around the Sylvian aqueduct, and there arborize about the cells of the third nerve nuclei. According to Darkschewitsch, a bundle of fibers leaves the mesial portion of the optic tract, pierces the thalamus, and reaches the oculomotor nucleus through the ventral portion of the posterior commissure. This bundle, he believes, may complete the reflex arc by which a connection is made between the retina and the ventral portion of the

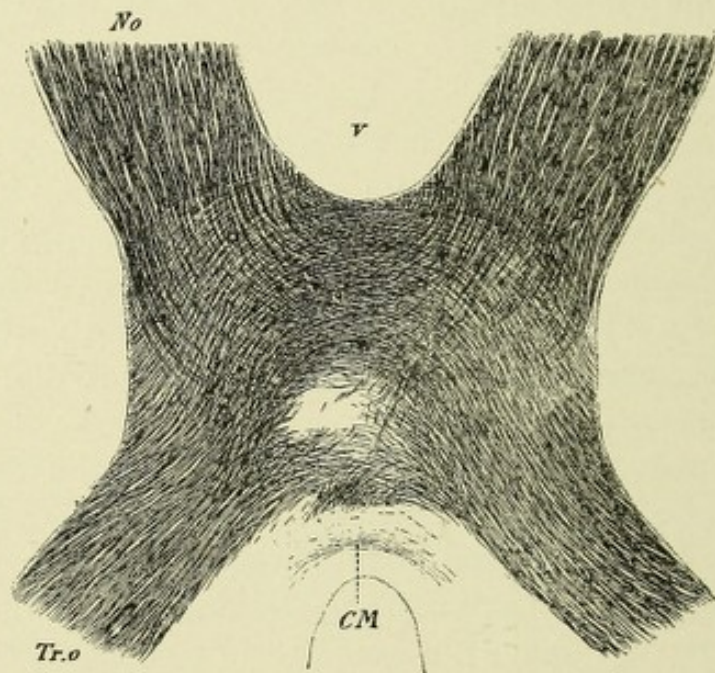


FIG. 138.—HORIZONTAL SECTION THROUGH THE OPTIC CHIASM OF A CHILD.—(After Koelliker.)

CM. Meynert's commissure. No. Optic nerve. Tr.o. Optic tract. v. Ventral concavity of chiasm.

third nerve nucleus, which, according to Kahler and Pick, govern the contraction of the pupil. The optic nerves are probably connected through their primary ganglion, by means of the median fillet or lemniscus, with the medulla oblongata and the spinal cord. (See Fig. 137.)

THE OPTIC CHIASM.

This commissure is oblong in shape, its longest diameter being from 10 to 12 mm.; it rests in the optic groove of the sphenoid bone. On each side the anterior perforated space and internal

carotid artery are located. A little above, and anteriorly, lies the lamina cinerea; posteriorly, is the tuber cinereum, with the infundibulum. The middle portion of the chiasm is occupied by fibers of the optic nerves, which decussate and pass to the opposite sides. Its lateral portions are occupied by those fibers of the optic nerves which do not decussate. The posterior portion of the chiasm is occupied by the so-called "inferior commissure of Gudden."* This commissure consists of a bundle of fibers for each side, which bundle, after decussating, joins the optic tract, forming its mesial portion. It then passes to the internal

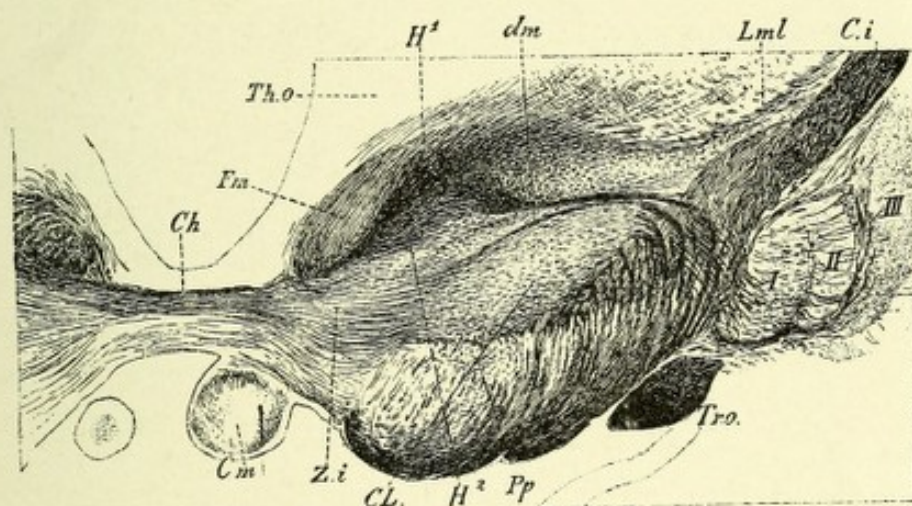


FIG. 139.—FRONTAL SECTION THROUGH THE INTERBRAIN.—(After Koelliker.)

Ch. Commissure of the hypothalamic nuclei. *Fm.* Fasciculus thalmonammillaris Vicq d' Azyr. *Th.o.* Optic thalamus. *dm.* Stratum zonale of hypothalamic nuclei. *H¹.* Field 1 of Forel. *Lml.* Lateral medullary lamina of optic thalamus. *Ci.* Internal capsule. *I, II,* and *III.* The three divisions of the lenticular nucleus. *Tr.o.* Optic tract. *Pp.* Pes pedunculi. *H².* Field 2 of Forel. *CL.* Luys' body. *Zi.* Zona incerta of Forel. *Cm.* Corpus mammillaria.

geniculate body. According to some authors, it continues by way of the posterior arm or brachium into the posterior corpus quadrigeminum. According to Obersteiner, part of this bundle passes by way of the lenticular loop (ansa lenticularis) into the lenticular nucleus, thus forming a crossed connection between that nucleus and the internal geniculate body.

Gudden's commissure also contains a fasciculus of fibers

* Hannover believes that a fasciculus of fibers exists on each side which is located in the most ventral part of the optic chiasm, and that they form a commissure whose function is to associate both retinae together.

occupying its innermost part which join the outermost part of the crus cerebri. These fibers probably come from the cortex of the occipital and temporal lobes. This commissure was discovered by Gudden, who enucleated the eyes in very young animals and, as a result, found that while both optic nerves and the primary optic ganglia were completely degenerated, the internal geniculate bodies and a fasciculus of fibers occupying the posterior portion of the chiasm, which showed no degenerative changes, remained, and hence could have no connection with vision.

Dorsal to Gudden's commissure is a fasciculus of fibers called Meynert's commissure. It has no connection with the optic tract, and is not concerned with vision. Its supposed origin is from collections of spindle cells located on each side of the tuber cinereum. These collections of cells form the basal optic ganglia. The axones of the cells pass in curves into the crus cerebri, and probably terminate about the cells of the subthalamic or Luys' nucleus (Fig. 138).

THE PITUITARY BODY.

This gland, also called hypophysis cerebri, has been described on page 323. It is divided into two portions or lobes: an anterior or glandular portion, which is the larger, partially surrounding the posterior, which is called the infundibular lobe. Between the two lobes is a closed canal, lined with epithelium. The glandular portion is developed from the ectoderm of the buccal cavity. The posterior or infundibular lobe is continuous with the infundibulum, and, like that body, is developed as an outgrowth from the floor of the third ventricle. According to Berkley, who has made an exhaustive study of the anatomy of this gland, the anterior portion contains nerves which belong to the sympathetic system only. Some are fine varicose fibers, with numerous ramifications coming off from the main stem at right or slightly obtuse angles. Others follow the course of the arteries, and give off from the main stem branches which course irregularly through the gland substance, crossing over or accompanying the large venous channels in the septa, to be

distributed upon the coils of the epithelial cells of the follicles, there terminating in clubbed extremities. No nerve-cells are found in the anterior portion of the gland. In the infundibular or posterior lobe of this gland are three distinct parts: First, an outer lamina of ependymal cells, arranged in several layers, which are separated by delicate connective-tissue trabeculae from the surrounding capsule. Secondly, an inner layer of epithelial cells of a secretory type, often arranged into distinct acini, which latter are separated by connective-tissue bands carrying blood-vessels. The acini occasionally coalesce, forming small cavities, which sometimes contain colloid material. Thirdly, a central region containing small round and polygonal cells separated by connective tissue, together with a few spindle or pear-shaped cells. The nerve-cells are found only in the ventral portion of the posterior lobe. They are divided into cells possessing one neuraxone (of which there are two forms—a large and a small oval or pyramidal) and a second form—those which possess two or more neuraxones. The large pyramidal cells of the first class possess many strong branching dendrites, which terminate in beautiful feathery tufts. The axones give off, close to the cell-bodies, a few collaterals, and terminate by breaking up into a number of fine branches, some of which are lost about other nerve-cells, while others end in networks among the epithelial cells along the border of the lobe. The small pyramidal cells differ from those just described, in that they possess dendrites, all of which, save one, are short and have hair-like processes on the main stem close to the cell-body, and terminate free in clubbed extremities. The cells of the second group are chiefly flask-shaped, and are widely distributed. They each possess from three to four dendrites, which grow gradually finer and terminate free. These cells possess from two to four very fine

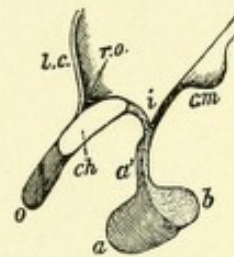


FIG. 140.—SAGITTAL SECTION OF THE PITUITARY BODY AND INFUNDIBULUM WITH ADJOINING PART OF THIRD VENTRICLE. —(Schwalbe, from Quain.)

- a. Anterior lobe. a'. A projection from it toward the front of the infundibulum. b. Posterior lobe connected by a stalk with the infundibulum, i. l.c. Lamina cinerea. o. Right optic nerve. ch. Section of optic chiasm. r.o. Recess of ventricle above the chiasma. cm. Corpus mamillare.

axis-cylinders, which apparently terminate about similar cells. In addition, there are several forms of cells found in various parts of the gland, such as small flask-shaped and pyramidal cells found in the central part of the gland, small spheric cells possessing dendritic processes which cover a large space, and

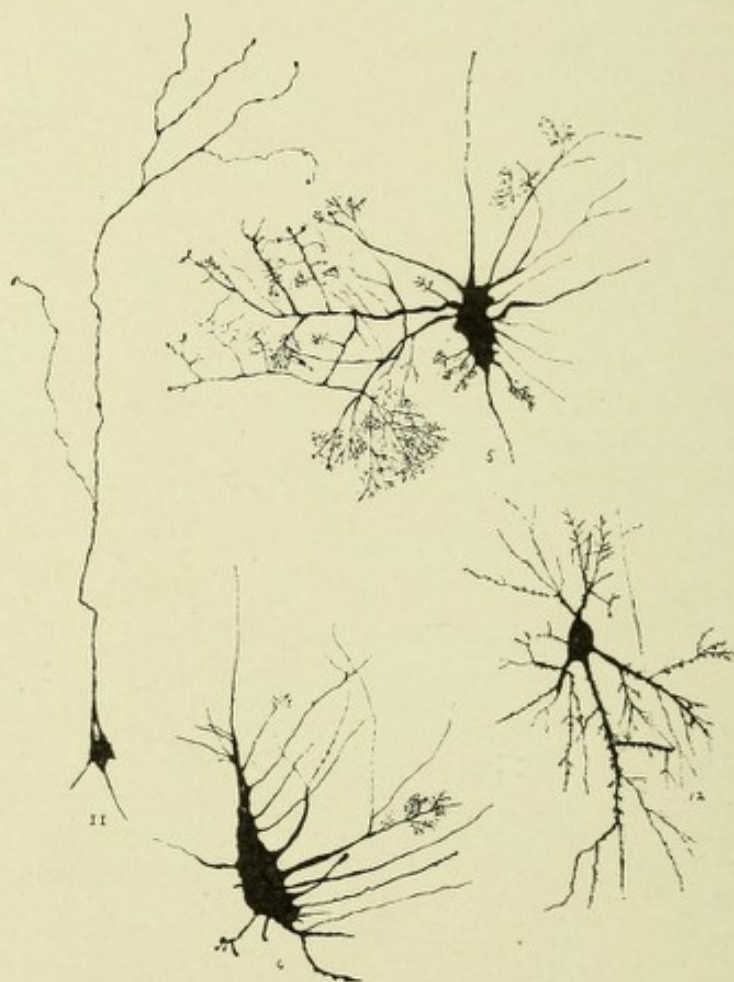

FIG. 141.—EXAMPLES OF SOME OF THE VARIOUS FORMS OF PYRAMIDAL CELLS FOUND IN THE VENTRAL PART OF THE POSTERIOR LOBE OF THE PITUITARY BODY.—(After Berkley.)

- 5 and 6. Irregularly pyramidal or oval cells with numerous dendrites terminating in feathery arborizations and a single neuraxone. 11. Pyramidal cell with very long apical dendrite. 12. Pyramidal cell with dendrites terminating in feathery tufts.

spheric cells whose processes end in tufts of fine filaments. Most of the axones from these various cells course upward toward the infundibulum, but Berkley was unable to follow any of the fibers into that body (Figs. 140 and 141).

THE TUBER CINEREUM.

The tuber cinereum is an elevation of gray matter between the corpora mammillaria behind, and the optic commissure in front, to which it is attached. It is continuous anteriorly with the lamina cinerea. From its middle portion extends downward and slightly forward a conic process,—the infundibulum,—which is connected with the posterior lobe of the pituitary body. The tuber and infundibulum correspond to a recess in the middle portion of the third ventricle.

THE INFUNDIBULUM.

Berkley has shown that the infundibular walls are very rich in neuroglia elements. These cells consist of two chief varieties: Elongate or slightly pyramidal forms, which begin just beneath the ventricular surface and extend almost through the wall to near its outer margin; they break up into a few fine branches, which are occasionally clubbed. The second type is a large spheric neuroglia cell with processes radiating from all parts of the cell-body. This form is found throughout the infundibular wall, but is more abundant on its inner portion. The nerve-cells are all multipolar, mostly pyramidal in shape, and possess one or more neuraxones, which are sparse in comparison with the neuroglia elements.

CHAPTER VII.

THE MEMBRANES OF THE BRAIN.

The membranes that surround the brain are three in number : (1) An external fibrous membrane—the dura mater ; (2) an internal vascular membrane—the pia mater ; (3) a very delicate membrane situated between the pia and dura—the arachnoid membrane.

DURA MATER.

The cerebral dura mater is a tough, rather thick, inelastic membrane, possessing a rough external or periosteal surface, and a smooth, glistening, internal surface lined with flattened endothelium. The fibrous tissue of which the dura mater is composed consists of two layers or laminæ, an outer and an inner, which are inseparable for the greater part of their extent ; but in certain localities they separate, forming channels which constitute the venous sinuses. These channels are lined with endothelium continuous with that of the inner coats of the veins. The external or outer surface of the dura forms the periosteum (endocranium) of the internal surface of the skull. In the adult the dura is rather loosely attached to the bones of the cranial vault, save along the line of the sutures, where it is intimately adherent by many small fibrous processes and blood-vessels which penetrate the bones. It is also firmly attached at the base of the skull, and gives off tubular, fibrous prolongations which blend with areolar sheaths of the cranial nerves as they pass through the various basal foramina, forming for these nerves tough, fibrous envelopes, which are continuous with the pericranium. On the outer side of each cavernous sinus the Gasserian ganglion is located, in a space between the dural laminæ, called the *cavum Meckelii*. The dura is closely adherent around

the margin of the foramen magnum, and becomes continuous through this foramen with the dura mater surrounding the spinal cord.

PROCESSES OF THE CEREBRAL DURA MATER.

The dura mater sends the following processes into the interior of the skull: the falx cerebri, the tentorium cerebelli, and the falx cerebelli.

The **falx cerebri**, or **processus falciformis major**, is a strong, curved process of dura mater, sickle-like in shape, which is located in the great longitudinal fissure, the convexity being above, the concavity below. Its narrow anterior part is attached to the crista galli of the ethmoid bone; its broad posterior part is connected with the middle of the upper surface of the tentorium cerebelli, along which line of attachment the straight sinus runs. Its convex superior surface has a rather broad attachment along the middle line of the under surface of the frontal, parietal, and occipital bones as far back as the internal occipital protuberance. Between the laminæ of this process exists a large venous space—the superior longitudinal sinus. Its inferior concave surface is free, and lodges the inferior longitudinal sinus; behind, it approaches the corpus callosum.

The Tentorium Cerebelli.—The tentorium cerebelli is a transverse arched process of the dura mater located between the inferior surface of the occipital lobes and the superior surface of the cerebellum, which latter surface it covers. The occipital lobes are supported by it, being thus prevented from exerting pressure on the cerebellum. The tentorium is decidedly convex along its median portion, forming a ridge to which is attached the posterior border of the falx cerebelli. This process gradually inclines downward in all directions toward its circumference, following the form of the superior surface of the cerebellum, and forming over it a roof-like structure. The convex posterior border of the tentorium is attached to the transverse ridges of the inner surface of the occipital bone, and here separates to form the lateral sinuses. In front it is united to the superior borders of the petrous por-

tions of the temporal bones, inclosing the superior petrosal sinuses. At the apex of the petrous portion of the temporal bone the external and internal borders meet, forming two processes, which cross each other, the former passing inward to the posterior, the latter forward to the anterior, clinoid processes. The free internal border is concave, and bounds a

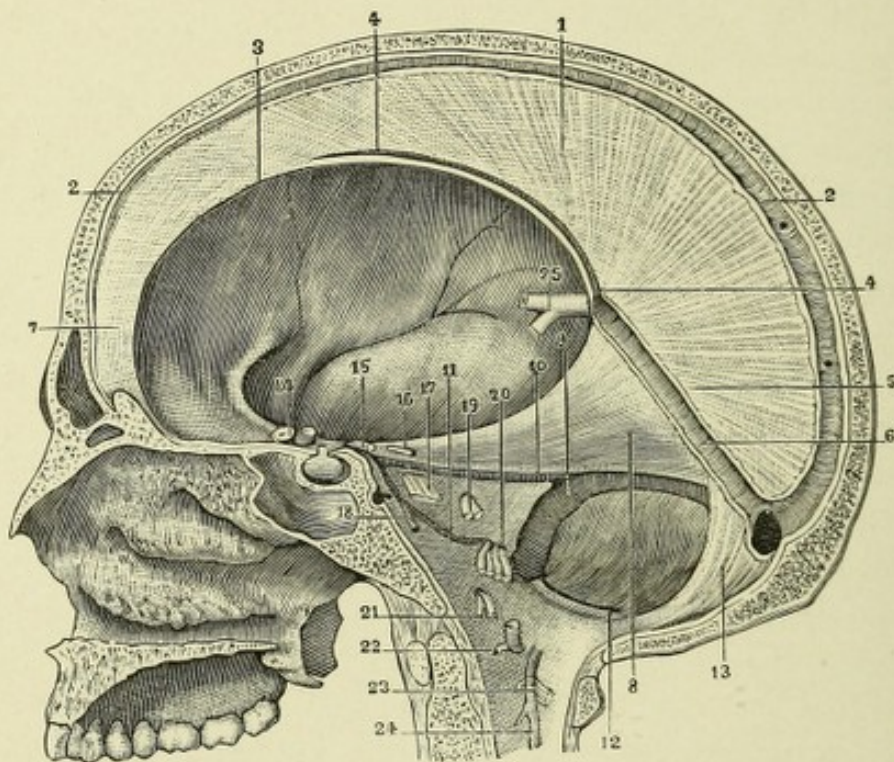


FIG. 142.—MEDISECTION OF BRAIN, SHOWING IMPORTANT SINUSES.

1. Falx cerebri. 2, 2. Its convex border, with the great longitudinal sinus. 3. Its concave border. 4, 4. Inferior longitudinal sinus. 5. Base of falx cerebri. 6. Straight sinus. 7. Apex of falx cerebri. 8. Right half of the tentorium, seen from below. 9. Right lateral sinus. 10. Superior petrosal sinus. 11. Inferior petrosal sinus. 12. Posterior occipital sinus. 13. Falx cerebelli. 14. Optic nerve. 15. Motor oculi. 16. Pathetic. 17. Trigemini. 18. Abducens. 19. Facial and auditory nerves. 20. Glossopharyngeal, pneumogastric, and spinal accessory nerves. 21. Hypoglossal nerve. 22. First cervical nerve. 23. Second cervical nerve. 24, 24. Upper extremity of ligamentum denticulatum.

triangular opening, within which are found the corpora quadrigemina and the crura cerebri.

The Falx Cerebelli, or Processus Falciformis Minor.—

This somewhat triangular-shaped process of dura mater extends downward, between the cerebellar hemispheres in the posterior incised cerebellar notch, from the middle of the pos-

terior border of the tentorium cerebelli, to which it is attached. Its posterior margin is united to the internal occipital crest, and as it approaches the foramen magnum it often divides into two small folds, which are lost on the sides of this foramen.

At the base of the skull the dura gives off a shelf-like process which forms a roof for the pituitary fossa and has a central opening through which passes the infundibulum. This process is called the diaphragma sellæ.

The dura mater is composed of white fibrous and elastic tissue, arranged in bundles, which cross each other rather obliquely, save in the falx and tentorium, where they have a radial arrangement. The inner surface of the dura is lined with flattened endothelium, as are the parts of the outer surface not attached to the bones. The dura mater is traversed by a system of connective-tissue spaces which are located between the bundles of connective tissue. These spaces are in reality lymphatic canals, and communicate with the subdural space. Within them exist large, flattened, connective-tissue cells. They can be injected by inserting a cannula directly into the membrane, when the injected material will escape into the subdural space. This fact is very important from a surgical point of view, because it readily explains how micro-organisms gain entrance through the dura and infect the meninges, producing abscess or extensive leptomeningitis. In the dura, on each side of the superior longitudinal sinus, exist small diverticuli, or venous spaces (*lacunæ venosæ laterales*), in which the middle meningeal veins frequently terminate; these spaces communicate both with the diploic veins and the longitudinal sinus.

The arteries which supply the dura mater are derived chiefly from the anterior, middle, and posterior meningeal. These vessels are very abundant, and, in general, course between the dura and the internal table of the skull, where they subdivide into a large number of small twigs, which penetrate the internal table of the skull, conveying nourishment to the bones. These so-called meningeal arteries are mainly distributed to the bones of the skull, the only one of the meninges which they supply being the dura mater, hence this term meningeal is somewhat misleading.

The arteries of the dura mater are accompanied by veins which receive blood from the dura and the cranial bones; after anastomosing with the diploic veins they empty into the various sinuses, with the exception of the veins which accompany the middle meningeal arteries, which leave the skull through the foramen spinosum to reach the internal maxillary vein.

The nerve supply of the dura is mainly by filaments from the fourth, the fifth, and twelfth cranial nerves, and from the sympathetic.

THE ARACHNOID MEMBRANE.

The arachnoid is an exceedingly thin membrane, made up of delicate bundles of fibrous tissue, and is covered both on its inner and outer surface with endothelium. It is located between the pia and dura mater, being separated from the former by the subarachnoid space and from the latter by the subdural space. This membrane passes over the various convolutions and fissures of the cerebrum and cerebellum without dipping into the fissures, with the exception of those that contain processes of dura mater. It also forms tubular sheaths, which accompany the nerve-fibers through their foramina. This membrane is easily demonstrated by simply injecting air beneath it by means of a small blow-pipe. Between the arachnoid and the pia exists a loose connective tissue, the subarachnoid tissue, which consists of numerous fibrous bands or trabeculæ lined by endothelium, which pass from the under surface of the arachnoid to the pia mater, the meshes between the trabeculæ forming spaces which differ as to size; these spaces in the subarachnoid tissue contain a large part of the cerebrospinal fluid, and are called subarachnoid spaces. It may be mentioned, however, that over some parts of the convexity and sides of the hemispheres the subarachnoid space is partially or completely obliterated, owing to the fusion of the arachnoid and pia, they being inseparably blended. Over the posterior two-thirds of the base there is a broad separation or space left between these two membranes, which interval forms the very large subarachnoid space. The arachnoid has but a limited blood supply, and, so far as I am aware, no nerve supply, although nerve filaments have been

found in the arachnoid of ruminants by Volkmann, Bochdalek, and Luschka. These come, according to Bochdalek, from the motor division of the trigeminus, from the facial, and from the spinal accessory nerves.

SUBARACHNOID SPACES.

Over the convexity of the cerebral convolutions only a slight separation exists between the arachnoid and the pia mater; hence the arachnoid space is very shallow; but over the base, especially the posterior two-thirds, a wide separation exists between these two membranes, so that very large spaces exist in the exceedingly loose meshwork of the subarachnoid tissue, which contain most of the cerebrospinal fluid. These spaces are continuous in front and behind with the subarachnoid spaces of the spinal cord. Two large subarachnoid spaces exist at the base of the brain: the subarachnoid space of the cerebellum and medulla oblongata (the "cisterna magna cerebellomedullaris") and the basal subarachnoid space.

The former, the space of the cerebellum and medulla, is situated between the dorsal surface of the medulla and the inferior surface of the cerebellum. It is separated in front from the cavity of the fourth ventricle by a process of pia mater,—the tela choroidea inferior,—which forms the roof of the lower part of this ventricle; above, it passes over the inferior surface of the vermis, extending laterally over the amygdalar lobes. This space is continuous below with the posterior arachnoid space of the spinal cord. It is in communication with the cavity of the fourth ventricle by an opening in the middle of the tela choroidea inferior, called the foramen of Magendie. Laterally, this space communicates with the cavity of the ventricle by two openings in the pia at the extremities of the lateral recesses, which are called the foramina of Key and Retzius.

The basal subarachnoid space extends in front of the medulla, pons, interpeduncular space, and crura cerebri, as far forward as the optic chiasm, and laterally to the margins of the temporal lobes. This large space is continuous with the anterior subarachnoid space of the cord, and, above, communicates with

several small spaces—one in front of the optic chiasm, one in each fossa Sylvii, and a space over the corpus callosum; posteriorly, it is continuous with the space of the cerebellum and medulla.

The cerebrospinal fluid which occupies the subarachnoid space is continuous with that within the cerebral ventricles

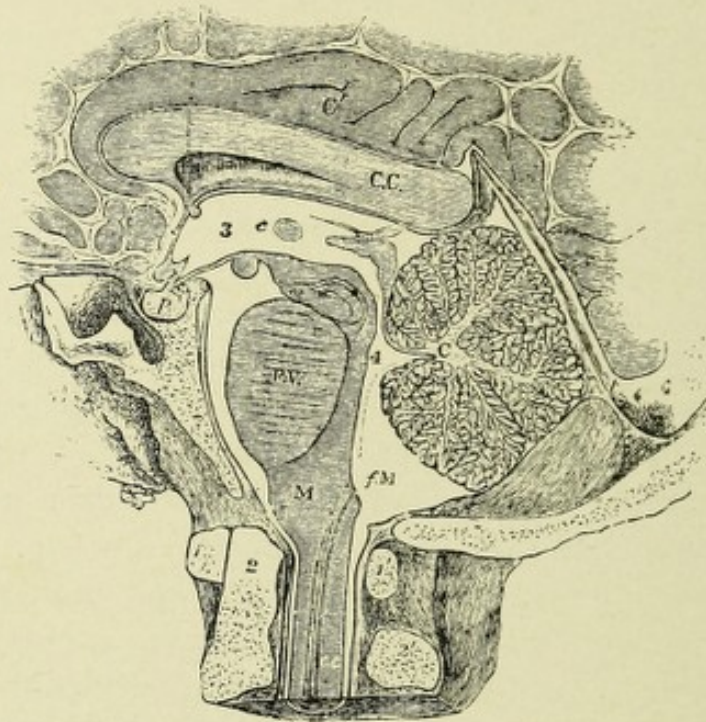


FIG. 143.—SECTION OF THE POSTERIOR AND LOWER PARTS OF THE BRAIN WITHIN THE SKULL TO EXHIBIT THE SUBARACHNOID SPACE AND ITS RELATION TO THE VENTRICLES. —(After Key and Retzius.) (From Quain.)

1, 1'. Atlas vertebra. 2. Odontoid process of the axis. 2', 3. Third ventricle. 4. Fourth ventricle. C.C. Corpus callosum. C'. Gyrus fornicatus. C. Cerebellum. t. Tentorium. p. Pituitary body. c.c. Central canal of the cord. fM, in the cerebellomedullary part of the subarachnoid space, is close to the foramen of Magendie, by which that space communicates with the fourth ventricle.

through openings in the pia mater of the medulla oblongata (foramina of Magendie, Key, and Retzius). It is also continuous with the fluid in the perineural and perivascular spaces. The cerebrospinal fluid forms a perfect water-bed, which protects and supports all that part of the base of the cerebrum, except the orbital part of the frontal lobes and the basal surface of the apices of the temporal lobes, which rest on membranes covering bone. This fluid also forms a bed for the pons, cerebellum, and medulla (Fig. 143).

THE PACCHIONIAN GLANDS, OR THE ARACHNOID VILLI.

These glandular-like bodies are collections of whitish granulations of variable size which begin to appear about the seventh year of life, and continue to grow as age advances. They are found in the following situations: (1) Along the superior longitudinal sinus, where they perforate the dura and become lodged into irregular pits or depressions in the calvarium; (2) projecting from the inner surface of the dura into the superior longitudinal sinus; (3) along the margin of the fissure of Sylvius; (4) on the surface of the pia near the margin of the hemisphere.

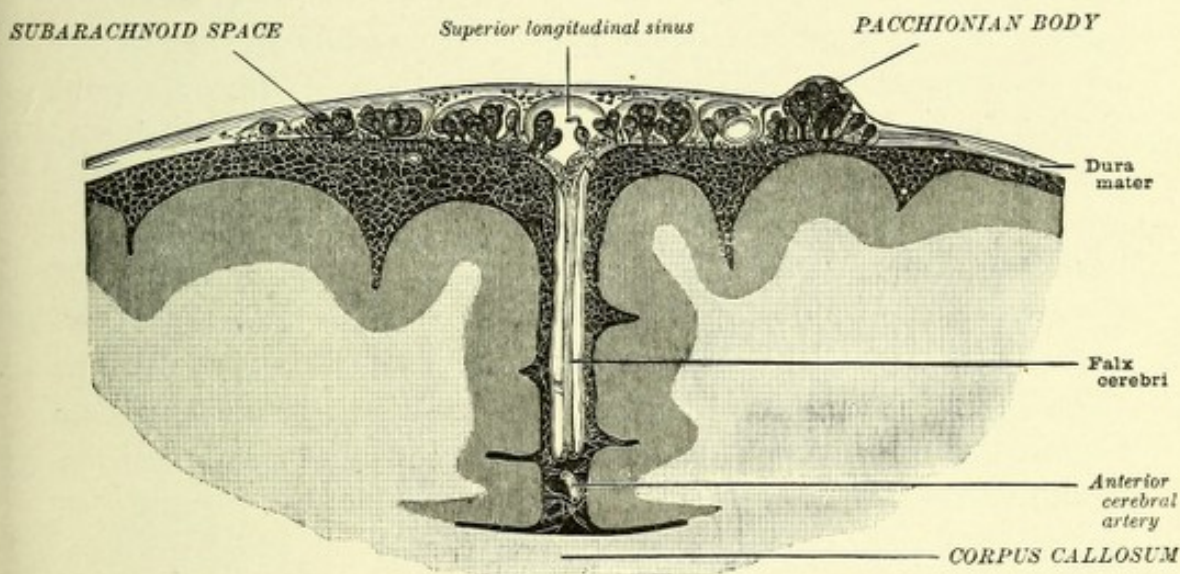


FIG. 144.—CORONAL SECTION THROUGH THE GREAT LONGITUDINAL FISSURE, SHOWING THE MENINGES.—(Key and Retzius.)

The Pacchionian bodies are not glandular in structure. Luschka has shown that they are the arachnoid villi, which have enlarged and in their growth have passed through small openings existing in the inner layer of the dura, which openings communicate with large venous spaces in that membrane on each side of the longitudinal fissure. In their growth outward they invaginate the outer layer of the dura, and by pressure cause the absorption of bone which produces the irregular pits in the calvarium in which they are lodged.

These bodies consist of a spongy network of connective

tissue, similar to and continuous with the subarachnoid tissue. They are covered by the outer layer of the dura and the arachnoid, and may serve for the outflow of lymph from the subdural and subarachnoid spaces into the sinuses of the dura mater, especially the superior longitudinal sinus (Fig. 144).

THE PIA MATER.

The pia mater of the brain is a very vascular membrane applied to the entire cortical surface of the cerebrum and cerebellum, and dips down into their various fissures and sulci. It sends a reduplication or fold into the ventricles of the brain, which forms the velum interpositum and choroid plexuses. Great numbers of small vessels which penetrate the cortex of the brain are given off from the inner surface of the pia mater. At the base of the brain the pia is much thickened, and invests the crura cerebri, pons, and medulla, and gives off to the central ganglia a number of long straight vessels which perforate the brain substance, forming the anterior and posterior perforated spaces. The pia mater consists of rich plexuses of blood-vessels, derived from the internal carotid and vertebral arteries, which are supported by delicate fibrous connective tissue, which tissue surrounds the blood-vessels and gives off tubular prolongations to the vessels which pass into the brain substance, forming for them loose perivascular sheaths, the spaces of which are continuous with the subarachnoid spaces.

The nerves distributed to the pia accompany the blood-vessels and are derived from the third, fifth, sixth, facial, glossopharyngeal, pneumogastric, spinal accessory, and sympathetic.

THE VELUM INTERPOSITUM AND CHOROID PLEXUSES.

The velum interpositum, or tela choroidea superior, is a duplication or fold of pia mater, triangular in shape, which has extended into the ventricles of the brain after passing through the transverse fissure of Bichat. This fold, the velum interpositum, consists of two lamellæ, a dorsal and a ventral, between which exists subarachnoid tissue. It lies beneath the fornix and

splenium of the corpus callosum, its dorsal lamella being united with the ventral surface of these bodies, and above the optic thalami and corpora quadrigemina, its ventral lamella uniting with the optic thalami.

It overlies the body of the third ventricle, forming for it a membranous roof, and extends over each optic thalamus as far as the oblique grooves on its superior surface. The posterior part or base of this triangular fold of pia mater is continuous with the pia mater covering the inferior surface of the occipital lobes and the superior surface of the cerebellum. The apex of the fold is bifid, each division terminating just dorsal to the ante-

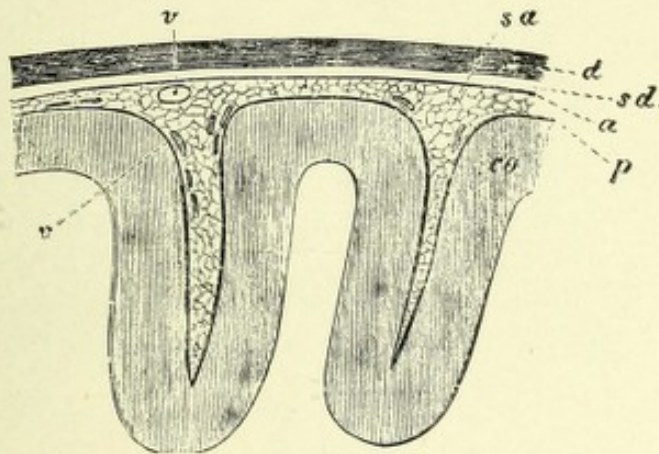


FIG. 145.—VERTICAL SECTION OF THE CORTEX CEREBRI AND ITS MEMBRANES. $\times 2\frac{1}{2}$.
—(After Landois and Stirling.)

co. Cortex cerebri. p. Intima piæ dipping into the sulci. a. Arachnoid, connected with p by means of the loose subarachnoid trabeculae in the subarachnoid space, sa. v, v. Blood-vessels. d. Dura. sd. Subdural space.

rior pillar of the fornix. Its lateral margin consists of a convoluted mass of highly vascular processes—the choroid plexuses of the lateral ventricles. These processes on each side pass through the choroid fissure into the descending horn of the lateral ventricles to their extremities, and they gradually converge anteriorly, and between the foramina of Monro they become continuous with each other. From this junction of the choroid plexuses of the lateral ventricles two small plexuses pass backward along the middle of the under surface of the velum interpositum, and descend into the cavity of the third ventricle to form the choroid plexus of that ventricle. The

choroid plexuses of both the lateral and third ventricles are covered by the ventricular epithelium, as is that part of the velum interpositum which covers the third ventricle.

The choroid plexus is made up of small processes of pia

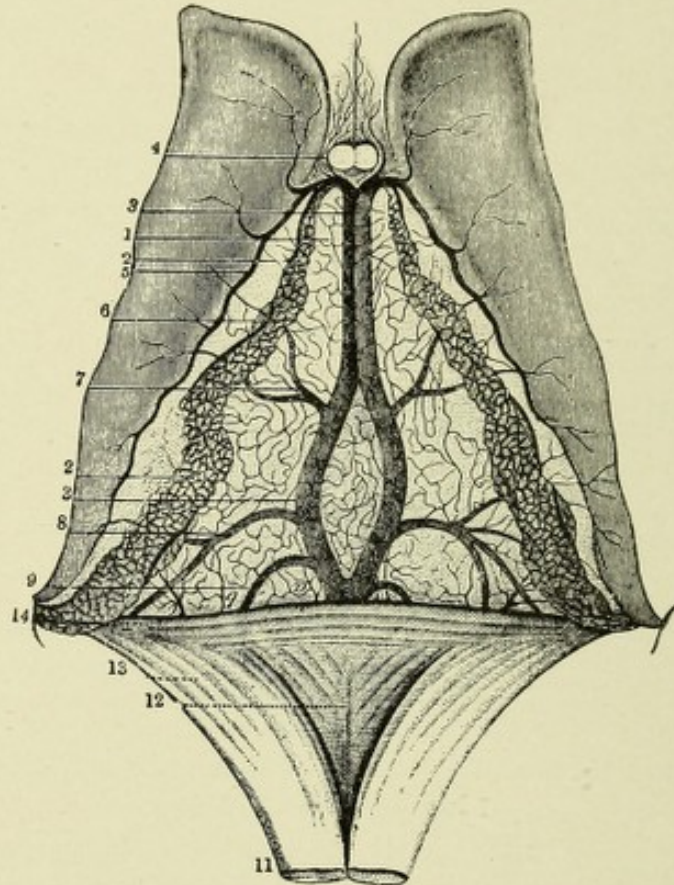


FIG. 146.—VIEW OF THE UPPER SURFACE OF THE VELUM INTERPOSITUM, CHOROID PLEXUSES, AND CORPORA STRIATA.—(From Sappey, after Vicq d'Azyr.)

1. Fore-part of the tela choroidea or velum interpositum. 2, 2. Choroid plexus. 3, 3. Left vein of Galen partly covered by the right. 4. Anterior pillars of the fornix divided in front of the foramen of Monro; on either side are seen small veins from the front of the corpus callosum and the septum lucidum. 5. Vein of the corpus striatum. 6. Convoluted marginal vein of the choroid plexus. 7. Vein rising from the thalamus opticus and corpus striatum. 8. Vein proceeding from the inferior cornu and hippocampus major. 9. One from the posterior cornu. 11. Fornix divided near its middle and turned backward. 12. Lyra. 13. Posterior pillar of the fornix. 14. The splenium of the corpus callosum.

mater, which consist principally of the ramifications of great numbers of small blood-vessels arranged in the form of glomeruli and held together by a delicate connective-tissue stroma, producing a villous-like appearance. These processes are cov-

ered by cubic epithelial cells, which in the new-born are ciliated; they usually contain a yellowish pigment or minute droplets of fat. The choroid plexuses are supplied by the anterior and posterior choroid arteries. The choroid veins return the blood from these plexuses, and at the foramen of Monro join the veins of the corpora striati, to form the veins of Galen (Fig. 146).

THE TELA CHOROIDEA INFERIOR AND CHOROID PLEXUSES OF THE FOURTH VENTRICLE.

The tela choroidea inferior is a process of pia mater analogous to the velum interpositum. It consists of two lamellæ separated by subarachnoid tissue, within which courses the posterior inferior cerebellar artery. The ventral lamella is prolonged from the medulla oblongata, and overlies the lower half of the fourth ventricle, forming, with the inferior medullary velum, a roof for that part of this ventricle. This portion of the ventral lamella is somewhat triangular in shape, its base being reflected over the inferior margin of the velum medullare inferioris, and its apex extending just below the obex. The dorsal lamella is reflected upon the inferior vermis and the amygdala of the cerebellum, where it becomes continuous with the pia mater. Both lamellæ are covered by epithelium.

CHOROID PLEXUSES OF THE FOURTH VENTRICLE.

From the inferior surface of the ventral lamella projects a series of small, vascular, villous tufts, covered by the epithelium lining the roof of the ventricle; these are the choroid plexuses of the fourth ventricle. They consist of a middle and a lateral set for each side, which are continuous with each other in front, and are called the middle and lateral choroid plexuses. The middle set is located on each side of the middle line of the ventral or inferior lamella, extending from the foramen of Magendie forward to the margin of the inferior medullary velum, over which margin the ventral lamella is reflected. Here the

two sets unite in the form of a letter T, the vertical part corresponding to the middle sets, while the horizontal part corresponds to the lateral sets. The lateral set of each side continues along the margin of the inferior medullary velum into the lateral recesses of the ventricle, terminating at the lateral openings in the pia mater.

CHAPTER VIII.

FORE-BRAIN OR PROSENCEPHALON.

The cerebrum is the largest part of the encephalon. It rests in front, in the anterior and middle fossa of the skull. It is supported behind by the tentorium cerebelli, which serves to separate it from the cerebellum. In man it forms about three-fifths of the entire encephalon. Its upper surface is ovoid and convex, narrow in front and broad behind. Its anteroposterior diameter is about eighteen cm. (seven inches), and its greatest transverse diameter, which corresponds to the parietal protuberances, is about thirteen cm. (five inches). Its under surface is somewhat irregular. In front the frontal lobe is seen resting in the anterior fossa, the temporal lobe occupying the middle fossa, and the occipital lobe resting upon the tentorium cerebelli. The cerebrum is divided into two hemispheres, right and left, by a deep cleft the longitudinal fissure. This great fissure extends to the base of the brain in front and behind, but is bridged at its middle by a broad band of fibers running transversely,—the corpus callosum, which is the great commissure of the cerebrum. This commissure forms a sort of floor for the superior division of this fissure, and lodges a long process of dura mater—the falx cerebri. Each hemisphere is convex on its outer surface, to rest against the concavity of the cranial vault. It is narrowed anteriorly, broadened posteriorly, and presents a flattened median surface, which forms the outer boundary or side of the great longitudinal fissure. The cerebrum is composed of both gray and white matter, the former entirely surrounding the latter. The surface of the gray investing matter presents various infoldings or depressions and elevations of different size. The elevations bear the name of gyri or convolutions; the depressions, of fissures or sulci. The

effect of the fissures and convolutions is to increase enormously the surface extent of gray matter,—the extent of surface in the fissures being double that of the convexity of the gyri,—upon the amount of which gray matter the higher intellectual attributes depend. As we descend in the scale of animal life, the convolutions become more simple and flattened, the fissures less deep and the cerebrum is greatly reduced in size.

FISSURES.

The fissures serve to divide the cerebrum into its lobes, and form its important anatomic landmarks. They are divided into the primary or interlobar fissures, and the secondary or intralobar fissures. The former are of great depth (twenty-five mm.—almost an inch; exceptionally, an inch or more), are constant, and, with slight variation have a uniform size, location, and direction. They are as follows: The great longitudinal fissure, subdivided into a superior and an inferior portion; the transverse or fissure of Bichat; the fissure of Sylvius; the fissure of Rolando; the parieto-occipital; the inter- or intraparietal; the callosomarginal; the calcarine; and the collateral.

The secondary fissures—often called sulci for the sake of distinction—are short and shallow, and do not present the typical marks as given above. They are numerous and complicated, and present many variations. The important ones will be mentioned in describing the lobes.

THE FISSURES OF THE EXTERNAL SURFACE OF EACH HEMISPHERE.

The **longitudinal fissure** separates the cerebrum into its hemispheres, completely dividing the anterior portion of the frontal lobe and the entire occipital lobe, the middle portion of the fissure being interrupted by the bridge of cross fibers—the corpus callosum.

The **transverse fissure**, in form like the letter U, separates the cerebrum above from the cerebellum below. This fissure is continuous on each side with the choroid fissure, which is

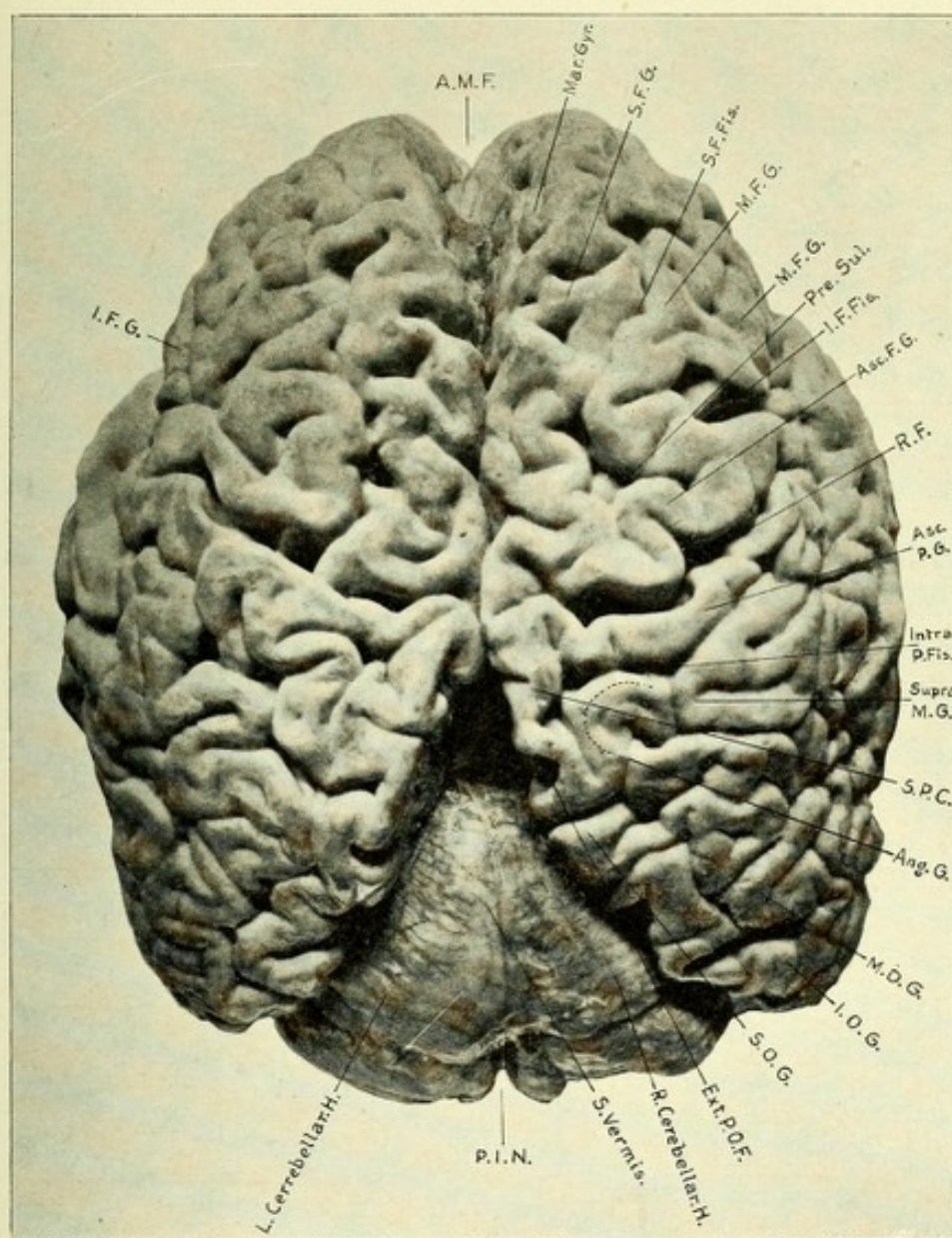



FIG. 147.—PHOTOGRAPH OF THE SUPERIOR SURFACE OF THE CEREBRUM.

A.M.F. Anterior median fissure (longitudinal). Mar. Gyr. Marginal gyrus. S.F.G. Superior frontal gyrus. S.F.Fis. Superior frontal fissure. M.F.G. Middle frontal gyrus. Pre. Sul. Precentral sulcus. I.F.Fis. Inferior frontal fissure. Asc.F.G. Ascending frontal gyrus. Intra. P.Fis. Intraparietal fissure. Supra. M.G. Supramarginal gyrus. S.P.C. Superior parietal convolution. Ang. G. Angular gyrus. M.O.G. Middle occipital gyrus. I.O.G. Inferior occipital gyrus. S.O.G. Superior occipital gyrus. Ext. P.O.F. External parieto-occipital fissure. R. Cerebellar H. Right cerebellar hemisphere. S. Vermis. Superior vermis. P.I.N. Posterior incised cerebellar notch. L. Cerebellar H. Left cerebellar hemisphere. I.F.G. Inferior frontal gyrus.



really a prolongation of the transverse fissure. The choroid fissure is due to an infolding of the median surface of the hemisphere wall, producing an arch-like groove between the fornix and the optic thalamus. It is closed by an invagina-

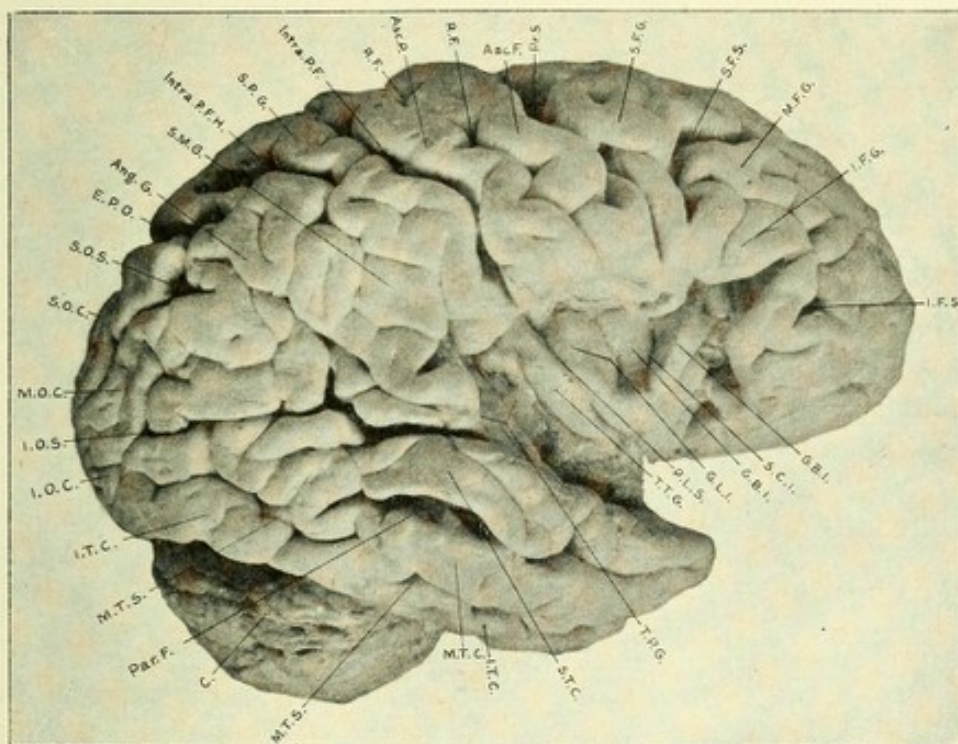


FIG. 148.—PHOTOGRAPH OF THE EXTERNAL SURFACE OF THE BRAIN.

I.F.S. Inferior frontal sulcus or fissure. I.F.G. Inferior frontal gyrus. M.F.G. Middle frontal gyrus. S.F.S. Superior frontal sulcus. S.F.G. Superior frontal gyrus. Pr.S. Precentral sulcus. Asc.F. Ascending frontal gyrus. R.F. Rolandic fissure. Asc.P. Ascending parietal convolution. Intra.P.F. Intraparietal fissure. S.P.G. Superior parietal gyrus. Intra.P.F.H. (Horizontal limb) Intraparietal fissure. S.M.G. Supramarginal gyrus. Ang.G. Angular gyrus. E.P.O. External parieto-occipital fissure. S.O.S. Superior occipital sulcus. S.O.C. Superior occipital convolution. M.O.C. Middle occipital convolution. I.O.S. Inferior occipital sulcus. I.O.C. Inferior occipital convolution. I.T.C. Inferior temporal convolution. M.T.S. Middle temporal sulcus. Par.F. Parallel fissure. C. Cerebellum. M.T.S. Middle temporal sulcus. M.T.C. Middle temporal convolution. I.T.C. Inferior temporal convolution. S.T.C. Superior temporal convolution. T.P.G. Temporoparietal annectant gyri. T.T.G. Transverse temporal gyrus. P.L.S. Posterior limiting sulcus. G.L.I. Gyrus longus insulæ. G.B.I. Gyrus brevis insulæ. S.C.I. Sulcus centralis insulæ.

tion of a process of pia mater (the choroid plexus) covered with ventricular epithelium. In order to expose this fissure, this process of pia mater must be rather forcibly removed, when a curved fissure will be seen on each side, extending from



the beginning of the descending horn of the lateral ventricle to the corresponding foramen of Monro. These fissures together form the great transverse fissure, which emerges between the corpora quadrigemina and the inferior surface of the occipital lobes above and the superior surface of the cerebellum below.

The **fissure of Sylvius** is the largest of the primary fissures, and the first one to be developed, appearing at about the third month of fetal life. It is in reality not a mere cleft, as are most of the other external fissures, but it is formed by the folding together of the hemisphere into an arch, the concavity being downward near the brain-stem. The wide space thus formed is termed the fossa or vallecule Sylvii. This fossa may be recognized in the human embryo as early as the fifth week. At the sixth fetal month this fossa diminishes in size and takes on a triangular form. This is due to the rapid growth of the frontal, parietal, and temporal lobes, their margins coming in contact with one another and overlapping the fossa to form opercula, or lids. The island of Reil is developed from the bottom of the original fossa, and is covered by the above-mentioned opercula, thus narrowing the fossa into the fissure of Sylvius. This fissure starts at the base of the brain, a little lateral to the anterior perforated space.* It passes outward and forward and reaches the external surface of the cerebrum, where it turns upward and backward, dividing into two limbs: a short anterior limb, which passes vertically upward into the lower frontal convolution, where it ends; and a long or horizontal limb, which passes backward and gradually upward to end in the division of the parietal lobe, called the supramarginal gyrus. It is common for this fissure to bifurcate at its termination. Deep in this fissure, hidden by the overlapping of the lower frontal and parietal lobes and the point of the temporal lobe, are a few small convolutions or gyri, called the island of Reil. This overlapping of the lobules is called the operculum, or cover. The Sylvian fissure separates the frontal and parietal lobes above from the temporal below.

* The anterior limb of the Sylvian fissure often gives off a short horizontal branch, which passes into the lower frontal gyrus, where it terminates.

The **fissure of Rolando**, or central fissure, is one of the most important anatomic landmarks on the external surface of the hemisphere. It is always present in man and the higher mammalia, develops toward the close of the fifth month of fetal life, and appears as two distinct primitive grooves, separated by a slightly elevated portion, which later becomes hollowed out, thus bringing about the junction of the two primitive fissures to form the fissure of Rolando. The Rolandic fissure is of great depth,—often an inch or more,—and is located near the middle of the hemisphere. It usually starts as a distinct notch on the median surface of the hemisphere in the paracentral lobule. Thence it takes an oblique course downward and slightly forward, and most often terminates just above and close to the horizontal limb of the Sylvian fissure; occasionally, however, it communicates with the latter fissure. The slope of this fissure makes an angle of about sixty-seven degrees with the superior margin of the hemisphere. It lies between two important convolutions, which have an ascending direction,—hence their name, ascending gyri,—and forms the boundary between the frontal lobe in front and the parietal lobe behind. The anterior ascending gyrus, which forms the anterior boundary of this fissure, is called the ascending frontal gyrus; the posterior one, the ascending parietal gyrus. These two gyri together, because of their position midway between the frontal and parietal lobes, have received the name of the central gyri or convolutions.

The **parieto-occipital fissure** (occipital of Wilder), developed at the fourth fetal month, is best marked on the median surface of the hemisphere; it is, however, seen on the outer surface as a deep and oftentimes wide notch, which separates the parietal lobe in front and the occipital behind. The external or outer portion of this cleft, which is called the external parieto-occipital fissure, forms an anatomic landmark second only in importance to the fissure of Rolando. The main portion of this fissure is to be found on the median surface of the hemisphere, where it is seen as a deep cleft passing obliquely downward and forward to unite with a fissure—the calcarine—soon to be described. This union produces a large Y-shaped junction, which incloses a very

important little wedge-shaped gyrus, the cuneus, which is the half-vision center.

The **intra- or interparietal fissure** serves to separate the parietal lobes into a superior and an inferior division. It develops at the sixth month of fetal life as two distinct sulci, one parallel to the fissure of Rolando, the other having a longitudinal course close to the margin of the hemisphere; they unite at the eighth or ninth month, producing a continuous fissure. This fissure starts near the horizontal limb of the Sylvian fissure, runs vertically upward, parallel to the Rolandic fissure, giving off a slight vertical sulcus, which continues upward. This is the so-called postcentral sulcus. The intraparietal fissure then makes an abrupt curve upward and backward, to terminate beyond the external parieto-occipital fissure. It is separated from the latter fissure by the superior occipital gyrus, and often joins the anterior occipital fissure. On its vertical course it forms the posterior boundary of the ascending parietal gyrus, and gives off the above-mentioned ascending branch just before it passes backward, called the postcentral sulcus. This fissure occasionally extends into the Sylvian.

The **calcarine fissure**, which unites with the median branch of the parieto-occipital fissure, branches in a T-shape from the posterior extremity of the occipital lobe, which is its point of origin. From this point it extends forward on the median surface, and unites with the parieto-occipital fissure, making with that fissure an acute angle, then passing forward and slightly downward, to terminate near the middle of the median surface of the temporal lobe. Its anterior portion, which is a deep cleft, produces in the posterior horn of the lateral ventricle a prominence known as the hippocampus minor, or calcar avis.

The **collateral fissure** is seen on the median surface of the temporal lobe; it is below the calcarine and runs parallel with it. It passes forward to near the commencement of the Sylvian fissure and ends in the tip of the temporal lobe. Between this fissure and the calcarine exists the lingual or middle occipitotemporal gyrus. The middle portion of this fissure produces a projection in the lateral ventricle called the eminentia collateralis.

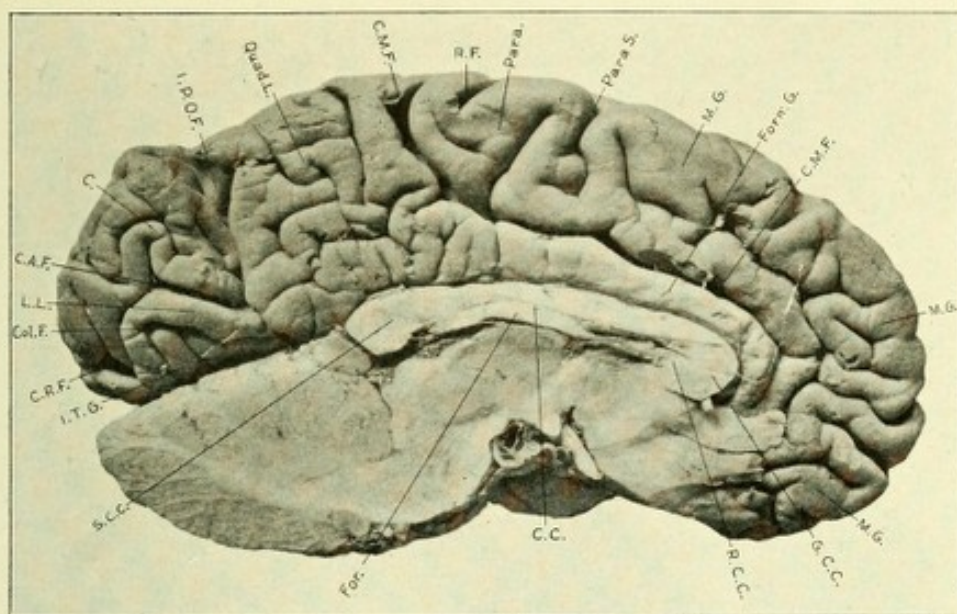


FIG. 149.—PHOTOGRAPH OF THE MEDIAN SURFACE OF THE BRAIN.

M.G. Marginal gyrus. C.M.F. Callosomarginal fissure. Forn.G. Gyrus fornicatus. Para. S. Paracentral sulcus. Para. Paracentral lobule. R.F. Rolandic fissure. Quad.L. Quadrante lobule. I.P.O.F. Internal parieto-occipital fissure. C. Cuneus. C.A.F. Anterior calcarine fissure. L.L. Lingual lobule or gyrus. Col.F. Collateral fissure. C.P.F. Posterior calcarine fissure. I.T.G. Inferior temporal gyrus. S.C.C. Splenium corpus callosum. For. Fornix. C.C. Corpus callosum. R.C.C. Rostrum of corpus callosum. G.C.C. Genu of corpus callosum.

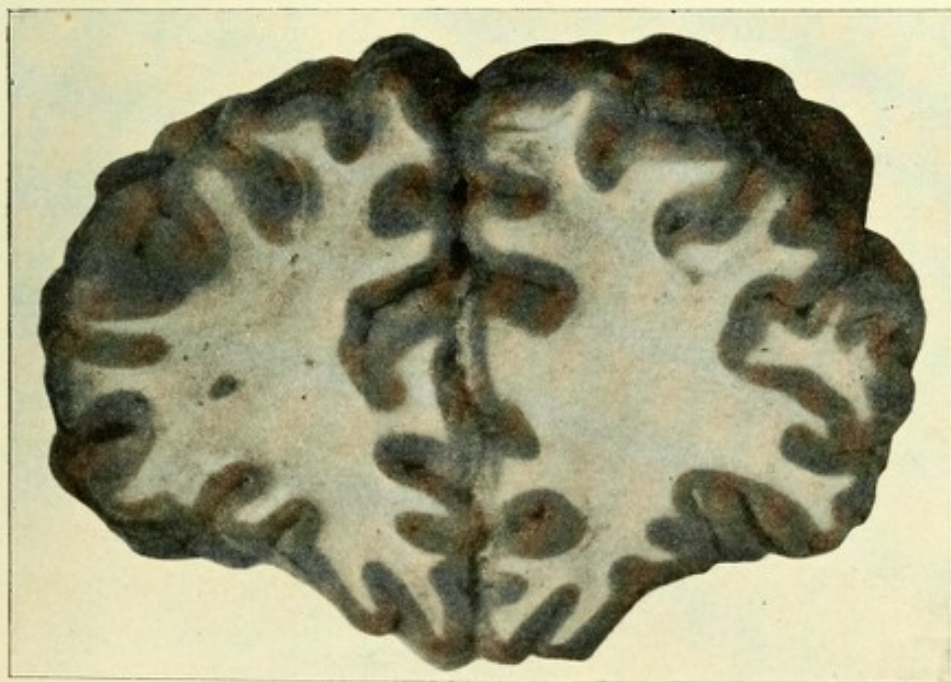



FIG. 150.—VERTICAL SECTION THROUGH FRONTAL LOBE.



The **callosomarginal** is a very long and somewhat tortuous fissure, located on the median surface of the hemisphere, and becomes developed at about the middle of the fifth month of fetal life. It begins in front, below the rostrum of the corpus callosum, near the anterior perforated space, passes upward, outward, and forward, pursuing a course parallel to the corpus callosum, then, turning backward, ends near the margin of the hemisphere, a little back of the fissure of Rolando.* It separates the marginal convolution above from the gyrus fornicatus below, and forms the anterior boundary of the quadrate lobe (Figs. 147, 148, and 149).

THE CONVOLUTIONS, GYRI, OR LOBULES.

The fissures—the Sylvian, Rolandic, and external parieto-occipital—are the great anatomic landmarks which serve to separate the external surface of the cerebral hemisphere into five lobes—viz., the frontal, parietal, temporosphenoid, occipital, and the central lobe, or island of Reil.

THE FRONTAL LOBE.

The frontal lobe in man constitutes about one-third of the whole cerebral hemisphere. It presents on transverse section the outline of a spheric triangle. That portion which rests on the orbital plate of the frontal bone is termed the orbital lobe. The entire frontal lobe is bounded posteriorly by the fissure of Rolando, which separates it from the parietal lobe. Its inferior boundary is the Sylvian fissure. Above, it forms part of the margin of the longitudinal fissure. Its external surface, which is convex, presents several convolutions or gyri, separated by sulci or secondary fissures. The three following gyri have a general direction from before upward and backward: The *first* or *superior frontal gyrus*, the longest of the three, runs parallel with the margin of the hemisphere of which it is a part, and is

* In many brains a fissure is prolonged backward from the main one through the quadrate lobe, terminating near the internal parieto-occipital fissure.



continuous with the marginal gyrus on the median surface, the latter being only the mesial surface of the first frontal gyrus. In front it reaches the apex of the frontal lobe; behind, it is often continuous with the ascending frontal gyrus, or it may be separated from the latter by the superior portion of the precentral sulcus. From the gyrus below it is separated by the superior frontal sulcus, a long, shallow fissure, running forward and downward. The *middle* or *second frontal gyrus* is much shorter but broader than its fellow above, runs from below upward and backward, and at its upper part is often made continuous with the ascending frontal convolution by a small annectant gyrus. The *inferior part of the dorsal portion* of this lobule is prevented from coming into contact with the ascending frontal by a vertical sulcus, which arises just above the fissure of Sylvius and runs parallel to the fissure of Rolando. This is the *precentral sulcus* above referred to. It is deeper than most of the sulci, and sometimes becomes continuous with the callosomarginal fissure (Schwalbe). It forms the anterior boundary of the ascending frontal or central gyrus, separating it from the second and third frontal gyri. This sulcus often presents an anterior limb, which is continuous with the inferior frontal fissure. The main sulcus, usually continuous, is, however, often separated into two or three divisions by small annectant gyri, which serve to connect the frontal gyri with the anterior central or ascending frontal gyrus. In the posterior part of the middle frontal gyrus of the left side exists the center in which are stored the muscular memories used in writing; hence, when destroyed agraphia occurs. The *third* or *inferior frontal gyrus* is the smallest of the three. It passes from the inferior portion of the ascending frontal anteriorly to the end of the frontal lobe. It forms the anterior operculum, which, together with the superior and inferior opercula, forms a roof for the island of Reil. It curves around both limbs of the Sylvian fissure, which produces indentations on the gyrus, and thus divides it into three parts. According to Broca, this gyrus is more developed in man on the left side, because of the fact that in its posterior area exists the motor speech center. It is separated from the second frontal gyrus by the inferior frontal sulcus, which starts

from about the middle of the precentral sulcus and passes forward to the frontal lobe, where it bifurcates. It is continuous below with the orbital lobe.

A very important part of the frontal lobe lies between the precentral fissure and the fissure of Rolando. This is the before-mentioned ascending frontal gyrus, also called the anterior central convolution. It begins below at the Sylvian fissure, where it is connected with the ascending parietal gyrus, passes upward, and unites on the median surface of the hemisphere with the ascending parietal gyrus, the junction being termed the paracentral lobule. Below, this convolution forms part of the superior

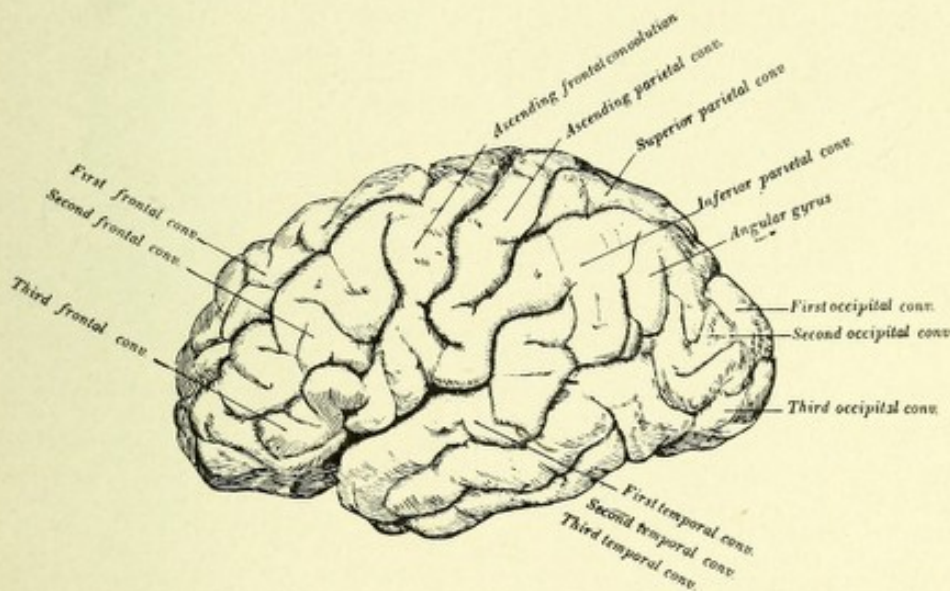


FIG. 151.—DIAGRAMMATIC REPRESENTATION OF THE LOBES OF THE CEREBRUM.

boundary of the fissure of Sylvius. It is connected with the three frontal lobules by small annectant gyri. That part of the frontal lobe anterior to the ascending frontal or anterior central gyrus is often called the prefrontal region or lobe.

The inferior surface of the frontal lobe, which rests upon the orbital plate of the frontal bone, is termed the orbital lobe. It is slightly concave, and has the form of a triangle, the base being directed anteriorly, the narrow portion or apex pointing posteriorly. It has near its median surface a well-marked sulcus or groove, which forms the lateral boundary of the basal portion of the superior frontal gyrus, or, as it is called

here, from its straight course, the gyrus rectus. In this groove rests the olfactory bulb and tract, and hence it is also called the olfactory sulcus. The margin of the lobe forms part of the marginal gyrus of the median surface. The orbital lobe is subdivided by the orbital or triradiate sulcus into three gyri. This sulcus is irregularly H-shaped, and might almost be called compound, being made up of a number of smaller sulci. Its posterior part curves laterally around from the Sylvian fissure, to end near the root of the olfactory tract. Three or four sulci, running from before backward, communicate with this branch. The divisions of the orbital lobe are the internal, anterior, and posterior gyri, which are the basal portions respectively of the superior, middle, and inferior frontal convolutions (Fig. 157).

THE PARIETAL LOBE.

This lobe occupies a large extent of a cerebral hemisphere. Its upper and outer surface is convex; its median surface is flat, forming part of the boundary of the superior longitudinal fissure, and is termed the quadrate lobe. The parietal lobe is located dorsal to the frontal, above the temporal, and ventral to the occipital lobes. Its anterior boundary is the fissure of Rolando, which separates it from the frontal lobe; its posterior boundary is the external parieto-occipital fissure, which is between it and the occipital lobe. Its lower boundary is the horizontal limb of the Sylvian fissure, which separates it from the temporosphenoid lobe. The intraparietal fissure separates this lobe into three convolutions—the ascending parietal and the superior and inferior parietal.

The **ascending parietal** or **posterior central gyrus** is between the fissure of Rolando in front and the ascending or vertical division of the intraparietal fissure behind. It ascends to the median surface, where it is continuous with the ascending frontal, the union of the two forming the paracentral lobule. It is separated from the superior parietal lobule by the postcentral sulcus, which is only a continuation or a branch of the intraparietal fissure. Below, it is also continuous with the ascending frontal or anterior central gyrus. This gyrus, with its fellow of

the frontal lobe, forms two very important gyri, which, from their central position, are termed the central convolutions (anterior and posterior), and from their important relation to the great motor tract they are termed the motor convolutions. From this extensive area the fibers arise which form the motor tract,

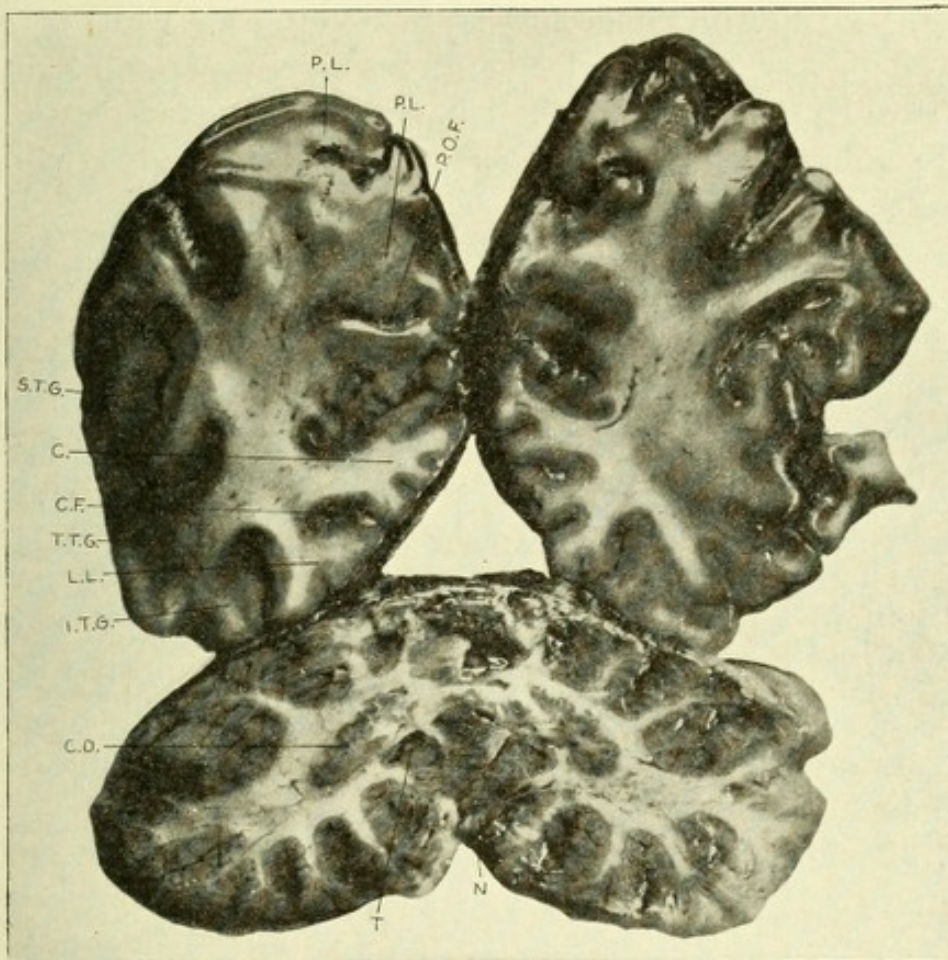


FIG. 152.—FRONTAL SECTION THROUGH PARIETAL, TEMPORAL, AND OCCIPITAL LOBES, TOGETHER WITH THE CEREBELLUM.

P. O. F. Parieto-occipital fissure. P. L. Parietal lobe. S. T. G. Superior temporal gyrus. C. Cuneus. C. F. Calcarine fissure. T. T. G. Middle temporal gyrus. L. L. Lingual lobule. I. T. G. Inferior temporal gyrus. C. D. Corpus dentatum. T. Tonsil. N. Nodule.

and into this and the adjacent parietal area pass the fibers of the sensory tracts.

The **superior parietal convolution** or lobule lies above the horizontal division of the intraparietal fissure, along the

margin of the hemisphere. It is dorsal to the upper part of the ascending parietal gyrus, being separated from it by the post-central sulcus. It extends backward to the occipital lobe, the dividing-line being the external parieto-occipital fissure.

The **inferior parietal convolution** is below the superior, being separated from it by the intraparietal fissure. It is continuous behind with the occipital lobe and in front with the lower part of the ascending parietal. Below, it is separated from the temporal lobe by the horizontal limb of the Sylvian fissure. It is made up of the supramarginal, angular, and postparietal convolutions, their principal direction being downward and arching around the end of the Sylvian and first temporal fissures. The *supramarginal gyrus* lies below and posterior to the intraparietal fissure, and between the inferior part of the ascending parietal lobule and the upper end of the horizontal limb of the Sylvian fissure, which it encircles. It is continuous behind with the angular and below with the first temporo-sphenoid gyri. The *angular gyrus* is just back of the supramarginal, with which it is continuous. Above, it is bounded by the intraparietal fissure; below, by the first temporal or parallel fissure, which it surrounds. It is connected posteriorly with the middle occipital gyrus by a small annectant convolution. The angular gyrus of the left side is of considerable clinical and physiologic interest, because in man it is the center for the visual memories of written language, and in the lower animals it is the center for the memories of objects seen. The *post-parietal gyrus* is that part of the inferior parietal lobule which surrounds the end of the second temporal fissure.

THE OCCIPITAL LOBE.

The occipital lobe is pyramidal in shape, forms the posterior extremity of the hemisphere, rests upon the tentorium cerebelli, is situated behind the parietal lobe, and above and behind the temporo-sphenoid. It is connected with these two latter by small annectant gyri. It is separated in front from the parietal lobe by the external parieto-occipital fissure; below, it is con-

nected with the posterior part of the temporosphenoid lobe. Its median surface forms the posterior margin of the superior longitudinal fissure, and it is separated in front from the quadrate lobe by the internal parieto-occipital fissure, and behind from the temporal lobe by the calcarine fissure. The occipital lobe is subdivided into three smaller convolutions or gyri by two constant sulci—the *anterior superior or vertical occipital sulcus*, and the *lateral or inferior occipital sulcus*. The former begins near the end of the lateral sulcus, from which it is separated by the inferior parietal annectant gyrus. It passes upward and forward, and ends just back of the external parieto-occipital fissure. Occasionally this fissure is joined by the posterior limb of the intraparietal fissure. Frequently, it becomes continuous with the end of the horizontal part of the intraparietal fissure. This sulcus separates the first or superior occipital convolution from the second. The *lateral or inferior occipital sulcus* runs obliquely upward and backward, where it branches Y-shaped, one branch passing to the extreme end of the occipital lobe; the other passes downward toward the calcarine fissure, where it ceases. This sulcus separates the second from the third occipital convolution.

The Occipital Convolutions.—The *first or superior occipital gyrus* is superior and mesial to the anterior occipital sulcus. Its general direction is from below upward. It brings the occipital lobe into relation with the parietal by means of the first annectant gyrus. The *second or middle occipital* is beneath the superior gyrus and between the anterior and inferior occipital sulci. It is much broader than the one above, and is somewhat quadrangular in outline. It is connected with the angular gyrus by the second annectant convolution, and with the middle temporal by the third annectant convolution. The *third or inferior occipital convolution* is situated below and behind the middle, from which it is separated by the inferior occipital sulcus. It forms the extreme posterior and inferior portion of the occipital lobe. It is connected with the lower temporosphenoid convolution by the fourth annectant gyrus.

THE INSULA, OR ISLAND OF REIL.

Deep in the Sylvian fissure, on the side of the cerebrum and near its base, is a group of small convolutions which were in embryonic life a part of the cortex, but now appear subcortical, being entirely concealed from view by the margins of the Sylvian fissure—the operculum. This small group of convolutions is called the insula, or island of Reil, because of its being isolated from the rest of the cerebral cortex, it being covered over by the opercula which are formed by the following parts—viz., the posterior margin of the third frontal forming the anterior operculum; the lower margin of the central convolutions, the superior operculum; and the apex of the temporosphenoid lobe, the inferior operculum. In a general way, when the operculum is referred to, the superior operculum is meant.

The gyri which compose the insula can only be seen when the margins of the Sylvian fissure are spread apart or cut away. They originate in the Sylvian fossa, a little outside of the anterior perforated space, and appear as a triangular area of gray matter, the base of which is upward and the apex downward and inward. The apex is distinctly elevated, and separates the fossa from the fissura Sylvii. This area is separated from the opercula by a fissure,—the sulcus limitans insulæ,—and is beset with several small, shallow sulci, which radiate fan-shaped from the apex to the base. One is deeper than the rest, and serves to subdivide this region into two divisions—a precentral and a post-central lobule. This is the central sulcus, or sulcus centralis insulæ, which has a direction much like the overlying fissure of Rolando, and is developed at the same time. The insula consists of a cluster of from five to seven small gyri—the gyri operi; their general direction is similar to the direction taken by the small sulci—namely, upward and forward. The more centrally located gyri have a vertical course. Within the fissure of Sylvius, and posterior to the insula, exist two or three small gyri which connect the superior temporal convolution with the inferior parietal lobe; these have been called the temporo-parietal convolutions.

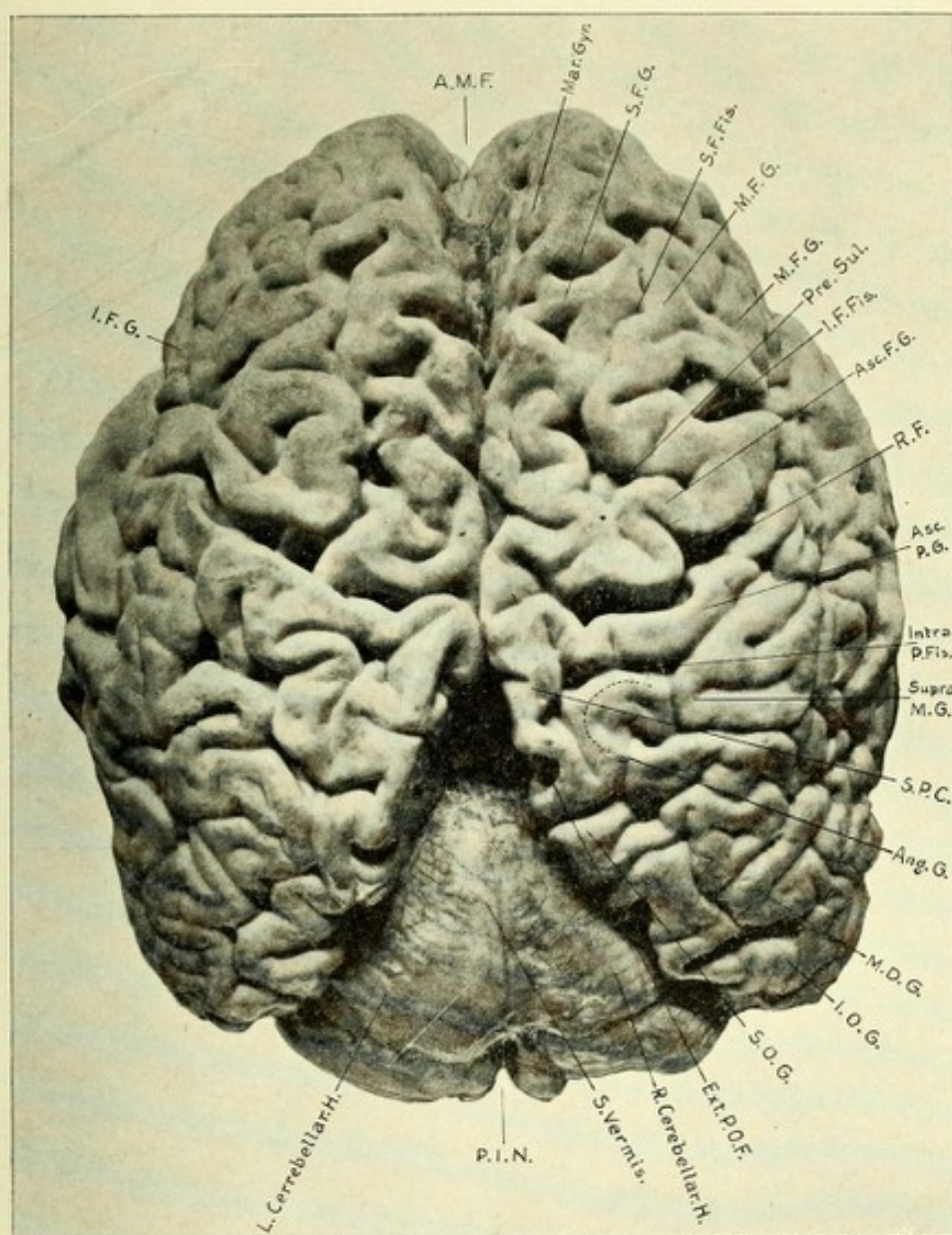



FIG. 153.—PHOTOGRAPH OF THE SUPERIOR SURFACE OF THE CEREBRUM.

A.M.F. Anterior median fissure (longitudinal). Mar. Gyr. Marginal gyrus. S.F.G. Superior frontal gyrus. S.F.Fis. Superior frontal fissure. M.F.G. Middle frontal gyrus. Pre. Sul. Precentral sulcus. I.F.Fis. Inferior frontal fissure. Asc.F.G. Ascending frontal gyrus. Intra. P.Fis. Intraparietal fissure. Supra. M.G. Supramarginal gyrus. S.P.C. Superior parietal convolution. Ang. G. Angular gyrus. M.O.G. Middle occipital gyrus. I.O.G. Inferior occipital gyrus. S.O.G. Superior occipital gyrus. Ext. P.O.F. External parieto-occipital fissure. R. Cerebellar H. Right cerebellar hemisphere. S. Vermis. Superior vermis. P.I.N. Posterior incised cerebellar notch. L. Cerebellar H. Left cerebellar hemisphere. I.F.G. Inferior frontal gyrus.



THE TEMPOROSPHENOID LOBE.

The temporosphenoid lobe is the portion of the cerebrum which is located in the middle fossa of the skull. It lies at a deeper level than either the frontal or occipital lobes, and is more circumscribed. It is bounded above and in front by the Sylvian fissure, which completely separates it from the frontal lobe and partially from the anterior part of the parietal lobe, being

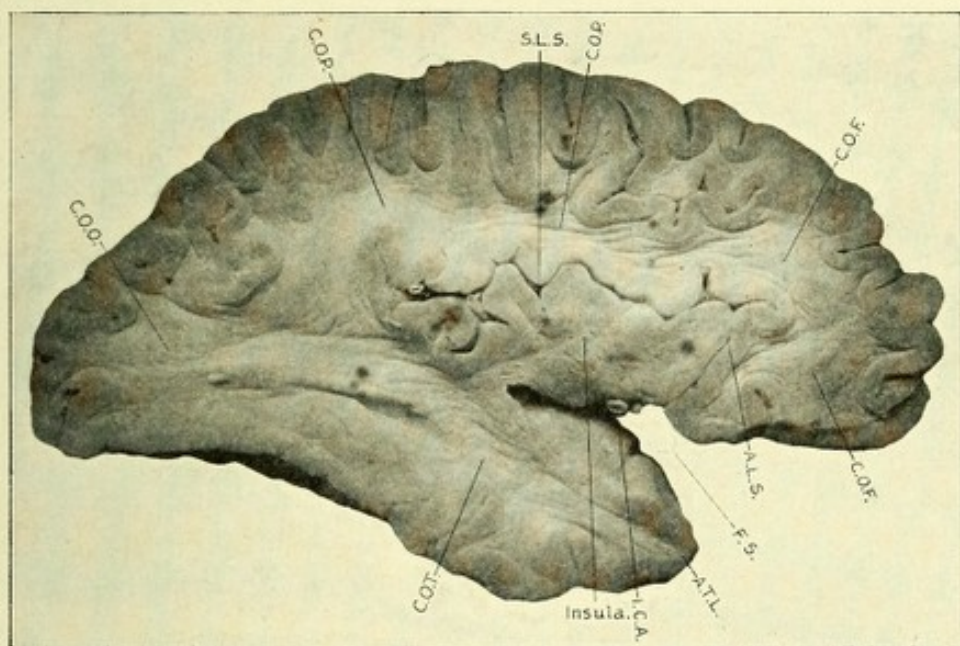


FIG. 154.—LONGITUDINAL SECTION THROUGH CEREBRAL HEMISPHERE TO SHOW THE CENTRUM SEMIOVALE OF THE FRONTAL, PARIETAL, OCCIPITAL, AND TEMPORAL LOBES.

C. O. F. Centrum semiovale of the frontal lobe. C. O. P. Centrum semiovale of the parietal lobe. S. L. S. Superior limiting sulcus. C. O. O. Centrum semiovale of the occipital lobe. C. O. T. Centrum semiovale of the temporal lobe. I. C. A. Internal carotid artery. A. T. L. Anterior extremity of temporal lobe. F. S. Sylvian fissure. A. L. S. Anterior limiting sulcus.

connected behind and above with the latter lobe. It blends behind with the occipital lobe, being partially separated from it by the inferior occipital fissure. The area in which both are blended is called the occipitotemporal region. Its external surface presents three gyri—the first or superior, the second or middle, and the third or inferior temporal.

The first or superior convolution is between the horizontal limb of the Sylvian fissure above, forming the inferior boundary of the latter fissure, and the superior temporal sulcus below.

This gyrus runs upward and backward, and is continuous behind with the supramarginal and angular gyri. The superior temporal sulcus—called also the parallel fissure, because of its position with respect to the Sylvian fissure—runs from before backward, then upward, and ends in the angular gyrus, which surrounds it. This sulcus separates the first from the second temporal convolution.

The second or middle temporal gyrus is between the second and superior temporal sulci, passes from before backward and upward, and is continuous with the lower part of the angular and the middle occipital gyri. The second temporal sulcus runs parallel to the one above, but is not so long or deep.

The third or inferior temporal convolution is below the middle temporal sulcus, and is separated from the occipitotemporal gyrus by the inferior occipital sulcus. It is connected with the occipital lobe by an annectant gyrus.* The posterior portion of the left superior and middle temporal gyri contains the sensory receptive center for the auditory memories of spoken language.

The median surface of the cerebral hemispheres presents six lobes, separated by five main fissures. The lobes are the marginal, gyrus fornicatus or the convolution of the corpus callosum, the quadrate or precuneus, the cuneate, lingual, uncinata, or gyrus hippocampus. The fissures are the callosomarginal, the internal parieto-occipital, the calcarine, collateral, dentate, or hippocampal fissure. Besides the convolutions and fissures, the median surface also presents the following structures: First, the divided transverse fibers of the corpus callosum. The anterior portion of this body is distinctly curved, and hence is called the genu, or knee. The enlarged posterior part is called the splenium, or pad. Between the two surfaces exists the body. Below, and connected with the under surface at the posterior extremity, exists the fornix, whose anterior part is separated from the corpus callosum by a thin triangular blade of white matter,—the septum lucidum,—which blends above with the

* A fourth temporal gyrus can be seen on the under surface of the temporal lobe, separated from the gyrus above the third temporal by the third temporal sulcus; below, this lobule is bounded by the collateral fissure.

anterior part of the corpus callosum and below with the fornix. Beneath the fornix is situated the outer surface of one of the central ganglia, called the optic thalamus. In the center of the thalamus is a bundle of transverse fibers, which brings the optic thalami into relation with each other. This transverse bundle of fibers is known as the middle commissure. Ventral to the fornix exists the anterior commissure.

CONVOLUTIONS OF THE MESIAL SURFACE.

The **marginal gyrus** or **convolution** is the median surface of the frontal and central gyri. It forms a large part of the

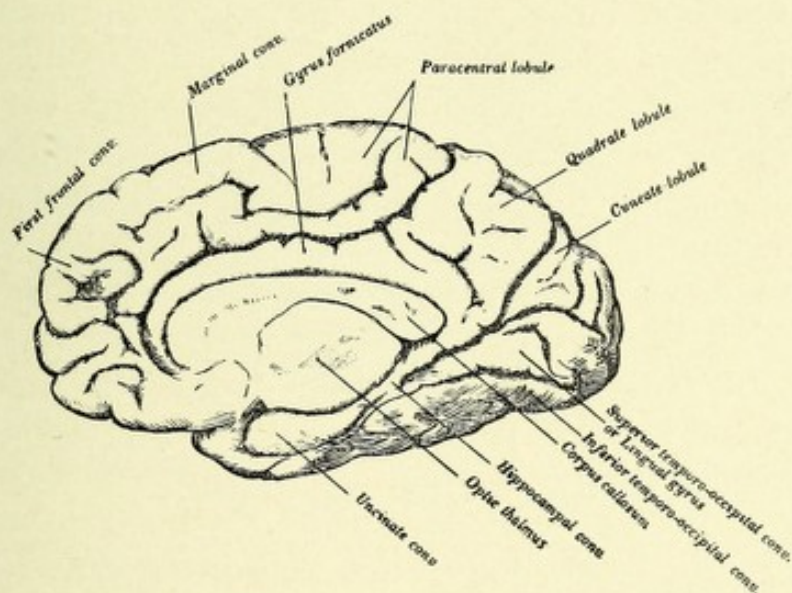


FIG. 155.—CONVOLUTIONS OF THE MESIAL SURFACE OF THE CEREBRUM.

boundary of the longitudinal fissure, and is the most extensive convolution of the median surface of the hemisphere. It is separated from the underlying convolution—the gyrus fornicatus—by the callosomarginal fissure, which also separates it from the precuneus or quadrato lobe, which lobe forms really the posterior marginal gyrus. In front of the upturned end of the callosomarginal sulcus, anterior to the quadrato lobe or precuneus, exists the paracentral lobule, it being the junction on the median surface of the hemisphere of the two central convolutions. It presents on its upper surface a deep and distinct notch, the

beginning of the fissure of Rolando. This lobule is limited in front by the paracentral sulcus, behind and below by the callosomarginal fissure. The marginal gyrus begins at the base of the brain just in front of the anterior perforated space, takes a course upward, forward, and then bends backward along the margin of the longitudinal fissure, ending at the termination of the callosomarginal fissure.

The **gyrus fornicatus**, or convolution of the corpus callosum, also called gyrus cinguli, is arch-like, and is situated between the marginal gyrus above and the corpus callosum below. Posteriorly, it is connected with the precuneus or quadrate lobe. It is a very extensive convolution, beginning below at the base of the brain, in the anterior perforated space. It then takes a curve upward and backward around the genu of the corpus callosum, forming a complete arch around that body. It then passes backward and curves downward, becoming narrowed at the isthmus of the gyrus fornicatus, and taking a direction forward, ends near the tip of the inferior part of the median surface of the temporal lobe.

The **quadrate lobe**, or **precuneus**, is somewhat square-shaped, and situated along the margin of the hemisphere, between the upturned end of the callosomarginal fissure in front and the internal parieto-occipital fissure behind, which latter fissure separates it from the cuneus. It is continuous above with the superior parietal lobule, being in reality its median surface; below, it is continuous with the gyrus fornicatus.

The **cuneus** is that very important little wedge-shaped or triangular lobule whose apex is downward and forward, and whose base broadens out along the margin of the hemisphere. It is situated between the internal parieto-occipital fissure in front and above and the calcarine below. When this region is destroyed on either side, there occurs a paralysis of the opposite halves of the visual fields; hence it is the half-vision center, each cuneus receiving visual impulses from the corresponding half of each retina.

The **lingual lobule**, also called the median occipitotemporal gyrus, is bounded above by the calcarine fissure, which separates it from the cuneus, and below by the collateral or occipitem-

poral fissure, which separates it from the fourth temporal gyrus. Anteriorly, it is continuous with the gyrus hippocampus.

The **limbic** or **falciform lobe** is bounded above by the callosomarginal fissure, below by the anterior part of the collateral fissure, and posteriorly by the postlimbic sulcus, which is only a slight vertical branch of the callosomarginal fissure. The fissures which serve to separate the limbic lobe are together called the limbic fissure. This area includes the gyrus fornicatus, the gyrus hippocampus, the dentate lobe, the septum lucidum, fornix, the anterior commissure, the peduncles of the corpus callosum, the nerves of Lancisi, or the striæ longitudinales, which form a rudimentary supracallosal gyrus, and a

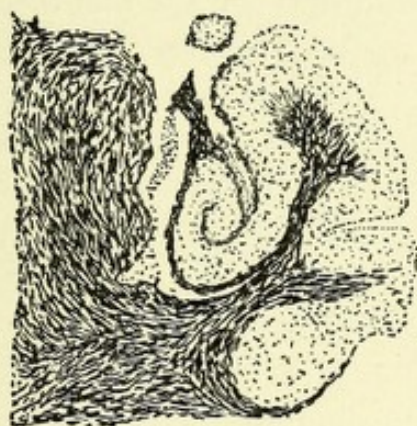


FIG. 156.—SECTION THROUGH LEFT GYRUS HIPPOCAMPUS. Showing the formation of the hippocampus major. Method of Weigert-Pal.

rudimentary gyrus beneath the corpus callosum, the gyrus infracallosus, or gyrus fornicis.

The slender extension of the gyrus fornicatus into the temporal lobe has received the name of **gyrus hippocampus**, or **subiculum cornu ammonis**. It embraces the lateral aspect of the crus cerebri, and is separated above from the optic thalamus by the dentate or hippocampal fissure, which fissure extends from the splenium of the corpus callosum downward and forward to the uncinate gyrus. It produces in the descending horn of the lateral ventricle an elevation called the hippocampus major, or cornu ammonis. Before reaching the tip of the temporal lobe the hippocampal gyrus becomes considerably thickened, and then

forms a recurved portion, which looks backward and inward, and is continuous with the fimbria of the fornix and the dentate gyrus. This recurved portion is called the uncinat gyrus, or simply uncus. Posteriorly, the gyrus hippocampus is continuous with the gyrus fornicatus and the lingual gyrus of the occipital lobe.

The **dentate gyrus**, or **fascia dentata**, is a narrow convolution with a toothed or notched appearance,—hence its name,—located between the fimbria and the gyrus hippocampus and being overlapped by the former. It starts just above the splenium of the corpus callosum, between it and the gyrus fornicatus, by a curved lamina,—the fasciola cinerea,—which is continuous with the lateral and mesial longitudinal striæ. It then extends forward and downward, and is separated from the gyrus hippocampus; it coalesces with the uncinat gyrus. The fimbria is a narrow layer of white matter, belonging to the cerebral hemisphere, alongside the dentate gyrus. It is continuous with the zone of horizontal fibers beneath the ependyma of the cornu ammonis, called the alveus, from which it receives an accession of fibers. It is continuous above with the posterior pillar of the fornix, being in part formed of its fibers. The fimbria overlaps the dentate gyrus, and presents on its mesial portion a hooked prolongation continuous with the choroid plexus. This gyrus is connected with the fornix and the gyrus fornicis, or gyrus infracallosus.

The above-described parts of the median surface of the cerebral hemisphere, which together constitute the limbic lobe, are in man not well developed, but in some of the lower animals whose sense of smell is very acute (osmatics) they are greatly developed, and have been termed, together with the olfactory bulb, the rhinencephalon.

THE BASE OF THE CEREBRAL HEMISPHERES.

This region consists of the bases of the anterior, middle, and posterior lobes. The anterior, which is the basal surface of the frontal lobe, rests upon the convexity of the orbit. It is separated from the middle or temporosphenoid lobe by the Sylvian

fissure. The middle lobe is the basal surface of the temporo-sphenoid, and rests in the middle fossa of the base of the skull. The posterior is the basal surface of the occipital lobe, and rests upon the tentorium cerebelli. The following anatomic points are to be observed upon the base of the brain, from before backward—viz., the longitudinal fissure, the orbital lobe, the olfactory bulb and tract of each side, the corpus callosum and its peduncles, the anterior perforated space of each side, the Sylvian fissure, the optic chiasm, nerves and tracts on each side, the lamina cinerea, the tuber cinereum, the infundibulum, the pituitary body, the corpora albicantia, the posterior perforated space, the third and fourth pair of cranial nerves, and the crura cerebri.

The **inferior longitudinal fissure** divides the anterior portion of the frontal lobe and the entire occipital lobe.

The **olfactory bulb** is, in man, a small, rather club-shaped swelling of gray matter which, with the olfactory tract, lies on the orbital surface of the frontal lobe and is lodged in the sulcus olfactorius. The bulb presents on its under surface several small, roundish elevations, which are the transversely divided olfactory nerves which have come from the rod-shaped cells of the olfactory mucous membrane of the upper nasal chamber after having passed through the foramina in the cribriform plate of the ethmoid bone. The olfactory bulb contains many nerve-cells, about the dendrites of which these peripheral olfactory nerve-fibers end.

The **olfactory tract** passes backward from the bulb and presents an inner or mesial and an outer or external root. The triangular area seen between the diverging roots of the olfactory tract is known as the trigonum olfactorium. The base of this cortical area is backward toward the anterior perforated space, the apex forward toward the junction of the two roots of the olfactory tract. Externally, it is continuous with the orbital lobe.

The **corpus callosum** terminates at the base of the brain as a narrow concave portion which is connected with the tuber cinereum by a thin band of gray matter—the lamina cinerea. It gives off two peduncles, which may be observed by raising and

pushing the optic chiasm backward. They run obliquely across the outer part of the anterior perforated space of each side, and probably end near the apex of the temporal lobes. Anteriorly, they pass around the genu of the corpus callosum and are continuous with the striæ longitudinales, or nerves of Lancisi.

The **anterior perforated spaces**, one on each side, are gray in color, and are formed by the lenticular nuclei of the corpora striati,—which have come to the surface of the base at this point,—are triangular in shape, and are perforated by numerous large and small blood-vessels, which pass from the middle cerebral arteries into the corpora striati. Each space is bounded in front by the orbital part of the frontal lobe and olfactory tract; behind, by the optic tract; externally, by the frontal and temporosphenoid lobes and by the beginning of the fossæ Sylvii. Internally, it is continuous with the lamina cinerea.

The Sylvian Fissure.—This begins at the base of the brain, in the anterior perforated space. Here it separates the frontal from the temporosphenoid lobe. This part of the fissure is called the fossa or vallecule Sylvii. It lodges the middle cerebral or Sylvian artery. On separating the margins of the temporosphenoid and frontal lobes which form the boundaries of this fissure, the prominent cluster of small gyri—the insula, or island of Reil—may be seen.

The Optic Chiasm or Decussation.—This is the junction of the two optic nerves. They form an incomplete decussation. The fibers coming from the inner or nasal halves of the two retinae, which supply the outer or temporal halves of the field of vision, decussate, and pass to the opposite optic tract. The fibers coming from the outer or frontal halves of the retinae do not decussate, but pass directly backward on the same side, to unite with the nasal fibers from the opposite sides of the retinae, they having decussated in the chiasm. The optic chiasm is located in the median portion of the base of the brain, in front of the tuber cinereum and behind the lamina cinerea, which latter is a thin blade of gray matter extending from the termination of the corpus callosum to the tuber cinereum, and is continuous on each side with the anterior perforated space. From

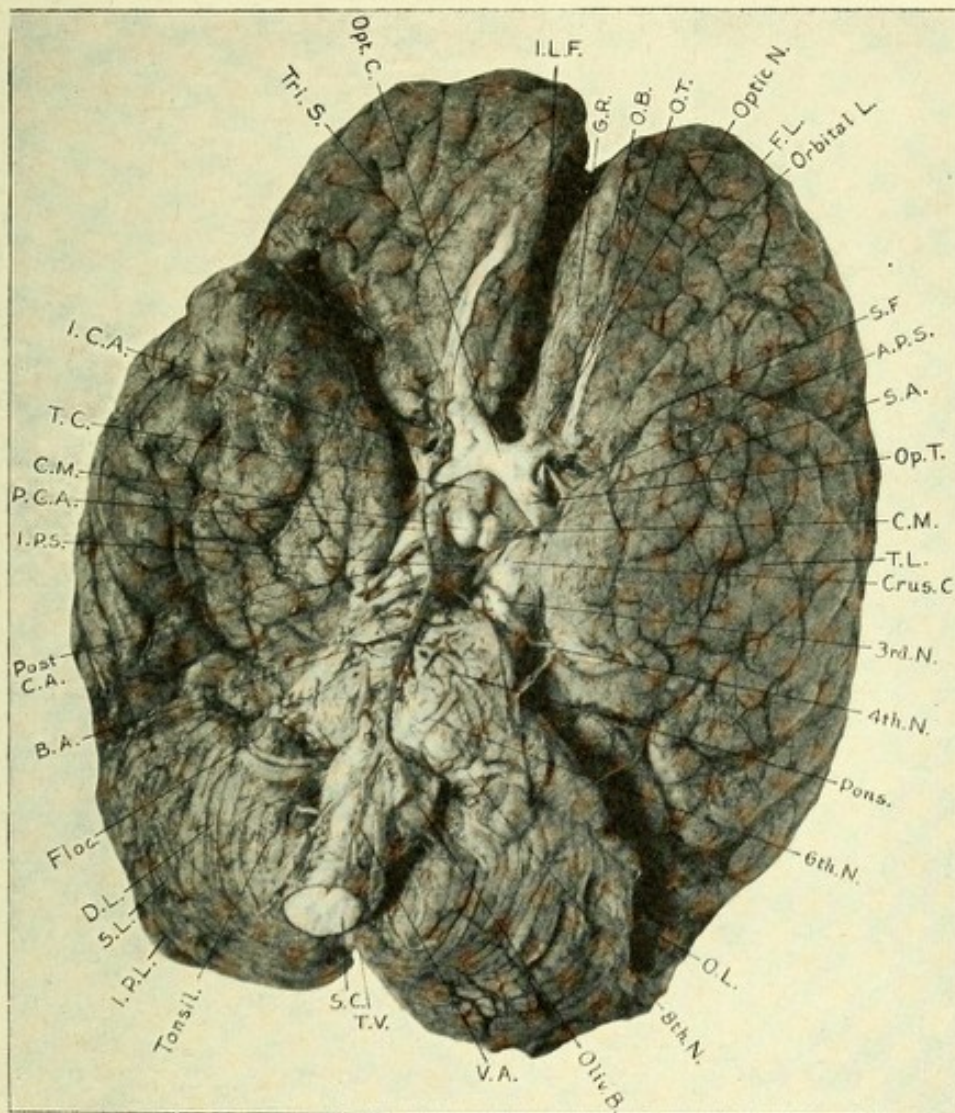



FIG. 157.—PHOTOGRAPH OF THE BASE OF THE HUMAN BRAIN.

I. L. F. Inferior longitudinal fissure. G. R. Gyrus rectus. O. B. Olfactory bulb. O. T. Olfactory tract. Optic N. Optic nerve. F. L. Base of frontal lobe. Orbital L. Orbital lobe. S. F. Sylvian fissure. A. P. S. Anterior perforated space. S. A. Sylvian artery. Op. T. Optic tract. C. M. Corpora mammillaria. T. L. Temporal lobe. Crus C. Crus cerebri. 3rd N. Third nerve. 4th N. Fourth nerve. Pons. Pons Varolii. 6th N. Sixth nerve. O. L. Occipital lobe. 8th N. Eighth nerve. Oliv. B. Olivary body. V. A. Vertebral artery. T. V. Tuber valvulae. S. C. Spinal cord. Tonsil. Amygdalum or tonsil. I. P. L. Inferior posterior lobe of cerebellum. S. L. Slender lobe. D. L. Digastric or cuneate lobe. Floc. Flocculus. B. A. Basilar artery. Post. C. A. Posterior cerebral artery. I. P. S. Interpeduncular space. P. C. A. Posterior communicating artery. T. C. Tuber cinereum. I. C. A. Internal carotid artery. Tri. S. Triradiate sulcus or fissure. Opt. C. Optic chiasm.



the optic chiasm on each side the optic tracts pass backward and outward toward the occipital lobe.

The **interpeduncular space** is a lozenge-shaped space situated behind the optic tracts, which form its anterolateral boundary, and in front of the crura cerebri,—the diverging peduncles of the cerebrum,—which form its posterolateral boundary. In this space exist, from before backward, the tuber cinereum, the infundibulum, the pituitary body, the corpora albicantia or mammillaria, the posterior perforated space, and the motor oculi, or third pair of cranial nerves.

The **tuber cinereum** is an elevation of gray matter extending from the corpora albicantia behind to the optic chiasm in front, to which it is attached. It is continuous with the lamina cinerea, and forms part of the floor of the third ventricle.

Passing downward and forward from its middle portion is a hollow, cone-shaped process, the **infundibulum**, which has attached to it the posterior lobe of the pituitary body. This funnel-shaped canal communicates with the cavity of the third ventricle, and is two or three lines in length.

The **pituitary body**, or **hypophysis cerebri**, is a reddish, vascular mass of an oval shape. It is situated in the sella turcica, in which it is retained by a process of dura mater derived from the inner wall of the cavernous sinus. It consists of two divisions or lobes—anterior and posterior. They differ in their development, the anterior lobe being developed from a tubular process of the ectoderm of the buccal cavity. This lobe is of a yellowish-gray color, and is made up of a number of slightly convoluted tubules or alveoli, which are lined by columnar epithelium, often bearing cilia. The tubules are united by a stroma of connective tissue, which conveys to the gland an abundant blood and lymphatic supply. It resembles very closely in structure the thyroid gland, and, like the latter, often contains colloid material. It is surrounded by a connective-tissue capsule. The posterior lobe is an outgrowth from the embryonic cavity, which soon becomes that of the third ventricle. This ventricle communicates with the pituitary body, during fetal life, by means of the infundibulum. In the adult the infundibulum is impervious, and is made up of a meshwork



of connective tissue containing spindle-shaped and branched cells, some of which are pigmented. A very interesting clinical fact is that in the disease recently described by Marie, of Paris, and named by him *acromegalia*,—and which is characterized by a great increase in the size of the head, the lower jaw, the hands and feet, and frequently of other bones, such as the scapula, clavicle, sternum, and ribs, the chest being often of enormous proportions and the spine being curved,—after death, in nearly all instances, an enlargement has been found of the pituitary body which varies in size, sometimes being as large as a Tangerine orange. The function of this body is absolutely unknown. Although it is in man a ductless gland, it must, however, lend to the economy an internal secretion which is conveyed to the blood by means of its lymph capillaries. In some manner, yet unknown, it probably assists in the maintenance of nutrition of the osseous system.

The Corpora Albicantia or Mammillaria.—These are two small, round eminences of white and gray matter, about the size of a pea, situated between the crura cerebri, behind the tuber cinereum and in front of the posterior perforated space. The white matter is arranged superficially in the form of a mantle (*stratum zonale*), and is formed chiefly by the anterior pillars or crura of the fornix, which, descending to the base of the brain, are reflected upon themselves and form for each body a covering of white matter. The fibers of these crura terminate among the nerve-cells within the albicantia. Each of these bodies is brought into relation with the optic thalamus by a bundle of fibers (bundles of *Vicq d'Azyr*, axones from the ventral nucleus of the thalamus), which pass downward and end among the nerve-cells of the albicantia. Both of the above-mentioned bundles produce a continuous conducting tract on each side between the ventral nucleus of the optic thalamus and the gyrus hippocampus (*cornu ammonis*). The interiors of the corpora albicantia contain two groups of nerve-cells, mesial and lateral, called their nuclei.

The **posterior perforated space** is a whitish-gray area located between the corpora mammillaria in front and the pons Varolii behind. Laterally this space is continuous on each side

with the substantia nigra of the tegmentum of the crura cerebri. It forms the back part of the floor of the third ventricle, and is perforated by numerous small vessels,—branches of the posterior cerebral and communicating arteries,—which pass into the interior to supply the interior part of the optic thalamus and walls of the third ventricle. The third nerves may be seen issuing from the interpeduncular space on each side, then passing forward around the crura cerebri.

The **crura cerebri**, or **peduncles of the cerebrum**, are seen on each side of the interpeduncular space, forming the outer boundary. Below, they are lost among the fibers of the pons. Above, they break up into numerous tracts, which radiate toward the cerebral cortex and the central ganglia. They are two very thick cylindric masses about three centimeters in length, and composed of large bundles of medullated nerve-fibers. They diverge in their course from below upward, and before entering the hemisphere they are crossed by the optic tracts. The fourth nerves may be seen winding around their outer parts, almost meeting the third nerves near their median surface, as the latter nerves curve around their inner parts. The crura cerebri enter the inner side of each hemisphere, and their fibers spread out between the optic thalamus and caudate nucleus on the inside and the lenticular nucleus on the outside, forming the internal capsule. Then they spread out fan-shaped, forming the corona radiata, and proceed to all parts of the cerebral cortex. A peduncle on transverse section consists of two parts of longitudinal fibers separated by an intermediate stratum of dark gray matter in which is embedded a large number of dark pigmented nerve-cells; hence its name—the locus niger, or substantia nigra. The superficial or ventral layer is called the crusta; the deeper or dorsal, the tegmentum, which is a continuation upward of the fillet and the formatio reticularis. These two layers of longitudinal fibers—superficial, or crustal, and deep, or tegmental—are made up of numerous long tracts of centripetal and centrifugal fibers. The former pass into the subthalamic region, central ganglia, and cerebral cortex; the latter, proceeding from the cerebral cortex and central ganglia, pass downward to enter the pons, cerebellum, medulla, and spinal cord.

OLFACTORY LOBE, BULB, NERVES, AND TRACTS.

The olfactory apparatus includes the regio-olfactoria, the olfactory nerves, the olfactory lobe or bulb, the trigonum olfactorium, the olfactory tracts, and the anterior commissure.

The regio-olfactoria, or olfactory region, consists of the upper part of the nasal septum, the root of the nose, and the upper and a part of the middle turbinated bones.

This region is covered by the olfactory mucous membrane, being thicker than is the Schneiderian mucous membrane, covering the parts below, which later is the true respiratory region, and is lined with stratified epithelium bearing cilia. The olfactory mucous membrane contains two chief forms of cells—columnar, non-ciliated, strongly pigmented, epithelial cells, the pigment giving to the olfactory mucous membrane a brownish-yellow color; and true olfactory nerve-cells, spindle or rod-like in shape, containing spheric nuclei. These olfactory nerve-cells are situated between the columnar cells, and are bipolar in form, their short, thick peripheral processes terminating on the surface of the mucous membrane, where they spread out in the form of a network, while their long, slender central ones (the fila olfactoria) pass beneath the epithelial cell-layer, to form the true olfactory nerves.

The Olfactory Nerves.—The olfactory nerves, twenty in number, consist of bundles of fine fibers (the fila olfactoria), which are the central coursing axones of the rod-shaped olfactory nerve-cells of the regio-olfactoria. They are non-medullated fibers, which course vertically upward and enter the cranial cavity through the foramina in the cribriform plate of the ethmoid bone, to reach the inferior surface or ventral part of the olfactory bulb, where they terminate in arborizations about the dendrites of the mitral cells within the olfactory glomeruli. These bipolar cells resemble closely the cells of a posterior spinal ganglion, possessing a peripheral axone which terminates free on the surface of the olfactory mucous membrane, and a central axone which terminates in the olfactory bulb. These cells, with their axones and terminals, form the peripheral or olfactory neurones of the first order.

The *olfactory lobe* is a hollow protrusion or fold which extends forward from the under surface of the wall of the cavity of the cerebral hemisphere. It forms a distinct ridge along the basal part of the hemisphere, from which it soon separates, being converted into a blind, tubular-like diverticulum, which communicates posteriorly with the cavity of the lateral ventricle. This diverticulum is early separated by a groove (the primary

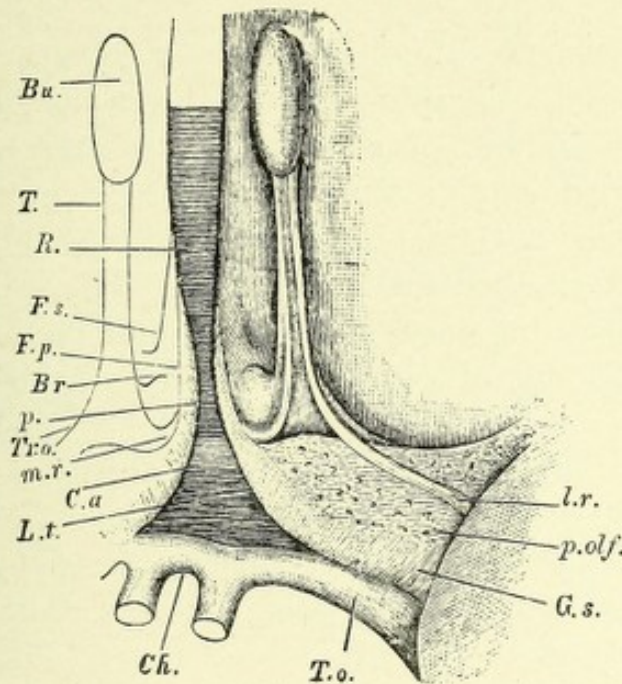


FIG. 158.—OLFACTORY LOBE OF THE HUMAN BRAIN.—(His.)—(After Quain.)

Bu. Olfactory bulb. *T.* Tract. *Tr.o.* Trigone. *R.* Rostrum of corpus callosum. *p.* Peduncle of corpus callosum, passing into *G.s.*, gyrus subcallosus (diagonal tract, Broca). *Br.* Broca's area. *F.p.* Fissura prima. *F.s.* Fissura serotina. *C.a.* Position of anterior commissure. *L.t.* Lamina terminalis. *Ch.* Optic chiasma. *T.o.* Optic tract. *p.olf.* Posterior olfactory lobule (or anterior perforated space). *m.r.* Mesial root. *L.r.* Lateral root of tract.

fissure of His) into an anterior and a posterior part. From the anterior part is developed the olfactory tract and bulb, and the trigonum olfactorium. From the posterior part is developed the posterior olfactory lobe, which comprises the peduncles of the corpus callosum, the inner and outer olfactory roots, and the anterior perforated space.

The olfactory lobe, which in many animals (osmatics) attains a very large size, is in man rudimentary, the anterior olfactory

lobe being represented by the olfactory tract and bulb and trigonum olfactorium, while the posterior lobe comprises the gray matter of the anterior perforated space.

The olfactory lobe contains, in most of the lower animals, a narrow, central cavity (the olfactory ventricle) lined with ciliated epithelium, which rests on a neuroglia basis and communicates with the anterior cornu of the lateral ventricle. In man no such cavity exists, it having been obliterated by an overgrowth of neuroglia.

The olfactory bulb, although a part of the cerebral cortex, presents certain peculiarities of structure which differ from it. It is an oval or club-shaped mass of gray matter, which forms a sort of elongated cap for the ventral portion of the olfactory tract. The bulb and tract are situated in the olfactory sulcus on the orbital surface of the frontal lobe. The inferior surface of the bulb rests on the cribriform plate of the ethmoid bone, through the foramina of which it is connected with the olfactory nerves.

Olfactory Bulb: Its Minute Anatomy.—The minute structure of the olfactory bulb can be best studied by making sagittal sections through it, after being stained by the method of Golgi. It will be found to consist of four well-defined layers; these are from without inward:

1. The layer of olfactory nerve-fibers.
2. The layer of olfactory glomeruli—stratum glomerulorum.
3. The molecular layer, or stratum gelatinosum.
4. The layer of central nerve-fibers.

1. *The outer layer, or layer of olfactory nerve-fibers*, consists of a thin, superficial layer of non-medullated nerve-fibers, which forms for the ventral portion of the bulb a slight stratum zonale, each individual fibril being the central axone of a rod-shaped nerve-cell from the olfactory mucous membrane. The fibers of the olfactory nerves pass into the underlying glomeruli. Each fibril, just before entering a glomerulus, separates into two or three divisions, which usually enter a single glomerulus; but, occasionally, they may pass into two glomeruli. Within the glomerulus the terminal divisions of the olfactory fibril frequently branch, forming antler-like terminations, which come into con-

tact with an olfactory end brush of an apical dendrite of a mitral cell.

2. *The Layer of Olfactory Glomeruli; the Stratum Glomerulosum.*—This layer contains many small, roundish bodies, from 30 to 50 μ in diameter, which are arranged alongside of one another, forming a continuous row beneath the layer of olfactory nerve fibers and above the molecular layer.

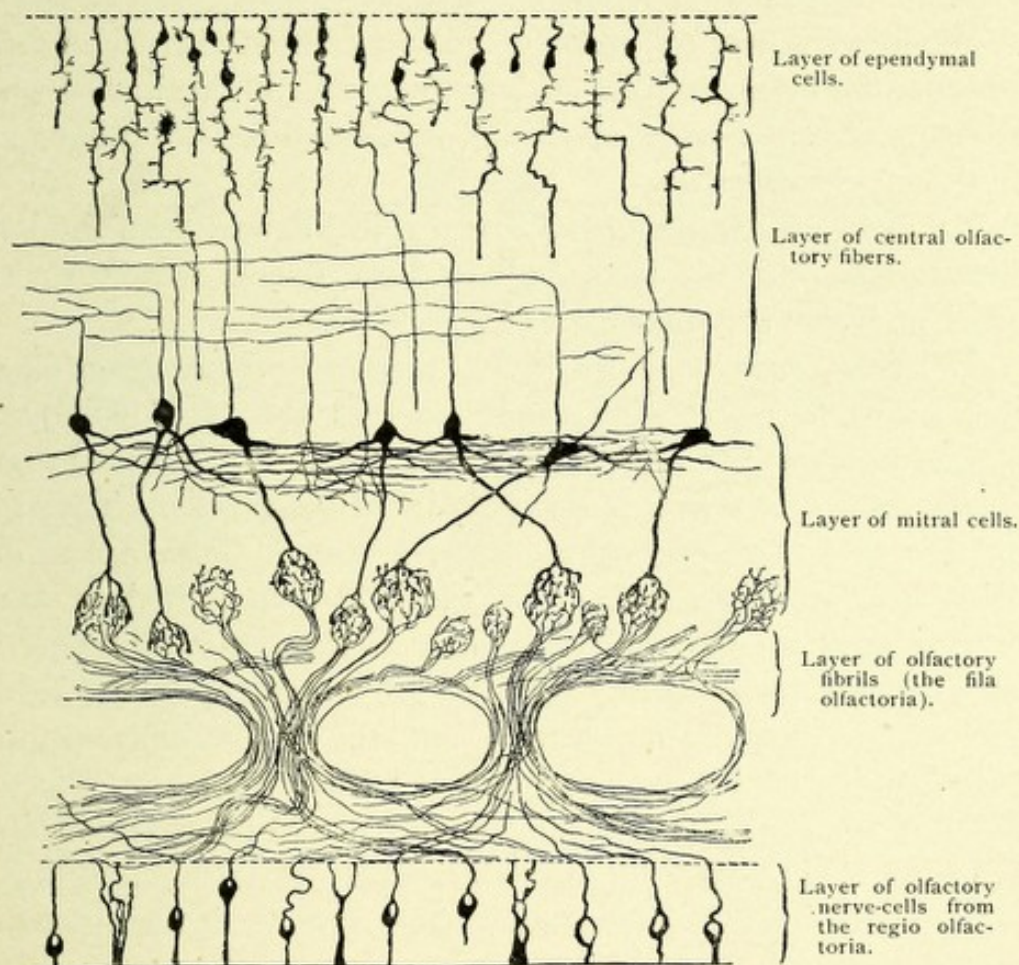


FIG. 159.—A SCHEMATIC REPRESENTATION OF THE PRINCIPAL ELEMENTS OF THE OLFACTORY BULB OF A MAMMAL.—(*Van Gehuchten.*)

Each glomerulus consists of the terminal arborization of an olfactory nerve-fiber, together with olfactory end brushes from the apical dendrites of mitral cells. These two forms of terminals produce an interlacing network or tuft of fibrils, which assume a spheric form. The glomeruli are nourished by a rich capillary plexus of vessels, which have descended from the overlying pia mater.

3. *The Molecular Layer, or Stratum Gelatinosum.*—In the outer part of the molecular layer may be seen numerous vertically ascending fibers, a part of which are lost in this layer; the remainder continue upward and surround the glomeruli by passing between them. This layer also contains the apical dendrites of the large and small mitral cells, as well as the terminal branches of the dendrites of the deeper-lying granular cells.

The inner part of the molecular layer contains two chief forms of cell—the deep and the superficial layers of mitral cells, which correspond to the large and small pyramidal cells of other parts of the cerebral cortex.

According to Ramón y Cajal, the apical dendrites of the large mitral cells possess from eighteen to twenty olfactory end brushes, which are distributed to as many glomeruli.

The large mitral or pyramidal cells are mostly triangular in shape, and from 30 to 50 μ in diameter; they are usually arranged in a single row or layer, although Koelliker states that it is common to find two or three layers of these cells. They give off two sets of dendrites, apical and lateral. The apical dendrites are, with rare exceptions, single in man, and they do not branch until they reach the interior of the olfactory glomeruli, each glomerulus receiving but a single apical dendrite. Within each glomerulus the dendrite terminates by breaking up into a globular-shaped, interwoven mass of fibers, to form an olfactory brush of fibers,—pennicilli olfactorii, (Koelliker),—each olfactory brush of fibers coming into contact with the terminal arborization of an olfactory nerve-fiber. The lateral dendrites of the mitral cells, two or three in number, spring from the lateral angles of the cell-body, and pursue a rather long, horizontal course parallel to the row of mitral cells, and terminate free. They form a layer of fibers which separates the deepest part of the molecular from the fourth or internal layer.

The axis-cylinder or axone of the large mitral cells springs from the angle at the base of the cell-body. It is a strong, thick process which descends vertically through the molecular layer, and between the granular cells to the inner part of the fourth layer, where it bends at a right angle and pursues a horizontal

course inward (centrally), passing into the olfactory tract. The collaterals from the axones of the large mitral cells pursue an upward course and terminate free in the deep or superficial part of the molecular layer.

The Superficial Layer of Medium and Small-sized Mitral Cells.—These cells are spindle or triangular in shape and resemble very closely the large mitral cells, save that they are smaller in size and their apical dendrites are much shorter.

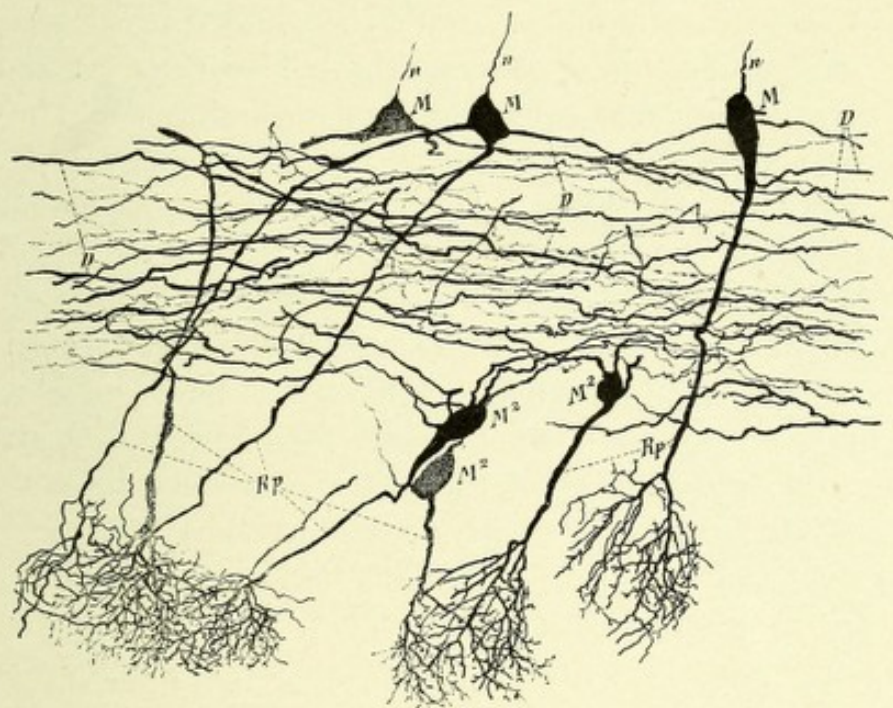


FIG. 160.—MITRAL CELLS FROM A MOUSE TWENTY-FOUR DAYS OLD.—(After Koelliker.)

D. Dendrites from mitral cells forming horizontal fibers. *M.* Deep layer of mitral cells. *M².* Superficial layer of mitral cells. *n.* Axones of deep mitral cells. *Rp.* Arborizations of apical dendrites of the mitral cells forming brushes of olfactory fibrils.

They possess both lateral and apical dendrites. The lateral dendrites pursue an oblique or horizontal course, ending free. Each apical dendrite, like that of the large mitral cell, terminates within an olfactory glomerulus, there breaking up into a tuft of fibers. The axis-cylinder processes of these cells pursue the same course as do those from the large mitral cells, passing into the fourth layer, where they take a horizontal course. The axones of these cells give off in their course fine collaterals, which have mostly a horizontal direction.

The Fourth Layer, or Layer of Central Nerve-fibers.—The outer part of this layer is occupied by a large number of very small granular cells arranged in rows, between which pass the descending axones of the mitral cells. These granular bodies are triangular, pyramidal, or spindle-shaped; they possess short, central branches or dendrites, and a single, long, delicate, peripheral or apical dendrite, which latter, toward its termination, frequently forks and ends in a brush of fine fibrils in the region of the glomeruli. Both the central and peripheral processes are studded with gemmules. No axis-cylinder processes have thus far been discovered coming from these cells. Cajal considers them to be nerve-cells whose axis-cylinders probably pass downward. Van Gehuchten thinks they are misplaced ependymal cells, while Koelliker believes they are neuroglia cells.

The inner part of this layer is mostly occupied by medullated nerve-fibers and collaterals; the former have both a centrifugal and a centripetal course. These fibers pass both in a horizontal and vertical or radial direction. The vertical fibers have several sources: first, terminal commissural fibers from the anterior commissure, which end about the olfactory glomeruli—these are the centrifugal fibers; second, ascending collaterals from the large mitral cells; third, descending axones from the large, medium, and small mitral cells.

The horizontal fibers are separable into those which are a part of the anterior commissure (hence called commissural) and those which form the olfactory tracts. The commissural bundles of fibers are located in the deepest part of this layer, adjacent to the olfactory ventricle. The fibers which together form the olfactory tract are more superficially located, consisting of the axones of the mitral cells. The inner border of the fourth layer is lined with ependymal cells.

The Olfactory Tracts.—The nerve-fibers of the olfactory bulbs collect at their posterior extremities as two well-marked bundles of fibers—the olfactory tracts.

Each olfactory tract forms for the bulb a distinct stalk or pedicle, which is narrowed at its point of emergence from the bulb and grows slightly broader as it courses backward. It is flattened on its ventral or inferior surface and ridged or convex

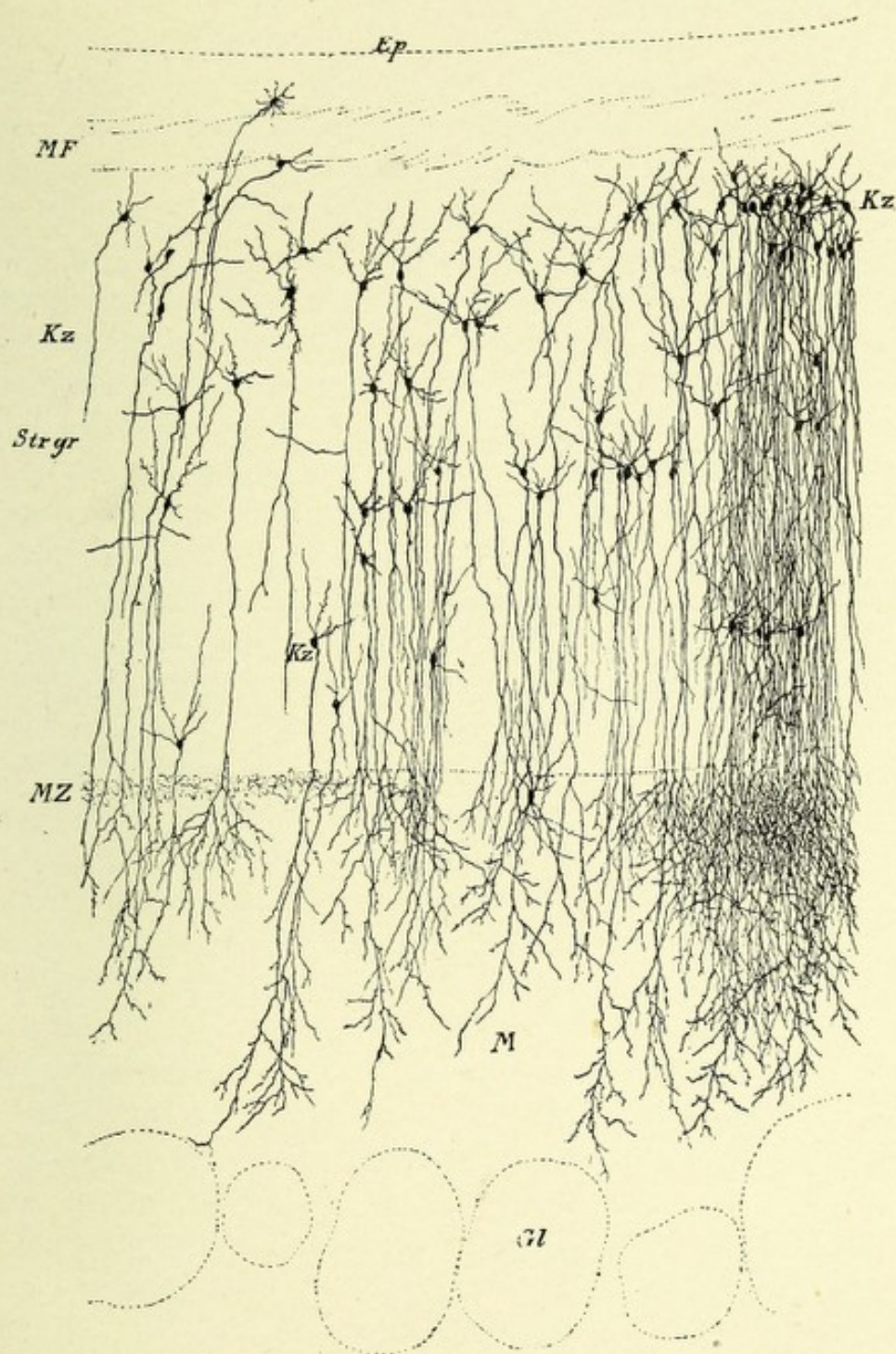


FIG. 161.—A FRONTAL SECTION THROUGH AN OLFACTORY BULB OF A SIX-WEEKS'-OLD CAT. Showing layer of granular cells.—(After Koelliker.)

Ep. Ependyma. *Gl.* Glomerule. *Kz.* Layer of granular cells. *M.* Molecular layer. *MF.* Layer of medullated fibers. *MZ.* Layer of mitral cells. *Str. gr.* Granular zone (stratum granulosum).



along the middle of its superior or dorsal surface; hence it is prismatic or triangular on transverse section. The olfactory tract and bulb is lodged in the olfactory sulcus of the orbital lobe, where some of its fibers become continuous along the inner side of the sulcus with the cortex of the frontal lobe. The olfactory tract contains two systems of fibers—the olfactory fibers proper (the axones of the mitral cells) and the commissural fibers from the anterior commissure. The former (true olfactory fibers) form the ventral part of the tract, while the commissural fibers occupy its dorsal part. The ventral bundle (true olfactory tract) separates posteriorly into two roots—an inner or mesial and an outer or lateral; these roots diverge from each other and inclose a triangular space of gray cortex—the trigonum olfactorium.

The Trigonum Olfactorium and Space of Broca.—These two areas form a part of the cortical gray matter of the base of the anterior olfactory lobe, which lobe is bounded internally and posteriorly by the primary fissure of His. This fissure separates it from the anterior part of the peduncle of the corpus callosum on its inner aspect, and from the posterior olfactory lobe (anterior perforated space) behind. This area has traversing it from before backward the diverging roots of the olfactory tract. That part of the area located between the olfactory roots is known as the trigonum olfactorium; it receives many fibers from the dorsal part of the tract, and forms the middle or dorsal root which comes from the anterior commissure. The portion of gray matter located between the internal root and the peduncle of the corpus callosum is called the *Area of Broca*; it receives fibers from the mesial or inner root.

The course of the root-fibers of the olfactory tract in man: The external, outer, or lateral root passes obliquely across the outer part of the anterior perforated space into the fossa Sylvii, where its fibers come into relation with the gyrus hippocampus, the uncinate gyrus, the cornu ammonis, and probably the amygdaloid nucleus. The inner or mesial root passes backward, inward, and upward around the area of Broca, to which it lends fibers and then passes in to the anterior extremity of the gyrus fornicatus, its fibers probably terminating among the



pyramidal cells of the cortex of this entire lobe. It will thus be seen that the olfactory tract and bulb have a connection both with the beginning and termination of the limbic or falciform lobe. This connection of the olfactory bulb and tract with the limbic lobe Broca aptly compares to a tennis-racquet, the olfactory tract corresponding to the handle and the limbic lobe to the circumference of the blade. Some of the fibers of the mesial root pass posteriorly beneath the gyrus fornicatus to the septum lucidum and fornix, and thence are continued into the white matter of the cornu ammonis.*

The dorsal or middle root is composed of commissural fibers from the anterior commissure which have decussated in the median line and pass into the olfactory tract through the trigonum olfactorium, terminating in the olfactory bulb about the glomeruli and mitral cells. This centrifugal tract of fibers forms an olfactory commissure and connects the olfactory bulb of one side with the hippocampal and uncinata region of the opposite side. Meynert believes that this root also contains fibers joining the two olfactory bulbs, and thus forms an olfactory chiasm.

THE ANTERIOR COMMISSURE.

The anterior commissure belongs to the cerebral hemisphere and associates in function those parts which are not united by the corpus callosum—*i. e.*, the temporal lobes in man and in osmatics the entire rhinencephalon. Like the fibers of the corpus callosum, the fibers of which this commissure is composed are probably the axones of the pyramidal cells of the cortex of the temporal lobe (lobus pyriformis in osmatics), the axones of one side passing across to arborize about the pyramidal cells of the temporal or pyriform lobe of the opposite side, and vice versa.

The anterior commissure is an arched bundle of fibers with its convexity forward and its two extremities spread out fan-

* According to some authors, the dorsal, middle, or commissural root contains only centripetal fibers (axones of the mitral cells), which cross in the median line and terminate in the hippocampal and uncinata region of the opposite side. These authors leave unexplained the termination of the centrifugal fibers of the olfactory tract.

shaped. It is free in its middle part, where it appears as a round bundle which courses along the anterior border of the third ventricle, crossing the space between the anterior pillars of the fornix. At the level of the base of the septum lucidum and ventral to the anterior pillars of the fornix it passes on each side through the basal part of the head of the caudate nucleus, and globus pallidus of the lenticular nucleus, and divides into two bundles which spread out fan-shape and radiate toward the cortex of the temporal lobe.

The two bundles of which the anterior commissure is composed are connected—the anterior with the opposite olfactory bulb, the posterior with the opposite temporal lobe; hence the anterior bundle is called the *pars olfactoria*; the posterior, the *hemispherical* bundle. The anterior bundle in man is very small, but in osmatics it attains a very great size, being about twice as large as the posterior bundle. The fibers of which this bundle is composed probably take their origin from the pyramidal cells of the temporal lobe (gyrus hippocampus and uncinate gyrus). From this extensive origin the fibers pass inward, converging in their course (many passing through the external capsule) through and beneath the lenticular nucleus and the basal part of the head of the caudate nucleus; the bundle then curves downward into the substance of the anterior perforated space, through which it passes into the peduncle of the opposite olfactory bulb, terminating about the olfactory glomeruli and mitral cells. This fasciculus also contains, according to Meynert, fibers which arise in the olfactory bulb of one side and pass to the olfactory bulb of the opposite side, thus forming a true olfactory chiasm. Most of the fibers (those coming from the temporal lobe) after decussating, however, pass to the olfactory bulb of the opposite side, thus establishing a cross-connection between the temporal lobe of one side and the olfactory bulb of the opposite side.

The posterior or hemispherical bundle takes its origin from the pyramidal cells of the temporal lobe and amygdaloid nucleus, and after passing through the external capsule and lenticular nucleus joins the middle part of the commissure, where its fibers decussate and then radiate to the opposite temporal lobe.

CHAPTER IX.

HISTOLOGY OF THE CEREBRAL CORTEX, TOGETHER WITH THE MINUTE ANATOMY OF THE CENTRUM OVALE.

THE HISTOLOGY OF THE CEREBRAL CORTEX.

If a section be made at right angles to the surface of the cerebral hemisphere, it will be seen to consist of an outer zone, dark-red in color, and an inner, homogeneous, whitish mass. The former is the cortex cerebri; the latter, a portion of the centrum semiovale, or white matter, of the hemisphere. The cortex, or rind, forms a complete mantle for each cerebral hemisphere; it varies from 2 to 4 mm. in thickness, being thinnest at the bottoms of the fissures and sulci, and thickest at the summit of the convolutions. Its thickness also varies as the situation of the section, being thickest over the central gyri and paracentral lobules, where it measures 4 mm., or about one-sixth of an inch, and thinnest over the occipital lobe, where it is one-half as thick. With the unaided eye or with a hand-lens the cerebral cortex, owing to differences in color of its gray and white matter, appears stratified, the layers being as follows, from without inward: First, the stratum zonale, or layer of outer tangential fibers, consisting of a narrow, white layer of mostly horizontal fibers, which are situated beneath the pia, and may be discovered on a fresh brain as a fine, white line, this layer being especially marked on the convolutions of the median and basal surfaces of the hemisphere, while not being very distinct on the lateral portions of the convexity of the brain. The second layer is located just beneath the superficial layer, and is termed the superficial gray layer. This layer, when observed beneath the microscope, is seen to be composed

mostly of small pyramidal cells, with their dendrites and the dendrites from cells more deeply situated. The third, or white layer of Vicq d'Azyr, or outer line of Baillarger, is best marked in the gyri bordering the calcarine fissure. The fourth, or second layer of gray matter, consists mostly of large pyramidal cells. The fifth layer, or inner white line of Baillarger, is similar to the third or outer white line of Baillarger, both of which are composed of medullated nerve-fibers, which are probably the collaterals from the axones of the pyramidal cells. Both of these lines of Baillarger form the middle tangential fibers. The sixth layer of the cortex, or third layer of gray matter, gradually blends with the underlying central white matter, and is composed of the polymorphous cells and pro-

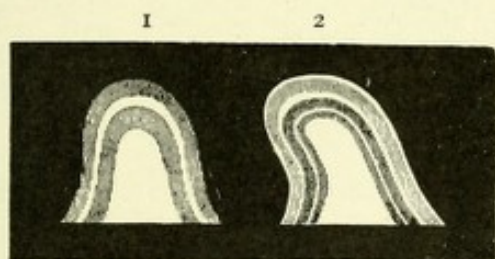


FIG. 162.—SECTIONS OF CEREBRAL CONVOLUTIONS.—(After Baillarger, from Quain.)

1. The appearance of a section of a convolution from the neighborhood of the calcarine fissure.
2. Shows the six layers ordinarily seen in the cerebral cortex when carefully examined with naked eye.

cesses. The inner layer of tangential fibers is just beneath the third layer of gray matter in the centrum ovale. This layer consists of fine and coarse fibers, which are arranged into superficial and deep bundles, which correspond to the association bundles. The superficial fibers form the short, and the deep fibers the long, bundles of association. This division into layers can not be distinguished by the unaided eye in all parts of the cortex, but in most fresh brains they may be easily differentiated. They are caused by large numbers of fine and coarse medullated nerve-fibers from the centrum ovale and from the various cortical cells. These fibers, after pursuing generally a vertical, but at times an oblique or horizontal, course, end about the cells of the cortex, or pass from those

The layers of cortical fibers.

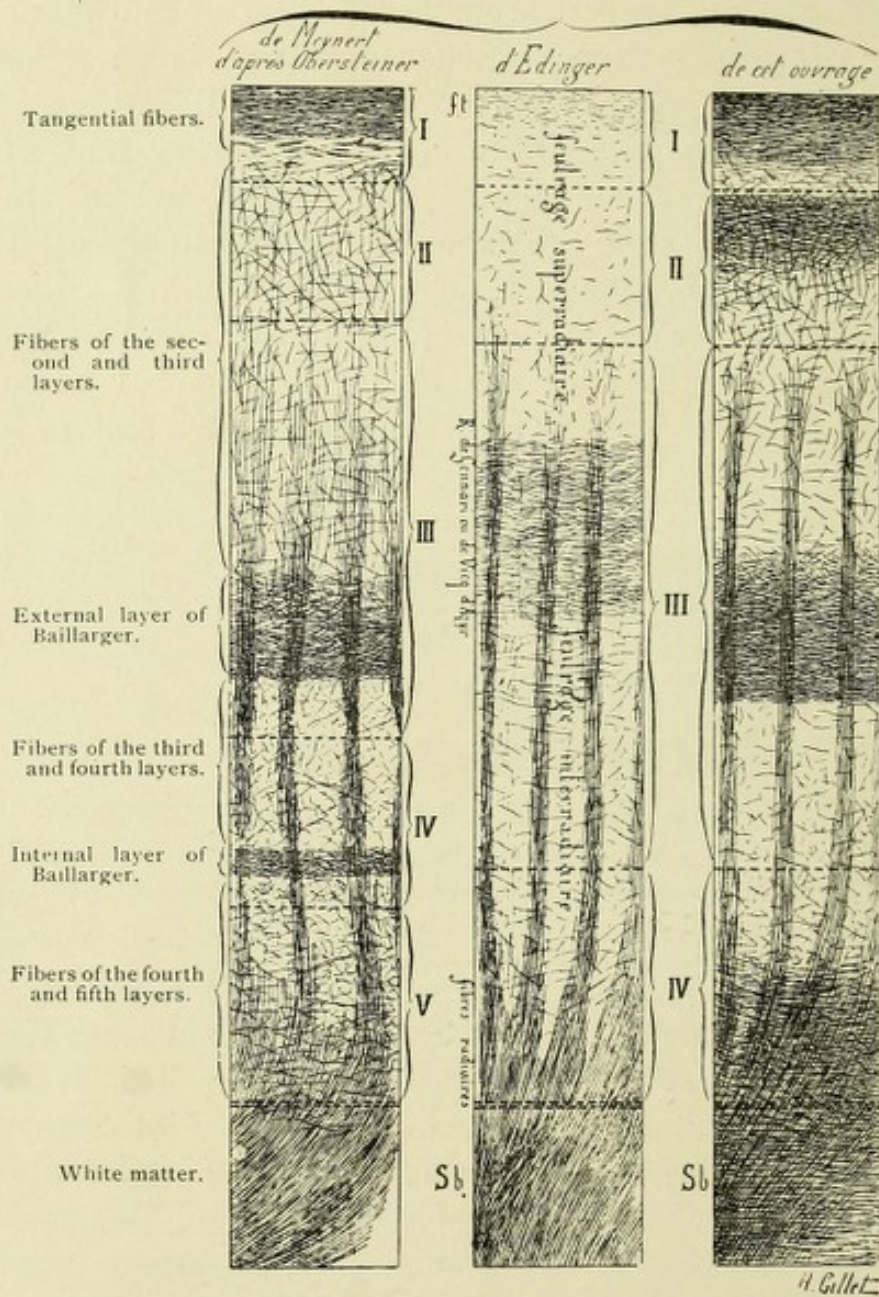


FIG. 163.—A SCHEME OF THE DISTRIBUTION OF NERVE-FIBERS OF THE CEREBRAL CORTEX. According to the views of Meynert, Obersteiner, Edinger, and Dejerine.—(After Dejerine.)

The dotted lines serve to distinguish the different layers of cells.

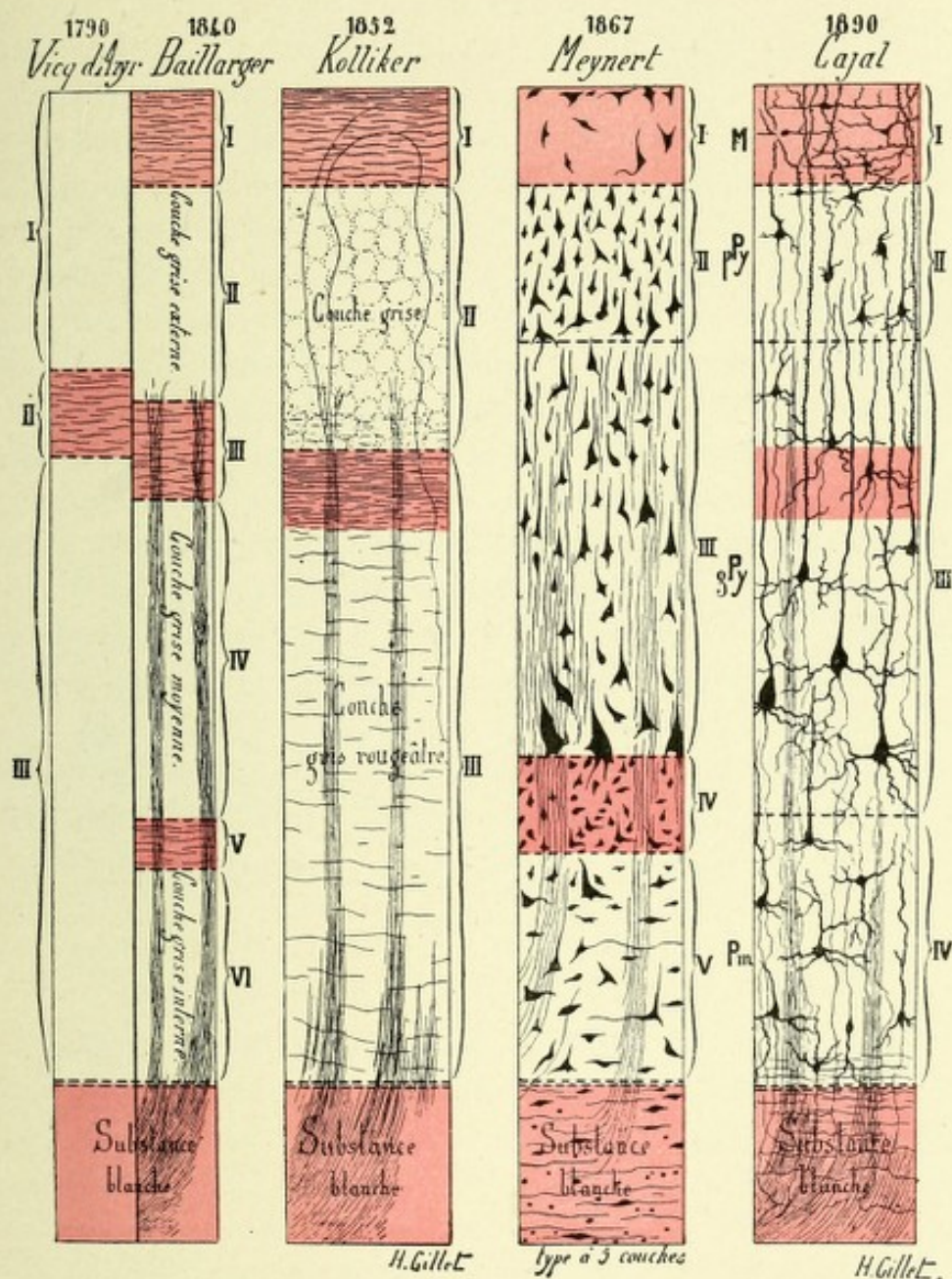



FIG. 164.—A SCHEME SHOWING THE DEVELOPMENT OF OUR KNOWLEDGE OF THE DIFFERENT CELL-LAYERS OF THE HUMAN CEREBRAL CORTEX FROM THE TIME OF VICQ D'AZYR, IN 1790, TO THE TIME OF CAJAL, IN 1890.—(After Dejerine.)

The first column represents the three layers of Vicq d'Azyr (1790), and the six layers of Baillarger (1840). The second column shows the three layers described by Koelliker (1852). The third column represents the five layers of Meynert (1867), while the fourth column illustrates the four layers of Cajal (1890).



cells as their axones to more distant parts. In their course they separate the cortical cells into columnar groups.

Special attention has been devoted to the study of the cerebral cortex during the last decad by Weigert, Bevan Lewis, Golgi, Cajal, Retzius, and Nissl, and most of our knowledge of its minute anatomy is owing to the introduction by these observers of the more modern methods of staining. To Golgi especially are we indebted, more than to any other worker, for a method of staining which has resulted in elucidating many unsolved problems in the histology of the cerebral cortex. The intricate maze of cells and fibers of which the cortex is composed may be divided, according to Ramón y Cajal, into four distinct layers. According to some observers (Meynert, Vicq d'Azyr, Baillarger), however, six or more layers are distinguishable; but it seems simpler to describe four layers, and to mention slight differences as to size and shape of the cells of the deepest layer which have resulted in the distinction of the six or more layers. These layers are as follows: First, the superficial or molecular layer; second, the layer of small pyramidal cells; third, the layer of large pyramidal cells; fourth, the layer of polymorphous cells.

LAYERS OF CORTICAL CELLS AND FIBERS.

The **superficial, molecular, or outer cortical layer** forms a very thin layer just beneath the pia. It is composed of nerve-fibers and terminals, dendritic processes from the underlying pyramidal cells, neuroglia cells and fibers, and a special variety of nerve-cells, called Cajal cells, from their discoverer. The nerve-fibers of this layer pursue mostly a horizontal course, and are best marked in the deeper part of this layer; they are very long, form the outer tangential fibers, and are the axones and collaterals from the cells of Cajal. This layer also contains the terminations of many centripetal fibers coming from the spinal cord, medulla, and cerebellum, as well as the terminations of a large number of commissural fibers and fibers of association. It also contains the axones from the cells of Martinotti, as well as the apical dendrites of the pyramidal cells, which end free in this

layer. The neuroglia fibers and cells of this layer exist just beneath the pia mater, where they form a distinct layer, and have among them only a few nerve-cells or fibers. The neuroglia cells are chiefly of the stellate variety; their processes are of considerable length, and form a rather thin but distinct layer of horizontal fibers. Of the Cajal cells there are three chief varieties—the fusiform or spindle-shaped, the triangular, and the polygonal. These three varieties exist in the human cortex and in the cortex of many of the lower animals. They have been found by the author in the cortex of the brain of the sheep as well as in the brains of mice and cats. The fusiform or spindle-shaped cells have their long axes directed horizontally. From each pole proceeds a horizontal process of great length, per-

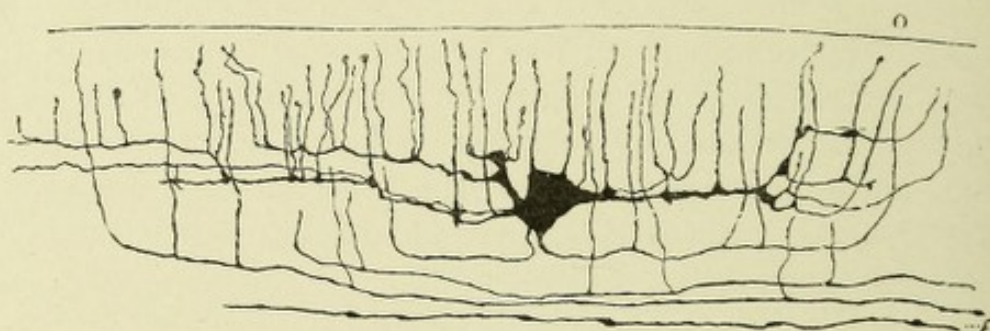


FIG. 165.—A CAJAL CELL IN COURSE OF DEVELOPMENT FROM SECTION OF ASCENDING FRONTAL GYRUS OF A HUMAN FETUS AT EIGHT MONTHS.—(After Retzius.)

fectly smooth, devoid of granules, and giving off in its course numerous fine branches, which leave the parent stem almost at right angles, and proceed vertically, many ending in small bulbs in the most superficial part of this layer. Others, after proceeding upward, divide into two or more terminating fibrils having a horizontal course. The triangular cell may possess two, three, or more processes. A common form is one with four processes—two vertical and two horizontal. The latter have a similar course, and give off vertical branches, just as does the spindle-cell, which gives off collaterals, which, with the axone, pursue a horizontal course, forming an outer tangential fiber.

The polygonal cells give off numerous dendrites and a single neuraxone, which proceeds downward, then becomes horizontal.

Its collaterals pursue the same course ; occasionally the neur-axone comes off from one of the main dendrites.

The second layer, or **layer of small pyramidal cells**. This layer consists of numerous small pyramidal cells arranged in rows occupying a considerable vertical extent. These cells are located just beneath the deep horizontal fibers of the superficial layer. The individual cells differ considerably in size and shape. A variety exists in the deepest part of this layer which seems

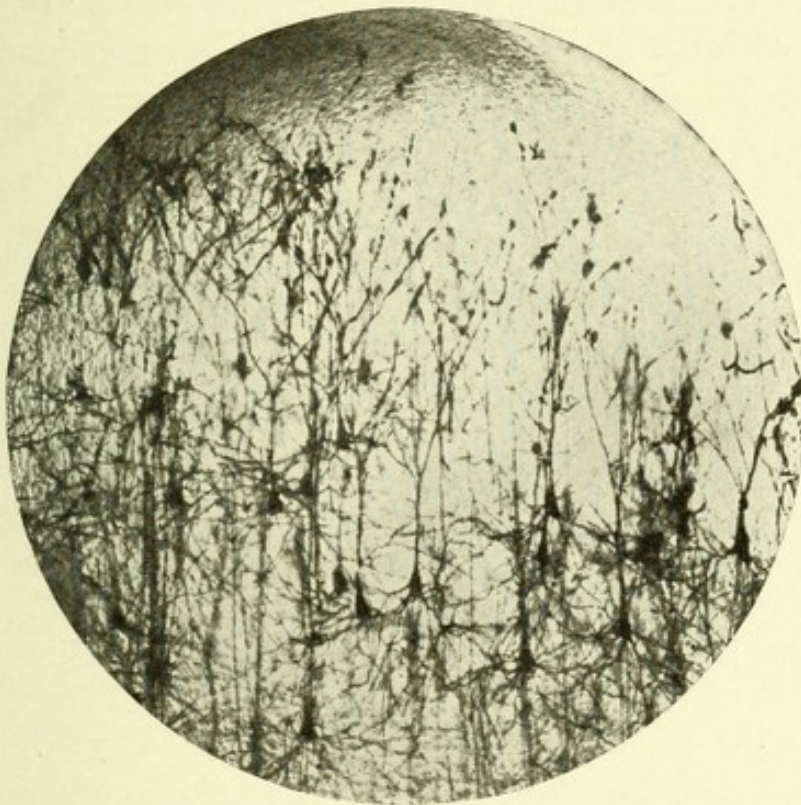

FIG. 166.—MICROPHOTOGRAPH OF SMALL PYRAMIDAL CELLS.

to be an intermediate form between the large and small pyramidal cells. In addition to the cell-groups of this layer, there are found numerous ascending axones from underlying cells, as well as the apical processes from the third or layer of large pyramidal cells. The small pyramidal cells are triangular in shape, 8 to 12 μ in diameter, and contain oval nuclei and nucleoli. Each cell possesses a single apical process, which is quite broad near its connection with the cell-body and becomes attenuated as it passes vertically upward into the superficial

layer. In their course they give off frequent branches, which further subdivide, and pursue a similar course to the main process, which latter terminates in the superficial part of the molecular layer, where occasionally the process forks. A few small dendrites spring from the surface of the cell-body. Two large dendrites come off from the base of each cell, each basal corner giving rise to one. They pursue a course somewhat obliquely to the plane of the vertical fibers of the cortex.

The dendrites as well as the apical processes are studded with minute club-shaped protoplasmic processes or gemmules. These gemmules may be beautifully seen on the dendrites of the pyramidal cells of the brain of a mouse or rat. The apical processes present at irregular intervals tuber-like or varicose swellings. In opposition to this statement it should be stated that many observers believe these tuberosities to be always of pathologic import, but, according to Lenhossek, they are due to local increases of chromophyllic particles. The axones from these cells usually spring from the middle of the base of the cells. They are very fine, perfectly smooth, and of uniform thickness throughout. They become medullated, and enter the white matter as medullated nerve-fibers. They give off at right angles collaterals which, according to Cajal, pass upward to end in the superficial layer of the cortex (Fig. 166).

The third layer, or **layer of large pyramidal cells**, contains, in addition to these cells, a great number of vertical fibers, many of which are doubtless centripetally coursing axones from the central ganglia, medulla oblongata, spinal cord, and cerebellum. Some of them, with their collaterals, terminate about the dendritic processes of the cells of this layer, while others continue upward and terminate in the superficial layer. This layer contains, in addition to its characteristic pyramidal cells, another class of cells whose axones course upward. These cells were first discovered by Martinotti, a pupil of Golgi, and hence have received the name of Martinotti's cells. A few small cells with numerous dendrites, possibly belonging to Golgi's second type, are also found in this layer.

The transition from the cells of the second to those of the third layer is a gradual one, the cells increasing in size as they

become more deeply situated, small pyramidal cells often being observed among the larger ones, and an occasional large pyramidal cell being seen in the second layer. The cells which are characteristic of this layer are much larger than those of the layer above, their average size being from 12 to 40 μ in diameter. Some of the largest, according to Bevan Lewis, are from 30 to 96 μ in length and 12 to 45 μ in breadth. Their dendrites are more numerous, and their apical processes of much greater length than those of the second layer. Each cell possesses a large,

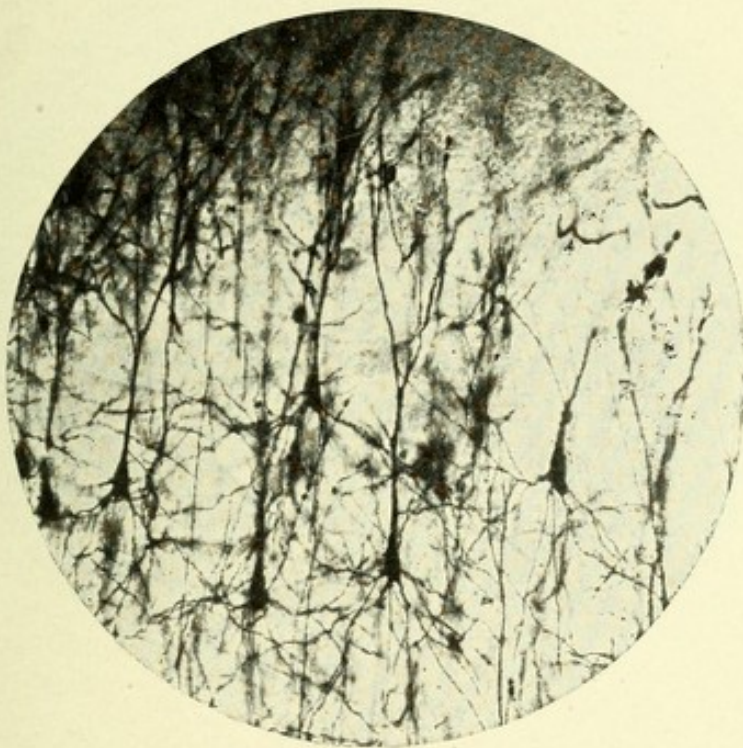


FIG. 167.—MICROPHOTOGRAPH OF LARGE PYRAMIDAL CELLS.

oval nucleus, which contains a nucleolus; these cells often contain a yellowish pigment, found most frequently near the base of the chief dendrite or axone. The cell-body is distinctly triangular or pyramidal, and gives off numerous dendrites, the largest of which proceed from the angles at the base of the cell. These latter dendrites frequently branch and pursue a diagonal course. The apical process or dendrite is of great length, broad near its point of connection with the cell-body, and gradually narrows as it ascends, and presents in its course beaded swellings or vari-

cosities. When it reaches the outer cortical layer it usually forks, each division breaking up into a number of fine terminals, which assume a horizontal course continuous with the superficial fibers of this layer. Occasionally, in man and in other

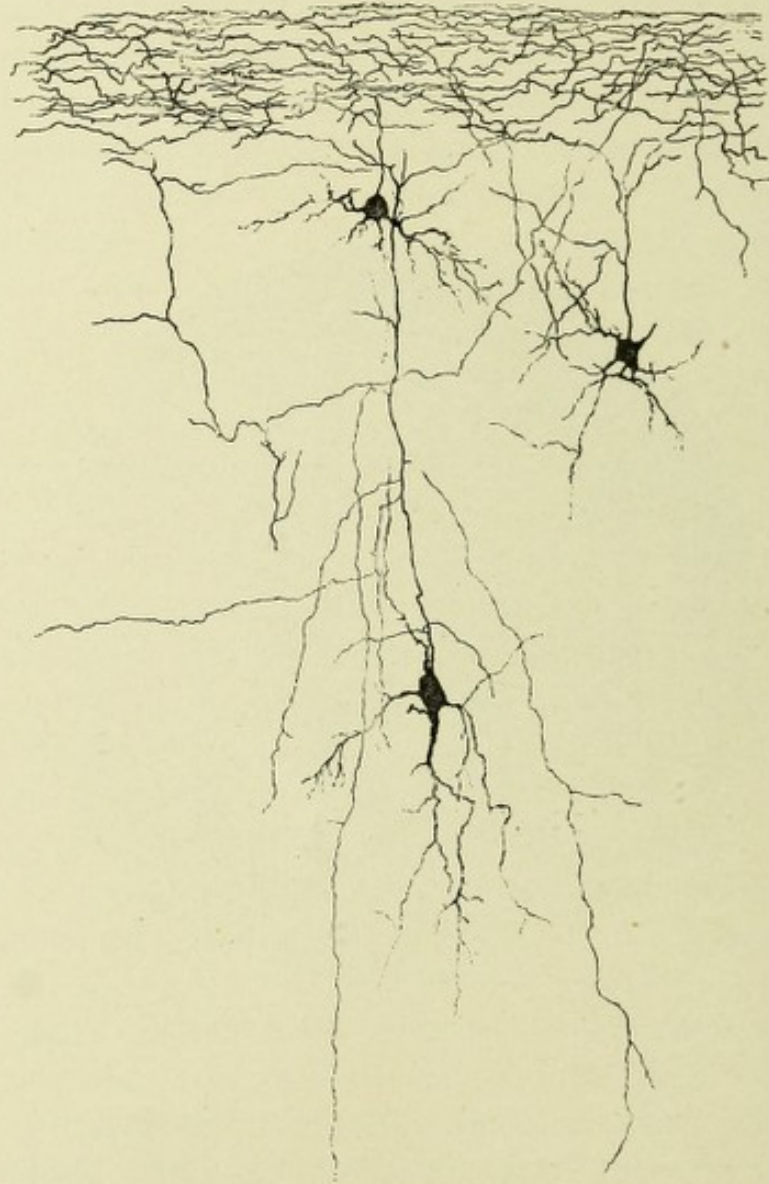


FIG. 168.—CELLS WITH ASCENDING AXONES FROM THE CORTEX OF THE GYRUS FORNICATUS OF A SIX-DAYS'-OLD MOUSE.—(After Koelliker.)

mammalia, the apical process branches when it reaches the level of the small pyramidal cells, both divisions continuing upward into the outer cortical layer, where they fork and then break up into a brush of terminal filaments. The dendrites are all

studded with gemmules. The axone or axis-cylinder process arises from the basal surface of the cell-body, usually close to its middle, and proceeds downward, is perfectly smooth, very fine, and has the longest course of any axone in the central nervous system. Proceeding from the cortex it continues through the central ganglia, brain-stem, pons, and medulla, to terminate about the motor cells of the spinal cord. Near its point of origin it

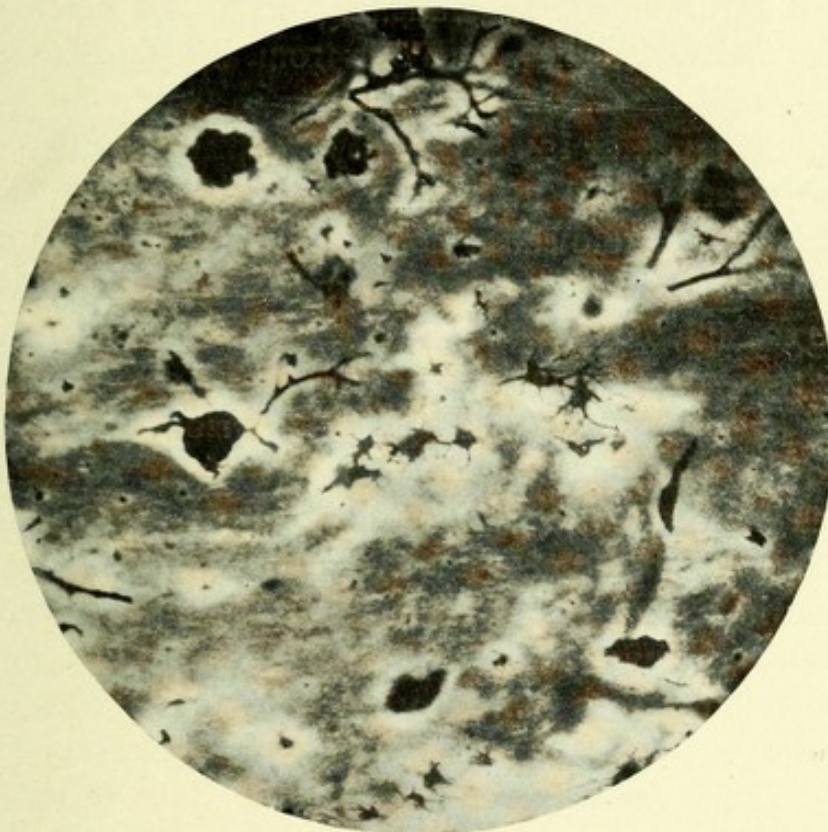


FIG. 169.—MICROPHOTOGRAPH OF POLYGONAL CELL OF THE FOURTH LAYER OF THE CEREBRAL CORTEX OF A MOUSE'S BRAIN.

gives off at right angles several collaterals, some of which, according to Cajal, turn upward and enter the superficial cortical layer, where they are lost among the horizontal fibers. Both axones and collaterals become medullated, the former entering the white matter of the centrum semiovale as motor nerve-fibers (Fig. 167).

The cells of Martinotti are found in the human cortex, chiefly among the large pyramidal cells, although scattered cells of this character may be found in the second layer. They are some-

what triangular or spindle-shaped, and to the casual observer appear like inverted pyramidal cells. Their axones, which are very fine, pass out of the apex of the cell and course upward, many of them reaching the superficial layer, where they divide, each division further subdividing into a number of long, horizontal branches, which terminate in beaded or varicose extremities. They also give off collaterals, mostly horizontal, some of which probably terminate in the molecular layer. Usually from two to four rather coarse, branching dendrites, which possess gemmules and varicosities, pass out from the base of the cell-body (Fig. 168).

The fourth layer, or **layer of polymorphous cells**. In this layer one meets with a number of triangular, polygonal, small pyramidal, and spindle cells; hence its name of layer of polymorphous cells. The two most common varieties of cells in this layer are the spindle and polygonal cells; in fact, this layer was formerly termed the spindle-cell layer. The spindle-cells have the long axes of their bodies placed horizontally or at right angles to the plane of the vertical fibers of the cortex. Each cell gives off two large dendrites, one from each pole, which pursue either a horizontal or a somewhat diagonal course. Their branches, which are given off at short intervals, are covered with gemmules. The axone proceeds from the cell-body, possesses collaterals, and passes obliquely into the white matter. The polygonal cells possess numerous short dendrites and long, descending axones, the latter passing into the white matter. These cells are very abundant in the cortex surrounding the calcarine fissure. The axones from all these cells become medullated, and probably form association fibers.

THE ANATOMY OF THE CORNU AMMONIS, OR HIPPOCAMPUS MAJOR, AND THE GYRUS DENTATUS.

The hippocampal gyrus, also called the subiculum cornu ammonis, is situated along the inferior portion of the median surface of the temporosphenoid lobe, adjacent to the crus cerebri. It is the extension into that lobe of the gyrus fornicatus. Just above it is located a deep cleft or sulcus, the dentate

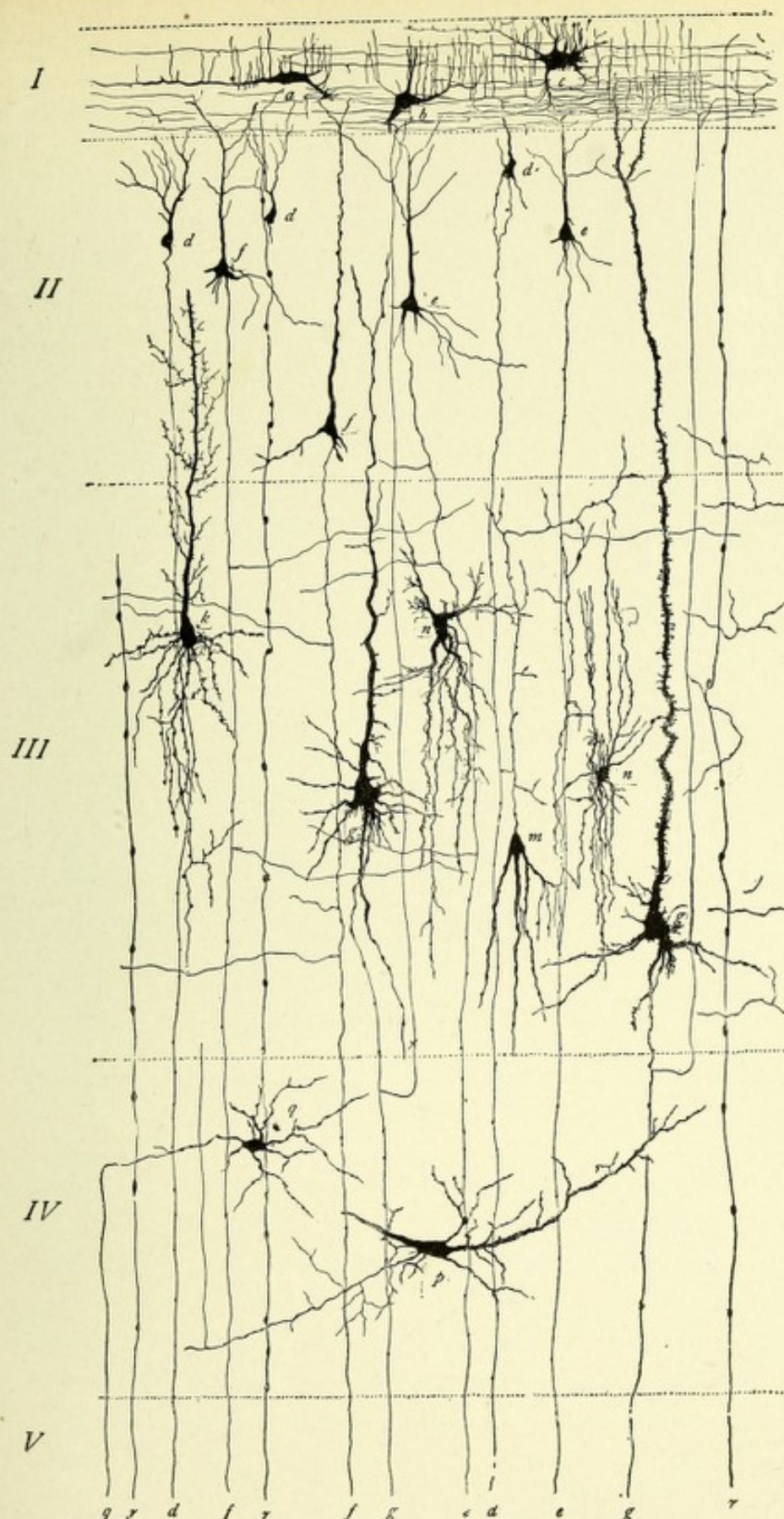



FIG. 170.—DIAGRAM OF THE CELLS OF THE CEREBRAL CORTEX.—(After Starr.)

- I.* Superficial or molecular layer. *a.* Fusiform. *b.* Triangular. *c.* Polygonal cells of Cajal.
II. Layer of small pyramidal cells. *d.* Smallest. *e.* Small. *f.* Medium-sized pyramidal cells with their axones descending to the white matter, giving off collaterals in their course.
III. Layer of large pyramidal cells. *g.* Largest (giant) pyramidal cells. *h.* Large pyramidal cell with very numerous dendrites. *i.* Martinotti cell with descending dendrites and ascending axone. *j.* Polygonal cells.
IV. Deep layer. *p.* Fusiform cell. *q.* Polygonal cell.
V. The white matter containing axones from pyramidal cells, *d, e, f, g,* and from cell of the deep layer, *q.* *r.* Neuroglia fiber.



fissure, which is a continuation of the transverse fissure, or fissure of Bichat. Inferiorly and dorsally, it is separated from the fusiform or inferior occipitotemporal gyrus by the fissure of the same name.

The gyrus hippocampus has the same histologic construction as the rest of the cerebral cortex until a point is reached where it becomes involuted or curves dorsomesially. This point is the subiculum proper. From this point on there is a peculiar transformation of the histologic elements, they partaking of the same character as those of the cornu ammonis, which this gyrus actually forms.

The cornu ammonis is the free ventricular portion of the

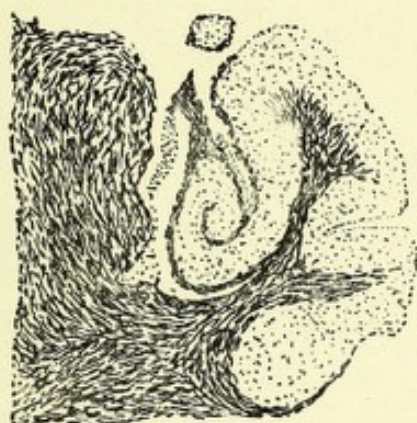

FIG. 171.—SECTION THROUGH LEFT GYRUS HIPPOCAMPUS. Showing the formation of the hippocampus major. Method of Weigert-Pal.

hippocampal gyrus, located in the descending horn of the lateral ventricle, and is an involution of the gyrus hippocampus, forming the hippocampal or dentate sulcus, located between it and the dentate gyrus, or fascia dentata. The general course of the gyrus is at first backward and slightly inward, forming the ventral or inferior lamina of the cornu ammonis; then forward and a little inward, forming the superior or dorsal blade of Ammon's horn. It then curves backward and terminates in the cleft or hilum of the dentate gyrus. It will thus be seen that it presents in its course a sort of spiral curve. Between the laminæ of the cornu ammonis is situated the dentate gyrus, and overlapping the dorsal or superior lamina is the free extremity



of the fimbria. From within outward this structure presents the following layers:

First, the epithelial layer, which is a part of the general ventricular epithelium—the ependyma. Upon this layer rests the choroid plexus.

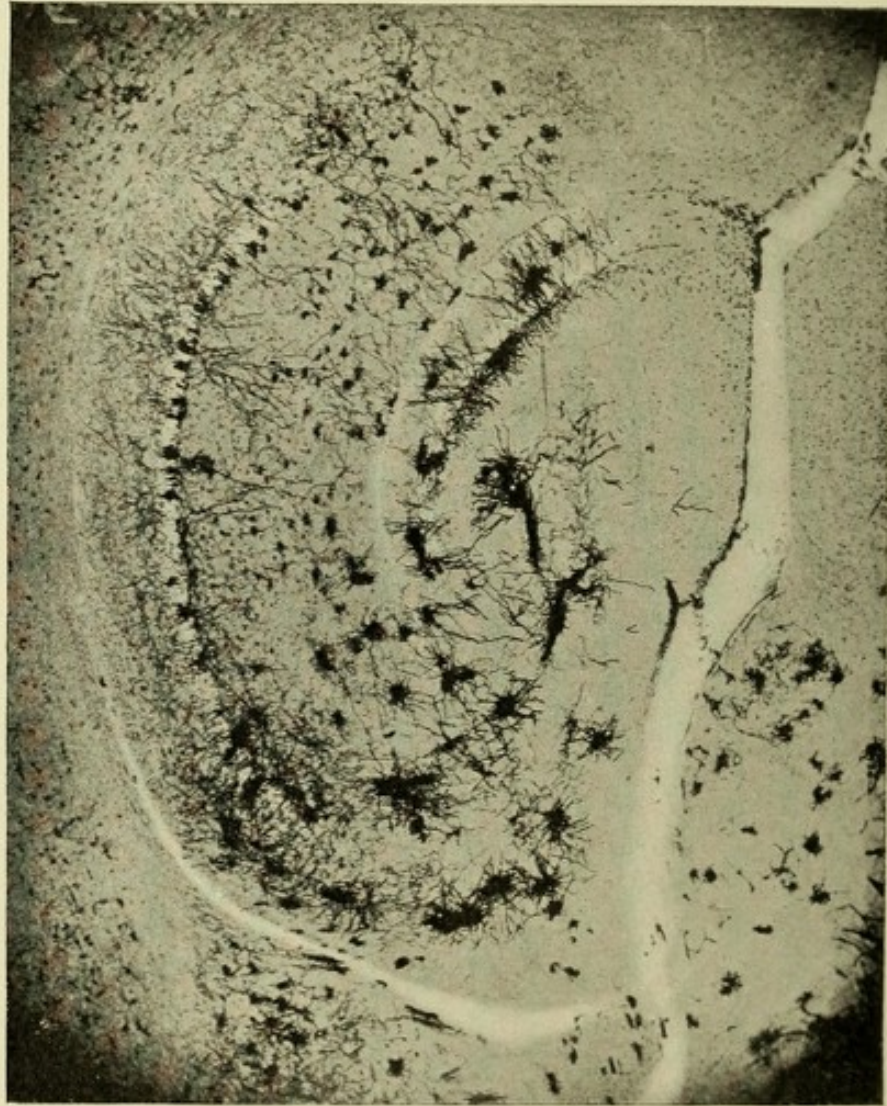

FIG. 172.—MICROPHOTOGRAPH OF A FRONTAL SECTION THROUGH THE BRAIN OF A MOUSE. Showing the peculiar involution of the gyrus hippocampus as it forms the cornu ammonis.

Second, the inner layer of horizontal fibers continuous with those of the white matter of the hemisphere, called the alveus.

Third, the layer of polymorphous cells, or stratum oriens, which corresponds to the fourth cortical layer.

Fourth, the layer of pyramidal cells, which represent the combined second and third pyramidal cell layers of the other parts of the cortex.

Fifth, the superficial layer, or substantia reticularis alba of Arnold. It corresponds to the outer or molecular layer of the cortex, and contains cells and fibers similar to those of that layer.

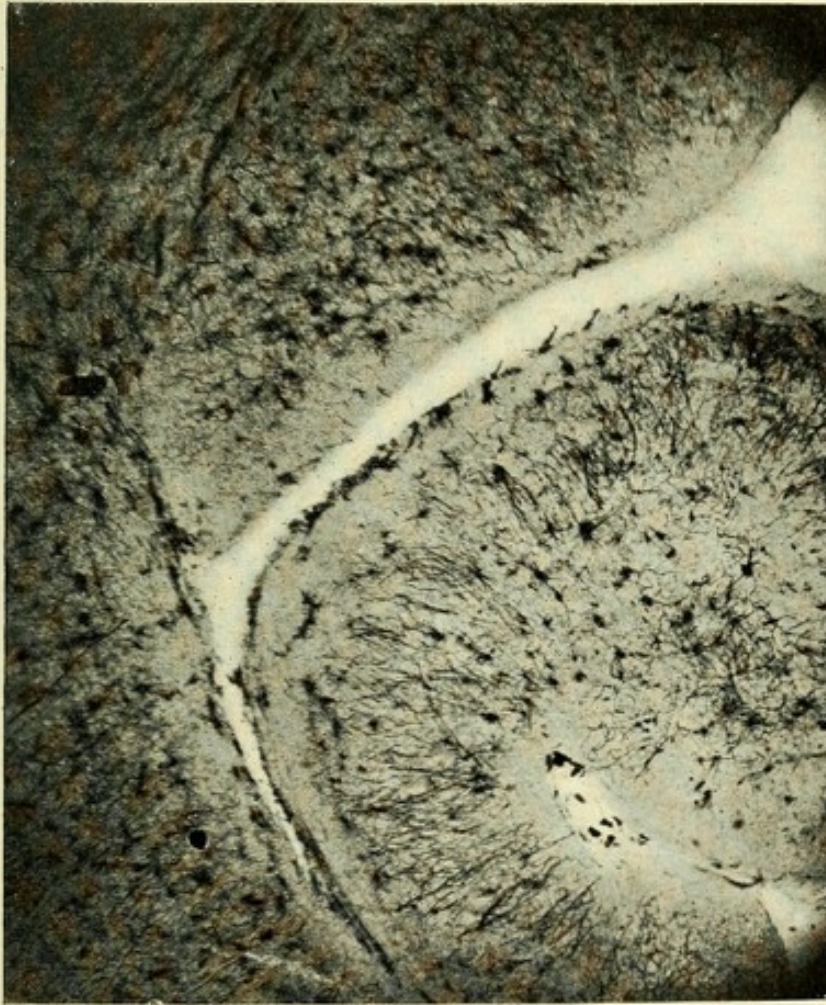


FIG. 173.—MICROPHOTOGRAPH OF CORNU AMMONIS OF A DOG'S BRAIN. Showing contour and formation of cornu ammonis.

This layer is divided into an outer and an inner portion. The former is called the stratum zonale, lamina medullaris circumvoluta, or stratum moleculare. The latter, which is much broader, consists of bundles of nerve-fibers, and is called the stratum lacunosum.

The first or epithelial layer consists of ciliated epithelial cells

with short or long radiating fibers. This layer rests upon the alveus and has resting upon it the process of the choroid plexus that descends into the middle cornu.

The second layer, or alveus, consists of fine and coarse horizontal fibers, having among them a few scattered polymorphous cells from the underlying layer—the stratum oriens. The nerve-fibers of this layer are the axones that issue from the bases of the pyramidal cells of the fourth layer; these axones become curved soon after leaving the cell-bodies, and assume a horizontal course. They give off collaterals, some of which pass into the next layer and end among the polymorphous cells; others course through the layer of pyramidal cells, ending just above them.

The third layer is the layer of polymorphous cells, and is called the stratum oriens. This layer corresponds to the fourth cortical layer, and contains cells of a like character. This layer contains, in addition to the basal dendrites of the pyramidal cells, which possess ascending axones, cells resembling or identical with those of Martinotti. In the deeper part of this layer the spindle or triangular cells predominate; the long axes of their cell-bodies are horizontal; their axones either terminate about the pyramidal cells or end in the superficial layer. According to Cajal, the cells with ascending axones pursue a course between the dendrites of the pyramidal cells and terminate about the bodies of these cells in a rich plexus of fibrils. A few axones continue into the deep part of the superficial layer, or stratum lacunosum.

Fourth, the pyramidal cell layer. This layer corresponds to the second and third cortical layers or the layers of small and large pyramidal cells of the rest of the cortex. The small and large cells are intermingled with one another, there being no distinction into layers. The smaller variety of cells may be considered rather scarce. The larger cells predominate; they are rather deeply situated, and resemble very closely the pyramidal cells of other parts of the cortex. The bodies are mostly triangular or spindle-shaped; their apical processes are very long, and branch closer to the cell-body than is the case with the other pyramidal cells throughout the cortex. Each branch leaves the stem at rather an acute angle; these branches further

subdivide into branchlets, all of which become clustered together into brushes of dendritic processes, which course through the deep part of the superficial layer—the stratum lacunosum—and terminate in horizontal filaments in the outer part of the superficial layer. The area just beneath the stratum lacunosum, which is occupied by the unbranched or but slightly branched

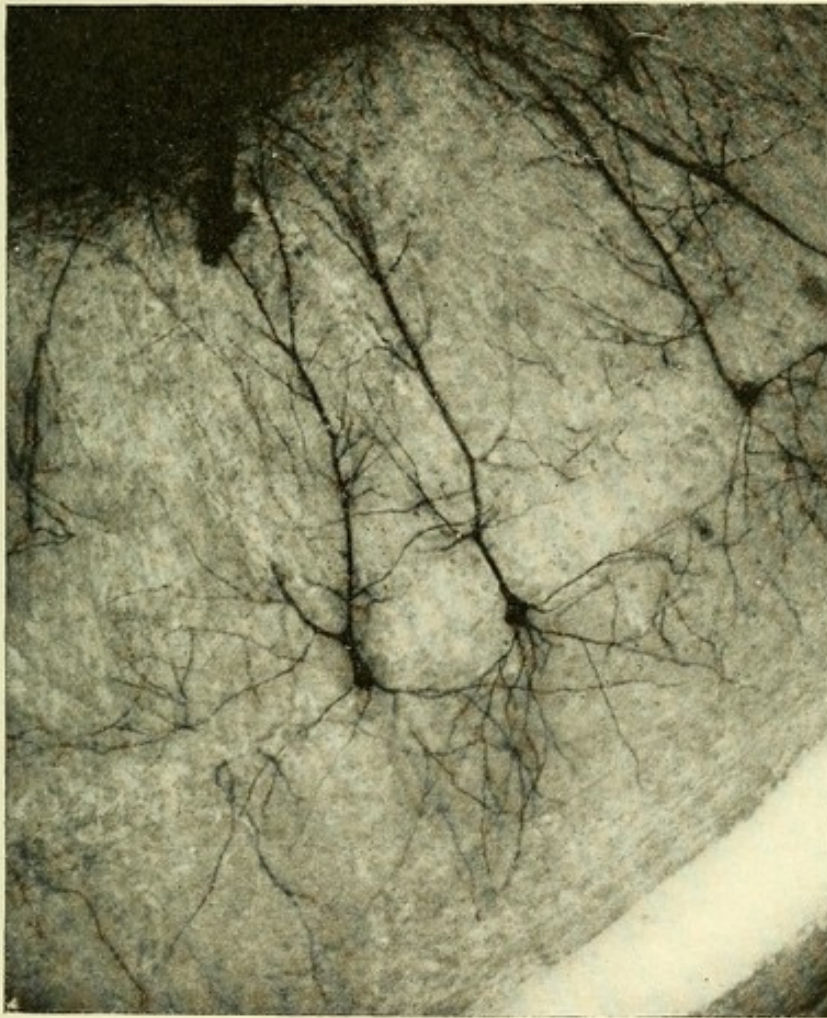


FIG. 174.—MICROPHOTOGRAPH OF CORNU AMMONIS OF A RAT'S BRAIN. Showing three large pyramidal cells.

apical processes of the pyramidal cells, is called the stratum radiatum. The basal dendrites of these cells are much the same as those of the pyramidal cells to be found elsewhere in the cortex, save that their processes are much shorter and that they branch more frequently. The axones proceed quite as often from a main basal dendrite as from the base of the cell-body ;

they pass into the alveus, where they form horizontal fibers. According to Cajal, the axones, on entering the alveus, bifurcate, both divisions becoming horizontal and pursuing a course opposite to each other. The collaterals given off from these axones terminate about the polymorphous cells or among the dendrites of the pyramidal cells. In the dorsal or superior laminae of the cornu ammonis of lower animals pyramidal cells exist which are

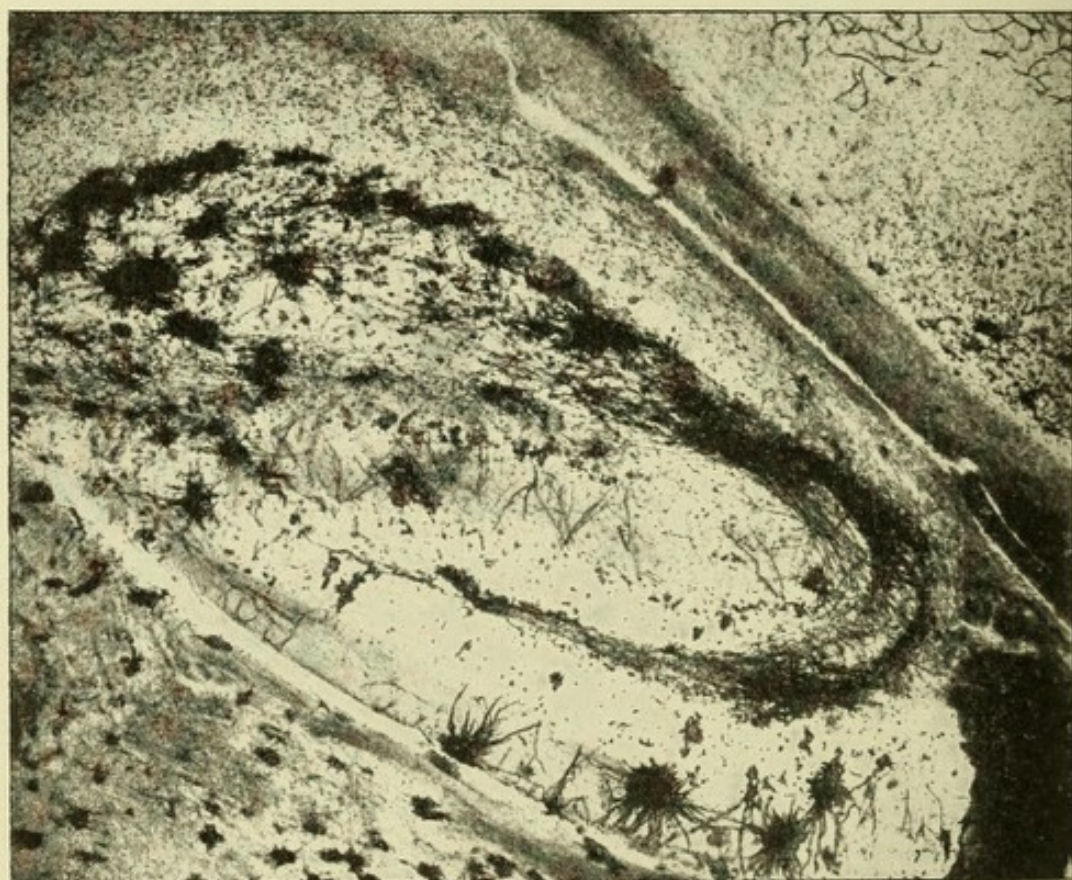


FIG. 175.—MICROPHOTOGRAPH THROUGH CORNU AMMONIS. Showing the deep part of the superficial layer, or stratum lacunosum.

very large; hence they are called giant pyramidal cells. Their apical processes are very short or wanting, the dendrites frequently springing directly from the apex of the cell-body; the axones from these cells pass into the fimbria. They give off collaterals which pass into the stratum lacunosum as medullated nerve-fibers, and terminate about the ascending dendritic processes of the ordinary pyramidal cells, thus associating the giant pyramidal cells with the ordinary type of pyramidal cells.

Fifth, or outer layer of the cornu ammonis, may be subdivided into a superficial portion, the *stratum moleculare* or *zonale*, and an inner, the *stratum lacunosum*. This latter consists of cells and a broad layer of nerve-fibers having a horizontal course—"tangential fibers." The fibers begin at the subiculum proper and course throughout the entire extent of the cornu ammonis. There are four chief sources for the fibers of this layer—namely, collaterals from the large and ordinary-sized pyramidal cells, collaterals from the fibers of the alveus, from the ascending axones from the polymorphous cells, and axones from the stellate and triangular cells of this layer. The cells of this layer have both ascending and descending dendrites; the former terminate in this layer or in the stratum zonale, the latter in the stratum oriens. The axones from these cells have a horizontal course, terminating in this layer or in the stratum zonale.

The outermost part of the superficial layer of the stratum zonale, or lamina medullaris involuta, corresponds to the molecular layer of the rest of the cortex. This latter consists of horizontal fibers and spindle- and stellate-shaped cells, the latter belonging to Golgi's second type. The axones of both varieties of cells terminate in this layer. The nerve-fibers of the layer as they approach the subiculum become continuous with those of the stratum lacunosum; this layer also contains the terminations of the apical processes of the pyramidal cells.

GYRUS OR FASCIA DENTATA.

This small gyrus consists microscopically of three distinct layers: an outer superficial layer, or stratum zonale; a middle or layer of small granular or pyramidal-shaped cells, often called the stratum granulosum; and an inner layer of polymorphous cells.

The superficial layer, or stratum zonale, consists of numerous medullated nerve-fibers, which have a horizontal course—"tangential fibers." They consist of the ascending axones from the cells of the innermost layer, or layer of polymorphous cells, and of collaterals and terminal fibers from the alveus of the cornu ammonis. This layer also contains the termination of the apical processes of the granular or small pyramidal cells.

The middle or second layer consists of small pyramidal or granular cells ; hence, often called the stratum granulosum. The cells of this layer are very small and are pyramidal or spheric in shape. They possess apical but no basal dendrites. The apical processes or dendrites terminate in the most superficial

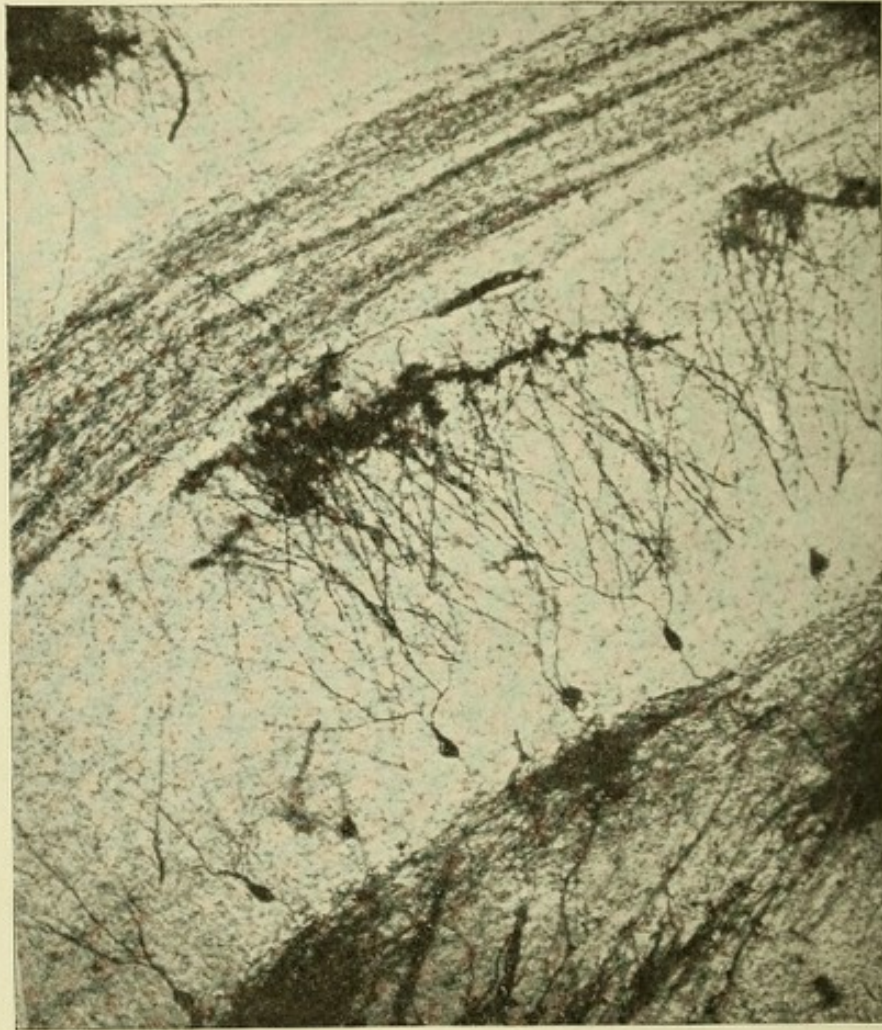


FIG. 176.—MICROPHOTOGRAPH OF SECTION THROUGH CORNU AMMONIS AND GYRUS DENTATUS (RAT'S BRAIN). Showing a group of small pyramidal cells of the gyrus dentatus.

part of the stratum zonale. The axones proceed from the base of the cell-bodies, and passing downward give off, in the layer of polymorphous cells, numbers of collaterals, which form, deep beneath the small pyramidal cell layer, a dense network of fibers. The axones continue downward until they reach the region of the large pyramidal cells of the terminal end of the cornu ammonis. In their course they frequently present vari-

cosities, which give these fibers the same appearance as the moss-like fibers of the cerebellum, and hence they are often called the moss-fibers of the fascia dentata. When they reach the region of the large pyramidal cells of the terminal end of the cornu ammonis they separate into two fasciculi, one of which

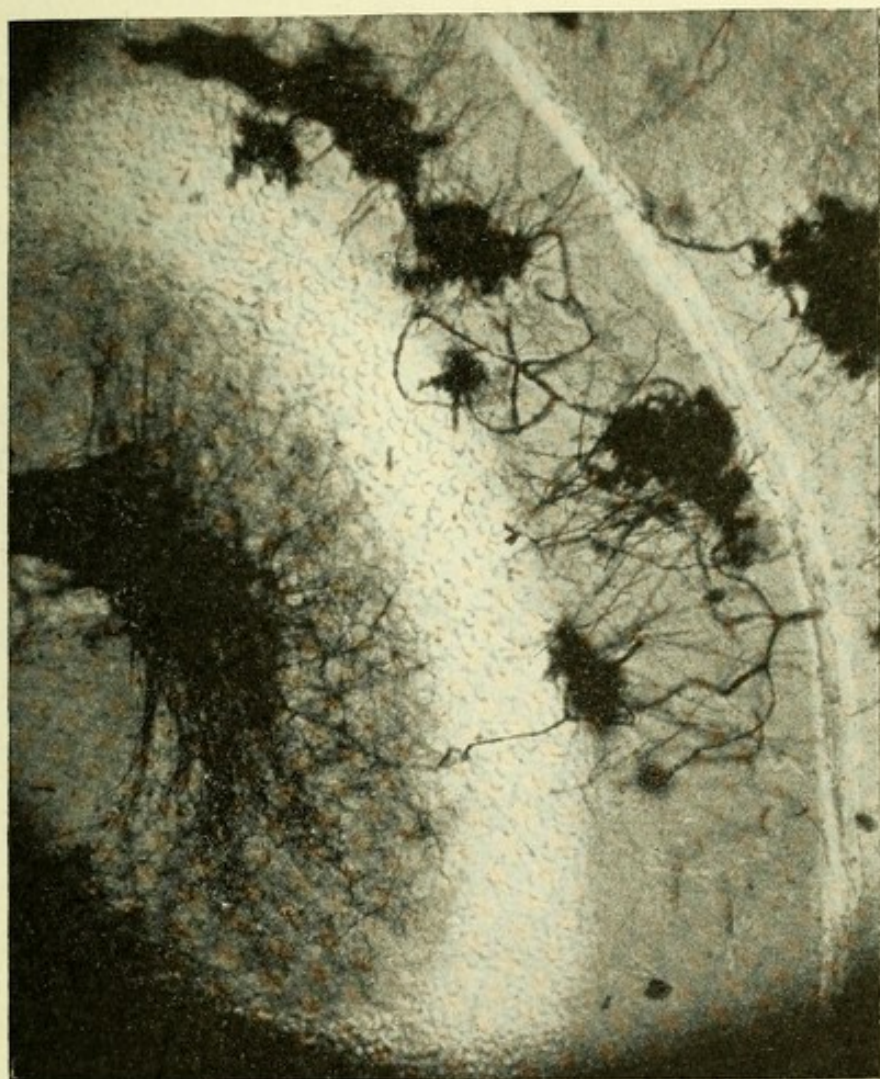


FIG. 177.—MICROPHOTOGRAPH OF SMALL PYRAMIDAL CELLS OF THE GYRUS DENTATUS AND THEIR AXONES, FORMING THE MOSS-LIKE FIBERS.

passes above the bodies of the pyramidal cells, to end about them and their apical dendrites; the other fasciculus courses beneath these same cells, terminating about their basal dendrites. These axones are associative in function, harmonizing the action of the large pyramidal cells of the cornu ammonis and those of the fascia dentata (Figs. 176 and 177).

The third, or layer of polymorphous cells, consists of three varieties of cells: (1) Cells whose axones proceed upward; (2) those which pass downward; and (3) cells of Golgi's second type. The bodies of the cells whose axones have an ascending course are pyramidal in shape; they possess both ascending and descending dendrites. The former course through the layer above, or stratum granulosum, and terminate in a brush of branchlets in the superficial layer. The latter descend and ramify in the deeper parts of the third layer. The axones from these cells course upward and reach the superficial layer, when they pursue a long, horizontal course. They give off numerous descending collaterals, which ramify between the small pyramidal cells, thus forming an intrapyramidal plexus. The cells whose axones have a descending course have a stellate or spindle form. Their axones continue downward through the layer of pyramidal cells of the cornu ammonis, and terminate as medullated nerve-fibers in the alveus.

The cells of Golgi's second type consist of many branched cells whose processes often reach the outer layer.

THE CENTRUM OVALE.

THE MINUTE ANATOMY.

A section made through the centrum semiovale conveys to one's mind no idea of the intricate maze or tangle of fibers of which the white matter is composed. To the naked eye it appears as a homogeneous, white mass, but if the brain be properly hardened by immersion in alcohol for a long period, its constituent fibers may be separated by teasing. By the most recent selective methods of staining, sections of this apparently homogeneous mass of white matter may be seen to consist microscopically of great numbers of medullated nerve-fibers passing in a variety of ways. As a result of embryologic and anatomic studies, and of investigations of secondary degenerations the result of pathologic changes, the following systems of fibers have been differentiated: First, fibers of association; second, the projection system of fibers; and third, the commissural fibers. The association tracts connect near or distant parts of the

same hemisphere, thus bringing the various regions of the hemisphere into intimate association with one another. The projection system connects definite anatomic areas of the cerebral cortex with distant parts lying below. Thus the tracts of which this system is composed pass through the centrum

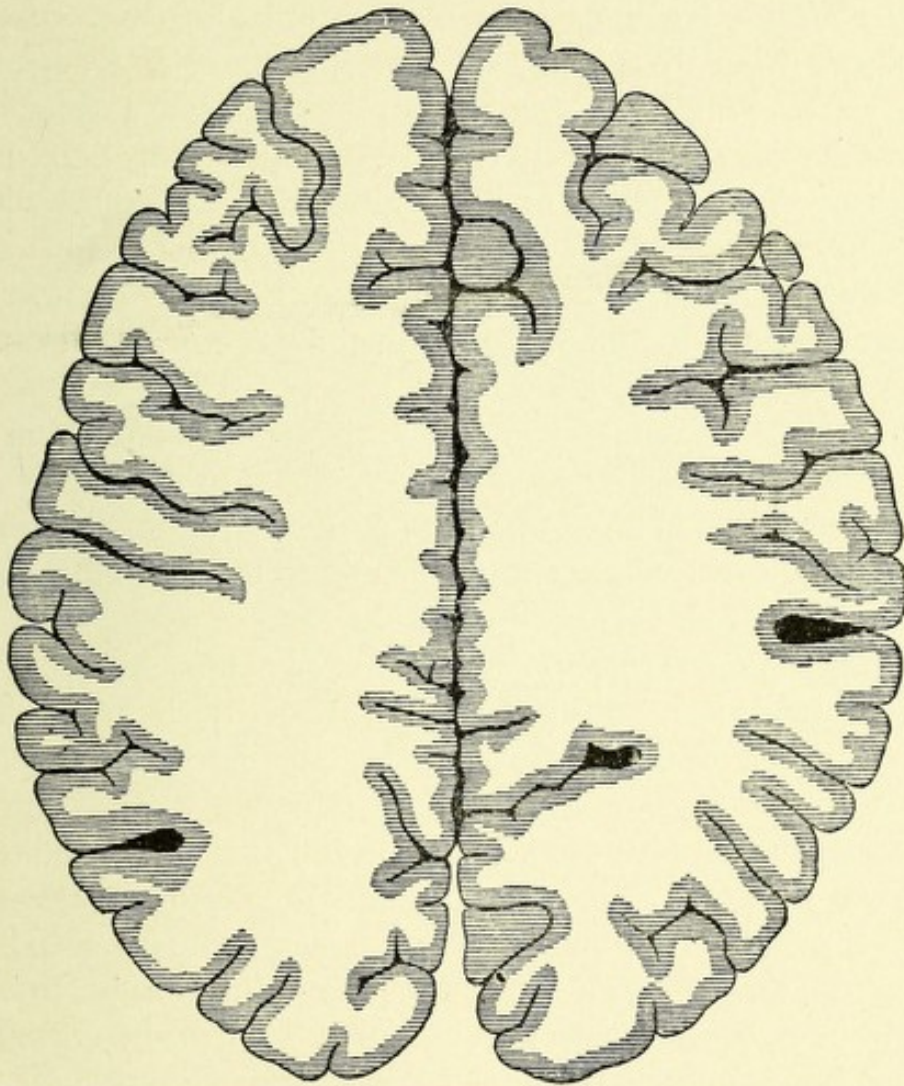


FIG. 178.—HORIZONTAL SECTION OF CEREBRUM ABOVE THE CORPUS CALLOSUM TO SHOW THE CENTRUM OVALE.—(After Van Gehuchten.)

semiovale (centrifugal fibers), on their way to the central ganglia, where a number of them end. The remaining bundles of fibers pass by way of the crura cerebri to the pons, cerebellum, medulla, and spinal cord. Other fasciculi belonging to this system, and having a centripetal course, serve to unite the spinal cord, cerebellum, pons, and basal ganglia with the cerebral

cortex. The commissural fibers pass from one cerebral hemisphere to the other, thus forming a bond of union between them.

The **association fibers** may be divided into short and long tracts. The former, or *fibræ arcuatæ propriæ*, lie in and just beneath the cortex, and unite closely adjacent cortical areas. It is very probable that most of the short fibers of association are the axones from the Cajal cells of the molecular layer of the cortex. The long tracts lie deeper beneath the cortex in the centrum semiovale, and unite different lobes of the hemisphere as well as distant parts of the same lobe. The association fibers represent the axones or collaterals of nerve-cells which connect the cells from which they spring with other cortical cells in the immediate neighborhood (short fibers), or with cells at a greater distance (long bundles of fibers). These axones and collaterals end in minute, tree-like ramifications among the cells to which they are destined. The short tracts or bundles of association fibers exist in large numbers throughout the hemispheres. They may be divided into two forms: first, tracts of fibers which pass beneath the cortex around the separate fissures, thus connecting one convolution with the two next adjacent gyri (*fibræ propriæ*); second, bundles of fibers which unite closely adjacent parts of the cortex, thus connecting each individual gyrus with the one next adjacent. These are the tangential fibers. By means of these association fibers each convolution is connected with every other convolution, thus bringing them into mutual relation. It is almost positive, according to Cajal, that most of the long fibers of association have their origin from the fusiform or polygonal cells of the fourth layer of the cortex and are their axis-cylinder processes. It is perfectly possible, however, that some of the association fibers may be the axones or collaterals of the pyramidal cells. The long tracts of association which connect distant parts of the same hemisphere are located rather deep beneath the cortex, in the centrum semiovale, and are divisible into the following important bundles:

The *cingulum* or *bundle of the gyrus fornicatus*, also called the *fasciculus arcuatus*, extends in an anteroposterior direction beneath the median surface of the hemisphere and above the

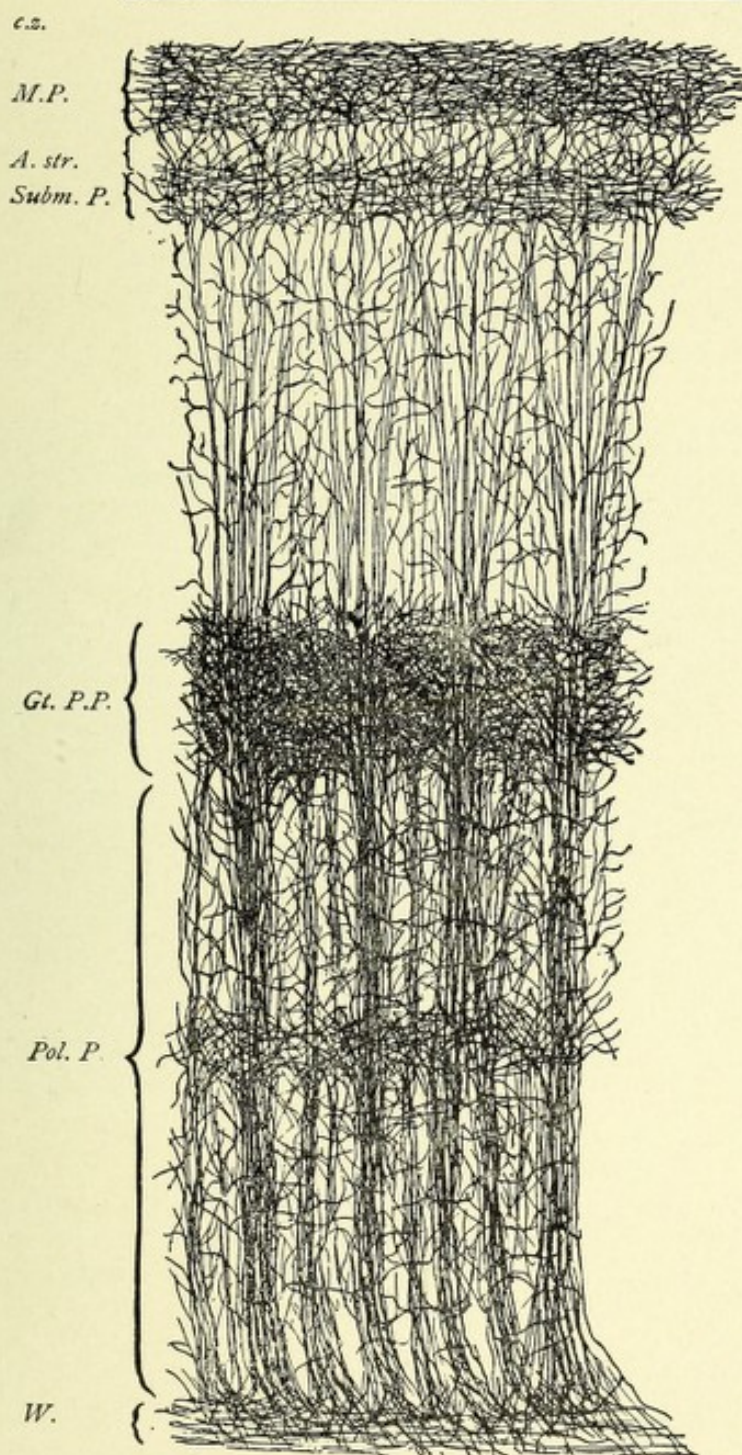


FIG. 179.—CORTEX OF HUMAN BRAIN. Showing the nerve-fiber systems and plexuses. Weigert's and Golgi's method combined.—(After Andriezen, from Starr's "Atlas.")

c.z. Clear zone. *M.P.* Molecular plexus in molecular layer. *A. str.* Ambiguous cell stratum. *Subm. P.* Submolecular plexus. *Gt. P. P.* Great pyramidal plexus. *Pol. P.* Polymorphic plexus. *W.* White substance.



corpus callosum, and constitutes the greater part of the white matter of the fornicate and hippocampal gyri. It passes in a curved manner, with its concavity downward and slightly forward, between the frontal and temporal lobes. The exact origin and termination of its fibers are unknown, but the following are the most generally accepted views :

1. Meynert believes that the anterior extremity of this bundle is in connection with the amygdaloid nucleus.
2. According to Broca, the cingulum connects the internal

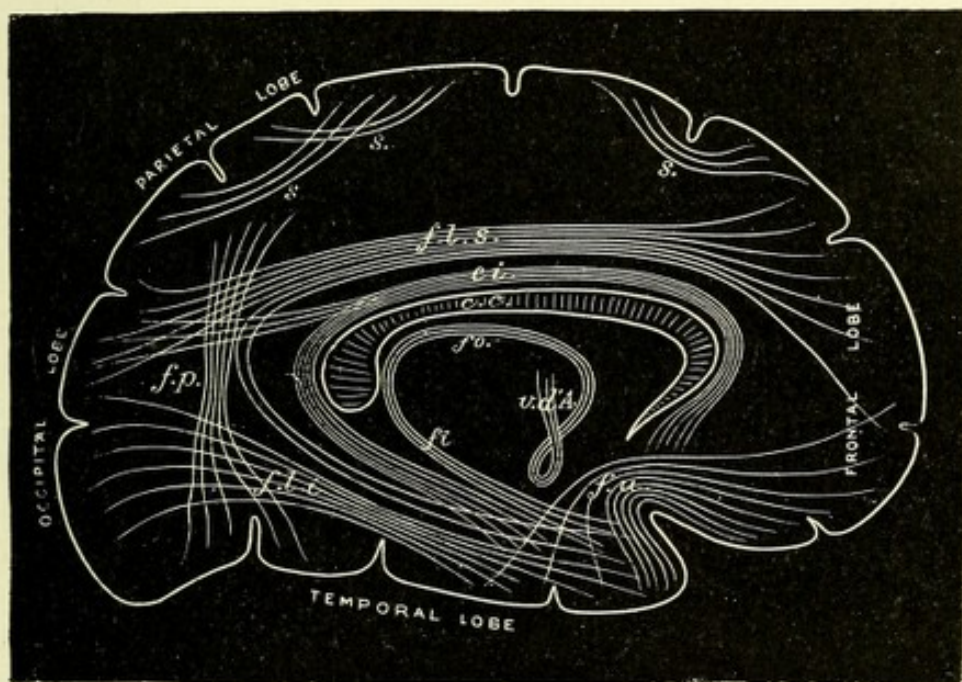


FIG. 180.—DIAGRAM OF THE ASSOCIATION-FIBERS OF THE CEREBRAL HEMISPHERE.

—(E. A. S., after Meynert, from Quain.)

- s.* Short association fibers, connecting adjacent gyri. *f.l.s.* Fasciculus longitudinalis superior. *c.i.* Cingulum. *f.p.* Fasciculus perpendicularis. *f.l.i.* Fasciculus longitudinalis inferior. *f.u.* Fasciculus uncinatus. *fo.* Fornix. *fi.* Fimbria. *v.d'A.* Bundle of Vicq d'Azyr.

and external roots of the olfactory nerves, he comparing this system to the frame of a tennis-racket, the olfactory roots representing the handle.

3. According to Beevor, the cingulum may be divided into three distinct fasciculi: an anterior fasciculus, which joins the anterior perforated space and internal olfactory root to the anterior extremity of the frontal lobe; a horizontal fasciculus, connecting the anterior part of the gyrus fornicatus to the marginal

convolution ; and a posterior fasciculus, connecting the hippocampal convolution to the lingual and fusiform lobules and to the extremity of the temporal lobe.

4. Von Monakow states that the cingulum starts in the occipitotemporal region and terminates in the frontal lobe.

The *fasciculus uncinatus* of Reil is the shortest of the long bundles of association. It is composed of fibers having their origin in the cells of the cortex of the anterior part of the first and second temporal convolutions, which extend in a curved manner just beneath the isle of Reil and close to the anterior perforated space, to the frontal lobe, in the following manner : The external fibers of this bundle, owing to the proximity of the inferior frontal and apex of the temporal lobes, describe a very sharp curve and pass to the cortex of the basal and convex surface of the inferior frontal gyrus, while the internal fibers present a more horizontal course and radiate to the orbital part of the first and third frontal gyri.

The *superior longitudinal fasciculus*, or *fasciculus arcuatus* of *Burdach*, passes through the centrum semiovale, external to the cingulum and beneath the lower border of the frontal and parietal convolutions, being situated above the level of the body of the corpus callosum. Beneath the supramarginal gyrus this fasciculus curves downward, backward, and then forward, its fibers spreading out fan-shaped and passing between the fibers of the corona radiata and corpus callosum, to terminate, according to Meynert, about the nerve-cells of the cortex of the convexity of the occipital and temporal lobes. In front it terminates in the convexity of the frontal lobe, the exact location of its anterior termination being still unsettled.

The Inferior Longitudinal Bundle.—The fibers of which this tract is composed come from all parts of the cortex of the occipital lobe. They are at first intermingled with the fibers of the corona radiata and corpus callosum, and pass through the white substance to collect into a small round bundle, which extends downward and forward just external to the descending horn of the lateral ventricle, increasing in size, to enter the temporal lobe. It receives in its course accessions of fibers from the cuneus, lingual, and fusiform lobules. At its termination it

radiates fan-shaped, giving off fibers to the temporal lobe, particularly to its anterior portion.

Fasciculus Occipito-frontalis (Forel and Onufrowicz).—The discovery of this tract resulted from the study of a case of deficient development of the corpus callosum, in which case the tapetum was found normal, while the corpus callosum was absent. This discovery of Forel and Onufrowicz has been confirmed by Muratoff, who found that, after complete section of the corpus

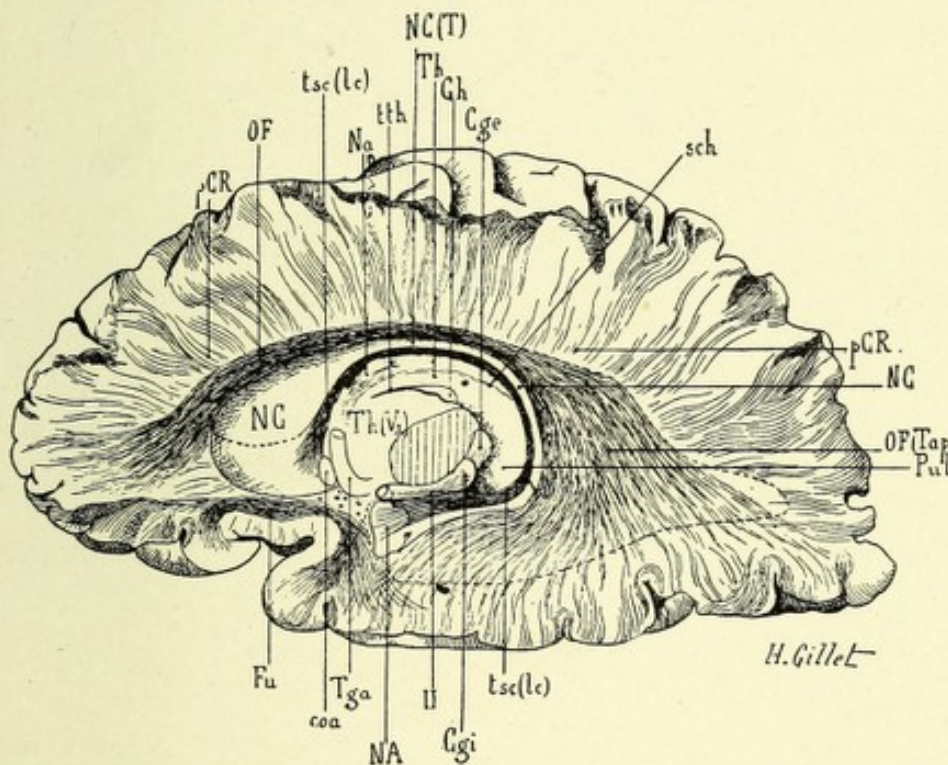


FIG. 181.—SEMIDIAGRAMMATIC REPRESENTATION TO SHOW THE FASCICULUS OCCIPITO-FRONTALIS, THE TÆNIA SEMICIRCULARIS AND THE FASCICULUS UNCINATUS.—(After Dejerine.)

Cge. External geniculate body. Cgi. Internal geniculate body. Coa. Anterior commissure. Fu. Fasciculus uncinatus. Gh. Ganglion of the habenula. NA. Amygdaloid nucleus. Aa. Anterior nucleus of optic thalamus. NC. Head of caudate nucleus. NC(T). Tail of caudate nucleus. NC(T). Body of caudate nucleus. OF. Fasciculus occipitofrontalis. OF(Tap). Part of the fasciculus occipitofrontalis forming the tapetum. pCR. Foot of corona radiata. Pul. Pulvinar. sch. Choroid sulcus. Tga. Anterior pillar of fornix. Th and Th(V₃). Optic thalamus. tsc(lc). Tænia semicircularis. tth. Tænia thalami. II. Optic tract.

callosum in dogs, the tapetum remained intact, and Kaufman found the tapetum intact in a case of softening involving the corpus callosum.

The fibers of which this tract is composed take their origin

from the cortex of the external and basal surface of the frontal lobe. They form a distinct bundle, located beneath and external to the corpus callosum and between the cingulum and the superior longitudinal bundle, being separated from the latter by the foot of the corona radiata. It describes a gentle curve, with the convexity upward, and courses along the external angle of the lateral ventricle beneath the ependyma, and, after forming the tapetum, radiates to the cortex of the external and basal surfaces of the occipitotemporal lobes.

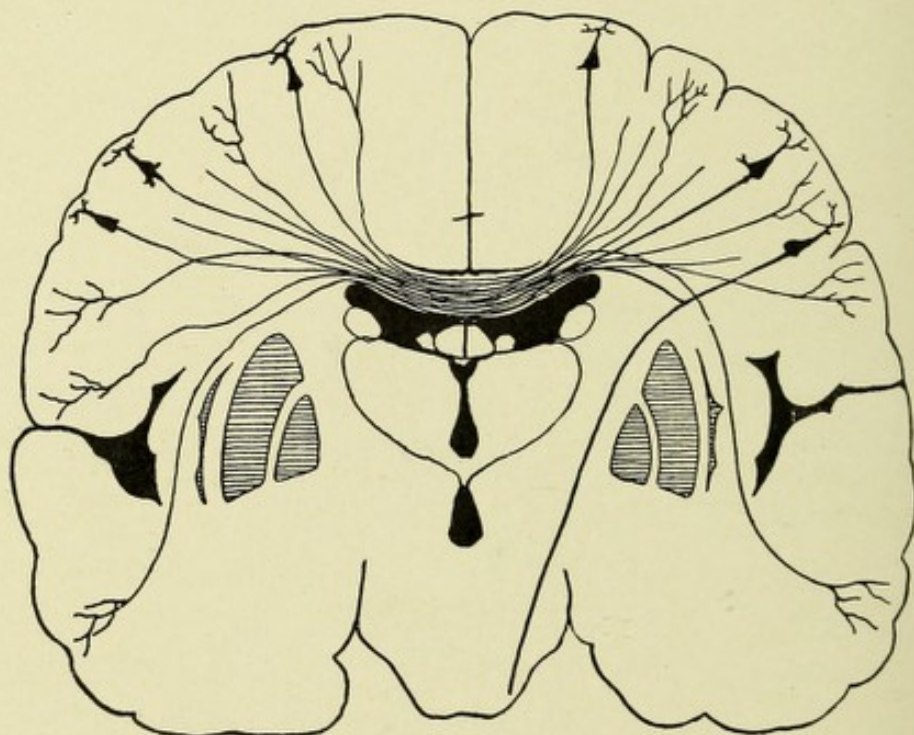


FIG. 182.—A SCHEME TO SHOW THE ORIGIN AND TERMINATION OF THE FIBERS OF THE CORPUS CALLOSUM.—(After Van Gehuchten.)

This tract joins the occipitotemporal lobes with the frontal lobe and the island of Reil, being connected to the latter by means of fibers which pass through the external capsule.

The Perpendicular Fasciculus of Wernicke.—This fasciculus is one of the shortest of the long bundles of association, and, in a general way, extends from the superior occipital lobule to the inferior occipital gyrus and fusiform lobule. This bundle may also connect with the inferior parietal lobe. It is a broad fasciculus of vertical fibers, whose width extends from the point of the occipital to the dorsal part of the parietal lobe. Von Mon-

akow doubts the existence in this region of any such bundle of association.

The fornix, as it serves the purpose of an association tract, may be considered here. It connects, by means of its fimbria, the gyrus hippocampus of each side with the corresponding corpus albicans, which latter body is connected with the optic thalamus both by means of a bundle of white fibers (Vicq d'Azyr) and by the anterior peduncle of the fornix. Thus the fornix serves as a band of connection between the optic thalamus and the cornu ammonis, through the gyrus hippocampus.

The commissural fibers which join the cerebral hemispheres consist, first, of fibers of the corpus callosum, and, secondly, of those of the anterior commissure. The corpus callosum is composed of great bundles of transversely arranged fibers which spring from the pyramidal and polygonal cells of the cerebral cortex, being their axis-cylinder processes or collaterals (Koelliker).^{*} The fibers join, according to Meynert, identical cortical areas of the frontal, occipital, and parietal lobes of both sides,[†] ending in arborizations about the pyramidal cells of the hemisphere opposite to their origin, the temporal lobes being united chiefly by means of the anterior commissure. According to Sherrington, there is a tendency for the fibers of the corpus callosum to separate, thus bringing distant as well as corresponding areas of the cortex into relation with one another. Hamilton states that the corpus callosum consists of projection fibers which start from the cortical cells of one side, pass through the centrum ovale, decussate and pass into the other side, take a downward course, divide into two bundles, the larger of which enters the internal capsule, losing some of its fibers in the optic thalamus, the remainder passing downward with the pyramidal fibers into the

^{*} According to Dejerine, the body of the corpus callosum does not present as simple a structure as has been commonly taught. It is not formed of regularly placed bundles of fibers, but of fibers which are more or less bound together, and so arranged that the superficial fibers of one side, after decussating, become the deep fibers of the other side, the anterior fibers of one hemisphere becoming the posterior fibers of the other hemisphere. It results from this double decussation that, if the corpus callosum contains commissural fibers which connect and associate symmetric and homologous regions of the two hemispheres, as Reil, Arnold, and Meynert teach, it also contains a great many fibers of association which unite asymmetric regions of the two hemispheres.

[†] The corpus callosum may also join the posterior parts of the temporal lobes.

pons, medulla, and possibly the spinal cord. The fibers of the smaller bundle pass into the external capsule, and possibly unite with the anterior commissure. The researches of Spitzka and Beevor seem to disprove Hamilton's claim.

The anterior commissure consists of a band of transverse fibers which connects the temporal lobes. The fibers of which the

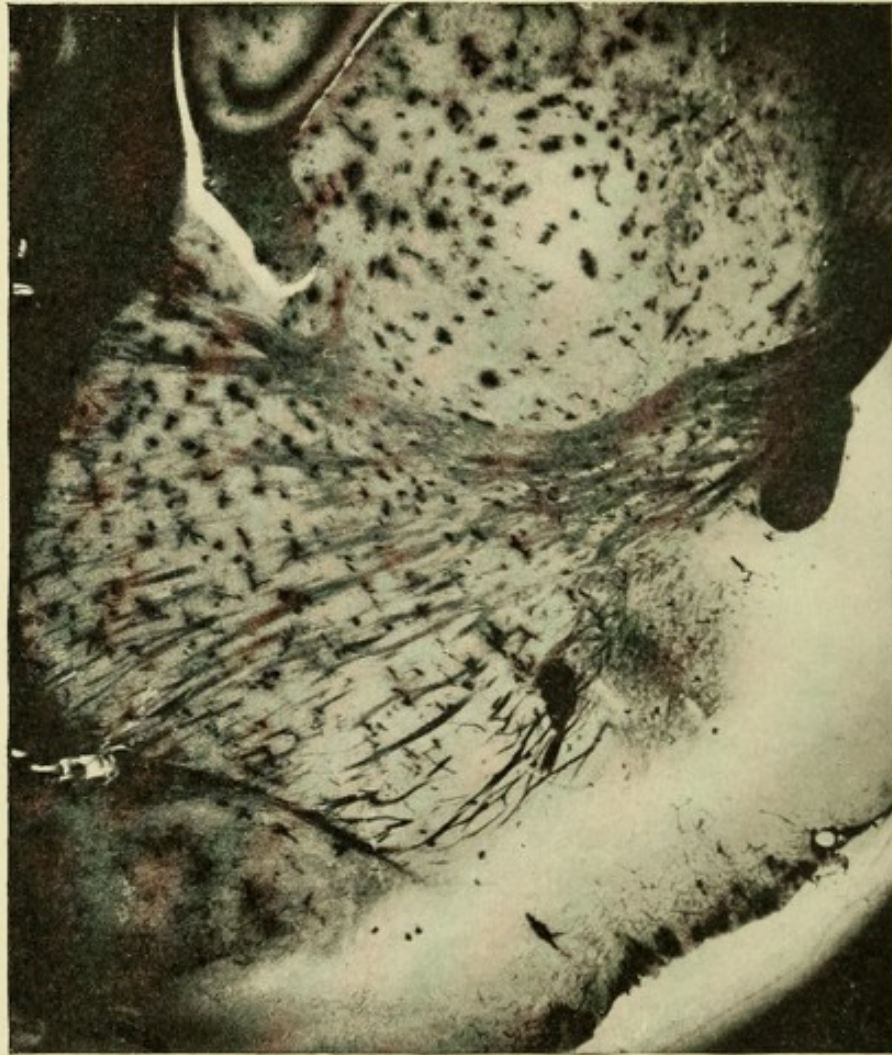

FIG. 183.—MICROPHOTOGRAPH SHOWING THE RADIATION OF THE FIBERS COMPOSING THE CORONA RADIATA OF A RAT'S BRAIN. Method of Golgi.

commissure is composed cross in the middle line just ventral to the third ventricle and anterior pillars of the fornix. They then take a curved direction laterally through the globus pallidus of the lenticular nuclei and beneath the putamen. The fibers then spread apart in a fan-shaped manner, to end among the cells of

the cortex of the temporal lobes. In man a small fasciculus of this commissure, derived from the olfactory tract, connects with the opposite hippocampal and uncinate gyri.

The cornu ammonis is connected with its fellow of the opposite side by a commissural band of fibers—the psalterium. These fibers, according to S. Ramon, represent the fine fibers of the alveus (inner layer of horizontal fibers of the cornu ammonis), which are the axones or collaterals of the pyramidal-cell layer of Ammon's horn.

The Projection System of Fibers.—The various tracts of which this system is composed have already been partly traced in describing the different anatomic divisions of which the cerebrospinal axis is composed. Here they will be traced throughout their entire course. It will be remembered that all the parts of the cerebral cortex are connected by a projection system of fibers with the optic thalamus. The following connections have been traced through the careful observations of von Monakow:

First, the cortex of the cornu ammonis is connected with the cells of the anterior tubercle of the optic thalamus through the fasciculus of Vicq d'Azyr and through the fimbria of the fornix.

Second, the cortex of the island of Reil, and that of the adjacent parts of the second and third frontal convolutions, are in anatomic relation, through a fasciculus of fibers which passes through the internal capsule, with the median nucleus of the thalamus.

Third, the cortex of the central convolutions is in relation, by a fasciculus of projection fibers which course through the capsule, with the lateral nucleus of the thalamus.

Fourth, the frontal lobe is connected, by a bundle of fibers which pass through the anterior limb of the internal capsule, with the anterior division of the ventral nucleus, the posterior division of this nucleus being connected with the operculum, the central gyri, and the gyrus supramarginalis.

Fifth, the posterior nucleus of the thalamus is in relation with the cortex lying between the temporal and occipital lobes.

Sixth, the pulvinar and external geniculate body, as well as the anterior corpus quadrigeminum, are in anatomic relation through the central optic tract—"optic radiation of Gratiolet"—

with the cortex of the occipital lobe, chiefly the cuneus and those parts of the cortex bordering on the calcarine fissure; this tract passes through the extreme posterior part of the posterior limb of the internal capsule.

Seventh, the corpus geniculatum internum of the thalamus and the posterior corpus quadrigeminum are in relation with the cortex of the first and second temporosphenoid gyri by means of the auditory tract.

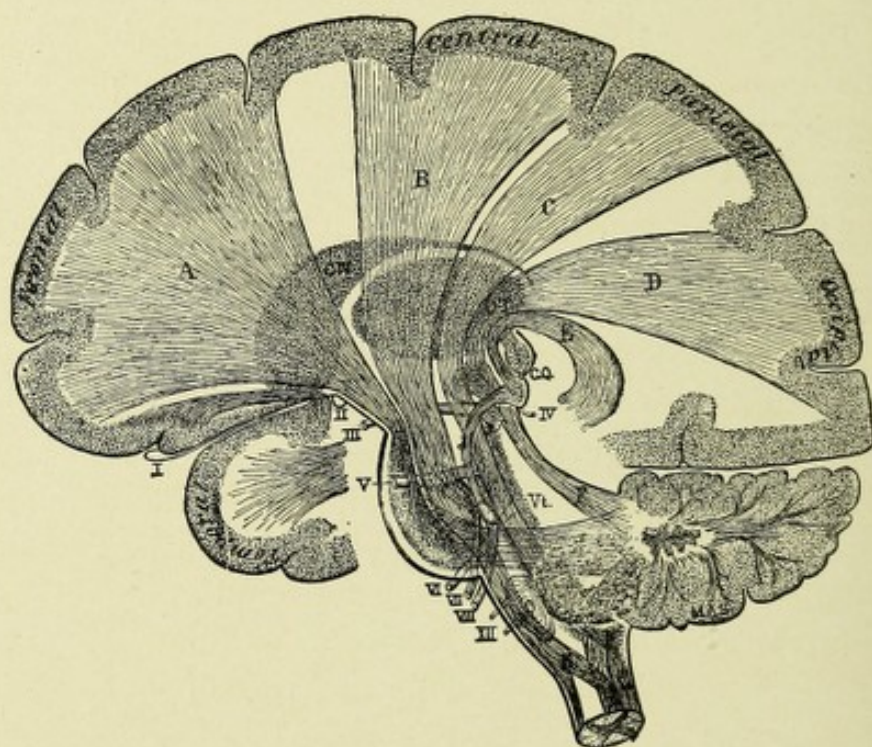


FIG. 184.—DIAGRAMMATIC ARRANGEMENT OF THE PROJECTION TRACTS CONNECTING THE CEREBRAL CORTEX WITH THE LOWER NERVE-CENTERS.—(After Starr.)

A. Frontocerebellar tract. B. Motor tract. C. Sensory tract. D. Visual tract from optic thalamus (OT) to the occipital lobe. E. Central auditory tract. F. Superior cerebellar peduncle. G. Middle cerebellar peduncle. H. Inferior cerebellar peduncle. CN. Caudate nucleus. C.Q. Corpora quadrigemina. Vt. Fourth ventricle. The numerals refer to the cranial nerves. J. Eighth nerve nucleus.

The long tracts of the projection system of fibers pass through the internal capsule into the crura cerebri, where they become separated into fasciculi, one body of these occupying the ventral part, or crusta, and the other the dorsal part, or tegmentum of each peduncle. The former are the prolongations of the axis-cylinder processes, or axones, of the pyramidal cells of the cortex. The following bundles occupy in the peduncle its anterior por-

tion—foot, or crusta : The frontocerebellar tract, the motor tract, and a tract connecting the occipital and temporal lobes with both cerebellar hemispheres, but chiefly with the cerebellar hemisphere of the opposite side.

The *frontocerebellar tract* is composed of axones from the pyramidal cells of the prefrontal lobes ; from this wide area of origin the fibers from this tract converge as they proceed down-

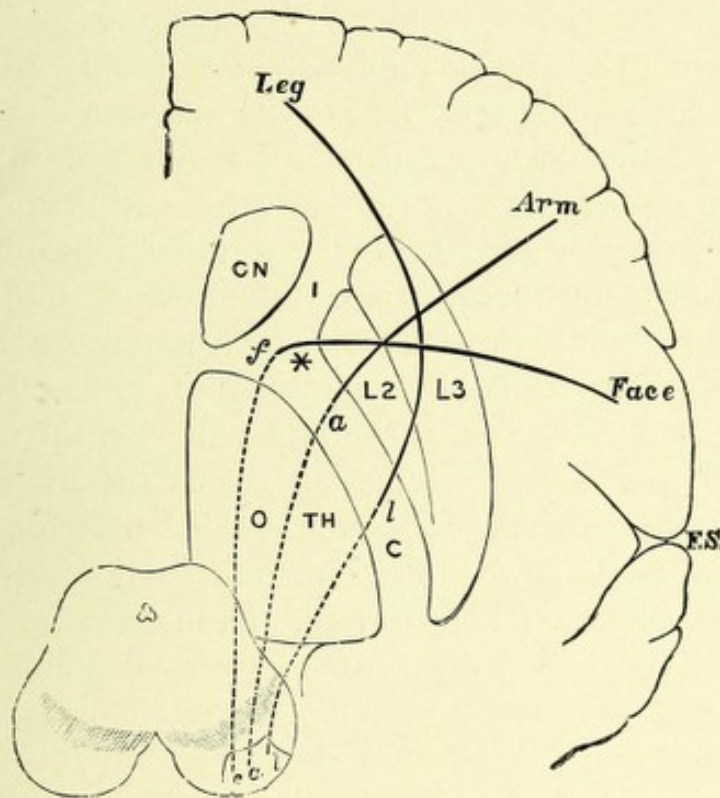


FIG. 185.—DIAGRAM TO SHOW THE RELATIVE POSITION OF THE SEVERAL MOTOR TRACTS IN THEIR COURSE FROM THE CORTEX TO THE CRUS.—(After Gowers.)

The section through the convolutions is vertical ; that through the internal capsule, I.C., horizontal ; that through the crus is again vertical. CN. Caudate nucleus. O.T.H. Optic thalamus. L2 and L3. The middle and outer parts of the lenticular nucleus. *f, a, l.* Face, arm, and leg fibers. The words in italics indicate the corresponding cortical centers.

ward, backward, and inward, through the centrum semiovale and between the caudate and lenticular nuclei, occupying the anterior division or limb of the internal capsule ; thence descending in the innermost part of the crusta, or foot of the crus cerebri, to the ventral part of the pons Varolii, ending about the cells of the nucleus pontis of the same side. The cells of the nucleus pontis are joined by fibers from both cerebellar hemi-

spheres ; chiefly, however, from the cerebellar hemisphere of the opposite side. These latter fibers are the axones from the cells of Purkinje of the same and of the opposite side, the fibers having decussated in the raphe. It will thus be seen that the prefrontal lobe is in anatomic connection with both cerebellar hemispheres, but chiefly with the cerebellar hemisphere of the opposite side.

The *motor tracts* consist of two divisions or neurones—a central and a peripheral. The fibers of which the central division of these tracts are composed take their origin from the motor area of the cerebral cortex, and are the axis-cylinder processes, or axones, of the large pyramidal or motor cells of the third layer of the cortex. The motor area of each hemisphere includes the posterior part of the prefrontal lobe, the anterior and posterior central, or, from their course, the ascending frontal and parietal gyri, with their union on the median surface of the hemisphere, called the paracentral lobule. It may be stated, in a general way, that the upper third of the motor area, including the paracentral lobule, innervates the muscles of the trunk and lower extremity, the middle third those of the upper extremity, while the lower third functionates the muscles of the face, tongue, mouth, and larynx—all of the opposite side. The posterior part of the left third frontal gyrus contains the memories necessary to innervate the motor speech processes. From this very extensive cortical area the axones of the motor cells pass through the centrum semiovale of Vieussens, converging as they proceed until they reach the internal capsule, where they are collected into distinct bundles which occupy the anterior two-thirds of the posterior division of the internal capsule, the posterior part of this division of the capsule being occupied by the sensory, optic, and auditory tracts. It will be remembered that the motor centers for the muscles of the face, tongue, mouth, and larynx occupy the lowest part of the motor area ; hence the fibers which proceed from the facial center have a course directly inward, while those from the centers located above—namely, the arm, leg, and trunk—have a course downward and inward ; thus the fibers from the face become located in the extreme anterior division of the posterior limb of the in-

ternal capsule, while the fibers from the arm, leg, and trunk areas are located just back of the facial fibers, in the order herein mentioned. In the left internal capsule the fibers that innervate the motor speech center pass a little anterior to those of the

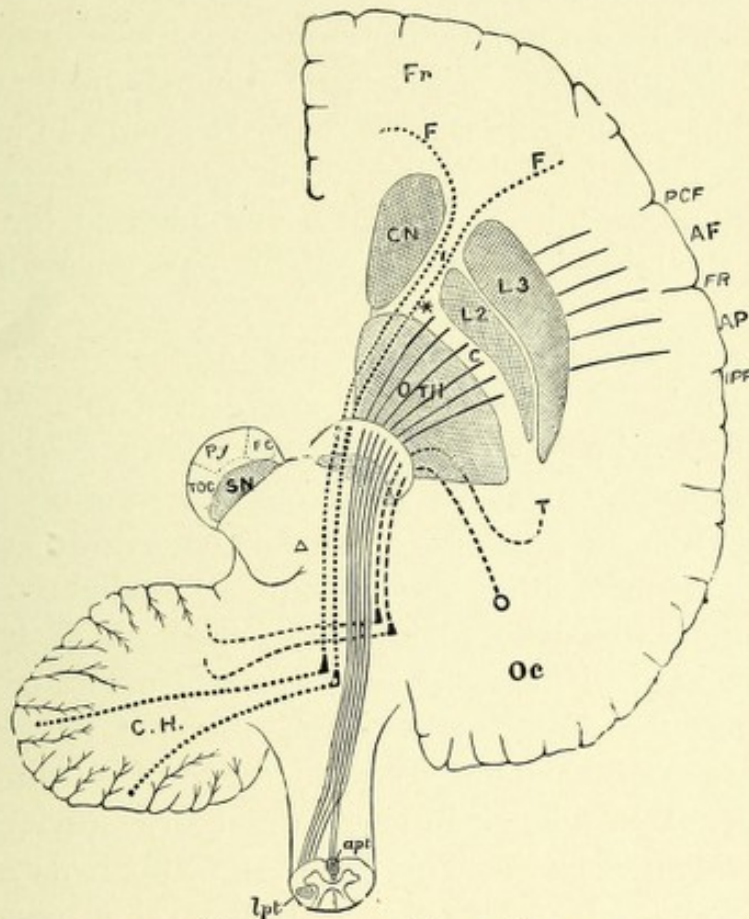


FIG. 186.—DIAGRAM OF THE COURSE OF THE MOTOR TRACT AS SHOWN IN A DIAGRAMMATIC HORIZONTAL SECTION THROUGH THE CEREBRAL HEMISPHERE, PONS, AND MEDULLA.—(After Gowers.)

Fr. Frontal lobe. Oc. Occipital lobe. A F. Ascending frontal, and A P, ascending parietal convolutions. P C F. Precentral fissure in front of the ascending frontal convolution. I P F. Interparietal fissure. A section of the crura is lettered on the left side. S N. Substantia nigra. Py. Region occupied by the pyramidal fibers (motor tract), which on the right are shown as continuous lines, converging in the white substance of the hemisphere, to pass through the posterior limb of I C, the internal capsule (the elbow of which is shown at *)—through the crus and pons, and to divide in the medulla into the decussating lateral pyramidal tract (*lpt*) and the direct anterior pyramidal tract (*apt*). F C. Fronto-cerebellar tract. Py. Pyramidal tract. T O C. Temporo-occipital cerebellar tract.

face. The fibers of each motor tract then enter the ventral portion or foot of the crus cerebri, occupying the middle two-fifths of its anterior surface; the tract then continuing spineward, reaches the ventral portion of the pons Varolii, where each tract

separates into several fasciculi, which lie between the superficial and deep transverse pontine fibers. On emerging from the inferior border of the pons, these fasciculi are again collected into a distinct bundle, one for each side, which form the fleshy columns seen on each side of the ventral fissure of the medulla oblongata—the anterior pyramids. These continue to the inferior portion of the medulla; at this point—namely, in the region of the first and second cervical nerves—there occurs an incomplete decussation, the so-called pyramidal or motor crossway. Here the majority of the fibers decussate and pass to the opposite side, while the minority do not cross, but pass down on the same side.

The crossed fibers descend throughout the entire length of the spinal cord, and occupy an extensive area in the posterior part of the lateral column; in the cord this crossed bundle of fibers receives the name of the crossed motor or pyramidal tract. This tract decreases in size from above downward, owing to the fact that many of its axones and their collaterals are constantly bending forward and inward to enter the gray matter of the anterior horn of the same side, there terminating in arborizations about the motor cells. The fibers of the direct pyramidal tract—also called uncrossed motor tract—continue downward on the same side, occupying a small area adjacent to the anterior median fissure. This bundle of fibers is called the column of Turck. It usually ceases at the level of the mid-dorsal region, although in exceptional cases it passes down to the lumbar region; in its descent its axones and collaterals pass, by means of the anterior commissure, to the anterior horn of the opposite side, ending at various levels about the motor cells therein contained.

It will thus be seen that the central division of the motor tract consists of collections of central motor neurones—the pyramidal cells, with their dendrites and axones, the course of the latter continuing without interruption until they end by arborizing about the motor cells contained in the anterior cornu of the side opposite to their origin. The central division of the motor tract also contains the central tracts for the various motor cranial nerves, which are as follows: The *oculomotor*, or *third pair*; the

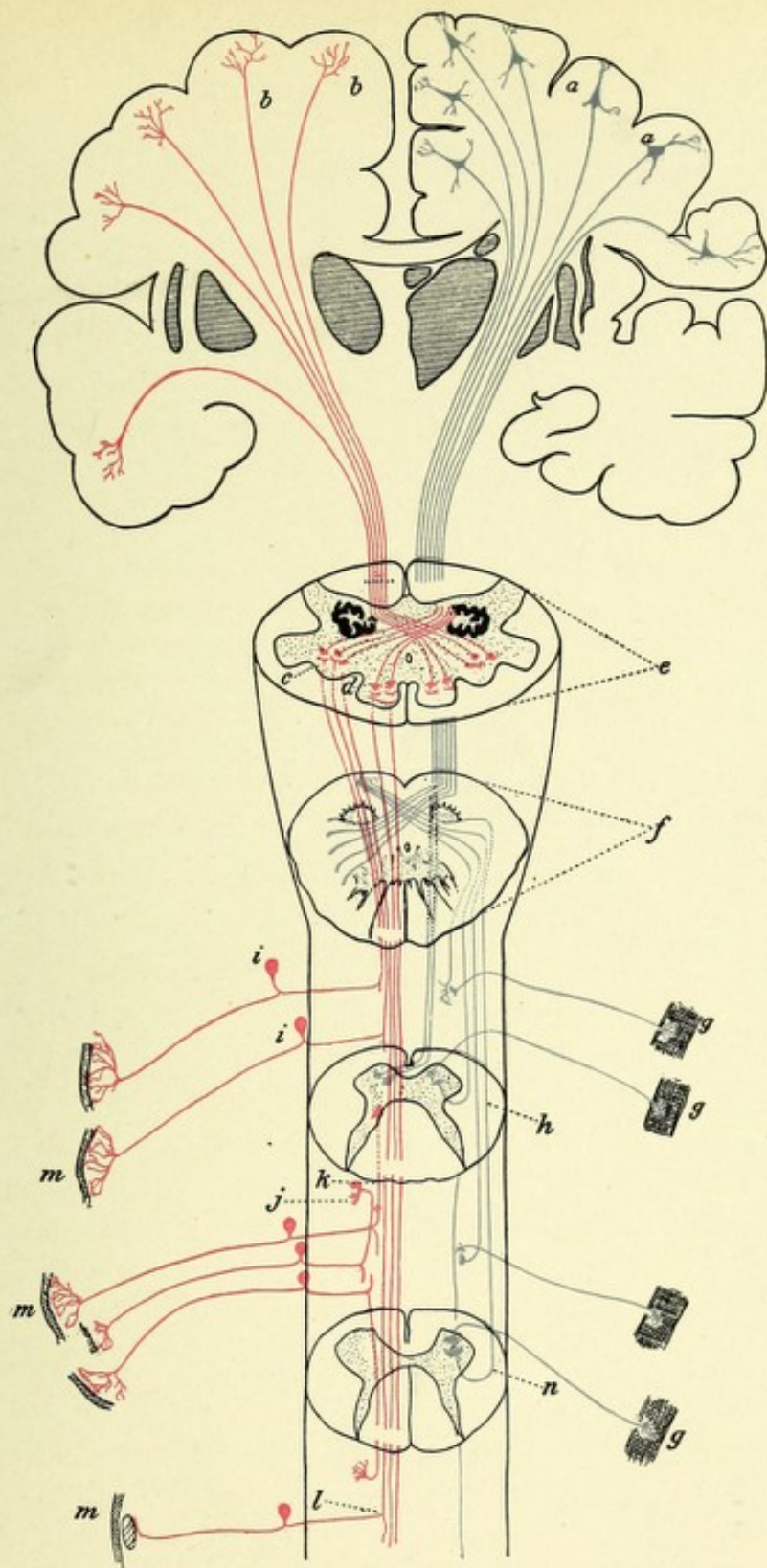


FIG. 187.—DIAGRAM INDICATING THE COURSE OF THE MOTOR AND SENSORY FIBERS OF THE SPINAL CORD AND MEDULLA.

a, a. Motor cells of the cerebral cortex. *b, b.* Arborizations of the fibers of the sensory tract in the cerebral cortex. *c.* Nucleus of the column of Burdach, showing terminal arborizations of the long sensory fibers of the cord. *d.* Nucleus of the column of Goll, showing terminal arborizations of the long sensory fibers of the cord. *e.* Section of the medulla, showing sensory decussation. *f.* Section of medulla, showing motor or pyramidal decussation. *g, g.* Motorial end plates. *h.* Section through the cervical region of the cord, showing termination in the anterior horn of the motor fibers of the direct pyramidal tract after they have crossed in the anterior commissure; also fiber of crossed pyramidal tract ending about anterior horn cell of same side. *i, i.* Posterior spinal ganglia. *j, k.* Sensory fibers of short course. *l.* Sensory fibers of long course, terminating in medulla. *m, m, m.* Sensory end organs. *n.* Section through lumbar cord.



trochlearis, or *fourth*; the *motor division of the fifth*, or *trigem-
inus*; the *abducens*, or *sixth pair*; the *seventh*, or *facial*; the
combined motor divisions of the *glossopharyngeal* and *pneumo-
gastric*, or *ninth and tenth pairs*; the *spinal accessory*, or *eleventh*;
and the *hypoglossal*, or *twelfth pair*. The exact cortical areas
from which the various central cranial nerve
tracts arise is only positively known for the
facial, motor division of the trigeminal, and the
hypoglossal; these all take their origin from the
cortex of the lowest third of the central convo-
lutions. These various tracts occupy the knee
of the internal capsule, and in the crus cerebri
they are located on the inner side of the pyr-
amidal tract; they continue downward in the
crus, pons, and medulla, until they reach the
level of their respective nuclei,—whose cells
give origin to the peripheral divisions of these
nerves,—when they decussate with their fellows
and pass to the nuclei of the opposite side, end-
ing about their nerve-cells. It is very probable,
owing to the fact that many of the motor
cranial nerves innervate bilaterally acting mus-
cles, that some of the fibers do not decussate,
but end about the motor cells of the same side.
The partial course of the peripheral division of
the motor cranial nerves has been discussed else-
where. The peripheral portion of each motor
tract consists of the motor cells of the anterior
cornu, with their axis-cylinder processes, which
latter form the anterior spinal nerve-roots.
They terminate in the motor end organs of the
various skeletal muscles.

This combination of motor nerve-cells, with
their axones and dendrites and their terminal endings in the
muscles, form the peripheral motor neurones. There is thus
formed by these two groups of neurones, central and peripheral,
a functionally continuous tract from the motor cortical region
of one cerebral hemisphere to the muscles of the opposite side
of the body.

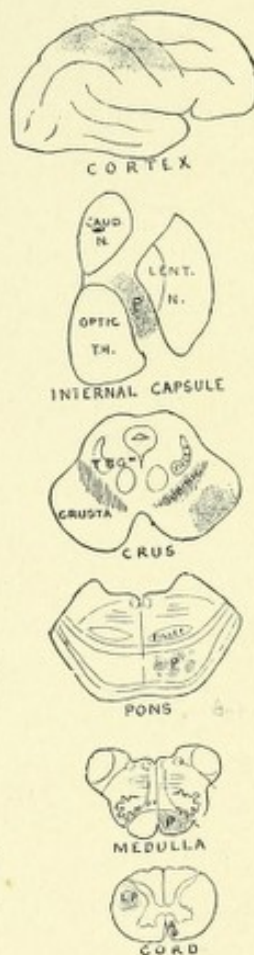


FIG. 188.—DIAGRAM
OF THE COURSE OF
THE PYRAMIDAL
OR MOTOR TRACT
OF THE RIGHT
HEMISPHERE.—
(After Gowers.)

The *occipital and temporal lobes are connected by a tract* with the opposite cerebellar hemisphere and slightly with the cerebellar hemisphere of the same side. The fibers of this tract are the axones from the pyramidal cells of the cortex of the occipital and temporal lobes. It was formerly thought that this fasciculus of fibers, after passing through the centrum semiovale, entered the extreme posterior part of the internal capsule, but Flechsig has proven that this is incorrect, and has shown that they course in part beneath the lenticular nucleus and in part between that nucleus and the external geniculate body, whence they enter the outer part of the foot, or crusta, of the cerebral peduncle and continue downward to the pons Varolii of the same side, where the individual fibers terminate about the cells of the nucleus pontis. The tract is further continued to the cortex of the opposite cerebellar hemisphere by means of the axones of the cells of Purkinje, which also terminate about the same cells of the nucleus pontis after having decussated in the raphe. This tract also communicates with the cerebellar hemisphere of the same side, owing to the fact that a few axones from the cells of Purkinje of that side terminate without decussating.

The Sensory Tract.—This tract conducts centripetally impressions of touch, pain, temperature, and muscular sense *via* the spinal cord, medulla, pons, brain-stem, and basal ganglia to the cerebral cortex, where the impressions are received as conscious perceptions. It forms the chief portion of the projection system of fibers existing in the dorsal part or tegmentum of the crus cerebri.

The fibers which compose this tract have their origin in the cells of the posterior spinal ganglia. Each ganglion cell gives off a single axone, which soon divides, Y-shaped, the thicker branch passing out to form a peripheral sensory nerve and to terminate in a sensory end organ, and the finer branch, as a posterior nerve-root, passing into the spinal cord just dorsal to the substantia gelatinosa Rolandi, where it divides into an ascending and descending branch.

The descending branches of the posterior nerve-roots have but a short longitudinal course in the posterior columns, when they curve inward and terminate in arborizations about the cells

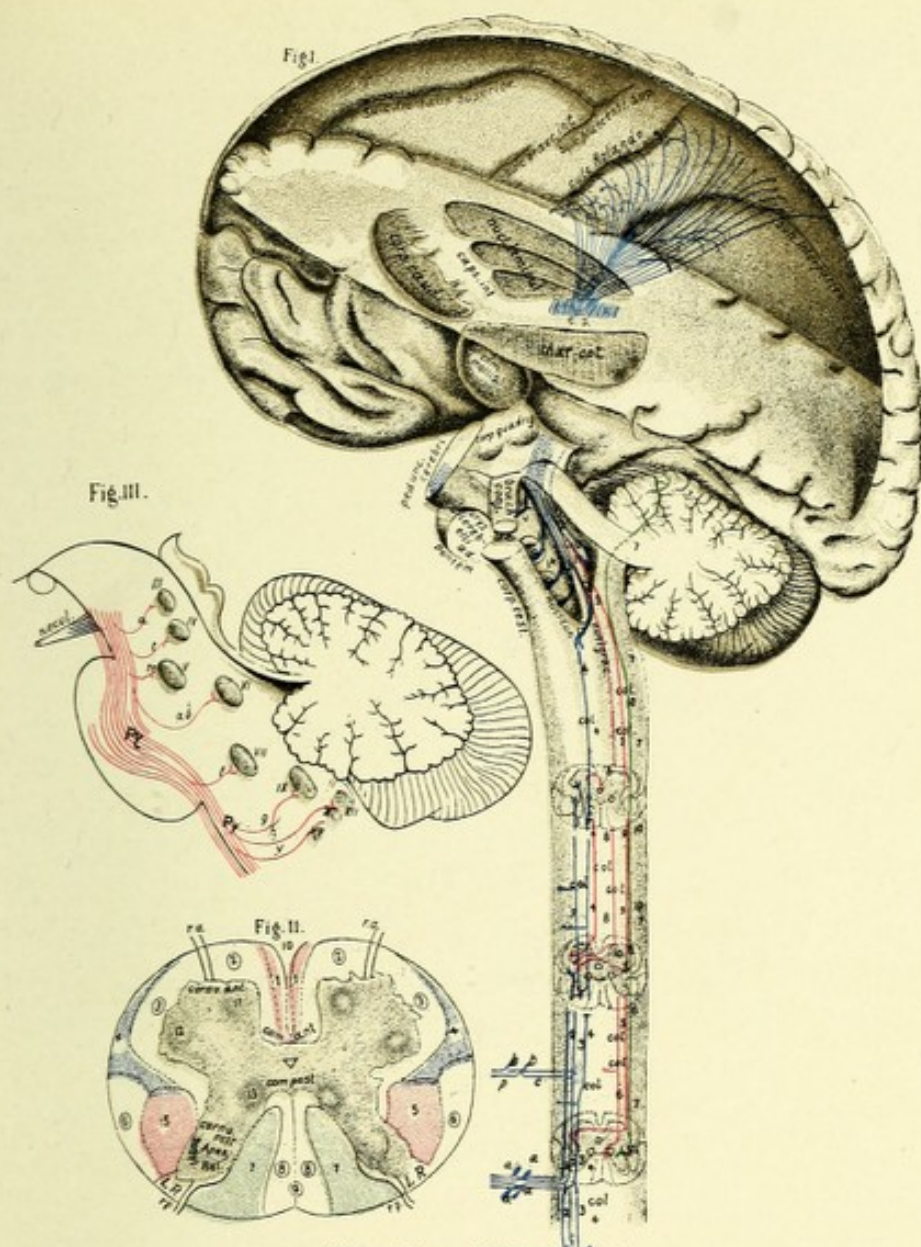



FIG. 189.—(After Sachs.)

Fig. I. Sensory tract. *a, b*. Cells of spinal ganglia, one fiber, *p*, forming part of sensory nerve the other fiber, *c*, entering a posterior root, fibers of the latter dividing into ascending and descending (1, 2, 3, 4) branches. Of the ascending branches, some (4) terminate with "end-brushes" in the nucleus cuneatus, and nucleus gracilis. *col*. Collateral fibers entering gray matter. 8. Fibers forming anterior ground bundle. 5, 6. Fibers forming lateral ground bundle. 10. Fibers forming Gowers' tract. 7. Fibers forming direct cerebellar tract.

Fig. II. *r.a*. Anterior root. *r.p*. Posterior root. *L.R*. Lissauer's marginal zone. 1. Direct pyramidal tract. 2. Anterior ground bundle. 3. Lateral ground bundle. 4. Gowers' anterolateral tract. 5. Crossed pyramidal tract. 6. Direct cerebellar tract. 7. Column of Burdach. 8. Column of Goll. 9. Posterior longitudinal septum. 10. Anterior longitudinal fissure. 11. Anterior median group of cells. 12. Posterolateral group. 13. Column of Clarke.

Fig. III. Relation of motor tract to nuclei of cranial nerves.—(After Flatau.)



of the gray matter of the cord. The ascending branches consist of two divisions—those which pursue a rather short longitudinal course and those which pursue a long course. The former enter the gray matter in curves, and terminate as do the descending branches. Some of the branches of long course pass upward into the postero-external column, or column of Burdach; while the greater number pursue a similar course in the postero-internal column, or column of Goll. All these fibers of long course continue upward until they reach the lower dorsal region of the medulla, where they bend nearly at right angles and terminate in brushes of fibrils about the nerve-cells of the nucleus cuneatus and nucleus gracilis. Both ascending and descending branches are constantly giving off in their course collaterals, which enter the gray matter and terminate about the intrinsic cells of the posterior horns and intermediate gray matter about the motor cells of the anterior horns (reflex collaterals) and about the cells of Clarke's column.

Gowers' tract, which is supposed to conduct sensations of temperature and pain, consists of axones which arise from the intrinsic cells located in the intermediate gray matter near the base of the anterior horn, around which cells collaterals from the posterior nerve-roots terminate. The axones from this group of intrinsic cells pass across the gray matter, probably in the anterior commissure, to the opposite side of the cord, where they turn upward and become located in the anterolateral periphery of the cord, ventral to the direct cerebellar and crossed pyramidal tracts. These fibers course upward until they reach the medulla oblongata, where some may be intercepted by the cells of the lateral nucleus. The tract then continues upward in the formatio reticularis, where it occupies a position dorso-lateral to the olivary body. At about the middle of the pons Varolii, according to Hoche, this bundle makes a distinct curve over the fifth nerve and enters the cerebellum by means of the superior cerebellar peduncle and velum medullare anticum. It is extremely probable that a part of the fibers of this tract continue brainward in the formatio reticularis, and terminate in part in the corpus quadrigeminum, and in part in the optic thalamus. The cortical termination of this part of the tract is prob-

ably in the parietal lobe, the fibers passing with those of the mesial fillet.

The largest portion of the sensory tract, whose axones have terminated about the cells of the nuclei cuneati and gracili, is farther continued by the axones from the cells of these nuclei, which axones pass ventromesially (internal arcuate fibers) to the region between the olivary bodies, where they decussate, forming the interolivary or superior sensory decussation. Each tract then turns upward just dorsal to the anterior pyramids, and is now termed the mesial fillet, lemniscus, or interolivary tract. In the pons it occupies the ventral portion of the *formatio reticularis*, and continues brainward through the ventral part of the tegmentum of the *crus cerebri* to the subthalamic region, where a small part of the fibers from the cells of the nucleus cuneatus terminate in the anterior corpus quadrigeminum. The main bundle of fibers from this nucleus passes to the outer side of Luys' body, and joins both the lenticular loop and Meynert's commissure. The first part of the bundle passes by way of the lenticular loop to the globus pallidus of the lenticular nucleus of the same side, while the remaining fasciculus passes to the lenticular nucleus of the opposite side by way of Meynert's commissure. The fasciculus of fibers of the fillet or lemniscus, which are the axones from the nucleus gracilis, give off collaterals which join the anterior corpus quadrigeminum, ending about the cells of the fifth layer. The main bundle of fibers of this fasciculus, however, continues ventrad, and terminates in arborizations about the cells of the ventral nucleus of the optic thalamus of the same side (von Monakow), the axones of which cells continue this tract through the posterior third of the posterior division of the internal capsule, whence they radiate through the centrum semiovale to the cortex of the postcentral and parietal lobes. The sensory tract receives in its course axones and collaterals from the various sensory end nuclei of the cranial nerves of the opposite side, with the exception of those from the auditory. These fibers form the central sensory tracts for the cranial nerves from whose end nuclei they originate.

CHAPTER X.

GENERAL ANATOMY OF THE INTERIOR OF THE CEREBRAL HEMISPHERES.

Horizontal or sagittal sections through a cerebral hemisphere show it to be made up entirely of gray and white matter, the former completely surrounding the latter, forming for it a convoluted mantle of a thickness nearly uniform. The white matter appears as a homogeneous white mass, presenting an irregularly oblong or oval shape, and is called, for each hemisphere, the *centrum semiovale* (Vieussens). The white matter, as seen on complete horizontal section of the entire cerebrum, is called the *centrum ovale major*. Sections of the *centrum ovale* present a number of small hemorrhagic points, which are the cross-sections of small blood-vessels. These points are called the *puncta vasculosa* (Fig. 190).

CORPUS CALLOSUM.

On separating the hemispheres, a broad band of transversely arranged fibers appears at the bottom of the longitudinal fissure. This is the corpus callosum, or the great transverse commissure of the cerebrum, connecting corresponding areas of the frontal, parietal, and occipital lobes. It is narrower in front than behind, is 7 to 8 cm. (about $3\frac{1}{2}$ inches) in length on its superior surface, and is from 5 to 6 cm. (about $2\frac{1}{4}$ inches) on its inferior surface, and extends farther forward than backward, reaching to a point within 3 cm. ($1\frac{1}{4}$ inches) of the anterior, and within 5 cm. (2 inches) of the posterior end of the hemispheres. It presents a gentle curve from before backward, its upper surface being convex, its lower, concave. Both ends are more thick-

ened than the intermediate portion, or body. The posterior extremity terminates free, and is rolled upon itself, forming an expanded portion called the splenium, or pad. The anterior extremity curves downward and backward between the frontal lobes, making a bend called the genu, or knee. It then con-

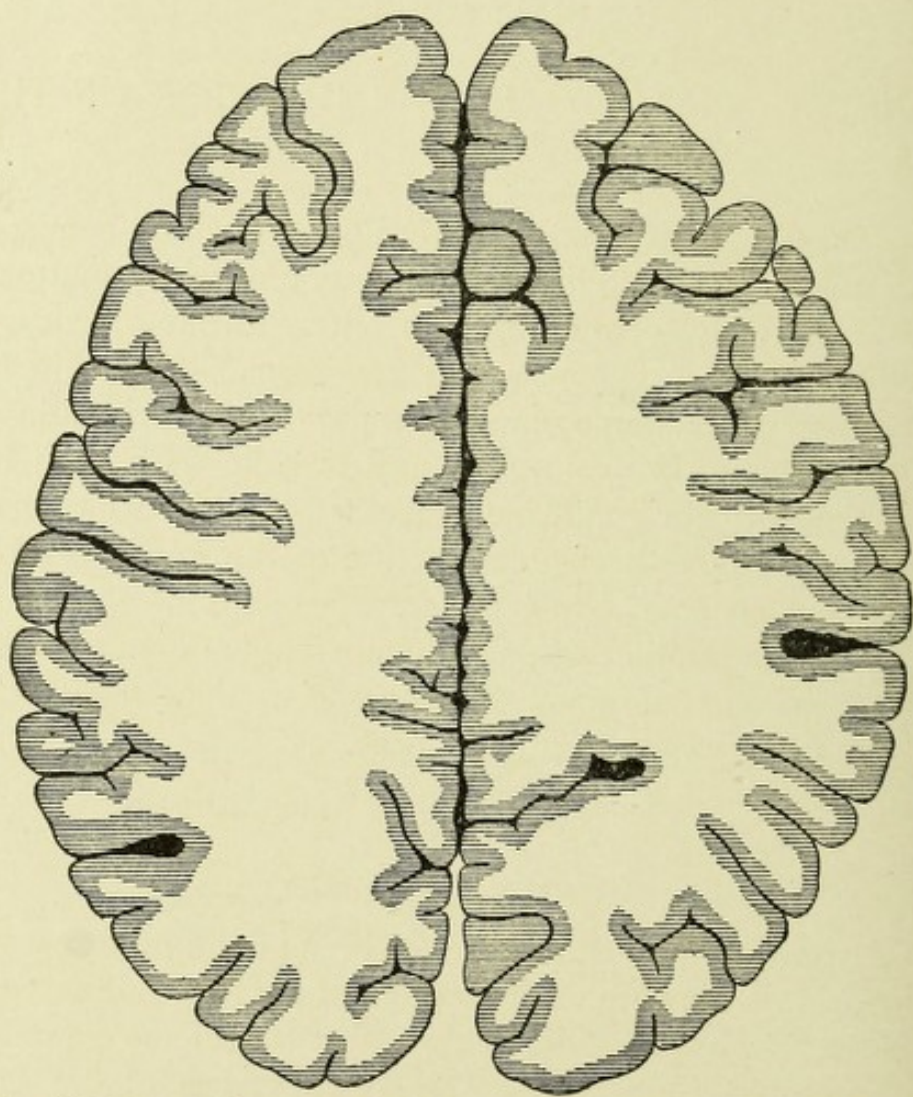


FIG. 190.—HORIZONTAL SECTION OF CEREBRUM ABOVE THE CORPUS CALLOSUM TO SHOW THE CENTRUM OVALE.—(After Van Gehuchten.)

tinues downward and backward, and at the base of the brain it blends with the lamina cinerea. This latter portion, the reflected part, is called the rostrum.

Two distinct white bands are given off at the termination of the corpus callosum, and are called its peduncles, one for each side. These peduncles diverge, pass across the posterior por-

tion of the anterior perforated space, and enter, each on its own side, the fossa of Sylvius. Thence they pass to the apices of the temporal lobes, where they terminate, possibly uniting with the inner olfactory roots.

On the upper surface of the corpus callosum are a number of minute transverse depressions, which indicate the course taken by most of its component fibers. A longitudinal furrow exists in the middle, and has on each side two small, white bundles of

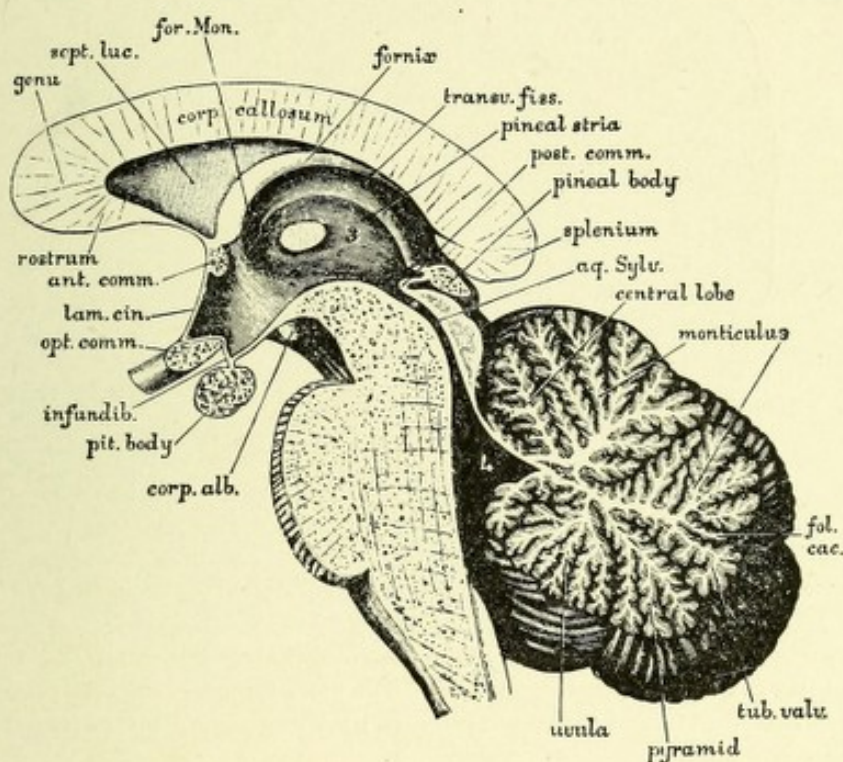


FIG. 191.—PORTION OF A MEDIAN SECTION OF THE BRAIN. Showing the corpus callosum, third ventricle, aqueduct of Sylvius, fourth ventricle, pons, cerebellum, etc.

fibers—the nerves of Lancisi. They are continuous anteriorly with the peduncles of the corpus callosum. Laterally, near the margins, are seen other fibers having a longitudinal course, called the striæ longitudinales laterales. Both the median and lateral striæ pass backward into the dentate gyrus. The median portion of the under surface of the corpus callosum is connected in front with the septum lucidum, and behind with the fornix. The transverse fibers of the corpus callosum are continuous with the white fibers of the centrum ovale, and inter-

lace with the various projection systems of fibers and continue to the cortex of each hemisphere. The main mass of the transverse fibers was formerly called the tapetum. The term tapetum is now applied to the association bundle of fibers described

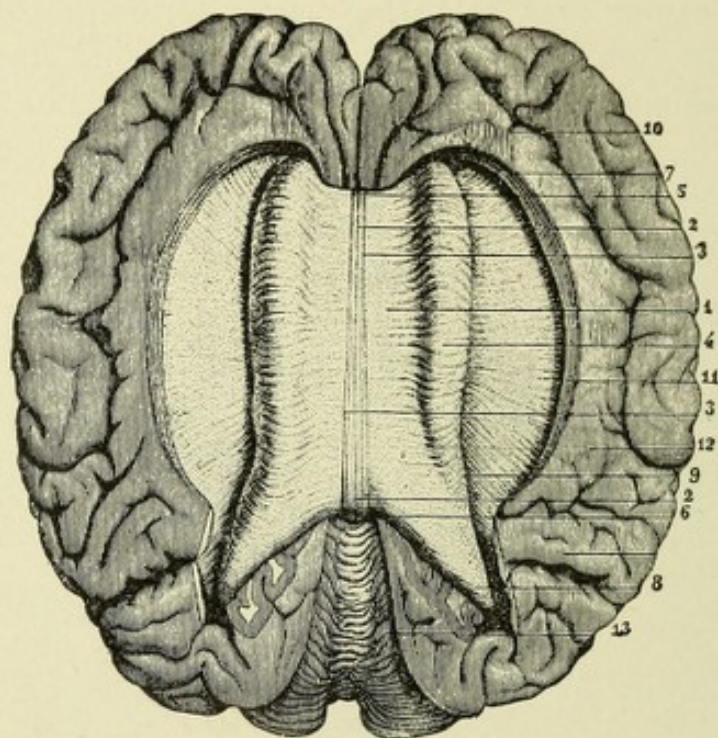


FIG. 192.—VIEW OF THE CORPUS CALLOSUM FROM ABOVE.—(From *Saphey after Foville, from Quain.*)

The upper surface of the corpus callosum has been fully exposed by separating the cerebral hemispheres and throwing them to the side. The gyrus fornicatus has been partly detached and the transverse fibers of the corpus callosum traced for some distance into the cerebral medullary substance.

1. The upper surface of the corpus callosum. 2. Median furrow or raphe. 3. Longitudinal striæ bounding the furrow. 4. Swelling formed by the transverse bands as they pass into the cerebrum, arching over the side of the lateral ventricle. 5. Anterior extremity or knee of the corpus callosum. 6. Posterior extremity. 7. Anterior, and 8, posterior, fibers proceeding from the corpus callosum into the frontal and occipital lobes respectively. 9. Margin of the swelling. 10. Anterior part of the gyrus fornicatus. 11. Fissure between the corpus callosum and this convolution opened out. Outside 12, is the termination of the callosomarginal fissure, and before 13 is the parieto-occipital fissure. 13. Upper surface of the cerebellum.

by Forel and Onufrowicz. The fibers of the corpus callosum, which pass forward into the frontal lobes, above the anterior cornu on each side, are termed the *forceps minor*; while those that come from the splenium, and curve backward into the occipital lobes, above the posterior cornua, are called the *forceps*

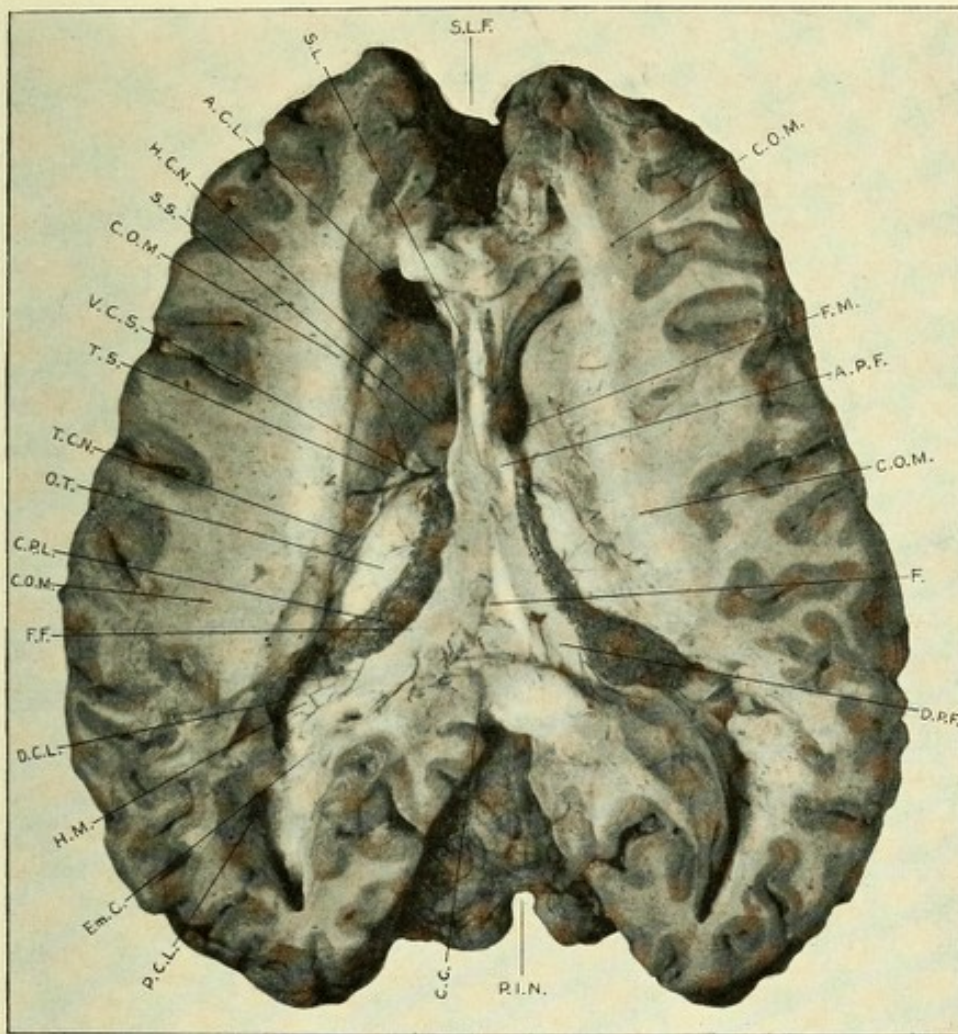



FIG. 193.—PHOTOGRAPH OF HORIZONTAL SECTION THROUGH CEREBRUM TO SHOW LATERAL VENTRICLES.

S.L.F. Superior longitudinal fissure. C.O.M. Centrum ovale minor. F.M. Foramen of Monro. A.P.F. Anterior pillar of fornix. F. Body of fornix. D.P.F. Descending or posterior pillar of fornix. P.I.N. Posterior incised cerebellar notch. C.C. Corpus callosum. P.C.L. Posterior cornu of lateral ventricle. Em.C. Eminence due to calcarine fissure called calcar avis or hippocampus minor. H.M. Hippocampus major. D.C.L. Descending cornu of lateral ventricle. F.F. Corpus fimbriatum. C.P.L. Choroid plexus of lateral ventricle. O.T. Optic thalamus. T.C.N. Tail of caudate nucleus. T.S. Tænia semicircularis. V.C.S. Vena corpora striata. S.S. Sulcus semilunaris. H.C.N. Head of caudate nucleus. A.C.L. Anterior cornu of lateral ventricle. S.L. Septum lucidum.



major. The median surfaces of the hemispheres, which overlap the corpus callosum, are called the labia cerebri. The space between them and the superior surface of the corpus callosum is frequently called the ventricle of the corpus callosum.

THE LATERAL VENTRICLES.

In order to expose the lateral ventricles, a horizontal section through the cerebrum should be made at a level with the corpus callosum, and then a longitudinal incision should be made through the corpus callosum on each side of its middle line or raphe, when the ventricular cavities will be exposed, the corpus callosum forming their roof. The lateral ventricles are the cavities of the secondary fore-brain and belong entirely to the hemispheres. They are situated deep in the centrum ovale, and do not communicate with each other, but communicate with the cavity of the primary fore-brain, the third ventricle, by an opening on each side, the foramen of Monro, which is the remains of a much larger passage, communicating in the fetus with the primary and the secondary fore-brain. The ventricular cavities are lined with ciliated epithelium of the columnar variety, which rests on a neuroglia basis—the ependyma. They contain normally a small amount of serum. Each ventricle consists of a middle portion or body with three extensions or cornua: the anterior, the middle, often called the lateral, or descending cornu, and the posterior cornu. The body of the ventricle lies between the foramen of Monro and the posterior extremity of the corpus callosum. Internally it is separated from its fellow by a thin blade of white matter, the septum lucidum, which septum is connected above with the under surface of the corpus callosum and below with the fornix. The ventricle has for its floor, from before backward, the intraventricular portion of the corpus striatum, or caudate nucleus, the tænia semicircularis, the optic thalamus, the choroid plexus, and one-half of the body of the fornix. The anterior cornu curves around the anterior extremity of the corpus striatum to reach the frontal lobe. It has for its front wall and roof the corpus callosum. On the inner side is the septum lucidum. On the outer side is the head of the caudate nucleus. The middle or



descending cornu is the largest and longest of the three. It passes at first backward and outward, then downward and forward, forming in its course a great curve around the back of the optic thalamus and crus cerebri. It then proceeds forward and inward to terminate near the apex of the temporal lobe close to the amygdalum. This cornu is roofed by the body of the corpus callosum and tapetum, and has prolonged into it the caudate nucleus, the corpus striatum, the tænia semicircularis, and a small part of the optic thalamus. It has for its floor the hippocampus major, or cornu ammonis, the pes hippocampus, the eminentia collateralis, and the fimbria of the fornix. The hippocampus major, or cornu ammonis,—so called because of its resemblance to a ram's horn,—is a curved eminence extending along the entire length of the floor of the descending horn. It is the ventricular portion of the gyrus hippocampus, and is due to the extension inward of the dentate or hippocampal sulcus of the mesial surface of the temporal lobe, the gray matter of which is separated from the cornu ammonis by a thin layer of white matter covered by ependymal tissue, called the alveus. This cornu, as it descends and approaches its termination, becomes enlarged and presents along its edges a number of digitations, which, from their resemblance to the paw of an animal, give it the name pes hippocampus.

EMINENTIA COLLATERALIS.

This is a white eminence between the cornu ammonis and the outer wall of the descending horn of the lateral ventricle, and is due to the extension inward of the collateral fissure. The trigonum ventriculi is the space between the eminentia collateralis and the cornu ammonis.

The fimbria, often called the corpus fimbriatum, is the prolonged posterior pillar of the fornix, which extends into the descending cornu, and can be traced forward to the uncinate gyrus. It is attached by its inner margin to the hippocampus major, while its outer border is free, and lies on the upper surface of the hippocampus.

The posterior cornu begins at the splenium of the corpus

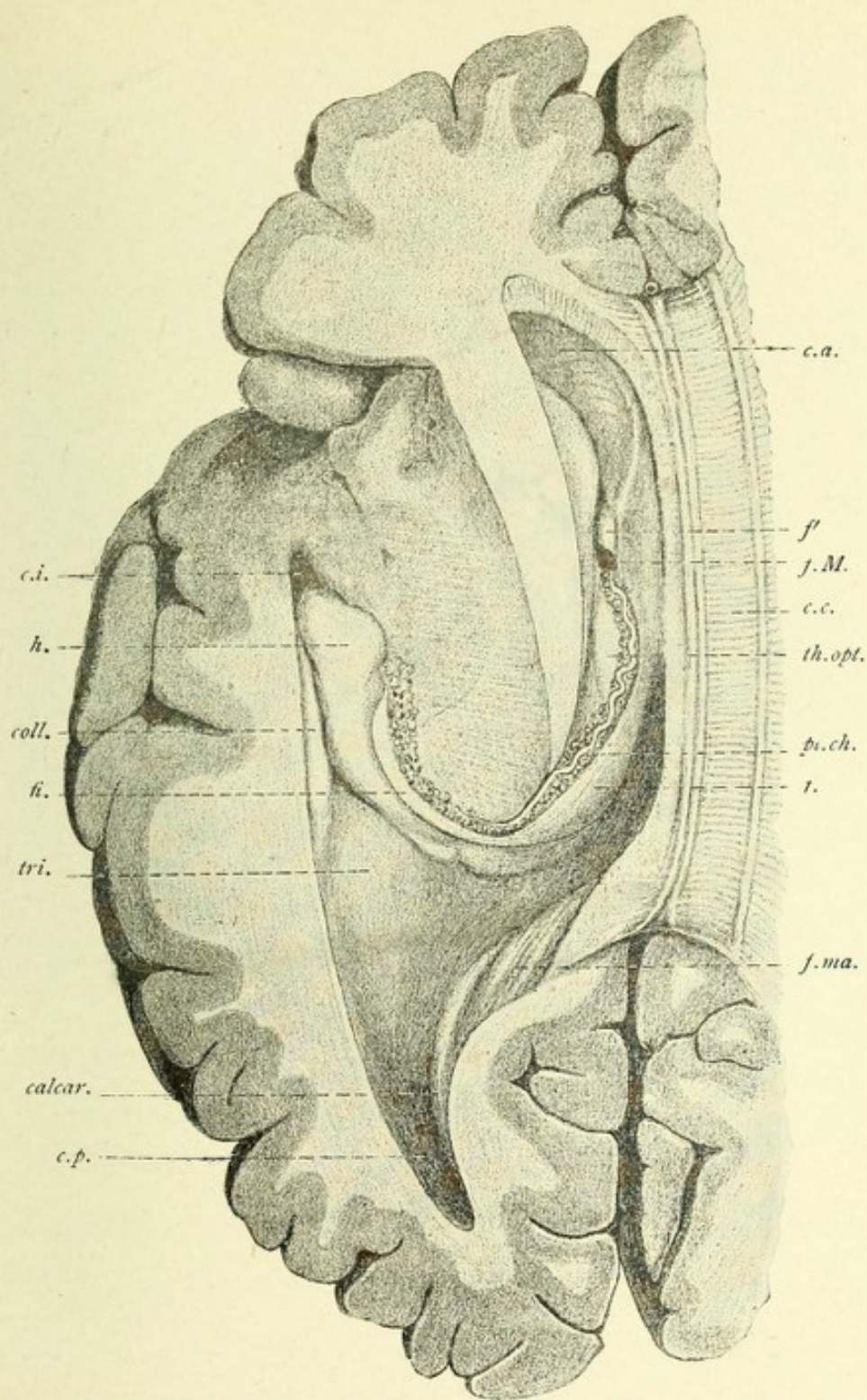



FIG. 194.—VIEW FROM ABOVE AND THE SIDE OF THE WHOLE LEFT LATERAL VENTRICLE.
Natural size.—(E. A. S. and G. D. T., from Quain.)

The insula has been sliced away and the middle or descending cornu, *c.i.*, exposed. Within this are seen the following parts: *c.i.* Entrance to cornu inferius. *h.* The hippocampus major. *coll.* The eminentia collateralis. *fi.* Fimbria, continued from the fornix. *tri.* Trigonum ventriculi. *calcar.* Calcar avis. *c.p.* Cornu posterius. *c.a.* Cornu anterius of ventricle. *f.* Fornix. *f'* Its anterior pillar. *f.M.* Foramen Monroi. *c.c.* Corpus callosum. *th.opt.* Thalamus opticus, anterior tubercle. *pl.ch.* Plexus choroides. *f.ma.* Forceps major.



callosum and curves backward and inward into the occipital lobe. It has for its upper and outer walls the tapetum. Its inner and lower walls have three projections. The upper is the marginal bundle of fibers of the corpus callosum, called the forceps posterioris. The middle projection is due to the calcarine fissure, which extends deep into the margin of the hemisphere and pushes before it the wall of this cornu, producing an eminence

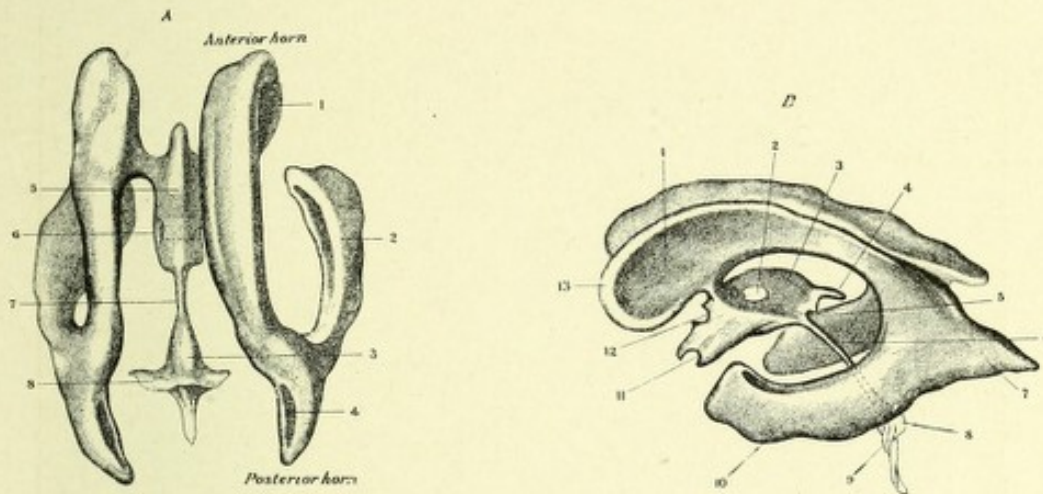


FIG. 195.—TWO VIEWS OF A PLASTER CAST OF THE CAVITIES OF THE CEREBRAL VENTRICLES.—(After Welcker, from Quain.)

A. From above: 1. Nucleus caudatus. 2. Middle cornu. 3. Fourth ventricle. 4. Calcar avis. 5. Third ventricle. 6. Middle or soft commissure. 7. Sylvian aqueduct. 8. Recessus lateralis. *B.* From the side: 1. Nucleus caudatus. 2. Middle commissure. 3. Optic thalamus. 4. Recessus suprapinealis. 5. Recessus pinealis. 6. Aqueduct of Sylvius. 7. Posterior cornu. 8. Fourth ventricle. 9. Recessus lateralis. 10. Middle or descending cornu. 11. Chiasm. 12. Anterior commissure. 13. Anterior cornu. The projections into the cavities of the structures which bound the ventricles are seen as impressions upon the cast.

called the hippocampus minor, or calcar avis. The lowermost projection is a thickening due to a bundle of white fibers—the inferior longitudinal fasciculus.

The floor of the body of the lateral ventricle contains the following bodies: the corpus striatum, the tænia semicircularis, the optic thalamus, and the choroid plexus. The latter will be described later.

THE CORPORA STRIATA.

The corpora striata, together with the claustral and amygdaloid nuclei, are the ganglia of the cerebral hemispheres. The corpora striata are situated deep in the cerebral hemispheres, ventrolateral to the optic thalami, being separated from the

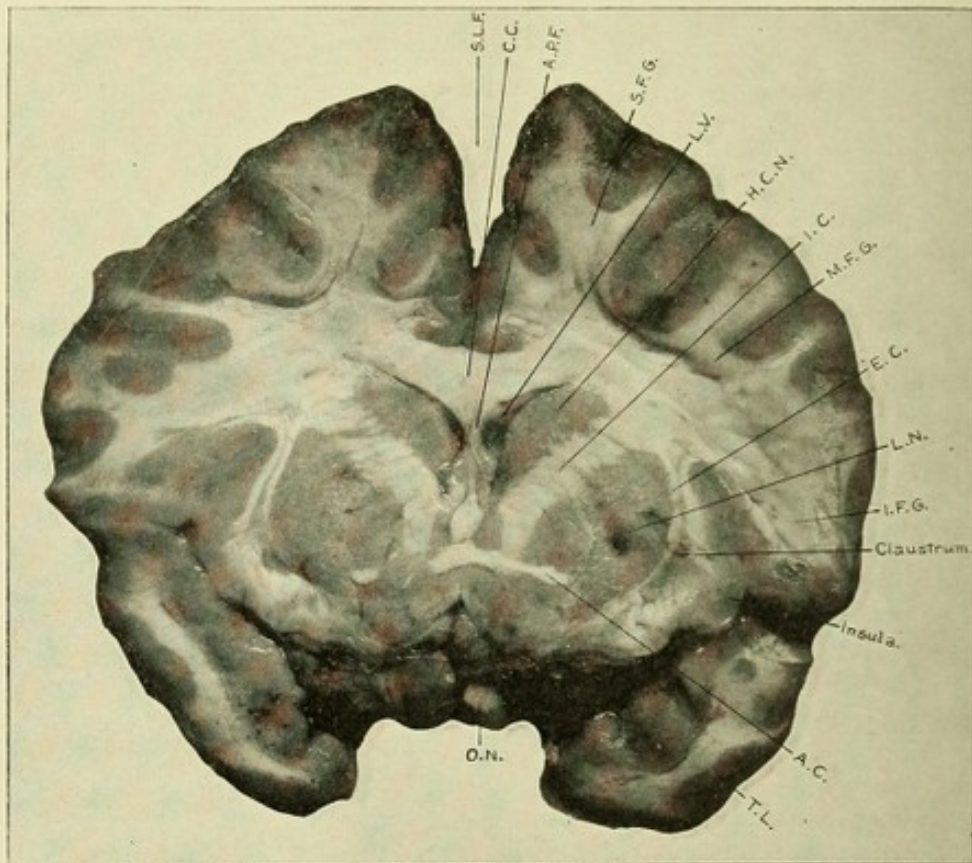


FIG. 196.—PHOTOGRAPH OF A SECTION THROUGH THE FRONTAL AND TIP OF TEMPORAL LOBES.

S.L.F. Superior longitudinal fissure. C.C. Corpus callosum. A.P.F. Anterior pillar of fornix. S.F.G. Superior frontal gyrus. L.V. Lateral ventricle. H.C.N. Head of caudate nucleus. I.C. Internal capsule. M.F.G. Middle frontal gyrus. E.C. External capsule. L.N. Lenticular nucleus. I.F.G. Inferior frontal gyrus. A.C. Anterior commissure. T.L. Temporal lobe. O.N. Optic nerve.

latter bodies by the *tænia semicircularis*, or *striæ corneæ*. They are so named because of their streaked appearance on transverse section, this appearance being due to the passage through them of the fasciculi of white fibers which compose the internal capsule. Each corpus may be described as an oval mass of

gray and white matter, located deep in the hemisphere, and consists of two parts—an extraventricular, or nucleus lenticularis, which is entirely embedded in the white matter, and an intraventricular portion, or caudate nucleus, which is within the lateral ventricle. This division of each corpus striatum is due to bundles of fibers from all parts of the cerebral cortex, which, converging, pass through this ganglion on their way to the crus cerebri. These fibers do not produce a complete separation of the lenticular from the caudate nucleus, as they are united anteriorly and posteriorly by slender tracts of fibers. The extraventricular or lenticular nucleus is bounded internally by the internal capsule, externally by the external capsule, which separates it from the claustrum, a thin layer of gray matter with a wavy margin. Inferiorly, it is bounded by the lenticular loop. Its horizontal section has the shape of a double convex lens; hence its name. On vertical section it is triangular in shape. It is separated into three zones by two laminæ of white fibers from the internal capsule, and by axones of its own cells on their way to the lenticular loop. The outer or larger part is called the putamen; the inner two zones, from their pale color, are called the globus pallidus. The intraventricular or caudate nucleus is pyriform in shape, and consists of an anterior expanded portion, or head, and a narrow posterior portion, or tail. The head forms the outer wall and part of the floor of the anterior cornu. The tail extends backward along the outer part of the floor of the lateral ventricle, then passes downward and forward into the descending cornu, terminating near its end in the amygdaloid nucleus or tubercle. It is covered by ependymal tissue, upon which rests the ciliated epithelium common to the ventricles. On its outer side is the internal capsule, which separates it from the lenticular nucleus. The caudate nucleus, with the optic thalamus, forms the inner boundary of the internal capsule. The two nuclei are continuous anteriorly with each other by small bands of gray matter in the ventral portion of the anterior limb of the capsule. The head of the caudate nucleus is continuous inferiorly with the anterior perforated space, which, in turn, is also connected with the anterior inferior extremity of the lenticular nucleus. Through the ventral

and basal portion of the lenticular and caudate nuclei passes a compact bundle of fibers—the anterior commissure. From the posterior end of the putamen, or the outer division of the lenticular nucleus, passes a process of gray matter into the roof of the descending horn of the lateral ventricle, which joins the tail of the caudate nucleus, thus uniting these two nuclei posteriorly.

Microscopic examination of these two nuclei shows that they contain two chief forms of multipolar cells—large rectangular and

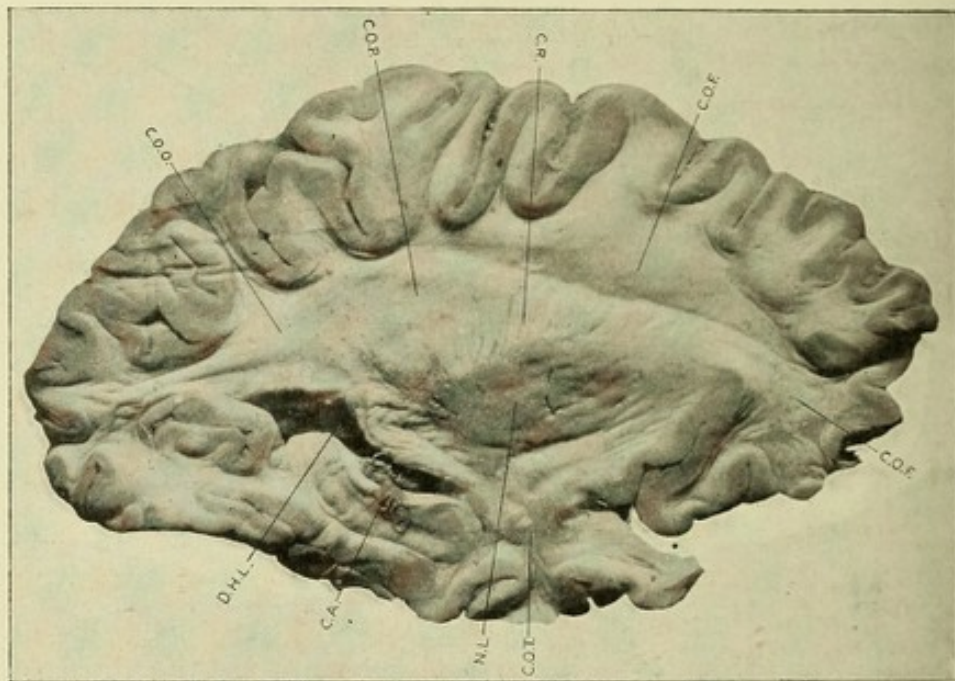


FIG. 197.—PHOTOGRAPH OF SAGITTAL (LONGITUDINAL) SECTION THROUGH A CEREBRAL HEMISPHERE.

C.O.F. Centrum ovale of frontal lobe. C.R. Corona radiata. C.O.P. Centrum ovale of parietal lobe. C.O.O. Centrum ovale of occipital lobe. D.H.L. Descending or middle horn of lateral ventricle. C.A. Cornu ammonis. N.L. Nucleus lenticularis. C.O.T. Centrum ovale of temporal lobe.

small triangular, polygonal, or spindle-shaped cells. The former are found, according to Koelliker, almost exclusively in the putamen, while the smaller cells are found throughout the globus pallidus and the caudate nucleus. According to Starr, both varieties are scattered indifferently throughout the gray matter, and are never associated into groups. The large cells have a slender body, from 36 to 70 μ long, and give off from each end one or two, occasionally three to five, very long dendrites, which

soon turn, nearly at right angles to the long axis of the cell-body. They have a very long course, and do not branch more than twice. Just prior to reaching their destination they fork. The axones come off either from a projection from the cell-body or

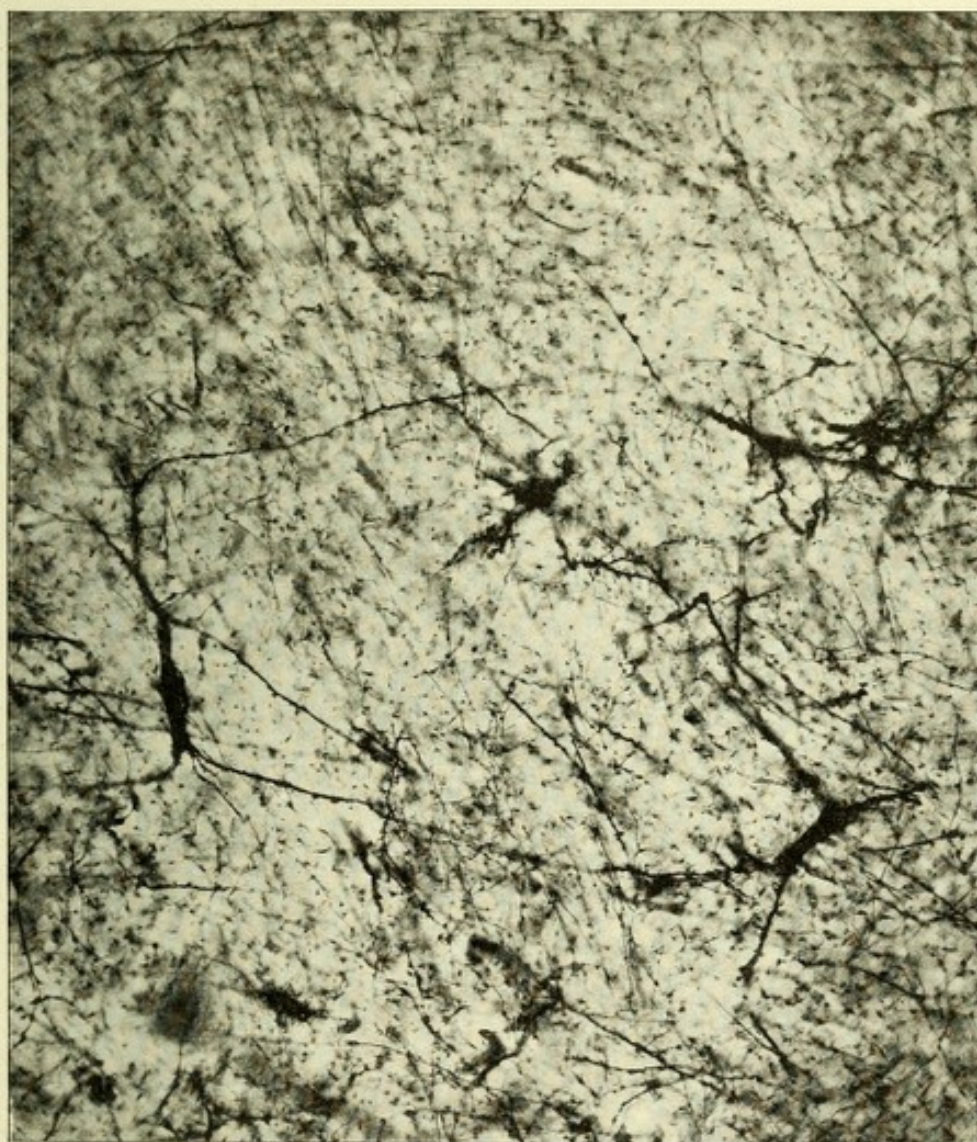


FIG. 198.—MICROPHOTOGRAPH OF LARGE RECTANGULAR CELLS OF CORPORA STRIATI.
Golgi method.—(After Starr.)

from the base of one of the dendrites. The cells of the globus pallidus and of the nucleus caudatus are practically the same in appearance, save that in the former they are smaller. They are from 20 to 40 μ in diameter, possessing, from all sides of the cell-body, many branching dendritic processes studded with

gemmules. The axones come from the cell-body, but their course is difficult to trace. Those from the large cells of the putamen pass either through the globus pallidus and enter the internal capsule to pass into the crus cerebri, or the greater number may pass by way of the lenticular loop (ansa lenticularis), to be described.

THE LENTICULAR LOOP, OR ANSA LENTICULARIS.

The lenticular loop is a rather large fasciculus of fibers which proceeds from the medullary laminae between the divisions of

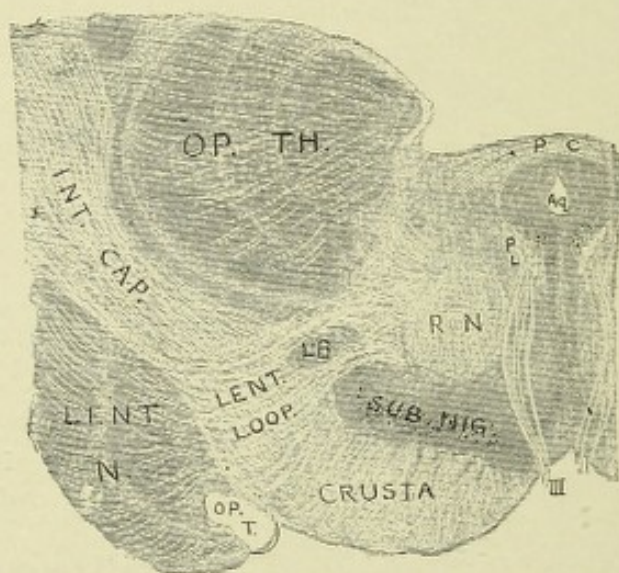


FIG. 199.—DIAGRAM OF A SECTION THROUGH THE CRUS, ETC., IN FRONT OF THE CORPORA QUADRIGEMINA.—(*Modified from Wernicke.*)

P. C. Posterior commissure. Aq. Aqueduct of Sylvius. P. L. Posterior longitudinal fibers. III. Third nerve. L. B. Luys' body. OP. T. Optic tract. O. P. T. H. Optic thalamus. Int. Cap. Internal capsule. Lent. Loop. Lenticular loop. R. N. Red nucleus. Lent. N. Lenticular nucleus.

the lenticular nucleus. These fibers have their origin chiefly from the cells of the outer division of the lenticular nucleus (the putamen), and, according to some observers, the loop receives accessions of fibers from the caudate nucleus and the cerebral cortex. This tract courses mesially beneath the globus pallidus, from which point the course and termination of its component fibers is much in dispute.

Von Monakow believes that the fibers of this tract are arranged into three distinct bundles—two anterior and one pos-

terior. The two anterior bundles pierce the internal capsule and crus cerebri in curves at the level of Luys' body, both bundles passing into that body; the most ventral bundle passes into the ventral surface of the body, terminating about its nerve-cells, while most of the fibers of the more dorsally placed bundle pass into the body through its dorsal portion; the remaining fibers unite with fibers of an unknown origin to pass forward and inward to the region of the tuber cinereum, where they terminate.

The posterior bundle—the largest of the three, and the one commonly called the lenticular loop—does not pierce the crus cerebri, but courses between the crus cerebri and the anterior pillar of the fornix, and then curves upward and inward to end in the gray matter beneath the ependyma of the third ventricle and in the optic thalamus.

According to von Bechterew, the lenticular loop also contains centripetally coursing fibers from the mesial fillet or lemniscus. These fibers are the axones from the cells of the nucleus cuneatus of the opposite side. They probably terminate about the cells of the globus pallidus. From these cells new fibers start out and pass upward through the centrum semiovale to arborize about the cells of the cortex of the central and parietal lobes. These cortical (sensory) neurones probably form the tegmental radiation of Edinger.

The axones from the cells of the caudate nucleus pass into the internal capsule; thence downward toward the base of the brain, where they curve backward to enter the optic thalamus and adjacent nuclei. A few axones from the cells of the caudate nucleus pass dorsolaterally through the internal capsule and globus pallidus to enter the lenticular loop.

THE TRACTUS STRIOTHALAMICUS (Edinger).

Edinger has discovered a tract of fibers which exists in all vertebrates, and takes its origin from the cells of the head of the caudate nucleus and from those of the putamen. These fibers form a distinct bundle, which passes downward through the anterior limb of the internal capsule to the base of the brain, whence they curve dorsally to reach the optic thalamus, where

most of them terminate ; a few fibers, however, continue backward beneath the optic thalamus and end in the posterior corpus quadrigeminum and in the substantia nigra (Fig. 200).

THE TÆNIA SEMICIRCULARIS.

The tænia, also called stria corneæ and stria terminalis, is a fasciculus of white fibers which forms the boundary between the nucleus caudatus of the corpus striatum and the optic thalamus. It is placed superficially in the side of a depression—the sulcus semilunaris—between the nucleus caudatus and optic

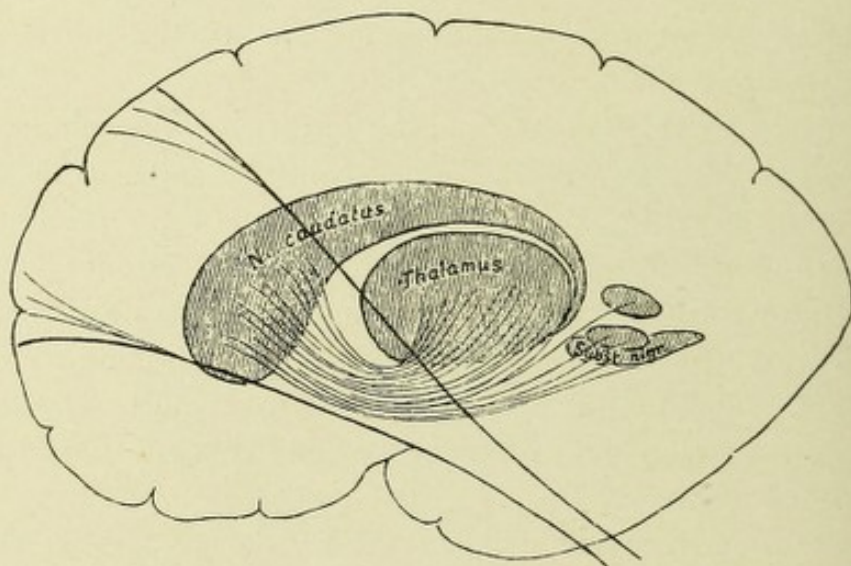


FIG. 200.—SCHEME SHOWING THE TRACTUS STRIOTHALAMICUS.—(After Edinger.)

thalamus. Beneath this bundle, occupying the bottom of the depression, is the vena corporis striati, which receives a number of superficial veins from the corpus striatum and optic thalamus and joins the vena Galeni. The anterior portion of the tænia descends, in front, between the anterior extremity of the optic thalamus and head of the caudate nucleus. Some of its fibers join the anterior commissure, and the remainder continue to the base of the brain and terminate in the gray matter of the anterior perforated space. Schwalbe, however, states that the tænia divides into two parts anteriorly, one of which is continuous with the anterior pillar of the fornix ; the other passes in front of the anterior commissure, to become lost in the gray

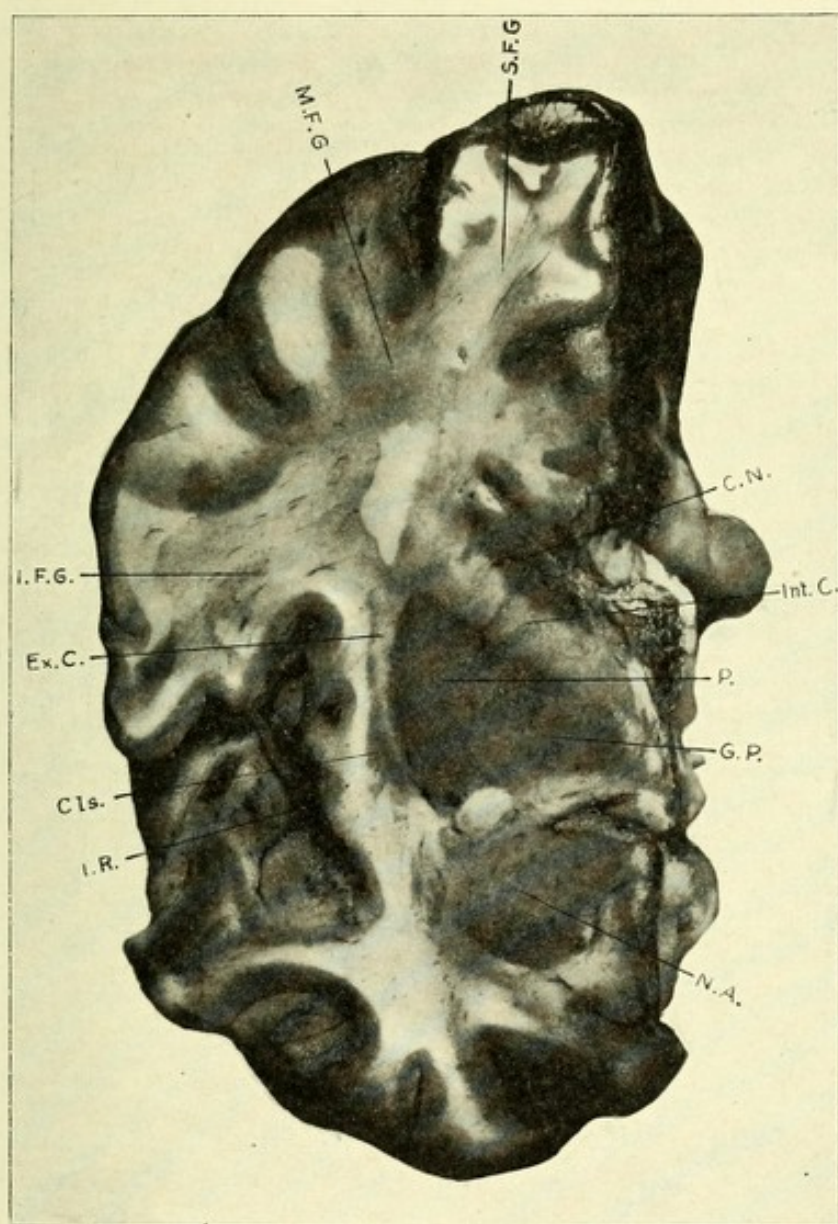


FIG. 201.—PHOTOGRAPH OF A LONGITUDINAL SECTION THROUGH A CEREBRAL HEMISPHERE TO SHOW THE GANGLIA OF THE HEMISPHERE.

S.F.G. Superior frontal gyrus. M.F.G. Middle frontal gyrus. I.F.G. Inferior frontal gyrus. Ex.C. External capsule. Cls. Claustrum. I.R. Insula or island of Reil. N.A. Nucleus amygdala. G.P. Globus pallidus of lenticular nucleus. Int.C. Internal capsule. C.N. Caudate nucleus.



matter between the septum lucidum and head of the caudate nucleus. Posteriorly, it passes, in conjunction with the tail of the caudate nucleus, into the descending cornu of the lateral ventricle, both terminating in the nucleus amygdala. The *nucleus amygdala* is a thickening of the cortex near the apex of the temporal lobe, producing a bulging in the roof of the descending cornu called the amygdaloid tubercle. It is dorsal to the nucleus lenticularis, with which it is probably continuous. The *claustrum* is a thin, wavy sheet of gray matter, having on its inner side a narrow strip of white matter—the external capsule—and on its outer side the cortex of the insula or island of Reil. Anteriorly, it blends with the nucleus amygdala (Obersteiner).

THE INTERNAL CAPSULE.

This receives its name because it bounds the lenticular nucleus internally, and is one of the most important parts, anatomically, of the whole nervous system. It is composed of a number of important tracts of medullated nerve-fibers, whose function is to bring the cerebral cortex into anatomic and physiologic relation with parts below—namely, the pons, cerebellum, medulla, and spinal cord. Hence, it must contain both centripetal and centrifugal tracts of fibers. The clearest type of its topography can be obtained from horizontal sections through the hemisphere and basal ganglia. It is a broad, homogeneous band of white matter (fasciculi cut across) between the lenticular nucleus on its outer and the caudate nucleus and optic thalamus on its inner side. It consists of two divisions or limbs,—an anterior and a posterior,—united with each other at an angle, which is called the knee or elbow of the capsule. The anterior portion or limb, which is the shorter, is between the lenticular nucleus on the outer side and the caudate nucleus on the inner side; and the posterior portion or limb is between the lenticular nucleus on the outside and the optic thalamus on the inside. Anteriorly, posteriorly, and superiorly it blends with the centrum semiovale. The fibers of which it is composed radiate fan-shaped toward all parts of the cortex, forming the corona radiata of Reil. Below, the internal capsule

is continuous with the *crus cerebri*. Experiments on animals, and clinical observations verified by pathologic researches in man, prove that the anterior limb of the capsule is composed of a tract of projection fibers going to the optic thalamus and of a tract of fibers connecting that portion of the frontal lobes which is in front of the central convolutions (the prefrontal lobe) with the opposite cerebellar hemisphere. This is the frontocerebellar tract. In the anterior two-thirds of the posterior limb is the great motor tract; the posterior third contains the tracts which convey touch, temperature, and muscle sense, as well as the optic and auditory tracts, and a tract of projection fibers connecting the temporal and occipital lobes with the opposite cerebellar hemisphere. Apart from the above-mentioned systems of fibers, the capsule contains, in addition, projection fibers which unite all parts of the cerebral cortex with each optic thalamus.

The exact location of the different tracts of which the internal capsule is composed is as follows: In the anterior limb are two tracts of fibers, the ventral of which is a projection bundle of fibers to the optic thalamus from the frontal lobe. It is of no great clinical importance. The dorsal bundle is a large fasciculus (frontocerebellar) collecting its fibers from all parts of the frontal lobe, and thence passing to the opposite cerebellar hemisphere via the nucleus pontis, a few fibers being connected with the cerebellar hemisphere of the same side.

The posterior limb contains the motor and sensory tracts. The motor tract, which occupies the anterior two-thirds of this limb, may be divided into the following fasciculi of fibers, enumerated from before backward: The most anterior bundle is made up of fibers conveying motor impulses to the facial muscles; it is located just ventral to the knee of the capsule. Posterior to the facial fibers, fibers come from before backward—the motor fibers to the hypoglossal nerve, to the arm, the leg, and the trunk, in regular order, as indicated by the diagram (Fig. 203).

Just dorsal to the motor or pyramidal part, occupying the posterior third of the capsule, is the sensory tract. The extreme posterior part of the posterior limb of the capsule contains the optic and auditory tracts, the latter being external to the former.

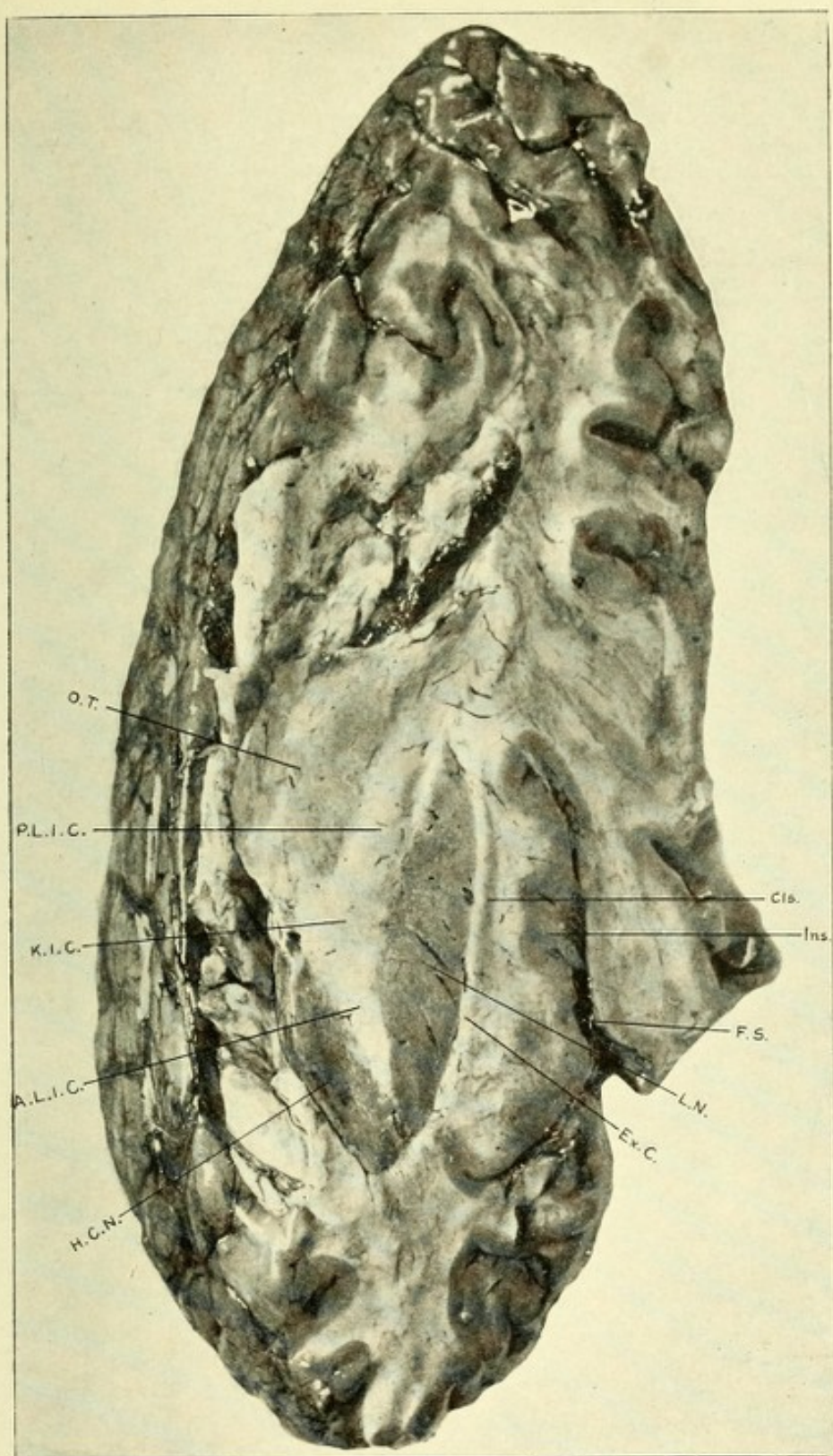



FIG. 202.—PHOTOGRAPH OF A HORIZONTAL SECTION THROUGH A CEREBRAL HEMISPHERE
TO RELATIONS OF INTERNAL CAPSULE.

O.T. Optic thalamus. P.L.I.C. Posterior limb of internal capsule. K.I.C. Knee of internal capsule. A.L.I.C. Anterior limb of internal capsule. H.C.N. Head of caudate nucleus. Ex.C. External capsule. L.N. Lenticular nucleus. F.S. Fissure of Sylvius. Ins. Insula. Cls. Caudate nucleus.



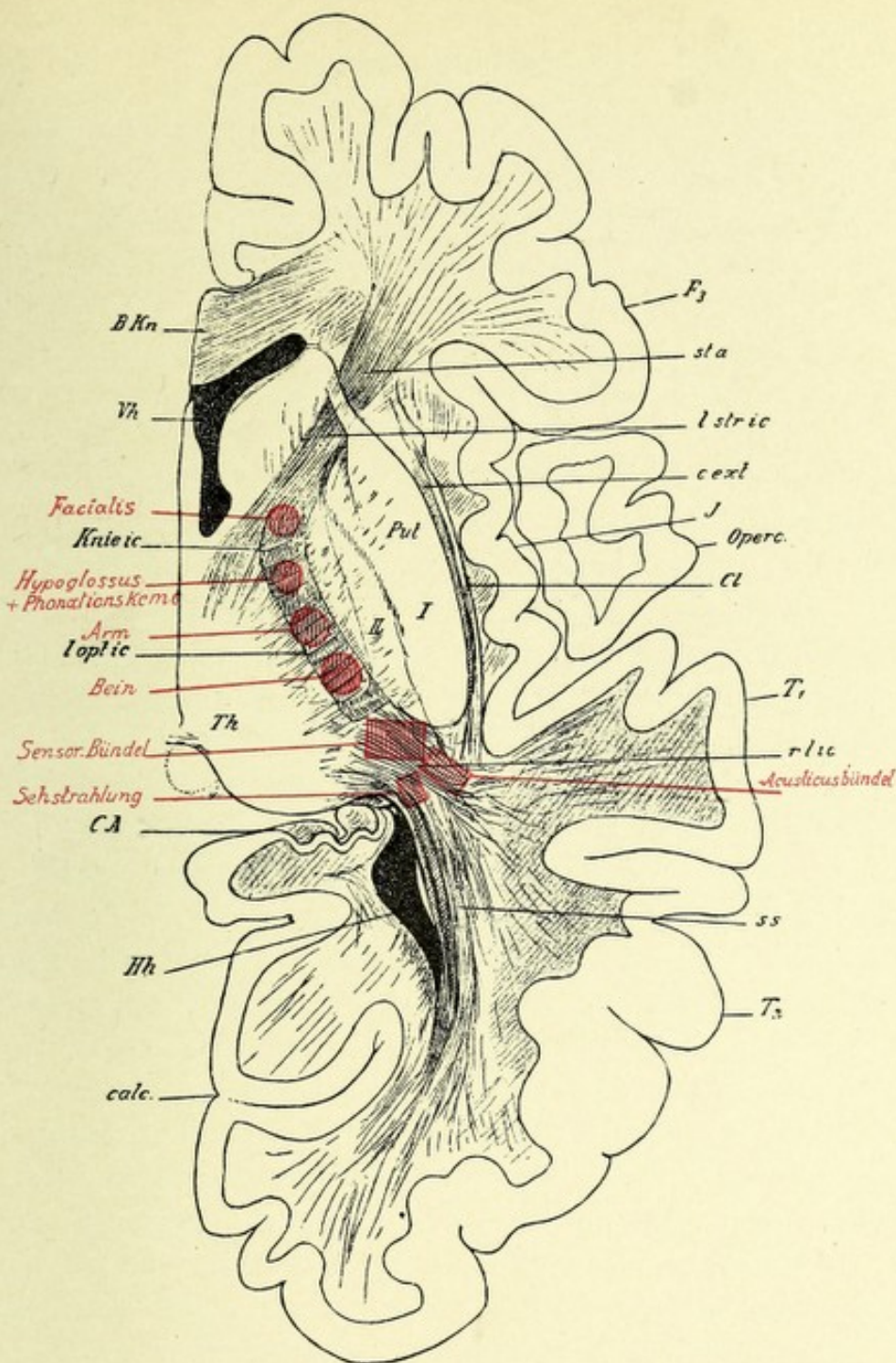



FIG. 203.—HORIZONTAL SECTION THROUGH THE RIGHT HEMISPHERE OF A MAN.

—(After von Monakow.)

The important parts of the internal capsule are colored red.

B.Kn. Knee of corpus callosum. *Vh.* Anterior horn of lateral ventricle. *F₃*. Inferior third frontal convolution. *l stric.* lenticulostriate division of internal capsule. *Knie ic.* Knee of internal capsule. *loptic.* Lenticulo-optic division of internal capsule. *Th.* Optic thalamus. *J.* Insular island of Reil. *Cl.* Caudate nucleus. *Operc.* Operculum. *T₁*. First temporal convolution. *rlic.* Retrolenticular region of internal capsule. *CA.* Ammonis horn. *calc.* Calcarine fissure. *Hh.* Posterior horn of lateral ventricle. *ss.* Optic radiation of Gratiolet. *T₂*. Second temporal convolution. *Facialis.* Position in capsule of facial bundle of fibers. *Hypoglossus.* Position of hypoglossal fibers. *Arm.* Position of arm fibers. *Bein.* Position of fibers for leg. *Sensor. bündel.* Sensory fibers. *Sehstrahlung.* Optic tract. *Acusticusbündel.* Auditory tract.



In addition to the before-mentioned tracts, the posterior limb of the capsule contains a fasciculus of fibers connecting the occipital and temporal lobes with the opposite cerebellar hemisphere, as well as projection fibers from the same source to the optic thalamus.

THE FORNIX.

The fornix is composed of longitudinally arched bundles of fibers consisting of symmetric halves—one for each hemisphere. It has a body and two pillars or columns for each side, one anterior and one posterior. It is located beneath the corpus callosum, with which it is continuous behind, being separated from it in front by the septum lucidum. The body of the fornix rests upon the velum interpositum, which separates it from the optic thalamus and third ventricle below. It is triangular in shape; broad behind, narrow in front. Its lateral surfaces form part of the floor of the body of each lateral ventricle. The anterior pillars, or columnæ fornicis, are two roundish bundles of nerve-fibers which descend through the gray matter of the third ventricle, behind the anterior commissure and in front of the foramen of Monro on each side, forming its anterior boundary. As they descend they diverge, leaving an interval which is occupied by the septum lucidum. They receive a few fibers from the tænia semicircularis, the crura of the pineal gland, and the septum lucidum. According to Koelliker, the tæniæ semicircularis do not unite with these pillars; on reaching the base of the brain they curve backward and upward, around the corpora albicantia, forming loops which make the white portion, or stratum zonale, of these bodies. They end in arborizations about the inner cell-groups of these bodies. These cell-groups also have terminating about them a fasciculus of fibers (axones from the cells of the ventral nucleus of the optic thalamus) which is called the bundle of Vicq d'Azyr, or fasciculus thalamomammillaris.

The posterior pillars of the fornix are two flattened bands—prolongations from the sides of the body of the fornix. At their commencement their upper surfaces are adherent to the under



surface of the corpus callosum. Between these diverging crura and the splenium of the corpus callosum exists a triangular area of white matter, the psalterium, which presents on its surface a number of transverse oblique and longitudinal lines. From the fancied resemblance these bear to the strings of a harp, this area is also called the lyra. The psalterium is a commissure between the cornua ammonis. Each crus curves downward and outward around the pulvinar of the optic thalamus, then enters the descending cornu of the lateral ventricle, giving off some fibers to the hippocampus major, while the rest continue along the inner border of the cornu to end in the gyrus hippocampus and uncinat gyrus. The latter fibers form the before-mentioned fimbria. The study of secondary degenerations proves that the fibers of the fornix really proceed from the cornu ammonis and region of the gyrus hippocampus and pass to the corpus mamillare.

THE SEPTUM LUCIDUM.

The septum lucidum forms the inner boundary of the lateral ventricles, and is united in front with the anterior portion (the genu) and the descending portion (the rostrum) of the corpus callosum. Posteriorly and inferiorly it unites with the fornix and its anterior peduncles. It is a triangular area of white matter, consisting of two very thin laminæ separated by a narrow closed space which contains a little fluid. This interval or space is termed the ventricle of the septum lucidum, or the fifth ventricle.

THE FIFTH VENTRICLE.

This ventricle does not communicate with the other ventricular cavities. It was originally a part of the great longitudinal fissure, but owing to the union of the hemispheres by the development of the corpus callosum above and the fornix below, that space which had been a part of the longitudinal fissure became a distinct cavity with walls of its own—the laminæ of the septum lucidum. These laminæ are formed of the mesial wall of the

hemispheres, and are thus composed of an internal layer of gray matter, covered with pia mater, similar to the cortex but much more delicate in structure ; a middle layer of white matter ; and an external layer of ependymal tissue, covered by an epithelial layer continuous with that lining the lateral ventricle.

CHAPTER XI.

THE BLOOD-VESSELS OF THE BRAIN.

An accurate acquaintance with the exact distribution of the blood-vessels that nourish the brain is of great importance, because of the fact that very many cerebral affections are due to their rupture or to obstruction by emboli or thrombi, all of which conditions are more frequent in the brain than in any other organ of the body. This is due to the large size of its main trunks of supply, as well as to their direct course in the blood stream. For this reason emboli are more easily swept into the vessels of the brain than into those of the other organs. Owing to the high arterial tension to which these vessels are more or less constantly subjected, they often early present degenerative changes in their walls, which increases the chance of rupture or of the formation of thrombi.

The cerebral blood-vessels are arranged in two systems—the cortical and the central or ganglionic. The former are for the nutrition of the convolutions and underlying white matter, and are distributed in the pia mater. They consist of two sets,—long and short,—which enter the cortex at right angles to its surface.

The long arteries, which supply a considerable part of the centrum semiovale, pass through the gray matter, penetrate the white matter for an inch or more, following the course of its nerve fasciculi, and communicate with each other by very fine capillary branches, which form elongated plexuses. Most of the shorter ones are distributed to the cortex only, although some of the longer branches reach the white matter just beneath the cortex. They anastomose very freely, forming distinct plexuses in the gray matter.

The central or ganglionic vessels nourish the central ganglia

and adjacent parts, and are terminal end arteries, there existing no anastomosis between them and the cortical vessels. While the terminal cortical vessels anastomose slightly with one another, this is insufficient, in case of their obstruction, to prevent a local necrosis of the areas which they nourish. Hence, the general statement may be made that the majority of the arteries of the brain are physiologically end vessels.*

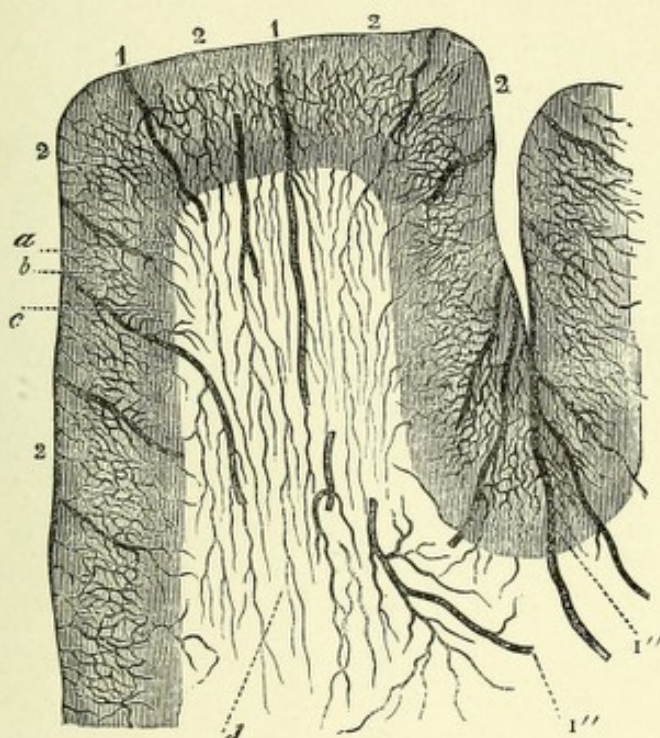


FIG. 204.—DISTRIBUTION OF ARTERIES IN THE CEREBRAL CORTEX.—(After Duret.)

1, 1. Medullary arteries. 1', 1'. In groups between the convolutions. 1''. Commissural arteries. 2, 2. Arteries of the cortex cerebri. a. Large meshed plexus in first layer. b. Closer plexus in middle layer. c. Open plexus in the gray matter next the white substance, with its vessels (a').

The arterial supply to the cerebrum comes from two sources—the internal carotids and the vertebrals.

* Physiologically considered, end arteries are such as are found in the brain or the heart, obstruction of which causes local death of the part they nourish. These arteries may not be strictly end arteries in the sense Cohnheim intended, for many of them anastomose with other terminal branches, but the collateral circulation thus established is insufficient of itself to maintain the nutrition of the part thus supplied when either terminal vessel is obstructed, their plugging, either by emboli or thrombi, always resulting in local areas of necrosis or softening, which usually give rise to definite localizing symptoms.

CAROTID ARTERIES.

The right internal carotid artery arises from the innominate artery, while the left has its origin from the highest point of the arch of the aorta, both carotids dividing at the upper border of the thyroid cartilage into external and internal branches, called respectively the external and internal carotid arteries.

The internal carotid of each side, continuing upward, reaches the cavity of the skull through the middle lacerated foramen, having passed through the carotid canal in the petrous portion of the temporal bone. It then passes through the cavernous sinus until it reaches the anterior clinoid process, where it pierces the dura mater and reaches the base of the brain at the beginning of the fissure of Sylvius. The vertebral arteries, which have their origin from the subclavian arteries, pass through all the foramina in the transverse processes of the vertebræ above the fifth cervical; during this course they give off several lateral spinal arteries, whose medullary branches pass with the spinal nerves to the spinal cord, supplying it and its membranes. They then pierce the dura mater and reach the interior of the skull through the foramen magnum. It is interesting to note that, owing to the direct course of the blood-stream in the left carotid artery,—it being continuous with that in the aorta,—emboli, which are frequently dislodged from diseased cardiac valves, more frequently pass into this vessel than into the right, because the latter artery arises from the innominate, which is given off from the aortic arch at an angle with the course of the blood-stream. This fact remains true for the vertebrals: the right has its origin from the subclavian after the latter vessel becomes horizontal, while the left arises from the subclavian in its upward course, and hence is in direct line of the blood-stream.

The internal carotid artery, after reaching the base of the brain, rests on the anterior perforated space at the inner portion of the Sylvian fissure, between the optic and oculomotor nerves. It terminates in the following branches: the anterior and middle cerebral, the posterior communicating, and the anterior choroid arteries.

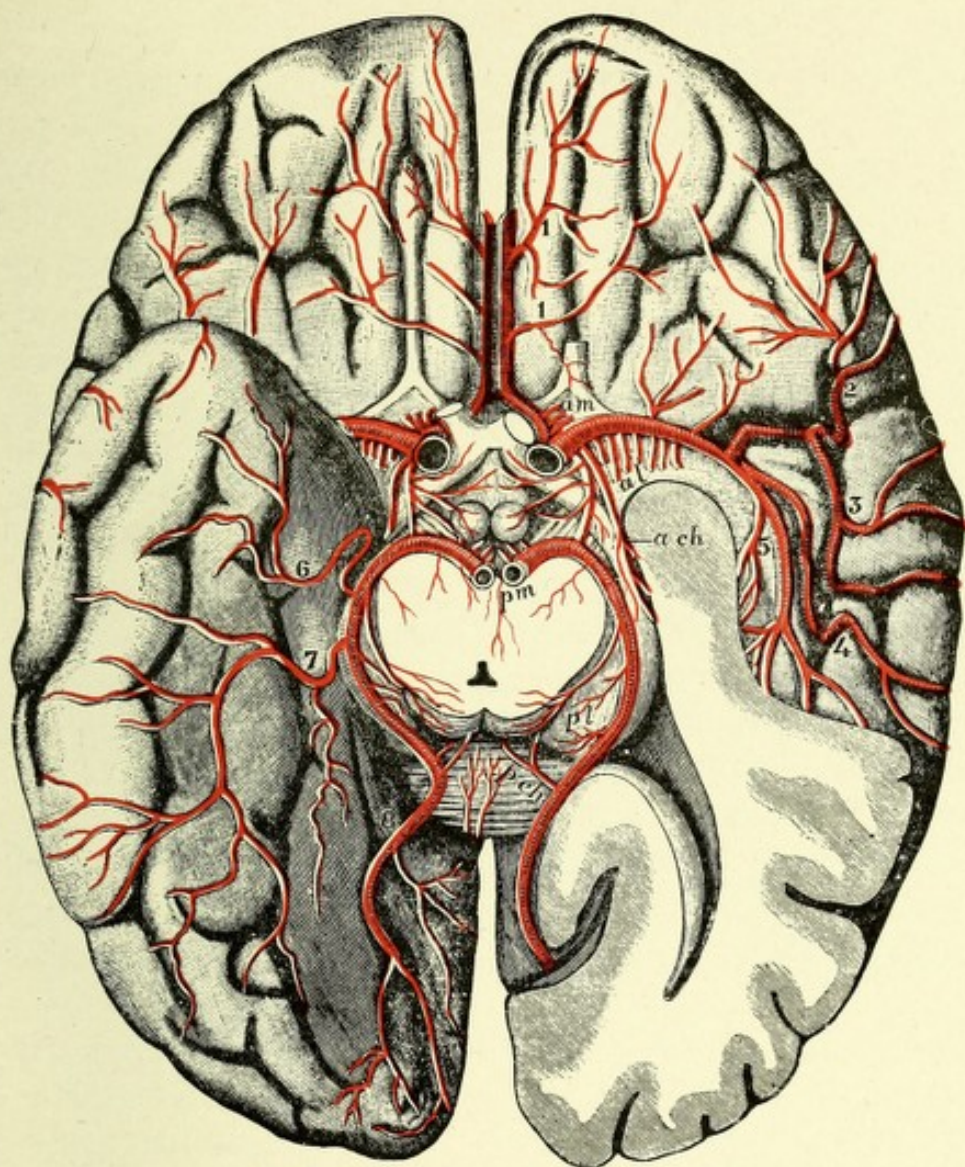



FIG. 205.—THE ARTERIES OF THE BASE OF THE CEREBRUM.—(G. D. T., after Duret, and from nature, from Quain.)

On the left side of the brain the temporal lobe is cut away so as to open the inferior and posterior horns of the lateral ventricle. The mid-brain is divided close above the pons and the posterior cerebral arteries are cut at their origin from the basilar.

Central arteries (to the basal ganglia): *am*. Anteromesial group arising from the anterior cerebral. *al*. Anterolateral group, from the middle cerebral. *pm*, *pl* (on the optic thalamus). Posteromesial and posterolateral groups, from the posterior cerebral.

Choroid arteries: *a ch*. Anterior, from the internal carotid. *p ch* (on the splenium). Posterior, from the posterior cerebral.

Peripheral arteries: 1, 1. Inferior internal frontal, from the anterior cerebral. 2. Inferior external frontal. 3. Ascending frontal. 4. Ascending parietal, and 5, temporoparietal, from the middle cerebral. 6. Anterior temporal, 7, posterior temporal, and 8, occipital, from the posterior cerebral.



THE ANTERIOR CEREBRAL ARTERY.

The anterior cerebral artery passes forward and inward across the anterior perforated space to reach the inferior longitudinal fissure between the frontal lobes, where it lies close to its fellow of the opposite side, and gives off a branch of communication with that vessel called the anterior communicating artery. It then passes forward around the genu of the corpus callosum, reaching its superior portion, and after giving off its cortical branches, it courses backward to terminate with the posterior cerebral artery.

The branches of the anterior cerebral artery are the anterior communicating, the central or ganglionic, the commissural, and the cortical. The anterior communicating artery is a small, transverse branch, about two lines in length, which connects the two anterior cerebral arteries. This communicating branch gives off two or three of the anteromedian arteries, which pass to the head of the caudate nucleus. The central or ganglionic branches are the anteromedian group of vessels, most of which come from the anterior cerebral, while a few come from the anterior communicating. They pass through the anterior perforated space and lamina cinerea to be distributed to the head of the caudate nucleus.

The commissural branches supply the corpus callosum. The cortical branches are the orbital, the marginofrontal, the callosomarginal, and the quadrate. The orbital branches supply the inner part of the orbital lobe and the olfactory bulb. The marginofrontal artery, which comes from the anterior cerebral as it rests on the corpus callosum, supplies the marginal gyrus, the convex surface of the superior and middle frontal gyri, and the superior portion of the ascending frontal convolution. The callosomarginal branch is distributed to the gyrus fornicatus. The quadrate artery nourishes the quadrate lobe, or precuneus. It will thus be seen that the cortical branches of the anterior cerebral artery supply the entire median portion of the cerebral hemisphere as far back as the cuneus, the first and second frontal, the upper part of the ascending frontal, together with the orbital lobe and olfactory bulb.

THE MIDDLE CEREBRAL OR SYLVIAN ARTERY.

The middle cerebral or Sylvian artery, the largest terminal branch of the internal carotid, lies in the Sylvian fissure. Its course is forward and outward until it reaches the island of Reil, where it divides into five cortical branches, which lie in the sulci of the insula; these branches are then continued on to the convex surface of the hemisphere, to supply a part of the frontal, most of the central, and the parietal convolutions, as well as a large part of the temporal lobe. The cortical branches of the Sylvian are the

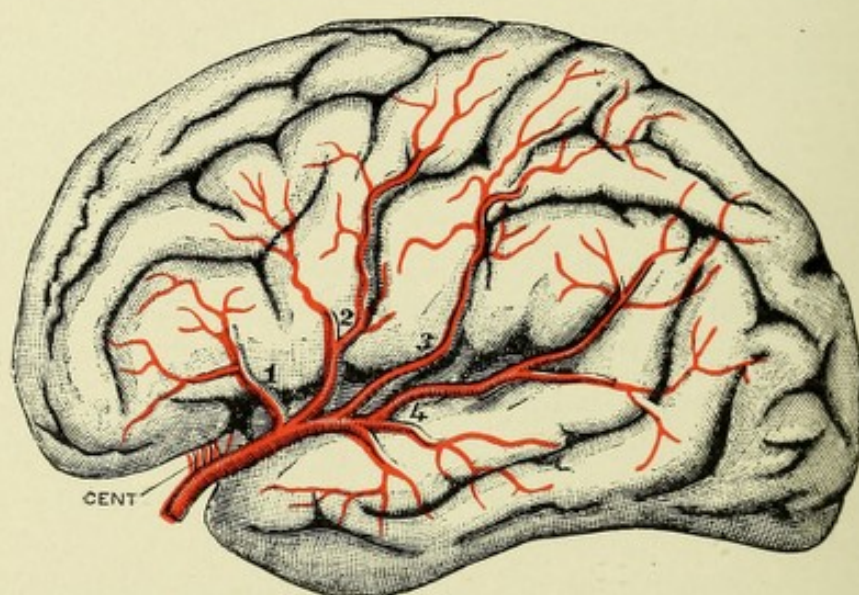


FIG. 206.—CORTICAL DISTRIBUTION OF THE MIDDLE CEREBRAL ARTERY (DIAGRAMMATIC).
—(G. D. T. after Charcot, from Quain.)

CENT. Anterolateral group of central arteries. 1. Inferior external frontal artery. 2. Ascending frontal artery. 3. Ascending parietal artery. 4. Parietotemporal artery.

inferior frontal, the ascending frontal, the ascending parietal, the parietotemporal, and the sphenoid.

The first or inferior frontal artery is distributed to the convex surface of the inferior frontal convolution. The second or ascending frontal supplies the lower two-thirds of the ascending frontal and the root of the second frontal, the upper third of the ascending frontal being supplied by the marginofrontal branch of the anterior cerebral artery. The third or ascending parietal artery is distributed to the whole of the ascending parietal, the superior parietal, and that part of the inferior parietal lobule

adjacent to the ascending parietal gyrus. The fourth, the parietotemporal artery, supplies the supramarginal, the angular, the posterior part of the inferior parietal, and the first and second temporal gyri. The fifth or sphenoid artery supplies the anterior part of the first and most of the second temporal convolutions.

The Central or Ganglionic Branches of the Middle Cerebral.—These branches arise from the middle cerebral close to its origin. They consist, first, of two small vessels which pass through the inner part of the floor of the Sylvian fissure to the head of the caudate nucleus; and, second, of numerous small vessels—the anterolateral arteries—which come

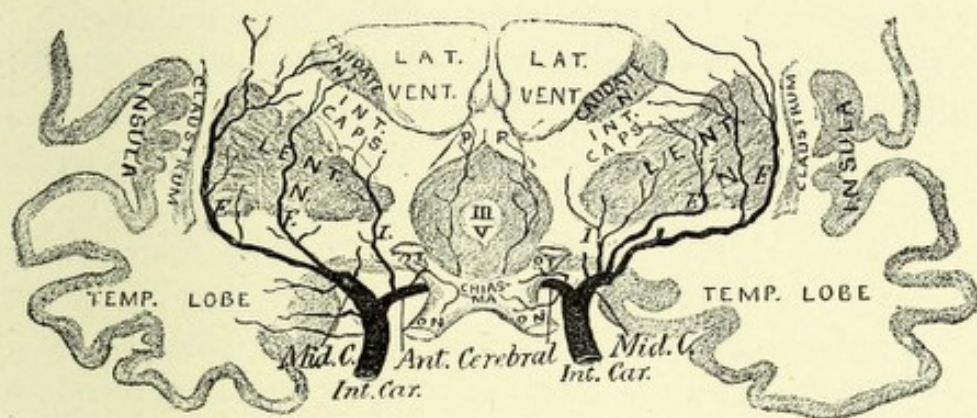


FIG. 207.—DIAGRAM OF THE BLOOD-SUPPLY TO THE CENTRAL GANGLIA BY THE LENTICULO-STRIMATE ARTERIES, EXTERNAL (*E*) AND INTERNAL (*I*).—(After Duret.)

III V. Third ventricle. P P. Pillars of the fornix. *Mid. C.* Middle cerebral artery.

off from the Sylvian at right angles and pass through the anterior perforated space to be distributed to the caudate nucleus, except its head, to the lenticular nucleus, the internal capsule, the external capsule, and a part of the optic thalamus.

These central or ganglionic branches of the Sylvian artery are grouped by Duret into internal and external branches. The internal branches pass through the inner segments of the lenticular nucleus and are distributed to that nucleus and to the internal capsule. The external vessels, which are divisible into an anterior and a posterior set, pass upward outside of the lenticular nucleus, pierce the third segment of the lenticular nucleus, and pass to the internal capsule. The anterior branches are called the

lenticulostriate arteries ; they pass to the lenticular and caudate nuclei, except the head of the latter. The posterior branches, or the lenticulo-optic arteries, supply the posterior parts of the internal capsule and the anterior and inner parts of the optic thalamus. The largest of the lenticulostriate arteries, which passes between the lenticular nucleus and the external capsule, and terminates in the caudate nucleus, is called, from its tendency to rupture, "the artery of cerebral hemorrhage" (Charcot).

POSTERIOR COMMUNICATING ARTERY.

The posterior communicating artery arises from the back part of the internal carotid before that vessel divides into the anterior and middle cerebral arteries. Occasionally it arises from this latter vessel. The communicating artery passes backward over the optic tract and crus cerebri, and joins the posterior cerebral, a branch of the basilar. In its course it gives off small branches of supply to the dorsal portion of the optic chiasm, to crus cerebri, infundibulum, and pituitary body, and to the corpora mammillaria. From the posterior part of this communicating branch a few small vessels are given off, which, with similar vessels from the posterior cerebral, form the postero-median ganglionic branches.

THE ANTERIOR CHOROID ARTERY.

The anterior choroid artery is a small, slender branch from the back part of the internal carotid, just external to the posterior communicating ; it courses backward on to the optic tract and crus cerebri, then passes beneath the uncinate gyrus, enters the transverse fissure at the lower part of the descending horn of the lateral ventricle, and supplies the hippocampus major, or cornu ammonis, the corpus fimbriatum, and the choroid plexus.

THE VERTEBRAL ARTERIES.

The vertebral arteries, after reaching the cranial cavity through the foramen magnum, course along the ventral portion of the medulla oblongata until they approach the lower border of the pons Varolii, where they unite to form the basilar artery, which is a mere prolongation of them. In their intracranial course each vessel gives off the following branches: the posterior meningeal, the anterior and posterior spinal, and the posterior inferior cerebellar artery. The posterior meningeal is a small vessel which leaves the vertebral at the foramen magnum; it supplies the falx cerebelli and the bone and dura mater of the posterior fossa of the skull. The anterior and posterior spinal arteries are described in connection with the blood-supply of the spinal cord. The posterior inferior cerebellar arteries are to be considered with the description of the nutrient vessels of the cerebellum, pons, and medulla.

THE BASILAR ARTERY.

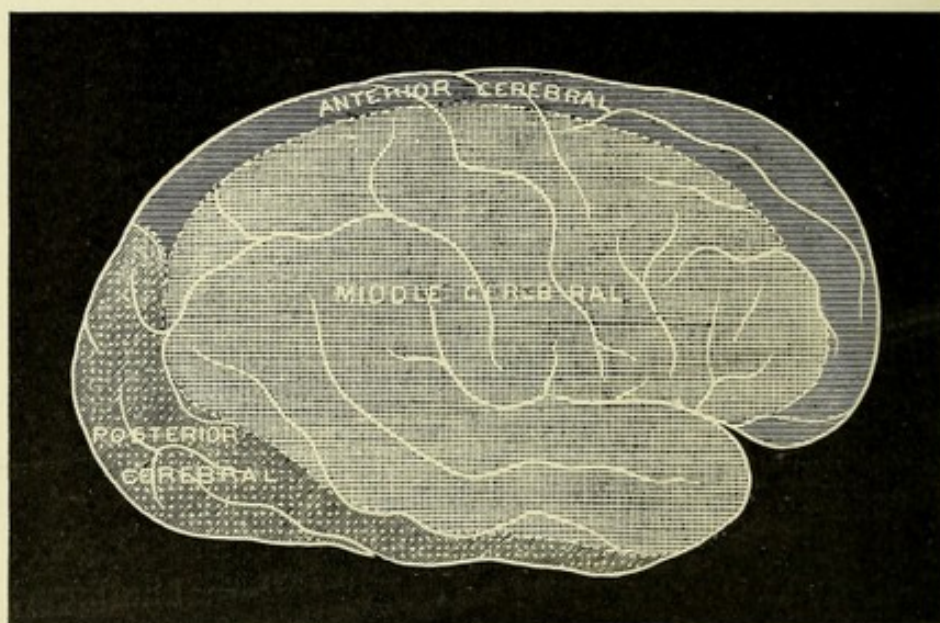
The basilar artery, a short but large vessel, is formed by the union of the two vertebrals. It rests in the median groove on the ventral surface of the pons, and extends from its inferior to its upper border, where it terminates by dividing into two branches—the posterior cerebral arteries. The branches of the basilar are the transverse or pontal, the internal auditory, the anterior cerebellar, the superior cerebellar, and the posterior cerebral. The pontal as well as the cerebellar branches will be described in connection with the blood-supply to the cerebellum, pons, and medulla. The internal auditory artery passes with the auditory nerve into the internal auditory meatus and is distributed to the internal ear (Fig. 209).

THE POSTERIOR CEREBRAL ARTERIES.

The posterior cerebral arteries, the terminal branches of the basilar, wind around the crura cerebri, and after receiving the posterior communicating branches from the internal carotids,

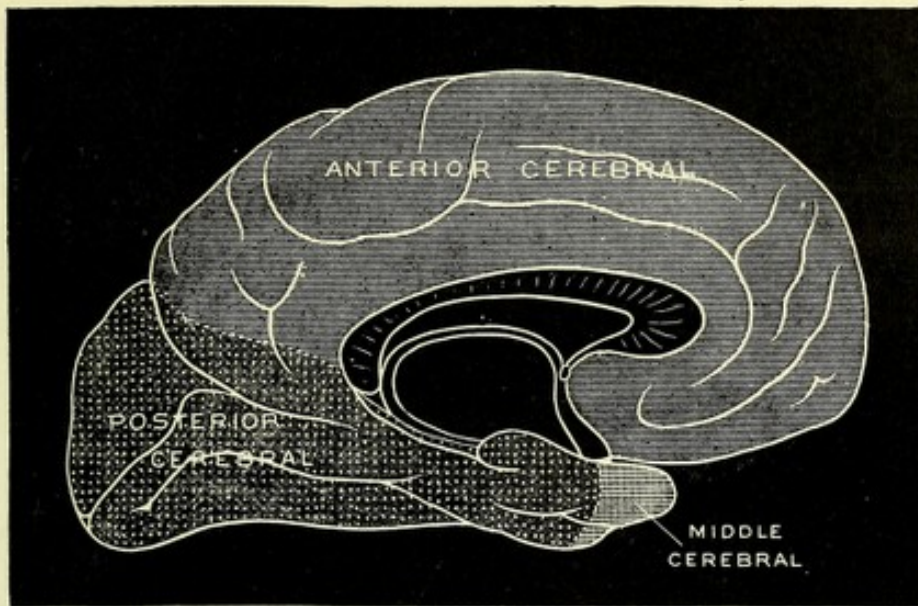
pass backward to reach the under surface of the cerebral hemispheres, and terminate in three branches, which are distributed to the occipital and temporal lobes. The branches of the posterior cerebral are the central, or ganglionic, and the cortical, or terminal. The central, or ganglionic, consist of the posteromedian, the posterior choroid, and the posterolateral. The posteromedian arteries consist of several small vessels which arise from the posterior cerebral close to its origin. These vessels, in connection with a few bearing the same name from the posterior communicating, pass through the posterior perforated space to supply the inner part of the optic thalamus and

A



walls of the third ventricle. The posterior choroid branch, which supplies the velum interpositum and choroid plexus, passes through the transverse fissure. The posterolateral vessels take their origin from the posterior cerebral after it has passed around the crus cerebri; they give branches to the crus cerebri, corpora quadrigemina, and posterior part of the optic thalamus. The cortical or terminal branches, three in number, are distributed as follows: (1) A branch to the uncinate convolution; (2) a branch to the superior part of the temporal lobe; (3) the temporo-occipital branch to the cuneus, the lingual gyrus, and the outer surface of the occipital lobe.

B



C

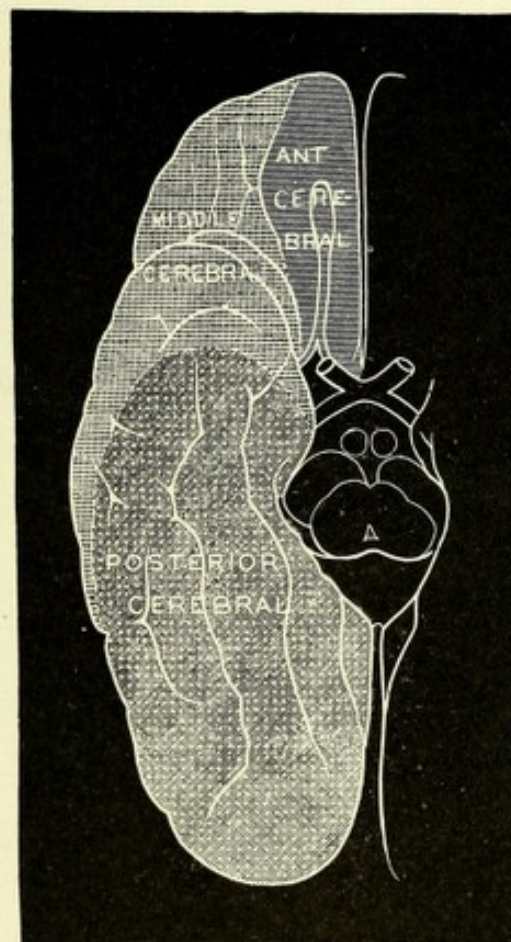



FIG. 208.—DIAGRAM SHOWING THE AREAS OF CORTICAL DISTRIBUTION OF THE ANTERIOR, MIDDLE, AND POSTERIOR CEREBRAL ARTERIES RESPECTIVELY.—(E. A. S., from Quain.)

A. Lateral aspect (see opposite page). B. Mesial aspect. C. Basal aspect. The area supplied by the middle cerebral frequently extends to the upper border of the hemisphere in the region of the parietal lobe, and therefore somewhat further than is represented in A.



THE CIRCLE OF WILLIS.

The branches of the internal carotids and vertebrals form at the base of the brain a remarkable anastomosis, called the circle of Willis. This circle is completed anteriorly by the anterior cerebral arteries and their branch of communication, the anterior

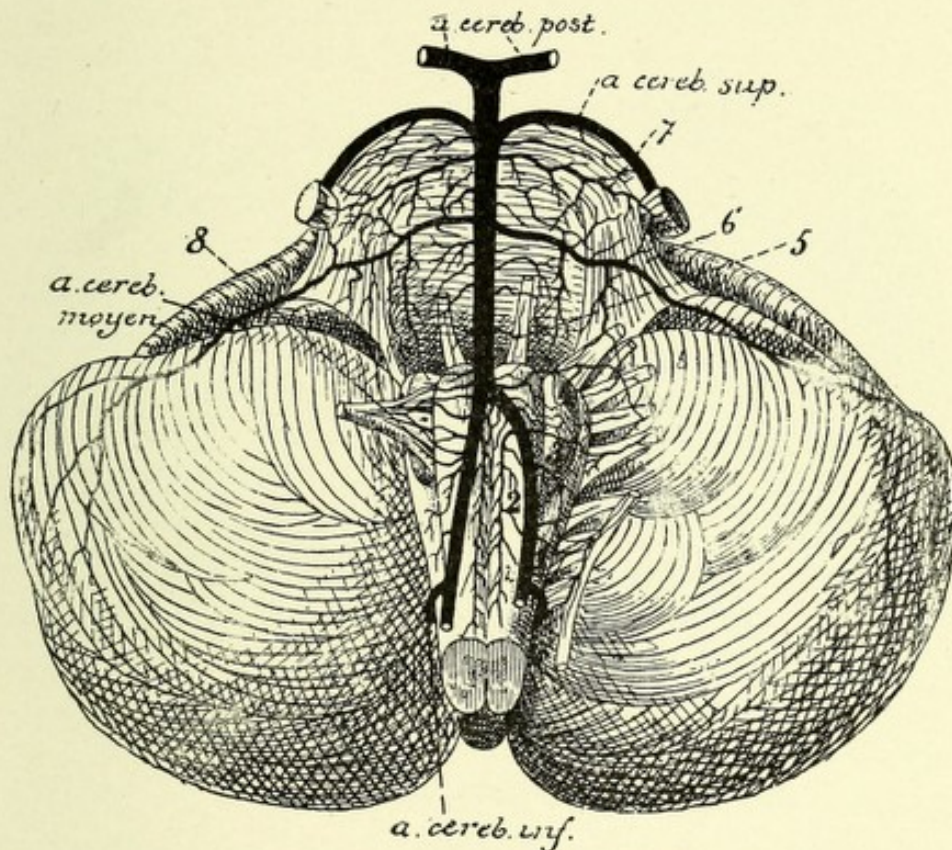


FIG. 209.—ARTERIES OF THE ANTERIOR SURFACE OF THE PONS AND MEDULLA.—(After Duret.)

- a. cereb. post.* Posterior cerebral artery. *a. cereb. sup.* Superior cerebellar artery. *a. cereb. moyen.* Middle cerebellar artery. *a. cereb. inf.* Inferior cerebellar artery.
 1. Root-arteries of spinal accessory nerve. 2. Anterior spinal artery. 3. Root-arteries of pneumogastric nerve. 4. Root-arteries of glossopharyngeal nerve. 5. Root-arteries of the oculomotor nerve. 6. Root-arteries of the facial and acoustic nerves. 7. Root-arteries of the trigeminal nerve. 8. Root arteries of hypoglossal nerve.

communicating; posteriorly, by the posterior cerebrals and point of the basilar; and laterally, by the internal carotids and posterior communicating arteries. This circle of anastomosis serves to equalize the blood-flow to the brain, and is the only means of communication between the cortical and central or

ganglionic blood-vessels. If either of the main trunks (carotids or vertebrals) are obstructed, the nutrition of the parts of the brain supplied by the branches of the obstructed vessels is not interfered with, because they are supplied through the circle of Willis by the remaining vessels, which are pervious.

The cerebellum, the pons Varolii, and the medulla oblongata are supplied with branches from the vertebrals and basilar arteries.

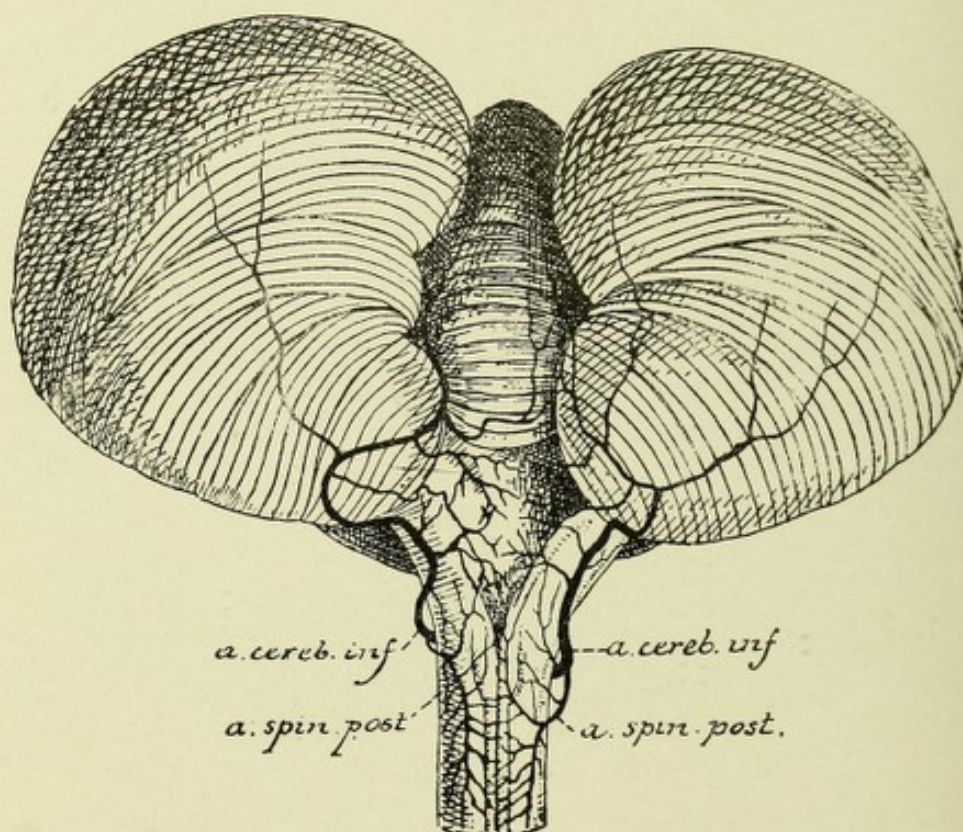


FIG. 210.—ARTERIES OF THE POSTERIOR SURFACE OF THE MEDULLA.—(After Duret.)

a. cereb. inf. Inferior cerebellar artery. *a. spin. post.* Posterior spinal artery.

BLOOD-VESSELS OF THE CEREBELLUM.

The blood-supply to the cerebellum is derived from three vessels—the superior, the middle, and the inferior cerebellar arteries. The superior cerebellar arteries take their origin from the basilar close to its point of division into the posterior cerebral arteries. Each vessel courses backward and outward over the pons Varolii, being separated from the posterior cerebral artery,

whose course it resembles, by the motor oculi, or third cranial nerve. It then courses around the crus cerebri, parallel with the fourth cranial nerve, and reaches the upper surface of the cerebellum, where it divides into an internal or superior vermiform branch, and an external or hemispherical branch. The former vessel passes backward along the superior vermiform process, anastomoses with the artery of the opposite side, and when it reaches the posterior notch of the cerebellum it joins the inferior vermiform artery, a branch of the posterior inferior cerebellar artery. The external or hemispherical branch runs backward over the superior surface of the cerebellum, supplying it, and terminates near the posterior part of this surface, where it anastomoses with the terminal hemispherical branch of the posterior inferior cerebellar artery. This artery also supplies branches to the velum interpositum, the superior medullary velum, or valve of Vieussens, the corpora quadrigemina, and the pineal gland.

The middle cerebellar—also called the anterior inferior cerebellar—arteries are branches of the basilar, and originate from that vessel just above the inferior border of the pons; their course is downward and outward across the pons to the anterior portion of the under surface of the cerebellum, which they supply. They anastomose with the posterior inferior cerebellar artery. This vessel, at the beginning of its course, is crossed by the abducens or sixth cranial nerve, and just as it passes upon the inferior surface of the cerebellum, it lies close to the facial and auditory nerves. In its course across the pons it gives off several rather large vessels for the supply of the middle cerebellar peduncles.

The inferior cerebellar arteries are also known as the posterior inferior cerebellar. This latter name serves to distinguish them from the middle cerebellar, which have, unfortunately, been named the anterior inferior cerebellar arteries. These two vessels are the largest branches of the vertebrals, and have their origin from them opposite the lateral surfaces of the medulla near its middle portion. Each vessel passes outward and backward across the restiform body and between the pneumogastric and hypoglossal nerve-roots; it then goes to the under surface

of the cerebellum, where it divides into two branches—an internal, or inferior vermiform, and an external, or hemispherical. The inferior vermiform branch passes backward between the vermiform process and the cerebellar hemisphere, supplies the vermiform process, and anastomoses with the vessels of the opposite side and the superior vermiform, a branch of the superior cerebellar artery. The external or hemispherical branch is distributed to the under surface of the cerebellum, and anastomoses along its outer margin with the middle and superior cerebellar arteries. This vessel also gives branches of supply to the choroid plexus of the fourth ventricle and to the restiform bodies.

ARTERIAL SUPPLY TO THE PONS VAROLII AND MEDULLA OBLONGATA.

The pons Varolii and medulla oblongata receive their arterial supply from a series of small vessels which come off directly from the basilar and vertebral arteries and from their branches—the anterior and posterior spinal and the inferior cerebellar arteries. The branches of the above-mentioned arteries which reach the interior of the pons and medulla have been divided by Duret into the three following sets:

First Set, the Median Arteries.—These are small vessels which pass parallel to one another through the median plane of the pons and medulla to reach the floor of the fourth ventricle, where they terminate by dividing into fine capillary plexuses for the supply of the cranial nerve nuclei and the beginning of their nerve-roots.

The second set, or root arteries, pass in a transverse manner around the outer portion of the pons and medulla to reach the point of emergence of the roots of the cranial nerves, where they divide into two branches—central and peripheral. The central branch continues with the nerve to its nucleus of origin, subdividing into a few parallel branches which terminate into a capillary plexus about the nucleus, inosculating with small twigs from the median arteries. The peripheral branch is distributed along the nerve-roots.

The third or lateral set of vessels continue around the lateral

and anterior columns of the medulla to be distributed to the restiform and olivary bodies as well as to the anterior pyramids.

The median arteries to the pons consist of a large number of parallel coursing vessels, which come off directly from the basilar

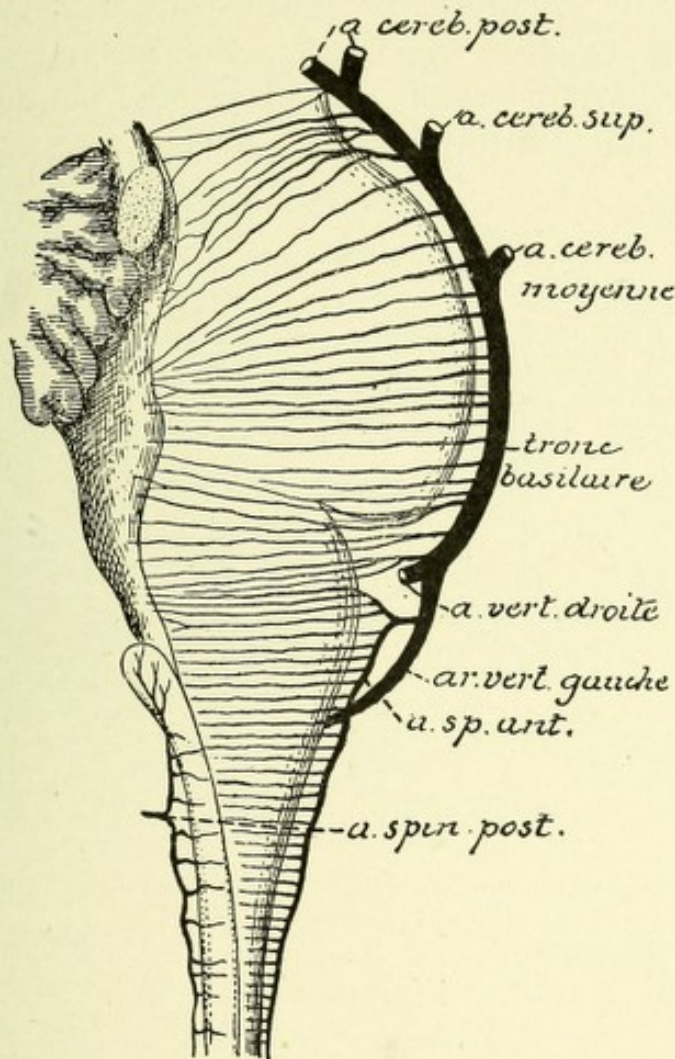


FIG. 211.—ANTERIOR AND POSTERIOR MEDIAN ARTERIES OF THE PONS AND MEDULLA.—
(After Duret.)

a. cereb. post. Posterior cerebral artery. *a. cereb. sup.* Superior cerebellar artery. *a. cereb. moyenne.* Middle cerebellar artery. *tronc basilaire.* Basilar artery. *a. vert. droite,* and *ar. vert. gauche.* Right and left vertebrals. *a. sp. ant.* Anterior spinal artery. *a. spin. post.* Posterior spinal artery.

and, passing backward, reach the floor of the fourth ventricle, where they terminate by subdividing into capillary plexuses for the nutrition of the following cranial nerve nuclei: the oculo-motor, trigeminal, abducens, facial, auditory, glossopharyngeal,

and pneumogastric. These branches also nourish the motor nerve-roots as they issue from their nuclei of origin, and the sensory nerve-roots as they pass into their respective nuclei. These median vessels anastomose with the termination of the nerve arteries.

The root-arteries to the pons are distributed to the nerve-roots of the oculomotor, trigeminal, abducens, and facial nerves.

The median arteries to the medulla come from the vertebrals and anterior spinal arteries, after pursuing a course similar to

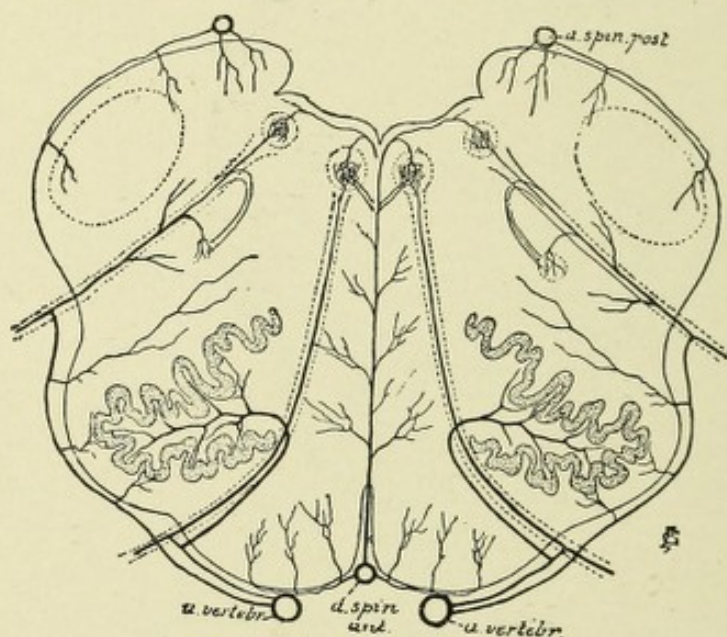


FIG. 212.—DIAGRAM TO SHOW PLAN OF DISTRIBUTION OF THE ARTERIES OF THE MEDULLA.—(After Duret.)

a. spin. post. Posterior spinal artery. *a. vertebr.* Vertebral artery. *a. spin. ant.* Anterior spinal artery.

the median vessels of the pons, and are distributed to the lower part of the facial, the pneumogastric, hypoglossal, and spinal accessory nuclei, and to their nerve-roots.

The root-arteries to the medulla give off collaterals which, with branches from the anterior spinal arteries, are distributed to the anterior pyramids, the hypoglossal nerve-roots, and the olivary bodies. The inferior cerebellar arteries give off several lateral branches which go to, and nourish, the restiform bodies and the formatio reticularis. These vessels also give off posterior branches for distribution to the choroid plexus and fourth

ventricle. The posterior aspect of the medulla receives branches of supply from the posterior spinal arteries, which nourish chiefly the posterior columns or pyramids.

THE VENOUS SYSTEMS OF THE BRAIN.

CHARACTERISTICS OF THE VEINS AND THE VENOUS CIRCULATION.

The veins of the brain differ from those in the other parts of the body in the following particulars: (1) Their walls are exceedingly thin, owing to the absence of a muscular coat; (2) they possess no valves; (3) they empty into venous sinuses; (4) they frequently anastomose by small and large branches; (5) they are less in number but much more capacious than the corresponding arteries; (6) the circulation through the superior veins of the cerebrum which empty into the superior longitudinal sinus is greatly retarded, first, by the fact that they are ascending in their course, and hence are not assisted by gravity; and, secondly, because they empty into the superior longitudinal sinus in a direction opposite to the current of blood in that sinus.

The circulation is further impeded by the absence of valves and muscular tissue, and by the presence in the sinuses of fibrous bands which stretch across their lumen. Dwight has suggested that, owing to the proximity of the carotid artery to the jugular vein, the circulation in that vein is hindered by the pulsations of the artery, thus tending to cause a retardation of the venous circulation of the brain. These facts help us to understand why venous thrombi so often occur in the veins and sinuses in many of the acute infectious diseases, and Gowers aptly states that the marvel is that thrombosis is not more common than it is.

THE CEREBRAL VEINS.

The cerebral veins may be divided into two sets—superficial or hemispherical, and deep or ganglionic. The superficial or hemispherical veins are further subdivided into the veins of the

base, which are found along the middle portion of the base of the brain, and into the veins of the convolutions, which course in the meshes of the pia mater covering the median and convex surface of the hemisphere. The deep or ganglionic set of veins

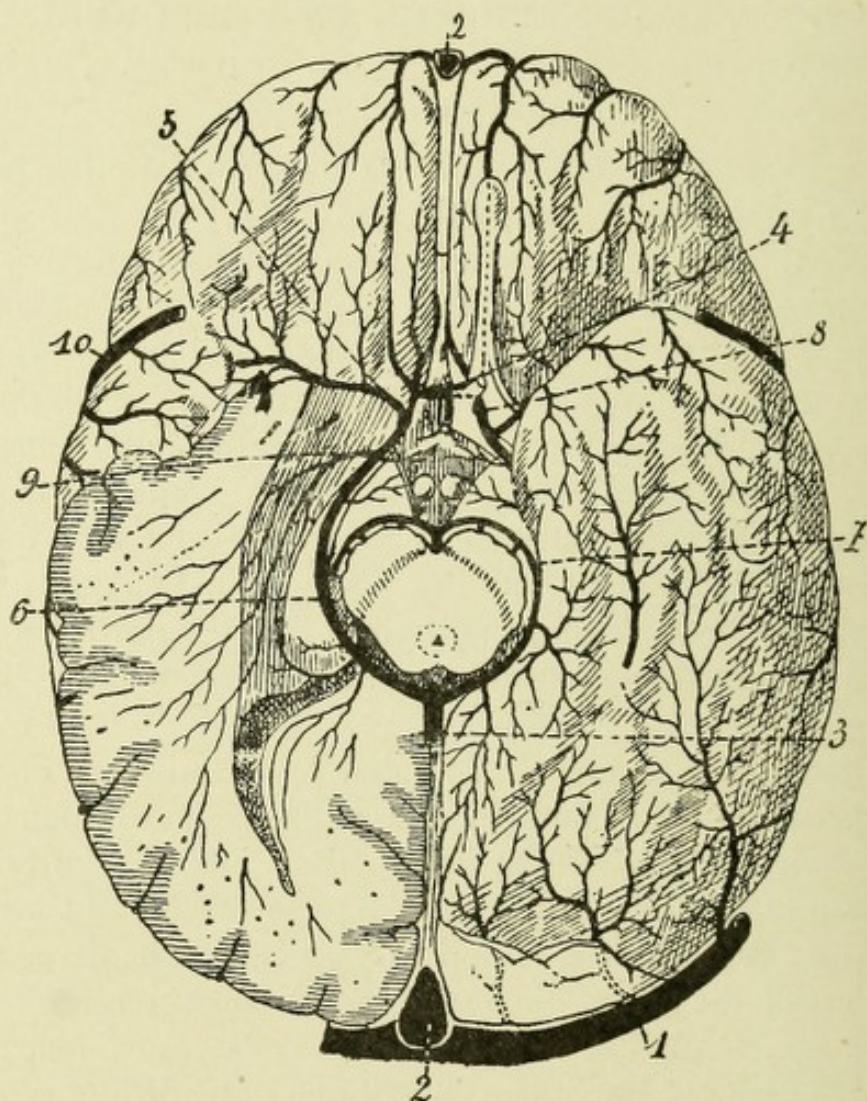


FIG. 213.—SUPERFICIAL VEINS OF THE BASE OF THE BRAIN.—(*After Testut.*)

1. Lateral sinus. 2. Superior longitudinal sinus. 3. Trunk resulting from the union of the veins of Galen with the basilar veins. 4. Anterior communicating vein. 5. Middle cerebral vein. 6. Basilar vein. 7. Posterior communicating. 8. Anterior cerebral vein. 9. Vein of the cornu ammonis. 10. Great anastomotic vein of Trolard.

originates in the central ganglia, and unites to form two rather large trunks—the veins of Galen.

The Superficial Veins.—The superficial veins of the base are the anterior cerebral, the middle cerebral, and the basilar.

The anterior cerebral vein, smaller than the corresponding artery, drains the median surface of the frontal lobe and the convex surface of the corpus callosum, and, coursing downward and backward, unites with the middle cerebral to form the basilar.

The middle cerebral vein, smaller than the corresponding artery, is situated in the fissure of Sylvius and overlying the convolutions of the island of Reil, receiving its blood from these convolutions.

The basilar is a large vein formed by the junction of the ante-

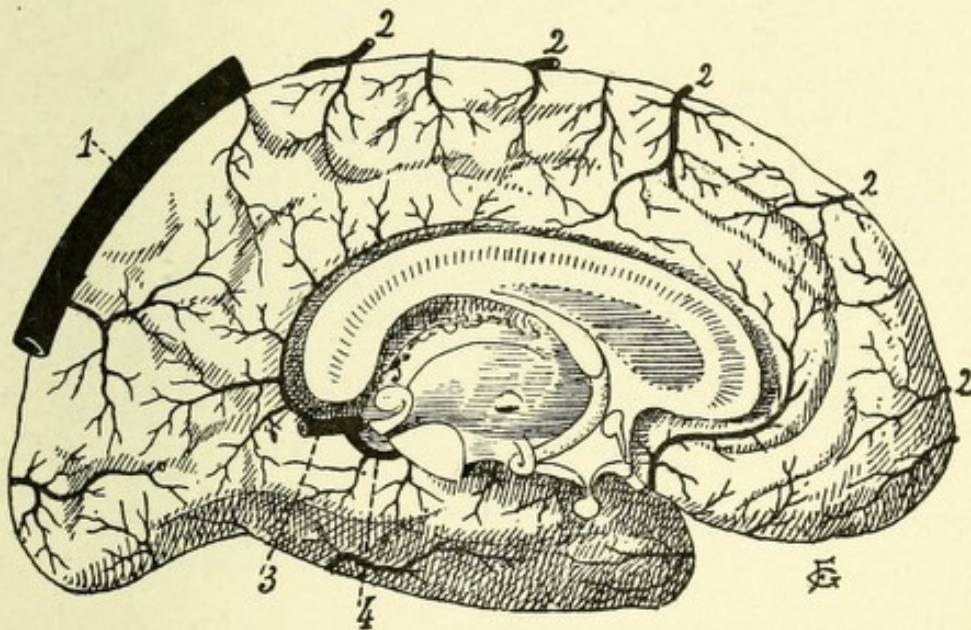


FIG. 214.—SUPERFICIAL VEINS OF THE INTERNAL SURFACE OF THE LEFT HEMISPHERE.—
(After Testut.)

1. Superior longitudinal sinus. 2. External ascending cerebral veins. 3. Venous trunk due to union of veins of Galen. 4. Basilar vein.

rior and middle cerebral veins; its course is backward across the cerebral peduncle and around the corpora quadrigemina, uniting at the middle line with its fellow of the opposite side and with the veins of Galen to form the straight sinus. It drains the optic tract and chiasm, infundibulum, corpora mamillaria, ventral surface of the cerebral peduncles, and a part of the basal surface of the temporosphenoid lobe. The two basilar veins are united in front of the pons Varolii by the posterior communicating vein, and the anterior cerebral veins are

united in front by the anterior communicating vein, thus forming a venous anastomotic circle, similar to the circle of Willis.

The Veins of the Convolution.—The veins of the convolutions may be grouped into three systems. The first system consists of numerous smaller systems which collect blood from the median surface of the cerebral hemisphere. Most of these ascend to empty into the superior longitudinal sinus. Some descend to empty into the inferior longitudinal sinus, while a few

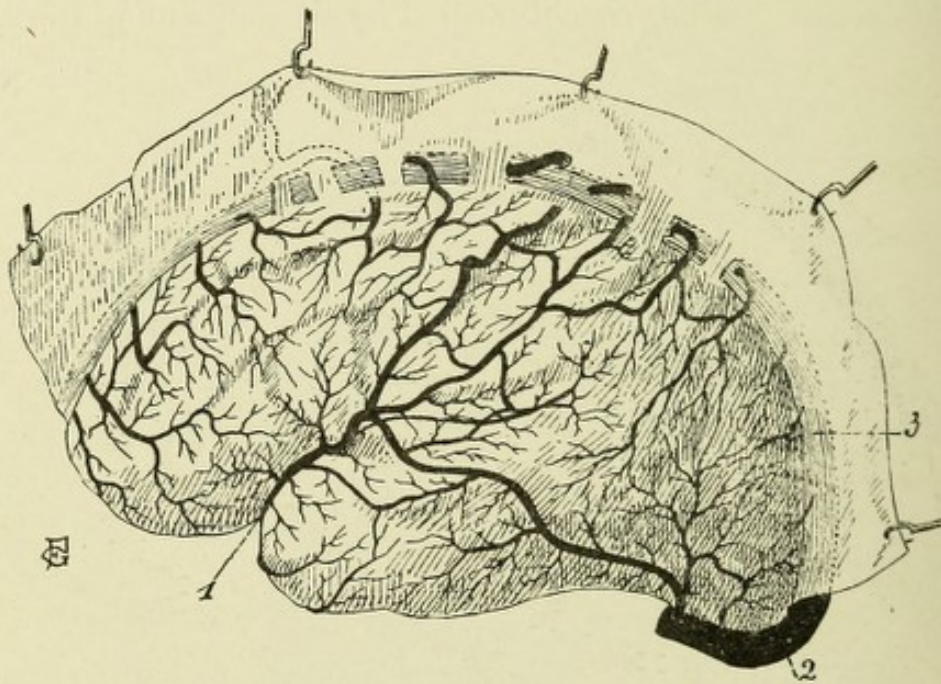


FIG. 215.—SUPERFICIAL VEINS OF THE EXTERNAL SURFACE OF THE LEFT HEMISPHERE.—
(After Testut.)

1. Great anastomotic vein of Trolard. 2. Lateral sinus.

descend to empty either into the anterior cerebral vein or the vein of Galen.

The second system consists of numerous vessels which drain the external surface, the cortex, and the underlying white matter of the cerebrum, the long venules extending upward from the capillary plexuses of the centrum ovale, the short venules collecting the blood from the capillary plexuses of the gray matter. They are divisible into two sets, a superior and an inferior. The superior set ascends to empty into the superior longitudinal sinus, and consists of several (eight to twelve) veins which anas-

tomose freely with one another and collect the blood from the superior convolutions of the frontal, parietal, and occipital lobes.

The inferior set descend to empty into the inferior longitudinal, lateral, superior petrosal, or cavernous sinuses, collecting blood from the inferior part of the frontal, parietal, and occipital lobes. A large vein of considerable importance, the *great anastomotic vein of Trolard*, extends from the superior longitudinal sinus above to the cavernous or the superior petrosal sinuses below. This vein has a course parallel to the fissure of Rolando and, at

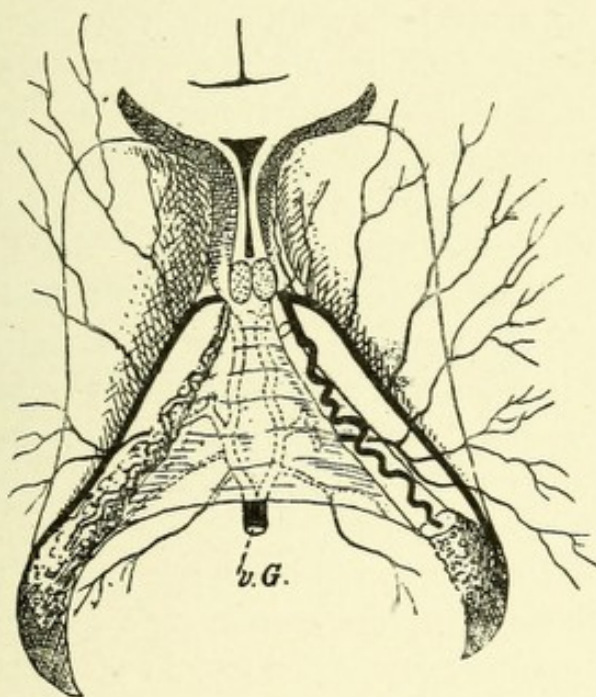


FIG. 216.—VEINS OF GALEN OR THE DEEP CEREBRAL VEINS.—(After Van Gehuchten.)

the level of the fissure of Sylvius, passes forward through that fissure to the sinus before mentioned. On its downward course it receives many anastomotic as well as terminal branches from the neighboring convolutions, and as it turns down along the fissure of Sylvius, it receives a large branch which brings this vein into anastomotic relations with the lateral sinus, called the posterior anastomotic vein of Labbé.

The third system consists of numerous small vessels which drain the basal surface of the cerebrum, and emptying in front into the anterior cerebral vein or the beginning of the superior

longitudinal sinus, and in the middle and posterior regions emptying into the middle cerebral vein or lateral sinus.

The Deep Cerebral Veins.—The deep or ganglionic veins receive their blood from the central ganglia, from the ventricular walls and underlying white matter, and from the choroid plexuses. They form two large venous trunks,—the veins of Galen,—which extend between the layers of the choroid plexuses to empty into the basilar veins close to their exit into the straight sinus. The veins of Galen are formed by the veins of the corpora striata, the choroid veins, and the veins of the septum lucidum.

The vein of each corpus striatum is quite large, and is located in a groove, the semicircular sulcus, which separates the optic thalamus from the caudate nucleus. It receives many small veins from the optic thalamus, caudate and lenticular nuclei, and the internal capsule, and at the foramen of Monro joins the choroid vein to form the vein of Galen.

Each choroid vein courses along the outer border of the choroid plexus from the descending cornu of the lateral ventricle, and extends upward and forward to the foramen of Monro, where it joins the vein of the corpus striatum to form the vein of Galen; it receives blood from the hippocampus major, the fornix, and the corpus callosum.

The vein of the septum lucidum, a long, slender vessel, receives blood from the septum lucidum, the anterior part of the corpus callosum, and the corresponding part of the lateral ventricle, and extends downward to join the vein of Galen near the foramen of Monro.

Each vein of Galen runs backward, parallel with its fellow, between the layers of the velum interpositum, and passes out of the brain through the transverse fissure, there joining its fellow to form a single trunk, the great vein of Galen, which enters the straight sinus.

VEINS OF THE CEREBELLUM.

The blood of the cerebellum is collected by two systems—the superior and inferior cerebellar veins. The superior cerebellar veins, which are distributed over the upper surface of the cere-

bellum, collect their blood from the surface to pass forward and inward over the surface of the superior vermis to empty, some in the straight sinus, others into the vein of Galen.

The inferior cerebellar veins, which are distributed over the

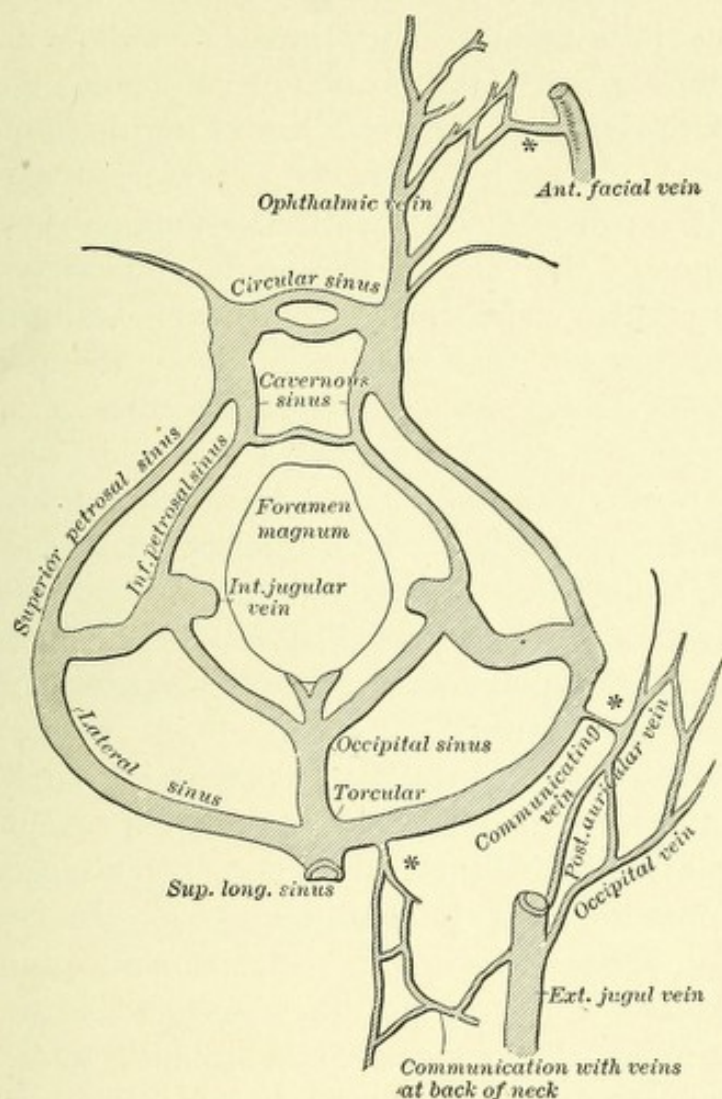


FIG. 217.—DIAGRAM SHOWING COMMUNICATIONS EXISTING BETWEEN THE LATERAL AND CAVERNOUS SINUSES AND THE EXTERNAL VEINS, INDICATED IN FIGURE BY *.—
(After Leube.)—(From Loomis and Thompson, "Practice of Medicine.")

under surface of the cerebellum, collect their blood from that surface and pass forward and outward to empty, some into the inferior petrosal and lateral sinuses, while others pass backward to the occipital sinuses.

THE VENOUS SINUSES.

The venous spaces of the cranium are inclosed between the two layers of the dura mater which form their walls, and are lined with endothelium continuous with that lining the veins which empty into them. They have extending across their lumen numerous rather firm bands of connective tissue, which in some of the spaces are arranged in a cavernous manner. These sinuses are, with but few exceptions, long, capacious channels, which collect blood from the various veins of the brain, and from some of the veins of the diploë, and carry it chiefly to the internal jugular vein. They are connected with the superficial veins of the external surface of the cranium by several emissary veins, which pass through foramina of the cranial bones. There are sixteen cranial sinuses, six of which are single and are placed in the median line, and five are arranged in pairs, one for each side. The single sinuses are the superior longitudinal, the inferior longitudinal, the straight, the occipital, the circular, and the transverse. The paired sinuses are the lateral, the superior petrosal, the inferior petrosal, the cavernous, and the sphenoparietal.

The **superior longitudinal sinus** (sagittal or falciform sinus) extends in a curved manner from the foramen cæcum to the internal occipital protuberance, occupying the attached margins of the falx cerebri. It is lodged in a median groove along the under surface of the calvarium. This sinus increases in size from before backward, and presents on transverse section a triangular appearance. Its lumen is crossed by several fibrous bands, and has projecting into it several Pacchionian bodies. The sinus terminates in the right lateral sinus, at the internal occipital protuberance, in a dilatation called the sinus confluens, or the torcular Herophili. Into this sinus empty the superior veins of the external and median surfaces of the convolutions, as well as a few from the basal surface, and numerous small veins from the diploë and dura mater. The middle meningeal veins often end in small diverticuli in the dura mater,—*lacunæ venosæ laterales*,—which communicate with the veins of the diploë. According to Trolard, these spaces act as compensating reservoirs

whenever, owing to any temporary obstruction to the circulation, the sinuses are overdistended, the blood passing from the spaces into the veins of the diploë and thence into the pericranial veins. An emissary vein enters this sinus from the pericranium through the parietal foramen, and in fetal life this sinus communicates through the foramen cæcum with the nasal veins. The superior longitudinal sinus is in connection with the cavernous or superior petrosal sinuses by the great anastomotic vein of Trolard.

The **inferior longitudinal sinus**, also called the falciform vein, is located in the concave border of the inferior surface of the falx cerebri. It begins about the junction of the anterior with the middle third of the falx cerebri, and extends backward in a curved manner to the point of union of the falx cerebri with the tentorium cerebelli, where it terminates in the straight sinus. It collects blood from some of the descending veins of the median surface of the hemispheres, as well as a few from the falx cerebri.

The Straight Sinus.—The straight sinus is located along the line of junction of the falx cerebri with the falx cerebelli, and is formed by the union of the inferior longitudinal sinus with the vein of Galen. It pursues an oblique course from above downward and backward, receiving in its course tributaries from the superior surface of the cerebellum and from the tentorium cerebelli, and usually terminates in the left lateral sinus or in the torcular Herophili. Rarely, the straight sinus has the occipital sinus emptying into it.

The Occipital Sinus.—The occipital sinus originates in two branches,—the so-called marginal sinuses,—one for each side, which, taking their origin from the termination of the lateral sinuses, course along the foramen magnum, and communicating with the posterior spinal veins, unite close to the internal occipital protuberance in a single trunk, the occipital sinus. This sinus is situated along the attached margins of the falx cerebelli, and after a short course backward, terminates either in one of the lateral sinuses, the torcular Herophili, or rarely in the straight sinus. It receives branches from the tentorium cerebelli and from the inferior surface of the cerebellum, and it com-

municates through the anterior condyloid foramen, by means of a venous plexus which surrounds the hypoglossal nerve, with the vertebral vein and with the anterior spinal plexus.

The Circular Sinus.—The circular sinus is formed by two transverse vessels which connect the cavernous sinuses, and are placed one in front and the other behind the pituitary body,

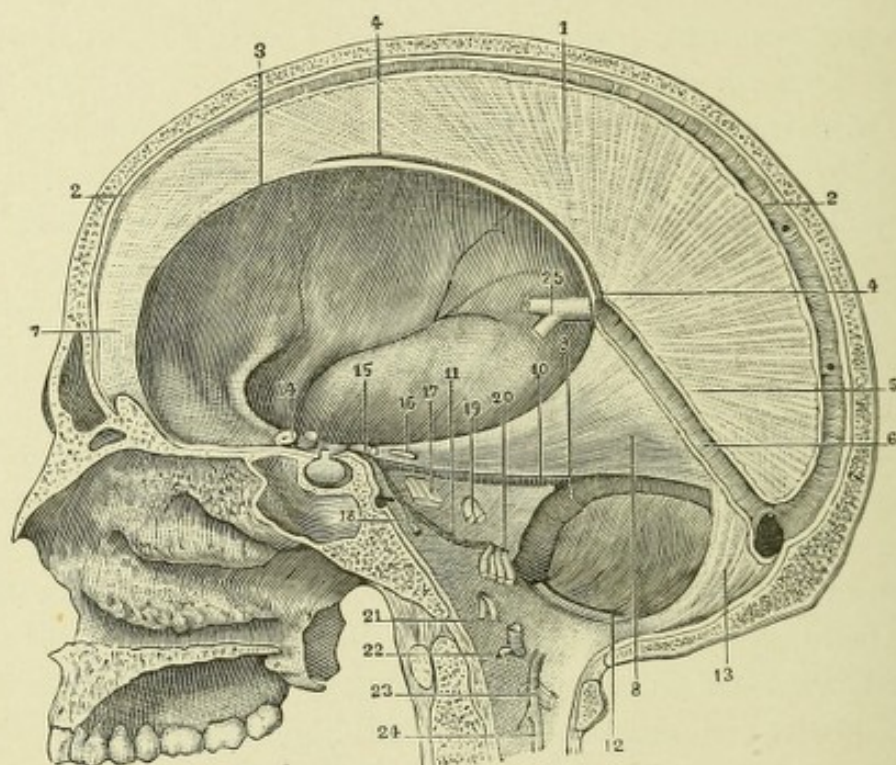


FIG. 218.—MEDISECTION OF BRAIN, SHOWING IMPORTANT SINUSES.

1. Falx cerebri. 2, 2. Its convex border, with the great longitudinal sinus. 3. Its concave border. 4, 4. Inferior longitudinal sinus. 5. Base of falx cerebri. 6. Straight sinus. 7. Apex of falx cerebri. 8. Right half of the tentorium, seen from below. 9. Right lateral sinus. 10. Superior petrosal sinus. 11. Inferior petrosal sinus. 12. Posterior occipital sinus. 13. Falx cerebelli. 14. Optic nerve. 15. Motor oculi. 16. Pathetic. 17. Trigemini. 18. Abducens. 19. Facial and auditory nerves. 20. Glossopharyngeal, pneumogastric, and spinal accessory nerves. 21. Hypoglossal nerve. 22. First cervical nerve. 23. Second cervical nerve. 24, 24. Upper extremity of ligamentum denticulatum.

or hypophysis cerebri, forming a venous circle about that body.

The Transverse or Basilar Sinus.—The transverse sinus consists of a venous plexus between the layers of the dura mater over the basilar process of the occipital bone. It has a transverse course between the two inferior petrosal sinuses, which it connects.

The Lateral Sinuses.—The right and left lateral sinuses are the very voluminous venous channels located between the layers of the tentorium cerebelli. They communicate at the internal occipital protuberance, the right usually being the continuation of the superior longitudinal sinus, while the left is a continuation of the straight sinus. Both increase in size as they proceed outward and forward, terminating by passing downward and inward to the jugular foramen, where they become continuous with the sinus jugularis or bulb of the internal jugular vein. These sinuses rest in a groove located on the inner surface of the occipital, the postero-inferior surface of the parietal, the mastoid portion of the temporal, and the jugular process of the occipital bones. These sinuses collect blood from some of the inferior cerebral and cerebellar veins, as well as from some of the veins of the pons Varolii and medulla. They communicate with the veins of the pericranium by means of emissary veins through the mastoid and posterior condyloid foramina, and have emptying into them the superior petrosal sinuses.

The Superior Petrosal Sinuses.—The superior petrosal sinuses are situated at the attached margins of the tentorium cerebelli, along the superior border of the petrous portion of each temporal bone. They connect the cavernous with the lateral sinuses. In their course from the cavernous to the lateral sinus, crossing the fifth pair of cranial nerves, they receive some of the inferior cerebral veins, and veins from the inner ear. They are sometimes connected with the superior longitudinal sinus by means of the great anastomotic vein of Trolard.

The Inferior Petrosal Sinuses.—The inferior petrosal sinuses are shorter but wider channels than the superior petrosal sinuses, and are located in a groove formed by the junction of the petrous portion of the temporal bone with the basilar portion of the occipital bones. They connect the cavernous sinuses with the beginning of the internal jugular veins. As they course across each jugular foramen, they separate the glossopharyngeal from the pneumogastric and spinal accessory nerves. They receive veins from the inferior surface of the cerebellum, from the pons and medulla, and from the middle ear.

The Cavernous Sinuses.—The cavernous sinuses, two in number, are very capacious and irregularly shaped blood-spaces located between the layers of the dura mater and extending backward from the inner opening of the sphenoid fissure to the apex of the petrous portion of the temporal bone, where they open into the superior and inferior petrosal sinuses. In front they are continuous with the ophthalmic veins and also receive the sphenoparietal sinuses and some of the inferior cerebral veins. They communicate with each other by means of the circular sinuses, and are usually connected on each side with the superior longitudinal sinus by means of the great anastomotic vein of Trolard.

These sinuses are traversed by numerous, mostly transversely arranged, fibrous bands, which divide the sinuses into a number

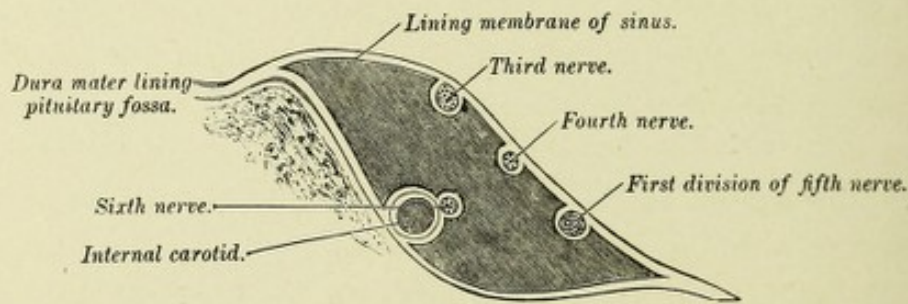


FIG. 219.—PLAN SHOWING THE RELATIVE POSITION OF THE STRUCTURES IN THE RIGHT CAVERNOUS SINUS, VIEWED FROM BEHIND.—(After Gray.)

of lacunæ lined by endothelium. Von Langer has shown that the cavernous sinuses were originally a plexiform network of veins, which, by the gradual fusion of their channels, produce the characteristic lacunar appearance. The internal carotid artery and the sixth cranial nerve are located along the inner wall of this sinus, while along the outer wall run the third, fourth, and the ophthalmic division of the fifth cranial nerves, all these structures being separated from the blood within the sinus by the lining membrane of the sinus.

The Sphenoparietal Sinus.—Each sphenoparietal sinus originates near the apex of the lesser wing of the sphenoid bone, in one of the meningeal veins, and, passing in a groove on the under surface of the lesser wing of the sphenoid bone, ex-

tends inward through a fold of the dura mater above the third nerve, to reach the cavernous sinus, with which it is continuous.

THE EMISSARY VEINS.

The following important emissary veins connect the venous sinuses with the extra cranial veins:

1. A vein, almost constant, passing from the lateral sinus through the mastoid foramen, empties into the occipital, post-auricular, or external jugular veins.

2. The ophthalmic vein passes backward through the orbital fissure, emptying into the cavernous sinus, thus establishing a connection between that sinus and the veins of the eyeball and orbit, as well as with the veins of the anterior portion of the scalp.

3. A vein passing through the parietal foramen and connecting the superior longitudinal sinus with the veins of the scalp of the parietal region.

4. A minute plexus of veins which pass through the anterior condyloid foramen, connecting the occipital sinus with the vertebral veins and the deep veins of the neck.

5. The posterior jugular vein, passing through the posterior condyloid foramen, connects the lateral sinus with the upper cervical or vertebral veins.

6. A rather large vein which passes through the foramen ovale and connects the cavernous sinus with the pharyngeal plexus.

7. A plexus of veins in the carotid canal connects the cavernous sinus with the internal jugular vein.

CHAPTER XII.

CEREBRAL LOCALIZATION.

Probably the most important subject from a clinical and scientific standpoint, in connection with the nervous system, is the question of cerebral localization—*i. e.*, that certain known areas of the brain preside over certain definite functions; and while not strictly a part of anatomy, its importance justifies its introduction here.

For many years it has been generally known that each cerebral hemisphere is in functional relation with the opposite side of the body, and even the discoveries of Thomas Hood in England and Bouillaud in France, that in several cases of speech-defect the frontal lobes were found affected, excited no general interest, since the doctrine of Flourens—namely, that while the brain was the seat of the higher mental faculties, they were not localizable, but evenly distributed throughout, and the brain acted as a whole—was commonly accepted.

The publication, however, in 1861, by Broca, of several cases of aphasia with autopsies, which enabled him, owing to the constant relation between the form of speech-defect and the lesion, to positively locate the motor speech-center in the left inferior frontal gyrus, was the starting-point of the study of cerebral localization. Shortly after, Hughlings Jackson, of London, recorded a number of cases in which partial or complete unilateral convulsions had occurred, the autopsies showing that certain circumscribed areas of the brain were found uniformly affected, thus proving the connection between irritation of certain areas of the brain and local convulsive movements.

The observations of Broca and Jackson, together with the publication of the experimental researches of Fritsch and Hitzig, of Berlin, in 1870, of Ferrier in 1873, and of Monk in

1881, completely disproved the hitherto accepted conclusion of Flourens and opened the way to a series of brilliant discoveries which have established cerebral localization upon a scientific basis.

Although there is still some difference of opinion among investigators as to the absolute limits of certain localizable areas, it is settled beyond dispute that there are fixed areas presiding over motion, language, and sight, and a strong presumption in favor of the localization of the various forms of common sensation, of most of the special senses, and of the higher intellectual faculties.

In the cerebral cortex there are localized areas governing

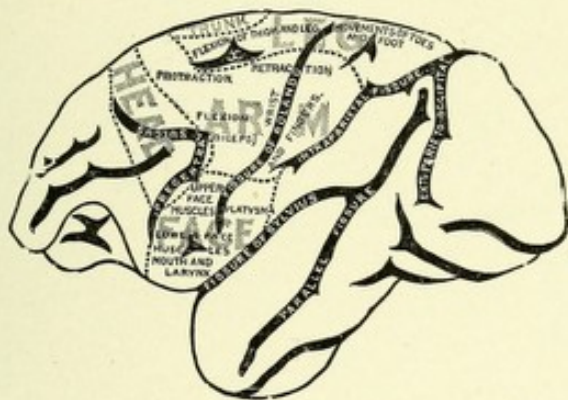


FIG. 220.—DIAGRAM OF THE MOTOR AREAS ON THE OUTER SURFACE OF A MONKEY'S BRAIN.—(*Horsley and Schäfer, from Landois and Stirling.*)

motion, common sensation, the special senses of sight, hearing, taste and smell, speech processes, and the higher mental faculties.

The cortical area governing motion, known as the motor area of the brain, is a large district of the cerebral cortex, lying on each side of the fissure of Rolando, between the precentral and intraparietal fissures. It comprises the posterior part of the inferior or third frontal gyrus, the ascending frontal and parietal, or, as they are often termed, the pre- and postcentral gyri, and their junction on the mesial surface of the hemisphere, the paracentral lobule. To this may be added the posterior part of the superior and middle frontal gyri and a part of the superior parietal lobule. The axones from the large pyramidal cells of this extensive area form the great motor tract, the course of

eral way the motor region, and by electric stimulation of certain small areas to map out separate centers for the movements of the leg, arm, face, and head, but he also showed that electric irritation of most of the prefrontal region, the temporal, occipital, and parts of the parietal lobe, was unattended by muscular movements, proving that these areas are not motor in function. More recently Ferrier's observations have been confirmed and other facts of interest have been added to our knowledge of localization through the efforts of Horsley, Schäfer, and Beevor. The delineation of the various subdivisions of the motor region in man has resulted from the study of a large number of care-

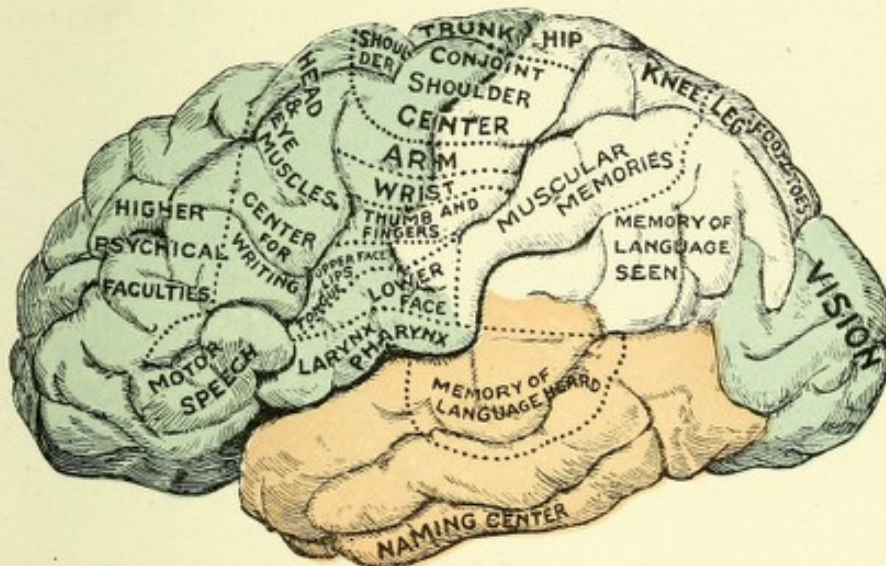


FIG. 222.—A DRAWING OF THE LEFT CEREBRAL HEMISPHERE (HUMAN). Showing the different localizable areas on the external surface.

fully reported cases with autopsies, and by the careful electric excitation of circumscribed areas of the cortex during its exposure for cerebral operations. In the main, these areas in man correspond with those located by Ferrier and others on the surface of the brain of monkeys. In a general way it may be stated that the *leg area* occupies the upper third, the *arm area* the middle third, and the *face area* the lower third of the motor region, or the ascending frontal and parietal gyri; while the trunk-muscles are chiefly represented on the median surface of these two gyri, the paracentral lobule. Monk, however, places the area for the trunk muscles in the prefrontal lobe.

The leg area occupies the upper third of the central gyri, the posterior part of the paracentral lobule, and the upper anterior part of the superior parietal lobule. Thus it occupies a greater anteroposterior surface than does the area of the arm or of the face. It consists of a series of centers, arranged from before backward, for the muscles governing the movements of the thigh, knee, foot, and toes.

The arm area, which occupies the middle third of the central gyri, is subdivided from above downward into centers for the movements of the shoulder, elbow, hand, and fingers. The center which presides over movements of the shoulder exists in

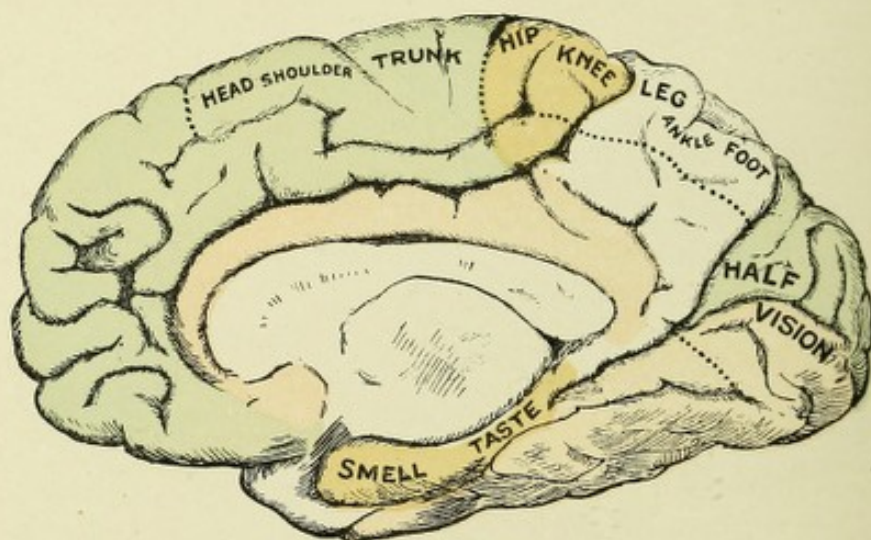


FIG. 223.—A DRAWING OF THE RIGHT CEREBRAL HEMISPHERE (HUMAN). Showing localizable areas on the median surface.

the upper part of this area, and *also in the anterior part of the paracentral lobule*. The center for the elbow is in the middle part of this area, and the centers for the hand and fingers are in the lower part.

The face area is located in the lower third of the ascending frontal and ascending parietal convolutions. It consists of two portions, an upper and a lower, for the corresponding facial muscles. In the upper part are centers for the orbicularis palpebrarum and occipitofrontalis muscles, and in the lower part, for the muscles of the lips, tongue, pharynx, and larynx.

The studies of Semon and Horsley, and the cases of Seguin and Dejerine, seem to prove the existence of a separate center

for the laryngeal muscles in the inferior part of the ascending and the root of the inferior or third frontal gyrus.*

There probably exists a separate center on each side for the elevation of the eyelids, through the action of the levator palpebræ superioris muscle. This center, according to Ferrier, Horsley, and Mott, is in the posterior part of the second frontal gyrus. In a few cases of ptosis, however, which have come to autopsy, lesions have been found in the angular gyrus. These were probably cases of reflex paralysis, the result of the lesion, from a failure to respond to visual excitations.

The cortical area for the muscles of the trunk and spine is a small part of the ascending frontal gyrus, close to the longitudinal sinus, and the part of the paracentral lobule located be-

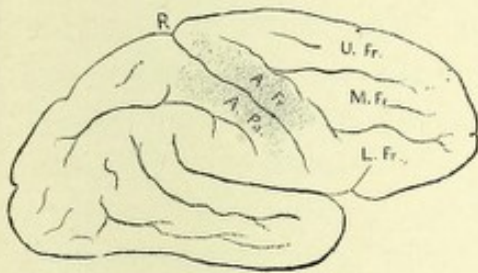


FIG. 224.—POSITION OF THE ARM.—
(After Gowers.)

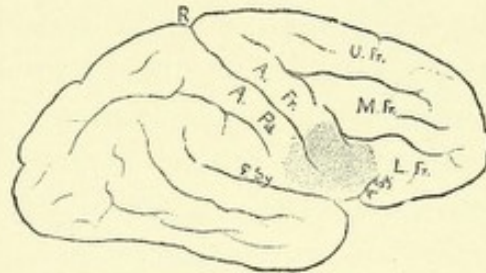


FIG. 225.—POSITION OF THE CENTER
FOR THE FACE AND TONGUE.—(After
Gowers.)

tween the centers for the leg and shoulder muscles. The exact position of the centers governing the movements of the head and eyes is not positively known. Their probable location is in the posterior part of the first and second frontal gyri adjacent to the ascending frontal, and on the mesial surface of the first frontal convolution.

Ferrier has proved, from the results of electric stimulation of the inferior part of the postcentral gyrus of the brain of a monkey, that a center exists there for the retraction of the angle of the mouth. Bramwell has recorded an interesting case, in confirmation of Ferrier's belief, of a woman who frequently had

* Herter has reported a case of left-sided ptosis, with slight dilatation of the left pupil and with paresis of the right arm and leg. The autopsy disclosed an area of softening one inch in diameter confined to the right angular gyrus. The right hemiparesis, he believed, was due to uremia.

convulsions, which always began in, and were often confined to, the right platysma myoides muscle, in which case a spicula of bone was found irritating the inferior margin of the postcentral gyrus. It must be remembered that while different areas exist for the innervation of the muscles of the trunk, leg, arm, and face, these areas are not sharply separated, but blend or interdigitate with one another.

The study of autopsies following cases of partial unilateral convulsions has proved that these centers exist only in the cortex. In that peculiar type of convulsion first described by Jackson, and from him called Jacksonian epilepsy, the initial symptom is always a spasm limited to a definite group of muscles, followed by a convulsion, more or less complete, of the same side, successive groups of muscles being involved in regular order. On section, the lesion has been found to be located in the opposite cerebral hemisphere, in the center presiding over the group of muscles in which the spasm started, and either in the cortex or in such a manner as to affect the cortex by pressure. Several recorded cases of recent date would seem to prove, however, that Jacksonian attacks may be produced by lesions of slow growth which irritate the motor tract below the cortex.

THE CORTICAL CENTERS FOR GENERAL SENSATIONS.

There is at present considerable disagreement among experimental physiologists with regard to the exact location in the cerebral cortex of the centers for the reception of the various forms of sensory impressions from the skin, mucous membranes, joints, and muscles. Ferrier believes that in the brain of the monkey, and hence presumably in man, these centers are located in the cortex of the gyrus fornicatus and hippocampal gyrus.*

* Charles K. Mills maintains, with Ferrier, that the receptive centers for general sensation are located in the cortex of the fornicate and hippocampal gyri. In support of his belief he refers to two cases reported by Saville, in both of which there was a loss of tactile sense consequent upon lesions of the fornicate gyrus and the underlying white matter. It seems to me, judging from the experience of von Monakow, that what is most needful to prove the existence of separate sensory centers in this region is to find the lemniscus degenerated, following such lesions. Of this no mention is made.

He bases his belief on the results of a number of experiments on monkeys, in which, after destruction of these areas, partial or complete loss of the various forms of general sensation occurred in the limbs of the opposite side of the body. He was careful in his experiments not to interfere with the integrity of the internal capsule or with the sensory cortical radiations from the capsule. He does not believe that the region bordering upon the fissure of Rolando (motor area) is concerned in the reception of sensory impressions, its only function being the excitation of motor impulses. While the results reached by Ferrier as to the location of the sensory centers seem conclusive, still they lack the support of many physiologists. Hitzig, Munk, Luciani, Horsley, and Mott seem to be in accord in locating the sensory centers in the region bordering on the fissure of Rolando—that is, in the motor area; and, according to these observers, this region is both motor and sensory in function, hence properly termed the sensorimotor area. They operated by either partially or totally extirpating from the brains of monkeys the various areas of this region, or by separating these areas from their nerve connections. They found that after such operations there was invariably induced paralysis, both of motion and sensation, in the limbs of the opposite side of the body; the extent of the loss depending upon the extent of the lesion. They also observed that if small areas of the motor region were destroyed, while both motor and sensory paralysis resulted, the former was nearly always permanent, whereas the latter would gradually and completely disappear. This Mott explains by the difference in the anatomic arrangement of the motor and sensory fibers; the former—originating from the motor cells, which are their trophic centers—being destroyed close to their origin, there results a complete disintegration of these fibers, with a corresponding permanent loss of function; whereas in the case of the latter, or sensory fibers,—which are on their way to the cerebral cortex, where they terminate, after having given off collaterals, by spreading out into cortical arborizations which occupy a large extent of surface,—it is perfectly conceivable that a small circumscribed lesion can not completely destroy the collaterals and

arborizations of the terminal fiber and the remaining branches quickly take up the function of the whole.

In confirmation of the views of the above-mentioned physiologists, that the motor area is also sensory in function,—destruction producing, in addition to motor paralysis, partial or complete loss of sensation in the opposite side of the body,—comes the collection of a large number of carefully recorded cases with autopsies. This has been accomplished through the labors of Horsley, Gowers, Westphal, Dejerine, Seguin, Dana, and Starr. Dana's twenty-five cases, twenty-one from literature and four personal, all prove that lesions of the central convolutions are attended by partial or complete loss of tactile, temperature, pain, and muscular senses in the limbs of the opposite side of the body.

Horsley found undoubted sensory defects after extirpating in man a large area of the motor region. He is of the opinion that the two outer layers of the pyramidal cells of the cortex are concerned in the impressions of tactile and muscular sense, while the deepest layer, or layer of large pyramidal cells, originates motor impulses.

Allen Starr, from an experience of thirty cases of cerebral operations on man, consisting of excisions of parts of the motor area, thinks that it is clearly determined that the tactile centers are situated in the Rolandic area, especially in the postcentral gyrus. He also relates an interesting case in confirmation of his belief that the cortical area for the reception of muscular sense impressions is in the posterior central and inferior parietal lobules. The patient had a bolt driven through the left parietal bone over the position of the hand area, which produced paralysis of the hand and arm, with but slight impairment of tactile, pain, and temperature sense, but with marked impairment of muscular sense. At the operation for elevating the depressed portion of the skull an extensive injury to the parietal cortex was found, with an abscess beneath the depressed bone. In addition to the knowledge gained by experimental and clinicopathologic observations in regard to the sensory centers of the cortex comes the evidence from the embryologic

studies of the sensory tract by Flechsig and Edinger, and from the study of secondary degeneration by von Monakow, both of which methods bring the same conclusion—viz., that the sensory fibers ("fillet" or "lemniscus") terminate in the cortex of the postcentral convolution and parietal lobe.* Hence the generally accepted conclusion in regard to the location of both motor and sensory centers in man is that they occupy in common the region about the fissure of Rolando.

Nothnagel, Luciani, Seppelli, and Flechsig long ago asserted that the parietal lobes were concerned in the reception of muscle sense impressions, and possibly of the other forms of general sensations.

Redlich, from an analysis of twenty cases of lesions confined to the parietal lobes, states positively that these lobes are the centers for muscle sense.

In a recent case of von Monakow's, of a lesion involving the white substance of the angular and supramarginal gyri, there was a marked disturbance of the muscle sense, without the slightest paresis. A microscopic examination of the central convolutions and the white matter beneath them elicited nothing abnormal.

Von Vetter reports a case of a woman with decided ataxia of the extremities of the left side, without the slightest disturbance of motion, in which a lesion the size of an apple was found located in the parietal lobes; the central convolutions were normal.

THE CENTERS OF VISION.

There seems to be a unanimity of opinion among physiologists and clinicians that the visual centers are located in the occipital lobes, chiefly in that part of the mesial surface bordering on the calcarine fissure, including the cuneus and the median occipitotemporal or lingual gyrus. The strongest opponent to this belief has been Ferrier, who claimed for a long time that the

* Von Monakow states that lesions located strictly in the motor region produce only degeneration of the motor tract, but when the parietal convolutions are involved, degeneration of the lemniscus occurs. The fact that no degeneration occurs in the sensory tract when the lesion is confined to the motor area may possibly be explained by the theory of Mott, above referred to.

visual centers of the monkey were located in the angular gyrus.* He has recently modified his opinion and includes with this area the occipital lobe, which together he has termed the occipito-angular gyrus. The experiments of Monk, Horsley, Brown, and Schäfer have conclusively shown in animals that the visual centers are located in the occipital lobes. Horsley and Schäfer found that extensive destruction of the occipital with a small part of the temporal lobes of a monkey's brain was followed by bilateral homonymous hemianopsia. Brown and Schäfer destroyed both angular gyri in a monkey without the occurrence of any loss of vision, which disproves the claim of Ferrier. M.

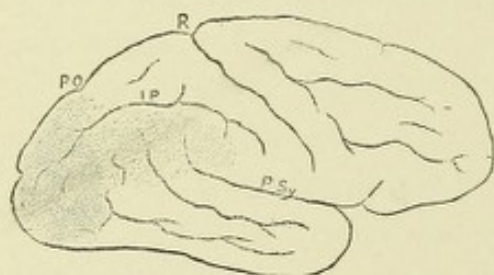


FIG. 226.—CORTICAL VISUAL CENTERS ON THE OUTER SURFACE OF THE HEMISPHERE. The darker shading indicates the region of the half-vision center (the precise limitation of which is not yet known); the lighter shading is that of the supposed higher visual center.—(After Gowers.)

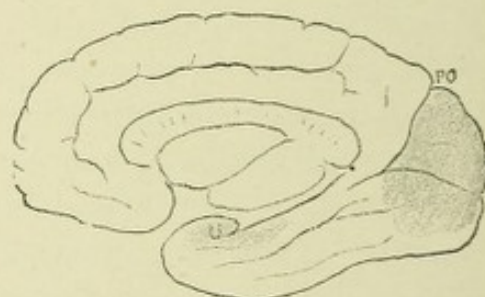

FIG. 227.—INNER ASPECT OF THE RIGHT HEMISPHERE. Probable position of the visual center in the occipital lobe and of the olfactory center in the uncinate gyrus (U).—(After Gowers.)

Allen Starr proves this fact in man by the collection of twenty-four cases of lesions of the angular gyrus without the slightest disturbance of vision. A number of clinical cases are on record which prove that the visual centers in man are located in the occipital lobes. Starr was able in 1884, from a collection of twenty-seven cases of lesions of the occipital lobe, to definitely locate the visual area in that lobe. Seguin, in 1886, reported forty cases from literature, all of which are confirmatory of the same fact.

The cases of Seguin, Hun, Monakow, Dejerine, and Henschen

* Ferrier still maintains that the macular fields or areas of central vision are in the angular gyri.

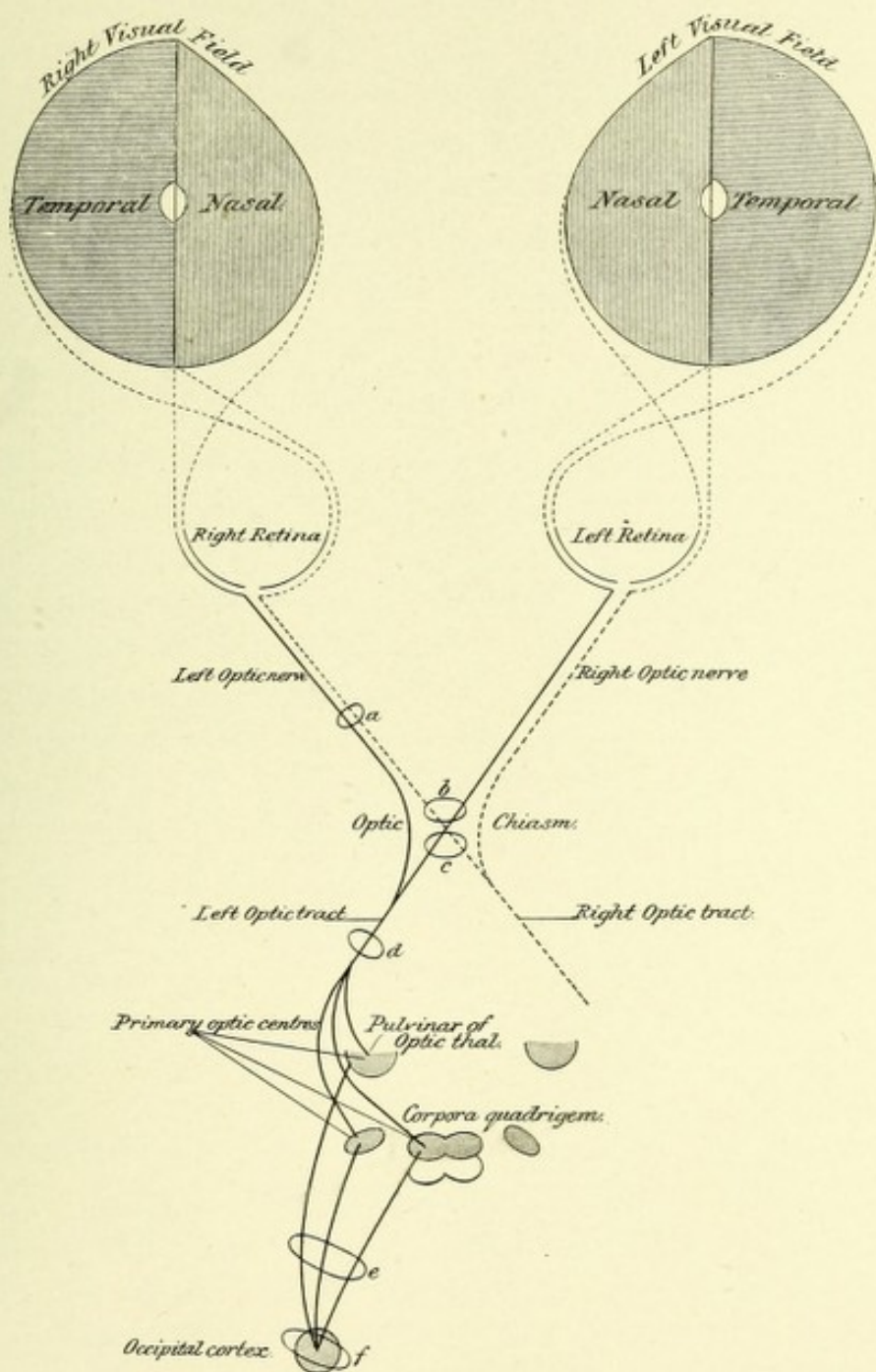


FIG. 228.—DIAGRAM OF COURSE OF OPTIC NERVE-FIBERS, FROM THE CORTEX TO THE RETINA.—(After Sahli, Modified and Extended, from Tyson.)



all show that lesions of that part of the mesial surface of the occipital and adjacent part of the temporal lobe bordering on the calcarine fissure are invariably attended by partial or complete bilateral homonymous hemianopsia—that is, a paralysis of the fields of vision opposite to the lesion. Hence, this area may be termed the half-vision center. The visual area may be affected by irritative or destructive lesions. In the former case the patient suffers from periodic nervous discharges, resulting in visual hallucinations, such as a sudden flash of light, frequently followed by temporary blindness in the opposite halves of the visual fields. Destruction of this area on one side produces the characteristic visual loss known as bilateral homonymous hemianopsia, while destruction of the visual areas of both sides produces total blindness. It will thus be seen that hallucinations of vision and bilateral homonymous hemianopsia are as characteristic for irritative or destructive lesions of the visual area as are partial unilateral convulsions and motor paralysis for lesions of the motor region. In order to understand the peculiar form of visual defect known as homonymous hemianopsia, it will be necessary to recall to mind the course of the optic tract. The fibers of this tract, which have their origin from the cells of the temporal half of each retina, do not decussate in the optic chiasm, but pass backward on the same side; while those that proceed from the cells of the nasal half of each retina cross over in the chiasm to join the fibers from the temporal half of the opposite retina, thus forming the optic tract of that side. The fibers then continue backward to terminate about the cells of the external geniculate body, the pulvinar of the optic thalamus, and the anterior corpus quadrigeminum. From the cells of these primary optic centers new fibers start out, which pass through the extreme end of the posterior division of the internal capsule and thence radiate through the centrum semiovale, to terminate about the cortical cells of the occipital lobe, chiefly the cuneus and lingual gyrus; thus, for example, the right occipital lobe has, terminating about its cortical cells, the fibers from the temporal half of the right retina and those from the nasal half of the left retina. It may be stated that the temporal halves of the retinae receive impulse from the nasal halves of

the visual fields, and the nasal halves of the retinae receive impulses from the temporal halves of the visual fields. Therefore, a lesion involving the right visual area in the occipital lobe will cause, owing to the fact that the right optic tract contains the fibers from the temporal half of the right and the nasal half of the left retina, a paralysis of the left halves of the visual field, because of a loss of function of the right halves of each retina. This defect is called bilateral homonymous hemianopsia.

RETINAL REPRESENTATION IN THE OCCIPITAL CORTEX.

The very interesting case reported by Henry Hun, in connection with others collated by Seguin and Henschen, seem to prove that the different quadrants of the retinae are represented by different areas of the median surface of the occipital cortex. In Hun's case there was a defect in the lower left quadrant of each field of vision, with a corresponding atrophy of the lower half of the right cuneus. Henschen locates the cortical center for the lower quadrant of each retina in the superior part of the lingual gyrus.

COLOR VISION.

In regard to a cortical center for the representation of color vision, nothing positive is known. Gowers believes it may be located in the anterior division of the occipital lobe, while Henschen places it in the vicinity of the calcarine fissure.

THE AUDITORY CENTERS.

Apart from the results of the experiments of Schäfer and Brown, physiologists and clinicians agree in locating the centers for audition in the temporal lobes. The above-mentioned physiologists experimented by destroying, on each side, the superior temporal lobes of six monkeys, and in one animal the entire temporal lobe was removed without producing the slightest loss of hearing, even of a temporary character. The experiments

of Ferrier, both those before and those undertaken since the publication of the results of the work of Schäfer and Brown, do not bear out the conclusions of these latter observers. Ferrier locates the auditory centers in the posterior part of the superior or first temporosphenoid convolution on each side. Electric excitation of this area on either side invariably produced in the monkey retraction or picking up of the opposite ear, associated with the opening of the eyes and dilatation of the pupils, with turning of the head and eyes to the opposite side. He further states that he placed a monkey on a table, and while all was still he made a shrill whistle close to the animal's right ear; immediately the ear was retracted and the animal turned with a look of intense surprise, with eyes widely opened and pupils dilated, toward the side from which the sound proceeded, thus proving that the stimulus of an external sound to a normal animal produced exactly the same phenomena as resulted from electric stimulation of the auditory center. The similar result in both cases is due to reflex action, in the former case to a stimulus (electric) applied directly to the auditory center, and in the latter case is due to stimuli carried to the same center by way of the auditory tract. These experiments, with others, on animals whose sense of hearing is very acute has led Ferrier to state that irritation of the superior temporosphenoid convolution of one side excites subjective auditory sensations of the ear of the opposite side, such as pricking of the ear and turning of the head and eyes toward the side. The destruction of this area on either side caused an absence of the usual reaction to the auditory stimuli coming from the ear opposite to the lesion after the ear on the side operated on was carefully plugged. Destruction of both superior temporal gyri caused complete absence of the response to auditory stimuli, which invariably attracted the attention of a normal animal. This seems conclusive proof that in the monkey there are two centers of hearing, one in each superior temporal gyrus, the destruction of one producing deafness in the opposite ear, and the destruction of both producing total deafness.

In man the centers of audition are located in the same parts of the temporal lobes as Ferrier has located them in the mon-

key. This has been proven by a few well-recorded cases with autopsies. These cases show that lesions of the superior temporal gyri give rise to two sets of symptoms—*i. e.*, those due to irritation and those due to loss of function. The former are simple discharges of energy from these centers, resulting in subjective auditory sensations which are referred to the ear opposite to the lesion; the latter cause partial or complete deafness. The irritative symptoms are often merely the premonitory symptoms or *auræ*, which precede the more general symptoms of the lesion. Such a mode of onset occurred in two cases reported by Gowers. In the first case the convulsions (general symptom) were always preceded by an auditory aura referred to the opposite ear. At the autopsy a tumor was found beginning in the superior temporal gyrus. In the second case the unilateral convulsions were preceded by an aura of loud noise, as of machinery. In this case a tumor was found involving the middle of the superior temporal gyrus. The cases of Shaw, Wernicke, Friedländer, and Mills prove conclusively that destruction of both superior temporal gyri in man produces total deafness. The combined results of physiologic experiments and pathologic observation leave no room for doubt that the centers of hearing are located in the superior temporal gyrus of each side. It seems probable that in man the sense of hearing of each ear is bilaterally represented, because of the fact that a lesion of the superior temporal gyrus of one side produces only partial deafness of the opposite ear, which deafness frequently passes away, whereas bilateral lesions occasion complete and permanent deafness. Against this theory of bilateral representation, and in support of the theory of a single center for the reception of auditory stimuli from the opposite ear, is the very important and well-known case of Bertillon, the statistician, who suffered from complete loss of hearing on the left side since childhood. At death the left superior temporal gyrus was found to be very much larger than that of the right side.

THE CENTERS FOR LANGUAGE.

Clinicopathologic investigations have positively shown that there are at least five distinctive cortical areas governing the various processes which are concerned in spoken, written, or sign language. These centers, in general, may be divided into two types,—sensory and motor,—and are as follows: First, a center for the reception of the memories of spoken words; second, a center for the reception of the memories of the appearance of objects as seen and of words as written; third, a center for the reception of the appearance of objects gained through the sense of touch; fourth, a center for the memory of the muscular movements necessary for the performance of articulate speech; fifth, a center for the memory of muscular movements concerned in writing. It may be mentioned, before describing the location of these various centers, that in the great majority of individuals who are right-handed from birth these centers are active only in the left cerebral hemisphere, and that in the left-handed they are active in the right hemisphere only. A possible explanation for this fact may be that of heredity and education. Bastian states, as to the causes which have determined the greater or almost exclusive influence of the left hemisphere in inciting speech movements, and, therefore, in acting upon the bulbar motor centers, only conjectures can be offered. It is, however, now pretty generally agreed that the immediate or proximate cause is to be found in the fact of the predominant use of the right hand, which entails a greater functional activity of the left hemisphere. This view rests principally upon the now ascertained fact that, in the great majority of cases in which aphasia has occurred as a result of brain-lesions in the right hemisphere, those so affected have been left-handed.

It is a well-known fact that in right-handed persons there is a greater convolitional development of the lower part of the left frontal lobe than the right. On examination of the brains of two left-handed persons, Bramwell found the opposite condition—that is, a greater development and complexity of the convolutions in the right frontal lobe.

It may also be stated that, in case of the destruction of any

one of these centers concerned in speech, the centers in the opposite hemisphere which have been inactive or latent gradually take on the function of the center which has been destroyed. The defect in speech is thus compensated for, this occurring the sooner the younger the individual affected.

THE CENTER FOR THE RECEPTION OF HEARD WORDS.

The experiments of Monk on the lower animals have positively located this center in the temporal lobes. This observer found, if he extirpated corresponding areas of the temporal lobes of each hemisphere of the dog's brain, that the animal, after sufficient time had elapsed for recovery from the shock of the operation, could recognize sounds as usual, and would give evidence of such recognition by the usual signs, such as pricking up of the ears, partial rotation of the head, etc., but these sounds conveyed no meaning; in other words, the animal did not understand what he heard. The familiar commands of his master, although heard, were not heeded, because the animal failed to recognize the meaning. To this condition Monk gave the name of mind-deafness. In man, the center for the reception of the memories of heard words is in the posterior half of the superior and middle temporal convolutions of the left side in right-handed persons, and in the same location in the right temporal lobe for left-handed persons. This statement is based upon data obtained from the study of the position of the lesion in a number of carefully recorded cases of sensory aphasia where the visual and motor speech-centers were found in a normal condition. Such cases have been recorded by Wernicke, Kussmaul, Seppilli, Hitzig, and Mills. Seppilli has collected seventeen cases, in all of which the lesion was located in the same area. Destructive lesions in this area of the temporal lobe produce the characteristic defect of speech known as auditory aphasia (Bastian), or mind-deafness (Kussmaul), as it is more commonly termed. In persons suffering from this affection, although the sounds of the words are heard as usual, the person is unable to understand what is said because the mental image of the object stored in that center and recalled by the

word has been destroyed. Broadbent, Kussmaul, and Charcot agree that a *center for ideas* exists and that its most probable location is in the lower posterior part of the outer surface of the temporal lobe. This center is in communication with all

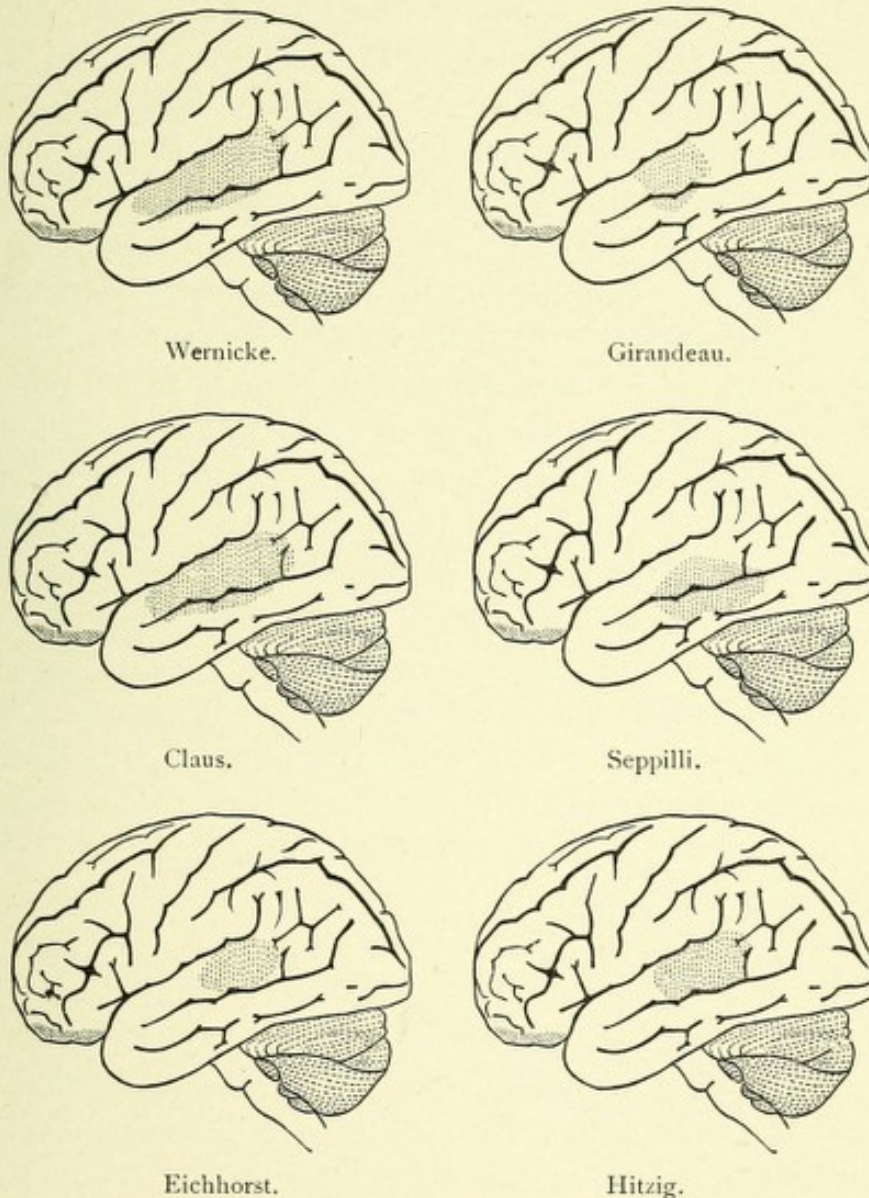


FIG. 229.—SITUATION OF LESIONS CAUSING WORD-DEAFNESS ONLY.—(From Starr.)

the receptive centers of the cortex by means of the association tracts. Thus, while the individual perceptions of an object are conducted to the various receptive centers of the cortex, the mental image, concept, or idea of the object, which is the result of the association of its various perceptions, is stored up in this

so-called center for ideas, each idea being symbolized by a name which is used in giving expression to it in speech. Disease of this center produces partial or complete inability on the part of the person affected to recall to mind the sounds of the words, and hence the words can not be spoken although they may be repeated after another. This form of speech-defect is called verbal or amnesic aphasia; the loss involves, particularly, proper names and substantives. In a case now under my observation the only defect is the loss of memory of proper names, the patient being unable to introduce to others his most intimate friends, because he can not recall to mind their names. Such patients, when they can not recall the proper names, frequently resort to a paraphrase so that they may convey the idea. Such was the case in a patient of Kussmaul, where there was a loss in the memory of nouns, but that of verbs was retained. A pair of scissors he called "that which one cuts with"; a window, "that through which one sees and through which light comes." In support of the existence of a center for ideas, Mills has recorded a very interesting case of verbal amnesia, with partial word-blindness but not letter-blindness, and with left lateral homonymous hemianopsia. At the autopsy a granular, tumor-like mass, about the size of a hickory-nut, was removed from the surface of the posterior fourth of the third temporal gyrus, and the posterior half of the third and a small part of the fourth temporal gyri were likewise involved. On section of the temporal lobe a tumor was disclosed, having its oldest part about the middle of the third temporal and passing slightly into the second temporal. In addition, a softened area, extending into the middle of the occipital lobe, was discovered. From the result of this case, Mills, who prefers to call this center the "naming center," locates it in the posterior part of the third and fourth temporal gyri. It may be true that in this location a separate center exists destruction of which produces verbal amnesia, but it is also true that this latter condition is also associated with partial word-deafness, and as a residual condition in cases of motor aphasia, the lesions in both of which cases are distinctly localizable.

THE CENTER FOR THE RECEPTION OF MEMORIES OF THE
APPEARANCE OF OBJECTS SEEN AND FOR THE APPEAR-
ANCE OF WORDS AS WRITTEN OR PRINTED.

The former center—*i. e.*, the center for the memories of seen objects—is located, according to Freund, in the right angular

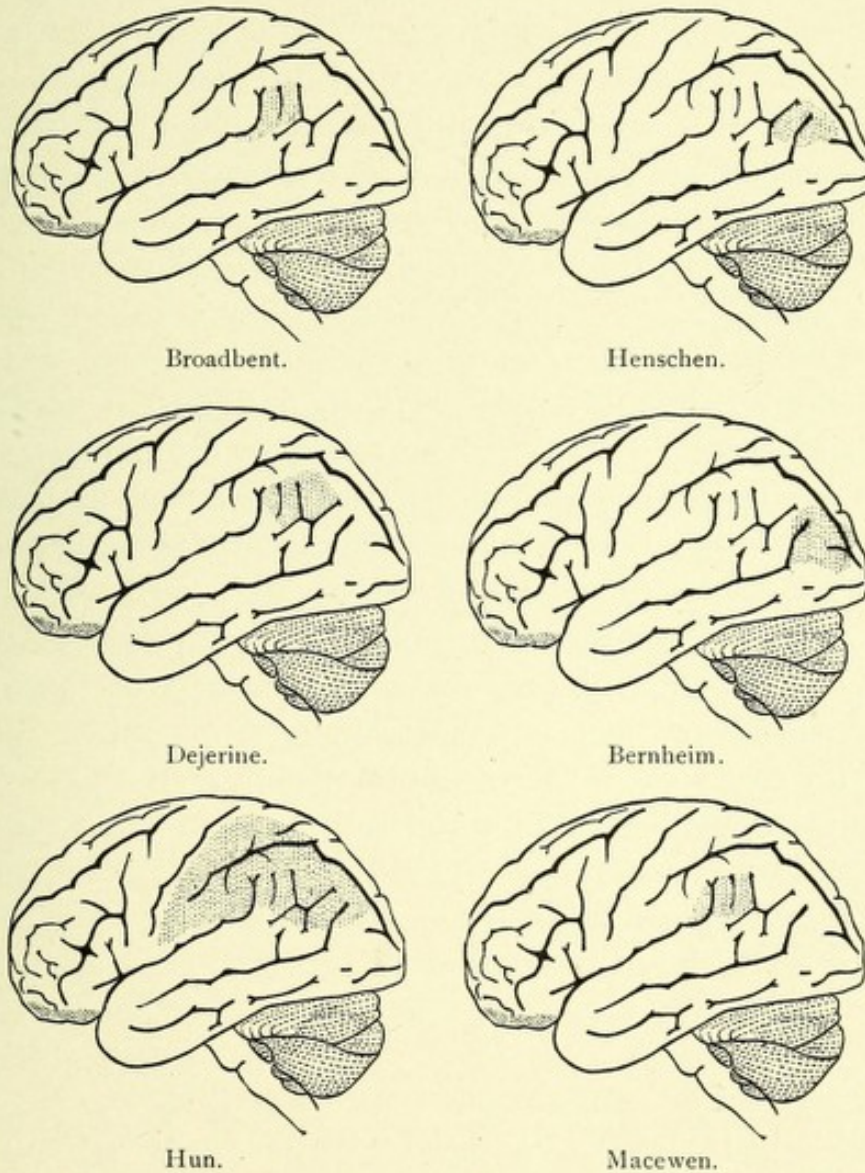


FIG. 230.—SITUATION OF LESIONS CAUSING WORD-BLINDNESS ONLY.—(From Starr.)

gyrus. Destruction of this area produces in man psychic or mind-blindness—that is, a condition in which a person so affected fails to recall to mind the visual image of the appearance of an object, although the object is perfectly seen. This condition is

entirely distinct from word-blindness, which latter condition is, in most instances, due to a lesion in the left angular gyrus. It may, however, be associated with the former condition, when a lesion will then be found in the angular gyrus of each side. Freund bases the foregoing statement upon the study of eight cases with autopsies, five from literature and three personal.

The center for the reception of the memories of the appearance of written or printed language is located in the angular gyrus of the left side in persons who are right-handed, and in the opposite side for those left-handed. The exact location of this center has been determined by the study of lesions found in a number of cases of pure word-blindness, all of which were located in the left angular gyrus, and were unaccompanied by visual defects.

Word-blindness, or alexia, is a condition in which written or printed words, although well seen, do not arouse in memory their visual images. The patient that is word-blind is able to recall the appearance of objects, unless he has at the same time mind-blindness, which latter condition is due, in most instances, to the lesion involving the angular gyrus of the right hemisphere. In complete word-blindness the patient is unable to write spontaneously, because the memories of the appearance of words are lost, and he is unable to read because the words, although seen, are without meaning. If this condition is incomplete, he may be able to recognize and name individual letters of a word without being able to recognize the word itself. Patients in this condition often have a perfect knowledge of numerals while they can not recognize words (Fig. 230).

THE CENTER FOR THE RECEPTION OF THE APPEARANCE OF OBJECTS GAINED THROUGH THE SENSE OF TOUCH.

Although much doubt exists at the present time as to the exact location of a center for the appearance of an object gained through the sense of touch, the study of the cases of sensory optic and tactile aphasia, recently reported by Johannes Vorster, prove that such a center probably exists in the central convolutions (sensorimotor area) and is connected both with

the angular gyrus and the auditory or sensory speech-center in the temporal lobe by association tracts of fibers. Vorster has collected seven cases of tactile aphasia from literature and has added one personal case, in all of which sensory optic aphasia existed.

In order to have tactile aphasia, both bundles of association connecting the tactile center with the angular gyrus and with the auditory sensory speech-center must be destroyed. Hence tactile aphasia must necessarily be accompanied by sensory optic aphasia. In sensory optic aphasia the patient is unable to name an object, although it is seen and recognized. He can recall the name of an object when heard and can name the object after having handled it. This indicates that the lesion has destroyed the association bundle connecting the left angular gyrus with the auditory receptive speech-center (inferior or longitudinal bundle); hence the sight of the object does not recall to mind its name, but through the sense of touch the tactile center is brought into relation with the auditory center (superior longitudinal bundle), and therefore the patient is able to name the object after having handled it.

In tactile aphasia, which is always combined with optic aphasia, both of the association bundles connecting the tactile center with the angular gyrus (tactile optic acoustic tract) and auditory center and the tactile acoustic tract connecting the tactile center with the auditory receptive speech-center are destroyed. The patient is not only unable to name a seen object, but is also unable to name the object through the aid of his tactile sense.

THE MOTOR SPEECH-CENTER, OR CENTER FOR THE RECEPTION OF THE MUSCULAR MEMORIES NECESSARY TO PRODUCE SPEECH.

To Broca is due the credit of having accurately located the motor speech-center in the posterior part of the inferior left frontal gyrus. This region is, therefore, in honor of the discoverer, called the area of Broca. This location he determined from the study of seventeen cases of aphasia with autopsies, in

sixteen of which the posterior part of the left inferior frontal gyrus was found destroyed, while in the other case it was also affected, but in addition to it the island of Reil and the parietal lobe. Since Broca's time, hundreds of clinical cases with autopsies have been recorded, which have verified his conclusions as to the location of this center. In this area are stored the motor memories necessary to give expression to thought through articulate speech.

When Broca's center is destroyed, there is produced the characteristic speech-defect known as motor aphasia, which condition is an inability, complete or partial, on the part of the person affected, to give vocal utterance to thought.

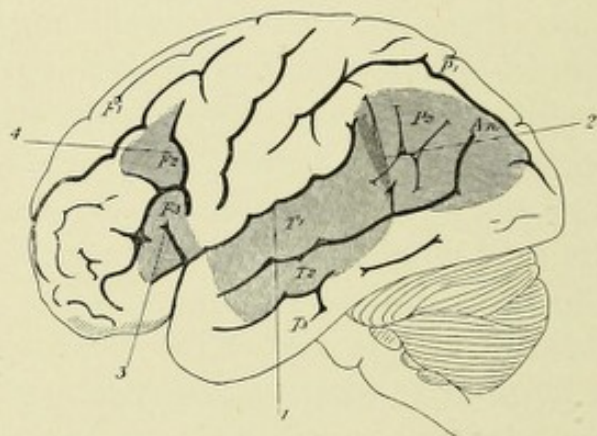


FIG. 231.—SITUATIONS OF LESIONS CAUSING APHASIA.—(After Starr, from Tyson.)

1. Lesion of word-deafness. 2. Lesion of word-blindness. 3. Lesion of motor aphasia. 4. Supposed lesion of agraphia.

In many cases of complete motor aphasia the patients may be able to give expression to a few very familiar words, like "yes" or "no," or other very short phrases. These "recurring utterances," as they are termed, are probably the result of the excitation of the right inferior frontal gyrus.

There is an actual loss of the power of speech without, in most cases, the slightest paralysis of the muscles concerned in the production of speech. The patient can not repeat words after another, nor can he read aloud. In many cases of motor aphasia there is also an inability to write—agraphia. Agraphia was so often found associated with motor aphasia that Trousseau, Jackson, and Gairdner were led to believe that writing

was performed through the medium of Broca's speech-center, and that a separate and distinct center for writing did not exist. Several cases with autopsies, however, have been recorded to prove that motor aphasia, when accompanied with agraphia, is due to destruction not only of Broca's speech-center, but also to the base of the second left frontal convolution—the probable center for writing. Such cases have been reported by Tamburini, Marchi, and Simon.

The loss of the faculty of writing does not exist in every case of motor aphasia in which the right hand is not paralyzed. Professor Oppenheim, of Berlin, has reported a case of pure motor aphasia in which the patient was able to say only the words "yes" and "no," but could write and paint during the whole period of his illness. Similar cases have been recorded by Kahler, W. Ogle, Guido Banti,* Wadham, and Byrom Bramwell. At the autopsy of three of these cases the lesion was strictly localized to Broca's center.

* A right-handed man, aged thirty-six, who was able to read and write correctly, had a sudden apoplectic attack in 1877. Recovering consciousness in a few minutes, he was found to be suffering from right hemiplegia and loss of speech. The paralysis of the limbs disappeared almost completely during the following night, although the inability to speak persisted.

The next day he was admitted into the hospital, and, on most careful examination, his condition was found by Guido Banti to be as follows: "The motility of the limbs of the right side had returned to their normal condition. There was no trace of paralysis of the face or tongue. The patient made ineffectual attempts to speak; he could not articulate a single word, not even isolated syllables. He was much affected by this mutism, and sought to make himself understood by gestures. I asked him if he knew how to write, and after he had made a gesture in the affirmative I gave him what was necessary and told him to write his name, which he did immediately. I put various other questions to him, to which he replied similarly by writing. I told him to give me a description of his illness and he wrote, without hesitation, the details above reported. I showed him various objects—pieces of money, etc.—telling him to write their names, and he did so without making any mistakes. Then, instead of giving him these directions by word of mouth, I wrote them to him, in order to thoroughly convince myself that he was able to understand writing. He replied to these questions with perfect correctness. He always wrote very rapidly, and did not seem to hesitate to choose his words. He made no mistakes in syntax or orthography. He could understand equally well ordinary writing and print, and when one spoke to him he grasped at once the meaning of the questions, and never wished to have them repeated. I next wrote him some most simple words, such as "pain," "vim," etc., and urged him ineffectually to read them aloud. I then pronounced myself some of the words, directing him to repeat them. He appeared to watch with great attention the movement of the lips whilst I spoke. He made some ineffectual efforts to obey, but he never succeeded in pronouncing a single word."

This patient died, in February, 1882, from an aneurysm of the aorta, and a patch of yellow softening was found situated in the posterior third of the third left frontal convolution, and extending for some millimeters only in the white substance.

The fact that the muscles concerned in articulation, owing to a lesion which causes motor aphasia, are not paralyzed is probably due, in most cases, to the fact that these muscles act bilaterally, and hence are bilaterally represented by centers of action in each cerebral hemisphere. These latter centers are located in the extreme posterior part of the third frontal and the lowest part of the ascending frontal and parietal gyri of each side. In order, therefore, to have a complete paralysis of the muscles of articulation, both centers must be destroyed. A few such cases are on record, one of the most typical of which has been described by Barlow.*

The motor speech-area then really consists of two parts: first, the true center for the storing of muscular memories of words for speech, and, secondly, the motor centers controlling the muscles necessary to pronounce the words. A lesion of the former causes true motor aphasia, while a lesion of the latter usually causes only a temporary paralysis of the muscles of articulation.†

Frequently, in people of limited education, who read little, and then only aloud or by moving the lip-muscles, the occurrence of motor aphasia is usually complicated by word-blindness, or alexia.

* See "British Medical Journal," July 28, 1877.

† The following case reported by Oder and copied from the book of Joseph Collin, on the "Faculty of Speech," shows that the exact location of the cortical center for the articulatory muscles is in the inferior part of the ascending frontal and parietal gyri. It also shows that this center is entirely distinct from the motor speech-center, and when destroyed on the left side, produces a condition of dysarthria identical with pseudobulbar paralysis.

A man sixty years old, who had previously been well, suddenly developed difficulty in speaking; speech became indistinct and blurred, and saliva trickled from the mouth. On admission into the hospital it was found that there was paresis of the right side of the face, more marked in the lower part and at the angle of the mouth, and not involving the orbicularis palpebrarum. He was perfectly conscious and understood all that was said to him, had no hemiplegia, and his only trouble was incapacity to enunciate words, due to difficulty in moving the tongue, lips, and other muscles of articulation. There was no aphasia, and the voice was normal. There was difficulty in swallowing liquids. He died five days after the onset of pneumonia. On examining the brain there was found, in the lower part of the left ascending frontal gyrus, just above the Sylvian fissure, a blood-clot which had pushed its way through the cortex, and had destroyed almost entirely the cortical substance of the lower end of the central convolutions. The foot of the third frontal convolution was normal.

THE CORTICAL CENTERS FOR WRITING.

Much doubt exists as to the exact location of the cortical area concerned in writing. Some authors believe, owing to the fact that motor aphasia and agraphia are so often combined, that no separate center exists for writing, this center being identical with that for speech. Bastian has shown, however, by the records

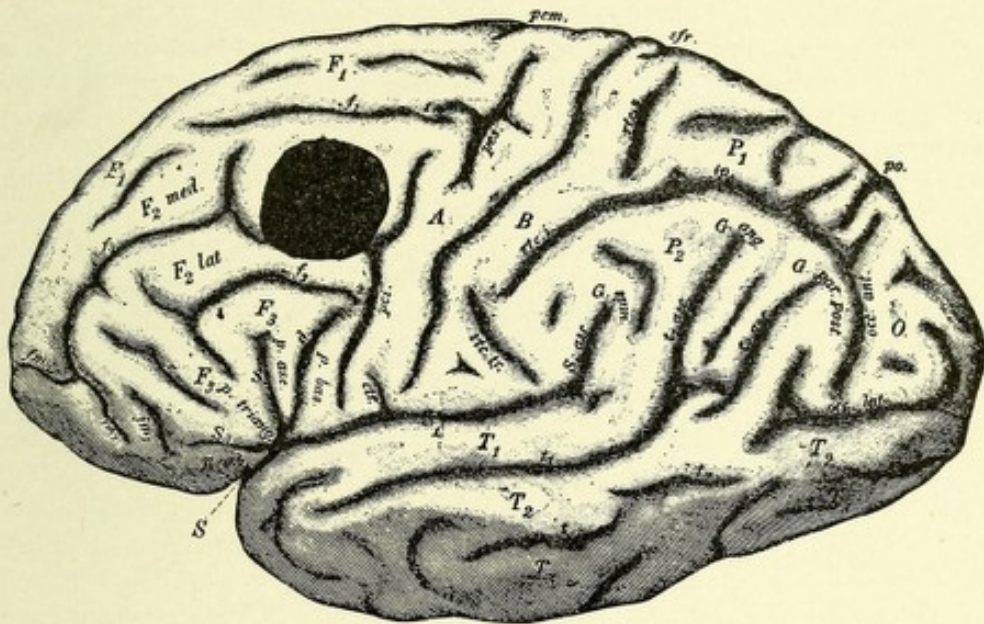


FIG. 232.—DIAGRAM SHOWING LOCATION OF TUMOR WHICH PRODUCED COMPLETE AGRAPHIA (AUTHOR'S CASE).

of several cases with autopsies, that when agraphia coexists with motor aphasia, it is usual to find the lesion involving the base of the second left frontal gyrus, together with Broca's center. In order to determine whether a separate center exists for the reception of the muscular memories concerned in writing, a case must be found in which a lesion of a certain locality must produce agraphia without motor aphasia, paralysis of the hand, or word- or mind-blindness.

The only case with autopsy which fulfils the before-mentioned requirements is the author's case of a glioma at the base of the second left frontal convolution, in which the only

localizing symptom was agraphia uncombined with any form of aphasia.*

* AUTHOR'S CASE OF AGRAPHIA.†—The patient, an intelligent Irish woman, received her education in the public schools. Her age is thirty-seven, and she has been married for fifteen years; has always enjoyed excellent health up to the onset of the present illness, which began about Christmas-time, 1897. At that time she began to fail in strength and had several attacks of vertigo without falling, and unattended with nausea or vomiting. A short time afterward she developed severe frontal and occipital headaches, with occasional attacks of vomiting. The headaches continued with increasing severity until the fatal issue. In March, 1898, she noticed that her sight was failing and that she could not read coarse print without the use of her glasses. At about the same time she began to complain of a numbness in the right arm. At no time during her illness did she have a unilateral or general convulsion. Her bowels have been rather constipated; has had perfect control over her bladder. Has menstruated regularly and in a normal manner. Patient converses intelligently, makes no errors, and her memory for past and recent events is good. At no time during her illness has she had the slightest difficulty in giving expression to her thoughts by articulate speech. Physical examination of chest elicited no morbid changes; throat normal, temperature normal, pulse 68. Examination, April 5, 1898. Patient five feet four inches in height; weight, 140 pounds. Head well formed and symmetric; no evidence of previous injury; no exostosis; percussion of scalp elicits no tenderness. Veins of forehead not prominent; pupils moderately and equally dilated, respond actively to light and accommodation. Wernicke's hemiopic pupillary phenomenon present. No hemianopsia. Marked optic neuritis of both eyes. Owing to paresis of the right external rectus muscle, the right eyeball could not be rotated outward, but its movements upward, downward, and inward were found normal; diplopia existed; excursion of left eyeball normal; color-vision normal. Drum-membranes appeared normal; hearing distance for watch in each ear was three feet. Movements of tongue normal; no fibrillation or atrophy. Senses of taste and smell normal. Soft palate and uvula move in a normal manner. No loss of sensation over buccal or pharyngeal mucous membranes. Movements of vocal cords perfect; no difficulty in swallowing. No stiffness of neck-muscles or those of spine. Both sides of face symmetrically formed; no evidence of facial paralysis. Patient is able to perform in a normal manner symmetric bilateral movements. Grip of right hand is slightly weaker than that of left. Dynamometer, inner scale, right, 50; left, 75. No muscular atrophy anywhere discoverable. Both fine and coarse movements of the right and left hands and arms normal. Movements of lower extremities normal. The strength of both sides alike. Careful examination of the skin of the entire body showed no sensory disturbances. No edema or other vasomotor changes. The most careful reinforcement failed to elicit the presence of patella tendon reflexes. No ankle-clonus; superficial reflexes present not exaggerated. No ataxia in upper or lower extremities. The sense of posture normal. She has always been right-handed. Romberg's symptom absent.

Speech.—Patient recognizes and names correctly any object placed before her. She can recognize and accurately name, with her eyes closed, any familiar object when placed in her right hand, such as coins and the like. She understands perfectly what is said to her. She recognizes familiar hymns. She can repeat words after another, and speaks voluntarily without the slightest hesitation, and always correctly. She can read correctly, with the aid of glasses, ordinary-sized print or writing. She recognizes numerals at once. The only difficulty present is a total inability to write. Although she understands perfectly written language and can read to herself or aloud, she can not write voluntarily nor form correctly a single letter, and can not write from dictation or copy. She holds the pen in a perfect manner and executes movements with it as if to write; her writing consisting, however, of nothing more than a series of united

† "The American Journal of the Medical Sciences," May, 1899.

Charcot and Dutil and, recently, Eskeridge have each reported a case which nearly fulfils the foregoing requirements. In the case of Charcot and Dutil a woman, after an apoplectic attack, had no symptom save that of pure motor agraphia. Some years later a similar attack produced motor aphasia, and, still later, recurring attacks resulted in the condition of speechlessness known as pseudobulbar paralysis. At the autopsy there was found a focus of softening in the foot of the second left frontal gyrus, one in the foot of the third left frontal, and three foci in the right hemisphere. It seems probable, owing to the long duration of the agraphia without aphasia, that the lesion causing the former was the focus of softening located at the foot of the second left frontal convolution, and the motor

curves. She was unable to write with her left hand, as she was not ambidextrous. The fine and coarse muscular movements of the right hand are executed in a perfect manner, and there exists no paralysis of the muscles of the hand, forearm, or arm. Before the present illness began she could write perfectly. She showed me some of her writing, which was excellent. This condition of complete agraphia continued throughout her illness, and was, with the exception of the gradual development of a slow cerebration, the only localizing symptom present. At no subsequent time was there found the slightest evidence of motor or any form of sensory aphasia. She never became paralyzed or developed any sensory symptoms, and hemianopsia or alexia were never present. She was operated upon July 19, 1898, and died July 21, 1898.

Autopsy, July 22, 1898, 10.30 A. M. The head only permitted to be examined. Opening in skull, 4.5 by 4.75 cm. Elevation of hernia cerebri above dura was 2 cm. Dura everywhere free; vessels of pia injected. Left cerebral hemisphere markedly hemorrhagic. Softening of the hernia cerebri and surrounding brain-tissue; pia not adherent, save at location of new growth which was found occupying the foot of the second frontal convolution, being distinctly separated from the arm-area by the precentral sulcus, which sulcus was in this case well developed. The growth was elevated about $\frac{1}{2}$ of a centimeter above the surrounding cortex, was slightly irregular in outline, of a distinctly firm consistency, and oval in appearance. Its longest diameter was $2\frac{1}{2}$ cm. The pia was intimately adherent to it. On section, the tumor was seen to extend downward and inward as far as the roof of the anterior cornu of the lateral ventricle and forward to near the apex of the frontal lobe. The left third or inferior frontal convolution, throughout its whole extent, was found macroscopically perfectly normal, as was its associated centrum ovale. The centrum ovale of the superior or first frontal convolution was, toward its ventral part, infiltrated by the growth. The motor convolutions, in their middle third, formed a part of the hernia cerebri. This area was filled with multiple capillary hemorrhages, the result of the sudden relief of the intracranial pressure, resulting in a hemorrhagic softening. The rest of the motor area and the underlying white matter was found normal. The supramarginal and angular gyri, with their associated white matter, were very carefully examined and found normal, as were the convolutions and white matter of the occipital and temporal lobes. The basal ganglia and internal capsules showed no naked-eye changes. The convolutions, centrum ovale, basal ganglia, and internal capsule of right cerebral hemisphere normal. The ventricles contained an excess of fluid. The brain-stem, pons, cerebellum, and medulla showed no macroscopic changes. Microscopic examination showed the tumor to be a glioma. The third left frontal convolution, with its associated white matter, was found normal.

aphasia, which appeared some years later, was due to the lesion found at the foot of the third left frontal gyrus. The pseudo-bulbar paralysis was doubtless due to the combined lesions found in the frontal regions of both hemispheres.

In Eskeridge's case a vigorous man, a farmer and stock-raiser by occupation for the last few years, began about a year ago to suffer from irregular attacks of a spasmodic nature, during which he would be dazed and temporarily unable to speak. Nine months later, when a careful examination of his condition was made, all sensory phenomena were found normal, and no paresis or paralysis of any muscles. With the right hand he registered on the dynamometer 230; left, 220. He complained of some headache, which was intermittent and located in the front of the head, more on the left side than on the right. There was no disturbance of the special senses. The fundus and papilla of each eye were normal. There was no sensory aphasia. The power of articulation was quite good, except that it was slow and long words were difficult for him to utter distinctly. He could talk, read printing and writing to himself or aloud, and understood what he read. There was no difficulty in propositionizing, and the movements of the lips and tongue were well preserved, except in uttering long and hard words; otherwise it was impossible to discover any defect in speech. In writing, as a rule, he formed his letters perfectly, but he transposed letters, words, phrases, and occasionally sentences, so that it was impossible to read what he had written. He had formerly been a good penman, and for two terms served as bill clerk in the House of Representatives of the State Legislature. Eskeridge had the patient under observation for about two months, and during this time he wrote a letter daily. The letters usually consisted of about eight or ten lines, and each day he spent two hours or more in writing and erasing words before he could complete his assigned task. At times he seemed to recognize his mistakes in spelling, and at others he did not recognize them, or was indifferent to them. On realizing a mistake in spelling he would often make a greater one in trying to correct it.

Finally, it was decided to recommend a surgical operation for

the removal of a supposed growth or cyst in the left frontal lobe. On December 5, 1895, Clayton Parkhill trephined over the foot of the left frontal convolution, found and removed a cyst containing about half an ounce of a straw-colored fluid. The cyst had destroyed the cortex over the area about $\frac{1}{2}$ of an inch in diameter, and extended into the white substance of the brain to the depth of nearly an inch.

These cases, with a somewhat similar one described by Pitres, seem to prove the existence of a separate and distinct cortical center concerned in writing, located in the posterior part of the second left frontal convolution, which area is just ventral to the area for the muscles which govern the finer movements of the fingers and hand, and having the same relation to writing-movements as the motor speech-center has to speech-movement.

SENSORY CENTER FOR WRITING.

Abundant clinical evidence exists to prove that lesions of the left angular gyrus frequently cause *agraphia*;* so that the statement may be made that a sensory center exists which is concerned in writing, located in the left angular gyrus, which center affects the motor center in a reflex manner by means of an association tract. Destruction of this tract in the centrum semi-ovale, or of the center, will produce *agraphia*. Lesions in the angular gyrus caused *agraphia* in five out of twelve cases collected by Allen Starr. When it is remembered that in order to write it is absolutely necessary to call to mind the memories of the appearance of the forms of letters, which memories are stored in the left angular gyrus, it is easily explainable why *agraphia* is produced by a lesion of this gyrus. Sensory *agraphia* is probably always accompanied by word- or mind-blindness. A pure case of sensory *agraphia* has not been recorded.

* The term *agraphia* (*ἀ*, *privative*, without; *γράφω*, writing) was introduced by W. Ogle to denote an inability on the part of the patient to write.

THE CENTERS WHICH PRESIDE OVER THE HIGHER INTELLECTUAL FACULTIES.

Both experimental and clinical research seem to place the centers which preside over the higher intellectual or psychic faculties in the prefrontal lobes. These centers include all that part of each frontal lobe placed in front of the ascending frontal convolution and separated from the latter by the precentral sulcus. It is positive that the motor speech-center is located in the posterior part of the left inferior frontal gyrus, and it is almost positive that the motor center for writing is on the same side in the posterior part of the second frontal gyrus. Whether or not, in man, centers exist in the posterior part of the superior and middle frontal gyri for the movements of the head and eyes is not positively known, although the experiments of Ferrier show that such centers do exist in the same-named convolutions of the monkey's brain. Hitzig long ago proved that electric irritation of the same area in dogs was unattended by muscular movements or any evidence of sensory disturbance. Later, he found that ablation of the same area in the same animals was never followed by any motor disturbance. Ferrier states that, apart from the fact that irritation of the roots of the superior and middle frontal gyri is attended by conjugate deviation of the head and eyes, with the dilatation of the pupils, irritation or ablation of the remainder of the frontal lobes is not attended by muscular movements, sensory disturbance, or motor paralysis. The very interesting experiments recently performed by Professor Bianchi on twelve monkeys and six dogs, of the removal of the frontal lobes, shows that no perceptible difference was noticed in the behavior or psychic manifestations of animals in which one side of the frontal lobe was mutilated, but when both frontal lobes were removed, decided psychic changes were noted, such as a listless condition with an expression of stupidity; the animals failed to respond to familiar calls, took no notice of the actions of other monkeys, and were easily terrorized, and when in danger, offered no defense. They walked aimlessly about their cages emitting cries as if afraid or angry, and when food mixed with filth was placed before them they ate it with avidity,

not rejecting the filth, and when sugar and plaster were mixed they devoured it as if it were merely sugar, thus showing that their comparative judgments and memories were defective. Professor Bianchi believes, from the results of his experiments, that the frontal lobes are the seat of the coordination and fusion of incoming and outgoing products of the several sensory and motor areas of the cortex, as well as of the emotive states which accompany all the perceptions, the fusion of which constitutes what has been called the psychic tone of the individual. Removal of the frontal lobes does not interfere with the perceptions taken singly, but destroys the physiologic fusion which forms the basis of the association, and thus the physical basis underlying recollection, judgment, and discrimination is destroyed. The results of clinicopathologic observations on man are confirmatory of the experiments of Professor Bianchi—namely, that the frontal lobes preside over the higher intellectual or psychic processes. These studies prove, however, that decided mental deterioration results when the lesions affect the prefrontal region of one side,* although greater mental disturbances occur when both sides are affected. Dr. R. J. Williamson, in an article entitled "The Symptomatology of Gross Lesions (Tumors and Abscesses) Involving the Prefrontal Region of the Brain," has reported five original cases and collected forty-five from literature, in which gross lesions occurred in the prefrontal region and were attended, with one exception, by marked mental changes, such as a stupid expression, the loss of the power of attention, mental hebetude,

* The following case of tumor is of especial interest, because it was completely localized to the centrum ovale of the right prefrontal lobe, and was not attended by any symptoms save of a mental character.

The patient was seen in consultation with Dr. John Morris, and presented the following history: Apart from occasional attacks of indigestion, he had been in good health up to February 1, 1898, at which time it was noticed that he acted strangely and was much less talkative than usual. He seemed oblivious to his surroundings, and all his actions were performed in a slow and very deliberate manner. His appetite at times was enormous, and at such times he would gorge himself with food to the utmost; he rarely vomited. The clerks in the post-office, where he was employed as a mail-distributor, had noticed that he acted strangely and would frequently err in distributing the mail. His whole mental condition seemed changed from that of intellectual activity to that of simple dementia. He would answer questions correctly, but would deliberate, thus consuming much time before giving the answers. His only complaint was a dull frontal and occipital headache, more or less continuous. At intervals of a few days to a week he would lapse into a semiconscious state, from which he could with difficulty be

loss of memory, and loss of spontaneity. The patients would take no notice of their surroundings, sleeping most of the time, or being in a condition of semistupor; were very slow to comprehend, and when asked a question, would take a long time to give the answer, although the latter was usually correct. This condition of slow cerebration has been aptly termed by Lloyd "inhibition of thought."

In an unreported case of the author's, where, at the autopsy, lesions were found involving both prefrontal lobes, there was loss of memory, mental hebetude, slow cerebration, complete loss of control of the rectal and vesical reflexes, and a distinct ataxic gait resembling cerebellar ataxia. It may be noted here that this latter symptom has been frequently observed by Bruns in cases of lesions of the prefrontal lobes.

THE CORTICAL CENTER FOR THE SPECIAL SENSE OF TASTE.

The exact location of the cortical center for the sense of taste is not known, although the experiments of Ferrier to determine the location of the olfactory center seems to prove that the center for taste is also located in the same region as that for smell—namely, in the anterior part of the hippocampal and uncinate gyri. Destruction of this region of one side produced a loss of the sense of taste on the side opposite to the lesion, while that to smell was lost on the same side. The sense of taste is so closely related to the sense of smell in man that it seems very probable that they are both subserved by the

aroused; this condition would last about twenty-four hours, when he would again appear normal, save that his mental condition was decidedly worse. Examination elicited no cranial nerve involvement. The optic discs were normal, as were motion and sensation. No incoordination existed. The reflexes were normal with the exception of both patella-tendon reflexes, which were absent. His cerebration was decidedly inactive; he never conversed spontaneously. When questions were put to him he appeared expressionless for quite a long time, and then would answer them correctly. He failed to remember dates, and also the character of his food from meal to meal. Slow cerebration was the dominant symptom throughout. He died May 15th; autopsy on the 16th. Brain normal, save that a very vascular growth (sarcoma) was found, which, with its surrounding area of softening, destroyed the centrum ovale of the entire right prefrontal lobe.

In this case, at least, although the patient was right-handed, nevertheless the right prefrontal lobe was evidently as much concerned in the elaboration of the higher mental processes as was the left.

same region. In the author's case referred to on the following page there was a loss both of the sense of smell and taste, due to the lesion (tumor) destroying by pressure the function of the right hippocampal and uncinate gyri.

THE CORTICAL CENTER FOR THE SPECIAL SENSE OF SMELL.

The *olfactory or cortical center for smell* is most probably located in that part of the recurved portion of the hippocampal lobule known as the uncinate gyrus. In this area the olfactory tract ends. This seems proved by the extirpation experiments of Gudden, who found that, after the olfactory bulb of one side was removed, the gyrus uncinatus of that side atrophied. Zuckerkandl, of Gratz, has shown, from the study of the brains of animals whose sense of smell is very keen (osmatics), that their olfactory bulbs and tracts, as well as the uncinate and hippocampal gyri, are very large, and form, on the basal surface of each temporal lobe, a pyriform swelling which is called the lobus pyriformis. On the contrary, in animals whose sense of smell is not well developed (anosmatics), the same parts are very small or atrophied. Ferrier has proved that the electric irritation of the hippocampal lobule in the monkey, cat, dog, or rabbit, invariably produced subjective olfactory sensations, such as torsion of the lip and nostril of the same side, this reaction being precisely the same as is produced in these animals by the direct application to the nostrils of some strong or disagreeable odor, and is evidently the outward or associated expression of excited olfactory sensation.

Ferrier destroyed extensively the temporal lobe, including the anterior extremity of the hippocampal gyrus, in four animals, and found, in addition to other sensory disturbances, a distinct loss of the sense of smell on the same side as the lesion.

The very few clinical cases with autopsies that are recorded indicate that in man the cortical center for smell is located in the uncinate gyrus.

Allan McLane Hamilton has reported a case of epilepsy in which the convulsions were always preceded by an aura of a disagreeable odor—sometimes of smoke and sometimes of a

fetid smell—without sensory disturbances, in which, at the autopsy, an area of softening in this region was found.

Griffith has reported a case with a loss of smell in the right nostril, the autopsy showing an erosion of the right uncinate gyrus.

Hughlings-Jackson reported a tumor of the right temporal lobe, the patient having had paroxysms with a dreamy state, with warnings of a crude sensation of smell.

Worcester cites a case of a farmer who had epilepsy, and who for several days had hallucinations of smell, such as a room full of smoke, or an odor like alcohol. At the autopsy there was found an area of red softening in the left uncinate gyrus.

In an unreported case of the author's, in which there was a loss of smell and taste, a large tumor was found springing from the anterior portion of the basal surface of the right temporal lobe, including the hippocampal and uncinate gyri.

THE LOCALIZATION OF LESIONS IN THE CENTRUM OVALE.

In a previous chapter the general and minute anatomy of the centrum ovale has been considered at length. It was found that this apparently homogeneous white mass consisted almost exclusively of medullated nerve-fibers, which were divisible into association, commissural, and projection systems. Hence the diagnosis of lesions of the centrum semiovale depends upon the result of the partial or complete destruction and consequent loss of function of these fibers. The function of the association fibers is to associate the various sensory perceptions which are received in near or distant parts of the cortex of the same hemisphere, and to form, by this association, perfect mental pictures. The commissural fibers bring the corresponding lobes of each hemisphere into harmonious relation with one another, while the projection fibers of which we have any positive knowledge are those which convey motor impulses from the cortex and those which conduct sensory impressions to the cortex. The development of this branch of localization is the work of the past five years, and has resulted from the collation of a number of

carefully recorded cases by Starr, Seguin, Wernicke, Freund, and many others.

Up to the present time several cases of subcortical tumors have been successfully removed, and a few cases of abscess in this region have been drained. Lesions which are located in the centrum semiovale near the internal capsule, owing to the convergence of the projection fibers as they enter the capsule, produce symptoms which may be identical in character to lesions in the capsule; while lesions located in the centrum semiovale just beneath the cortex, owing to a divergence of the projection fibers, produce symptoms almost identical with those produced on or in the cortex.

There are no symptoms of a general character which absolutely stamp the lesion as being either cortical or subcortical. According to Seguin, the absence or late appearance of headache would lend support to the diagnosis of a subcortical lesion. Clinical experience does not confirm this statement.

A careful study of the recorded cases of lesions in the centrum semiovale of the prefrontal lobe shows that the symptoms induced are identical in character with those produced by similar lesions of the cortex. Seguin has reported a case of agraphia, the result of a lesion in the centrum semiovale, beneath the base of the second left frontal gyrus; and several cases of motor aphasia have been reported in which a lesion was found beneath the third left frontal gyrus; but in none of these cases have any symptoms been present by which the lesion could have been distinguished from a cortical lesion. Dejerine has reported two cases of complete aphemia (mutism), in both of which lesions were found in the centrum semiovale, beneath the third left frontal convolution, but involving the white matter of the inferior part of the central gyri.

LESIONS OF THE CENTRUM SEMIOVALE BENEATH THE MOTOR AREA.

In the motor area a lesion, either cortical or subcortical, may be followed by paresis or paralysis of an arm, a leg, or the face, on the side opposite to the lesion. In the great majority of the

recorded cases of cortical lesions convulsions of a Jacksonian type have preceded the weakness or paralysis, while in most subcortical lesions the paralysis has been very gradual in its onset, and the unilateral convulsions (Jacksonian) have appeared after the paralysis, coming on late or perhaps not at all.

If with this gradual mode of onset, together with the late appearance of partial or complete unilateral convulsions, there is added paresthesia, followed by a gradually increasing anesthesia of a limb, one may be almost positive in diagnosing a centrum semiovale lesion beneath the sensorimotor area.

Wernicke has proved, by the records of several cases, that if a lesion is located in the white matter (centrum semiovale) beneath the island of Reil, and destroys the association bundles of fibers (fasciculus uncinatus and cingulum) connecting the sensory receptive center in the left temporal lobe with the motor or emissive speech-center in the posterior part of the third left frontal convolution, there will occur a form of speech-defect called *paraphasia*, or the *aphasia of conduction*. Such patients understand perfectly what is said to them and can articulate perfectly, but they fail to connect their ideas with the proper words, and hence are constantly using wrong words.

CENTRUM SEMIOVALE OF THE TEMPORAL LOBE.

There are no symptoms whereby a lesion located in the centrum semiovale of the right temporal lobe (in the right-handed) can be diagnosticated. If, however, the lesion be located in the white matter of the left upper and middle temporal gyri, incomplete sensory aphasia will occur. Wernicke has shown that total deafness central in origin is due to a lesion in the centrum semiovale of each temporal lobe destroying the auditory tract.

LOCALIZATION OF LESIONS IN CENTRUM OVALE OF THE PARIETAL LOBE.

M. Allen Starr has proven, by the record of four cases, that a lesion in the centrum semiovale beneath the left angular gyrus may destroy the fibers which conduct sensory visual impressions

from the common sight-center to that gyrus and thus cause incomplete word-blindness (subcortical alexia). The patient being unable to read, if his hand be made to trace the letters by the hand of another person, or raised type be used, can recognize the letters, he having energized the visual perceptive center (angular gyrus) through his muscle and tactile sense perceptions.

A lesion beneath the parietal lobe will produce, the nearer the lesion is located to the cortex, partial or complete anesthesia of a limb; the nearer the lesion is to the internal capsule, the more general and complete the anesthesia will be. Von Monakow has reported a case where a lesion located in the white matter of the supramarginal and angular gyri produced a marked disturbance of muscular sense without the slightest paralysis.

CENTRUM SEMIOVALE OF THE OCCIPITAL LOBE.

Freund has shown, by a critical résumé of eight cases, that sensory optic aphasia (the inability to name objects although the objects are seen and recognized) with hemianopsia are the only symptoms which would enable one to locate a lesion in the centrum semiovale of the left occipital lobe.

LESIONS OF THE CORPUS CALLOSUM.

No symptoms are at present known by means of which lesions in the centrum semiovale affecting the callosal fibers can be diagnosed. Theoretically, as suggested by M. Allen Starr, one would expect, if these commissural fibers were destroyed, an inability to perform corresponding bilateral movements, which would occur only after involvement of the fibers beneath the motor areas. This symptom has been entirely overlooked by most observers that have reported cases of lesions of the corpus callosum.

LOCALIZATION OF LESIONS OF THE INTERNAL CAPSULE.

No symptoms exist by means of which one can locate a lesion in the anterior division of the internal capsule ventral to its knee. Owing to destruction of the frontocerebellar tract, which would occur with such a lesion, one would expect symptoms referable to the frontal lobe and cerebellum.

A lesion involving the anterior two-thirds of the posterior limb would destroy the motor tract and cause a complete hemiplegia of the opposite side of the body. In those cases of hemiplegia where the leg is most involved anesthesia occurs more commonly, owing to the proximity of its fibers to the sensory tract. A lesion involving the posterior third of the internal capsule would destroy the fibers of the sensory tract and produce a complete hemianesthesia of the opposite side. This may or may not involve the loss of the special senses on the side of the anesthesia.

BASAL GANGLIA.

Lesions which have been found involving the corpus striatum or optic thalamus have induced no symptoms that could not be explained by encroachment upon the internal capsule. In several reported cases of so-called pseudobulbar paralysis lesions have been found in the lenticular nuclei. In a few cases of athetosis, unaccompanied by hemiplegia, lesions were found in both optic thalami.

LOCALIZATIONS OF LESIONS OF THE CORPORA QUADRIGEMINA.

The important connection of the quadrigeminal bodies with the visual and auditory paths, with the superior cerebellar peduncles, and with the nuclei of the ocular nerves is sufficient to indicate what a variety of symptoms one would expect to find should these bodies become diseased. Nothnagel long ago pointed out that only two focal symptoms occurred, the result

of such diseases, which were absolutely diagnostic. These symptoms are, at first, a slowly increasing cerebellar ataxia, identical with that occasioned by disease of the middle lobe (vermis) of the cerebellum, and a gradually increasing but not entirely symmetric ophthalmoplegia. The ocular muscles most often affected are the superior and inferior recti, but all of them may, in turn, become involved. According to Bruns, in lesions of the corpora quadrigemina, the ophthalmoplegia most often precedes the ataxia; this fact is very valuable in differentiating lesions of these bodies from a cerebellar lesion, in which the ataxia is always the first event and the ophthalmoplegia, the result of the extension of the disease, is secondary. Neurologists are quite generally agreed that when the lesion involves the anterior corpora quadrigemina, we have, in addition to the ophthalmoplegia, at first a contraction of the pupils (irritation miosis), and, later, dilatation of the pupils, with a loss of the light reflex. If the posterior bodies are also involved, deafness will occur; this latter symptom is due to the implication of the lateral fillet, which is the central auditory path, and is connected chiefly with the opposite auditory nuclei.

LOCALIZATION OF LESION IN THE CRURA CEREBRI.

Within each cerebral peduncle are compressed a number of tracts, the two most important of which are the motor and sensory. Coming out of the interpeduncular space are the third pair of cranial nerves,—the motor oculi,—each one of which courses around the peduncle, reaching its ventral portion. Hence a circumscribed lesion located in the ventral part of the crus cerebri will produce, owing to the destruction of the motor tract and third nerve, a paralysis of the muscles of the opposite arm, leg, and lower part of the face, a typical cerebral hemiplegia, and a paralysis of all the muscles of the eyeball of the side of the lesion, with the exception of the superior oblique and external rectus, producing external strabismus, ptosis, and dilatation of the pupil. If the lesion is sufficiently deep to implicate the sensory tract (fillet) of the tegmentum, hemianesthesia on the side opposite to the lesion will also occur. This symptom,

coupled with hemiplegia on the same side and third nerve paralysis on the side opposite to the hemiplegia, is pathognomonic of a peduncular lesion.

LOCALIZATION OF LESIONS IN THE PONS VAROLII.

Small unilateral lesions in the upper part of the pons may be so placed that only a hemiplegia of the ordinary type will occur, which can not be distinguished from that produced by a lesion within the internal capsule. If, however, the lesion is located in the lower half of the pons, a few characteristic symptoms will be found, the more typical of which is an alternate hemiplegia, or hemianesthesia, "so-called crossed paralysis,"—that is, a paralysis of motion or sensation involving the leg and arm on the side opposite to the lesion, with a complete facial paralysis, peripheral in type, on the side of the lesion. This type of paralysis is due to pressure or destruction of the motor or sensory tract on the side of the lesion, both of which cross in the medulla and supply the opposite side of the body with motion or sensation, together with destruction of the facial nucleus, or nerve, which supplies the facial muscles on the same side as the lesion and opposite to the paralyzed limbs. If the lesion involves the sensory nucleus or nerve-roots of the trigeminal, there is at first a numbness, followed by anesthesia of the face on the side corresponding to the lesion, with anesthesia or motor paralysis on the side opposite to the facial anesthesia. Owing to implication of the middle cerebellar peduncle, staggering, or a tendency to fall, may occur toward the side of the lesion. Equally characteristic of a pons lesion is a paralysis of the abducens nerve, producing double vision and internal strabismus on the side of the lesion, with a hemiplegia on the opposite side.

In acute destructive lesions of the pons above the nucleus of origin of the abducens or sixth nerve, such as hemorrhage or thrombosis, conjugate deviation of the head and eyes often occur, both usually turning toward the paralyzed side and away from the side of the lesion. Irritative lesions of the pons, such as tumors, cause conjugate deviation of head and eyes toward the side of lesion. Bilateral lesions of the pons are not very rare ;

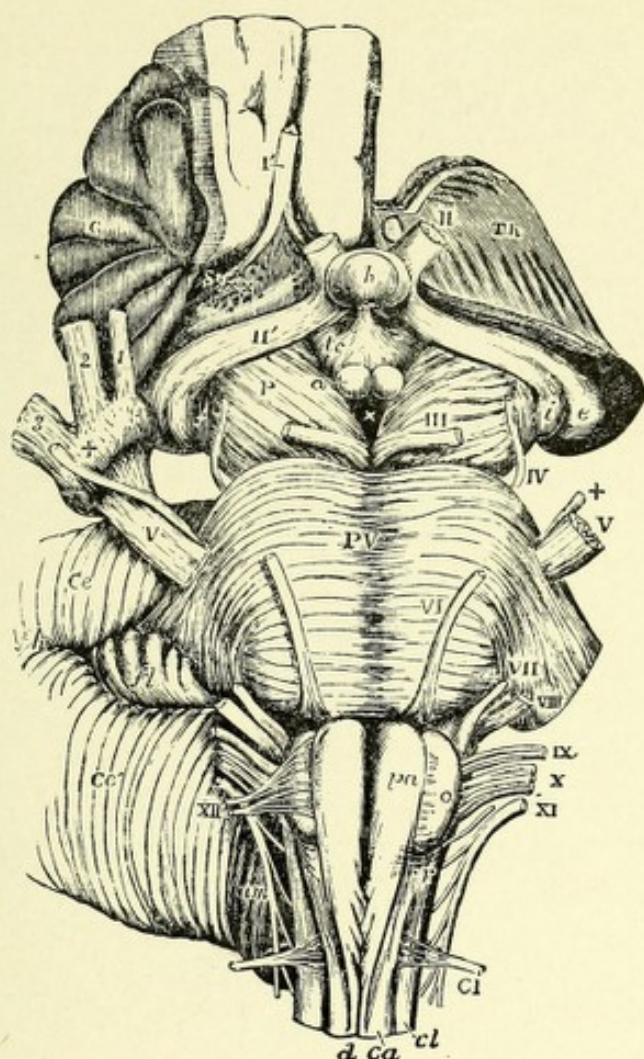



FIG. 233.—VIEW FROM BEFORE OF THE MEDULLA OBLONGATA, PONS VAROLII, CRURA CEREBRI, AND OTHER CENTRAL PORTIONS OF THE ENCEPHALON (Natural size).—(Allen Thomson.)—(From Quain's "Anatomy.")

On the right side the convolutions of the central lobe, or island of Reil, have been left, together with a small part of the anterior cerebral convolutions; on the left side these have been removed by an incision carried between the thalamus opticus and the cerebral hemisphere.

I'. The olfactory tract cut short and lying in its groove. II. The left optic nerve in front of the commissure. II'. The right optic tract. Th. The cut surface of the left thalamus opticus. C. The central lobe or island of Reil. Sy. Fissure of Sylvius. X X. Anterior perforated space. e. The external corpus geniculatum. i. The internal corpus geniculatum. h. The hypophysis cerebri or pituitary body. tc. Tuber cinereum with the infundibulum. a. One of the corpora albicantia. P. The cerebral peduncle or crus. III. Close to the left oculomotor nerve. X. The posterior perforated space.

The following letters and numbers refer to parts in connection with the medulla oblongata and pons. PV. Pons Varolii. V. The greater root of the fifth nerve. +. The lesser or motor root. VI. The sixth nerve. VII. The facial. VIII. The auditory nerve. IX. The glossopharyngeal. X. The pneumogastric nerve. XI. The spinal accessory nerve. XII. The hypoglossal nerve. CI. The suboccipital or first cervical nerve. pa. Pyramid. o. Olive. d. Anterior median fissure of the spinal cord, above which the decussation of the pyramids is represented. ca. Anterior column of cord. r. Lateral tract of bulb continuous with cl, the lateral column of the spinal cord.



they occasion bilateral motor or sensory paralysis, more or less complete, usually accompanied with difficult deglutition and articulation.

LOCALIZATION OF CEREBELLAR LESIONS.

Despite the numerous and important anatomic connections of the cerebellum with the rest of the cerebrospinal axis, only two focal diagnostic symptoms exist by means of which a cerebellar lesion may be localized. These are, in the order of their importance, cerebellar ataxia, or staggering, and vertigo. Cerebellar ataxia, which is a disturbance of equilibrium in standing or walking, occurs in two forms. In the first, or common form, most frequently observed in lesions of the middle lobe, or worm, the gait is staggering; the patient walks with his feet wide apart and sways from side to side very like a drunken man; he may walk in a zigzag manner or have a tendency to fall forward, backward, or to one or the other side. In this form there is no loss of muscular sense, and Romberg's symptom is usually absent. In the second form, which is very rare, the patient's gait resembles that of locomotor ataxia. Closure of the eyes increases the ataxia, and Romberg's symptom is nearly always present.

Vertigo, although a common general symptom of cerebral disease, exists in no other affection so early, or is so constant and intense as in cerebellar disease. The patient either feels as if all objects were turning around him or as if he were turning around in space. While cerebellar ataxia and vertigo, coupled with nystagmus and other general symptoms referable to brain diseases—headache, vomiting, optic neuritis—are almost pathognomonic of a cerebellar lesion, they do not indicate the exact situation in the cerebellum of the lesion.

LESIONS OF THE MIDDLE LOBE, OR WORM.

Lesions of this lobe are nearly always accompanied by the most exquisite cerebellar ataxia combined with severe vertigo. Nothnagel long ago pointed out that cerebellar ataxia is always



due to a lesion of the middle lobe or is the result of the secondary involvement of that lobe by the encroachment upon it of a lesion which has had its origin in a cerebellar hemisphere. The above statement of Nothnagel is supported both by Gowers and by M. Allen Starr ; the latter observer states that the occurrence of staggering indicates that the middle lobe is either the seat of the tumor or is encroached upon by a tumor in the hemisphere. If the ataxia occurs early in relation to the general symptoms, it is the middle lobe in which the tumor began. If it occurs late, after months of suffering, the tumor has started in a cerebellar hemisphere, giving rise to general symptoms, and has at last reached the middle lobe, producing the local symptoms.

According to Flourens and Renzi, experimental destruction of the anterior part of the worm, or middle lobe, causes an inclination to fall forward ; while a lesion of the central and posterior parts causes the head to be pulled backward, with a tendency to fall in the same direction. Bastian believes that a tendency to fall forward exists when the lesion involves the inferior worm ; but when the lesion involves the superior worm, a tendency to fall backward occurs.

Several cases have been recorded to support the following statement of Wetzel and Bohm—namely, that cerebellar incoordination, or ataxia, only occurs in disease of the posterior part of the middle lobe ; when the lesion exists in the anterior part, no incoordination occurs.

LESIONS OF THE CEREBELLAR HEMISPHERES.

Lesions in either hemisphere of the cerebellum only become localizable when the lesion encroaches upon the middle lobe or adjacent parts—crus, pons, or medulla. The recent experiments of Luciani and Turner seem to prove that when a lesion is located in a cerebellar hemisphere, paresis occurs in the extremities corresponding to the side of the lesion. Ferrier, on the contrary, states that lesions of the cerebellum, while interfering with the mechanical adjustments against bodily equilibrium, do

not cause paralysis of voluntary motion. The above statement of Luciani and Turner does not seem to be supported by clinical evidence. In most cases of cerebellar disease accompanied by motor weakness or paralysis, this has occurred on the side opposite to the lesion, the result of pressure on the pyramidal tract above the motor cross-way, either in the crus, pons, or medulla; with this paresis or paralysis there is often an exaggeration of the patella tendon reflex, together with ankle-clonus. The only case in man with which I am acquainted, where paresis occurred on the same side as the lesion, was one of an abscess of a cerebellar hemisphere reported by Turner. The fact that the patient always staggers toward the same side is of no great clinical value in locating the hemisphere affected, as it is impossible to know whether the lesion be irritative or destructive in character. Beevor has had two cases, in both of which staggering occurred on the side opposite to the lesion, in one of which a growth was successfully diagnosed and removed.

Cranial-nerve symptoms usually occur at first on the side of the lesion; hence internal strabismus, facial paralysis,—either sensory or motor,—deafness, or retraction of the head point toward an involvement of the cerebellar hemisphere on that side. If, with the late appearance of ataxia, there occurs unilateral cranial nerve involvement, together with hemiplegia of the opposite side, one may be positive in locating the lesion in the cerebellar hemisphere corresponding to the side of the cranial nerve involvement and opposite to the paralyzed side.

LESIONS OF THE MIDDLE CEREBELLAR PEDUNCLE.

Experimental division in animals of the middle cerebellar peduncle results in a rapid rotation of the animal around its longitudinal axis, and, according to Magendie, Renzi, and Schiff, toward the side of the section; but, according to Luciani, away from the side of the section. Lesions in the middle peduncle cause in man a similar tendency to rotation around the long axis of the body and toward the side of the lesion, together with, as was pointed out by Nonat, a divergence of the eyes,

the eye on the side of the injury being directed downward and inward, while the eye of the sound side is turned upward and outward.

LOCALIZATION OF LESIONS IN THE MEDULLA OBLONGATA.

Owing to the proximity, in the ventral part of the medulla of the motor and sensory tracts, and, in the dorsal part, of the nuclei of the bulbar nerves, small lesions usually cause bilateral symptoms. In case of a lesion in the ventral part of the medulla, bilateral motor and sensory paralysis may occur. This may or may not be associated with symptoms referable to the involvement of the various bulbar nerve-nuclei in the dorsal part of the medulla. A unilateral lesion involving the most ventral part of the medulla, implicating the hypoglossal nerve, will cause paralysis of the leg and arm on the side opposite to the lesion, with a unilateral paralysis of the tongue on the same side. In case of lesions of the dorsal part we get primarily symptoms referable to implication of the bulbar nerve nuclei. In lesions of sudden onset, such as hemorrhage or vascular occlusion, instantaneous death is likely to ensue, owing to the obliteration of function of the respiratory and cardiac centers.

The characteristic combination of symptoms diagnostic of lesions of the medulla are those known under the name of labioglossolaryngeal paralysis. This characteristic form of paralysis is due to a very slowly progressing bilateral degeneration of the nerve-cells of the motor bulbar nuclei. This degeneration usually starts in the nuclei of the hypoglossal nerves, and in turn affects the nuclei of the spinal accessory, glossopharyngeal, pneumogastric, and, occasionally, the facial. As a result of this degeneration the following symptoms occur:

At first, paresis, followed by wasting and paralysis of the muscles of the tongue, with difficulty in articulation; this is soon followed by weakness and wasting of the orbicularis oris, and usually of some of the other muscles of expression, owing to paralysis of the tongue, soft palate, and muscles of deglutition; mastication and deglutition become very difficult, liquids being

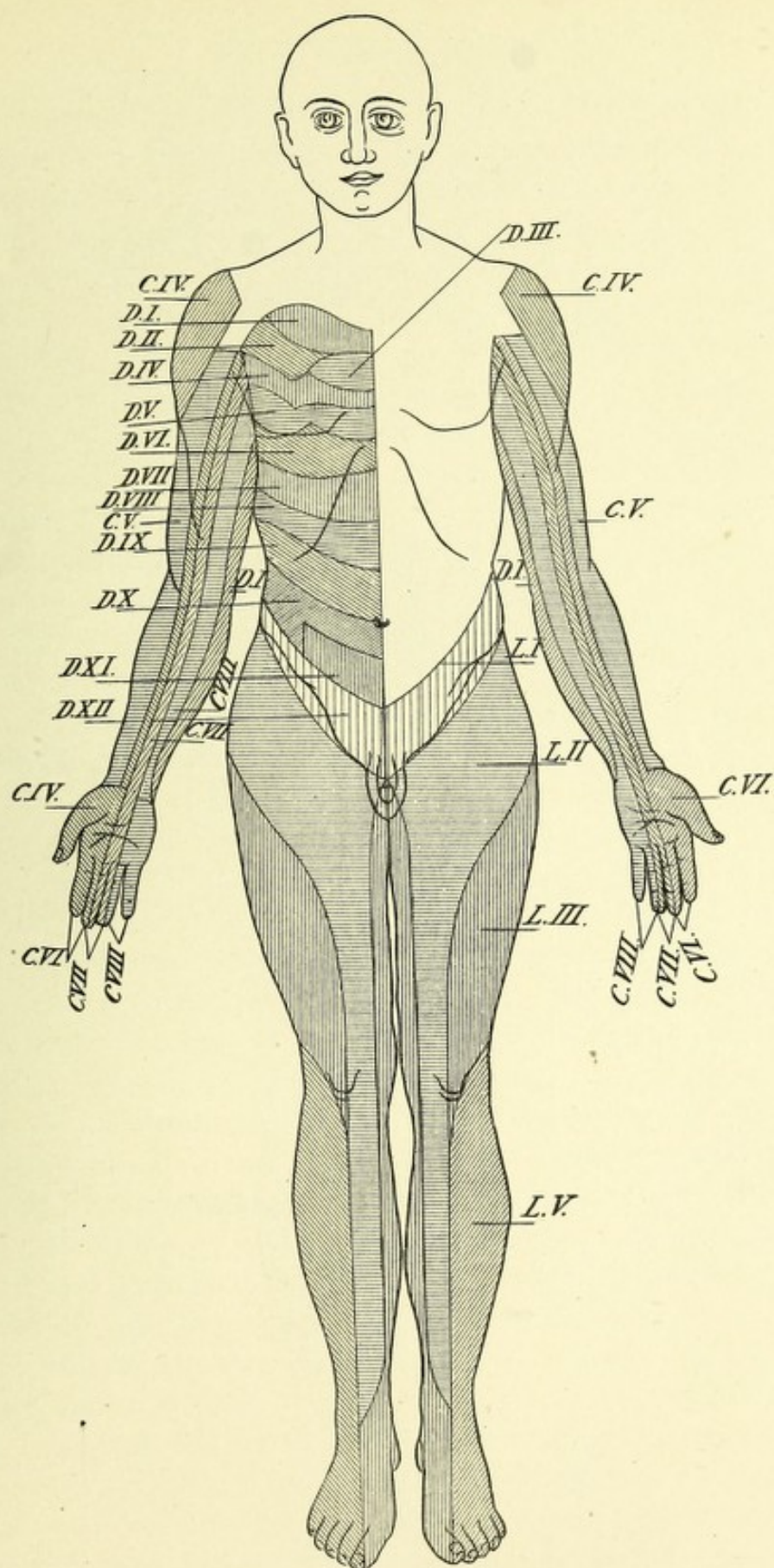


FIG. 234 A.—DIAGRAM OF SKIN AREAS CORRESPONDING TO DIFFERENT SPINAL SEGMENTS.—(From Tyson, after Starr.)

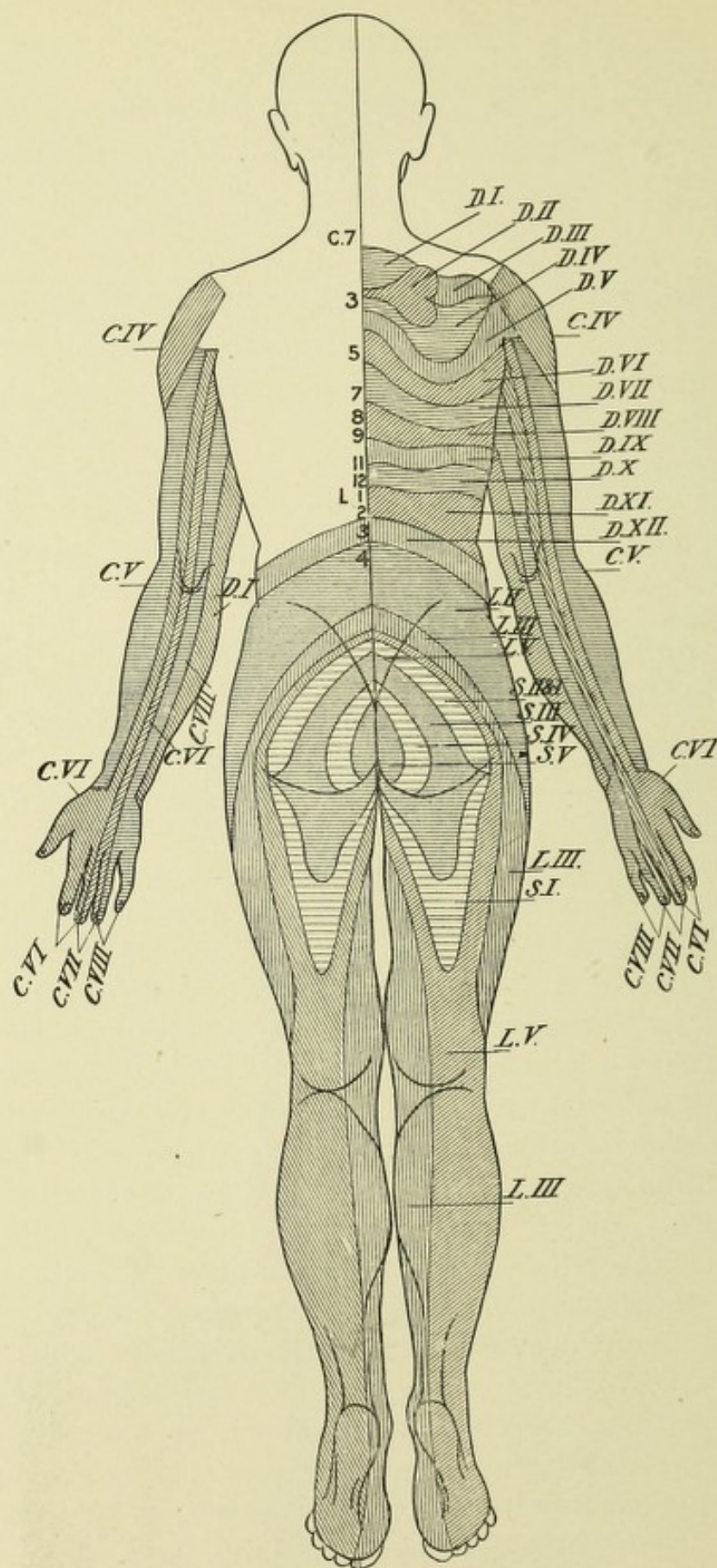


FIG. 234 B.—DIAGRAM OF SKIN AREAS CORRESPONDING TO DIFFERENT SPINAL SEGMENTS.—(From Tyson, after Starr.)

frequently regurgitated through the nose. As a result of the involvement of the nuclei of the spinal accessory nerves, laryngeal symptoms supervene, such as weakness of the voice, difficulty in coughing, and marked difficulty in phonation. Because of the paralysis of the epiglottis, particles of food frequently lodge in the larynx or bronchi, often giving rise to insufflation pneumonia.

There is a rare form of *bulbar paralysis* acute in onset, probably of an infectious nature, accompanied by the same symptoms as previously described, only being much more rapid in their development, death usually resulting within a few weeks. This affection resembles acute poliomyelitis of children, but the prognosis is much more grave.

In many cases of tumor involving the medulla oblongata diabetes mellitus, polyuria, bradycardia, tachycardia, and Cheyne-Stokes respiration have been observed, in addition to the before-mentioned symptoms.

LOCALIZATION OF SPINAL-CORD LESIONS.

The symptoms available for diagnosis and localization of spinal-cord diseases may be divided into two great groups,—motor and sensory,—corresponding in a general way to the ventral and dorsal parts of the cord.

The motor symptoms may be due to affections of the upper (corticospinal) or lower (spinomuscular) motor neurones, each of which produces a perfectly distinct and classic type of paralysis. If the upper motor neurones are separated at any part of their course from their trophic cells in the motor area of the cerebral cortex, there results a secondary degeneration downward, involving the direct and crossed pyramidal or motor tracts, which gives rise to a type of paralysis having the following characters: All the muscles are equally involved, though the limbs are incompletely paralyzed. The muscles are usually not wasted, save from disuse, and they are continually in a state of partial or complete tonic contraction, giving rise to stiffness and rigidity. The electric reactions are normal; muscular irritability

is greatly increased, the slightest tap producing prompt muscular contraction; the reflexes, both superficial and deep, are greatly

exaggerated, ankle- and knee-clonus being usually present. As a result of this form of paralysis, locomotion is much interfered with and a characteristic spastic gait is developed. The patient assists himself with two canes; his chest is bent forward; the legs move forward very stiffly by the aid of the trunk-muscles, the toes scraping the ground, and the knees frequently interlocking—cross-legged progression.

Very rarely cases occur in which a primary degeneration of the motor tracts in the cord (spinal part of the corticospinal tracts) has been found with symptoms identical in character with those previously described. This very chronic disease was first described by Erb in 1875, and is generally known as *Erb's palsy*, *primary lateral sclerosis*, or *spasmodic paralysis*.

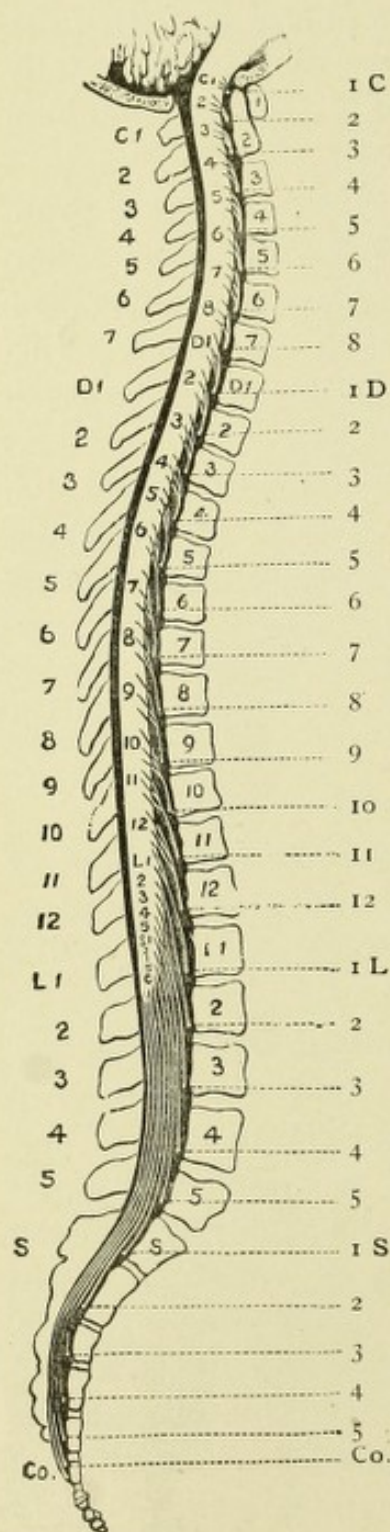


FIG. 235.

FIG. 235.—DIAGRAM (FRAMED FROM AN ORIGINAL INVESTIGATION) SHOWING THE RELATION OF THE VERTEBRAL SPINES TO THEIR BODIES AND TO THE ORIGIN OF THE SEVERAL NERVE-ROOTS.—(After Gowers.)

It will be seen that the ends of the vertebral spines are opposite the middle of their own bodies only in the lumbar region; they correspond to the lower edge of their own bodies in the cervical and the last two dorsal vertebrae, and to the upper part of the body below in the rest of the dorsal region. Each cervical spine is nearly opposite the lower roots of the nerve below. The vertebra prominens is opposite the first dorsal roots, and from the third to the tenth dorsal the spines correspond to the second root below; the eleventh spine corresponds to the first and second lumbar nerves, the twelfth to the third, fourth, and fifth; the first lumbar to the first, second, and third sacral nerves, while the top of the cord is opposite the upper part of the second lumbar.

When the lower or spinomuscular neurones are affected, there results a paralysis of another type, equally characteristic, and easily recognized. In this form all the muscles of a limb or limbs, or, what is more common, only certain groups of muscles, are involved. The muscles are completely paralyzed, are very flabby, become atrophied, and present the reaction of degeneration, with usually a loss of the deep reflexes. The limbs never become stiff; contractures, however, are frequent. This form of paralysis is always due to disease of the cells of the peripheral motor neurones in the anterior horns of the spinal cord. The most common type of this disease is *infantile spinal paralysis* or *poliomyelitis anterior acuta*. When these motor cells become slowly degenerated, there occurs a typical form of spinal-cord disease known as *progressive muscular atrophy*; in this disease there occurs a very gradual wasting of the muscles in an orderly manner, beginning usually in the muscles of the ball of the thumb and interossei, or about the shoulder, and gradually involving the muscles throughout the body. In *amyotrophic lateral sclerosis* there is a combination of muscular wasting and spasmodic rigidity, very gradual in its progress, the wasting usually involving the muscles of the upper extremities, and the weakness and rigidity the lower. This disease indicates symmetric bilateral lesions of both the central and peripheral motor neurones. It is really a combination of the symptoms of progressive muscular atrophy in addition to those of spinal spastic paralysis, or lateral sclerosis.

The sensory symptoms due to lesions of the spinal cord are disturbances of pain, tactile, temperature, and muscular senses. These various forms of sensory impressions are conveyed brainward by the sensory tracts of the cord. While much doubt exists as to the exact paths for their conduction, it is highly probable that pain and temperature sense impressions are conducted by Gowers' anterolateral ascending tract on the side opposite to their point of entrance, the sensations being carried by collaterals from axones of the cells of the posterior spinal ganglia (posterior nerve-roots) to cells existing in the central gray matter of the same side, the impulses being further conveyed by the axones of these latter cells through the anterior

commissure to Gowers' tract of the opposite side. A lesion, then, of the central gray matter usually causes a loss of both of these senses, producing analgesia and thermo-anesthesia on one or both sides. Tactile and muscular sense impressions are conveyed *via* the posterior nerve-roots into the posterior columns; the muscular sense impressions pass upward on the same side, while the tactile pass across and upward on the opposite side; hence a lesion of the posterior columns will produce anesthesia and ataxia of one or both sides. The function of the direct cerebellar tract is not known, although most observers agree with Flechsig—that it also conducts muscular sense impressions. Owing to the fact that all forms of sensation are conveyed to the cord by means of the posterior nerve-roots, a lesion of these roots at their junction with the cord, or in the columns of Burdach, will occasion at first irritative symptoms, paresthesia, neuralgic pains, ataxia, and, later, anesthesia, analgesia, and thermo-anesthesia. These symptoms may come on rapidly, the result of pressure from a new growth, when they are at first unilateral, or they may appear very gradually from a slowly progressing degeneration, as in locomotor ataxia, when they are bilateral.

The symptoms of this latter affection are so characteristic of degeneration of the posterior nerve-roots and columns that they will be enumerated here. In the early stage very severe pains occur, stabbing or neuralgic in character; also various forms of sensory disturbances included under the head of paresthesia. Loss of patella tendon reflexes and of the reflex contraction of the pupils to light are among the earliest symptoms. In the second stage all of these symptoms are continued and exaggerated, and there is added marked incoordination or ataxia, with local areas of anesthesia and analgesia, retardation to the conduction of painful impressions, and a gait more or less characteristic,—the patient usually walks with the aid of canes, his eyes being fixed on his feet in order to guide their movements, which are irregular and jerky, the feet flying outward and the heels coming down to the ground with a stamp. In the third stage the lesion involves the anterior horns, and there is added muscular atrophy with paralysis of the extremities.

Syringomyelia, which is a disease resulting in cavity formation in the central gray matter of the cord, is characterized by the symptoms of progressive muscular atrophy, spinal in type, with sensory and vasomotor disturbances,—chiefly analgesia and thermo-anesthesia,—the first being due to a destruction of the

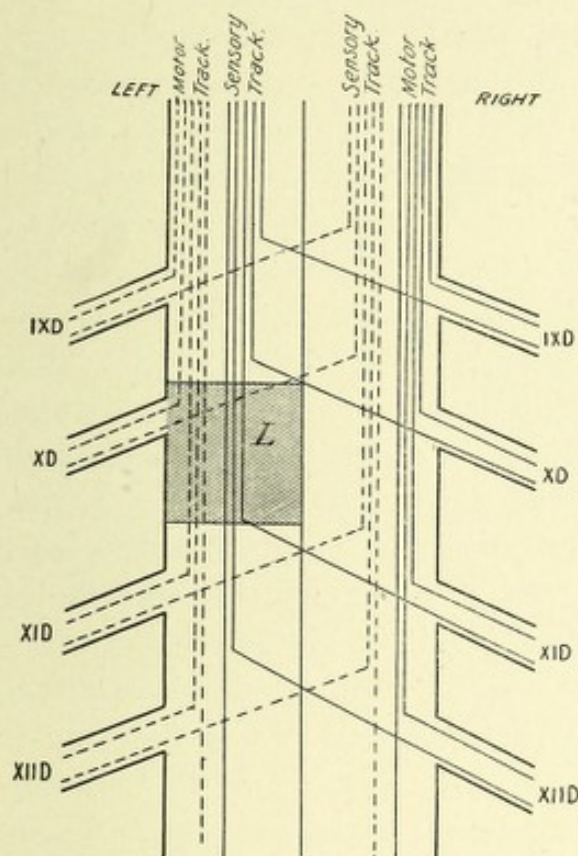


FIG. 236.—DIAGRAM OF LESION SHOWING BROWN-SÉQUARD'S PARALYSIS.—(After Starr, from Tyson.)

L. Lesion in left half of cord cuts off motor impulses to left leg, sensory impulses from right leg, and sensory impulses from eleventh dorsal nerve.

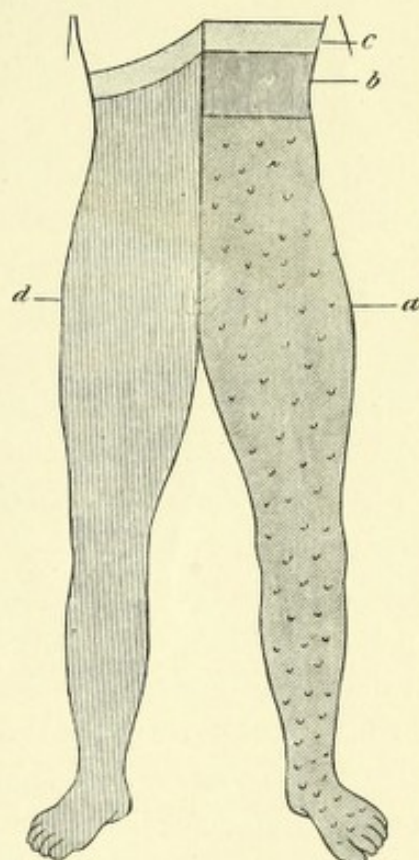


FIG. 237.—SCHEMA SHOWING CHIEF SYMPTOMS IN LEFT UNILATERAL LESION OF THE DORSAL CORD.—(After Erb, from Tyson.)

Oblique shading signifies motor and vasomotor paralysis; vertical, cutaneous anesthesia; dots, cutaneous hyperesthesia. *b.* Small anesthetic zone. *c.* Small hyperesthetic zone.

motor cells of the anterior horns, and the latter being due to the destruction of the cells of origin or fibers of Gowers' tract.

There is an affection of the cord known as ataxic paraplegia, characterized clinically by weakness, ataxia, and an increase of the reflexes, and pathologically by a slow-going degeneration or sclerosis of the lateral and posterior columns.

The symptoms due to a unilateral lesion of the cord are hyperesthesia, motor paralysis, and incoordination on the side of the lesion, with a loss of tactile, painful, and temperature senses on the side opposite to the lesion. This combination of symptoms is called *Brown-Séquard's paralysis* (Figs. 236 and 237).

In complete transverse lesions of the cord (myelitis, hemorrhage, traumatism) in the *cervical region* there will occur at first a total paralysis of motion, and usually of sensation in the arms and legs and the trunk, with a subsequent atrophy of the muscles innervated by the cells of the anterior horns destroyed by the lesion, the anesthesia existing as high as the level of the lesion. The reflexes of the upper extremities will probably be lost, whereas those of the lower extremities will be exaggerated, ankle- and knee-clonus present; the bladder and rectum are paralyzed. In the *dorsal region* the upper extremities escape, but paralysis of motion and sensation exists below the level of the lesion—the reflexes are exaggerated. In the *lumbar region* paralysis of motion and loss of sensation occurs below the level of the lesion; if in the upper part the patella tendon reflexes are lost, ankle-clonus may be present; here, also, as in the cervical regions, the muscles become wasted, owing to the destruction of the cells of the anterior horns (peripheral motor neurones).

In the *sacral region* incomplete paraplegia, incomplete sensory paralysis, anesthesia of the outer parts of each lower extremity, as well as the perineum and scrotum, occur, together with paralysis and anesthesia of the bladder and rectum. No ankle-clonus is present. Patella reflexes may be present.

In regard to the diagnosis of the exact location and extent of any spinal-cord lesion, recourse may be had to the excellent table prepared by Starr, which is appended to the text. These are the result of the study of a large number of spinal-cord lesions with autopsies, in which the same location of the lesion produced the same symptoms. It must be remembered that the peripheral sensory nerves anastomose so freely that to get a total anesthesia of any part of the skin, the sensory fibers from two adjacent segments of the cord must be destroyed.

LOCALIZATION OF THE FUNCTIONS OF THE SEGMENTS OF THE
SPINAL CORD.—(After M. Allen Starr.)

SEGMENT.	MUSCLES.	REFLEX.	SENSATION.
II. and III. C.	Sternomastoid. Trapezius. Scaleni and neck. Diaphragm.	Hypochondrium (?). Sudden inspiration produced by sudden pressure beneath the lower border of ribs.	Back of head to vertex. Neck.
IV. C.	Diaphragm. Deltoid. Biceps. Coracobrachialis. Supinator longus. Rhomboid. Supra- and infraspinatus.	Pupil, fourth to seventh cervical. Dilatation of the pupil produced by irritation of neck.	Neck. Upper shoulder. Outer arm.
V. C.	Deltoid. Biceps. Coracobrachialis. Brachialis anticus. Supinator longus. Supinator brevis. Rhomboid. Teres minor. Pectoralis (clavicular part). Serratus magnus.	Scapular. Fifth cervical to first dorsal. Irritation of skin over the scapula produces contraction of the scapular muscles. Supinator longus. Tapping its tendon in wrist produces flexion of forearm.	Back of shoulder and arm. Outer side of arm and forearm, front and back.
VI. C.	Biceps. Brachialis anticus. Pectoralis (clavicular part). Serratus magnus. Triceps. Extensors of wrist and fingers. Pronators.	Triceps. Fifth to sixth cervical. Tapping elbow tendon produces extension of forearm. Posterior wrist. Sixth to eighth cervical. Tapping tendons causes extension of hand.	Outer side of forearm, front and back. Outer half of hand.
VII. C.	Triceps (long head). Extensors of wrist and fingers. Pronators of wrist. Flexors of wrist. Subscapular. Pectoralis (costal part). Latissimus dorsi. Teres major.	Anterior wrist. Seventh to eighth cervical. Tapping anterior tendons causes flexion of wrist. Palmar. Seventh cervical to first dorsal. Stroking palm causing closure of fingers.	Inner side and back of arm and forearm. Radial half of the hand.
VIII. C.	Flexors of wrist and fingers. Intrinsic muscles of hand.		Forearm and hand, inner half.
I. D.	Extensors of thumb. Intrinsic hand muscles. Thenar and hypothenar eminences.		Forearm, inner half. Ulnar distribution to hand.
II. to XII. D.	Muscles of back and abdomen. Erectores spinæ.	Epigastric. Fourth to seventh dorsal. Tickling mammary region causes retraction of the epigastrium. Abdominal. Seventh to eleventh dorsal. Stroking side of abdomen causes retraction of belly.	Skin of chest and abdomen, in bands running around and downward corresponding to spinal nerves. Upper gluteal region.

LOCALIZATION OF THE FUNCTIONS OF THE SEGMENTS OF THE SPINAL CORD.—(*Continued.*)

SEGMENT.	MUSCLES.	REFLEX.	SENSATION.
I. L.	Iliopsoas. Sartorius. Muscles of abdomen.	Cremasteric. First to third lumbar. Stroking inner thigh causes retraction of scrotum.	Skin over groin and front of scrotum.
II. L.	Iliopsoas. Sartorius. Flexors of knee (Remak). Quadriceps femoris.	Patella tendon. Striking tendon causes extension of leg.	Outer side of thigh.
III. L.	Quadriceps femoris. Inner rotators of thigh. Abductors of thigh.		Front and inner side of thigh.
IV. L.	Abductors of thigh. Adductors of thigh. Flexors of knee (Ferrier). Tibialis anticus.	Gluteal. Fourth to fifth lumbar. Stroking buttock causes dimpling in fold of buttock.	Inner side of thigh and leg to ankle. Inner side of foot.
V. L.	Outward rotators of thigh. Flexors of knee (Ferrier). Flexors of ankle. Extensors of toes.		Back of thigh, back of leg, and outer part of foot.
I. to II. S.	Flexors of ankle. Long flexor of toes. Peronei. Intrinsic muscles of foot.	Plantar. Tickling sole of foot causes flexion of toes and retraction of leg.	Back of thigh. Leg and foot, outer side.
III. to V. S.	Perineal muscles.	Foot reflex. Achilles tendon. Overextension of foot causes rapid flexion; ankle-clonus. Bladder and rectal centers.	Skin over sacrum. Anus. Perineum. Genitals.

The Divisions of the Cerebral Cortex According to Flechsig.—Flechsig has shown from the investigation of the embryonic cerebrum that the fibers of the sensory paths are the first to receive their myelin, the fibers of each path developing one after the other, beginning with the fibers conducting olfactory sensations and ending with those carrying auditory impressions. By this study Flechsig has shown that these developing paths terminate in four distinct cortical areas or spheres, which have received from him the name of projection or sensory spheres; these areas occupy about one-third of the whole cortex, the remaining two-thirds being devoid of fibers of projection, but contain fibers of association, which develop or ripen (become medullated) after birth, and serve to connect the projection or sensory spheres with the centers of association. Flechsig has,

therefore, divided the human cerebral cortex into two great divisions—the projection or sensory spheres and the centers of association.

The projection or sensory spheres include, first, the tactile sphere, or somesthetic area, which occupies the entire region between the fossa Sylvii up to the corpus callosum, and includes the central convolutions, the paracentral lobule, and the dorsal parts of the three frontal gyri and the middle third of the gyrus fornicatus. In this area the fibers of the median fillet or lemniscus terminate, conducting all sensations which inform us of the condition of the body. This area also includes the great motor region, from which arise all voluntary motor impulses.

The olfactory sphere includes the trigonum olfactorium, the anterior perforated space, and the uncinate gyrus, which is in contact with the island of Reil, and the adjacent hippocampal gyrus.

The visual sphere includes that part of the median surface of the brain bordering on the calcarine fissure and about which terminates the optic tract.

The auditory sphere includes the transverse temporal gyri, about which terminates (lateral fillet) the auditory tract.

The zones or centers of association consist of three distinct areas: First, the posterior association center, composed of the lingual, the fusiform, the parietal, and the inferior temporal convolutions, together with anterior part of the outer surface of the occipital lobe; second, the median association center, consisting of the island of Reil; third, the anterior association center, which consists essentially of the prefrontal lobes. Flechsig believes that these centers of association are the areas of the cerebral cortex which are concerned in the higher intellectual faculties—memory, judgment, and reason.

CHAPTER XIII.

THE EMBRYOLOGY OF THE CENTRAL NERVOUS SYSTEM.

Very early in embryonic life—about the age of twenty-four hours in the chicken—there occurs in the epiblast a central axial portion, the so-called medullary plate, which soon becomes much thickened along its sides, forming longitudinal ridges,—the medullary ridges or folds. The trough-like space between the ridges is called the medullary groove. The medullary folds continue to grow dorsally, and, arching over the medullary groove, fuse with each other at the mid-dorsal line, thus converting the groove into a canal called the neural tube or canal. This canal early presents at its cephalic end three vesicular enlargements, separated by corresponding constrictions. These enlargements are the primary cerebral vesicles, from which the encephalon is developed. The remainder of the canal is of a uniform diameter and goes to form the spinal cord. By the proliferation of the cells surrounding the neural tube, or canal, the integral parts of the central nervous system become developed, the canal, much reduced in size, remaining to form the central canal of the spinal cord and the ventricles of the brain. Thus it is seen that the entire nervous system is epiblastic in origin.

The brain is developed from the three primary cerebral vesicles, called, respectively, the anterior primary vesicle, or fore-brain; the middle primary vesicle, or mid-brain; and the posterior primary vesicle, or hind-brain. This latter vesicle soon becomes much thickened on the anterior part of the dorsal wall, to form the cerebellum; this unequal development dividing this vesicle into two parts, called the fourth and fifth cerebral vesicles, or the

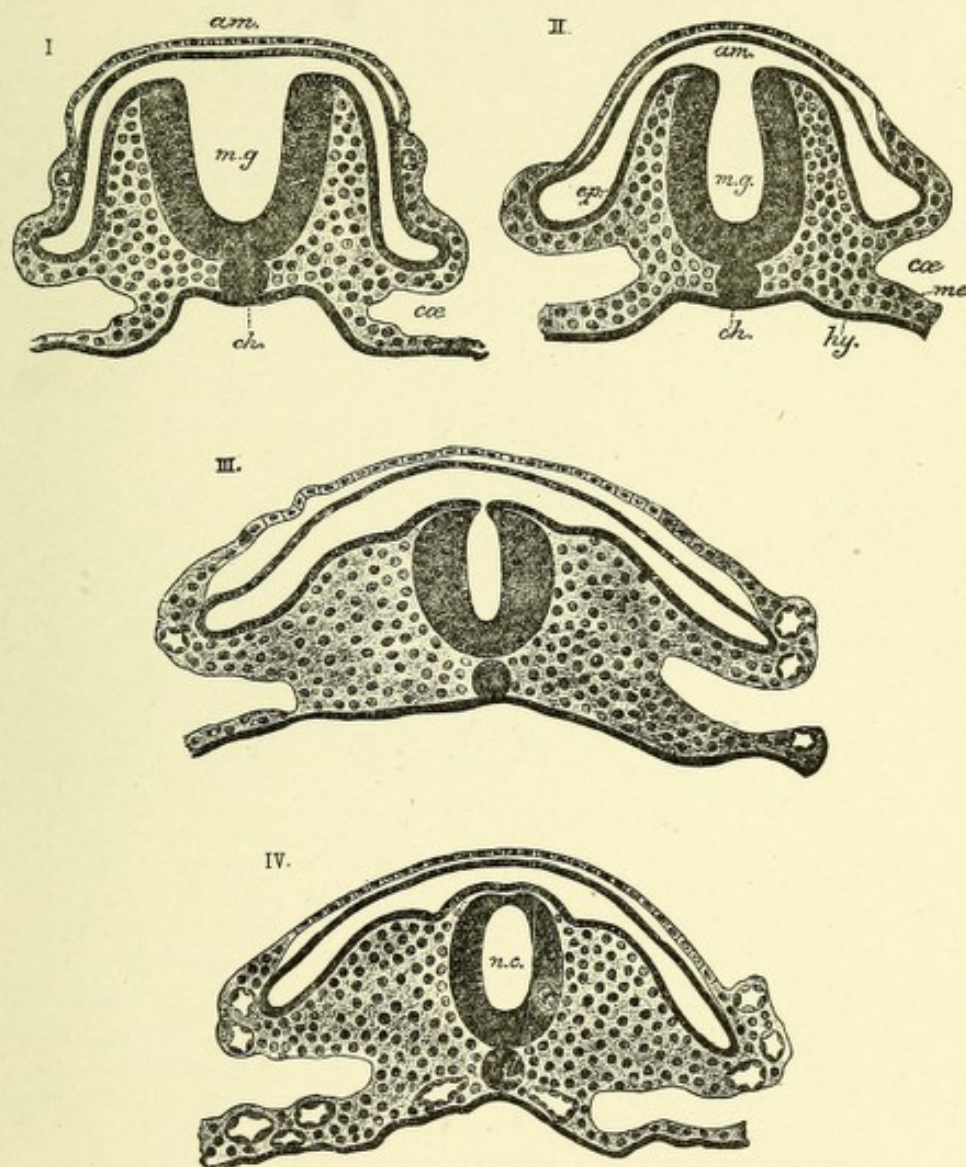



FIG. 238.—SECTIONS SHOWING STAGES IN THE CONVERSION OF THE MEDULLARY GROOVE INTO THE NEURAL CANAL. From the tail end of an embryo of the cat.—(*E. A. S.*, from Quain.)

ep, me, hy. Epiblast, mesoblast, and hypoblast. *m.g.* Medullary groove. *n.c.* (in IV). Neural canal. *ch.* Notochord. *coe.* Celom. *am.* Tail-fold of the amnion.



epencephalon, and the metencephalon or myelencephalon. From the former is developed the cerebellum and pons Varolii, while from the latter is developed the medulla oblongata.

The first primary vesicle, or fore-brain, also becomes divided into two parts by a process of budding, which starts from its anterior wall as a single small vesicle, whose growth is exceedingly rapid and chiefly in an upward and dorsal direction. From this vesicle is developed the cerebrum. It is called the prosencephalon, while the posterior part of the primary vesicle, or fore-brain, is now called the diencephalon, thalamencephalon, or inter-

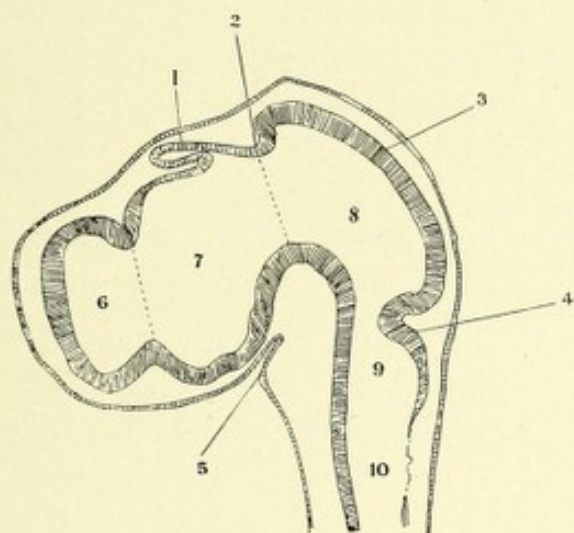


FIG. 239.—LONGITUDINAL SECTION OF HEAD OF A FOUR-AND-A-HALF-DAY CHICK. The five brain-vesicles are fairly well developed.—(After von Mihalkovics, from Edinger.)

1. Pineal gland. 2. Posterior commissure. 3. Corpora quadrigemina. 4. Cerebellum. 5. Fundament of the hypophysis. 6. Cerebral cavity. 7. Thalamencephalic cavity, or third ventricle. 8. Aqueductus. 9. Cerebellar cavity. 10. Cavity of medulla. The last two together form the fourth ventricle.

brain. There are thus formed, by the division of the primary fore-brain and the hind-brain into two parts, five secondary cerebral vesicles, the central cavities of which communicate with one another. They are as follows: First, the secondary fore-brain, or prosencephalon; second, the remains of the original primary fore-brain, now called thalamencephalon, or 'tween-brain; third, the mesencephalon, which is the unaltered second or middle primary vesicle, or mid-brain; fourth, the epencephalon, or hind-brain ("Nachhirn"); and, fifth, the metencephalon, or after-

TABLE OF THE VARIOUS PARTS OF THE BRAIN DERIVED FROM EACH EMBRYONIC BRAIN-VESICLE.

NEURAXIS.	FLOOR.	VENTRAL ZONE (His).	DORSAL ZONE (His).	ROOF.	CAVITY.
Spinal cord,	Ant. septum.	Ant. horn. Ant. commissure. Ant. column and ant. part of lateral columns. Nucleus of origin of all motor spinal nerves.	Cervix and post. horns. Post. gray commissure. Post. part of lateral columns except crossed pyramidal tract. Post. columns. Nucleus of termination of all sensory spinal nerves and of part of trigeminus.	Post. part of post. septum.	Central canal.
Metencephalon,	Raphe.	Region of ant. pyramids of bulb. Nuclei of motor nerves: twelfth, eleventh, sixth, and motor part of seventh and tenth.	Inf. cerebellar peduncles. Nuclei of columns of Goll and Burdach. Sup. and inf. olivary systems. Acoustic tubercle. Ala cinerea. Nucleus of termination of sensory part of ninth and tenth nerves. Cochlear part of eighth and part of the fifth.	Obturator membrane of fourth ventricle. Obex and tenia of fourth ventricle.	Fourth ventricle.
Epencephalon,	Raphe.	Region of pons. Motor origin of fifth pair.	Cerebellum. Middle cerebellar peduncles. Nucleus of termination of vestibular part of eighth and of part of fifth pair.	Vermis. Valvules of Tatin.	
Isthmus (His). (Constriction between epencephalon and mesencephalon.)	Raphe.	Sup. part of pons. Nucleus of origin of small motor descending part of fifth pair and nucleus of origin of fourth pair.	Superior cerebellar peduncles.	Valve of Vieussens.	
Mesencephalon,	Raphe. Post. perforated substance.	Region of cerebral peduncles. Nucleus of origin of third pair.	Ant. and post. corpora quadrigemina. Triangular fasciculus of isthmus. (Lateral band of Reil.)	Membrane uniting the corpora quadrigemina.	Aqueduct of Sylvius.
Thalamencephalon,	Ant. part of post. perforated substance. Tuber cinereum and infundibulum.	Subthalamic region of Forel. Mammillary bodies. Ext. and int. geniculate bodies. Optic tract and chiasm. Retina.	Optic thalamus. Middle commissure.	Post. commissure. Pineal gland. Tenia of thalamus. Ganglion of habenula. Obturator membrane of third ventricle.	Third ventricle.
Prosencephalon,	Lamina cinerea.	Not present.	Cerebral cortex, olfactory lobe, and centrum ovale. Pyramidal tracts. Corpus callosum. Fornix. Septum lucidum. Ant. commissure. Corpus striatum. Insula.		Lateral ventricle.

brain. The subjoined table, from Dejerine, indicates the different parts of the cerebrospinal system derived from each encephalic vesicle.

THE DEVELOPMENT OF THE SPINAL CORD.

That part of the neural tube not concerned in the formation of the cerebral vesicles is converted into the spinal cord. This tube is oval on cross-section, and can very early be differentiated into a right and a left half by a thickening due to cell-growth or multiplication of its lateral walls. The upper and lower walls, or the roof and floor, remain very thin and form later the commissures, the former forming the posterior or dorsal commissure, while the latter forms the anterior or ventral commissure.

The cells of which the walls of the neural tube are composed consist at first of a single layer of cells having a distinctly epithelial character. They are very long, extend in a radial manner throughout the entire thickness of the walls, and lie very close to each other, thus having a palisade-like appearance. While the epithelial character of the cells is preserved, there may be distinguished an inner and an outer clear zone without nuclei, the middle zone containing all the nuclei, which are increased in numbers as development progresses. Between the inner clear zones of these epithelial cells and toward the central cavity there appears at the fourth or fifth week, in the human embryo, a number of cells spheric in shape, 10 to 14 μ in diameter, with nuclei, which present one or another stage of karyokinesis. These are the germinating cells or "Keimzellen" of His. They are early transformed into neuroblasts, or primitive nerve-cells, by a lengthening out of their cell-body and the formation of a single protoplasmic stalk, or axis-cylinder, which forms a nerve-fiber. Along with the growth of the walls of the neural tube, the epithelial cells increase in length, become vacuolated, lose their definite cell-boundary, and their protoplasm becomes filled with perforations. The individual cell appears as if possessed of branching processes united with those from adjacent cells, and thus forms a network which extends throughout the

entire thickness of the embryonic cord. This network has been termed by His myelospongium, or neurospongium, and the cells from which it is formed are called spongioblasts, they being the primitive neuroglia cells. They are at this stage elongated and oblong in form, and have oval nuclei. Each spongioblast possesses two main processes—an outer and an inner, or peripheral

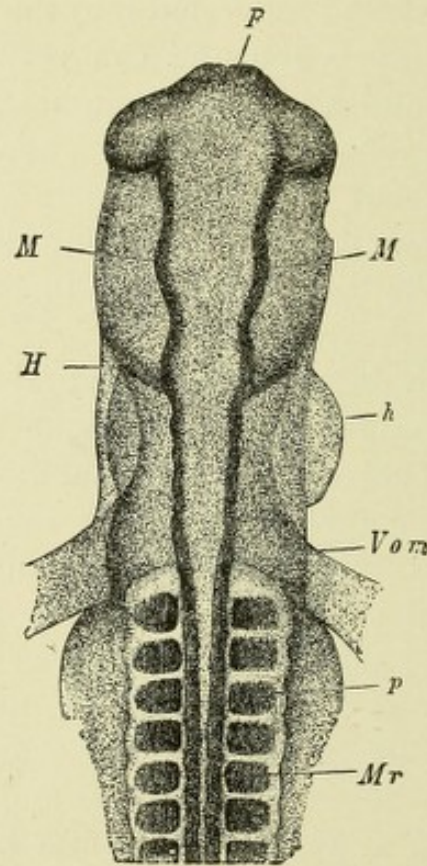


FIG. 240.—FORE-PART OF THE EMBRYO VIEWED FROM THE DORSAL SIDE.—(After Koelliker, from Quain.)

F. Fore-brain. *e.* Ocular vesicles. *M.* Mid-brain. *H.* Hind-brain. *h.* Part of the heart seen bulging to the right side. *Vom.* Omphalomesenteric or vitelline veins entering the heart posteriorly. *Mr.* Medullary canal, spinal part. *p.* Protovertebral somites.

and central. The inner or central processes course inward to the inner boundary, where they break up into fine branches, which unite to form a close network called the internal limiting membrane. The outer or peripheral processes branch and form a network, which is most distinct in the outer layer. At a later stage these spongioblasts become thickened near the position of their nuclei; the nuclei proliferate rapidly and then migrate,

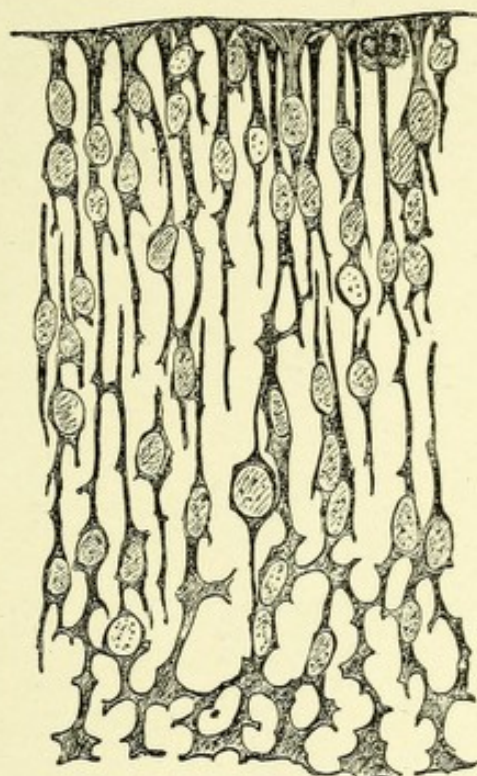


FIG. 241.—MYELOSPONGIUM FROM SPINAL CORD OF THREE-AND-A-HALF-WEEKS' HUMAN EMBRYO.—(*His, from Quain.*)

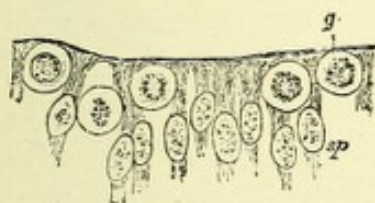


FIG. 242.—INNER ENDS OF SPONGIOBLASTS (*sp*) WITH GERMINAL CELLS, *g*, BETWEEN THEM. From spinal cord of human embryo.—(*His, from Quain.*)

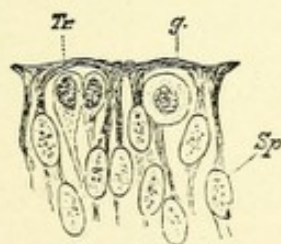


FIG. 243.—INNER ENDS OF SPONGIOBLASTS (*Sp*). A germinal cell (*g*) and two transitional cells (*Tr*) from spinal cord of human embryo.—(*His, from Quain.*)

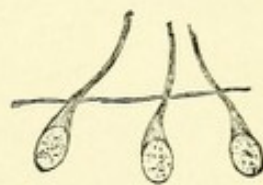



FIG. 244.—THREE NEUROBLASTS, EACH WITH A NERVE-FIBER PROCESS GROWING OUT BEYOND THE BASEMENT MEMBRANE OF THE EMBRYONIC SPINAL CORD.—(*His, from Quain.*)



accumulating about the central canal and along the periphery of the medullary wall of the neural tube. Many of the cells lose their central processes, the outer process alone remaining; soon this process is also lost, and lateral branches having developed, the elongated configuration of the cells is lost, the cells being transformed into the spheric neuroglia or stellate cells of Deiter.

Other spongioblasts which have accumulated about the central canal form for it its epithelial lining, or ependyma. These ependymal cells have fine radiating processes which pass through the entire thickness of the gray and white matter of the embry-

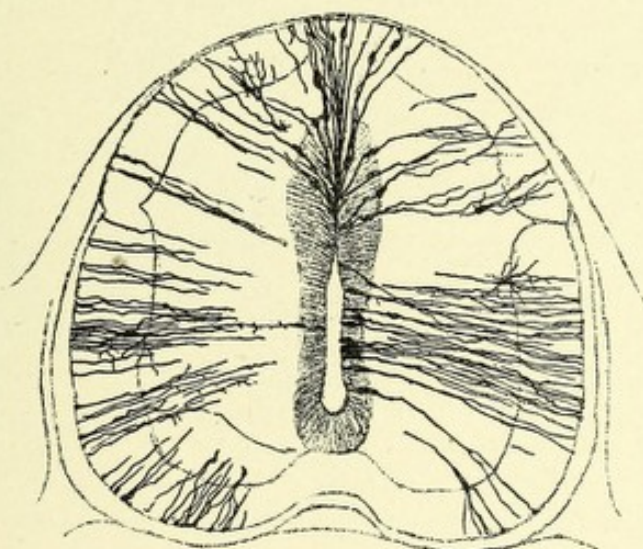


FIG. 245.—EPENDYMAL FIBER OF MARROW OF A SEVEN-DAYS'-OLD EMBRYO OF A CHICKEN.—(After Golgi.)

onic cord. About the fifth week of embryonic life their free surfaces develop cilia, which extend into the central cavity. These ependymal cells are identical in character with neuroglia cells. At a period when the neuroblasts, or nerve-cells, can be well differentiated, the medullary wall of the neural tube may be divided into three layers: First, the outer neuroglia layer, or the Randschleier of His, in which location the white matter is developed. Second, the middle or mantle layer, the habitat for the neuroblasts, or the region of the gray matter. Third, the inner layer of ependymal cells.

The researches of His have shown that both the spongio-

blasts from which the neuroglia cells are developed and the neuroblasts from which the nerve-cells and fibers are developed are formed from cells of the epiblast, which are identical in character. This observation of His has recently been confirmed by Ramón y Cajal, who states that cells which, from their form and position, would be classed as spongioblasts, frequently alter their shape and, throwing out axis-cylinder processes, become converted into nerve-cells and fibers. The neuroblasts of the primitive nerve-cells are pear-shaped, owing to the development from each of an elongated protoplasmic process which becomes the axone of the future nerve-cell. The cells at this period do not possess dendrites, they being developed much later. The neuroblasts are capable of motion and frequently alter their position.

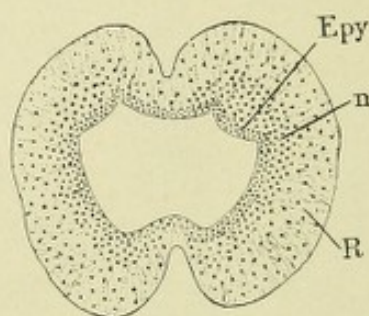


FIG. 246.—LOWER END OF THE SPINAL CORD OF A HUMAN EMBRYO OF THREE MONTHS.
—(*From Minot.*)

Epy. Ependymal layer. n. Neuroblast layer. R. Outer neuroglia layer, or Randschleier.

The study of a transverse section of the human embryonic cord at the fourth week shows it to be composed of an outer neuroglia layer, the Randschleier, in the meshes of which the white matter is developed; of a middle or mantle layer, occupied by neuroblasts, from which the gray matter is developed; and, lastly, an inner layer of ependymal cells.

The neuroblasts found distributed throughout the middle layer tend to collect into two large groups, which are located in the outer and ventral part of this layer and constitute in the human embryo of six weeks the chief portion of each half of the cord. The more ventral portions of these groups form the anterior horns or cornua, the cells being motor in function. The axones of these cells pass, in slight curves, through the ventral

portion of the outer layer, to form the primitive anterior spinal nerve-roots. The processes of the more dorsally located neuroblasts do not leave the embryonic cord, but pass into the meshes of the myelospongium, where, according to His, they meet resistance, and hence their direction is changed into an upward

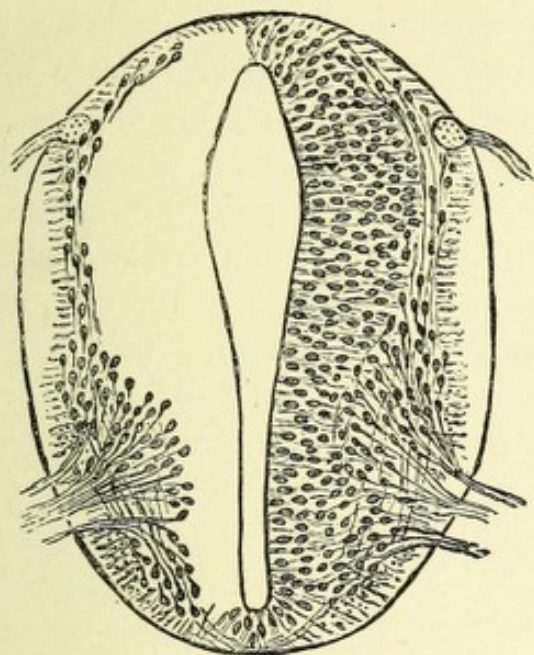


FIG. 247.—SECTION OF SPINAL CORD OF FOUR WEEKS' HUMAN EMBRYO.—(*His, from Quain.*)

The posterior roots are continued within the cord into a small longitudinal bundle which is the rudiment of the posterior white column. The anterior roots are formed by the convergence of the processes of the neuroblasts. The latter, along with the elongated cells of the myelospongium, compose the gray matter. The external layer of the cord is traversed by radiating fibers which are the outer ends of the spongioblasts. The anterior commissure is beginning to appear. This figure is much more magnified than the next one.

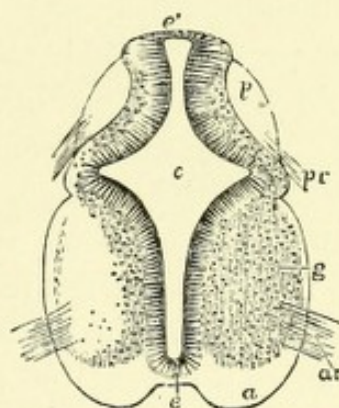


FIG. 248.—TRANSVERSE SECTION OF THE CERVICAL PART OF THE SPINAL CORD OF A HUMAN EMBRYO OF SIX WEEKS.—(*After Koelliker, from Quain.*)

c. Central canal. *e.* Its epithelial lining. *e'* (superiorly). The original place of closure of the canal. *a.* The white substance of the anterior columns. *g.* Gray substance of anterolateral horn. *p.* Posterior column. *ar.* Anterior roots. *pr.* Posterior roots.

and downward course. These neuroblasts, with their processes, form the intrinsic cells and fibers of the cord.

A cross-section of the cord at the sixth or eighth week shows the central canal elongated ventrodorsally and presenting, near its middle on each side, a lateral extension which cuts deeply into each lateral wall of the medullary tube, thus dividing the primitive cord into the ventral and dorsal zones of His. At

this stage can be seen issuing from the neuroblasts of the ventral zones fibers proceeding ventrally to reach the outside of the cord forming the anterior or motor nerve-roots. Entering the dorsal zones, fibers may be seen which are the axones of the embryonic posterior spinal ganglia. At a later period in development the central cavity decreases in size until about the tenth week, when its walls almost coalesce between the dorsal zones, leaving only a small triangular-shaped opening in its most dorsal extremity. Still later all traces of the cavity are obliterated, there remaining only the central canal.

At the sixth week no trace exists of the anterior and posterior longitudinal fissures. The former is due to an arrest of development of the floor of the central cavity, and a corresponding rapid development of the ventral zones resulting in two bulgings which never coalesce, but become approximated in the median line, leaving a fissure between them. In this fissure is found a process of connective tissue from the pia. The so-called posterior fissure is doubtless the remains of the dorsal part of the central cavity, being indicated as a mere slit, which contains a process of neuroglia from the ependymal cells of its dorsal wall. This process was named the posterior longitudinal fissure by early anatomists, from its resemblance to the anterior fissure, and the probability of its containing a process of pia, and, although later anatomists have proved the falsity of this view, it is still, owing to long usage, convenient to retain the old name, and hence in the description of the spinal cord it is so recognized.

The anterior horns depend, for their growth, upon the conversion of the germinating cells of the mantle layer into neuroblasts, and the subsequent growth of the latter into complete motor neurones.

The cells of the posterior horns are probably derived from the dorsal part of the mantle layer. The cervix of each posterior horn is formed by the narrow part of the gray matter connecting the dorsal and ventral zones and located opposite the central furrow or groove.

The white matter of the cord is developed in the outer layer, or Randschleier of His. This layer forms a complete covering

for the mantle layer, or gray matter. In the dorsal zone on each side exists an oval projection of the Randschleier, called the oval bundle of His, which extends from the entrance of the most ventrally placed posterior root to near the mid-dorsal line, and contains longitudinally coursing fibers from the embryonic posterior spinal ganglia. Increasing in size, each bundle extends backward to the arch formed by the union of the dorsal zones with the roof of the medullary tube. This arch gives rise to the columns of Goll, which become united, owing to the obliteration of the small triangular opening, this being the remains

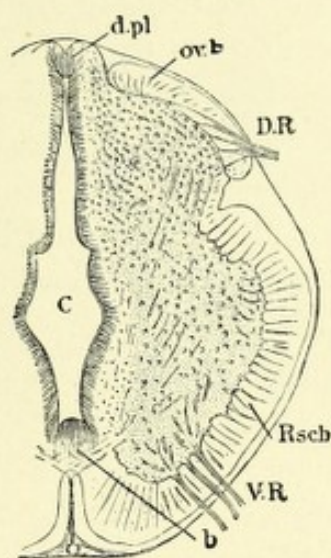


FIG. 249.—TRANSVERSE SECTION OF THE SPINAL CORD FROM THE UPPER DORSAL REGION OF A HUMAN EMBRYO OF SIX WEEKS.—(After His, from Minot.)

d.pl. Deck-plate. ov.b. Oval bundle of dorsal zone. D.R. Dorsal root. Rsch. Randschleier of ventral zone. b. Floor-plate. V.R. Ventral root.

of the dorsal periphery of the central cavity, which lies between them. The oval bundle continues to grow dorsomesially and, becoming situated between Goll's columns and the gray matter, unites with its fellow of the opposite side to form the columns of Burdach. This oval bundle is connected with the dorsal part of the outer layer, or Randschleier, which forms a covering for the ventral zone by a narrow portion located at the bottom of a sulcus, called the central groove. This narrow portion begins to grow rapidly, and completely obliterates the central groove. At this point on each side are developed the lateral

pyramidal tracts. In that part of the outer layer, or Randschleier, located between the ventral fissure and the exit of the axones of the neuroblasts of the ventral zone (anterior horns) are formed the anterior columns of the cord, while that portion located between the oval bundle and the exit of the same nerve-fibers gives rise to the lateral columns.

The posterior spinal ganglia take their origin from cells of the epiblast located just external to the medullary ridges of each side, and when these ridges meet at the mid-dorsal line to form the neural tube, these groups of cells also unite at the median line to form a slightly elevated portion of the epiblast, which is termed the neural crest. At regular intervals along each side of this crest corresponding to the middle of the mesoblastic somites, or provertebra, lateral projections, or outgrowths of cells appear, which separate from the neural crest to form the primitive posterior spinal ganglia.

The embryonic cells of the spinal ganglia are bipolar in form, each cell possessing both a central and a peripheral axone. The former enter the dorsal columns of the cord and form the sensory nerve-roots, while the latter have a peripheral course, and are destined to terminate in sensory end organs. Toward the end of embryonic life most of these cells become unipolar, either by fusion of their protoplasmic processes or, what is more probable, by an outgrowth of a protoplasmic stalk. This stalk or pedicle divides T-shaped, one division passing into the dorsal part of the cord as a posterior spinal nerve-root, where it again divides into a long ascending and a short descending branch. The other process passes peripherally as a periphery sensory nerve-fiber and terminates in a sensory end organ.

The fibers of the columns of the cord have their origin from the various parts of the brain, as well as from the spinal cord and posterior spinal ganglia. They are simply the lengthened-out axis-cylinder processes of the cells of these regions which have grown in the direction in which they convey impulses. These fibers are at first all non-medullated, but receive their myelin sheaths at later periods of development. Flechsig has shown that the fibers of the different columns of the cord receive their myelin at certain definite periods of embryonic life,



FIG. 250.—SECTIONS ACROSS THE REGION OF THE CALAMUS SCRIPTORIUS OF THE BRAIN.
—(*His, from Quain.*)

A. Region of the glossopharyngeal ganglion. B. Of the auditory facial ganglion.

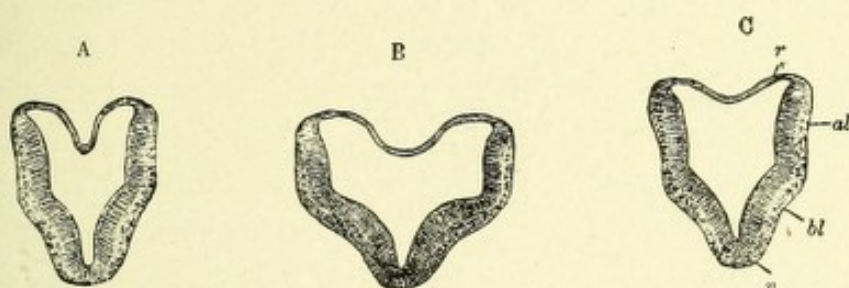


FIG. 251.—SECTIONS ACROSS THE FOURTH VENTRICLE OF A SOMEWHAT OLDER EMBRYO.—(*His, from Quain.*)

A. Section taken through the lower part. B. Across the widest part (trigeminus region). C. Through upper part (cerebellar region). *r.* Roof of neural canal. *al.* Alar lamina. *bl.* Basal lamina. *v.* Ventral border.

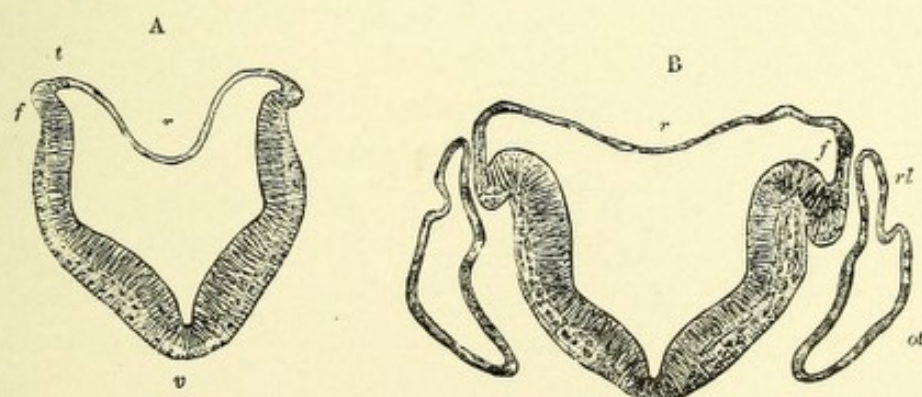



FIG. 252.—SECTIONS ACROSS THE LOWER HALF OF THE FOURTH VENTRICLE OF A STILL OLDER EMBRYO. Showing gradual opening out of the neural canal and the commencing folding over of the alar lamina (at *f*).—(*His, from Quain.*)

v. Ventral border. *t.* Tenia. *ot.* Otic vesicle. *rl.* Recessus labyrinthi.

In the succeeding stage (not here represented) the angle at *v* has almost disappeared, the fold *f* has extended over the alar lamina, and the two thickened halves are in the same horizontal plane, covered by a greatly expanded and thinned-out roof.



so that the location and course of the various tracts can be easily demonstrated.

The embryonic cord completely fills the cavity of the spinal canal up to the beginning of the fourth month, but at birth, owing to a more rapid development of the spinal canal, the lowermost part of the cord (coccygeal portion) reaches only to the level of the third lumbar vertebra, and in the adult to the lower part of the first lumbar. This apparent ascent of the cord alters the course of the nerve-roots running out of it. At first these roots leave the cord nearly at right angles, but later, owing to the before-described changes, these fibers have an oblique or a nearly longitudinal course within the spinal canal. In the lumbar and sacral parts of the cord these descending fibers form the cauda equina. The cervical and lumbar enlargements are well differentiated at the fourth month of fetal life.

The membranes and the blood-vessels of the cord are both derived from the mesoblast, which has formed a canal around the neural tube.

DEVELOPMENT OF THE MEDULLA OBLONGATA.

The medulla oblongata is developed from the fifth or after-brain vesicle—the metencephalon. Although the medulla differs in shape from the spinal cord, its development is essentially the same. Early in the growth of the after-brain vesicle there is to be distinguished a floor (Bodenplatte), lateral walls, and a roof (Deckplatte). From thickenings of the floor and lateral walls are developed (third month) the anterior and lateral columns, continuous with those of the cord. From the roof no nerve-cells are developed, and it retains its epithelial character and becomes spread out over quite an extensive surface, forming a covering to the cavity of the metencephalon, or fourth ventricle. Later, this covering becomes blended with the under surface of the pia, which is very vascular, the vessels being arranged into two rows of villous processes which grow into the cavity of the after-brain vesicle, to form the choroid plexuses of the fourth ventricle, or tela choroidea inferior.

Transverse section of the metencephalon in an embryo of

about three weeks shows the primitive medulla to be more or less shield-shaped, with a triangular medullary cavity. This appearance is due to the growth laterally of the thin dorsal wall or roof which forms the base, while the dorsal halves of the lateral walls are spread widely apart; their ventral halves, which meet the dorsal at a distinct angle, gradually converge and join the floor of the medullary wall in the median line. The angle of junction of the dorsal and ventral parts of each lateral wall serves to separate the medullary walls into the dorsal and ventral zones of His. Owing to the widening of the medullary tube and the expansion of the roof, the dorsal and ventral zones are brought nearly into one plane. Along the edge of the dorsal zone a fold, by which the edge is arched outward and downward,

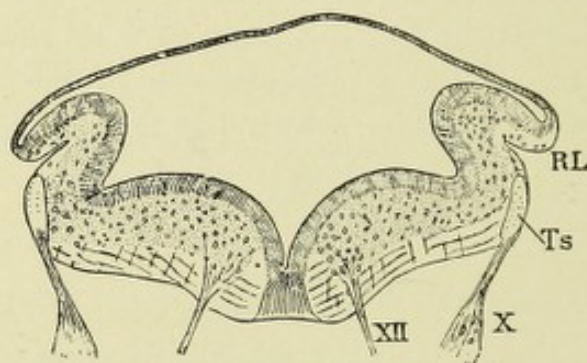


FIG. 253.—TRANSVERSE SECTION OF THE MEDULLA OBLONGATA OF HIS' EMBRYO RU (LENGTH OF BACK, 9.1 MM.).—(After W. His, from Minot.)

RL. Rhomboid lip. Ts. Tractus solitarius. X. Vagus nerve. XII. Hypoglossal nerve.

is formed and is separated from the dorsal zone by an external notch. This fold has been called the fold of the rhomboid fossa—the Rautenlippe.

The walls of the metencephalon, as well as those of the rest of the cerebral vesicles, may be early differentiated, owing to an orderly arrangement of the spongio- and neuroblasts, into three distinct layers—an outer neuroglia or white matter (the Randschleier), the middle mantle or gray matter, and the inner or ependymal layer.

The lower boundary of the dorsal zones is indicated by an oval-shaped area on each side containing longitudinal nerve-fibers, axones, and collaterals from the cerebral ganglia: these are the solitary bundles or tracts. They are homologous with

the oval bundles of the Randschleier of the spinal cord. The ventral zones are separated from each other above by a median groove, which begins at a point where the central canal widens and extends to the aqueduct of Sylvius. On each side of this groove is developed an eminence which later is called the *eminentia teres*. The ventral zones are separated laterally from the dorsal by a less prominent groove, the remains of which are indicated in the adult by the *fovea anterior* and *posterior*. The fold, or *Rautenlippe*, on each side grows downward and unites with the main fold of the dorsal zone; by so doing it surrounds the solitary bundle, displacing it inward, so that it comes to occupy a deeper position. At this stage the dorsal

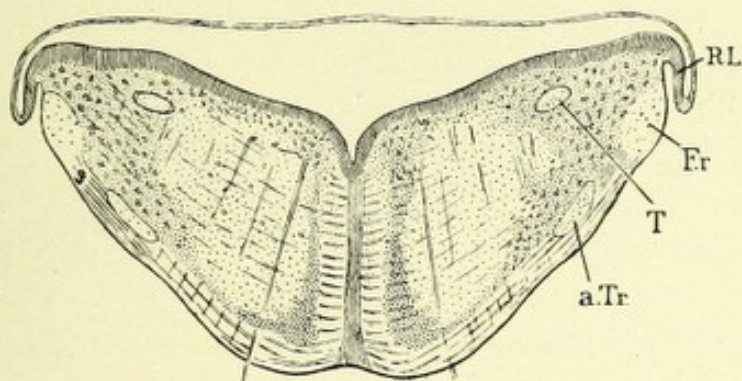


FIG. 254.—TRANSVERSE SECTION OF THE MEDULLA OBLONGATA OF HIS' EMBRYO MR.
—(After W. His, from Minot.)

T. Tractus solitarius. RL. Secondary rhomboid lip. F.r. Funiculus restiformis. a.Tr. Ascending trigeminal tract.

and ventral zones are in about the same plane, the groove separating them being nearly obliterated. In the dorsal zone are developed the restiform body, the clava, the solitary bundle, and the descending trigeminal nucleus and tract. The nucleus of Burdach's column is probably derived from the *Rautenlippe*.

The neuroblasts of the dorsal zone that are developed during the fourth week form the arcuate fibers. The neuroblasts of this zone which are formed later migrate in tracts, both within and outside of the solitary bundle, into the lower part of the ventral zone, where, with other neuroblasts, they form the olivary body.

The raphe, which is a neuroglia partition between the ven-

tral zones, arises from a thickening of the floor of the medullary wall. It is the place of crossing of fibers from one side of the medulla to the opposite; no neuroblasts can migrate across this partition.

The neuroblasts of the gray matter (mantle layer) of the ventral zone enter chiefly into the production of the formatio reticularis; those that have migrated from the dorsal zone form the main and accessory olivary bodies. The layer of neuroblasts beneath the ependyma gives rise to the motor cranial nuclei in this region. In the outer layer (neuroglia), or Randschleier, are developed the white columns of the medulla. This outer layer is divided by the exits of the ventral nerve-roots (hypoglossal) into a median or ventral and lateral regions corresponding to the anterior and lateral columns of the cord. In the dorsal part of the median region are developed longitudinal fibers which collect into bundles and form the posterior longitudinal bundles. At the fourth month large numbers of longitudinal fibers appear in the ventral parts of the median region; these fibers form the anterior pyramids. The lateral region of each side contains the fibers of the restiform body, some arcuate fibers, descending trigeminal nerve-fibers, solitary bundle, and nucleus of Burdach's columns.

CEREBELLUM AND PONS.

The cerebellum and pons Varolii are developed from the fourth cerebral vesicle, or epencephalon. This vesicle is continuous behind with the metencephalon, or fifth vesicle, the two together forming the elongated, somewhat boat-shaped cavity—the embryonic fourth ventricle. The epencephalon is separated from the metencephalon, or mid-brain, by a narrow constricted part of the neural tube, called by His the isthmus. The cerebellum grows out from the dorsal wall or roof of the fourth cerebral vesicle, and becomes located between the medulla oblongata and the isthmus. From the floor of this vesicle the pons Varolii becomes developed. As early as the third month the transverse fibers so characteristic of the pons may be distinguished. The growth of the pons is very rapid, and proceeds

pari passu with that of the cerebellum. The lateral walls give rise to the middle cerebellar peduncles. The cerebellum appears at first as a budding forward of the dorsal wall of the epencephalon, which, as it grows, forms a distinct transverse thickening or ridge overhanging the thin roof of the medulla oblongata. At about the third month of embryonic life the middle portion of this ridge increases in size, and becomes

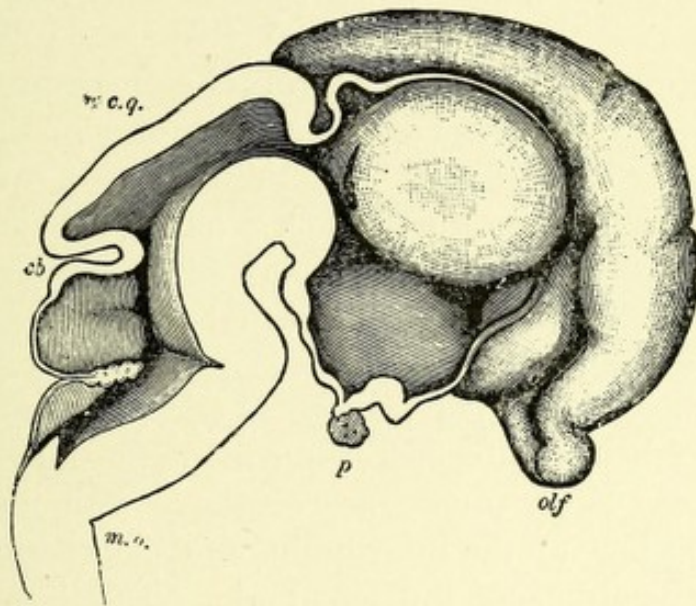


FIG. 255.—MEDIAN SECTION THROUGH THE BRAIN OF A TWO AND A HALF MONTHS' FETUS.—(*His, from Quain.*)

The mesial surface of the left cerebral hemisphere is seen in the upper and right-hand part of the figure; the large cavity of the third ventricle is bounded above and in front by a thin lamina; below is seen the infundibulum and pituitary body. Filling the upper part of the cavity is the thalamus opticus; in front and below this is the slit-like foramen of Monro. Behind the thalamus is seen another slit-like opening which leads into the still hollow external geniculate body.

olf. Olfactory lobe. *p.* Pituitary body. *c.q.* Corpora quadrigemina. *cb.* Cerebellum. *m.o.* Medulla oblongata.

differentiated from the lateral parts by the development of four rather deep transverse grooves or fissures, which serve to divide it into three permanent lobes. The middle portion or lobe is called the worm, or vermis. From now on the lateral parts increase greatly in size, growing outward on each side to form the cerebellar hemispheres, right and left. The cerebellum, or expanded roof of the fourth cerebral vesicle, is connected in front with that of the mid-brain, and behind with the choroid

plexus of the after-brain vesicle, or fourth ventricle, by two lamellæ of white matter—the anterior and posterior or superior and inferior medullary velum (Figs. 255 and 256).

CORPORA QUADRIGEMINA, CRURA CEREBRI, AND AQUEDUCT OF SYLVII.

THE THIRD CEREBRAL VESICLE (SECOND PRIMITIVE VESICLE),
MESENCEPHALON, OR MID-BRAIN.

This part of the embryonic neural tube develops very rapidly, and, in consequence of the cephalic curvatures of the medullary tube, it at first occupies the summit of the brain vesicles. In front it is continuous with the fore-brain, and behind with the hind-brain. Owing to the much more rapid development of the hemispheric vesicles, together with that of the cerebellum, the mid-brain is completely covered in. In man only a small part of the brain is developed from this vesicle. Its walls become uniformly thickened, thus narrowing the cavity into a small permanent canal, which communicates above with the third ventricle, or ventricle of the inter-brain, and below with the fourth ventricle, or ventricle of the hind-brain. This narrowed canal is called the aqueduct of Sylvius. From the thickened anterior wall (floor) the peduncles of the cerebrum (*crura cerebri*) are developed; these appear at the third month as two rounded, longitudinal ridges on each side of the median line. It is probable that a large part of the posterior perforated space is also developed from this same area, and appears in the adult as a triangular gray lamina between the *crura cerebri*. The dorsal region or roof of the mid-brain becomes much thickened, and is divided at the third month into two lateral halves by the development of a median groove, and these halves are again separated at the fifth month by the appearance of a transverse groove, into four parts, two ventral and two dorsal; these are the *corpora quadrigemina*.

**OPTIC THALAMI, INFUNDIBULUM, PITUITARY BODY,
PINEAL GLAND, CORPORA MAMMILLARIA, AND
OPTIC CHIASM.**

The first primitive cerebral vesicle, or fore-brain, owing to the development by a process of budding out of its ventral wall of a secondary vesicle whose growth is exceedingly rapid, becomes located between this fully developed secondary fore-brain, or

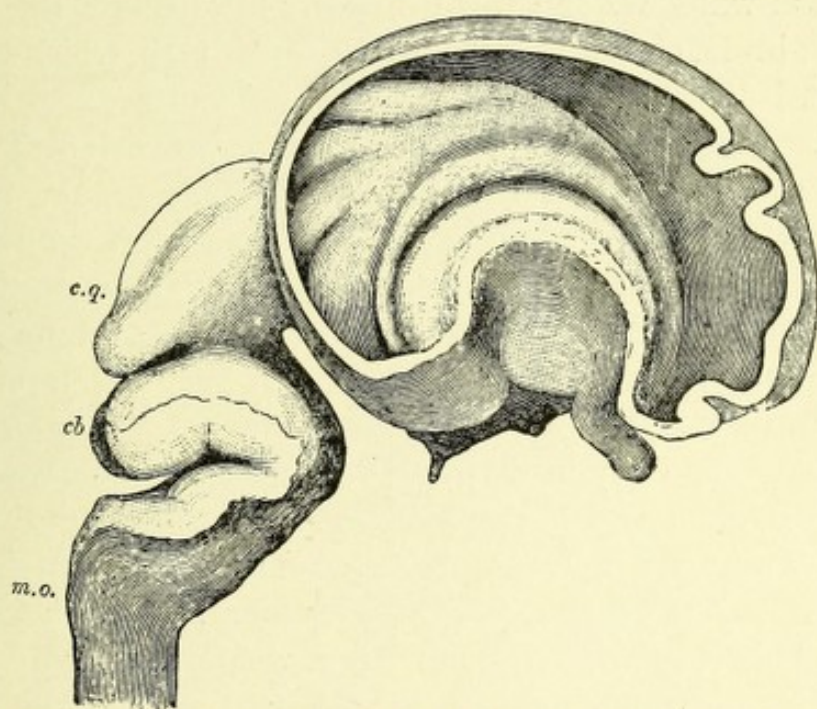


FIG. 256.—FETAL BRAIN OF THE THIRD MONTH —(*His, from Quain.*)

The brain is represented in profile, but the external wall of the right hemisphere has been removed to show the interior of the lateral ventricle with the corpus striatum curving around the bend of the fossa of Sylvius. The curved projections above the corpus striatum are infoldings of the mesial wall of the hemisphere vesicle. The lettering is the same as in figure 255.

prosencephalon, and the mid-brain; hence its name, diencephalon, inter-brain or between-brain. The inter-brain at the fifth week is oblong in shape, distinctly narrowed at its anterior extremity where it joins the cerebral hemispheres, less so at its posterior extremity, which is attached to the mid-brain. From its walls grow out on each side at a very early period two hollow protrusions, the primary optic vesicles, the details of which will be considered later. Its cavity (third ventricle) communicates with the cavities of the cerebral hemispheres (lateral ventricles)

by an opening on each side which at first is very large, but later becomes exceedingly narrowed, owing to the growth of the cerebral hemispheres. These openings of communication are termed the foramina of Monro. Posteriorly, the cavity communicates with the cavity of the hind-brain (fourth ventricle) by means of the central canal of the mid-brain (aqueduct of Sylvius).

Each **optic thalamus** is formed by a marked thickening of the lateral walls, which grow gradually inward into the cavity of the inter-brain, converting it into a narrow cleft, which is permanent, and located between the convex surfaces of the optic thalami. This cleft is called the third ventricle. The inner convex surfaces of the optic thalami meet across the middle of this space, their union forming the middle or soft commissure.

At the beginning of the fourth week the floor of the inter-brain cavity is prolonged downward, forming a funnel-shaped diverticulum, which remains throughout life, and is called the **infundibulum**. Connected with the apex of the infundibulum is the pituitary body, or hypophysis cerebri. The roof of this cavity resembles that of the hind-brain, from the fact that it persists as a simple epithelial layer which unites with the under surface of the pia mater, the two together forming a fold which is deflected into the cavity, and from which are suspended the choroid plexus (*tela choroidea superior*) of the third ventricle.

In connection with the growth of the inter-brain mention must be made of the evolution of two as yet functionally unknown parts—the pineal gland, or epiphysis cerebri, and the pituitary body, or hypophysis cerebri. The former takes its origin from the roof; the latter from the floor of the inter-brain.

The **pineal gland** develops in man at about the sixth week as a median dorsal budding or outgrowth from the roof of the inter-brain at a point where it becomes continuous with the roof of the mid-brain. It has at first a tubular shape resembling somewhat the finger of a glove. In all vertebrates except man it is directed forward in its growth, and is retained in that position, but in man it develops in an opposite direction, coming to lie on the mid-brain roof.

It terminates blind, but its cavity is at first continuous with

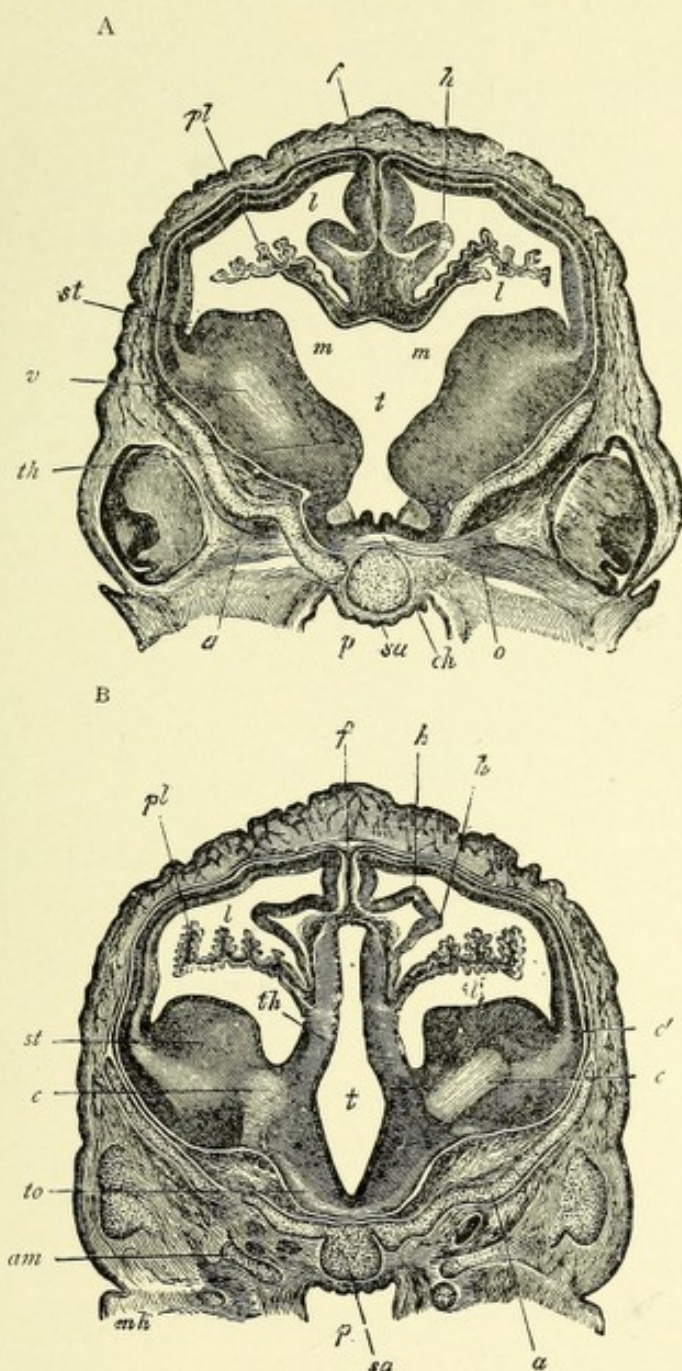



FIG. 257.—TRANSVERSE SECTIONS THROUGH THE BRAIN OF A SHEEP'S EMBRYO OF 2.7 CM. IN LENGTH.—(After Koelliker, from Quain.)

In A, the section passes through the foramina of Monro; in B, through the third and lateral ventricles somewhat further back. *st.* Corpus striatum. *th.* Optic thalamus. *t.* Third ventricle. *c, c'.* Rudiment of internal capsule and corona radiata. *l.* Lateral ventricle with choroid plexus, *pl.* *h.* Hippocampus major. *f.* Primitive falx. *a.* Orbitosphenoid. *sa.* Presphenoid. *p.* Pharynx. *ch.* Chiasma. *o.* Optic nerve. *m, m.* Foramina of Monro. *to.* Optic tract. *mk.* Meckel's cartilage.



that of the third ventricle. Later in its development, budding processes appear from thickenings of its walls, which divide the cavity of the gland into a number of compartments or follicles which are lined with cylindric ciliated epithelium. In man the follicles tend to become solid and contain deposits of calcareous matter. In the roof of the inter-brain, just dorsal to the pineal gland, fibers appear having a transverse course, connecting the posterior parts of the optic thalami. They form the posterior commissure. In reptiles, according to Spencer, the pineal gland remains as a long stalk whose distal or peripheral end lies beneath the epidermis, having passed through an

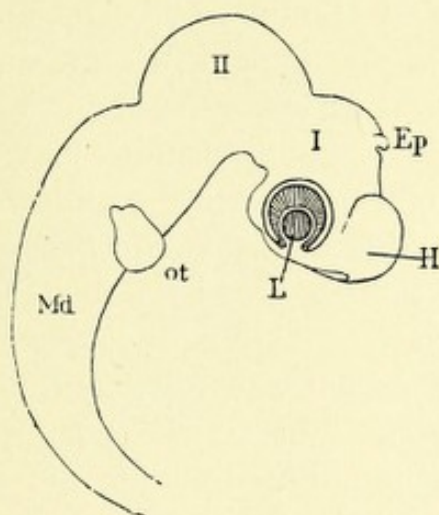


FIG. 258.—BRAIN OF A CHICK EMBRYO, FOURTH DAY.—(After Duval, from Minot.)

I. First, II, second, cerebral vesicle. Ep. Epiphysis or pineal gland. H. Cerebral hemisphere. L. Lens, surrounded by the optic vesicle. ot. Otocyst. Md. Hind-brain.

opening in the roof of the skull (parietal bone), called the parietal foramen. This portion of the sac enlarges into a hollow globe, which soon becomes flattened. The wall next to the epidermis thickens to form a lens-like structure, while the opposite part of the wall to which the stalk, is attached has a retina-like construction.

In the region of the retina nucleated cells, together with pigment, have been observed, and in the stalk, nerve-fibers are found. The development of this body in reptiles, the formation of a lens- and retina-like structure, together with the presence of cells and pigment in the latter, and the presence of

nerve-cells in the stalk, all indicate that it must be a true but rudimentary eye.

The **pituitary body**, or *hypophysis cerebri*, has a double origin from the epiblast, it being developed in part from the oral cleft and in part from the floor of the inter-brain. In man at the sixth week there is developed from the oral cleft a hollow protrusion upward and backward toward the inter-brain. This protrusion is called the pouch of Rathke, or the pocket of the hypophysis. This pouch becomes constricted at its origin, but remains connected for a long time with the oral cavity by a narrow canal or duct, which eventually becomes obliterated. At about the same time a somewhat similar protrusion forms from the floor of the inter-brain (*infundibulum*), which enlarges downward and backward toward the hypophysis, the end of which subsequently becomes fused with the posterior wall of the hypophysis, there being no communication between either cavity. The sac of the hypophysis toward the end of the second month (*His*) develops a number of projecting processes or buds which increase in size and branch, and have developed between them numerous blood-vessels. Ultimately, these processes become separated from the parent sac and, continuing to grow, form with that sac a distinct lobe, to the posterior wall of which is applied the end of the *infundibulum*, the latter resting in a slight depression between two lateral thickenings of the lobe. The ventral portion of the pituitary body is termed the glandular portion, while the dorsal part is called the infundibular portion. In both divisions of the gland nerve-fibers exist, but in the glandular portion they belong only to the sympathetic system. From the floor of the inter-brain are developed, in addition to the *infundibulum*, the *corpora mammillaria*, *tuber cinereum*, ventral part of the posterior perforated space, and the optic chiasm.

The ***corpora mammillaria***, or ***albicantia***, appear at first as a roundish elevation of the floor in the median line, which later become divided by a median depression into two permanent tubercles. The small, elevated portion of the floor which slopes toward the *infundibulum* is known as the *tuber cinereum*. Its development is but imperfectly understood.

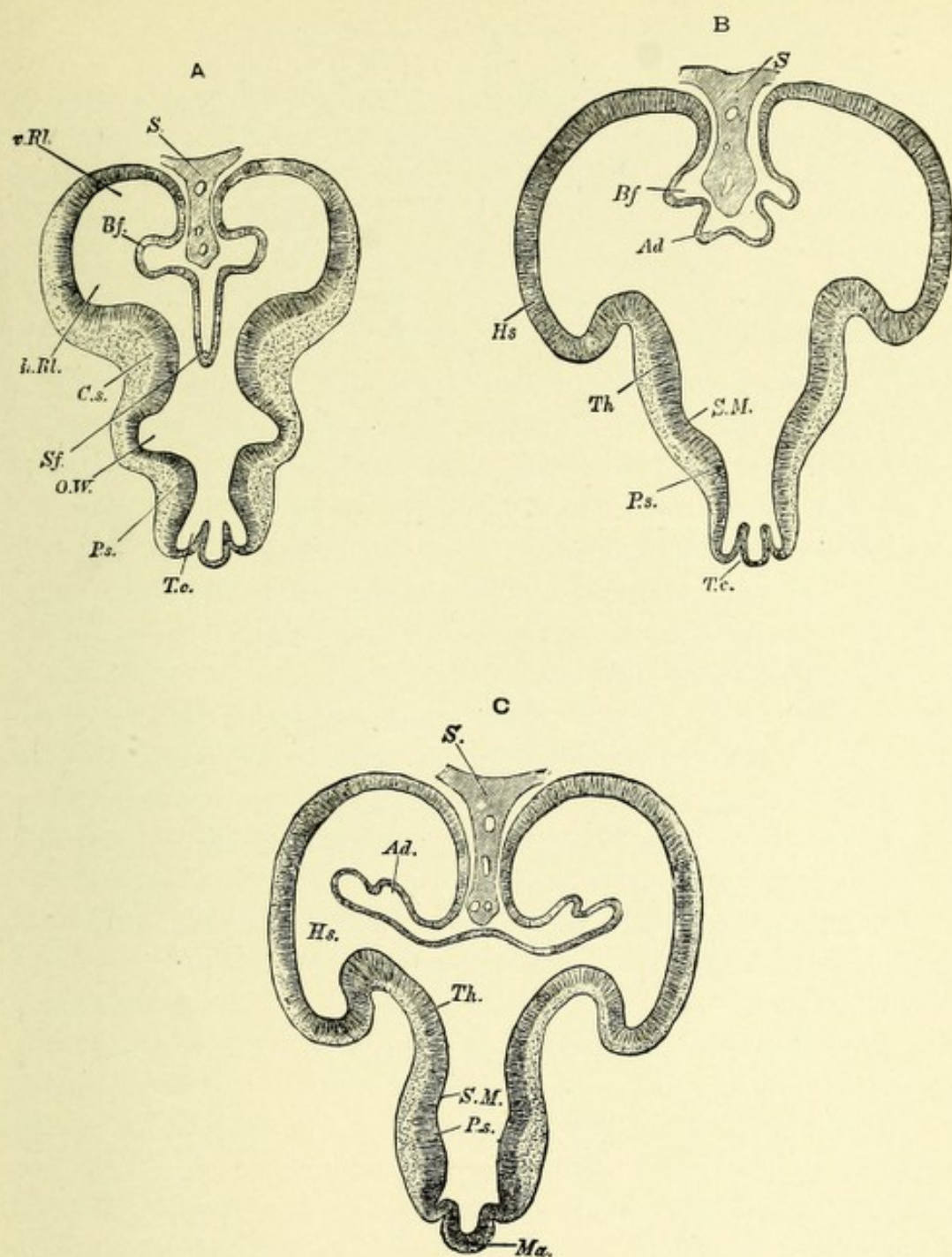



FIG. 259.—THREE SECTIONS THROUGH THE FORE-BRAIN OF A FOUR AND A HALF WEEKS' EMBRYO.—(*His, from Quain.*)

- A. Through the lower anterior part of the fore-brain. *S.* Falx. *Sf.* Fold of roof passing below falx toward the third ventricle. *Bf.* Fold forming the sulcus ammonis. *v.Rl.*, *h.Rl.* Anterior and posterior parts of olfactory lobe. *C.s.* Corpus striatum. *O.W.* Groove continuous with optic stalk. *Ps.* Pars subthalamica. *T.c.* Tuber cinereum.
- B. Section a little further back. *Sf.* is replaced by a less prominent but broader fold of the roof, *Ad.*, which subsequently receives the choroid vessels, and is, therefore, the choroid fold. *Hs.* Hemisphere vesicle. *Th.* Thalamus. *S.M.* Sulcus of Monro, below and behind the thalamus.
- C. Still further back. *Ad.* Choroid fold here projecting into lateral ventricles, but still free from mesoblast and blood-vessels. *Ma.* Mammillary tubercle. The other lettering as before.



The Optic Chiasm.—From the ventral part of the floor of the inter-brain there is formed a transverse ridge-like thickening through which later the fibers of the optic nerves pass; this is primitive optic chiasm.

DEVELOPMENT OF THE CEREBRAL HEMISPHERES.

The secondary fore-brain, or prosencephalon, develops at first as a single vesicle from the ventral wall of the primary fore-brain. This vesicle soon enlarges forward and upward and becomes divided by an infolding of the medullary wall in the median line in front, and above into two hemispherical vesicles, right and left. The groove produced as a result of the deep infolding of the medullary wall carries a process of connective tissue from the mesoblast, which becomes the falx cerebri, and the groove is called the longitudinal fissure. The median walls of each hemisphere come close together, being only separated by the falx cerebri lodged in the longitudinal groove; owing to this fact the median surfaces become flattened. Just in front of the ventral wall (lamina terminalis of His) of the cavity of the inter-brain (third ventricle), the median walls of the hemispheres are not separated by the falx cerebri, but form a solid septum somewhat triangular in shape, continuous behind with the lamina terminalis, in front with the corpus callosum, and below with the corpora striata. Within this septum in man is found a closed cavity which does not communicate with the general ventricular cavities; it is termed the fifth ventricle. The walls of the hemispherical vesicles are at first very thin, each inclosing a very large cavity—the lateral ventricle. The lateral ventricles communicate with the cavity of the inter-brain (third ventricle) by very large openings on each side—the foramina of Monro. These foramina gradually decrease in size, owing to an increase in growth of their walls, until they are converted into mere slit-like openings.

In connection with the study of the further development of the cerebral hemispheres must be considered, first, its extraordinary growth; second, the infolding of its thin walls to form a few deep primary fissures with corresponding projections into the ventricular cavities; third, the development of the commis-

tures through which each hemisphere is brought into functional relation with the other ; fourth, the development of numerous other infoldings or fissures varying in depth, but without corresponding internal projections.

The hemispherical vesicles grow very rapidly at first, forward, upward and outward, and then backward, so that at the third month they cover the region of the inter-brain (optic thalami), at the end of the fourth month they reach the mid-brain (corpora quadrigemina), and at the beginning of the sixth month they have completely covered the corpora quadrigemina and the

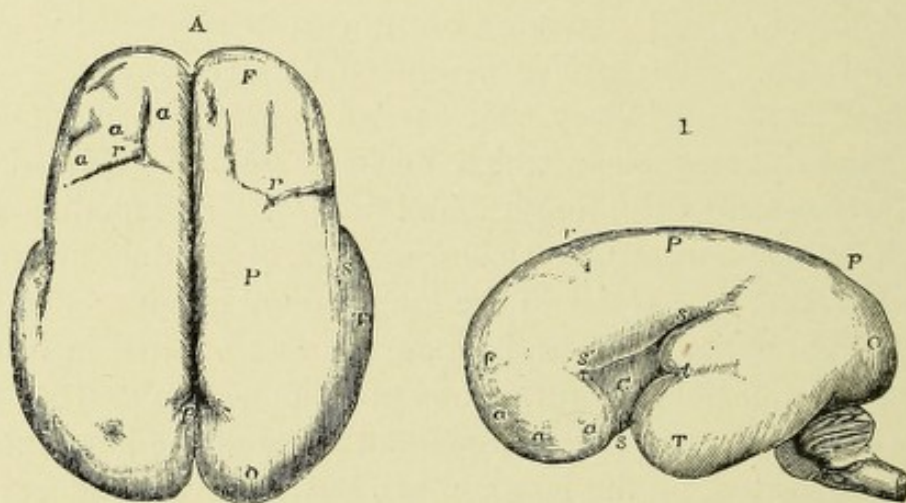


FIG. 260.—THE SURFACE OF THE FETAL BRAIN AT SIX MONTHS.—(*R. Wagner, from Quain.*)

This figure shows the formation of the principal fissures. A. From above. B. From the left side. F. Frontal lobe. P. Parietal. O. Occipital. T. Temporal. a, a, a. Slight appearance of sulci in the frontal lobe. s. Sylvian fissure. s'. Its anterior division. Within it, C, the central lobe. r. Rolandic sulcus. p. Parieto-occipital fissure.

greater part of the cerebellum, beyond which they project at the seventh month. (See Figs. 257, 259, and 260.)

The Fossa or Fissure of Sylvius.—This is the first primary sulcus to appear. It may be recognized as early as the fifth week of fetal life. It is at first discernible as a broad, shallow depression, which becomes gradually deeper, being due to an infolding of the convex walls of the hemispherical vesicle at the middle of its lower margin. The inner part of the wall of the depression becomes very much thickened, and forms an elevation which extends along the whole length of the floor of

the hemisphere, and projects into the cavity of the lateral ventricle. This is the primitive corpus striatum, and the thickening of which it is a part is continuous posteriorly with that part of the inter-brain which forms the optic thalamus. (See Fig. 257.) A part of this thickening on each side continuous with the outer part of the optic thalamus assists in the formation of the cerebral peduncles. The outer part of the hemispherical wall, which forms the floor of the fossa of Sylvius, afterward becomes the insula, or island of Reil, which at the ninth month is converted into a number of small gyri (gyri breves insula) by the formation of several small sulci. At the

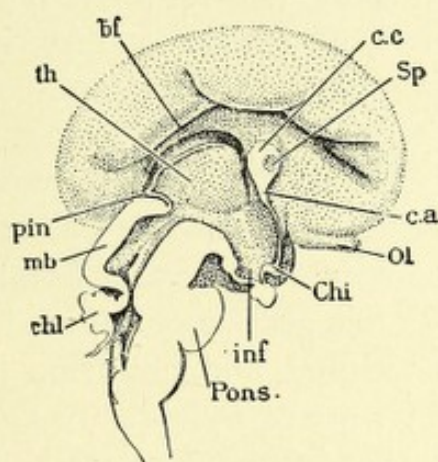


FIG. 261.—BRAIN OF A HUMAN EMBRYO OF ABOUT THREE MONTHS (ACCORDING TO MARCHAND, FOUR MONTHS).—(After F. Marchand, from Minot.)

th. Optic thalamus. bf. Bogenfurche. c.c. Corpus callosum. Sp. Septum lucidum. c.a. Anterior commissure. Ol. Olfactory lobe. Chi. Optic chiasma. inf. Infundibulum. Pons. Pons Varolii. cbl. Cerebellum. mb. Mid-brain. pin. Pineal gland.

fifth month the fossa of Sylvius becomes much deeper, of greater length, and has an oblique direction. The margins of the fossa, increasing in size, approach each other and completely conceal from view the island of Reil, forming for it an operculum, thus converting the fossa into the fissure of Sylvius. The anterior limb of the fissure is formed by an infolding of the wall just in front of the fossa of Sylvius. Owing to the formation of the fossa of Sylvius each hemisphere is divided into two primary lobes, one ventral, the other dorsal, to the fossa. The ventral one is called the frontal lobe, while the dorsal receives the name of the

temporal lobe. A part of this latter lobe develops backward toward the cerebellum and forms the occipital lobe (Fig. 260).

The lateral ventricles, because of the before-mentioned changes, are much reduced in size, and conform more or less to the shape of the hemisphere, being somewhat arched or ring-like in shape. That part of the lateral ventricle remaining in the frontal lobe is termed the anterior cornu, the portion which descends into the temporal lobe is called the middle or descending cornu, while the part which extends backward and inward into the occipital lobes is the posterior cornu.

Along the median line of the hemisphere is developed a fold which produces an external groove and a corresponding internal ridge. This groove is the **primary fissure, or Bogenfurche of His**. It begins in front at the olfactory lobe, which it divides into an anterior and a posterior part, and continuing backward in a curved direction joins a corresponding groove, the hippocampal sulcus, which is also the result of an infolding of the median wall of the temporal lobe. There is thus formed a long, arched fissure; hence its name, arcuate fissure, "Bogenfurche." The posterior end of this groove or fissure branches and forms the internal parieto-occipital and calcarine fissures. This primary fissure and the fissure of Sylvius are the only ones formed by an infolding of the hemisphere walls, all others being simple depressions of these walls. The internal ridge corresponding to the primary fissure or groove has the same arched course. The posterior half of the ridge forms the hippocampus major, or cornu ammonis, and that part of the ridge which corresponds to the branch known as the calcarine fissure develops the hippocampus minor, or calcar avis. Nothing is known of the further development of the anterior half of this ridge. The narrow portion of the hemisphere wall located just below this ridge is called the Randbogen, or gyrus arcuatus, a large part of which is occupied by the corpus callosum. The part of the Randbogen just dorsal to the corpus callosum is beset with a number of small, transverse ridges, and forms the dentate lobe; the posterior end becomes bent upon itself, forming the uncinat gyrus (Figs. 260 and 261).

The Choroid Fissure.—There appears in man at about

the fifth week of embryonic life an infolding into the lateral ventricle of the dorsal margin of the median surface of each hemispherical wall, which occasions an arch-like groove—the choroid fissure. This fissure extends from the foramen of Monro to the apex of the temporal lobe. It embraces the upper convex part of the corpus striatum and carries into the lateral ventricle a fold of vascular pia. The median wall which takes part in the formation of this fissure does not become thickened, but remains very thin, consisting only of a single layer of epithelium which becomes ultimately adherent to the outer surface of the pia, forming a covering for it. The very vascular pia now grows rapidly within the lateral ventricle, and consists of a number of villous tufts which at first quite fill the cavity of the ventricle, but later there is a considerable free space about them. These vascular folds on each side form the choroid plexuses of the lateral ventricle, and are continuous with the choroid plexus of the third ventricle by means of the foramen of Monro. In adult life the choroid plexus of each lateral ventricle becomes confined to the body and descending cornu of this ventricle.

DEVELOPMENT OF THE COMMISSURAL SYSTEM OF THE CEREBRAL HEMISPHERES.

At about the third month of fetal life fusion occurs between the median walls of the cerebral hemisphere in front of the terminal lamina, and forms a triangular septum continuous behind with the lamina and below with the corpora striata. The fusion of the walls occurs only at the periphery of this area, no union occurring in the middle portion. This middle portion, which forms the largest part of the area, is the septum lucidum and contains a closed cavity—the fifth ventricle. From this triangular area the anterior commissure, the corpus callosum, fornix, and septum lucidum take their origin. The anterior commissure is first made manifest by a local thickening just beneath the Bogenfurche and in front of the foramen of Monro, and consists of a few transverse fibers.

The genu of the corpus callosum is formed from the anterior

part of the triangular area; the pillars of the fornix from the posterior part, the intermediate or larger portion located between the fornix and genu of the corpus callosum, forms the septum lucidum.

Between the fifth and sixth months the union of the hemi-

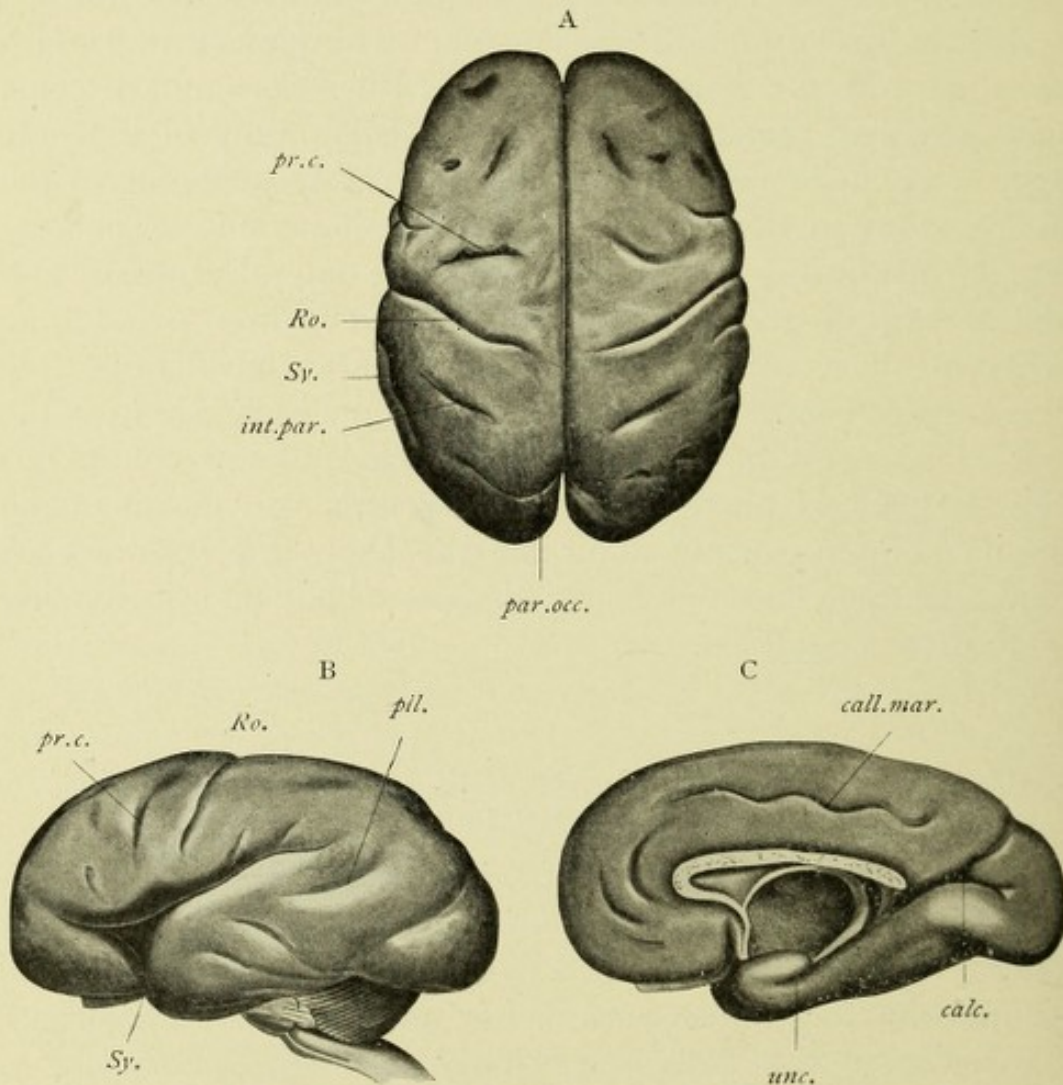


FIG. 262.—FETAL BRAIN OF THE BEGINNING OF THE EIGHTH MONTH.—(Mihalkovics, from Quain.)

A. From above. B. From the side. C. Mesial surface. *Ro.* Rolandic sulcus. *Sy.* Sylvian fissure. *par.occ.* Parieto-occipital. *calc.* Calcarine. *pr.c.* Precentral. *pill.* Parallel. *int.par.* Intraparietal. *call.mar.* Callosomarginal. *unc.* uncus.

spheres has extended backward, and involves that part of the hemispherical walls between the Bogenfurche above and the choroid fissure below, and is called the marginal arch, gyrus arcuatus, or Randbogen. From the anterior part of this curved ridge

originates the body and splenium of the corpus callosum and the fornix. The curved groove located above the body of the corpus callosum is the remains of the anterior part of the Bogenfurche, and is termed the fissure of the corpus callosum. The posterior part, located in the temporal lobes, forms the hippocampal fissure.

THE EVOLUTION OF THE FISSURES OF THE CEREBRAL HEMISPHERE.

The primary fissures are all formed by involutions of the hemispherical walls, with the production of corresponding elevations within the lateral ventricles. The secondary fissures are mere indentations or grooves of the surface of the brain without the production of internal ridges within the lateral ventricles. The primary fissures have already been described in connection with the general growth of the hemispherical vesicle. They comprise the fossa and fissure of Sylvius; the arcuate fissure, or Bogenfurche; the hippocampal, the parieto-occipital, and the calcarine fissures.

The secondary fissures are the callosomarginal, the fissure of Rolando, precentral, and the various other fissures of the frontal, parietal, and occipital lobes, together with those of the island of Reil.

The **callosomarginal fissure** takes its origin at the fifth month of fetal life in front and above the corpus callosum, by the union of two or three smaller fissures. Posteriorly, this fissure is prolonged backward and upward by joining a few shorter sulci, terminating just dorsal to the fissure of Rolando. That part of the hemispherical mantle between the callosomarginal fissure and the corpus callosum is called the gyrus fornicatus.

The Fissure of Rolando.—This fissure usually develops toward the end of the fifth month, and appears as two distinct limbs or grooves—an upper and a lower. The lower groove, much the larger, has a slight oblique direction, and when fully developed, forms the lower two-thirds of the fissure. It reaches downward almost to the fissure of Sylvius. Above, it is separated from the upper groove by an elevation of the cerebral

cortex (mantle). The upper groove or limb is much shorter and deeper than the lower, and is separated from the margin of the hemisphere by a narrow strip or cortex. The two limbs at first ununited soon join by the formation of a groove which runs over the summit of the intervening elevated portion of the cortex. Later in the course of development this fissure becomes much deeper and the elevated portion is displaced to the bottom of it, where it remains as a permanent elevation, indicating the point of junction between the two primitive grooves of which this fissure is composed. The fissure of Rolando forms the anatomic division between the frontal and parietal lobes.

The **precentral sulcus or fissure** originates at the end of the sixth fetal month in two distinct portions located in front of the fissure of Rolando. These portions usually remain entirely distinct from each other, although they occasionally unite. Between this sulcus and the fissure of Rolando develops the ascending frontal or anterior central convolution.

The **fissures or sulci of the island of Reil** are developed during the fifth and sixth months of embryonic life, and consist of three vertical sulci named from before backward—the precentral, the central, and the postcentral. The precentral sulcus appears as if continuous with its precentral fissure, the central sulcus with the fissure of Rolando, and the postcentral with the intraparietal fissure.

The **various fissures of the frontal, parietal, temporal, and occipital lobes** are formed about the sixth month of fetal life. In the frontal and temporal lobes their course is chiefly longitudinal, while in the parietal and occipital lobes their course is either oblique or vertical. These fissures serve to separate the above-mentioned lobes into gyri or lobules.

The development of the interior intraparietal and collateral fissures are worthy of separate description.

The *inter- or intraparietal fissure* appears at the sixth month as two distinct limbs—one dorsal to the fissure of Rolando and running parallel to it; the other has horizontal course below the margin of the hemisphere. The two sulci join during the eighth month, to form the main fissure. The intraparietal fissure separates the parietal lobe into a superior and an inferior parietal lobule.

The *collateral or occipitotemporal fissure* is formed at the sixth month. It consists of a deep, long, horizontal fissure located on the median surface of the temporal lobe near its lower margin, and produces an eminence in the descending horn of the lateral ventricle, known as the *eminencia collateralis*, or *pes accessorius*. By many this fissure is considered to be an infolding of the hemispherical wall, and should be classified with the primary fissures.

DEVELOPMENT OF THE CRANIAL NERVES.

The cranial nerve-roots are arranged into ventral or motor and dorsal or sensory. They are developed in a manner entirely similar to the spinal nerves. The neuroblasts in the upper cervical region of the cord form on each side two distinct longitudinal columns of cells, which are continued brainward along the floor of the cerebral vesicles, as far forward as the ventral part of the mid-brain. These two columns of neuroblasts correspond, in the fully developed cord, to the cell-groups existing in the ventral and lateral horns, and hence are distinguished as the ventral and lateral columns of (neuroblasts) cells. The neuroblasts of the ventral columns give origin to the following pairs of motor cranial nerves—viz.: hypoglossal, abducens, patheticus, and motor oculi. The neuroblasts of the lateral columns form the spinal accessory, motor divisions of the glossopharyngeal and pneumogastric (nucleus ambiguus), the facial and the motor division (portio minor) of the fifth or trigeminus.

The sensory fibers of the cranial nerves, with the exception of the optic and olfactory, are developed before the complete closure of the neural tube, from an outgrowth on each side called the neural bands, which serve to connect the dorsal part of the medullary ridges with the external epiblast. Soon this connection with the external epiblast is lost, and the two neural bands become united just dorsal to the point of junction of the medullary ridges, to form the neural canal. There is thus formed a neural crest, which extends along the mid-dorsal part of the neural tube as far brainward as the ventral part of the mid-brain

roof. This crest posteriorly is continuous with the neural crest of the spinal cord. From the paired outgrowths of the neural crest are developed the sensory ganglia of the cranial nerves, the fibers of which nerves represent the peripheral and central processes of the cells of these ganglia. These ganglia are in order, from below upward, the jugular, the petrosal, the geniculate, the auditory, and the Gasserian. They give origin, respect-

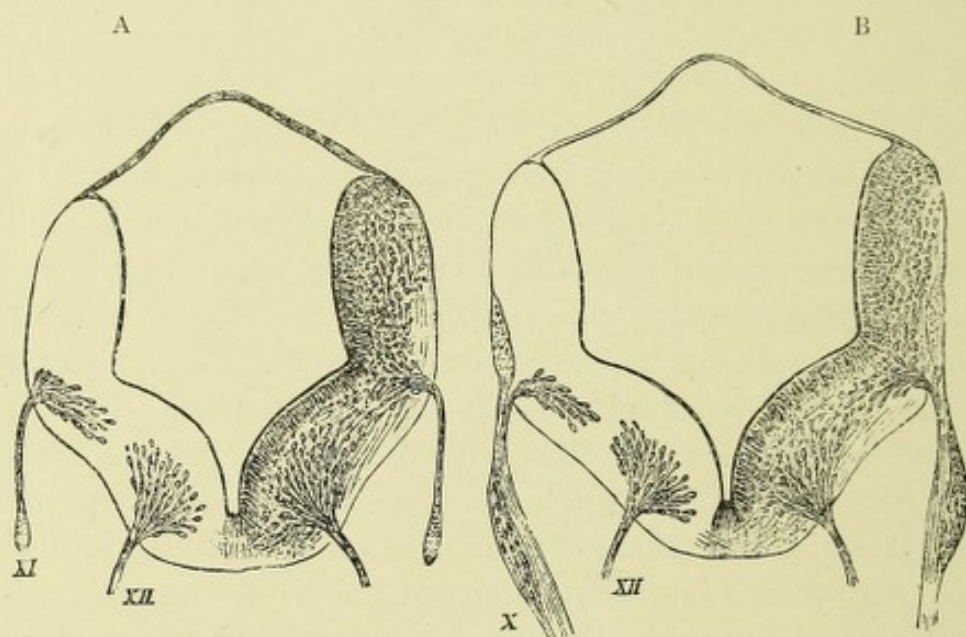


FIG. 263.—SECTIONS ACROSS THE HIND-BRAIN OF A HUMAN EMBRYO, 10 MM. LONG.—
(His, from Quain.)

In A, the origin of the spinal accessory and hypoglossal nerves is shown, the fibers of both arising from groups of neuroblasts in the basal lamina of the neural tube. In B, one of the roots of the hypoglossal is still seen, and, in addition, the root of the vagus nerve. This is represented as in part arising like that of the spinal accessory in A, from a group of neuroblasts in the basal lamina, and in part from a bundle of longitudinally coursing fibers placed at the periphery of the alar lamina, and corresponding in situation to the commencing posterior white columns.

ively, to the sensory divisions of the pneumogastric, the glosso-pharyngeal, the facial, the auditory, and the trigeminal nerves.

The ganglia, which are connected with the sensory cranial nerves, have the same histologic formation as do the posterior spinal ganglia. As development goes on, these ganglia shift their position and become more ventrally located.*

* All cells of the cerebral ganglia, with the exception of those of the auditory ganglia, become, later in development, unipolar.

The primitive cerebral ganglia contain embryonic cells bipolar in shape, each cell possessing a central and a peripheral axone. The central axones enter the cephalic part of the neural tube as sensory cranial nerve-fibers, and terminate about certain special collections of nerve-cells in the dorsal zones of different

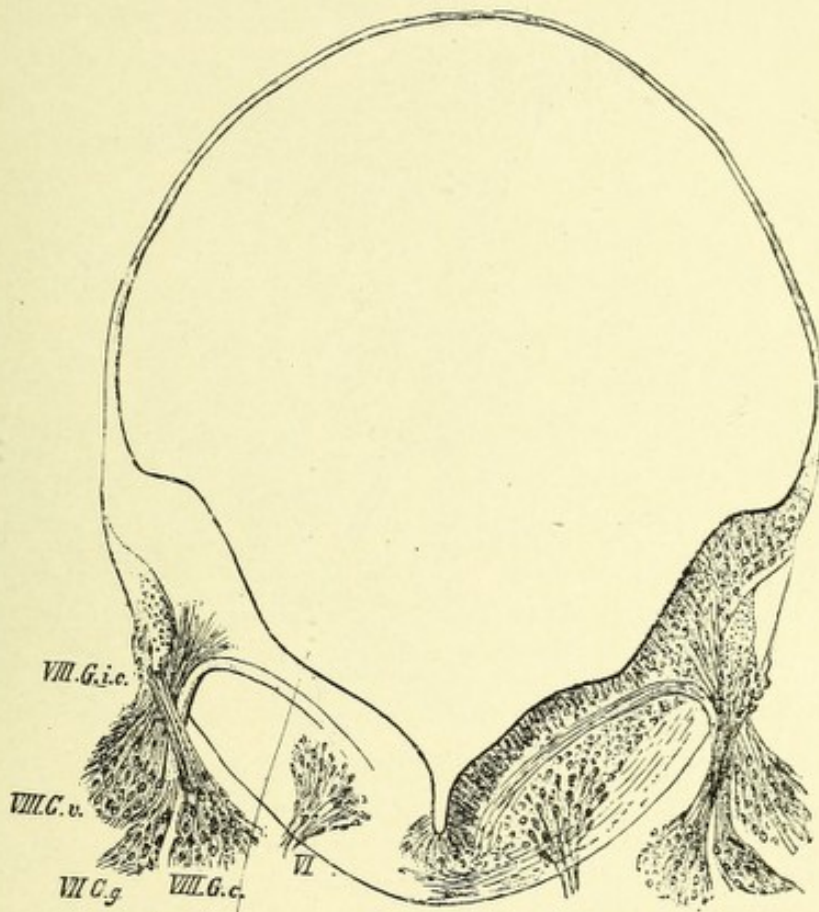


FIG. 264.—SECTION FROM THE SAME EMBRYO AT THE EXIT OF THE FACIAL NERVE. •
(Several sections have been combined to form this figure.)—(*His, from Quain.*)

VI. Fibers of sixth nerve taking origin from group of neuroblasts in basal lamina. VII.G.g. Ganglion geniculi of the facial. VIII.G.i.c. Intracranial ganglion of auditory. VIII.G.v. Ganglion vestibuli. VIII.G.c. Ganglion cochleæ.

segments of the neural tube. These groups of cells form for the central axones (sensory nerve-fibers) terminal end nuclei (formerly called the nuclei of origin for those nerves); the periphery (sensory) axones grow outward and join sensory end organs.

Central sensory axones from the cells of the ganglia connected with the pneumogastric and glossopharyngeal nerves penetrate

the medulla, and, curving downward, form on each side two oval bundles of descending fibers—the solitary bundles. These bundles at first are superficially located, but later become displaced rather deeply inward, and may be seen as roundish bundles, one on each side, slightly ventrolateral to the sensory end nuclei of the pneumogastric and glossopharyngeal nerves.

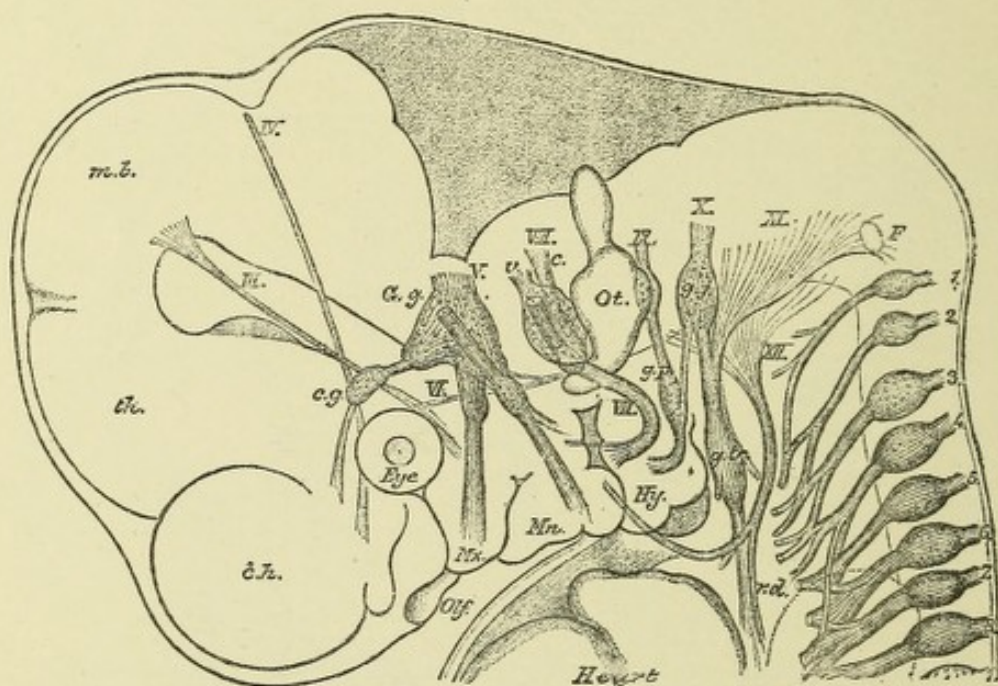


FIG. 265.—CRANIAL NERVES OF A HUMAN EMBRYO, 10.2 MM. LONG.—(His, from Quain.)

The cranial nerves are indicated by Roman, the spinal nerves by Arabic, numerals.

c.h. Cerebral hemisphere. *th.* Thalamencephalon. *m.b.* Mid-brain. *Mx.* Maxillary process. *Mn.* Mandibular arch. *Hy.* Hyoid arch. The facial nerve is seen to send a branch (chorda tympani) across the hyomandibular cleft. *G.g.* Gasserian ganglion. *c.g.* Ciliary ganglion. *v.* Vestibular, and *c.* cochlear, part of auditory. *g.p.* Ganglion petrosum of glossopharyngeal. *g.j.* Ganglion jugulare of vagus. An anastomosis is seen between these. *g.tr.* Ganglion trunci of vagus. *F.* Ganglion described by Froiep as belonging to the hypoglossal. *r.d.* Ramus descendens of hypoglossal. *ot.* Otic vesicle. The eye is also represented, and a part of the heart.

DEVELOPMENT OF THE OLFACTORY LOBE.

The olfactory lobe is formed about the fourth week of embryonic life as a hollow protrusion or fold of the hemispherical wall, extending forward from the ventral part of the under surface of the hemispheric vesicle, to form a distinct longitudinal ridge, separated by an internal groove. This pro-

trusion soon partially separates from the hemisphere, to form a blind, tubular-like process which is only connected at its base or posterior part with the hemispherical wall, its cavity communicating with the lateral ventricle, of which it is a part. The primitive olfactory lobe is crossed by the primary fissure, or *Bogenfurche* of His, which divides it into a ventral and a dorsal part. The ventral part gives origin to the olfactory tract and bulb and the trigonum olfactorium; from the dorsal part is developed the inner and outer olfactory roots, the peduncles of the corpus callosum, and the anterior perforated space.

The first process in the development of the olfactory nerves is the separation of the olfactory plates, which are the thickened parts of the epiblast united to the walls of the fore-brain vesicle. This takes place by an ingrowth of a process of the mesoblast. The second stage is the formation, by karyokinesis, of neuroblasts from the ectodermal cells of the olfactory plates. These neuroblasts soon assume a bipolar shape, and together form on each side a ganglion which lies between the epiblast (olfactory plate) and the olfactory lobe. At the end of the fifth week this ganglion grows upward and backward, and becomes located in a groove just dorsal to the anterior division of the olfactory lobe. It then grows ventrally, and surrounding the olfactory bulb, becomes fused with it, thus forming a superficial layer around it. The exact development of the peripheral olfactory nerves is not at present known. According to His, the bipolar cells of the above-described ganglia lengthen at each pole into centripetal or central olfactory nerve-fibers, and centrifugal or peripheral olfactory nerve-fibers, the latter being distributed to the olfactory mucous membrane. It seems more reasonable to believe that this ganglionic mass which forms the superficial gray layer, capping the ventral half of the olfactory bulb, gives origin to the mitral cells, whose axones form the central olfactory nerve-fibers and whose dendrites assist in the formation of the olfactory glomeruli, the peripheral olfactory apparatus consisting of the olfactory cells of the Schneiderian mucous membrane with their processes. (See page 325.)

DEVELOPMENT OF THE RETINA AND OPTIC NERVES.

The optic vesicles are developed as hollow protrusions, one from each side wall of the primary fore-brain. It will be remembered that the ventral wall of the fore-brain expands, and growing rapidly, forms the cerebral hemispheres, thus changing the position of the fore-brain so that it becomes located between the prosencephalon and the mid-brain, and is called the inter- or between-brain. Hence, the optic vesicles are attached on each side to the ventral wall of the inter-brain, just in front of the infundibular region. The distal part of each optic vesicle enlarges upward and outward, while the proximal hollow part becomes narrowed and is connected with the ventral wall of the brain. This narrow part is called the stalk, or pedicle of the optic vesicle, and is the rudiment of the optic nerve. The most prominent part of the optic vesicle joins the adjacent external epiblast, which becomes thickened and is thrust inward, pushing before it a part of the front wall and pedicle of the optic vesicle. The front wall of the optic vesicle is so completely invaginated that it nearly meets the posterior wall, and causes an almost complete obliteration of the cavity of the optic vesicle. The concavity thus formed, containing the involuted epiblast, is called the optic cup. The anterior or inner wall of this cup becomes much thickened, to form the retina, while the posterior or outer wall remains thin, and has deposited within its epithelial cells pigment, forming the pigment layer of the choroid. This hollow involuted portion of the epiblast forms the rudiment of the lens and becomes separated from the adjacent external epiblast by the closure of its mouth, remaining within the cavity of the optic cup close to its anterior wall. Later, owing to the more rapid growth of the walls of the optic cup and the slow growth of the lens, it becomes displaced forward and occupies the mouth of the cup, and has developed between it and the thickened anterior wall of the cup or retina, the vitreous humor.

During the time of the invagination of the epiblast to form the lens, a groove is formed along the lower border of the optic vesicle, extending backward from the epiblast to the stalk of the

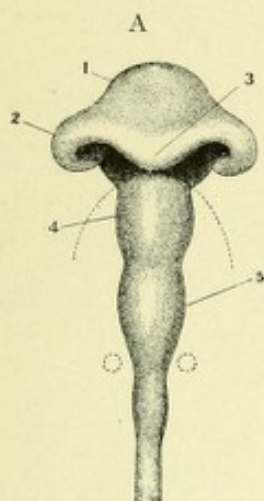


FIG. 266, A.—BRAIN OF CHICK OF SECOND DAY, VIEWED FROM BELOW, TO SHOW THE FORMATION OF THE OPTIC VESICLES BY OUTGROWTH OF THE SIDE OF THE FORE-BRAIN, AND AT THE SAME TIME BY THE FOLDING OVER OF THE ENLARGED PART, THE PRODUCTION OF A GROOVING OR CUPPING OF THE VESICLES.—(*His, from Quain.*)

1, 4, 5. Fore-, mid-, and hind-brain. 2. Optic vesicle. 3. Infundibulum.

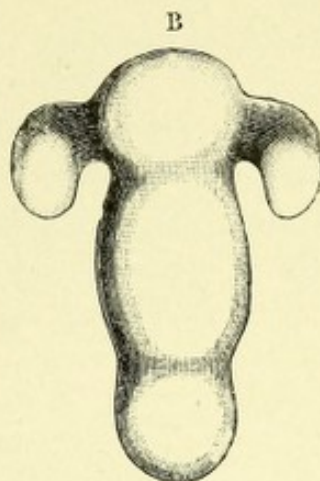


FIG. 266, B.—BRAIN OF HUMAN EMBRYO OF THREE WEEKS. Showing the primary optic vesicles as outgrowths from the fore-brain.—(*His, from Quain.*)

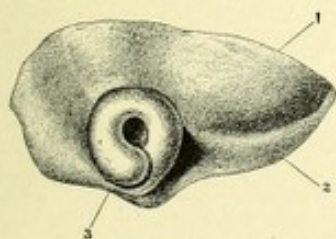


FIG. 267.—SIDE VIEW OF ANTERIOR PART OF BRAIN OF MORE ADVANCED HUMAN EMBRYO. Showing the primary optic vesicle folded and cupped.—(*His, from Quain.*)

1. Cerebral hemisphere (part of). 2. Olfactory lobe. 3. Optic cup.

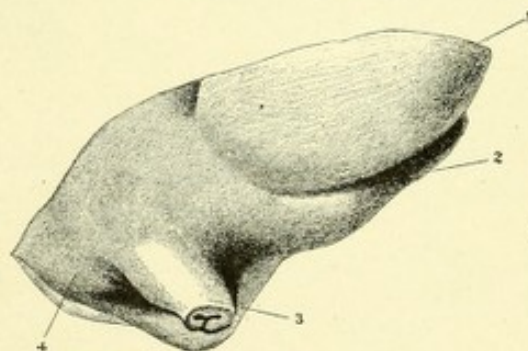



FIG. 268.—SIDE VIEW OF THE SAME PART OF THE BRAIN IN A STILL MORE ADVANCED EMBRYO, THE EYE HAVING BEEN CUT AWAY.—(*His, from Quain.*)

1. Cerebral hemisphere. 2. Anterior part of the olfactory lobe. 3. Cut end of optic stalk, showing the manner in which it is folded. 4. Tuber cinereum.



vesicle, whose walls do not coalesce, there remaining a cleft or fissure which receives the name of the choroid fissure; through this fissure a portion of vascular mesoblastic tissue surrounding the optic vesicle gains entrance to the cavity of the optic cup behind the lens, and forms the vitreous humor. This choroid fissure soon becomes obliterated by the coalescence of its walls, and thus the cavity of the optic vesicle is completely walled in, and is filled with the vitreous humor.

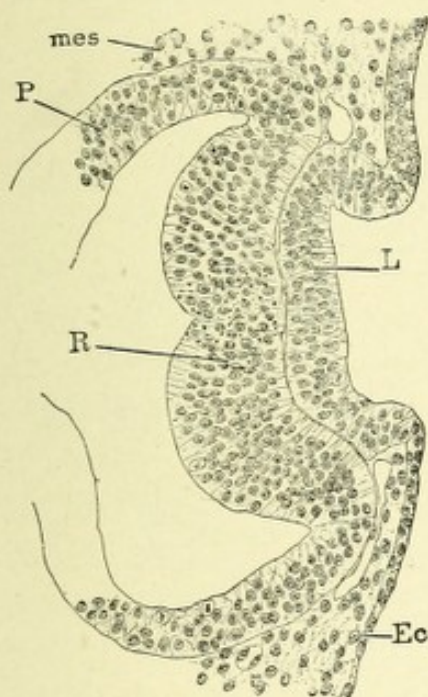


FIG. 269.—RABBIT EMBRYO OF TEN AND ONE-HALF DAYS; SECTION OF THE LENS ANLAGE.—(From Minot.)

mes. Mesoderm. P. Pigment layer. R. Retina. L. Lens. Ec. Ectoderm.

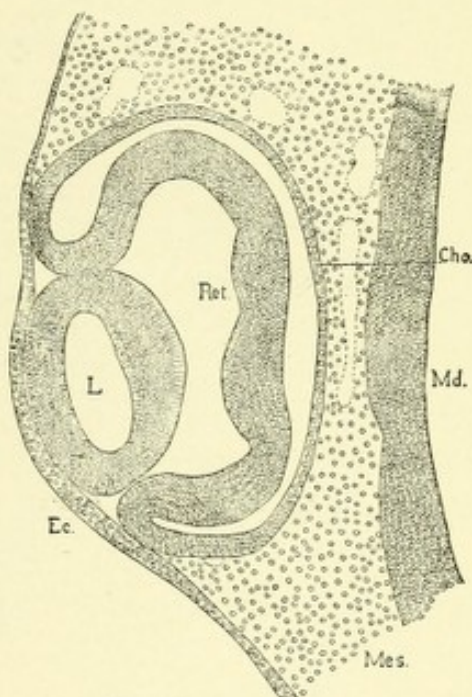


FIG. 270.—VERTICAL SECTION OF THE EYE OF A CHICK EMBRYO OF THE THIRD DAY.—(From Minot.)

Ec. Ectoderm. L. Lens. Ret. Retina. Cho. Choroid layer. Md. Wall of brain. Mes. Mesenchyma. $\times 128$ diam.

The closure of this fissure begins in front and gradually proceeds backward toward the retina; a small portion remains open, through which passes the arteria centralis retina, which courses inward to the concavity of the retina, where it branches, some branches passing through the vitreous, and being distributed to the posterior surface of the lens, producing the tunica vasculosa. The mesoblast which surrounds the optic cup, owing to increase in size of the latter, becomes condensed and forms for it a dis-

tinct investment, this being the outline of the eyeball. The portion of this investment within the cavity of the optic cup and close to the retina forms the choroid, while the external portion develops into the sclerotic coat.

The process of mesoblast which grows in between the lens and the external epiblast has developed within it a cavity which separates the mesoblastic process into two layers, an anterior

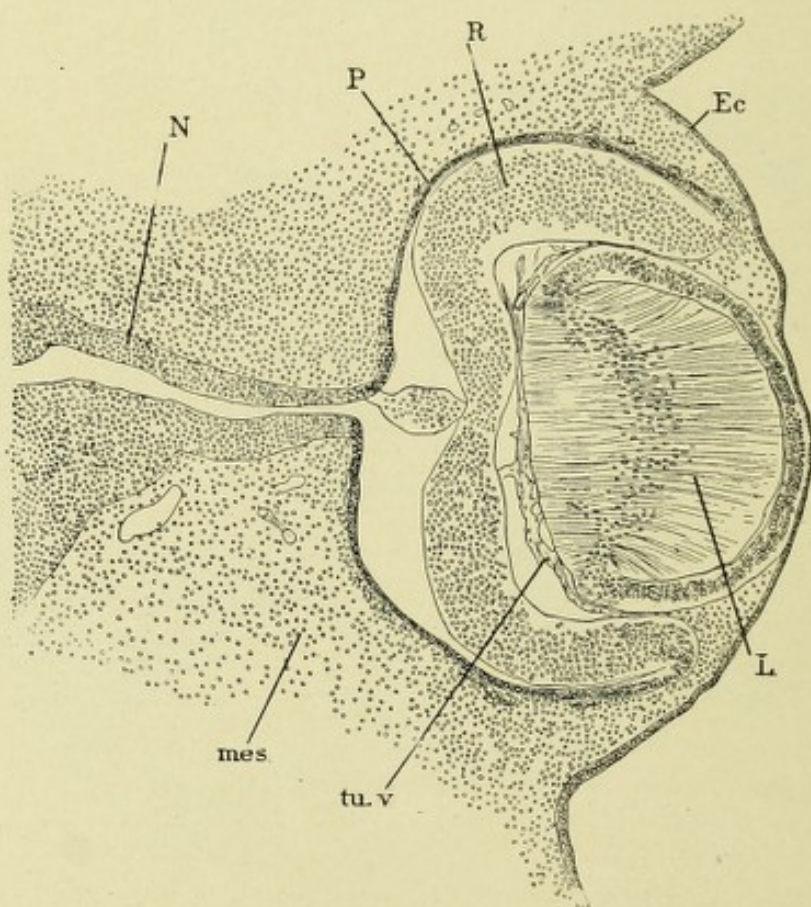


FIG. 271.—RABBIT EMBRYO OF THIRTEEN DAYS; SECTION OF THE EYE.—(From Minot.)
N. Optic nerve. P. Pigment layer. R. Retina. Ec. Epidermis. L. Lens. tu.v. Tunica vasculosa. mes. Mesenchyma.

and a posterior. From the anterior is developed the cornea, with the exception of its epithelium, while the posterior layer forms the iris. The cavity, at first between the two layers, but now located between the cornea and lens, is called the anterior chamber, and contains the aqueous humor.

The **retina** is developed from the inner (really the anterior) wall of the optic cup. The external (outer or posterior) wall

becomes thinned, has pigment deposited within its cells, and forms the pigment layer of the retina (choroid). Separating the retina proper from the pigment layer is the *membrana limitans externa*. The construction of the retina is not unlike that of the wall of the embryonal brain, consisting at first of several layers of elongated, nucleated spindle cells, which are transformed partly into nerve-cells and fibers, and partly into neuroglia cells and fibers, the latter forming the so-called sustentacular or supporting tissue. The retina grows rapidly in thickness; this is due to a multiplication of its cells, which become arranged into three layers, corresponding to similar layers in the walls of the embryonal nervous system. These are the ependymal layer or outer part, the mantel or intermediate layer, and the *Randschleier* or layer of nerve-fibers. The layer of nerve-fibers is separated from the vitreous by the *membrana limitans interna*.

The cells of the ependymal layer, which are located next the *membrana limitans externa*, form the outer nuclear layer, the layer of rods and cones, and possibly the molecular layer and the inner nuclear layer. The cells corresponding to the middle or mantel layer give origin to the inner molecular layer and the layer of ganglionic nerve-cells. The inner layer, or *Randschleier*, is the layer of nerve-fibers. The rods and cones are developed from elongated sensory cells in the outer nuclear layer.

The rods and cones of the retina are developed in man at birth, but in all animals that are born blind they are probably not developed until after birth. They first appear as small and large roundish projections over the surface of the external limiting membrane, the small projections being the cones, the large ones, the rods. Each of these projections is an outgrowth of cells which form the outer nuclear layer of the retina. They become elongated and penetrate the pigment layer, in which their tips become embedded.

The Optic Nerves.—The hollow optic stalks, or peduncles, of the optic vesicles which are attached to the ventral part of the inter-brain become solid by the growth of their walls and the consequent obliteration of their cavities. Each optic stalk is continuous anteriorly with the retina, and receives from the cells

of its ganglionic layer many axones which grow inward (centripetal fibers) into the optic stalk, and finally reach the primary optic ganglia of the same and the opposite side, terminating in arborizations about their nerve-cells. The crossed fibers form a chiasm (optic chiasm) in front of the infundibulum by passing through a ridge formed between the roots of the optic stalks. In many of the lower animals this decussation is complete, but in man it is incomplete. The optic stalk also contains fibers, axones of the cells of the primary optic ganglia, which grow outward (centrifugal fibers) through the optic stalk and ultimately terminate about the cells of the retina.

The solid optic stalks contain, at the time of the obliteration of their cavities, radially placed neuroglia cells whose processes form a meshwork through which the previously-mentioned nerve-fibers pass.

CHAPTER XIV.

TECHNIC OF THE MACROSCOPIC AND MICROSCOPIC EXAMINATION OF THE BRAIN AND SPINAL CORD.

In order to expose the brain, an incision through the scalp should be made, extending from one mastoid process to the other. Use a short scalpel, and cut from within outward to prevent injury to the hair. If this is found very heavy, as in some women, it is wise to part it at a line across the vertex, from mastoid to mastoid, and then braid each fold, one forward, the other backward, protecting them from soiling by covering with gauze. Dissect the anterior flap free from the temporal muscles and carry it forward nearly to the margin of the orbit. The posterior flap should be dissected back as far as the occipital protuberance.

The bone should now be bared of the temporal muscles and pericranium along the line of incision, which extends in a circular manner across the frontal bones behind the orbital ridges, thence downward and backward across the temporal and occipital bones to the occipital protuberance. Care should be taken not to saw through the inner table for fear of injuring the brain-tissue. The incision can be finished by severing the inner table with the chisel and mallet. When the calvaria is nearly free, it may be removed by inserting into the anterior part of the incision a blunt hook and pulling sharply backward.

With a blunt-pointed scissors cut through the dura along the lines corresponding to the incision, and fold each side of the dura inward, thus exposing the hemispheres; next, separate the falx cerebri from the crista galli by passing a knife downward on the left side to the falx, and then cut to the right until it gives way, pull the dura gently backward and let it hang.

The brain being exposed, with one hand push backward the frontal lobes and cut the exposed cranial nerves and carotid arteries close to their foramina. Then lift each temporal lobe in order, and cut through the tentorium cerebelli close to its attachment to the petrous bone. Supporting the convexity with the palm of one hand, tilt the brain backward, separating it from the cord as low down as possible, after having severed the cranial nerves from their points of attachment to the pons and medulla. The brain now being free, can be lifted gently out of the skull.

Of the several methods in use for sectioning the fresh brain, those described by Virchow and Pitres are all that could be desired to determine the location and extent of cerebral lesions. The method of Dejerine, while not so commonly used, is better for preserving fresh sections for subsequent microscopic study.*

VIRCHOW'S METHOD.

In this method the brain is placed on a flat surface, with its base down; the hemispheres are then carefully spread apart so as to expose the corpus callosum. A longitudinal incision is now made, close to the margin of the hemisphere, through the corpus callosum, into the body of the lateral ventricle, care being taken not to injure the basal ganglia; the incision is then extended forward and backward so as to expose the whole length of the ventricle with its anterior and posterior cornua. A second longitudinal incision is made outside of the basal ganglia, from one end of the hemisphere to the other. Incisions of a like character are to be made in the hemisphere of the opposite side. As many more longitudinal incisions through each hemisphere can be made as seems desirable, care being taken not to cut through the pia, as this membrane serves to

* METHOD OF DEJERINE.—The brain, resting on its upper surface, is first sectioned by a complete transverse incision through it, the incision starting through the ventral part of the pons just in front of the trigeminal nerves. The occipital and frontal lobes are separated by transverse incisions beginning at each extremity of the corpus callosum. A horizontal cut through each hemisphere is now made just above the caudate nucleus. If it is desirable to separate the attached cerebral hemispheres, this may be done by an incision through the corpus callosum and middle of the interpeduncular space.

hold the sections together, so that after the brain is sectioned they can be properly replaced. The remains of the corpus callosum and fornix are next cut through and reflected backward by passing the knife through the foramina of Monro, thus exposing the velum interpositum and choroid plexuses. By pulling back the velum interpositum, the third ventricle is brought into view. The corpora quadrigemina may be seen by cutting through the posterior pillars of the fornix. Frontal or transverse sections are now made from before backward through the basal ganglia. A longitudinal section is next made through the pineal gland, corpora quadrigemina, and worm (vermis) of the cerebellum, exposing the aqueduct of Sylvius and the fourth ventricle. The cerebellum is further divided by making median horizontal sections radiating from its peduncles. The brain is now turned over and the pons and medulla are divided into sections by several transverse incisions.

This method of Virchow is not suitable for further microscopic study, because the brain is already too much cut up. The following method of Pitres is well adapted for the gross and microscopic study of the sections :

PITRES' METHOD.

In this method the lateral ventricles are exposed in the same manner as in Virchow's method.

The pons, medulla, and cerebellum are separated from the hemispheres by cutting transversely through the crura cerebri, and may be sectioned in the same manner indicated in Virchow's method. The cerebral hemispheres are detached from one another by a longitudinal incision through the third ventricle. Each hemisphere is further divided into the following six sections by incisions made parallel to the fissure of Rolando and extending completely through the gray and white matter :

1. *Prefrontal Section*.—This section is made through the frontal lobe, five centimeters ventral to the fissure of Rolando. It shows the gray and white matter of that lobe.

2. *The pediculofrontal section* passes through the foot or base

of the three frontal convolutions, showing the ventral parts of the insula or island of Reil, the lenticular and caudate nuclei, and the internal capsule.

3. *The frontal section* is through the ascending frontal convolution, and shows the optic thalamus and lenticular and caudate nuclei, the internal and external capsules, the claustrum, the descending horn of the lateral ventricle, and the insula.

4. *The parietal section* passes through the ascending parietal convolution, and shows, in addition to the parts shown in the frontal section, the hippocampus major divided transversely.

5. *The pediculoparietal section* is made through the parietal lobe, three centimeters dorsal to the fissure of Rolando, and shows the tail of the caudate nucleus and the dorsal part of the optic thalamus.

6. *The occipital section* is through the occipital lobe, one centimeter anterior to the external parieto-occipital fissure, and shows the gray and white matter of the occipital lobe.

If it is not advisable to section the brain in its fresh state, it may be permitted to harden in a ten per cent. solution of formalin for a week or ten days, when it can be divided into a series of frontal or sagittal sections.

This method is particularly useful for the study of the gross or microscopic appearance and situation of lesions. It preserves the normal difference in color between the gray and white matter, and permits of staining by the methods of Weigert, Golgi, Nissl, and Van Gieson. Another solution which will be found useful to harden the cerebrospinal axis entire is Orth's fluid. It may be changed each day for three days. At the expiration of three weeks the hardening is complete, when it may be transferred to alcohol. This method permits of staining after the before-mentioned methods, save Nissl's. An excellent and well-known preservative solution for hardening the brain or spinal cord is Müller's fluid. This fluid consists of potassium bichromate 2 to $2\frac{1}{2}$ parts, sodium sulphate 1 part, water 100 parts. This fluid should be renewed each day for a week; it takes from six weeks to three months to harden properly. Specimens are then transferred directly into alcohol. This method of hardening is particularly useful for staining, by

Weigert's method, the Cox-Golgi, or by Berkley's modification of the Golgi method.

ORTH'S FLUID.

Potassium bichromate,	2 to 2.5 parts
Sodium sulphate,	1 part
Water,	100 parts
Formaldehyd (forty per cent. solution),	10 parts.

THE REMOVAL OF THE SPINAL CORD.

To remove the spinal cord, the body is placed with the face downward, the head projecting over the end of the table, with the chest elevated by placing a block beneath it. An incision is now made over the spinous processes of the vertebra to the bone extending from the occipital protuberance to the sacrum. The soft parts covering the vertebral lamina are dissected away from each side. The vertebral lamina are sawed through or cut, by means of a chisel, from the upper cervical to the lower lumbar. The lamina being free, the cervical arches are cut through with a chisel and the spinal processes of the lumbar vertebra are freed from their ligaments in the same manner. The dorsal portion of the spine with its processes can now be stripped away its whole length. The nerve-roots are severed on each side with a narrow-bladed knife. The membranes and cord are cut across high in the cervical region; the cord is then lifted from its position by taking hold of the dura with the forceps and separating it from above downward with a scissors and the handle of a scalpel. After the cord is removed, the dura is cut through longitudinally both in front and behind. The cord being supported by the fingers, is divided by a sharp scalpel into a number of transverse sections two centimeters apart.

DIFFERENTIAL STAINS FOR THE VARIOUS ELEMENTS OF THE NERVOUS SYSTEM.

In this description mention will be made of some of the methods which have been found particularly useful in staining

the elements of the nervous system. If the student is desirous of becoming familiar with all the methods now in use, he should consult the excellent works of V. Kahlden, B. Pollack, Mallory and Wright. The differential stains may be divided into those useful for staining nerve-cells and their protoplasmic granules, those for delineating the contour of cell-bodies and their protoplasmic processes, those for myelin sheaths, and those for neuroglia tissue. These do not include certain general stains to be described hereafter, which are not considered differential in character.

Staining of Nerve-cells after the Method of Nissl.—Small cubes of fresh nervous tissue 1 to 1½ centimeters in diameter, after having been hardened in ninety-six per cent. alcohol, are fastened to blocks by dipping the base of each cube into thick celloidin. Sections are cut very thin and placed into ninety-six per cent. alcohol. They are stained for about five minutes in the following solution of methylene-blue, which has been previously heated over a flame until it bubbles :

Methylene-blue (B. patent),	3.75
Venetian soap,	1.75
Aqua destillata,	1000

They are next differentiated in anilin oil 10 parts, alcohol (ninety-six per cent.) 90 parts, until the color ceases to be discharged in coarse clouds. Each section is now placed on a glass slide and thoroughly and carefully dried with filter-paper, and then cleared in oil of cajuput, again dried and washed with a little benzine ; lastly, add a few drops of benzine collophonium, and pass slide through a flame to drive off excess of benzine ; this ignites the benzine, which should be immediately blown out. This process should be repeated a few times until all the benzine is evaporated ; heat the slide, and cover with a thin cover-glass. By this method the cell-body with its protoplasmic granules are beautifully stained.

To Stain Nerve-cells with Thionin.—(1) Harden in ninety per cent. alcohol, then in absolute alcohol, or in formalin followed by alcohol ; (2) embed specimens in celloidin or paraffin ; (3) stain sections for five minutes in concentrated solution of thionin ; (4) wash quickly in water ; (5) differentiate in anilin

oil 1 part, absolute alcohol 9 parts; (6) clear in oil cajuput; (7) then in xylol; (8) xylol balsam.

Method of Bevan Lewis.—This method is well adapted for the study of the different cell-layers of the cortex as they normally exist. The nerve-cells, with their protoplasmic processes retaining their original size and shape, not having been altered by hardening reagents. This method also stains the axis-cylinder processes, neuroglia tissue, pia mater, and the connective tissue about blood-vessels.

A piece of brain-tissue about one inch in length and three-fourths of an inch thick is removed, care being taken to include the entire cortex and the overlying pia mater. It is then cut into fine sections by means of a freezing microtome. These sections are conveyed on the blade of the microtome knife to distilled water, and then immediately floated on to glass slides, the superfluous water being permitted to drain away. The sections are then covered for a few seconds with a one-fourth of one per cent. solution of osmic acid. This short contact with osmic acid simply fixes the myelin without producing a distinct osmic acid staining. The sections are now washed in distilled water for five or ten minutes. Each section is again floated on to a glass slide, the excess of water being drained off. They are stained on the slide for from a half to one hour with a one fourth of one per cent. solution of anilin blue-black. They are then washed in water and again floated on glass slides, where they are permitted to dry by exposure to the atmosphere. When thoroughly dry, they are mounted in Canada balsam. The nerve-cells and fibers are stained a bluish-gray color.

The following method, a **modification of Kronthal's**, is a very useful one, not only to show the nerve cell-body and its protoplasmic granules, but stains the axone and the dendritic processes, as well as the neuroglia. It stains capillary blood-vessels very beautifully. Fresh nervous tissue (brain or cord) is obtained, and a small bit of the gray matter is placed on a cover-glass, and is covered by another cover-glass. The two cover-slips are pressed together so as to spread the tissue out into as thin a layer as possible. The separated covers are permitted to dry in the air, and are stained for forty minutes in a

saturated solution of methylene-blue, then washed in water for a minute or two, dried in the air, and mounted in Canada balsam.

Golgi's Method for Staining Nerve-cells and Their Processes.—This method depends for its efficacy upon the precipitation of silver or mercury salts in the protoplasm of the nervous tissue. It was by this method discovered that the nervous system was made up of a multitude of units or neurones, which are perfectly independent anatomically and physiologically of each other.

Golgi's Rapid Method.—Harden small specimens (1 to $1\frac{1}{2}$ cm.) of young, fresh, nervous tissue in ten or more volumes of three per cent. bichromate of potash solution 4 parts, one per cent. osmic acid solution 1 part, in the dark for from two to eight days, depending upon what particular part of the nervous tissue you desire to impregnate. For neuroglia it must remain from two to three days; for nerve-cells, three to five days; for nerve-fibers, five to seven days.

The specimen, after having hardened, should be washed in three-fourths of one per cent. solution of silver nitrate and then placed for one or two days in one per cent. solution of silver nitrate. The section is next dehydrated for thirty minutes in ninety-six per cent. alcohol, and then cut without embedding between hardened liver, or by dipping it into thick celloidin and fastening it to a block, which is placed in chloroform to secure immediate hardening of the celloidin. The sections, not cut too thin, are dehydrated in absolute alcohol for a short time and cleared in cedar, clove, or bergamot oil, and mounted in Canada balsam with or without cover-slip.

Golgi's Slow Method.—Small cubes of fresh nervous tissue are placed in a recently prepared two per cent. solution of bichromate of potassium at room temperature for two to six weeks, or until sufficiently hard. They are then placed in 0.75 per cent. solution of silver nitrate for from one to four days, or in 0.5 per cent. solution of corrosive sublimate for two or three weeks. Proceed as in rapid method.

Berkley's Method of Impregnation.—The brain or cord is hardened in Müller's fluid until it is sufficiently hard to admit

of thin sections not more than three mm. in thickness. These are immersed in a mixture of a three per cent. solution of potassium bichromate and one per cent. osmic acid, in the proportion of one hundred parts of the former to twenty of the latter. In this mixture the pieces remain for three or five days; they are then removed from the fluid, dried slightly on filter-paper to remove any superfluous bichromate. They are next washed for a few minutes in a weak solution of silver nitrate, and then are placed into the staining mixture, which consists of two drops of ten per cent. solution of phosphomolybdic acid to each sixty cubic centimeters of a one per cent. solution of silver nitrate in distilled water. This mixture should be made fresh each time. Specimens remain in this solution from three to five days. Cut and mount as for Golgi specimens.

Cox's Modification of the Golgi Sublimate Method.—This method, because of its simplicity, is particularly useful for beginners. It stains all the elements.

A small tube of fresh tissue is permitted to remain for six weeks in summer and for three weeks in winter in the following mixture:

Five per cent. solution of potassium bichromate, . . .	20
Five per cent. solution of corrosive sublimate, . . .	20
Five per cent. solution of potassium chromate, . . .	16
Aqua destillata,	40

Sections are cut and mounted, as in the Golgi rapid method. Tissue previously hardened in Müller's fluid can be impregnated by this method. Bevan Lewis has recently modified this method by adding to the sections on a slide, after having come out of alcohol, a few drops of liquor potassæ and immediately washing off with a little distilled water. The addition of the liquor potassæ has the effect of bringing out the elements with intense blackness.

Weigert's Method of Staining the Myelin Sheaths.—To Weigert is due the credit of discovering a unique method of staining the myelin sheaths, which has become classic. It depends upon the fixation of the myelin with chrome salts so that it can not be dissolved by alcohol or ether, and acts as

a distinct mordant, permitting the myelin to stain very deeply with hematoxylin.

1. Harden the tissue in Müller's or Erlitzky's fluid.
2. Transfer specimens from hardening fluid immediately into ninety-six per cent. alcohol; then embed in celloidin.
3. Sections should be cut very thin and placed into equal parts of water and a saturated neutral solution of copper acetate for twenty-four hours.*
4. Stain for from thirty minutes to twenty-four hours in the following solution of hematoxylin :

Hematoxylin (Gruber's or Merck's),	1
Alcohol absolute,	10
Lithium carbonate,	1
Aqua destillata,	ad 100

5. Wash in water and differentiate for a few minutes to half hour in—

Borax,	2
Potassium ferricyanid,	2.5
Aqua destillata,	100

6. Wash immediately in water, dehydrate in alcohol, clear in xylol or origanum oil, and mount in Canada balsam.

Of the many modifications of Weigert's original method, the one devised by Pal is most generally used and gives very satisfactory results :

1. Harden specimens as for Weigert's method.
2. Place section for overnight in three per cent. solution potassium bichromate, or for several hours in a one-half per cent. solution of chromic acid.
3. Stain sections in Weigert's hematoxylin for twenty-four to forty-eight hours.
4. Wash in water plus four per cent. of a saturated solution of lithium carbonate, until sections appear of a uniform deep-blue color.

* Weigert now recommends instead of this solution :

Copper acetate,	5
Acetic acid, 36 per cent. solution,	5
Chrome alum,	2.5
Water,	ad 100

5. Differentiate in a freshly prepared one-third per cent. solution of potassium permanganate until gray matter appears yellowish brown, about half a minute.

6. Continue differentiation in the following solution until the gray matter appears white and the white matter is of a dark-blue color :

Oxalic acid,	1
Potassium sulphite,	1
Distilled water,	200

If sections do not differentiate quickly, transfer them again to permanganate solution for a few seconds and then repeat step 6.

7. Wash thoroughly in water, dehydrate in ninety-five per cent. alcohol, clear in xylol or origanum oil, and mount in Canada balsam.

ERLITZKY'S FLUID.

Potassium bichromate,	2.5
Cuprum sulphate,5
Aqua,	100.0

Specimens harden at room temperature in from ten to fourteen days.

Marchi's Method.—1. Fix small pieces (2–3 mm.) of nervous tissue for eight to fourteen days in Müller's fluid.

2. Transfer to a mixture composed of equal parts of Müller's fluid and one per cent. solution of osmic acid for six to twelve days.

3. Wash in running water for twenty-four hours.

4. Harden in alcohol, embed in celloidin, cut, and mount in Canada balsam containing no chloroform.

This method is very useful in studying secondary degenerations.

NEUROGLIA STAINS.

Differential Stain for Neuroglia Fibers.—*Method of Mallory.*—1. Fix very fresh human nervous tissue in a four per cent. aqueous solution of formaldehyd for four or more days.

2. Place in a saturated aqueous solution of picric acid four to eight days.

3. Transfer to a five per cent. aqueous solution of bichromate

of ammonia for four to six days in the incubator at 37° C., or for three to four weeks at room temperature; change solution on the second day.

4. Place directly into alcohol.
5. Embed in celloidin.
6. Fasten sections to slide by means of ether vapor.
7. Stain in anilin-gentian violet fifteen to twenty minutes.
8. Wash off with normal salt solution.
9. Iodin solution 1 : 2 : 100 for one minute, or a stronger solution for a few seconds.
10. Wash thoroughly with water.
11. Dry with filter-paper.
12. Decolorize in equal parts of anilin oil and xylol.
13. Wash off thoroughly with xylol.
14. Mount in xylol balsam.

The neuroglia, nuclei, and to some extent red blood-corpuscles are stained blue. The other tissue elements are colorless.

Mallory's Phosphotungstic-acid Hematoxylin Method for Staining Neuroglia.—1. Fix in four per cent. aqueous solution of formaldehyd four days.

2. Saturated aqueous solution of picric acid four days.
3. Five per cent. aqueous solution of bichromate of ammonium four days to six days in incubator, or three or four weeks at room temperature.
4. Stain sections in phosphotungstic-acid hematoxylin four to twenty-four hours.
5. Wash in water.
6. Alcohol.
7. Clear in oleum origani cretici.
8. Mount in xylol balsam.

Neuroglia fibers and nuclei are stained blue, connective tissue deep pink, axis-cylinders light pink, myelin sheaths yellow, protoplasm of ganglia cells and dendrites purplish or bluish gray. Mallory recommends staining sections at first lightly in Van Gieson's mixture, which stains the axis-cylinders a deep-red color.

STAINS FOR AXIS-CYLINDER PROCESSES.

Neutral carmin is an excellent stain for axis-cylinders, also stains nerve-cells very well. Sections should remain in it for twenty-four hours, when they should be thoroughly washed in water, dehydrated in alcohol, cleared in clove oil, and mounted in Canada balsam. To prepare neutral carmin, dissolve without heat one gram of carmin in 50 c.c. of aqua destillata, plus 5 c.c. aqua ammonia. Expose the mixture to the air until no ammoniacal odor exists; filter, and keep tightly corked.

To stain axis-cylinders with **nigrosin** proceed as follows :

1. Stain sections for five or ten minutes in a saturated watery solution of nigrosin.
2. Decolorize in dilute alcohol, then in absolute alcohol.
3. Clear in oil of origanum; mount in Canada balsam.

This very simple method gives beautiful results. It stains well the ganglion cells and their protoplasmic processes. Degenerated areas are stained a bluish black.

Van Gieson's Method.—1. Specimens should be hardened in Müller's fluid or alcohol.

2. Stain for from five minutes to one-half an hour in alum hematoxylin.
3. Wash thoroughly in water.
4. Stain for three to five minutes in Van Gieson's solution, which consists of one per cent. aqueous solution of acid fuchsin, 15 c.c. saturated aqueous solution of picric acid, 50 c.c. aqua destillata.
5. Wash in water for a short time.
6. Dehydrate in alcohol; clear in clove oil; mount in Canada balsam.

The axis-cylinders and ganglion cells are deep red, myelin sheaths yellow, neuroglia red, nuclei lilac.

STAINS FOR END ORGANS, TERMINATIONS OF NERVES, AND COLLATERAL BRANCHES.

Method of Gerlach.—1. Tissue should be hardened in one or two per cent. solution of ammonium bichromate for three weeks ; when specimen is sufficiently hard, it should be sectioned under water without the use of alcohol. Put sections in a $\frac{1}{100}$ per cent. solution of chlorid of gold and potassium.

2. Acidulate with a few drops of hydrochloric acid for twelve hours, or until they become of a slight violet color.

3. Wash in a very weak solution of hydrochloric acid, 1 : 2000.

4. Put sections in a $\frac{1}{10}$ per cent. solution of hydrochloric acid, and in sixty per cent. alcohol for ten minutes.

5. Absolute alcohol ; clear in clove oil ; mount in Canada balsam.

Method of Freud.—1. Harden specimens at first in Ertlitzky's or Müller's fluid, then in alcohol.

2. Embed in celloidin, cut sections and place them in a one per cent. solution of chlorid of gold for three to five hours.

3. Wash in water and bring sections for reduction in a solution composed of sodium hydrate 1, aqua destillata 5, for three minutes.

4. Wash in water and place sections for from five to fifteen minutes in ten per cent. solution of potassium iodid, until sections appear reddish violet.

5. Wash in water, dehydrate in alcohol, clear in xylol, and mount in Canada balsam.

Method of S. Ramón y Cajal to show the collaterals.—

1. Rather thin sections of fresh rabbit's brain are brushed over with a saturated solution of methylene-blue (B. Gruber), or methylene-blue in a powder is dusted over the sections ; after three-quarters of an hour the sections are washed in weak saline solution.

2. Fix in solution of—

Ammonium molybdate,	10
Distilled water,	100
Hydrochloric acid,	10 drops

for two or three hours.

3. Wash in water to remove excess of ammonium molybdate, and harden for three to four hours in—

Formalin,	40
Distilled water,	60
One per cent. solution platinum chlorid,	5

4. Wash quickly to remove the formalin for several minutes in a three per cent. alcoholic solution of platinum chlorid. Embed in paraffin.

5. Thick sections are dehydrated in alcohol absolute with the addition of $\frac{1}{3}$ per cent. platinum chlorid; clear in xylol; mount in Canada balsam.

Ehrlich's Vital Methylene-blue Method (*Modified by SemiMeyer*).—1. Hypodermic injection of methylene-blue BX solution (saturated at 37° C.), 2 c.c. at intervals of fifteen to thirty minutes. Ready after three to six injections.

2. Brain to be cut into two or three pieces and put into the following solution for twenty-four hours at a temperature of 32° F.:

Ammonium molybdate,	10
Distilled water,	100
Hydrochloric acid, conc.,	10 drops.

3. Wash in running water for two hours.

4. Place specimens in eighty per cent. alcohol for one-half to one hour, then in ninety-five per cent. alcohol for same length of time, and then into several changes of absolute alcohol. All No. 4 at ice temperature (32° F.).

5. Xylol (several times to be renewed); embed in paraffin.

6. Cut, clear in xylol, and mount in Canada balsam.

GENERAL STAINS.

Hematoxylin is the most useful of the general stains. It stains the nuclei and connective tissue, and stains quite well the ganglion cells and processes. The following formulæ contain hematoxylin as the base, and will be found useful in staining nervous tissue:

PHOSPHOMOLYBDIC-ACID HEMATOXYLIN (MALLORY).

Hematoxylin crystals,	1.75 grams
One-half per cent. aqueous solution of phosphomolybdic acid,	200 c.c.

Expose solution to light in a bottle plugged with absorbent cotton; it will be ready for use in six weeks.

1. Stain section from twenty minutes to one hour.
2. Wash in two or three changes of fifty per cent. alcohol until celloidin becomes completely decolorized.
3. Dehydrate in ninety-five per cent. alcohol, clear in clove oil, and mount in balsam.

EHRLICH'S ACID HEMATOXYLIN.

Hematoxylin crystals,	2 grams.	
Alcohol, absolute,	60 c.c.	
Acetic acid (glacial),	3 c.c.	} Saturated with ammonia alum.
Water,	60 c.c.	
Glycerin,	60 c.c.	

This solution is exposed to the light for three weeks, when it is ready for use. Specimens are stained for a few minutes, washed in water, dehydrated in alcohol, cleared in xylol or oil, and mounted in Canada balsam.

AQUEOUS ALUM HEMATOXYLIN SOLUTION.

Hematoxylin crystals,	1
Saturated aqueous solution of ammonia alum,	100
Water,	300
Thymol,	a few crystals.

The solution should be exposed to the light for about two weeks, when it is ready for use. The author prefers this solution to Delafield's. Excellent contrast stains are eosin and anilin blue-black; the latter stains the axis-cylinders and protoplasmic processes.

Stain with alum hematoxylin for a few minutes, then place sections in watery solution of eosin until sections are stained red, wash in water, dehydrate quickly in alcohol, clear in clove oil, and mount in Canada balsam.

Stain with alum hematoxylin for a few minutes, then place sections direct in a five per cent. watery solution of anilin blue-black for a few seconds, wash, clear, and mount as above. The nerve-cells are stained bluish, while the neuroglia cells are stained a lilac.

INDEX.

- A.**
- Abducens nerve, 166
- Accessory nucleus, 76, 185
- Acervulus cerebri, 247
- Acoustic nucleus, anterior, 173
ventral, 172
- Acousticocerebellar tract, 166, 177, 207
- Adventitial lymph-space, 58, 63
- Agraphia, 472
- Ala cinerea, 135
- Alexia, 470
- Alternate hemiplegia, 490
- Alveus, 318, 354, 356, 394
- Amacrine cells, 265
- Amnesic aphasia, 468
- Amygdaloid nucleus, 399
- Amygdalum, 190
- Amyotrophic lateral sclerosis, 501
- Anastomotic vein, great, 439
posterior, 439
- Angular gyrus, 308
- Ansa lenticularis, 402
- Anterior cerebral artery, 422
choroid artery, 424
commissure of spinal cord, 74
communicating artery, 421
inferior cerebellar arteries, 431
- Anterolateral arteries, 423
- Aphasia, amnesic, 468
motor, 472
of conduction, 486
tactile, 471
verbal, 468
- Apices cornuum posteriores, 74
- Aqueduct of Sylvius, 210
development of, 530
Sylvian, 132
- Arachnoid, cerebral, 284
spinal, 65
villi, 287
- Arantius, ventricle of, 135, 136
- Arborization, 200
- Arborizations, interepithelial, 38
- Arcuate fibers, 164
anterior external, 204
antero-external, 165
external, 204
internal, 144
postero-external, 165
- Area of Broca, 335
posterior, of medulla, 126
- Areas, lateral, of medulla, 126
- Arkyostichochrome nerve-cells, 21
- Arm-area of cerebral cortex, 451, 452
- Arnold, substantia reticularis of, 355
- Arterial supply of cerebrum, 417
to medulla oblongata, 432
to pons Varolii, 432
- Arteries, anterior inferior cerebellar, 431
anterolateral, 423
carotid, 418
inferior cerebellar, 431
lenticulo-optic, 424
lenticulostriate, 424
long, of brain, 416
middle cerebellar, 431
of brain and cord, 58
of cerebral dura mater, 283
posterior cerebral, 425
superior cerebellar, 430
vertebral, 425
- Artery, anterior cerebral, 421
choroid, 424
communicating, 421
ascending frontal, 422
parietal, 422
basilar, 425
inferior frontal, 422
internal auditory, 425
marginofrontal, 421
middle cerebral, 422
of cerebral hemorrhage, 424
parietotemporal, 423
posterior communicating, 424
meningeal, 425
quadrate, 421
sphenoid, 423
Sylvian, 422
- Articular end bulbs, 40
- Ascending frontal artery, 422
parietal artery, 422
- Association, centers of, of cerebral cortex, 507
fibers of centrum ovale, 364
zones of, of cerebral cortex, 507
- Astrocytes, 56
- Ataxic paraplegia, 503
- Atrophy, progressive muscular, 501

- Auditory artery, internal, 425
 centers, 462
 nerve, 171
 connections of, 175
 dorsomesial nucleus of, 174
 nucleus, anterior, 173
 dorsolateral, 174
 dorsomesial, 174
 sphere of cerebral cortex, 507
- Axilemma, 34
- Axioplasm, 33
- Axis-cylinder, 31
 nigrosin for staining, 571
 of Purkinje, 32
 process, 47, 49
 processes, stains for, 571
- Axone, 31, 47, 49
- B.**
- Back-muscles, nucleus for, 79
- Baillarger, outer line of, 339
- Basal ganglia, lesions of, 488
- Basilar artery, 425
 sinus, 444
 vein, 437
- Basket cell of cerebellum, 28
 cells, 199
- Bechterew and Flechsig, central tegmental tract of, 152
 nucleus of, 175, 182
 olivary tract of, 105
- Berkley's method of impregnation, 566
- Bipolar nerve-cells, 24
- Blood-supply of spinal cord, 122
- Blood-vessels, cortical, 416
 of brain, 416
 of central nervous system, 58
 of cerebellum, 430
- Bodenplatte, 525
- Bodies, olivary, 126
 restiform, 164
- Body, Luys', 259, 260
 Nissl, 18
 pituitary, 276
- Bogenfurche of His, 542
- Boundary zone, 114
- Brachia conjunctiva, 202
- Brachial enlargement of spinal cord, 69
- Brain, blood-vessels of, 416
 central vessels of, 416
 ganglionic vessels of, 416
 long arteries of, 416
 membranes of, 280
 motor area of, 449
 technic of microscopic and macroscopic examination of, 559
 venous systems of, 435
- Brain-sand, 247
- Broca, area of, 335, 471
 space of, 335
- Brown-Séquard's paralysis, 504
- Buds, 200
- Bulb, 69, 125
 of internal jugular vein, 445
 olfactory, 319, 328
 fourth layer of, 332
- Bulb, olfactory, large mitral cells of, 330
 layer of central nerve-fibers of, 332
 molecular layer of, 330
 outer layer of, 328
 pyramidal cells of, 330
 superficial layer of medium and small-sized cells of, 331
- Bulbar paralysis, acute, 499
- Bundle, comma-shaped, 99
 hemispherical, 337
 inferior longitudinal, 368
 Meynert's, 257
 of gyrus fornicatus, 364
 of Vicq d'Azyr, 253, 324, 413
 posterior, 337
 longitudinal, 82
 nucleus of, 230
 superior longitudinal, 230
 triangular, 105
- Burdach, column of, 84, 91, 99, 126
 nucleus of, 144
 fasciculus arcuatus of, 368
- Buschzellen, 254
- C.**
- Cajal cells, 50, 52, 343
 varieties of, 344
 commissural nucleus of, 158
 method of staining, 572
- Calamus scriptorius, 132, 136
- Calcar avis, 300, 397
- Calcarine fissure, 300
- Callo-marginal fissure, 303, 545
- Canal, central, of spinal cord, 74, 122
 neural, 508
- Capillaries of nervous system, 60
- Caps, nuclear, 18
- Capsule, internal, 399, 407
 localization of lesions of, 488
- Caput cornu, 72
- Carmin, neutral, for staining axis-cylinders and nerve cells, 571
- Carotid arteries, 418
- Cauda equina, 69
- Caudate nucleus, 399
- Cavernous sinuses, 446
- Cavum Meckelii, 280
- Cell-bodies, 47
- Cell-group for upper extremity, 79
- Cell-processes, 30
- Center for ideas, 467
 reception of appearance of objects gained through sense of touch, 470
 of heard words, 466
 of memories for appearance of objects seen and of words written or printed, 469
 of muscular memories necessary to produce speech, 471
 retraction of angle of mouth, 453

- Center for smell, 483
 for taste, 482
 for writing, sensory, 479
 half-vision, 461
 olfactory, 483
- Centers, auditory, 462
 cortical, for general sensations, 454
 for writing, 475
 for language, 465
 of association of cerebral cortex, 507
 of vision, 457
 which preside over higher intellectual faculties, 480
- Central canal of spinal cord, 74, 122
 convolutions, 307
 anterior, 305
 gyrus, posterior, 306
 sulcus, 310
 vessels of brain, 416
- Centrum ovale, association fibers of, 364
 localization of lesions in, 484
 minute anatomy of, 338, 362
 of parietal lobe, lesions of, 486
 semiovale, lesions of, beneath motor area, 485
 of occipital lobe, 487
 of temporal lobe, lesions of, 486
- Cerebellar arteries, inferior, 431
 middle, 431
 superior, 430
 commissures, 207
 hemisphere, lobules of inferior surface of, 190
 lobules of superior or dorsal surface of, 190
 hemispheres, lesions of, 494
 tract connecting occipital and temporal lobes with, 221
 lesions, localization of, 493
 peduncle, inferior, 182, 203
 middle, lesions of, 495
 peduncles, 202
 middle, 203
 superior, 202, 229
 tract, anterolateral descending, 104
 descending, 204
 direct, 90, 95, 143, 204
 sensory, 166, 177
 tracts, direct, 203
 sensory, 207
 veins, inferior, 441
 superior, 440
- Cerebello-olivary tract, 160, 164, 207
- Cerebellum, 186
 anterior commissure of, 207
 basket cell of, 28
 blood-vessels of, 430
 connections of, 187
 of vestibular nerve with, 176
 cortex of, 198
 development of, 528
 inferior peduncles of, 188
- Cerebellum, inferior vermiform process of, 186
 lesions of middle lobe of, 493
 of worm of, 493
 middle lobe of, 186
 peduncles of, 188
 minute anatomy of, 193
 peduncles of, 188
 posterior commissure of, 208
 superior peduncles of, 188
 upper surface of, 187
 veins of, 440
 vermiform process of, 186
 worm of, 186, 188
- Cerebral arachnoid, 284
 arteries, posterior, 425
 artery, anterior, 421
 middle, 422
 central branches of, 423
 ganglionic branches of, 423
 cortex, auditory sphere of, 507
 centers of association of, 507
 connection of optic thalamus with, 251
 divisions of, according to Flechsig, 506
 histology of, 338
 layers of, 338
 olfactory sphere of, 507
 projection spheres of, 507
 sensory spheres of, 507
 stratum zonale of, 338
 tangential fibers of, 339
 visual sphere of, 507
 zones of association of, 507
 dura mater, 280
 hemisphere, development of commissural system of, 543
 evolution of fissures of, 545
 primary fissures of, 545
 secondary fissures of, 545
 hemispheres, base of, 318
 development of, 538
 general anatomy of interior of, 387
 hemorrhage, artery of, 424
 localization, 448
 peduncles, 220
 pia mater, 288
 vein, anterior, 437
 middle, 437
 veins, 435
 deep, 440
 superficial, 436
 vesicles, primary, 508
 secondary, 511
- Cerebrospinal fluid, 286
- Cerebrum, 293
 anterior commissure of, 336
 arterial supply of, 417
 central fissure of, 299
 choroid fissure of, 297
 convolutions of, 303

- Cerebrum, convolutions of mesial surface of, 315
 fissures of, 294
 of external surface of, 294
 gyri of, 303
 inferior longitudinal fissure of, 319
 lobules of, 303
 longitudinal fissure of, 293, 294
 peduncles of, 325
 secondary fissures of, 294
 transverse fissure of, 294
- Cervical enlargement of spinal cord, 69
 region of spinal cord, 117
- Cervix cornu, 72
- Charcot, posterior root-zone of, 91
- Chiasm, optic, 274
 development of, 539
- Choroid artery, anterior, 424
 fissure of, 542
 of cerebrum, 297
 plexuses, 288
 of fourth ventricle, 291
 vein, 440
- Chromophyllic granules, 18
- Chromoplasm, 17
- Ciaglinski, long sensory tract of, 106
- Cingulum, 364
- Circle of Willis, 429
- Circular sinus, 444
- Cisterna magna cerebellomedullaris, 285
- Clarke, Lockhart, vesicular column of, 83
- Clastrum, 407
- Clava, 131
- Cochlear nerve, 171
- Collateral branches, stains for, 572
 fissure, 547
- Collaterals, 50
- Color-vision, 462
- Column, anterior, of spinal cord, 84
 lateral, connections of vestibular nerve with, 177
 of Burdach, 84, 91, 99, 126
 nucleus of, 144
 of Flechsig, 83, 90, 143, 203
 of Goll, 84, 91, 99, 126
 nucleus of, 131, 144
 of Lissauer, 114
 postero-internal, of spinal cord, 91
 vesicular, 83
- Columns, anterior, of medulla, 126
 lateral, ground bundles of, 107
 nuclei of, 143
 of medulla, 126
 of spinal cord, 84
 of Türk, 89
 posterior, course of fibers of, 97
 of spinal cord, 84
- Comma-shaped bundle, 99
 fasciculus, 114
- Commissural cells of spinal cord, 83
 nucleus of Cajal, 158
 system of cerebral hemisphere,
 development of, 543
- Commissure, anterior, 372, 400
 of cerebellum, 207
- Commissure, anterior, of cerebrum, 336
 of spinal cord, 74
 gray, of spinal cord, 74, 75
 inferior, of Gudden, 275
 Meynert's, 276
 middle, of third ventricle, 245
 posterior, of cerebellum, 208
 of pineal gland, 248
 of spinal cord, 74, 75
 soft, of third ventricle, 245
 white, of spinal cord, 74
- Commissures, cerebellar, 207
 of spinal cord, 71
- Communicating artery, anterior, 421
 posterior, 424
- Conarium, 246
- Conduction, aphasia of, 486
- Conus medullaris, 69
 terminalis, 115
- Convolution, anterior central, 305
 first temporal, 313
 inferior parietal, 308
 temporal, 314
 marginal, 315
 middle temporal, 314
 of corpus callosum, 316
 second temporal, 314
 superior temporal, 313
 third temporal, 314
- Convolutions, central, 307
 motor, 307
 occipital, 309
 of cerebrum, 303
 of mesial surface of cerebrum, 315
 superior parietal, 307
 temporoparietal, 310
 veins of, 438
- Cord, central ligament of, 69
 dorsal, 69
 spinal, 64
- Cornu ammonis, 353, 394
 anatomy of, 350
 commissural tract, 100, 101
- Cornua, anterior, of spinal cord, 72
 of lateral ventricle, 393
 of spinal cord, 72
- Corpora albicantia, 324
 development of, 536
 mammillaria, 324
 development of, 536
 quadrigemina, 210
 development of, 530
 lesions of, 488
 restiformia, 188, 203
 striata, 398
 trapezoidea, 175, 180
- Corpus callosum, 293, 319, 371, 387
 convolution of, 316
 genu of, 414
 lesions of, 487
 peduncles of, 388
 ventricle of, 393
- ciliare, 194
 dentatum, 194
 fimbriatum, 394

- Corpus striatum, vein of, 440
trapezoideus, 194
- Corpuscles of Golgi, 43
Pacinian, 41
tactile, 39
Vater's, 41
- Cortex, cerebral, auditory sphere of, 507
centers of association of, 507
divisions of, according to
Flechsig, 506
histology of, 338
layers of, 338
olfactory sphere of, 507
projection spheres of, 507
sensory spheres of, 507
tangential fibers of, 339
visual sphere of, 507
zones of association of, 507
of cerebellum, 198
pyramidal cells of, 28
stratum zonale of, 338
- Cortical area for muscles of trunk and spine,
453
governing motion, 449
blood-vessels, 416
cells, layers of, 343
center for general sensations, 454
for smell, 483
for taste, 482
for writing, 475
fibers, layers of, 343
layer, molecular, 343
outer, 343
superficial, 343
- Cox's modification of the Golgi sublimate
method of staining, 567
- Cranial nerve, fifth, superior or accessory nu-
cleus of, 240
nerves, development of, 547
eleventh pair of, 139
fourth pair of, 240
sensory fibers of, 547
third pair of, 235
twelfth pair of, nuclei of origin
of, 151
- Crossed paralysis, 490
- Crosses of Frohmann, 34
- Cross-legged progression, 500
- Crura cerebri, 325
development of, 530
lesions of, 489
- Crusta, 220, 325
- Culmen, 189
- Cuneate lobule, 190
- Cuneus, 316
- Cup, optic, 552
- Cytochrome nerve-cells, 22
- D.**
- Deckplatte, 525
- Declive, 189
- Decussation, interolivary, 144, 224
motor, 140
optic, 320
posterior pyramidal, 144
- Decussation, pyramidal, 140
sensory, 144
superior sensory, 224
- Degeneration, secondary, 87
- Deiter, large-celled nucleus of, 174
nucleus of, 182
protoplasmic processes of, 47
spider-cells of, 56
- Dejerine's method of sectioning brain, 560
- Dendrites, 47, 48
function of, 48
number of, 48
- Dentate gyrus, 318
ligament, 66
- Diaphragma sellæ, 283
- Diencephalon, 511
- Digastric lobule, 190
- Dorsal cord, 69
funiculi, course of fibers of, 97
region of spinal cord, 116
- Doyère, eminences of, 45
- Dura, 64
mater, cerebral, 280
arteries of, 283
nerve-supply of, 284
processes of, 281
- E.**
- Edinger, tegmental radiation of, 403
- Edinger's nucleus, 230
- Ehrlich's vital methylene-blue method of
staining, 573
- Eleventh pair of cranial nerves, 139
- Embryology of central nervous system, 508
- Eminences of Doyère, 45
- Eminentia cinerea, 135
collateralis, 300, 394
teres, 168
- Emissary veins, 447
- End bulbs, articular, 40
of Krause, 40
- Endocranium, 280
- Endoneurium, 36
- End-organs, stains for, 572
- Enlargement, brachial, of spinal cord, 69
cervical, of spinal cord, 69
lumbar, of spinal cord, 69
- Epencephalon, 186
- Ependyma, 135, 354, 393
- Epidural space, 64
- Epineurium, 36
- Epiphysis cerebri, 246
- Erb's palsy, 500
- Eyelids, elevation of, center for, 453
- F.**
- Face-area of cerebral cortex, 451, 452
- Facial nerve, 168
connections of, 171
- Falciform lobe, 317
sinus, 442
vein, 443
- Falx cerebelli, 282

- Falx cerebri, 281
 Fascia dentata, 318, 359
 Fasciculi cerebrospinalis lateralis, 90
 garland-like, 208
 teretes, 135
 Fasciculus arcuatus, 364, 368
 cerebellospinalis, 75
 inferior longitudinal, 39
 occipitofrontalis, 369
 olivary, 105
 perpendicular, 370
 retroflexus, 257
 superior longitudinal, 368
 thalamomammillaris, 253, 413
 uncinatus, 368
 ventrolateralis superficialis, 103
 Fasciola cinerea, 318
 Fibers, projection-system of, 373
 Fibræ arcuatae propria, 364
 Fibrillæ, primitive, 33
 Fields of innervation, 45
 Fifth cranial nerve, superior or accessory
 nucleus of, 240
 ventricle, 414
 Fila olfactoria, 326
 Fillet, internal or mesial, connections of vestibular nerve with, 177
 lateral, 181, 228
 connections of vestibular nerve with, 177
 mesial, 144, 180, 223
 Filum terminale, 69, 92
 Fimbria, 318, 394
 Fissure, anterior longitudinal, of spinal cord, 71
 calcarine, 300
 callosomarginal, 303, 545
 central, of cerebrum, 299
 choroid, 542
 of cerebrum, 297
 collateral, 547
 dorsal, of spinal cord, 71, 72
 inferior longitudinal, of cerebrum, 319
 interparietal, 300, 546
 intraparietal, 300, 546
 lateral, 300
 longitudinal, of cerebrum, 293, 294
 occipital, 299
 occipitotemporal, 547
 of Rolando, 299, 545
 of Sylvius, 298
 development of, 540
 parieto-occipital, 299
 posterior longitudinal, of spinal cord, 71
 of spinal cord, 72
 postero-intermediate, of spinal cord, 72
 precentral, 546
 prepyramidal, 190
 primary, 542
 Sylvian, 320
 transverse, of cerebrum, 294
 ventral, of spinal cord, 71
 Fissures of cerebral hemisphere, evolution of, 545
 Fissures of cerebrum, 294
 of external surface of cerebrum, 294
 of frontal lobe, 546
 of island of Reil, 546
 of occipital lobe, 546
 of parietal lobe, 546
 of temporal lobe, 546
 primary, of cerebral hemisphere, 545
 secondary, of cerebral hemisphere, 545
 of cerebrum, 294
 Flechsig, anterior ground-bundles of, 90
 columns of, 83, 90, 143, 203
 nucleus vestibularis of, 175
 posterior ground-bundle of, 91
 Fleece, 197
 Flocculus, 190
 Fluid, cerebrospinal, 286
 Folds, medullary, 508
 Foramen cæcum, 125
 of Magendie, 132, 285
 of Monro, 246
 Foramina of Key and Retzius, 285
 Forceps major, 393
 minor, 390
 posterioris, 397
 Fore-brain, 293
 Formatio reticularis, 146, 180
 alba, 148, 180
 grisea, 146, 180
 Fornix, 249, 373, 413
 Fossa of Sylvius, development of, 540
 Sylvii, 298
 Fourth pair of cranial nerves, 240
 Fovea inferior, 135
 superior, 135
 Frænulum lingulae, 189
 Freud, method of staining of, 572
 Frohmann, crosses of, 34
 lines of, 33
 Frontal artery, ascending, 422
 inferior, 422
 gyrus, ascending, 305
 first, 303
 inferior, 304
 middle, 304
 second, 304
 inferior part of dorsal portion of, 304
 superior, 303
 third, 304
 lobe, 303
 fissures of, 546
 Frontocerebellar tract, 222, 353
 Funiculi, dorsal, course of fibers of, 97
 teretes, 135
 Fuss, 220

 G.
 Galen, veins of, 440
 Ganglia, basal, lesions of, 488
 of sensory cranial nerves, 548
 spinal, 109
 Ganglion cell, 17
 habenulae, 249, 257
 interpeduncular, 258

Ganglion, spinal, posterior, 71
 Ganglionic cells of retina, 264
 vessels of brain, 416
 Garland-like fasciculi, 208
 Gemmules, 48, 200
 Geniculate body, external, 250
 internal, 250
 lateral, 250
 Genu of corpus callosum, 414
 Gerlach, method of staining of, 572
 Giant pyramidal cells, 29
 Glands, Pacchionian, 287
 Glia-cells, 56
 Globus pallidus, 399
 Glomeruli, olfactory, layer of, 329
 Glossopharyngeal nerve, 155
 motor nucleus of, 158
 Golgi, corpuscles of, 43
 Golgi's method for staining nerve-cells and
 their processes, 566
 rapid method of staining, 566
 slow method of staining, 566
 Goll, column of, 84, 91, 99, 126
 nucleus of, 131, 144
 Gowers and Bechterew, anterolateral ascend-
 ing tract of, 233
 anterolateral ascending tract of, 80,
 90, 103
 Gowers' tract, 385
 Granular nerve-cells, 24
 Granules, chromophyllic, 18
 of Nissl, 18
 protoplasmic, 18
 Gray commissure, 74, 75
 matter of spinal cord, 71
 neuroglia of, 121
 substance, intermediate, 74
 Groove, medullary, 508
 posterolateral, of spinal cord, 72
 Ground bundle of fibers, lateral, 233
 posterior, 91
 bundles, anterior, 107
 function of, 107
 of Flechsig, 90
 of lateral columns, 107, 234
 Gudden, inferior commissure of, 275
 Gyri of cerebrum, 303
 Gyrochrome nerve-cells, 22
 Gyrus, angular, 308
 ascending frontal, 305
 parietal, 306
 cinguli, 316
 dentatus, 359
 anatomy of, 350
 first frontal, 303
 occipital, 309
 fornicatus, 316
 bundle of, 364
 hippocampal, 350
 hippocampus, 317
 inferior frontal, 304
 occipital, 309
 lingual, 300
 marginal, 315
 middle frontal, 304
 occipital, 309

Gyrus, occipitotemporal, middle, 300
 posterior central, 306
 postparietal, 308
 rectus, 306
 second frontal, 304
 occipital, 309
 superior frontal, 303
 occipital, 309
 supramarginal, 308
 third frontal, 304
 occipital, 309
 uncinate, 318

H.

Half-vision center, 461
 Helweg, triangular bundle of, 105
 Hematoxylin as a general stain, 573
 Hemiplegia, alternate, 490
 Hemispherical bundle, 337
 Hemisphere, cerebral, development of com-
 missural system of,
 543
 evolution of fissures
 of, 545
 primary fissures of, 545
 secondary fissures of,
 545
 Hemispheres, cerebral, base of, 318
 development of, 539
 general anatomy of
 interior of, 387
 Hilum of olivary body, 160
 Hippocampal gyrus, 350
 Hippocampus major, 394
 anatomy of, 350
 minor, 300, 397
 His, Bogenfurche of, 542
 spaces of, 58
 Horn of spinal cord, head of, 82
 neck of, 72
 Horns, anterior, of spinal cord, 72
 lateral, of spinal cord, 72
 posterior, of spinal cord, 72, 122
 Hypoglossal nuclei, connections of, 152
 nucleus of Roller, 152
 Hypophysis cerebri, 246, 276, 323

I.

Ideas, center for, 467
 Incisures of Lantermann, 35
 of Schmidt, 35
 Infantile spinal paralysis, 501
 Inferior cerebellar arteries, 431
 frontal artery, 422
 Infundibulum, 246, 279, 323
 development of, 532
 Innervation, fields of, 45
 Insula, 310
 Intellectual faculties, higher, centers which
 preside over, 480
 Interannular segment, 34
 Interbrain, 244, 511
 Intercallatum, 263

- Intermediate gray substance, 74
 Internal auditory artery, 425
 capsule, 399, 407
 localization of lesions of, 488
 Internodal segment, 34
 Interolivary decussation, 144, 224
 Interparietal fissure, 300, 546
 Interpeduncular ganglion, 251, 258
 space, 323
 Intraparietal fissure, 300, 546
 Intrinsic cells of spinal cord, 80
 Island of Reil, 310
 Iter a tertio ad quartum ventriculum, 211
- J.**
- Jugular vein, internal, bulb of, 445
- K.**
- Karyochrome nerve-cells, 22
 Karyoplasm, 17
 Keimzellen, 513
 Key, 131
 and Retzius, foramina of, 285
 Krause, end bulbs of, 40
 ventriculus terminalis of, 74
 Kronthal's method of staining, modification of, 565
 Kühne, fields of innervation of, 45
- L.**
- Labbe, posterior anastomotic vein of, 439
 Labia cerebri, 393
 Lacunæ venosæ lateralis, 283, 442
 Lamina medullaris circumvoluta, 355
 involuta, 359
 Laminæ medullares, 252
 Lancisi, nerves of, 389
 Language, centers for, 465
 Lantermann, incisures of, 35
 Laryngeal muscles, center for, 453
 Lateral arteries of pons and medulla, 432, 434
 columns, nuclei of, 143
 fissure, 300
 limiting layers, 90, 107
 nuclei, 143
 sinuses, 445
 ventricles, 393
 Leg-area of cerebral cortex, 451, 452
 Lemniscus, lateral, 181, 228
 mesial, 144, 223
 Lenticular loop, 399, 402
 nucleus, 399
 Lenticulo-optic arteries, 424
 Lenticulostriate arteries, 424
 Lewis, Bevan, method of staining of, 565
 Ligamentum denticulatum, 66
 Lingula, 132
 Limbic lobe, 317
 Lines of Frohmann, 33
 Lingual gyrus, 300
 lobule, 316
 Lingula, 188
 Lissauer, column of, 114
 Lissauer's tract, 106
 Lobe, falciform, 317
 frontal, 303
 limbic, 317
 occipital, 308
 olfactory, 327
 development of, 550
 orbital, 305
 parietal, 306
 quadrate, 306, 316
 slender, 193
 temporosphenoid, 313
 Lobule, cuneate, 190
 diaphragmatic, 190
 inferior semilunar, 193
 lingual, 316
 paracentral, 305
 postcentral, 310
 precentral, 310
 Lobules of cerebrum, 303
 of inferior surface of cerebellar hemisphere, 190
 of superior or dorsal surface of cerebellar hemisphere, 190
 Lobus centralis, 189
 gracilis, 193
 quadratus, 190
 Localization, cerebral, 448
 Locomotor ataxia, 502
 Locus cæruleus, 243
 niger, 263, 325
 Long arteries of brain, 416
 Longitudinal sinus, inferior, 443
 superior, 442
 Loop, lenticular, 399, 402
 Lumbar enlargement of spinal cord, 69
 region of spinal cord, 115
 Luys' body, 259, 260
 Lymphatics of nervous system, 58, 61
 Lymph-canals, perivascular, 58
 Lymph-space, adventitial, 58, 63
 Lymph-spaces, pericellular, 63
 Lyra, 414
- M.**
- Magendie, foramen of, 132, 285
 Mallory, method of, for staining neuroglia fibers, 569
 Mallory's phosphotungstic-acid hematoxylin for staining neuroglia, 570
 Marchi and Lowenthal, anterolateral descending tracts of, 90, 104, 204
 Marchi's method of staining, 569
 Marginal convolution, 315
 gyrus, 315
 sinus, 443
 Marginofrontal artery, 421
 Martinotti, cells of, 349
 Median arteries of pons and medulla, 432, 433
 Medulla, anterior columns of, 126
 pyramids of, 126
 lateral areas of, 126
 columns of, 126

- Medulla, median septum of, 146
 oblongata, 69, 125
 arterial supply to, 432
 development of, 525
 lesions of, 496
 posterior area of, 126
 raphe of, 146
 spinalis, 64
 transverse section of, at level of first
 cervical nerve, 137
 transverse section of, at level of
 motor crossway, 140
 transverse section of, near junction
 with pons, 166
 Medullary folds, 508
 groove, 508
 plate, 508
 ridges, 508
 velum, inferior, 132, 194
 superior, 131, 194
 Medullated nerve-fiber, 49
 nerve-fibers, 31
 Membrana limitans interna of retina, 263
 Membrane, external limiting, of retina, 264
 Membranes of brain, 280
 Meningeal artery, posterior, 425
 Menisques, tactile, 42
 Mesencephalon, 210, 530
 Methylene-blue method of staining, Ehrlich's
 vital, 573
 Meynert's bundle, 257
 commissure, 276
 Mid-brain, 530
 minute anatomy of, 212
 region of, 210
 Middle cerebellar arteries, 431
 cerebral artery, 422
 zone of spinal cord, 74
 Mind-blindness, 469
 Mitral cells, large, of olfactory bulb, 330
 of olfactory bulb, superficial layer
 of medium and small-sized,
 331
 Molecular cortical layer, 343
 layer of olfactory bulb, 330
 of retina, external, 266
 inner, 265
 Monro, foramen of, 246
 Monticulus cerebelli, 189
 Motion, cortical area governing, 449
 Motor aphasia, 471
 area, lesions of centrum semiovale be-
 neath, 485
 of brain, 449
 cells of spinal cord, 76
 convolutions, 307
 decussation, 140
 nerve-organs, 45
 nerve-plates, 45
 nerve-roots, 112
 nerves, terminations of, 45
 neurones, peripheral, 76
 nucleus of vagus and glossopharyngeal
 nerve, 158
 oculi nerve, 235
 speech-center, 471
 Motor sprays, 45
 tract, 220, 408
 tracts, 376
 Mouth, angle of, center for retraction of, 453
 Müller's fluid, 562
 Multipolar nerve-cells, 24
 Muscle-spindle, 43
 Muscular atrophy, progressive, 501
 Myelin, 34
 sheath, Weigert's method of staining,
 567
 Myelospongium, 514
- N.
- Naming center, 468
 Nates, 211
 Nerve cell-bodies, 47
 Nerve-cells, arkyostichochrome, 21
 bipolar, 24
 cytochrome, 22
 forms or varieties of, 24
 Golgi's method for staining, 566
 granular, 24
 gyrochrome, 22
 histology of, 17
 karyochrome, 22
 multipolar, 24
 of Purkinje, 25
 of spinal cord, 76
 somatochrome, 18
 staining of, after the method of
 Nissl, 564
 with thionin, 564
 stichochrome, 21
 corpuscle, 17
 fiber, medullated, 49
 fibers, 30, 31
 medullated, 31
 non-medullated, 31, 35
 olfactory, layer of, 320
 Remak's 35
 sympathetic, 35
 organs, motor, 45
 plates, motor, 45
 roots, 70
 anterior, 112
 motor, 112
 posterior, 113
 sensory, 113
 Nerves, cranial, development of, 547
 motor, terminations of, 45
 of Lancisi, 389
 olfactory, 326
 sensory, terminations of, 38
 spinal, 108
 terminations of, stains for, 572
 Nerve-supply of cerebral dura mater, 284
 Nerve-terminations, peripheral, 37
 Nerve-trees, 47
 Nerve-unit, 17, 47
 Nerve-vesicle, 17
 Nervi nervorum, 37
 Nervous process, 31
 system, central, embryology of, 508

- Nervous system, differential stains for various elements of, 563
 Nervus masticatorius, 184
 Neural canal, 508
 tube, 508
 Neuraxone, 31, 47, 49
 Neurilemma, 35
 Neurocytes, 47
 Neurodendron, 47
 Neuroglia, 52
 cells, 56
 fibers, differential stains for, 569
 of gray matter of spinal cord, 121
 of spinal cord, 117
 stains, 569
 subpial, of spinal cord, 83
 Neurokeratin, 34
 Neurone, 17, 47
 motor, 51
 of second type, 52
 Neurones, classification of, 50
 long, 50
 motor, peripheral, 76
 of the first order, 76
 Neuroplasm, 33
 Neurospongium, 514
 Neutral carmin, for staining axis-cylinders and nerve-cells, 571
 Nidus avis, 190
 Nigrosin for staining axis-cylinders, 571
 Nissl body, 18
 granules of, 18
 method of, staining of nerve-cells after, 564
 Nodes, Ranvier's, 34
 Nodus, 189
 Non-medullated nerve-fibers, 31, 35
 Nuclear caps, 18
 layer of retina, inner, 265
 outer, 266
 Nucleus accessorius, 173
 ambiguus, 158
 amygdala, 407
 amygdaloid, 399
 arciformis, 163
 caudate, 399
 cuneatus, 131, 144
 emboliformis, 194
 for the back-muscles, 79
 globosus, 194
 gracilis, 131, 144
 hypothalamicus, 260
 lenticularis, 399
 magnocellularis diffusus, 149
 pontis, 179
 reticularis tegmenti, 146, 234
 sacral, 83
 subthalamicum, 260
 vestibularis, 174, 175
 O.
 Obex, 132
 Occipital convolutions, 309
 cortex, retinal representation in, 462
 fissure, 299
 Occipital gyrus, first, 309
 inferior, 309
 middle, 309
 second, 309
 superior, 309
 third, 309
 lobe, 308
 fissures of, 546
 lesions of centrum semiovale of, 487
 sinus, 443
 sulcus, anterior superior, 309
 inferior, 309
 lateral, 309
 vertical, 309
 Occipito-cerebellar tract, 221
 Occipito-temporal fissure, 547
 gyrus, middle, 300
 Oculomotor nucleus, connections of, 238
 Olfactory bulb, 319, 328
 fourth layer of, 332
 large mitral cells of, 330
 layer of central nerve-fibers of, 332
 molecular layer of, 330
 outer layer of, 328
 pyramidal cells of, 330
 superficial layer of medium and small-sized mitral cells of, 331
 center, 483
 glomeruli, layer of, 329
 lobe, 327
 development of, 550
 nerve-fibers, layer of, 328
 nerves, 326
 region, 326
 sphere of cerebral cortex, 507
 sulcus, 306
 tract, 319, 332
 roots of, 335
 Olivary bodies, 126, 159
 accessory, 160
 superior, 176, 180
 body, 143
 connections of vestibular nerve with, 177
 hilum of, 160
 fasciculus, 105
 tract, 105
 Operculum, anterior, 304
 Optic chiasm, 274, 320
 development of, 539
 cup, 552
 decussation, 520
 nerve-fibers of retina, 264
 nerves, course of, 268
 development of, 552, 557
 recess, 246
 thalami, 248
 connection of, with cerebral cortex, 251
 thalamus, 249
 anterior nucleus of, 252
 tubercle of, 249
 connections of, 258

- Optic thalamus, development of, 532
 - lateral nucleus of, 249, 253
 - median nucleus of, 253
 - peduncles of, 252
 - posterior nucleus of, 253
 - surfaces of, 249
 - ventral nucleus of, 253
- tract, connections of, 273
- tracts, course of, 268
- vesicle, pedicle of, 552
 - stalk of, 552
- Orbital lobe, 305
- Orth's fluid, 563

P.

- Pachionian glands, 287
- Pacinian corpuscles, 41
- Palsy, Erb's, 500
- Paracentral lobule, 305
- Paralysis, acute bulbar, 499
 - Brown-Séquard's, 504
 - crossed, 490
 - infantile spinal, 501
 - spasmodic, 500
- Paraphasia, 486
- Paraplegia, ataxic, 503
- Paraxones, 50
- Parietal artery, ascending, 422
 - convolution, inferior, 308
 - superior, 307
- gyrus, ascending, 306
- lobe, 306
 - fissures of, 546
 - lesions of centrum ovaie of, 486
- Parieto-occipital fissure, 299
- Parietotemporal artery, 423
- Pars olfactoria, 337
- Pathetic nerve, 240
- Pedicle of optic vesicle, 552
- Peduncle, inferior cerebellar, 182
- Peduncles, cerebellar, 202
 - superior, 229
- cerebral, 220
- of cerebellum, 188
- of cerebrum, 325
- of corpus callosum, 388
- of optic thalamus, 252
- of pineal gland, 246
- Pedunculus conarii, 247
- Pennicilli olfactorii, 330
- Perforated space, posterior, 324
 - spaces, anterior, 320
- Pericellular lymph-spaces, 63
- Perineurium, 36
- Peripheral nerve terminations, 37
- Perivascular lymph canals, 58
- Perpendicular fasciculus, 370
- Pes hippocampus, 394
 - pedunculi, 220
- Petrosal sinuses, inferior, 445
 - superior, 445
- Pia mater, 65
 - cerebral, 288
 - nerves of, 288
- Pigment-layer of retina, 267

- Pineal gland, 246
 - development of, 532
 - peduncles of, 246
 - posterior commissure of, 248
- Pitres' method of sectioning brain, 561
- Pituitary body, 267, 276, 323
 - development of, 536
- Plate, medullary, 508
- Plexuses, choroid, 288, 289
- Poliomyelitis anterior acuta, 501
- Polygonal cells, 254
- Polymorphous cells, layer of, 350
- Pons, development of, 528
 - transverse section of, 179
- Varolii, 178
 - arterial supply to, 432
 - lesions of, 490
- Postcentral lobule, 310
 - sulcus, 300
- Posterior cerebral arteries, 425
 - communicating artery, 424
 - meningeal artery, 425
- Postparietal gyrus, 308
- Precentral fissure, 546
 - lobule, 310
 - sulcus, 304, 546
- Precuneus, 316
- Prepyramidal fissure, 190
- Primary fissure, 542
- Primitive fibrillæ, 33
 - sheath, 35
- Processus ad cerebrum, 188
 - ad medullam, 188
 - ad pontem, 188
 - falciformis major, 281
 - minor, 282
 - reticularis, 74
- Progression, cross-legged, 500
- Progressive muscular atrophy, 501
- Projection spheres of cerebral cortex, 507
 - system of fibers, 373
- Prosencephalon, 293, 511
- Protoplasmic buds, 48
 - granules, 18
 - processes, 48
 - of Deiter, 47
- Psalterium, 373, 414
- Pulvinar, 249, 253
- Purkinje, axis-cylinder of, 32
 - cells of, 200
 - nerve-cells, 25
- Putamen, 399
- Pyramid, 189
- Pyramidal cells, giant, 29
 - large, layer of, 346
 - of cortex, 28
 - of olfactory bulb, 330
 - small, layer of, 345
- decussation, 140
 - posterior, 144
- nuclei, 163
- tract, 220
- tracts, anterior, 89
 - crossed, 91
 - direct, 89, 92
- Pyramids, anterior, 140

Pyramids, anterior, of medulla, 126
posterior, 131

Q.

Quadrate artery, 421
lobe, 306, 316

R.

Radiation, tegmental, 403
Ranvier, tactile menisques of, 42
Ranvier's nodes, 34
Raphe, 527
of medulla, 146
Rautenlippe, 526
Recess, optic, 246
Red nucleus, 259, 261
connections of, 262
Regio olfactoria, 326
Reil, fasciculus uncinatus of, 368
island of, 310
fissures of, 546
sulci of, 546
Remak's nerve-fibers, 35
Restiform bodies, 131, 164
Retina, 263
development of, 552, 556
external limiting membrane of, 264
molecular layer of, 266
ganglionic cells of, 264
inner molecular layer of, 265
nuclear layer of, 265
membrana limitans interna of, 263
optic nerve-fibers of, 264
outer nuclear layer of, 266
pigment layer of, 267
rods and cones of, 266, 557
Retinal representation in the occipital cortex, 462
Ridges, medullary, 508
Rindenschicht, 119
Rods and cones of retina, 266, 557
Rolando, fissure of, 299, 545
substantia gelatinosa of, 73
tubercle of, 137
Roller, hypoglossal nucleus of, 152
Roof nucleus of Stilling, 194
Root arteries, 123
anterior, 123
of pons and medulla, 432, 434
posterior, 123
zone, posterior, of spinal cord, 84, 91
Roots, anterior, of spinal nerves, 108
posterior, of spinal nerves, 108
Rostrum, 414

S.

Sacral nucleus, 83
Sagittal sinus, 442
Schmidt, incisures of, 35
Schultze, comma-shaped bundle of, 99
Schwann, white substance of, 34
Sclerosis, amyotrophic lateral, 501

Sclerosis, primary lateral, 500
Secondary degeneration, 87
Segment, interannular, 34
internodal, 34
Semilunar lobe, posterior superior, 190
lobule, inferior, 193
Sensations, general, cortical center for, 454
Sensory center for writing, 479
cerebellar tract, direct, 166, 177, 207
cranial nerves, ganglia of, 548
decussation, 144
fibers of cranial nerves, 547
nerve-roots, 113
nerves, terminations of, 38
spheres of cerebral cortex, 507
tract, 382, 408
long, in gray matter, 106
tracts of the spinal cord, 95
Septomarginal descending tract, 100, 102
Septum, intermediate, 91
lucidum, 414
vein of, 440
median, of medulla, 146
postero-intermediate, 126
ventral, of spinal cord, 71
Sheath, primitive, 35
tubular, 35
Sinus, basilar, 444
circular, 444
confluens, 442
falciform, 442
inferior, longitudinal, 443
jugularis, 445
marginal, 443
occipital, 443
sagittal, 442
sphenoparietal, 446
straight, 443
superior longitudinal, 442
transverse, 444
Sinuses, cavernous, 446
inferior petrosal, 445
lateral, 445
superior petrosal, 445
venous, 442
Sixth nerve, nuclei of, connections of vestibular nerve with, 177
Slender lobe, 193
Slit, anterolateral, of spinal cord, 72
Smell, cortical center for, 483
Somatochrome nerve-cells, 18
Space, interpeduncular, 323
of Broca, 335
posterior perforated, 324
Virchow-Robin, 58
Spaces, anterior perforated, 320
subarachnoid, 285
*Spasmodic paralysis, 500
Speech-center, motor, 471
Sphenoid artery, 423
Sphenoparietal sinus, 446
Spider-cells of Deiter, 56
Spinal accessory nerve, 139
arteries, anterior, 122
lateral, 123
posterior, 122

- Spinal cord, 64
 accessory nucleus of, 76
 anterior column of, 84
 commissure of, 74
 cornua of, 72
 horns of, 72
 longitudinal fissure of, 71
 anterolateral mixed zone of, 90
 slit of, 72
 blood-supply of, 122
 central canal of, 74, 122
 cervical enlargement of, 69
 region of, 117
 commissural cells of, 83
 commissures of, 71
 complete transverse lesions of, 504
 cornua of, 72
 development of, 513
 dorsal enlargement of, 69
 fissure of, 71, 72
 region of, 116
 extent of, 66
 gray matter of, 71
 head of, horns of, 72
 intrinsic cells of, 80
 lateral columns of, 84
 horns of, 72
 lesions, localization of, 499
 lumbar enlargement of, 69
 region of, 115
 middle zone of, 74
 motor cells of, 76
 neck of, horns of, 72
 nerve-cells of, 76
 neuroglia of, 117
 posterior columns of, 84
 commissure of, 74, 75
 fissure of, 72
 horns of, 72, 122
 longitudinal fissure of, 71
 root-zone of, 84, 91
 postero-intermediate fissure of, 72
 postero-internal column of, 91
 posterolateral groove of, 72
 removal of, 563
 sensory tracts of, 95
 subpial neuroglia of, 83
 technic of macroscopic and microscopic examination of, 559
 thoracic region of, 116
 transverse section of, at different levels, 114
 veins of, 124
 ventral fissure of, 71
 septum of, 71
 white commissure of, 74
 matter of, 71, 83
 ganglia, 109
 posterior, function of, 112
 ganglion, posterior, 71
 nerves, 108
 posterior roots of, 108
 Spitzka, intercallatum of, 263
 Spongioblasts, 265, 514
 Sprays, motor, 45
 Stains, differential, for various elements of nervous system, 573
 for axis-cylinder processes, 571
 for collateral branches, 572
 for end organs, 512
 for terminations of nerves, 572
 general, 573
 neuroglia, 569
 Stalk of optic vesicle, 552
 Stellate cells, 56, 254
 Stichochrome nerve-cells, 21
 Stilling, red nucleus of, 261
 roof nucleus of, 194
 sacral nucleus of, 83
 substantia gelatinosa centralis of, 74
 tegmental nucleus of, 261
 Strahlenzellen, 254
 Straight sinus, 443
 Stratum gelatinosum, 330
 glomerulorum, 329
 granulosum, 360
 intermedium, 259
 lacunosum, 355, 356, 357, 359
 moleculare, 355, 359
 oriens, 354, 356
 radiatum, 357
 zonale, 248, 324, 355, 359
 of cerebral cortex, 338
 Stria terminalis, 249, 404
 Striæ acusticæ, 135
 cornæ, 398, 404
 Subarachnoid space, 65
 spaces, 285
 Subiculum cornu ammonis, 317, 350
 Subpial neuroglia layer, 119
 of spinal cord, 83
 Substantia ferruginea, 182
 gelatinosa centralis, 74
 of Rolando, 73
 Rolandi, 122
 nigra, 220, 259, 263, 325
 reticularis alba, 355
 Subthalamie region, 259
 Sulci, 294
 of island of Reil, 546
 Sulcus, anterior superior occipital, 309
 centralis insulæ, 310
 choroideus, 249
 inferior occipital, 309
 lateral occipital, 309
 lateralis, 220
 limitans insulæ, 310
 oculomotorius, 220, 237
 olfactory, 306
 postcentral, 300
 precentral, 304, 546
 vertical occipital, 309
 Superior cerebellar arteries, 430
 Supramarginal gyrus, 308
 Sylvian aqueduct, 132
 artery, 422
 fissure, 320
 Sylvius, aqueduct of, 210
 development of, 530

- Sylvius, fissure of, 298
 development of, 540
 fossa of, development of, 540
 Sympathetic nerve-fibers, 35
 Syringomyelia, 503

T.

- Tactile aphasia, 471
 corpuscles, 39
 menisques, 42
 Tænia cornu, 249
 semicircularis, 249, 398, 404
 Tangential fibers of cerebral cortex, 339
 Tapetum, 390
 Taste, cortical centers for, 482
 Tegmental nucleus, 194, 261
 radiation, 403
 tract, central, 163
 Tegmentum, 220, 223, 325
 Tela choroidea inferior, 285, 291
 Telodendrons, 47, 50
 Temporal convolution, first, 313
 inferior, 314
 middle, 314
 second, 314
 superior, 313
 third, 314
 lobe, fissures of, 546
 lesions of centrum semiovale, 486
 Temporocerebellar tract, 221
 Temporoparietal convolutions, 310
 Temporosphenoid lobe, 313
 Tenia, 132
 Tentorium cerebelli, 186, 281
 Testes, 211
 Thalamencephalon, 244, 511
 Thionin, staining of nerve-cells with, 564
 Third pair of cranial nerves, 235
 Thoracic region of spinal cord, 116
 Tonsil, 190
 Torcular Herophili, 442
 Tract, acousticocerebellar, 166, 177, 207
 anterolateral ascending, 80, 193, 233
 function of, 104
 descending cerebellar, 104
 central tegmental, 163
 cerebello-olivary, 160, 164, 207
 connecting occipital and temporal lobes
 with cerebellar hemispheres, 221
 cornu commissural, 100, 101
 descending cerebellar, 204
 direct cerebellar, 83, 95
 pyramidal, 92
 sensory cerebellar, 166, 177
 frontocerebellar, 222, 375
 Gowers', 385
 Lissauer's, 106
 long sensory, in gray matter, 106
 motor, 108, 220
 occipitocerebellar, 221
 olfactory, 319
 roots of, 335
 olivary, 105
 Tract, pyramidal, 220
 sensory, 382, 408
 septomarginal, descending, 100, 102
 temporocerebellar, 221
 uncrossed pyramidal, 92
 Tracts, anterior pyramidal, 89
 anterolateral ascending, of Gowers, 90
 descending, 90
 crossed motor, 90
 pyramidal, 90, 91
 direct cerebellar, 90, 143, 203
 pyramidal, 89, 91
 sensory cerebellar, 207
 motor, 376
 olfactory, 332
 sensory, of the spinal cord, 95
 Tractus striothalamicus, 403
 Transverse sinus, 444
 Triangular bundle, 105
 Trigeminal nerve, accessory nucleus of, 240
 cerebral connections of, 185
 motor root of, 182, 184
 nuclei of origin of, 182
 sensory root of, 182
 Trigonum habenulae, 249
 olfactorium, 335
 ventriculi, 394
 Trochlear nerve, 240
 Trolard, great anastomotic vein of, 439
 Trunk and spine, muscles of, cortical area for, 453
 Tube, neural, 508
 Tuber cinereum, 279, 323
 valvulae, 190
 Tubercle, 399
 anterior, of optic thalamus, 249
 of Rolando, 131, 137
 Tuberculum acusticum, 173, 174
 anterior, 252
 nervi facialis, 168
 Tubular sheath, 35
 Tunica adventitia of arteries, 58
 intima of arteries, 59
 media of arteries, 59
 Türk, columns of, 89
 Twelfth pair of cranial nerves, nuclei of, 151

U.

- Uncinate gyrus, 318
 Uncus, 318
 Upper extremity, cell-group for, 79
 Uvula, 189

V.

- Vagus, 155
 motor nucleus of, 158
 Valleculla, 186
 Sylvii, 298
 Valve of Vieussens, 132, 194
 Van Gieson's method of staining, 571
 Vater's corpuscles, 41
 Vein, anterior cerebral, 437
 basilar, 437

- Vein, choroid, 440
 falciform, 443
 great anastomotic, 439
 middle cerebral, 437
 of corpus striatum, 440
 of septum lucidum, 440
 posterior anastomotic, 439
 Veins, cerebral, 435
 deep cerebral, 440
 emissary, 447
 inferior cerebellar, 441
 of cerebellum, 440
 of convolutions, 438
 of Galen, 440
 of nervous system, 60
 of spinal cord, 124
 superficial cerebral, 436
 superior cerebellar, 440
 Velum interpositum, 288
 medullary, inferior, 132, 194
 superior, 131, 194
 Venous sinuses, 442
 systems of brain, 435
 Ventral septum of spinal cord, 71
 Ventricle, fifth, 414
 fourth, 131
 choroid plexuses of, 291
 of Arantius, 125, 136
 of corpus callosum, 393
 third, middle commissure of, 245
 region of, 244
 soft commissure of, 245
 Ventricles, lateral, 393
 cornua of, 393
 Ventriculus terminalis, 74
 Verbal aphasia, 468
 Vermiform process of cerebellum, 186
 inferior, 186
 Vermis, 186, 187, 188
 inferior surface of, 189
 superior surface of, 188
 Vertebral arteries, 425
 Vesicle, second primitive, 530
 third cerebral, 530
 Vesicles, primary cerebral, 508
 secondary cerebral, 511
 Vesicular column, 83
 Vestibular nerve, 171, 172
 connections of, 176
 of, with cerebellum, 176
 of, with internal or mesial fillet, 177
 of, with lateral column, 177
 of, with lateral fillet, 177
 of, with nuclei of sixth nerve, 177
 of, with olivary body, 177
 Vicq d'Azyr, bundle of, 253, 324, 413
 white layer of, 339
 Vieussens, valve of, 132, 194
 Villi, arachnoid, 287
 Virchow-Robin space, 58
 Virchow's method of sectioning brain, 560
 Vision, centers of, 457
 Visual sphere of cerebral cortex, 507
- W.**
- Wedge, 131
 Weigert's method of staining the myelin sheath, 567
 Wernicke, perpendicular fasciculus of, 370
 White matter of spinal cord, 71, 83
 substance of Schwann, 34
 Wilder, occipital fissure of, 299
 Willis, circle of, 429
 Word-blindness, 470
 Worm of cerebellum, 186, 188
 superior, 187
 Wrisberg, nerve of, 168
 Writing, cortical center for, 475
 sensory center for, 479
- Z.**
- Zona incerta, 259
 Zone, anterolateral mixed, of spinal cord, 90
 middle, of spinal cord, 74
 Zones of association of cerebral cortex, 507

