

**A manual of the physical diagnosis of thoracic diseases / by E. Darwin Hudson.**

**Contributors**

Hudson, E. Darwin 1843-1887.  
University of Bristol. Library

**Publication/Creation**

New York : William Wood, 1887.

**Persistent URL**

<https://wellcomecollection.org/works/jdsuczbs>

**Provider**

Special Collections of the University of Bristol Library

**License and attribution**

This material has been provided by This material has been provided by University of Bristol Library. The original may be consulted at University of Bristol Library. where the originals may be consulted.

This work has been identified as being free of known restrictions under copyright law, including all related and neighbouring rights and is being made available under the Creative Commons, Public Domain Mark.

You can copy, modify, distribute and perform the work, even for commercial purposes, without asking permission.



Wellcome Collection  
183 Euston Road  
London NW1 2BE UK  
T +44 (0)20 7611 8722  
E [library@wellcomecollection.org](mailto:library@wellcomecollection.org)  
<https://wellcomecollection.org>



F294

UNIVERSITY OF BRISTOL.

Medical Library.

June 1939.

Store 572542

SHELF


D.A.


J. FAWN & SON,  
15, QUEEN'S ROAD,  
BRISTOL.

1 →

A. W. P.







A  
MANUAL  
OF THE  
PHYSICAL DIAGNOSIS  
OF  
THORACIC DISEASES

BY  
E. DARWIN HUDSON, Jr., A.M., M.D.

PROFESSOR OF GENERAL MEDICINE AND DISEASES OF THE CHEST IN THE NEW YORK POLYCLINIC,  
PHYSICIAN TO BELLEVUE HOSPITAL, ETC.



---

NEW YORK  
WILLIAM WOOD & CO., PUBLISHERS  
56 & 58 LAFAYETTE PLACE  
1887



COPYRIGHT BY  
WILLIAM WOOD & COMPANY  
1887.



---

PRESS OF  
STETTINER, LAMBERT & CO.,  
22, 24 & 26 READE ST.,  
NEW YORK.

TO

JAMES R. LEAMING, M.D.,

WHOSE WISE COUNSEL AND WARM FRIENDSHIP THE  
AUTHOR HAS ENJOYED FOR MANY YEARS,  
THIS VOLUME, IN GRATEFUL ACKNOWLEDGMENT,  
IS AFFECTIONATELY  
INSCRIBED.

THE UNIVERSITY OF CHICAGO

PHILOSOPHY DEPARTMENT  
1100 EAST 58TH STREET  
CHICAGO, ILLINOIS 60637  
TEL: 773-936-3700

## PREFACE.

---

IN the preface of his book an author is expected to explain to his readers the object and aim of his work, together with its general plan, and often to make due acknowledgment of his obligations to other authors, or to friends who have assisted him in his undertaking.

In the present instance, this common expectation cannot be realized, since the talented author of this volume suddenly sickened and died just after the manuscript had been placed in the printer's hands. On me, his friend, has devolved the melancholy duty of correcting the proof-sheets of the work, and also of speaking for him to his readers.

The volume is the outcome of the author's needs as a teacher in the New York Polyclinic. In 1885, he privately printed a small book entitled "Essentials of the Physical Diagnosis of Thoracic Diseases," which was circulated among the members of his class, and to a limited extent, also, among his personal friends. The work was found both convenient and useful, and therefore, by an elaboration of its material, the present volume was prepared.

He has carefully collated the opinions of the best authors, frankly avowing his personal preferences, and has drawn freely upon his own experience and observation.

Keeping strictly in view the object aimed at, he has avoided unnecessary verbiage and over-elaboration, presenting the essential facts in a manner best calculated to fix the reader's attention.

In the synopses of diseases, this condensation is seen to the best advantage, and here, also, its value will probably be most highly appreciated.

Though lacking the advantage of his final revision, the book is presented to the profession with the firm conviction that it will meet with a generous welcome.

LAURENCE JOHNSON, M.D.

NEW YORK, July, 1887.

# CONTENTS.

## CHAPTER I.

### PRINCIPLES OF PHYSICAL DIAGNOSIS.

	PAGE
Topography of Thorax—Boundaries and Contents of Various Regions— Methods of Physical Diagnosis—Inspection of Healthy Chest; Form, Movements—Unhealthy Chest, Bulging, Retraction, Proclivitas, Dis- tortion; Abnormal Movements; Palpation—Fremitus, Respiratory, Vocal, Tussal—Mensuration of Size, Motion, and Volume of Air. . . .	1-18

## CHAPTER II.

### PRINCIPLES OF PERCUSSION, AND APPLICATION TO HEALTHY CHEST.

Immediate and Mediate; Origin of Mediate Percussion—Forms of Ham- mer and Pleximeter—Mode of Percussing—Properties of Percussion Sound—Duration, Intensity, Pitch, Quality—Percussion Sound over Muscle, Heart, Lungs—Over several Areas of Thorax—Corson's Posi- tions for Examination of the Chest—Composite Nature of Percussion Sound. . . . .	19-31
---	-------

## CHAPTER III.

### PERCUSSION OF THE ABNORMAL CHEST.

Changes in Duration, Intensity, Pitch, Quality—Percussion in Thickened Pleura, Pleuritic Effusions, Slight Pulmonary Consolidations, Ad- vanced Consolidations—Line of Dulness in Pleurisy; Old View, New View—Ellis' Line—Percussion in Bronchitis, Emphysema—The Sense of Resistance in Percussion—Myoidema of Graves and Stokes, Gairdner, Tait. . . . .	32-36
--	-------

## CHAPTER IV.

### AUSCULTATION.

Definition. Sounds to be Heard—Their Properties—Methods of Auscul- tation—The Stethoscope—Solid Stethoscopes—The Binaural Stetho- scope—Arguments for and against Use of Stethoscope—Normal Re-	
---	--

	PAGE
spiratory Sound—Characteristics—Elements of Normal Breath Sound—Muscular Sussurus—Vocal Resonance—Normal Whisper—Normal Tussal Resonance.....	37-49

## CHAPTER V.

### ACOUSTICS OF NORMAL AND ABNORMAL CHEST SOUNDS.

Chest Acoustics—Abnormal Sounds Referable to Respiratory Organs—Classification of these Sounds—Modification of Normal Sounds—Adventitious Sounds—Interpretation of Modified and Adventitious Sounds—Their Special Study—Illustrations of Abnormal Respiratory Sounds—Study of Abnormal Voice Sounds—Study of Whisper Sounds—Study of Cough Sounds—Adventitious Sounds in Air Passages—Dry Râles—Moist Râles—Recapitulation of Râles—Abnormal intra-Pleural Sounds—Rules for Differentiating Them—Adventitious Râles Produced in the Pulmonary Parenchyma—Auscultatory Percussion—The “Bell Metal” Test—Succussion—Determining Size and Relation of Surrounding Organs—The Microscope as an Aid to Diagnosis—Aspiration and Hypodermic Puncture.....	50-76
---	-------

## CHAPTER VI.

### SYNOPSES OF RESPIRATORY DISEASES.

1. Acute Bronchitis of Adults. 2. Capillary Bronchitis. 3. Chronic Bronchitis. 4. Asthma. 5. Pleuritis. 6. Emphyema. 7. Pneumo-hydrothorax. 8. Hydrothorax. 9. Pneumonia. 10. Œdema of Lung. 11. Pulmonary Apoplexy. 12. Pulmonary Infarction. 13. Gangrene of Lung. 14. Emphysema. 15. Phthisis Pulmonalis. 16. Modern View of Phthisis. 17. Syphilis of Lungs. 18. Brown Induration. 19. Carcinoma of Lung, Pleura, and Bronchi.....	77-96
--	-------

## CHAPTER VII.

### HEART DISEASES.

Anatomical and Topographical Data—Location of Heart—Deep Cardiac Region—Superficial Cardiac Region—Location of Heart Valves—Anatomy of Heart—Methods of Examining Heart, Inspection, Mensuration, Palpation, Percussion, Auscultation—Duration of Heart Sounds—Characteristics of Heart Sounds—Theories of Causes of Heart Sounds—Functional Diseases of Heart.....	97-124
---	--------

## CHAPTER VIII.

### SYNOPSES OF HEART DISEASES.

1. Valvular Diseases of the Heart. 2. Cardiac Hypertrophy. 3. Cardiac Dilatation. 4. Fatty Heart. 5. Endocarditis. 6. Ulcerative Endocarditis. 7. Pericarditis. 8. Hydro-pericardium. 9. Synopsis of	
--	--


	PAGE
Organic Murmurs. 10. Anæmic Murmurs. 11. Extra Cardiac Murmurs. Aneurism of the Thoracic Aorta: Different Portions of Arch of Aorta. Aneurism. Definition, Pathology, Symptoms, Physical Signs. Special Symptoms and Signs of Aneurism of Ascending, Transverse, and Descending Portions.....	125-143

## CHAPTER IX.

## RELATION OF THE PULSE TO CARDIAC DISEASE.

1. The Palpation of Pulse in the several Diseases of Heart. 2. Sphygmography. Different Sphygmographs. Study of Different Parts of Normal Tracing. Changes due to Cardiac Obstructions and Insufficiencies. Dicrotism..... 144-146





## LIST OF ILLUSTRATIONS.

---

FIG.	PAGE
1. Anterior regions of the chest, after Walshe, . . . . .	2
2. Contents of anterior regions of the chest, after Quain, . . . . .	4
3. Regions of the back, . . . . .	8
4. Outline of contents of posterior thoracic regions, after Quain, . . . . .	9
5. Contents of the posterior regions of the body, . . . . .	10
6. Flint's cyrtometer, . . . . .	15
7. Quain's stethometer, . . . . .	15
8. Barnes' spirometer, . . . . .	16
9. Hutchinson's spirometer, . . . . .	16
10. Winterich's percussion hammer, . . . . .	19
11. Ivory pleximéter, . . . . .	19
12. Flint's percussor, . . . . .	19
13. Flint's pleximeter, . . . . .	19
14. Percussion resonance and dulness of front of chest, after Piorry, . . . . .	24
15. Percussion resonance and dulness of posterior regions, after Piorry, . . . . .	25
16. Position for percussion of front of chest, . . . . .	26
17. Position for percussion of lateral regions, . . . . .	27
18. Position for percussion of posterior regions, . . . . .	28
19 and 20. Areas of dulness and flatness of phthisis at each apex, after Piorry, . . . . .	32
21, 22. Areas of flatness in pleurisy with effusion, . . . . .	33
23-24. "Ellis" or "Letter S" line, . . . . .	34
25. Myoidema, . . . . .	35
26-31. Straight stethoscopes, . . . . .	38
32, 33. Cammann's stethoscopes, . . . . .	39
34. Allison's differential stethoscope, . . . . .	40
35. Air-passages and lobules, . . . . .	44
36. Bifurcation of trachea and bronchi, . . . . .	44
37. Terminal bronchus and vesicles, . . . . .	45
38. Schematic representation of air vesicles, . . . . .	45
39. Distribution of terminal tubes and vesicles, . . . . .	46
40. Tracings of muscle waves, after Marcy, . . . . .	47
41. Consolidation of apex, . . . . .	54
42. Consolidation with cavities, . . . . .	54
43. Dilated bronchi, after Loomis, . . . . .	55
44. Emphysema, terminal tubes and air sacs dilated, . . . . .	55
45. Advanced stage of the foregoing, . . . . .	55

FIG.	PAGE
46. Section of emphysematous lung, . . . . .	56
47-49. Pleurisy with effusion, . . . . .	57, 58
50. Consolidations of lung, . . . . .	58
51. Pneumohydrothorax, . . . . .	59
52. Diagram illustrating dry and moist râles, . . . . .	61
53. Diagram of catarrhal process, . . . . .	62
54. Transverse section of thorax, . . . . .	64
55. Cammann's cylindrical auscultator, . . . . .	69
56. Cammann's intra-costal auscultator, . . . . .	69
57 58. Constantine Paul's stethoscope, . . . . .	70
59. Page's percussion hammer, . . . . .	71
60. Dieulafoy's aspirator, . . . . .	73
61, 62. Tiemann & Co.'s aspirator, . . . . .	74
63. Tubercular sputum, with bacilli, after Eichhorst, . . . . .	75
64. Tubercle bacilli with spores, after W. Cheyne, . . . . .	75
65. Asthma crystals, after Frankel, . . . . .	76
66. Peribronchitis, chronic, . . . . .	93
67. Thickened pleura, . . . . .	93
68. Location of the heart, after Walshe, . . . . .	98
69. Relation of the heart to the great vessels, . . . . .	99
70. Relation of the heart to the diaphragm and left lobe of the liver, . . . . .	100
71, 72. Apex of the heart in hypertrophy with dilatation, . . . . .	105, 106
73. Cammann's cardiometer, . . . . .	109
74. Increase of pericardial area in hydropericardium, . . . . .	109
75. Hypertrophy of the left ventricle, after Loomis, . . . . .	113
76. Increased area in enlargement of heart, after Piorry, . . . . .	113
77. Hypertrophy of right ventricle, after Loomis, . . . . .	114
78. Hydropericardium, . . . . .	114
79. Left ventricle in systole, after Dalton, . . . . .	132
80. Left ventricle in diastole, after Dalton, . . . . .	132
81. Line of propagation of heart murmurs, . . . . .	135
82. Relation of the aorta to surrounding structures, after Gray, . . . . .	138
83. Relation of the aorta to œsophagus, bronchi, heart, and valves, after Gray, . . . . .	139
84. Area of dulness of aneurism, after Piorry, . . . . .	140
85. Aneurism of junction of ascending and transverse arch, after Doty, . . . . .	141
86. Relations of descending arch, . . . . .	142
87. Thoracic aorta in the back, . . . . .	143
88. Marcy's sphygmograph, . . . . .	144
89. Dudgeon's sphygmograph, . . . . .	145
90. Holden's sphygmograph, . . . . .	145
91-93. Pulse tracing, after Loomis, . . . . .	145, 146

# THORACIC DISEASES.

## CHAPTER I.

### PRINCIPLES OF PHYSICAL DIAGNOSIS.

Our system of physical examination of the chest, as developed by Avenbrugger, Laennec, and Piorry, has received numerous amendments and additions from a host of investigators and teachers in Europe and America. The more prominent of these abroad are Skoda, Allison, Gairdner, and Walshe; and not less valuable and original are the contributions in our own country, of Flint, DaCosta, Loomis, Leaming, Camman, and Clark.

The profession has come to regard physical diagnosis, in the hands of experts, as affording exact knowledge of the conditions of the intra-thoracic organs. It is accepted, as a fact fully established, that, by the application of acoustic laws, certain combinations of physical signs lead to an immediate and correct diagnosis in most cases of thoracic disease.

### REGIONAL ANATOMY OF THE CHEST.

Before entering upon the study of physical signs, it is essential to have thorough knowledge of the normal chest, the structure of its walls, and the situation and size of the intra-thoracic organs—that is, the regional anatomy or topography of the chest.

### TOPOGRAPHY OF THORAX.

#### REGIONS OF THE CHEST.

- |                      |   |  |
|----------------------|---|--|
| 1. Anterior Regions. | { | <ol style="list-style-type: none"><li>1. Supraclavicular.</li><li>2. Clavicular.</li><li>3. Infraclavicular.</li><li>4. Mammary.</li><li>5. Inframammary.</li><li>6. Suprasternal.</li><li>7. Upper sternal.</li><li>8. Lower sternal.</li></ol> |
|----------------------|---|--|

- |                       |   |                    |
|-----------------------|---|--------------------|
| 2. Lateral Regions.   | } | 1. Axillary.       |
|                       |   | 2. Infra-axillary. |
| 3. Posterior Regions. | } | 1. Upper scapular. |
|                       |   | 2. Lower scapular. |
|                       |   | 3. Infra-scapular. |
|                       |   | 4. Interscapular.  |

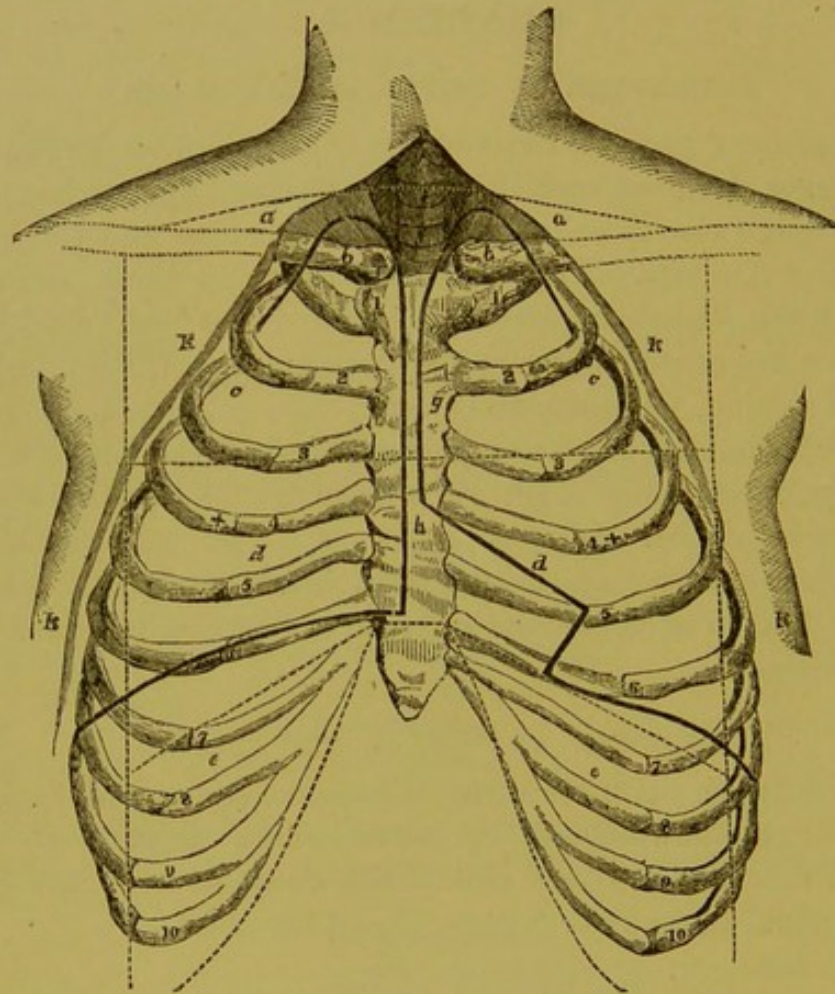


FIG. 1.—ANTERIOR REGIONS OF THE CHEST (WALSHE).

a, Supraclavicular; b, clavicular; c, infraclavicular; d, mammary; e, inframammary; f, suprasternal; g, upper sternal; h, lower sternal.

ANTERIOR REGIONS.

1. Supraclavicular.

*Boundaries.*

- |                            |           |  |
|----------------------------|-----------|--|
| (a) Internal,              | . . . . . | Trachea.   |
| (b) Superior and external, |           | Line drawn from upper part of trachea to acromion process. |
| (c) Inferior,              | . . . . . | Upper border of clavicle.                                  |
- It is a triangular space.

## THE STRUCTURES CONTAINED ARE :

- |                     |                        |
|---------------------|------------------------|
| (1) Apex of lung.   | (4) Subclavian artery. |
| (2) Carotid artery. | (5) Subclavian vein.   |
| (3) Jugular vein.   |                        |

## 2. Clavicular.

Location, behind the inner three-fifths of the clavicle.

## THE STRUCTURES CONTAINED ARE :

- |                        |                       |
|------------------------|-----------------------|
| (A) On right side.     | (B) On left side.     |
| 1. Lung tissue.        | 1. Carotid artery.    |
| 2. Subclavian artery.  | 2. Lung tissue.       |
| 3. Arteria innominata. | 3. Subclavian artery. |

## 3. Infraclavicular.

*Boundaries.*

- |                       |  |
|-----------------------|--|
| (a) Internal, . . . . | Edge of sternum.   |
| (b) Superior, . . . . | Lower border of clavicle.  |
| (c) External, . . . . | A line falling vertically from<br>junction of middle and outer<br>third of clavicle. |
| (d) Inferior, . . . . | Lower border of third rib.   |

## THE STRUCTURES CONTAINED ARE :

- |   |  |
|---|--|
| (A) On right side.  | (B) On left side.  |
| 1. Superior lobe of lung.   | 1. Superior lobe of lung.  |
| 2. Main bronchus behind<br>second costal cartilage.                           | 2. Main bronchus a little<br>below the second costal<br>cartilage.                                     |
| 3. Descending vena cava.  | 3. A portion of pulmonary<br>artery immediately be-<br>hind the second sterno-<br>costal articulation. |
| 4. Portion of arch of aorta,<br>behind second costo-<br>sternal articulation. | 4. Base of heart at lower<br>boundary.   |

## 4. Mammary.

*Boundaries.*

- |                       |   |
|-----------------------|---|
| (a) Internal, . . . . | Edge of sternum.  |
| (b) Superior, . . . . | Lower border of third rib.  |
| (c) External, . . . . | A vertical line continuous with<br>the outer boundary of infra-<br>clavicular region. |
| (d) Inferior, . . . . | Lower border of sixth rib.  |

On the right side in this region the thin sharp border of the lung very nearly corresponds to the inferior boundary. But below the lower border of fifth rib the thin portion of lung overlies the liver. The liver is sometimes pushed up into the fourth intercostal space.

On the left side a section is taken out of the lung to afford space for the heart. The lung extends in front as far as the fourth sternocostal articulation, where the anterior border passes outward to the outer end of the fifth cartilage, then obliquely inward to lower border of outer end of the sixth costal cartilage, then outward.

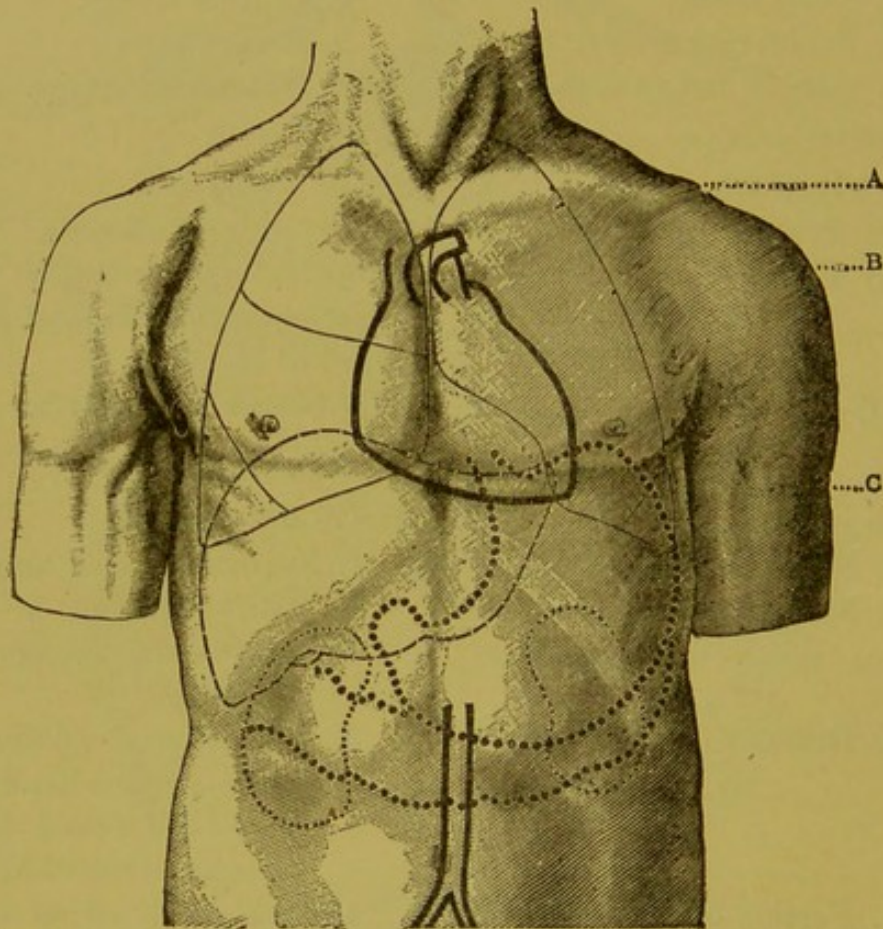


FIG. 2.—SHOWING CONTENTS OF ANTERIOR REGION OF THE CHEST (AFTER QUAIN).

STRUCTURES WITHIN THE MAMMARY REGION.

(A) On right side.

1. Lung.
2. Liver.
3. Right auricle and right superior angle of right ventricle close to ster-

(B) On left side.

1. Lung.
2. Left auricle.
3. Left ventricle.

num, between third and fifth ribs.

4. Apex of left ventricle and portion of apex of right ventricle, in fifth intercostal space, one inch within and two inches below nipple.

(a) Nipple varies somewhat in position. May be said to be, usually, on the fourth rib, at junction of costal cartilage and rib, or in fourth intercostal space.

(b) Fissure between upper and middle lobes of right lung passes obliquely upward and backwards from fourth cartilage; fissure between middle and lower lobes, upwards and backwards from fifth interspace; fissure between lobes of left lung begins at fifth interspace, below the nipple.

5. Inframammary.

*Boundaries.*

- |               |           |  |
|---------------|-----------|--|
| (a) Superior, | . . . . . | Lower border of sixth rib.                                   |
| (b) Inferior, | . . . . . | Curved line corresponding to the free border of ribs.        |
| (c) Internal, | . . . . . | Inferior portion of sternum.                                 |
| (d) External, | . . . . . | The continuation of the external boundary of mammary region. |

STRUCTURES WITHIN THE INFRAMAMMARY REGIONS.

- |                              |                                   |
|------------------------------|-----------------------------------|
| (A) On right side.           | (B) On left side.                 |
| 1. Lung on full inspiration. | 1. Portion of left lobe of liver. |
| 2. Liver.                    | 2. Stomach.                       |
|                              | 3. Portion of spleen, sometimes.  |

6. Suprasternal.

This region is the hollow space immediately above the notch of the sternum, and bounded on either side by the sterno-cleido mastoid muscle.

STRUCTURES WITHIN THE SUPRASTERNAL REGION.

1. Trachea.
2. Arteria innominata at lower right angle.



3. Arch of aorta sometimes reaches to its lower border, where it may often be felt, on firm pressure downward.

7. Upper sternal.

This region includes the space behind the sternum from the notch to the lower border of the third rib.

STRUCTURES WITHIN THE UPPER STERNAL REGION.

1. Lung in front.
2. Bifurcation of trachea at upper border of second rib.
3. Ascending aorta at lower end of region.
4. Transverse aorta, crossing on level with second rib.
5. Innominate artery, at junction of second right costal cartilage.
6. Portion of right auricle in lower part.
7. Aortic valves, midway between centre of sternum and lower edge of left third costal cartilage.
8. Pulmonary valves, one-half inch higher than the aortic, on left edge of sternum.

The position of the lung in mid-sternum varies somewhat during inspiration and expiration.

8. Lower sternal.

This region corresponds to that portion of the sternum which lies below the lower border of the third rib.

STRUCTURES WITHIN THE LOWER STERNAL REGION.

1. Portion of body of lung on right side in front, on the left side also as far as the fourth sterno-costal articulation.
2. Greater part of right ventricle.
3. Smaller part of left ventricle.
4. The mitral valves, in the upper part of this region, that is just below the level of the third rib or on a level with the fourth rib, situated close to the left edge of the sternum.
5. The tricuspid valves, situated at about the same level as the mitral, but to the right, nearer to the median line and more superficial.
6. Attachment of heart to diaphragm.
7. Small portion of liver.
8. Portion of stomach, sometimes.

LATERAL REGIONS.

1. Axillary. *Boundaries.*  
 (a) Superior, . . . . The axilla.

- (b) Inferior, . . . . . A line carried backward from the lower boundary of mammary region (sixth rib) to inferior angle of scapula.
- (c) Interior, . . . . . The vertical line which forms the common external boundary of the anterior regions.
- (d) Posterior, . . . . . The external border of scapula.

This region corresponds laterally with the mammary in front, and contains on both sides lung substance, with the main bronchi, deeply seated.

2. Infra-axillary.

*Boundaries.*

- (a) Superior, . . . . . Inferior boundary of axillary region.
- (b) Inferior, . . . . . Edges of false ribs.
- (c) Anterior, . . . . . Common vertical line, external boundary of infra-mammary.
- (d) Posterior, . . . . . Line of external border of scapula continued downward.

This region corresponds laterally to the inframammary, and contains above, on both sides, the lower edges of the lung, sloping downward and backward. Below, on the right side, is the liver; on the left, the stomach and spleen.

POSTERIOR REGIONS.

1. Upper scapular.

*Boundaries.*

- (a) Superior, . . . . . Second rib.
- (b) Inferior, . . . . . Spine of scapula.
- (c) Internal, . . . . . Internal border of scapula.
- (d) External, . . . . . External border of scapula.

Occupied by lung substance.

2. Lower scapular.

*Boundaries.*

- (a) Superior, . . . . . Spine of scapula.
- (b) Inferior, . . . . . Inferior angle of scapula.
- (c) Internal, . . . . . Internal border of scapula.
- (d) External, . . . . . External border of scapula.

Occupied by lung substance.

3. Infrascapular.

*Boundaries.*

- (a) Superior, . . . . . Inferior angle of scapula and seventh dorsal vertebræ.

- (b) Inferior, . . . . . The twelfth rib.  
 (c) Internal, . . . . . The spinous processes of the  
 vertebrae.  
 (d) External, . . . . . Posterior boundary of the infra-  
 axillary.

## 4. Interscapular.

*Boundaries.*

- (a) Superior, . . . . . Line of second rib.  
 (b) Inferior, . . . . . Line of sixth rib and inferior  
 angle of scapula.  
 (c) Internal, . . . . . Vertebral column, dorsal spinous  
 processes.  
 (d) External, . . . . . Internal border of scapula.

By means of Corson's position for percussing the posterior surface of the chest, these traditional landmarks and regions are changed. The interscapular region is increased threefold (see Chapter on Percussion).

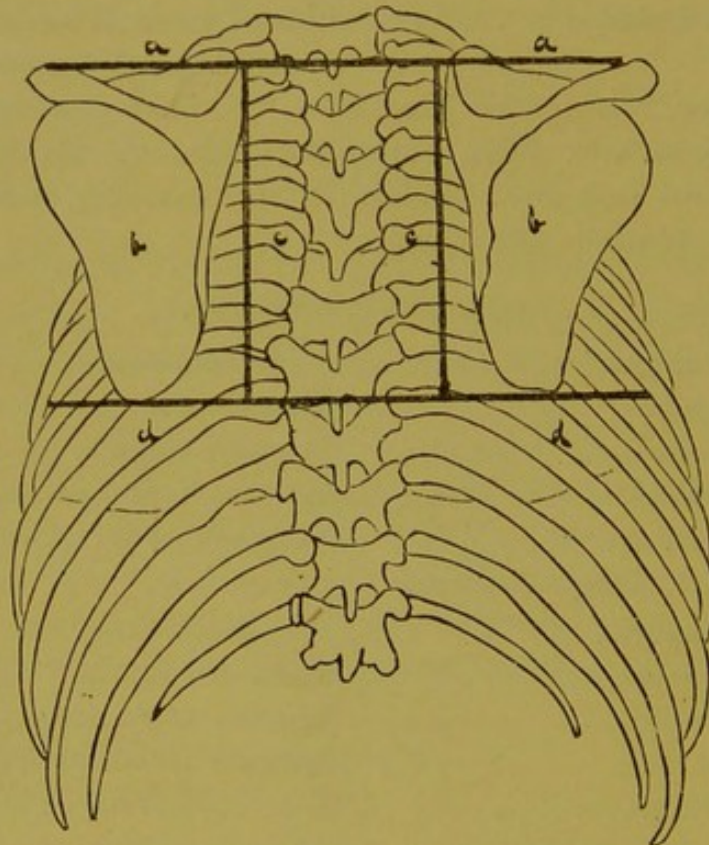


FIG. 3.—REGIONS OF BACK.

*a a*, Suprascapular; *b b*, scapular (including upper and lower scapular of Walshe); *c c*, interscapular; *d d*, infrascapular.

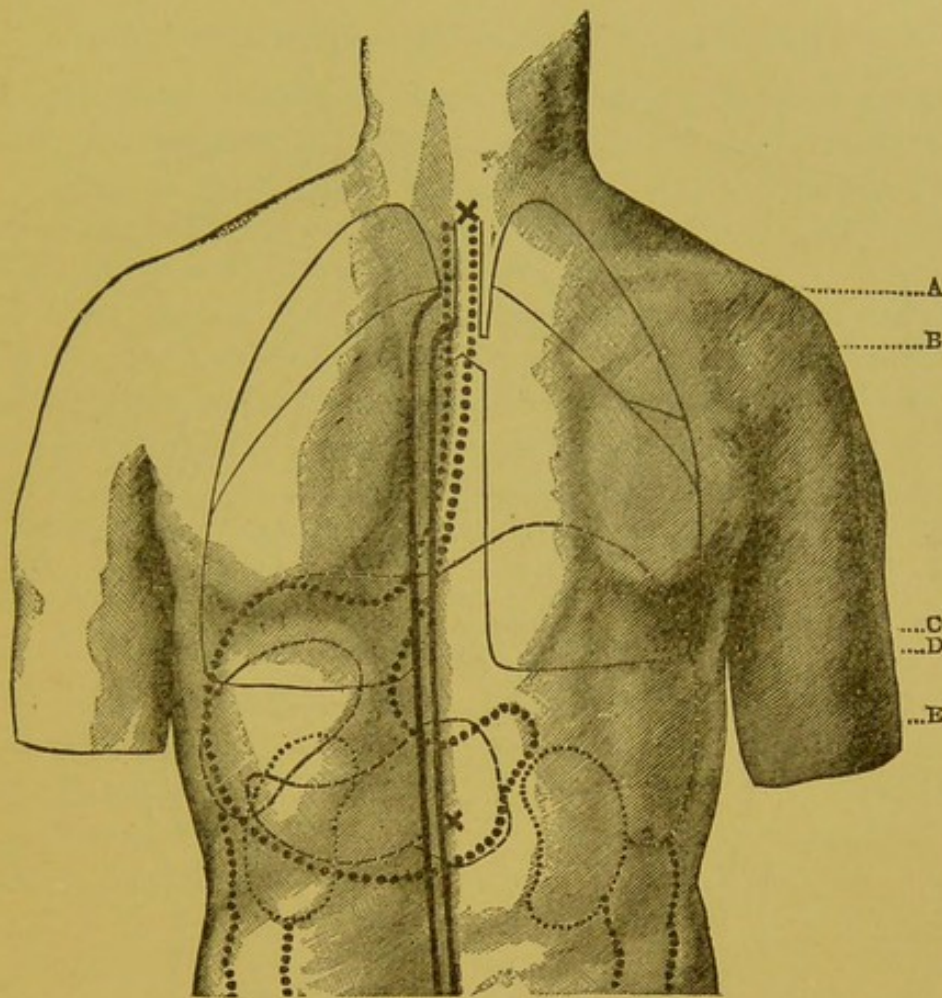


FIG. 4.—Outline of contents of posterior thoracic regions (from Quain).

STRUCTURES WITHIN THE UPPER, LOWER AND INFRASCAPULAR REGIONS.

A.) On right side.

1. Lung, to the eleventh rib.
2. Liver, immediately underneath the surface, between eleventh and twelfth ribs.
3. Small portion of kidney.

(B.) On left side.

1. Lung, to eleventh rib.
2. Intestines, internally.
3. Spleen, externally.
4. Descending aorta, close to the spine.
5. Portion of the kidney, more than on right side close to spine.

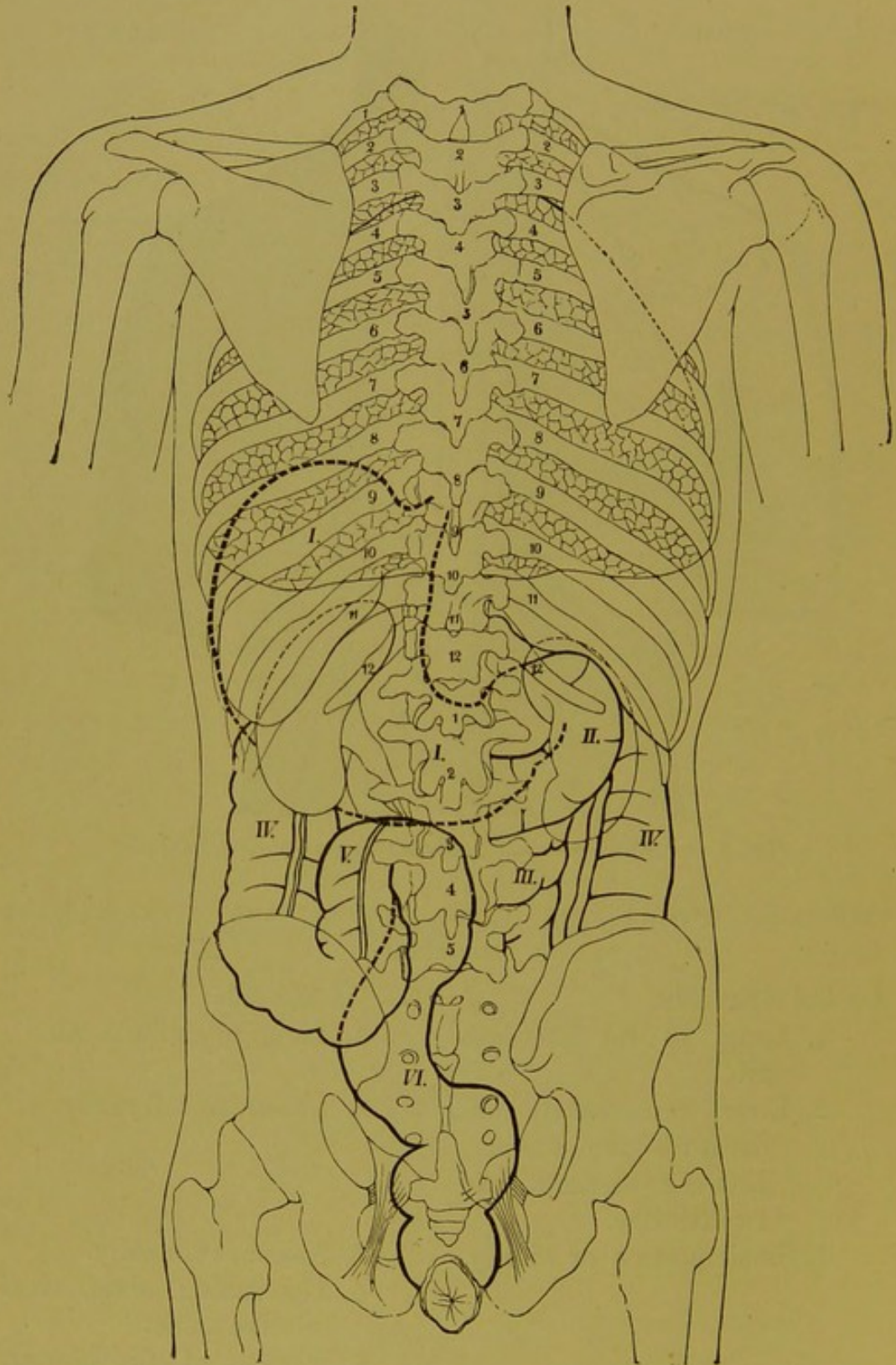


FIG. 5.—Contents of posterior regions, relations of lungs to ribs, by numbers, to scapulæ, stomach, liver, and diaphragm.

## STRUCTURES WITHIN THE INTERSCAPULAR REGIONS.

These regions contain, on both sides, lung substance, the main bronchi, and the bronchial glands. Opposite the third dorsal vertebrae (the second rib in front), is the bifurcation of the trachea. The left also contains the œsophagus, and from the upper part of the fourth dorsal vertebra downward, the descending aorta.

The useful signs posteriorly, in health, are few. From the second to the sixth rib behind, sounds of air in the trachea and main bronchial tubes are heard. At the seventh or eighth dorsal vertebra on the left side is the point corresponding to the situation of the mitral valve. It is in this neighborhood that mitral murmurs are readily heard. They may also be heard as high up as the fifth dorsal.

## METHODS OF PHYSICAL DIAGNOSIS.

- |                  |                                   |
|------------------|-----------------------------------|
| 1. Inspection.   | 6. Auscultatory Percussion.       |
| 2. Mensuration.  | 7. Succussion.                    |
| 3. Palpation.    | 8. Determining situation and size |
| 4. Percussion.   | of surrounding organs.            |
| 5. Auscultation. |                                   |

## INSPECTION.

Is the actual observation of a person's chest. As a means of diagnosis it is secondary in importance to auscultation and percussion, yet is of considerable value. By inspection we recognize the form size, and general movements of the chest. In order to recognize changes of disease it is necessary to have exact knowledge of the features presented in health.

## FORM OF HEALTHY CHEST.

The natural form of a normal chest is a cone with apex upward. Let us look at the different regions of the chest.

The supraclavicular region in health is slightly concave. The suprasternal region is always a deep hollow. The infraclavicular slightly convex. The upper sternal is about level. The lower sternal is always somewhat hollow. The mammary and inframammary are rotund. The intercostal spaces are always slightly concave in both inspiration and expiration, unless there be a superabundance of adipose tissue.

The two sides are very nearly symmetrical. It is estimated that not over twenty per cent of people have a perfectly symmetrical chest. The most common deviations from a perfect form are slight curvatures of the spinal column. Slight modifications are consistent with health. The main point is to see if the volumes of two sides are about equal.

#### NORMAL MOVEMENTS.

1. THORACIC MOVEMENTS.—In inspiration, we observe the sternum moves forward, all the ribs except the lower four go upward and outward. The lower four move outward directly, or outward and downward. The ribs all separate from each other in inspiration. In expiration, reverse movements.

2. ABDOMINAL MOVEMENTS.—Diaphragm ascends, and abdomen falls, in expiration; reverse, in inspiration.

---

#### DEPARTURES FROM HEALTHY FORM.

- |                |                 |
|----------------|-----------------|
| 1. Expansion.  | 5. Proclivitas. |
| 2. Bulging.    | 6. Elevation.   |
| 3. Retraction. | 7. Curvature.   |
| 4. Depression. | 8. Distortion.  |

#### EXPANSION AND BULGING.

By expansion we mean a general enlargement of one side or of the whole chest; by bulging, a partial enlargement at one point—enlargement due to causes within the chest. In asthma and general vesicular emphysema we have an example of expansion. The shoulders are raised, all the muscles of respiration are in a state of tension, that is, all the muscles in upper part of thorax. The chest is enlarged in every way.

Ordinary emphysema from obstructive causes produces bulging in the supra- and infra-clavicular regions. In pleuritis, bulging occurs in the mammary and axillary regions after effusion has taken place. Enlarged heart causes bulging in precordial region. Bulging in inframammary region on right side results from enlarged liver; on the left side, from enlarged spleen.

## RETRACTION AND DEPRESSION.

Retraction implies general reduction of the whole chest or of one side; depression has reference to a more local drawing in of the chest-walls.

Pleuritic effusion occurs, filling up the pleural cavity, so that the lung is compressed, and becomes bound down by inflammatory adhesions. After the fluid is absorbed, the lung does not again expand to its previous dimensions. In this case, atmospheric pressure acts upon the external surface, causing a retraction of the side.

Depression occurs from a cavity in the lung, from true croup, acute or chronic laryngitis, and from atelectasis, and local pleuritic adhesion.

Expansion and bulging are due to internal and not to external causes. Retraction and depression are due to the co-operation of an external cause, namely: pressure of the atmosphere.

## PROCIDENTIA AND ELEVATION.

These terms may apply to changes either in the whole or a part of the chest.

PROCIDENTIA.—Falling of the shoulders and lungs lower than natural, over atrophied or contracted lungs.

ELEVATION.—The lungs fixed higher than normal, or raised in the inspiratory act, as in emphysema.

## CURVATURE AND DISTORTION.

1. Lateral curvature of the spine is frequently the result of contraction of one lung or of chronic changes in the pleura, with enfeeblement of the respiratory muscles. Angular curvature is associated with early malnutrition, and the existence of chronic bronchitis, asthma, and emphysema.

2. The most common form of distortion is the "pigeon-breast." This is constituted by a flattening of chest laterally, and an arching forward of the sternum. Causes: rachitis, atelectasis, or non-expansion of the bronchial tubes in early life, whooping cough, croup, and bronchitis.

The deformity is not due wholly to rachitis, but to the partial and uneven filling of the bronchial tubes, to laryngeal or bronchial constriction and co-operation of external atmospheric pressure.



## ABNORMAL MOVEMENTS.

1. The antero-posterior motion of sternum, and the upward and outward motion of the ribs, are diminished in all contracted chests, as in fibroid and tubercular phthisis; also in the atrophied chests of the aged, with senile calcification and rigidity of the costal cartilages; also in emphysematous (barrel-shaped) chest.

2. The costal motion is diminished unilaterally by phthisical and pneumonic consolidations, by pleuritic effusion, and pleuritic adhesions and thickening.

3. Marked sinking in of the suprasternal notch, of the supraclavicular and infraclavicular spaces, of the intercostal spaces, and of the epigastrium—one or all—synchronous with inspiration are indicative of diminished elasticity of the intrathoracic structures. When more general or bilateral, then chronic diffuse disease, as extensive bronchopneumonia, chronic bronchitis, peribronchitis, or fibroid phthisis are likely to exist. Laryngeal or tracheal obstruction may be the cause.

When unilateral or local, thickened pleura or local pleuritic adhesions are likely to exist.

## PALPATION.

Palpation—the act of laying on the hand. It is less useful than inspection, in ascertaining general size, form, and movement, but is useful in determining local expansion, and the character of vibrations.

The palmar surface of the hand should be laid gently and evenly on the surface. If the hand be applied to the surface of the chest while a person is speaking, a tremulous vibration will be felt. If the individual coughs, a vibration is perceived. Bronchitic râles, pleuritic friction, and aneurismal thrill will also give rise to a vibration or fremitus. Hence we have,

1. Respiratory fremitus—Produced by breathing.
2. Vocal fremitus—Produced by the voice.
3. Tussal fremitus—Produced by cough.
4. Bronchitic or mucous fremitus—Produced by bronchitis.
5. Pulsatile fremitus—Produced by aneurism.
6. Friction fremitus—Produced by pleurisy.

Ordinarily when we use the term fremitus we mean vocal fremitus.

Palpation may also detect fluctuation. In pneumo-hydrothorax, or in a very large cavity where air passes in and out, the sensation of fluctuation may be felt by the hand. Such fluid is more often

detected by succussion. In order to have succussion, there must be both fluid and air in the cavity.

RESPIRATION.—The frequency and rhythm of respiration are also noted by palpation. The average in the adult is eighteen to twenty respirations per minute. Having counted the respirations, put one hand on the radial pulse and count pulsations, noting the relation between the two.

Normally the ratio of respiration to pulse is as one to four. It takes four times as long for the blood to go through the systemic as through the pulmonic circulation.

In disease the pulse respiration ratio is subject to much variation. In chorea it has been observed to be—

Pulse : respiration :: 9 : 1, and in hysteria, pulse : respiration :: 5 : 1.

#### MENSURATION.

There are many measurements, but the principal is the circular taken on the level of the sixth costal cartilage. The average circular

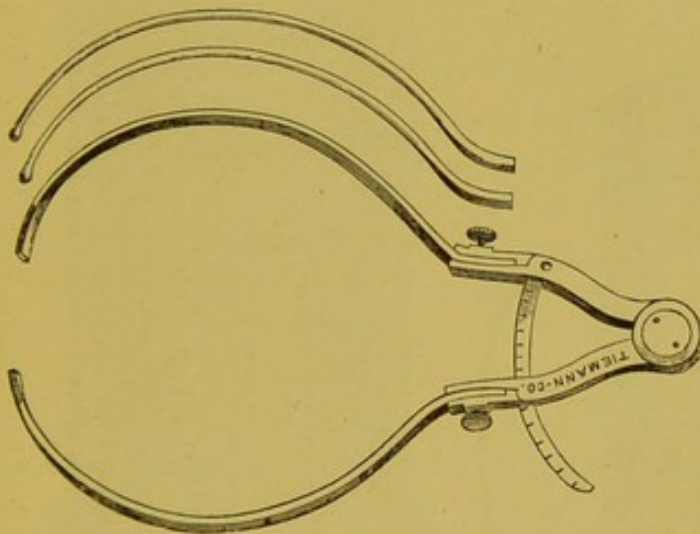


FIG. 6.

FIG. 6.—FLINT'S CYRTOMETER, with malleable arms of lead for mapping size and shape of chest.

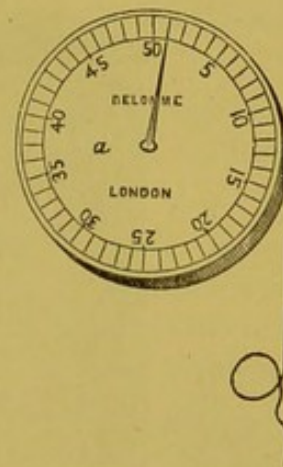


FIG. 7.

FIG. 7.—QUAIN'S STETHOMETER, with spring index, for measuring size of chest and degree of respiratory motion.

chest measurement of a healthy adult male, five feet eight inches in height, midway between inspiration and expiration, is 33 inches. It may go as high as 44, or as low as 27 inches. The average is a little less for women.

## DIFFERENCE OF RESPIRATION OF MEN AND WOMEN.

Respiration in the male is mostly abdominal, in the female mostly thoracic. This is in part owing to dress, but chiefly to sex, as women in pregnancy are obliged to use the thoracic muscles in respiration.

## CIRCULAR EXPANSION.

In ordinary quiet respiration, the circular expansion varies from one-fourth or one-half an inch to one inch. It may be as high as two



FIG. 8.—BARNES' SPIROMETER.

FIG. 9.—HUTCHINSON'S SPIROMETER.

inches. If a person takes a forced expiration, and the chest be measured, and then a full inspiration and the measurement be taken, the difference will represent the full expansive power. It varies from two and one-half to three and one-half inches, but may be

more. The expansive power for women should be about the same, though their stature is less.

#### QUANTITIES OF AIR.

The capacity for air is measured by a spirometer. The air habitually in the lungs, or capable of being introduced into them by respiration, is divisible into various quantities :

- |                       |                       |
|-----------------------|-----------------------|
| 1. Persistent air.    | 4. Tidal air.         |
| 2. Residual air.      | 5. Complementary air. |
| 3. Supplementary air. |                       |

#### DEFINITIONS.

1. *Persistent air* is that which cannot be removed from the lung structure by any possibility, not even by heavy pressure after death. It is, however, removed by disease.

2. *Residual air* is that which is never expired while the thoracic wall is intact, but which escapes when the chest-wall is opened on the cadaver, and atmospheric pressure collapses the lungs.

3. *Supplementary air* is that which is not expired in ordinary breathing, but may be ejected by a forcible expiration.

4. *Tidal air* is that which goes in and out in ordinary respiration.

5. *Complementary air* is that which may be inhaled by a forced inspiration after an ordinary inspiration.

The first three Dr. Walshe calls *stagnant air*; the last three represent the total breathing volume and are the only quantities which can be measured by the spirometer. The average amount of tidal air for a healthy adult male is 26 cubic inches for each inspiration. The greatest amount which the average male can inspire is 174 cubic inches. Thus it is evident we do not use one-half our lung power, even in health.

#### RELATIVE LENGTH OF INSPIRATION AND EXPIRATION.

Inspiration, 5.

Expiration, 4.

Rest, 1.

This relation is changed in disease. In advanced emphysema expiration is two or three times as long as inspiration.

## CHARACTER OF THE TWO ACTS.

Inspiration begins gently, increases gradually in intensity, till it reaches the middle of the act, then gradually dies away, and is immediately followed by expiration.

Expiration begins actively, then instantaneously and gently passes into rest.

## CHAPTER II.

### PERCUSSION.

PERCUSSION is the method of eliciting sounds from the chest in health and disease, by striking the chest-wall with the finger tips or the percussion hammer. There are two methods :

1. Immediate percussion.
2. Mediate percussion.

#### IMMEDIATE PERCUSSION

Is the direct striking of the surface of the chest with the hand or fingers. This is seldom practised.

#### MEDIATE PERCUSSION

Consists in the interposition of some medium between the striking hammer or fingers and the chest. This is by far the most com-




FIG. 10.—WINTERICH'S PERCUSSION HAMMER.



FIG. 11.—IVORY PLEXIMETER.

mon mode of percussion. It was originated by Avenbrugger and reduced to a science by Piorry and Laennec. When the hammer



FIG. 12.—FLINT'S PERCUSSOR.



FIG. 13.—FLINT'S PLEXIMETER.

is used, the interposed medium is a plate of rubber or ivory called a pleximeter. The hammer and pleximeter are useful for

clinical teaching, to elicit very clear sounds and for uniformity of stroke.

The hammer of Winterich and the ivory pleximeter have been chiefly used abroad. Flint substituted a hammer of elastic rubber, with handle of hard-rubber or ebony, and a pleximeter of hard-rubber.

It is far better in practice to rely upon the fingers.

#### MODE OF PERCUSSING.

One finger of the left hand is used as a pleximeter or medium and one or more fingers of the right hand are employed as a hammer. The palmar surface of the interposed finger should be placed in accurate and firm contact with the surface. Percussion with one finger may be performed by moving it at the metacarpo-phalangeal articulation (the knuckle). Such a method, however, requires much practice to perfect it, and the stroke will bring out only delicate sounds.

The rule is to strike from the wrist, without moving elbow or shoulder. We thus describe an arc of a circle and bring the finger at right angles upon the surface. The blow should be quick and sharp, and the finger instantly removed, in order to let the chest vibration continue. When percussing over cavities, and not desiring the sound to reverberate, the finger may be retained in contact. A single percussion stroke over a given point is by many regarded as better than repeated strokes. Others, as Flint, prefer a succession of five or seven strokes.

#### PERCUSSION DEVELOPS

Sounds indicative of :

1. The degree of elasticity or tension of the chest-wall.
2. The condition of the contained organs.

#### PROPERTIES OF THE PERCUSSION SOUND.

1. *Duration*, the length of sound as regards time.
2. *Intensity*, resonance, amplitude, or volume of sound.
3. *Pitch*, referring to length of sound wave, the acuteness, dulness, or flatness of sound.
4. *Quality*, what the sound suggests as to the condition of organs underneath.

## (1) DURATION.

The duration of the percussion sound varies perceptibly in different parts of the chest. It is longer, for instance, over the lung substance than over the heart or liver.

A certain relation exists between the four properties of sound: duration, intensity, pitch, and quality.

With high pitch there is diminished intensity, hard quality, and brief duration. With low pitch, more intensity, softer quality, and longer duration.

## (2) INTENSITY OR RESONANCE.

The resonance is not due wholly to the underlying organ. The sound produced by percussing over the lungs differs from that caused by percussing over the liver. The difference is due, in part, to the proper tissue of the organs; in part, to the fact that the lungs contain air which modifies the sound, and in part, to their position in the chest and relation to other organs. Again, the sound over the heart and the liver, both solid organs, is slightly different; that which the heart gives out is more intense, of longer duration, and lower pitch than that over the liver.

Intensity or resonance, therefore, is due to :

- (a) Consistency of the organ.
- (b) Its contents—air or fluid.
- (c) The shape and elasticity of the walls encasing it.

## (3) PITCH

Refers to the length of the sound wave. We define it ordinarily by saying it is the acuteness or dulness of the sound. Over anything solid, as the heart or liver, we get high pitch; over anything less solid, as over the normal pulmonary tissue, we get low pitch.

The greater the quantity of air the lower the pitch. Pitch is highest over liquids, as over pleuritic effusion, because liquids are most dense. Over gases, pitch is very low indeed. In percussing, we find pitch high over the liver, heart, and muscle; low over lung tissue, and over stomach lower still.

Pitch frequently has connection with duration. When the pitch is high, the duration is short; when the pitch is low, the duration is long.



## (4) QUALITY.

Quality or timbre suggests the nature of the subjacent or underlying organs. We have hardness, softness, and hollowness. The hollow type occurs under three varieties, the tubular, amphoric, and cracked metal.

The *Hard* quality is wooden, resembling that yielded by mediate percussion on a table. It follows percussion over the solid viscera, or over an infiltrated or solidified lung.

The *Soft* quality is that yielded by percussing over normal pulmonary tissue and has been likened to the sound of a drum covered with coarse woollen cloth.

The *Tubular* quality is that produced by air in an elongated defined cavity. This quality is to be detected over the trachea, and over the primary bronchi.

When anything solid lies between the large bronchi and the costal surfaces, this sound is sometimes obtained; thus it may occur in the interscapular region from enlarged bronchial glands, and over a great part of the back in case of intrathoracic tumor.

Small excavations in the lung, and dilatation of the bronchi may produce this quality of percussion note.

*Amphoric* quality is the tubular on a large scale. It resembles the sound produced by tapping the cheek when the mouth is closed, and fully but not tensely inflated. The common source of this sound is a cavity of large size near the surface, and provided with hard and thin walls.

*Cracked Metal*.—Cracked pot or cracked metal quality is an air impulse sound—air in a cavity rushing against its walls. The amphoric quality is almost always coupled with this quality. In the same patient, percussion with mouth and nostrils closed will produce amphoric sound, and percussion with the mouth and nose open will produce cracked-pot sound. It resembles the sound resulting from striking the back of the hands, loosely folded across each other, against the knee, the contained air being forced out quickly between the fingers at each blow. If the chest of a crying infant be percussed in expiration, the resonance will be of cracked-metal quality, and it can be produced by percussion on the elastic chest-wall of most young persons.

*Tympanitic* quality results from an unusual amount of air contained within a cavity with elastic walls. The sound is drum-like.

Typical tympanitic sound occurs in pneumothorax, and over the stomach, or intestines when distended by flatus.

The sounds developed by percussion are not always dependent on an organ lying immediately beneath. Sound may be conveyed across the chest. It must be remembered that the whole chest is an acoustic box—all the contained organs modifying the sounds.

#### MUSCLES.

The percussion note of muscles is non-resonant, high, hard, and brief, as elicited by percussing the muscles of the shoulder or arm.

#### HEART.

The heart is only a great muscle, hence its percussion note (superficial area) is high-pitched and hard. These qualities are less marked where it is overlapped by the lung (deep area). Thus we have superficial and deep sounds over an organ.

#### LUNGS.

The breathing surface of the lung is formed by the dividing bronchi and bronchioles and air-vessels, with elastic or connective tissue to hold them together. The normal properties of percussion sound differ somewhat over different places.

In the infraclavicular region the intensity is considerable, the quality is true pulmonary—pitch low—duration distinctly perceptible. In the right mammary region the pitch rises some, even at the upper part, and is very perceptibly elevated at and below the fourth intercostal space, owing to the contiguity of that hard, solid organ, the liver (Walshe—Law of consonance). Others explain this relatively high pitch of the right infraclavicular region as due to the greater thickness of the pectoralis major on this side, owing to the “right-handed” habit of most persons. A third explanation, and one quite generally accepted, is the proximity of the right primary bronchus and its branches, with peribronchial structures, to the thoracic wall. On the left side, according to the law of consonance, the heart will also influence the pitch of the percussion note of the superimposed pulmonary area.

The left infraclavicular region is usually taken as affording the standard normal pulmonary percussion note (“normal pulmonary resonance”). Flint compares the normal percussion note to the sound elicited by percussing a loaf of bread covered with a napkin.

The line of pulmonary resonance at the base of the left lung in front, and the transition from resonance of lung to flatness of the liver on the right side, may be varied by forced inspiration and forced expiration as much as three or four inches, and Flint mentions as great a variation as seven inches in exceptional cases (see Flint, "Manual of Auscultation and Percussion," p. 54, 4th edit., 1885).

The intensity in the right inframammary region is diminished, in consequence of the presence of the liver beneath the surface; the pitch is high, the duration short, and the quality is "hepatic" or wooden. The note is usually regarded as superlatively "flat," as distinguished from the lesser degree of high pitch, "dull," and the

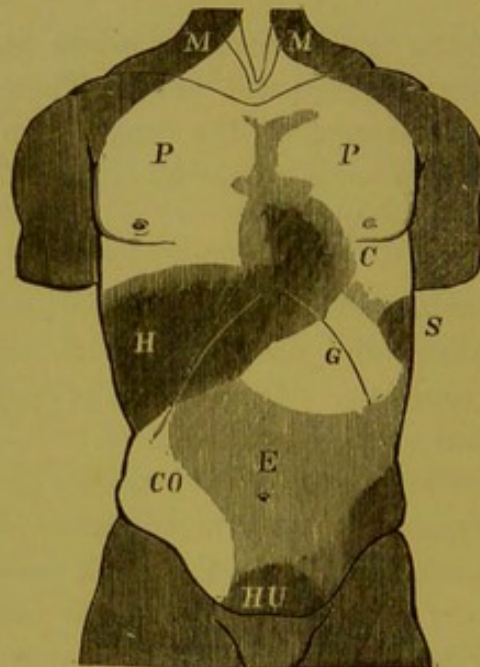


FIG. 14.—Showing areas of percussion resonance and dullness of front of chest (Piorry).

opposite low-pitched condition of lung, intestine, stomach, etc.—"resonant."

The suprasternal region gives tubular resonance. In the upper sternal region the sound is of a somewhat mixed character; and also in the lower sternal region, where the stomach may further modify the sound. It is in this region that difficulty is often encountered in tracing the line of demarcation between the liver and the heart. The diaphragm intervenes between the two organs, but the percussion note of one differs so little from that of the other that it is often practically impossible to define the line of contact.

A good rule in that case is to draw a line from the point of the

heart's apex beat to the apex of the angle formed by the union of the upper free edge of the liver with the right free edge of the heart.

Over the trachea and large bronchial tubes the percussion sound is tubular in quality, its intensity full, owing partly to the contained air and partly to the walls of the tubes themselves; the pitch is low, neither hollow nor tympanitic, and the duration is long and ringing.

Over the aorta, gentle percussion gives a true pulmonary percussion note; deep percussion lessens the duration and resonance, raises the pitch and makes the quality hard. If an aneurismal tumor exists, the same modifications, intensified, will be present over a larger area.

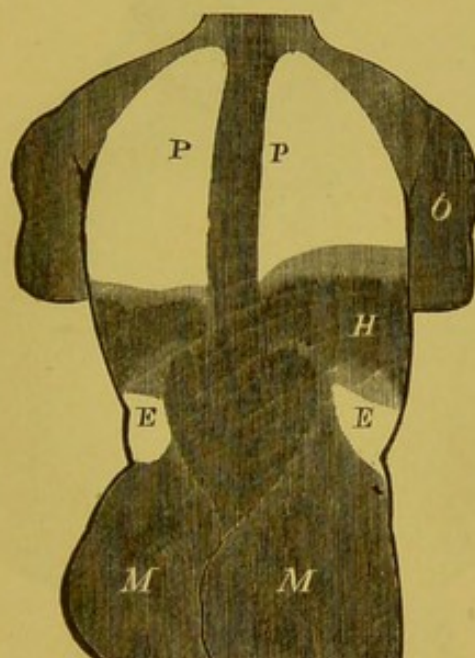


FIG. 15.—Percussion resonance and dulness of posterior regions (Piorry).

The posterior thoracic regions do not give the pulmonary sound so well as the anterior regions, because of the thickness of the dorsal muscles. When the scapulæ are carried outward in the second position of Corson (see below), the interscapular areas are nearly doubled and sometimes more than doubled, and the muscles being rendered tense and thin, a normal pulmonary percussion note is elicited, which continues as we descend and percuss the infrascapular regions. Below the eleventh rib of the right side the note is high-pitched, hard, hepatic. By forced inspiration the liver line may be lowered (behind) one or two inches. Resonance does not extend as far down on the right side as on the left. On the left

side of the chest, posteriorly, below the eleventh rib, the spleen, if large, or the stomach and intestines may modify the percussion note.

The lateral regions of the chest are more highly resonant. On the right side the percussion sound loses in volume and rises in pitch as we go downwards toward the liver. Below the sixth rib on the left side the sound is modified by the spleen and stomach.

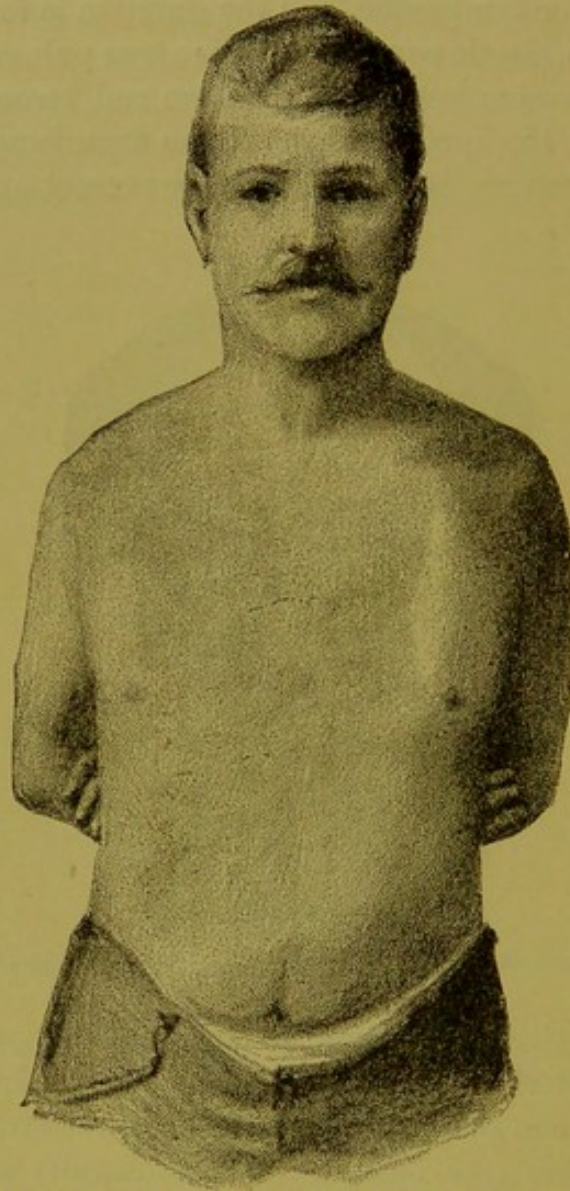


FIG. 16.—Position for percussion of front of chest; from a photograph by the author.

The percussion note varies in character during the different periods of the respiratory act and according as the respirations are quiet or exaggerated.

The sound over the stomach is tympanitic, and over the intestines, according as they are empty, full of fæces, or distended with gas, varies from tonelessness to tympanitic resonance.

The spleen gives the same hard, toneless, hepatic quality of sound that the liver does. It is located in the left inframammary region from the eighth rib to the free border of the ribs and back of the axillary line.

*Positions of Patient for Percussion. (Dr. Corson.)*

*First Position (for Anterior Examination).*

Shoulders well thrown back; arms folded behind the back, to make tense the muscles on the front of the chest (Fig. 16).

*Second and Third Position (for Lateral Examination).*

In the one (Fig. 17) the hands are clasped upon the top of the

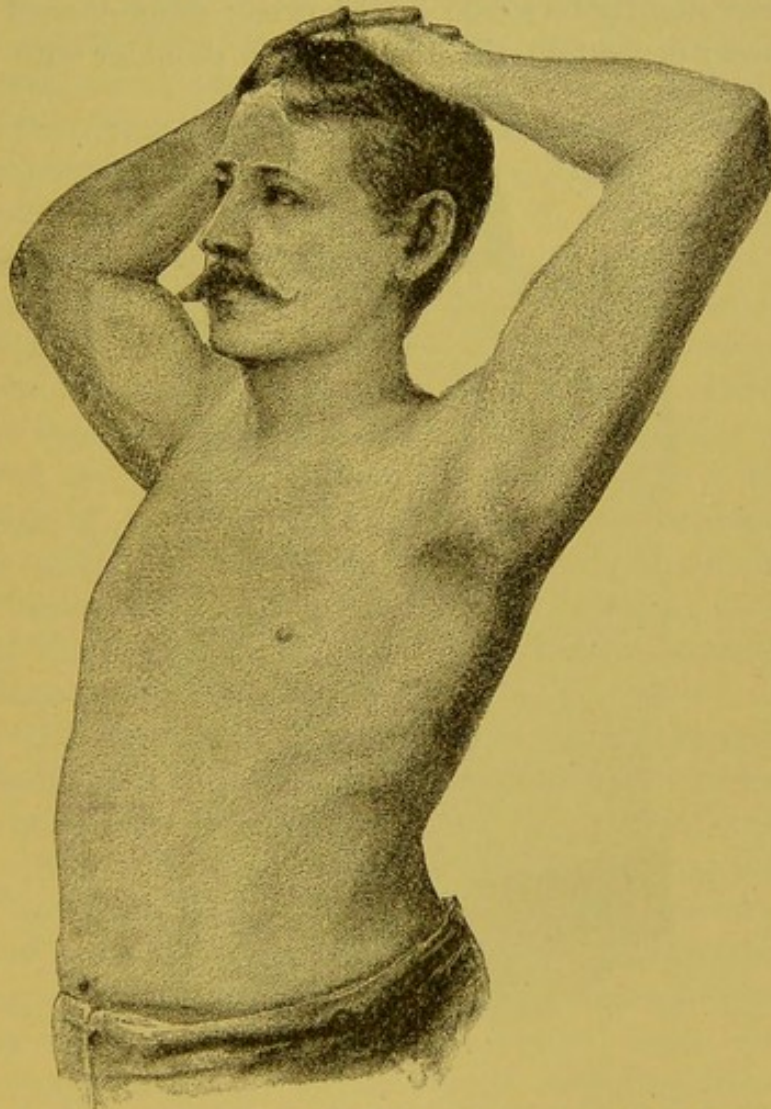


FIG. 17.—Position for percussion of lateral regions; from a photograph by the author.

head, in the other the arms are carried above the head and curved horizontally, side by side, or each hand clasping the opposite wrist.

The examination in the axillary line high up, with the arm carried over the head, should be made in all cases. It must have come to the notice of very many physicians in private practice, but more often in the grouped cases of general hospitals, that in cases of irregular pleuro-pneumonia, and in low and indefinite forms of pneumonia—the product of squalor, dissipation, malaria, or secondary to phthisis—the initial area of pneumonic consolidation, as evidenced by bronchial breathing (and percussion) has been found only in the axilla.

*Fourth Position (for Posterior Examination).*

Body bent slightly forward; head bowed; arms crossed in front of the chest; or better still to clasp each shoulder with opposite hand (Fig. 18.)

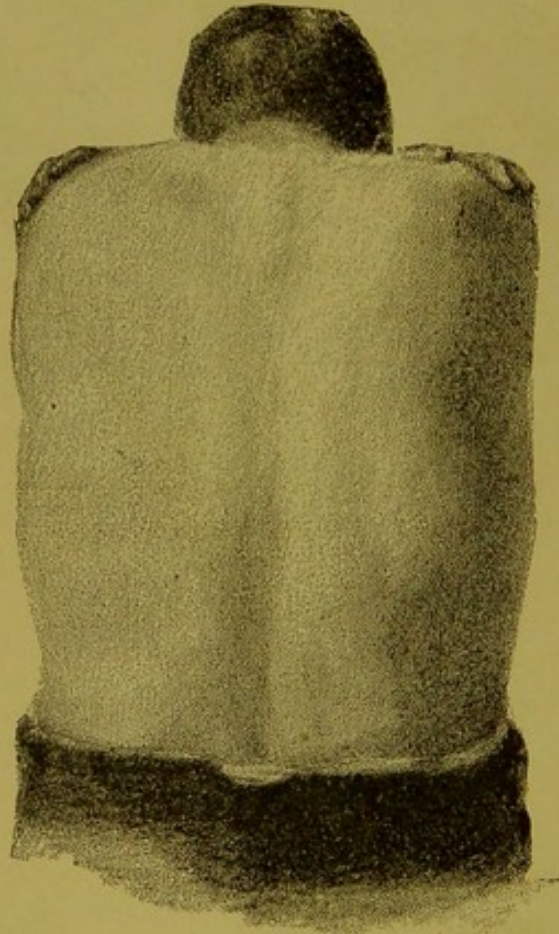


FIG. 18.—Position for percussion of posterior regions; from a photograph by the author.

I cannot better express my conviction that the resort to this fourth position of Corson is a matter of the greatest importance in physical

diagnosis than by quoting from my monograph, on the "Physical Examination of Weak Chests."<sup>1</sup>

"The importance of the interscapular exploration is such as to warrant a fuller consideration. It is here that we have the larger bronchial trunks and the hilus of each lung close to the posterior wall of the thorax. But in the ordinary postures, with the head erect and arms hanging by the side, or even with the arms loosely folded in front, the interscapular spaces are relatively valueless for physical diagnosis. The scapula, on either side, covers the chest from the first to the eighth rib, and comes within an inch of the processes of the vertebræ. This intervening space on each side of the spine is filled in deeply by the rhomboideus minor and major, which span it obliquely from the vertebræ to the scapula, and to complete the muscular envelopment the trapezius extends from its median origins at the occiput, the ligamentum nuchæ, the cervical and twelve dorsal vertebræ, in converging bands, over the interscapular space and scapular blade, to its attachment on the spine of the scapula. The value of the upper half of the back for percussion is therefore slight, over these thick flaccid muscles and this interposed bony plate. Most physicians recognize this condition and obviate it, in a measure, by directing the patient to fold the arms. By a forward motion of the arms, the claviculo-scapular union, being essentially fixed, serves as a point of rotation, while the tension of the deltoid on the spine of the scapula directly antagonizes the trapezius and draws the scapula laterally with slight rotation. Dr. Corson, more than any other person, has emphasized the importance of taking advantage of the great mobility of the scapulæ as a means of increasing the interscapular area.

"If the arms be crossed in front, each upward, at an angle of 45°, and the hand on either side is made to grasp the convexity of the shoulder, the clavicular attachments and the deltoid so elevate, rotate, and draw outward the scapulæ, that the interscapular space is increased more than twofold, and the previously flaccid and thick muscles are rendered tense and thin, lying firmly on the ribs, and interposing no obstacle to percussion and auscultation of the bronchi, and of the upper inner borders of the lungs. Each intrascapular area, before a rectangle of one inch width, extending from the first

<sup>1</sup> "The Physical Examination of Weak Chests, and Differential Diagnosis of the several Forms of Early Phthisis." New York Medical Record, May 9th, 1885.



to the eighth rib, is converted into a trapezoid whose upper truncated apex is fully two inches wide and whose base is between three and four inches broad. The lower angle of the scapula is elevated to the seventh rib. This great gain in space, however, is not more important than is the advantage from the thinning out of the trapezius and rhomboidei. Finally, if the patient's head be bowed, and the neck forcibly incurvated forward, the tension of the levator anguli scapulæ is added; it increases the elevation of the scapulæ by half an inch, and adds to the general tension of the dorsal muscles. The scapulæ have not only been moved laterally, but the thin plates, as located, are firmly held between tense muscles, and interpose a greatly diminished obstruction to conduction of sounds. I would urge the resort to this position as greatly facilitating the study of chronic bronchitis, peribronchial fibroid, and, indeed, of all forms of bronchial and pulmonary diseases."

In properly interpreting the diagnostic significance of a percussion note, we must remember that the chest-wall and great vessels are factors of the sound. I again quote from my paper on "The Physical Examination of Weak Chests."

"Although most authors and teachers of physical diagnosis recognize the composite nature of the pulmonary percussion sound, and the several factors which unite to produce it, yet the impression still prevails that it is essentially the product and exponent of the underlying lung. It would be undesirable to detract in the slightest degree from the confidence reposed in the diagnostic value of percussion. But the exclusively pulmonary origin of percussion sound is easily disproved. This is most easily accomplished by a brief reference to the percussion note of emphysema. If, in emphysema, the percussion note were to correspond to the volume of air within the coalesced air-vessels, and in the stretched infundibuli and dilated terminal bronchi, we should obtain by percussion the prolonged, low-pitched, tympanitic sound which the novice in physical diagnosis is always prepared to hear. To his surprise, the sound, although possessed of some tympanitic quality, is curtailed in duration, and in its initial portion, at least, is raised in pitch. The explanation is simple. The emphysematous lung is an aggregation of fused air-vessels and distended terminal air-passages; it is a dilated lung, with much of its elastic tissue absorbed and deprived of its expiratory contractibility. The overlying bony thorax is, therefore, in a state of inspiratory fixation, and so tense or rigid that it

does not vibrate. Hence the contact of the percussion finger tips with a rigid thorax elicits a sound relatively high in pitch and devoid of vibration or duration. I will mention one further fact bearing upon this question. The middle and lower sternal regions overlie the anterior mediastinum, which contains the great vessels, and also cover the body of the heart. Yet, in some elastic chests, percussion over the lower half of the sternum—the keystone of the elastic respiratory arch—elicits, not flatness, the product of underlying solid structures, but a sound essentially of pulmonary quality. The elasticity of the chest-wall is undoubtedly an essential factor of, or contributor to, the percussion note.”

## CHAPTER III.

### PERCUSSION OF THE ABNORMAL CHEST.

IN percussing the abnormal chest, we note modifications or departures from the normal standard, viz.:

Change in duration of the percussion note.  
“ intensity “ “ “  
“ pitch “ “ “  
“ quality “ “ “

The percussion note indicative of thickened pleura, pleuritic effusions, and pulmonary consolidations, becomes shortened in duration, diminished in intensity, raised in pitch, and of lessened pulmonary quality, or there may be entire absence of pulmonary quality with a new quality diagnostic of the changed physical condition. Dulness

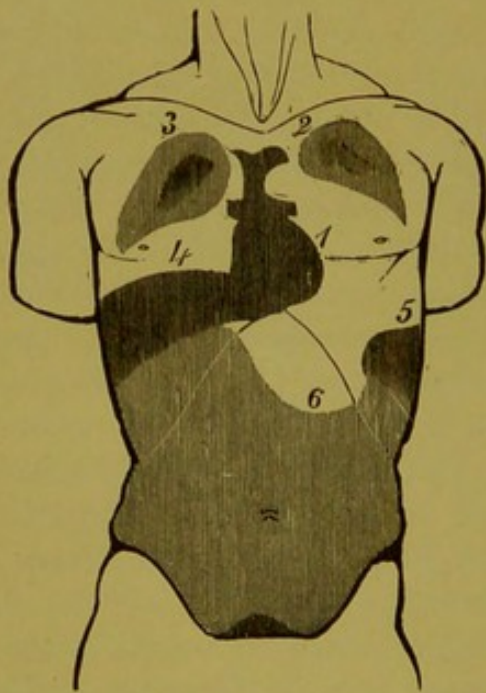


FIG. 19.

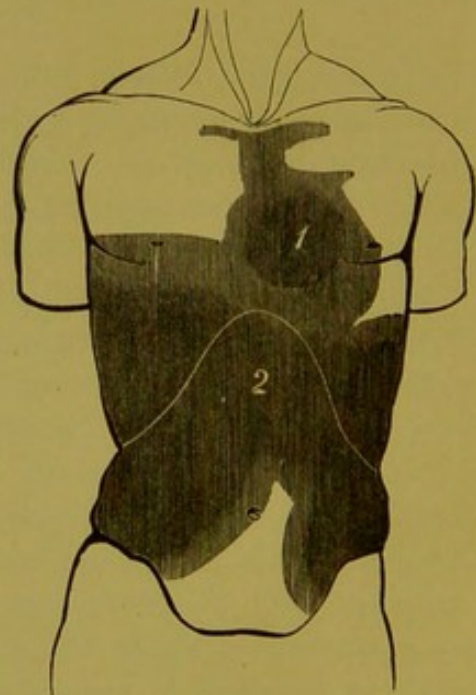


FIG. 20.

Areas of dulness and flatness of phthisis at each apex.—Piorry.

sions, and pulmonary consolidations, becomes shortened in duration, diminished in intensity, raised in pitch, and of lessened pulmonary quality, or there may be entire absence of pulmonary quality with a new quality diagnostic of the changed physical condition. Dulness

and flatness are the terms usually employed to indicate partial or complete removal of "pulmonary resonance" or "normal percussion note."

Thus slight consolidations give "dulness," *i. e.*, lessened duration, diminished intensity, raised pitch, and lessened or absent pulmonary quality (see Fig. 19). Pronounced consolidation gives "flatness," *i. e.*, short duration, want of intensity, high pitch, and hepatic or wooden quality (see darker shaded centre of Fig. 19).

In pleurisy with effusion (see Figs. 20, 21, 22), there is absolute

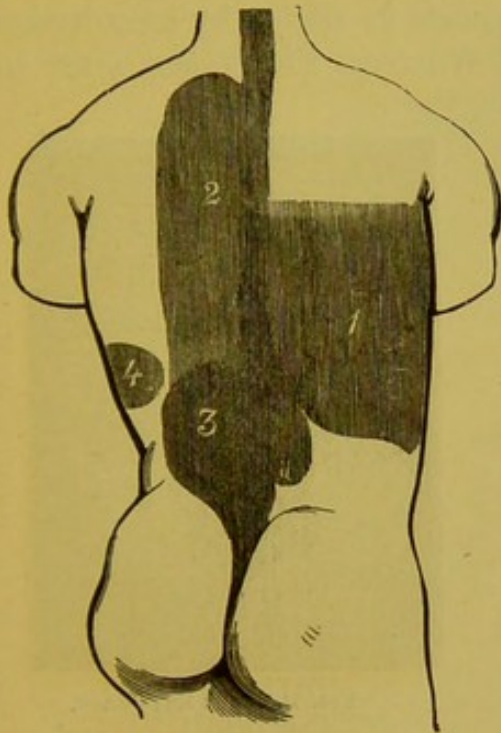


FIG. 21.

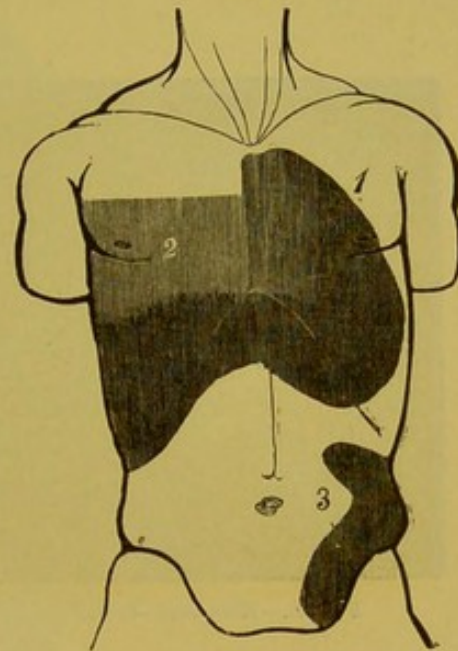


FIG. 22.

flatness—a note short, devoid of intensity or volume, superlatively high-pitched, and wooden in quality.

In pleurisy, also, the line of transition from pulmonary resonance to flatness is often abrupt, as shown in Figs. 20–22, and is changed by change of position of the patient's body, as illustrated in Fig. 21 (the shading of the left side of the chest indicating the location of the fluid when the patient is lying on the right side).

Fig. 20 also illustrates the flatness of pneumonia of the right lower lobe—a percussion note superlatively short in duration, wanting in intensity or volume, high in pitch, and wooden in quality. In thickened pleura, there are variable degrees of dulness and flatness.

In bronchitis, the percussion note is essentially normal. In some cases of acute bronchitis, the resonance may be slightly intensified. In chronic cases, there is often dulness or flatness due to interstitial pneumonia and defective expansion of lung.

In emphysema, as already stated, the rarefaction of the lung tissue lessens its elasticity and often renders the bony thorax rigid or fixed. Hence the percussion note is "vesiculo-tympanitic" (Flint), *i. e.*, short in duration, variable in intensity and pitch and of tympanitic quality.

The statement with reference to the fluid level of percussion dulness (and also of transition from sounds to silence by auscultation) in pleurisy demands modification. Whereas Piorry and most au-

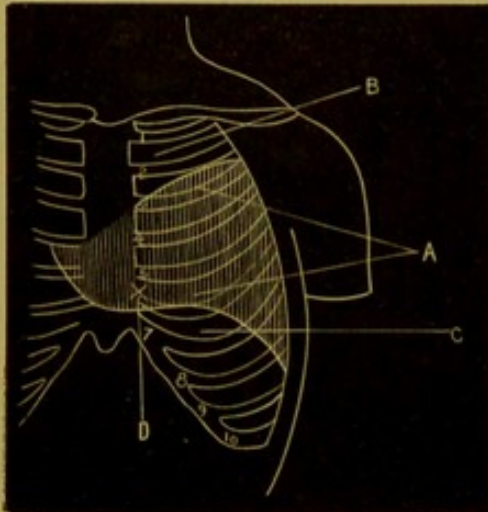


FIG. 23.—Ellis line—front.

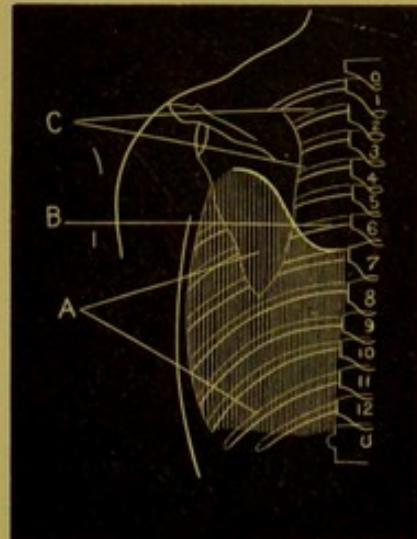


FIG. 24.—Ellis line—back.

thors until recently described the line of dulness as horizontal (see Figs. 20, 21, 22), it is now generally conceded that the "Ellis line," as shown by Garland and others, is demonstrable in a considerable number of effusions, half or two-thirds filling the pleura. Thus, as shown in Figs. 23, 24, the line of dulness is a letter S, or warped letter S, low behind near the vertebral column, going in a curve obliquely upward and around the side, where the fluid level is highest, and again descending in a slightly curved line in front to the mid-sternum or part way across the opposite side, if the fluid accumulation has compressed the opposing lung and displaced the heart. The area of relative resonance behind near the spine is due to the lung near its root resisting the invasion of the fluid. The difference on the side and in front must result from the distribution of

the stiff bronchi in the lung, rendering its collapse less in the lateral than in the antero-posterior axis.

*The Sense of Resistance in Percussion.*

The subject of percussion would be incomplete without mention of the impressions received by the interposed finger, which is the medium or intermedium employed as a substitute for the pleximeter. The finger receives the percussion stroke, transmits it to the chest-wall, and in return is met with a variable degree of resistance, ac-

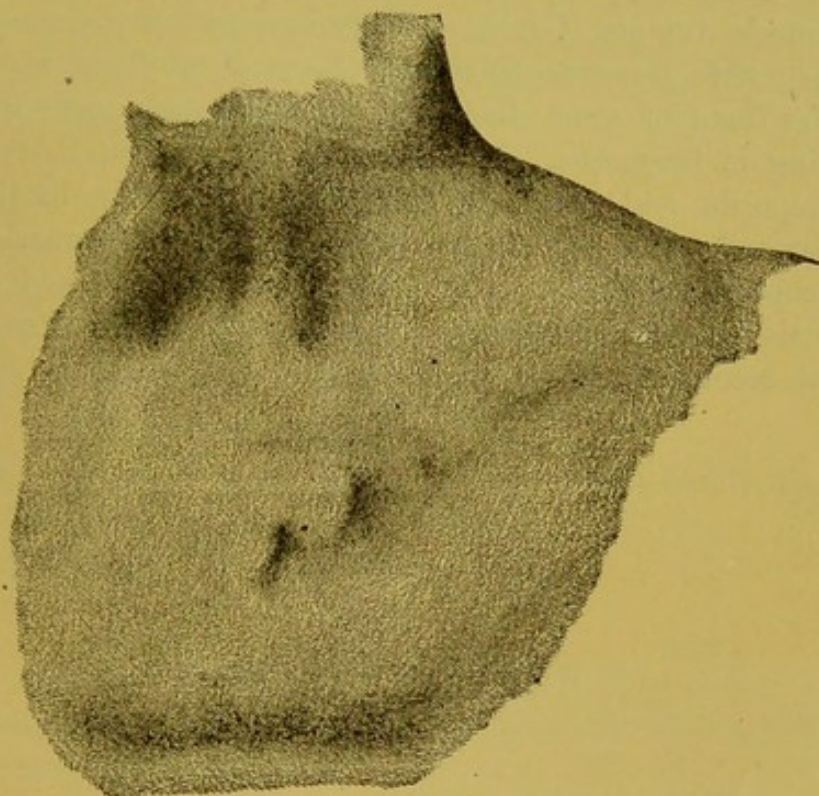


FIG. 25.—Myoidema—cutaneous reflex of Graves and Stokes, Gardner, Finlayson, and Tait. Photographed by the author from a patient in Bellevue Hospital (four seconds exposure).

ording as the chest-wall is elastic and yielding, or rigid and ossified, and again according as the intrathoracic contents are elastic and cushion-like (normal lung), or hard and resisting in variable degree (mildly so in a poorly expanded chest and in early phthisis, more pronounced in advanced phthisis and in pneumonia, superlatively hard and resisting over pleuritic fluid, the liver, heart apex, or tumors). The interposed finger acquires a trained expertness—a “*tactus eruditus*” as applied to chest signs—in estimating the density and resiliency of chest-contents and chest-wall.

*Myoidema a Product of Immediate Percussion.*

While immediate percussion (direct blows upon the chest-wall, with no interposition of the finger or other medium) is not resorted to to elicit acoustic signs, it does develop an associated sign—little reflexes of the skin and also of the pectoralis major. They chiefly respond to quick percussion with the finger tips in actively progressing or fully developed phthisis, and are indicative of the effect of elevated temperature and tissue waste upon the thoracic action of the spinal cord (Fig. 25). The clinical coincidence of this “peculiar momentary starting and elevation of the skin” (Finlayson), these muscle tumors (Graves and Stokes) or “myoidema” (Lawson Tait), with the true tubercular form of phthisis, renders the search for them of some diagnostic value, though more important as bearing in prognosis. Myoidema is chiefly found over tubercular deposits and areas of softening and cavity in the infra-clavicular and upper part of mammary region. The muscle tumors are perceptibly resisting to feel, are conoidal, blanched in color, and remain raised from three to five seconds, in rare instances eight to twelve seconds.

## CHAPTER IV.

### AUSCULTATION.

AUSCULTATION means the application of the ear to the chest for the detection of normal and abnormal sounds.

By auscultation of the respiratory organs, we may hear

1. Normal breath sounds.
2. Normal voice sounds.
3. Abnormal breath sounds.
4. Abnormal voice sounds.
5. New sounds.
  - (a.) Sound resulting from a combination of above.
  - (b.) Sounds having no connection with either voice or breath sounds.

We distinguish in these sounds the following properties :

- |               |             |
|---------------|-------------|
| 1. Duration.  | 4. Quality. |
| 2. Intensity. | 5. Rhythm.  |
| 3. Pitch.     |             |

#### THESE PROPERTIES DEFINED.

1. *Duration*, the period or persistence of the sound, usually proportionate to intensity.

2. *Intensity* is the degree of resonance, the volume, or amplitude of the sound.

3. *Pitch* refers to the acuteness of sound, whether the sound is high or low.

4. *Quality* is that property which reveals something of the character of the substance emitting or conducting the sound.

5. *Rhythm* refers to the recurrence of sounds, whether this be uniformly regular, or irregular and jerking.

#### METHODS OF AUSCULTATION.

1. *Immediate*, if the ear is applied to the chest.
2. *Mediate*, if an instrument be used.



## THE STETHOSCOPE.

The instrument used in mediate auscultation is a stethoscope. The original stethoscope of Laennec was a hollow cylinder of wood, having an expanded end, its longitudinal axis being parallel with the grain of the wood.

Stethoscopes have also been made of other materials, as glass, gutta-percha, metal, and ivory, but wood is preferable.

Their shape has been modified by various auscultators to meet fancied acoustic requirements, but the straight stethoscopes of Stokes

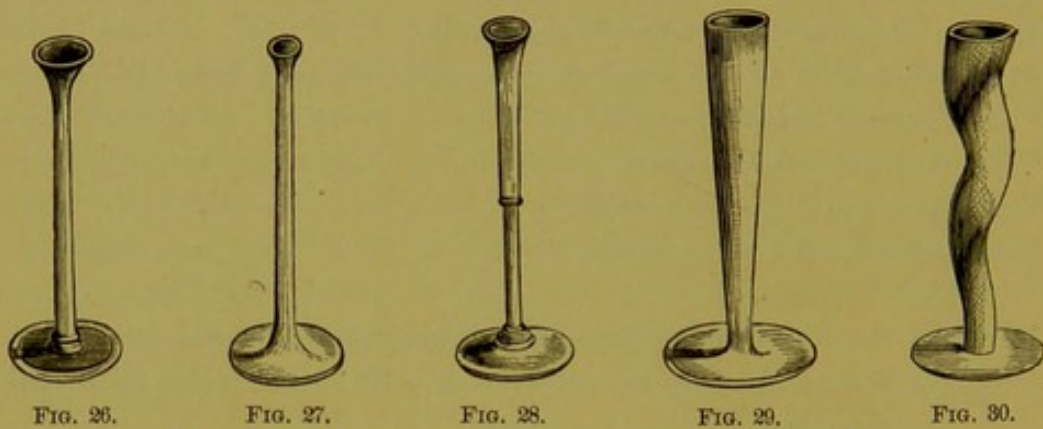


FIG. 26. FIG. 27. FIG. 28. FIG. 29. FIG. 30.  
Straight stethoscopes of various patterns (Hughes Bennett).

and Dobell abroad, and of Barclay, Loomis, and others in this country, are essentially of one pattern.

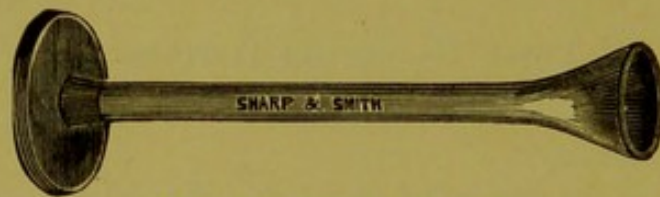

FIG. 31.—Barclay's Stethoscope.

The Barclay is simplest in form and most generally used. The solid stethoscopes are usually perforated by a central bore, extending the entire length; the necessity or advantage of this is doubtful, and many of the best, as "Cammann's auscultator" and "intercostal auscultator" (see Figs. 55, 56, p. 69), are without bore. The value of the solid and straight perforated stethoscope is not generally appreciated, owing to the greater convenience, attractiveness, and applicability of the binaural stethoscope of Cammann, which, in this country at least, is almost synonymous with stethoscope, so little is any other used or known.

## THE DOUBLE OR BINAURAL STETHOSCOPE.

The binaural stethoscope was invented by the late Dr. Cammann, of New York, and is very largely used in this country. Its use is discouraged by many English and Continental writers. Their criticism is that it not only intensifies sounds, but also materially changes them, altering their pitch and quality. While this criticism is in a measure true, yet the relative properties of different chest

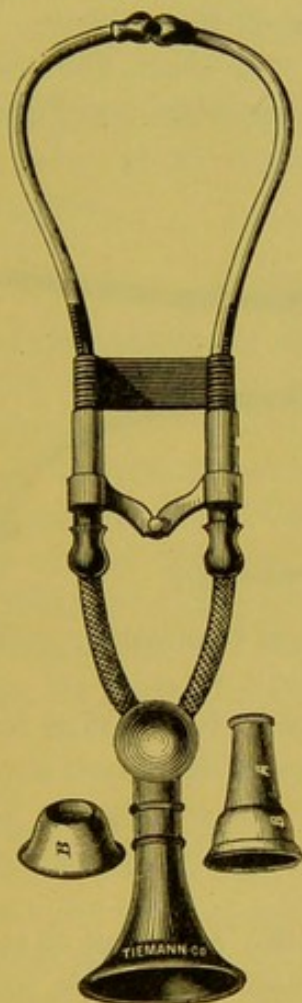


FIG. 32.

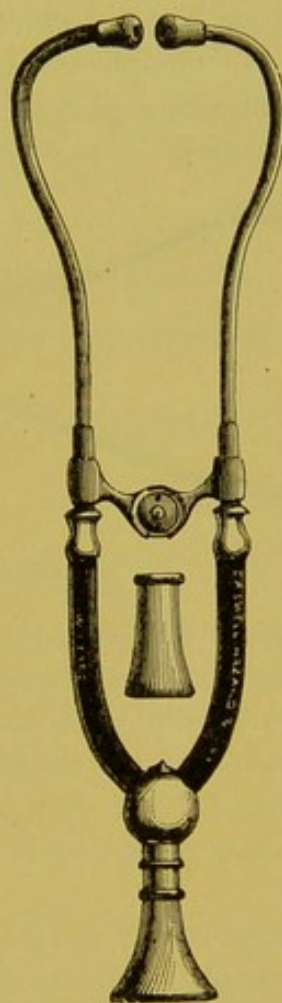


FIG. 33.

FIG. 32.—Cammann's stethoscope with Snelling's rubber bell.  
 FIG. 33.—Cammann's stethoscope—Ford's spring.

sounds, normal and abnormal, as heard by the stethoscope can be compared, and the modification due to the instrument, as well as adventitious sound developed in the instrument itself, come to be excluded by the practised ear. The intensification of sound then becomes a desideratum and the localization of sound by the instrument is of equal value.

The original instrument as devised by Cammann has been variously modified as to shape of the ear tubes, the pectoral or receiving tube, and the length of the intermediate flexible rubber tubes. The interposition of very flexible tubes, as figured in Da Costa, and of friction sockets of hard-rubber for separating the metal tubes, injure the acoustic qualities of the instrument. The substitution of the spring joint of Ford (see Fig. 33) for the elastic band or spiral spring is desirable, as the latter often are vibrated by the breath of the listener or his movements or those of the patient. A non-disjointing or "one-piece" stethoscope, with short, fine elastic rubber tubes connecting pectoral tubes and ear tubes (see Figs. 32, 33) should be selected.

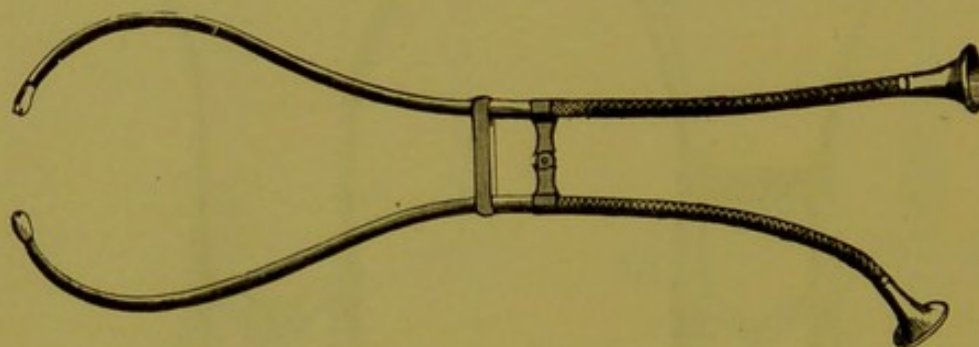


FIG. 34.—Allison's differential stethoscope.

Snelling's soft rubber cup is employed on Cammann's stethoscope in examining emaciated patients.

The Scott Allison differential stethoscope is intended for coincident observation of the two sides. It is still employed abroad, but has never found favor in this country. The sounds can be better appreciated and compared if heard consecutively by the Cammann instrument.

The habitual use of the stethoscope to the exclusion of the ear is to be deprecated. I advise dependence upon the ear in most cases of well-defined chest disease. The stethoscope may be further employed to confirm doubtful signs. Most cases may with advantage be subjected to careful examination by the unaided ear and stethoscope alike, but it is unfortunate to destroy the training of the ear and create a dependency on the stethoscope.

## SPECIAL REASONS FOR USE OF THE STETHOSCOPE RATHER THAN THE EAR.

### (MEDIATE AUSCULTATION.)

1. The localization of sound, as of a small cavity or heart-lesion.
2. The intensification of certain sounds, not distinctly developed.
3. The exclusion of extraneous sound in noisy habitations or lecture rooms.
4. The avoidance of chest exposure. The delicacy of ladies is favored.
5. In hospital and dispensary, or other charitable practice, it obviates contact of the lecturer with the bodies and clothes of uncleanly patients.

### OBJECTIONS TO THE USE OF THE STETHOSCOPE.

1. The interposition of the stethoscope may intensify and otherwise modify and change sounds.
2. The training of the ear is liable to be neglected, and confidence in its interpretations lessened.
3. Too habitual use of the stethoscope, with its intensification of sounds, in clinical teaching and practice, may positively impair the previous delicacy of the ear for sounds of normal intensity.

These objections will not hold with persons who employ the stethoscope for its legitimate use, conjointly with direct listening.

### AUSCULTATION IN HEALTH.

We listen to the chest in health, to detect

1. Normal respiratory sounds.
2. Normal voice sound (vocal resonance).
3. Normal whisper sound.
4. Normal cough (voluntary) sound (tussal resonance).

#### 1. NORMAL RESPIRATORY SOUND.

We first listen to the respiratory sounds. The respiratory act is double, yet in one-fourth of all healthy persons (in quiet breathing) expiratory sound is wanting, *i. e.*, in one-fourth of all normal chests (in ordinary respiration), only inspiration is heard (Walshe). In three-fourths of normal chests, expiration is faintly heard, and in but one-fourth or one-third as long as expiration. And yet expiration as a physical act is four-fifths as long as inspiration. This is im-

portant to remember, since the auscultator, while resting his head on the patient's chest, takes cognizance of the duration and rhythm of the thoracic movements, as well as of the respiratory sound.

RATIO OF INSPIRATION TO RESPIRATION.

1. As a physical act.

Respiratory rhythm	{	Inspiration.....5
		Expiration.....4
		Rest.....1

2. As producing sound (heard over the chest surface).

Inspiration, 3 to 4.

Expiration, 1.

But if the stethoscope be held to the slightly opened mouth of a person in normal breathing, the inspiratory and expiratory sounds will be found to have the same relative duration or period as the physical acts which determine them. The explanation is simple: 1st, in inspiration the inspired air is drawn into a system of steadily diminishing tubes and against numerous bifurcations and septa, as well as into expanding alveoli and intervesicular structures; thus air and tube friction sounds and tissue expansion sounds are developed. 2d, the entire volume of produced sound is moving towards the chest-wall, and the ear or stethoscope of the listener. Reversely: 1st, in expiration the air retreats out of a system of steadily increasing tubes; a lesser air and tube friction sound is thus produced. 2d, the lesser sounds thus produced are receding away from the chest-wall and the ear of the listener. Such an understanding of inspiratory and expiratory forces and acoustics is essential to the intelligent interpretation of the abnormal changes in expiratory sound as to duration and pitch.

CHARACTER OF NORMAL INSPIRATORY SOUND.

Inspiration (as heard over the chest-wall) is a soft, breezy sound, neither moist nor dry. It is faint at its inception, increases in intensity or volume to its mid-period, and gradually subsides. The inspiratory sound occupies the entire period of the physical act of inspiration. It has normal or full *duration*, normal *intensity*, low *pitch*, and true pulmonary *quality*. Its rhythm is steady, uniform, continuous. The inspiratory sound, like the inspiratory movement of the thorax upon its completion, is immediately followed by

the expiratory sound. Any perceptible interval following inspiratory sound and preceding the expiratory sound is indicative of abnormal conditions, except when patients from nervousness or fright of examination hold back the expiratory act.

#### CHARACTER OF NORMAL EXPIRATORY SOUND.

The expiratory sound (as heard over the chest-wall) is not one-third or one-fourth as long as the inspiratory sound. It is more flowing, more hollow (Walshe), and the vesicular quality (breezy and soft) is wanting (Flint). By some it is described as higher, by others as lower in pitch than inspiratory sound. The latter is the more correct statement. Unlike inspiratory sound, the expiratory sound does not extend over the entire period of the expiratory physical act or expiratory movement of the thorax. It begins coincident with the expiratory act, but continues over only the first third or at most half of the expiratory period. The expiratory sound follows immediately after inspiratory sound without interval, but expiratory sound is followed by a distinct period of rest.

#### THE RESPIRATORY MOVEMENTS.

Respiration is automatic or involuntary under most circumstances. This is what we designate *quiet* or *normal respiration*. When voluntary effort is superadded, we then have *exaggerated* or *forced* respiration.

Inspiration is the product of active forces; the expansion of the bony thorax by muscular traction increasing the volume of the thoracic cavity, thus inviting, by suction and external atmospheric pressure, an ingress of air through the mouth and air passages. Expiration is relatively a passive act, a subsidence or collapse of thoracic and abdominal parietes and diaphragm, with contractility of pulmonary tissue and air tubes, and consequent retreat of the expiratory currents.

#### ELEMENTS OF THE NORMAL RESPIRATORY SOUND.

1. Air and tube friction sound, developed in the pharynx.
2. " " " " " " larynx.
3. " " " " " " trachea.
4. " " " " " " bronchi.

5. Sound developed in the air vesicles.
6. " " " parenchyma of lung.
7. " " " muscles of chest-wall (muscular sussurus).

1. The pharyngeal element of inspiratory sound may be heard by gently placing the stethoscope beneath the ramus of the jaw. It is

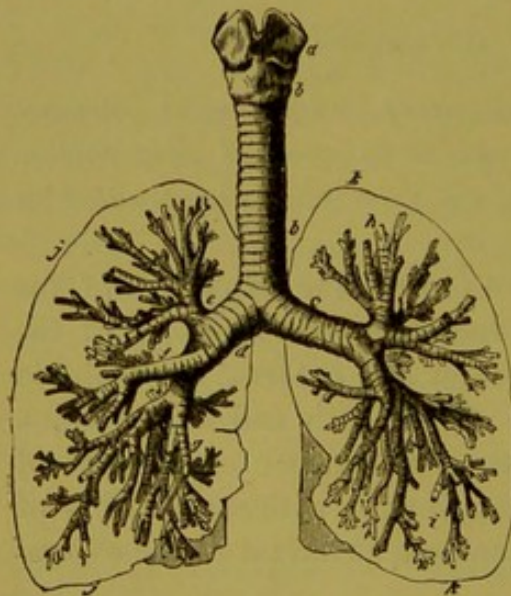


FIG. 35.

FIG. 35.—Air passages and lobules—site of normal respiration.

FIG. 36.—Showing bifurcation of trachea and bronchi.

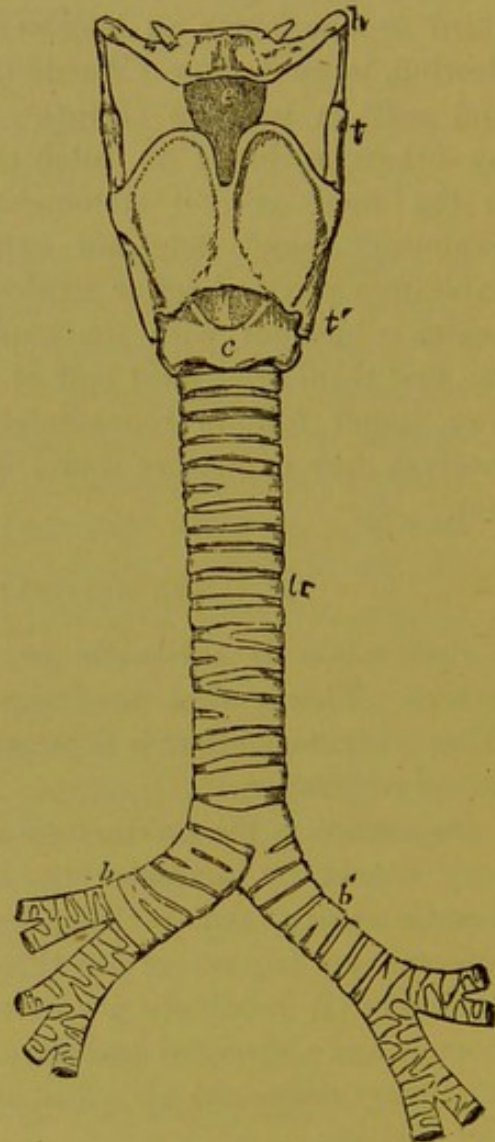


FIG. 36.

faint if the pharynx is not constricted or tumefied by mucous or submucous swelling or enlargement of the tonsils, and does not enter into normal respiratory sound as heard over the chest-wall.

2. The laryngeal element of inspiration and expiration is more

pronounced, and may be demonstrated in all persons, by placing the stethoscope over the side of the larynx. It also is heard over the upper part of the trachea, but is not conveyed to the chest surface over the lungs proper. But laryngeal sound, when exaggerated and stridulous as in laryngitis, stenosis, etc., may extend to the front and sides of the chest.

Obstruction or roughening is therefore essential to sufficiently intensify pharyngeal and laryngeal sounds to render them observable as elements of respiratory sound.

3. The tracheal element is audible with the ear or stethoscope over the upper sternal region. In inspiration the incoming air comes against the sides and bifurcation of the trachea, and a sound

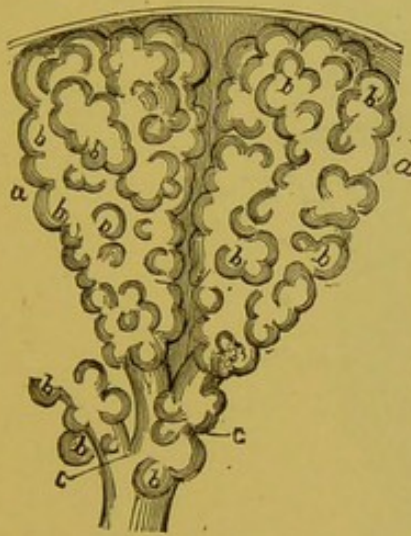


FIG. 37.

FIG. 37.—Terminal bronchus and vesicles.

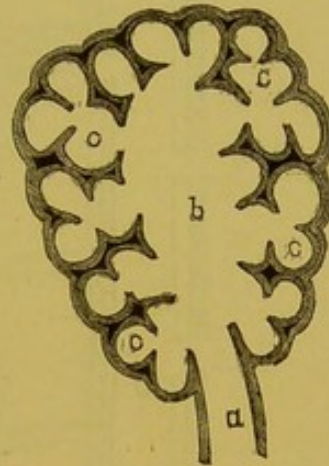


FIG. 38.

FIG. 38.—Schematic representation of air vesicles.

of tubular and hollow character is contributed to inspiratory sound, and in a lower degree to expiratory sound.

4. The bronchial element. In a precisely similar manner, but to a greater degree, owing to the repeated bifurcation or subdividing and branching of the bronchi, air and tube friction sounds are developed, and contribute to the bulk of the respiratory sound.

The degree to which the tracheal and bronchial elements are present differs with age and sex.

The tubular or bronchial element is more marked in children, and both inspiration and expiration may be intense and harsh, designated "puerile breathing," and expiration may also be heard during the entire period as a physical act. Such sounds in an adult would de-



note disease. Women breathe largely with the upper part of the chest. We are more apt to hear the expiratory sound in women, and the bronchial element is harsher in men.

5. The vesicular element.

Vesicular breathing is a breezy, fine, continuous sound, at least continuous in inspiration. It is essentially absent in expiration

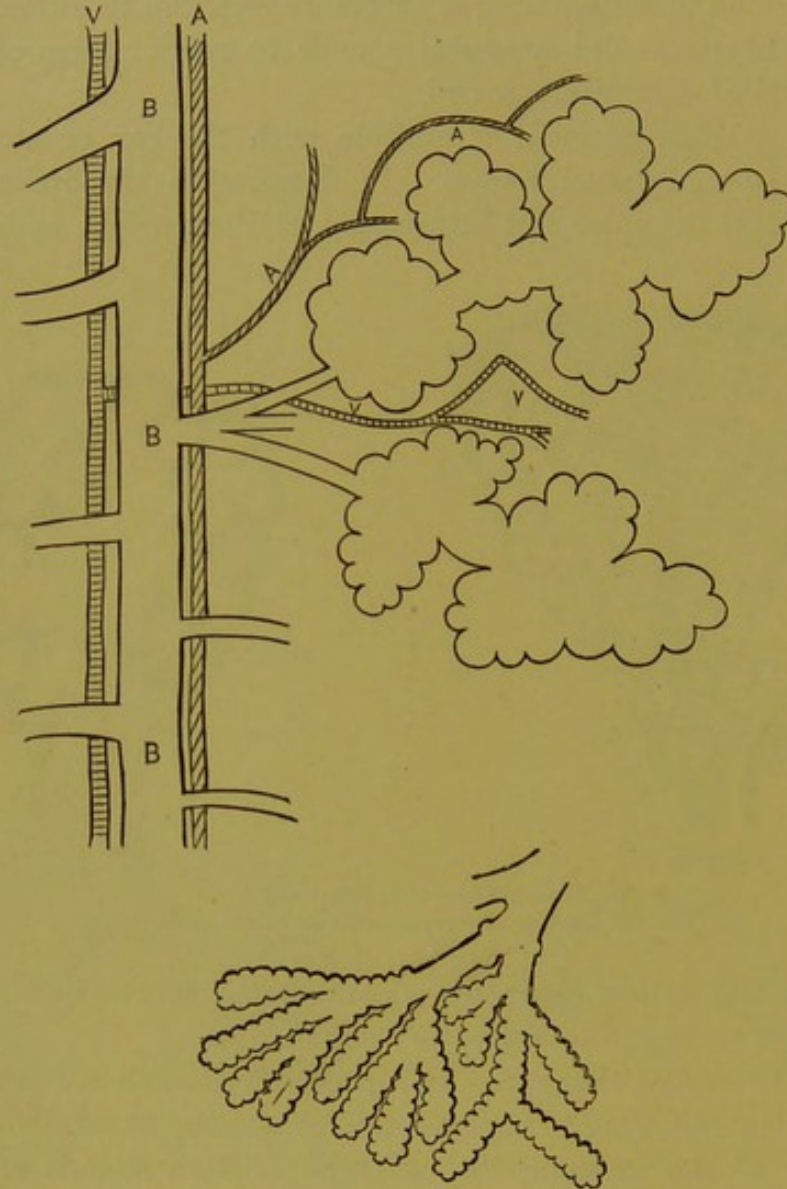


FIG. 39.—Distribution of terminal tubes and vesicles (Woodhead).

(Flint). There are many and opposing theories as to the cause of the normal vesicular sound. Some claim that air in passing through the ultimate bronchial tubes, and by dilatation of their walls, produces the vesicular murmur.

According to the views of others, as the air leaves the ultimate bronchial tubes, which are more or less rigid, and which terminate

in the more expanded and elastic infundibuli, the changed pressure or release from the confined tubes to the air spaces is the cause of the sound termed vesicular.

6. The parenchymatous element. Some authorities maintain that the inspiratory expansion of the air vesicles is adequate to create fine sound in the interstitial or extra-vesicular tissues of the lung, producing or contributing to produce the so-called "vesicular" sound.

#### 7. THE ELEMENT OF MUSCULAR SUSSURUS.

The muscular action going on in the chest-wall gives rise in some persons to a peculiar buzzing sound, termed muscular sussurus; its




FIG. 40.—Tracings of muscle waves (Marcy); cause of sussurus.

amount does not seem to be directly as the muscularity of the individual. It is increased by efforts of all kinds, as for instance, that of maintaining an uncomfortable posture; it is continuous, not synchronous with respiration, and rather increases than diminishes in intensity when the breath is held. It may in some places be suspended by putting the muscles in a state of relaxation, but in the infra-axillary regions, where it is sometimes highly marked, it cannot be thus arrested.

The recognition by all practitioners and students of the precise nature of this sound is of the utmost importance. I am satisfied

that it is a common source of error to misinterpret this fine, low-pitched, multitudinous sound as a product of vesicular expansion, and to regard it as evidence of healthful lung expansion.

The habit of having patients "breathe deeply" or "hold the breath," either exercising the muscles or placing them in a condition of tension, invariably develops this misleading sound; quiet breathing and holding the breath at the end of expiration eliminate it.

## 2. THE NORMAL VOICE SOUNDS.

### VOCAL RESONANCE.

If we put our ear to the surface of a healthy chest while the person is speaking, we do not distinguish the distinct and separated syllables spoken, but instead the "vocal resonance." It is a reverberation of the voice in the air passages, and brought to the ear through normal lung, a medium of poor conducting quality. It is therefore low in pitch, of about the quality of the speaker's voice, but disseminated, reverberating, resonant, and vague and distant. It varies according as the speaker's voice is high pitched or a low-pitched bass or baritone, being more pronounced with low-pitched voices. It also depends largely upon the size or calibre of the bronchi. The custom with Prof. Flint was to direct his students to listen with the stethoscope, during phonation, first over the larynx, next over the trachea and large bronchi, and finally over the pulmonary substance. Such a procedure gives one the most correct conception of the modification of the laryngeal voice after dissemination in the system of bronchi and transmission through pulmonary structure.

On the other hand, changes in pulmonary structure modify the *normal pulmonary resonance*. When the air sacs are dilated and the pulmonary tissues have lost resiliency, as in emphysema, vocal resonance is lessened. Reversely, in consolidation of the lung from any cause, as inflammatory exudation of pneumonia or a deposit of tubercle in the lung, the vocal resonance is modified and raised in pitch by the better conducting mediums, and becomes bronchial voice or bronchophony.

When fluid is present in the pleura, if but a thin stratum, it modifies the vocal resonance by giving it a nasal or goat-bleating quality, designated *ægophony*; if the fluid be abundant, being a bad conductor, as a rule voice and vocal resonance are partially or completely masked.

When, however, the pleural cavity is tensely distended with fluid, especially with pus in empyema, a marked degree of bronchial voice may be present. This has been variously explained as: 1, conducted by the chest-wall from the compressed lung above; 2, as transmitted by bands of pleuritic adhesions; 3, as produced in a stratum of collapsed lung immediately above the fluid which has replaced it.

In auscultating the voice, it is proper to stop the opposite ear with the finger to exclude the external transmission of the patient's voice.

### 3. THE NORMAL WHISPER.

The very slight whisper conduction in health is an important negative sign. Whispering is an expiratory act, and special syllables or words phonated in whisper are heard distinctly by the stethoscope over the larynx, but are not heard over the area of lung structure except as faint, puffing sounds or exaggerated expiratory sound.

### 4. THE TUSSAL RESONANCE.

#### *Normal Conduction of the Cough Sound.*

The remarks made as to the production of vocal resonance and its modification in disease will apply to tussal resonance. It is a valuable corroborative sign.

The above enumeration of the sounds to be observed and studied in the healthy chest does not differ materially from that given by Flint.

It differs chiefly in more fully emphasizing the composite nature of normal respiratory sound, especially inspiration, its reference to the confusing element of muscular sussurus, and the addition of tussal resonance (voluntary cough).

Flint recapitulates the sounds as heard in health as follows:

1. Normal laryngeal and tracheal respiration.
2. Normal vesicular murmur.
3. Normal vocal resonance.
4. Normal bronchial whisper.

Before proceeding to the consideration of the sounds detected by auscultation of the respiratory organs in disease, it may be well to state the acoustic laws applicable to the chest in both health and disease.

## CHAPTER V.

### ACOUSTIC LAWS APPLICABLE TO NORMAL AND ABNORMAL SOUNDS DEVELOPED IN THE RESPIRATORY ORGANS.

#### CHEST ACOUSTICS. (Walshe.)

- |   |   |   |
|---|---|---|
| 1. <i>Unison resonance.</i><br>Reinforcement by thoracic walls. | } | Methods<br>of development<br>of sounds. |
| 2. <i>Consonance.</i><br>Reinforcement by other organs.         |   |   |
| 3. <i>Echo.</i>   |   |   |

#### (1) UNISON RESONANCE.

By unison resonance is meant the reinforcement of sound by the thoracic walls, as occurs in the box of a guitar or violin, when notes are produced from their strings, or as when a music box, instead of being held in the air, is placed on a table. There can be little doubt that in the natural condition of the chest the principle of unison resonance is illustrated.

#### (2) CONSONANCE.

By consonance in music is meant the reproduction of certain notes of instruments or of the voice by other instruments standing near. It is difficult to prove that there is in the chest a repetition of sound by consonance, but contiguous structures, notably the liver, stomach, and intestines, exert a modifying influence upon the chest sounds.

#### (3) ECHO.

Repetition of sounds. The echo is not heard over the vesicles, but in a cavity, as in phthisis or pneumothorax.

#### ABNORMAL SOUNDS REFERABLE TO THE RESPIRATORY ORGANS.

We should study the abnormal sounds, as we did the normal, with reference to their five essential *properties* (Walshe), viz. :

- Duration,
- Intensity (volume, amplitude),
- Pitch,
- Quality,
- Rhythm (regularity of development and recurrence).

The term resonance, as employed in both percussion and auscultation, cannot be said to correspond exclusively to intensity, but comprises elements of full duration, intensity, and low pitch. It is proper to speak of the resonance of sound, but the term is generally descriptive rather than specific.

CLASSIFICATION OF ABNORMAL SOUNDS REFERABLE TO DISEASES OF THE RESPIRATORY ORGANS.

1. MODIFICATIONS OF THE NORMAL SOUNDS.

<ul style="list-style-type: none"> <li>1. Modifications of respiratory sounds.</li> <li>2. Modifications of voice sounds.</li> <li>3. Modifications of whispered sounds.</li> <li>4. Modifications of cough sounds.</li> </ul>	}	by	<ul style="list-style-type: none"> <li>1. Change in shape and calibre of air passages.</li> <li>2. Changes in mucous and submucous lining of air passages.</li> <li>3. Changes in peribronchial connective tissue.</li> <li>4. Changes in air vesicles, as to expansion, contraction, and contents.</li> <li>5. Changes in pulmonary parenchyma, intervesicular or interstitial tissue.</li> <li>6. Changes in visceral and parietal pleura.</li> <li>7. Changes in the contents of the pleura.</li> <li>8. Changes in thoracic parietes.</li> </ul>
--	---	----	--

2. ADVENTITIOUS SOUNDS.

Produced in	{	<ul style="list-style-type: none"> <li>1. The air passages {                             <ul style="list-style-type: none"> <li>a—large,</li> <li>b—medium,</li> <li>c—small.</li> </ul> </li> <li>2. The air vesicles.</li> <li>3. The parenchyma of interstitial lung structure.</li> <li>4. The pleural cavity.</li> <li>5. The pleural walls, either separated or adherent.</li> </ul>
-------------	---	--

The above classification is not an arbitrary or artificial one; neither is it theoretical. It is logical and natural, based upon the physical conditions with which we have to deal, of the structures producing the sounds and the structures transmitting or conducting them to the ear.

*Interpretation of Modified Sounds.*

The modification may be in development or conduction. Laryngeal, bronchial, and vesicular abnormalities are the chief causes of modified development of sound. Pathological changes in the pulmonary parenchyma and vesicular arteries and in the pleura are the chief causes of modification of normal sounds by induction. Frequently, auscultation alone cannot determine to what extent the modified sound is the product of developmental causes, or the product of changes in the conducting media. The conjoined methods of palpation, percussion, and auscultation may be necessary in order to definitely or even approximately diagnose the diseased conditions which are the cause of the abnormal properties or modifications which we observe.

*Interpretation of Adventitious Sounds.*

The interpretation of adventitious sounds must vary for different conditions. In some instances, the sound is specific and pathognomonic of a single underlying pathological condition or lesion. More often it may represent several possible morbid conditions of the subjacent structures, and a process of differential diagnosis must be conducted.

In such a differentiation we may be compelled to go beyond simple acoustic laws, and include clinical history, symptomatology, and pathological data.

Important points in the interpretation of adventitious sounds will be :

1. The co-existence of adventitious and normal sounds in the same area.
2. The replacement of normal by adventitious sounds in a given area.
3. The gradual transition from normal to adventitious sounds in a given area, or existence in marked contrast in adjacent areas, or on the corresponding parts of the opposite sides of the chest.
4. Properties of the adventitious sounds which by acoustic law denote a definite condition.
5. Empirical knowledge, based upon clinical experience of diseases having the observed sounds and pathological data as to the lesions found to exist associated with such sounds.

SPECIAL STUDY OF ABNORMAL RESPIRATORY SOUNDS.

The respiratory sounds in disease may undergo, according to Walshe,

- |            |   |  |   |
|------------|---|--|---|
| Changes of | } | 1. Duration and intensity.               |   |
|            |   | ( <i>a.</i> ) Exaggerated.               | ( <i>c.</i> ) Suppressed.               |
|            |   | ( <i>b.</i> ) Weak.                      |   |
|            |   | 2 Rhythm :                               |   |
|            |   | ( <i>a.</i> ) Jerking.                   | ( <i>d.</i> ) Unfinished.               |
|            |   | ( <i>b.</i> ) Divided.                   | ( <i>e.</i> ) Altered ratio of inspira- |
|            |   | ( <i>c.</i> ) Deferred.                  | tion to expiration.                     |
|            |   | 3. Quality, pitch, and rhythm combined : |   |
|            |   | ( <i>a.</i> ) Harsh.                     | ( <i>b.</i> ) Blowing.                  |
|            |   | Rude.                                    | Tubular.                                |
|            |   | Bronchial.                               | Cavernous.                              |
|            |   |  | Amphoric.                               |

Flint gives a much simpler classification and that which is generally followed by teachers and practitioners in this country, viz.: Taking "vesicular respiration" as the condition of healthy breath sound, he classified the departures as

1. Broncho-vesicular respiration.
2. Bronchial                               "
3. Vesiculo-cavernous               "
4. Broncho-cavernous               "

"Vesicular respiration" is indicative of normal activity of the vesicles and normal elasticity and structure of the interstitial tissues and other conducting media.

"Broncho-vesicular respiration" denotes a diminution in the vesicular quality of respiratory sound, and a raised pitch with bronchial quality, the product of slight interstitial deposit, consolidation, or conditions for better conduction of sound.

"Bronchial respiration" or "bronchial breathing" (see Fig. 41) denotes absence of the vesicular quality and the conduction to the ear of the bronchial or tubular element of breath-sound, greatly raised in pitch by reason of the consolidated structures through which it has to pass.

"Vesiculo-cavernous respiration" (Fig. 42) designates a condition where pulmonary structure immediately surrounding a cavity gives rise to normal or vesicular sounds, which are heard associated with the cavernous sound.



“Broncho-cavernous respiration” (Fig. 42) is the product of a consolidated area immediately surrounding an excavation, the two sounds being heard associated or coincident.

For the description of typical diseases, this classification is most useful and practical. The term “broncho-vesicular,” devised by Dr. Flint, has come to be generally used in place of the terms “harsh,” “rude,” and even “tubular,” formerly employed to designate the quality of respiration existing in slight pulmonary consolidations.

But for purposes of exact differential diagnosis in complicated

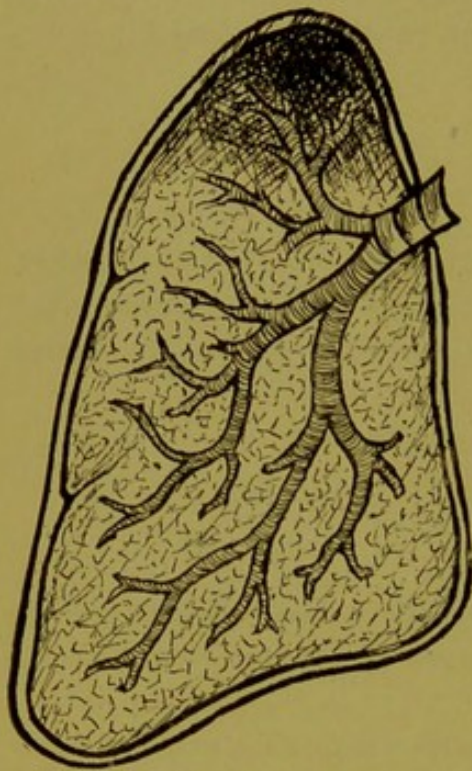


FIG. 41.

FIG 41.—CONSOLIDATION OF APEX.

Bronchial breathing, voice, and cough; dulness on percussion, plastic pleural sounds, and bronchial râles.

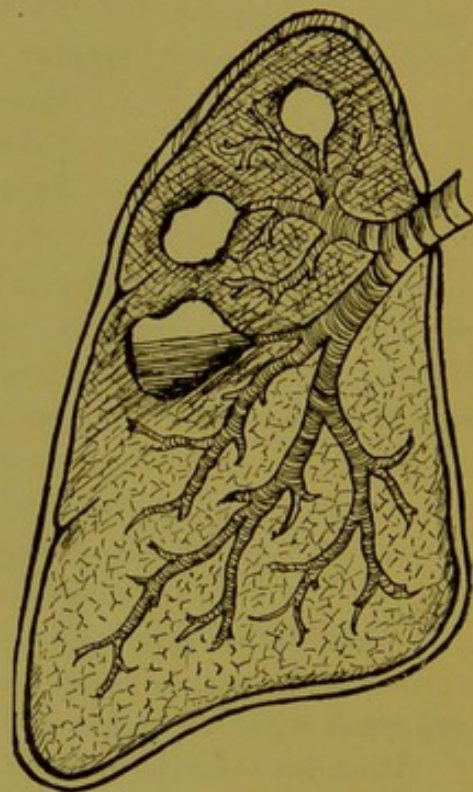


FIG. 42.

FIG. 42.—CONSOLIDATION WITH CAVITIES.

Bronchial breath and voice cavity; also gurgles.

cases, as of chronic bronchitis, associated bronchitis and emphysema, fibroid phthisis, the broader enumeration of Walshe serves a most useful purpose.

1. Duration and intensity: *a*, exaggerated—in bronchitis.  
*b*, weak in convalescence.  
*c*, suppressed—in fibroid phthisis, pleuritic thickening, and intrapleural fluid.

2. Rhythm: *a*, wavy breathing in nervous respiration, in slight peribronchitis.

*b*, divided breathing } in various degrees of bron-  
*c*, jerking breathing } chial thickening, peribron-  
 chial exudation, chronic interstitial pneumonia,  
 fibroid, and tubercular phthisis.

When the heart's action is violent, throwing the blood into the

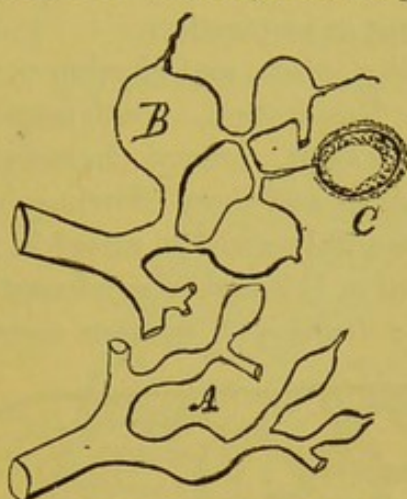


FIG. 43.—DILATED BRONCHI (Loomis).  
 Retarded expiration; cavernous expiration.

lung with force sufficient to interrupt or divide the respiratory act, we have a divided breathing, an inspiration with four or five parts.

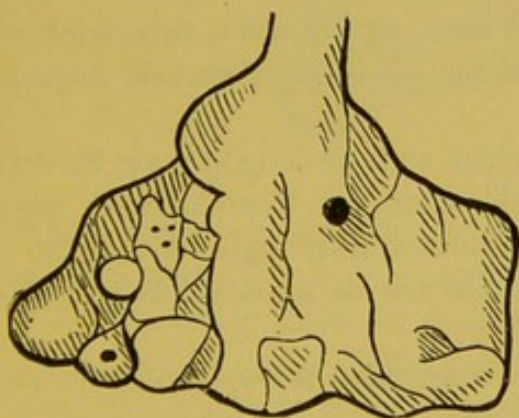


FIG. 44.  
 FIG. 44.—Emphysema, terminal tubes and air sacs dilated.  
 FIG. 45.—Advanced stage of above.

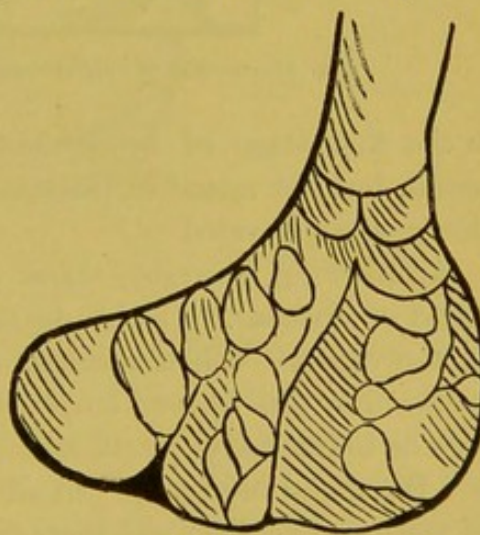


FIG. 45.

(*d*) Deferred Inspiration.—When the inspiratory action commences and continues for a short time before sound is produced, it is said to be deferred. This is remarked in emphysema. (See Figs. 44, 45, 46.)

(e) Unfinished Inspiration.—In certain cases the inspiratory sound ceases before the chest expansion has been completed. This occurs only over exceptional cases of consolidation.

(f) Deferred expiration or altered ratio of inspiration and expiration is to be noticed.

In health, expiration is one-third or one-fourth of inspiration. In emphysema, expiration is greatly prolonged, and may be twice or even four times as long as inspiration.

### 3. Changes in quality, pitch, and rhythm combined.

(a) Harsh or Rude Respiration.—Both inspiratory and expiratory sounds have lost their soft, breezy character, and have become sharper, higher in pitch, and more blowing in character; the expiratory sound is perceptibly audible, raised in pitch, and prolonged. Harsh or rude respiration is heard in condensation of the lung to a slight degree. In the dryness of mucous membrane of bronchi, as

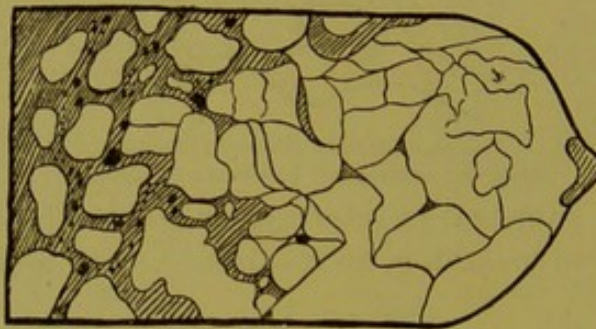

Fig. 46.—Section of emphysematous lung showing portion of surface.

in the first stage of bronchitis, we have an air and a tube friction sound, but not raised in pitch. All the elements of normal respiration are exaggerated.

(b) Blowing Sounds.—Low pitched and prolonged may be diffused or tubular. Cavity, bronchial cavity, or bronchiectasis may be the cause. When musical or resonant, as though blowing in a bottle, they are termed amphoric. Cavernous sounds differ in degree as to intensity, pitch, and quality.

“Bronchial breathing” in all nomenclatures is respiration devoid of vesicular quality, and high in pitch.

### SPECIAL STUDY OF ABNORMAL VOICE SOUNDS.

As already described, in health we have normal vocal resonance. We may have:

1. *Exaggerated Vocal Resonance*.—When one lung is expanded

unduly, as when vicariously performing the work of an opposite lung crippled by pneumonia or pleurisy. Also in healthy persons with unusually low-pitched bass or baritone voice.

2. *Diminished Vocal Resonance*.—In most cases of feebly-developed, poorly-expanded narrow chests, also in fibroid phthisis, thickened pleura and pleuritic adhesions with retraction of chest-walls.

3. *Absence of Vocal resonance* over pleuritic fluid.

4. *Ægophony* or “goat-bleating.”—Nasal quality of the con-

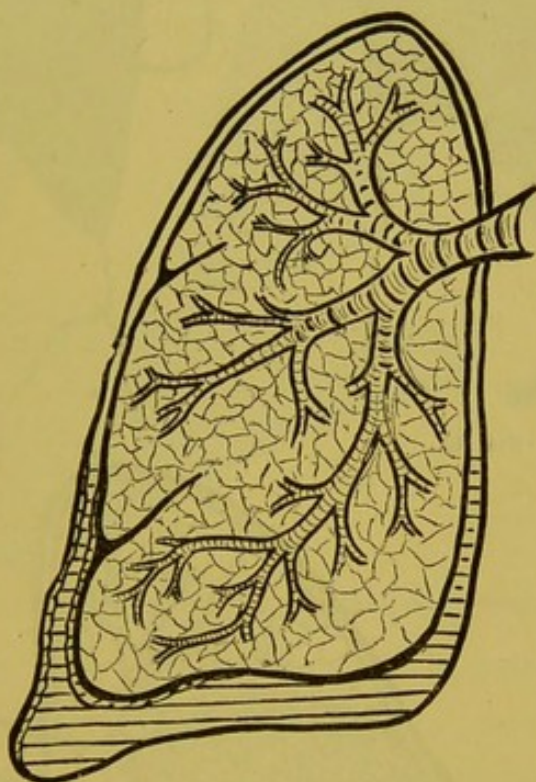


FIG. 47.

ducted voice. Heard over a thin stratum of fluid in pleura or at upper border of large accumulation of fluid in pleura.

5. *Bronchial Voice* or “*Bronchophony*.”—The product of consolidation of the media between the bronchial tubes and the ear. The voice comes to the ear raised in pitch to a variable degree, according as the infiltration is slight or pronounced. In absolute solidification, the phonations come high-pitched and distinct to the ear. In lobar pneumonia, the high-pitched voice may seem under the ear.

6. *Cavernous Voice*.—The voice is directly under the ear, but low-pitched, and in quality varying according as the cavity be large

or small, moist or dry, and ragged and irregular, or symmetrical and well-defined, favorable to resonance and echo.

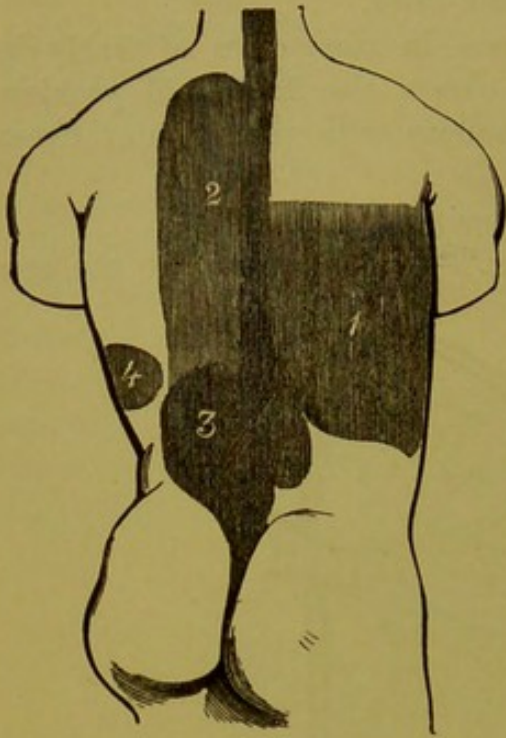


FIG. 48.

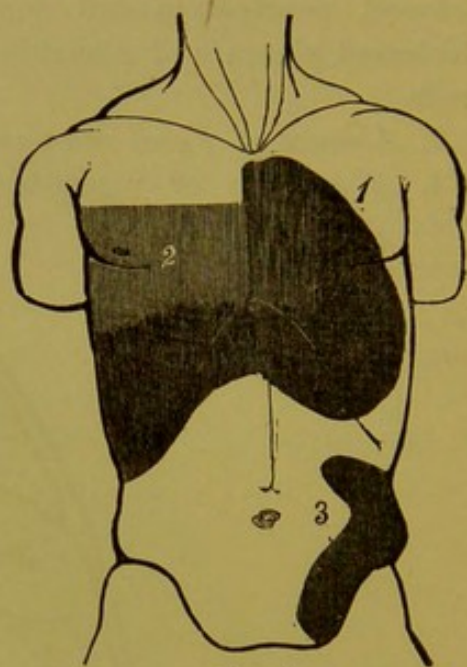


FIG. 49.

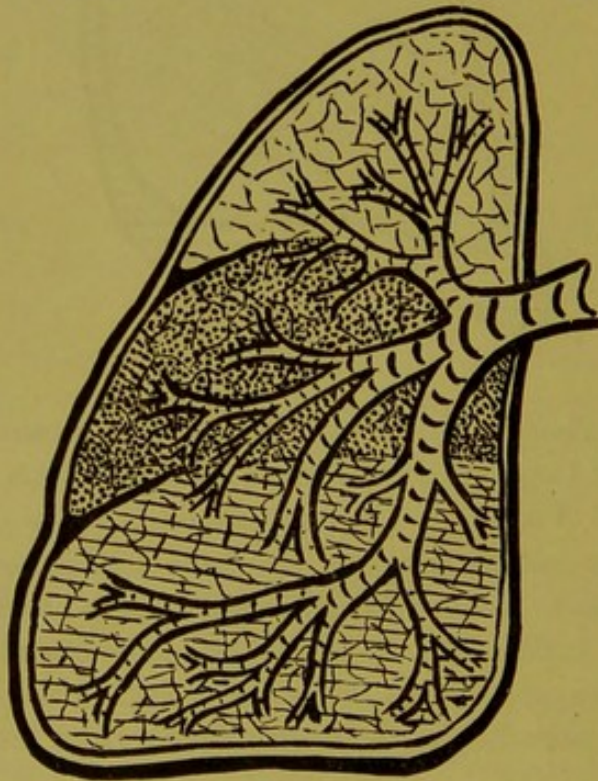


FIG. 50.

7. *Pectoriloquy* (speaking in the chest).—A quality of voice immediately under the ear like that employed by ventriloquists. The

low-pitched voice seems resonated in a chamber beneath the surface. Pectoriloquy is produced in exceptionally large cavities, free of secretions and freely communicating with a bronchus. It more often is produced in a pleural cavity distended with air and com-

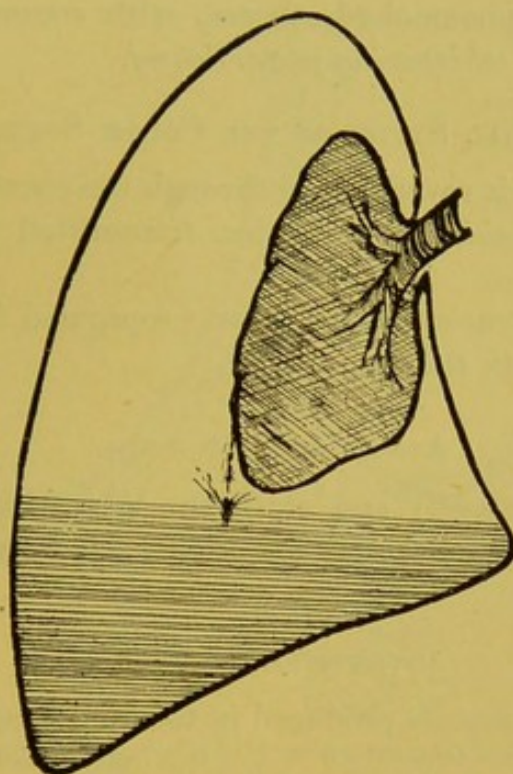


FIG. 51.—Pneumohydrothorax, amphoric breathing, pectoriloquy, succussion.

municating freely with a bronchus, *i. e.*, in pneumothorax and pneumohydrothorax.

#### SPECIAL STUDY OF THE WHISPER SOUNDS.

As already stated, whisper is an expiratory act, and is a physical act productive of feeble sound waves. Over a healthy lung, whisper, whether quiet or the result of special effort, is faintly heard as an exaggerated expiratory sound or puff. In disease, whisper is a most delicate aid to careful diagnosis.

1. *Whisper is enfeebled or absent* in dilatation of the air sacs, emphysema, dilated bronchi, many cases of peribronchitis, chronic bronchitis, and fibroid phthisis, and especially thickened pleura and pleuritic effusions.

2. *Whisper is raised in pitch* by even slight interstitial deposit. Hence "*bronchial whisper*" or "*whispering bronchophony*" is a most valuable evidence of incipient lung disease.

3. *Whisper is cavernous* when resonated in a cavity, and as heard with the small tube of the stethoscope, is often the surest means of distinguishing a very small cavity which would not give cavernous voice.

4. *A whisper resonated in a large cavity*, as in the pleura of pneumothorax or pneumohydrothorax, with communicating bronchus, is designated *whispering pectoriloquy*.

#### SPECIAL STUDY OF THE COUGH SOUNDS.

Cough in health is reverberated through the chest low in pitch.

It may be "*bronchial cough*" when transmitted through areas of consolidation.

It may be "*cavernous cough*" when propagated from the bronchi into a cavity beneath the ear.

#### ADVENTITIOUS SOUNDS.

It remains to classify and study the adventitious sounds with reference to the portion of the respiratory apparatus in which they are developed.

#### ADVENTITIOUS SOUNDS.

- |    |   |
|----|---|
| 1. | Adventitious sounds produced in the air passages. |
| 2. | “ “ “ “ air vesicles.                             |
| 3. | “ “ “ “ pleura.                                   |
| 4. | “ “ “ “ lung substance.                           |

#### *Adventitious Sounds Produced in the Air Passages and Air Vesicles.*

These are ordinarily designated *râles* (the synonymous term *rhonchi* has been abandoned). *Râles* are sounds produced by :

1. Constriction of the air passages.
2. Dryness of the air passages.
3. Moisture or accumulation of secretion in the air passages.

#### *Dry Râles.*

Dry *râles* are produced in the bronchi only. They result from contracted calibre at different points. If due to spasmodic contraction, as in asthma, the *râles* are temporary and shifting. If due to mucous and submucous tumefaction, as in the dry stage of bronchitis, the dry *râles* are more persistent. If due to permanent

contractions and thickening, as in chronic bronchitis, they are permanent.

When produced in tubes of large calibre, the dry râles are low-pitched and resonant, and are designated :

1. Sonorous râles.

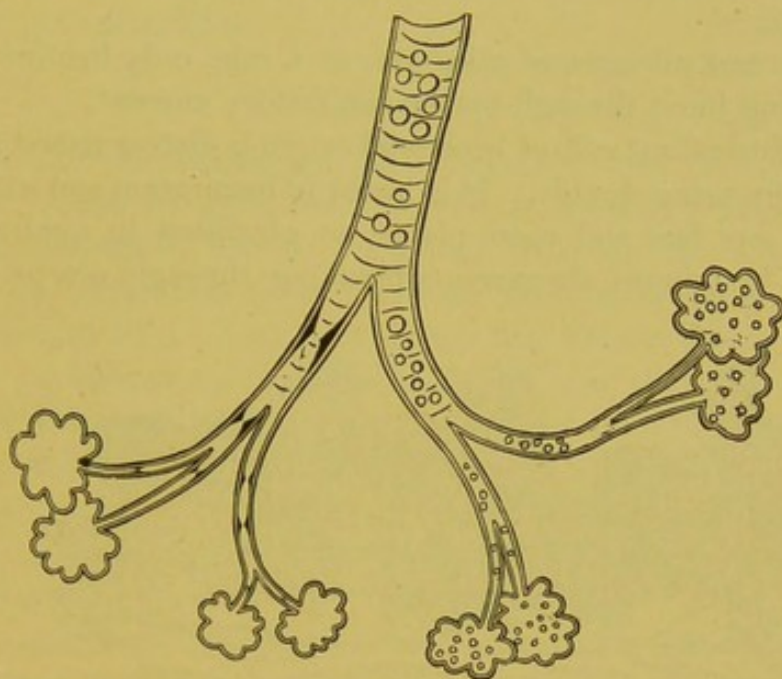


FIG. 52.—DIAGRAM ILLUSTRATING DRY AND MOIST BRONCHIAL RALES (after Da Costa and Lcomis).

Points of contraction; sonorous and sibilant râles; bubbles denote the mucous, submucous, subcrepitant, and crepitant râles.

When produced in tubes of lesser calibre, they are higher pitched—piping, cooing, hissing—and are designated :

2. Sibilant râles.

#### *Moist Râles.*

They are the product of the action of currents of respired air upon mucus, sero-mucus, or muco-pus lodged in the bronchi and blocking the ingress and egress of the air. Their coarseness or fineness is determined by the size of the tubes in which they are produced and the viscosity or liquidity of the secretion.

1. Tracheal râles—as heard over the trachea in the dying and in excessive hæmoptysis, or overloading of air passages with serum by use of jaborandi.

2. Mucous râles—heard over larger bronchi.

3. Submucous râles—heard over medium bronchi.



4. Sub-crepitant râles—heard over finer bronchi, chiefly in children (capillary bronchitis) and broncho-pneumonia of adults.

5. Crepitant râles—heard over periphery of lungs or a limited pulmonary area.

Tracheal râle or gurgle is apt to be both inspiratory and expiratory; the fluid lies in the trachea, and ebbs and flows with respiration.

Mucous and submucous râles are, as a rule, only inspiratory, the mucus being burst through by the inspiratory current.

The *subcrepitant râle* of bronchial origin is distinguished from the crepitant by being double. It is heard in inspiration and expiration. It is also less fine and more plastic or glutinous in quality. It is produced by minute air currents breaking through mucus in small

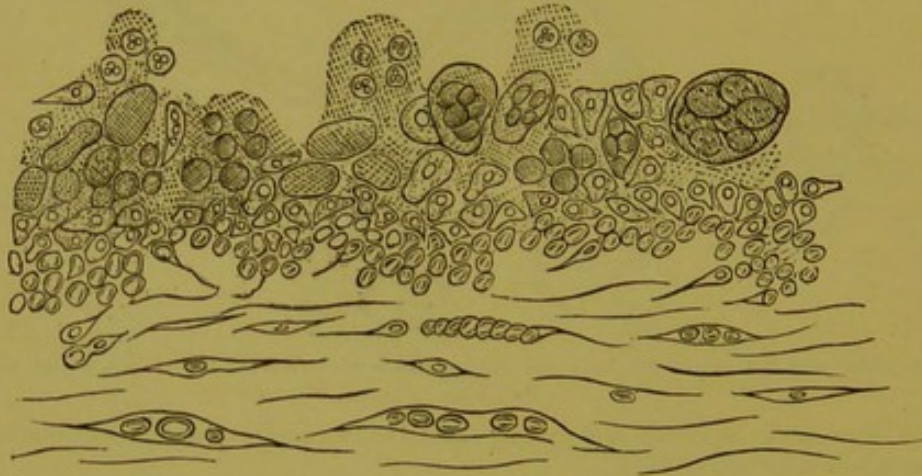


FIG. 53.—DIAGRAM OF CATARRHAL PROCESS.

Swelling of mucosa, proliferation of epithelia, and throwing off of mucoid corpuscles and mucin (Thierfelder).

bronchial tubes. It is heard in suffocative catarrh or capillary bronchitis. Subcrepitant râles, however, unless uniformly diffused over both lungs, are quite likely to be of pleural origin.

The subcrepitant râle, as heard over extensive areas of tubercular lung, was formerly associated with the diagnosis of softening or second stage of phthisis. It is in such cases either a subcrepitant râle of bronchial origin, due to collateral hyperæmia or local catarrhal process, or, in other cases, a plastic intrapleural subcrepitus, due to plastic pleuritis provoked by the tuberculosis reaching the pulmonary surface and investing pleura.

The crepitant râle is a single sound, high-pitched, fine, and crackling at the end of the inspiratory act. It is described as fine as the

crackling of salt on a hot stove, or the crackling of the hair rubbed by the finger-tip on the temple or back of the ear. It is best heard in cases of acute lobar or croupous pneumonia in the transition period from the first to second stage. Until recently but one explanation of crepitant râle was entertained; that it was produced in the air vesicles by the ingress of inspired air. This view is still held by a majority of authorities.

*The Crepitant Râle.*

As to the mechanism of its production there is divergence of opinion. One theory is that the râle is produced by air breaking through exudation matter. Another, that the air sacs being collapsed, on inspiration their glutinous walls separate, giving rise to the crepitant râle. The same sound may be simulated by pressing a piece of sponge rubber close to the ear and then letting it relax. In its relaxation it produces far more sound than in its compression. Still another theory is, that it is due to stretching of the inter-vesicular tissue. The inflammatory exudation, it is claimed, starches or stiffens, as it were, the intervesicular tissue, and renders its expansion more difficult and productive of sound.

It has long been claimed by Leaming that the crepitant râle of pneumonia is produced in the pleura, the product of an associated plastic pleuritis. Loomis takes the same view. The general opinion yet prevails, however, that crepitant râle as heard in pneumonia is vesicular in origin.

In addition to the above, certain crepitating and creaking sounds are developed in thickened bronchial walls, much as the same sounds are produced in thick walls of phthisical cavities.

Walshe gives a classification of sounds produced in the air-passages which differs but little from the one we have given, but a comparison of the two may help to call attention to the more essential features of these adventitious respiratory sounds.

RECAPITULATION.

ABNORMAL SOUNDS PRODUCED IN AIR PASSAGES.

(*Walshe.*)

Whistling.	{ High-pitched—Sibilant.
	{ Low-pitched—Sonorous.
Crepitating.	

Crackling.	{	Dry.	
		Moist.	
Bubbling.	{	Small.	{ Subcrepitant.
			{ Submucous.
	{	Large.—Mucus.	{ Simple.
			{ Hollow.

Bronchial affections are most numerous of all pulmonary affec-

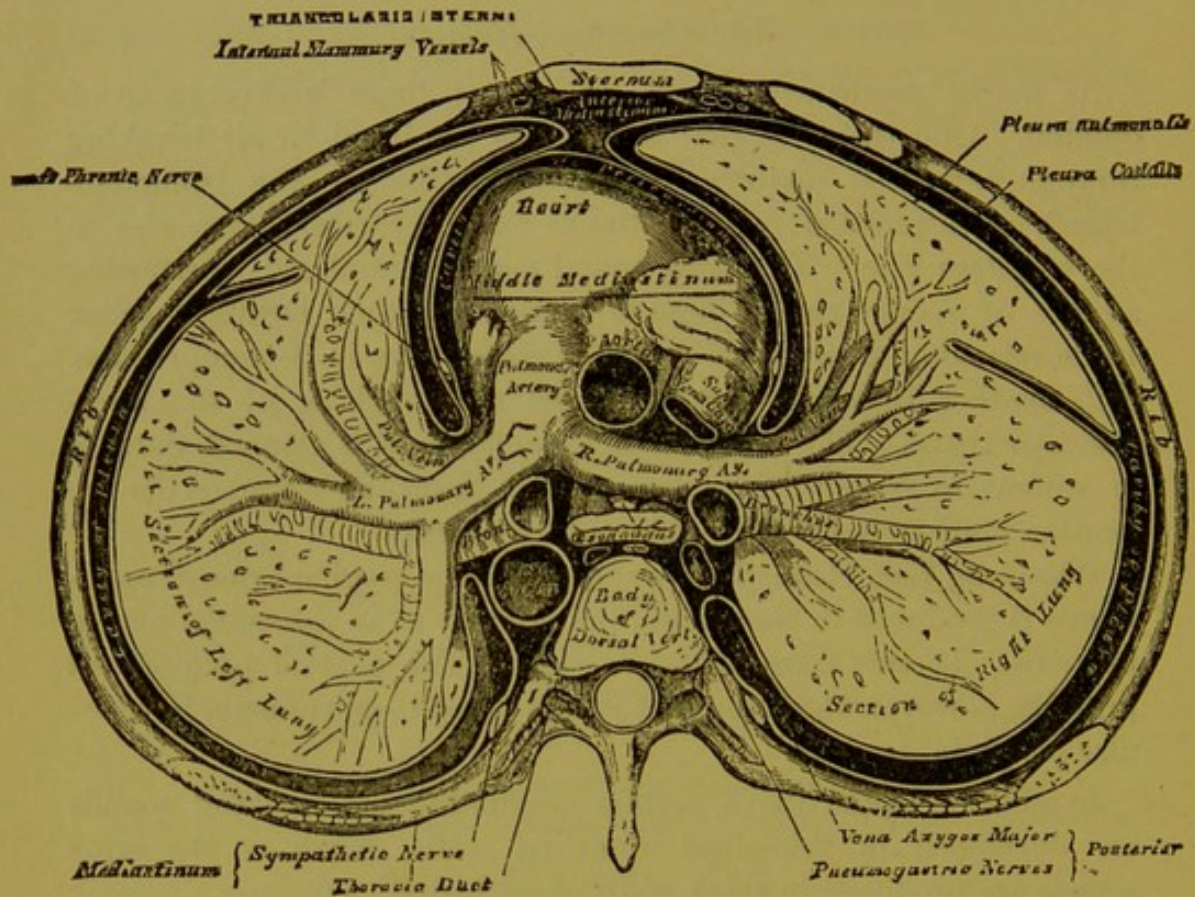


FIG. 54.—A transverse section of the thorax, showing the relative position of the viscera and the reflections of the pleuræ.

tions, so that their signs, mucous, submucous, sibilant, and sonorous râles, are the most common signs heard by the practitioner.

#### ADVENTITIOUS SOUNDS PRODUCED IN THE PLEURA.

In health there is no sound produced by the colliding of the two opposed pleural walls. Their smoothness and moisture allow them to glide noiselessly upon each other. When these conditions have become modified by disease, the gliding is accompanied with different degrees of sound, the product of pleuritic attrition, of tension of

fine and coarse adhesion, of disturbance of plastic exudation matter, or the warping and bending of thickened pleura.

Walshe has recognized the frequent occurrence and variety of intra-pleural sounds, and classifies them as follows :

#### ABNORMAL PLEURAL SOUNDS.

(*Walshe.*)

- |                   |                     |
|-------------------|---------------------|
| 1. Single.        | 2. Jerking—Divided. |
| 1. Faint.         | 2. Loud.            |
| (a.) Attrition. { | Grazing.            |
|                   | Rubbing.            |
| (b.) Creaking.    | (d.) Rumbling.      |
| (c.) Crackling.   |                     |

#### INTRA-PLEURAL SOUNDS—WHEN HEARD.

Intra-pleural sounds are chiefly inspiratory.

When due to attrition, they may occupy the entire period of inspiration.

When due to tension of adhesions, they may be developed only at the end of the inspiratory act, as the adhesions are brought into tension.

When due to tension of plastic exudation, whether spread over the pleura or interspersed among adhesions, the sounds are likely to occupy the middle and latter part of the inspiratory act, and also may be present in a lesser degree during the expiratory act.

#### QUALITIES OF INTRA-PLEURAL SOUNDS.

The sounds produced by attrition of pleural surfaces are, as a rule, single or continuous, and may have the quality of friction, rubbing, grazing, creaking, or even rumbling. The more pronounced sounds are the product of roughened, thickened, corrugated pleura.

Quite as often there is a series of divided or jerking sounds, varying in character as above stated, heard most intensely in inspiration, and to a lesser degree, if at all, in expiration.

Again, the intra-pleural sounds may differ at different periods in the same chest, according as we have recent, acute, or subacute pleuritis, localized, secondary, or intercurrent pleuritis, dry plastic pleurisy, sero-plastic or serous pleurisy, or chronic pleurisy with adhesion, agglutination, or pleuritic thickening.

The first condition in inflammation of the pleura is a removal of the fluid or moisture which lubricates the part. The surfaces are next denuded of epithelium, tumefied, and roughened. The movements of these surfaces give rise to a grating, rubbing sound, found entirely in recent cases. If two denuded and villous surfaces have grown together at points, the pulling or stretching of these adhesions may give rise to subcrepitant or plastic râles.

Creaking sounds are often pronounced. They are only to be compared with creaking of thickened bronchus, or of the thick wall of a phthisical cavity.

The recognition of the frequency of intra-pleural lesions, and the systematic classification of their physical signs, have resulted chiefly from the writing and teachings of Dr. James R. Leaming, of New York. Most clinical teachers now acknowledge the positive physical evidences of the different forms of local and general pleuritis, recent and chronic. Yet there is much difference of opinion. The late Dr. Flint maintained a conservative opinion, and did not admit the frequent occurrence of intra-pleural sound, except the friction sound of the first or dry stage of subacute pleurisy (pleurisy with effusion). He regarded most of the sounds, both dry and moist, by others referred to the pleura, as of bronchial origin. Local subcrepitus, even if brilliant, explosive, high-pitched, and "tearing," and directly under the ear, he regarded, not as evidence of local plastic pleuritis, but as produced in the smaller bronchi immediately beneath the pleural investment and lung surface. Sir Andrew Clark, on the other hand, has published in detail his acceptance of the intra-pleural production of the great variety of dry and moist sounds as classified by Walshe and Leaming. As already stated, Dr. Loomis has intimated that even the crepitus or crepitant râle heard in pneumonia is the product of a co-existent plastic pleuritis.

#### RULES FOR DIFFERENTIATING INTRA-PLEURAL SOUNDS.

1. Attrition, simple friction, high-pitched, synchronous with respiration, and either single or double, is due to dryness of the pleura. Percussion resonance will be normal, and no auscultatory evidences of bronchial catarrh or pulmonary consolidation will be present.

2. Rubbing, rumbling sound, usually divided when synchronous with respiration and most often double, is likely to be of pleu-

ritic origin. It is usually heard directly under the ear, and presents associated evidences of the roughened and thickened pleura and adhesions, viz.: 1. By inspection, retraction of intercostal spaces synchronous with inspiration. 2. By palpation, distinct pleuritic fremitus, or sense of contact of roughened surfaces. 3. By percussion, raised pitch, *i. e.*, dulness or even flatness. 4. By auscultation, marked diminution of vocal resonance, obscuration of the whispered voice, obscuration of cough sound, and feeble, distant, or marked, or even absent respiratory sound. The hypodermic exploring needle distinguishes between this thickening of pleura and a stratum of fluid circumscribed.

3. It is far more difficult to positively distinguish the moist intrapleural râles from sounds similar in nearly all respects, which have their origin in the fine bronchi. Given a limited or diffused area of subcrepitus or crepitus beneath the ear, how are we to decide whether the cause is plastic pleuritis or localized pulmonary hyperæmia or inflammation, with exudation of serum, sero-lymph, or lymph into capillary bronchi?

*a.* As to the crepitant râle, when fine and high-pitched, and heard only in inspiration, when co-existing with contiguous bronchial breathing, bronchial whisper, bronchial voice and cough, marked flatness on percussion, and increased vocal fremitus, the crepitus must be referred to pulmonary consolidation—pneumonia. The history of the attack and nature of sputum is often of aid.

When, however, the crepitus is localized, is over an area of tuberculosis or other infiltration, and is persistent for some time without pronounced bronchial breathing or voice, flatness on percussion, and when associated with constant tearing dry cough, *i. e.*, no expectoration, the râle must be regarded as of pleuritic origin.

*b.* The subcrepitant râle is more typically the râle of plastic pleuritis. It may be single or double. It is moist, brilliant, explosive, developed in the latter part of inspiratory effort, and is usually heard in inspiration only, although sometimes it is expiratory. It has been described by Leaming as suggestive of the tearing of a piece of wet flannel.

How are we to determine whether the subcrepitus beneath our ear is pleuritic or the product of a local catarrhal process, a local bronchopneumonia, or transudation of sero-albumin (bronchorrhœa) in an area of infiltration, obstructed circulation, and active irritation?

1. The subcrepitus of local catarrhal process is usually more liquid

in quality, lower in pitch, is associated with râles of coarser grade, and with moist cough, *i. e.*, some degree of expectoration. With such catarrhal cause of the subcrepitus will exist associated evidences of slight infiltration, slightly raised pitch of percussion note, broncho-vesicular breathing, or even an element of bronchial whisper, voice, and cough. Even with all these evidences of local infiltration and adequate cause for local catarrhal origin, the râles are often so brilliant, explosive, near the ear, and of such uniform and persistent character, that local plastic pleuritis over unsound lung must be the diagnosis.

When, however, the subcrepitus is tearing, brilliant, explosive, high-pitched, near the ear, the râles are of a uniform size and character, are uninfluenced, neither modified, suspended, nor removed by forced efforts at cough and expectoration, are accompanied by expectoration, are chiefly heard towards the end of the inspiratory act, they can safely be asserted to be of intra-pleural origin, a product of plastic pleuritis. (The subcrepitus of the finer bronchi is developed earlier in inspiration and runs through the act, and is more often both inspiratory and expiratory.)

Often too, there is slight dulness on percussion, due to the tumefaction of the inflamed pleura, and the cough, voice, and breath sounds, instead of being raised in pitch and of bronchial quality, are marked and distinct. The locality of the area of râles, and the history of the attack as to initial chill, stitch in the side, and localized pain may also enter into the diagnosis of doubtful cases. All pleuritic ailments are peculiarly painful. Areas of local hyperæmia and catarrhal process develop, on the other hand, insiduously and painlessly.

#### ADVENTITIOUS SOUNDS PRODUCED IN THE PULMONARY PARENCHYMA.

The very many typical and diagnostic physical signs of changes of the pulmonary parenchyma of pneumonia and phthisis (tubercular, catarrhal, fibroid) are chiefly the result of change in the characteristics of normal voice, whisper, cough, and health sounds, or alterations incident to their conduction, and have been enumerated. They are *feeble or absent vesicular murmur, exaggerated, rude, harsh, or broncho-vesicular respiration, bronchial breathing, bronchial whisper, bronchial voice and cough, cavernous whisper, cavernous voice, cavernous breathing, pectoriloquy.* The truly

new or adventitious sounds as distinguished from the above are few, and chiefly relate to cavities. They are :

1. Gurgles, produced in large cavities by the ingress of air below the surface of accumulated liquid.

2. Creaking in the thickened walls of large cicatrized cavities, associated with amphoric breathing, cavernous whisper and voice.

3. Metallic tinkle and succussion—when the cavities are large and symmetrical, permitting of the shaking up of the liquid, and its subsequent dropping from the dome of the cavern upon the fluid surface below, with fine silvery or metallic tinkle or splash.

### AUSCULTATORY PERCUSSION.

The method of physical exploration designated “auscultatory percussion” was devised by Drs. Alonzo Clark and Cammann, of New York, in 1840. It consists in listening, by aid of the stethoscope, over a solid viscus, while percussion strokes are made over the



FIG. 55.—Cammann's Cylindrical Auscultator.  
Solid Cedar.



FIG. 56.—Cammann's Intra-Costal Auscultator.

organ, but more especially across the organ in the line of its various axes—vertical, horizontal, and oblique. The moment the border of the organ is reached, immediate cognizance of the fact is taken by the listener, owing to the direct conduction of the sound by the organ. By percussing towards the organ from various sides, and marking the points of approach, we may map out with great exactitude the contour of the organ, and determine its precise size and shape. While as a process it is most useful for defining the size and shape of the liver, spleen, and heart, yet it is also applicable to examination of the lungs, in determining the line of demarcation between lung and liver, lung and spleen, lung and heart, and the extent of pleuritic effusions downward, the extent of pneumonic consolidations, and the size and locations of neoplasms within the thorax or encroaching upon it from the abdominal cavity. Auscultatory percussion, to be well performed, requires :

1st. That the stethoscope be held firmly down upon the integument over the organ.



2d. That the percussion be *deep*, that is, the interposed finger be firmly pressed down upon the area percussed, and the blow delivered with firmness and force. Cammann employed for this purpose the solid cylindrical stethoscope (Fig. 55) to obviate the transmission of the percussion note by the ribs; he further devised the "Intra-Costal Auscultator," a wedge-shaped stethoscope, capable

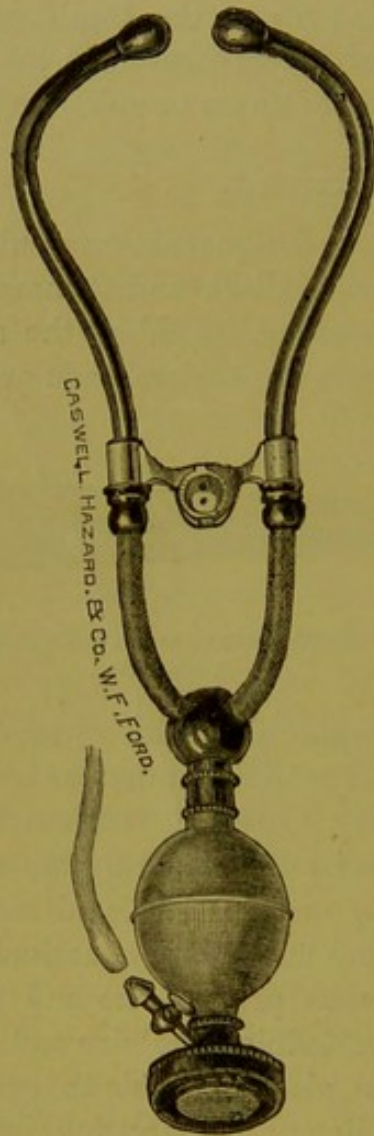


FIG. 57.

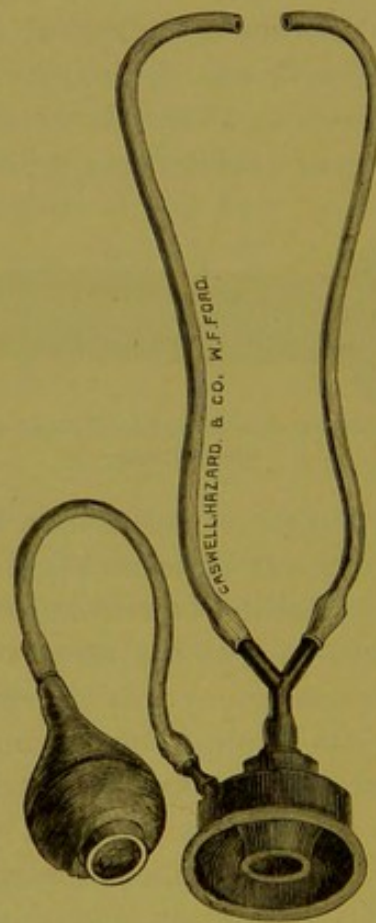


FIG. 58.

of being pressed down in the intercostal spaces upon the organ, and avoiding deceptive transmission of sound by the ribs. Such a wedge-shaped tube has also been employed in the binaural stethoscope. From my use of this method, I regard it an invaluable and essential aid to correct physical diagnosis, yet not so exact as its originator and many advocates would assert. I believe that it at

times tends to error, and hence its results should always, when possible, be compared with those obtained by simple deep percussion, and by palpation also when this is admissible.

For most thorough auscultatory percussion, the physician should have an assistant to percuss while he listens and holds the stethoscopic tube firmly over the part. Or the patient may hold the tube on, and the operator have both hands free to percuss.

Heinemann's attachment to the Cammann stethoscope is intended to enable the physician to perform auscultatory percussion without an assistant. It consists of a chin piece adjustable at different distances to suit the size of the listener's head, with which, by his chin and a rod or stiffener going down to the pectoral tube, he keeps the instrument steady and firmly in situ while he percusses and listens. Constantine Paul's instrument (see Figs. 57, 58)




FIG. 59.—Page's Percussion Hammer.

attempts a similar result in another way, by means of an air chamber outside of the pectoral tube and a rubber bulb for exhausting the air; the pectoral tube is held in place by suction, leaving the listener's hands free for percussion. But the pectoral tube is too lightly pressed on the integument for deep percussion, and will fail to give exact results. The use of Cammann's wedge-shaped solid stethoscope, or of his binaural stethoscope with smaller tube, and co-operation of an assistant, always give the best results.

I may add that for mapping out the contour of an organ before the class, the ingenious percussion hammer of Page is of value. It is used as a hammer, and the point to be noted having been reached, the hammer is reversed and used as a marker. A small cylinder contains "stage paint," a gummous pigmented material which may be ejected by turning the screw cap of the cylinder.

## BELL METAL TEST.

For large cavities and pneumothorax, Gairdner and Finlayson have described a combination of percussion and auscultation applicable to the study of large symmetrical cavities of the apices with cicatricial walls. A coin placed over the anterior apex region is percussed upon, while the auscultator applies his ear to the supra-scapular or scapular region, and perceives a brilliant metallic or musical resonation of the stroke. The sign is illustrated most typically in pneumothorax, the compressed air intensifying the bell-like sound.

## SUCCUSSION.

Succussion consists in forcibly shaking the patient's body with a view of eliciting splashing sounds of accumulated fluid partially filling cavities. It is most pronounced in pneumo-hydrothorax. The splashing fluid emits a brilliant succussion sound, intensified and raised in pitch by the increased pressure to which the retained air is subjected by a distended and tense chest-wall. Rarely is succussion heard, to a lesser degree, in very large tubercular cavities of even interior and cicatrized.

## DETERMINING THE SIZE AND SITUATION OF SURROUNDING ORGANS.

As an associated method of diagnosis, it becomes necessary to determine the location and size of contiguous organs, at least in so far as they come in contact with the lungs or infringe upon the pulmonary area. Thus the liver dulness has to be distinguished from pneumonia and pleurisy of the right side, as well as from thickened and carcinomatous pleura; the left lobe of the liver from the apex of heart; the spleen, stomach, and heart from the left lung; the heart, great vessels, aneurism and mediastinal tumors from disease of either lung. Palpation, percussion, and auscultatory percussion are our means of determining the size and shape of organs contiguous to the lungs.

## ASPIRATION AND HYPODERMIC PUNCTURE.

The physical diagnosis of pleuritic effusion, either free or circumscribed, of empyema and hydrothorax, often cannot be definitely made without resort to exploratory puncture. The distinction be-

tween a thickened pleura and a thin stratum of fluid often can be made only by this means. In certain cases of empyema, and even of serous effusion, an element of bronchial voice and breathing is present, which is misleading and creates an impression of the existence of pulmonary consolidation which only puncture will remove. A long needle attached to the usual hypodermic syringe,

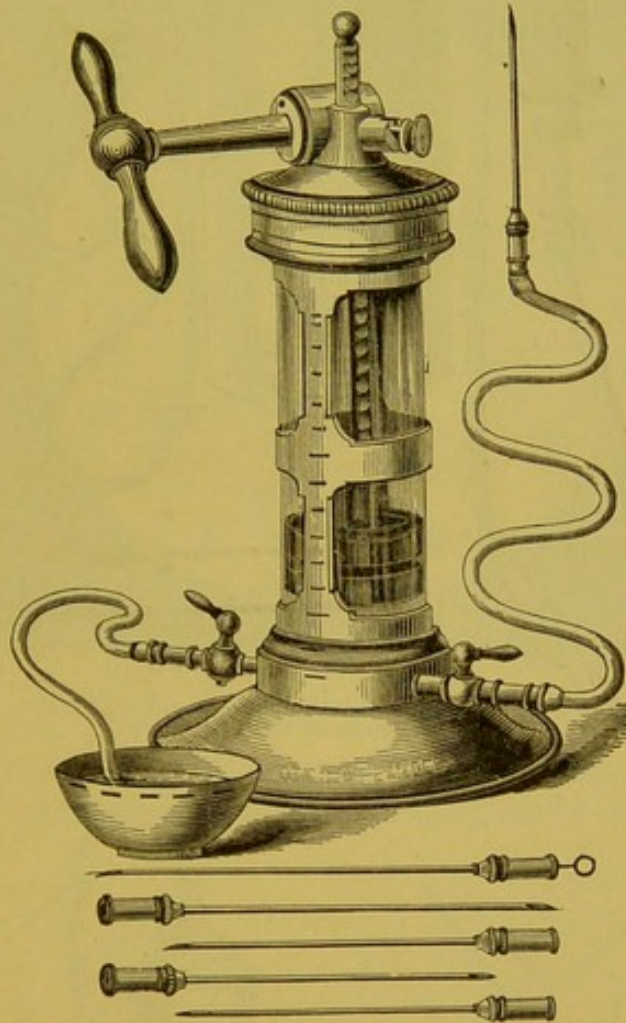


FIG. 60.—Dieulafoy's Aspirator.

or one of larger size, is to be employed. In all cases the needle should be clean and well carbolized. No harm results from such exploratory puncture, even when repeated.

The longer tubes of the aspirator (see Figs. 60, 61, 62) permit deeper puncture and free rotation in various directions, and give an approximate idea of the volume of liquid, and of the presence or absence of circumscribing adhesions.

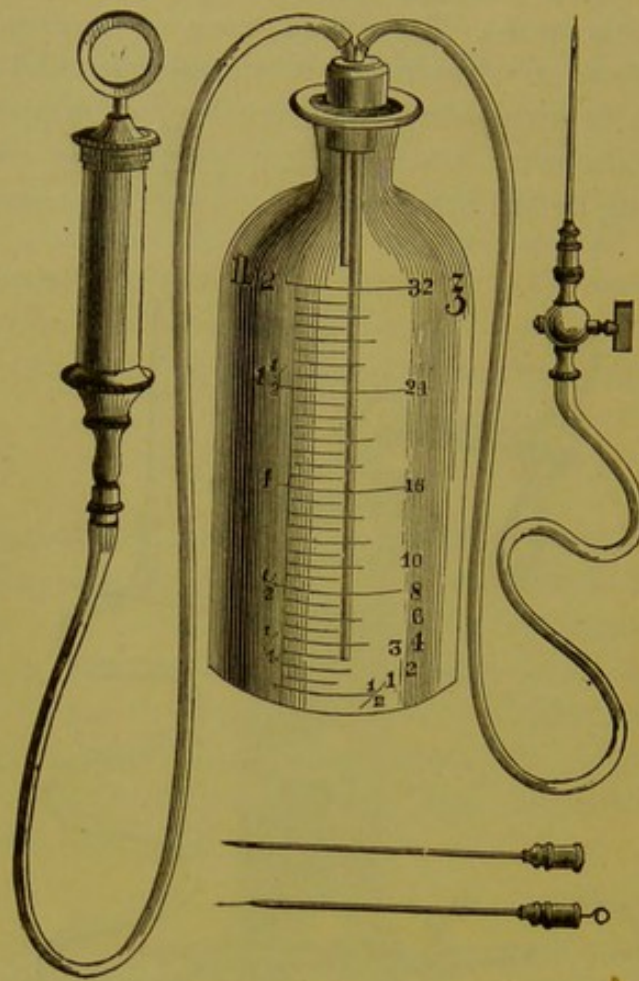


FIG. 61.—Tiemann &amp; Co.'s Aspirator.

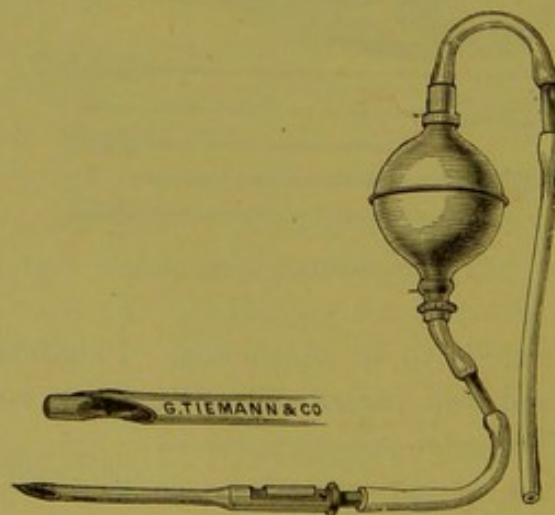


FIG. 62,

THE MICROSCOPE AS AN AID TO DIAGNOSIS OF RESPIRATORY DISEASE.

The detection of tubercle bacilli is essential to complete the physical study of a case of phthisis, influencing our interpretation of the signs of consolidation as the product of the specific tubercle or

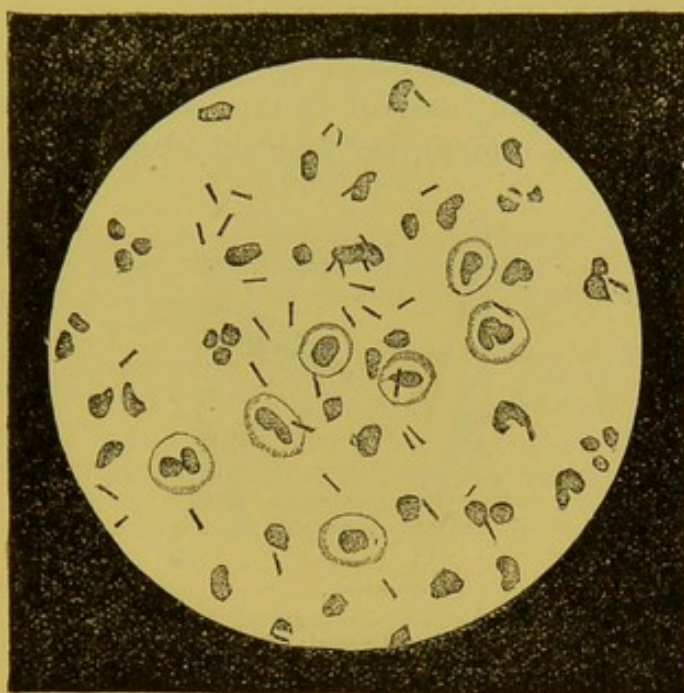


FIG. 63.—Tubercular Sputum—with Bacilli (Eichhorst).

of simple interstitial inflammatory process. The causative relation of the bacillus tuberculosis to phthisis is as yet not fully




FIG. 64.—Tubercle Bacilli with Spores (W. Cheyne).

settled. But its presence so frequently coincides with the existence of the true tubercular form and fatal cases, and its periodic appearance and disappearance so often coincide with periods of failing health and improvement, that it is most desirable both to detect it as a cause, and also to exclude it as an aid to negative diagnosis.

The technique of the bacillus search can be easily acquired. It consists in compressing a drop of the suspected sputum between thin glass covers, drying over the flame of a spirit lamp, staining in solution of fuchsin, subsequently bleaching with very dilute nitric acid and examination under high magnifying power (objective from  $\frac{1}{4}$  to  $\frac{1}{10}$ ). The characteristic beads and rod-like masses are seen in Figs. 63, 64).

#### ASTHMA CRYSTALS.

In the sputum of many cases of asthma, chiefly those accompanied by much bronchial catarrh, we find acicular or long octahedral




FIG. 65.—Asthma Crystals (Frankel).  $\times 500$ .

crystals. Less frequently they are found in the mucus and mucoserum of simple catarrhal bronchitis. Whether they sustain any uniform or causative relation to asthmatic paroxysms or paroxysmal and spasmodic cough is undecided.

## CHAPTER VI.

### SYNOPSIS OF ACUTE BRONCHITIS OF ADULTS.

Definition.	Inflammation of bronchial tubes.
Pathology.	<p>Submucous hyperæmia; acute catarrhal process.</p> <p>1st Stage.—Surface dry and tumefied.</p> <p>2d Stage.—Surface bathed with serum, sero-mucus, mucus, or muco-pus.</p> <p>Calibre of tubes } Submucous congestive swelling.  may be changed by } Local spasm of muscular and elastic coats.  } Adhesion of viscid mucus.</p>
Causes.	<p>“Taking cold;” chilling surface; inhalation of hot and cold air; irritant vapors; atmospheric causes (influenza). Secondary in specific blood states:—measles, typhoid and typhus fevers, variola, etc.</p>
Symptoms.	<p>May or may not be preceding coryza:—</p> <p>Soreness, rawness, tightness, oppression in upper sternal region, increased by cough; little or no fever in most cases; heavy, deep, sonorous, paroxysmal cough; no dyspnœa; inspiration long and full. Sputum in the first stage scanty or absent. In the second stage, at first, sputum is serous, transparent, frothy; later, white, viscid, opaque—mucus; later, yellow, tenacious, muco-pus. (Mucin and epithelial scales.)</p>
Physical Signs.	<p>Both stages, normal percussion resonance; normal vesicular sounds by auscultation. First stage—breathing dry, puerile, exaggerated; sonorous and sibilant râles. Second stage—mucous and sub-mucous râles, of various degrees of liquidity; to and fro gurgles in main bronchi. All removed or modified by cough or expectoration.</p>
Diagnosis.	<p>Normal percussion resonance and vesicular sounds; moist and dry râles, bilateral. A symmetrical disease. Absence of chill, of “stitch in side,” and of high fever; successive changes in sputum.</p>
Prognosis.	<p>Good. In adult does not extend to pneumonia, but some cases become chronic. Epidemics more severe—broncho-pneumonia.</p>
Treatment.	<p>Prophylactic—warm clothes, diet, air, exercise. Abortive—opiates, diaphoretics, saline purge. Palliative—anti-spasmodics and expectorants, supporting remedies, fomentations, counter-irritants.</p>



## SYNOPSIS OF CAPILLARY BRONCHITIS.

(SUFFOCATIVE CATARRH.)

Definition.	A form occurring in young children. A bronchitis of small tubes. Often an obstruction of small (fine) tubes and collapse of lobules; sometimes extending to vesicles (lobular, catarrhal pneumonia).
Pathology.	Inflammation of smaller bronchi, catarrhal products, choking of tubes, more or less lobular consolidation.
Causes.	Predisposing.—Early infancy, great weakness, errors of diet. Exciting.—Colds, measles, etc.
Symptoms.	Labored respiration, sinking of suprasternal notch and epigastrium, exhaustion, imperfect oxygenation, pallor, coolness, carbon dioxide poisoning, little pain or oppression. If any sputum, white small bodies, or tenacious mucus.
Physical Signs.	Percussion normal; auscultation—subcrepitant râle in inspiration and expiration.
Diagnosis.	Age, labored breathing, asthenia; resonant chest, pathognomonic subcrepitus (double). If extended to vesicles, crepitant râle. If plugging of bronchus and collapse of lobules, there may be a local area of high pitch and bronchial breathing. If collapse is extensive, retraction of chest on inspiration, and sinking at suprasternal notch and epigastrium.
Prognosis.	Always grave.
Treatment.	Support vigorously by diet, quinine, chloride and carbonate of ammonia, musk, stimulants, as needed; oil-silk jacket, poultices often renewed; mild counter-irritants; warm, moist, uniform air; oxygen. Emesis, if needed to eject mucus.

## SYNOPSIS OF CHRONIC BRONCHITIS.

Definition.	Acute attack often leaves bronchi liable to frequent subacute attacks, which may result ultimately in chronic bronchitis. A variable form of sequelæ of previous bronchial catarrhs.
Pathology.	Varying in different cases, including one or more of the following pathological states : 1. Simple chronic catarrh or relaxed, thickened mucous surface. 2. Changes of calibre of bronchi. General relaxation or dilatation. Local relaxation. Local contraction or obliteration. (Cirrhosis of lung the result.) 3. Local ulceration of mucous surface. Local ulceration of all the coats. 4. Peri- or extra-bronchial inflammatory deposits. 5. The same broken down, leaving cavity opening into bronchus. 6. Resultant chronic pneumonia, indurations.
Causes.	1. Predisposing.—Gouty and rheumatic diathesis, alcoholism, habitual indigestion and mal-assimilation, cardiac incompetency. 2. Exciting.—Recurring attacks of acute and subacute bronchitis; air laden with dust or foreign matter.
Symptoms.	Chronic cough, for months and years, without great loss of flesh, strength, or appetite. Chronic catarrh of bronchi; quantity, color and viscosity of secretion, determined by extent and kind of lesion.
Physical Signs.	Varying with simple bronchial, peri-bronchial, or pulmonary lesions, with dilated bronchi, bronchial cavity, peri-bronchitis, or cirrhosis of lung. Simulates every form and stage of phthisis. Contractions give sibilant and sonorous râles: accumulations of mucus give all grades of moist râles and gurgles; excavations and dilatations give cavernous and tubular blowing sounds, both inspiratory and expiratory; thickened bronchus gives creaking, "leathery" sounds; peri-bronchitis and chronic interstitial pneumonia give absence of vesicular sound, sometimes bronchial breathing, at other times feeble breathing, dulness on percussion, contracted chest, and diminished expansion.
Diagnosis.	To be differentiated from tuberculosis.
Prognosis.	Persistent, often incurable, but slow progress; remissions and exacerbations.
Treatment.	Hygienic, tonic. Climate. Chest expansion. Palliate symptoms according to case. Balsamic inhalations. Iodide of potassium.

## SYNOPSIS OF ASTHMA.

Definition.	A functional disease ; labored obstructed respiration, due to spasm of bronchi, usually with bronchial catarrh.
Pathology.	Theory of hyperæmia of par vagum. No known lesion of asthma. May be co-existing lesions of acute or chronic bronchitis, emphysema, etc.
Causes.	Often obscure or unknown. Hereditary in forty per cent of cases. Excited by cold air, dust, vapor, fatigue, mental effort, excitement ; especially indigestion and bad ventilation (foul air of sleeping room), flatulence, constipation, uterine disturbance (reflex action). Most common in men. Special form—" Hay asthma " or autumnal catarrh, sometimes due to emanations of flowering vegetation.
Symptoms.	Attack often sudden (rarely gradual, with preceding catarrh). Often at night in sleep. Increasing sense of obstruction to admission of air ; suffocation ; face anxious ; respiratory muscles fixed ; orthopnoea ; head thrown back ; gasping ; dilated nares ; obstructed venous circulation ; in head and neck, symptoms of carbonic acid gas accumulation ; fatigue ; exhaustion. Relief sudden or gradual, with lingering bronchial catarrh.
Physical Signs.	Normal pulmonary resonance, or vesiculo-tympanitic resonance on percussion. Fine tube and vesicular sounds may be wanting or feeble. Expiration long and changing, composed of numerous sibilant and sonorous râles, of varied and changing intensity, pitch, and quality. Moist râles of bronchial catarrh exist.
Diagnosis.	Paroxysms sudden ; physical signs, definite recovery from attack, complete and speedy, seldom any permanent dyspnoea.
Prognosis.	May cause emphysema. Remotely affects the heart.
Treatment.	Of paroxysms : Faulkner's method (iodine over pneumogastriacs). Oxygen, chloroform, hot liquor, strong coffee. Hypodermic use of morphia and atropia. Stramonium. Quebracho. Nitro cigarettes. Of intervals: Quinine. Iodide of potassium. Tonics. Diet. Change of climate.

## SYNOPSIS OF PLEURITIS.

Definition.	Inflammation of pleura with accumulation of inflammatory products on free surface, or in the pleural cavity.
Pathology.	Hyperæmia of subserous vessels; surface denuded of epithelium; rough, hazy, later escape of exudation, may be plastic, sero-plastic, or wholly serous. If adhesions, they are due to contact and adhesion of opposed villous surfaces. (Plastic exudation not material of adhesions. It may remain entangled and undergo caseous change—tubercle of pleura, or become calcified, so-called osseous plates.) General adhesions may obliterate pleural cavity. Local adhesions may encapsulate serum. Excess of serum—lung collapsed at hilus of lung. Too long collapsed, may be bound down by adhesions, expansion prevented, and air-sacs agglutinated. Lesser adhesions—lesser results. Pleuritic serum may become purulent (see empyema). Pleurisy often located near superficial tubercle. Tubercle perforating pleura causes pneumo-hydrothorax (which see).
Causes.	Acute—due to cold. Secondary—in blood states and acute disease. Local—co-existent with superficial tubercle.
Symptoms.	1st Stage.—Chill, stitch in side, febrile action, incomplete restrained breathing. Irritable dry cough. Later—pain relieved and dyspnœa developed, due to pressure of serum on lung and diaphragm. If empyema—frequent chills, weakness, foul tongue, sallow skin. Tubercle develops or typhoid state liable. If perforation—sudden, excessive dyspnœa; symptoms of collapse.
Physical Signs.	Depend on plasticity and movement of exudation. Rough surface gives a to-and-fro friction sound. Adhesions give every variety of fine and coarse râles unaffected by cough. Layers of thickened pleura and exudation give percussion dulness, and render voice and breath sounds muffled, vague, and distant. Over serum, chest-wall is full and immovable. Intercostal spaces bulge, percussion flat—high in pitch, short duration, wooden quality. Upper line of dulness abrupt, horizontal, changing with position of the body (old view). Recent view—upper border of dulness lowest in front, highest in side, lower behind; "the curved line of Ellis" or "letter S line." Over serum, absence of marked breath and voice sounds. Exceptionally bronchial voice and bronchial breathing are heard over serum, and especially over pus, variously explained as due to adhesions, to unusual tension of chest-wall, and to section of condensed lung dipping into fluid. Ægophony at surface of fluid; nasal quality of voice. Vocal fremitus wholly absent. Over the compressed lung, respiratory sounds are harsh and raised in pitch, vocal resonance intensified. In excessive accumulation of serum, the heart is displaced; especially serum in left pleura may push heart entirely to right of sternum. In perforation, signs of serum below and above tympanitic resonance on percussion, and by auscultation sometimes pectoriloquy, and splashing of the serum, called succussion. See Figs. 23, 24.
Diagnosis.	Friction double at onset. Later, plastic, subcrepitant râles, unaffected by cough; dulness on percussion; absence of voice and breath sounds; absence of fremitus and diminished chest movements over fluid. Positive diagnosis of presence and extent of fluid, whether serum or pus, by hypodermic syringe or exploring needle of aspirator. Distinguished from pneumonia: Sounds conveyed in pneumonia. Crepitant râle in pneumonia. Distinguished from hydrothorax: Both sides involved. Non-inflammatory.
Prognosis.	Many evanescent cases unsuspected. Most serous and sero-plastic cases recover. Excessive plasticity cripples lung. Permanent adhesions may cause local congestion or inflammation of lung, local or general emphysema. May, by causing irritation, favor infiltration and caseous masses (crude yellow tubercle) in lung. Empyema often grave. See p. 82. Pneumo-hydrothorax bad. See p. 83.
Treatment.	Abortive.—Dry cups to the side. Active counter-irritation—prompt saline cathartic. Antiphlogistic—antispasmodic—anodynes for cough. When exudation is complete.—Aid process of absorption. No depressing measures. Food, quinine, iron, alcohol, fresh air, exercise. Absorption aided by mild counter-irritation. Ol. terebinthinæ, or ungt. iodini comp.; also by iodide of potassium. In slow absorption, perform paracentesis or aspirate.

## SYNOPSIS OF EMPHYEMA.

Definition.	A form of subacute pleurisy in which the sero-plastic effusion becomes purulent.
Pathology.	Early lesions of pleurisy, viz.: removal of endothelium of pleural surface; later surfaces become roughened and in patches eroded or ulcerated. Tendency to associated thickening of pleura, subserous tumefaction, concretion in thick pleura, miliary tubercles in pleura and lung.
Causes.	Traumatism, admitting air, as by broken rib, perforating wound, perforation from tubercular lung, communication with bronchus. Low states of system—scrofula, tubercle, syphilis, alcoholism, sepsis, secondary pleurisy in course of low-type disease. Admission of air or impurities on unclean exploring or aspirating needles in simple pleurisy.
Symptoms.	Early symptoms of pleurisy with effusion, viz.: chill, stitch in side, dyspnoea, restricted breathing. Later, daily excursion of temperature (hectic), with high range, 102° to 105°, with or without chills, with sweating, failing strength and appetite, delayed and prolonged convalescence.
Physical Signs.	Early, the physical signs of pleurisy with effusion, viz.: fulness of side and intercostal spaces, diminished respiratory movement, lessened or absent fremitus, dulness on percussion, line of ægophony, silence over fluid. Later, distention of side and intercostal spaces increases; flatness over entire side, extreme displacement of heart, and depression of liver and diaphragm, may be “pulsating emphyema,” heart motions transmitted, and also marked bronchial breathing, whisper, and voice.
Diagnosis.	Diagnosis.—Daily excursion of temperature, high temperature, sweating, debility, prolonged convalescence or failing health. Definite diagnosis by hypodermic needle (long for exploration) or by aspiration.
Prognosis.	Always serious. Depends on efficiency of evacuation and intrapleural antiseptics. Liability of death by exhaustion, by pyæmia, or tuberculosis.
Treatment.	In mild cases, repeated aspiration of the pus, and vigorous diet, tonics, stimulants, antipyretics to control temperature (quinine, antipyrin), sulphide of calcium, salicin, or glyco-phenic acid internally to limit tendency to suppuration. Serious cases—thorough aspiration and washing of cavity with bichloride solution (1 to 2,000), or counter-opening and drainage under antiseptic dressings, with resection of rib, if necessary, for free drainage. Emphyema is frequently circumscribed, and, following successive aspirations, the adhesive process lessens the pus-cavity until obliterated.

## SYNOPSIS OF PNEUMO-HYDROTHORAX.

Definition.	Presence of fluid in pleura, with superimposed air. Fluid usually serum; may be pus (pneumo-pyothorax).
Pathology.	Associated lesions of causative disease, as of penetrating wound of chest, fractured rib, tuberculosis of lung, emphysematous pouch; fluid—serous, sero-purulent or purulent—in lower part of pleura. Air (not gas) above.
Causes.	Perforation of pleura. 1. Either internally from bronchus through normal lung by violent paroxysmal cough (rare), or from softening tubercle or cavity near lung surface, or rupture of emphysematous lobule of lung. 2. Externally by penetrating wound or compound fracture of rib penetrating pleura.
Symptoms.	Often sudden local pain or stitch, shock, apprehension or collapse at time of perforation. Later—Extreme dyspnoea, may be orthopnoea (necessity to breathe in sitting posture), labored heart action, pallor, cold extremities, cyanosis; extreme cases, collapse.
Physical Signs.	Distention of side, suspended respiratory motion, usually absence of fremitus over both fluid and air, percussion flatness over fluid, tympanitic resonance over air; by auscultation, feeble or absent voice, whisper and breath sounds below (over area of fluid); above (over area of air) may be to and fro, hissing sound of air entering and leaving cavity through valvular opening; if opening is larger, double blowing or cavernous, amphoric sound. Voice admitted to cavity, if connection with bronchus is free, and pectoriloquy results. With percussion on coin in front of chest, ear behind detects bell-metal sound. Shaking patient's body—by listening we hear succussion or splashing of fluid, and often its metallic tinkle when dropping from dome of distended pleura upon the surface of fluid below. The tension of cavity and compressed air intensify the sound.
Diagnosis.	Distended thorax—tympanitic resonance, pectoriloquy, succussion.
Prognosis.	Serious—if associated with pre-existing disease.
Treatment.	<p>Energetic supporting measures—Carbonate of ammonia, musk, alcoholic stimulants to counteract shock.</p> <p>Subsequently maintain strength by rich diet, milk punch, carbonate or chloride of ammonia, quinine. Control temperature. If fluid is abundant, possibly aspiration (not if point of perforation closes, better to allow fluid to remain for a time and by accumulation displace the air which is absorbed). Great danger of gangrene of pleura from careless or uncleanly aspiration. Data show best results from supporting measures and avoiding surgical interference (drainage).</p>

## SYNOPSIS OF HYDROTHORAX.

Definition.	Serous transudation partially filling both pleural cavities—a non-inflammatory process.
Pathology.	Simple blood serum or sero-albumin filling both pleural cavities to the same extent, except where previous adhesions in one cavity may limit its capacity. Associated pathological causes of dropsy, as impoverished blood, Bright's disease, and cardiac changes.
Causes.	All the causes of general dropsical effusions—viz., anæmia, spanæmia, hydræmia—cardiac dilatation, renal disease.
Symptoms.	General debility, impaired strength and appetite, dyspnœa, orthopnœa, pallor, suffusion, cool surface, cold extremities.
Physical Signs.	Diminished chest expansion at base on both sides. Lessened vocal fremitus at base on both sides. Zone or section at each base behind of flatness on percussion, with normal pulmonary resonance above; this line of transition changed by changed position. By auscultation, normal vocal resonance and respiration down to line of flatness, then ægophony or immediate transition to muffling or absence of voice, cough, and respiratory sounds. Exploratory puncture demonstrates presence of serum on both sides.
Diagnosis.	Presence of dropsy elsewhere or of cardiac or renal disease. Dyspnœa, flatness on percussion, absence of breath and voice sounds. Serum detected by exploratory puncture.
Prognosis.	Usually a grave complication of already serious disease. If due to remedial systemic causes, with absence of organic changes in heart or kidneys, prognosis is more favorable.
Treatment.	If accumulation is limited, improve health by rest, feeding, stimulants, and active tonics. When dyspnœa is extreme, use drastic purge, active diuretics, favor sweating by vapor bath, etc., at the same time maintaining strength. For critical disturbance of respiration and heart action, partially relieve each pleural cavity by aspiration. Iodide of iron preferable as tonic and absorbent. Digitalis and nux vomica to sustain heart action, alcohol and ammonia to keep up respiratory and circulatory functions.

SYNOPSIS OF PNEUMONIA.

ENGLISH CLASSIFICATION.	GERMAN PATHOLOGICAL CLASSIFICATION.
Pneumonia. Pneumonitis. Lobar Pneumonia. (Popular names. Inflammation of Lungs. Lung fever.)	Croupous Pneumonia.
Chronic Pneumonia.....	Chronic Interstitial Pneumonia.
Cirrhosis of Lung.....	Catarrhal Pneumonia.
Capillary Bronchitis—with Lobular Pneumonia, and collapse of Lobules.....	

PNEUMONIA.

PNEUMONITIS, INFLAMMATION OF THE LUNG, CROUPOUS PNEUMONIA.

Definition.	A local inflammatory disease of the lungs, usually idiopathic, with exudation of coagulable lymph into the air-sacs.
Pathology.	1st Stage.—Congestion. 2d Stage.—Red hepatization; solid, coagulated cell contents; white blood corpuscles (exudation corpuscles), fibrin, albumin, salts, hæmatin. Stasis in capillaries. 3d Stage.—Gray hepatization. Fatty metamorphosis of cell contents. Exudation removed by absorption and expectoration. Rarely leaves chronic consolidations. Often pigmentation due to transuded hæmatin-melanine. Usually (slight or great) coexisting local pleuritis.
Causes.	Age.—More often in adults. Sex.—More often in males. Exposure to damp and cold. Exhaustion. Secondary in acute fever, and septic blood condition.
Symptoms.	Marked chill or rigor—local stitch—rapid respiration, 30, 40, 60. Increased temperature—pulse full, frequent; may be active delirium; bloody, "rust-colored," sputum; short suppressed cough; anxious, painful face; dilatation of nares; circumscribed flush of cheek. Asthenic cases and in old age, may be no chill, little fever and no pain; delirium low, wandering; sputum dark, "prune juice," mahogany-colored; pulse weak and rapid, or slow. Assumes a typhoid form.
Physical Signs.	Differ in the three stages. Three stages usually coexist in different lobes, hence physical signs vary in different parts of lung. 1st Stage. (Hyperæmia.) Slight dulness on percussion; tube-sounds harsh; vesicular element of sound muffled. Early signs doubtful; with exudation crepitant râle present—fine crackles in inspiration only. 2d Stage. (Solidification.) Crepitus ceases; flatness on percussion (high pitch, short duration, wooden quality). Auscultation—bronchial breath and bronchial voice. Fremitus diminished. 3d Stage. (Liquefaction—resolution.) Returned crepitant râle—"râle redux." Sub-mucous and mucous râles. Dulness on percussion. Gradual return of normal, "breezy," "vesicular" respiration. Crepitus of local pleurisy may coexist.
Diagnosis.	Chill, fever, pain; circumscribed blush, rapid breathing, bloody sputum; flatness; crepitant râle; voice and breath bronchial—"râle redux."
Prognosis.	In healthy adults, recovery; resolution often by fifth day; the rule is in nine to twelve days. Weak and aged—typhoid form—often fatal. Very rarely develops phthisis.
Treatment.	May abort early by derivatives—diaphoresis, cathartics, cupping. Early period. Allay fever. Aconite, ammonia, fomentations, poultices, mild diet. Later period—Prevent asthenia, favor resolution. Diet, tonics, stimulants.



## SYNOPSIS OF ŒDEMA OF LUNG.

Definition.	Transudation of serum and sero-albumin into the finer air-passages and pulmonary vesicles, either general or local, acute or chronic.
Pathology.	Pulmonary hyperæmia, either acute or chronic, active or passive. In chronic forms usually the associated lesions of chronic bronchitis, peri-bronchitis, and chronic interstitial pneumonia, often with condition of chronic arterio-capillary fibrosis throughout the body.
Etiology.	The acute form, due to arterial or active congestion, often develops in suffocative forms of broncho-pneumonia, pleuro-pneumonia, and double pneumonia. The acute passive form is the common result of cardiac failure, in cardiac dilatation, fatty heart, uræmia. Also due to hypostasis in aged, bed-ridden, and persons exhausted by adynamic diseases.
Symptoms.	Dyspnoea, orthopnoea, labored respiratory movements, anxious look, suffused face and neck, cyanosis, cool, moist surfaces, cold extremities, feeble pulse and circulation. Temperature subnormal. Often serous or frothy sputum, may be sanious.
Physical Signs.	Inspection—labored respirations, sinking at epigastrium and supra-sternal notch. Palpation—mucous fremitus. Percussion—negative. Auscultation—moist râles in larger bronchi, with finer crepitating râles in smaller bronchi and vesicles. Sometimes there is dulness on percussion, and absence of auscultatory sounds at the base of both lungs, due to co-existing hydrothorax. Heart-sounds irregular, labored, and often evidencing associated or causative heart disease.
Prognosis.	Varies with character of attack. If actively congestive, may be relieved by bleeding, purging, counter-irritants, dry or wet cups, free diuresis, vigorous diaphoresis, etc. If occurring in the course of renal or heart disease, it is more serious and liable to recur.
Treatment.	If acute, congestive, suffocative, bleeding may give immediate relief. Full dose of calomel with addition of resin of podophyllum, elaterium, or pulvis purgans. Local and free use of dry and wet cups. If passive, due to heart failure, support heart with ammonia, Hoffman's anodyne, nitrite of amyl, alcoholic stimuli. Small hypodermics of Magendie's solution (℥ ii.-iii.) frequently repeated. Digitalis to sustain heart. Stimulating enemata (turpentine) to unload bowels, and stimulate splanchnic ganglia; dry cups, poultices over kidneys; hot-air baths, free dry cupping over dependent portions of chest.

## SYNOPSIS OF PULMONARY APOPLEXY.

Definition.	The effusion of a large amount of blood from ruptured pulmonary artery, with laceration of pulmonary substance.
Pathology.	Usually associated with degeneration of the walls of pulmonary vessels, the sequence of alcoholism, syphilis, or wasting disease. Pulmonary structure much lacerated, extensive collateral hyperæmia and œdema.
Etiology.	May occur in persons deteriorated by chronic rheumatism, gout, syphilis, chronic uræmia, and especially if there be atheromatous arteries. May be immediately induced by violent exercise, especially if the heart be hypertrophied.
Symptoms.	Sudden attack of extreme dyspnoea, suffocation, suffusion, collapse, expectoration of sanious serum, blood, or in fatal cases with extensive pneumorrhagia.
Physical Signs.	Unilateral evidences of the source of blood. A large or small area of muffled respiratory and voice sounds, more or less abundant râles and gurgles, and sometimes perceptibly raised pitch on percussion.
Prognosis.	Usually bad. Death often immediate or imminent. Less often, recovery with secondary degenerative changes—inflammatory and phthisical.
Treatment.	Immediate—supine position, blood determined to extremities and surfaces by warmth and sinapisms. Heart sustained by minute hypodermics (¶ i.-ii.-iii.) of Magendie's solution, by ammonia, nitrite of amyl, alcohol. Ergot by the mouth or hypodermically at short intervals. Ice bag to the site of apoplexy.

## SYNOPSIS OF PULMONARY INFARCTION.

Definition.	Primarily—the withdrawal of arterial blood from a limited area of lung substance by embolic plugging of the nutrient artery of the area. Secondly, lessened nutrition and degeneration of the pulmonary structure.
Pathology.	The condition is usually the result of lodgment of extraneous plug (embolus). It may also result from thrombosis due to changes in arterial walls. The disintegrated blood subsequently transudes the walls, the infarcted area softens or becomes cheesy, the veins fill with thrombi. Localized pneumonia may ensue.
Etiology.	Any disease of the right side of the heart or venous circulation may lead to plugging of branches of pulmonary artery—dilated right ventricle, lesions of pulmonary orifice, aneurismal clots, phlebitis, clots from uterine sinuses, débris of foci of sepsis or pyæmia.
Symptoms.	If connected with sepsis, pyæmia, ulcerative endocarditis (of right side), aneurism, those diseases represented by symptoms. In other cases, attacks of failure of right side of heart permit of intracardial clots, subsequently washed into pulmonary arteries. Attack characterized by chill or chilliness, dyspnoea, local discomfort or pain, sometimes sanious expectoration.
Physical Signs.	Area corresponding to the area of discomfort or pain, dull on percussion, and on auscultation there is absence or muffling of respiratory, whisper, and voice sounds.
Diagnosis.	From lobar and lobular pneumonia, by lower temperature and less frequent respiration than either. Also by less harassing cough. Absence of crepitant râle and bronchial breathing, voice, whisper, and cough. Associated pyæmia, septic or cardiac phenomena.
Prognosis.	When occurring in course of puerperal state may be instantly fatal, usually with right heart obstruction. When associated with pulmonary valvular disease or phlebitis, may not recur, and ultimate recovery ensue. When occurring in sepsis, pyæmia, ulcerative endocarditis, or adynamic disease, prognosis bad.
Treatment.	Immediate efforts to maintain circulatory equilibrium. Perfect quiet on the back, avoidance of effort, movement, or excitement. Moderate restraint of thoracic movements by chest bandage. Use of antipyretic measures, should elevated temperature indicate secondary pneumonia. Sustaining treatment to counteract further sepsis, and secondary or recurring attacks. Chloride of ammonium, tincture of iron to maintain nutrition of blood and lessen coagulation, necrosis and sepsis.

## SYNOPSIS OF GANGRENE OF LUNG.

Definition.	Death of areas of lung tissue <i>en masse</i> , and either limited to lobules, or diffuse, including a larger area, as a part or whole of one lobe or one lung.
Pathology.	Varies with the form and cause. Hence in drunkards, maniacs, and senility associated with advanced degeneration of vessels and vitiated blood-elements; in sepsis, with embolic and thrombic sequelæ; in congestive and pneumonic cases, co-existent diffused hyperæmia and pulmonary consolidation.
Etiology.	Of diffuse form—acute hyperæmia and inflammation, with lowered nutrition of blood and depressed vital powers—inadequate to insure resolution. Hence occurring in the pneumonias of drunkards, the aged, insane, or when secondary to typhoid, sepsis, pyæmia. More localized gangrene may result from infarction, or from foreign body in bronchus; still more circumscribed from fetid bronchitis.
Symptoms.	Symptoms of primary disease or etiological factor. Tendency to adynamic form of symptoms, collapse, and evidences of sepsis. Development of fetid breath and fetid, discolored sputum. In favorable cases, with completion of gangrenous process there is rapid recovery.
Physical Signs.	At first, evidences of areas of infarction, hyperæmia, or centric pneumonia, usually associated localized pneumonia, bronchopneumonia, and pleuritis. Later, communication with bronchus gives evidences of cavity.
Diagnosis.	Physical signs of local consolidation in a low type of disease, or in a patient with lowered vitality, together with irregularity of temperature, evidences of sepsis, fetid sputum, and later of excavation.
Prognosis.	Unfavorable when occurring in the course of low-type disease or sepsis, or when complicating extensive pneumonic process, or traumatism. More favorable when due to foreign bodies or fetid bronchitis.
Treatment.	Vigorous fortification of general strength against sepsis and exhaustion. Heroic use of food, stimulants, tonics. External antiseptics—sulpho-carbolate of soda, terebin, salicin, salicylates, sulphide of calcium, or glycophenic acid. Inhalations of antiseptics and stimuli to bronchial surfaces and interior of antrum, viz., steam impregnated with turpentine, tr. benzoin co., carbolic or glycophenic acid; inhalation of oxygen.

SYNOPSIS OF EMPHYSEMA.  
PULMONARY, VESICULAR EMPHYSEMA.

Definition.	A local chronic disease, due to rarefaction of pulmonary structure and dilatation of air sacs.
Pathology.	May be general vesicular emphysema or often of upper lobes only, or confined to but few lobules. Lungs do not collapse on opening thorax. May be distinct cysts, or poutings on the surface; feel soft, elastic. Progressive lesions, enlarged air sacs, obliterated alveoli, perforation of cell-walls, cells coalesce, cysts of small or large size. Fatty degenerations and destruction of intercellular tissue. Capillaries obliterated; their blood leaves pigmentation. Obstructed lung circulation causes dilatation of right heart, hence general venous retardation, favoring chronic diseases of the viscera.
Causes.	Lobular emphysema, is "vicarious," caused in inspiration, compensating adjacent, atrophied, solidified, or collapsed lobules. General vesicular emphysema always due to excess of inspired air over that expelled in expiration, as in chronic bronchitis with thickening and relaxation of tubes. Usually fatty degeneration and atrophy of connective-tissue. Emphysema of upper lobes only, due to expiratory force and obstruction at glottis; in pertussis, chronic cough, heavy lifting, gymnasts, porters, musicians, etc. Rarely fatty degeneration is primary. Very rarely due to rigid thorax.
Symptoms.	Dyspnœa, labored breathing, respiration and circulation easily disturbed. Often bad circulation, disease of heart, chronic disease of distant parts.
Physical Signs.	Emphysema of lobules not often detected; general and of upper lobes, resonance vesiculo-tympanitic. Pitch depends on associated condition of pulmonary parenchyma and degree of distention and "inspiratory fixation," or bony rigidity of thorax. Respiratory sounds feeble. Inspiration deferred or shortened. Expiration prolonged, blowing, low in pitch; variety of sibilant and sonorous râles. Chest full, rotund; intercostal spaces full. Expansion slight. Rising of chest <i>en masse</i> . Muscles of neck and chest fixed. Broad, short neck in typical case. Others, small, contracted chest. General emphysema, diaphragm depressed, heart also resting on it, and becoming almost horizontal.
Diagnosis.	Heart apex outward; liver may be depressed. Distinguished from asthma by the frequent co-existence of chronic bronchitis.
Prognosis.	Can be alleviated; rarely cured.
Treatment.	Progress checked by removing cause; avoid cold. Cure laryngeal obstruction, also chronic bronchitis. Improve tone of elastic tissue by hygienics, diet, quinine, pot. iod.

## SYNOPSIS OF PULMONARY CONSUMPTION OR PHTHISIS.

Pulmonary Consumption considered according to the older pathology of the school of Laennec, Louis, etc.

Definition.	Wasting disease of the lungs. A local expression of a blood state, of a specific diathesis. Due to tubercular deposits and their complications.
Pathology.	<p>1st Stage.—Tuberculization.—Deposit of tubercle usually yellow or crude; rarely miliary. Yellow tubercles coalesce, form caseous masses. Involved tissues atrophy. Caseous masses shrink; compensative emphysema; usually at apices coexisting localized pleurisy, bronchitis, pneumonia.</p> <p>2d Stage.—Softening.—Caseous masses become pultaceous by imbibition of serum, and pus due to ulceration and infiltration of adjacent tissue. Tissue destroyed, vessels obliterated or eroded; usually opening into bronchi.</p> <p>3d Stage.—Cavities.—Due to evacuation of tubercular pus. May be large or small, smooth or ragged. Wall may be exposed, lung tissue infiltrated with tubercles, exudation matter, or may be cicatricial tissue. Large vessels and bands of fibrous tissue may bridge over large cavities. Cavity may open freely into bronchus, or by a valvular opening. Cavities may contain mucus or pus; they may contract, granulate, and heal.</p>
Causes.	<p>Great predisposing cause tubercular diathesis, usually hereditary; sometimes induced by environment. Obscure relation to scrofulous, strumous, and eczematous diathesis. Possibly contagious and endemic through agency of the tubercle bacillus.</p> <p>Developing and exciting causes.—All depressing influences—indigestion, bad diet, privation of food, overwork, exposure to cold and damp, dissipation, close confinement at work in foul air, sedentary occupations, stooping, inhaling dust, indoor life, want of exercise and chest expansion, damp changing climate, low altitude, depressing diseases, as typhoid fever, measles, small-pox, syphilis.</p>
Symptoms of First Stage.  Physical Signs of First Stage.	<p>1st Stage.—Variable; may be indigestion, debility, increased temperature, emaciation, and loss of strength. Short accelerated breathing, pallor, increase of temperature in the afternoon. May be early hæmoptysis (bronchorrhagia), early pleural plastic exudation, fugitive or fixed pains due to dry pleurisy. Cough and expectoration of local bronchitis; may be hoarseness.</p> <p>Inspection.—Small chest, sinking under clavicles, and in intercostal spaces. Frequent, shallow, and feeble breathing.</p> <p>Mensuration.—Reduced circumference and expansion.</p> <p>Palpation.—Increased vocal fremitus, frequent breathing, and feeble expansion.</p> <p>Percussion.—Dulness—slight or marked—raised in pitch, of short duration, of wooden quality. May be sense of resistance.</p>

SYNOPSIS OF PULMONARY CONSUMPTION, Etc.—*Continued.*

Physical Signs. (Continued.)	Auscultation.—Weakened respiration, absence of vesicular murmur, bronchial breathing. Inspiration raised in pitch. Expiration prolonged and raised in pitch; bronchial voice, bronchial whisper, and bronchial cough; increased vocal fremitus; respiration may be wavy, jerking, divided—cog-wheel respiration; heart sounds conveyed.
Second Stage.	2d Stage.—Hectic more marked; expectoration more free; contains muco-pus—pus, tubercular pus, fibrous tissue, casts, shreds, etc.—(Pulmonary elements), fat granules, fatty cells, cholesterin. Sputum is nummular, <i>i. e.</i> , coin-shaped masses at bottom of frothy fluid; decline of health, strength, flesh; in women, loss of menses in this or early stage, or later; liability to hemorrhage from the eroded vessels; night sweats. Immediate Percussion.—Myoidema often observed. Auscultation.—Subcrepitant râle over softened part. Râles of collateral hyperæmia or associated catarrhal process.
Third Stage.	3d Stage.—Increased debility, emaciation, flatness of chest, short, quick, labored breath, bad appetite, weak stomach—nausea, especially from fatty food—vomiting, reflex after cough. Cough hard and sputum copious, especially in the morning. Debility increased by severe afternoon hectic, profuse night sweats, excessive expectoration, anorexia. Sometimes colliquative diarrhœa; face sunken, cadaveric; eyes staring; breath gasping; tongue dry and brown; fingers clubbed; liability to severe or fatal hemorrhage, due to erosion of vessels in cavities.
Symptoms.	
Physical Signs.	Inspection—May be flatness—retraction. Percussion—May be dulness; or resonance over large superficial cavities; cracked-pot sounds. Auscultation—Cavernous, amphoric respiration, voice whisper, and cough; gurgles, pectoriloquy, ægophony, metallic tinkle.
Diagnosis.	From chronic bronchitis and emphysema, by history, physical signs, and presence of bacilli.
Prognosis.	Always uncertain and guarded. Early stages most favorable, yet extreme cases may be checked. Prognosis determined by temperament, family history, habits, treatment, and climate.
Treatment.	To prevent, cure, arrest, and to prolong life: Preventive.—Attend to ventilation, digestion, clothing, exercise, occupation, chest expansion, out-door life, climate. Lessen cough and secretion.—Anti-spasmodics, balsamics, anodynes, counter-irritants. Regulate digestion and bowels.—Create appetite, aid digestion, support strength. Bismuth, bark, pepsin, milk, cream, butter, kumyss, peptonized milk, fats, ol. morrhuæ, glycerin, pancreatic emulsion, wine, whiskey, hypophosphites, etc. Alterative and absorbent effect.—Bichloride of mercury, arsenic. Stop fever and night sweats.—Quinine, sulphuric acid, ergot, atropine; sage infusion, dry salted towels. Relieve fugitive pain.—Anodynes, counter-irritants. Relieve occasional vomiting.—Check diarrhœa.

## MODERN CLASSIFICATION OF PHTHISIS PULMONALIS.

(Niemeyer, Rindfleisch, Sir Andrew Clarke, etc.)

1. Catarrhal phthisis.
2. Fibroid phthisis.
3. Tubercular phthisis.

1. Catarrhal phthisis is the most frequent form, developing preferably in persons of phthisical and strumous diathesis, but also in many others, quite free from such dyscrasia, as the result of poor food, bad

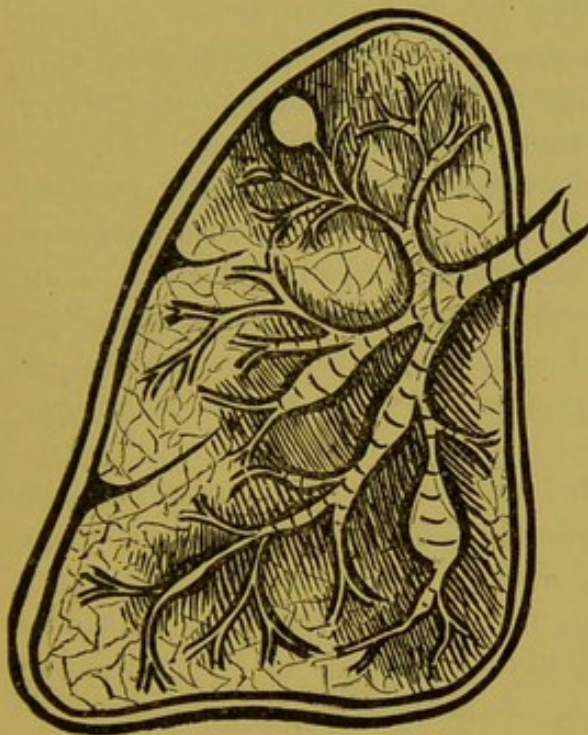


FIG. 66.

FIG. 66.—Peribronchitis, chronic; fibroid phthisis; dilated bronchi and cavity.

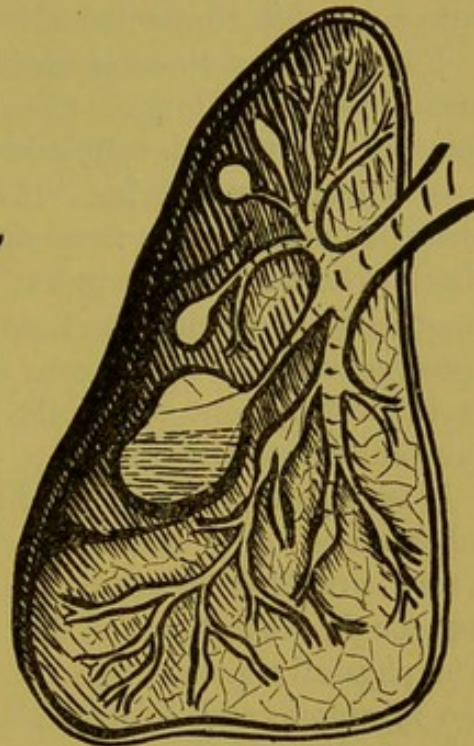


FIG. 67.

FIG. 67.—Thickened pleura, adhesions; fibroid phthisis of pleuritic origin.

air, indoor life, sedentary and constraining occupations, impure exhalations, and dust incident to special trades, debilitating disease, either acute or chronic, dissolute habits, changeable climate, residence in low, damp situations. The choking of terminal bronchi and air sacs with catarrhal products, peribronchial and intervesicular hyperæmia and infiltration, are first steps in pathology. Lobules and areas of interstitial tissue thus consolidated tend to caseation, softening, cavities. Such cheesy matter (crude tubercle of older authors) when softened (tubercular pus) poisons pulmonary lymphatics, setting up lymphangitis with exudation of round-cell elements into the



reticulum of lymphoid tissue, thus producing the opalescent, semi-opaque, gray tubercle, the miliary tubercle, Bayles' tubercle, larger tubercle cells of von Schoefel, etc. The physical signs of phthisis, as already given, apply to the several stages of this form of phthisis.

2. Fibroid phthisis, occurring as a product of chronic bronchitis in its various forms—peribronchitis, bronchiectasis, bronchial obliteration—occurring as a product of thickened pleura, chronic pleurisy, or more gradually as a progressive infiltration of pulmonary interstitial tissues, as a result of gouty or rheumatic vice, of habitual alcoholism, or syphilis. Often coexistent with cirrhotic liver and spleen, or with contracted kidneys.

Physical signs, those given in chronic bronchitis, thickened pleura, and cirrhosis of lung. Caseous nodules, softening, and cavities, may develop with the physical signs of these conditions.

3. Tubercular Phthisis. It develops chiefly in persons of tubercular parentage. Less frequently it appears as the result of great shock to health, extreme privation, sepsis from bad food, water, or air, emanations of drainage, and especially damp soil (Lænnec, Benedikt). Tubercle bacillus would seem to be a cause of active contagion and rapid development of family groups and local endemics of acute tubercular phthisis.

It assumes two forms. 1. First and less frequent, acute miliary tuberculosis, gray tubercle disseminated throughout the lungs. There is rapid failure of health, elevated temperature, hectic, sweating, cough, exhaustion, and death, often without caseation or cavities. The physical signs are often negative, the diagnosis being made by the symptoms and by exclusion. 2. More often the deposition of tubercles provokes bronchial catarrh, and after a brief period of rapidly failing health and persistent high temperature, the physical signs of bronchial and pulmonary catarrh become pronounced, and later the signs of areas of consolidation (interstitial fibroid, later caseation), softening, and cavities. The physical signs of phthisis as described under the old pathology now again apply.

*Summary.*—It may, therefore, be stated that, while the modern pathological distinctions as to phthisis lead us to a broader and more discriminating consideration of the disease, the application of the rules of physical diagnosis has remained essentially unmodified.

In pursuing the physical diagnosis of any case of phthisis, we discover the common presence of associated cirrhosis of the lung, thickened pleura, and acute and chronic bronchial catarrh. These

conditions may in some cases be antecedent and curative, in others concurrent, in others the sequel or complication of a true tubercular phthisis.

Originally, all phthisis was regarded as tubercular. In the last twenty years, the opposite view has prevailed, viz., that a large part of phthisical cases are the product of inflammatory diseases of the chest, leaving crippling lesions and tendencies to degenerative changes. The views of Niemeyer especially tended to this conclusion, and so does our fuller knowledge of the intra-pleural lesions.

But the detection of the tubercle bacillus (see Fig. 64) tends to give strength to the theory of the specific nature of phthisis rather than its dietetic, inflammatory, and degenerative origin.

These explanations have been so fully entered into to emphasize the fact that the student of physical diagnosis must conjoin a most careful history of his patient in order to rightly interpret the physical signs.

#### SYNOPSIS OF SYPHILIS OF THE LUNG.

Opinion is divided as to the presence of distinctive syphilitic lesions of the lungs, other than the presence of gummata. Gummata will give no physical signs or symptoms indicative of their presence. They will provoke special symptoms according to their size and location, as irritative bronchitis and bronchorrhœa, local pleuritis, local interstitial pneumonia.

More often syphilis is merely a factor in deteriorating the general health, and aids in inducing or hastening the progress of phthisis. The diagnosis is suggested by the knowledge of the syphilitic taint in the patient, and confirmed by the marked relief of the phthisical symptoms following free use of antisyphilitic agencies—mercury and iodide of potassium.

#### BROWN INDURATION OF THE LUNG.

*Definition and Pathology.*—A condition of chronic interstitial infiltration of pulmonary parenchyma, interstitial deposition of blood pigment, atrophy, contraction, and obliteration of pulmonary arterioles and alveolar structure, the result of chronic passive hyperæmia due to cardiac disease. There is often associated emphysema of the periphery of the lungs, the brown induration being more marked in the centre of the lungs around and in the peribronchial areas and nearer the inner borders of the lungs. The lung structure, viewed macroscopically, is often of a salmon or light copper-red hue.

*Etiology.* Due to cardiac incompetency, especially insufficiency or stenosis, or both, of the mitral valve, with ventricular dilatation.

*Symptoms.*—Diminished vital capacity, chronic dyspnoea, often dry cough, "winter cough," rarely bronchorrhœa or catarrhal bronchitis. Associated defective nutrition, poor digestion, hepatic and renal symptoms.

*Physical Signs.*—Chest poorly expanded. Respiratory sounds feeble, percussion resonance lessened, raised pitch. Inspiratory sounds notably lessened, often with feeble, prolonged expiration of associated emphysema. Coexistent heart signs are mitral/systolic, and præ-systolic murmurs, displaced apex, diffused apex impulse, vibratile apex beat, and increased cardiac area, to the left.

*Diagnosis.*—By the foregoing physical signs and symptoms, with coexistent mitral disease. To be discriminated from emphysema, chronic bronchitis, fibroid phthisis, contracted chest of chronic pleuritic thickening—chiefly by history and heart signs.

*Prognosis.*—Slowly progressive, concurrent and co-operative with primary, causative heart disease.

*Treatment.*—Directed to sustaining the enfeebled heart and maintaining the general nutrition of the body. Milk diet (peptonized milk, kumyss), cod-liver oil, tonics, massage, mild regular exercise, out-door life, dry pure atmosphere, cautious methodical chest expansion.

Long-continued use of bichloride of mercury and arsenic in small doses is beneficial.

#### CARCINOMA OF THE LUNG, PLEURA, AND BRONCHIAL GLANDS.

Cancer within the thorax is most often secondary to cancer in other parts. It is usually the encephaloid form, less often scirrhous or epithelial. When extensive pleuritic thickening or large areas of flatness on percussion with associated absence of respiratory and conduction sounds exist, then with exclusion of phthisis, and of serous effusion by means of hypodermic puncture or exploratory aspiration, cancer becomes a possible cause of physical signs. If solid growth is rapid and displaces other organs, a suspicion of cancer is warranted. If cachexia, rapidly failing health, carcinomatous history or primary cancer, the diagnosis is strengthened. In cancer of the pleura, there is usually a coexistent accumulation of sanguineous serum in the pleural cavity.

## CHAPTER VII.

### DISEASES OF THE HEART.

#### TOPOGRAPHY OF THE NORMAL HEART.

THE correct interpretation of cardiac physical signs presumes a correct knowledge of the anatomical structure, topographical anatomy, and normal functional action of the heart.

The heart is commonly regarded as located on the left side of the chest, whereas, in fact, it is situated in part to the right of the sternum, underlies the entire mid-sternal region, and not more than half of its area is on the left side. The location of the heart differs slightly in health in different individuals, according to development of the chest, muscularity, short or long-chest, etc. Yet a pretty uniform average location as cited below can be observed as a standard, and any departure from it should not be considered a healthy deviation until further examination for evidences of disease has resulted negatively. The size of the heart in cadavers varies not only with previous robust health or feeble nutrition, but also according as the heart at the time of death was left in a state of systolic contraction or diastolic relaxation. The average size of the healthy heart, then, is arrived at, by combining post-mortem measurements with many accurate measurements made in health by means of careful percussion, and especially auscultatory percussion of the area of cardiac dulness.

The vertical and transverse measurements of the heart are usually adequate to estimate the normal or abnormal size of the heart. *The heart extends vertically from the upper border of the third left costal cartilage to the lower border of the sixth left costal cartilage; transversely, the heart extends from a point one-half to three-quarters of an inch to the right of the sternum across to a point half an inch within the left nipple.* The left nipple has always been taken as a landmark for the location of the left border of the heart, and also of the apex beat. It must, however, be remembered that the nipple varies in location in men according to development of

their thoracic muscles, adipose, etc., and also that many of the diseases which chiefly change the size and location of the heart, as pericarditis with effusion, dilatation, hypertrophy, also bulge the præcordial area of the mammary region, and displace the nipple. Especially in women, owing to the variable size and pendulousness of the breast, the nipple becomes an indefinite location. By the nipple-location, then, it is proper to say, we mean a point at the junction of the fourth costal cartilage and rib.

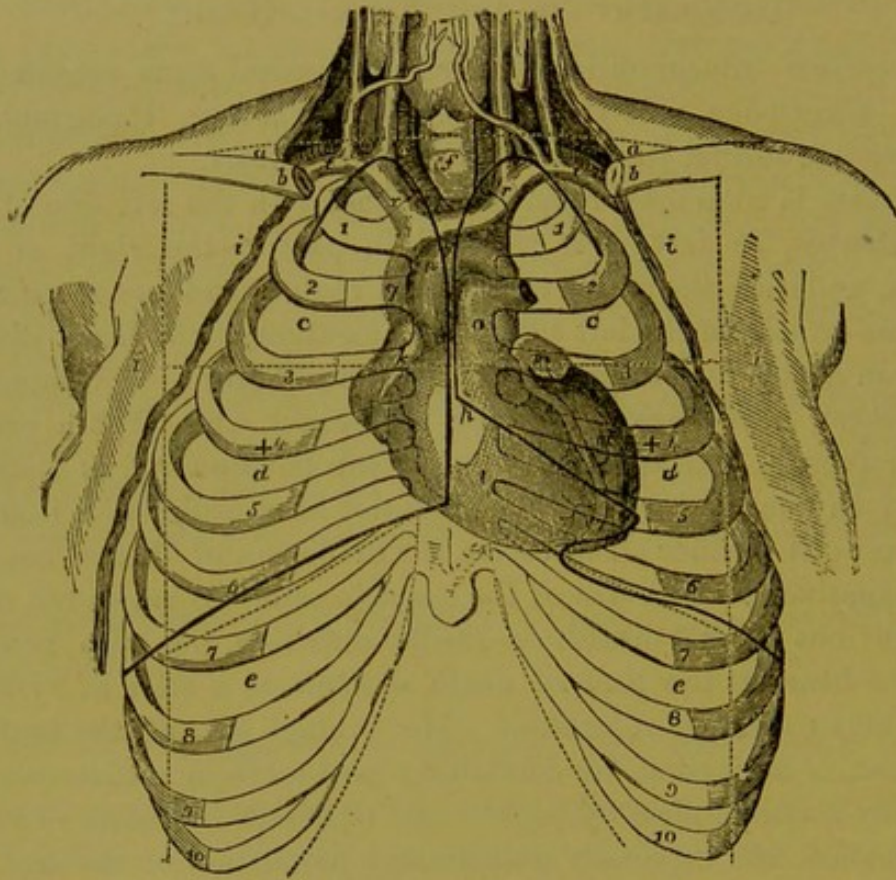


FIG. 68.—Location of the heart (Walshe).

With reference to the anterior chest regions, the heart is found as follows. See Fig. 68.

Deep Cardiac Region.	{	Heart occupies all of lower sternal region.
		“ “ part of right mammary region.
		“ “ “ of left mammary region.
		“ “ slightly right and left infra-clavicular region.

The exact contour of the deep cardiac region is to be determined

by deep (firm) percussion, or by careful auscultatory percussion, especially with aid of Cammann's intra-costal auscultator (see Fig. 56), and may be mapped out on the patient's chest by pen and ink, or Page's admirable marking hammer (see Fig. 59). But the left lung overlaps the heart invariably in inspiration and expiration. The area of the heart not overlapped by lung in quiet breathing is designated the superficial cardiac region.

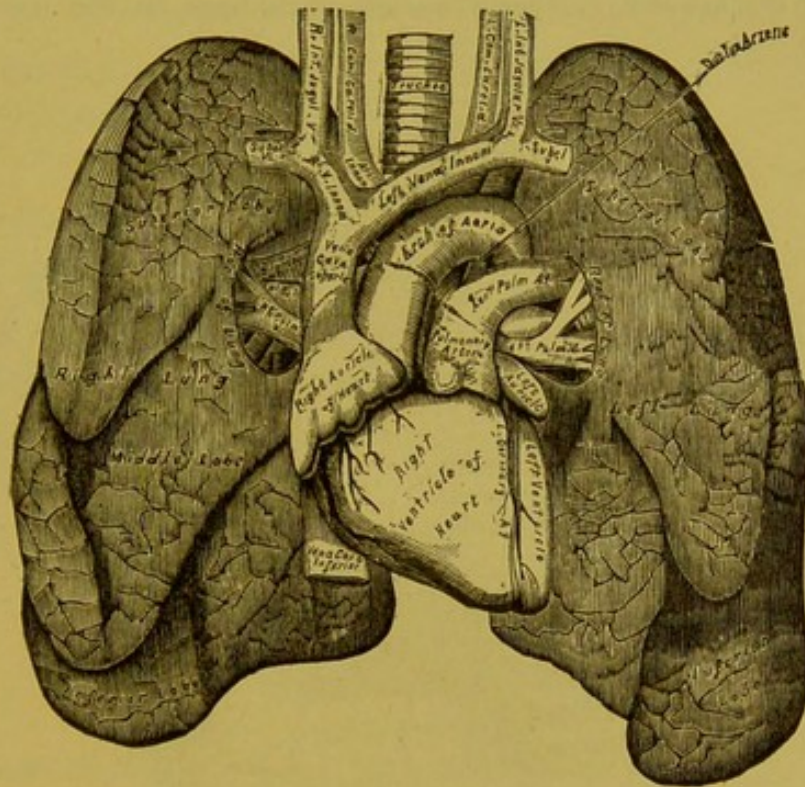


FIG. 69.—Showing relation of the heart to the great vessels, air passages, and lungs. The lungs have been pushed behind the heart to more fully show it.

This is shown in Fig. 68 (Walshe). It may be thus stated :

Superficial  
Cardiac  
Region.

Part not overlapped by lung—a triangle whose apex is at the fourth left costal articulation with the sternum, one side extending downwards and outwards to the union of the fifth rib with its cartilage, the shorter side downwards and inwards to the sixth rib and sternum, the long side being the left sternal border.

In private practice and clinical teaching, to demonstrate this tri-

angle, I am in the habit of putting the tip of my left index finger at the junction of the fourth left cartilage with the sternum, letting my hand drop so that the index finger lies along the left sternal edge, the thumb extends upwards and outwards to about the junction of the fifth rib with its cartilage, and with the index finger of the right hand I inclose the remaining side of the triangle. This, as a rule, covers the area of the superficial cardiac region, and superficial cardiac dulness in health. The normal topographical relations of the heart to the great vessels at its base, to the œsophagus,

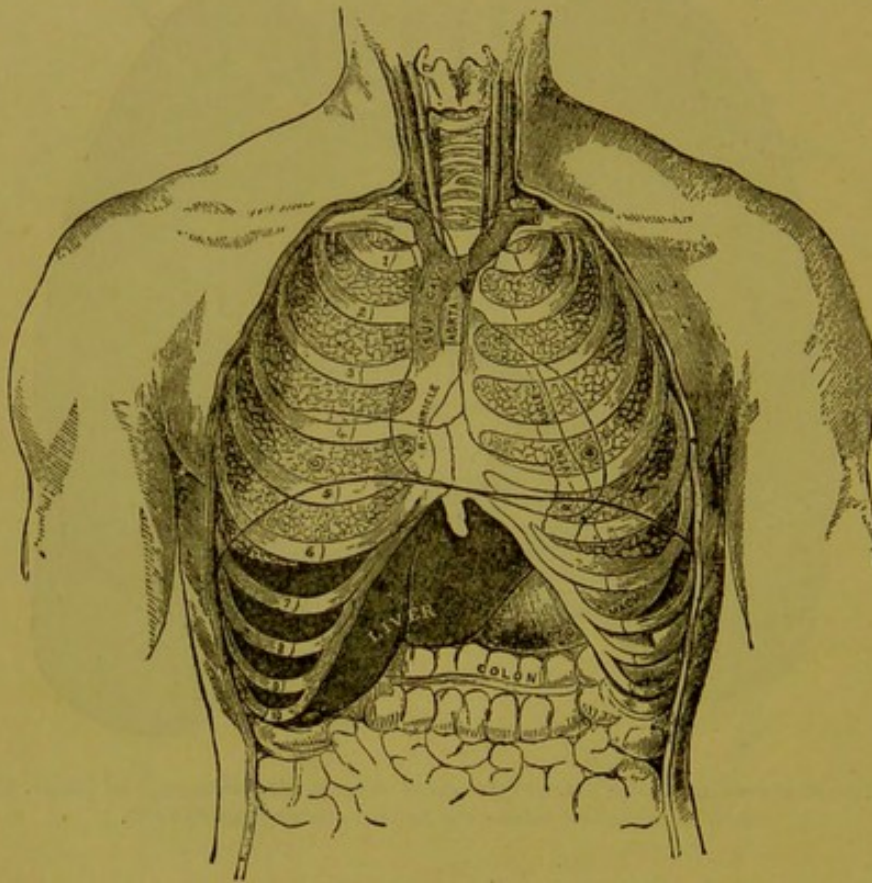


FIG. 70.—Relation of the heart to the diaphragm and left lobe of the liver.

trachea, bronchi, the lungs, the pleuræ investing the inner borders of the lungs, the diaphragm, stomach, and left lobe of the liver are to be considered.

It is to be borne in mind that the heart is pendulous, free within the pericardium, suspended by the great vessels; that the parietal pericardium is attached to the pleura and indirectly with the diaphragm.

Although most of the diseases of the heart, and most of the cardiac murmurs and other physical signs are connected with the left

side of the heart, yet it must be remembered that the right side of the heart overlaps or masks the left, and approaches the anterior chest-wall (see Fig. 69). The apposition of the right ventricle and anterior chest-wall, and especially of the diaphragm and left lobe of the liver, are to be remembered, since epigastric pulsation or fulness of cardiac origin is due to the transmission of cardiac pressure or pulsation from the right side of the heart by the left lobe of the liver.

#### TOPOGRAPHY OF THE HEART IN DISEASE.

Changes in the location of the heart, it will be seen, therefore, may result from :

- |  |   |  |
|--|---|--|
| 1. Changes in size of the heart itself.                    | { | Hydropericardium.<br>Hypertrophy.<br>Dilatation.<br>Atrophy.   |
| 2. Changes in the great vessels.                           | { | Aneurism of the aorta pushing the heart to one side.   |
| 3. Changes in the mediastinal space (substernal region).   | { | Enlarged glands.<br>Malignant tumors.  |
| 4. Changes in the lungs.                                   | { | Emphysema of the lungs pushing the heart down.<br>Atrophy of the lungs in phthisis uncovering the heart.   |
| 5. Changes in the pleura.                                  | { | Accumulation of serum pushing the heart to the opposite side.<br>Adhesions pulling the heart out of place. |
| 6. Changes in the the stomach.                             | { | Dilatation of the stomach lifting the diaphragm and heart.   |
| 7. Changes in the liver.                                   | { | Fatty, waxy, malignant, hydatid liver, hypertrophic cirrhosis pushing the heart up.                        |
| 8. Changes in the peritoneal cavity and abdomen generally. | { | Ascitic fluid, malignant diseases, ovarian cysts crowding up the diaphragm and heart.                      |



## SPECIAL CARDIAC TOPOGRAPHY.

## LOCATION OF THE CARDIAC VALVES.

Much confusion in the location and interpretation of cardiac murmurs results from the discrepancy in the statements of different authors of prominence on physical diagnosis. More especially does this remark apply to the location of the aortic valve, which has been asserted and pictured in a standard work as located at the right border of the sternum ; and again by another, at the mid-sternum.

Practically, the aortic and pulmonary valves may be stated to be beneath the articulation of the third left costal cartilage with the sternum, at its lowest point. More exactly, the pulmonary valve is at this point, while the aortic valve is half an inch nearer the median line. Almost at the same point, topographically, but at different antero-posterior depths behind the sternum, are the higher portions of the mitral and tricuspid valves. As stated by Walshe, a radius of one-half an inch includes a part of all the valves, and the mitral is but one-half an inch from the tricuspid. Reference to Fig. 69, showing the relation of the great arteries at the base of the heart, will indicate the contiguity of the two basic valves, with the pulmonary slightly to the left.

Fortunately, in practice this nearness of the pulmonary to the aortic area, and of the tricuspid to the mitral, makes little or no confusion, as the murmurs of the right side of the heart are so infrequent as to be unimportant, and so associated with other symptoms and signs, as cyanosis, venous pulsation in the neck, etc., as to prevent any error in the interpretation of the local sounds, even if the direction of their propagation is uncertain. Even the statement of normal location of valves may lead us astray in interpreting murmurs, if too rigidly adhered to ; for it must be remembered that, associated with the more pronounced cardiac murmurs, there is often such marked hypertrophy and dilatation of the cardiac chambers that the left ventricle and apex are changed in location, and a marked change of location results in the site of the valves and in the location and direction of the line of transmission or propagation of the murmurs. Again, the associated dilatation of the aorta and its branches greatly exaggerates the conduction of both normal cardiac sounds and cardiac murmurs. The location of the aortic and mitral valves, therefore, are always to be chiefly borne in mind, and in proper time, as the heart apex is deviated to left or right, and the left ventricle

dilated, or the heart displaced on its side or upwards or downwards, an estimate arrived at of the distance these valves have been removed from their normal site.

The normal location of the heart valves may be thus recapitulated :

LOCATION OF HEART VALVES.

Pulmonary.—Left edge of the sternum near the lower edge of the third cartilage.

Aortic.—A little lower, midway between the edge of the sternum and the median line.

Tricuspid.—Middle of the sternum, obliquely from the third left to the fourth right interspace.

Mitral.—One-quarter of an inch below the aortic. Horizontally across the sternum opposite the fourth left articulation.

It is desirable even in our study of physical signs to have in mind some conception of the size of the organ, and its several parts, producing the sounds which we hear and the symptoms we observe. This is further necessary as we employ morbid specimens to illustrate the changes causing the disease we are observing, as well as to have normal standards of measurement for such cases as we follow to a fatal termination and autopsy.

*Weight of the Heart.*

Average male,  $9\frac{1}{2}$  oz. (Walshe).

“ 10–12 oz. (Gray).

Female, 8–10 oz. “

*Size.*

Length, . . . . .	5 inches.
Width, . . . . .	$3\frac{1}{2}$ “
Thickness, . . . . .	$2\frac{1}{2}$ “

*Thickness of Heart Walls.*

Thickness of right auricle, . . . . .	1 line ( $\frac{1}{12}$ of an inch)
“ “ left, “ . . . . .	$1\frac{1}{2}$ lines.
“ “ septum, . . . . .	4 lines.
“ “ right ventricle, . . . . .	$2\frac{1}{2}$ to 3 lines.
“ “ left, “ . . . . .	4 to 5 lines.

*Capacity of Ventricles.*

Capacity of right ventricle, . . . . .	2 fl. oz.
“ “ left “ . . . . .	2 fl. oz.

---

## METHODS OF EXAMINATION OF THE HEART.

The methodical examination of the heart is conducted in precisely the same manner as already detailed for the exploration of the chest. It includes :

1. *Inspection.*
2. *Mensuration.*
3. *Palpation.*
4. *Percussion.*
5. *Auscultation.*

And secondarily :

6. *Auscultatory percussion.*
7. *Determining the relation to contiguous organs.*

## 1. INSPECTION.

- We notice :
1. The degree of præcordial fulness or contraction.
  2. The quiescence or movement of the præcordial region as a whole.
  3. The location of the apex beat or impulse.
  4. The character of the apex beat.
  5. Retraction of intercostal spaces synchronous with heart action.

1. *Præcordial Fulness.*—In a normal chest, the præcordial (left mammary) region should be slightly fuller than the right.

In case the præcordial region be symmetrically enlarged or bulging, it indicates hypertrophy, eccentric hypertrophy, dilatation, or hydropericardium.

In case the præcordial region be flat, it indicates fatty heart, atheromatous heart, or atrophied senile heart.

2. *Motion of Præcordial Region as a Whole.*—*a.* In most healthy adults, with moderate development of muscles and subcutaneous adipose, the præcordial region is quiescent in ordinary activity of respiration and circulation, *i. e.*, no noticeable motion can be observed synchronous with the heart's action, except at the apex beat in the fifth space. Let the healthy patient, however, exercise violently, or even breathe rapidly and forcibly a number of times, and the entire præcordial region will be seen to heave slightly with

each systole of heart. If the patient be lean, this is more perceptible, whereas in persons with much adipose the heart motion will be less marked, even under the stimulus of exercise or forced breathing.

*b.* When the entire heart area is perceptibly shaken by each contraction of the heart, it suggests hypertrophy, though it may result from intense cardiac excitement.

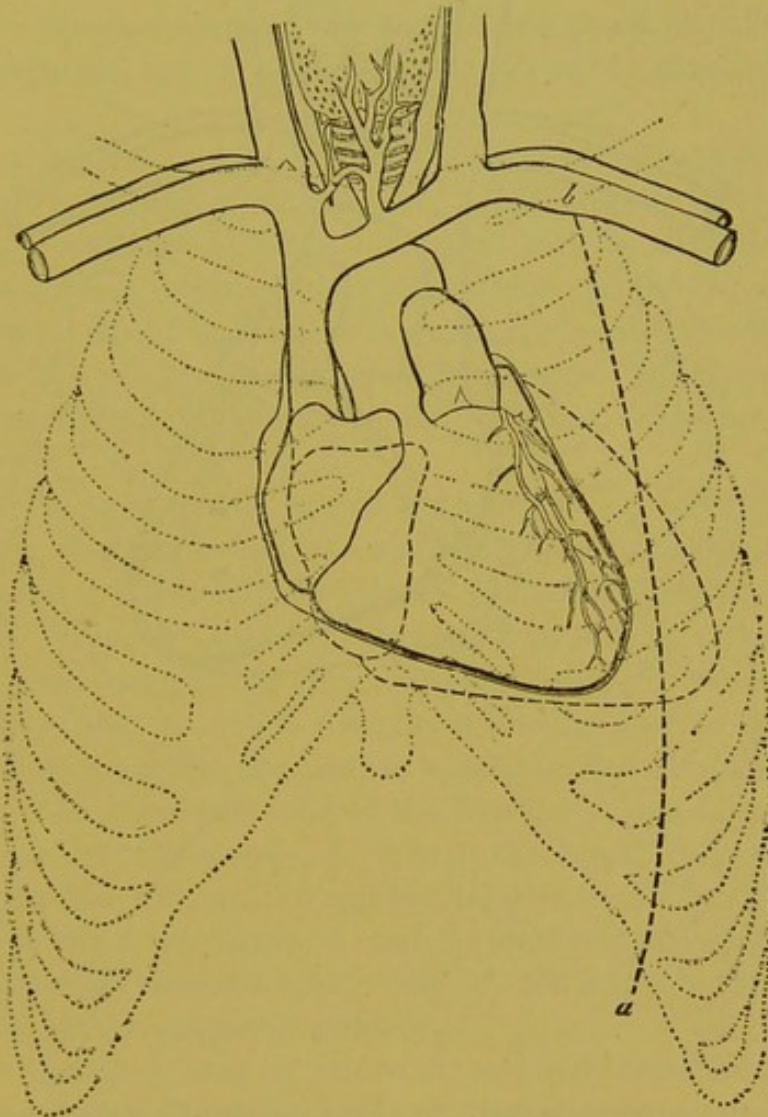


FIG. 71.—Apex carried to the left of the nipple line by hypertrophy and dilatation (Von Dusch).

*c.* When the entire præcordial region is perceptibly moved by each heart movement, and the motion as observed is wave-like or tremulous, eccentric hypertrophy or advanced dilatation is likely to be present. Exceptions exist, as in very anæmic and nervous persons as well as in convalescents from exhaustive disease. A relaxation of the left ventricular wall probably exists in these states, which

may be recovered from by discreet management, rest, and cardiac tonics.

*d.* When the præcordial region up to the cardiac base, without being shaken, perceptibly displays in the third and fourth intercostal spaces the cardiac motion, we infer that the overlapping edges of the

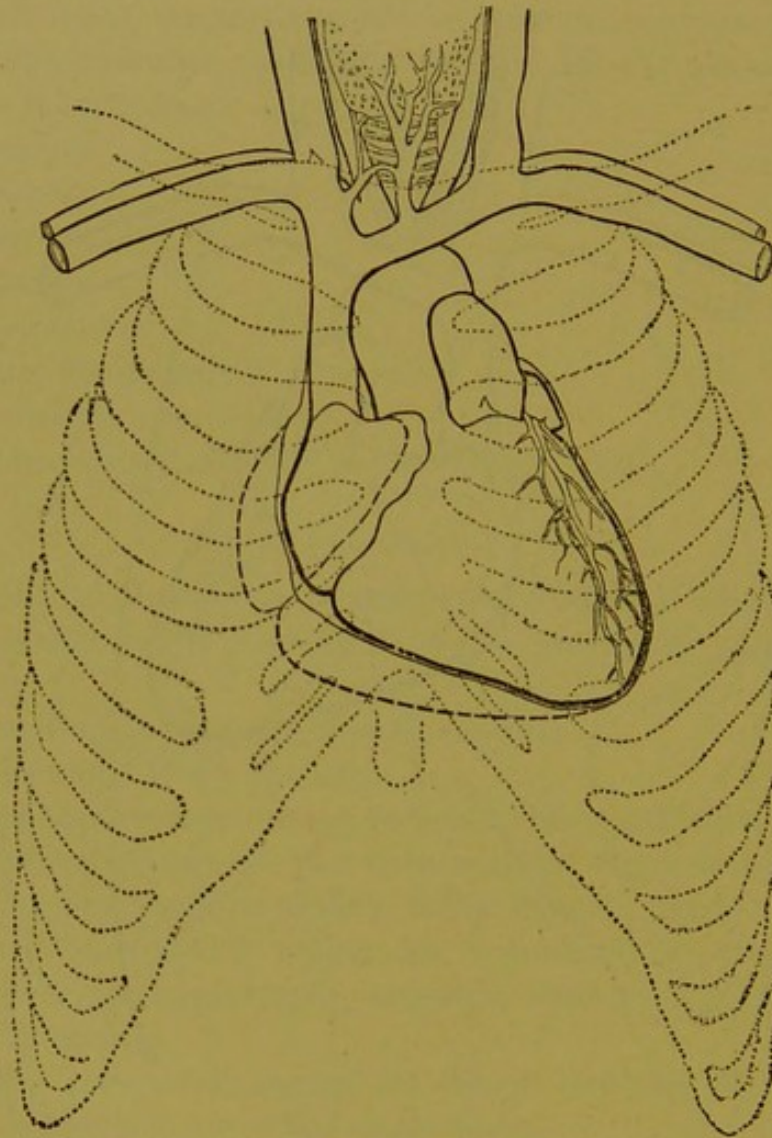


FIG. 72.—Apex carried to the right. Hypertrophy or dilatation of the right ventricle (Von Dusch).

lungs have been atrophied or contracted by phthisical processes, and that the heart is wholly uncovered and permitted to move in direct apposition with the chest-wall. Thus, not only the whole ventricular, but even the auricular wave is perceived. This is an important diagnostic inspection sign of advanced phthisis with cavity of the left lung.

*e.* When the entire præcordial region is devoid of motion synchronous with the heart action, even under the excitement of exercise or forced breathing, it denotes an atrophied or fatty heart.

3. *Location of the Apex Beat.*—The location of the apex beat is one of the most important and most practical points in the physical examination of the heart. The normal location of the apex beat, in most cases, at once excludes hypertrophy, dilatation, pericardial effusion, and the displacements of the heart, down by emphysema, up by liver enlargements, and to either side by pleuritic effusions and adhesions.

The apex beat, as a rule, is in the fifth intercostal space, one and a half inches below and within the left nipple (nipple location, junction of fourth cartilage and rib). Various authors state this differently, as two inches below and one inch within the nipple, etc. But slight variations in the location of the apex are consistent with health, according as the patient be short or long chested (the ribs and their cartilages standing well out from the sternum, or going down at acute angle).

*a.* When the apex beat is carried outward and downward beneath the nipple, or outward beyond the mammary line (linea mammillaris) the usual cause is either hypertrophy or dilatation of the heart. See Fig. 71. *b.* When the apex beat is carried far outside of the nipple line and upwards around the side, dilatation usually is the cause. *c.* When the apex beat is outside the nipple line and carried upward in the direction of the axilla, the heart is usually on its side and has been pushed up by enlarged left lobe of the liver, or drawn to the left by pleuro-pericardial adhesions. *d.* When the apex beat is carried nearer the median line, or the cardiac impulse is chiefly transmitted to the epigastrium, the cause is usually enlargement of the right ventricle, although simple hypertrophy of the left lobe of the liver will account for the epigastric pulsation.

*e.* When the apex beat is removed vertically upward from the fifth to the fourth or third left intercostal space, the cause is usually pressure of the diaphragm upwards either by greatly enlarged liver, or hydroperitoneum, ovarian dropsy, or other abdominal tumor or accumulation.

*f.* When the heart is pushed down by the overlapping and pressure of emphysematous lungs, the apex is depressed. Some authors state, as I think erroneously, that the apex goes to the right of its normal site. I have carefully examined many cases of emphysema,

both in my wards at Bellevue Hospital and in my clinics at the New York Polyclinic, as well as in private practice, and believe, as held by many authorities, that the apex of the depressed heart goes to the left. The diaphragm loses its dome-like convexity when pressed down by emphysematous lungs, and the depressed heart tends to lie on its side with the apex outwards.

#### 4. *Character of the Apex Impulse.*

Second in application, and often more positively diagnostic, is the character of the apex beat. In health, the apex should not only beat in the fifth intercostal space, but, as enunciated by good authority, the beat should be "*punctuate*" or definitely located, as it were, almost by a point which can be covered by one finger tip. Departures from this punctuate apex beat are more or less characteristic of different cardiac diseases.

*a.* When in an oblique light the apex beat is seen to be not punctuate but diffused, it denotes an enlargement of the heart. If this area of diffused or disseminated apex beat be moved with regularity and force, and appears essentially as a shaking or lifting of the chest-wall over the apex, hypertrophy is to be inferred.

*b.* If the area of the apex beat be diffused, and also wavy in its movement, dilatation is to be inferred.

*c.* If the area of apex beat moves but slightly, or, as often happens, so slightly or imperceptibly as to give no clue to the site of the apex, we infer atrophied heart, fatty heart, senile heart, or great debility of the heart, as in invalidism.

#### 5. *Retraction of Intercostal Spaces over the Heart.*

When in the præcordial region it is observed that intercostal spaces, either as a whole or at single points, are drawn in or have movement synchronous with the action of the heart, there is a strong presumption that a former pleuritis over the region of the heart has left adhesions which transmit the heart motion to the chest-wall, and even that pericarditis may also have occurred, and that pleuro-pericardial adhesions are the cause of the intercostal movements.

## 2. MENSURATION.

Mensuration or measurement has a limited application to cardiac diagnosis, but is largely applied in connection with percussion and

auscultatory percussion. The following measurements of the præcordial area may be made, viz., the vertical measurement from the upper border of the third rib to the inner border of the sixth; the transverse

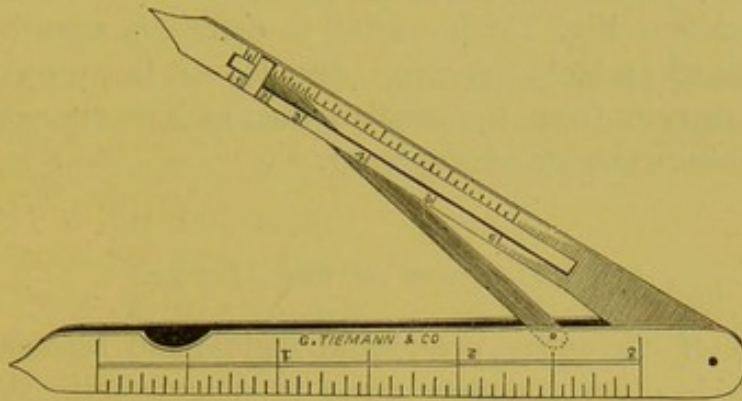


Fig. 73.—Cammann's Cardiometer.

from the median line to the left nipple; and that around the entire left side, as contrasted with the right. Any great increase in the size of the heart, as from advanced hypertrophy or great dilatation, will cause prominence of the region, spreading of the ribs, and in-

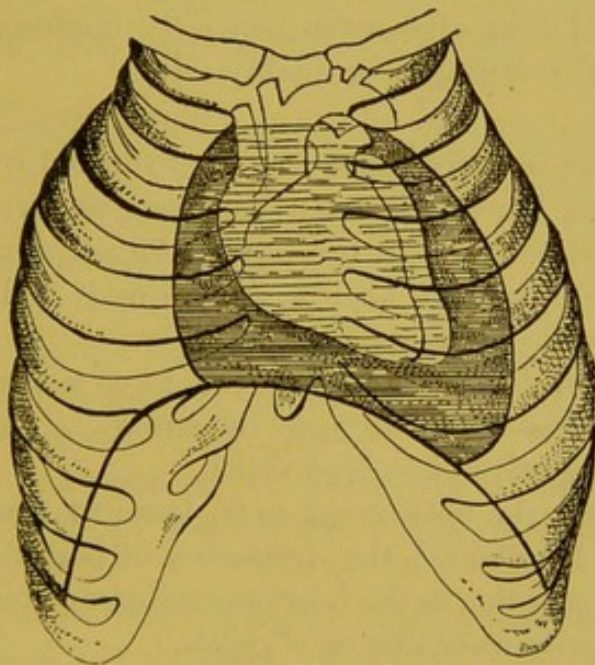


FIG. 74.—Showing increase of pericardial area in hydropericardium.

crease of the distance from the third to the sixth rib. It will also carry the nipple somewhat outwards toward the axilla, and increase the entire measurement of the left side; especially in extensive hydro-



pericardial effusions will the præcordial region fairly bulge, the nipple being well carried to the left, and both vertical and transverse lines lengthened. The left ventricular margin, as determined later by percussion, is carried far to the left. The cardiometer of Cammann (see Fig. 73) is useful to definitely record in inches and fractions of an inch the exact distance of the nipple and left ventricular margin from the median line, as also the vertical and transverse measurements of the heart.

### 3. PALPATION OF THE HEART.

Palpation of the entire præcordial region, and especially of the apex region, is often adequate alone to diagnose the normal heart, or the particular form of cardiac disease.

First, the hand may be flatly and firmly laid on over the entire præcordial region. We thus may take cognizance of the general characteristics of the heart's action, viz.:

- |                              |   |                            |
|------------------------------|---|----------------------------|
| 1. The force                 | } | of the heart's<br>impulse. |
| 2. The duration              |   |                            |
| 3. The rapidity or frequency |   |                            |
| 3. The character or quality  |   |                            |

*a.* If the heart is normal, the force is firm and well-defined, the duration of each impulse is perceptible and uniform in successive beats; the heart beats about the normal 72 per minute, unless excited by exercise, and in quality its stroke is definite, free from tremor or wave-like sensation.

*b.* If the heart is hypertrophied, the force is greatly increased, the duration is less—more abrupt—the stroke is more rapid, and in quality is suggestive of excited action.

*c.* In dilatation, the force is apt to be lessened, the duration may or may not be lengthened, the frequency of beat varies above and below normal, according as the heart is excited or quiescent, and the quality is especially wave-like or vibratile.

*d.* In fatty, atheromatous, senile, and atrophied hearts the force is greatly diminished, the duration of the beat is less, their frequency often below normal, and the quality is chiefly feebleness only, sometimes with tremor or waviness. With the hand on the heart, we also may observe the synchronism of the heart action with the pulse

at the wrist or in the carotid artery. This is sometimes essential before proceeding to auscultate, since in tremulous and feeble hearts, and in some cases of disturbed rhythm associated with extreme dilatation, it is hard to say what period of the heart sounds is systolic, what diastolic.

Even more practical than the application of the hand to the præcordial region is palpation of the apex beat or apex impulse with the tips of the fingers. We thus again study :

- |                  |   |                   |
|------------------|---|-------------------|
| 1. The force     | } | of the apex beat. |
| 2. The duration  |   |                   |
| 3. The rapidity  |   |                   |
| 4. The character |   |                   |

and also its :

5. Synchronism with cardiac systole and the pulse in the carotid and radial arteries. What has been said as to full duration and rapidity of præcordial impulse suffices for the apex also. But the quality of the apex beat must be specially stated.

*a.* In health, the apex properly located in the fifth intercostal space must be punctuate, practically covered by one, or two at most, finger tips, it must have normal force, duration, and frequency, and in quality be devoid of any trace of vibration, weariness, or thrill.

*b.* In hypertrophy, the apex beat as felt by the finger tips has increased area, or is disseminated or diffused, is increased in force, is abrupt, accelerated, and suggests in quality increased size, strength, and nearness of the impinging heart.

*c.* In dilatation, the apex beat is diffused, may need all the finger tips to cover it, is lacking in force, usually increased in duration, may be rapid or slow, usually is irregular or intermitting, and in character is perceptibly vibratile or wave-like.

*d.* When mitral stenosis or obstruction exists, the apex beat is peculiarly vibratile—a fine vibration or thrill, generally regarded as diagnostic.

*e.* In the several forms of feeble heart, palpation with the finger tips often fails to find the apex. The apex beat is wanting in force, short in duration, often slow, and retreating or distant in quality.

#### 4. PERCUSSION OF THE HEART.

The percussion of the heart consists essentially in mapping out :

1. The deep cardiac region.

## 2. The superficial cardiac region.

For this purpose, the use of the fingers as hammer and interposed medium are sufficient, although, if desired, the hammer and pleximeter of Winterich or Flint (see Figs. 10, 13) can be employed.

To be accurate, the percussion of the heart areas must be made with great care. The index finger of the left hand must be placed *in the intercostal space*, and must be *held firmly upon the part*; the blow must be delivered *lightly and firmly* with one or more finger tips of the right hand, thus constituting *deep percussion* as distinguished from *superficial or light percussion*. As already stated and figured (see page 98, Fig. 68), the *deep area of cardiac dulness* or *deep cardiac region* corresponds to the full size and shape of the heart and its investing pericardium. This extends in health from the upper border of the fifth rib to the lower border of the sixth, and laterally from half to three-quarters of an inch to the right of the sternum to within half an inch of the left nipple (fourth articulation of rib and cartilage).

The *superficial cardiac region* and area of *dulness* are variously stated and figured by different authors; and undoubtedly this area varies in different healthy persons according to the width and length of the chest, the degree of development of the lungs, the muscular development, and individual peculiarities.

But it is essentially a triangular space from the articulation of the fourth left costal cartilage with the sternum downwards and outwards to the union of fifth cartilage and rib, then downward and inward to sixth cartilage, and the longer side coinciding with the left border of the sternum. As stated (see page 100), it may be inclosed by the index finger and thumb of left hand and index finger of right hand.

By percussion of the heart in disease, we seek to determine:

1. Changes in the size of the heart.
2. Changes in the location of the heart.

## 1. CHANGES IN SIZE OF THE HEART AS SHOWN BY PERCUSSION.

*a.* Diminished area of cardiac dulness in rare instances denotes a small heart, as senile atrophied, fatty or atheromatous heart. As a rule, however, it is due to the overlapping of emphysematous lungs.

*b.* Increase of the deep cardiac area is usually to the left, as disease of the left ventricle is most frequent. As shown in Fig. 71, the area of dulness is carried far outside of the left nipple. This increase in size to the left is still more pronounced in advanced dila-

tation. The apex may descend if the diaphragm be depressed by co-existing emphysema, but quite as often is carried laterally outward

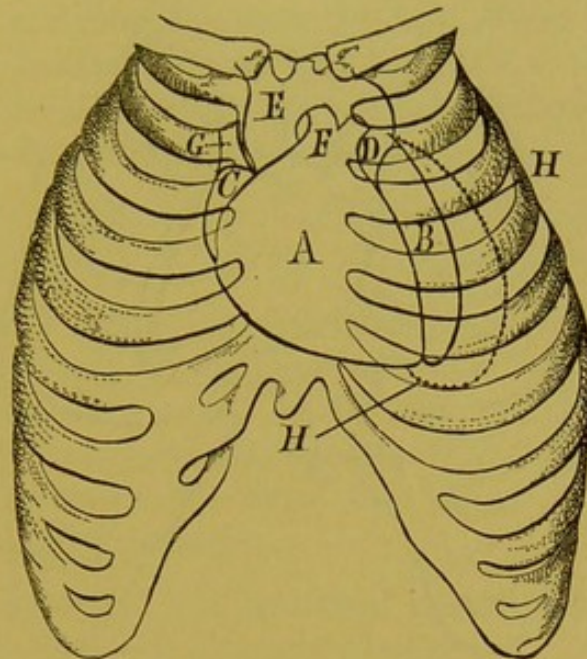


FIG. 75.—Hypertrophy of left ventricle; cardiac area of dulness increased to the left (Loomis).  
or even goes upward in extreme cases, the heart resting somewhat

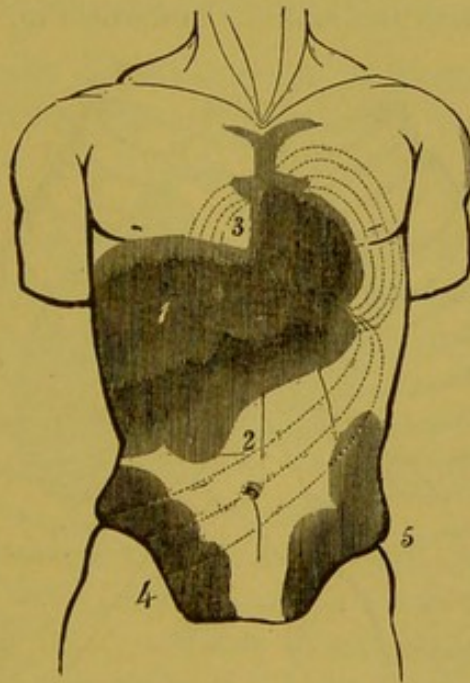


FIG. 76.—Dotted lines denote area of increased size of the heart in enlargement of the left and right sides (Piorry).

on its side, and reclining on the side of the dome-like diaphragm. Niemeyer compares the displacement of the apex of enlarged hearts

to a gliding of the heart off the side of the roof-like or dome-like diaphragm in seeking greater accommodations within the chest.

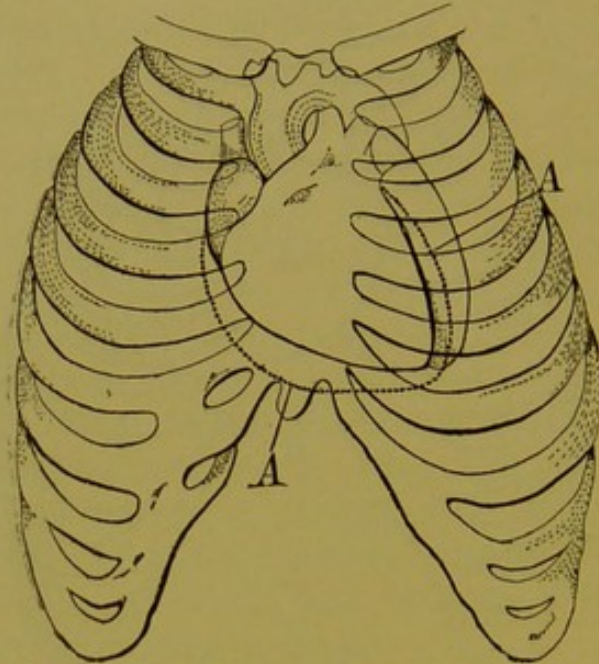


FIG. 77.—Increase of cardiac dullness to the right. Hypertrophy of the right ventricle (Loomis).

In extreme cases of hypertrophy and dilatation, the deep cardiac area extends far out to the axillary line (see Fig. 75).

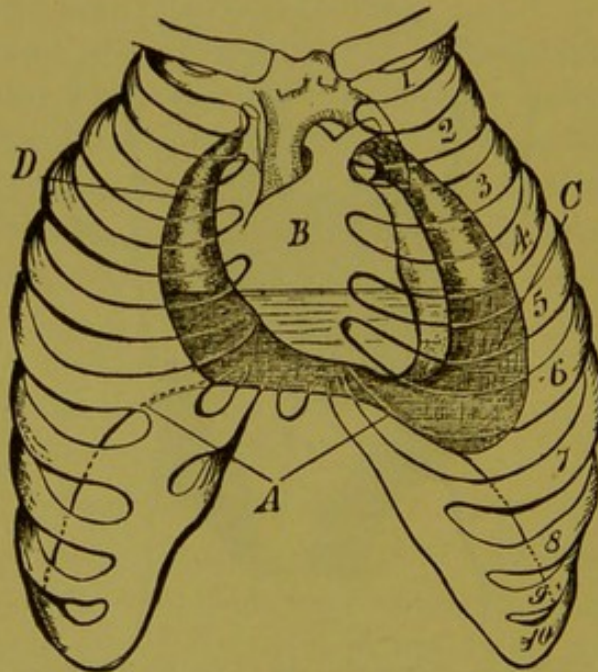


FIG. 78.—Hydropericardium.

*c.* In hypertrophy or dilatation of the right ventricle, the area of dullness is increased to the right (see Fig. 77).

*d.* When pleuritic fluid fills the left pleura, the heart may be displaced to the right, even as far as wholly beyond the right side of the sternum, and reversely, when the right pleura is full of fluid, the area of heart dulness will be carried well over to the left of the sternum. Percussion alone may not suffice to demonstrate this without the aid or confirmation of auscultatory percussion.

*e.* Pleuritic adhesions may draw the heart far over to one or other side; the area of dulness will then be correspondingly displaced.

*f.* The area of dulness in hydropericardium is peculiar. Owing to the gravitation of the fluid in the pericardium, the normal area of dulness—broadest at the base of the heart and less at the apex—is inverted, as well as enlarged, downwards and to the left. A pyriform area of dulness with broad base below is the result, and the entire area is greatly enlarged.

*g.* As already stated, the superficial area of dulness varies greatly in health. In disease it is chiefly affected by:

1. Changes in size of the heart.
2. Changes in location of the heart.
3. Expansion or contraction of adjacent lung.

1. In hypertrophy and dilatation, the triangle of superficial dulness is enlarged and swung to the left, *i. e.*, the long side no longer coincides with the left edge of the sternum, but changes with the changed site of the apex.

2. When the heart is pushed to the left or right by pleuritic fluid, or drawn by adhesions, or displaced by abdominal accumulations or growths, or lies on its side, the triangle is modified variably in size and location.

3. Emphysema of the left lung may overlap the heart and obliterate the superficial area, or, as often occurs, greatly reduce its size.

Phthisis of the left lung may so retract the borders of the lung that the heart is more fully uncovered, comes more fully in apposition with the chest-wall, and the triangular superficial area is increased. This detailed study of the deep and superficial areas is not theoretical or merely to complete a systematic classification, but often contributes positively to settle a diagnosis, as well as to complete a clinical demonstration of a case before the class.

## POSITION FOR PERCUSSING THE HEART.

The positions already described (see pp. 27, 28) and pictured (see Figs. 16, 17, 18) for examination of the chest are of service in percussing the heart. As a rule, the heart cannot be well mapped out when the patient is reclining. He should preferably stand with arms folded behind his back. If too feeble, sitting is next to be preferred, or if in bed, a semi-recumbent position supported by pillows. The heart thus is brought in contact with the anterior chest-wall.

## AUSCULTATORY PERCUSSION OF THE HEART.

To confirm the results of deep percussion of the two cardiac areas, auscultatory percussion is often of greatest value. Either Cammann's double stethoscope (see Fig. 33), or his wedge-shaped auscultator (see Fig. 56) is placed over the heart and held there by the listener, or an assistant, or the patient. The heart is then approached from every direction with a line of percussion strokes, and the points of arrival over the heart are marked. These several points are then connected by a line of ink or other marking material, and the size and contour of the heart accurately figured.

## 5. AUSCULTATION OF THE HEART.

The auscultation of the normal heart, and a familiarity with all the acoustic phenomena of its healthy action, and of the deviations from the average standards of cardiac sounds within the range of health in different individuals, are essential preliminaries to the study and proper interpretation of abnormal cardiac sounds, termed bruits or murmurs.

## AUSCULTATION OF THE NORMAL HEART.

In listening to the normal heart, we observe :

1. The frequency of the heart's action.
2. " rhythm " " "
3. " duration of the first sound.
4. " " " " rest.
5. " " " second sound.
6. " " " " rest.
7. " quality " first sound.
8. " " " second sound.

1. *Frequency of the Heart's Action.*—When sitting or standing, or walking or exercising quietly, the average adult pulse ranges from 72 to 80 per minute. It is proportionately more frequent in young adults, adolescents, and children, ranging from 80 to 90. In new-born infants it ranges as high as 112 to 124. On the other hand, in persons past 60 years, the heart beats below 70, 65, or even 60. The stableness or unstableness of the heart-beat under excitement is to be noticed. This is largely a matter of temperament. Phlegmatic and stolid persons will evidence little or no acceleration of the heart's action even upon moderate exercise, quick walking, or forced, rapid breathing, while emotional and nervous persons will exhibit sudden increase in the heart-beats, even from the influence of a physician's examination. Again, certain normal hearts are but little influenced by aggravated conditions of the patient, as constipation, gross errors of diet, alcoholism; whereas other equally healthy hearts in persons of neurotic habit are excited to a frequency of 120 or higher by slight disturbing causes, as the drinking of ice-water, flatulence, fatigue. The persistent depression of the heart's action in young adults to 50, 40, or even 30 is an occasional result of costiveness, inactive liver, acholia, cholæmia, etc., a condition of the heart usually relieved promptly by the free use of cholagogue cathartics.

2. *Rhythm of the Heart's Action.*—By the rhythm of the heart's action we understand the regular and uniform recurrence of successive cardiac beats, without intermission or irregularity. It also presupposes that the periods of the two sounds and two rests are of proper and uniformly recurring duration. It is, however, to be remembered that after 60 years of age it is not indicative of heart disease to have a uniformly recurring intermission, as an intermission every ten, twenty, or thirty beats, provided the heart's action is otherwise normal. The innervation of the heart proceeds primarily from the medullary centre, but the rhythm is also influenced by the numerous ganglia (variously estimated from three hundred to five hundred in number) imbedded in the heart substance. It is further influenced or disturbed by the great splanchnic ganglia. Hence a regular recurring intermission during a term of days, months, or even years, may be consistent with normal heart, and be the result of neurotic habit, centric nerve disorder, or of chronic defect of assimilation—notably defective liver function.

3-6. *Duration of the Two Sounds and Two Rests.*—If the entire



period of complete cardiac action be analyzed, it will be found an easy task to estimate the portion of this period occupied by the contraction of the heart, its relaxation and rest, as well as the intervals between the two acts. The first sound of the heart essentially covers the period of heart contraction or systole. The second sound occupies the first portion of the period of heart relaxation or diastole, while the second rest or period of silence completes the diastolic period.

To illustrate, let the whole period of heart action be represented by 10.

We shall then have :	Duration of the first sound, . . .	4
	“ “ “ rest, . . .	1
	“ “ second sound, . . .	2
	“ “ “ rest, . . .	3
		— 10

If the listener, still keeping his ear or stethoscope over the heart, will with the index finger of his right hand feel the radial pulse, or better the carotid (remembering that the arterial pulses are in time but slightly behind the cardiac systole), he will demonstrate :

1. That the first sound is synchronous with the systolic or contractile period of the heart.

2. That the second sound is synchronous with the diastolic or relaxing period of the heart.

7-8. *The Quality of the First and Second Sounds.*—The ear applied over the cardiac area at once recognizes two distinct, regularly recurring sounds. They have distinct and opposite characteristics. The first is long, the second is short. The first is a booming sound, the second a “click.” The first is relatively low-pitched, the second relatively high-pitched. The first sound is recognized as a sound which “develops,” *i. e.*, has distinguishable parts; thus it is lower pitched at its outset or first half, whereas on its second half it becomes a little higher in pitch and has greater volume or intensity. Thus (Walshe) the first part of the first sound is like “ou,” the second part like “bb,” the whole first sound a developed, growing or swelling sound like “oubb.” Dr. Leaming has described the first sound as “llug,” of which the formative parts would be “ll” and “ug.”

The second sound is not a complex, developed, or growing sound, with parts of differing pitch and intensity. It is a single sound, abruptly produced, of uniform pitch and intensity. It has

been variously represented, as "dup," "tup," and "ta" (as in rosetta).

The first sound is best heard over the anterior ventricular wall and apex; the second sound, over the base of the heart—the aortic and pulmonary valves. The sequence of the normal heart sounds thus may be represented by letters, and I think it of the utmost value for the student and teacher to bear these letters in mind as standards of normal sounds, and by which to estimate departures, slight or pronounced, constituting evidence of cardiac disease.

Thus Dr. Flint describes the first sound as "lub," the second as "dup," the whole heart's action as "lub-dup," "lub-dup," "lub-dup."

Dr. Leaming would describe the heart's action as "llug-te," "llug-te," "llug-te."

Walshe makes a further distinction which is by no means fanciful and will well repay any observer to study and verify. If we listen over the left ventricle, we hear the first sound distinctly as "oubb," and the second sound less distinctly as "dup;" *i. e.*, both sounds "oubb-dup."

But if we place the ear over the basic valves, we now hear the first sound less distinctly (because away from the seat of its production) as "up," and the second sound more distinctly (because over the seat of its production) as "tup." Hence the heart sounds heard in health are:

1. At the apex and over ventricle, "oubb-dup."
2. At the base, "up-tup."

As a rude way of simulating the rhythmic recurrence, general quality, and duration of the heart's sounds, I have been in the habit of representing the first sound by a sliding blow of the palmar surface of the thumb on a table, and the second sound by an immediately succeeding blow with the tip of the index finger of the same hand. These two strikes and the sounds which they elicit—the one long, gliding, booming, and resonant, the other short, abrupt, high-pitched—fairly illustrate the cardiac rhythm.

To recapitulate:

{	Cardiac sounds (Flint) "lub-dup"—"lub-dup."
	"      "      (Leaming) "llug-te"—"llug-te."
	"      "      (Walshe)
	at apex—"oubb-dup"—"oubb-dup."
	at base—"up-tup"—"up-tup."

Either of the foregoing may be taken as fairly representing the normal heart-sounds.

#### CAUSATION OF CARDIAC SOUNDS.

A correct conception of the causes of the first sound of the heart, and a recognition of its composite character, I regard as essential to a proper interpretation of various slight modifications of and departures from the normal standard so often met with in practice.

1. The first sound has been asserted by different authors to be the product wholly or chiefly of each one of the following causes :

1. Muscular sussurus and friction upon each other of the several muscular bands constituting the ventricular wall.
2. Movements of blood currents, and action of blood elements *inter se, i. e.*, wave or current sounds.
3. Friction of blood currents within the left ventricle upon the trabeculated structure of the ventricle—its columnæ carneæ and chordæ tendineæ.
4. Vibration of the closing mitral valves.
5. Vibration of the chordæ tendineæ, made tense by closure of mitral valves.
6. Vibration of the chest-wall.
7. Impulse of the heart—its impact against the chest-wall.
8. Præcordial friction, the gliding and turning of the heart within the pericardium, in its systolic movement.

Walshe regards the first sounds as in some degree due to each and all of these causes—constituting them the factors of a composite first sound. Flint regarded the impact of the heart and vibration of the valves as chief causes, and Leaming ascribes the first sound as musically produced by vibration of the valves and chordæ. The author regards the composite or complex origin of the first sound, as held by Walshe, to be substantiated by many temporary functional heart-sounds, induced by disturbances of one or more of the factors. Irregular action of the muscular structures of the heart in chorea develops a temporary murmur, which would strengthen the belief that muscle friction is a factor of heart-sound. In anæmic and hydræmic cases, there is often developed a functional apex murmur which passes away when the blood becomes normal.

2. The second sound is also composite, due to the synchronous closure of the aortic and pulmonary valves.

### AUSCULTATION OF THE HEART IN DISEASE.

1. *In Functional Diseases of the Heart.*
2. *In Organic Diseases of the Heart.*

#### 1. FUNCTIONAL DISEASES OF THE HEART.

1. Disturbed action incident to general anæmia, causing hæmic, or anæmic murmurs.

2. Neuroses of the heart.	{	Hyperæsthetic,	{	<i>Intermission,</i> <i>Irregularity,</i> <i>Palpitation,</i> <i>Spasm.</i>
	{	Atonic,	{	<i>Cardiac Tremor,</i> <i>Syncope,</i> <i>Paralysis,</i> <i>Angina Pectoris.</i>

#### 2. ORGANIC DISEASES OF THE HEART.

- |                                |                           |
|--------------------------------|---------------------------|
| 1. <i>Anæmia.</i>              | 11. <i>Atheroma.</i>      |
| 2. <i>Congestion.</i>          | 12. <i>Hemorrhage.</i>    |
| 3. <i>Endocarditis.</i>        | 13. <i>Embolism.</i>      |
| 4. <i>Pericarditis.</i>        | 14. <i>Aneurism.</i>      |
| 5. <i>Myocarditis.</i>         | 15. <i>Rupture.</i>       |
| 6. <i>Hydro-pericardium.</i>   | 16. <i>Injuries.</i>      |
| 7. <i>Atrophy.</i>             | 17. <i>Malformations.</i> |
| 8. <i>Hypertrophy.</i>         | 18. <i>Syphilis.</i>      |
| 9. <i>Dilatation.</i>          | 19. <i>Tubercle.</i>      |
| 10. <i>Fatty Degeneration.</i> | 20. <i>Cancer.</i>        |

### FUNCTIONAL DISEASES OF THE HEART.

#### 1. ANÆMIC MURMURS.

In anæmia, the blood is in an impoverished, watery condition. Examples of profound anæmia are often seen in young girls who just after puberty become very pale, even to their lips and gums, have palpitation of the heart, and difficult breathing on slight exertion. In such persons the motion of the blood *inter se* produces in the heart and blood-vessels a soft blowing sound, which may also

range in intensity from a gentle to a very violent murmur; this anæmic or hæmic murmur, however, usually lacks the friction, harsh grating, sawing character of organic murmurs. It is best heard at the base of the heart, at the junction of the third left cartilage with the sternum, and is also heard throughout the large arterial trunks, the innominate and subclavian arteries, and down the sternum to the tip of the xyphoid cartilage. The sound is carried simply by convection. In cases of extreme anæmia, there are also venous murmurs in the neck—a continuous humming, called “bruit du diable.”

#### DIAGNOSIS OF ANÆMIC MURMURS.

1. Character—soft and blowing.
2. Originated at the base of the heart and carried along the course of the large vessels.
3. Occur in anæmic persons.
4. Loudest during or after violent exercise.

#### 2. NEUROSES OF THE HEART.

Disorders due to nerve causes.

Nerve power of heart.—The heart is an involuntary muscle, which receives a constant supply of motor power from the pneumogastric nerve, and the superficial and deep cardiac ganglia.

All over the surface of the heart, and in its substance, are numerous little ganglia, connected together and constantly supplying stimulus for the heart's action and rhythm.

#### IRREGULARITY AND INTERMISSION.

The most common of all causes of irregularity, intermission, and palpitation is indigestion. Irritation of one branch of the pneumogastric nerve—the gastric—disorders the other branches, and produces palpitation and dyspnœa.

Excessive use of tea and coffee, and especially of tobacco, is a cause; the latter acts not only by producing dyspepsia through excessive action of the salivary glands, but directly through the nervous system.

Alcoholic habit causes first a violent, then an irregular heart action. Fright, excitement, excessive mental effort, great fatigue from overwork, or absence of sleep will give rise to irregularity in the heart's action.

It not infrequently happens that an organic murmur coexists with great irregularity and intermission. The tendency is for the physician to view the case with alarm, and estimate the case as critical, ascribing the cardiac irregularity to the organic changes. Yet rest, food, digitalis, and strychnia entirely remove the irregularity, leaving only the murmur. It is then evident that the same toxic agents, emotional and depressing influences, which disturb a normal heart, still more disturb a diseased heart. In extreme cases of cardiac irregularity, therefore, both with and without the presence of murmurs, it is necessary to defer the diagnosis as to an organic lesion and actual weakening of the heart muscle until the heart has been rested, the circulation equalized, cardiac and general tonics employed, and the patient examined under various conditions of rest, exercise, etc.

#### SPASM.

The action of the heart in a child who has chorea is typical cardiac spasm. In this condition is often heard an intra-ventricular or functional apex murmur. It is produced by irregular contractions of the columnæ carneæ and strata of cardiac muscle, and is heard either as a modification of the first sound or at the completion of the second sound at the apex. Distinct reduplication of the first and also of the second sound may thus result from a synchronous action of the different portions of the heart's structure.

#### TREMOR.

When a person has indulged in dissipation until the nervous system is exhausted, there will be a tremulous action of the heart discernible by palpation.

#### SYNCOPE.

Syncope is that form of fainting which is due to failure of the heart's action. The cessation may be temporary, with temporary cerebral anæmia, from failure of the heart to send blood to the brain, or the cardiac relaxation may be complete, and death ensue. The failure to contract is usually due to deficient nerve force. If merely transient, its cause being a temporary derangement of the nerve centres, we have vertigo, unconsciousness, feeble action of the heart, or action altogether inappreciable, face ashen or pallid, and surface cool; after a brief time the heart resumes its work. If syncope continue a long time, a heart clot may form; this will give rise to a murmur

for a considerable length of time; and it may lead to embolism, occurring months later.

#### PARALYSIS OF THE HEART.

Shock or injury to the sympathetic nerve may be so great that it never reacts to supply stimulus for the heart's action.

Diphtheria, cerebro-spinal meningitis, typhus fever, and some other diseases occasionally cause paralysis of the heart.

#### ANGINA PECTORIS

is placed among neuroses because its lesion is not known. Its pathology is supposed to be in many cases embolism or occlusion of the coronary vessels. All its symptoms may occur in organic disease.

#### THE ORGANIC DISEASES OF THE HEART.

The organic diseases of the heart are comprehensively considered in the following synopses. The pathology bears upon diagnosis, and the prognosis and treatment so often have to be revised and modified in relation to ultimate diagnosis that they have in each disease been included in its consideration.

## CHAPTER VIII.

### SYNOPSIS OF HEART DISEASES.

#### CARDIAC HYPERTROPHY.

Definition.	Enlargement of the heart as a whole, or of the walls of any one of its cavities—the result of increased effort of the heart.
Pathology.	Hypertrophy of left ventricle more often than of right ventricle; rarely auricles. Increase of weight, size, thickness of walls. Concentric hypertrophy: Thickening of walls at expense of cavity. Eccentric hypertrophy: Hypertrophy with dilatation. Due to hypertrophy of existing muscular fibres. Possibly new fibres developed. Hypertrophy, at first a conservative process, changes to dilatation and fatty metamorphosis after long standing.
Causes.	Of left ventricle: Aortic valvular lesions. Mitral valvular lesions. Atheroma of aorta and arteries. Obstructed circulation in viscera. Pericardial adhesions. Habitual violent work or exercise. Of right ventricle: Emphysema and other chronic lung disease; obstructive pulmonary valvular disease. Mitral lesions. (Indirectly.)
Symptoms.	Full, strong pulse in hypertrophy of left ventricle. Fulness of carotids and temporals. Liability to congestion of brain if the heart is over active. With hypertrophy of right ventricle, a slow venous circulation, dyspnoea, coexisting lung disease.
Physical Signs.	Inspection.—Fulness of præcordial region, and heaving apex beat. Apex lower and outward—hypertrophy of left ventricle. Mensuration.—Nipple carried outward; increased distance from third to sixth rib. Palpation.—Violent apex beat, and changed location. Percussion.—Increased area of dulness to the left, and down, for the left ventricle, to right of sternum for right ventricle. Auscultation.—Valvular murmurs of the lesion causing hypertrophy. The accentuated first sound and the sharp, loud, abrupt click of the second sound.
Diagnosis.	Præcordial fulness: increased area of dulness; full, strong pulse; strong cardiac impulse; displaced apex; valvular lesion; intensified normal second sound, due to aortic resiliency. Often associated hypertrophy of aorta and arteries of neck.
Prognosis.	In simple hypertrophy good, if life be regular and no increase of lesion. Bad, if hypertrophy is associated with dilatation. Danger of cerebral congestion; dilatation, fatty degeneration, etc.
Treatment.	Quiet life; light work; temperance; plain diet. Keep excretion free. Avoid causes of increased lesion.



## CARDIAC DILATATION.

Definition.	Enlargement of the heart, or one or more of its cavities, with thinning of their walls.
Pathology.	Increase of size of heart; cavities increased in size and capacity; walls thin, often in state of fatty degeneration; lesion of mitral or aortic valves as a rule; valves may be separated secondary to dilatation; rarely hypertrophy co-exists, second in order, and conservative; more often walls are thin, even as parchment (rare).
Causes.	Mechanical internal dilating power of blood during diastole (rest—relaxation of heart). Usually due to mitral regurgitation or aortic regurgitation; also due to softening, relaxation, fatty degeneration of heart-walls, in acute fevers of low malignant type.
Symptoms.	Weak pulse—often intermittent, irregular; slow, imperfect venous return circulation; dyspnoea, bad digestion; passive congestion of lungs, kidneys, and liver; cold extremities; pale or cyanosed face; liability to syncope; œdema of lungs; general anasarca.
Physical Signs.	Præcordial fulness; weak, heaving, wavy motion over heart; not a strong defined impulse; nipple carried outward; increased distance from third to sixth rib; increased area of dulness; heart sounds weakened; loud abnormal sounds indicating mitral or aortic regurgitation. May be coexistent mitral direct murmur and thrill at apex.
Diagnosis.	Weak pulse; weak, wavy impulse; large area of dulness; regurgitation, dyspnoea; attacks of syncope; intermission and irregularity of pulse; general weakness; secondary disorders of other organs.
Prognosis.	Always bad.
Treatment.	A quiet life; avoid heavy work, active exercise, excitement, dissipation, and indigestion. Preserve full action of bowels, kidneys, and skin. Improve the general health by plain food, quinine, strychnine, and iron. Regulate the heart's action by digitalis or convallaria. Combat cardiac failure by alcohol, morphine, Hoffman's anodyne, nitrite of amyl.

## FATTY HEART.

## QUAIN'S DEGENERATION.

Definition.	A destructive metamorphosis of the muscular structure of the heart. (Distinguished from mere deposition of adipose on the heart of obese persons.)
Pathology.	Heart—pale yellow, soft, small (unless dilatation coexist). Striæ of muscular fibres grow faint, disappear; replaced by fatty granules, oil globules, and atheroma. Sequel of myocarditis.
Causes.	Indolent life; rheumatism, gout; alcoholism; old age; acute fevers of low type; climacteric changes; atheroma or embolism of the coronary arteries.
Symptoms.	Weak circulation; feeble pulse; cold extremities; pallor, cyanosis; weak heart impulse; liability to syncope; cerebral anæmia. Weak heart-sounds, intermission, irregularity; dyspnoea, sighing, irregular breathing (Cheyne's symptom). Coexisting arcus senilis, and atheroma of arteries in old people.
Physical Signs.	No præcordial prominence; no perceptible apex beat. May be reduced area of dulness; sounds feeble, often distant. May be aortic or mitral murmurs due to atheroma on valves.
Diagnosis.	Age, general health, habits, arcus senilis, weak pulse, often syncope, faint heart-sounds. Often contracted liver and kidneys.
Prognosis.	Bad. Liability to death by syncope. Milder cases—impaired strength, general feebleness and emaciation.
Treatment.	Arrest progress by good diet, temperance, tonics. Avoid syncope; avoid dilatation; avoid sudden or great effort. Treat syncope by stimulants.—Alcohol, ammonia, Hoffman's anodyne, nitrite of amyl, etc.

## ENDOCARDITIS.

Definition.	Inflammation of the endocardium.—A local disease usually secondary to and complicating overloading of the blood with irritant morbid material.
Pathology.	Removal of epithelium.—Surface hazy, granular; congestion of subserous vessels; development of villi; infiltration of tissue producing roughened, thickened, villous surface, or masses (vegetations). May be hair-like processes, or pedunculated polypoid bodies. Inflammatory products may be re-absorbed or remain; may be fibrous or become calcareous; may cause atrophy, hypertrophy, distortion, retraction, etc., of valves. Polypoid masses may be detached and cause embolism of other viscera.  Endocarditis usually on the left side of the heart only. Endocarditis of foetus in utero on the right side of the heart. Vegetations may grow from the fibrin of the blood.
Causes.	Rheumatism, Bright's disease, scarlatina. Rarely typhus, typhoid, variola, rubeola, diphtheria, sepsis.
Symptoms.	Often none. May be dyspnoea, præcordial pain, irritable action of the heart. Often not diagnosed.
Physical Signs.	Sounds induced by valvular lesions. Aortic direct friction murmur; mitral murmurs. They disappear if absorption results; or increase if the lesion extends.
Diagnosis.	By daily auscultation during the course of causative diseases, to detect friction murmurs.
Prognosis.	No immediate danger. Danger of valvular disease.
Treatment.	Treatment of primary disease. Subsequent use of quinine, iodide of potassium, and mercury to promote absorption.

## ULCERATIVE ENDOCARDITIS.

Definition.	Inflammation of cardiac valves tending to disintegration. Probably two forms—one due to a specific microbe; another, a chronic recurring inflammation in previously thickened valves.
Pathology.	In the non-specific form, the valves are the seat of old, fibroid vegetations which are poorly vascularized, and with the recurrence of the inflammatory process these become necrosed, either ulcerating or sloughing en masse. In the specific form, there are specific germs present, susceptible of culture and reproducing the disease when inoculated. The pathology includes the emboli and septic foci in other organs, resulting from carrying the débris of intra-cardial ulceration into the circulation.
Etiology.	1. Recurring rheumatic endocarditis, syphilitic endocarditis, and arthritis deformans. 2. Specific microbes.
Symptoms.	Usual symptoms of extreme endocarditis, viz., excited cardiac action, præcordial discomfort, dyspnœa, orthopnœa, pulsation of the arch of the aorta and vessels of the neck. Superadded are recurring chilliness or chills with exacerbations of temperature, indicative of embolic or septic invasions or plugging of arteries. Hemiplegia from cerebral embolism, loss of pulse in an extremity, local spots of anæsthesia and ecchymosis. Characteristic septic temperature line, failing strength, exhaustion.
Physical Signs.	Usually pronounced cardiac murmurs, most often aortic and frequently double. Cardiac area increasing from dilatation. Apex impulse growing feeble and diffused.
Diagnosis.	By coincidence of cardiac murmurs, cardiac enfeeblement, pulsating vessels, continued elevated and variable temperature, long period of illness, evidences of embolism and sepsis, local parts and patches of ecchymosis and petechiæ.
Prognosis.	Bad in all forms. Non-specific cases may recover. Syphilitic cases, even extreme, may do well under special treatment. Specific cases always bad.
Treatment.	Rest in recumbent position. Cardiac support—digitalis, convallaria, caffeine. Control temperature by antipyrin or quinine. Salicin valuable when rheumatism is present. Iodide of potassium and mercurial baths for syphilitic form. In septic form, internal antisepsis—sulpho-carbolates, etc. In all cases vigorous diet, milk and stimulants.

## PERICARDITIS.

Definition.	Inflammation of the serous pericardium.—A local inflammation rarely idiopathic or traumatic; usually the result of overloading the blood with irritant, morbid matter.
Pathology.	Congestion of subserous vessels; removal of epithelium; surface hazy, granular; reddened patches; development of granulations; vascular villi; friction of surfaces; liable to adhere; patches of complete union; thin bands, fibres, etc., due to contact of granulating surfaces. Absorption may be complete; may leave white patches on heart, hairy processes, fine or coarse adhesions. Serum compresses heart, distends pericardium. Serum absorbed, surfaces again in contact. Myocarditis may coexist.
Causes.	Rheumatism, Bright's disease, scarlatina, other acute fevers, sepsis; rarely traumatic—rarely idiopathic.
Symptoms.	Præcordial pain, tenderness; often pain in left shoulder and arm; flushed face; throbbing temporals; rarely delirium. Full, bounding, cord-line pulse.
Physical Signs.	Early.—To-and-fro pericardial friction murmurs; heart-sounds increased, apex beat violent, pulse full and frequent. With effusion.—Fulness of præcordial region; increased area of dulness; friction sound lost; heart-sounds feeble; may be distant. Later.—Muffled friction may return; normal action of heart and normal area of dulness.
Diagnosis.	To-and-fro friction; area of dulness. [Hydro-pericardium has no friction sound, no fever, and coexists with general dropsy.]
Prognosis.	Generally good. Pericardial adhesions may cause hypertrophy.
Treatment.	Treat primary disease. Locally—anodyne, alkaline fomentations for pain. Lower frequency of pulse.—Aconite, digitalis, veratrum. Later.—Quinine, iodide of potassium, and mercurials for absorption. For extensive effusions, aspirate the pericardial fluid with the "dome" trocar.

## HYDROPERICARDIUM.

Definition.	As distinguished from pericarditis with effusion, this is a non-inflammatory accumulation of serum in the pericardial sac, as a rule associated with general anasarca and serum in other cavities.
Pathology.	Negative; no inflammatory process, and serum clear or straw-colored, free from flocculi of lymph.
Etiology.	Usually a watery condition of blood; advanced anæmia, hydræmia, or chlorosis. Frequently advanced albuminuria. Scurvy, pernicious anæmia, and leucocythæmia are causes. More often results from failing circulation from cardiac enfeeblement (dilatation, valvular incompetency), with associated venous retardation, and general lessened nutrition.
Symptoms.	Dyspepsia, orthopnoea, vertigo, syncope, præcordial fulness, distress or pain (dull, cyanosed face, weariness, languor, sluggish intellect, feeble pulse, cool surfaces. Digestion poor; bowels torpid; kidneys inactive.
Physical Signs.	Inspection.—Præcordial fulness, also absence of apex impulse and general præcordial motion. Palpation.—Absence of cardiac impact and apex impulse. If fluid is abundant, no cardiac motion, or exceptionally the reverse, pronounced, wave-like cardiac thrill. Percussion.—Area of cardiac dulness increased (superficial area) and broadened in apex region. Tendency to pyriform cardiac area of dulness. Auscultation.—Heart sounds greatly enfeebled and distant.
Diagnosis.	Coexistence of general œdema, fluid in pleuræ and peritoneal cavity. Increased area of dulness, feeble heart-sounds, dyspnoea, feeble pulse.
Prognosis.	Bad as a complication of primary disease and dropsy elsewhere.
Treatment.	Sustain the heart by brandy, ammonia, musk, Hoffmann's anodyne and liberal diet. Hasten absorption by iodide of iron and iodide of potassium. Use laxatives or drastics carefully. In grave cases aspirate the pericardium.

ENUMERATION OF THE VALVULAR DISEASES OF THE HEART.

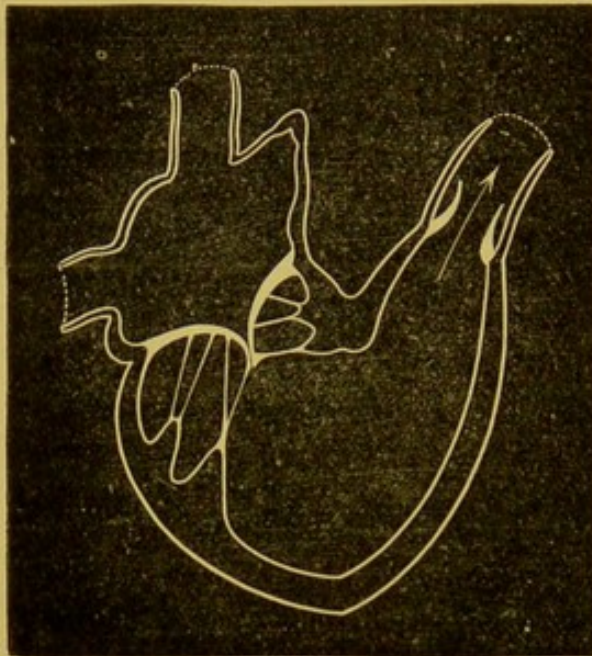


FIG. 79.—Left ventricle in systole (Dalton).

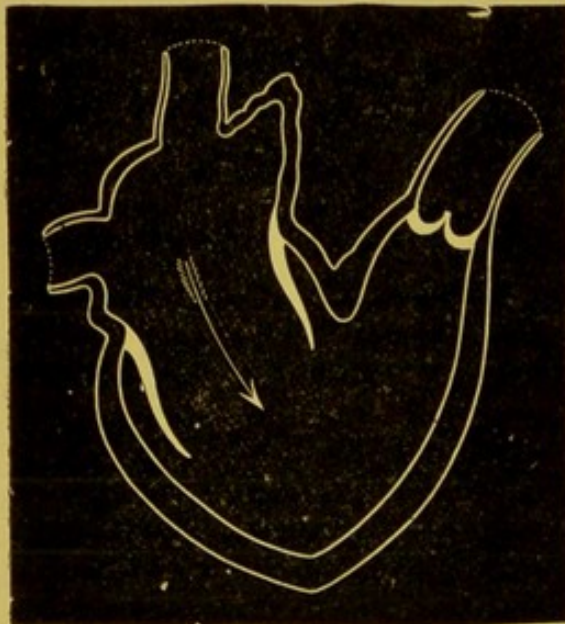

FIG. 80.—Left ventricle in diastole (Dalton).

(1.) SYSTOLIC.

(a.) Left side of the heart:

1. *Aortic obstruction*.—Obstacle to outward flow of blood through aortic orifice.
2. *Mitral regurgitation*.—Leakage of blood through mitral valve into left auricle.

(b.) Right side of heart:

1. *Pulmonary obstruction*.—Obstacle to outward flow of blood through pulmonary orifice.
2. *Tricuspid regurgitation*.—Leakage of blood through tricuspid valve into right auricle.

(2.) DIASTOLIC.

(a.) Left side of heart:

1. *Aortic regurgitation*.—Leakage of blood through aortic orifice into left ventricle.
2. *Mitral obstruction*.—Obstacle to flow of blood from left auricle to left ventricle.

(b.) Right side of heart:

1. *Pulmonary regurgitation*.—Leakage of blood through pulmonary orifice into right ventricle.
2. *Tricuspid obstruction*.—Obstacle to flow of blood from right auricle to right ventricle.

ENUMERATION OF THE CARDIAC MURMURS.

FUNCTIONAL.	
(1) Functional.	<p>1. <i>Systole of heart</i>—</p> <p>a. Anæmic murmurs; blowing in quality; heard at base of heart and diffused over chest, especially in course of vessels.</p> <p>b. Intraventricular murmur, heard at early part of systole at apex; "modified first sound," "smoker's murmurs," etc.</p> <p>2. <i>Diastole of heart</i>—</p> <p>Reduplicated second sound heard at aortic and pulmonary orifice; due to nervous action of two sides of the heart; resiliency of aorta and pulmonary arteries unequal, aortic and pulmonary valves do not close synchronously.</p>
ORGANIC.	
(2) Organic.	<p>1. <i>Systole of heart—Left ventricle</i>—</p> <p>1. <i>Obstructive</i>.—Obstruction at aortic valves friction, etc.; heard at aortic orifice and over arch of aorta (at third left and second right sterno-costal articulation.)</p> <p>2. <i>Regurgitation</i>.—Insufficiency of mitral valve; regurgitation of blood into left auricle; heard at apex in front. May also be heard around left side and behind in the left vertebral groove, from fifth to eighth ribs.</p> <p><i>Right ventricle</i>—</p> <p>1. <i>Obstructive</i>.—Obstruction at pulmonary valves; friction murmur, superficial, intense, localized over valve—third left sterno-costal articulation, may exist behind second left cartilage.</p> <p>2. <i>Regurgitant</i>.—Insufficiency of the tricuspid valve; heard at mid-sternum, opposite third or fourth cartilages.</p> <p>2. <i>Diastole of heart—Left ventricle</i>—</p> <p>1. <i>Obstructive</i>.—Obstruction at mitral valve; friction murmur at apex only. Præsystolic, <i>i. e.</i>, in latter part of diastole.</p> <p>2. <i>Regurgitant</i>.—Insufficiency of aortic valves; murmur heard at base, and conveyed down sternum to apex of heart replaces second sound.</p> <p><i>Right ventricle</i>—</p> <p>1. <i>Obstructive</i>.—Obstruction at tricuspid valve; friction of blood coming from auricle to ventricle; murmur heard over central cardiac area.</p> <p>2. <i>Regurgitant</i>.—Insufficiency of pulmonary valves; heard over pulmonary valves and down right side of heart.</p>

ANÆMIC MURMURS.

Where occur.	<p>Occur in anæmic women mainly.</p> <p>" " feeble and aged.</p> <p>" " pregnancy.</p> <p>" " course of blood disease.</p> <p>" " convalescence.</p>
When heard.	<p>Heard during systole only.</p> <p>" widely diffused over chest.</p> <p>" loudest at base of heart.</p> <p>" over arch of aorta and (transmitted by convection) over thoracic aorta down side of sternum to zyphoid cartilage; over innominate, carotids, subclavian.</p> <p>" loudest when patient is fatigued, active, or excited.</p> <p>" less when quiet.</p> <p>Diminished by tonic treatment, digitalis, rest.</p>
Character.	<p>Character.—Soft, blowing, or loud violent systolic murmur at base. May have grating, filing, rasping, sawing, musical qualities.</p> <p>Distinguished from organic by absence of friction, and by test of time and treatment.</p> <p>Accompanied with symptoms of anæmia, debility, indigestion, hysteria, etc.</p>

PERICARDIAL MURMURS.

	<p>Pericardial murmurs, when typical, are "double," "to-and-fro," "see-saw" sounds synchronous with the heart's action. They may in quality be friction-like, grating, rasping, sawing, humming, singing; heard over the præcordial area, and apparently near the ear of listener. Single friction sounds, either single or double, may be pericardial or "pleuro-pericardial."</p>
--	---



## EXTRA-CARDIAC MURMURS.

These are faint, puffing, or blowing sounds, synchronous with the heart's action, but suspended with suspended breathing; also termed "cardio-respiratory" murmurs; variously explained as due to pressure of the heart in motion on the overlapping edges of the lungs, to pleuro-pericardial adhesions, etc.

## CARDIAC MURMURS.

TABLE OF SYNONYMOUS TERMS USED BY DIFFERENT AUTHORS.

Systole of Heart.	1. At Aortic Orifice. Aortic Systolic. " Obstructive. " Direct.	Diastole of Heart.	3. At Aortic Orifice. Aortic Diastolic. " Regurgitant. " Insufficient. " Indirect.
	2. At Mitral Orifice. Mitral Systolic. " Insufficient. " Regurgitant. " Indirect.		4. At Mitral Orifice. Mitral Diastolic. " Obstructive. " Direct. " Præsystolic.

The most frequent and important organic murmurs to recognize are :

1. Aortic systolic (obstructive, direct).
2. Mitral systolic (regurgitant, indirect).
3. Mitral præ systolic (obstructive, direct). Very much less frequently we meet with
4. Aortic diastolic (regurgitant, indirect).

The above are all murmurs of the left side of the heart, products of endocarditis, atheroma, traumatism, and resulting from rheumatism, uræmia, and acute diseases.

Of the murmurs of the right side of the heart, two are definitely recognizable, but very rare, viz. :

5. Pulmonary systolic (obstructive, direct).
6. Tricuspid systolic (regurgitant, indirect).

These two murmurs are so infrequent that the clinical presump-

tion, when physical signs are not conclusive, is always in favor of the origin of the murmurs on the left side of the heart.

7. Tricuspid præ systolic (obstructive, direct) is pathologically and theoretically possible, but not likely to be diagnosed.

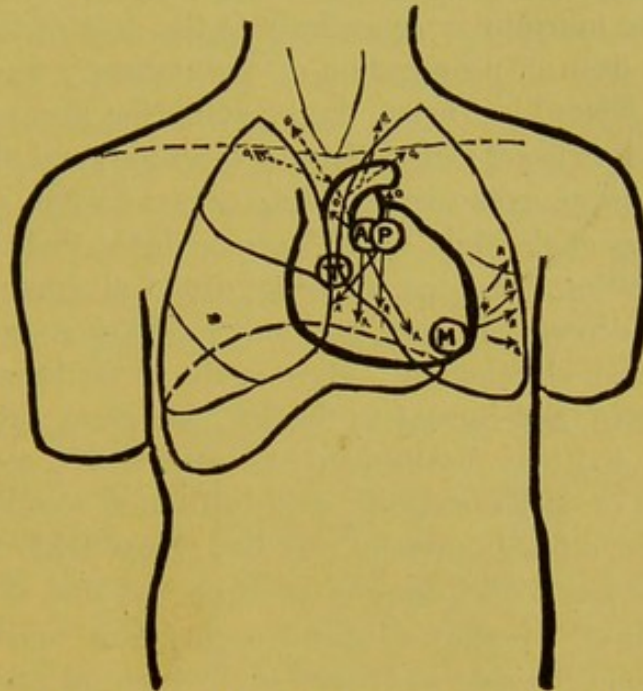


FIG. 81.—LOCATION AND LINE OF PROPAGATION OF HEART MURMURS.

A, aortic direct, up into aorta and vessels ; AR, aortic regurgitant ; P, pulmonic direct up to left second cartilage ; PR, pulmonic regurgitant down over right ventricle ; T, tricuspid area ; M, local, mitral direct ; M, around sides and back, mitral regurgitant.

8. The pulmonary diastolic (regurgitant, indirect) is likely to be detected only when coexistent with well-defined pulmonary systolic murmur.

#### ON LOCALIZING MURMURS.

It is desirable, in localizing the point of origin of murmurs as well as their line of conduction or propagation, to bear in mind the location of the heart as a whole, the direction of its vertical and transverse axes (*i. e.*, whether it is normally pendent or is turned on its side, or deflected to the right or left), since with a change of location the line of propagation is changed. Hence palpation for the apex beat, and mapping out of the deep and superficial cardiac regions by percussion, must have preceded auscultation. Thus an aortic regurgitant murmur should be propagated downwards from the site of the aortic valve to the apex beat. But if, by dilatation of the

left ventricle, the apex is carried far outside of the nipple or even to the axillary line, then the base will have been dragged down, and the murmurs heard at least one space lower than normal, viz., at the fourth costal junction with the sternum, and be propagated, not downwards, but obliquely outward and downwards or almost outwards. As a whole, the murmur is so entirely to the left of the sternum as to be over the line of propagation of pulmonary regurgitation, yet the proofs of dilated left heart, the presumption always in favor of disease of the left heart rather than of the right, and the absence of epigastric pulsation, cyanosis, pulsating cervical veins, and other evidences of disease of the right heart, leave no doubt that the murmur is aortic regurgitation. So, too, an aortic direct murmur may seem to be propagated directly upward, and may establish a strong presumption of pulmonary obstruction. Here again, if the heart is hypertrophied and dilated, and carried to the left, the great artery—aorta—is also dilated, and may disseminate the obstructive sound. Unless other evidence of aortic stenosis, as reduplicated second sound, cyanosis, etc., exist, a basic murmur can, in a large majority of instances, be set down as aortic, despite its origin and line of conduction.

The question of whether a mitral regurgitant murmur must be conducted around the side and heard in the back may be answered as follows:

1. A mitral regurgitant murmur is always systolic, and heard at the apex.

2. It may or may not be transmitted by the chest-wall around to the axillary line or beyond. Usually it is so transmitted.

3. It may also appear behind in the left vertebral groove, between the fifth and eighth ribs. When thus heard, it conclusively confirms the mitral regurgitant origin of the murmur, rather than mitral diastolic, mitral præ systolic, or functional apex murmurs. But its absence does not in the least disprove the murmur being in part organic and mitral regurgitant. It is pretty generally conceded that the murmur, when heard in the left vertebral groove, does not get there by conduction around the side, but rather by convection, or transmission by the regurgitant current of blood up through the insufficient mitral valve into the left auricle (which is usually dilated), and back through solid structures to the vertebral groove.

## COEXISTENCE OF SEVERAL MURMURS.

It is not uncommon for two, three, or even four murmurs to co-exist. If the heart be pretty nearly normal in position, size, and strength, and its rhythm be regular, then the several distinct murmurs can be recognized. But when extreme dilatation of the part, together with displacement and marked irregularity and intermission of the organ, all coexist with these several murmurs, the problem becomes most difficult. A double mitral and single aortic direct often coexist, less often double mitral and double aortic, and occasionally double aortic and single mitral. Whether murmurs in the right side of the heart can be recognized in the presence of the louder murmurs of the left side, the author doubts. They certainly can exist, but it is doubtful if they can be heard.

## PROPAGATION OF HEART MURMURS IN GREAT VESSELS.

Heart murmurs are often heard with astonishing clearness over the arch of the aorta, the innominata, the carotid and subclavians, as well as over either lung apex, and behind, above and over the scapulæ. This is chiefly due to the fact that, with hypertrophy and dilatation of the heart accompanying the louder murmurs, there is usually a state of dilatation of the great vessels and a ready propagation of the heart-sounds.

## ON DOUBLE BASIC MURMURS.

When basic murmurs are double, the question always must be answered, are these murmurs :

1. Cardiac.
2. Pericardial.
3. Aneurismal.

The pericardial murmurs can be excluded by the absence of the history of pericarditis, absence of præcordial tenderness, and absence of peculiar friction-like, "see-saw" quality, and "nearness to ear" which characterizes them.

The aneurismal murmurs usually are more to the right or higher up, are peculiarly booming in character, have associated thrill and pressure evidences of aneurism, and often the coexistent heart-sounds can be heard over the heart in situ or displaced. (See Aneurism.)

Finally, it may be stated that in all complicated cases of cardiac or extra-cardiac murmurs, long and careful study, repeated consecu-

tive examinations, with time for the heart to rest and regain equilibrium, are requisite for a final diagnosis.

### ANEURISM OF THE THORACIC AORTA.

1. Of ascending arch within pericardium.
2. Of junction of ascending and transverse arch.
3. Of transverse arch.

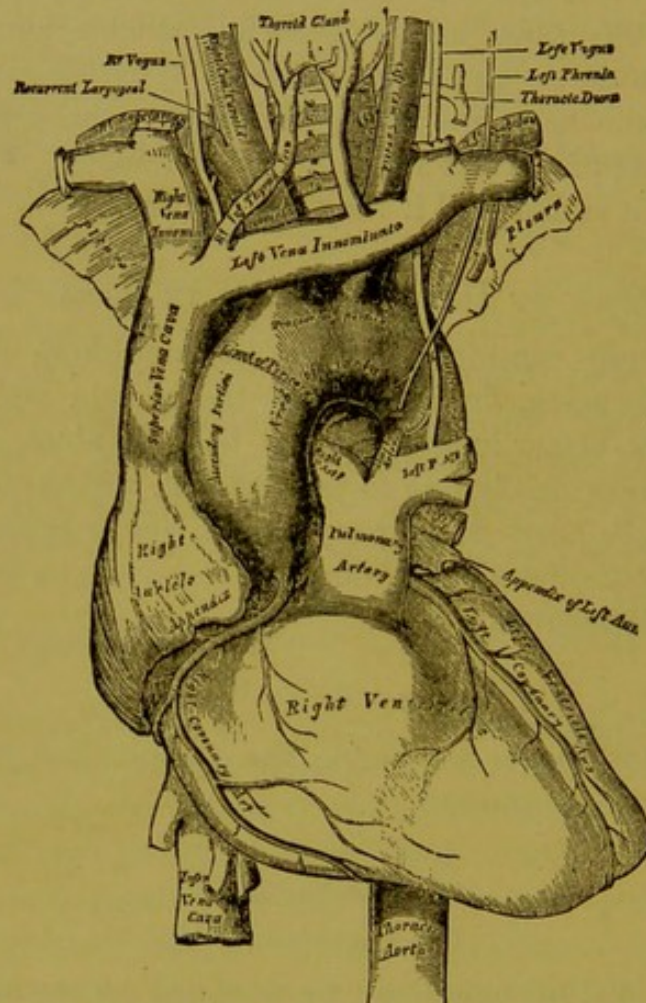


FIG. 82.—Relation of several parts of aorta to surrounding structures (Gray).

4. Of descending arch.
5. Descending aorta within thorax.

**DEFINITION.**—Aneurism—properly a local dilatation of an artery, forming a tumor containing blood and laminated fibrin. Its walls are the remnants of the vessel-walls, and the investing fibrous sheath, usually much hypertrophied.

**PATHOLOGY AND ÆTIOLGY.**—Usually caused by endarteritis, atheroma and calcification of the wall of an artery, and atrophic weak-

ening; syphilis, rheumatism, gout, and local injury lead to these degenerations. Cardiac force then dilates the weakened part. Violent exercise, and vocations causing extreme and continued vascular and intracardiac tension are especially liable to produce aneurism.

Aneurism may be fusiform, sacculated, or dissecting. The cavity may be full of fluid blood, or be partially or wholly filled with laminated fibrin.

An aneurism of the aorta, by pressure, may set up inflammation of adjacent parts, as of apices of lungs, pleura, bronchi. It may

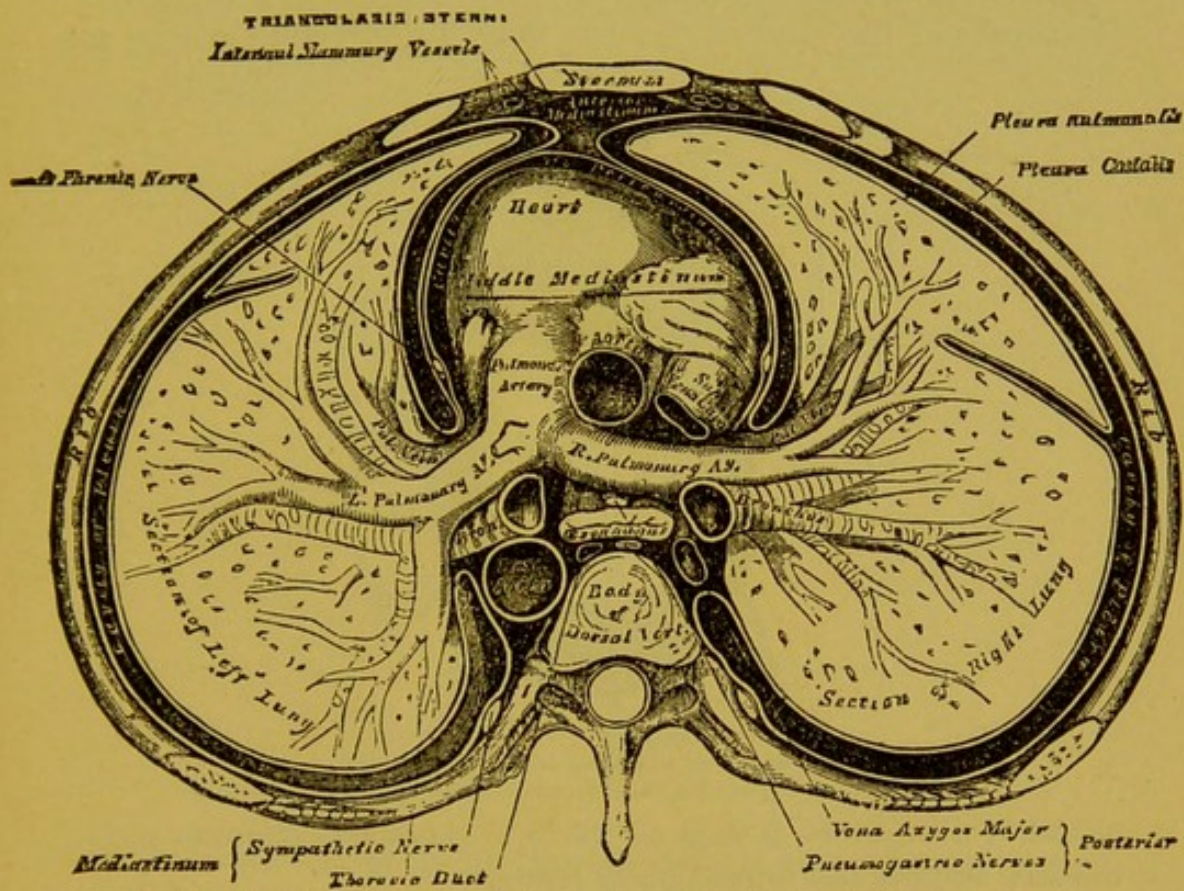


FIG. 83.—Showing relation of aorta to œsophagus, bronchi, heart, and valves (Gray).

cause absorption of ribs and costal cartilages anteriorly, or of vertebræ posteriorly, may compress the trachea, bronchi, œsophagus, vena cava ascendens, innominate vein. The sac may rupture into the pleura, trachea, bronchi, pericardium—or externally, beneath or through eroded integument.

**SYMPTOMS.**—Aneurism of the ascending portion of the aorta, as a rule, produces irritation of the apex of the right lung and its investing pleura, evidenced by cough, expectoration, local discomfort, dyspnoea, local lancinating and pulsatory pain.

Aneurism of the ascending and transverse aorta, also involves the right recurrent laryngeal nerve, inducing laryngeal spasm, irritability, and aphonia.

Aneurism of the ascending portion may obstruct the right pulmonary bronchi or bronchus to the upper lobe of the right lung. Aneurism of the transverse portion compresses the trachea, cutting off air to the lung, and irritating both recurrent laryngeals. Orthopnoea, laryngeal spasm, shallow chest expansion, supra-sternal and epigastric sinking, and anorexia are often marked.

Aneurism of the descending arch disturbs only the left recurrent laryngeal and the apex of the left lung, its investing pleura and

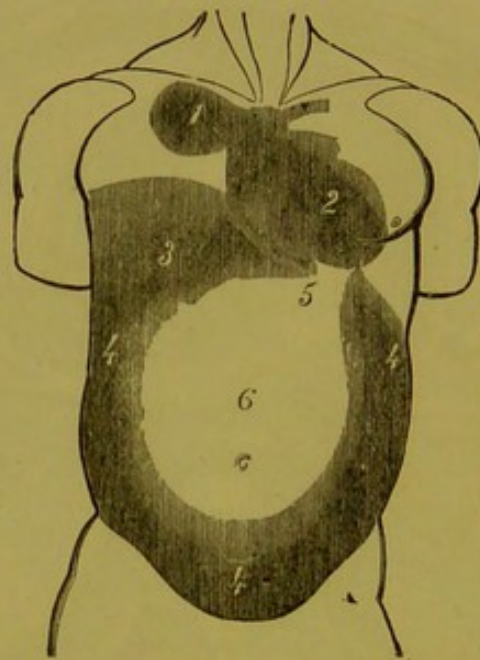


FIG. 84.—Area of dulness of aneurism (Piorry).

bronchi; discomfort is then on the left side of the sternum and of the left scapula and interscapular regions.

**PHYSICAL SIGNS.—INSPECTION.**—In its early stage aneurism may show nothing. Later, vibration and bulging are observed in the second intercostal space to the right of the sternum, or, if of transverse portion, pulsation may appear in the suprasternal notch and extend up the cervical vessels. In aneurism of the descending portion, the bulging is to the left of the sternum, at the second cartilage. Later, the sternum, ribs, and cartilages may bulge over the aneurism or be eroded, and the spheroidal pulsating tumor is seen to the right or left of the sternum.

Vascular swelling and cyanosis of the head, neck, arms, and thorax

denote pressure on the vena cava descendens. If the venosity exists on the right side only, the pressure is over the innominate vein.

**PALPATION.**—Vibratile pulsation, or thrill, is detected in the intercostal spaces, through the sternum, or in the suprasternal notch; after erosion, the tumor gives distensile sensation.

**PERCUSSION.**—Area of dulness in the upper sternal region, extending to the right or left or up into the suprasternal notch.

Auscultatory percussion is often of greatest value in accurately defining the exact size and contour of aneurismal tumors.

**AUSCULTATION.**—**ANEURISM OF THE ASCENDING ARCH.**—Double bruit on the right side of the sternum, in the second space, both sounds possessing the variable quality of friction, rasping, sawing,

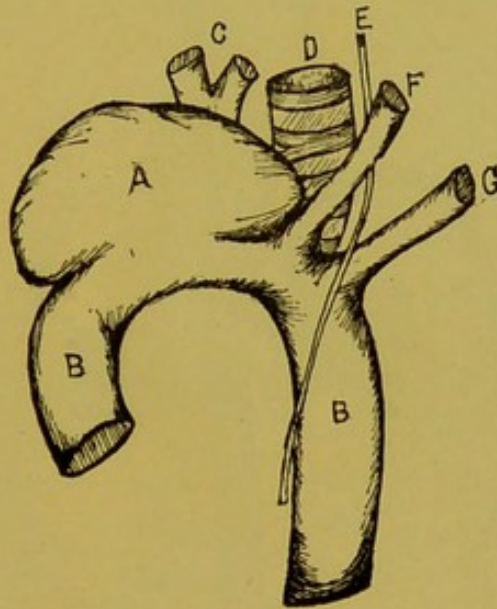


FIG. 85.—Aneurism of junction of ascending and transverse arch (Doty).

whistling, ringing, or booming; the sounds are measurably conducted down the sternum and up into the cervical vessels.

The conduction of the aneurismal bruit into the vessels of the neck, axilla, etc., depends upon the degree of associated dilatation of the arterial branches radiating from the aneurism. The systolic sound or bruit of aneurism is caused by the entrance of blood into the aneurismal sac; the diastolic bruit is caused by the recoil of the sac and expulsion of blood into the aortic current. If the aneurism is fusiform, there may be little or no bruit. The degree of bruit depends upon the shape of the sac and size of its orifice. An enormous aneurism may be so filled in with laminated fibrin as to have but a small cavity and little or no bruit.



The second sound of the heart is usually discernible to the left of the sternum, thus differentiating double aortic murmur. Pressure on the apex may have developed local plastic pleuritic râles, local pneumonic crepitus, or stridulus by pressure on the bronchus; respiratory sounds are lessened or absent in the lung.

**ANEURISM OF THE TRANSVERSE ARCH.**—Double bruit, heard with stethoscope, deep in the suprasternal notch, over the upper end of the sternum and up the vessels of the neck. Aneurism of the transverse arch is quite apt to be fusiform, or extremely dilatated, and may or may not have a commensurate bruit and thrill.

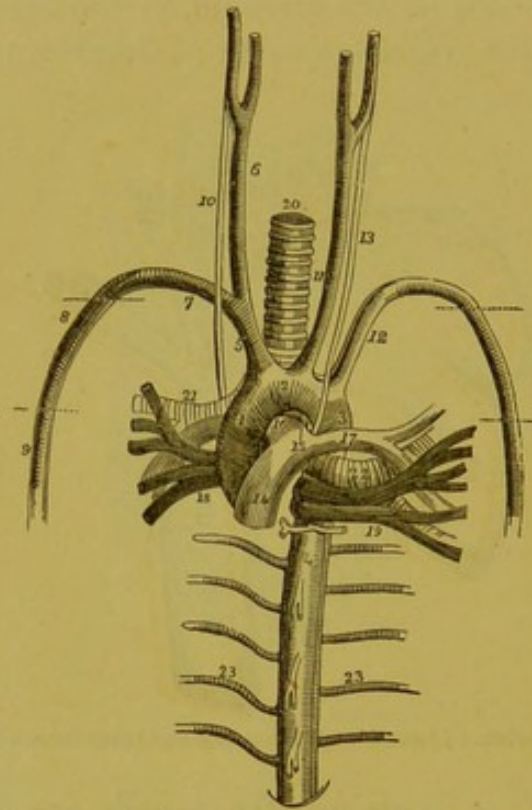


FIG. 86.—Relations of descending arch.

The heart-sounds are heard separately. Tracheal stridulus is very distinct at the point of pressure, and the respiratory sounds are very feebly developed throughout both sides of the chest.

**ANEURISM OF THE DESCENDING ARCH.**—Double bruit of “aneurismal quality,” heard to the left of the sternum, above the base of the heart; but best heard in the back, in the left vertebral groove, and in the interscapular region.

**DIAGNOSIS.**—By tumor, area of dulness, pulsating, distensile and thrilling sensations to touch, by characteristic double bruit, and associated symptoms, as pressure on air passages, pleura, lung apex, ver-

tebræ, and nerves; also by exclusion of the cardiac origin of the tumor, cardiac thrill, and cardiac bruits.

The radial, axillary, subclavian, and carotid pulses, as well as the pulsation of the abdominal aorta and femoral arteries, are to be studied. Modified, diminished, or absent pulse in a given artery denotes either obstruction of its origin and continuity by a clot or fibrinous process extending from the aortic tumor, or the dispersing

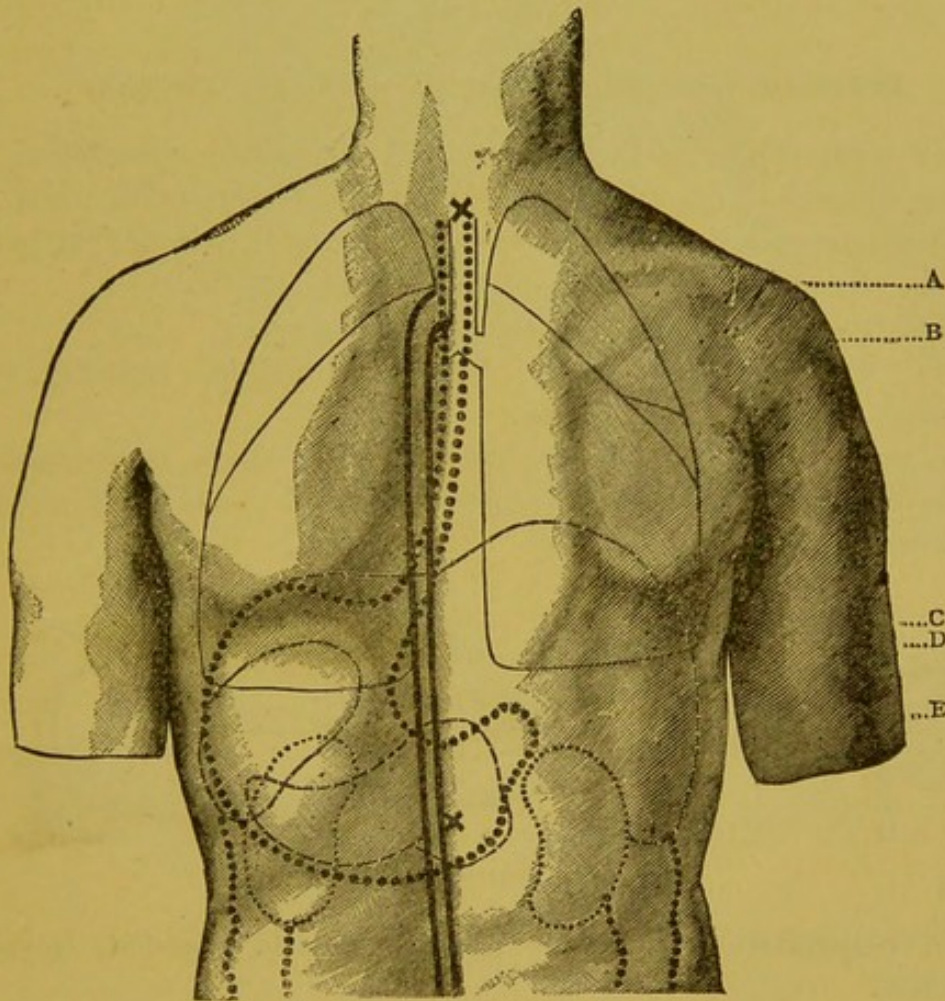


FIG. 87.—Showing thoracic aorta in the back.

of the cardiac force in the distensile aneurismal sac, thus aiding in differentiating the location of the aneurismal tumor and its contents.

**PROGNOSIS.**—Always unfavorable; aneurism may rupture externally or internally into lung, pleura, bronchi, trachea, or pericardium. Death also by inanition, asphyxia, exhaustion.

**TREATMENT.**—Diminish arterial tension by quiet living; keep the bowels open; avoid overloading the stomach; avoid, also, emotional excitement, fatigue, and alcoholism. Enforced rest in the recumbent position, cardiac sedatives and exclusive meat diet favor hyperinosis and filling of the sac with laminated fibrin.

## CHAPTER X.

### RELATION OF THE PULSE TO CARDIAC DISEASE.

THE study of the pulse is an essential part of the observation of cardiac disease. The pulse is chiefly studied at the wrist. For all practical purposes its palpation with the finger tips is all that is required. As related to cardiac disease we find in

Cardiac hypertrophy, *the radial pulse* full, strong.

“ dilatation, “ “ “ compressible, lacking volume, irregular, intermitting.

Fatty heart, *the radial pulse* is feeble, small volume, compressible.

Aortic obstruction with hypertrophy, *the radial pulse* is full, strong, abrupt, shotty.

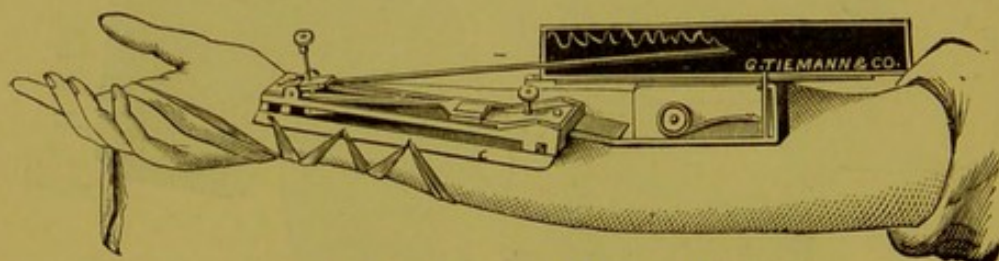


FIG. 88.—Marey's sphygmograph.

Aortic regurgitation, *the radial pulse* smooth, rounded, lacking apex.

Mitral regurgitation, *the radial pulse* compressible, rounded, often irregular.

Mitral obstruction, *the radial pulse* presents nothing distinctive.

The sphygmograph is an instrument chiefly useful for clinical teaching and record, to reproduce in tracing the characters of the pulse in health and disease, and the behavior of the heart under the influence of drugs. It is of no special value in the practice of medicine, beyond the above-stated uses. Marey's sphygmograph was first used and still continues to be the most practical one we have.

Dudgeon's is convenient, and, being less expensive, is most in use.

In this country, also Holden's and Pond's are much used, but neither afford so uniformly reliable tracings as Marey's or Dudgeon's.

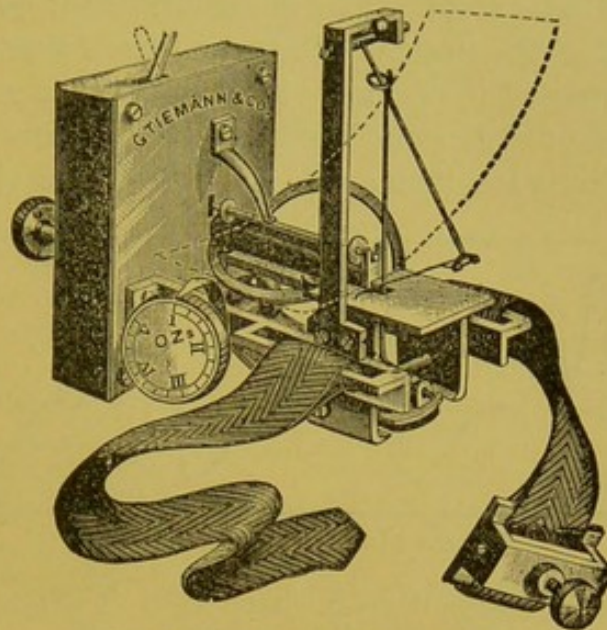


FIG. 89.—Dudgeon's sphygmograph.

The sphygmographic tracing consists of an up line, representative in length and uprightness of the force and rapidity of the contrac-

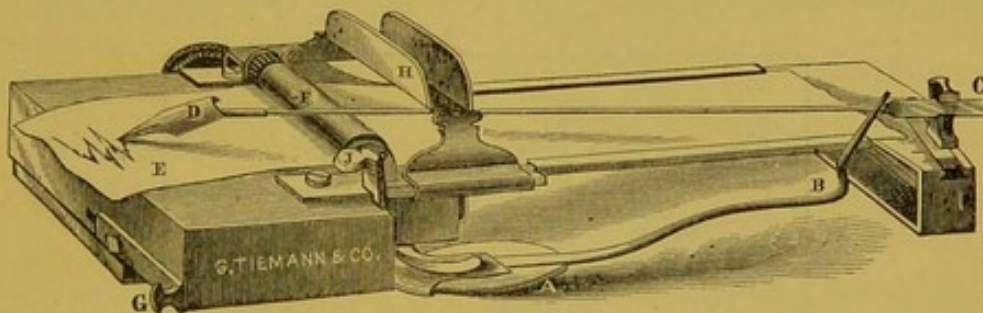


FIG. 90.—Holden's sphygmograph.

tion of the left ventricle; of an apex or crest more or less pointed according as the heart is strong, the aortic orifice free of obstruction,

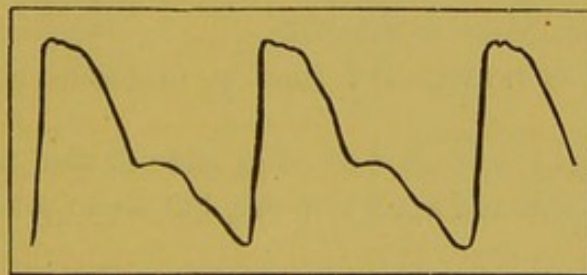


FIG. 91.—Pulse tracing (Loomis).

*not  
normal  
High tension*

and the cardiac valves intact (permitting no regurgitations during diastole); and the line of descent to the vibratile curve, the first part

of which represents the falling and closing with vibration of the aortic valves under the superimposed blood in the aorta and the contraction of the elastic aorta. The remainder of the curve represents the diastolic rest of the heart. When the line of ascent is relatively short, and the apex of the central vibrating curve is relatively high, a double tipped or "dicrotic" pulse is demonstrated, and denotes that cardiac force is less than aortic and vascular recoil.

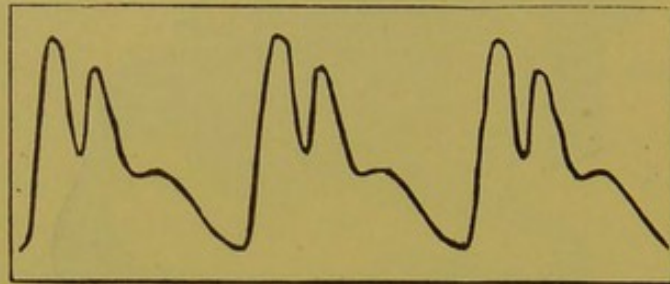


FIG. 92.—Dicrotic tracing (Loomis).

*This is the  
pre-dicrotic  
wave*

A vertical line of ascent with sharp apex is often diagnostic of cardiac hypertrophy, but may also result from febrile excitement.

Aortic regurgitation lessens the acuteness of the apex, giving a rounded-tipped tracing. Mitral regurgitation does much the same thing. So often do these obstructions or regurgitations coexist with

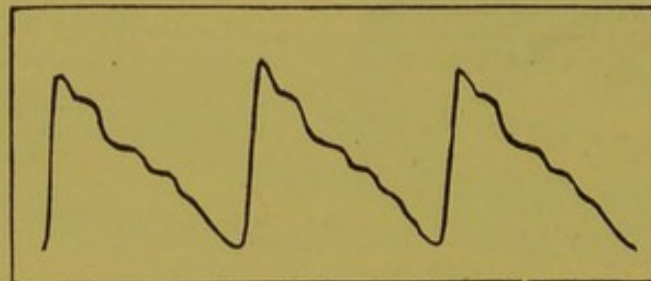


FIG. 93.—Pointed tracing in hypertrophy (Loomis).

cardiac hypertrophy or dilatation, or with cardiac enfeeblement, irregularity, or intermission, that the tracing becomes complex and of doubtful representative meaning.

The number of waves in a tracing represent the frequency of heart's action.

Sphygmography is applied to other arteries than the radial, and to the præcordial area and apex impulse, but to no practical purpose.

*The author appears to know little of  
this subject*

## INDEX.

---

- Abnormal movements, 12  
  respiratory sounds, 53
- Absence of vocal resonance, 57
- Acoustic laws, 50
- Acute bronchitis, synopsis of, 77
- Adventitious sounds, 52
- Ægophony, 57
- Air and tube friction sound, 43  
  complementary, 17  
  persistent, 17  
  residual, 17  
  supplementary, 17  
  tidal, 17
- Anæmic murmurs, 121
- Aneurism of ascending arch, 141  
  of descending arch, 142  
  of transverse arch, 142  
  of the thoracic aorta, 138  
  physical signs of, 140
- Angina pectoris, 124
- Aorta, aneurism of, 138
- Aortic obstruction, 132  
  regurgitation, 132
- Apex beat, location of, 108  
  impulse, character of, 188
- Apoplexy, pulmonary, 87
- Aspiration, 72
- Asthma, 80  
  crystals, 76
- Auscultation, 37  
  immediate, 37  
  mediate, 37  
  in health, 41  
  of aneurism, 141  
  of the heart in disease, 121  
  of the normal heart, 116
- Auscultatory percussion, 96  
  sounds, 37  
    duration, 37  
    intensity, 37  
    pitch, 37  
    quality, 37  
    rhythm, 37
- Axillary region, 6
- Bacilli, tubercle, 75
- Bell-metal test, 72
- Bronchial cough, 60  
  respiration, 53  
  voice, 57  
  whisper, 59
- Bronchitis, acute, 77  
  capillary, 78  
  chronic, 79
- Bronchophony, 57
- Broncho-cavernous respiration, 53
- Broncho-vesicular respiration, 53
- Brown induration of the lung, 95
- Bulging and expansion of chest, 12
- Capillary bronchitis, 78
- Carcinoma of the lung, pleura, and  
  bronchial glands, 96
- Cardiac dilatation, synopsis of, 126  
  hypertrophy, synopsis of, 125  
  murmurs, enumeration of, 133  
  murmurs, synonyms of, 134  
  region, deep, 98  
  region, superficial, 99  
  sounds, causation of, 120  
  valves, location of, 102
- Cardiometer, Cammann's, 109

- Catarrhal phthisis, 93  
 Cavernous cough, 60  
     voice, 57  
 Chest, abnormal movements of, 14  
     acoustics, 50  
     anterior regions of, 1  
     circular expansion of, 16  
     curvature and distortion of, 13  
     depression (and retraction) of, 13  
     expansion and bulging, 112  
     lateral regions of, 2  
     posterior regions of, 2  
     procidentia and elevation of, 13  
     regional anatomy of, 1  
     retraction and depression of, 13  
 Chronic bronchitis, 79  
 Clavicular regions, 3  
 Complementary air, 17  
 Consonance, 50  
 Cough sound, 49  
 Creaking, 69  
 Curvature and distortion of chest, 13  
  
 Deferred expiration, 56  
     inspiration, 55  
 Depression (and retraction) of chest,  
     13  
 Differential stethoscope, 40  
 Diminished vocal resonance, 57  
 Distortion (and curvature) of chest, 13  
 Divided breathing, 55  
 Dulness, 33  
 Duration of percussion sound, 2  
  
 Echo, 50  
 Elements of normal respiratory sound,  
     43  
 Elevation (and procidentia) of chest, 13  
 Ellis line, 34  
 Emphysema, pulmonary, synopsis of,  
     90  
     synopsis of, 82  
 Endocarditis, synopsis of, 128  
     ulcerative, 129  
 Exaggerated breathing, 54  
     respiration, 43  
     vocal resonance, 56  
 Expansion and bulging of chest, 12  
 Extra-cardiac murmurs, 134  
 Fatty heart, synopsis of, 127  
  
 Fibroid phthisis, 93  
 Flatness, 133  
 Forced respiration, 43  
 Form of healthy chest, 11  
 Functional diseases of the heart, 121  
  
 Gangrene of the lung, synopsis of, 89  
 Gurgles, 69  
  
 Harsh respiration, 56  
 Healthy chest, form of, 11  
 Heart, auscultation of, 116  
     auscultatory percussion of, 116  
     diseases of, 97  
     diseases, synopsis of, 125  
     examination of, 104  
     inspection of, 104  
     irregularity and intermission of,  
         123  
     mensuration, 109  
     neuroses of, 122  
     organic diseases of, 124  
     palpitation of, 110  
     paralysis of, 124  
     percussion of, 111  
     sounds, duration of, 117  
     sounds, quality of, 118  
     spasm of, 123  
     topography of normal, 97  
     topography of, in disease, 101  
     tremor, 123  
     valvular diseases of, 132  
     walls, thickness of, 103  
     weight of, 103  
 Heart's action, frequency of, 117  
     action, rhythm of, 117  
 Hydropericardium, synopsis of, 131  
 Hydrothorax, synopsis of, 84  
 Hypertrophy of left ventricle, 113  
     of right ventricle, 114  
 Hypodermic puncture, 72  
  
 Infra-axillary region, 7  
 Infraclavicular regions, 3  
 Inframammary regions, 5  
 Infrascapular region, 7  
 Inspection, 11  
 Inspiration and expiration, relative  
     length of, 17  
     and respiration, ratio of, 42

- Intensity of percussion sound, 21  
 Interscapular region, 8  
 Intracostal auscultator, 69  
 Intrapleural sounds, 65
- Jerking breathing, 55
- Lateral regions, 6  
 Letter "S" line, 34  
 Lower scapular region, 7  
   sternal region, 6
- Mammary region, 3  
 Mensuration, 15  
 Metallic tinkle, 69  
 Methods of physical diagnosis, 11  
 Mitral obstruction, 132  
   regurgitation, 132  
 Modified sounds, 52  
 Movements, abnormal, 12  
   normal, 12  
   thoracic, 12  
 Murmurs, coexistence of several, 137  
   double basic, 137  
   how localized, 135  
   propagation of, in vessels, 137  
 Muscular sussurus, 47  
 Myoidema, 36
- Normal expiratory sound, 42  
   inspiratory sound, 42  
   movements, 12  
   respiratory sound, 41  
   voice sounds, 48  
   whisper, 49
- Oedema of the lungs, synopsis of, 84  
 Organic disease of the heart, 124
- Page's percussion hammer, 71  
 Palpation, 14  
 Paralysis of the heart, 124  
 Pectoriloquy, 58  
 Percussion, 19  
   auscultatory, 69  
   hammer, 19  
   immediate, 19  
   mediate, 19  
   mode of, 20
- Percussion note of heart, 23  
   of lungs, 23  
   of muscles, 23  
   of abnormal chest, 32  
   positions for, 27  
   sound, 20  
     duration, 21  
     intensity, 21  
     pitch, 21  
     quality, 22  
     resonance, 21  
 Pericarditis, synopsis of, 130  
 Persistent air, 17  
 Phthisis, modern classification of, 93  
   synopsis of, 91  
 Physical diagnosis, methods of, 11  
   principles of, 1  
 Pitch of percussion sound, 21  
 Plastic pleuritis, 66  
 Pleural sounds, 64  
 Pleuritis, synopsis of, 81  
 Pleximeter, 19  
 Positions for percussion, 27  
 Posterior regions, 7  
 Pneumo-hydrothorax, synopsis of, 83  
 Pneumonia, synopsis of, 85  
 Procidentia and elevation of chest,  
 13  
 Properties of percussion sound, 20  
 Pulmonary apoplexy, synopsis of, 87  
   consumption, synopsis of, 91  
   infarction, synopsis of, 88  
   obstruction, 132  
   regurgitation, 132  
   resonance, 23  
 Pulse, relation to cardiac disease, 144
- Quality of percussion sound, 22  
 Quiet respiration, 43
- Râles, 60  
   crepitant, 63  
   dry 60  
   moist, 61  
   mucous, 61  
   sibilant, 61  
   sonorous, 61  
   subcrepitant, 62  
   submucous, 61  
   tracheal, 61



- Ratio of inspiration to respiration, 42  
 Relative length of inspiration and expiration, 17  
 Residual air, 17  
 Resonance of percussion sound, 21  
   tussal, 49  
   unison, 50  
 Respiration of men and women, 16  
 Respiratory movements, 43  
 Retraction and depression of chest, 13  
   of intercostal spaces, 108  
 Rhonchi, 60  
 Rude respiration, 56
- Sense of resistance in percussion, 35  
 Sounds, adventitious, 52  
   modified, 52  
 Spirometer, 16  
 Sphygmograph, 144  
 Stethoscope, 38  
   advantages of, 41  
   disadvantages of, 41  
 Succussion, 69, 72  
 Suffocative catarrh, 78  
 Supplementary air, 17  
 Suppressed breathing, 54  
 Supraclavicular regions, 2  
 Suprasternal regions, 5  
 Sussurus, muscular, 47  
 Syncope, 123  
 Syphilis of the lung, synopsis of, 95  
 Synopsis of acute bronchitis, 77  
   of capillary bronchitis, 78  
   of chronic bronchitis, 79  
   of asthma, 80  
   of cardiac dilatation, 126  
   of cardiac hypertrophy, 125  
   of emphysema, 90  
   of empyema, 82  
   of endocarditis, 128  
   of fatty heart, 127  
   of gangrene of the lung, 89  
   of heart diseases, 125  
   of hydro-pericardium, 131  
   of hydrothorax, 84  
   of œdema of the lung, 86
- Synopsis of pericarditis, 130  
   of phthisis, 91  
   of pleuritis, 81  
   of pneumo-hydrothorax, 83  
   of pneumonia, 85  
   of pulmonary apoplexy, 87  
   of pulmonary consumption, 91  
   of pulmonary emphysema, 90  
   of pulmonary infarction, 80  
   of syphilis of the lung, 95  
   of ulcerative endocarditis, 129
- Thoracic movements, 12,  
 Thorax, topography of, 1  
 Tidal air, 17  
 Topography of normal heart, 17  
 Tricuspid obstruction, 132  
   regurgitation, 132  
 Tubercle bacilli, 75  
 Tubercular phthisis, 93  
 Tubular resonance, 24  
 Tussal resonance, 49  
 Tympanitic resonance, 26
- Ulcerative endocarditis, synopsis of  
 129  
 Unfinished respiration, 56  
 Unison resonance, 50  
 Upper sternal region, 6  
 Upper scapular region, 7
- Voice sounds, normal, 48  
 Vesiculo-cavernous respiration, 53  
 Ventricles, capacity of, 104  
 Valvular diseases of the heart, 132
- Wavy breathing, 55  
 Weak breathing, 54  
 Weight of the heart, 103  
 Whisper, cavernous, 60  
   enfeebled or absent, 59  
   normal, 49  
   raised in pitch, 59  
 Whispering bronchophony 59  
   pectoriloquy, 60



