

A directory for the dissection of the human body / by John Cleland.

Contributors

Cleland, John, 1835-1925.
Mackay, John Yule.
University of Bristol. Library

Publication/Creation

London : Smith, Elder, 1888.

Persistent URL

<https://wellcomecollection.org/works/c5meftfn>

Provider

Special Collections of the University of Bristol Library


License and attribution

This material has been provided by This material has been provided by University of Bristol Library. The original may be consulted at University of Bristol Library. where the originals may be consulted. This work has been identified as being free of known restrictions under copyright law, including all related and neighbouring rights and is being made available under the Creative Commons, Public Domain Mark.

You can copy, modify, distribute and perform the work, even for commercial purposes, without asking permission.



Wellcome Collection
183 Euston Road
London NW1 2BE UK
T +44 (0)20 7611 8722
E library@wellcomecollection.org
<https://wellcomecollection.org>



B4a

UNIVERSITY COLLEGE, BRISTOL.

Medical Library.

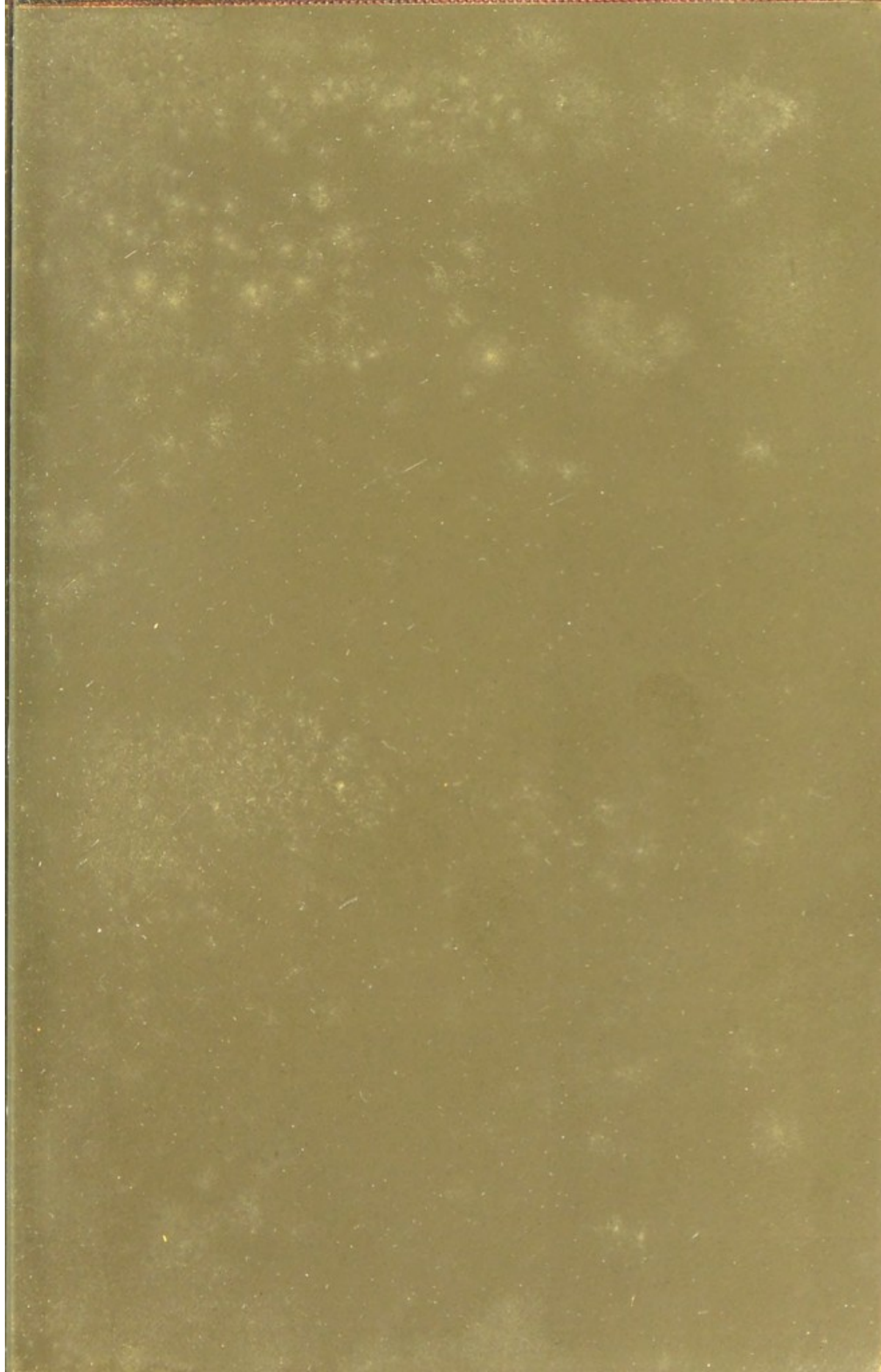
December 22nd 1893

Store 570722

SHELF

D.A.


J. FAWN & SON
QUEENS ROAD
BRISTOL.



SH

D.

DISSECTION
OF
THE HUMAN BODY



19c

A DIRECTORY
FOR THE
DISSECTION OF THE HUMAN BODY

BY
JOHN CLELAND, M.D. LL.D. F.R.S.
PROFESSOR OF ANATOMY IN THE UNIVERSITY OF GLASGOW

THIRD EDITION
THOROUGHLY REVISED BY
JOHN YULE MACKAY, M.D.
SENIOR DEMONSTRATOR OF ANATOMY IN THE UNIVERSITY OF GLASGOW

LONDON
SMITH, ELDER, & CO., 15 WATERLOO PLACE
1888

[All rights reserved]

UNIVERSITY
OF BRISTOL
MEDICINE

PREFACE.

THE following pages have not been written with the view of interfering with works of Anatomical Demonstrations or Systematic Anatomy, but are intended to supplement such books. The student ought to study the 'subject' in the dissecting-room, and his books at home; and he ought never to be encouraged in the too common error of looking on his dissections as mere illustrations for the statements of the text-book. Yet it is necessary that he should be guided in his dissections, both that he may make them in such a manner as to display the anatomy to the greatest advantage, and that he may recognise the structures by the names by which they are known. To these two purposes of guidance these pages are exclusively devoted; and they differ from the directions which were published in the seventh edition of 'Quain's Anatomy,' by the far more complete carrying out of the second purpose, so as to render this a work totally distinct from that referred to. The author's effort has been, by the omission of all description, to give to the student who seeks to learn, scalpel in hand, a fuller assistance in the practical difficulties which he is likely to meet with than could be afforded in a

work devoted to description either in the systemic form of arrangement or that of demonstrations.

It is expected of the student that before coming to the dissecting-room he should glance over, each evening, a portion of work in this book, and consult his descriptive manual sufficiently to have an intelligent idea of what he is to exhibit on the subject next day. Taking with him this book to the dissecting-room, he will with its aid cultivate his manipulative powers and his observation; and on his return home he will recur to his text-book, and find how far his own observations agree with those of more experienced men. He will find it also an invaluable habit, of more than mere anatomical advantage in after life, to devote a short time each day before he quits his dissection to taking written notes and sketches of what he sees before him. The extent to which this will relieve the strain on his memory in remembering details will more than repay the trouble.


Naturally, the plan of this book is adverse to the evil but too prevalent habit of seeking to substitute for real knowledge of anatomy a mere appearance of knowledge; yet the author ventures to hope that even as an aid in preparing for examinations it may not be useless, but will afford to the student who has carefully dissected the means of easily reviving before his mind the picture of the parts as he has seen them.

CONTENTS.

	PAGE
PREFACE	v
THE USE OF INSTRUMENTS	1
THE ORDER OF DISSECTION	8
DISSECTION OF THE BACK AND THE UPPER LIMB	10
The Back	10
The Spinal Cord	16
The Pectoral Region and Axilla	18
The Scapular Region and Shoulder	24
Subcutaneous Structures of Arm and Forearm	26
Brachial Region	28
Front of the Forearm	31
Front of the Hand	33
Back of the Forearm and Hand	37
The Articulations	40
DISSECTION OF THE LOWER LIMB	43
The Gluteal Region	43
The Popliteal Space and Back of the Thigh	48
The Front of the Thigh	50
The Back of the Leg	59
The Sole of the Foot	62
The Front of the Leg and Dorsum of the Foot	65
The Knee-joint and Articulations of the Foot	69

	PAGE
DISSECTION OF THE HEAD AND NECK	73
Scalp and Back of the Neck	73
Exposure and Removal of the Brain	77
Base of Brain and its Vessels	81
Dissection of the Brain from above	85
Superficial Dissection of the Neck	94
Posterior Triangle	95
Anterior Triangle	97
Deep Dissection of the Root of the Neck	100
The Face	102
Temporal and Zygomatic Region	107
The Sublingual Region	110
Parts within the Cranium	112
The Orbit	114
Deep Dissections of Nerves and the Internal Ear	118
Pharynx, Larynx, Tongue and Nares	123
Vertebral Muscles and Articulations	128
The Eyeball	129
DISSECTION OF THE THORAX	134
The Parietes	134
The Pleura and Parts adjacent	135
The Pericardium and Heart	139
The Air Tubes and Interior of the Lungs	144
The Œsophagus and other Parts	145
DISSECTION OF THE ABDOMEN AND PELVIS	147
The Perinæum	147
The Abdominal Wall	151
The Testicle and its Coverings	161
Peritoneum and Position of Viscera	163
The Mesenteric Vessels and the Intestines	168
The Cœliac Axis, and the Viscera supplied by it	171
Solar Plexus, Supra-Renal Capsules, Kidneys, Aorta, and Vena Cava	175
The Posterior Abdominal Wall	178
The Pelvis	181
The Pelvic Viscera	187
The Ligaments of the Pelvis	190

A DIRECTORY
FOR THE
DISSECTION OF THE HUMAN BODY.



THE USE OF INSTRUMENTS.

THE instruments with which the student of practical anatomy requires to provide himself are knives, forceps, scissors, hooks, a needle, and a small blowpipe; all of which are usually collected in the cases sold for the use of dissectors. In addition, there are various instruments commonly provided in the dissecting-room; and the principal of these are saws, bone-nippers, chisels, and mallets.

The knives or scalpels may vary in length of blade from one and a half to two inches, measuring from the handle to the point. The form of the cutting edge should be rounded towards the extremity, so as to form a curve. This curve is of the utmost use in dissection, especially in the removal of integuments and exposure of muscles; and in sharpening the scalpel care should be taken to preserve its form. A knife without any such rounding, with the cutting edge extending in a straight line to the

point, is sometimes found in dissecting cases, and is used in physiological experiments ; but to the practical anatomist it is of no service save for one purpose, namely, following branches of nerves ; and for this the only requisite is a sharp point, which every scalpel should have.

Dissecting forceps should be sufficiently weak in the spring to be used for a length of time without wearying the fingers, and should taper gradually to the points. At the points it is unnecessary for them to be narrower than one-sixteenth of an inch, as the smallest structure can be grasped and managed with facility with forceps of that breadth of point, provided that the teeth or serrations where the points are in apposition are fine and fit into one another with perfect accuracy. Forceps need not be more than four and a half inches in length.

The mode of handling the scalpel and forceps is a matter of importance, on which the success and comfort of the dissector greatly depends. The forceps ought always to be held lightly between the forefinger and thumb, their upper part moving over the forefinger. Never, on any account, should this instrument be grasped in the palm of the hand like a fork, neither should it be used to lay hold of firm and bulky structures, which can be better held with the fingers. Small branches of nerves may be seized with it without harm, but neither muscles nor arteries should ever be so seized. These structures are seriously damaged by being pinched, and should, therefore, be left untouched, while the connective tissue around them is removed ; or they may be

lightly turned aside with the closed forceps, without being held between the teeth of the instrument.

The scalpel ought never to be held with the handle in the palm of the hand and the forefinger on the back of the blade, like a bistoury, save only in making incisions. It is usually held like a pen between the forefinger and thumb, while the extremity of the middle finger furnishes a slight support on which it may be turned so as to direct the cutting edge towards or away from the dissector at will. The management of the scalpel varies a little, according as it is used for the dissection of large muscles or vessels and nerves. In laying bare a large muscle, such as the superficial muscles of the back, buttock, breast and abdomen, it takes as little time to make the dissection clean and display the structures properly as to bring the muscles into view in a less successful fashion, with the fascia left adherent in patches, and the cutaneous nerves destroyed. So far as the display of the muscular fibres is concerned, the following are the directions to be attended to :

1. Having raised a small portion of the fascia or integument to be removed, grasp it firmly between the fingers and thumb, and pull on it so as to make it tense. This is best done by laying the second joint of the forefinger of the left hand on the surface of the tissue to be removed, seizing with the thumb the raised edge of the tissue so as to press it against the forefinger, and turning the wrist so as to stretch the tissue over the forefinger. A furrow will thus be formed bounded on one side by the muscle and on the

other by the fascia held up : and at the bottom of the furrow there will be seen between the muscle and fascia a stretched film of semitransparent connective tissue, which must be all removed along with the fascia.

2. Place, therefore, the point of the scalpel not where the film passes into the fascia, but on the line where the film and the muscle touch. Then keeping the point close to the muscle, and the cutting edge a little turned towards the fascia, and guiding the stroke with the eye in every part of its course, bring the scalpel with a long slow sweep along the furrow. The film will thus be divided by the curved edge of the blade, and start back into the stretched fascia, and rapid progress will be made in denuding the muscle of every particle of its envelope.

3. Attention has to be paid to the direction of the muscular fibres. The usual instruction is to dissect parallel to these. But this requires the muscles to be placed on the stretch, and it is not always convenient to obtain that advantage ; while if the muscles be relaxed, and the dissection be conducted in the line of their fibres, it will often happen that the parallelism of the fibres will be interfered with, and the appearance of the dissection damaged. On this account it is advisable to keep the line of dissection sufficiently oblique to the direction of the muscular fibres to admit of the fascia being pulled in that direction, the fibres thus being rendered tense and kept parallel at the spot under dissection. By paying attention to this rule, the muscles of the abdomen can always with ease be made perfectly

clean, without the preliminary of inflating the abdominal cavity, a clumsy and inelegant proceeding still recommended by some. Whatever the direction chosen in relation to the muscular fibres, care should be taken so to regulate the line of dissection that the margin of the undissected part, where it meets with the dissection, shall not be allowed to take the form of a concavity, which prevents the textures from being properly stretched.

In dissecting blood-vessels it is still more important than in the dissection of muscles that while the point of the scalpel is brought near to the structure, so as to make it perfectly clean, the edge shall be slightly turned away from it, so as to prevent injury to its walls.

In tracing nerves, rapid and effective work can often be done by laying hold of the branch to be followed, turning the back of the scalpel towards it, and placing the point close to it, then running the scalpel along its course, so as to divide the connective tissue which binds it down.

The flattened extremity of the handle of the scalpel is not without its purpose. It is useful in separating structures which are loosely adherent, and has the advantage that with it the dissector feels his way between structures without running the risk of injuring them by cutting. It may be thus used in separating fasciæ and laying bare their adhesions, in separating in a preliminary fashion the contents of large spaces like the axilla from the surrounding walls, and in following out the planes of contact of muscles which are either in close associa-

tion or happen to be more than usually soft. So also it is often invaluable to the surgeon in the excision of tumours.

Scissors should be held with the thumb and ring finger. The manipulations for which they are required in the dissecting-room are few compared with those for which they are used in surgery and in making anatomical preparations. It may be noted that, whatever opinions may be held as to the utility of being able to use instruments with the left hand, scissors in the left hand, if in the slightest degree loose or blunt, are always at a disadvantage, because the blades are so made that while the thumb of the right hand, when it pushes on its blade, presses it against its fellow, the thumb of the left hand, if it be allowed to push, pushes its blade away from its fellow.

Hooks and other retentive devices ought to be used as sparingly as possible. They can be avoided very much by attention to the position of the subject, and by learning to keep parts aside by stretching the little fingers of both hands. Hooks are always liable to tear; they keep the parts in an unnatural position, and prevent their being moved freely about. The command over all the fingers not engaged in holding the scalpel or forceps, to push aside the textures in a deep dissection, is a most valuable acquirement for a practical surgeon, and will often make him independent of spatulæ and assistants.

The saw and bone-nippers are instruments which it is most important that the student should learn in

the dissecting-room to handle dexterously, since in surgery they are indispensable. Before using the saw, the bone should be laid perfectly bare by division of the periosteum. A preliminary stroke backwards at the part to be divided should be made to help the saw to catch sufficiently, and the succeeding sweeps should be long and light. On no account can a lateral movement be allowed for completing the division; as such an action, however natural when a difficulty is experienced, is not only destructive to the instrument, but liable to leave a jagged fracture of the bone. In the use of bone-nippers, also, all wriggling or lateral movement must be avoided. The bone to be divided should be firmly grasped, and the section made entirely by pressing the handles together. The flat side of the blades should be always turned towards the portion of bone to be preserved, as on that side only can it be secured, by proper use of the instrument, that the bone shall exhibit a direct cut unbroken by splintering. Bone-nippers are often made too long in the blade. It ought to be remembered that the shorter the blades, the greater the leverage. They ought to become narrower gently from the base to the point.

THE ORDER OF DISSECTION.

THE dissection of the body may be conveniently divided into five parts. These are—the upper limb, the lower limb, the head and neck, the thorax, and the abdomen. Two dissectors may be set to work on each of the last three parts ; while, in the case of the limbs, either one or two dissectors may be appointed to each, as may be necessary. If the subject be a male, at least one day should be devoted to the dissection of the perinæum before the other dissections are commenced, as the surgical anatomy of that region cannot be well appreciated after dissection of the lower limbs, nor in other than the lithotomy position.

After the dissection of the perinæum in the case of a male, or immediately on being brought into the rooms in the case of a female, the subject should be laid on its face, for the dissection of the hinder part of the scalp and neck, the muscles and other structures of the back, the spinal cord, the buttock, the back of the thigh, and the popliteal space. These dissections may usually be completed in four days, after which the subject may be turned. The upper limbs ought not to be removed from the body until not only the axilla has been fully dissected, but the dissectors of

the neck have had an opportunity, in conjunction with the dissectors of the arms, to trace the continuity of the structures which pass from one region into the other. This will usually be accomplished within four days; and on the fifth day after turning the subject the dissectors of the thorax may commence.

Although it is necessary to fix a stated time as a standard to regulate the turning of the body and the removal of the upper limbs, it will be found practically that, when mutual good feeling and a common spirit of industry exist, students may beneficially accommodate one another as regards the periods for these proceedings. And in a school where such good feeling exists, it may be further mentioned, no student need ever be idle at the times when it unavoidably happens that he is unsupplied with a part, as, with a little tact, he can always be learning from the dissections of others, without incommoding the dissectors who are at work.

It is essential to comfort that, when a part is allotted to two dissectors, their hours of attendance and period of study shall sufficiently correspond. It is therefore desirable that as far as possible students should arrange among themselves with regard to partners.

DISSECTION OF THE BACK AND UPPER LIMB.

1. **The Back.** — The subject being placed on its face, with the chest and pelvis supported by means of blocks, let an incision be made from the seventh cervical spine down the middle line to the most prominent part of the sacrum, another from the acromion to the upper end of the mesial incision, and a third along the crest of the ilium to the sacrum. If the subject be fat, it will be found convenient to dissect the integument of the flap thus formed carefully separate from all the subcutaneous tissue ; but if the subject be lean, it is quite possible to make a thoroughly clean dissection of the muscles at once, and at the same time save all the cutaneous nerves.¹

Extending from the dorsal spines to the spine of

¹ In this University it is the rule to dissect the skin perfectly free from all the subcutaneous adipose tissue, then to reflect that tissue in a sheet and remove it. By this means a source of uncleanness is got rid of, while the integument is preserved as an efficient protection to the part, beneath which there may be applied cloths with preservative fluids. If this plan be followed in the present dissection, it becomes alike unnecessary and undesirable to make a cutaneous incision from the twelfth dorsal spine to the fold of the axilla, as is sometimes recommended.

the scapula will be found the lower portion of the *trapezius* muscle, while in the remainder of the region marked out by the cutaneous incisions is the *latissimus dorsi*. In raising the fascia outwards from the middle line, the *cutaneous* branches of the *posterior divisions* of the spinal nerves will be detected as they emerge; and each, as it is found, may be followed through the fascia, or drawn out from it, while the dissection of the muscle is continued. Those from the six upper dorsal nerves appear near the mesial line, being derived from the inner branches of the posterior divisions; the succeeding cutaneous nerves in both dorsal and lumbar region are further out, being derived from the outer branches. The upper and lower borders of the *latissimus dorsi* muscle are to be made distinct from the subjacent parts; and in the fascia over its outer edge will be found the posterior branches of the lateral twigs of the intercostal nerves. The origins of the muscle from the ilium and lower ribs and from the inferior angle of the scapula are to be dissected out. In the interval between the *trapezius* and *latissimus dorsi* are to be noted a portion of the *rhomboideus major* and a portion of the thoracic wall, varying in extent according to the position of the scapula.

The *trapezius* muscle is to be divided by means of a vertical incision about an inch from the spines of the vertebræ; and, in association with the dissectors of the head and neck, this incision may be continued through the cervical part of the muscle. Close to its deep surface are the *superficial cervical* artery and the *spinal accessory* nerve and one or two branches

from the cervical plexus, which are on no account to be damaged, even by a junior dissector, but to be preserved, so as to have their continuity from above displayed by the dissectors of the head and neck.

The *rhomboideus major* and *minor* muscles are to be freed from fascia, care being taken not to injure their nerve, as it passes beneath their upper border; and when those muscles have been divided by a vertical incision near their vertebral extremity, this nerve (a branch from the fifth cervical), together with the *posterior scapular* artery, may be seen in its continuity by the dissectors of the head and neck and upper limb together. The peculiar tendinous attachment of the *rhomboideus major* to the scapula is to be exhibited from the deep side. On the upper border of the scapula the insertions of the *levator anguli scapulæ* and *omohyoid* should be exhibited; and the *suprascapular artery* and *nerve* may be noted as they pass respectively above and below the suprascapular ligament, but will be better seen in a later dissection.

The *latissimus dorsi* is to be divided by an incision beginning at its upper border, two inches from the mesial line, and curving downwards and outwards to the outer border an inch below the last rib. Let the inner part be then raised, so as to exhibit the connection with the *lumbar aponeurosis* and the origin from the crest of the ilium; and in raising the outer part, let the costal slips of origin be brought into full view, as well as their interdigitation with the *external oblique* muscle of the abdomen. Also dissect out the posterior border of the *external oblique* muscle between the last rib and the ilium, and the

small portion of the *internal oblique* left uncovered by the external ; and note the continuity of the lumbar aponeurosis with that on which the internal oblique muscle is seen resting, namely, the posterior aponeurosis of the *transversalis abdominis* muscle ; but leave all these structures undivided. The division of the rhomboid and latissimus dorsi permits the scapula to be sufficiently drawn away from the thoracic parietes to bring into view the deep surface of the *serratus magnus*, extending forwards from the deep side of the vertebral margin of the scapula ; and the lower margin of that muscle can be studied as well as the relation of its superior margin to the *levator anguli scapulæ*, a muscle with which in some animals it is quite continuous. Close to the upper margin of the serratus magnus, and passing downwards in front of it to supply it, will be found the *external respiratory nerve of Bell*. The nerve passes through the fibres of the middle scalenus muscle a little lower than the nerve to the rhomboids.

There is now laid bare an aponeurosis which covers in the deep muscles of the back, and is called the *vertebral aponeurosis* in the dorsal part of its extent, and more frequently the *lumbar* in its lower part. Along with this aponeurosis, passing outwards to the upper and lower ribs respectively, are the *serratus posticus superior* and *inferior* muscles. These are to be defined and studied, and, together with the vertebral aponeurosis, are then to be divided, when the *erector spinæ* muscle will be brought into view. Before beginning the examination of the erector spinæ, it is well that the *splenius*, a fleshy muscle of

the neck, extending upwards and outwards from the middle line to the skull and upper cervical transverse processes, should be divided near its mesial attachment, if it has not been already divided by the dissectors of the head and neck, as it ought to be. The *complexus*, the large muscle ascending beneath the splenius from transverse processes to the skull, will thus be laid bare, and between the splenius and complexus, to the outer side of the latter, a small muscle, the *trachelo-mastoid*, which is the uppermost prolongation of the erector spinæ.

The *erector spinæ* consists of an outer and an inner column, and these will be easily separated, one from the other, with the aid of the vessels and nerves lying between them, especially the external branches of the posterior divisions of the dorsal nerves, with the accompanying branches of the intercostal arteries and tributaries of intercostal veins. The outer column being dissected outwards, and its fasciculi and its tendons, which are at its outer border, carefully exhibited, the fibres of its lower part, the *ilio-costalis* (or *sacro-lumbalis*) will be seen to be inserted into the angles of the lower ribs; while new fibres, constituting the *musculus accessorius*, arise from the lower and are inserted into the angles of the upper ribs; and the second continuation, the *cervicalis ascendens*, arising from the upper ribs, ascends into the neck. The inner column of the erector spinæ cannot be dissected out until its inner border is freed by a somewhat artificial separation of the *spinalis dorsi*, or the tendinous and muscular fibres arising from lower dorsal and inserted into upper dorsal spines;

also some tendinous fibres of connection with the lower part of the subjacent *semispinalis* usually require division. Then the *longissimus dorsi*, constituting the main part of the inner column of the erector spinæ, is to have its insertions, as far as possible, individually dissected out, so as to show that they consist of an outer series of muscular slips attached to ribs and lumbar transverse processes, and an inner series, more tendinous, attached to dorsal transverse and lumbar accessory processes. At the upper part, this muscle will be found prolonged into the neck by the *transversalis colli*, a muscle connected by both origins and insertions with transverse processes and lying close to the border of the splenius; while the *transversalis colli* is in turn prolonged to the skull by the trachelo-mastoid muscle already mentioned.

The *complexus* muscle is to be divided, if this has not already been done, by the dissectors of the head and neck. The *semispinalis* muscle, usually divided into *semispinalis dorsi* and *semispinalis colli*, will then be seen with fibres directed upwards and inwards over several vertebræ, extending from transverse processes as low as the middle of the back up to the spine of the axis. Below the lower margin of the *semispinalis*, which is marked by flat tendons, part of the *multifidus spinæ* is visible, a muscle whose fibres likewise pass upwards and inwards, but are much shorter, while the muscle as a whole is greatly longer. To show the lower part of the *multifidus spinæ*, the aponeurotic origins of the *longissimus dorsi* from the lumbar spines and sacrum must be divided, which will likewise permit a more complete dissection being made of the

lowest insertions of that muscle ; and to show the upper part of the multifidus spinæ, ascending as high as the axis, the semispinalis must be divided in its whole extent. The multifidus spinæ by dissection inwards from its outer attachments may be shown to consist of a series of fan-shaped parts ; the outer fibres are most superficial and pass over several vertebræ, deeper fibres are shorter, while the deepest of all in the dorsal region extend between contiguous vertebræ and are called *rotatores spinæ*. After the study of these, the *levatores costarum*, small muscles extending outwards and downwards from the extremities of the dorsal transverse processes, and connected with the fibres of the external intercostal muscles, claim attention. In series with the levatores costarum, in the lumbar region, are the *external intertransverse* muscles, between succeeding transverse processes, while a set of *internal intertransverse* muscles will be found passing from accessory to mammillary processes. Typical *intertransversales* muscles, and also *interspinales* muscles exist in the neck.

2. The Spinal Cord.—Senior dissectors may now proceed to exhibit the spinal cord by opening the spinal canal. The laminae of the vertebræ are to be denuded of muscle ; the head is to be allowed to hang over the end of the table, and the concavity of the lumbar part of the vertebral column is to be straightened as much as possible, by means of blocks under the abdomen. The laminae of the lumbar and dorsal region are then to be divided partially with the saw, care being taken to direct the saw somewhat inwards, so as not to divide the transverse processes instead of

opening into the spinal canal. The saw-cuts ought to be continued downwards and made to meet near the lower end of the sacrum ; the divided portion of the sacrum should be raised with the chisel, and the series of laminae removed from below upwards in a continuous chain united by the *ligamenta subflava*, by completing their division with the bone-nippers. The extensibility and resiliency of the *ligamenta subflava* will thus be exhibited.

The sheath of *dura mater*, with its prolongations round the nerves, can now be cleared with the handle of the scalpel so as to show the spinal ganglia, and in some instances (most conveniently in the lower dorsal region) the nerves may be traced out to show their bifurcation into anterior and posterior divisions. The *dura mater* is to be carefully opened by slitting it down the middle : and then will be seen the origins of the spinal nerves in pairs by anterior and posterior roots, the *ligamenta denticulata* binding the cord to the *dura mater* in the spaces between the successive nerves, and the delicate *arachnoid* membrane surrounding the spinal cord. The loose transparent sheath which the *arachnoid* forms round the *cauda equina*, or collected bundle of lumbar and sacral nerves, can be exhibited advantageously with the aid of the blowpipe, or by introducing the handle of the scalpel beneath it ; and when it has been laid open, the cord is seen closely invested with its vascular sheath, the *pia mater*, and terminating in the *filum terminale*, a silvery thread which will be found among the trunks of the *cauda equina*, and is to be followed to its attachment.

By dividing the cord and dura mater above, and the nerves as they leave the spinal canal, the whole may be removed and spread out for further examination ; and some at least of the nerve-roots should be followed through the dura mater to show the relations of the two roots to the ganglia. Lastly, if the subject be quite fresh, sections may be made through the cord at different levels ; or, if the subject has been long preserved in salt, an interesting result may be obtained by running water on the cut upper end of the cord, and thus removing its proper texture, while the pia mater will be left empty, but with the firm roots of the nerves attached to it in series in front and behind.

Within the spinal canal after removal of the cord, the rich plexus of veins should be noted.

3. The Pectoral Region and Axilla.—The subject having been turned on its back, and the shoulders supported by a block, so as to throw the chest forwards, a mesial incision is to be made along the sternum ; from the upper end of this another is to be carried to the outer end of the clavicle, and thence along the arm to the fold of the axilla ; while a third is to be directed transversely from the lower end of the sternum, as far as the border of the latissimus dorsi.

If the subject be a female, a circular incision with a radius of an inch is to be described round the mammilla, so as to leave that part intact when the rest of the integument is raised. The extent of the mamma is to be exhibited by removal of the surrounding adipose tissue ; and on raising the circular portion of integument till it is left attached only at

the extremity of the nipple, the *galactophorous ducts*, each with its *ampulla*, or dilatation, beneath the cutaneous areola, will be seen ; and in young adults they may be traced inwards, and their orifices may be displayed by passing bristles through them. On subsequent removal of the fascia from the pectoralis major muscle beneath, the important connections of the mamma with it will be seen ; and, lastly, a vertical incision should be made through the gland in such a manner as to bisect the nipple.

Beneath the subcutaneous fascia are the *pectoralis major* muscle and the forepart of the *deltoid*, the pectoralis extending from the chest and inner end of the clavicle, and the deltoid from the outer part of the clavicle and from the shoulder, while between the two is the *cephalic vein*. In removing the fascia from these muscles, the following cutaneous nerves may be preserved : the *anterior cutaneous* branches of the six upper *intercostal* nerves emerging with corresponding branches of blood-vessels from the fore part of the intercostal spaces, the *descending cutaneous* branches of the *cervical plexus* crossing over the clavicle, and the anterior twigs of the *lateral cutaneous* branches of the third and succeeding *intercostal* nerves, turning inwards over the axillary border of the great pectoral muscle. The lower part of the fibres of the *platysma myoides*, the cutaneous muscle of the neck, will also be seen crossing the clavicle.

After the pectoralis major muscle has been thoroughly exposed, its clavicular attachment should be divided, and the divided portion of the muscle should be reflected, care being taken of the cephalic

vein as it dips down to join the axillary, and of the *external anterior thoracic* nerve which comes forwards on the upper side of the axillary artery to supply the muscle. On removal of some adipose tissue, the subclavicular space will now be seen, bounded externally by the upper part of the *pectoralis minor*, and in it the *costo-coracoid* membrane, attached to the clavicle above and continuous below with the sheath of the axillary vessels; also the *superior thoracic* and *acromio-thoracic* arteries, with the *humeral* branch of the latter lying along the cephalic vein. The *costo-coracoid* membrane is to be removed to expose the *subclavius* muscle, and the axillary vessels and the nerves of the brachial plexus will be brought into view.

The axillary space is now to be dissected from below, the sternal part of the great pectoral muscle remaining intact. To enable the arm to be extended at right angles to the trunk, a board may be slipped beneath the shoulder. With a view to the study of the connections of the axillary fascia, the integument should be removed separately: the fascia of the *pectoralis major* should then be reflected from the border and deep surface of that muscle till its continuity with the investment of the *pectoralis minor* is seen; then the fascia concealing the *latissimus dorsi* should be divided and traced forwards till the continuity of the axillary fascia with the pectoral fascia, the axillary sheath of the vessels and the aponeurosis of the arm is seen. The adipose and other contents of the space are to be separated with the help of the handle of the scalpel as much as possible from the

walls of the axilla. In this way will be brought into view the *lateral cutaneous* branches of the upper *intercostal* nerves as they pierce the thoracic wall ; and these are to be followed out, especially the highest of the series, the *intercosto-humeral* nerve, which is the lateral cutaneous branch of the second intercostal, and crosses the axilla, piercing its fascia, to be distributed on the inner and back part of the arm. The lateral cutaneous offsets of the succeeding intercostal nerves after piercing the serratus magnus divide each into an anterior and a posterior branch. The lymphatic glands of the axilla, receiving lymphatics from the arm, the back, the mamma and the walls of the chest, should now be cleared from the tissue in which they are imbedded, and the remaining adipose tissue and fascia within reach should be removed. The *long thoracic* artery will be seen towards the front of the space, and the *subscapular* artery at the back (sometimes sending a branch forwards on the thoracic wall) ; while, in the deep part of the middle of the space, distributed to the glands, is the *alar thoracic*. The *long subscapular* nerve lying close to the subscapular artery passes down to supply the latissimus dorsi ; and the so-called *posterior thoracic* nerve or *external respiratory nerve of Bell* (from the fifth and sixth cervical trunks) descends from the neck, behind the great vessels and nerves, on the surface of the serratus magnus, to which it is distributed. These structures being exhibited and preserved, let the *axillary* vessels and *brachial plexus* of nerves where they emerge from the axilla be brought thoroughly into view ; and also the origins of the *anterior* and

posterior circumflex arteries given off immediately below the subscapular.

The remainder of the pectoralis major is to be divided about three inches from its insertion, and as the *pectoralis minor* is brought into view, some twigs of the *internal anterior thoracic* nerve may be seen piercing that muscle and passing on to the pectoralis major. There are likewise laid bare by the reflection of the pectoralis major the common origin of the *coraco-brachialis* muscle and *short* head of the *biceps* from the coracoid process external to the pectoralis minor, and further out, in the bicipital groove of the humerus, the round tendon of the *long* head of the *biceps*. The pectoralis minor having been cleaned and studied is to be divided, and the internal anterior thoracic nerve is to be found entering its deep surface, and is to be traced back to its emergence on the under side of the axillary artery. The internal and external anterior thoracic nerves will be found to be united to one another by a branch crossing in front of the artery. The whole course of the axillary vessels can now be cleared, and their relations to the trunks of the brachial plexus, above, underneath and beyond the pectoralis minor, studied. The whole of the axillary branches of artery already individually mentioned can be seen in series, and the three great cords of the brachial plexus giving off their branches as follows: the external cord (outside the vessels) giving off the external anterior thoracic, the musculo-cutaneous, and the outer head of the median; the inner cord (inside the vessels) giving off the internal anterior thoracic, the nerve of Wrisberg, the internal cutaneous,

the ulnar, and the inner head of the median nerve; the posterior cord (behind the vessels) giving off the three subscapular, the circumflex, and the musculo-spiral. The *long subscapular* nerve has already been dissected out, the *second* is now seen passing to the subscapular muscle and the teres major, while the *short subscapular*, situated deeper in the axilla, ends altogether in the subscapular muscle, and will be better seen after removal of the limb.

On the fourth day after the turning of the subject, the *sterno-clavicular articulation* can be studied by dissecting out the *inter-clavicular* and *costo-clavicular* ligaments, and dividing the *anterior* ligament sufficiently to expose the interior of the joint and the *inter-articular fibro-cartilage*, then moving the limb about so as to exhibit the relations of the articular surfaces one to another in different positions of the limb and the tension or relaxation of the various ligamentous structures in those positions, while the *posterior* ligament, which is closely connected with the costo-coracoid, remains untouched. The clavicle may then be sawn across, or, in the event of the dissection of the neck being sufficiently advanced, and it being deemed advisable, it may be disarticulated from the sternum. The continuity of all vessels and nerves passing from the neck to the limb, including the *supra-scapular* artery and nerve, is now to be studied in conjunction, if possible, with the dissector of the neck, and they are then to be divided, and the serratus magnus is to be brought more fully into view by pulling the limb outwards from the body. The three parts of this muscle,

and the directions of their fibres, can then be studied, and the separation of the limb from the body may be completed by dividing the serratus magnus, levator anguli scapulæ, and omo-hyoid muscles.

4. The Scapular Region and Shoulder. — The scapular attachments of all the muscles which have been divided in separating the limb from the body should be carefully dissected out and trimmed, if this have not been fully done at an earlier stage. So also the dissection of the axillary vessels and axillary part of the brachial plexus should be completed ; the *short subscapular* nerve, ending in the *subscapularis* muscle, will probably be brought into view for the first time ; and the *subscapularis* muscle should be cleaned. The insertion of the pectoralis major should be carefully dissected, so as to display the manner in which the lower fibres of the muscle turn in under the upper part, and in which the tendon is folded so as to form a hem to the anterior border of the axilla. The latissimus dorsi should likewise be traced up to its insertion ; the bursa between its tendon and that of the teres major should be exhibited, and the *teres major* should be cleaned, and the relation between those two muscles studied. A block should now be placed under the axillary border of the scapula, and the integuments should be dissected from the great muscle of the shoulder, the *deltoid* muscle, care being taken of the cutaneous branches of the *circumflex* nerve curving round its hinder border. The manner in which the aponeurosis covering the infra-spinatus muscle splits at the posterior border of the deltoid,

so as to pass partly on to its surface and partly beneath it, should be noted. When the deltoid muscle has been properly studied, so far as it can be seen on its outer aspect, it should be divided near its origin ; the large bursa beneath it, extending between the acromion and the shoulder-joint, should be inspected, and the *posterior circumflex* artery and the *circumflex* nerve should be displayed on the deep surface of the deltoid, and the extent of the insertion of the muscle made distinct. At this stage also the attachment of the *long head* of the *triceps* muscle of the arm into the axillary border of the scapula should be fully displayed, and the manner should be noticed in which it subdivides the interval between the scapula, *teres major* and neck of the humerus, leaving a quadrangular space above, through which the *circumflex* nerve and *posterior circumflex* artery pass backwards, and a triangular space below, through which the *dorsal* branch of the *subscapular* artery takes its course. The investing aponeurosis is to be removed from the *infraspinatus* muscle, and that muscle is to be distinguished from the *teres minor* which lies on its axillary border. The nerve to the *teres minor* is to be traced from the *circumflex*, and its gangliform swelling noted : and then the *teres major* and *minor* muscles may be studied together, so as to show their antagonistic actions in rotating the humerus when elevated. The *supraspinatus* muscle, occupying the *fossa supraspinata*, is to be dissected out in its course beneath the acromion, which, however, does not interfere with its exposure. It is then to be raised from its origin, and the *supra-*

scapular nerve and artery are to be followed beneath it, as, after supplying it, they pass behind the neck of the scapula into the *infraspinatus* muscle. The *infraspinatus* is to be likewise raised, and the *dorsal* branch of the *subscapular* artery followed, as it rami-fies beneath it.

Lastly, the *subscapularis* muscle is to be dissected from its origin, the tendinous septa attached to ridges of the *subscapular fossa* are to be noted ; and the bursa connected with the shoulder-joint and situated between the muscle and the neck of the scapula is to be examined.

5. Subcutaneous Structures of Arm and Forearm.

—As a general rule, it is advisable to make a longitudinal incision down the front of the limb, and to remove the integument at once as far as the wrist, so as to get a continuous view of the subcutaneous veins and nerves throughout this region ; but sometimes the imperfect preservation of the part, or other reasons, may suggest the expediency of leaving the forearm untouched until after the brachial dissection is completed. When the skin as far as the wrist has been reflected, it will be well, before attempting to remove the subcutaneous fat, to trace the *intercosto-humeral* nerve to its distribution, if this be not already done ; then to follow the *nerve of Wrisberg* (*lesser internal cutaneous*) from its origin from the internal brachial cord to its termination between the olecranon and inner condyle of the humerus ; also to trace the *internal cutaneous* branch of the *musculo-spiral* nerve from its origin near the axilla to its distribution on the inner side of the arm. One or two

branches will also be found springing from the internal cutaneous nerve near the axilla and ramifying on the inner side of the upper arm.

The subcutaneous fat should then be removed with care in a direction from above downwards, so that the other cutaneous nerves may be detected and preserved as they escape from the aponeurosis of the limb : and we shall suppose this to be done as far as the wrist. On the inner side of the arm about the middle, the *internal cutaneous* nerve pierces the aponeurosis, either as a single trunk or after division into its two branches, *anterior* and *posterior*. On the outer side, in the line of the external intermuscular septum, appear the *two external cutaneous* branches of the *musculo-spiral* nerve. In front, at the bend of the elbow, the *musculo-cutaneous* or *external cutaneous* nerve appears by the outer side of the tendon of the biceps. At the back, over the olecranon, is a synovial bursa which sometimes becomes inflamed ; and on the inner side there is usually a small lymphatic gland. In the forearm, on the outer side, in front, will be found the distribution of the *anterior* branch of the *musculo-cutaneous*, and in the upper part the terminal twigs of the *upper external cutaneous* branch of the *musculo-spiral* nerve, while, behind, the *posterior* branch of the *musculo-cutaneous* extends as far as the wrist, reinforced by the *inferior external cutaneous* branch of the *musculo-spiral*. On the inner side the *internal cutaneous* will be followed to the wrist, its *anterior* branch in front, and its *posterior* branch on the dorsal aspect, the anterior branch sometimes joined by a small branch from the

ulnar. Near the wrist, the *dorsal* branch of the *ulnar* nerve, for the inner fingers, will be found emerging from the aponeurosis on the inner side, and the *radial* nerve destined for the outer fingers, emerging on the outer side ; while in front care must be taken not to injure the *palmar* branch of the *median* nerve, just above the annular ligament. A *palmar* branch of the *ulnar* nerve reaches the hand and is to be sought for in front of the ulnar artery.

The cutaneous veins of the arm and forearm must also be carefully studied. Those on the outer and inner sides of the forearm, into which the veins from the dorsal surface pour their contents, are collected near the bend of the elbow into a *radial* and an *ulnar* vein, while in front there ascends another smaller trunk, the *median*, which below the bend of the elbow is very constantly joined by a *deep median* branch, and immediately thereafter divides into *median-cephalic* and *median-basilic*. These, joining the radial and ulnar respectively, form the *cephalic* and *basilic* veins which ascend on the outer and inner side of the front of the arm, the cephalic remaining superficial as has been seen, and the basilic dipping in below the middle of the arm to join the deep veins.

6. Brachial Region.—The aponeurosis having been removed from the front of the arm, the *biceps* muscle extending from scapula to forearm may be first dissected out. On its inner side above will be found the *coraco-brachialis* descending with the short head of the biceps from the coracoid process, and pierced by the *musculo-cutaneous* nerve. This nerve may be at once followed down, and its muscular branches

may be exhibited ; namely, that to the *coraco-brachialis*, given off as it pierces it, and branches to the biceps and brachialis anticus as it passes down between them to become superficial on the outer side of the former. The aponeurotic part of the insertion (*semilunar fascia*) of the biceps, extending inwards between the brachial artery and median-basilic vein, and important in connection with venesection, is to be specially noted. The *brachial* artery with the *median* nerve in front of it, and with its *venæ comites* joined by the basilic, and ending in the axillary vein, may now be dissected out. At its commencement will be seen the *superior profunda* branch accompanying the musculo-spiral nerve as it passes backwards into the musculo-spiral groove ; a little lower down is the *inferior profunda* branch accompanying the ulnar nerve down to the interval between the olecranon and inner condyle of the humerus, where both become concealed by the flexor carpi ulnaris muscle ; and a little above the elbow the *anastomotic* branch will be seen extending inwards on the brachialis anticus. Also various muscular twigs are to be noted, and the *nutrient* branch entering the humerus near the level of the insertion of the coraco-brachialis.¹

¹ The artery of the upper limb is so subject to variations that it is right to attract the dissector's attention to those which he is most liable to meet with. The median nerve may be behind the vessel, and the subscapular, the two circumflex, and the two profunda arteries may all arise together from a common trunk. Frequently the brachial artery divides at a high level (or the division may even take place in the axilla), and the artery prematurely separated may be the radial ; or the usually situated trunk may furnish the radial and the

The aponeurosis is to be removed from the back of the arm and the single muscle occupying that region, the *triceps extensor-brachialis*, is to be dissected. Its long and its outer head of origin are to be raised from the musculo-spiral groove by the separation of their fibres from those continuous with the inner or short head; and a good dissector can manage this without division of the muscle, so as to lay bare the whole course of the musculo-spiral groove, and show the complete distinctness of the outer and long heads from the deep part of the muscle. If the aponeurosis be now removed from a small portion of the back of the forearm, between the olecranon and external condyle of the humerus, the *anconeus* muscle will be laid bare, and its continuity with the horizontal lowest fibres of the triceps demonstrated. Its nerve, given off from the musculo-spiral high up in the musculo-spiral groove, should also be traced down to it through the deep fibres of the triceps. The *musculo-spiral* nerve and *superior profunda* branch of the brachial artery should then be traced forwards through the external intermuscular septum, and followed down between the *brachialis anticus* internally and the origins of the *supinator longus* and *extensor carpi radialis longior* muscles on their outer side. The branches of the musculo-spiral to these two muscles and its twig to the *brachialis anticus*

interosseous of the forearm, while the abnormal high branch is termed ulnar; or lastly, the interosseous alone may be given off high. Also a vas aberrans may rise above from the otherwise normal trunk and join one of the arteries of the forearm below.

beneath the biceps should be made out ; and it may be at once traced down to its division on the upper part of the radius into *radial* nerve, continuing downwards to become cutaneous, and the *posterior interosseous* which is seen piercing the *supinator brevis* muscle to reach the back of the forearm. Alongside of the musculo-spiral nerve and its divisions is the anastomosis of the superior profunda artery with the radial recurrent, and on the inner side of the brachialis anticus is the anterior ulnar recurrent artery ascending to meet the anastomotic artery. At a later stage the dissector will find the *posterior recurrent branch* of the *ulnar* anastomosing behind the internal condyle with the *inferior profunda* and *anastomotic arteries*, and behind the external condyle the *recurrent branch* of the *posterior interosseous artery* anastomosing with a branch of the *superior profunda*. The remainder of the space in front of the elbow, bounded inferiorly and internally by the *pronator radii teres*, should be brought fully into view. In it the *median nerve* passes down internal to the bifurcation of the brachial artery, the *ulnar* artery inclines inwards and crosses beneath the median nerve, separated from it by the deep head of origin of the pronator teres, and the *radial* artery inclines outwards towards the radial nerve.

7. Front of the Forearm.—On removal of the aponeurosis of the limb from this region there comes into view on the outside the remainder of the *supinator longus* muscle with the *radial* nerve and artery internal to it, the artery giving off above, under cover of the muscle, the *radial recurrent*, which

anastomoses with the superior profunda, and, at the wrist, the *superficial volar* to the hand and a small *anterior carpal* branch. Occupying the rest of the forearm is seen a group of five superficial flexor muscles descending from the internal condyle of the humerus. Of these the outermost is the *pronator radii teres*, previously brought partially into view; its insertion on the outer side of the radius, as well as the deep ulnar head of origin which separates the median nerve from the ulnar artery beneath it, can now be fully studied. Internal to this muscle are found in series from without inwards, the *flexor carpi radialis*, the *palmaris longus* (which, however, is often absent), the *flexor sublimis digitorum*, and the *flexor carpi ulnaris*. Of these the flexor sublimis is the largest, and it will be seen to have an additional origin from the radius, along by the lower border of the pronator teres : its four tendons where they pass beneath the anterior annular ligament at the wrist are disposed in pairs, those for the third and fourth fingers being in front of the other two. On raising this muscle for its complete dissection, without dividing it, there may be obtained a complete view of the *median* nerve from the elbow to the wrist, giving branches to the superficial flexors, with the exception of the flexor carpi ulnaris ; and also in the upper part of the forearm the origin of its deep branch the *anterior interosseous*, will be seen. The course of the *ulnar* artery will now also be completely exhibited ; giving off at the upper part the *anterior* and *posterior ulnar recurrents*, passing respectively in front of and behind the inner condyle of the humerus to anastomose

with the anastomotic and inferior profunda, and immediately afterwards the *interosseous* artery, which at once divides into *anterior* and *posterior interosseous*, the latter piercing between the bones to the back of the forearm. At the wrist will be seen the origins of the *anterior* and *posterior carpal* branches of the *ulnar* artery. In contact with the artery on its inner side in the lower half of the forearm is the *ulnar* nerve, and this is to be traced up to the part already exposed behind the inner condyle of the humerus; and its branches to the flexor carpi ulnaris and inner half of the flexor profundus digitorum should be seen.

The deep muscles can now be displayed without division of the superficial group, or by dividing, at most, the radial origin of the flexor sublimis digitorum. Two of the deep muscles are longitudinal, namely, the *flexor longus pollicis* to the outside, and the *flexor profundus digitorum* more internally; and on turning these aside, one from the other, there will be seen in the lower part of the forearm the remaining deep muscle, the *pronator quadratus*, with its fibres placed transversely. Descending to the pronator quadratus, on the interosseous membrane, can be seen the *anterior interosseous* nerve and artery whose origins have been already noted.

8. The Front of the Hand.—An incision may be made down the centre of the palm and crossed by another at the roots of the fingers, and the fingers and thumb may be laid open by means of an incision down the middle of each. The palmar branches of the median and ulnar nerves may be followed. The *palmar fascia* is then to be exposed, and the firmness

with which the skin is bound down to it will be noted. The central or principal part will be seen to expand towards the fingers ; and at the further end transverse fibres will be observed binding its slips together. A thinner part will be found dying away on each side over the region of the thumb and little finger, and care must be taken to preserve on the inner side of the hand the transverse fibres of the *palmaris brevis* muscle, extending transversely from the palmar fascia to the skin at the edge of the palm. Continuing the dissection down to the fingers, a view will be obtained of the sheaths of the flexor tendons, consisting of almost cartilaginously strong transverse fibres opposite the first and second phalanges, and of little more than some delicate crucial bands over the joints. Also the *anterior digital* nerves and arteries running down the sides of the fingers, after escaping from underneath the palmar fascia, may be at once dissected out, and note should be taken of the Pacinian bodies coming off like minute bunches of grapes from the nerves, and usually capable of being easily distinguished from the fat in which they are imbedded.

On reflection of the palmar aponeurosis the *superficial* palmar arch of artery and the *median* and *ulnar* nerves will be laid bare. The superficial palmar arch will be found to be continuous with the ulnar artery, and to be completed by anastomosis with the superficial volar branch of the radial, and to give off at its commencement a *deep branch*, which sinks down between the muscles of the little finger, and afterwards the *digital* branches for the three inner fingers

and ulnar side of the forefinger ; while the thumb and radial side of the forefinger are supplied from the radial artery. Both median and ulnar nerves will be seen giving off muscular branches soon after entering the palm ; and care must be taken not to divide these when following the nerves onwards to the digits. The median nerve divides into five digital branches, one for each side of the thumb, a third for the outer side of the forefinger, and a fourth and fifth branch each splitting up to supply respectively the adjacent sides of the fore and middle fingers and those of the middle and ring fingers. The little finger and inner side of the ring finger are similarly supplied by the ulnar nerve. It may be here shortly stated that the muscular branches of the median nerve supply the two outer lumbricales muscles and the short muscles of the thumb, with the exception of the adductor and inner head of the flexor brevis ; while the ulnar nerve supplies branches to the muscles of the little finger, and sends down a deep branch along with the deep branch of the ulnar artery, to supply two inner lumbricales, the interossei, the adductor pollicis, and the inner half of the flexor brevis pollicis.

The *anterior annular* ligament of the wrist should be examined and divided ; the large and surgically important bursæ lubricating the tendons beneath it should be observed, and the tendons should be separated and followed to their insertions. The *flexor carpi radialis* will be traced into a special fibrous compartment, and on to its insertion into the second metacarpal bone. In raising the common flexors, the

origins of the *lumbricales* muscles from the flexor profundus will be brought into view, and their nerves must at this stage be traced into them; but the insertions of the lumbricales cannot be fully seen till the extensor digitorum is dissected. The sheaths on the fingers are to be cut open, and the disposition of the tendons, with the slender *vincula accessoria* attached to their deep surface, is to be seen, as well as the extent of their thecæ up into the palm.

The short muscles of the thumb and little finger must next be examined. The *abductor pollicis* is recognised by its parallel fibres and free edges as it passes down to the outer side of the first phalanx. The *opponens pollicis* is distinguished from the flexor brevis, which covers it, by its fibres being inserted into the metacarpal bone along its length; while, on the inner side of the thumb, the *adductor pollicis* is sufficiently distinct as it comes from the third metacarpal bone. The remaining mass of muscle arising by two heads and likewise inserted into the first phalanx of the thumb by two insertions, an outer and inner, constitutes the *flexor brevis*. The *abductor* and *flexor minimi digiti* are separated by the deep branches of the ulnar nerve and artery, and the *opponens minimi digiti* is distinguished by being inserted into the length of the metacarpal bone. These muscles having been seen, the deep branches of the ulnar artery and nerve are to be followed, and the artery will be a guide to the *deep palmar arch* (from the radial), which it completes. The *recurrent, superior perforating* and *palmar interosseous* branches of the deep palmar arch are to be dissected, as also the

princeps pollicis and *radial branch of the index finger* given off from the radial artery as it enters the hand.

9. **The Back of the Forearm and Hand.**—The remaining integuments being removed, the superficial veins and the distribution of the radial and ulnar nerves on the back of the hand will be followed out; the radial nerve supplying two fingers and a half completely, and the ulnar supplying the little finger and ulnar side of the ring finger, while the adjacent sides of the middle and ring fingers are usually supplied by a trunk formed partly from both nerves. The aponeurosis is to be afterwards removed from the back of the forearm, care being taken to preserve at the back of the wrist a thickened portion, the *posterior annular ligament*, which is fastened to the lower ends of the radius and ulna by septa, which form a series of compartments, through which the extensor tendons pass. A series of seven muscles will be observed to radiate from the outer edge of the humerus, the outermost of which is the *supinator longus*, already dissected; while internal to it, in series from without inwards, lie the *extensores carpi radiales longior et brevior*, the *extensor communis digitorum*, the *extensor minimi digiti*, the *extensor carpi ulnaris*, and, on the inner and upper border of this, the *anconeus*, already dissected. The others are to be dissected now; and the compartment occupied by each tendon in the posterior annular ligament at the back of the wrist is to be studied. The extensor minimi digiti will be distinguished by its passing through a separate compartment of the annular ligament,

between the radius and ulna. On the back of the hand the processes given off from the tendon of the ring finger to the tendons of the middle and little finger will be observed, as also the thin transverse aponeurotic band connecting the tendons of the middle and fore finger. The tendons of the extensor communis are to be followed on the fingers, so as to show the insertion of their middle fibres into the second phalanx, and of their lateral fibres into the third phalanx; and on clearing the expansions on the back of the first phalanges, and resuming the dissection of the *lumbricales*, it will be demonstrated that those muscles terminate in the extensor expansions, while other fibres will also be found coming from the *interossei* to join the expansions.

On raising the extensor communis digitorum, and turning it somewhat inwards, without dividing it, the five deep muscles will be brought into view, as well as the distribution of the posterior interosseous nerve and the artery of the same name. Four of the deep muscles emerge from beneath the extensor communis digitorum, namely, in series from below upwards, the *extensor indicis* passing through the sheath with the common extensor, the *extensor secundi internodii pollicis* passing through a sheath by itself, and the *extensores primi internodii et ossis metacarpi pollicis* passing through a single compartment of the annular ligament: and higher up than any of these is the *supinator brevis* muscle embracing the neck of the radius. Piercing the supinator brevis, the *posterior interosseous* nerve will be found. It supplies branches to the supinator brevis, extensor

carpi radialis breviar, extensor communis digitorum, extensor minimi digiti, and extensor carpi ulnaris, and to the extensors of the thumb and index fingers, and terminates after passing on to the back of the wrist beneath the tendon of the extensor indicis, in a gangliform swelling from which articular branches are distributed to the joint. The *posterior interosseous* artery comes into view where it passes back between the oblique ligament and interosseous membrane; its branch, the *interosseous recurrent*, is to be followed up behind the external epicondyle of the humerus, and the main vessel is to be traced to its ramifications. Also, the termination of the *anterior interosseous* artery, after piercing the interosseous membrane, is to be seen on the back of the wrist. The *radial* artery is to be dissected out in the part of its course where it winds round beneath the extensor tendons of the thumb to reach the interval between the heads of origin of the abductor indicis, and pass forwards to end in the deep palmar arch. The branches given off by the radial artery in this part of its course are also to be sought out; namely, its *metacarpal* branch supplying branches to the second interosseous space, and the smaller *posterior carpal* branch, and *dorsal arteries of the thumb and index finger*. The *posterior carpal arch* is formed by the anastomosis of the posterior carpal branches of the radial and ulnar arteries respectively, and from it the *interosseous arteries* of the third and fourth spaces spring; another dorsal branch is supplied by the *posterior carpal* of the *ulnar*.

The *transverse ligament* binding the heads of the

four inner metacarpal bones on their palmar aspect may now be dissected and divided, and the *interossei* muscles may be studied; namely, the three palmar interossei, arising each from the metacarpal bone of the finger to which it belongs, and inserted respectively into the ulnar side of the forefinger and the radial side of the ring and little fingers; and the four dorsal interossei, arising each from two metacarpal bones, the first of them, the *abductor indicis*, being the muscle between whose heads of origin the radial artery passes forwards, while the two next are inserted one on each side of the middle finger, and the fourth is inserted on the ulnar side of the ring finger.

10. The Articulations.—Before proceeding to this dissection, a careful revisal should be made of all the parts which have been dissected and preserved; the various muscles may be divided, and the student may exercise himself in recognising the cut portions by means of their attachments. The joints are then to be examined in series from above downwards.

In the *coraco-clavicular articulation* the *conoid* and *trapezoid* ligaments are to be distinguished, and the bursa between them is to be noted, as also the positions in which the ligaments are respectively tightened. The *acromio-clavicular* articulation should then be dissected, and studied in connection with the coraco-clavicular ligaments. Two ligaments passing across different parts of the scapula next demand attention, viz. the *suprascapular* ligament above the notch for the nerve of the same name, and the *coraco-acromial* or *deltoid* ligament; and

the dissector may then proceed to clear away the muscles which surround the shoulder-joint. The insertion of the *subscapular* muscle will be seen to differ from the others supporting the joint in that it pierces the capsule instead of adhering to it, and the bursa extending underneath the muscle communicates with the cavity of the joint where the capsule is pierced. An *accessory* or *coraco-humeral* band will be found strengthening the upper part of the capsule; and when the capsule has been studied the opening beneath the subscapular muscle may be enlarged to display the interior of the joint with the long head of the biceps muscle traversing it, and the *glenoid* ligament surrounding the scapular surface, and to allow the movements of the surfaces to be seen.

At the elbow, the surface of the joint having been fully exposed, the *orbicular* ligament, binding the radius to the ulna, and the *external* and *internal lateral* ligaments, are to be dissected out; and then the membranes in front and behind, which are called anterior and posterior ligament, but have no ligamentous action, may be in great part removed, so as to permit of the relations of the surfaces of the bones in different positions of the limb being observed. The *interosseous* membrane and *oblique* ligament between the shafts of the ulna and radius may next be examined, and then the region of the wrist may be dissected. Here, also, after observation of the outside of the joints, the ligamentous bands should be dissected out and openings through the weaker parts of the capsules should

be made sufficient to allow the movements of surfaces to be seen. Thus, the lower radio-ulnar articulation may be opened in front, so as to exhibit the upper surface of the *triangular cartilage*; and openings in front and behind may be made to display the movements of the radius on the first row of carpal bones, the movements of one row on the other, and of the bones of each row one on another; and until these examinations have been made and the mobility of the metacarpal bones at their carpal ends has been studied, the lateral ligaments and as many other strong bands as possible should be left intact. The articulation of the thumb with the trapezium should next be examined, and the articulations of the metacarpal bones with the phalanges,¹ and of the phalanges one with another; and afterwards the carpal joints should be thoroughly laid open to show the interosseous ligaments between them and between the carpal ends of the metacarpal bones, and to bring into view the extent of the synovial cavities.

¹ The metacarpo-phalangeal articulations of the four inner digits deserve particular attention, as they exhibit a well-marked important and unique arrangement which anatomists have overlooked. When the student has dissected out the *anterior* ligament, he will find that its fibres are arched, and act as a sling for the head of the metacarpal bone, preventing over-extension; and on bending the joints he will find that the *lateral* ligaments are put on the stretch by their metacarpal attachments being situated far back, and that thus it happens that the fingers have only one position in flexion, while in extension, the looseness of the lateral ligaments permits separation and approximation.

DISSECTION OF THE LOWER LIMB.

1. **The Gluteal Region.**—The subject being placed on its face, with blocks under the pelvis, an incision is to be made from the middle line outwards, along the crest of the ilium ; and another, commencing at the same point, is to be carried down to the lower end of the sacrum, then outwards, so as to reach a point about six inches below the great trochanter.¹ The largest cutaneous nerves of this region cross down over the crest of the ilium, and will be found the more easily by attending to the circumstance that while the adipose tissue on the back is continued down in an uninterrupted sheet over the *gluteus maximus*, a distinct deeper layer of fat fills up the hollow between the crest of the ilium and the upper border of that muscle ; and it is between the two layers that the nerves descend. The nerves descending over the crest of the ilium are :—Two or three branches from *posterior divisions* of *lumbar* nerves, which cross by the outer margin of the erector spinæ muscle, and in front of them the lateral branches of the *last dorsal* and *ilio-hypogastric* nerves. Still further forwards, below the anterior superior spine of

¹ See footnote, p. 10.

the ilium, may be found some twigs of the posterior branch of the *external cutaneous* nerve of the thigh, the main trunk of which, however, does not encroach on the gluteal region. Turning upwards round the inferior border of the *gluteus maximus* muscle are some branches of the *small sciatic* nerve, which may be sought for by cutting down on the lower border of the muscle, or may be more conveniently found when the subcutaneous fat and fascia have been reflected as far as that border. Piercing the *gluteus maximus*, close to its origin, are some small branches from the *posterior divisions* of the upper *sacral* nerves, and turning over the lower border near its inner edge the *perforating cutaneous branch* of the sacral plexus: these are to be preserved in order that their deep relations may be dissected out.

The adipose tissue is now to be removed, so as to lay bare the strong *fascia lata* (aponeurosis of the lower limb) covering the anterior part of the *gluteus medius* muscle, between the crest of the ilium and the upper border of the *gluteus maximus*; and when that border, extending from the back part of the ilium to a point a little above the great trochanter, is reached, it will be observed that the fascia splits into a deep and a superficial part, so as to invest the muscle. This circumstance having been noted, it will be unnecessary, except for a special demonstration of the fascia, to leave the layer covering the muscle; and the muscular fibres may be at once cut down on, and the surface of the muscle displayed. The inferior border of the *gluteus maximus* is to be thoroughly dissected out in its whole extent as far as its insertion

into the femur, and the synovial bursa usually present between it and the tuberosity of the ischium should be sought for. But the part of the border of the gluteus maximus internal to the ischial tuberosity bounds the ischio-rectal fossa, and the fat which fills that fossa is on no account to be interfered with, as it belongs to the perinæum.

The muscle is then to be divided close to its attachment to the ilium, sacrum and coccyx ; and as it is reflected there will come into view the branches of artery and nerve which enter it. The arteries are the *superficial* branch of the *gluteal artery* and lower down the *sciatic artery*. The nerve is the *inferior gluteal* from the *sacral plexus*. These branches of vessels and nerves must be divided to allow of the complete reflection of the muscle, and then the large bursa over the great trochanter will be brought into view, and the dissector will be able to make out clearly the insertion of the upper part of the gluteus maximus into the fascia lata, and of the lower part into the femur. As the muscle is being reflected the *small sciatic nerve*, which passes beneath its lower border, is to be carefully preserved.

The fascia lata is to be removed from the upper part of the gluteus medius, and the parts exposed by the reflection of the gluteus maximus are to be cleaned, namely—in order from above downwards, the remainder of the gluteus medius, and, emerging from the great sacro-sciatic foramen, the trunks of the *gluteal artery* and vein, the *pyriformis* muscle, the *sciatic artery* and vein, the *great sciatic nerve* (with its little artery accompanying it), and the *small sciatic*

nerve ; then the great *sacro-sciatic ligament*, and in front of it the spine of the ischium with the *small sacro-sciatic ligament* extending inwards from it, and the *pubic vessels* and *nerve* and the *nerve to the obturator internus* passing over it into the pelvis ; and emerging from the small sacro-sciatic foramen the *obturator internus* tendon, with the *gemellus superior* and *inferior* above and below it.

Piercing the great sacro-sciatic ligament will be found the *coccygeal* branch of the *sciatic* artery and the *perforating cutaneous* nerve from the sacral plexus, and either upon the surface or within the substance of the ligament two or three loops of nerve formed by the junction of the external branches of the posterior primary divisions of the last lumbar and upper four sacral nerves. The branches forming these loops may be traced back to another set of loops upon the posterior surface of the sacrum close to the foramina through which the posterior divisions of the nerves emerge. Extending outwards from the outer edge of the tuberosity of the ischium is the *quadratus femoris* muscle, which, together with the *gemellus inferior*, is supplied by a small nerve from the sacral plexus emerging under cover of the great sciatic nerve and descending between the obturator internus tendon and the bone. Internal to this are seen, descending from the ischial tuberosity, the combined origin of the *semi-tendinosus* and long head of the *biceps*, and the flat tendon of the *semi-membranosus*, from which that muscle takes its name, coming from a facet of the tuberosity higher up than the combined origin of the two other hamstring muscles, and covered by it as it

passes down. Close to the insertion of the gluteus maximus the *first perforating branch* of the *deep femoral* artery will be found upon the surface of the adductor magnus muscle.

The deep branches of the gluteal artery will be seen coming off from the parent trunk, and passing forwards beneath the gluteus medius; and they may be taken as a guide for the separation of that muscle from the *gluteus minimus* which it conceals. The gluteus medius is to be separated from the ilium, so as to show the extent of its origin as far forwards as the position of the body renders convenient; but its most anterior part is to be left to be dissected when the subject is turned. The *superior* and *inferior* branches of the gluteal artery will then be exposed; and the *superior gluteal* nerve, a branch from the lumbo-sacral cord, will be seen to supply the gluteus medius and minimus muscles, and to send a branch further forward than can at present be traced, which will afterwards be followed into the tensor vaginae femoris. The *gluteus minimus* should be detached from the ilium in the same manner as the gluteus medius, to show the extent of its origin; and, beneath it, on the upper border of the acetabulum, will be seen the posterior tendon of the rectus femoris muscle, which, however, will be better studied after the subject is turned.

In contact with the femoral attachment of the lower border of the quadratus femoris is the upper border of the *adductor magnus* muscle passing forwards and inwards, which ought to be dissected out. Above the quadratus femoris, by dissecting down to

the neck of the femur, the *obturator externus* tendon will be seen. The tendon of the obturator internus ought to be divided to display the bursa between it and the ischium, as also the remarkable manner in which it is divided into parts on its deep surface. The dissector may also divide the quadratus femoris and clear the surface of the obturator externus muscle with the handle of the scalpel, noting the insertion of the *psoas* and *iliacus* muscles into the small trochanter, without injury to other parts. Above and below the quadratus femoris will be found the ascending and transverse branches respectively of the *internal circumflex* artery, which pass backwards to anastomose with the *sciatic* artery and first *perforating* branch of the deep femoral.

2. The Popliteal Space and Back of the Thigh.—

That the form and boundaries of the popliteal space may be seen before the displacement of the hamstring muscles, a transverse incision should be made about four inches above the bend of the knee, and another about two inches below the bend, and the inner ends of these should be united by a third incision, and the flap of integument thus defined should be reflected outwards. On the removal of the superficial fat, the fascia lata, strengthened in this part by numerous transverse fibres, will be brought into view, and, towards the lower part, the *external* or *short saphenous* vein dipping in to join the popliteal vein. Immediately beneath the fascia the *small sciatic nerve* descends along the middle of the space, and is generally easily found, as it closely accompanies a large tributary of the saphenous vein, which is similarly

placed. The fascia may be reflected, and then the space is to be cleared by dissecting out the boundaries and afterwards laying bare the large vessels and nerves ; by which means the fat will be thrown into large isolated masses which can easily be removed. The space is bounded above by the *biceps* on the outside and by the *semi-membranosus* with the *semi-tendinosus* internal to it on the inside ; and is bounded below by the two heads of the *gastrocnemius* muscle, with the small belly of the *plantaris* muscle appearing from underneath the external head.

The structures within the space to be brought into view at present may be shortly mentioned. The *external popliteal* nerve lies close to the biceps muscle, and gives off some cutaneous branches, particularly the *peroneal communicating* branch descending to the short saphenous nerve at the back of the leg ; and it sends in two *articular* twigs to the outer part of the knee-joint. The *internal popliteal* nerve descends in the middle of the space and sends two or three twigs to the back and inner part of the joint, and at the lower part of the space gives off *sural* branches to the gastrocnemius, plantaris and soleus muscles, and the *tibial communicating* branch for the formation of the short saphenous. The *popliteal* artery and vein lie close together, the vein superficial and, except at the lower part, external to the artery ; and, inasmuch as the *popliteal* artery enters the popliteal space from the front by turning round the inner side of the femur, it is deeper than the internal popliteal nerve and to its inner side above, while, being destined to divide into two vessels below, the inner of which is

accompanied by the continuation of the nerve, it is naturally crossed by the nerve in the lower part of the space. The origins of the five *articular* branches of the popliteal artery will also be seen at this time, namely, an *outer* and *inner superior articular* branch, an *outer* and *inner inferior articular*, and an *azygos* branch coming off directly or from the upper and outer branch. The articular twigs of nerve already alluded to correspond with the arteries; and before the popliteal trunk is cleaned the small branch of the *obturator nerve* to the knee-joint, if not previously exhibited, should be seen piercing the adductor magnus and descending on the artery to reach the back of the joint.

The integument and fascia lata separating the popliteal from the gluteal dissection are to be divided. The great and small sciatic nerves can then be traced backwards to the gluteal dissection. The *muscular branches* of the former nerve to the biceps, semi-tendinosus, and semi-membranosus muscles may be at the same time followed, as also another to assist the supply of the adductor magnus. The three hamstring muscles are to be fully dissected out, including the short head of the *biceps*; and the shortness of the fibres of the *semi-membranosus* and the tendinous intersection of the *semi-tendinosus* are to be noted. Also the posterior surface of the *adductor magnus* muscle should be thoroughly exhibited, and the various arteries which perforate it should be attended to, namely, the four *perforating* branches of the profunda femoris, and the *popliteal*.

3. The Front of the Thigh.—The subject having

been turned, and the pelvis supported with blocks, the examination of the parts concerned in femoral hernia will be the first thing to occupy the dissector of the lower limb. An incision should be carried inwards along the fold of the groin from the anterior superior spine of the ilium ; from the inner end of the first incision another should be carried downwards for about four inches ; and from the lower end of this a third should be carried outwards transversely.¹ The integument having been reflected outwards, the subcutaneous fat or superficial fascia is to be removed in like manner, care being taken not to pass so high as to interfere with the fascia of the groin to be dissected by the dissector of the abdomen. In doing this, the lymphatic glands and all vessels and nerves are to be left undisturbed. The lymphatic glands will be seen to form two groups ; the upper group oblique, and receiving lymphatics from the integuments of the abdomen, the lower part of the back and genital organs, the lower group vertical, and receiving the superficial lymphatics of the limb. The trunk of the *long* or *internal saphenous vein* is seen ascending, receiving usually a large tributary on its inner side, and disappearing from view above. Also some smaller vessels are brought into view, namely, the *superficial epigastric* artery and vein passing upwards on the abdomen, the *superficial circumflex iliac* passing outwards and upwards, and the *superior* and *inferior superficial pudic* extending inwards. Super-

¹ The upper of these three incisions may be omitted if the dissection be arranged in concert with that of the groin, made by the dissectors of the abdomen.

ficial to the position of the femoral artery, the *crural* branch of the *genito-crural* nerve makes its appearance ; and more internally some small twigs of the *ilio-inguinal* nerve.

The fascia where the internal saphenous vein disappears is to be carefully cleared, the ducts and other structures connected with the lymphatic glands over it being preserved ; and it will be found to consist of comparatively loose structure embracing the saphenous vein, perforated by the ducts and blood-vessels of the lymphatic glands and connected round about with the firmer fascia lata ; this is the *cribriform fascia*. Passing the handle of the scalpel in underneath the saphenous vein where it dips in to join the femoral, a well-defined margin of the fascia lata will be found beneath it, namely, the *inferior falciform process* of the *saphenous opening*. Following this margin upwards and outwards it will be found to become less defined, being continued into the cribriform fascia ; but it becomes again more definite above and internal to the entrance of the vein, where it forms the *superior falciform process*. The part of the fascia lata external to this opening is what is called the *iliac portion*, while the part internal to it, in which the superior and inferior falciform processes terminate, and which, between these processes, is continued underneath the femoral vessels, is what is termed the *pubic portion*. The limits of the saphenous opening having been examined, its outer border may be divided, when the femoral artery and vein surrounded by the *crural sheath* will be fully brought into view ; and if two incisions be made through the

sheath, one over the artery and another more internally over the vein, these vessels will be seen to occupy separate compartments, while on the inside of the vein a third compartment short and blind will be found containing often a small lymphatic gland ; and it is this third compartment which is termed the *crural canal*, and which is distended by the descent of femoral hernia. Inserting the tip of the little finger into this canal, a firm resistance will be felt on the inner side, which is caused by the margin of *Gimbernat's ligament*.

The integument may now be reflected from the rest of the thigh and from the surface of the knee-joint, and the subcutaneous fat should be removed in a direction from above downwards, so as to bring the cutaneous nerves into view without injuring them as they emerge from the fascia lata. A little below the anterior superior spine of the ilium the *external cutaneous nerve* will be found emerging in two parts, the anterior a couple of inches below the posterior, and supplying the outer side of the thigh. On the fore part of the thigh, about four inches or more below the groin, the *middle cutaneous* branch of the anterior crural appears, usually divided into two parts, and descends to the front and inner side of the knee. The *internal cutaneous* nerve, also from the anterior crural, having previously given one or two offsets which accompany the internal saphenous vein, is likewise divided into two branches before it pierces the fascia lata ; the outer branch appears some inches above the knee, on the inner side of the thigh, while the inner is found lower down,

and descends to the inner side of the leg. In front of the last-mentioned nerve a branch of the *internal saphenous* nerve is to be found on the inside of the knee, and in connection with it there is sometimes a cutaneous branch from the *obturator*. On the surface of the patella is the synovial bursa, effusion into which is termed 'housemaid's knee.'

The aponeurosis is now to be removed from the front of the thigh, leaving, however, a strip from the crest of the ilium to the outer side of the knee ; and the structures exposed are to be freed from connective tissue. The *sartorius* muscle crossing the thigh in its whole length from above downwards and inwards, is to be dissected out, and its nervous supply coming off from the cutaneous branches of the anterior crural nerve is to be shown. The hollow between the upper border of the sartorius and the groin, sometimes named *Scarpa's triangle*, is next to be studied. In it are to be found, close to the outside and under cover of the sartorius, the attachment of the *rectus femoris* to the anterior inferior spine of the ilium, and, internal to this, the conjoined *psaos* and *iliacus* muscles, the iliacus to the outside and muscular, the psaos to the inside and tendinous ; and on the groove between them is the trunk of the *anterior crural* nerve. To the inner side of the nerve are the femoral artery and vein ; and to the inner side of the vessels, and passing down behind them, the *pectineus muscle*. Internal to the pectineus is the *adductor longus*, and still more internally the *adductor gracilis* muscle forms the inner border of the thigh, while in an interval

between the adductor longus and pectineus is seen a small portion of the *adductor brevis* descending from behind the former to be inserted behind the latter. The commencement of the *profunda femoris* artery will also be seen in the space, with the origins of its *external* and *internal circumflex* branches.

Below the level of Scarpa's space the femoral artery, with the vein now placed behind it, is to be followed downwards where it is covered by the sartorius muscle, and below the middle of the thigh it will be seen to become covered by a tendinous expansion stretching from the tendons of the adductors longus and magnus behind to the vastus internus in front, which conceals it till it pierces the tendon of the adductor magnus. In the passage thus formed, termed *Hunter's canal*, it gives off the *anastomotica magna*, and is accompanied by the internal saphenous nerve, a branch of the anterior crural.

The *adductor gracilis* muscle may now be examined in its whole extent, its nerve from the obturator being preserved; and the relations of the lower attachments of the *sartorius*, *gracilis* and *semi-tendinosus* muscles below the knee may be made out. Behind the lower end of the sartorius the *internal cutaneous* and *internal saphenous nerves* will be found piercing the fascia. Attention may then be directed to the region external to the upper part of the sartorius. Immediately outside it is the *tensor vaginae femoris*, connected with the strip of fascia lata which has been left; and from its insertion a deep slip of fascia extends upwards beneath the rectus femoris to the hip-

joint. Behind the tensor vaginae femoris are the remaining parts of the *gluteus medius* and *minimus*, and when the *gluteus medius* is reflected the branch of the *gluteal nerve* to the tensor vaginae may be seen. The tensor vaginae femoris is to be divided, and the *gluteus medius* and *minimus* are to be thoroughly dissected to their attachments, to show the precise extent of their insertions, as well as the bursa between them and the great trochanter, and the arch of fibres, by means of which the *gluteus minimus* is connected with the upper part of the capsule of the hip-joint. Above the hip-joint the *posterior* or *reflected tendon* of the *rectus femoris* is again seen, and the whole of this muscle may be now dissected out and the direction of its fibres noted. Also the three other parts of the *quadriceps extensor cruris*, of which the *rectus* forms a part, may be displayed, namely, the *vastus externus* and *internus*, with their fibres directed respectively downwards and inwards and downwards and outwards, and the straight-fibred *crureus* between them. Along with the muscles on the outside of the thigh there ought also to be dissected the *ascending*, *transverse*, and *descending* branches of the *external circumflex artery* anastomosing, the former two with the *gluteal* and *perforating*, and the latter with the arteries around the knee.

The branches of the *anterior crural nerve* may now be dissected out continuously from the parent trunk, and will be seen to fall naturally into two groups, a superficial cutaneous set whose only muscular branches are those to the *sartorius* and *pectineus*, and a deep set which, with the exception of the

internal saphenous branch, is entirely muscular, supplying the different parts of the quadriceps extensor femoris. The branch to the vastus internus also gives off an articular branch to the knee which descends on the internal intermuscular septum with a branch of the *anastomotica magna*. The *accessory obturator* nerve, when present, passes over the brim of the pelvis, internal to the great vessels, to aid in the supply of the pectineus muscle, which otherwise receives a twig from the *obturator* nerve.

The pectineus and adductor longus are next to be divided and dissected well up to their attachments. The *adductor brevis* will thus be brought into view with the anterior division of the obturator nerve upon its surfaces, and the course of the *profunda femoris* artery, and the origins of its four perforating branches may be studied. When these have been examined, let the adductor brevis be divided, and now the *posterior* division of the *obturator* nerve will be seen, and the branches of the obturator nerve to all the adductor muscles can be made out. The *internal circumflex* artery is to be followed, and will be seen dividing into two branches, an *ascending* or *anterior* branch distributed in the adductors brevis and gracilis and the obturator externus muscle, and anastomosing with the obturator artery, and a *transverse* or *posterior* branch which has already been seen from behind. The *obturator externus* muscle is also to be cleaned, its relation to the hip-joint noted, and the distribution of the *obturator* artery outside the pelvis examined. A small branch to the hip-joint will be seen to enter the joint at the notch of the acetabulum,

given off either by the posterior division of the internal circumflex or by the obturator artery.

The examination of the adductor magnus muscle may now be completed, and the muscle may be divided : also the examination of the quadriceps extensor cruris may be completed by first dividing the rectus femoris ; secondly, making an incision through the whole length of the vastus internus about an inch from the origin of its superficial fibres, so as to show the interval of bare bone between the origin of this muscle and the crureus ; and thirdly, making another incision vertically through the crureus to display not only the inferior limit of its origin, but also the few fibres underneath it attached to the ascending part of the synovial membrane of the knee-joint, and termed *subcrureus*.

The obturator externus and psoas and iliacus muscles may now be divided, and between the common tendon of the last two muscles and the capsule of the joint a large synovial bursa is to be noted. The capsule of the hip-joint is now to be dissected ; its deficiency at the back part can be easily brought into view by flexing and abducting the femur, and its strength in front is to be noted, where it has added to it the *accessory, ilio-femoral* or *Y-shaped* ligament descending from the anterior inferior spine of the ilium, its inner fibres directly downwards, and its outer fibres, as far outwards as the base of the great trochanter ; and it will be seen that it is in connection with this most important ligament that the anterior intertrochanteric line is so rough. The relations of the head of the femur to the acetabulum in

different positions of the limb are to be noted in connection with the subject of dislocations of the joint, namely, its projection forwards in extension with the toes turned outwards, together with the variation caused by adduction, and its projection backwards on turning the toes inwards, with the variations according to the degree of flexion and adduction. The capsule is afterwards to be opened to show the *cotylloid*, *transverse* and *round* ligaments, and the surfaces of the joint. Sometimes it is preferable, instead of dissecting the hip-joint in this way, to saw through the femur and leave this joint to be dissected by the dissectors of the pelvis, who will have an opportunity of opening into it from the deep surface of the innominate bone, so as to show the action of the round ligament without injury to the capsule.

4. The Back of the Leg.—The limb having been separated from the trunk, an incision is to be made down the back of the leg as far as the heel, and the integument reflected. In the superficial fascia of the calf, the terminal branches of the small sciatic nerve will be found. On removal of the subcutaneous fat the *external* and *internal saphenous* veins will be brought into view as far as the ankle. The external passes behind the outer malleolus, accompanied by the *external saphenous* nerve, whose double origin has been already noticed, and whose inner root lies at first beneath the fascia lata in the furrow of the gastrocnemius muscle. The *internal* or *long saphenous vein* passes in front of the inner malleolus in company with the nerve of the same name, and the terminal branches of the internal cutaneous nerve

will be found on the inner side of the leg. The aponeurosis of the limb being removed, the muscles of the calf are seen, namely, the *gastrocnemius*, and underneath it the *soleus* appearing at the sides.

When they have been cleaned, the *gastrocnemius* may be divided near its upper part and its heads of origin may be separated and dissected closely up to the femur, so as to show the transverse position of the line of origin of the inner head and the longitudinal and lower position of the outer head. Beneath the inner head and separating it from the tendon of the semi-membranosus a bursa is found which usually communicates with the knee-joint. The tendinous expansions on the opposed surfaces of the soleus and *gastrocnemius* are to be noted, and between them the tendon of the *plantaris* muscle, which may be divided. The *plantaris* muscle is sometimes absent. The *popliteal* artery is now laid thoroughly bare as far as the lower border of the *popliteus* muscle, where it divides into *anterior* and *posterior tibial*; its relation to the internal popliteal nerve at the lower part can be more fully seen; and the nerve from the internal popliteal to the *popliteus* muscle is to be found descending outside the vessels to the lower border of the muscle, beneath which it turns; also the branch to the soleus, which is of larger size, will be followed down. The *popliteus* muscle will be observed to be covered with an aponeurosis, which may be either raised at the present stage or left untouched till the knee-joint is dissected, as until then the femoral attachment and the action of the *popliteus* cannot be properly studied.

The tibial and fibular attachments of the *soleus* muscle may now be divided close to the bone, attention being paid to their extent ; and the deep surface of the soleus muscle is to be carefully cleaned, and the dissection carried into the substance of the muscle so as to exhibit the remarkable arrangement of the short muscular fibres. The *tendo Achillis*, or common tendon of insertion of the gastrocnemius and soleus muscles, is to be dissected closely down to the calcaneum, and the bursa between it and the upper part of the calcaneal tuberosity is to be displayed. The bulk of the gastrocnemius and soleus may then be removed.

The fascia covering the deep layer of muscles is now fully seen, and is to be removed ; when, on the fibular side will be found the *flexor longus pollicis*, on the tibial the *flexor longus digitorum*, and between them and partially covered by an aponeurotic connection joining those two muscles, the *tibialis posticus*. Descending superficial to the flexor longus digitorum are the *posterior tibial* artery with its *venæ comites* and the *posterior tibial* nerve. In the upper part of its course the nerve furnishes branches to the three muscles, and at the ankle a cutaneous branch which sends twigs to the heel, and passes on to the sole of the foot. The *posterior tibial* artery gives off near its origin the *peroneal*, and it also furnishes various small branches, namely, the *nutrient* artery of the tibia, a branch *communicating with the peroneal* near the ankle, and muscular branches. The *peroneal* artery will be seen to pass beneath the flexor longus pollicis, and to be surrounded by its fibres close to

the fibula, and to give off, besides muscular twigs, the *nutrient* artery of the fibula, the *anterior peroneal* perforating the interosseous membrane near its lower end, and the *communicating* branch, the other extremity of which has been seen in connection with the posterior tibial. The region between the inner malleolus and the calcaneal tuberosity is to be dissected so as to show the thickened band of the aponeurosis of the limb extending between those two points and termed *internal annular* ligament; the synovial sheaths surrounding the tendons of the three deep muscles of the back of the leg are to be laid open, and the relations of the tendons to one another, to the bones, and to the posterior tibial artery and nerve are to be noted.

5. The Sole of the Foot.—The foot is to be conveniently disposed on a block; an incision is to be made along the middle as far as the toes, and there crossed by a transverse one. The integument being reflected, the *plantar cutaneous* branch of the *posterior tibial* nerve is to be followed out, and the plantar aponeurosis cleared from fat, when an inner and outer set of small nerves and vessels will be found appearing in the furrows between its middle or main portion and the outer and inner parts which spread over the sides of the sole. The skin of the toes is to be laid open, and the sheaths of the flexor tendons are to be exposed, and the *digital* arteries and nerves are to be dissected out. The plantar aponeurosis is then to be separated from the subjacent structures, and divided at the back part, when the superficial layer of muscles will be brought into

view, consisting of *abductor pollicis* internally, *flexor brevis digitorum* in the middle, and *abductor minimi digiti* externally. The *flexor brevis digitorum* is to be divided near its calcaneal end, and its branch of nerve from the internal plantar found. By the reflexion of the flexor brevis, the tendon of the *flexor longus digitorum*, dividing into four, will be brought into view; crossed by it and connected with it is the tendon of the *flexor longus pollicis*, and joining it from behind the partly fleshy, partly tendinous *musculus accessorius*; while connected with the tendons into which it divides are four small fleshy slips, the *lumbricales* muscles. Crossing the *musculus accessorius*, and passing forwards, are the *external plantar* artery and nerve, the artery disappearing beneath the outer tendon of the flexor longus digitorum to be continued into the plantar arch, while the nerve, after giving off a branch to the *musculus accessorius*, one to the *abductor minimi digiti*, which will be better seen by partially dividing the broad origin of that muscle from the calcaneum, and one to the *flexor minimi digiti*, sends in its deep branch along with the plantar arch and continues on to furnish digital branches to the outer side of the fifth toe and the adjacent sides of the fourth and fifth. The calcaneal origin of the *abductor pollicis* may now be divided, and the bifurcation of the posterior tibial artery and nerve into *external* and *internal plantar* will be seen, and the internal artery and nerve may be followed on from their origin. The *internal plantar* artery, much smaller than the external, will be traced to the inner side of the great toe; the *internal*

plantar nerve, larger than the external, will be seen giving off a branch to the abductor pollicis, and dividing into four digital nerves supplying respectively the inner side of the great toe, and the adjacent sides of the first and second, second and third, and third and fourth toes ; and from the first of these branches the nerve to the flexor brevis pollicis will be found coming off, and from the second and third the nerves to the two inner lumbricales. At this stage of the dissection the tendinous sheaths on the toes should be dissected out and divided, and the arrangement of the tendons within them should be examined ; but the dissection of the insertions of the lumbricales must be left till a later period.

The posterior tibial nerve and the tendons of the long flexors must now be divided below the ankle and reflected, and the short muscles of the great and little toes, together with the *plantar arch* and *deep* branch of the *external plantar* nerve, are to be dissected out. In reflecting the tendons, care is to be taken not to injure the nerves to the two outer lumbricales, coming from the branch named. The other twigs from the same branch are distributed to the adductor pollicis, the transversus pedis and the interossei ; the two outer interossei may, however, receive their twigs from the inner digital branch of the external plantar. The *abductor pollicis* will be distinguished by having its fibres collected to a distinct tendon on the inner side of the great toe ; the *flexor brevis pollicis* lies next, and is fleshy and inserted in two heads, with which are connected the two sesamoid bones of the ball of the toe ; the *adduc-*

tor pollicis, placed to the outside of the flexor, is a wide muscle crossing the sole obliquely, so as to conceal to a considerable extent the interossei; and the *transversus pedis* lies transversely, arising close to the heads of the metatarsal bones, and must not be destroyed in dissecting out the vessels and nerves superficial to it. The *flexor minimi digiti* will be easily distinguished from the *abductor* by being fleshy and arising from the fifth metatarsal bone.

The flexor brevis and adductor pollicis are now to be divided, and the exact extent of their origins is to be carefully made out. A complete view of the plantar arch will thus be obtained, showing its inosculation in the first interosseous space with the dorsal artery of the foot. Its four digital branches to the three outer interdigital spaces and outer side of the little toe will be seen, and also the three posterior perforating branches passing up through the three outer interosseous spaces. In the first interosseous space will be found the *arteria magna pollicis* usually coming off from the termination of the dorsal artery of the foot, but sometimes continuous rather with the plantar arch; it supplies the adjacent sides of the first and second toes and a branch to the inner side of the great toe. The interossei muscles will be better dissected at a later stage.

6. The Front of the Leg and Dorsum of the Foot.

—A block may be placed under the knee, and on removing the remaining integument and the subcutaneous fat, there will be found, above, the distribution of *cutaneous* branches of the *external popliteal* nerve, and in the lower part of the leg the trunk of

the *musculo-cutaneous* nerve piercing the fascia lata. On the dorsum of the foot the arch of vein from which the external and internal saphenous take origin will be seen ; the *external saphenous* nerve will be traced principally to the outer and also to the inner side of the little toe, the *internal saphenous* nerve to the inner side of the foot, and the *musculo-cutaneous* nerve to the inner side of the great toe and the adjacent sides of the second and third, of the third and fourth, and of the fourth and fifth toes; while the *anterior tibial* nerve will be found becoming cutaneous between the first and second metatarsal bones, and supplying digital branches to the adjacent sides of the first and second toes.

The aponeurosis is now to be removed, with the exception of the bands constituting the *anterior annular ligament*. Of these, the most important forms a strong loop round the extensor longus digitorum and peroneus tertius muscles, and is attached to the fore part of the calcaneum in the hollow between it and the astragalus ; somewhat irregular bands continue inwards from this loop, the strongest band passing superficial to the extensor pollicis and on the deep surface of the tibialis anticus. The upper part of the aponeurosis of the leg had better be removed from below upwards, as it gives origin on its deep surface to muscular fibres. The four muscles of the front of the leg are now to be dissected fully out. Two of them are seen in the whole extent of the leg, namely, the *tibialis anticus* internally, and the *extensor longus digitorum* externally ; continuous with the lower border of the latter is the origin of the *peroneus*

tertius, and rising deeply between the two longer muscles is the *extensor pollicis*. Lying deeply on the interosseous membrane are the *anterior tibial* vessels and nerve: the artery will be seen piercing the membrane from behind, and immediately giving off a *recurrent* branch to the knee, while near the ankle it gives off an *external* and *internal malleolar* branch. The nerve may be traced back through the fibres of the extensor longus digitorum, and downwards beneath the anterior annular ligament to the foot. It distributes branches to the four muscles upon the front of the leg and divides upon the dorsum of the foot into two branches, an external, enlarged at its termination like the posterior interosseous nerve of the arm, and supplying branches to the extensor brevis digitorum and the articulations of the foot, and an internal, cutaneous in its distribution. Beneath the peroneus tertius will be found, piercing the interosseous membrane, the anterior peroneal artery.

On the foot, after the tibialis anticus and peroneus tertius have been traced to their insertions, and the extensor pollicis to the great toe, the tendons of the extensor longus digitorum to the four outer toes are to be dissected out; also the *extensor brevis digitorum* arising from the fore part of the os calcis and passing obliquely forwards and inwards to the four inner toes; and the nerve to that muscle is to be found coming from the external division of the anterior tibial. The continuation of the anterior tibial artery, called *dorsal* artery of the foot, is to be followed to its disappearance between the heads of origin of the first

dorsal interosseous muscle ; and its relation to the tendon of the extensor pollicis, which crosses it, is to be noted. Its *tarsal* and *metatarsal* branches are to be traced, with the *dorsal digital* branches derived from the latter. The insertion of the lumbricales muscles into the expansions of the extensor tendons of the four outer toes should now be seen, and the mode of insertion of the middle part of each expansion into the second phalanx and of the lateral fibres into the last phalanx should be made out.

The *peroneus longus* and *brevis* muscles are now to be dissected. Their nerves will be found given off from the *musculo-cutaneous* ; and the division of the external popliteal nerve into musculo-cutaneous and anterior tibial will be found in close connection with the origin of the *peroneus longus*. The *peroneus brevis* will be followed behind the external malleolus to its insertion into the tuberosity of the fifth metatarsal bone. The *peroneus longus* will be seen entering the groove on the cuboid bone ; but the sheath which contains it in its course across the sole to the base of the first metatarsal bone cannot be opened at present without injury to the ligaments of the foot.

Lastly, the *interossei muscles* are to be dissected ; and to do this thoroughly the *transverse metatarsal ligament* must be sacrificed. Three *plantar interossei* will be found arising from the plantar surface of the three outer metatarsal bones, and inserted on the inner sides of the corresponding first phalanges ; and four *dorsal interossei* arising from the adjacent metatarsal bones bounding each of the interosseous

spaces, are inserted, the innermost into the inner side of the first phalanx of the second toe, and the others into the outer sides of the second, third, and fourth toes.

7. The Knee-joint and Articulations of the Foot.

—The insertions of muscles around the knee, if not thoroughly followed out previously, are to be so now ;¹ and the anastomoses of the *articular* branches of the *popliteal* artery, the *anastomotic* of the *femoral* and the *recurrent* of the *anterior tibial*, followed as far as possible. The *vasti* and *crureus* muscles are to be dissected as separate as possible from the underlying superior and lateral pouches of the joint, and the *ligamentum patellæ* is to be brought out clearly, the bursa between it and the tibia being laid open and attended to the more particularly, as it is liable to inflammation. The *internal* and *external lateral* ligaments are to be dissected out, and the flexion, extension, and rotation in the flexed position, allowed at the knee studied. The *semi-membranosus* tendon is then to be followed to its three divisions, one taking part in forming the *posterior ligament*, another passing forwards under cover of the internal

¹ In the vicinity of the knee-joint a number of bursæ are to be found, two of which, namely, that placed under the common tendon of the quadriceps muscle and the one which separates the inner head of the gastrocnemius from the semi-membranosus, usually communicate with the joint. The others are to be found respectively in front of the patella, beneath the patellar ligament, beneath the tendons of the gracilis and semi-tendinosus, beneath the tendon of the biceps, and between a portion of the semi-membranosus tendon and the groove on the tibia.

lateral ligament, and the third expanding into the aponeurosis of the popliteus muscle. This aponeurosis is to be removed, and the *popliteus* muscle is to be followed up to its insertion into the femur under cover of the external lateral ligament. The joint may then be opened from above, in front of the lateral ligaments; and in the interior will be found a pad of fat, or so-called Haversian glands, below the patella, with the *ligamentum mucosum* passing from the middle of it to the fossa between the condyles of the femur, and two lateral folds called *alar* ligaments extending laterally from it. The extent of the synovial membrane should be studied; the *external* or *anterior crucial*, and the *posterior* or *internal crucial* ligament should be shown, and their degree of tension in different positions of the joint noted, and the loose parts of the walls of the joint should be removed so as to let the *semilunar cartilages* be more fully seen, and to allow of a detailed inspection of the relations of those cartilages and of the articular surfaces of the bones in different positions of the joint.

The upper and lower tibio-fibular articulations are next to be studied, as well as the interosseous membrane; and for this purpose the muscles are to be completely removed from the leg. The upper tibio-fibular joint presents an *anterior* and *posterior* ligament and a synovial membrane for study. The lower joint presents an *anterior* and *posterior* ligament and a long band, the *transverse* ligament, which deepens the concavity for the ankle-joint below the posterior ligament, and also an *interosseous ligament* which, however, cannot be seen till, at the end of the

whole dissection, the bones are separated ; its synovial cavity is a prolongation from the ankle-joint. The ankle-joint presents little which can be called an anterior or posterior ligament, although scattered fibres in its capsule are described by those names : but it has strong *lateral* ligaments, the internal one spreading out below to be attached to the scaphoid, calcaneum and astragalus, the external consisting of three distinct parts related one to another as the edges diverging from one angle of a cube, the anterior and posterior parts attached to the astragalus, and the middle part descending to the os calcis. These lateral ligaments are to be cleaned and the rest of the wall of the joint removed ; and the movements are then to be studied. The articulations of the astragalus, with the calcaneum and scaphoid, next demand attention ; and the dorsal membrane uniting the head of the astragalus with the scaphoid may be removed, as also the synovial membrane between astragalus and calcaneum behind, so as to allow the movements to be properly seen ; but the *interosseous astragalo-calcaneal* ligament can only be seen from the side at present, and cannot be laid bare till the bones are separated. The *inferior* and *external calcaneo-scaphoid* ligaments, which support the head of the astragalus, can, however, be studied now, and it will be seen how elasticity is secured to the inner arch of the foot by the weight of the body forcing down the head of the astragalus so as to make tense the inferior calcaneo-scaphoid ligament.

The remaining ligaments of the dorsum and sole

of the foot should be thoroughly cleaned. Numerous short dorsal bands will be found uniting the tarsal and metatarsal bones. On the under surface fibres will be seen prolonged from the tendon of the tibialis posticus to the three cuneiform and the cuboid, and the second, third, and fourth metatarsal bones; also the *ligamentum longum plantæ*, or long calcaneo-cuboid ligament, will be seen, and, after its removal the short *calcaneo-cuboid*.

The transverse and longitudinal arches of the foot should now be studied, and the ligaments of the phalangeal and metatarso-phalangeal articulations; and the bones may finally be disarticulated, to show the extent of the synovial membranes and the disposition of the various interosseous ligaments.

DISSECTION OF THE HEAD AND NECK.

1. **Scalp and Back of the Neck.**—The subject being placed with the face downwards, and a block put under the chest, let an incision be made from the seventh cervical spine to the vertex of the head, and let two others be made respectively from the ear and from the tip of the shoulder, to meet the first incision at its upper and lower extremities. On reflexion of the flap of integument thus marked out, there will be brought into view, in the neck, principally portions of two muscles, viz. the cervical part of the *trapezius*, with cutaneous branches of the posterior divisions of the third, fourth, and fifth cervical nerves on its surface, and, external to it, the posterior part of the cranial attachment of the *sternomastoid*; while between the two is a small and variable extent of the *splenius*, a broad muscle with fibres directed upwards and outwards; and sometimes even a portion of the *complexus* is visible internal to the cranial attachment of the splenius. Piercing the upper part of the complexus and trapezius is the *great occipital* nerve, derived from the posterior division of the second cervical; and external to it the *occipital* artery, a branch of the external carotid:

these are both to be traced upwards on the scalp. Nearer the middle line a small branch from the *third cervical* nerve is to be found ; while further out, along the posterior border of the sterno-mastoid, the *small occipital* nerve, a branch of the cervical plexus, will be seen ascending. Beneath these structures is the posterior fleshy belly or occipital part of the *occipito-frontalis* attached to the superior curved line below, and ending above in its aponeurosis, which is likewise to be brought into view, so as to show its close connection with the subcutaneous fat, and its free movement on the pericranium underneath. By dissecting close to the back of the ear, the little *retrahens aurem* muscle will be found passing forwards from the mastoid process, and underneath it the *posterior auricular* branch of the external carotid artery, as also the *posterior auricular* branch of the facial nerve supplying the *retrahens aurem* and occipital part of the *occipito-frontalis* muscle. By turning the head well to one side, and making an additional incision, the *attollens aurem* muscle, descending to the ear, and the *attrahens aurem* in front of it, may be also dissected at present ; or they may be left till another opportunity.

If the small occipital nerve be followed down it will be found to emerge from beneath the posterior border of the sterno-mastoid, and a little lower the trunk of the *great auricular* nerve will be seen turning over the border of the muscle. Still lower the *superficial cervical* nerve passes forwards round the posterior edge of the muscle, but this nerve is not to be followed at the present stage of the dissection.

Passing backwards across the space between the sterno-mastoid and the trapezius are the *spinal accessory* nerve, and lower down some branches of the *cervical plexus* destined for the supply of the latter muscle.

The cervical part of the trapezius should be divided by means of a vertical incision made in co-operation with the dissector of the upper limb; and along with him the *spinal accessory* nerve and *superficial cervical* artery descending on the deep surface of the trapezius should be dissected out. Along with the spinal accessory the branches from the cervical plexus already mentioned are to be followed. The different nerves are often freely connected with one another beneath the muscle. The *splenius* muscle, which can be distinguished from the portions of the erector spinæ along its lower border by its fibres passing from spines to transverse processes, is next to be cleaned, and afterwards divided vertically about an inch from the middle line, and its attachments dissected up to their bony connections, so as to distinguish the *splenius capitis* and *splenius colli*, and bring into view the stout muscle on which it lies, namely, the *complexus*, as also the thin strip of fibres, the *trachelo-mastoid* muscle ascending between the splenius and the outer part of the complexus muscle. Also the *occipital* artery close to the skull is to be cleared in the part of its course beneath the trachelo-mastoid and splenius muscles, and its *cervical* branch is to be followed downwards.

If in conjunction with the dissector of the arm

the levator anguli scapulæ be dissected out and drawn aside, a view will be obtained of the *scalenus medius* and *scalenus posticus* muscles descending to the first and second ribs respectively. Piercing the middle scalene muscle the *nerve to the rhomboids*, and below it the *external respiratory nerve of Bell*, both from the brachial plexus, will be observed, and at the anterior border of the levator scapulæ, in normal circumstances, the dissector may expose the termination of the *transverse cervical* artery from the thyroid axis of the subclavian breaking up into superficial cervical and posterior scapular branches.

The complexus muscle is to be detached from the occipital bone and reflected, and the *deep cervical* artery, anastomosing with the cervical branch of the occipital, is to be dissected. Upon the deep surface of the complexus there will be found the internal branches of the posterior primary divisions of the second, third, fourth, and fifth cervical nerves. These pass from the neighbourhood of the intervertebral foramina inwards beneath the complexus muscle, and their cutaneous branches, already noticed, reach the surface near the middle line. The first three are occasionally joined to one another as they lie beneath the muscles. It will now be observed that the muscles laid bare fall into two groups, one above and the other below the spine of the axis. Those below the axis, consisting of the *semispinalis* and muscles covered by it, are to be left to the dissectors of the upper limbs, while those above the axis may be dissected forthwith. Passing obliquely upwards and outwards from the spine of the axis to the transverse

process of the atlas is to be seen the *obliquus capitis inferior* muscle, and passing up from the transverse process of the atlas to the skull is the *obliquus capitis superior*; extending upwards from the spine of the axis to the occipital bone is the *rectus capitis posticus major*, while partly under cover of it and partly visible on its inner side is the *rectus capitis posticus minor* extending to the occipital bone from the posterior tubercle of the atlas. The *great occipital* nerve is seen passing over these muscles; and in the triangular space left between the obliqui and recti muscles will be found the *sub-occipital* nerve emerging above the atlas, and giving off branches to all four muscles, and the *vertebral* artery passing inwards over it.

Should the above dissection be completed in the first two days, the dissector may employ the remaining two days before the subject is turned on its face either in dissecting the brain, if the subject be fresh and it be decided to dissect the brain *in situ*, or in dissecting the orbit according to the directions given at page 114.

2. Exposure and Removal of the Brain.—The brain may be removed, with the subject placed either on the back or on the face; and, although the position on the back is that more frequently chosen, there is good authority in favour of the position on the face, and it is questionable that it does not afford as much facility as the other. The process of exposure is the same in either case.

In a *post-mortem* examination of a body to be afterwards seen by the friends of the deceased, it is

advisable to divide the scalp by an incision from ear to ear, so that the appearance of the face shall not be injured when the calvarium is replaced after examination of the brain ; but for anatomical purposes it is preferable to direct the incision along the middle line from above the nose to the occipital tuberosity. The knife is to be carried quite down to the bone, dividing the integument, subcutaneous fat, occipitofrontal aponeurosis and the pericranium ; and with the fingers and handle of the scalpel the pericranium is then to be detached from the skull and the scalp is to be reflected. At the sides, however, it will be found that the *temporal aponeurosis* will remain attached along by the temporal ridge with the *temporal* muscle taking origin beneath it ; and these structures must be divided at the level at which the saw is to be carried round the skull. This level should be in front about an inch above the orbits, and behind should pass through the protuberance or most prominent part of the occipital bone, a little lower down when the subject is on its face than when it is placed on its back. Only the external table of the skull is to be sawn through : the inner table should be left uninjured. To divide the inner table resort is to be had to the chisel and mallet, with which it may be cracked completely round by a few sharp strokes. The chisel may then be inserted in the middle line in front or behind, and turned forcibly round so as to tear the calvarium away from the *dura mater* on its deep aspect.

In the middle line of the exposed part of the *dura mater* will be seen a venous channel contained

in its substance, the *superior longitudinal sinus*, which should be opened into, so as to exhibit its shape and dimensions; and on each side of this will be seen, particularly in old subjects, irregular bodies, the *Pacchionian corpuscles*, which will be understood more distinctly when the dura mater is raised. Also the *middle meningeal* artery is seen branching on each side. The dura mater is now to be divided on a level with the edge of the skull, except only where it is deeply connected in the middle line in front and behind. The *arachnoid space* will be thus opened into, and the dura mater should be raised on each side towards the middle line. Then numerous veins from the surface of the brain will be seen crossing the space and turning forwards on the walls of the superior longitudinal sinus before entering that channel, so that the currents of blood emerging from them are opposed to the current in the sinus. On dividing these veins the cerebral hemisphere may be slightly turned outwards, and the *falx cerebri*, a process of the dura mater, will be seen descending in the longitudinal fissure between the hemispheres, being attached in front to the crista galli of the ethmoid bone, and behind to a transverse septum of dura mater, the *tentorium cerebelli*, and having in its free edge between those attachments a minute vein, the *inferior longitudinal sinus*. The reflected lateral portions of the dura mater and the falx may now be divided vertically with the scissors a little behind the attachment into the crista galli.

The brain may be examined *in situ*, or removed in order that it may be hardened with spirit. If it

is not intended to use preserving agents, examination of the upper and interior parts of the brain *in situ*, before removal of the basal parts, is to be preferred to immediate removal, as it allows the interior to be seen without accidental laceration or disturbance, and when the anterior parts have been first disposed of, the base can be spread out advantageously for display.

The method of removal varies according to the position of the subject.

If the subject be on its face, the posterior lobes of the hemispheres should be raised ; the edge of the knife should be applied to the free margin of the tentorium close to the border of the petrous portion of the temporal bone, and by a firm cut the *fourth* and *fifth* nerves may be divided along with the tentorium without being previously brought into view. The knife is then to be carried along the outer attachment of the tentorium to within an inch of the middle line ; at the middle of the free edge the *veins of Galen*, emerging from the interior of the brain, are to be divided, and tentorium and falx may then be thrown back, the lobes of the cerebellum raised, the spinal cord and *vertebral* arteries in front of it divided as low down in the spinal canal as possible, and the nerves divided in series from below upwards, close to the places where they pierce the dura mater. After dividing the *third* pair, the *infundibulum* will be seen descending to the *pituitary body* in the sella turcica, and on division of it, on each side further forward will be found the *internal carotid* artery with the *optic* nerve immediately in front of it;

and on division of these the brain can be removed, care being taken to raise with it the *olfactory* lobes from their resting-places on the cribriform plate of the ethmoid bone.

If the subject be lying on its back when the brain is to be removed, the anterior lobes of the hemispheres, with the *olfactory* bulbs, are to be first raised, the *optic* nerves, *internal carotid* arteries, *infundibulum* and *third* pair of nerves are then to be severed; and after that the *tentorium* is to be divided near its attachment, the *fourth* and *fifth* nerves being divided along with it, then the other nerves in series, and afterwards the *vertebral* arteries and spinal cord; while last of all, when the brain has been dislodged, it is necessary to divide the *veins of Galen* to prevent the choroid plexus being torn from its place.

If the brain is to be preserved, it will be advisable, if possible, to examine the blood-vessels of the base at once, and the whole or the greater part of the arachnoid and pia mater should be removed, so as to lay open the sulci and allow ready entrance to the spirit. The cerebellum should also be lifted up a little from the posterior lobes of the cerebrum to allow the pia mater to be dissected at the back of the corpus callosum, so as to give the spirit ingress into the ventricles.

3. Base of Brain and its Vessels.—Some folds of calico moistened with spirit having been arranged like a nest on a plate, so as to support the hemispheres, the brain is laid on it with the base turned upwards. The student will then observe, in the first place, the main masses of the encephalon. He will

notice that the *medulla oblongata*, the expanded continuation upwards of the *spinal cord*, is terminated above by a transverse structure, the *pons Varolii*, that the pons is continued on each side into a grey laminated structure, the *cerebellum*, which forms much the larger bulk of the part which was removed from beneath the tentorium ; and that above the pons Varolii a pair of divergent pillars, the *crura cerebri*, pass upward to disappear under cover of the cerebral hemispheres. He will further note, in a general way, the projection of each *hemisphere* into *anterior, middle, and posterior lobes*, and the separation of the two first by the *fissure of Sylvius* ; also the existence of a *rhomboid space* between the two middle lobes, bounded behind by the *crura cerebri*, and in front by the *optic commissure*, from which the *optic nerves* take origin and the *optic tracts* diverge in a backward direction.

The arrangement of the arachnoid membrane or serous envelope of the brain, and of the pia mater or vascular covering, may now be examined. The region between these two membranes constitutes the *subarachnoid space*, and demands particular attention, not only over the sulci of the cerebellum and cerebral hemispheres, but over the rhomboid space, the fissure of Sylvius, and round the *isthmus cerebri*, or narrow part between the cerebrum and cerebellum ; also over the interval between the cerebellum and medulla oblongata, called the opening into the *fourth ventricle*.

The arteries to be studied on the surface of the brain are the following. Behind are the *vertebral* arteries on the medulla oblongata, giving off the *pos-*

terior spinal, the *anterior spinal*, and the *posterior inferior cerebellar*; the *basilar* artery formed by the union of the two *vertebrals*, lying on the pons Varolii and giving off the *anterior inferior cerebellar* arteries, the *superior cerebellar* arteries and small *transverse* arteries, and the *acoustic* artery to supply the internal ear; and the *posterior cerebral* arteries, the two vessels into which the *basilar* divides. At the origin of these arises a mesial bunch of minute vessels which dip into the brain at the *posterior perforated spot* at the back of the rhomboid space; and further out the *posterior communicating* artery on each side joins the *posterior cerebral*. Further forwards are the divided *internal carotid arteries*, giving off the *posterior communicating*, and dividing into *anterior* and *middle cerebral*. At its commencement the *middle cerebral* artery gives off the *choroid* artery, which is a vessel entering by the fissure between the *crus cerebri* and *middle lobe* of the brain to supply the *choroid plexus* of the *lateral ventricle*; also a brush of small vessels dipping directly into the brain, and by their apertures of entrance forming the *anterior perforated spot*. Joining the *anterior cerebral* artery with its fellow is the exceedingly short *anterior communicating* artery, which closes in front the circle of anastomosis completed behind by the *posterior cerebral* and *posterior communicating* arteries, and known as the *Circle of Willis*.

The surface of the brain is now to be more fully exposed by the removal of the *arachnoid* and *pia mater*, care being taken not to injure the origins of the nerves; and the arteries also are to be taken

away as soon as their relations to the nerves have been noted.

On laying open the fissure of Sylvius, the *gyri operti*, or *island of Reil*, will be brought into view, lying in the bifurcation of the fissure, and bounded in front and behind by the *orbital* and *temporal* convolutions, and externally by the *lower frontal*, a convolution which has received much attention in the history of the malady known as aphasia. The origins of the *olfactory tract* are next to be noted. The lower portion of one or both of the anterior lobes may then be pared away so as to exhibit the *reflected part* of the *corpus callosum* lying in the longitudinal fissure, and terminating in two *peduncles* directed backwards and bounding the *lamina cinerea*, a delicate part of the floor of the brain, descending to be attached to the upper surface of the optic commissure. Behind the optic commissure, the contents of the rhomboid space claim attention : namely, from before backwards, the *tuber cinereum* or lamina of which the infundibulum is a prolongation, the *corpora albicantia*, the posterior perforated spot, and the *third* pair of nerves. The *fourth* pair of nerves and the *optic tracts* may at this stage be followed round the *crura cerebri* to their origins by raising the cerebellum carefully ; but they will be seen more fully afterwards from above. The *fifth* nerve is seen emerging from the pons Varolii in two parts, the small motor root placed higher up than the larger or sensory portion. Between the pons and the medulla oblongata is to be found, close to the middle line, the *sixth* nerve ; and further outwards, in the angle between the pons, me-

dulla and the *flocculus* or *subpedunculated lobe* of the cerebellum, is the *seventh* nerve, in two parts, the innermost of which is the *portio dura* or *facial*, and the outer the *auditory* nerve or *portio mollis*.

The *medulla oblongata*, on being carefully denuded of its membranes, is seen to exhibit on each side of the middle line three elevations—the *anterior pyramid*, the *olivary body*, and the *restiform body*, the latter entering the cerebellum. In front of the olivary body is the *ninth*, or *hypoglossal* nerve; and between the olivary and restiform bodies are the three nerves constituting the parts of the *eighth*, viz. above, a small division, the *glosso-pharyngeal*, below it the much larger *vagus* or *pneumogastric*, and lowest of the three the *spinal accessory*, the whole origin of which can seldom be removed with the brain. In the anterior mesial fissure is to be laid bare the *decussation* of the pyramids, and beneath the olivary body the *arciform fibres* will be seen.

4. Dissection of the Brain from above.—This dissection is made best on a preserved specimen, or on a brain *in situ*; but if the brain be in the recent condition, and has already been examined from below, care must be taken in turning it over, so as not to allow the hemispheres to fall separate and tear the internal parts. The convolutions and sulci may be first examined, but these can only be studied with advantage on a hardened specimen denuded of its membranes.

Behind the first portion of the fissure of Sylvius and beneath its posterior limb will be noticed the *temporo-sphenoidal* lobe, and the three convolutions

of its outer surface will be found to be continuous behind with the parietal and occipital lobes, the *superior* one passing into the *supra-marginal*, and the *middle* into the *angular* gyrus of the parietal lobe, while the *inferior* reaches back into the occipital lobe as the lowest of the *annectant convolutions*. The *fissure of Rolando* extends downwards and slightly forwards from the vertex to a spot a little behind the place where the fissure of Sylvius divides into its two limbs, and it may always be readily distinguished on account of its position between the first and second vertical convolutions on the outer surface of the hemisphere, counting from before backwards. The region in front of it, the *frontal lobe* of many authors, exhibits a vertical convolution, the *ascending frontal*,¹ and three others which run in an antero-posterior direction and are named the *superior*, *middle* and *inferior frontal* convolutions. On the orbital or under surface of the frontal lobe these three convolutions are arranged round the *tri-radiate sulcus* in such a manner that the superior is continuous with the *inner*, the inferior with the *posterior*, and the middle with the *anterior* convolution.

The *parietal lobe* lies behind the fissure of Rolando, and on the outer surface of the hemisphere is directly continuous with the occipital and the posterior part of the temporo-sphenoidal lobes, but on the inner surface of the hemisphere it is, as will be afterwards noticed, clearly demarcated from the occipital lobe by the *parieto-occipital fissure*. The upper end of this

¹ It is well to note that this convolution is named by Gratiolet the 'anterior ascending parietal.'

fissure, however, indents the margin of the hemisphere, and an imaginary line drawn downwards from this, upon the outer surface, would cross the annectant convolutions and limit the parietal lobe behind. Within the parietal lobe will be noticed an *upper* and lower lobule separated from one another by the *intraparietal sulcus* which, commencing below behind the fissure of Rolando, runs upwards for some little distance and then bends backwards through the lobe. The inferior parietal lobule is further subdivided into two convolutions, the *supra-marginal* which surrounds the upturned end of the posterior limb of the fissure of Sylvius, and the *angular* behind it. Immediately behind the fissure of Rolando lies the vertical or *ascending parietal convolution*. Upon the outersurface of the *occipital lobe* three convolutions are usually described, the *superior*, *middle*, and *inferior*.

Within the longitudinal fissure the disposition of the arachnoid and pia mater is to be noted, and the anastomoses of the *anterior* and *posterior cerebral* arteries; the *corpus callosum* will be seen at the bottom of the fissure. With a large knife with a wet blade one hemisphere is now to be cut horizontally across a little above the level of the corpus callosum. The mesial surface of the hemisphere which is still uncut should now be examined. Passing from the front backwards along the edge of the hemisphere is the *marginal convolution*, and close to the corpus callosum lies the *callosal convolution* or *gyrus fornicatus*. These two convolutions are separated from one another by the *calloso-marginal fissure*, which when traced backwards is found to turn upwards and terminate

on the edge of the hemisphere a little in front of the parieto-occipital fissure. Between the callosomarginal and the parieto-occipital fissure lies the *quadrate* lobule. Further back upon the inner surface of the occipital lobe the *calcarine fissure* is seen extending backwards, and the portion of the surface between it and the parieto-occipital fissure is the *cuneate* lobule. The lower portion of the mesial surface cannot be examined until the lateral and the third ventricles have been studied. But in displaying these cavities the student must leave the lower portion of one hemisphere intact in order to see the remaining convolutions and fissures.

Lay bare the whole upper surface of the corpus callosum ; note the transverse direction of its fibres, the longitudinal mark termed *raphe* in the middle line, and the elevations on each side called *nerves of Lancisi*, the thick posterior border or *bourrelet*, and the *genu* or curve downwards in front. By means of two longitudinal incisions, one on each side of the corpus callosum, open into the two *lateral ventricles* separately, cutting away as much of the substance of the hemispheres as is necessary to show the whole extent of the floor. The lateral ventricles will then be seen to be separated one from the other by the *septum lucidum*, and in the floor of each will be seen from before backwards the *corpus striatum*, with the *foramen of Monro* internal to it, a delicate band called *tænia semicircularis*, the anterior and outer part of the *optic thalamus*, the *choroid plexus of the lateral ventricle*, and a moiety of the sheet of white brain substance called the *fornix*. The cul-de-sac in

front is the *anterior cornu* of the lateral ventricle. The *posterior cornu*, extending back in the posterior lobe, is to be laid open in its whole length, and on its inner side will be seen an elevation, the *hippocampus minor*, which may be shown to correspond with the calcarine fissure. The *middle* or *descending cornu* is marked by the choroid plexus and *posterior crus of the fornix* passing into it, and is to be exhibited in its whole length, on one side, by placing the point of the knife in the cornu and cutting upwards outside the corpus striatum, and freely in the outward direction, so as to remove a large block of the hemisphere. By this section the striated structure from which the corpus striatum is named is exhibited; and in the descending cornu are seen the elevation termed *hippocampus major*, the *tænia hippocampi* or *corpus fimbriatum* internal to it continued down from the posterior crus of the fornix, and the *choroid plexus*; also at the extremity of the cornu, the *pes hippocampi*, the expanded and digitated extremity of the hippocampus major. The corpus callosum is now to be cut across about an inch from the posterior border; the septum lucidum in front of this is to be divided with scissors, and the part of the corpus callosum thus liberated is to be reflected forwards or removed. Between the two layers of the septum lucidum the *fifth ventricle* can now be seen; a view is also obtained of the whole upper surface of the *fornix*.

For the removal of the fornix the best mode of proceeding is to make two cuts, severing the remaining posterior parts of the corpus callosum from the hemispheres. Each cut should be directed forwards

and outwards from the point where the back of the corpus callosum passes into the hemisphere, and is to be carried through the posterior crus of the fornix, without injury to the underlying reflexion of pia mater. The back part of the corpus callosum can then be lifted up, and the fornix attached to it can be reflected forwards, so as to exhibit the appearance on its under surface named *psalterium* or *lyra*, caused by transverse fibres properly belonging to the corpus callosum being bounded on each side by a longitudinal half of the fornix : also the dipping down of the *anterior crura* of the fornix will be seen. The reflexion of pia mater, called *velum interpositum*, of which the choroid plexuses of the lateral ventricles are the vascular edges, is now exposed, with the veins of Galen running down the middle ; and, on the side on which the descending cornu has been dissected, the posterior lobe of the hemisphere may be lifted up and the *transverse fissure* of the brain, by which the velum interpositum and choroid plexus enter from without, may be laid open to the bottom of the cornu. By this means the posterior part of the gyrus fornicatus will be displayed, with the *sulcus hippocampi* between it and the tænia hippocampi, and the so-called *fascia dentata* at the bottom of the sulcus.

The choroid plexus is to be divided on each side at the entrance into the descending cornu ; the pia mater behind the velum interpositum is to be raised from the *corpora quadrigemina*, which it covers, and as it is reflected forwards, care is to be taken to separate from it, without injury, a body about the size of a small pea, the *pineal body*, which is attached

delicately in front of the corpora quadrigemina; the velum interpositum can then be raised completely, so as to display the *third ventricle* beneath, and on the under surface of the velum interpositum the *choroid plexus of the third ventricle*. In the third ventricle attention is to be paid to the connection of the pineal body with the rest of the brain by a folded white lamina called the *posterior white commissure*, and to the pair of *peduncles* of the pineal gland lying on the edges where the white upper surfaces of the optic thalami meet their vertical inner surfaces, which as well as the whole floor of the third ventricle are of grey matter. The *anterior white commissure* is seen in the fore part of the ventricle crossing in front of the anterior crura of the fornix, while the *middle or soft commissure* unites the optic thalami, but is sometimes absent. The anterior extremity of the *aqueduct of Sylvius* or *iter a tertio ad quartum ventriculum* will be recognised below the posterior white commissure. Between the corpora quadrigemina and optic thalamus on each side the little elevations called *outer and inner corpora geniculata*, in connection with the optic tract, are to be noted; and between the corpora quadrigemina and cerebellum the *valve of Vieussens* (or *anterior velum*) with the *superior crura* of the cerebellum or *processus a cerebello ad testes* on the sides of it, and the *fourth* pair of nerves arising from its fore part.

At this stage it is advisable, if the base have been previously examined, to divide the *isthmus cerebri*, separating the cerebrum from the posterior parts of the encephalon by a cut passing through the valve of Vieussens above and the crura cerebri below. In

the section the *locus niger* will be seen. The right and left portions of the cerebrum should be separated by an incision in the middle line; the parts displayed in section should be studied, and one of the anterior crura of the fornix should be followed down to the corresponding corpus albicans, and its fibres traced as they twist within that structure and turn upwards into the optic thalamus.

The remaining convolutions and fissures of the inner surface of the hemisphere can now be displayed. The *gyrus fornicatus* will be seen turning round the posterior end of the corpus callosum to become merged with the *uncinate convolution*, and the continuation of the parieto-occipital and calcarine fissures beyond their junction will be noticed passing down to the point where the two convolutions meet. Above the uncinata convolution lies the *dentate fissure*, and beneath it the *collateral fissure*. In removing the pia mater from the dentate fissure the student should note its continuity with the choroid plexus of the descending cornu, and on looking into the fissure he should see the white *tænia hippocampi*, and beneath it the *fascia dentata*, the edge of the superficial grey matter of the hemisphere. The *tænia* and *fascia dentata* may both be followed forwards to the hook-like end of the uncinata convolution. Beneath the collateral fissure is the *inferior temporo-occipital convolution*. By transverse section it may be shown that the dentate fissure corresponds to the projection of the hippocampus major, the collateral fissure to the eminentia collateralis, and the calcarine fissure to the hippocampus minor.

A series of horizontal sections of the base of one hemisphere may now be made. In the region of the corpus striatum there will be noticed externally the grey surface of the *island of Reil* with a layer of white matter adjacent ; passing inwards a long grey nucleus, the *claustrum*, is reached, and further inwards a band of white fibres, the *external capsule* ; the grey *lenticular nucleus* follows next, separated from the *caudatē* or *intra-ventricular nucleus* by another band of white fibres, the *internal capsule*. Behind the nucleus caudatus lies the grey matter of the *optic thalamus*.

Divide on each side the restiform body and the pons Varolii where they are about to enter the cerebellum, forming the *inferior* and *middle crura*. The fourth ventricle will thus be laid open ; the groove called *calamus scriptorius* will be seen on its floor, continued up from the opening of the central canal of the spinal cord. Fibres of the *auditory nerve* will be seen extending to the middle line, and lower down the delicate flap called the *ligula* ; also internal to the restiform *bodies* are the *posterior pyramids*, whose fibres may be traced beneath the grey matter of the floor towards the cerebrum. The various lobes and laminae of the cerebellum may now be studied ; but it is only necessary here to mention the *amygdala* placed on each side of the vallecule, behind the *flocculus*, and, in the vallecule, the *inferior vermiform process*, divided from behind forwards into parts named the *pyramid*, *uvula*, and *nodule* or *laminated tubercle*. If care be taken in removing the membranes it will be seen that the hollow of the fourth ventricle

is prolonged laterally along the whole length of the peduncle of the flocculus. At each side of the laminated tubercle is a thin layer of cerebral substance, the *posterior velum*, bounding the *nidus avis* or vestige of the original cavity of the cerebellum seen in the fœtus and lower kinds of vertebrata. The cerebellum should now be divided by mesial section ; and another vertical incision should be made backwards and outwards, so as to exhibit the corrugated grey centre called *corpus dentatum*, found in each lateral half. A similarly shaped centre, the *olivary nucleus*, is seen on transverse section through the olivary body of the medulla oblongata.

5. Superficial Dissection of the Neck.—It is necessary that the surgically important region in which the third part of the subclavian artery lies, behind the sterno-mastoid muscle, should be studied before the removal of the arm ; and it is well that in conjunction with the dissection of the arm an examination should be made of the structures passing into it from the neck ; the posterior triangle should therefore be dissected during the first three days after the subject has been laid on its back, and on the morning of the fourth day the clavicle should be either divided or disarticulated.

The shoulders of the subject having been raised by a block, the head should be allowed to hang back over the end of the table, with the face inclined away from the side to be dissected. A mesial incision may be made from the sternum to the chin, and another outwards along the clavicle to the acromion to join the incisions already made from behind, care

being taken not to injure the muscular fibres of the thin subcutaneous sheet of muscle, the *platysma myoides*, and the branches of cutaneous nerves descending over the clavicle. Reflect the skin towards the face, and at the same time display underneath it the *platysma myoides* muscle; then let this also be reflected upwards, and dissect the trunks of superficial veins and nerves. The principal superficial veins are the *anterior* and *external jugular* veins, and they present varieties in different subjects; but the anterior is distinguished by dipping down to the deep structures in front of the sterno-mastoid muscle, while the external jugular dips down behind that muscle. The nerves to be sought are the superficial branches of the cervical plexus, and radiate from the middle of the posterior border of the sterno-mastoid muscle; the *small occipital* ascends along the posterior border of the muscle; the *great auricular* is directed towards the interval between the ear and the jaw; the *superficial cervical* turns directly forwards before dividing over the anterior triangle or part of the neck in front of the sterno-mastoid muscle; and the *descending* branches, stretching over the posterior triangle, are distinguished as *supra-sternal*, *supra-clavicular*, and *supra-acromial*.

6. Posterior Triangle.—In pursuing the dissection just made, a considerable amount of loose connective tissue will be found, in which the descending cutaneous branches of the cervical plexus are imbedded. This is now to be removed; the posterior border of the *sterno-mastoid* muscle and anterior border of the *trapezius* are to be cleared, and the

disposition of the fascia stretching between them is to be noted. In the lower part of the space will be seen the posterior belly of the *omo-hyoid* muscle extending backwards and downwards, and bound down by an important layer of deep fascia, which invests it and is attached inferiorly to the clavicle. This belly of muscle subdivides the posterior triangle. The superior division may be cleared out first. In its upper part, connected with the descending cutaneous nerves, will be found the *spinal accessory* nerve, which is to be followed from its place of exit from the sterno-mastoid to its disappearance beneath the trapezius muscle, and also two or three muscular branches from the cervical plexus. A chain of lymphatic glands (*glandulæ concatenatæ*) is to be displayed along by the posterior border of the sterno-mastoid muscle. Forming the floor of this upper part of the posterior triangle will be found the upper portions of the *splenius capitis* and *colli*, of the *levator anguli scapulae*, and of the *scaleni* muscles.

The deep fascia binding down the posterior belly of the omo-hyoid muscle is now to be removed, and the dissection of the inferior division of the posterior triangle proceeded with. The *external jugular* vein is to be followed to its termination in the subclavian vein, which may also be cleaned in the outward direction; the transverse cervical artery with its vein will be next found crossing outwards; the *scalenus anticus* muscle is to be cleared, with the *phrenic nerve* on its surface; and emerging from beneath the outer border of that muscle will be found in series, from above downwards, the two upper trunks

of the brachial plexus, and the *subclavian* artery. Arising from the front of the upper trunk the small nerve to the subclavius muscle is to be dissected out. The upper trunk of nerve will be seen to be formed by the union of the fifth and sixth, while the second consists of the seventh nerve ; the artery will be seen to curve over the apex of the pleural sac ; and in many instances the *posterior scapular* artery, usually reckoned as a division of the transverse cervical, will be noticed arising from it in the space. Behind the clavicle will be found the *suprascapular* artery and vein.

7. Anterior Triangle.—The surface of the *sternocleido-mastoid* muscle should now be completely cleaned, as well as the muscles in front of it, viz. the *sterno-hyoid*, *sterno-thyroid*, and anterior belly of the *omo-hyoid* ; and at the same time care should be taken of the branches to these muscles from the loop formed by the *hypoglossal* nerve with communications from the cervical plexus, as also of the various layers of fascia in the middle line. One layer of fascia will be found extending between the sterno-mastoid muscles of opposite sides, and attached to the furcula of the sternum ; another between the sterno-hyoid and sterno-thyroid muscles of opposite sides ; and a third still deeper, extending down into the thorax. These and the other structures met with near the middle line are to be studied in relation to the operation of tracheotomy. The other structures are the *inferior thyroid* veins, the *ima thyroidea* artery (when it is present), the *isthmus of the thyroid*

body above, the *innominate* artery below, and on each side of the trachea the *common carotid*.

In the upper part of the anterior triangle of the neck is to be exposed the *digastric* muscle, the posterior belly of which, together with the *stylo-hyoid* muscle extending from behind the ear to the hyoid bone, separates the district below the chin known as the digastric space from the neck proper. The nerve (from the third division of the fifth) to the anterior belly of the digastric will be found at its outer border near the jaw, and, traced backwards, will be seen to be one of the branches of a small trunk, the other branch of which enters, from the superficial aspect, the *mylo-hyoid*, the flat muscle beneath the anterior belly of the digastric. The superficial and larger part of the *submaxillary gland* must at the same time be dissected out, with the trunk of the *facial* artery, which is in close connection with it and furnishes it with twigs, and gives off, as it passes across the space, its *submental* branch ; but the deep part of the gland, passing beneath the border of the mylo-hyoid muscle, may be left undisturbed at present. Also disappearing beneath the border of the mylo-hyoid muscle, not far from the hyoid bone, is the trunk of the *hypoglossal* nerve ; and by following it backwards a little way, there will be reached its branch to the *thyro-hyoid* muscle, and about half an inch further back the descending branch (*descendens noni*), which is to be completely dissected out to its distribution, and to have its connections with the cervical plexus followed up. The *thyro-hyoid* muscle can be dissected out by

raising the sterno-hyoid from its surface without dividing it, and close to the thyroidal attachment of the sterno-thyroid muscle the *external laryngeal* branch of the *superior laryngeal* nerve is to be found, and it should be followed to its destination in the *crico-thyroid* muscle. This muscle, with its fellow and the *crico-thyroid membrane* which the pair of muscles partially cover, together with a small twig of the superior thyroid artery directed across the membrane, capable of giving trouble in laryngotomy, may be studied at once.

The sheath of the *common carotid* artery and *internal jugular* vein, where those vessels are crossed by the upper border of the anterior belly of the omohyoid muscle, should now be opened, the position of the artery, vein and *pneumogastric* nerve noted, and the artery followed up so as to display the *external* and *internal carotid* arteries as far as the stage of the dissection permits. The veins will be followed at the same time, and the communication between the tributaries of the external and internal jugular by means of the *facial communicating* is to be noted ; after which it may be convenient to divide the external jugular. Also, behind the sheath of the great vessels the cervical cord of the *sympathetic* nerve will be seen ; but it may be advisable to leave its careful dissection to a later period. The first branch of the external carotid artery to be followed is the *superior thyroid*. Its offset to the *sterno-mastoid* muscle sometimes comes off separately from the main trunk ; another offset, the *superior laryngeal*, will be seen piercing the thyro-hyoid membrane ; and piercing

along with it is the *superior laryngeal* nerve, which may be traced back towards the pneumogastric. The other offsets of the superior thyroid artery, namely, the *inferior hyoid* and the *crico-thyroid*, having been shown, the termination of the artery in the thyroid body is to be exhibited, and the *thyroid body* should be dissected fully out, so as to show the whole lateral lobe, the termination of the *inferior thyroid* artery and the superior and middle thyroid veins. The *lingual* artery at present can be followed no further than the point where it becomes concealed by passing beneath the hyo-glossus muscle. Immediately above it is the facial artery, whose two first branches, the *ascending palatine* and *tonsillar*, can now be displayed at their origins. The *ascending pharyngeal* branch of the external carotid may also be shown at its origin by raising the trunk. Coming off from the external carotid behind are the *occipital* and *posterior auricular*; the occipital, crossed by the hypoglossal nerve, is to be traced upwards, and the posterior auricular can be followed to its distribution.

8. Deep Dissection of the Root of the Neck.—

The *sterno-cleido-mastoid* muscle is to be divided, and its attachments are to be thoroughly dissected out. On the fourth day after the subject has been placed on its back, the clavicle having been divided by the dissector of the arm (or removed at the sterno-clavicular articulation, if it has been so agreed on), a view is to be obtained of the passage of the *brachial plexus* from the neck into the axilla. From the brachial plexus will be seen given off the following branches above the clavicle, besides the phrenic

and the nerve to the subclavius muscle already preserved :—from the back of the cord formed by union of the anterior divisions of the fifth and sixth spinal nerves, the *suprascapular* nerve ; from the same two trunks before they join, the *posterior thoracic* nerve (external respiratory nerve of Bell) destined for the serratus magnus muscle ; and from the back part of the fifth, the branch *for the rhomboid* muscles.

The first part of the subclavian artery, internal to the scalenus anticus muscle, now demands attention ; and the arrangement of this, as well as the lower part of the common carotid artery, is to be compared on the right and left sides of the body. But before proceeding with this, the junction of the internal jugular and subclavian veins to form the *right* or *left innominate* vein is to be seen to ; and the angle of junction between the subclavian and internal jugular veins is to be carefully dissected in search, on the left side, for the *thoracic duct* which curves forwards and downwards to open at this point, and on the right side for the short and much smaller though corresponding structure, the *right thoracic duct*. In the dissection of the left side arrangement ought to be made with the dissectors of the thorax to see the thoracic duct in its continuity. The *vagus* nerve is to be followed down ; and on the right side, after crossing the subclavian artery, it will be seen to give off its *recurrent laryngeal* branch. On both sides the recurrent laryngeal nerve will be found passing up in the angle between the trachea and œsophagus. One or two branches of the sympathetic may pass in front of the right subclavian

artery, and are to be preserved ; but they can be better followed at a later stage. Three branches of the subclavian artery appear prominently, one directed downwards, namely, the *internal mammary*, and the other two upwards, namely, the *vertebral* and the *thyroid axis*. In dissecting the vertebral artery, care must be taken not to injure the sympathetic nerve, the third cervical ganglion of which lies close beside it, sending branches round it. The three branches of the thyroid axis, namely, the *inferior thyroid*, the *transverse cervical*, and the *suprascapular*, have already been seen in their distribution ; their continuity will now be displayed ; and the *ascending cervical* branch of the inferior thyroid artery will be traced upwards in the line of contact of the scalenus anticus and the rectus capitis anticus major. To see the *superior intercostal* artery, the subclavian must be pulled a little forward, as the origin of this branch is on its posterior aspect, where it begins to be crossed by the scalenus anticus : it enters immediately into the chest ; but before doing so, it is usually the source of the *deep cervical*, which passes back below the transverse process of the seventh cervical vertebra.

9. The Face.—It is sometimes deemed desirable to devote one side of the face to the study of the muscles, and the other to the vessels and nerves. There is, however, no real difficulty in making a tolerably complete dissection of all the structures on both sides.

To display the frontal region, a mesial incision may be made from the root of the nose to the vertex of the head. It will be convenient then to make

another incision outwards from the middle line to the inner canthus of the eye, and carry it round by the margins of the eyelids. This will allow the very superficial *orbicularis palpebrarum* muscle to be dissected out ; and the *tendo oculi* at its inner part is to be studied, especially its relation to the nasal duct, which will be understood on comparing the dissection with a skull. The integument of the forehead, as far back as the ear, may then be reflected. Near the middle line will be found the *supratrochlear* branch of the *ophthalmic* nerve, and *frontal* branch of the *ophthalmic* artery ; and further outwards, ascending from the supraorbital notch, the *supraorbital* branch of the same nerve and the corresponding branch of the *ophthalmic* artery. Beneath the *supratrochlear* and close to the inner angle of the eye is the *infratrochlear* nerve and the *nasal* branch of the *ophthalmic* artery. Extending upwards from under cover of the *orbicularis palpebrarum* is the *frontalis* muscle, or frontal belly of the *occipito-frontalis* lost in aponeurosis extending over the cranium ; and its innermost fibres are prolonged downwards on the nose to form the *pyramidalis nasi*, which differs from the *frontalis* in having its fixed attachment below. On reflecting the *frontalis* the *corrugator supercilii* will come into view attached to the inner end of the superciliary ridge, and extending upwards and outwards in an expanded form for a considerable distance in close connection with the deep surface of the *frontalis*. Farther out, on the temporal region, will be found the ramifications of the *temporal* artery with the branches of the *auriculo-temporal* division of the *inferior maxillary*

nerve, and in front of this the uppermost branch of the *facial* nerve, emerging from underneath the parotid gland and directed towards the forehead and angle of the eyelids. The *temporal* division of the *temporo-malar* nerve is to be sought for on the surface, about an inch above the zygoma and a little behind the margin of the orbit. Also at this time the *attrahens* and *attollens aurem* muscles, in front of and above the ear, are to be dissected, if not already seen with the dissection of the back of the scalp.

If the incision above the ear be now prolonged downwards in front of it to join the dissection in the neck, the remaining integument of the face may be removed from behind forwards toward the middle line. The outline of the *parotid gland* prolonged a little over the jaw, with the duct (*Stenson's*) extending forwards from it to enter the mouth, is to be brought into view ; also the little outlying portion of the gland termed *socia parotidis*, and the *transverse facial* branch of the temporal artery above the duct and the various remaining trunks of the *facial* nerve issuing from beneath the anterior border of the gland and diverging as they pass forward ; also the minute *malar* branch of the *superior maxillary* nerve emerging from a foramen on the front of the malar bone.

The continuation of the *platysma myoides* is to be followed over the jaw, and its posterior fibres may be traced to the angle of the mouth, forming the *risorius muscle of Santorini*. Two muscular slips, the *zygomaticus major* and *minor*, are next to be exhibited descending from the malar prominence to the angle of the mouth ; and internal to them, arising beneath

the orbit and crossed by the facial artery is the *levator proprius labii superioris*, with the outer border of which the zygomaticus minor is usually connected. More internally, descending on the side of the nose, is the *levator communis labii superioris alæque nasi*; and on the ridge of the nose is the terminal twig of the *nasal* branch of the *fifth* nerve, emerging between the bone and cartilage; while lower down is the very small *depressor alæ nasi*, arising from the incisor fossa and inserted into the septum and back part of the ala of the nose. The course of the main trunks of the *facial* artery and vein is to be traced from their appearance on the face in front of the masseter muscle to their termination in the *angular* artery and vein internal to the orbit; and the *lateral nasal* branch of the artery will also be seen. Two deeper muscles and a nerve are now to be displayed, to a certain extent under cover of the *levator proprius labii superioris*. The nerve, the *infraorbital*, emerges from the canal of the same name; it is the terminal part of the second division of the fifth nerve, and sends large branches to the upper lip. The muscles rise from the canine fossa, and are the *levator anguli oris* directed downwards and outwards, and the *compressor naris* widening as it extends inwards on the nose. The *buccinator*, the flat muscle which supports the mucous membrane of the mouth between the upper and lower jaws, is now to be cleaned so far as it is yet laid bare; and the pad of fat between its back part and the *masseter* muscle is to be taken away; and on the surface of the *buccinator* there should be found the *buccal* branch of the *internal*

maxillary artery and the *buccal* nerve from the inferior maxillary trunk.

Below the mouth the *depressor anguli oris* will be seen extending directly downwards; and internal to it, slightly concealed by it, the fibres of the flat *depressor labii inferioris* pass upwards and inwards, extending to the middle line. The remaining muscle of this region, the *levator menti*, can be seen to most advantage by first everting the lower lip and removing the mucous membrane from the upper border of the levatores menti of both sides where they arise from the incisor fossæ of the lower jaw, and then making a mesial incision through the integument of the chin but leaving the lip undivided, when their fibres will be seen spreading downwards and inwards towards the surface. The depressor labii is to be divided, and beneath it there will be seen emerging from the mental foramen the *mental* branches of the *inferior dental* artery and nerve, the artery a branch of the internal maxillary, and the nerve a branch of the third division of the fifth. Beneath the depressor anguli oris and anastomosing with the mental artery is the *inferior labial* branch of the facial.

The lips ought now to be everted as much as possible, and held in that position while the mucous membrane is dissected off so as to show the *buccal glands* like small lentils, and the deep surface of the *orbicularis oris* muscle. Being the deepest of the muscles of the oral orifice, the orbicularis is best dissected in this manner, which displays also the attachment of some of its fibres to the upper and lower jaws, and the *coronary* branches of the facial artery

completing a circle round the mouth. Lastly, the cartilages of the nose should be dissected, so as to display the form of the *alar cartilages* and their distinctness from the *triangular and septal cartilages*.

10. Temporal and Zygomatic Region.—Let the branches of the *facial* nerve be traced back through the parotid gland, and the main trunk followed up to the stylo-mastoid foramen. The two little branches given off at that point and supplying the stylo-hyoid muscle and the posterior belly of the digastric should also be found. The parotid gland is then to be removed: its intimate connection with the terminal part of the external carotid, and the origins of the internal maxillary and temporal arteries, will in doing this be noted, as well as its relations to muscles and to the part of the cervical fascia known as the *stylo-maxillary* ligament which extends between the lower part of the styloid process and the angle of the jaw, with its lower edge the more superficial, and in cases of enlargement of the glands forms a septum between the parotid and submaxillary glands.

The *temporal fascia* is now to be laid bare, and an incision is to be made along the upper border of the zygoma, so as to show that the temporal fascia is divided here into two layers with fat between them, among which lies the *temporal* branch of the *superior maxillary* nerve, the terminal branches of which have been already noted. The fascia is then to be completely divided so as to lay bare the *temporal* muscle. The *masseter* muscle is to be properly cleaned, and its artery and nerve may be found as they emerge from the sigmoid notch of the lower jaw and enter its upper

and back part, where a portion of the deep division of the muscle is left uncovered by the superficial.

The zygomatic arch is to be divided with the bone-nippers, as far forwards and as far back as possible, namely, in front of and behind the origin of the masseter, and the masseter is to be reflected downwards and separated from the greater part of the ramus of the jaw, so as to show the extent of its attachments. The surface of the *temporal* muscle is then to be examined. The handle of the scalpel is to be passed in closely beneath the attachment of the temporal muscle to the coronoid process, so as to make sure of separating from its deep surface the buccal branch of nerve; and by means of two cuts with the bone-nippers, one directed downwards from the sigmoid notch, and the other backwards from the lower part of the anterior border of the ramus, the coronoid process and fore part of the ramus are to be detached. The temporal muscle can then be reflected upwards, and what is known as the pterygoid space will be brought into view, and may be further exposed by clipping away all but the posterior border of the ramus of the jaw.

On cleaning away the adipose tissue, the *external pterygoid* muscle will be found occupying the zygomatic fossa and directed back to the neck of the jaw; and on its surface the *internal maxillary* artery lies in its course from the parotid region where it has been seen arising, till where it dips between the heads of the external pterygoid muscle into the pterygo-maxillary fossa.¹ As it comes forward below

¹ While this is the more common arrangement, it is to be

the ramus of the jaw the artery gives off the *middle meningeal* branch upwards and the *inferior dental* in a downward direction, and rests on a strong membrane descending from the spinous process of the sphenoid bone to the sharp edge of the opening of the inferior dental canal, namely, the structure known as the *internal lateral ligament* of the temporo-maxillary articulation. Further forwards the artery gives off muscular branches, namely, the *deep temporal*, *pterygoid*, and *masseteric*; and these are to be exhibited. Also in this space are to be seen various branches of the *inferior maxillary* or third division of the *fifth* nerve; three of these appear above the external pterygoid muscle, namely, the *masseteric* already identified, and an *anterior* and *posterior deep temporal* to the temporal muscle; piercing the external pterygoid is the *buccal nerve* already alluded to, destined to supply the mucous membrane internal to the buccinator muscle and the skin upon its surface; and appearing beneath the external pterygoid are two larger trunks, the anterior of which is the *gustatory* or *lingual* branch, while the posterior is the *inferior dental*, and is seen to enter the inferior dental canal, and, before doing so, to give off the *mylo-hyoid* branch, the termination of which has been already seen. Subjacent to these trunks the *internal pterygoid* muscle is seen emerging from beneath the external pterygoid and passing downwards and backwards to the angle of the jaw. The course of the inferior dental canal may be laid open with the nippers, so noted, however, that in many cases the artery passes along the deep surface of the muscle.

as to display the nerves and arteries going to the teeth.

The remaining part of the ramus of the jaw is now to be divided, and the temporo-maxillary articulation is to be studied. This cannot be done perfectly; for to study the whole anatomy and movements of this articulation it is necessary to devote the head of a young adult subject specially to the purpose. But the *external lateral* ligament and the *capsule* and *interarticular cartilage* can be seen, and also that the forward movement of the condyle in opening the mouth is a consequence of the mode of attachment of the external lateral ligament, and that the condyle takes the interarticular cartilage forwards with it. In disarticulating the joint, care is to be taken to keep the knife close to the capsule, so as not to injure the *auriculo-temporal* nerve. The *external pterygoid* muscle may then be reflected forwards, and its nerve may be found, after which the muscle may be altogether removed. This allows the *auriculo-temporal* nerve to be traced out from its origin from the inferior maxillary trunk; also the *chorda-tympani* joining the gustatory nerve at an acute angle from behind, and the *middle meningeal* artery passing up to the foramen spinosum, and giving off the *small meningeal* branch which enters by the foramen ovale. The *pterygo-maxillary ligament* separating the buccinator muscle from the superior constrictor should also be studied.

11. The Sublingual Region.—The tip of the tongue should be laid hold of and pulled forwards; and it may be found convenient to retain it in that

position by means of a stitch attached to the nasal septum: if, however, this common, though unnecessary expedient be resorted to, the tongue should be replaced in its proper position as soon as the dissection has been made, that the natural relations of parts in the floor of the mouth may be understood. The anterior belly of the digastric muscle and the mylo-hyoid muscle are to be divided near their maxillary attachment; and the lower jaw is to be sawn through near the symphysis. The divided portion of the jaw is to be turned upwards and the parts beneath dissected. In the fore part of the dissection will be seen the deep part of the submaxillary gland, with the duct of the gland (*Wharton's duct*) passing forwards to the lower part of the frænum of the tongue. Close to this, adherent to the mucous membrane of the mouth, is the *sublingual gland*, about the size of an almond, with ducts too minute to be studied without making a special dissection (*ducts of Rivini*), some of them joining the submaxillary duct, and others opening independently; and crossing the submaxillary duct is the *gustatory* nerve, whose distribution along the side of the tongue is to be followed; and with the lower border of which, as it lies close to the submaxillary gland, is connected the minute *submaxillary ganglion*, giving branches to the gland. The branch passing from the nerve to this ganglion can be traced into continuity with the *chorda-tympani*. Further in the fore part of the dissection, resting on the mylo-hyoid, is the *genio-hyoid* muscle, and resting on the genio-hyoid is the inferior border of the *genio-glossus*, the back part of whose lingual attachment is still

hid by the *hyo-glossus* ; and crossing the lower part of the *hyo-glossus*, to enter the *genio-glossus*, is the *hypoglossal* nerve. Reaching the tongue from behind and decussating with the upper attachment of the *hyo-glossus*, is the *stylo-glossus* muscle ; diverging from the *stylo-glossus* in a downward direction is the *stylo-pharyngeus* muscle ; and curving forwards over that muscle is the *glosso-pharyngeal* nerve. On dividing the *hyo-glossus* muscle, the *lingual* artery can be followed forwards, giving off the *superior hyoid*, the *dorsal artery of the tongue*, and the *sublingual* branch, and ending in the *ranine* artery to the tip of the tongue. In front of the place where the gustatory nerve descends into the sublingual region, the attachment of the *superior constrictor* of the pharynx to the jaw is seen.

12. Parts within the Cranium.—The head is to be well raised with blocks, so as to bring the interior of the base of the skull conveniently into view. The place at which each cranial nerve pierces the *dura mater* is to be noted, and also the attachments of the divided *falx cerebri* and *tentorium cerebelli*, and the mesial process of *dura mater* beneath the *tentorium*, called *falx cerebelli*. The *superior longitudinal sinus*, along the upper border of the *falx cerebri*, already opened in part of its extent, is to be followed down to the level of the *tentorium*, where it ends in the *torcular Herophili* and divides into the two *lateral sinuses*. Along the inferior border of the *falx cerebri* is the *inferior longitudinal sinus*, which has more the character of a vein than of a sinus. On reaching the *tentorium* this sinus is joined by the *veins of Galen*,

which were cut across in removing the brain ; and the blood from these two sources flows to the torcular along the *straight* sinus in the angle of union of the falx cerebri with the tentorium. In the falx cerebelli will be found the *occipital* sinus, also leading into the torcular Herophili. The *lateral* sinuses are to be laid open in their whole course down to the jugular foramen ; and there the commencement of the jugular vein is to be seen with the three parts of the *eighth* nerve internal to it, and the *inferior petrosal* sinus running along the occipital border of the petrous bone and separating the *glosso-pharyngeal* nerve from the *pneumogastric* and *spinal accessory* as it falls into the jugular vein. Along the free border of the petrous bone the *superior petrosal* sinus is to be laid open ; and, between the two inferior petrosal sinuses, across the basilar process of the occipital bone, is the *transverse* sinus. An incision is now to be carried from a position immediately outside the point of exit of the third nerve, backwards and then outwards, to that of the fifth, and is to be prolonged a little way forward and outward, and on raising the flap of dura mater so made, the *cavernous* sinus will be brought into view ; and by incisions round the opening where the infundibulum descended to the pituitary body, the *circular* sinus uniting the two cavernous sinuses will be laid open. The positions in the walls of the cavernous sinus of the *third*, *fourth*, *ophthalmic* division of the *fifth*, and *sixth* nerves and the *internal carotid* artery are to be observed ; and the dura mater should be dissected from the other two divisions of the fifth nerve, and the trunk of the nerve should be raised so

as to get a complete view of the *Gasserian ganglion* and of the motor root of the nerve passing under the ganglion to join the third or inferior maxillary division ; but the artery should not be much interfered with, if the carotid and cavernous plexuses of the sympathetic are to be afterwards sought ; and, indeed, the best plan is to leave the sinus on one side uninjured for that dissection. The *pituitary body* may be removed from the sella turcica and examined. By stripping the dura mater from the bone, the trunk of the *middle meningeal artery*, after entering the skull, may be brought into view ; and in well-injected subjects it may be possible to see the branch to the *hiatus Fallopii*, the *small meningeal* branch entering by the foramen ovale, the *anterior meningeal* artery entering by the side of the cribriform plate from the ethmoidal artery, the *posterior meningeal* branch of the occipital artery entering by the jugular foramen, and *meningeal* branches of the *vertebral* artery.

13. The Orbit.—The frontal bone should be divided with the saw, either vertically or in a direction downwards and outwards, so as to open into the orbit near its inner side, immediately external to the fovea trochlearis, and care must be taken not to direct the edge of the saw inwards lest the nasal branch of the ophthalmic nerve be injured as it passes through the anterior internal orbital canal. Another saw-cut should be made through the side of the skull, downwards and forwards, to the sphenoidal fissure ; the ascending process of the malar bone should be divided with the bone-nippers ; the piece of bone between the saw-cuts is then to be separated by a

smart blow of the mallet and turned forwards or removed without injury to the facial structures on its surface ; and the unroofing of the orbit, back to the cavernous sinus, should be completed by further use of the bone-nippers. The dura mater investing the contents of the orbit is then to be slit open, and the *frontal* branch of the *ophthalmic* nerve will be seen passing forwards and dividing into the *supra-trochlear* and *supra-orbital*, which may be followed into continuity with the facial dissection. Also, passing forwards in the middle will be seen the *levator palpebræ* muscle going forwards to the cartilage of the upper lid, and the *superior rectus* muscle of the eyeball immediately below it. A little internal to this is the *superior oblique* muscle, which is to be followed forwards to its pulley at the fovea trochlearis of the frontal bone, and is to be traced thence to the eyeball. Near the back part of this muscle by its outer edge and on its upper surface the *fourth* nerve will be seen entering it, and this is to be traced back into continuity with the dissection in the cavernous sinus. Also, the frontal nerve is to be traced backwards, when it will be found, at the back of the orbit, to give off a smaller branch, the *lachrymal*, which is to be traced to the lachrymal gland at the upper and outer part of the eye, and will be found to send branches forwards to the outer half of the upper eyelid.

A quantity of fat may now be removed most effectually and rapidly by moving the scalpel backwards and forwards, with its edge directed to one side, so as to push the fat with the flat of the blade

and isolate it from the important structures lying more or less longitudinally. Crossing the *optic* nerve will be seen the *ophthalmic artery* giving off the *lachrymal* and *supra-orbital* at the back of the orbit. As it crosses the optic nerve, it gives off a series of minute branches, the *central artery of the retina* and the *ciliary* arteries ; further forwards it sends *ethmoidal* branches into the anterior and posterior internal orbital foramina and branches to the muscles ; and in front it ends in *palpebral*, *nasal*, and *frontal* branches. The *external rectus* muscle is to be thoroughly exposed so as to show its two heads of origin ; and between these are to be found the other nervous trunks entering the orbit, namely, in series from above downwards, the *upper* division of the *third* nerve, the *nasal* branch of the *ophthalmic*, the *lower* division of the *third*, and the *sixth* nerve. On the outer side of the optic nerve the *lenticular ganglion* is to be found with its long root from the nasal nerve, as well as a branch from the sympathetic entering it from behind, and its short root from the inferior division of the third nerve coming up from below, while its branches of distribution, the short ciliary nerves, extend forwards and pierce the sclerotic. The *nasal* nerve is to be traced forwards to the anterior internal orbital foramen by which it leaves the orbit. It crosses the optic nerve, and gives off the *long root* of the ganglion which is to be sought between the heads of the external rectus, and further forwards the *long ciliary* branches, and the *infratrochlear*, which is to be followed forward to the lower eyelid and side of the nose. The *third* nerve is also to be traced ; its upper division to the

upper rectus muscle and the levator palpebræ may always be easily found, as its branches enter the deep surface of the muscles; its lower division to the *inferior* and *inner recti* and *inferior oblique* is of considerable size. The *sixth* nerve is to be followed into the *external rectus* muscle. The *inferior oblique* muscle is best brought into view by dividing the conjunctiva below the eyeball, and seeking for the muscle at its origin at the inner part of the orbit, near its margin.

There remain still for examination the lachrymal apparatus, the inner surface of the eyelids, and the tensor tarsi muscle. The *carunculæ*, *plica semilunaris*, and *puncta lachrymalia* should be looked at in the living subject; and, after that, bristles may be passed into the puncta on the dead subject, and an effort made to follow the *canaliculi*. The levator palpebræ muscle is then to be divided, and the orbicularis palpebrarum and the eyelids should be raised from their connections above, below, and on the outside, and turned over towards the nose. By this means the tarsal conjunctiva, with the outlines of the *Meibomian glands* and subjacent *tarsal cartilages* visible through it, is brought into view, and the deep surface of the inner part of the *orbicularis* muscle can be dissected so as to display the fibres behind the tendo oculi and the extension over the lachrymal sac constituting the *tensor tarsi*. The *lachrymal sac* may be laid open and the entrance of the canaliculi into it exhibited; and a probe may be passed down to test the direction and width of the nasal duct; or the catheterisation of the duct from the nose may be practised according

to the surgical rules ; but on one side the duct should be left uninjured for future examination.¹

14. Deep Dissections of Nerves and the Internal Ear.—The contents of the orbit having been removed, the foramen rotundum and infra-orbital canal are to be carefully laid open with the bone-nippers, to exhibit the *superior maxillary* nerve and its branches. Opposite the spheno-maxillary fossa this nerve gives off the *temporo-malar* branch, which must be sought for near the anterior part of the outer wall of the orbit before that portion of the bone is removed ; two *communicating* branches to *Meckel's ganglion* are next detached ; immediately in front of these the two *posterior dental* branches will be found descending on the tuberosity of the upper jawbone, while in the fore part of the infra-orbital canal is given off the *anterior dental* branch. For the purpose of examining the posterior dental branches the outer part of the orbital wall may be removed entirely, and afterwards the tuberosity of the superior maxillary bone may be nipped away with the bone-nippers till the anterior wall of the spheno-maxillary fossa is removed. There will then be obtained a view of the *spheno-maxillary* or *Meckel's ganglion*, with the *nasal* and *naso-palatine* branches passing through the spheno-palatine foramen, the *three palatine* branches, one of them much larger than the others, extending downwards, and the *Vidian* nerve, with the minute branch termed

¹ When the dissection of the orbit has been completed the eyeball may be removed and preserved in spirit and water for future examination, according to the directions given at page 129.

pharyngeal, passing backwards. Also the *internal maxillary* artery, ending in *posterior dental*, *infra-orbital*, *palatal*, *Vidian*, and *nasal* branches, will be seen. The anterior dental nerve may now be followed down for a short distance in the anterior wall of the maxillary antrum, and the dissector should seek for the communicating branches extending along bony canals between the anterior and posterior dental nerves.

The side of the skull should now be removed down to the level of the petrous bone, the portion of the sphenoid bone external to the foramen ovale may be taken away, and the Vidian canal may be laid open so as to follow the *Vidian* nerve backwards ; it will be found to divide—one branch, the *large deep petrosal*, joins the carotid plexus of the sympathetic, while the other, the *great superficial petrosal*, may be traced by the outside of the carotid artery to the hiatus Fallopii on the anterior surface of the petrous bone. By breaking open the foramen ovale, the inferior maxillary can be laid bare from its origin ; its branch to the internal pterygoid will be seen to reach that muscle from behind, and at the upper part of that branch on the deep side of the parent trunk will be found the *otic ganglion*, connected also with the auriculo-temporal nerve. In this dissection the *Eustachian tube* is within view, and can be still more fully displayed in that part of its cartilaginous extent which is close to the base of the skull, by removing the thin lamina of the great wing of the sphenoid bone internal to the foramen ovale. The branches of the otic ganglion can then be seen, one backwards to the *tensor tympani*, which is a small muscle lying

along the Eustachian tube, and the other downwards to the *tensor* or *circumflexus palati*, which muscle is seen arising in part from the downward-curving outer border of the cartilage of the tube. On one side, however, it is well to refrain from this dissection, in order that at a later period the ganglion may be seen from the deep aspect.

Proceeding now to the dissection of the ear, the pinna may be first dissected by removal of the integument, so as to show the cartilage and muscles. On the foremost part of the *helix* is its *greater* muscle, and below this, at its extremity, dipping into the concha, is its *smaller* muscle. On the outside of the *tragus* and *antitragus* are the two muscles which take name from those eminences; while on the back of the pinna are two small muscles, one, the *transverse*, stretching across the groove corresponding to the antihelix, and the other, the *oblique*, across the groove corresponding to the lower of the two parts into which the antihelix divides above. The pointed inferior extremity of the helix, the absence of cartilage from the lobule, and the manner in which the cartilage is folded round so as to form the outer part of the external auditory canal, also the *fissures of Santorini*, are all to be exhibited.

The wall of the cranium being now sawn down to the level of the petrous part of the temporal bone, the osseous part of the auditory canal is to be laid open with the nippers, care being taken not to injure the *membrana tympani*; the course of the *tensor tympani* muscle is also to be followed backwards, and the tympanic cavity gently unroofed. With a

little nicety, the deep part of the Glasserian fissure can also be opened, so as to expose in its continuity the chorda tympani, and show the attachment of the processus gracilis of the malleus. The action of the *tensor tympani* muscle can now be studied, and the arrangement of the *malleus*, *incus*, and *stapes*; also the tendon of the *stapedius muscle* will be seen passing forwards through the perforation of the pyramid to the neck of the stapes. The continuity of the middle ear with the Eustachian tube in front and the mastoid cells behind should also be noted, and the mastoid process should be opened in order fully to exhibit the latter.

When the tympanum has been studied, the general arrangement of the *labyrinth* should be examined. A full view of this part can only be obtained in specimens specially prepared; but with a few judicious applications of the bone-nippers, beginning by laying open the internal auditory meatus from above and extending the unroofing process forwards and backwards, the *cochlea* may be seen to lie with its base at the forepart of the cribriform plate, its cavity coiled in two circles and a half round the *modiolus* or central pillar from which the *lamina spiralis* projects into it; and the cavity of the *vestibule* will be opened into, opposite the hinder part of the cribriform plate, while the *semicircular canals* can be seen in section, the superior canal crossing the axis of the pars petrosa vertically, the posterior lying close to its posterior surface, and the external placed horizontally. In making this dissection the first care should be to follow the *portio dura* of the *seventh* nerve to

the place where it turns downwards, and to show the *great* and *small superficial petrosal* nerves joining its geniculate ganglion ; and in doing this the cochlea and vestibule will be more or less fully exposed. The *fenestra ovalis* and *fenestra rotunda* should be looked at from the vestibular side, and the mode noted in which the stapes is pressed inwards at the former when the handle of the malleus is pulled in. Afterwards, the descending part of the aquæductus Fallopii may be laid open, and at the same time the muscular belly of the *stapedius* muscle, which lies close to the facial nerve, may be exposed, as also the origin of the *chorda tympani* from the facial nerve.

The styloid process should now be nipped across, and together with the muscles attached to it should be turned forwards ; the upper parts of the *glossopharyngeal*, *vagus* and *spinal accessory* nerves should be dissected out, and the *pharyngeal* branch of the *vagus* should be traced from its origin to its destination. The remaining portion of the temporal bone bounding the jugular fossa should be separated and carefully raised, and in doing this it is possible to find the *auricular* branch of the *vagus* (*Arnold's*) entering the bone ; and the *tympanic* branch of the *glossopharyngeal* nerve (*Jacobson's*) may possibly be seen entering the spiculum between the jugular fossa and carotid canal. The carotid canal should be fully laid open, so as to enable the part of the bone external to it to be everted and expose completely in the foramen lacerum posticum the passage of the eighth nerve out of the cranium, and the connections of its parts ; also the *petrous* and *jugular ganglia* of the

glosso-pharyngeal nerve, and the *ganglia* of the *root* and *trunk* of the *vagus*.

The uppermost ganglion of the *sympathetic* can now also be dissected out. Its connections upwards should be traced along the internal carotid artery into the *carotid* and *cavernous plexus*, also its *communications* with the four upper cervical nerves, and its *cardiac* branch. Its *pharyngeal* branches uniting by the side of the middle constrictor with branches from the pneumogastric and glosso-pharyngeal to form the *pharyngeal plexus* should also be noted. Tracing the sympathetic cord downwards, its *middle* and *lower cervical ganglia* in the lower part of the neck, and their connection respectively with the fifth and sixth and with the seventh and eighth spinal nerves, are to be shown, as also their cardiac branches.

15. Pharynx, Larynx, Tongue and Nares.—The main trunks of the blood-vessels having been removed, the trachea and œsophagus are to be divided at the root of the neck, and the pharynx is to be raised from the prevertebral muscles and followed up to the base of the skull. An *occipital ligament of the pharynx* will be seen running back to the tubercle on the basilar process of the occipital bone, and is to be severed. By means of the chisel and mallet the skull is to be divided so as to separate the part to which the pharynx is attached from the hinder part; and if on one side the petrous part of the temporal bone still remains, the section should be made to pass behind it.

The pharynx should now be distended with tow. The *glosso-pharyngeal* nerve, the *pharyngeal* branch

of the *vagus*, and the *superior* and *recurrent laryngeal* nerves, together with the *laryngeal* and *ascending pharyngeal* arteries, and *palatal* and *tonsillar* branches of the facial, should be followed as far as practicable, and the *superior*, *middle*, and *inferior* constrictor muscles of the pharynx, with the longitudinal and circular fibres of the œsophagus, should be displayed. In connection with the superior constrictor the part of the pharynx above its superior border is to be noted, and also the pterygo-maxillary ligament separating this muscle from the buccinator. The middle constrictor will be seen to overlap the upper, and to be in turn overlapped by the inferior. The relations of the upper border of the superior constrictor to the *levator* and *tensor palati*, and of the middle constrictor to the stylo-pharyngeus, are to be shown.

After the dissection of the outside of the pharynx has been completed, the interior is to be brought into view by an incision extending down the middle, and another carried transversely close to the skull. The posterior nares, the pillars of the fauces, with the tonsils between them, the glottis, the œsophagus, and the Eustachian tubes opening above the soft palate, are to be studied. The muscles of the soft palate are then to be dissected. First, the view of the *levator* and *tensor palati* should be completed. The relation of the levator to the membranous floor of the Eustachian tube will be seen, and the student can judge for himself if there be any possibility that the extremity of that tube can be open, as is often alleged, when the muscle is swollen by contraction. Also the course of the tendon of the *tensor* or *circumflexus*

palati round the hamular process, and its insertion in part into the hard palate should be seen. From the extremity of the cartilage of the Eustachian tube the few fibres termed *salpingo-pharyngeus* will be seen to descend when present, and running down the uvula the pair of muscles named *azygos*. If the palate and tongue be now pulled in opposite directions, and the wall of the pharynx kept on the stretch with pins, the parts will be in the position most favourable for the display of the two muscles on each side descending from the palate, namely, the *palato-glossus* in front of the tonsil, and the *palato-pharyngeus* spreading out behind to the middle line of the pharynx.

The larynx and tongue are now to be separated from the parts above, and on the surface of the tongue the three kinds of *papillæ*, namely, *filiform*, *fungiform*, and *circumvallate*, are to be studied, especially the V-shaped arrangement of the circumvallate. The extrinsic muscles of the tongue should be dissected up as far as possible, and the intrinsic muscles then examined. Between the genio-glossus and hyoglossus will be found the longitudinal muscle, the *inferior lingualis*, and by removal of the mucous membrane of the dorsum, the *superior lingualis*. The *vertical* and *transverse* sets of muscular fibres, as well as the terminal arrangement of the fibres of the genio-glossus, are best exhibited by thin transverse sections held up against the light.

The aperture of the *glottis*, the arrangement of the *epiglottis*, and, so far as can be seen without dissection, the *vocal cords* having been seen, the mucous membrane is to be removed from the back

of the larynx, and the *superior* and *inferior laryngeal* nerves should be dissected out, so as to exhibit the muscular branches of the latter and the communication of the two nerves under cover of the thyroid cartilage. On the back of the cricoid cartilage will be seen the two *posterior crico-arytenoid* muscles; above them, on the arytenoid cartilages, the transverse fibres of the *arytenoideus*; and, on its surface, the decussate oblique bands of the *aryteno-epiglottidei muscles*. On further removing the mucous membrane the *cornicula laryngis* (cartilages of Santorini) will be seen surmounting the arytenoid cartilages and the *cuneiform* cartilages of Wrisberg producing a swelling in the epiglottidean fold in front of them. The form of the cartilages of the larynx is to be studied, and the crico-arytenoid and crico-thyroid articulations and the movements which they permit. The thyro-hyoid membrane and lateral ligaments are also to be examined, and the hyoid bone and remains of the tongue may then be removed. The epiglottis may be dissected out so as to show its form and connections at the base.

To see the remaining muscles of the larynx, the greater part of one half of the thyroid cartilage may be removed by a vertical incision near the middle line, carried down to about a line from the lower border, and another directed backwards from this, when the upper attachment of the *crico-thyroid* muscle will be seen more fully. The fibres of the *lateral crico-arytenoid* muscle will be observed converging to the outer angle of the arytenoid cartilage, and, above it, passing backwards to the base of the same cartilage, the *thyro-arytenoid* muscle occupying the fold

in which the vocal cord is situated. If now the mucous membrane above the true vocal cord on the side so far dissected be removed, a good view of the folds of the true and false vocal cords of the opposite side, and the *ventricle* between them, will be obtained, with the *sacculæ* extending from the forepart of the ventricle. The movements of the thyroid and arytenoid cartilages on the cricoid cartilage, their influence on the position and tension of the vocal cords, and the muscles by which they are effected ought to be carefully studied.

The nasal fossæ are now to be examined ; and for this purpose the cribriform plate and the portions of the frontal and sphenoid bones in front and behind it should be sawn close to the middle line on the side least dissected ; the saw should then be withdrawn, and the palate should be sawn through on the same side from below. The septum of the nose should be denuded of its mucous membrane and the *naso-palatine* nerve should be looked for in its course from Meckel's ganglion to the anterior palatine foramen ; and in a favourable specimen it, as well as the accompanying branch of the internal maxillary artery, may be traced to the palate, and the communication of the nerves of opposite sides called *ganglion of Cotunnus* may be shown. The *three meatus* of the nose are to be next examined. The relations of the upper meatus to the ethmoidal cells and sphenoidal sinus, the opening of the maxillary antrum into the middle meatus, and the communication of that meatus with the frontal sinus through the infundibulum in its forepart should be looked at ; also the direction, in the inferior meatus, which a probe or canula must

take to reach the nasal duct and the Eustachian tube. The inferior turbinated bone should then be in part removed to exhibit the character of the orifice of the nasal duct.

If the parts be in good condition an additional dissection of the *otic ganglion* from the deep aspect may now be made. The pterygo-maxillary fossa should then be opened into by removal of the ascending plate of the palate-bone piecemeal with the aid of bone-nippers and scissors; and the descending branches of *Meckel's ganglion* should be followed to their distribution in the palate. The *large palatine* branch will be found descending with the *superior* or *descending palatine* artery, a branch of the internal maxillary artery; while the *small* or *posterior palatine* nerve and the *external palatine* occupy the small canals of the same names. A dissection may now be made, as before directed, of the remaining ear.

16. Vertebral Muscles and Articulations.—It remains for the dissector to examine the muscles attached to the vertebræ. The *scaleni* muscles still remain uninjured: the *anterior* has been already seen; and, of the fibres behind the position of the subclavian artery, those attached to the first rib constitute the *middle*, and those proceeding to the second the *posterior scalenus*. Nearer the middle line, in front of the vertebræ, is the *rectus capitis anticus major* ascending to the skull; and under cover of it the *rectus capitis anticus minor*; while between the recti and scaleni and the middle line is the *longus colli* muscle. Ascending from the transverse process of the atlas is the *rectus capitis lateralis*.

If the muscles behind the vertebræ have not yet been dissected, they ought to be examined now according to the directions already given (p. 77).

The vertebral muscles are to be cleared away, and the movements permitted between the cervical vertebræ examined : also the upper end of the anterior common ligament will be seen. The laminæ are then to be cut across, if this has not been previously done for the examination of the spinal cord ; and it will be noticed that the *ligamenta subflava* between the lower vertebræ are replaced between the occipital bone, atlas and axis by white fibrous tissue. Within the spinal canal the upper part of the *posterior common ligament* is seen, and connected with it the flat band from the body of the axis to the occipital bone. When this has been reflected, the *transverse ligament* of the atlas, with the upper and lower appendage which give it a *cruciate* form, will be seen ; and also the *lateral odontoid* or *check* ligaments passing outwards to the occipital bone from the odontoid process of the axis, and between them the delicate *middle odontoid* ligament. The character of the movements of the articular surfaces of the atlas, axis, and occipital bone is then to be noticed, as well as the bursa behind and in front of the odontoid process ; and the movements permitted by the articulations of the six lower cervical vertebræ should also be studied. If the parts be in a state of particularly good preservation, a vertical transverse section may be made through some of the vertebræ to exhibit the joints of Luschka at the sides of the intervertebral discs.

17. **The Eyeball.**—This organ should now be dis-

sected, and as the dissection cannot be made perfectly complete on the eyeball of the subject, a pair of ox eyes may with advantage be used ; and the earliest opportunity should be taken for a repetition on a perfectly fresh human eye. The eye of an infant is perfectly suitable. If a weak solution of bichromate of potash be used, such as may be obtained by shaking a crystal for a moment in water till it gives it a straw colour, and an aperture be made in the sclerotic to admit the solution into the interior, the dissection will be facilitated, and the specimen may be preserved for any length of time without loss of transparency of the vitreous humour. The solution may be changed for spirit without further opacity taking place than serves to exhibit the hyaloid membrane ; but the outer layers of the lens are rendered opaque. In this way I have prepared specimens which have remained without deterioration for many years.

A preliminary view may be obtained by making a transverse vertical section of one eye, which may be done by piercing through the sclerotic and other tunics half-way back, and dividing them round about with the scissors. In the posterior part will be seen the *sclerotic* tinted on its deep surface with brown connective tissue, the *membrana fusca* ; inside this, the *choroid* coat much more loaded with pigment in the ox than in the human subject ; internally, the *retina* ; and between retina and choroid the *pigmented hexagonal epithelium*,¹ which, in a bichromate of potash

¹ Without doubting the microscopic phenomena which led Max Schultze to count this epithelium as part of the retina, I still consider that it has a greater claim to be called the epithelium of the choroid, and venture to think that there

preparation, will often separate in scaly patches like tinder. The retina is seen to be firmly attached at the *optic pore*, and from this the retinal artery branches out. In the human eye the *yellow spot of Sömmering* (*macula lutea*) is seen in the axis of the eye, its yellow colour contrasting with the delicate pink of the rest of the retina ; in the ox eye there is no such spot, and the optic pore is further removed from the axis. In the ox eye a portion of the choroid presents a bright glistening appearance from the presence of a structure named *tapetum*, and opposite this the hexagonal epithelium is destitute of pigment ; but in the human eye there is no tapetum.

In the anterior half of the divided eyeball is seen the anterior margin of the retina, smooth in the ox, but dentated in the human subject and named *ora serrata*. In the axis of the eye, through the vitreous humour, is seen the *crystalline lens* with the aperture of the pupil in front of it, and outside of this the *iris* and the radiating structures named *ciliary processes*. The *crystalline lens* and *vitreous humour* may be allowed to drop away from their connections ; or their separation may be assisted with the handle of the scalpel. The ciliary processes and back of the iris may then be washed so as to remove from them the dense pigment adhering to them ; the sclerotic and cornea may be everted, and the connection of the

is conclusive proof of this view in the mode of development ; the structure in question and the bacillary layer of the retina being different parts of one epithelium, lining opposed surfaces of the primary optic vesicle. Their true morphology is determined by their original continuity, not by their subsequent contiguity and adhesion.

tunica media (of which the choroid is the posterior and the iris the anterior portion) with the sclerotic may be examined. Between the sclerotic and choroid will be found the divided *ciliary* nerves derived from the lenticular ganglion. Let the connection of the iris and choroid with the sclerotic be gently broken up with the handle of the scalpel, so as to detach them from the outer coat of the eye, and at the place of connection there will be seen a white ring between choroid and iris, the *ciliary muscle*, and in front of this a canal opened into, the *circular sinus*, in front of which is a very delicate torn edge, the *ligamentum pectinatum*. The iris in the ox differs from that of the human subject in having a horizontally elongated pupil, and in the *circular* muscular fibres round the pupil being much more distinctly separated from the *radiating* fibres at the circumference. Sections should be made to show the passage of the sclerotic into the *cornea*, and the lamination of the cornea. The laminae are considerably separated when bichromate of potash is used.

Turning now to the lens and forepart of the vitreous humour, there is seen a series of plications, *zonule of Zinn*, corresponding with the ciliary processes; and if a blowpipe or nozzle of a syringe be introduced between these plications, close to the lens, and air or colouring matter introduced, a demonstration will be had of the *canal of Petit*, bounded in front by the *suspensory* ligament. If a slight score be then made on the front of the lens, its *capsule* will be ruptured, the crystalline lens will fall out, and both lens and capsule may be fully examined.

While one eyeball is examined in the easy way now described, on the other the tunics may be removed in series. For this purpose the first incision into the sclerotic should be made well forward where it is thinnest; and in carrying the cut made with the scissors round about, care must be taken not to injure the choroid; and the ciliary nerves also may be preserved. A cut may then be made back to the optic nerve; the sclerotic may be everted; and then it may be cut away close to the optic nerve. The forepart of the sclerotic, with the cornea, may then be detached as in the former dissection, if the dissector chooses. The choroid is next to be removed. It can be torn away easily in shreds, the tears taking a direction from before backwards determined by the course of the arterioles which constitute an important part of its structure. A view will thus be obtained of the retina in its position on the surface of the vitreous humour; and on removing the retina, the vitreous humour, the lens and the transparent membranes will be obtained intact.

If the student has been careful in his manipulations a dissection similar to either of those above described may be made in the eyeball of the subject. The sclerotic and cornea may be thoroughly examined, and the ciliary nerves may be traced. The choroid, iris, and ciliary muscle may be displayed; and when the eyeball is opened, the lens with its capsule and the hyaloid can be easily separated. The retina, however, as a rule cannot be exhibited.

DISSECTION OF THE THORAX.

1. **The Parietes.**—Before the fifth day after the subject has been placed on the back, the upper limbs should be removed by the dissectors of those parts, and then the dissection of the thorax may be commenced.

The *external intercostal* muscles should be displayed in as great a part of their extent as possible; and they should be dissected away from some of the intercostal spaces, so as to show the direction of the *internal intercostal* muscles beneath them. Also the *intercostal* nerves of the upper six spaces may be shown between the muscles, and with them the *intercostal* arteries, each with its collateral branch running along the upper border of the rib below; and the anastomoses of these arteries with the *internal mammary* should be made out. On the left side the course of the internal mammary artery may be exhibited by the removal of the second and four succeeding costal cartilages; then, in order to exhibit the relations of the pericardium and pleural cavities to the thoracic walls, the corresponding costal cartilages of the other side may be divided close to the ribs, and the ribs on both sides whose cartilages have been divided may be removed, together with the subjacent pleura, back as

far as can be conveniently reached in the position of the body, the sternum meanwhile remaining intact. The anterior border of each pleural sac can now be observed, the right lying close to the middle line below, or crossing it, and the left receding from the middle line, also the extent of the interval between the borders of the two sacs, which is known as the *anterior mediastinum*, and is in its lower part widened out and inclined to the left. The lungs should also be inflated from the windpipe, so as to give an idea of the extent to which they descend between the ribs and diaphragm in inspiration. After this, the sternum is to be sawn across through the manubrium and removed, and on the side on which the cartilages are left a view will be obtained of the *triangularis sterni* muscle and internal mammary artery from the deep aspect ; and also the articulations of the costal cartilages and sternum may be examined. Two or three more of the ribs may be taken out of the way by separating them from their costal cartilages, and nipping them across in a line with those above them.

2. The Pleura and Parts adjacent.—The lungs are to be raised, and any fluid or other impurities sponged away from the pleural cavities. If the parietal and pulmonary layers of the pleura be anywhere adherent, the adhesions are to be broken down with the fingers; and it is important to observe that, excepting only the reflections of the pleural membrane and the lung itself, no part of the dissection need be seriously defective on account of any amount of pleuritic adhesion or phthisical alterations ; for, if only healthy

chests were made use of in the dissecting-room, the student would be badly supplied with material. The reflections of the pleural sac from the parietes to the lungs and over the pericardium are to be observed, and beneath the root of the lung the fold termed *ligamentum latum pulmonis*.

The lungs are then to be carefully examined, both in the inflated and the collapsed condition. The division of the right lung into three lobes, and the left into two, will be noted, as well as the form and position of the lobes; also the other points in which the lungs differ by reason of the unsymmetrical position of the heart and spleen, viz. height, breadth, and form of anterior border.

Passing down on each side in front of the root of the lung will be found the *phrenic nerve*, a branch mainly of the fourth, receiving also a fasciculus from the fifth cervical trunk, and accompanying it the *comes nervi phrenici*, a small branch of the internal mammary artery; and on following the nerve upwards, it will be seen quite at the upper part of the chest to cross the trunk of that artery.

In the upper part of the anterior mediastinum there is often found a mass of brownish-coloured fat, the remains of the *thymus* gland; and on removal of this, the *left innominate vein* will come into view crossing the branches of the aortic arch and uniting with the *right innominate vein* to form the *vena cava superior*. These veins should be dissected out, together with the branches joining them, viz. the *inferior thyroids*, *internal mammaries*, and *superior intercostals*; and also, joining the *vena cava superior*

above the root of the right lung, the *great vena azygos*. The transverse part of the arch of the aorta is now also seen, with the *innominate, left common carotid* and *left subclavian* arteries coming off from it; and on lifting up and turning aside the left lung, the continuation of the arch into the descending aorta can be observed. Crossing the arch of the aorta between the origins of the left common carotid and left subclavian artery is the *left pneumogastric* nerve, and internal to it the *cardiac* branch given off by the left pneumogastric in the lower part of the neck, and sometimes that from the first cervical ganglion. The origin of the *recurrent laryngeal* branch of the left pneumogastric turning round the arch of the aorta is to be dissected out, as also the cardiac branches given off from the recurrent laryngeal; and immediately internal to this nerve will be found a tough fibrous structure connected with the concavity of the aortic arch, which is the *ductus arteriosus*.

The main trunk of the left pneumogastric nerve is to be followed downwards, and its branches to the front of the root of the left lung (*anterior pulmonary plexus*) are to be traced; and the lung is then to be thrown forward and kept in that position with a string if necessary, while the course of the pneumogastric is dissected further, and the branches going to the back of the root of the lung, together with the filaments joining them from the thoracic ganglia of the sympathetic nerve to form the *posterior pulmonary plexus*, are to be brought into view. Pursuing the dissection in a forward direction, the constituents of the root of the lung are to be made plain; namely,

from above downwards, *left pulmonary artery*, *left bronchus* and *left pulmonary veins*, and along with these the *left bronchial* arteries given off from the aorta, and *left bronchial vein* opening usually into the superior intercostal. Then, continuing the dissection backwards, the pleura is to be stripped from the aorta and from the back part of the thoracic wall, and the *sympathetic ganglionic chain* lying on the necks of the ribs is to be dissected out, together with the *great splanchnic* nerve arising by separate origins from different ganglia from about the fifth to about the ninth. The condition of the dissection of the abdomen will probably not allow these nerves to be displayed in the lower part hid by the convexity of the diaphragm till a later period. The courses of the sympathetic branches to the lung are to be exhibited from the ganglia; and the double connection of each ganglion with the corresponding spinal nerve should also be shown. The fat and connective tissue should be cleared away from the back part of the intercostal spaces, so as to show the intercostal nerves and arteries lying on the external intercostal muscles, and the posterior margins of the internal intercostals at some distance from the vertebræ. Also the arrangement of the intercostal veins is to be preserved, the lower veins followed into the left vena azygos, and those of the upper spaces followed so as to show whether they pour their blood into the vena azygos or left innominate vein, or both, as the case may be. The lung may then be replaced in its position.

The right lung is next to be turned forwards, and the *right pneumogastric* nerve, lying outside the su-

perior vena cava, is to be followed downwards ; its *cardiac* and *anterior pulmonary* branches are to be made out, as on the left side, and so also the *posterior pulmonary* plexus, the *sympathetic chain*, and the great *splanchnic nerve* are in like manner to be dissected. The *great vena azygos* will be seen curving forwards above the root of the lung to open into the superior vena cava ; and when the root of the lung is dissected, the points in which it differs from that of the left lung are to be observed ; namely, the bronchus entering at a higher level than the artery, the bronchial vein opening into the vena azygos, and the usually single bronchial artery arising sometimes from an intercostal vessel. Lying in loose tissue internal to the vena azygos will be found a slender white tube, the *thoracic duct*, sometimes double in part of its course ; and internal to this is the *œsophagus*. With a little care, the thoracic duct may be even now traced up as it crosses the middle line in the upper part of the chest, behind the œsophagus and arch of the aorta, ascending behind the left pleura to end in the neck, at the angle of junction of the left internal jugular and subclavian veins. The arrangement of the intercostal veins entering the great vena azygos is to be exhibited, and also the left vena azygos opening into the great azygos vein on its inner side about half-way down the thorax. The lung is then to be returned into its position.

3. The Pericardium and Heart.—The extent and relations of the fibrous layer of the pericardium having been examined from the exterior, the sac is to be opened into by an incision in its whole length, crossed

by one dividing it transversely close to the diaphragm. The reflections of the serous layer are then to be examined. The positions of parts are to be observed ; namely, the *apex* of the heart directed forwards, downwards, and to the left ; the *auriculo-ventricular sulcus* lying obliquely, with the right side lower than the left ; the *anterior* and *posterior interventricular sulcus* making the relative positions of the right and left ventricle, the right ventricle being placed below and in front of the left ; the two *auricular appendices*, one on each side of the two arterial trunks ; the *pulmonary* artery springing from the right ventricle, the *aorta* appearing on its right side, and the sulcus between them in the middle line ; lastly, the positions of the veins ; the *superior* and *inferior vena cava* entering the right auricle from above and below, and, at the upper and back part of the pericardial cavity, the *pulmonary veins* entering the left auricle from each side.

The pericardium may now be dissected away from the arch of the aorta, care being taken of the cardiac nerves, and the arch is to be studied in detail. In like manner the pulmonary artery, and then the systemic and pulmonary veins successively, are to be exhibited and examined. The *right* and *left coronary arteries* are then to be dissected, the right one arising from the right *sinus of Valsalva*, and sending a branch along the posterior interventricular sulcus, the left arising from the anterior sinus of Valsalva, and giving off at its commencement a branch which descends in the anterior interventricular sulcus. In close connection with these arteries will be found the

coronary plexus, in which the cardiac nerves ramify before they descend on the surface of the ventricles. Also, in the auriculo-ventricular sulcus is the *coronary vein*, which may be slit up in the part of its course beneath the left auricle, to show the pair of valves by which it is guarded at a point about an inch from its termination, where it receives the name of *coronary sinus*. One tributary of this vein entering it from above, the *oblique vein of Marshall*, is specially interesting, as being the vestige of a left superior vena cava in early foetal life.

The right auricle is to be laid open by cutting and turning down a flap from the anterior wall, care being taken in making the incision not to approach too closely the opening of the lower vena cava, lest there be injured the *Eustachian valve* on the anterior and inner side of the orifice. Within the right auricle, the most important points to notice are the *fossa* and *annulus ovalis* on the septum between the auricles, the *auriculo-ventricular opening*, the opening of the *coronary sinus* placed between the auriculo-ventricular opening and back part of the vena cava inferior and guarded by the *valve of Thebesius*, smaller openings of veins called *foramina Thebesii*, and the *musculi pectinati* of the anterior wall and appendix.

The right ventricle may now be conveniently opened by an incision a little to the right of the anterior interventricular sulcus, from which another may be carried along by the inferior border of the auriculo-ventricular sulcus, care being taken not to injure the anterior cusp of the *tricuspid* or right auriculo-ventricular valve. The convexity of the

interventricular septum, the infundibular extension of the ventricle upwards to the pulmonary artery, and the way in which it falls short of the apex having been noted, the other peculiarities of this ventricle will be better studied by comparing it with the left. The left ventricle may be exposed after the same fashion as the right, by means of a longitudinal incision close to the septum and another carried outwards along the base; but the longitudinal incision should terminate before reaching the apex, and should be then continued transversely, so as to expose both the *anterior* and *posterior musculus papillaris* without injury. The cusps of the *mitral* or *bicuspid* valve can then be studied, when it will be noted that the *chordæ tendineæ* of adjacent margins of cusps are gathered together to their corresponding *musculus papillaris*, and that the *chordæ tendineæ* arise at different levels on the backs of the cusps. The passage up to the aorta is on the right side and in front of the right cusp. Turning then to the right ventricle, the student will be able to contrast with the mitral valve the three cusps, anterior, posterior, and mesial, of the *tricuspid* valve, united by a connecting fringe at the base, and having their *chordæ tendineæ* irregularly disposed. Also the much more copious network of *trabeculæ* in the walls of the left ventricle will attract his attention.

Before opening the left auricle, the inferior vena cava should be divided and the heart turned upwards, so as to show the position of the auricle with its posterior wall symmetrically disposed across the middle line, and the pulmonary veins opening into it from

each side. The posterior wall may then be divided by an incision across its lower part, carried upwards at each extremity close to the entrance of the veins. The freedom of the whole auricle from *musculi pectinati*, save only in the appendix, will be seen, and some irregular depressions opposite the interauricular septum. A probe may be passed from the right auricle forwards under cover of the *annulus ovalis*, and in many instances will pass into the left auricle through a narrow channel, the remains of the foetal *foramen ovale*.

The arch of the aorta may now be cut across in the middle of its ascending part, and, while the *superficial cardiac* nerves are still left intact, those passing down in front of the trachea to form the *deep plexus* may be dissected fully out; the *cardiac ganglion* may be found close between the aorta and pulmonary artery, and the plexus may be traced onwards to the coronary vessels, on which the nerves have already been exposed. The pulmonary artery and veins and the vena cava superior being then divided, the heart will be removed from the body. The competency of the arterial valves, both aortic and pulmonary, may be tested by pouring water into the vessels; and the three dilatations, or *sinuses of Valsalva*, opposite the three pouches of the valve in each artery, may be examined. The auricles may then be removed, note being taken of the complete absence of continuity of their muscular fibres with those of the ventricles. The auriculo-ventricular openings will then be seen lying side by side, with the aortic orifice between and in front of them, and

the orifice of the pulmonary artery in front of the aortic. In the angle between the aorta and two auriculo-ventricular openings will be found a small nodule of cartilage, with fibres extending from it. Lastly, the aortic orifice and that of the pulmonary artery are to be slit open between two of the adjacent sinuses of Valsalva, so as to show the three pouches of which each semilunar valve consists, each with thin *lunulae* at the sides, and a stronger part in the centre coming to a thickened point close to the margin, called *corpus Arantii*. Also, in two of the aortic sinuses of Valsalva the origins of the coronary arteries will be seen, above the level of the segments of the valve.

4. The Air Tubes and Interior of the Lungs.—

The lungs are to be removed by dividing the trachea ; and the *bronchi* are to be dissected out. The greater size of the right bronchus and more descending course of the left are to be noted, and the arrangement of their cartilages. The bronchial tubes are then to be followed as far as possible through the substance of the lung, and the mode of branching noted, as well as the gradual change in character of the cartilages, which at first are arranged so as to keep the tubes thoroughly open, then degenerate into mere scattered nodules.

The *trachea* should be dissected from behind ; the fibrous coat should be laid open, and beneath it will be found numerous separate little glands, which send their ducts through the subjacent muscular coat to the mucous membrane. The connections of the muscular coat with the cartilages are to be

exhibited, and the mucous membrane is then to be divided, and its glandular orifices and longitudinal markings noted. The bronchi and succeeding tubes should be examined by slitting them open to show the mucous membrane. Sections should also be made through healthy portions of the lung, to familiarise the eye with the appearance of the vessels and bronchial tubes in section and the framework of connective tissue between the lobules ; and the lightness of the tissue may be tested by throwing portions into water.

5. The Œsophagus and other Parts.—The structures in the posterior mediastinum now demand further attention. The aorta and termination of the *left vena azygos* can be more fully displayed, the *œsophagus* can be properly cleaned, its curves can be seen, and the *right* and *left pneumogastric* nerves can be exhibited on it. The *thoracic duct* is to be followed up, if this has not been already done ; and, by an arrangement with the dissectors of the head and neck, it may be pursued round the apex of the left lung to its termination in the angle of junction of the left subclavian and left internal jugular vein. Then the lower part of the thoracic portion of the sympathetic chain, together with the *greater* and *smaller splanchnic nerves*, should be traced to their passage through the diaphragm ; and the diaphragm itself may be examined, so far as it can be seen from the thorax.

Lastly, the articulations of the ribs and dorsal vertebræ are to be dissected out. Sometimes it will happen that the dissectors of the abdomen have by

this time removed the pelvis and lower lumbar vertebræ, in which case all the vertebræ which remain can be examined by the thoracic dissectors ; but if that be not the case, a division should be made about the level of the tenth dorsal vertebra ; and in any circumstances, the first vertebra and costal arch should be left to the dissectors of the head and neck. In front of the vertebræ will then be seen part of the *anterior common* ligament and the *stellate* or *anterior costo-vertebral* ligaments. Behind, the laminae have probably been already removed, and the *posterior common* ligament will be seen behind the bodies of the vertebræ. The *posterior costo-transverse* ligaments, passing from the tips of the transverse processes to the outer ridges of the tubercles of the ribs, require little dissection ; and the *long costo-transverse* ligaments will be seen on removal of the muscular fibres from the intervals between successive transverse processes. The movements permissible at the heads and tubercles of the ribs, as well as between the vertebræ, may then be examined, so far as the imperfect character of the specimen allows ; and the vertebræ may then be separated to show the *ligamentum colli costæ* between each rib and its corresponding transverse process, and also the interior of the costo-vertebral joint, with its *interarticular* ligament. To exhibit fully, however, the movements of the vertebræ and ribs requires a thorax and vertebral column to be devoted to the purpose ; and even then it is to be remembered that the respiratory movements cannot be imitated after death.

DISSECTION OF THE ABDOMEN AND PELVIS.

1. **The Perinæum.**—If the subject be a male, at least one day after it is placed on the table should be devoted to the dissection of the perinæum from below. For this purpose a lithotomy staff should be passed into the bladder, and the subject should be placed in the position usual for the operation of lithotomy, either by tying the hand and foot of each side together, or, as is better, by means of a simple frame for the purpose, with upright spokes to hold back the lower limbs. The perinæum should then be brought to the edge of the table, and, if necessary, should be elevated by means of a block under the pelvis. Sometimes it is required to tie the penis and scrotum to the handle of the staff.

An incision should be made outwards on each side from the depression in front of the anus known as the central point of the perinæum ; and from the same point two backward incisions should be made so as to enclose the anus, behind which a mesial prolongation may be carried back to the coccyx. The *superficial sphincter* lying immediately below the integument is then to be laid bare, and the flaps of skin turned outwards. The dissector can then satisfy

himself that on each side of the anus there is a hollow filled with fat, the *ischio-rectal fossa*, while in front there is a firm boundary of fascia and other structures. A cut from before backwards being made down into the middle of the right fossa, it will be seen that a superficial pad of fat is separated from a deeper layer, and that in the plane of separation are the *inferior hæmorrhoidal* vessels and the posterior twig of the *perinæal* branch of the pudic nerve, on their way to the surface. After finding and following these structures, the walls of the fossa should be exhibited, namely, on the outside the *obturator fascia*, the margin of the *gluteus maximus* muscle behind, and internally the *levator ani* and *coccygeus* muscles covered by the *anal fascia*. Emerging between the levator ani and coccygeus muscles, a small branch from the *fourth sacral* nerve will be found coming to the surface. In front, the dissector should be satisfied, at this stage of the dissection, with feeling the position of the staff in the membranous portion of the urethra, and should beware of injuring the fasciæ. This dissection should be repeated on the left side of the body; and in doing this the dissector will do well first to divide the fat filling the fossa, as it would be divided in the lateral operation of lithotomy, and to note the depth to which such an incision might be carried, and feel the position of the groove of the staff between the bulb of the urethra and the prostate. The mesial incision should then be prolonged forwards, and the integument reflected from the anterior division of the perinæum.

In the anterior half of the perinæum, a superficial fascia or layer of the rete adiposum will be found continuous with that over the thighs and with the contents of the ischio-rectal fossa, and beneath it a layer of membranous fascia bound down to the arch of the pubes at the sides, and dipping down to be connected with the margin of the triangular ligament behind. This is what is sometimes called *Colles's fascia*, and is important in the history of urinary infiltrations, as it prevents urine extravasated by injury of the spongy portion of the urethra from passing backwards into the hinder part of the perinæum and down into the thighs. Before it has been much laid bare a blow-pipe should be introduced under it, and it should be inflated so as to exhibit that the district beneath it is cut off alike from the back part of the perinæum and from the thigh, and also that on one side it is separated from the other behind the scrotum by a mesial septum, which being imperfect in front, allows the air, after it has reached the scrotum, to pass from one side to the other. As it extends forwards into the scrotum, this fascia will be noticed to become thicker, being continuous with the involuntary muscular tunic called the *dartos*. Entering beneath this fascia from behind will be found the two *anterior perinæal* branches of the pudic nerve, and external to them, crossing in front of the ischial tuberosity, the *inferior pudendal* branch of the small sciatic nerve; also entering from behind is the *perinæal* branch of the pudic artery. These three scrotal nerves are to be followed out after division of the fascia; and the perinæal artery will be seen to

give off the *transverse perinæal* branch before passing forwards. In the space exhibited by removal of the deep layer of superficial fascia are seen, in the middle the *bulb* covered over by the *accelerator urinæ* or *bulbo-cavernosus* muscle, and on each side the *crus penis* clothed with the fibres of the *erector penis* or *ischio-cavernosus* muscle ; while behind, closely connected with the fascia where it dips deeply, is a thin muscular slip, the *transversus perinæi*. These muscles are to be dissected out, and beneath them, when they are separated, will be seen the *anterior* layer of the *subpubic fascia*, otherwise called the *triangular ligament*.

On division of the triangular ligament as close to the arch of the pubes as possible, and dissecting it towards the middle line, there will come into view the muscles situated between it and another membrane stretched across the arch of the pubes, viz. the *deep layer* of the *subpubic fascia*. They are the *deep transversus perinæi*, which is a small band directed outwards and forwards from the central point of the perinæum, and beneath it the transverse fibres of the *constrictor urethræ* passing partly in front of and partly behind the urethra. Near the base of the triangular ligament will also be seen the *artery of the bulb* passing inwards from the pudic artery : it is placed not far off from the deep incision in lithotomy and might be injured if arising unusually far back, or more probably by an improper extension of the deep incision too far forwards. Under cover of the mesial attachment of the deep transverse muscles is a pair of small bodies, *Cowper's glands*, the slender ducts of which, in a

favourable subject, may be traced forwards. On the left side, the *pubic* artery and nerve may now be dissected out as far as is possible in the present dissection, when the origins of the branches already exhibited will be brought into view, as well as the *artery to the corpus cavernosum*. The anterior edge of the *levator ani* muscle, which passes directly forwards on the deep surface of the deep layer of sub-pubic fascia and supports the prostate, is now to be dissected out on both sides; and if the attachment of the *superficial sphincter* to the central point of the perinæum be divided, and the rectum pushed back with the handle of the scalpel, a most instructive view of the prostate gland and lowest part of the bladder, as seen when separated from the rectum, may be obtained.

2. The Abdominal Wall.—This dissection may be begun as soon as the subject is laid on its back.

It will sometimes be found expedient to make on one side a continuous dissection of the flat muscles throughout their whole extent, and to reserve the lower part of the abdominal wall on the other side for a special examination of the parts through which inguinal hernia may take its course; but in the directions about to be given a plan is recommended by which all the structures may be exhibited conveniently on one side; and the intelligent dissector will be able, with the consent of his partner, to modify those directions so as to suit particular circumstances.

A mesial incision deviating to one side at the umbilicus is to be made from the lower end of the

sternum to the pubes ; and another incision, if not already made by the dissector of the arm, is to be carried transversely outwards from the upper end of this, as far as the border of the latissimus dorsi ; while, if the skin is intact at the fold of the groin, a third may be directed inwards from the upper iliac spine. The integument is then to be removed from the lower or inguinal portion of the abdominal wall, situated below the last incision, and it is preferable that arrangement be made with the dissector of the lower limb to raise in one flap continuous with it the integument of the upper part of the thigh and so avoid an incision along the fold of the groin. In the subcutaneous tissue underneath will be found two sets of branches of the femoral artery and vein, viz. the *superficial circumflex iliac* vessels directed upwards and outwards, and the *superficial epigastric* directed upwards and inwards. These vessels course superficial to a deeper and more membranous layer of the superficial fascia, sometimes distinguished as *Scarpa's fascia* ; and this may be conveniently brought into view by cutting down on the subjacent aponeurosis of the external oblique muscle at the level of the transverse cutaneous incision, and raising the fascia from the aponeurosis with the handle of the scalpel, then dividing it in the middle line and continuing the separation, when it will be seen to be firmly bound down a little below the level of *Poupart's ligament*, while towards the middle line the space beneath it is continued into the labium in the female, and the scrotum in the male ; a circumstance of importance, explaining why urinary infiltrations pass

upwards on the abdomen, but not down into the thighs. At the lower and inner part of the portion of the aponeurosis of the external oblique muscle brought into view there is a separation in its fibres, the *external* or, more properly, *superficial abdominal ring*; and, emerging from this opening in the male is the *spermatic cord*, consisting of structures descending to the testicle; while in the female the same position is occupied by the *round ligament of the uterus*, a structure passing down to be attached in the labium, and, except when the uterus is much enlarged, greatly smaller than the spermatic cord in the male. A little above the superficial abdominal ring, the terminal branch of the *ilio-hypogastric* nerve pierces the aponeurosis, while through the ring comes the *ilio-inguinal* nerve to terminate in the pubic integuments.

The integument may now be reflected from the rest of the abdominal wall; and the subcutaneous fat is then to be removed from the structures underneath, so as at once to clear the aponeurotic anterior wall of the *sheath of the rectus abdominis* muscle, separated from that of the opposite side by the *linea alba* in the middle line; and in removing the fat a series of four or more *anterior cutaneous* branches of the *lower intercostal* nerves with corresponding *intercostal* vessels in company, are to be preserved and followed out from their emergence through the sheath of the rectus muscle; while the terminal branches of these nerves pierce the sheath of the rectus close to its inner margin, they frequently give off cutaneous twigs which pierce the outer margin of the muscle.

Further out will be found the *linea semilunaris* indicating the outer margin of that sheath, and external to this the aponeurosis of the *obliquus externus* muscle continued, towards the side of the abdomen, into its muscular fibres, which are directed outwards and upwards. As the reflection of the fascia from the surface of those fibres is continued, there will be found emerging from between them, along the side, the *lateral cutaneous* branches of the lower intercostal nerves; and these, being at once pursued to their distribution, will be found each to divide into an *anterior* and *posterior* branch, respectively turning forwards and backwards. Also near the crest of the ilium two trunks will be found turning down over the gluteal region, namely, the lateral branch of the *last dorsal nerve*, and behind it the *iliac* branch of the *ilio-hypogastric*. These nerves having been preserved, the dissection is to be pursued further back, till the posterior border of the external oblique muscle of the abdomen is reached in the hollow outside the position of the erector spinæ muscle; and the attachments of the muscle to the eight lower ribs, and their interdigitation with origins of the *latissimus dorsi* and *serratus magnus* muscles are to be made distinct.

An oblique incision is to be made through the external oblique muscle about two inches from the costal attachments in such a manner as to separate them from the rest of the muscle; and each costal slip of attachment, as well as the insertion into the crest of the ilium, is to be dissected out and reflected. An incision is then to be directed inwards from the anterior superior spine of the ilium, across the fibres

of the aponeurosis, to the sheath of the rectus muscle ; the remainder of the muscle above the incision is to be reflected inwards as far as it can be raised, and the *obliquus internus* muscle is to be cleaned. The posterior fibres of this muscle are directed upwards and forwards ; and in raising the external oblique from its surface it will be seen that a small angular part behind is left uncovered by it.

The internal oblique muscle is to be dealt with in a manner similar to the external oblique ; that is to say, it is to be divided near its attachments to the cartilages of the lower ribs so as to liberate both them and the insertion into the crest of the ilium, and an incision is to be carried inwards from the ilium in front, leaving the lower part of the muscle undissected in the meantime ; and the upper part is to be reflected inwards to the sheath of the rectus, so as to lay bare the transversalis muscle. Between the internal oblique and the transversalis the trunks of the lower intercostal nerves will be found ; they are to be preserved as the muscles are being separated. The *transversalis abdominis* muscle cannot be seen in its entirety at present ; but the parallel disposition of its fibres can be seen, also its origin from the crest of the ilium, and the connection of its anterior aponeurosis with the sheath of the rectus muscle, and of its posterior aponeurosis with the sheath formed by the lumbar fascia for the erector spinæ.

The sheath of the *rectus abdominis* muscle may now be opened by means of an incision in its whole length, about an inch from the middle line. The muscle adheres to the anterior wall of its sheath at

three or four places where it is crossed by tendinous intersections, and those adhesions must be divided without injury to the muscle. The anterior wall of the sheath can then be turned outwards and inwards, the structure of the linea alba separating the sheaths of opposite sides can be examined, and the muscle may be raised from the posterior wall of the sheath. In the lower part of the sheath, ascending from the pubes to the linea alba, is the *pyramidalis* muscle, in front of the rectus. The series of lower intercostal nerves will be seen piercing the rectus muscle; and underneath it, entering the sheath from the outside, in the lower part, is the *deep epigastric* artery, which ought to be traced in its course up through the muscle; while the *superior epigastric*, coming from the internal mammary, may be traced in the muscle from above downwards, and in many instances its anastomosis with the deep epigastric will be easily exhibited. The structure of the sheath of the rectus muscle is to be examined by raising the dissected portions of the oblique muscles, and observing the splitting of the aponeurosis of the internal oblique, and the union of its divisions with the aponeuroses of the external oblique and transversalis muscles in front and behind the rectus. Also in the lower part of its extent is to be noted the extreme weakness of the posterior wall of the sheath. The lower margin of the strong upper portion of the posterior wall of the sheath, which, it will be noticed, corresponds pretty closely with a line drawn between the most prominent parts of the iliac crests, is called the *fold of Douglas*. The deep epigastric artery enters the

sheath a little below the fold of Douglas and at the place where it enters there are often to be noticed two diverging aponeurotic bands, one passing inwards towards the pubes, and the other passing downwards and outwards external to and continuous with the conjoined tendon, close to the margin of the deep abdominal ring.

The deep inguinal dissection is now to be proceeded with. The lower portion of the aponeurosis of the external oblique muscle is to be raised with the handle of the scalpel from the parts beneath, and is to be divided by an incision continued immediately outside the sheath of the rectus muscle down to the pubes. The *external* and *internal pillars* of the superficial abdominal ring will thus be brought more fully into view, so that their attachments may be studied, together with the *intercolumnar fascia*, a thin membranous sheath continued from the margins of the ring, down on the surface of the spermatic cord in the male, and less distinctly developed in the female. Beneath the portion of the aponeurosis of the external oblique muscle now reflected, fibres of the internal oblique muscle, taking origin from the upper two-thirds of Poupart's ligament, extend inwards, the upper fibres lying in a transverse direction and those below arching more and more downwards ; while from the lower third of Poupart's ligament in the male, other muscular fibres take origin, which turn downwards on the surface of the spermatic cord, and constitute the main part of the *cremaster* muscle, represented in the female by a smaller group of muscular fibres somewhat detached

from the rest of the internal oblique muscle. Passing the handle of the scalpel between the divided edge of the internal oblique and the still uninjured transversalis muscle, the student will now proceed to investigate the relations of the lower parts of these two muscles, one to the other. He will find them usually not very distinctly separated below ; but the *superficial* branch of the *deep circumflex iliac* artery, directed upwards and outwards between them, will serve for a guide ; and he will divide the fibres of the internal oblique close to Poupart's ligament, and turn them inwards. He will then find that the fibres strictly belonging to the transversalis muscle cease at a somewhat higher level than those of the internal oblique, and that the lower fibres of both muscles are continued into an aponeurotic expansion, the *conjoined tendon*, which is directed downwards to the pubes. This will be seen to more advantage on dividing and reflecting inwards the lower part of the transversalis muscle in the same way as the internal oblique was divided. Also, the upper fibres of the cremaster muscle may be raised from their position ; and if the handle of the scalpel be introduced between them and the spermatic cord, the dissector will see the thin expansion of fascia connected with its fibres, named the *cremasteric fascia*.

There is now brought into view a continuous sheet of thin fascia, *fascia transversalis*, lying beneath the transversalis muscle, attached to Poupart's ligament, and stronger in the neighbourhood of that structure than in the upper and inner part of the dissection. The part of the spermatic cord laid bare by

the reflection of the internal oblique and transversalis muscle is seen to emerge from a deep position by turning over a crescentic margin of aponeurotic fibres, and this is what is termed the *internal* or *deep abdominal ring*. On examination the ring will be found not to present a complete perforation, but to have from its margins a thin membranous sheath prolonged down on the spermatic cord : this is the *infundibuliform fascia*, and although but a delicate and seemingly unimportant film, is worthy of the dissector's attention on account of its liability, like other fasciæ already mentioned, to undergo enormous thickening in cases of hernia. Beneath the transversalis fascia, between it and the peritoneum, is a layer of loose adipose tissue, the *subperitoneal fat* ; also passing upwards and inwards beneath the spermatic cord, and internal to the deep abdominal ring, is the *deep epigastric* artery with an accompanying vein, and curving upwards and outwards is the *deep circumflex iliac* artery.

At this stage it is advisable to divide the recti muscles and open into the cavity of the abdomen by means of a transverse incision at the level of the umbilicus. Lifting up the lower part of the abdominal wall, it will then be seen that it is thrown into three fossæ below, one in the middle with a slight cord, the *remains of the urachus* extending up in the middle line from the fundus of the bladder to the umbilicus, and one on each side separated from the middle fossa by the *obliterated hypogastric* arteries, which, ascending on the sides of the bladder, pass likewise to the umbilicus. The deep epigastric artery

either corresponds in position with the obliterated hypogastric, or lies a little to the outside of it, so as to leave an intermediate little peritoneal fossa between it and that structure. Now an oblique inguinal hernia, leaving the abdominal cavity at the deep abdominal ring, follows the course of the spermatic cord as far as the superficial ring, and that course is named the *inguinal canal*; while, on the other hand, a direct inguinal hernia leaves the abdomen internal to the epigastric artery, either passing internal to the obliterated hypogastric also, or, in the event of an intermediate fossa existing, passing down through it, external to the obliterated vessel: the student will therefore take note of the relations which each form of hernia must necessarily have to surrounding parts, especially to the epigastric artery which is internal to an oblique hernia and external to a direct; and he will observe what structures will be pushed before the hernia so as to form its coverings.

The fascia transversalis and subperitoneal fat of the groin are now to be turned aside from the peritoneum which is to be detached from them and from the deep side of Poupart's ligament. By this means a view will be obtained, from the inside, of the relations of the *transversalis fascia* bound down to Poupart's ligament below, and the *iliac fascia* reaching that structure from the iliac fossa, and also of the parts involved in the descent of a femoral hernia. Over the *external iliac* artery and vein, where they are continuous with the femoral vessels, an arch formed by the fascia transversalis will be seen, the *deep crural arch*, and on the inside of the artery a

small space, the *crural* ring, crossed by the thin *septum crurale*, and forming the upper extremity of the *crural canal* in the thigh, through which femoral hernia is wont to descend. The origins of the circumflex iliac and epigastric arteries from the external iliac will be made evident, and in a certain number of cases the *obturator* artery, which more frequently comes from the internal iliac, will be seen to arise in whole or in part from the epigastric, an arrangement which complicates the relations of a femoral hernia when the descending artery passes internal to the crural ring. After examination of these things, Poupart's ligament may be more fully examined than was possible previously, and *Gimbernat's ligament* may be seen, consisting of the fibres extending outwards along the pectineal line from Poupart's ligament, and abutting on the inner margin of the crural canal seen in the thigh.

3. The Testicle and its Coverings.—The scrotum is to be laid open from the front, and the student should satisfy himself that its coat of involuntary muscle, the *dartos*, formerly seen to be continuous with Colles's fascia in the perinæum, is continuous also with Scarpa's fascia in the groin. The cremaster muscle is to be followed down over the testicle ; its fibres are connected by fascia, and besides those already seen passing down from Poupart's ligament, there is a smaller set extending up to the pubes, partly continuous by arches with the outer set, and partly taking origin from below ; but this inner part of the cremaster is inconstant and variable. Laying open the cremasteric tunic, the dissector will seek

the *genital* branch of the *genito-crural nerve* supplying the cremaster, also the *cremasteric artery*, a small branch of the epigastric. He will then follow the infundibuliform fascia downwards, and show its continuity with the *fascia propria* of the testicle, and will proceed to dissect separate the elements of the spermatic cord. The *vas deferens* is recognised by its toughness, which gives it the feeling of whipcord; and the *spermatic artery*, a branch of the aorta, together with the copious spermatic veins and nerves, will be easily distinguished. Also, in close connection with the vas deferens is the *deferent artery*, a small branch derived from the superior vesical.

The testicle is now to be removed by dividing the spermatic cord, and is to be laid out for dissection on the table or on a flat dish with a little spirit or water in it. The vas deferens and other structures of the cord are to be followed to the testicle. The *tunica vaginalis*, or serous investment of the testicle, is then to be opened by an incision made down the front, when the body of the testicle enclosed in the *tunica albuginea* with the serous covering reflected over it will come into view, with the *lobus major* of the *epididymis* above, the *lobus minor* below, and the body of the epididymis on the outside, separated from the testis by a *digital fossa*. In front of the lobus major will be found a little appendage, and sometimes a cyst or two, the *hydatid of Morgagni*, a vestige of the Wolffian body. The parietal layer of the tunica vaginalis, and the rest of the tissue round the testicle, may now be cleared away, the continuity of the vas deferens and lobus minor of the epididymis at the

lower end of the testicle may be exhibited, and the epididymis may be partially unravelled. The lobus major may be now raised from the tunica albuginea, and beneath it, if the dissection be made carefully, a series of little cones may be displayed with their apices next to the testes, their bases connected with the epididymis: these are the *coni vasculosi*, from ten to fifteen in number, and, if difficulty be found in exhibiting them, they may be stretched on glass, and dissected with transmitted light. The tunica albuginea, the fibrous investment of the testis proper, is now to be divided down the front, and from its deep surface thin *septa*, which must be severed, will be seen to pass between the masses of the secreting substance. Also it will be found to be lined with a thin coating of loose tissue, which in finely injected specimens is seen to consist principally of small blood-vessels, forming the *tunica vasculosa*. In fluid, the secreting substance is readily separated into a multitude of lobules, and these are easily shown by slight teasing to consist of delicate convoluted tubules, very slightly adherent to one another. On dividing the testicle transversely, a section of the *mediastinum testis*, or *corpus Highmorianum*, will be seen, a projection forwards from the back of the tunica albuginea; but the entrance of the seminal tubules by *vasa recta* into this mediastinum, the *rete testis* in its substance, and the emergence of the *vasa efferentia* to form the *coni vasculosi*, are matters too delicate to be seen without resort to special modes of preparation.

4. Peritoneum and Position of Viscera. — The

abdominal cavity is to be thoroughly opened by the completion of a crucial incision extending longitudinally from sternum to pubes, and through the umbilicus from side to side. The position of the viscera should be first examined. Above, in the right hypochondriac and the epigastric region, is the liver; and the extent which it occupies is to be noted. In the left hypochondriac and the epigastric region is the stomach, varying in bulk according to the degree of inflation; and when the cardiac extremity of the stomach is raised, the spleen, attached to it well back on the left, will be brought into view. Below the stomach, connected closely by peritoneum with its pyloric end, the transverse colon crosses the front of the abdomen; and between it and the great curvature of the stomach is the pendulous *great* or *gastro-colic* omentum, sometimes hanging down over the colon and small intestines, and sometimes crumpled up in small bulk. Following the transverse colon to the right, and turning the small intestines a little to the left, the student will see the hepatic flexure where the ascending colon is continued into the transverse, and below this he will feel the right kidney; and pursuing the ascending colon downwards, he will find the *intestinum cæcum* consisting of *caput cæcum coli* and *vermiform appendage* in the right iliac region. Let him observe the termination of the small intestine in the cæcum, turn the transverse colon and great omentum upwards, and follow the small intestine up from the termination of the *ileum*, throwing it to the right side till he arrives at the commencement of the *jejunum*, which he will recognise from its being the

uppermost portion of the small intestine separated by mesentery from the abdominal wall. At this point he will see half the breadth of the last inch or so of the duodenum crossed by the commencement of the mesentery ; and he will do well to trace without injury to the peritoneum the partially concealed course of the duodenum between the pylorus and its termination at this point. This is the more to be attended to as inaccurate statements are currently taught. First, he will note the terminal part of the duodenum referred to as seen on the left of the mesentery ; then turning the mesentery to the left he will see a portion on the right side between it and the transverse colon, and then above the colon he will see the first part of the duodenum continued from the pylorus. Returning then to the transverse colon, let him follow it to its splenic flexure : beneath this let him see the position of the left kidney ; and let him follow the *descending colon* down to the sigmoid flexure, and the sigmoid flexure into the *rectum*. Raising the small intestines out of the pelvis, let him sponge away any grumous fluid which may be collected there, and examine the position of the bladder, the depth of the recto-vesical fossa, and in the female, the uterus and the ovaries, with the Fallopian tubes in front of them and the deep part of the round ligaments of the uterus.

In examining the position of the viscera, so far as has been now recommended, the student cannot have failed to note much of the disposition of the peritoneum, particularly below the level of the transverse colon ; but it is necessary to give it more special

study. Gathering the small intestine in his hands, he will satisfy himself of the extent and direction of the line of attachment of the mesentery to the abdominal wall, and will observe to what extent the ascending and descending colon, sigmoid flexure, and rectum are clothed. Then turning to the bladder, he will see that at its sides and above it the peritoneum is thrown into folds determined, in some measure, by the position of the obliterated hypogastric artery; the part above the bladder, between the two obliterated vessels, forming the *anterior false ligament*; the more horizontal portions, where the vessels are in contact with the bladder, forming the *lateral false ligaments*; and the vertical parts behind the contact of those vessels being termed the *posterior false ligaments*. In the female, on each side of the uterus, the peritoneum forms what is called the *broad ligament* or *ala vespertilionis*, bifurcating into an anterior part containing the Fallopian tube, and a posterior part acting as mesentery to the ovary and the round ligament of the ovary. After noting these points a pad of cloth or tow moistened with spirit may be pressed into the recto-vesical fossa, that the parts may be dry and firm before the time arrives to dissect them.

Attention is next to be given to the ligaments of the liver. The transverse colon is to be returned to its natural position, and the hand is to be thrust back above the liver, when the whole upper surface of that organ will be found to be clothed with peritoneum, and the peritoneum thrown into two fossæ by the *falciform* or *suspensory ligament*, in the free edge of which is a fibrous cord, the *obliterated umbilical vein*,

coming up from the umbilicus. Then turning to the under surface of the liver, it will be seen that it is clothed with peritoneum back to its posterior margin at the two sides, and that at the right and left extremity the peritoneum meets back to back with the folds proceeding from the upper surface, so as to form the *right* and *left triangular ligaments*; but in the region between these two ligaments it will be observed that there is a large extent of thick posterior border where the folds from above and below do not meet; and this broad attachment is what is called the *coronary ligament*. In the middle of the under surface the peritoneum does not pass back to the posterior border of the liver, but is reflected about half-way back, at the *portal fissure*, to the pylorus and commencement of the duodenum, so that a portion of the under surface is concealed. But on the right side of this reflection, between it and the posterior wall of the abdomen, is an opening, the *foramen of Winslow*, which admits the finger into a cavity expanding behind the stomach and bounded by the concealed part of the liver above. The reflection of peritoneum in front of the foramen of Winslow is the *gastro-hepatic* or *small omentum*; the concealed lobe of liver is the *lobulus Spigelii*; and the cavity into which the foramen of Winslow expands is the *sac of the great omentum*, or *smaller sac of the peritoneum*. This sac is now to be opened, and this can be done very effectually and without injury to any important structure by an incision four or five inches long immediately below the arteries running along the great curvature of the stomach. It will be found then that the sac

of the great omentum descends into the pendulous peritoneum in front of the transverse colon, so that the peritoneum in question is simply a much elongated omentum or fold joining the stomach to the colon. The continuation of the same layers from the colon to the posterior wall of the abdomen is called the *transverse mesocolon*. Also the lobulus Spigelii can now be seen, and, in the posterior wall of the sac, the pancreas lying transversely with the splenic artery and vein above it. On thrusting the hand upwards behind the stomach, the gastro-hepatic omentum is seen to be continued on the left into the *gastro-phrenic ligament*; and at the left side of the stomach the fold joining that viscus to the spleen is displayed, the *gastro-splenic omentum*. The peritoneal relations of the duodenum can also now be more fully seen.

5. The Mesenteric Vessels and the Intestines.—

The transverse colon is to be again thrown upwards against the ribs, and the small intestines are to be turned over to the left side. The exposed layer of peritoneum of the mesentery is then to be stripped off, and the process of stripping is to be continued till the whole series of ramifications of blood-vessels belonging to the jejunum, ileum, and ascending and transverse colon is exposed. The arteries will be seen to emanate from one trunk, the *superior mesenteric*, which gives off from one side numerous branches to the small intestine, and from the other the *middle colic*, *right colic*, and *ileo-colic* branches. The main arches of anastomosis and the small arches on their convexities are to be cleared as far as the intestinal

wall, partly by scraping with the handle of the scalpel, and partly by means of careful dissection, so as to expose not only the arches and the accompanying branches of the mesenteric vein, but also numerous twigs of sympathetic nerve, and the mesenteric glands with afferent lacteal trunks entering them, and efferent vessels proceeding upwards and backwards from them. The small intestines are then to be turned to the right side, and the left branch of the middle colic artery is to be followed till it leads to the *left colic* branch of the *inferior mesenteric artery*; the peritoneum is then to be stripped from that artery and its other branches, namely, the branch to the *sigmoid flexure* and the *superior hæmorrhoidal* branching down to the rectum.

At this stage it is well to follow back the nerves which accompany the inferior mesenteric artery, and dissect out the *aortic plexus*, which consists mainly of two lateral cords descending on the aorta and passing onwards below its bifurcation to unite in the upper part of the pelvis to form a band about half an inch or more in breadth, the *hypogastric* plexus.

It is convenient in most instances, on account of the intestines being bulky with gaseous contents, to remove them before proceeding to the dissection of the celiac axis. This is to be done by tying the intestine at two places about an inch apart at the commencement of the jejunum, and similarly at two places in the sigmoid flexure, and dividing the intestine between each pair of ligatures, then seizing the cut end of the jejunum with the left hand, and holding the edge of the knife against it, and severing by

a slight sawing movement the mesentery from the intestine, which is quickly liberated and pulled rapidly away. The great intestine is then removed with ease. The intestines thus removed are to be taken to a water tap, the jejunal end is to be fitted on to the tap, and water is to be run through them until the contents are completely washed away. They may then be arranged on a table and moderately inflated, so as to assist the study of the length of the different parts, the gradual diminution of the diameter of the small intestine from its commencement to its termination, the sacculation of the colon, the arrangement of its three longitudinal muscular bands, and the irregular disposition of the circular fibres by which the sacculation is determined. The ileum may then be divided about two or three inches from the cæcum ; a small portion may be removed from its lower end and inflated, and a similar portion from the upper end of the jejunum may be similarly inflated, and both parts may be hung up to be examined when dried ; while the remainder of the small intestine is to be slit open along the side by which it was attached, and immediately inspected. It may be slit either with the aid of a pair of scissors made with one of the blades long and blunt for that purpose, or with equal convenience this may be done by impaling a small piece of costal cartilage on one of the blades of a pair of ordinary dissecting scissors, and thrusting the blade so protected into the intestine. The student will then observe the greater development and frequency of *valvulae conniventes* in the upper part of the intestine and their disappearance below, also the

much greater length and number of the villi in the upper than in the lower part, a circumstance which will be seen to advantage by placing portions of the intestine in water. *Peyer's patches* of closed follicles, the so-called *agminated glands*, will also be seen in the ileum, if the subject is quite recent: or in any case the form of the patches, about a third of an inch in breadth, marked out by depressions which the follicles occupied, will be seen.

6. The Cœliac Axis and the Viscera supplied by it.—On turning the stomach upwards, there will be found arising from the front of the aorta below the narrow entrance into the lesser sac of the peritoneum a short artery, the *cœliac axis*, dividing into the hepatic, splenic, and gastric artery. These are to be dissected out with as little injury as possible to the sympathetic nerves accompanying them; and to make the dissection with comfort, it will probably be necessary to divide the forepart of the diaphragm and to divide and turn aside the lower ribs. The *gastric artery* or *coronary artery* of the stomach may be dissected first; it is the uppermost of the three, and is known by its passing up behind the smaller sac to reach the œsophageal end of the stomach, and course thence along the small curvature to anastomose with the pyloric branch of the hepatic artery. The *splenic artery* is next to be followed along the upper border of the pancreas, and forwards on the left side of the smaller sac to reach the spleen; and in this course it will be seen to give off the *great pancreatic* and several small pancreatic branches, and nearer its terminal distribution to the spleen, several *vasa brevia*

to the stomach, and the *left gastro-epiploic* which runs from left to right on the great curvature of the stomach. Lastly, the *hepatic* artery will be observed passing forwards below the neck of the smaller sac and in front of the foramen of Winslow, and therefore lying between the folds of the small omentum. It divides into the *right* and *left hepatic* artery before entering the liver, and it is from the right hepatic that the small *cystic artery* is given off to the gall-bladder. But before its bifurcation the hepatic artery will be seen to give off other branches, namely, the *pyloric* branch which runs from right to left to meet the coronary artery on the small curvature of the stomach, and the much larger *gastro-duodenal* branch which again divides into *right gastro-epiploic* anastomosing with the left gastro-epiploic on the great curvature of the stomach, and the *superior pancreatico-duodenal* which meets the *inferior pancreatico-duodenal* branch of the superior mesenteric on the concavity of the duodenum. This last-named branch may be followed to its source, and the superior mesenteric may be dissected up to its origin beneath the pancreas.¹ The three branches of the cœliac axis are each accompanied by a plexus of sympathetic nerves, which takes its name from the artery. These should be recognised and followed back to the cœliac plexus.

Returning the stomach to its natural position, the dissector should now remove the whole of the remain-

¹ To prevent confusion it is necessary to warn the student that one or both of the branches to the liver may come from the superior mesenteric artery.

ing peritoneum of the small omentum, and bring fully into view the common bile-duct (*ductus communis choledochus*) to the right of the hepatic artery, and trace up from it the two ducts with which it is continuous, namely, the *cystic duct* coming from the gall-bladder, and the *hepatic duct* formed by the union of right and left ducts ; also, behind the duct and artery, the *portal vein* will be brought into view. At this stage the terminal branches of the right and left pneumogastric nerves should be followed respectively from the back and front of the œsophagus, down on the stomach, and in a good subject filaments may be traced from them to the hepatic, cœliac, and splenic plexuses. The portal vein is then to be traced up to its bifurcation into right and left portal before entering the liver, and backwards to its sources of origin so as to show the veins of the intestines uniting into superior and inferior mesenteric veins, and passing up behind the pancreas to fall into the splenic vein and to be joined by the coronary vein of the stomach. The manner in which the pancreas is expanded at its right extremity, so as to form what is designated its head, filling up the concavity of the duodenum, is now to be noticed, and by a slight search into the centre of the body of the gland, the main duct of the pancreas will be found. This duct is to be traced through the length of the gland to its termination in the duodenum, close to the bile-duct ; and near its termination it will be found joined from below by a smaller duct from the lower part of the head.

The liver, stomach, duodenum, pancreas and spleen are now to be removed ; and for this purpose

it is well first to raise the duodenum, and to dissect out the broad fibrous band by which its termination is attached to the left crus of the diaphragm ; then to lay bare the inferior vena cava at the back of the foramen of Winslow, tie it, if there be blood in it, and divide it above the ligature. The next step is to tie the œsophagus at the entrance of the stomach, and cut above the ligature, then to proceed to sever the peritoneal connections of the liver, and lastly to divide the vena cava immediately above the liver, and to cut the branches of the cœliac axis, when the viscera to be removed will be completely separated from the body. The stomach and duodenum are to be washed and inflated, so as to show the form of the inflated stomach, the direction of its different muscular fibres and the increased muscularity at the pylorus. They may then be slit open, so as to exhibit the depression in which the bile duct and pancreatic duct terminate, the large and numerous valvulæ conniventes and villi of the duodenum, the disposition of the mucous membrane at the pylorus, the thick spongy and smooth character of the gastric mucous membrane and the rugæ into which it is thrown. The spleen is to be examined in section, so as to show its pulp and trabeculæ ; portions of its capsule are to be torn off, to show its strength and connections ; and a part of the organ may be kneaded in water, so as to remove the pulp from its trabecular skeleton ; and if after the pulp has been thoroughly removed the compressed structure from which it has been pressed be laid for a while in water, it will recover its original form, thus

beautifully exhibiting the trabeculæ and demonstrating their elasticity.

The liver, separated from the other viscera removed with it, is to be laid with its under surface uppermost. There will then be seen the division into right and left lobes by the *longitudinal fissure*, the *portal fissure* at right angles to this, and in front of the right extremity of the portal fissure the fissure containing the *gall bladder*, and in the posterior border that containing the *inferior vena cava*; also in front of the portal fissure the *quadrate lobe*, behind it the *lobulus Spigelii*, and to the right of the lobulus Spigelii the eminence called *lobulus caudatus*. In the longitudinal fissure the obliterated umbilical vein is to be traced backwards; and at the portal fissure it will be found connected with the right portal vein, while behind that fissure it is continued into a fibrous band, the obliterated *ductus venosus*, leading back to the inferior vena cava. The disposition of arteries, veins, and ducts in the portal fissure is to be dissected out; sections are to be made through the organ, so as to show its appearance and the difference between the sections of branches of the hepatic veins in immediate contact with the hepatic tissue and remaining open, and the sections of the portal veins, hepatic arteries and ducts running together and surrounded by a common fibrous sheath, the *capsule of Glisson*. Also the gall-bladder is to be opened and washed, so as to show its peculiar finely honey-combed mucous membrane.

7. Solar Plexus, Supra-renal Capsules, Kidneys, Aorta, and Vena Cava.—The kidneys are to be freed

from the loose fat in which they are imbedded : but caution is to be exercised in removing the fat at their upper ends, lest damage be done to the *suprarenal capsules*, which will be recognised as a pair of flat structures, an inch or more in height and less than two inches in breadth, of a dull brownish-yellow colour ; with a little care they are easily preserved, and the numerous small vessels and nerves entering them seen. Laying hold of the divided end of the inferior vena cava, the dissector may follow the tributaries of that vessel backwards towards their origin ; viz. the small veins from the diaphragm and suprarenal capsules ; the large *renal* veins, the left one of which crosses the aorta ; the *spermatic* veins in the male, or *ovarian* veins in the female, opening, the right one into the vena cava direct, and the left one into the left renal vein ; lower down, four *lumbar* veins on each side ; and, lastly, the two *common iliac* veins, by the union of which the vena cava inferior is formed, and the small *middle sacral* vein between them. The union of the common iliac veins is crossed by the right common iliac artery ; and the relations of these parts are not to be disturbed.

The cœliac axis will be found to be surrounded by a thick meshwork of nerves, the *cœliac plexus* ; and when this is followed back and traced outwards at the sides, it is seen to extend into a larger plexus, with a large knotted-looking ganglion, or clump of ganglia on each side : the whole plexus is called the *solar plexus*, and the ganglionic masses the *semilunar ganglia*. From this plexus, the smaller plexuses are to be traced along the arteries from which they are

named ; viz. besides those already seen, the phrenic, the supra-renal, the superior mesenteric, the renal, and the spermatic or ovarian below the renal, to supply the intestines, kidneys, and testicles or ovaries. The great splanchnic nerves will be seen piercing the crura of the diaphragm to reach the semilunar ganglia, while the smaller splanchnic nerves, piercing the diaphragm, end in the cœliac and renal plexuses. Still continuing the dissection of the sympathetic nerves downwards, we come to the aortic plexus, the exhibition of which has been already recommended at a prior period.

The dissector having displayed these plexuses is now in a position to make a continuous dissection of the abdominal aorta from the diaphragm to its bifurcation ; and he may also dissect out the common and external iliac arteries and veins ; and crossing over those great vessels he will see the ureters, and the spermatic or ovarian vessels, descending in front of them. In addition to the aortic branches already seen, he will now observe the branches to the parietes ; viz. the *phrenic arteries* given off immediately on entering the abdomen, the *lumbar arteries* four on each side, and the middle sacral descending from the bifurcation. By raising the right crus of the diaphragm a little from the aorta, the commencement of the thoracic duct, called *receptaculum chyli*, may be brought into view. On the sides of the vertebræ are the commencing right and left *vena azygos* in connection with the lumbar veins.

The position of the kidneys in relation to the vertebræ and other structures of the abdominal wall

is to be observed, as also the relations of the structures at the hilus; namely, the vein in front, the ureter behind, and the artery between. The kidney is then to be removed, the fibrous capsule is to be divided and stripped off, and a vertical transverse incision is to be made through the organ to display its internal structure. The division into *cortical* and *medullary* substance is to be noted. With a lens there may be noted in a healthy kidney, not only the alternation of granular and striated appearance in the cortex, but also minute vesicles in the granular part, which are the *Malpighian bodies*. The origin of the ureter in a dilated *pelvis* subdivided into *calyces* containing each one of the *Malpighian pyramids* into which the medullary part is thrown, will be noted; and the pyramids may be counted; and if one of them be squeezed, fluid will emerge from its apex; and with a lens a number of little depressions at the apex may be seen, into which the uriniferous tubules open.

8. The Posterior Abdominal Wall.—The diaphragm has been necessarily injured in the foregoing dissections; but even if its anterior attachments have been removed, its posterior parts and its central tendon remain intact, and are now to be dissected on the under surface. If the anterior parts of the ribs have been preserved, the attachments of the diaphragm to the six lower, and the interdigitation of its attachments with those of the transversalis muscle are to be exhibited; then its two crura arising from the bodies of the vertebræ, the *ligamentum arcuatum internum* arching over the *psoas magnus* as it extends from the body to the transverse process of the first

lumbar vertebra, and the *ligamentum arcuatum externum*, arching from the first transverse process to the last rib over the *quadratus lumborum*, are all to be dissected out. Also, the positions and mode of formation of the openings for the aorta, œsophagus and vena cava inferior are to be observed.

The *psoas magnus* and *iliacus* muscles are next to be cleaned, as also the *psoas parvus*, if present. The presence of the *psoas parvus* is recognised by its long and broad shining tendon on the surface of the *psoas magnus*. In cleaning the *psoas magnus*, care is to be taken of the *genito-crural* nerve, which pierces it, either as one trunk, or in two places after separation into genital and crural branches. The genital branch is to be traced to the inguinal canal, and the crural branch to its point of emergence from the abdomen outside the external iliac artery. Outside the *psoas magnus* are to be dissected out the *fascia iliaca* and the *iliacus* muscle, also the upper branches of the lumbar plexus; namely, the *ilio-hypogastric* nerve crossing the *quadratus lumborum* to the outer part of the crest of the ilium; the *ilio-inguinal* distinguished from the *ilio-hypogastric*, when separate from it, by crossing a small part of the *iliacus* muscle; the *external cutaneous* passing to the anterior superior spine of the ilium; and the large trunk of the *anterior crural* hid in the groove between the *psoas* and *iliacus* muscles. Inside the *psoas* will be found the remaining branch of distribution of the lumbar plexus, the *obturator nerve*, making for the obturator foramen, but occasionally giving off a small branch, the *accessory obturator*, which passes over the pubic bone, and

furnishes, when present, a branch to the pectineus muscle.

The psoas muscle is to be detached from its origins, so as to exhibit its separate origins from bodies and transverse processes of vertebræ, and lay bare the lumbar plexus from which the nerves already seen arise. The anterior divisions of the first and second lumbar nerves will be seen each to give off two branches of distribution and a communicating branch to the nerve below : while the third and fourth give off together two branches, and the fourth sends a communicating branch to the fifth lumbar. The ilio-hypogastric and ilio-inguinal are the branches from the first lumbar, the external cutaneous and genito-crural the two from the second, the anterior crural and obturator the branches from the third and fourth ; and the cord formed by the fifth lumbar nerve joined by the communicating branch of the fourth, is called the *lumbo-sacral* cord, and enters the pelvis. Internal to the psoas muscle is the lumbar part of the sympathetic chain, resting on the bodies of the vertebræ ; and in the groove of each vertebral body long communicating branches pass between each lumbar nerve and the corresponding sympathetic ganglion. There are usually two such branches connected with each nerve, but this is liable to variation. Turning now to the region of the quadratus lumborum muscle, the student will dissect the deep surface of the remains of the transversalis muscle, and will observe that it sends in a thin aponeurosis in front of the quadratus lumborum ; and on dividing this, and turning inwards the outer edge of the quadratus,

he will see the strong attachment of the posterior aponeurosis of the transversalis to the transverse processes; and, bearing in mind that he has already seen the continuation of the same aponeurosis superficial to the erector spinæ, he will understand the disposition referred to when the posterior aponeurosis of the transversalis abdominis is said to be continued into three layers. The quadratus lumborum is next to be dissected, showing its attachments to the last rib, iliac crest and ilio-lumbar ligament, and the fibres ascending and descending from the transverse processes.

9. **The Pelvis.**—The pelvis is to be separated from the upper part of the trunk by sawing through the vertebral column about the level of the second or third lumbar vertebra. All unseemly portions of integument and muscle on the outside of the preparation, left by the dissectors of other parts, are to be removed; and if one or both hip-joints have been left undissected by the dissectors of the lower limbs, their capsules are now to be freed from their surroundings, and the psoas and iliacus muscles are to be followed to their insertion. Poupart's ligament may be detached from the ilium, and any points not hitherto exhibited in its disposition are to be examined before clearing away the remains of the abdominal muscles; also the circumflex iliac artery is to be followed up and its anastomosis with the ilio-lumbar artery seen. Likewise the obturator membrane should be cleared on the outside, and the branches of the obturator artery on its surface exhibited.

[*The Perinæum in the Female* ought at this time

to be dissected. The integuments are to be reflected inwards and removed. At the central point of the perinæum will be found to converge the superficial *sphincter ani* disposed as in the male, the *sphincter vaginae* extending round the orifice of the vulva (representing the accelerator urinæ muscles of the male), and the *transversus perinæi* disposed as in the male. On each side of the rectum the *ischio-rectal* fossa is to be cleaned out, showing the *inferior hæmorrhoidal* and *superficial perinæal* branches of the *pudic artery*, also the perinæal branches of the pudic nerve coming to the surface through a considerable depth of fat inside the ischial tuberosity, and the inferior pudendal branch of the small sciatic turning inwards to join them in front of the tuber ischii. Still removing the fat, the dissector will find the fossa to be bounded, as in the male, internally by the *levator ani* with a layer of *anal fascia* on its surface, externally by the *obturator fascia*, and in front by a barrier formed by the dipping in of the deep layer of superficial fascia attached at the sides to the arch of the pubes, to join the *triangular ligament*, which in the female is split into two by the vulva. In the anterior part of the perinæum beneath the superficial fascia just mentioned will be found the *crura* of the *clitoris* arising from the pubic arch and embraced by erector muscles like the corresponding structures in the male. More internally, a highly complicated plexus of veins, *bulbus vestibuli*, invading the nymphæ or labia minora (corresponding with the corpus spongiosum in the male), will be found extending forwards to unite with its fellow in forming the *glans clitoridis*.

Beneath the crus clitoridis and bulbus vestibuli will be found the triangular ligament already mentioned ; and in young subjects the *glands of Bartholin* (corresponding with Cowper's glands in the male) will be found at the back of the vulva sending their ducts forwards to open at the side of the hymen or of the *carunculæ myrtiformes* which indicate the situation which the hymen had occupied.]

The peritoneum is to be stripped from the walls of the pelvis, when the cavity will be found to be limited beneath it on the sides and in front by fascia descending from near the brim, the *pelvic fascia*. This will be seen to be firmly connected below with the sides of the bladder, forming its *lateral true ligaments*, and to be continued in front into a couple of short bands with a slight fossa between, the *anterior true ligaments*. At the back of the pelvic cavity the stripping down of the peritoneum will lay bare the division of the hypogastric plexus to form the two pelvic plexuses for the supply of the pelvic viscera, and the *internal iliac* vessels with their visceral branches gathered so as to form, with the fascia between them, a sheet directed forwards and having the obliterated hypogastric artery at its upper edge.

A dissection must now be made for the more complete display of the fasciæ of the pelvis ; and for this purpose, if the walls of the ischio-rectal fossa or the obturator fascia have been damaged on either side in the dissection of the perinæum, the opposite side should be chosen. Much the neatest plan of making this dissection is to arrange it so that not

only the arch of the pubes and ischial attachments of the obturator fascia shall be left uninjured, but likewise the brim of the pelvis ; and this can always be managed with a little care by means of a single section with the saw, carried close by the brim of the pelvis, in such a direction as to remove a great part of the thickness of the ischial tuberosity and pass as near as possible to the sacro-sciatic notches without breaking into them. By this means the hip-joint can be removed intact, and an opportunity will be gained of opening into the acetabulum without injury to the capsule of the joint, and thus studying the action of the ligamentum teres. The opening in the pelvic wall is to be enlarged with the bone-nippers as far as is possible without injury to any fascia, and the obturator internus muscle is to be removed from its position, and the peculiar divided arrangement of its tendon may be looked at before it is thrown aside. A view will then be obtained of the *obturator fascia*, attached above to a *white line* seen extending from the spine of the ischium to the back of the pubes, and below to an arch formed by bone, except at the back part, where it passes internal to the small sciatic notch, and is attached to the sacro-sciatic ligaments. Also, above the white line is seen the *undivided pelvic fascia*, with the obturator vessels and nerves piercing it in front. It is continued below the white line into the *recto-vesical fascia* on the upper surface of the levator ani muscle. And, if the student have any doubt of the inaccuracy of those descriptions which describe the obturator and pelvic fasciæ as one continuous structure, he may convince

himself by observing that fibres of the levator ani muscle are always continued up above the white line to be attached along with the pelvic fascia to the horizontal ramus of the pubic bone. The part of the brim of the pelvis left for the attachment of the undivided pelvic fascia is to be removed with the bone-nippers or saw. The manner in which the rectovesical fascia splits up to invest the rectum and bladder, together with the prostate gland in the male and the vagina in the female, is to be examined ; also the anterior fibres of the levator ani are to be fully dissected out so as to show their position between the anterior ligament of the bladder and the posterior layer of the subpubic fascia.

If the bladder be partially inflated through one of the ureters, and a little tow be introduced into the rectum and vagina, the examination of the investment of these viscera with fascia will be facilitated, and the distribution of the visceral branches of the vessels and nerves better shown. The internal iliac artery will be seen to give off from the origin of the obliterated hypogastric artery the *superior vesical* branch, and, lower down, the *inferior vesical* to the lower part of the bladder and the vesiculæ seminales and prostate, and, below this, the *middle hæmorrhoidal* to the lower part of the rectum ; and in the female there are, in addition, a *uterine* and a *vaginal* branch, the one ascending and the other descending on the side of the viscus from which it is named. Besides these branches, the internal iliac gives off a number of others, namely, the *obturator* accompanying the nerve of the same

name, but sometimes replaced by a branch from the epigastric ; the *pubic* quitting the pelvis by the great sciatic notch, beneath the pyriformis muscle, and re-entering below the spine of the ischium, and now to be followed in its course bound down by the obturator fascia till it terminates in the dorsal artery of the penis and artery of the corpus cavernosum ; the *sciatic* likewise passing below the pyriformis ; the *gluteal* emerging above the pyriformis ; the *ilio-lumbar* dividing into lumbar and iliac branches which anastomose with the last lumbar and circumflex iliac respectively ; and the *lateral sacral* descending on the sacrum and giving off branches which enter the anterior sacral foramina.

In following the branches of the internal iliac artery, the dissector will meet with the principal trunks of the *sacral plexus*. He will see the formation of this plexus by the union of the lumbo-sacral cord with the anterior divisions of the three upper sacral nerves, and part of the fourth ; much the greater part of the plexus joining to form the *great sciatic* nerve, which with the *small sciatic* emerges below the pyriformis. He will dissect the *gluteal* nerve, which emerges with the gluteal artery, and trace it to its origin from the lumbo-sacral cord. He will then follow the *pubic* nerve from its origin to its distribution, and will complete the superficial dissection of the penis by the complete removal of the integument, displaying the dorsal arteries and nerves, and following the dorsal veins back through the triangular ligament, then laying bare the fibrous exterior of the corpora cavernosa and corpus spongiosum, and dis-

secting the glans sufficiently from the extremities of the corpora cavernosa to show that it is distinct from them.

The remainder of the ischium and descending ramus of the pubes may be removed, and the viscera withdrawn from their natural position, so as to allow the origin of the *pyriformis* muscle and also the *fourth* and *fifth* sacral and the *coccygeal* nerve to be dissected out on the sacrum. The dissection of the sympathetic chain is to be continued down from the point where it was left off in the lumbar region, and its ganglia and communications are to be traced down to the *ganglion impar* in front of the coccyx. Below this in the middle line, a lobulated structure, the size of a lentil, may be found, the so-called *coccygeal gland*. Turning the viscera still more outwards, a dissection may be made of the coccygeus and levator ani muscle from above, so as to exhibit them as a muscular floor to the pelvis, justifying the term *pelvic diaphragm* sometimes used.

10. The Pelvic Viscera.—The viscera are to be removed by dividing the attachments of the corpora cavernosa, the structures attaching the urethra beneath the symphysis, and the levator ani, coccygeus and coccygeal attachment of the superficial sphincter ani.

The relation of the rectum to the prostate and bladder in the male, and to the vagina in the female, is to be examined, and the rectum is then to be dissected separate from the other organs. The accumulation of circular fibres forming the *deep sphincter ani* is to be shown, and the rectum is to be slit open, so as

to show the appearance of its mucous membrane, and the slight transverse plications into which it is thrown, sometimes called *folds of Houston*.

The ureters are to be followed down to their points of entrance into the bladder, and the arrangement of the muscular fibres of the bladder is to be examined. This will be seen to be highly complex ; and the most striking points are a superficial strip of vertical fibres in front and behind, spreading out above, and fibres circling with all degrees of obliquity. At the upper end is the urachus.

In the male the prostate and copious prostatic plexus of veins, and the membranous part of the urethra are to be cleared, and the vasa deferentia and vesiculæ seminales are to be dissected out. The vesiculæ seminales will be seen to be each doubled on itself ; and they are to be cut into, to show the reticular character of their mucous membrane. On continuing the dissection down to the prostate, the junction of vas deferens and the duct of the vesicula seminalis to form the *ejaculatory duct* will be brought into view ; and a deep mesial part of the prostate behind the entrance of the ejaculatory ducts, and separated by them from the main mass of the gland lying in front of them and around them, will be distinguished, which is the *middle lobe* of the prostate. It may be well to divide the penis about the middle, to note the appearance of the corpora cavernosa and corpus spongiosum on transverse section, and the section of the artery in each corpus cavernosum, then to slit the urethra in the distal portion from beneath, so as to show the dilatation of the urethra called *fossa*

navicularis immediately inside the orifice. The remaining portion of the urethra is to be slit open from above by a cut carried close to one side of the septum of the corpora cavernosa, so as to lay bare the septum, then continued in a straight line on through the membranous and prostatic portions of the urethra and the front of the bladder. The recesses in the spongy part of the urethra, as well as the appearance of the mucous membrane, are to be noted ; also the dilatation in the bulb and the thickening of the corpus spongiosum at that part. In the prostatic part are to be noted the flat and wide form of the urethra in the middle of the prostate, and the constriction at the neck of the bladder ; also in the floor, a little elevation called *verumontanum* with a minute cul-de-sac in the forepart of it called the *sinus peculiaris* or *uterus masculinus* ; immediately in front of this the openings of the ejaculatory ducts, and in the hollow at the sides of the *verumontanum* the openings of the tubules of the prostate. Within the bladder are specially to be noted the valvular openings of the ureters, and the space between these and the neck termed the *trigone*.

In the female, the bladder and urethra are to be slit open from above, and the *trigone* examined as in the male. The vagina is to be cut open by an incision carried along one side, and its rugæ are to be examined : they are most prominent in the lower part, especially in front. The *os uteri* projecting into the upper end of the vagina will next attract attention, and will be found to vary from various causes, such as age and child-bearing ; but in the virgin its aperture is trans-

verse and the anterior lip the more prominent. The form of the uterus is to be examined, and it is to be cut open from the front, the incision bifurcating above, so as to show the cavity of the *cervix* with its ribbed mucous membrane, the *os internum*, the smooth mucous lining of the uterine cavity, and the termination of the Fallopian tubes at the upper angles. The Fallopian tubes and ovaries are to be studied, and the ovarian division of the ligamentum latum is to be held up to the light to look for the little transverse tubes in its folds, which constitute the *parovarium*, or *organ of Rosenmüller*.

11. The Ligaments of the Pelvis.—Returning to the walls of the pelvis, the student has to examine the concentrically laminated structure of the symphysis pubis, the *greater* and *lesser sacro-sciatic* ligaments, and the *ilio-lumbar* and *sacro-vertebral* ligaments extending to the ilium and sacrum from the transverse process of the last lumbar vertebra. The sacro-iliac articulation is then to be examined. Its *anterior* ligament, situated really below the joint in the erect posture of the body, is little more than periosteum, but the *posterior sacro-iliac* ligament is of great strength to bear the weight of the trunk, and cannot be fully seen without dividing the anterior ligament and laying open the joint. The clothing of the articular surfaces with cartilage is very variable, but in all cases it consists originally of two distinct layers of articular cartilage. The actions of the pelvic ligaments, however, cannot be studied except in a pelvis which is quite uninjured. The articulations of the lumbar vertebræ one with another should be

examined, their laminae and the back of the sacral canal being removed now, if they have not been previously taken away for the dissection of the spinal cord. The *ligamenta subflava* will then be noted, and the capsules of the joints between the articular processes ; also the lower parts of the *anterior* and *posterior* common ligaments. But what is most important to dissect in this part of the vertebral column is the arrangement of the *intervertebral discs*, which reach in this region the maximum of development, permitting a full display of the arrangement of the peripheral layers of fibres and the more pulpy central structure.

Faint, illegible text, possibly bleed-through from the reverse side of the page.

