

A junior course of practical zoology / by the late A. Milnes Marshall ... and the late C. Herbert Hurst.

Contributors

Marshall, A. Milnes.
Hurst, C. Herbert.
Gamble, F. W. 1869-1926.
University of Bristol. Library

Publication/Creation

London : Smith, Elder & co., 1899.

Persistent URL

<https://wellcomecollection.org/works/v6ecrf6r>

Provider

Special Collections of the University of Bristol Library


License and attribution

This material has been provided by This material has been provided by University of Bristol Library. The original may be consulted at University of Bristol Library. where the originals may be consulted.
This work has been identified as being free of known restrictions under copyright law, including all related and neighbouring rights and is being made available under the Creative Commons, Public Domain Mark.

You can copy, modify, distribute and perform the work, even for commercial purposes, without asking permission.



Wellcome Collection
183 Euston Road
London NW1 2BE UK
T +44 (0)20 7611 8722
E library@wellcomecollection.org
<https://wellcomecollection.org>



158

B3a

UNIVERSITY OF BRISTOL.

Medical Library.

September 1931

Store 570762







Digitized by the Internet Archive
in 2015

<https://archive.org/details/b21443592>



PRACTICAL ZOOLOGY

With numerous Illustrations, 8vo. 21s.

VERTEBRATE EMBRYOLOGY.

A Text-book for Students and Practitioners.

By the late A. MILNES MARSHALL, M.D., D.Sc., M.A., F.R.S.

Professor in the Victoria University; Beyer Professor of Zoology in Owens College; late Fellow of St. John's College, Cambridge.

London: SMITH, ELDER, & CO., 15 Waterloo Place, S.W.

THE FROG : an Introduction to Anatomy, Histology, and Embryology.

By the late A. MILNES MARSHALL, M.D., D.Sc., M.A., F.R.S.

Professor in the Victoria University; Beyer Professor of Zoology in Owens College, Manchester; late Fellow of St. John's College, Cambridge. Sixth Edition, Revised and Illustrated, crown 8vo. 4s.

LECTURES ON THE DARWINIAN THEORY,

Delivered by the late ARTHUR MILNES MARSHALL.

Professor of Zoology in Owens College, Manchester. Edited by C. F. MARSHALL, M.D. Demy 8vo. xx. 236 pp. With 37 Illustrations, mostly from Original Drawings and Photographs. Cloth, uncut. 3s. 6d.

By the same Author and Editor.

BIOLOGICAL LECTURES AND ADDRESSES

(The Modern Study of Zoology: The Influence of Environment on the Structure and Habits of Animals: Embryology as an Aid to Anatomy: The Shapes and Sizes of Animals: Death: The Recapitulation Theory, &c.). Crown 8vo. viii. 364 pp. Cloth, uncut. 3s. 6d.

DAVID NUTT, 270-271 Strand.

A JUNIOR COURSE
OF
PRACTICAL ZOOLOGY

BY THE LATE

A. MILNES MARSHALL, M.D., D.Sc., M.A., F.R.S.

PROFESSOR IN THE VICTORIA UNIVERSITY; BEYER PROFESSOR OF
ZOOLOGY IN OWENS COLLEGE, MANCHESTER; FORMERLY
FELLOW OF ST JOHN'S COLLEGE, CAMBRIDGE

AND THE LATE

C. HERBERT HURST, Ph.D.

LECTURER IN THE VICTORIA UNIVERSITY
DEMONSTRATOR AND ASSISTANT LECTURER IN ZOOLOGY IN
OWENS COLLEGE, MANCHESTER

FIFTH EDITION

REVISED BY F. W. GAMBLE, M.Sc.

DEMONSTRATOR AND ASSISTANT LECTURER IN ZOOLOGY, OWENS COLLEGE,
MANCHESTER

LONDON
SMITH, ELDER, & CO., 15 WATERLOO PLACE
1899



TO THE
STUDENTS OF OWENS COLLEGE

THIS BOOK IS DEDICATED
BY THEIR SINCERE WELL-WISHERS

THE AUTHORS



PREFACE

TO

THE FIFTH EDITION.

AFTER the death of Dr. Hurst in the spring of this year, I was asked to undertake the revision of the present edition of this book. My connection with Professor Milnes Marshall and Dr. Hurst enabled me the more readily to comply with this request. No new matter involving a change in the plan of the work has been added. I have, however, thought it well to recast the chapters on technique, and to adopt many of the alterations and additions which have been suggested by a constant use of the last (1895) edition. My friend and colleague, Mr. J. H. Ashworth, has aided me very signally throughout, and I must also express my indebtedness to Professor Hickson, and to Mr. F. J. Cole, Demonstrator in the Zoological Department of University College, Liverpool, for his assistance in correcting the account of the nerves and lateral sense-organs of the Dog-fish. The digits of the bird's wing—a subject on which Dr. Hurst held the heterodox view of their homology with the third, fourth, and fifth digits of the reptilian hand—I have named topographically, a *via media* which has the recommendation of not implying a conclusion based on evidence which cannot be presented in this work.

F. W. GAMBLE.

OWENS COLLEGE: December 1898.



PREFACE TO THE FIRST EDITION.

THIS BOOK has been written in the hope that it may meet the wants of those who desire to obtain a practical acquaintance with the elements of animal morphology, and who find the existing manuals insufficient for their purpose.

The animals selected for description are those which are generally accepted as suitable types for a junior laboratory course. They are of convenient size, and can all be obtained readily and at small cost: they include characteristic representatives of the more important of the great groups of animals; and they give opportunity for very varied methods of examination. A student who works conscientiously through the book will thus acquire a good insight into the leading facts of animal structure, and a technical knowledge of the principal methods of research.

In the mode of treatment adopted the practical character of the book has been made paramount. Directions for dissection have throughout been printed in italics, and a system of indentation has been adopted to render the subdivisions more distinct. In almost all cases the descriptions are so arranged that the whole dissection can be performed on a single specimen: if more than one can be obtained, the order in which the several sections are taken may be varied; but in every case each of the main systems—vascular, nervous, etc.—should be dissected in its entirety, for in this way alone can a proper idea of its relations be obtained.

No attempt has been made to write exhaustive descriptions of the several animals; neither has strict uniformity of

treatment been specially aimed at. Portions of the subject which experience has shown to present special difficulties are treated at what may appear undue length; while, on the other hand, the limits of time ordinarily available for laboratory work have led to the almost entire omission of systems, such as the muscular, which are of subordinate educational value.

Although this is essentially and professedly a laboratory text-book, yet morphological explanations have been freely admitted; and this from a conviction that a student best grasps the meaning of anatomical facts if the explanation is given him while the facts are actually before his eyes.

Illustrations have been introduced somewhat sparingly, for it is of the utmost importance that they should not be allowed to replace the drawings which a student must make from his own dissections. The majority of the figures here given are new, and have been drawn expressly for the book by Mr. Hurst or myself. The drawings on the wood were made by Mr. P. Hundley, and the blocks engraved by Mr. G. Pearson: both these gentlemen have taken great pains to render the figures at once faithful and artistic.

Throughout the whole time of preparation of this volume I have had the constant co-operation and assistance of my friend Mr. C. H. Hurst. Several of the chapters were originally drawn up by him, and in all I have had the advantage of his aid, but for which the publication of the book might have been greatly delayed. Considerable pains have been taken to avoid mistakes, but it is curiously difficult to succeed in this, and corrections or suggestions from those who use the book will be very gratefully received.

A. M. M.

CONTENTS.

INTRODUCTION.

	PAGE
Observation of animals during life—Drawing—Methods of killing animals—Dissection—Injection—Microscopical examination—Drawing with the camera lucida—Measuring of microscopical objects—Use of hardening and staining reagents—Section-cutting—Mounting microscopical objects—Preparation of skeletons	xix

CHAPTER I.

PROTOZOA.

Amœba—Paramecium—Opalina—Vorticella	1
---	---

CHAPTER II.

HYDRA.

Examination of a living specimen—Examination of transverse sections	14
---	----

CHAPTER III.

THE LIVER-FLUKE OF THE SHEEP. *Fasciola (Distomum) hepatica.*

The mature liver-fluke—The life-history of the liver-fluke	27
--	----

CHAPTER IV.

THE LEECH. *Hirudo medicinalis*.

	PAGE
External characters—Dissection—Examination of transverse sections	39

CHAPTER V.

THE EARTHWORM. *Lumbricus herculeus*.

External characters—Dissection—Examination of transverse sections	59
---	----

CHAPTER VI.

THE FRESHWATER MUSSEL. *Anodonta cygnea*.

The shell—Dissection of the mussel—Examination of transverse sections	81
---	----

CHAPTER VII.

THE EDIBLE SNAIL. *Helix pomatia*.

External characters—Dissection of the snail	109
---	-----

CHAPTER VIII.

THE CRAYFISH. *Astacus fluviatilis*.

External characters—Dissection—The arteries as seen in an injected specimen	132
---	-----

CHAPTER IX.

THE COCKROACH. *Periplaneta Americana*.

Habits—External characters—Dissection	161
---	-----

CHAPTER X.

THE LANCELET. *Amphioxus lanceolatus*.

	PAGE
External characters—Anatomy—Dissection—Examination of transverse sections	179

CHAPTER XI.

THE DOG-FISH. *Scyllium canicula*.

External characters—The skeleton—The abdominal viscera—Dissection of the digestive system—Dissection of the respiratory system—Dissection of the circulatory system—Dissection of the renal and reproductive systems—Dissection of the nervous system—Dissection of the sense organs	210
--	-----

CHAPTER XII.

THE SKELETON OF THE RABBIT. *Lepus cuniculus*.

The axial skeleton—The appendicular skeleton	283
--	-----

CHAPTER XIII.

DISSECTION OF THE RABBIT. *Lepus cuniculus*.

External characters—The abdominal viscera—Dissection of the digestive system—The thoracic viscera—Dissection of the circulatory system—Dissection of the renal and reproductive systems—Dissection of the neck—Dissection of the sympathetic nervous system—Dissection of the head—Dissection of the brain	325
--	-----

CHAPTER XIV.

THE SKELETON OF THE FOWL. *Gallus domesticus*.

The axial skeleton—The appendicular skeleton	396
--	-----

CHAPTER XV.

DISSECTION OF THE PIGEON. *Columba livia*.

	PAGE
External characters—Dissection of the pectoral muscles—Dissection of the air-sacs—Dissection of the digestive system—Dissection of the circulatory system—Dissection of the trachea and lungs—Dissection of the renal and reproductive systems—Examination of the brain—The sense organs	424

APPENDIX.

Reagents for killing, hardening, and preserving—Reagents used in staining—Clearing reagents—Mounting media—Microtomet's media—Cements for fixing down sections cut in paraffin—Injection fluids	459
---	-----

INDEX	469
-----------------	-----

LIST OF ILLUSTRATIONS.

FIGURE	PAGE
1-8. <i>Amœba</i>	2
9. <i>Paramecium aurelia</i>	4
10. <i>Vorticella</i>	9
11. <i>Hydra</i> : Diagrammatic longitudinal section	15
12. " Section of the body-wall, highly magnified	17
13. <i>Fasciola hepatica</i> : Diagrammatic figure of the digestive, ex- cretory, and nervous systems	29
14. " The reproductive system	31
15-19. " A series of stages in the life-history	34
Fig. 15. The free-swimming embryo	
" 16. A sporocyst, containing rediæ	
" 17. A young redia	
" 18. An adult redia, containing a daughter- redia and cercariæ	
" 19. A free cercaria	
20. <i>Hirudo medicinalis</i> : The ventral surface	43
21. " Diagrammatic figure of the vascular, renal, re- productive, and nervous systems	43
22. " Diagrammatic transverse section through the middle of the body	54
23. <i>Lumbricus herculeus</i> : Longitudinal vertical section through the anterior part of the animal	64
24. " Plan of the reproductive organs	71
25. " Diagrammatic transverse section through the middle of the body	77
26. <i>Anodonta cygnea</i> : Dissection from the right side, to show the heart and gills	90
27. " Dissection from the right side, to show the diges- tive and renal systems	96
28. " Diagrammatic transverse section through the middle of the ventricle	106
29. <i>Helix pomatia</i> : Dissection from the right side, to show the mantle-cavity	115
30. " Dissection from the right side, to show the diges- tive and reproductive systems	120
31. " Section along the axis of the shell, transverse to the foot	130
32. <i>Astacus fluviatilis</i> : Transverse section through the abdomen .	134
33. " The oral appendages	140
34. " Diagrammatic transverse section through the thorax	144
35. " Dissection of a male from the right side	148

FIGURE		PAGE
36.	<i>Periplaneta Americana</i> : The head, front view	163
37.	„ The head, from behind	163
38.	„ Dissection of a male from the right side	168
39.	„ Dissection of the hinder part of the abdomen of a female	177
40.	<i>Amphioxus lanceolatus</i> : A young specimen, seen from the right side	180
41.	„ Transverse section through the anterior part of the pharynx	201
42.	„ Transverse section through the hinder part of the pharynx	205
43.	„ Transverse section passing through the atrial pore	207
44.	„ Transverse section passing through the anus	208
45.	<i>Scyllium canicula</i> : The skull and visceral skeleton from the right side	218
46.	„ The skull and visceral skeleton from the ventral surface	224
47.	„ The pelvic girdle and fins from the ventral surface	229
48.	„ The pectoral girdle and fins from the ventral surface	231
49.	„ Longitudinal vertical section through the head and anterior part of the body	238
50.	„ The venous system	240
51.	<i>Scyllium catulus</i> : The arterial system	246
52.	<i>Scyllium canicula</i> : Transverse section passing through the posterior dorsal fin	251
53-54.	„ Dissections of the renal and reproductive systems of the female	257
55-56.	„ Dissection of the renal and reproductive systems of the male	260
57.	<i>Scyllium catulus</i> : Dissection of the brain and cranial nerves	264
58.	<i>Lepus cuniculus</i> : Selected vertebræ	287
59.	„ The skull from the right side	295
60.	„ Skeleton of the left hand	318
61.	„ Skeleton of the left foot	318
62.	„ Dissection of a male from the left side	330
63.	„ Dissection of the neck	364
64.	„ Diagrammatic transverse section through the head, showing the tympanic cavity and auditory ossicles	376
65.	„ Dissection of the brain from the right side	380
66.	„ Ventral surface of the brain	383
67.	„ Dissection of the brain from above	387
68.	„ Transverse section of the brain, passing through the third ventricle	390
69.	„ Median section of the brain	392
70.	„ Transverse section of the brain, passing through the cerebellum	394
71.	<i>Gallus domesticus</i> : The left half of the skeleton, from the right side	398
72.	„ The skull from the right side	405
73.	<i>Columba livia</i> : Dissection from the right side	436

INTRODUCTION.

THE following pages contain a brief summary of the methods ordinarily employed in the dissection and microscopical examination of animals. They are not intended to form an exhaustive account of anatomical technology; and in many cases they are repetitions of the practical directions given in other parts of the book.

I. ON THE OBSERVATION OF ANIMALS DURING LIFE.

All animals should be carefully observed alive before they are dissected, for by this means alone it is possible to obtain a clear idea of the uses and mode of action of many organs, such as the tentacles of Hydra, the odontophore of a snail, the scaphognathite of a crayfish, etc.

II. ON DRAWING.

Careful drawings must always be made, both of the living animal and of all dissections and preparations. These drawings should be made to scale, in a book kept for the purpose, and on one side of the page only.

Correctness of outline is of more importance than minute detail; and the usefulness of the drawings is greatly increased by the systematic use of diagrammatic colouring. A separate colour should be employed for each system of organs, the several parts of which may be indicated by gradations of tint.

As a rule, the more bulky organs, as the liver, should be coloured with dull tints, and the brighter colours reserved for the smaller and less conspicuous parts. Arteries are usually coloured red, and veins blue.

III. ON THE METHODS OF KILLING ANIMALS.

The method of killing is of considerable importance, and careful attention should be paid to the directions given at the commencement of each chapter.

Two methods of killing animals are in general use, and the one to be chosen depends upon whether the specimen is to be (1) dissected and examined temporarily, or (2) converted into permanent microscopical preparations.

For the first purpose chloroform is useful. Three or four minutes' immersion is sufficient, after which the animal should be washed in water. This answers well for the leech and earthworm. For killing crayfish, boiling water may be employed, and snails die well-expanded if drowned in warm water.

For the second purpose a reagent is employed which not only kills the tissues, but penetrates and 'fixes' them, so that they are but slightly affected by subsequent treatment. The choice of the reagent depends upon the size and texture of the specimen, and the purpose for which it is intended (see Appendix). Strong alcohol is the simplest and most generally applicable, but does not give the best results for histological work. For Protozoa osmic acid or the vapour of glacial acetic acid is useful. For Hydra, Perenyi's fluid. For larger animals a mixture of 90 parts concentrated corrosive sublimate solution and 10 parts glacial acetic acid is a good reagent. The specimen must be subsequently washed in alcohol.

IV. ON DISSECTION.

The object of dissection is to separate the several organs from one another, so far as is necessary to define their boundaries and display their relations to one another. It consists mainly in the removal of the connective tissue which binds the parts together and obscures their outlines.

The necessary instruments are the following:—

1. Two or three scalpels, of different sizes.

2. Two pairs of forceps ; one large and one small. Both pairs should be straight, and should have roughened tips to secure a firmer hold.

3. Two pairs of scissors ; one pair large and strong for general dissection, the other pair small for finer work. The latter pair should have the blades either bent at an angle—elbow scissors—or else curved. In selecting scissors, care should be taken to see that they cut quite to the points of the blades.

4. A pair of bone-forceps or very stout scissors, for cutting bone and other hard substances.

5. A pair of stout needles, firmly mounted in handles.

6. A pair of the finest sewing-needles, mounted in wooden handles. Only about a quarter of an inch of the needle should project. They are used for teasing histological preparations.

7. A seeker, *i.e.* a blunt needle mounted in a handle, and bent at an obtuse angle half an inch from the end.

8. A pocket-lens, containing two or three lenses mounted in a handle, and giving when combined a magnifying power of at least six diameters.

9. A razor, and some means for keeping it sharp.

10. A blowpipe of metal or glass, with the end bent at an angle.

11. A glass tube drawn out to a point at one end, and fitted with an india-rubber cap at the other : for use in washing dissections, and in injection.

For the dissection of the larger animals, as the dog-fish or rabbit, a deal board, about two feet long by a foot and a half wide, may be used ; to this the animal should be fastened by pins, or by steel awls with wooden handles.

Smaller animals, and special parts of larger ones, should be dissected under water, which supports the parts and greatly facilitates the dissection. For this purpose an ordinary white pie-dish with sloping sides is well adapted, the bottom being fitted with a soft deal board weighted with lead, or a sheet of cork cemented in with marine glue. A similar but smaller dish may be used for dissecting under spirit.

Animals, such as the cockroach, which are difficult to fix

with pins, may be cemented down with melted wax, or they may be half imbedded in a plate of paraffin, and the plate then fixed down with pins in the dissecting-dish.

For fine work a dissecting microscope affords great assistance. The pocket-lens may be turned into one by fitting one end of a wine-cork into the handle or case of the lens, and passing a stout pin transversely through the other end. The pin should be stuck upright into the dissecting-board, with the lens over the part to be dissected: focussing is effected by sliding the cork up and down the pin. A lens-holder is, however, more convenient.

The following rules for dissection should be carefully observed:—

1. Before commencing a dissection, fix the animal down firmly to the dissecting-board or dish.

2. In fixing an animal with pins, stick them in obliquely, so that their heads do not get in the way or obscure the dissection.

3. Dissect under water, unless the animal is too large. Change the water as soon as it gets dirty. A gentle stream of water allowed to play upon the dissection is often a valuable aid.

4. Never cut away anything until you are quite certain what it is you are removing.

5. Put the part you are dissecting slightly on the stretch. This applies more particularly to blood-vessels, nerves, ducts, and muscles.

6. In cleaning blood-vessels, nerves, etc., dissect along them, and not across them; and avoid laying hold of them with the forceps.

7. The dissection is in many cases greatly facilitated by placing the specimen in spirit for a day or so before dissecting it. In some cases the dissection may with advantage be performed under spirit.

8. Always keep your instruments clean and sharp. Be careful not to blunt your fine scissors or scalpels by using them for cutting hard parts.

9. If you get in a muddle, stop, and wash the dissection thoroughly under the tap before proceeding further.

Successive slices cut from an animal, or part of an animal, with a razor are often exceedingly instructive ; this is especially the case with the mussel and snail, and with the brains of the rabbit and pigeon. The specimens must be previously hardened with spirit or other reagent, and the slices should be examined in water or spirit.

V. ON INJECTION.

The injection of coloured fluids into the blood-vessels or ducts of an animal renders them much easier to see, and to follow to their distribution.

The colouring matter used must not be soluble in, or affected by, any of the fluids in which the specimen is afterwards to be dissected, hardened, or preserved. The most convenient are French blue, Prussian blue, chrome yellow, vermilion, and carmine.

In the case of the larger animals, freshly prepared plaster of Paris forms, if coloured, a convenient substance for injection : it solidifies in the vessels, and so does not escape if a vessel is cut during the dissection.

For smaller animals, thick gum-water or white of egg may be injected cold, or a jelly made of gelatin and water injected warm : the animal should afterwards be put into alcohol to harden the injection. If the animal is not to be dissected after injection, water coloured with any of the above pigments may be used with advantage, and this is particularly useful for the alimentary and excretory systems of the liver-fluke.

For injecting small animals, a suitable syringe consists of a glass tube with an india-rubber cap fitted on one end, the other end being drawn out to a point sufficiently fine to enter the vessel to be injected. After the tube is drawn out in the flame and cut off, its sharp edges must be slightly rounded off by holding for a moment in the flame. Several such cannulæ of various sizes should be kept ready.

For injecting larger animals, such as a rabbit, with plaster of Paris, the blood must first be washed out of the vessels by

injecting warm salt-solution. The following apparatus is necessary, and must all be placed on the table ready for use before the animal is killed; for the blood coagulates after death so rapidly as to allow no time to look for instruments.

1. Cannulæ; glass ones are the most convenient; they should be of various sizes, to fit the several vessels which it is proposed to inject, and each should have a slight constriction near the tip, so that it may be firmly secured in the vessel by a ligature. The largest cannula that will enter the vessel should be used.

2. A glass syringe, capable of holding about an ounce of fluid. A larger syringe is liable to get blocked up.

3. Several pieces of strong india-rubber tubing, about an inch long, to connect the nozzle of the syringe with the cannula, both of which they must fit rather tightly.

4. Two or three glass plugs to fit the india-rubber tubing.

5. A dish of water or salt-solution, in which all the cannulæ and india-rubber connections are laid, to displace the air from them.

6. Fine plaster of Paris.

7. A mortar and pestle.

8. Colouring matter, such as vermilion previously rubbed up with water: it must be well shaken before use.

9. A piece of muslin to strain the injection through. It must be well wetted before use.

10. A jar into which to strain the injection.

11. A jar containing about half a pint of salt-solution (.75 per cent.), at a temperature of 38° to 40° C.

12. Dissecting-board, pins, scalpels, scissors, two pairs of forceps, seeker, thin string or thread, and two or three pairs of 'bull-dogs.' These last are very short spring-forceps, the spring being so arranged as to close the forceps. They are convenient to stop the escape of blood or injection from any vessels that may have been cut.

The injection should be performed close to a large sink, over which is a water-tap with a foot or two of wide india-rubber tubing attached.

When everything is ready, kill the animal, and as soon as

it is dead, lay it open, cutting as few blood-vessels as possible. Expose the root of the aorta or other vessel from which it is intended to inject the animal; choose a cannula of the right size: fit it with an india-rubber connection; fill it with salt-solution, and stop the end of the connection with a glass plug. Pass a ligature round the vessel: make a longitudinal slit in the vessel; insert the cannula; tighten the ligature upon it, and tie it with a bow. If the ligature be too tight it will cut the vessel. Fill the syringe with the warm salt-solution: remove the plug from the cannula: press the body of the animal slightly, to remove some of the blood from its vessels, and to get rid of any clot that may have formed close to the cannula. Inject the salt-solution, to force the remaining blood from the vessels before it can coagulate; and wash or sponge the blood away. If the arteries are being injected, the vena cava and portal veins should be cut open to allow free escape of the blood, and *vice versa*.

Mix the plaster of Paris in the mortar, stirring in the colour, and making the plaster thin. Strain it rapidly through the muslin, and inject immediately with the syringe. When the vessels appear to be well injected, remove the syringe and insert the glass plug, and wash the animal to get rid of blood and any injection that may have escaped.

Allow the animal to remain two or three hours in cold water before dissecting it or putting it into spirit.

VI. ON MICROSCOPICAL EXAMINATION.

The microscope affords the means of investigating the structure of minute animals, and the finer details of those of larger size. The microscopical examination of the special organs of the larger animals is of great importance, and must on no account be neglected.

The microscope consists of a body and a stand. The body is a tube of metal carrying the lenses, which are the essential part of the instrument.

The stand supports the body in such a way that the latter may be moved up and down without any lateral movement.

It also supports a stage, which ought to be horizontal, to hold the object to be examined. The stage has a round hole in its centre, through which light may be transmitted through the object by a mirror fixed below the stage. This aperture is usually much larger than is necessary; but the excess of light, and especially the light far from the optical axis of the lenses, is cut off either by means of diaphragms, of which there is a series, of various sizes, fixed in such a way as to allow of their being easily changed, or by an 'iris-diaphragm.'

The combination of lenses at the upper end of the body is the *eye-piece*; the combination at the lower end is the *objective*.

One or two eye-pieces, and two objectives of different magnifying powers, $\frac{1}{2}$ inch or low power, and $\frac{1}{6}$ or $\frac{1}{8}$ inch or high power, are required.

An object can be seen clearly through a microscope only when it is at a certain definite distance from the objective; and this distance varies with different objectives and eye-pieces, and to a slight extent with different observers. An objective of high power requires to be nearer to the object than does one of lower power. The regulation of this distance is called *focussing*, and is effected in two ways.

The *coarse adjustment* of focus is made by simply sliding the body up or down, with a slight twisting movement, through the tube of the stand in which it is supported, or else by a rack and pinion worked by a milled head.

The *fine adjustment* is effected by means of a screw, the position of which differs in different microscopes, but which should be so placed that it can readily be worked with either hand. By turning the head of the screw from left to right, in the direction of the hands of a watch, the body of the microscope is lowered, and the objective brought nearer to the object; by turning in the reverse direction, the objective is raised.

In using the microscope the following rules are to be carefully observed:—

1. Examine every object with the low power first. Having adjusted the eye-piece and the objective, turn the mirror so as to reflect the light up the body of the microscope; place

the object on the stage under the objective, and carefully lower the body with a screwing motion till the objective is about a quarter of an inch from the cover-glass; then look through the eye-piece, and gradually raise the body till the object becomes distinctly visible. Focus accurately with the fine adjustment screw. With the high power, begin with the objective close to the cover-glass, and then proceed as before.

2. Never examine an object with the high power unless it is protected by a cover-glass. Take extreme care never to let the objective touch the cover-glass, and never to touch the face of the objective or allow any dirt to get on it. The face of an objective cannot be cleaned without doing harm to it.

3. Keep both eyes open when looking through the microscope. Also get into the habit of using either eye.

4. When examining an object, keep one hand on the fine adjustment, and keep screwing it up and down slightly. In this way parts of the object at different depths are brought into focus, and a much clearer idea of the object is obtained.

5. With a high power, use a small diaphragm: the amount of light will be somewhat diminished, but the clearness and definition much increased.

6. See that the body of the microscope slides smoothly in its tube. If it does not, remove it, and clean it by rubbing with a few drops of olive oil; wipe off the oil before replacing in the tube. Clean the inside of the tube in the same way.

7. The object may appear indistinct from dirt in any of the following places, *i.e.* on the eye-piece, the objective, or the cover-glass. If it be on the cover-glass, the dimness varies when the slide is moved; if on the eye-piece, it varies when this is rotated; if not on either of these, it must be on or in the objective.

The eye-piece and the lower surface of the objective may be cleaned with chamois-leather or silk. If the objective is smeared with glycerin, wash it carefully, then dry with a soft handkerchief. Canada balsam, which sometimes gets on the objective, may be removed with a drop of benzol on a handkerchief. It is, however, safer to leave this to an optician or to the demonstrator, as a very small quantity of benzol

getting inside the rim which carries the lens may lead to the separation of the two lower lenses from each other, rendering the objective useless.

VII. ON DRAWING WITH THE CAMERA LUCIDA.

In making a drawing of an object seen with a microscope, it is often found difficult to draw all parts of it on the same scale of magnification; and as a result, such drawings are liable to give a false idea of the form of an object, and of the relative sizes of its parts.

This source of error may be obviated by the use of a camera lucida, by means of which a sheet of paper laid on the table at the side of the microscope is visible at the same time as the object under the microscope. The magnified image appears to lie upon the paper, and by tracing out its lines with a pencil, an accurate outline is easily obtained. As, however, the use of the apparatus involves the loss of a large proportion of the light from the object, only outlines should be so drawn, and the details should be filled in after removal of the camera from the microscope.

VIII. ON MEASURING MICROSCOPIC OBJECTS.

The eye-piece micrometer is a plate of glass, the upper surface of which is either engraved with a scale, or divided into a number of equal squares by cross-lines ruled upon it. This is placed between the lenses of the eye-piece of the microscope in such a position that the scale can be seen distinctly on looking through the microscope.

The stage micrometer is a slide on which a scale is engraved, divided to, say, hundredths of a millimeter.

To measure a minute object, focus it under the microscope with the eye-piece micrometer in position; read off the apparent size on the scale of the micrometer; replace the slide by the stage micrometer and read off upon that the actual value of the noted number of divisions of the eye-piece micrometer.

The value of each division on the eye-piece micrometer will obviously vary when the objective is changed or the length of the microscope tube is altered.

By means of a camera lucida a scale may be drawn upon a sheet of paper laid at the side of the microscope, coinciding with the apparent image of the stage micrometer seen through the microscope, and this scale may then be used to measure directly the size of an object seen at the same time through the microscope. One such scale for each power of the microscope may conveniently be drawn in the notebook which is to receive the drawings, and the student will then be able to determine the real size of any object drawn in the book with the aid of the camera.

Eye-pieces and stages are also constructed in which the measurement is accomplished by means of a fine screw with a divided head. To use the micrometer stage, the slide bearing the object is laid upon it, one edge of the image is made to coincide with a mark upon the eye-piece micrometer or a slip of glass in the same position. The screw of the stage is then turned till the opposite edge of the image coincides with the same mark, the distance through which the slide has been moved is then read off on the divided head of the screw, and this distance is, of course, the diameter of the object.

IX. ON THE USE OF HARDENING AND STAINING REAGENTS.

Reagents are used for fixing, hardening, and staining specimens. Those required for general use are few in number, and directions for their preparation will be found in the Appendix.

1. Fixing has already been explained. To obtain good results it is necessary to employ either small animals or small portions of large ones. Use a relatively large bulk of the fixing fluid, and wash for several hours in water or alcohol.

2. Hardening is necessary in the case of soft animals or of tissues to be cut into slices. Grades of alcohol 50 per cent., 70 per cent., and 90 per cent. are successively employed after

fixation and washing. In other cases (*e.g.* the fresh-water mussel) a weak solution of chromic acid ($\frac{1}{4}$ per cent.) in water serves well. For the brain of the rabbit and pigeon ordinary methylated spirit is convenient.

3. Staining not only makes the tissues more distinct, but also affords insight into their minute structure.

Most stains will not penetrate a living organism or tissue. Methylene blue, however, is an exception, and therefore of great value. It is employed in very dilute solutions (see Appendix) for the study of small transparent forms (*e.g.* *Paramecium*, *Hydra*) and for the tracing out of nerves and nerve-cells in higher animals. For rapidly staining dead but fresh tissues and such as have been fixed and washed in water, safranin and dahlia are useful, especially for Protozoa, developing spermatozoa of the earthworm, leech, and crayfish. The stain must only be allowed to act for two or three minutes, and then the surplus carefully removed by distilled water.

Carmines is a generally useful stain, especially Grenacher's borax-carmines. As this is an alcoholic stain, specimens should be placed in it from 50 per cent. alcohol. After the staining is completed the object should be transferred to acid-alcohol for a few minutes or hours according to its size.

Picrocarmines is an aqueous solution, and directly applicable to objects washed after fixing. Treat subsequently with 50 per cent., 70 per cent., and acid-alcohol.

Hæmatoxylin (especially Meyer's acid-hæm-alum, see Appendix) gives excellent results if used with due care, but a trace of acid or turpentine may completely destroy the colour.

X. ON CUTTING SECTIONS.

Many points in anatomy and histology may be best made out by examination of microscopical sections, that is, slices cut so thin as to allow of their being examined under the microscope by transmitted light.

The hardened object, supported, if necessary, between two pieces of carrot, may be held between the fingers and thumb, and sections sliced off it freehand with a sharp razor.

The **microtome** or section-cutting machine, however, gives better results. It consists essentially of three parts: a clamp or other contrivance for holding the object to be cut, means of guiding the razor, and a 'feeding' arrangement. These parts are so arranged that the razor can be drawn smoothly across the object to be cut, taking off a section at each stroke, the 'feeding' arrangement bringing the object into the path of the razor, and the amount of 'feed' determining the thickness of the section.

In the simplest form of microtome the razor is drawn by hand over a smooth plate, the object to be cut being pushed up through a hole in the centre of the plate by means of a screw or other 'feeding' arrangement placed below.

More complicated microtomes have been devised to obviate the wearing of the edge of the razor by friction upon the plate; to render it possible to cut the object in any desired direction; to cut more evenly, more easily, and more rapidly; and to yield sections in a string or ribbon, so as to simplify and expedite the mounting of large series of sections.

The preparation of an object for cutting in a microtome depends to some extent upon the nature of the object and the number of sections required, as well as the purpose for which they are intended. The object has in any case to be supported by impregnating it with some homogeneous substance which is firm enough without being brittle or too hard. The **freezing method** is the simplest of all, but it is not easily applicable when a large number of sections are required mounted in consecutive series, nor when very thin sections are required. The tissue to be cut is first soaked in gum-water, then placed on the freezing-plate of the microtome and cooled by an ether-spray or a freezing mixture underneath. The frozen mass is cut when just thawing.

The **imbedding method** is more complicated, but has many advantages. The specimen, which may be stained previously, is dehydrated by soaking in absolute alcohol; the alcohol is then removed by soaking in turpentine, xylol, or better, oil of cedar-wood, and the object is then transferred to paraffin kept just melted in a water-oven, the temperature not being

allowed to rise above 60° C. Paraffin melting at 55° or 56° C. is the best, though a softer paraffin may be used in a cold room, if it be found that the hard paraffin crumbles before the razor. When the object is thoroughly permeated, it is transferred to a small trough of paper with just enough paraffin to form on cooling a block completely enclosing it. It must be cooled as quickly as possible by placing the trough in a dish containing cold water, as the paraffin is liable to crystallise if allowed to cool slowly. A couple of L-shaped blocks of metal, resting on a plate of glass or metal so as to form a box of adjustable size, may be used in the place of the paper trough. The block containing the object is fixed in the microtome; the most efficient of all contrivances for this purpose is, perhaps, a grooved metal plate which is simply warmed slightly and pressed against the end of the block, and then cooled quickly as soon as the block has begun to melt. The further procedure depends entirely upon the particular microtome used. The sections are to be mounted as described in section XI.

XI. ON MOUNTING MICROSCOPICAL OBJECTS.

The most convenient slide for microscopical objects is a slip of glass three inches long and one inch wide, or for large series of sections the slide may be 1½ inch wide. The glass should be free from air-spaces and other flaws, and the edges should be ground.

Cover-glasses must be very thin (No. 1) and free from flaws. For single objects square covers ($\frac{1}{2}$ to $\frac{7}{8}$ inch) are best, and for series of sections oblong covers, which should not come within $\frac{1}{16}$ inch of the edge of the slide; space should also be left at one end for a label.

‘Cells’ are required to protect thick objects from the pressure of the cover-glass. Thin flat rings of tin are good, and should be cemented to the slide with gold size or ‘brown cement;’ or a ring of the cement painted on with a brush and allowed to dry may be used as a cell for thinner objects.

No cell is required for sections. Copper, brass, and vulcanite cells are to be avoided.

An object may be **mounted dry** by fixing it to the slide in the centre of a cell with a very small quantity of collodion or gum-water, or of solution of shellac in creasote or alcohol. When the cement is dry, a cover of the same diameter as the cell is to be laid over it, and secured by varnishing at the edge with any of the cements sold for the purpose.

More usually it is advisable to mount an object in a liquid or solid medium. Such are glycerin, which is liquid; Farrant's medium, and Canada balsam, which are liquids becoming solid; and glycerin-jelly, which is solid when cold.

An object, stained or otherwise, to be mounted in glycerin or Farrant's medium may be transferred to it direct from water—great care being taken to avoid introducing air. The drop of glycerin, etc., used should be just large enough to spread out to the edge of the cover. When glycerin is used, the cover must be fixed by means of gold size or other cement applied round the edge with a small paint-brush.

To mount in glycerin-jelly the object is first soaked in glycerin and then in melted glycerin-jelly (*see Appendix*); it is then transferred to a drop of the melted glycerin-jelly upon the slide, and the warm cover, previously wetted with the melted jelly to aid in excluding air, is immediately placed upon it and held in position till the jelly solidifies. Avoid heating more than is necessary. The edges of the cover may be cemented as above, but this is not absolutely necessary.

To mount an object in Canada balsam, it must, after staining, be dehydrated by soaking in absolute alcohol; then soaked in oil of cedar-wood or xylol, till the alcohol is removed; and, lastly, placed in the drop of balsam upon the slide and covered.

Mounting sections cut in paraffin. Take a clean dry slide and spread evenly over it with the finger a very thin layer of glycerin and albumen (*see Appendix*), so that the slide appears to be only slightly greasy. An excess of glycerin and albumen must be avoided, otherwise the sections will be cloudy. Place the sections perfectly flat upon the

slide, and press them down gently with the finger. Warm gently in an oven or over a flame till the paraffin is just melted, and immerse the slide in turpentine for two or three minutes to dissolve out the paraffin from the sections. Lift the slide out of the turpentine, drain and remove the excess of turpentine with a duster, place a drop of balsam over the sections while still moist with turpentine, and cover. In the case of sections stained with hæmatoxylin it is advisable, after removing the excess of turpentine, as described above, to run oil of cedar-wood over the sections in order to completely remove the turpentine, which tends to oxidise and decolourise hæmatoxylin, and thus destroys the stain.

In some cases it is necessary to stain sections on the slide. The following is a convenient method: Fix the section with glycerin and albumen, and remove the paraffin by warming the slide and placing it in turpentine as described above. When the paraffin is all dissolved out, place the slide in absolute alcohol for a few minutes to remove the turpentine. Then pass the slide gradually through 90 per cent., 70 per cent., 50 per cent. alcohol. If an alcoholic stain (*e.g.* borax carmine, alcoholic safranin, etc.) is to be used, the slide is now placed in stain. If an aqueous stain (*e.g.* hæmalum, etc.) is to be used, the slide must be placed in 30 per cent. alcohol, then in water, and then into stain. After being in stain the requisite amount of time, the excess of stain is removed by washing in some suitable reagent, and the slide is then passed gradually through 50 per cent., 70 per cent., 90 per cent. to absolute alcohol, where it is allowed to remain a few minutes in order to thoroughly dehydrate. After dehydration oil of cedar-wood is poured over the sections till the alcohol is all removed and the oil flows freely over the slide. The excess of oil is then removed, balsam placed on the sections, and they are covered in the usual way.

Curled or crumpled sections should be straightened before mounting, so that all the parts of the object lie in one plane. This can be done as follows: Smear the slide with glycerin and albumen, and place a few drops of clean (or distilled) water on the slide. Place the crumpled sections on the

water, and very gradually warm the slide. As the water becomes warm the creases will disappear, and the sections will lie perfectly flat on the water. Great care must be taken not to melt the paraffin, as this causes great contraction and spoils the sections completely. When the sections are quite flat, the water may be drained off, or removed by the application of blotting-paper. The slide is then placed for a few hours in an oven or incubator whose temperature is lower than the melting-point of the paraffin used. When quite dry the slide is warmed to melt the paraffin, placed in turpentine, and treated in the usual way.

XII. ON PREPARING SKELETONS.

Skeletons of rabbits, fowls, etc., may be prepared by maceration or by boiling. Before macerating the bones should have most of the flesh cut off; they are then to be put into cold water and left for several weeks for the remaining flesh to rot away. They will afterwards require copious washing, and may then be bleached by exposure to direct sunlight for two or three weeks, during which time they should be repeatedly dipped into water and then left to dry. This same process also removes much of the offensive smell of freshly macerated bones. Both these effects may, however, be more quickly produced by steeping the bones in a clear solution of bleaching powder, and afterwards washing them in running water.

Boiling the bones and then picking off the flesh yields skeletons serving all the purposes of the student, though not so white as those obtained by maceration.

The preparation of cartilaginous skeletons is described at p. 215.



PRACTICAL ZOOLOGY.

CHAPTER I.

THE PROTOZOA.

A PROTOZOOON is an animal which consists of only one cell, the morphological equivalent of a single cell of any of the tissues of a higher animal.

Protozoa are always of small size, and are usually microscopic.

I. AMŒBA.

This protozoon is found at the bottoms of freshwater pools, and in damp situations. It may be obtained in autumn by placing the dying stalks of the bean plant, or fallen leaves of most trees, in water for a few days. Its indefinite and ever-changing shape is characteristic, and has gained for it the name 'proteus animalcule.' There are several forms, the largest of which are just visible to the naked eye, while others are exceedingly minute.

Place a drop of water containing Amœbæ on a slide ; cover ; and search for the animals with a low power of the microscope. When found, examine them with a high power.

A. General appearance.

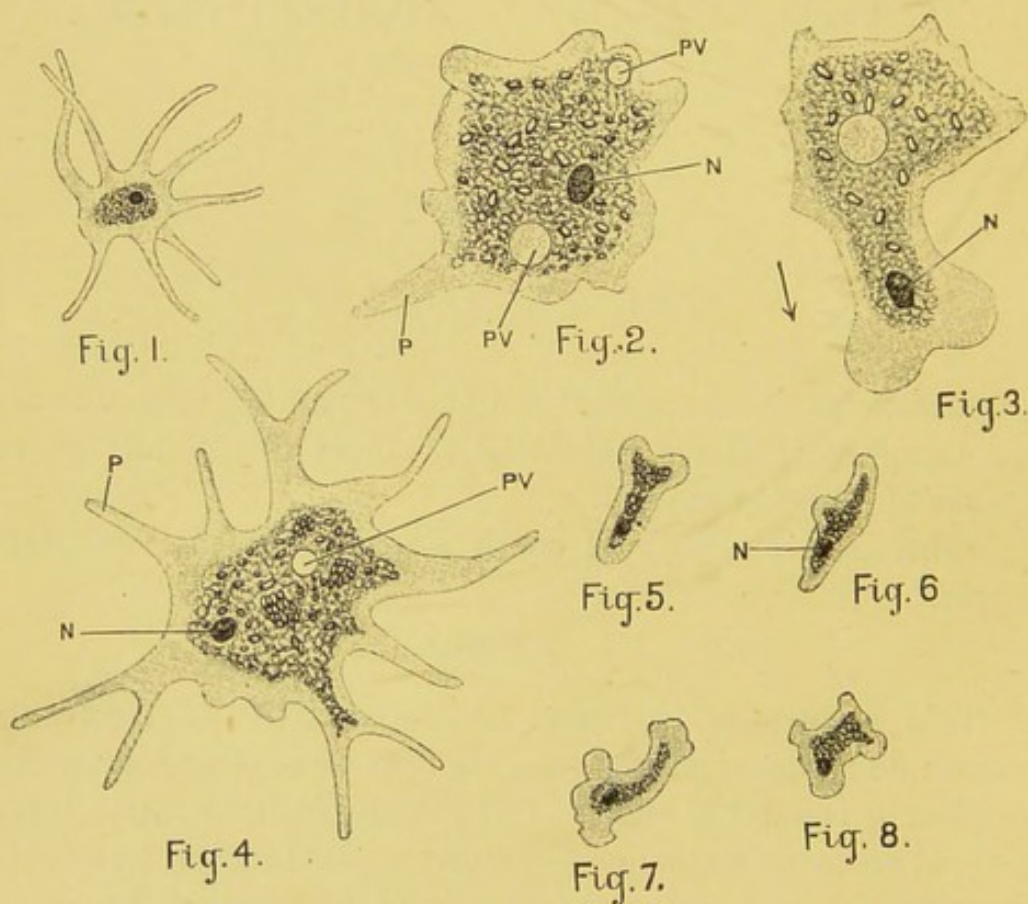
The animal is an irregular mass of protoplasm, running out into blunt processes or **pseudopodia**, the protrusion and

retraction of which cause great changes in the form of the cell. The pseudopodia may branch slightly.

B. Structure.

The whole body is a naked mass of protoplasm, of which two portions are distinguishable.

1. The **ectosarc** is the clearer outer portion of the body.



FIGS. 1 to 8.—*Amœba* ; $\times 400$. (C. H. H.)

Figs. 2 and 3 were drawn from the same specimen, which was moving in the direction shown by the arrow. Fig. 4 is a form with branching pseudopodia. Figs. 5 to 8 were drawn from one specimen at intervals of about twenty seconds.

N, nucleus. P, pseudopodium. PV, pulsating vacuole.

2. The **endosarc** is the granular central portion. Its flowing movements, which accompany the protrusion and retraction of the pseudopodia, are rendered obvious by the **granules** contained in it.

Within the endosarc make out the following structures.

- a. **Vacuoles** are spaces filled with fluid, which is less dense than the surrounding protoplasm. They contain in many cases foreign particles taken in as food.
- b. The **pulsating vacuole** is a space filled with a watery fluid. It is fairly constant in position, and pulsates rhythmically. More than one may be present. *Time its pulsations.*
- c. The **nucleus** is a spherical or ovoid body, denser or more highly refractive than the rest of the endosarc. During life it is not easily seen, but it is rendered obvious by killing the animal with acetic acid (1 per cent.), or by staining with safranin. More than one may be present.

C. Movements.

The constant but slow change of form already referred to is known as 'amœboid movement.' Pseudopodia are protruded from any point of the surface, and can be completely withdrawn, and a slow crawling movement of the whole animal can be effected by their means. Pseudopodia may also surround particles of food and then be withdrawn, bringing the food particles into the body.

Draw a specimen of Amœba several times at intervals of half a minute, indicating the direction of flow of the particles by means of arrows. Compare the drawings, and note the differences of form even in sluggish specimens in which movement was not obvious.

Feed with indigo or carmine, or other finely divided pigment, and note that food is taken in at almost all parts of the surface.

D. Reproduction.

Amœba multiplies by **fission**; that is, the whole mass divides into two, each containing a portion of the nucleus, of the endosarc, and of the ectosarc of the original cell.

II. PARAMECIUM AURELIA.

This is a free-swimming freshwater protozoon found in abundance amongst decaying vegetable matter. It differs from *Amœba* in its more definite shape ; in the more marked differentiation of ectosarc and endosarc ; in the presence of cilia and the absence of pseudopodia ; in its active locomotion by means of cilia ; and in the possession of a definite mouth, and of definite dorsal and ventral surfaces, and anterior and posterior ends.

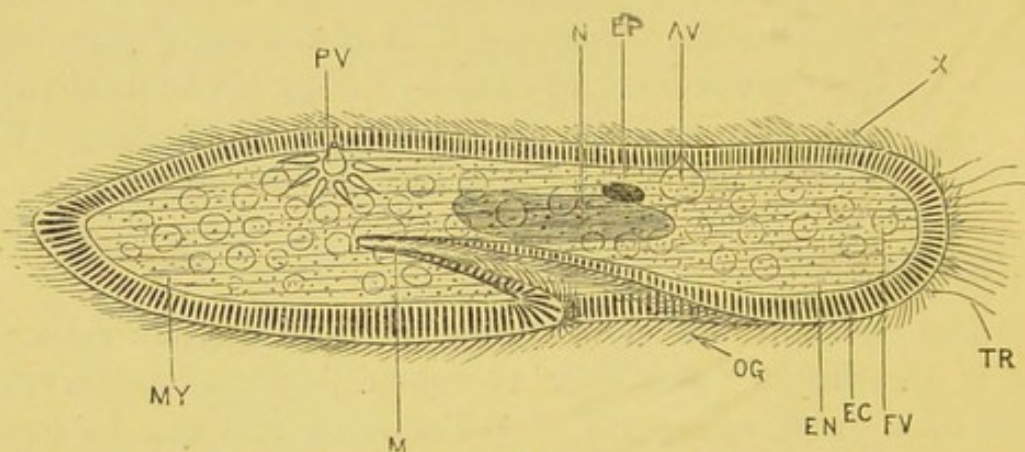


FIG. 9.—*Paramecium aurelia*, seen from above and slightly from the right side ; $\times 300$. (C. H. H.)

AV, anterior pulsating vacuole. EC, ectosarc : the lines running across it indicate the trichocysts. EN, endosarc. EP, paranucleus. FV, food-vacuole. M, mouth. MY, 'myophan' striation. N, nucleus. OG, oral groove. PV, posterior pulsating vacuole, in systole. TR, discharged trichocyst threads. X, cilia.

Put a drop of water containing Paramecia on a slide ; spread a very little cotton wool over it, to limit the movements of the animals ; cover, and examine with low and high powers.

A. General appearance.

The animal is an elongated somewhat flattened body about $\frac{1}{100}$ inch in length, rounded at its narrower anterior end, and bluntly pointed at the broader posterior end.

It swims actively by means of cilia distributed over its entire surface. Near the middle of the ventral or oral surface is an oblique groove leading to the mouth.

B. Structure.

The two layers, ectosarc and endosarc, are much more sharply defined than in *Amœba*.

1. The **ectosarc** is the comparatively firm outer layer, the elasticity of which preserves the general form of the body. Its deeper part is marked by longitudinal or oblique '**myophan**' striations, which vary in distinctness with the movements of the animal, and are probably due to longitudinal wrinkling of the inner surface of the ectosarc.

a. The **cuticle** is the delicate superficial and stiffer layer, serving as a protective covering for the underlying protoplasm, of which it is the differentiated external layer.

b. The **cilia** are very numerous delicate vibratile filaments arising from the layer of ectosarc immediately beneath the cuticle, through which latter they project. They are of uniform size over the entire surface, and extend into the oral groove. Their rapid movements serve both for locomotion and for the ingestion of food.

c. The **trichocysts** are minute oval sacs arranged side by side in the deeper part of the ectosarc, perpendicular to the surface, and in such numbers as to form an obvious layer. When the animal is irritated a stiffish thread can be shot out from each of these trichocysts, and project on the surface beyond the cilia. They are protective and offensive weapons.

d. Two **pulsating vacuoles** are situated in the substance of the ectosarc of the dorsal or aboral region, one at about a third of the animal's length from each end. In diastole they are nearly spherical, but at the moment of systole, or contraction, they become stellate, and canals can then be seen radiating from them. They also open to the exterior at the same moment.

- e. The **oral groove** runs obliquely backwards along the ventral surface from near the anterior end to the **mouth**, which is placed a little behind the middle of the length of the animal. Its cilia are directed towards the mouth, and drive water and food particles into it.
 - f. The **mouth** is an oval aperture in the ectosarc at the hinder end of the oral groove, through which the food passes into the endosarc.
 - g. The **anus** is an aperture between the mouth and the hinder end of the body. It is visible only at the moment of extrusion of faecal matter.
2. The **endosarc** is the more fluid granular protoplasm forming the central portion of the cell-body.
- a. The **food-vacuoles** are spherical spaces in the endosarc filled with water containing food-particles.
 - b. The **circulation of the endosarc** is rendered obvious by the food-vacuoles and the granules, which are carried round in a definite direction.
 - c. The **nucleus** is an elongated ovoid body near the centre of the cell-body.
 - d. The **paranucleus** is a much smaller body applied to one side of the nucleus, and resembling it in appearance. In some cases both nucleus and paranucleus appear to be situated in the ectosarc rather than in the endosarc.

C. Reproduction.

1. **Fission** is the most usual method, and is effected in the following manner. A transverse constriction appears on the surface of the animal, and deepens till the body is divided into two, each having a portion of the original nucleus and paranucleus, and each becoming a perfect Paramecium.
2. **Conjugation** is not a mode of reproduction, but is closely connected with it. Two Paramecia become

united by their ventral surfaces, and, after swimming about together for some time, separate and become independent again. During and after this union certain changes occur in the nuclei and paranuclei of both individuals, resulting in the so-called 'rejuvenescence,' and followed by rapid and repeated fission of the two Paramecia.

Kill the Paramecia by running a drop of acetic acid (1 per cent.) under the cover-glass; and then stain with dahlia or carmine.

The nucleus and the discharged trichocysts are well seen in specimens so treated.

III. OPALINA.

Opalina is a protozoon usually found living in large numbers in the large intestine of the frog. From its large size and the ease and certainty with which it can be obtained, it is a very convenient form for examination.

Slit up the large intestine of a freshly pithed frog; scrape away the contents together with the epithelial lining of the intestine, and dilute with salt solution (.75 per cent.). Examine a drop of the mixture microscopically.

A. General appearance.

Opalina is a flattened, asymmetrically oval body, about $\frac{1}{35}$ inch long, covered with cilia by means of which it swims actively. It has neither mouth nor anus.

B. Structure.

1. The **ectosarc** is thinner than in Paramecium. There are no pulsating vacuoles, and no trichocysts.
 - a. The **cuticle**, if present at all, is exceedingly thin.
 - b. The **cilia** are of equal size over the whole surface.
 - c. 'Myophan' striations are obvious: they are mainly longitudinal.

2. The **endosarc** contains no food-vacuoles, owing to the fluid nature of the food ; this also accounts for the absence of a mouth, the nutriment being absorbed by the whole surface of the cell-body.

- a. The nuclei are numerous.

C. Reproduction.

This is effected by oblique or transverse **fission**.

Kill the Opalinæ by running a drop of acetic acid (1 per cent.) under the cover-glass ; and then stain with safranin or carmine.

The nuclei are well seen in specimens so treated.

D. Encystment.

Opalinæ have been observed to become encysted, or enclosed in a cyst, and in this state they leave the body of the frog and are subsequently swallowed by tadpoles. Within the cyst the Opalina divides into numerous small spores, which are liberated in the tadpole and develop into Opalinæ.

IV. VORTICELLA.

Vorticella, which is just recognisable with the naked eye, differs from the two preceding infusorians in being attached by a contractile stalk to plants or other objects, often to other aquatic animals ; it may, however, under certain conditions, become detached from its stalk and swim freely:

Both freshwater and marine forms of Vorticella are known. The following description applies more particularly to some of the larger freshwater species, but most of the marine forms closely resemble these.

Vorticella may be distinguished from allied genera which are often found with it by its unbranched stalk, and by the spiral form which this assumes on contraction.

Mount a specimen in a drop of water together with a bit of the weed or other substance to which it is attached. Examine it microscopically.

VORTICELLA.

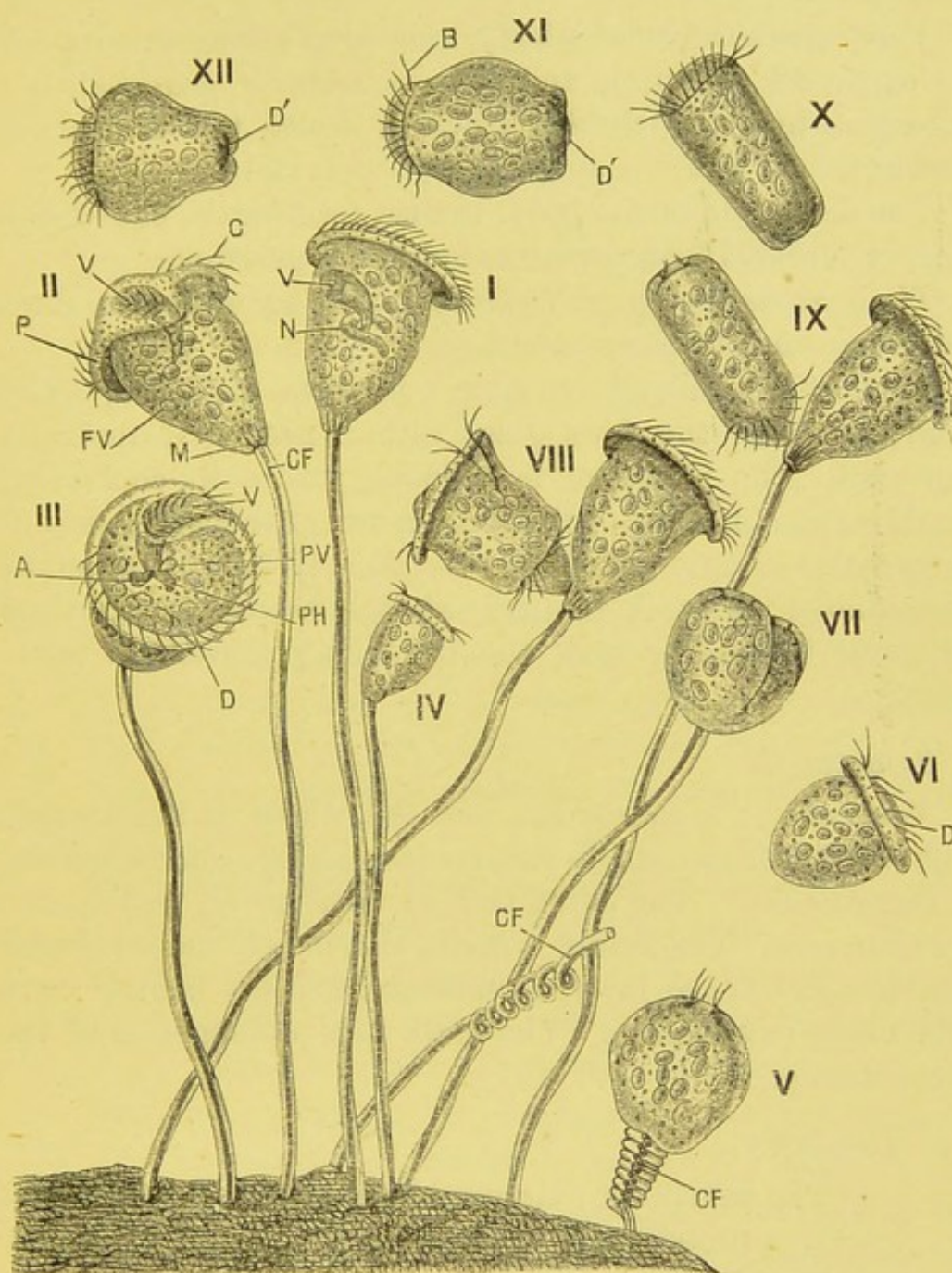


FIG. 10.—A group of *Vorticellæ* ; $\times 220$. (C. H. H.)

Figs. I, II, and III show the animal in various positions. IV is a much smaller specimen drawn to the same scale. V shows a specimen made to contract by action of alcohol. VI is detached from its stalk, and swimming away freely disc forward. VII, VIII, IX show three stages of fission. X, XI, and XII show the separated individual swimming by means of the aboral circle of cilia : XI is slightly contracted, XII strongly contracted after the cover-glass has been tapped.

A, Food-vacuole discharging contents at anus. C, cilia of the disc. CF, contractile fibre of stalk. D, disc. D', disc retracted. FV, food-vacuole. PH, pharynx. PV, pulsating vacuole. P, peristome. M, myophan striation. N, nucleus. V, vestibule.

A. General appearance.

Vorticella consists of a **body**, somewhat conical in shape in the expanded condition, and with its apex or proximal end prolonged into the slender **stalk** by which the animal is attached.

The distal end of the body, or **disc**, forming the base of the cone, is bordered by a prominent rim, the **peristome**.

The various species of Vorticella differ somewhat in form and proportions from one another.

Vorticella is highly irritable, and when disturbed, as by lightly touching the cover-glass with a needle, it instantly contracts. The peristome is suddenly turned in, concealing the disc and cilia, and at the same moment the stalk is suddenly coiled up into a corkscrew spiral. If the irritation be discontinued, the stalk gradually straightens out, the disc and peristome become everted, and the ciliary movement is resumed.

B. Structure.

Vorticella is a Protozoon, and the whole of the animal, stalk and all, is one single cell, comparable to a single Amœba or Paramecium. The entire animal consists of protoplasm, in which, as in Paramecium, a distinction may be made between the outer and firmer layer, or **ectosarc**, and the central more fluid mass, or **endosarc**. The stalk is a prolongation of the ectosarc only.

1. The body.

- a. The **cuticle**, or outermost layer of the ectosarc, forms a protective investment to the whole body.
- b. The **disc** is the distal or free end of the animal: it is slightly convex.
- c. The **peristome** is the projecting lip or rim surrounding the disc, and separated from it by a circular groove.
- d. The **vestibule** is a conical pit-like depression between the disc and the peristome: it marks the 'ventral' surface of the animal.

- e. The **pharynx** is a narrow continuation of the inner end of the vestibule, extending deep into the endosarc.
- f. The **anus** is a small opening into the vestibule, visible only at the moment of extrusion of faecal matter.
- g. The **cilia** are arranged in an incomplete ring round the margin of the disc, in the groove between the disc and peristome: they also line the vestibule and pharynx. They produce a current which runs round the disc in the direction opposite to that of the hands of a watch, then down the vestibule near its ventral surface, and, after a turn in the upper part of the pharynx, up along the dorsal wall of the vestibule to the exterior. The appearance of a long 'vestibular seta' in the dorsal part of the vestibule is due to the movements of the vestibular cilia. The cilia serve to sweep food particles into the interior of the animal.
- h. **Food-vacuoles**, enclosing food particles, may often be seen circulating in the endosarc.
- i. The **pulsating vacuole** is a spherical cavity, situated between the disc and the vestibule, and opening into the latter. It pulsates rhythmically.
- k. The **nucleus** is an elongated curved rod lying in the endosarc, about the middle of the body.
- l. A longitudinal '**myophan**' **striation** is visible in the deeper layer of the ectosarc, especially at the proximal end of the body, close to the stalk.

2. The stalk.

- a. The **cuticle** forms a thick covering to the stalk: to its elasticity the straightening of the stalk after contraction is probably due.
- b. The **contractile band** running down inside the cuticular sheath of the stalk is continuous above

with the deeper, 'myophan,' layer of the ectosarc of the body. The spiral shortening of the stalk is due to its contraction. In a specimen in which this band had been broken, it was seen to be drawn up suddenly towards the body at each inversion of the disc; the stalk, however, remaining straight.

C. Reproduction.

1. **Fission.** The cell-body becomes broader from side to side, and a constriction appears across its distal surface. This constriction extends downwards till it reaches the base of the cone close to the stalk, dividing the cell-body into halves. Of these, one is like the parent, and remains attached to the stalk. The other, while still attached to the base of the first, develops an **aboral circle of cilia** near its base, becomes detached, and swims away by means of the aboral cilia. After a time it attaches itself by its base to some submerged object, loses its aboral cilia, and forming a stalk by elongation of its base becomes a *Vorticella* similar to the parent from which it has been cut off. The process of fission may be completed in from one to two hours.
2. **Conjugation** occurs sometimes, but it is unlike the conjugation of *Paramecium* in two important points. First, the conjugation is between two dissimilar forms: an ordinary large stalked form, and a much smaller free-swimming form which has originated by repeated division of a large form. Secondly, the union of the two is a complete and permanent fusion, the smaller being absorbed into the larger.

This permanent fusion of a small active cell with a relatively large fixed cell, followed by a division of the fused mass, presents a striking analogy to the process of sexual reproduction occurring in higher animals.

3. **Encystment** may occur after conjugation, and apparently as the result of it. The disc becomes retracted;

the cell-body usually separates from its stalk, becomes spherical, and secretes a cyst around itself; the nucleus enlarges and becomes greatly elongated and then moniliform, and finally breaks up into a number of 'spores.' These are ovoid bodies, each with a circlet of cilia. The cyst ruptures and the spores escape and swim freely, multiplying by fission: later on each becomes attached by the end surrounded by the cilia and develops a disc at the opposite end, loses its original zone of cilia, and grows up into an ordinary Vorticella.

This process is not of frequent occurrence.

D. Action of Reagents.

1. *Kill some Vorticellæ with acetic acid (1 per cent. or weaker). Stain with safranin or carmine, and mount in glycerine or balsam.*

The nucleus will be stained, and its shape and relations can be well studied.

2. Weak solutions of poisons, such as acetic acid, corrosive sublimate, &c., cause the animal to retract its disc, and the stalk to gradually coil up into a close spiral, and then break off close to the base of the cone. In the natural condition the cell-body may separate in the same way from the stalk and swim away to a fresh resting-place, when scarcity of food or other adverse circumstance renders this advantageous.

CHAPTER II.

HYDRA.

HYDRA is a small freshwater animal, abundant in ponds and ditches and in slowly moving streams.

It consists of a tubular body about a quarter of an inch in length, one end of which is closed, while the opposite end is open and forms the mouth, a short distance below which is a circle of tentacles, usually six to eight in number.

Both the tentacles and the body are extremely contractile. The former, when the animal is disturbed, can be almost completely withdrawn, and the latter may shrink up so as to become a mere knob.

Hydra is usually attached by its closed basal end or foot to water-weeds or other bodies. By contractions of the foot it can crawl along slowly, and it can also progress more rapidly by fixing itself alternately by the mouth and foot, arching the body with a looping movement like a caterpillar. It is carnivorous, and by means of the nematocysts with which its tentacles are studded can paralyse and kill animals nearly as big as itself and of active habits.

Hydra receives its name from its remarkable power of recovery from injury. A specimen may be cut into two or more pieces, either transversely or longitudinally, and each fragment will not only survive, but within a short time will become a complete hydra. The entire animal may even be regenerated from a single tentacle.

At least three species of Hydra are described as occurring commonly in this country. Of these *H. viridis* is distinguished by its green colour and its smaller size, *H. fusca* is brown in colour, and *H. vulgaris* almost colourless.

It is uncertain, however, how far these species are really distinct from one another, and the following description will apply to any of them.

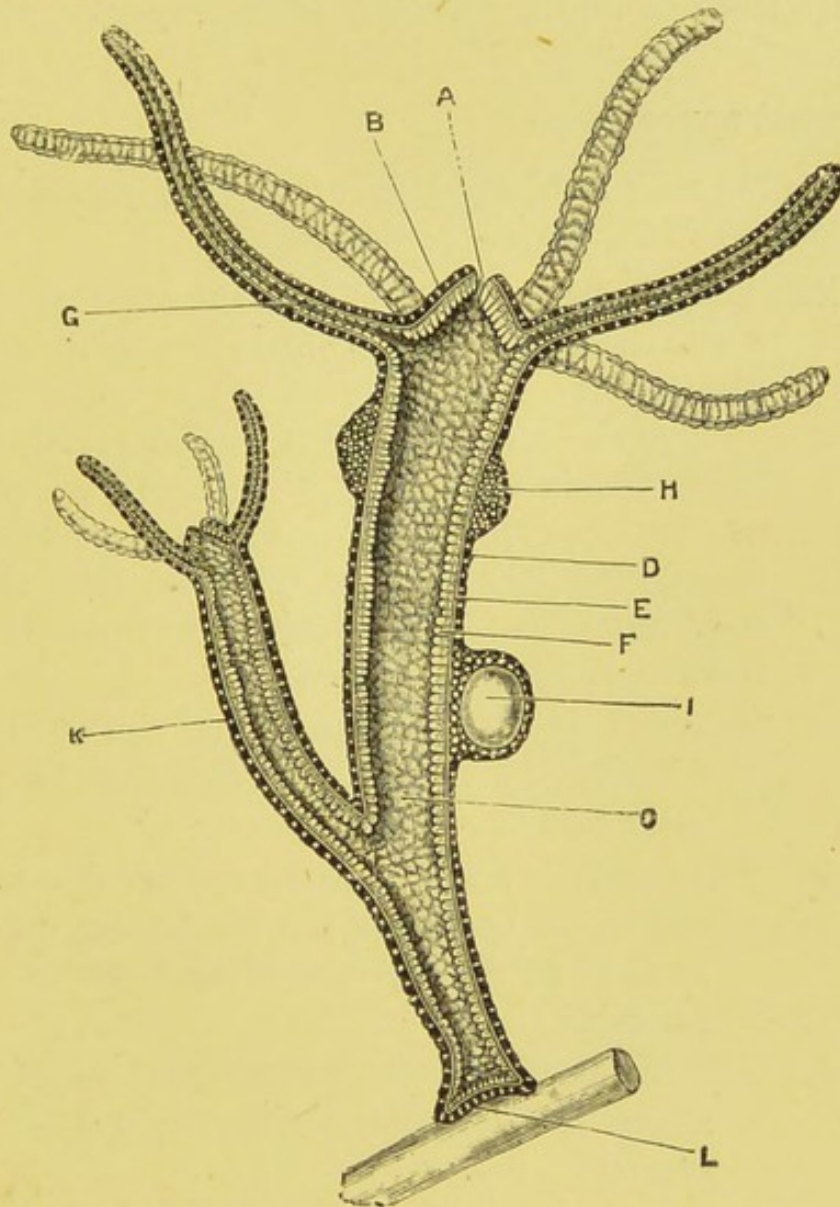


FIG. 11.—**Hydra.** A diagrammatic longitudinal section of a specimen with ripe reproductive organs, and with a fully formed bud; $\times 12$. (A. M. M.)

A, mouth. B, hypostome. C, enteron or digestive cavity. D, ectoderm. E, mesogloea. F, endoderm. G, cavity of one of the tentacles. H, testis. I, ripe ovum in the ovary. K, fully formed bud, with mouth and tentacles. L, foot, by which the Hydra is attached to a piece of weed.

I. EXAMINATION OF A LIVING SPECIMEN.

Cut off a small piece of weed with a Hydra attached to it; place it on a slide in a drop of water, and put a cover-

glass over it. If the *Hydra* is detached or fixed to the side of the tank, take it up with a dipping tube, and place it on a slide in a drop of water, with a small piece of weed for the animal to attach itself to, and to protect it from pressure. Cover as before.

A. General appearance.

Leave the slide until the Hydra has fully expanded, and then examine it with a low power.

1. The **body** is tubular: its cavity, the **enteron**, opens to the exterior at the mouth, and serves as the digestive cavity of the animal.

The shape of the body varies very greatly according to the degree of elongation or contraction. It is usually more slender in its proximal or basal half than in the distal portion, but when fully extended is of nearly uniform diameter throughout. It is often distended locally by food.

- a. The **foot** is the closed proximal end of the body which forms a kind of sucking disc for attachment to water-weeds, &c.
 - b. The **mouth** is a small aperture at the free or distal end of the body. It can be greatly dilated, so as to allow the entrance of food-masses of considerable size.
 - c. The **hypostome** is the conical part of the body above the tentacles, with the mouth at its summit.
2. The **tentacles** are hollow processes of the body-wall, usually six to eight in number, and arranged in a single whorl round the base of the hypostome, which is the widest part of the body. Their cavities open into the general digestive cavity of the animal.

The tentacles, which have a warty appearance, are extremely contractile. When fully extended they are two or three times the length of the body; when fully contracted they are scarcely visible.

They are capable of free and active movement, and are used for capturing and paralysing the prey, which they then, by their contraction, transfer to the mouth.

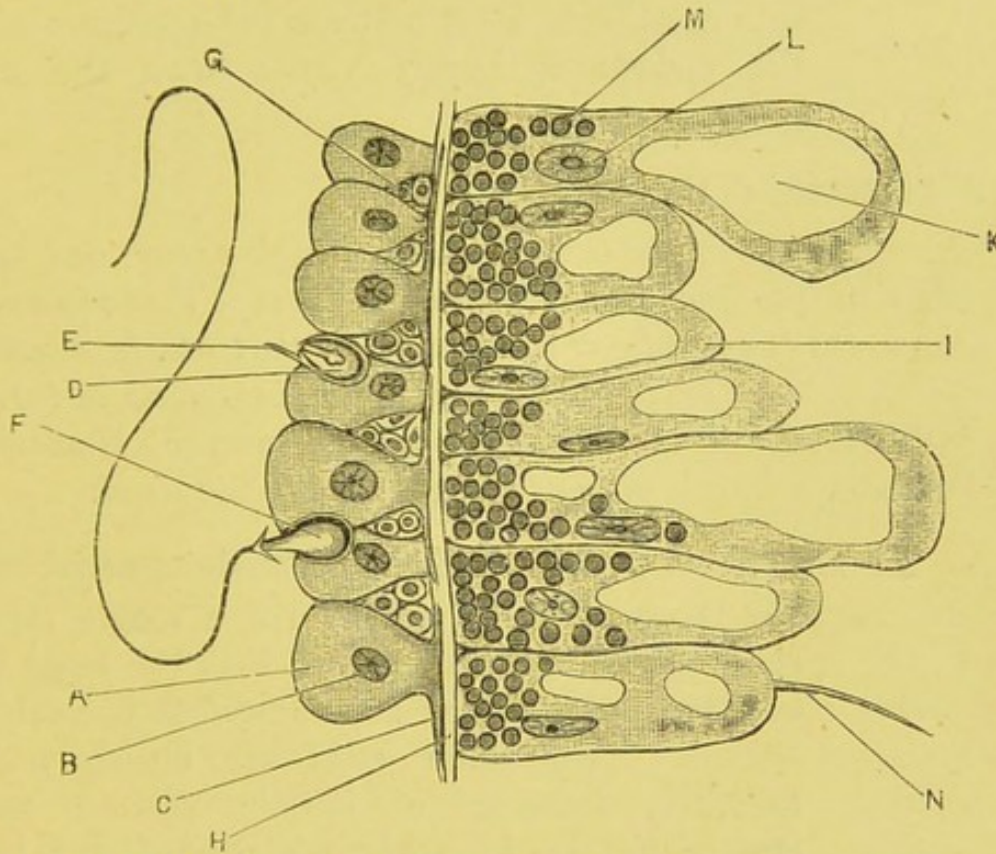


FIG. 12.—*Hydra viridis*. A small portion of alongitudinal section through the body-wall: $\times 800$. (A. M. M.)

A, one of the large ectoderm cells. B, nucleus of a large ectoderm cell. C, muscular tail of a large ectoderm cell. D, an undischarged nematocyst lying within its parent cell, or enidoblast. E, enidocil. F, a nematocyst with discharged thread. G, interstitial cell. H, mesogloea. I, endoderm cell. K, vacuole of endoderm cell. L, nucleus of endoderm cell. M, chlorophyll corpuscle. N, flagellum of endoderm cell.

B. Structure.

1. Structure of the body-wall.

Examine the body-wall more closely with the low power, and note its division into layers.

- a. The **ectoderm** is the outermost layer of the body. It is colourless, and forms about a third of the entire thickness of the wall.
- b. The **endoderm** is the inner layer, lining the digestive cavity, and forming about two-thirds of the

thickness of the body-wall. It is coloured green or brown according to the species of *Hydra* examined.

- c. The **mesogloea**, or **supporting lamella**, is a very thin gelatinous layer between the ectoderm and the endoderm, hardly visible with the low power.

2. Structure of the tentacles.

Examine one of the tentacles with a high power, and note its division into layers corresponding to those of the body-wall. Examine (1) the middle of the breadth of the tentacle, altering the focus so as to bring the several layers into view in turn; and (2) the edge of the tentacle, where by proper adjustment of the focus a profile view of the cells can be obtained.

- a. The **ectoderm** is a cellular layer made up as follows.

- i. The **large ectoderm cells** form a single layer, covering the whole surface of both the tentacles and the body. They are somewhat conical in shape. Their outer ends are closely fitted together, forming a mosaic pattern very clearly visible in surface views of the tentacle. Their inner ends, which rest directly on the supporting lamella, are narrower, and separated from one another by intervals of varying extent: these inner ends are produced into slender muscular processes or 'tails,' which lie parallel to the long axis of the tentacle, and closely applied to, or imbedded in, the mesogloea.

The shape of these large ectoderm cells varies very greatly with elongation and contraction of the tentacle. When contracted they are widened transversely, and their outlines are very distinct; when elongated their length considerably exceeds their width.

- ii. The **interstitial cells** are small rounded cells placed

in little clusters between the inner or basal ends of the large ectoderm cells.

- iii. The **nematocysts** or 'thread cells' are sharply defined oval capsules, filled with fluid and enclosing a long hollow spirally wound filament, formed by doubling in of the wall of the capsule at one pole. They develop within certain of the interstitial cells called **cnidoblasts**, and lie, when mature, in and between the large ectoderm cells, causing marked projections on the surface.

The **cnidoblast**, or cell within which the nematocyst is developed, persists as an enveloping capsule, and is produced at its outer or free surface into a small process, the **cnidocil**.

The nematocysts can be discharged or exploded, the contained hollow filament being shot out with great force and velocity. In this process of discharge, which is brought about by contraction of the cell in which the nematocyst lies, the basal part of the thread is discharged first, and, being provided with barbs, of which there are three principal and several smaller ones, fixes itself at once in the body against which the thread is shot, and into which the remainder of the filament is then propelled.

The discharge of these filaments appears to be under the control of the Hydra: they exert a marked numbing or paralysing influence on animals into which they are shot, and are the means by which the Hydra captures its prey. A nematocyst once discharged cannot be used again, and is cast off.

Besides these large nematocysts, much smaller ones, with short thick threads devoid of barbs, occur in large numbers in the tentacles. Their function is unknown.

Nematocysts of both the larger and the

smaller kinds occur in the body-wall, though less abundantly than in the tentacles.

iv. The **nerve-cells**. Certain small stellate cells found in the ectoderm are described as nerve-cells. A connection between them and the cells enclosing the nematocysts has been traced, and it is possible that they are concerned in the discharge of the latter.

b. The **endoderm** consists of a single layer of large granular and vacuolated cells lining the cavity of the tentacle. Many of these bear **flagella**.

Focus the middle of the thickness of the tentacle : note the flagella of the endoderm cells, and the stream of nutrient particles up and down the cavity of the tentacle.

c. The **mesoglœa** is the thin gelatinous layer between the ectoderm and the endoderm.

Focus the side of the tentacle at the middle of its thickness, and the mesoglœa will be seen as a thin transparent layer between the ectoderm and the endoderm.

Sharply tap the microscope so as to cause the Hydra to retract its tentacles.

In the contracted condition of the tentacle the ectoderm and endoderm are both strongly wrinkled transversely, but the mesoglœa is not. This shows that contractility is specially associated with the mesoglœa ; the real contracting elements are the muscular 'tails' of the ectoderm cells applied to or imbedded in its substance.

d. Discharge of the nematocysts.

Focus one of the tentacles with the high power : then place a drop of acetic acid on the slide and allow it to run under the cover-glass.

As the reagent reaches the tentacles these will be retracted and their nematocysts discharged in consequence of the irritation. Some of the

nematocysts will remain in the ectoderm with their threads projecting freely ; others will separate completely.

Examine, and draw the nematocysts, showing their shape, the threads with their enlarged basal portions, and the barbs.

Search for specimens with partially discharged threads ; and note that the threads are turned inside out in the process of discharge.

C. Reproduction.

Hydra reproduces asexually and sexually.

1. Asexual reproduction.

- a. **Gemmation** or budding consists in the formation of a hollow outgrowth from the side of the body, which acquires a mouth and tentacles at its distal end, and ultimately constricts at its base, separates from the parent, and becomes an independent animal.

The rate of budding depends largely on the supply of food and on temperature. If a rapidly budding Hydra be transferred to water in which there is little or no food to be obtained, the formation of the buds will be stopped, and buds already formed may even be absorbed.

A single Hydra may give rise to more than one bud at once, and these may develop secondary buds before separating from the parent animal. In this way temporary colonies may be formed, which, however, sooner or later break down into their component units.

- b. **Fission.** A Hydra may be cut in two, and each half will live and become a perfect animal. The process of fission, however, very rarely occurs naturally.

2. Sexual reproduction.

Hydra is hermaphrodite, the same animal having both testes and ovaries. Contrary to the rule among

hermaphrodite animals, the reproductive organs are extremely simple in structure, and the animals are capable of fertilising their own ova.

- a. The **testes** are conical or spherical swellings of the body-wall, varying in number from one or two to twenty. They are usually situated near the oral or distal end of the body, not far below the tentacles; but when numerous they may extend along the greater part of the length of the body. Each testis is formed by local proliferation of the interstitial cells of the ectoderm, giving rise to small conical heaps, which project externally and are covered on their outer surfaces by capsules formed from the large ectoderm cells.

The interstitial cells, after repeated divisions, become converted into spermatozoa by modification of their nuclei to form the heads, and elongation of their protoplasm to form the long swimming tails. When fully formed they are discharged by rupture of the capsule at its most prominent point.

Select a Hydra in which the testes are large; put it in a drop of water on a slide; cover it; and, by gentle pressure on the cover-glass, rupture one of the testes, and so discharge the spermatozoa. Examine with a high power.

The **spermatozoa** are filiform bodies about $\frac{1}{500}$ inch in length. Each consists of a small ovoid highly refractive head, containing the nucleus, and a long active thread-like tail.

- b. The **ovaries** usually develop a little later than the testes. In *Hydra viridis* there is seldom more than a single ovary present at a time, but in the brown species there may be as many as eight. They form, when ripe, spherical projections of the body-wall considerably larger than the testes, and situated as a rule nearer the basal end of the animal. In each ovary only a single ovum is

produced. The ovary is formed like the testis by multiplication of the interstitial cells to form a small swelling : one of these cells, near the centre of the heap, soon becomes larger than the rest and becomes the **ovum**. This grows rapidly at the expense of the other cells of the ovary, which form a capsule around it and supply it with nutriment. The ovum is at first amœboid, so as to come into contact with a large number of the nutrient cells. When it has reached its full size it becomes spherical or ovoid ; the capsule then thins away and ruptures at its summit, and, shrinking back, leaves the outer half of the ovum exposed to the water, and ready to receive the spermatozoa.

After fertilisation the ovum segments, forms a hard capsule around itself, becomes detached from the parent, and, falling to the bottom of the tank or pond in which the animal is living, develops after a time into a young Hydra.

II. EXAMINATION OF PREPARED SPECIMENS.

A. Disintegrated Specimens.

Kill a Hydra with 1 per cent. acetic acid ; then add a large drop of water, cover, and examine with low and high powers.

The cells are loosened from one another and may now be examined separately.

1. The ectoderm cells.

- a. The large ectoderm cells will be found isolated in various parts of the preparation. They are somewhat conical in shape, their outer ends being broad and containing the large nuclei. Their inner ends are much narrower, and are produced into slender muscular processes or tails. These tails lie on the outer surface of the supporting

lamella, and partially imbedded in its substance. Their direction is mainly longitudinal, *i.e.* parallel to the long axis of the animal, and it is probably on them that the contractility of the animal (p. 20) depends.

- b. The **interstitial cells** are much smaller, and usually remain in small clusters. Within some of them the early stages of development of the nematocysts may be seen.
- c. The **nematocysts**. In specimens killed with acetic acid, nematocysts are frequently met with in which the thread is only partially protruded, and in which the relations of the capsule to the thread can be easily determined.
- d. The **nerve cells**. The small stellate cells supposed to be nerve cells may sometimes be seen. They are better seen in specimens treated with methylene blue.

- 2. The **mesoglœa** may be seen in teased preparations in the form of transparent shreds or sheets of greater or less extent, on the outer surface of which a distinct longitudinal striation is present, caused by the muscular tails of the large ectoderm cells.

On the inner surface of the mesoglœa transverse fibres occur which appear to be connected with the endoderm cells, and are probably muscular in function.

- 3. The **endoderm cells** are very variable in shape, and during life are amœboid. Each commonly contains one or more vacuoles, which may be so large as to reduce the protoplasm of the cell to a very thin peripheral lamella. The outer end of each cell, next to the mesoglœa, contains in *Hydra viridis* a number of small spherules coated with chlorophyll, to which the green colour of the animal is due. In the brown species of *Hydra* similar bodies are present, but devoid of chlorophyll.

The endoderm cells may also contain, in addition to particles of food, little clusters of brown or black granules, probably formed by breaking down of the chlorophyll grains. The flagella are seldom preserved in teased specimens.

B. Transverse Sections.

Examine a series of transverse sections through the body of Hydra. To prepare these kill the animal in the expanded condition by Perenyi's fluid; transfer first to 70 per cent. and then to 90 per cent. alcohol; stain with hæmatoxylin, and then imbed in paraffin and cut it into thin sections with a microtome.

1. The ectoderm.

- a. The **large ectoderm cells** are well seen in such sections; their muscular tails, which are mainly longitudinal in direction, are cut transversely, and appear as a row of highly refractive dots on the outer surface of the mesogloea.

At the basal end or foot of the Hydra the ectoderm cells are more columnar in shape, contain longitudinal rows of granules, and are probably glandular.

On the outer surface of the ectoderm cells there is a thin cuticular layer, more obvious in the brown than in the green Hydra.

- b. The **interstitial cells** are well seen in sections through the body or tentacles, but are absent in the foot.
- c. The **nematocysts** are very abundant in the tentacles, less numerous in the body, and absent in the foot. In specimens killed with osmic acid, few if any of them will be discharged.
- d. The **testis or ovary** may be cut across and should be looked for.

2. The **mesogloea** is seen in transverse sections as a very thin transparent layer, between the ectoderm and the endoderm.
3. The **endoderm cells** differ greatly in shape in different parts of the body and at different times. During life they are amœboid, and their processes may extend so far as to almost obliterate the cavity of the animal. They contain vacuoles, which are often so large that the cell-substance is reduced to a thin peripheral lamella. The nucleus is usually nearer the outer or basal end, and is flattened in shape. The flagella can very seldom be seen in sections.

In the foot the endoderm cells are much smaller than in the body, and form a layer of short columnar or almost cubical cells containing granular concretions.

CHAPTER III.

THE LIVER-FLUKE OF THE SHEEP.

Fasciola (Distomum) hepatica.

THE adult liver-fluke is a flat unsegmented worm, about an inch and a half long, living in the bile-ducts of certain domestic animals, and notably in those of the sheep, in which it gives rise to the destructive disease known as liver-rot. It very rarely occurs in man.

The animal is hermaphrodite, and its eggs, which have thick chitinous shells, are deposited in enormous numbers in the bile-ducts of the sheep or other host, from which they pass into the alimentary canal, ultimately escaping with the fæces. From these eggs, if deposited in damp places or in water, larvæ are produced which lead a free existence for a short time, but very soon become parasitic within the body of *Limnæa truncatula*, an amphibious snail. Two or more asexually produced generations now succeed: and the last of these encyst on grass. These encysted forms are swallowed with the grass by sheep, and passing into their bile-ducts become the adult sexually mature flukes.

This alternation of sexual and asexual generations, living parasitically within different hosts, is a very characteristic feature in the life history of many parasitic worms.

I. THE MATURE LIVER-FLUKE.

Slit open the bile-ducts in the liver of an infected sheep, and transfer the living flukes to a dish of warm salt-solution (.75 per cent.) to clean them.

1. *Inject the excretory system of one fluke, and the*

alimentary canal of another, with a thin injection, such as freshly precipitated Prussian blue, suspended in water. Inject the coloured fluid, by means of a very fine glass cannula provided with an indiarubber cap, into the hinder end of the animal; in the middle line for the excretory system, and about 1 mm. from it for the alimentary canal. Place the animals between glass slips, and tie the slips together with cotton. Put the slips with the animals between them into alcohol (90 per cent.) for twelve hours or more, when the specimens may be dehydrated, cleared, and mounted in balsam.

2. Squeeze a specimen somewhat more tightly between two glass slides, and leave it in corrosive acetic mixture (see Appendix) for five or six hours. - Wash well with 50 per cent., 70 per cent., 80 per cent. alcohol for about two days. Pass gradually down to water, and stain with weak hæmalum for twelve hours. Wash for the same length of time in 1 per cent. alum solution. Then pass gradually through water, 50 per cent., 70 per cent., 90 per cent., to absolute alcohol (two hours). Clear in cedar-wood oil, and mount in balsam.

A. External Characters.

1. In **form** the animal is flat and oval, with a blunt triangular projection from its broad anterior end. Its length is about an inch and a half, its breadth about half an inch.
2. The **mouth** is an oval aperture at the anterior end, in the middle of the cup-shaped **anterior sucker**.
3. The **ventral sucker** is a muscular cup in the mid-ventral line, near the junction of the triangular anterior portion with the broader part of the body.
4. The **genital aperture**, through which the penis may be protruded, is on the ventral surface between the two suckers, and slightly nearer the posterior one.
5. The **cuticle** is a thin layer covering the whole animal. Its surface is covered with minute backwardly directed, pointed **scales**, which are best seen in a specimen kept in spirit and dried at the moment of examination.

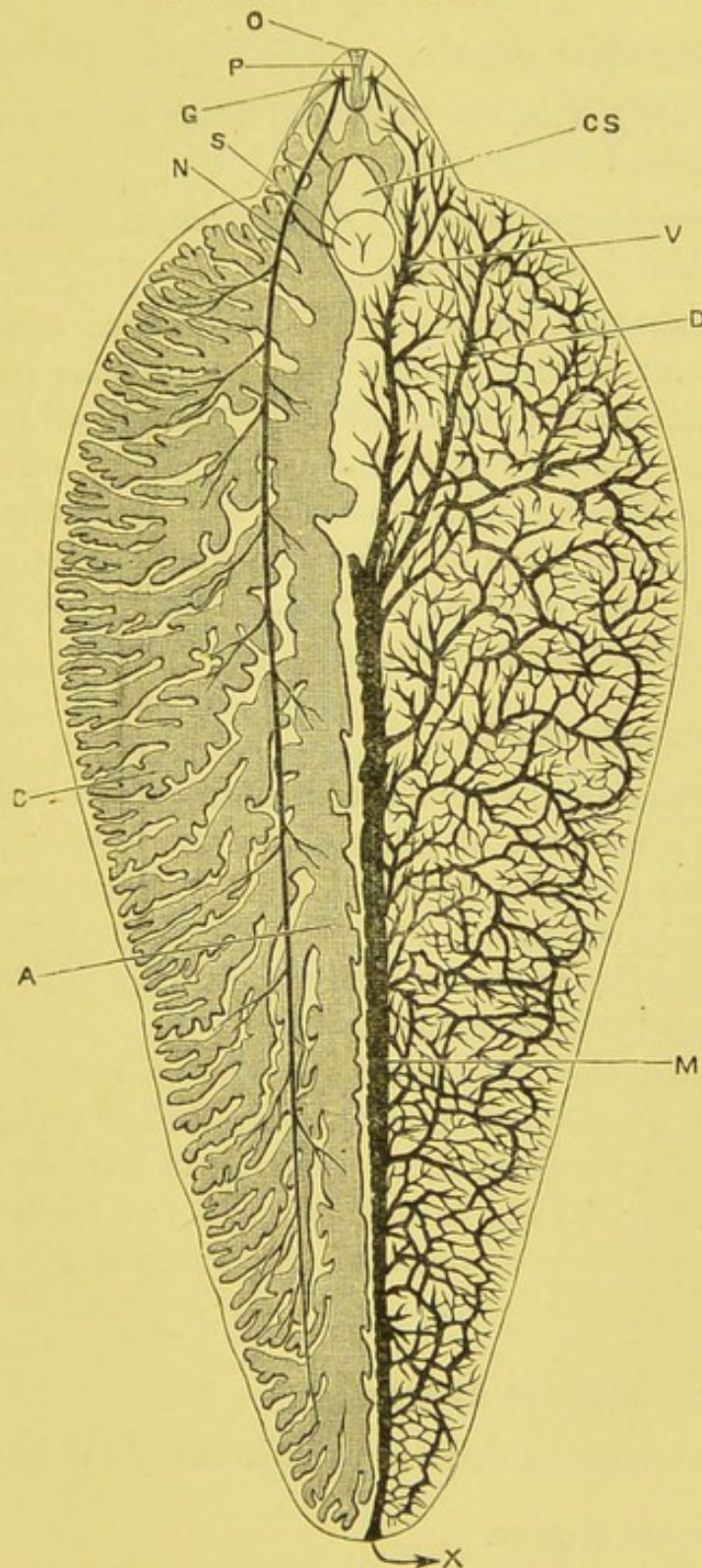


FIG. 13. — *Fasciola hepatica* from the ventral surface; $\times 4$.
(After Sommer.)

The alimentary and nervous systems only are shown on the left side of the figure, the excretory system alone on the right side of the figure.

A, right main division of the alimentary canal. C, one of its diverticula. CS, cirrus-sac. D, left anterior dorsal trunk of excretory system. G, lateral ganglion. M, main trunk of excretory system. N, lateral nerve. O, mouth. P, pharynx. S, ventral sucker. V, left anterior ventral trunk of excretory system. X, excretory pore.

B. The Alimentary Canal.

1. The **pharynx** is an ovoid muscular mass immediately behind the mouth.
2. The **œsophagus** is a very short straight thin-walled tube behind the pharynx.
3. The **intestine**, into which the œsophagus opens just in front of the genital aperture, divides immediately into a right and a left limb, each of which runs to the hinder end of the body, giving off numerous small cæca on its inner side, and many large branched ones on its outer side; the whole intestine forming a series of cæcal tubes ramifying all over the body without anastomoses.

C. The Excretory System.

This is usually invisible except in injected specimens. It consists of a network of minute and much-branched ducts, which commence with slightly dilated ends into which project long flame-shaped cilia. The small ducts freely anastomose with one another, and open into larger transverse ducts, which in turn open into the main duct.

The **main duct** is a medium tube of considerable size, formed by the union of four **anterior ducts**, a dorsal and a ventral on each side, at about a quarter of the animal's length from the anterior end: from this point the main duct runs directly backwards to open to the exterior by a terminal median pore.

D. The Reproductive System.

This is complicated, as in most hermaphrodite animals.

1. The male organs.

- a. The **testes** are much-branched tubes, lying in the middle part of the body, and extending over about half its length and half its width. The two testes are about equal in extent, one lying behind the other.

- b. The vasa deferentia are two in number, one arising near the middle of each testis. They run forwards as far as the ventral sucker, where they open into the vesicula seminalis.

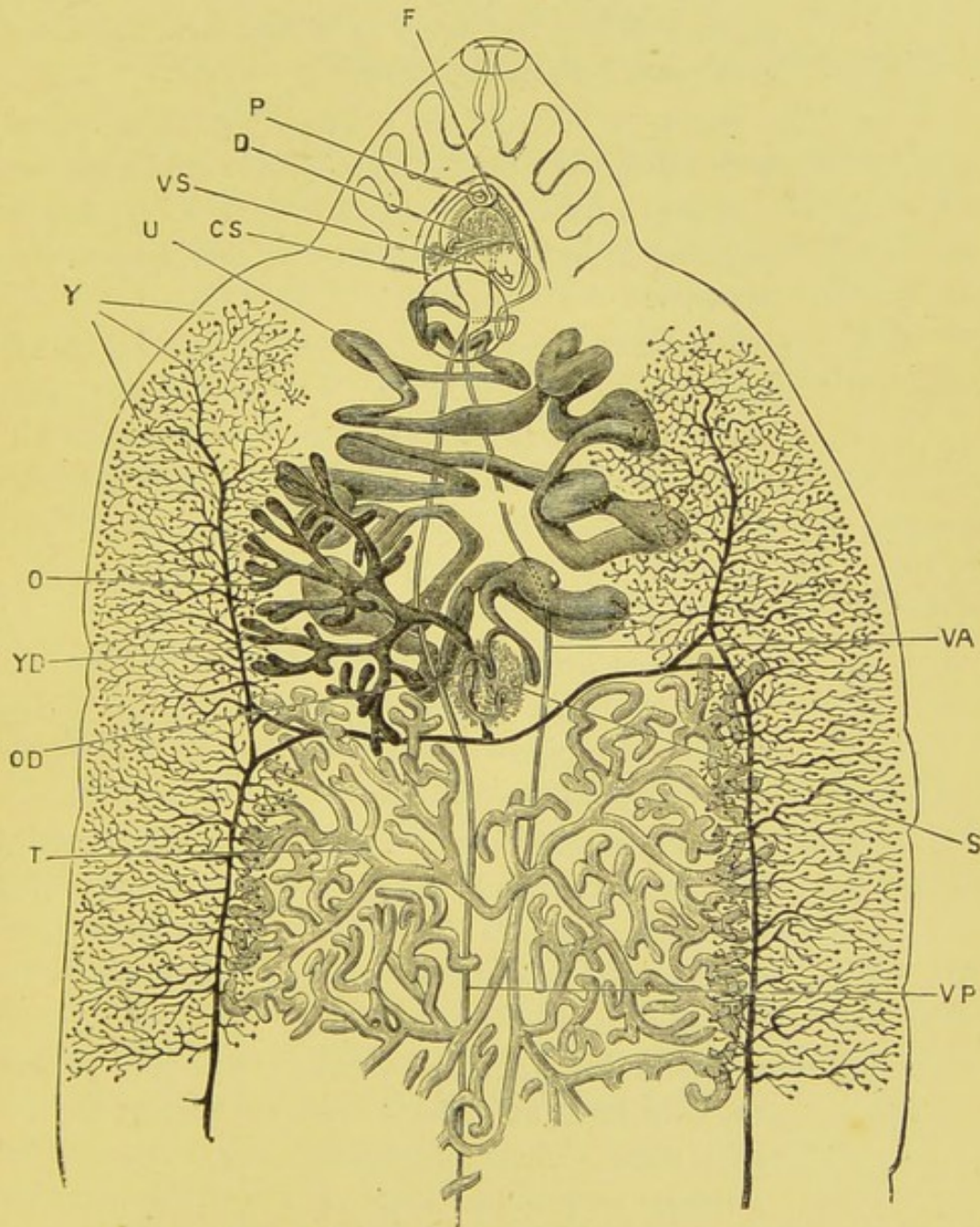


FIG. 14.—*Fasciola hepatica*. Reproductive organs, from the ventral surface; $\times 6$. (After Sommer.)

CS, cirrus-sac. D, ductus ejaculatorius. F, aperture of the oviduct. O, ovary. OD, ovarian duct. P, penis. S, shell-gland. T, anterior testis. U, uterus. VA, vas deferens from anterior testis. VP, vas deferens from posterior testis. VS, vesicula seminalis. Y, yolk-gland. YD, duct of yolk-gland.

- c. The **vesicula seminalis** is an elongated sac lying above, and somewhat in front of, the ventral sucker.
- d. The **ductus ejaculatorius** is a fine tube running from the vesicula seminalis to the end of the penis. When the penis is withdrawn this duct is thrown into convolutions.
- e. The **penis** or 'cirrus' is a large muscular organ which lies, when withdrawn, within the cirrus sac, a space in front of the ventral sucker. It can be protruded by evagination, and the ejaculatory duct then lies within it.
- f. The **cirrus-sac** is a cavity between the ventral sucker and the genital aperture. The penis lies in it when withdrawn, as do also the vesicula seminalis and a small accessory gland which surrounds the ejaculatory duct.

2. The female organs.

- a. The **ovary** is branched and tubular: it lies on the right, or rarely on the left side in front of the anterior testis, and its branches unite to form the narrow **ovarian duct**.
- b. The **yolk-glands** are very numerous small rounded masses, scattered along two areas extending along the sides of the body from end to end, and each nearly one quarter of the whole width of the animal.
- c. The **vitellarian ducts**, or ducts of the yolk-glands, unite to form an anterior and a posterior duct on each side. These unite about the junction of the anterior and middle thirds of the animal, forming a transverse duct, which runs inwards to open into the median **yolk-reservoir**: from this a single **median vitellarian duct** runs a short distance forwards and unites with the ovarian duct to form the oviduct.

Close to the junction is the opening of a short duct, the **vagina** or 'canal of Laurer,' which opens externally in the middle line on the dorsal surface.

- d. The **shell-gland** is a median glandular mass, really an aggregate of unicellular glands, surrounding the junction of the ovarian and median vitellarian ducts.
- e. The **oviduct**, or 'uterus,' is a wide, much-convoluted tube, commencing at the point of union of the ovarian and vitellarian ducts in the midst of the shell-gland, and lying between the shell-gland and the genital aperture. Its convolutions extend halfway across the animal, and numerous eggs can be seen within it.
- f. The **aperture of the oviduct** is at the base of the penis, and on its left side. When the penis is fully withdrawn a slight cavity, the 'genital sinus,' is formed, into the left side of which the oviduct then opens.

E. The Nervous System.

This cannot be made out with certainty in specimens prepared as above. It can be seen in a specimen rendered transparent by caustic potash, though such preparations are very perishable. It may also be made out in sections.

It consists of a nerve-collar round the pharynx, with two lateral ganglia and a median ventral one. From these arise nerves, of which two large lateral ones are the chief. These two run backwards, one on each side of the body (fig. 13).

II. LIFE HISTORY OF THE LIVER-FLUKE.

The free-swimming larvæ may be obtained by removing eggs from the bile-ducts of an infected sheep and hatching them in a shallow vessel of water in a warm room. Sporocysts and

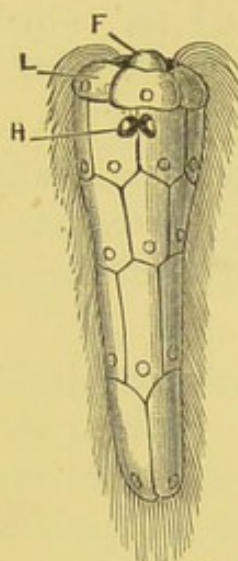


FIG. 15
× 250

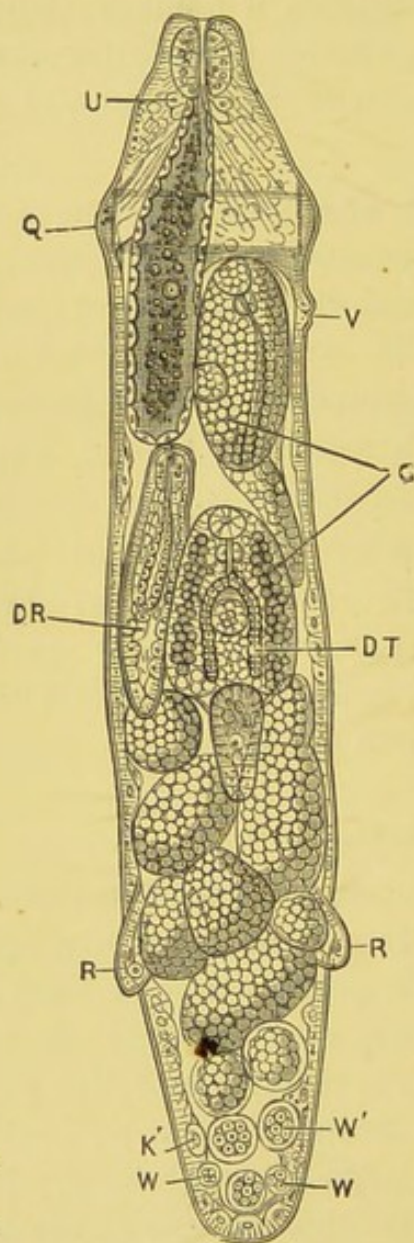


FIG. 18
× 70

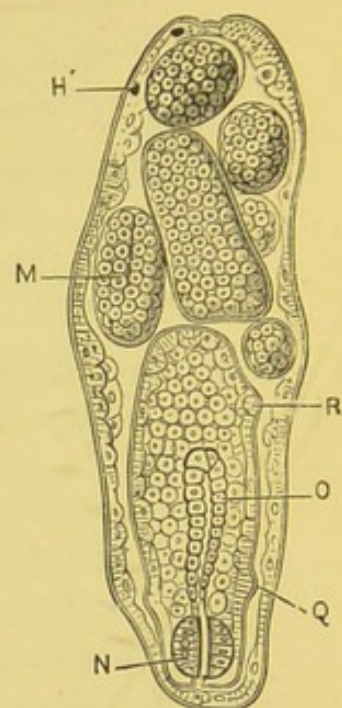


FIG. 16
× 115

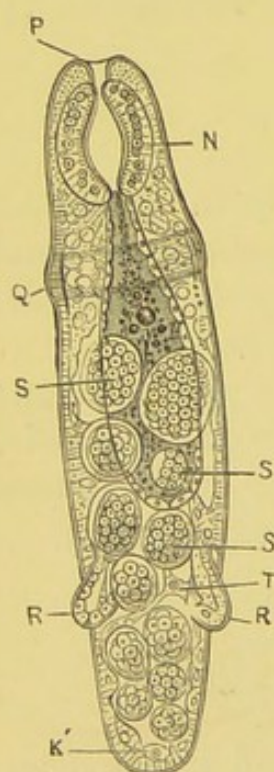


FIG. 17
× 115

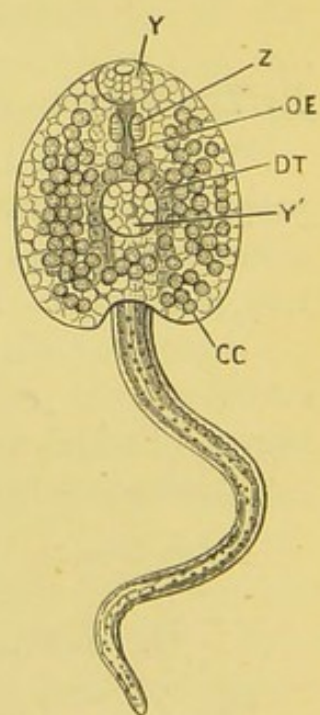


FIG. 19
× 80

rediae may be obtained from specimens of *Limnæa truncatula*, kept in the same vessel.

The main features in the life history are as follows.

A. The **First Generation** is produced sexually, but is itself asexual.

1. The **eggs**, laid in large numbers in the bile-ducts of the sheep or other infected mammal, pass with the bile into the intestine, and so escape from the body. They are ovoid bodies 0·005 inch long and 0·003 inch broad, enclosed in smooth brownish chitinous shells. Within each shell are a single ovum or germ-cell and a large number of yolk-cells. After the escape of the egg from the body of the host segmentation occurs, an embryo develops, and a circular operculum at one end of the shell opens to allow it to escape.
2. The **free larva** is conical, with a short papilla at its broad anterior end; the whole surface is covered with long cilia, enabling the larva to swim rapidly. Two eye-spots are present, and two flame-cells, probably excretory. The ectoderm is a single layer of flattened cells, usually arranged in five transverse

FIGS. 15 to 19.—*Fasciola hepatica*. Five stages in the life history. (After Thomas.)

FIG. 15.—The free-swimming larva.

FIG. 16.—A sporocyst, containing developing rediae.

FIG. 17.—A young redia. The shaded area represents the digestive sac.

FIG. 18.—An adult redia, containing one daughter-redia, two cercariae approaching maturity, and germs in various stages. The shaded area represents the digestive sac.

FIG. 19.—A free cercaria.

The following letters have the same signification in the five figures:—C, nearly ripe cercariae. CC, cystogenous cells of cercaria. DR, daughter-redia. DT, limbs of the digestive tract. F, head-papilla. H, eye-spots. H', the same degenerating. K', germinal cell. L, epaulet-like cells of first row of ectoderm cells. M, embryo in optical section; gastrula stage. N, pharynx of redia. O, digestive sac. OE, œsophagus of cercaria. P, lips of redia. Q, collar of redia. R, processes of redia serving as feet. S, embryos between the morula and gastrula stages. T, trabeculae crossing body-cavity of redia. U, cells in redia supposed to be glandular. V, birth-opening, by which cercariae and daughter-rediae escape from the redia. W, morula, still retained in the body-wall. W', larger morula. Y, oral sucker of cercaria. Y', ventral sucker. Z, pharynx of cercaria.

bands : within is a mass of granular cells. When this larva meets with *Limnæa truncatula*, a small amphibious snail, the head-papilla becomes elongated, and by means of it the larva bores its way into the snail. Unless the larva happens to come across a *Limnæa* within about eight hours after its escape from the egg, it dies.

3. Development of the **sporocyst**. Within the snail, usually in its pulmonary chamber, the ectoderm cells of the larva swell, lose their cilia, degenerate, and are thrown off ; the remainder grows rapidly, and in two or three weeks becomes an elongated sac, .024 inch long. This sac, the **sporocyst**, has an outer structureless cuticle, a thin muscular layer, and an epithelial layer lining the cavity.

The eye-spots, though losing their form, persist ; and ciliated excretory funnels are present. Such sporocysts sometimes, though rarely, multiply by transverse fission in the early stages of their development.

B. The **Second Generation** consists of **Rediæ**, which are produced asexually within the sporocyst, and are themselves asexual.

1. From the epithelium of the sporocyst, cells are budded off which segment to form solid masses or **morulæ** lying in the cavity of the sporocyst. Each of these becomes flattened on one side, and then invaginated to form a **gastrula** : this increases in size, elongates, and develops into a **redia**. The rediæ so formed force their way out of the sporocyst and become free : the wound in the sporocyst heals, and other rediæ are formed in the same way within it.
2. The **free rediæ** wander about in the snail, increasing in size and being especially abundant in the liver. The **adult redia** (fig. 18) is a cylindrical body about .06 inch long, with a collar-like ridge running round it

near the anterior end, and with a pair of blunt processes projecting from the hinder part of the ventral surface, which aid in locomotion. The body-wall resembles that of the sporocyst in structure, but is more muscular, and has definite excretory canals which commence as funnels with 'flame-shaped' bunches of cilia.

The alimentary tract is a comparatively short blind sac, with walls one cell thick: the mouth is at the anterior end, and behind it the wall of the sac is thickened to form a strong muscular pharynx.

From the inner surface of the body-wall of the redia, cells are budded off which develop into gastrulæ as in the sporocyst: these may become rediæ like the parent, or may develop into cercariæ. Both rediæ and cercariæ may be formed in the same redia.

C. The **Third Form** is a **Cercaria** (fig. 19). These are not necessarily the third generation, for several generations of rediæ may intervene between them and the sporocyst.

1. Within the parent redia the embryo develops a long tail near its hinder end, an anterior sucker round the mouth, and a posterior sucker on the ventral surface. Its alimentary tract, which is at first solid, becomes bifurcated to form the two limbs of the intestine, the portion in front of the bifurcation forming a pharynx and a short œsophagus. A single redia may contain about twenty such cercariæ at one time.
2. The ripe cercariæ, which measure nearly 1 mm. in length, including the tail, escape from the redia by an aperture just behind the collar. At first they are very active, and work their way out of the snail: as this snail, *Limnæa truncatula*, is amphibious, they may be set free either in water or on damp grass. In either case they shortly lose their tails, and encyst on grass or some other plant.

3. In the encysted condition the cercariæ are swallowed by sheep with the grass. They then again become active, escaping from their cysts, and working their way along the bile-ducts, where they grow rapidly, and develop in about six weeks into sexually mature flukes.

CHAPTER IV.

THE LEECH. *Hirudo medicinalis*

THE leech is an elongated flattened worm, from three to five inches in length, and provided with a muscular sucker at each end. The body is marked externally by a series of transverse constrictions dividing it into rings or annuli, and is capable of considerable elongation and contraction.

Leeches occur in freshwater pools and marshes in this country, but far more abundantly on the Continent. They either swim freely by vertical undulations of the body, or progress in a looping manner, attaching themselves alternately by the anterior and posterior suckers. The leech lives on the blood of higher animals: it lays its eggs in a cocoon, which it buries in a hole in the bank of the pond it inhabits.

Leeches are 'segmented animals,' *i.e.* several of the organs are repeated, usually in pairs, at regular intervals along part or the whole of the length of the body: The **segments** or **somites**, as indicated by the internal organs, are much less numerous than the annuli, five of these latter corresponding to each somite, except near the ends of the body.

This segmental arrangement affects markedly the nervous, excretory, and reproductive systems, and to a less degree the circulatory and digestive organs.

Leeches intended for dissection should be killed with chloroform.

I. EXTERNAL CHARACTERS.

1. The **shape** varies greatly with the degree of elongation or contraction. The body is broadest a little way

behind the middle of its length, and is oval in transverse section, the dorsal surface being more convex than the ventral.

2. The **annuli**, or rings, into which the body is divided by a series of transverse grooves, are about ninety-five in number, and occur throughout the whole length of the body except its extreme ends. They bear small papillæ which are more obvious when the body is in the contracted condition.
3. The **colour** differs greatly in different individuals. The dorsal surface is darker than the ventral, and is usually marked by three pale longitudinal stripes on each side, the middle and outer of which are interrupted by dark dots. These dots are markedly larger, especially in the middle stripe, at every fifth annulus, the annulus so marked being the hindmost of a somite. The most anterior of the five annuli making up a somite bears a transverse ring of small white dots. Towards the two ends of the body the somites are shorter and contain fewer annuli.
4. The **suckers**.
 - a. The **anterior sucker** is oval, with the longer axis longitudinal. It is placed on the ventral surface of the anterior end, and is cupped in the centre to form the buccal cavity. It may be regarded as formed by the fusion of the **prostomium**, a part in front of the mouth, with the first two annuli of the first somite.

The prostomial portion is very commonly folded down over the mouth as a kind of lip.
 - b. The **posterior sucker** is circular, and larger than the anterior one. It is composed of six segments fused together, and is imperforate.
5. **External openings**.
 - a. The **mouth** is a funnel-like depression in the anterior sucker, at the bottom of which are the three jaws.

- b. The **anus** is a very small aperture on the dorsal surface in, or just in front of, the constriction separating the posterior sucker from the body.
- c. The **genital apertures**. The leech is hermaphrodite : the male and female apertures are separate, and are both on the ventral surface in the median line.
 - i. The **male aperture** is a small hole with tumid lips at the hinder border of the twenty-fourth annulus, *i.e.* in the second annulus of the sixth somite. From it the muscular penis is often seen protruding.
 - ii. The **female aperture** is less conspicuous than the male, and is placed one somite further back, *i.e.* at the hinder border of the twenty-ninth annulus, the second annulus of the seventh somite.
- d. The **apertures of the nephridia**, or excretory organs, are minute paired openings on the ventral surface of the body in the hindmost annulus of each somite from the second to the eighteenth inclusive.

Hold the leech in your hand with the ventral surface upward. Dry it with a cloth, and then gently squeeze it : minute drops of fluid will exude from the nephridial apertures, which are thus rendered clearly visible.

II. DISSECTION OF THE LEECH.

Stretch the leech slightly with the fingers and fix it under water with the dorsal surface upward, putting the pins through the sides of the suckers so as to avoid injury to the nerve-ganglia.

Make a longitudinal incision through the skin, a little to one side of the middle line, taking care not to damage the alimentary canal, which lies close beneath the skin. Carefully dissect off the integument from the alimentary canal along the

whole length of the animal, and pin out the flaps right and left. Wash thoroughly under the tap. Note at once the dorsal blood-sinus, which runs along the dorsal wall of the alimentary canal.

A. The Digestive System.

The alimentary canal of the leech runs straight from mouth to anus. Along the greater part of its length it is a wide tube, whose capacity is much increased by paired lateral diverticula, and is further capable of great distension.

A leech can draw as much as three times its own weight of blood, a great part of which is often spontaneously discharged. The digestion of a full meal may take as long as nine months in an adult animal.

Clean the dorsal wall of the alimentary canal along its whole length, taking care not to damage the supra-œsophageal ganglia. If the canal is empty, its walls are white and readily distinguished; if full, it appears red from the contained blood, and is less easy to dissect. Wash frequently under the tap during the dissection.

1. The **mouth** is a conical depression in the anterior sucker, at the bottom of which are the **jaws**. These are three laterally compressed muscular cushions arranged radially, one being dorsal and anterior, and the other

FIG. 20.—*Hirudo medicinalis*, seen from the ventral surface. (After A. G. Bourne.)

The numbers 1 to 23 indicate the somites; the numbers I. to V. the five annuli of the twelfth somite.

A, anterior sucker, with the mouth. B, posterior sucker. G, male aperture. H, female aperture. N, nephridial apertures.

FIG. 21.—*Hirudo medicinalis*. A diagrammatic figure of the renal, nervous, and reproductive systems. The animal has been opened along the mid-dorsal line, pinned out, and the alimentary canal removed. (After A. G. Bourne.)

The somites are numbered 1 to 23, and their boundaries are indicated by the dotted lines.

CG, supra-œsophageal ganglion. EP, left epididymis. G 1, the first of the twenty-three post-oral ganglia. GL, glandular enlargement of the oviduct. L, lateral vessel. LA, latero-ventral branch of lateral vessel. LD, latero-dorsal branch. LL, latero-lateral branch. N 1, the first of the seventeen nephridia of the left side. O, nerve-collar. OV, ovisac containing the left ovary. PE, penis. T 4, the third testis of the left side. VD, vas deferens.

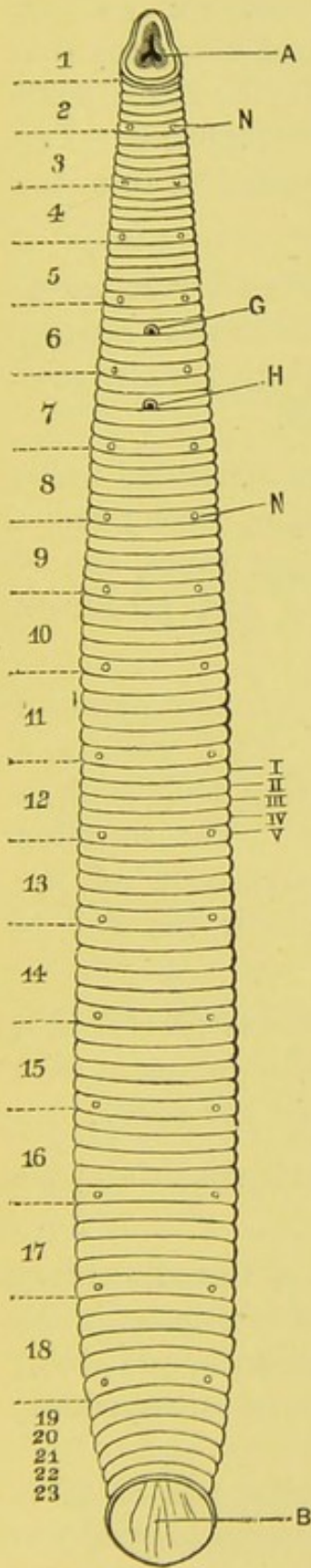


Fig. 20

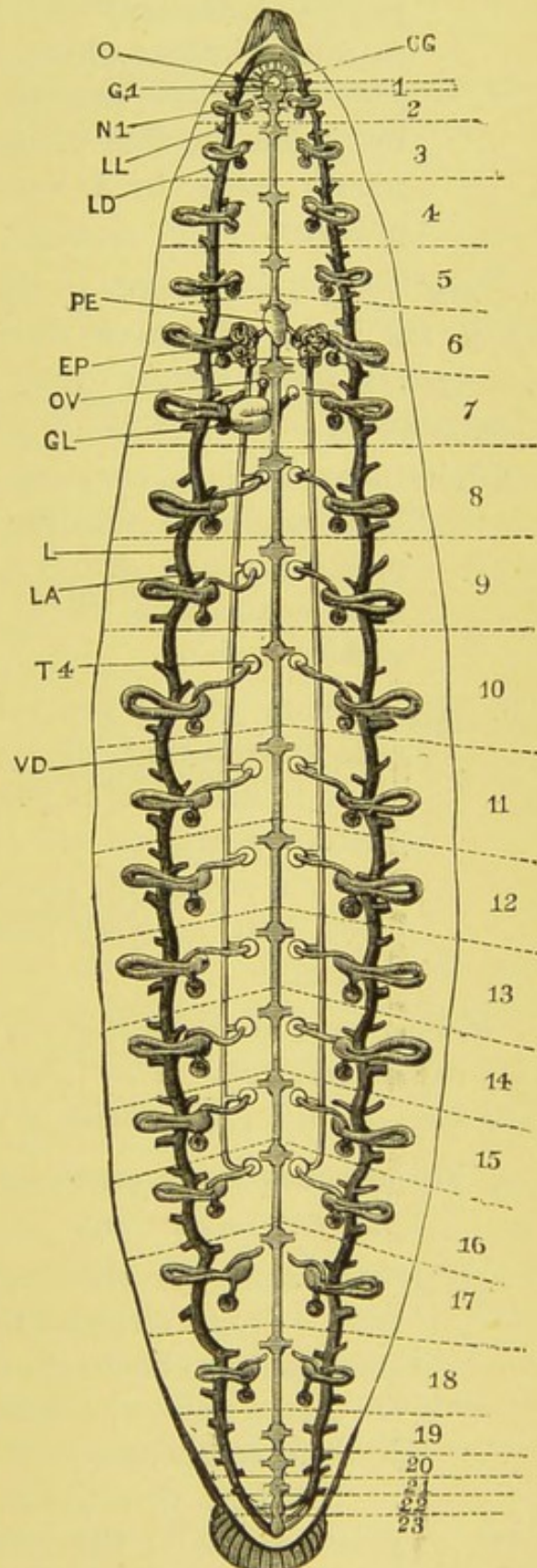


Fig. 21

two ventro-lateral: each cushion is covered by a thin chitinous cuticle, which is thickened along the free edge of the jaw, and notched into the sharp teeth by which the bite of the leech is produced. The mouth leads, by a very small aperture, into the pharynx.

Snip away the margin of the anterior sucker so as to expose the jaws. Examine them from the ventral surface with a pocket lens: remove one of them and examine it with a low power of the microscope to see the teeth.

2. The **pharynx** is an oval sac with very muscular walls. It is connected with the body-wall by strong radial muscles, which give it a villous appearance, and by their contraction dilate its cavity and produce a sucking action.

3. The **salivary glands** are very large granular pyriform cells surrounding the pharynx. Each cell is a gland in itself, and is produced into a long stalk or ductile opening on one of the jaws. The secretion has the power of preventing coagulation of the blood, and so very greatly facilitates the act of sucking.

Remove part of the wall of the pharynx, and tease it on a slide in salt solution. The large pyriform gland-cells, with their long ductules, will easily be seen with a low power.

4. The **œsophagus** is a short narrow tube leading from the pharynx to the crop.

5. The **crop** is by far the largest part of the alimentary tract. It is a straight thin-walled tube lying in the somites from the fourth to the fourteenth, and giving off eleven pairs of lateral diverticula corresponding to these somites.

Of these diverticula the anterior two or three pairs are small; the remainder increase gradually in size from before backwards; and the hindmost pair are much larger than any of the others, extending

backwards through several somites, and lying alongside the intestine.

The crop and its diverticula have their walls thrown into very numerous folds, projecting internally.

Slit up the crop along the mid-dorsal line, wash out its contents thoroughly, and pass a seeker into the several diverticula of one side, slitting them open along their whole length.

6. The **stomach** is a small spherical slightly bilobed dilatation immediately behind the crop, lying between the basal portions of the backwardly directed last pair of diverticula, and opening behind into the intestine.

7. The **intestine** is a narrow straight tube running from the stomach to the anus. Its inner wall projects as a spiral fold into the cavity.

Slit open the intestine with scissors along the mid-dorsal line; wash it thoroughly, and note the spiral folding of its wall.

B. The Cœlom and the Blood-vessels.

In the leech there is no obvious body-cavity, the space between the integument and the alimentary canal being filled up by muscle, connective tissue, and other structures.

A complicated system of tubular channels runs through all parts of the body, and is filled with a red fluid, the blood, which contains numerous colourless corpuscles. The principal channels are of two kinds, some having muscular, others non-muscular walls. The former are regarded as the true **blood-vessels**, and the latter, which may be termed **sinuses**, as parts of the body-cavity or cœlom, which is in some kinds of leeches more extensive, but is in *Hirudo* reduced to a system of canals which have acquired communications with the blood-vessels.

The arrangement and relations of these vessels and sinuses are best determined by the microscopical examination of sections, and will be described later on: the broad features,

most of which can be made out without difficulty by dissection, are as follows :

1. The **Sinuses**, or parts of the cœlom.

- a. The **dorsal sinus** is a longitudinal tube running along the dorsal surface of the whole length of the alimentary canal. It communicates posteriorly with the ventral sinus by fine vessels which pass between the intestine and the terminal diverticula of the crop. It has already been seen (p. 42).

Dissect away the alimentary tract completely, from the œsophagus backwards, taking great care not to damage the underlying organs. The further dissection is greatly facilitated by putting the leech into strong spirit for ten minutes or so.

- b. The **ventral sinus** is a median tube running along the body beneath the alimentary canal. Within it the ventral nerve-chain lies. It communicates with a series of **peri-nephrostomial sinuses**, lying on the dorsal surfaces of the testes; and also with the capillary system on the walls of the crop.

2. The **Blood-vessels**.

- a. The **lateral blood-vessels** are a pair of longitudinal vessels running in a sinuous course along the sides of the body. They are connected together by transverse vessels which pass across beneath the ventral sinus. They send branches to the intestine, the nephridia, and the reproductive organs.
- b. The **cutaneous plexuses** are very abundant, and connect the sinuses and blood-vessels in various places, putting them in free communication with one another. Their microscopical characters will be described later on.

C. The Excretory System.

The excretory organs of the leech consist of a series of seventeen pairs of **nephridia** or **segmental organs**, lying in the somites from the second to the eighteenth inclusive. They lie at the sides of and below the alimentary canal, and open to the exterior by paired apertures on the ventral surface.

1. Structure of a nephridium (figs. 21 and 22).

Each nephridium is a cellular rod, thicker in the middle than at the ends, and bent on itself so as to form a loop, the two limbs of which are anterior and posterior respectively. The looped portion lies at the side of the alimentary canal, extending up into the dorsal part of the body: the ends lie in the ventral region, that of the anterior limb being in most cases prolonged inwards almost to the median plane, and that of the posterior limb being rolled up on itself. From the anterior limb a duct runs back to a vesicle with muscular walls, which opens to the exterior on the ventral surface of the body.

The cellular rod is traversed by a complicated system of ducts, which perforate the individual cells, and receive minute ductules ramifying in the substance of the cells.

The whole nephridium is invested by a pigmented connective-tissue capsule, and receives a very abundant supply of blood from branches of the lateral vessels, the efferent stream passing inwards through the peri-nephrostomial sinus to the ventral sinus.

Dissect carefully one of the nephridia about the middle of the body, noting its several parts, and their relations to one another and to other organs.

Remove another nephridium from the body, and dissect it on a slide in a drop of water: examine it with low and high powers of the microscope.

Snip off with fine scissors the dorsal half of one of the testes, with the testis-lobe of the nephridium: mount it on a

slide in a drop of water, and examine with low and high powers.

The entire nephridium consists of the following parts.

- a. The **testis-lobe** forms the ventral half of the anterior limb of the loop. It is a cylindrical rod, the inner end of which lies in the peri-nephrostomial sinus on the dorsal surface of the testis. This end is slightly enlarged, and has a cauliflower-like appearance, the cells covering it being spongy and ciliated, and often depressed at their ends.

This inner end of the testis-lobe probably corresponds to the funnel-like opening of the nephridium into the body-cavity in the earth-worm (p. 68).

- b. The **main lobe** is the thickest part of the rod : it is continuous with the outer end of the testis-lobe, and forms the anterior limb, the bend, and half of the posterior limb of the loop.
- c. The **apical lobe** is separated by a slight constriction from the posterior limb of the main lobe. It runs downwards and inwards, diminishing slightly in thickness, and ends in a coiled-up extremity, the apex of which is closely attached to the junction of the testis-lobe and the main lobe.
- d. The **vesicle-duct** is a short narrow tube arising from the anterior limb of the main lobe at its junction with the testis-lobe, and running backwards beneath the apical lobe to the vesicle.
- e. The **vesicle** is a somewhat flattened sac with muscular walls : it lies behind the rest of the nephridium, and opens to the exterior by a short duct, the opening being on the ventral surface of the body and in the hindmost annulus of the somite in which the nephridium lies.

2. Microscopic structure of a nephridium (fig. 22).

Remove a nephridium from a freshly killed specimen ;

place it on a slide in a drop of 0.75 per cent. salt solution, and spread it out with needles so as to show the mutual relations of its several parts.

Remove another nephridium in the same way, and tease it slightly.

Cover the specimens and examine with low and high powers.

- a. The **testis-lobe** consists of a spongy mass of cells traversed irregularly by ductules.
- b. The **main lobe** consists of large granular cells, traversed by a very complicated system of fine branching ductules which pass across from cell to cell, and are lined by a cuticular layer.
- c. The **apical lobe** consists of cells traversed by much larger ductules, most of the cells being merely hollow cylinders placed end to end to form tubes.
- d. The **main duct** of the gland is also formed of cylindrical cells placed end to end, the passage being intracellular. It commences at the apex of the apical lobe, passes back along this lobe and along the posterior and anterior limbs of the main lobe, enters the apical lobe again, and goes right round the loop a second time, and then passes as the vesicle-duct to the vesicle.
- e. The **vesicle**, which is extremely dilatable, possesses a muscular coat, and is lined by a ciliated epithelium, as is also the short passage leading from it to the exterior.
- f. The **blood-vessels** form a very fine capillary plexus lying between the individual cells of the nephridium.

3. Special characters of the nephridia.

- a. The nephridia in the second to the seventh somites, in which there are no testes, have the testis-lobe short or absent, and devoid of the cauliflower-

like end. These anterior nephridia are smaller than the succeeding ones.

- b. From the eighth to the sixteenth somites, *i.e.* those in which the testes are situated, the nephridia have the characters detailed above.
- c. The two hindmost pairs of nephridia, in the seventeenth and eighteenth somites respectively, have well-developed testis-lobes, with cauliflower heads lying in peri-nephrostomial sinuses.

D. The Reproductive System.

Leeches are hermaphrodite, but do not impregnate their own ova.

1. The male organs.

- a. The **testes** are nine pairs of spherical sacs lying in the somites from the eighth to the sixteenth inclusive. They are situated in the ventral region of the body at the sides of the ventral sinus. Each pair lies mainly in the second, but partly in the first annulus of the somite in which it occurs.

The segmental repetition of the testes is noteworthy. Sometimes a tenth and even an eleventh pair of testes may be present, and occasionally the numbers are unequal on the two sides of the body.

Remove one of the testes, and tease it on a slide in salt solution. Cover, and examine with low and high powers.

Spermatozoa in various stages of development will be seen.

- b. The **vasa efferentia** are a series of short sinuous ducts which run outwards from the testes, and open into the vasa deferentia.
- c. The **vasa deferentia** are a pair of longitudinal tubes which run forwards in a sinuous course along

the ventral body-wall, about midway between the testes and the vesicles of the nephridia.

In front of the first pair of testes they continue their course through the seventh somite, and in the sixth enter the epididymes.

- d. The **epididymes** are a pair of convoluted tubular bodies with thick white walls, lying in the sixth somite. They secrete a substance by which the spermatozoa are aggregated into spermaphores. From the inner side of each a short duct leads to the base of the penis, the duct of the right side passing under the nerve-chain.
- e. The **penis** is a pyriform body lying in the sixth somite. It is wide at its base, narrow and tubular in its distal part, and can be protruded some distance through the male genital aperture in the second annulus of this somite.

2. The **female organs** lie entirely in the seventh somite.

- a. The **ovaries** are a pair of minute filamentous bodies enclosed in small spherical sacs, lying close to the mid-ventral line.
- b. The **oviducts** are a pair of slender tubes leading from the sacs of the ovaries, which unite to form a much-convoluted duct surrounded by unicellular-gland cells, and opening into the vagina. The right oviduct passes under the nerve-chain.
- c. The **vagina** is a thick-walled tube, opening to the exterior at the female genital pore in the second annulus of the seventh somite.

E. The Nervous System.

The nervous system consists of a pair of supra-oesophageal ganglia, a nerve-collar, and a double gangliated cord extending the whole length of the ventral body-wall. From the ganglia nerves run outwards to the various parts of the body.

1. The **supra-oesophageal ganglia** are a pair of closely apposed bodies in the dorsal wall of the anterior end of the pharynx, immediately behind the jaws. They supply the jaws, the eyes, and other parts of the anterior end of the body.
2. The **nerve-collar** is very small, and closely surrounds the anterior end of the pharynx.
3. The **ventral nerve-chain** lies in the ventral sinus, which must be slit open to expose it. It consists of two halves very closely apposed in the median plane. There are twenty-three pairs of ganglia, lying in the first annuli of their respective somites. The successive pairs of ganglia are much closer together at the two ends of the body than they are along the middle portion of its length.

The first, or **sub-oesophageal ganglia**, are really multiple, and give off five pairs of nerves.

The last, or twenty-third, are also multiple, and give several branches to the posterior sucker.

From each of the other pairs of ganglia two pairs of nerves are given off, supplying the corresponding somite.

F. Sense Organs.

1. **Eyes.** The leech has ten eyes, seen as minute black dots, arranged round the dorsal edge of the anterior sucker. Each consists of a pigmented cup, filled with rod-like bodies, and receiving a nerve at its base. The eyes differ very little from smaller cup-like segmental sense-organs found on the first annulus of each segment throughout the body. Their structure can only be made out by examination of microscopical sections.

III. EXAMINATION OF TRANSVERSE SECTIONS.

Many points in the anatomy of the leech can only be determined by examination of microscopical preparations,

and for this purpose transverse sections of the body are the most instructive. Of these half a dozen or more should be examined, as the appearances will necessarily differ according to the particular organs and parts through which the section happens to pass.

The following description is a general one, and will apply to any section through the middle region of the body.

A. Shape.

A transverse section of the body of a leech is oval in outline, the transverse diameter being the greater, and the ventral surface being flatter than the dorsal.

B. The Integument.

1. The **cuticle**. The most superficial layer is a thin structureless elastic cuticle, which is secreted by the underlying epidermis, and is shed and renewed at frequent intervals during life.

2. The **epidermis** consists of a single layer of columnar nucleated cells, wider at their outer than at their inner ends.

- a. The **epidermal glands**. Certain of the epidermal cells are modified to form unicellular glands. These may remain in the epidermal layer as **mucous glands**, or they may sink down into the muscular layers, as in the case of the **salivary glands**, and of the **clitellar glands** of the fifth to the seventh somites, which latter secrete the cocoon in which the eggs are laid.

In all cases each cell is a complete gland in itself, and preserves its communication with the surface by means of a long slender ductule.

3. The **dermis** is a layer of some thickness lying between the epidermis and the muscular coats. It consists of a jelly-like matrix containing numerous branched corpuscles. It is traversed by pigmented fibres, which branch and anastomose very freely, and penetrate between the epidermal cells: to these the colour

of the skin is due. There are also in the dermis irregularly arranged muscle-fibres, chiefly transverse in direction, and a very abundant capillary plexus, the branches of which penetrate between the inner ends of the epidermal cells. It is by means of this cutaneous capillary system that respiration is effected.

C. The Muscles.

The muscles of the leech consist of long fusiform cells arranged either singly or in bundles. Each muscle-cell consists of an outer cortical layer which is striated longitudinally, and a central medullary portion composed of granular protoplasm and containing the nucleus. The cortical layer is sharply marked off from the medullary portion, so that in a transverse section of a muscle-cell it appears as a ring, radially striated, and surrounding a central finely granular mass.

1. The **outer or circular layer of muscles** consists of fibres, which encircle the body transversely. The layer itself is not much thicker than the epidermis, but the transverse muscles of the dermis should, perhaps, be grouped with it.
2. The **middle or oblique layer of muscles** is more deeply placed, and is separated from the circular layer by a stratum of connective tissue. The fibres run obliquely round the body.

FIG. 22.—*Hirudo medicinalis*. A diagrammatic transverse section through the middle of the body. On the left side of the figure the whole of a nephridium is drawn, in order to show its relations: the anterior surface of the section is towards the spectator, and the two limbs of the main lobe of the nephridium are slightly displaced, being represented as inner and outer, instead of anterior and posterior respectively. (A. M. M.)

A, crop. AL, apical lobe of nephridium. AM, anterior limb of main lobe of nephridium. B, right diverticulum of crop. C, left diverticulum of crop. CU, cuticle. D, epidermis. DS, dorsal sinus. E, layer of circular and oblique muscles. F, longitudinal muscle-layer. G, cauliflower head of nephridium. I, vesicle of nephridium. K, external aperture of nephridium. LV, lateral vessel. N, nerve-cord. O, testis with developing spermatozoa. P, vas deferens. PM, posterior limb of main lobe of nephridium. PS, perinephrostomial sinus. R, section of nephridium. S, intracellular ductules of nephridium. TL, testis-lobe of nephridium. VS, ventral sinus. X, botryoidal tissue. Y, dorso-ventral muscles.

3. The inner or longitudinal layer of muscles lies immediately within the oblique layer, and is by far the thickest of the three layers.

The fibres run longitudinally, and are therefore seen in transverse section. They are arranged in bundles, and have a very characteristic appearance, looking, for the reason noticed above, like rings of various sizes packed together in groups, and usually more or less polygonal from mutual pressure. Each ring is really a transverse section of a single muscle-cell.

4. The dorso-ventral muscles are bundles of muscle-fibres crossing the body more or less obliquely from the dorsal to the ventral surface. They pass between the bundles of longitudinal muscles and through the oblique and circular layers, their ends spreading out just beneath the epidermis.

D. The Alimentary Canal.

A section across the middle portion of the body will cut the crop, of which the median portion and the lateral diverticula will in most sections appear separate from each other.

The walls consist of an outer connective-tissue layer with a few muscular fibres, and an inner lining formed of a single layer of short columnar epithelial cells. The folds into which the inner surface is thrown involve the connective-tissue layer as well as the epithelium.

E. The Blood-vessels and Sinuses.

These two systems, corresponding to the vascular and coelomic systems of higher animals, are in free communication with each other. They are readily recognised in sections, owing to the deeply staining clotted blood with which they are filled.

1. The dorsal and ventral sinuses lie in the median plane, above and below the crop respectively. They have thin non-muscular walls, and the ventral one encloses the nerve-chain.

2. The **peri-nephrostomial sinuses** are easily recognised in sections which pass through the testes, on the dorsal surfaces of which they lie.
3. The **lateral vessels** are large and have distinct muscular walls.
4. The **capillaries** are very thin-walled tubes, the distribution of which can easily be followed owing to the contained blood. The intercellular plexuses of the epidermis and of the nephridia should be specially noticed.

The capillaries are directly continuous in various parts of the body with brown pigmented fibres, similar to those of the dermis already described.

5. The **botryoidal tissue** consists of a network of vessels, the channels of which are irregular in width and the walls formed of large granular pigmented cells which project as irregular rounded swellings.

These curiously swollen vessels occur in great abundance around the crop, immediately within the longitudinal muscle-layer. They are in free communication with the ordinary blood-capillaries.

F. The Excretory Organs.

The nephridia have already been fully described. The details of their structure, and more especially the intracellular network of ductules, and the intercellular capillary plexuses, can be readily made out in transverse sections, and should be carefully studied. The structural differences in various parts of the organ should be noted, and particularly the head of the testis-lobe, which lies in the peri-nephrostomial sinus.

G. The Reproductive Organs.

1. The **testes** are seen, if the section happens to pass through them, as spherical sacs lying at the sides of the ventral sinus, and containing groups of spermatozoa in various stages of development.

2. The **vasa deferentia** lie to the outer sides of the testes : each is a thick-walled tube, with a small central lumen.

H. The Nervous System.

The nerve-chain lies in the ventral sinus, and is readily recognised. Its double character is very obvious in transverse section, and if the section passes through a ganglion the large pyriform nerve-cells can be well seen. Between and below the two halves of the ventral chain lies a slender longitudinal nerve, the **intermediary nerve**.

CHAPTER V.

THE EARTHWORM. *Lumbricus herculeus*.

THE earthworm lives in burrows in moist earth, through which it makes its way by alternate elongation and contraction of its body, aided by small stiff setæ projecting from its surface.

It is a pinkish worm about six inches long, cylindrical in front, flattened posteriorly. Its food consists of organic matter derived chiefly from the soil, which it swallows in enormous quantities. The worm is hermaphrodite, and lays its eggs in a chitinous cocoon, which also contains packets of spermatozoa and an albuminous fluid.

The body is marked by transverse grooves dividing it into annuli, of which there are about one hundred and fifty. This external annulation corresponds with an internal segmentation, the body-cavity being divided into chambers by transverse septa, which are placed opposite the external grooves. Nearly all the organs exhibit a corresponding segmental arrangement, there being one pair of nephridia and one nerve-ganglion in each segment or somite throughout the greater part of the animal's length, the blood-vessels, muscles, and setæ being also disposed segmentally.

Two closely allied genera of earthworms, *Lumbricus* and *Allolobophora*, occur commonly in this country, each represented by several species.

The several species differ from one another in the position and arrangement of certain of the reproductive organs, and in other minor points. The following description, taken from *Lumbricus herculeus*, the largest of the commoner species,

will however apply with but slight alterations to any of the others.

The worm is most conveniently killed by dropping it into chloroform for a few minutes before dissection.

I. EXTERNAL CHARACTERS.

1. **Form.** The body is cylindrical along the greater part of its length, flattened in its hinder part. It is pointed in front, blunt behind, and is thickest about one-third of its length from the anterior end.
2. **Colour.** The earthworm is of a pale pinkish or yellowish colour, replaced in front by a dark purplish brown, which extends a considerable distance backwards as a mid-dorsal stripe. The hinder end is also tinged with brown. The dorsal blood-vessel can be seen through the integument, appearing as a dark-coloured wavy line along the dorsal surface.
3. The **annuli**, into which the body is divided externally by transverse grooves, are larger and more obvious in front than behind. Each annulus corresponds to a segment, and is subdivided by smaller grooves, the number of which varies in different regions of the body, and also on the dorsal and ventral surfaces.
4. The **prostomium**, or cephalic lobe, is the rounded lobe forming the extreme anterior end of the worm. In *Lumbricus* it extends backwards on the dorsal surface so as to completely intersect the first annulus and meet the second. In *Allolobophora* it extends about halfway through the first annulus.
5. The **clitellum**, or **cingulum**, is the thickened integument of the dorsal and lateral surfaces of the thirty-second and five following segments, but varies slightly both in position and extent in different specimens and at different times of the year. In other species of earthworm it occupies other segments.

6. The **cuticle** is a delicate chitinous membrane investing the whole body of the worm. It may usually be detected by its iridescence, and can be readily stripped off a worm which has been killed by chloroform, or one which has been macerated a few hours in water.

Examined microscopically it shows a series of oblique lines, intersecting each other at right angles, and minute highly refractive thickenings at many of the points where the lines intersect.

7. The **setæ** are short chitinous spines implanted in the body-wall, and arranged in two double rows along each side of the body, each segment, except the first and last, bearing four pairs. They may be felt on drawing the worm through the fingers from head to tail. The setæ are to be regarded as special localised thickenings of the cuticle.

The setæ are easily isolated by boiling a bit of a worm in a solution of caustic potash : they should then be washed and mounted in glycerine, or dried and mounted in balsam.

Each seta is sigmoidally curved : it is thickest at its middle, and tapers towards each end.

8. External apertures.

- a. The **mouth** is a small crescentic aperture on the ventral surface of the first segment. It is overhung by the **prostomium**.
- b. The **anus** is an oval aperture at the hinder end of the body.
- c. The **genital apertures** are four pairs.
 - i. The **apertures of the vasa deferentia** are situated on the ventral surface of the fifteenth segment, one on each side, slightly to the outer side of the inner double row of setæ. They are transverse slits, with tumid lips.
 - ii. The **apertures of the oviducts** are similarly situated in the fourteenth segment. They are

small pores not seen so easily as the male apertures, their lips not being tumid.

iii. The **apertures of the spermothecae or receptacula seminis**, of which there are two pairs, are situated in the grooves between the segments and in the line of the outer row of setæ, the first pair between segments ix. and x., the posterior pair between segments x. and xi.

d. The **excretory apertures** are best seen in a specimen which has been hardened in spirit, and dried with a cloth immediately before examination. Each segment, except the first three and the last, has one on each side, either on the ventral surface a little in front of the outer seta of the inner double row, or, in some segments, high up on the side of the animal.

To see these apertures, strip off the cuticle from the anterior part of the worm, and examine the worm with a pocket lens, squeezing it slightly so as to cause fluid to exude from the apertures.

e. The **dorsal pores**, though small, are often visible to the naked eye. They open mid-dorsally in the grooves between the segments, and place the cœlom in communication with the exterior.

The first one is between segments x. and xi. and opens into segment xi. Behind this point they occur regularly in every intersegmental groove.

II. DISSECTION OF THE EARTHWORM.

Extend the animal under water with the dorsal surface upwards, fixing it down by two pins through the sides of the fourth segment and two near the hinder end. Cut through the body-wall from end to end, close to the mid-dorsal line. Gently raise the flaps with the forceps, and note the trans-

verse septa dividing the body-cavity into segments. Carefully pin out the flaps right and left with fine pins, stretching them well as you do so.

It will save much time in determining the positions of some of the important organs if the pins are placed in definite segments; say the tenth, fifteenth, and twentieth.

A. The Cœlom.

The **cœlom**, or body-cavity, is a large space, within which the alimentary canal and other viscera lie. It is divided into segments by transverse septa, which connect the alimentary canal with the body-wall. The **septa** correspond to the external annuli throughout the whole length of the body, except in two regions: (1) in front of the fourth segment, where they are absent; (2) in the region of the gizzard, where they are slightly irregular in arrangement. The cœlom contains a fluid with numerous amœboid corpuscles.

B. The Digestive System.

The **alimentary canal** is a straight tube running from the mouth to the anus, and is divisible into the following regions.

1. The **buccal cavity** is small, and is situated in the first three segments. The opening of the mouth in the ventral part of the first segment has soft lips and no teeth.
2. The **pharynx**, which follows the buccal cavity, has thick muscular walls connected with the body-wall by strands of muscle which run obliquely backwards, perforating the anterior septa. The pharynx extends backwards about as far as the sixth or seventh annulus when the animal is in an average condition of extension; but it lies entirely in front of the septum dividing the fifth segment from the sixth (fig. 23).
3. The **œsophagus** is a straight tube extending from the pharynx to the thirteenth or fourteenth segment. When the animal is not fully extended the

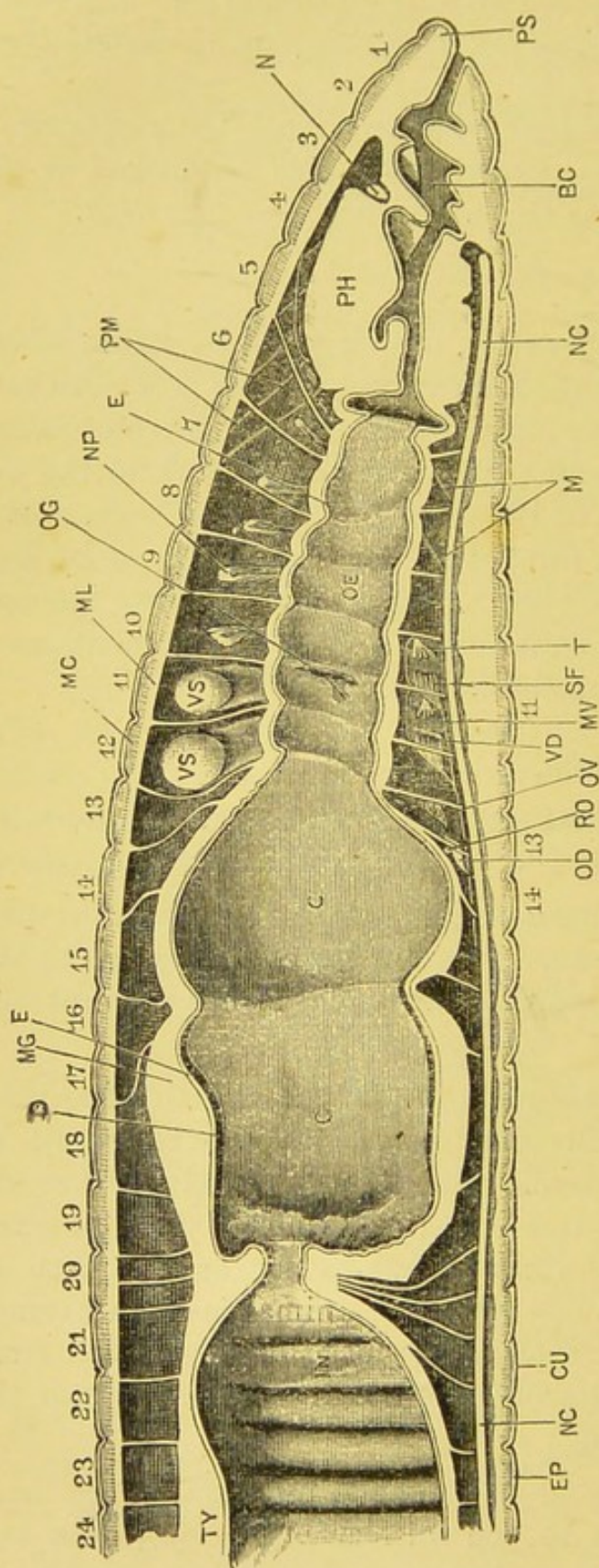


FIG. 23.—*Lumbricus herculeus*. Longitudinal vertical section through the anterior portion of the animal. (C. H. H.)

BC, buccal cavity. C, crop. CU, cuticle. D, thickened cuticle of gizzard. E, epithelium of alimentary canal. EP, epidermis. G, gizzard. IN, intestine. M, retractor muscles of the anterior part of the oesophagus. MC, circular muscles of body-wall. MG, muscular wall of gizzard. ML, longitudinal muscles of body-wall. MV, posterior median vesicula seminalis. N, dorsal portion of nerve-collar cut across. NC, ventral nerve-chain. NP, nephridium. OD, oviduct. OE, oesophagus. OG, aperture of oesophageal pouch: the passage runs forwards as indicated by the arrow. OV, ovary. PH, pharynx. PM, retractor muscles of pharynx. PS, prostomium. RO, receptaculum ovarum. SF, seminal funnel, the expanded mouth of the vas efferens. T, anterior testis. TY, typhlosole. VD, vas deferens. VS, posterior lateral vesiculae seminales. 1-24, the first twenty-four segments.

œsophagus appears dilated in each segment, and constricted where it perforates the septa.

- a. The **œsophageal pouches** are a pair of short lateral diverticula of the œsophagus lying in segment x., and opening into the œsophagus at the anterior end of segment xi. At certain seasons they contain concretions of more or less crystalline calcareous matter, chiefly calcium carbonate.

To see these œsophageal pouches, press aside the large white vesiculæ seminales which hide them.

- b. The **œsophageal glands** are two pairs of lateral protuberances on the sides of the œsophagus in segments xi. and xii. They are hollow, and their cavities, which are subdivided by a large number of horizontal lamellæ, contain a milky calcareous fluid. They are local thickenings of the glandular walls of the œsophagus, and their numerous cavities open into the œsophageal pouches.
4. The **crop** is a large dilated portion of the alimentary canal in segments xiii. to xvi., but when filled it encroaches upon the segments in front, pushing the septa before it (fig. 23).
5. The **gizzard** extends from the sixteenth segment backwards to about the twentieth. Its walls are very thick and muscular, and it has a thick chitinous lining.
6. The **intestine** is a thin-walled sacculated tube running straight backwards from the gizzard to the anus.
 - a. The 'hepatic cells' are a layer of yellow peritoneal cells surrounding the intestine and in close relation with the blood-vessels.

Cut the intestine open along one side, and wash out its contents.

- b. The **typhlosole** is a prominent median longitudinal ridge projecting into the cavity of the intestine

from its dorsal wall, of which it is a fold. Its surface is marked by transverse folds.

C. The Circulatory System.

The blood is a fluid coloured bright red by hæmoglobin and containing colourless corpuscles. Several of the larger vessels contract rhythmically, and especially the five pairs of 'hearts.'

For the dissection of the circulatory system a fresh worm should be taken. Owing to the dark red colour of the contained blood the vessels can be easily traced. The animal should be killed with chloroform.

1. The **dorsal vessel** is a large median vessel running along the dorsal surface of the alimentary canal throughout its whole length, and dividing in front into branches which ramify over the pharynx. It can be seen through the skin in the living animal, and the flow of blood in it is from behind forwards.

A large **lateral œsophageal vessel** runs along each side of the œsophagus, and communicates with the dorsal vessel in the tenth segment. Branches of it ramify over the pharynx and over the œsophageal glands and pouches.

From the alimentary canal the blood is returned to the dorsal vessel by **intestinal vessels**, of which there are in the region of the intestine two pairs to each segment, and which are surrounded by the 'hepatic cells.'

2. The **ventral vessel** is a median vessel running backwards below the alimentary canal the whole length of the animal: in it the blood flows backwards.
3. The '**hearts**' are five pairs of large vessels lying in segments VII. to XI., and connecting the dorsal with the ventral vessel. During life they are rhythmically contractile, the contractions passing along them from above downwards, commencing with the hindmost

pair, and driving the blood from the dorsal to the ventral vessel. In the fresh state each has frequently a moniliform appearance.

4. **Neural vessels.** These are smaller longitudinal vessels in close relation with the nerve-cord which runs along the floor of the body-cavity in the mid-ventral line (see p. 79).
 - a. The **subneural vessel** is median, and lies immediately beneath the nerve-cord along its whole length.
 - b. The **lateral neural vessels** are a pair of smaller longitudinal vessels lying along the sides of the nerve-cord.
5. The **nephridial vessels** supply the nephridia or excretory organs (see p. 68).
 - a. The **afferent nephridial vessels** arise from the ventral vessel, one pair in each segment, and run outwards to the nephridia, supplying all three loops.
 - b. The **efferent nephridial vessels** return the blood from the nephridia to the parietal vessels.
6. The **parietal vessels.** In each segment the subneural and dorsal vessels are connected by a pair of parietal vessels, which run on the inner surface of the body-wall, and receive smaller vessels from it.

D. The Excretory System.

This consists of a series of tubular **nephridia** or 'segmental organs,' arranged in pairs corresponding to the segments along the whole length of the animal, excepting the first three and the last segments, from which they are absent. They are largest in the region of the œsophagus.

Each nephridium is a long tube thrown into loops, which are closely applied together and suspended in the body-cavity close to its wall. The tube commences with a minute ciliated mouth—the **nephrostome**—opening into the body-cavity; then

follows a long and very slender portion, to which succeeds a shorter and wider part; the terminal portion is still wider and has muscular walls, and opens distally to the exterior at the aperture already seen on the surface.

1. **Examination of a nephridium *in situ*** (fig. 25).

Remove an inch or so of the intestine, so as to expose the nephridia fully. Wash gently under the tap, and then examine with a pocket lens or dissecting microscope.

The nephridia are seen as opaque white loops lying along the inner surface of the body-wall, and extending from near the mid-ventral line almost to the mid-dorsal line. Each is in relation with two segments, the funnel and a very short length of the tube lying in the anterior of the two, and the rest of the tube with the external opening in the posterior.

Examine one of the nephridia more closely, noting its parts.

- a. The **nephrostome** is a minute funnel lying in the body-cavity close to the mid-ventral line, and connected by a short stalk—the first part of the nephridial tube—with the septum behind it.
- b. The **looped portion of the tube** lies in the segment behind that containing the funnel. Three loops can easily be made out, of which the middle one is the longest and reaches almost to the mid-dorsal line; while the outer one is the widest and leads to the external aperture.

The three loops may be conveniently distinguished (see fig. 25) as the **long loop**, the **short loop**, and the **terminal loop** respectively.

The terminal portion always enters the body-wall at about the level of the outer seta of the inner double row. The external pore is connected with it, in those segments in which it opens dorsally, by a channel in the body-wall.

2. Microscopical structure of a nephridium.

Carefully remove by fine pointed forceps, an entire nephridium with a very small part of the septum which it traverses. If the worm has been killed with chloroform, the ciliated portions of the nephridium may be still working. Examine in salt solution.

Examine with low and high powers.

- a. The funnel is ciliated, its border consisting of a row of large cells with very distinct nuclei. The **nephrostome** or open mouth of the funnel can be easily seen: it is often partially blocked up by a small mass of coelomic corpuscles.
- b. The first part of the tube, or '**narrow tube**,' is very slender and its relations are difficult to determine. Starting from the funnel it runs straight back through the septum into the posterior of the two segments with which the nephridium is connected. In this segment it runs in a somewhat irregular course along both limbs of the short loop, and along the proximal limb of the long loop, it then bends back sharply on itself, and returns, following the same path, to the base of the short loop, where it passes into the second part of the tube. The duct of the '**narrow tube**' is an intracellular one, traversing the individual cells, which are placed end to end like drain-pipes. The '**narrow tube**' is ciliated along part, but not the whole of its length.
- c. The second part of the tube, or '**middle tube**,' forms the proximal limb of the long loop. The duct is here also an intracellular one: it is much wider than that of the '**narrow tube**,' and is ciliated along its whole length.
- d. The third part of the tube, or '**wide tube**,' commences with a dilated portion of the **ampulla**, at the apex or bend of the long loop: beyond this

it forms the distal limb of the long loop, both limbs of the short loop, and a portion of the proximal limb of the terminal loop. The duct in this portion of the tube is wide, intracellular, and non-ciliated; and its walls consist of very granular protoplasm.

- e. The fourth part of the tube, or 'bladder,' forms part of the proximal, and the whole of the distal limb of the terminal loop. It is much wider than the rest of the tube; it is lined by epithelium; and its walls, which are non-glandular, contain interlacing muscular fibres. The 'bladder' opens to the exterior by the aperture already seen. (See pages 62 and 68.)

E. The Reproductive System.

The earthworm is hermaphrodite. The reproductive organs are lodged in segments ix. to xv., *i.e.* in the region of the œsophagus.

1. The female organs consist of a pair of ovaries; a pair of oviducts, with a receptaculum ovarum opening into each; and two pairs of spermathecae.

- a. The ovaries, which lie in segment xiii., are a pair of small white pyriform bodies attached to the septum forming the anterior wall of the segment, and hanging freely from it into the coelom below the œsophagus.

To see the ovaries and oviducts stretch the body-wall transversely and longitudinally, and look for them with a hand lens.

- b. The oviducts are a pair of short tubes, the wide mouths of which are placed in the hinder part of segment xiii., one opposite each ovary.

From the points where they perforate the septum, the oviducts run outwards and slightly backwards to their external openings on the ventral surface of segment xiv.

- c. The receptacula ovarum are a pair of reniform sacs, attached to the anterior wall of segment XIV. just above the oviducts, into the upper part of the funnel-like mouths of which they open.
- d. The spermothecæ or receptacula seminis are two

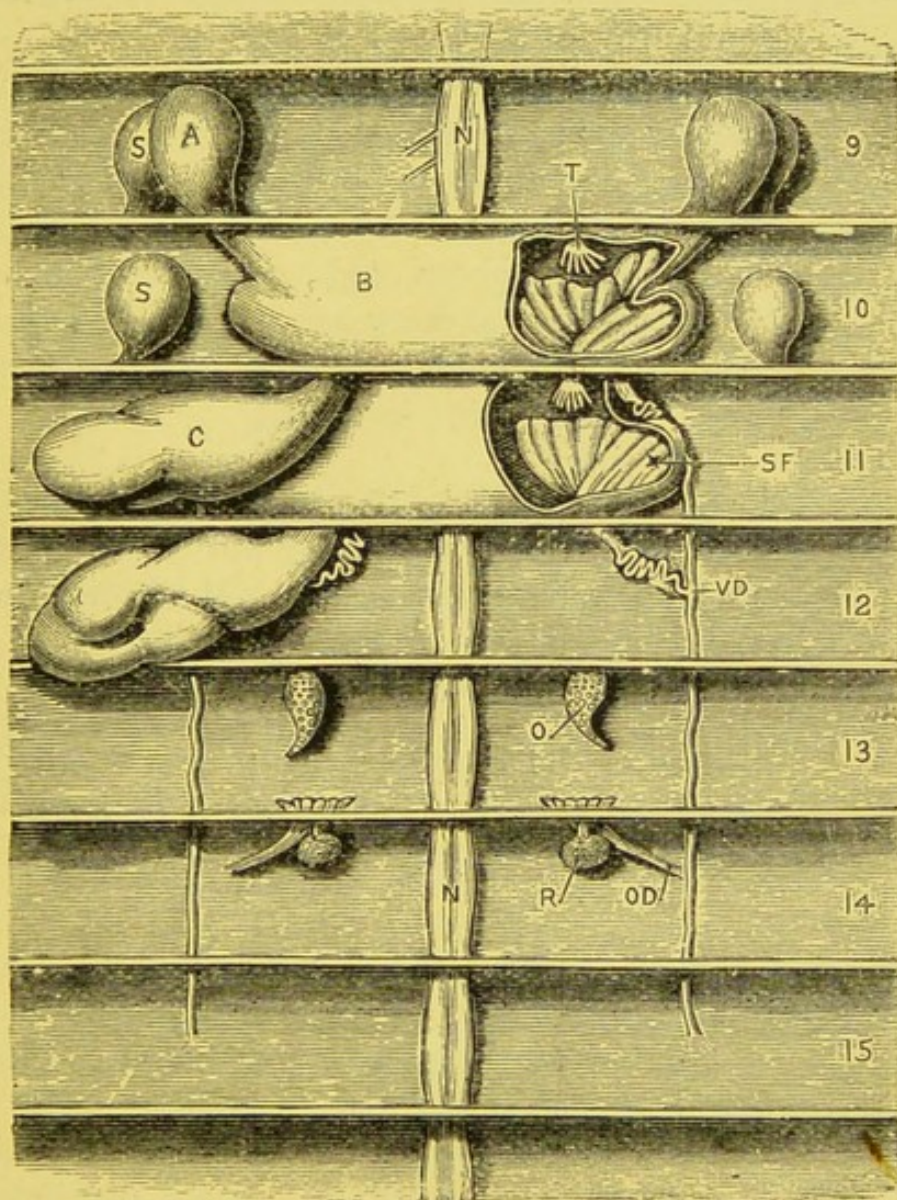


FIG. 24.—*Lumbricus herculeus*. Plan of the reproductive organs as seen from above after removal of the alimentary canal. The body-wall is pinned down flat. (C. H. H.)

A, anterior lateral vesicula seminalis. B, first median vesicula seminalis. C, posterior lateral vesicula seminalis. N, nerve-cord. O, ovary. OD, oviduct. R, receptaculum ovarum. S, spermotheca. SF, seminal funnel lying in the median vesicula seminalis. T, testis. VD, vas deferens: the reference line indicates the point where the posterior vas efferens opens into it. 9 to 15, ninth to fifteenth segments.

pairs of globular sacs lying in the hinder parts of segments ix. and x. respectively. Their ducts, which are short, run backwards and open to the exterior in the grooves between the ninth and tenth, and the tenth and eleventh segments, respectively, just within the line of the outer double row of setæ.

In these the seminal fluid received from another worm is stored, and from them it is poured out into the egg-case or cocoon in which the eggs are laid.

In *Allolobophora*, and exceptionally in *Lumbricus*, the spermothecae are situated in segments x. and xi., their ducts passing forwards to open in the same position as above.

2. The male organs consist of two pairs of testes; two pairs of seminal funnels, leading into a pair of vasa deferentia; and median and lateral vesiculæ seminales.
 - a. The vesiculæ seminales vary greatly in form and size with the season of the year. When fully developed they form conspicuous milk-white or pinkish bodies at the sides of the œsophagus, and overlapping this.
 - i. A pair of anterior lateral vesiculæ seminales lie in segment ix. They are opaque white bodies attached to the posterior wall of the segment, one at each side of the œsophagus.

Some earthworms have a similar pair in segment x., but these are not developed in *Lumbricus*.
 - ii. Two pairs of posterior lateral vesiculæ seminales lie in segments xi. and xii. respectively. They are very much larger than the anterior vesiculæ, especially at certain seasons, and are attached to the anterior septa of their respective segments

somewhat nearer the median plane than the anterior vesiculæ.

- iii. A thin-roofed **median vesicula seminalis**, of considerable size, is situated in each of the segments x. and xi. below the œsophagus, which must be removed to expose them. Within each are a pair of **testes** and a pair of **seminal funnels**. With the anterior of these median vesiculæ the anterior lateral vesiculæ and the first pair of posterior lateral vesiculæ communicate. The second pair of posterior lateral vesiculæ open in similar fashion into the second median vesicula.

The median vesiculæ are absent in *Allolobophora*.

- b. The **testes** are two pairs of small flattened digitate bodies, attached to the septa in front of segments x. and xi. respectively, and projecting freely into the cavities of the median vesiculæ seminales, not far from the nerve-cord.

To see the testes, open the two median vesiculæ seminales without injuring the structures within them. Wash carefully.

- c. The **seminal funnels** are large opaque white much-folded membranous funnels, of which one pair is situated in each median vesicula seminalis, the open mouth being turned towards the testes, and almost enclosing them. Their narrow ends perforate the hinder septa of their respective segments (x. and xi.), and are continuous with the vasa efferentia.
- d. The **vasa deferentia**. From the posterior end of each seminal funnel a fine convoluted tube, the **vas efferens**, runs outwards and backwards on the ventral body-wall. The two vasa efferentia of each side unite in segment xii., and the vasa deferentia so formed run back to open to the

exterior by the apertures already seen on the ventral surface of segment xv. The vasa deferentia are slightly imbedded in the body-wall, and their exposure requires care.

3. Microscopical examination of the reproductive organs, and of their contents.

- a. **The ovaries.** *Remove an ovary entire ; examine in salt-solution ; then stain with carmine or hæmatoxylin, dehydrate, clear, and mount in balsam.*

The proximal and thicker end of the ovary is a solid mass of cells from which the ova are formed : the distal portion contains ripe ova. Each ovum is a large cell with very distinct nucleus and nucleolus. The nucleolus is stained by carmine more deeply than the rest of the cell.

- b. **The receptacula ovarum.** *Remove one and examine it as above.*

Ova may be seen in it at certain seasons.

- c. **The contents of the spermothece.** *Remove a spermothece and transfer it to a slide. Tease it in salt-solution and examine with low and high powers.*

The seminal fluid in the spermothece contains innumerable mature spermatozoa, each of which is an exceedingly fine filament with a slightly thickened rod-like head at one end.

- d. **The testes.** *Remove a testis ; stain, dehydrate and clear it, and tease it in balsam : mount another in salt-solution. Examine with a high power.*

The **spermogonia** are cells, each of which by division gives rise to **spermocytes**. Only the earliest stages of the division occur in the testes, masses of spermocytes leaving them with numerous nuclei and tuberculated surfaces.

e. The contents of the vesiculæ seminales. Cover-glass method.

1. Remove a portion of one of the vesiculæ seminales to a slide, tease with needles and dilute to three or four times its bulk with normal salt-solution.
2. By means of a pipette spread a small drop of this liquid evenly over the surface of a clean cover-glass. Invert this and hold it over the mouth of a bottle containing glacial acetic acid for several seconds in order to kill and 'fix' the cells (*i.e.* to coagulate the protoplasm of the cells).
3. Warm very gently over a flame until the preparation begins to dry. Then cover with a drop of dahlia solution (.25 per cent.) and allow to stain for three minutes.
4. By means of a pipette wash with water and mount in a drop of glycerine on a slide.
5. Examine under the microscope and draw the several stages shown.

The vesiculæ contain spermatozoa in all stages of development:—(1) the massed spermatocytes as they leave the testis; (2) a stage in which the tubercles, or **spermatids**, are more distinct and are produced outwards into filaments; (3) later stages in which the filaments are elongated to form the tails of the spermatozoa, while the bodies of the spermatids form their rod-like heads.

A part of the spermatocyte-mass remains unchanged in the centre of the mass and is called the **blastophore**.

F. The Nervous System.

This consists of a ventral cord, swollen slightly in each segment; and a pair of dorsal ganglia in front, connected with

the ventral cord by a pair of connectives running round the sides of the alimentary canal.

1. The **nerve-collar** is a small ring of nervous substance surrounding the buccal sac just in front of the pharynx, in the third segment. It consists of a pair of pyriform **supra-oesophageal ganglia**, united by their broader ends in the median plane, and sending large nerves to the prostomium; a pair of lateral connectives running round the sides of the buccal sac; and a pair of closely apposed ventral ganglia, the first pair of the ventral series.

2. The **ventral nerve-cord**.

Remove the alimentary canal, from the pharynx backwards, without injuring the nerve-collar and ventral cord.

The cord runs along the ventral body-wall in the middle line, giving off three pairs of nerves in each segment along nearly the whole length of the body. The cord is slightly swollen opposite the middle of the segments, the swellings or ganglia being more conspicuous in the hinder part of the body.

III. EXAMINATION OF TRANSVERSE SECTIONS OF THE INTESTINAL REGION.

The structure of the body-wall and alimentary canal, and many other points in the anatomy of the earthworm, are best understood from a microscopical examination of transverse sections of the whole animal.

To prepare these sections, kill a worm with the corrosive-acetic mixture; cut out about half an inch from the middle of its length, and leave this in the mixture for four hours. Wash it well, and transfer to spirit. Carefully syringe out the contents of the intestine. Stain with hæmalum; imbed; and cut into transverse sections with a microtome. Mount the sections in order.

Examine with low and high powers.

A. Shape.

The section is nearly circular in outline. The dorsal surface is indicated by the typhlosole, the ventral by the nerve-cord.

B. The Integument.

1. The cuticle is a thin structureless superficial layer, often

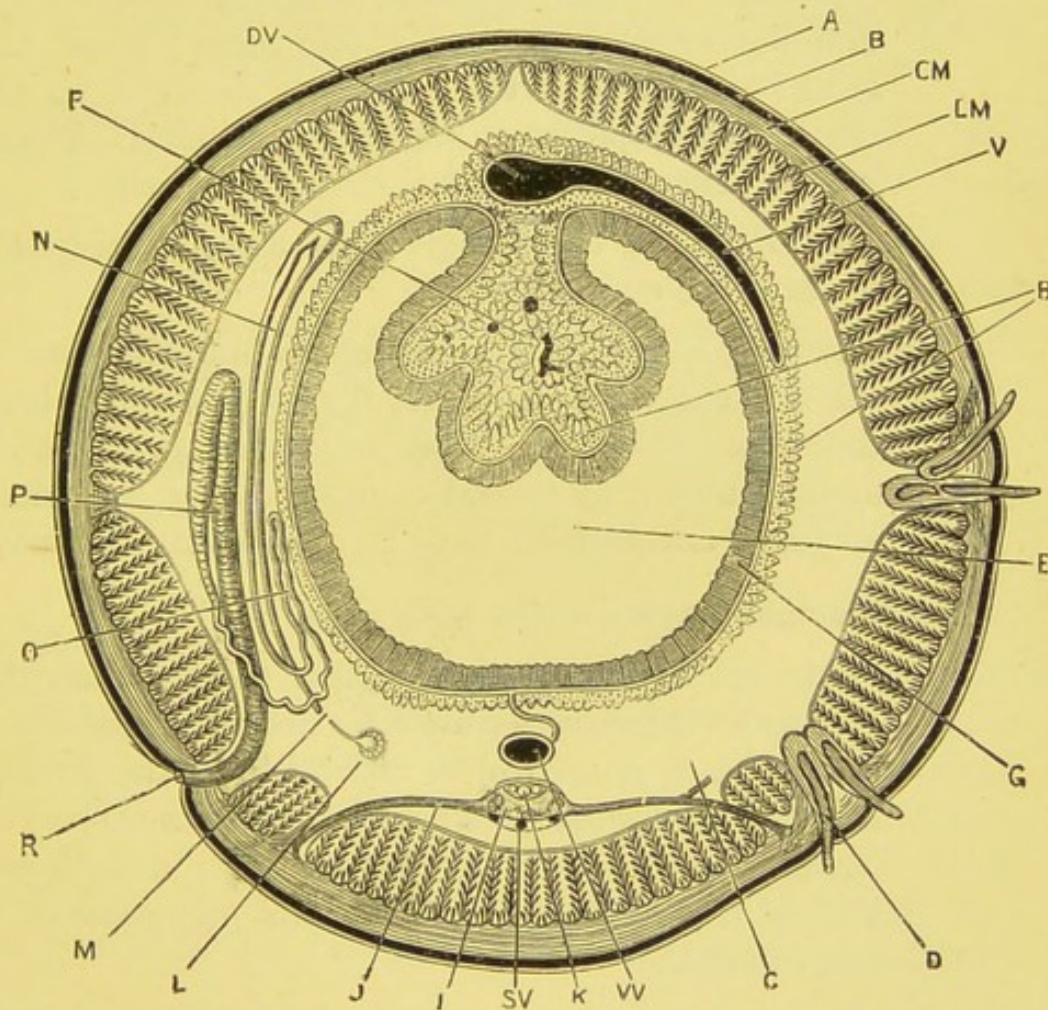


FIG. 25.—*Lumbricus*. A diagrammatic transverse section through the middle of the body. On the left side of the figure a nephridium is shown, and on the right side the setæ. The septa are not shown, and parts only of the circulatory system are represented. (A. M. M.)

A, cuticle. B, epidermis. C, coelom. CM, layer of circular muscles. D, seta. DV, dorsal vessel. E, cavity of intestine. F, typhlosole, filled with 'hepatic' cells. G, epithelium of intestine. H, 'hepatic' cells. I, ventral nerve-cord. J, nerve. K, 'giant fibres.' L, nephrostome. LM, layer of longitudinal muscles. M, the point where the nephridium perforates the septum between two segments: between the two cut ends the convoluted 'narrow tube' is intercalated, which is not shown in the figure. N, the first or long loop of the nephridium. O, the second or short loop of the nephridium. P, the third or terminal loop of the nephridium. R, external aperture of the nephridium. SV, subneural vessel. V, intestinal vessel. VV, ventral vessel.

separated by the action of the reagents from the underlying epidermis.

2. The **epidermis** lies immediately below the cuticle. It consists of a single layer of columnar cells, set side by side at right angles to the surface, with nuclei near their bases. Many of these cells have the character of 'goblet cells,' being distended by a granular secretion formed within them ; other cells lying between these are extremely slender. In the clitellum the epidermis is greatly thickened. Blood-vessels penetrate between the epidermal cells.
3. The **dermis** is an exceedingly thin layer immediately beneath the epidermis.
4. The **setæ** are lodged in sacs, which are invaginations of the skin extending deep into the body, through both the muscular layers. They are cuticular structures, and are moved by special muscles. Setæ in various stages of development may be seen within the sacs.

C. The Muscular Layers of the Body-wall.

1. The **external layer**, which is rather thicker than the epidermis, consists of transverse fibres running round the body : it is completely interrupted at the grooves between the segments. The connective tissue between the muscle-fibres is pigmented slightly : in the dorsal wall of the œsophageal region this pigmentation is very marked.
2. The **internal layer** is very much thicker than the external. It consists of longitudinal fibres, arranged on the sides of a series of radial longitudinal sheets, and having a feather-like appearance in transverse section.

D. The Cœlom, or Body-cavity.

This is the space around the intestine, between it and the body-wall. It is lined by a thin peritoneal epithelium, and contains a colourless fluid, with numerous amœboid corpuscles.

E. Intestine.

This occupies the middle of the section. Its diameter is about half that of the body of the worm.

1. The **typhlosole** is a fold of the dorsal wall extending into the intestine from above, narrowing its cavity, and making it crescentic in transverse section.
2. The **epithelium** lining the intestine consists of a single layer of columnar ciliated cells.
3. The **muscular layer** of the intestinal wall is thin. The fibres, which are nearly all transverse in direction, are imbedded in a connective-tissue layer.
4. The ' **hepatic** ' **peritoneal cells** lie outside the muscular layer around the vessels which return the blood from the intestine to the dorsal vessel. They are elongated granular cells of large size, and generally arranged radially to the surface of the intestine. They are very abundant in the cavity of the typhlosole, which they almost completely fill.

F. The Nephridia.

These lie at the sides of the alimentary canal. Their appearance in transverse sections varies greatly according to the part of the nephridium through which the section happens to pass. By reference to the description of a nephridium, on page 68, it will be fairly easy to identify the parts present in any particular section that may be examined.

G. The Septa.

Owing to their obliquity, parts of the septa are present in nearly all transverse sections, and lie in the body-cavity between the body-wall and the alimentary canal. Each septum is a thin sheet of connective tissue, in which are circular and radial muscles. The ventral edge of the septum is not attached to the body-wall near the middle line, a gap being left around the nerve-cord through which the coelomic fluid can pass from one segment to another.

H. The Nerve-cord.

This lies near the ventral surface, just within the longitudinal muscle-layer, and is enclosed in a double connective-tissue sheath, between the two layers of which is a stratum of longitudinal muscle-fibres.

In the sheath lie three longitudinal blood-vessels, a **sub-neural** below the cord, and a pair of **lateral neural vessels** at the sides. Along the dorsal surface of the cord are three 'giant-fibres' probably of nervous nature. The fibrous connective tissue of the sheath extends into the cord, dividing its fibres into two main bundles, and subdividing each of these into smaller ones. **Nerve-cells** of large size, each with distinct nucleus and nucleolus, form a layer along the whole length of the ventral and lateral surfaces of the cord: they are more abundant in the ganglionic enlargements.

I. The Blood-vessels.

These are readily recognised by the deeply stained blood-clots with which they are filled. The larger vessels have muscular walls. Besides the neural vessels just mentioned the following may be recognised:—

1. The **dorsal vessel** lies in the body-cavity above the intestine. It is of large size, and has masses of 'hepatic' cells at its sides.
2. The **intestinal vessels** lie in the walls of the intestine: they are surrounded by 'hepatic' cells, and may in some sections be seen to open into the dorsal vessel.
3. The **ventral vessel** lies between the nerve-cord and the intestine, and is connected with the latter by a median sheet of vascular connective tissue.
4. The **nephridial vessels**.
5. The **capillaries of the skin**.

CHAPTER VI.

THE FRESHWATER MUSSEL. *Anodonta cygnea*.

THE body of the mussel is enclosed in a shell, the two halves or valves of which cover the right and left sides of the body respectively. These valves, which are hinged together along the median dorsal line, can be opened to a slight extent by means of an elastic ligament along the hinge-line, and closed by powerful adductor muscles. When the valves are closed they completely conceal all parts of the body.

Mussels vary a good deal in size according to their age ; a fair-sized specimen is about four and a half inches long, one and a half thick, and two and a half from the dorsal to the ventral edge.

The mussel lives in freshwater ponds and streams, with its anterior end buried somewhat obliquely in the mud of the bottom, and the posterior end projecting up into the water. By means of a muscular foot it can plough its way slowly along the bottom of the pond. Its food consists of minute organisms, both animal and vegetable, which are swept in at the hinder end of the shell by ciliary currents and carried forwards to the mouth, the stream of water so kept up serving for respiration as well as nutrition.

The sexes are distinct. The young embryos are retained within the gills of the mother during the early stages of their development ; they then hatch and attach themselves to fish. While attached they increase considerably in size and undergo a distinct metamorphosis. Finally they detach themselves, and adopt the mode of life of the adult.

I. THE SHELL.

The shell is a cuticular product formed by the underlying epidermis. It is, therefore, entirely outside the body, and incapable of growth except by addition of new rings or new layers to the part already formed. It consists of an organic basis impregnated with calcareous salts.

A. The Outer Surface of the Shell.

1. **Shape.** The anterior end of the shell is rounded, the posterior end more pointed, and the dorsal hinge-line straight.
2. The **umbo** is the oldest part of each valve. It is close to the hinge-line, and about a quarter of the length of the shell from its anterior end.
3. The **lines of growth** are the concentric curves on the surface of the shell, marking successive stages in its growth. Each of these lines was at one time the margin of the shell.

The shell does not grow uniformly in all directions. Growth is much more rapid towards the ventral than towards the dorsal surface, and more rapid posteriorly than anteriorly: hence the umbo or oldest part is close to the dorsal edge, and nearer the anterior than the posterior end.

4. The **ligament** connects the two valves together along the mid-dorsal line: it is a median, imperfectly calcified, and elastic part of the shell itself. It is very narrow at the anterior part of the hinge-line, and much broader behind. As the valves are only kept closed by contraction of the adductor muscles, they will open as soon as these muscles relax. Hence in dead specimens the valves always gape, owing to the unopposed action of the elastic ligament.

B. The Inner Surface of the Shell.

Wedge open the valves of the shell with the handle of a

scalpel or other instrument, so that the ventral edges of the valves are about half an inch apart, and the adductor muscles can be clearly seen. Note the mantle-lobes or flaps lining the shell-valves, and with a scalpel separate the right mantle-lobe from the shell.

Identify the positions of the adductor muscles by comparison with fig. 26, and detach with a scalpel first the anterior, then the posterior adductor muscle from the right valve, keeping the edge of the knife close to the shell. As soon as this is done the valves will gape open about half or three-quarters of an inch, owing to the action of the ligament. Bend back the right valve of the shell, and remove it completely, cutting through the ligament along the hinge-line. Clean the detached valve, and examine it.

1. The **inner surface** has a white pearly appearance, except round the edge. The lines of growth are visible, but not nearly so plainly as on the outside.
2. The **hinge** is a smooth longitudinal ridge extending backwards from the umbo along the dorsal edge of the shell. When the valves are closed, the two hinges are in contact opposite the umbo, but gradually diverge from each other behind it.
3. The **ligament**, which is very strong and elastic, commences in front of the umbo, and extends back along the straight dorsal edge of the shell, being very narrow in front, but wider behind.
4. The **muscular impressions** are slight depressions in the surface of the shell at the places of attachment of the adductor and other muscles.
 - a. The **anterior adductor impression** is a large oval slightly depressed area, with its long axis vertical, close to the anterior end of the shell, and nearer the dorsal than the ventral edge.
 - b. The **anterior retractor impression** is small, and continuous with the posterior border of the anterior adductor impression.

- c. The **protractor impression** is a separate small impression, about $\frac{1}{8}$ inch behind the lower part of the anterior adductor impression.
 - d. The **posterior adductor impression** is near the dorsal edge and posterior end of the shell, below and behind the hinder end of the ligament. It is rather larger than the anterior adductor impression, and is oval in shape, with the longer axis horizontal.
 - e. The **posterior retractor impression** is small, and continuous with the upper and anterior edge of the posterior adductor impression.
 - f. The **pallial line**, or line of attachment of the mantle to the shell, runs nearly parallel to the ventral edge of the shell, and about half an inch from it. It connects the hinder border of the posterior adductor impression with the ventral edge of that of the anterior adductor.
5. The **paths of shifting of the muscles** are slight triangular depressions, converging from the margins of the several muscular impressions towards the umbo. They mark the boundaries of the paths along which the muscles have shifted during the growth of the shell. In the young state, when the umbo and the part immediately around it form the whole valve, adductor and other muscles are present in the same relative positions as in the adult: during the growth of the shell by addition of new matter round its margin the muscles gradually shift outwards, increasing in size as they do so.

C. The Structure of the Shell.

If the shell be broken across, and the edge examined with a pocket lens, it is seen to consist of three layers.

1. The **periostracum** or outer layer is thin, horny, and uncalcified. To it the brownish-green colour of

the shell is due. It is commonly, but erroneously, spoken of as the 'epidermis' of the shell.

In the growth of the shell this layer is the first to be formed, and the free edge of the shell, especially round the ventral border and the posterior end, consists of it alone. It is formed by the thickened edge of the mantle-fold.

The periostracum is reflected over the edge of the shell, and lines a narrow strip of its inner surface round the ventral border and at the two ends.

2. The **middle or prismatic layer** forms about half the thickness of the shell: it is very densely calcified, and consists of numerous polygonal prisms placed side by side, and obliquely to the surface of the shell.

Like the periostracum, it is formed by the edge of the mantle. It is visible on the outer surface of the shell at places where, as at the umbo, the periostracum has been rubbed off. It can also be seen round the margin of the shell on its inner surface.

3. The **inner, nacreous or pearly layer** lines the whole of the inner surface of the shell except a narrow marginal strip. Its thickness differs in different parts and increases with the age of the mussel. It consists of a number of superposed laminæ laden with calcareous particles. It is formed by the surface of the body and mantle in contact with the shell.

Pearls are formed in animals closely allied to the mussel by concentric deposits of this nacreous layer around foreign bodies, such as grains of sand.

II. DISSECTION OF THE MUSSEL.

In dissecting the mussel, a small brush may with great advantage be used to remove the mucus and to clean the several parts.

Leave the animal in the left valve of the shell, and fix it down firmly to the dissecting-board under water. Pins can be passed through the ligament.

A. External Characters.

1. The **muscles**. The **anterior** and **posterior adductors** are easily recognised, and form useful landmarks. Their fibres run transversely from one valve to the other, and by their contraction close the shell.

Close to the adductors are the smaller **protractor** and **retractor** muscles of the foot, the origins of which have already been seen on the inner surface of the shell.

The **protractor** is behind the lower border of the anterior adductor, and the **anterior retractor** is behind the upper part of the same muscle. The **posterior retractor** is continuous with the upper and anterior border of the posterior adductor.

2. The **right mantle-lobe** is the flap of integument which covers the side of the body: it is in contact during life with the inner surface of the shell, to which it is attached along the pallial line. Its inner surface is ciliated.

Dorsally it is continuous with the body-wall, of which it is an outgrowth. Its ventral border is free and grooved, this free border secreting the outer and middle layers of the shell.

The mantle-lobe begins in front above the middle of the anterior adductor muscle, and runs round its anterior border as a narrow fringe. Opposite the part of the body between the two adductor muscles the mantle-lobe is very wide, extending from near the dorsal border to the ventral edge of the shell.

At the hinder end of the animal, below the posterior adductor, the margin of the mantle which here bounds the inhalant aperture is very greatly

thickened and pigmented, and bears a fringe of tentacular processes.

Immediately behind the posterior adductor the mantle-lobe fuses with its fellow of the opposite side, and the fused borders run forwards along the dorsal surface of the posterior adductor for about half an inch. They then separate and continue forwards, as a pair of narrow fringes bounding a shallow groove, for about half an inch further, where they cease.

3. The **left mantle-lobe**, which can as yet be only imperfectly seen, agrees exactly with the right, the animal being bilaterally symmetrical.
4. The **pallial or mantle cavity** is the space between the right and left mantle-lobes. In it lie the foot and the greater part of the visceral mass, the gills, and other organs.

It is divided by a horizontal partition, formed by the bases of the gills, into two chambers of very unequal size:—(1) the large ventral **branchial chamber**; (2) the smaller dorsal **supra-branchial passages**, which unite behind to form the **cloacal chamber**.

5. The **pallial openings**. If a mussel be placed in a vessel of water with a layer of mud or sand at the bottom and left to itself, it will assume the position described above, the anterior end being buried somewhat obliquely in the mud, and the posterior end projecting into the water. The valves will be slightly opened, and streams of water, which can be rendered clearly visible by adding a little colouring matter, will pass in and out of the posterior end, the incoming or inhaled stream being ventral, the exhaled dorsal.

This current is maintained by the cilia of the mantle, gills, and palps: it serves to bring water for nutrition and respiration, and to carry away the

faecal matter and excretory and reproductive products.

- a. The **inhalant aperture**, through which the inhaled stream enters the branchial chamber, is a vertical slit at the hinder end of the body: it is bordered laterally by the thickened posterior edges of the mantle-lobes, which bear the tentacular fringes. Below, it is incompletely closed by the approximation of the edges of the mantle-folds; and above, it is separated from the exhalant aperture by a horizontal partition formed by the fusion of the gills of the two sides with each other.
- b. The **exhalant or cloacal aperture** is much smaller than the inhalant opening, and lies immediately dorsal to this, and behind the posterior adductor muscle. It is bounded laterally by the thickened mantle-borders, which have here no tentacles.

Pass a seeker into the cloacal opening, and forwards along the supra-branchial cavity above the gills. Note the partition between the exhalant and inhalant apertures.

6. Organs lying in the branchial chamber.

Turn back the right mantle-lobe as fully as possible.

- a. The **foot** and **visceral mass** form a large laterally compressed oblong mass, about half the length of the shell, and lying between the two adductors. The upper two-thirds, which are paler in colour, form the visceral mass: the lower or ventral third forms a powerful muscular foot, orange-red in colour, which can be protruded between the valves in front, and is used by the animal for working its way along the bed of the pond in which it lives.
- b. The **gills** are two pairs of large lamellar organs lying at the sides of the visceral mass, between it and the mantle, and extending back beneath

the posterior adductor to the hinder end of the mantle-cavity. The outer gill is, in the female, often greatly distended with embryos.

- c. The **labial palps** are two pairs of triangular folds lying at the sides of the anterior part of the visceral mass, between the anterior adductor and the gills. Each pair consists of a couple of lamellæ, of about equal size, attached along their dorsal borders to the body-wall, and marked on their apposed surfaces by close-set transverse ridges.

7. The **external apertures**.

- a. The **mouth** is in front, between the anterior adductor and the anterior border of the foot.

Pass a seeker into the mouth, and note that it passes vertically upwards behind the anterior adductor, into the stomach.

The mouth is bordered by anterior and posterior lips, formed by the labial palps. The outer palp is continuous with its fellow of the opposite side, forming a low ridge-like anterior lip, immediately behind the anterior adductor. In a similar manner the two inner palps are continuous with each other and form a posterior lip, in front of the foot.

The deep groove between the outer and inner palps of each side thus leads directly into the mouth. The palps are richly ciliated, so that any food-particles that come within the range of their action are swept into the groove and carried forwards to the mouth.

- b. The **anus** opens into the cloacal cavity, close to its external opening.

Insert a seeker into the groove between the margins of the mantle-lobes above the posterior adductor, and pass it back over the adductor into the cloacal cavity. Slit up this canal so as to expose thoroughly the hinder part of the rectum, and the anus.

Insert a seeker into the anus and pass it upwards and forwards along the rectum as it lies on the dorsal surface of the posterior adductor.

B. The Gills.

Cut away the right mantle-lobe completely with scissors, cutting along the base of the palps, round the anterior end of the gills, and back along the attached base of the outer gill. Take care not to damage the parts to which the mantle is attached.

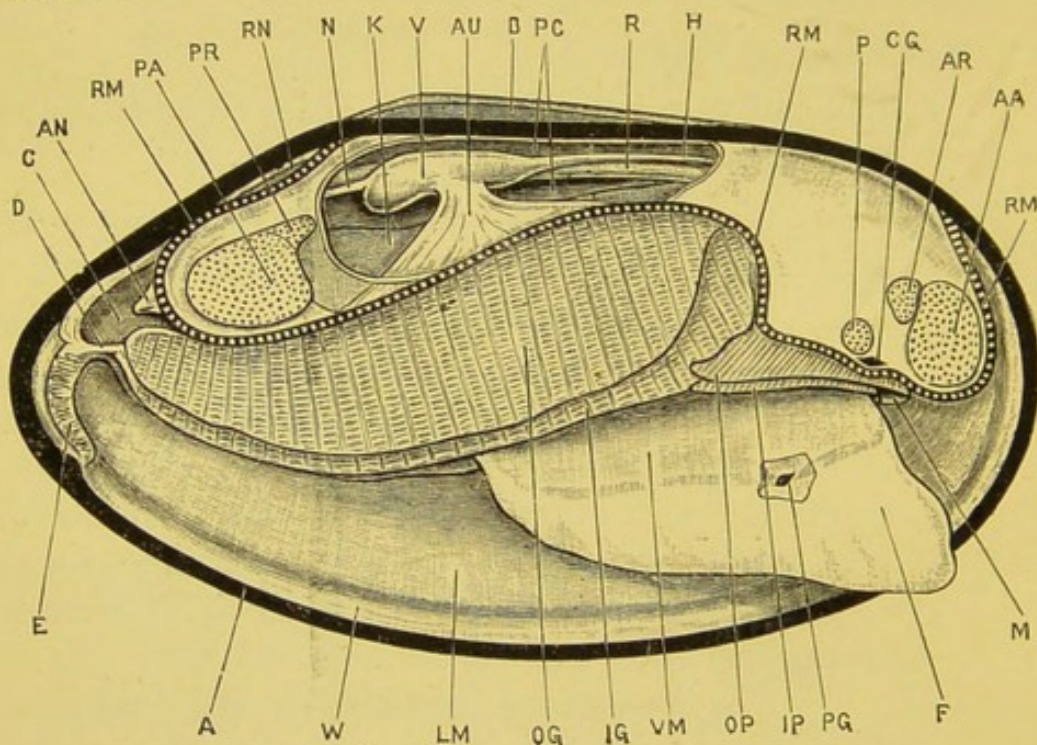


FIG. 26.—*Anodonta cygnea*. Diagrammatic view from the right side. The right valve of the shell and the right mantle-lobe have been removed, and the pericardial cavity opened from the right side. The line of attachment of the right mantle-lobe is indicated by the strong dotted line. (A. M. M.)

A, margin of the left valve of the shell in which the animal is lying. AA, anterior adductor muscle. AN, anus. AR, right anterior retractor muscle. AU, right auricle. B, ligament of the shell. C, cloacal cavity. CG, right cerebral ganglion. D, partition between the inhalant and exhalant apertures. E, tentacles bordering inhalant aperture. F, foot. H, anterior aorta. IG, inner gill of right side. IP, inner labial palp of right side. K, kidney. LM, left mantle-lobe. M, mouth. N, posterior aorta. OG, outer gill of right side. OP, outer labial palp of right side. P, right protractor muscle. PA, posterior adductor muscle. PC, pericardial cavity. PG, right pedal ganglion. PR, right posterior retractor muscle. R, rectum. RM, line of attachment of right lobe of mantle. RN, space between right and left lobes of mantle above the posterior adductor muscle. V, ventricle. VM, visceral mass. W, edge of left mantle-lobe.

Each gill consists of two lamellæ, continuous along their ventral borders. Each lamella is formed of very numerous vertical gill-filaments and horizontal bars, united to form a kind of trellis-work with very small meshes, the greater number of which are blocked up by fusion of the deeper surfaces of the filaments with one another.

The two lamellæ of each gill are further connected at intervals by thick vertical ridges, parallel to the vertical filaments. In the case of the inner gill these ridges are at intervals of about twenty filaments: in the outer gill they are more numerous, occurring at about every seventh filament.

1. The outer gill.

- a. The **outer lamella** of the outer gill is attached along the whole length of its dorsal border to the inner surface of the mantle, close to its line of origin from the body-wall. This line of attachment of the gill runs obliquely across the body, its anterior end being near the dorsal surface a little below and behind the umbo, while its posterior end is below and behind the posterior adductor.
- b. The **inner lamella** of the outer gill is attached along its whole length to the outer lamella of the inner gill, and in front to the body-wall.

Turn the outer gill back, so as to see its attachment to the inner gill.

2. The inner gill.

- a. The **outer lamella** of the inner gill is attached along its whole length, as just noticed, to the inner lamella of the outer gill.
- b. The **inner lamella** of the inner gill differs in its attachment at different parts of its length.

Turn the inner gill back, so as to expose the dorsal border of its inner lamella.

- i. The **anterior part** of the dorsal border, about a quarter of its total length, is attached to the side of the visceral mass.
 - ii. The **middle portion** has a free edge, and extends back as far as the hinder border of the foot.
 - iii. The **posterior part**, behind the foot, is fused with the corresponding lamella of the gill of the opposite side, forming the partition between the inhalant and exhalant chambers of the mantle-cavity.
3. The **supra-branchial or exhalant passages** are wide longitudinal channels running just above the bases of the gills, and continuous with the interlamellar spaces of the gills.

Alongside the foot there are two such passages on each side, one above the outer gill, and one above the inner gill. The latter communicates with the large branchial chamber through the longitudinal slit between the inner lamella of the gill and the hinder part of the visceral mass.

Behind the foot there are only three passages, the two inner ones becoming continuous with each other; and beneath the posterior adductor the three unite to form a wide shallow passage, opening behind into the cloacal chamber.

Pass a seeker into the cloacal cavity, and then forwards along the supra-branchial passages above the bases of the gills. Lay open first the outer passage of the right side, and then the inner one; taking care not to damage the kidney, which lies immediately above them. Note that the inner passages of the two sides are continuous with each other behind the foot, and that they communicate with the branchial cavity through the slits between the inner gills and the body.

The respiratory stream of water, kept up by the cilia on the mantle and gills, enters at the inhalant aperture, passes forwards along the branchial cavity,

and then through the meshes of the gills into the supra-branchial passages. It then passes backwards along the supra-branchial passages to the cloacal cavity, and so out.

Respiration is probably effected mainly by the inner surfaces of the mantle-lobes, and not by the gills.

4. The structure of the gills.

Cut the gills across, and examine the cut edges with a pocket lens. Separate the two lamellæ from each other; and mount small pieces of them and examine with the microscope.

For a more minute study of the structure of the gills microscopical sections should be made through various parts.

The individual filaments are slender vertical laterally compressed rods, the inner edges of which, *i.e.* those turned towards the space between the two lamellæ of the gill, are in most cases expanded laterally, and fused with their neighbours.

The filaments are clothed with a single layer of ciliated epithelial cells, which are cubical over the greater part of the surface, but columnar along the outer edge, a row of cells along each side of this outer edge having peculiarly long cilia. Each filament is strengthened by a double chitinous rod, which lies close to its outer border.

The inner or deeper parts of the bars consist chiefly of **lacunar tissue**, *i.e.* a loose network of branched cells, the meshes of which contain blood. Distinct blood-vessels are comparatively few in number; they are large, and lie principally in the inter-lamellar rods which bolt together the two lamellæ of each gill.

C. The Circulatory System.

1. The **pericardial cavity** is an elongated space of considerable size lying along the dorsal surface of the

animal, ventral to the ligament, and above the bases of the gills. It contains the heart and is traversed by the rectum. Its walls are thin and semitransparent behind; thicker and spongy in front. Through them the pulsations of the heart can be seen.

Open the pericardial cavity by a longitudinal incision along the right side, and cut away as much of its walls as is necessary to expose the heart fully.

2. The **heart** consists of three chambers, a median ventricle, and right and left auricles; the latter returning to the ventricle the blood from the mantle-lobes and gills of the right and left sides respectively.

a. The **right auricle** is a triangular sac with very thin transparent walls. The base of the triangle lies along the dorsal border of the gills of the right side, from which it receives blood; the apex is attached to the side of the ventricle about the middle of its length, and opens into it by a valved aperture.

To see the auricle, press the gills down gently.

b. The **left auricle** is similar to the right, and returns the blood from the left gills and mantle-lobe.

c. The **ventricle** is an elongated thick-walled muscular sac of a reddish colour, lying in the middle of the pericardial cavity, and receiving the auricles laterally. Its posterior end is enlarged and bilobed.

The ventricle surrounds the rectum, which runs straight through the pericardial cavity from end to end, apparently traversing the ventricle, though not doing so in reality. In the early stages the ventricle lies completely below the rectum, but during development its anterior end extends up at each side, and the two processes meet each other and unite above the rectum, completely surrounding it.

3. The arteries.

There are two main arteries, one arising from each end of the ventricle, which convey the aërated blood from the heart to all parts of the body. Their main branches may be followed by injecting them from the ventricle.

- a. The **anterior aorta** is a continuation of the anterior end of the ventricle: it runs forwards along the dorsal surface of the rectum, enters the visceral mass, and divides into **visceral** and **pedal arteries**, which supply the anterior two-thirds of the animal.
- b. The **posterior aorta** arises from the posterior end of the ventricle, and runs backwards beneath the rectum: it divides into right and left branches, which supply the hinder part of the body.

4. The **veins**, except the largest ones, cannot be dissected without injecting them, and even then they are difficult to follow. They may, however, be identified in sections of hardened specimens (p. 107).

- a. The **vena cava** is a median longitudinal vessel lying beneath the floor of the pericardium: it receives, in front, large veins returning blood from the foot and visceral mass; and behind, much smaller vessels from the posterior part of the body.
- b. The **afferent branchial veins** are a pair of large vessels, running along the lines of attachment of the outer and inner gills to each other. Vessels arise from them which carry blood to the gills.
- c. The **efferent branchial veins** run along the bases of the outer lamellæ of the outer gills: they return to the auricles the blood from the gills, and also receive at their anterior and posterior ends large vessels returning aërated blood from the mantle-lobes.

5. The course of the circulation.

The ventricle receives arterial blood from the auricles, and drives it through the arteries all over the body. The blood from the foot and viscera is

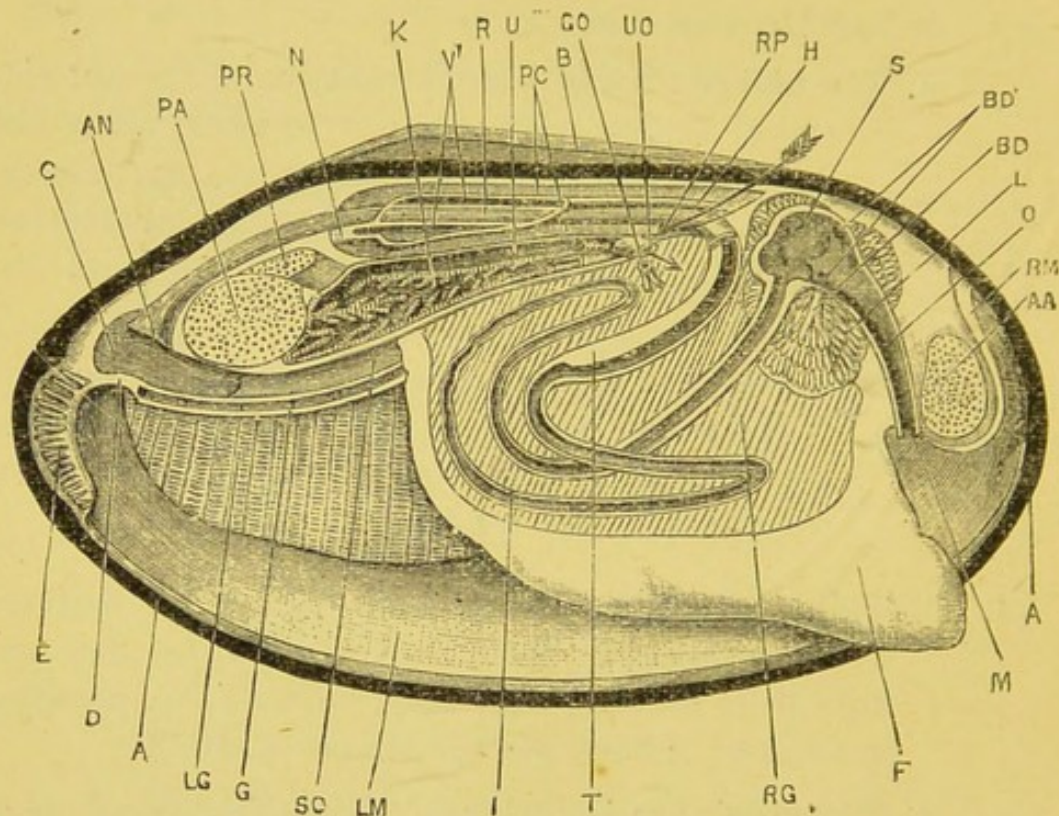


FIG. 27.—*Anodonta cygnea*. Diagrammatic view from the right side. The right valve of the shell, the right mantle-lobe, the right gills, and the right auricle have been removed. The alimentary canal has been laid open from the right side as far as the point where it enters the pericardial cavity. The pericardial cavity, the ventricle, and the right kidney and ureter have been laid open from the right side. The longer arrow passes from the pericardial cavity through the right reno-pericardial aperture into the right kidney. The shorter arrow passes through the external aperture of the right ureter. (A. M. M.)

A, margin of the left valve of the shell in which the animal is lying. AA, anterior adductor muscle. AN, anus. B, ligament of the shell. BD, bile-duct. BD', openings of bile-ducts into stomach. C, cloacal cavity. D, septum between the cloacal and branchial cavities. E, tentacles bordering inhalant aperture. F, foot. G, line of fusion of inner lamellæ of right and left inner gills. GO, genital aperture. H, anterior aorta. I, intestine. K, kidney. L, liver. LG, inner gill of left side. LM, left mantle-lobe. M, mouth. N, posterior aorta. O, oesophagus. PA, posterior adductor muscle. PC, pericardial cavity. PR, right posterior retractor muscle. R, rectum. RG, genital gland—ovary or testis. RM, line of attachment of right lobe of mantle. RP, right reno-pericardial aperture. S, stomach. SC, median supra-branchial canal, lying above the inner gills. T, typhlosole. U, right ureter. UO, external opening of right ureter. V', cavity of ventricle.

returned to the vena cava, from which it passes through the kidneys to the gills. From the gills it is returned by the efferent branchial veins to the auricles. The blood from the mantle-lobes is returned direct to the auricles, and does not pass through either the kidneys or the gills.

The circulation is in great part carried on through irregular channels or lacunæ.

D. The Kidneys.

The kidneys, or 'organs of Bojanus,' are paired, and lie side by side just beneath the pericardium.

Each kidney is a wide thin-walled tube, doubled on itself so that its two ends are closely approximated. These ends are anterior, and placed opposite the anterior end of the pericardium, while the loop is posterior and lies against the posterior adductor muscle.

The two limbs of the loop are very different: the ventral limb, or **kidney proper**, has spongy walls, and is lined throughout by a darkly pigmented glandular epithelium, so that the whole limb appears black. The dorsal limb, or **ureter**, is a wide thin-walled tube which conveys the excretory products forwards to the external opening.

Dissect the right kidney as described below, examining first the ureter, and then the glandular portion.

1. The **external opening of the ureter** is on the side of the body, between the two lamellæ of the inner gill, and a short distance in front of the point at which its inner lamella becomes free from the body.

Turn back the gills of the right side, and pass one blade of a fine pair of scissors between the lamellæ of the inner gill, through the anterior end of the slit between the inner lamella and the body. Cut forwards through the inner lamella parallel to its base, and about an eighth of an inch from this. Separate the cut edges of the lamella, and gently brush the parts clean.

The opening of the ureter is a small hole, with rather prominent white lips. Almost immediately below it is another and less conspicuous opening, the **aperture of the genital duct** which should be recognised at once.

2. The **ureter**.

Remove the gills of the right side completely, cutting along their lines of attachment to the body and mantle. Inflate the ureter through its external opening, and slit it up along its whole length.

The ureter is a wide thin-walled passage lying above and to the outer side of the kidney. Its roof is continuous with, and inseparable from, the floor of the pericardium; and its floor is continuous with the roof of the kidney. On its inner side it is separated from the ureter of the other side by the vena cava. The two ureters communicate with each other through a large slit-like opening near their anterior ends.

3. The **kidney** appears as an elongated black body lying beneath the ureter. Posteriorly it enlarges considerably, and is in close contact with the posterior adductor muscle, which it partially embraces.

Lay open the kidney longitudinally with scissors.

Its walls are thrown into thick spongy folds, clothed with a black glandular epithelium. The enlarged posterior end opens into the hinder end of the ureter.

4. The **reno-pericardial openings** are a pair of crescentic slits at the anterior end of the pericardial cavity, in the angle between the rectum and the floor of the pericardium; they lead from the pericardial cavity into the anterior ends of the right and left kidneys respectively.

Find the reno-pericardial opening on the right side, and pass a seeker through it, and backwards along the kidney. Slit open the passage, using the seeker as a guide.

The pericardial cavity is developmentally a part of the body-cavity or coelom. Hence in the mussel, as in the earthworm and in many other animals, the kidneys are tubular organs with glandular walls, leading from the body-cavity to the exterior.

From the external apertures the excretory products are carried back by the outward respiratory stream along the supra-branchial passages to the cloacal cavity, and so out.

E. The Nervous System.

The nervous system of the mussel consists of three main pairs of ganglia widely distant from one another, but united by nerve-connectives, and giving off nerves which supply the various organs.

The ganglia are about the size of large pin-heads, and are of a bright orange colour, which renders them easy to see.

1. The **cerebral ganglia** are placed one on each side of the hinder border of the mouth, just above the line of attachment of the mantle-lobe, and below and in front of the protractor muscle.

The ganglion lies very close to the surface, just beneath the skin, and is readily exposed if its exact position be determined first.

The two cerebral ganglia are connected together by a commissure which runs round the front of the mouth. Each ganglion also gives nerves to the palps, the anterior adductor muscle, and other adjacent parts, and is joined to the other ganglia of its side by nerve-connectives.

The cerebral ganglia of the mussel probably correspond to the cerebral (supra-oesophageal) and pleural ganglia of other molluscs, such as the snail.

2. The **pedal ganglia** are a pair of closely apposed ganglia about as large as the cerebral. They are situated in the foot, just above the junction of the visceral portion with the foot proper, and about

a third of the length of the foot from its anterior end.

To find the pedal ganglia, split the anterior part of the foot with a scalpel in the median plane, and dissect the two halves apart until the ganglia are met with. The junction of the muscular and visceral portions is very clearly defined, and the ganglia lie close to it, in the visceral portion.

Each pedal ganglion gives nerves to the foot. The auditory organ or **otocyst**, which lies a little behind and below the ganglion, is innervated from the cerebral ganglion.

3. The **cerebro-pedal connectives** are a pair of nerve-cords connecting the cerebral ganglia with the pedal ganglia. They run in an almost straight course between the two ganglia, and are easily exposed.
4. The **visceral** or **parieto-splanchnic ganglia** are a pair of closely apposed ganglia, on the ventral surface of the posterior adductor muscle about the middle of its length.

Pass a seeker into the cloacal cavity, and along the median supra-branchial passage, and lay open this latter, if it has not already been done. The visceral ganglia are then readily found in the position noted above.

From the ganglia nerves are distributed to the posterior adductor, the mantle, and other parts.

5. The **cerebro-visceral connectives** are a pair of long nerve-cords which connect the cerebral with the visceral ganglia.

From each cerebral ganglion the connective curves upwards and backwards through the visceral mass, lying close to the surface. It then runs backwards along the inner surface of the kidney to the visceral ganglion. The part in relation with the kidney is very easy to dissect: in front of the kidney the dissection is more troublesome, but presents no serious difficulty.

F. The Digestive System.

1. The **alimentary canal** is a convoluted tube the greater part of which lies in the visceral mass, imbedded in the liver and generative organ, while the terminal portion runs back through the pericardial cavity to the anus.

Insert a seeker into the mouth, and, using this as a guide, slit up the œsophagus and stomach with scissors. Slit open in a similar fashion the whole length of the intestine, beginning at the rectum and working backwards to the stomach (cf. fig. 27, p. 96).

- a. The **mouth** lies immediately behind the anterior adductor, and between the lips formed by the palps: there are no jaws. The food, which consists of minute organisms of various kinds, both animal and vegetable, is swept in at the hinder end of the shell by the inhaled stream of water, and carried forwards to the mouth by the action of the cilia covering the palps.
- b. The **œsophagus** is a short straight tube passing almost vertically upwards behind the anterior adductor.
- c. The **stomach** is a slightly dilated chamber whose cavity is partially subdivided by folding of its walls.
- d. The **intestine** arises by a small orifice from the ventral surface of the stomach, and runs backwards and downwards into the visceral mass, where it is closely surrounded by the generative gland. It follows the course shown in fig. 27, and finally passes into the rectum.
- e. The **rectum**, which is rather wider than the intestine, runs upwards through the visceral mass to the anterior end of the pericardial cavity, through which it runs horizontally backwards, surrounded by the ventricle. Behind the pericardial cavity it

turns slightly downwards, runs over the posterior adductor, and opens into the cloacal cavity by a slit-like anus.

The ventral wall of the rectum is folded so as to form a prominent longitudinal ridge, the **typhlosole**, projecting into its cavity. This typhlosole is largest at the junction of the rectum with the intestine.

2. The **liver** is a large many-lobed digestive gland surrounding the stomach and adjacent parts of the œsophagus and intestine, and opening into the stomach by several **bile-ducts**.

G. The Reproductive System.

The sexes are separate. The reproductive organs are simple, and very similar in the two sexes.

The **ovary**, or **testis**, is very large, and, when the sexual products are ripe, forms the greater part of the visceral mass between the foot and the kidneys. The ducts of each side converge to the genital aperture which lies on the side of the body immediately below the opening of the ureter.

Tease a small portion of the ovary, or testis, in salt solution or glycerine; cover, and examine it with low and high powers.

In the female the eggs, after they escape from the genital aperture, pass in large numbers into the space between the two lamellæ of the outer gill, which they distend very greatly. Here they develop into embryos known as **glochidia**, which are in many respects very unlike the parent. They have bivalved shells, each valve of which is triangular and incurved at its apex so as to form a sharp tooth, the teeth of the two valves constituting an efficient pair of pincers. There is only a single adductor muscle: the gills are absent or rudimentary, as also is the foot. A long coiled filament serves to anchor the glochidium to the gill of the parent.

Take a female in which the outer gills are distended with

embryos ; cut the gill across ; remove some of the embryos, mount them on a slide in water, and examine them with a microscope.

III. EXAMINATION OF TRANSVERSE SECTIONS.

Several points in the anatomy of the mussel, and notably the relations of the gills, kidneys, and heart are best studied by means of a series of transverse sections.

For this purpose take a good-sized specimen, and put it into $\frac{1}{4}$ per cent. chromic acid, wedging the valves slightly open so that the acid may have free access to the branchial cavity. After a couple of days transfer it to spirit, and keep it till wanted.

To make the sections, remove both valves of the shell carefully ; place the animal on a board, and cut it transversely with a razor into a series of slices about a quarter of an inch thick ; arrange the sections in order in a dissecting dish under water ; examine and draw them.

The most instructive sections are those passing (1) through the renal and reproductive apertures ; (2) through the middle of the ventricle ; (3) through the posterior adductor. The chief features of these sections are as follows.

A. Transverse Section through the Renal and Reproductive Apertures.

The section passes through the widest part of the body, a little way behind the umbo.

1. The **mantle-folds** arise very close to the dorsal surface, one on each side of the pericardial cavity. The folded margin which secretes the two outer layers of the shell should be noticed.
2. The **visceral mass** is large and laterally compressed, and lies in the middle of the section between the two mantle-lobes. The chief part of its substance is made up of the lobes of the **ovary**, or **testis**. The

ventral edge of the visceral mass is produced into the wedged-shaped muscular foot.

3. The **alimentary canal**. The coils of the intestine are seen in the visceral mass, imbedded in the generative gland, and cut across about half a dozen times. Lying in the pericardial cavity in the median line immediately beneath the dorsal surface is the rectum, in which the **typhlosole** or fold of its ventral surface is well seen.
4. The **gills** lie in the dorsal half of the mantle-cavity, between the visceral mass and the mantle. The attachments of their lamellæ to the body-wall are well seen. The inner lamella of each inner gill is attached to the base of the visceral mass.

At the base of each gill is the **supra-branchial passage**, along which the respiratory stream of water flows backwards to the cloacal cavity.

5. The **circulatory system**.
 - a. The **pericardial cavity** is nearly circular in outline; its roof and sides are thick and spongy, forming what is spoken of as **Keber's organ**.
 - b. The **anterior aorta** lies on the dorsal surface of the rectum, and its cavity is slit-like in section.
 - c. The **vena cava** lies in the median plane between the excretory organs and the visceral mass.
 - d. The **afferent branchial vessels** lie one on each side, just above the attachment of the outer lamella of the inner gill and inner lamella of the outer gill.
6. The **excretory organs** are paired, and lie between the pericardium and the visceral mass.
 - a. The glandular portions, or **kidneys proper**, are cut across close to their anterior ends. They are seen as a pair of small tubes, with glandular longitudinally folded walls, lying side by side just

above the visceral mass and opposite the bases of the inner gills.

If the section has passed a little in front of the excretory apertures, the reno-pericardial passages from the pericardial cavity to the anterior ends of the kidneys are well seen.

- b. The **ureters** are cut through at the part where they communicate with each other across the median plane: they appear as a wide cavity immediately below the pericardium and above the kidneys. The external openings are to the outer sides of the kidneys, between the two lamellæ of each inner gill.
7. The **reproductive apertures** are immediately ventral to the excretory apertures; they may be followed with a seeker into ducts leading from the genital gland.

B. Transverse Section through the Middle of the Ventricle.

1. The **mantle-lobes** have the same appearance as in the previous section.
2. The **visceral mass** is cut across close to its posterior end, and hence is much smaller than in the previous section; it is occupied almost entirely by the ovary, or testis.
3. The **alimentary canal**. The intestine is cut across twice in the visceral mass; and the rectum with the typhlosole is cut across as it lies in the pericardial cavity.
4. The **gills**. The attachments of the gills are the same as in the previous section, except that the inner lamella of the inner gill ends in a free edge above.

At the base of each gill, between its lamellæ, is a wide **supra-branchial passage**. The inner canal of each side communicates with the branchial cavity through the slit between the unattached inner lamella of the gill and the base of the visceral mass.

5. The **circulatory system**.

- a. The pericardial cavity is very much larger and has thinner walls than in the previous section : it is triangular in shape.

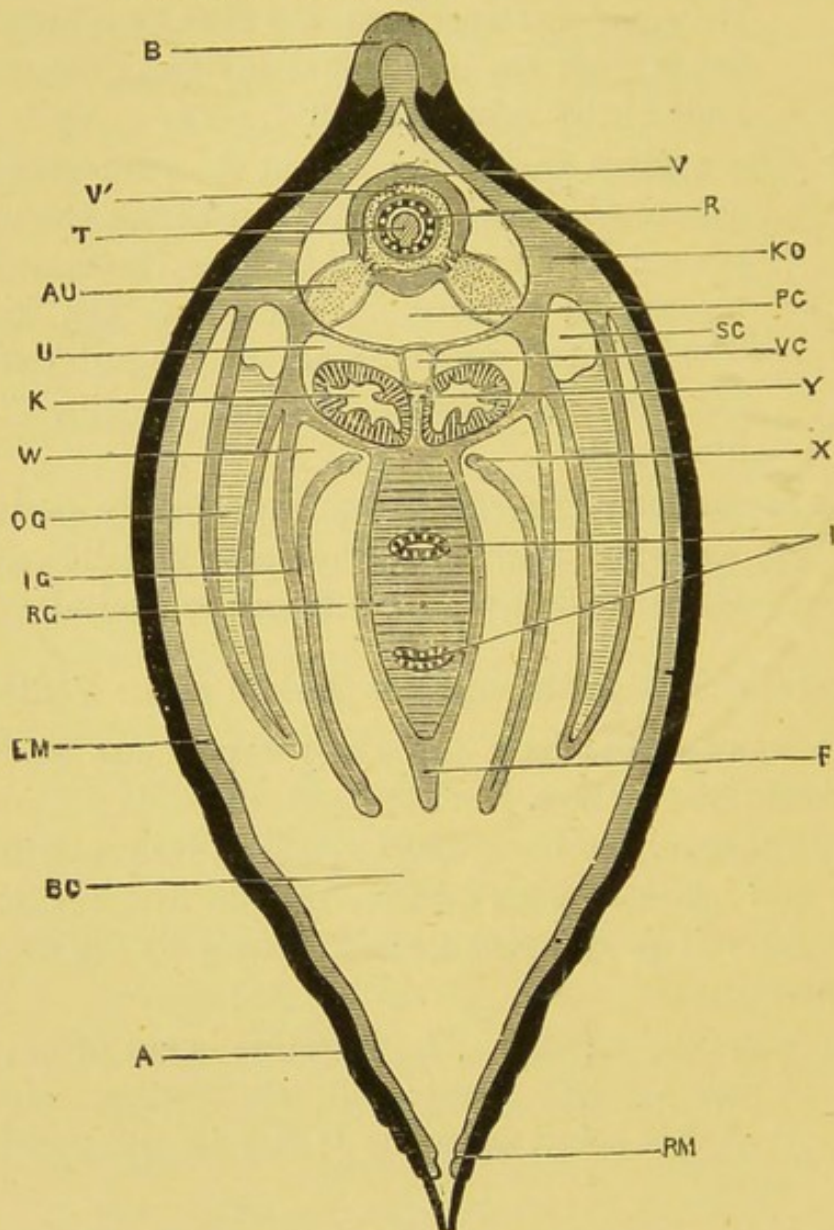


FIG. 28.—*Anodonta cygnea*. Transverse section of the animal passing through the middle of the length of the ventricle. The cavity of the heart is dotted. (A. M. M.)

A, shell. AU, left auricle. B, ligament. BC, branchial cavity. F, foot. I, intestine. IG, left inner gill. K, left kidney. KO, Keber's organ of the right side. LM, left mantle-lobe. OG, left outer gill. PC, pericardial cavity. R, cavity of rectum. RG, genital gland, ovary, or testis. RM, edge of right mantle-lobe. SC, supra-branchial canal of right outer gill. T, typhlosole. U, left ureter. V, wall of ventricle. V', cavity of ventricle. VC, vena cava. W, supra-branchial canal of left inner gill. X, free upper edge of the inner lamella of the right inner gill : between this edge and the body is the slit through which the branchial cavity communicates with the supra-branchial canal of the inner gill. Y, the right cerebro-visceral connective.

- b. The **ventricle** surrounds the rectum : its outer wall is thick and muscular, its inner wall thin.
 - c. The **auricles** are a pair of very thin-walled sacs lying at the sides of the pericardial cavity. Each is attached along its outer side to the wall of the cavity, and by its inner border to the ventricle, into which it opens by a slit-like valved aperture.
 - d. The **vena cava** is a median thin-walled tube lying in the floor of the pericardium.
 - e. The **afferent branchial vessels**, right and left, lie just above the attachment of the outer lamella of the inner gill and inner lamella of the outer gill.
6. The **excretory organs**.
- a. The **kidneys** are two wide tubes with thick spongy walls, whose epithelium is glandular, pigmented, and folded. They lie below the pericardium, above the visceral mass, and opposite the bases of the inner gills. Their inner walls are in contact with each other below ; and are separated dorsally by the vena cava, from which large sinuses enter them.
 - b. The **ureters** are a pair of thin-walled tubes lying along the dorsal surface and outer sides of the kidneys, immediately below the pericardium. They are separated from each other in the median plane by the vena cava.
7. The **nervous system**.

The connectives between the cerebral and visceral ganglia lie side by side, between the two kidneys and immediately below the vena cava.

C. Transverse Section through the Middle of the Posterior Adductor Muscle.

- 1. The **posterior adductor** is a large mass of transverse muscular bands running across the dorsal part of the section.

2. The gills are cut across close to their hinder ends, and are small. The inner lamellæ of the two inner gills are united with each other in the median plane, forming a horizontal septum which separates the large branchial chamber below from the wide but shallow supra-branchial or exhalant chamber.
3. The rectum lies immediately dorsal to the adductor muscle. The typhlosole is still present.
4. The visceral ganglia lie side by side on the ventral surface of the adductor.

CHAPTER VII.

THE EDIBLE SNAIL. *Helix pomatia*.

THE snail is a terrestrial animal, feeding on leaves and other vegetable matter which it rasps off with its toothed tongue or odontophore. The dorsal surface of the body carries a spirally coiled univalve shell, which lodges most of the viscera, and within which the entire animal can be withdrawn for protection. It breathes air by means of a pulmonary chamber, formed by a fold of skin—the mantle—on the dorsal surface. It is hermaphrodite, but incapable of self-fertilisation.

The edible snail occurs in many parts of England, and can be readily obtained from dealers. On account of its large size it is preferable to the commoner English species, *H. aspersa*, to which, however, the following description will apply with but slight modification.

Snails are best killed by putting them in cold water and then running a layer of very hot water on to the surface, when they die in an expanded condition in about two hours. In winter the mouth of the shell is closed by a plate of hardened mucus, the epiphragm, which must be removed before putting the snail in water. When dead the snail should be put into spirit for a short time before it is dissected, in order to facilitate the removal of the mucus.

I. EXTERNAL CHARACTERS.

A. Before Removal of the Shell.

1. The shell is a right-handed conical spiral, each turn of which overlaps and conceals the greater part of the

preceding turn. In the fully formed shell there are about four and a half turns in the spiral.

The shell is placed obliquely on the back of the animal with its apex to the right: its mouth is in front, and faces downwards and to the right. Like the shell of the mussel it is a cuticular structure, *i.e.* it is outside the epidermis and is non-cellular. It has therefore no power of interstitial growth, but can only increase in size by the addition of new shell-matter round its free edge or mouth.

The shell will be more fully described after its removal from the body.

2. **The part of the animal outside the shell.** This consists chiefly of the head and the foot, and will vary greatly according to the degree of protrusion of the animal from the shell. It has a mammillated surface.
 - a. **The head** is the rounded anterior extremity of the animal. It bears the two pairs of tentacles and the mouth.
 - i. **The posterior or dorsal tentacles** are a pair of long fleshy cylindrical processes of the dorsal surface of the head. They are very freely movable, and can be completely withdrawn by invagination when the animal is disturbed. Each bears an eye at its extremity, which is only visible when the tentacle is fully protruded.
 - ii. **The anterior or ventral tentacles** are a pair of much smaller processes arising from the sides of the head, below and in front of the larger tentacles. Like these latter, they can be completely withdrawn by invagination.
 - b. **The foot** is a large flattened muscular expansion of the ventral wall of the body. It is of an elongated oval shape, commencing in front with a rounded anterior border immediately below and behind the head, and narrowing behind to a long pointed

extremity. A median longitudinal groove runs along its ventral surface.

- c. The **collar** is a thickened fleshy rim surrounding the mouth of the shell, and separated by a deep groove from the body which it encircles. It is thicker at the sides than in front or behind, and is especially thick on the right side in the angle of the mouth of the shell.

d. The **external apertures**.

- i. The **mouth** is a small aperture on the ventral surface of the anterior end of the head. It is bordered at the sides by two prominent **lateral lips**, and is separated from the foot by a less conspicuous **inferior lip**.

Pass a seeker into the mouth, and then upwards and backwards into the cavity of the buccal mass.

- ii. The **genital aperture** is on the right side of the head, behind and below the larger tentacle, and immediately behind the posterior edge of the right lip. From it a groove runs backwards along the dorsal surface of the body: a similar groove runs along the left side.

Pass a seeker into the genital aperture, and backwards along the genital passage.

- iii. The **respiratory** or **pulmonary aperture**. On the right side of the collar at its widest part is a deep notch, at the dorsal end of which is a large round hole, the **respiratory aperture**, leading into the pulmonary chamber.

Wash away the mucus from the collar on the right side; clean the notch in the collar, and pass a seeker through the respiratory aperture into the pulmonary chamber.

- iv. The **anus** is a smaller slit-like hole, immediately below and to the right of the respiratory aperture. From it a spout-like groove runs forwards to the edge of the collar.

Clean the anal opening and groove, and pass a seeker into the anus and back along the rectum.

- v. The **aperture of the pedal mucous gland** is immediately below the inferior lip, between the head and the foot.

Pass a seeker into the aperture, and backwards along the gland, and lay the gland open along its whole length.

B. After Removal of the Shell.

Twist the animal out of the shell, taking care not to damage the upper part of the body in so doing. The shell comes off readily if the snail has been put in spirit for a short time after drowning.

1. The Shell.

- a. The **colour** differs a good deal in different specimens. The ground colour is a yellowish brown, marked by darker longitudinal bands running round the spiral, and by obliquely transverse lines corresponding to the lines of growth.
- b. The **nucleus** is the oldest part of the shell, at the top of the spiral, corresponding to the umbo of the mussel-shell.
- c. The **mouth** is oval, and notched posteriorly by the penultimate turn of the shell. Its lip is smooth and slightly everted.
- d. The **lines of growth** are transverse ridges parallel to the mouth, and indicating successive positions of the mouth during the growth of the shell.
- e. The **umbilicus** is an opening on the under surface of the shell leading into the hollow axis or **columella**. It is sometimes closed.

Clip away one half of the shell with bone forceps, and grind the cut edges flat on a file or stone.

- f. The **columella** is the axial portion of the shell round which it is coiled ; it is formed by the inner

wall of the several turns, each of which overlaps rather more than half of the preceding one.

g. The **structure of the shell**. The shell, like that of the mussel, consists of three layers, of which the outer and middle ones are formed by the collar, and consequently can only increase by additions round the mouth of the shell. The inner layer is formed by the integument covering the visceral mass.

- i. The **periostracum** or **outer layer** is horny and uncalcified. To it the colour of the shell is due. It is usually rubbed off the uppermost turns of the shell, leaving the middle layer exposed.
- ii. The **middle layer** is much the thickest of the three. It is densely calcified, and has an opaque porcellanous appearance.
- iii. The **inner** or **nacreous layer** has a glistening, pearly appearance, and a very smooth surface. It is formed by the superposition of a number of delicate densely calcified laminae.

2. The **visceral hump** is the part of the snail which is permanently lodged within the shell. It is the elongated and spirally coiled dorsal part of the animal, and contains the greater part of the viscera. It is covered by a very thin layer of integument which secretes the nacreous layer of the shell, and which is sufficiently transparent to allow the several organs to be seen through it.

For convenience of description the basal or largest turn of the spiral, commencing with the collar, will be spoken of as the first turn, the next as the second, and so on.

Place the snail in a dissecting dish under water, and determine the positions of the organs mentioned below. Note that the outer side of the spiral corresponds to the animal's left side, and the inner side to the animal's right.

- a. The **kidney** is a large somewhat triangular body, of a yellowish-white colour and granular appearance, lying about halfway round the first turn of the spiral, opposite to the collar.
- b. The **pericardium**, enclosing the heart, is an oval sac, lying immediately to the left of the anterior half of the kidney, which is notched to receive it.
- c. The **mantle**, forming the thin roof of the respiratory cavity, extends forwards along the dorsal surface and left side of the body, from the pericardium and kidney to the collar.
- d. The **liver** is a dark reddish-brown mass, which begins immediately beyond the pericardium and kidney, and extends to the top of the spiral.
- e. The **intestine** is a thin-walled tube, much paler in colour than the liver, and appearing on the surface at one or two places in the first and second turns of the spiral.
- f. The **rectum** runs along the right border of the first half-turn of the spiral, just below the ridge-like thickening which borders the right or inner side of the spiral.
- g. The **albumen gland** is a large white or yellowish mass at the junction of the first and second turns of the spiral. It separates the right and left lobes of the liver from each other.
- h. The **hermaphrodite gland** is a small yellowish body on the inner side of the upper half on the second turn of the spiral.
- i. The **columellar muscle**, by which the animal can be retracted within the shell, runs along the right or inner side of the spiral, and is attached to the columella in the upper half of the first turn.

II. DISSECTION OF THE MANTLE-CAVITY AND ORGANS IN RELATION WITH IT.

The respiratory or mantle cavity of the snail lies along the dorsal surface, commencing at the collar, and extending backwards rather more than three-fourths of the way round the first turn of the spiral. The mantle is a transverse fold of skin which, arising from the dorsal surface of the visceral

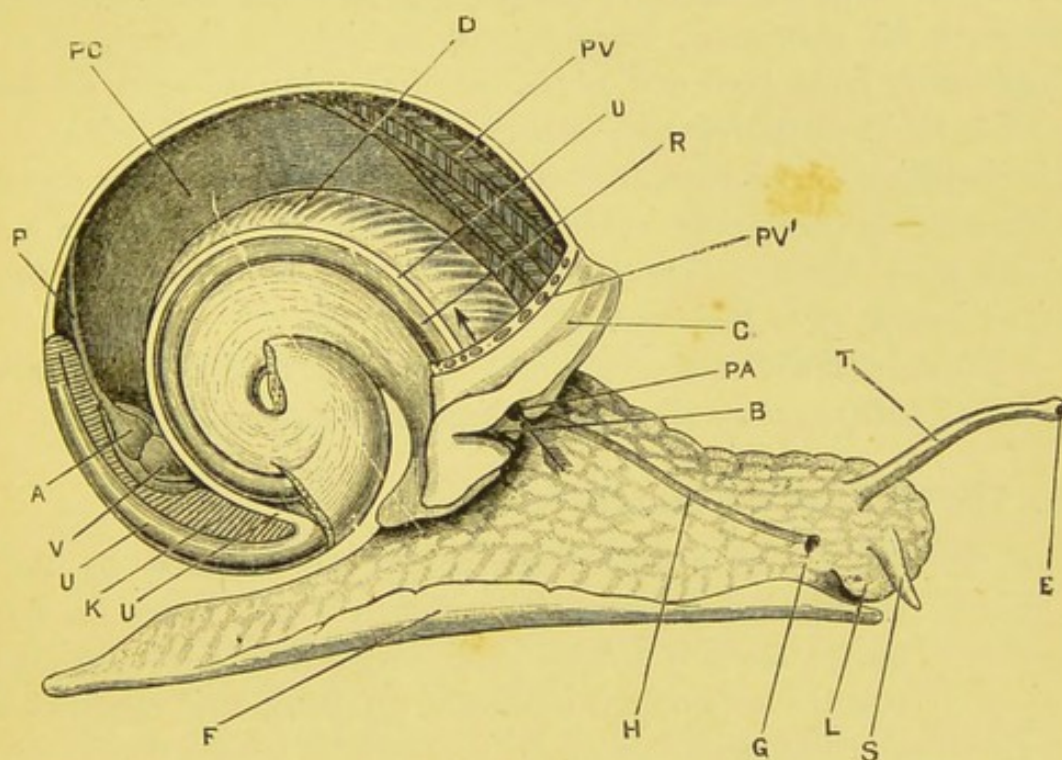


FIG. 29.—*Helix pomatia*. Dissection from the right side to show the mantle-cavity and organs in relation with it. The arrow passes through the pulmonary aperture into the mantle-cavity. The shell and the upper part of the spiral visceral mass have been removed. (A. M. M.)

A, auricle. B, anus. C, collar. D, dorsal body-wall forming the floor of the mantle-cavity. E, eye. F, foot. G, genital aperture. H, groove leading to genital aperture. K, kidney. L, lip. P, pulmonary vein. PA, pulmonary aperture. PC, pulmonary or mantle cavity. PV, pulmonary vessels in roof of mantle-cavity. PV', cut ends of pulmonary vessels. R, rectum. S, anterior tentacle. T, posterior tentacle. U, ureter. V, ventricle.

mass, grows forwards along the back, ending in front in a thickened rim, the collar. Between the mantle-fold and the back of the animal is the large mantle-cavity, which at first opens anteriorly by a wide orifice. Fusion of the collar with

the body-wall reduces this orifice to a small round aperture on the right side, the **respiratory or pulmonary aperture**, through which air alternately enters and leaves the cavity during respiration.

In close relation with the mantle-cavity are the rectum, the heart, and the kidney and ureter.

Place the snail in a dissecting dish under water, and pin it firmly down through the foot, with the dorsal surface upward. Open the mantle-cavity by a transverse incision through its thin roof, immediately behind the collar. Cut backwards from each end of the incision along the sides of the cavity to its posterior end, cutting along the left side close to the junction of the mantle and body-wall, and along the right side about a quarter of an inch to the left of the prominent ridge that borders this side, midway between this and the right border of the kidney.

Turn back the roof of the mantle-cavity, and pin it down so as to fully expose the pericardium and kidney.

A. The Walls of the Mantle-cavity.

1. The **roof and sides of the cavity** are formed by the **mantle** itself, a thin fold of skin which bears on its under surface a very rich network of large blood-vessels, especially abundant in front and along the right side.

These vessels, in which the blood is aërated, unite to form a large trunk, the **pulmonary vein**, which takes back the oxygenated blood to the heart, running along the left side of the kidney.

The mantle is greatly thickened in front to form the collar: posteriorly it is thickened by the kidney and pericardium, both of which lie in its substance.

2. The **floor of the cavity**, which is formed by the dorsal wall of the body, is muscular, and strongly arched from side to side. Contraction of its muscles causes flattening of the floor, and protrusion of the body further out of the shell, and thus enlarges the cavity,

causing an inrush of air through the pulmonary aperture. On retraction of the body the floor resumes its previous convex shape, diminishing the size of the cavity and effecting expiration.

By alternate protrusion and retraction of the body the air in the mantle-cavity is continually renewed, and the cavity thus becomes a lung.

B. The Organs in relation with the Mantle-cavity.

1. The pericardial cavity and heart.

- a. The **pericardial cavity**, which has already been seen from the exterior, is oval, thin-walled, and half an inch or more in length. It lies in the roof of the mantle-cavity at its posterior end and left side, and is in close contact with the left side of the kidney about the middle of its length.

Open the pericardial cavity to expose the heart.

- b. The **heart** has two chambers, of about equal size.

- i. The **auricle** is proximal, *i.e.* nearer the collar, and has thin walls. It receives in front the pulmonary vein, which returns to it oxygenated blood from the lung.
- ii. The **ventricle** is the pear-shaped distal division of the heart, with thick muscular walls. It receives oxygenated blood from the auricle, and drives it through the aorta to all parts of the body.

The blood-vessels will be described later on.

2. The kidney and ureter.

- a. The **kidney** is a large pale yellow triangular body in the posterior part of the roof of the mantle-cavity. Its left side is notched to receive the pericardium, which lies close against it.
- i. The **reno-pericardial canal** is a narrow ciliated passage leading from the pericardial cavity to

the kidney. Its pericardial opening is about the middle of the length of the cavity, opposite the ventricle, and close to the inner or ventral border of the septum between the pericardial cavity and the kidney.

The reno-pericardial passage is difficult to make out. To see it, take a fresh snail, make a small hole into the pericardial cavity, and inject into it carmine or other colouring matter suspended in water. This will pass into the kidney along the passage, which can then be followed.

- ii. The **structure of the kidney**. The kidney is a sac lined by a glandular epithelium, and with its walls thrown into a large number of lamellar folds projecting into its cavity.

Slit open the kidney longitudinally: wash it out with a gentle stream of water, and note its structure.

- b. The **ureter** is a thin-walled duct which commences at the proximal end of the kidney and runs back along its right side to the distal end. It then turns sharply forwards, and runs along the right side of the mantle-cavity to its anterior end, lying dorsal to the rectum, and just within the prominent ridge-like fold that marks the junction of the roof and right side of the mantle-cavity.

In front it opens into the mantle-cavity immediately above and to the right of the pulmonary aperture. The opening is slit-like, and is continued as two divergent grooves with prominent lips, which run down the right and left sides of the pulmonary aperture, the right groove being continuous below with the spout-like aperture of the rectum.

Insert one blade of a pair of scissors into the pulmonary aperture from the outside, and cut through the collar, keeping close to the left side of the aperture. Turn the right lip of the aperture over to the right side. Pass a seeker into the

rectum from the anus so as to identify it. Note the ureter running along the right side of the rectum, but dorsal to it in the natural position of the parts. Trace the ureter forwards to its opening, and inflate it with a blowpipe. Insert a seeker into the opening; and, using this as a guide, slit up the ureter along its whole length, following it back to the hinder end of the mantle-cavity, and then forwards close alongside the kidney to its anterior end, into which it opens.

3. The **rectum** is a wide tube running along the right side of the mantle cavity, ventral to the ureter. It opens in front at the anus, which has already been seen.

Insert a bristle or seeker into the rectum from the anus, and note carefully the relations of the anus and the respiratory and renal apertures.

III. DISSECTION OF THE DIGESTIVE SYSTEM.

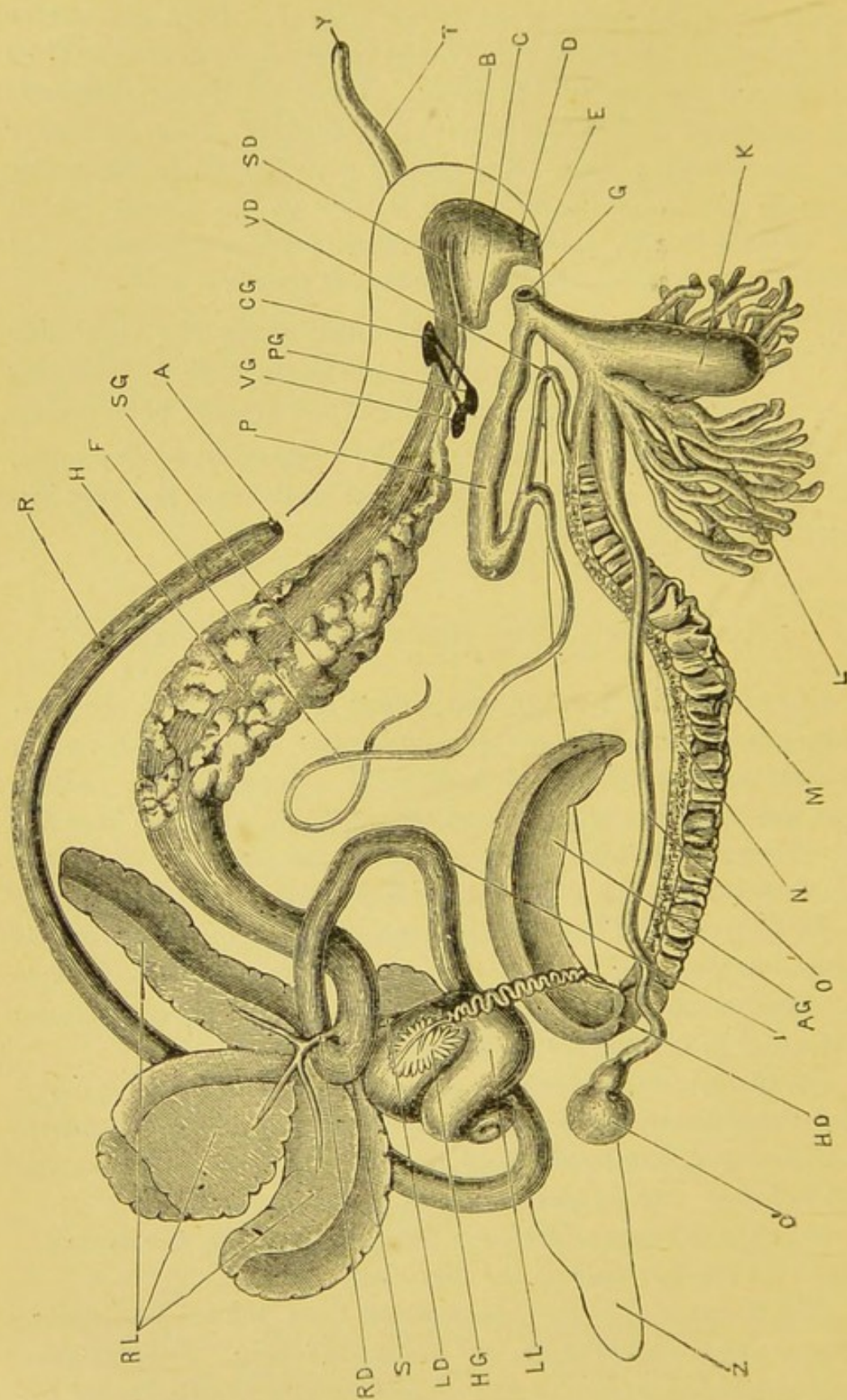
Cut away the part of the collar to the left of the pulmonary aperture. Detach the right side of the collar, with the anal aperture, from the body-wall. Separate the rectum from the body by cutting along the right side of the mantle, just below the rectum, as far back as the hinder end of the mantle-cavity. Turn the rectum back, and pin it down.

Make a median longitudinal incision through the floor of the mantle-cavity, and continue it forwards along the head to its anterior end. Dissect the flaps away from the underlying parts, and pin them out right and left.

Carefully remove the thin skin covering the spiral visceral mass; and unravel the reproductive organs, which are white in colour and very bulky, and the alimentary canal, the coils of which are very intimately connected with the liver.

Arrange the reproductive organs on the right, the digestive organs on the left side of the dissection.

The removal of the integument from the visceral mass requires care, but presents no great difficulty. Special care is needed at the posterior end of the mantle-cavity, where the parts are rather firmly bound together.



The dissection is greatly facilitated by frequent washing under the tap.

A. The Alimentary Canal.

The alimentary canal is a convoluted tube, of nearly uniform size along the greater part of its length, but presenting special features in its anterior portion.

1. The **buccal mass** or pharynx is the enlarged anterior end of the canal, into which the mouth opens. It forms a prominent rounded mass in the head, with stout muscular walls, and will be more fully examined at a later stage of the dissection (p. 128). It contains the **odontophore**.

Insert a seeker into the mouth, and note that it passes upwards and backwards into the buccal mass.

2. The **œsophagus** is a narrow thin-walled tube, which arises from the dorsal surface of the buccal mass and runs backwards, passing into the crop.
3. The **crop** is a large fusiform thin-walled dilatation of the alimentary canal, lying partly in front of the visceral hump, partly in the first turn of the spire. It is widest about the middle of its length, and gradually narrows behind.
4. The '**stomach**' is a slightly dilated loop of the alimentary canal, between the crop and the intestine. It lies close to the surface of the visceral hump, near the commencement of the second turn of the spire, and between the right and left lobes of the liver.

FIG. 30.—*Helix pomatia*. Dissection from the right side to show the digestive and reproductive systems. (A. M. M.)

A, anus. AG, albumen gland. B, buccal mass. C, sac of radula. CG, cerebral ganglion. D, jaw. E, mouth. F, flagellum. G, genital aperture. H, crop. HD, hermaphrodite duct. HG, hermaphrodite gland. I, intestine. K, dart sac. L, mucous glands. LD, left bile-duct. LL, left lobes of liver. M, female portion of the common duct. N, male portion of the common duct. O, receptaculum seminis. O', dilated end of receptaculum seminis. P, penis, retracted. PG, pedal ganglion. R, rectum. RD, right bile-duct. RL, right lobe of liver. S, 'stomach.' SD, salivary duct. SG, salivary gland. T, tentacle. VD, vas deferens. VG, viscero-pleural ganglion. Y, eye. Z, posterior end of foot.

Its mucous membrane is thrown into longitudinal folds.

5. The **intestine** describes a somewhat S-shaped course, and is imbedded in the liver, from which it is not very easy to separate it. From the stomach it runs back round the first turn of the spiral, lying in a groove on the outer side of the left lobe of the liver, to the hinder end of the mantle-cavity, where it passes into the rectum. It is superficial along a great part of its course.
6. The **rectum** has already been traced along the right side of the mantle-cavity to the anus.

B. The Digestive Glands.

1. The **salivary glands** are a pair of large white lobulated glands lying on the upper surface and the sides of the crop, to the walls of which they are attached by numerous strands of connective tissue. Their ducts, which are long and slender, run forwards and open into the buccal mass, one on each side of the œsophagus.
2. The **liver** is a very large bilobed gland, of a reddish-brown colour, which forms a large part of the visceral hump.
 - a. The **left lobe of the liver** is the larger of the two, and is partially subdivided into three lobes. It lies in the upper half of the first turn of the spire, immediately behind the mantle-cavity, and is grooved on its outer surface by the intestine. It has three main ducts, which unite to open by a single large aperture into the left side of the stomach.
 - b. The **right lobe of the liver** occupies the greater part of the second and upper turns of the spire. It is separated from the left lobe by the posterior end of the crop, the stomach and the commence-

ment of the intestine, and the albumen gland. It has one large duct, which opens into the right side of the stomach, almost opposite to the left duct, but slightly beyond it.

Slit up the stomach, and wash out its contents. Note the openings of the bile-ducts, and follow these with a seeker into the lobes of the liver.

IV. DISSECTION OF THE REPRODUCTIVE SYSTEM.

The snail is hermaphrodite, but does not fertilise its own ova. As is usual in such cases, the reproductive organs are extremely complex.

1. The **hermaphrodite gland** is a small yellowish body lying on the inner side of the second turn of the spire, and closely imbedded in the right lobe of the liver. Within it both ova and spermatozoa are produced.

Place a small piece of the hermaphrodite gland on a slide in a drop of water: tease it slightly: cover; and examine with low and high powers.

The gland consists of a number of finger-like follicles, in each of which ova are developed in the outer wall, and spermatozoa in the more central part. The ova are large round granular cells, with very large reticulate nuclei: the spermatozoa, which are generally aggregated in wisp-like bundles, have small rod-like heads and very long tails.

2. The **hermaphrodite duct** is a very sinuous duct of a whitish colour, lying along the inner side of the spire close to the columella, and opening into the inner side of the albumen gland.
3. The **albumen gland** is an elongated compact yellowish-white body, varying greatly in size at different times. It lies in the upper half of the first turn of the spire

along its inner side, between the stomach and the left lobe of the liver.

4. The **common duct** arises from the end of the albumen gland, close to the point of entrance of the hermaphrodite duct, and runs forwards through the body almost to the head, lying along the right side of the crop and œsophagus, and slightly ventral to these.

It is very wide, and along the greater part of its length is incompletely divided by a longitudinal septum into two parallel ducts. Of these one, the walls of which are thrown into very numerous and prominent transverse folds, serves for the passage of the ova; while the other, which transmits the spermatozoa, has a comparatively smooth surface, but has its walls thickened by a whitish glandular prostatic mass. At their anterior ends the two ducts separate completely from each other as **oviduct** and **vas deferens** respectively.

Slit open the common duct longitudinally; and note the septum, which partially divides it into male and female ducts.

5. The male duct and its accessory organs.

- a. The **vas deferens** is a slender slightly convoluted tube of uniform diameter, which runs forwards along the inner side of the female organs, between these and the buccal mass, passes under the retractor muscle of the right upper tentacle, and then runs back to open into the base of the penis.
- b. The **flagellum** is a long tubular diverticulum, which arises from the vas deferens just before it reaches the penis. It lies along the dorsal surface of the crop and other viscera. In it the spermatozoa are agglutinated together to form a long rod-like body, the **spermatophore**.
- c. The **penis** is a muscular tube continuous with the vas deferens, and lying somewhat obliquely across the œsophagus just behind the buccal mass; it

opens to the exterior at the genital pore, through which it can be protruded.

To the penis is attached the **retractor penis** muscle, a narrow muscular band, which arises from the floor of the mantle-cavity, and runs downwards and forwards to its insertion.

6. The female duct and its accessory organs.

- a. The **oviduct** is a short thick-walled tube, running forwards from the point at which it leaves the vas deferens.
- b. The **vagina** is a thick-walled tube into which the oviduct opens in front, and which runs forwards to open with the penis at the common genital pore.
- c. The **mucous glands** are two tufts of tubular glands, opening by a pair of apertures into the vagina: each tuft consists of thirty to forty finger-like processes.
- d. The **dart sac** is a large pyriform sac opening into the vagina just beyond the mucous glands. It has very thick walls, and contains a quadrangular calcareous spicule.
- e. The **spermatheca**, or **receptaculum seminis**, is a long caecal diverticulum from the hinder end of the vagina. It lies alongside the common duct, and its hinder end is expanded into a globular dilatation just behind the pericardium and kidney. It is of about the same length as the flagellum, and serves to lodge the spermatophore received from another snail.

A small diverticulum is very commonly given off about a third of its length from the vagina. In *H. aspersa* this is largely developed and forms the longer portion of the spermatheca.

Care must be taken not to mistake the spermatheca for the vas deferens, nor to cut away its

globular dilatation during the dissection of other parts.

V. DISSECTION OF THE NERVOUS SYSTEM.

The nervous system consists of paired ganglia, of commissures and connectives uniting them, and of nerves running from these central organs to all parts of the body. The chief ganglia with their commissures and connectives form a nerve-collar encircling the anterior end of the alimentary canal. When the head is protruded this collar surrounds the œsophagus immediately behind the buccal mass; but when the head is retracted the buccal mass is pulled back through the collar, which then lies in front of it.

The ganglia are enveloped in a rather dense layer of connective tissue, which must be removed before their shape can be determined.

1. The **supra-œsophageal** or **cerebral ganglia** are a pair of closely apposed pyriform masses, forming a broad transverse band across the dorsal surface of the alimentary canal.

From the outer ends of the ganglia large nerves run to both pairs of tentacles and to the lips.

From their under or ventral surface a pair of **buccal nerves** run forwards alongside the œsophagus, and end in a pair of small **buccal ganglia**, which lie at the outer sides of the salivary ducts close to their openings into the buccal mass. The buccal ganglia are connected by a transverse commissure, and from them nerves arise supplying the buccal mass.

From the posterior and outer border of each supra-œsophageal ganglion two stout connectives pass downwards and slightly backwards to the sub-œsophageal ganglia. Between these two on each side is the slender **auditory nerve**.

2. The **sub-œsophageal ganglia** are a number of closely approximated ganglionic masses, the boundaries of

which are difficult to determine. The anterior aorta runs through the centre of the mass, marking the division between the antero-inferior portion, or **pedal ganglia**, and the postero-superior portion, or **viscero-pleural ganglia**.

- a. The **pedal ganglia** are a pair of closely apposed masses, from which a number of large nerves pass to the foot.
- b. The **viscero-pleural ganglia** consist of at least two pairs of ganglionic masses, closely apposed to each other and to the pedal ganglia. From them large nerves pass outwards to the viscera and to the body-wall.

3. The structure of the ganglia.

Remove one of the ganglia ; place it in 1 per cent. acetic acid for a short time to soften the connective tissue, and then tease it on a slide in glycerine. Cover ; and examine it with low and high powers.

The **nerve-cells** are large granular cells with very large and distinctly reticulate nuclei, and with long branching processes by which they are connected with one another and with the nerve-fibres.

VI. THE SENSE ORGANS.

1. The **eyes** are placed one at the end of each of the larger tentacles, and are only exposed when these are fully protruded. Each receives a branch from the large nerve supplying the tentacle.

Each eye is a small spherical vesicle, the wall of which is strongly pigmented in its posterior portion, and lined by a layer of retinal cells. The cavity of the vesicle is partially filled by a large cuticular lens, which projects into it from its anterior wall.

2. The '**auditory**' organs are a pair of small spherical sacs imbedded in the substance of the pedal ganglia,

and containing numerous minute calcareous otoliths. They are placed at the ends of the auditory nerves, which connect them with the supra-œsophageal ganglia.

VII. DISSECTION OF THE BUCCAL MASS.

Remove the nerve-collar. Cut across the œsophagus and salivary glands about a quarter of an inch behind the buccal mass, and fix down the buccal mass firmly by pins through its retractor muscles. Note the horny jaw, seen as a dark transverse hoop across the front of the buccal mass: and the sac of the radula, which forms a rounded projection from its hinder end.

Slit up the œsophagus with scissors along the mid-dorsal line, and continue the cut forwards along the buccal mass as far as the jaw. Separate the two sides so as to expose the cavity of the buccal mass.

1. The **radula** is a brownish-yellow chitinous ribbon lying on the floor of the buccal cavity, and having its free surface produced into an immense number of minute backwardly directed teeth, arranged in very regular transverse rows.

The hinder end of the radula is folded longitudinally on itself, and lodged in a tubular sac, which projects freely behind the buccal mass, and within which the radula is formed as a cuticular secretion of its epithelial lining. The anterior end is opened out and rests on a cartilaginous cushion. By means of protractor and retractor muscles, the organ can be protruded from the mouth, and worked backwards and forwards with a licking or rasping action. As it wears away in front, it is replaced by growth forwards from its hinder end.

The radula with the cushions and the muscles together make up the **odontophore**.

Dissect out the radula; boil in 5 per cent. caustic potash;

and mount it on a slide in a drop of water or glycerine, with its toothed surface upward. Examine it with low and high powers.

2. The **jaw** is a semicircular chitinous bar, strongly ridged on its posterior surface, against which the odontophore works.

Dissect out the jaw and examine it with a lens or the microscope.

VIII. THE CIRCULATORY SYSTEM.

The dissection of the circulatory system must be performed on a second snail.

It is greatly facilitated by injecting the vessels with a coloured fluid. The arteries should be injected from the ventricle, and the pulmonary vein and its branches from the auricle. The venous system must be injected from several places; the right pulmonary sinus is easily injected both forwards and backwards, and the pedal sinuses may also be injected.

1. The arterial system.

From the ventricle arises a single large vessel, the **aorta**. This gives off almost at once a large **visceral artery**, which runs along the upper surface of the liver to the top of the spiral, supplying both lobes of the liver, the intestine, and the reproductive organs.

The aorta itself runs forwards along the right side of the crop, between it and the common duct, giving off large branches to the salivary glands and body-wall. It then continues its course forwards along the under surface of the œsophagus; pierces the sub-œsophageal ganglionic mass, passing between the pedal and visceropleural ganglia; gives off a large **pedal artery** which runs back along the foot; and finally divides into large branches supplying the tentacles and buccal mass.

2. The venous system.

The venous system consists partly of tubular vessels with definite walls, and partly of irregular lacunar spaces, the exact relations of which to the arteries and to the body-cavity are not determined.

Two large irregular **pedal sinuses** lie in the foot, one on each side of the pedal gland.

A **visceral sinus** commences at the top of the

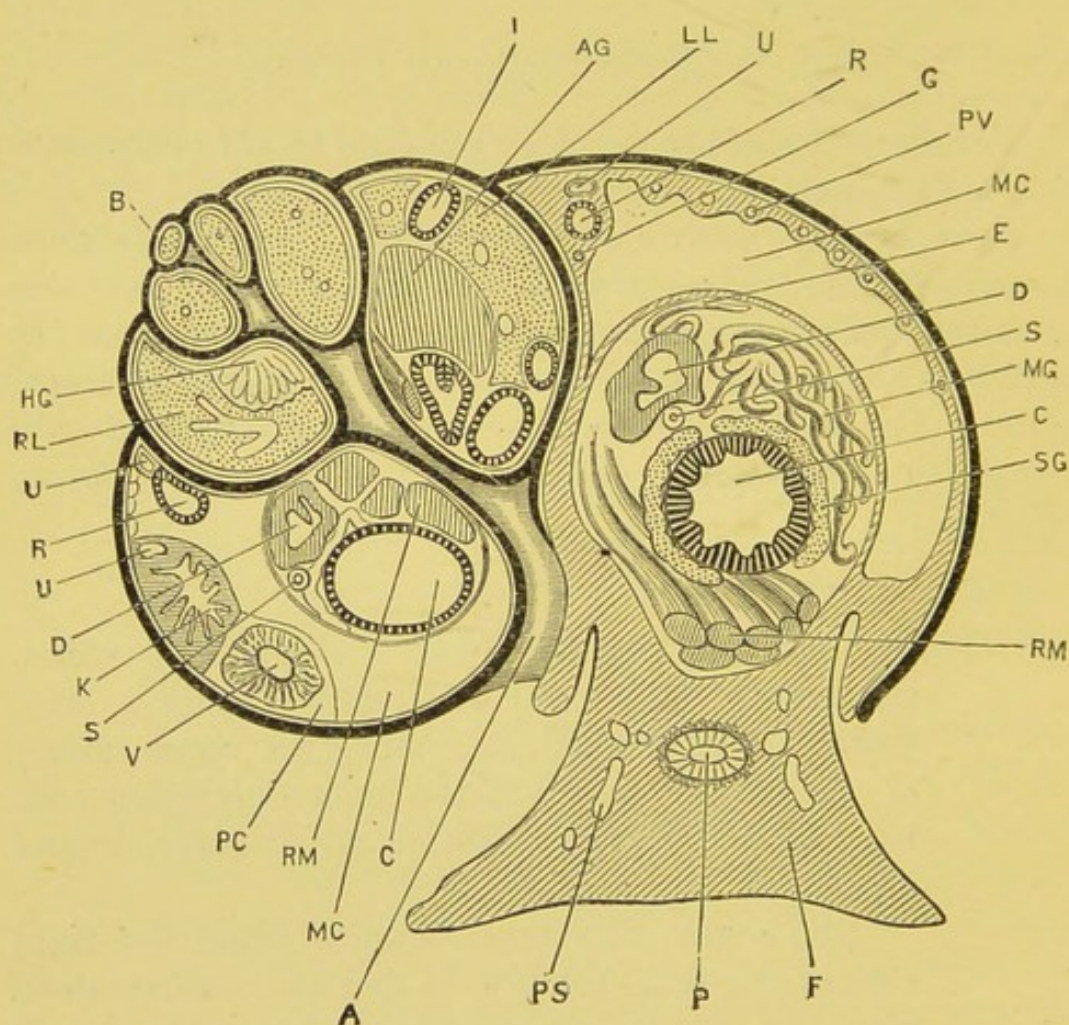


FIG. 31.—*Helix pomatia*. Section taken along the axis of the shell, and transversely to the foot. The shell is represented by the thick black line. (A. M. M.)

A, umbilicus. AG, albumen gland. B, nucleus of shell. C, crop. D, common duct. E, flagellum. F, foot. G, pulmonary sinus. HG, hermaphrodite gland. I, intestine. K, kidney. LL, left lobe of liver. MC, mantle-cavity or lung. MG, mucous glands. P, pedal gland. PC, pericardial cavity. PS, pedal sinus. PV, pulmonary vessels. R, rectum. RL, right lobe of liver. RM, retractor muscles. S, spermatheca. SG, salivary gland. U, ureter. V, ventricle.

spiral and runs down it, receiving branches from the various organs, to the posterior end of the mantle-cavity, where it opens into the **pulmonary sinus**, a large vein running all round the mantle-cavity at the junction of its sides and floor. Along the right side the pulmonary sinus lies immediately ventral to the rectum, to which it is closely attached, and from which it receives numerous small veins. From the pulmonary sinus the blood is carried to the roof of the mantle cavity by the afferent pulmonary vessels: these run parallel to one another in the roof of the mantle-cavity, interdigitating with the efferent vessels, with which they are connected by a network of thin-walled vessels in which the blood is aërated. The efferent vessels unite to form the **pulmonary vein**, a large trunk running straight back in the roof of the mantle-cavity to the heart. Just before reaching the auricle, the pulmonary vein receives a large **renal vein** from the kidney.

CHAPTER VIII.

THE CRAYFISH. *Astacus fluviatilis*.

THE freshwater crayfish is fairly common in many of the streams of England and Ireland, hiding in holes under the banks. It is of a greenish grey colour; and in form as well as in internal structure it closely resembles the lobster, to which it is nearly related. It moves about slowly, half walking on its long thoracic legs, half swimming, but when alarmed darts suddenly backwards by violent flexion of its tail or abdomen.

The hard external cuticle of the crayfish is transversely jointed, to allow movements of the body and limbs; and this segmentation affects also those internal organs which are directly concerned with locomotion, *i.e.* the muscles, and the nerves and blood-vessels supplying them. No segmentation, however, is to be seen in the alimentary canal or its glands, and none in the excretory and reproductive systems: in this respect the crayfish differs widely from such animals as the leech, in which these systems are arranged segmentally.

Each segment of the crayfish, except the last, bears a pair of jointed appendages. These differ greatly in the various regions of the body, but all are modifications of one common type, and serially homologous with one another. The anterior ones form tactile organs; those in the region of the mouth act as jaws, and the remainder as organs of locomotion. The foremost pair of these latter are of great size, and end in powerful pincers, used for prehension of food and for offensive and defensive purposes.

The crayfish is carnivorous, seizing its food, and tearing it to pieces by means of the large pincers, aided by the smaller

pincers of the next two pairs of legs, and then cutting it up into little bits with the jaws, which are placed at the sides of the mouth. The real chewing is effected afterwards in the stomach itself.

The sexes are distinct. The male and female are very similar, but the abdomen is broader in the female.

The eggs are comparatively large, and are carried about by the female, attached to the abdominal appendages, until the young are hatched. The newly hatched crayfish differs considerably in form from the adult, but has the full number of appendages already present. It remains for a time attached by its pincers to the appendages of the mother, but soon takes to independent life. To allow for the growth of the animal, the cuticle, which is incapable of interstitial growth, is cast off periodically, and a new one secreted. This **ecdysis**, or shedding of the cuticle, occurs three or more times during the first year of the animal's life, and afterwards about once a year, or less often. It involves not merely the external investment of the body and limbs, but the covering of the gills and sense organs, and to a certain extent the lining of the alimentary canal.

Crayfish may be killed almost instantaneously by dropping them into boiling water.

I. EXTERNAL CHARACTERS.

The body of the crayfish is very obviously divisible into an anterior unjointed portion, the **cephalothorax**, and a jointed and flexible hinder portion, the **abdomen**.

A. Examination of a Typical Segment of the Body.

Examine in detail the third or fourth segment of the abdomen, noticing the following points.

1. The **cuticular investment** or **exoskeleton** of the segment is hardened by calcification, except the portions at the joints, which remain soft to allow of movement. Each hardened portion is called a **sclerite**.

- a. The **tergum** is the convex dorsal plate of the exoskeleton.
- b. The **sternum** is the ventral transverse bar between the bases of the limbs.
- c. The **pleura** are a pair of plates projecting down at the sides.
- d. The **epimera** are the portions of hardened cuticle between the pleura and the bases of the limbs. They are very small in this segment.

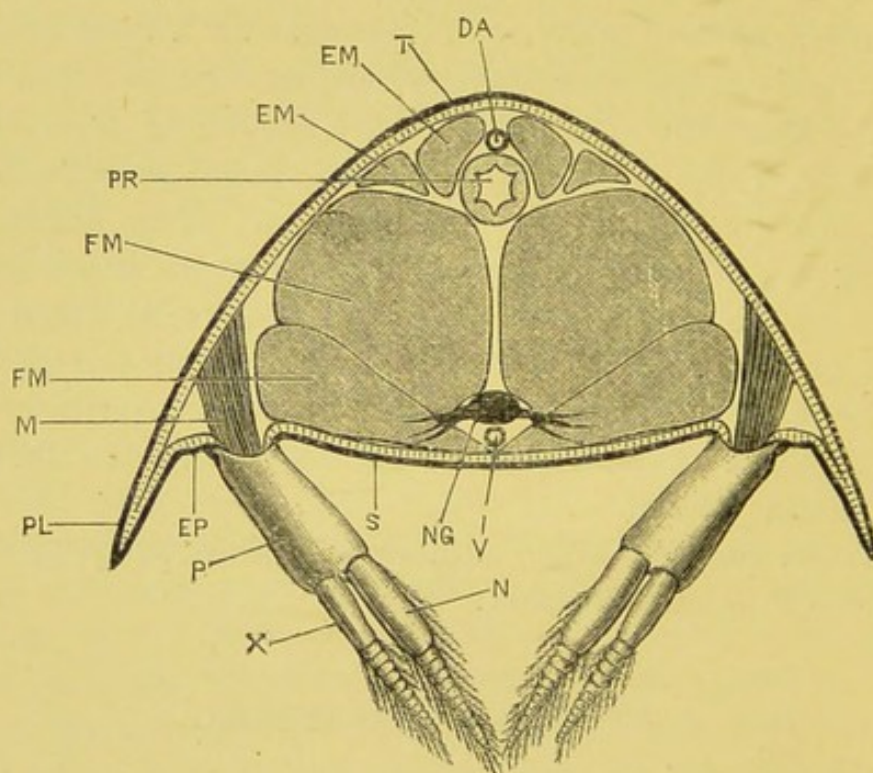


FIG. 32.—*Astacus fluviatilis*, var. *nobilis*. Transverse section through the abdomen. (C. H. H.)

DA, dorsal abdominal artery. EM, extensor muscles of the abdomen. EP, epimeron. FM, flexor muscles of the abdomen. M, muscles of the appendage. N, endopodite. NG, nerve-ganglion. P, protopodite: the proximal segment, which is very short, has been almost entirely cut away; its length is indicated by the notch on the outer side of the protopodite. PL, pleuron. PR, proctodæum. S, sternum. T, tergum. V, ventral abdominal artery. X, exopodite.

- e. Soft **uncalcified** portions connect the segment with those in front of and behind it, and allow movement of one segment upon another.
- f. The **joints** between the successive segments are provided with a rounded peg or pivot at each side

on the anterior margin of the tergum, near its junction with the pleuron. This peg fits into a corresponding depression in the hinder margin of the segment next in front, and serves as a fulcrum in the flexion and extension of the abdomen: it also prevents movement of the abdomen from side to side.

2. The **appendages** are attached to the sides of the ventral surface of the segment, between the epimera and the ends of the sternum, by soft patches of cuticle, the **arthrodial membranes**. Each appendage consists of a two-jointed basal portion, the **protopodite**, and of two many-jointed filaments borne on its distal end. These are the **endopodite** and the **exopodite**, the former of which is nearer the median plane.

B. The Body.

This is obviously composed of two parts, the cephalothorax and the abdomen.

1. The **cephalothorax** is composed of thirteen segments fused together, the fusion being so complete that the segmentation is not recognisable on the dorsal and lateral surfaces, though it can still be seen below.

The cephalothorax is encased laterally and dorsally by a large shield, the **carapace**. This is divided into cephalic and thoracic portions, covering respectively the head and the thorax of the animal, by the shallow **cervical groove**, which runs transversely across its dorsal surface, and obliquely forwards at the sides. The thoracic portion of the carapace arises as an outgrowth from the hinder border of the head, which grows back over the thoracic segments, and is continuous with them dorsally.

- a. The **head**, or part in front of the cervical groove

is composed of five segments. In it are to be noticed the following structures.

- i. The **rostrum** is a median pointed prolongation of the carapace, extending forwards from its anterior end.
 - ii. The **eyes** are paired and mounted on movable stalks, one at each side of the rostrum.
 - iii. The **mouth** is far back on the ventral surface of the head, and almost hidden by the jaws. It is bounded in front by a fleshy protuberance, the **labrum**.
- b. The **thorax**, or part behind the cervical groove, is composed of eight segments. The following points are to be noticed in it.
- i. The **thoracic portion of the carapace** is divided by two longitudinal grooves about half an inch apart, the **branchio-cardiac grooves**, into a **median dorsal portion** covering the heart, and two large plates, the **branchio-stegites**, which extend down at the sides of the thorax and cover the gills.
 - ii. The **sterna** of the thoracic segments are all fused together, except the hindmost, which is movable.
2. The **abdomen** is composed of seven movable segments, united by peg and socket joints, which allow of movements in a vertical plane only, the limit of extension possible being nearly a straight line.
- a. The **first abdominal segment** is smaller than the succeeding ones, and is devoid of pleura.
 - b. The segments from the **second** to the **sixth** are essentially like the typical segment already examined.
 - c. The **seventh** abdominal segment, or **telson**, is much flattened dorso-ventrally, and is devoid of pleura

and of appendages: it is divided transversely by an imperfect hinge, and its ventral surface, which is only slightly calcified, is perforated by the longitudinal slit-like anus.

C. The Appendages.

These are all reducible to a common type composed of the three parts **protopodite**, **exopodite**, and **endopodite**, already seen in the appendage of the typical segment, together with an **epipodite**, which may be a simple plate or may bear gill plumes. From such a typical form all the appendages of the crayfish can be derived by variations in form and relative size of the various parts, or by total suppression of one or more parts.

In the following description the appendages are numbered from before backwards, and are distinguished by the large Roman numerals **I.** to **XIX.**

Remove the appendages of the right side one by one, beginning with the hindmost, and taking special care to remove each appendage entire. The characters of the smaller ones can be best made out by examination in a drop of water, between two slips of glass.

1. The **abdominal appendages**, excepting the hindmost, are of small size, and serve in the female to carry the eggs. The last or twentieth segment has no appendages.

XIX. The **sixth abdominal appendages** are broad and lamellar, and form with the telson the powerful tail-fin.

- i. The **protopodite** is short, broad, and undivided.
- ii. The **endopodite** is a flat oval plate, fringed at its free edge with setæ.
- iii. The **exopodite** is similar, but larger, and divided by a transverse hinge into two parts.

XVIII. The fifth abdominal appendage is a small swimmeret.

- i. The **protopodite** is two-jointed, the small proximal segment being named **coxopodite**, the longer distal segment the **basipodite**.
- ii. The **endopodite** is a many-jointed filament covered with setæ. Its first segment is the largest.
- iii. The **exopodite** is similar, but smaller.

XVII. and **XVI.** These two pairs of appendages closely resemble **XVIII.**

XV. In the female this resembles **XVIII.**, but is liable to reduction, and may be absent.

In the male it is normally turned forwards and is specially modified for transferring the spermatozoa to the female. The **protopodite** and **exopodite** resemble those of **XVIII.**, but the large proximal segment of the **endopodite** is produced distally on its inner side into a short plate, rolled longitudinally upon itself to form an imperfect tube: the remainder of the **endopodite** is a small jointed rod as in **XVIII.**

XIV. In the female this is reduced or absent.

In the male it is modified for the same purpose as **XV.** It is an unjointed rod, the distal portion of which is flattened and rolled upon itself to form an imperfect tube. It is probably formed of the **protopodite** and **endopodite** fused together.

2. The **thoracic appendages**, of which there are eight pairs, fall readily into two groups: a **posterior group** of five pairs of large appendages, **XIII.** to **IX.**, used for walking and prehension, and devoid of **exopodites**; and an **anterior group** of three pairs of **maxillipedes** or foot-jaws, **VIII.** to **VI.**, which possess both exo-

podites and endopodites, and aid in passing food to the mouth.

The thoracic appendages can be more easily removed, and their relations determined, if the branchiostegite be first cut away.

XII. The last but one of the thoracic legs may be taken as a type of the series.

i. The **protopodite** consists of two segments, of which the first, or **coxopodite**, is short and broad, and bears a large gill and a tuft of long fine hairs, the 'coxopoditic setæ.' The second segment, or **basipodite**, is much smaller, and bears the endopodite.

ii. The **endopodite** consists of five segments, named as follows, beginning at the proximal end:—**ischiopodite**, **meropodite**, **carpopodite**, **propodite**, and **dactylopodite**. Of these the meropodite and the propodite are the longest, and the dactylopodite is clawlike.

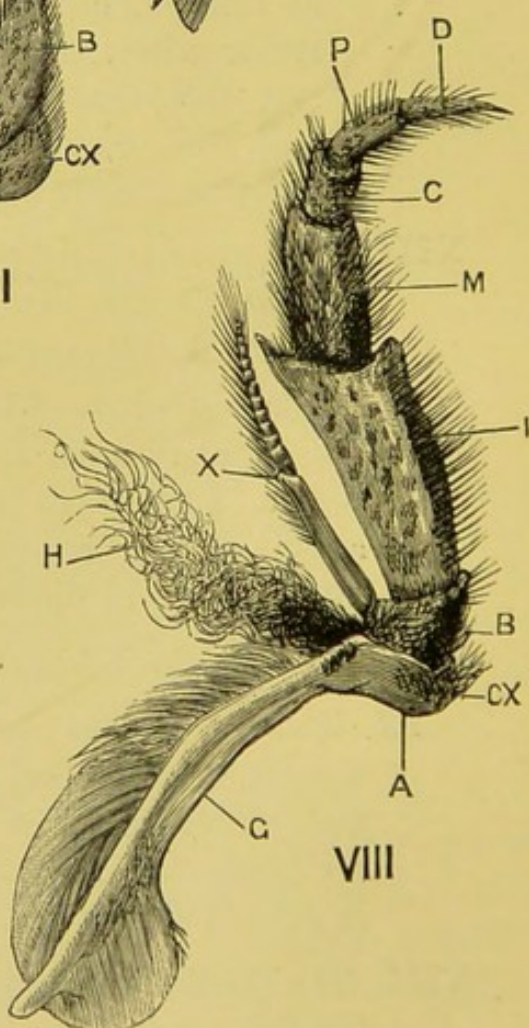
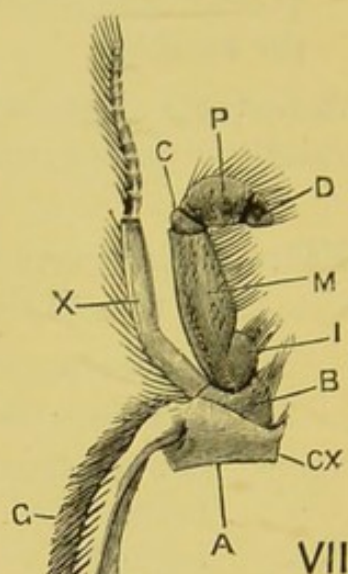
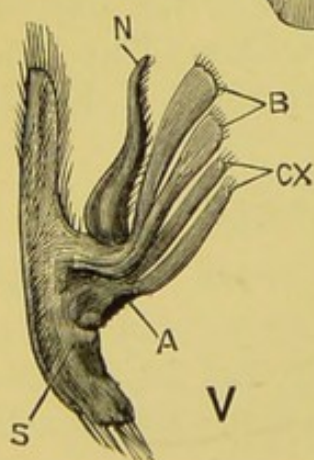
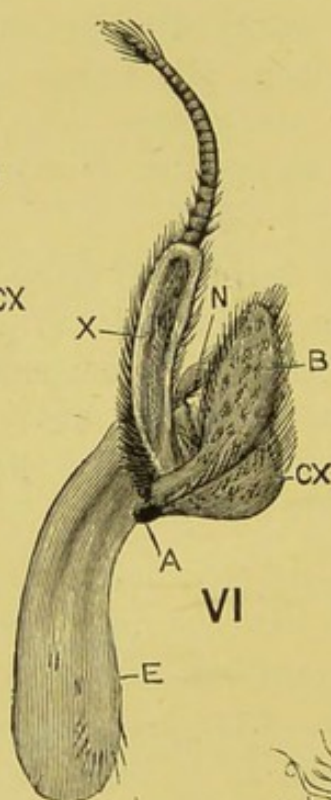
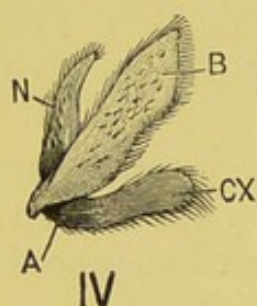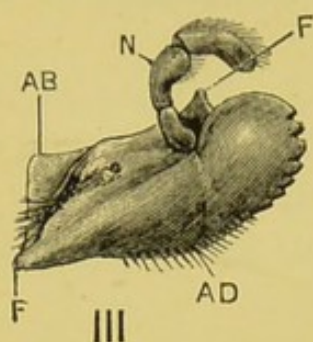
XIII. This, the last thoracic leg, differs from **XII.** in having no gill. In the male the coxopodite is perforated at its inner angle by the **genital pore**.

XI. This resembles **XII.**, but the propodite is prolonged distally so as to form with the dactylopodite, a chele or pair of pincers. The inner angle of the coxopodite is perforated by the **genital pore** in the female.

X. This is like **XI.**, but has no genital pore.

IX. This is similar to **X.**, but much larger and stouter, the terminal chele being especially large and powerful. The basipodite and ischiopodite are firmly fused together, as happens occasionally in other limbs of the series.

VIII. The third maxillipede is directed forwards under the five appendages in front of it.



- i. The **protopodite** consists of **coxopodite**, bearing a gill and coxopoditic setæ; and **basipodite**, bearing endopodite and exopodite.
- ii. The **endopodite** consists of five segments, named as in the legs. The first segment or ischiopodite is the largest and is fused with the basipodite.
- iii. The **exopodite** is slender, and consists of a long proximal segment and a distal many-jointed filament.

VII. The **second maxillipede** is smaller and less firmly calcified than **VIII.**, which it resembles in form; but the exopodite is larger than in **VIII.**, and the endopodite smaller, its largest segment being the meropodite, and all its joints being movable.

VI. The **first maxillipede** is smaller and softer than **VII.**

- i. The two segments of the **protopodite** are expanded on the inner side, forming a large two-lobed lamella. A broad plate, the **epipodite**, takes the place of a gill.
 - ii. The **endopodite** is very small and two-jointed.
 - iii. The **exopodite** resembles that of **VII.**
3. The **head appendages** consist of three pairs of **oral appendages** or **jaws**, **V.** to **III.**, placed at the sides of the mouth, and two pairs of **pre-oral appendages**, **II.** and **I.**, at the front of the head.

V. The **second maxilla** consists of a protopodite, an endopodite, and on the outer side an exopodite

FIG. 33.—*Astacus fluviatilis*, var. *nobilis*. The oral appendages of the right side seen from below and behind; $\times 2\frac{1}{2}$. (C. H. H.)
 III, the mandible. IV and V, the first and second maxillæ. VI, VII and VIII, the three maxillipedes.

A, region of attachment to body-wall. AB and AD, points of insertion of abductor and adductor muscles of mandible. B, basipodite. C, carpopodite. CX, coxopodite. D, dactylopodite. E, epipodite. F, pivots of mandible. G, gill. H, coxopoditic setæ. I, ischiopodite. M, meropodite. N, endopodite. P, propodite. S, scaphognathite. X, first segment of exopodite.

which is subservient to respiration, the **scaphognathite**.

- i. The **protopodite** consists of two segments, coxopodite and basipodite, each of which is expanded on its inner side into a bilobed lamella.
 - ii. The **endopodite** is small, pointed, and unjointed.
 - iii. The **scaphognathite** or **exopodite** is an elongated plate attached by the middle of its inner edge to the outer side of the basipodite. It serves to keep a current of water flowing through the gill-chamber (p. 146).
- IV. The **first maxilla** is small. The two segments of the protopodite extend inwards as thin curved lamellæ, and the endopodite is a small plate to their outer side. There is no exopodite.
- III. The **mandible** consists of a very stout undivided **protopodite**, forming the powerful jaw at the side of the mouth; and an **endopodite**, which forms a small three-jointed palp, lying in a groove on the front of the protopodite.

Before removing the mandible, note the position of the two pivots about which it turns, and the points of insertion of the tendons of its abductor and adductor.

Immediately in front of the first maxilla and behind the mandible is a small unjointed plate, leaf-like in form. It is not regarded as a true appendage, but as an outgrowth of the **metastoma**, which forms the posterior and lateral borders of the mouth.

- II. The **antenna** consists of protopodite, exopodite, and endopodite, the last of which forms the long 'feeler.'
- i. The **protopodite** consists of two segments; the first, or coxopodite, being very broad, and projecting only very slightly from the surface of the head; on its ventral surface is a tubercle perforated

posteriorly by the **renal aperture**. The second segment, or basipodite, is also short and stout, and bears the endopodite and exopodite.

- ii. The **endopodite** has three stout basal segments and a long slender many-jointed feeler. The first segment is divided longitudinally into an inner and an outer part, movable on each other, and thus allowing rotation of the next segment.
- iii. The **exopodite** is a stout sharp-pointed blade, the **scaphocerite**.

I. The **antennule** is smaller than the antenna.

- i. The **protopodite** is three-jointed, the basal segment being much the largest, and containing the 'auditory' organ, which opens on its dorsal surface. The aperture is three-cornered, and is guarded by a series of plumose setæ, which extend across it from its outer lip.
- ii. The **endopodite** and **exopodite** are two many-jointed filaments, the exopodite being slightly the larger.

D. The Gills and Gill-chambers.

The gills are highly vascular external outgrowths from the sides of the thorax and from its appendages. In them respiration occurs, this process consisting in an interchange, by diffusion through the thin cuticle, of the gases dissolved in the water and in the blood. The gills are enclosed and protected by downward growths of the carapace at the sides of the thorax, the **branchiostegites**.

- 1. The **branchial chambers** are situated one at each side of the thorax, between the body and the branchiostegite.

Expose the left branchial chamber by cutting away the branchiostegite of that side; and fix the animal on its right side under water.

The chamber is bounded on its inner side by the thoracic wall, and on its outer side by the

branchiostegite. It is open below and behind, and the former opening is partially stopped by the basal segments of the legs. The greater portion of the chamber is occupied by the gills; but in front of them, and just behind the line of the cervical groove, is a channel, the **cervical canal**. In this canal the scaphognathite works to and fro with a sculling

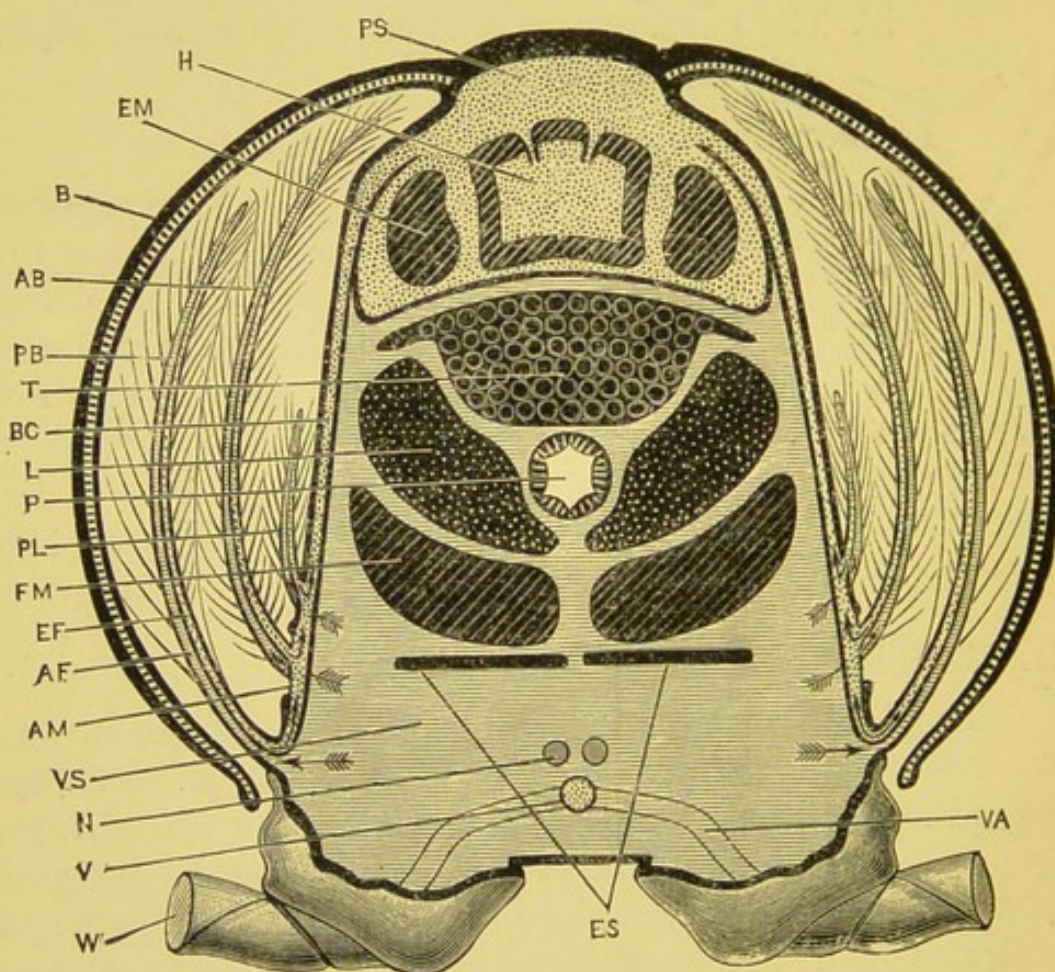


FIG. 34.—*Astacus fluviatilis*. Diagrammatic transverse section through the thorax. The dotted spaces contain arterial blood. The spaces shaded with horizontal lines contain venous blood. The arrows indicate the direction of the blood circulation. (C. H. H.)

AB, arthrobranchia: only one is figured on each side. AF, afferent vessel of gill. AM, arthrodiol membrane. B, branchiostegite. BC, branchio-cardiac canal. EF, efferent vessel of gill. EM, extensor muscle of the abdomen. ES, endophragmal skeleton. H, heart, showing the dorsal ostia, with their valves. L, liver. PM, flexor muscle of the abdomen. N, nerve-connective. P, proctodæum. PB, podobranchia. PL, pleurobranchia. PS, pericardial sinus. TL, testis, with roots of vasa deferentia. V, ventral thoracic artery. VA, artery supplying leg. VS, ventral blood-sinus: it contains numerous large muscles moving the limbs, which are not represented in the figure. W, one of the legs, cut off short.

movement, driving the water forwards out of the gill-chamber, and discharging it in front just below the renal aperture. (See Section E, p. 146.)

2. The gills may be described in three groups according to their position of attachment.

a. **Podobranchiæ** are gills attached to the coxopodites of appendages **VII.** to **XII.** The coxopodite of **VI.** bears a large epipodite in place of a gill.

b. **Arthrobranchiæ** are gills arising from the arthrodial membranes at the bases of the thoracic appendages. At the base of each of the limbs **VIII.** to **XII.** are two arthrobranchiæ, an anterior and a posterior one; and attached to the arthrodial membrane of **VII.** is a single one.

c. **Pleurobranchiæ** are gills arising from the side-wall of the thorax, above the ridges which form the dorsal boundaries of the arthrodial membranes. The crayfish has only one well-developed pleurobranchia on each side, on the thirteenth segment, but abortive ones are found on the next two or three segments in front.

The following table shows the number and arrangement of the gills in the crayfish.

Rud.= Abortive rudiment. Ep.=Epipodite.

Segment	VI.	VII.	VIII.	IX.	X.	XI	XII.	XIII.	Totals
Podobranchiæ	Ep.	1	1	1	1	1	1	0	6 + Ep.
Arthro. anterior	0	1	1	1	1	1	1	0	6
Arthro. posterior	0	0	1	1	1	1	1	0	5
Pleurobranchiæ	0	0	0	0	Rud.	Rud.	Rud.	1	1 + 3 Rud.

Verify the above table by carefully counting the gills, and turning them down as they are checked off in the table.

3. The structure of the gills is different in the different groups.

Remove and examine in turn a pleurobranchia, an arthrobranchia, and a podobranchia.

- a. The **pleurobranchiæ** and **arthrobranchiæ** resemble bottle-brushes, each consisting of a series of delicate **branchial filaments** arranged upon a central stem, which is traversed by afferent and efferent blood-vessels. It is in the branchial filaments that respiration is effected, diffusion taking place through the thin cuticle covering them.
- b. A **podobranchia** is more complicated, and consists of (i.) a **basal plate** arising from the outer surface of the coxopodite, and covered with finely plumose setæ; (ii.) a **stem** arising from the dorsal border of the basal plate close to its apex; (iii.) a **lamina**, which is a corrugated plate borne on the distal end of the stem, doubled longitudinally upon itself, and beset with small hooked setæ; and (iv.) a **plume**, which arises from the apex of the stem and resembles an arthrobranchia. The plume and the outer face of the stem are covered with **branchial filaments**.

E. **Demonstration of the Respiratory Current of water through the gill-chamber.**

Place a living crayfish in a shallow dish of water; and, when the animal is at rest, run into the dish close to the bases of the hinder legs, by means of a pipette, a few drops of water coloured with suspended carmine or other pigment. Watch the currents entering under the edges of the branchiostegites behind, and issuing in front from the mouths of the cervical canals.

Open the cervical canal of one side by making two cuts, one immediately behind the cervical groove, the other parallel to it and a quarter of an inch further back; and removing the strip between the two cuts. Lay the animal on its side in the water, and observe the sculling movements of the scaphognathite, driving the water forwards out of the cervical canal.

II. DISSECTION OF THE CRAYFISH.

The several systems are described below in the order in which it will be most convenient to dissect them : this order may be varied if found desirable.

A. The Circulatory System.

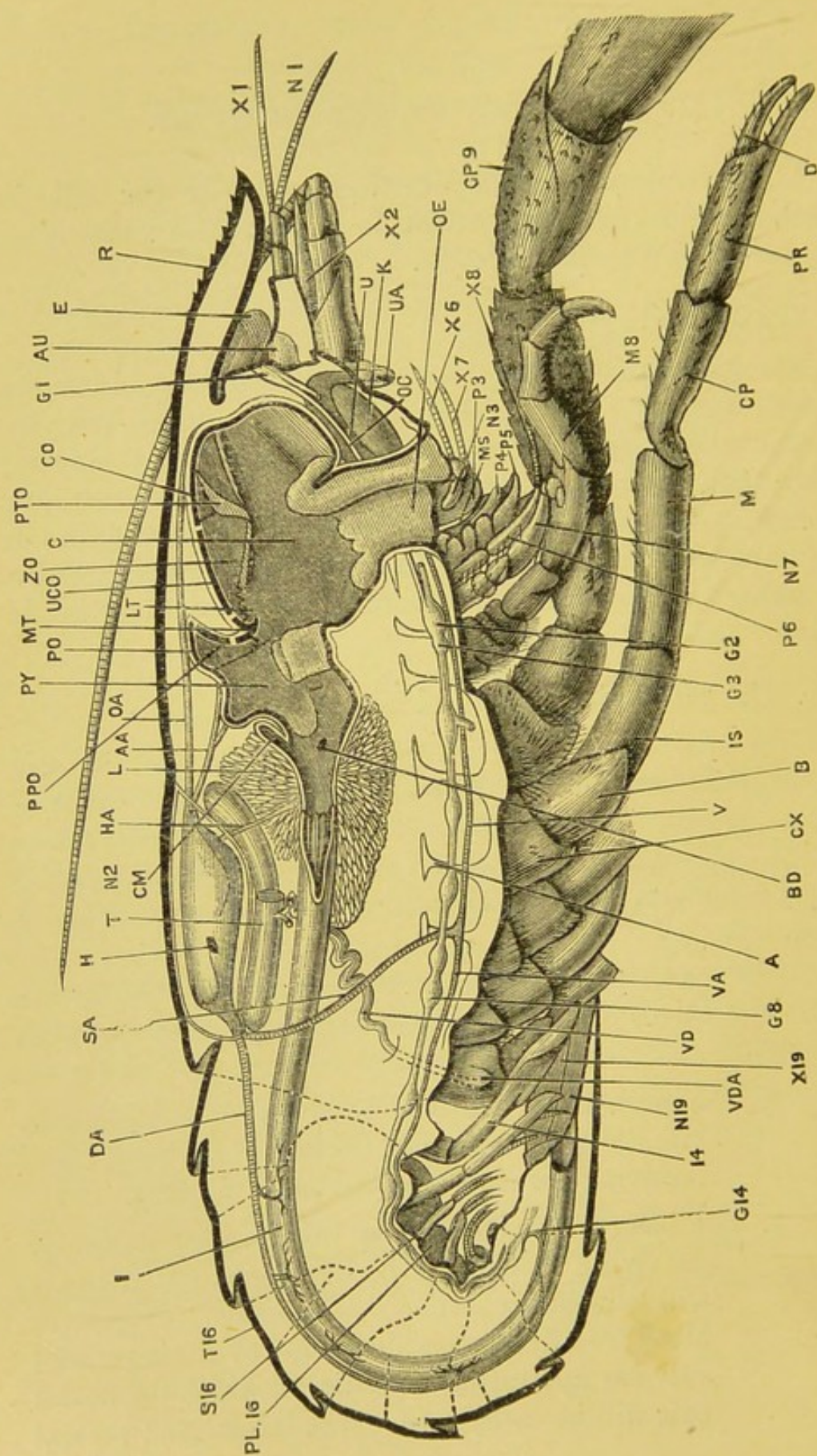
The blood of the crayfish, which is slightly bluish, is carried from the heart to the various parts of the body by arteries which open into large lacunar spaces or sinuses, bathing the several organs : from these it passes to the gills, in which it is aërated, and from which it is conveyed through the branchiocardiac canals to the pericardial sinus. From the sinus it enters the heart through the apertures in its walls.

1. The pericardial sinus and heart.

With stout scissors carefully cut through the thoracic portion of the carapace along the outer side of each branchiocardiac groove, taking care not to injure the structures beneath. Connect the two cuts in front by a transverse cut along the cervical groove, and remove the portion of carapace so isolated.

Cut through the skin underlying the carapace, and turn it aside, thus laying open the pericardial sinus and exposing the heart.

- a. The **pericardial sinus** is a cavity of considerable size, lying in the dorsal portion of the thorax and receiving the arterial blood from the gills.
- b. The **heart** is a polygonal thick-walled muscular sac lying in the pericardial sinus. If living it will be seen to contract rhythmically. It receives blood from the pericardial sinus by three pairs of valvular apertures, the **ostia**, of which the dorsal pair will be easily seen. The lateral and ventral



pairs will be better seen at a later stage of the dissection.

c. The roots of the arteries are rather small and transparent, and hence difficult to see. They arise from the two ends of the heart, and should be noticed at the present stage of the dissection, though the arteries themselves are best seen in an injected specimen, and will be described later (p. 159).

- i. From the anterior end of the heart arise a median ophthalmic artery and a pair of antennary arteries; and behind and below these a pair of hepatic arteries.
- ii. From the hinder end of the heart arises the large median dorsal abdominal artery, and immediately below this the large median sternal artery, which latter can be better seen at a later stage.

FIG. 35.—*Astacus fluviatilis*, var. *nobilis*. Dissection of a male from the right side. The right side of the body-wall with its appendages, and the right side of the œsophagus, stomach, and mesenteron, have been removed. The thick black line represents the cut edge of the cuticle. (C. H. H.)

A, endophragmal skeleton. AA, antennary artery. AU, 'auditory' sac. B, basipodite of the tenth appendage. BD, aperture of left bile-duct into the mesenteron. C, cardiac chamber of the stomach. CM, cæcum. CO, cardiac ossicle. CP 9, carpopodite of tenth appendage. CP 3, carpopodite of ninth appendage. CX, coxopodite of tenth appendage. D, dactylopodite of the same. DA, dorsal abdominal artery. E, eye. G 1, supra-œsophageal ganglion. G 2, sub-œsophageal ganglion. G 3, second post-œsophageal ganglion. G 8, last thoracic ganglion. G 14, last abdominal ganglion giving off posterior visceral and other nerves. H, right lateral ostium of the heart. HA, hepatic artery. I, proctodæum. IS, ischiopodite of the tenth appendage. K, kidney. L, liver. LT, lateral tooth. M, meropodite of the tenth appendage. MS, metastoma. MT, median tooth. M 8, meropodite of the eighth appendage. N 1, N 3, etc., endopodites of first, third, etc., appendages. OA, ophthalmic artery. CC, left para-œsophageal connective: the greater part of the right one has been removed. OE, œsophagus. PL 16, pleuron of the sixteenth segment. PO, pyloric ossicle. PPO, prepyloric ossicle. PR, propodite of the tenth appendage. PTO, pterocardiac ossicle. PY, pyloric chamber of the stomach. P 3, P 4, P 5, protopodites of the third, fourth, and fifth appendages. R, rostrum. SA, sternal artery. S 16, sternum of the sixteenth segment. T, testis: the right anterior lobe has been removed. T 16, tergum of the sixteenth segment. U, ureter. UA, aperture of the ureter. UCO, urocardiac ossicle. V, ventral thoracic artery. VA, ventral abdominal artery. VD, left vas deferens: the right one has been cut off short. VDA, aperture of the left vas deferens. X 1, X 2, etc., exopodites of first, second, etc., appendages. ZO, zygocardiac ossicle. 14, the fourteenth appendage.

- d. The **alæ cordis** are three pairs of fibrous bands which hold the heart in position by connecting it with the walls of the pericardial sinus.

Remove the branchiostegite and turn down the gills of the left side, unless this has already been done.

2. The **branchiocardiac canals** are a series of channels in the body-wall, conveying blood from the gills to the pericardial sinus. They can be seen through the transparent body-wall running from the bases of the gills, and converging to open into the sides of the pericardial sinus.

Cut a gill off close to its base, and blow into the cut end of the efferent blood-vessel with a blowpipe, or inject some coloured fluid into it, and observe the air or coloured fluid entering the pericardial sinus.

B. The Reproductive System.

Carefully remove the side-wall of the thorax, and expose the reproductive organs.

a. In the male.

- i. The **testis** is a soft white body lying immediately below the pericardial sinus, and extending backwards a little behind it. It consists of a pair of anterior lobes, and a median posterior lobe.
- ii. The **vas deferens** of each side is a long convoluted tube, running from the junction of the anterior and posterior lobes of the testis to the external aperture on the coxopodite of the last thoracic leg. Before the breeding season it will be found filled with an opaque white seminal mass.

Treat a small piece according to directions on p. 75 ; cover, and examine it with low and high powers.

- iii. The **spermatozoa** are flattened spheroidal cells

from which project tangentially a number of stiff immobile curved processes.

b. In the female.

- i. The **ovary** is a saccular organ situated below and at the sides of the pericardial sinus, and extending some distance behind it. Like the testis it consists of two anterior lobes and a posterior one.
- ii. The **oviduct** of each side is a short wide almost straight tube, running from about the middle of the length of the ovary, with which it is continuous, to the external opening on the coxopodite of appendage **XI.**, the last thoracic leg but two.

C. The Digestive System.

The alimentary canal of the crayfish is a tube running in a nearly straight line from the mouth to the anus. Of this tube the middle portion or **mesenteron**, which is very short, is alone formed from the primitive alimentary tract of the embryo, and the 'liver' is an outgrowth of it. The **stomodæum** or anterior portion of the canal and the **proctodæum** or hind portion, which together form almost the whole length of the canal, are both formed by invagination of the external surface of the body; and both have a chitinous lining which is continuous, at the mouth and anus respectively, with the chitinous external covering of the body.

1. The digestive glands.

- a. The 'liver' is a large bilobed body, of a brown or greenish colour, lying in the thorax at the sides of the alimentary canal. Each lobe is much branched and hollow, and its secretion enters the mesenteron by a wide **bile-duct**, which will be seen later on in the dissection.

2. The alimentary canal.

Remove the abdominal terga, the genital duct, and the

greater part of the liver of the left side, and as much of the muscles and cephalic carapace as is necessary to expose the alimentary canal.

- a. The **stomodæum**, or first portion of the alimentary canal, has a chitinous lining.
 - i. The **mouth** is an oval aperture on the ventral surface, between the jaws.
 - ii. The **œsophagus** is a short wide tube, running vertically upwards from the mouth.
 - iii. The **stomach** is a spacious dilatation of the alimentary canal, occupying the greater part of the head, and extending a short distance into the thorax. It consists of a larger **cardiac chamber** in front, and a smaller **pyloric chamber** behind, separated from each other by a constriction. Its chitinous lining is thick, and some parts of it are especially hardened, forming the **gastric mill**, a complex mechanism of 'ossicles' supporting three large and strongly calcified **teeth**. These structures will be seen at a later stage of the dissection.
- b. The **mesenteron** or **mid-gut**, which follows the stomach, is very short and devoid of chitinous lining. On each side it receives a wide bile-duct from the liver, and its dorsal wall is produced into a small **cæcum**.
- c. The **proctodæum** or **intestine** is a long narrow straight tube, running from the hinder end of the mesenteron to the **anus**. It has a chitinous lining throughout, and its inner surface presents longitudinal and slightly spiral ridges beset with small papillæ.

The **anus** is a longitudinal slit on the ventral surface of the telson: it can be closed by approximation of its sides.

Remove a piece of the intestine, and examine its inner

surface under water with a low power of the microscope, to see the ridges and papillæ.

- d. The **gastric mill** is a complex structure made up of numerous **sclerites**, or hardened portions of the cuticle lining the stomach, by means of which the chewing of the food is effected: the principal sclerites will alone be described here, viz. five median dorsal pieces and two pairs of lateral pieces, the others being small and of less importance.

Remove the entire stomach from the body, avoiding injury to the structures around the œsophagus; place it in a dish under water, and carefully clean away the muscles.

- i. The **cardiac ossicle** is a broad transverse sclerite in the roof of the cardiac chamber of the stomach.
- ii. The **urocardiac ossicle** is a median dorsal sclerite in the hinder wall of the cardiac chamber. Its upper end is broad, and hinged to the hinder edge of the cardiac ossicle; its lower end is narrow, and directed downwards and backwards.
- iii. The **pyloric ossicle** is a narrow transverse sclerite in the anterior part of the dorsal wall of the pyloric chamber.
- iv. The **prepyloric ossicle** lies in the anterior wall of the pyloric chamber, and is hinged above to the anterior border of the pyloric ossicle.
- v. The **median tooth** is a strong calcified sclerite, at the junction of the cardiac and pyloric chambers. With its upper surface are articulated the urocardiac ossicle in front and the prepyloric behind.
- vi. The **pterocardiac ossicles** are attached one to each end of the cardiac ossicle by oblique

hinges. Their lower ends are curved backwards.

vii. The **zygocardiac ossicles** are a pair of stout sclerites, running from the outer ends of the pyloric ossicle forwards, downwards, and outwards, to the ventral extremities of the pterocardiacs. Their ventral margins are curved inwards to form a pair of stout plates, calcified at their inner borders to form the **lateral teeth**. The inner edge of each lateral tooth bears a row of denticles, which decrease in size from before backwards.

viii. The **filter**. The aperture between the cardiac and pyloric chambers is much narrowed by lateral folds; and the cavity of the pyloric chamber itself is reduced by two lateral and a median ventral fold to a narrow three-rayed fissure.

All these folds bear short close-set hairlike setæ, which cross one another from opposite sides so as to form a very efficient filter or strainer, permitting the passage only of fluid or of very finely divided solid particles.

The gastric mill is put into action by muscles arising from the carapace and attached to the cardiac and pyloric ossicles, which, by their contractions, they pull away from each other. The cardiac ossicle moving forwards pulls the urocardiac and the median tooth with it, and the prepyloric ossicle rotates forwards with them, giving a downward movement to the hinder part of the tooth, and causing its apex to rotate forwards. The same movement of the cardiac ossicle forwards, and of the pyloric backwards, causes the zygocardiacs to pull back the pterocardiacs, which rotate about the oblique hinges, pressing the

zygocardiacs inwards, and bringing the lateral teeth together in the median plane.

Pull the cardiac and pyloric ossicles forwards and backwards respectively with forceps, when the three teeth will be seen to come together.

D. The Excretory System.

1. The **kidneys**, or 'green glands,' are a pair of rounded and somewhat flattened bodies, of a light green colour, lying in the ventral part of the head, in front of the mouth.
2. The **ureters** are a pair of wide thin-walled sacs, lying one on the dorsal surface of each kidney. Each ureter communicates directly with the cavity of its kidney, and opens to the exterior by an aperture already seen on the hinder surface of a tubercle on the basal segment of the antenna.

Inflate the ureter by blowing air in at its external aperture.

E. The Endophragmal Skeleton. (Fig. 35, p. 148.)

In the thorax a series of calcified plates project inwards from the cuticle of the ventral surface, forming an internal skeleton, which gives origin to the muscles of the legs and to the powerful flexor muscles of the abdomen.

F. The Nervous System.

1. The **central nervous system** consists of a series of ganglia arranged in pairs, and united by paired bundles of nerve-fibres, or **connectives**, to form a chain, which runs along the whole length of the body close to the mid-ventral line. The two ganglia of each pair are usually fused indistinguishably.
 - a. The **pre-oesophageal ganglionic mass**, or 'brain,' is a white mass of considerable size, situated just behind and slightly above the bases of the anten-

nules. It gives off nerves supplying the eyes, the antennules, and the antennæ.

- b. The **para-œsophageal connectives** are a pair of long nerve-cords, on each side of the œsophagus, connecting the 'brain' with the hinder part of the nervous system. They are connected with each other by a transverse commissure, immediately behind the œsophagus.
- c. The **post-œsophageal ganglionic mass** is an ovoid mass, lying a short way behind the mouth. From it arise the nerves supplying the mandibles, both pairs of maxillæ, and the first and second maxillipedes.
- d. The **thoracic nerve-chain** consists of six ganglionic masses, united by paired connectives, and supplying the appendages from the third maxillipedes to the last thoracic legs. The first one is situated immediately behind the post-œsophageal ganglionic mass, with which it is closely connected. The connectives between the fourth and fifth ganglionic masses diverge slightly, and the sternal artery (p. 160) passes between them.

The thoracic nerve-chain lies beneath the endophragmal skeleton, which must be removed to expose it.

- e. The **abdominal nerve-chain** consists of six ganglionic masses, joined by connectives, and supplying the abdominal segments and their appendages. The hindmost ganglionic mass is larger than the others, and supplies both the nineteenth segment and the telson.

2. The visceral nervous system.

This can only be dissected in a specimen in which the alimentary canal has been left undisturbed.

- a. The **anterior visceral nerve** is a median nerve formed, just in front of the œsophagus, by the

union of a median nerve from the 'brain' with two pairs of nerves arising from ganglionic swellings on the para-oesophageal connectives. From the union of these, the nerve runs up in front of the stomach to branch out on its dorsal wall.

- b. The **posterior visceral nerve** arises from the hindmost ganglionic mass of the abdominal nerve-chain, and runs forwards along the ventral surface of the intestine.

G. The Organs of Special Sense.

Besides tactile organs, *i.e.* the antennules, antennæ, and the palps of the oral appendages, the crayfish has eyes, and 'auditory' and olfactory organs.

1. The **eyes**, on movable stalks, have already been seen at the sides of the rostrum.

a. External characters of the eye.

Remove one of the eye-stalks, and examine it carefully with a lens.

The '**cornea**' is the transparent, apparently black, cap of uncalcified cuticle covering the end of the eye-stalk, and bounded by an oval outline. Its surface is divided into quadrangular facets by lines crossing each other nearly at right angles, each facet corresponding to one of the elements of which the compound eye consists.

b. Structure of the eye as seen in a longitudinal section.

Carefully divide the eye-stalk and eye longitudinally into two halves. The calcified portion of the cuticle is best cut with scissors, the remainder with a sharp knife. Examine one of the cut surfaces with a strong lens.

The eye consists of a number of conical bodies arranged in a radiate fashion, their bases being turned outwards and formed by the corneal facets, and their apices being directed inwards and

connected with the optic ganglion. Each of these component elements is isolated optically from its neighbours by pigment.

- i. The **cornea** is thin, and the strips of cuticle separating its facets scarcely differ from the facets themselves.
- ii. The **crystalline pyramids** are transparent conical bodies arranged radially and abutting upon the cornea, each pyramid corresponding to one corneal facet. They are separated from one another by layers of pigment near their outer ends.
- iii. The inner ends of the pyramids are imbedded in a black **pigmented layer**, in which lie a series of radially arranged **rods** and **fusiform bodies**, each of the latter being surrounded by a layer of brilliant pigment, either white or pink.
- iv. The **optic ganglion** occupies the centre of the eye. Its surface is deeply pigmented.
- v. The **optic nerve** lies in the axis of the eye-stalk, and connects the optic ganglion with the 'brain.'

2. The '**auditory**' **organs** are lodged in the basal segments of the antennules, and open to the exterior on their dorsal surfaces by three-cornered apertures, guarded by fringes of plumose setæ.

Remove an antennule entire. Holding it firmly between the fingers, carefully remove with scissors the inner and outer walls of the basal segment, taking care not to injure the 'auditory' sac itself. Clear away the muscles surrounding the sac, and the setæ from the aperture.

With a fine-pointed syringe wash out the contents of the 'auditory' sac—a collection of sand and other foreign matter from the water in which the animal lives, to which the name 'otolith' has been given.

Examine the sac in water or glycerine on a slide under a low power of the microscope.

- a. The '**auditory**' sac is a transparent ovoid chitinous sac, continuous at its opening with the cuticle of the antennule.
 - b. The **sensory setæ** are nearly straight simple pointed setæ varying greatly in size, the outer ones being the largest. The larger ones are arranged in parallel curved lines along the floor and inner wall of the sac; of these there are two rows behind, the number increasing to five or more in front. Parallel to these runs a row of very minute setæ on the inner side.
 - c. The **sensory nerve** supplying these rows of setæ may have been removed with the muscles, but should be looked for.
3. **Olfactory setæ.** On the ventral surface of each joint of the exopodite of the antennule are two tufts of fine sensory setæ. Under a low power of the microscope each is seen to consist of two segments, of which the distal one is much the longer, and is flattened. They are probably olfactory in function.

III. THE ARTERIES AS SEEN IN AN INJECTED SPECIMEN.

Bore a small hole in the carapace immediately above the heart: inject with Prussian blue, using a syringe just large enough to fill the hole. Dissect from the left side, removing the left half or more of the carapace, and such parts of the liver, genital gland and duct, and of the side-wall and muscles of the abdomen as may be necessary to expose the following arteries.

1. The **ophthalmic artery** is a median artery arising from the anterior end of the heart and running forwards over the stomach, then curving downwards to supply the front of the stomach and the œsophagus.

2. The **antennary arteries** arise from the anterior end of the heart, one on each side of the ophthalmic artery. Each runs forwards, outwards, and downwards over the side of the stomach, to which it sends a **gastric artery**; and then forwards to the anterior end of the head, supplying the kidney, antenna, antennule, and eye, and sending a branch to the rostrum. On its way it gives off numerous small arteries to the muscles of the regions which it traverses.
3. The **hepatic arteries** arise from the ventral surface of the heart near its anterior end, and supply the liver, in which they are buried.
4. The **sternal artery** is single, and arises from the hinder end of the heart, whence it runs directly downwards, passing to the right or left of the intestine, and between the connectives uniting the fourth and fifth ganglion-pairs of the thoracic nerve-chain (p. 156). It then divides into two arteries, running forwards and backwards respectively.
 - a. The **ventral thoracic artery** runs forwards beneath the nerve-chain, supplying the sternal region of the thorax, and the appendages from the hindmost ambulatory legs to the mandibles.
 - b. The **ventral abdominal artery** is a large median vessel given off by the sternal artery on reaching the ventral region of the body. It runs backwards beneath the nerve-chain, and supplies the ventral region of the abdomen and the abdominal appendages.
5. The **dorsal abdominal artery** is a large median artery arising from the ventral part of the hinder end of the heart, and running backwards just above the intestine to the hinder end of the body, supplying the intestine, muscles, and other parts of the dorsal region of the abdomen. It communicates at its hinder end with the ventral abdominal artery.

CHAPTER IX.

THE COCKROACH. *Periplaneta Americana*.

THE common cockroach or 'black beetle' of our kitchens and bakehouses—*Periplaneta (Blatta) orientalis*—is not a true beetle, but an insect belonging to the order *Orthoptera*, of which grasshoppers, locusts, and crickets are also members. This species differs only slightly from *P. Americana*, which has been chosen for description because it is larger and more easily dissected than the common form. *P. Americana* may be found in large numbers on board ships and at most docks.

Cockroaches are active insects, of nocturnal habits, hiding away in the daytime and coming out to feed at night. They will devour almost any animal or vegetable substance.

The whole animal is covered by a chitinous cuticle which is thick and hard, and of a dark-brown colour, except at the joints, where it is soft and paler. By these joints the body is divided transversely into segments, which are movable on one another except in the head. As in the crayfish the segmentation affects certain of the internal organs, as the muscular and nervous systems, but is not shown by the digestive, excretory, or reproductive organs.

The female lays its eggs in a hard oblong capsule, in which they are placed side by side. The young develop without metamorphosis, *i.e.* when newly hatched they resemble the adult in form and habits, though they are devoid of wings. During growth the cuticle is shed several times. The wings appear at the last ecdysis, when the animal attains sexual maturity: the female of *P. orientalis* is, however, wingless.

I. HABITS.

Watch the living animal in a glass vessel, noting especially the positions of its legs and head; also the mode of using the long antennæ, and the maxillary and labial palps.

Watch the respiratory movements of the abdomen. Feed with sopped bread, and watch the lateral movement of the jaws.

II. EXTERNAL CHARACTERS.

Kill the animal by pouring two or three drops of chloroform upon it.

A. The Body.

The body is divided into **head**, **thorax**, and **abdomen**, each of which is composed of several segments. A small **neck** connects the head with the thorax.

1. The **head** is broad from side to side, and short from before backwards, and is produced downwards into a broad process bearing the jaws. Owing to its shortness and vertical elongation, it has a deceptive appearance of being bent downwards and backwards beneath the thorax.
 - a. The **epicranium** covers the dorsal and posterior surfaces of the head. It is divided into right and left halves by a median suture which divides in front into two, running obliquely outwards to the **fenestræ** (p. 163).
 - b. The **clypeus** is a broad plate covering the front of the head, below the epicranium.
 - c. The **labrum** is a smaller plate hinged to the lower edge of the clypeus, and forming the anterior or 'upper' lip.
 - d. The **genæ**, or 'cheeks,' are a pair of vertical plates covering the sides of the head, behind and below the eyes.

- e. The eyes are large black reniform elevations, one on each side of the head. They are compound, each having very numerous hexagonal facets.
 - f. The fenestræ are a pair of small white oval patches to the inner sides of the bases of the antennæ.
2. The neck is short and slender: its cuticular covering is soft and white, with the exception of seven thickened patches or sclerites which are hard and brown. Of these sclerites two are slender trans-

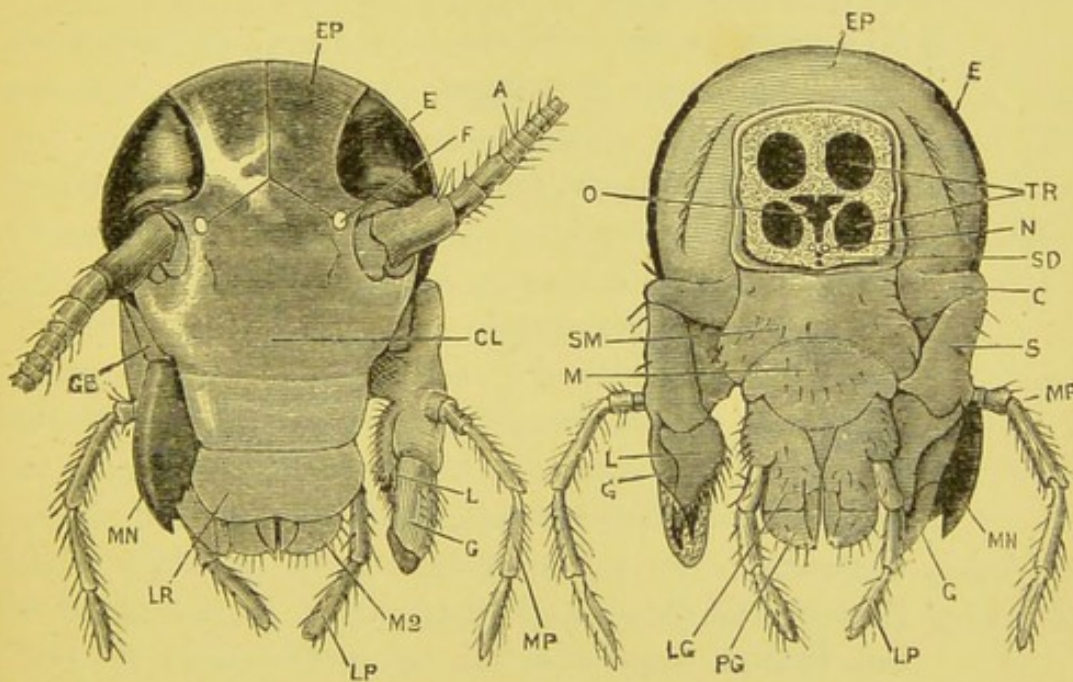


FIG. 36.—*Periplaneta Americana*. The head, front view. (C. H. H.)

A, antenna. CL, clypeus. E, eye. P, epicranium. F, fenestra. G, galea. GE, gena. L, lacinia. LP, labial palp. LR, labrum. MN, mandible (the left mandible has been removed). MP, maxillary palp. M2, second maxilla.

FIG. 37.—*Periplaneta Americana*. The head from behind. (C. H. H.)

E, EP, G, L, LP, MN, and MP, as in the preceding figure. C, cardo. LG, ligula. M, mentum. N, nerve-connective. O, oesophagus. PG, paraglossa. S, stipes. SD, salivary ducts. SM, submentum. TR, cervical tracheæ.

verse bars on the ventral surface; a third is median and dorsal, and almost divided into two longitudinally; the remaining four are much larger, and form two pairs at the sides of the neck.

3. The thorax consists of three segments.

- a. The prothorax is the first and longest segment of

the thorax. Its **tergum**, the **pronotum**, is prolonged forwards over the neck.

- b. The **mesothorax** is smaller, and its tergum bears at its anterior corners a pair of **elytra**, or wing-covers. These are folds of skin and cuticle which extend backwards beyond the hinder end of the abdomen, and are movably articulated to the mesothoracic tergum or **mesonotum**.

[The elytra are abortive in the female of *P. orientalis*.]

- c. The **metathorax**, or hindmost segment of the thorax, bears a pair of **wings**, which are membranous outgrowths of the body-wall, like the elytra, but broader, thinner, and more movable. By means of these the animal is able to fly. When not in use they are folded longitudinally like a fan and covered by the elytra.

[The female of *P. orientalis* has no wings.]

- 4. The **abdomen**, which forms rather more than half the length of the body, is broad from side to side, especially in the female, and is flattened dorso-ventrally. Its cuticular investment is softer than that of the head and thorax. It is composed of ten distinct segments, but the hinder ones are telescoped within one another, so that the full number are not seen at once. The **podical plates** may represent the tergum of an eleventh segment.

- a. The **terga** are cuticular plates covering the dorsal surface of the abdomen and overlapping one another from before backwards. They are broad from side to side, but short from before backwards. Of the ten only eight are obvious, the eighth and ninth being hidden by the seventh through the telescoping of this part of the body. The tenth is prolonged backwards into a thin horizontal plate, deeply notched in its posterior border.

[In *P. orientalis* the eighth and ninth terga are hidden by the seventh in the female only.]

- b. The **podical plates** are a pair of small cuticular plates at the sides of the anus. (Fig. 39, p. 177.)

To see the podical plates, lift up the tenth tergum with the forceps.

- c. The **cerci** are a pair of many-jointed styles, attached under the lateral edges of the tenth tergum and projecting backwards.

- d. The **sterna** on the ventral surface resemble the terga on the dorsal surface. The first is rudimentary.

In the **male** the ninth sternum bears a pair of styles.

In the **female** the seventh sternum is produced backwards into a large boat-shaped process, which forms the lower wall of the large genital pouch. The hinder sterna are modified in relation with the sexual apparatus, and are completely hidden by the seventh.

B. The External Apertures.

1. The **mouth** opens on the ventral surface of the head, behind the labrum and between the jaws.
2. The **anus** is at the hinder end of the body, beneath the tenth abdominal tergum and between the inner margins of the podical plates.
3. The **genital aperture** is single, and is placed at the hinder end of the body, below the anus. It is larger in the female than in the male, and will be better seen at a later stage of the dissection.
4. The **stigmata**, or spiracles, are the respiratory apertures, twenty in number. There are two large thoracic ones on each side, one between the prothorax and the mesothorax, and the other between the mesothorax and the metathorax. A pair of abdominal stigmata are situated between the lateral margins of the tergum, and the sternum at the anterior end of each of the first eight abdominal segments.

To see the stigmata, examine from the ventral surface, stretching the abdomen slightly. The stigmata are at the apices of small backwardly projecting spout-like processes, which lie just beneath the anterior angles of the several terga.

C. The Appendages.

1. The head appendages are four pairs.

- a. The **antennæ** are very long, slender, many-jointed, and freely movable filaments, inserted into a pair of oval arthrodial membranes just in front of and below the eyes.

To see the next three pairs of appendages, fix the animal down on its back by means of a pair of small pins passed through the sides of its prothorax. Bend the ventral part of the head forwards, and fix it in that position by means of crossed pins.

Examine the appendages in situ, noting their positions.

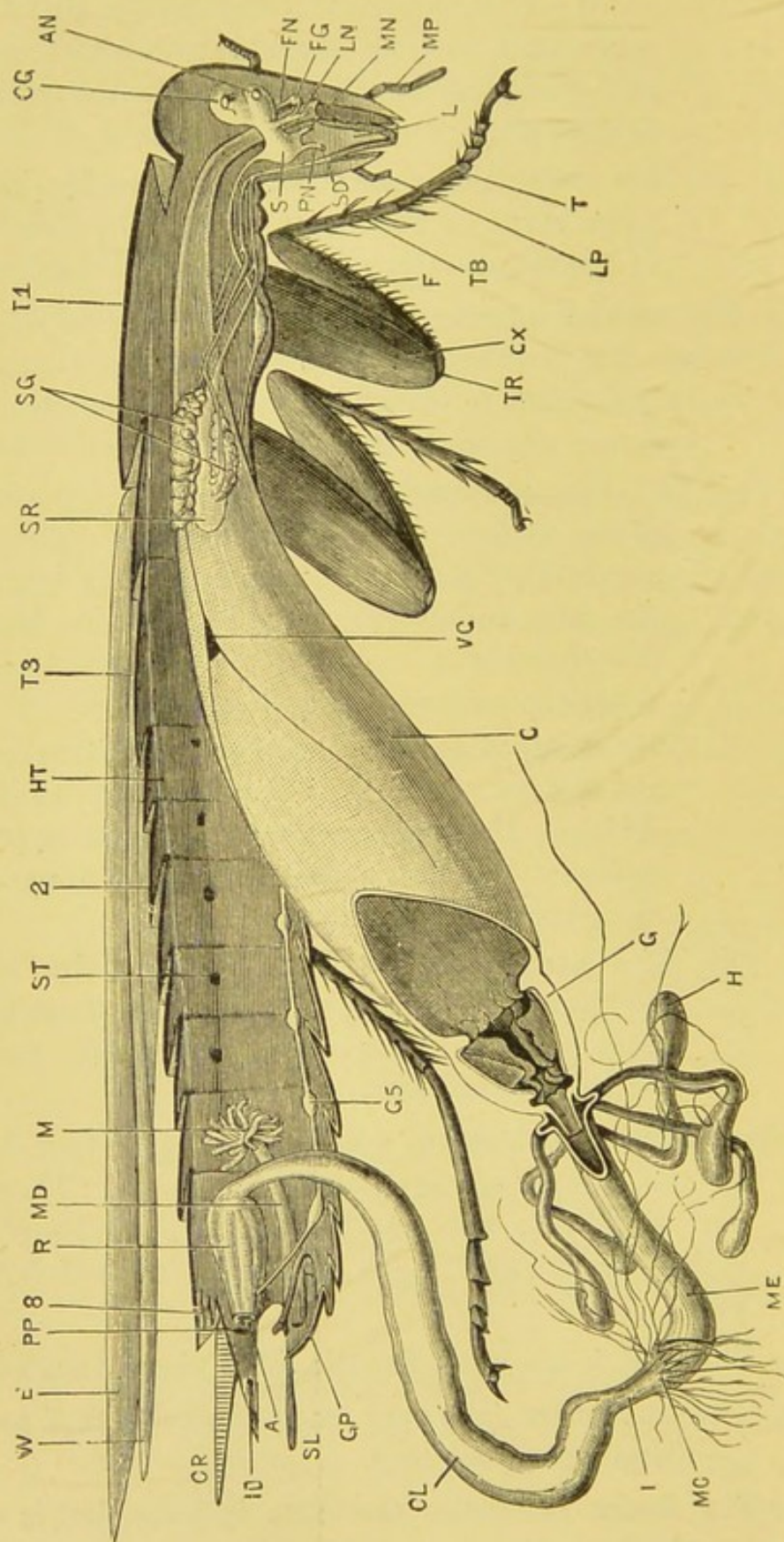
Remove the whole of the labium (S M to P G, fig. 37) without injury to the structures beneath it. Mount it in glycerine.

Similarly remove and mount the right first maxilla and the right mandible.

- b. The **mandibles** are a pair of stout jaws, strongly toothed on their inner margins, and working sideways. They lie immediately below the genæ, and articulate with the epicranium and with the clypeus.
- c. The **first maxillæ** are situated behind the mandibles. Each consists of the following parts.
 - i. The **protopodite** consists of two segments, the **cardo** or proximal piece and the **stipes** or distal piece.
 - ii. The **endopodite** has two divisions, an inner and an outer. The inner division, or lacinia, is a hard blade pointed at the end, and provided with stiff setæ along its inner border. The outer division, or **galea**, is softer and is elon-

gated: on the inner surface of its distal end is an oval cushion covered with short curved stiff setæ, and notched to receive the point of the lacinia.

- iii. The **exopodite** or **maxillary palp** is a five-jointed palp, borne on the outer side of the distal end of the stipes. Its first two segments are short.
- d. The **second maxillæ** are similar in shape to the first maxillæ, but smaller. They are fused together in the median plane by their protopodites, and together constitute the **labium** or posterior lip.
 - i. The two **protopodites** are fused in the median plane to form a two-jointed plate. The **submentum** or proximal segment is the larger of the two, and is very broad from side to side. The distal segment, or **mentum**, is smaller, and bears the endopodites and exopodites.
 - ii. The **endopodites** are together sometimes called the **ligula**. Each is divided into an outer division, the **paraglossa**, corresponding to the galea of the first maxilla; and an inner division, corresponding to the lacinia.
 - iii. The **exopodites** are three-jointed palps corresponding in form and position to those of the first maxillæ. The stump supporting each is called the **palpiger**.
- 2. The **thoracic appendages** are three pairs of legs, borne by the sterna of the thoracic segments. They are very similar to one another, but the hindmost are rather the largest. Each leg consists of the following parts.
 - a. The **coxa** is the stout flat proximal piece of each leg.
 - b. The **trochanter** is a very small piece attached to the distal end of the coxa.
 - c. The **femur** resembles the coxa in form, but is more slender.



- d. The tibia is a slender straight segment armed with strong spines.
- e. The tarsus, or foot, is six-jointed, each segment having a soft white setose patch under its distal end, giving the animal a foothold in climbing steep or slippery surfaces. The terminal piece or pulvillus is small and bears a pair of claws.
3. Abdominal appendages are very rare amongst adult insects. The anal cerci already described, and possibly also the styles on the ninth sternum of the male, may be appendages, as also may the gonapophyses; but it is doubtful whether these really belong to the same category as the appendages of the head and thorax.

The gonapophyses belong to the genital apparatus, and will be described later.

III. DISSECTION OF THE COCKROACH.

Fix the animal down with the dorsal surface upwards. This may be done by drying it with blotting paper, and immersing its under surface in melted paraffin or wax, and holding it in this position till the wax is cool: or the animal may be fixed to a board by means of small pins passed through the lateral regions of the mesothorax and of the abdomen.

FIG. 38.—*Periplaneta Americana*. The male dissected from the right side. The testes and vasa deferentia are not figured. (C. H. H.)

A, anus. AN, antennary lobe of supra-oesophageal ganglion, with antennary nerve cut short. C, crop. CG, supra-oesophageal ganglion. CL, colon. CR, anal cercus. CX, coxa. E, elytron. F, femur. FG, frontal ganglion. FN, visceral nerve. G, gizzard. GP, one of the gonapophyses. G 5, fifth abdominal ganglion. H, hepatic caecum. HT, heart. I, ileum. L, lingua. LN, nerve to labrum. LP, labial palp. M, mushroom-shaped gland. MC, Malpighian caeca opening into junction of mesenteron and ileum: they are much longer and more numerous than indicated. MD, ejaculatory duct. ME, mesenteron. MN, maxillary nerve. MP, maxillary palp. PN, labial nerve. PP, podical plate, diagrammatically drawn. R, rectum. S, sub-oesophageal ganglion. SD, salivary duct just above its opening into the mouth. SG, salivary glands. SL, style borne by ninth sternum. SR, salivary receptacle. ST, one of the abdominal stigmata. T, proximal joint of the tarsus. TB, tibia. TR, trochanter. T 1, first thoracic tergum, or pronotum. T 3, third thoracic tergum, or metanotum. VG, visceral ganglion. W, wing. 2, tergum of second abdominal segment. 8, tergum of eighth abdominal segment. 10, tergum of tenth abdominal segment.

Cut off the elytra and the wings. Carefully cut through the terga of the abdomen and thorax close to each side, and remove the terga, avoiding injury to the heart, which lies just beneath.

A. The Circulatory System.

1. The heart is a straight chambered tube running along the mid-dorsal line of the abdomen and thorax. It receives blood through paired lateral openings or ostia, arranged segmentally, and drives it forwards by rhythmical contractions.

B. The Digestive and Excretory Systems.

The alimentary canal, with its glandular appendages, is situated almost entirely in the abdomen, and is enveloped in an opaque-white dendritic mass, the **fat-body**.

Expose and unravel the alimentary canal and its appendages. In dissecting the salivary ducts great care must be taken not to injure the nervous system in the head.

1. The alimentary canal is short, and slightly convoluted in its hinder part. It may be divided according to its mode of development into three regions; viz. the **stomodæum** and the **proctodæum**, which are invaginations of the anterior and posterior ends of the embryo respectively; and the **mesenteron**, or middle portion, which alone is formed from the primitive alimentary tract of the embryo.
 - a. The **stomodæum** has a chitinous cuticular lining, continuous with the cuticular investment of the head; and is divided into the following regions.
 - i. The **buccal cavity** is lodged in the head, and its posterior wall is raised up to form an elongated fleshy tongue or **lingua**.

The **salivary duct** opens by a median aperture in the angle between the **lingua** and the **labium** (fig. 38).

- ii. The **œsophagus** is a narrow tube running from the mouth through the nerve-collar and along the neck. It is laterally compressed in the cervical region.
- iii. The **crop** is a large thin-walled pyriform sac, extending through the thorax and far into the abdomen. It is not separated by any distinct line of demarcation from the œsophagus.
- iv. The **gizzard**, or proventriculus, is a pyriform sac, with thick muscular walls. Within it is a series of six large cuticular teeth, and behind these six small elevations covered with setæ, which serve as a strainer.

Lay the gizzard open to expose the teeth.

- b. The **mesenteron** is a short narrow tube extending backwards from the hinder end of the gizzard.

Lay the mesenteron open, and note the funnel-like prolongation of the gizzard extending into it.

- c. The **proctodœum** is the convoluted hinder portion of the alimentary canal, and is lined by a thin chitinous cuticle. It is divided into the following regions.

- i. The **ileum** is a short narrow tube, the commencement of which is marked by the attachment of the numerous fine thread-like Malpighian tubules.
- ii. The **colon** is much wider and longer than the ileum, and is constricted at its hinder end.
- iii. The **rectum** is the short dilated terminal portion of the alimentary canal. Its wall has six longitudinal ridges, projecting internally. It ends at the **anus**, between the podical plates.

2. The digestive glands.

- a. The **salivary glands** are two pairs of diffuse white glands on the sides of the anterior part of the crop.

The **salivary receptacles** are a pair of thin-walled sacs, one on each side of the crop, between the two glands of its side.

The **ducts of the receptacles** run forwards and unite beneath the nerve-cord at the hinder end of the neck to form a median duct, which runs forwards to open into the mouth, behind the base of the lingua.

The **ducts of the salivary glands** unite to form one duct on each side: the two ducts thus formed run forwards and unite beneath the nerve-cord in the hinder part of the neck to form a median duct: this runs forwards between the nerve-cord and the median duct of the receptacles, and opens into the latter at the anterior end of the neck.

Having made out the anatomical relations of the salivary glands, receptacles, and ducts, remove the whole apparatus. Stain it with carmine; dehydrate, mount in balsam, and examine with the microscope.

Nuclei are visible in the walls of the ducts, and in the secretory cells of the glands.

The **chitinous lining** of the ducts shows a spiral thickening.

- b. The '**hepatic**' **cæca** are eight or seven cæcal diverticula of the anterior end of the mesenteron. They are convoluted and club-shaped.

Note the openings of the hepatic cæca into the mesenteron.

3. The **excretory system** consists of sixty or more **Malpighian tubules**, which are fine filamentous diverticula of the anterior end of the ileum, arranged in six bundles. They are very long and convoluted, and are interlaced among the tracheæ and the filaments of the fat-body all through the abdomen.

C. The Respiratory System.

The respiratory system consists of a series of **tracheal tubes** containing air. These commence at the respiratory apertures,

or **stigmata** on the sides of the thorax and abdomen, and ramify through all parts of the body. Expiration is effected by contraction of the muscles of the body, which compress the tracheæ; inspiration, by dilatation of the tracheæ through the elasticity of their cuticular lining.

The readiness with which air is carried to all parts of the body, through the great perfection of the respiratory system, accounts for the extreme imperfection of the circulatory system in an animal which is otherwise very highly organised.

1. The **tracheal tubes** when full of air are silvery white.

Remove a large trachea, and examine it microscopically in water.

a. The **cuticular lining** has a very strong spiral thickening, which gives great elasticity to the tube.

b. The **cells** which form the organised wall of the tube, and secrete the chitinous lining, are thin and not easily seen till stained.

*Stain with carmine, and note the **nuclei** of the cells.*

Remove small portions of muscle from the leg, of the fat-body, of the salivary gland, etc., and note and examine the fine tracheal tubes ramifying through them. Stain as above.

D. The Nervous System.

The nervous system consists of supra-œsophageal and sub-œsophageal ganglia, and para-œsophageal connectives in the head; a double ventral chain in the thorax and abdomen; and a visceral nervous system in relation with the alimentary canal. (Fig. 38, p. 168.)

1. The **cephalic nervous system**.

If the buccal cavity has already been exposed, a second specimen will probably be necessary for the dissection of the nervous system of the head.

Fix the head, with the anterior surface upwards, by means of a fine pin through the upper part of the epicranium and another between the mandibles.

Remove the clypeus and the anterior portion of the epicranium with scissors or the point of a scalpel, taking care not to injure the ganglia, which lie close beneath the clypeus. Carefully expose and clean the following structures, avoiding injury to the cephalic portion of the visceral nervous system.

- a. The **supra-oesophageal**, or 'cerebral,' **ganglia** are a pair of large closely apposed ganglia close to the anterior surface of the head. They are supported by an internal chitinous framework, the **tentorium**.
- i. The '**hemispheres**' are the large rounded upper parts of the ganglia. From them arise the large **optic nerves**.
- ii. The **antennary lobes** are the smaller and lower portions of the ganglia. From them the **antennary nerves** arise.

Turn the head and fix it with the right side uppermost. Remove the gena and mandible, and as much as is necessary of the first maxilla, submentum, and mentum, to expose the following structures on the right side.

- b. The **para-oesophageal connectives** are a pair of short thick bands of nervous tissue, running round the sides of the oesophagus, from the lower part of the supra-oesophageal ganglia to the sub-oesophageal ganglia. From each a nerve arises supplying the labrum, as well as a nerve belonging to the visceral system.
- c. The **sub-oesophageal ganglia** are a pair of large ganglia lying between the submentum and the oesophagus. Below they give off several nerves, of which the two largest on each side supply the maxillary and labial palps. Above, they give off connectives, which run back through the neck and form the anterior part of the ventral chain.

2. The ventral chain.

Fix the cockroach with the dorsal surface uppermost: remove the gizzard, mesenteron, and proctodæum; and turn the crop aside.

The ventral chain consists of a double series of ganglia, with double connectives, running along the ventral wall of the body.

A pair of closely apposed ganglia lie in each of the three thoracic segments, and a pair of smaller ganglia in each of the first six abdominal segments. The last pair are the largest of the abdominal ganglia, and give off nerves to the various parts of the sixth and succeeding segments.

3. The **visceral nervous system** arises as a pair of nerves, one from the anterior part of each para-oesophageal connective. The two nerves, after giving off a pair of nerves to the labrum, unite in the **frontal ganglion**, a small median ganglion on the anterior wall of the oesophagus, just below the antennary lobes. From this ganglion a median **recurrent nerve** runs backwards on the oesophagus, beneath the supra-oesophageal ganglia, from which it receives a pair of gangliated nerve-trunks; it then continues its course backwards, as a median nerve, along the oesophagus and crop to a small triangular ganglion on the dorsal surface of the crop, about the middle of its length. From this ganglion two branches run obliquely backwards over the surface of the crop.

E. Sense Organs.

1. The **tactile organs** have already been examined. They are the antennæ, the maxillary palps, the labial palps, and the anal cerci.
2. The **eyes** are very large compound organs which agree in essential characters with those of the crayfish. The **corneal facets** are hexagonal.
3. The **fenestræ** are perhaps sense organs, but their function is unknown.

F. The Reproductive System.

1. In the male.

- a. The **testes** are a pair of organs lying immediately below the fourth and fifth terga of the abdomen. They are imbedded in the fat-body, and are hence difficult to find.
- b. The **vasa deferentia** are a pair of exceedingly narrow tubes leading from the testes to the **vesiculæ seminales**.
- c. The **vesiculæ seminales**, together known as the 'mushroom-shaped gland,' are two tufts of white glandular cæca, opening into the slightly dilated anterior end of the **ejaculatory duct**.
- d. The **ejaculatory duct** is a short muscular tube opening behind to the exterior, just below the anus.
- e. The **gonapophyses** are a series of strong chitinous hooks and plates, forming a complex copulatory organ. They are asymmetrical, and surround the genital aperture.

2. In the female.

- a. The **ovaries** are two sets of elongated tubular organs in the hinder part of the abdomen. Each set consists of eight tubes, united in front and attached by a ligament to the dorsal wall of the thorax. Behind and below they unite to form the oviducts. Each tube has a moniliform appearance, from the bulgings caused by the contained **ova**: in the hinder and lower part of the tube the ova are large and nearly mature; those in the upper part of the tube are in various earlier stages of development.

At the time of laying, one ovum escapes from each ovarian tube, and the sixteen are laid side by side in a capsule.

- b. The oviducts, formed as above, are a pair of short wide tubes, which unite, and open to the exterior by a median vertical slit in the eighth sternum.
- c. The spermatheca consists of two unlike and unequal cæca of small size, opening by a median aperture on the ninth sternum. It lies close behind the last nerve-ganglia of the ventral chain.

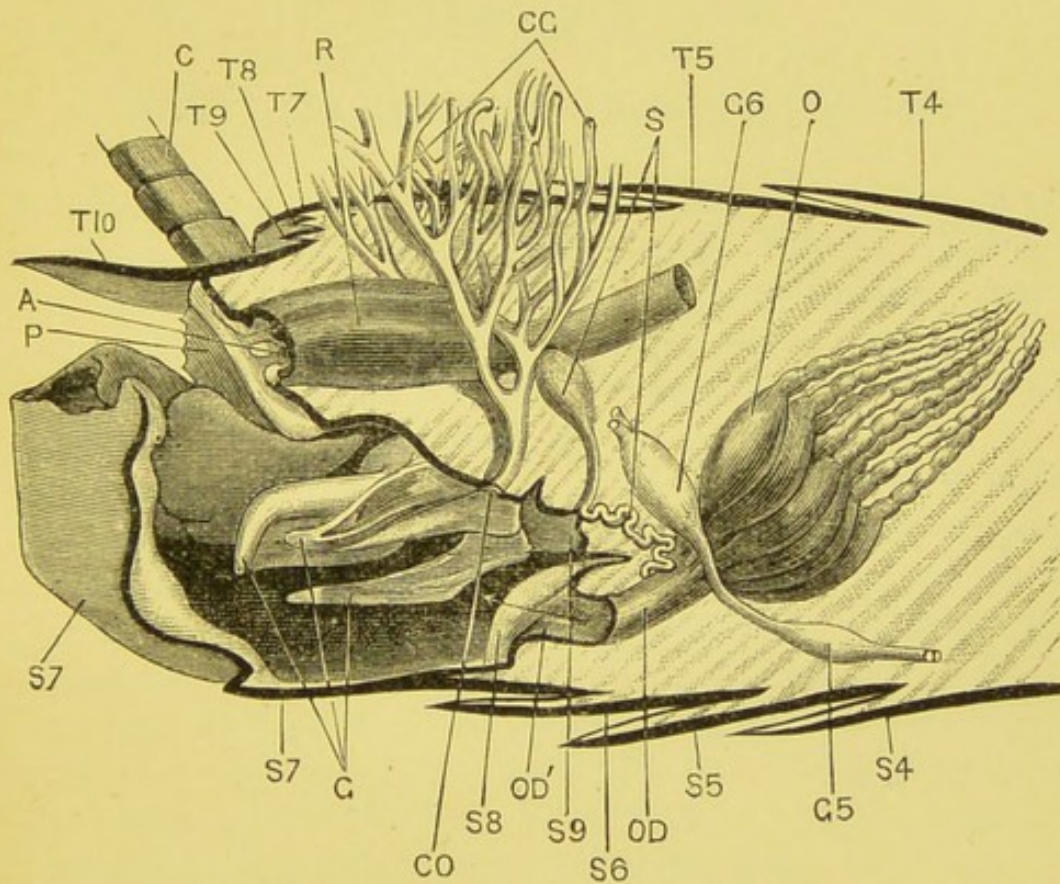


FIG. 39.—*Periplaneta Americana*. The hinder part of the abdomen of the female dissected from the right side to show the reproductive apparatus. The right ovary with its duct has been removed, and only a small portion of the colleterial glands is shown. The thick black lines represent the cut edges of the terga, sterna, etc. $\times 8$ (C. H. H.)

A, anus. C, anal cercus. CG, colleterial glands. CO, aperture of ducts of colleterial glands. G, gonapophyses. G5 and G6, the last two abdominal nerve-ganglia. O, left ovary. OD, left oviduct. OD', median oviduct. P, podical plate. R, rectum. S, the two divisions of the spermatheca. S4, S5, etc., fourth and following sterna. T4, T5, etc., fourth and following terga.

- d. The colleterial glands are a pair of much-branched tubular glands, whose ducts open separately, but

close together, behind the spermotheca, and between the inner gonapophyses.

- e. The **gonapophyses** are six symmetrically arranged processes, strongly chitinised on their outer surfaces. They are outgrowths from the sternal surface, between the vulva and the anus ; and aid in depositing the eggs.

CHAPTER X.

THE LANCELET. *Amphioxus lanceolatus*.

AMPHIOXUS is a small semi-transparent fish-like animal, about a couple of inches in length, found in the English Channel, the Mediterranean and other seas. It is of sluggish habits and usually remains buried in the sand, either completely or with the anterior end alone protruding; but if disturbed it swims actively by rapid lateral movements of the body.

Though distinctly belonging to the great group of vertebrate animals, *Amphioxus* is in several important respects simpler than any of the more familiar members of the group. Indeed, in spite of its fish-like appearance and habits, the differences between *Amphioxus* and an ordinary fish, such as a dog-fish or whiting, are of greater morphological importance than those separating fish from the most highly organised vertebrates, such as birds or mammals. It is therefore necessary to divide vertebrates into two main divisions, the first of which, **Acrania**, includes *Amphioxus* and a probably degenerate group, the ascidians; while the second division, **Craniota**, includes all remaining vertebrates, from fish to mammals.

Owing to the small size of *Amphioxus*, it is not practicable to determine all the points in its anatomy by dissection. The method of procedure adopted in the case of the other animals dealt with in this book will in consequence be departed from to some extent; and the present chapter will be arranged under three heads.

I. A description of the anatomy of *Amphioxus*.

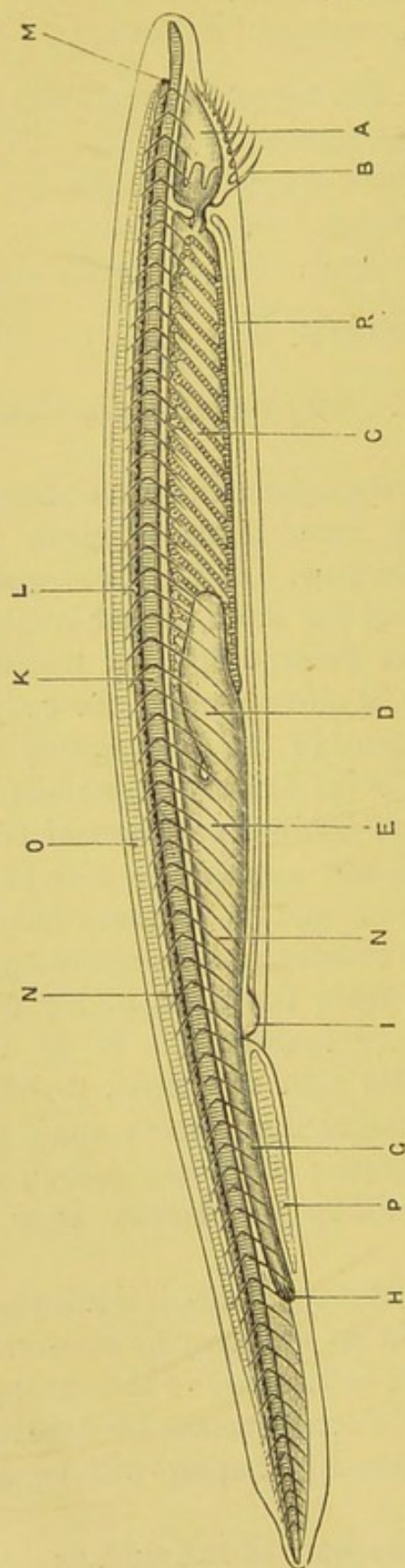


FIG. 40.—*Amphioxus lanceolatus*. A young specimen, viewed from the right side as a transparent object.

In the adult the gill-slits are much more numerous. (A. M. M.)

A, buccal cavity. B, buccal tentacles. C, pharynx. D, liver. E, stomach. G, intestine. H, anus. I, atrial pore. K, notochord. L, spinal cord. M, eye. N, septa separating the myotomes from one another. O, skeleton of dorsal fin. P, skeleton of ventral fin. R, transverse muscles in the floor of the atrial cavity.

- II. Directions for the dissection of *Amphioxus*; by which the more salient points in its anatomy may be determined.
- III. Descriptions of transverse sections taken through different regions, and examined as microscopical objects.

I. THE ANATOMY OF AMPHIOXUS.

A. External Characters.

1. The **shape**. *Amphioxus* is elongated, pointed at both ends, and compressed from side to side, especially towards the posterior end. There is no obvious head, and no trace of limbs.
2. The **fins**. A low **dorsal fin** runs along the mid-dorsal line from end to end of the animal, becoming more prominent at the hinder end as the upper lobe of the **caudal fin**.

The ventral surface bears a median fin in its posterior third, but in front of this is flattened, so that the body is triangular in transverse section. The sides of this flattened surface are bordered by the **lateral fins**, or **metapleural folds**.

3. The **myotomes**. The sides of the body are marked by a series of > shaped lines, formed by septa of connective tissue which divide the great lateral muscles of the body into segments or **myotomes**.
4. The '**mouth**' or opening of the oral vestibule is a large oval aperture on the ventral surface of the anterior end of the body, and is fringed on each side by a series of ciliated **tentacles** or **cirri**.
5. The **anus** is on the ventral surface, not far from the hinder end of the body. It is placed a little to the left of the median plane, at the base of the caudal fin.
6. The **atrial pore** is a median aperture on the ventral surface, bordered by prominent lips. It is in front

of the anus, at the junction of the ventral and lateral fins, and about one-third the length of the animal from its hinder end. Through it the water escapes which has been taken in at the mouth with the food and which serves for respiration.

B. The Skeletal System.

The skeleton of *Amphioxus* is extremely simple, and contains neither bone nor cartilage.

1. The **notochord** is a median elastic rod which traverses the body from end to end, lying rather nearer the dorsal than the ventral surface, and between the central nervous system and the alimentary canal. It is in contact with the integument at the two ends of the body; and it serves to slightly stiffen the animal.

It consists of cells in which, at an early stage, large vacuoles appear: these vacuoles increase in size and ultimately almost completely fill the cells, rendering their outlines difficult to trace. On the dorsal and ventral surfaces of the notochord, the cells are comparatively unaltered.

In higher vertebrates also a notochord is formed in early stages of development, but it is afterwards replaced more or less completely by the vertebral column.

2. The **buccal skeleton**. At each side of the mouth is a curved bar, resembling the notochord in structure. Each bar is divided transversely into a number of short segments, and from these filaments arise which support the buccal cirri, which vary from twenty to forty in number, becoming more numerous as age advances.
3. The **skeleton of the median fins**. Along the whole of the dorsal fin, except at its extreme anterior and posterior ends, is a longitudinal series of connective-tissue compartments filled with a gelatinous substance. The compartments are more than twice as

numerous as the segments of the body. A similar, but double, structure extends along the ventral fin, between the anus and the atrial pore.

4. The **branchial skeleton**. A series of elastic rods are developed in the walls of the pharynx to support the gill-arches. Their arrangement will be described with the alimentary canal.
5. The **connective-tissue skeleton**. The connective tissue of *Amphioxus* is very dense, and forms a kind of skeleton, of which the following are the chief parts.
 - a. The **sheath of the notochord** is a thick sheath closely surrounding the notochord.
 - b. The **neural sheath** surrounds the central nervous system, and is continuous below with the notochordal sheath.
 - c. The **septa** are sheets of connective tissue which run outwards from the notochordal and neural sheaths to the integument. They separate the successive muscle-segments, or myotomes, from one another; and their lines of insertion into the integument form the > shaped markings along the sides of the animal. The septa on the two sides of the body are not paired, but alternate with one another.

C. The Muscular System.

1. The **lateral muscles** are by far the largest part of the muscular system. They form the side-walls of the body along its whole length, and are divided, as noticed above, into muscle-segments or **myotomes** by the connective-tissue septa. The muscle-fibres run longitudinally, *i.e.* parallel to the axis of the body; and it is by alternate contractions of these muscles on opposite sides of the body, aided by the elasticity of the notochord, that the lateral undulatory swimming movements of the animal are produced.

There have been found to be 61 myotomes on each side of the body in a considerable number of specimens.

2. The **ventral muscles** form a sheet covering the ventral surface of the body from the mouth to the atrial pore. The muscle-fibres run transversely from side to side, and by their contraction expel the water from the atrial cavity.
3. Smaller muscle-bundles are found in relation with the mouth and its cirri, with the gill-apparatus, and with the anus and atrial pore.

Nearly all the muscles are striated.

D. The Digestive and Respiratory Systems.

The alimentary canal is a nearly straight tube, the anterior part of which is so modified as to allow of the escape of water taken in at the mouth with the food, and to utilise this water for respiration, as is the case in aquatic vertebrates generally.

1. The **buccal cavity** or oral vestibule is bounded laterally by folds, within which and near their free margins are the curved bars which support the cirri. There are no jaws.

The anterior part of the buccal cavity is lined by a single layer of short columnar epithelial cells, some of which bear short flagella. In the hinder part of the cavity the epithelium is altogether different, the cells being very long and slender and provided with long flagella. The boundary between these two regions is marked by a sharply defined sinuous line (fig. 40, p. 180).

2. The **velum** is a muscular diaphragm between the buccal cavity and the pharynx, opposite the anterior angle of the seventh myotome. It is perforated below its middle by an aperture which leads upwards and backwards into the pharynx, and the hinder border of which is fringed with a circle of twelve backwardly

projecting cirri. This aperture appears to correspond to the mouth of higher vertebrates.

3. The **pharynx** is a wide sac, forming about half the length of the alimentary canal. It is attached along its mid-dorsal line to the under surface of the sheath of the notochord, from which it hangs down freely into the atrial cavity. Its sides are perforated by a large number of slit-like apertures—the **gill-slits**—which run obliquely downwards and backwards. The parts of the pharyngeal wall between the successive slits are narrow bars—the **gill-arches**—each of which is strengthened by an **axial rod** of a chitinous substance. These arches are of two kinds, arranged alternately: the axial rods of the third, fifth, etc., arches being forked at their ventral ends, while the alternate rods are unsplit. Each double gill-slit is originally a single one, but becomes divided in the course of development by the downgrowth of the unsplit bar from its dorsal end. The split bars may hence be called **primary rods**, and the unsplit ones **secondary rods**. Like the myotomes, the gill-arches are not in pairs, but alternate on the two sides of the body.

The successive gill-arches are connected by horizontal bars, of which there are usually three or more crossing each slit, so that the pharynx has the character of an open meshwork. The inner surface of each gill-slit is lined by columnar flagellate cells, which maintain a continual stream of water through the gill-slits from the pharynx to the atrial cavity, the stream serving to aerate the blood in the vessels of the arches as it passes over them. The inner edge of each bar also bears flagellate cells separated from those lining the gill-slits by two groups of cells bearing very short cilia.

Along the mid-dorsal line of the pharynx is the deep **epibranchial groove**, lined by a single layer of long columnar ciliated cells. A band of similar

cells runs along the **endostyle** or mid-ventral wall of the pharynx, which is folded longitudinally in its hinder part to form a groove. The endostyle also contains mucous glands.

4. The **intestine** commences at the hinder end of the pharynx, close to the dorsal surface, and runs straight to the anus. It is a direct continuation of the epibranchial groove, and at its commencement is very narrow: further back it dilates considerably; and this expanded part, which is sometimes called 'stomach,' is produced into a large pouch-like sac—the **liver**—which runs forwards some distance along the right side of the pharynx, and ends blindly in front.

E. The Atrial Cavity.

The boundaries and relations of this cavity can best be determined by the examination of a series of transverse sections.

The **atrial** or **epipleural cavity** is the large place which surrounds the pharynx at the sides and below: into it the stream of water passes from the pharynx through the gill-slits, to escape finally from the **atrial pore**.

The atrial cavity develops in the embryo as a groove along the under surface of the body; by fusion of its lips the groove becomes a tube, which ends blindly in front, but retains its opening behind at the atrial pore. The cavity extends laterally so as to surround the pharynx both below and at the sides, lying between the pharynx and the muscular body-wall.

The epithelium lining the atrial cavity is supported by a layer of connective tissue, and usually contains a good deal of brown pigment, which renders it easy to trace. It is represented by the thick black line in figs. 41-43, which shows its distribution in different regions of the body. It lines the inner surface of the atrial folds, covers the outer surface of

each of the gill-arches, and invests the liver and the anterior portion of the intestine.

On the primary gill-arches this layer of atrial epithelium is wider than on the secondary arches, and towards the dorsal surface of the pharynx it rises up to form the **suspensory folds** of the pharynx, which run across from the dorsal part of the sides of the pharynx to the inner surface of the atrial folds and separate the atrial cavity below from the dorsal cœlomic canals above.

The atrial cavity commences opposite the anterior end of the pharynx, and extends back almost as far as the anus; behind the atrial pore it is confined to the right side of the body.

F. The Cœlom or Body-cavity.

This can only be traced by means of sections.

The **cœlom**, or body-cavity, is perfectly distinct from the atrial cavity, though its boundaries are not easy to follow, and its relations differ considerably in different regions of the body. It contains during life a coagulable fluid.

1. **Behind the atrial pore** the cœlom is a cavity of some width surrounding the intestine and separating it from the body-wall.
2. **In front of the atrial pore** it becomes greatly reduced, owing to the increased size of the atrial cavity: it is, however, easily recognisable as a narrow space immediately surrounding the intestine and the liver.
3. **In the region of the pharynx** the cœlom is much subdivided and more difficult to trace. Its chief divisions are as follows:—
 - a. The **dorsal cœlomic canals** are a pair of wide spaces lying at the sides of the dorsal part of the pharynx, between the atrial folds and the suspensory folds of the pharynx.
 - b. The **branchial cœlomic canals** are a series of tubular cavities in the primary gill-arches, lying within the

folds into which the atrial epithelium is thrown along the outer sides of these arches. These cavities are very small in the ventral portions of the arches, but widen out towards their dorsal ends, and open, as shown in figs. 41 and 42, into the large dorsal cœlomic canals above the suspensory folds. Branchial cœlomic canals also traverse the skeletal rods of the secondary gill-arches.

- c. The **endostylar cœlomic canal** is a space, in which the cardiac aorta runs, below the endostyle. The branchial cœlomic canals of both primary and secondary gill-arches communicate with it.
- d. A series of **perigonadial cœlomic spaces** surround the reproductive organs.

G. The Circulatory System.

The main features of the circulatory system can be made out by examination of a series of transverse sections.

There is no heart, but the general course of the circulation is the same as in other gill-breathing vertebrates. The blood is colourless and contains but few corpuscles.

The principal vessels are as follows.

1. The **cardiac aorta** is a median longitudinal vessel, running forwards along the ventral wall of the pharynx in the endostylar cœlomic canal.
2. The **aortic arches** are a series of vessels running up the pharyngeal bars or gill-arches. There appear to be three in each bar, the cœlomic, the somatic, and the visceral. The **cœlomic aortic arch** is the outermost of the three and in the primary bars lies close to the atrial epithelium in the wall of the branchial cœlomic canal, while in the secondary bars it appears to lie within the skeletal rod. The **somatic aortic arch** runs along the inner edge of the skeletal rod. The **visceral aortic arch** runs near the inner edge of the

bar. The aortic arches open above into the dorsal aortæ. Those of the primary pharyngeal bars alone arise directly from the cardiac aorta. The cœlomic aortic arches of adjacent bars communicate with each other by vessels in the horizontal bars of the pharynx.

3. The **dorsal aortæ** are a pair of longitudinal vessels into which the aortic arches of both primary and secondary gill-arches open at their dorsal ends. They lie just beneath the notochord, one on each side of the epibranchial groove, and project into the dorsal cœlomic canals.

The dorsal aortæ carry the aërated blood backwards : they unite at the hinder end of the pharynx to form a single vessel, which runs back along the dorsal surface of the intestine.

4. The **portal veins** are vessels running in the cœlom along the ventral surface of the intestine : they collect the blood from the intestine and carry it forwards to the liver, where they break up into capillaries.
5. The **hepatic veins** are vessels which collect the blood from the liver and carry it backwards along the dorsal surface of the liver. On reaching the junction of the liver and intestine, they unite to form a single vessel, which runs forwards along the ventral surface of the pharynx and becomes the **cardiac aorta**.
6. A longitudinal vessel runs along the inner side of each atrial fold, and supplies the myotomes and reproductive organs.

H. The Lymphatic System.

Distinct from the cœlomic spaces is a system of lymphatic spaces associated with the myotomes, nerve-roots, and other parts ; of these the most conspicuous are a pair of large **metapleural canals** running longitudinally within the metapleural folds.

I. The Excretory System.

Three kinds of excretory organs have been described in Amphioxus.

1. The **pigmented canals** discovered by Lankester are possibly excretory. These are a pair of short wide funnels, with deeply pigmented walls, placed in the twenty-seventh segment of the body, opposite the hinder end of the pharynx. They lie, one at each side of the body, in the dorsal coelomic canals above the suspensory folds of the pharynx. Each tube is attached along its outer side to the body-wall, and opens by its wider end into the atrial cavity; in front it is considerably contracted, but appears to open into the coelomic canal.
2. Müller's **renal papillæ** are numerous pigmented papillæ on the floor of the atrial cavity.
3. Weiss and Boveri have recently discovered a series of curved **excretory tubules** lying in the dorsal coelomic canal along each side of the pharynx. Each tubule communicates with the coelom by one or more openings and with the atrial cavity by a single opening on the outer side of a secondary pharyngeal bar, close to its dorsal end.

K. The Nervous System.

The nervous system of Amphioxus consists of: (1) the **central portion**, which, as in other vertebrates, is a tube of nervous matter lying in a sheath of connective tissue immediately above the notochord, and extending almost the entire length of the body; (2) the **peripheral portion**, which consists of the nerves connecting the central portion with the various parts of the body.

The nervous system can be well seen in transverse sections of adults, or by examination of young specimens mounted whole. If fresh specimens can be obtained, the entire nervous system can be isolated by placing them in 20 per cent. nitric

acid for three days, then washing thoroughly and leaving in water for a day. By this treatment the connective tissue is so softened and loosened that on shaking the bottle the nervous system is readily and completely separated from all the other parts. It may then be transferred to alcohol, stained, and mounted in the usual manner.

1. The **central nervous system** or **spinal cord** is of nearly uniform diameter along the greater part of its length: it diminishes slightly in size towards the anterior end, and much more markedly near the posterior end, where it is very slender.

The central canal lies much nearer the ventral than the dorsal surface: it is very small except at the extreme front end, where it expands to form the **ventricle**. From the anterior end of this a small diverticulum arises which in early life communicates by a pore with a ciliated pit on the dorsal surface and left side of the anterior end of the body. Through this pit the central canal of the nervous system at first opens directly to the exterior, but the pore closes during development.

At intervals along the spinal cord are spots of black pigment, contained in cells in the floor of the central canal.

2. The **peripheral nervous system** consists of nerves of two kinds: (1) nerves which arise by single roots, and, except in the case of the first pair, from the dorsal surface of the spinal cord; (2) nerves arising by multiple roots, and from the ventral surface of the cord.

- a. **Nerves arising by single roots.** These apparently correspond to the dorsal or sensory roots of the spinal nerves of other vertebrates. Only the first two pairs have ganglionic enlargements. The first and second are purely sensory nerves, and the remainder are chiefly sensory.

- i. The first pair of nerves arise from the ventral surface of the anterior end of the central nervous system, and supply the anterior fin. Their branches have ganglionic swellings near their distal ends.
- ii. The second pair of nerves are much larger. They arise from the dorsal surface of the spinal cord behind the first pair. Each divides into three main branches, supplying the anterior fin. The finer branches have ganglionic enlargements near their distal ends.
- iii. The third pair of nerves are much smaller than the second, and arise immediately behind them. They supply the parts about the mouth.
- iv. The fourth pair of nerves arise from the dorsal surface of the spinal cord, a short distance behind the third pair; the nerve of the right side being a short distance behind that of the left side.
- v. The fifth pair of nerves are still more oblique, the right nerve arising some distance behind the left.

The succeeding nerves, along the whole length of the cord, arise alternately on the two sides. These nerves run outwards along the connective-tissue septa separating the myotomes, and divide into branches supplying the skin and, to a limited extent, muscles.

- b. Nerves arising by multiple roots. These apparently correspond to the ventral or motor roots of the spinal nerves of other vertebrates.

They arise from the ventral surface of the spinal cord along nearly its whole length, alter-

nating with the dorsal nerves ; a ventral nerve on one side being opposite a dorsal nerve on the other. Each arises by a large number, thirty or more, of very slender rootlets, placed one in front of another, the entire breadth of a ventral root being nearly equal to the interval between two successive roots. The several rootlets do not unite, but pass separately through the connective-tissue sheath of the cord, and end in the myotomes.

L. The Sense Organs.

The sense organs of *Amphioxus* are extremely simple in structure, and differ markedly from those of the higher vertebrates in being unpaired:

1. The pit-like depression of the skin which in the young places the central canal of the nervous system in communication with the exterior has been described as an **olfactory organ**. In the adult it is connected by a solid stalk with the roof of the ventricle.
2. The 'eye' is a rounded pigment-spot in the anterior wall of the ventricle, *i.e.* at the extreme anterior end of the central nervous system.

M. The Reproductive Organs.

The sexes are distinct, but the males and females are alike except as regards the microscopic structure of their reproductive organs. There are no genital ducts.

1. The female.

The **ovaries** are a series of saccular organs of a horseshoe shape, arranged in a row along the inner surface of the atrial fold on each side of the pharynx, and extending back as far as the atrial pore. They lie in cavities, which are extensions of the coelom into the atrial folds ; these cavities are easily recognisable while the ovaries are young, but become almost obliterated when the ova ripen.

The ova, when mature, are discharged into the

atrial cavity by dehiscence of the proper wall of the ovary and of the atrial membrane. The discharged ova, together with the ovaries, form a bulky mass, which causes great distension of the atrial cavity and distortion of the pharynx and other organs.

The ova, which measure $\frac{1}{250}$ inch in diameter, sometimes pass through the gill-slits into the pharynx, and escape through the mouth; in other cases they are discharged through the atrial pore.

2. The male.

The testes are similar in form and position to the ovaries; and the spermatozoa, when ripe, are discharged, like the ova, into the atrial cavity, from which they escape by the atrial pore.

II. DISSECTION OF AMPHIOXUS.

Take an adult specimen which has been macerated for about a day and a half or longer in 20 per cent. nitric acid; and dissect it as described below.

Specimens which have been preserved in alcohol serve perfectly well for this purpose. The effect of the nitric acid is to soften and loosen the connective tissue, and so render the dissection much easier.

1. External Characters.

Place the animal under water in a small dissecting dish. Determine all the external characters, as described on p. 181.

Lay the animal on its left side, and fix it down by two small pins passed through the body slightly nearer the ventral than the dorsal border, one pin passing through the buccal cavity about one-sixteenth of an inch from the anterior end; the other through the tail, behind the anus, and about one-eighth of an inch from the hinder end of the body.

2. The skin.

With needles or fine forceps strip off the skin from the

right side of the body ; stain and mount a piece, and examine it under the microscope.

The skin consists of two layers :—

- a. The **epidermis** is a single layer of short columnar and somewhat dumbbell-shaped cells, with a thick **cuticle** on their outer ends.
- b. The **dermis** is a very thin layer of connective tissue, underlying and supporting the epidermis. It is so thin that it is often difficult to recognise it in specimens treated in this way ; but it will be easily seen in transverse sections of the animal.

Strip off the myotomes of the right side one by one with needles or fine forceps ; commencing just behind the anus and working forwards until nearly the whole of the myotomes of the right side have been removed, a few only being left at the anterior and posterior ends of the animal.

In removing a myotome, take hold of its anterior end or angle, and very carefully draw it off backwards, taking care not to pull away the reproductive or other underlying organs.

3. The **notochord** is a conspicuous yellow rod traversing the animal from end to end ; lying rather nearer the dorsal than the ventral surface, and at the level of the angles of the myotomes.
4. The **spinal cord** is a white band lying immediately dorsal to the notochord.
5. The **skeleton of the dorsal fin** extends along the whole length of the dorsal surface except the extreme anterior and posterior ends : it is a firm gelatinous rod, divided transversely into segments which are much more numerous than the myotomes.
6. The **skeleton of the ventral fin** is a similar but double structure on the ventral surface, extending from the atrial pore to the anus.
7. The **reproductive organs** are a series of squarish masses

lying along the ventral edge of the anterior three-fourths of the length of the animal.

Remove two or three of the reproductive organs: put them on a slide in a drop of glycerine: tease them, and examine with a microscope.

The **ovary** of the female consists of large rounded and polyhedral ova, with large nuclei: *cf.* fig. 42.

The **testis** of the male has a finely granular appearance: the spermatozoa, when ripe, consisting of minute heads with long thread-like tails.

8. The **transverse muscles** of the ventral body wall in the pharyngeal region are well seen, immediately ventral to the reproductive organs.

Remove the reproductive organs of the right side completely, so as to expose the alimentary canal along its whole length.

9. The **atrial cavity** is the space surrounding the walls of the pharynx at the sides and below. It opens to the exterior by the atrial pore.

10. The **alimentary canal** runs nearly straight from mouth to anus: it consists of the following parts:

a. The **buccal cavity** is the most anterior portion: the mouth opening into it below, is bordered by tentacles, which increase in length from before backwards.

b. The **pharynx**, which is in part concealed by the liver, forms about half the length of the alimentary canal: it is crossed by close-set parallel lines, oblique to the axis of the body, and marking the positions of the **gill-clefts**; these do not quite reach either the mid-dorsal or mid-ventral lines, where the wall of the pharynx is formed by the **epibranchial band** and the **endostyle** respectively.

c. The **oesophagus** is a short narrow tube leading from

the dorsal surface of the hinder end of the pharynx to the intestine.

- d. The **intestine** is wider in front, and narrows behind, running back to the anus.
- e. The **liver** is a large saccular diverticulum from the front end of the intestine, which extends forwards along the right side of the hinder two-thirds or more of the pharynx.

To make out the relations of the pharynx, œsophagus, and intestine to one another, carefully remove the liver.

11. The structure of the alimentary canal.

a. The buccal tentacles.

Remove the entire buccal skeleton, with the tentacles in both sides, carefully dissecting it with needles from its attachments. Stain it with picrocarmine; mount on a slide in glycerine, and examine with the microscope.

A jointed skeletal bar borders the buccal aperture on each side, and supports the buccal tentacles.

b. The pharynx.

Remove a portion of the pharynx carefully: divide it along the mid-dorsal line, and spread it out flat on a slide; stain it; mount in glycerine, and examine with the microscope.

The arrangement of the gill-arches and gill-clefts, and their relation to the endostyle, can be well made out.

Remove a second length of the pharynx, and with a fine brush pencil off the epithelium from the gill-arches. Treat a third portion with a solution of caustic potash. Mount in glycerine, and examine with the microscope.

The **primary** or split rods, and the **secondary** or unsplit rods (compare p. 185), can be readily made out; also the horizontal bars connecting the successive pairs of primary rods together, and the relations of the rods to the endostyle.

12. The nervous system.

Remove the nerve-cord along its entire length: stain it; mount on a slide in glycerine, and examine with the microscope.

The dorsal roots of the nerves and their alternate arrangement are well seen (compare pp. 191, 192).

13. The structure of the notochord.

Remove a piece of the notochord: stain it; mount in glycerine, and examine with the microscope.

The notochord breaks up very readily into transverse discs.

III. EXAMINATION OF TRANSVERSE SECTIONS.

Many points in the anatomy of Amphioxus are determined far more easily by an examination of transverse sections of the animal than by dissection. For this purpose a specimen should be cut by means of a microtome, and the sections mounted on slides in their proper sequence. It is only necessary to examine in detail a few of the more typical ones.

A. Transverse Section passing through the Buccal Cavity.

1. **General characters.** The dorsal surface is indicated by the laterally compressed dorsal fin: the ventral surface by the mouth-opening, which is bordered at the sides by the thickened lips; within the buccal cavity are usually seen sections of the tentacles. About the middle of the section is the notochord, and above this is the spinal cord. At the sides are the myotomes, separated from one another by connective-tissue septa.

2. The **skin** consists of two layers.

a. The **epidermis** is a single layer of short columnar cells, with a thick cuticle on their outer ends.

- b. The **dermis** is a very thin layer of connective tissue underlying and supporting the epidermis.

3. The **skeletal system**.

- a. The **notochord** is oval in section, the longer axis being vertical. It is crossed by numerous wavy transverse bands, the spaces between which are occupied by a homogeneous substance : this latter is the coagulated semifluid matter occupying the vacuoles of the notochordal cells, the outlines of which are indicated by the wavy bands.

Near the surface of the notochord, and especially in the dorsal region, cells may be seen which have undergone comparatively little modification.

- b. The **connective tissue** forms a thick deeply staining investment to the notochord, which is prolonged upwards to enclose the spinal cord, and outwards to form the septa : these latter separate the myotomes from one another, and are continuous at their outer borders with the dermis.
- c. The **buccal skeleton**. Sections of the segmented rods which strengthen the lips are seen bordering the entrance to the buccal cavity : a smaller rod occupies the axis of each tentacle. In structure these rods resemble the notochord.
- d. The **skeleton of the dorsal fin**. The dorsal fin is filled with a homogeneous gelatinous substance, which is stained slightly by reagents.

4. The **muscles**.

- a. The **myotomes** are seen in section as squarish masses of muscle, lying along the sides of the body in the compartments formed by the septa. Owing to the obliquity of the myotomes, three or more are cut in each transverse section, and owing to their > shape each myotome is cut twice. The myotomes of the two sides are not opposite, but alternate with each other.

- b. Other much smaller muscles are seen in connection with the buccal skeleton and tentacles.

5. The **buccal cavity**.

The epithelium lining the buccal cavity consists of a single layer of cells, which in the anterior and ventral part are short and columnar, but in the posterior and dorsal region are much elongated, slender and flagellate.

6. The **nervous system**.

- a. The **spinal cord** lies in a connective-tissue sheath immediately above the notochord. In transverse section it is somewhat triangular, with rounded angles, and is rather wider from side to side than it is dorso-ventrally.

The **central canal** lies nearer the ventral than the dorsal surface: it is lined by short columnar ciliated cells, and immediately below it are the large deeply pigmented cells already mentioned (p. 191). From the central canal a narrow vertical slit extends upwards to the dorsal surface of the cord, both the canal and the slit being bordered by large nerve-cells. In young specimens the slit is open above, but in adults it is closed by connective tissue, and by processes of the nerve-cells growing across it from side to side. The greater part of the cord has a finely punctate appearance, caused by the cut ends of the nerve-fibres.

- b. The **nerves** can only be recognised in sections which happen to pass through their roots.
 - i. The **dorsal nerves** arise by large single roots from the sides of the cord, about midway between the dorsal and the ventro-lateral angles.
 - ii. The **ventral nerves** arise by very minute and multiple rootlets from the ventro-lateral angles of the cord.

B. Transverse Section through the Anterior Part of the Pharynx.

1. General characters. The section is triangular in shape, the apex being formed by the dorsal fin, the base by the ventral surface, and the basal angles by the metapleural folds. The pharynx, perforated by the gill-slits, and surrounded by the atrial cavity, lies below the notochord.

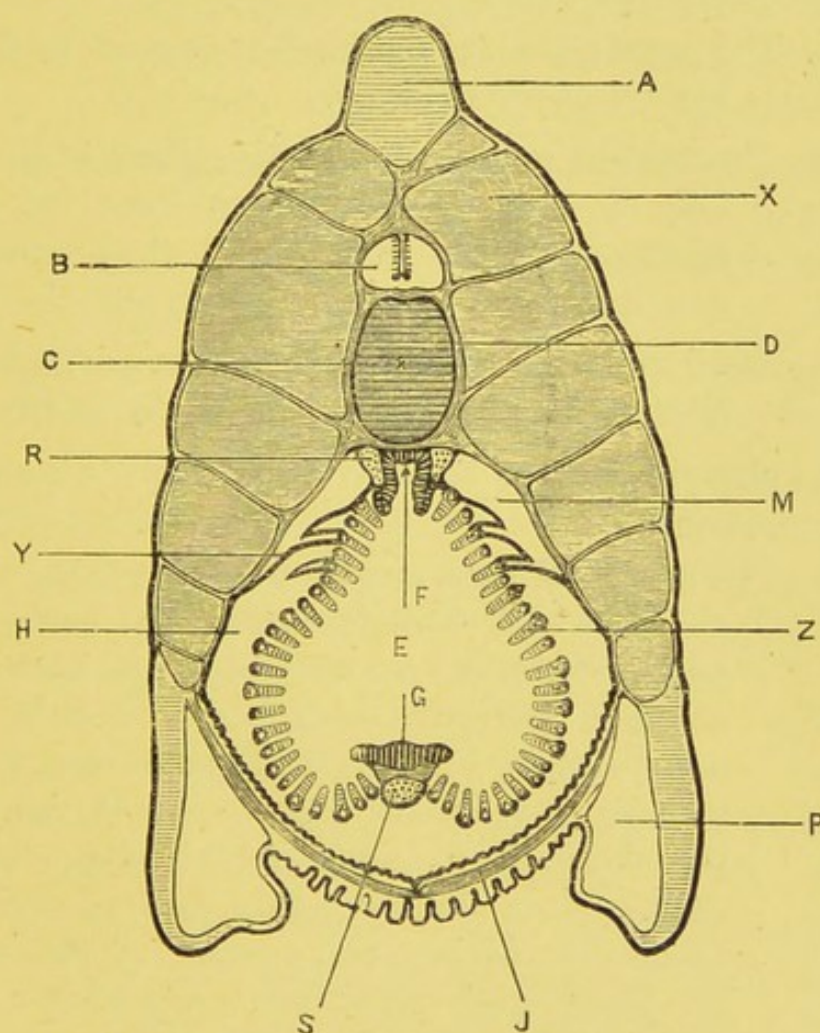


FIG. 41.—*Amphioxus lanceolatus*.—Transverse section through the anterior part of the pharynx of an adult specimen. The boundary of the atrial cavity is indicated by a thick black line. (A. M. M.)

A, skeleton of dorsal fin. B, spinal cord. C, notochord. D, connective-tissue sheath surrounding notochord. E, cavity of pharynx. F, epibranchial groove of pharynx. G, endostyle, which in this anterior part is flattened out or even convex. H, atrial cavity. J, transverse muscles in floor of atrial cavity. M, dorsal coelomic canal. P, metapleural canal. R, left dorsal aorta. S, endostylar coelomic canal in which the cardiac aorta lies. X, myotome. Y, suspensory fold of pharynx, separating the dorsal coelomic canal from the atrial cavity. Z, gill-arch or branchial bar; the triangular white spot represents the cut surface of the skeletal rod of the arch.

2. The **skin** of the ventral surface is thrown into deep folds to allow for the distension of the atrial cavity when the reproductive organs attain their full size. Its general characters are the same as in A.
3. The **skeletal system** is the same as in A, except that the branchial skeleton is present, and that there is no buccal skeleton.
4. The **muscular system**.
 - a. The **myotomes** are similar to those of section A, but considerably larger.
 - b. The **ventral muscles** form a thin sheet in the atrial fold of each side, extending from the lowest myotome to the mid-ventral line, where the muscles of the two sides meet in a median raphe.
 - c. Small muscular bands are present in the suspensory folds of the pharynx and in the gill-arches.
5. The **pharynx** is of an inverted heart shape in transverse section.
 - a. The **branchial bars**, or **gill-arches**. Owing to their obliquity and extreme closeness to one another, twenty or more bars may be cut on each side in a single section. Each bar is clothed on its outer surface by the **atrial epithelium**, which is a single layer of columnar cells. Within this is the skeletal rod, deeply grooved along its inner edge. From the rod a thin plate of connective tissue extends inwards, clothed on each side by the **pharyngeal epithelium**, a single layer of very long columnar flagellate cells.

The branchial bars are alternately large and small, the difference being especially marked at their outer edges. The large ones are the primary, and the small ones the secondary bars.

In the large primary bars a small space is visible between the atrial epithelium and the skeletal rod. This space, the branchial coelomic

canal, which is part of the coelom, is much larger in the dorsal than in the ventral bars of the section, and in the most dorsal ones it is a space of considerable size, the atrial epithelium being produced outwards for some distance. The uppermost two or three of these outward prolongations of the atrial epithelium unite together to form the **suspensory folds** of the pharynx, which sling it to the inner surface of the atrial folds, the branchial coelomic canals opening here into the dorsal coelomic canals (fig. 41).

- b. The **epibranchial groove** is a deep median groove in the dorsal wall of the pharynx immediately beneath the notochord. It is lined by columnar epithelium.
 - c. The ventral wall of the pharynx is formed by a flat or slightly convex plate, the **endostyle**, covered by a layer of columnar epithelial cells.
6. The **atrial cavity** surrounds the sides and ventral surface of the pharynx, lying between it and the atrial folds, and communicating with the cavity of the pharynx through the gill-slits. The atrial epithelium consists of a single layer of pigmented columnar cells, and is often much folded on the ventral wall.
7. The **coelom** is much subdivided in this region: its principal divisions are as follows:
- a. The **dorsal coelomic canals** are a pair of large irregular spaces at the sides of the epibranchial groove, above the suspensory folds of the pharynx, and between these and the atrial folds.
 - b. The **branchial coelomic canals** are the cavities in the primary branchial bars, between the atrial epithelium and the skeletal rods. They all open at their dorsal ends into the dorsal coelomic canals.
 - c. The **endostylar coelomic canal** is a median space in

the ventral region of the endostyle. It encloses the cardiac aorta.

8. The **metapleural canals** are a pair of large spaces, triangular in section, lying in the metapleural folds.
9. The **circulatory system**. The larger vessels can be recognised in sections, by the coagulated blood which they contain.
 - a. The **cardiac aorta** is a median vessel lying in the endostylar coelomic canal.
 - b. The **dorsal aortæ** are a pair of vessels lying one on each side of the epibranchial groove.
 - c. The **aortic arches** lie in the branchial bars, both primary and secondary (see p. 188).
10. The **nervous system** is the same as in section A.

C. Transverse Section passing through the Hinder Part of the Pharynx.

1. **General characters**. The section is larger than B, passing through the thickest part of the body. It is triangular in shape, the angles being formed by the dorsal and lateral fins respectively. The section passes through the laterally compressed pharynx, on the right side of which is the liver. The reproductive organs project into the atrial cavity from the inner sides of the atrial folds.

The cutaneous, skeletal, muscular, and nervous systems are practically the same as in section B.

2. The digestive system.

- a. The **pharynx** has the same structure as in section B, but differs markedly in shape, being greatly compressed laterally, so that its two sides are almost in contact with each other; both **endostyle** and **epibranchial groove** are well marked.
- b. The **liver** lies at the right side of the pharynx, and is oval in section. Its walls are thick, and consist

of a single layer of very long and slender flagellate cells, resting on a thin outer wall of connective tissue.

3. The **atrial cavity** has the same general relations as in section B. The atrial epithelium covers the outer surfaces of the branchial bars, and the **suspensory**

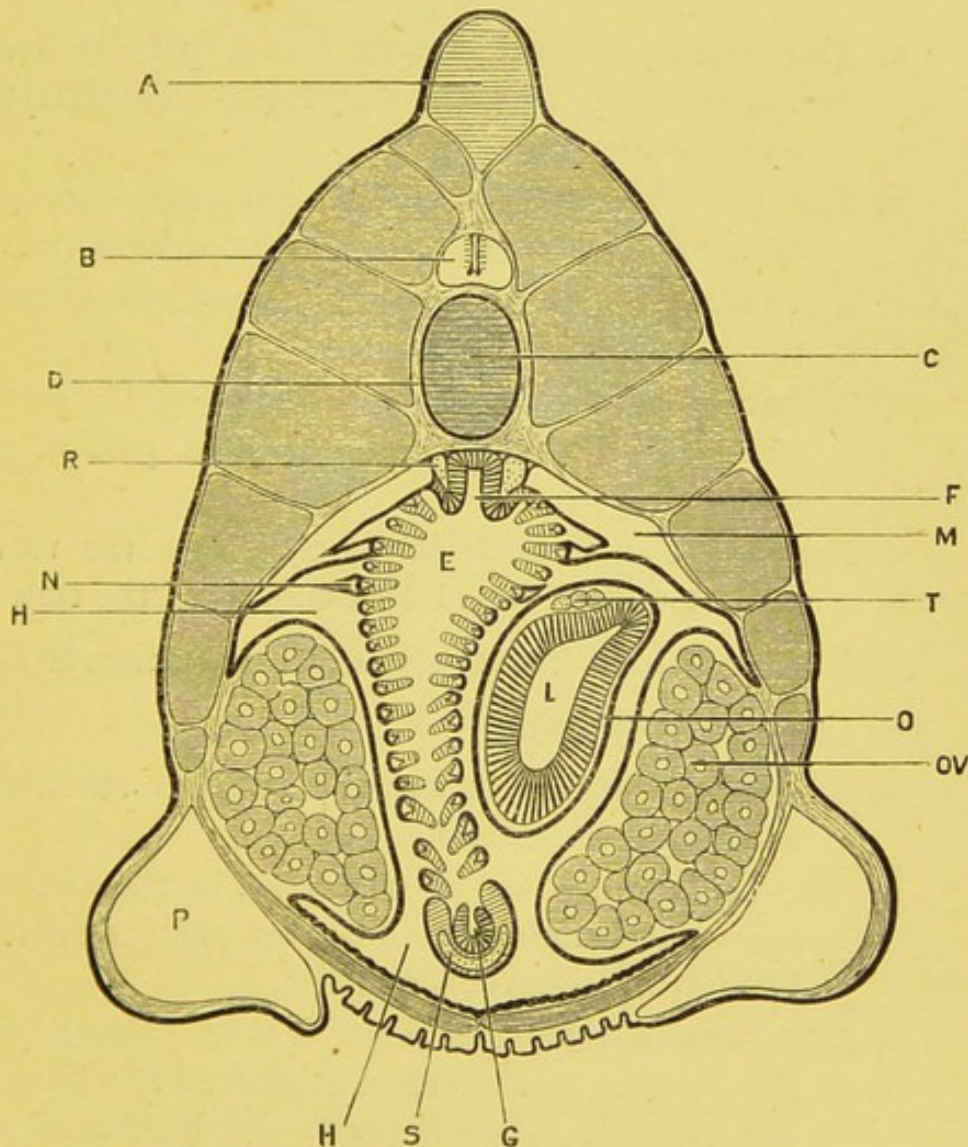


FIG. 42.—*Amphioxus lanceolatus*. Transverse section through the hinder part of the pharynx of an adult female, passing through the liver and ovaries. The boundary of the atrial cavity is indicated by a thick black line. (A. M. M.)

A, skeleton of dorsal fin. B, spinal cord. C, notochord. D, connective-tissue sheath of notochord. E, cavity of pharynx. F, epibranchial groove. G, endostyle. H, atrial cavity. L, liver. M, dorsal coelomic canal. N, branchial coelomic canal. O, coelomic space surrounding liver. OV, ovary. P, metapleural canal. R, left dorsal aorta. S, endostylar coelomic canal. T, hepatic veins.

folds of the pharynx; and is continued downwards over the inner surfaces of the atrial folds, covering the reproductive organs, and being thrown into folds along the ventral wall of the atrial cavity. It also forms an investment to the liver.

4. The **cœlom** is still more subdivided than in Section B; its main divisions are as follows.
 - a. The **dorsal cœlomic canals** are a pair of large spaces above the suspensory folds of the pharynx, as in section B.
 - b. The **branchial cœlomic canals** are a series of cavities in the primary branchial bars, as in section B.
 - c. The **endostylar cœlomic canal** is a median space in the endostyle.
 - d. A space surrounding the liver, between its proper wall and the atrial epithelium, is part of the cœlom.
 - e. Paired spaces immediately surrounding the reproductive organs are also extensions of the cœlom.
5. A pair of large **metapleural canals** lie in the lateral fins.
6. The **circulatory system**.
 - a. The **cardiac aorta**, the **dorsal aortæ**, and the **aortic arches** are as in section B.
 - b. The **portal veins** lie on the liver, in the cœlomic space surrounding it. They are often difficult to identify in transverse sections.
 - c. The **hepatic veins** are three or four vessels lying side by side on the dorsal surface of the liver, in the cœlomic space between the liver and the atrial membrane investing it.
7. The **reproductive organs** occupy similar positions in the two sexes. They are masses, varying in size according to the degree of ripeness of the ova or spermatozoa, lying on the inner sides of the atrial folds, and projecting into the atrial cavity.

D. Transverse Section passing through the Atrial Pore.

1. **General characters.** The section is smaller than the preceding one, and the myotomes reach much further down the sides. The intestine is cut across, but the

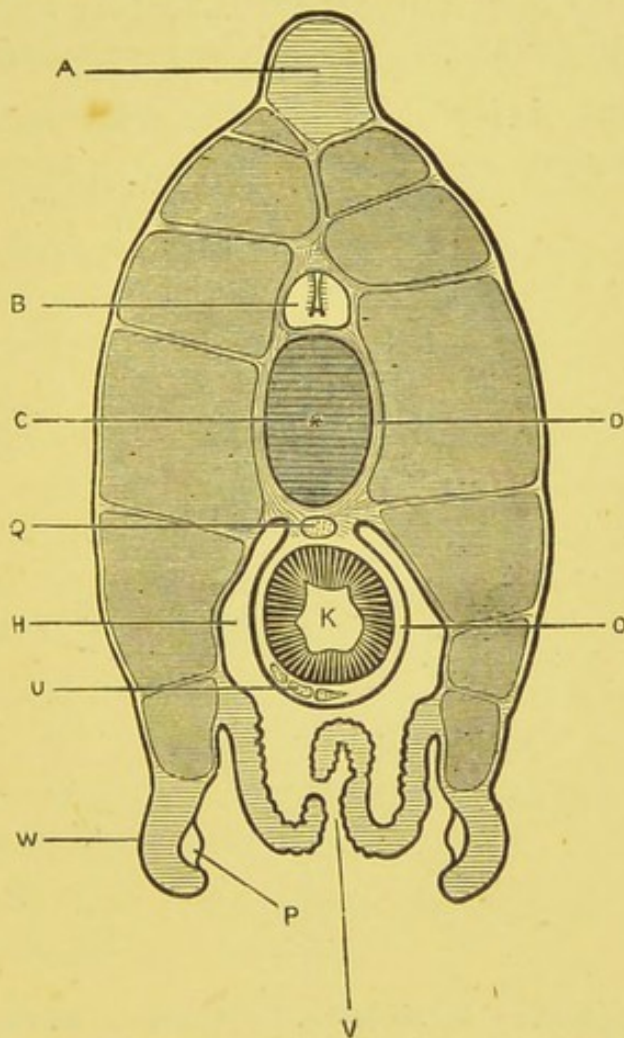


FIG. 43.—*Amphioxus lanceolatus*. Transverse section of an adult specimen, passing through the atrial pore. The boundary of the atrial cavity is indicated by a thick black line. (A. M. M.)

A, skeleton of dorsal fin. B, spinal cord. C, notochord. D, connective-tissue sheath of notochord. H, atrial cavity. K, intestine. O, coelomic space surrounding intestine. P, metapleural canal. Q, dorsal aorta. U, portal veins. V, atrial pore, represented diagrammatically. W, metapleural folds.

section lies entirely behind the reproductive organs. The metapleural folds are present, but are much smaller than in sections B and C, and between them in the median plane is the atrial pore.

The skin, and the skeletal, muscular, and nervous

systems are practically as in section B, except that the ventral muscles are absent.

2. The **intestine** is circular in section. Its walls are thick and, like those of the liver, consist of a single layer of very long and slender epithelial cells, resting on a thin connective-tissue basement membrane.
3. The **atrial cavity** surrounds the sides and the ventral surface of the intestine, and opens to the exterior at

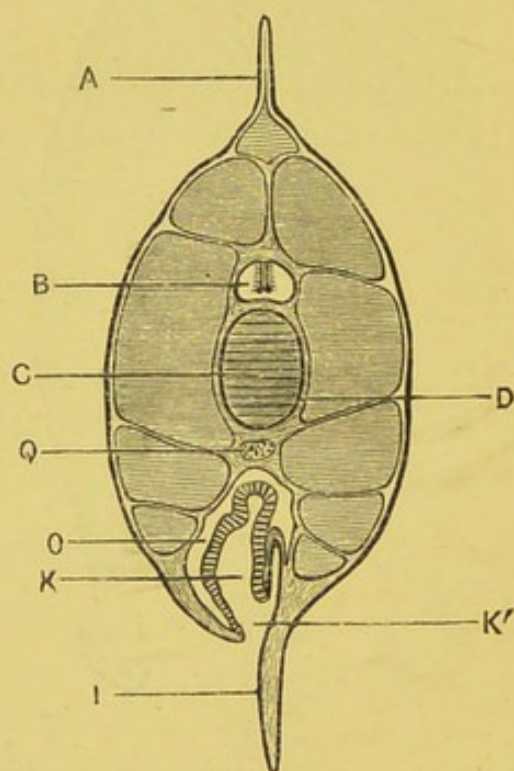


FIG. 44.—*Amphioxus lanceolatus*. Transverse section of an adult specimen, passing through the anus. (A. M. M.)

A, dorsal fin. B, spinal cord. C, notochord. D, connective-tissue sheath of notochord. I, ventral fin. K', intestine. K, anus. O, coelom. Q, dorsal aorta.

the **atrial pore** in the mid-ventral line between a pair of thickened and prominent lips, which are prolonged backwards like a spout.

4. The **coelom** is reduced to a narrow space surrounding the intestine, between its proper wall and the atrial membrane.
5. The **metapleural canals** are very greatly reduced in size.

6. The circulatory system.

- a. The **dorsal aorta** is a median vessel, between the notochord and the intestine.
- b. The **portal or sub-intestinal veins** are three or four vessels lying side by side on the ventral surface of the intestine, in the coelomic space surrounding it.

E. Transverse Section passing through the Anus.

1. **General characters.** The section is much smaller than the preceding ones. It is oval, with median dorsal and ventral fins, and the notochord occupies its centre.

The section passes behind the atrial cavity, which is therefore entirely absent in it.

The skin and the skeletal, muscular, and nervous systems are practically as in section B, except that the ventral muscles are absent.

2. The **intestine** lies below the notochord, and the **anus** is on the left side of the ventral fin.
3. The **coelom** is a space surrounding the dorsal and lateral surfaces of the intestine.
4. The **dorsal aorta** is a median vessel in the connective tissue below the notochord.

CHAPTER XI.

THE DOG-FISH. *Scyllium canicula*.

THE dog-fish, together with the sharks and skates, belongs to the group of fish known as Elasmobranchs, the great majority of which are powerful swimmers, of carnivorous habits, and exceedingly voracious. One of the chief characters of the group is that almost the whole of the internal skeleton remains cartilaginous throughout life: hence Elasmobranchs are frequently spoken of as cartilaginous fish.

There are several kinds of dog-fish found off our own coasts. The following description is taken from one of the most abundant species, but will apply with but slight changes to any of the common forms. Skates differ markedly from dog-fish in external appearance, owing to the enormous size of their pectoral fins, which form the great lateral wing-like expansions of the body: as regards internal structure, however, the differences are comparatively unimportant, and a skate might easily be dissected by following the directions given in this chapter. All the measurements here given are taken from a dog-fish of about two feet in length, which will be found the most convenient size for dissection.

Scyllium canicula, like most other species of dog-fish, lays eggs, which are of large size, and enclosed in horny capsules produced at their angles into long spirally twisted strings for attachment. In many cases the eggs are retained within the oviduct during part or the whole of their development; and in some few species a still closer relation is established between the mother and the embryo, similar in many respects to the placenta of mammals, whereby the embryo obtains

during its development a supply of nutriment direct from the mother.

I. EXTERNAL CHARACTERS.

Lay the dog-fish on a board, and determine the following points.

A. General Appearance.

The body is greatly elongated : it is broadest about the level of the pectoral fins, in front of which it is flattened dorso-ventrally, ending in the blunt rounded snout. The hinder part of the body is compressed laterally, and tapers gradually to the end of the long slender tail, the hindmost three or four inches of which are bent up at an angle.

The general colour is grey ; paler on the ventral surface, and marked on the dorsal and lateral surfaces with dark brown spots. The entire surface is covered with small **scales**, and along each side of the head and body there runs a slight longitudinal groove, the **lateral line**.

B. The Fins.

The fins are flattened outgrowths arising from various parts of the body. Each is supported by an internal cartilaginous skeleton, and is usually triangular in shape, the base or attached border being very commonly free at its posterior end.

1. Median Fins.

- a. The **dorsal fins** are two in number, the anterior and larger one being placed about the middle of the length of the body, and the posterior one a short distance further back.
- b. The **caudal fin** forms a vertical fringe round the posterior four or five inches of the tail. Its dorsal portion is narrow, its hinder end truncated, and its ventral portion partially subdivided into a small posterior and a large anterior lobe.

- c. The **anal fin** is on the ventral surface opposite the interval between the two dorsal fins.
- 2. **Paired fins**, representing the limbs of higher vertebrates.
 - a. The **pectoral fins** are the largest of all the fins, and project horizontally outwards from the sides of the ventral surface of the body, just behind the head.
 - b. The **pelvic fins** are smaller than the pectoral, and are placed on the ventral surface of the body, a little way in front of the middle of its length. Their inner borders touch each other, and in the male are fused together behind.

In the male a part of each pelvic fin is separated from the rest of the fin, and specially modified to form a copulating organ or '**clasper**:' this is a stout backwardly directed rod, deeply grooved along its inner and dorsal surface. The groove leads forwards into a sac which lies just beneath the skin of the ventral surface of the body, close to the median line, and ends blindly about an inch in front of the pelvic girdle.

C. External Apertures.

1. Median apertures.

- a. The **mouth** is a large transverse crescentic opening on the under surface of the head, a short distance from its anterior end.
- b. The **cloacal aperture** is on the ventral surface of the body between the pelvic fins, *i.e.* in front of the middle of the length of the body. It gives exit to faecal matter from the intestine, and to the renal and genital products.

2. Paired apertures.

- a. The **nostrils** are a pair of large circular apertures on the under surface of the head in front of the

mouth, with which they are connected by wide grooves covered by flaps of skin.

- b. The **spiracles** are a pair of small apertures on the sides of the head, just behind the slit-like openings of the eyes. They are really a pair of gill-clefts.

Pass a seeker down one of the spiracles into the mouth.

- c. The **gill-clefts** are a series of five vertical slits on each side of the neck, in front of and slightly above the pectoral fins. They open obliquely backwards, and during life give exit to the water passed from the mouth over the gills for the purpose of respiration.

Pass a seeker through the gill-clefts into the mouth.

- d. The **cloacal pouches** are a pair of pocket-like depressions at the sides of the cloacal aperture and between the pelvic fins.
- e. The **cloacal papillæ** are attached in front of the cloacal pouch, with their apices directed backwards. Each is traversed by a canal (peritoneal canal) which opens anteriorly into the body-cavity and posteriorly by the **abdominal pores** into the cloacal pouches. The pores are minute, and are only open in mature dog-fish.

3. Scattered apertures.

- a. The apertures of the **sensory** and **ampullary canals** are rows of minute openings arranged symmetrically on the surface of the head. The openings of the ampullary system are especially abundant on the snout. They lead into tubes of considerable length, which lie beneath the skin and are filled with a transparent gelatinous substance.

Squeeze the head so as to press out the gelatinous substance, and so render the openings of the tubes more obvious.

D. The Scales and Teeth.

1. The **scales**. The whole surface of the body is covered with small **placoid scales**, which are special developments of the skin.

- a. **General arrangement**. The scales are larger on the dorsal than on the ventral surface, and differ somewhat in shape in different parts of the body. Their projecting points are directed backwards, so that the finger can be readily passed along the body from the head to the tail, but meets with considerable resistance in the reverse direction.

- b. **Structure of the scales**.

Cut out a small piece of skin, and boil it for a few minutes in a solution of caustic potash to isolate the scales. Mount them in glycerine, and examine with the microscope.

Each scale consists of a bony base, usually four-lobed, from which a pointed spine of dentine, capped with enamel, projects backwards.

2. The **teeth** are really the enlarged scales of the skin covering the jaws. They are arranged in several rows, and have their points directed backwards.

II. THE SKELETON.

The skeleton of the dog-fish forms an important link between the exceedingly simple condition seen in *Amphioxus* and the complicated bony framework of the higher vertebrates.

In the embryo a rod-like **notochord** extends down the back, immediately beneath the central nervous system and dorsal to the alimentary canal, similar to that of *Amphioxus*, except that it does not quite reach to the anterior end of the body. Around this notochord a sheath of cartilage is formed, which in the head gives rise to the base of the skull, and in

the body becomes divided transversely into segments, the **centra** or bodies of the vertebræ, the flexibility of this region being thereby increased.

Above the centra **neural arches** are formed, which surround and protect the brain and spinal cord; and below them **hæmal arches**, which tend to encircle the body cavity.

Besides this axial skeleton a visceral skeleton is developed around the anterior part of the alimentary canal, and skeletal elements are also formed in relation with the fins.

The greater part of the skeleton consists throughout life of cartilage. It is hardened in many places by deposition of calcareous salts. True bone is developed in the centra of the vertebræ.

The skeleton of the dog-fish is best prepared by taking a specimen which has been some days in spirit, dipping it in hot water a few degrees below boiling point for a few minutes, in order to soften the connective tissue, and then scraping or brushing away the soft parts until the skeleton is clean. Specimens so prepared must not be allowed to dry, but should be kept in weak spirit.

A. The Vertebral Column, or 'Backbone.'

A trunk vertebra consists of a **centrum**, traversed by the notochord; a dorsal or **neural arch**, surrounding the spinal cord; and **transverse** or **hæmal processes**. In the caudal or tail vertebræ of the dog-fish the hæmal processes unite ventrally, forming a **hæmal canal** which encloses the caudal artery and vein.

The structure of the vertebral column is best made out by cutting sagittal, transverse, and horizontal sections through various parts of its length with a strong knife, and comparing these with one another.

1. The **centra** are short cylinders of cartilage, about as long as they are wide, connected together by intervertebral ligaments of strong connective tissue, which allow slight movement between the successive vertebræ and free flexion of the column as a whole.

Each centrum is a ring, thin at its ends, but thickened on its inner side in the middle of its length, so that the cavity is hourglass-shaped (fig. 49, p. 238). The inner surface of the ring is lined by a layer of bone.

The notochord persists throughout the whole length of the column: it is greatly constricted opposite the middle of each vertebra, but thickened almost to the full width of the column in the intervertebral spaces.

2. The hæmal arches.

In the anterior part of the vertebral column the centra are flattened ventrally, and produced laterally into blunt horizontal **transverse processes** which bear at their ends movably articulated cartilaginous **ribs** about half an inch in length.

Further back the transverse processes become more prominent and project ventrally as **hæmal processes**, causing the under surface of the column to appear grooved.

In the tail the ribs are absent, and the hæmal processes of each vertebra meet and unite mid-ventrally, thereby completing the hæmal arch, which encloses the caudal artery and vein.

At the hinder end of the tail, opposite the caudal fins, the hæmal arches are produced downwards into median **hæmal spines**.

The hæmal arches develop independently of the vertebral centra, but become connected with them at a very early date.

3. The **neural arches** are made up of elements of three kinds: **neural processes**, **neural plates**, and **neural spines**.

- a. The **neural processes**, forming the bases of the neural arches, are blunt processes projecting

upwards from the sides of each centrum opposite its middle.

- b. The **neural plates** are a series of thin hexagonal plates of cartilage which form the sides of the neural canal (figs. 45 and 49). On each side there are twice as many neural plates as there are vertebræ, the neural plates being placed alternately opposite the middles of the vertebræ, and opposite the intervertebral intervals. The former or **vertebral neural plates** are fused in the adult with the tops of the neural processes, and have their posterior borders notched for the passage of the ventral roots of the spinal nerves. The dorsal roots of the nerves pass out through notches in the posterior borders of the **intervertebral neural plates**.

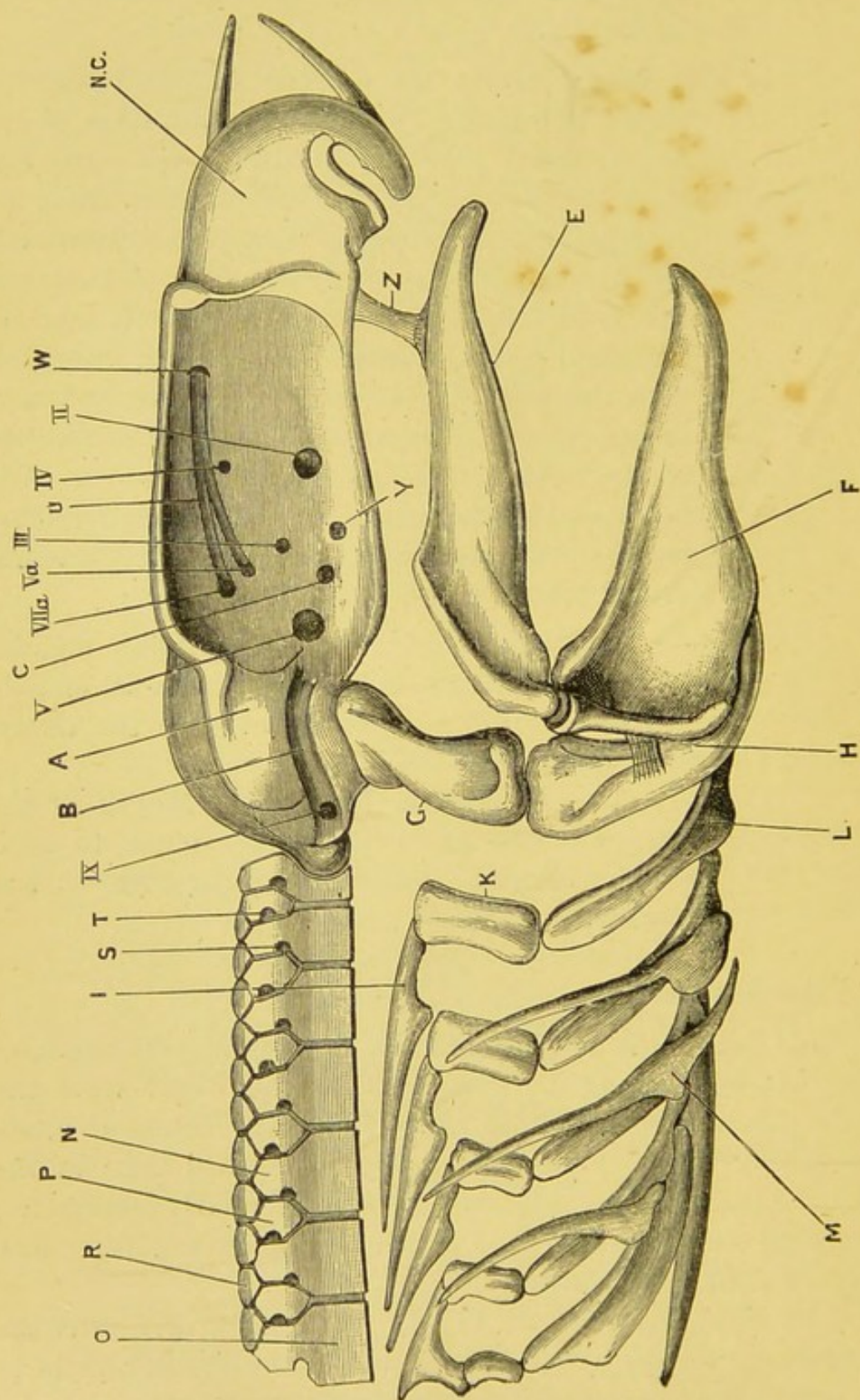
- c. The **neural spines** are a series of median nodules of cartilage, wedged in between the dorsal ends of the neural plates so as to complete the neural arches above.

Along the greater part of the length of the column there are two neural spines to each vertebra, but in places the arrangement is less regular.

B. The Skull.

The skull of the dog-fish remains cartilaginous throughout life, thereby escaping the complications that result from the development of bone: in it, also, the several factors of which the skull is made up are more easily determined than in the higher forms. For these reasons it is peculiarly instructive, affording an important clue to the complex condition met with in higher vertebrates.

The skull consists of (1) an axial tube, the **cranium proper**, open at both ends, which lodges the brain, and is to be regarded as an anterior unsegmented continuation of the vertebral column; and (2) the **olfactory** and **auditory sense-**



capsules, which are cartilaginous capsules investing the nose and the ear respectively. These latter are at first independent of the cranium, but in the adult fuse with it, forming lateral expansions of its anterior and posterior ends. This fusion of the sense-capsules and cranium is so complete that they will be described together.

1. General form of the skull.

The skull is a somewhat oblong box of cartilage, deeply hollowed at the sides to form the orbits, which lodge the eyes, and ending in front in a short pointed rostrum formed by three converging rods.

The olfactory capsules are thin-walled lateral expansions of the anterior end of the skull, in front of the orbits; and the auditory capsules are more massive projections behind the orbits.

Examine the several surfaces of the skull in succession, identifying the parts described below.

2. The dorsal surface of the skull.

- a. The **olfactory capsules** are a pair of large oval cartilaginous cups at the anterior end of the skull: they have very thin walls and are easily torn. Their long axes are placed somewhat obliquely,

FIG. 45.—*Scyllium canicula*. The skull and visceral skeleton with the anterior part of the vertebral column, seen from the right side. The labial cartilages and gill-rays are omitted. (A. M. M.)

A, auditory capsule. B, post-orbital groove. C, inter-orbital canal. E, upper jaw. F, lower jaw. G, hyo-mandibular cartilage. H, cerato-hyal. I, pharyngo-branchial. K, epi-branchial. L, cerato-branchial. M, extra-branchial. N, vertebral neural plate. NC, olfactory capsule. O, centrum of vertebra. P, intervertebral neural plate. R, neural spine. S, foramen for the ventral root of a spinal nerve. T, foramen for the dorsal root of the same nerve. U, orbital grooves, lodging the ophthalmic branches of the fifth and seventh nerves. W, aperture at end of orbital groove through which the ophthalmic branches of the fifth and seventh nerves leave the orbit. Y, foramen for hyoidean artery. Z, ethmo-palatine ligament.

II, optic foramen. III, foramen for third nerve. IV, foramen for fourth nerve. V, foramen for the main branches of the fifth and seventh nerves, and for the sixth nerve. Va, foramen for the ophthalmic branch of the fifth nerve. VIIa, foramen for the ophthalmic branch of the seventh nerve. IX, foramen for the ninth or glosso-pharyngeal nerve.

and they are separated from each other by a thin median **internasal septum**.

- b. The **rostrum** is formed by three cartilaginous bars, of which two run forwards from the upper surface of the olfactory capsules, converging in front; while the third is an anterior prolongation of the floor of the cranium, or brain-case.
- c. The **anterior fontanelle** is a large, almost circular hole in the roof of the skull, between and behind the olfactory capsules. During life it is closed by a connective-tissue membrane, in connection with the inner surface of which is the **pineal body**.
- d. The **supra-orbital crests** are prominent curved ridges of cartilage running along the sides of the skull from the olfactory to the auditory capsules, and forming the dorsal boundaries of the orbits. Along the inner side of each crest, between it and the cranium, is a shallow longitudinal groove in which lies a bundle of sensory canals.
- e. The **foramina for the ophthalmic nerves** are a pair of small apertures behind and to the outer sides of the anterior fontanelle, and to the inner sides of the supra-orbital crests. Through them the ophthalmic branches of the fifth and seventh nerves pass from the orbit to the dorsal surface of the olfactory capsules.
- f. The **auditory capsules** are large lateral projections at the hinder end of the skull. They lodge the auditory organs, certain parts of which can be recognised without dissection.
- i. Between the two auditory capsules there is a median depression, at the bottom of which are a pair of holes. Each hole leads downwards and outwards into a canal, the **aquæductus vestibuli**, which opens below into the internal ear.

Pass a seeker down the aquæductus vestibuli on one side into the ear.

- ii. From the outer side of the aperture of the aquæductus vestibuli on each side, a ridge runs forwards and outwards across the skull-roof and towards the orbit. In this lies the **anterior vertical semicircular canal** of the ear, which can usually be seen through the cartilage.
- iii. A similar ridge, running backwards and outwards from the same point, lodges the **posterior vertical semicircular canal**.
- iv. The **external or horizontal semicircular canal** can usually be seen through the cartilage, lying to the outer side of the other two canals, and with its convexity directed outwards.

3. The side of the skull.

- a. The **rostrum and olfactory capsule** have already been seen.
- b. The **orbit** is the deep oval concavity at the side of the skull, extending from the olfactory to the auditory capsule, and bounded above and below by the prominent **supra-orbital** and **sub-orbital ridges**. It lodges the eyeball and its muscles, and is traversed by numerous nerves; the rest of the space being occupied by the large **orbital blood-sinus**.

Identify the following structures within the orbit. (See fig. 45.)

- i. The **orbito-nasal foramen** is a small round hole at the anterior inferior angle of the orbit, through which the veins of the anterior part of the head communicate with the orbital sinus.
- ii. The **optic foramen** is a large hole about the middle of the length of the orbit and near its ventral border. Through it the optic nerve enters the orbit.

- iii. The **foramen for the third nerve** is a small hole in the inner wall of the orbit, about a quarter of an inch behind the optic foramen and a little above it.
- iv. The **foramen for the fourth nerve** is a very small hole near the dorsal border of the inner wall of the orbit, vertically above the optic foramen, or very slightly behind this.
- v. The **foramen for the fifth and seventh nerves** is a large hole at the posterior and ventral angle of the orbit, immediately in front of the auditory capsule. Through it the main branches of the fifth and seventh nerves, and also the sixth nerve, enter the orbit.
- vi. The aperture of the **inter-orbital canal** is a small round hole in front of and a little below the foramen for the fifth and seventh nerves, and below and behind the foramen for the third nerve. The canal traverses the base of the skull, and places the orbital blood sinuses of the two sides in communication with each other.
- vii. The **foramen for the hyoidean artery** lies a little in front of, and slightly below, the opening of the inter-orbital canal. Through it the hyoidean artery enters the skull.
- viii. The **foramina for the ophthalmic branches of the fifth and seventh nerves**. These nerves enter the orbit through two holes near its hinder end, just in front of the auditory capsule, and above the foramen for the main branches of the fifth and seventh nerves: the aperture for the ophthalmic branch of the seventh nerve is the larger of the two, and is placed slightly above and behind that for the fifth. From these apertures shallow grooves run forwards

along the inner wall of the orbit, close to its dorsal border, to the foramen by which the two nerves leave the orbit: this is situated at the antero-superior angle of the orbit, and has already been seen on the dorsal surface of the skull.

c. The **articular surface for the hyo-mandibular cartilage** is a concave depression on the side of the hinder end of the skull, below the auditory capsule.

d. The **post-orbital groove** is a deep horizontal groove immediately above the articular surface for the hyo-mandibular cartilage, and overhung by the projecting ledge of the auditory capsule which lodges the horizontal semicircular canal: it lodges during life the venous canal through which the orbital sinus communicates with the anterior cardinal sinus.

The anterior end of the groove is bridged over by stout ligamentous tissue.

e. The **foramen for the glosso-pharyngeal nerve** is at the hinder end of the floor of the post-orbital groove, behind and below the horizontal semicircular canal of the ear.

4. The **ventral surface of the skull.**

a. The base of the skull is a broad flat plate of cartilage, crossed almost transversely a little behind its middle by a pair of grooves in which the carotid arteries lie. At the point of meeting of the grooves in the middle line is an aperture through which the internal carotid artery enters the skull.

b. The **apertures of the olfactory capsules** are large, but are considerably reduced by the **nasal cartilages**, which are liable to be torn in cleaning

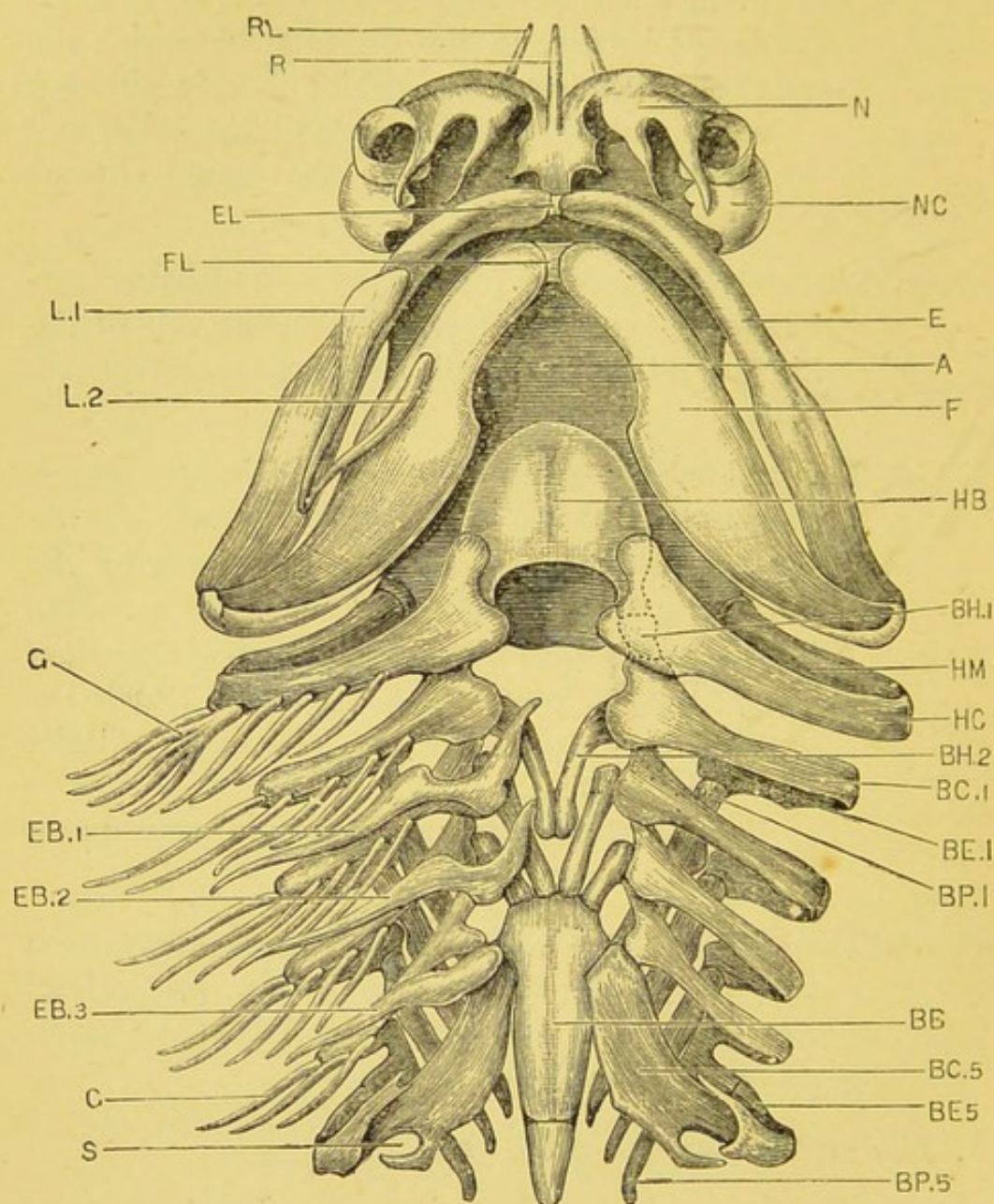


FIG. 46. — *Scyllium canicula*. The skull and visceral skeleton seen from the ventral surface. The labial cartilages, extra-branchials, and gill-rays of the left side have been removed. (A. M. M.)

A, base of skull. BB, basi-branchial. BC 1, BC 5, first and fifth cerato-branchials. BE 1, BE 5, first and fifth epi-branchials. BH 1, first hypo-branchial, represented as though seen through the cerato-hyal. BH 2, second hypo-branchial. BP 1, BP 5, first and fused fourth and fifth pharyngo-branchials. E, upper jaw. EB 1, EB 2, EB 3, first, second, and third extra-branchials. EL, ligament connecting the two halves of the upper jaw. F, lower jaw. FL, ligament connecting the two halves of the lower jaw. G, gill-ray. HB, basi-hyal. HC, cerato-hyal. HM, hyo-mandibular cartilage. L 1, L 2, labial cartilages. N, nasal cartilage. NC, olfactory capsule. R, median bar of rostrum. RL, lateral bar of rostrum. S, notch for Cuvierian sinus.

the skull. Within the capsules are seen the large foramina, closed in the natural condition by fenestrated membranes, through which the olfactory nerves enter.

5. The posterior end of the skull.

To see this properly, the skull must be separated from the vertebral column.

- a. The **foramen magnum** is the large median hole through which the spinal cord enters the skull before expanding into the brain.
- b. The **notochord** enters the base of the skull immediately below the foramen magnum.
- c. The **condyles** are a pair of rounded prominences at the sides of the notochord, and below the foramen magnum: they articulate with the first vertebra.
- d. The **foramen for the pneumogastric nerve** of each side is at the bottom of a pit-like depression at the side of the foramen magnum, below and to the inner side of the auditory capsule.

C. The Visceral Skeleton.

This consists of a series of cartilaginous hoops or arches placed one behind another, and encircling the anterior part of the alimentary canal. In conformity with the shape of the mouth and pharynx, which they surround, the hoops are wide from side to side, and compressed dorso-ventrally.

The first arch gives rise to both upper and lower jaws.

The second or hyoidean hoop is large, and plays an important part in slinging the jaws to the skull.

The third and succeeding hoops are more slender: they surround the pharynx and support the gills.

To see the visceral skeleton properly, a roll of paper should be passed in at the mouth-opening, and backwards through the several hoops.

1. The **first** or **mandibular arch** is very greatly modified ; its ventral part is large and stout and forms the lower jaw. The upper jaw is formed as an outgrowth from its anterior edge.
 - a. The **upper jaw** consists of a pair of stout cartilaginous rods, wide behind and narrowing towards their anterior ends, where they are united across the middle line by ligament. They extend forwards as far as the openings of the olfactory capsules, and are connected by stout **ethmo-palatine ligaments** with the base of the skull, at the antero-inferior angles of the orbits. They bear teeth along the ventral surface of the anterior two-thirds of their length, but these are lost in skulls prepared as described.
 - b. The **lower jaw** consists of a pair of wide flattened bars of cartilage, which are movably hinged with the upper jaw behind, and bound together by a median ligament in front. It lies, when the mouth is shut, parallel to and immediately behind the upper jaw. It bears teeth along the dorsal surface of the anterior two-thirds of its length on each side, but these are lost in skulls prepared as described.
2. The **second** or **hyoidean arch** is incomplete above : it consists of a pair of rods the dorsal ends of which articulate with the sides of the skull, while the ventral ends are connected together by a median plate of cartilage. Each rod is further divided into an upper and a lower segment.
 - a. The **hyo-mandibular cartilage**, or upper segment, is a short stout bar of cartilage, projecting almost horizontally outwards from the skull, but slightly downwards and backwards. Its inner and upper end articulates with a concave surface on the side of the skull, near its hinder end, and immediately

below the post-orbital groove: its outer end articulates with the lower segment of the arch opposite the angle of the mouth. To its hinder border are attached a series of rods of cartilage—**gill-rays**—which support the gill-folds.

The hyo-mandibular cartilage in the dog-fish is spoken of as the **suspensorium**, because it forms the skeletal link between the jaws and the skull.

Skulls, like that of the dog-fish, in which the hyoidean arch forms the suspensorium of the lower jaw, are spoken of as **hyostylic**.

- b. The **cerato-hyal**, or lower segment of the hyoidean arch, is a longer and more slender bar which runs forwards and inwards in the floor of the mouth, just behind the lower jaw, and partly overlapped by it. It bears gill-rays along its posterior border.
 - c. The **basi-hyal** is a broad median plate of cartilage, lying in the floor of the mouth behind the lower jaw. It is rounded anteriorly, and produced behind into two horns which are attached by ligaments to the dorsal surfaces of the cerato-hyals.
3. The **branchial arches** are the remaining five visceral arches; they diminish in size from before backwards, and each is divided into four segments on each side.
- a. The **pharyngo-branchials**, the most dorsal elements, are flattened rods running forwards and outwards in the roof of the pharynx. The anterior ones are connected with their fellows of the opposite side by ligament; and the last two of each side are much smaller than the others, and fused together.
 - b. The **epi-branchials** are short broad plates attached to the outer ends of the pharyngo-branchials.

With the exception of the hindmost they bear gill-rays along their posterior borders.

- c. The **cerato-branchials** are stout rods running forwards and inwards in the ventral wall of the pharynx, and bearing gill-rays along their posterior borders. The fifth or hindmost cerato-branchial is shorter but much broader than the others; it has no gill-rays; and its posterior border is deeply notched to lodge the Cuvierian sinus (p. 242).
 - d. The **hypo-branchials** are small rods in connection with the inner ends of the first, second, third, and fourth cerato-branchials. The first hypo-branchial, which is very small, is directed forwards, and connects the first cerato-branchial with the basi-hyal. The three hinder hypo-branchials are larger, and are directed backwards.
 - e. The **basi-branchial** is an elongated flattened median plate, pointed behind. It is connected with the two hinder pairs of hypo-branchials in front, and at the sides with the fifth cerato-branchials. With these latter, it strengthens and supports the dorsal wall of the pericardial cavity. (Fig. 49, p. 238.)
 - f. The **extra-branchials** are three pairs of elongated curved rods lying along the outer sides of and beneath the second, third, and fourth branchial arches.
4. The **labial cartilages** are two pairs of slender cartilaginous rods in the folds of skin at the sides of the mouth.

D. The Skeleton of the Fins.

1. The median fins.

The skeleton of the **dorsal fins** consists of a series of parallel rods of cartilage, the **basal cartilages**, sloping upwards and backwards, and calcified along their axes. The lower or basal ends of the rods

often unite together, and the dorsal ends support one or more rows of closely fitting polygonal plates. On each side of this median cartilaginous skeleton is a series of slender elongated horny fibres, derived from the skin.

The other median fins are similar to the dorsal ones, except that the cartilaginous elements may be reduced to a longitudinal basal rod, or may even be completely absent.

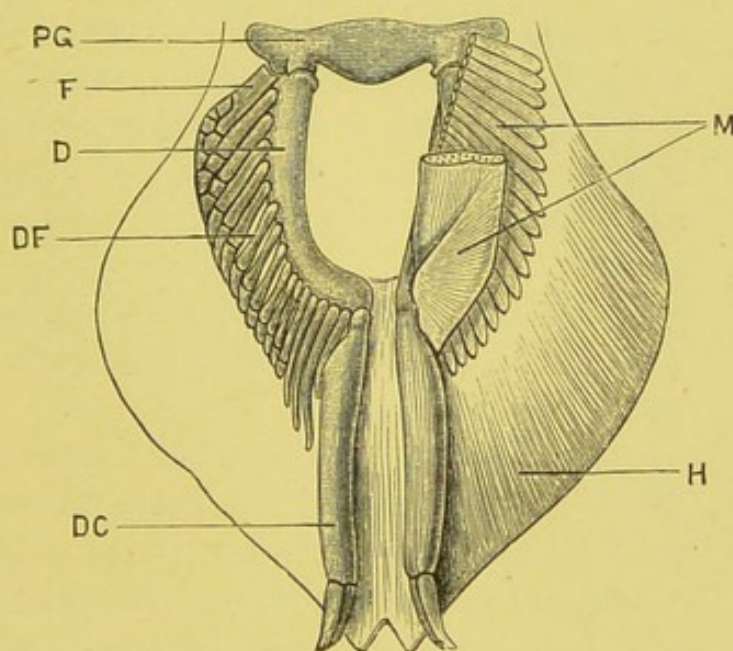


FIG. 47.—*Scyllium canicula*. The pelvic girdle and fins of a male seen from below. In the right fin the cartilaginous skeleton is shown, in the left the muscles and the horny dermal fibres. (A. M. M.)

D, basi-ptyergium. DC, posterior end of the basi-ptyergium, forming the skeleton of the clasper. DF, radial cartilages. F, anterior radial, articulating directly with the pelvic girdle. H, horny fibres. M, muscles. PG, pelvic girdle.

2. The paired fins are essentially similar to the median fins, and are probably to be regarded as local enlargements of lateral fins, which originally extended along the sides of the body.

It is convenient to take the posterior or pelvic fins before the pectoral, as their structure is simpler.

- a. The pelvic girdle is a nearly straight bar of cartilage, placed transversely across the ventral region of the body, about half an inch in front of the

cloaca. The ends of the bar are produced forwards into blunt processes, and bear on their posterior surfaces the articular facets for the pelvic fins.

- b. The **pelvic fins**. The cartilaginous skeleton of each fin consists of a slightly curved basal rod, the **basi-ptyrgium**, which lies along the inner side of the fin, and articulates in front with the pelvic girdle. From the outer side of the basi-ptyrgium a series of parallel cartilaginous **radial cartilages**, about fourteen in number, run outwards and backwards, supporting at their ends smaller polygonal plates. The anterior one or two of the radials may articulate independently with the pelvic girdle.

In the adult male, the posterior end of the basi-ptyrgium is produced backwards into the skeleton of the clasper.

Besides the cartilaginous skeleton, horny fibres like those of the median fins are present in great numbers on both surfaces of the fin.

- c. The **pectoral girdle**, which lies immediately behind the last branchial arch, is considerably larger than the pelvic, and consists of a hoop of cartilage incomplete above.

The ventral portion of the hoop is produced forwards into a flattened process, which forms part of the floor of the pericardial cavity, and is hollowed dorsally to receive the ventricle of the heart.

At each side the arch is thickened, and bears on its outer border a triple articular facet for the basal cartilages of the fin.

- d. The **pectoral fin** has three basal cartilages, the **pro-ptyrgium**, **meso-ptyrgium**, and **meta-ptyrgium**, articulating with the three facets on the pectoral girdle. Of these the pro-ptyrgium is the smallest, and the meta-ptyrgium, which

extends along the inner or attached border of the fin, and corresponds to the basi-ptyerygium of the pelvic fin, is much the largest.

From the outer borders of the basal cartilages a series of close-set radial cartilages diverge: of these the pro-ptyerygium supports a single large one; the meso-ptyerygium also supports one,

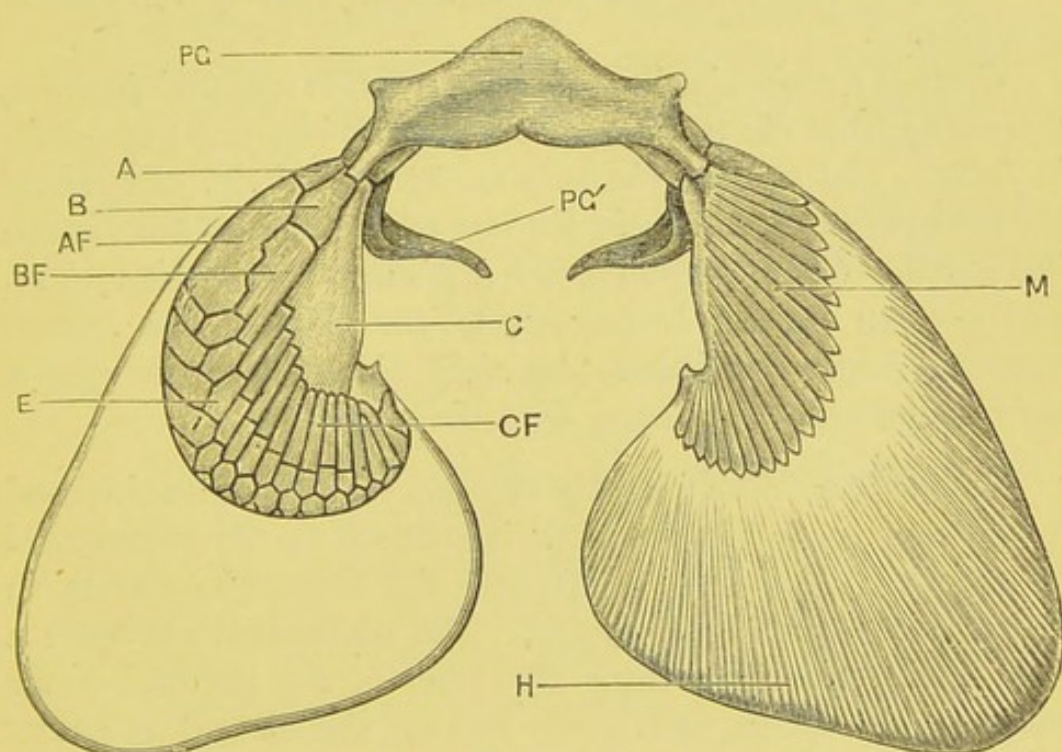


FIG. 48.—*Scyllium canicula*. The pectoral girdle and fins of a male seen from the ventral surface. In the right fin the cartilaginous skeleton is shown, in the left the muscles and horny dermal fibres. (A. M. M.)

A, pro-ptyerygium. AF, pro-ptyerygial radial. B, meso-ptyerygium. BF, meso-ptyerygial radial. C, meta-ptyerygium. CF, meta-ptyerygial radial. E, polygonal cartilaginous plates. H, horny fibres. M, muscles of fin. PG, ventral portion of pectoral girdle. PG', dorsal portion of pectoral girdle.

which is, however, split distally into two or three; while the meta-ptyerygium supports twelve or more much narrower radials.

To the outer ends of the radials two or more rows of polygonal plates of cartilage are attached, forming the peripheral portion of the skeleton.

Horny fibres are present in large numbers, as in the pelvic fins.

III. THE ABDOMINAL CAVITY AND VISCERA.

Lay the dog-fish on its back on the dissecting-board, and pin it down through the fins. Determine the positions of the pectoral and pelvic girdles by feeling them through the skin, the pectoral girdle being a little in front of the pectoral fins, and the pelvic girdle a short distance in front of the cloacal aperture.

Open the abdominal cavity by a median ventral incision, extending from the pelvic girdle behind to the pectoral girdle in front. Cut through the body-wall transversely, just behind the pectoral girdle, and pin the two flaps down to the dissecting-board. Cut through the pelvic girdle in the median plane, and prolong the cut backwards to the level of the cloacal aperture, keeping a little to its right side. Wash or sponge out the abdominal cavity.

The **cœlom** or **body-cavity** extends forwards into the head in the embryo, but in the adult is reduced to the **pericardial cavity** which lodges the heart, and the **abdominal cavity** in which lie the principal viscera. The **abdominal cavity** is a wide space extending from the level of the pectoral girdle backwards as far as, or slightly beyond, the cloacal aperture, where it communicates with the exterior through the abdominal pores (p. 213).

Pass a seeker from the abdominal cavity through one of the abdominal pores to the exterior.

Identify the positions and relations of the following organs before proceeding further with the dissection.

1. The **liver** is a very large solid organ of a brownish yellow colour, attached by a median **suspensory ligament** to the anterior wall of the abdominal cavity. It consists of two lobes of about equal size, which are united in front, and extend back along the sides of the abdominal cavity for the greater part of its length.
2. The **stomach** is a wide U-shaped tube lying between the

lobes of the liver, and extending about two-thirds the length of the abdominal cavity.

3. The **spleen** is a large brownish-red body attached to the loop of the stomach, and sending a long narrow lobe along its distal limb.
4. The **pancreas** is a whitish, laterally compressed body about an inch and a half long, lying in the angle between the distal limb of the stomach and the intestine. Its anterior end is expanded and gives off a small ventral lobe, which is closely applied to the intestine.
5. The **intestine** is a wide and nearly straight tube, running along the right side of the abdominal cavity from the stomach to the cloaca.
6. In the female the **ovary** is single, and attached by a delicate median fold of peritoneum to the wall of the abdominal cavity. The contained ova give its surface a tuberculated appearance.

In the male the **testes** are a pair of elongated solid bodies of a whitish colour, lying along the dorsal region of the anterior two-thirds of the abdominal cavity. Their hinder portions fuse together.

7. The **peritoneum** is a smooth membrane lining the abdominal cavity, and reflected downwards from the mid-dorsal line as a double sheet, the **mesentery**, which invests the alimentary canal and other viscera, and attaches them to the body-wall.

The mesentery is well developed at the hinder end of the abdominal cavity, but is interrupted by one or more large fenestræ opposite the greater part of the length of the intestine.

8. The **kidneys** are covered by the peritoneum, but can be recognised as a pair of slightly elevated longitudinal ridges, one on each side of the mid-dorsal line of the abdominal cavity, and extending nearly its whole length.

IV. DISSECTION OF THE DIGESTIVE SYSTEM.

In dissecting the alimentary canal, be careful not to injure the blood-vessels in relation with it: these lie for the most part in the mesentery.

A. The Alimentary Canal.

1. The **mouth** and **pharynx**. The detailed examination of these parts is best deferred until the circulatory system is dissected.
2. The **œsophagus** is a short wide tube, which enters the abdominal cavity at its anterior end and expands almost at once into the stomach.

Pass the handle of a scalpel or seeker through the mouth, and down the œsophagus into the stomach.

3. The **stomach** is U-shaped. Its proximal limb, which is very wide and directly continuous with the œsophagus, extends back nearly to the hinder end of the abdominal cavity; it then turns sharply forwards to form the distal limb, which is shorter and much narrower.
4. The **intestine** is separated from the distal limb of the stomach by a slight pyloric thickening. Its proximal part is about equal in width to the stomach, alongside which it lies; but it soon dilates to form the wide **ileum**, the surface of which is marked spirally by blood-vessels, corresponding to the line of attachment of the spiral valve. At its hinder end the intestine narrows to form the **rectum**, which, after a course of about an inch and a half, opens to the exterior at the **cloacal aperture**.

a. The spiral valve.

Open the intestine along its whole length by a longitudinal incision along its right side. Wash out its contents. Carefully cut away with scissors the ventral wall from the several turns

of the spiral valve, and turn it over to the left side, so as to fully expose the cavity of the intestine. Wash freely.

The spiral valve is a membranous fold, attached along one edge to the inner surface of the intestine, round which it runs spirally. The fold is about an inch and a half wide at its anterior end, but gradually diminishes in width towards the posterior end, and disappears at the commencement of the rectum. The first turn of the spiral is a long one, but the succeeding ones, of which there are usually seven or eight, are only about a quarter of an inch apart. The general appearance of the valve is that of a series of cones one within another, the apices of the cones being usually directed forwards, but sometimes at the hinder end backwards.

The valve serves to retard the passage of food down the intestine, and to increase the extent of its absorptive surface.

B. The Glands.

1. The liver has been described above.

a. The **gall-bladder** is a large irregular sac imbedded in the anterior part of the left lobe of the liver, close to the median plane.

b. The **bile-duct** leaves the gall-bladder between the two lobes of the liver, and almost in the median plane. It receives ducts from the lobes of the liver, and runs back along the ventral margin of the mesentery to the intestine, along which it runs for a short distance to open into the commencement of the ileum. The bile-duct has a total length of about three inches.

Find the duct along the edge of the fold of mesentery between the liver and the intestine : make an incision in its walls, and inject it with a coloured fluid such as Prussian

blue injection: follow it forwards to the liver and gall-bladder, and backwards to its opening into the intestine.

2. The **pancreas** has been described above (p. 233).

a. The **pancreatic duct** runs forwards through the pancreas close to its ventral border. It leaves the gland at the posterior angle of its ventral lobe, and at once enters the ventral wall of the intestine about an inch beyond the pylorus: it runs in the wall of the intestine for about half an inch, and opens just to the outer side of the line of attachment of the spiral valve.

Find the duct along the ventral border of the pancreas: trace it to the intestine: slit open the intestine, and trace the duct backwards in its wall as a white ridge ending in a very small papilla. It is easier to follow after injection with a coloured fluid.

3. The **rectal gland** is a thick-walled tube, about three-quarters of an inch long, lying in the abdominal cavity dorsal to the rectum. From its hinder end a duct runs forwards along the edge of the mesentery to open into the dorsal wall of the rectum.

Cut the gland across about the middle of its length. Note the thickness of its walls and the small size of its cavity. Pass a bristle down the gland and duct into the rectum; and slit open the rectum to see the opening of the duct.

V. DISSECTION OF THE RESPIRATORY SYSTEM.

The dog-fish breathes by **gills**, which are vascular folds of the mucous membrane of the pharynx, supported by the branchial arches. Respiration is effected by streams of water, which, entering at the mouth, pass between the branchial arches, over the gills, and out through the gill-clefts.

1. The **gills**.

Expose the gills on the left side by prolonging the external apertures upwards and downwards with scissors.

The gills are series of closely set, soft, and highly vascular folds of mucous membrane, radiating outwards from the cartilaginous branchial arches, and supported by the gill-rays.

Gills are borne on the posterior surface of the hyoid arch, and on both the anterior and posterior surfaces of each of the four following arches. The inner borders of the branchial arches have cartilaginous processes, which hinder the passage of food to the gill-clefts. The last branchial arch bears no gill.

2. The pseudobranchs.

Slit up the spiracle of the left side in the same way as the gill-clefts.

The pseudobranch is a rudimentary gill, consisting of about half a dozen small parallel folds, on the anterior wall of the spiracle. Its presence shows that the spiracle is really a gill-cleft.

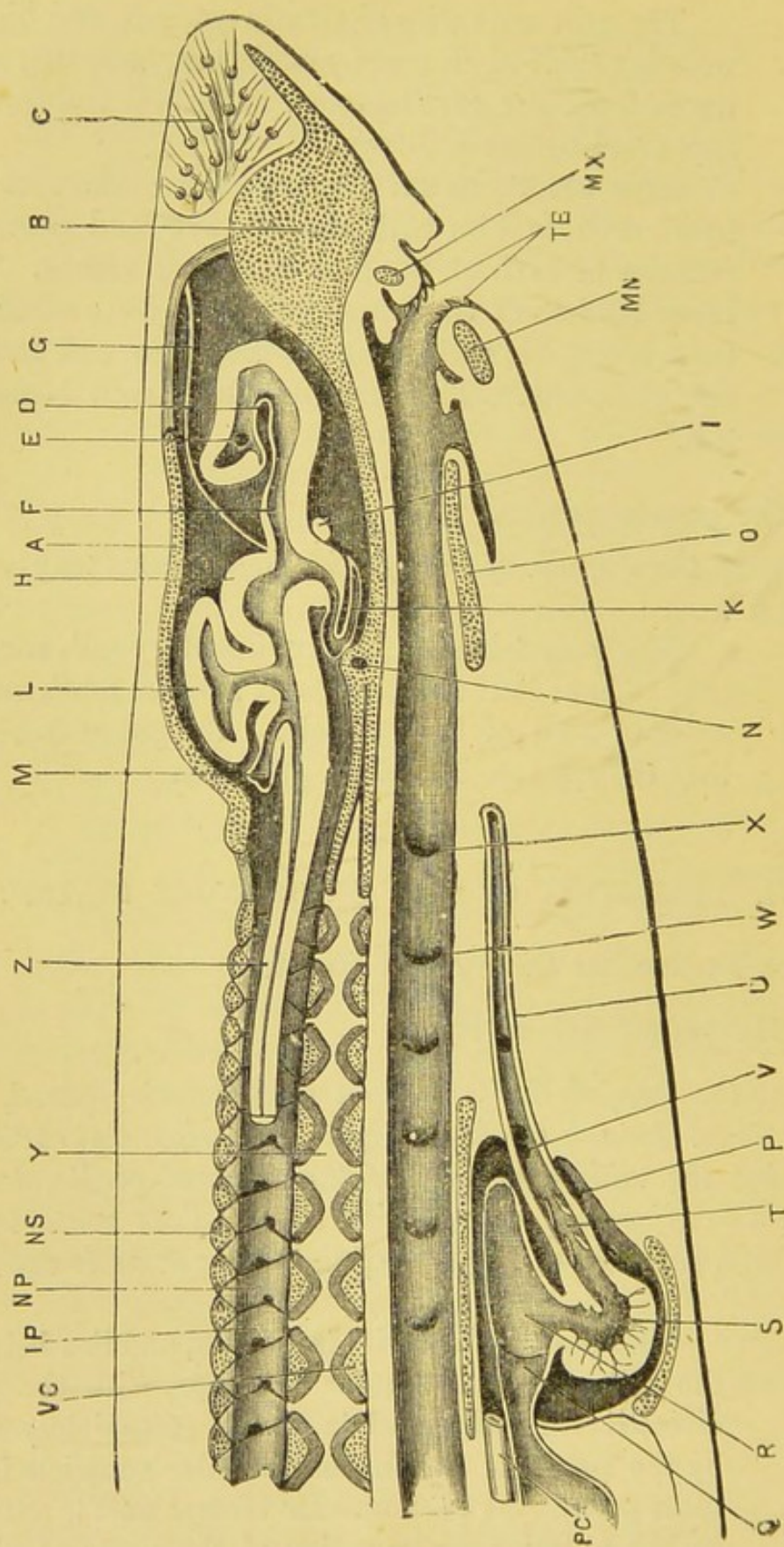
VI. DISSECTION OF THE CIRCULATORY SYSTEM.

A. The Pericardial Cavity and Heart.

1. The pericardial cavity.

Lay the dog-fish on its back on the dissecting-board, and pin it down through the fins. Open the pericardial cavity by removing the middle portion of the pectoral girdle, taking care not to injure the heart, which lies in close contact with it. Cut away the ventral wall of the cavity so as to expose it fully.

The pericardial cavity is median, and lies between the gills; it is triangular in shape, with the apex directed forwards, and is almost completely filled by the heart, of which the globular ventricle is the most prominent portion. Its ventral wall is stiffened by the anterior prolongation of the pectoral girdle,



and its dorsal wall by the wide basi-branchial plate and the fifth cerato-branchials.

2. The **heart** is a single tube bent on itself in an **S-shape**, and dilated to form a series of chambers separated by transverse constrictions.

Determine the position and general characters of the divisions of the heart in order from behind forwards, pressing them aside when necessary, but making no further dissection.

- a. The **sinus venosus** is a thin-walled transversely placed tube, attached along its whole length to the posterior and dorsal wall of the pericardial cavity. It receives laterally the veins returning blood from the body, and opens in front into the auricle by a median aperture.

To expose the sinus venosus, press the ventricle slightly forwards.

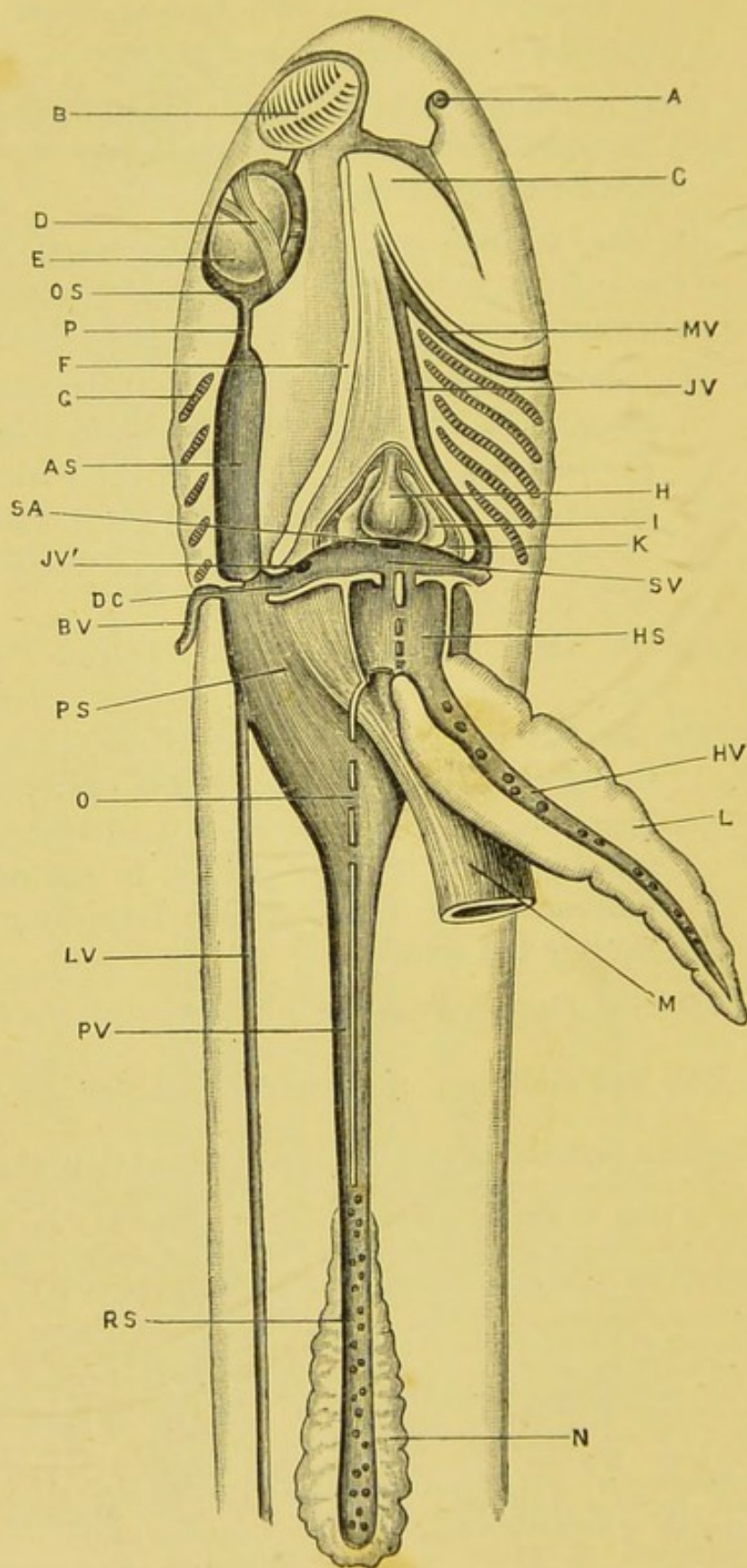
- b. The **auricle** is a large thin-walled sac, occupying the dorsal half of the pericardial cavity. It is triangular in shape, with its posterior angles produced into processes which, in the natural position of the parts, project laterally at the sides of the ventricle.

To expose the auricle, push the globular ventricle to one side.

- c. The **ventricle** is a thick-walled globular sac lying

FIG. 49.—Scyllium canicula. A longitudinal and vertical section through the head and anterior part of the body. The section of the brain is taken a little to one side of the median plane, and the spinal cord has been cut across a short way behind the brain. The cut surfaces of the cartilaginous skeleton are dotted. (A. M. M.)

A, roof of the cranium. **B**, internasal septum. **C**, ampullary canals. **D**, fold of the wall of the hemisphere in which lies the choroid plexus. **E**, aperture leading from the cerebral ventricle to the olfactory ventricle. **F**, third ventricle. **G**, stalk of the pineal body. **H**, optic lobe. **I**, optic chiasma. **IP**, inter-vertebral neural plate. **K**, pituitary body. **L**, cerebellum. **M**, restiform body. **MN**, lower jaw. **MX**, upper jaw. **N**, interorbital sinus. **NP**, vertebral neural plate. **NS**, neural spine. **O**, basi-hyal, supporting the tongue. **P**, pericardial cavity. **PC**, pericardio-peritoneal canal. **Q**, sinus venosus. **R**, auricle. **S**, ventricle. **T**, conus arteriosus. **TE**, teeth. **U**, cardiac aorta. **V**, aperture of afferent branchial vessel. **VC**, vertebral centrum. **W**, first branchial cleft. **X**, spiracle or hyo-mandibular cleft. **Y**, notochord. **Z**, spinal cord.



ventral to the auricle, and forming the most conspicuous part of the heart.

d. The **conus arteriosus** is a cylindrical tube, running forwards from the ventricle to the anterior end of the pericardial cavity.

3. The **pericardio-peritoneal canal** is a median passage about an inch long, opening in front into the hinder end of the pericardial cavity dorsal to the sinus venosus, and running backwards along the ventral surface of the œsophagus, to open behind into the abdominal cavity. Its anterior opening is large and conspicuous; the opening into the abdominal cavity, which may be double, is smaller and slit-like.

Find the pericardial opening in the middle line, immediately dorsal to the sinus venosus. Insert a seeker, and pass it down the canal into the abdominal cavity.

B. The Venous System.

The venous system of the dog-fish consists of three great divisions: (1) the **veins opening into the sinus venosus**, which return blood from all parts of the body to the heart; (2) the **hepatic portal system**, which conveys to the liver the blood from the alimentary canal, pancreas, and spleen; (3) the **renal portal system**, which conveys to the kidneys the blood from the part of the body behind the cloaca.

1. The veins opening into the sinus venosus.

FIG. 50.—*Scyllium canicula*. Dissection of the venous system from the ventral surface. The right half of the lower jaw, the right lobe of the liver, and the alimentary canal from the œsophagus backwards have been removed. (A. M. M.)

A, nostril. AS, anterior cardinal sinus. B, right olfactory organ. BV, subclavian vein. C, left half of lower jaw. D, fifth nerve, and buccal branch of seventh nerve crossing the orbit. DC, Cuvierian sinus. E, right eye. F, cut edge of floor of mouth. G, first branchial cleft. H, ventricle. HS, left hepatic sinus. HV, left hepatic vein. I, auricle. JV, left inferior jugular sinus. JV', opening of right inferior jugular sinus into Cuvierian sinus. K, pericardial cavity. L, left lobe of liver. LV, right lateral vein. M, œsophagus, cut across. MV, hyoidean sinus. N, kidney or metanephros. O, communication between the right and left posterior cardinal sinuses. OS, orbital sinus. P, post-orbital sinus. PS, posterior cardinal sinus. PV, posterior cardinal vein. RS, apertures of renal veins into posterior cardinal veins. SA, aperture from sinus venosus to auricle. SV, sinus venosus.

These veins are most readily traced by following them back from the sinus venosus, and they will be described in this way, though it must be remembered that the flow of blood in them during life is towards the sinus venosus. They are chiefly remarkable for their enormous size in places, the dilated portions being spoken of as **sinuses**.

To dissect the veins, slit open the ventral wall of the sinus venosus transversely, and wash out the contained blood : then follow the veins with a seeker, slitting them open along their ventral walls, and washing out the blood. If preferred, they may be injected with plaster of Paris, or they may be inflated with air.

- a. The **hepatic sinuses** open into the sinus venosus by a pair of apertures in its posterior wall, close to the median plane and near the dorsal surface. The apertures lead into a pair of wide sinuses, separated from each other by an imperfect septum, and lying immediately behind the pericardium, between it and the liver, and ventral to the oesophagus.

Slit open one of the hepatic sinuses, and follow it back into the corresponding lobe of the liver, noting its large size and the numerous veins opening into it.

- b. The **Cuvierian sinuses** are a pair of rather narrow tubes, forming lateral continuations of the sinus venosus, the wall of the pericardium marking the boundary between the two. Each is about a quarter of an inch long, and curves upwards from the sinus venosus round the side of the oesophagus, lying in a notch in the posterior border of the fifth cerato-branchial cartilage. Each Cuvierian sinus receives about the middle of its course the **inferior jugular sinus**, and at its dorsal end the **great anterior and posterior cardinal sinuses**.

- i. The **inferior jugular sinus**, which is of small

size, can be traced forwards and inwards along the outer wall of the pericardial cavity; and then forwards, in the floor of the mouth.

Take especial care not to injure the branchial arteries (p. 248).

- ii. The **anterior cardinal sinus** opens into the Cuvierian sinus by a small aperture placed immediately behind the fifth cerato-branchial cartilage, and guarded by a very perfect valve of which the ventral flap is much the larger.

From this opening the sinus extends forwards as a wide irregular space, immediately above the gill-arches. In front of the first gill this sinus communicates with the orbit by the narrow **post-orbital sinus**. This passes above the spiracle and below the ear, and opens in front into the large **orbital sinus** which surrounds the eyeball and its muscles, and is usually filled with blood-clots. The orbital sinuses of the two sides communicate with each other by the **inter-orbital sinus**, which runs across in the floor of the skull, between the hinder parts of the orbits.

Just in front of the first gill the anterior cardinal sinus receives the large **hyoidean sinus**, which lies in a groove on the outer surface of the hyo-mandibular cartilage, and may be followed downwards and inwards to the floor of the mouth, where it communicates with the inferior jugular sinus.

Find the opening of the left anterior cardinal sinus into the Cuvierian sinus; insert a seeker into it, turn the fish over, and lay open the cardinal sinus along its whole length by slitting through its dorsal wall; wash out the blood-clots, and follow it forwards to the orbit. Follow the hyoidean sinus, from the anterior end of the cardinal sinus, downwards along the hyo-mandibular cartilage to the floor of the mouth.

- iii. The **posterior cardinal sinus** extends back along the dorsal surface of the abdominal cavity close to the median plane, its dorsal wall being firmly united to the body-wall, and its ventral surface covered by the peritoneum. Its anterior end forms a very large thin-walled sac, three-quarters of an inch or more in width. In front it lies at the side of the œsophagus, and close to the hepatic sinus; further back it lies dorsal to the œsophagus, and alongside its fellow of the other side, with which it communicates freely. Behind this point, *i.e.* about two inches behind the pericardium, the sinuses of the two sides narrow considerably, and run back side by side to the hinder end of the abdominal cavity, lying between the kidneys, from which they draw blood by numerous **renal veins**. The right sinus extends to the hinder end of the kidneys, but the left usually commences further forwards.

Slit open the ventral walls of both sinuses at their anterior ends, and wash out the blood; note the enormous size of the sinuses and their free communication with each other, dorsal to the œsophagus. Pass a seeker backwards along the right sinus to its commencement between the posterior ends of the kidneys (fig. 50); but do not lay it open in this hinder part, lest the reproductive organs and the cloaca should be injured.

At its anterior end, immediately to the outer side of its opening into the Cuvierian sinus, the posterior cardinal sinus receives the **subclavian vein**, which returns blood from the pectoral fin and adjacent parts of the body-wall, and runs in a groove along the inner surface of the pectoral girdle. Further back, the **lateral vein** opens, and where the œsophagus passes between the two posterior cardinal sinuses, each of these has on its ventral

surface the opening of the **genital sinus**, which surrounds the reproductive organ.

2. The renal portal system.

The blood from the tail is returned by the **caudal vein**, which lies below the caudal artery in the hæmal arches of the vertebræ. Opposite the hinder ends of the kidneys the caudal vein divide into the **right and left renal portal veins**, which run forwards along the dorsal edges of the right and left kidneys respectively, receiving branches from the body-wall, and entering the kidneys along their whole length.

The dissection of the renal portal system should be postponed till after that of the urino-genital system, in order to avoid damaging the cloaca.

Cut across the tail about two inches behind the cloaca. Find the caudal vein lying in the hæmal arches of the vertebræ, ventral to the caudal artery; trace the vein forwards with a seeker, or inject it, and then dissect it out.

3. The hepatic portal system.

The **hepatic portal vein** is formed by the union of two veins, one from the main lobe of the spleen and the other from the intestine. It runs forwards in the mesentery along the dorsal border of the pancreas; and, receiving veins from the pancreas and from the stomach, enters the liver a little to the right of the median plane.

Find the hepatic portal vein at the point where it enters the liver, a little to the right of the junction of the two lobes, and follow it backwards, turning aside the viscera as may be necessary, but not cutting anything.

C. The Arterial System.

The arterial system may conveniently be described under three heads: (1) the **afferent branchial vessels**, which carry the venous blood from the heart to the gills to be aerated;

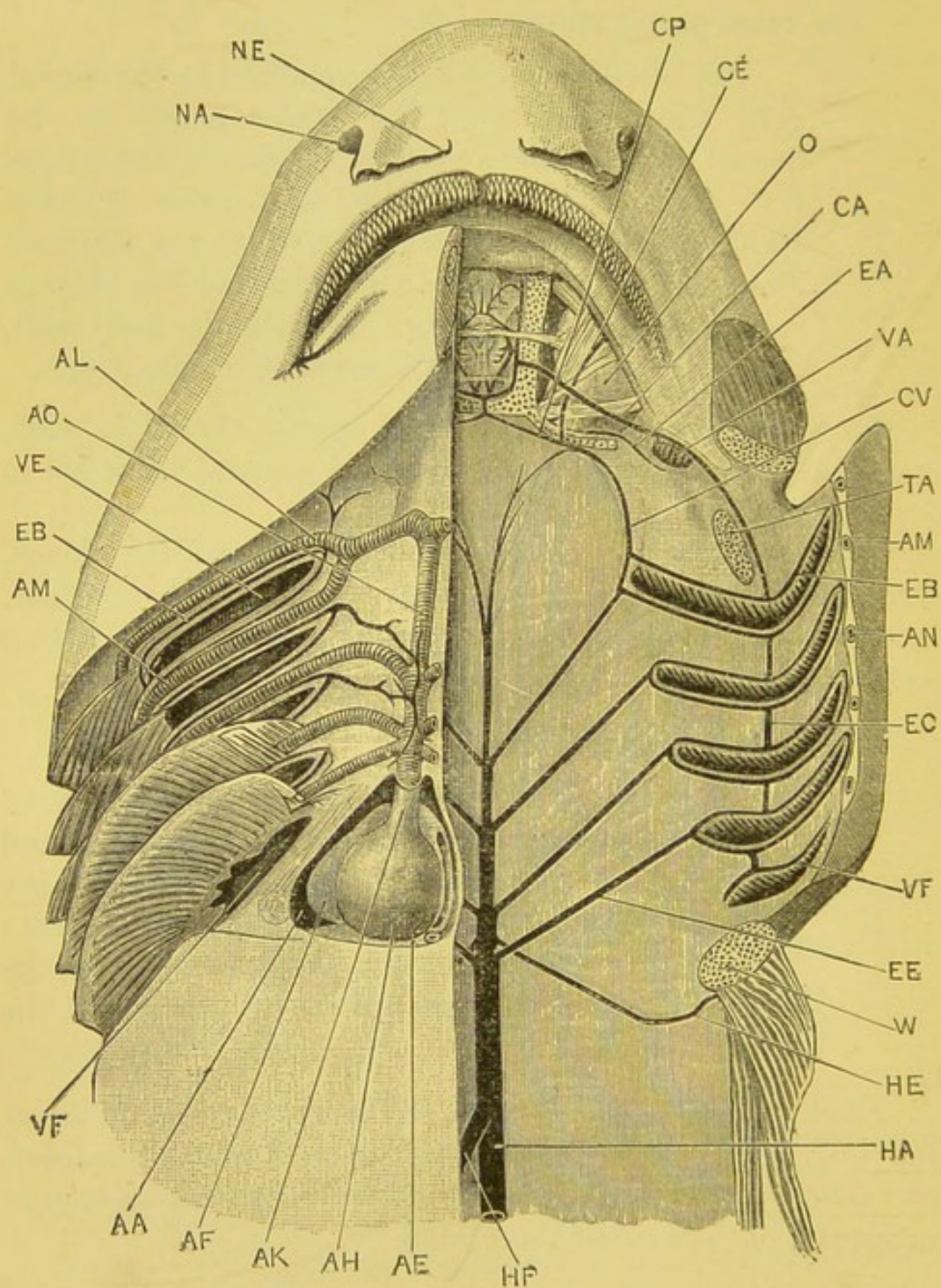


FIG. 51.

(2) the **efferent branchial vessels**, which collect the aerated blood from the gills ; and (3) the **dorsal aorta**, which is formed by the union of the efferent branchial vessels, and conveys arterial blood to the body generally.

1. The afferent branchial vessels.

The afferent branchial vessels are most easily followed by injecting them from the conus arteriosus, but this must not be done if the heart is to be dissected in the same specimen.

Trace the cardiac aorta forwards from the conus arteriosus, and follow its branches on the left side to the gills, removing as much of the muscles of the under surface of the head and of the gills as is necessary to expose the vessels thoroughly.

a. The **cardiac aorta** is a direct continuation forwards of the conus arteriosus. It is a median vessel lying beneath the floor of the mouth and pharynx, and deeply placed in the muscles of the under part of the head. It is little more than an inch in length, and gives off laterally the five pairs of branchial arteries.

b. The **branchial arteries** arise in pairs from the cardiac aorta, and carry the blood from it to the gills. The two hindmost pairs arise close together

FIG. 51.—*Scyllium catulus*. Dissection from below to show the arterial system. The floor of the mouth has been cut through a little to the left of the median plane, and the left half turned outwards. The lower jaw, the lower portion of the hyoid arch, and the whole of the branchial skeleton have been removed on the left side. The floor of the brain-case and that of the left orbit have been removed. On the right side the skin and muscles and portions of some of the gills have been removed. (C. H. H.)

AA, pericardial cavity. AE, sinus venosus. AF, auricle. AH, ventricle. AK, conus arteriosus. AL, AM, and AN, first, second, and third branchial arteries, in hyoid, and first and second branchial arches respectively. AO, cardiac aorta. CA, hyoidean artery. CE, external carotid artery. CP, internal or posterior carotid artery. CV, carotid artery. EA, post-spiracular artery. EB, anterior limb of first efferent branchial loop. EC, communicating vessel between second and third efferent branchial loops. EE, fourth epibranchial artery, bringing blood from gills of fourth and fifth clefts. HA, dorsal aorta. HE, subclavian artery. HF, coeliac artery. NA, nostril. NE, nasal flap : in this species the two flaps are not united as in *S. canicula*. O, eyeball. TA, hyo-mandibular cartilage cut across. VA, spiracle with pseudo-branch. VE and VF, first and fifth branchial clefts. W, pectoral girdle cut across, with a portion of the muscles of the pectoral fin.

or sometimes by a common trunk, immediately in front of the pericardial cavity. The third pair arise about a quarter of an inch further forwards. At its anterior end, about midway between the pericardial cavity and the mouth, the cardiac aorta divides into right and left branches, each of which again divides into the two anterior branchial arteries of its side.

The first or anterior branchial artery runs along the outer border of the hyoid arch, extending nearly to its dorsal end, and giving off branches to the gill borne by the arch.

The four hinder branchial arteries follow similar courses along the outer borders of the first four branchial arches, extending almost to their dorsal ends, and giving off numerous anterior and posterior branches to the gills borne by these arches.

2. The efferent branchial vessels.

The efferent branchial vessels can easily be injected from the caudal artery in the following manner. Cut across the tail about a couple of inches behind the cloaca. Find the caudal artery in the hæmal arches of the vertebral column, lying immediately below the vertebral centra, and dorsal to the caudal vein. Inject the caudal artery with plaster of Paris, coloured with carmine, and rapidly strained to remove any particles large enough to plug the vessels. Lay the animal in cold water for an hour.

Insert one of the blades of a strong pair of scissors into the mouth, and cut back horizontally along the left side through the gill-arches, as far back as the last gill-arch; from the hinder end of this incision cut transversely across the floor of the pharynx, behind the heart, to the corresponding point on the opposite side. Turn the floor of the mouth, with the heart, over to the right side.

Wash the mouth and pharynx thoroughly. Dissect off the mucous membrane from the roof of the mouth; find the efferent

branchial vessels running inwards and backwards from the gill-slits, and follow them, on the right side, outwards to the gills, and inwards to the dorsal aorta in the middle line.

The efferent branchial vessels form loops, one of which runs round the margin of each of the first four branchial clefts, and receives the arterial blood from the gills of that cleft. A single vessel, *i.e.* a half-loop, runs along the anterior border of the fifth branchial cleft, and opens into the loop of the fourth cleft. Each loop communicates with the next one about the middle of its length by a short horizontal vessel.

From the ventral ends of the loops small arteries arise, which supply the floor of the mouth and adjacent parts.

From the dorsal ends of the loops, four main **efferent trunks**, or **epibranchial arteries**, arise on each side : these run backwards and inwards in the roof of the mouth to the middle line, where they unite in pairs to form the median **dorsal aorta**.

- a. The **carotid artery** is a small vessel which arises on each side from the dorsal end of the efferent vessel of the hyoidean gill, just in front of the origin of the first efferent trunk. It runs forwards and inwards across the ventral surface of the skull, opposite the hinder border of the orbit ; and divides, about one-third of an inch from the middle line, into **external** and **internal carotid arteries**. Of these the former runs forwards and outwards across the floor of the orbit, and supplies the upper jaw and snout ; while the latter, continuing its course in a groove in the ventral surface of the skull, passes through a median foramen into the cranial cavity. In the foramen the two internal carotids cross each other, each uniting within the cranial cavity with the hyoidean artery of the opposite side.

- b. The hyoidean artery arises from the anterior limb of the first loop about the middle of its length, in line with the connecting vessels between the successive branchial loops, and runs forwards to the anterior wall of the spiracle, where it gives branches to the pseudobranch. It then continues its course forwards and inwards across the floor of the orbit, crossing ventral to the external carotid artery, and, entering the skull by a small hole, $\frac{1}{8}$ inch in front of the inter-orbital foramen, joins with the internal carotid artery of the opposite side, and divides into branches supplying the brain.

3. The dorsal aorta and its branches.

The anterior pair of efferent branchial vessels unite about the level of the inner openings of the fourth gill-clefts, forming the **dorsal aorta**, into which the hinder vessels open in pairs.

In front of the point of union of the first efferent branchial vessels the aorta is continued forwards beneath the skull as a slender vessel: after a short course this divides into right and left branches which, running outwards, join the carotid arteries just before their division into external and internal carotids.

The dorsal aorta runs backwards along the whole length of the body, lying in the trunk just below the vertebral column, and in the tail, where it becomes the **caudal artery**, in the hæmal arches of the vertebræ. It gives off branches supplying the whole of the body behind the head.

The anterior part of the aorta should be dissected between the kidneys; the posterior part, which is deeply placed between and behind the kidneys, is best seen by dissecting one of the kidneys from the body-wall and turning it inwards. The posterior part is, however, best left until the excretory system is dissected.

The principal branches of the dorsal aorta are the following.

- i. The **subclavian arteries** are a pair of vessels, which arise from the dorsal surface of the aorta between the third and fourth pairs of efferent branchial vessels, and run outwards and backwards in the body-wall and along

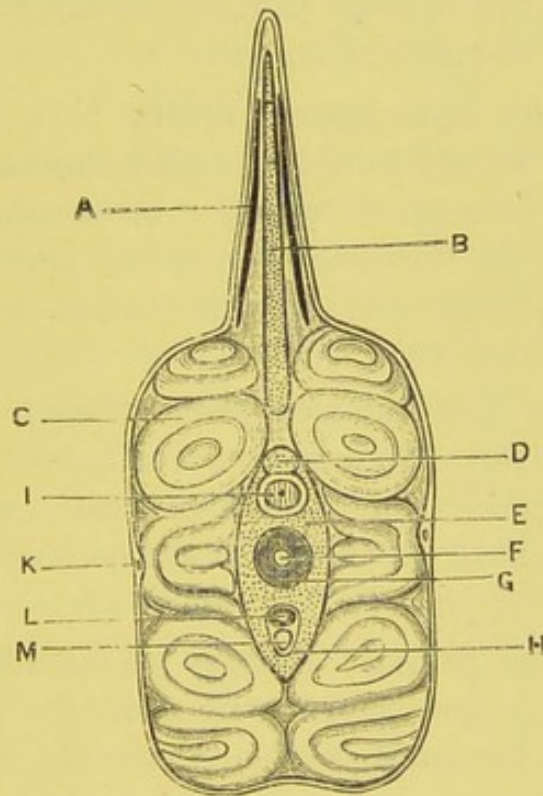


FIG. 52.—*Scyllium canicula*. Transverse section passing through the posterior dorsal fin. (A. M. M.)

A, horny fibre. B, basal cartilage of the dorsal fin. C, nototomes. D, neural spine. E, base of neural arch. F, notochord. G, calcified portion of centrum. H, haemal arch. I, spinal cord. K, lateral vein. L, caudal artery. M, caudal vein.

the hinder border of the pectoral girdle to the pectoral fins, which they supply.

- ii. The **cœliac artery** is a large median vessel arising from the ventral surface of the aorta, about half an inch behind the openings of the last pair of efferent branchial vessels. It runs backwards in the mesentery close to the dorsal surface of the stomach, and divides into two

main branches, one of which supplies the proximal end of the stomach and the liver, and the other the first part of the intestine and the pancreas.

- iii. The **anterior mesenteric artery** is a median vessel arising from the aorta about an inch and a half behind the cœliac artery. It supplies the intestine and rectum, and gives branches to the genital organs.
- iv. The **lieno-gastric artery** is a median vessel arising from the aorta immediately behind the mesenteric artery. It supplies the loop of the stomach between its proximal and distal limbs, and also the spleen and part of the pancreas.
- v. The **posterior mesenteric artery** is a small median vessel arising from the aorta about an inch and a half behind the lieno-gastric, and running backwards in the mesentery to the rectal gland, which it supplies.
- vi. The **parietal arteries** are small paired vessels arising at intervals along the whole length of the aorta, and supplying the body-walls.
- vii. The **renal arteries** are small paired vessels arising from the parietal arteries, and supplying the kidneys, which they enter from the dorsal surface.

The dissection of the renal arteries should be postponed until after the dissection of the reproductive organs and cloaca.

To see the arteries, dissect one kidney away from the body-wall and turn it inwards, so as to expose its dorsal surface.

- viii. The **iliac arteries** are a pair of small vessels leaving the aorta near the hinder end of the body-cavity, and running outwards in the body-walls to the pelvic fins, which they supply.

D. Dissection of the Heart.

Remove the floor of the mouth, with the heart and pericardium; and pin it down in a dish under water, with the ventral surface upwards. Open and examine the several cavities of the heart in the order given below, washing out the contained blood by a stream of water.

Open the ventricle by a horizontal incision, and continue the cut forwards along the right side of the conus arteriosus to its anterior end. Turn the ventral portions of both ventricle and conus over to the left side.

1. The **conus arteriosus** contains two sets of valves, each set consisting of three valves.

The posterior set is just in front of the ventricle, and the anterior and larger set about the middle of the length of the conus. Each valve is thick in its central part, thin and membranous at the edges.

2. The **ventricle** has very thick muscular and spongy walls, and a small central cavity. The opening from the auricle is a transverse slit guarded by a two-lipped valve, and is placed in the dorsal wall of the ventricle near its hinder end, and slightly to the left side.

3. The **auricle**.

Cut across the conus at its anterior end; open the auricle by horizontal incisions along its lateral and anterior borders, turn the ventral wall back, and wash out the blood from the cavity.

The walls of the auricle are thin, with radiating muscular bands; the cavity is very large and triangular in shape. The opening leading from the sinus venosus is a vertical slit in the posterior wall of the auricle; and the transverse aperture leading to the ventricle is in the ventral wall, and slightly to the left of the median plane.

4. The **sinus venosus** has already been laid open. Its walls are thin, with a very feebly developed muscular network. The sinu-auricular aperture is a median

vertical slit in the anterior wall, to the left of the ventral end of which is a small aperture from the **coronary sinus**, which returns to the sinus venosus the blood from the walls of the heart.

VII. DISSECTION OF THE RENAL AND REPRODUCTIVE SYSTEMS.

These two systems have already been seen in part, but may now be examined more fully. They are originally independent of each other, but in the course of development become associated, owing to the genital ducts being formed from parts of the kidney-ducts.

The **kidneys** are paired organs, lying side by side along the whole length of the dorsal wall of the abdominal cavity. Each consists at an early age of its development of a number of convoluted tubules, placed one behind another, and opening at one end into the abdominal cavity: at their other ends they open into a longitudinal duct, the **segmental duct**, which runs the whole length of the kidney, and opens in front into the abdominal cavity and behind into the cloaca.

During development, in many vertebrates, each kidney appears in three portions: an anterior part or **pronephros**, which is small and abortive in the dog-fish and other Elasmobranchs; a middle portion, the **mesonephros** or **Wolffian body**, including the greater part of the length of the primary kidney (largely developed in most ordinary fish); and a posterior portion or **metanephros**, formed from its hinder part.

The ducts also undergo division. The **segmental duct** becomes split longitudinally into two separate ducts: the **Müllerian duct**, which loses its connection with the kidney; and the **Wolffian duct**, into which the kidney tubules open. At a later stage several of the hinder kidney tubules unite to form an independent duct, the **metanephric duct** or **ureter**.

In the female the right and left Müllerian ducts unite in front, so as to open into the abdominal cavity by a single

median aperture, and become converted into the oviducts; the Wolffian body is small and unimportant; while the metanephros and its ducts form the functional kidney and ureters of the adult.

In the male the Müllerian ducts are abortive and functionless; the mesonephric tubules become connected with the testis, and act as vasa efferentia, conveying the spermatozoa to the mesonephric or Wolffian duct which acts as vas deferens. The metanephros and metanephric ducts, as in the female, become the functional kidney and ureters. The tubules of the kidney have persistent nephrostomes opening into the body-cavity.

TABLE SHOWING THE EMBRYONIC AND ADULT CONDITIONS OF THE KIDNEYS AND THEIR DUCTS.

Embryo	Female	Male
Pronephros . . .	Absent.	Absent.
Wolffian body . . .	Abortive.	Mesonephros.
Metanephros . . .	Kidney.	Kidney.
Müllerian duct . . .	Oviduct.	Abortive.
Wolffian duct . . .	Small in front, dilating behind to form urinary sinus.	Vas deferens, urino-genital sinus, and sperm-sac.
Metanephric ducts . . .	Ureters.	Ureters.

A. The Female.

1. The **ovary**, which is single, is an elongated soft lobulated mass, varying a good deal in size, but usually about two or three inches long in specimens of the size described. It lies in the abdominal cavity a little to the right of the median plane, and is attached to the dorsal wall by a narrow fold of peritoneum, which is very easily torn. The ova form conspicuous rounded projections on the surface of the ovary, and when fully formed are half an inch or more in diameter.
2. The **oviducts**, which are formed from the **Müllerian ducts** of the embryo, are a pair of tubes running

along the dorsal wall of the abdominal cavity ventral to the kidneys, and not far from the median plane. Their anterior ends curve inwards round the sides of the œsophagus, and unite immediately in front of the liver, to open into the abdominal cavity by a median ventral slit, through which the ova enter the oviducts from the abdominal cavity.

About a third of its length from the anterior end, each oviduct expands to form the thick-walled **oviducal gland**, which secretes the horny capsules of the eggs. Behind the glands the oviducts are large and dilatable, with longitudinally folded walls: their posterior ends unite, and open by a large median aperture into the dorsal wall of the shallow cloaca, immediately behind the rectum. This aperture is closed in the young female by a thin membrane, the **hymen**.

Find the anterior opening of the oviducts in the suspensory ligament of the liver, immediately behind the pericardial wall: insert a seeker through it into the oviducts, and follow one of these back to the cloaca, slitting through its ventral wall.

3. The **kidneys** extend nearly the whole length of the abdominal cavity, lying dorsal to the peritoneum, and one at each side of the vertebral column. The anterior half or more of each kidney, the **mesonephros**,

FIG. 53.—*Scyllium canicula*. Dissection of a female from the ventral surface, to show the renal and reproductive systems. The right lobe of the liver and the alimentary canal from the œsophagus to the rectum have been removed. An arrow is passed up the left oviduct, which is cut open to show its point. (A. M. M.)

FIG. 54.—Further dissection of the renal and reproductive systems. The left oviduct is removed; and the right oviduct and the urinary sinuses are laid open. (A. M. M.)

A, auricle. AP, abdominal pore. B, pericardial cavity. C, cloaca. E, œsophagus. F, pelvic fin. G, gill-slit. L, liver. O, ovary. OD, oviduct. OD', oviduct laid open. OG, oviducal gland. OV, egg in the oviduct. P, abdominal opening of oviduct. PG, pelvic girdle. R, rectum. RO, opening of rectum into cloaca. S, Wolffian body or mesonephros. SD, Wolffian duct. T, metanephros. TD, metanephric ducts or ureters. TO, openings of ureters into urinary sinus. UP, urinary papilla. US, urinary sinus. V, ventricle.

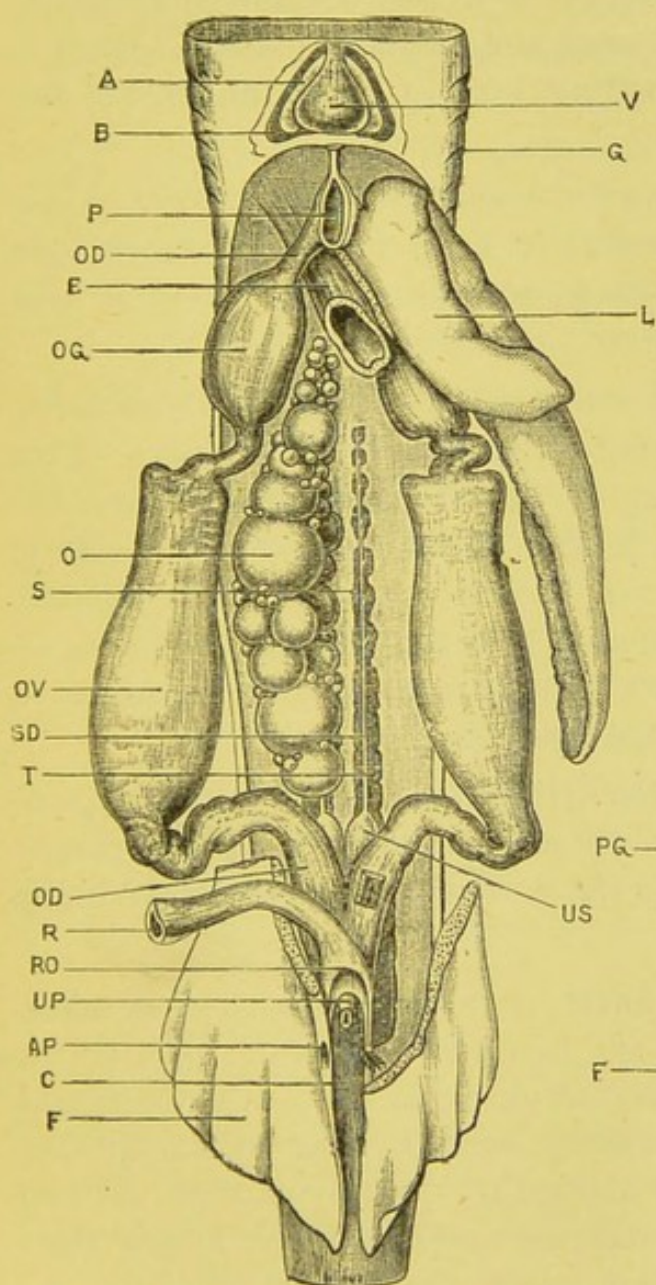


FIG. 53.

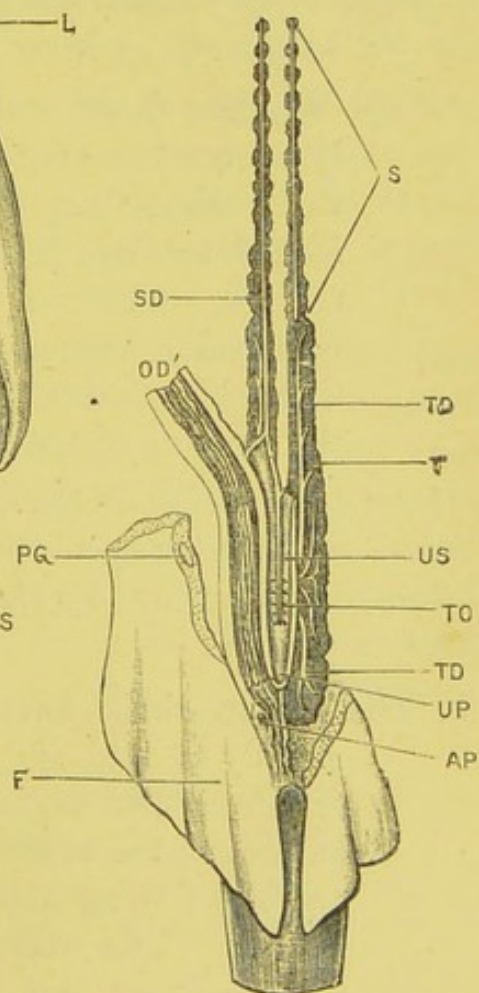


FIG. 54.

is abortive, and appears as an ill-defined tract of soft yellowish-brown degenerate gland-tissue, arranged in patches corresponding to the vertebræ.

The **metanephros**, which forms the posterior third or so of the kidney, is a well-developed, compact, laterally compressed, and lobulated mass of a brownish colour, extending back as far as the level of the cloaca.

Dissect off the peritoneum from the ventral surface of one of the kidneys, so as to expose it along its whole length. At the hinder end dissect the metanephros along its outer side from the body-wall, so as to see its full size.

4. The **Wolffian ducts** are a pair of straight narrow tubes lying on the ventral surface of the kidneys along their whole length. Their posterior ends are enlarged to form a pair of tubular sacs, the **urinary sinuses**, which run back side by side, unite together posteriorly, and open into the cloaca at the apex of the small **urinary papilla** in the posterior margin of the opening of the oviducts.

Find the opening at the apex of the urinary papilla: pass a seeker through the opening and forwards along the urinary sinus of one side: slit up the ventral wall of the sinus along its whole length.

5. The **metanephric ducts** or **ureters** are slender tubes, usually four to six in number on each side, which run from the metanephros to open into the dorsal surface of the **urinary sinus** by four to six slit-like apertures lying along the septum between the two sinuses. The anterior ureter is much longer than the others.

Find the ureters, lying on the ventral surface of the metanephros, and trace them back to the urinary sinus. Slit up the sinus, unless this has already been done, and examine its dorsal wall to see the openings of the ureters.

6. The **cloaca** is a shallow depression between the pelvic

fins. In the female there are three openings into it: the rectum in front, the genital aperture in the middle, and the urinary sinus behind.

B. The Male.

1. The **testes** are a pair of soft elongated bodies lying along the dorsal wall of the abdominal cavity, and in the adult united with each other at their hinder ends. Like the ovary they are attached to the body-wall by delicate folds of peritoneum which are very easily torn, so that in many specimens the testes appear to lie free in the abdominal cavity.
2. The **vasa efferentia** are a number of very slender ducts which arise on each side from the dorsal surface of the testis, and run forwards in the fold of peritoneum to the Wolffian body, which they enter at its anterior end.
3. The **kidneys**. Each kidney is, as in the female, divided into an anterior part, the Wolffian body or **mesonephros**, forming about half of its entire length; and a posterior part or **metanephros**. The mesonephros differs from that of the female in being a well-developed lobulated glandular body along its whole length. The metanephros, as in the female, is a laterally compressed mass of considerable size, especially thick at its hinder end.

Dissect off the peritoneum from the ventral surface of one of the kidneys, so as to expose it along its whole length. At the hinder end dissect the metanephros from the body-wall along its outer side, so as to see its full size.

4. The **Wolffian ducts** are a pair of thick-walled tubes running in a very sinuous course, one along the ventral surface of the whole length of each Wolffian body, from which it receives numerous segmentally arranged tubules. Opposite the junction of Wolffian body and metanephros it dilates rather suddenly into a wide thin-walled tube, the **vesicula seminalis**,

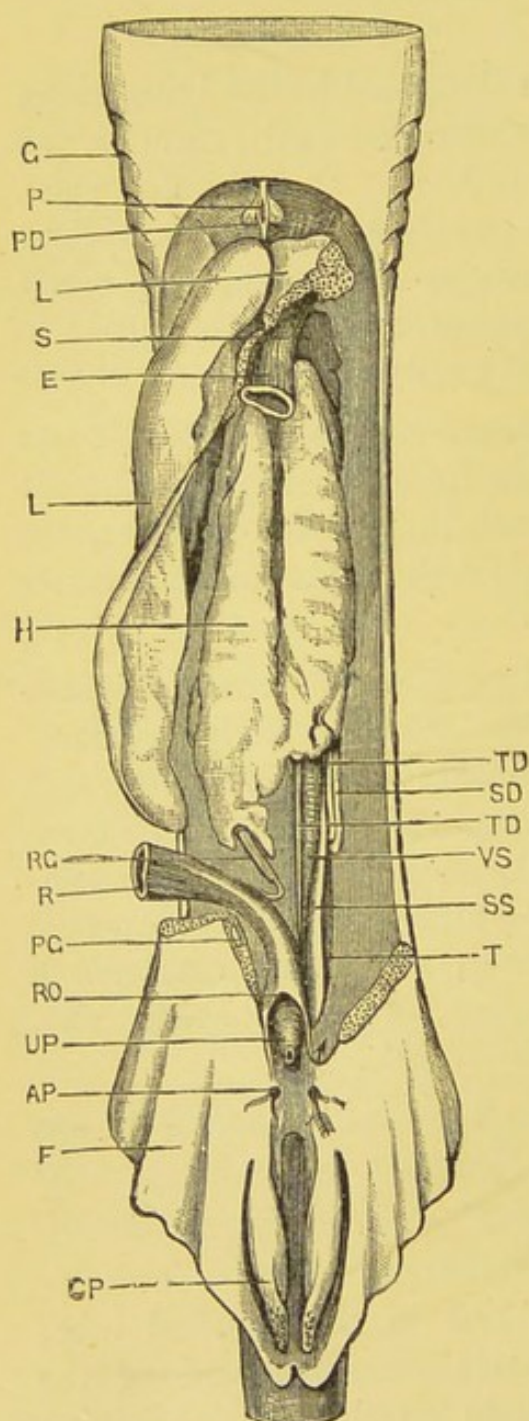


FIG. 55.

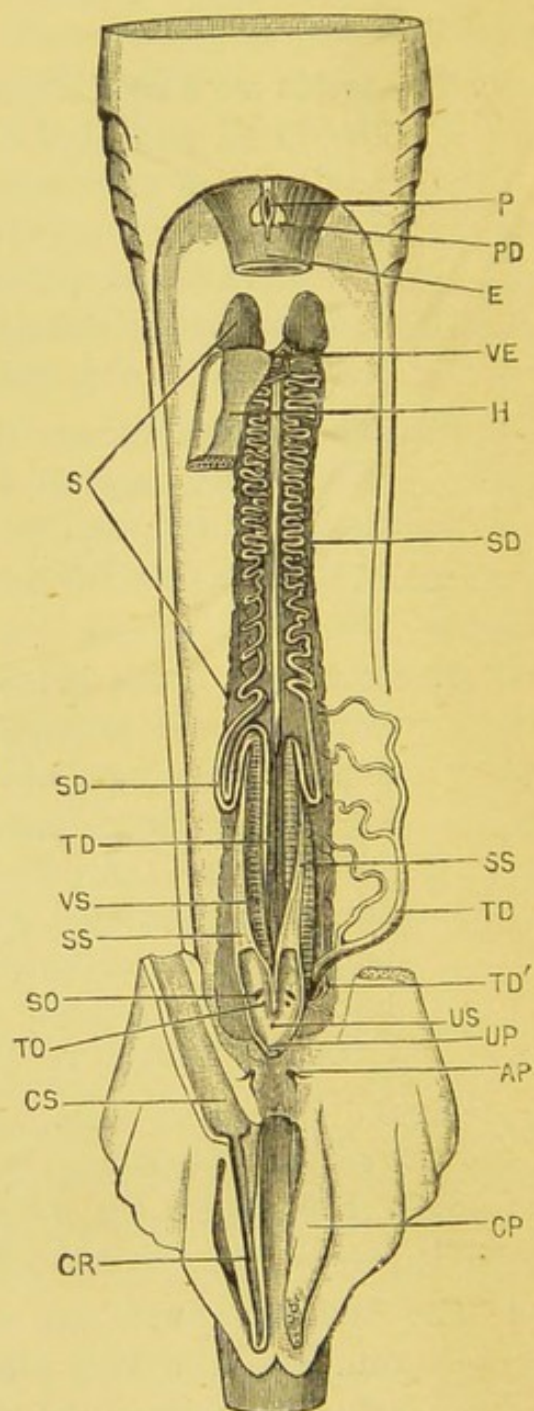


FIG. 56.

which runs straight back along the ventral surface of the metanephros to open into the **urino-genital sinus**, just in front of the cloaca. The walls of the *vesicula seminalis* are marked by close-set transverse lines, corresponding to internal foldings of its lining membrane.

The Wolffian duct acts as **vas deferens**, conveying the spermatic fluid from the testis to the exterior, besides acting as the excretory duct for the mesonephros.

Dissect the Wolffian duct of one side away from the ventral surface of the mesonephros, noting the tubules it receives from this; and follow it back to the cloaca.

5. The **sperm-sacs** are a pair of thin-walled tubes lying along the ventral surfaces and the outer sides of the *vesiculae seminales*, to which they are closely attached, and which they about equal in length. Each sperm-sac ends blindly in front, and dilates behind to form the **urino-genital sinus**.

Dissect away the sperm-sac from the vesicula seminalis and follow it back to the urino-genital sinus.

FIG. 55.—*Scyllium canicula*. Dissection of a male from the ventral surface, to show the renal and reproductive systems. The left lobe of the liver and the alimentary canal from the oesophagus to the rectum have been removed. The excretory organs of the left side only are shown. An arrow passes through the left abdominal pore into the abdominal cavity. (A. M. M.)

FIG. 56.—Further dissection of the renal and reproductive organs. The liver and the greater part of the testis have been removed. The right metanephric duct is shown in its natural position; the left duct has been displaced outwards. The urino-genital sinuses of both sides have been laid open. (A. M. M.)

AP, abdominal pore. CP, clasper. CR, groove in clasper. CS, sac continuous with groove in clasper. E, oesophagus. F, pelvic fin. G, gill-slit. H, testis. L, liver. P, abdominal opening of Müllerian ducts. PD, abortive Müllerian duct. PG, pelvic girdle. R, rectum. RG, rectal gland. RO, opening of rectum into cloaca. S, Wolffian body or mesonephros. SD, Wolffian duct or vas deferens. SO, opening of Wolffian duct into urino-genital sinus. SS, sperm-sac. T, metanephros. TD, metanephric duct or ureter. TD', ducts from hinder part of metanephros, joining the ureter as it reaches the urino-genital sinus. TO, opening of ureter into urino-genital sinus. UP, urino-genital papilla. US, urino-genital sinus. VE, vasa efferentia. VS, *vesicula seminalis*, the dilated hinder end of the Wolffian duct.

6. The **urino-genital sinus** of each side is the posterior end of the sperm-sac: the vesicula seminalis and the ureter open into it. About a quarter of an inch behind these openings the sinuses of the two sides unite, and then open into the cloaca by a small aperture at the apex of the **urino-genital papilla**, which is situated immediately behind the opening of the rectum.

Find the opening at the apex of the urino-genital papilla: pass a seeker through the opening, and forwards along the urino-genital sinus and sperm-sac of one side: slit up the ventral wall of the sinus and sac along their whole length: examine, and pass a seeker into the orifices of the vesicula seminalis and ureter.

7. The **metanephric ducts** are usually five in number on each side; they arise from the outer border of the ventral surface of the metanephros at intervals along its length. The four anterior ducts, after a short course, unite to form a wide thin-walled tube, the **ureter**, which runs backwards along the inner side and dorsal surface of the vesicula seminalis to open into the urino-genital sinus, immediately to the inner side of the opening of the Wolffian duct; just before reaching the sinus the ureter is joined by the fifth or hindmost duct, from the posterior portion of the kidney. From three to five smaller ducts open separately into the urino-genital sinus a little further back.

The metanephric ducts are more easily followed after injecting them with a coloured fluid from the ureter, which is a wide tube, lying along the inner side of the vesicula seminalis.

8. The **cloaca** is the shallow depression between the pelvic fins into which, in the male, the rectum opens in front and the urino-genital sinus behind.
9. The **Müllerian ducts** are abortive in the male, their

anterior ends alone being present. A small pocket-like sac in the suspensory ligament of the liver, between it and the pericardium, represents the abdominal opening of the oviducts of the female. From this sac the ducts can be traced a short distance round the sides of the œsophagus.

10. The **claspers** (see p. 212).

11. The **spermatozoa** are delicate thread-like structures, each with a thickened head round which a spiral membrane runs.

VIII. DISSECTION OF THE NERVOUS SYSTEM.

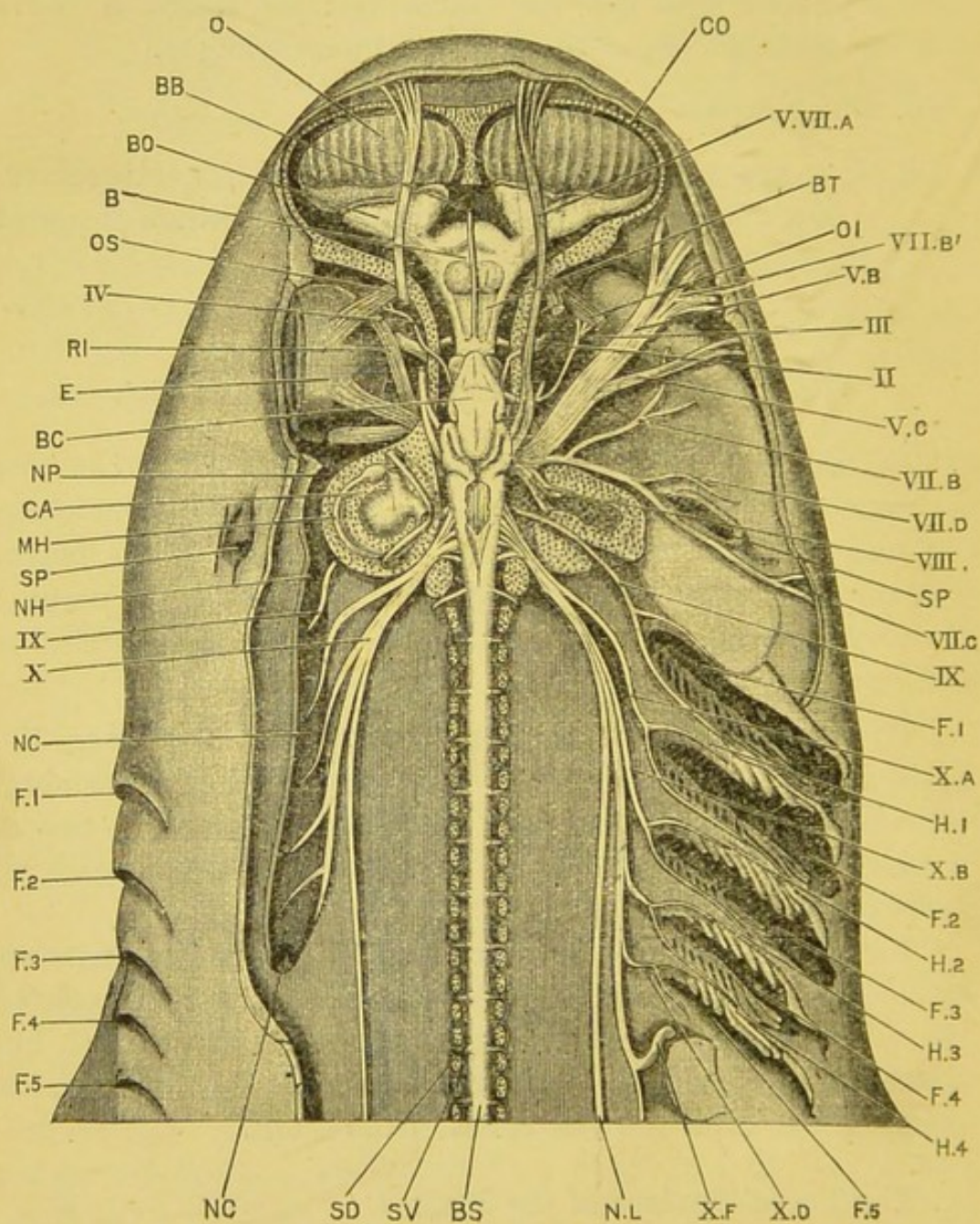
For this purpose a dog-fish should be taken which has been hardened in spirit, the roof of the skull having been previously removed so as to allow the spirit free access to the brain. The specimen must be moistened from time to time to prevent the nerves drying up, or else should be dissected in water or weak spirit.

The nervous system consists of (1) a **central portion**, the brain and spinal cord, lodged within the skull and vertebral column respectively; and (2) a **peripheral portion**, the nerves themselves, which connect the brain and spinal cord with all parts of the body.

From the mode of its development the central nervous system is tubular; and it retains this character throughout life. The central canal is very small in the spinal cord, but widens out considerably in the brain, its local dilatations being spoken of as the **ventricles** of the brain.

A. The Dorsal Surface of the Brain.

Remove the skin from the dorsal surface of the head. Dissect away the eyelids on the right side so as to open up the orbit. Slice away the roof of the cranium so as to expose the brain fully, slicing through the auditory capsule on the right side, but leaving it uninjured on the left.



The brain nearly fills the cranial cavity: it is narrow between the orbits, but expands considerably in front of them. As seen from above, the following parts are visible in order from before backwards.

1. The **prosencephalon** is the most anterior and the largest division of the brain. It is a smooth somewhat globular mass, lying in the expanded anterior part of the cranial cavity, between the olfactory capsules and the orbits. It is marked in front by a shallow median groove, and is sharply separated behind from the succeeding part of the brain. It corresponds to the cerebral hemispheres of higher vertebrates.
2. The **olfactory lobes** are a pair of large oval masses, arising by stout stalks from the sides of the prosencephalon, their distal surfaces being closely applied to the olfactory capsules.
3. The **thalamencephalon** is the narrow portion of the brain immediately behind the prosencephalon; its roof is very thin, so that the cavity, or **third ventricle**, can be seen through it. From the hinder part of the roof arises the **pineal body**, a slender tubular process which extends forwards over the prosen-

FIG. 57.—*Scyllium catulus*. Dissection of the brain and cranial nerves from the dorsal surface. The right eye has been removed. The cut surfaces of the cartilaginous skull and vertebral column are dotted. About two-thirds the natural size. (A. M. M.)

B, prosencephalon. BB, pineal body. BC, cerebellum. BO, olfactory lobe. BS, spinal cord. BT, thalamencephalon. CA, auditory capsule. CO, olfactory capsule. E, eye. F.1-F.5, first to fifth branchial clefts. H.1-H.4, first to fourth branchial arches. MH, external or horizontal semicircular canal. NC, anterior cardinal sinus. NH, opening of hyoidean sinus into anterior cardinal sinus. NL, nerve of the lateral line. NP, post-orbital sinus. O, olfactory organ. OI, obliquus inferior. OS, obliquus superior. RI, rectus internus. SD, dorsal root of spinal nerve. SP, hyomandibular cleft or spiracle. SV, ventral root of spinal nerve.

II, optic nerve. III, third nerve. IV, fourth nerve. V, VII, A, ophthalmic branches of fifth and seventh nerves. V. B, maxillary branch of fifth nerve. V. C, mandibular branch of fifth nerve. VII. B', buccal branch of seventh nerve. VII. B, palatine branch of seventh nerve. VII. C, hyoidean branch of seventh nerve. VII. D, 'prespiracular' branch of seventh nerve. VIII, auditory nerve. IX, ninth or glosso-pharyngeal nerve. X, tenth or pneumogastric nerve. X. A, branch of pneumogastric nerve to second branchial cleft. X. B, branch of pneumogastric nerve to third branchial cleft. X. D, branch of pneumogastric nerve to fifth branchial cleft. X. F, visceral branch of pneumogastric nerve.

cephalon, and ends in a slightly dilated knob attached to the membranous roof of the skull some little distance in front of the brain.

4. The **optic lobes** are a pair of closely apposed ovoid protuberances lying in the narrowest part of the cranial cavity opposite the middle of the orbits. Their posterior halves are overlapped and concealed by the cerebellum.
5. The **cerebellum** is a long flattened oval body arising from the dorsal surface of the brain immediately behind the optic lobes, and extending forwards over them, and backwards for an equal distance over the medulla oblongata. Its surface is slightly grooved.
6. The **medulla oblongata** is the part of the brain behind the cerebellum. Its roof is very thin, and liable to be torn away so as to expose its cavity, the **fourth ventricle**. Its sides are thickened, especially in front, where they give origin to the roots of the fifth, seventh, and eighth cerebral nerves. Immediately above these roots, and below the posterior projection of the cerebellum, the medulla is produced into a pair of large lateral wing-like processes, the **restiform bodies**, which are united with each other beneath the overhanging cerebellum.

B. The Orbit.

This should be examined before the dissection of the nerves is proceeded with. If the eyelids have been removed as directed above, no further dissection is necessary. Wash out the blood-clots from the orbital sinus with a stream of water, avoiding injury to the nerves.

1. The **eyeball** is almost hemispherical in shape, its outer or corneal surface being very flat.
2. The **eye-muscles**, by which the movements of the eye are effected, are six narrow muscular bands which arise from the skull-wall and are inserted into the eyeball: they are arranged in two groups.

- a. The **recti muscles** are four in number. They arise close together, near the hinder end of the orbit, and diverge outwards to be inserted into the eyeball.
- i. The **rectus superior** runs outwards and forwards to be inserted into the dorsal surface of the eyeball.
 - ii. The **rectus internus**, or **anterior**, runs forwards between the skull-wall and the eyeball, and is inserted into the anterior surface of the latter.
 - iii. The **rectus externus**, or **posterior**, is the hindmost of the eye-muscles, and runs directly outwards behind the eyeball, to be inserted into its posterior surface.
 - iv. The **rectus inferior** runs outwards and forwards beneath the eyeball, and is inserted into its ventral surface.

The origin of the rectus inferior can be seen from above, between the other recti muscles ; to see its insertion, turn the eyeball up.

- b. The **oblique muscles** are two in number. They arise close together at the anterior end of the orbit, and run backwards and outwards to the eyeball.
- i. The **obliquus superior** is inserted into the dorsal surface of the eyeball, just in front of the insertion of the rectus superior.
 - ii. The **obliquus inferior** is inserted into the ventral surface of the eyeball, just in front of the insertion of the rectus inferior.

To see the obliquus inferior, turn the eyeball up.

C. The Cranial Nerves (fig. 57).

These should be dissected before the brain is removed, in order that their entire course may be seen.

Dissect the nerves on the right side, leaving the left side for the dissection of the sense-organs.

The ophthalmic branches of the fifth and seventh nerves, which run through the orbit close to the skull-wall, and dorsal to all the eye-muscles, should be identified at once ; and care must be taken not to injure them (see pp. 270 and 271).

1. The **olfactory 'nerves'** arise on each side in two large bundles from the anterior surface of the olfactory lobe, and pass at once through the sieve-like membrane separating the cranial cavity from the nose. They end in the folds of the large olfactory organ.

Dissect the olfactory nerves from the dorsal surface, taking care to preserve the ophthalmic branches of the fifth and seventh nerves, which run forwards across the olfactory lobe, but separated from this by the cartilaginous cranium.

2. The **optic nerve** enters the orbit through a foramen in the side wall of the skull, near its ventral surface, and about midway between the origins of the recti and of the oblique muscles. In the orbit it is enclosed in a very tough connective-tissue sheath, and runs straight outwards to the eyeball.

Press the eye-muscles aside to see the optic nerve between the recti and obliqui. The course of the nerve within the skull will be seen when the brain is removed.

3. The **third nerve, or motor oculi**, is a rather slender nerve which, arising from the ventral surface of the brain below the optic lobes, runs outwards and slightly backwards to the skull-wall, which it perforates about a quarter of an inch behind the optic nerve, and immediately in front of the origins of the recti muscles.

In the orbit it divides at once into three branches, of which the first supplies the rectus internus, and the middle one the rectus superior. The hindmost branch passes downwards between the rectus superior and rectus externus close to their origins, and then

forwards, ventral to the rectus inferior, which it supplies, to the obliquus inferior, in which it ends. As it crosses the rectus inferior it is joined by a branch from the fifth nerve.

Gently press away the optic lobe from the skull-wall, so as to see the third nerve within the skull, and also the point at which it enters the orbit. In the orbit the branches to the rectus internus and rectus superior are easily dissected from above. To trace the branch to the obliquus inferior place the fish on its side, and turn the eyeball upwards so as to expose the nerve from below.

4. The **fourth** or **pathetic nerve** is a very slender nerve which arises from the dorsal surface of the brain, in the angle between the optic lobe and the cerebellum, and almost in the median plane. From the brain it runs forwards and outwards to the skull-wall, which it perforates a little in front of the middle of the orbit, dorsal to the optic nerve, and immediately ventral to the ophthalmic branches of the fifth and seventh nerves. In the orbit it runs outwards and forwards to the posterior border of the obliquus superior, in which it ends.

Though very slender, the fourth nerve is easy to trace. Lift up the front end of the cerebellum to see its origin between the cerebellum and the optic lobes; trace it forwards within the skull, and in the orbit outwards to the obliquus superior.

5. The **fifth, seventh, and eighth nerves** arise very close together from the side of the medulla at its widest part, opposite the posterior part of the cerebellum. The eighth or auditory nerve, which is the hindmost of the three, enters the auditory capsule at once; while the fifth and seventh nerves pass outwards through the skull-wall, by a foramen at the posterior and inner angle of the orbit, immediately behind the origins of the recti muscles.

Gently press away the medulla from the skull-wall until the nerve-roots come into view, and then carefully cut away the skull-wall and the auditory capsule until the roots are fully exposed.

a. The **fifth** or **trigeminal nerve** has three main branches.

i. The **ophthalmic branch** arises from the anterior border of the root of the nerve, close to the brain. It runs forwards and upwards for about a quarter of an inch within the skull, and then perforates the skull-wall to enter the orbit, above and a little in front of the origins of the recti muscles.

In the orbit it runs forwards close to the skull-wall, alongside of and immediately below the ophthalmic branch of the seventh nerve, and dorsal to all the eye-muscles. At the anterior and inner angle of the orbit it passes through a canal between the olfactory capsule and the cranium, crosses the olfactory lobe, and continuing its course forwards divides into branches, which supply the skin of the dorsal surface of the snout.

Gently press away the brain from the skull-wall to see the root and the part of the nerve within the cranium, taking care not to confound it with the ophthalmic branch of the seventh nerve which lies immediately dorsal to it. In the orbit dissect from the side, and in front of the orbit from above.

The main stem of the fifth nerve on entering the orbit (accompanied by the buccal branch of the seventh) runs forwards and outwards across its floor as a broad ribbon-like band, easily mistaken in spirit specimens for a muscle. Near the outer margin of the orbit this separates into the maxillary and mandibular branches. The buccal branch of the seventh nerve lies between and dorsal to these.

Turn the eye up; trace the nerve across the floor of the orbit, and follow its branches to their distribution.

- ii. The **maxillary branch**, which is the anterior of the three, turns over the upper jaw at the anterior border of the orbit, and divides into branches which run forwards to supply the region of the upper jaw.
 - iii. The **mandibular branch**, the posterior of the three, crosses the upper jaw, and then curving round the angle of the mouth, where it lies very close to the surface, runs forwards along the lower jaw. It supplies the muscles moving the lower jaw.
6. The **sixth nerve** is very slender, and arises from the ventral surface of the medulla near the median plane, and a short way behind the roots of the fifth and seventh nerves; it passes out through the same foramen with these nerves, lying below them and separated from them by dense connective tissue. It supplies the rectus externus.

To see the part of the sixth nerve within the skull, cut through the roots of the fifth and seventh nerves, and press the brain aside. In the orbit the nerve can be seen along the inferior border of the rectus externus.

7. The **seventh or facial nerve** has four main branches.
- i. The **ophthalmic branch** arises from the dorsal edge of the medulla, immediately behind the cerebellum. It runs forwards for about a quarter of an inch within the skull, and then enters the orbit through a foramen above and a little behind the origins of the recti muscles. In the orbit it runs forwards close to the skull-wall, alongside of and dorsal to the ophthalmic branch of the fifth nerve. It supplies the sensory ampullæ and sensory canal of the supra-orbital region.

To see the root, which is large, press the brain away from the skull. The dissection is the same as for the corresponding branch of the fifth nerve.

The main stem of the seventh nerve enters the orbit immediately behind the fifth, and divides almost at once into three main branches.

Turn the eye up and dissect the nerve from the side, following the branches to their distribution.

- ii. The **buccal branch** arises from the brain along with the ophthalmic. It accompanies the maxillary and mandibular branches of the fifth nerve, lying dorsal to these on the floor of the orbit. It supplies the sensory ampullæ and the sensory canal of the infra-orbital region.
- iii. The **palatine branch** is a slender nerve which runs forwards and outwards across the floor of the orbit, immediately behind the main stem of the fifth nerve: it then turns forwards beneath this nerve and runs along the upper jaw, sending branches to the roof of the mouth.
- iv. The **hyoidean or post-spiracular branch** is a much stouter nerve, which runs straight outwards along the posterior wall of the orbit towards the spiracle. Continuing its course outwards and backwards, in close contact with the anterior wall of the auditory capsule, it passes along the posterior border of the spiracle, where it lies just beneath the skin, and then runs downwards and backwards along the anterior border of the hyoid arch, giving off an external mandibular branch to the ampullæ and sensory canal of the hyo-mandibular region.

Close to its origin it gives off a number of

small 'pre-spiracular' branches, one or more of which pass to the anterior wall of the spiracle and to the pseudobranch.

8. The **eighth or auditory nerve**, immediately after its origin, enters the auditory capsule through a hole in the anterior end of its inner wall, and divides into branches supplying the several parts of the internal ear.

Slice away the auditory capsule down to the level of the root of the auditory nerve, and trace the nerve into it.

9. The **ninth or glosso-pharyngeal nerve** arises from the side of the medulla, about an eighth of an inch behind the auditory nerve and nearer the ventral surface. It at once enters a foramen on the inner side of the auditory capsule and about the middle of its length, and, passing horizontally outwards and backwards along a canal in the floor of the capsule, emerges at its posterior and outer angle, opposite the upper end of the first branchial cleft, where it divides into two branches.

- i. The **anterior or pre-branchial branch** is the smaller of the two, and runs down the posterior border of the hyoid arch.
- ii. The **posterior or post-branchial branch** is larger, and runs down the anterior border of the first branchial arch.

Press away the medulla from the skull-wall to see the root of the nerve, about an eighth of an inch behind the auditory nerve: slice away the auditory capsule horizontally to expose the nerve in the canal, and then follow the branches along the branchial arches.

10. The **pneumogastric nerve or vagus** is a large nerve, which arises by a number of roots from the side of the hinder part of the medulla. The root of the **lateral-line nerve** is dorsal to that of the glosso-pharyngeal.

The vagus, accompanied for some distance by the lateral-line nerve, runs outwards and backwards

through the skull-wall, emerging at its hinder end between the cranium and the auditory capsule. It then runs horizontally backwards, parallel to the vertebral column, and a short distance to its outer side, lying along the inner wall of the anterior cardinal sinus, and giving off numerous branches.

Press away the medulla from the skull-wall to see the roots of origin of the vagus. Slice away horizontally the hinder end of the skull to expose the nerve in this part of its course. Lay open the anterior cardinal sinus by slitting up its dorsal wall; wash out the contained blood, and identify the branches of the vagus running along its inner wall and across its floor. Dissect these branches out, and follow them to their distribution.

- i. The **branchial nerves**, which are four in number, run backwards and outwards in the floor of the anterior cardinal sinus to the upper ends of the four hinder, *i.e.* second to fifth, branchial clefts. Each then divides into a smaller anterior and a larger posterior branch, which supply the two borders of the corresponding cleft, just as the glosso-pharyngeal supplies the two borders of the first branchial cleft.
- ii. The **visceral or intestinal nerves** are continuations backwards of the trunk from which the branchial nerves arise; they give off several branches, of which the most important are the **cardiac nerves** to the heart, and the **gastric nerves** to the stomach.

The **nerve of the lateral line** arises dorsal to the root of the ninth nerve. It runs backwards above and to the inner side of the branchial division of the vagus, continuing its course to the hinder end of the body and parallel to the lateral line, the sense-organs of which it supplies. It is probably to be associated with the seventh nerve.

D. Dissection of the Brain.**1. Removal of the brain.**

Cut across the medulla a short way behind the roots of the vagus. Cut through the olfactory nerves so as to separate the olfactory lobes from the nasal capsules ; and cut through the several cranial nerves one by one, about midway between the brain and the skull-wall. Turn out the brain from the cranium, taking care not to damage the pituitary body : this latter lies on the under surface of the brain, opposite to the optic lobes, and in a hollow of the skull-floor, to which it is firmly attached, and from which it must be dissected away.

Examine the skull after removal of the brain, and identify the several nerve-stumps and their foramina of exit.

2. The ventral surface of the brain.

Place the brain in spirit, with the ventral surface upwards, and identify the following structures.

- a. The **prosencephalon** is marked by a shallow median groove ; posteriorly it is directly continuous with the thalamencephalon.
- b. The **olfactory lobes** have much the same appearance as from the dorsal surface.
- c. The **optic chiasma** is formed by the decussation of the optic nerves on the under surface of the thalamencephalon. Beyond the chiasma the nerves diverge outwards towards the foramina in the skull-wall which lead to the orbits.
- d. The **infundibulum** consists of a pair of prominent oval swellings, sometimes called **lobi inferiores**, on the under surface of the thalamencephalon, immediately behind the optic chiasma.
- e. The **pituitary body** is a thin-walled sac immediately behind the infundibulum, and attached to it. It is produced laterally into two thin-walled pouches, the **sacci vasculosi** ; and it has along its ventral surface a median tubular body of

unknown function, the anterior end of which is connected with the infundibulum, the posterior end being, in the natural condition of the parts, attached to the floor of the skull.

- f. The **roots of the third nerves** arise from the ventral surface of the brain close to the middle line, and opposite the junction of the infundibulum with the pituitary body.

Lift up the pituitary body and infundibulum so as to expose the third nerves fully.

- g. The **medulla oblongata** is narrow in front : it widens considerably opposite the roots of the fifth and seventh nerves ; and then narrows again as it passes back into the spinal cord.

- h. The **roots of the sixth nerves** arise from the ventral surface of the medulla, near the middle line, and a short distance behind the level of the roots of the fifth and seventh nerves.

3. The cavities of the brain.

Bisect the brain by a median vertical incision along its whole length. Slice away the inner surface of one half of the prosencephalon until the cavity within it is fully exposed.

The brain, as already noticed, is tubular, and its cavity is continued into all the principal lobes or processes, which may be regarded as formed by foldings of its wall, or rather by unequal growth at various parts. The roof of the brain varies greatly in thickness at different parts, but the floor is nearly uniform throughout (*cf.* fig. 49, p. 238).

- a. The **lateral ventricles** are a pair of large laterally compressed cavities in the prosencephalon, separated from each other by a median vertical septum. Posteriorly they open into the cavity of the thalamencephalon, and on their outer sides they are prolonged into the olfactory lobes.

The posterior wall of the prosencephalon, just in front of and above the thalamencephalon, is produced on each side into a very thin-walled fold, which projects forwards into the lateral ventricle nearly to its anterior end. Between the two layers of the fold are numerous blood-vessels forming the **choroid plexus**.

- b. The **third ventricle** is a cavity within the thalamencephalon : it communicates in front with the lateral ventricles, above with the very narrow cavity of the stalk of the pineal body, behind with the cavity beneath the optic lobes, and below with the infundibulum.
- c. The **pituitary body** is a sac with very thin walls, standing in this respect in marked contrast to the infundibulum, which has thick walls. Its cavity communicates in front with that of the infundibulum, and behind with that of the tubular body which lies on its ventral surface.
- d. The **optic lobes, cerebellum, and restiform bodies** are all hollow outgrowths from the dorsal surface of the brain. Their walls are of moderate thickness, excepting the dorsal ends of the restiform bodies, which are very thin.
- e. The **fourth ventricle** is the cavity in the medulla, beneath and behind the cerebellum : its sides and floor are thick, its roof very thin.

E. The Spinal Cord and Nerves.

Slice away the roof of the neural canal horizontally, so as to expose the dorsal surface of the spinal cord.

Gently press the cord away from the side of the canal, to expose the roots of the spinal nerves.

1. The **spinal cord** lies in the neural canal of the vertebral column. It is flattened dorso-ventrally ; marked by median longitudinal grooves or fissures along its dorsal and ventral surfaces ; and traversed throughout

its whole length by a narrow **central canal**, continuous in front with the fourth ventricle of the brain.

2. The **spinal nerves** arise in pairs from the sides of the spinal cord. Each nerve arises by two roots, a **dorsal** or sensory root, and a **ventral** or motor one: of these the dorsal root is some distance in front of the corresponding ventral one, the successive dorsal and ventral roots alternating at about equal intervals along the sides of the spinal cord.

Each dorsal root arises from the spinal cord as a single trunk with a ganglionic enlargement on it, and passes out from the neural canal through a notch in the hinder margin of the intervertebral neural plate. The corresponding ventral root arises by three or more rootlets from the spinal cord, and passes out from the neural canal through a smaller notch in the hinder margin of the vertebral neural plate. Outside the vertebral column the two roots unite to form the spinal nerve.

IX. DISSECTION OF THE SENSE ORGANS.

A. The Nose.

Dissect out one of the olfactory organs from its capsule: cut it across transversely about the middle; wash it, and examine its structure.

The olfactory organ is a sac, the walls of which are thrown into a large number of transverse folds attached in pairs to a median septum. Each fold is covered by a soft mucous membrane, the surface of which is increased by secondary foldings. The olfactory nerves enter the organ from the dorsal surface, and spread out in the folds.

The great size of the olfactory organ, and of the nerves it receives, is very characteristic of Elasmobranch fishes.

B. The Eye.

Remove one of the eyes by cutting across the eye muscles and the optic nerve. Snip off the remains of the muscles, and

divide the eye into an inner and an outer half by cutting all round it equatorially. Place the two halves under water in a dissecting dish.

The walls of the eye consist of three concentric layers, and within its cavity, near the outer side, is the spherical lens about the size of a pea.

1. The **sclerotic**, or outermost coat of the eye, is thin and cartilaginous. It invests the whole of the eye except the part covered by the cornea.
2. The **cornea** is an oval patch on the outer surface of the eye, through which the light enters. It is about half an inch long and a quarter of an inch broad, and is almost flat. It consists of transparent connective tissue, and is continuous at its edges with the sclerotic.
3. The **choroid** is a black opaque membrane, lying within the sclerotic. It adheres closely to the sclerotic, and is firmly attached to the line of union of sclerotic and cornea. Beyond this line it is continued into the **iris**, which lies free behind the cornea, and is perforated in its centre by an elongated oval slit, the **pupil**, through which light passes to the interior of the eye.

The inner surface of the choroid, especially in the inner half of the eye, is covered by a glistening silvery membrane, the **tapetum**.

4. The **retina** is a delicate membrane lying on the inner surface of the choroid, and readily separating from it except at the point of entrance of the optic nerve, where it adheres firmly, and is continuous with the nerve. It is the only part of the eye sensitive to light.
5. The **lens** is a solid spherical body, suspended in the eye immediately behind the pupil. During life it is transparent, and serves to bring the rays of light to a focus on the retina.

The spherical shape of the lens, together with the flatness of the cornea, is very characteristic of aquatic animals.

C. The Ear.

The ear consists of a membranous sac, or **vestibule**, filled with fluid, and produced into three curved tubes, the **semicircular canals**, which lie in planes of which each is at right angles to the other two. Each canal opens at both its ends into the vestibule.

The whole sac is lodged within the cartilaginous auditory capsule, which is firmly united with the side of the hinder end of the skull.

*Scrape clean the hinder end of the skull, so as to expose the left auditory capsule fully. Note, on the dorsal surface, the prominent ridges lodging the **anterior and posterior vertical semicircular canals**, the former running backwards and inwards from the hinder margin of the orbit, and the latter backwards and outwards to the posterior end of the skull. Note also, at the inner side of the point of meeting of the two canals, a hole leading downwards and outwards into a canal, the **aquæductus vestibuli**.*

Hold the skull in your left hand and carefully pare away the cartilage with a sharp scalpel until the several parts of the auditory organ are fully exposed. Owing to the transparency of the cartilage, the parts can be seen before they are met with, and the dissection, though requiring care, is not difficult.

1. The **vestibule** is a laterally compressed sac, lying in the lower and inner part of the auditory capsule. It is partially divided into two; contains milky calcareous concretions; and communicates with the dorsal surface of the head by the **aquæductus vestibuli**, which is a persistent relic of the involution of the dorsal integument from which the ear is developed.

Pass a seeker down the aquæductus vestibuli into the vestibule.

2. The **semicircular canals** are three in number. They open at both ends into the vestibule, and each is dilated at one end into an oval **ampulla**, which receives a branch of the auditory nerve.
 - i. The **anterior vertical canal** has its ampulla at the anterior end close to the orbit.
 - ii. The **posterior vertical canal** is the longest of the three, and forms an almost complete circle. Its ampulla is at its posterior and inferior end, on the ventral wall of the skull.
 - iii. The **horizontal canal** lies in the wing-like lateral process of the auditory capsule, behind the orbit: its ampulla is at its anterior end, close to that of the anterior vertical canal.
3. The **auditory nerve** enters the auditory capsule on its inner side, and at once divides into branches, which can be traced to the vestibule and to the ampullæ of the semicircular canals.

D. The Sensory and Ampullary Canals.

The dog-fish possesses at least two kinds of tegumentary sensory organs. (1) The **sensory canals**, a continuous system, developed along certain lines on the head, the jaws, and down the sides of the body forming 'the organs of the lateral line.' These structures are found in almost all fishes. (2) The blind and more or less short **ampullary canals** not found outside the group of Elasmobranchs, and distinguished from the sensory canals by the swellings or ampullæ at their blind ends.

These ampullæ are collected principally into a large mass at the anterior end of the snout, in front of the cranial cavity; and two smaller masses at the sides of the head, between the nose and the orbit. From these masses the tubes diverge to their external openings on the dorsal and ventral surfaces of the head. The tubes are filled with a transparent gelatinous matter, which can be squeezed out from their openings.

The function of the two canal systems is not known with certainty, but they are generally believed to be sense organs

of some kind. The nerves supplying them in the head are the ophthalmic, buccal, and external mandibular branches of the seventh nerve.

Squeeze the head of a fresh specimen, so as to make the gelatinous matter exude, and so render the openings visible.

Remove the skin from the dorsal and ventral surfaces of the head, an operation much facilitated by dipping the head into hot water for a few moments : identify the masses of ampullæ and the nerves in connection with them, and trace the tubes outwards and backwards to their openings. Some of the tubes which run along the dorsal surface of the skull, between the cranium and the orbit, are some inches in length.

Cut out a small piece of the mass of ampullæ : put it on a slide in a drop of water : separate the parts with needles : cover, and examine under the microscope. Note the ampullæ, their internal divisions, the nerves supplying them, and the tubes.

CHAPTER XII.

THE SKELETON OF THE RABBIT.

Lepus cuniculus.

IN the early stages of development the skeleton of the rabbit consists entirely of cartilage. This primary cartilaginous skeleton agrees in general plan with the skeleton of the dog-fish.

The skeleton of the adult rabbit is made up of bone, together with a small amount of cartilage. The bones are of two chief kinds.

(1) **Cartilage-bones** are so called from their arising in direct relation with the pre-existing cartilage. They make up the greater part of the adult skeleton.

(2) **Membrane-bones** are developed independently of the primary cartilaginous skeleton, and are almost confined to the head. They are to be regarded as dermal bones which have lost their connection with the skin, and become in many cases firmly united with the underlying cartilage and cartilage-bones: they are morphologically equivalent to the bony plates forming the bases of the scales in the dog-fish.

The **sesamoid bones** form a third class. These are small nodules of bones developed within the tendons of certain of the limb-muscles close to the joints: they modify the action of these muscles by altering the direction in which they pull.

The teeth of the rabbit are cutaneous structures, comparable to the scales or teeth of the dog-fish; they are,

however, in the adult so intimately associated with the bones of the jaws that they may conveniently be described with the skeleton. The hairs and claws, which are special developments of the epidermis, or surface-layer of the skin, will be described in the next chapter.

The rabbit's skeleton may be divided, like that of the dog-fish, into **axial** and **appendicular** portions, which will be dealt with successively.

The following points in the rabbit's skeleton should be noticed as characteristic of the great majority of mammals, and separating them from lower vertebrates.

Epiphyses are present at the ends of the vertebral centra, as well as at the ends of the long bones of the limbs; and the successive vertebræ are connected by intervertebral ligaments: the cervical vertebræ are seven in number. The sternum is transversely jointed. In the skull, there is a completely ossified occipital ring, with two condyles: the cranial and olfactory cavities are separated by a bony cribriform plate: there is not a distinct para-sphenoid on the under surface of the skull: the lower jaw articulates directly with the squamosal: there are three or four small but distinct auditory ossicles. The teeth form a single but discontinuous row round the margin of each jaw. In the shoulder girdle, the coracoid is reduced to a small process of the scapula; and there is no interclavicle. The ankle-joint is situated between the tibia and fibula above, and the proximal tarsal bones below: the fourth and fifth carpalia, and the corresponding tarsalia, fuse to form a single bone in each limb: the preaxial digit, corresponding to the thumb, has two phalanges, while the others have each three. In the rabbit the first digit of the hind limb, corresponding to the great toe in man, is abortive: in other mammals it has two phalanges like the thumb.

Examine the prepared skeletons and make drawings to scale of the several parts.

I. THE AXIAL SKELETON.

A. The Vertebral Column or 'backbone.'

This consists of a series of bony rings or **vertebræ**, placed end to end so as to form a tube, which stiffens the back, and lodges and protects the spinal cord. The successive **vertebræ** are movably articulated with one another, and their centra are separated by **intervertebral discs** of fibro-cartilage, except in the sacrum, where a certain number are fused together to support the pelvis.

The **vertebræ** fall readily into five groups, named as follows from before backwards:—

- (1) The **cervical** or neck **vertebræ**.
- (2) The **thoracic** or chest **vertebræ**, which bear movably articulated ribs.
- (3) The **lumbar** **vertebræ**, which are the largest of the series, and bear no ribs.
- (4) The **sacral** **vertebræ**, which are fused together and support the pelvis.
- (5) The **caudal** or tail **vertebræ**.

1. General characters of a vertebra.

Examine, as a type, the second lumbar vertebra.

- a. The vertebra is tubular, the cavity or **neural canal** being traversed during life by the spinal cord.
- b. The **centrum** or **body** is the thickened ventral wall of the tube, forming the floor of the neural canal. It corresponds in position to the notochord of the embryo, which it replaces (*cf.* p. 214).
- c. The **epiphyses** are two thin plates of bone applied to the ends of the centrum, with which they fuse after the animal is full grown.
- d. The **neural arch** forms the sides and roof of the neural canal, and presents at each end, close to the centrum, a pair of **intervertebral notches** for

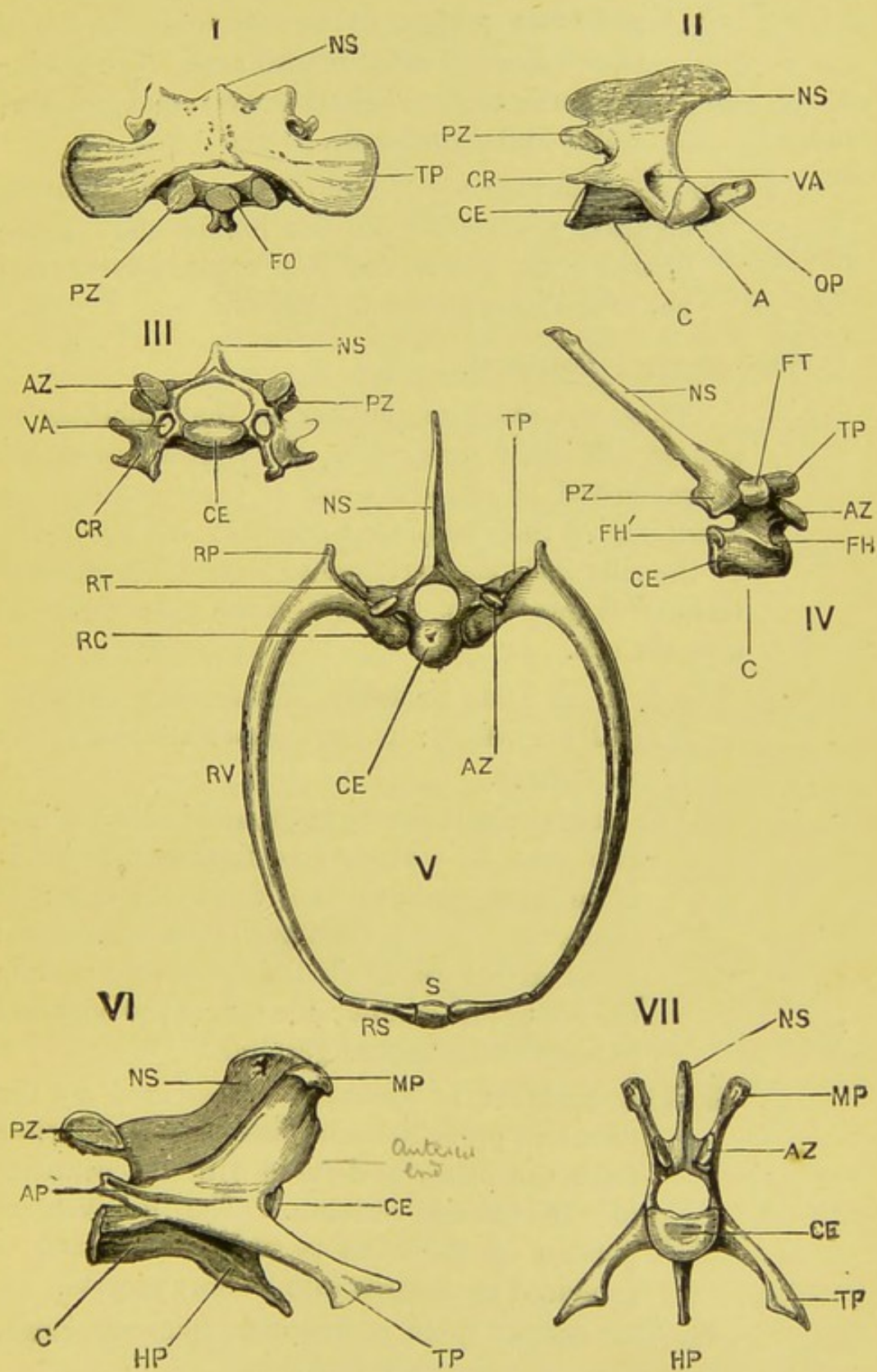
the passage of the spinal nerves, the posterior notches being much the deeper.

- e. The **neural spine** or **spinous process** is a median dorsal crest, projecting upwards and forwards from the top of the neural arch.
- f. The **hypapophysis** is a median ventral process from the under surface of the centrum, projecting downwards, forwards, and slightly to the right.
- g. The **transverse processes** are a pair of large flattened processes with expanded ends, projecting forwards, downwards, and outwards from the sides of the centrum.
- h. The **zygapophyses** or **articular processes** are borne on the two ends of the neural arch : they articulate with those of the adjacent vertebræ, so as to limit torsion of the vertebral column, and lateral displacement of the contiguous vertebræ.
- i. The **pre-zygapophyses**, or **anterior articular processes**, project upwards from the anterior end of the neural arch. The articular surfaces are concave, and turned inwards towards each other : above them the processes extend upwards in this vertebra to form the stout **metapophyses**.

FIG. 58.—*Lepus cuniculus*. Selected vertebræ. (A. M. M.)

- I. First cervical vertebra, or atlas, from the dorsal surface.
- II. Second cervical vertebra, or axis, from the right side.
- III. Fifth cervical vertebra ; anterior surface.
- IV. Fourth thoracic vertebra, from the right side.
- V. Fourth thoracic vertebra, and fourth pair of ribs ; anterior surface.
- VI. Second lumbar vertebra, from the right side.
- VII. Second lumbar vertebra ; anterior surface.

A, articular surface for atlas. AP, anapophysis. AZ, anterior or pre-zygapophysis. C, centrum. CE, epiphysis of centrum. CR, cervical rib. FH, facet for capitulum or head of the fourth rib. FH', facet for capitulum of the fifth rib. FO, facet for odontoid process. F'r, facet for tubercle of fourth rib. HP, hypapophysis. MP, metapophysis. NS, neural spine, or spinous process. OP, odontoid process. PZ, post-zygapophysis. RC, capitulum or head of rib. RP, process of rib for attachment of ligaments. RS, sternal portion of rib. RT, tubercle of rib. RV, vertebral portion of rib. S, sternum. TP, transverse process. VA, vertebralarterial canal.



- ii. The **post-zygapophyses**, or **posterior articular processes**, project backwards from the top of the hinder end of the neural arch. The articular surfaces are slightly convex, and face outwards and downwards.
- i. The **anapophyses** are a pair of small backwardly directed processes from the hinder end of the neural arch, below the post-zygapophyses and above the intervertebral notches.

2. The cervical vertebræ.

These are seven in number in the rabbit, as in almost all other mammals. As a group they are characterised by the shortness of their centra; the small size of their spinous processes; and the fusion of the ribs with the vertebræ to form the perforated transverse processes, through which the vertebral arteries run.

- a. The **first, or atlas vertebra**, differs very markedly from all the others: its more important characters are as follows.
 - i. The **neural canal** is very large, and is divided into two parts by a transverse ligament, which is often preserved in the dried skeleton: of these, the upper and larger is the true neural canal, giving passage to the spinal cord; while the lower and smaller one lodges the odontoid process of the second vertebra.
 - ii. The **centrum** is probably represented by the odontoid process, which has become detached from the atlas, and fused with the centrum of the second vertebra. The mid-ventral portion of the atlas is very narrow, and is produced backwards into a short process.
 - iii. The **neural spine** is an inconspicuous ridge, most prominent in front.
 - iv. The **transverse processes** are broad horizontal

lamellæ, perforated at their bases by longitudinal **vertebrarterial canals**. In front of each transverse process the canal is continued upwards as a groove to a foramen in the neural arch, through which the vertebral artery enters the neural canal and the first spinal nerve leaves it.

Along the inner and hinder border of each transverse process is a deep groove, corresponding to an intervertebral notch, for the passage of the second spinal nerve.

- v. The **articular surfaces**. The anterior end of the atlas has two very large deeply concave surfaces, for articulation with the condyles of the skull : the posterior end has two much smaller facets for the second vertebra.

b. The **second or axis vertebra**.

- i. The **centrum** is broad and flat, and is produced in front into the conical **odontoid process**, which is probably the centrum of the atlas vertebra. The suture between the odontoid process and the body of the axis is easily seen in young rabbits.
- ii. The **neural spine** forms a large vertical crest, very prominent in front, and bifid behind.
- iii. The **transverse processes** are small backwardly directed spines, perforated at their bases by the vertebrarterial canals.
- iv. The **anterior articular surfaces** are large and convex, and situated at the sides of the anterior end of the centrum.
- v. The **post-zygapophyses** project backwards from the hinder edge of the neural arch, their articular surfaces facing downwards and outwards.

c. The remaining cervical vertebræ:—third to seventh.

- i. The **centra** are short, broad from side to side, thin from above downwards, and obliquely truncated at the ends. The centrum of the seventh vertebra bears at its posterior end a pair of facets, which form parts of the articular surfaces for the heads of the first pair of thoracic ribs.
- ii. The **neural spines** are small, excepting that of the seventh vertebra.
- iii. The **transverse processes** are perforated at their bases by the vertebrarterial canals: beyond these they divide into dorsal and ventral portions, of which the latter, the **inferior lamellæ**, form prominent bony plates, except in the seventh vertebra, from which they are absent.
- iv. The **zygapophyses** are borne on the sides of the neural arches; the anterior facing upwards and inwards, the posterior downwards and slightly outwards.

3. The thoracic vertebræ.

These are usually twelve, sometimes thirteen, in number, and are characterised by bearing movably articulated ribs. The neural spines are long, especially in front: that of the tenth or **anticiinal vertebra** is nearly vertical, those in front of it sloping backwards, and those behind forwards. The posterior two or three thoracic vertebræ are larger than the others, and gradually approach the lumbar vertebræ in size and shape.

a. A typical thoracic vertebra:—any one of the first six.

- i. The **centrum** is short, and thick from above downwards. On each side in front is a small facet, which, with a similar one on the hinder edge of the vertebra next in front, forms the

articular surface for the head of the rib. At the posterior end are a similar pair of facets for the ribs of the succeeding vertebra.

- ii. The **neural arch** is notched, both in front and behind, for the passage of the spinal nerves.
- iii. The **transverse processes** are short, stout, and horizontal, and bear on their under surfaces the articular facets for the tubercles of the ribs.
- iv. The **neural spine** is long and slender, and slopes obliquely backwards.
- v. The **zygapophyses**. The pre-zygapophyses face upwards and outwards, the post-zygapophyses downwards and inwards.

b. The posterior three or four thoracic vertebræ.

- i. The **centra** are larger than in the anterior thoracic vertebræ: the facet for the head of each rib is confined to the anterior end of the centrum, the posterior end having no articular surface.
- ii. The **neural spines** are lower than in the anterior vertebræ, but longer from before backwards.
- iii. The **transverse processes** are placed further back, and have no articular facets for the ribs.
- iv. **Metapophyses** appear in the ninth thoracic vertebra, and increase considerably in size in the succeeding ones. They are usually confluent with the pre-zygapophyses in all except the ninth thoracic vertebræ.

4. The lumbar vertebræ.

These are usually seven in number: the most anterior one may, however, bear ribs, in which case it is reckoned as a thirteenth thoracic vertebra, and the lumbar vertebræ are then reduced to six.

The characters of a typical lumbar vertebra have already been described : as a group they are characterised by their large size, and the great development of their processes, especially the transverse processes. They increase in size from before backwards, the last but one being the largest. The first two have hypapophyses : the last one has a short stout centrum, and a stout crest-like neural spine.

5. The **sacral vertebrae**.

Strictly speaking, the sacral vertebrae are those of which the expanded ribs directly support the pelvis ; and of these the rabbit has only one, or at most two. A certain number of the succeeding vertebrae, which are fused with one another and with the last true sacral vertebra, are, however, commonly included under the same name, the whole fused mass being spoken of as the **sacrum**. Reckoned in this way the rabbit has three or more sacral vertebrae, the lines of boundary between which can easily be made out in spite of their fusion.

- a. The **first sacral vertebra** is much the largest, and is produced laterally into a pair of large wing-like expansions which support the pelvis, and are probably modified ribs fused with the vertebra. The **neural spine** is large and nearly vertical.
- b. The **hinder sacral vertebrae** are much smaller, and decrease in size from before backwards. Their number is variable, increasing with age through fusion with the anterior caudal vertebrae.

The anterior outer border of the second sacral vertebra just touches the pelvis, but it is doubtful whether any true costal element is present in it.

6. The **caudal vertebrae**.

These are about sixteen in number : they decrease in size from before backwards, gradually losing all their processes, and ultimately the neural arches as

well ; the hindmost vertebræ being reduced to mere rod-like centra.

B. The Ribs and Sternum.

These form, with the thoracic vertebræ, the skeletal framework of the wall of the thorax, which plays an essential part in the mechanism of respiration, besides protecting the thoracic viscera, and giving origin to some of the extrinsic muscles of the fore-limbs.

1. The **ribs** are curved bony rods, movably articulated with the vertebræ above, and connected at their lower ends with the sternum. There are in the rabbit twelve, or sometimes thirteen, pairs.

a. A **typical rib**, such as the fifth, consists of two portions of very unequal size, joined together almost at right angles.

i. The **vertebral portion**, which is the larger part of the rib, is a flattened rod of bone, strongly curved above, nearly straight below. The dorsal end or **capitulum** articulates with a concave surface, furnished partly by the centrum of the corresponding vertebra, and partly by that of the vertebra next in front. A short way beyond the capitulum, and on the dorsal surface of the rib, is the **tubercle** or surface for articulation with the transverse process of the corresponding vertebra ; and immediately beyond the tubercle is a short vertical projection for the attachment of ligaments.

ii. The **sternal portion** is a short bar of calcified or imperfectly ossified cartilage, connecting the lower end of the vertebral portion with the sternum.

b. The **ribs in general**. The ribs increase in length from the first, which is very short, to the sixth, behind which they diminish. The first nine pairs

of ribs have both capitular and tubercular articulations with the vertebræ : in the remaining three (or four) pairs, which are more slender than the anterior ones, the tubercles are absent, and the capitular articulations, which alone are present, are confined to the corresponding vertebræ.

The sternal portions of the first seven pairs articulate directly with the sternum : the remaining ones do not reach the sternum, though those of the eighth and ninth pairs are closely connected with the ribs in front of them.

2. The **sternum** is an elongated laterally compressed median rod, situated in the ventral wall of the thorax, and divided transversely into segments or **sternebræ**. It is developed in connection with the ventral ends of the ribs, and consists at first of right and left halves.

The anterior segment or **manubrium** is much the largest, and is produced ventrally and in front into a prominent keel.

Behind the manubrium come four segments of about equal length, then a very short segment, and finally the **xiphisternum**, a long slender bony rod ending behind in a horizontal plate of cartilage.

The first pair of ribs articulate with the sides of the manubrium, and the succeeding six pairs between the several **sternebræ**.

C. The Skull.

As in the dog-fish, the skeleton of the head is made up of **cranium proper**, **olfactory** and **auditory capsules**, and **visceral skeleton**, but the visceral skeleton, including jaws, hyoid bone, and auditory ossicles, is in the rabbit so closely associated with the other parts that it is convenient to describe the whole of these parts under the general term 'skull.'

In the adult rabbit, the original cartilaginous skull is almost completely replaced by bones. In addition to these carti-

lage-bones, *membrane-bones* are largely developed; and the two groups of bones, though primitively distinct, become intimately and immovably united to form a complex structure, in which the several morphological components, and even the boundaries of individual bones, are difficult to determine, and of which the essential composition can only be ascertained by a study of the embryonic stages.

In the following description the *membrane-bones* are described in connection with the **cartilage-bones** with which they are most closely associated, and their names are printed in italics. Though it is convenient to deal with the membrane-

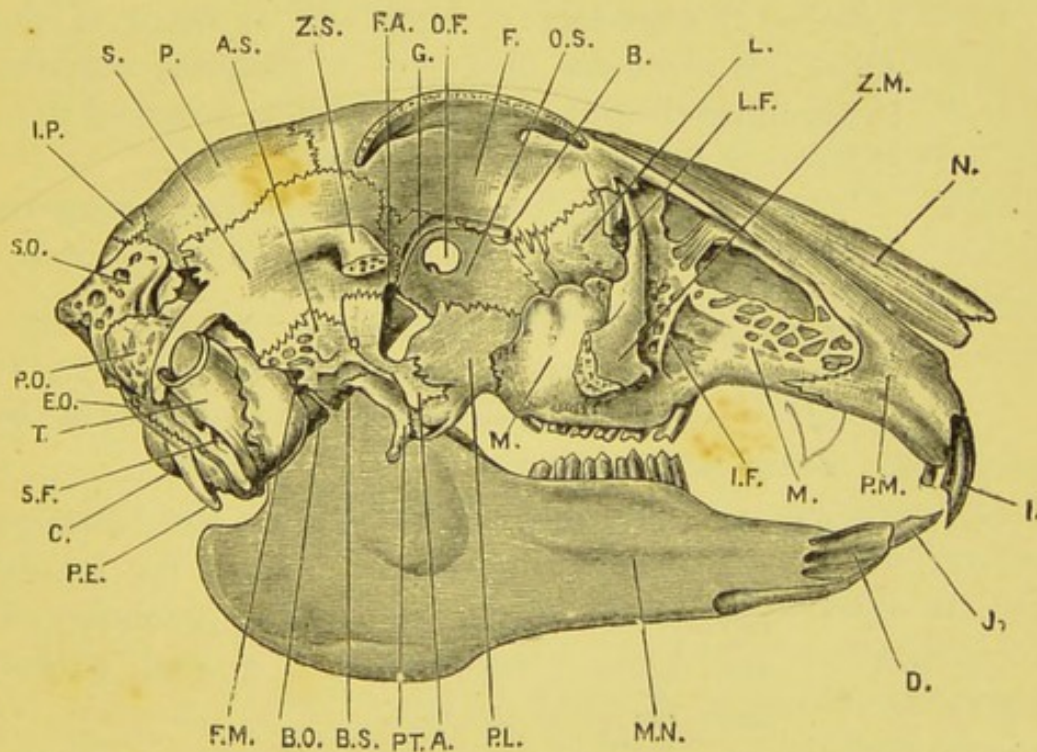


FIG. 59.—*Lepus cuniculus*. The skull from the right side. The middle portion of the zygomatic arch and the right half of the mandible have been removed. (A. M. M.)

A, external pterygoid process of ali-sphenoid. AS, ali-sphenoid. B, internal orbital foramen. BO, basi-occipital. BS, basi-sphenoid. C, occipital condyle. D, mandibular symphysis. EO, ex-occipital. F, frontal. FA, foramen lacerum anterius. FM, foramen ovale, confluent with the foramen lacerum medium. G, orbital groove, for ophthalmic division of trigeminal nerve. I, anterior upper incisor. IF, infraorbital foramen. IP, inter-parietal. J, lower incisor. L, lacrymal bone. LF, lacrymal foramen. M, maxilla. MN, mandible. N, nasal bone. OF, optic foramen. OS, orbito-sphenoid. P, parietal. PE, par-occipital process of ex-occipital. PL, palatine bone. PM, pre-maxilla. PO, periotic. PT, pterygoid. S, squamosal. SF, stylo-mastoid foramen. SO, supra-occipital. T, tympanic bones. ZM, zygomatic process of maxilla, cut short. ZS, zygomatic process of squamosal, cut short.

bones in this way, it must be borne in mind that, inasmuch as they are primitively independent of the cartilaginous skeleton, any attempt to group them according to the divisions of this primary skeleton must be more or less arbitrary.

1. The **cranium proper** or brain-case forms the posterior part of the skull; and is situated almost completely behind the **orbits**, or sockets for the eyeballs. The anterior or facial part of the skull is not in a line with the base of the cranium, but is deflected downwards through an angle of about 60° .

The bones of the cranium proper are arranged in a series of **segments** or rings, one in front of the other: of these the hindmost or **occipital segment** is the most obvious, and is very easily detached from the rest of the skull as a bony ring.

Care must be taken not to confuse these segments with *vertebræ*, with which they do not correspond.

- a. The **occipital segment** consists entirely of cartilage-bones, which may fuse together inseparably. It articulates with the first *vertebra* by means of the **occipital condyles**.
 - i. The **basi-occipital** is a flat median bone, forming the floor of the hinder part of the cranial cavity. It forms the ventral boundary of the foramen magnum, and a small part of each occipital condyle.
 - ii. The **ex-occipitals** bound the foramen magnum laterally, and form the greater part of the condyles. Each is produced at its outer side into a long downwardly directed **par-occipital process**, which is closely applied to the posterior surface of the **tympanic bulla**.
 - iii. The **supra-occipital** is a large median bone, which completes the occipital segment above. The whole bone is markedly cancellous, and its outer surface is raised into a prominent shield-

shaped elevation, giving attachment to the muscles raising the head.

b. The **parietal segment** consists of both cartilage-bones and membrane-bones. It is situated in front of the occipital segment, with which it is in contact above and below; while at the sides the two segments are separated by the interposition of the auditory capsules and the squamosal bones.

i. The **basi-sphenoid** is a median bone placed directly in front of the basi-occipital, with which it is connected by a thin plate of cartilage. Seen from below it is triangular, with the apex directed forwards. On its upper or dorsal surface is a depression, the **sella turcica**: this lodges the pituitary body, and is bounded behind by the large overhanging **posterior clinoid process**; while its floor remains unossified as the **pituitary foramen**.

ii. The **ali-sphenoids** are a pair of wing-like bones ankylosed with the sides of the basi-sphenoid, and forming parts of the floor of the cranial cavity. From the ventral surface of each ali-sphenoid there projects downwards a vertical plate of bone, the **external pterygoid process**, which is placed nearly transversely to the longitudinal axis of the skull, and is connected along its inner edge with the palatine bone: it is perforated at its base by three foramina, of which the innermost and largest transmits the internal maxillary artery and vein, and the two outer ones transmit branches of the mandibular division of the fifth nerve.

Between the ali-sphenoid and the anterior end of the basi-sphenoid on each side is a large slit-like notch, the **foramen lacerum**

anterior or **sphenoidal fissure**, through which the third, fourth, and sixth nerves, and the first and second divisions of the fifth nerve pass out from the cranial cavity into the orbit.

At the posterior border of each ali-sphenoid is a deep notch, the **foramen ovale**, for the passage of the third division of the fifth nerve.

- iii. The *parietals* are a pair of flattened membrane-bones, meeting each other in the mid-dorsal line at the sagittal suture, and forming a great part of the roof of the cranial cavity.

From the posterior and outer angle of each parietal a thin plate runs down on the inner surface of the squamosal, which latter bone separates the parietal from the ali-sphenoid.

- iv. The *interparietal* is a small median bone in the roof of the skull, between the parietals and the supra-occipital.

- c. The **frontal segment** surrounds the anterior end of the brain: it is placed in front of the parietal segment, with which it articulates closely.

- i. The **pre-sphenoid** is a median laterally compressed bone in front of the basi-sphenoid, and connected with it by cartilage. It forms the lower margin of the **optic foramen**, a large aperture through which the optic nerves enter the orbits from the cranial cavity, and the two orbits communicate in the dried skull with each other. The upper and posterior border of the pre-sphenoid is produced backwards into the small **anterior clinoid processes**, which bound the sella turcica in front.

- ii. The **orbito-sphenoids** are a pair of lamellar bones, which are fused with the pre-sphenoid, the boundary between the two being indistinguishable. They surround the optic foramen, be-

hind which they form part of the wall of the cranium and of the orbits, uniting suturally with the ali-sphenoids and with the frontals and squamosals. In front of the optic foramen the orbito-sphenoids are continued forwards as a pair of vertical laminae, diverging from each other at an acute angle, and forming parts of the inner walls of the orbits.

- iii. The *frontals* are a pair of large membrane-bones completing the frontal segment. They unite suturally with each other in the mid-dorsal line, with the parietals behind, and with the orbito-sphenoids below.

The frontals form the roof and sides of the anterior part of the cranial cavity, and meet each other on its floor in front: they extend forwards into the region of the nose. The outer surface of each frontal forms the upper part of the wall of the orbit, and bears a prominent crescentic **supra-orbital process**, in front of which it sends forwards a slender process between the maxilla and premaxilla.

- d. The **ethmoidal region** lies entirely in front of the cranial cavity, and is in close relation with the olfactory organs.
- i. The **mes-ethmoid** is a median vertical plate of cartilage, which extends forwards and downwards in front of the pre-sphenoid as the **septum narium** separating the right and left olfactory cavities from each other.

Its upper and posterior border is ossified and expanded laterally into the **cribriform plate**, which is placed obliquely across the anterior end of the cranial cavity, in the plane of the base of the skull, and is perforated by a number of holes through which the olfactory nerves pass from the brain to the nose.

2. The **sense-capsules**. Each of the organs of special sense has in the embryo rabbit, as in the dog-fish, a protecting investment of cartilage or strong connective tissue. In the case of the olfactory and auditory organs these capsules are closely connected with the cranium, and in the adult are more or less extensively ossified. Membrane-bones are also developed in immediate relation with the sense-capsules, and may conveniently be considered with them.

a. **Bones in relation with the olfactory capsules**. The olfactory capsules are very large in the rabbit, and occupy a great part of the facial portion of the skull. They are so closely connected with the ethmoidal region and with the upper jaw, that certain of the bones may be referred, with equal propriety, to either of these divisions.

i. The *nasals* are a pair of elongated membrane-bones, forming the roof of the nasal cavities. They unite suturally with the frontals behind, and with each other in the median plane.

ii. The **ethmo-turbinals** are intricately folded laminae of bone, fused to the lower surface of the cribriform plate of the ethmoid, and occupying the upper and posterior part of each nasal cavity.

iii. The **maxillo-turbinals** are a pair of somewhat similar, but more delicate and more complex bones, lying in the anterior portion of the nasal cavities, in front of the ethmo-turbinals.

iv. The **naso-turbinals** are a pair of thin laminae of bone, folded to form pouches, and fused with the under surfaces of the nasal bones.

v. The *vomers* are a pair of slender blade-like bones, fused with each other along their ventral margins, and embracing the lower edge of the mes-ethmoid cartilage. Behind they are

expanded laterally, and connected with the ethmo-turbinals.

b. Bones in relation with the optic capsules.

The *lacrymals* are a pair of small lamellar bones forming part of the anterior walls of the orbits, and loosely wedged in between the frontals and the maxillæ. Each is notched at its outer border for the passage of the lacrymal duct: this is supported by a process of the bone which extends forwards into the nose.

The lacrymals correspond to the most anterior of a series of small bones bordering the orbits in bony fishes.

c. Bones in relation with the auditory capsules (cf. fig. 64, p. 376).

- i. The **periotics** are the bones which replace the cartilaginous capsules enclosing the organs of hearing in the embryo. Each ossifies from three centres; but the several bones—**pro-otic**, **epiotic**, **opisthotic**—early unite to form an irregular mass, which fits loosely into the side-wall of the cranium, between the occipital segment and the squamosal, and which readily falls out from the dried skull.

In each periotic there may be distinguished a dense **petrous portion**, enclosing the essential part of the organ of hearing: and a porous **mastoid portion**, which forms its outer and posterior part, and is produced downwards into the **mastoid process**, lying immediately in front of the par-occipital process of the ex-occipital bone.

On the inner surface of each periotic, as seen in a bisected skull, there are two depressions. Of these the upper and larger one the **floccular fossa**, lodges the floccular lobe of

the cerebellum. The lower one is divided by a ridge of bone into two, of which the anterior one is the opening of the **aquæductus Fallopii**, transmitting the facial nerve ; and the posterior one is that of the **meatus auditorius internus**, through which the auditory nerve enters the internal ear.

The anterior border of the periotic is produced inwards into a prominent crest of bone which projects into the cranial cavity, and, together with a similar but smaller ridge on the supra-occipital, separates the cerebral and cerebellar fossæ from each other.

On the outer surface of the petrous portion of the periotic, and seen only after removal of the tympanic bone, are two small apertures. Of these the anterior and more conspicuous one is the **fenestra ovalis**, in which the stapes often remains wedged ; while the posterior and more irregularly shaped one is the **fenestra rotunda**, which is close to the posterior edge of the bone, and overhung by the mastoid process. Immediately below the fenestra ovalis is a rounded swelling, the **promontory**, within which the **cochlea** lies.

- ii. The *tympanics* are a pair of somewhat flask-shaped bones, imperfect on their inner sides, and closely applied to the outer surfaces of the periotics. The expanded body of the flask, or **bulla**, encloses the **tympanic cavity** ; and the upwardly directed neck, or **meatus auditorius externus**, supports the cartilage of the large external ear. Within the bulla, at the base of the meatus, is an incomplete bony ring, across which the **tympanic membrane** is stretched during life.

The Eustachian tube leaves the tympanic cavity by an aperture at the antero-inferior

angle of the tympanic bone, between it and the periotic, and passes forwards to the posterior nasal chamber (p. 375).

The bony canal by which the facial nerve leaves the skull runs along the posterior border of the tympanic, between it and the mastoid process of the periotic, and opens below at the **stylomastoid foramen**.

On the ventral surface of the tympanic bone, near its inner border, is a conspicuous foramen, through which the internal carotid artery enters the skull.

- iii. The **auditory ossicles** (see fig. 64) are most conveniently examined with the bones of the auditory capsules, on account of their close connection with the organs of hearing; though, morphologically, they belong to the mandibular and hyoidean arches.

They form on each side a chain of small bones stretching across the tympanic cavity from the tympanic membrane to the fenestra ovalis.

- α. The **malleus** consists of a small body and two processes. The larger process, or **manubrium**, is blade-like, and is attached along the greater part of its length to the tympanic membrane, the tip being near the centre of the membrane. The shorter process, which is anterior, articulates with a small fossa on the inner surface of the tympanic bone.

- β. The **incus** is a minute somewhat pyriform bone: its head bears in front a saddle-shaped articular surface for the body of the malleus, and is produced behind into a short process, which articulates with a

fossa on the outer surface of the periotic bone, just above the fenestra ovalis.

The narrow end or stalk of the incus projects downwards: its tip is bent inwards, and has attached to it a very small bony disc, the **os orbiculare**.

- γ. The **stapes** is a very small stirrup-shaped bone, articulating by its arch with the **os orbiculare**, and attached by its basal plate to the membrane closing the fenestra ovalis.

3. **The jaws.** The cartilaginous maxillary and mandibular arches of the embryo, corresponding to the upper and lower jaws of the dog-fish, disappear almost completely during development; the jaws of the adult rabbit consisting of membrane-bones developed around and in front of these arches.

a. **Bones in relation with the maxillary arch.** These are very closely connected with the cranium and with the olfactory capsules.

- i. The *pterygoids* are a pair of narrow vertical plates of bone, attached to the base of the skull at the junction of the basi-sphenoid with the ali-sphenoids. The posterior border of each pterygoid is free, and ends below in the curved **hamular process**, while the anterior border unites with the palatine and ali-sphenoid. On the outer side of the pterygoid, between it and the external pterygoid process of the ali-sphenoid, is the triangular **pterygoid fossa**.

- ii. The *palatines* are a pair of nearly vertical plates of bone, attached above to the ventral border of the pre-sphenoid, and behind to the pterygoids and ali-sphenoids, thus completing the anterior boundaries of the pterygoid fossæ. They form the side-walls of the posterior

narial passage, which they separate from the orbits. In front they are produced inwards into the horizontal **palatal processes**, which meet each other in the median plane in the roof of the mouth, opposite the grinding teeth, forming the posterior third of the bridge of bone supporting the hard palate.

- iii. The *maxillæ* are a pair of large irregular bones forming a large part of the skeleton of the upper jaw and of the face.

The body, or **alveolar portion**, of each maxilla projects into the front part of the orbit, and is excavated by the **alveoli** or sockets for the grinding teeth. Its inner surface is covered by the palatine behind; and in front is produced inwards into the horizontal **palatal process**, which meets its fellow in the median plane, and forms the anterior part of the bony bridge supporting the hard palate.

From the outer side of the body arises the stout **zygomatic process**, which is prolonged upwards into the **orbital process**, forming the anterior boundary of the orbit. In front, the maxilla is prolonged into the large fenestrated **facial plate**, which forms the lateral boundary of the olfactory chamber, and is perforated just above the first grinding tooth by the **infra-orbital foramen**, for the passage of the maxillary division of the trigeminal nerve.

- iv. The *premaxillæ* are a pair of bones forming the anterior part of the upper jaw, and lodging the incisor teeth: they articulate with the maxillæ behind, and with each other in the median plane in front.

The upper and posterior angle of each premaxilla is produced backwards into a long **nasal process**, which lies along the outer

border of the nasal bone, and above the maxilla and the anterior process of the frontal.

On the under surface of the skull, bounded laterally by the premaxillæ and maxillæ, and behind by the hard palate, is a large triangular aperture, divided longitudinally into the slit-like **anterior palatine foramina** by the **palatal processes** of the premaxillæ, a pair of thin longitudinally rolled laminæ attached in front to the premaxillæ, and enclosing the organs of unknown function known as Jacobson's organs.

- v. The *jugals* or *malars* are a pair of laterally compressed bars forming the greater part of the length of the **zygomatic arches**, which bound the orbits below. Their anterior ends are fused with the zygomatic processes of the maxillæ, and posteriorly they articulate along their dorsal edges with the squamosals.

b. **Bones in relation with the mandibular arch.**

The uppermost part of the mandibular arch is said to give rise to the **incus** and **malleus**, which have already been described in connection with the auditory capsule (p. 303).

- i. The *squamosals* are a pair of slightly curved bony plates, which complete the side-walls of the cranial cavity, lying in front of the periotics, and articulating with the parietals, frontals, orbito-sphenoids, and ali-sphenoids.

From the hinder border of each squamosal a slender **post tympanic process** arches backwards over the external auditory meatus, lying along the outer surface of the periotic.

From the outer surface of the squamosal arises a stout **zygomatic process**, which bears on its under surface the articular facet for the mandible : beyond the facet it bends down-

wards, to articulate by an expanded end with the jugal bone, and so complete the zygomatic arch.

- ii. The *mandible*, or lower jaw, consists of a pair of somewhat triangular plates of bone, firmly united in front, and articulating by their posterior and upper angles with the zygomatic processes of the squamosals.

The anterior portion of each half or **ramus** is stout; it lodges an incisor tooth in front, and further back, on its upper margin, the grinding teeth. The hinder part of the ramus is much thinner: its postero-inferior border, or **angle**, is rounded, and inflected along its margin; its posterior border, above the angle, is deeply notched: its upper border is thickened to form the longitudinally elongated condyle, which articulates with the squamosal in such a way as to allow free movement of the jaw backwards and forwards, but very restricted movement from side to side: its anterior border is deeply grooved, the outer lip or **coronoid process** being inflected.

On the inner surface of each ramus, just behind the grinding teeth, is the **inferior dental foramen**, through which the mandibular nerve enters to supply the teeth.

4. The **hyoid bone** lies in the floor of the hinder part of the mouth, between the rami of the mandible.

It consists of a median **body**, and two pairs of backwardly projecting **cornua**, of which the posterior are the larger.

The anterior cornua are the ventral ends of the hyoidean arches, the dorsal end of each of which has aborted. The middle piece has separated off as a small bone (**stylo-hyal**) attached to the par-occipital process. The posterior cornua are the lower ends,

and only persistent parts, of the first pair of branchial arches.

5. Apertures on the surface of the skull.

After the several bones have been examined, the positions of the more important foramina should be determined, most of which have already been seen. Except when otherwise stated, the several apertures are paired.

a. Foramina for the passage of cranial nerves.

- i. The **optic foramen** is a large round median hole in the orbito-sphenoids : it transmits the optic nerves : and in the dry skull puts the two orbits in communication with the cranial cavity and with each other.
- ii. The **foramen lacerum anterius**, or **sphenoidal fissure**, is a vertical slit below and behind the optic foramen, and between the basi-sphenoid and ali-sphenoid. Through it the **third**, **fourth**, and **sixth** nerves, and the **ophthalmic** and **maxillary** divisions of the **fifth**, enter the orbit from the cranial cavity. In most mammals the maxillary division of the fifth nerve leaves the skull by a separate aperture, the **foramen rotundum**, which in the rabbit is confluent with the sphenoidal fissure.
- iii. The **internal orbital foramen** perforates the inner wall of the orbit, about a quarter of an inch in front of the optic foramen, and at the anterior end of a groove which curves back over the optic foramen towards the sphenoidal fissure. Through it the **nasal branch** of the ophthalmic division of the fifth nerve passes from the orbit into the cranial cavity, which it enters just behind the lower edge of the cribriform plate.
- iv. The **infra-orbital foramen** is on the side of the

face, in front of the zygomatic process of the maxilla : it transmits the **infra-orbital branch** of the maxillary division of the fifth nerve from the orbit to the face.

- v. The **anterior palatine foramen** or **foramen incisivum** is a large slit-like aperture, extending from the bony bridge of the palate almost to the incisor teeth, and imperfectly separated from its fellow by the palatal processes of the pre-maxillæ. Through it pass the **naso-palatine branch** of the maxillary division of the fifth nerve, and the naso-palatine canal.
- vi. The **posterior palatine foramen** is a small hole in the bony palate, at the junction of its maxillary and palatine portions : it transmits the **anterior palatine branch** of the maxillary division of the fifth nerve, and the blood-vessels of the palate.
- vii. The **foramen lacerum medium** is an irregular aperture on the under surface of the skull, between the ali-sphenoid and the periotic, just in front of the tympanic bulla. Its anterior part, which represents the separate **foramen ovale** of other mammals, transmits the **mandibular division** of the fifth nerve.
- viii. The **stylomastoid foramen** is a small aperture about the middle of the posterior border of the tympanic bone, between it and the mastoid process of the periotic. Through it the main trunk of the **seventh, or facial, nerve** leaves the skull.
- ix. The **foramen lacerum posterius** is an irregular fissure on the under surface of the hinder end of the skull, between the occipital condyle and the tympanic bulla. It transmits the **glossopharyngeal, pneumogastric, and spinal accessory nerves**, and the internal jugular vein.

- x. The **condylar foramina** are a couple of holes running obliquely through the ex-occipital, just in front of the condyle. They transmit the two divisions of the **hypoglossal** nerve, and are best seen through the foramen magnum.

b. **Other important apertures in the skull.**

- i. The **anterior narial opening** is at the anterior end of the skull, and is bounded by the nasals and the premaxillæ. It is single in the dried skull, but divided in the natural condition by the vertical cartilaginous septum narium.
- ii. The **lacrymal foramen** is formed by a deep notch in the outer border of the lacrymal bone, completed in front by the orbital process of the maxilla. It leads into the canal along which the **lacrymal duct** runs into the nose.
- iii. The **pituitary foramen** is a median hole, perforating the floor of the pituitary fossa in the centre of the basi-sphenoid: in the natural condition it is closed by membrane.
- iv. The **carotid foramen** perforates the ventral surface of the tympanic bone near its inner border, close to the occipital condyle: through it the internal carotid artery enters the skull.
- v. The opening of the **Eustachian canal** is on the under surface of the skull, at the anterior and inner angle of the tympanic bone, immediately behind and to the inner side of the foramen lacerum medium: through it the **Eustachian tube** passes from the tympanic cavity to the posterior narial chamber.
- vi. The **external auditory aperture** is the large upwardly directed opening of the neck of the tympanic bone, round the edge of which the cartilage of the external ear is attached.

- vii. The **foramen magnum** is the large median hole at the hinder end of the skull, surrounded by the bones of the occipital segment. It is traversed by the central nervous system, and marks the boundary between the brain and the spinal cord.

6. The teeth.

The teeth are cutaneous structures developed from the mucous membrane of the mouth. They consist of an extremely hard outer layer of **enamel**, which is epidermal in origin ; and a central less hard portion of **dentine**, which is developed from the dermis. The dentine is hollow, its cavity containing the pulp of the tooth, which receives vessels and nerves through the large aperture at its base. Surrounding the lower part of the tooth, and filling up the folds of its surface, is a thin layer of bone, the **crusta petrosa** or **cement**.

It is characteristic of the teeth of the rabbit, which is herbivorous, that the aperture at the base of each does not become constricted, but remains wide open, the teeth continuing to grow throughout life : whereas in most mammals the base of the tooth sooner or later becomes narrowed to form a **root** or **fang**, the aperture becoming almost obliterated, and the growth of the tooth ceasing entirely.

The teeth of the rabbit do not form a continuous series, as in man, but the front teeth or **incisors** are separated by a great gap or **diastema** from the group of **grinding teeth** in the hinder part of the mouth. The rabbit has no teeth corresponding to the canine teeth of other mammals.

a. The teeth of the upper jaw.

- i. The **incisors** are two pairs of teeth at the front of the upper jaw, lodged in alveoli in the pre-maxillæ.

a. The **anterior incisors** are long, and curved almost into semicircles, the greater part of each being lodged in an alveolus which extends almost to the hinder end of the bone. Along the anterior surface the enamel is thick, and folded so as to form a longitudinal groove. Behind and at the side it is much thinner, and hence wears away sooner, rendering the cutting edge chisel-shaped.

β. The **posterior incisors**, which are lodged in alveoli immediately behind the anterior ones, are much smaller and slightly curved.

ii. The **grinding teeth** form a set of six teeth on each side, borne by the maxilla, and divisible into two groups.

a. The **premolars** are the three anterior grinders of each side, and are distinguished from the posterior ones by the fact that, like the incisors, they are preceded in early life by 'milk' or deciduous teeth, which in the rabbit are shed shortly after birth.

Each premolar is flattened from before backwards, and each of the two hinder ones has a deep groove along its outer surface which carries the enamel almost across the tooth, giving rise to a prominent ridge on the grinding surface.

β. The **molars** are the three posterior grinders on each side; they differ from the premolars in having no deciduous predecessors. The first two are similar to the premolars; the last is small and not grooved.

b. The **teeth of the lower jaw.**

i. The **incisors** are two in number, and project forwards from the anterior end of the mandible.

They are similar to the large upper incisors, but are less strongly curved and are not grooved: the alveoli in which they are lodged extend back in the jaw as far as the anterior grinders.

ii. The **grinding teeth** form a set of five on each side, placed opposite those of the upper jaw, and like these are divisible into two groups. They differ from the upper grinders in being curved so as to be convex instead of concave outwards.

a. The **premolars** are the two anterior grinders on each side. They are somewhat similar to the upper ones, but narrower from side to side. The outer surface of the first, which is the larger of the two, is marked by two deep longitudinal grooves, and that of the second by a single groove. The inner surface of each is less deeply grooved than the outer.

β. The **molars** are the three hinder grinders on each side; they are similar to the second premolars, but have no deciduous predecessors: the hindmost one is smaller and simpler than the other two.

II. THE APPENDICULAR SKELETON.

The appendicular skeleton comprises the bones of the two pairs of limbs, and the girdles which support them. The bones of the limbs are mostly elongated, and provided with epiphyses at their ends.

A. The Pectoral Girdle.

This lies outside the ribs, and is attached to the axial skeleton by muscles and ligaments only. In the rabbit, as in nearly all other mammals, it is very incomplete: the dorsal

or scapular portion on each side is well developed, but the ventral or coracoid portion is almost entirely absent, being represented merely by a small knob of bone fused with the scapula: the clavicles also are imperfect.

- i. The **scapula** is a triangular plate of bone, of which the apex is directed downwards and forwards, and is expanded and hollowed on its ventral surface to form the shallow **glenoid cavity**, with which the head of the humerus articulates.

Of the three borders, the anterior or **coracoid** border is nearly straight; the posterior or **glenoid** is slightly concave; and the dorsal or **suprascapular**, which is the shortest of the three, is convex and supports the cartilaginous **suprascapular**.

The **spine** is a prominent ridge running along the outer surface of the scapula, nearly parallel to and a short distance behind the coracoid border. It is continued ventrally into a free downwardly directed process, the **acromion**, from the posterior border of which the long **metacromion** projects backwards.

The coracoid border is continuous below with the **coracoid process**, which overhangs the glenoid cavity, and is produced inwards into a blunt hook. This is a distinct bone in the young rabbit, and is the sole representative of the coracoid portion of the pectoral girdle.

- ii. The **clavicle** is a slender curved cartilage-bone, rather less than an inch in length, and is attached to a ligament running from the scapula to the sternum.

Small cartilaginous nodules occur, one at the outer and two at the inner end of the clavicle.

B. The Fore-Limb.

The fore-limb of the rabbit corresponds to the upper limb of man, and may be divided, like this, into arm, forearm, wrist, and hand. The relative positions of these several divisions are considerably altered from the primitive condition, and are best understood by comparing them with the human arm in the following manner.

Extend your right arm horizontally outwards from the shoulder, with the palm of the hand vertical and the thumb upwards: there may now be distinguished a ventral or **flexor** surface; a dorsal or **extensor** surface; a **preaxial** border, along which are the thumb and the radius; and a **postaxial** border, along which are the little finger and the ulna.

Next bend the elbow at right angles, so that the fingers point forwards, and bring the whole arm down to the side, rotating it through 90° , so that the preaxial border becomes the outer and the postaxial border the inner one. Now pronate the hand, turning it through 180° , so that the thumb is brought to the inner side, and the palm directed downwards. Place the rabbit's skeleton in front of you, with the vertebral column vertical, the head directed upwards, and the limbs pointing away from you, and the right fore-limb will correspond in position to your own right arm. Note that the preaxial border is on the outer side in the arm, and on the inner side in the hand, while in the forearm the two bones cross each other obliquely. The hand in the rabbit is fixed permanently in the prone position—that is, with the palm turned downwards.

1. The arm contains only a single bone.

- i. The **humerus** is an elongated bone, articulating by its enlarged proximal **head** with the glenoid cavity of the scapula, and at its distal end, by the **trochlea**, with the bones of the forearm.

At the proximal end of the bone, in front of the head, is the longitudinal **bicipital groove**, for the tendon of the biceps muscle: this is bounded on its inner side by the **lesser tuberosity**; and on its outer side by the **greater**

tuberosity, a large roughened projection continued as a ridge down the anterior surface of the bone as far as its middle.

The **trochlea** at the distal end of the bone is an oblique pulley-like surface, divided in front by a ridge, and articulating with the radius and ulna to form the elbow-joint. Immediately above the trochlea, in front and behind, are the **supra-trochlear fossæ**, which communicate with each other through the **supra-trochlear foramen**: the posterior or **olecranon fossa** is much the larger of the two, and lodges the olecranon process of the ulna when the arm is extended.

2. The **forearm** contains two bones, of about equal size, immovably articulated, though not ankylosed, with each other.

i. The **radius**, or preaxial bone, lies in front of the ulna at the proximal end of the forearm, but in the distal half lies along its inner or preaxial side.

It is an elongated bone, slightly convex forwards. Its proximal end or head articulates with both grooves of the trochlea of the humerus, and also with the anterior surface of the ulna; its distal and larger end articulates with the bones of the wrist.

ii. The **ulna**, or postaxial bone of the forearm, has a greatly enlarged proximal end, on the anterior surface of which are the **sigmoid notch** for articulation with the trochlea, and also two small articular surfaces for the radius. Behind the elbow-joint, the bone forms the large laterally compressed **olecranon process**. The distal end of the ulna is small, and articulates with the carpus.

3. The **wrist**. In the rabbit the wrist or **carpus** consists of nine small bones, of which one, the **pisiform**, is commonly regarded as a sesamoid bone or ossification in the tendon of a muscle, but by some anatomists is considered to be a vestige of a sixth digit. The arrangement of the remaining eight can best be understood by comparison with more primitive types.

The typical carpus consists of nine bones, arranged in a proximal row of three, articulating with the radius and ulna ; a distal row of five, each of which supports one of the digits ; and a central bone wedged in between the proximal and distal rows. In the rabbit the arrangement is as follows.

- a. The **proximal row of carpals** consists of the three typical bones.
 - i. The **radiale**, or **scaphoid**, is on the inner or preaxial side, and articulates with the radius.
 - ii. The **intermedium**, or **semilunar**, is the middle bone of the three, and articulates with the radius.
 - iii. The **ulnare**, or **cuneiform**, is the outer or postaxial bone of the proximal row, and articulates with the ulna.
- b. The **central bone**.
 - i. The **centrale** is a small bone, articulating with the distal surfaces of the intermedium and radiale, and appearing to belong to the distal row of carpals.
- c. The **distal row of carpals** consists of four bones, the two outermost of the typical carpus having fused to form a single bone.
 - i. The **first carpale**, or **trapezium**, is on the inner or preaxial side of the wrist ; it articulates with the radiale, and supports the first metacarpal.
 - ii. The **second carpale**, or **trapezoid**, articulates

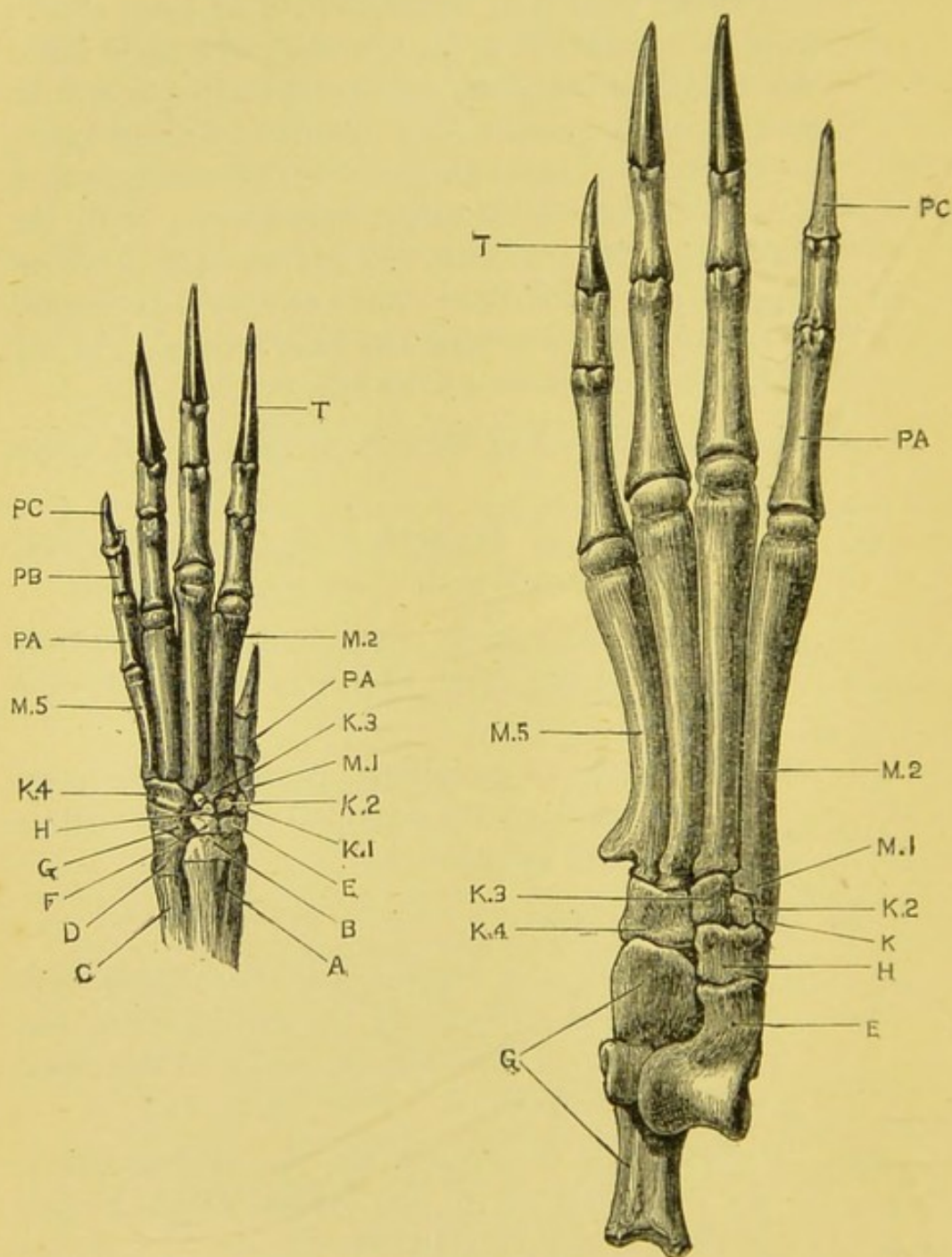


FIG. 60.

FIG. 61.

with the radiale and centrale, and supports the second metacarpal.

iii. The **third carpal**, or **os magnum**, is very small : it articulates with the intermedium, the centrale, and the third metacarpal.

iv. The **fourth and fifth carpalia** are fused to form the **unciform** bone, which is much larger : it articulates with the ulnare, and supports the fourth and fifth metacarpals.

d. The **pisiform** is a small bone on the posterior or flexor surface of the carpus, and articulates with the distal end of the ulna and with the ulnare.

4. The **hand** in the rabbit has five digits, as in man : the bones of each consist of a proximal **metacarpal**, followed by the **phalanges**, the last of which, the unguis phalanx, is conical and slightly curved, and supports the claw.

The **pollex**, or preaxial digit, corresponding to the thumb in man, is much shorter than the others, and has only two phalanges, while each of the other digits has three.

Sesamoid bones are developed in the tendons of the flexor muscles, opposite the metacarpo-phalangeal and certain other joints.

FIG. 60.—*Lepus cuniculus*. Skeleton of the left hand, extensor surface. The pisiform bone is not seen in this view. Natural size. (C. H. H.)

A, radius. B, epiphysis of radius. C, ulna. D, epiphysis of ulna. E, radiale. F, intermedium. G, ulnare. H, centrale. K.1, K.2, K.3, first three carpalia. K.4, unciform bone. M.1, M.2, M.5, first, second, and fifth metacarpals. PA, proximal phalanges of first and fifth digits. PB, PC, middle and unguis phalanges of fifth digit. T, claw.

FIG. 61.—*Lepus cuniculus*. Skeleton of the left foot, extensor surface. Natural size. (C. H. H.)

E, astragalus. G, calcaneum. H, naviculare. K, process representing first tarsale. K.2, K.3, second and third tarsalia. K.4, cuboid. M.1, M.2, first (rudimentary) and second metatarsals fused together. M.5, fifth metatarsal. PA, PC, proximal and unguis phalanges of second toe. T, claw enclosing unguis phalanx of fifth toe.

C. The Pelvic Girdle.

The pelvic girdle, which supports the hind-limb, consists of two halves, which, though primitively nearly at right angles to the vertebral column, are in the adult rabbit almost parallel to it. They are firmly attached to the sacrum in front, and to each other in the ventral **symphysis** behind.

Each half, or **os innominatum**, consists of three bones—**ilium**, **ischium**, and **pubes**—and presents about the middle of its outer surface a deep cup-shaped **acetabular cavity** for the femur, in the formation of which all the three bones take part.

- i. The **ilium** is the anterior and dorsal member of the girdle, corresponding to the scapula in the pectoral girdle. It is expanded and blade-like in front, and narrowed behind. On its inner or **sacral** surface, a little way in front of the acetabulum, is a roughened crescentic surface for articulation with the sacrum; while its outer surface is divided by a longitudinal ridge into ventral or **iliac**, and dorsal or **gluteal fossæ**. The ilium forms about half of the acetabulum, the lines of boundary between it and the ischium and pubes being easily seen in the young skeleton.
- ii. The **ischium** forms the posterior and dorsal portion of the os innominatum, and is separated from the pubes by the large oval **obturator foramen**. It forms about a third of the acetabulum, behind which it bears on its inner surface the sharp, backwardly directed **ischial spine**. Its posterior part is flattened, the margin being thickened to form the **ischial tuberosity**, which is raised on its outer surface into a prominent hooked process. The ischium corresponds to the coracoid in the shoulder-girdle.
- iii. The **pubes** is the smallest bone of the three. Its acetabular portion ossifies separately in

the rabbit, as a small **cotyloid bone**, completing the margin of the acetabulum below. The pubes unites along its ventral border with its fellow of the opposite side to form the anterior part of the **symphysis**, the hinder portion of which is formed by the ischium; the line of union between these two bones is visible only in the skeletons of very young rabbits.

D. The Hind-Limb.

The hind-limb is much larger than the fore-limb, and like this is divisible into four main portions.

In the hind-limb the departure from the primitive condition is much less marked than in the fore-limb. The whole limb has rotated forwards through about a right angle, so that the preaxial border is directed inwards, and the postaxial outwards; the original dorsal surface being turned forwards, and the ventral surface backwards.

1. The **thigh**, like the arm, contains a single bone, the femur. Certain sesamoid bones in connection with the knee-joint may be considered with it.

- i. The **femur** is an elongated bone, consisting of a cylindrical shaft and two enlarged extremities.

The proximal end bears on its inner or preaxial side the prominent rounded **head**, which articulates with the acetabulum to form the hip-joint. To the outer side of the head, and forming the end of the bone, is a large rough process, the **great trochanter**: between this and the head, on the posterior surface of the bone, is a deep pit, the **trochanteric** or **digital fossa**.

On the inner or preaxial side of the bone, immediately below the head, is a rough ridge, the **lesser trochanter**; opposite to which on

the outer or postaxial side is the prominent **third trochanter**.

The lower or distal end of the bone bears two large **condyles** which articulate with the tibia. These are separated from each other by the **intercondylar notch**, which is continuous with a deep groove on the front of the bone, along which the patella slides.

- ii. The **patella**, or knee-pan, is a large sesamoid bone in the tendon of the extensor muscles of the leg. It is connected by ligaments with the tibia, and slides in the groove on the front of the lower end of the femur.

At the back of the knee-joint are smaller sesamoids, the **fabellæ**.

- 2. The **leg** contains two bones, which are very unequal in size, and in the adult are fused together distally.

- i. The **tibia**, or preaxial bone of the leg, is a stout and straight bone, the longest in the body. Its enlarged proximal end, which is triangular in section, bears on its upper end two oval surfaces for articulation with the condyles of the femur. Below the head is the prominent **cnemial crest**, extending some distance down the anterior surface of the bone.

The distal end of the tibia, which is indistinguishably fused with the lower end of the fibula, bears an articular surface for the astragalus.

- ii. The **fibula**, or postaxial bone, is very slender: its proximal end is distinct, and articulates with a facet on the outer surface of the head of the tibia.

Its distal portion is completely fused with the tibia, and bears at its end an articular surface for the calcaneum.

3. The **tarsus** (fig. 61) consists, in the rabbit, of six bones, arranged, like the bones of the wrist, in a proximal and a distal row, with a central bone between them. The typical tarsus exactly corresponds to the typical carpus in number and arrangement of bones.

a. The **proximal row of tarsals** consists of two bones.

i. The **astragalus**, which probably corresponds to the **tibiale** and **intermedium** of the typical tarsus fused together, lies on the inner or preaxial side of the tarsus: it articulates by a prominent pulley-like surface with the distal end of the tibia.

ii. The **calcaneum**, or **fibulare**, is the largest bone of the tarsus: it lies along the outer side of the astragalus, articulating with the fibula, and is produced backwards into the large **calcaneal process** or **heel**.

b. The **central bone**.

i. The **naviculare**, or **centrale**, is placed immediately in front of the astragalus. It sends forwards a large process along the ventral surface of the foot.

c. The **distal row of tarsals** consists of three bones, the innermost or preaxial bone of the typical tarsus being absent, together with the digit which it supports, though probably represented by the process at the proximal end of the second metatarsal; while the two outer tarsalia, like the corresponding carpalia, fuse together.

i. The **second tarsale**, or **meso-cuneiform**, is very small: it articulates with the navicular, and supports the second metatarsal.

ii. The **third tarsale**, or **ecto-cuneiform**, lies to the outer side of the meso-cuneiform. It articulates with the navicular, and supports the third metatarsal.

iii. The **cuboid**, formed by the fusion of the **fourth** and **fifth tarsalia**, is a much larger bone, on the outer side of the foot: it articulates with the **calcaneum** and **navicular**, and supports the fourth and fifth metatarsals.

4. The **foot** of the rabbit has only four toes, the preaxial digit of the typical foot, corresponding to the great toe in man, having almost completely disappeared.

Each of the four digits consists of a long metatarsal bone, followed by three phalanges, the last of which bears a claw.

The second (apparent first) metatarsal has at its proximal end a backwardly directed process, which articulates with the navicular: this is a distinct bone in the young rabbit, and probably represents the entocuneiform and the metatarsal of the lost first toe or hallux (see fig. 61, p. 318).

CHAPTER XIII.

DISSECTION OF THE RABBIT.

THE rabbit may be taken as a type of the Mammalia; and the following points should be noted as characteristic of the great majority of the members of the group.

The distinguishing features of the skeleton have been noted in the preceding chapter.

Externally the body is covered with hair: the urino-genital and anal apertures are distinct from each other: and there are large external ears.

As regards the viscera:—Mammary glands are present, opening to the exterior on teats placed on the ventral surface of the body. The heart has four chambers: there is a single aortic arch in the adult, formed from the fourth left arch of the embryo: the blood is hot, and the red corpuscles non-nucleated. There is a complete diaphragm; and the lungs, which are not attached to the ribs, are completely surrounded by pleuræ. The ureters open directly into the bladder. In the brain there is a corpus callosum, connecting the hemispheres; and corpora quadrigemina in place of corpora bigemina, or four optic lobes in place of two. The cochlea is coiled spirally.

The ova are extremely small, and are retained within the uterus during almost the whole period of their development. The embryo receives a constant supply of nutriment direct from the mother by means of the placenta, a structure in which the blood vessels of the embryo and of the mother are

brought into very close relation, so that diffusion can readily take place from one to the other.

In the following account the several systems are described one by one, in order that each may be studied in its entirety as far as practicable, and the mutual relations of its several parts demonstrated. This method is the best, and should be followed whenever possible. If, however, it is intended to perform the whole dissection on a single rabbit, it will be found advisable to somewhat modify the order of proceeding.

For dissection, rabbits should be taken that are not less than six months old, or the reproductive organs will not be fully developed. They may be killed by pouring a few drops of solution of cyanide of potassium into the mouth, or else by chloroform, or by drowning or by coal gas in a lethal chamber. If cyanide is used the mouth must be well washed after death.

The brain should be removed at once and put into strong spirit. (See p. 378.)

I. EXTERNAL CHARACTERS.

The whole body is covered with hairs variously coloured ; and is obviously divided into head, neck, trunk, a short tail, and two pairs of limbs.

A. The Head.

Note the general form of the head. Determine the position of the mandible, the zygomatic arches, the supra-orbital processes of the frontals, and other parts of the skull, by feeling through the skin.

1. The **mouth** is a small transverse aperture on the under surface of the front of the head, bounded by the soft hairy **lips**. The upper lip is divided by a median cleft, which connects the mouth with the nostrils, and leaves the upper incisors exposed.
2. The **nostrils** are a pair of oblique slits at the end of the hairy snout.

3. The **eyes** are large, and placed at the sides of the head. Each eye is protected by an upper and a lower eyelid, fringed with scanty eyelashes; and by a third eyelid, or **nictitating membrane**, a hairless fold of opaque white skin, which lies within the other eyelids, and can be pulled across the eyeball from the anterior angle or **canthus**.
4. The **vibrissæ** or whiskers are long stiff tactile hairs, at the sides of the snout, and above and below the eyes.
5. The **external ears** or **pinnæ** are very large and freely movable. Each is folded longitudinally, and is supported by cartilage at its base, where it surrounds the external auditory aperture.

B. The Trunk.

This is divided into an anterior portion or **thorax**, stiffened laterally by the ribs; and a posterior part or **abdomen**.

Feel through the skin, and determine the positions of the vertebral column, the ribs, and the sternum.

1. The **anus** is a small median aperture beneath the base of the tail.
2. The **perinæal pouches** are a pair of hairless depressions of the skin, in front of and at the sides of the anus: into them open the ducts of the **perinæal glands**, the secretion of which has the strong smell characteristic of the rabbit.
3. The **urino-genital aperture** is situated in both sexes in front of the anus.
 - a. In the **male** the aperture is placed at the end of the long cylindrical **penis**, which can be retracted within a loose sheath of skin, the **prepuce**.
 - b. In the **female** the opening, or **vulva**, is slit-like and larger than in the male; and its anterior margin is produced into a small fleshy process, the **clitoris**, which corresponds to the penis of the male.

4. The **scrotal sacs**, found in the male only, are a pair of prominent oval pouches of skin, at the sides of the penis, into which the testes descend.
5. The **teats** or **mammæ** of the female are four or five pairs of small papillæ, perforated by the openings of the ducts of the **mammary** or **milk glands**. They are arranged at intervals along the ventral surface of the thorax and abdomen; the most anterior pair being about two and a half inches apart and an inch behind the elbow, and the hindmost pair opposite the thighs and rather more than an inch apart.

C. The Limbs.

1. The **fore-limbs**, as far as the elbows, are closely applied to the sides of the thorax and hidden by the skin of the trunk. The several bones of the shoulder-girdle and limb, which have been already studied in the skeleton, can easily be identified by feeling them through the skin. The palmar surface of the paw is hairy: the innermost digit or pollex is shorter than the others, not reaching the ground. All the digits bear claws.
2. The **hind-limbs** are much longer than the fore-limbs. The pelvic girdle and the several bones of the limb can be felt through the skin. In the foot the innermost digit or hallux is absent, and the remaining four are long and clawed. The plantar surface or sole of the foot is hairy.

II. THE ABDOMINAL VISCERA.

Remove the skin from the trunk and limbs. Lay the rabbit on its back, and fasten it down to the dissecting-board by pins through the limbs.

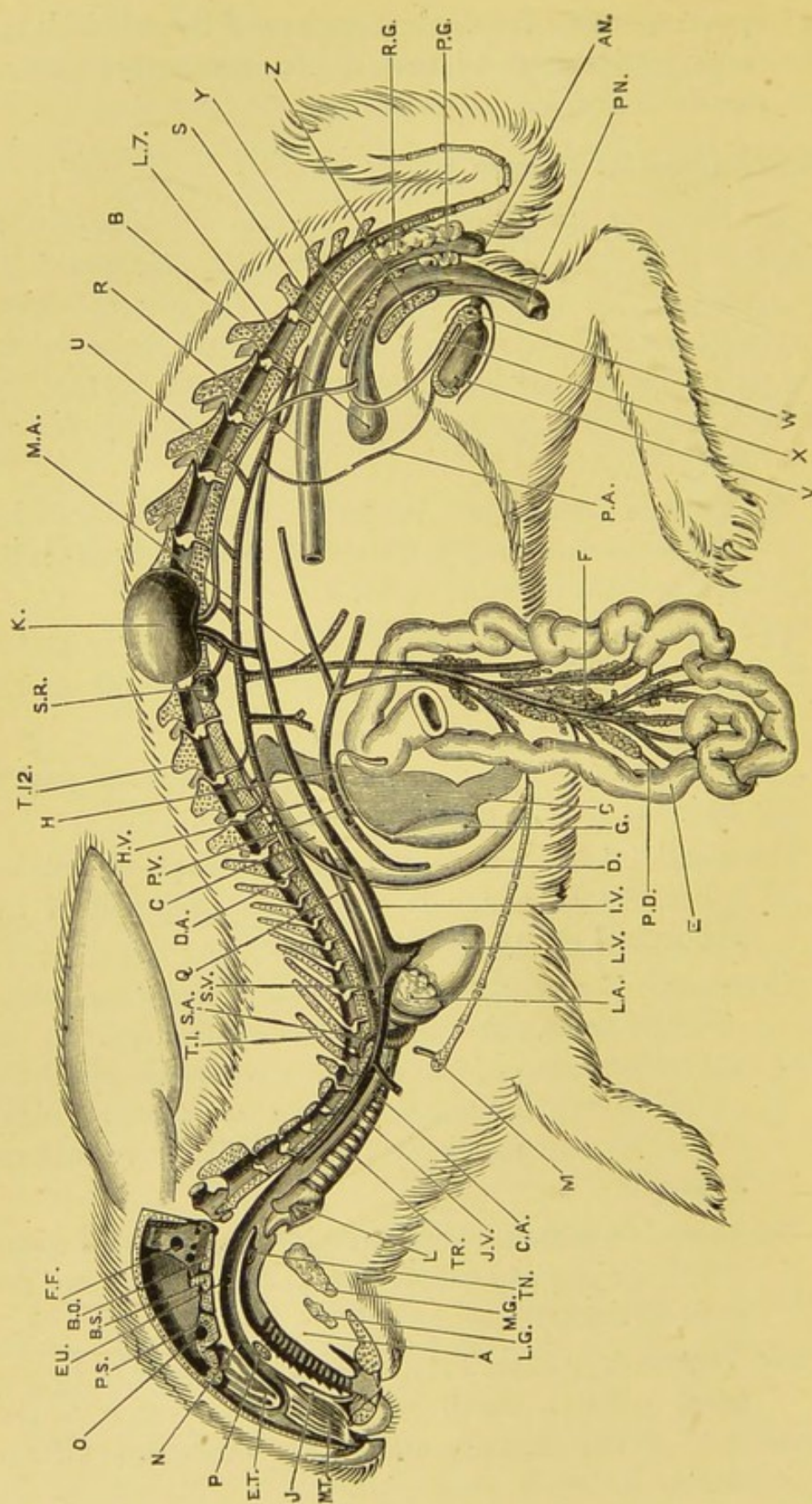
A. The **mammary glands** in the female lie immediately beneath the skin. They are yellowish, fatty-looking, dendri-

form masses, covering the ventral surface of the whole length of the thorax and abdomen ; their ducts may easily be traced, converging to the teats.

B. The Abdominal Viscera in situ.

Open the abdominal cavity by a median incision through its ventral wall, from the hinder end of the sternum to the pubic symphysis, taking care not to injure the viscera. From the anterior end of the incision cut outwards for about two inches on each side, just behind the ribs, and pin out the flaps right and left. Note the positions of the following viscera, without disturbing them.

1. The **liver** is a large dark-red body at the anterior end of the abdominal cavity, extending further back on the left side than on the right.
2. The **stomach** lies immediately behind the liver and is partially covered by it : its surface is smooth and of a bluish white colour.
3. The **duodenum** is a narrow pinkish tube, a small part of which is seen to the right of the stomach.
4. The **small intestine** is a long narrow much-convoluted tube, part of which is seen at the left side of the abdominal cavity, behind the liver.
5. The **cæcum** is a very wide tube, of a dark colour, coiled on itself and marked by a spiral constriction. In the natural position of the parts it covers almost all the other viscera behind the stomach. On the right side the cæcum ends in the pale fleshy **vermiform appendix**.
6. The **colon** is a wide tube, with markedly sacculated walls, running obliquely across the abdomen between the folds of the cæcum.
7. The **rectum** is a white tube, dilated at intervals by the faecal pellets : small parts of it are seen to the right of the stomach, and at the hinder end of the abdomen.



8. The **bladder** is a thin-walled sac at the posterior end of the abdomen, just in front of the pubic symphysis.

Turn the alimentary canal over to the right side, without cutting or tearing anything, to expose the following parts.

9. The **spleen** is an elongated dark-red body lying behind the stomach, and attached to its left or cardiac end.
10. The **kidneys** are a pair of compact ovoid bodies attached to the dorsal wall of the abdomen; the right one being immediately behind the liver, and the left one about an inch and a half further back. In front of each kidney is a small round yellow **adrenal body**.
11. The **diaphragm** is a muscular partition forming the anterior wall of the abdomen, and separating it from the thorax. To see it the liver should be pressed back.
12. The **peritoneum** is a glistening membrane which lines the abdominal cavity. The **mesentery** is a double layer of peritoneum, reflected from the dorsal wall of the abdomen, which at its margin supports and encloses the alimentary canal: between its two layers blood-vessels, lymphatics, and nerves pass to and from the various organs. The **omentum** is a special

FIG. 62.—**Lepus cuniculus**. Diagrammatic view from the left side. The head and vertebral column are represented in longitudinal section; the lungs, the left half of the liver, the stomach, the greater part of the intestine, and the brain and spinal cord have been removed, and the loop of the duodenum spread out. (A. M. M.)

A, tongue. AN, anus. B, bladder. BO, basi-occipital. BS, basi-sphenoid. C, liver. CA, carotid artery. D, diaphragm. DA, aorta. E, duodenum. ET, ethmo-turbinal. EU, aperture of Eustachian tube. F, pancreas. FF, floccular fossa. G, gall bladder. H, bile-duct. HV, opening of hepatic vein into posterior vena cava. IV, posterior vena cava. J, organ of Jacobson. JV, left external jugular vein. K, kidney turned up. L, larynx, bisected. LA, left auricle. LG, sublingual gland. LV, left ventricle. L7, seventh lumbar vertebra. M, manubrium of the sternum, with the sternal portion of the first rib. MA, anterior mesenteric artery. MG, submaxillary gland. MP, maxillo-turbinal. N, posterior nasal chamber. O, optic foramen. P, hard palate. PA, spermatic artery. PD, pancreatic duct. PG, perineal gland. PN, penis. PS, pre-sphenoid. PV, portal vein. Q, oesophagus. R, hinder part of the rectum. RG, rectal gland. S, uterus masculinus. SA, left subclavian artery. SR, suprarenal body, displaced. SV, left anterior vena cava. TN, right tonsil. TR, trachea. T1, first thoracic vertebra. T12, twelfth thoracic vertebra. U, ureter. V, testis. W, epididymis. X, vas deferens. Y, prostate. Z, pelvic symphysis.

fold of peritoneum, extending backwards from the stomach and loaded with fat.

13. The **cœliac** and **mesenteric ganglia** and the nerves connecting them should now be recognised. They lie in the mesentery near the vertebral column. (See p. 372.)

14. The portal vein and its branches should be identified (p. 345).

III. THE DIGESTIVE SYSTEM.

In this section the abdominal portion of the digestive system will alone be considered: the buccal cavity, pharynx, salivary glands, and œsophagus will be described later.

A. External Characters of the Digestive System.

1. The stomach.

Expose the stomach fully, by turning the liver forwards, and the intestine over to the animal's left.

The stomach is much dilated at its left or **cardiac end**; narrower towards the right or **pyloric end**; and markedly curved, the concavity being directed forwards. Near the left end of its anterior border is the **cardia**, or opening of the œsophagus; and from the thick-walled pyloric end a small aperture, the **pylorus**, leads to the duodenum.

2. The **duodenum**, or first portion of the intestine, runs from the pylorus along the right side of the abdominal cavity almost to its hinder end: it then turns back on itself, forming a U-shaped loop. In the mesentery connecting the two limbs of the loop are the large duodenal vessels.

3. The pancreas.

Turn the duodenal loop over to the left side without injuring the mesentery, and spread it out over the other viscera.

The pancreas is a diffuse fat-like gland of a pinkish colour, scattered in the mesentery of the duodenal loop. It lies mainly around the large vessels of the loop, and is more compact at its anterior end.

The **pancreatic duct** commences in front, and runs backwards through the gland, receiving smaller ducts from its several lobes; it opens into the inner side of the distal limb of the duodenal loop, about three inches beyond the bend.

Open the duodenum, opposite to the entrance of the pancreatic duct; wash out the contents; note the aperture of the duct, and insert a bristle into it.

4. The **liver** is a large solid organ, thick in the middle and thinner towards the edges. Its anterior surface is convex and fits against the diaphragm, to which it is attached by a median vertical fold of peritoneum, the **suspensory ligament**: its posterior surface is concave, and lies against the stomach.

a. The **lobes of the liver**.

- i. The **left central lobe** lies against the left half of the diaphragm.
- ii. The **left lateral lobe** lies between the left central lobe and the stomach, to the cardiac end of which it is applied. It is the largest of the lobes, and is partially subdivided.
- iii. The **Spigelian lobe** fits into the concave anterior border of the stomach, and is much the smallest of the lobes.
- iv. The **right central lobe** lies against the right half of the diaphragm, and is grooved on its posterior surface for the gall-bladder.
- v. The **caudate lobe** lies along the right side and dorsal surface of the pyloric end of the stomach. Its posterior margin is hollowed

to fit the right kidney: its inner and anterior border is connected by a bridge of liver-tissue with the Spigelian lobe.

- b. The **gall-bladder** is an elongated thin-walled sac, rather less than an inch in length, of a dark green or brown colour, and lying in the groove in the posterior surface of the right central lobe of the liver.
- c. The **bile-duct** is a narrow tube, about two inches long, running backwards from the smaller and dorsal end of the gall-bladder to open into the dorsal surface of the duodenum, about a third of an inch beyond the pylorus. It receives ducts from the several lobes of the liver, and lies in the mesentery immediately to the right of the large portal vein.

Open the duodenum opposite the opening of the bile-duct; wash out its contents, and find the aperture of the duct on a small papilla. The bile-duct is most easily traced from the duodenum forwards, and may with advantage be first injected from a point about half an inch from the duodenum.

Unravel the coils of the intestine, freeing them from one another by cutting through the mesentery along its line of attachment to the intestine. Leave the duodenal loop and the rectum, with their mesenteries, untouched. Carefully avoid injuring or removing the cæliac and mesenteric ganglia and the associated nerves (see p. 372).

Lay out the intestine on the dissecting-board, so as to show the relations and proportions of its several parts. Avoid all unnecessary injury to the blood-vessels, and ligature any that bleed.

- 5. The **small intestine**, which is directly continuous with the duodenum, is about seven or eight feet in length, and of uniform diameter throughout.

- a. **Peyer's patches** are slightly thickened oval spots, granular in appearance, and about a third of an

inch in diameter, which occur at intervals along the whole length of the small intestine, on the side opposite to the attachment of the mesentery.

- b. The **sacculus rotundus** is the dilated distal end of the small intestine, opening into the side of the cæcum about an inch from its proximal ends. Its walls have the structure of Peyer's patches.

6. The **cæcum** and **vermiform appendix**.

The cæcum is a large thin-walled diverticulum of the alimentary canal, at the junction of the small intestine and colon. It is about twenty inches long and an inch or more in diameter, and is marked externally by a spiral constriction which runs twenty to thirty times round it. The small intestine opens into the side of the cæcum about an inch from its proximal end; a large Peyer's patch in the wall of the cæcum being continuous with the sacculus rotundus.

Proximally, the cæcum passes directly into the colon, while distally it ends blindly in the thick-walled finger-like **vermiform appendix**. This latter is about four inches long, and its walls resemble Peyer's patches in appearance and structure.

In the rabbit the cæcum is of enormous size, as in most herbivorous mammals with simple stomachs.

7. The **colon** is about a foot and a half in length. The first part of it is very markedly sacculated, the sacculations lying in three longitudinal rows, separated by smooth areas of unequal width. Towards the rectum the walls become smooth.

8. The **rectum** or terminal portion of the intestine is a narrow tube, about two and a half feet in length, pale in colour, and presenting a moniliform appearance, owing to the contained faecal pellets. At its hinder end it passes through the pelvic cavity to the anus.

B. Internal Structure of the Alimentary Canal.**1. The stomach.**

Slit up the stomach along its posterior surface : wash out its contents, and examine it under water.

The wall of the stomach consists of an outer peritoneal investment; a middle muscular layer, thickened at the pyloric end; and an inner layer of mucous membrane, which is raised into irregular longitudinal folds. The pyloric orifice is narrowed by a prominent muscular rim.

2. The small intestine.

Cut out a small piece from the wall, and examine its inner surface under water.

The villi are minute tag-like processes of the mucous membrane, covering its surface, and giving it a velvety appearance.

Peyer's patches present a honeycombed appearance, the depressions being occupied by smooth convex lymph-follicles, and bordered by villi.

3. The cæcum.

Remove the cæcum from the body, cutting across the small intestine and the colon about an inch from it. Take the cæcum to the sink, and slit it open longitudinally : wash out its contents thoroughly, and examine under water.

The inner surface is papillose, and raised along the line of the external constriction into a prominent spiral fold, a quarter of an inch or more in width. The opening from the sacculus rotundus is small and circular; that into the colon is much larger.

Cut the vermiform appendix across to see the thickness of its wall; and slit it open to examine its inner surface, which is similar to that of Peyer's patches, but with smaller follicles.

4. The **colon**.

Slit open part of the colon; wash; and examine under water, noting the papillose surface and the sacculations of the wall.

5. The **rectum**.

Examine a part of the rectum in a similar manner, and note its smooth mucous membrane.

IV. THE THORACIC VISCERA.

Open the thorax by a transverse incision just in front of the diaphragm: cut through all the ribs except the first along each side, and remove the ventral wall of the thorax as a triangular piece, taking great care not to injure the vessels and other structures beneath it.

Identify and examine the following parts without any further dissection.

1. The **thymus** is a pale soft glandular-looking body in the anterior part of the thorax. It is very variable in size, being larger in the young animal, and sometimes extending back so as to overlap the heart.
2. The **heart**, enclosed in the thin transparent **pericardium**, lies in the middle of the thorax: it is dark in colour and conical in form; the apex being directed backwards and slightly to the left; and the base, with the roots of the great vessels, forwards.
3. The **lungs** are a pair of pink spongy bodies at the sides of the thorax, and filling the greater part of its cavity. Each lung collapses as soon as the side of the thorax on which it lies is opened.

The lungs lie quite free in the thoracic cavity, except at their roots, where the blood-vessels and bronchi enter them. The left lung is divided into two lobes; and the right into four, of which the smallest and hindmost lies across the median

plane behind the heart, and closely applied to the œsophagus.

4. The **diaphragm** is a thin partition, separating the thoracic cavity from the much larger abdominal cavity. Its marginal portion is muscular, the fibres arising from the inner surface of the hinder ribs and from the vertebral column, and converging to be inserted into the thinner tendinous central portion. The muscular margin is specially developed in the dorsal region, forming two stout **pillars** arising from the lumbar vertebræ.

The diaphragm is arched so as to present a very convex surface towards the thorax: by contraction of its muscular portion, in the act of inspiration, this convexity is diminished and the thoracic cavity thereby enlarged. The small size of the thoracic relatively to the abdominal cavity should be noticed.

5. The **phrenic nerves** are a pair of slender white cords lying between the heart and the lungs, and easily seen on pressing these apart. Posteriorly they divide into branches supplying the muscular portion of the diaphragm (see fig. 63, p. 364).

Their origin from the fourth cervical nerves will be seen in the dissection of the neck (p. 368).

6. The **pleuræ**. Each side of the thorax is lined by a glistening membrane, the **pleura**, which is reflected over the lung at its root in the same way as the peritoneum is reflected over the abdominal viscera. The right and left pleural sacs are separated from each other by the **mediastinal cavity**, the greater part of which is occupied by the heart and pericardium, the posterior part remaining vacant.

During life the lungs are distended so as to almost fill the thoracic cavity, the **visceral layer** of the pleuræ, covering the lungs, being closely applied to the **parietal layer** lining the thorax, so that the pleural cavities are practically obliterated.

Each pleura being an air-tight sac, the lungs follow the movements of the ribs and diaphragm; so that enlargement of the thoracic cavity causes expansion of the lungs, and hence inspiration.

7. The **œsophagus** is a narrow muscular tube, running through the thorax immediately ventral to the vertebral column, and readily seen on raising the left lung.
8. The **pneumogastric nerves**. At the anterior end of the thorax the pneumogastric nerves lie parallel to the phrenic nerves, and a little nearer the median plane. Further back the pneumogastriks lie dorsal to the heart and to the roots of the lungs, and close to the vertebral column; the left nerve lying on the œsophagus, the right nerve a little to its right side. The nerves are readily seen on turning aside the lungs and heart.

V. DISSECTION OF THE CIRCULATORY SYSTEM.

A. The Heart and the Roots of the Great Vessels.

Remove the thymus and the parietal layer of the pericardium, and carefully clean the base of the heart and the roots of the great vessels, avoiding injury to the nerves.

1. The **heart**. The ventricular portion of the heart, which forms almost the whole of the exposed ventral surface, is marked by a groove which runs from the base obliquely backwards and to the right, indicating the division into right and left ventricles.

The auricles lie at the base of the heart, on its dorsal aspect, the auricular appendices being the only parts of them visible on the ventral surface.

- a. The **right ventricle** forms the right side of the ventricular portion, but does not reach to the apex. It is soft to the touch.

- b. The **left ventricle** forms the left side and apex of the heart; and is firmer than the right ventricle, owing to the greater thickness of its walls.
- c. The **left auricle** is anterior to the left ventricle, and is largely concealed by the great vessels. It is produced ventrally into the **auricular appendix**.
- d. The **right auricle** is dorsal to the base of the right ventricle, and is produced in front into the **auricular appendix**.

2. The roots of the great vessels.

a. Opening into the right auricle.

- i. The **right anterior vena cava** returns blood from the right side of the head, neck, and thorax, and from the right fore-limb. It enters the thorax at its anterior end, and runs back along the inner side of the right lung, to open into the right auricle by an aperture in its dorsal wall.
- ii. The **left anterior vena cava** returns blood from the left side of the head, neck, and thorax, and from the left fore-limb. It runs back along the inner side of the left lung, and crosses between the heart and the root of the left lung, to open into the left side of the right auricle.
- iii. The **posterior vena cava** returns blood from all parts of the body behind the diaphragm. It enters the thorax through an aperture in the diaphragm and runs forwards, slightly to the right of the median plane, to open into the posterior end of the right auricle.

b. Arising from the right ventricle.

- i. The **pulmonary artery** conveys the venous blood from the heart to the lungs. It arises from the anterior border of the right ventricle in

the mid-ventral line, and arches over to the dorsal surface of the left auricle, where it divides into the right and left pulmonary arteries, supplying the two lungs.

c. Opening into the left auricle.

- i. The **pulmonary veins** return the blood from the lungs to the heart. There are two main veins on each side, which converge to open into the dorsal surface of the left auricle.

d. Arising from the left ventricle.

- i. The **aorta** conveys arterial blood from the heart to all parts of the body. It arises from the middle of the base of the heart, dorsal to the root of the pulmonary artery, runs forwards about half an inch, and then arches over to the left side, and runs back along the left side of the vertebral column. Its thoracic portion is readily seen on turning aside the left lung.

The **ductus arteriosus** is a ligamentous band, connecting the aorta with the pulmonary artery, just before the division of the latter into right and left branches. During embryonic life it forms a tubular connection between the two vessels.

In cleaning the ductus arteriosus, take care not to injure the left recurrent laryngeal nerve which loops round it (see fig. 63, p. 364).

B. The Veins.

The veins form three distinct systems, communicating with one another only through capillaries, and containing different kinds of blood.

(1) The first of these systems consists of the three *venæ cavæ*, with the veins opening into them: these bring to the right auricle venous blood from the body generally, and from the liver.

(2) The second or **portal system** collects the blood from the walls of the alimentary canal, and from the pancreas and spleen, and conveys it to the liver.

(3) The third or **pulmonary system** conveys arterial blood from the lungs to the left auricle.

In dissecting the veins it is convenient to follow them from the larger to the smaller trunks, and they will be described in this order; it must be remembered, however, that the flow of blood is in the reverse direction. Care must be taken not to cut the veins, especially at the anterior end of the thorax, as the blood obscures the dissection, and the vessels themselves, when empty, are difficult to follow, owing to the thinness of their walls. If by chance a large vein is cut, it must be ligatured immediately, to stop the bleeding.

During the dissection of the veins take great care not to damage or remove the arteries or nerves lying near them.

1. The **system of the venæ cavæ.**

a. The **right anterior vena cava** has already been seen. It is formed by the union of the jugular and subclavian veins, immediately in front of the first rib.

i. The **azygos cardinal vein** is a median vein which runs forwards in the mid-dorsal line of the thorax, lying close to the vertebral column and along the right side of the aorta. It receives branches from the posterior seven or eight intercostal spaces of both sides of the body. Opposite the level of the auricles it passes round the right side of the œsophagus and trachea, to open into the vena cava close to the auricle.

ii. The **right anterior intercostal vein** is a small vein returning blood from the anterior four or five intercostal spaces of the right side, and opening into the vena cava just in front of the azygos vein.

- iii. The **right internal mammary vein** runs forwards on the inner surface of the ventral thoracic wall, near the middle line, and opens into the vena cava opposite the first rib.
- iv. The **right subclavian vein** returns blood from the fore-limb and shoulder.

In dissecting the next two veins, take great care to avoid injury to the muscles, vessels, and nerves of the neck.

- v. The **right external jugular vein** is a large vein running along the side of the neck. It is formed in front by the union, just behind the angle of the jaw, of the **anterior** and **posterior facial veins**, returning blood from the face and ear.
- vi. The **right internal jugular vein** is a small vein returning blood from the brain, and running down the neck alongside the trachea, to open into the right external jugular vein close to its union with the subclavian.
- b. The **left anterior vena cava** resembles the right, except that it receives no azygos vein, and that its course in the thorax is somewhat different, as already described (p. 340).
- c. The **posterior vena cava** is a large median vein, commencing at the hinder end of the abdomen, and running forwards close to the vertebral column and to the right (or left) of the aorta. In front, it leaves the abdominal wall and becomes imbedded in the dorsal surface of the liver, beyond which it enters the thorax through an aperture in the central tendon of the diaphragm, and runs forwards, as already described (p. 340), to open into the right auricle.

The following are the principal veins opening into the posterior vena cava.

In dissecting these veins, take care not to damage the

arteries, which accompany and roughly correspond to them, or the renal and reproductive organs, or the nerves in the mesentery.

- i. The **phrenic veins** are small veins in the substance of the diaphragm, opening into the vena cava as it passes through this.
- ii. The **hepatic veins** are large vessels returning blood from the several lobes of the liver, and opening into the portion of the vena cava imbedded in the liver. There are four chief ones.
- iii. The **renal veins** are a pair of large veins running inwards from the kidneys to the vena cava, the right and shorter one being about three-quarters of an inch in front of the left.
Each renal vein receives a small vein from the corresponding adrenal body, and a much larger one from the dorsal wall of the abdomen.
- iv. The **spermatic veins** in the male [or **ovarian veins** in the female] are a pair of small veins returning blood from the testes [or ovaries], and opening into the vena cava near the hinder end of the abdomen. The left one frequently opens into the renal vein, or the ilio-lumbar vein.
- v. The **ilio-lumbar veins** are paired, and return blood from the hinder part of the abdominal walls, opening into the vena cava about the level of the anterior border of the thigh. The left one often receives the spermatic [or ovarian] vein, and opens into the renal vein.
- vi. The **external iliac veins** are a pair of large veins returning blood from the hind-limbs, and opening into the vena cava at the hinder end of the abdomen, about an inch in front of the pubic symphysis. They receive small

veins from the bladder [and in the female from the uterus].

They are direct continuations of the **femoral veins**, which lie along the inner or preaxial borders of the thighs.

- vii. The **internal iliac veins** return blood from the backs of the thighs, and, running forwards through the pelvic cavity, unite about half an inch behind the external iliacs to form the commencement of the posterior vena cava.

- 2. The **portal system** consists of the veins conveying blood from the whole length of the alimentary canal from the stomach backwards, and also from the pancreas and spleen. These veins lie in the mesentery, and converge to form the main trunk, or **portal vein**: this lies close alongside the posterior vena cava and, entering the liver, divides into branches supplying its several lobes.

The portal system is best seen in a freshly killed animal on opening the abdomen and turning the viscera aside. The veins are large and usually gorged with blood, and care must be taken not to injure them, as they bleed very freely.

The following are the main trunks which unite to form the portal vein.

- i. The **lieno-gastric vein** returns blood from the walls of the stomach and from the spleen.
- ii. The **duodenal vein** returns blood from the duodenum and pancreas.
- iii. The **anterior mesenteric vein** is formed by the union of veins from the whole length of the small intestine, and from the cæcum, the colon, and the greater part of the length of the rectum.
- iv. The **posterior mesenteric vein** lies in the mesorectum or hindmost part of the mesentery,

and returns blood from the terminal portion of the rectum.

3. The **pulmonary system** consists of the pulmonary veins, which have already been described (p. 341).

C. The Arteries.

The arteries form two distinct systems, of which one, the **aortic system**, conveys arterial blood from the left ventricle to all parts of the body ; while the other, or **pulmonary system**, carries venous blood from the right ventricle to the lungs. The arteries are thicker-walled, and hence paler in colour, than the veins.

The aortic system should be dissected first. Clean the aorta along its whole length, and follow the arteries arising from it to their distribution.

During the dissection of the arteries, take great care not to damage or remove the nerves lying near them.

1. The **aorta** arises from the base of the left ventricle, and, turning towards the left side to form the **arch of the aorta**, runs backwards through the thorax and abdomen. It lies on the ventral surface of the vertebral column, and divides about an inch in front of the level of the pubic symphysis into the two **common iliac arteries**.

2. Arteries arising from the aorta in the thorax.

- a. The **innominate artery** arises from the commencement of the arch of the aorta : it gives off, close to its origin, the **left carotid artery**, and then runs forwards a short distance and divides into the **right subclavian** and **right carotid arteries**.
- i. The **right subclavian artery** runs outwards just in front of the first rib : it gives branches to the shoulder, and runs on as the **brachial artery** into the right fore-limb. Its principal branches are the following.

- a. The **vertebral artery** arises from the subclavian just beyond its origin, and passing dorsalwards enters the vertebrarterial canal of the cervical vertebræ, along which it passes, supplying the spinal cord and the brain.
- β. The **internal mammary artery** arises from the subclavian just before it leaves the thorax, and runs backwards along the inner surface of the ventral wall of the thorax.

The next two arteries may be better seen during the dissection of the neck. If dissected now, the greatest care must be taken not to injure the nerves (see fig. 63).

- ii. The **right carotid artery** runs forwards alongside the trachea, supplying the neck. The ramus descendens of the hypoglossal nerve crosses it. Opposite the angle of the jaw, it divides into (1) the **internal carotid artery**, which enters the skull through the carotid foramen to supply the brain; and (2) the **external carotid artery**, which supplies the right side of the head and face.
- iii. The **left carotid artery** corresponds to the right carotid in its course and distribution.
- b. The **left subclavian artery** arises from the left side of the arch of the aorta: its course and branches correspond to those of the right subclavian.
- c. The **intercostal arteries** are a series of small paired arteries, arising from the dorsal surface of the aorta, and running outwards on the inner surface of the thoracic walls, one behind each rib.

3. Arteries arising from the aorta in the abdomen.

In examining these arteries the mesentery must not be cut.

- a. The **cœliac artery** is a large median vessel, arising from the ventral surface of the aorta, about half

an inch behind the diaphragm. It runs in the mesentery, and divides into the **hepatic artery** supplying the liver, and the **lienogastric artery** supplying the stomach and spleen.

- b. The **anterior mesenteric artery** is a large median vessel, arising from the aorta about three-quarters of an inch behind the celiac artery. It divides into numerous branches, which run in the mesentery to supply the duodenum, pancreas, small intestine, cæcum, and colon.
- c. The **renal arteries** are paired, the right one arising just behind the anterior mesenteric artery, and the left a little further back. Each gives a small branch to the muscles of the back, and then runs outwards to the kidney.
- d. The **spermatic arteries**, in the male, are a pair of very small arteries, which arise about a couple of inches behind the left renal artery, and run backwards and outwards along the dorsal surface of the abdomen to enter the epididymes at their anterior ends.

The **ovarian arteries**, in the female, arise in the same position as the spermatic, but run outwards and slightly forwards to the ovaries.

- e. The **posterior mesenteric artery** is a median vessel, arising from the aorta about an inch in front of its division into the common iliacs. It supplies the hinder part of the rectum.
- f. The **lumbar arteries** are small median arteries, arising from the dorsal surface of the aorta, and dividing into right and left branches supplying the body walls.
- g. The **median sacral artery** is a small vessel arising from the dorsal surface of the aorta, shortly before its division, and running along the ventral surface of the sacrum to the tail. It is to be regarded as the posterior continuation of the aorta.

- h. The **common iliac arteries**, formed by the apparent bifurcation of the aorta, run backwards and outwards to the hind-limbs, along which they are continued as the **femoral arteries**. In the abdomen each gives off the following branches.
 - i. The **ilio-lumbar artery** runs outwards along the posterior part of the dorsal wall of the abdomen.
 - ii. The **internal iliac artery** runs backwards along the dorsal wall of the pelvic cavity.
 - iii. The **vesical artery** is a small branch which runs backwards to the bladder. In the female it also supplies the uterus.
- 4. The **pulmonary artery** has already been described (p. 340).

Follow the branches of the pulmonary artery into the lungs.

D. The Thoracic Duct.

The **thoracic duct** is a slender thin-walled tube running forwards through the thorax, and lying immediately to the left of and dorsal to the aorta. Between the third and fourth ribs it expands somewhat, and then turning inwards traverses the thymus and opens into the left anterior vena cava close to the left subclavian vein.

The thoracic duct receives lymphatic vessels from almost all parts of the body, and places these in communication with the venous system.

E. Dissection of the Heart.

Cut across the great vessels, about half an inch from the heart, carefully avoiding injury to the pneumogastric and recurrent laryngeal nerves (see pp. 366 and 367). Remove the heart, and pin it down under water with the dorsal surface upwards, passing the pins through the ventricles and the arch of the aorta. Clean the roots of the several vessels.

1. The auricles.

Cut away the outer walls of both auricles so as to expose cavities. Wash out the contained blood.

- a. The **right auricle**. The wall of the auricle is thin ; that of the **auricular appendix** is thicker, and is marked internally by muscular ridges.

i. The **orifices of the venæ cavæ**.

The **right anterior vena cava** opens into the anterior part of the auricle.

The **left anterior vena cava** opens into the left side of the posterior end of the auricle : just before its opening it receives the **coronary vein**, returning blood from the substance of the heart.

The **posterior vena cava** opens into the dorsal surface of the auricle, in front of the left anterior vena cava.

- ii. The **Eustachian valve** is a membranous fold, between the orifices of the left anterior vena cava and of the posterior vena cava. During foetal life it directs the blood from the posterior vena cava through the **foramen ovale** into the left auricle.

- iii. The **septum auricularum** is a thin partition between the right and left auricles. In it is an oval patch, the **fossa ovalis**, close to the opening of the posterior vena cava. This is thinner than the rest of the septum, and is perforated in the embryo by the **foramen ovale**, which sometimes persists in the adult, and is guarded by a membranous valve with **chordæ tendineæ**. Even when the foramen is closed, the notched edges of the valve, and remnants of the **chordæ tendineæ** are often recognisable.

- iv. The **right auriculo-ventricular aperture** is a

wide crescentic opening leading into the right ventricle.

b. The **left auricle**. The wall of the auricle is thin : that of the **auricular appendix** is thicker, and is marked by a network of muscular ridges.

i. The **apertures of the pulmonary veins**. The veins of the two sides unite as they enter the dorsal surface of the auricle.

ii. The **left auriculo-ventricular aperture** is large circular funnel-like opening, leading into the left ventricle.

2. The ventricles.

Cut across the ventricles about one-third of an inch from the apex ; note the shapes of the cavities.

The cavity of the right ventricle is crescentic in section : its wall is comparatively thin, embracing and half surrounding the left ventricle.

The left ventricle has very thick walls, and a small irregular cavity.

a. The right ventricle.

Remove the auricles, and cut short the aorta and pulmonary artery. Remove the outer wall of the right ventricle, by longitudinal incisions through its dorsal and ventral walls, and a transverse incision across its base a short distance behind the anterior border. Avoid injury to the valve.

i. The **tricuspid valve** guards the right auriculo-ventricular aperture, and is formed of three membranous flaps attached round its margin. The borders of the flaps project into the ventricle, and are connected by tendinous strings, the **chordæ tendineæ**, to muscular processes of the wall of the ventricle, the larger of which are known as **musculi papillares**.

- ii. The **orifice of the pulmonary artery** is at the left anterior angle of the ventricle, and is guarded by three pocket-like **semilunar valves**, the free edges of which are directed away from the ventricle.

Note the position of the valves from above; slit up the pulmonary artery between two of them, and examine them.

b. The left ventricle.

Remove the outer wall in the same manner as that of the right ventricle.

- i. The **mitral valve**, guarding the left auriculo-ventricular aperture, resembles the tricuspid valve, except that there are only two flaps, and the muscoli papillares are much larger.
- ii. The **orifice of the aorta** is at the base of the ventricle, immediately to the right of the mitral valve. It is guarded by three **semilunar valves**, one of which is dorsal, and the other two ventro-lateral in position. Immediately beyond the two latter valves the **coronary arteries**, which supply the heart, arise from the aorta.

The heart of a sheep may be dissected with advantage, and it differs so little from that of the rabbit, that the foregoing description applies, with very little modification, to it. The chief differences are the union of the two anterior venæ cavæ before entering the auricle, and the presence of a muscular 'moderator' band crossing the cavity of the right ventricle obliquely.

VI. DISSECTION OF THE RENAL AND REPRODUCTIVE SYSTEMS.

In the rabbit, as in the dog-fish, certain parts of the primitive kidneys and their ducts lose their excretory function, and

become converted into accessory genital organs and genital ducts. Owing to the close connection of the two systems, they may, in the adult, be conveniently considered together, though it must be remembered that the connection is merely a secondary one (*cf.* pp. 254-255).

In the male rabbit the pronephros is absent or abortive; the mesonephros, or Wolffian body, acquires an intimate connection with the testis, and becomes converted into the caput epididymis, the proximal part of the Wolffian duct becoming converted into the cauda epididymis, while its distal portion becomes the vas deferens.

In the female, the pronephros is absent; the Müllerian duct becomes the oviduct; the mesonephros or Wolffian body and its duct are absent, or abortive.

In both sexes alike, the metanephros and its duct become the kidney and ureter respectively.

The bladder of the rabbit arises as a ventral diverticulum of the rectum, and is at first entirely independent of the kidney ducts, which open into the dorsal wall of the rectum, a condition retained throughout life in the frog. During development the ducts shift round so as to open into the bladder, which then separates from the rectum and acquires a separate opening to the exterior, through which the urinary and genital products leave the body.

It is convenient to describe the two sexes separately, as they differ very greatly; and to include in the account certain glands in the neighbourhood of the rectum.

A. The Male Rabbit.

1. The renal system.

- a. The kidneys are a pair of dark red bodies about an inch and a quarter long, imbedded in fat in the dorsal wall of the abdomen, outside the peritoneum. Each is of a flattened ovoid shape, with a notch, the hilus, on its inner side where the ureter and blood-vessels enter and leave it.

Bisect one of the kidneys, longitudinally, from its outer

edge; and turn the ventral half inwards, so as to expose the cut surfaces.

- i. The **cortical substance** forms the superficial layer of the kidney; the Malpighian bodies, which are confined to it, give it a dotted appearance.
 - ii. The **medullary substance**, forming the deeper part of the kidney, is radially striated, and consists mainly of the non-glandular parts of the tubules. The inner surface of the medullary substance projects as a conical process, the **pyramid**, on which the tubules open.
 - iii. The **pelvis** is the expanded anterior end of the ureter, which lies in the cavity of the kidney, and receives the urine from the apertures on the pyramid.
- b. The **ureters** are a pair of slender tubes, running back from the kidneys along the dorsal wall of the abdomen, a short distance from the middle line. At the hinder end of the abdomen they turn inwards and open into the bladder, opposite the anterior border of the pubic symphysis.
- c. The **bladder** is a thin-walled muscular sac, of which the anterior end, in front of the pubic symphysis, can alone be seen at this stage of the dissection.

2. The reproductive system.

The testes, in early life, lie against the dorsal wall of the abdomen, close to the kidneys. Before maturity, however, they separate from the dorsal wall, and pass through the inguinal canals into the scrotal sacs.

- a. The **scrotal sacs** are a pair of muscular pouch-like diverticula of the abdominal wall, lying ventral to the pelvis and close to the median plane. Each

scrotal sac communicates with the abdominal cavity through the narrow **inguinal canal**.

Slit up one of the scrotal sacs along its ventral surface to expose the testis lying in it. Lay open the inguinal canal.

b. The testes.

The testes are a pair of elongated ovoid bodies, of a pink colour, varying greatly in size at different times, and about an inch and a half in length when fully developed. They are attached to the hinder ends of the scrotal sacs, but can easily be pulled back into the abdominal cavity.

c. The epididymes are a pair of irregular masses of convoluted tubes, lying along the inner edges of the testes. Each epididymis consists of (1) a soft pinkish body, the **caput epididymis**, in close contact with the anterior end of the testis: (2) a narrow band, extending backwards from the caput along the testis: and (3) a larger, more conical, and much-convoluted body, the **cauda epididymis**, lying at the posterior end of the testis, and connected by a short cord, the **gubernaculum**, with the bottom of the scrotal sac.

The epididymes are the modified Wolffian bodies of the embryo, the tubules of which grow into the testes, and so form the **vasa efferentia**, through which the spermatozoa escape from the testes.

The spermatic arteries and veins enter and leave the epididymes at their anterior ends.

d. The vasa deferentia are a pair of whitish tubes one of which arises from each cauda epididymis and runs forwards, alongside the testis, to enter the abdominal cavity through the inguinal canal. Within the abdomen it loops round the ureter from the outer to the inner side, and runs back to the neck of the bladder. The first part of

its course is sinuous, but further forwards it becomes straighter.

The vasa deferentia are the modified Wolffian ducts of the embryo.

*Dissect both scrotal sacs from the abdominal wall, and turn them forwards with the testes and vasa deferentia. Determine with the finger the boundaries of the pubes and ischia. Cut longitudinally through the muscles ventral to the pelvis, about half an inch from the middle line on each side, and down to the bone. Scrape clean the descending rami of the pubes and ischia, and cut through them with bone-forceps in front of, and behind, the obturator foramen on each side. Remove the pelvic symphysis, which is now isolated; carefully dissecting it from the underlying parts. Note the **corpora cavernosa**, a pair of hard ligamentous bodies running backwards from the hinder border of the ischia to the penis; and cut them across close to the ischia.*

Inflate the bladder and urino-genital canal by means of a blowpipe inserted into the terminal aperture of the penis, and tie a ligature round the penis half an inch from its end, to prevent the air escaping.

Clean the various structures in the order given below.

- e. The **urethra**, or **urino-genital canal**, is the continuation backwards of the neck of the bladder through the pelvic cavity. It is a straight tube, with thin and very vascular walls, and lies immediately dorsal to the pelvic symphysis, and ventral to the rectum. Behind the symphysis it is continued into the penis.
- f. The **penis** is an elongated body, projecting from the ventral surface of the animal, immediately behind the pelvic symphysis and in front of the anus. It is traversed by the urethra, through which the urinary and genital products are discharged. The posterior wall of the penis is very vascular, and forms the **corpus spongiosum**; while its anterior surface is stiffened by the **corpora**

cavernosa. The free end of the penis is soft, and obliquely truncated; and is invested by a loose sheath of skin, the **prepuce**. The external aperture of the urethra is a slit-like opening on its posterior surface.

g. The **uterus masculinus** is a large median sac, slightly bilobed in front, attached to the dorsal surface of the urino-genital canal, into which it opens, and extending forwards along the dorsal surface of the bladder to about the middle of its length.

h. The **posterior ends of the vasa deferentia** are slightly dilated, and run back, side by side, along the dorsal surface of the neck of the bladder, between it and the uterus masculinus. They open separately into the ventral wall of the uterus masculinus, just in front of its communication with the urino-genital canal, and opposite the hinder end of the obturator foramen.

Slit up the uterus masculinus along one side with scissors. Note the large aperture leading into the urino-genital canal, and, just in front of this, the small paired openings of the vasa deferentia.

i. The **prostate** is a series of glandular masses, grouped around the dorsal surface and sides of the uterus masculinus and vasa deferentia, and opening by short ducts into the urino-genital canal. There are four or five lobes, the largest of which is an **anterior lobe**, closely applied to the dorsal wall of the uterus masculinus, and bilobed in front: behind this is a smaller **posterior lobe**, sometimes divided into two: a pair of still smaller **lateral lobes** lie in the angle between the vasa deferentia and the uterus masculinus.

k. **Cowper's glands** are a pair of glandular bodies, varying greatly in size, and placed on the dor-

sal wall of the urino-genital canal, behind the prostate.

- l. The **rectum** is a white tube, with rather thick muscular walls, lying dorsal to the urino-genital organs, and close to the ventral surface of the sacrum.
- m. The **perinæal glands** are a pair of elongated glandular bodies, dark in colour, and about three-quarters of an inch long. They lie at the sides of the penis, and in the anterior walls of the perinæal sacs, into which their ducts open.
- n. The **rectal glands** are a pair of pale yellowish bodies, much larger than the perinæal glands, and lying along the sides and posterior surface of the last two inches of the rectum.

Slit up with scissors the urino-genital canal along its whole length, in the mid-ventral line.

- o. The **aperture of the uterus masculinus** is a large crescentic opening in the dorsal wall of the urino-genital canal.
- p. The **verumontanum** is a small vascular papilla, immediately behind the aperture of the uterus masculinus.
- q. The **apertures of the ducts of the prostatic glands** are small slit-like openings at the sides of the verumontanum.

The Female Rabbit.

1. The **urinary system** is the same as in the male, except that the ureters open into the bladder much further forwards, close to its anterior end.
2. The **reproductive system.**

Remove the pelvic symphysis as in the male (p. 356); and inflate the vagina and bladder with a blowpipe, inserted into the vulva. Ligate the vestibule about an inch in front of the vulva to prevent the air escaping.

- a. The **ovaries** are a pair of oval bodies, of a pale yellowish colour, and about three-quarters of an inch long, attached to the dorsal wall of the abdomen, behind the kidneys and about an inch in front of the crests of the ilia.

On their surfaces the **Graafian follicles**, each of which contains an ovum, are visible as small rounded semi-transparent projections.

- b. The **oviducts** are formed from the Müllerian ducts of the embryo. Their anterior ends are narrow, and form the Fallopian tubes : the middle portions are wider, and become the uteri, within which the young are developed ; and the posterior ends unite to form a median tube, the vagina.

- i. The **Fallopian tubes** are a pair of narrow slightly convoluted tubes, about the size of the ureters. They lie along the free edges of the **broad ligaments**, a pair of folds of peritoneum suspending them from the dorsal wall of the abdomen.

The anterior ends of the Fallopian tubes form wide membranous funnel-shaped mouths, lying along the outer sides of the ovaries, and attached to their anterior ends.

- ii. The **uteri**, which are continuous with the posterior ends of the Fallopian tubes, are a pair of thick-walled tubes, which vary enormously in size according to the presence or absence of embryos and the stage of their development. The two uteri open by separate apertures into the anterior end of the vagina.

- iii. The **vagina** is a very wide median tube, commencing a little in front of the crests of the ilia, and extending straight back to unite, within the pelvic cavity, with the neck of the bladder, at the commencement of the vestibule.

- c. The **vestibule** or urino-genital canal is a wide

median tube, commencing opposite the hinder end of the obturator foramen, and running back ventral to the rectum, through the pelvic cavity, to the vulva. Its walls are very vascular, and correspond to the corpus spongiosum in the male.

d. The **clitoris** is a small rod-like body, corresponding to the penis of the male, and lying in the anterior or ventral wall of the vestibule, just within its external opening. It ends in a soft conical body, the **glans clitoridis**, and is connected with the ischia by two **corpora cavernosa** similar to those of the male, but smaller.

e. **Cowper's glands** are small, and lie on the dorsal wall of the vestibule, opposite the hinder border of the pelvic symphysis.

f. The **perinæal** and **rectal glands** are similar to those of the male (p. 358).

Slit up with scissors the vestibule and the hinder part of the vagina along one side. Note the great vascularity of the walls, the position and relations of the clitoris, and the opening of the bladder into the vestibule.

Slit up the anterior part of the vagina along the mid-ventral line, to expose the openings of the uteri into the vagina. Note the very prominent lips of these openings.

VII. DISSECTION OF THE NECK.

A special dissection of the neck is desirable, on account of the great importance of the structures contained in it, more particularly the nerves. (See fig. 63, p. 364.)

Lay the rabbit on its back on a dissecting-board; and pin back the head so as to extend the neck fully. Make a median ventral incision through the skin of the neck, and dissect the skin away from the underlying parts, taking care not to damage the muscles.

A. The Hyoid Bone.

The **body of the hyoid** is a transverse bar of bone, deeply placed between the rami of the mandible, and about midway between the hinder end of the mandibular symphysis and the angles of the jaw.

The **posterior cornua of the hyoid** are a pair of slender rods of bone, about half an inch long, running backwards and outwards from the outer angles of the body of the hyoid, parallel to the angles of the jaw.

Determine the position and shape of the hyoid by feeling with the finger.

B. The Muscles of the Neck.

A few of the more prominent of the ventral muscles of the neck are alone described here.

Identify and carefully clean them.

1. The **sterno-mastoid muscles** are a pair of narrow but strong muscular bands, which arise from the anterior end of the sternum, close to the middle line, and run obliquely forwards and outwards, across the front of the neck, to be inserted into the mastoid processes of the skull immediately behind the ears.

Cut through the right sterno-mastoid close to its origin from the sternum, and turn it forwards. Near its anterior end, note, and carefully preserve, a branch of the spinal accessory nerve, which enters the muscle on its inner side, about half an inch behind the angle of the jaw.

2. The **sterno-hyoid muscles** are a pair of broad but thin muscular bands running along the ventral surface of the neck. They arise from the dorsal surface of the anterior end of the sternum, where the two are fused, and run forwards along the neck. A little behind the angle of the jaw, the two muscles diverge slightly from each other, and are inserted into the bases of the posterior cornua of the hyoid. Their hinder ends are covered by the sterno-mastoids.

3. The **stylo-hyoid muscles** are a pair of short muscles, running almost transversely across the neck, opposite the angles of the jaws. They arise from the under surfaces of the tympanic bullæ, close to the insertions of the sterno-mastoid muscles, and are inserted into the tips of the posterior cornua of the hyoid.
4. The **mandibular muscles** are a pair of slender muscles, triangular in shape, which arise from the tips of the par-occipital processes of the ex-occipital bones by long thin tendons, running forwards and inwards, dorsal to the stylo-hyoid muscles, and parallel to the rami of the mandible. The anterior part of each is muscular, and is inserted into the inner surface of the ramus of the mandible close to the symphysis.
5. The **sterno-thyroid muscles** are a pair of thin bands of muscle, lying immediately dorsal to the sterno-hyoid muscles, and seen on dissecting along the outer borders of the latter. They are fused posteriorly, and arise from the sternum as a median band in common with the sterno-hyoid: further forwards the muscles diverge, and run along the ventral surface and sides of the trachea, to be inserted into the sides of the thyroid cartilage.

C. The Blood-vessels of the Neck.

The two most important, on each side, are the following:

1. The **external jugular vein** has already been seen (p. 343).
2. The **carotid artery** runs forwards along the outer borders of the sterno-hyoid and sterno-thyroid muscles. (See p. 347.)

Clean the carotid artery carefully, taking great care to avoid injuring the nerves which lie close alongside it, and a nerve, the ramus descendens of the hypoglossal, which crosses its ventral surface about the level of the thyroid cartilage.

D. The Trachea.

The **trachea** or **windpipe** is a straight tube, running down

the neck almost in the middle line. It is only partially exposed at present, but will be seen better in the course of the dissection. Its anterior end, the **larynx**, which lies almost immediately behind the hyoid, is dilated, and surrounded on its ventral and lateral surfaces by the wide **thyroid cartilage**, which forms a prominent median swelling in the throat, between the rami of the mandible. Behind this is the annular **cricoid cartilage**, which is wide dorsally and narrow ventrally. Behind the cricoid the trachea narrows slightly, and is strengthened by a series of cartilaginous rings, incomplete along the mid-dorsal line. The trachea runs backwards along the neck, and, entering the thorax, divides about the level of the middle of the heart into the right and left **bronchi**, which enter the right and left lungs respectively.

E. The Thyroid Body.

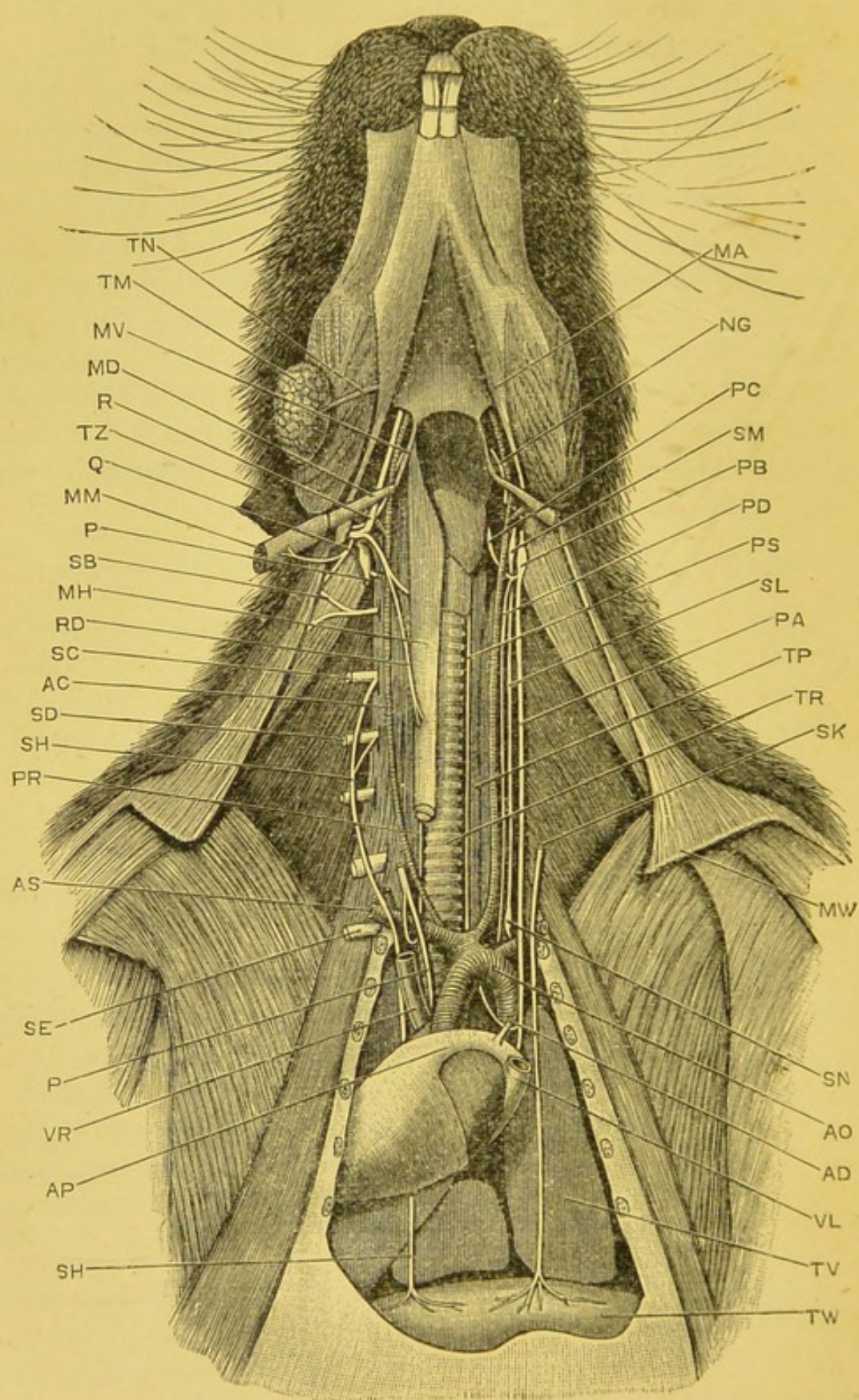
The **thyroid** is a soft vascular body, consisting of a pair of lateral lobes at the sides of the anterior part of the trachea, connected by a narrow median lobe, which runs across the ventral surface of the trachea a short way behind the thyroid cartilage.

F. The Nerves of the Neck.

Expose and clean the following nerves on either the right or the left side of the neck.

1. The **spinal accessory nerve**, the eleventh cranial nerve, leaves the skull by the foramen lacerum posterius, between the auditory capsule and the ex-occipital bone, in company with the pneumogastric and glossopharyngeal nerves. Outside the skull it runs almost vertically downwards for about half an inch, and then divides into branches distributed to the sterno-mastoid and other muscles.

The branch to the sterno-mastoid has already been seen (p. 361). Follow this back to its junction with the main stem of the nerve, and then trace this latter up to the base of the skull.



2. The **hypoglossal nerve**, the twelfth cranial, is a stout nerve which leaves the skull by the condylar foramina, immediately behind the foramen lacerum posterius, and lies at first very close to the pneumogastric, glosso-pharyngeal, and spinal accessory nerves. Outside the skull it runs downwards and inwards for about half an inch, and then turns forwards, crossing the internal carotid artery near the point of division of the carotid into internal and external carotids. It then runs forwards and inwards along the dorsal surface of the stylo-hyoid muscle, and parallel to the posterior cornu of the hyoid, to the base of the tongue, in the muscles of which it ends.

The hypoglossal nerve is readily found, where it turns forwards between the carotid artery and the stylo-hyoid muscle; it should be followed from this point backwards to the skull, and forwards to the tongue.

- a. The **ramus descendens** is a branch of the hypoglossal, which arises from the main nerve just before it reaches the internal carotid artery. It runs

FIG. 63.—*Lepus cuniculus*. Dissection to show the nerves of the neck. The hinder part of the trachea is pushed slightly to the right side, and the thyroid body is removed. Two-thirds natural size. (C. H. H.)

AC, right carotid artery. AD, ductus arteriosus, with loop of left recurrent laryngeal nerve passing behind it. AO, arch of aorta. AP, root of pulmonary artery. AS, right subclavian artery, with loop of right recurrent laryngeal nerve passing behind it.

MA, mandibular muscle. MD, stylo-hyoid muscle. MH, sterno-hyoid muscle; the sterno-thyroid is seen at the hinder end where both muscles are cut across. MM, sterno-mastoid muscle. MV, posterior cornu of hyoid. MW, clavicle.

NG, glosso-pharyngeal nerve. P, anterior and posterior portions of right pneumogastric nerve. The middle portion has been removed. PA, left pneumogastric nerve. PB, ganglion of the pneumogastric nerve. PC, anterior laryngeal nerve. PD, depressor nerve. PR, PS, right and left recurrent laryngeal nerves. Q, spinal accessory nerve. R, hypoglossal nerve. RD, descending ramus of the hypoglossal: its connections with the first and second spinal nerves are not shown. SB, great auricular nerve arising from the third cervical spinal nerve. SC, SD, SE, fourth, fifth, and eighth cervical spinal nerves. SH, SK, right and left phrenic nerves: the anterior portion of the left one has been removed. SL, cervical sympathetic nerve. SM, anterior cervical ganglion. SN, middle cervical ganglion.

TM, submaxillary gland. TN, Wharton's duct. TP, œsophagus. TR, trachea. TV, lung. TW, diaphragm. TZ, ear, cut off short. VL, VR, left and right anterior venæ cavæ.

backwards along the outer side of the carotid for about half an inch. It then crosses the carotid, about the level of the hinder border of the thyroid cartilage, and runs backwards on the sterno-thyroid muscle, to which as well as to the sterno-hyoid it sends branches. It receives fibres from the first and second spinal nerves.

The ramus descendens is easily found crossing the carotid about the point named above, and should be traced backwards along the sterno-thyroid muscle, and forwards to the point at which it leaves the main stem of the hypoglossal.

3. The **pneumogastric or vagus nerve**, the tenth cranial, is a stout nerve which leaves the skull by the foramen lacerum posterius, presenting a very distinct ganglionic swelling near its origin. It runs downwards and backwards until it reaches the carotid artery, and then straight backwards along the neck, lying immediately to the outer side of, and slightly dorsal to, the carotid artery. Entering the thorax, it runs alongside the œsophagus to the stomach, where it ends.

Its principal branches are the following :

Find the pneumogastric nerve in the neck, along the outer side of the carotid artery. Follow it backwards along the neck to the thorax, and forwards to the skull.

- a. The **anterior laryngeal nerve** is a small nerve, arising from the pneumogastric opposite the upper border of the thyroid cartilage. It runs almost directly inwards, passing dorsal to the carotid artery, and ends in branches distributed to the mucous membrane of the larynx, and to the crico-thyroid muscle.

The sole difficulty in dissecting the anterior laryngeal nerve lies in the possibility of confusing it with the ramus descendens of the hypoglossal. This is avoided if it be remembered that, while both nerves cross the carotid artery, the ramus descendens

lies ventral to the artery, and the anterior laryngeal, dorsal to it.

- i. The **depressor nerve** is a very slender branch of the anterior laryngeal nerve, which runs backwards along the neck: it lies dorsal to the carotid artery, and along the inner side of the main stem of the pneumogastric nerve, very close to the sympathetic nerve-trunk. It ends in the heart.

Find the depressor nerve where it leaves the anterior laryngeal nerve, about the level of the posterior end of the thyroid cartilage, and follow it backwards along the neck. Its dissection in the thorax is difficult.

- b. The right **posterior or recurrent laryngeal nerve** arises from the pneumogastric nerve at the posterior end of the neck. It loops round the subclavian artery, and then runs forwards along the neck, lying alongside the trachea, and dorsal to the carotid artery, or slightly to its inner side. It supplies all the muscles of the larynx, except the crico-thyroid.

On the left side, the nerve is not given off until after the pneumogastric has entered the thorax. It loops round the ductus arteriosus, and then runs forwards along the neck to the larynx. (See fig. 63.)

Find the nerve, as it loops round the subclavian artery, or on the left side the ductus arteriosus and arch of the aorta; and follow it forwards along the neck to the larynx.

The curious course of the recurrent laryngeal nerves is explained by the shifting backwards of the heart which occurs during development. As this shifting involves the roots of the great vessels, these nerves, which are originally straight, become pulled out into loops.

- c. **Branches of the pneumogastric to the heart, lungs,**

and *œsophagus*. These are of small size, and are given off in the thorax: the cardiac branches end in a plexus, lying between the roots of the aorta and pulmonary artery.

Turn the lungs and heart over to one side: follow the pneumogastric backwards through the thorax, alongside the œsophagus, and trace out its branches.

4. The **cervical sympathetic nerve** lies alongside the trachea, to the inner side of the carotid artery, and in close proximity to the depressor nerve.

About the level of the angle of the jaw, and dorsal to the stylo-hyoid muscle, it has a small oval swelling, the **anterior cervical ganglion**, and at the posterior end of the neck, a short distance in front of the subclavian artery, there is a similar swelling, the **middle cervical ganglion**.

The sympathetic nerves are of a pale pinkish colour, and are not nearly so easy to see as the white cords of the pneumogastric and its branches.

5. The **great auricular nerve** is a large branch of the third spinal nerve, given off immediately after the nerve emerges from the spinal canal, between the second and third cervical vertebræ. It runs vertically upwards to the base of the ear, lying along the posterior border of the parotid gland (p. 375), and about half an inch behind the angle of the jaw: it then runs along the outer surface of the pinna of the ear, as far as its tip, lying just beneath the skin.

The nerve can easily be felt as a cord running along the pinna, or seen by holding the ear up to the light, and looking through it.

Having determined its position in one of these ways, cut down upon it, and follow it to the tip of the ear, and downwards to its point of origin from the third spinal nerve.

6. The **phrenic nerve** is a branch of the fourth cervical nerve, which arises just beyond the point of emer-

gence of this nerve from the neural canal, and runs back alongside the vertebral column. Entering the thorax it continues its course backwards, lying between the heart and the lungs, and ends in the diaphragm, which it supplies with motor fibres.

In the neck it crosses the roots of the hinder cervical nerves almost at right angles. It receives a small branch from the fifth cervical nerve, and sometimes one from the sixth, as it passes them.

To expose the phrenic nerve gently press the heart and lung apart. Follow the nerve back to the diaphragm, and forwards along the neck to its origin.

G. The Larynx.

The larynx, or organ of voice, is the anterior part of the trachea. The thyroid and cricoid cartilages form its outer wall, and it is protected in front by the epiglottis.

Make a medium longitudinal section through the anterior part of the trachea.

1. The **epiglot'is** is a curved plate of cartilage covered by mucous membrane, attached to the anterior and ventral border of the larynx. When food is being swallowed it closes over the glottis like a lid, preventing the passage of the food into the larynx.
2. The **thyroid cartilage** forms the most anterior ring of the trachea: it is about half an inch in length along the mid-ventral line, but is incomplete dorsally.
3. The **cricoid cartilage**, or second ring of the trachea, is a complete ring, lying immediately behind the thyroid. It is narrow ventrally, but wide dorsally; and articulates with the postero-dorsal angles of the thyroid cartilage.
4. The **arytenoid cartilages** are a pair of cartilaginous nodules, articulated to the anterior edge of the dorsal surface of the cricoid cartilage.
5. The **ventricles of the larynx** are a pair of shallow

lateral depressions of the mucous membrane of the inner surface of the larynx.

6. The **vocal cords** are a pair of folds of mucous membrane, strengthened by elastic ligaments, and forming the posterior lips of the ventricles. They are attached dorsally to the arytenoids, and at their ventral ends to the thyroid cartilage. It is by their vibration that the 'voice' is produced.
7. The **glottis** is the median slit between the vocal cords, through which the air passes to and from the lungs.
8. The **false vocal cords** are folds of mucous membrane similar to the vocal cords: they form the anterior boundaries of the ventricles.

VIII. THE SYMPATHETIC NERVOUS SYSTEM.

The sympathetic nervous system consists of a double chain of ganglia, lying at the sides of and ventral to the spinal column; and of the commissural cords connecting them with one another, and with the spinal nerves. From the ganglia nerves are given off, some of which follow the arteries, and end in their muscular coats, while others unite to form plexuses, with ganglionic enlargements, in the thorax and abdomen, in relation with the heart and the abdominal viscera.

The dissection of the sympathetic nervous system, which is not easy, is best performed on a freshly killed rabbit.

A. The **gangliated sympathetic cords** are a pair of longitudinal nerve trunks running alongside the vertebral column, and linking together the series of ganglia through which the sympathetic system communicates with the spinal and cranial nerves.

1. The **cervical sympathetic nerve** has already been seen in the dissection of the neck (p. 368). It runs alongside the depressor nerve and close to the trachea, and presents three ganglionic enlargements.

- a. The **anterior cervical ganglion** is an elongated pink ganglion lying to the inner side of the ganglionic enlargement of the pneumogastric nerve, and slightly ventral to this. It is partially hidden by the stylomastoid muscle, and is by far the largest of the cervical ganglia.
 - b. The **middle cervical ganglion** is a fusiform thickening of the sympathetic cord immediately in front of the subclavian artery.
 - c. The **posterior cervical ganglion**, with which is usually fused the **first thoracic ganglion**, is a stellate ganglion, lying dorsal to the subclavian artery, and between this and the first rib; it receives branches from the last cervical and first one or more thoracic spinal nerves.
2. The **thoracic portion of the gangliated cord** of each side runs along the inner surface of the dorsal wall of the thoracic cavity, crossing the heads of the ribs. Small ganglia are developed on it at the points where it receives branches from the several thoracic spinal nerves. Of these ganglia the first is usually fused with the posterior cervical ganglion, and other variations may occur.

The posterior part of the thoracic portion of the sympathetic nervous system is readily exposed by turning the lung over to the opposite side; the anterior portion is closely connected with the vessels and other structures at the anterior end of the thorax, and requires careful dissection.

3. The **abdominal portion of the gangliated cord** of each side runs along the sides of the bodies of the lumbar vertebræ, and is continued through the pelvic region into the tail. It has ganglionic enlargements at the places where it receives branches from the several spinal nerves.
- B. The **abdominal plexuses** are formed by nerves which are given off from the ganglia of the main longitudinal cords.

They are mostly composed of non-medullated fibres, and are hence difficult to follow. The principal components of these plexuses are the following.

1. The **greater splanchnic nerve** arises from the ninth and tenth thoracic ganglia, and runs backwards through the dorsal portion of the diaphragm to end in the cœliac ganglion.
2. The **lesser splanchnic nerve** arises from the eleventh and twelfth thoracic ganglia, and runs alongside the greater splanchnic nerve to the cœliac ganglion.
3. The **cœliac ganglion** is a flattened oval body of a pinkish colour, lying in the mesentery immediately in front of the anterior mesenteric artery, and about an inch from the aorta. It receives the greater and lesser splanchnic nerves of both sides.
4. The **anterior mesenteric ganglion**, which is also unpaired, lies in the mesentery immediately behind the anterior mesenteric artery, and close to the cœliac ganglion, with which it is connected by several nerves.
5. The **posterior mesenteric ganglion** lies in the mesentery upon the posterior mesenteric artery close to the point where this branches out to supply the rectum. It is connected with the anterior mesenteric ganglion by nerves which can be seen running in the mesentery parallel to its dorsal edge.

From these three ganglia of the mesentery, nerves are given off which form plexuses supplying the abdominal portion of the digestive system. These nerves and plexuses are closely associated with the arteries, but it is nearly impossible to follow them to their distribution.

IX. DISSECTION OF THE HEAD.

Remove the skin from the head. Lay the rabbit on its right side: insert one blade of the scissors into its mouth.

and cut back through the cheek on the left side between the upper and lower teeth: continue the cut backwards across the jaw with bone forceps and scissors: turn the left ramus of the lower jaw down, breaking the two rami apart at the symphysis, so as to expose the buccal cavity fully. Wash freely.

1. The roof of the mouth.

- a. The **palate**, or median part of the roof, is long and narrow, and separates the buccal from the nasal cavity. Its anterior half, the **hard palate**, is raised into hard transverse ridges, against which the tongue works; the posterior half, or the **soft palate**, is smooth and soft, and ends behind in a free notched border, nearly opposite the angle of the jaw.
- b. The **upper teeth**, comprising the **incisors** at the front of the palate, and the **grinders** at the sides opposite the junction of hard and soft palates, have already been described (p. 311).
- c. The **naso-palatine canals**, which connect the nasal and buccal cavities, open in a pair of grooves running backwards from the small posterior incisors, and about an eighth of an inch behind these.
- d. The **tonsils** are a pair of small pits at the sides of the posterior part of the soft palate, near its hinder border. The outer wall of each is much thickened, forming a papilla which nearly closes the opening.

2. The floor of the mouth.

- a. The **tongue** is an elongated muscular mass, attached along the greater part of its length to the floor of the mouth, and produced in front into a free flattened tip.

The surface of its hinder part is hard and slightly elevated; that of the anterior part is

softer and dotted over with small white **taste papillæ**, which are especially numerous at and under the tip.

At the sides of the tongue, opposite the last molar teeth, are a pair of oval patches, the **papillæ foliatæ**, the surfaces of which are crossed obliquely by close-set parallel ridges, in which are imbedded numerous taste-bulbs.

About a quarter of an inch above and behind the **papillæ foliatæ** are a pair of **circumvallate papillæ**, which are small and white, and surrounded by circular grooves.

- b. The **lower teeth**, already described with the skeleton (p. 312), are placed opposite the corresponding teeth of the upper jaw, and bite against them.
3. The **sides of the mouth** are smooth and soft, with the exception of a hairy patch on each side, between the incisor and molar teeth.
4. The **pharynx** is a continuation backwards of the buccal cavity, beyond the margin of the soft palate. The mouth and the posterior narial chamber open into it in front; behind it is continued into the œsophagus; and ventrally it communicates through the glottis and trachea with the lungs.

To expose the pharynx, extend the cut backwards about an inch beyond the tongue.

- a. The **glottis** is a large opening in the floor of the pharynx, a short way behind the tongue, leading into the trachea, or windpipe.
- b. The **epiglottis** is a thin bilobed cartilaginous flap, forming the anterior boundary of the glottis, and projecting into the pharynx behind the tongue, opposite the free edge of the soft palate. During the act of swallowing it is folded back over the glottis, so as to close its entrance.

5. The **posterior nasal chamber** lies above the soft palate, which separates it from the buccal cavity.

Lay open the nasal chamber by slitting up the soft palate along the median line, from behind forwards.

- a. The **orifices of the Eustachian tubes** are a pair of oval apertures at the sides of the roof of the chamber, about the middle of its length.

The Eustachian tubes connect the tympanic cavities with the posterior nasal chamber. The tympano-Eustachian passage is the modified hyomandibular pouch of the embryo, corresponding to the spiracle of the dog-fish. Its connection with the ear is purely secondary, the passage serving to keep the pressures of air on the two sides of the tympanic membrane equal.

Pass a seeker backwards and outwards, along one of the Eustachian tubes, into the tympanic cavity. (Cf. fig. 64.)

- b. The **organs of Jacobson** are a pair of small tubular bodies enclosed in the palatal processes of the premaxillæ, and lying in the floor of the anterior part of the nasal cavities. Each communicates in front with the nostril, and through the nasopalatine canal with the mouth.

Cut away with bone forceps the left side of the nasal chamber from behind forwards, so as to lay the cavity completely open. Remove the mesethmoid cartilage, and note the arrangement of the turbinal bones, and the relations of Jacobson's organs.

6. The **salivary glands** are large and paired.

Dissect from the right side.

- a. The **parotid gland**, the largest of the salivary glands, is a soft pinkish mass lying in front of and below the external auditory meatus, between this and the hinder edge of the mandible. It is very variable in size, and may extend beyond the

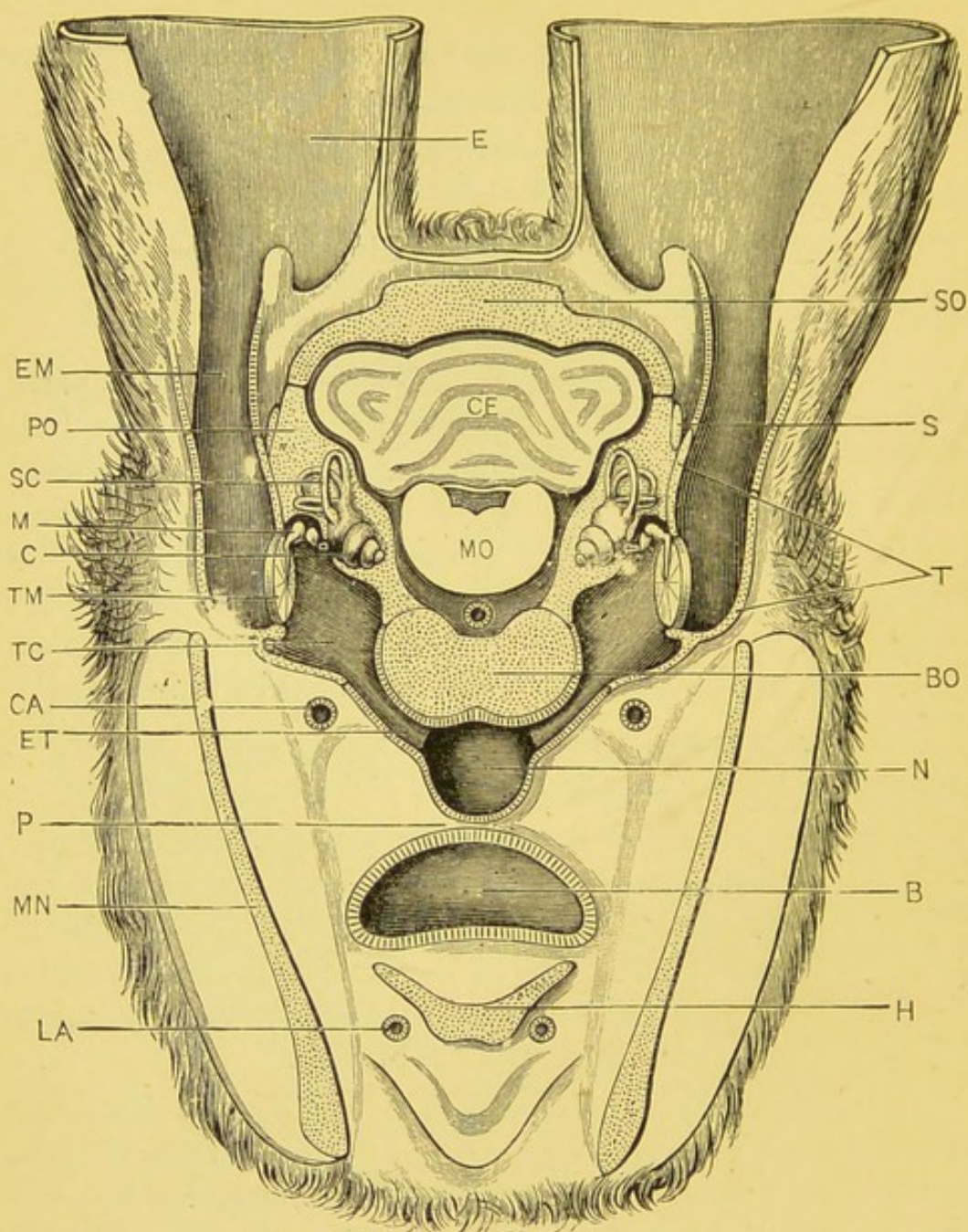


FIG. 64.—*Iepus cuniculus*. Diagrammatic section across the head to show the relations of the internal ear, tympanic cavity and membrane, and the auditory ossicles. The section is drawn as seen from the front, and is taken along a line joining the reference letters SO and MN in fig. 59, p. 295. The external ears are cut short, and the floccular lobes of the cerebellum, which lie between the three semicircular canals on each side, are omitted entirely. (A. M. M.)

B, buccal cavity. BO, basi-occipital. C, cochlea. CA, right external carotid artery. CE, cerebellum. F, external ear or pinna. EM, external auditory meatus. ET, Eustachian tube. H, body of the hyoid. LA, right lingual artery. M, malleus; to its inner side are seen the incus and stapes. MN, mandible. MO, medulla oblongata. N, posterior nasal chamber. P, soft palate. PO, periotic. S, post-tympanic process of squamosal. SC, anterior vertical semicircular canal. SO, supra-occipital. T, tympanic bone. TC, tympanic cavity. TM, tympanic membrane.

angle of the jaw and some distance forwards along its inner surface.

The duct of the parotid, or **Stenonian duct**, leaves the gland at its anterior border, and runs forwards just beneath the skin, parallel to and about a quarter of an inch below the zygomatic arch. It opens into the mouth by a small aperture on the inner side of the cheek, opposite the second upper premolar tooth.

- b. The **infra-orbital gland** is an irregular lobulated mass, about three-quarters of an inch long, lying below and in front of the eye, partly above the zygomatic arch and partly hidden by it.

The duct runs downwards to open into the mouth, close to the Stenonian duct.

- c. The **sub-maxillary gland** is a compact reddish ovoidal mass, lying close to its fellow between the angles of the mandible, and in front of the larynx.

The duct, **Wharton's duct**, leaves the outer side of the gland near its hinder end, and runs forwards along the inner side of the jaw to open into the floor of the mouth, midway between the lower incisors and the root of the tongue, the openings of the ducts of the two sides being about an eighth of an inch apart.

Dissect from the ventral surface. To follow the duct into the mouth, turn the halves of the lower jaw aside.

- d. The **sublingual gland** is an elongated flattened reddish body, about three-quarters of an inch long, lying along the inner side of the ramus of the mandible, between this and Wharton's duct.

The ducts open separately on the floor of the mouth.

X. DISSECTION OF THE BRAIN.

The brain should be removed directly after the rabbit is killed, and placed at once in strong spirit, as it decomposes rapidly. It is well to put a loose pad of cotton wool in the bottom of the bottle, and place the brain upon it, in order to prevent flattening from contact with the glass, and to ensure free access of the spirit to all parts of the surface; the brain should be turned over after it has been a few hours in spirit.

To remove the brain, first skin the head; then expose the brain by snipping away, with the bone forceps, the roof and sides of the skull, beginning at the foramen magnum, and working forwards. Take special care in the region of the ears to avoid injury to the floccular lobes of the cerebellum, which are lodged in the floccular fossæ of the periotic bones (p. 301).

*Having completely removed the roof and sides of the cranium and cut through the **dura mater**, a tough fibrous membrane which lines the cranial cavity, cut across the spinal cord about half an inch behind the foramen magnum, and turn out the brain from behind forwards, lifting it up gently with the handle of a scalpel.*

Note and identify the several nerve-roots as you do so, and cut through them in order, close to the skull-wall, so as to leave as much of the roots as possible attached to the brain.

Place the brain in spirit at once, handling it with great care, as it is very soft and easily damaged. Leave it in spirit for three or four days, and then dissect it as described below.

The several divisions of the rabbit's brain are the same as those of the brain of a dog-fish, the most important differences between the two being, (1) the great size of the cerebral hemispheres, which overlap and conceal the dorsal and lateral surfaces of the thalamencephalon and optic lobes; (2) the greater size and more complicated structure of the cerebellum; (3) the much greater development of the transverse commissures, connecting the two halves of the brain with each other.

Remove the hardened brain from spirit and examine it in a small dish of water or weak spirit.

A. The Brain-membranes.

1. The **dura mater** is the tough connective-tissue membrane which lines the cranial cavity. The greater part or the whole of it is left in the skull on removal of the brain. It projects into the cranial cavity as a median vertical fold, the **falx cerebri**, which lies between the hemispheres; and a transverse fold, the **tentorium**, which separates the hemispheres from the cerebellum.
2. The **pia mater** is a much thinner and very vascular layer of connective tissue, which closely invests the brain. The blood-vessels running to and from the brain lie in it.

B. External Characters of the Brain.

Strip off the pia mater from the brain with fine forceps as completely as possible, taking great care on the base of the brain not to drag away the nerve-roots.

1. The dorsal surface of the brain.

- a. The **cerebral hemispheres**, which form the anterior two-thirds of the brain, are a pair of broad triangular bodies, pointed in front and closely apposed to each other along the median plane.

Their surfaces are smooth and convex: they are marked by a few shallow grooves, or **sulci**; and are divided by rather more conspicuous grooves at their outer edges into anterior or **frontal**, and posterior or **parietal lobes**.

The two hemispheres are connected with each other by a large transverse commissure, the **corpus callosum**, which is easily seen on gently separating the hemispheres with the handle of a scalpel.

- b. The **olfactory lobes** are a pair of large club-shaped bodies, projecting forwards from beneath the anterior ends of the hemispheres.
- c. The **thalamencephalon** is covered by the hemispheres, and cannot be seen from the dorsal surface.
- d. The **corpora quadrigemina**, or **optic lobes**, are two pairs of rounded elevations on the dorsal surface of the brain, and almost completely covered by the hemispheres.

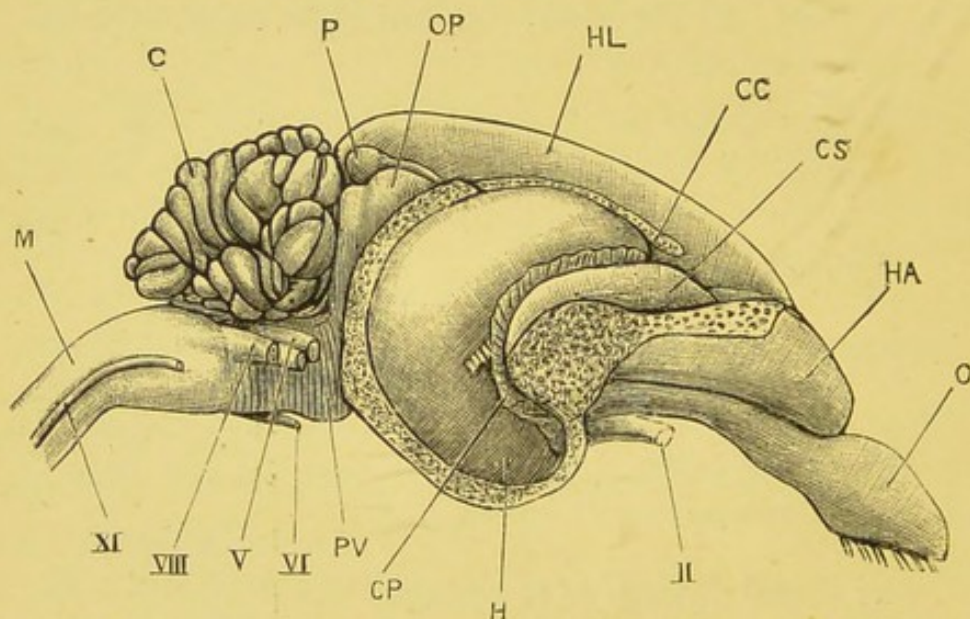


FIG. 65.—*Lepus cuniculus*. The brain dissected from the right side.
× 2. (C. H. H.)

C, cerebellum. CC, corpus callosum. CP, choroid plexus. CS, corpus striatum. HA, frontal lobe of right hemisphere. HL, left hemisphere. H, hippocampus major. M, medulla oblongata. O, olfactory lobe. OP, anterior optic lobe. P, pineal body. PV, pons Varolii.

II, root of optic nerve. V, root of trigeminal nerve. VI, root of abducent nerve. VIII, root of auditory nerve; immediately in front of it is seen the root of the facial nerve. XI, spinal accessory nerve.

- e. The **cerebellum** is a large transversely elongated mass, lying behind the hemispheres. It is divided into a large median lobe, the **vermis**, and two **lateral lobes**, to the outer sides of which are the small rounded **floccular lobes**.

The whole surface of the cerebellum is marked by close-set folds, mainly transverse in direction.

- f. The **medulla oblongata** is the part of the brain

beneath and behind the cerebellum. It is somewhat flattened dorso-ventrally, is widest in front, and gradually narrows behind, passing into the spinal cord.

- + i. The **velum medullæ anterius**, or **valve of Vieussens**, is a thin transparent membrane, connecting the hinder border of the optic lobes with the cerebellum, and roofing over the anterior part of the fourth ventricle. It lies beneath the anterior part of the cerebellum, which must be gently pressed backwards to expose it.
- + ii. The **velum medullæ posterius** is a thin transparent membrane, forming the roof of the posterior part of the fourth ventricle : it is covered in front by the cerebellum.
- g. The **pineal body** is a small rounded median body, lying on the optic lobes, and connected by a stalk with the roof of the thalamencephalon.

It is visible on the dorsal surface, in the angle between the hinder ends of the cerebral hemispheres and the cerebellum, but is very liable to be torn away with the **dura mater**. It has been shown to be a degenerate eye.

2. The ventral surface of the brain.

- a. The **cerebral hemispheres**, as seen from below, are closely apposed in front, but diverge posteriorly.

About the middle of its length the inner border of each hemisphere presents a notch, which is continued outwards across the surface of the hemisphere as a shallow groove, the **Sylvian fissure**, separating the **frontal lobe** from the **temporal**.

- b. The **olfactory lobes** lie, in their hinder portions, along the under surface of the frontal lobes of the hemispheres, extending back as far as the

Sylvian fissures. In front, they project some distance beyond the hemispheres.

- c. The **infundibulum** is a median rounded elevation, lying between the temporal lobes, about the middle of the length of the brain: at its apex is the rounded vascular **pituitary body**. This latter is usually left behind in the pituitary fossa in the base of the skull when the brain is removed, and a slit-like aperture is then left at the apex of the infundibulum, leading into the third ventricle.
- d. The **optic chiasma** is a transverse band of nerve-fibres, lying immediately in front of the infundibulum. From its anterior border the **optic nerves** arise, and from its outer ends the **optic tracts** may be followed backwards towards the optic lobes by gently pressing the temporal lobes aside.
- + e. The **corpus mamillare**, or **corpus albicans**, is a small rounded median elevation, immediately behind the infundibulum.
- f. The **pons Varolii** is a stout band of transverse nerve-fibres, which crosses the ventral surface of the medulla, opposite the posterior ends of the hemispheres. It connects the two sides of the cerebellum with each other.
- g. The **crura cerebri** are two large bands of nerve-fibres, immediately in front of the pons Varolii, which run forwards, diverging from each other, and connect the medulla oblongata with the hemispheres.
- h. The **medulla oblongata**, as seen from the ventral surface, is broad in front and gradually narrows behind. It is marked by a median **ventral fissure**, bordered by two narrow bands, the **ventral pyramids**. At the outer sides of the pyramids,

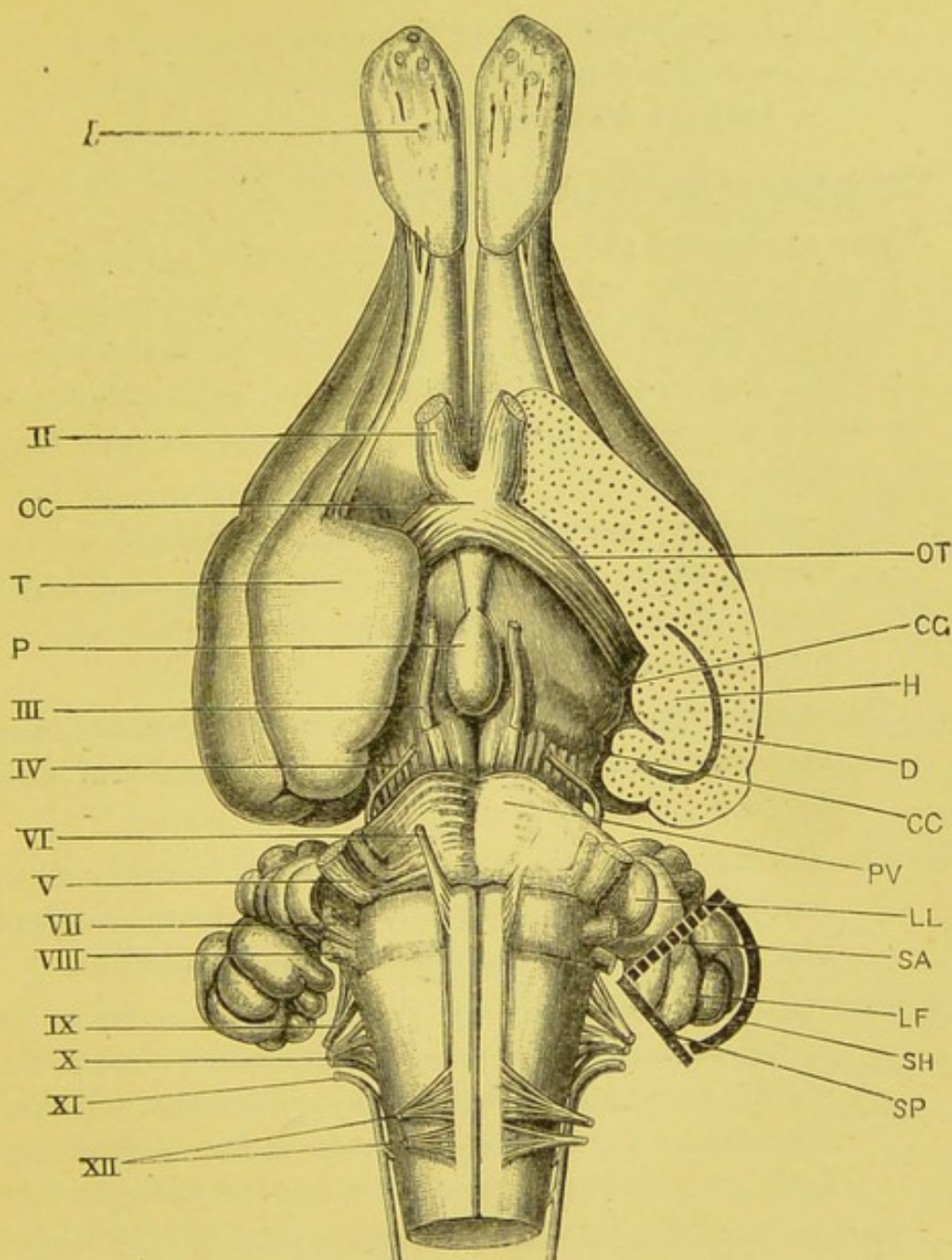


FIG. 66.—*Lepus cuniculus*. The ventral surface of the brain. The greater part of the left temporal lobe has been sliced off horizontally. The positions of the three semicircular canals of the left side are indicated by the thick lines surrounding the floccular lobe of the cerebellum; $\times 2$. (A. M. M.)

CC, crus cerebri. CG, corpus geniculatum. D, descending cornu of left lateral ventricle. H, hippocampus major. LF, floccular lobe of cerebellum. LL, lateral lobe of cerebellum. OC, optic chiasma. OT, optic tract. P, pituitary body. PV, pons Varolii. SA, anterior vertical semicircular canal. SH, horizontal semicircular canal. SP, posterior vertical semicircular canal. T, temporal lobe of cerebral hemisphere.

I, olfactory lobe, with roots of olfactory nerves. II, optic nerve. III, third nerve, or motor oculi. IV, pathetic nerve. V, trigeminal nerve. VI, sixth or abducent nerve. VII, facial nerve. VIII, auditory nerve. IX, glosso-pharyngeal nerve. X, pneumogastric nerve. XI, spinal accessory nerve. XII hypoglossal nerve.

immediately behind the pons Varolii, are a pair of oblong patches of transverse nerve-fibres, the *corpora trapezoidea*.

C. The Roots of the Cerebral Nerves.

There are twelve pairs of cerebral or cranial nerves in the rabbit, all of which, with the exception of the fourth pair, arise from the ventral surface or from the sides of the brain.

Identify, and clean the nerve roots on one side of the brain, in the order given below, taking great care not to drag them away from the brain.

1. The **olfactory nerve** arises, by many roots, from the ventral surface of the anterior end of the olfactory lobe. These roots are almost necessarily left behind in taking out the brain.
2. The **optic nerve** is a stout nerve, running forwards from the anterior border of the optic chiasma, and then curving outwards.
3. The **oculo-motor nerve** is small, and arises from the inner border of the crus cerebri, close to the middle line, and immediately behind the corpus mammillare.
4. The **pathetic nerve** is very small. It arises from the dorsal surface of the valve of Vieussens, close to the middle line, and just behind the optic lobes. It then runs round the side of the brain to the ventral surface, lying between the cerebellum and the optic lobe.

Find the nerve on the ventral surface, and follow it round the side of the brain to its origin.

5. The **trigeminal nerve** is very large, and arises by two closely apposed roots from the side of the hinder border of the pons Varolii. Of the two roots the inner and smaller one is motor, the larger outer one sensory in function.
6. The **abducent nerve** is very slender, and arises from the ventral surface of the medulla, close to the middle line, and immediately behind the pons Varolii.

7. The **facial nerve** arises from the outer side of the anterior end of the corpus trapezoideum, immediately behind the trigeminal nerve.
8. The **auditory nerve** is large, and arises from the side of the medulla, immediately behind and to the outer side of the facial nerve.
- 9 and 10. The **glosso-pharyngeal** and **pneumogastric nerves** arise close together, by many slender rootlets, from the side of the medulla, close behind, and a little above the root of the auditory nerve.
11. The **spinal accessory nerve** arises from the side of the medulla and spinal cord by about ten rootlets, the most anterior of which is just behind the pneumogastric, and the hindmost as far back as the fifth spinal nerve.
12. The **hypoglossal nerve** arises by a number of rootlets from the ventral surface of the medulla, close to the middle line, and to the outer side of the ventral pyramid.

D. The Structure of the Brain.

The brain is, from the mode of its formation, tubular; its cavity being directly continuous with the central canal of the spinal cord. From a very early stage it presents a series of dilatations or **vesicles**, partially separated from one another by constrictions. Of these vesicles, the first or most anterior one is the **fore-brain**, or **thalamencephalon**, from which the **cerebral hemispheres** arise as hollow outgrowths; the second vesicle is the **mid-brain** or **mesencephalon**; and the succeeding ones, of which there are at least four or five, are spoken of collectively as the **hind-brain**. The cavities of the vesicles remain in communication with one another throughout life, and are spoken of in the adult as the **ventricles** of the brain.

1. Dissection of the Brain.

a. The cerebral hemispheres.

Lay the brain with its dorsal surface upward, and gently

press the hemispheres apart: note the position of the corpus callosum.

Then, with the back of a knife, peel off the portion of the right hemisphere lying above the corpus callosum. Keep the brain wet with spirit.

i. The **corpus callosum** is a broad horizontal band of fibres connecting the two hemispheres.

ii. The **structure of the hemisphere.**

a. The outer layer or **cortex** is a superficial investment of grey matter, about an eighth of an inch thick.

β. The central or **medullary** portion consists of white matter, *i.e.* of medullated nerve-fibres. The fibres of the corpus callosum spread out into, and are continuous with it.

iii. The **lateral ventricle**, or cavity of the hemisphere.

Cut through the corpus callosum on the right side, so as to open the lateral ventricle beneath it. Lift up the corpus callosum, and carefully cut it away, so as to expose the ventricle fully, leaving a narrow strip along its inner edge.

The lateral ventricle, opposite the middle of the hemisphere, is wide from side to side, but shallow dorso-ventrally. Anteriorly, it extends forwards as a narrow vertical slit, the **anterior cornu**, which lies nearer the inner than the outer surface of the hemisphere.

Posteriorly, the lateral ventricle curves backwards and inwards towards the hinder end of the hemisphere, as the **posterior cornu**; and from its outer side, a little behind the middle of the hemisphere, a **descending cornu** runs outwards and downwards, and then curves round in the temporal lobe to the ventral region, running forwards and inwards almost to the anterior end of the lobe, and ending opposite the infundibulum.

Open up the descending cornu along its whole length, by carefully cutting away the outer and ventral walls of the temporal lobe.

- iv. The **hippocampus major** is a prominent convex ridge, projecting into the floor and inner side of the descending cornu, along its whole length. Compare fig. 65, p. 380.

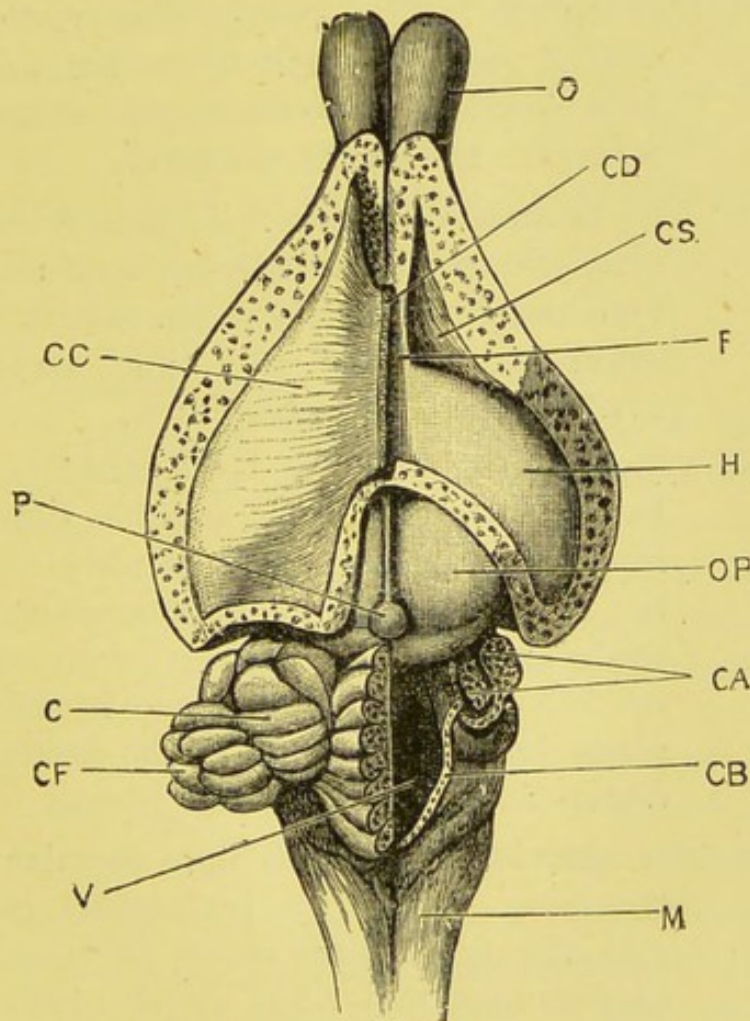


FIG. 67.—*Lepus cuniculus*. The brain dissected from above. Enlarged. (C. H. H.)

C, lateral lobe of cerebellum. CA, pillars of cerebellum. CB, cut edge of velum medullæ posterius. CC, corpus callosum: the right half is removed. CD, cut edge of corpus callosum. CF, floccular lobe of cerebellum. CS, corpus striatum. F, anterior limit of body of fornix. H, hippocampus major. M, medulla oblongata. O, olfactory lobe. OP, anterior optic lobe. P, pineal body. V, fourth ventricle.

- v. The **corpus striatum** is a thickened part of the wall of the hemisphere, forming the outer side

and floor of the anterior part of the lateral ventricle. It lies in front of the hippocampus major, from which it is separated by a deep groove, running obliquely backwards and outwards across the floor of the ventricle.

Cut away carefully the outer wall of the anterior cornu of the lateral ventricle, including the corpus striatum.

+ vi. The **septum lucidum** is the thin vertical inner wall of the hinder part of the anterior cornu. It is placed opposite the corpus striatum, and ventral to the corpus callosum.

vii. The **foramen of Monro** is a small hole immediately beneath the hinder border of the septum lucidum, through which the lateral ventricle communicates with the third ventricle, or cavity of the thalamencephalon.

+ viii. The **posterior pillar of the fornix** is a narrow band, lying along the anterior edge of the hippocampus major. Posteriorly it follows the hippocampus into the descending cornu; while anteriorly it becomes continuous with its fellow of the opposite side in the median plane, forming the **body of the fornix**, immediately above the foramen of Monro.

ix. The **choroid plexus** is a thin vascular fold of the inner wall of the hemisphere, projecting into the descending cornu in front of the hippocampus major, and closely applied to the anterior surface of the latter along its whole length.

+ x. The '**fifth ventricle**' is a median vertical cleft between the right and left hemispheres. It lies below the corpus callosum and above the fornix, and is bounded laterally by the inner walls of the two hemispheres (septum lucidum).

It is merely a part of the space between

the two hemispheres, partially enclosed by the corpus callosum and the fornix; and is not, properly speaking, a 'ventricle' at all.

To expose the fifth ventricle from above, carefully remove the narrow strip of the corpus callosum that has been left along the inner side of the hemisphere, and the fifth ventricle will be seen as a narrow cleft between the two hemispheres.

- + xi. The **hippocampal sulcus** is a deep groove on that surface of the temporal lobe which lies upon the thalamencephalon. It lies within the inwardly projecting fold of the hemisphere which forms the hippocampus major.

Remove the temporal lobe completely, and the hippocampal sulcus will be seen on its inner surface.

b. The fore-brain, or thalamencephalon.

- i. The **optic thalami** are a pair of large lateral thickenings of the sides of the fore-brain, immediately in front of the optic lobes, and overlapped by the temporal lobes of the hemispheres. They are separated by grooves from the corpora striata in front, and the optic lobes behind.

- + On the outer and ventral surface of each optic thalamus, near its anterior end, is a rounded elevation, the **corpus geniculatum**.

- ii. The **optic tracts** are a pair of narrow bands, which can be traced backwards and upwards from the outer ends of the optic chiasma, over the surface of the optic thalami, to the anterior borders of the optic lobes.

Take hold of the anterior end of the right optic tract with the forceps, and strip it off the optic thalamus, so as to see its origin from the optic lobe.

- + iii. The **velum interpositum** is a thin membrane forming the roof of the third ventricle. On

its upper surface is a plexus of blood-vessels, continuous with the choroid plexuses of the lateral ventricles.

- iv. The **pineal body** is connected by a tubular stalk with the hinder end of the velum interpositum.

Remove the velum interpositum, so as to open the third ventricle.

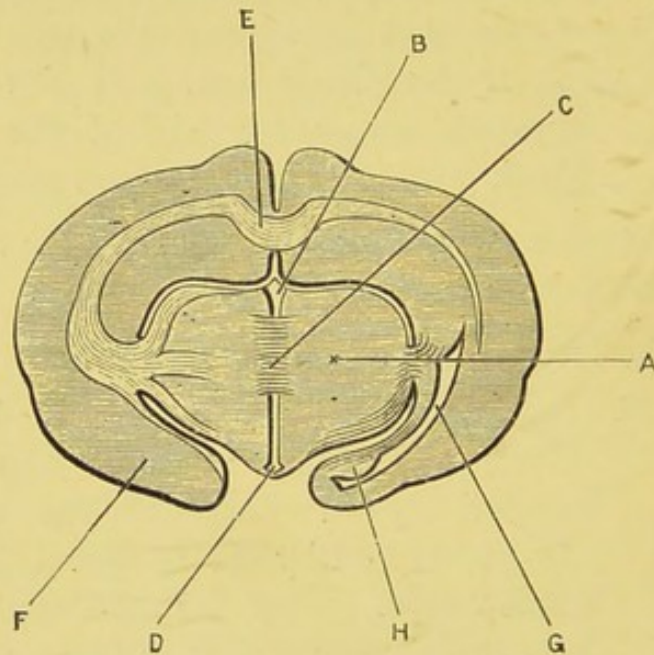


FIG. 68.—*Lepus cuniculus*. Transverse section of the brain, passing through the middle commissure of the third ventricle. The shading indicates diagrammatically the distribution of white and grey matter. The section is taken somewhat obliquely, so as to show different parts on the two sides. (A. M. M.)

A, optic thalamus, forming the side-wall of the third ventricle. B, part of the third ventricle above the middle commissure. C, middle commissure. D, infundibulum. E, corpus callosum. F, temporal lobe of the left cerebral hemisphere. G, descending cornu of the right lateral ventricle. H, hippocampus major.

- v. The **third ventricle**, or cavity of the fore-brain, is a median vertical cleft between the optic thalami. It is very narrow from side to side, and communicates through the foramina of Monro with the lateral ventricles.
- c. The **mid-brain**, or **mesencephalon**.
- i. The **corpora quadrigemina**, or optic lobes, form

the dorsal portion of the mid-brain, and are now well seen.

- ii. The **crura cerebri** form the base of the mid-brain : after removal of the optic tracts they can be traced forwards and outwards from the anterior border of the pons Varolii to the optic thalami.

2. Longitudinal section of the brain.

Divide the brain into right and left halves by a median longitudinal section. Place the left half in a small dish of spirit, and examine its inner surface.

If the dissection has been properly performed, the left half of the brain will be uninjured. If it has been damaged, a second brain should be taken, and bisected as directed above.

a. The cerebral hemisphere.

- i. The **corpus callosum** is seen cut across, and its boundaries can easily be determined.
- + ii. The **body of the fornix** is a thin median band lying below the corpus callosum. It is continuous with this latter behind, but in front diverges from it considerably, the space between the two being the fifth ventricle.

b. The fore-brain, or thalamencephalon.

- i. The **third ventricle**, though very narrow from side to side, is of considerable depth from the dorsal to the ventral surface. Owing to its narrowness, its boundaries are difficult to determine.

The outline of the third ventricle can be rendered more obvious by adding a little ink or other colouring matter to the spirit in which the brain is examined.

- ii. The **commissures of the third ventricle** are three bands of transverse fibres, connecting the right and left halves of the thalamencephalon with each other. Of the three the middle

one alone really crosses the cavity of the ventricle.

- † α . The **anterior commissure** is a small band of transverse nerve-fibres, in the substance of the anterior wall of the ventricle, and immediately in front of the fornix.

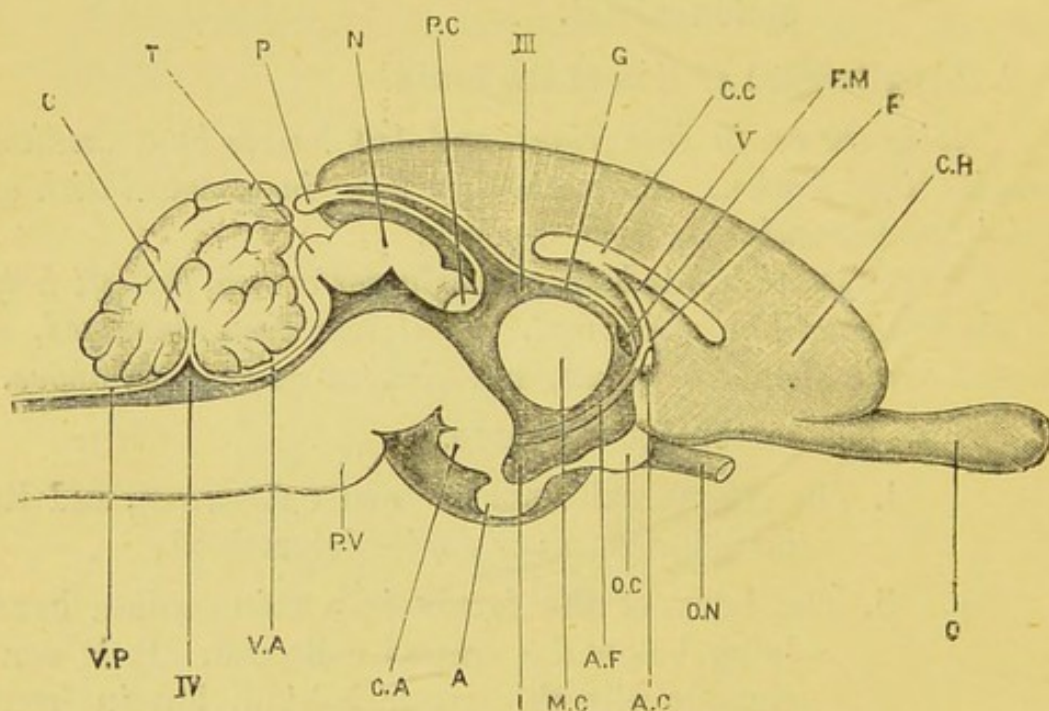


FIG. 69.—*Lepus cuniculus*. A longitudinal and vertical section brain, taken in the median plane. (A. M. M.)

A, pituitary body. AC, anterior commissure. AF, anterior pillar of the fornix, seen in the wall of the third ventricle. C, cerebellum. CA, corpus albicans. CC, corpus callosum. CH, inner surface of left cerebral hemisphere. F, body of the fornix. FM, foramen of Monro. G, velum interpositum. I, infundibulum. MC, middle commissure. N, anterior optic lobe or 'nates.' O, olfactory lobe. OC, optic chiasma. ON, left optic nerve. P, pineal body. PC, posterior commissure. PV, pons Varolii. T, posterior optic lobe, or 'testis.' VA, velum medullae anterioris, or valve of Vieussens. VP, velum medullae posterius.

III, third ventricle. IV, fourth ventricle. V, fifth ventricle.

- β . The **middle commissure** is a very large band of fibres, connecting the two optic thalami across the ventricle. It is nearly circular in outline, and crosses the ventricle about its middle, filling up the greater part of it.

- † γ . The **posterior commissure** is a small band of transverse fibres in the roof of the hinder

end of the third ventricle, just in front of the optic lobes.

- + iii. The **velum interpositum**, which forms the roof of the third ventricle, has already been seen and removed.
- iv. The **stalk of the pineal body** is a tubular prolongation, upwards and backwards, of the roof of the ventricle, just in front of the posterior commissure.
- + v. The **lamina terminalis** is the thin anterior wall of the ventricle.
- vi. The **optic chiasma** appears in this section as a thickening in the floor of the anterior end of the ventricle.
- vii. The **infundibulum** is a funnel-like depression of the floor of the ventricle, about the middle of its length: to its apex the pituitary body is attached.
- + viii. The **corpus albicans** is a rounded swelling on the ventral surface of the floor of the ventricle, in the hinder wall of the infundibulum.
- ix. The **foramen of Monro** is a vertical slit-like opening at the anterior end of the ventricle, between and slightly above the anterior and middle commissures. It leads from the third to the lateral ventricle.
- + x. The **anterior pillar of the fornix** is a slender band of nerve-fibres in the side-wall of the ventricle, running backwards and downwards from the body of the fornix, beneath the middle commissure, to the corpus albicans, in which it ends.
- c. The **mid-brain, or mesencephalon**.
 - i. The **Sylvian aqueduct, or iter a tertio ad quartum ventriculum**, is the cavity or ventricle of the mid-brain.

ii. The **optic lobes**, or **corpora quadrigemina**, have moderately thick walls, and form the roof of the Sylvian aqueduct, which is prolonged a short distance into them.

iii. The **crura cerebri**, which form the floor of the Sylvian aqueduct, are very thick.

d. The hind-brain.

i. The **fourth ventricle**, or cavity of the hind-brain, is moderately wide from side to side, but shallow from above downwards. It has a very thin roof, but thick floor and sides.

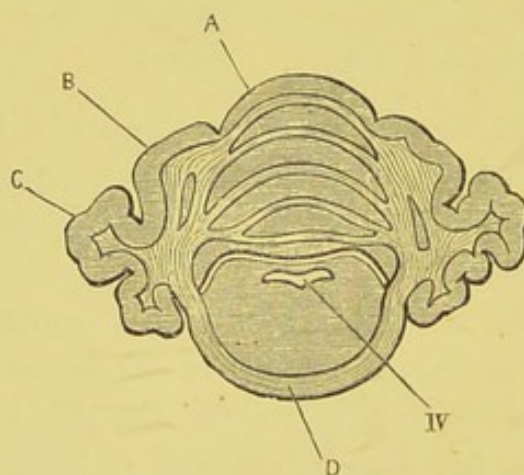


FIG. 70.—*Lepus cuniculus*. Transverse section of the brain, passing through the widest part of the cerebellum. The shading indicates diagrammatically the distribution of white and grey matter. (A. M. M.)

A, vermis, or middle lobe of the cerebellum. B, lateral lobe of the cerebellum. C, floccular lobe of the cerebellum. D, transverse fibres of the pons Varolii. IV, fourth ventricle.

+ ii. The **velum medullæ anterius**, or **valve of Vieussens**, is a thin membrane extending from the optic lobes to the cerebellum, and forming the roof of the anterior half of the fourth ventricle.

+ iii. The **velum medullæ posterius** is a thin membrane, forming the roof of the posterior half of the fourth ventricle.

- iv. The **cerebellum** is attached to the dorsal surface at the junction of the *vela medullæ anterieus* and *posterius*. It consists of an outer layer of grey matter, which is very deeply folded, and a central much-branched mass of white matter, the section having a tree-like appearance, which has given rise to the name **arbor vitæ**.
- v. The **pons Varolii** is seen, in transverse section, crossing the ventral surface of the anterior part of the hind-brain, opposite the *velum medullæ anterieus*.

3. Transverse sections of the brain.

If another brain can be obtained, it should be cut with a razor into a series of transverse sections, about an eighth of an inch thick, and the sections arranged in order in a dish of spirit.

Such a series of sections affords very instructive views of the mutual relations of the several parts of the brain.

CHAPTER XIV.

THE SKELETON OF THE FOWL.

Gallus domesticus.

THE fowl's skeleton is, on account of its larger size, more convenient for study than that of the pigeon. The differences between the two are of but slight importance, and the following description will practically apply to either.

The bird's skeleton consists essentially of the same parts as the rabbit's, but presents certain special characteristics, of which the more important are: (1) the great lightness of the bones, many of which contain large air cavities; (2) the extensive fusion of primitively distinct bones with one another during development; (3) the modifications in the limb-girdles and limbs, fitting birds for bipedal locomotion and for flight.

As in the case of the rabbit's skeleton, the names of the *membrane-bones* are printed in italics, those of the **cartilage-bones** in thick type.

I. THE AXIAL SKELETON.

The axial skeleton, as in other vertebrates, is divisible into skull and vertebral column.

A. The Vertebral Column.

As compared with the rabbit's, the vertebral column of the bird is distinguished by (1) the great length and flexibility of the neck, the cervical portion being nearly equal in length to the whole of the rest of the column; (2) the rigidity of the

thoracic and abdominal portions of the column, owing to the fusion of their component vertebræ; (3) the great length of that portion of the vertebral column with which the pelvis is connected; (4) the small number of the caudal vertebræ, and the fusion of the posterior ones to form the pygostyle; (5) the absence of epiphyses.

The vertebral column may be divided into cervical, thoracic, sacral, and caudal regions: the boundaries between these being ill defined, and the sacral portion being further divisible into three sub-sections.

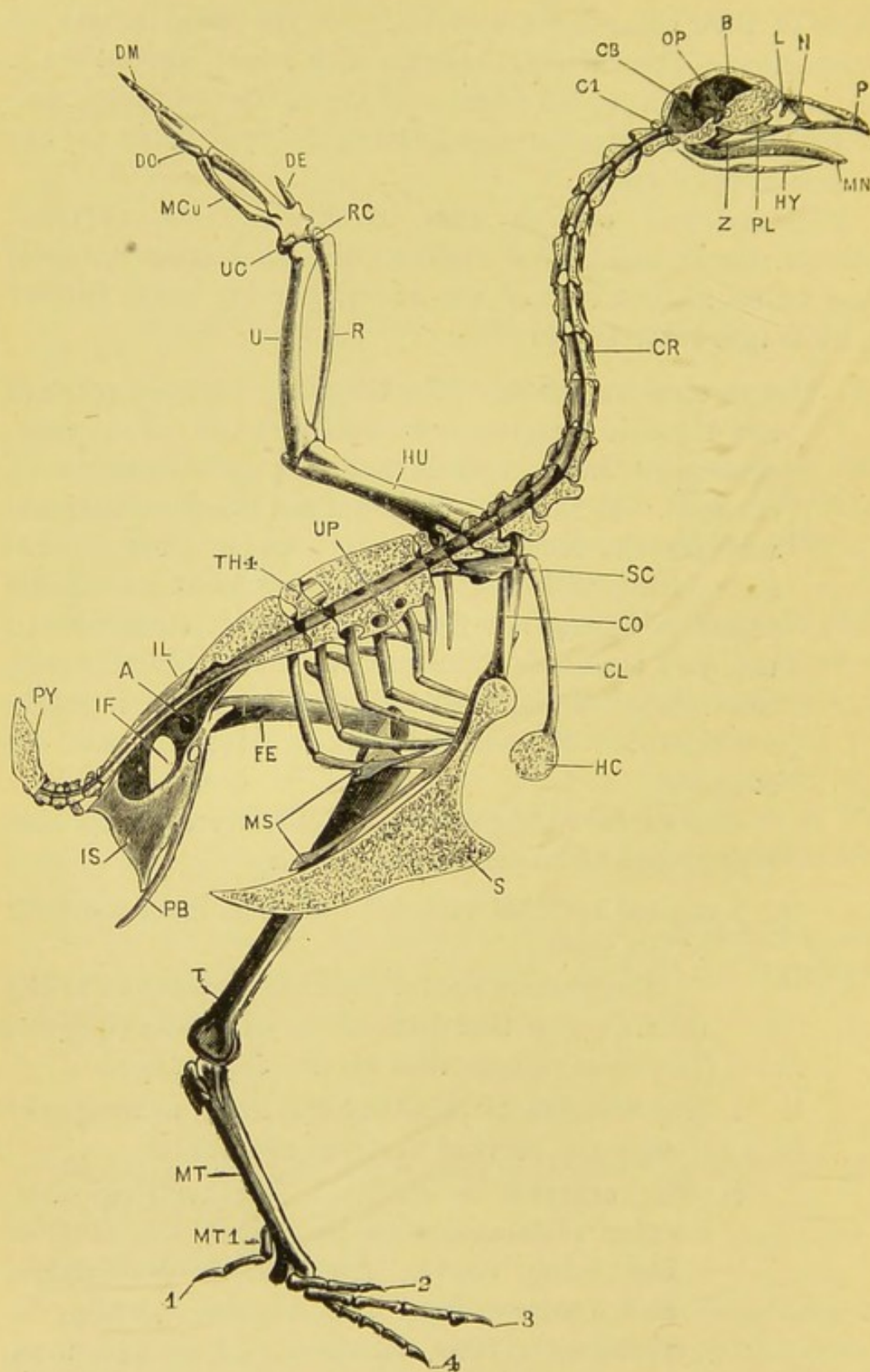
1. **The cervical vertebræ.** The boundary between cervical and thoracic vertebræ is an arbitrary one, of no morphological value, and is not easy to determine in the fowl. It is usual to count as the first thoracic vertebra the most anterior one which bears a rib articulating with the sternum, and to name all the vertebræ in front of this one cervical. Reckoned in this way there are sixteen cervical vertebræ, the two hindmost of which bear well-developed and movably articulated ribs, which, however, do not reach the sternum.

In the following description the vertebral column is supposed to be placed horizontally.

- a. **A typical cervical vertebra:** any one from the sixth to the tenth.

The parts of the vertebra are the same as in the rabbit, except that there are no terminal epiphyses. The chief peculiarities are the following:—

- i. The vertebra is very long and light, as compared with the cervical vertebra of a rabbit.
- ii. The **centrum** is slender. The terminal articular surfaces are saddle-shaped, the anterior one being convex from above downwards, and concave from side to side; while the posterior surface, which is larger and more prominent, is concave from above downwards, and convex from side to side. These saddle-



shaped articular surfaces are very characteristic of the cervical vertebræ of birds.

- iii. The **neural arch** is shorter than the centrum, and is deeply notched in the middle line, both in front and behind. The neural arch is also notched behind, on both sides, for the passage of the spinal nerves.
- iv. The **neural spine** is rudimentary in the middle cervical vertebræ.
- v. The **transverse processes and cervical ribs**. At the anterior end of the vertebra an irregular process projects outwards at each side, which is perforated at its base by a large foramen, and is produced at its hinder border into a sharp backwardly directed process.

This process is really a rib, which, as in the cervical vertebræ of the rabbit, is fused with the vertebra; the foramen at its base transmits the vertebral artery and corresponds to the notch between the capitulum and tuberculum of the rib.

- vi. The **zygapophyses**.

The **pre-zygapophyses** are borne on the upper surfaces of the transverse processes: their articular surfaces are flat, and face upwards and inwards.

The **post-zygapophyses** project backwards from the posterior border of the neural arch,

FIG. 71.—*Gallus domesticus*. The left half of the skeleton. The skull, vertebral column, and sternum are bisected in the median plane. (C. H. H.)

A, acetabulum. B, cerebral fossa. CB, cerebellar fossa. CL, clavicle. CO, coracoid. CR, cervical rib. C1, first cervical vertebra. DE, DM, DO, preaxial, middle, and postaxial digits of the wing. FE, femur. HC, hypocleidium. HU, humerus. HY, hyoid. IF, ilio-sciatic foramen. IL, ilium. IS, ischium. L, lacrymal bone. MCu, metacarpal bone of ulnar digit. MN, mandible. MS, metosteon. MT, tarso-metatarsus. MT1, metatarsal bone of first digit. N, nasal bone. OP, optic foramen. P, premaxilla. PB, pubes. PL, palatine bone. PY, pygostyle. R, radius. RC, radial carpal bone. S, keel of the sternum. SC, scapula. T, tibio-tarsus. TH4, fourth thoracic vertebra. U, ulna. UC, ulnar carpal bone. UP, uncinate process of rib. Z, infra-orbital bar.

1, 2, 3, 4, 5, the first, second, third, fourth, and fifth digits of the foot.

their articular surfaces facing downwards and outwards.

- b. The **atlas**, or first vertebra, is very short and ring-like. Its ventral portion is thickened, resembling a centrum, and is notched above to receive the odontoid process of the axis; its anterior surface is deeply cupped to articulate with the occipital condyle of the skull. The posterior border of the neural arch is produced backwards into zygapophyses, articulating with the second vertebra.
- c. The **axis** or second vertebra is, with the exception of the atlas, the smallest of the cervical series: it has a blunt neural spine, but no transverse processes, and no ribs. The centrum is produced in front into the slender **odontoid process**.
- d. The **remaining cervical vertebræ**. The third and fourth cervical vertebræ are shorter than the succeeding ones, and have short thick ribs, and lateral wing-like ridges placed obliquely along their sides. The middle cervicals are the longest of the series, and the hinder ones are shorter and more massive. The last cervical vertebra is fused with the first thoracic.

The neural spines are present, though small, in the anterior cervical vertebræ; they are well developed in the hinder ones, but are almost absent in the middle ones of the region.

The hypapophyses are well developed in the hindmost half-dozen cervical vertebræ.

The ribs are more than half the length of the vertebræ in the middle of the neck, but are blunt and inconspicuous in the twelfth to the fourteenth vertebræ. In the fifteenth the ribs are well developed, and movably articulated with the vertebra: and in the sixteenth they are still larger, and resemble the thoracic ribs, but do not meet the sternum,

2. The **thoracic vertebræ** are five in number. The three anterior ones are fused together and with the last cervical vertebra: their centra, arches, and various processes being confluent, and the neural spines and hypapophyses forming continuous dorsal and ventral ridges.

The fourth thoracic vertebra is free; and the fifth is fused with the first sacral vertebra, its transverse processes abutting against and fusing with the ilia.

3. The **sacrum** consists of fourteen or fifteen vertebræ, fused together and supporting the ilia. It may be divided into the following regions.

- a. The three anterior sacral vertebræ are firmly fused together, and with the last thoracic vertebra. They have stout transverse processes, which abut against the ilia, and which in the first one two are single, but in the third are divided into dorsal and ventral portions, the latter being very stout and projecting directly outwards from the broad centrum. The neural spines of these vertebræ are fused to form a vertical crest of bone, which is continuous in front with that of the last thoracic vertebra, and fused along its edge with the dorsal edges of the ilia.
- b. Behind these come four or five shorter vertebræ, with broad centra fused together. Their transverse processes, which have no ventral elements, are united to form bony plates, which support the ilia along their outer margins.

Between the bodies of these vertebræ and the ilia are the deep hollows in which lie the middle lobes of the kidneys.

- c. Next come seven vertebræ, the centra of which are compressed laterally in the anterior ones, and dorso-ventrally in the hindmost two or three. The transverse processes, except in the last, are

double ; the dorsal elements fusing to form bony plates, continuous with those of the vertebræ in front of them. The ventral elements of the transverse processes are rod-like in the case of the first four or five vertebræ, and are regarded as ribs, because they ossify independently of the centra : in the hinder vertebræ, they are smaller. The first pair of these ribs are much stouter than the rest : they are placed in the adult opposite the acetabula, with the walls of which they are connected by bony ridges running across the inner surfaces of the ilia, and separating the fossæ for the middle and posterior lobes of the kidneys from each other. In the embryo, and in the young chick, these ribs are some distance behind the acetabula, and are no larger than those of the succeeding vertebræ.

It is very doubtful how many of these vertebræ, and which ones, correspond to the sacral vertebræ of other vertebrates, usually two in number. Huxley considers that group (b) are the true sacral vertebræ, on the ground that the spinal nerves associated with them unite to form the sacral plexus. Gegenbaur and others hold that two or more of the vertebræ in group (c) are the true sacral ones, on account of their possessing separately ossified ribs.

4. The **caudal vertebræ** consist of four or five free ones, and a terminal **pygostyle**. This latter, which supports the **rectrices**, or large tail feathers, is much larger than the others, and triangular in shape. It is formed by the fusion of five or six vertebræ, which are distinct in the embryo.

B. The Ribs and Sternum.

1. The ribs.

- a. The **cervical ribs**. As already noticed, the last two cervical ribs of each side are alone movably arti-

culated, the remainder being fused with the transverse processes of the corresponding vertebræ.

Of these two, the first is small, but has distinct capitular and tubercular articulations: the second is larger and bears on its posterior border a backwardly projecting **uncinate process**, which overlaps the next rib.

- b. The **thoracic ribs** are five on each side, and slightly increase in size from before backwards: each consists of vertebral and sternal portions, meeting at an angle.
 - i. The **vertebral portions** are flattened and slightly curved bars of bone, which articulate by capitular and tubercular surfaces with the centra and transverse processes of their respective vertebræ. **Uncinate processes** project backwards from the posterior borders of all, except the last, or sometimes the last two.
 - ii. The **sternal portions** are slender nearly straight rods of bone, which run forwards and downwards, from their junctions with the vertebral portions, to the side of the anterior part of the sternum, with which they articulate.
- 2 The **sternum**, or breastbone, is very large, and projects back far beyond the ribs, and over the greater part of the wall of the abdomen. Its ventral surface is raised into a prominent vertical crest or keel, which gives origin to the muscles moving the wings.
 - i. The **body of the sternum** is a somewhat boat-shaped plate of bone: it is wide and stout in front, and perforated on its concave dorsal surface by apertures, through which the air-sacs communicate with the cavity of the bone: it is narrow in the middle portion of its length, but widens somewhat behind.
 - ii. The **manubrium** is a small vertical plate of bone,

projecting from the anterior end and ventral surface of the body.

- ii. The **carina**, or **keel**, is a very prominent triangular crest projecting downwards from the ventral surface of the sternum, and slightly thickened along its anterior border, which is concave.
- iv. The **metostea** are a pair of large processes, projecting backwards from the sides of the anterior end of the body of the sternum. Each divides, close to its origin, into two large flattened processes, the **external** and **middle xiphoid processes**, which are expanded at their hinder ends.
- v. The **costal surfaces** are the lateral borders of the body, in front of the metostea; they are notched for the sternal ends of the ribs.
- vi. The **costal processes** project forwards and outwards, in front of the costal surfaces.
- vii. The **coracoid grooves** are a pair of deep transverse grooves on the anterior end of the body of the sternum, continuous with each other, across the median plane, through a hole in the base of the manubrium. With them the ventral ends of the coracoid bones articulate.

C. The Skull.

The chief characteristics of the bird's skull are :—(1) its great lightness; (2) the very extensive fusion of the bones of the cranium with one another, most of the cranial sutures being closed, and the outlines of the bones obliterated, by the end of the first year; (3) the large size of the orbits, which are separated from each other by a thin vertical **interorbital septum**; (4) the prolongation of the face forwards into a long conical toothless beak.

The skull consists of the same essential parts as that of the rabbit, from which, however, it differs in the following important points: (1) there is only a single occipital condyle,

for articulation with the atlas vertebra; (2) the base of the skull is strengthened by a large membrane-bone, the *basi-temporal*; (3) the orbits are placed almost entirely in front of the cranium, instead of below it, and are separated from each other only by the thin interorbital septum; (4) the lower jaw is connected with the squamosal by a movably articulated bone, the *quadrate*; (5) there is only a single auditory ossicle, the *columella*; (6) there are no teeth.

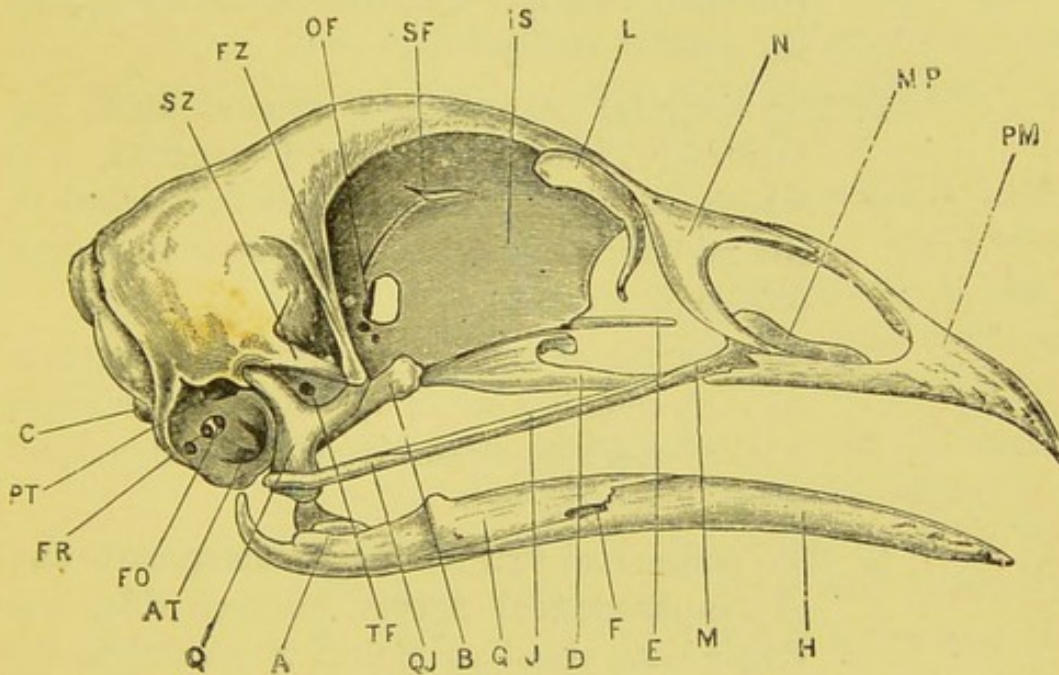


FIG. 72.—*Gallus domesticus*. The skull from the right side. (A. M. M.)

A, articular surface of the mandible. AT, anterior tympanic recess, leading to the Eustachian tube. B, pterygoid. C, occipital condyle. D, palatine. E, vomer. F, mandibular foramen. FO, fenestra ovalis. FR, fenestra rotunda. FZ, zygomatic process of frontal bone. G, supra-angular. H, dentary. IS, inter-orbital septum. J, jugal. L, lacrymal. M, maxilla. MP, maxillo-palatine process of maxilla. N, nasal. OF, optic foramen. PM, premaxilla. PT, posterior tympanic recess. Q, quadrate. QJ, quadrato-jugal. SF, olfactory foramen. SZ, zygomatic process of squamosal. TF, foramen for fifth nerve.

The fowl's skull consists of cranial and facial portions which are loosely connected together, and capable of slight movement upon each other. The cranial portion consists of the cranium proper, or brain case, and the auditory capsules: the facial part is formed by the jaws and the olfactory capsules.

1. The cranial portion of the skull is a somewhat conical box of bone, the base of the cone forming the hinder

end of the skull, and the apex being directed forwards. In the young skull the outlines of the component bones can easily be followed, but in the adult they are indistinguishable. The following are the main points to be noticed.

a. The hinder end of the cranium.

- i. The **foramen magnum** is a large nearly circular aperture, in the middle of the posterior end of the skull, through which the spinal cord enters the cranial cavity.
- ii. The **occipital condyle** is a rounded knob, immediately below the foramen magnum, into which it projects slightly. It is notched in the mid-dorsal line, and has below it a deep pit-like depression.
- iii. The **foramen of exit for the hypoglossal nerve**, on each side, is a small aperture, immediately to the outer side of the occipital condyle, and slightly ventral to it.
- iv. The **foramen of exit for the pneumogastric and glosso-pharyngeal nerves**, on each side, is a larger hole, about an eighth of an inch to the outer side of that for the hypoglossal nerve, and midway between the condyle and the rim of the tympanic cavity.
- v. To the outer side of the above foramen, and between it and the tympanic rim, is a group of three or four larger holes: some of these lead into the tympanic cavity; while the most ventrally situated one is the entrance to the **carotid canal**, which traverses the base of the skull, and lodges the carotid artery.
- vi. The **lambdoidal crest** is a prominent ridge of bone surrounding the dorsal half of the hinder end of the skull, and separating the occipital from the parietal region.

b. The ventral surface of the cranium.

- i. The **base of the skull** is wide behind. The **basi-sphenoid** is covered by the broad transverse *basi-temporal*, a membrane-bone which forms part of the boundaries of the tympanic cavities, and probably corresponds to the posterior part of the para-sphenoid of the frog.

In front of the basi-temporal the base of the skull is narrow, and formed by the *rostrum*, or thickened ventral border of the inter-orbital septum, which probably represents the anterior part of the *para-sphenoid*.

- ii. The **anterior openings of the Eustachian canals** are a pair of small holes, close to the median plane, and opening into a deep notch between the anterior end of the basi-temporal bone and the rostrum.
- iii. The **foramina of exit for the carotid canals** are a pair of small holes, near the middle line, and immediately to the outer sides of the Eustachian apertures. They are connected with each other by a canal, traversing the base of the skull.

Pass a bristle along the carotid canal of one side, and through the transverse canal from side to side.

c. The side of the cranium.

- i. The **tympanic cavity** is a hemispherical depression, at the side of the hinder end of the skull, bounded above by the *squamosal* and below by the *basi-temporal*. The **tympanic membrane** is attached just within its prominent lip.

Within the tympanic cavity can be seen the following.

- a. The **fenestral recess** is an oval depression in the middle of the cup, divided by a partition into an upper hole, the **fenestra ovalis**,

and a lower, the *fenestra rotunda*. The former of these lodges during life the inner end of the auditory ossicle or *columella*, a slender bar of bone and cartilage, the outer end of which is attached to the tympanic membrane.

- β. The **posterior opening of the Eustachian canal** is a funnel-like depression, at the ventral and anterior corner of the tympanic cavity. The tube into which it leads passes forwards and inwards, between the *basi-temporal* and the *basi-sphenoid*, to open, as already seen, on the base of the skull, close to the middle line.

Pass a bristle along the Eustachian canal of one side, from behind forwards.

- γ. The **anterior tympanic recess** is a slit-like depression, immediately above the posterior opening of the Eustachian canal, with which it is often confluent.
- δ. The **posterior tympanic recess** is a large depression, close to the dorsal border of the tympanic cavity, and just above the fenestral recess.
- ii. The **zygomatic process of the squamosal** is a thin bar of bone, which projects forwards almost horizontally from the anterior and upper edge of the tympanic cavity. Its distal end often meets, and fuses with, the post-orbital process of the frontal bone.
- iii. The **articular surface for the quadrate** is a depression on the side of the skull, immediately in front of the tympanic cavity, between it and the zygomatic process of the squamosal.
- iv. The **foramen of exit for the trigeminal nerve** is a round hole in the side of the skull, below

and in front of the articular surface for the quadrate.

- v. The **orbit** is a very large depression in the side of the skull, which lodges the eyeball; it is bounded above by the *frontal* bone; in front, by the *frontal* and *lacrymal* bones, the latter of which is produced downwards at its anterior end into a slender curved process. Behind, the orbit is bounded by the frontal with its post-orbital process, and by the **alisphenoid**; and on the inner side it is separated from the orbit of the other side by the **inter-orbital septum**, a thin vertical plate of bone, formed by the coalescence of the **pre-sphenoid** and **orbito-sphenoid** behind, and the **mes-ethmoid** in front and above. The lower edge of the septum is thickened and covered by a membrane-bone, the *rostrum*, which forms the anterior part of the *para-sphenoid*.

Below, the orbit is very incomplete; its outer margin is formed by the slender zygomatic arch, and its floor, nearer the middle line, is formed in part by the *palatine* and *pterygoid* bones.

- vi. The **foramen of exit for the olfactory nerves** is a median opening, at the anterior end of the cranium, and is continued forwards as a horizontal slit, between the inter-orbital septum and the frontal bones.
- vii. The **optic foramen** is a large median hole in the orbito-sphenoid bones, opening into the posterior part of the orbits, and continued forwards as a semicircular notch in the inter-orbital septum.
- viii. The **foramina of exit for the third and fourth nerves** are small holes, immediately to the

outer side of the optic foramen, and sometimes confluent with it.

d. **The dorsal surface of the cranium.**

The dorsal surface of the cranium is rounded, and formed almost entirely by the *parietal* and *frontal* bones. It is broad behind, narrower in front; and separated by a sharp almost transverse line from the facial part of the skull. The anterior ends of the frontal bones diverge slightly from each other, and allow the mesethmoid to come to the surface between them.

2. The **facial portion of the skull** lies below and in front of the cranial portion, with which it is only loosely connected. It consists of (1) the olfactory capsules, and the bones associated with them; (2) the skeletal elements of the jaws, and the hyoid apparatus.

- a. **The olfactory capsules and associated bones.** The olfactory capsules themselves remain in a cartilaginous condition throughout life, and are therefore absent in macerated skulls. They are separated only by a thin vertical septum, and almost completely fill the conical space which, in the dried skull, lies between the anterior end of the orbit and the tip of the beak. Each olfactory capsule has its cavity complicated by a spirally rolled lamina of cartilage, which projects inwards from its outer wall.

In relation with the olfactory capsules are the following bones.

- i. The *nasals* are a pair of thin lamellar bones, which cover the sides of the hinder ends of the olfactory capsules. Behind, they are fused with the anterior ends of the frontals: while their anterior borders are divided by deep notches into superior and inferior processes, which embrace the external narial openings,

and are closely connected with processes of the *premaxillæ*.

- ii. The *vomer* is a slender median bony rod, which lies below the hinder part of the olfactory capsules, and immediately in front of the *rostrum*. It is paired in some birds.
- b. The **upper jaw**. The bones of the upper jaw, as seen from the ventral surface, form on each side two bony arcades, which are fused together in front to form the beak, and are closely approximated behind, but widely separated from each other along the greater part of their course. The inner arcade is formed by the pterygoid and palatine bones, which articulate with the rostrum : the outer arcade consists of the slender sub-orbital bar and the premaxilla.

The upper jaw is connected with the anterior end of the frontals, and with the mesethmoid. Posteriorly, it is slung up to the side of the skull, just in front of the tympanic cavity, by the quadrate bones.

- i. The *pterygoid* is a short stout bone, forming the hinder part of the inner arcade. It articulates at its outer and posterior end with the inner surface of the quadrate, and at its inner and anterior end with the rostrum, along which it can slide.
- ii. The *palatine* is a slender horizontal bar of bone lying in front of the pterygoid, and forming the greater part of the inner arcade. Behind, it articulates with the pterygoid, and is expanded into a broad lamella, which articulates with the rostrum along its inner edge. In front, the palatine is wedged in between the maxilla and the premaxilla.
- iii. The *premaxilla* is a triradiate bone, the anterior part of which is ankylosed with its fellow in

the median plane to form the tip of the beak, while the three processes diverge backwards.

The ascending or nasal process, which is much the longest of the three, is a long slender bar of bone, which runs backwards and upwards, closely applied to its fellow of the opposite side, and along the inner side of the nasal bone, to the mesethmoid, with which it is connected. The bone is very thin and elastic at its hinder end, so as to allow of a certain amount of movement of the facial on the cranial portion of the skull.

The outer or maxillary process runs backwards and slightly outwards, forming part of the margin of the upper jaw. The nasal and maxillary processes of the premaxilla, together with the superior and inferior processes of the nasal bone, surround the large aperture at the side of the beak in which the external narial opening lies.

The inner or palatine process, the smallest of the three, is a narrow plate of bone which extends horizontally backwards, a short distance from the median plane. It forms part of the roof of the mouth, and is connected behind with the anterior end of the palatine bone.

- v. The *maxilla* is a slender rod of bone, lying behind and to the inner side of the maxillary process of the premaxilla, and forming part of the sub-orbital bar. Its anterior end is expanded into a thin horizontal lamina of bone, the *maxillo-palatine process*, which projects inwards towards the median plane, lying dorsal to the palatine bone.
- v. The *jugal* is a very slender rod, which forms the middle portion of the sub-orbital bar. It lies

dorsal to the other two components of the bar, and its exact limits are not recognisable in the adult.

- vi. The *quadrato-jugal* is the hindmost of the three components of the sub-orbital bar. Its posterior end is thickened, and articulates with the outer side of the distal end of the quadrate. In front it extends forwards as far as the maxilla, being overlapped for a considerable part of its length by the jugal.
- c. The **mandibular arch** is divided into two portions of very unequal length, placed almost at right angles to each other. The proximal part is the **quadrate** bone, which connects both the upper and lower jaws with the cranium: the distal portion, forming the lower jaw, is of much greater length, is fused with its fellow in front, and is composed of several bones firmly united together.
 - i. The **quadrate**, which forms the suspensorium, is a stout triradiate bone. Its proximal or dorsal arm articulates with a cup-like depression in the squamosal, at the anterior and upper border of the tympanic cavity, between this and the base of the zygomatic process.

The distal or ventral arm, which is the stoutest of the three, is expanded transversely at its lower end, and bears the articular surface for the lower jaw: it also articulates at its outer edge with the quadrato-jugal, and along its inner margin with the pterygoid.

The third or anterior arm of the quadrate is a more slender process, which projects forwards and inwards into the hinder part of the orbit, lying parallel to and above the pterygoid.
 - ii. The **mandible**, or lower jaw, consists of a pair of long laterally compressed rami, thickened and expanded at their hinder ends, where

they articulate with the quadrates, and firmly united together in the median plane in front. Like the upper jaw it bears no teeth, but is covered by a horny epidermal sheath.

Each ramus of the mandible really consists of five bones, one of which is developed in the primary cartilaginous arch, while the others are formed around it.

- a.* The **articular** forms the expanded posterior end of the ramus. On its dorsal surface is the elongated and slightly concave articular surface for the quadrate: behind this the bone is produced backwards and upwards into the curved posterior articular process; and on the inner side into a similar but stouter internal articular process.

The articular is continuous in front with Meckel's cartilage, the cartilaginous bar of the mandibular arch, which persists, even in the adult, along the greater part of the length of the mandible, ensheathed in membrane-bones.

- β.* The *angular* is a splint-like bone which underlies the articular, and extends forwards along the ventral edge and inner surface of the proximal half of the lower jaw.

- γ.* The *supra-angular* forms the dorsal part of the posterior third of the mandible, along both outer and inner surfaces. Its dorsal border is raised into a small coronoid process, about the middle of its length.

- δ.* The *dentary* is the largest of the bones of the jaw, and forms the distal half of each ramus: it is fused with its fellow in front at the symphysis: and posteriorly it extends back along the ventral border of the supra-

angular, between this and the angular, as far as the articular.

ε. The *splenial* is a thin lamina of bone, applied to the inner surface of each ramus of the jaw, along the middle half of its length.

d. The **columella** and the **hyoid apparatus**. These may conveniently be considered together, as the columella is, according to most authorities, the uppermost part of the hyoid arch, just as the quadrate is of the mandibular.

i. The **columella** is a minute and slender rod of bone, the proximal end of which is expanded into an oval plate, fitted into the **fenestra ovalis** of the tympanic cavity; while the outer or distal end, which is cartilaginous and divided into three diverging arms, is attached to the tympanic membrane. It serves to convey the sound-vibrations from the tympanic membrane to the membrane closing the fenestra ovalis, and so to the internal ear.

Owing to its small size and slight attachment, the columella is often lost in macerated skulls: it may, however, sometimes be found projecting from the fenestra ovalis.

ii. The **hyoid apparatus** is a bony framework, lying in the floor of the mouth, and supporting the tongue. It consists of a median jointed rod of bone and cartilage, formed of **glosso-hyal**, **basi-hyal**, and **basi-branchial**; to the sides of which are attached in front the short **cerato-hyals**, and further back, the elongated and jointed **thyro-hyals**, the ventral portions of the first branchial arches.

II. THE APPENDICULAR SKELETON.

A. The Pectoral Girdle.

The pectoral girdle is stout, and is firmly connected with the sternum to give support to the wings. It differs markedly from that of the rabbit in the large size of the coracoid, which is almost perpendicular to the scapula; and in the completeness of the clavicle.

- i. The **scapula** is a long flattened blade-like bone, which in the natural condition of the parts lies above the ribs, a short distance from and almost parallel to the vertebral column. It is connected by muscles with both the ribs and the vertebræ. Its anterior end, which is expanded and firmly connected with the coracoid, bears on its outer surface a shallow depression forming part of the glenoid cavity; and is produced forwards, at its inner border, into a process which helps to form the canal for the tendon of the second pectoral muscle.
- ii. The **coracoid** is a stout straight bone, running from the shoulder to the anterior end of the sternum. Its upper end is connected behind and at its inner side with the scapula, and bears on its outer surface a cup-shaped depression, which forms the greater part of the glenoid cavity.

Above the glenoid cavity, the coracoid is produced upwards and inwards into a strong process, which, with the corresponding process of the scapula, completes the **foramen triosseum**, through which the tendon of the second pectoral muscle passes to its insertion into the back of the humerus. This process also articulates with the clavicle.

The lower end of the coracoid is broad and

flattened, and bears a transversely elongated surface, articulating with the anterior end of the sternum.

- iii. The **clavicles** are a pair of slender curved bones, whose upper ends are slightly expanded, and connected, as described above, with the coracoids; while their lower ends are fused together to form a median laterally compressed plate.

The two clavicles together form the furcula or 'merrythought.'

B. The Fore-Limb or Wing.

The wing of the bird corresponds to the fore-limb of the rabbit, but differs from it in several respects, the more important of which are: (1) the presence of only three digits; and (2) the fusion of the distal row of carpal bones with the three persistent metacarpals to form a compound bone, the **carpo-metacarpus**.

When the wing is extended for flight, its surfaces and borders correspond to those of the primitive vertebrate limb, the preaxial border being directed forwards, the postaxial backwards, and the dorsal and ventral surfaces upwards and downwards respectively. When the wing is folded, in the position of rest, the three main divisions—arm, fore-arm, and hand—are bent on each other like the letter Z, the elbow pointing backwards, and the wrist forwards. Owing to a slight rotation at the shoulder-joint, and a slight obliquity of the elbow-joint, the dorsal surface of the arm now faces inwards and upwards; that of the fore-arm outwards and slightly upwards: while in the hand, which is bent on the fore-arm in a position of extreme abduction, the dorsal surface faces almost directly outwards.

- 1. The **arm** has only a single bone.

- i. The **humerus** is an elongated slightly curved bone, expanded at both ends.

The proximal end, or **head**, presents a large convex vertically elongated surface for articulation with the glenoid cavity, bordered

by two tuberosities, which are preaxial and postaxial respectively.

The preaxial tuberosity is small, but is continued along the bone as the prominent forwardly directed **deltoid ridge**: this gives insertion to the great pectoral and deltoid muscles; while a small tubercle at its proximal end, and partly on the extensor surface, marks the insertion of the tendon of the second pectoral muscle, or elevator of the wing.

The postaxial or greater tuberosity is much larger, and has on its extensor surface a deep pit, the **pneumatic foramen**, leading to an air-cavity in the shaft of the bone.

The distal end of the humerus bears a trochlear articular surface for the radius and ulna; the radial surface being preaxial, and placed obliquely to the long axis of the bone; the ulnar surface being postaxial, and transverse to the axis.

2. The **fore-arm** has two bones, which are separate from each other along their whole length.

i. The **radius** is slender and nearly straight. Its proximal end, or head, presents a terminal cup-shaped articular surface for the preaxial condyle of the humerus; and its distal end articulates with the carpus.

ii. The **ulna** is rather longer and much stouter than the radius, and is slightly curved. Its proximal and larger end has a large articular surface for the postaxial tubercle of the humerus, beyond which it projects as the blunt **olecranon process**. Its distal end articulates with the carpus, and with the radius.

3. The **wrist** consists, in the embryo, of two rows of carpals, a proximal row of two and a distal row of three. Of

these the two proximal carpals persist in the adult, while those of the distal row fuse with the metacarpals to form the compound **carpo-metacarpus**.

- a. The **proximal row of carpals** consists of two small irregular bones.
 - i. The **radiale** lies between the end of the radius and the manus.
 - ii. The **ulnare** is a larger, more irregular bone, which articulates proximally with the ulna, and is notched distally to receive the carpo-metacarpus. It is very freely movable.
4. The **manus**. In the embryo there are three separate metacarpals. It is not certain whether they correspond to those of the three outer, middle, or inner digits. In the adult they fuse together, and with the distal row of carpals, to form the **carpo-metacarpus**. A small nodule of cartilage to the outer side of these disappears completely, or, according to some authorities, fuses with the postaxial metacarpal.
 - a. The **carpo-metacarpus** is an elongated bone, in which the three component metacarpals can easily be distinguished.
 - i. The **preaxial metacarpal** is very short and stumpy, forming a small projection on the preaxial side of the proximal end of the bone.
 - ii. The **middle metacarpal** is a stout straight bone, enlarged at its ends, and giving off near its proximal end a process from its ulnar side.
 - iii. The **postaxial metacarpal** is slightly curved, and is more slender than the middle one, with which it is fused at both ends.
 - b. The **phalanges**.
 - i. The **preaxial digit** has two phalanges, the terminal one being small.
 - ii. The **middle digit** has three phalanges, the proximal

one being large and lamellar, and the distal one very small.

- iii. The **postaxial digit** has only a single phalanx.

C. The Pelvic Girdle.

The pelvic girdle consists of the same three elements on each side—**ilium**, **ischium**, and **pubes**—as the mammalian pelvis, from which, however, it differs widely in form. The three component bones are firmly united to form the **os innominatum**; and at the junction of the three is the **acetabulum**, or socket for the head of the femur, which is partially membranous at its bottom.

- i. The **ilium** is an elongated lamellar bone, which extends a considerable distance both in front of and behind the acetabulum. Its inner border is connected along nearly its whole length with the sacral vertebræ and their processes. The outer surface of the anterior part is concave, that of the posterior part convex: the inner surface of the bone forms, with the adjacent vertebræ, two deeply concave depressions in which the kidneys lie. On the outer surface, immediately behind and above the acetabulum, is a projection, the **anti-trochanter**, which bears on its outer surface an articular facet for the great trochanter of the femur.
- ii. The **ischium** is a flattened lamellar bone, projecting almost horizontally backwards from the acetabulum, of which it forms about a third. It is separated from the ilium, just behind the acetabulum, by the oval **ilio-sciatic foramen**, behind which the two bones are fused together.
- ii. The **pubes** is a long slender bar of bone, which projects downwards and backwards, parallel to the lower border of the ischium. It forms a

very small part of the ventral border of the acetabulum, in front of which it extends forwards as a blunt **pre-pubic process**.

Behind the acetabulum, the pubes and ischium are separated by the slit-like **obturator foramen**, behind which the two bones are fused for a short distance. The hinder end of the pubes is thickened, and extends some distance beyond the ischium.

D. The Hind-Limb.

In the bird's leg there is the same extensive fusion of the bones which is characteristic of other parts of the skeleton. There are no free tarsals, the proximal row having fused with the tibia, and the distal row with the metatarsals.

The position of the limb is the same as in the rabbit; the knee pointing forwards, and the preaxial border being internal along the whole length of the limb.

1. The **thigh** has only a single bone.

- i. The **femur** has a cylindrical slightly curved shaft, and enlarged ends. The proximal end is produced on its inner side into a rounded **head**, articulating with the acetabulum. On the outer or postaxial side of the head is an irregular process, the **great trochanter**. Between this and the head, at the proximal end of the bone, is the articular surface for the anti-trochanter of the ilium.

The distal end of the femur presents in front a deeply grooved pulley-like surface for the **patella**, a sesamoid bone in the tendon of the extensor muscle of the leg: this surface is bounded laterally by two prominent condylar ridges, which articulate with the tibia; the outer or postaxial condyle having on its posterior surface a deeply grooved facet for the upper end of the fibula.

2. The leg.

i. The **tibio-tarsus** is a large stout nearly straight bone, considerably longer than the femur: it is formed by fusion of the tibia with the proximal row of tarsals. The proximal extremity of the bone is much enlarged, and bears at its end two surfaces which articulate with the condyles of the femur; on its extensor surface is the prominent **cnemial crest**, into which the tendon of the extensor muscle of the thigh is inserted, beyond the patella.

The distal end of the bone has a prominent pulley-like articular surface for the tarso-metatarsus. The distal portion, corresponding to the tarsal bones, is easily detached in the young fowl.

ii. The **fibula** is a slender bone, closely applied to the outer or postaxial surface of the **tibio-tarsus**, with which it is often fused. Its proximal end is enlarged, and articulates with the femur; the rest of the bone is very slender, and usually does not reach to the ankle.

3. The **ankle-joint** is between the proximal and distal rows of tarsals: these at a very early age fuse with the tibia and metatarsus respectively, so that in the adult there are no free tarsal bones.

4. The **pes**. The first four digits are present: the metatarsal of the first is small and imperfect: those of the next three are large, and are fused with one another and with the distal tarsal row. The fifth or postaxial digit, corresponding to the little toe in man, is represented by a rudimentary metatarsal.

a. The **tarso-metatarsus** is a stout straight bone, about as long as the femur, and formed by the fusion of the distal tarsal row with the second, third, fourth, and fifth metatarsals. Its proximal end is enlarged, and bears terminally two cup-shaped

facets for the tibio-tarsus ; on its posterior surface is a prominent ridge, deeply grooved behind, and traversed at its base by a longitudinal canal, for the passage of the tendons of the flexor muscles of the toes. Behind the ridge, two sesamoid bones are usually present.

In the shaft of the bone, three metatarsals can easily be distinguished. They do not lie quite parallel to one another, the middle one being slightly posterior to the other two at its proximal end, and anterior distally.

At the distal end of the bone, the three metatarsals separate from one another, and each ends in a pulley-like surface for the corresponding digit.

- b. The **first metatarsal** is incomplete, its distal end alone being ossified. It is a small irregular nodule of bone, attached by ligament to the inner and posterior surface of the tarso-metatarsus, a short distance above its distal end.
- c. The **digits**. The four preaxial digits are present. In many domestic fowls, notably Dorkings, an extra or supernumerary toe is present on the inner side of the foot. The true fifth, or postaxial digit, is always absent.
 - i. The **hallux**, or great toe, is connected with the first metatarsal, and directed backwards. It consists of two phalanges, the last one bearing a claw.
 - ii. The **second toe** is directed forwards and slightly inwards. It has three phalanges, the last one clawed.
 - iii. The **third toe** is the largest and is directed forwards. It has four phalanges, the terminal one clawed.
 - iv. The **fourth toe** is directed forwards and outwards. It has five phalanges, and the distal one is clawed,

CHAPTER XV.

DISSECTION OF THE PIGEON. *Columba livia*.

BIRDS are in many respects the most highly differentiated vertebrates. While agreeing in their essential morphological characters with the other air-breathing vertebrates, and more especially with reptiles, they present a number of very special characters, chiefly connected with the power of flight.

The modifications in the skeleton have been noticed in the preceding chapter: in the other systems the most noteworthy features are:—(1) the development of feathers, which are very highly specialised products of the epidermis; (2) the great size of the pectoral muscles, by which flight is effected; (3) the prolongation of the bronchi through the lungs into spacious thin-walled air-sacs, lying between the viscera, and prolonged into several of the bones; (4) the persistence of the fourth right aortic arch, instead of, as in mammals, the fourth left, to form the arch of the aorta; (5) the lateral, instead of dorsal, position of the optic lobes of the brain; and (6) in the female, the disappearance, during development, of the ovary and oviduct of the right side.

Physiologically, the most interesting points are:—the high temperature of the blood, which exceeds that of mammals, varying between 100° and 110° F. in different birds; and the modification in the mechanism of respiration, expiration being the active movement, and inspiration almost purely passive.

Birds are oviparous, and the eggs, which are of large size, are protected by calcareous shells. The eggs are fertilised in the upper part of the oviduct before the shell is formed, and

hence commence to develop before they are laid. The egg contains within itself sufficient nutriment for the development of the chick up to the time of hatching : and all that is necessary to ensure development is that the egg, after it is laid, should be kept at about the temperature of the parent's body. This is in most birds effected by incubation, a task usually fulfilled by the hen bird, but sometimes wholly or in part by the cock.

The food of the pigeon consists largely of hard seeds, and small stones are swallowed with it.

Pigeons should be killed with chloroform, otherwise the lice with which they are invariably infested may prove a great nuisance. Before the dissection is commenced, the bird should be thoroughly plucked, with the exception of one of the wings, on which the feathers may be left till later.

I. EXTERNAL CHARACTERS.

Excepting the lower joints of the legs and the toes, nearly the whole surface of the body is covered with feathers.

A. The Main Divisions of the Body.

1. The **head** is elongated antero-posteriorly, and produced in front into a pointed horny **beak**.

At the base of the beak is a naked swollen patch of skin, the **cere**.

At the sides of the head are the large eyes, each provided with upper and lower lids, and with a well-developed third eyelid, or **nictitating membrane**, a semi-transparent fold of skin which can be drawn across the eye from its anterior angle with great rapidity.

2. The **neck** is very long and flexible.

3. The **trunk** is deep dorso-ventrally, and somewhat compressed from side to side. Along the mid-ventral

line is a prominent ridge, formed by the ventral border of the carina, or keel of the sternum.

Posteriorly the trunk ends in a short blunt tail.

B. The Limbs.

1. The wing.

Identify the several bones of the wing by feeling them through the skin. Note also the varying positions of the surfaces of the several divisions of the wing, when it is extended and folded respectively (p. 417).

The **ala spuria**, or **bastard wing**, is a small tuft of feathers attached to the phalanx of the preaxial digit.

2. The leg.

The toes and the tarso-metatarsal region are, except in some domesticated breeds, devoid of feathers and covered with large horny epidermal scales. The ends of the toes are provided with horny claws.

C. The feathers.

The possession of feathers, which are specially modified epidermal structures, is one of the most characteristic features of the bird.

1. Structure of a feather.

Pull out one of the large feathers from the wing or tail; and note in it the following points.

a. The **scapus**, or **stem**, is a stiff axial rod, running the whole length of the feather. It consists of two dissimilar portions.

i. The **calamus**, or **quill**, is the tubular semi-transparent proximal portion, the base of which is inserted in the skin. At the proximal end of the quill there is a small aperture, the **inferior umbilicus**; and at its distal end, between the quill and the vane, there is a second aperture, the **superior umbilicus**.

- ii. The **rachis**, or **shaft**, is the distal solid portion of the stem. It is a tapering, flexible, elastic rod, square in transverse section, and grooved along its ventral surface.
- b. The **vexillum**, or **vane**, is the flattened portion of the feather, attached along the sides of the rachis. It is made up of barbs and barbules.
 - i. The **barbs** are a series of narrow elastic laminae, attached by their bases along the two sides of the rachis, perpendicular to the plane of the vane.
 - ii. The **barbules** are much smaller processes, which form fringes along the sides of the barbs: they bear hooklets, which hold together the adjacent barbs, and so give the feather that resistance to the air on which the bird's power of flight depends.

2 Varieties of feathers.

- a. The **quill feathers** are the large feathers of the wings and tail: they are of two kinds.
 - i. The **remiges**, or wing-quills, have the inner or posterior half of the vane much broader than the outer or anterior half. They are divided into groups in accordance with the bones to which they are attached (fig. 73, p. 436).

The **primary quills** are those attached to the bones of the manus. They are eleven in number, of which six are attached to the middle metacarpal, and are hence called **metacarpal quills**: one, **ad-digital**, is attached to the phalanx of the postaxial digit; two, **mid-digital**, to the proximal phalanx of the middle digit: and two, **pre-digital**, one of which is small, are attached to the distal phalanx of the middle digit.

The **secondary quills** are those attached to the ulna.

- ii. The **rectrices**, or tail-quills, have the two halves of the vane about equal in size. They are used by the bird for steering during flight.

There are twelve in the wild rock-pigeon, but may be more in domestic breeds.

- b. The **coverts** are the smaller feathers which cover the bases of the quills of the wings and tail.
- c. The **contour feathers** are the short soft feathers covering the body generally. The barbules are less perfectly developed than in the quill-feathers, so that the barbs easily separate from one another, especially at the base of the vane.
- d. The **filoplumes** are the minute rudimentary feathers left in the skin after the bird has been plucked. Each consists of a hair-like stem, with a very rudimentary vane at its apex.

3. Arrangement of the feathers.

The feathers are attached to certain definite areas of the skin, known as **pterylæ**, the intervening tracts or **apteria** being devoid of feathers. This arrangement is not very obvious in the pigeon, in which the feathers are more uniformly distributed than in many birds. Apterium may, however, be seen in the mid-ventral and mid-dorsal regions of the body, and along the outer surfaces of the proximal segments of the wings.

D. External Apertures.

a. Median apertures.

- i. The **mouth** is a wide slit-like opening in the long pointed beak.
- ii. The **cloacal aperture** is a transverse slit, with prominent lips, on the ventral surface of the body, below the base of the tail.

b. Paired apertures.

- i. The **nostrils** are a pair of oblique slit-like apertures, between the beak and the cere.

- ii. The **external auditory apertures** are a pair of circular openings, below and slightly behind the posterior or outer angles of the eyes. Each is surrounded by a circlet of small backwardly directed feathers, the **auriculars**.

Each leads inwards, and slightly backwards and downwards, to the tympanic cavity.

II. DISSECTION OF THE PECTORAL MUSCLES.

Remove the skin from the ventral surface of the thorax and from one shoulder, so as to fully expose the first pectoral muscle. Clean this muscle along its whole length, defining its boundaries carefully. Ligature the large blood-vessels.

1. The **first or great pectoral muscle** is large and triangular, and forms the greater part of the side of the breast. It arises from the whole length of the ventral half of the keel of the sternum, from the whole length of the clavicle, and from the lateral part of the body of the sternum. Its fibres run forwards and outwards, converging to a broad flat tendon, which is inserted into the deltoid ridge of the humerus. From the anterior border of the muscle, near the shoulder, a slip is sent off to the skin.

The great pectoral is the main depressor of the wing, and the most important of the muscles of flight.

Cut through the great pectoral muscle, transversely to its fibres, and about the middle of its length. Turn the two halves of the muscle aside, so as to clearly define its origin and insertion; then cut away the muscle entirely.

2. The **second pectoral muscle** is a smaller and more deeply placed muscle, similar in shape to the first pectoral, and completely covered by it.

It arises from the dorsal part of the side of the keel of the sternum, and from the inner part of the

ventral surface of its body. Its fibres run forwards and outwards, converging to be inserted into a long tendon, which passes through the **foramen triosseum**, formed by the scapula, coracoid, and clavicle, and reaches the back of the shoulder-joint, where it is inserted into the dorsal surface of the humerus, near the deltoid ridge.

Owing to the course taken by its tendon, the muscle elevates the wing, and so opposes the great pectoral muscle.

To see the insertion of the tendon of the second pectoral muscle, remove or push aside the deltoid muscle, which covers the back of the shoulder-joint. Test the action of the muscle by pulling the tendon.

3. The **third pectoral muscle** is a small triangular muscle, arising from the outer border of the ventral two-thirds of the coracoid, and from the costal process of the sternum. Its fibres run forwards and outwards, to be inserted into the postaxial border of the head of the humerus. It aids the great pectoral muscle in depressing the wing.

III. DISSECTION OF THE AIR-SACS.

The air-sacs are large but very thin-walled sacs, lying mainly along the sides and dorsal surface of the body-cavity. They communicate, as already noticed, with the bronchi, and they play a very important part in the mechanism of respiration of the bird.

Expiration is effected by the thoracic and abdominal muscles, which compress the thorax and abdomen, driving the air from the air-sacs, through the lungs and trachea.

Inspiration is effected by the elastic expansion of the thorax and abdomen on relaxation of the muscles: this expansion causes an inrush of air along the trachea, through the lungs and into the air-sacs, the lungs being thus filled with fresh air.

A complete dissection of the air-sacs is not easy to per-

form, and involves a good deal of damage to other structures. The main features in their distribution and relations can, however, be easily determined, as described below. The dissection of the air-sacs must precede that of the other systems, as if they are once cut into, the walls of the sacs collapse and they can no longer be inflated.

The air-sacs are nine in number : a median **interclavicular**, a pair of **cervical** or **pre-bronchial**, two pairs of **thoracic** or **intermediate**, and a pair of **abdominal** or **posterior**.

Make a median ventral incision through the skin of the neck, and pin out the flaps. Note the œsophagus, a wide fleshy median tube ; and the trachea, which lies to the left of the œsophagus, and is easily recognised by the close-set rings by which it is surrounded.

Separate the trachea from the surrounding tissues in the hinder part of the neck, and pass a ligature round it. Slit open the trachea about the middle of its length ; pass a blow-pipe down the trachea through the slit, and tie it firmly in. Inflate the lungs and air-sacs through the blowpipe, and tighten the ligature round the trachea to prevent the air escaping.

Make a mid-ventral incision through the skin from the posterior edge of the sternum to the cloaca, and a transverse incision along the posterior border of the sternum. Carry the incisions through the muscles of the abdominal walls, taking care not to injure the viscera beneath, and reflect the flaps outwards.

1. The **posterior** or **abdominal air-sacs** are a pair of large sacs, with very thin transparent membranous walls, which lie along the dorsal wall of the pelvic cavity, ventral to the kidneys but dorsal to the intestine. At the hinder end of the abdomen they come close up to the ventral surface when inflated.

Each communicates with the posterior border of the corresponding lung, near its outer angle.

2. The **posterior thoracic air-sacs** are a pair of rather smaller sacs, lying along the outer sides of the anterior

ends of the abdominal sacs. They lie mainly posterior to the lungs, but overlap the ventral surfaces of their hinder ends.

Each communicates with the outer and posterior angle of the corresponding lung.

3. The **anterior thoracic air-sacs** cover the ventral surfaces of the anterior two-thirds of the lungs, and extend back so as to overlap the posterior thoracic sacs. They lie at the sides of the thorax, and are in extensive contact with the ribs and with the pericardium.

Each communicates with the ventral surface of the lung, rather in front of the middle of its length, and not far from the median plane of the body.

4. The **interclavicular air-sac** is a median sac, formed by the fusion of two originally distinct ones. It consists of (1) a median portion, which surrounds the hinder end of the trachea, and can easily be seen in the angle between the two clavicles; and (2) lateral diverticula, one of which runs forwards along each side of the trachea, while others pass outwards, beneath the coracoid, and open into large **axillary air-sacs** in the neighbourhood of the shoulder-joints, which communicate with the cavities of the humeri.

The interclavicular air-sac opens into the ventral surface of each lung, immediately in front of the point of entrance of the main bronchus.

5. The **cervical air-sacs** are much smaller, and lie in front of the lungs at the base of the neck, alongside the vertebral column.

They communicate with the anterior angles or apices of the lungs.

The position, extent, and relations of the air-sacs can be best made out in a bird in which they have been distended with a solution of chromic acid (2 per cent.), and the whole bird then thoroughly hardened by immersion in the same solution for about a week. The specimen is then to be preserved in spirit.

IV. DISSECTION OF THE DIGESTIVE SYSTEM.

A. The Buccal Cavity.

Open the mouth slightly ; cut through the cheek, parallel to the jaws, for about half an inch on each side ; and turn down the floor of the mouth so as to expose the cavity fully. Note the following structures.

1. The **posterior narial apertures** are a pair of long narrow apertures, lying side by side in the roof of the mouth. The anterior two-thirds of their length is hidden by a pair of prominent folds of the mucous membrane of the palate.
2. The **aperture of the Eustachian tubes** is a median opening, behind the posterior narial apertures.

Pass a bristle through the aperture, and along the right and left Eustachian tubes to the tympanic cavities.

3. The **tongue** is triangular, ending in front in a sharp forwardly directed point ; and produced behind into a pair of backwardly directed lobes, fringed with fine horny processes.
4. The **glottis** is an oval aperture, with tumid lips, in the floor of the mouth, just behind the tongue.
5. The **entrance to the œsophagus** is large and wide, and situated behind the glottis.

B. The Abdominal Viscera in situ.

Lift up the hinder end of the sternum, and cut through its sides about midway between the dorsal and ventral surfaces. Cut through the coracoids and clavicles about the middle of their length. Detach the sternum with a scalpel from the underlying parts, and remove it entirely.

1. The **falciform ligament** is a median vertical sheet of peritoneum, connecting the dorsal surface of the sternum with the viscera : it is continuous in

front with the pericardium, and behind with the omentum.

2. The **oblique septum**, a fibrous membrane attached to the pericardium, and extending backwards, separating the air-sacs from the general body-cavity.
3. The **heart**, which is still enclosed in the pericardium, is large and conical, with the apex directed backwards. It lies in the anterior part of the thorax.
4. The **lungs** are spongy bodies lying at the sides of, and dorsal to, the heart, and very largely concealed by it.
5. The **liver** is a solid lobed organ, of a dark red colour, lying behind, and at the sides of the heart.
6. The **great omentum** is a fold of mesentery loaded with fat, covering the viscera behind the liver. It is continuous in front with the falciform ligament.

Lift up the great omentum to expose the organs covered by it.

7. The **gizzard** is a large firm body, lying immediately behind the left lobe of the liver.
8. The **duodenum** is a loop of intestine, lying along the right side of the abdominal cavity, and embracing the **pancreas**.
9. The **intestine** forms a convoluted mass in the hinder part of the abdomen.

C. The Alimentary Canal.

Unravel the intestine by cutting through the mesentery close to it, but taking care not to touch the duodenal loop.

Note the veins in the mesentery, which collect the blood from the alimentary canal, and converge to form the **portal vein**, which enters the liver in the notch between its right and left lobes.

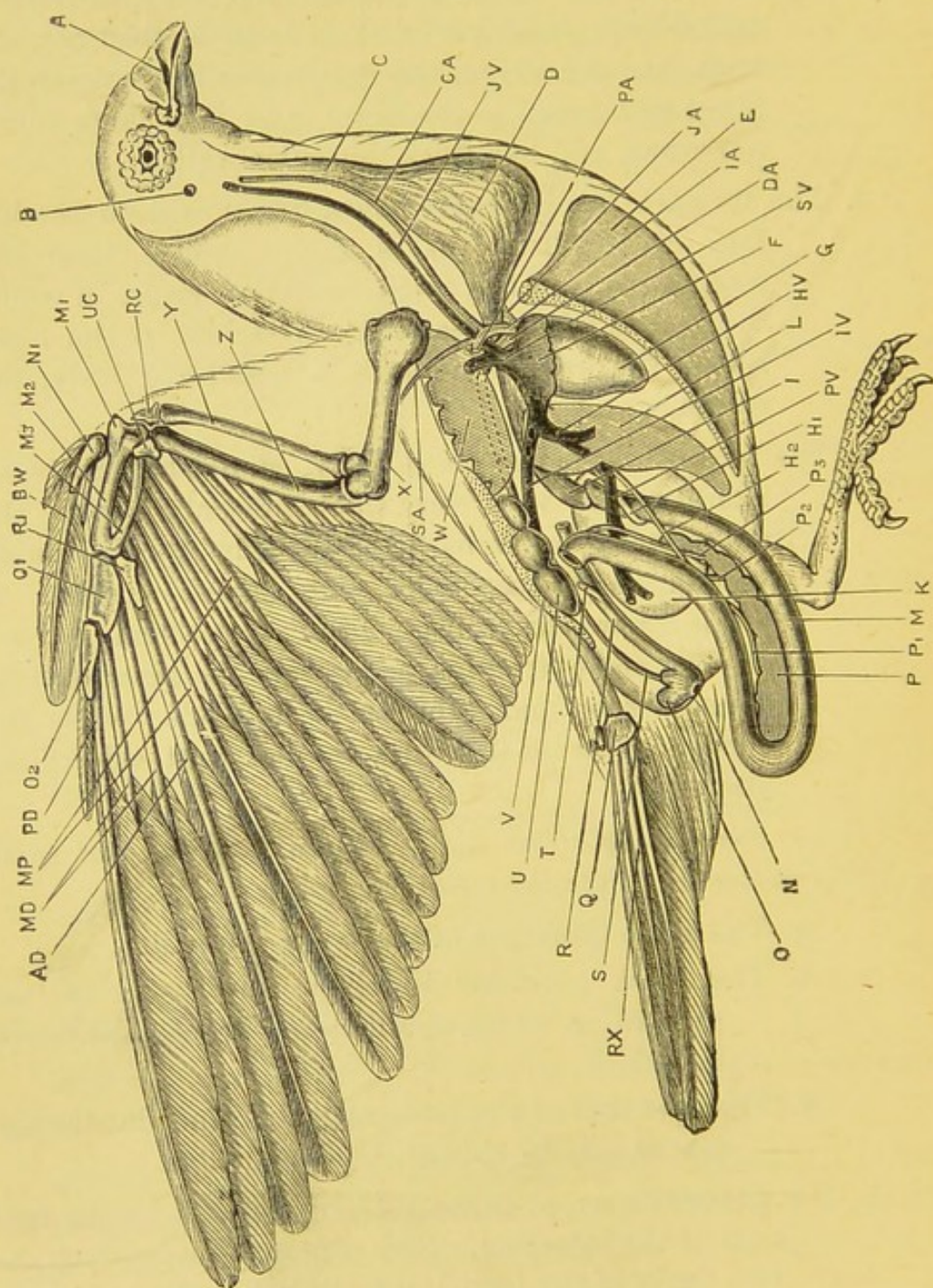
Note also, and preserve, the **posterior mesenteric vein**, which runs in the mesenterial fold connecting the rectum with the dorsal wall of the abdomen.

1. The **œsophagus** commences at the hinder part of the buccal cavity, and runs back through the neck and thorax to the stomach. In the neck it is thin-walled, and dilates behind to form a large bilobed sac, the **crop**. In the thorax the œsophagus lies between the lungs and dorsal to the heart, and it is here much narrower, and has thick muscular walls.
2. The **stomach**, or **proventriculus**, lies dorsal to the left lobe of the liver: it is rather wider than the œsophagus, and has thick glandular walls, in which the gastric juice is secreted. Attached to the right side of the proventriculus is a small red body, the **spleen**.
3. The **gizzard** is a large hard body, somewhat flattened laterally, and with very thick muscular walls, the muscular fibres radiating outwards from a bluish tendon in the centre of each lateral surface. It forms a powerful mill for grinding the food.

The proventriculus opens into the gizzard at its dorsal border, and rather to the left side; while the duodenum leaves it a little to the right side of the same spot.

Split open the gizzard along its ventral edge, and wash out the contents. Note the following points:—

- a. The great thickness of the muscular walls.
 - b. The thick cuticular lining to the cavity of the gizzard, in which small stones are usually found imbedded.
 - c. The openings of the proventriculus and duodenum, placed side by side at the dorsal edge.
4. The **duodenum** is a U-shaped loop, formed by the first part of the intestine. The pancreas lies between the two limbs of the loop, the further dissection of which will be postponed until the liver and pancreas are examined.
 5. The **small intestine** is a much-convoluted tube, of nearly



uniform diameter, and about two feet and a half in length.

6. The **rectum**, or terminal portion of the intestine, is about an inch and a half long. Its commencement is marked by a pair of small cæcal processes, the **rectal diverticula**. Posteriorly, the rectum opens into the cloaca, the examination of which should be deferred until the kidneys have been dissected.

D. The Liver.

The liver is divided into a larger right, and a smaller left lobe, the surfaces of which are hollowed and grooved to receive the heart, duodenum, and gizzard.

The **bile-ducts** are two in number, and open into the duodenum.

1. The **left bile-duct** is a wide tube, about an inch long, which, emerging from the notch between the right and left lobes of the liver, runs backwards to open into the proximal limb of the duodenum, about half an inch beyond the gizzard.
2. The **right bile-duct** is longer and narrower. It leaves the liver near the dorsal margin of the right lobe,

FIG. 73.—*Columba livia*. Dissection of the male from the right side. Half the liver and the greater part of the intestine have been removed. In the right wing, the bones and the arrangement of the primary and secondary feathers are shown. The reproductive organs are omitted. (A. M. M.)

A, nostril. AD, ad-digital primary feather. B, external auditory meatus. BW, bastard wing. C, œsophagus. CA, right carotid artery. D, crop. DA, aorta. E, keel of the sternum. F, right auricle. G, right ventricle. HV, hepatic vein. H 1, left bile-duct. H 2, right bile-duct. I, distal end of proventriculus or stomach. IA, right innominate artery. IV, posterior vena cava. JA, left innominate artery. JV, right jugular vein. K, gizzard. L, liver. M, proximal limb of duodenum. MD, the two mid-digital primary feathers. MP, the six metacarpal primary feathers. M 1, preaxial metacarpal. M 2, middle metacarpal. M 3, postaxial metacarpal. N, cloacal aperture. N 1, preaxial digit of manus. O, bursa Fabricii. O 1, proximal phalanx of middle digit of manus. O 2, distal phalanx of middle digit of manus. P, pancreas. PA, right pectoral artery. PD, pre-digital primary feather. PV, portal vein. P 1, first pancreatic duct. P 2, second pancreatic duct. P 3, third pancreatic duct. Q, pygostyle. R, Rectum. RC, radial carpal bone. RX, rectrices or tail feathers. R 1, ulnar digit of manus. S, ureter. SA, right subclavian artery. SV, right anterior vena cava. T, rectal diverticulum. U, kidney. UC, ulnar carpal bone. V, pelvis. W, lung. X, humerus. Y, radius. Z, ulna.

and runs back to open into the distal limb of the duodenum, about the junction of its middle and distal thirds.

E. The Pancreas.

The pancreas is a compact pinkish gland lying in the loop of the duodenum, along nearly the whole of its length, and grooved by it.

The **pancreatic ducts** are three in number, and all open into the distal limb of the duodenum.

The first two ducts leave the right border of the gland about the middle of its length, and run forwards, parallel to each other, to open close together into the distal limb of the duodenum, about the middle of its length, and close to the right bile-duct.

The third pancreatic duct is longer than the others. It leaves the gland near its anterior end, and runs forwards to open into the distal limb of the duodenum, close to its junction with the small intestine.

Pin out the duodenum on a dissecting board, and expose the bile-ducts and pancreatic ducts. The dissection is best performed under water, and from the dorsal surface.

V. DISSECTION OF THE CIRCULATORY SYSTEM.

A. The Heart.

The heart of the bird is large, and is divided into four chambers, those of the right side being completely separated from those of the left. The right side of the heart receives the blood which is brought back by the veins from all parts of the body, and drives it to the lungs to be aërated: from the lungs it is returned to the left side of the heart, and thence driven all over the body through the arteries. The right side of the heart therefore contains venous blood, and the left side arterial blood.

Open the pericardial cavity so as to expose the heart fully; and dissect away the connective tissue and fat from the vessels at the base of the heart.

The heart is conical, with the apex directed backwards and slightly to the left side. A line of fat, which encircles it, marks externally the division into auricular and ventricular portions.

1. The **auricular portion** is anterior in position, and forms the base of the cone. It is thin-walled, dark in colour, and divided into right and left auricles, the division being indicated externally by a line of fat.
2. The **ventricular portion** is posterior, and forms the apex of the cone. It is much thicker-walled than the auricular portion, and paler in colour. The division between right and left ventricles is not obvious externally.

B. The Veins.

The veins should be dissected before the arteries, as they lie for the most part nearer the surface. Great care must be taken not to cut or tear them, as bleeding occurs freely, and is apt to be very troublesome. If a complete dissection is required, the venous system should be injected from either the femoral or the jugular vein.

1. **Veins opening into the right auricle.** The right auricle receives the venous blood from the whole of the body by three large veins, the **venæ cavæ**.

- a. The **right anterior vena cava** returns blood from the right side of the head and neck, the right wing, and the right side of the breast.

It is a short wide vein, about a quarter of an inch in length, opening into the right anterior angle of the right auricle: it is formed by the union of three principal veins.

- i. The **right jugular vein** runs along the right side of the neck, close to the vertebral column, and dorsal to the œsophagus.

Anteriorly it unites with the left jugular vein, on the under surface of the base of the

skull. In its course down the neck it receives veins from the side of the neck and from the crop; and at the posterior end of the neck it is joined by the **vertebral vein**.

ii. The **right brachial vein** returns blood from the wing.

iii. The **right pectoral vein** is the largest of the three. It returns blood from the pectoral muscles, and receives also the **internal mammary vein**, which runs along the inner surface of the thoracic wall.

b. The **left anterior vena cava** returns blood from the left side, by veins corresponding to those opening into the right vena cava. At the base of the heart, it runs transversely across the dorsal surface of the left auricle, to open into the left border of the right auricle.

To see the opening of the left vena cava into the auricle, lift up the apex of the heart, and turn it forwards.

c. The **posterior vena cava** returns blood from the posterior part of the body, including the liver.

It is formed by the union of the two **iliac veins** a short distance behind the liver. The vein, so formed, runs forwards through the substance of the right lobe of the liver, close to its dorsal surface; it receives the **hepatic veins** as it leaves the liver, and then runs forwards as a short wide vessel to open into the posterior surface of the right auricle.

Turn the heart forwards, to expose the posterior vena cava as it enters the right auricle. Follow it back through the liver, slitting it up and washing out the contained blood. Note the openings of the hepatic veins, and follow them with a seeker into the liver. Follow the vena cava back, behind the liver, to the point where it is formed by the union of the right and left iliac veins.

2. The veins of the kidneys.

The veins in connection with the kidneys are best dissected in specimens injected from the femoral vein. Their relations may, however, be determined in an uninjected specimen by slitting them open and following them with a seeker.

The kidneys are a pair of elongated three-lobed bodies, lying against the ventral surface of the ilia, at the sides of the sacrum.

The general arrangement of the veins is as follows:—

Two large veins enter each kidney, the **femoral** and the **hypogastric**, returning blood from the leg and the intestine respectively. They traverse the kidney and unite within it. The common trunk formed by their union is joined by the **renal vein**, returning blood from the substance of the kidney itself, and emerges from the inner side of the kidney as the **iliac vein**, which unites with its fellow of the opposite side to form the **posterior vena cava**.

- a. The **posterior mesenteric vein** is a median vein, running backwards in the mesentery supporting the rectum: it collects the blood from the hinder part of the small intestine, and from the rectum and cloaca. Opposite the posterior end of the kidneys it receives a small median **caudal vein** from the tail, and at once divides into the right and left hypogastric veins.
- b. The **hypogastric vein** of each side is joined by the **internal iliac vein** from the inner surface of the pelvic cavity, and then enters the kidney at its posterior end: it runs forwards through the posterior and middle lobes of the kidney, and joins the **femoral vein**, in the groove between the middle and anterior lobes. It receives blood from the dorsal and outer portions of these two lobes.

- c. The **femoral vein** returns the blood from the leg. Entering the kidney at its outer side, between the middle and anterior lobes, it is joined, as just noticed, by the **hypogastric vein**: a little further on it receives the **renal vein**, returning blood from the inner and ventral portions of the two hinder lobes of the kidney, and smaller veins from the anterior lobe: and it finally emerges from the kidney as the **iliac vein**.
- d. The **iliac vein**, formed in this way by the junction of the **femoral**, **hypogastric**, and **renal veins**, leaves the kidney at its inner border, between its anterior and middle lobes; and then runs forwards, uniting opposite the anterior end of the kidney with the **iliac vein** of the other side, to form the **posterior vena cava**.

3. The hepatic portal system.

The **portal vein** lies in the omentum, between the two bile-duets, and on reaching the liver divides into two branches, one supplying each lobe. It conveys to the liver the blood from the greater part of the length of the alimentary canal, and is formed by the union of three chief veins.

- a. The **gastro-duodenal vein** returns the blood from the right side of the gizzard, from the duodenum, and from the last loop of the small intestine.
- b. The **anterior mesenteric vein** returns blood from the greater part of the length of the small intestine.
- c. The **posterior mesenteric vein** returns blood from the hinder part of the small intestine, and from the rectum. The blood in the anterior part of this vein flows forwards to the portal vein, that in the hinder part backwards to the hypogastric veins.

4. Veins opening into the left auricle.

The **pulmonary veins**, which are extremely

short, open into the posterior surface of the left auricle.

Turn the heart forwards : open the left auricle : wash out the contents ; and pass a seeker along the pulmonary veins into the lungs.

C. The Arteries.

1. The **pulmonary artery** is a single trunk, which arises from the anterior end of the right ventricle, close to the ventral surface and a little to the left of the median plane. It divides soon after its origin into right and left pulmonary arteries.

a. The **left pulmonary artery** is short, and passes direct to the left lung, which it enters in front of the pulmonary vein, and ventral to the left bronchus.

b. The **right pulmonary artery** passes dorsal to the other arterial trunks, to enter the right lung in front of the bronchus.

2. The **aorta** arises from the base of the left ventricle, lying between the two auricles, and to the right of, and slightly dorsal to, the pulmonary artery. It gives off almost immediately the very large **right and left innominate arteries**, and then continues its course as the **dorsal aorta**.

a. The **left innominate artery** is a short wide artery, which divides, after a course of about a quarter of an inch, into two vessels of very unequal size.

i. The **left carotid artery**, which is much the smaller of these two vessels, runs forwards along the neck, lying close to its fellow of the opposite side, in a groove along the ventral surface of the vertebral column.

About half an inch from its origin it gives off the **vertebral artery**, which runs forwards

along the side of the neck, in the vertebral canal of the cervical vertebræ.

Opposite the angle of the jaw, the **carotid artery** divides into **external** and **internal carotid arteries**.

- a. The **external carotid artery** supplies the tongue, the muscles of the jaws, and other parts of the head.
- β . The **internal carotid artery** enters the skull by a foramen in its base, and supplies the brain.
- ii. The **subclavian artery**, which is much the larger of the two branches of the innominate, runs outwards, and divides, after a course of not more than an eighth of an inch, into the **brachial** and **pectoral arteries**.
 - a. The **brachial artery** runs straight outwards to the wing, giving a branch to the shoulder-joint.
 - β . The **pectoral artery** is a large vessel, very little smaller than the innominate itself: it runs outwards and backwards, looping round the outer side of the sternal end of the coracoid, to enter the deeper surface of the great pectoral muscle, in which it divides into numerous branches.
- b. The **right innominate artery** has branches exactly corresponding to those of the left innominate.
- c. The **dorsal aorta**, which is rather smaller than either of the innominate arteries, arches over to the right side, crosses the right pulmonary artery, and then runs backwards along the mid-dorsal line of the thorax and abdomen. Its principal branches are as follows.
 - i. The **cœliac artery** is a median vessel which arises about the level of the auriculo-ventricular septum of the heart. It runs back in the

mesentery, and divides into branches which supply the stomach, gizzard, and part of the intestine.

- ii. The **anterior mesenteric artery** is a median vessel, which arises about a quarter of an inch behind the coeliac artery, and runs backwards in the mesentery, dividing into branches which supply the greater part of the length of the intestine.
- iii. The **anterior renal arteries** are a pair of small vessels, which arise from the aorta opposite the anterior ends of the kidneys, and supply their anterior lobes. From the artery of the left side a branch is given off to the ovary.
- iv. The **femoral arteries** are paired, and arise opposite the anterior lobes of the kidneys. They pass outwards, dorsal to the kidneys, to supply the extensor muscles of the thigh. Each gives off a **pubic artery**, which runs backwards along the ventral border of the pubes.
- v. The **sciatic arteries** are a pair of larger vessels which arise opposite the middle lobes of the kidneys: they pass outwards and backwards, between the middle and posterior lobes of the kidneys, and through the ilio-sciatic foramina, to supply the flexor muscles of the thighs and the muscles of the legs.

Each sciatic artery gives off a **middle renal artery** to the middle lobe of the kidney, and a **posterior renal artery** to the posterior lobe.
- vi. The **posterior mesenteric artery** is a median vessel, which arises opposite the hinder ends of the kidneys, and supplies the rectum and cloaca.
- vii. The **internal iliac arteries** are a pair of vessels

arising about the same level as the posterior mesenteric artery, and running outwards and backwards along the hinder part of the pelvis.

- viii. The **caudal artery** is the terminal portion of the dorsal aorta: it runs along the ventral surface of the caudal vertebræ.

D. Dissection of the Heart.

The heart may be dissected in situ, or the vessels may be cut across about a quarter of an inch from it, and the heart removed and placed under water in a dissecting dish.

1. The auricles.

Slit up the outer wall of the two auricles with scissors, and wash out the contained blood.

a. The right auricle.

i. The openings of the venæ cavæ.

Pass a seeker into these openings, and note their positions relatively to the cavities of the heart.

- ii. The **Eustachian valve** is a muscular fold, projecting into the cavity of the auricle, on the right side of the opening of the posterior vena cava.

- iii. The **septum auricularum** is a thin muscular partition, dividing the right and left auricles from each other. Near its centre is a thin oval patch, the **fossa ovalis**, marking the position of the **foramen ovale** of the embryo.

- iv. The **right auriculo-ventricular aperture** is a large crescentic opening in the posterior wall of the auricle.

b. The left auricle.

- i. The **openings of the pulmonary veins** are in a small recess of the dorsal wall of the auricle.

- ii. The **left auriculo-ventricular aperture** is circular.

2. The ventricles.

Cut across the ventricles transversely, about the middle of their length. Note the shapes of the cavities, and the thickness of their walls.

- a. The **right ventricle** wraps round the right side of the left ventricle. Its outer wall is comparatively thin, and its cavity is crescentic in transverse section.
 - i. The **right auriculo-ventricular valve** is a muscular flap, projecting into the ventricular cavity, on the right side of the auriculo-ventricular aperture. It is connected by **chordæ tendineæ** with the wall of the ventricle.
 - ii. The **aperture of the pulmonary artery** is at the extreme anterior end and left side of the ventricle.

Pass a seeker from the ventricle along the pulmonary artery, and lay this open with scissors.

- a. The **semilunar valves** are three crescentic pocket-like flaps, guarding the entrance to the artery.
- b. The **left ventricle** has very thick spongy walls, except at the apex, where it is thin. Its cavity is somewhat irregular in shape, but is more or less circular in transverse section.
 - i. The **left auriculo-ventricular or mitral valve** is formed by two membranous flaps, which project into the ventricle. Their hinder borders are attached by **chordæ tendineæ** to muscular processes of the ventricular wall, the **musculi papillares**.
 - ii. The **aperture of the aorta** is at the anterior end of the ventricle, and at its right side. In the natural position of the parts, it lies dorsal to the aperture of the pulmonary artery.

Pass a seeker from the ventricle along the aorta, and lay it open with scissors along its right side.

- a. The **semilunar valves** are three pocket-like flaps, similar to those of the pulmonary artery.

VI. DISSECTION OF THE RESPIRATORY SYSTEM.

Remove the heart, if this has not already been done, and also the alimentary canal and liver. Clean the trachea and the ventral surface of the lungs.

1. The **trachea**, or windpipe, is a tube which commences in front at the glottis, runs back along the neck, and divides in the thorax into two bronchi, entering the right and left lungs respectively.

It is surrounded by a series of closely set rings, which are ossified ventrally, and cartilaginous dorsally.

In the anterior part of the neck the trachea is ventral to the œsophagus; further back it lies along its left side. In the thorax, where it again lies ventral to the œsophagus, it divides into the two bronchi, which run outwards and backwards to enter the lungs on the ventral surface and near their anterior ends.

2. The **lungs** are a pair of spongy bodies, attached to the dorsal and dorso-lateral walls of the anterior part of the thorax. They are covered ventrally by the **pleura**, an anterior continuation of the peritoneum. Their inner edges lie close together, separated from each other in the median plane by the projecting centra of the thoracic vertebræ, and by the dorsal aorta.

Remove the pleura from the ventral surface of one lung; and separate the lung from the thoracic wall, noting its close attachment to this wall, and the grooves in its surface which lodge the ribs.

3. The **syrix**, or '**lower larynx**,' is the organ of voice of the pigeon, and is formed by the dilated hinder end of the trachea, and the commencement of the bronchi.

Cut across the trachea about an inch in front of its bifurcation. Make two lateral incisions, with scissors, along the sides of the trachea and bronchi, and turn down the ventral wall.

- i. The **tympanum** is the cavity of the lower end of the trachea and commencement of the bronchi.
- ii. The **membrana tympaniformis interna** is the mucous membrane lining the inner wall of the commencement of each bronchus.
- iii. The **membrana semilunaris** is a delicate vertical fold of mucous membrane, extending forwards into the tympanum from the angle of bifurcation of the trachea : by its vibration the voice is produced.
- iv. The **pessulus** is a slender bar of cartilage running across the tympanum, in the substance of the membrana semilunaris, from the dorsal to the ventral surface.

4. The structure of the lungs.

Pass a seeker along one of the bronchi, and slit it open with scissors. Follow the branches of the bronchus through the lungs, and note the openings of the various air-sacs described above (pp. 431-432).

VII. DISSECTION OF THE RENAL AND REPRODUCTIVE SYSTEMS.

These may conveniently be considered together, because, as in the rabbit, the genital ducts are in both sexes formed from what were originally parts of the excretory system.

In the male the vas deferens is formed from the meso-

nephric or Wolffian duct: in the female the oviduct is formed from the Müllerian duct. In both sexes the kidneys and ureters of the adult are formed on each side from the hindmost division of the kidney of the embryo, *i.e.* the metanephros, and the metanephric duct.

A. The Male Pigeon.

1. The renal system.

- a. The **kidneys** are a pair of solid three-lobed bodies, lodged in cavities bounded by the ilia and sacrum, immediately behind the lungs. Their ventral surfaces are covered by peritoneum. There is no distinction between cortical and medullary portions, and no pelvis.
- b. The **ureters** are a pair of straight narrow tubes. Each arises in the substance of the anterior lobe of its kidney, emerges between the anterior and middle lobes, and runs backwards along the inner side and ventral surface of the middle and posterior lobes, and then straight back to the dorsal wall of the cloaca.

Slit up one of the ureters, and follow it into the anterior lobe of the kidney, noting the openings of smaller ducts into it at intervals along its length.

- c. The **adrenals** are a pair of small elongated yellowish bodies, attached to the ventral surface of the anterior ends of the kidneys, alongside the iliac veins. They have no physiological connection with the kidneys.

2. The reproductive system.

- a. The **testes** are a pair of oval bodies, attached by a fold of peritoneum to the inner borders of the anterior lobes of the kidneys, and lying in contact with their ventral surfaces.
- b. The **vasa deferentia** emerge from the inner sides of the posterior ends of the testes, and run back

along the outer borders of the ureters as a pair of sinuous tubes with opaque walls.

Their hinder ends are dilated into small vesiculæ seminales, which open into the cloaca.

3. The **cloaca** is a shallow cup-like depression into which the rectum, ureters, and genital ducts open.

a. The **rectum** opens in the ventral wall of the cloaca.

Slit up the rectum along one side, and note its opening into the cloaca.

b. The **urino-genital pouch** is a saccular diverticulum of the dorsal wall of the cloaca, separated from the rectum by a transverse fold. The ureters open into it dorsally and close to the middle line; and to their outer sides are the openings of the vasa deferentia, on the apices of a pair of small papillæ.

c. The **posterior chamber of the cloaca** is a thin-walled dilatation of the dorsal wall of the cloaca, behind the urino-genital pouch, and close to the external cloacal opening: into its dorsal surface a glandular diverticulum, the **bursa Fabricii**, opens in young birds, but is usually absent in the adult.

B. The Female Pigeon.

1. The **renal system** is the same as in the male.

2. The **reproductive system**.

a. The **ovary**. In the embryo a pair of ovaries are present, but of these the right one disappears during development, and the left alone persists. This is a large irregular-shaped body, suspended in a fold of peritoneum opposite, and partly in front of, the anterior lobe of the left kidney. Numerous ova in various stages of development project from its surface.

b. The **oviducts**. The left oviduct is a wide convoluted

tube, thin-walled in front, thick behind and lying along the left side of the pelvic cavity. In front it opens into the body-cavity by a long oblique slit-like mouth, which is in close contact with the ovary. Posteriorly it opens into the cloaca.

The right oviduct is rudimentary : it has the form of a slender tube, opening behind into the cloaca, and usually not more than half an inch in length.

The egg, when discharged from the ovary, consists of the 'yolk' only : the 'white' is an albuminous substance formed round the yolk by the walls of the middle portion of the oviduct ; and the shell is secreted by the hindmost part of the oviduct shortly before the egg is laid.

3. The **cloaca** is similar to that of the male, but larger.

a. The **rectum** has the same relations as in the male.

b. The **urino-genital pouch**. The openings of the ureters are in the anterior wall of the pouch, about an eighth of an inch apart. The openings of the oviducts are to the outer sides of those of the ureters, the opening of the left oviduct being much larger than that of the rudimentary right one.

c. The **posterior chamber** is as in the male.

VIII. EXAMINATION OF THE BRAIN.

A. Removal of the Brain.

Cut through the skin of the top of the head along the middle line, and turn the flaps aside. Expose and scrape clean the bones of the roof of the skull. Slice off with a scalpel the skull-roof, taking care not to injure the brain, which lies very close to the bone.

Cut away, bit by bit, the roof and sides of the skull, with the scalpel and stout scissors, so as to expose the brain thoroughly, leaving one ear uninjured. Remove the neural arches of the first two vertebræ, and divide the spinal cord transversely. Turn out the brain carefully, cutting across the several nerve-roots one by one. Place the brain in a bottle of strong spirit, with a pad of loose cotton-wool at the bottom, and leave it for two or three days until it is thoroughly hardened. Examine it in weak spirit.

B. External Characters of the Brain.

1. The dorsal surface.

- a. The **cerebral hemispheres** are a pair of large pyriform bodies, closely applied to each other in the median plane. Their surfaces are nearly smooth, and their anterior ends bluntly pointed.
- b. The **olfactory lobes** are a pair of small conical bodies, projecting forwards from the anterior ends of the hemispheres.
- c. The **pineal body** is a small oval body, immediately behind the hemispheres, and in the angle between them.
- d. The **optic lobes** are a pair of smooth ovoid bodies at the sides of the brain, behind and rather below the hemispheres.
- e. The **cerebellum** is a median elongated oval body, marked by a number of transverse fissures. In front it is in contact with the hemispheres; behind, it overlaps the medulla; and laterally, it lies above the optic lobes.
- f. The **medulla oblongata** is thick and wide: its anterior end is covered by the cerebellum, and posteriorly it is continuous with the spinal cord.

2. The ventral surface of the brain.

- a. The **optic chiasma**, formed by the crossing of the

optic nerves, lies between and slightly in front of the optic lobes.

- b. The **infundibulum** is a small median process, immediately behind the optic chiasma. It is connected with the pituitary body, which is usually left in the skull when the brain is removed.

C. Bisection of the Brain.

Divide the brain into right and left halves by a median longitudinal section, so as to expose its cavities.

- a. The **third ventricle**, or cavity of the fore-brain, is of considerable extent from before backwards, and dorso-ventrally; but is very narrow from side to side. It opens in front by lateral apertures, the **foramina of Monro**, into the **lateral ventricles** of the hemispheres. Its roof is produced upwards into the stalk of the pineal body, and its floor is depressed to form the infundibulum.
- b. The **Sylvian aqueduct**, or cavity of the mid-brain, is small, but communicates laterally with large cavities in the optic lobes.
- c. The **fourth ventricle**, or cavity of the hind-brain, is wide from side to side, but shallow dorso-ventrally.

IX. THE SENSE ORGANS.

A. The Eye.

1. The eyelids.

The upper eyelid is only slightly movable: the lower one very freely so.

The **nictitating membrane**, or **third eyelid**, is a fold at the anterior angle of the eye, lying within the other eyelids, between them and the eyeball. It can be pulled obliquely downwards and backwards over the front of the eyeball with great rapidity.

2. The muscles of the eyeball.

Open the orbit by removing its dorsal wall with strong scissors, taking care not to damage the nictitating membrane.

- a. The **muscles moving the eyeball** are essentially the same as those of the dog-fish or rabbit.

Remove the eyeball completely, cutting through the muscles and the optic nerve as far as possible from the eyeball.

- b. The **muscles of the nictitating membrane** are two in number, and lie close to the inner or orbital surface of the eyeball.

Snip away with scissors the recti and obliqui muscles.

- i. The **quadratus**, or **bursalis muscle**, is an oblong sheet of muscle, lying in close contact with the inner surface of the eyeball. Its fibres arise along the dorsal edge of the eyeball and run downwards, ending just above the optic nerve in a free border, which forms a tubular tendinous sheath for the tendon of the pyramidalis muscle.
- ii. The **pyramidalis** is a small muscle, somewhat triangular in shape. It arises from the inner surface of the ventral part of the eyeball, below, and a little anterior to, the entrance of the optic nerve. From this origin its fibres run upwards and backwards, converging to form a long thread-like tendon, which, passing through the tubular sheath of the quadratus, runs down on the inner surface of the eyeball, and then under it, to be inserted into the ventral border of the nictitating membrane.

By the combined action of these two muscles the rapid movement of the nictitating membrane is effected.

3. The structure of the eye.

Place the eye under water, and divide it by an equatorial incision into two halves.

The general structure of the eye is the same as that of other vertebrates; but the following points are of special interest.

- a. The **pecten** is a vascular pigmented fold, which projects into the cavity of the eye from its orbital surface, ventral to the entrance of the optic nerve. It is folded longitudinally like a fan; and its function is unknown.
- b. The **lens** is, as in terrestrial animals generally, much flatter than that of the dog-fish.
- c. The **sclerotic plates** are a ring of small flat bones, overlapping one another, and surrounding the eye, just behind the junction of the cornea and the sclerotic.

B. The Ear.

1. The tympano-Eustachian passage.

This is the modified hyo-mandibular cleft of the embryo, corresponding to the spiracle of the dog-fish. Its connection with the ear is of a purely secondary character. It serves to keep the air in the tympanic cavity at the same pressure as outside.

- a. The **external auditory meatus** is the outer part of this passage, from the exterior to the tympanic membrane. The external aperture is a circular hole on the side of the head, behind and below the posterior border of the orbit.

Cut away the lower jaw. Cut away the external meatus carefully with scissors, so as to expose the tympanic membrane.

- b. The **tympanic membrane** is a thin transparent septum, separating the external meatus from the tympanic cavity.

- c. The **columella** is a small rod of bone and cartilage, lying on the inner side of the tympanic membrane, but easily seen through it. It lies almost horizontal, its free anterior end forming a slight projection in the centre of the membrane.

The columella is formed from the uppermost part of the cartilage of the hyoidean arch, and probably corresponds to part, or the whole, of the hyo-mandibular cartilage of the dog-fish.

Cut across the tympanic membrane in front of the columella, to open the tympanic cavity.

- d. The **tympanic cavity** is the middle dilated portion of the tympano-Eustachian passage. On its inner wall is the fenestra ovalis, into which the posterior end of the columella is inserted.
- e. The **Eustachian-tube** is the innermost division of the tympano-Eustachian passage. It is a narrow tube, leading from the anterior and lower angle of the tympanic cavity, and running forwards and inwards between the proper base of the skull and the basi-temporal bone. The Eustachian tubes of the two sides unite, and open into the roof of the mouth by a median aperture, just behind the posterior border of the narial opening, and in front of the transverse ridge forming the hinder border of the palate.

2. The auditory organ.

The essential organ of hearing is imbedded in the side-wall of the skull. It is, however, easy to dissect, as the layer of bone immediately investing it is very firm and compact, and so preserves the shape of the organ, while the rest of the bone is soft and spongy, and easily removed.

Remove the hinder part of the side of the skull, containing the auditory organ; and carefully pick away with scalpel and

forceps the outer spongy layer of bone, until the shape of the organ can be clearly seen.

- a. The **anterior vertical semicircular canal** lies, in the natural position of the parts, close alongside the posterior border of the optic lobe and the side of the cerebellum.
- b. The **posterior vertical semicircular canal** lies almost immediately below the anterior vertical canal.
- c. The **horizontal semicircular canal** lies opposite the lower border of the optic lobe and the hinder end of the cerebellum.

The three semicircular canals, as in other vertebrates, are in planes each at right angles to the other two.

APPENDIX

LIST OF REAGENTS.

I. REAGENTS FOR KILLING, HARDENING, AND PRESERVING.

ABSOLUTE ALCOHOL.

Use.—Hardening reagent, but most used for dehydrating specimens before clearing them in oil of cloves or turpentine.

ALCOHOL (Spirit).

It is used of the following strengths: 90 per cent., 70 per cent., 50 per cent., 30 per cent.

Preparation.—90 per cent. alcohol is the ordinary 'methylated spirit.' The weaker solutions are obtained by diluting it with water.

Use.—(1) For preserving specimens; not weaker than 70 per cent.

(2) Hardening reagent; 90 per cent.

(3) For dissolving the intercellular substance of certain tissues, so that the cells may be isolated by teasing; 30 per cent.

CHROMIC ACID, 10 per cent. solution.

Preparation.—Dissolve 10 grms. chromic acid crystals in 100 c.c. water.

Use.—As a fixing and hardening reagent it must be reduced to a 1 per cent. or .5 per cent. solution by addition of water before use ; and osmic acid may be added to it.

CORROSIVE SUBLIMATE, solution.

Preparation.—Saturate water with mercuric chloride : 1 litre dissolves about 70 grms.

Use.—(1) As a hardening reagent it is used cold.

(2) For killing small animals it may be used warm or cold.

After use it should be washed out in alcohol to which a little tincture of iodine is added.

CORROSIVE-ACETIC, mixture.

Preparation.—Take 90 vols. of concentrated sublimate solution and add 10 vols. of glacial acetic acid.

Use.—An excellent fixative for general work. Wash out in alcohol.

FLEMMING'S SOLUTION.

Preparation.—Fifteen parts chromic acid (1 p. c.), 4 parts osmic acid (2 p. c.), 1 part glacial acetic acid.

Use.—Good fixative and hardening reagent. Wash well in water.

MULLER'S FLUID.

Preparation.—Dissolve 25 grms. potassium bichromate and 10 grms. sodium sulphate in 1 litre water.

Use.—Hardening reagent. It also dissolves intercellular substance, so that the cells may be separated by teasing.

OSMIC ACID (OsO_4), 2 per cent. solution.

Preparation.—Dissolve 1 gm. 'osmic acid' crystals in 50 c.c. distilled water. Keep in the dark.

Use.—For killing microscopic animals the vapour is a good fixative. Before using the solution, it is to be diluted with 1 to 3 times its bulk of water.

PERENYI'S FLUID.

Preparation.—Dissolve 1.5 gm. chromic acid crystals in about half a litre of water. Add 40 c.c. strong nitric acid. When cold add 300 c.c. 90 per cent. alcohol (methylated spirit), and make up to 1 litre with water. The solution becomes violet-coloured.

Use.—Hardening reagent, especially useful for embryos. Tissues after remaining in the fluid 2–4 hours should be washed in 70 per cent. alcohol.

PICRIC ACID, saturated solution.

Preparation.—Saturate water with picric acid by shaking it up with the crystals. Allow to stand: decant before use.

Use.—Hardening reagent. Wash out with alcohol.

PICRIC ACID, Kleinenberg's solution.

Preparation.—To 900 c.c. distilled water add 18 c.c. strong sulphuric acid, and add picric acid crystals to concentration.

Use.—Hardening reagent.

ACETIC ACID, glacial and 1 per cent. solution.

Preparation.—Dissolve 10 c.c. glacial acetic acid in water: make up to 1 litre with water.

Use.—(1) For clearing tissues, and especially for rendering nuclei more distinct.

(2) For killing small animals the vapour of glacial acid is effective.

FORMALDEHYDE (*Formol, formalin*).

Preparation.—Dilute the 40 per cent. solution to 4 per cent.

Use.—For preserving animals.

II. REAGENTS USED IN STAINING.

ALUM CARMINE.

Preparation.—Dissolve 200 grms. ammonia alum in water : boil 10 to 20 minutes with excess of carmine : filter : make up to 1 litre with water : add a few drops of carbolic acid to preserve from mould.

Use.—Stain for hardened tissues. It may be diluted with 4 times its bulk of water or less.

BORAX CARMINE (Grenacher's).

Preparation.—Dissolve 12·5 grms. carmine and 20 grms. borax in 500 c.c. water : add 500 c.c. 70 per cent. alcohol : allow to stand two or three days : filter.

Use.—Stain for tissues which have been hardened. May be used warm (50° C.) or cold. The tissues should afterwards be treated with acid alcohol. For staining objects which are to be mounted whole, it should be diluted with several times its bulk of 40 per cent. alcohol, and the treatment with acid alcohol should be prolonged.

ACID ALCOHOL.

Preparation.—To 100 c.c. of 70 per cent. alcohol add 25 c.c. hydrochloric or nitric acid.

Use.—For differentiating the parts of stained specimens, and for removal of surplus stain.

PICROCARMINE.

Preparation.—Dissolve 10 grms. carmine in 40 c.c. strong ammonia and 2 litres water. Add 50 grms. picric acid. Shake well a few minutes : allow to stand : and decant. Allow to stand a few days, stirring occasionally. Evaporate to dryness over a water bath. To every 2 grms. of dry residue add 100 c.c. water.

Use.—Stain. It may be used with advantage for specimens hardened with osmic acid or otherwise. Subsequent im-

mersion for a short time in acid alcohol improves the effect in the case of some tissues. If the object be dehydrated rapidly, or by means of alcohol containing picric acid, a double-stained effect may be obtained, some tissues being stained yellow and others red.

MEYER'S ACID HÆMALUM.

Preparation.—Dissolve 1 grm. hæmatein in 50 c.c. 90 per cent. alcohol. Dissolve 50 grms. alum in 1 litre distilled water. Mix and allow to settle. Add 20 c.c. glacial acetic acid and a crystal of carbolic acid or thymol.

Use.—For staining tissues in bulk or sections on the slide. In either case the object must be brought down to water, and after staining washed in 1 per. cent. alum-solution.

It is preferable to Kleinenberg's solution in being (1) of definite composition, (2) less affected by light, and (3) keeps better.

METHYLENE BLUE.

Preparation.—Dissolve $\frac{1}{10}$ grm. in 100 c.c. salt-solution.

Use.—For staining small animals in life. It brings out the gland-cells, muscle-cells, and nerve elements. A small quantity should be diluted with twenty times its bulk of distilled water.

DAHLIA, .25 per cent. solution.

Preparation.—Dissolve $\frac{1}{4}$ grm. in 100 c.c. distilled water.

Use.—For staining Protozoa and cover-glass preparations.

SAFRANIN.

Preparation.—Dissolve $\frac{1}{2}$ –1 grm. in 100 c.c. water or 50 per cent. alcohol.

Use.—A nuclear stain for the same objects as Dahlia.

III. CLEARING REAGENTS

(i.e. REAGENTS FOR REMOVING ALCOHOL OR PARAFFIN, AND RENDERING THE OBJECT PERMEABLE BY BALSAM).

OIL OF CLOVES.

Use.—To remove alcohol from an object before mounting it in balsam. The object must be left in the oil till it becomes transparent: if left too long the object may become brittle. It is liable to destroy the colour of objects stained with hæmatoxylin.

OIL OF CEDAR-WOOD.

Use.—Same as oil of cloves. It is less liable to injure specimens stained with hæmatoxylin, and is also useful for clearing before imbedding.

TURPENTINE.

Use.—To remove paraffin from sections (see Introduction, p. xxxii), which should only remain in it long enough for the paraffin to be dissolved.

CREASOTE AND TURPENTINE.

Preparation.—Mix 100 c.c. creasote with 400 c.c. turpentine: allow to stand till clear.

Use.—Same as turpentine, but must not be used for sections cemented down with shellac.

IV. MOUNTING MEDIA.

SALT SOLUTION, .75 per cent.

Preparation.—Dissolve 7.5 grms. common salt in 1 litre water.

Use.—Living or fresh tissues are usually examined in it.

GLYCERIN.—Used either pure, or diluted with an equal bulk of water.

Use.—For mounting microscopical objects.

GLYCERIN JELLY.

Preparation.—Soak gelatin in water till soft; pour off excess of water; melt, and while still fluid but *cool* add one-eighth of its bulk of white of egg: mix thoroughly: boil: strain through flannel: to strained fluid while still hot add half its volume of a mixture of equal parts of glycerin and camphor water.

Use.—For mounting microscopical objects which are too transparent when mounted in balsam (see Introduction, p. xxxi).

FARRANT'S MEDIUM.

Preparation.—Dissolve 400 grms. white gum arabic in 400 c.c. water without heat, stirring occasionally: add 200 c.c. glycerin: strain through clean flannel if necessary. Keep in a stoppered bottle with a piece of camphor.

Use.—Same as glycerin-jelly, but it is used cold, and objects may be transferred to it direct from water. It soon hardens at the edges: ringing with varnish is therefore unnecessary.

CANADA BALSAM.

Preparation.—May be used as bought from the chemist, or diluted to a suitable consistency with benzol. Still better, evaporate to dryness: powder and dissolve in chloroform, benzol, or xylol: benzol is best.

Use.—The most useful of all media for mounting stained objects. (For method of using, see Introduction, p. xxxi.)

V. MICROTOMIST'S MEDIA.**GUM-WATER.**

Preparation.—Dissolve gum-arabic in 3 times its weight of water without heat: allow to stand: strain if necessary.

Use.—For impregnating objects to be cut by the freezing microtome.

PARAFFIN.

Melting-point about 56° C.

Use.—For imbedding objects to be cut into sections.

SOFT PARAFFIN.

Melting-point about 40° C.

Use.—To smear the sides of the block that is being cut, so as to ensure the sections cohering by their edges into a continuous ribbon.

**VI. CEMENTS FOR FIXING DOWN SECTIONS
CUT IN PARAFFIN.****GLYCERIN AND ALBUMEN.**

Preparation.—Mix equal volumes of fresh white of egg and glycerin. Keep a piece of camphor in the bottle.

Use.—For fixing sections in order upon the slide. For full directions see Introduction, p. xxxi, where directions for staining sections on the slide are also given

SHELLAC AND ALCOHOL.

Preparation.—Dissolve perfectly dry bleached shellac in absolute alcohol: allow to stand two or three weeks: decant. Keep in a bottle with a cap ground to fit. Dilute with absolute alcohol when it becomes too thick to flow evenly.

Use.—For fixing sections in order upon the slide. If the film becomes white and opaque on drying, warm it to 60° C. till the opacity disappears.

COLLODION AND OIL OF CLOVES.

Preparation.—Mix equal parts of collodion and oil of cloves.

Use.—Same as above. The slide is smeared very slightly with the mixture and the sections laid upon the film while still moist. Then proceed as with shellac and oil of cloves.

If the solution becomes too stiff, dilute with ether.

VII. INJECTION FLUIDS.

CARMINE INJECTION FLUID.

Preparation.—Rub up carmine in water : add ammonia drop by drop till the carmine is dissolved : filter : evaporate at a gentle heat, stirring constantly to get rid of the ammonia. Rub up the residue with camphor water.

Use.—For injecting small animals and parts of animals. It must be well shaken before use.

PRUSSIAN-BLUE INJECTION FLUID.

Preparation.—To a weak solution of ferric chloride add a few drops of hydrochloric acid, and then pour in enough of a stronger solution of potassium ferrocyanide to cause complete precipitation. The fluid should be deep blue, but transparent, and the precipitate too fine to be seen with the naked eye.

PLASTER-OF-PARIS INJECTION.

Preparation.—Rub up fine plaster of Paris with water, in a mortar, to the consistency of thin cream. Colour to the required tint with carmine injection fluid or with French blue. Strain through fine muslin.

Use.—For injecting blood-vessels, &c., of rabbits and other large animals. It must be used immediately after preparation. (See Introduction, p. xxi.)

GELATIN INJECTION.

Preparation.—Soak gelatin in water till thoroughly soft. Pour off the superfluous water : melt, and stir into it carmine injection fluid, or other insoluble colouring substance, and a few drops of carbolic acid ; or if preferred the gelatin may be soaked in camphor water, and carbolic acid is then unnecessary. Stir till almost cold. The injection is solid when cold.

Use.—For injection of specimens of which it is proposed to make sections. It is to be melted, and kept well stirred

during injection. If the specimen is large or difficult to inject, the whole operation must be performed in a vessel of water as hot as the hand can bear it.

WHITE-OF-EGG INJECTION.

Preparation.—Rub up fresh white of egg with carmine injection, or other colouring fluid which will not cause coagulation of the albumen.

Use.—For injecting specimens of which sections are to be cut. It is used fresh, and the specimen is then placed in alcohol, or in hot water, to coagulate the albumen.

GUM INJECTION.

Preparation.—Make a thick mucilage of gum-arabic and cold water.

Use.—Inject cold, previously colouring as desired. Plunge the specimen into alcohol, and the injection will solidify.

INDEX.

- Abdomen : *Crayfish*, 136 ; *Cockroach*, 164
 Abdominal appendage : *Crayfish*, 137-138 ; *Cockroach*, 169
 Abdominal pore : *Dog-fish*, 213, 232
 Abdominal viscera : *Dog-fish*, 232 ; *Rabbit*, 328 ; *Pigeon*, 433
 Acetabulum : *Rabbit*, 320 ; *Fowl*, 420
 Acromion : *Rabbit*, 314
 Adrenal body : *Rabbit*, 331 ; *Pigeon*, 450
 Air sac : *Pigeon*, 430
 Ala cordis : *Crayfish*, 150
 Ala spuria : *Pigeon*, 426
 Albumen gland : *Snail*, 114, 123
 Ali-sphenoid : *Rabbit*, 297 ; *Fowl*, 409
 Alimentary canal, *see* Digestive System
 Alternation of generations : *Liver-fluke*, 27
 Alveolus : *Rabbit*, 305
 AMCEBA, 1-3
 AMPHIOXUS, 179-209 ; external characters, 181 ; skeletal system, 182 ; muscular system, 183 ; digestive and respiratory systems, 184 ; atrial cavity, 186 ; coelom, 187 ; circulatory system, 188 ; excretory system, 190 ; nervous system, 190 ; sense organs, 193 ; reproductive system, 193 ; dissection, 194 ; transverse sections, 198
 Anapophysis, *see* Vertebra
 Angular bone : *Fowl*, 414
 Ankle, *see* Tarsus
 Ankle-joint : *Fowl*, 422
 Annulus : *Leech*, 40 ; *Earthworm*, 60
 Anodonta, *see* Mussel
 Antenna : *Crayfish*, 142 ; *Cockroach*, 166
 Antennule : *Crayfish*, 143
 Anti-trochanter : *Fowl*, 420
 Anus : *Paramecium*, 6 ; *Vorticella*, 11 ; *Leech*, 41 ; *Earthworm*, 61 ; *Mussel*, 39, 102 ; *Snail*, 111 ; *Crayfish*, 152 ; *Cockroach*, 165, 171 ; *Amphioxus*, 181, 209 ; *Rabbit*, 327
 Aorta : *Mussel*, 95 ; *Snail*, 129 ; *Rabbit*, 341, 346 ; *Pigeon*, 443-446
 cardiac : *Amphioxus*, 188, 204 ; *Dog-fish*, 247
 dorsal : *Amphioxus*, 189, 204, 209 ; *Dog-fish*, 249, 250 ; *Pigeon*, 444
 Aortic arch : *Amphioxus*, 188 ; *Rabbit*, 346 ; *Pigeon*, 424
 Aperture, *see also* Foramen
 auditory : *Crayfish*, 143 ; *Rabbit*, 310, 327 ; *Pigeon*, 429
 cloacal : *Mussel*, 88 ; *Dog-fish*, 212 ; *Pigeon*, 428
 excretory : *Liver-fluke*, 30 ; *Leech*, 41 ; *Earthworm*, 62 ; *Mussel*, 97, 105 ; *Snail*, 118 ; *Crayfish*, 143
 exhalant : *Mussel*, 88
 external : *Leech*, 40 ; *Earthworm*, 61 ; *Mussel*, 89 ; *Snail*, 111 ; *Cockroach*, 165 ; *Dog-fish*, 212 ; *Pigeon*, 428
 genital : *Liver-fluke*, 28, 33 ; *Leech*, 41 ; *Earthworm*, 61 ; *Mussel*, 98, 105 ; *Snail*, 111 ; *Crayfish*, 139 ; *Cockroach*, 165
 inhalant, *Mussel*, 88
 of Eustachian canal : *Rabbit*, 310 ; *Fowl*, 407, 408
 of Eustachian tube : *Rabbit*, 375 ; *Pigeon*, 433
 on surface of skull, *see* Foramen

- Aperture, posterior narial: *Pigeon*, 433
 reno-pericardial: *Mussel*, 98; *Snail*, 117
 respiratory: *Snail*, 111, 116; *Cockroach*, 165
 urino-genital: *Rabbit*, 327; *Dog-fish*, 262
- Appendage: *Crayfish*, 132, 135, 137-143; *Cockroach*, 166-169
 abdominal: *Crayfish*, 137; *Cockroach*, 169
 head: *Crayfish*, 141; *Cockroach*, 166
 thoracic: *Crayfish*, 138; *Cockroach*, 167
- Apteria: *Pigeon*, 428
- Aquæductus Fallopii: *Rabbit*, 302
 vestibuli: *Dog-fish*, 220, 280
- Arbor vitæ: *Rabbit*, 395
- Arm, *see* Fore-limb
- Arteries: *Mussel*, 95; *Snail*, 129; *Crayfish*, 149, 159; *Dog-fish*, 245; *Rabbit*, 346; *Pigeon*, 443; *see also* Aorta
- Artery, brachial: *Rabbit*, 346; *Pigeon*, 444
 branchial: *Dog-fish*, 247
 carotid: *Dog-fish*, 249; *Rabbit*, 347, 362; *Pigeon*, 443-444
 caudal: *Dog-fish*, 250; *Pigeon*, 446
 celiac: *Dog-fish*, 251; *Rabbit*, 347; *Pigeon*, 444
 coronary: *Rabbit*, 352
 epibranchial: *Dog-fish*, 249
 femoral: *Pigeon*, 445
 hepatic: *Rabbit*, 348
 hyoidean: *Dog-fish*, 250
 iliac: *Dog-fish*, 252; *Rabbit*, 349; *Pigeon*, 445
 ilio lumbar: *Rabbit*, 349
 innominate: *Rabbit*, 346; *Pigeon*, 443, 444
 intercostal: *Rabbit*, 347
 lieno-gastric: *Dog-fish*, 252; *Rabbit*, 348
 lumbar: *Rabbit*, 348
 mammary: *Rabbit*, 347
 mesenteric: *Dog-fish*, 252; *Rabbit*, 348; *Pigeon*, 445
 ovarian: *Rabbit*, 348
 parietal: *Dog-fish*, 252
 pectoral: *Pigeon*, 444
 pubic: *Pigeon*, 445
 pulmonary: *Rabbit*, 340; *Pigeon*, 443
 renal: *Dog-fish*, 252; *Rabbit*, 348; *Pigeon*, 445
 sacral: *Rabbit*, 348
 sciatic: *Pigeon*, 445
 spermatic: *Rabbit*, 348
 subclavian: *Dog-fish*, 251; *Rabbit*, 346, 347; *Pigeon*, 444
 vertebral: *Rabbit*, 347; *Pigeon*, 443
 vesical: *Rabbit*, 349
- Arthrobranchia: *Crayfish*, 145, 146
- Arthrodial membrane: *Crayfish*, 135
- Articular bone: *Fowl*, 414
- Articular process, *see* Vertebra
- Arytenoid cartilage: *Rabbit*, 369
- Astacus, *see* Crayfish
- Atlas vertebra: *Rabbit*, 288; *Fowl*, 400
- Atrial cavity: *Amphioxus*, 186, 196, 203, 205, 208
- Atrial epithelium: *Amphioxus*, 202
- Atrial pore: *Amphioxus*, 181
- Auditory aperture, *see* Aperture
- Auditory capsule: *Dog-fish*, 220; *Rabbit*, 301
- Auditory organ: *Mussel*, 100; *Snail*, 127; *Crayfish*, 158; *Dog-fish*, 279; *Pigeon*, 457
- Auditory ossicle: *Rabbit*, 303; *Fowl*, 408, 415; *Pigeon*, 457
- Auricle: *Mussel*, 94, 107; *Snail*, 117; *Dog-fish*, 239, 253; *Rabbit*, 340, 350, 351; *Pigeon*, 446
- Auricular feathers: *Pigeon*, 429
- Axis vertebra: *Rabbit*, 289; *Fowl*, 400
- Backbone, *see* Vertebral column
- Barb: *Pigeon*, 427
- Barbule: *Pigeon*, 427
- Basal cartilages: *Dog-fish*, 228, 230, 231
- Basi-branchial: *Dog-fish*, 228

- Basi-hyal : *Dog-fish*, 227
 Basi-occipital : *Rabbit*, 296
 Basipodite, *see* Appendage : *Crayfish*
 Basi-pterygium : *Dog-fish*, 230
 Basi-sphenoid : *Rabbit*, 297 ; *Fowl*, 407
 Basi-temporal : *Fowl*, 407
 Beak : *Pigeon*, 425
 Bile-duct : *Mussel*, 102 ; *Snail*, 122, 123 ; *Crayfish*, 151, 152 ; *Dog-fish*, 235 ; *Rabbit*, 334 ;
 Pigeon, 437
 Birds, characters of, 396, 424
 Bladder : *Earthworm*, 70 ; *Rabbit*, 331, 353, 354 ; *see also* Sinus, urinary and urinogenital ;
 also Nephridium
 Blastophore : *Earthworm*, 75
 Blatta, *see* Cockroach
 Blood : *Leech*, 45 ; *Earthworm*, 66 ; *Mammals*, 325 ; *Pigeon*, 424
 Blood-Sinus : *Leech*, 45-46, 56 ; *Snail*, 130, 131 ; *Crayfish*, 147 ; *see also* Sinus, Lacuna,
 Vein
 Blood-vessel : *Leech*, 45-46, 57 ; *Earthworm*, 66, 80 ; *Mussel*, 95 ; *Snail*, 129 ; *see also*
 Circulatory system, Artery, Vein
 Body-cavity, *see* Coelom
 Bojanus, organ of : *Mussel*, 97
 Bone : *Dog-fish*, 214, 215
 Bone, cartilage : *Rabbit*, 283, 294
 membrane : *Rabbit*, 283, 295
 sesamoid : *Rabbit*, 283, 319 ; *see also* Patella
 Botryoidal tissue : *Leech*, 57
 Brain : *Dog-fish*, 263, 275 ; *Rabbit*, 378 ; *Pigeon*, 452
 Brain-case, *see* Cranium
 Brain, cavity of, *see* Ventricle
 Brain-membrane : *Rabbit*, 379
 Branchia, *see* Gill
 Branchial arch : *Dog-fish*, 227
 Branchial bar : *Amphioxus*, 185, 202
 Branchial chamber : *Mussel*, 87, 108 ; *Crayfish*, 143
 Branchial vessels : *Dog-fish*, 247-249
 Branchio-cardiac canal : *Crayfish*, 150
 Branchio-cardiac groove : *Crayfish*, 136
 Branchiostegite : *Crayfish*, 136, 143
 Bronchus : *Rabbit*, 363
 Buccal cavity : *Earthworm*, 63 ; *Cockroach*, 170 ; *Amphioxus*, 184, 196, 200 ; *Rabbit*, 372 ;
 Pigeon, 433
 Buccal mass : *Snail*, 121, 128
 Budding : *Hydra*, 21
 Bulla, tympanic : *Rabbit*, 302
 Bursa Fabricii : *Pigeon*, 451

 Cæcum : *Rabbit*, 329, 335, 336
 Calamus : *Pigeon*, 426
 Canal, ampullary : *Dog-fish*, 213, 281
 branchio-cardiac : *Crayfish*, 150
 carotid : *Fowl*, 406, 407
 central : *Amphioxus*, 191, 200
 Eustachian : *Rabbit*, 310 ; *Fowl*, 407, 408
 interorbital : *Dog-fish*, 222
 naso-palatine : *Rabbit*, 373
 neural, *see* Vertebra
 of Laurer : *Liver-fluke*, 33
 pericardio-peritoneal : *Dog-fish*, 241
 reno-pericardial : *Mussel*, 98 ; *Snail*, 117
 semicircular : *Dog-fish*, 220-221, 279-280 ; *Pigeon*, 458
 sensory : *Dog-fish*, 213, 271, 272, 281
 urino-genital : *Rabbit*, 356, 359
 vertebrarterial, *see* Vertebra
 Capitulum : *Rabbit*, 293 ; *Pigeon*, 403
 Carapace : *Crayfish*, 135
 Cardia : *Rabbit*, 332
 Cardo : *Cockroach*, 166
 Carina : *Fowl*, 404
 Carpo-metacarpus : *Fowl*, 418-419

- Carpopodite, *see* Appendage
 Carpus : *typical*, 317 ; *Rabbit*, 317 ; *Fowl*, 418 ; *see also* Carpo-metacarpus
 Cartilage-bone : *Rabbit*, 283, 294
 Centrum : *Dog-fish*, 215 ; *see also* Vertebra, *typical*
 Cephalo-thorax : *Crayfish*, 135
 Cerato-branchial : *Dog-fish*, 228
 Cerato-hyal : *Dog-fish*, 227
 Cercaria : *Liver-fluke*, 37
 Cerci : *Cockroach*, 165, 169
 Cere : *Pigeon*, 425
 Cerebellum : *Dog-fish*, 266, 277 ; *Rabbit*, 380, 394 ; *Pigeon*, 453
 Cerebral hemispheres : *Dog-fish*, 265 ; *Rabbit*, 379, 381, 385 ; *Pigeon*, 453
 Cervical canal : *Crayfish*, 144
 Cervical groove : *Crayfish*, 135
 Cervical ribs : *Pigeon*, 399
 Chele : *Crayfish*, 139
 Chiasma, optic : *Dog-fish*, 275 ; *Rabbit*, 382, 393 ; *Pigeon*, 453
 Chlorophyll : *Hydra*, 24
 Chordæ tendineæ : *Rabbit*, 351 ; *Pigeon*, 447
 Choroid : *Dog-fish*, 279
 Choroid plexus : *Dog-fish*, 276 ; *Rabbit*, 388
 Cilia : *Paramecium*, 5, 6 ; *Opalina*, 7 ; *Vorticella*, 11
 Clingulum, *see* Clitellum
 Circulation, course of : *Mussel*, 96 ; *Crayfish*, 147
 Circulatory system : *Leech*, 45-46, 56-57 ; *Earthworm*, 66, 80 ; *Mussel*, 93, 104, 105-107 ;
 Snail, 129 ; *Crayfish*, 147, 159 ; *Cockroach*, 170 ; *Amphioxus*, 188
 204, 209 ; *Dog-fish*, 237 ; *Rabbit*, 339 ; *Pigeon*, 438
 Cirrus : *Liver-fluke*, 32 ; *Amphioxus*, 181
 Cirrus-sac : *Liver-fluke*, 32
 Clasper : *Dog-fish*, 212, 230
 Clavicle : *Rabbit*, 314 ; *Fowl*, 417
 Clinoid process : *Rabbit*, 297, 298
 Clitellum : *Earthworm*, 60, 77
 Clitoris : *Rabbit*, 327, 360
 Cloaca : *Dog-fish*, 258, 262 ; *Pigeon*, 451, 452
 Cloacal aperture : *Mussel*, 88 ; *Dog-fish*, 212 ; *Pigeon*, 428
 Cloacal chamber : *Mussel*, 87, 92
 Cloacal pouch : *Dog-fish*, 213
 Cloacal papillæ : *Dog-fish*, 213
 Clypeus : *Cockroach*, 162
 Cnemial crest : *Rabbit*, 322 ; *Fowl*, 422
 Onidoblast : *Hydra*, 19
 Onidocil : *Hydra*, 19
 Cochlea : *Rabbit*, 302, 325
 COCKROACH, 161-178 ; external characters, 162 ; appendages, 166 ; circulatory system
 170 ; digestive system, 170 ; excretory system, 172 ; respiratory system,
 172 ; nervous system, 173 ; sense organs, 175 ; reproductive system,
 176
 Cocoon : *Leech*, 39 ; *Earthworm*, 59, 72
 Cœlom : *Leech*, 45, 56 ; *Earthworm*, 63, 78 ; *Mussel*, 99 ; *Amphioxus*, 187, 203, 206, 208
 209
 Cœlomic canal : *Amphioxus*, 187, 188, 203, 206
 Collar : *Snail*, 111
 Colon : *Cockroach*, 171 ; *Rabbit*, 329, 335, 337
 Columba ; *see* Pigeon
 Columella : *Snail-shell*, 112 ; *Fowl*, 408, 415 ; *Pigeon*, 457
 Commissure, of brain : *Rabbit*, 392 ; *see also* Corpus callosum, Pons Varolii
 Condyle, of skull : *Dog-fish*, 225 ; *Rabbit*, 296 ; *Fowl*, 406
 Conjugation : *Paramecium*, 6-7 ; *Vorticella*, 12
 Conus arteriosus : *Dog-fish*, 241, 253
 Coracoid : *Fowl*, 416 ; *Rabbit*, 284
 Coracoid process : *Rabbit*, 314
 Cornea : *Crayfish*, 158 ; *Cockroach*, 175 ; *Dog-fish*, 279
 Coronoid process : *Rabbit*, 307 ; *Fowl*, 414
 Corpus albicans : *Rabbit*, 382, 393
 callosum : *Rabbit*, 379, 386, 391
 cavernosum : *Rabbit*, 356-357, 360
 geniculatum : *Rabbit*, 389
 mammillare, *see* Corpus albicans

- Corpus or Corpora quadrigemina : *Rabbit*, 325, 380, 390, 394
 spongiosum : *Rabbit*, 356
 striatum : *Rabbit*, 387
 trapezoidea : *Rabbit*, 384
 Cotyloid bone : *Rabbit*, 321
 Covert feathers : *Pigeon*, 428
 Coxa : *Cockroach*, 167
 Coxopodite : 139
 Cranium : *Dog-fish*, 217 ; *Rabbit*, 296 ; *Fowl*, 405
 CRAYFISH, 132-160 ; external characters, 133 ; appendages, 137 ; gills, 143 ; circulatory system, 147 ; reproductive system, 150 ; digestive system, 151 ; excretory system, 155 ; nervous system, 155 ; sense organs, 157 ; injected specimen 159
 Cribriform plate : *Rabbit*, 299
 Cricoid cartilage : *Rabbit*, 363, 369
 Crop : *Leech*, 44 ; *Earthworm*, 65 ; *Snail*, 121 ; *Cockroach*, 171 ; *Pigeon*, 435
 Crura cerebri : *Rabbit*, 382, 391, 394
 Cutaneous blood-vessels : *Leech*, 46
 Cuticle : *Paramecium*, 5 ; *Opalina*, 7 ; *Vorticella*, 10 ; *Liver-fluke*, 28, 36 ; *Leech*, 53 ; *Earthworm*, 61, 77 ; *Mussel*, see *Shell* ; *Snail*, see *Shell* ; *Crayfish*, 132, 133-135 ; *Cockroach*, 161 ; *Pigeon*, see *Gizzard*
 Dactylopodite : *Crayfish*, 139
 Dart-sac : *Snail*, 125
 Dentary bone : *Fowl*, 414
 Dermis : *Leech*, 53 ; *Earthworm*, 78 ; *Amphioxus*, 195, 199
 Development : *Liver-fluke*, 33-38 ; *Mussel*, 81, 102 ; *Crayfish*, 133 ; *Cockroach*, 161 ; *Dog-fish*, 210, 254-255 ; *Rabbit*, 325 ; *Bird*, 424
 Diaphragm : *Rabbit*, 331, 338
 Digestive system : *Liver-fluke*, 30 ; *Redia*, 37 ; *Cercaria*, 37 ; *Leech*, 42, 56 ; *Earthworm*, 63, 79 ; *Mussel*, 101, 104, 105, 108 ; *Snail*, 119 ; *Crayfish*, 151 ; *Cockroach*, 170 ; *Amphioxus*, 184, 197, 202, 204, 208, 209 ; *Dog-fish*, 234 ; *Rabbit*, 332 ; *Pigeon*, 433
 Digit : *Rabbit*, 319, 324 ; *Fowl*, 419, 423
 Disc : *Vorticella*, 10
 Distomum, see *Liver-fluke*
 DOG-FISH, 210-282 ; external characters, 211 ; skeleton, 214 ; abdominal cavity and viscera, 232 ; digestive system, 234 ; respiratory system, 236 ; circulatory system, 237 ; renal and reproductive systems, 254 ; nervous system, 263 ; sense organs, 278
 Duct, bile : *Mussel*, 102 ; *Snail*, 122, 123 ; *Crayfish*, 151, 152 ; *Dog-fish*, 235 ; *Rabbit*, 334 ; *Pigeon*, 437
 common genital : *Snail*, 124
 hermaphrodite : *Snail*, 123
 lacrimal : *Rabbit*, 301
 mesonephric, see *Wolffian*
 metanephric : *Dog-fish*, 254-255, 258, 262 ; *Rabbit*, 353 ; *Pigeon*, 450
 Müllerian : *Dog-fish*, 254, 255, 262 ; *Rabbit*, 353 ; *Pigeon*, 450
 of salivary receptacles : *Cockroach*, 172
 ovarian : *Liver-fluke*, 32
 pancreatic : *Dog-fish*, 236 ; *Rabbit*, 333 ; *Pigeon*, 438
 pronephric, see *Müllerian*
 salivary : *Snail*, 122 ; *Cockroach*, 170, 172 ; *Rabbit*, 377
 segmental : *Dog-fish*, 254
 Stenonian : *Rabbit*, 377
 vitellarian : *Liver-fluke*, 32
 Wharton's : *Rabbit*, 377
 Wolffian : *Dog-fish*, 254-255, 258, 259 ; *Rabbit*, 353, 355-356 ; *Pigeon*, 449-450
 Ductus arteriosus : *Rabbit*, 341
 Ductus ejaculatorius : *Liver-fluke*, 32 ; *Cockroach*, 176
 Duodenum : *Rabbit*, 329, 332 ; *Pigeon*, 434, 435
 Dura mater : *Rabbit*, 379
 Ear, see *Auditory Organ*
 EARTHWORM, 59-80 ; external characters, 60 ; coelom, 63 ; digestive system, 63 ; circulatory system, 66 ; excretory system, 67 ; reproductive system, 70 ; nervous system, 75 ; transverse sections, 76
 Ecdysis : *Crayfish*, 133 ; *Cockroach*, 161
 Ectoderm : *Hydra*, 17, 18-20, 23-24, 25

- Ectosarc : *Amœba*, 2 ; *Paramecium*, 5 ; *Opalina*, 7 ; *Vorticella*, 10
 Egg : see *Ovum*
 Elytron : *Cockroach*, 164
 Embryo : *Liver-fluke*, 35 ; *Mussel*, 80, 102 ; *Crayfish*, 133 ; *Rabbit*, 325
 Encystment : *Opalina*, 8 ; *Vorticella*, 12
 Endoderm : *Hydra*, 17, 20, 24, 26
 Endophragmal skeleton : *Crayfish*, 155
 Endopodite : *Crayfish*, 137 ; see also *Appendage*
 Endosarc : *Amœba*, 2-3 ; *Paramecium*, 6 ; *Opalina*, 8 ; *Vorticella*, 10
 Endostyle : *Amphioxus*, 186, 196, 203, 204
 Epibranchial cartilage : *Dog-fish*, 227
 Epibranchial band or groove : *Amphioxus*, 185, 196, 203, 204
 Epicranium : *Cockroach*, 162
 Epidermis : *Leech*, 53 ; *Earthworm*, 78 ; *Amphioxus*, 195, 198 ; *Rabbit*, 284
 Epididymis : *Leech*, 51 ; *Rabbit*, 355
 Epiglottis : *Rabbit*, 369, 374
 Epimeron : *Crayfish*, 134
 Epitotic : *Rabbit*, 301
 Epiphragm : *Snail*, 109
 Epiphysis, of vertebra : *Rabbit*, 285
 Epipleural cavity : *Amphioxus*, see *Atrial cavity*
 Epipodite : *Crayfish*, 137, 141
 Ethmoidal region : *Rabbit*, 299
 Ethmo-turbinal : *Rabbit*, 300
 Eustachian canal : *Rabbit*, 310 ; *Fowl*, 407, 408
 Eustachian tube : *Rabbit*, 375 ; *Pigeon*, 457
 Eustachian valve : *Rabbit*, 350 ; *Pigeon*, 446
 Excretory system : *Liver-fluke*, 30, 37 ; *Leech*, 47 ; *Earthworm*, 67 ; *Mussel*, 97 ; *Snail*, 117 ; *Crayfish*, 155 ; *Cockroach*, 172 ; *Amphioxus*, 190 ; *Dog-fish*, 254-263 ; *Rabbit*, 352, 358 ; *Pigeon*, 449 ; see also *Vacuole*, pulsating
 Ex-occipital : *Rabbit*, 296
 Exopodite : *Crayfish*, 135 ; see also *Appendage*
 Exoskeleton : *Crayfish*, 133-135
 Extra-branchial : *Dog-fish*, 228
 Eye : *Leech*, 52 ; *Snail*, 127 ; *Crayfish*, 157 ; *Cockroach*, 163, 175 ; *Amphioxus*, 193 ; *Dog-fish*, 266, 278 ; *Rabbit*, 327 ; *Pigeon*, 454
 Eyelid : *Pigeon*, 454
 Eye-muscle, see *Muscle*

 Fabella : *Rabbit*, 322
 Fallopian tube : *Rabbit*, 359
 Falx cerebri : *Rabbit*, 379
 Fasciola, see *Liver-fluke*
 Fat-body : *Cockroach*, 170
 Feather : *Pigeon*, 426
 Femur : *Cockroach*, 167 ; *Rabbit*, 321 ; *Fowl*, 421
 Fenestra : *Cockroach*, 163, 175
 Fenestra ovalis : *Rabbit*, 302 ; *Fowl*, 407, 415
 Fenestra rotunda : *Rabbit*, 302 ; *Fowl*, 407
 Fenestra recess : *Fowl*, 407
 Fibula : *Rabbit*, 322 ; *Fowl*, 422
 Filoplume : *Pigeon*, 428
 Fin : *Amphioxus*, 181, 182, 199 ; *Dog-fish*, 211, 228
 Fission : *Amœba*, 3 ; *Paramecium*, 6 ; *Opalina*, 8 ; *Vorticella*, 12 ; *Hydra*, 21
 Flagellum : *Hydra*, 20 ; *Snail*, 124
 Floccular fossa : *Rabbit*, 301
 Floccular lobe : *Rabbit*, 380
 Fontanelle : *Dog-fish*, 220
 Food : *Amœba*, 3 ; *Paramecium*, 6 ; *Opalina*, 8 ; *Vorticella*, 11 ; *Hydra*, 14 ; *Leech*, 39 ; *Earthworm*, 59 ; *Mussel*, 81, 101 ; *Snail*, 109 ; *Crayfish*, 132 ; *Cockroach*, 161 ; *Dog-fish*, 210
 Foot : *Hydra*, 16, 26 ; *Mussel*, 88 ; *Snail*, 110 ; *Rabbit*, 324 ; *Fowl*, 422 ; *Pigeon*, 426
 Foramen, anterior palatine : *Rabbit*, 306, 309
 condylar : *Rabbit*, 309
 for internal carotid artery : *Dog-fish*, 223 ; *Rabbit*, 303, 310
 ilio-sciatic : *Fowl*, 420
 incisivum : *Rabbit*, 309
 inferior dental : *Rabbit*, 307
 infra-orbital : *Rabbit*, 305, 308

- Foramen, internal orbital : *Rabbit*, 308
 lacerum anterius : *Rabbit*, 297, 308
 lacerum medium : *Rabbit*, 309
 lacerum posterius : *Rabbit*, 309
 lacrymal : *Rabbit*, 310
 magnum : *Dog-fish*, 225 ; *Rabbit*, 310 ; *Fowl*, 406
 obturator : *Rabbit*, 320 ; *Fowl*, 421
 of Monro : *Rabbit*, 388, 393 ; *Pigeon*, 454
 optic : *Dog-fish*, 221 ; *Rabbit*, 298, 308
 orbito-nasal : *Dog-fish*, 221
 ovale : 309 ; *Rabbit*, 350 ; *Pigeon*, 446
 pituitary : *Rabbit*, 310
 posterior palatine : *Rabbit*, 309
 rotundum : 308
 stylomastoid : *Rabbit*, 303, 309
 triosseum : *Fowl*, 416 ; *Pigeon*, 430
- Foramina of exit for cranial nerves
 for 1st cranial nerve (olfactory) : *Dog-fish*, 223 ; *Rabbit*, 299 ; *Fowl*, 409
 for 2nd cranial nerve (optic) : *Dog-fish*, 221 ; *Rabbit*, 298, 308 ; *Fowl*, 409
 for 3rd cranial nerve (oculo-motor) : *Dog-fish*, 221 ; *Rabbit*, 297-298, 308 ; *Fowl*, 409
 for 4th cranial nerve (pathetic) : *Dog-fish*, 221 ; *Rabbit*, 297-298, 308 ; *Fowl*, 409
 for 5th cranial nerve (trigeminal) : *Dog-fish*, 222 ; *Fowl*, 408
 for ophthalmic branch of 5th : *Dog-fish*, 220, 222 ; *Rabbit*, 297-298, 308
 for maxillary branch of 5th : *Rabbit*, 297, 305, 308
 for mandibular branch of 5th : *Rabbit*, 297, 309
 for 6th cranial nerve (abducent) : *Dog-fish*, 222 ; *Rabbit*, 297-298, 308
 for 7th cranial nerve (facial) : *Dog-fish*, 222 ; *Rabbit*, 303, 309
 for ophthalmic branch of 7th : *Dog-fish*, 220, 222
 for 8th cranial nerve (auditory) : *Rabbit*, 301-302
 for 9th cranial nerve (glosso-pharyngeal) : *Dog-fish*, 223 ; *Rabbit*, 309 ; *Fowl*, 406
 for 10th cranial nerve (pneumogastric) : *Dog-fish*, 225 ; *Rabbit*, 309 ; *Fowl*, 406
 for 11th cranial nerve (spinal accessory) : *Rabbit*, 309
 for 12th cranial nerve (hypoglossal) : *Rabbit*, 309-310 ; *Fowl*, 406
- Fore-brain : *Rabbit*, 385, 389, 391-393 ; see also *Thalamencephalon*
 Fore-limb : *Rabbit*, 315, 328 ; *Fowl*, 417
 Fornix : *Rabbit*, 388, 391, 393
 Fossa ovalis : *Rabbit*, 350 ; *Pigeon*, 446
 FOWL, skeleton of, 396-423 ; vertebral column, 396 ; ribs and sternum, 402 ; skull 404
 appendicular skeleton, 416
 Frontal bone : *Rabbit*, 299 ; *Fowl*, 409, 410
 Frontal segment : *Rabbit*, 298
 Funnel, nephridial : *Leech*, 48 ; *Earthworm*, 67, 68
 seminal : *Earthworm*, 73
 Furcula : *Fowl*, 417
- Galea : *Cockroach*, 166
 Gall-bladder : *Dog-fish*, 235 ; *Rabbit*, 334
 Gallus, see *Fowl*
 Ganglion, see *Nerve-ganglion*
 Gastric mill : *Crayfish*, 153
 Gastrula : *Liver-fluke*, 36
 Gemmation : *Hydra*, 21
 Gena : *Cockroach*, 162
 Generations, alternation of : *Liver-fluke*, 27
 Genital sinus : *Liver-fluke*, 33
 Germ-cell : *Liver-fluke*, 35
 Giant-fibres : *Earthworm*, 80
 Gill : *Mussel*, 88, 90, 104, 108 ; *Crayfish*, 145 ; *Dog-fish*, 236
 Gill-arch : *Amphioxus*, 185, 197, 202 ; see also *Branchial arch*
 Gill-ray : *Dog-fish*, 227, 228
 Gill-slit : *Amphioxus*, 185, 196 ; *Dog-fish*, 213
 Gizzard : *Earthworm*, 65 ; *Cockroach*, 171 ; *Pigeon*, 434, 435
 Gland, albumen : *Snail*, 114, 123 ; *Pigeon*, see *Oviduct*
 chitellar : *Leech*, 53
 colleterial : *Cockroach*, 177
 Cowper's : *Rabbit*, 357, 360

- Gland, digestive : *Crayfish*, 151 ; *Cockroach*, 171-172 ; *Dog-fish*, 233, 235-236
 epidermal : *Leech*, 53
 green : *Crayfish*, 155
 hermaphrodite : *Snail*, 114, 123
 infra-orbital : *Rabbit*, 377
 mammary : *Rabbit*, 328
 mucous : *Leech*, 53 ; *Snail*, 125
 mushroom-shaped : *Cockroach*, 176
 cesophageal : *Earthworm*, 65
 oviducal : *Dog-fish*, 256
 parotid : *Rabbit*, 375
 pedal : *Snail*, 112
 perinaeal : *Rabbit*, 327, 358, 360
 prostatic : *Rabbit*, 357
 rectal : *Dog-fish*, 236 ; *Rabbit*, 358, 360
 salivary : *Leech*, 44, 52 ; *Snail*, 122 ; *Cockroach*, 171 ; *Rabbit*, 375-377
 she 1 : *Liver-fluke*, 33
 sublingual : *Rabbit*, 377
 submaxillary : *Rabbit*, 377
 thyroid : *see* Thyroid body
 yolk : *Liver-fluke*, 32
- Glochidium : *Mussel*, 102
 Glottis : *Rabbit*, 370, 374 ; *Pigeon*, 433
 Gonapophysis : *Cockroach*, 169, 176, 178
 Graafian follicle : *Rabbit*, 359
 Green gland : *Crayfish*, 155
 Growth : *Mussel-shell*, 82, 84 ; *Snail-shell*, 112, 113 ; *Crayfish*, 133
 Gubernaculum : *Rabbit*, 355
- Hæmal arch : *Dog-fish*, 215, 216
 Hæmal process : *Dog-fish*, 216
 Hæmal spine : *Dog-fish*, 216
 Hæmoglobin : *Earthworm*, 66
 Hallux : *Rabbit*, 324 ; *Fowl*, 425
 Hamular process : *Rabbit*, 304
 Hand : *Rabbit*, 319
 Head : *Snail*, 110 ; *Crayfish*, 135 ; *Cockroach*, 162 ; *Rabbit*, 326, 372 ; *Pigeon*, 425
 Heart : *Earthworm*, 66 ; *Mussel*, 94, 107 ; *Snail*, 117 ; *Crayfish*, 147 ; *Cockroach*, 170 ; *Dog-fish*, 237-241, 253 ; *Rabbit*, 337, 339, 349 ; *Sheep*, 352 ; *Pigeon*, 434, 438, 446
 Helix, *see* *Snail*
 Hepatic cæcum : *Cockroach*, 172
 Hepatic cell : *Earthworm*, 65, 78
 Hermaphrodite duct : *Snail*, 123
 Hermaphrodite gland : *Snail*, 114, 123
 Hind-brain : *Rabbit*, 380-381, 394
 Hind-limb : *Rabbit*, 321, 328 ; *Fowl*, 421 ; *Pigeon*, 426
 Hinge of mussel-shell, 83
 Hippocampus major : *Rabbit*, 387
 Hirudo, *see* *Leech*
 Humerus : *Rabbit*, 315 ; *Fowl*, 417
 HYDRA, 14-26 : general appearance, 16 ; structure, 17-21 ; reproduction, 21-23 ; disintegrated specimens, 23-25 ; transverse sections, 25-26
 Hydra, species of, 14
 Hymen : *Dog-fish*, 256
 Hyoid bone : *Rabbit*, 307, 361 ; *Fowl*, 415
 Hyoidean arch : *Dog-fish*, 226 ; *Rabbit*, 307 ; *Fowl*, 415 ; *Pigeon*, 457
 Hyomandibular cartilage : *Dog-fish*, 226
 Hyostylic skull : *Dog-fish*, 227
 Hypapophysis, *see* *Vertebra*
 Hypo-branchial : *Dog-fish*, 228
 Hypobranchial groove : *Amphioxus*, *see* *Endostyle*
 Hypostome : *Hydra*, 16
- Neum : *Cockroach*, 171 ; *Dog-fish*, 234
 Ilium : *Rabbit*, 320 ; *Fowl*, 420
 Incisor : *Rabbit*, 311, 312
 Incus : *Rabbit*, 303
 Infundibulum : *Dog-fish*, 275 ; *Rabbit*, 382, 393 ; *Pigeon*, 454
 Integument : *Leech*, 53 ; *Earthworm*, 77 ; *Snail*, 113 ; *Amphioxus*, 194-195, 198

- Internasal septum : *Dog-fish*, 219
 Interorbital canal : *Dog-fish*, 222
 Interorbital septum : *Fowl*, 404, 409
 Interparietal : *Rabbit*, 298
 Interstitial cell : *Hydra*, 18, 19, 22, 23, 25
 Intestine : *Liver-fluke*, 30, 37; *Leech*, 44; *Earthworm*, 65, 79; *Mussel*, 101, 104; *Snail*, 114, 122; *Crayfish*, 152; *Cockroach*, 171; *Amphioxus*, 186, 197, 208, 209; *Dog-fish*, 233, 234; *Rabbit*, 329, 334, 336; *Pigeon*, 434, 435-437
 Ischiopodite : *Crayfish*, 139
 Ischium : *Rabbit*, 320; *Fowl*, 420
 Iter a tertio ad quartum ventriculum, *see* Sylvian aqueduct

 Jacobson's organ : *Rabbit*, 375
 Jaw : *Leech*, 42; *Snail*, 129; *Crayfish*, 141-142; *Dog-fish*, 226; *Rabbit*, 304-307; *Fowl*, 411-415
 Jugal : *Rabbit*, 306; *Fowl*, 412

 Kidney : *Mussel*, 97, 98, 104, 107; *Snail*, 114, 117; *Crayfish*, 155; *Amphioxus*, 190; *Dog-fish*, 233, 254, 256, 259; *Rabbit*, 331, 353; *Pigeon*, 450
 Killing, mode of : *Amœba*, 3; *Paramecium*, 7; *Opalina*, 8; *Vorticella*, 13; *Hydra*, 25; *Liver-fluke*, 27-28; *Leech*, 39; *Earthworm*, 60, 76; *Snail*, 109; *Crayfish*, 133; *Cockroach*, 162; *Rabbit*, 326; *Pigeon*, 425

 Labial cartilage : *Dog-fish*, 228
 Labial palp : *Mussel*, 89; *Cockroach*, 167
 Labium : *Cockroach*, 167
 Labrum : *Crayfish*, 134; *Cockroach*, 162
 Lacinia : *Cockroach*, 166
 Lacrymal bone : *Rabbit*, 301; *Fowl*, 409
 Lacuna : *Mussel*, 97
 Lacunar tissue : *Mussel*, 93
 Lambdoidal crest : *Fowl*, 406
 Lamella, inferior : *Rabbit*, 290
 Lamina terminalis : *Rabbit*, 393
 Lancelot, *see* *Amphioxus*
 Larynx : *Rabbit*, 369; *Pigeon*, 449
 Lateral line : *Dog-fish*, 211, 281
 LEECH, 39-58; external characters, 39; digestive system, 42; coelom and blood-vessels, 45; excretory system, 47; reproductive system, 50; nervous system, 51; sense organs, 52; transverse sections, 52
 Leg : *Crayfish*, 138-139; *Cockroach*, 167; *see also* Hind-limb
 Lens : *Dog-fish*, 279; *Pigeon*, 456
 Lepus, *see* *Rabbit*
 Life-history : *Liver-fluke*, 33; *Crayfish*, 133; *Cockroach*, 161
 Ligament, broad : *Rabbit*, 359
 ethmo-palatine : *Dog-fish*, 226
 falciform : *Pigeon*, 433
 of jaws : *Dog-fish*, 225, 226
 of mussel-shell, 82, 83
 suspensory, of liver : *Dog-fish*, 232; *Rabbit*, 333
 Ligula : *Cockroach*, 167
 Limb, *see* Fore-limb, Hind-limb, Appendage, Leg
 Limnæa truncatula, 35, 36, 37
 Lingua : *Cockroach*, 170
 Lip : *Snail*, 111; *Rabbit*, 326
 Liver : *Mussel*, 102; *Snail*, 114, 122; *Crayfish*, 151; *Amphioxus*, 186, 197, 204; *Dog-fish*, 232; *Rabbit*, 329, 333; *Pigeon*, 434, 437
 LIVER-FLUKE, 27-38; external characters, 28; alimentary canal, 30; excretory system, 30, 37; reproductive system, 30; nervous system, 33; life-history, 33
 Lobi inferiores : *Dog-fish*, 275
 Locomotion : *Amœba*, 3; *Paramecium*, 4; *Vorticella*, 12; *Hydra*, 14; *Leech*, 39; *Earthworm*, 59; *Mussel*, 81, 88; *Crayfish*, 132; *Amphioxus*, 179, 183
 Lumbricus, *see* *Earthworm*
 Lung : *Snail*, 115-117; *Rabbit*, 337; *Pigeon*, 434, 448, 449
 Lymphatics : *Amphioxus*, 189; *Rabbit*, 349

 Malleus : *Rabbit*, 303
 Malpighian body : *Rabbit*, 354
 Malpighian tubule : *Cockroach*, 172

- Mammaræ: *Rabbit*, 328
 Mammalian skeleton, characters of, 284
 Mammals, characters of, 325
 Mandible: *Crayfish*, 142; *Cockroach*, 166; *Rabbit*, 307; *Fowl*, 413
 Mandibular arch: *Dog-fish*, 225; *Rabbit*, 306; *Fowl*, 413
 Mantle: *Mussel*, 86, 103; *Snail*, 114
 Mantle-cavity: *Mussel*, 87; *Snail*, 115-119
 Manubrium mallei: *Rabbit*, 303
 Manubrium sterni: *Rabbit*, 294; *Fowl*, 403
 Manus: *Rabbit*, 319; *Fowl*, 419
 Mastoid portion: *Rabbit*, 301
 Mastoid process: *Rabbit*, 301
 Maxilla: *Crayfish*, 141, 142; *Cockroach*, 166, 167; *Rabbit*, 305; *Fowl*, 412
 Maxillary arch: *Rabbit*, 304
 Maxilliped: *Crayfish*, 139, 141
 Maxillo-palatine process: *Fowl*, 412
 Maxillo-turbinal: *Rabbit*, 300
 Meatus auditorius externus: *Rabbit*, 302; *Pigeon*, 456
 Meatus auditorius internus: *Rabbit*, 302
 Meckel's cartilage: *Fowl*, 414
 Mediastinum: *Rabbit*, 338
 Membrane-bone: *Rabbit*, 283, 295
 Mentum: *Cockroach*, 167
 Meropodite: *Crayfish*, 139
 Mesencephalon: *Rabbit*, 385, 390, 393
 Mesenteron: *Crayfish*, 151, 152; *Cockroach*, 170, 171
 Mesentery: *Dog-fish*, 233; *Rabbit*, 331
 Mesethmoid: *Rabbit*, 299; *Fowl*, 409
 Mesogloea, *see* Supporting lamella
 Mesonephros, *see* Wolffian body
 Mesonotum: *Cockroach*, 164
 Meso-pterygium: *Dog-fish*, 230
 Mesothorax: *Cockroach*, 164
 Metacarpus: *Rabbit*, 319; *Fowl*, 419
 Metacromion: *Rabbit*, 314
 Metanephros: *Dog-fish*, 254-255, 256, 259; *Rabbit*, 353; *Pigeon*, 450
 Metapleural canal: *Amphioxus*, 189, 204, 206, 208
 Metapleural fold: *Amphioxus*, 181
 Metapophysis, *Rabbit*, 286; *see also* Vertebra
 Meta-pterygium: *Dog-fish*, 230
 Metastoma: *Crayfish*, 142
 Metatarsus: *Rabbit*, 324; *Fowl*, 422-423
 Metathorax: *Cockroach*, 164
 Metosteon: *Fowl*, 404
 Mid-brain, *see* Mesencephalon
 Mid-gut, *see* Mesenteron
 Molar teeth: *Rabbit*, 312, 313
 Morula: *Liver-fluke*, 36
 Mouth: *Paramecium*, 6; *Hydra*, 16; *Liver-fluke*, 28; *Leech*, 40, 42; *Earthworm*, 61, 63; *Mussel*, 89, 101; *Snail*, 111; *Crayfish*, 136, 152; *Cockroach*, 165; *Amphioxus*, 181, 196, 198; *Dog-fish*, 212; *Rabbit*, 326; *Pigeon*, 428; *see also* Buccal cavity
 Muscle, bursalis: *Pigeon*, 455
 columellar: *Snail*, 114
 mandibular: *Rabbit*, 362
 of eyeball: *Dog-fish*, 266; *Pigeon*, 455
 of neck: *Rabbit*, 361
 of nictitating membrane: *Pigeon*, 455
 pectoral: *Pigeon*, 429
 pyramidalis: *Pigeon*, 455
 quadratus: *Pigeon*, 455
 retractor penis: *Snail*, 125
 sterno-hyoid: *Rabbit*, 361
 sterno-mastoid: *Rabbit*, 361
 sterno-thyroid: *Rabbit*, 362
 stylo-hyoid: *Rabbit*, 362
 Muscle-process: *Hydra*, 24, 25
 Muscular impression: *Mussel-shell*, 83

- Muscular system : *Leech*, 55 ; *Earthworm*, 78 ; *Mussel*, 86 ; *Amphioxus*, 183, 199 ; *see also* Muscle
- Musculi papillares : *Rabbit*, 351 ; *Pigeon*, 447
- Mushroom-shaped gland : *Cockroach*, 176
- MUSSEL, 81-108 ; shell, 82 ; external characters, 86 ; gills, 90 ; circulatory system, 93 ; excretory system, 97 ; nervous system, 99 ; digestive system, 101 ; reproductive system, 102 ; transverse sections, 103
- Myophan striation : *Paramecium*, 5 ; *Opalina*, 7 ; *Vorticella*, 11
- Myotome : *Amphioxus*, 181, 183, 199
- Nacreous layer : *Mussel-shell*, 85 ; *Snail-shell*, 113
- Nasal bone : *Rabbit*, 300 ; *Fowl*, 410
- Nasal cartilage : *Dog-fish*, 223
- Nasal chamber : *Rabbit*, 375
- Naso-turbinal : *Rabbit*, 300
- Neck : *Cockroach*, 163 ; *Rabbit*, 360-370 ; *Pigeon*, 425
- Nematocyst : *Hydra*, 19, 20, 24, 26 ; discharge of, 20-21
- Nephridium : *Leech*, 47-50, 57 ; *Earthworm*, 67-70
- Nephrostome : *Earthworm*, 67, 69
- Nerve, antennary : *Cockroach*, 174
- auditory : *Snail*, 126 ; *Crayfish*, 159 ; *see also* 8th cranial nerve
- branchial : *Dog-fish*, 274
- buccal : *Snail*, 126 ; *Dog-fish*, 272
- cardiac : *Dog-fish*, 274 ; *Rabbit*, 367
- cranial : *Dog-fish*, 267-274 ; *see also* Nerve roots
- 1st cranial (olfactory) : *Dog-fish*, 268
- 2nd cranial (optic) : *Dogfish*, 268
- 3rd cranial (oculo-motor) : *Dog-fish*, 268
- 4th cranial (pathetic) *Dog-fish*, 269
- 5th cranial (trigeminal) : *Dog-fish*, 269, 270
- 6th cranial (abducent) : *Dog-fish*, 271
- 7th cranial (facial) : *Dog-fish*, 269, 271
- 8th cranial (auditory) : *Dog-fish*, 269, 273, 281
- 9th cranial (glosso-pharyngeal) : *Dog-fish*, 273
- 10th cranial (pneumo-gastric or vagus) : *Dog-fish*, 273 ; *Rabbit*, 366-368
- 11th cranial (spinal accessory) : *Rabbit*, 363
- 12th cranial (hypoglossal) : *Rabbit*, 365
- depressor : *Rabbit*, 367
- descendens noni, *see* Ramus descendens
- gastric : *Dog-fish*, 274
- great auricular : *Rabbit*, 368
- intermediary : *Leech*, 58
- laryngeal, anterior : *Rabbit*, 366
- laryngeal, posterior : *Rabbit*, 367
- mandibular : *Dog-fish*, 270
- maxillary : *Dog-fish*, 271
- of lateral line : *Dog-fish*, 273, 274
- of neck : *Rabbit*, 263-269
- ophthalmic : *Dog-fish*, 270, 271, 282
- optic : *Crayfish*, 158 ; *Cockroach*, 174 ; *see also* 2nd cranial nerve
- palatine : *Dog-fish*, 272
- phrenic : *Rabbit*, 338, 368
- post spiracular : *Dog-fish*, 272
- pre-spiracular : *Dog-fish*, 273
- pulmonary : *Rabbit*, 367
- recurrent laryngeal : *Rabbit*, 367
- spinal : *Dog-fish*, 278
- splanchnic : *Rabbit*, 372
- sympathetic : *Rabbit*, 368, 370-372
- visceral : *Crayfish*, 156, 157 ; *Cockroach*, 175 ; *Dog-fish*, 274
- Nerve-cell : *Hydra*, 20, 24 ; *Leech*, 58 ; *Earthworm*, 80 ; *Snail*, 127
- Nerve-chain, *see* Nervous system
- Nerve-collar : *Liver-fluke*, 33 ; *Leech*, 52 ; *Earthworm*, 76 ; *Snail*, 126
- Nerve-commissure : *Mussel*, 99
- Nerve-connective : *Mussel*, 100 ; *Crayfish*, 155-156 ; *Cockroach*, 174
- Nerve-cord, *see* Nervous system
- Nerve-ganglion, buccal : *Snail*, 126
- cerebral : *Mussel*, 99 ; *Snail*, 126 ; *Cockroach*, 174
- cervical : *Rabbit*, 368, 371

- Nerve-ganglion, *cœliac* ; *Rabbit*, 332, 372
 frontal : *Cockroach*, 175
 mesenteric : *Rabbit*, 332, 372
 optic : *Crayfish*, 158
 parieto-splanchnic, *see* Visceral
 pedal : *Mussel*, 99 ; *Snail*, 127
 post-œsophageal : *Crayfish*, 156 ; *Cockroach*, 174
 pre-œsophageal : *Crayfish*, 155 ; *Cockroach*, 174
 sub-œsophageal : *Leech*, 52 ; *Snail*, 126 ; *Cockroach*, 174
 supra-œsophageal : *Leech*, 52 ; *Earthworm*, 76 ; *Snail*, 126 ; *Cockroach*, 174
 visceral : *Mussel*, 100, 108
 viscero-pleural : *Snail*, 127
- Nerve-roots, cranial : *Dog-fish*, 267-274 ; *Rabbit*, 384-385
 spinal : *Amphioxus*, 191-192, 198, 200 ; *Dog-fish*, 278
- Nervous system : *Hydra*, 20, 24 ; *Liver-fluke*, 33 ; *Leech*, 51, 58 ; *Earthworm*, 75, 80 ;
Mussel, 99 ; *Snail*, 126 ; *Crayfish*, 155 ; *Cockroach*, 173-175 ; *Amphioxus*, 190, 198, 200 ; *Dog-fish*, 263 ; *Rabbit*, 363, 370, 378 ; *Pigeon*, 452
- Neural arch : *Dog-fish*, 216 ; *see also* Vertebra
- Neural canal, *see* Vertebra
- Neural plate : *Dog-fish*, 216
- Neural process : *Dog-fish*, 216
- Neural spine : *Dog-fish*, 217 ; *see also* Vertebra
- Nictitating membrane : *Rabbit*, 327 ; *Pigeon*, 425, 454, 455
- Nose, *see* Olfactory organ
- Nostril : *Dog-fish*, 212 ; *Rabbit*, 326 ; *Pigeon*, 428
- Notochord : *Amphioxus*, 182, 195, 198, 199 ; *Dog-fish*, 214, 215, 225
- Nucleolus, *see* Paranucleus
- Nucleus : *Amœba*, 3 ; *Paramecium*, 6 ; *Opalina*, 8 ; *Vorticella*, 11 ; *Snail-shell*, 112
- Oblique septum : *Pigeon*, 434
- Occipital condyle : *Dog-fish*, 225 ; *Rabbit*, 296 ; *Fowl*, 406
- Occipital segment : *Rabbit*, 296
- Odontoid process : *Rabbit*, 289 ; *Fowl*, 400
- Odontophore : *Snail*, 121, 128
- œsophageal pouches : *Earthworm*, 65
- œsophagus : *Liver-fluke*, 30 ; *Leech*, 44 ; *Earthworm*, 63 ; *Mussel*, 101 ; *Snail*, 121 ; *Crayfish*, 152 ; *Cockroach*, 171 ; *Dog-fish*, 234 ; *Rabbit*, 339 ; *Pigeon*, 435
- Olecranon process : *Rabbit*, 316 ; *Fowl*, 418
- Olfactory capsule : *Dog-fish*, 219 ; *Rabbit*, 300 ; *Fowl*, 410
- Olfactory lobe : *Dog-fish*, 265 ; *Rabbit*, 380, 381 ; *Pigeon*, 453
- Olfactory organ : *Crayfish*, 159 ; *Amphioxus*, 193 ; *Dog-fish*, 278
- Omentum : *Rabbit*, 332 ; *Pigeon*, 434
- OPALINA, 7-8
- Opisthotic : *Rabbit*, 301
- Optic chiasma : *Dog-fish*, 275 ; *Rabbit*, 382, 393 ; *Pigeon*, 453
- Optic foramen : *Dog-fish*, 221 ; *Rabbit*, 308 ; *Fowl*, 409
- Optic lobe : *Dog-fish*, 266, 277 ; *Rabbit*, 380, 394 ; *Pigeon*, 453
- Optic thalamus : *Rabbit*, 389
- Optic tract : *Rabbit*, 382, 389
- Oral groove : *Paramecium*, 6
- Orbit : *Dog-fish*, 221-223, 266 ; *Fowl*, 409
- Orbito-sphenoid : *Rabbit*, 298 ; *Fowl*, 409
- Os innominatum : *Rabbit*, 320 ; *Fowl*, 420
- Os orbiculare : *Rabbit*, 304
- Ossicle, auditory : *Rabbit*, 303 ; *Fowl*, 408, 415 ; *Pigeon*, 457
- Ossicles of stomach : *Crayfish*, 153
- Otocyst : *Mussel*, 100 ; *Snail*, 127
- Ovarian duct : *Liver-fluke*, 32
- Ovary : *Hydra*, 22-23 ; *Liver-fluke*, 32 ; *Leech*, 51 ; *Earthworm*, 70, 74 ; *Mussel*, 102 ;
Crayfish, 151 ; *Cockroach*, 176 ; *Amphioxus*, 193, 195-196, 206 ; *Dog-fish*, 233,
 255 ; *Rabbit*, 359 ; *Pigeon*, 451
- Oviduct : *Liver-fluke*, 33 ; *Leech*, 51 ; *Earthworm*, 70 ; *Snail*, 125 ; *Crayfish*, 151 ; *Cockroach*, 177 ; *Dog-fish*, 255 ; *Rabbit*, 359 ; *Pigeon*, 451
- Ovum : *Hydra*, 23 ; *Liver-fluke*, 35 ; *Earthworm*, 74 ; *Mussel*, 102 ; *Snail*, 123 ; *Cockroach*, 176 ;
Amphioxus, 194 ; *Dog-fish*, 210, 255 ; *Rabbit*, 325, 359 ; *Bird*, 424 ; *Pigeon*, 452
- Palatal process : *Rabbit*, 305
- Palate : *Rabbit*, 373
- Palatine bone : *Rabbit*, 304 ; *Fowl*, 411

- Pallial cavity, *see* Mantle-cavity
 Pallial line : *Mussel-shell*, 84
 Palp, labial : *Mussel*, 89 ; *Cockroach*, 167
 mandibular : *Crayfish*, 142
 Palp, maxillary : *Cockroach*, 167
 Palpiger : *Cockroach*, 167
 Pancreas : *Dog-fish*, 233 ; *Rabbit*, 332 ; *Pigeon*, 438
 Papilla, circumvallate : *Rabbit*, 374
 foliata : *Rabbit*, 374
 urino-genital : *Dog-fish*, 262
 Paraglossa : *Cockroach*, 167
 PARAMECIUM, 4-7
 Paranucleus : *Paramecium*, 6
 Para-sphenoid ; *Fowl*, 409
 Parietal bone : *Rabbit*, 298 ; *Fowl*, 410
 Parietal segment : *Rabbit*, 297-298
 Par-occipital process : *Rabbit*, 296
 Patella : *Rabbit*, 322 ; *Fowl*, 421
 Pearl, 85
 Pecten : *Pigeon*, 456
 Pectoral fin : *Dog-fish*, 212, 230
 Pectoral girdle : *Dog-fish*, 230 ; *Rabbit*, 313 ; *Fowl*, 416
 Pelvic fin : *Dog-fish*, 230
 Pelvic girdle : *Dog-fish*, 229 ; *Rabbit*, 320 ; *Fowl*, 420
 Pelvis of kidney : *Rabbit*, 351
 Penis : *Liver-fluke*, 32 ; *Lecch*, 51 ; *Snail*, 124 ; *Rabbit*, 327, 356
 Pericardial cavity : *Mussel*, 93, 104, 106 ; *Snail*, 117 ; *Dog-fish*, 237
 Pericardial sinus : *Crayfish*, 147
 Pericardium : *Snail*, 114 ; *Rabbit*, 337
 Perineal pouch : *Rabbit*, 327
 Periostracum : *Mussel-shell*, 84 ; *Snail-shell*, 113
 Periotic : *Rabbit*, 301
 Periplaneta, *see* *Cockroach*
 Peristome : *Vorticella*, 10
 Peritoneum : *Earthworm*, 78 ; *Dog-fish*, 233 ; *Rabbit*, 331
 Pes : *Rabbit*, 324 ; *Fowl*, 422
 Pessulus : *Pigeon*, -49
 Petrous portion : *Rabbit*, 301
 Peyer's patch : *Rabbit*, 334, 336
 Phalanges : *Rabbit*, 319, 324 ; *Fowl*, 419, 423
 Pharyngo-branchial : *Dog-fish*, 227
 Pharynx : *Vorticella*, 11 ; *Liver-fluke*, 30 ; *Lecch*, 44 ; *Earthworm*, 63 ; *Snail*, 121 ;
 Amphioxus, 185, 197, 202, 204 ; *Rabbit*, 374
 Pia mater : *Rabbit*, 379
 PIGEON, 424-458 ; external characters, 425 ; pectoral muscles, 429 ; air-sacs, 430 ; digestive
 system, 433 ; circulatory system, 438 ; respiratory system, 448 ; renal and
 reproductive systems, 449 ; brain, 452 ; sense organs, 454
 Pigmented canals : *Amphioxus*, 190
 Pineal body : *Dog-fish*, 265 ; *Rabbit*, 381, 390, 393 ; *Pigeon*, 453, 454
 Pinna : *Rabbit*, 327
 Pituitary body : *Dog-fish*, 275, 277 ; *Rabbit*, 382, 393 ; *Pigeon*, 454
 Pituitary foramen : *Rabbit*, 297, 310
 Pituitary fossa, *see* *Sella turcica*
 Placenta : *Rabbit*, 325
 Pleura : *Rabbit*, 338 ; *Pigeon*, 448
 Pleurobranchia : *Crayfish*, 145
 Pleuron : *Crayfish*, 134
 Podical plate : *Cockroach*, 164, 165
 Podobranchia : *Crayfish*, 145, 146
 Pollex : *Rabbit*, 319
 Pons Varolii : *Rabbit*, 382, 395
 Pore, abdominal : *Dog-fish*, 213, 232
 Pore, dorsal : *Earthworm*, 62
 Post-axial border of limb : *Rabbit*, 315, 321 ; *Fowl*, 417
 Post-orbital groove : *Dog-fish*, 223
 Post-zygapophysis, *see* *Vertebra*
 Pre-axial border of limb : *Rabbit*, 315, 321 ; *Fowl*, 417, 421
 Premaxilla : *Rabbit*, 305 ; *Fowl*, 411
 Premolar : *Rabbit*, 312, 313

- Prepuce : *Rabbit*, 327, 357
 Pre-sphenoid : *Rabbit*, 298 ; *Fowl*, 409
 Pre-zygapophysis, *see* Vertebra
 Primary quill : *Pigeon*, 427
 Prismatic layer : *Mussel-shell*, 85
 Proctodæum : *Crayfish*, 151, 152 ; *Cockroach*, 170, 171
 Pronephros : *Dog-fish*, 254 ; *Rabbit*, 353
 Pronotum : *Cockroach*, 164
 Pro-otic : *Rabbit*, 301
 Propodite : *Crayfish*, 139
 Pro-ptyergium : *Dog-fish*, 230
 Prosencephalon : *Dog-fish*, 265, 275
 Prostate : *Rabbit*, 357
 Prostomium : *Leech*, 40 ; *Earthworm*, 61
 Prothorax : *Cockroach*, 163
 Protodipite : *Crayfish*, 139 ; *see also* Appendage
 PROTOZOA, 1-13
 Proventriculus : *Cockroach*, 171 ; *Pigeon*, 435
 Pseudobranch : *Dog-fish*, 237
 Pseudopodia, 1-3
 Pterygoid bone : *Rabbit*, 304 ; *Fowl*, 411
 Pterygoid fossa : *Rabbit*, 304
 Pterygoid process : *Rabbit*, 297
 Pteryla : *Pigeon*, 428
 Pubes : *Rabbit*, 320 ; *Fowl*, 420
 Pulvillus : *Cockroach*, 169
 Pupil : *Dog-fish*, 279
 Pygostyle : *Fowl*, 402
 Pylorus : *Rabbit*, 332
 Pyramid of kidney : *Rabbit*, 354

 Quadrate : *Fowl*, 413
 Quadrato-jugal : *Fowl*, 413
 Quill : *Pigeon*, 426
 Quill-feather : *Pigeon*, 427

 RABBIT, 283-395 ; vertebral column, 285 ; ribs and sternum, 293 ; skull, 294 ; teeth, 311 ;
 appendicular skeleton, 313 ; external characters, 326 ; abdominal viscera,
 328 ; digestive system, 332 ; thoracic viscera, 337 ; circulatory system, 339 ;
 renal and reproductive systems 352 ; dissection of neck, 360 ; sympathetic
 nervous system, 371 ; dissection of head, 372 ; dissection of brain, 378
 Rachis : *Pigeon*, 427
 Radial cartilage : *Dog-fish*, 230, 231
 Radius : *Rabbit*, 316 ; *Fowl*, 418
 Radula : *Snail*, 128
 Ramus descendens of 12th cranial nerve : *Rabbit*, 365
 Receptaculum ovarum : *Earthworm*, 71, 74
 Receptaculum seminis, *see* Spermatheca
 Rectal diverticula : *Pigeon*, 437
 Rectrix : *Fowl*, 394 ; *Pigeon*, 428
 Rectum : *Mussel*, 94, 101 ; *Snail*, 114, 119 ; *Cockroach*, 171 ; *Dog-fish*, 234 ; *Rabbit*, 329, 335,
 337, 358 ; *Pigeon*, 447, 451, 452
 Redia, 36-37
 Rejuvenescence : *Paramecium*, 7
 Remex : *Pigeon*, 427
 Reno-pericardial canal : *Snail*, 117
 Reproduction : *Amœba*, 3 ; *Paramecium*, 6 ; *Opalina*, 8 ; *Vorticella*, 12 ; *Hydra*, 21-23 ;
Liver-fluke, 33-37 ; *Snail*, 123
 Reproductive system : *Liver-fluke*, 30 ; *Leech*, 50, 57 ; *Earthworm*, 70 ; *Mussel*, 102 ; *Snail*,
 123 ; *Crayfish*, 150 ; *Cockroach*, 176 ; *Amphioxus*, 193, 195, 206 ; *Dog-*
fish, 254 ; *Rabbit*, 352-360 ; *Pigeon*, 449-452
 Respiration : *Leech*, 55 ; *Mussel*, 93 ; *Snail*, 116-117 ; *Crayfish*, 143, 146 ; *Cockroach*, 172 ;
Amphioxus, 185 ; *Dog-fish*, 236 ; *Pigeon*, 430
 Respiratory system : *Snail*, 115 ; *Cockroach*, 165, 172 ; *Amphioxus*, 184, 196, 197 ; *Dog-fish*,
 236 ; *Pigeon*, 430, 448-449 ; *see also* Gill, Lung
 Restiform body : *Dog-fish*, 266, 277
 Retina : *Dog-fish*, 279
 Rib : *Dog-fish*, 216 ; *Rabbit*, 293 ; *Fowl*, 402
 Rostrum : *Crayfish*, 136 ; *Dog-fish*, 219 ; *Fowl*, 407, 409

- Sacculus rotundus : *Rabbit*, 335
Saccus vasculosus : *Dog-fish*, 275
Sacrum : *Rabbit*, 292 ; *Fowl*, 401
Salivary receptacle : *Cockroach*, 172
Scale : *Dog-fish*, 213
Scaphocerite : *Crayfish*, 143
Scaphognathite : *Crayfish*, 142, 146
Scapula : *Rabbit*, 314 ; *Fowl*, 416
Scapus : *Pigeon*, 426
Sclerite : *Crayfish*, 133, 153 ; *Cockroach*, 163
Sclerotic : *Dog-fish*, 278
Sclerotic plate : *Pigeon*, 456
Scrotal sac : *Rabbit*, 328, 354
Scyllium, see *Dog-fish*
Secondary quill : *Pigeon*, 427
Segmental organ, see Nephridium
Segmentation : *Leech*, 39 ; *Earthworm*, 59 ; *Crayfish*, 132 ; *Cockroach*, 161
Segmentation of skull : *Rabbit*, 296
Sella turcica : *Rabbit*, 297
Semircular canal : *Dog-fish*, 220-221, 280-281 ; *Pigeon*, 458
Seminal funnel : *Earthworm*, 73
Sense-capsules : *Dog-fish*, 217 ; *Rabbit*, 300
Sense-organs : *Leech*, 52 ; *Mussel*, 100 ; *Snail*, 127 ; *Crayfish*, 157 ; *Cockroach*, 175 ;
Amphioxus, 193 ; *Dog-fish*, 278 ; *Pigeon*, 454
Septum : *Earthworm*, 63, 79 ; *Amphioxus*, 183, 199
Septum auricularum : *Rabbit*, 350 ; *Pigeon*, 446
Septum interorbital : *Fowl*, 404, 409
Septum lucidum : *Rabbit*, 388
Septum narium : *Dog-fish*, 219 ; *Rabbit*, 310
Septum obliquum : *Pigeon*, 434
Sesamoid bone : *Rabbit*, 283, 319 ; see also Fabella, Patella
Seta : *Earthworm*, 61, 78
Shell : *Mussel*, 82 ; *Snail*, 109, 112
Shell-gland : *Liver-fluke*, 33
Sinus, blood : *Leech*, 45, 46, 56 ; *Snail*, 130 ; *Crayfish*, 147
 anterior cardinal : *Dog-fish*, 242, 243
 coronary : *Dog-fish*, 254
 Cuvierian : *Dog-fish*, 242
 genital : *Dog-fish*, 245
 hepatic : *Dog-fish*, 242
 hyoidean : *Dog-fish*, 243
 inferior jugular : *Dog-fish*, 242
 inter-orbital : *Dog-fish*, 222, 243
 orbital : *Dog-fish*, 221, 243
 posterior cardinal : *Dog-fish*, 242, 243
 post-orbital : *Dog-fish*, 243
 venosus : *Dog-fish*, 239, 241, 253
Sinus, genital : *Liver-fluke*, 33
 urinary : *Dog-fish*, 258
 urino-genital : *Dog-fish*, 262
Skate, 210
Skeleton : *Amphioxus*, 182, 195, 197, 199 ; *Dog-fish*, 214 ; *Rabbit*, 283 ; *Fowl*, 306
Skeleton, appendicular : *Rabbit*, 313 ; *Fowl*, 416
 axial : *Rabbit*, 285 ; *Fowl*, 396
 branchial : *Amphioxus*, 185, 197
 buccal : *Amphioxus*, 182, 197, 199
 endophragmal : *Crayfish*, 155
 of fins : *Amphioxus*, 182, 195, 199 ; *Dog-fish*, 228
 mammalian, 284
 visceral : *Dog-fish*, 225
Skin, see Integument
Skull : *Dog-fish*, 217 ; *Rabbit*, 294 ; *Fowl*, 404
SNAIL, 109-131 ; external characters, 109 ; mantle-cavity, 115 ; digestive system, 119 ;
 reproductive system, 123 ; nervous system, 126 ; sense organs, 127 ; buccal
 mass, 128 ; circulatory system, 129
Somite : *Leech*, 39
Spermatid : *Earthworm*, 75
Spermatozoa : *Hydra*, 22 ; *Leech*, 50 ; *Earthworm*, 74-75 ; *Snail*, 123 ; *Crayfish*, 150 ;
 Amphioxus, 194 ; *Dog-fish*, 263

- Spermocyte: *Earthworm*, 75
 Spermogonia: *Earthworm*, 74
 Spermatophore: *Leech*, 51; *Snail*, 124
 Spermothea: *Earthworm*, 71, 74; *Snail*, 125; *Cockroach*, 177
 Sperm-sac: *Dog-fish*, 261
 Sphenoidal fissure: *Rabbit*, 297-298
 Spinal cord: *Amphioxus*, 191, 198, 200; *Dog-fish*, 27
 Spinous process, *see* Vertebra
 Spiracle: *Cockroach*, 165, 172; *Dog-fish*, 213
 Spiral valve: *Dog-fish*, 234
 Spleen: *Dog-fish*, 233; *Rabbit*, 331; *Pigeon*, 425
 Splenial: *Fowl*, 415
 Sporocyst, 36
 Squamosal: *Rabbit*, 306; *Fowl*, 407, 408
 Stapes: *Rabbit*, 304
 Sternebra: *Rabbit*, 294
 Sternum: *Crayfish*, 134, 136; *Cockroach*, 165; *Rabbit*, 294; *Fowl*, 403
 Stigma: *Cockroach*, 165, 172
 Stipes: *Cockroach*, 166
 Stomach: *Leech*, 45; *Mussel*, 101; *Snail*, 121; *Crayfish*, 152, 153; *Amphioxus*, 186; *Dog-fish*, 232; *Rabbit*, 329, 331, 336; *Pigeon*, 435
 Stomodæum: *Crayfish*, 151, 152; *Cockroach*, 170
 Stylo-hyal: *Rabbit*, 307
 Submentum: *Cockroach*, 167
 Suborbital ridge: *Dog-fish*, 221
 Sucker: *Liver-fluke*, 28, 37; *Leech*, 40
 Sulcus: *Rabbit*, 379, 389
 Supporting lamella: *Hydra*, 18, 20, 24, 26
 Supra-angular: *Fowl*, 414
 Supra-branchial passage or chamber: *Mussel*, 87, 92, 104, 105, 108
 Supra-occipital: *Rabbit*, 296
 Supra-orbital crest: *Dog-fish*, 220, 221
 Supra-orbital process: *Rabbit*, 299
 Suprascapula: *Rabbit*, 314
 Suspensorium: *Dog-fish*, 227
 Suspensory fold of pharynx: *Amphioxus*, 187, 203, 205
 Swimmeret, *see* Abdominal appendage
 Sylvian aqueduct: *Rabbit*, 393; *Pigeon*, 454
 Sylvian fissure: *Rabbit*, 381
 Symphysis pubis: *Rabbit*, 321
 Syrinx: *Pigeon*, 449

 Tapetum: *Dog-fish*, 279
 Tarso-metatarsus: *Fowl*, 422
 Tarsus: *Cockroach*, 169; *Rabbit*, 318, 323
 Teat: *Rabbit*, 328
 Teeth: *Crayfish*, 153, 154; *Cockroach*, 171; *Dog-fish*, 214, 226; *Rabbit*, 283, 311
 Telson: *Crayfish*, 136
 Tentacle: *Hydra*, 16, 18; *Mussel*, 88; *Snail*, 110; *Amphioxus*, 181, 196, 197
 Tentorium: *Cockroach*, 174; *Rabbit*, 379
 Tergum: *Crayfish*, 134; *Cockroach*, 164
 Testis: *Hydra*, 22; *Liver-fluke*, 30; *Leech*, 50, 57; *Earthworm*, 73, 74; *Mussel*, 102; *Crayfish*, 150; *Cockroach*, 176; *Amphioxus*, 194, 196, 206; *Dog-fish*, 233, 259; *Rabbit*, 354, 355; *Pigeon*, 450
 Thalamencephalon: *Dog-fish*, 265, 277; *Rabbit*, 380, 385, 389; *Pigeon*, 454
 Thoracic appendage: *Crayfish*, 138; *Cockroach*, 167
 Thoracic duct: *Rabbit*, 349
 Thorax: *Crayfish*, 136; *Cockroach*, 163; *Rabbit*, 327, 337
 Thread-cell: *Hydra*, 19, 20, 24, 26; *see also* Trichocyst
 Thymus: *Rabbit*, 337
 Thyroid body: *Rabbit*, 363
 Thyroid cartilage: *Rabbit*, 363, 369
 Tibia: *Cockroach*, 169; *Rabbit*, 322
 Tibio-tarsus: *Fowl*, 422
 Tongue: *Cockroach*, 170; *Rabbit*, 373; *Pigeon*, 433
 Tonsil: *Rabbit*, 373
 Trachea: *Rabbit*, 362; *Pigeon*, 448
 Tracheal tube: *Cockroach*, 172-173
 Transverse process: *Dog-fish*, 216; *see also* Vertebra

- Trichocyst : *Paramecium*, 5, 7
 Trochanter : *Cockroach*, 167 ; *Rabbit*, 321 ; *Fowl*, 421
 Tubercle : *Rabbit*, 293
 Tympanic bone : *Rabbit*, 302
 bulla : *Rabbit*, 296, 302
 cavity : *Rabbit*, 302 ; *Fowl*, 407 ; *Pigeon*, 457
 membrane : *Rabbit*, 302 ; *Fowl*, 407 ; *Pigeon*, 456
 Tympano-Eustachian passage : *Pigeon*, 456
 Typhlosole : *Earthworm*, 65, 79 ; *Mussel*, 102, 104
 Typical segment : *Crayfish*, 133

 Ulna : *Rabbit*, 316 ; *Fowl*, 418
 Umbilicus of feather : *Pigeon*, 426
 of snail-shell, 112
 Umbo : *Mussel-shell*, 82
 Uncinate process : *Fowl*, 403
 Ureter : *Mussel*, 97, 98, 105, 107 ; *Snail*, 118 ; *Crayfish*, 155 ; *Dog-fish*, 254, 258, 262 ; *Rabbit*, 354 ; *Pigeon*, 450
 Urethra : *Rabbit*, 356
 Urino-genital canal, *see* Urethra, Vestibule
 pouch : *Pigeon*, 451, 452
 Uterus : *Liver-fluke*, 33 ; *Rabbit*, 359
 Uterus masculinus : *Rabbit*, 357, 358

 Vacuole : *Hydra*, 24, 26
 Vacuole, food : *Amoeba*, 3 ; *Paramecium*, 6 ; *Vorticella*, 11
 pulsating : *Amoeba*, 3 ; *Paramecium*, 5 ; *Vorticella*, 11
 Vagina : *Liver-fluke*, 33 ; *Leech*, 51 ; *Snail*, 125 ; *Rabbit*, 359
 Vagus, *see* Nerve, 10th cranial
 Valve, Eustachian : *Rabbit*, 350 ; *Pigeon*, 446
 mitral : *Rabbit*, 352 ; *Pigeon*, 447
 of Vieussens : *Rabbit*, 381, 394
 semilunar : *Rabbit*, 352 ; *Pigeon*, 447, 448
 spiral : *Dog-fish*, 234
 tricuspid : *Rabbit*, 351
 Vane : *Pigeon*, 427
 Vas deferens : *Liver-fluke*, 31 ; *Leech*, 50, 58 ; *Earthworm*, 73 ; *Snail*, 124 ; *Crayfish*, 150 ; *Cockroach*, 176 ; *Dog-fish*, 261 ; *Rabbit*, 355 ; *Pigeon*, 450
 Vas efferens : *Leech*, 50 ; *Earthworm*, 73 ; *Dog-fish*, 259 ; *Rabbit*, 355
 Vein, azygos cardinal : *Rabbit*, 342
 brachial : *Pigeon*, 440
 caudal : *Dog-fish*, 245 ; *Pigeon*, 441
 coronary : *Rabbit*, 350
 duodenal : *Rabbit*, 345
 facial, *Rabbit*, 343
 femoral : *Rabbit*, 345 ; *Pigeon*, 442
 gastro-duodenal : *Pigeon*, 442
 hepatic : *Amphioxus*, 189, 206 ; *Rabbit*, 341 ; *Pigeon*, 440
 hypogastric : *Pigeon*, 441
 iliac : *Rabbit*, 344 ; *Pigeon*, 441-442
 ilio-lumbar : *Rabbit*, 344
 intercostal : *Rabbit*, 342
 internal iliac : *Pigeon*, 441
 internal mammary : *Rabbit*, 343 ; *Pigeon*, 440
 jugular : *Rabbit*, 343 ; *Pigeon*, 433
 lateral : *Dog-fish*, 244
 lieno-gastric : *Rabbit*, 345
 mesenteric : *Rabbit*, 345 ; *Pigeon*, 434, 441, 442
 ovarian : *Rabbit*, 344
 pectoral : *Pigeon*, 440
 phrenic : *Rabbit*, 344
 portal : *Amphioxus*, 189, 206 ; *Dog-fish*, 245 ; *Rabbit*, 345 ; *Pigeon*, 434, 442
 pulmonary : *Snail*, 116 ; *Rabbit*, 341 ; *Pigeon*, 442
 renal : *Dog-fish*, 244 ; *Rabbit*, 344 ; *Pigeon*, 441-442
 renal portal : *Dog-fish*, 245
 spermatic : *Rabbit*, 344
 subclavian : *Dog-fish*, 240 ; *Rabbit*, 343
 vertebral : *Pigeon*, 432
 Veins : *Mussel*, 95 ; *Snail*, 130 ; *Dog-fish*, 241 ; *Rabbit*, 341 ; *Pigeon*, 439 ; *see also* Sinus

- Veins of kidney : *Pigeon*, 441
 Velum : *Amphioxus*, 184
 Velum interpo-ritum : *Rabbit*, 329, 393
 Velum medullæ : *Rabbit*, 381, 391
 Vena cava : *Mussel*, 95, 104, 107
 Vena cava, anterior : *Rabbit*, 340, 342-343 ; *Pigeon*, 439, 440
 posterior : *Rabbit*, 340, 343 ; *Pigeon*, 440
 Ventricle of brain : *Dog-fish*, 276-277 ; *Rabbit*, 385
 lateral : *Dog-fish*, 276 ; *Rabbit*, 386 ; *Pigeon*, 454
 Ventricle of brain, third : *Dog-fish*, 265, 276 ; *Rabbit*, 390 ; *Pigeon*, 454
 fourth : *Dog-fish*, 266, 277 ; *Rabbit*, 394 ; *Pigeon*, 454
 fifth : *Rabbit*, 388
 Ventricle of heart : *Mussel*, 94, 107 ; *Snail*, 117 ; *Dog-fish*, 239, 253 ; *Rabbit*, 339, 340, 351-352 ; *Pigeon*, 447
 Ventricle of larynx : *Rabbit*, 369
 Ventricle of nervous system : *Amphioxus*, 191
 Vermiform appendix : *Rabbit*, 329, 335, 336
 Vermis cerebelli : *Rabbit*, 382
 Vertebra anticlinal : *Rabbit*, 290
 caudal : *Rabbit*, 292 ; *Fowl*, 402
 cervical : *Rabbit*, 288 ; *Fowl*, 397
 lumbar : *Rabbit*, 285, 291
 sacral : *Rabbit*, 292 ; *Fowl*, 401
 thoracic : *Rabbit*, 290 ; *Fowl*, 401
 typical : *Rabbit*, 285
 Vertebral column : *Dog-fish*, 215 ; *Rabbit*, 285 ; *Fowl*, 396
 Vertebral column, development of : *Dog-fish*, 214
 Vertebralarterial canal, *see* Vertebra, cervical
 Verumontanum : *Rabbit*, 358
 Vesicula seminalis : *Liver-fluke*, 32 ; *Earthworm*, 72, 75 ; *Cockroach*, 176 ; *Dog-fish*, 259 ; *Pigeon*, 451
 Vessel, *see* Blood-vessel
 Vestibule : *Vorticella*, 10 ; *Rabbit*, 359
 Vestibule of ear : *Dog-fish*, 280
 Vexillum : *Pigeon*, 427
 Vibrissa : *Rabbit*, 327
 Villi : *Rabbit*, 336
 Visceral hump : *Snail*, 113
 Visceral mass : *Mussel*, 88, 103
 Visceral nervous system : *Crayfish*, 146 ; *Cockroach*, 175
 Visceral skeleton : *Dog-fish*, 225
 Vitellarium, *see* Yolk-gland
 Vocal cord : *Rabbit*, 370
 Vocal organ, *see* Larynx, Syrinx
 Vomer : *Rabbit*, 300 ; *Fowl*, 411
 VORTICELLA : 8-13
 Vulva : *Rabbit*, 327

 Wing : *Cockroach*, 164 ; *Fowl*, 417 ; *Pigeon*, 426
 Wolffian body : *Dog-fish*, 254, 256, 259 ; *Rabbit*, 353
 Wrist, *see* Carpus

 Xiphisternum : *Rabbit*, 294
 Xiphoid process : *Fowl*, 404

 Yolk-cell : *Liver-fluke*, 35
 Yolk-gland : *Liver-fluke*, 32
 Yolk-reservoir : *Liver-fluke*, 32

 Zygapophysis, *see* Vertebra
 Zygomatic arch : *Rabbit*, 306
 Zygomatic process : *Rabbit*, 305, 306 ; *Fowl*, 403



SMITH, ELDER, & CO.'S PUBLICATIONS.

JUST PUBLISHED. With Illustrations. Demy 8vo. 12s. 6d.

ALBUMINURIA AND BRIGHT'S DISEASE. By N. TIRARD, M.D., F.R.C.P., Physician to King's College Hospital and to the Evelina Hospital for Sick Children.

THERAPEUTICS: its PRINCIPLES and PRACTICE. By H. C. WOOD, M.D., LL.D., Professor of Materia Medica and Therapeutics and Clinical Professor of Diseases of the Nervous System in the University of Pennsylvania. Being the Tenth Edition of 'A TREATISE ON THERAPEUTICS,' Rearranged, Rewritten, and Enlarged. 8vo. 18s.

OCULAR THERAPEUTICS. By L. DE WECKER, Professor of Clinical Ophthalmology, Paris. Translated and Edited by LITTON FORBES, M.A., M.D., F.R.G.S., late Clinical Assistant, Royal London Ophthalmic Hospital. With Illustrations. Demy 8vo. 16s.

A PRACTICAL TREATISE on DISEASES of the HEART and GREAT VESSELS, including the Principles of their Physical Diagnosis. By the late WALTER HAYLE WALSH, M.D. Fourth Edition, thoroughly Revised and greatly Enlarged. Demy 8vo. 16s.

A PRACTICAL TREATISE on DISEASES of the LUNGS; including the Principles of Physical Diagnosis and Notes on Climate. By the late WALTER HAYLE WALSH. Fourth Edition, Revised and much Enlarged. Demy 8vo. 16s.

AUSCULTATION and PERCUSSION, together with the other Methods of Physical Examination of the Chest. By SAMUEL GEE, M.D. With Illustrations. Fourth Edition. Fcp. 8vo. 6s.

HANDBOOK of MODERN CHEMISTRY, INORGANIC and ORGANIC. By the late MEYMOTT TIDY, M.B., F.C.S., Professor of Chemistry and of Medical Jurisprudence and Public Health at the London Hospital; one of the Official Analysts to the Home Office; Medical Officer of Health for Islington; late Deputy Medical Officer of Health and Public Analyst for the City of London; Master of Surgery, &c. &c. Second Edition, Revised and Enlarged. Demy 8vo. 18s.

An INDEX of SYMPTOMS as an AID to DIAGNOSIS. By RALPH WINNINGTON LEFTWICH, M.D., late Assistant-Physician to the East London Children's Hospital. Fcp. 8vo. 5s.

* * * Each Symptom is followed by an Alphabetical List of Diseases in which it occurs.

ELLIS'S DEMONSTRATIONS of ANATOMY: being a Guide to the Knowledge of the Human Body by Dissection. ELEVENTH EDITION. Edited and Revised by G. D. THANE, Professor of Anatomy, University College, London. With 252 Illustrations. Small 8vo. 12s. 6d.

ILLUSTRATIONS of DISSECTIONS. In a Series of Original Coloured Plates the size of Life, representing the Dissection of the Human Body. By G. V. ELLIS and G. H. FORD. Imperial folio. 2 vols. half-bound in morocco, £6. 6s. May also be had in Parts separately. Parts 1 to 28, 3s. 6d. each; Part 29, 5s.

London: SMITH, ELDER, & CO., 15 Waterloo Place.

SMITH, ELDER, & CO.'S PUBLICATIONS.

NEW EDITION OF PLAYFAIR'S 'SCIENCE AND PRACTICE OF MIDWIFERY.'

NINTH EDITION. With over 200 Illustrations and 8 Plates. 2 vols. Demy 8vo. 28s.

A TREATISE on the SCIENCE and PRACTICE of MIDWIFERY.

By W. S. PLAYFAIR, M.D., LL.D., F.R.C.P., Physician-Accoucheur to H.L. and R.H. the Duchess of Saxe-Coburg and Gotha (Duchess of Edinburgh); Emeritus Professor of Obstetric Medicine in King's College; Consulting Physician for the Diseases of Women and Children to King's College Hospital; to the General Lying-in Hospital, the Evelina Hospital for Children, &c.; late President of the Obstetrical Society of London; Examiner in Midwifery to the Universities of Cambridge and London, and to the Royal College of Physicians.

A SYSTEM of OBSTETRIC MEDICINE and SURGERY, THEORETICAL

and CLINICAL. For the Student and Practitioner. By ROBERT BARNES, M.D., Consulting Obstetric Physician to the St. George's Hospital, &c.; and FANCOURT BARNES, M.D., Consulting Physician to the British Lying-in Hospital. The Section on Embryology contributed by the late Professor MILES MARSHALL. Complete in 2 vols. with numerous Illustrations. 8vo. Vol. I., 18s. Vol. II., 20s.

A MANUAL of MIDWIFERY for MIDWIVES. By FANCOURT BARNES,

M.D., M.R.C.P., Consulting Physician to the British Lying-in Hospital, &c. EIGHTH EDITION. With Illustrations. Crown 8vo. 6s.

The EVOLUTION of the DISEASES of WOMEN. By W. BALLS-

HEADLEY, M.A., M.D. Cantab., F.R.C.P. Lond.; Lecturer on Midwifery and the Diseases of Women at the University of Melbourne; Honorary Physician to the Women's Hospital; President of the Section of Obstetrics and Gynaecology at the Intercolonial Medical Congress, Sydney, N.S.W., 1892; late President of the Medical Society of Victoria, &c. With numerous Illustrations. Demy 8vo. 16s.

A SYNOPTICAL GUIDE to the STUDY of OBSTETRICS: being an

Aid to the Student in the Class-room, in Private Study, and in Preparing for Examinations. By ROBERT BARNES, M.D., Consulting Obstetric Physician to St. George's Hospital, &c. Crown 8vo. 3s.

CLINICAL and PATHOLOGICAL OBSERVATIONS on TUMOURS

of the OVARY, FALLOPIAN TUBE, and BROAD LIGAMENT. By ALBAN H. G. DORAN, F.R.C.S., Assistant-Surgeon to the Samaritan Free Hospital, formerly Anatomical and Pathological Assistant to the Museum of the Royal College of Surgeons of England. With 32 Illustrations. 8vo. 10s. 6d.

GENERAL and DIFFERENTIAL DIAGNOSIS of OVARIAN

TUMOURS, with Special Reference to the Operation of Ovariectomy, and Occasional Pathological and Therapeutical Considerations. By WASHINGTON L. ATLEE, M.D. With 39 Illustrations. 8vo. 20s.

The QUESTION of REST for WOMEN DURING MENSTRUATION.

By MARY PUTNAM JACOBI, M.D., Professor of Materia Medica in the Women's Medical College, New York. With Illustrations. 8vo. 12s.

The SURGERY of DEFORMITIES. A Manual for Students and Practi-

tioners. By NOBLE SMITH, F.R.C.S. Edin., L.R.C.P. Lond., Surgeon to the City Orthopaedic Hospital and Surgeon to the All Saints' Children's Hospital. With 118 Illustrations. Crown 8vo. 10s. 6d.

London: SMITH, ELDER, & CO., 15 Waterloo Place.

SMITH, ELDER, & CO.'S PUBLICATIONS.

A TREATISE on SURGERY: its PRINCIPLES and PRACTICE. By T. HOLMES, M.A. Cantab., F.R.C.S., Consulting Surgeon to St. George's Hospital; Memb. Associé de la Soc. de Chir. de Paris. FIFTH EDITION. Edited by T. PICKERING PICK, Surgeon to, and Lecturer on Surgery at, St. George's Hospital; Senior Surgeon, Victoria Hospital for Children; Member of the Court of Examiners, Royal College of Surgeons of England. With 428 Illustrations. Royal 8vo. 30s.

'Mr. Pick has revised the whole book most thoroughly, has carefully brought it up to date, and has incorporated a great deal of the modern teaching in pathology and practical surgery. . . . We are sure that this edition will largely add to the great reputation which this text-book has for a long time had.'—LANCET.

'This edition may fairly claim to have been brought thoroughly up to the level of the most recent knowledge, and no doubt will retain the place which this favourite handbook has gained as one of the standard treatises on surgery.'

BRITISH MEDICAL JOURNAL.

A DICTIONARY of PRACTICAL SURGERY. By VARIOUS BRITISH HOSPITAL SURGEONS. Edited by CHRISTOPHER HEATH, F.R.C.S., Hulme Professor of Clinical Surgery in University College, London; Surgeon to University College Hospital; Member of the Council and Court of Examiners of the Royal College of Surgeons of England. In 2 vols. comprising 1,864 pages. THIRD EDITION. Royal 8vo. 32s., bound in cloth; or, in half-morocco, marbled edges, 42s.

'Altogether the work is a credit to the energy of authors, editor, and publisher, and will rank highly wherever British surgery is consulted, and wherever the English language is understood. All its contributors are to be congratulated upon its appearance.'

BRITISH MEDICAL JOURNAL.

'The Dictionary will stand undoubtedly as one of the most trustworthy works of reference published in modern times upon practical surgery, and will form a valuable and almost essential occupant of the practitioner's library.'

LONDON MEDICAL RECORD.

An INDEX of SURGERY: being a Concise Classification of the Main Facts and Theories of Surgery, for the Use of Senior Students and others. By C. B. KEETLEY, F.R.C.S., Surgeon to the West London Hospital and to the Surgical-Aid Society. FOURTH EDITION. Crown 8vo. 10s. 6d.

'Will, we trust, for many years be kept up to the imperious demands of surgical progress. The system of arrangement is just what the system in such a publication should

ever be, purely alphabetical, and the text is written in as elegant and intelligible English as can be expected in condensations and abridgments.'—BRITISH MEDICAL JOURNAL.

ANTISEPTIC SURGERY: its PRINCIPLES, PRACTICE, HISTORY, and RESULTS. By W. WATSON CHEYNE, M.B., F.R.C.S., Assistant-Surgeon to King's College Hospital, and Demonstrator of Surgical Pathology in King's College. With 145 Illustrations. 8vo. 21s.

MANUAL of the ANTISEPTIC TREATMENT of WOUNDS. For Students and Practitioners. By W. WATSON CHEYNE, M.B., F.R.C.S., Assistant-Surgeon to King's College Hospital; Surgeon to the Paddington Green Children's Hospital, &c. With Illustrations. Crown 8vo. 4s. 6d.

The DESCRIPTIVE ATLAS of ANATOMY. A Representation of the Anatomy of the Human Body. In 92 Royal 4to. Plates, containing 550 Illustrations. Introducing Heitzmann's Figures, considerably modified, and with many Original Drawings from Nature. By NOBLE SMITH, F.R.C.S. Edin., L.R.C.P. Lond.; Surgeon to the City Orthopædic Hospital, and Surgeon to the All Saints' Children's Hospital. Bound in half-leather, 25s.

'Certainly one of the most remarkable publications of the day. The great advantage which it presents is that all the attachments of bones, the arteries, veins, &c., are copiously lettered and described *in situ*; and the

arteries and veins are coloured. The book is one of great utility and merit, and reflects credit on the artist, and also on those who have produced it.'

BRITISH MEDICAL JOURNAL.

London: SMITH, ELDER, & CO., 15 Waterloo Place.

SMITH, ELDER, & CO.'S PUBLICATIONS.

DISEASES of the BONES: their PATHOLOGY, DIAGNOSIS, and TREATMENT. By THOMAS JONES, F.R.C.S. Eng., B.S. Lond., Surgeon to the Manchester Royal Infirmary; Lecturer on Practical Surgery in the Owens College, Victoria University; Consulting Surgeon to the Children's Hospital, Pendlebury, Manchester. With 7 Chromo-lithographic Plates, 9 Etchings, and 77 Woodcuts. 8vo. 12s. 6d.

A HANDBOOK of OPHTHALMIC SCIENCE and PRACTICE. By HENRY E. JULER, F.R.C.S., Ophthalmic Surgeon to St. Mary's Hospital; Surgeon to the Royal Westminster Ophthalmic Hospital; Consulting Ophthalmic Surgeon to the London Lock Hospitals. SECOND EDITION, Revised, with numerous Illustrations. 8vo. 21s.

'Altogether the book is one of which we are able to speak in terms of unqualified approval.'—BRITISH MEDICAL JOURNAL.

'A very good and reliable work, which represents satisfactorily the present state of ophthalmic science and practice.'—LANCET.

VERTEBRATE EMBRYOLOGY. A Text-Book for Students and Practitioners. By the late A. MILNES MARSHALL, M.D., D.Sc., M.A., F.R.S., Professor in the Victoria University; Beyer Professor of Zoology in Owens College; late Fellow of St. John's College, Cambridge. With numerous Illustrations. 8vo. 21s.

'Will be extremely useful to all teachers and students of biology. . . . An eminently practical treatise.'—NATURE.

'The book is welcome, and we do not doubt

but that it will obtain the popularity which it so well deserves. The care and accuracy with which it has been written will render it most useful to the student and to the teacher.'

BRITISH MEDICAL JOURNAL.

A MANUAL of GENERAL PATHOLOGY. By JOSEPH F. PAYNE, M.D., F.R.C.P., late Fellow of Magdalen College, Oxford; Physician and Joint-Lecturer on Pathological Anatomy at St. Thomas's Hospital; Examiner in Pathology in the University of Oxford; late Examiner in Medicine to the Royal College of Surgeons of England, &c. With Illustrations. Crown 8vo. 12s. 6d.

The FUNCTIONS of the BRAIN. By DAVID FERRIER, M.D., LL.D., F.R.S., Professor of Forensic Medicine, King's College; Physician to King's College Hospital; Physician to the National Hospital for the Paralyzed and Epileptic. SECOND EDITION, Rewritten, with many New Illustrations. 8vo. 18s.

'No scientific medical man's library can be said to be complete without Dr. Ferrier's book, which contains the records of the

author's own work, as well as those of other observers of repute.'—LANCET.

The LOCALISATION of CEREBRAL DISEASE. By DAVID FERRIER, M.D., F.R.S., Assistant-Physician to King's College Hospital; Professor of Forensic Medicine, King's College. With numerous Illustrations. 8vo. 7s. 6d.

A PRACTICAL TREATISE on TRAUMATIC SEPARATION of the EPIPHYSES; including the Anatomy of the Epiphyses, the Pathological Anatomy, Symptoms, Treatment, and Results of Traumatic Separations. By JOHN POLAND, F.R.C.S., Surgeon to the City Orthopædic Hospital; Visiting Surgeon to the Miller Hospital, and formerly Senior Demonstrator of Anatomy and Surgical Registrar to Guy's Hospital. Royal 8vo. 926 pages, with 337 Illustrations, and SKIAGRAMS. £2. 12s. 6d.

AND BY THE SAME AUTHOR. With 19 SKIAGRAMS. Royal 8vo. 5s.

The SKIAGRAPHIC ATLAS. Showing the Development of the BONES of the WRIST and HAND for the Use of Students and others.

London: SMITH, ELDER, & CO., 15 Waterloo Place.

SMITH, ELDER, & CO.'S PUBLICATIONS.

A SYSTEM of SURGERY: Pathological, Diagnostic, Therapeutic, and Operative. By SAMUEL D. GROSS, M.D., LL.D., D.C.L. Oxon. SIXTH EDITION, greatly Enlarged and thoroughly Revised. With upwards of 1,600 Illustrations. 2 vols. 8vo. £3. 10s.

A COURSE of PRACTICAL HISTOLOGY. By EDWARD ALBERT SCHÄFER, LL.D., F.R.S., Jodrell Professor of Physiology, University College. SECOND AND CHEAPER EDITION. With numerous Illustrations. Crown 8vo. 7s. 6d.

'We are very much pleased with Mr. Schäfer's book. It is clearly written, well and originally illustrated, and possesses the merit of being both concise and complete. In conclusion, we may say that any student who has gone fairly over the ground covered

by this treatise will find that he has not only gained a mastery over the modern methods of microscopical investigation, but a sound knowledge of the several structures of which the body is composed.'

LANCET.

ATLAS of HISTOLOGY. By E. KLEIN, M.D., F.R.S., Lecturer on Histology at St. Bartholomew's Medical School; and NOBLE SMITH, F.R.C.S. Edin., L.R.C.P. Lond., &c., Surgeon to the City Orthopaedic Hospital, and Surgeon to the All Saints' Children's Hospital. A complete Representation of the Microscopic Structure of Simple and Compound Tissues of Man and the Higher Animals, in carefully executed coloured engravings, with Explanatory Text of the Figures, and a Concise Account of the hitherto ascertained facts in Histology. Royal 4to., with 48 Coloured Plates, bound in half-leather, £4. 4s.; or in 13 Parts, 6s. each.

MANUAL of PATHOLOGICAL HISTOLOGY. By CORNIL and RANVIER. Translated by authority from the New and Re-written French Edition, with the original Illustrations. Vol. I. Histology of the Tissues. Demy 8vo. 21s. Vol. II. Special Pathological Histology. Lesions of the Organs. Part I. Demy 8vo. 12s. Part II. Demy 8vo. 16s.

'We may safely recommend the work as the foremost text-book of its class, and we are certain that it will now be widely studied by many to whom the original was a closed book.'

LANCET.

ELEMENTS of HUMAN PHYSIOLOGY. By Dr. L. HERMANN, Professor of Physiology in the University of Zürich. Second Edition. Entirely recast from the Sixth German Edition, with very copious Additions and many additional Woodcuts by ARTHUR GAMGEE, M.D., F.R.S., Brackenbury Professor of Physiology in Owens College, Manchester, and Examiner in Physiology in the University of Edinburgh. Demy 8vo. 16s.

REFERENCE BOOK of PRACTICAL THERAPEUTICS. By VARIOUS AUTHORS. Edited by FRANK P. FOSTER, M.D., Editor of the *New York Medical Journal*, &c. 2 vols. 8vo. £2. 10s.

A GUIDE to THERAPEUTICS. By ROBERT FARQUHARSON, M.P., M.D. Edin., F.R.C.P. Lond., late Lecturer on Materia Medica at St. Mary's Hospital Medical School, &c. FOURTH EDITION, thoroughly Revised. Crown 8vo. 7s. 6d.

A TREATISE on the THEORY and PRACTICE of MEDICINE. By the late JOHN SYER BRISTOWE, M.D. Lond., Fellow and formerly Censor of the Royal College of Physicians; Senior Physician to, and Joint-Lecturer on Medicine at, St. Thomas's Hospital; President of the Society of Medical Officers of Health; Examiner in Medicine to the Royal College of Surgeons; formerly Examiner in Medicine to the University of London, and Lecturer on General Pathology and on Physiology at St. Thomas's Hospital. SEVENTH EDITION. 8vo. 21s.

London: SMITH, ELDER, & CO., 15 Waterloo Place.

SMITH, ELDER, & CO.'S PUBLICATIONS.

An INDEX of MEDICINE: a Manual for the use of Senior Students and others. By SEYMOUR TAYLOR, M.D., M.R.C.P., Senior Assistant-Physician to the West London Hospital. With Illustrations. Crown 8vo. 12s. 6d.

'Dr. Seymour Taylor may certainly be congratulated on the success of his labours. He has produced exactly what he desired,

and the book may confidently be recommended to those for whom it is intended.'

LANCET.

CLINICAL MANUAL for the STUDY of MEDICAL CASES. Edited by JAMES FINLAYSON, M.D., Physician and Lecturer on Clinical Medicine in the Glasgow Western Infirmary. With Special Chapters by Prof. GAIRDNER on the Physiognomy of Disease; Dr. ALEXANDER ROBERTSON on Insanity; Dr. JOSEPH COATES on the Throat; Prof. STEPHENSON on Disorders of the Female Organs; and Dr. SAMSON GEMMELL on Physical Diagnosis. THIRD AND CHEAPER EDITION, Revised, with Illustrations. Crown 8vo. 8s. 6d.

The TREATMENT of PHTHISIS. By ARTHUR RANSOME, M.D., M.A. Cantab., F.R.S.; Consulting Physician to the Manchester Hospital for Consumption and Diseases of the Chest and Throat; Examiner in Sanitary Science at Cambridge and Victoria Universities. Demy 8vo. 7s. 6d.

BY THE SAME AUTHOR.

The CAUSES and PREVENTION of PHTHISIS. Being the Milroy Lectures for 1890. Crown 8vo. with Charts and Maps, 5s.

RESEARCHES on TUBERCULOSIS. The Weber-Parkes Prize Essay, 1897. Demy 8vo. limp cloth, 2s. 6d. net.

On the PRINCIPLES and EXACT CONDITIONS to be OBSERVED in the ARTIFICIAL FEEDING of INFANTS; the PROPERTIES of ARTIFICIAL FOODS; and the DISEASES which ARISE from FAULTS of DIET in EARLY LIFE. By W. B. CHEADLE, M.D., Physician to St. Mary's Hospital, and Lecturer on Medicine, &c. FOURTH EDITION, Revised. Crown 8vo. 5s.

The MINERAL WATERS and HEALTH RESORTS of EUROPE. With Notes on the Treatment of Chronic Diseases by Spas and Climates, and Hints as to the Simultaneous Employment of various Physical and Dietetic Methods. By HERMANN WEBER, M.D., F.R.C.P., Consulting Physician to the German Hospital and to the Royal National Hospital for Consumption, Ventnor, &c.; and FREDERICK PARKES WEBER, M.D., M.R.C.P., Physician to the German Hospital. New, Revised, and Enlarged Edition, with a Map. Demy 8vo. 10s. 6d.

'A most useful and valuable addition to balneological literature.'

JOURNAL OF BALNEOLOGY & CLIMATOLOGY.

'This admirable digest of the principal European Spas and after-cures will now in-

contestably take the lead in all English works of the kind. . . Drs. Weber have placed themselves, in so far as British Balneo-therapeutic works are concerned, *hors concours*.'

QUEEN.

COLLECTED CONTRIBUTIONS on DIGESTION and DIET. With an Appendix on the Opium Habit in India. By Sir WILLIAM ROBERTS, M.D., F.R.S. SECOND EDITION. Crown 8vo. 5s.

The ELEMENTS of PHYSIOLOGICAL and PATHOLOGICAL CHEMISTRY. A Handbook for Medical Students and Practitioners. by T. CRANSTOUN CHARLES, M.D., F.C.S., &c., Master of Surgery; Lecturer on Practical Physiology. St. Thomas's Hospital, London; late Medical Registrar, St. Thomas's Hospital &c. &c. With 38 Woodcut Illustrations and 1 Chromo-lithograph. Demy 8vo. 12s. 6d.

London: SMITH, ELDER, & CO., 15 Waterloo Place.





