

**Filariasis and elephantiasis in Fiji ; being a report to the London School of Tropical Medicine.**

**Contributors**

Manson-Bahr, Philip Heinrich, Sir, 1881-  
London School of Hygiene and Tropical Medicine

**Publication/Creation**

London : Witherby, 1912.

**Persistent URL**

<https://wellcomecollection.org/works/bmpvjmxk>

**Provider**


London School of Hygiene and Tropical Medicine

**License and attribution**

This material has been provided by This material has been provided by London School of Hygiene & Tropical Medicine Library & Archives Service. The original may be consulted at London School of Hygiene & Tropical Medicine Library & Archives Service. where the originals may be consulted. Conditions of use: it is possible this item is protected by copyright and/or related rights. You are free to use this item in any way that is permitted by the copyright and related rights legislation that applies to your use. For other uses you need to obtain permission from the rights-holder(s).



Wellcome Collection  
183 Euston Road  
London NW1 2BE UK  
T +44 (0)20 7611 8722  
E [library@wellcomecollection.org](mailto:library@wellcomecollection.org)  
<https://wellcomecollection.org>



b. MS

LSHTM



0011231140






Digitized by the Internet Archive  
in 2015

<https://archive.org/details/b213566658>

FILARIASIS  
AND ELEPHANTIASIS  
IN FIJI







# FILARIASIS AND ELEPHANTIASIS IN FIJI

BEING A REPORT TO THE LONDON SCHOOL OF TROPICAL MEDICINE.

BY

P. H. BAHR

M.A., M.B., B.C., D.T.M.&H., Cantab., M.R.C.S., Eng., L.R.C.P., Lond.

WITH MANY COLOURED AND MONOCHROME PLATES, NUMEROUS  
CHARTS AND A MAP.

LONDON :

WITHERBY & CO. 326 HIGH HOLBORN W.C.

1912.

1415

Printed by WITHERBY & CO.  
at their Printing Press in  
Middle Row Place London



## CONTENTS.

---

	PAGE
List of Appendices .. .. .	vi.
List of Illustrations .. .. .	vii.
Text .. .. .	pp. 1-82
Appendices .. .. .	pp. 83-190
Bibliography .. .. .	p. 191

## LIST OF APPENDICES.

	PAGE
I. Temperature and rainfall in Suva, average for fifteen years .. .. .	83
II. Variations in number of microfilariae found in consecutive examinations of the same persons .. .. .	83
III. Microfilaria rate at various ages. Males .. .. .	84
IV. Microfilaria rate at various ages. Females .. .. .	85
V. Details of circumstances under which adult filariae are discovered ..	86
VI. Percentage tables, relation of microfilariae to lesions associated with their presence .. .. .	88-90
A. Microfilariae present, no signs of disease.	
B. Microfilariae associated with clinical signs of disease.	
C. Microfilariae absent, clinical signs of disease present.	
D. Value of epitrochlear gland in diagnosis.	
VII. Table to show proportion of those with microfilariae in their blood, without clinical signs of filarial disease, to the total number in whom microfilariae were found. .. .. .	90
VIII. The number of microfilariae in the blood, no indication of severity of the lesion. .. .. .	91

### FIJIANS.

IX. Eosinophilia .. .. .	92-114
A.—Microfilariae, no ova of intestinal parasites.	
B.—Microfilariae, ova of intestinal parasites present.	
C.—No microfilariae, no ova of intestinal parasites.	
D.—No microfilariae, ova of intestinal parasites present.	
E.—Frequency of intestinal parasites in Fijians.	
F.—Eosinophilia in elephantiasis.	
G.—Periodicity in eosinophilia in <i>F. bancrofti</i> and <i>F. loa</i> , infections and Chart of <i>F. loa</i> .	
H.—Eosinophilia in other forms of filarial diseases.	
I.—Eosinophilia in elephantiasis (a) without microfilariae in blood; (b) with microfilariae in blood.	

### EUROPEANS.

J.—Europeans born in Colony without microfilariae.	
K.—Europeans born in Colony with microfilariae.	
L.—Europeans born in Colony with signs of filariasis, but no microfilariae.	
X. Details of cases of orchitis and lymphangitis .. .. .	115-119
XI. Periodicity (A) Fijians, (B) Indians, (C) Solomon Islanders, (D) Europeans. Charts I.-XX. .. .. .	119-131
XII. Temperatures during months in which transmission experiments with various species of mosquito were made .. .. .	132
XIII. Development of filariae and measurements at different stages of development .. .. .	133-145
(A) In <i>Culex fatigans</i> .	
(B) In <i>Stegomyia pseudoscutellaris</i> .	
(C) In <i>Stegomyia fasciata</i> .	
(D) In <i>Culex jepsoni</i> .	
XIV. (A) Showing numbers of microfilariae imbibed by individual mosquitoes. .. .. .	146
(B) Showing that practically all microfilariae ingested develop in the thorax of <i>Stegomyia pseudoscutellaris</i> .. .. .	147
(C) Showing numbers capable of being transmitted through one mosquito .. .. .	148

# APPENDICES—continued

	PAGE
XV. Measurement of microfilariae in the blood .. .. .	149
XVI. Post-mortem on a case of filariasis, microfilariae without periodicity present in the blood .. .. .	149
XVII. Inequality of distribution of filariasis in Fiji .. .. .	150-156
XVIII. Table of glandular enlargement associated with cases of elephantiasis in different regions of the body .. .. .	157-159
XIX. Details of cases of filarial abscess .. .. .	159-161
XX. Details of cases of hydrocele and enlarged testes .. .. .	161
XXI. Details of cases of fugitive swellings resembling Calabar Swellings .. .. .	163
XXII. Details of cases of thrombosis .. .. .	163
XXIII. Details of cases of synovitis .. .. .	164
XXIV. Investigation on enlarged glands (1) Epitrochlear, (2) Groin glands .. .. .	165, 166
XXV. Details of case of recurrent orchitis with appearance of microfilariae in tunica vaginalis and chart .. .. .	170
XXVI. (A) Details of cases of filarial fever, (B) Post-mortem on a Fijian who died after an attack of filarial fever .. .. .	172, 173
XXVII. Details of cases of septic infection following on filarial invasion of the lymphatic glands .. .. .	175
XXVIII. Cultures of lymph from elephantoid tissue .. .. .	177
XXIX. Details of cases of filariasis and elephantiasis in Europeans, and of a case of lymphatic oedema in a Fijian .. .. .	178
XXX. Details of dissections of tissue in elephantiasis scroti, and post-mortem on such a case .. .. .	188
XXXI. Experiments with microfilariae in different sera and solutions .. .. .	182
XXXII. Details of action of various drugs <i>in vivo</i> and charts of four cases .. .. .	184
XXXIII. Detailed observations on <i>Stegomyia pseudoscutellaris</i> , its habits and larvae .. .. .	188-190

## LIST OF ILLUSTRATIONS.

### PLATES.

1 Microfilariae in the act of uncoiling in their chorionic envelopes .. .. .	10
2 Large lymphatic gland from a case of pedunculated groin glands; <i>vide</i> also Photograph VII.—(Coloured) .. .. . facing	10
3 Section of a filaria in lymphangitis of the forearm .. .. .	14
4 <i>Stegomyia pseudoscutellaris</i> . (Coloured) .. .. . facing	18
5 <i>Culex jepseni</i> . (Coloured) .. .. . facing	18
6 Development of alimentary canal in the filarial larva .. .. .	19
7 Section of thorax of <i>S. pseudoscutellaris</i> two days after feeding on microfilaria-infected blood .. .. .	20
8 Section of thorax of <i>S. pseudoscutellaris</i> four days after feeding on microfilaria-infected blood .. .. .	20
9 Section of thorax <i>S. pseudoscutellaris</i> ten days after feeding on microfilaria-infected blood .. .. .	21
10 Filariae in proboscis on the fifteenth day of development .. .. .	22
11 Degenerate and chitinified filaria in mosquito's thorax. .. .. .	23
12 Infection of <i>Stegomyia pseudoscutellaris</i> , with two broods of filariae .. .. .	26
13 Camera lucida drawings of different stages observed in development of the larval filaria in the mosquito .. .. .	28
14 Camera lucida drawings of terminal papillae of the larval filaria when fully developed in mosquito .. .. .	31
15 Entrance of filaria into skin of human host .. .. .	33
16 <i>Stegomyia pseudoscutellaris</i> in act of sucking .. .. .	34
17 Microfilaria showing central cell mass. (Coloured) .. .. . facing	36
18 Adult female filaria on section in groin gland .. .. .	42
19 Details of a female filaria on section, highly magnified .. .. .	44
20 Enlargement of epitrochlear glands in natives, traced from photographs .. .. .	45
21 Calcifying filaria in dilated lymphatic trunk .. .. .	50
22 Section of calcified filaria in the epitrochlear gland .. .. .	54
23 Section of female filaria in an abscess .. .. .	55
24 Thickened lymphatic vessel containing dead filariae .. .. .	57

PLATES—continued.

	PAGE
25 Fibrotic changes in epitrochlear gland owing to filarial invasion, and section of dead filariae in groin glands. . . . .	61
26 Showing dead filaria and embryos in epitrochlear gland and pathological changes on section . . . . .	63
27 Macroscopic section of enlarged groin gland to show contrast between cortex and medulla. (Coloured) . . . . . facing	62
28 Changes in mesenteric and lumbar glands from a patient the subject of attacks of filarial fever . . . . .	64
29 Dead filaria in epididymis of a Fijian, the subject of frequent attacks of filarial fever. (Coloured) . . . . . facing	64
30 Eosinophiles in section of filariated lymphatic gland. (Coloured) . . facing	66
31 Epididymis, calcified filaria in vasa efferentia . . . . .	66
32 Uterus of dead filaria and appearance of gland on section: septic infection supervening in a filariated gland . . . . .	70
33 Section of dead filaria in the tissue of elephantiasis scroti . . . . .	75
34 <i>Filaria immitis</i> on section in superior vena cava of dog . . . . .	76

PHOTOGRAPHS.

1 Microphotograph of sections of <i>Stegomyia pseudoscutellaris</i> infected with larval filariae, eighth day. (Hot weather) . . . . .	23
2 Microphotograph of sections of <i>Stegomyia pseudoscutellaris</i> infected with larval filariae, twelfth day. (Hot weather) . . . . .	24
3 Microphotograph of section of <i>Stegomyia pseudoscutellaris</i> , eleventh day after infection (August, cool weather) to show slower rate of development observed in the cool months . . . . .	24
4 Microphotograph of two filariae leaving the proboscis of mosquito . . . . .	32
5 Elephantiasis of both arms, showing lymphatic swellings above the internal condyles . . . . .	46
6 Elephantiasis of right arm, with disorganization of wrist-joint . . . . .	47
7 Pedunculated groin glands and double hydroceles . . . . .	48
8 Enlarged masses of glands in the groin . . . . .	49
9 Microphotograph of commencement of calcification in a female filaria removed from epitrochlear gland . . . . .	52
10 Calcifying female filaria removed from dilated lymphatic (same as Pl. XXI.). . . . .	52
11 Microphotograph of calcified filaria in efferent lymphatic vessel. (Dr. John Bell, Hong Kong) . . . . .	53
12 Enlarged microphotograph of the same. (Dr. John Bell) . . . . .	53
13 Microphotographs of sheathed and unsheathed microfilariae in hydrocele fluid . . . . .	59
14 Case of hydrocele associated with elephantiasis scroti, in which great numbers of calcified filariae were found in hydrocele sac at operation . . . . .	59
15 Elephantiasis scroti in which a dead filaria was found at operation . . . . .	73
16 Early case of elephantiasis scroti . . . . .	74
17 Breeding place of <i>Stegomyia pseudoscutellaris</i> , a brackish creek at Loma-Loma . . . . .	80



# FILARIASIS AND ELEPHANTIASIS IN FIJI.

Being a Report to the London School of Tropical Medicine

by

P. H. BAHR, M.A., M.B., B.C., D.T.M.&H., Cantab.,  
M.R.C.S., Eng., L.R.C.P., Lond.

The researches detailed below were carried out in the Fiji Islands during the year 1910, and were made possible by a grant of £500, generously placed at the disposal of the London School of Tropical Medicine by Lord Sheffield for tropical research.

The subjects chosen for investigation by the Committee of the Tropical School were :—

- (1) Elephantiasis and filarial diseases
- (2) Epidemic and endemic dysentery

the two important diseases of the Colony.

The author of this Paper was chosen as the representative of the School.

A complete laboratory outfit was acquired, at a total cost of over £200. A first-class passage for myself and a second-class for my assistant to Sydney were given by the P. & O.S.N. Co., and free passages from Sydney to Fiji for myself and my wife by the Union Company of New Zealand. To both these steamship Companies my best thanks are due, and also to E. W. Blessig, Esq., of Bletchingley, Surrey, for providing me with £300 for skilled laboratory assistance, thereby enabling me to economize my time and to extend the scope of the work.

I arrived in Fiji on January 12th, 1910, and started work in a laboratory constructed on the verandah of a house which was leased for a year.

The Fijian Government, at the suggestion of the late Governor, Sir Everard im Thurn, K.C.M.G., C.B., and with the sanction of the Secretary of State, appointed me Honorary Pathologist to the Colonial Hospital, Suva, at an honorarium of £100.

I wish to acknowledge my indebtedness to the Government in giving me an official status while in the Colony, for without this any extended research would not have been possible. I was thereby afforded every assistance from those officials and native chiefs with whom I came in contact. Moreover, I was enabled to visit, in a Government cutter, the islands of the isolated eastern group (*vide map*), where elephantiasis and its associated diseases are rife—a journey which, under ordinary circumstances, would not have been practicable. By the advice of the Chief Medical Officer, the Hon. G. W. A. Lynch, I was given the assistance of a native medical student, Jesse by name, who possessed a knowledge of English, and who was invaluable in dealings with the natives and in interpreting their language.

The researches being more or less complete, I left the Colony on February 21st, 1911, and, travelling via Canada, reached London on March 28th.

I wish to acknowledge my thanks to all the officials of the Fijian Government with whom I came into contact, and with all of whom I have preserved the most friendly relations. Their kindly sympathy and aid in Suva, and especially in the isolated districts, were of the utmost value to me. To the Medical Staff of the Colony my best thanks are also due, particularly to the Hon. G. W. A. Lynch, the Chief Medical Officer; to Drs. E. Prideaux, J. F. Smalley, F. N. Smartt, of the Colonial Medical Service, and others for their great interest and assistance in enabling me to collect the data detailed below. More especially I wish also to acknowledge my indebtedness to Sir Patrick Manson, K.C.M.G., F.R.S., for many suggestions of great value, freely given during the course of this investigation, and especially for his assistance in the arrangement and writing of this Paper; to Dr. C. W. Daniels, late Director of the Tropical School, and to Dr. R. T. Leiper, who has critically examined many of my specimens of adult filariae, and whose valuable commentary on the subject he has permitted me to incorporate with this report; to Colonel Alcock, C.I.E., F.R.S., who has identified the mosquito intermediaries for me, and to Dr. G. C. Low for useful criticisms and aid in my study of the past literature of filariasis, to the Nursing Staff of the Colonial Hospital, Suva, for assistance in collection of blood specimens at night-time, I am also under heavy obligation. I should also like to acknowledge here my thanks to my able and conscientious assistant, Mr. W. J. Muggleton, to whose care and industry many of the sections illustrated in the text are due, and also to Mr. Robert McKay, of the London School of Tropical Medicine, for his assistance with the microphotographs.

Before proceeding with my report, it seems advisable to say something about the country and the people it refers to.

Fiji comprises a group of about 250 islands, of which only the larger are to any extent inhabited (*vide* map). These latter comprise the islands of Vitilevu, Vanualevu, Taveuni and Ovalau. The total area of all the islands of the group is about equal to that of Wales. The more important islands are of volcanic origin. The mountains in the centre rise to 4,000 feet, and are clothed to their summits with dense vegetation. All the islands are surrounded by coral reefs. The distance from the most westerly to the most easterly islands of the group is about 300 miles.

The aboriginal natives, or Fijians, belong to the darker of the Polynesian races and number, all told, some 87,390. There is also a large East Indian population of 35,406; these are mostly imported coolies, under indenture, and living on the coconut, banana and sugar plantations.

The population also comprises some 3,393 Europeans, 1,854 half-caste Fijians, and 3,000 imported labourers from the Solomon Islands.

The large Fijian and Indian populations do not intermingle much, intermarriage being almost unknown. Hardly any Solomon Island women are imported; the great majority of the Solomon Islanders eventually return to their own islands.

In the Fiji group, as in many other Pacific islands, there are mountain and coast tribes. These used to be in a state of perpetual warfare with each other, and did not intermingle; since the establishment of the Pax Britannica, in 1874, this barrier to free intercourse has been broken down.

The Fijians are now to some extent civilized; but, although they profess Christianity, it cannot be said that they are Europeanized to any great extent.

The chief towns are necessarily the chief ports. Suva, on the large island of Vitilevu, is the present capital, and is the seat of Government. It contains 1,112 Europeans, and a variable number of natives and other races. Levuka,\* on the island of Ovalau, is the old native capital; its population is about 450 Europeans.

The rainfall is a heavy one, and varies in different parts of the islands. In 1910 it measured 107 inches in Suva. The greatest daily rainfall recorded in one day is 26.50 inches. The rainfall is extended over the whole year, but is greatest in the hottest months.

The climate is cool for the tropics. The hottest season extends from November to March. The highest temperature, 96°F., recorded in 1910, was in February; the lowest, 61°F., was in July. In Appendix I. a table will be found giving the mean maximum and minimum temperatures, together with the rainfall, for the last fifteen years.

Hurricanes and gales occasionally occur and do great damage. A disastrous hurricane swept the islands of Vitilevu and Ovalau in March, 1910, and did great damage in Suva.

There are a great many rivers in Fiji. The most important are the Rewa, Navua, Singatoka, Nadi and Ba rivers in Vitilevu. On the alluvial flats are situated the chief sugar fields. These are artificially irrigated, and are worked by the Indian population. In Vanualevu there is one important river, the Labasa, at the mouth of which is situated a sugar plantation and a mill.

Inter-island communication is still very primitive, and is carried on chiefly by small steamships and cutters.

There are few good roads; inland communication is mostly effected by native paths.

The banana and coconut plantations, the latter mainly in the islands of the eastern group, are situated along the coast lines.

The native Fijian population, being in the main a maritime and fishing one, is located principally along or near the coast. There are few large towns in the interior. The natives of the eastern or Lau group (*vide* map) are the most prosperous, a large admixture of Tongan blood being found there.

The food of the Fijians in their native villages consists almost entirely of yams and dalos (*Calocasia esculenta*)—both starchy foods, and of native fruits and fish. In the centres of civilization they are fond of tinned meats, especially salmon when they can get it. With the exception of the pig, which has run wild, the Fijian rarely keeps any domestic animal. The Indians live to a great extent on rice. This they cultivate in the vicinity of their settlements, which, in many instances, they contrive to occupy after the term of indenture is finished. The Solomon Islanders are the best labourers in the group, and are employed mostly in the coconut plantations.

The natives wear no headgear, but are very proud of their upstanding curly hair. They wear a singlet or cotton shirt and a waist-cloth or "sulu," held up by a leather belt. They walk barefooted.

There is no poverty in Fiji. There is a system of communalism prevalent which the Government is doing its best to suppress. It is called "kere-kere," or begging, by means of which all goods become common property. Their wants are few, and a Fijian who has become rich by his own exertions is almost unknown.

\* Levuka is a common Fijian name for a town; another one of the same name is referred to in the text, this latter being the capital of the small island of Lakemba.

## PREVALENT DISEASES.

An epidemic of measles, in 1874, swept off over a quarter of the indigenous population.

Anopheles mosquitos do not occur in the group, and consequently there is no malaria. Yaws is almost universal amongst the natives. Leprosy is fairly common. The lepers are now being segregated on the island of Mokagai. Tuberculosis is common, especially where natives come much into contact with the white man; it carries them off with alarming rapidity. Syphilis is unknown amongst the Fijians, and gonorrhoea is very rare; both of these diseases are common amongst the Indian population. Bacillary dysentery occurs in epidemics, and used to claim a number of victims. Amoebic dysentery, apparently rare amongst Fijians, is very prevalent amongst the Indians in certain of the sugar districts.

## FILARIASIS.

I will not attempt to review the literature of filariasis as a whole, but a résumé of that part of it which refers more especially to filariasis in the Pacific is desirable.

Very early in the modern history of these parts the extreme frequency of elephantiasis was noted. When the pathological relationship of *Filaria sanguinis hominis* to this disease began to be recognized, certain investigators remarked on the extreme prevalence of filariae in the blood of the natives of certain groups, Samoa for example.

It<sup>1</sup> has been variously estimated that from one-twentieth to one-third of the total populations in some islands develop elephantiasis. The appearance of these extreme forms of the disease occurring in Samoa became familiar from the excellent photographs sent home by Dr. Davies of that island. Later,<sup>2</sup> from slides sent by the last-named gentleman, Dr. Manson (Sir Patrick Manson) proved that over half of those Samoans who were suffering from various elephantoid diseases harboured microfilariae in their blood. In<sup>3</sup> 1895 Surgeon V. G. Thorpe (now Fleet-Surgeon, R.N.) examined the blood of a number of natives of Tonga, and found 41 per cent. of the male and 32 per cent. of the female adult population harboured filariae; in Fiji he ascertained that 25 per cent. of the population were similarly infected. Morgan Finucane,<sup>4</sup> in 1901, exhibited photographs of cases of elephantiasis scroti in Fiji; some of the photographs were of extreme cases such as are rarely seen nowadays, for since the influx of medical men into these islands most of such cases have been operated on. Dr. G. W. A. Lynch<sup>5</sup> (now C.M.O., Fiji) examined the blood of 608 natives and found 25·68 per cent. infected with filariae. Brunwin<sup>6</sup> in 1909, from 274 examinations, estimates the proportion at 24·2 per cent. B. M. Wilson<sup>7</sup> also in 1909, in routine examination of 1,000 cases, found 38·8 per cent. infected; he estimates that 33 per cent. of total population, 43·3 per cent. males and 34·9 per cent. females, harbour microfilariae. It will be seen that the figures of the last three investigators are in close agreement.

French investigators, also working in the French Pacific possessions, have left records. In Wallis Islands, Brochard<sup>8</sup> found a microfilaria in the blood of the islanders. Dubruel<sup>9</sup>, in Tahiti, states that in the island of Mooréa, where elephantiasis is very prevalent, in the night blood of 200 inhabitants he did not find a single parasite, an observation entirely at variance with the experience of others. It is to be noted

that he gives no description of his methods, nor of the quantity of blood examined.

American investigators have been busy in the Philippines. Ashburn and Craig<sup>10 11 12</sup> found a microfilaria in the blood of nine natives. Phalen and Nichols<sup>13 14</sup> found among 933 Filipinos 2.6 per cent. infected, and gave a map of the distribution of *filaria nocturna* in those islands based on the examination of 6,604 individuals.

Diesing<sup>15</sup> (1909) reports a case of filariasis in New Guinea. From New Caledonia the records are scanty. Lang and Noc<sup>16</sup> found *filaria nocturna* four times in 117 examinations made during a residence of twenty years in that island. Nicolas<sup>17</sup> records a case of chyluria occurring there.

The Solomon Islands and New Hebrides have been too lately investigated by medical men for any extensive series of blood examinations to have been made. As will be seen later, a certain small proportion of the natives of the former were found to harbour *microfilaria nocturna*; on the other hand over half showed signs of recent malaria, which is very prevalent in both groups. I met with a case of filariasis in a New Hebridean. I have been assured by observant travellers that elephantiasis is almost unknown in the Solomon group.

The value of these various observations would have been very much enhanced had the workers adopted the same methods and specified the time at which their blood examinations were made, and also the quantity of blood scrutinized. It is to be hoped that in future some uniform system of observation will be adhered to.

#### TECHNIQUE.

The method of preparing blood-films described by Manson in his "Tropical Diseases," and the method of measuring definite quantities of blood as described by Low, are those I employed throughout. I found it simple, quick and reliable. The standard quantity has been 16 c. mm. of blood and has been strictly adhered to. This measurement is of use in accurately determining the periodicity and in conducting observations as to the actual number of parasites present in the circulation. The slides were examined immediately after being dehaemoglobinized. It was found that if the slides were left undehaemoglobinized for more than twenty-four hours the haemoglobin became fixed, and examination correspondingly more difficult. A certain number of each batch of slides were stained, without being fixed, in dilute carbol fuchsin; others, after fixing in alcohol and ether, were stained with haematoxylin with the view of determining the minute characteristics of any microfilariae that might be present. I may mention here that upon one occasion in making a consecutive series of slides from the same patient, a considerable variation in the number of microfilariae present was noticed, showing that they are not uniformly distributed throughout the peripheral blood-stream (Appendix II.). A number of observations were made to determine whether the act of squeezing the finger to obtain a larger supply of blood was responsible in any way for this variability in the number of microfilariae. No influence of this description could be recognized.

#### CONCLUSIONS.

In the course of my investigations, I have been enabled to confirm many of the observations of previous workers on filariasis. My principal work on this helminthiasis, however, has been directed more especially

as it concerns the Fijians. I have arrived at certain conclusions, and these, for convenience, I shall, in the first instance, state categorically, before giving in detail the evidence on which they are founded.

1. A large proportion, 27·1 per cent., of Fijians harbour microfilariae in their blood.

2. This figure does not represent the aggregate liability of the Fijian to filarial infection. There are reasons for believing that, at one time or another, nearly every Fijian is the subject of filariasis. These reasons, together with the preceding (1), are : (A) Adult filariae are to be found in the lymphatics and other tissues without the presence in the blood of corresponding microfilariae ; (B) A large proportion of Fijians are affected with what in common with others I regard as filarial disease, and in whom no microfilariae can be found in the blood. That is to say, the proportion of Fijians carrying microfilariae (27·1 per cent.) added to the number of Fijians affected by filarial disease but without microfilariae (25·4 per cent.) amounts to 52·5 per cent. of the entire population ; (C) All Fijians, as well as foreigners for some time resident in Fiji, exhibit a well-marked eosinophilia, and this in the absence of evidence of infection with intestinal or other metazoal parasites ; (D) Patients with microfilariae in their blood have lost, while under observation, their microfilariae.

3. In the present state of our knowledge it cannot be definitely stated whether the Fijian filaria is a new species, or whether it is *Filaria bancrofti* with the habit of its microfilariae, as regards periodicity, modified by local circumstances.

(A) In favour of its being a distinct species are the following : Its larval form (microfilaria) exhibits in the blood no periodicity : i.e. contrary to what happens elsewhere in the case of *Filaria bancrofti*, it occurs in equal abundance in the blood at all hours of the day or night. While capable of development in *Culex fatigans*, the favourite intermediary of *Filaria bancrofti*, this mosquito is not nearly so efficient an intermediary in Fiji as it is in other countries, or as is *Stegomyia pseudoscutellaris*, the common mosquito in this group of islands.

(B) In favour of the Fijian filaria being identical with *Filaria bancrofti* are the following : The Fijian microfilaria is morphologically identical with microfilaria bancrofti. The parental form of the Fijian microfilaria, as far as can be ascertained at present, is identical with *Filaria bancrofti*. Both nematodes live in the same tissues, and are associated with the same diseases. *Stegomyia pseudoscutellaris* is an efficient intermediary for *Filaria bancrofti*. As regards adaptation to intermediary hosts, there is, therefore, a corresponding capacity.

4. Assuming that the Fijian filaria is *Filaria bancrofti*, it may be that the absence of periodicity in the former is a partial adaptation to, and impressed on it by, the habits of its usual intermediary host in Fiji, viz. *Stegomyia pseudoscutellaris*, a mosquito which feeds by day only.

5. The absence of periodicity in the Fijian filaria does not depend on any racial peculiarity in the human host, for : (A) If a native of India or of the Solomon Islands harbouring microfilaria bancrofti comes to reside in Fiji, his microfilariae retain their habits of nocturnal periodicity ; (B) When such a stranger acquires filarial infection in Fiji, the corresponding microfilariae exhibit no such nocturnal periodicity, but in this respect comport themselves in the same way as do the microfilariae of the native Fijian.

6. The principal pathological expression of filarial infection is the same in Fiji as elsewhere, viz., elephantiasis.

7. The lower extremities and scrotum are the parts of the body most frequently affected.

8. In comparison with the natives of China, India and the West Indies, the natives of Fiji, and probably of other South Pacific Islands, are peculiarly liable to elephantiasis of the upper extremities.

9. On the other hand they seem to be less liable to chyluria, lymph scrotum, varicose groin glands, and other forms of lymphatic varix depending on filarial obstruction of the thoracic duct above the points of entrance of the chyle vessels.

10. The explanation of these possible peculiarities in the Fijian disease is not apparent.

11. In many cases adult filariae occur in large numbers in the tissues, especially in lymphatic glands and vessels, but also in other organs, as the epididymis, testis and tunica vaginalis.

12. In the latter circumstance may lie a contributory cause of the infecundity of the Fijian as a whole.

13. In the situations mentioned the adult filariae may die, and may become cretified.

14. The adult filariae is not an unusual cause of abscess, of hydrocele, of enlarged testes and of thickening of lymphatic vessels, and of fugitive swellings resembling Calabar Swellings.

15. Whether alive or cretified, the adult filariae are the direct cause of fibrosis and blocking of glands and lymphatics.

16. Eosinophile cells are present in large numbers around both living and calcified filariae.

17. Calcified filariae have been found in the interior, and blocking the vasa efferentia, of the epididymis.

18. Microfilariae emitted by the parent worm may not reach the general circulation, perishing in the gland or organ in which the worm is lying.

19. Periodical discharges of microfilariae may be a factor in the production of lymphangitis, orchitis and funiculitis.

20. After such inflammatory attacks the parent worm may perish.

21. Lymph from such inflammatory foci may be sterile, or it may be the seat of bacterial invasion.

22. Lymph from inflamed elephantoid tissue is usually sterile.

23. The precise mechanism of the production of elephantiasis has yet to be determined, but that the filaria is the principal factor is hardly open to doubt.

24. Certain parasiticide drugs in medicinal doses have no manifest influence on the circulating microfilariae.

25. The absence of microfilariae from the blood in the case of undoubted infection with living filariae requires explanation. A similar anomaly occurs in other filarial infections in man, e.g. in *Filaria loa* and in *Filaria volvulus*.

26. Surgical and medical treatment of filarial disease is unsatisfactory.

27. Mosquito destruction, carried out on the same lines as for malaria and yellow fever, is the only means likely to prove of service in eradicating or seriously mitigating this important helminthiasis.

I propose to deal with each of these conclusions in the order stated. In several instances they are based on a mass of uninteresting statistical matter; this I have relegated to a series of appendices, contenting myself in the text of this report with a summary of the principal results obtained.

## I. A large proportion of Fijians harbour microfilariae in their blood.

1,320 people of all ages and for the most part of Fijian blood (*vide* Appendices III. and IV.), were examined for microfilariae. 804 of these were males and 516 females. 30.4 per cent of the former, and 23.9 per cent. of the latter were found infected. That is 27.1 per cent. of the total population examined; a figure slightly lower than the 33 per cent. estimate given by Dr. Wilson, and slightly higher than that given by Dr. Lynch.

Tables are given in the Appendix (Nos. III. and IV.) showing the age incidence reckoned in decades. The incidence is greatest in both sexes after the twentieth year. The youngest Fijian in whose blood microfilariae were found was a girl of five years of age. Comparatively more females than males were found to be infected below the age of ten years. Due allowance, however, must be made in these instances for the small numbers examined. The statistics given by Sir Patrick Manson in China, and later by Dr. Duncan Whyte,<sup>23</sup> show that the incidence of infection in that country also increases with age.

In Fiji, as in countries where filariasis is common, it appears to be the rule that the incidence of infection is greatest in the male sex. The exception to this rule is British Guiana, where Daniels and Conyers<sup>18</sup> found twice as many females infected as males.

In my tables it will be noted that the greatest number of people examined ranged in age from ten to thirty years, the explanation being that natives of this age are more accessible for examination than are the very young and the elderly.

The microfilaria rate in different parts of the Fiji Islands varies considerably, and in direct ratio with the number of cases of elephantiasis and other filarial diseases present (Appendix No. XVII.). Thus in the town of Bau, which lies just off the large island of Vitilevu, the microfilaria rate per total population is 12.5 per cent.; whilst on the island of Lakemba, 200 miles away, it is 36.5 per cent., or nearly three times that number.

## II. (a)—Adult filariae are to be found in the lymphatics without the presence in the blood of corresponding microfilariae.

Under this heading I have grouped some observations on the conditions under which these and other adult filariae were found, and also on their measurements while alive. The minute anatomy and identification of the species will be dealt with later by Dr. Leiper.

Measurements were all made in normal saline on a glass slide. The living filariae, on being placed in the solution, were gently heated till they stretched themselves out and became motionless. The excess of saline solution was then blotted away and measurements of length ascertained by means of a fine compass and millimetre scale. Measurements of breadth and other details were made by means of a micrometer eyepiece. After measurement the worms were plunged into boiling 70 per cent. alcohol for transmission to Dr. Leiper. I give below a summary of twelve measurements, eight females and four males. The letters distinguishing each specimen refer to further particulars given in the text.

In making a filarial census of a town or district the aid of the native chief or "Roko" was invoked. As his word is law, it was easy to procure all the natives for examination.

## SUMMARY OF MEASUREMENTS OF LIVE FILARIAE.

TABLE I.—FEMALES.

	A. Adult.	B. Adult.	C. Adult.	D. Immature.	E. Imma- ture.	F. Adult.	G. Adult.	H. Adult.
Length.	65 mm.	55 mm.	65 mm.	42 mm.	31 mm.	50 mm.	50 mm.	67 mm.
Breadth.	177 mm.	222 mm.	206 mm.	1824 mm.	135 mm.	15 mm.	128 mm.	153 mm.
Vaginal opening from mouth.	76 mm.	69 mm.	69 mm.	64 mm.	435 mm.	434 mm.	69 mm.	6 mm.
Anus from tip of tail.						24 mm.		21 mm.

TABLE II.—MALES.

	A.	B.	C.	D.
Length	29 mm.	25 mm.	25 mm.	28 mm.
Breadth.	1296 mm.	129 mm.	09 mm.	09 mm.

1. Female (Table I., A) found in a filarial abscess, uterus packed with embryos and ova. Numerous embryos observing no periodicity present in the circulation (*vide* Appendix XI., Chart XX.).

2. Three perfect females (Table I., B, C, D) and two perfect males (Table II., A, B) found in a large epitrochlear gland removed at operation from a Fijian. No other signs of filariasis, no microfilariae ever found in blood. One male and female found inextricably coiled round each other. Two females (C, D) found coiled up dormant in cortex of gland, but reviving on heating in normal saline. No microfilariae were found in gland juice. One female was found smaller than the others and apparently immature; the uterus was packed with ova, but contained no embryos. In all thirteen filariae, or portions of separate filariae, were taken from this one gland.

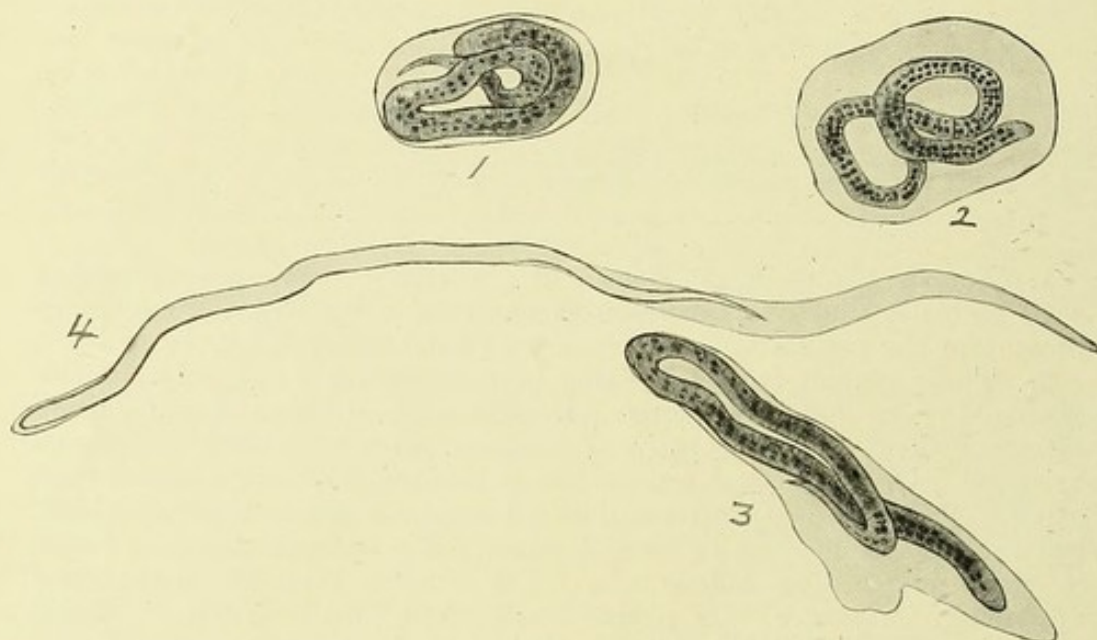
3. An immature female measuring only 31 mm. in length (Table I., E) and part of a small male found in an enlarged epitrochlear gland. No microfilariae were present in the circulation. The uterus of the female was packed full of ova, but no embryos were seen. One calcified filaria, was also seen in the gland.

4. A perfect male, and an apparently immature female (Table II., C, and Table I., F), removed from enlarged inguinal gland. No microfilariae were found in the blood. No ripe embryos found in the uterus of the female, though several ova were in the process of differentiation in the anterior part of the uterus. Part of another female was found, from whose uterine tubes streams of ova emerged into the normal saline solution. On being gently warmed, the contained embryos became active, stretching out the chorionic envelope to form the sheath of the living microfilaria. This process was watched for some considerable time and bore out Sir Patrick Manson's hypothesis, founded on observations on the filaria of *Corvus torquatus* in China, that the sheath is really the embryonic egg capsule. Slides showing the process were made and sketched (Plate I.).

The uncoiling of the embryos within the sheath has recently been observed by Huffman<sup>35</sup> in the case of *Filaria loa*.

Several dead and calcified filariae were also found in this gland. The male filaria, together with a piece of the gland tissue from which it had been removed, was placed in the incubator at 37° C. for 4½ hours. It became very active and swam about, but did not attempt to enter the gland tissue.

5. A perfect female (Table I., g) found in the centre of a mass of pedunculated groin glands (Plate II., and Phot. 7) together with part of a recently dead male. From the vaginal orifice of the female great numbers of microfilariae stretched out in their sheaths were seen emerging, but were apparently dead. No coiled embryos emerged from the vagina; as has been suggested by Daniels,<sup>51</sup> this orifice is probably too narrow to permit of their escape. No microfilariae were found in the blood.

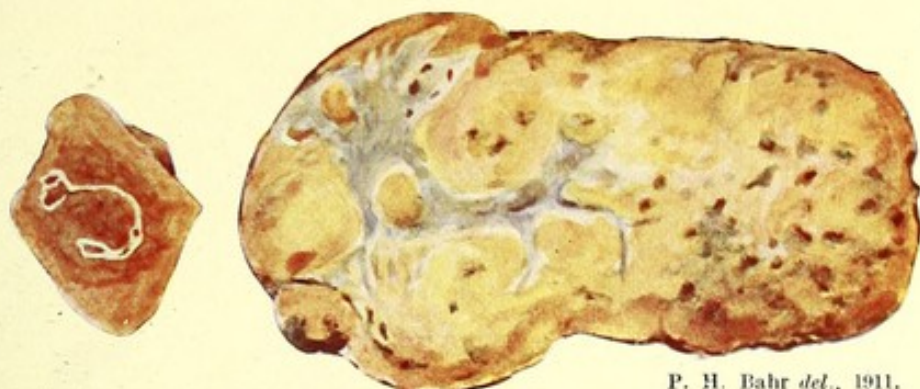

P. H. Bahr del., 1911.

### PLATE I.

Microfilariae emerging from the uterus of the parent filaria, uncoiling in their chorional envelopes. Drawn at different stages.—Camera lucida, oil immersion lens.

6. A perfect female (Table I., h) and a perfect male (Table II., d) obtained from a mass of varicose groin glands dissected post-mortem. Microfilariae were present sparingly in the blood; they exhibited no periodicity. Nine months before the patient's death they could not be discovered in the blood, but both ova, microfilariae and their empty sheaths could always be seen in lymph of these glands procured by puncture. Many of the microfilariae so procured were small, with the sheath distended anteriorly and posteriorly, similar to those seen emerging from the uterus of the adult in other instances. The female, though apparently fully adult, did not contain any embryos, but only ova. Numbers of calcified filariae were found as well. It is interesting to note that a continued high temperature of a hectic type, often reaching 102° F. and 103° F., over a period of nine months, and continued absorption of tubercular toxins, appeared to exert no influence on the life of the filariae. The patient died of widespread tuberculosis.



P. H. Bahr *del.*, 1911.

Fig. 2.

Fig. 1.

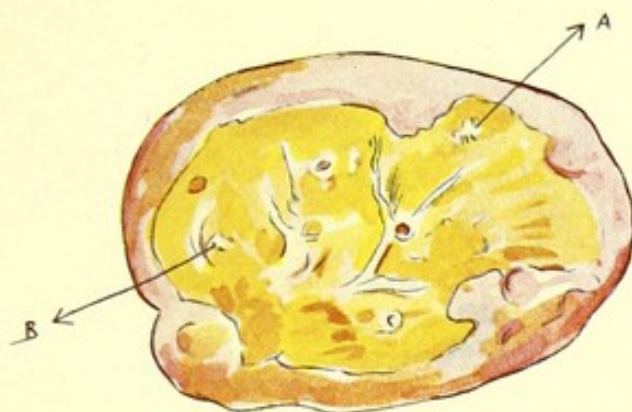## PLATE II.

Fig. 1.

Enlarged groin gland removed from a mass of pedunculated glands (*vide* Phot. VII). An adult male and female filaria were found in the centre of this specimen on dissection. The drawing of the section of this gland is actual size, to scale.

Fig. 2.

A calcified filaria from the same gland magnified ten diameters.



P. H. Bahr *del.*, 1910.

## PLATE XXVII.

Inguinal gland, excised from a mass of enlarged and varicose groin glands, showing contrast between fibrous medulla and adenomatous cortex. Calcified filariae were found in this specimen, both in the cortex and in the medulla. A and B, masses of calcified filariae. The drawing of the gland on section is actual size, to scale.

For a description of this specimen, *vide* p. 62.

[To face p. 10.

- II. (c)—Eosinophilia. All Fijians, as well as foreigners for some time resident in Fiji, exhibit a well-marked eosinophilia, even in the absence of infection with intestinal and other metazoal parasites.

The large number of Fijians infected with microfilariae, together with the large number affected with filarial disease unaccompanied by microfilariae, and the almost universal presence of a high eosinophilia with no evidence of the presence of intestinal parasites, suggest that at some time or other all Fijians have been the subjects of filarial invasion. A high degree of eosinophilia was found in nearly all the Fijians examined by me, whether microfilariae were present in the blood-stream or not. Wilson, in Fiji,<sup>7</sup> has examined a series with this point in view. He gives an average eosinophilia of 14–18 per cent. both in normal Fijians, in those with microfilariae without filarial lesions, in those with microfilariae in association with filarial disease, and in those with filarial disease without microfilariae. Brochard<sup>8</sup> gives an eosinophilia of 13–18·7 per cent. in Wallis Islanders affected. It is to be noted that neither of these investigators made leucocyte total counts, or examined the faeces for ova. Duncan Whyte<sup>23</sup> finds the greater the number of microfilariae the greater the eosinophilia.

Gulland,<sup>33</sup> making leucocyte and differential count during the day and during the night in a person affected with *filaria nocturna*, found a corresponding periodicity of the eosinophilia. Whyte's figures support this statement, but Calvert's,<sup>24</sup> who made a similar investigation, do not.

A Fijian in whom I studied the point showed an equal eosinophilia both in day and night blood (*vide* Appendix IX. G), and in another case, a Solomon Islander with *filaria nocturna*, even fewer eosinophiles were found at night than during the daytime, when no microfilariae were present. In the case of an infection with *Filaria loa* from West Africa, in which numbers of the associated microfilariae were present in the finger blood during the daytime only, a simultaneous record of the relative number of eosinophile cells was also made. The result is illustrated graphically (Appendix IX. G). No corresponding variation in the relative number of eosinophiles was noted.

A complete blood examination was made in twenty otherwise normal Fijians with microfilariae and in twenty without. These were further subdivided into those in whose stools ova of intestinal parasites were found, and those in whose stools no such ova were discovered. The result is given in tabular form in the Appendix IX., A, B, C, D. It will be seen from these that by estimating the gross number of eosinophiles present per c. mm. blood, and by the percentage of the eosinophiles to the total number of leucocytes counted, the eosinophilia varies from 13–15 per cent. in each instance. The white and red blood counts were made with Thoma-Zeiss pipettes; of the whites never fewer than 768 squares were counted; and in estimating the red corpuscles at least sixty-four squares were counted. The blood film for the differential count was, after fixing, stained with haematoxylin (Delafield's) for ten minutes, and with watery eosin for thirty seconds, and 300 cells were always counted. The haemoglobin index was estimated by Tallequist's method. It is to be noted that neither the number of the white nor of the red blood corpuscles was affected in any serious degree by filariasis (Appendix IX., A, B, C, D) nor by the presence of intestinal parasites. The degree of eosinophilia does not differ in those harbouring few or many microfilariae.

The Fijians are liable to infection with intestinal parasites, which do not seem to affect their general health. A table (Appendix IX. E) is given showing that, from examination of 209 stools of normal Fijians, 74.6 per cent. are infected with some intestinal parasite or other. A large percentage, 27.8 per cent., harbour ankylostomes, or more probably *Necator americanus*, yet no Fijian was seen exhibiting any clinical signs of ankylostomiasis. Anaemia, cardiac failure, or oedema from this cause are apparently unknown amongst them, though the East Indian immigrants suffer greatly from ankylostomiasis. The frequency of infection with intestinal parasites apparently varies in different localities (*vide* Appendix IX. E). Whyte<sup>34</sup> has given tables to show that the greater the infection with one kind of parasite, and also the greater the variety of parasites present, the greater is the eosinophilia. This does not seem to hold good in Fijians. A similar investigation of eleven Fijians affected with elephantiasis gave an eosinophilia of 8.9 per cent. (*vide* Appendix IX. F), and forty cases of elephantoid disease in Fiji (one Indian case included) gave an eosinophilia of 12.7 per cent. (IX. H). An equally high eosinophilia appears to be present in cases of elephantiasis whether microfilariae are present in the circulation or not; this was deduced from an investigation of thirty cases (*vide* Appendix IX. I).

In order to ascertain if racial or climatic influence was responsible for the high degree of eosinophilia obtaining in Fiji, the blood of a number of Europeans born in the Colony was investigated. As will be seen from the tables (Appendix IX. J) the result obtained was an average eosinophilia of 3.4 per cent., slightly higher than that found in Europeans at home. A stool examination was not feasible in these cases. An average eosinophilia of 7.7 per cent. was found in six Europeans harbouring microfilariae (*vide* Appendix IX. K); neither the red nor white blood corpuscles, nor the haemoglobin index, appeared to be affected in these. An eosinophilia of 8.7 per cent. was found in eleven Europeans (Appendix IX. L) suffering from various symptoms of filarial disease without any microfilariae in the circulation.

It may be noted here that in cases where microfilariae are absent from the blood-stream, it is possible that they were present in small numbers, so as not to be apparent in a slide containing the relatively small quantity of blood examined. But in no instance did the examination of a larger quantity of blood (1-2 c.c.) abstracted from a vein and centrifuged in citrate solution (1 per cent., plus an equal quantity of .7 per cent. saline) demonstrate their presence when they could not be found in three slides of blood containing 16 c.mm. each.

## II. (d)—Patients with microfilariae in the blood have lost, while under observation, their microfilariae.

In seven instances the disappearance of microfilariae from the blood-stream was noted during a series of four hourly observations with measured quantities of blood. In every case some inflammatory disturbance preceded the disappearance. In no instance were microfilariae very abundant in the blood-stream. Three times the microfilariae disappeared completely in the course of twenty-four hours; once when temperature at the time was quite normal. In no instance after repeated examination were they ever found again.

CASE 1. After a typical attack of orchitis and adenitis, the microfilariae, which were never numerous, disappeared from the patient's

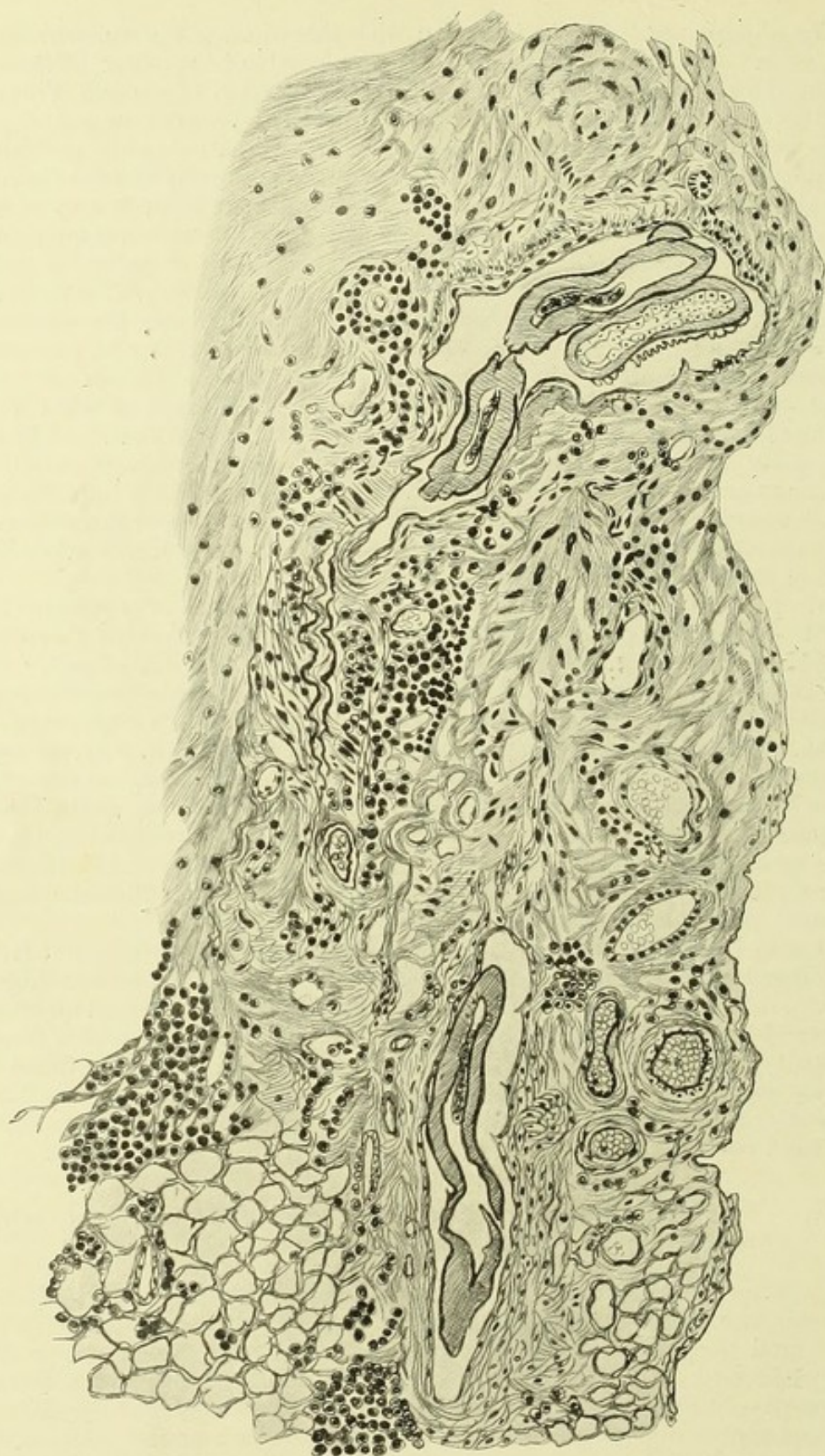

PLATE III.

P. H. Bahr *del.*, 1911.

Microscopical section of an adult filaria in an inflammatory mass situated over the internal condyle of the humerus. From a case of filarial lymphangitis.—Camera lucida.

blood, nor could they be found therein subsequently; previous to their disappearance microfilariae were obtainable by puncture of the inflamed glands. The temperature was of a hectic type. A fortnight after admission, pus, growing *Streptococcus pyogenes* in pure culture, was obtained from the right groin. The patient, who was a Fijian, subsequently died.

CASE 2. In this instance, too, the microfilariae were never numerous. The patient, a Fijian, had a typical attack of orchitis, followed by lymphangitis of the left arm. Microfilariae were not to be found in the blood after the fourth day of the illness when the temperature was 102° F. An inflammatory mass appeared above the internal condyle of the left arm. One microfilaria was found on puncture of this swelling. The lymph so obtained proved sterile on culture. The inflammatory mass was excised. On examining a section microscopically part of an adult filaria was found in a lymphatic space, surrounded by eosinophile cells and inflammatory tissue (Plate III.). The patient was subsequently admitted at various times with attacks of adenitis and orchitis. The lymph from gland-punctures was always found to be sterile on culture.

CASE 3. The patient, a Fijian, was admitted to hospital at various times suffering from adenitis and orchitis. Lymph obtained by gland-puncture was sterile. The microfilariae, which were never numerous, disappeared from the circulation when the temperature became normal, i.e. within twenty-four hours.

CASE 4. A European, twenty-two years resident in the South Seas. Microfilariae were fairly numerous in the blood-stream; they exhibited no periodicity. The patient, while under observation, had two typical attacks of lymphangitis in the left leg. After the temperature became normal the microfilariae disappeared, and were not found subsequently.

CASE 5. Double orchitis in a Fijian, accompanied by adenitis of the groin glands; microfilariae in the blood. Lymph obtained by puncture of the inflamed glands remained sterile on culture. The microfilariae disappeared from the blood-stream within twenty-four hours when under observation, and while the temperature registered 104° F.

CASE 6. A European patient born in the Colony; lymphangitis and adenitis of right leg; microfilariae exhibiting no periodicity sparingly present in the blood-stream. No microfilariae were found in the blood after the second attack of lymphangitis. Cultures of lymph remained sterile.

CASE 7. The patient was an Indian born in the Colony. He was admitted with a temperature of 105° F., but no other physical sign of disease. He was under observation extending altogether over a period of nine months. Microfilariae were quite numerous in the blood at first, and showed no periodicity. They gradually diminished in number, and after a second attack of fever completely disappeared. (For further details of these cases *vide* Appendix X.)

It is difficult to account for the disappearance of microfilariae in so short a period as twenty-four hours, as was the case in three of these patients. This phenomenon has been noted by many observers, and doubtless is the explanation of several of the reputed therapeutic cures<sup>21</sup> of filariasis. To understand the mechanism by which the disappearance is accomplished it is necessary to know the life-span of the microfilariae in the blood. I know of no observations in man which throw any light on this point, but Fülleborn<sup>22</sup> has investigated the subject in the dog. He injected a puppy with a quantity of heart's blood containing numerous

microfilariae (*Filaria immitis*) from another dog. Not only were the microfilariae found in the blood for a space of ten months after, but they appeared to become more numerous. Even assuming that infection with adult worms was in this instance excluded, it would seem that the life of a microfilaria in the blood-stream is a long one. If this observation on *F. immitis* applies equally to *F. bancrofti* it becomes difficult to account for the disappearance in so short a time in my patients of their microfilariae, on the assumption that it was brought about solely through the death of the parent worm. Experiments *in vitro* were made in the hope that they would shed more light on this point, but without success (Appendix XXXI.). Living microfilariae *bancrofti* were placed in citrate of soda solution to which various sera were subsequently added. The experiments were not very convincing, but as far as they go they tend to show (1) that no immunity reaction is developed in blood infected with microfilariae; (2) that microfilariae can live equally well (A) in normal serum, (B) in serum from cases of elephantiasis, (C) in serum from cases of orchitis and lymphangitis obtained during the attack, and after the disappearance of microfilariae from the circulation. Once they remained alive for nine days in serum from a man suffering at the time with filarial fever, but without microfilariae in his blood. In the course of these experiments I found that the microfilaria lives best at temperatures lower than that of the human body. *In vitro* and in sterile solutions, even at normal blood temperatures, they never lived very long, and they all perished in a shorter time in the few experiments undertaken at higher temperatures, probably, as far as could be ascertained, owing to the more rapid reduction of the oxygen present. It was noted that all microfilariae died directly the oxy-haemoglobin became reduced.

The disappearance of the microfilariae has been attributed by Primrose<sup>25</sup> to the removal of the adult worm by surgical operation, but, as pointed out by Manson,<sup>21</sup> their disappearance in this instance had to be ascribed to the subsequent attack of lymphangitis. In his experience he has noticed this occurrence several times.

### III. 1 (a)—Periodicity. The microfilaria of Fiji observes no periodicity.

This was first pointed out by Thorpe<sup>3</sup> in the Tonga islands. The microfilaria he found there and in Fiji was considered at first to be identical with microfilaria nocturna, whose periodicity had been disturbed by the irregular habits of the islanders. Lynch<sup>5</sup> found that in 156 filaria-infected Fijians microfilariae were present in both day and night blood in 105. Brunwin found no periodicity in the course of his inquiry, nor did Wilson<sup>7</sup>—in this case with measured quantities of blood.

In 1906 Ashburn and Craig<sup>10</sup> described a microfilaria with no periodicity occurring in the blood of a Filipino suffering from chyluria. From certain characteristics observed they regarded it as a new species, *Filaria philippinensis*. To the characteristics they mention I will refer later. In 1907<sup>11</sup> they reiterated their views, based on a study of four additional cases. They also described the development of this filaria in *Culex fatigans*. In 1909<sup>12</sup> a paper was read before the Society of Tropical Medicine by Captain Craig in which he repeats the statement made in previous papers; this paper was criticised by Low. To this criticism Captain Craig has replied<sup>13</sup> pointing out that the lack of periodicity is a constant feature. To this Low has again answered.<sup>20</sup>

Phalen and Nichols<sup>13</sup> showed that *filaria nocturna* is widely distributed in the Philippines, and have determined the periodicity in at least one case by a two-hourly examination of the blood in each locality visited. In a later paper<sup>14</sup> they deduce from an examination of 6,804 specimens of blood taken at night only that the filaria is very unequally distributed in the Philippines. These observations, however, and the difficulty of identifying *Filaria philippinensis* by the descriptions given being borne in mind, afford no reliable evidence as to the frequency, actual or relative, of the two varieties in the Philippines. They do not discuss the question of periodicity in different races, nor of the influence of long residence or recent arrival.

Leber and Prowazek<sup>15</sup> in Samoa lately described the microfilaria of that group. They found that it exhibited no periodicity.

Brochard<sup>8</sup> has found that the microfilaria of the Wallis Islanders observes no periodicity, and compares it with the descriptions of *Filaria philippinensis*, but prefers to wait for the discovery of the adult worm before naming it as such.

As regards my own observations, the tables given in Appendix XI. sufficiently prove, I think, that in the Fijian, whether normal or the subject of filarial disease, the microfilaria observes no periodicity in the blood-stream. The Charts accompanying Appendix XI. (Nos. I.-XIV.) were made from observations on ten different Fijians. Four were perfectly normal males. Charts were made, giving the numbers of microfilariae observed in the blood abstracted simultaneously from a finger of each hand. One of these Fijians was the subject of hydrocele, another of ankylosis of the hip, while three were suffering from elephantiasis. Out of 114 persons harbouring microfilariae no periodicity was present in ninety-one. The others had a very small infection, numbering but one or two microfilariae per slide, and consequently were of little, if of any value in determining periodicity. I may state that in making these observations great care was taken that the blood was duly measured (16 c.mm.) and was always procured at the same hour, viz. between 10 and 11 a.m. and 10 and 11 p.m.

III. (a)—While capable of developing in *Culex fatigans*, the favourite intermediary of *Filaria bancrofti*, this mosquito is not nearly so efficient an intermediary in Fiji as it is in other countries, or as is *Stegomyia pseudoscutellaris*, the common mosquito of the group of islands.

Seven species of mosquito, identified subsequently by Colonel Alcock, C.I.E., F.R.S., were collected in the neighbourhood of my laboratory in Suva. Some of these were met with in other localities, as described in Appendix XVII. Stated in the order of prevalence they are as follows:

*Stegomyia pseudoscutellaris* (Theob.) (Coloured Plate IV.). This species, established early in 1910 from specimens sent home from Fiji by Mr. J. P. Jepson, is a purely day-biting insect, and is undoubtedly the commonest mosquito in Fiji. It is distinguished from its congener *Stegomyia scutellaris*—which does not occur in Fiji—by its more extensive thoracic markings and the incompleteness of the abdominal bands. The larvae are very similar to those of *Stegomyia scutellaris*, but differ in having more and differently shaped spines on the penultimate abdominal segment. Further details regarding the habits of this species, the larvae and their food, will be found under Appendix XXXIII.

*Culex fatigans* (Wied) was bred in the laboratory all the year round but more sparingly, however, during the cool season. Larvae were found in a dark fresh-water tank, in kerosene tins and in artificial breeding-pools, placed round the laboratory. It is a purely night-feeding species.

*Culex jepsoni* (Theob.) (Coloured Plate V.). Another new species determined from specimens sent to England early in 1910. I found it breeding in open sheets of water. When alive, it is easily distinguished from *Culex fatigans* by its marked banded proboscis. It is a large, heavy mosquito, feeding equally well both night and day. *C. fatigans* and *C. jepsoni* feed well in captivity on banana, apple, etc., but considerable difficulty was experienced in starving them to the right degree of voracity that ensured their feeding on blood.

*Finlaya poecila* (Theob.) appeared at night sparsely in March, and again in September and October. A very shy-feeding species, and only females were found. I never succeeded in breeding it from the larva.

*Stegomyia fasciata* (Fab.) was bred from larvae in the laboratory. It is a rare mosquito in the country in Fiji, but common in the town of Suva. Captive specimens fed equally well both day and night.

*Culex nocturnus* (Theob.), a species only described from Fiji. It is recognizable by its banded legs and abdominal markings. It bred sparingly in stagnant water round my house, but never in numbers sufficient for experiment.

*Phoniomyia* (prox. *nitidiventer*) (Giles) was hatched out in quantities from larvae found in an old kerosene tin in April, 1910. The imagines were all females. No males were ever seen. It was never met with again.

#### MOSQUITO AS AN INTERMEDIARY OF THE FILARIA.

I made a series of observations on the development of the filaria in the mosquito in the following species. Only mosquitoes bred in captivity, and only "no periodicity" microfilariae were employed:—

*Culex fatigans*; *Stegomyia pseudoscutellaris*; *Stegomyia fasciata*; *Culex jepsoni*.

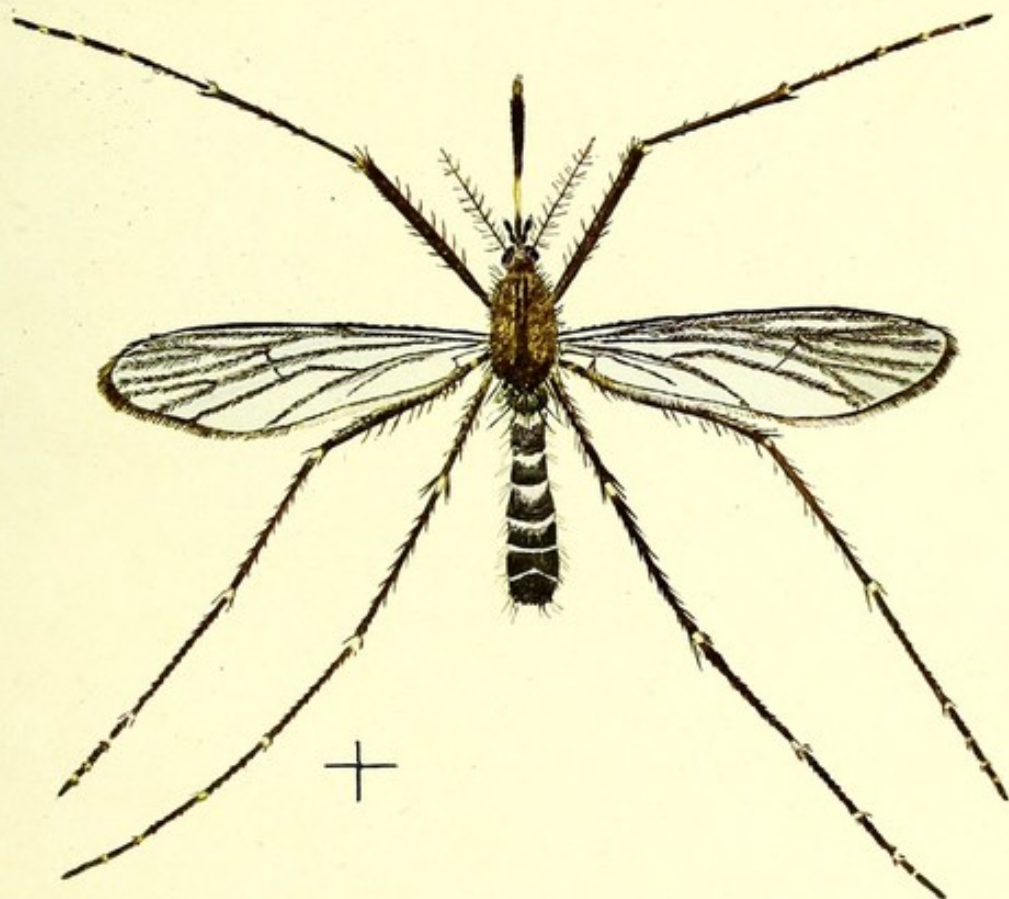
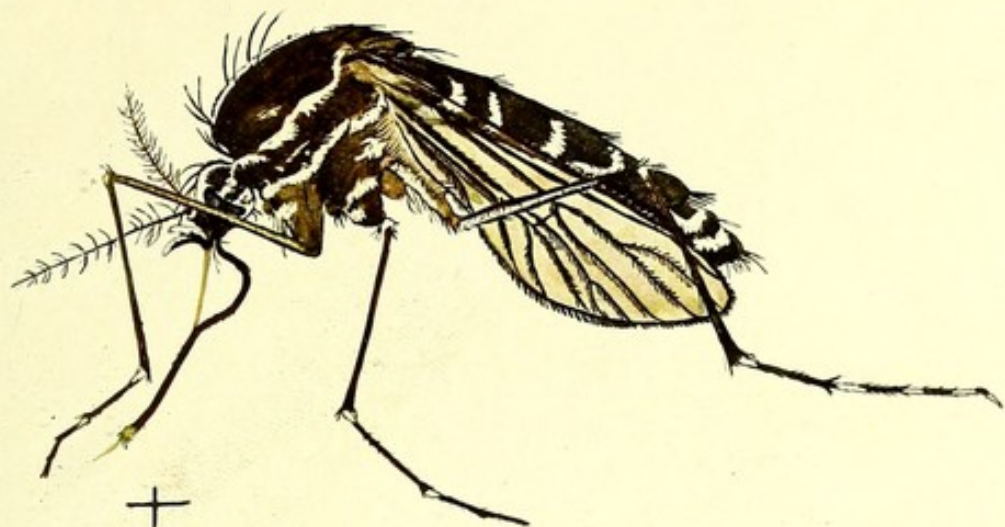In making these experiments in order, so far as possible, to obtain uniformity of conditions, certain precautions were necessary.

#### THE TEMPERATURE OF THE ATMOSPHERE.

Appendix XII. gives the average mean, maximum and minimum temperatures during the months in which the experiments were pursued. It will be gathered from this that the very limited range of temperature experienced in Fiji has little influence in determining the actual development of the filaria in the mosquito. The temperature was higher in May and June, when the main work with *Culex fatigans*, *Stegomyia fasciata* and *Culex jepsoni* was undertaken, than in August and September, when the first experiments with *Stegomyia pseudoscutellaris* were begun.

#### THE NUMBER OF MICROFILARIAE IN THE CIRCULATION FAVOURABLE FOR EXPERIMENT.

To ensure success it was found that the microfilaria infection had to be neither too small nor too large. In order to arrive at the optimum degree of infection certain experiments had to be made. An estimate



P. H. Bahr del., 1911.

**PLATE IV. (upper figure).**

*Stegomyia pseudoscutellaris* (Theob.) ♀, Fiji

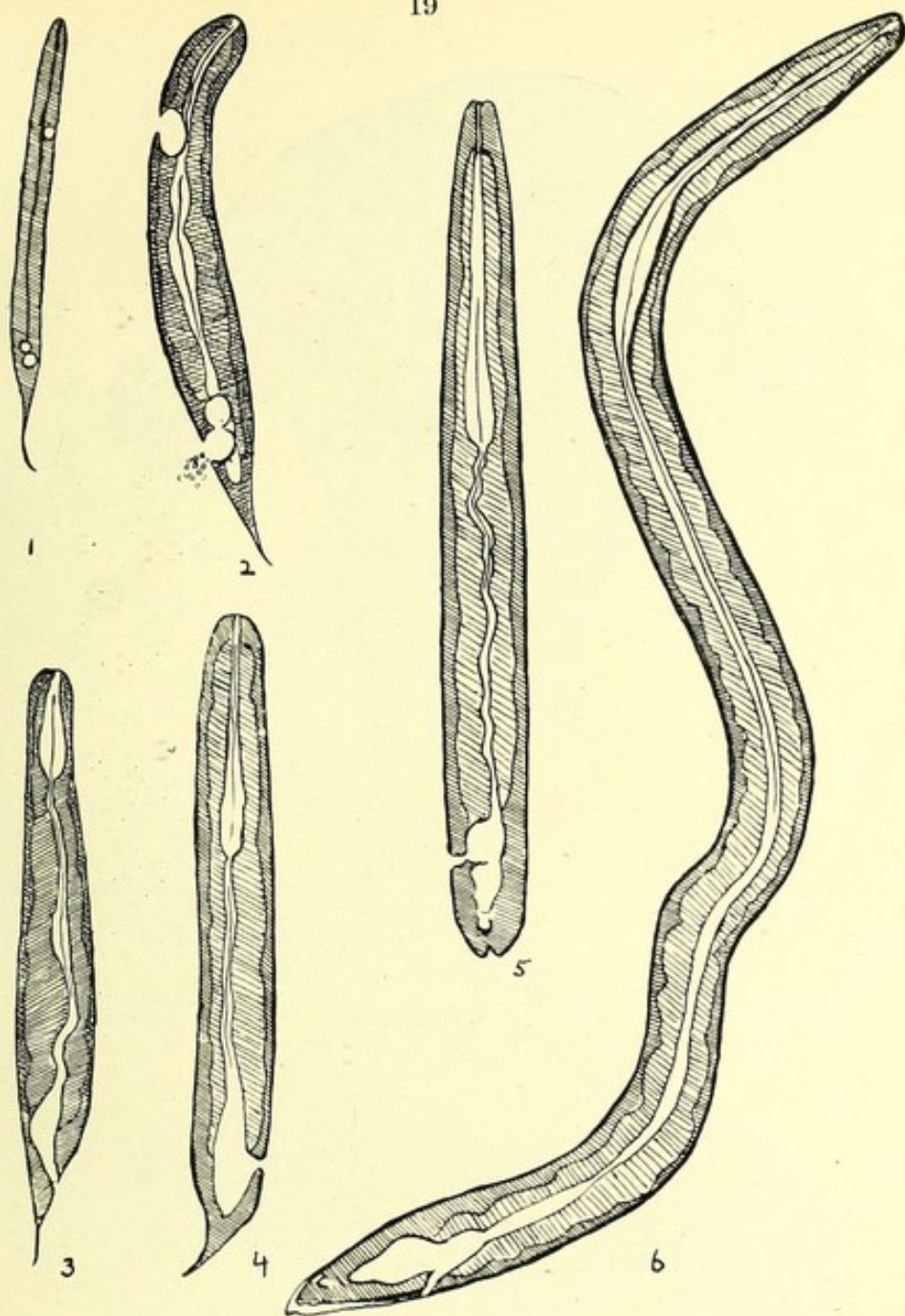
**PLATE V. (lower figure).**

*Culex jepsoni* (Theob.) ♀, Fiji.

The + under each figure represents the actual size of the insect.

[To face p. 18.





P. H. Bahr del., 1911.

## PLATE VI.

To illustrate the development of the intestinal canal. Drawn from living specimens of larval filariae.

Camera lucida drawings to scale.

1. Fourth day in *Stegomyia pseudoscutellaris* (17th Aug.). Length .171 mm. Breadth ant. .009 mm. Breadth post. .01 mm. Ant. V-spot .054 mm. from ant. extremity. Post. V-spot .044 mm. from post. extremity. Tail .021 mm. in length.

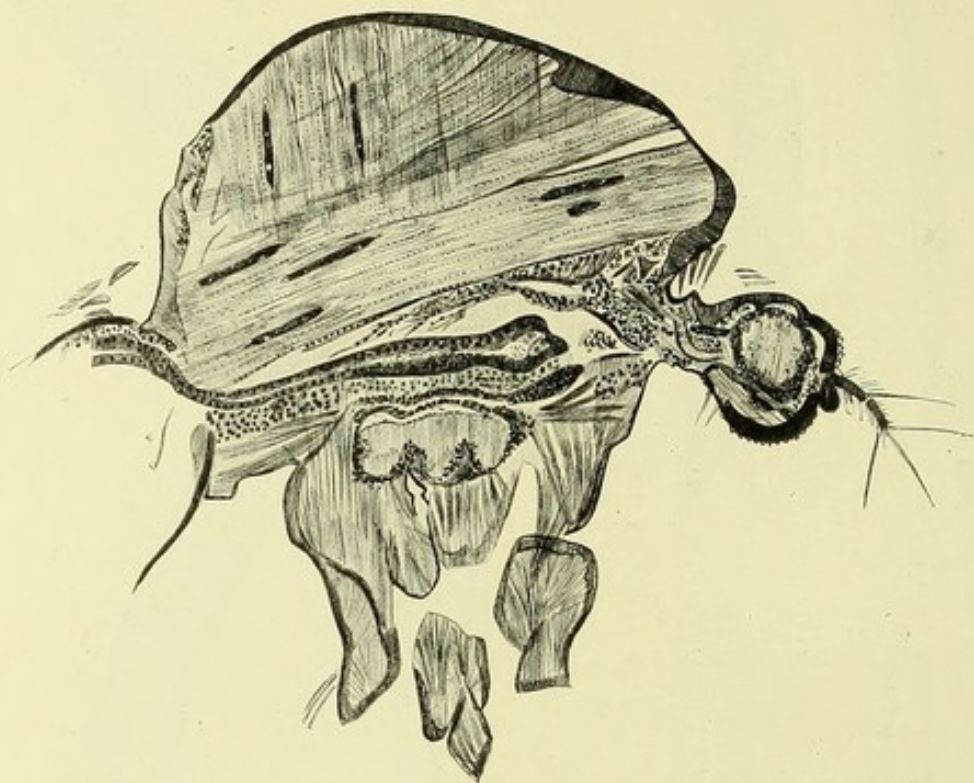
2. Tenth day in *Stegomyia pseudoscutellaris* (29th Aug.). Length .21 mm. Breadth ant. .024 mm. Breadth post. .03 mm. Ant. V-spot .044 mm. from ant. extremity. Post. V-spot .06 mm. from post. extremity.

3. Seventh day in *Stegomyia pseudoscutellaris* (4th Aug.). Length .225 mm. Breadth ant. .015 mm. Breadth post. .024 mm.

4. Tenth day in *Stegomyia pseudoscutellaris* (1st Sept.). Developed from embryo with nocturnal periodicity. Length .255 mm. Breadth ant. .024 mm. Breadth post. .018 mm.

5. Sixteenth day in *Culex fatigans* (3rd July). Length .36 mm. Breadth ant. .024 mm. Breadth post. .018 mm.

6. Sixteenth day in *Stegomyia pseudoscutellaris* (7th Sept.). Length .84 mm. Breadth ant. .015 mm. Breadth post. .024 mm. Oesophageal bulb .194 mm. from ant. extremity.

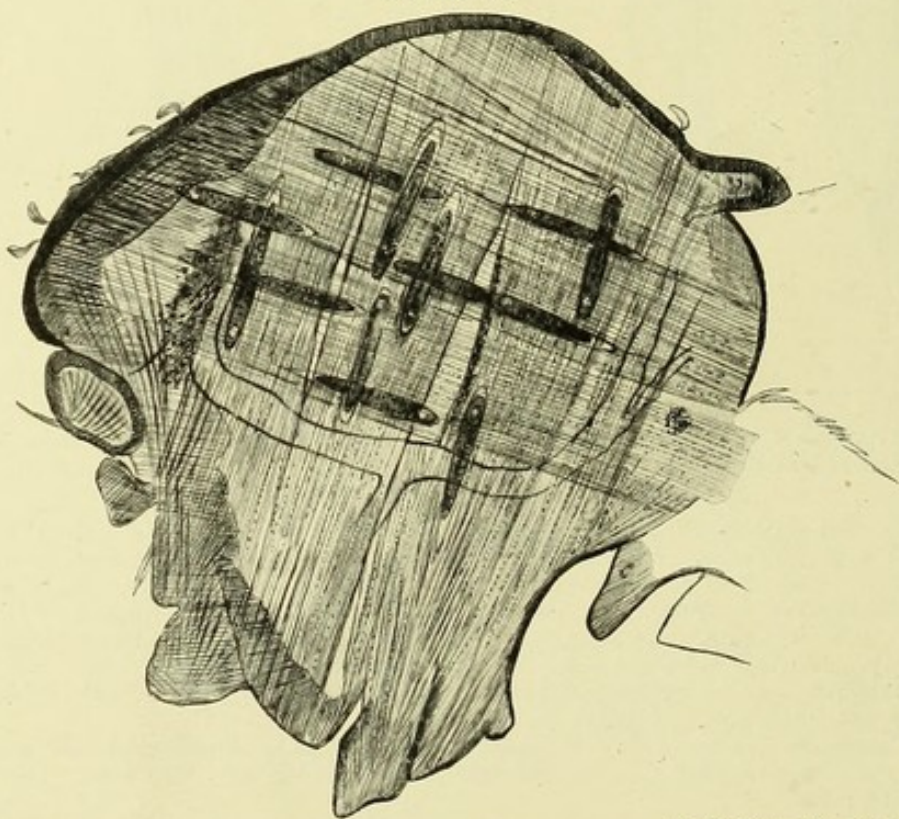


P. H. Bahr del., 1911.

### PLATE VII.

Larval filariae in *Stegomyia pseudoscutellaris*, second day after infection during the hot weather in November.—Camera lucida.

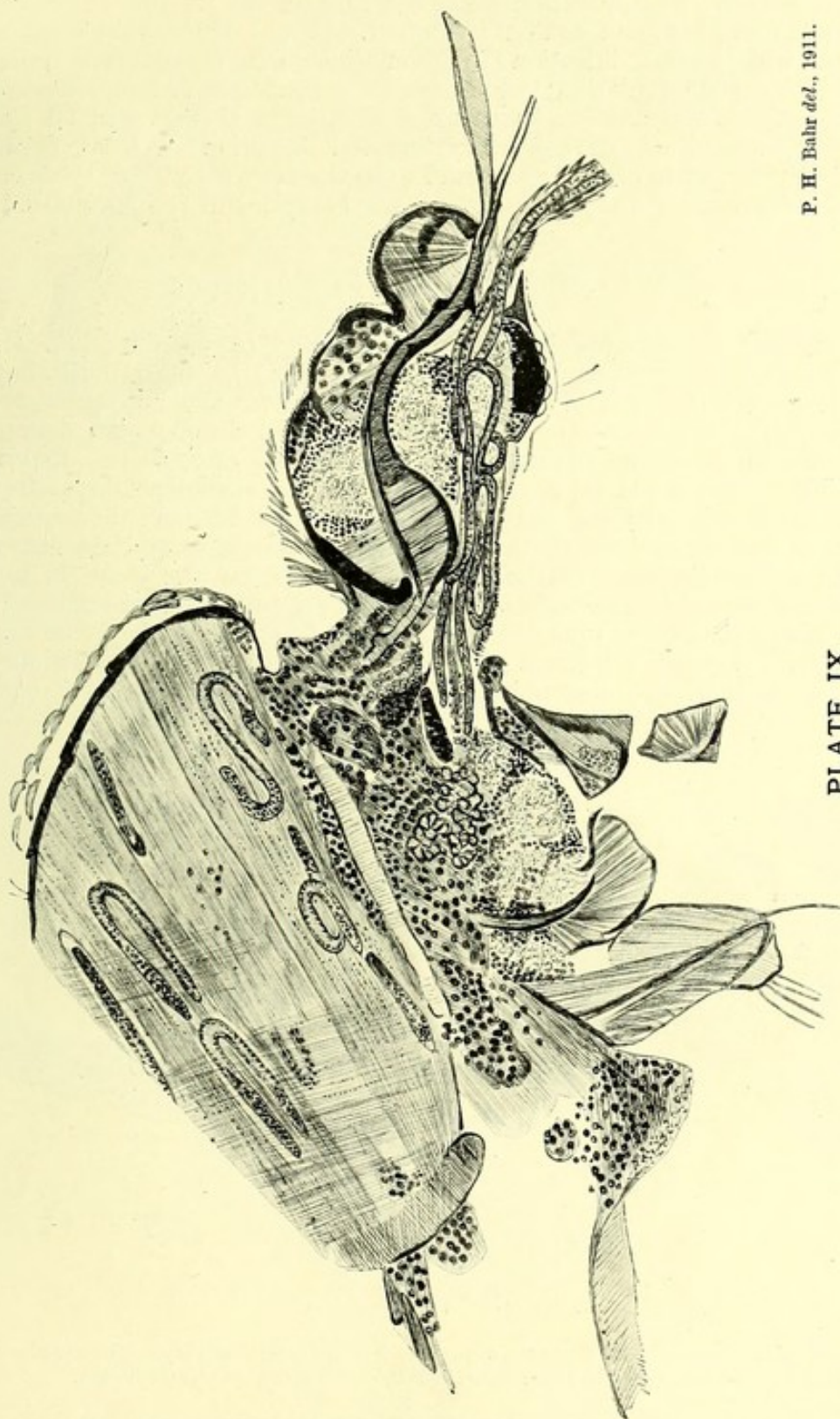
### THORAX.



P. H. Bahr del., 1911.

### PLATE VIII.

Filariae in *Stegomyia pseudoscutellaris*, fourth day after infection during the hot weather, November.—Camera lucida.



P. H. Bahr del., 1911.

PLATE IX.

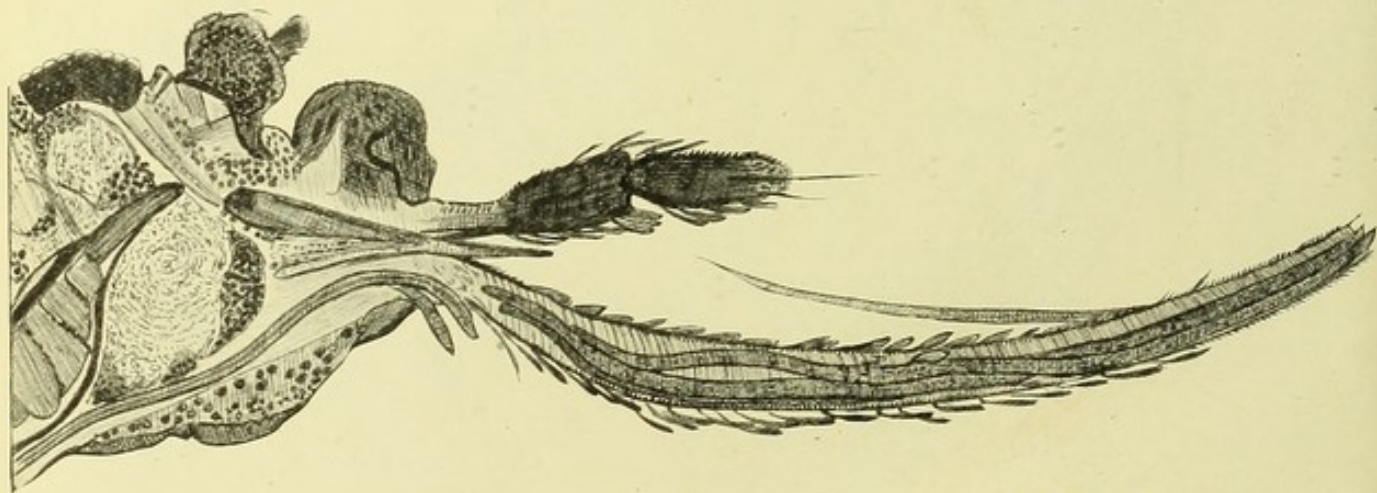
Filariae in thorax and travelling forward into proboscis on the tenth day of development in *Stegomyia pseudoscutellaris*, November, 1910.—Camera lucida.

of the average number of microfilariae present in the blood of a selected patient was first made (*vide* Appendix II.). Mosquitoes, after feeding on the patient, were dissected immediately, and the number of microfilariae in the stomach contents counted. It was found that from a patient with a small infection (7 microfilariae per 16 c. mm.) they failed to imbibe any microfilariae; whilst from a patient with 220 microfilariae per 16 c. mm. the number taken up was so large that nearly all the infected mosquitoes died. Ultimately an infection of from 40-60 microfilariae, per 16 c. mm. was found to be the most favourable both for the development of the filaria and for the longevity of the mosquito.

#### EXPERIMENTS WITH *CULEX FATIGANS*.

Some of the infected insects were dissected (Appendix XIII. A). Others were preserved for sectioning in celloidin. It was proved that the development of the microfilariae took place normally but sparingly. In the majority the infection died out altogether, although the insects were fed on the same patient as was the species next to be alluded to. The larvae could be recognized, as long as seventeen days after ingestion, as minute elongated forms stretched out between the muscle fibres of the mosquito's thorax. No further development had taken place; the nuclear core of the microfilaria and even the break in the column of cells, so characteristic of the embryo, could still be recognized.

In May a filaria was found in the proboscis of a *Culex fatigans* on the nineteenth day after feeding. In no instance after the seventh day were more than two developing filariae found in the thorax of one.

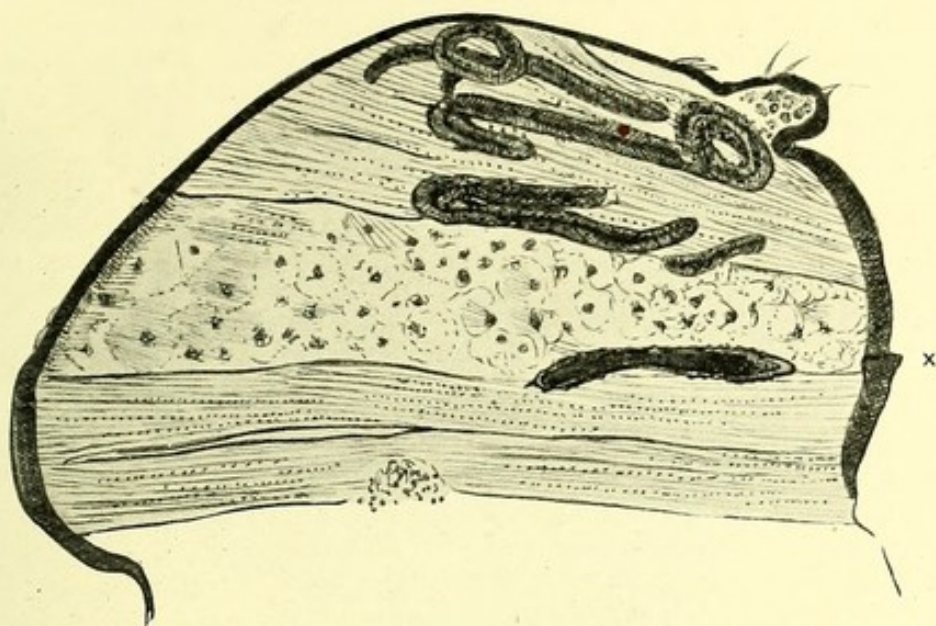


P. H. Bahr del., 1911.

#### PLATE X.

Head and proboscis of *Stegomyia pseudoscutellaris*, fifteen days after feeding, showing two filariae lying in head and three in proboscis.—Camera lucida.

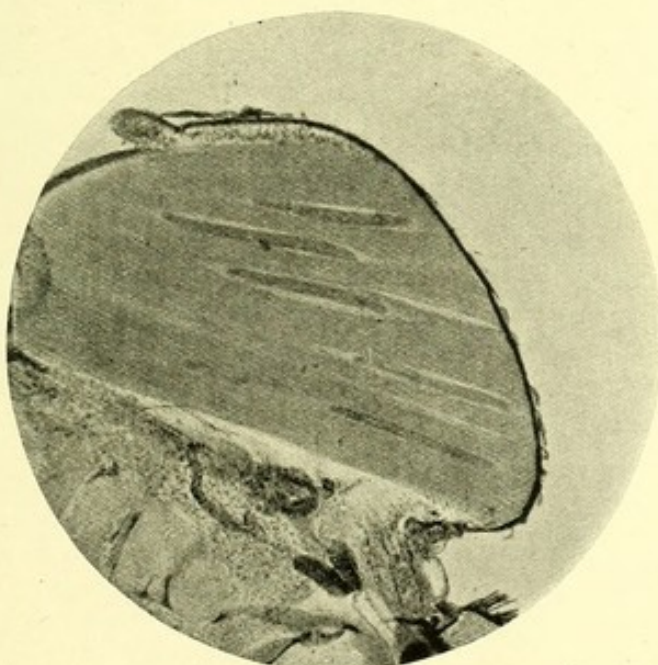
(N.B.—The cephalic ends of two filariae are protruding from the under-surface of the head. It must be understood that this is not their natural situation, but that they have been forced into this position in cutting the section.)



P. H. Bahr del., 1911.

# PLATE XI.

Showing dead form of filaria (marked x), encased apparently in chitin, in thorax of *Stegomyia pseudoscutellaris*.—Camera lucida.

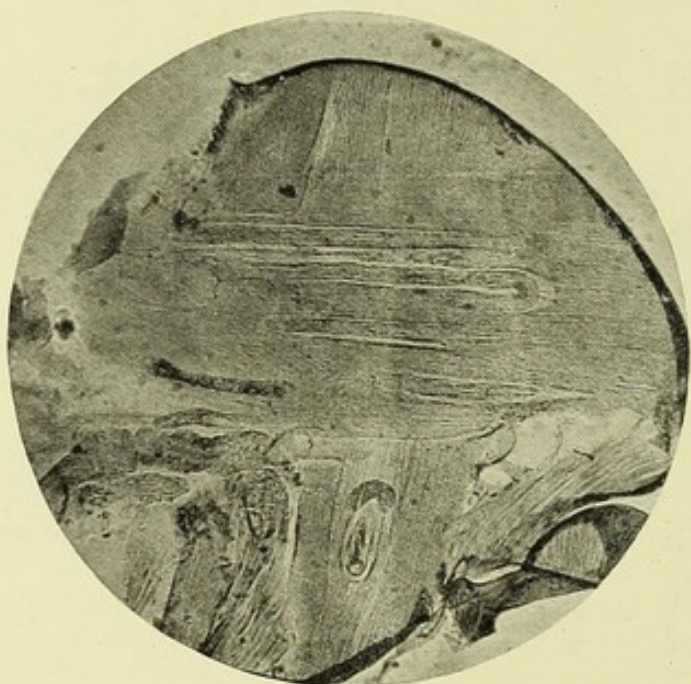


Microphot., P. H. Bahr.

# PHOTOGRAPH I.

Eighth day of development.

Developing filariae in *Stegomyia pseudoscutellaris* during the hot weather, November, 1910.

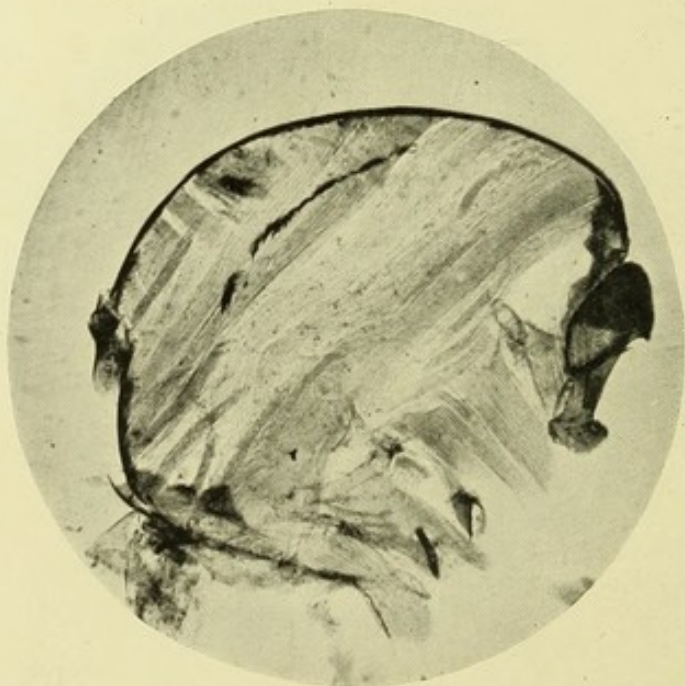


*Microphot., P. H. Bahr.*

### PHOTOGRAPH II.

Twelfth day of development.

Developing filariae in *Stegomyia pseudoscutellaris* during the hot weather, November, 1910.



*Microphot., P. H. Bahr.*

### PHOTOGRAPH III.

Filariae in *Stegomyia pseudoscutellaris*, eleventh day after infection during the cool weather, August, 1910. To show contrast in stage of development during the hot and cool months.

It is important to note that Ashburn and Craig, in their description of the development of *Filaria philippinensis* in *C. fatigans*, state that although as many as fifty-one filariae were found in the thorax on the eighth day, yet in a great many instances the filariae died out altogether, and that it was unusual to find more than four to six filariae undergoing the complete cycle; frequently only one was found in the proboscis. The experience of these observers agrees with mine as regards this species of mosquito. They observed no development in stegomyiae (species not mentioned). They state further that complete development in *C. fatigans* took fourteen or fifteen days.

Degenerating forms of filariae were found from time to time (Appendix XIII. A). In a great many of my filaria-fed mosquitoes no filariae could be found. I may add that each insect was carefully examined before dissection, and as *C. fatigans* is the only species of culex in Fiji with *unbanded legs* the identification was easy and reliable, and further, that all the preserved specimens brought home for sectioning were identified by Colonel Alcock. These celloidin sections bear out my statements, as regards the relative inefficiency of *C. fatigans* as an intermediary of the filaria in Fiji. Numbers of filariae can be seen in sections of the thorax in insects killed on the sixth or seventh day after feeding; they appear to be developing normally. After this point in many instances, all that can be found is an elongated mass of packed nuclei representing the filaria. The stages towards complete development in *C. fatigans* were the same (Pl. VI.) as in the next species of mosquito, but were affected at a much slower rate.

#### EXPERIMENTS WITH STEGOMYIA PSEUDOSCUPELLARIS.

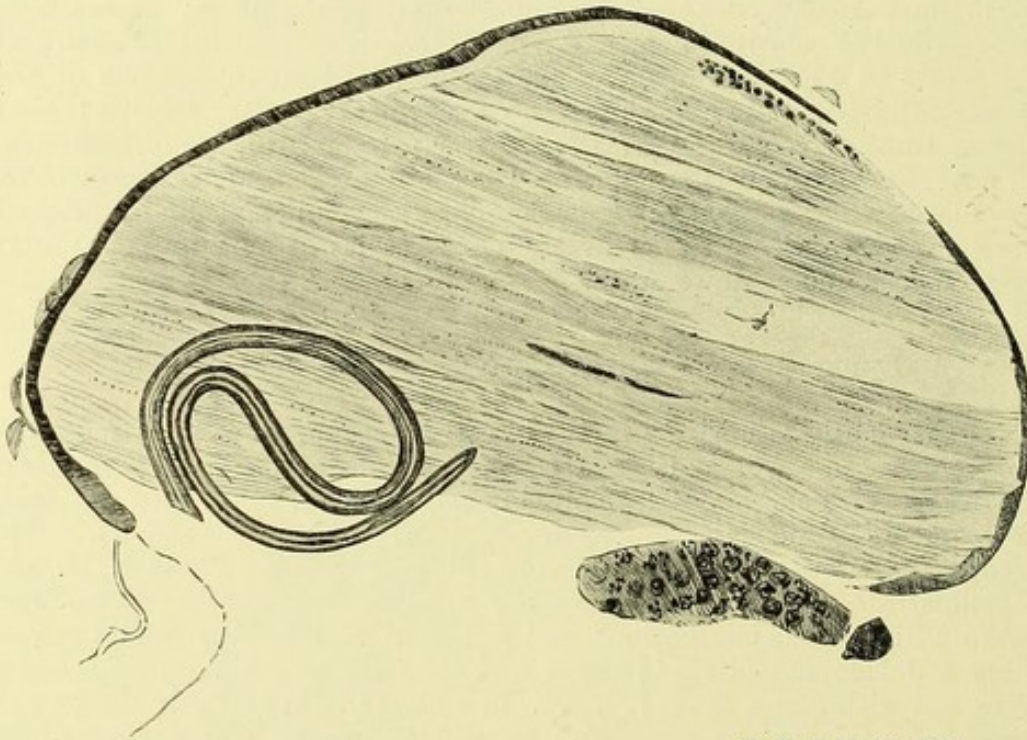
Details of dissections of forty infected specimens of this mosquito are given in Appendix XIII. B, showing the great numbers of filariae which may develop in this species, the rate of their development, and the measurements at different periods. The accompanying plates and photographs (Pl. VII.-X., and Photos. I., II., and III. illustrate these points. Very few dead or degenerating forms were seen on dissection, but curious and apparently chitinified bodies resembling a developing filaria in shape and actually enclosing their remains were met with many times (Pl. XI.) in sections. Apparently the rate of development is in some measure dependent on the temperature of the atmosphere. In experiments extending over a period of five months, viz. from July to the beginning of November, a period of twenty-one days elapsed before the filariae were found in the proboscis, whilst in similar experiments in November and December, when the maximum mean temperature was about five degrees higher than in the previous months, complete development was observed on the thirteenth day, and in certain celloidin sections of mosquitoes infected during the latter months such filariae were found in the proboscis on the tenth.

#### EFFECT OF DEVELOPING FILARIAE ON THEIR MOSQUITO INTERMEDIARY.

The developing filariae had a deleterious effect on the health of the mosquito. Heavily infected mosquitoes can be readily recognized; the attitude and general appearance betray the infected insect. It becomes more and more sluggish until, ultimately, it is unable to insert its stilettes.

Observations on the infected mosquito showed that of those fed on small infections nearly all lived till the twenty-first day, but out of a batch of 200 fed on a patient with an average of seventy-one microfilariae per 16 c. mm. blood only seventeen survived to that time. The filariae in these seventeen survivors were all found in the proboscis. The period at which the infected mosquitoes died depended apparently upon the degree of development of the filaria, and the rate of development upon the temperature. Thus in July and August the greatest number of mosquitoes died on the tenth day after feeding, in the hotter weather of November on the sixth day. From these observations it followed that an individual with a moderate infection may be a greater danger to the community than one with a large infection.

The last few days, that is when the filaria has entered the proboscis, appear to be the critical time for the mosquito. In one batch twenty-



P. H. Bahr del., 1911.

## PLATE XII.

Section of thorax of *Stegomyia pseudoscutellaris*, showing large coiled filaria ready to emerge, and small form of only two days development.—Camera lucida.

three mosquitoes were alive on the fifteenth day after infection; though fed on blood in the meantime only three of them lived four days longer.

Heavily infected stegomyiae were kept alive for twenty-nine days; for the last nine days, instead of being fed on blood, they had subsisted on bananas. On dissection no filariae were found in the proboscis, although as regards others of the same batch numerous filariae were found in the proboscis of all of them. The filariae in the banana-fed insects had in all probability left the proboscis while feeding on the fruit. This observation is in agreement with Fülleborn's experience, but at variance with that of Manson, Low, and Vincent on *Filaria immitis*.

In order to ascertain whether or not the stegomyia is an absolutely efficient intermediary, it is necessary to know the average number of microfilariae imbibed by the individual mosquito, and also, whether all those imbibed complete their development as far as the mosquito phase is concerned. This point it was necessary to ascertain, seeing that some have stated that the number of microfilariae taken into the mosquito's stomach is in excess of those present in a like amount of finger blood.

Ashburn and Craig<sup>11</sup> state that in their experience the mosquito (*Culex fatigans*) manages to abstract forty or fifty or more times as many microfilariae than are present in a similar volume of the circulating blood, and suggest that the mosquito might thus be of practical value in revealing embryos in the blood of those cases of elephantiasis in which filariae, though believed to be present, owing to scantiness were seldom found. Fülleborn<sup>28</sup> has investigated this subject. By weighing mosquitoes before and after feeding, and by estimating the haemoglobin in the latter, he was able to calculate the actual amount of blood imbibed. By this means he showed that the excess of microfilariae in the stomach of the mosquito is explained by the rapid absorption of the blood serum by the insect during feeding. Serum is commonly seen exuding from the anus of the mosquito directly after, or even during, a meal; thus very soon after a feed the abdomen becomes greatly reduced, and any filariae it may contain correspondingly concentrated. The mosquito, Fülleborn concludes, has no selective power, nor could he find that the secretion of its salivary glands exerted any chemiotactic influence on the microfilariae.

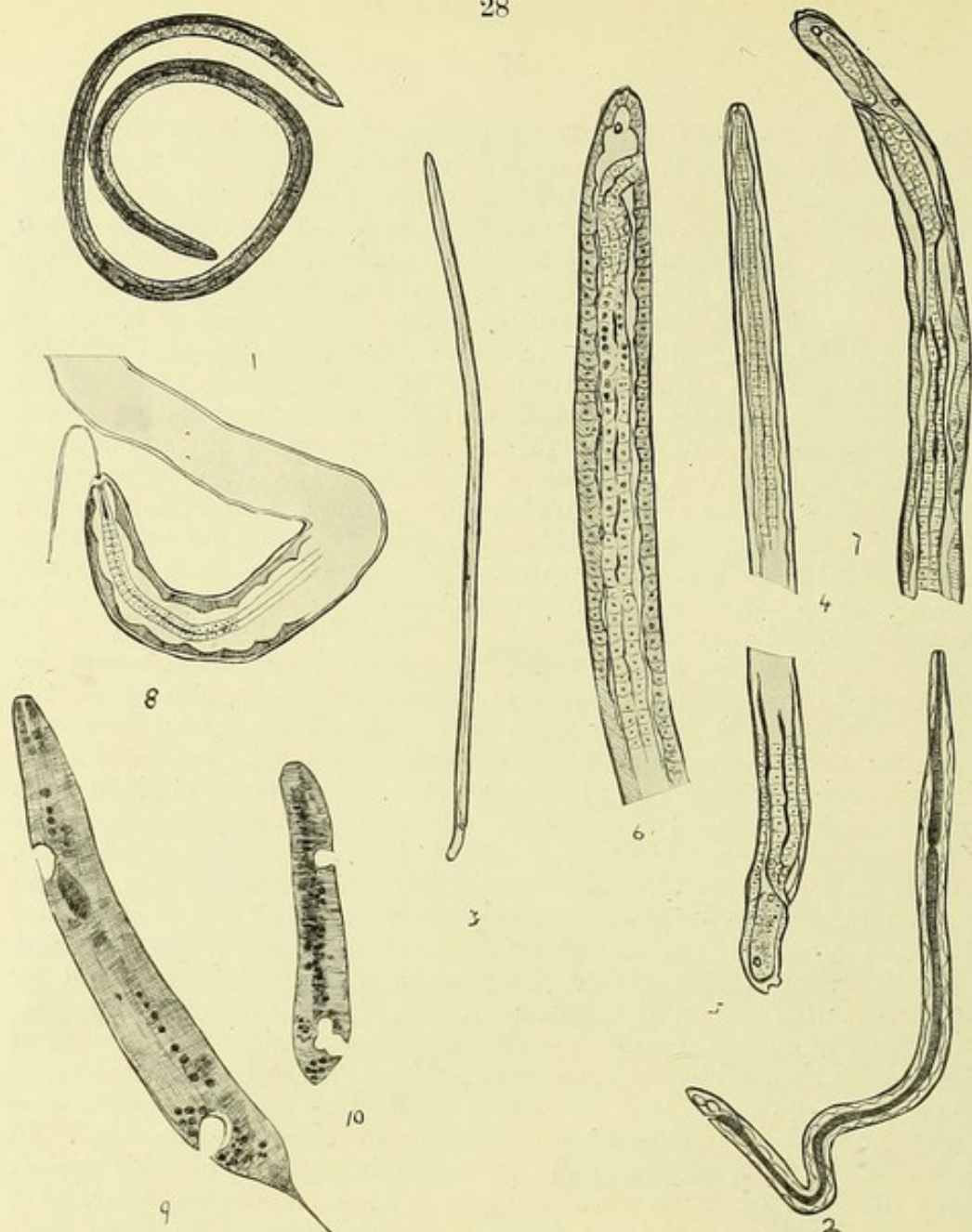
Table XIV. A (Appendix) is compiled from the dissection of a number of stegomyiae directly after feeding on the blood of a patient whose microfilariae had been estimated by frequent observation. The amount of blood present in the dissected stomachs was roughly estimated by comparison with smears of known quantities of finger blood.

In this way it was possible to estimate approximately the number of microfilariae imbibed by each mosquito. From this series of observations I was led to conclude that all filariae imbibed by *Stegomyia pseudoscutellaris* proceed to complete development in their intermediary. In Appendix XIV. B, figures will be found in support of this point. Large numbers of filariae, all at the same stage of development, were found in the thorax of these insects; in one instance no fewer than thirty-eight large forms were found on the sixteenth day after feeding.

An attempt was made to transmit two separate broods of filariae through the same mosquito (Appendix XIV. c.). On the tenth day after feeding on an infected man, the same stegomyiae were re-fed on the same patient. Till it was ascertained by the dissection of several of these insects that the first brood had all left the proboscis, the mosquitoes were fed on guinea-pig's blood. On the twenty-first day after the first feed of blood the filariae of the second brood were all found to have entered the proboscis.

In another experiment designed to ascertain the capacity of the mosquito as regards the number of filariae which it could rear successfully, no fewer than fifty-four filariae were found—thirty-three of the first and twenty-one of the second brood—in a single insect killed on the thirteenth day after the first feed of blood—all the filariae of the first brood were over 1 mm. in length (*vide* Pl. XII.).

These experiments show that *S. pseudoscutellaris* is an efficient intermediary for the Fijian filaria, and that the individual mosquito is capable of transmitting several generations of the parasite.



## PLATE XIII.

P. H. Bahr del., 1911.

Camera lucida drawings to show details in the structure of the developing filaria. Figs 1-8 from live specimens; 8-10 were stained with haematoxylin and are highly magnified.

Fig 1. Fifteenth day in *Stegomyia pseudoscutellaris*; shows the chyle intestine and position of anus. Length 1.26 mm. Breadth ant. .015 mm.; post. .024 mm.

Fig 2. Same stage as No. 1. Length .93 mm. Breadth .033 mm. Oesophageal bulb .21 mm. from ant. end.

Fig 3. Long form in head of *Stegomyia pseudoscutellaris* at the eighteenth day of development. Length 1.2 mm.

Fig 4. Head of No. 3.

Fig 5. Tail end of No. 3, showing two terminal and one postanal papillae.

Fig 6. Tail of filaria, fifteenth day of development, magnified to show postanal and developing terminal papillae.

Fig 7. Tail of filaria developing from *microfilaria nocturna*, on the twentieth day in *Stegomyia pseudoscutellaris*. Length .99 mm. Breadth .024 mm. Anus .036 mm. from tail. Three terminal and one postanal papillae.

Fig 8. Filaria thirteen days in *Stegomyia pseudoscutellaris* apparently ingesting a muscle fibre. Length .61 mm. Breadth .027 mm.

Fig 9. Arrested and degenerating form of larval filaria in *Culex jepsoni*, on the twelfth day after infection.

Fig 10. The same in *Culex jepsoni*, on the nineteenth day after feeding on infected blood.

All, where not mentioned, are developed from "no periodicity" microfilariae.

*Stegomyia fasciata*.—Details of dissections of a number of infected specimens are given in the Appendix (XIII. c). All the microfilariae evidently entered the thorax, but only in one instance were they seen to develop beyond a very early stage, although they could be recognized at this stage of development in a lifeless state, as long as seventeen days after the infection. In one individual, however, further development was observed. In this instance the filariae measured 2-3 mm. in length, and possessed a definite alimentary canal; the dissection was made on the twelfth day after the infection. Celloidin sections of a number of infected *Stegomyia fasciata* bear out my statement as regards the inefficiency of this species of mosquito. In only one insect out of the number examined could a filaria be found showing the development of the alimentary canal. In this instance also twelve days had elapsed since infection. It is quite possible therefore that very occasionally development *may* proceed in this species; I never found, however, filariae in the proboscis.

*Culex jepsoni* (Appendix XIII. d.).—A great number of this species were bred and fed in captivity. It was ascertained that the microfilariae enter the thorax quite normally, but no development beyond the "sausage" stage takes place. These stumpy forms could be recognized in the thorax up to the nineteenth day after feeding (Pl. XIII., Nos. 9 and 10). After the last few days no signs of life were seen in any of these arrested forms. There is then no evidence that this species is an efficient intermediary.

#### DEVELOPMENT OF THE FILARIA IN *S. PSEUDOSCUPELLARIS* AND *C. FATIGANS*.

The different forms assumed at various stages of development in the two species, *Stegomyia pseudoscutellaris* and *Culex fatigans*, have been studied in detail in fresh dissections in normal saline solution, and in celloidin sections of the thorax.

As regards the actual mode of development, I have little to add to what has already been written on the subject<sup>37-42</sup>. That there is a variation in the rate of development in the different months, and even in the same mosquito, is shown in the Appendix (Table XIII. B, and Photos. I., II., and III.). Even forms in the proboscis vary considerably in length (from .9-1.6 mm.).

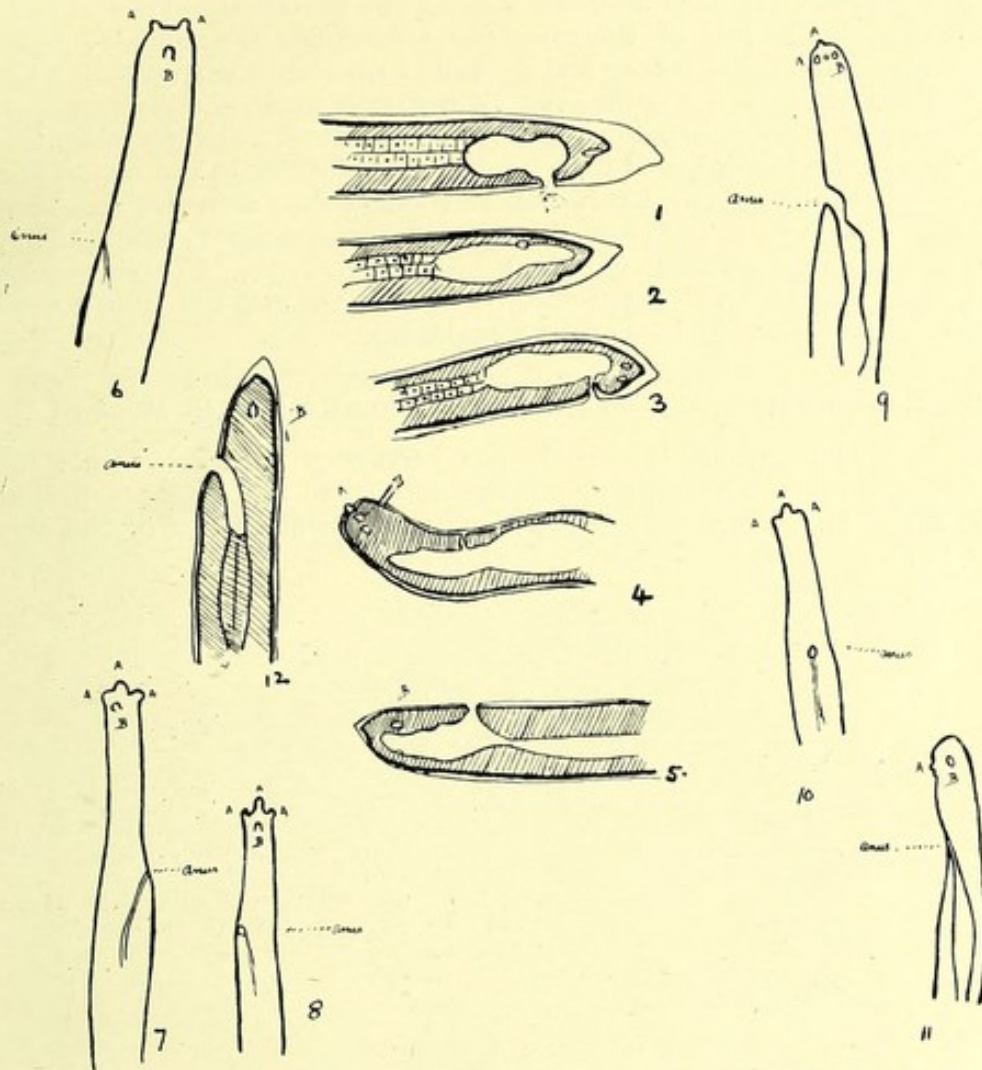
After entering the mosquito's stomach the microfilariae very soon cast their sheaths, usually within an hour and a half; this is the rule, but I have found sheathed forms in the stomach contents on the second day after feeding. Within twenty-four hours the great majority have entered the thorax. After two days the filaria begins to broaden out, and the posterior V-spot appears as a large vacuole. Soon after the anterior V-spot becomes very apparent. Multiplication of the nuclei in the interior of the filaria now takes place and it assumes the "sausage" form. At this time, in some earlier, in others later, the tail becomes a mere stump. Very often it is moved independently, the body of the filaria at this stage being apparently incapable of movement. Generally from the third to the fifth day masses of cells seem to push forward from the anterior V-spot to the anterior end, and form the oesophagus. No inversion of the epithelium to form the mouth, so far as I could ascertain, takes place. Later a definite perivisceral cavity forms, the cells arranging themselves into two layers, one layer lining the body cavity, the other constituting the alimentary canal. The posterior V-spot now

greatly enlarges and definitely becomes the anus, which remains sub-terminal up to the time of full development. At the same time the anterior V-spot becomes displaced by the multiplication of nuclei and finally disappears.

The alimentary canal is now complete. A postanal prolongation of the gut (or at least a collection of cells of the same character as those constituting the gut) is noticeable in a great many specimens (*vide* Pl. XIII., 5 and 7)—an appearance noted by Ashburn and Craig also. There is, however, a vacuolated space often to be seen in the same situation (*vide* Pl. XIII., Figs. 2 and 6). An oesophageal bulb and a constriction giving a distinct valvular appearance, situated about the junction of the first and second fourth of the alimentary canal, appear when the worm has attained about .5 mm. in length; it may be noted that this disappears before the filaria enters the proboscis. About this stage the anus becomes a mere slit, and in some specimens can be recognized only with difficulty. The diagrams (Pl. VI.) I have given represent the development of the alimentary canal and anus. They were prepared from camera lucida drawings made at various stages of development. The formation of the oesophageal bulb is also shown. Up to the time the filaria appears in the proboscis there seems to be a constriction or even septum between the intestine proper and the rectum (Pl. XIII., Fig. 7); apparently there is no communication between them. When the worm is about .6 mm. in length a considerable space between the body cells and the cuticle is often apparent (Pl. XIV., Figs. 1, 2, 3, 4, and 5). Probably at this time an ecdysis takes place, as has also been described by James.<sup>41</sup> The terminal papillae now begin to make their appearance as definite outgrowths from the body, and a constriction appears posterior to the anus, giving the appearance of a definite "hump" in that region (Pl. XIV. Figs. 7 and 8). The terminal papillae are apparently three in number; another can be distinguished somewhat more anteriorly. Annett, Dutton and Elliott<sup>42</sup> state there are four papillae; Ashburn and Craig<sup>43</sup> could only distinguish three. Their appearance, according as they are viewed, differs considerably, and possibly their number is variable (Pl. XIV., Figs. 6, 7, 8, 9, and 10). The usual arrangement of the extreme caudal end of the filaria suggests a large knob with two lateral and smaller excrescences. In some instances these lateral excrescences appear to be wanting (Pl. XIV., Fig. 6). It is exceedingly difficult to make certain about these papillae. The one situated more anteriorly can be made out only on careful focussing. The papillae probably function in assisting the filaria in progression; I have watched the filaria adhering to the coverglass by this organ.

As regards absorption and excretion, little evidence could be gained. Once, as shown in Pl. XIII., Fig. 8, a large form was seen on dissection to be trailing a long shred dangling from its mouth; on staining, this shred was seen to be a muscle fibre from the mosquito's thorax. Whether this appearance of feeding was accidental or not, I am not prepared to say. Granules were often observed emerging from the posterior V-spot at an early stage and throughout the whole cycle of development.

In celloidin sections of mosquitoes fed during the hot weather (Pl. VII.—X. and Photos. 1 and 2) the filariae are seen to lie at first parallel to and between the bundles of muscle fibre, but after the eighth day they are found coiled up in all sorts of attitudes. After the filariae have left the thorax and entered the proboscis, no spaces between the muscle fibres, such as might indicate their original resting place, can be made out.



P. H. Bahr del., 1911.

## PLATE XIV.

Camera lucida drawings from living larval filariae to show appearance of terminal papillae when seen from different points of view. Figs. 1-5 show the probable ecdysis of cuticle, and development of tail papillae. All were taken from the thorax of the same mosquito.

A = terminal. B = postanal papillae.

Fig. 1. Length .69 mm.  $\times$  .027 mm. breadth.

" 2. " .63 "  $\times$  .027 " "

" 3. " .66 "  $\times$  .027 " "

" 4. " .66 "  $\times$  .027 " "

" 5. " .68 "  $\times$  .027 " "

" 6. In the proboscis; 1.38 mm.  $\times$  .018 mm.

" 7. Developed from *microfilaria nocturna*, twenty-one days in the thorax of *Stegomyia pseudoscutellaris*. Length 1.23 mm. Breadth .018 mm.

" 8. Developed from *microfilaria nocturna*. Length 1.38 mm. Breadth .018 mm.

" 9. Twenty days in the thorax of *Stegomyia pseudoscutellaris*. Length 1.17 mm. Breadth .021 mm.

" 10. Twenty-one days after infection in the proboscis of *Stegomyia pseudoscutellaris*. Length 1.34 mm. length. Breadth .018 mm.

" 11. Twenty-one days after ingestion; in the proboscis of *Stegomyia pseudoscutellaris*. Length 1.53 mm. Breadth .018 mm.

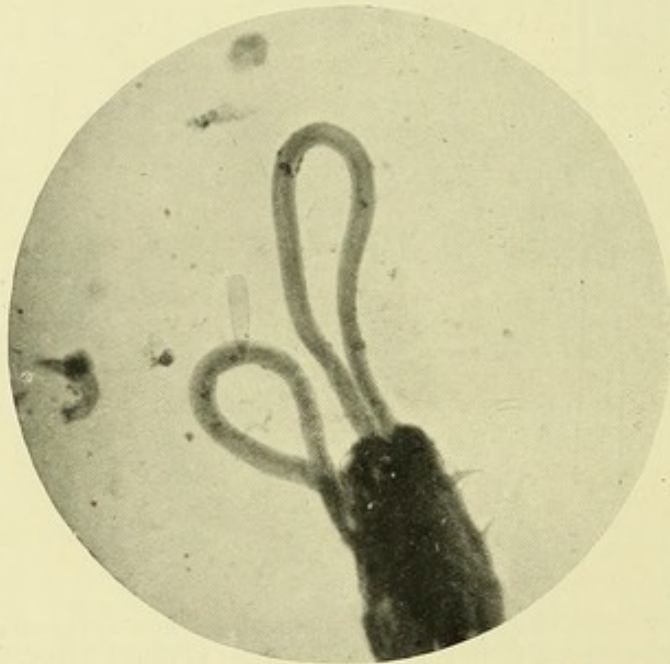
" 12. Sixteen days in the thorax of *Stegomyia pseudoscutellaris*. Length .84 mm. Breadth .024 mm.

Large forms often mistake their way to the proboscis. Thus I have found them in the legs of the mosquito, among the malpighian tubules where Low also found them; and actually in the stomach itself. In the proboscis forms, apart from the alimentary canal, no evidence of generative or other internal organs could be made out with certainty.

Forms from the proboscis were kept in welled slides in tap water, and in normal saline solution, but never lived longer than seven hours. They became much more active when the solutions were gently warmed. They made no attempt to feed, but swam aimlessly about. The suggestion that water may be an alternative route of entrance into the human host, is therefore not absolutely without foundation.

#### MODE OF ENTRY OF THE FILARIA INTO THE HUMAN HOST.

On several occasions the filaria has been seen to emerge from the proboscis through Dutton's membrane, often two and three at a time (*vide* Phot. 4). That the filariae enter through the pores of the skin



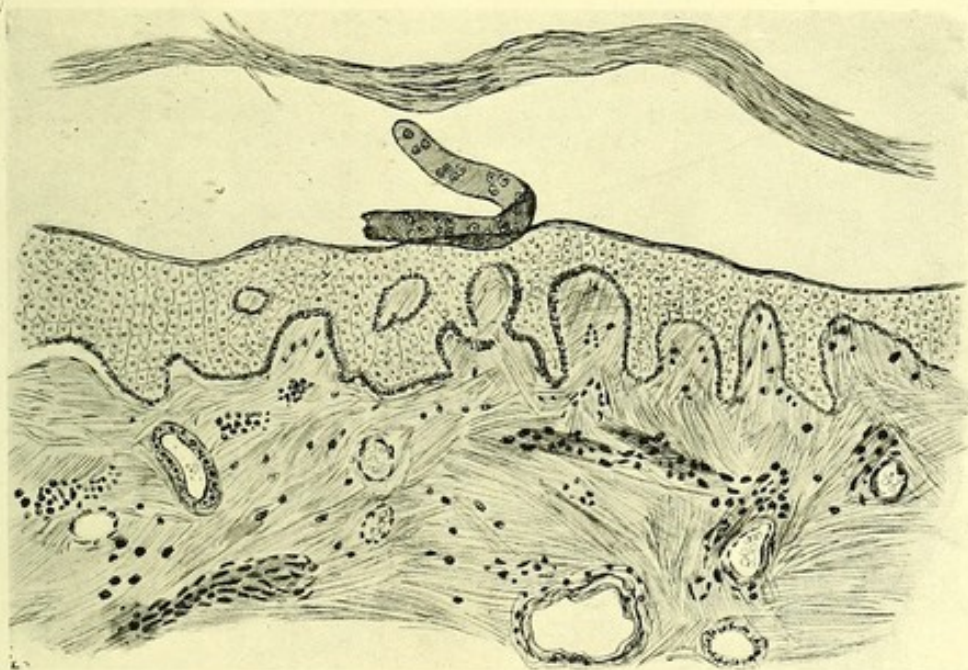
Microphot, P. H. Bahr.

#### PHOTOGRAPH IV.

Two filariae emerging from proboscis of *Stegomyia pseudoscutellaris*.

there appears to be little doubt. By ingeniously devised experiments Fülleborn<sup>28</sup> has shown this in the case with *Filaria immitis*. In his series of excellent microphotographs the filariae are all seen entering the skin much in the same way as the ankylostoma larva enters it. In some of my experiments infected stegomyiae were allowed to feed on certain areas of a native's hand at intervals during a period of three days, before the hand was amputated for extensive ulceration. These areas were marked and afterwards sectioned. In the 2,000 sections examined I found only one structure which could be regarded as being of filarial origin, probably part of the cuticle of a filaria (Pl. XV.). A similar experiment was attempted with a guinea-pig, a small area of whose back had been shaved, but the sections of skin were not a success.

More convincing experiments, however, were afterwards made on a person who volunteered for this purpose. An area on the back of the hand was shaved and ringed with blue pencil. Large larval filariae obtained from the mosquito by dissection in normal saline (sixteenth day of development) were removed from the slide on the point of a fine needle. They could be seen wriggling about on the needle quite distinctly with the naked eye; I watched them for a time with a hand lens enlarging thirty diameters. When placed on the skin, after a few convulsive movements, they suddenly disappeared, apparently through the orifices of the gland ducts. Six filariae from the thorax and two from the proboscis of different mosquitoes were employed in this manner, and all disappeared with the same lightning-like rapidity. One of the filariae, injured in removing it from the slide, could be distinctly



P. H. Bahr del., 1911.

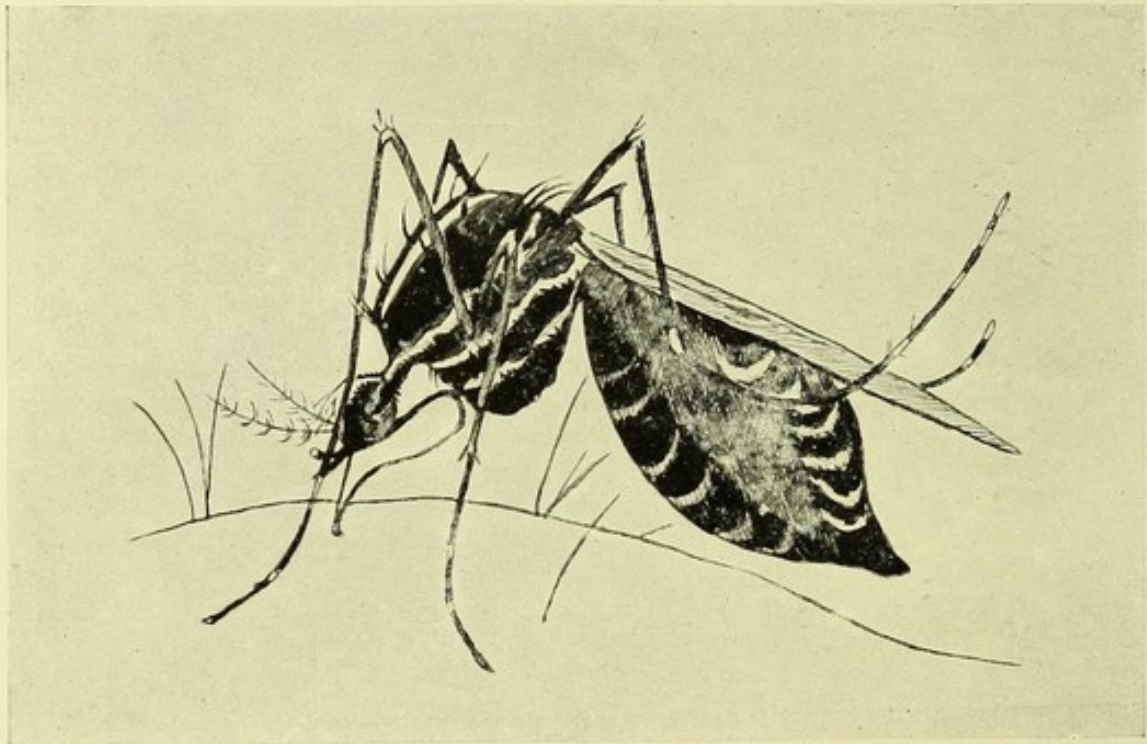
#### PLATE XV.

Section through human skin removed after being bitten by infected *Stegomyia*. The stratum corneum has been separated in sectioning; below it is a cylindrical body, resembling a tube, of the same size and shape as a filaria. This tube is doubled up and lying on the stratum malpighii. There are numbers of nuclei in the little structure. It may possibly represent the cuticle of the filaria which has undergone an ecdysis before entering the deeper layers of the skin.—Camera Lucida.

seen lying on the surface of the skin. That it could be so clearly seen when dead is in favour of my view that the others all entered the human host, and in accordance with their normal habit. That the filariae enter the human host by boring their own way through the skin, and not by the puncture made by the mosquito, is obvious when one considers the mosquito in the act of feeding. Plate XVI. shows a *stegomyia* drawn in the act. The labium is bent almost double, the stilettos emerging from under the cover of the labium enter the skin, completely plugging the hole they have made. The filariae, therefore, cannot possibly enter by this route.

III. (b)—The Fijian microfilaria is morphologically identical with *Microfilaria bancrofti*.

I think, from its general characters, and especially from its lack of periodicity, that in Fiji I was dealing with the microfilaria described by Ashburn and Craig<sup>10</sup> under the name *Filaria philippinensis*. Although, apart from the absence of periodicity, I failed to discriminate the larva from that of *Filaria bancrofti*, these observers make the following as points of distinction, and on these base their claim for its being a new species. They assert that this microfilaria lacks periodicity; secondly, that the sheath is tightly applied to the body so that the larva cannot move up or down in the sheath; thirdly, that it is slightly narrower than microfilaria bancrofti; fourthly, that it is capable "at times" of progressive movement; fifthly, that the posterior V-spot is marked by a



P. H. Bahr del., 1910.

PLATE XVI.

*Stegomyia pseudoscutellaris* in act of feeding, showing stilettes entering the skin between the labellae of the buckled-up labium.—Drawn from life.

papilla from which gas and fluid containing granules may be seen to escape; and sixthly, that the sheath ends in a thread-like extremity quite as delicate as the flagellum of a trypanosome. As pointed out by Low, even if they do obtain, these are very minor differences, and do not justify the creation of a new species; certainly as regards the Fijian filaria they do not obtain. I examined a great many microfilariae in Fiji, but cannot reconcile, in every respect, my findings with those of Ashburn and Craig. I examined them alive in fresh blood, in dried and fixed blood, in normal saline, in citrate solution, in hydrocele fluid, and

stained in a variety of ways, but failed to make out any differences from *microfilaria bancrofti*, whether as regards the sheath or in other respects. I have compared, under separate microscopes, the Fijian *microfilaria* with *microfilariae* obtained from undoubted *Filaria bancrofti* infection (*vide* Appendix XI., Charts XV. and XVIII.), but have been unable to recognise any differences, whether in their movements or in their morphological characters. As regards the tightness of the sheath mentioned by Ashburn and Craig, no difference between the two kinds of *microfilariae* could be observed in the amount and character of the movements within the sheath.

The flagellar-like termination which these authors describe is, I must admit, very deceptive. In watching the *microfilariae* in a wet blood film, the movement of the red blood corpuscles in the wake of the worm gives one the impression of its being caused by the action of a terminal flagellum; but the simulated flagellum is in reality only the collapsed and empty posterior portion of the sheath. They mention a small papilla; this certainly, in some instances, can be made out in the position of the posterior V-spot, but I have never seen the granular material exuding therefrom which they claim to have observed.

*Measurements.*—In the Appendix (Table XV.) are given the measurements of a number of *microfilariae* from Fijian blood. They were made from blood films in which the *microfilariae* were beginning to be sluggish; also from *filariae* in normal saline, in citrate solution, and in hydrocele fluid. No essential difference could be made out as between these measurements and those for *microfilaria bancrofti*, whether obtained by myself or given by other workers.

*Anterior end.*—As regards the cephalic apparatus, I was not able to arrive at a clear conception of its peculiar features, nor was I able to further elucidate the *modus operandi* of its various parts. The finer details are so delicate, and the movements so rapid, that the liability to optical delusion is great. I was, however, able to confirm the presence of a fang, or at least the appearance of such an organ. It is protruded and retracted with such lightning-like rapidity as to be almost invisible; I failed to stain it. In many examples in wet blood films *microfilariae* were seen adhering as it were to the coverglass by the collapsed anterior portion of the sheath; they seemed to be held captive in this way, and were making frantic efforts to get free. The posterior part of the sheath is also very adhesive, and in virtue of this property of the sheath the worms were able to locomote slightly, hitching themselves forwards or backwards as the case might be. At the anterior extremity, and apparently at the spot whence the fang is protruded, I could make out a bright pyramidal spot, but as to the connection and function of this feature I am unable to conjecture. The prepuce I could ascertain to be serrated, and I thought six-lipped, but on this point also it was impossible to be certain. The striation of the body of the *microfilaria* appeared to me to begin at about  $6\ \mu$  from the anterior end.

The anterior V-spot I found to conform with Rodenwaldt's<sup>29</sup> description, that is, it is oval in form when viewed sideways, with a minute opening directed outwards; I was unable to recognize the genital and excretory cells which he describes and figures.

In certain specimens, and after a great many failures, I succeeded in staining the "*central viscus*" with dilute Giemsa (Pl. XVII.). Only a proportion of the *microfilariae* on any given slide could be stained so as to show this feature. In the posterior half of the worm, and terminating

in a globular swelling, runs a red-staining "granular mass" (Manson), the "Innenkörper" of Fülleborn<sup>31</sup> occupying the space termed the central viscus. By staining *in vivo* with dilute neutral red solution, and then decolorizing by means of strong electric light, Fülleborn has been able to demonstrate this body in *microfilaria bancrofti*, *microfilaria perstans*, and in *microfilaria loa*. He gives excellent microphotographs of the body in the two latter *microfilariae*. He considers it to be a mass of reserve material; not glycogen, as it does not give the reactions of that substance. I have been able to demonstrate this body in *microfilaria bancrofti*, and also in *microfilariae* just as they were emerging from the parental vulva. In "vital" staining by Fülleborn's method I did not have much success, although in hydrocele fluid (tinted with dilute neutral red) this mass stood out as a highly refractile spiral line, contrasting strongly with the surrounding nuclei. It appeared to end in a bulbous extremity. By staining with Leishman and eosin azur II., numbers of bright red staining granules occupying the central viscus were made out. In Samoa, Leber and V. Prowazek<sup>55</sup> have demonstrated lately this same viscus in the non-periodic *microfilaria* of that group of islands. They believe the *filaria* found there to be the same species as that described by Ashburn and Craig.

*Microfilariae* which from some cause had lost their sheaths were studied in "ringed" blood slides and in hydrocele fluid in which many examples had lost their sheaths. Those in blood slides kept on ice were, after twenty-four to thirty-six hours, found to be sheathless, especially those *filariae* lying near the edge of the specimen. The sheathless form measured about 270  $\mu$  by 6  $\mu$ . No special cephalic armature could be made out in them; the fang was certainly not apparent. In one or two specimens I saw granular excrescences at the head end, and was at a loss to know whether they were the result of degenerative changes, such as are extremely common in unsheathed forms.

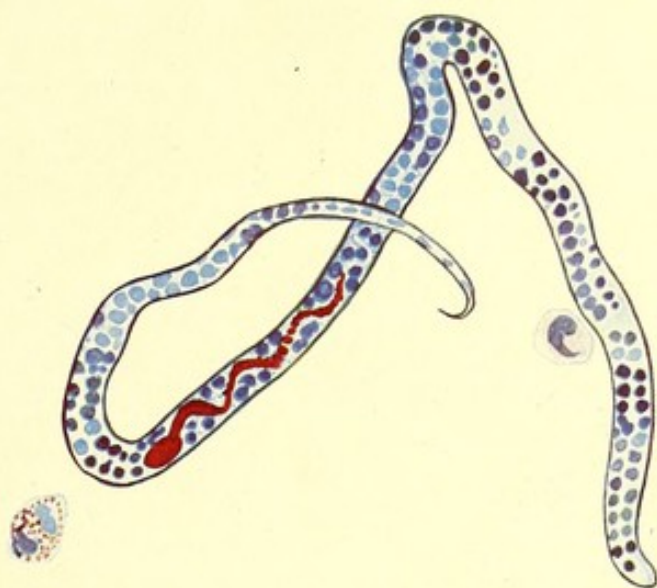
III. (b)—The parental form of the Fijian *microfilaria* is, so far as can be ascertained, identical with *Filaria bancrofti*.

#### A NOTE ON THE ADULT FILARIAE FOUND BY DR. P. H. BAHR IN FIJIANS.

By R. T. LEIPER, M.B., D.Sc. (Helminthologist, London School of Tropical Medicine).

On his return from Fiji, Dr. P. H. Bahr sent to the Helminthological Department of the London School of Tropical Medicine, for confirmatory diagnosis, a number of adult *filariae* obtained at operations and post-mortems on natives of Fiji.

The following information, which accompanied the specimens, will enable the reader to identify the individual specimens with the particular cases from which they were derived, when these are mentioned in other parts of the Report. Reference may also be made thus for details regarding the habitat and bionomics of the worms, and the character and incidence of the embryo *filariae* in the blood.



P. H. Bahr *del.*, 1911.

# PLATE XVII.

The non-periodic microfilaria stained by dilute Giemsa for half an hour, showing "central cell mass" of Manson or "Innenkörper" of Fülleborn.

Camera lucida drawing  $\times 1,200$  diameters.

(N.B.—The sheath is not stained in this specimen.)

[To face p. 36.



Case.		Length.	Breadth.	
1. Javalo	♂ <i>Filaria</i> adult (Sect. II., Table A)	29 mm.	0.1296 mm.	In epitrochlear lymphatic gland. Preserved in 70% alcohol.
2. Javalo	♀ <i>Filaria</i> adult (Sect. II., Table B)	55 mm.	0.2226 mm.	Found coiled up with 1. Preserved in 70% alcohol.
3. Javalo	♂ <i>Filaria</i> adult (Sect. II., Table B)	25 mm.	0.129 mm.	In epitrochlear gland. Preserved in 70% alcohol.
4. Javalo	♀ <i>Filaria</i> ? immature (Sect. II., Table D)	42 mm.	0.1824 mm.	No microfilariae in uterus.
5. Taomba	♀ <i>Filaria</i> (Sect. II., Table E)	31 mm.	0.135 mm.	In epitrochlear gland. No embryos in uterus. On slide in glycerine jelly.
6. Waca	♀ <i>Filaria</i> (Sect. II., Table G)	50 mm.	0.128 mm.	In pedunculated groin gland. On slide in canada balsam.
7. Senavelete	♀ <i>Filaria</i> containing live microfilariae			In femoral gland. On slide in canada balsam.
8. Thomasi	♀ <i>Filaria</i> adult (Sect. II., Table A)	65 mm.	0.177 mm.	In epitrochlear abscess. On slide in canada balsam.
9. Thomasi	<i>Filaria</i>			Fragment; on slide in glycerine jelly.
10. Taomba	♀ <i>Filaria</i> immature			In epitrochlear gland. On slide in canada balsam.
11. Javalo	♂ <i>Filaria</i>			Found coiled up together in epitrochlear gland.
	♀ <i>Filaria</i> (Sect. II., Table C)	65 mm.	0.206 mm.	On slide in canada balsam.
12. Reupeni	♂ <i>Filaria</i> (Sect. II., Table D)	28 mm.	0.09 mm.	In enlarged groin glands.
	and ♀ (Sect. II., Table H)	67 mm.	0.153 mm.	Preserved in 70% alcohol.
13. Senavelete	♀ <i>Filaria</i> (Sect. II., Table F)	50 mm.	0.15 mm.	} In femoral glands. Preserved in formalin.
	♂ <i>Filaria</i> (Sect. II., Table C)	25 mm.	0.09 mm.	

TOTAL : 16 worms, five males and eleven females, from 6 cases.

N.B.—The tables referred to above will be found in Section II. of the Report. Readers wishing to refer to this will find further information there, one table being allotted to female, the other to male filariae.

Of these, 5 to 10 inclusive were mounted on microscopical slides; the others were preserved, as stated, either in 70 per cent. alcohol or in formalin. With the exception of measurements, no details were obtainable from Nos. 6, 7, 8, 9, 10 and ♀ of 11. The remaining specimens were undamaged.

The presence of the parasites in the lymphatic system, their association with well-known lesions, and their size and general appearance, suggest at once, of course, that the worms belong to the species *Filaria bancrofti*,

or to a very closely allied form. The *Filaria bancrofti* and the pathological lesions commonly associated with it have been recorded from almost every country within the tropics of Cancer and Capricorn. On the one hand these records differ in some cases so distinctly from others as to have suggested to a number of writers that probably several species exist having more or less the same habitat and pathological associations as *F. bancrofti*, but differing in minute structure of adult and embryo, in geographical distribution and intermediary host. Thus we have the *Filaria sanguinis hominis*, Lewis, of India and China, the *Filaria sanguinis hominis aegyptiaca*, Sonsino, of Egypt, and the *Filaria wuchereri*, da Silva, of Brazil. These are at the present time grouped under the name *Filaria bancrofti*, which belongs primarily to the variety which obtains in Australia. The embryo, *Filaria powelli*, from Bombay, possibly comes under the same heading. In Japan *Filaria taniguchii* has been described as a different form. In the Philippines an embryo has acquired local distinction under the distressing nomenclature "*Microfilaria philippinensis*", and in British Guiana an adult as the parent of *Filaria ozzardi*. On the other hand a good deal of confusion has arisen through the description and illustration under the name of *Filaria bancrofti* of an obviously different species now known as *Filaria magalhæsi*.

In the course of the present investigation a comparison has been made between the specimens received from Fiji and (A) Cobbold's original type, a female collected by Bancroft in Australia; (B) male and female specimens, in the London School of Tropical Medicine, derived from India; and (C) male and female specimens collected in British Guiana by Dr. Minett. The conclusion arrived at is, that these particular specimens at all events certainly belong to one and the same species, viz. *Filaria bancrofti*, Cobbold, 1877.

The identity of species is based upon the following characters: (A) the size and general similarity of the body; (B) the knob-like head bearing two series of tiny papillae; (C) the slight thickening of the cuticle lining the mouth; (D) the size and shape of the oesophagus; (E) the outline of tail in male and female; (F) the presence of exceedingly delicate, closely set, but regular, transverse lines in the cuticle, which vary considerably in distinctness. In the male (which is absent in the type): (G) the details of structure of the two dissimilar spicules; (H) the presence of a cup-like chitinous "accessory piece"; (I) the number and general arrangement of the papillae, which are small; (J) the corrugations of the pre-anal cuticle with its alternating striped and smooth bands; (K) the very rare peculiarity of having more than four pairs of papillae pre-anal; (L) the simple testicular tube which reaches forwards uncoiled to within a short distance of the posterior end of the oesophagus; (M) the snowdrop-like termination of the testicular tube.

In the female: (N) the position of the vulva; (O) the curious pyriform enlargement at the terminal end of the vagina; (P) the long muscular vaginal tube; (Q) the position of the anus; (R) and the relative position of the intestino-oesophageal inosculation and the vaginal orifice; (S) the absence of lateral papillae at the tip of the tail. While certain of the above characters might be held very properly to characterize a separate genus of Filariinae, to which the various alleged species might belong, the minuter details given, such as those concerning the relationships of various orifices and organs, could scarcely be regarded as of other than specific significance.

III. (b)—Both nematodes live in the same tissues and are associated with the same diseases.

*Filaria bancrofti* has been found many times, and always in association with the lymphatic system, by other investigators. In the course of this inquiry, live adult filariae, as already related, were found six times in Fijians, and always in association with lymphatic glands, whether procured by surgical operations or in post-mortem examinations. Dead and calcified filariae were found a great number of times, usually in association with lymphatic tissues, but also in other organs, as detailed in the following list:—

*Lymphatic glands*: (1) inguinal, both sets; (2) iliac glands; (3) lumbar; (4) mesenteric; (5) bronchial; (6) superficial cervical; (7) epitrochlear (five times).

*Organs*: (1) testis (once); (2) epididymis (four times); (3) spermatic cord (once); (4) tunica vaginalis (hydrocele sac wall) three times. From Appendix VI., B and C. in which the forms of filarial disease met with are tabulated and their order of frequency given, it will be seen that it is just those organs in which the adult filariae are most frequently found, viz. the lymphatic glands, that are most frequently the seat of filarial disease in Fiji.

III. (b)—*Stegomyia pseudoscutellaris* is an efficient intermediary host for *Filaria bancrofti*.

By placing cages containing these mosquitoes in a strong light, they were induced to feed at night on the blood of a Solomon Islander (Appendix XI., Chart 18) with microfilaria bancrofti showing well-marked nocturnal periodicity. The infection was not a large one, and the mosquitoes did not feed at all readily. Nevertheless, I was able to study the development of this filaria in those laboratory-fed stegomyiae, and on three separate occasions to determine the efficiency of this insect as a host for that microfilaria. All stages were exactly similar to those observed in my experiments with the Fijian variety, and the ingested filariae developed, both as regards numbers and rapidity, in the same remarkable way. In one stegomyia no fewer than five filariae were found in the proboscis on the twenty-first day. The development of microfilaria bancrofti in *Culex fatigans* was not attempted.

III. (b)—As regards adaptation to intermediary hosts, there is a corresponding capacity.

This subject has been dealt with under III. 1 (b) and III. 2 (d).

IV. Assuming that the Fijian filaria is *Filaria bancrofti*, it may be that the absence of periodicity in the former is a partial adaptation to, and impressed on it by, the habits of its usual intermediary host in Fiji, *Stegomyia pseudoscutellaris*, a mosquito which feeds by day only.

In one case of elephantiasis scroti with enlarged epitrochlear and groin glands, the submaxillary glands also were enlarged.

- V. (a)—If a native of India or of the Solomon Islands comes to reside in Fiji, his microfilariae retain, at least for a time, their habit of nocturnal periodicity.
- V. (b)—When a stranger acquires a filarial infection in Fiji, the corresponding microfilariae exhibit no such periodicity, but in this respect comport themselves in the same way as the microfilariae of the native Fijian.

The nocturnal appearance of microfilaria bancrofti in the peripheral blood-stream can be regarded as a remarkable natural adaptation of the parasite to the habits of its favourite intermediary host. The night-biting *Culex fatigans* has been shown, in most countries where this filaria occurs, to be the selective host. In Fiji, however, my experiments tended to show the day-biting species *Stegomyia pseudoscutellaris* to be the selective host in preference to *Culex fatigans*. Should the nocturnal periodicity of the one microfilaria be regarded as an adaptation to the habits of its intermediary host, then the lack of periodicity of the other microfilaria can possibly be explained in a similar manner.

In the large number of Indians and Solomon Islanders examined by me in Fiji, only in those who had been resident in the islands under a period of two years were microfilariae having a nocturnal periodicity met with (Appendix XI., B and C); whereas in those who had resided there for over that length of time, only microfilariae without periodicity were encountered. I had the opportunity of frequently examining, over a period of three months, the blood of a recently arrived filariated Solomon Islander; on no occasion were microfilariae found in his peripheral blood after 10 a.m. (Appendix XI., Chart XVIII.).

In 120 East Indian indentured coolies microfilaria bancrofti (filaria nocturna) was found in five (Appendix XI. B), all of them resident in Fiji under three years. It is true that one gave his term of residence as nine years, but as he was a Madrassese, and as no reliable interpreter could be procured, there is some doubt about his statement.

Of the 120 East Indian coolies, seven harboured microfilariae observing no periodicity. These seven coolies had been resident in Fiji for periods ranging from four to thirty years.

It may be well again to point out, in explanation of the relative rarity of filarial infection in Indians in Fiji as compared to the native Fijians, that the two races never intermarry and rarely intermingle. I was told that there was only one family of mixed Indian and Fijian blood in the islands. The two races dwell apart in separate villages, and there is no communication between them. Consequently the Indians are little exposed to infection from the Fijians. There is only one instance of an Indian acquiring elephantiasis of the leg in Fiji; he had lived in a Fijian village on the island of Taveuni for eight years. The comparative rarity of the nocturnal filaria among the indentured Indian coolies may be partly explained by the careful elimination of all infirm and diseased coolies, and consequently all showing signs of filariasis, elephantiasis and enlarged glands, both at the port of shipment in India and at the port of arrival in Fiji.

I was given to understand that filarial disease is rare in the Solomon Islands. I found, however, six cases of *F. bancrofti* infection amongst new arrivals who were undergoing medical inspection.

In seven Solomon Islanders who had resided in Fiji from ten to thirty years I found microfilariae observing no periodicity (Appendix XI. c).

A considerable number of Europeans, scattered about the islands in isolated spots, were found to have filariasis. Thus in Loma Loma, a town on Vanua Balavu, in the Eastern or Lau group, out of nine Europeans examined, four had microfilariae and one lymphangitis and orchitis, but no microfilariae. In every instance in which microfilariae were found in a European, they were of the non-periodic type (Appendix XI. d).

#### FILARIAL PERIODICITY.

The subject of filarial periodicity is as complex as it is interesting. There is nothing I regret more in connection with my work in Fiji than that I have been unable to throw any light on this interesting phenomenon. So far from throwing light on it, by confirming Thorpe and others in their statements as regards the absence of periodicity in the Fijian microfilaria, and by providing Dr. Leiper with parent worms which he pronounces to be identical with *Filaria bancrofti*, which elsewhere produces a microfilaria with nocturnal habits, if anything, I have added to the complexity. In attempting to explain the object and mechanism, so to speak, of filarial periodicity, we have to bear in mind that the phenomenon is exhibited by two species of microfilariae, which, though practically identical as regards size, shape, anatomical features and movement, exhibit exactly opposite periodicities, and that a third with exactly the same size, shape, anatomical features and movement, and having the same parent as the nocturnal microfilaria exhibits no periodicity whatever. And, further, that in not a few instances of genuine nocturnal microfilaria infection, as recorded by Manson,<sup>26</sup> Low,<sup>22</sup> Calvert,<sup>24</sup> Primrose,<sup>25</sup> and others, an occasional microfilaria can be found in the peripheral blood during the day.

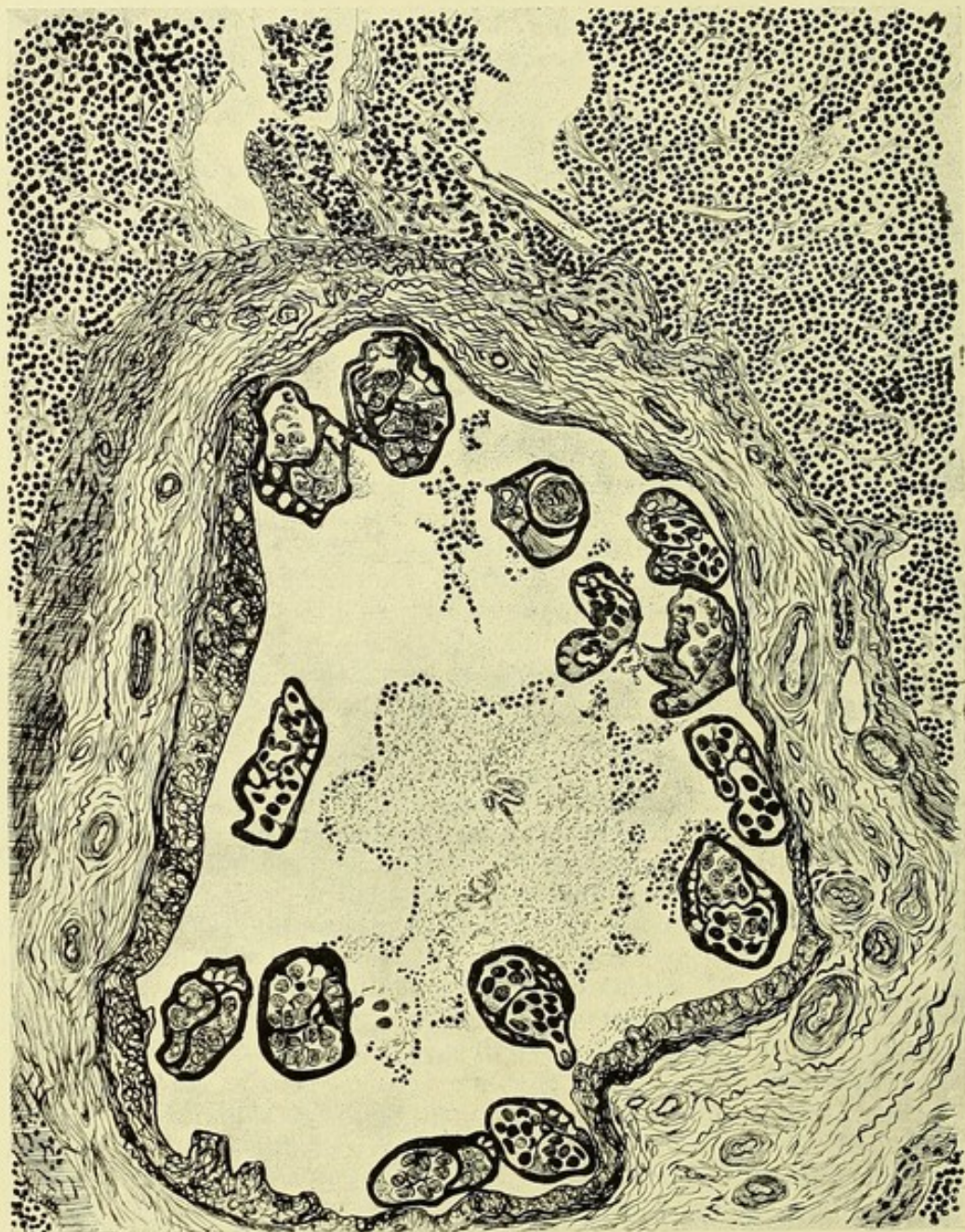
Thus such speculation as that which attributes the periodicity of the microfilariae to the dilatation of the peripheral<sup>26</sup> capillaries occurring during sleep must be dismissed as untenable. For why should the diurnal filaria be unaffected by this surface congestion, and why should the Fijian microfilaria be equally indifferent to it?

The same objection applies to the hypothesis investigated and upset by Manson and Whyte<sup>23</sup> that light and darkness had something to do with the periodicity of microfilaria bancrofti, a hypothesis afterwards so convincingly upset by Stephen Mackenzie's<sup>66</sup> experiments showing the inverting effect of change of the habits of the host as regards the times of sleeping and waking.

Then, again, and for the same reasons, Whyte's<sup>23</sup> hypothesis that periodicity depends on the oxygen supply, is equally untenable. In a post-mortem of a West Indian with microfilariae, who died suddenly at eight in the morning, a time when the microfilariae had left the peripheral circulation, Manson<sup>26</sup> found the microfilariae in vast numbers in the thoracic viscera, more particularly the lungs, and Low,<sup>27</sup> made a similar observation in a negro of St. Kitts. Fülleborn<sup>28</sup> had a similar experience in a Chinese who died of beri-beri.

In discussing this question of periodicity, too much must not be made of the presence of large numbers of microfilariae in the lungs, for even in the case of microfilariae observing no periodicity, these organs are generally crowded with the larvae in numbers greatly in excess of what is found in the general circulation. Thus, in Uganda, Low<sup>30</sup> found

microfilaria perstans most often in the lungs, and Fülleborn<sup>28</sup> has shown that *microfilaria immitis* of the dog is far more abundant in lung and heart blood than in the peripheral circulation. In a dog dissected by me, and which had died of *Filaria immitis* infection, the microfilariae were



P. H. Bahr del., 1911.

#### PLATE XVIII.

Microscopical section of an adult female filaria lying in a lymphatic space with greatly thickened walls, in the substance of a lymphatic gland. Note the microfilariae lying in the lymph and the fibrosis of the gland tissue.—Camera lucida.

In the case from which this specimen was taken, microfilariae were present in the blood, but observed no periodicity.

more abundant in the internal organs (and in the order stated, viz. liver, heart, lung, kidney and spleen) than in the peripheral blood. I found some in the kidneys, where Rodenwaldt<sup>29</sup> says they are finally disposed of when effete.

In one observation the non-periodic microfilaria of Fiji observing no periodicity was found post-mortem in greatest numbers in the lungs. The man was a Solomon Islander who died suddenly at eight o'clock in the morning. He had been ten years in Fiji, and it had been ascertained during life that he had great numbers of microfilariae in his blood. The details of the post-mortem examination are given in Appendix XVI. Parts of a male and of a female adult filaria were found in sections of enlarged inguinal glands from the left groin (Pl. XVIII. and XIX.). The bronchial and lumbar glands were also enlarged, but in these no adults were found. The greatest number of microfilariae were found in smears and in sections made from the lungs. The order in the various organs was as follows: Lungs, internal jugular vein, liver, spleen, testis; none were discovered in sections of the kidney.

Rodenwaldt<sup>29</sup> considers that periodicity depends on blood pressure, and is devising apparatus wherewith to test his hypothesis. Fülleborn<sup>28</sup> failed to demonstrate that the rate of the blood-flow had any influence on the behaviour of microfilariae. Strange to say, I failed to find a single microfilaria in placental blood from a heavily-infected woman. It is hardly necessary to say that the blood of newly-born infants of two filariated mothers gave negative results.

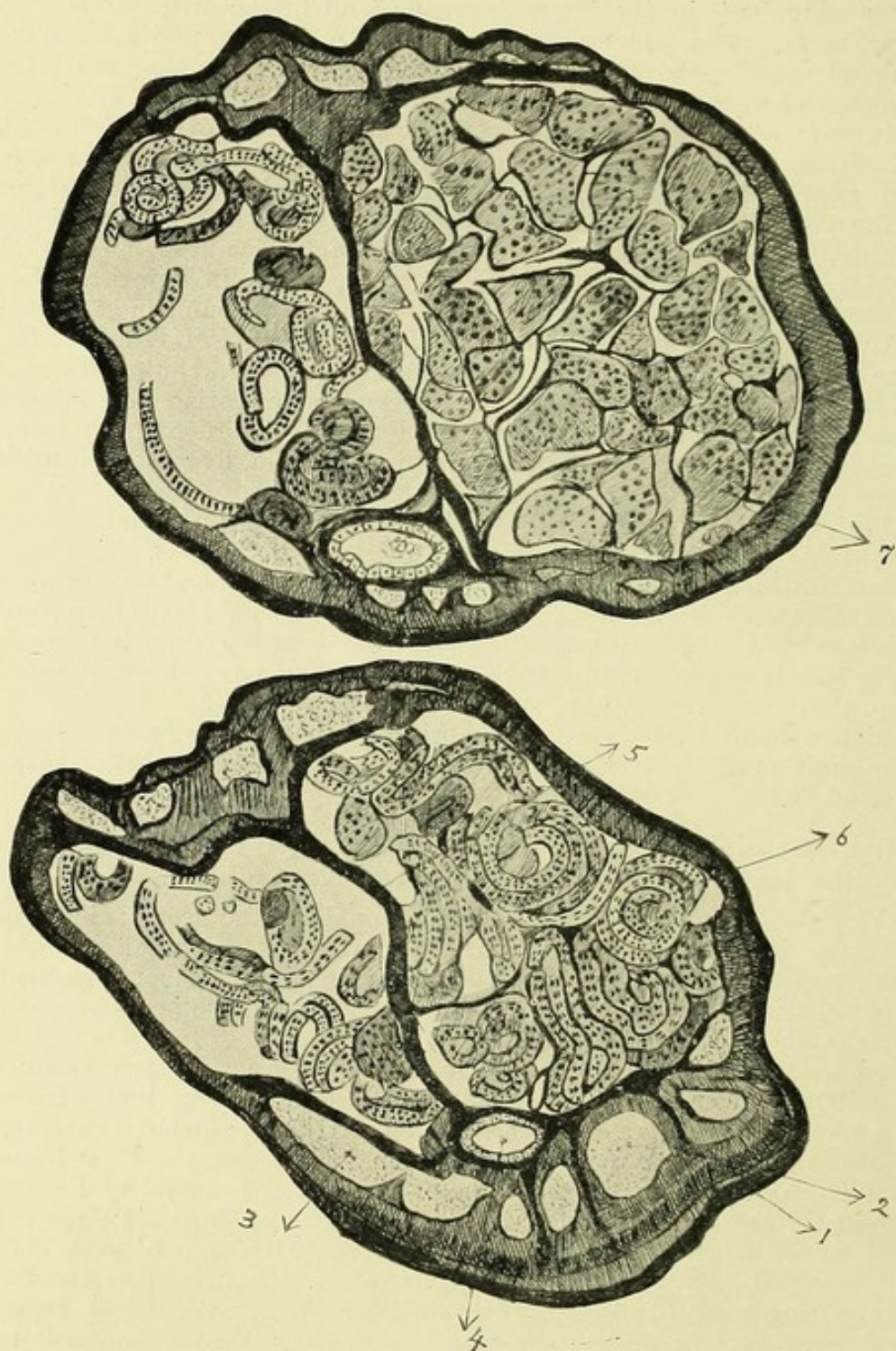
It is evident that a great deal more work has yet to be expended on this question of filarial periodicity before a satisfactory solution can be arrived at.

#### VI. The principal pathological expression of filarial infection is the same in Fiji as elsewhere, viz. elephantiasis.

Elephantiasis is a common disease throughout the group; in certain localities it is extremely frequent. The rate for the total population examined was 3.56 per cent. Males were found to be more frequently affected than females; the rate for the former being 4.8 per cent. and for females about a third of that, viz. 1.5 per cent.

Appendix XVII. shows that the incidence of filariasis is very unequally distributed in the different islands of the group; and that wherever the microfilaria rate is a high one, that of filarial disease and of elephantiasis is also high, just as Low and Daniels have shown for the West Indies<sup>31</sup> and Demerara. Thus in the town of Levuka, the capital of Lakemba island, of the males over twenty years of age examined, 44.1 per cent. had microfilariae, 85.6 per cent. were affected with signs of some filarial disease, and 22.2 per cent. had elephantiasis. On the other hand, by contrasting these figures with others in the same table it will be seen that wherever the microfilaria rate is low, there the elephantiasis rate is low also.

I may mention here that in Fiji, elephantiasis (Appendix XVII.) and its associated diseases are coast diseases. From my own observation, and I am confirmed in this by others, I feel justified in stating that elephantiasis is rare in the inland districts and away from the mangrove swamps. This exactly conforms with what I observed on the distribution of *Stegomyia pseudoscutellaris*. These mosquitoes were encountered in the greatest number in the island of Lakemba, and there it was that the greatest percentage of elephantiasis was found. The towns there are



P. H. Bahr *del.*, 1911.

### PLATE XIX.

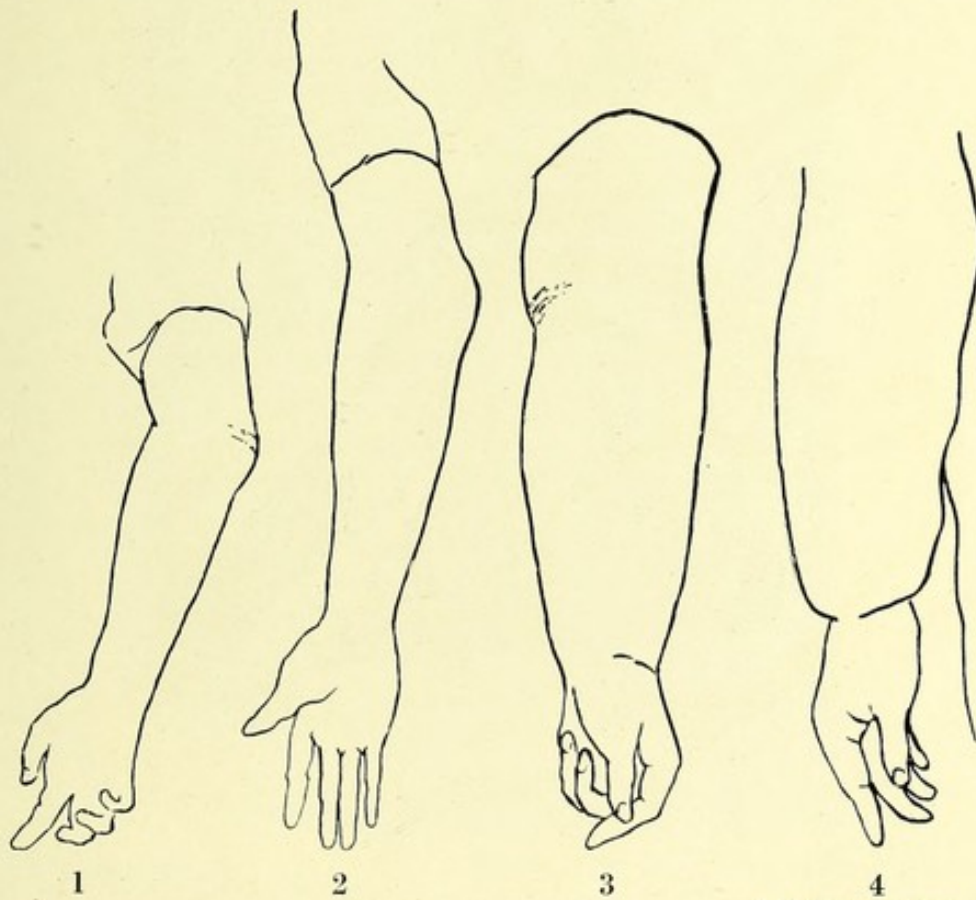
To show details of structure of female filaria from groin gland on section. Same specimen as Plate XVIII. but enlarged.—Camera lucida.

- |                               |                         |
|-------------------------------|-------------------------|
| 1. Cuticle.                   | 4. Alimentary canal.    |
| 2. Muscle cells of body wall. | 5. Interuterine septum. |
| 3. Perivisceral spaces.       | 6. Coiled embryos.      |
| 7. Ova.                       |                         |

situated in the midst of mangrove swamps, the favourite haunt of *S. pseudoscutellaris*. In fact these mosquitoes were far more commonly met with in the Eastern part of the group, admittedly the stronghold of elephantiasis in Fiji, than in the large island of Vitilevu, where elephantiasis is rare.

**VII. & VIII.** The lower extremities and scrotum are the parts of the body most frequently affected.

A very small experience in the filarial disease of Fiji suffices to convince the observer of this, but it appears to me that in comparison with natives of China, India and the West Indies, the natives of Fiji, and probably of other South Pacific islands, are far more liable to elephantiasis of the upper extremities. Thus in forty-seven cases of elephantiasis encountered




P. H. Bahr del., 1911.

**PLATE XX.**

Tracings from photographs showing enlargement of epitrochlear glands.

1. Enlarged epitrochlear in a Fijian female aged 25. There were numerous scars of abscesses. Numbers of microfilariae were found in the blood.
2. Enlarged epitrochlear gland in Fijian male, aged 26. There were no microfilariae in the blood.
3. Elephantiasis of both arms in a Tongan female, aged 50. The epitrochlear glands on both sides were enlarged, but there were no microfilariae in the blood. (Note abscess scars over the internal condyle).
4. Elephantiasis of the arm of a curious shape with a well-marked constriction at the wrist, in a Tongan female, aged 55. There was enlargement of the epitrochlear glands, but no microfilariae in the blood.

in native Fijians, the legs and scrotum were affected in twenty-four; the arms alone in ten; arms and legs in six; both arms, legs and scrotum in five; arms and scrotum in one; breast in one. Thornhill<sup>53</sup> mentions elephantiasis of the arms as occurring, though rarely, in Ceylon. In the Pacific (Society Islands) Tribondeau<sup>52</sup> mentions elephantiasis of the arms as occurring in fourteen out of sixty-three cases. This condition I found to be much commoner in females than in the male population in Fiji. Out of eight cases of elephantiasis amongst the former, five, or about three-fourths, had elephantiasis of the arm, as against a third amongst the male cases.



Phot. P. H. Bahr.

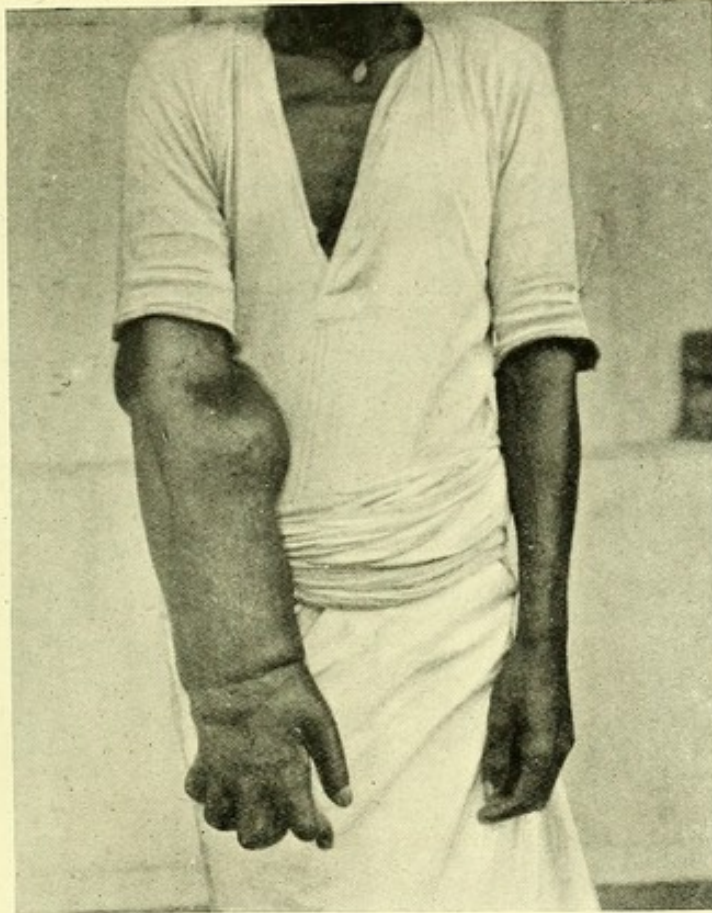#### PHOTOGRAPH V.

Elephantiasis of both arms, showing lymphatic swellings above internal condyle.

Manson states that in China, in 95 per cent. of all cases of elephantiasis, the lower extremities alone are affected.<sup>48</sup> Low<sup>49</sup> in the West Indies, and Daniels<sup>18</sup> in Demerara, found the same thing. Similar figures have been given for India.

Several of the cases of elephantiasis of the arm that came under observation had curious baggy swellings above the condyles, which, when aspirated, yielded abundant lymph (*vide* Phot. V.). Often there were marks of abscesses situated above the internal condyle (*vide* Pl. XX.).

Enlarged epitrochlear glands, which are very common amongst the Fijians (Pl. XX., 1 and 2), and form prominent and noticeable tumours, were not infrequently, although not generally (*vide* Appendix XVIII.), met with in cases of elephantiasis of the forearm. Varicosity of the epitrochlear glands (analogous to varicose groin glands) was observed in a young man without any signs whatever of elephantiasis in arms and legs. A photograph is given (No. VI.) showing enlargement of the



*Phot. P. H. Bahr.*

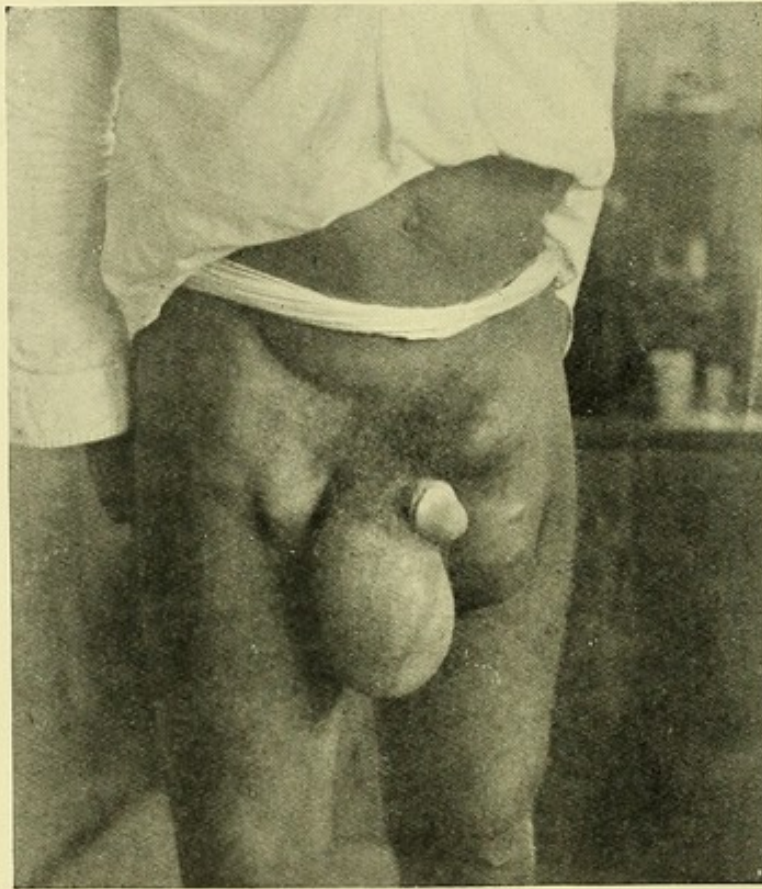#### PHOTOGRAPH VI.

Elephantiasis of arm and disorganization of wrist joint. *Microfilariae* present in blood. (Left leg was also affected).

epitrochlear gland and a lymphatic swelling situated over the external condyle in elephantiasis of the right arm; in this case the left leg was also affected, and in addition to this there was contraction of the fingers and complete disorganisation of the wrist joint.

It would be interesting to know whether this seeming peculiarity in the Fijian, and probably other South Pacific islanders, as regards the regions of the body attacked by elephantiasis, bears any relation to the habits of the people or to the seat of filarial invasion. At night-time the Fijian is in the habit of lying with his body uncovered. Nowadays nearly all of them have mosquito nets which, I may mention, are not in

every instance mosquito-proof. The mosquito net, however perfect, would not protect them during the day-time—the time when *S. pseudoscutellaris* is abroad. Both sexes are in the habit of working in the day-time, and with bare arms. The women commonly wear print blouses, fastened at the elbow, the men singlets, not reaching above the shoulders. The women remain, to a great extent, in their houses, especially so in the Eastern group, where there is an admixture of Tongan blood; while the men, in a half-naked condition, work in their dalo and yam patches, where they are much more liable to attacks from *S. pseudoscutellaris*, which is by preference a bush rather than a domestic mosquito (*vide* under heading XXVII.).



Phot. P. H. Bahr.

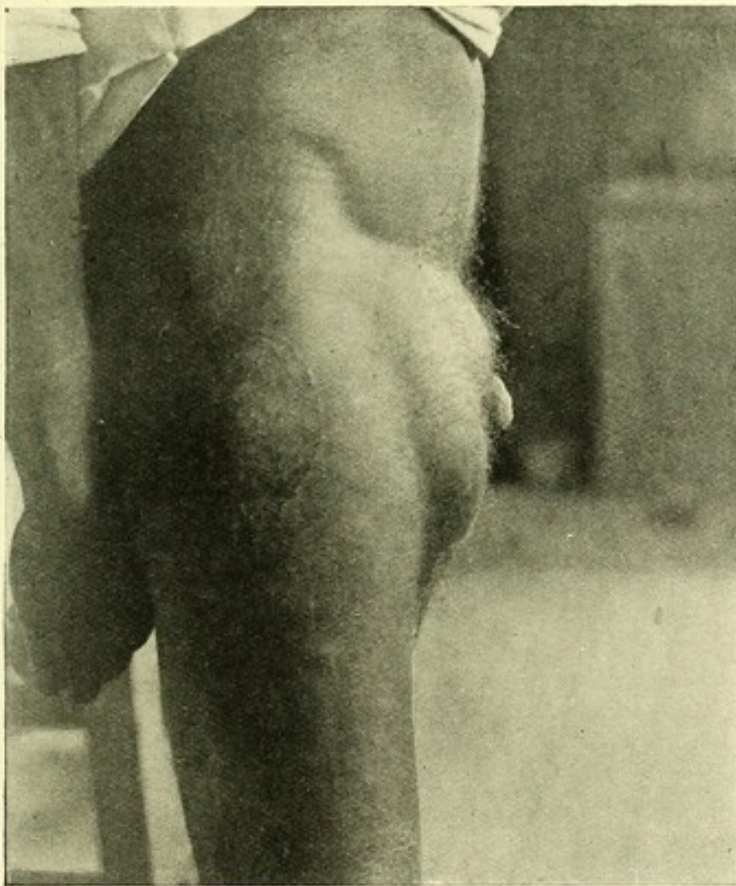
#### PHOTOGRAPH VII.

Pedunculated groin glands in a Fijian with double hydroceles. These glands (*vide* Pl. II.), containing adult ♂ and ♀ filariae, were removed at operation. No microfilariae were found in the blood. There were also masses of enlarged glands in right groin.

IX. & X. On the other hand they are less liable to chyluria, lymph scrotum, varicose groin glands and other forms of lymphatic varix depending on filarial obstruction of the thoracic duct above the points of entrance of the chyle vessels.

The explanation of these possible peculiarities in the Fijian disease is not apparent.

*Chyluria*.—I did not meet with a single case of this affection. Finucane<sup>1</sup> alludes to its rarity in Fiji. I found the records of only two cases in the archives of the Colonial Hospital at Suva relating to the last seven years. Dr. B. Glanvill Corney, I.S.O., for twenty-seven years a medical officer in Fiji, and for many years C.M.O., wrote me that in all his experience he remembers only one case of a Fijian with chyluria; in this case the chyluria was associated with lymph scrotum. The patient had resided, previously to coming back to Suva, his native place, in Rotumah (a dependency of Fiji) for twelve or thirteen years. Brochard<sup>8</sup> mentions



Phot., P. H. Bahr.

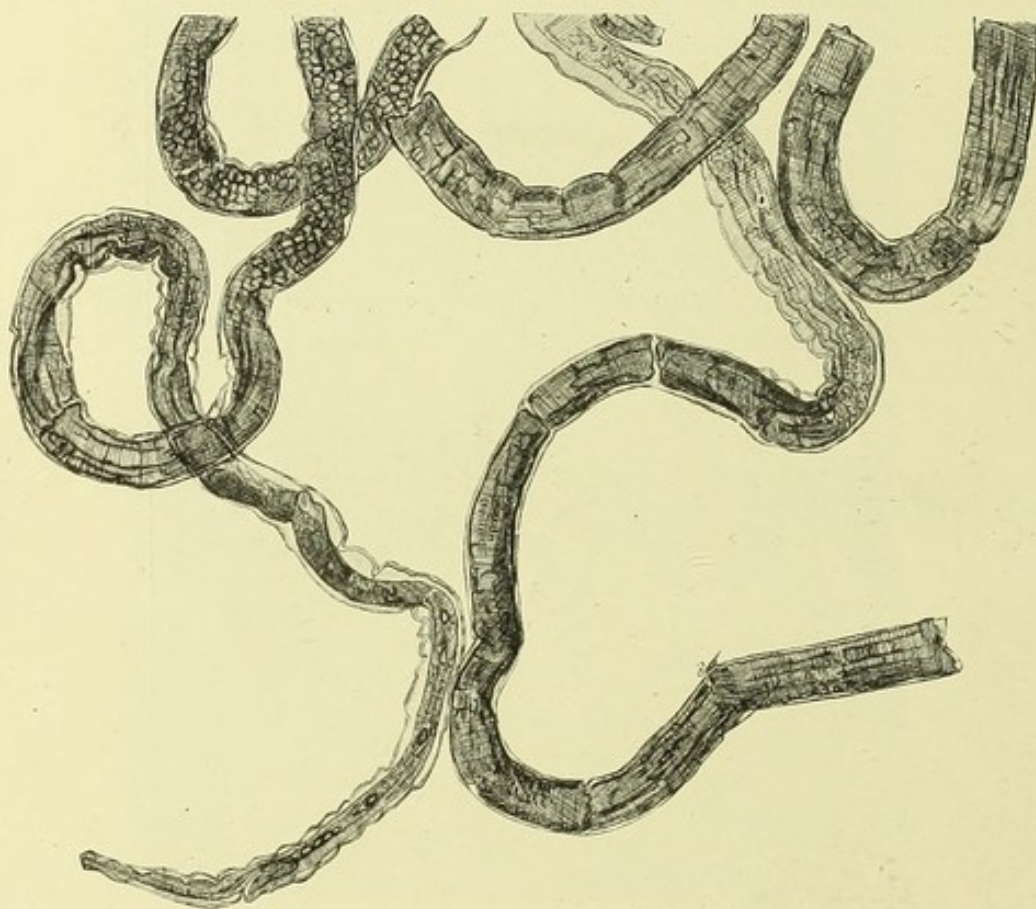
#### PHOTOGRAPH VIII.

Masses of enlarged glands in right groin; no microfilariae found in the blood.

chyluria as being rare in the Wallis Islanders. Scheube,<sup>16</sup> remarking on this fact, noted that haematochyluria is said to be the commonest manifestation of filariasis in Egypt, where elephantiasis is comparatively rare. In the island of Savaii, Samoa,<sup>55</sup> Leber and Prowazek only saw one case of chyluria.

*Lymph scrotum*.—I did not see a single case answering to the published descriptions.

*Varicose groin glands.*—Only one reducible lymphatic varix situated in the groin was met with in a Fijian. The mass was soft and doughy, and no puncture yielded abundant lymph. It contained several small, hard lymphatic glands. With this exception, in all the rest of the cases described as varicose glands, and met with by me in Fiji, the lymphatic masses were composed of enlarged and fibrosed lymphatic glands, often two to three inches in length, from which on puncture only a small quantity of lymph could be aspirated, and that with difficulty (Photos. VII. and VIII.). Although the varicose type is rare, those indurated lymphatic masses are extremely common amongst the Fijians, as shown in statistical tables (Appendix VI., B and C). A number of these glands were excised at operation or post-mortem, and in nearly every case live or dead filariae were found in them, as will be presently described.



P. H. Bahr del., 1911.

#### PLATE XXI.

Camera lucida drawing of calcifying filaria. Breadth, .178 mm. Removed from cyst in a brachial lymphatic, six weeks after an attack of lymphangitis.

XI., XII. & XIII. In many cases adult filariae occur in large numbers in the tissues, especially in lymphatic glands and vessels, but also in other organs such as the epididymis, testis and tunica vaginalis.

In the latter circumstance may lie a contributory cause of the infecundity of the Fijian.

In the situations mentioned the adult filariae may die and may become cretified.

Under III. (2) c, a list has been given of the situations in which adult filariae, or their calcified remains, have been found. The fact that on the death of the parental filaria calcification may occur, just as with *Filaria medinensis* and with *Filaria loa* (figured by Fülleborn),<sup>31</sup> was first described by Wise,<sup>36</sup> who found post-mortem in the pelvis of the kidney and in the testes certain small, yellow bodies having the distinctive shape and structure of a filaria.

Although at the time ignorant of Wise's discovery, I had no difficulty in finding similar bodies in almost every example of pathologically enlarged lymphatic tissue examined by me in Fiji.

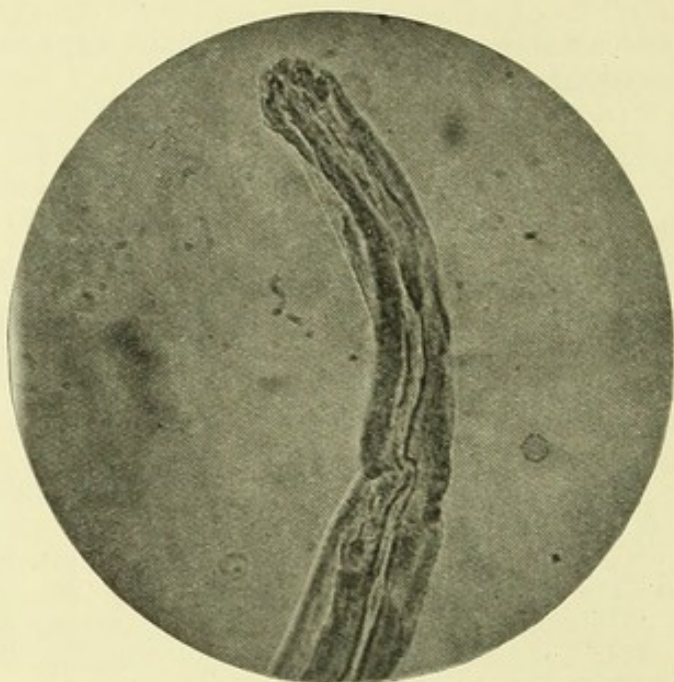
*Calcification* proceeds by the laying down of lamellar plates of calcium carbonate in the interior of the worm. Microphotograph IX., of the anterior part of a female found lying in an enlarged epitrochlear gland, shows this. In a complete and lately defunct specimen (Pl. XXVI.), found in the same gland, the process had just commenced. A later stage was observed in a specimen (Pl. XXI. and Microphot. X.) taken from a dilated and thickened lymphatic vessel in the arm. The almost perfect state of preservation of this calcified worm is remarkable. Not only is the cuticle preserved, but also the details of the alimentary canal and uterus, and even the calcified ova and embryos can still be recognized. A still later stage of calcification is shown in the excellent microphotographs (Nos. XI. and XII.) for which I am indebted to Dr. John Bell of Hong Kong. A completely calcified filaria is seen blocking an efferent lymphatic. With a higher magnification columnar fragments of calcium carbonate can be seen occupying the central portion of the worm. I took this specimen from a mass of enlarged groin glands removed at operation.

It would seem that at a later stage the calcareous deposit becomes gradually absorbed; at all events in my dissections of enlarged groin glands, minute yellow spicules, representing the mummified remains of the filaria, were often found. Similar bodies can be found in the tissues, also in the epididymis, testis and tunica vaginalis, but only by careful dissection. They appear as minute, yellow, oval filaments often coiled up in delicate cyst-like structures about the size of a millet seed, the nature of which can be recognized on clearing the tissues in glycerine, or some other suitable reagent.

I need not give the details of the many instances in which I found these bodies in tissues; three instances, in which the opportunity of a post-mortem examination made a careful search of all the tissues possible, must suffice:—

(1). A Fijian male, aged 60. No microfilariae found in the blood. Said to have died suddenly of heart failure after an attack of filarial fever. Altogether the remains of fourteen adult filariae were found, viz., five in the epididymis of both testes, but none in the substance of the testes; three in the enlarged lumbar glands; two in the enlarged mesenteric glands; three in the enlarged bronchial glands; one in an enlarged superficial cervical gland; one in an enlarged epitrochlear gland.

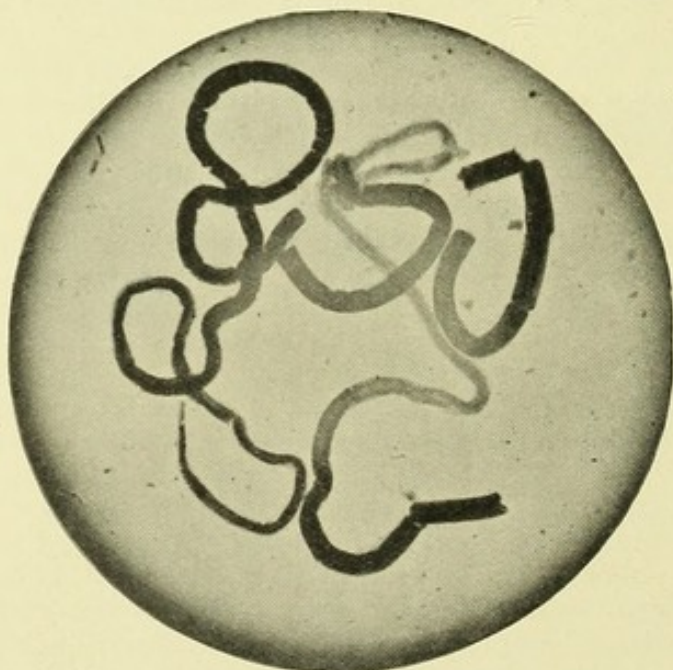
(2). A Fijian male, aged 50. Two microfilariae found in smears of heart's blood. No live adult worm found. Calcified filariae found in the epididymis of the right testis.



*Microphot., P. H. Bahr.*

#### PHOTOGRAPH IX.

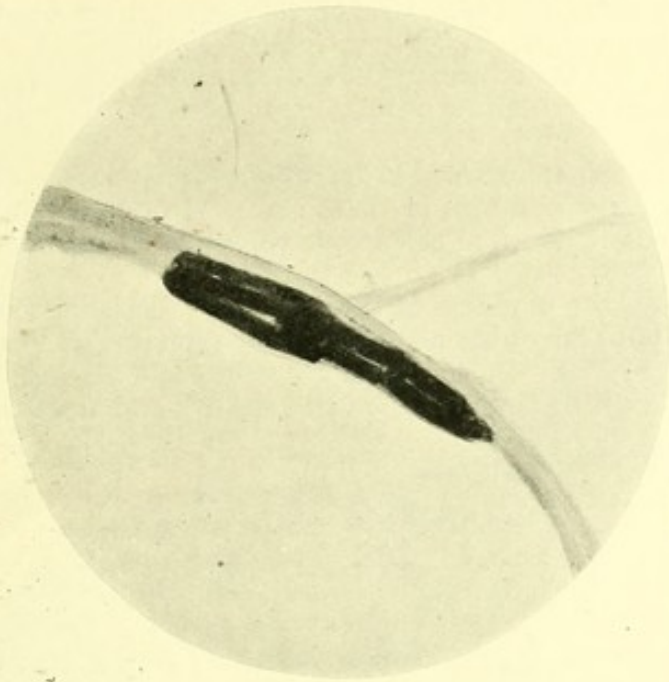
Commencement of calcification in anterior end of dead ♀ filaria, taken from the centre of an epitrochlear gland.



*Microphot., P. H. Bahr*

#### PHOTOGRAPH X.

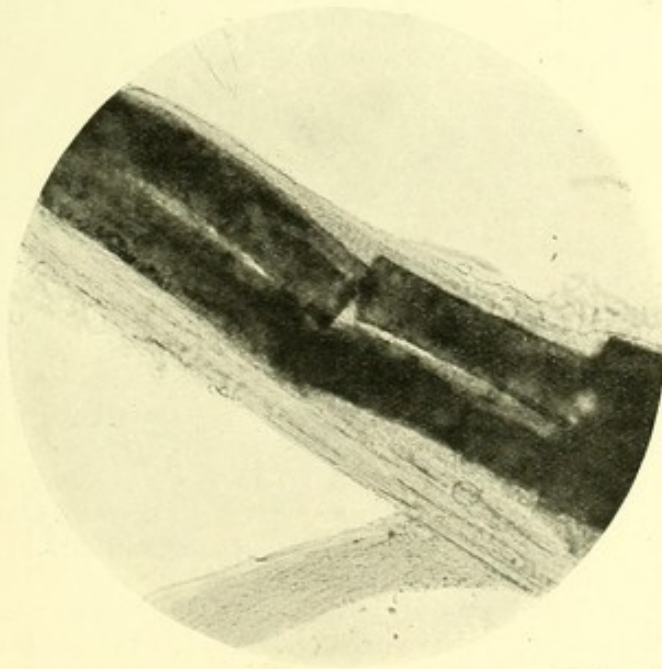
Calcifying filaria removed from thickened brachial lymphatic trunk (*vide* Pl. XXI.).



*Microphot., Dr. John Bell.*

**PHOTOGRAPH XI.**

Calcified filaria from efferent lymphatic vessel, dissected out from enlarged glands of groin removed at operation— $\times 200$ .



*Microphot., Dr. John Bell.*

**PHOTOGRAPH XII.**

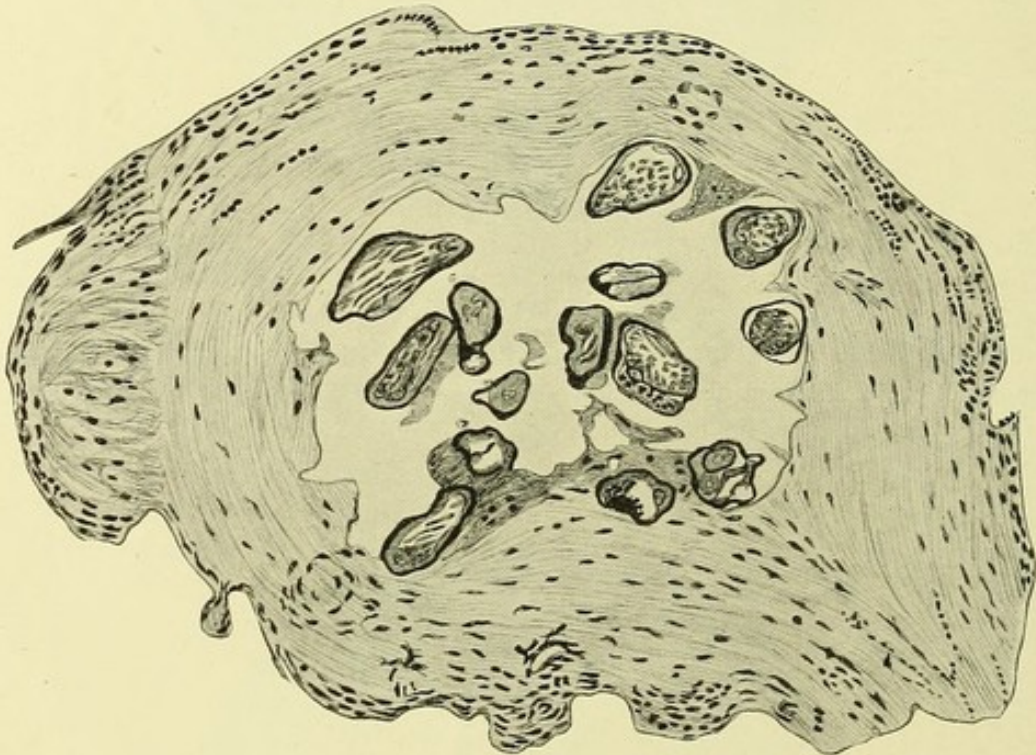
Details of the same.

—  $\times 480$ .

(3) A Fijian male, aged 45. Died of widespread tuberculosis. Enlarged and varicose groin gland on the right side. Numbers of calcified filariae found in the following:—enlarged right iliac and inguinal glands (from the latter three live filariae were taken); both epididymes; the right spermatic cord.

In the tunica vaginalis excised at operations for hydrocele calcified filariae were found in large numbers in three cases. In one instance they were specially abundant, forming calcareous cords in the substance of the sac wall.

On account of the hardness of these calcified filariae, good microscopic sections were not easily obtained. Decalcification in Von Ebner's solution gave the best results. In many instances in such sections, the original structure of the filaria is well shown, and the ova and larvae in the uterine



P. H. Bahr *del.*, 1911.

## PLATE XXII.

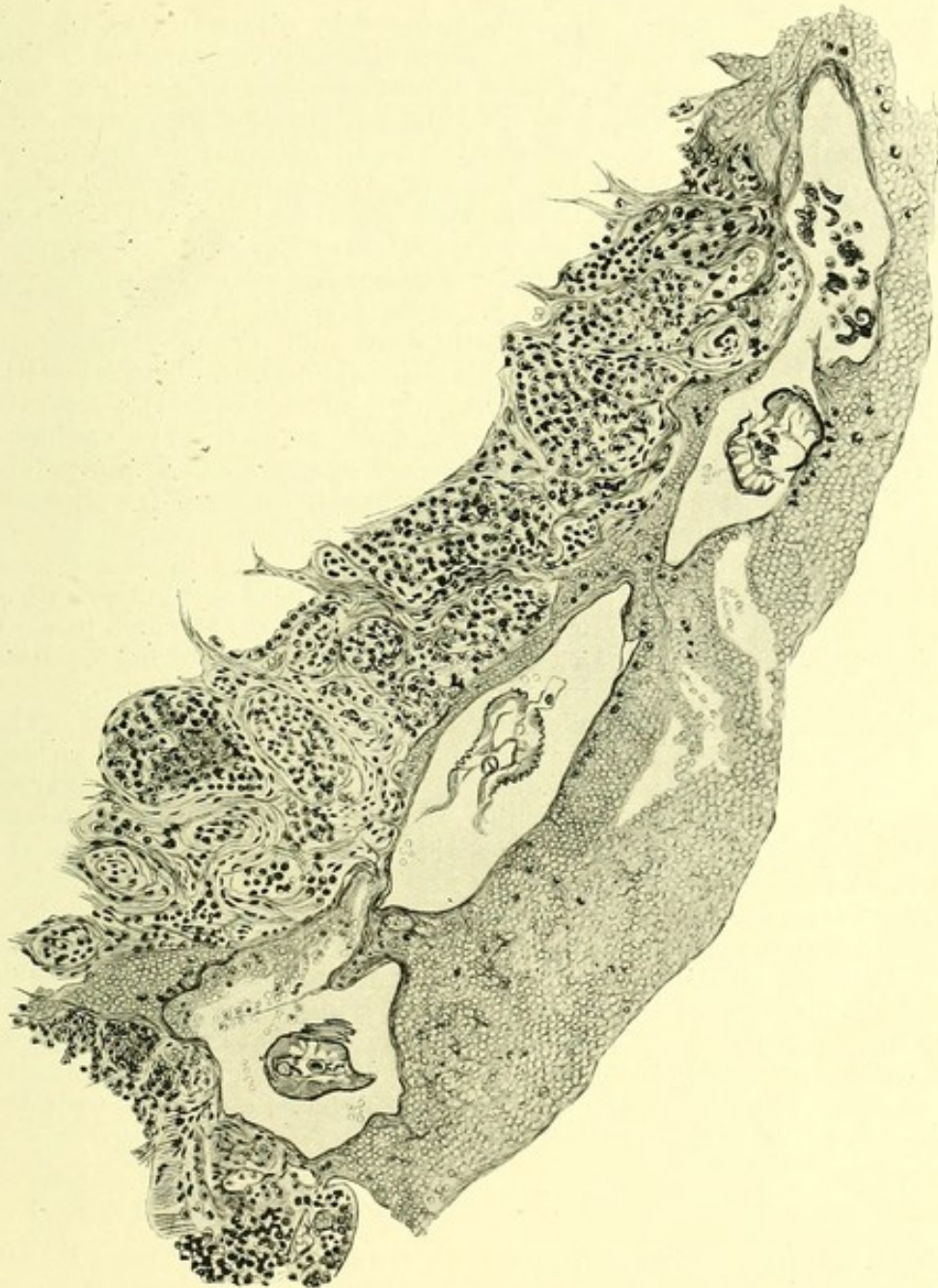Section of calcified filaria in an epitrochlear gland, showing that the structure, even the ova and embryos, can still be recognized.—Camera lucida.

tubes can easily be recognized (Pl. XXII.). In others nothing but a calcified shell with the septum dividing the two uterine tubes is all that can be made out. In others again, a mass of amorphous calcareous crystals is all that is visible. But in every instance the filarial remains, no matter at what state of degeneration, are surrounded by, and encapsuled in, thick strands of fibrous tissue.

Sections of calcified filariae, dissected out from the tissues removed at operation and post-mortem, have been obtained in the following: Epitrochlear gland, five cases; epididymis, twice; pedunculated groin glands, once; bronchial and mesenteric glands, once.

The Fijians, like all Polynesians, are not a productive race. Many reasons have been advanced as accounting for this. The rate of decrease

of the population was at one time so serious that a commission was appointed by the Government to inquire into its cause. Is it unreasonable to suppose that the frequency of the infection of the genital organs in the Fijians by the filaria, and consequent impairment of function, may contribute to the racial infecundity?



P. H. Bahr del., 1911.

### PLATE XXIII.

Section of a female filaria lying in an epitrochlear abscess. The filaria is situated apparently in a lymphatic space, surrounded by haemorrhages and inflammatory cells. *Staphylococcus pyogenes aureus* and *albus* were cultivated from the pus.—Camera lucida.

- XIV. The adult filaria is not an unusual cause of abscess, of hydrocele, of enlarged testes, of thickening of lymphatic vessels and of fugitive swellings resembling Calabar Swellings.

#### ABSCCESS.

Portions of adult filariae<sup>54</sup> have been found by others in that type of abscess so frequent in tropical countries, which has been ascribed to this cause. Such abscesses, of apparently spontaneous origin, are very common amongst the Fijians in the substance of the gastrocnemii, in the popliteal space, in the groin and in the substance of the quadriceps extensor, and also in the upper extremity, over the internal condyle of the humerus, in the axilla, in the substance of the latissimus dorsi and serratus magnus muscles. From the statistics of filarial infections given in the Appendix (VI., B and C), such abscesses occurred in 57.7 per cent. of the males and 54.5 per cent. of the females.

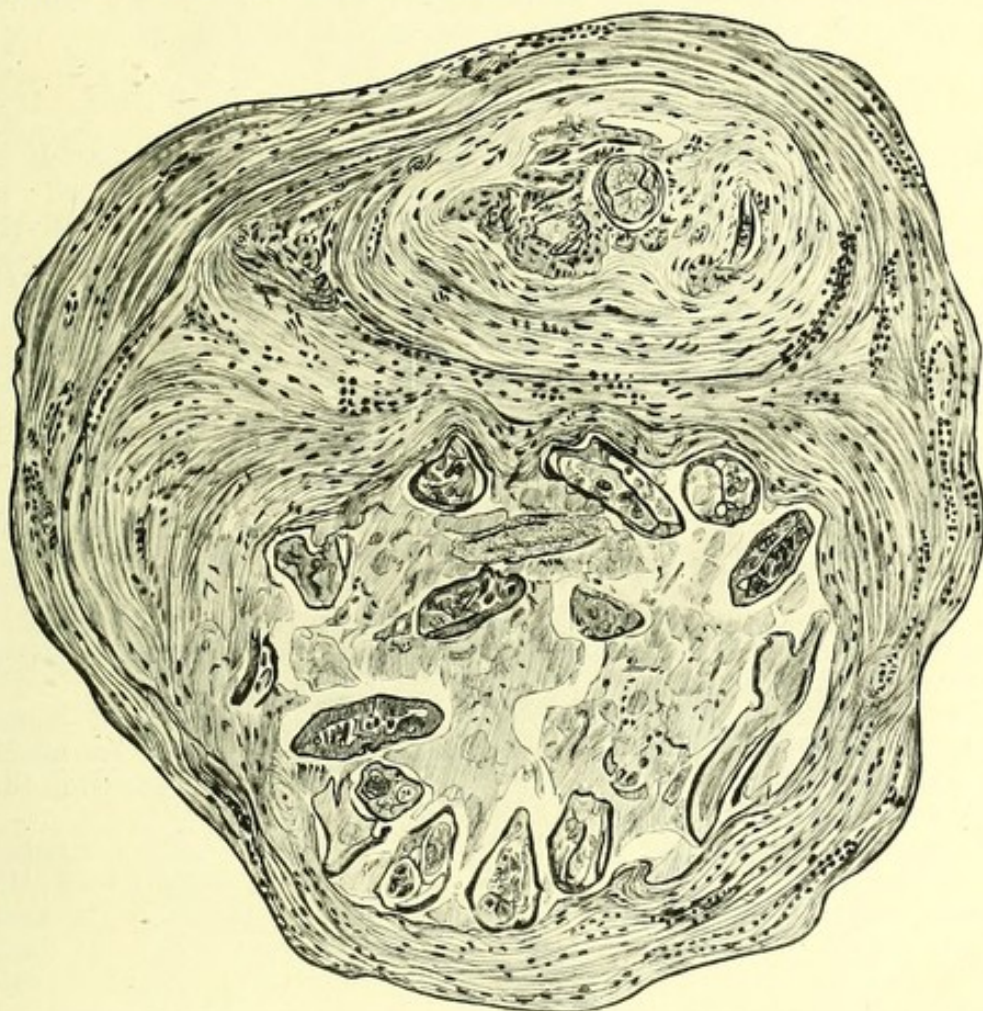
In the case of a Fijian, two recently dead adult female filariae were removed from an inflammatory swelling containing pus. The mass was situated over the internal condyle of the humerus, and apparently connected with the epitrochlear gland. Cultures of the pus on blood and on ordinary agar yielded *Staphylococcus pyogenes aureus* and *Streptococcus pyogenes*. Smears revealed a great preponderance of lymphocytes and breaking down red blood corpuscles. In microscopical sections of the tissue (Pl. XXIII.) portions of a female were found in what I took to be a lymphatic space surrounded by haemorrhages and inflammatory tissue. In these sections numbers of microfilariae can be seen in close proximity to the parent. In this case a great number of microfilariae were present in the blood (Appendix XI., Chart II.).

Details of a number of similar cases will be found in Appendix XIX. It will be noted that in every one of these the pus, on cultivation, yielded pyogenic cocci. The case just detailed started as an ordinary lymphangitis with a rigor and thickening and tenderness of the lymphatic trunks involved. In this case the chain of evidence indicates that the parent filariae were the cause in the first instance of the inflammatory attack, that in some manner a haemorrhage was caused, that this in turn became infected with pyogenic cocci, and that the death of the filariae, the originators of the trouble, was the result. I consider it probable that in the majority of cases dead filariae, lying in pus swarming with pyogenic cocci, ultimately become so disintegrated that they are no longer recognizable. In one case, however, in which a groin gland was situated beneath and adherent to the scar of an old abscess, a complete calcified filaria was found in the cortex of the gland.

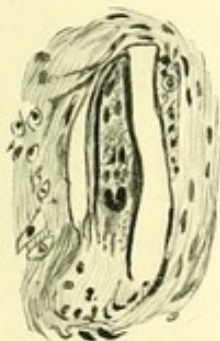
#### HYDROCELES AND ENLARGED TESTES.

These are very prevalent in some districts amongst the male Fijians (Appendix XVII., Bau), and are, as a rule, one of the most common and striking expressions of filarial disease. Most of the cases investigated were associated with elephantiasis of the scrotum. The hydrocele fluid proved sterile on culture in every case. In only one case—an Indian four years resident in Fiji—were microfilariae found in the fluid. They were in great numbers, and some of them very active. Empty sheaths, dead and sheathless forms were common (Microphot. XIII.), showing that the sac of the tunica vaginalis is not

their normal habitat. Some were very small and with their nuclei undifferentiated, resembling certain forms obtainable from the uterus of the adult. In such hydroceles numerous calcified filariae were found on dissection of the sac wall, and were often exceedingly well preserved.



1.

P. H. Bahr *del.*, 1911.

2.

P. H. Bahr *del.*, 1911.

#### PLATE XXIV.

1. Section of a thickened brachial lymphatic containing portions of dead filariae undergoing disintegration and blocking the lumen of the vessel. Note the large amount of fibrosis.

2. Giant-cell formation within the calcified shell of the dead filaria.—Camera lucida.

In one such case the hydrocele was associated with elephantiasis scroti (Phot. XIV.). The filariae were massed together, forming great plaques and thick calcareous strands in the substance of the sac wall. Sections of these hydrocele sacs do not shed much light on their pathology. There

is apparently great hypertrophy of the fibres of the cremaster internus muscle. In the epididymis of an enlarged testis carrying a hydrocele, a ragged cavity, in the wall of which were calcified filariae, was discovered. The corresponding testis was enlarged, tough and fibrosed, and on dissection one calcified filaria was found in it also. The reader is referred to Appendix XX. for the details of eleven additional cases.

#### THICKENING OF LYMPHATIC VESSELS.

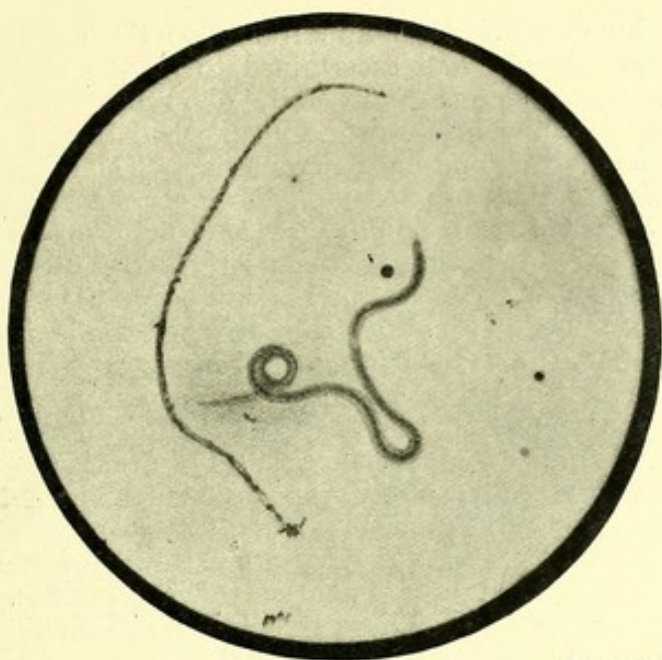
The lymphatics of the upper arm, or of the thigh, could be felt as thickened cords in 9·7 per cent. of all the filarial cases examined; in several this constituted the only objective sign. Owing to the relatively small calibre of those lymphatic trunks a considerable amount of thickening must be undergone before they become palpable; it is therefore quite likely that minor degrees were overlooked. In a Fijian, whose case I have already mentioned (Appendix XI., Chart XX.) and in whom numerous microfilariae were present, such a thickened cord could be felt in his upper arm immediately above the internal condyle. It was excised, and a strand two inches long dissected out from a mass of surrounding inflammatory tissue. On teasing out this strand in normal saline, a thickened lymphatic with numerous cystic dilatations was discovered. From one of these dilatations the specimen figured (Pl. XXI., Phot. X.) was removed. Sections were made of another of these dilatations (Pl. XXIV.) displaying the partially calcified remains of filariae, lying in a mass of amorphous material, and surrounded by coarse strands of fibrous tissue.

The filaria during its lifetime, as well as after its death, exerts an influence on the wall of the vessel in which it lies. The enormous invasion of the vessel by fibrous tissue in such a case is well shown in the specimen illustrated in Pl. XVIII.

Further blockage of the lymphatics seems to be contributed to by the proliferation of the lining endothelium (see Pl. XXVI., 2). Vessels, such as that depicted, are common in sections of filariated lymph glands. Sections were cut of the vessel from which the dead filaria depicted in Pl. XXVI., fig. 1, was removed. The worm in this instance was taken from an enlarged epitrochlear gland in which, in addition, many calcified filariae were also found.

#### FUGITIVE SWELLINGS LIKE CALABAR SWELLINGS.

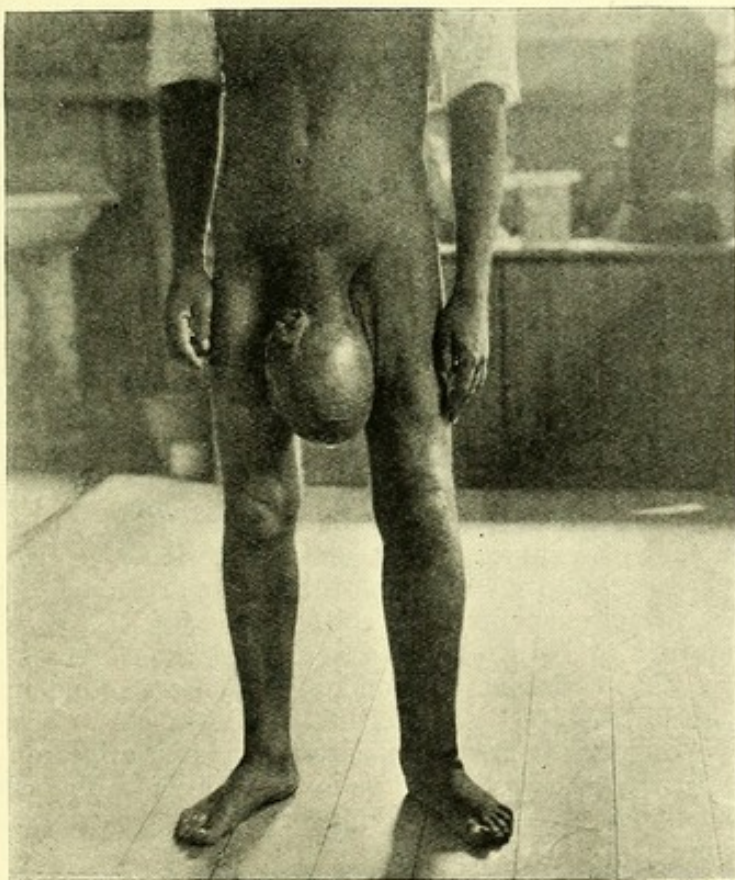
Evanescent swellings, appearing on the arms and thighs without any other assignable cause, have lately been shown to occur in natives and Europeans in West Africa in association with *Filaria loa*. Of these Thompson<sup>56</sup> in his original description says: "The swellings are about half the size of a goose's egg; they are painless though somewhat hot, both objectively and subjectively; they do not pit on pressure, and they usually disappear in three days." Fugitive swellings, apparently of a similar nature, found at the bend of the elbow and along the inner side of the biceps, were reported by Young<sup>57</sup> as occurring in a native of Jamaica. One of these was excised and found to consist of dilated lymphatic tissue. From an inflammatory mass adherent to the skin on the opposite arm a living *Filaria bancrofti* was removed. Swellings, in all probability of the same nature, were observed in subjects of filarial disease in Fiji. Curious, ill-defined and singularly evanescent



*Microphot., P. H. Bahr.*

### PHOTOGRAPH XIII.

Sheathed and unsheathed microfilariae in hydrocele fluid.



*Phot., P. H. Bahr.*

### PHOTOGRAPH XIV.

Hydroceles associated with elephantiasis scroti and left leg. A great number of calcified filariae were found in the hydrocele sac walls at operation.

inflammatory lumps made their appearance on the scalp and thigh of my Fijian cook, whom I had ascertained to be the subject of filarial infection. He was under constant daily observation for ten months. I saw a similar swelling in a European; he had been resident in the Colony for sixteen years, and had microfilariae. The lump was situated on the inner side of the upper arm, on the inner margin of the biceps. It was about the size of a two-shilling piece and slightly painful. Beneath it a thickened cord with a cystic dilatation could be felt. Soon after the appearance of the swellings the patient had a rigor and fever. A similar lump, smaller and not so painful, then made its appearance about the centre of the flexor surface of the forearm. When examined a fortnight later both swellings had disappeared, and a small amount of subcutaneous thickening only remained. A red inflammatory mass of a similar nature was noticed on the inner aspect of the thigh in a European whose case has been related already and who suffered from two attacks of lymphangitis while under observation. The mass was painful, and red streaks of lymphangitis extended from it. Thickened lymphatic cords could be traced upwards to the inflamed and swollen groin glands. The mass on the thigh was aspirated; the fluid so obtained proved sterile on culture. After a week the swelling could no longer be felt.

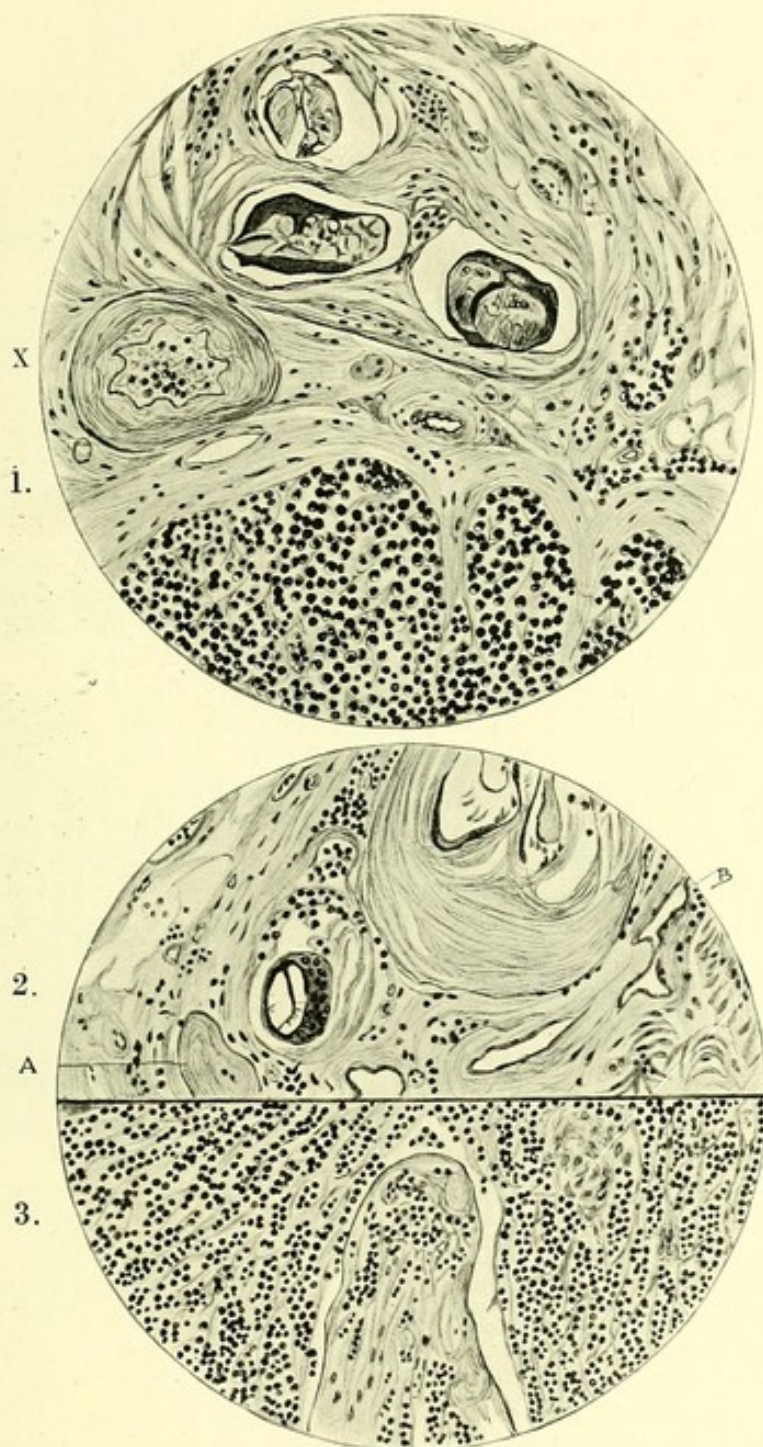
Inflammatory masses situated in the abdominal wall were met with twice. In neither case were microfilariae present in the blood. In both there was a high intermittent temperature and leucocytosis. In these also the aspirated fluid was sterile. One was operated on and the mass excised, but no adult filaria was found on dissection. In both patients the painful masses dispersed as rapidly and mysteriously as they had come. Further details of such cases will be found in Appendix XXI.

There can be no doubt, I think, about the filarial causation of the foregoing lesions. I am not so confident, however, that such an etiology applies to the three conditions I shall next allude to; the evidence is not so complete, although one is inclined to think that their association with other forms of recognized filarial disease is of too frequent occurrence to be merely a chance coincidence.

*Thrombosis* of large veins I noted four times. Details of the cases will be found in Appendix XXII. Thrombosis of sudden onset of the median, axillary, internal saphena and femoral veins was noted. Besides filariasis, no other recognizable cause could be conjectured. Microfilariae were not present in the blood of any of the cases. In two cases there was distinct evidence of a superimposed septic infection.

*Synovitis*.—Two cases of synovitis of the knee, of sudden onset, ending in ankylosis, were encountered (see Appendix XXIII.). There was high temperature in both. One had enlarged groin glands containing numbers of calcified filariae, and microfilariae were found in the blood and in the gland exudate. The second had a typical attack of filarial adenitis and orchitis immediately preceding the appearance of the synovitis. In both cases the knee was considerably swollen, and a thin, purulent sterile fluid (containing no microfilariae) was aspirated from the joints.

*Haemorrhage*.—Adult filariae have been found in the centre of blood clots by Daniels and Wise. Haemorrhage in connection with filariasis was noted by me twice in Fiji. The first case was in connection with a filarial abscess (Pl. XXIII.). The second occurred in connection with



## PLATE XXV.

P. H. Bahr del., 1911.

1. Section of an enlarged inguinal gland removed at operation, showing portion of a calcified filaria, encapsuled by fibrous tissue. A lymphatic vessel with thickened walls and extensive fibrosis of the gland tissues is seen at X. A giant cell is seen lying between two separate sections of the filaria.

2. Section of an enlarged groin gland showing calcified filariae *in situ* encapsuled by fibrous tissue. A giant cell appears to have formed round one section of a dead filaria. A represents a fibrous nodule from which a portion of a calcified filaria has been absorbed. B, an accessory lymph space.

3. Extensive fibrosis of lymphatic tissue. A section of an epitrochlear gland, from which thirteen adult filariae were removed.—Camera lucida.

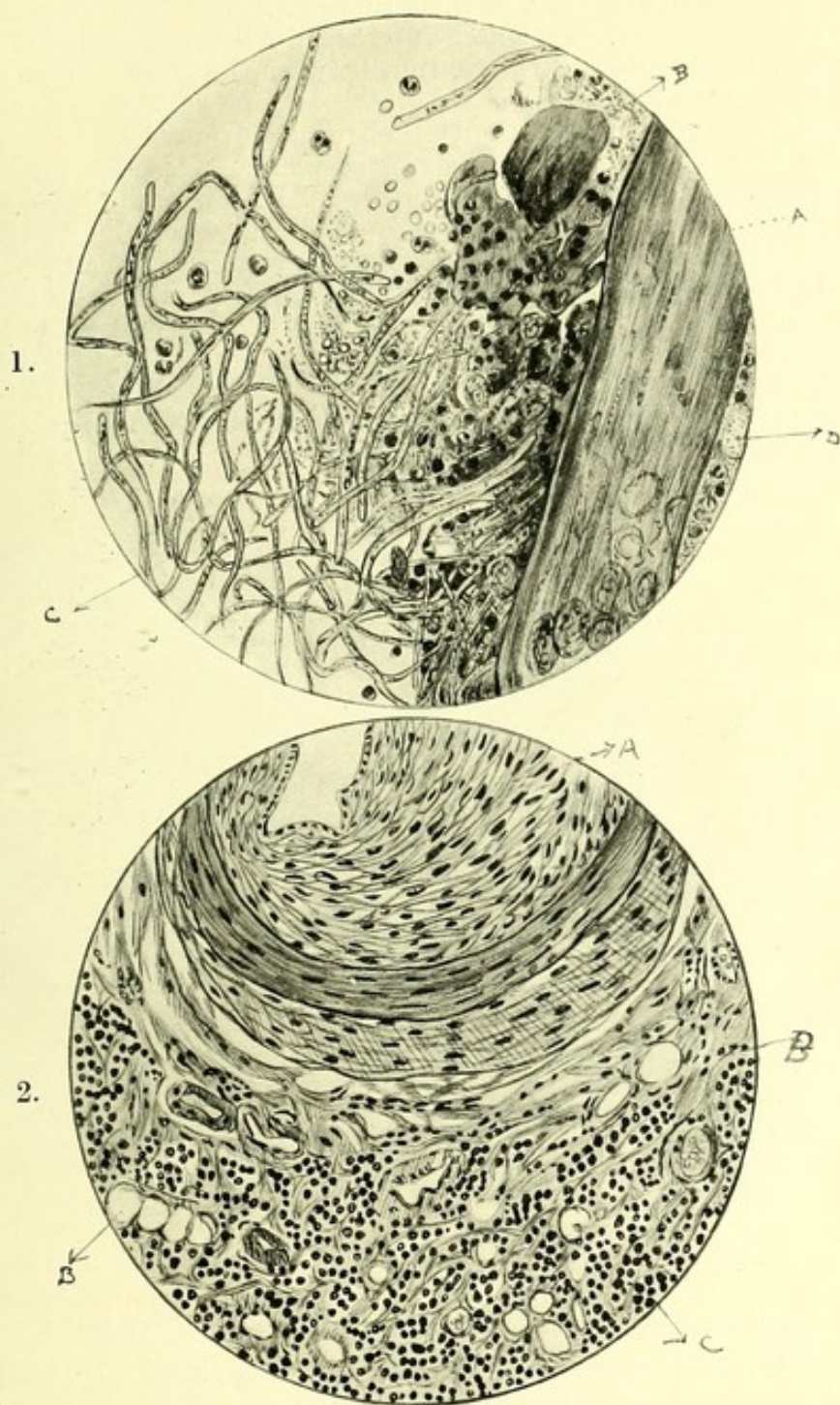
the lymphatics of the spermatic cord. A Fijian was admitted to hospital with a typical attack of orchitis and frequent rigors. A nodule, the size of a filbert nut, was present in the substance of the spermatic cord. This was exquisitely tender. The inguinal glands on both sides were enlarged, and there were numerous microfilariae in the blood. The lump was excised and carefully examined macro- and microscopically. It was found to consist of numerous old and recent haemorrhages encapsuled in fibrous tissue. No adult filarial remains were found in it.

**XV. Whether alive or calcified, the filariae are the direct cause of fibrosis and blocking of glands and lymphatics.**

As may be gathered from what I have said already, enlargement of the groin glands and epitrochlear glands is frequent in Fijians; in fact it is the commonest manifestation of filarial disease among them (Appendix VI., B and C). After the discovery of the adults in enlarged epitrochlear glands removed at operation, I paid special attention to this point, with the result that in 1,264 persons these glands were found to be enlarged in 281 instances, 34.6 per cent. of whom had microfilariae in their blood, and 65.4 per cent. had not (Appendix VI. D).

(A) *Epitrochlear glands*.—The changes induced in these glands by the filariae were studied in five specimens removed by operation. Details of the cases will be found in Appendix XXIV. (1). Pl. XXV. (3) was drawn from a section of a lymphatic gland in which thirteen adult worms were found. It will be seen that there is great hyperplasia of fibrous tissue, strands of which run through the whole substance of the gland; giant cells are also present, but in small numbers. The trabeculae are greatly thickened, and the lymphocytes are collected in clusters between the strands of fibrous tissue. The lymphatic channels are greatly thickened, and in some places completely blocked and merely represented by nodules of fibrous tissue (Pl. XXV. (2), A). Dilated blood-vessels are seen in the centre of these glands and numerous spaces (Pl. XXV. (2), B) filled with coagulated lymph which may possibly represent accessory lymph channels. In those glands in which calcified filariae were found, numerous giant cells are also seen. These are peculiarly large, generally oval in shape, and differ considerably in appearance from giant cells of tubercular origin. The nuclei, as a general rule, are large and are arranged radially around the periphery of the cell. In no instance were tubercle bacilli or cocci found, although searched for in every case; indeed there was never any apparent reason for suspecting that these enlarged glands were of a tubercular nature.

(B) *Groin glands*.—The changes induced by the presence of the filariae in the pathologically enlarged glands were studied in eleven cases, details of which will be found in Appendix XXIV. (2). In three of these living filariae were found, and in nearly all the others portions of calcified specimens. Some of the individual glands were very large, as that depicted in Pl. II., which was over three inches in length. The central part is fibrosed, the cortical hypertrophied. Sections of many of my specimens show this change (Pl. XXVII.). The lymphocytes are seen to be aggregated into little islands surrounded by fibrous and inflammatory tissue. In the cortical portion, thickened lymphatic trunks with lumina almost completely occluded (Pl. XXV., fig. 1) are frequently seen. In the sections, portions of calcified filariae, surrounded by thick



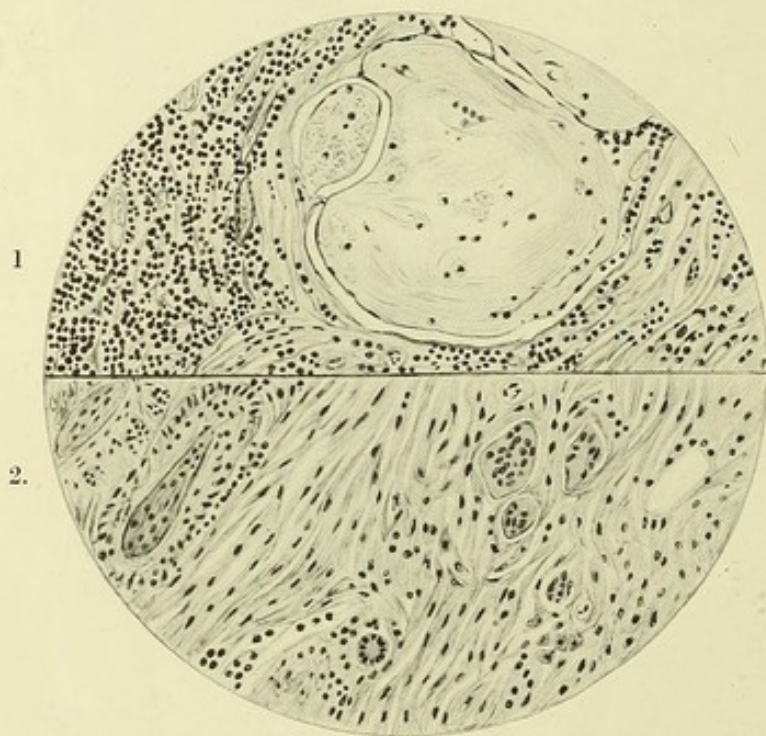
P. H. Bahr *del.*, 1911.

### PLATE XXVI.

1. Dead and disintegrating filaria removed from (A), a caseous focus in an enlarged epitrochlear gland, (B) caseous material, (C) microfilariae undergoing disintegration, (D) filarial ova, eosinophiles, and lymphocytes.

2. Section through area from which the specimen figured in (1) was removed. (A) Lymphatic vessel blocked by the proliferation of the endothelium; (B) spaces filled with lymph; (C) greatly fibrosed lymphatic tissue.—Camera lucida.

strands of fibrous tissue, and in some cases giant cells, are common. In some instances the calcification has proceeded to such a degree that the outline of the parasite and the septum between the uterine tubes are all that can be recognized (Pl. XXV., 2). In one section a giant cell, apparently produced in response to the irritation caused by this foreign body, lies in close apposition to a calcified filaria. Close by, nodules of fibrous tissue of concentric structure (Pl. XXV. (2), A) are seen, representing, I conjecture, areas from which the calcified remains of a filaria have been absorbed. The complete absorption of these remains is probably a matter of time, for in one of these enlarged glands no calcified filariae could be found, although the changes invariably associated with their presence were very evident. A completely calcified filaria was removed (Microphot. XI.) from the efferent and thickened lymphatic channels of such a gland. In one case (Appendix XXIV.), examined post-mortem, numbers of calcified filariae were found in various parts of



P. H. Bahr *del.*, 1911.

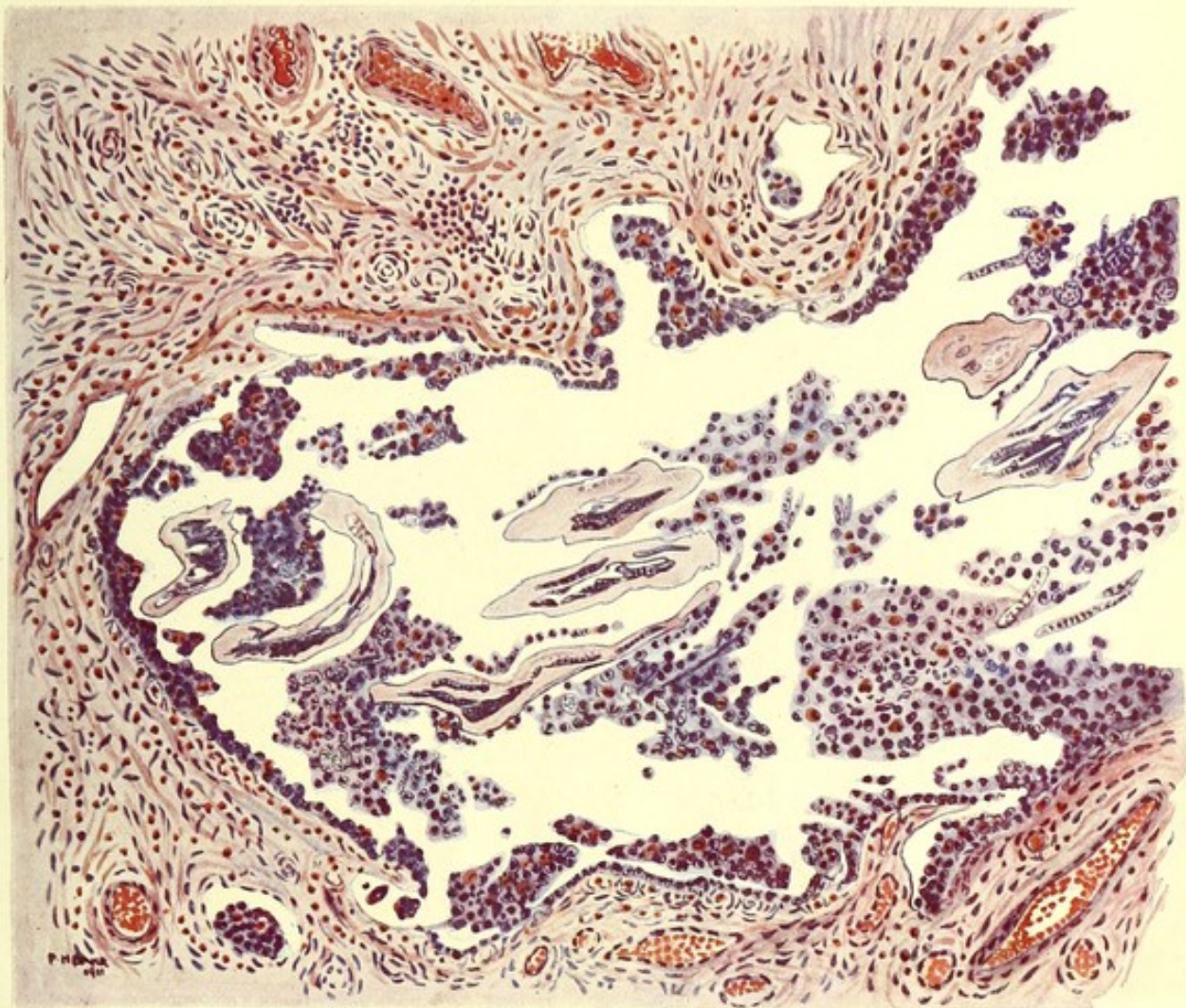
### PLATE XXVIII.

1. Section of enlarged mesenteric gland showing areas of amorphous material, probably organizing stagnated lymph, enclosed in hyaline fibrous tissue. There is marked fibrosis of the gland substance.

2. Section of a lumbar gland from the same case showing masses of hyaline tissue and giant cell formation.—Camera lucida.

the body, especially in the epididymis, and living filariae in enlarged glands in the right groin. The abdominal lymphatics were in a varicose condition. An enlarged groin gland, removed from another man with elephantiasis of the leg on the same side, was found to be studded with calcified filariae, and showed, microscopically, changes similar to those already described.

Fibrosis of a similar nature, and associated with an excess of eosinophile cells in the glandular substance, was noted in sections of the inguinal,



P. H. Bahr *del.*, 1911.

## PLATE XXIX.

Microscopical section of the epididymis. A female filaria, undergoing disintegration, is seen in a space surrounded by lymphocytes, pus cells, and eosinophiles, amongst which numerous embryos can be recognized. The fibrosis of the surrounding tissue is marked. From a Fijian who died after an attack of filarial fever. Section stained by haematoxylin and eosin.

[To face p. 64.]



lumbar and posterior mediastinal glands of a Fijian in whose blood microfilariae were found post-mortem. Calcified filariae were found in the right epididymis.

In a post-mortem I was fortunate enough to obtain of a Fijian who is said to have died after an attack of filarial fever,\* a large number of calcified filariae were found in the different tissues, and sections were made of the inguinal, iliac, pelvic, lumbar, mesenteric, bronchial, and epitrochlear glands. They all exhibit varying degrees of the characteristic fibrosis.

In the lumbar glands (five microscopically examined) giant cells of an oval shape, and often of a large size, are seen surrounded by a peculiar hyaline substance in which fibroblasts can be distinguished (Pl. XXVIII., 2). In the mesenteric glands (Pl. XXVIII., 1) similar structures can be found, and also circular areas of amorphous material, staining pink with eosin. In the centre of these a few lymphocytes are to be seen. It has been suggested to me that these structures (which are extremely numerous in my sections) represent areas of stagnated and organizing lymph.

The influence which the living filaria exerts in the vessel wall in which it lives, is shown in the specimen depicted in Pl. XVIII. In addition to this thickening there is fibrosis of the surrounding glandular tissue. In the centre of the vessel is a mass of coagulated lymph containing a few microfilariae.

*Epididymis.*—In sections of the right epididymis of this last case, portions of a recently dead and disintegrating filaria (Pl. XXIX.) were found in a cavity surrounded by polymorph, lymphocyte, and eosinophile cells. Intermingled with these were ova and microfilariae. No structures resembling the vasa efferentia remain, the space occupied by the filaria being surrounded by thick bands of fibrous tissue and dilated blood and lymph vessels.

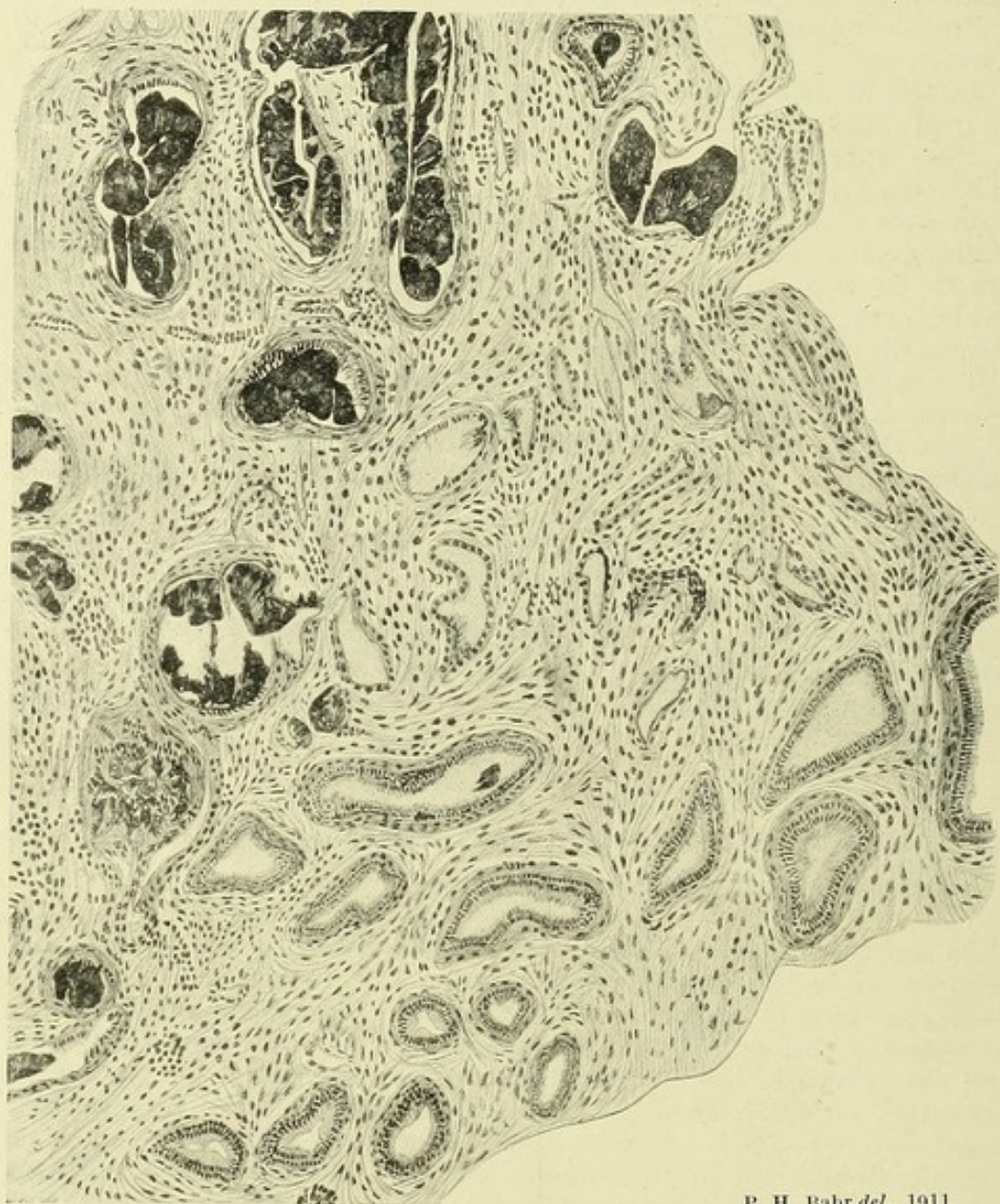#### XVI. Eosinophile cells are present in large numbers around both the living and the calcified filariae.

As has been related already, great numbers of eosinophile cells have been found in the grumous substance usually found surrounding live filariae in the substance of a lymphatic gland. Smears of this substance consisted of eosinophile cells, lymphocytes, a few red blood corpuscles, and amorphous bodies of a crystalline nature, possibly excreted by the parasite. In microscopical sections the eosinophile cells become very apparent if the slide is treated with eosin for about ten minutes and then partially decolorized in 70 per cent. alcohol. In all sections of enlarged glands, with only two exceptions, these cells were noted in great profusion (Pl. XXX.). They apparently lie among the strands of fibrous tissue enclosing one of the islands or collections of lymphoid cells I have already mentioned (p. 62). Similar collections of eosinophile cells have been seen in the section of a filarial abscess (Pl. XXIII.); round a filaria in a case of lymphangitis (Pl. III.); in the epididymis (Pl. XXIX.); and in a thickened lymphatic trunk (Pl. XXIV.).

\* This post-mortem will be more fully treated under heading X. and Appendix XXVI. B.

**XVII. Calcified filariae have been found in the interior of and blocking the vasa efferentia.**

In one instance, sections were obtained of a calcified filaria dissected out from the substance of the epididymis. The calcareous material was, to a great extent, removed by Von Ebner's solution. The resulting

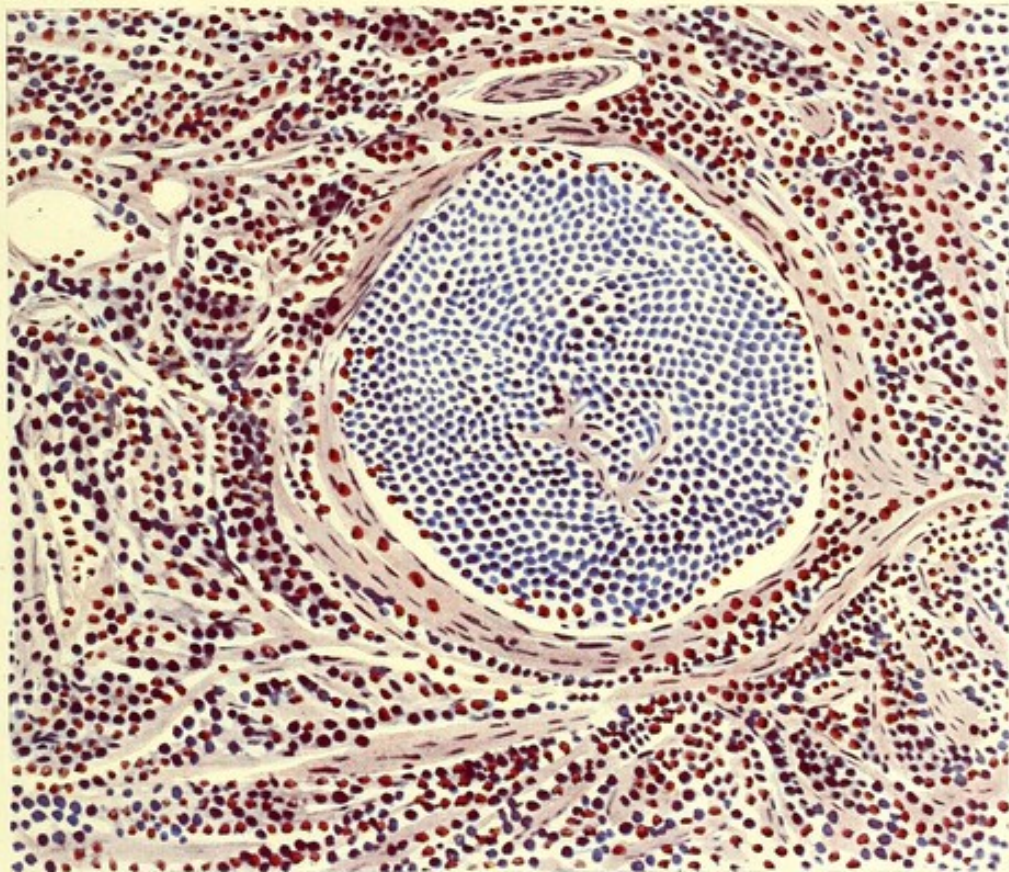


P. H. Bahr *del.*, 1911.

**PLATE XXXI.**

Section of a calcified filaria in the epididymis, showing the manner in which the vasa efferentia are blocked and their function destroyed.—Camera lucida.

preparation is illustrated in Pl. XXXI. Dark staining amorphous masses, representing the remains of the filaria, and are seen lying in the lumen of the vasa efferentia. In several sections part of the ciliated epithelium is visible; in others it appears to have been completely destroyed.



P. H. Bahr *del.*, 1911.

### PLATE XXX.

Microscopical section of an enlarged lymphatic gland (from a pedunculated mass in the groin), showing fibrosis of the gland's substance and a great number of eosinophile cells. The lymphocytes are aggregated into clumps; eosinophile cells are found at the periphery of these clumps and scattered throughout the fibrous stroma. From a Fijian male, aged 25.

Section stained by haematoxylin and eosin.

[To face p. 66.]



This specimen was obtained from a case of elephantiasis of the scrotum in which the testes were enlarged, and contained a ragged abscess cavity, discharging thick pus.

It can be readily understood how, if these vessels be a frequent habitat of the adult filaria, this circumstance will contribute to the further impairment of the function of the generative organs.

**XVIII. Microfilariae emitted by the parent worm may not reach the general circulation, perishing in the gland or organ in which they are lying.**

Since filariae of both sexes have been found together in the same lymphatic glands, it is not unreasonable to suppose that their microfilariae are emitted in the substance of these glands, whence they may endeavour to reach the general circulation. Such microfilariae were obtained by gland puncture on six occasions. Once I found them in hydrocele fluid, and once in purulent fluid from the tunica vaginalis. In two instances, both cases of lymphangitis, they were found in the gland juice immediately before their disappearance from the blood-stream.

In three cases the microfilariae were small, with sheath distended anteriorly and posteriorly, and nuclear structure still undifferentiated, resembling closely the small forms I have often seen emerging from the vaginal orifice of the adult worm.

In two instances, besides the microfilariae, filarial ova and empty sheaths were found in considerable numbers. It is specially to be noted that in one of these instances *no microfilariae could be found in the blood, but appeared there some eight months later*. In one of the cases the microfilariae in the newly-drawn lymph exhibited no signs of life.

Eight microfilariae were obtained in gland lymph from a case of lymphangitis of the leg in association with elephantiasis. They did not differ from those found in considerable numbers in the blood.

In a case of hydrocele, microfilariae abounded in the fluid when only a few could be found in the blood-stream. Of those in the hydrocele many were dead, and empty sheaths and sheathless forms were frequently encountered. I conjecture that when the fibrosis of the gland substance has advanced to a certain point, the microfilariae are unable to reach the lymph-stream and, consequently, the blood-stream. Else how account for the absence of microfilariae in those cases in which sexually mature female filariae were observed actually emitting living larvae, and yet none of these larvae could be found in the blood.

**XIX. Periodical discharges of microfilariae may be a factor in the production of lymphangitis, orchitis and funiculitis.**

Microfilariae, as related in the last paragraph, were discovered in lymph from the implicated glands in cases of lymphangitis.

I have notes of one case of recurring orchitis in which microfilariae were obtained from the tunica vaginalis at the commencement of each attack. The patient was the Fijian cook already alluded to. Being my own servant, I was able to make frequent and minute observations. While in my service he had three attacks of orchitis. Judging from the many counts made over a period of ten months the number of microfilariae present in his circulation was wonderfully constant (*vide* Appendix XXV. and Chart). No disappearance, or even marked diminution took place

either before, during or after any of the attacks of orchitis. During the first there was local inflammation of the glands of the *left* groin, the temperature of which was constantly one degree higher than that of the axilla. The adenitis was followed by inflammation of the *right* testis. A second attack, five months later, was ushered in by inflammation of the left testis, followed by a similar condition in the right. The spermatic cord of the left side was inflamed and tender, and a definite, inflammatory mass could be distinguished in its substance. During this attack a collection of fluid was noticed in front of the right testis. On aspiration, purulent fluid containing great numbers of live microfilariae was obtained; several sheathless forms and empty sheaths were also found in the fluid. In ringed preparations the microfilariae died almost immediately; whilst in samples of finger blood, taken simultaneously and treated in a similar manner, they lived thirty-six hours. Immediately after the attack this collection of fluid disappeared. The appearance of a similar swelling, containing identically the same kind of fluid and microfilariae, coincided with the third attack of orchitis. On this occasion quite 9 c.c. of fluid were aspirated. Cultures of the inflammatory fluid, made on several occasions, remained sterile. At the conclusion of my observations on this man, a similar swelling, unaccompanied by fever, was noted in the tunica vaginalis of the left side; it contained cloudy straw-coloured fluid in which a very few live microfilariae were found. In the case of those swellings, called Calabar Swellings, produced by *Filaria loa*, it has been suggested by Manson<sup>45</sup> that the outpouring of embryos into the surrounding tissues by the parent worm may be a factor in their production. In one subject, in whose blood microfilariae with a well-marked diurnal periodicity were found, he was able to demonstrate great numbers in lymph drawn from the centre of one of these swellings. The facts of the case related above would suggest that the sudden outpouring of microfilariae into the glandular substance in the first instance, and into the tunica vaginalis in the second, was connected with the respective attacks of adenitis and orchitis. Continued attacks of a similar nature would result in the production of a hydrocele, a contingency which actually did take place.

Anyone who has studied this condition will scarcely deny that the etiology of this form of endemic orchitis and lymphangitis are in all probability similar, and that if this be the explanation of the origin of the attack in the former, it must also hold good in the latter.

A case of lymphangitis of the arm was recorded in a Fijian in whose blood no microfilariae could be found (Appendix XXV). The lymph from this case as in all the others, was sterile.

From the detailed notes in the Appendix, it will be seen that a moderate leucocytosis was noted in every case of lymphangitis or orchitis accompanied by a high temperature.

## XX. After such inflammatory attacks the parent worm may perish.

The death of the parent filaria has been adduced as explaining the disappearance of the microfilariae from the blood. With the exception of my cook's case and one other, the disappearance of microfilariae was noted in seven out of nine cases of lymphangitis and orchitis which came under my notice.

Plausible as this explanation appears to be, it does not assist us in understanding the course of events in those few cases where no diminution in the number of microfilariae was noted. I conjecture that in these

cases several female filariae were present in some other part of the lymphatic system, and that they were responsible for the microfilariae in the blood; and that the worms, the cause of the inflammatory reaction, had never succeeded in getting their offspring into the circulation. It may be that the attacks of lymphangitis are due to the sudden emission of microfilariae, and that the absorption of some toxic substance, liberated by their destruction, leads, not only to the inflammatory disturbance, but also to the death of the parent worm.

That the presence of microfilariae may not be essential to the production of filarial lymphangitis, was indicated by one typical case (Appendix XXV.) in which the lymphatics of the forearm were attacked. In this case no microfilariae could be found, either in aspirated lymph or in the blood.

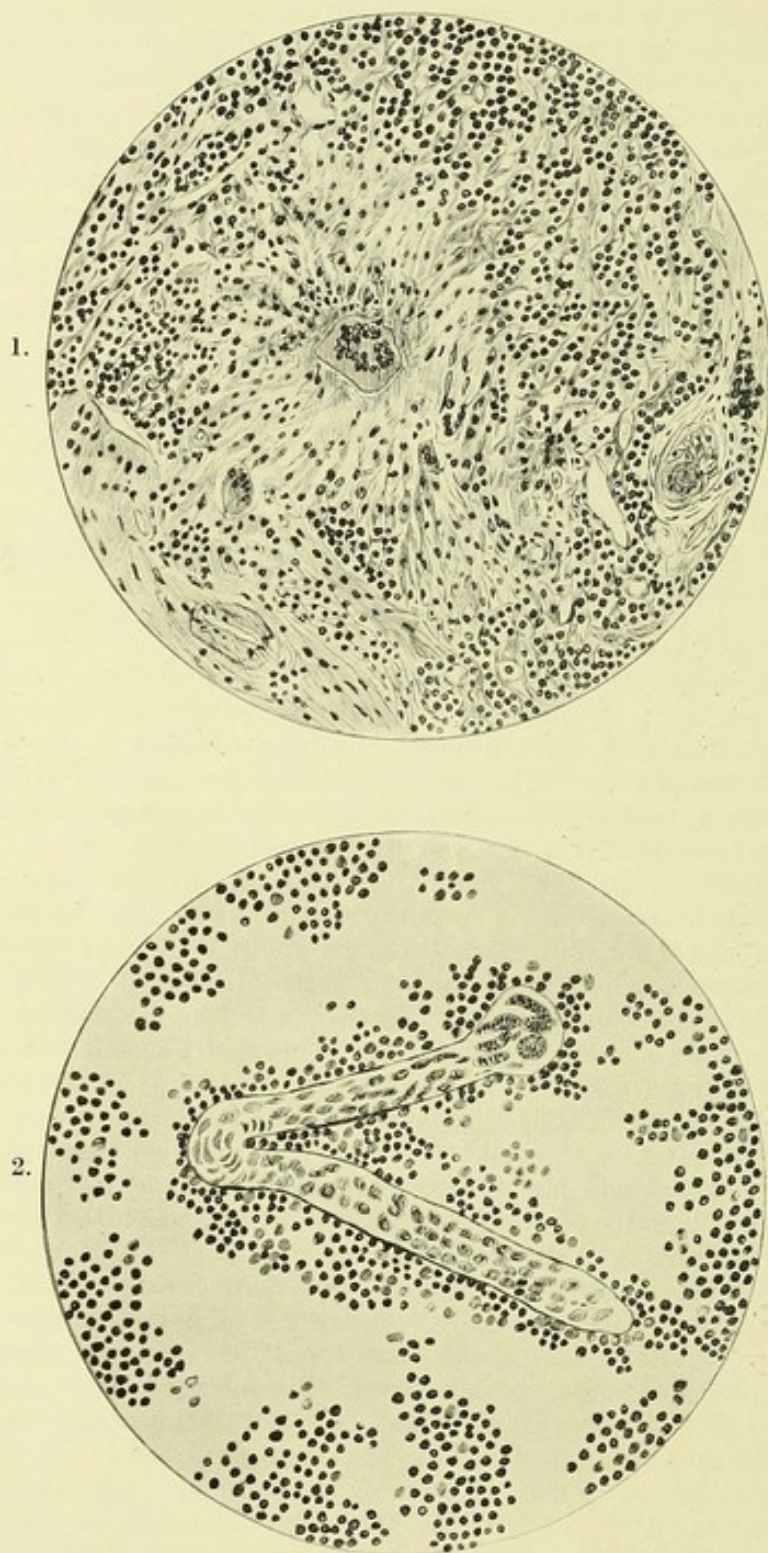
It will be remembered that the dead and calcified filariae which I found were located in the usual seats of lymphangitis (epitrochlear and groin glands). The remarkable specimen figured in Pl. XXI. and Microphot. X. was obtained from brachial lymphatics which, six weeks previously, had been attacked with severe inflammation.

#### "LILIWA"

Is a form of filarial disease, not yet alluded to, which appears to be a purely febrile condition. This form of fever is common in heavily-infected districts, and is unassociated with any clinically recognizable inflammatory trouble. It is termed by the natives "*liliwa*" (i.e. rigor), in contradistinction to the lymphangitis of the extremities, which is known as "*wanganga*". It is not unreasonable to ascribe it to the absorption of the dead filariae or their products.

Six cases were studied in detail (Appendix XXVI. A). The onset is sudden, and is ushered in by rigor. The eyes are blood-shot, the skin hot and burning; often there is vomiting. There is marked leucocytosis. In four cases no microfilariae were present in the blood; in one (described in Appendix X., Case 7) they disappeared after a second attack. There were marked bronchitic signs (these also were noted in cases of lymphangitis and orchitis) and the temperature often reached 104° and 105° F. The attacks are usually of short duration, and at the end of forty-eight hours all symptoms had disappeared.

I was fortunate enough to obtain a post-mortem on a case of this sort. The patient died suddenly, apparently of heart failure (details in Appendix XXVI. B). A great many calcified filariae were found in the lymphatic glands, which were all enlarged and showed on section extensive fibrosis and giant cell formation, and, especially in the mesenteric glands, the curious structure depicted in Pl. XXVIII. There were marked signs of back pressure in all the organs. The spleen was dark and diffuent. No microfilariae were found in the many blood smears made, nor could the presence of any septic organism be substantiated. In the substance of the right epididymis there was distinct evidence of the recent death of a parent filaria (Pl. XXIX.) and of destruction of the microfilariae, great numbers of the latter, in a disintegrating condition, being found in yellow purulent material which exuded from the epididymis on section. No bacterium could be demonstrated in this material, nor any live filariae in the tissues, after an extensive search.



P. H. Bahr del., 1911.

### PLATE XXXII.

1. Section of iliac gland, from a Solomon Islander with adenitis and synovitis of hip-joint, showing fibrosis of gland substance and giant cell formation. *Staphylococcus pyogenes albus* was cultivated from the lymph.

2. Part of the uterus of a disintegrating filaria containing ova and embryos found in smears of caseous material which exuded from the same gland.—Camera lucida.

**XXI. Lymph from such inflammatory foci may be sterile or may be the seat of bacterial invasion.**

In every case in which cultures were made from lymph aspirated from non-inflamed enlarged glands (Appendix XXIV.) the lymph proved to be sterile. The precautions taken in every case were the same. To obviate contamination with skin organisms, the skin was first seared with a red-hot metal rod; the needle of the syringe was also heated in the flame before insertion.

Similar precautions were adopted in making cultures from cases of lymphangitis (Appendix X.), but whether the lymph was inoculated on to agar, blood agar, or hydrocele fluid, it proved to be sterile after forty-eight hours incubation.

In cases when the glands continued to be inflamed for a long period it was otherwise. In one case (Appendix X., Case 1) there was direct evidence of the infection of the lymphatic glands coincident with the disappearance of the microfilariae from the blood, the pyogenic infection leading eventually to a fatal result. In another case, evidence of a similar sepsis was obtained. The case was that of a Solomon Islander, admitted with typical adenitis of the glands of the right groin. His temperature remained high, and the hip-joint became inflamed. The enlarged external iliac glands were removed. *Staphylococcus pyogenes albus* was cultivated from lymph from these glands, obtained both before and during the operation. On cutting open one of the removed glands, beads of putty-like material exuded from the surface of the sections, and in this a portion of the uterus of a recently dead filaria containing embryos was detected (Pl. XXXII., 2). No tubercle bacilli could be demonstrated in smears of the purulent material. The microscopic findings were (Pl. XXXII.) very similar to those figured in Pl. XXVIII. In the sections, numbers of large giant cells, lying in a peculiar hyaline substance and amongst the strands of fibrous tissue, are to be seen. After operation the patient made an uninterrupted recovery, and all symptoms disappeared.

The second case, though starting as a typical filarial adenitis, developed a psoas abscess, due to *Staphylococcus albus*. The history of two additional cases was similar and in all probability their etiology was the same (Appendix XXVII.).

Instances of a like nature have been recorded in British Guiana by Wise,<sup>44</sup> especially one in which a blood-stained effusion was found in the substance of the psoas muscle containing portions of an adult worm and great numbers of unsheathed microfilariae, and, as he remarks, all the conditions were favourable for the development of a psoas abscess in the presence of a pyogenic organism.

Such cases are very instructive in view of early treatment, for the fibrosis of the lymphatic glands in filarial infection must tend to lower the resistance of the body to infection by the tubercle bacillus, as well as by pyogenic organisms.

The Fijians are extremely liable to tuberculosis, and die from that cause in great numbers. Glandular tuberculosis is often found post-mortem. Two instances of tubercular infection of glands were noted. A Fijian had typical attacks of filarial adenitis of the axillary glands. The glands became enlarged and matted together, and eventually broke down, leaving a discharging sinus. No septic organisms could be found in the pus, but tubercle bacilli were demonstrated in sections of the glands removed at operation. A second case died of general tuberculosis after

operation for elephantiasis of the scrotum. The groin glands became enlarged and eventually broke down, discharging pus in which tubercle bacilli were found. In one gland, which was excised, calcified filariae were found. Microscopical sections presented the typical picture of a tubercular gland.

## XXII. Lymph from inflamed elephantoid tissue is usually sterile.

Lymph obtained by puncture with a sterile syringe from non-inflamed elephantoid tissue invariably proved sterile (Appendix XXVIII.).

I had only one opportunity of investigating a case of elephantiasis during one of the inflammatory attacks. The pathological process seemed to me to be entirely similar to that observed in ordinary cases of filarial lymphangitis. The case was that of a male Fijian, 33 years of age, with elephantiasis of both legs, the left arm, and the scrotum. He had numerous rigors, and there was adenitis of the glands of the left groin, together with lymphangitis of the left leg. There was great tenderness in the glands and along the course of the lymphatics. The skin over the gland of the left groin was seared, and a considerable amount of lymph abstracted. The cultures on blood agar proved sterile. There were numerous microfilariae in the blood, and they were also found in the gland lymph.

All observers are agreed that, as a rule, repeated attacks of lymphangitis precede the production of elephantiasis; cases, however, have been recorded by Low<sup>49</sup> in the West Indies and by others elsewhere, in which there had been no febrile or inflammatory attack. Such a case came under my notice in Fiji. The patient was a white trader who, though suffering from decided elephantiasis of both legs, was quite positive that he had never suffered from acute lymphangitis (Appendix XXIX.).

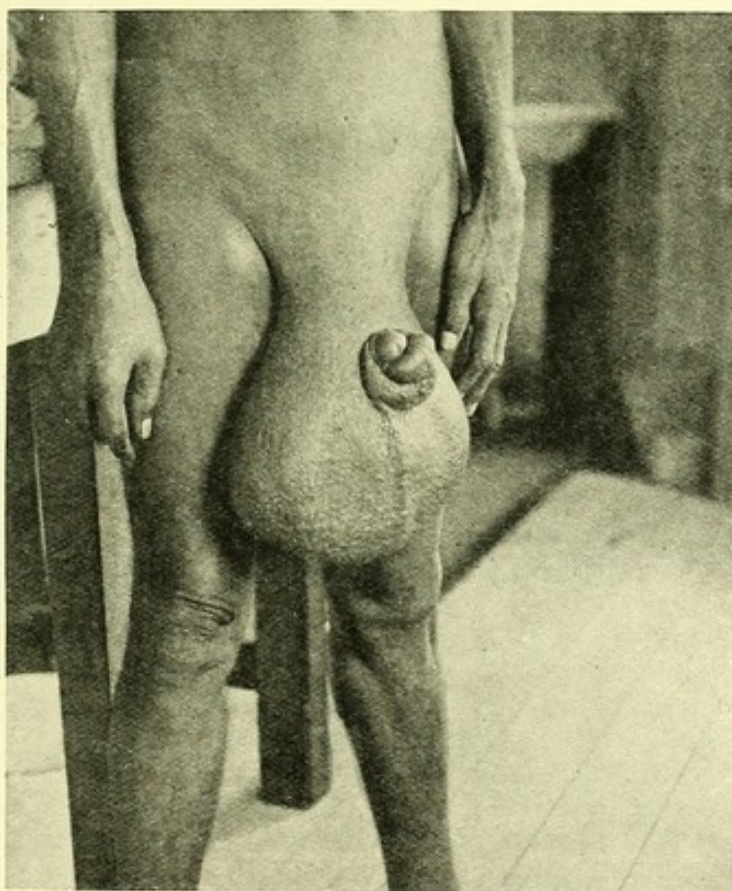
There is a popular belief in these islands that on leaving the endemic area these inflammatory attacks cease. I have notes of the case of a European lady with elephantiasis of both legs, who was a constant martyr to these attacks while in Fiji (Appendix XXIX., 2), but who enjoyed perfect health when absent in New Zealand.

One United States citizen, whose history appeared reliable, began to suffer from lymphangitis, leading to elephantiasis of both legs, after only three months' residence in Fiji (Appendix XXIX., 3). Usually, however, a longer residence in the endemic area is necessary before the appearance of the familiar symptoms, as may be gathered from the details of cases of four Europeans given in Appendix XXIX., 4. One of these suffered from his first attack of adenitis and orchitis after one-and-a-quarter years residence in Lakemba.

Le Dantec<sup>47</sup> found a diplococcus in the subcutaneous tissues in elephantiasis and in association with a staphylococcus in the blood. On injecting the staphylococcus into a rabbit's ear, he produced in that organ frequent erysipelatoid attacks, followed by an elephantoid condition. Dubruel,<sup>9</sup> in Tahiti, found a similar streptococcus in the blood and serum in cases of lymphangitis, but does not give any details of his technique. Le Dantec's staphylococcus has been termed the "lymphococcus." It has been further investigated by Foulerton<sup>58</sup> and Miss Whittingham; they pronounce it to be identical with *Staphylococcus pyogenes albus*. Lately, Leber<sup>55</sup> and Prowazek found streptococci in filarial swellings, and in the blood of a European who suffered from lymphangitis in Samoa. In the elephantiasis occurring in temperate zones and known as elephantiasis nostras, with concurrent lymphangitis, Sabouraud<sup>47</sup> has demonstrated a

streptococcus in the blood during the erysipelatoid attacks. In the remarkable case quoted by Sampson Handley<sup>50</sup> diplococci were cultured from the blood of the arm and lymph of the leg, and the condition of the patient, who suffered from marked elephantiasis of the leg, rapidly improved on treatment with a vaccine made from these organisms. In addition to this it has been shown that septic infection concurrent with filarial disease is of frequent occurrence.

The prima facie evidence for the streptococcal nature of acute erysipelatoid attacks in elephantiasis is therefore a strong one. In my own experience a case of marked lymphatic oedema of the arm, accompanied by febrile disturbances, and secondary to an axillary abscess, was studied. *Staphylococcus pyogenes albus* could be cultivated from the lymph which



Phot., P. H. Bahr.

#### PHOTOGRAPH XV.

A case of elephantiasis scroti. The uterus of a dead and disintegrating filaria was found in this case in the centre of the diseased tissue.

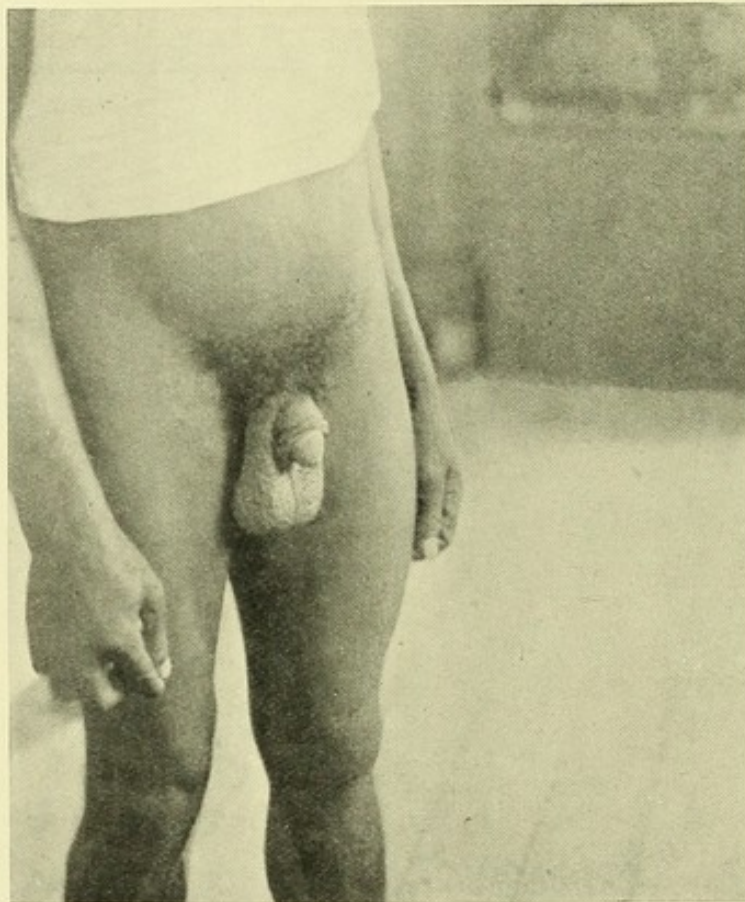was easily obtained from the swelling. Microfilariae were abundant in the patient's blood, and in the centrifuged deposit of the lymph obtained from the arm their sheaths could be found. In three months time after the first onset the oedema had all dispersed, but microfilariae were still present in the blood, and in almost the same numbers (Appendix XXIX., 5).

Against the necessity for infection of the lymph-stream by pyogenic organisms, in at least some of these cases, we have the facts that

elephantiasis does sometimes develop without the concurrence of any febrile disturbance, and that lymph abstracted with aseptic precautions from the inflamed tissue has proved sterile on culture.

**XXIII.** The precise mechanism of the production of elephantiasis has yet to be determined, but that the filaria is a principal factor is hardly open to doubt.

The frequent absence of microfilariae from the blood in cases of elephantiasis has been advanced as an argument against the filarial production of this disease. In the preceding paragraphs I have, however,



*Phot., P. H. Bahr.*

#### **PHOTOGRAPH XVI.**

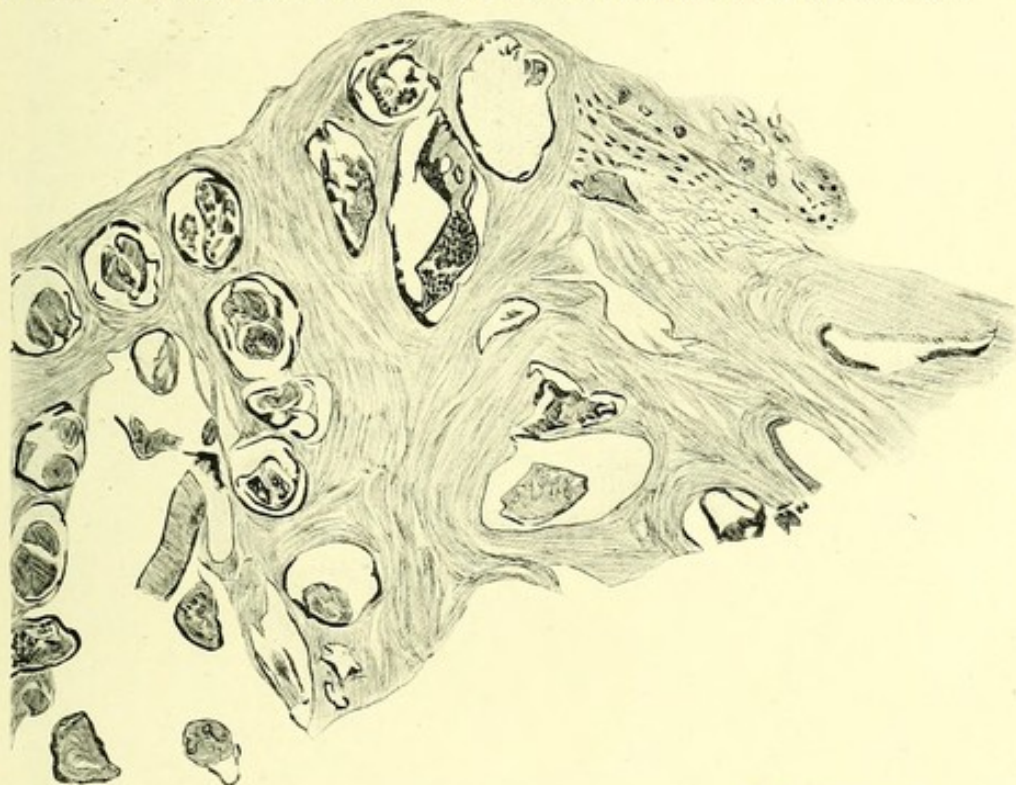An early case of elephantiasis scroti. No microfilariae were found in the blood.

attempted to show that in the case of lymphatic glands, the enlargement of which is undoubtedly due to the presence of filariae, microfilariae are even more frequently absent than they are in cases of ordinary elephantiasis. Thus the microfilaria rate for all cases of elephantiasis was found to be 38.2 per cent., while that for enlarged glands alone was 31.1 per cent. (Appendix VI.c). Therefore the filarial theory of the production of elephantiasis, if anything, receives support from these statistics.

A more telling argument, however, is the epidemiological one. The higher the percentage of microfilariae in a district, the higher is the

elephantiasis rate (Appendix XVII.). Thus in the main town of Lakemba island (Levuka) the elephantiasis rate was 7.3 per cent., the microfilaria rate 32.4 per cent., and the filarial disease rate 69 per cent.; whereas in the district of Bau on the main island, where there is no, or very little elephantiasis, the microfilaria rate was only 12.5 per cent., and the filarial disease rate 36.3 per cent. These statistics agree in the main with those given by Low<sup>22</sup> for the West Indies, and by Daniels<sup>65</sup> for British Guiana and for Central Africa, and for wherever the subject has been adequately studied.

In dissections of elephantoid tissue proper, the remains of filariae are not usually found—possibly because not properly sought for; but in the enlarged fibrosed groin glands, removed at operation in a case of elephantiasis of the legs, great numbers of calcified filariae were discovered.



P. H. Bahr *det.*, 1911.

### PLATE XXXIII.

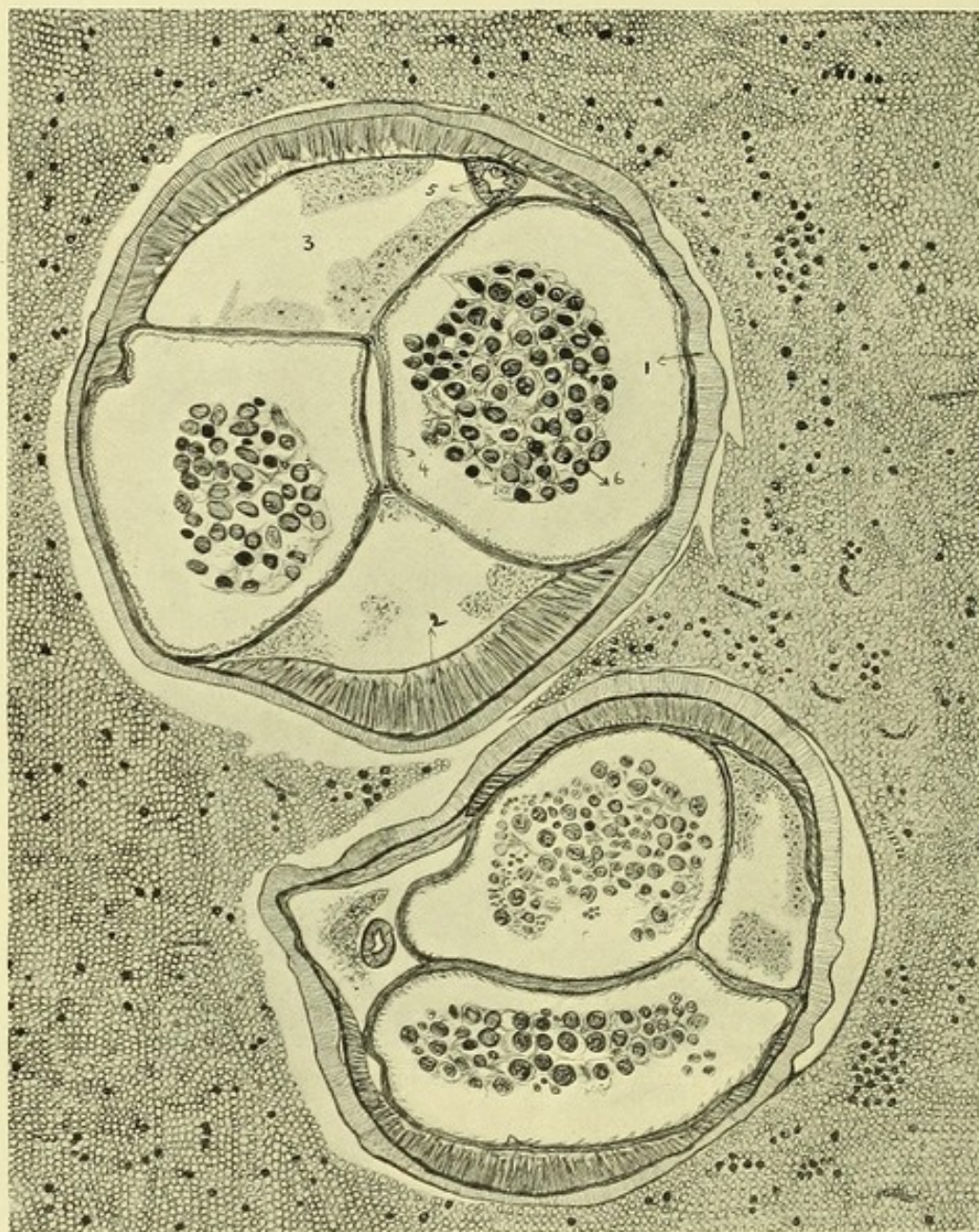
Dead filaria embedded in the blubbery tissue in a case of elephantiasis scroti.—  
Camera lucida.

My experience in this direction has been limited mainly to elephantoid scrota removed at operation. In these I constantly found embedded in the peculiar blubbery tissue certain small, yellow pultaceous areas. In smears from one of these areas (Phot. XV.) the uterus of a dead filaria containing embryos, and similar to that figured in Pl. XXXII., was recognized; and in a second case, in a section of another such minute yellow body, a dead filaria, surrounded by a peculiar hyaline substance and giant-cell formation, was encountered (Pl. XXXIII.). In the case first mentioned, microfilariae were present in the blood; in the second, none could be found.

Phot. XVI. is from an early case of elephantiasis scroti. The entire scrotum was thickened, the skin rough, the testes enlarged, the prepuce

and sheath of the penis infiltrated and thickened, and the glands of both groins enlarged, but there were no hydroceles. In this case also there were no microfilariae in the patient's blood.

In judging of the rôle of the filaria as an etiological factor in elephantiasis we must not attach too much importance, either to the presence or absence



P. H. Bahr del., 1911.

#### PLATE XXXIV.

Section of a female *Filaria immitis* in the superior vena cava of dog, showing structure of a filaria on transverse section. Microfilariae can be seen amongst the surrounding blood cells.

- |                         |                         |
|-------------------------|-------------------------|
| 1. Cuticle.             | 4. Interuterine septum. |
| 2. Muscle cells.        | 5. Alimentary canal.    |
| 3. Perivisceral cavity. | 6. Ova.                 |

Camera lucida

of microfilariae in the blood. In two of these three cases they could not be found, yet in two cases there was unquestionable evidence of filarial invasion. Very probably, with a knowledge gained from this experience, minute search would have revealed similar evidence in the other.

Little information bearing on the etiology of elephantiasis is to be obtained from the study of sections of elephantoid tissue. In five cases examined, the microscopical appearances were, to a great extent, similar. Dilated lymph and blood channels were very evident; there were collections of lymphoid cells in a peculiar hyaline substance (probably connective tissue swollen with lymph resembling that found in the lymphatic glands, Pl. XXVIII.), and bundles of the hypertrophied dartos muscle (Appendix XXX.).

Objections may be advanced by sceptics as to the filarial origin of elephantiasis, to the effect that the bodies figured and described in the foregoing pages were not really the remains of filariae. Their careful study will show that I have made no mistakes in diagnosis. Pl. XXXIV. is drawn from a section of *Filaria immitis* lying in the superior vena cava of a dog. It shows the main anatomical features of a filaria as seen in section. These are (1) the cuticle, (2) the layer of muscle cells in the body wall, (3) the two uterine tubes and the septum between them, (4) the perivisceral cavities, and (5) the alimentary canal. These structures, more or less transformed by disintegration, can be recognized in the sections of dead and calcified filariae figured in my drawings. Brumpt gives similar figures of *Filaria loa* and *Filaria volvulus* in the last edition of his "Précis de Parasitologie."

Arguments against the filarial theory of elephantiasis have been advanced by various writers. Those brought forward by Dubruel<sup>9</sup> and by Prout,<sup>59</sup> for example, are based on very slender evidence—evidence which, in the light of some of the facts I have already related, is capable of quite another interpretation.

The lymphatic glands draining those regions of the body attacked by elephantiasis are not invariably fibrosed and enlarged; for instance, should one leg be affected by elephantiasis, enlargement of the groin glands on the side of the apparently normal member is of common occurrence. Similarly, the epitrochlear glands, though very often enlarged in elephantiasis of the forearm, are not invariably so affected.

To illustrate the apparent lack of connection between elephantiasis of one part and disease of the associated lymphatic glands, I have drawn up a table (Appendix XVIII.).

The blockage of lymphatics, which is universally recognized as an essential condition in elephantiasis, may be situated in the lymphatic vessels as well as in the glands. It appears to me that this blockage may be brought about in one or all of the following ways, examples of each of which I have already given.

A. *Blockage of lymphatic vessels* (1) by the body of the living filaria, or by its cretified remains; (2) by changes, peripheral fibrosis and proliferation of the endothelium in the vessel wall, in response to chronic irritation so induced.

B. *Blockage of lymphatic glands* by extensive fibrosis of the gland substance, or by blockage of the efferent and afferent lymphatic trunks.

The inference that lymph stasis is produced in this manner is not in accordance with Manson's well-known hypothesis that the lymphatic capillaries become blocked by aborted filarial ova. The plugging of lymph capillaries by filarial ova does in all probability

take place, but not solely by the process of abortion. Their emission from the parental uterus may admit, I think, of another explanation than that given by Manson.

In my experience such ova were obtained by puncture of the groin glands on several occasions. It is improbable that these ova were aborted into the lymph-stream by way of the vaginal orifice, for, as has been suggested by Daniels, the vulva is too narrow to permit of their passage through this outlet.

I am inclined to believe that these ova are really set free from the uterus after the death of the parent worm. Such uterine tubes, with contained ova still in a perfect state of preservation, were found frequently on dissection of enlarged lymphatic glands. I found that protrusion of the uterine tubes and their contents took place immediately a small rent in the cuticle was made in either the living or the recently defunct worm. The escape of the uterine tubes and their contents into the surrounding tissues would also take place in a similar manner after the death of the worm and during its disintegration in the centre of a lymphatic gland.

In a post-mortem on a case of elephantiasis scroti, the only one I obtained, the value of my observations was rather marred by a co-existing and extensive tuberculosis (Appendix XXX., 3). The obstruction in the lymphatics in this case appeared to be situated in the lumbar region.

In my opinion the induction of tropical elephantiasis can best be explained by a hypothesis to the effect that the blockage of the lymphatic channels draining the implicated area is brought about by their frequent and long-continued invasion by adult filariae.

#### XXIV. Certain parasiticide drugs in medicinal doses have no manifest influence on the circulating microfilariae.

Intravenous injections of antimony tartrate, atoxyl, and quinine were tried, but in no case was any diminution, transient or permanent, noted in the numbers of circulating microfilariae.

Experiments *in vitro* (Appendix XXXI.) were also undertaken on microfilariae obtained by centrifuging citrated blood. Known quantities of the drug used were then added to the filarial concentrate in sterile well-slides. Although a certain amount of variation in the duration of life of the microfilariae was noted on different occasions and in different solutions, yet antimony tartrate appeared the most toxic. Distilled water having been found to exert an action on the life of the microfilariae, the solutions were made as isotonic as possible by dissolving the drugs in normal saline. Although in the more concentrated solutions (1:2000) of antimony tartrate and of quinine these drugs were markedly toxic, in very high dilutions—1:10,000 and even more so in 1:20,000—with the exception of antimony tartrate, they appeared to have very little effect. The order of toxicity was antimony tartrate, quinine bishydrochloride, atoxyl. Atoxyl is stated by Ehrlich<sup>52</sup> to be inert as a parasiticide *in vitro*, and that *in vivo* its toxic action depends on a reduction product, "paramidophenylarsenoxyl," in this respect differing from "606."

Antimony tartrate was given intravenously to three cases (Appendix XXXII.); the dose was 1 grain in 10 c.c. normal saline. No effects were noted either in the patient or on the number of parasites.

Atoxyl, 1 grain in 10 c.c. normal saline, was injected on three occasions, twice in one patient; no effects were noted.

Quinine bihydrochloride, five grains in 2 c.c. distilled water, also intravenously, had no appreciable effect on the microfilariae.

O'Brien<sup>60</sup> has reported a case in which after injection of atoxyl the microfilariae decreased in numbers, but did not entirely disappear. His figures are not very convincing. Leber and Prowazek noted no diminution in their numbers following on injections of thymol, quinine, methylene blue, and "606".

Treatment of enlarged glands by radium has been advocated by Havelock Charles;<sup>61</sup> the glands in his case diminished in size, but as to any effect on the number of microfilariae, no mention is made.

Injection of *Staphylococcus aureus* vaccine (obtained from a filarial abscess) was tried as a sort of forlorn hope, on the speculation that the absorption of the toxins of pyogenic organisms might have some prejudicial influence on the microfilariae; the result was negative (Appendix XXXII. and charts).

**XXV.** The absence of microfilariae from the blood in the case of undoubted infection with living filariae requires explanation; a similar apparent anomaly occurs in other filarial infections in man, e.g. in *Filaria loa* and in *Filaria volvulus*.

In a case reported by Argyll-Robertson<sup>62</sup> of an adult male of *Filaria loa* in the eye, and which was described by Manson, no microfilariae were found in the blood, although the patient suffered from Calabar Swellings and a gravid adult female worm was subsequently removed from the eye.

Thompstone<sup>63</sup> described Calabar Swellings as occurring frequently in cases where no microfilariae could be found in the blood. Low<sup>64</sup> describes several cases in which the patients suffered from Calabar Swellings, and in whom there was proof of the presence of this parasite, yet no microfilariae could be found in the blood. Manson<sup>65</sup> also describes several instances of a similar nature, and commenting on the fact, observes that:—

(1) The microfilariae may be present in the blood in numbers so small as to be missed.

(2) The microfilariae may be only intermittently discharged from the parental uterus or intermittently circulating.

Lastly, Manson<sup>65</sup>, in a case with microfilariae and Calabar Swellings was able to demonstrate in great numbers microfilariae in a drop of tissue juice obtained by aspiration from the centre of one of the swellings. This fact lends support to his hypothesis that the emission of the embryos by the parent worm into the connective tissue is the cause of these swellings. He considers that these swellings represent a tissue reaction in the interests of the parasite, since it must lead to a flow of lymph to and from the part in which the microfilariae are emitted, and so assist them to reach the circulation. This does not explain, however, the absence of microfilariae from the blood in those numerous cases in which the Calabar Swellings are of frequent occurrence, yet no microfilariae can be found in the circulation, it may be for years after the first attack and while the swellings continue to recur. If this pathological effect of the parasite be really produced in the way Manson has conjectured, then in a very large proportion of those cases the object, so to speak, of the act—namely, the lodgment of the embryos in the blood—is defeated, and we must conclude that it is thwarted by some other factor, of which we are still ignorant.

A similar condition exists in infections with *Filaria volvulus*, in which the microfilariae are never found in the blood-stream, but in numbers in the connective tissue in immediate proximity to the parent worm.

In the case of *Filaria bancrofti* it is conceivable that the embryos, if produced in the centre of a fibrosed gland, where the opportunities of entrance and egress are very limited, may be unable to reach the circulation, even should they escape from the gland in which they were born (the epitrochlear gland for instance), for they must necessarily pass through other lymphatic glands, where they stand a further chance of being arrested.

The embryos produced by adult filariae lying in lymphatic channels and glands in the interior of the body, having a route with proportionately fewer obstructions to traverse, are more likely to reach the blood-stream



Phot., P. H. Bahr.

#### PHOTOGRAPH XVII.

Probable main breeding place of *Stegomyia pseudoscutellaris* in Loma-Loma on Vanua Balavu. A brackish creek, flanked with mangroves and other vegetation, flowing through the native town.

than are those coming from the extremities. In this may lie the explanation of those cases exhibiting numerous microfilariae in the blood, but no other objective symptoms of filarial infection.

Where the lymphatic channels have been the seat of a filarial invasion over a considerable period, there is bound to be a degree of fibrosis commensurate with the duration and intensity of that invasion, and any embryos produced on the distal side of that obstruction will have a proportionately diminished chance of gaining the circulation. In this or in similar ways the frequent absence of larvae from the circulation in gross filarial disease may be best accounted for.

XXVI. and XXVII. Surgical and Medical Treatment of Filarial Disease is unsatisfactory.

Mosquito destruction, carried out on the same lines as for malaria or yellow fever, is the only means likely to prove of service in mitigating this important form of helminthiasis.

Surgical treatment of filarial disease is at best only palliative. Moreover, operation for elephantiasis scroti is often followed by a similar condition of the leg. In nearly every instance where, in the course of this inquiry, large masses of glands were removed, a haematocele or a lymphocele formed at the seat of operation. Medical treatment is even less satisfactory.

Although we know something of the pathological effects of this parasite, it is probable that further research will show that yet other pathological conditions are to be ascribed to its presence.

The increasing prosperity of these islands is attracting more white settlers every year. In certain districts a large proportion of whites are infected with the filaria, and are thereby exposed to a great deal of inconvenience, if not danger to life. As I have endeavoured to show, nearly all the natives are infected.

Manifestly, in view of the future of these islands, it is important that measures be instituted to combat so grave an infection. The special recommendations which occur to the writer are based on the following facts :—

*Stegomyia pseudoscutellaris*, the commonest mosquito in the Fiji group, is the chief carrier of the local filaria. I have endeavoured to learn something of its habits. My observations are detailed in Appendix XXXIII. *S. pseudoscutellaris* is a strictly day-biting species, and is especially abundant in mangrove swamps. Its food appears to consist entirely of blood; there was no proof that it obtains its nourishment in any way from the mangroves. Dilute copper sulphate solution (1 gr. to the gallon) is very prejudicial to the life of the larva.

My recommendations are :—

(1) In towns and villages white settlements should be separated by a considerable space from the native quarters, which, as in the case of malaria, act as a constant source of infection.

(2) The neighbourhood of sluggish and brackish creeks should be avoided as much as possible, and their banks should be kept clear of vegetation.

(3) The mangroves on the foreshore of all larger towns should be cut down.

(4) Large collections of water such as reservoirs, which cannot be screened or drained, should be treated with copper sulphate in weak solution (1 gr. to the gallon, which is considerably less than the strength—1 in 50,000—used in reservoirs in England) to keep them free from algae and other vegetation, as well as larvae. The strength of the copper sulphate must be kept up by frequent additions after heavy rains.

(5) Mosquito nets being of little use in the case of day-biting mosquitoes, mosquito-proof houses, or at least one mosquito-proof room in each house, should be a more frequent feature in the country districts than at present.

I may remark that stegomyiae are found elsewhere than in the swamps, but nowhere in such prodigious numbers. They do not breed in the mangrove swamps in which the water is very salt. The vast numbers

often present in such localities were found to depend on the direction of the prevailing wind; they had been blown from the nearest appropriate breeding ground.

The breeding ground of *S. pseudoscutellaris* is fresh, or, preferably, brackish water, such as occurs in the creeks to be found running through every Fijian village (Phot. XVII.), especially in the eastern islands. The favourite breeding season is in the hot months (November–February). The pupae hatch out eight days after oviposition. The food of the larvae appears to be mainly decaying vegetable matter. The larvae were not found in any number in the wells and other collections of fresh water in the villages, although in such water *Culices* were found to be breeding freely.

I may mention that a few of the wild stegomyiae caught outside the native town of Loma-Loma, on Vanua Balavu, were found to be infected naturally, and that large filaria larvae were found in celloidin sections of an insect caught on an uninhabited islet in Suva harbour.

#### SUGGESTIONS FOR FURTHER WORK ON FILARIASIS.

The following suggestions for further investigations on filariasis in the islands of the Pacific have occurred to me:—

(1) If *Filaria bancrofti* and the filaria found in Fiji be really the same species, can the periodicity of the imported microfilaria *bancrofti* be disturbed by long residence in these islands?

(2) Does the periodic variety of *Filaria bancrofti* normally occur in any of the islands of the Pacific, and if so, what are the chief mosquito intermediaries in these islands?

(3) The explanation of the apparent relative inefficiency of *Culex fatigans* as an intermediary host in Fiji.

(4) The exact pathology of filarial lymphangitis.

(5) More detailed research on the pathology of elephantiasis.

(6) Determination of the life-span of the microfilaria by injection of human blood containing the parasites into a monkey, or a filaria-free man.

(7) The stages of development of *Filaria bancrofti* following its entrance into the human host, and the route it traverses from the skin.

(8) The explanation of the supposed cessation of attacks of lymphangitis on leaving the endemic area.

(9) The determination of the respective geographical ranges of *Stegomyia pseudoscutellaris* and the non-periodic filaria.

(10) The determination of the microfilaria, the adenitis and elephantiasis rates of all the Pacific Islands.

(11) The determination of the cause or causes of filarial periodicity.

(12) How comes it about that, in those places where reinfection of individuals must be constantly going on, cases of extreme degrees of hyper-infection are not more frequent?

(13) In explanation of the absence of microfilariae in the blood of persons manifestly filariated, my observations suggest the following hypothesis: The majority of the larval filariae placed on the skin find their way into lymphatic vessels, and so into the glands, where, though arrested, they continue to develop and attain maturity. In consequence of the fibrosis they determine, or other cause, these filariae fail to get their young into the circulation. Perhaps, as sometimes happens, an anastomosis of lymphatic channels is established. I suggest that, as a rule, it is only, or especially, those filariae which attain and live in lymphatic channels unguarded by glands, that succeed in getting their young into the blood. To support this hypothesis I suggest careful search in the type of lymphatic vessel referred to, especially the thoracic duct.

## APPENDIX I.

MEAN maximum and minimum temperatures and rainfall for fifteen years, 1894-1909, at Suva, Fiji :—

	Maximum.		Minimum.		Rainfall.
January ..	87.5	..	72.6	..	11.636 inches
February ..	88.6	..	73.0	..	15.324 "
March ..	87.9	..	73.6	..	11.766 "
April ..	84.7	..	71.4	..	7.457 "
May ..	82.2	..	70.8	..	8.33 "
June ..	80.5	..	70.7	..	2.133 "
July ..	79.5	..	68.0	..	2.633 "
August ..	78.8	..	67.4	..	4.958 "
September ..	81.4	..	69.9	..	4.256 "
October ..	82.3	..	69.7	..	9.169 "
November ..	83.4	..	72.3	..	21.742 "
December ..	86.3	..	72.7	..	12.902 "

## APPENDIX II.

To show variation in the number of microfilariae in different slides each containing 16 c. mm. blood taken from the same individual, and at the same time of day—Fijian blood :—

A. *Case Solomoni*—

No signs or symptoms of filarial disease.

	Date.	Time.	No. of microfilariae present in peripheral blood :—
3 slides	5.IX.10	10 a.m.	27, 73, 61 : Average 53.
12 slides	5.XII.10	2 p.m.	67, 59, 57, 57, 55, 49, 46, 44, 40, 36, 32, 28 : Average 47.

B. *Case Tiveta Tailemaitonga*—

No signs or symptoms of filarial disease.

	Date.	Time.	No. of microfilariae present in peripheral blood :—
6 slides	14.VIII.10	2 p.m.	294, 255, 239, 236, 234, 134, 202 : Average 226.
12 slides	23.IX.10	2 p.m.	120, 113, 92, 82, 72, 69, 68, 52, 50, 48, 43, 42 : Average 71.

C. *Case Enere Bose*—

Repeated attacks of orchitis and adenitis

	Date.	Time.	No. of microfilariae present in peripheral blood :—
12 slides	29.VI.10	12 a.m.	7, 6, 5, 5, 5, 4, 3, 2, 2, 1, 0 : Average 2.3.

D. *Case Sijane—*

Synovitis of hip-joint.

	Date.	Time.	
8 slides	14.VII.10	2 p.m.	69, 65, 64, 51, 42, 30, 28 : Average 49.

E. *Case Isaiah—*Enlarged epitrochlear glands,  
multiple abscesses.

	Date.	Time.	
12 slides	29.VII.10	12 a.m.	74, 71, 103, 86, 101, 78, 76, 70, 95, 65, 66, 79 : Average 80.

F. *Case Sutherie—*Solomon Islander. *Filaria nocturna*.

	Date.	Time.	
6 slides	18.VIII.10	10 p.m.	5, 19, 25, 15, 15, 15 : Average 15.
„	22.VIII.10	10 p.m.	1, 4, 4, 10, 12, 14 : Average 7.
„	23.VIII.10	10 p.m.	12, 13, 18, 24, 25, 25 : Average 18.
„	24.VIII.10	10 p.m.	2, 9, 10, 11, 13, 15 : Average 10.
„	25.VIII.10	10 p.m.	19, 12, 26, 13, 9, 10 : Average 15.

## APPENDIX III.

SHOWING number of *Male* Fijians harbouring microfilariæ in their blood at different ages. The calculations have been made from blood examinations made in the day-time only. The youngest examined for microfilariæ was under a year, the oldest was computed to be over 85 years ; neither of these was infected :—

Age.	Number examined.	Number infected.	Percentage infected.
Under 6 years	23	0	0 per cent.
6-10 „	49	1	2.04 „
10-20 „	222	35	15.7 „
20-30 „	212	74	34.7 „
30-40 „	118	56	47.5 „
40-50 „	83	37	44.7 „
50-60 „	58	26	44.8 „
60 years and over	39	16	41.0 „
	<u>804</u>	<u>245</u>	<u>30.4 per cent.</u>

Included amongst these were : twenty-four natives of pure Tongan blood, resident in Fiji ; four natives of pure Samoan blood, resident in Fiji ; one native of Futuna ; and one native of New Hebrides.

The youngest male Fijian harbouring microfilariæ was 8 years ; he had only one microfilaria to 16 c. mm. of blood. The next youngest was 10 years ; he had five microfilariæ. The oldest was about 70 years.

With the possible exception of those who have been educated in New Zealand and Australia, no Fijian knows his own age, so that the ages given in this table must be regarded as approximate only.

#### APPENDIX IV.

SHOWING number of *Female* Fijians harbouring microfilariae in their blood at different ages. The calculations were made from day blood. The youngest examined was a year old; the oldest was computed to be about 80.

Age.	Number examined.	Number infected.	Percentage infected.
Under 6 years	12	1	8·3 per cent.
6-10 "	44	3	6·8 "
10-20 "	125	29	23·2 "
20-30 "	157	33	21·0 "
30-40 "	86	21	24·4 "
40-50 "	40	10	25·0 "
50-60 "	34	8	23·4 "
60 years and over	18	8	44·4 "
	<u>516</u>	<u>113</u>	<u>23·8 per cent.</u>

Amongst these were: twenty-eight natives of pure Tongan blood, resident in Fiji; three Samoans, resident in Fiji; three Fijian-European half-castes; and one Samoan-European half-caste.

The youngest female Fijian harbouring microfilariae was five years of age. The glands in both groins were enlarged, as were also the epitrochlear glands on both sides. She had fifty-seven microfilariae in 16 c. mm. of blood. Two girls of 8 years were found with microfilariae, but neither of them had enlarged glands or other signs of filarial disease. A child of 2½ years was seen with epitrochlear glands on each side the size of a thrush's egg, for which no cause could be ascertained. Microfilariae were not found in her blood.

The Fijians, although they are not permitted by the Government to leave the group for any of the white colonies unless a sum of £100 is deposited as a surety for their safe return, are great travellers amongst their own islands. For an estimation of filarial incidence it is therefore desirable to know whether in any given individual the infection may possibly have been contracted in some other country. Thus, of the total number of male Fijians, twelve had visited Tonga, thirteen had visited Tonga and Samoa, three the island of Rotumah (300 miles north of Fiji), two had visited New Zealand, three Samoa alone, four Australia, one Australia and the Solomon Islands, and one Tonga, Samoa, the Solomon islands and Tahiti. Sixteen of the Tongans had revisited their native island, and one Samoan his. Thus, in this total of 804 men examined, only fifty-eight had ever been out of Fiji. Of the 516 women, six had visited Tonga and Samoa, one Samoa alone; eleven Tongans had visited Tonga and two Samoa.

## APPENDIX V.

GIVING further details, not mentioned in the text, of the discovery of parental forms.

(1). Fijian male, *act.* 24. Filarial abscess situated over right epitrochlear gland. Excision. One perfect female was found, apparently recently dead (could not be revived on heating). Uterus packed with embryos and ova. Many live microfilariae found in blood and in exudate. Anterior end of another female found, whose uterus was also packed with microfilariae. The cuticle of the perfect female was slightly torn, and from the rent protruded one of the uterine tubes discharging ova and embryos. Length of female, 65 mm.; breadth, .177 mm.; distance of vaginal orifice from anterior extremity, .76 mm.

There were present in the circulation 100 microfilariae per 16 c. mm. in the day-time and a similar number at night. After removal of the adults the number of microfilariae present did not diminish (*vide* Periodicity Chart XX.).

(2). Fijian male, *act.* 24. Enlarged epitrochlear gland (right arm), size of a pigeon's egg, hard and moveable; no other signs of filariasis. Numbers of slides of measured blood examined; no microfilariae were found. Two c.c. blood abstracted from median basilic vein into 1 per cent. citrate solution and centrifuged; no microfilariae found. The gland was carefully excised. The capsule was thickened and very vascular. The efferent and afferent lymphatics were large and apparent. The gland was bisected, and several active filariae were found in the centre. Some had been torn in the dissection. Parts of five females were found, still moving actively, with the uterine tubes and alimentary canal protruding through the cuticle. Five additional perfect females were isolated, and two perfect males, besides a third lacerated specimen. Two males and two females were placed in watch-glasses with normal saline in the incubator at 37 C., and kept for one-and-a-half hours. At the end of that time it was found that the two females had coiled themselves up to such an extent that they could not be unravelled, and broke up in an attempt to do so. One male with protruded spicules was found coiled round a female. The tail end of the male was lying near the vaginal orifice of the female, from which I infer they had been *in coitu* when discovered. The remaining three females and two males were measured in normal saline, by warming which the worms became inactive, and lay stretched out in a position favourable for accurate measurement when the superfluous saline was blotted away. Two females, one small, were found coiled up in the cortex of the gland; at first they seemed dormant, but both became active when placed in warm saline solution. They were in a cyst-like structure, surrounded by a putty-like material which, when examined, was found to consist of some crystalline substance and great numbers of eosinophile cells. Altogether thirteen live filariae were taken out of this gland. No microfilariae were found in the gland juice or in sections. Six c.c. of blood were abstracted from a vein six months afterwards, but still no microfilariae could be found. The filariae, after measurement, were plunged into hot 70 per cent. alcohol for preservation and transmission to Dr. Leiper of the London School of Tropical Medicine.

Measurements as follows:—

1. Female. Length, 55 mm.; breadth, .222 mm.; distance of vaginal opening from anterior extremity .69 mm.

2. Female. Length, 65 mm.; breadth, .206 mm.; distance of vaginal opening from anterior extremity, .69 mm.
3. Immature female. Uterus contained only ova, no ripe embryos. Length, 42 mm.; breadth, .1824 mm.; distance of vaginal opening from cephalic end, .64 mm.

None of the microfilariae observed emerging from the vaginal orifice of the female showed any signs of life when under microscopic examination.

- (1) Male. Length, 29 mm.; breadth, .1296 mm.
- (2). Male. Length, 25 mm.; breadth, .129 mm.

The entire length of two spicules which protruded from the cloaca of these males was measured. The larger measured .432 mm., the smaller .2 mm.

(3). Tongan, *aet.* 36. Matted mass of epitrochlear glands was removed from an otherwise normal subject who, five days previously, had had an attack of filarial fever. The mass consisted of two glands, and was about the size of a pigeon's egg. Frequent examination ascertained that microfilariae were absent in the circulation. In the capsule of one gland part of a recently severed and still active male was found, measuring only .087 mm. in diameter.

In the centre of the glandular mass was a small immature female with uterus packed full of immature ova.

Immature female. Length, 31 mm.; breadth, 135 mm.; opening of vagina from cephalic end, .435 mm.

No microfilariae were found in the gland juice.

(4). Fijian male, *aet.* 30. Mass of enlarged inguinal glands (oblique set) on the right side, removed at operation. The glands were hard and shotty. There was also a mass about the size of a duck's egg on the left side. Numerous slides made from blood before and after operation, but no microfilariae could be found; 1 c.c. blood abstracted from cephalic vein and centrifuged gave a negative result. The mass, when removed, was found to consist of several glands matted together, each showing on section an adenomatous cortex and a fibrous medulla. Several dead and calcified filariae were found in the gland, and also an immature but perfect female having a small rent in the cuticle from which the uterine tubes protruded. No microfilariae were found in smears of the gland-juice.

Immature female. Length, 50 mm.; breadth, .15 mm.; opening of the vagina from cephalic end, .434 mm.; opening of anus from posterior extremity, .25 mm.

Male. Length, 25 mm.; breadth, .09 mm.

(5). Fijian male, *aet.* 30. Mass of pedunculated groin glands (*vide* Phot. VII.), size of a man's fist, removed at operation. Out of this mass the two largest and very vascular glands, measuring 9 cm. by 5.5 cm., and consisting of a fibrous medulla and adenomatous cortex, were dissected (*Vide* Pl. II.). Great numbers of calcified filariae were found in the centre. An active female and part of a recently dead male filaria were found. From the vaginal orifice of the former great numbers of apparently dead microfilariae emerged. The uterine tubes protruded through a small rent in the cuticle in the posterior part of the worm.

Two c.c. blood from the median basilic vein were centrifuged in citrate solution, and numerous ordinary blood slides were examined, but no microfilariae were found. Smears of the gland juice also were equally barren.

Adult female. Length, 50 mm.; breadth, .128 mm.; vaginal orifice from anterior extremity, .69 mm.

(6). Fijian male, *aet.* 45, who died of pulmonary tuberculosis. Patient had been under observation for ten months. Unripe embryos and sheaths of microfilariae had been from time to time obtained from enlarged groin glands by puncture. When first seen, in March, 1910, the blood contained no microfilariae, though they were searched for repeatedly; 2 c.c. were at this time abstracted from median basilic vein into citrate solution, and centrifuged with the same result. Eight months later one microfilaria was found in three slides of measured blood, and a few days later three microfilariae were found per slide; a twelve-hourly periodicity chart was kept, but no periodicity was detected. At the post-mortem only one microfilaria was found in smears made from spleen blood. Large mass of groin glands were dissected out post-mortem.

In the centre of this mass a complete adult male and a complete female filaria, alive and active, were found. Portions of another dead male and another dead female were also found, besides portions of extruded uterine tubes packed with ova. A great many calcified filariae were also discovered. The uterus of the living female worm, although she was a large specimen, did not contain any embryos, but only ova, none of which were seen to emerge from the vaginal orifice.

Adult female.—Length, 67 mm.; breadth, .153 mm.; vaginal opening, .6 mm. from mouth; anus, .21 mm. from tip of tail.

Adult male.—Length, 28 mm.; breadth, .090 mm.

## APPENDIX VI.

SHOWING percentages of male and female Fijians of all ages infected with filarial disease; comparison between the two sexes. 804 males and 516 females examined.

A. Microfilariae present; no clinical signs of filarial disease.	
Males.	Females.
77 = 9.5 per cent.	81 = 15.6 per cent.
B. Microfilariae present; signs of filarial disease.	
Males.	Females.
159 = 19.7 per cent.	33 = 6.3 per cent.
C. Microfilariae absent; clinical signs of filarial disease present.	
Males.	Females.
287 = 36.6 per cent.	95 = 18.4 per cent.
Total filarial infection:—	
Males.	Females.
523 = 64.8 per cent.	209 = 40.3 per cent.

Under the heading of filarial disease I have included the following: Enlarged glands, especially groin glands and epitrochlears; varicose groin glands; hydroceles; enlarged testes; elephantiasis; arthritis of probable filarial origin, and frequently ending in ankylosis; filarial fever and lymphangitis, when present at time of examination. Abscess mostly situated in groin, axilla and over internal condyle of humerus; intramuscular abscess (in serratus magnus, latissimus dorsi and quadriceps extensor) of otherwise unexplainable origin.

## SUBDIVISIONS OF HEADINGS B &amp; C.

## B. Microfilariae present in association with signs of filarial disease.

MALES : TOTAL 159.		Microfilariae in	
Enlarged glands and varicose groin glands	54.7 per cent. of cases.		
Hydrocele ; enlarged testes ; elephantiasis ; filarial fever ; arthritis	.. .. . 39.0	..	..
Abscess (occurred in 95 out of total number of this type of case)	.. .. . 57.7	..	..
Abscess only sign of filarial disease in 13	.. 8.1	..	..
Elephantiasis in 16, as follows: Leg 4 ; arm 3 ; arm and leg 2 ; scrotum 2 ; scrotum and leg 1 ; arm, leg and scrotum 3 ; arm and scrotum 1	10.0	..	..
Thickened lymphatics, felt as a cord in upper arm or thigh, in 10. In half of these it was the only sign	.. .. . 6.2	..	..

FEMALES : TOTAL 33.		Microfilariae in	
Enlarged glands and varicose groin glands	.. 54.5 per cent. of cases.		
Elephantiasis ; arthritis ; filarial fever	.. 9.0	..	..
Abscess (occurred in 18 out of total number of this type of case)	.. .. . 54.5	..	..
Abscess, only sign of filarial disease, in 13	.. 39.4	..	..
Elephantiasis, 2 cases—both of arm	.. 6.0	..	..
Thickened lymphatics in 3. Only sign of filarial disease in 1	.. .. . 9.0	..	..

Varicose groin glands are included with enlarged groin glands, seeing that only in one instance did the condition correspond with the published descriptions of this type of disease in some other countries. In Fijians these glandular swellings cannot to any extent be reduced by pressure. They are composed of greatly enlarged and fibrosed glands, often 2-3 inches in diameter, and situated in a tangled mass of lymphatic vessels. When punctured the lymph can be extracted, but only with difficulty.

As superficial glands, especially the inguinal set, are usually enlarged in natives, I have not included any glands as "enlarged" which were not bigger than a large pea.

## C. Microfilariae absent ; signs of filarial disease.

MALES : TOTAL 287.			
Enlarged glands and varicose groin glands	.. .. . in 60.2 per cent. of total number.		
Hydrocele ; enlarged testes ; elephantiasis ; filarial fever ; arthritis	.. .. . 24.7	..	..
Abscess occurred in 108 of total number, i.e.	.. .. . 37.6	..	..
Abscess the only sign of filarial disease	.. 6.2	..	..
Elephantiasis in 23, as follows: Leg 5 ; arm 3 ; arm and leg 2 ; scrotum 8 ; scrotum and leg 3 ; arm, leg and scrotum 2	.. .. . 8.7	..	..
Thickened lymphatics in upper-arm and thigh. In one-half of these it constituted the only sign	.. .. . 14.3	..	..

## FEMALES : TOTAL 95.

Enlarged glands and varicose groin glands .. .. .	in 52.5 percent. of total number.
Hydrocele; enlarged testes; elephantiasis; filarial fever; arthritis .. ..	8.4 .. ..
Abscess occurred in 43 of total number .. .. .	45.2 .. ..
Abscess the only sign of filarial disease ..	12.6 .. ..
Elephantiasis in 6, as follows: Leg, 1; arm, 2; arm and leg, 2; breast, 1 ..	6.3 .. ..
Thickened lymphatics in 9. In 7 of these it constituted the only sign ..	9.4 .. ..

## Elephantiasis rate for total Fijian population examined.

Number examined, 1,320. Number of cases of elephantiasis, 47;  
Rate, 3.56 per cent.

Of these 47, 18 had microfilariae in circulation = 38.2 per cent.

## MALES.

Elephantiasis rate = 4.8 per cent.

## FEMALES.

Elephantiasis rate = 1.5 per cent.

## MALES.

In 39 cases of elephantiasis, 41 per cent. had microfilariae.

In 260 cases of glandular enlargement, 33.4 per cent. had microfilariae.

## FEMALES.

In 8 cases of elephantiasis, 2, or 25 per cent., had microfilariae.

In 71 cases of glandular enlargement, 22.5 per cent. had microfilariae.

## D. THE VALUE OF EPITROCHLEAR GLAND AS A DIAGNOSTIC SIGN.

1,264 cases were specially examined for presence of enlarged epitrochlear glands. These were found to be enlarged in 281 instances; of these cases 97, or 34.6 per cent., harboured microfilariae. 184, or 65.4 per cent., had no microfilariae.

These statistics include representatives of all the races residing in Fiji: Europeans, Fijians, Indians, Tongans, Samoans and Solomon Islanders.

## APPENDIX VII.

TABLES showing relative percentage, at various ages, of those cases in which microfilariae were found in the blood, but who exhibited no signs of filariasis, to total number infected with microfilariae at the corresponding age.

Age.	Number infected.	MALES.		Percentage.
		Number without signs.		
1-10 ..	0 ..	0 ..		0 per cent.
10-20 ..	35 ..	11 ..	31.1	..
20-30 ..	74 ..	23 ..	31.0	..
30-40 ..	56 ..	19 ..	35.7	..

## FEMALES.

Age.	Number infected.	Number without signs.	Percentage.
1-10 ..	4 ..	3 ..	75.0 per cent.
10-20 ..	29 ..	22 ..	75.8 „
20-30 ..	33 ..	23 ..	69.6 „
30-40 ..	21 ..	12 ..	57.1 „

Ratio of those harbouring microfilariae, without clinical signs, to total filarial infection—

Males.  
14.5 per cent.

Females.  
38.7 per cent.

## APPENDIX VIII.

SHOWING that the number of microfilariae present in the circulation is no indication of the severity of the lesions present.

## (1). With no sign of filarial disease :

Below 5 micro- filariae per 16 c. mm. blood.	5-20 micro- filariae per 16 c. mm. blood.	20-100 micro- filariae per 16 c. mm. blood.	100-300 micro- filariae per 16 c. mm. blood.	300 microfilariae or over per 16 c. mm. blood.
31.2 per cent.	35.3 per cent.	27.0 per cent.	5.9 per cent.	.5 per cent.

## (2). With signs of filarial disease :

Below 5 micro- filariae per 16 c. mm. blood.	5-20 micro- filariae per 16 c. mm. blood.	20-100 micro- filariae per 16 c. mm. blood.	100-200 micro- filariae per 16 c. mm. blood.	300 microfilariae or over per 16 c. mm. blood.
23.3 per cent.	30.5 per cent.	32.0 per cent.	11.8 per cent.	2.4 per cent.
These include 7 cases ele- phantiasis, 5 hydroceles, 2 varicose en- larged groin glands, 4 enlarged testes, 6 abscess, 21 enlarged glands.	These include 3 cases ele- phantiasis, 2 hydroceles, 4 enlarged & varicose groin glands, 2 enlarged testes, 20 abscess, 25 enlarged glands.	These include 5 cases ele- phantiasis, 5 hydroceles, 6 enlarged & varicose groin glands, 1 enlarged testis, 16 abscess, 25 enlarged glands, 2 arthritis.	These include 2 cases ele- phantiasis, (227 micro- filariae), 3 hydroceles, 5 enlarged & varicose groin glands, 7 abscess, 6 enlarged glands.	These include 1 enlarged & vari- cose groin gland 2 abscess, 2 enlarged glands (hav- ing 430 and 427 micro- filariae in blood respec- tively).

The highest count registered was 469 microfilariae per 16 c. mm. blood ; the patient, a man, showed no signs whatever of filarial disease.

## APPENDIX IXa.

Eosinophilia.			Microfilariae in blood.		No ova of Intestinal Parasites.		Fijians.	
Microfilariae in 16 c. mm.	Sex.	Age.	Symptoms or signs.	White blood count per c.mm. Average of 768 squares. Thoma-Zeiss.	Red blood per c. mm. Average of 64 squares. Thoma-Zeiss.	Haemoglobin.	Differential count. 300 cells.	Number of eosinophiles per c. mm.
A.M. 43 P.M. 56	Male	35	Nil	7,700	5,500,000	100 per cent.	Polymorphs 65 Lymphocytes 17 Eosinophiles 15 Large Mononuclears 3	1,155
A.M. 14 P.M. 9	Male	21	Nil	7,480	4,587,000	100 "	Polymorphs 47 Lymphocytes 52 Eosinophiles 17 Large Mononuclears 4	1,271
A.M. 3 P.M. 2	Male	20	Nil	5,000	4,212,500	100 "	Polymorphs 58 Lymphocytes 26 Eosinophiles 12 Large Mononuclears 4	550
A.M. 130 P.M. 156	Male	35	Nil	5,312	4,050,000	100 "	Polymorphs 48 Lymphocytes 29 Eosinophiles 19 Large Mononuclears 4	1,008
A.M. 7 P.M. 2	Male	40	Nil	3,500	5,800,000	100 "	Polymorphs 49 Lymphocytes 36 Eosinophiles 12 Large Mononuclears 3	420
A.M. 14 P.M. 9	Female Examined	18 6 months after.	Nil	6,800 Few ova of <i>Tricocephalus</i>	4,187,000 <i>dispar</i> found.	100 "	Polymorphs 48 Lymphocytes 32 Eosinophiles 16 Large Mononuclears 4	1,088
A.M. 1 P.M. 0	Female	20	Nil	8,948	5,524,000	100 "	Polymorphs 57 Lymphocytes 31 Eosinophiles 9 Large Mononuclears 3	886
Average of total ...	...	...	...	6,391	4,837,142	100 per cent.	Polymorphs 53 Lymphocytes 31 Eosinophiles 14 Large Mononuclears 2	911 = Eosinophilia average of 14.2 per cent.

N.B.—All those without ova in faeces examined again six months later. All were still free from intestinal ova except in one case already referred to.

## APPENDIX IXb.

*Eosinophilia.* Microfilariae in blood with ova of Intestinal Parasites. Fijians.

Microfilariae in 16 c. mm.	Sex.	Age.	Symptom or signs.	White blood count.	Ova.	Red blood count.	Haemoglobin.	Differential count. 300 cells.	Number of eosinophiles. per c. mm.
A.M. 5 P.M. 8	Female	28	Nil	6,240	<i>Tricocephalus dispar</i>	5,000,000	90 per cent.	Polymorphs 64 Lymphocytes 24 Eosinophiles 9 Large Mononu- clears	571
A.M. 0 P.M. 1	Male	30	Nil	6,800	<i>Tricocephalus dispar</i>	2,024,000	90 "	Polymorphs 54 Lymphocytes 24 Eosinophiles 20 Large Mononu- clears	1,360
A.M. 45 P.M. 53	Male	30	Nil	5,600	<i>Tricocephalus dispar, Ascaris lumbricoides</i>	3,980,000	80 "	Polymorphs 2 Lymphocytes 50 Eosinophiles 20 Large Mononu- clears	1,512
A.M. 2 P.M. 1	Male	21	Nil	7,800	<i>Tricocephalus dispar</i>	2,024,000	80 "	Polymorphs 3 Lymphocytes 49 Eosinophiles 35 Large Mononu- clears	1,092
A.M. 8 P.M. 6	Male	30	Nil	8,736	<i>Tricocephalus dispar</i>	5,375,000	100 "	Polymorphs 2 Lymphocytes 56 Eosinophiles 25 Large Mononu- clears	1,048
A.M. 6 P.M. 7	Female	20	Nil	7,800	<i>Tricocephalus dispar</i>	4,987,000	100 "	Polymorphs 7 Lymphocytes 46 Eosinophiles 22 Large Mononu- clears	2,262
A.M. 110 P.M. 100	Male	40	Nil	6,240	<i>Tricocephalus dispar</i>	5,690,000	100 "	Polymorphs 3 Lymphocytes 48 Eosinophiles 32 Large Mononu- clears	998

## APPENDIX IXb.—continued.

*Eosinophilia.* Microfilariae in blood with ova of Intestinal Parasites. Fijians.

Microfilariae in 16 c. mm.	Sex.	Age.	Symptoms or signs.	White blood count.	Ova.	Red blood count.	Haemoglobin.	Differential count. 300 cells.	Number of eosinophiles. per c. mm.
A.M. 4 P.M. 13	Male	21	Nil	4,680	<i>Ankylostoma duodenale</i>	3,600,000	90 per cent.	Polymorphs 36 Lymphocytes 42 Eosinophiles 18 Large Mononu- clears 4	842
A.M. 77 P.M. 63	Male	40	Nil	6,800	<i>Tricocephalus dispar</i>	4,362,000	80 "	Polymorphs 41 Lymphocytes 29 Eosinophiles 29 Large Mononu- clears 1	1,972
A.M. 7 P.M. 8	Male	24	Nil	5,800	<i>Tricocephalus dispar</i>	6,650,000	100 "	Polymorphs 49 Lymphocytes 43 Eosinophiles 5 Large Mononu- clears 3	290
A.M. 17 P.M. 14	Male	21	Nil	4,000	<i>Tricocephalus dispar</i>	4,780,000	100 "	Polymorphs 62 Lymphocytes 23 Eosinophiles 13 Large Mononu- clear 2	520
A.M. 18 P.M. 25	Male	21	Nil	6,500	<i>Ankylostoma duodenale</i>	5,162,000	100 "	Polymorphs 63 Lymphocytes 25 Eosinophiles 11 Large Mononu- clears 1	715
A.M. 1 P.M. 4	Male	20	Nil	8,400	<i>Tricocephalus dispar</i>	5,737,750	100 "	Polymorphs 79 Lymphocytes 14 Eosinophiles 4 Large Mononu- clears 3	336
Average of total ...	...	...	...	6,568	...	4,404,384	96 per cent.	Polymorphs 54 Lymphocytes 28 Eosinophiles 15 Large Mononu- clears 3	1,039 = Eosinophilia average of 15.5 per cent.

## APPENDIX IXc.

<i>Eosinophilia.</i>			No microfilariae in blood.			No ova of intestinal parasites.			Fijians.	
Microfilariae per 16 c. mm.	Sex.	Age.	Symptoms or signs.	White blood count.	Ova.	Red blood count.	Haemoglobin	Differential count. 300 cells.	Number of eosinophiles. per c. mm.	
0	Female	20	Nil	7,176	0	3,825,000	100 per cent.	Polymorphs 55 Lymphocytes 30 Eosinophiles 12 Large Mononu- clears 3	860	
0	Male	20	Nil	6,866	0	5,237,500	100 "	Polymorphs 49 Lymphocytes 36 Eosinophiles 12 Large Mononu- clears 3	823	
0	Male	21	Nil	5,404	0	5,537,500	100 "	Polymorphs 69 Lymphocytes 18 Eosinophiles 9 Large Mononu- clears 4	486	
0	Male	21	Nil	8,424	0	4,650,000	100 "	Polymorphs 59 Lymphocytes 24 Eosinophiles 12 Large Mononu- clears 5	1,010	
0	Female	19	Nil	8,112	0	2,812,500	80 "	Polymorphs 36 Lymphocytes 40 Eosinophiles 18 Large Mononu- clears 6	1,459	
0	Female	20	Nil	5,928	0	6,487,000	90 "	Polymorphs 52 Lymphocytes 32 Eosinophiles 12 Large Mononu- clears 4	698	
0	Male	21	Nil	7,800	0	3,987,500	80 "	Polymorphs 57 Lymphocytes 17 Eosinophiles 24 Large Mononu- clears 2	1,872	

APPENDIX IXc.—*continued.*

<i>Eosinophilia.</i>		No microfilariae in blood.		No ova of intestinal parasites.		Fijians.	
Microfilariae per 16 c. mm.	Sex.	Age.	Symptoms or signs.	White blood count.	Ova.	Red blood count.	Haemoglobin.
0	Male	20	Nil	6,240	0	4,137,500	90 per cent.
							Polymorphs 53 Lymphocytes 34 Eosinophiles 10 Large Mononu- 3 clears 3
							624
Average of total	...	...	...	6,994	...	4,584,312	92 per cent.
							Polymorphs 54 Lymphocytes 29 Eosinophiles 13 Large Mononu- 4 clears 4
							979 =Eosinophilia average of 13.9 per cent.

All examined six months later. No ova of intestinal parasites found.

## APPENDIX IXd.

*Eosinophilia.* No microfilariae in blood. Ova of intestinal parasites. Fijians.

Microfilariae.	Sex.	Age.	Symptom or signs.	White blood count.	Ova.	Red blood count.	Haemoglobin.	Differential count. 300 cells.	Number of eosinophiles, per c. mm.
0	Female	21	Nil	6,552	<i>Ankylostoma duodenale</i> <i>Tricocephalus dispar</i>	4,787,500	100 per cent.	Polymorphs 55 Lymphocytes 29 Eosinophiles 10 Large Mononuclears 6	655
0	Male	22	Nil	5,392	<i>Tricocephalus dispar</i>	4,387,000	100 "	Polymorphs 51 Lymphocytes 24 Eosinophiles 19 Large Mononuclears 6	1,024
0	Male	20	Nil	5,616	<i>Tricocephalus dispar</i>	3,762,500	70 "	Polymorphs 69 Lymphocytes 19 Eosinophiles 10 Large Mononuclears 2	561
0	Male	20	Nil	7,176	<i>Ankylostoma duodenale</i>	5,350,000	70 "	Polymorphs 56 Lymphocytes 27 Eosinophiles 11 Large Mononuclears 6	789
0	Male	21	Nil	7,176	<i>Tricocephalus dispar</i>	3,600,000	80 "	Polymorphs 48 Lymphocytes 41 Eosinophiles 8 Large Mononuclears 3	573
0	Male	19	Nil	5,610	<i>Ankylostoma duodenale</i> <i>Tricocephalus dispar</i>	6,625,000	70 "	Polymorphs 42 Lymphocytes 30 Eosinophiles 24 Large Mononuclears 4	1,346
0	Male	20	Nil	6,864	<i>Tricocephalus dispar</i>	3,262,500	100 "	Polymorphs 31 Lymphocytes 25 Eosinophiles 43 Large Mononuclears 1	2,949

## APPENDIX IXd.—continued.

Eosinophilia.				No microfilariae in blood.		Ova of intestinal parasites.		Fijians.	
Microfilariae per 16 c. mm.	Sex.	Age.	Symptoms or signs.	White blood count.	Ova.	Red blood count.	Haemoglobin.	Differential count.	Number of eosinophiles. per c. mm.
0	Female	20	Nil	6,864	<i>Tricocephalus dispar</i>	5,112,500	100 per cent.	Polymorphs 49 Lymphocytes 32 Eosinophiles 13 Large Mononuclears 6	891
0	Male	23	Nil	8,424	<i>Tricocephalus dispar</i>	3,350,000	80 "	Polymorphs 59 Lymphocytes 35 Eosinophiles 5 Large Mononuclears 1	421
0	Male	24	Nil	6,240	<i>Tricocephalus dispar</i> <i>Ankylostoma duodenale</i>	3,975,000	100 "	Polymorphs 55 Lymphocytes 32 Eosinophiles 10 Large Mononuclears 3	624
0	Male	21	Nil	6,848	<i>Ankylostoma duodenale</i>	5,350,000	100 "	Polymorphs 70 Lymphocytes 20 Eosinophiles 6 Large Mononuclears 4	410
0	Male	22	Nil	8,112	<i>Tricocephalus dispar</i>	4,790,000	100 "	Polymorphs 63 Lymphocytes 25 Eosinophiles 10 Large Mononuclears 2	811
Average of total	...	...	...	7,295	...	4,554,500	89 "	Polymorphs 54 Lymphocytes 29 Eosinophiles 14 Large Mononuclears 3	921 =Eosinophilia average of 13.5 per cent.

It should be noted that one Fijian male had an eosinophilia of 43.0 per cent. without microfilariae or any signs of filariasis, and this was found to be constant. Five months afterwards it was 37.0 per cent.

## APPENDIX IXe.

### Frequency of Intestinal Parasites amongst Fijians.

Examination of 209 stools :—

156, or 74·6 per cent., had ova of some intestinal parasite ; 58, or 27·8 per cent., had ova of *Ankylostoma duodenale* or *Necator americanus* ; 77, or 37·2 per cent., had ova of *Tricocephalus dispar* ; 21, or 27·2 per cent., had ova of *Tricocephalus* and *Ankylostoma*.

Ova of *Ascaris lumbricoides* were found only three times, twice being in association with *Tricocephalus* and *Ankylostoma*. Ova of Cestodes were not found at all.

There is considerable variation in the percentages of Fijians infected in different districts.

1. Nasinu School. Boys 8-18 years : near Suva. Seventy-three examined. 42·4 per cent. had ova of parasites ; 30·1 per cent. had *Ankylostoma duodenale* ; the rest, *Tricocephalus dispar*.

2. High School, Suva. Between 6-14 years of age. Thirty-two examined, male and female. 71·8 per cent. had ova of parasites ; 40·6 per cent. *Ankylostoma duodenale* ; the rest, *Tricocephalus dispar* ; two had *Ascaris* ova.

3. Boys' School, Lakemba, Lau group. Males between 8-18. Forty-seven examined. 46·8 had ova of parasites ; 42·7 per cent. had ova of *Tricocephalus dispar* ; only 4·1 per cent. had ova of *Ankylostoma duodenale*.

Of seventeen adult worms removed post-mortem from three Fijians Dr. Leiper has ascertained that no fewer than fourteen are adult *Necator americanus*.

## APPENDIX IXf.

Eosinophilia. Fijians with elephantiasis.

Micro-filariæ. per 16 c. mm.	Sex.	Age.	Affection.	White blood count.	Ova.	Red blood count.	Haemoglobin.	Differential count.	Number of eosinophiles. per c. mm.
A.M. 0 P.M. 0	Male	45	Elephantiasis left leg and left arm.	5,616	<i>Ankylostoma duodenale</i>	5,112,500	70 per cent.	Polymorphs 60 Lymphocytes 27 Eosinophiles 9 Large Mononu- clears 4	504
A.M. 1 P.M. 9	Male	40	Elephantiasis right arm and left leg.	8,756	<i>Ankylostoma duodenale</i> <i>Tricocephalus dispar</i>	3,200,000	100 "	Polymorphs 80 Lymphocytes 15 Eosinophiles 4 Large Mononu- clears 1	350
A.M. 0 P.M. 0	Male	22	Elephantiasis right leg. Enlarged testes. Enlarged glands	10,608	?	5,362,500	100 "	Polymorphs 40 Lymphocytes 46 Eosinophiles 11 Large Mononu- clears 3	1,166
A.M. 0 P.M. 0	Male	58	Elephantiasis both legs, slight of scrotum. Testis en- larged.	9,984	?	5,250,000	70 "	Polymorphs 68 Lymphocytes 15 Eosinophiles 11 Large Mononu- clears 6	1,097
A.M. 0 P.M. 0	Female	55	Elephantiasis left arm. Abscesses.	7,800	?	4,450,000	100 "	Polymorphs 56 Lymphocytes 23 Eosinophiles 18 Large Mononu- clears 3	1,404
A.M. 0 P.M. 0	Male	60	Elephantiasis both arms and legs.	5,616	?	4,000,000	100 "	Polymorphs 77 Lymphocytes 17 Eosinophiles 4 Large Mononu- clears 2	224

## APPENDIX IXf.—continued.

Eosinophilia. Fijians with elephantiasis.

Microfilariae	Sex.	Age.	Affection.	White blood count.	Ova.	Red blood count.	Haemoglobin.	Differential count.	Number of eosinophiles per c. mm.
A.M. 0 P.M. 0	Male	29	Elephantiasis scroti. Enlarged groin glands (? tubercular). Elephantiasis left leg and scrotum.	11,544	<i>Ankylostoma duodenale</i>	5,050,000	100 per cent.	Polymorphs 74 Lymphocytes 18 Eosinophiles 5 Large Mononuclears 3	577
A.M. 0 P.M. 0	Male	45		6,884	<i>Tricocephalus dispar</i>	5,500,000	100 "	Polymorphs 83 Lymphocytes 12 Eosinophiles 2 Large Mononuclears 3	149
A.M. 0 P.M. 0	Male	45	Early elephantiasis left leg.	7,176	Nil.	4,712,500	100 "	Polymorphs 77 Lymphocytes 14 Eosinophiles 5 Large Mononuclears 4	358
A.M. 2 P.M. 2 (Average of 3 slides)	Male	60	Elephantiasis scroti. Double varicose groin glands.	8,072	<i>Tricocephalus dispar</i>	4,300,000	100 "	Polymorphs 43 Lymphocytes 36 Eosinophiles 19 Large Mononuclears 2	1,533
A.M. 0 P.M. 0	Male	40	Elephantiasis scroti and left leg	6,552	<i>Tricocephalus dispar</i>	3,762,500	100 "	Polymorphs 51 Lymphocytes 33 Eosinophiles 9 Large Mononuclears 7	589
Total average of 11 cases				8,055		4,609,090	95 "	Polymorphs 65 Lymphocytes 23 Eosinophiles 9 Large Mononuclears 3	722 = Eosinophilia average of 8.9 per cent.

## APPENDIX IXg.

\* Periodicity in eosinophilia.

	Microfilariae per 16 c. mm.	White blood count.	Ova of parasites.	Differential count.	Eosinophiles per c. mm.
(1) Eleri Bose, Fijian, 21. 28. IX. 10.	10 a.m. 3 (average of 3 slides) 10 p.m. 6 (average of 3 slides)	7,176 7,800	<i>Tricocephalus</i> <i>dispar</i>	P. 63. E. 5 L. 25. M. 7 P. 63. E. 3 L. 30. M. 4	358 234
(2) Sutherie, Solomon Islander, 30. <i>Filaria</i> <i>bancrofti</i> , with nocturnal periodicity. 25. X. 10	10 a.m. 0 (average of 3 slides) 10 p.m. 11 (average of 3 slides)	7,800 8,012	<i>Tricocephalus</i> <i>dispar</i> <i>Ankylos. duod.</i>	P. 59. E. 11 L. 24. M. 6 P. 49. E. 10 L. 35. M. 6	858 800



## APPENDIX IXh.

*Eosinophilia* in filarial diseases other than elephantiasis. 14 Fijians and 1 Indian.

Number of microfilariae per 16 c. mm.	Sex.	Age.	Affection.	White blood count.	Ova.	Red blood count.	Haemoglobin.	Differential count. 300 cells.	Number of eosinophiles. per c. mm.
A.M. 97 P.M. 72	Male	21	Ankylosis left hip-joint. Filarial abscess.	7,508	?	4,500,000	100 per cent.	Polymorphs 56 Lymphocytes 30 Eosinophiles 12 Large Mononuclears 2	825
1 in 3 slides	Male	45	Enlarged and varicose groin glands. Male and female adult filariae found p.m. Hydrocele, left.	9,068	<i>Tricocephalus dispar</i>	2,812,500	100 "	Polymorphs 81 Lymphocytes 15 Eosinophiles 2 Large Mononuclears 2	180
A.M. 2 P.M. 2	Indian Male	22		6,552	?	4,800,000	80 "	Polymorphs 72 Lymphocytes 17 Eosinophiles 5 Large Mononuclears 6	327
A.M. 0 P.M. 0	Male	24	Enlarged epitrochlear gland, right. 5 male, 4 adult female filariae found.	9,048	?	6,337,000	90 "	Polymorphs 67 Lymphocytes 23 Eosinophiles 8 Large Mononuclears 2	723
3 in 4 slides	Male	28	Hydrocele, left; enlarged groin glands, right.	7,800	<i>Ankylostoma duodenale</i> <i>Tricocephalus dispar</i>	4,137,500	100 "	Polymorphs 46 Lymphocytes 37 Eosinophiles 15 Large Mononuclears 2	1,170
A.M. 0 P.M. 0	Male	30	Pedunculated groin gland. Double hydrocele. Male & female adult filariae found.	6,552	<i>Tricocephalus dispar</i>	5,725,000	90 "	Polymorphs 55 Lymphocytes 17 Eosinophiles 23 Large Mononuclears 5	1,506

## APPENDIX IXh.—continued.

Eosinophilia in filarial diseases other than elephantiasis. 14 Fijians and 1 Indian.

Number of microfilariae per 16 c. mm.	Sex.	Age.	Affection.	White blood count.	Ova.	Red blood count.	Haemoglobin.	Differential count. 300 cells.	Number of eosinophiles per c. mm.
1 in 3 slides	Male	60	Enlarged groin glands; enlarged testes.	7,488	<i>Ankylostoma duodenale</i> <i>Tricocephalus dispar</i>	4,575,000	100 per cent.	Polymorphs 83 Lymphocytes 13 Eosinophiles 2 Large Mononuclears 2	149
A.M. 38 P.M. 20	Male	45	Double enlarged groin glands; double hydrocele.	4,992	<i>Tricocephalus dispar</i>	5,287,500	80	Polymorphs 56 Lymphocytes 27 Eosinophiles 12 Large Mononuclears 5	598
A.M. 0 P.M. 0	Male	35	Enlarged epitrochlear and groin glands; double hydrocele.	6,864	?	5,125,000	100	Polymorphs 48 Lymphocytes 42 Eosinophiles 5 Large Mononuclears 5	343
A.M. 0 P.M. 0	Male	20	Enlarged femoral gland. Male and female adult, filariae found.	6,864	<i>Ankylostoma duodenale</i> <i>Tricocephalus dispar</i>	5,875,500	100	Polymorphs 59 Lymphocytes 25 Eosinophiles 12 Large Mononuclears 4	823
A.M. 0 P.M. 0	Male	20	Enlarged testes.	6,866	<i>Ankylostoma duodenale</i>	6,437,000	100	Polymorphs 64 Lymphocytes 21 Eosinophiles 10 Large Mononuclears 5	686
A.M. 0 P.M. 0	Male	25	Pedunculated groin glands.	7,176	<i>Ankylostoma duodenale</i>	5,337,500	100	Polymorphs 42 Lymphocytes 18 Eosinophiles 36 Large Mononuclears 4	2,582

APPENDIX IXh.—*continued.**Eosinophilia* in filarial diseases other than elephantiasis. 14 Fijians and 1 Indian.

Number of microfilariae per 16 c. mm.	Sex.	Age.	Affection.	White blood count.	Ova.	Red blood count.	Haemoglobin.	Differential count. 300 cells.	Number of eosinophiles per c. mm.
A.M. 2 (Average 3 slides)	Male	25	Enlarged testes.	4,992	?	5,012,500	100 per cent.	Polymorphs 58 Lymphocytes 21 Eosinophiles 15 Large Mononuclears 6	750
A.M. 0 P.M. 0	Male	45	Enlarged groin glands.	6,866	<i>Tricocephalus dispar</i>	5,162,000	100 "	Polymorphs 73 Lymphocytes 15 Eosinophiles 9 Large Mononuclears 3	617
A.M. 0 P.M. 0	Male	28	Enlarged groin glands.	6,240	Nil	5,175,000	100 "	Polymorphs 50 Lymphocytes 30 Eosinophiles 15 Large Mononuclears 4	936
Average of total				6,991		5,066,500	96 "	Polymorphs 61 Lymphocytes 23 Eosinophiles 12 Large Mononuclears 4	814 =Eosinophilia average of 12.7 per cent.

## APPENDIX IX.

*Eosinophilia* in Fijians with elephantiasis in whom only a differential count was made. 300 cells counted in each instance.

Without microfilariæ in blood.

Affection.	Number of microfilariæ per 16 c. mm.	Differential count.	Affection.	Number of microfilariæ per 16 c. mm. blood.	Differential count.
Male. Elephantiasis right leg. Enlarged groin glands. Elephantiasis scroti.	0	Polymorphs 62 Lymphocytes 22 Eosinophiles 10 Large Mononuclears 6	Male. Elephantiasis right leg.	58	Polymorphs 57 Lymphocytes 26 Eosinophiles 11 Large Mononuclears 6
Male. Slight elephantiasis both legs.	0	Polymorphs 75 Lymphocytes 15 Eosinophiles 5 Large Mononuclears 5	Male. Elephantiasis both legs. Double enlarged groin glands.	87	Polymorphs 47 Lymphocytes 39 Eosinophiles 9 Large Mononuclears 5
Male. Elephantiasis scroti. Double enlarged groin glands.	0	Polymorphs 63 Lymphocytes 25 Eosinophiles 8 Large Mononuclears 4	Male. Elephantiasis left leg.	4	Polymorphs 47 Lymphocytes 32 Eosinophiles 16 Large Mononuclears 5
Male. Elephantiasis scroti and penis. Enlarged groin glands.	0	Polymorphs 51 Lymphocytes 32 Eosinophiles 11 Large Mononuclears 6	Male. Elephantiasis both legs and scrotum.	3	Polymorphs 37 Lymphocytes 33 Eosinophiles 25 Large Mononuclears 5
Male. Elephantiasis both arms and both legs.	0	Polymorphs 54 Lymphocytes 34 Eosinophiles 9 Large Mononuclears 3	Male. Elephantiasis both arms and scrotum.	87	Polymorphs 35 Lymphocytes 53 Eosinophiles 9 Large Mononuclears 3
Male. Elephantiasis scroti and left arm.	0	Polymorphs 74 Lymphocytes 18 Eosinophiles 5 Large Mononuclears 3	Male. Elephantiasis both arms.	35	Polymorphs 44 Lymphocytes 34 Eosinophiles 17 Large Mononuclears 5

With microfilariæ in blood.

APPENDIX IXi.—*continued*.

*Eosinophilia* in Fijians with elephantiasis in whom only a differential count was made. 300 cells counted in each instance.

Without microfilariae in blood.      With microfilariae in blood.

Affection.	Number of microfilariae per 16 c. mm.	Differential count.	Affection.	Number of microfilariae per 6 c. mm. blood.	Differential count.
Male. Elephantiasis right arm. Hydrocele. Enlarged varicose groin glands.	0	Polymorphs 39 Lymphocytes 29 Eosinophiles 22 Large Mononuclears 10	Male. Elephantiasis both arms and legs and scrotum.	41	Polymorphs 42 Lymphocytes 41 Eosinophiles 12 Large Mononuclears 5
Male. Early elephantiasis both arms.	0	Polymorphs 47 Lymphocytes 39 Eosinophiles 9 Large Mononuclears 5	Male. Slight elephantiasis left arm.	10	Polymorphs 56 Lymphocytes 31 Eosinophiles 8 Large Mononuclears 5
Male. Slight elephantiasis right arm.	0	Polymorphs 42 Lymphocytes 43 Eosinophiles 10 Large Mononuclears 5	Female. Elephantiasis both arms; left slight.	2	Polymorphs 34 Lymphocytes 42 Eosinophiles 20 Large Mononuclears 4
Female. Elephantiasis left arm, both legs.	0	Polymorphs 31 Lymphocytes 47 Eosinophiles 17 Large Mononuclears 5	Male. Elephantiasis both legs, right arm and scrotum.	8	Polymorphs 39 Lymphocytes 34 Eosinophiles 24 Large Mononuclears 3
Female. Elephantiasis right arm, both legs.	0	Polymorphs 62 Lymphocytes 31 Eosinophiles 6 Large Mononuclears 1	Male. Elephantiasis both legs, both arms, penis, and scrotum.	2	Polymorphs 21 Lymphocytes 42 Eosinophiles 19 Large Mononuclears 8
Male. Elephantiasis left leg.	0	Polymorphs 44 Lymphocytes 42 Eosinophiles 10 Large Mononuclears 4	Male. Elephantiasis left arm and both legs.	227	Polymorphs 56 Lymphocytes 33 Eosinophiles 6 Large Mononuclears 5

APPENDIX IXi.—*continued*.

*Eosinophilia* in Fijians with elephantiasis in whom only a differential count was made. 300 cells counted in each instance.

Without microfilariae in blood.				With microfilariae in blood.	
Affection.	Number of microfilariae per 16 c. mm.	Differential count.	Affection.	Number of microfilariae per 16 c. mm.	Differential count.
Male. Elephantiasis scroti and hydroceles. Enlarged and varicose groin glands.	0	Polymorphs 51 Lymphocytes 30 Eosinophiles 16 Large Mononuclears 3	Male. Elephantiasis left arm. Enlarged groin glands. Hydrocele	91	Polymorphs 51 Lymphocytes 40 Eosinophiles 6 Large Mononuclears 3
Male. Elephantiasis scroti. Double hydroceles.	0	Polymorphs 40 Lymphocytes 38 Eosinophiles 14 Large Mononuclears 8			
Female. Elephantiasis both legs. Double enlarged and varicose groin glands.	0	Polymorphs 52 Lymphocytes 24 Eosinophiles 20 Large Mononuclears 4			
Male. Elephantiasis scroti. Double hydroceles.	0	Polymorphs 46 Lymphocytes 26 Eosinophiles 18 Large Mononuclears 10			
Male. Elephantiasis right leg, and scrotum. Double hydroceles and enlarged varicose groin glands.	0	Polymorphs 43 Lymphocytes 42 Eosinophiles 11 Large Mononuclears 4			
Average of total		Polymorphs 52 Lymphocytes 32 Eosinophiles 11 Large Mononuclears 5	Average of total		Polymorphs 45 Lymphocytes 37 Eosinophiles 13 Large Mononuclears 5

## APPENDIX IXj.

*Eosinophilia* in Europeans, born and resident in Fiji, without microfilariae in blood or other signs of filarial infection.

Sex.	Age.	Residence.	Symptoms or signs.	White blood count.	Red blood count.	Haemoglobin.	Differential count. 300 cells.	Eosinophiles per c. mm.
Male	21	Born in Fiji	Nil	6,800	5,250,000	100 per cent.	Polymorphs 58 Lymphocytes 32 Eosinophiles 5 Large Mononu- clears 5	340
Male	33	"	Nil	6,864	—	80 "	Polymorphs 61 Lymphocytes 31 Eosinophiles 4 Large Mononu- clears 4	274
Female	21	"	Nil	5,616	3,678,500	100 "	Polymorphs 36 Lymphocytes 59 Eosinophiles 3 Large Mononu- clears 2	168
Female	42	"	Nil	6,864	5,637,500	100 "	Polymorphs 43 Lymphocytes 50 Eosinophiles 1 Large Mononu- clears 6	68
Female	21	"	Nil	4,680	4,070,000	100 "	Polymorphs 63 Lymphocytes 21 Eosinophiles 2 Large Mononu- clears 4	93
Male	29	"	Nil	6,864	5,475,000	100 "	Polymorphs 62 Lymphocytes 33 Eosinophiles 2 Large Mononu- clears 3	137

APPENDIX IXj.—*continued.*

*Eosinophilia* in Europeans, born and resident in Fiji, without microfilariae in blood or other signs of filarial infection.

Sex.	Age.	Residence.	Symptoms or signs.	White blood count.	Red blood count.	Haemoglobin.	Differential count. 300 cells.	Eosinophiles per c. mm.
Female	31	Born in Fiji	Nil	5,928	5,287,500	100 per cent.	Polymorphs 63 Lymphocytes 28 Eosinophiles 6 Large Mononu- clears 3	354
Female	27	"	Nil	4,680	5,037,500	100 "	Polymorphs 55 Lymphocytes 38 Eosinophiles 1 Large Mononu- clears 6	46
Female	25	"	Nil	6,240	3,962,500	100 "	Polymorphs 59 Lymphocytes 35 Eosinophiles 4 Large Mononu- clears 2	249
Female	33	"	Nil	7,176	4,560,000	100 "	Polymorphs 58 Lymphocytes 29 Eosinophiles 6 Large Mononu- clears 7	426
Average of total ...	...	...	...	6,171	4,774,266	98 "	Polymorphs 56 Lymphocytes 36 Eosinophiles 3 Large Mononu- clears 5	215 = Eosinophilia average of 3.4 per cent.

## APPENDIX IXk.

*Eosinophilia* in Europeans, born and resident in Fiji, with microfilariæ.

Number of microfilariæ per 16 c. mm.	Sex.	Age.	Residence.	Symptoms or signs.	White blood count.	Red blood count.	Haemoglobin.	Differential count. 300 cells.	Eosinophiles. per c. mm.
A.M. 8 P.M. 5	Male	52	12 years in Samoa 10 years in Fiji	Lymphangitis; hydroceles	10,000	—	—	Polymorphs 65 Lymphocytes 18 Eosinophiles 12 Large Mononuclears 5	1,200
A.M. 1 P.M. 2	Female	21	Born in Fiji	Fever	4,680	5,061,000	100 per cent.	Polymorphs 49 Lymphocytes 39 Eosinophiles 5 Large Mononuclears 7	234
A.M. 5	Male	72	52 years in Fiji	Nil	7,176	3,570,000	100	Polymorphs 56 Lymphocytes 30 Eosinophiles 6 Large Mononuclears 8	430
A.M. 74	Male	21	Born in Fiji	Lymphangitis of arm. Enlarged epitrochlear glands	8,112	6,278,500	100	Polymorphs 57 Lymphocytes 34 Eosinophiles 3 Large Mononuclears 6	243
A.M. 55	Male	53	31 years in Colony	Nil	4,992	—	100	Polymorphs 63 Lymphocytes 20 Eosinophiles 12 Large Mononuclears 5	598
A.M. 34	Male	43	16 years in Colony	Lymphangitis	11,544	5,537,000	100	Polymorphs 46 Lymphocytes 43 Eosinophiles 8 Large Mononuclears 3	920
Average of total ...	...	...	...	...	7,750	5,111,625	100	Polymorphs 56 Lymphocytes 30 Eosinophiles 8 Large Mononuclears 6	604 = Eosinophilia average of 7.7 per cent.

## APPENDIX IXI.

*Eosinophilia* in Europeans, born or resident in Fiji, with signs of filariasis. No microfilariæ.

Number of microfilariæ per 16 c. mm.	Sex.	Age.	Residence.	Symptoms or signs.	White blood count.	Red blood count.	Haemoglobin.	Differential count. 300 cells.	Eosinophiles per c. mm.
Nil	Male	77	52 years in Fiji	Lymphangitis Ankylosis of left knee	7,167	5,425,000	100 per cent.	Polymorphs 65 Lymphocytes 23 Eosinophiles 5 Large Mononuclears 7	358
Nil	Female	50	37 years in Fiji	Elephantiasis both legs Varicose enlarged groin glands	3,100	—	—	Polymorphs 84 Lymphocytes 8 Eosinophiles 6 Large Mononuclears 2	186
Nil	Male	29	3 years in Fiji	Abscess left hip-joint Adenitis	11,250	3,350,000	80 "	Polymorphs 71 Lymphocytes 19 Eosinophiles 7 Large Mononuclears 3	787
Nil	Male	53	13 years in Fiji	Elephantiasis both legs	7,800	—	—	Polymorphs 37 Lymphocytes 36 Eosinophiles 25 Large Mononuclears 2	1950
Nil	Male	27	1½ years in Fiji (Lakemba)	Orchitis and adenitis	—	—	—	Polymorphs 63 Lymphocytes 19 Eosinophiles 10 Large Mononuclears 8	—
Nil	Male	66	46 years in Fiji (Lakemba)	Elephantiasis both legs	—	—	—	Polymorphs 62 Lymphocytes 20 Eosinophiles 12 Large Mononuclears 6	—

APPENDIX IX1.—*continued.**Eosinophilia* in Europeans, born or resident in Fiji, with signs of filariasis. No microfilariae.

Number of microfilariae per 16 c.mm.	Sex.	Age.	Residence.	Symptoms or signs.	White blood count.	Red blood count.	Haemoglobin.	Differential count. 300 cells.	Eosinophiles per c. mm.
Nil	Male	33	10 years in Fiji	Lymphangitis of arm, orchitis	5,616	—	—	Polymorphs 55 Lymphocytes 33 Eosinophiles 6 Large Mononuclears 6	336
Nil	Male	43	Born in Fiji	Lymphangitis and adenitis	6,240	3,825,000	50 per cent. (Ankylostome ova in faeces)	Polymorphs 53 Lymphocytes 37 Eosinophiles 8 Large Mononuclears 2	498
Nil	Male	24	1½ years in Fiji (Lakemba)	Axillary abscess	6,864	6,062,500	—	Polymorphs 42 Lymphocytes 51 Eosinophiles 2 Large Mononuclears 4	136
Average of total	...	...	...	...	6,894	...	...	Polymorphs 58 Lymphocytes 28 Eosinophiles 9 Large Mononuclears 5	607 =Eosinophilia average of 8.7 per cent.

## APPENDIX X.

Further details of cases mentioned in the text. II. (d).

1. Orchitis ; adenitis ; disappearance of microfilariae ; psoas abscess ; abscess of hip-joint ; sapraemia ; post-mortem examination.

Fijian male, *aet.* about 20. Admitted to hospital on February 5th, 1910, with a history of pyrexia, pain in his right thigh and right testicle. The temperature in the right groin was 105° F., a degree higher than in corresponding axilla. Pulse 120.

The tongue was furred and dry, and the man looked ill.

The right testis was enlarged, hot and tender, and the epididymis could be distinctly felt. The inguinal glands on the same side were enlarged and very tender. These glands were punctured, and smears and two cultures were made from the fluid obtained ; it proved sterile. Slides of blood averaged two microfilariae per 16 c. mm. In the smears from the glands four microfilariae, corresponding in appearance with those found in the blood, were found. The urine showed a faint cloud of albumen on boiling. The temperature remained of a hectic type, and was constantly one degree higher in the right groin than in the opposite groin or in the axilla. Four days after admission the groin glands were punctured again, but no microfilariae could be found in the juice, nor from this date onwards *could any be found in the blood, though repeatedly searched for*—blood slides being taken four-hourly for twenty-four hours, nor in 2 c.c. of blood abstracted from a vein and centrifuged. Two weeks after admission the symptoms became more definitely located to the hip-joint. The patient lay with hip flexed and everted, and there was intense pain on jarring the knee. The testis had regained its normal size, but the groin glands still remained enlarged and painful. An indefinite mass could now be felt above Poupart's ligament on the right side. The patient became very emaciated and assumed a septic appearance. The left leg became greatly swollen, measuring six inches more in circumference in the middle of the thigh than on the right.

Six weeks after admission pus was obtained by puncture of the inguinal glands. Smears showed no microfilariae ; but chains of streptococci were met with, which, on blood agar, grew a pure culture of *Streptococcus pyogenes*. An operation was performed. From an incision below the adductor longus, two pints of thick greenish pus escaped, from which *Streptococcus pyogenes* was grown in pure culture. The abscess proved to be burrowing extensively into the substance of the hamstring muscles and upwards into the abdomen. The femur was found eroded and necrosed in places. One enlarged inguinal gland removed showed on section intense inflammatory changes, but no filarial remains were found either in the glands or in the centrifuged pus. Leucocytosis at this stage amounted to 10,000. No eosinophiles could be found ; their seeming absence was explicable by the polymorphonuclear leucocytosis.

A month after the operation the patient died, probably from septic absorption.

#### Post-mortem.

At the post-mortem the operation wound was gangrenous. On passing a finger upwards the neck of the femur and acetabulum were found to be bare. All the organs in the thorax and abdomen were healthy.

There were no intestinal parasites. The mesentery and thoracic duct were removed and teased out in normal saline, but no filariae were present. All the lumbar glands were enlarged and injected. No dilatation of the lymphatics in front of the aorta was noted. There was most extensive necrosis of the pelvic girdle and acetabular cavity. The crest of the ilium was eaten away to a depth of 2 mm. On opening the hip-joint the whole of the cartilage of the head of the femur was eroded and the acetabulum cavity a mass of gangrenous shreds. From thence fistulae led in all directions, some along the ramus of the pubes, others beneath Poupart's ligament into the hamstring muscles. The femoral artery and vein had alone escaped destruction. The process had extended through the obturator foramen, where all the vessels and nerves were destroyed. The greater part of the adductor muscles and periosteum of the neck of the femur were destroyed. The psoas and iliacus muscles were entirely destroyed by the same process. No erosion of the vertebrae was noted. Testes and spermatic cords were carefully examined and found to be healthy. All the connective tissue in thorax and abdomen and muscles of both thighs were carefully searched for remains of parental worms, but none were found. No microfilariae were found in smears from various organs, nor in sections of lung tissue. The brain and membranes were found to be normal. There was a thrombosed posterior auricular vein on the left side, containing a small quantity of bright yellow pus.

2. Lymphangitis and orchitis. Disappearance of microfilariae from blood-stream. Adult filariae found in sections made from excised inflammatory mass (Pl. III.)

Fijian male, *aet.* 36. Sudden pain in left testicle. Temperature of left groin 105.6° F., in axilla one degree lower. Respiration rapid. Left testis enlarged and acutely painful; spermatic cords thickened. Urine when first passed very thick with phosphates; no albumen; no blood.

Microfilariae at 10 a.m. two per 16 c. mm., at 10 p.m. ten per 16 c. mm. A four-hourly chart made of the microfilariae over a period of three days showed they were always present in small numbers. On the fourth day, when the temperature was 101.2 F. they disappeared from the circulation and were never found subsequently. With the abatement of the symptoms in the testis, the left arm suddenly became swollen from just above the wrist to the upper arm. There was a brawny infiltrated mass over the internal condyle, which was very hot and tender. This mass was punctured and one microfilaria was found in two smears of the lymph, which afterwards proved sterile on culture. Inflamed and thickened lymphatic cords could be felt extending along the brachial artery to the axilla. The lymphatics in the antecubital space were similarly affected. Five days after the first symptoms were noted in the arm the inflamed mass was dissected out, and on incising this about two minims of yellow purulent fluid exuded. Under a dissecting microscope a mass of tangled and thickened lymphatics was seen coursing through the mass. No microfilariae were seen in the exudate, but, on section, portions of an adult (apparently male) worm were found in a lymphatic space surrounded by round-celled infiltration and oedematous inflammatory tissue (Pl. III.) Amongst the round cells a great many eosinophiles were noted. No cocci or other organisms could be demonstrated by appropriate stains.

### 3. Lymphangitis ; orchitis ; adenitis ; disappearance of microfilariae.

Fijian male, about 26. Admitted with enlarged glands in both groins after an attack of lymphangitis. Microfilariae were present sparingly in the circulation, numbering 1-4 per 16 c. mm. Eleven months later he was re-admitted with inflammation of glands of right groin. Temperature 101.4 F. Glands of groin enlarged and tender ; tenderness on deep palpation in both iliac fossae. Both testes were normal.

Rigor whilst in hospital. Temperature 101° F. ; vomiting ; pain started in glands of right groin and shot down to the knee. Gland juice obtained by aspiration showed no microfilariae, and was sterile on culture. Leucocytes were 16,500, red cells 4,850,000 ; eosinophiles 4 per cent. Microfilariae in the blood averaged five per 16 c. mm. The temperature remained raised, and a typical attack of orchitis on the right side set in. The groin glands still remained painful. The next day, when the temperature had become normal, the testes were still swollen. The leucocytes numbered 7,100, the eosinophiles 8 per cent., and now the microfilariae had disappeared and could not be found on subsequent examination. It is to be noted in this case that the microfilariae disappeared whilst the temperature was normal.

### 4. Lymphangitis and adenitis in a European ; disappearance of microfilariae.

European male, *aet.* 52. Twenty-two years resident in South Seas. History of repeated attacks of lymphangitis, and of abscess in axilla sixteen years ago. Enlarged testes two years. Enlarged groin glands two years. Old malarial spleen (infection contracted in Mauritius in 1884). Tertiary syphilitic scars and gummata. Enlarged liver (alcoholic). Aortic regurgitation. The glands of both groins were enlarged to size of pigeons' eggs and were very hard. There was a small hydrocele on the left side. Microfilariae were present in circulation, five at 10 a.m. per 16 c. mm., and two at 10 p.m. Four days after admission his temperature rose to 100° F. He had pain in his left thigh, followed by an attack of lymphangitis in the corresponding leg. The leg was marked by red indefinite lines extending from internal malleolus to saphenous opening. Leucocytes numbered 10,000 and eosinophiles 5 per cent. The microfilariae were still present. The following day the left leg was distinctly larger than the right, and very painful to the touch. The temperature still remained raised. Four days after the initial attack the temperature became normal, and the lymphangitis had disappeared, leaving a hot, tender swelling over the internal malleolus. Aspirated gland juice from inguinal glands showed no microfilariae. A fortnight later he had a rigor in the middle of the night, followed by an attack of lymphangitis in the left leg. Temperature 102° F. Red streaks were seen coursing up the leg from the internal malleolus to the saphenous opening. Groin glands were enlarged, but not tender. No orchitis. Microfilariae still present in the circulation. The attack lasted a week, during which the temperature was raised. The erysipelatoid inflammation remained confined to the dorsum of the foot towards the termination of the attack. The blood was examined after the temperature had become normal, but no microfilariae were found again. Two months later he was visited in a native village in a

remote island, where he lay in a dying condition from heart failure. No microfilariae were found in his blood. He had not had any more attacks of lymphangitis. The only trace remaining of the last two attacks was a slight thickening over the internal malleolus. The inguinal glands were no bigger than before. A short time after this the patient died.

##### 5. Orchitis and adenitis ; disappearance of microfilariae.

Fijian male, *aet.* 30. Sudden pain in right testis. Temperature 102.4° F., rising to 104° F. The right testis was swollen, retracted, and acutely painful. There was great tenderness and rigidity in right iliac fossa, apparently due to inflammation of the pelvic glands on that side. Microfilariae were present in the blood. A four-hourly chart of the microfilariae was kept ; they were found to average 1.9 in slides of measured quantities of blood. The white cells numbered 11,500, red cells 4,612,000, eosinophiles 7 per cent. The left testis became affected immediately after the inflammation of the right had subsided, and there was pain and tenderness on palpation in the corresponding iliac fossa. On the third day the temperature became normal; the leucocytes numbered 7,400, and eosinophiles 21 per cent. Microfilariae were still present. Three months later he was again admitted with a temperature of 104° F., pain in glands of left groin and left hip-joint. The inguinal glands were distinctly swollen. There was tenderness on palpation over left iliac fossa. The microfilariae averaged three per measured slide, the leucocytes 17,400, eosinophiles 12 per cent. Cultures made from aspirated lymph from the inflamed groin glands on hydrocele fluid and agar remained sterile. No microfilariae were found in the exudate. On the following day inflammation of the right testis set in, and was accompanied by pain and tenderness in the right iliac fossa. The temperature, which had dropped to normal, rose again to 104° F. *No microfilariae could now be found in the blood ;* 1 c.c. blood was abstracted from the cephalic vein and centrifuged with a negative result. Thus they had disappeared completely from the circulation within twenty-four hours. None were subsequently found, though the blood was repeatedly examined during the ensuing month.

##### 6. Lymphangitis right leg ; disappearance of microfilariae.

European male, *aet.* 43. Born in the Colony. History of repeated attacks of lymphangitis recurring every month. Rigor. Temperature 103° F., followed by adenitis and lymphangitis of the right leg. The pain started in the glands of the right groin, which were enlarged and tender, red streaks running down the thigh. A hard, tender, inflammatory thickening was found situated at the mid-point of the thigh on the inner side, but there was no orchitis. The blood contained microfilariae sparingly, averaging about one per measured slide (16 c. mm.) Leucocytes were 21,800 ; eosinophiles 3 per cent. He was very anaemic ; ankylostoma ova were found in the stools. Cultures were made from the aspirated lymph from the inflammatory mass mentioned above and were sterile. The exudate contained no microfilariae, but a few lymphocytes. A second rigor, followed by a second attack of lymphangitis, was noted a day later. The starting point was apparently the inflammatory thickening in the thigh. There was great tenderness

on palpation over the right iliac fossa. The microfilariae had disappeared from the circulation and were not subsequently encountered. The temperature, after a few oscillations, became normal on the sixth day, the leucocytes now numbering 6,200, and eosinophiles 8 per cent. The thickening in the left thigh was still apparent at the time of his discharge, but the groin glands on the right side had become greatly reduced in size.

#### 7. Filarial Fever ; disappearance of microfilariae.

Indian male, *aet.* 18. Born in Fiji. Admitted with a temperature of 105.8° F. No other clinical signs. Microfilariae exhibiting no periodicity were quite numerous in the blood, averaging from 3-8 per measured slide. Temperature gradually fell to normal on the third day. Eight months later he was re-admitted in a similar condition. Only one microfilaria was found in three slides of measured blood. Nine months after the first attack of fever he was again repeatedly examined, but now the microfilariae had completely disappeared.

N.B.—Signs of acute bronchitis were almost invariably noted in these cases during the height of the fever.

## APPENDIX XI.

### PERIODICITY.

A.—Fijians. Microfilariae in circulation. No periodicity. (When only one or two microfilariae are found in blood at night it must not be accounted as evidence of periodicity. Vide Appendix I.)

372 Fijians, Samoans and Tongans. Measured quantity of blood taken 10 a.m. and 10 p.m. on day of examination. Of the 372 individuals mentioned, 114 had microfilariae. Of the latter, 91 had numbers of microfilariae, more or less evenly distributed in the blood both by night and day; 48 had more at night-time; 43 had more by day; 17 had microfilariae at night only, but of these 15 had a very scanty infection (2 had two microfilariae, and 13 had one only per slide). In one case in which they were most plentiful at night a four-hourly chart was kept, but no definite periodicity could be recognized (*vide* Chart IV.) Six had microfilariae by day only; of these 3 had a very scanty infection, never more than one microfilaria being found per slide. In three cases, in which more than one was found in the daytime, a four-hourly chart was kept, but no periodicity could be established (*vide* charts to follow).

B.—Indian Immigrants. Fresh arrivals—nocturnal periodicity.  
Resident some considerable time—no periodicity.

120 examined, 115 males and 5 females. Measured quantities of blood as before. 12 (10 per cent.) had microfilariae. Five had microfilariae only at night in considerable numbers; none of these had any signs of filariasis. These had been resident in Fiji 9, 3, 3, 2, 2 years respectively. As regards the first (9 years) there is some doubt, as the

patient talked only Madrasee and an interpreter could not be secured.

It must be remembered that the great majority of the Indian population in Fiji are males, only one female being imported to every three males.

Seven had microfilariae by day and night; two had signs of filarial disease, one filarial fever, the other hydrocele (fluid contained microfilariae) and enlarged testes.

As regards length of residence in Fiji, one was born in Fiji, the others had been there 30, 24, 20, 14, 9, and 4 years respectively. Of the remaining 107 without microfilariae only one had enlarged glands.

There is only one Indian in Fiji known to be the subject of elephantiasis; he lives in a Fijian village on the island of Taveuni (*vide* map).

**C.—Solomon Islanders.** Fresh arrivals show nocturnal filarial periodicity. Old residents show no periodicity.

131 examined, 130 males and 1 female. 15, or 11·4 per cent., had microfilariae.

#### Recent Arrivals.

88 (ranging from 15 to 35 years of age) were new arrivals from their own islands (some had worked in Queensland before). The remaining 42 had been resident in Fiji for some years.

In the new arrivals signs of malaria were found. 31 (35 per cent.) had enlarged spleens. Microscopical examination showed degeneration of the red cells in almost every such case; crescents of the subtertian parasite were found only once.

Of these 88 new arrivals 6 had microfilariae in considerable numbers at night only. One from New Caledonia had three during the daytime and twenty-eight at night. Another had two during daytime and forty-three at night. The two other Solomon Islanders had night filariae only; they had been ten or more years resident in Fiji, and showed but scanty infections—only one and three microfilariae at night respectively. The only signs of filarial disease in the six were enlarged glands in two cases.

#### Older Residents.

Seven had microfilariae in considerable numbers night and day. These had been resident 30, 30, 25, 20, 10, 10, and one only 2 years in Fiji, respectively. One had slight elephantiasis of both legs, one double varicose groin glands and hydrocele, one enlarged groin glands and testes. Among those with microfilariae there were ten cases of enlarged glands.

No Solomon Island women are imported, only able-bodied men.

#### European Residents : no periodicity.

Thirty-five Europeans were examined. Seventeen came from the neighbourhood of Suva, where, being more civilized, they stood less chance of infection. The remainder came from the eastern or Lau group, where filarial diseases are rife, and where the Europeans are brought into more intimate contact with the natives. Twenty-two were males, thirteen females. Six, or 17·1 per cent., harboured microfilariae in equal numbers

day and night (all cases from eastern group). Five suffered from filarial diseases; four had lymphangitis; one multiple abscesses; one had no symptoms whatever. Of those without microfilariae three suffered from elephantiasis of the legs (resident in Fiji 46, 37, and 13 years); one from lymphangitis, one from enlarged and varicose groin glands, two from enlarged glands.

Fourteen of those examined were born in Fiji; one, suffering from symptoms of filariasis, had been there three years, the remainder ten to fifty years.

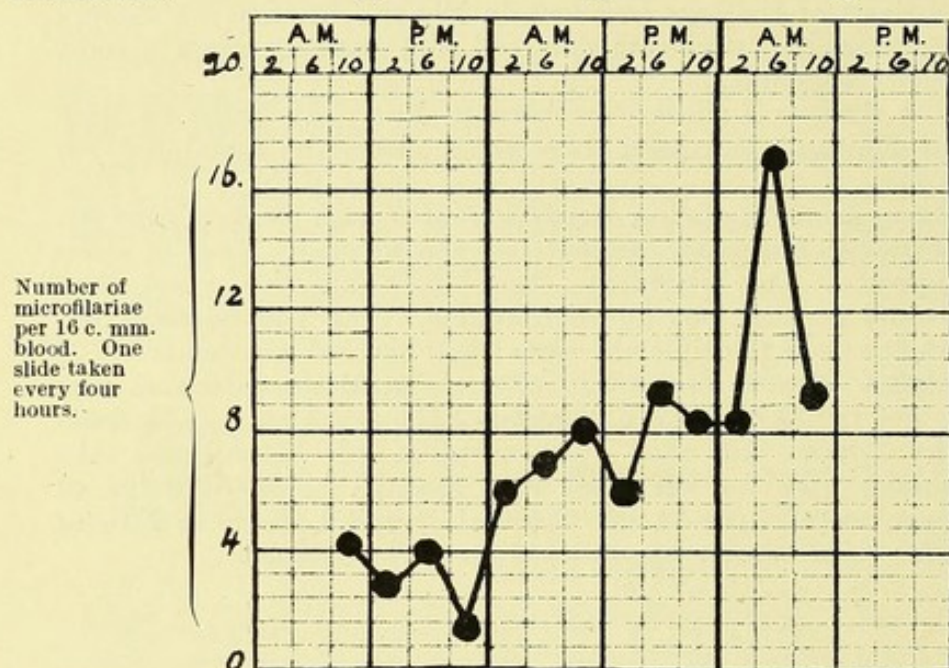
In one place, Loma-Loma, on the island of Vanua Balavu, nine out of a total of eleven European residents were examined. Four of these were not infected. One (resident there one and half year) had lymphangitis and orchitis, but no microfilariae. Four had microfilariae, two lymphangitis; one multiple abscesses; and one old gentleman of 73 had microfilariae without any other of the sign of the infection.

This must not be taken as an indication of the prevalence of filariasis amongst the whites, for with the exception of Loma-Loma the whites examined were for the most part selected cases. Twelve of these, however, were nurses in the Colonial Hospital, born in Fiji, or their relations; these cannot be regarded as selected cases.

---

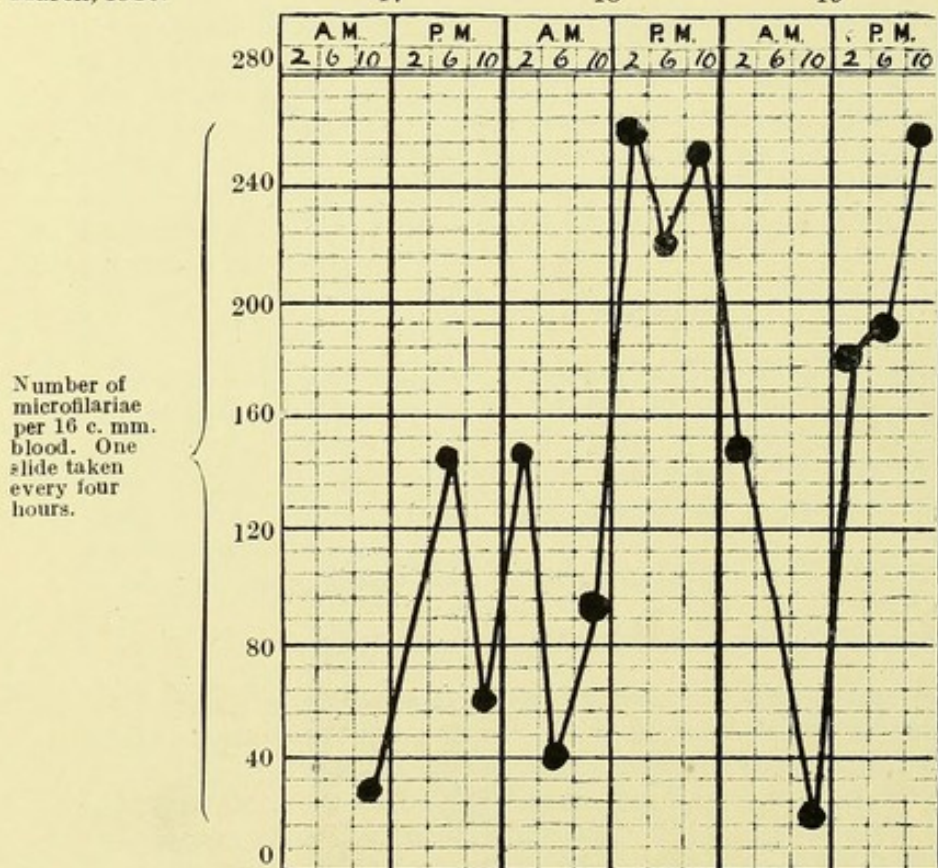
## Appendix XI.—CHART I.—Four Hour Chart of Filaria with no periodicity.

Name : Samuelli. Race : Fijian male, aet. 60. Physical State : Normal.  
 March, 1910. 17 18 19



## CHART II.—Four Hour Chart of Filaria with no periodicity.

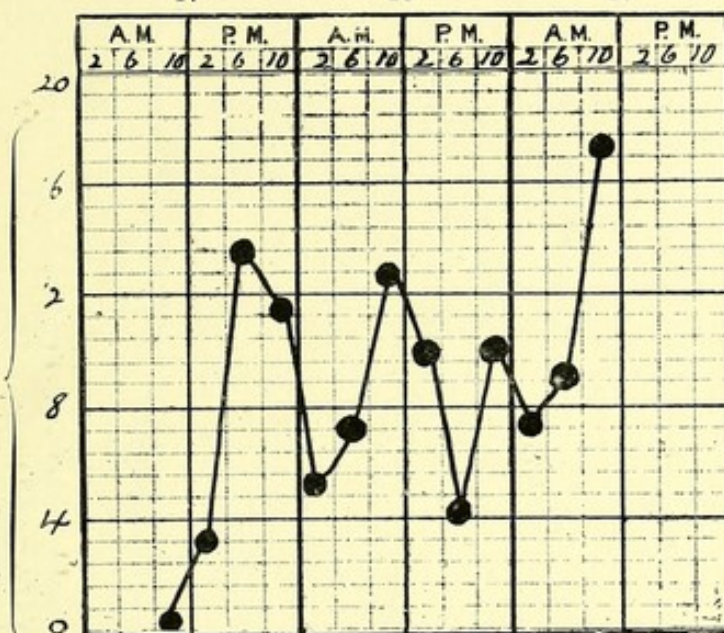
Name : Tiveta Tailemaitonga. Race : Fijian male, aet. 25. Physical State : Normal.  
 March, 1910. 17 18 19



### CHART III.—Four Hour Chart of Filaria with no periodicity.

Name : Urai. Race : Fijian male, *aet.* 24. Physical State : Normal.  
March, 1910. 17 18 19

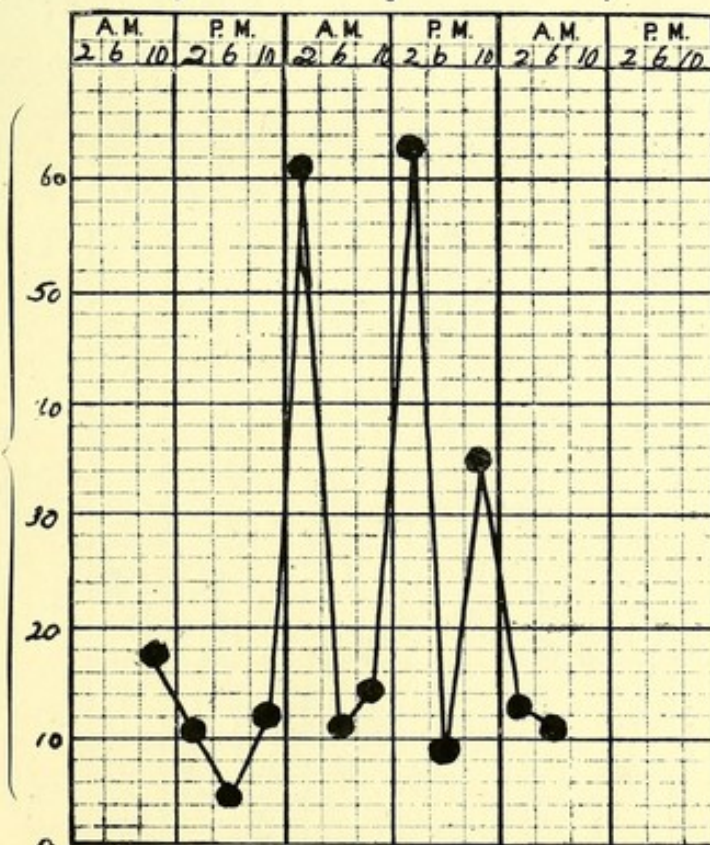
Number of  
microfilariae  
per 16 c. mm.  
blood. One  
slide taken  
every four  
hours.



### CHART IV.—Four Hour Chart of Filaria with no periodicity.

Name : Solomoni. Race : Fijian male, *aet.* 21. Physical State : Normal.  
March, 1910. 5 6 7

Number of  
microfilariae  
per 16 c. mm.  
blood. One  
slide taken  
every four  
hours.



# CHART V.—Twelve Hour Chart of Filaria with no periodicity.

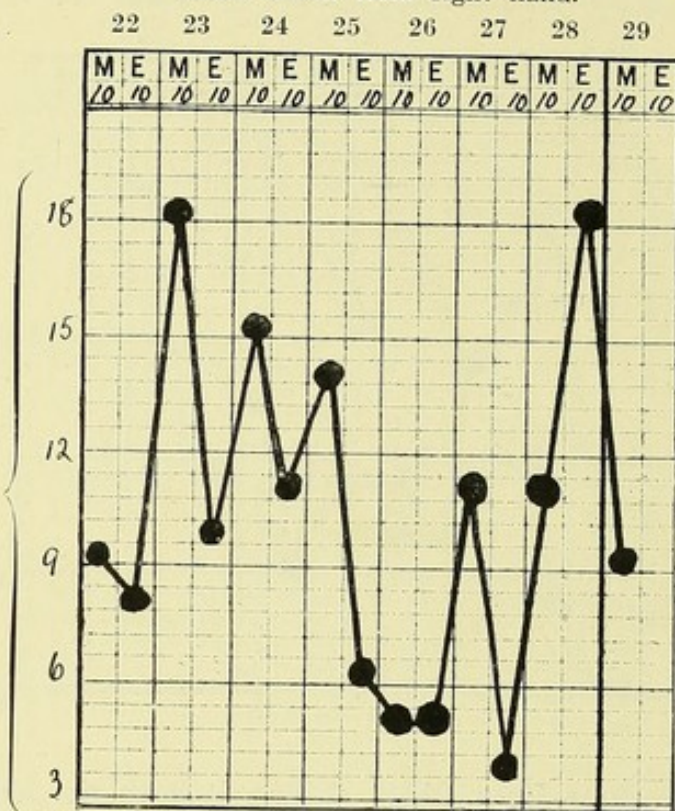
Name : Samu. Race : Fijian male, *aet.* 55.

Physical State : Lymphatic oedema left arm ; axillary abscess.

Blood taken from right hand.

January, 1910.

Number of  
microfilariae  
per 16 c. mm.  
blood. Average  
of three slides  
taken 10 a.m.,  
and of three  
slides taken  
10 p.m.



# CHART VI.—Twelve Hour Chart of Filaria with no periodicity.

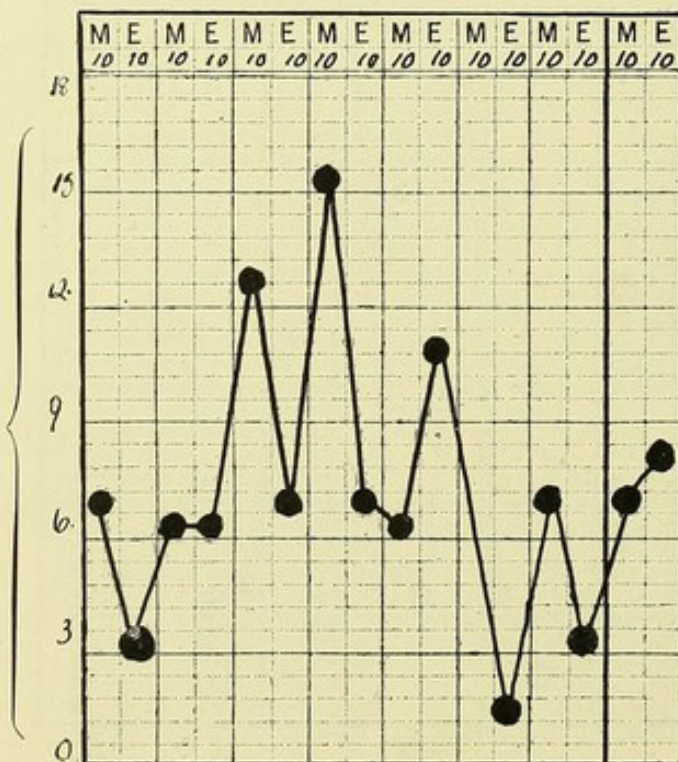
Name : Samu. Race : Fijian male, *aet.* 55.

Physical State : Lymphatic oedema left arm ; axillary abscess.

Blood taken from left hand, the affected side.

January, 1910.

Number of  
microfilariae  
per 16 c. mm.  
blood. Average  
of three slides  
taken 10 a.m.,  
and of three  
slides taken  
10 p.m.

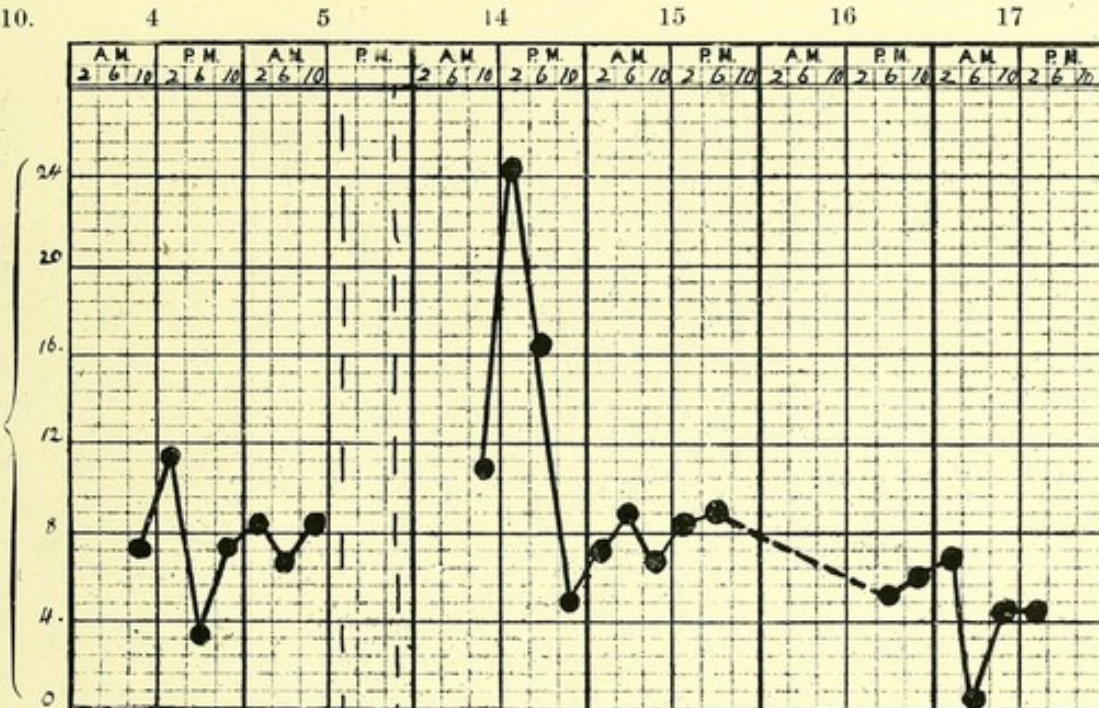


# CHART VII.—Four Hour Chart of Filaria with no periodicity.

Name : Samu. Race : Fijian male, *act.* 55.

Physical State : Lymphatic oedema left arm ; axillary abscess.

February, 1910.

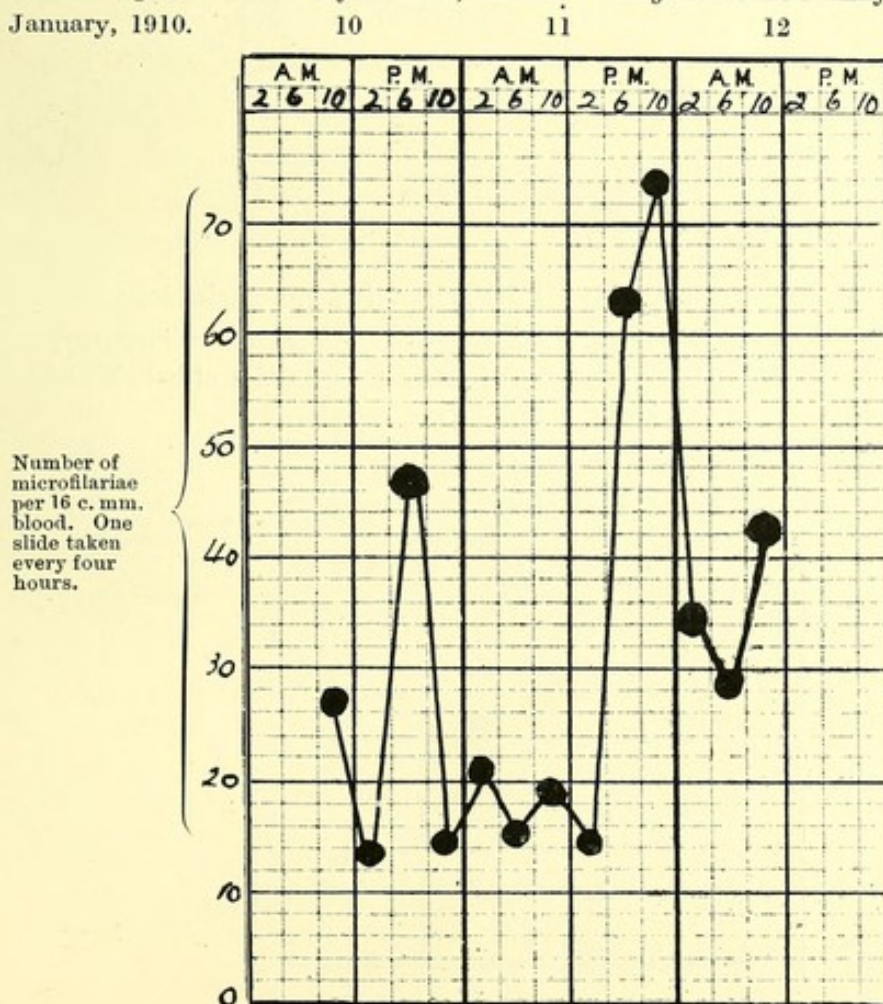


Number of microfilariae per 16 c. mm. of blood. One slide taken every four hours.

# CHART VIII.—Four Hour Chart of Filaria with no periodicity.

Name : Sigane. Race : Fijian male, *act.* 21. Physical State : Ankylosis left hip-joint.

January, 1910.



Number of microfilariae per 16 c. mm. of blood. One slide taken every four hours.

CHART IX.—Four Hour Chart of *Filaria* with no periodicity.

*Name* : Avisai. *Race* : Fijian male, *aet.* 25. *Physical State* : Hydrocele.

February, 1910.

22

23

24

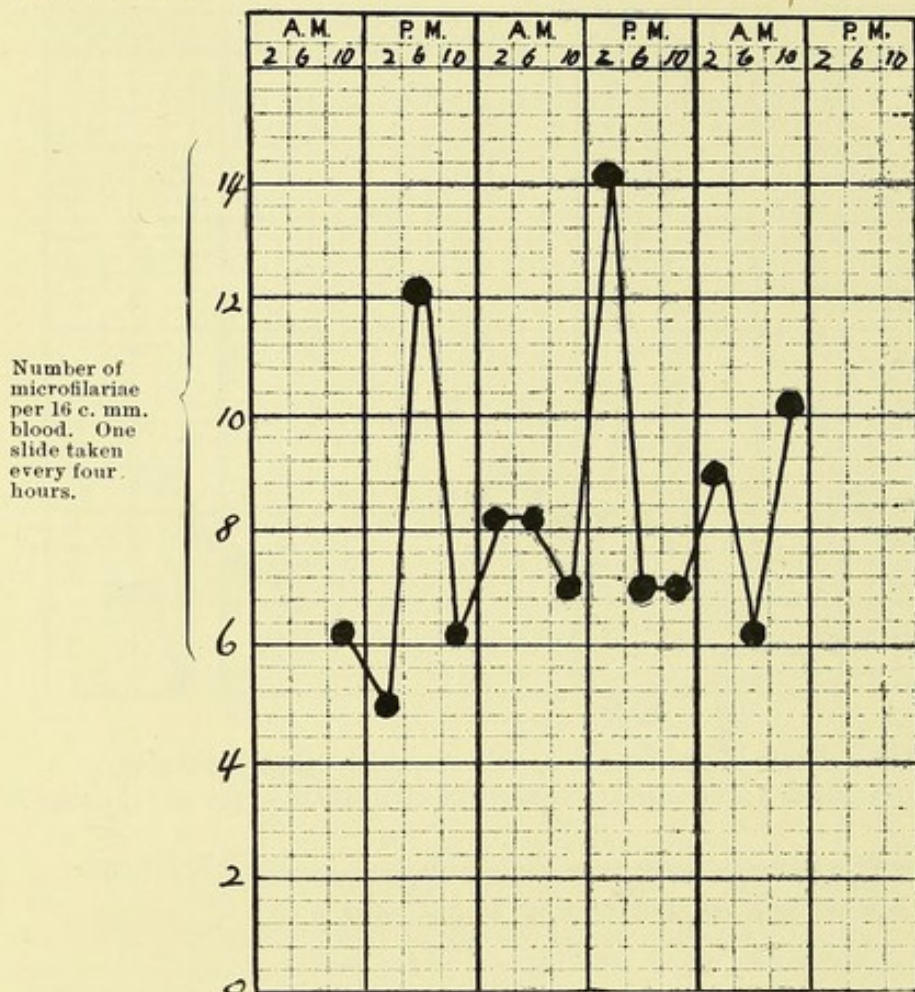


CHART X.—Four Hour Chart of *Filaria* with no periodicity.

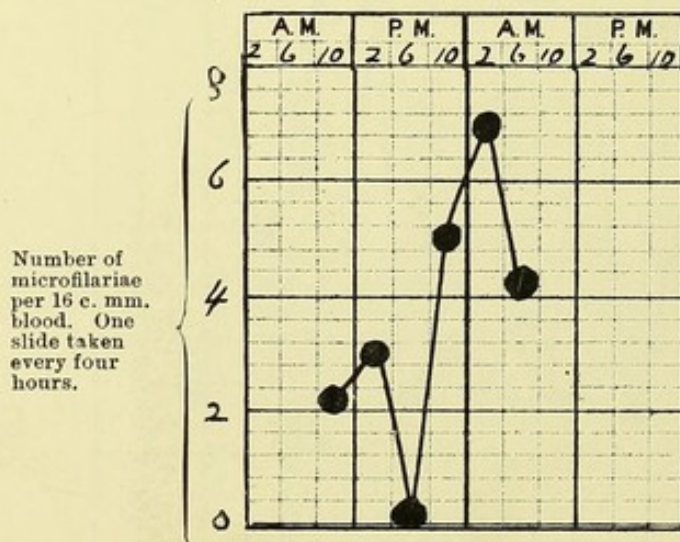
*Name* : Salinai.      *Race* : Fijian female, *aet.* 25.      *Physical State* : Pregnancy.

Male baby born on March 12th : No microfilariae found in three slides of baby's blood.

March, 1910

11

12



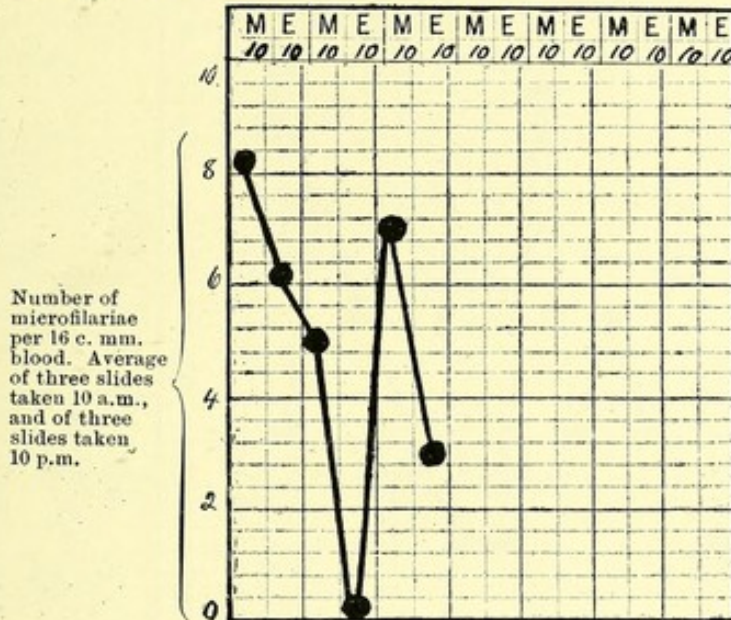
### CHART XI.—Twelve Hour Chart of Filaria with no periodicity.

Name : Sainimere. Race : Fijian female, *act.* 22. Physical State : Pregnancy.

Male baby born February 18th : No microfilariae in three slides of baby's blood.

Average of three slides taken 10 a.m. Three slides taken 10 p.m.

February, 1910. 2 3 4 5 6 7 8

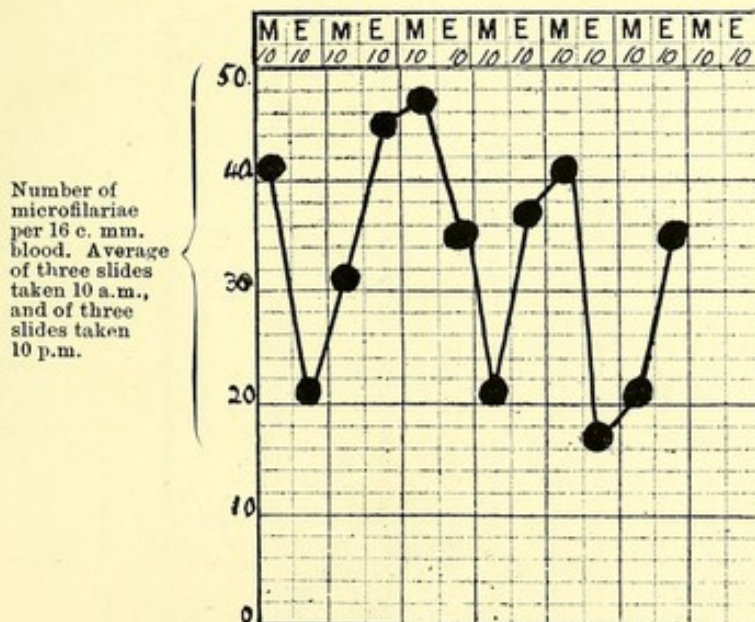


### CHART XII.—Twelve Hour Chart of Filaria with no periodicity.

Name : Petero. Race : Fijian male, *act.* 45.

Physical State : Elephantiasis of scrotum and left leg.

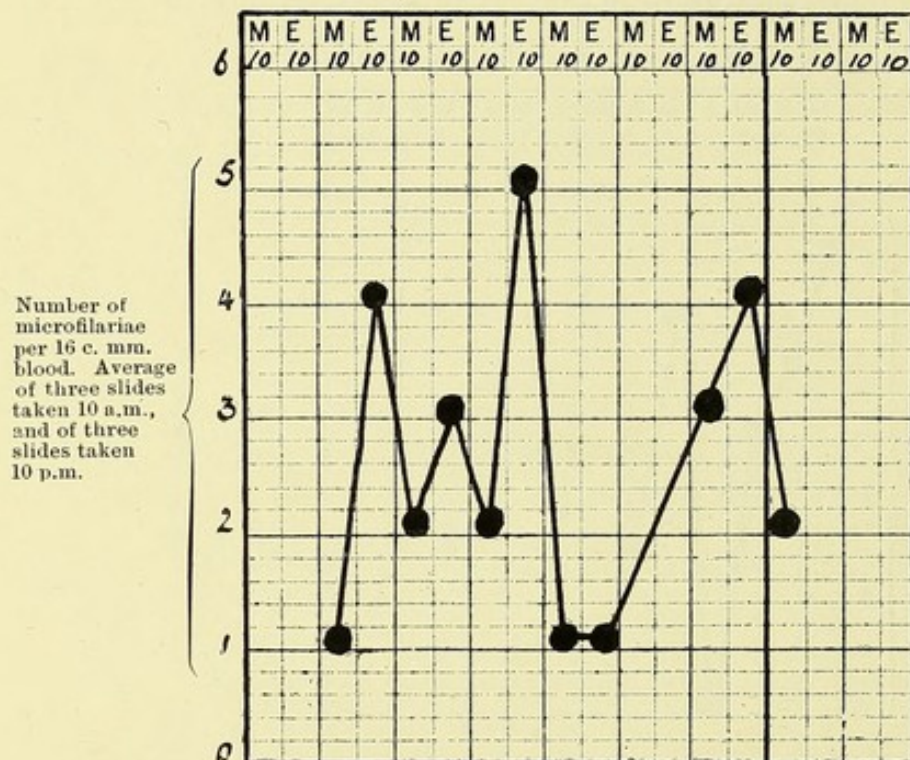
November, 1910. 15 16 17 18 19 20 21



### CHART XIII.—Twelve Hour Chart of Filaria with no periodicity.

Name : Kalopate. Race : Fijian male, *act.* 60. Physical State : Elephantiasis scroti.

December, 1910. 7 8 9 10 11 12 13 14 15



### CHART XIV.—Four Hour Chart of Filaria with no periodicity.

Name : Ferimo. Race : Fijian male, *act.* 40.

Physical State : Elephantiasis of right arm and left leg.

April, 1910.

11

12

13

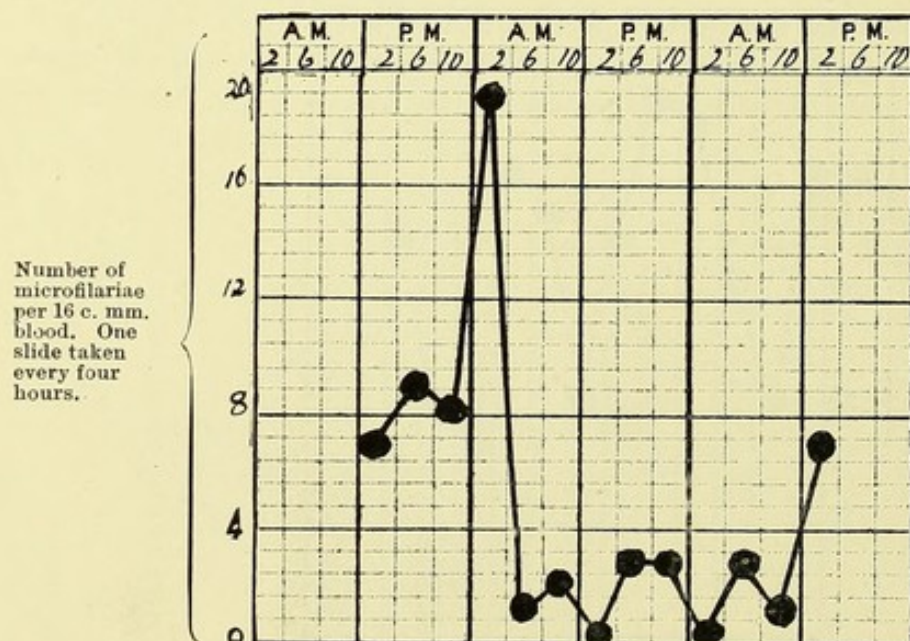


CHART XV.—Four Hour Chart of *Filaria* with nocturnal periodicity.

*Name* : Jam Basha.    *Race* : Indian male, *aet.* 26.    *Physical State* : Normal.

*Residence in Fiji*: Three years.

April, 1910.

27

28

29

30

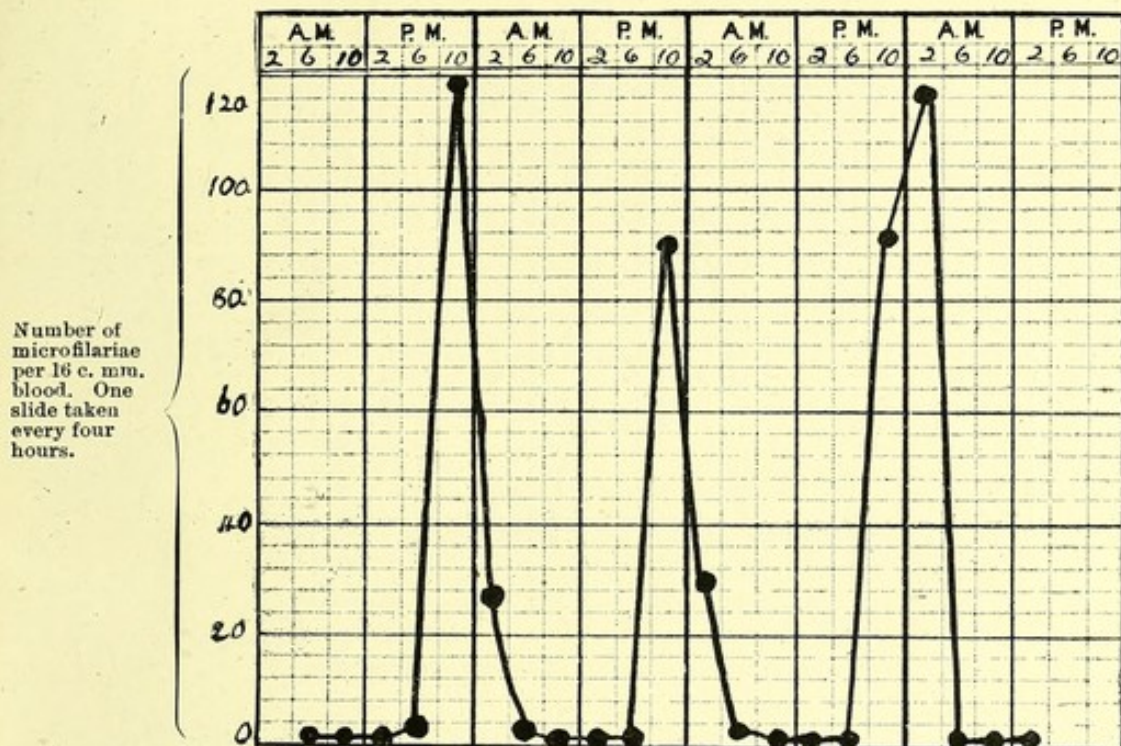


CHART XVI.—Four Hour Chart of *Filaria* with no periodicity.

*Name* : Jukdio. *Race* : Indian male, *aet.* 22. *Physical State* : Left hydrocele.

(Microfilariae found in hydrocele fluid.)

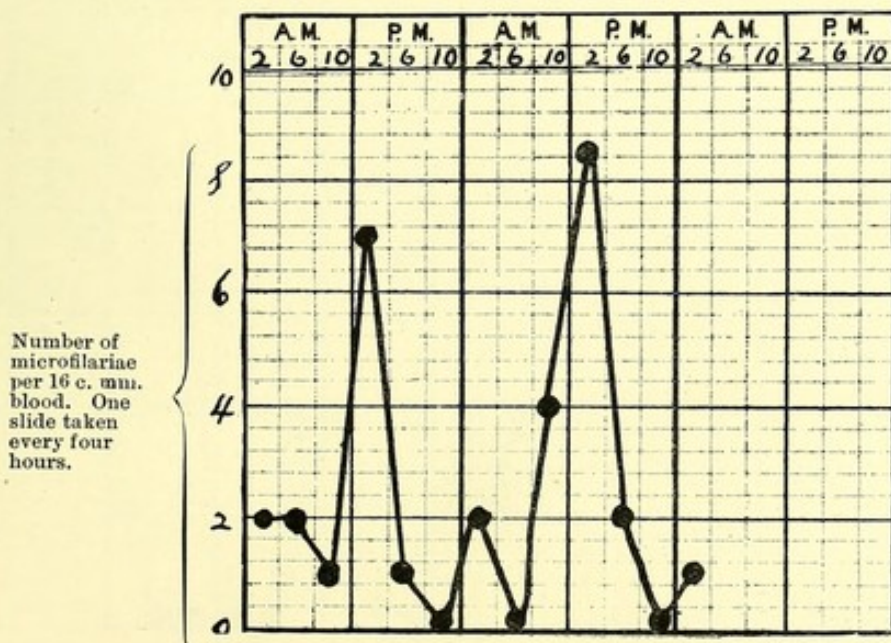
*Residence in Fiji*: Four years.

May, 1910.

19

20

21

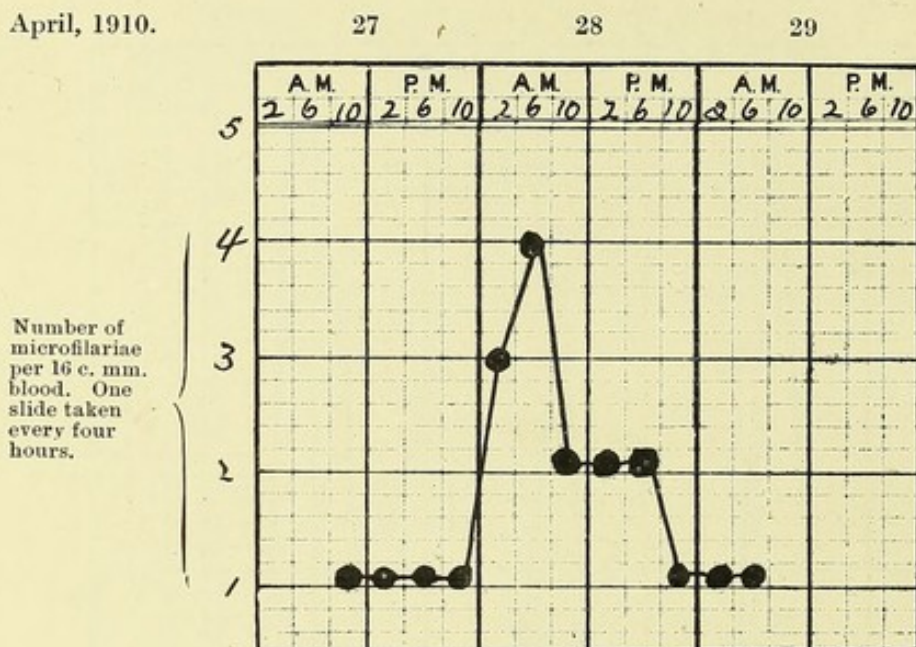


# CHART XVII.—Four Hour Chart of Filaria with no periodicity.

Name : Kandhi. Race : Indian male, *act.* 29. Physical State : Normal.

Residence in Fiji : Ten years.

April, 1910.

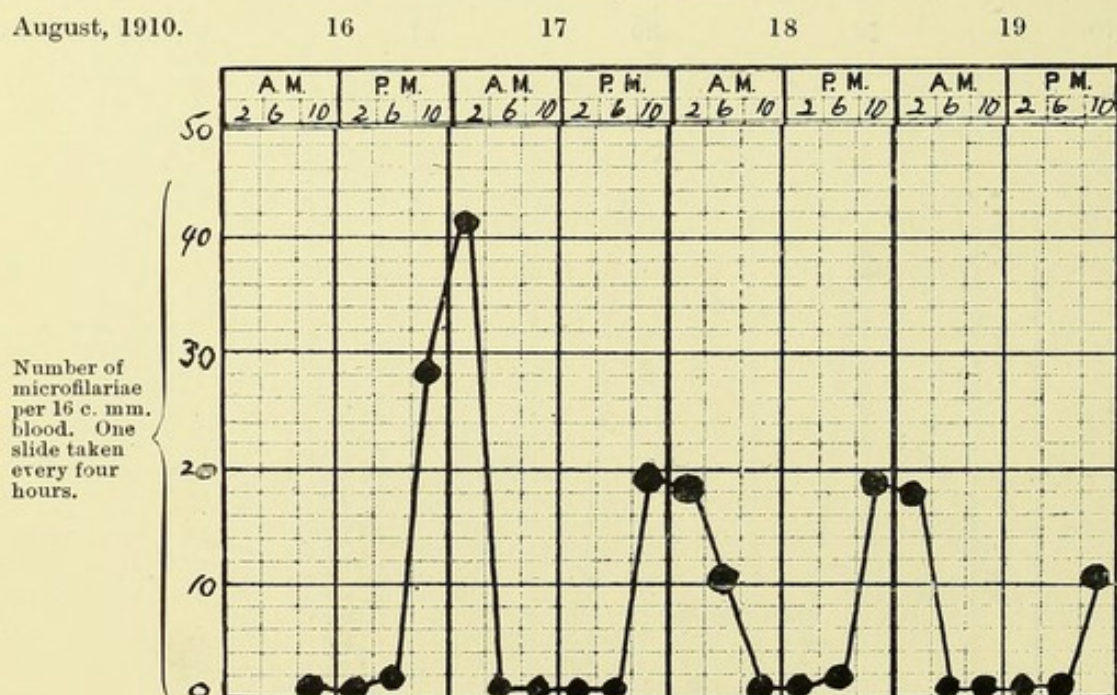


# CHART XVIII.—Four Hour Chart of Filaria with nocturnal periodicity.

Name : Sutherie. Race : Solomon Islander, male, *act.* 30. Physical State : Normal.

Residence in Fiji : Newly arrived from the Solomon Islands ; eight years previously in Queensland.

August, 1910.



# CHART XIX.—Twelve Hour Chart of Filaria with no periodicity.

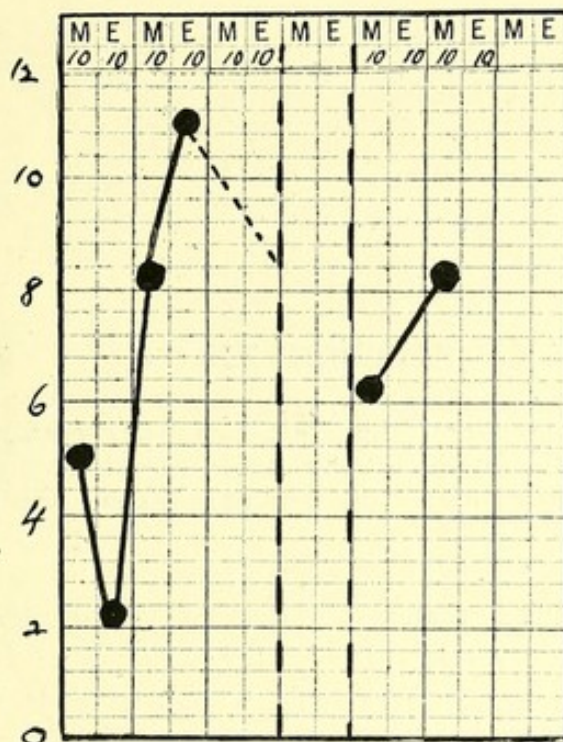
Name : J. F. Race : German male, *act.* 52. Physical State : Filariasis, enlarged glands, lymphangitis.

Residence in Fiji : Ten years ; twelve years previously in Samoa.

April, 1910.

1 2 3 18 19

Number of microfilariae per 16 c. mm. blood. One slide taken 10 a.m., and one slide taken 10 p.m.



# CHART XX.—Four Hour Chart of Filaria with no periodicity.

Discovery of adult filariae.

Name : Thomasi. Race : Fijian male, *act.* 24. Physical State : Filarial abscess.

April, 1910.

29

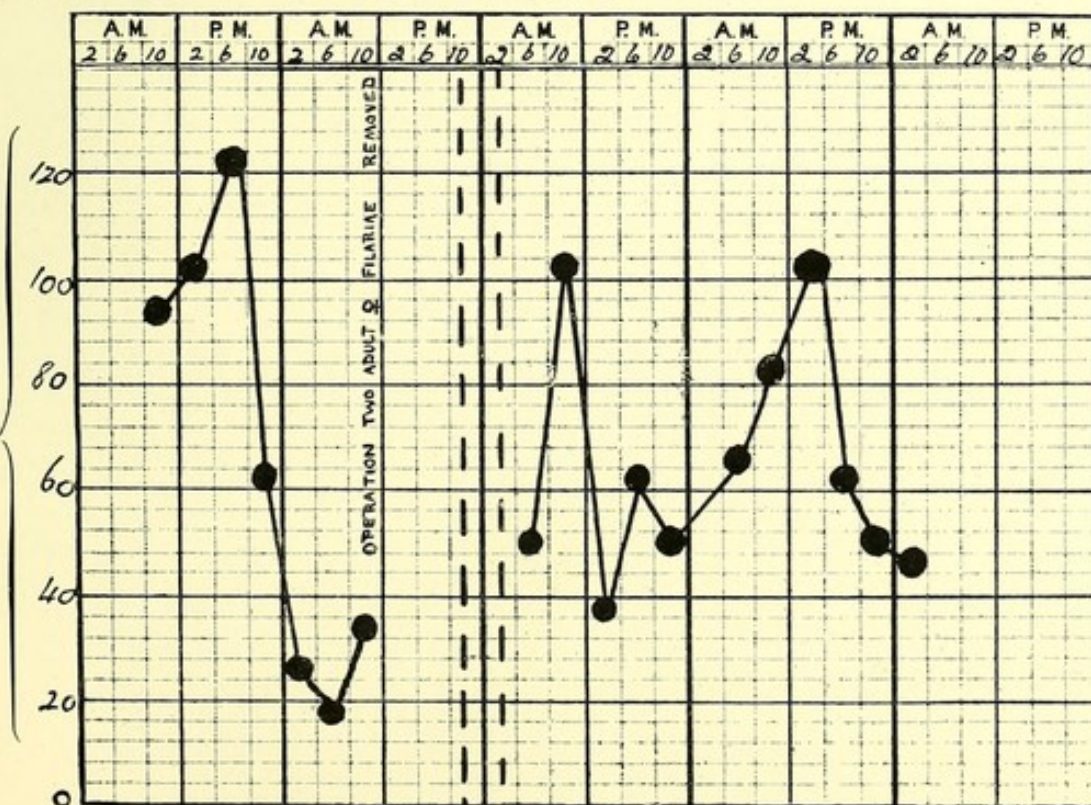
30

May 3

4

5

Number of microfilariae per 16 c. mm. blood. One slide taken every four hours.



## APPENDIX XII.

Table showing maximum, minimum mean temperatures and rainfall during the months in which transmission experiments with different species of mosquitoes were undertaken. (From Fiji Government Gazette.)

Species of Mosquito : *Culex fatigans*, *Stegomyia fasciata*, *Culex jepsoni*.

1910. Suva.		Mean Maximum.	Mean Minimum.	Rainfall.	Humidity.
May ..	..	83.1° F.	71.2° F.	14.123 ins.	80.6
June	..	79.1 „	69.1 „	9.894 „	79.5

Species of Mosquito : *Stegomyia pseudoscutellaris*.

August	..	78.7° F.	67.5° F.	8.959 ins.	80.4
September	..	78.9 „	69.1 „	12.914 „	79.8
October	..	81.2 „	70.6 „	19.328 „	80.4
November	..	83.6 „	72.0 „	12.725 „	82.7
December	..	86.6 „	74.4 „	9.586 „	78.7

## APPENDIX XIIIa.

*Culex fatigans*—120 bred and fed in captivity. Development of filariae in 17 specimens dissected; the remainder were preserved for sectioning in celloidin.

Microfilaria infection of patient per 16 c. mm. blood.	Day after feeding.	Date.	No. found in stomach.	No. found in thorax.	No. found in proboscis.	Measurements.	Remarks.
150	5th day	May 30th	None	27 sausage-shaped forms.	None	—	—
7	8th day	May 28th	"	None	"	—	Infection probably too small.
7	13th day	June 2nd	"	One large broad form alive.	"	—	Moving sluggishly.
7	13th day	June 2nd	"	None	"	—	Infection probably too small
7	14th day	June 3rd	"	One large developing form.	"	—	Moving sluggishly.
7	14th day	June 3rd	"	One large developing form.	"	—	Infection probably too small.
2 others dissected at same time contained nothing.							
11	15th day (2 specimens)	June 4th	None	None	"	—	—
47	16th day	May 23rd	"	4	"	—	—

APPENDIX XIIIa.—*continued.**Culex fatigans*—120 bred and fed in captivity. Development of filariae in 17 specimens dissected.

Microfilaria infection of patient per 16 c. mm. blood.	Day after feeding.	Date.	No. found in stomach.	No. found in thorax.	No. found in proboscis.	Measurements.	Remarks.
150	16th day	July 3rd	None	3	None	Length .. (1) .360 mm. Breadth .. (2) .330 mm. .. .024 mm. .024 mm.	Sluggish undulatory movements.
7	17th day (2 specimens)	June 20th	"	—	"	—	Infection probably too small.
150	19th day	June 13th	"	One long, narrow degenerating form.	"	—	—
150	19th day	June 13th	"	—	1	Length .. (1) 1.602 mm. Breadth .. .018 mm.	Lived 3 hours in distilled water in wetted slide.
150	20th day	June 14th	"	—	None	—	—

## APPENDIX XIIIb.

Table of measurements of larval filariae showing degree of development, at different intervals after feeding on infected blood, in *Stegomyia pseudoscutellaris* (dissection of 40 specimens).

Microfilaria infection of patient per 16 c. mm. blood.	Day after feeding.	Date.	No. found in stomach.	No. found in thorax.	No. found in proboscis.	Measurements.	Remarks.
80	2nd day	July 29th	3	18	None	—	—
80	2nd day	July 29th	8	13	"	—	—
226	2nd day	Aug. 17th	9	13	"	—	—
226	3rd day	Sept. 10th	None	10	"	(1) (2) (3) Total length .103 mm. .135 mm. .141 mm. Length of tail .015 mm. .015 mm. .015 mm. Breadth .. .012 mm. .012 mm. .012 mm.	—
226	4th day	Aug. 19th	"	43	"	(1) (2) (3) (4) Total length .179 mm. .165 mm. .171 mm. .135 mm. Breadth .. .009 mm. .009 mm. .009 mm. .009 mm. Length of tail .015 mm. .015 mm. .015 mm. .015 mm. Ant. V-spot from head .061 mm. .052 mm. .054 mm. .044 mm. Post. V-spot from tail .. .045 mm. .045 mm. .044 mm. .040 mm.	—
80	7th day	Aug. 4th	"	48	"	(1) (2) (3) (4) Length .. .184 mm. .198 mm. .225 mm. .204 mm. Breadth ant. .015 mm. .022 mm. .015 mm. .021 mm. " post. .030 mm. .021 mm. .024 mm. .024 mm. Length of tail No tail No tail .015 mm.	Sluggish undulatory movements of body. Tail, when present, moved independently.
8 micro-filaria nocturna at 10 p.m.	7th day	Aug. 29th	"	2	"	(1) Length .. .210 mm. Breadth ant. .024 mm. " post. .030 mm. Length of tail Very short	—

APPENDIX XIIIb.—*continued.*Table of measurements of larval filariae showing degree of development, at different intervals after feeding on infected blood, in *Stegomyia pseudoscutellaris* (dissection of 40 specimens).

Microfilaria infection of patient per 16 c. mm. blood.	Day after feeding.	Date.	No. found in stomach.	No. found in thorax.	No. found in proboscis.	Measurements.		Remarks.
8 micro-filaria nocturna at 10 p.m.	10th day	Sept. 1st	None	2	None	(1) Length .. . Breadth .. " at head Length of tail	(2) .203 mm. .024 mm. .018 mm. .015 mm.	Sluggish movements of body and independent movements of tail.
226	10th day	Aug. 25th	"	14	"	(1) Length .. . Breadth mid " at head	(2) .210 mm. .030 mm. .024 mm. (3) .244 mm. .024 mm. (4) .254 mm. .030 mm. .024 mm.	—
80	11th day	Aug. 8th (warm weather for time of year)	"	5	"	Length . . . . Breadth ..	(1) .70 mm. .03 mm. (2) .24 mm. .03 mm. (3) .42 mm. .03 mm. (4) .33 mm. (5) .03 mm.	Great variation in size. Larger forms very active.
53	12th day	Oct. 31st	"	8	"	Length .. . Breadth .. Oesophageal constriction	.540 mm. .030 mm. .18 mm. from head.	Oesophageal bulb well marked.
80	14th day	Aug. 11th (warm weather for time of year)	"	18	"	Length .. . Breadth .. Constriction of oesophagus well marked .24 mm. from head. 3 caudal papillae	(1) 1.05 mm. .03 mm. Oesophageal constriction .45 mm. .03 mm. (2) Oesophageal constriction not marked. Anus .03 mm. from tail	Great variation in size. Very active; granular matter escaping from anus in some specimens.
226	14th day	Aug. 29th	"	?	"	Length .. . Breadth ant. " post. 3 caudal papillae	(1) .940 mm. .021 mm. .024 mm.	

## APPENDIX XIIIb.—continued.

Table of measurements of larval filariae showing degree of development, at different intervals after feeding on infected blood, in *Stegomyia pseudoscutellaris* (dissection of 40 specimens).

Microfilaria infection of patient per 16 c. mm. blood.	Day after feeding.	Date.	No. found in stomach.	No. found in thorax.	No. found in proboscis.	Measurements.	Remarks.
226	14th day	Sept. 5th	None	?	None	Length .. .640 mm. Breadth ant. .015 mm. " post. .024 mm. 4 caudal papillae (1)	
71	14th day	Dec. 7th (hot weather)	"	13	"	Length .. .740 mm. (1)	
5	15th day	Nov. 3rd (hot weather)	"	11	"	Length .. 1.23 mm. Breadth .. .024 mm. (1) (2) (3) .960 mm. 1.260 mm. .030 mm. .024 mm.	
Microfilaria nocturna at 10 p.m.	15th day	Dec. 8th (hot weather)	"	3	5	—	Mosquito had been dead for several hours. All filariae were still alive.
226	16th day	Aug. 31st	"	20	None	Length .. .660 mm. Breadth ant. .027 mm. " post. .027 mm. (1) (2) (3) (4) .570 mm. .660 mm. .780 mm. .024 mm. .021 mm. .018 mm. .027 mm. .027 mm. .024 mm. (5) (6) Length .. .690 mm. Breadth ant. .018 mm. " post. .024 mm.	All became very active when slide was gently heated.
226	16th day	Sept. 7th	"	38	"	Length .. 1.140 mm. Breadth ant. .018 mm. " post. .024 mm. (1) (2) (3) .840 mm. .018 mm. .024 mm. Oesoph. constrict. from head .150 mm. .15 mm. .194 mm.	Great variation in size. Smaller forms shedding cuticle. Caudal papillae forming.

APPENDIX XIIIb.—*continued.*

Table of measurements of larval filariae showing degree of development, at different intervals after feeding on infected blood, in *Stegomyia pseudoscutellaris* (dissection of 40 specimens).

Microfilaria infection of patient per 16 c. mm. blood.	Day after feeding.	Date.	No. found in stomach.	No. found in thorax.	No. found in proboscis.	Measurements.	Remarks.
47	16th day	Dec. 19th (hot weather)	3 wand'r'd into stomach.	12 (3 in head)	2	—	20 fully developed forms capable of being transmitted.
47	16th day	Dec. 19th (hot weather)	6 lying amongst Malpighian tubules.	12	3	—	Forms in proboscis observed to emerge through Dutton's membrane; 21 fully developed forms.
47	16th day	Dec. 19th (hot weather)	1	(2 in head)	2	—	5 fully developed forms.
47	17th day	Dec. 20th (hot weather)	1	2	3	—	6 fully developed forms.
47	17th day	Dec. 20th (hot weather)	1	2	None	—	—
Microfilaria nocturna 11 at 10 p.m.	18th day	Nov. 18th (hot weather)	None	11 (4 in head)	"	Length .. 1.2 mm. Breadth .. .018 mm.  Thoracic forms (1) (2) Length .. 1.200 mm. .810 mm. Breadth ant. .018 mm. .018 mm. " post. .024 mm. .024 mm.	11 fully developed forms.
	19th day	Aug. 16th	None	26	2	(3) (4) Length .. .960 mm. .992 mm. Breadth ant. .018 mm. .021 mm. " post. .024 mm. .024 mm. 4 caudal papillae 4 caudal papillae	Some forms in thorax were dead and degenerating, presenting a granular appearance.

## APPENDIX XIIIb.—continued.

Table of measurements of larval filariae and degree of development, at different intervals after feeding on infected blood, in *Stegomyia pseudoscutellaris* (dissection of 40 specimens).

Microfilaria a infection of patient per 16 c.mm. blood.	Day after feeding.	Date.	No. found in stomach.	No. found in thorax.	No. found in proboscis.	Measurements.	Remarks.
226	20th day	Sept. 11th	None	5	None	<div> <div>(1)</div> <div>(2)</div> </div> Length .. 1.170 mm. 1.400 mm. Breadth ant. .021 mm. .021 mm. " post. .030 mm. .030 mm.	—
53	20th day	Sept. 26th	"	1	4	—	Four forms from proboscis were placed in wetted slide in distilled water and lived 4 hours at room temperature.
Microfilaria nocturna 5 at 10 p.m.	20th day	Sept. 14th	"	1	None	Length .. .990 mm. Breadth .. .012 mm.	—
53	20th day	Sept. 26th	"	8	3	<div> <div>Thoracic forms.</div> <div>(1)</div> <div>(2)</div> <div>(3)</div> </div> Length .. 1.560 mm. 1.110 mm. .660 mm. Breadth .. .018 mm. .021 mm. .024 mm. Length 1.230 mm. 1.410 mm. 1.440 mm. Breadth .. .021 mm. .018 mm. .018 mm.	Eight forms from thorax, ringed and kept in normal saline at room temperature, lived 7 hours.
226	21st day	Sept. 12th	"	2	2	<div> <div>Thoracic forms.</div> <div>(1)</div> <div>(2)</div> </div> Length .. .986 mm. 1.530 mm. Breadth .. .018 mm. .015 mm. (ant.) Tail .. 3 papillae .018 mm. (post.) 4 caudal papillae.	—

APPENDIX XIIIb.—*continued.*Table of measurements of larva filariae showing degree of development, at different intervals after feeding on infected blood, in *Stegomyia pseudoscutellaris* (dissection of 40 specimens).

Microfilaria infection of patient per 16 c. mm. blood.	Day after feeding.	Date.	No. found in stomach.	No. found in thorax.	No. found in proboscis.	Measurements.	Remarks.
226	21st day	Sept. 12th	None	3	2	Proboscis form. (1) Length .. 1.340 mm. Breadth .. .018 mm. Tail .. . 3 papillae.	Ringed and kept in distilled water in welled slide at room temperature. Lived 5 hours.
226	21st day	Sept. 12th	"	3	3	—	Obtained from a dead mosquito. Forms apparently dead in proboscis, but revived on warming. Watched piercing Dutton's membrane. Ringed and kept in distilled water at room temperature. Lived 1 hour.
226	21st day	Sept. 12th	"	1	5	Proboscis forms. (1) (2) (3) Length .. 1.440 mm. 1.410 mm. 1.470 mm. Breadth, head .015 mm. .015 mm. .015 mm. " middle .018 mm. .018 mm. .018 mm. " tail .012 mm. .012 mm. .012 mm. 4 caudal papillae.	One from proboscis kept in tap water in welled slide at room temperature. Lived 2 hours.

APPENDIX XIIIb.—*continued.*Table of measurements of larval filariae and degree of development, at different intervals after feeding on infected blood, in *Stegomyia pseudoscutellaris* (dissection of 40 specimens).

Microfilaria infection of patient per 16 c. mm. blood.	Day after feeding.	Date.	No. found in stomach.	No. found in thorax.	No. found in proboscis.	Measurements.	Remarks.
Microfilaria nocturna 10 at 10 p.m.	21st day	Sept. 12th	None	5	None	Thorax. (1) (2) (3) Length .. 1.350 mm. 1.230 mm. 1.380 mm. Breadth ant. .012 mm. .012 mm. .015 mm. " middle .018 mm. .018 mm. .018 mm. " post. .012 mm. .015 mm. .024 mm. 4 caudal papillae 4 caudal papillae 4 caudal papillae	No difference observed between these forms developing in this mosquito from microfilaria nocturna and the other forms aforementioned.
53	21st day	Sept. 27th	"	None	1	—	Placed in distilled water in welled slide at room temperature. Lived 6 hours.
53	21st day	Sept. 27th	"	4	3	Thorax. (1) Length .. 1.380 mm. Breadth .. .018 mm.	2 in proboscis seen to emerge together through Dutton's membrane; forms from thorax kept alive in distilled water for 6 hours.
Microfilaria nocturna. 3 at 10 p.m.	21st day	Sept. 27th	"	None, (2 in head)	3	—	2 proboscis forms kept in welled slide in distilled water at room temperature and lived 2 hours.
Microfilaria nocturna 11 at 10 p.m.	21st day	Nov. 20th	"	5	None	—	—
Microfilaria nocturna 11 at 10 p.m.	22nd day	Nov. 21st	2	3	"	Proboscis forms. (1) (2) (3) Length .. 1.360 mm. 1.200 mm. 1.230 mm. Breadth .. .018 mm. .018 mm. .018 mm.	—

## APPENDIX XIIIc.

*Stegomyia fasciata*—55 bred and fed in captivity. Development of filariae in 35 specimens dissected; the remainder were preserved for sectioning in celloidin. N.B.—No development took place beyond a certain stage; in only one specimen were signs of further development beyond this stage observed.

Microfilaria infection of patient per 16 c. mm. blood.	Day after feeding.	Date.	No. found in stomach.	No. found in thorax.	No. found in proboscis.	Measurements.	Remarks.
150	24 hours	May 26th	2 un-sheathed forms	22	None	—	Forms in thorax very active.
17	3rd day	May 23rd	None	2 stumpy forms	"	—	—
7	3rd day	May 25th	"	2 stumpy forms	"	—	—
150	3rd day	June 6th	"	13	"	—	Elongated forms, very active.
150	5th day	June 8th	"	6	"	(1) .179 mm. Length .. .149 mm. Breadth .. .018 mm. Tail .. .015 mm. (2) .189 mm. (3) .021 mm. .015 mm.	Tail moved independently.
150	6th day (2 specimens)	May 31st	"	10	"	—	Forms motile.
7	10th day (2 specimens)	May 30th	"	1 degenerating form	"	—	—
150	10th day	June 13th	"	8	"	(1) .360 mm. Length .. .240 mm. Breadth .. .027 mm. (2) .330 mm. (3) .027 mm. Alimentary canal and anus were differentiated. These were the most advanced forms ever seen in this species.	Forms appeared to be dead. No movements observed.

## APPENDIX XIIIc.—continued.

*Stegomyia fasciata*—55 bred and fed in captivity. Development of filariae in 35 specimens dissected; the remainder were preserved for sectionizing in celloidin. N.B.—No development took place beyond a certain stage; in only one specimen were signs of further development beyond this stage observed.

Microfilaria infection of patient per 16 c. mm. blood.	Day after feeding.	Date.	No. found in stomach.	No. found in thorax.	No. found in proboscis.	Measurements.	Remarks.
150	10th day (5 specimens)	June 13th	None	1 each; small stumpy forms in 3 specimens.	None	—	—
7	12th day (2 specimens)	June 1st	"	None	"	—	—
150	12th day	June 6th	"	2 degenerating forms.	"	—	—
150	12th day (2 specimens)	June 6th	"	1 degenerating form.	"	—	—
7	13th day	June 1st	"	None	"	—	—
7	14th day (2 specimens)	June 3rd	"	"	"	—	—
150	14th day (2 specimens)	June 8th	"	2 degenerating forms.	"	Length .. .0158 mm. Breadth .. .009 mm. Length of tail .. .015 mm.	—
150	15th day (7 specimens)	June 9th	"	1 degenerating form.	"	—	—
150	17th day	June 20th	"	1 degenerating form.	"	Length .. .0179 mm. Breadth .. .009 mm. Length of tail .. .015 mm.	—
150	17th day (2 specimens)	June 20th	"	—	"	—	—

## APPENDIX XIII.

*Culex jepsoni*—63 bred and fed in captivity. Development of filaria in 25 individuals of this species dissected; in no instance had development proceeded beyond a certain stage. The remaining specimens were preserved for sectioning in celloidin.

Microfilaria infection of patient per 16 c. mm.	Day after feeding.	Date.	No. found in stomach.	No. found in thorax.	No. found in proboscis.	Measurements.	Remarks.
430	14 hours	July 14th	34	None	None	—	All except two were sheathless.
150	5th day	June 18th	3 sheathless	3	"	(1) Length .. .190 mm. (2) Breadth .. .168 mm. (3) Tail .. .009 mm. (2) Breadth .. .009 mm. (3) Tail .. .015 mm.	—
150	7th day	June 17th	"	4	"	(1) Length .. .147 mm. (2) Breadth .. .147 mm. (3) Tail .. .015 mm. (2) Breadth .. .012 mm. (3) Tail .. .015 mm.	Movements very sluggish. Independent movements of tail.
150	11th day	June 21st	"	1	"	(1) Length .. .126 mm. (2) Breadth .. .021 mm. (3) Tail .. .015 mm.	Form dead and evidently degenerating. A granular mass.
150	12th day	June 22nd	"	10	"	(1) Length .. .180 mm. (2) Breadth ant. .021 mm. (3) Breadth post. .024 mm.	—
150	13th day (4 specimens)	June 31st	"	3	"	(1) Length .. .120 mm. (2) Breadth .. .015 mm. (3) Length .. .120 mm. (2) Breadth .. .024 mm. (3) Length .. .120 mm. (2) Breadth .. .015 mm.	Large vacuolated ant. and post. V-spots. Granular matter exuding from post. V-spot.

## APPENDIX XIII.—continued.

*Culex jepsoni*—63 bred and fed in captivity. Development of filaria in 25 individuals of this species dissected; in no instance had development proceeded beyond a certain stage.

Microfilaria infection of patient per 16 c. mm.	Day after feeding.	Date.	No. found in stomach.	No. found in thorax.	No. found in proboscis.	Measurements.	Remarks.
150	14th day (4 specimens)	July 1st	None	None	None	—	—
150	15th day	June 25th	"	"	"	—	—
150	17th day (2 specimens)	June 27th	"	"	"	—	—
150	17th day	June 27th	"	11	"	—	Degenerating forms.
150	17th day	June 27th	"	5	"	—	Degenerating forms.
150	18th day	June 28th	"	None	"	—	—
150	19th day (2 specimens)	June 29th	"	"	"	—	—
150	19th day (3 specimens)	June 29th	"	2	"	Length .. .14 mm. Breadth .. .024 mm. Tail .. .012 mm.	—
150	20th day	June 30th	"	None	"	—	—

## APPENDIX XIVA.

Table to show that the number of microfilariae in blood imbibed by the mosquito is not in excess of the number in a corresponding amount of the circulating blood: that is, the mosquito, *quâ* the microfilaria, has no selective power.

Mosquito's stomach, immediately after feeding, dissected out and a smear of the blood made and compared with a measured smear of blood taken from patient at the same time.

Species.	Amount of blood in mosquito's stomach.	Number of microfilariae in stomach blood.	Number of microfilariae in patient's circulating blood per 16 c. mm.	Number in the amount of patient's circulating blood equal to that found in mosquito.
(1) <i>Stegomyia pseudo-scutellaris</i>	4 c. mm. blood	5 micro-filariae.	80 (average of 12 slides)	20
(2) " "	2.6 "	7 "	71 "	11
(3) " (Fed on patient in open)	3.2 "	5 "	" "	14
(4) " "	2.2 "	4 "	" "	10
(5) " "	2.6 "	3 "	" "	11
(6) " "	2.6 "	9 "	" "	11
(7) " "	2.6 "	9 "	" "	11
(8) " "	3.2 "	10 "	" "	14
(9) " "	3.2 "	15 "	" "	14
(10) " "	2.2 "	4 "	" "	10
(11) " "	2.0 "	4 "	" "	11
(12) " "	2.2 "	15 "	" "	10
(13) " "	3.2 "	18 "	" "	14
(14) " (fed on patient in cage)	4.0 "	14 "	47 "	12
(15) " "	4.0 "	21 "	" "	12
(16) " "	4.0 "	12 "	" "	12
(17) " "	4.0 "	11 "	" "	12
(18) " "	4.0 "	16 "	" "	12
(19) " "	4.0 "	14 "	" "	12
(20) " "	4.0 "	10 "	" "	12
(21) " "	4.0 "	22 "	" "	12
(22) " "	3.2 "	4 "	" "	9
(23) " "	3.2 "	6 "	" "	9
(24) " "	3.2 "	15 "	" "	9
(25) " "	3.2 "	9 "	" "	9
(26) " "	5.3 "	22 "	" "	16
(27) " (fed on patient in open)	.53 "	0 "	247 (average of 6 slides)	8
(28) " "	1.06 "	14 "	" "	16
(29) " "	1.06 "	24 "	" "	16
(30) " "	1.06 "	6 "	" "	16
(31) " "	.7 "	5 "	" "	11
(32) " "	.53 "	1 "	" "	8
(33) " "	.43 "	2 "	" "	7
(34) " "	.8 "	12 "	" "	13
(35) " "	.8 "	11 "	" "	13
(36) " "	.6 "	2 "	" "	10
(37) " "	.6 "	4 "	" "	10
(38) " "	.6 "	4 "	" "	10
(39) " (fed on patient in cage)	4.0 "	95 "	226 "	56
(40) " "	2.0 "	7 "	" "	28
(41) " "	2.0 "	13 "	" "	28

## APPENDIX XIVb.

Table showing that practically all microfilariae imbibed by *Stegomyia pseudoscutellaris* develop in thorax and come to maturity.

Estimated average number of microfilariae imbibed.	Date after feeding on infected blood.	Number of larval filariae found in thorax of mosquito.
37 per <i>Stegomyia pseudoscutellaris</i>	3rd day	25
37        "	4th   "	43
37        "	10th  "	20
11        "	14th  "	13
11        "	15th  "	8
12        "	16th  "	20
13        "	16th  "	5
12        "	17th  "	6

These calculations were made from the same batches of mosquitoes as those referred to in Appendix XIVa.

## APPENDIX XIVc.

Experiment to determine the total infective capacity of *Stegomyia pseudoscutellaris*. Two separate broods of filariae were successively put through the same batch of mosquitoes. After ten days had elapsed since the first feeding, they were fed again on the same patient. After ascertaining that the filariae of the first brood had arrived at the proboscis (on the fourteenth day), the infected *stegomyiae* for a period of five days were fed on a guinea-pig, thus permitting the filariae that had attained the proboscis to emerge. After twenty-five days from the first feeding, the filariae of the second brood were found in the proboscis.

Date.	Microfilaria infection of patient.	Estimated number of micro-filariae imbibed by <i>stegomyia</i> at each infection.	Age of filariae first brood.	Filariae found in abdomen.	Filariae found in thorax.	Filariae found in proboscis.	Age of filariae of second brood.	Filariae found in abdomen.	Filariae found in thorax.	Filariae found in proboscis.	Total filarial infection.
3.1.11	247 per 16 c. mm.	11	14 days	None	30	3	4 days	None	21	None	54
3.1.11	"	11	14 "	"	3	None	4 "	"	22	"	25
6.1.11	"	11	17 "	1	None	7	7 "	"	14	"	22
11.1.11	"	11	22 "	1	"	None	12 "	"	7	"	7
12.1.11	"	11	23 "	None	"	"	13 "	"	34	"	34
13.1.11	"	11	24 "	"	"	"	14 "	"	None	4	4
14.1.11	"	11	25 "	"	"	"	15 "	"	8	6	14

## APPENDIX XV.

Measurements of microfilariae without periodicity, in blood, in normal saline, in citrate solution and in hydrocele fluid.

Length of microfilariae and position of anterior V-spot.

Length.			
(1)	300 $\mu$	ant. V-spot	80 $\mu$ from cephalic end.
(2)	255 "	"	81 "
(3)	300 "	"	75 "
(4)	255 "	"	75 "
(5)	310 "	"	75 "
(6)	270 "	"	75 "
(7)	255 "	"	75 "

Length and breadth.		Length and breadth.	
(1)	240 $\mu \times 7 \mu$	(8)	255 $\mu \times 6 \mu$
(2)	260 " $\times 7$ "	(9)	270 " $\times 6$ "
(3)	262 " $\times 6$ "	(10)	270 " $\times 6$ "
(4)	277 " $\times 6$ "	(11)	240 " $\times 6$ "
(5)	262 " $\times 6$ "	(12)	270 " $\times 6$ "
(6)	270 " $\times 7$ "	(13)	240 " $\times 6$ "
(7)	270 " $\times 7$ "	(14)	260 " $\times 7$ "

## APPENDIX XVI.

Post-mortem examination of a Solomon Islander, male, *aet.* 30 ; ten years resident in Fiji.

Admitted to hospital with acute respiratory distress; general subcutaneous oedema, most marked in the face and thighs; and dilatation of the heart. The liver pulsated and was enlarged and tender. The spleen was enlarged and tender (probably from old-standing malaria). The knee-jerks were present and there was no tenderness of the calves. The temperature was slightly raised to 99° F. at night. No ova of intestinal parasites were found in the faeces.

Examination of the blood on the 2nd of March, 1910, revealed 35 microfilariae at 10 a.m. and 128 at 10 p.m. per 16 c. mm. blood. Some were stained in a variety of ways; others were kept on ice for several days. They presented all the characteristics of sheathed microfilariae as already described. The patient died suddenly at 8 a.m. on the 3rd of March.

A complete post-mortem was made immediately. There was great oedema of all the tissues, and much fluid in the pleural cavities in the pericardium and peritoneum. All the blood that could be obtained was collected in a bucket and carefully searched for parental filariae. The heart was flabby and enlarged. No atheroma of the vessels was noted. The liver was enlarged and typically nutmeg, and weighed 60 ounces. The spleen, 20½ ounces, was soft and dark, with capsule greatly thickened. Right kidney and suprarenal healthy, left kidney hydronephrotic. The glands at the portal fissure, bronchial and lumbar glands, were all enlarged and were carefully dissected, but no filariae were found in them. The lymphatic tissue in front of the aorta and in the posterior mediastinum, the mesentery, great omentum, and recto-vesical connective tissue were removed and dissected in normal saline, but no adult filariae were

found. Blood smears were made from the lung, internal jugular vein, liver, spleen, testes, vesiculae seminales, and the numbers of microfilariae covered by two square coverslips were counted with the following result :—

Lung	..	..	average	63	microfilariae.
Internal jugular vein	..	..	..	40	..
Liver	..	..	..	35	..
Spleen	..	..	..	11	..
Vesiculae seminales	..	..	..	0	..

Sections of the organs show microfilariae in greatest abundance in the intervalveolar capillaries of the lung. The liver shows fatty degeneration of the cells and increase of interstitial fibrous tissue. Microfilariae abound in the intralobular veins. In the spleen microfilariae can be recognized in the capillaries of the spleen pulp. In the kidney and testes none could be found. In the cortex of the left inguinal gland portions of a male and adult female filaria were found on section.

## APPENDIX XVII.

### Inequality of distribution of filariasis in Fiji.

#### Bau.

This, the ancient native capital of Fiji, is situated on an island at the mouth of the river Rewa (*vide* map), and is separated from the mainland by a narrow strait half a mile wide and fordable at low tide. The estimated population is 4-500. Night-feeding mosquitoes (*Culex*) are very common. No day mosquitoes occur, save when the wind blows from the mainland. 169 of the inhabitants were examined—83 males and 86 females. There is not a single case of elephantiasis in Bau.

#### 1.—MALES OVER 20 YEARS OF AGE (52 EXAMINED).

With no microfilariae or signs	-	-	-	-	-	15
With microfilariae in blood and signs of filariasis	-	-	-	-	-	8
2 hydrocele—3 enlarged testis—3 enlarged glands.						
Microfilariae in blood without signs of filariasis	-	-	-	-	-	8
Signs of filariasis, but no microfilariae	-	-	-	-	-	21
7 hydrocele—9 enlarged testis—5 enlarged glands.						

Microfilaria rate 30·7 per cent.

Filarial disease rate 73 per cent.—(i.e. cases with microfilariae without signs, microfilariae with signs, and with signs of filarial disease, but no microfilariae).

The absence of abscess and the large proportion of testicular affections are to be noted.

## 2.—MALES UNDER 20 YEARS OF AGE (31 EXAMINED).

With no microfilariae or signs	-	-	-	-	-	27
With microfilariae in blood and signs of filariasis	-	-	-	-	-	0
Microfilariae in blood without signs of filariasis	-	-	-	-	-	0
Signs of filariasis, but no microfilariae	-	-	-	-	-	4

All enlarged glands.

Microfilaria rate 0 per cent. Filarial disease 12.9 per cent.

## 3.—FEMALES OVER 20 YEARS OF AGE (45 EXAMINED).

With no microfilariae or signs	-	-	-	-	-	28
With microfilariae in blood and signs of filariasis	-	-	-	-	-	0
Microfilariae in blood without signs of filariasis	-	-	-	-	-	5
Signs of filariasis, but no microfilariae	-	-	-	-	-	12

1 abscess—11 enlarged glands.

Microfilaria rate 11.1 per cent. Filarial disease rate 37.7 per cent.

## 4.—FEMALES UNDER 20 YEARS OF AGE (41 EXAMINED).

With no microfilariae or signs	-	-	-	-	-	37
With microfilariae in blood and signs of filariasis	-	-	-	-	-	0
Microfilariae in blood without signs of filariasis	-	-	-	-	-	0
Signs of filariasis, but no microfilariae	-	-	-	-	-	3

Enlarged glands.

Microfilaria rate 0 per cent. Filarial disease rate 7.3 per cent.

For total number examined :—

Elephantiasis rate 0 per cent.

Microfilaria rate 12.5 per cent.

Filarial disease rate 36.3 per cent.

## Loma-Loma.

Chief town of the island of Vanua Balavu (or Vanua Vua) in the eastern or Lau group, and situated 200 miles from Suva. The official return gives 124 inhabitants for the township. It lies on the sea front, bounded on each side by brackish creeks and mangrove swamps, in which *Stegomyia pseudoscutellaris*, the commonest mosquito there, swarms. *Stegomyia fasciata* and *Culex jepsoni* were also noted and were bred from larvae.

In Loma-Loma town 132 persons of all ages were examined. They were ordered to present themselves for this purpose by the head man. Afterwards a house-to-house visitation was made, so that I am convinced that very few, save small children in arms, escaped examination. This description of my method of conducting the investigation applies to all the places visited, and from which the following statistics were obtained; included among those under Loma-Loma are the three neighbouring villages Uruoni, Levukana, and Naruciva, in which 30, 30, and 16 inhabitants respectively were examined.

## MALES OVER 20 YEARS (87 EXAMINED).

With no microfilariae or signs of filariasis	-	-	-	-	21
With microfilariae and signs of filariasis	-	-	-	-	26
Including 2 hydrocele—2 enlarged and varicose groin glands—15 abscess—7 enlarged glands.					
With microfilariae and no signs of filariasis	-	-	-	-	13
Signs of filariasis, but no microfilariae	-	-	-	-	27
Including 2 elephantiasis—2 hydrocele—4 enlarged and varicose groin glands—7 abscess—11 enlarged glands.					
Microfilaria rate 44·8 per cent. Filarial disease rate 75·8 per cent.					

\* \* \* So numerous were the *Stegomyia pseudoscutellaris* that over 100 were caught on one person in less than twenty minutes just outside the village. They were found breeding in two fresh-water wells; the majority, however, probably bred in the brackish swamps amongst the mangroves.

## MALES UNDER 20 YEARS (32 EXAMINED).

With no microfilariae or signs of filariasis	-	-	-	-	22
With microfilariae and signs of filariasis	-	-	-	-	2
Enlarged glands.					
With microfilariae and no signs of filariasis	-	-	-	-	4
Signs of filariasis, but no microfilariae	-	-	-	-	4
1 abscess—3 enlarged glands.					
Microfilaria rate 18·7 per cent. Filarial disease rate 31·2 per cent.					

## FEMALES OVER 20 YEARS (57 EXAMINED).

With no microfilariae or signs of filariasis	-	-	-	-	30
With microfilariae and signs of filariasis	-	-	-	-	3
1 elephantiasis—2 abscess.					
With microfilariae and no signs of filariasis	-	-	-	-	16
Signs of filariasis, but no microfilariae	-	-	-	-	8
1 elephantiasis—3 abscess—1 arthritis—3 enlarged glands.					

## FEMALES UNDER 20 YEARS (46 EXAMINED).

With no microfilariae or signs of filariasis	-	-	-	-	34
With microfilariae and signs of filariasis	-	-	-	-	3
2 abscess—1 enlarged glands.					
With microfilariae and no signs of filariasis	-	-	-	-	6
Signs of filariasis, but no microfilariae	-	-	-	-	3
1 abscess—2 enlarged glands.					

Therefore for total examined :—

Elephantiasis rate 1·8 per cent.  
 Microfilaria rate 32·8 per cent.  
 Filarial disease rate 50 per cent.

## Lakemba.

Having an area of 11,500 acres, it is one of the largest islands of the eastern group, and has a bad reputation for filariasis. It is generally considered to be the stronghold of elephantiasis in Fiji. The soil is very fertile, volcanic in origin, and heavily wooded. There are numerous brackish creeks. A large one flows through the main town (called Levuka). Mosquitoes swarm, *Stegomyia pseudoscutellaris* being very abundant in the mangrove swamps and in the native huts. *Culex fatigans* and *Stegomyia fasciata* breed commonly in the fresh-water cisterns in which rain-water is collected. Night mosquitoes (*Culex*) are said to be very numerous in hot weather, and day mosquitoes (*Stegomyia*) all the year round.

The number of inhabitants of Lakemba Island totals 879 (official return); of these 446 were examined. Out of the total of 303 inhabitants in Levuka town 266 were examined, a house-to-house visitation being made.

## 1.—MALES OVER 20 (77 EXAMINED).

With no microfilariae or signs of filariasis	-	-	-	-	6
With microfilariae and signs of filariasis	-	-	-	-	31
8 elephantiasis—2 hydrocele—1 enlarged testis—5 enlarged and varicose groin glands—1 arthritis—7 abscess—7 enlarged glands.					
Microfilariae, but no signs of filariasis	-	-	-	-	3
With signs of filariasis, but no microfilariae	-	-	-	-	32
8 elephantiasis—5 hydrocele—1 enlarged testis—1 enlarged and varicose groin gland—12 abscess—6 enlarged glands.					

Elephantiasis rate 22·2 per cent.

Microfilaria rate 44·1 per cent.

Filarial disease rate 85·6 per cent.

With no microfilariae or signs of filariasis 8·4 per cent.

N.B.—50 per cent. of males over 20 had microfilariae in blood.

## 2.—MALES UNDER 20 (77 EXAMINED).

With no microfilariae or signs of filariasis	-	-	-	-	6
With microfilariae and signs of filariasis	-	-	-	-	10
Microfilariae, but no signs of filariasis	-	-	-	-	3
With signs of filariasis, but no microfilariae	-	-	-	-	38
Microfilaria rate 16·8 per cent. Filarial disease rate 66·2 per cent.					

## 3.—FEMALES OVER 20 YEARS (79 EXAMINED).

With no microfilariae or signs of filariasis	-	-	-	-	30
With microfilariae and signs of filariasis	-	-	-	-	15
1 elephantiasis—4 abscess—10 enlarged glands.					
Microfilariae, but no signs of filariasis	-	-	-	-	12
With signs of filariasis, but no microfilariae	-	-	-	-	22
3 elephantiasis—9 abscess—10 enlarged glands.					
Microfilaria rate 34·1 per cent. Filarial disease rate 70·8 per cent.					

## 4.—FEMALES UNDER 20 YEARS (38 EXAMINED).

With no microfilariae or signs of filariasis	-	-	-	-	17
With microfilariae and signs of filariasis	-	-	-	-	5
2 abscess—3 enlarged glands.					
Microfilariae, but no signs of filariasis	-	-	-	-	9
With signs of filariasis, but no microfilariae	-	-	-	-	7
1 abscess—6 enlarged glands.					

Microfilaria rate 36·8 per cent. Filarial disease rate 55·2 per cent.

Therefore for Levuka town, of the total inhabitants examined, 226 in number,

The Elephantiasis rate was 7·3 per cent.

„ Microfilaria rate was 32·4 per cent.

„ Filarial disease rate was 69·0 per cent.

Three other villages, lying four to eight miles away from the main town—names: Wacaca, Waitabu and Sungalo—were investigated.

The first named contained sixty-five inhabitants, including four cases of elephantiasis, of whom all were examined. It is situated on the coast by the side of a brackish creek, surrounded by mangrove swamps. Rain-water, stored in large cement tanks with a tin roofing, is drunk; it is clear and apparently breeds no mosquitoes. The commonest mosquito was *Stegomyia pseudoscutellaris*, which swarmed. *Stegomyia fasciata* was also common. The next village, Waitabu, with one case of elephantiasis, contained forty-one inhabitants, all of whom were examined. No stegomyiae were seen here, and were said not to be abundant, the village lying about two miles inland. Sungalo, the next village, with five cases of elephantiasis, lies on the coast, with a brackish creek on either side. Seventy inhabitants were examined. The water supply is from a cement rain-water tank.

## MALES OVER 20 YEARS (70 EXAMINED).

With no microfilariae or signs of filariasis	-	-	-	-	13
With microfilariae and signs of filariasis	-	-	-	-	23
3 elephantiasis—6 hydrocele—2 enlarged and varicose groin glands—4 abscess—8 enlarged glands.					
Microfilariae, but no signs of filariasis	-	-	-	-	5
With signs of filariasis, but no microfilariae	-	-	-	-	29
5 elephantiasis—5 hydrocele—1 enlarged testis—4 enlarged and varicose groin glands—5 abscess—9 enlarged glands.					

Elephantiasis rate 11·4 per cent. Microfilaria rate 40·0 per cent.

Filarial disease rate 81·4 per cent.

## MALES UNDER 20 YEARS (30 EXAMINED).

With no microfilariae or signs of filariasis	-	-	-	-	17
With microfilariae and signs of filariasis	-	-	-	-	0
Microfilariae, but no signs of filariasis	-	-	-	-	1
With signs of filariasis, but no microfilariae	-	-	-	-	12
1 hydrocele—2 abscess—9 enlarged glands.					

Microfilaria rate 3·3 per cent. Filarial disease rate 43·3 per cent.

## FEMALES OVER 20 YEARS (54 EXAMINED).

With no microfilariae or signs of filariasis	-	-	-	-	32
With microfilariae and signs of filariasis	-	-	-	-	7
1 enlarged and varicose groin gland—3 abscess—3 enlarged glands.					
Microfilariae, but no signs of filariasis	-	-	-	-	5
With signs of filariasis, but no microfilariae	-	-	-	-	10
1 elephantiasis—5 abscess—4 enlarged glands.					
Microfilaria rate 22·2 per cent. Filarial disease rate 42·5 per cent.					

## FEMALES UNDER 20 YEARS (25 EXAMINED).

With no microfilariae or signs of filariasis	-	-	-	-	15
With microfilariae and signs of filariasis	-	-	-	-	1
1 enlarged gland.					
Microfilariae, but no signs of filariasis	-	-	-	-	4
With signs of filariasis, but no microfilariae	-	-	-	-	5
2 abscess—3 enlarged glands.					
Microfilaria rate 20 per cent. Filarial disease rate 40 per cent.					

Total for villages in Lakemba (179 persons examined) :—

Elephantiasis rate 5 per cent.

Microfilaria rate 25·7 per cent.

Filarial disease rate 56·9 per cent.

## The Island of Oneata

Lies twenty miles to the south-east of Lakemba. It is a very fertile, rugged island, of some 720 acres in extent. The number of inhabitants is given officially as 185, 114 of whom were examined. This island is famed throughout Fiji as being the worst island for mosquitoes in the group. There is a large fresh-water swamp, with many reeds and much marshy vegetation, in the centre of the island, where the mosquitoes breed in great numbers. Thence they are carried by the wind in swarms. There is a Fijian myth which attributes the great number of mosquitoes to the agency of one of their ancient gods. There are two villages, one of which gets its water by pipes from a spring, the other from a cement tank. The mosquito seen in greatest numbers was *Culex jepsoni*. *Stegomyia pseudoscutellaris* was also seen, but not nearly so commonly as in Lakemba. It is said that the mosquitoes are so numerous that in certain parts the natives cannot keep pigs, and that, before the introduction of mosquito nets, the inhabitants had on occasions to camp out on the reef by the sea-shore for the night. It is to be noted that though the mosquitoes are so common elephantiasis is, as compared with Lakemba, a rare disease.

## MALES OVER 20 YEARS (31 EXAMINED).

With no microfilariae or signs of filariasis	-	-	-	-	5
With microfilariae and signs of filariasis	-	-	-	-	11
1 elephantiasis—2 hydrocele—3 enlarged and varicose groin glands—1 abscess—4 enlarged glands.					
Microfilariae, but no signs of filariasis	-	-	-	-	2

With signs, but no microfilariae - - - - - 13  
 1 elephantiasis—4 hydrocele—3 enlarged and varicose groin glands—  
 2 abscess—2 enlarged glands.

Elephantiasis rate 6.7 per cent. Microfilaria rate 41.9 per cent.  
 Filarial disease rate 83.8 per cent.

MALES UNDER 20 YEARS (24 EXAMINED).

With no microfilariae or signs of filariasis - - - - - 15  
 With microfilariae and signs of filariasis - - - - - 4  
 Microfilariae, but no signs of filariasis - - - - - 0  
 With signs, but no microfilariae - - - - - 5  
 Enlarged glands.

Microfilaria rate 16.6 per cent. Filarial disease rate 37.5 per cent.

FEMALES OVER 20 YEARS (35 EXAMINED).

With no microfilariae or signs of filariasis - - - - - 20  
 With microfilariae and signs of filariasis - - - - - 3  
 1 abscess—2 enlarged glands.  
 Microfilariae, but no signs of filariasis - - - - - 6  
 With signs, but no microfilariae - - - - - 6  
 3 abscess—3 enlarged glands.

Microfilaria rate 25.7 per cent. Filarial disease rate 42.8 per cent.

FEMALES UNDER 20 YEARS (24 EXAMINED).

With no microfilariae or signs of filariasis - - - - - 19  
 With microfilariae and signs of filariasis - - - - - 1  
 Enlarged gland.  
 Microfilariae, but no signs of filariasis - - - - - 2  
 With signs, but no microfilariae - - - - - 2  
 Enlarged glands.

Microfilaria rate 12.5 per cent. Filarial disease rate 20.8 per cent.

Total for Oneata :

Elephantiasis rate 1.5 per cent.

Microfilaria rate 22.5 per cent.

Filarial disease rate 47.2 per cent.

Summary of Statistics.

	Island of Bau.	Loma-Loma.	Oneata Island.	Lakemba Island.
Elephantiasis rate	0 per cent.	1.8 per cent.	1.5 per cent.	8.7 per cent.
Microfilaria rate	12.5 „	32.8 „	22.5 „	36.5 „
Filarial disease rate	36.3 „	50.0 „	47.2 „	75.8 „

## APPENDIX XVIII.

Table to ascertain whether the seat of obstruction can be determined from the presence of enlarged glands in elephantiasis.

Elephantiasis of one part only.	Visible obstruction.	Associated filarial disease.
(1) Elephantiasis scroti.	Enlarged glands, right groin.	Double hydrocele.
(2) Lymphatic oedema left arm. Male.	Enlarged axillary and pectoral glands (left).	—
(3) Elephantiasis scroti.	Enlarged glands, right groin.	Double hydrocele.
(4) Elephantiasis right breast. Female.	Enlarged pectoral gland, right.	Axillary abscess.
(5) Elephantiasis left leg. Female.	Enlarged glands, left groin.	—
(6) Elephantiasis right leg. Male.	Enlarged glands both groins.	Hydrocele, left. Enlarged testis, right.
(7) Elephantiasis left arm. Male.	None	Numerous abscesses over internal condyle, right.
(8) Elephantiasis right leg. Male.	Enlarged glands both groins.	—
(9) Elephantiasis left leg. Male.	Enlarged glands both groins.	—
(10) Elephantiasis scroti.	Enlarged glands both groins.	Abscess left thigh.
(11) Elephantiasis scroti.	Enlarged glands both groins.	Abscess left leg.
(12) Elephantiasis left arm. Female.	None	Enlarged glands both groins. Abscesses left thigh.
(13) Elephantiasis right arm. Female.	None	Abscesses both groins.
(14) Elephantiasis left leg. Male.	Enlarged glands left groin.	Left epitrochlear glands enlarged.
(15) Elephantiasis scroti.	Enlarged glands both groins.	Hydrocele, left.
(16) Elephantiasis scroti.	None	Double hydrocele.
(17) Elephantiasis scroti.	Enlarged gland right groin.	Double hydrocele.
(18) Elephantiasis left arm. Male.	None	Double hydrocele. Enlarged epitrochlear gland, right. Enlarged groin gland, left.
(19) Elephantiasis scroti.	Enlarged glands both groins.	Hydrocele, right.
(20) Elephantiasis scroti.	Enlarged gland both groins	—

Elephantiasis of more than one part.	Visible obstruction.	Associated filarial disease.
(1) Elephantiasis left arm and left leg. Male.	None	Multiple abscesses.
(2) Elephantiasis right arm and left leg. Male.	Varicose lymphatics at bend of elbow, also enlarged glands right groin.	Abscesses in left groin.
(3) Elephantiasis of both legs. Male.	Enlarged glands both groins.	Both testes enlarged.
(4) Elephantiasis of both arms and legs. Slight elephantiasis scroti.	Enlarged epitrochlear glands, right.	—
(5) Elephantiasis right leg and scrotum.	Enlarged glands right groin.	Both testes enlarged.
(6) Elephantiasis both legs and scrotum.	Enlarged glands both groins.	—
(7) Elephantiasis both legs. Male.	Enlarged glands left groin.	Abscess right thigh.
(8) Elephantiasis both legs and scrotum.	None	—
(9) Elephantiasis both arms and scrotum.	None	Enlarged testes. Hydrocele, right. Abscesses left arm.
(10) Elephantiasis both legs. Male.	Enlarged glands left groin.	Abscess right thigh.
(11) Elephantiasis of both legs and scrotum.	None	Enlarged epitrochlear glands, left.
(12) Elephantiasis of both arms and scrotum.	None	Enlarged testes. Hydrocele right. Abscesses left arm.
(13) Elephantiasis both arms and legs. Male.	Both epitrochlear glands enlarged. Enlarged groin glands both sides.	Enlarged testes. Abscess left groin.
(14) Elephantiasis both arms. Male.	Enlarged glands both groins.	Double hydrocele.
(15) Elephantiasis left arm and both legs. Male.	Enlarged epitrochlear gland, left, and enlarged groin glands, left.	—
(16) Elephantiasis both arms. Male.	Both epitrochlear glands enlarged. Enlarged groin glands both sides.	—
(17) Elephantiasis left arm and both legs. Female.	Enlarged epitrochlear glands both sides.	—
(18) Elephantiasis right arm and both legs. Female.	None	—

Elephantiasis of more than one part.	Visible obstruction.	Associated filarial disease.
(19) Elephantiasis both arms. Female.	Enlarged epitrochlear glands, left.	Abscess right groin.
(20) Elephantiasis both legs and scrotum.	None	Enlarged epitrochlear glands, right. Double hydrocele and enlarged testes. Abscess right leg.
[(21) Elephantiasis both legs. Female.	Enlarged glands left groin.	Abscess left groin and right breast.
[(22) Elephantiasis both legs, scrotum and right arm.	None	Abscess both groins.
[(23) Elephantiasis both legs, scrotum and both arms.	Enlarged glands left groin.	Abscess left arm.
(24) Elephantiasis right leg and scrotum.	Enlarged glands both groins.	Abscesses right groin.
(25) Elephantiasis both legs, left arm and scrotum.	Enlarged glands right groin.	Abscess right groin. Hydrocele, right.
(26) Elephantiasis left leg and scrotum.	Enlarged glands both groins.	Double hydrocele.
(27) Elephantiasis scrotum and left leg.	Enlarged glands both groins.	Hydrocele, left.

## APPENDIX XIX.

## Details of cases of abscess of probable filarial origin.

1. *Fijian male, aet. 24*, was admitted to hospital with a typical attack of filarial lymphangitis. Temperature 102.6° F. (left axilla), pulse 120, and frequent rigors. There was a painful lump over the right internal condyle about the size of a half-crown. It was hot and tender to the touch. The edges were indefinite, and the lymphatics in the course of the brachial artery could be palpated and were tender. There were numerous microfilariae in the blood (Appendix XI., Chart 20). Leucocytes numbered 18,800 per c. mm., the red cells 3,050,000, while a differential count showed 5 per cent. of eosinophiles. The skin began to get very hot and shiny over the lump, and it was evident that an abscess was forming. On incision, two recently dead female filariae were found. A small amount of thick pus, like an elongated cord, exuded. Cultures were made with great precaution from the pus, on blood and ordinary agar. Some was taken up by means of a platinum loop, and some aspirated into a syringe. All cultures grew *Staphylococcus pyogenes aureus* and *Streptococcus pyogenes*. Three smears stained by methylene blue showed one microfilaria in the pus. The pus cells were peculiar ;

very few polymorphonuclear cells were seen, but the cells appeared mostly to be lymphocytes and breaking down red corpuscles. Immediately after the operation the temperature became normal. Part of the inflammatory mass dissected out at operation was sectioned microscopically, and portions of a female filaria were found (*vide* Pl. XXIII.) lying in a lymphatic space surrounded by haemorrhage and inflammatory tissue, and microfilariae were seen lying in a lymph space. No cocci could be demonstrated in microscopical sections by appropriate stains, but a great many eosinophile cells could be demonstrated in the surrounding tissues. The morning after the operation the lymphatics could still be felt as thickened cords. There were scars of numerous other abscesses on the patient's body, three in the left groin, others on the inner surface of both the left and right upper arms.

2. *Fijian male, aet. 30.* A large abscess situated at posterior border of the right axilla in the substance of latissimus dorsi. Temperature 103.8° F. Four ounces of thick yellow pus evacuated; a similar swelling in the left gluteus maximus yielded no pus on incision. Scars of numerous other abscesses were situated in the right axilla and on the posterior border of the scapula on the same side. There was no history of injury. There were numerous old yaws ulcers on both legs. Smears of pus showed numerous staphylococci, and *Staphylococcus pyogenes aureus* was grown on culture. Microfilariae were numerous in blood-stream—47 at 10 a.m. and 30 at night per 16 c. mm. blood. None were seen in smears of the pus.

3. *Fijian male, aet. 24.* Temperature 99.8° F. A large hard, fluctuating painful swelling, size of goose's egg, situated about half-way up left humerus on the inner side. Enlarged and painful gland in corresponding axilla. The leucocytes numbered 11,300. Differential count showed 8 per cent. of eosinophiles. Microfilariae were numerous in the blood, forty-four per 16 c.mm. There were marks of other abscesses in the left axilla.

The abscess, several inches in diameter, was situated in the substance of the biceps muscle and contained 15 ounces of thick, yellow, creamy pus. Cultures on agar grew *Staphylococcus pyogenes albus*. Smears of pus showed no microfilariae, but clusters of staphylococci were seen. The pus cells appeared to be mostly breaking down lymphocytes; there were also a great many eosinophiles and a few polymorphs.

4. *Fijian male, aet. 45.* Elephantiasis of left leg; abscess on dorsum of left foot, three inches below external malleolus; scars of old abscesses in left gastrocnemius; double enlarged and varicose groin glands; enlarged left testis.

Blood contained no microfilariae; the white cells numbered 7,100, red cells 4,700,000, and eosinophiles 5 per cent. The abscess was incised. Smears of the pus revealed numbers of lymphocytes, eosinophiles, and polymorph cells, together with chains of streptococci. A culture on agar grew colonies of *Streptococcus pyogenes*.

5. *Fijian male, aet. 24.* Patient stated that he had had a lump in left groin for fourteen days. This had become a fluctuating swelling about size of hen's egg, surrounded by dense inflammatory tissue. Temperature 101.8° F. No microfilariae found in blood. The abscess was punctured with a sterile syringe and a quantity of purulent fluid withdrawn. No microfilariae were found in the pus. Cultures on agar grew *Staphylococcus pyogenes albus*; cultures were made on a subsequent occasion with the same result.

6. *Fijian male, aet. 18.* Sudden pain in enlarged glands in right groin. Ankle-joint of same side painful and swollen. Tenderness along the course of the lymphatics. Glands of groin inflamed and tender. Temperature 99° F. White blood cells 10,290. Eosinophiles 18 per cent. Microfilariae averaged 6 per 16 c. mm. blood.

On puncture the groin gland exuded cloudy lymph, containing great abundance of lymphocytes, but no microfilariae. On agar this lymph grew pure cultures of *Staphylococcus pyogenes albus* in forty-eight hours.

7. *Fijian male, aet. 15.* Abscess size of a duck's egg in right groin. Blood no microfilariae, white cells 9,600, red cells 6,487,000, eosinophiles 15 per cent. On incision thick cloudy pus obtained, consisting of polymorphs, lymphocytes, a few eosinophiles and red blood corpuscles. Bunches of staphylococci were seen, but no microfilariae. Inoculated on to agar grew pure culture of *Staphylococcus pyogenes aureus*.

8. *Fijian male, aet. 20.* Rigors lasting off and on for four days. A large abscess developed in latissimus dorsi about six inches below angle of right scapula. Temperature 100.6° F. White cells 13,700; red cells 5,050,000; eosinophiles 4 per cent. Microfilariae (average of three slides) numbered 127 at 10 a.m. and 139 at 10 p.m. On incision a cyst-like cavity found in the substance of latissimus dorsi muscle containing thick grumous pus. Films of this pus show no microfilariae, but numerous polymorph pus cells and staphylococci. Culture of pus grew *Staphylococcus pyogenes aureus* in pure growth.

Six days later a hard swelling appeared in the substance of triceps muscle on the same side, but disappeared without suppuration.

## APPENDIX XX.

### Details of Investigations on cases of hydrocele and enlarged testes, not mentioned in the Text.

1. *Fijian male, aet. 30.* Double hydrocele in association with elephantiasis scroti. At operation the right hydrocele was found to be lobulated and contained straw-coloured fluid. Hydroceles of the cord were also present. Fluid was aspirated by syringe and remained sterile on culture. When centrifuged, cholesterin crystals and lymphocytes were found.

2. *Fijian male, aet. 40.* Double hydrocele in association with elephantiasis scroti. Contained straw-coloured fluid. Cultures from each hydrocele remained sterile. Fluid was centrifuged and contained cholesterin crystal and lymphocytes.

3. *Indian male, aet. 22;* four years in Fiji. Left hydrocele. No other sign of filariasis. Hydrocele fluid straw-coloured, sterile on culture. Few microfilariae in blood exhibiting no periodicity. Hydrocele fluid contained numerous live microfilariae, some sheathed, others sheathless (*vide* Phot. XIII.), also great numbers of dead forms and empty sheaths. Microfilariae lived thirty-six hours in this fluid.

4. *Fijian male, aet. 24.* Right hydrocele, size of a goose's egg, lobulated. Fluid procured at operation was centrifuged, but nothing was found. Sac walls were teased out in normal saline, but no filariae found.

5. *Fijian male, aet. 28.* Left hydrocele in association with enlarged and varicose groin glands on the right side. At operation straw-coloured fluid obtained; centrifuged, but nothing found. On culture it remained sterile. Mass of gelatinous blubbery tissue found lying round the spermatic cord. In hydrocele sac walls, which were very thick and vascular, numbers of calcified filariae were found in a good state of preservation. The right testis and epididymis were enlarged. From the lower pole of the testis, a cyst with thick calcareous walls and enclosing brown sebaceous-like material was shelled out. A similar mass found at the upper pole consisted of inflammatory tissue enclosing a calcified filaria. Sections of this hydrocele sac wall show bundles of unstriated muscle fibres (cremaster internus) surrounded by proliferating fibrous tissue, dilated blood and lymphatic vessels. No lining layer of epithelial cells could be recognized.

6. *Fijian male, aet. 29.* Right hydrocele in association with elephantiasis of the scrotum and enlargement of both sets of groin glands. Straw-coloured fluid was centrifuged, but nothing found; it was sterile on culture. No calcified filariae found in sac wall. On section of hydrocele sac wall bundles of unstriated muscle fibres of the cremaster internus were seen. Fibrous tissue was very abundant, enclosing large blood and lymph vessels. Again no lining epithelium could be distinguished.

7. *Fijian male, aet. 30.* Double hydroceles associated with pedunculated groin glands on the left and enlarged groin glands on the right. The right hydrocele was lobulated. The epididymes were very vascular and enlarged. Cultures were made from fluid and were sterile. In the centrifuged fluid nothing was found. Dissection of the sac walls also yielded no filariae.

8. *Fijian male, aet. 45.* Right hydrocele associated with slight elephantiasis scroti, and elephantiasis of the left leg; double enlarged groin glands. Straw-coloured fluid was centrifuged, but nothing found. Hydrocele sac, tough and vascular, was dissected and great numbers of well-preserved calcified filariae were found, often three and four together. Sections of the sac wall show bundles of muscle fibres surrounded by thick bands of fibrous tissue enclosing dilated lymph spaces and blood-vessels. No lining epithelium could be distinguished.

9. *Fijian male, aet. 60.* Right hydrocele associated with elephantiasis of the scrotum, and double enlarged groin glands. At operation the straw-coloured hydrocele fluid was centrifuged, but nothing found. No filariae were found on dissection of the sac wall.

10. *Fijian male, aet. 25.* Left hydrocele. Operation. Straw-coloured fluid obtained and centrifuged; nothing found. No filariae found on dissection of the sac wall.

11. *Fijian male, aet. 40.* Left hydrocele associated with elephantiasis of scrotum and left leg; double enlarged groin glands. Straw-coloured fluid centrifuged; great number of cholesterol crystals found. The sac walls were calcified to a great extent. This calcification consisted of thick cords filled with amorphous masses of calcium carbonate. When cleared in creosote, numbers of coiled and calcified filariae could be seen in the surrounding tissue. A discharging ulcer on the surface of the scrotum was found to communicate with a purulent cavity in the right epididymis. A calcified filaria was found coiled up in the fibrosed testicular substance. Sections of this hydrocele sac wall show bundles of the cremaster internus, each bundle enclosed by strands of fibrous tissue.

## APPENDIX XXI.

## Details of diffuse inflammatory swellings.

1. *Fijian male, aet. 23.* Admitted with a temperature of 100° F., once reaching 102° F. An indefinite hard mass, the size of a tangerine orange, appeared in the abdominal wall in the left lumbar region, but quickly disappeared again. A day later a smaller one appeared just above the level of the umbilicus on the right side. This was very painful and tender to the touch. The epitrochlear glands and glands of the right groin were enlarged. Leucocytes numbered 14,000. Eosinophiles 22 per cent. No microfilariae were present in the blood. A week after admission the lump was explored and found to be situated in the substance of the external oblique muscle. Cultures were made from fluid aspirated by means of a syringe, but remained sterile. The mass was carefully dissected in normal saline, but no filariae or their remains were found. The patient made an uninterrupted recovery, and no more swellings appeared.

2. *Fijian male, aet. 30.* Admitted with numerous abscesses and high temperature—104° F. One was opened at the posterior border of the axilla, a second on the outer surface of the left leg below the knee, a third in the substance of the pectoral muscles on the left side. No microfilariae were found in the blood. A hard lump about the size of a tangerine orange appeared in the left lumbar region, apparently situated in the substance of the muscle, but not attached to the skin. The temperature remained irregular, rising to 100° F. at night. The mass was aspirated and a small quantity of blood-stained fluid obtained which remained sterile on culture. No microfilariae were found in the exudate. Aspiration was repeated on a subsequent occasion with a similar result. The leucocytes numbered 11,250, and the eosinophiles 13 per cent. A month later the mass still preserved the same features, but was less painful. On discharge the lump had disappeared. Three months after he was seen in his native village. He was then quite normal and had had no recurrence of the trouble.

## APPENDIX XXII.

## Thrombosis was noted in four cases.

1. *A Solomon Islander, aet. 30,* infected with *microfilaria nocturna*, whose chart is given in Appendix XI., Chart XVIII, suddenly developed a thrombosis of the median vein in the left arm. The arm was painful and there was a slight rise of temperature to 99° F. There was no local cause to account for it. The leucocytes at the time numbered 5,900, and eosinophiles 6 per cent.

2. *A Fijian male, aet. 28.* Admitted complaining of pain in the left side of the neck and shoulder. A thrombosis suddenly developed, involving the axillary, median basilic, and median veins. This cleared up without a rise of temperature or any other disturbance. The blood contained no microfilariae; leucocytes numbered 6,500. Eosinophiles 21 per cent.

Thrombosis in association with septic infection was noted twice.

3. *A European, aet. 28.* Thrombosis of the internal saphena vein, together with adenitis of the groin, a staphylococcal infection of the pelvic glands and a high eosinophilia.

4. *A Fijian male, aet. 50.* Admitted with large right hydrocele and enlarged glands in left groin. His temperature was of an intermittent type, reaching 102° F. and 103° F. A thrombosis of the femoral vein on the left side appeared. An abscess developed at the site of the thrombosis, and *Streptococcus pyogenes* was cultivated from the pus. Pus next appeared in the left knee-joint. This was opened. Films of pus showed quantities of streptococci and pus cells. Three weeks later, pus appeared in right popliteal space and streptococci were again demonstrated in films and on culture. The temperature became normal, and the patient was discharged with an oedematous swelling of both legs. The blood contained no microfilariae. Leucocytes numbered 10,900. Eosinophiles 21 per cent.

#### APPENDIX XXIII.

Details of cases of synovitis of probable filarial origin.

1. *A Fijian male, aet. 60,* was admitted with painful enlargement of right knee-joint and temperature of 100° F., falling to normal in the daytime. There were enlarged matted glands in the left groin and the left testis was enlarged and heavy. Both spermatic cords were much thickened and lobulated. The blood contained but one microfilaria per measured slide. Under an anaesthetic the glands of the left groin were removed and found to contain calcified filariae. The right knee-joint was aspirated; a considerable amount of fluid was found in the subcrureus pouch. The fluid was purulent and consisted of quantities of polymorphonuclear cells. No organisms were found, and it remained sterile on culture. A certain degree of ankylosis took place, and the knee-joint could not be extended beyond an angle of 70°, though flexion was possible. A considerable amount of fluid and thickening remained, but the pain disappeared. On his discharge, two months afterwards, the affected knee still measured two inches more in circumference than the left. Microfilariae could still be found sparingly in the blood.

2. *A Fijian male, aet. 23,* had a violent rigor in the middle of the night with a typical attack of orchitis in right testis and adenitis of glands of right groin. The next day his right knee-joint was found to be enlarged and very painful. Another rigor ensued and his temperature went up to 104° F. The knee-joint was opened and a quantity of purulent fluid evacuated. The joint was flushed out with saline and weak carbolic solution and a tube inserted. The inflammation of the groin glands subsided and the temperature became normal. A considerable amount of ankylosis and thickening ensued. Four months later the knee-joint could be flexed to a right angle and measured one inch more in circumference than the left. No microfilariae were found in the blood.

## APPENDIX XXIV. (1).

## Enlarged epitrochlear glands due to presence of live or calcified filariae.

Macroscopically all such glands presented the same appearance. They were very vascular; the capsule was thickened and they lay in a mass of yellow matted lymphatic tissue; on section a quantity of yellow putty-like material exuded from certain areas.

1. *Fijian, aet. 24.* Enlarged gland right arm, size of a pigeon's egg. No microfilariae in the circulation. Thirteen adult worms removed from this gland. On section numerous yellow spots were observed from which, on pressure, caseous material exuded. This was apparently formed of inspissated lymph. Numerous live adult filariae were found in the medulla as well as in the cortex of the gland. No microfilariae were found in the gland juice or in microscopical sections. A quantity of grumous material was found round coiled and, apparently, dormant filariae in the cortex. No dead or calcified filariae were discovered on careful dissection. Microscopical sections from two portions of the gland show the same structure. Great fibrosis, giant-cell formation and collections of lymphoid cells. There are spaces in the substance probably representing accessory lymph spaces (*vide* Pl. XXV. 3). Great numbers of eosinophiles are seen throughout the sections.

2. *Fijian, aet. 30.* Mass of glands, size of pigeon's egg, removed at operation. No microfilariae found in the blood. In the peripheral portions of the gland six complete calcified filariae were seen. Two live filariae, male and female, were found. On section the same yellow caseous material exuded from several points. No microfilariae were found in the gland juice. Microscopical sections show great fibrosis of the gland enclosing spaces full of lymphocytes, giant-cell formation and again great numbers of eosinophile cells.

3. *A Solomon Islander, aet. 30.* Enlarged epitrochlear glands, size of haricot beans, removed from both arms. Numerous microfilariae with nocturnal periodicity in the blood. On dissection a calcified filaria was found in one gland, the other was greatly fibrosed. On microscopical section the remains of a calcified filaria were seen in a lymph space surrounded by fibrous tissue. There was great fibrosis of the gland substance, only a few collections of lymphoid cells being found. In other sections lymphatic vessels with greatly thickened walls and lumina completely blocked by fibroblasts were seen.

4. *Fijian, aet. 30.* Enlarged epitrochlear glands, each size of a thrush's egg, removed after an attack of orchitis and fever. No microfilariae found in blood. These glands were very tough and fibrous. On dissection one calcified filaria was found. Microscopical sections show masses of lymphoid cells surrounded by fibrous tissue and numbers of eosinophile cells.

5. *Fijian, aet. 34.* A matted mass of glands in the right arm removed; double hydroceles, but no microfilariae in the blood. The glands were very adherent to surrounding structures. The afferent and efferent lymphatics and blood-vessels were large and thickened. On section the medulla was very fibrous, the cortex much softer and more adenomatous. Five completely calcified filariae were found in the cortical substance. In a space about the size of a hemp seed, containing putty-like material, a coiled and recently dead filaria was discovered. The process of calcification had evidently just begun. Disintegrating

microfilariae were observed in great numbers, together with lymphocytes, polymorphs, red blood corpuscles and eosinophile cells. No organisms were found in the exudate (Pl. XXVI., 1). Plaques of substance staining pink with eosin are observed in the interior of the worm, representing probably the commencement of calcification. The head end of another specimen, in which evidences of calcification are also apparent (Phot. IX.), was present in the gland substance, together with portions of a uterine tube containing ova. Microscopical sections from different portions of the gland were made. Pl. XXVI., 2, is drawn from such a section. Greatly fibrosed lymphatic tissue with dilated lymph spaces made up the greater portion of the gland. A structure representing probably a lymphatic channel, the lumen of which was almost completely blocked by proliferating endothelium, is shown in this figure. A great number of eosinophile cells were noted throughout the section. In another section portions of a calcified filaria, similar to those shown in Pl. XXV., Fig. 1, were found surrounded by fibrous tissue. A culture from the lymph of this gland was made at the operation and remained sterile.

#### APPENDIX XXIV. (2).

Enlarged groin glands, due to the presence of live or calcified filariae.

1. *Solomon Islander*, aet. 30. Enlarged inguinal glands obtained post-mortem. Patient had numerous microfilariae in the blood, exhibiting no periodicity. The lumbar glands were also enlarged. In sections portions of a perfect male and female were found. These were the only filariae discovered. Sections of the female filaria are shown in the plate, apparently in a dilated lymphatic vessel with greatly thickened walls; the lumen of the vessel contained lymphocytes, coagulated lymph and a few microfilariae (Pl. XVIII.) The surrounding glandular tissue shows considerable fibrosis.

2. *A Fijian*, aet. 49. Under observation for nine months. In life there was a mass of enlarged glands in the right groin, about the size of a duck's egg; this mass was only partially reducible on pressure. Above it the oblique set of glands was enlarged, hard and shotty. He had frequently febrile bronchitic attacks and tubercular signs at the right apex. No microfilariae were present in the blood; 1.5 c.c. was abstracted from the median basilic vein and centrifuged with a negative result; slides also were made of the blood four-hourly for twenty-four hours on several occasions. Lymph was abstracted by means of a syringe from gland puncture and, on centrifuging this, numbers of discarded sheaths of microfilariae were found. Cultures were made from the lymph on blood agar and were sterile.

Eight months after the first examination the patient was admitted again with haemoptysis. Gland puncture was again sterile. One microfilaria was found in three measured slides of blood and during the subsequent week they were found almost every time they were searched for. Just before death the microfilariae disappeared again from the blood, but were found on two occasions in considerable numbers in lymph from gland puncture. It was noticeable that they did not resemble those found in the blood, but had large overlapping sheaths at the head and tail; their nuclear structure was undifferentiated and they resembled those unripe forms found in the uterus of the adult.

At the post-mortem there were widespread indications of tuberculosis. The thoracic duct and receptaculum chyli were searched for filariae, but none were found. There was a quantity of jelly-like tissue lying in front of the aorta which, when punctured, exuded clear lymph. A similar mass of varicose lymphatics accompanied the right common iliac artery. The mass of enlarged groin glands was dissected out, together with a thick strand of lymphatic tissue which ran up beneath Poupart's ligament to join the dilated lymphatics accompanying the common iliac artery on the right side. The following glands were dissected: anterior mediastinal, bronchial, epitrochlear, lumbar, and cervical, also the lymphatic tissue in front of the aorta and in the portal fissure. One calcified filaria was found in an enlarged gland lying over the left common iliac artery, but nothing was found in the gland on the opposite side. In the right epididymis numbers of calcified filariae, rolled up into hard yellow nodules, and a few in the substance of the spermatic cord, were seen. Numbers were also found in the epididymis on the left side. A small translucent hydrocele was found situated in front of the left testis. No microfilariae were found in the fluid, nor any calcified filariae in the sac walls. Only one microfilaria was found in smears of the spleen out of a number made from various organs. The enlarged groin gland on the right side was situated in the centre of a mass of yellow lymphatic tissue. It was very fibrous and a quantity of clear lymph exuded on section. Great numbers of disintegrated calcified filariae were found. The whole section of the gland appeared studded with them. In the very centre of the gland a live and complete male and female filaria were found. No microfilariae were found in smears of the gland juice nor in microscopic sections. Microscopic sections of the glands show interlacing fibrous bands enclosing masses of lymphoid cells and a great preponderance of eosinophile cells. Dead and calcified filariae are seen (Pl. XXV., 2). surrounded by strands of fibrous tissue, and in one instance a giant cell is seen in close proximity.

3. *Fijian male, aet. 22 years.\** Elephantiasis of the right leg for five years; enlarged inguinal gland, right side, size of a thrush's egg. The right testis was hard and enlarged and there was a small hydrocele. The left epitrochlear gland was enlarged. A culture on blood agar was made from the lymph from this gland immediately after removal and was found to be sterile. The gland, which was fibrous on section, was found to be studded with calcified filariae, no less than ten being actually found. Several were found in thickened efferent lymphatic trunks. Microscopical section shows great fibrosis of the glandular tissue enclosing areas of lymphoid cells. No microfilariae were found in the blood.

4. *Fijian, aet. 28.* Enlarged groin glands on the right side with slight elephantiasis of the scrotum and large hydroceles. The inguinal gland on the left side was also slightly enlarged. Microfilariae were found sparingly in the blood, about one per slide. The glandular mass on the right side could be slightly reduced on pressure. In aspirated lymph, containing no blood, one small microfilaria with undifferentiated nuclear structure was seen. At the operation one large gland about the size of a hen's egg was shelled out from a tangled mass of surrounding yellow lymphatic tissue; beneath it lay a smaller one, about the size of a pigeon's egg. On section the cortex of the gland was strawberry-

\* This is the youngest patient with elephantiasis noted.

red in colour and clearly demarcated from the yellow fibrous medulla. Scrapings yielded a milky juice. No microfilariae were found in the gland juice. In both glands many calcified filariae were found both in the cortex and in the medulla, but much more numerous in the latter. In the smaller gland a complete calcified filaria was found blocking an efferent lymphatic trunk, and has been figured in an excellent microphotograph by Dr. Bell (Phot. XI.). Microscopical sections of several portions of a calcifying filaria, undergoing disorganization, show in the interior of the worm fibroblasts, eosinophiles and giant-cell formation. The gland substance shows a remarkable invasion by fibrous tissue. (Pl. XXV., 1).

5. *Fijian, act. 29.* Elephantiasis of the scrotum; enlarged inguinal gland on the left side removed. No microfilariae were found in the blood. In the right gland there was a discharging sinus which proved to be tubercular; it contained but one calcified filaria and numerous caseating areas, evidently tubercular. Four months afterwards the man died, and extensive tuberculosis was revealed at post-mortem. Microscopically the gland had all the characteristics of a tubercular gland, and tubercle bacilli could be demonstrated in the caseous material.

6. *Fijian, act. 60.* Enlarged inguinal glands forming a prominent mass on the right side; enlarged left testis; acute synovitis of the right knee. The mass of glands could only be slightly reduced by pressure in the recumbent position. Gland puncture yielded lymph containing one small microfilaria, similar to those before described, and a few sheaths. The lymph obtained was sterile on agar. A large gland, about the size of a small hen's egg, was removed from a mass of coiled, matted and thickened lymphatics. On section it presented a yellow fibrous medulla and a well-demarcated pink adenomatous cortex. A drawing was made to scale to show this remarkable difference (*vide* Pl. XXVII.). Three calcified filariae were found in this: two in the medulla and one in the cortex. The blood contained microfilariae sparingly, only one to each measured slide of blood. No microfilariae were noted in the gland juice.

Microscopical sections were made through the adenomatous cortex and through the medulla. In the former situation clumps of lymphocytes were seen enclosed by fibrous strands and dilated lymph and blood-vessels with thickened walls were frequently encountered. The remainder of the gland was to a great extent composed of fibrous tissue, fat cells and dilated blood-vessels. No excess of eosinophiles was noted in this instance. A large lymphocele formed immediately after the operation.

7. *Fijian, act. 30.* Pedunculated groin glands on both sides; double hydrocele (Phot. VII.). The glands on the right side constituted a mass about the size of a man's fist which could not be reduced. By palpation large hard masses could be made out representing both the vertical and oblique set of glands on both sides. Similar bodies could also be distinguished extending above Poupart's ligament, representing probably the enlarged iliac glands. Both epitrochlear glands were enlarged. On puncture, clear lymph, sterile on culture, was obtained. The lymph continued to exude for some time. The blood contained no microfilariae, though 2 c.c. were abstracted from a vein and centrifuged. The mass of pedunculated glands was dissected out. They were covered with a layer of cord-like lymphatics and were very vascular. A cord of the thickness of the index finger could be traced upwards

beneath Poupart's ligament, and downwards into Hunter's canal. The two largest glands measured 9 cm.  $\times$  5 cm. individually. A drawing was made actual size (Pl. II.), of the largest. These glands consisted of a fibrous medulla and a vascular pink adenomatous cortex. A number of calcified filariae were found in the cortex and in the medulla. Part of a male and a perfect living female filaria were found in the centre. No microfilariae were found in the centrifuged gland juice.

Microscopical section shows strands of fibrous tissue dividing the gland into many small nodules, and also a great excess of eosinophiles.

8. *Fijian, aet. 45.* Enlarged groin glands on both sides; double hydrocele, slight elephantiasis of scrotum; enlarged epitrochlear glands on both sides. Lymph abstracted by puncture contained no microfilariae and was sterile on culture on agar. At operation enlarged glands were dissected out from the mass in the right groin; round the gland was a large accumulation of matted and vascular lymphatic tissue. No filariae found on dissection of the gland in normal saline. Microfilariae were abundant in blood; averaging, in three slides, thirty-eight in daytime, twenty at night.

On microscopical section the remains of two calcified filariae were seen lying apparently in a lymph space surrounded by greatly thickened and fibrosed walls (*vide* Pl. XXV., Fig. 1). Giant cells were observed in this area. A great number of eosinophile cells seen in the gland substance. The lymphatic tissue of the gland is almost wholly replaced by fibrous tissue.

9. *Fijian male, aet. about 20.* Enlarged hard and movable oblique inguinal glands in left groin. No pelvic glands could be palpated. Slightly enlarged glands in the right groin. The epitrochlear gland on the right side was enlarged. Glands in left groin were aspirated; no microfilariae found in the lymph which was sterile on culture on agar. 1 c.c. of blood, extracted from cephalic vein into citrate solution, was centrifuged, but no microfilariae were found. On section the glands were tough and fibrous in the centre, but had a distinct adenomatous cortex. Gland juice contained no microfilariae. Several pieces of calcified filariae were found in the yellow fibrous tissue in the medulla of the gland. In the cortex a complete living male and female filaria were found, together with part of another female.

Microscopical sections of the gland show areas of lymphoid cells enclosed by bands of fibrous tissue and a marked excess of eosinophile cells.

10. *Fijian male, aet. 20.* Enlarged inguinal glands both groins. Enlarged left testis and epididymis. Abscess scar in the left groin; markedly enlarged glands underneath it. Pelvic glands not palpable. No microfilariae found in slides of the blood. Enlarged glands from both groins removed at operation. One on the left side was found to be adherent to the skin beneath the abscess mark. On dissection one small calcified filaria found in an area containing some caseous material. Cultures on agar made from the glands by aspiration after removal were sterile. No calcified filariae were found in the gland on the right side. No microfilariae were found in the gland juice. Smears made of the caseous material showed a preponderance of eosinophile cells, but no tubercle bacilli or other organisms.

Microscopical sections of the gland show fibroblasts extending between groups of lymphoid cells, but not to such a marked degree as noted in sections aforementioned. A great number of eosinophile cells was noted.

11. *Fijian, aet. 25.* A mass of irreducible pedunculated groin glands on the left side, size of a duck's egg. Oblique set of inguinal glands enlarged on both sides, hard and shotty. No obvious enlargement of pelvic glands noted. There was an abscess scar in the left groin, situated over the mass. Testes were normal. No microfilariae in the blood. The pedunculated mass was removed at operation and found extending as a solid cord, the thickness of the index finger, underneath Poupart's ligament into the abdomen and down into Hunter's canal. A mass of matted lymphatic vessels surrounded the enlarged gland, and it was firmly adherent to surrounding structures. The gland, on section, was very tough and fibrous. There were a number of small areas containing caseous matter of which smears were made and found to consist to a great extent of lymphocytes and eosinophile cells. No living or calcified filariae were found (the gland had been preserved in formalin, thus making dissection a difficult task). A culture on agar, made from the lymph aspirated at the time of removal, proved sterile.

Microscopical sections show islands of lymphoid cells surrounded by bands of fibrous tissue and a great excess of eosinophile cells.

In addition to these cases the large irreducible mass of glands figured in Phot. VIII. was investigated. The individual glands which could be felt in the midst of an indefinite doughy swelling measured over three inches in length. No enlarged glands could be felt in the pelvis. Lymph was abstracted by means of a syringe and remained sterile on culture. No microfilariae were found in the lymph; there were none in the blood.

Only one case corresponding to the recognized descriptions of varicose groin glands was seen. This was in a *Fijian male, aet. 28*, who had a swelling in the left groin which could be reduced in the recumbent position. On palpation small shotty glands could be distinguished in the interior of the swelling. On puncture clear lymph continued to ooze out for some time. No microfilariae were found in this exudate or in the blood.

#### APPENDIX XXV.

*Fijian, aet. 21.* This man was under constant observation for ten months and was watched through three such attacks. Being my cook, I had every opportunity for making observations. The microfilariae were not very numerous in the blood-stream and remained remarkably constant throughout the whole time. Thus, in:—

April, 1910	Average of 3 slides	8 per 16 c. mm.
June, 1910	12	2.3
August, 1910	3	5
September, 1910	3	3
October, 1910	3	1
"	3	3
"	3	3
December, 1910	3	3
February, 1911	3	6

Previous to these observations he had had three attacks of adenitis in the left groin; these glands were distinctly enlarged.

# Chart to APPENDIX XXV.—Four Hour Chart.

Name : Enere Bose. Race : Fijian male, aet. 25. Filarial Orchitis.

Red=Temperature in left groin.  
Black=Temperature in left axilla.

Red=Temperature in right groin.  
Black=Temperature in left axilla.

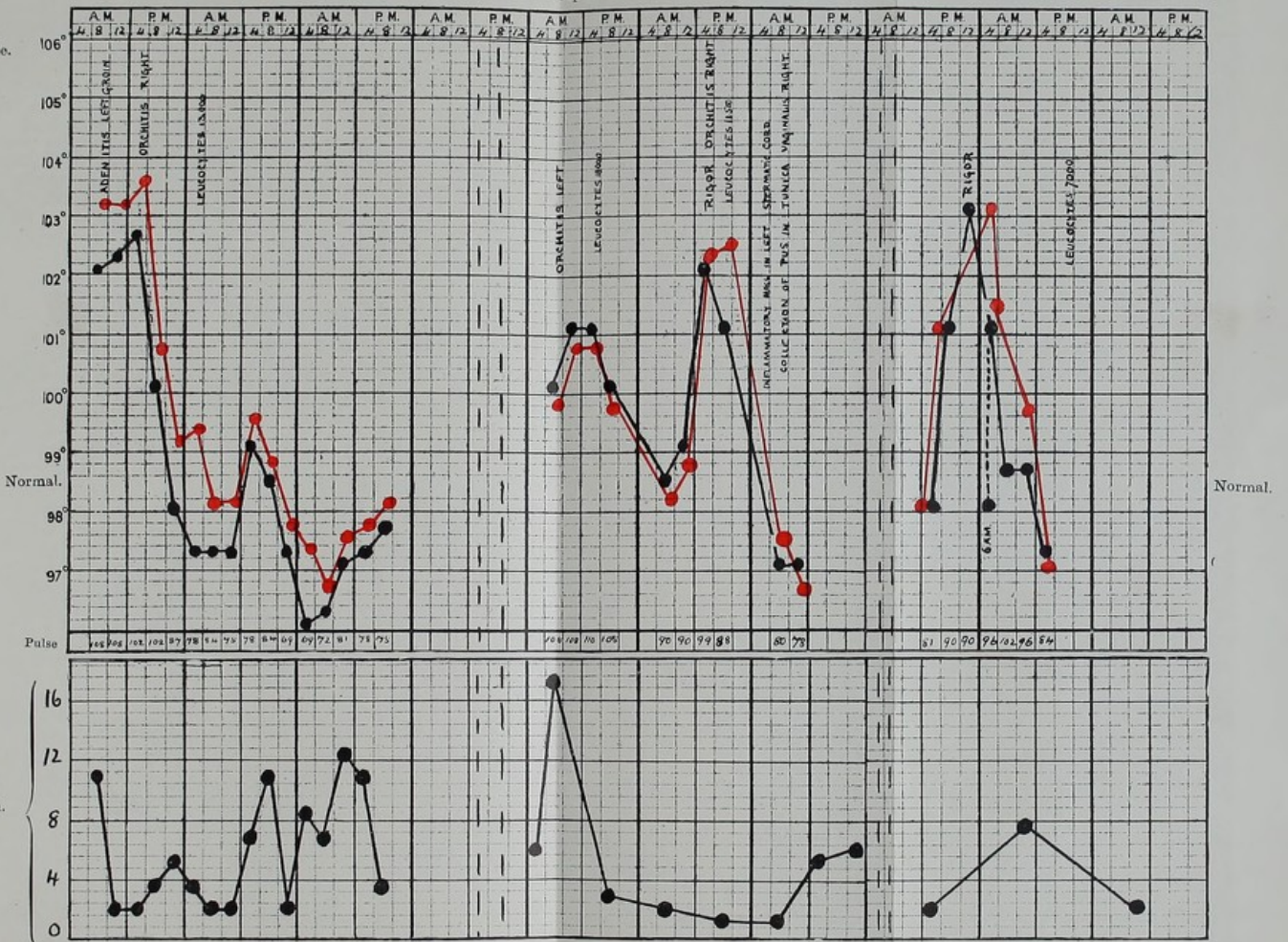
FIRST ATTACK ORCHITIS.

SECOND ATTACK ORCHITIS.

THIRD ATTACK ORCHITIS.

April, 1910.

Temperature  
Fahrenheit scale.



Four Hour Chart of filaria with no periodicity, taken simultaneously.



First attack while under observation: April, 1910. Sudden rigors which continued all the night, together with intense pain in glands of left groin. The right testis was enlarged and painful; epididymis hard and painful and acutely tender on palpation. The temperature in the left groin was a degree higher than in the corresponding axilla (*vide* chart). Leucocytes 13,000, eosinophiles 0 per cent. (his eosinophilia previous to the attacks ascertained to be 5 per cent.). Eyes were blood-shot. The patient complained of headache, and he had vomited twice. Inguinal glands were punctured; this lymph on culture on blood agar proved sterile. In two days the temperature became normal and the right testis regained its normal size. The man remained in perfect general health till September, although from time to time small painful red swellings appeared in various parts of his body.

Second attack: He went to bed perfectly well, had a sudden rigor, attended with pain in his left testis. Temperature was 100.8° F. in left groin and axilla. The left testis was retracted, swollen and intensely painful; the epididymis was enlarged. Pulse was 108 and dicrotic. His eyes were bloodshot. Leucocytes 18,000, eosinophiles 1 per cent. The inguinal glands on the affected side were not enlarged or painful. The next day his temperature in left axilla was normal, in left groin 99° F. At mid-day he had another rigor and intense pain in the other, the right testis, which became swollen and retracted. He complained of pain in his back and a definite circumscribed lump could be felt in the substance of the left spermatic cord. A small circumscribed translucent swelling appeared in the tunica vaginalis in front of the right testis; it had developed in twenty-four hours. This swelling was aspirated and 2 c.c. of turbid straw-coloured fluid was obtained. Two cultures were made on blood agar and remained sterile. The fluid was seen to be packed with corpuscles, mostly polymorphs, with a few lymphocytes and mononuclears and a few red blood corpuscles. It was swarming with active microfilariae. They were more abundant than in the bloodstream. Measured quantities (16 c. mm.) were found to contain a very variable number, from two to thirty-seven in each slide. Several microfilariae were seen to be dead and undergoing granular degeneration. Several were sheathless and empty sheaths were seen. The fluid did not coagulate on standing and deposited a thick layer of pus cells. Ringed preparations of microfilariae from the blood and those in purulent fluid were kept under the same conditions at room temperature. Those in the blood lived thirty-six hours, those in the purulent fluid died almost immediately. This swelling disappeared in a few days. The corresponding testis was explored with a syringe, but no microfilariae could be abstracted.

Third attack: Towards the end of the same month, when I examined him, he was perfectly normal, at 5.45 p.m.; at 6.30 p.m. he had a rigor and the right testis became swollen and acutely tender. Pain was referred to the right spermatic cord and to the right side of the abdomen. A fluid swelling could again be made out in the same situation as before. This was aspirated and 9 c.c. of a custard-like fluid with a reddish tinge obtained. The pus cells at first consisted for the most part of lymphocytes, red cells,\* and a very few polymorphs. Measured slides of this purulent fluid contained on an average five to thirteen

\*These red cells may have escaped by diapedesis owing to the intensity of the inflammatory process. Special care was taken that no blood entered the syringe on puncture.

microfilariae per 16 c. mm. The temperature fell to normal and the right testis became reduced to normal size. On September 28th the swelling in front of it was again punctured and 6 c.c. of purulent fluid withdrawn. Polymorph cells were now found in profusion; cultures remained sterile. Microfilariae were still present in the fluid, but in nothing like the former numbers. Measured slides showed an average of from three to six microfilariae per 16 c. mm. The fluid was clearer than two days before. It was neutral to litmus and became solid on heating. The leucocytes now numbered 7,100 and eosinophiles 5 per cent. For some time after this he complained of constant pain in both testes. A fortnight later all signs of the swelling had disappeared.

A few days before I left Fiji (February 1911), the patient was again examined. The right testis remained the same size as at the commencement of observations and was apparently normal. In front of the left, on the other hand, there was a translucent hydrocele the size of a pigeon's egg. With a syringe a quantity of straw-coloured fluid was aspirated which contained live microfilariae, but so sparsely that they could not be estimated correctly in measured quantities of fluid. The fluid contained numerous lymphocytes, a few red blood corpuscles, very few polymorphs and eosinophiles.

**Lymphangitis of forearm. No microfilariae in blood.**

*Fijian male, aet. 18.* Sudden rigor. Temperature 101° F. Right forearm was distinctly larger than left, measuring one inch more in circumference. Enlargement of right epitrochlear gland. Leucocytes 11,000, eosinophiles 11 per cent. No microfilariae were found in blood, though 1 c.c. was abstracted into citrate solution and centrifuged. Clear fluid aspirated from arm; cultures on blood agar remained sterile.

## APPENDIX XXVI. (a).

### Filarial fever.

Case 1. Vide also under Appendix X., Case 7.

2. *Fijian female, aet. 20.* Seen in the morning at 10 a.m., and was perfectly normal. An hour later had a rigor and temperature of 102° F. No external signs and no microfilariae in blood-stream. Leucocytes numbered 18,000, and eosinophiles 2 per cent. The next morning her temperature was normal; leucocytes numbered 7,400, and eosinophiles 5 per cent.

3. *Fijian male, aet. 24.* Sudden rigor. Temperature 103.4° F. No external signs; skin hot and dry. A few hours later temperature was 100.6° F.; leucocytes 14,300, and eosinophiles 2 per cent. The next morning the temperature was normal again; leucocytes numbered 10,000, and eosinophiles 8 per cent. No microfilariae were found in the blood-stream.

4. *Fijian male, aet. 25.* Large left hydrocele; right testis normal; enlarged glands both groins. Sudden rigor; temperature 102° F. No external signs of acute lymphangitis. No microfilariae found in blood-stream. Leucocytes 9,600, eosinophiles 1.3 per cent. Two days later the temperature was normal, leucocytes numbered 7,800, eosinophiles 7 per cent.

5. *Fijian male, aet. 30.* Sudden rigor. Temperature  $104.8^{\circ}\text{F}$ . No external clinical signs. Microfilariae fairly abundant in circulation, averaging from two to fifteen per measured quantity of blood. Leucocytes numbered 21,800; no eosinophiles were found in 300 white cells counted. In three days the temperature became normal. No diminution in the number of microfilariae was noted.

6. *Fijian male, aet. 40.* Sudden rigor; violent abdominal pain; temperature  $101^{\circ}\text{F}$ .; respirations rapid. Left hydrocele; thickening of both spermatic cords; slight enlargement of groin glands on both sides. Lower part of abdomen intensely tender and resonant; palpation impossible. No microfilariae found in blood. Leucocytes 14,800, eosinophiles 4 per cent. Two days after original attack, temperature became normal, but abdomen still very tender in pelvic region. When palpation became possible nothing abnormal could be detected. His leucocytes then were 8,000, and eosinophiles 10 per cent.

N.B.—Signs of bronchitis were noticed in every one of these cases when the fever was at its height.

#### APPENDIX XXVI. (b).

##### Post-mortem examination.

*Fijian male, aet. 60.* The subject of frequent attacks of filarial fever.

The body was that of a well-nourished man who was found dead in his cutter in Suva Harbour. It was still warm when the post-mortem was commenced. The presence of unchewed food in the mouth indicated that death must have been very sudden.

Enlarged cervical glands formed a prominent mass on the left side of the neck.

Thorax.—There were old adhesions at the apices of either lung; the bronchi were full of aspirated food; the lungs congested and oedematous at the base. The bronchial glands were enlarged. There was a quantity of pericardial fat, and the walls of all the chambers of the heart were distended and flabby. Slight atheroma of the root of the aorta was present. All the valves were healthy.

Abdomen.—The intestines were healthy. Three ankylostomes were found in the jejunum; there were a few superficial ulcerations in the sigmoid. The spleen was small and diffuent. The liver weighed 74 ozs., and was friable and fatty on section. The kidneys were congested with dark blood. The cortex of both was much diminished, and there were some granulations on the surface of the right. The prostate was enlarged. The right testis was tough and large. On section the epididymis was seen to be composed mostly of fibrous tissue from which yellow putty-like material exuded on pressure. In smears of this great numbers of disintegrating microfilariae were found. (The majority were sheathless and they stained indifferently, the nuclear structure being ill-defined.) A great many empty sheaths were seen. They resembled the microfilariae found in an epitrochlear gland—see Pl. XXVI. No tubercle bacilli or cocci could be demonstrated in this material. Two calcified filariae were found in the epididymis. There was no hydrocele.

Microscopical sections of the epididymis are most interesting. Portions of a female filaria can be seen in a space surrounding polymorphonuclear cells, lymphocytes and eosinophiles, and amongst these microfilariae and ova can be recognized (Pl. XXIX.). The remaining structure is formed almost entirely of fibrous tissue; no vasa efferentia can be made out. A noticeable fact is the number of eosinophile cells in the surrounding tissue.

The following lymphatic glands were found to be markedly enlarged:—The inguinal, the external and internal iliac, the lumbar (some of which were  $1\frac{1}{2}$  inches in length), all the mesenteric, the bronchial and the superficial cervical. In the internal iliac, lumbar and mesenteric, macroscopic changes were noted on section. The centre of each was occupied by round and oval areas composed of the same yellow, friable, putty-like material as noted in the epididymis. Calcified filariae were found in the lumbar, bronchial, mesenteric, superficial cervical and epitrochlear glands. They were especially numerous in the bronchial group. The lymphatics accompanying the spermatic vein were thickened, forming a prominent cord. The thoracic duct was searched for, but not found.

All the matted lymphatic tissue in the posterior part of the abdomen and the mesentery was teased out in normal saline solution, but no live adult worms were found. In the thorax the lymphatic tissue in the posterior mediastinum was treated in a similar manner.

Microscopical sections of the glands are of great interest.

(1). Section of inguinal gland shows more or less normal structure, but considerable fibrosis of the capsule and trabeculae.

(2). Internal iliac gland shows round masses of lymphocytes enclosed in fibrous tissue, and a great preponderance of eosinophile cells.

(3). Internal iliac gland No. 2 shows even more pronounced fibrosis and stenosed lymphatic vessels.

(4). Lumbar gland No. 1 (Pl. XXVIII., 2) shows little glandular structure remaining; it is composed principally of ramifying bands of hyaline fibrous tissue enclosing giant cells and stenosed lymphatic vessels. The giant cells are of great size, and the nuclei are large and arranged for the most part round the periphery of the cell. No tubercle bacilli or cocci can be made out by appropriate stains. Although I do not mention it each time, in the case of every section in which giant cells were found, the tissue was stained and searched for tubercle bacilli.

(5). Lumbar gland No. 2 similar to the last.

(6). Lumbar gland No. 3 shows large round homogeneous areas stained faintly pink with eosin, in which a few lymphocytes and fibroblasts can be distinguished.

(7 and 8). Lumbar glands Nos. 4 and 5 show exactly similar structure to the preceding.

(9). Mesenteric gland (Pl. XXVIII.) shows large areas of hyaline material (probably stagnated lymph), but no giant cells.

(10). A section of a calcified filaria (decalcified by Von Ebner's solution), from the same gland, shows the worm enclosed in dense concentric rings of fibrous tissue in which the details of the structure of a filaria can still be recognized.

(11). Bronchial gland shows great fibrosis of the glandular tissue surrounding a calcified filaria. The fibrous strands enclose in their meshes lymphocytes and endothelial cells filled with pigment.

(12). Epitrochlear gland shows considerable fibrosis; enlarged lymph vessels with thickened walls containing in many cases coagulated lymph.

Sections of liver show marked signs of venous engorgement and fatty degeneration of the liver cells.

Spleen engorged with blood in which a number of polymorphs can be distinguished. No organisms found when stained by Weigert's method or by methylene blue.

Pancreas also engorged. Fatty infiltration of glandular substance.

Kidneys, venous engorgement. Degeneration of lining cells of the urinary tubules. Lumen filled with coagulated material.

Lungs, marked signs of back pressure and fibrosis. The interalveolar capillaries are engorged and in some cases blood is extravasated into the alveoli.

The brain was engorged and oedematous. There were no haemorrhages.

Four smears each were taken from the heart's blood, lungs, liver, spleen, pancreas and kidney, but no microfilariae were found in any of them.

Smears of various glands were stained for pyogenic organisms, but none could be found.

#### APPENDIX XXVII.

Details of cases of septic infection following on inflammation of probable filarial origin.

1. *A Solomon Islander, male, aet. 22.* Two years resident in Fiji; admitted in rigor, with a temperature of 102° F., complaining of pain in glands of left groin and in the lumbar region. The glands of left groin were definitely enlarged, hard and tender. The spermatic cord of left side thicker than on right and painful on palpation. Definite masses could be made out in left iliac fossa. Spleen enlarged 1½ inches below the costal margin (from old-standing malaria). White cells 15,000, reds 4,500,000, eosinophiles 2 per cent. Blood, no microfilariae. The enlarged and hard iliac glands situated above Poupart's ligament (external iliac glands) were punctured. Lymph from these glands remained sterile on culture. The temperature remained raised for three weeks; the pelvic glands continued tender on deep palpation and there was definite pain on flexing and extending hip-joint. Two and a half months later, he was readmitted with hard and painful iliac glands and pain referred to hip-joint on left side. The external iliac glands were larger than before and were hard and tender. An indefinite mass could be felt in left iliac fossa. Great pain was experienced on flexing and rotating hip-joint on that side. There was slight flattening of left gluteus maximus, but no shortening of the femur could be made out. The temperature was still raised to 99° F. at night. The blood contained no microfilariae. The white cells numbered 10,600 per c. mm., and the red cells as before; eosinophiles 7 per cent. The glandular mass above Poupart's ligament was seared and punctured; the fluid obtained contained polymorph, lymphocyte and eosinophile cells, and on culture grew *Staphylococcus pyogenes albus*.

The symptoms referred to the hip-joint grew worse and the patient lay now with hip flexed and rotated outwards. He was operated on; two hard and enlarged glands were dissected out from behind the

peritoneum. On section a number of cheesy areas were found scattered throughout the substance. Two cultures were made from the gland substance abstracted by means of a sterile syringe and grew pure culture of *Staphylococcus albus*.

In smears of the cheesy material no tubercle bacilli, cocci, or microfilariae could be demonstrated, but the uterus of an adult filaria containing ova and microfilariae was found (Pl. XXXII., 2). Sections were made through different parts of the gland substance and revealed fibrosis and giant-cell formation. The giant cells, which are of great size, were situated in a homogeneous area, composed of fibroblasts and hyaline substance, in which by repeated staining by Ziehl-Neelsen method no tubercle bacilli could be demonstrated. The surrounding tissue was packed with inflammatory cells and lymphocytes (Pl. XXXII., 1).

Three hours after operation the patient had a rigor with a temperature of 104° F., but the wound healed by first intention, the pain in the hip-joint disappeared, and the patient walked out of the hospital without a limp, two weeks after the operation.

2. *A Solomon Islander, male, aet. 30.* Three years in Fiji; admitted for constant pain in glands of left groin and hip-joint. Temperature of a hectic type, 100-103° F. at night. There was a large swollen mass of matted glands in the left groin, hot and tender to the touch. An indefinite swelling could be made out on deep palpation in the left iliac fossa. Testes were normal. Blood contained no microfilariae. Glands were punctured, but no microfilariae found in gland juice. Aspirated fluid on culture grew *Staphylococcus pyogenes albus* and on a second occasion *Staphylococcus pyogenes albus* and *aureus*. Leucocytes 10,000; eosinophiles 4 per cent.

A fortnight after admission the symptoms became more definitely located to the hip-joint. At the operation an incision between the hamstring and adductor muscles was made, and a quantity of dark green pus escaped with great force. About two pints were evacuated which on culture yielded pure growth of *Staphylococcus pyogenes albus*. On examination tracks were found leading into hamstring muscles and up to the ramus of the pubes, which was laid bare and necrosed. The whole capsule of the hip-joint was destroyed and bare bone could be felt on the neck of the femur. Smears of pus showed numerous staphylococci. A tube was inserted, drainage was free, and the wound soon healed. Seventeen days after the operation the patient was walking about with a joint freely movable in every direction and painless. Blood examination gave the white cells as 5,200 per c. mm., and eosinophiles 10 per cent. No microfilariae were found.

3. *A European, male, aet. 29.* Three years resident in Fiji; admitted with inflamed glands in left groin. Three weeks previously had a large abscess in substance of right gastrocnemius muscle. He was unable to sleep at night on account of pain in left groin. An indefinite tender mass could be palpated in left iliac fossa. Temperature of hectic type up to 102° F. at night. Patient was emaciated and septic in appearance. No microfilariae were found in blood. Leucocytes 11,250 per c. mm., red cells 3,350,000, eosinophiles 7 per cent. Stools contained no ova. On puncture of an inguinal gland one sheath of a microfilaria was found and on culture the gland juice grew *Staphylococcus pyogenes albus*. Testes were normal. During the week after admission the symptoms became definitely located to the hip-joint, and the inflammatory mass in left iliac fossa more apparent. Thigh remained flexed

and everted. The patient was unable to extend it on account of pain. The internal saphena vein now became thrombosed and formed a definite, hard, moveable cord.

At operation an incision was made above the anterior superior spine and a mass of infiltrated tissue was found lying behind the peritoneum. This was carefully dissected away and a loculus was discovered containing thin purulent fluid. The finger was introduced and a matted mass of pelvic glands found, leading downwards to the pelvis. Culture made from the fluid grew *Staphylococcus pyogenes aureus* in pure culture. The thickened tissue round the dorsum ilii was explored and similar fluid obtained, and also from the hip-joint. The wound was drained and the patient did well, leaving the hospital after an illness of four months. On discharge there remained a small sinus discharging clear fluid. All the movements of the hip-joint were free, easy and painless. No shortening could be made out. The left thigh was wasted and measured half inch less than the right. There was still some thickening in the left iliac fossa. Seven months after the original illness he was examined again. He was in perfect health and all the pelvic thickening had disappeared.

4. *A Fijian male, aet. 21.* In hospital with abscess in left groin invading the hip-joint, which, after discharging for two months, left him with a ankylosed hip; there was a simultaneous attack of orchitis, and he had a small hydrocele on the left side. The whole of the left leg was considerably wasted, being  $2\frac{1}{2}$  inches less in circumference in the middle of the thigh than the opposite member. There was absorption of the neck of the femur, measurements being  $\frac{3}{4}$  inch less on the left than on the right side. Blood contained great numbers of microfilariae, averaging from forty to ninety per 16 c. mm. (Appendix XI., Chart VIII.). When seen, five months after discharge, he was able to walk leaning on a bamboo pole. The sinus had quite healed.

## APPENDIX XXVIII.

### Cultures of lymph from elephantoid tissue.

	Culture medium.	
	Agar	After 48 hours incubation.
(1). Lymph from enlarged groin gland and from elephantiasis of scrotum, removed at operation.		sterile
(2). Lymph from elephantiasis of scrotum.	"	"
(3). Lymph from elephantiasis of arm.	"	"
(4). Lymph from elephantiasis of arm.	Blood agar	"
(5). Lymph from elephantiasis of arm.	"	"
(6). Lymph from elephantiasis of arm.	Agar	"
(7). Lymph from elephantiasis of arm.	"	"
(8). Lymph from elephantiasis of left leg.	"	"
(9). Lymph from elephantiasis of scrotum and from enlarged groin glands.	"	"

## APPENDIX XXIX.

## Details of three cases of elephantiasis in Europeans.

1. *F. G.*, trader, *aet.* 66. Resident forty-six years in Fiji; after twenty-six years' residence came to live in Lakemba (the most heavily infected island in the group). There he suffered from enlargement of both arms which he stated afterwards disappeared. Hydroceles developed and were tapped. His left leg began to swell painlessly; the right followed. He is positive that *he never suffered from lymphangitis*. He had an abscess in the right calf  $1\frac{1}{2}$  years ago.

Both testes were found to be slightly enlarged, and there was slight thickening of the scrotum, also elephantiasis of both legs below the knee. The flexure at the ankle was obliterated, the swelling being continued on to the dorsum of the foot as far as the toes. There was no enlargement of the groin glands. Both epitrochlear glands were enlarged. No microfilariæ were found in the blood.

2. *Mrs. F.*, *aet.* 50. Resident in Fiji thirty-seven years. Suffered from elephantiasis of left leg, and recurring attacks of lymphangitis, which proved very troublesome. These attacks began after five years' residence, and recurred about three or four times every year. She described the attacks as coming on suddenly with a rigor; the glands of the groin became enlarged and very tender; red streaks appeared extending from knee to ankle. The left leg, the one always affected, gradually began to get larger. The patient was positive that the leg *always became larger with each attack of lymphangitis* and subsided again. The fever lasted generally three days and she was generally unable to get about again for a week. After her last two confinements she had had trouble in the affected leg owing to thrombosis. On examination the left leg was  $1\frac{1}{2}$  inches larger in circumference than the right. The skin was rough and discoloured. The flexure of the ankle was obliterated and there was a puffy swelling on the dorsum of the foot which pitted slightly on pressure. There were localized thickened areas of skin situated in front of the tibia, just below the knee. Both sets of groin glands were enlarged. The patient was positive that *when away from Fiji she never suffered from lymphangitis*. She spent three years in New Zealand and never had an attack there. I saw the patient once during an attack of fever; this was preceded by a rigor. The groin glands were very tender and were more enlarged than on the previous examination. The skin below the knee was intensely red, hot and tender; her temperature was  $101^{\circ}$  F. Leucocytes 13,000, eosinophiles 1 per cent. Her normal eosinophilia was afterwards determined to be 4 per cent. No microfilariæ were ever found in the blood.

3. *H. B.*, a planter, *aet.* 53. Resident in Fiji thirteen years. Began to get attacks of lymphangitis after three months residence. First had attacks in his left arm, then attacks of orchitis. Lymphangitis in both legs supervened and glands in both groins became enlarged. In the last five years both legs had swollen up after each attack. The attacks were now frequent and were ushered in by rigors, the glands in the popliteal space enlarging; red streaks which course down to the internal malleolus may or may not appear. On examination he had marked elephantiasis of both legs below the knee, the calf and flexure of ankle were obliterated, the skin thickened and rough. There was a marked swelling on the dorsum of the foot, which did not extend quite to the

toes. The glands of both groins were enlarged and hard; both testes were enlarged, but there were no hydroceles. No microfilariae were found in the blood.

(4)—Details of four cases of filarial disease in Europeans; with special reference to length of residence in Fiji before the appearance of symptoms.

A. A. B., a trader, *aet.* 43. Sixteen years' residence in Colony; had no symptoms of filariasis until a few months before observations commenced. Then a circular and thickened red patch appeared about half-way up the right upper arm on the inner side. At first it was painful, but a week before the case came under observation he had rigors and a typical attack of filarial lymphangitis. Besides this, there was a small tender cyst-like structure situated immediately over the cephalic vein on the flexor surface of the same arm. The red patch disappeared in about a week and only a thickening remained. About 34 microfilariae were found per slide, and his eosinophilia was 8 per cent.

B. A. M. H., *male, aet.* 27. In Fiji one and a quarter years, during which time he had orchitis, accompanied by adenitis of groin glands, twice. The epitrochlear gland in his right arm was enlarged and a similar condition was noted in the glands of both groins. No microfilariae were found in his blood. His eosinophilia was 8 per cent.

C. T. S., *male, aet.* 33, storekeeper. Ten years in Fiji and three years in a highly infected district (Loma-Loma). After one and a half year's residence there he had an attack of orchitis in left testis and was laid up for ten days. A second attack of orchitis occurred three weeks before my observations were made. Left testis and the glands of both groins were swollen and painful. Six weeks before observations commenced he had an attack of lymphangitis in right arm, apparently starting from the epitrochlear gland which became enlarged and painful. The whole forearm became swollen, red streaks of lymphangitis were noticed; axillary glands were enlarged. No microfilariae were found in the blood. His eosinophilia was 6 per cent.

D. N. C., *male, aet.* 77, trader. Fifty-two years in Fiji. First attack of lymphangitis in right arm occurred after twenty-four years' residence; did not have another attack till fourteen years ago, when the same situation was similarly affected. Then his left knee-joint suddenly became swollen and at the same time an abscess in his left groin developed. Being unable to obtain medical attendance, the abscess in his knee-joint burst into the left popliteal space and left him with complete ankylosis and his knee became bent at a right angle. Three years ago he had an attack of lymphangitis in his left leg. On examination his knee-joint was found to be completely ankylosed; there was a great thickening and the patella was adherent to the femoral facet. No microfilariae were found in the blood. An eosinophilia of 5 per cent. was present. The groin glands were not markedly enlarged.

(5)—Lymphatic oedema secondary to axillary abscess; Staphylococcic infection of lymph; Microfilariae in blood.

*Fijian male, aet.* 55. Admitted with marked swelling of left arm, extending from the first interphalangeal joints of the fingers to the elbow. The circumference of the affected arm was two inches greater at the

elbow and one inch at the wrist than that of the right side. His temperature was 104° F. There was a large axillary abscess and on opening this the temperature became normal. The oedema of the arm persisted. The skin pitted easily on pressure and quantities of fluid could be withdrawn from the connective tissue by means of a syringe; this fluid on blood agar grew *Staphylococcus pyogenes albus*. Microfilariae were found in the blood and their sheaths in the lymph from the arm. The swelling now began to subside gradually and a fortnight later it had disappeared. Three months later he was seen again and the arm found to be quite normal. The microfilariae still persisted in the circulation and were equally numerous.

### APPENDIX XXX.

Details of minute dissections of five scrota removed at operation.

1. *Fijian male, aet. 35.* No microfilariae found in blood. Scrotum weighed thirty pounds. A layer of thick tissue was found, about two inches thick and cutting like an unripe pear, beneath the skin. In the lower part of the scrotum this indurated tissue was about four inches thick. Surrounding the testes was a blubbery mass in which dilated and thickened lymphatics and veins could be seen. The lymph which exuded coagulated almost immediately. The whole mass was dissected up after operation. A cheesy mass about the size of a walnut was found; scrapings of this showed large numbers of eosinophile cells. Microscopical sections of the thickened integument show numerous bundles of dartos muscle, connective tissue swollen with lymph, collections of lymphocytes, dilated blood-vessels and numerous dilated lymph-vessels. Stained by Weigert's stain the connective tissue fibres show up very plainly. In sections through the blubbery portion large masses of lymphoid cells are seen amid hyaline connective-tissue fibres.

2. *Fijian male, aet. 40.* No microfilariae found in blood. Scrotum weighed eight pounds. In the lower portion the tissue was of the consistency of an unripe pear and measured three-quarters of an inch in thickness. Round the testes was a diffuse blubbery mass, containing enlarged veins and thickened lymphatics. The lymph which exuded from the amputated scrotum coagulated almost immediately. Several small yellow areas were found in the substance, containing putty-like material. Sections of the tissues in the main resemble those of the foregoing cases.

3. *Fijian male, aet. 29.* No microfilariae in blood. Scrotum weighed four pounds. The firm integumental tissue was about three quarters of an inch thick, being thickest at the lower part of scrotum. Large amount of blubbery tissue was situated around the testes and spermatic cords. The lymph which exuded coagulated almost immediately. A number of yellow areas varying in size from a shilling piece to a hemp-seed were found scattered through the substance containing the putty-like material; smears made of this show no tubercle or other bacilli, but great numbers of eosinophile cells. The groin glands on the left side removed at the same time showed caseous areas which on section proved to be tubercular. Calcified filariae were found in them. Sections were

made through three of the putty-like masses described above; two of these show marked giant-cell formation, surrounded by inflammatory cells and fibrous tissue. In the third, the remains of a *dead filaria surrounded by strands of peculiar hyaline connective tissue* were discovered. A drawing is given of this (Pl. XXXIII.) Sections of the thickened integumental tissue show dilated blood and lymph spaces, bundles of dartos muscle and hyaline connective tissue swollen with lymph. In sections of the blubbery tissue quantities of coagulated lymph, large lymph spaces and dilated blood-vessels are seen.

After the operation the groin glands on the right side broke down and discharged tubercular pus; a perineal abscess of tubercular origin formed and there were marked signs of pulmonary tuberculosis. Some months later this patient died.

The value of the post-mortem was somewhat detracted from by extensive tuberculosis. The body was very emaciated. There were dense adhesions between the lobes of both lungs and between both layers of the pleura. The substance of the lungs was packed with caseating tubercular foci and miliary tubercles. There was a large amount of ascites due to tubercular peritonitis and a tubercular perforation of the caecum. The surface of the liver was studded with miliary tubercles, and there were caseating tubercles in the substance. The spleen was packed with tubercles and the intestinal mucosa covered with tubercular ulcers. The iliac and lumbar glands were enlarged and contained caseating tubercular foci. The lymphatic tissue lying in front and on each side of the abdominal aorta and iliac vessels was in a varicose condition and when punctured exuded clear lymph. The thoracic duct was not found. The lymphatics accompanying the spermatic arteries were thickened, but not varicose. Both testes were enlarged. They were tough and fibrous and the epididymis was converted into a mass of fibrous tissue. No calcified filariae or their remains were found.

4. *Fijian male, aet. 60.* Microfilariae found sparingly in blood. Scrotum weighed eight pounds when removed. The integumental layer was for the most part firm and of the consistency of an unripe pear. The central blubbery mass contained quantities of lymph which coagulated immediately. Blubber-like tissue was found surrounding the testes which were hard and enlarged; the spermatic cords were thickened and nodular. A number of circular areas containing yellow, putty-like material were found; smears of this substance show numbers of polymorphonuclear cells, and a portion of a *uterus of a dead filaria* containing ova could be recognised. Microscopical sections of the integumental tissue show numerous bundles of dartos muscle, connective tissue swollen with lymph, dilated lymph spaces and blood-vessels, and collections of lymphocytes.

5. *Fijian male, aet. 40.* No microfilariae found in blood. The scrotum weighed eight pounds. A large ulceration at the base communicated with an abscess cavity in the right epididymis. The whole of the elephantoid tissue which was of the consistency of an unripe pear was dissected; the central blubbery tissue was found, as in other cases. Sections show large bundles of dartos muscle, connective tissue swollen with lymph, dilated lymph spaces and collections of lymphocytes.

## APPENDIX XXXI.

## Experiments with microfilariae in different sera and solutions.

Technique. Live microfilariae were obtained in great numbers for experimental purposes as follows:—The same patient (Tiveta, Appendix XI., Chart II.) was used throughout. The skin over the median basilic vein was cleansed with ether and alcohol and perchloride solution (1-1000). A l.c.c. syringe sterilized and containing  $\frac{1}{8}$ th c.c. of 1 per cent. citrate solution was inserted into the vein, and  $\frac{1}{8}$ ths c.c. of blood aspirated. The blood so obtained was ejected into a centrifuge tube, previously sterilized, containing more sterilized citrate solution. This tube was then centrifuged. When all the red corpuscles had been thrown down, the microfilariae were found coiled up and adhering to one another in the "buffy" layer. Measured quantities of these were pipetted off with a sterilized Thoma-Zeiss pipette and placed in definite quantities of different solutions and sera in sterilized well slides.

## Experiment 1. Room temperature.

1. Microfilariae + serum of patient from whom microfilariae were obtained. Dilution of serum with normal saline 1 in 3. Lived three days.
2. Microfilariae + serum of patient in an attack of filarial fever (temperature 102°). Equal parts of solution containing microfilariae and serum. Lived nine days.
3. Microfilariae + serum of a patient (Henry) immediately before third attack of orchitis. Lived three days.
4. Microfilariae + serum of same patient (Henry) immediately after third attack of orchitis. Lived seven days.
5. Microfilariae lived in the citrate solution in which they were abstracted three days.

## Experiment 2. Room temperature.

1. Microfilariae + normal saline solution, equal parts. Lived forty-eight hours.
2. Microfilariae + serum of European (P. H. B.) Equal parts. Lived five days.
3. Microfilariae + serum of patient with elephantiasis scroti. Dilution of serum with normal saline 1 in 4. Lived five days.
4. Microfilariae + atoxyl 1/2,000,000 (in normal saline). Lived sixty hours.
5. Microfilariae + antimony tartrate 1/2,000,000 (in normal saline). Dead in twenty-four hours.
6. Microfilariae + quinine bihydrochloride 1/2,000,000 (in normal saline). Dead in twenty-four hours.

## Experiment 3. Room temperature.

1. Microfilariae + atoxyl (in normal saline) 1/10,000. Lived thirty-six hours.
2. Microfilariae + antimony tartrate 1/10,000 (in normal saline). Lived three and a half hours.
3. Microfilariae + antimony tartrate 1/7,500 (in normal saline). Lived three and a half hours.
4. Microfilariae + quinine bihydrochloride 1/10,000 (in normal saline). Lived fourteen hours.
5. Microfilariae + sterilized and distilled water, equal parts. Lived fourteen hours.

**Experiment 4. Room temperature.**

1. Microfilariae + atoxyl (in normal saline) 1/2,000. Lived eight hours.
2. Microfilariae + antimony tartrate (in normal saline) 1/2,000. Lived half an hour.
3. Microfilariae + normal saline equal parts. Lived sixteen hours.
4. Microfilariae + serum of patient with filarial fever (temperature 102° F.). Lived three days.
5. Microfilariae + quinine bihydrochloride 1/2,000 (in normal saline). Lived half an hour.

**Experiment 5. Room temperature.**

1. Microfilariae + normal saline equal parts. Lived thirty hours.
2. Microfilariae + sterilized and distilled water. Lived twenty-four hours.
3. Microfilariae + antimony tartrate (in normal saline) 1/10,000. Lived two and a half hours.
4. Microfilariae + quinine bihydrochloride (in normal saline) 1/10,000. Lived thirty hours.
5. Microfilariae + atoxyl (in normal saline) 1/10,000. Lived seventy hours.

**Experiment 6. Room temperature.**

1. Microfilariae + serum from Solomon Islander with synovitis of hip-joint and adenitis. Temperature 101° F. Lived four days.
2. Microfilariae + serum of patient (Henry) with filarial orchitis. Temperature 101-2° F. Lived eighteen hours.
3. Microfilariae + serum of patient with filarial orchitis. Temperature 104°. Lived three days.
4. Microfilariae + serum of European (P.H.B.) one part microfilariae, three parts serum. Lived twenty-four hours.
5. Microfilariae + serum of European (W.J.M.) one part microfilariae, three parts serum. Lived twenty-four hours.
6. Microfilariae + serum of European (E.M.B.) one part microfilariae, three parts serum. Lived twenty-four hours.

In the tubes containing citrate solution, placed in the incubator at 37° C., the microfilariae never lived more than twelve hours. This fact appeared in some way to be connected with the reduction of the haemoglobin. The solutions remained sterile; cultures, made from this fluid after three days in the incubator, on agar showed no growth. The same result was noted from a series of experiments with microfilariae in various solutions in welled slides: the reduction of oxy-haemoglobin at this high temperature takes place more rapidly, thereby depriving the microfilariae of their supply of oxygen. In hydrocele fluid at room temperature the microfilariae lived thirty-six hours.

Experiments were undertaken to find out whether the microfilariae are unable to stand higher degrees of temperature than that of normal blood. Considerable difficulty was experienced in using welled slides on account of the water of condensation accumulating and obscuring the view. Centrifuge tubes containing microfilariae in blood and citrate solution were placed in a water bath at varying temperatures. A sterile

clinical thermometer was placed inside each tube to record the temperature more accurately. Drops of fluid were taken out at varying intervals and examined to see if all the microfilariae were still alive.

1. At 104° F. Lived six hours. (Control at room temperature lived three days).

2. At 108° F. All dead after eight hours.

In all such experiments great reduction of the haemoglobin was noted.

## APPENDIX XXXII.

The action of certain drugs, when injected intravenously, on the numbers of circulating microfilariae.

### Antimony tartrate.

1. *Fijian male, aet. 24.* Fracture of right leg. No symptoms of filariasis. Numerous microfilariae found in the blood.

1 gr. antimony tartrate in 10 c.c. normal saline injected into median basilic vein. No diminution in the numbers of microfilariae was noted. Observations were continued for four days after the injection. No rise of temperature was noted after the injection.

2. *Fijian male, aet. 30.* No signs of filarial disease. A number of microfilariae in blood. 1 gr. antimony tartrate in 10 c.c. normal saline injected into median basilic vein. No diminution in the numbers noted. There was no rise in temperature after the injection.

3. *Fijian male, aet. 26.* Operation for tumour in left spermatic cord. History of attacks of lymphangitis; thickened lymphatics in right arm. Injection of 1 gr. antimony tartrate in 10 c.c. normal saline into median vein. No decided diminution in the numbers of microfilariae noted. A count was made every twelve hours for three days before the injection and for five days afterwards when the microfilariae numbered 11 per measured slide. Before the injection they averaged 16 per measured slide.

### Atoxyl.

4. *Fijian male, aet. 40.* Enlarged and varicose groin glands, right. In hospital for septic toe. Injection of atoxyl 1 gr. in 10 per cent. solution (normal saline) into median basilic vein on two occasions. No diminution in the numbers of microfilariae, or rise of temperature, was noted. In order to ascertain whether the toxins of a *Staphylococcus pyogenes aureus* isolated from a filarial abscess would prove inimical to the microfilariae, a vaccine of 100,000,000 cocci was injected subcutaneously into the same patient immediately after the injection of atoxyl. On this occasion too, no diminution of the microfilariae in the blood was noted.

5. *Solomon Islander, aet. 30* with *filaria nocturna*. Two injections of atoxyl, 1 gr. in normal saline on two separate occasions. No definite diminution in the number of microfilariae which could be ascribed to this drug, or alteration of their periodicity, was noted. From inspection of the chart it certainly seems as if a small diminution had taken place, and observation extending over

the subsequent three months showed them always to be present at night in smaller numbers. In October 11 were counted (an average of three slides).

### Quinine.

6. *Fijian male, act. 23.* Physical condition good. No symptoms of filariasis. Injected extravenously with 5 gr. quinine bihydrochloride in 2 c.c. sterile normal saline. No diminution of microfilariae noted. Before the injection he had an average of 21 (three slides counted) microfilariae per 16 c. mm. blood. Observation two days after the injection showed an average of 26 microfilariae (three slides counted). There was no rise in temperature following the injection.

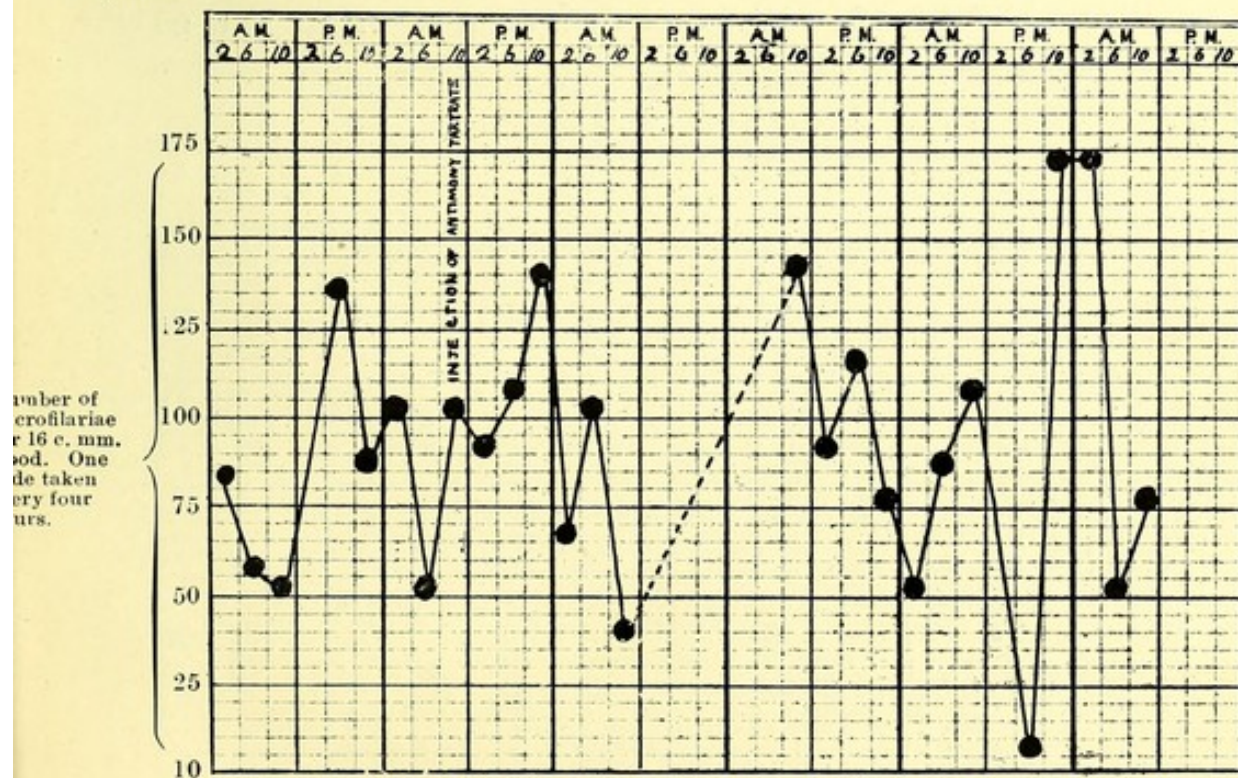
### Staphylococcus vaccine.

7. In addition to the case already mentioned, a *Fijian male, act. 26*, with no symptoms of filarial disease, was injected subcutaneously with a vaccine of 100,000,000 *Staphylococcus pyogenes aureus*, isolated from a filarial abscess. 42 (average of three slides) microfilariae per 16 c. mm. were present at the time of inoculation. No rise of temperature was noted. A count was made every day after the injection, and on the third they averaged 46 per 16 c. mm., and a fortnight later 48.

## APPENDIX XXXII.—Case I.—Four Hour Chart of Filaria with no periodicity. Injection of antimony tartrate 1 gr.

Name : Wanganese. Race : *Fijian male, act. 24.*

May, 1910. 25 26 27 28 29 30



APPENDIX XXXII.—Case III.—Four Hour Chart of *Filaria* with no periodicity. Injection of antimony tartrate 1 gr.

Name : Sakiusa. Race : Fijian male, *aet.* 26.

May, 1910.

31

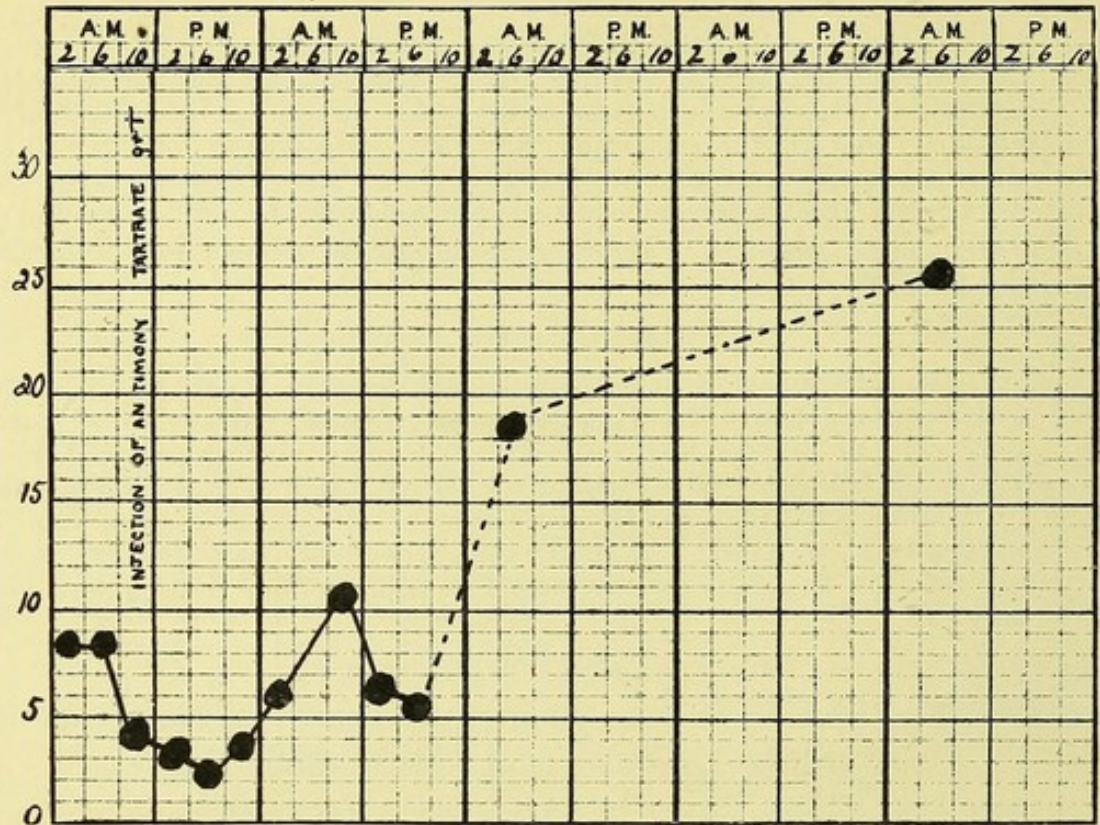
June 1

2

3

4

Number of microfilariae per 16 c. mm. blood. One slide taken every four hours.



APPENDIX XXXII.—Case IV.—Four Hour Chart of *Filaria* with no periodicity. Injection of atoxyl 1 gr. in 10% solution.

Name : Aminio. Race : Fijian male, *aet.* 40.

August, 1910.

16

17

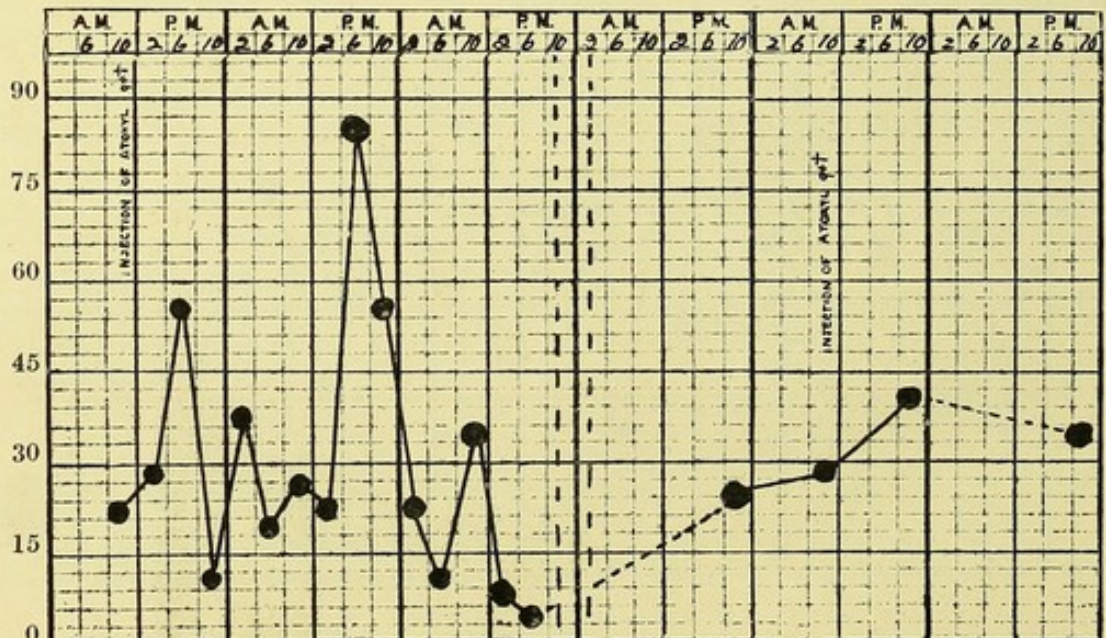
18

23

24

25

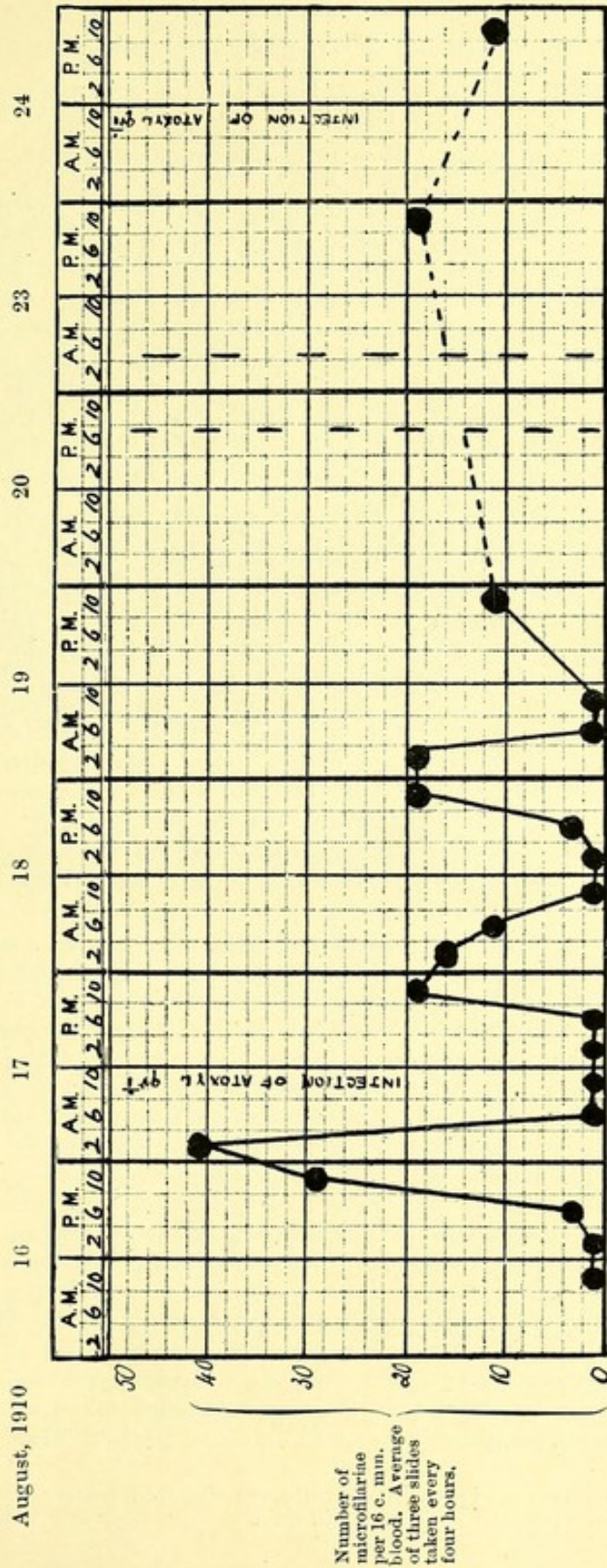
Number of microfilariae per 16 c. mm. blood. Average of three slides every four hours.



APPENDIX XXXII.—Case V.—Four Hour Chart of *Filaria* with nocturnal periodicity.

Injection of atoxyl 1 gr. in 10% solution.

*Name*: Sutherie. *Race*: Solomon Islander, male, *aet.* 30.



## APPENDIX XXXIII.

Observation on habits of *Stegomyia pseudoscutellaris*.

*Stegomyia pseudoscutellaris* being undoubtedly the commonest mosquito in Fiji, any extended observation I was able to make on its habits may not be out of place. It is found in great quantities all along the coast line, particularly in the mangrove swamps. In the native villages of the eastern islands, where elephantiasis and other diseases of filarial origin are very prevalent, it swarms, but inland it is not seen in anything like the same numbers. It is a bold feeder\* and, unlike *Culex fatigans*, is easily captured while feeding. Being a purely day-feeding species, it was only with difficulty induced to feed at night and then only on the strongly illuminated side of the cage. In localities where this mosquito is common I almost entirely failed to breed it from larvae collected in fresh water, though on the sides of a brackish creek, so commonly found running through Fijian villages (Phot. XVII.), I had no difficulty in capturing 200 imagines from off the back of one native in twenty minutes. There is an island in Suva Harbour very appropriately named Mosquito Island. It is about a quarter of a mile in circumference, fringed with mangrove swamps and clothed with coconut trees and rank vegetation. There is not a single pool of fresh water in the island, yet *S. pseudoscutellaris* swarms there to such an extent that I never had any difficulty in filling my cages with 2-300 specimens fed on infected blood during a quarter of an hour's stay. Having satisfied myself experimentally that they cannot breed in seawater, the swamps of the adjoining mainland were searched for larvae with a negative result. Further observation confirmed the fact that they were only to be found on the island when the wind blew from direction of certain brackish water creeks in the vicinity, perhaps explaining a fact frequently remarked on in this group, *that these mosquitoes are especially common on barren islets, where no fresh water is to be found*.

These wild caught insects laid eggs in captivity and from them the laboratory-bred mosquitoes, with which my experiments were made, were raised. Four days after feeding on blood the eggs were laid, generally on blades of grass at the sides of the vessel. In the cool months (August) the eggs hatched in four days and the imagines appeared thirteen days later, making a total of seventeen days for the entire cycle. But in the hot weather the whole cycle from ovum to imago was shortened to a minimum of eight days. Copulation in this, as in other mosquitos, takes place immediately after the imago emerges. Ova apparently are not laid until the mosquito has had a meal of blood. Considerable difficulty was experienced in keeping these insects in captivity. They do not appear to thrive for long on banana, apple, water-melon, jam, raisins or pineapple, like *Stegomyia fasciata* or the Culicines. I had much more success by feeding them daily on human blood. They are especially blood-thirsty insects and apparently require a blood feed every day. Thus one particular specimen I kept under observation had its fill of blood daily for fifteen days. *Culex fatigans* and *Culex jepsoni*, on the other hand, seemingly required but one feed of blood every ten days.

\* On several occasions this mosquito was observed feeding on the dead bodies of natives, in which the blood was still fluid.

Almost directly they refuse to suck blood they die. From the predilection of this species for mangrove swamps, it might be inferred that the insect manages to abstract some nutriment from this plant; this does not appear to be the case. A number of mangrove shoots were put into the cages, but I could not convince myself that the mosquitoes, though they settled frequently on the leaves, managed to abstract any nutriment from them. It is difficult to discover on what these insects feed in a state of nature on these barren islands where they are found in such profusion. Of human beings or other mammals there are none; there are, however, a number of birds of the genus *Ptilotis*, from which they may obtain their supply of nutriment.

### Larvae.

Jars of fresh, brackish (75 per cent. normal saline) and sea-water containing blades of grass were placed in the mosquito cages. After a few days it was found that the greatest number of eggs were laid in the brackish water. Though some eggs were deposited in sea-water they never underwent any development. Most larvae when placed in sea-water died almost immediately, though very advanced forms immediately pupated. From a number of experiments it was discovered that the larvae thrive best in normal saline solution, and, as may be conjectured, no visible difference could be detected between the perfect insects, whether bred in fresh water or in normal saline solution.

The larvae are very active and secretive and are always found at the bottom of the vessel, hidden away under the blades of grass placed in the water; they did not thrive well in the light.

### Food of the larvae.

The larvae appeared to feed almost exclusively on the decaying vegetable matter collected at the bottom of the bowls.

In the bowls containing fresh-water microscopic animal life—amoebae, actinosphaenia, vorticellae, paramoecia and euglenae—were found in abundance. In fresh-water bowls a green deposit of algae soon made its appearance, but in the bowls containing normal saline nothing of the sort was noticed; vorticellae were the only animalculae ever observed in bowls containing this solution. Vessels of normal saline solution containing blades of grass were left exposed to the air of the laboratory for weeks without any development of algae being noticed within them. Ova of the mosquito were placed in sterilized water containing grass which had been boiled for half an hour; the larvae developed normally and the imago appeared in fifteen days. The sediment was examined microscopically and only a few diatoms were found. When too many larvae were present in the water of one bowl the development of one and all was considerably retarded.

### Action of dilute copper sulphate solution on the larvae.

Experiments with dilute copper sulphate solution were made to test its effect on the larvae. The strength used was 1 gr. to a gallon of water (1 oz. in 437 gallons). This is considerably less than that used in fresh-water reservoirs (1 oz. in 312 gallons). It was found that although ova placed in this solution hatched, the larvae died within

twenty-four hours, notwithstanding the vegetable matter added as before. Larvae, however, in a further state of development would live and thrive in copper sulphate solution as long as vegetable matter in sufficient quantity was present. This strength of copper sulphate solution killed off all amoebae and algae and *Culex fatigans* and stegomyia larvae died of starvation in such water if no vegetable matter was present. So tenacious of life are these advanced larvae that one stegomyia larva was observed to live seventeen days in such solution, but without advancing in development, and a larva of *Culex fatigans* remained alive a month under similar conditions.

The effect of copper sulphate solution on a large scale was tried in a large swimming bath which previously used to be one of the main breeding areas of mosquitoes in the vicinity. For seven months, while thus treated, not a single mosquito larva was ever found in it. After a heavy rainfall a certain amount of copper sulphate had to be added to keep up the strength of the solution.

## BIBLIOGRAPHY.


- 1 Manson. B.M.J., 1894 (1), June, p. 1186.
- 2 *id.*, *ib.*, 1896 (2), p. 1379.
- 3 Thorpe, Surgeon, V.G., R.N. B.M.J., 1896 (2), p. 922.
- 4 Finucane, Morgan J. Lancet, 1901 (1), p. 23.
- 5 Lynch, G. W. A. *ib.* 1905 (1), p. 21; and Journ. Trop. Med., April, 1905, p. 99.
- 6 Brunwin. Journ. Trop. Med., 1909, Dec., p. 365.
- 7 Wilson, B. M. Elephantiasis and Filariasis in Fiji. Polynesian Gazette Office, Levuka, Fiji, July, 1909.
- 8 Brochard, V. Bull. Soc. Path. Exot., 1910, III., pp. 138 & 610.
- 9 Dubruel, C. M. E. *ib.*, 1909, II., p. 355.
- 10 Ashburn & Craig. Am. Journ. Med. Sci., Sept., 1906.
- 11 *id.* Philipp. Journ. Sci., II., No. 1, March, 1907.
- 12 Craig. Trans. Soc. Trop. Med. & Hyg., May, 1909.
- 13 Phalen and Nichols. Philipp. Journ. Sci. B., III., 1908, pp. 293, 305.
- 14 *id.*, *ib.*, IV., No. 2, 1909, p. 127.
- 15 Diesing. Arch. für Schiffs- und Tropenhyg., III., 1899, No. 1, p. 20.
- 16 Lang & Noc. Arch. de Parasitol., VII., 1903, p. 377.
- 17 Nicolas. Bull. Soc. Path. Exot., 1910, p. 737.
- 18 Daniels & Conyers. Brit. Guiana Med. Ann., 1896, pp. 46 & 53.
- 19 Craig. Journ. Trop. Med., Aug., 1909, p. 239.
- 20 Low, G. C. *ib.*, Sept., 1909, p. 256.
- 21 Manson. B.M.J., 1904 (1), p. 72: Discussion on Dr. Primrose's paper.
- 22 Low, G. C. Journ. Trop. Med., Feb., 1908, p. 59.
- 23 *id.* Lancet, 1908 (1), p. 279.
- 24 Whyte, Duncan. Journ. Trop. Med., 1909, Jan., p. 175.
- 25 Calvert. Johns Hopkins Bull., 1902, p. 133.
- 26 Primrose. B.M.J., 1903 (2), p. 1262.
- 27 Manson. *ib.*, Sep., 1899 (2), p. 644.
- 28 Low, G. C. Journ. Trop. Med., April, 1902, p. 117.
- 29 Fülleborn. Beiheft Archiv für Schiffs- und Tropenhyg. (8), Nov., 1908.
- 30 Rodenwaldt, E. *ib.* (10), Nov., 1908.
- 31 Low, G. C. B.M.J., 1903 (1), p. 723; also Journ. Trop. Med., June 1st, 1903, p. 130.
- 32 Fülleborn. Beiheft Archiv für Schiffs- und Tropenhyg. (9), Nov., 1908, p. 25—*vide* Text, Fig. 1 and Pl. III., No. 37.
- 33 Tribondeau. Arch. de Méd. Nav., LXXIV., 1900, p. 107.
- 34 Gulland. B.M.J., 1902 (1), p. 831. Journ. Trop. Med., Sept., 1903, p. 277.
- 35 Whyte, Duncan. Lancet, 1910 (2), p. 297.
- 36 Huffman, O. V. Parasitology IV., No. 1., 1911, p. 77.
- 37 Wise, K. W. Brit. Guiana Med. Ann., 1908, p. 35.
- 38 Manson. Devel. Fil. sang. hom., and on the mosquito considered as a nurse. Journ. Linn. Soc., Zoology, XIV., 1878, p. 304.
- 39 *id.*, *ib.*, 1884, II., April 18th, p. 367.
- 40 Bancroft, T. Journ. Trop. Med., 1899, p. 91.
- 41 Low, G. C. B.M.J. (1), June, 1900, p. 1456.
- 42 James, S. F. *ib.*, 1900 (2), p. 533; and Indian Med. Gaz., 1900, XXXV., p. 169.
- 43 Low, G. C. *ib.*, Sept., 1901 (1), p. 1336.
- 44 Dutton, J. E. *ib.*, Sept., 1901 (2), p. 612; and Thompson Yates, Lab. Report IV., p. 1.
- 45 Wise, K. W. Brit. Guiana Med. Ann., 1908, p. 46.
- 46 Manson. Trans. Soc. Trop. Med. and Hyg., March, 1910, p. 247.
- 47 Scheube. Krankheiten der warmen Länder, 1910, p. 734.
- 48 Le Dantec. Précis de Path. Exot. p. 777; Sabouraud, Annales de Dermatologie. Quoted by Le Dantec.
- 49 Manson. Trop. Diseases, 1907, p. 630.
- 50 Low, G. C. Journ. Trop. Med., March 15th, 1911.
- 51 Sampson Handley. Lancet, 1909 (1), p. 31.
- 52 Daniels, C. W. Brit. Guiana Med. Ann., 1896, p. 679.
- 53 McDonagh, J. E. R. Lancet, 1910 (2), p. 1198.
- 54 Thornhill. Ind. Med. Gaz., Oct. 10th, 1897, XXXII.
- 55 Preston Maxwell. B.M.J., Sept. 7th. 1901, II., p. 609.

BIBLIOGRAPHY—*continued*

- 55 Leber & Prowazek. Archiv für Schiffs- und Tropenhyg. July, 1911, XXV., No. 13, p. 416.
- 56 Thompstone. Journ. Trop. Med., 1899, p. 89.
- 57 Young, C. W. B.M.J., 1897 (1), p. 1037.
- 58 Quoted by Sampson Handley. Lancet, 1910 (1), p. 1052.
- 59 Prout, W. T. B.M.J., 1902 (2), p. 879.
- 60 O'Brien. Journ. Trop. Med., 1908, p. 150.
- 61 Havelock Charles. Lancet, 1909 (2), p. 224.
- 62 Argyll-Robertson & Manson. Ophth. Soc. Journ., 1895, p. 154.
- 63 Low, G. C. Journ. Trop. Med. Jan., 1911, p. 5.
- 64 Manson. *ib.*, Nov., 1903, p. 347.
- 65 Daniels, C. W. *ib.*, June, 1901, p. 193.
- 66 Stephen, Mackenzie. Trans. Path. Soc. Lond., XXXIII., 1882, p. 394.



394



931-1  
933-111  
934-1  
936-11

938-1111

1939-11

1941-111

1944-1



