

**A report on two cases of a peculiar form of hand infection : due to an organism resembling the koch-weeks bacillus / by John R. McDill and Wm B. Wherry.**

**Contributors**

McDill, John R.

Wherry, W. B.

London School of Hygiene and Tropical Medicine

**Publication/Creation**

Manila : Bureau of Public Printing, 1904.

**Persistent URL**

<https://wellcomecollection.org/works/h2mpsx9u>

**Provider**

London School of Hygiene and Tropical Medicine

**License and attribution**

This material has been provided by This material has been provided by London School of Hygiene & Tropical Medicine Library & Archives Service. The original may be consulted at London School of Hygiene & Tropical Medicine Library & Archives Service. where the originals may be consulted. Conditions of use: it is possible this item is protected by copyright and/or related rights. You are free to use this item in any way that is permitted by the copyright and related rights legislation that applies to your use. For other uses you need to obtain permission from the rights-holder(s).



Wellcome Collection  
183 Euston Road  
London NW1 2BE UK  
T +44 (0)20 7611 8722  
E [library@wellcomecollection.org](mailto:library@wellcomecollection.org)  
<https://wellcomecollection.org>

JQK

904

McDILL (J.R.) A report on two cases  
of a peculiar form of hand infection,  
due to an organism resembling the Koch-Weeks  
bacillus. By J.R. McDill and W.B. Wherry.

Manila, 1904.

BUREAU OF GOVERNMENT LABORATORIES.

BIOLOGICAL LABORATORY.

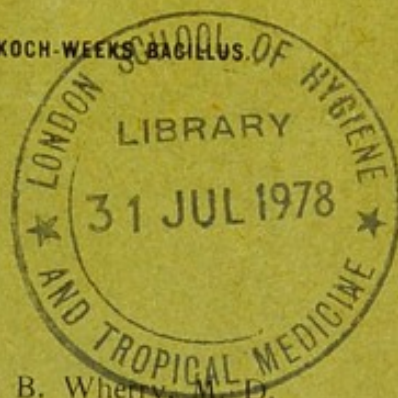
A REPORT ON

TWO CASES OF A PECULIAR FORM OF HAND INFECTION,

DUE TO AN ORGANISM RESEMBLING THE KOCH-WEEKS BACILLUS.

BY

John R. McDill, M. D., and Wm. B. Wherry, M. D.



JQK

(p.)

1904

SCN

MANILA:  
BUREAU OF PUBLIC PRINTING.  
1904.



LSHTM



001131391X

JAK (P)

1904

1903.—No. 10.

DEPARTMENT OF THE INTERIOR.

BUREAU OF GOVERNMENT LABORATORIES.

---

BIOLOGICAL LABORATORY.

---

A REPORT ON

# TWO CASES OF A PECULIAR FORM OF HAND INFECTION,

DUE TO AN ORGANISM RESEMBLING THE KOCH-WEEKS BACILLUS.

---


BY

John R. McDill, M. D., and Wm. B. Wherry, M. D.

---

MANILA:  
BUREAU OF PUBLIC PRINTING.  
1904.





## LETTERS OF TRANSMITTAL.

---

OFFICE OF THE SUPERINTENDENT OF LABORATORIES,

*Manila, P. I., November 2, 1903.*

SIR: I have the honor to forward herewith a paper entitled "A Report on Two Cases of a Peculiar Form of Hand Infection; Due to an Organism Resembling the Koch-Weeks Bacillus," by John R. McDill, M. D., Manila, P. I., and Wm. B. Wherry, M. D., Bacteriologist Biological Laboratory.

I am, very respectfully,

PAUL C. FREER,

*Superintendent Government Laboratories.*

Hon. JAMES F. SMITH,

*Acting Secretary of the Interior, Manila, P. I.*

---

BIOLOGICAL LABORATORY,

*Manila, P. I., October 14, 1903.*

SIR: I have the honor to transmit herewith for publication a report from the Biological Laboratory on two cases of a peculiar form of hand infection, due to an organism resembling the Koch-Weeks bacillus, by Dr. John R. McDill of Manila, P. I., and Dr. Wm. B. Wherry, Bacteriologist, of this Laboratory.


Very respectfully,

RICHARD P. STRONG,

*Director Biological Laboratory.*

Dr. PAUL C. FREER,

*Superintendent Government Laboratories, Manila, P. I.*



Digitized by the Internet Archive  
in 2015

<https://archive.org/details/b21355046>



## A REPORT ON TWO CASES OF A PECULIAR FORM OF HAND INFECTION DUE TO AN ORGANISM RESEMBLING THE KOCH-WEEKS BACILLUS.

[By John R. McDill, M. D., Manila, P. I., and Wm. B. Wherry, M. D., Bacteriologist, Biological Laboratory.]

Two cases of acute finger infection, one accidentally inoculated from the other, having certain unusual clinical characteristics have come under our observation. The appearance and symptoms of these cases differed so much in some respects from the ordinary inflammations of the coverings of the hand that the pathogenic organisms found present were carefully investigated.

*Case I.*—This case occurred in Dr. W., a hospital surgeon; his account of it being as follows:

During April he had been treating cases of acute suppurating conjunctivitis and one case of leg infection which ended in septicaemia. On April 22, three days after an operation on the septicaemia case, Dr. W. noticed a small, painful, reddish papule on the tip of his right forefinger. This increased a little in size and about four days later the papule was incised. No pus was found. The swelling increased and two days after the incision, the finger was again lanced on April 28, by a nurse, Miss B., who pricked her own finger during the operation.

The secretion from the wound was comparatively clear and serous in character. The edges of the incision formed an elevated, pinkish, granular, cauliflower-like mass of tissue.

About the end of the second week the pain became so severe that it interfered with sleep and the whole wound was thoroughly curetted.

By the end of the third week the cauliflower-like tissue had re-formed and the pain increased again, the whole finger becoming greatly swollen at the same time. Pus was now detected in the first proximal phalanx. This was opened. By the twenty-eighth day pus had formed on the dorsal surface of the hand between the first and second metacarpal bones. During this time the other



fingers did not swell, but the whole body of the hand was swollen to about twice the normal size.

From this time on the discharge and pain steadily decreased with the swelling. In the course of about four weeks, finger motions gradually returned. The temperature ran a rather irregular course, being highest,  $102^{\circ}$  F., on the 17th. About the 21st it reached normal. The pain was intense and not affected by heat or cold. There was great mental depression and complete loss of appetite. Dr. W. lost 13 pounds in weight. The general course of treatment was a varied use of bichloride dressings, 5 per cent carbolic acid baths, or constant immersion in saturated acetate of aluminum.

*Case II.*—On April 28, 1903, Miss B., hospital nurse, while making an incision into Dr. W.'s finger for a painful papule, accidentally pricked the pulp of the index finger of her left hand with the point of the knife used. Some bichloride of mercury solution was immediately applied and followed by 95 per cent alcohol compresses. No pain was felt in the minute puncture and after twelve hours the compresses were removed.

Thirty-six hours later a fullness and throbbing began in the end of the finger and at the end of another twenty-four hours a small, painful, intracutaneous vesicle appeared at the site of the knife wound. This was opened under antiseptic precautions and a fraction of a drop of clear fluid liberated. The minute cavity was freely exposed and a saturated solution of acetate of aluminum was kept in contact with the opening and with the entire finger as well, for four days. No relief was experienced. Upon changing the dressings daily, a slight staining, equivalent to two or three drops of wound secretion, was noticeable. No redness or swelling appeared.

Throughout the second week incessant shooting pains were experienced in the finger. The digital arteries pulsated with a wire-like tension. The sensation of painful throbbing and fullness gradually increased, but still no redness or swelling of the finger appeared nor was there local or general rise of temperature.

The general condition of the patient up to this time was that of pronounced mental and physical prostration, vigilance and sleeplessness, and anorexia with vomiting. Some rest was secured through the exhibition of large doses of trional or hypodermatic injections of morphine.

By May 12, fourteen days after infection, the lesion had grown to a diameter of 6 or 8 millimeters, was circular and had a soft,



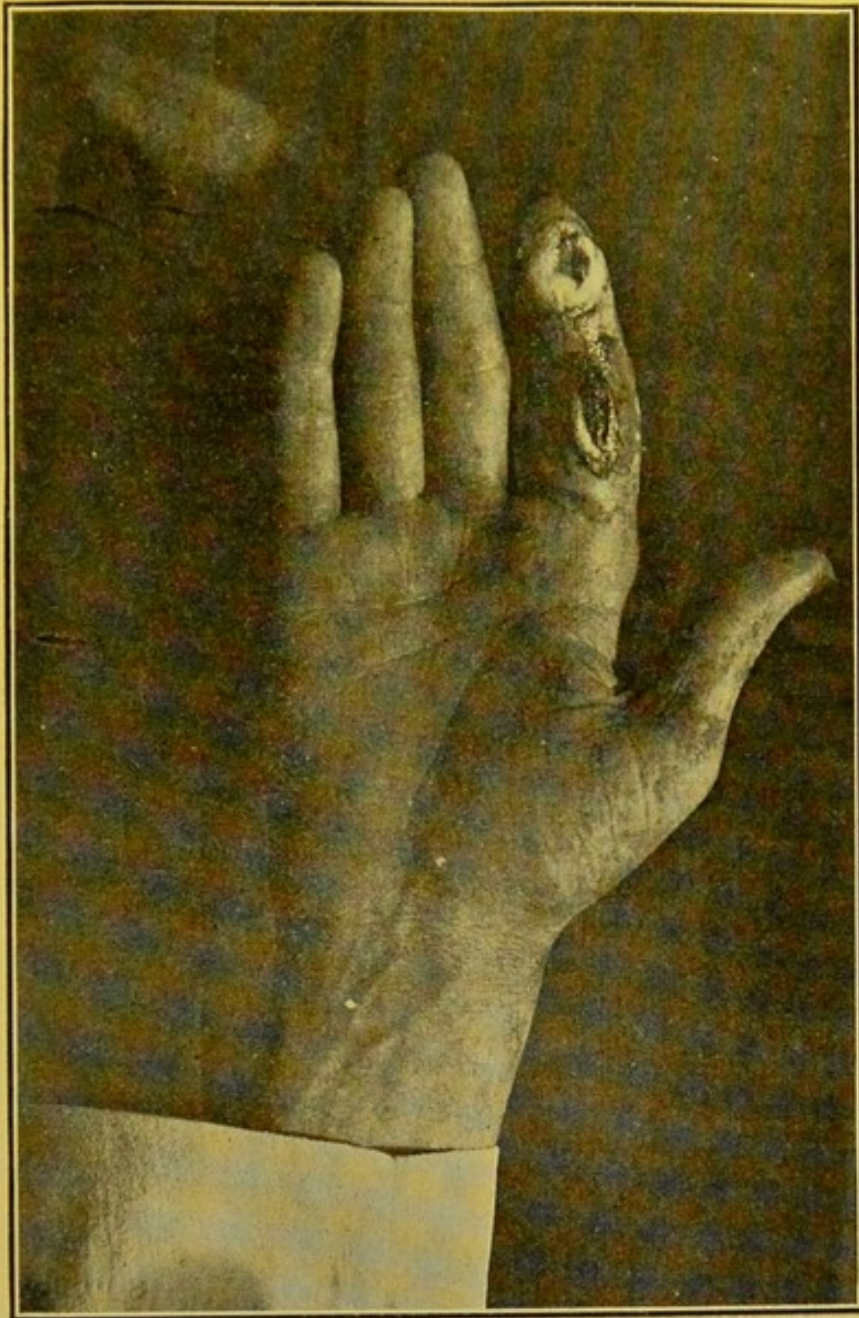


PLATE I.—Dr. W.'s hand. The photograph was taken at a time when retrogressive changes had set in. At the tip of the forefinger some remains of the cauliflower-like granulations may still be seen. (Photo by Martin.)



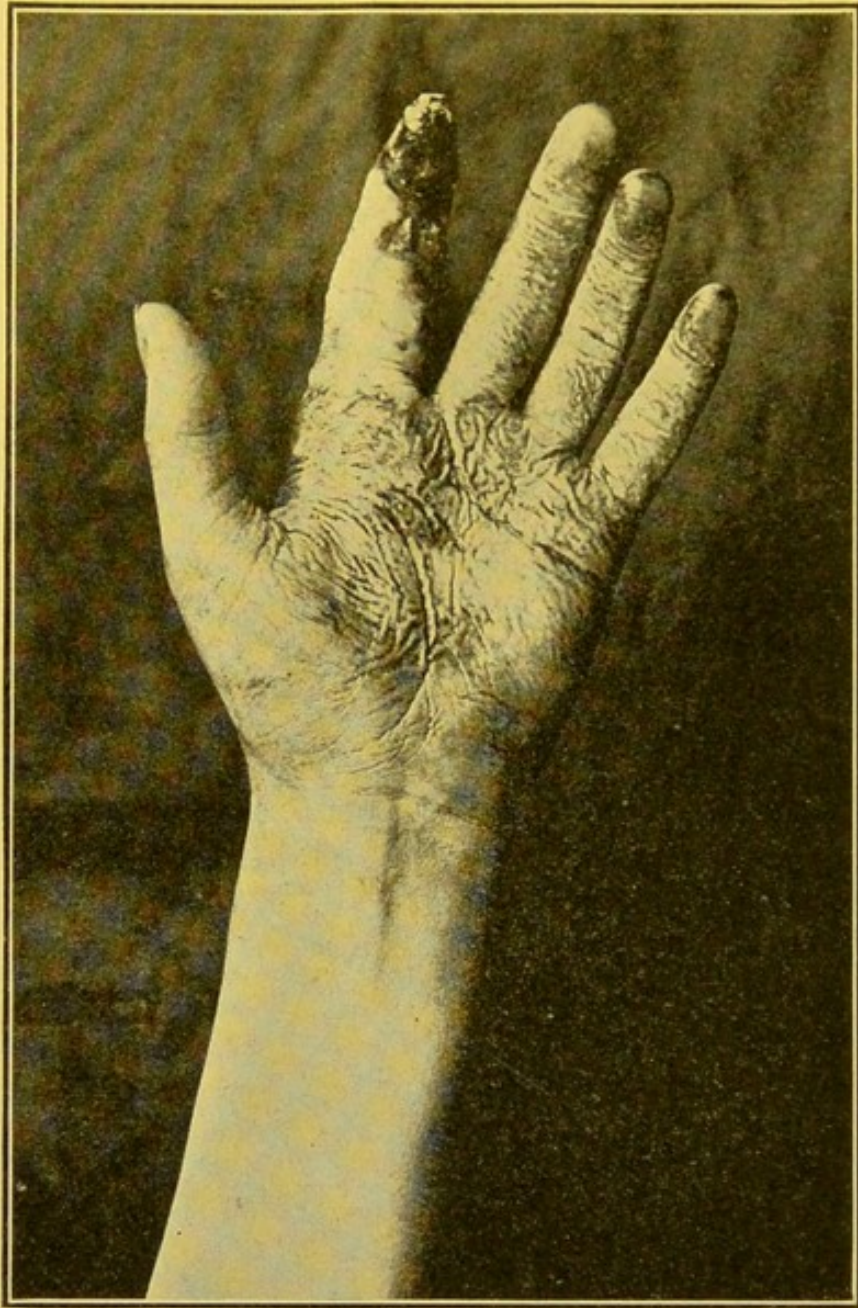


PLATE II.—A photograph of Miss B.'s hand, taken at a time when gangrene of the forefinger had set in. (Photo by Martin.)



nonbleeding, slightly elevated reddish surface which produced a small amount of secretion daily. On this date, May 12, a general anæsthetic was given and the well-like lesion thoroughly curetted. The small curette fell almost of its own weight through the granulations which seemed filamentous, long, and attached by one end to the bone and could be waved about by the instrument which came at once upon an exposed bony surface of the terminal phalanx. The curetted wound was swabbed dry with gauze, 95 per cent carbolic acid carefully applied to the cavity and covered with a mild, wet mercuric chloride dressing. Complete relief was experienced for thirty-six hours, then the former symptoms returned with increased severity.

On the sixteenth day, under local anæsthesia, the curetting was repeated and a wet dressing of saturated solution of acetate of aluminum applied. No relief resulted and about the eighteenth day, some swelling of this finger, the two adjacent fingers, and of the back of the hand began and the painful symptoms became even worse.

The patient was again given a general anæsthetic on the twentieth day. The terminal phalanx was perforated at its center with a very small ear gouge, with the hope of relieving a pain of central osseous origin. The distal interphalangeal articulation did not seem to be infected. Then an incision 2 centimeters in length was made over the swollen center of the first phalanx on its palmar surface and carried down to and into the sheath of the flexor profundis tendon. Through this opening an irrigating fluid passed readily out at the defect in the end of the finger. A localized swelling on a line with the index finger in the palm of the hand was also incised and found to be principally an œdema, but a small circumscribed collection of turbid fluid was also found.

A constant irrigation of cold, saturated solution of acetate of aluminum was kept moving through the finger wound along the course of the tendon sheath for about four days.

By this time the third and fourth fingers and the entire hand had swelled considerably and evidences of gangrene of all tissues of the end of the finger were apparent. For three days previous to the appearance of this tissue necrosis, the patient had kept the entire hand in a basin of ice-cold aluminum acetate solution, in addition to the constant irrigation, because the immersion gave some relief from pain.



On June 2 chloroform was given and a typical amputation made. The terminal phalanx, which was lying loose, and the distal articular end of the second phalanx were scarified. Upon drawing upon the long flexor tendon, nearly 3 inches of necrotic tendon pulled out easily. Healing progressed favorably.

From May 15 to May 25 there were occasional rigors and the afternoon temperature twice reached 102° F., but usually ranged between 99° and 101°. During this period nutrient enemata with brandy were necessary.

Acute inflammations of the soft parts of the hands are of much more importance than those of the feet as the usefulness of the hand exceeds that of the analogous parts of the foot. Surgeons treat all these inflammatory processes, usually described as *panaris* or *panaritium*, as if a disease of one causative origin, and direct all efforts to preserve the functional uses of hand and fingers. It may be questioned if this is in accord with the present state of our knowledge of these conditions, but actual results bear out the general practice in a striking way and will continue to do so until specific agents have been produced with which one can more successfully combat the special pathogenic microbes of these inflammations.

König's conclusion still holds good, "That scarcely in any other of the daily occurring diseases do such bad results follow neglect, or are such favorable functional issues obtained from correct treatment, as in *panaritium*."

How much can be preserved here by care and skill and how much lost of the capital of existence by neglect!

Every *panaritium* is the expression of a traumatic inflammation whether we are able to discover the point of entrance of the infective matter or not.

Koch's culture experiments have shown that in every case, one kind of germ or another or several together can be found in the inflammatory exudate and they are usually briefly described as *pyogenic bacteria*. Streptococci, staphylococci, and, in rare exceptions, bacilli such as the *Proteus* and *Coli communis* have been found, and the clinical course of all seem much alike and to be modified similarly by the anatomical peculiarities of the part first affected.

The usual history of extension of the destructive processes along the paths of least resistance has given rise to the imperative thera-

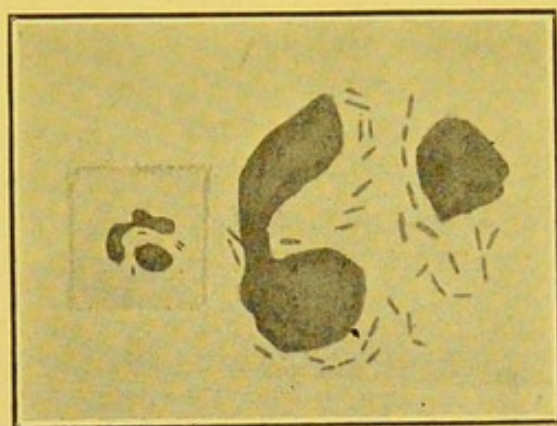


FIG. I.—Drawn from a coverslip preparation from Miss B.'s finger. It shows a polymorphonuclear phagocyte containing numerous bacilli (enlarged to show the morphology and irregular staining of the rods). The small figure to the left shows another cell from the same preparation as seen with the Zeiss oil im.  $\frac{1}{2}$ , oc. 3.



peutic law—incision, disinfection, and drainage as soon as possible and let the cuts be made too soon and too deep and long rather than too late.

Severe pain is usually explained by interference with circulation as a result of local pressure from swelling and its attendant tissue necrosis and thus the usual panaris resembles in many ways a furunculous inflammation. The second phenomenon which often surprises the beginner is the early appearance of redness and swelling of the dorsum of the hand when the primary focus of infection is beneath the volar surface and where eventually the pus is almost always found. This has its practical significance, and its pathogenic and anatomic causes are too well understood to need description here.

These two cases differed clinically, it will be seen from the usual finger and hand infection, in the slowness of the infective process, the absence of pus formation, and the invariable accompanying redness and swelling, in the earlier stages. Then the severity of pain and physical prostration seemed out of proportion to the extent of the lesions. The course of the infection was determined, as in any panaris by the anatomical peculiarities of the tissues successively involved. The most striking feature of the treatment was, perhaps, the total failure to favorably influence the progress of the disease by ordinary approved surgical measures. The necrosis of half of Miss B.'s finger was more extensive than was expected, although few cases escape without any tissue loss in severe inflammatory affections of these parts. It is probable that the prolonged immersion of the hand in the ice-cold antiseptic solution had something to do with reducing the vitality of the tissues.

#### BACTERIOLOGICAL EXAMINATION.

Coverslip preparations of the muco-purulent discharge from Dr. W.'s and Miss B.'s fingers show numerous leucocytes and mucous threads. Occasionally a cell is seen containing a number of thin influenza-like bacilli (see Fig. I). Some of these organisms lie without the cells, singly and in groups. The rods often lie side by side, or may occur end to end, in pairs or short chains. Sometimes they are so short as to appear coccoid. In the preparations from Miss B.'s finger, the bacilli are much more numerous than in those from Dr. W.'s finger—often lying outside of the leucocytes



in masses or groups of a hundred or more rods, or, again, in short chains of eight or ten bacilli. They stain well with carbol thionin or carbol fuchsin diluted 1:10. Often they take the stain evenly, but may appear segmented, or stain more intensely at the poles—especially when carbol thionin is used. They do not retain the stain in Gram's method. When colored with hot carbol fuchsin, they lose the dye when one-fourth per cent acetic acid or ordinary alcohol is applied. In size they vary from about one-half to three microns in length, by less than one-half micron in breadth (Zeiss oc. microm).

Throughout the acute stage of the infection this bacillus was present in considerable numbers and apparently in pure culture. When the acute symptoms had subsided, it could be found only with difficulty and finally disappeared. After gangrene appeared in Miss B.'s finger, nothing but the staphylococcus pyogenes albus could be isolated.

Numerous attempts at cultivating the bacillus were made and at first without success. Inoculations of the secretion upon plain agar<sup>1</sup> slants, agar smeared with human blood, ascitic fluid agar, and glucose agar, grown aerobically and anaerobically (pyrogallie-acid method), remained sterile during ten to fourteen days' observation.

Finally, pieces of tissue removed in an aseptic manner from Miss B.'s finger were forced into the substance of a slant of ascitic fluid agar and incubated at body temperature. No growth appeared during the first three days' incubation, but on the fourth day one of the pieces of tissue was surrounded by a halo of cloudiness which gradually increased in density and finally assumed a yellowish color, especially near the surface of the slant. Transplants upon ascitic fluid agar showed no growth in twenty-four hours, but in forty-eight hours a delicate, typhoid-like, whitish growth could be

---

<sup>1</sup>The "ordinary" media used was prepared according to the directions of the American Committee (Reports and Papers of the American Public Health Association, 1898, XVIII, p. 60), with a reaction of 1 per cent acid to phenolphthalein. The ascitic fluid agar was kindly furnished by Mr. Lindquist of the First Reserve Hospital laboratory. It was prepared by mixing equal parts of fluid glucose agar and ascitic serum and then sterilized by the intermittent method. For better methods of preparing human serum media, see Eyre, Jour. of Path., 1900, VI, 6, and Libman, N. Y. Med. Rec., 1903, LXIII, 237.



seen along the line of inoculation. This gradually assumed a lemon-yellow color. Stained preparations from this growth showed small, slender rods resembling those seen in the preparations made directly from the purulent exudate. When suspended in a hanging drop of bouillon, these rods were very actively motile. They lost the color when Gram's method was applied.

Notwithstanding the difficulty experienced in obtaining the first culture, the bacillus adapted itself to a saprophytic existence and grew readily upon the "ordinary" media. In no instance could growth be detected with the naked eye after twenty-four hours' incubation, but it was evident in forty-eight hours. (This peculiarity persisted in 10 or 12 transplants during two months' cultivation, but after about three months of saprophytic existence, the growth, though faint, is visible in twenty-four hours.)

*Cultural characteristics.*—On a slant of nutrient agar the growth is visible in forty-eight hours as a distinctly yellowish streak, confluent below, with small, circular, isolated colonies above, and much more luxuriant than that upon ascitic fluid agar. In a stained preparation the bacilli appear thicker than when taken from ascitic fluid agar and show a considerable change in their morphology, most of them being spherical or coccoid, others ovoid and in pairs. A few appear as distinct rods. They are nonmotile when suspended in a drop of bouillon. When an isolated colony from such an agar slant or from an agar plate is transplated upon ascitic fluid agar, the growth reverts in its appearance to the more delicate type, while the organisms all assume the thin bacillary form—actively motile when suspended in a drop of bouillon.

When plated in agar, pin-point-sized colonies are visible in forty-eight hours and in four or five days reach a diameter of one-half millimeter. In forty-eight hours the superficial colonies appear, under a low-power lens, as uniformly granular disks with translucent edges. In four days coarser granulations may be seen about the central position of the disks, and the colonies assume a chrome-yellow color. Those colonies, situated between the agar and the Petri dish, spread out like the superficial colonies and have the same appearance microscopically, but are unpigmented.

In bouillon a faint, uniform cloudiness appears in forty-eight hours. In the hanging drop short nonmotile rods may be seen. In a week the fluid is densely clouded, a precipitate collects at the



bottom of the tube, while a yellowish-white pellicle is formed on the surface. The pellicle, if unbroken, becomes thick and wrinkled in the course of ten or twelve days. No indol is produced.

*In Dunham's peptone solution* a faint turbidity appears in four days. No pellicle is formed and the growth is gradually precipitated. No indol is produced.

*In nutrient gelatin* (20 per cent, liquified by the warm weather) growth appears as small isolated colonies floating on the surface and scattered throughout the medium. No peptonization occurs during five days' growth, at about 28° to 30° C. for the gelatine solidifies readily when placed upon ice.

*In litmus milk* no visible change is produced during the first four days. In a week there is slight reduction of the litmus at the bottom of the tube. In twelve days the litmus is completely reduced, excepting at the surface, where it is still blue for a depth of 2 or 3 mm. No coagulation occurs.

*In stab cultures in glucose agar and litmus lactose agar* no particular changes are produced. A granular growth appears along the upper portions of the stab, while on the surface a smooth, circular, elevated growth appears. This gradually changes in color from a lemon to a chrome yellow.

*In glucose bouillon in the fermentation tube* no gas is produced and the closed arm remains clear during twelve days' observation.

*On a slant of potato* the first growth appears in four days as minute lemon-yellow colonies. In eight days the colonies are confluent, of a chrome-yellow color and present a wrinkled surface. In ten days the surface is elevated into snake-like folds. When stained from an eight-day potato culture, the bacilli appear as irregularly clubbed rods. Nothing resembling spores can be stained.

#### INOCULATION EXPERIMENTS.

(1) Monkey No. 260<sup>1</sup> received a subcutaneous injection, in the chest, of 1½ c. c. of a physiological salt solution emulsion of the purulent secretion from Miss B.'s finger. No result followed. A few days later a small piece of tissue curetted from Miss B.'s finger was placed under the skin of the chest and the wound covered with flexible collodion. Four days later a small amount of purulent

<sup>1</sup>The monkeys used in these experiments were the common red monkey of the Philippines.



secretion appeared through cracks in the collodion dressing. This contained pus cells and a few small bacilli which could not be grown upon plain agar. In a few days the wound had healed completely.

(2) Monkey No. 261 received a subcutaneous injection in the chest of  $1\frac{1}{2}$  c. c. of a well-clouded emulsion of the purulent secretion from Dr. W.'s finger. Microscopical examination of the pus showed that numerous bacilli were present. In forty-eight hours a pea-sized nodule appeared at the site of injection. Two days later this had completely disappeared and the monkey remained well during a month's observation. Then it received in the tip of the right forefinger, an injection of one-half c. c. of a twenty-four-hour bouillon culture of the bacillus isolated from Miss B.'s finger. Microscopically, the culture showed numerous coccoid bodies and short rods. No particular change was noticed during the first two weeks' observation, but in the course of a month the monkey's hand showed an inflammatory process affecting the first three fingers. The tip of the forefinger was gangrenous, and the middle and ring fingers showed swollen, globular, whitish tips. Cover-slip preparations showed cocci and bacilli—many of the latter were very minute rods, losing the stain when Gram's method was applied. They could not be isolated upon ordinary agar plates; and plates made with human serum, according to the method of Pakes,<sup>1</sup> were rapidly overgrown by other organisms. The staphylococcus aureus and albus and some unidentified, large, rapidly-growing bacilli were present in considerable numbers. The animal was chloroformed and at the autopsy nothing in particular was noticed, excepting swelling and congestion of the right axillary glands. Sections from the spleen, liver, and kidney appeared normal. Those from the right forefinger showed that the inflammatory process was apparently limited to the outer layers of the skin, the malpighian layer being almost wholly replaced by a mass of nuclear fragments and many cocci and bacilli. The interpapillary pegs of the epidermis showed marked canthosis, long, slender processes of epithelium running deep into the subcutaneous tissue. The subcutis showed almost no infiltration.

(3) A young rabbit, No. 269, received in the subcutaneous tissue of the left ear an injection of about one-eight c. c. of a densely

<sup>1</sup>See Eyre, loc. cit.



clouded, seven-day-old bouillon culture of the bacillus isolated from Miss B.'s finger. This was followed by hyperæmia at the site of the injection, but no inflammatory process resulted.

(4) A young rabbit, No. 272, received an intravenous injection of one-half c. c. of an emulsion of the same bacillus taken from a seven-day-old culture on ascitic fluid agar. It remained well during two weeks' observation, when it escaped.

(5) Guinea pig, No. 270, received an intraperitoneal injection of 1 c. c. of a seven-day-old bouillon culture of the same bacillus. It remained well during a month's observation.

*Results of the agglutination test:* Blood for these tests was obtained from Dr. W.'s ear and from Miss B.'s infected finger at the time when the infectious process was in a retrogressive stage. Both specimens failed to agglutinate the bacillus, in two hours, at a dilution of 1:10.

There were several cases of acute contagious conjunctivitis in the hospital at the time when Dr. W.'s finger was infected. The bacilli in the cover-slip preparations from these cases correspond in their morphology, size, and staining reactions with those in the preparations from Dr. W.'s and Miss B.'s fingers. They also correspond in their morphology, distribution, and staining reactions with the descriptions of the Koch-Weeks bacillus. They could not be cultivated upon the ordinary media nor upon agar smeared with human blood. As we believe the organism described above to be the Koch-Weeks bacillus itself, or a closely related "type" of this organism, it seems desirable to append a description of this bacillus and of other organisms described as resembling it.

*Acute contagious conjunctivitis* (otherwise known as acute or epidemic catarrhal conjunctivitis, muco-purulent conjunctivitis, or vulgarly as "pink-eye") is a highly contagious, muco-purulent inflammation of the conjunctiva, accompanied by some swelling of the lids (Weeks). The disease is self-limited, passing through an acute stage and then gradually subsiding. Recovery usually occurs in from two to three weeks. The disease is said to be especially prevalent in Egypt, but it occurs throughout the globe.

The specific cause of the disease, a small bacillus, was first seen in a case of conjunctival catarrh by Koch (1), in Egypt (1883), and cultivated and proved to be the specific microorganism by Weeks (2) in America (1886). Therefore the virus is usually



known as the Koch-Weeks bacillus. Their work has since been confirmed by Kartulis (3) in Egypt, Morax in France, and Wildbrand, Sanger, and Stalin (4) in Germany.

The Koch-Weeks bacillus is described<sup>1</sup> as a minute, nonmotile rod (0.25 by 1 micron) resembling the influenza bacillus or that of mouse septicæmia. In acute cases the bacilli occur in large numbers in the muco-purulent secretion, often being taken up in considerable numbers by the phagocytes. In subacute cases they may be scarce, and in the later stages of the disease they disappear entirely. They often lie in pairs, end to end, or sometimes in short chains within and outside of the pus cells of the secretion. They stain well with the ordinary dyes, but do not retain the stain when Gram's method is applied.

When transferred from the human body to artificial media, this organism is even more restricted in its conditions of growth than the influenza bacillus, as it rarely grows upon agar smeared with human blood, the best medium being human serum agar. According to Kartulis (3), "When incubated at a temperature between 28° to 30° C., the growth is first visible to the naked eye in a period of thirty to forty hours. At first it appears along the line of inoculation as small greyish-white points. Gradually the points unite into a small streak which is raised considerably above the surface of the medium. At this time the culture becomes glossy and darker in color. The borders are uneven and well formed and very much indented. For a long time the growth retains the described form, but it dries gradually and then resembles the backbone of a fish. Growth upon agar-agar and gelatine is feeble. Gelatine is not liquefied. Microscopically, in a very young culture the bacillus appears somewhat plumper than those in the cells; in a very old culture they are somewhat larger and thicker. Spore formation has not been observed."

*Pathogenicity.*—"Transmission to the conjunctiva of animals is unsuccessful. Kartulis has obtained positive results, in human beings, in only one case out of six, and that with cultures 10-20 generations old. Weeks, on the other hand, reports several successful inoculations into human beings. His cultures, however, were not pure, but contained, besides the conjunctivitis bacillus, *Xerosis bacilli* (diphtheria group)" (5).

<sup>1</sup>The only literature within our reach is that in Flüggé-Mikroorganismen (5) and an article by Kartulis (3).



*Other organisms described as resembling the Koch-Weeks bacillus.*—"Another organism exceedingly like the previous, apparently differing from it only in the rather wider conditions of growth, is Müller's bacillus" (6).

"*Bacillus pseudoconjunctivitis* (5).—Discovered by Kartulis in the conjunctival secretions in a case at Alexandria and turned over to the author. These bacilli are nonmotile and just as small as the preceding ones, and likewise neither stain according to Gram nor form spores. Their cultures are rather prolific, with a canary-yellow pigmentation. The gelatine cultures liquefied first, although quite slowly, but later the liquefaction disappeared and the needle-point cultures assumed the form of a nail with flat, canary-yellow heads. On potatoes a well spread-out, light-brownish deposit was formed.

"*Bacillus aeris minutissimus* (5).—Was obtained by Doctors Jbrahim Bey and Faud Bey in the air at the Institute of Hygiene in Bonn. It is similar to the preceding ones, but forms a light-yellowish pigment. It is not pathogenic for animals.

"*Bacillus aureus minutissimus* (5).—Also isolated by Jbrahim and Faud on plates exposed to the air. Morphologically similar to the preceding ones, but motile; does not stain according to Gram; does not form spores; liquefies gelatine. On potatoes it forms a luxuriant golden pollulation. It produced septicæmia in mice and abscesses in rabbits."

We are inclined to consider the organism isolated from Miss B.'s finger as identical with or as a closely related type of the Koch-Weeks bacillus. In addition to its similar morphology, the difficulty with which it was cultivated and the characteristic delay in the appearance of the growth, speak for such an identity. "We may have slightly overestimated its size, for ocular micrometry is a rather inaccurate method. As to the limits of accuracy in micrometry, a competent authority says: "I assume that  $0.2\ \mu$  is the limit of precision in microscopic measures, beyond which it is impossible to go with certainty." (W. A. Rogers, Proc. Am. Soc. Miers., 1883, p. 198.) Further, if the statement by Abbe be true (quoted from Lehmann and Neumann) that the limit of microscopic vision lies between  $0.1$  and  $0.2\ \mu$ , then obviously, the diameter given by others for this bacillus, i. e.,  $0.25\ \mu$ , is too small.

We have further found the bacillus to be actively motile when



taken from a recent culture on ascitic fluid agar and suspended in bouillon. However, it is nonmotile when grown upon the ordinary media.

The ability to produce pigment and a greater adaptability to a saprophytic mode of existence suggests a closer resemblance to the organism described as *B. pseudoconjunctivitis*, but these faculties are variable ones in many species of microorganisms. For instance, the variability in power of pigment production shown by the *Staphylococcus aureus* or *B. pyocyaneus* may be mentioned. Again, it has often been noticed that microorganisms isolated from a virulent form of a disease, e. g., hemorrhagic septicæmia in cattle, or cholera asiatica, do not possess a corresponding degree of pathogenicity and grow luxuriantly upon artificial media. So it is possible that in our case we happened to obtain a growth not of the more virulent and less saprophytic type of organisms present in the tissues but of those that had a tendency toward a saprophytic mode of existence.

As for the histological changes which this organism is able to produce, we can not make any definite statements. It is possible that the marked canthosis occurring in the finger of monkey No. 261 may indicate the way in which the cauliflower-like verrucoid growth of tissue, occurring in the human cases, was produced.

#### REFERENCES CITED IN THE TEXT.

- (1) S. Gaffky, Arbeiten aus dem Kaiserl. Gesundheitsamte, 3.
- (2) Archives of Ophthalmology, 1886, XV, No. 4, or, N. Y. Med. Rec., May 31, 1887.
- (3) Cent. f. Bakt. u. Parasitenk, 1887, I, 289.
- (4) Jahrbuch d. Hamb. Staatskrankenanstalten, 3 Bd., 94.
- (5) Flügge-Mikroorganismen, 1896, II, 440 and 441.
- (6) Muir and Ritchie, Manual of Bacteriology, Am. Ed. 1903, 201. (Müller's article will probably be found in the Wien. Med. Wehnschr., 1897).



