

**Protozoa and disease, comprising sections on the causation of smallpox, syphilis, and cancer. Part II / by J. Jackson Clarke.**

**Contributors**

Clarke, James Jackson.  
London School of Hygiene and Tropical Medicine

**Publication/Creation**

London : Baillière, Tindall and Cox, 1908.

**Persistent URL**

<https://wellcomecollection.org/works/nv9aff74>

**Provider**

London School of Hygiene and Tropical Medicine

**License and attribution**

This material has been provided by This material has been provided by London School of Hygiene & Tropical Medicine Library & Archives Service. The original may be consulted at London School of Hygiene & Tropical Medicine Library & Archives Service. where the originals may be consulted. Conditions of use: it is possible this item is protected by copyright and/or related rights. You are free to use this item in any way that is permitted by the copyright and related rights legislation that applies to your use. For other uses you need to obtain permission from the rights-holder(s).



Wellcome Collection  
183 Euston Road  
London NW1 2BE UK  
T +44 (0)20 7611 8722  
E [library@wellcomecollection.org](mailto:library@wellcomecollection.org)  
<https://wellcomecollection.org>



# PROTOZOA AND DISEASE

---

J. JACKSON CLARKE





# LIBRARY

Date 11th December 1933

Class Mark 6 HA Accession No. 20539



*In preparation.*

**THE CAUSE OF CANCER,**  
Being Part III of  
**PROTOZOA AND DISEASE.**

By J. JACKSON OLARKE, M.B., F.R.C.S.,  
Senior Surgeon to the Hampstead and North-West  
London Hospital, &c.

*Already published, price 7s. 6d. each Part,*

PART I. "Most opportune."—*Lancel.*

PART II. (Including the Causation of Small-pox,  
Syphilis, and Sarcoma) "Demands serious atten-  
tion."—*British Medical Journal.*

BAILLIERE, TINDALL & COX,  
8, Henrietta Street, Covent Garden, London.

REGISTERED AS A NEWSPAPER.]

*Bm 1. Oct 9 1909*

LSHTM



0011219589



My dear Samuel Clarke

I was very glad to

find you so much better  
you have only to keep  
clear of speculations and  
controversial matters to  
obtain the reputation you  
deserve

WDS



Jackson Clarke  
J.B. F.R.C.S.  
I am kind of return the  
book if found.

PROTOZOA AND DISEASE

PART II.



6 HA



PROTOZOA AND  
DISEASE

COMPRISING

SECTIONS ON THE CAUSATION OF SMALLPOX,  
SYPHILIS, AND CANCER

BY

J. JACKSON CLARKE

M.B. LOND., F.R.C.S.

FORMERLY PATHOLOGIST TO ST. MARY'S HOSPITAL; AND CURATOR OF THE MUSEUM, DEMONSTRATOR  
OF BACTERIOLOGY, AND PROVISIONAL TEACHER OF BIOLOGY IN THE MEDICAL SCHOOL

AUTHOR OF 'MORBID GROWTHS AND SPOROZOA,' 'POST-MORTEM EXAMINATIONS,' 'SURGICAL  
PATHOLOGY AND PRINCIPLES,' ETC.

PART II.



LONDON  
BAILLIÈRE, TINDALL AND COX  
8, HENRIETTA STREET, COVENT GARDEN

1908



20539



To  
MY WIFE







## CONTENTS

CHAPTER	PAGE
I. INTRODUCTORY - - - - -	I
II. STUDIES OF NON-PARASITIC PROTOZOA - - - - -	9
III. NOTES ON CERTAIN PARASITIC PROTOZOA - - - - -	19
IV. NOTES ON SOME TROPICAL DISEASES - - - - -	28
V. NOTES ON TICKS - - - - -	37
VI. PIROPLASMOSIS - - - - -	41
VII. SMALL-POX AND VACCINIA - - - - -	44
VIII. SYPHILIS AND YAWS - - - - -	55
IX. CYSTIC DISEASE OF THE URINARY TRACT IN MAN - - - - -	68
X. DEFINITION OF THE TERM 'CANCER,' ETC. - - - - -	77
XI. GRANULATION TISSUE—THE NORMAL 'GRANULOMA' OF DEFENCE AND REPAIR - - - - -	81
XII. ON THE STRUCTURE OF AN ALVEOLAR SARCOMA OF THE HUMAN BREAST AND ITS MEANING - - - - -	87
XIII. ON THE STRUCTURE OF A ROUND-CELLED SARCOMA OF THE HUMAN TESTIS, WITH AN INTERPRETATION - - - - -	106
XIV. VARIOUS HUMAN SARCOMAS - - - - -	115
XV. ON THE INFECTIVE GENITAL TUMOURS OF DOGS - - - - -	126
APPENDIX - - - - -	137
INDEX - - - - -	138





## LIST OF ILLUSTRATIONS

FIG.	PAGE
1. MOLLUSCUM CONTAGIOSUM - - - - -	6
2. TRICHOSPHERIUM SIEBOLDII - - - - -	10
3. COLPODA CUCULLUS - - - - -	17
4. SPIROCHÆTA ZIEMANNI, STAGES OF, IN THE GNAT - - - - -	21
5.       "       "       "       "       "       " - - - - -	22
6. SPIROCHÆTA AND SPIRONEMA - - - - -	23
7. TRYPANOSOMA NOCTUÆ - - - - -	25
8. LEISHMANIA DONOVANI - - - - -	33
9. TICKS - - - - -	37
10. PIROPLASMA CANIS - - - - -	42
11. RABBIT'S CORNEA FORTY-EIGHT HOURS AFTER VACCINATION - - - - -	45
12. GUINEA PIG'S CORNEA SEVENTY-TWO HOURS AFTER VACCINATION - - - - -	46
13. CYTORYCTES VARIOLE - - - - -	50
14. BODIES FORMED IN VARIOLOUS LYMPH - - - - -	52
15. EPIDERMAL CELLS AND PROTOZOA IN SECONDARY SYPHILIS - - - - -	56
16. THE MARGIN OF A SYPHILITIC ULCER - - - - -	57
17. PART OF THE EPIDERMIS IN SECONDARY SYPHILIS - - - - -	58
18. BODIES OBSERVED IN A SCRAPING OF A TERTIARY SYPHILITIC ULCER - - - - -	60
19. SECTION OF A RABBIT'S CORNEA SEVENTY-TWO HOURS AFTER INOCULATION WITH SYPHILIS - - - - -	61
20 BIS. SPIROCHÆTÆ - - - - -	64
21. THE LEFT KIDNEY, URETER, AND BLADDER IN A CASE OF CYSTIC DISEASE OF THE URINARY TRACT - - - - -	69
22. IBID. : SECTION OF A CYST - - - - -	70
23. IBID. : ANOTHER PART OF THE SAME SECTION - - - - -	71
24. IBID. : PART OF A SECTION SHOWING SIX CYSTS - - - - -	72
25. IBID. : COVER-GLASS PREPARATION SHOWING AMŒBOID BODIES - - - - -	73
26. IBID. : PART OF A CYST AND CONTENTS MORE HIGHLY MAGNIFIED - - - - -	74
27. GRANULATION TISSUE UNITING THE ENDS OF A TENDON FORTY-EIGHT HOURS AFTER DIVISION - - - - -	82
28. THE SAME AT THE END OF NINETY-SIX HOURS - - - - -	83
29. TYPES OF NUCLEI IN FIBROBLASTS - - - - -	85



FIG.	PAGE
30. ALVEOLAR SARCOMA OF THE HUMAN BREAST (MACROSCOPIC VIEW) -	88
31. IBID. : JUNCTION OF SARCOMATOUS WITH NORMAL TISSUE -	89
32. IBID. : A FULLY DEVELOPED PART OF THE TUMOUR ( $\times 800$ DIAMETERS)	91
33. IBID. : PHOTOGRAPH SHOWING AN INTRANUCLEAR BODY -	92
34. IBID. : PHOTOGRAPH SHOWING INTRANUCLEAR BODY ATTACHED TO NUCLEAR MEMBRANE -	92
35. IBID. : PHOTOGRAPH SHOWING NUCLEUS WITH SEVERAL INTRA- NUCLEAR BODIES, AND AMŒBOID BODY FORMING GEMMULES -	93
36. IBID. : DIFFERENT STRUCTURES IN ( $\times 1,000$ DIAMETERS) -	94
37. IBID. : FARTHER STRUCTURES IN -	98
38 AND 39 BIS. GRANULATION TISSUE -	100
40 BIS. ALVEOLAR SARCOMA -	101
41. SARCOMA OF TESTIS ( $\times 60$ DIAMETERS) -	107
42. IBID. : $\times 800$ DIAMETERS -	108
43. IBID. : VARIOUS CELL-FORMS IN -	110
44. IBID. : SCHEMATIC INTERPRETATION OF -	111
45. SARCOMA CELL AND CELL-INCLUSIONS -	115
46. MYXOSARCOMA, CELLS FROM ( $\times 1,000$ DIAMETERS) -	117
47. SARCOMAS OF BONE -	119
48. PERIOSTEAL SARCOMA : CELLS AND CELL-INCLUSIONS -	121
49. INFECTIVE TUMOUR OF DOGS : MACROSCOPIC VIEW OF SECTION -	128
50. IBID. : INITIAL STAGE -	129
51. IBID. : THE MIDDLE STAGE -	130
52. IBID. : THE FULLY DEVELOPED STAGE -	131
53. VARIOUS CELL-FORMS, CHIEFLY FROM INFECTIVE TUMOUR OF DOGS	134

# PROTOZOA AND DISEASE

## PART II

### CHAPTER I

#### INTRODUCTORY

FOUR years ago, when the first part of this work appeared, important advances had been made in our knowledge of the *Sporozoa*. Among these advances the discovery of the sexual phase was then still recent, and the relationship of the hæmatozoa of malaria to the coccidia had only just been established.

In the interval progress<sup>1</sup> has been most marked in respect of another class of the protozoa, the *Flagellata*. The most striking and important of these advances in our knowledge of the causes of disease will be outlined in the following pages, and the state of knowledge in regard to other diseases suspected of being caused by protozoa will be indicated.

In this introductory chapter the first place will be given to a brief study of some non-parasitic protozoa, because it is only by being familiar with such forms that we can hope to recognise and

<sup>1</sup> No one can think of this progress in protozoology without recalling the names of two investigators—J. E. Dutton and Fritz Schaudinn—who lost their lives from infection contracted whilst studying the sphere of protozoa in the causation of disease. Dutton was the first to give us a detailed account of a case of human trypanosomiasis. Schaudinn's many brilliant contributions to protozoology mark an epoch in the science. Some of his work on the hæmoflagellates of birds, and his discovery of the spirochaeta or spironema of syphilis, and others of his contributions to protozoology, will be referred to below.



understand any pathogenic protozoa that have hitherto escaped recognition.

A perusal of even the following brief notes, from which many points are necessarily omitted, will show that steady progress has been achieved in the pathology of tropical diseases, amongst which the foremost place must be reserved for malaria.<sup>1</sup>

We are indebted to Schaudinn for making our knowledge of the protozoa of malaria more nearly complete. Among other points he has explained the occurrence of relapses, such as may occur after a long interval, when the disease has apparently been cured. Such relapses appear to be brought about by female gametocytes, or 'sporonts.' These females outlive all other forms of the parasite in the human host, and when the resistance of the latter is lowered, whether from intemperance, exposure to cold, or some other cause, parthenogenetic multiplication of the parasites occurs. The *Parthenogenesis* is described as follows: 'The nucleus of the gametocyte divides into two parts; one is rich in chromatin and stains deeply, while the other is pale and stains feebly. The body becomes partially constricted into two parts, one consisting of denser protoplasm, with most of the pigment and the pale nucleus. This portion of the body, with its contents, is ultimately abandoned as residual protoplasm; the other portion has lighter protoplasm and less pigment, and contains the darker nucleus. This portion proceeds to sporulate, as in the schizogony, and produces a number of merozoites, which attack red blood-corpuscles, and give rise to a fresh endogenous cycle, and consequently a relapse of the fever.'<sup>2</sup>

The more salient features of recent contributions to our knowledge of other tropical diseases, such as *sleeping-sickness*, *kala-azar*, *splenomegaly*, and *Delhi boil*, are given in Chapter IV. of this volume. What promises to be an elucidation of *beri-beri* has been published more recently.

<sup>1</sup> When we speak of malaria as a tropical disease it should be with a mental reserve to the effect that the disease was once common in the fens of our own country, and the disease is still by no means limited to the tropics.

<sup>2</sup> E. A. Minchin, article 'Protozoa' in Allbutt and Rolleston's 'System of Medicine,' vol. ii., part. ii.



As the result of the zeal of workers abroad, we have now more definite knowledge of the infectious diseases more or less peculiar to the tropics than we have of our own fevers. It may be asked whether this is because the parasites that cause disease in the tropics are larger or, like the flagellates, more readily recognised as parasites than those that constitute the infections of temperate climates; or whether it may be that the conditions of investigation are better in India and other British colonies than they are at home. In spite of the work that has been done, the nature of the infection of some tropical diseases still demands elucidation. *Dengué*, a fever compared to influenza by Manson, and *yellow fever* are still under investigation. The position of the pathology of yellow fever is particularly interesting. It has been established, mainly by the late Walter Reed, Major in the American Army, that the *Stegomeia fasciata*, a gnat which breeds chiefly about houses, is the sole carrier of the disease; and by covering water-butts and preventing chance collections of water these gnats are kept down and the spread of the disease is stopped. By these simple measures this disease has been practically stamped out in many seaports and other places previously notorious for it.<sup>1</sup>

Among the ectoparasites that carry protozoan and other infective diseases, ticks of various kinds have recently been shown to play a more important part than was previously suspected. A tick was mentioned in Part I. as the carrier of the destructive cattle disease caused by a piroplasma. Recently an important advance has been made in our knowledge of the piroplasmata by Christophers,<sup>2</sup> who has traced the complete life-history of *P. canis*, as observed in India, the more important part of the parasite's life being passed in the gut and tissues of a tick.

Tick-fever is a name given to the African remittent fever, which, like the European fever of the same name, is associated with

<sup>1</sup> The whole history of yellow fever emphasizes the immense value of a new idea which is at the same time a rational induction based upon wide observation. Without Manson's 'mosquito-malaria' theory neither our knowledge of the mode of convection of malaria nor that of yellow fever would have become known.

<sup>2</sup> S. R. Christophers, *Brit. Med. Journ.*, January 12, 1907.



spirillum-like organisms. For these reasons a short chapter on ticks is included in this volume.

Some other diseases have been found to be associated with the presence of protozoa. One of these diseases is a little tumour, a recurrent papilloma of the septum of the nose, as described by O'Kinealy.<sup>1</sup> Professor Minchin has relegated to the sporozoa the interesting parasites abundantly present in this affection.

But what of our measles, scarlet fever, small-pox, chicken-pox, mumps, whooping-cough, and other too familiar infectious and contagious diseases of unknown causation? In two instances, small-pox and hydrophobia, bodies that are widely believed to be protozoa appear within the cells, and these appearances are now of importance in medical practice, being an important element in diagnosis, and as such they should be studied in every medical school throughout the world; and this quite apart from any agreement as to whether these bodies are protozoa or not having been arrived at.

With regard to small-pox, it has now been well established for at least five years<sup>2</sup> that certain hyaline bodies—the *Cytoryctes variolæ* of Guarnieri—that appear in the corneal cells of rodents within twenty-four hours after inoculation with variolous or vaccine matter are specific, and may be relied on for making a diagnosis in doubtful cases of small-pox. Had this knowledge been made general in our profession by instruction given in medical schools, some serious errors of diagnosis would have been avoided.

With regard to hydrophobia, hyaline bodies (Négri's corpuscles) appear most prominently in the cells of the brain and nerve-ganglia. Négri showed in 1904 that these bodies are as distinctive of hydrophobia as *Plasmodium* is of malaria, and he and his assistants have succeeded in establishing the conviction that these 'Négri' corpuscles are sufficiently characteristic to afford a quick and safe diagnosis of rabies, a preparation obtained by pressing a cover-glass upon the cut surface of the *Cornu Ammonis* being all that is required. This is

<sup>1</sup> O'Kinealy, Proceedings of Laryngological Society, London, vol. x., April 3, 1903.

<sup>2</sup> Since Wasielewski (*Zeit. für Hygiene*) proved that Guarnieri's bodies are specific for small-pox and vaccinia.



the most rapid mode of diagnosing hydrophobia in the fresh cadaver of a suspected animal, and by this means priceless time may be saved in deciding whether Pasteur treatment is required by a bitten person.

It is remarkable that, after the lapse of fifteen years since Guarnieri first described the *Cytoryctes* as a protozoon, biologists and pathologists are still without any general agreement as to their nature. The subject is one that requires the closest personal application before anyone is justified in forming an opinion. Among those who have worked longest at this subject is a biologist who ranks among the foremost authorities on protozoa, Professor Calkins, who has recently written :

‘ Perhaps the majority of pathologists and some biologists are opposed to this interpretation, and these bodies, like the Négri bodies, are more commonly regarded as specific secretions or degenerations than as protozoa. I have no doubt myself, from long study of these organisms, that they are protozoa, and believe that, with fresh material and by using the stain (Giemsa’s) that Dr. Williams has so successfully used for *Neuroryctes*, the last doubter will be convinced.’

Many other workers share this opinion, which I quote here because it is one that none can afford to neglect, and it becomes the more weighty when it is remembered that biologists, to whom classification is so important that they look with suspicion on anything that is *incertæ sedis*, are apt to be more reluctant than pathologists to accept biological discoveries in pathology. In this connection we must remember that, had we waited for the position of the *Plasmodium malariae* to be settled in classification before accepting it as a protozoon, we should have been still waiting for that most important piece of knowledge, which has done so much to ameliorate the condition of thousands of human beings, and has opened up new pathways in science. An outline of the chief recent contributions to our knowledge of the *Cytoryctes variolæ* will be given below, a notice of the Négri corpuscles, or *Neuroryctes*, being reserved for the next part of this work.



*Contagious Epithelioma, or Molluscum Contagiosum.*—Recent observations on this disease may ultimately help to prove the true character of the *Cytoryctes Guarnieri*. In birds the affection so closely resembles that of the same name in man that the two affections may be reasonably assumed to be of kindred character. In the human subject during epidemics of small-pox the lesions are not infrequently mistaken for those of the latter disease, and in birds the term 'bird-pox' is sometimes used for it. Now, the typical molluscum corpuscle, which is in appearance an inert, homogeneous-looking body, I know from personal observation, of which I have some recent confirmation, to be a protozoon, which under suitable conditions which as yet I have not fully determined, breaks up into a swarm of flagellate bodies (see Fig. 1).

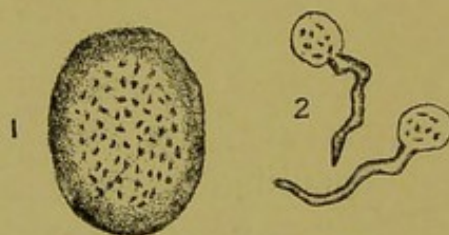


FIG. 1.—MOLLUSCUM CONTAGIOSUM.

1, Molluscum body with oscillating particles ; 2, flagellate bodies derived from the same.

Juliusberg<sup>1</sup> has found that the virus is filterable, but the incubation period is twice as long when filtered virus is inoculated as when the material of the lesions is used directly.

Burnet<sup>2</sup> found that inoculation of the cornea was followed by the appearance in the corneal cells of bodies like the amœboid stage of Guarnieri's bodies in the vaccinated cornea. In conjunction with my own observation, this discovery of Burnet's is of the utmost significance, and goes far to support the view that Guarnieri's bodies are not only specific for small-pox and vaccinia, but are themselves one phase of a protozoon that causes the disease.

<sup>1</sup> Juliusberg, 'Ueb. das Epithelioma Contagiosum von Taube und Huhn, *Deutsch. Med. Woch.*, 1904, Nr. 43, p. 794.

<sup>2</sup> Ét. Burnet, *Annales de l'Inst. Pasteur*, September 25, 1906.



*Trachoma*.—Inclusions resembling those that occur in the cells of cancers were described in the cells of the mucosa of the eyelids in cases of trachoma or 'granular lids' by N. C. Ridley in 1894.<sup>1</sup> These bodies have been rediscovered and described by Halberstaedter and von Prowazek.<sup>2</sup> The latter succeeded in inoculating one eye of an orang-outang, and the animal's other eye became auto-inoculated. Prowazek regards certain red-staining granules as the infective bodies.

*Syphilis*.—This infective fever, 'diluted by time' with its hereditary transmission, is one of the most tragic phenomena of human existence. It may, of course, be a pure coincidence that Schaudinn discovered mobile spiral bodies that he regarded as protozoa ten years after I had described as protozoa certain hyaline and cell-like bodies in syphilitic tissues. It may also be a coincidence that twelve years after I had found that inoculation of the rabbit's cornea with matter from a primary syphilitic sore was followed by the appearance of hyaline bodies comparable to the *Cytoryctes variolæ*, the cornea and other parts of the rabbit's eye should be found to be suitable media for the study of the pathological processes of syphilis, including the appearance of the spiral bodies (*Spirochæta* or *Spironema luis*). Some consideration of these questions and of work relating to them will be found in the following pages. It required much time before it was realized that syphilis formed one of the group of the exanthemata or infective fevers in which skin eruptions are marked symptoms. Another aspect of syphilis is, to my mind, equally striking; I mean the formation of syphilitic lesions that closely simulate tumours, whether of epithelial or of connective-tissue type. This aspect of the pathology of syphilis also will be dwelt on in the following pages.

*Cancer*.—At present a general impression appears to prevail that the parasitic view of cancer has been definitely relinquished. Recourse to works of reference<sup>3</sup> on infectious diseases shows that

<sup>1</sup> N. C. Ridley, Transactions of Ophthalmological Society, vol. xiv.

<sup>2</sup> Halberstaedter and von Prowazek, *Arch. aus. d. K. Gesund.*, vol. xxvi., part. i., 1907.

<sup>3</sup> Such as the 'Jahresbericht über . . . Pathogenen Mikro-organismen' of von Baumgarten and Tangl.



this impression is erroneous; in every country workers and thinkers of repute uphold this view, one aspect of which I have held for fifteen years. In 1893 I wrote: 'There is now so much evidence for regarding cancer as a mode of psorospermiosis that even the most sceptical may take it as a working hypothesis. New lines of research and a hopeful prospect for preventive medicine are opened up. With regard to surgical practice, only a thorough application of measures at present employed is suggested.'<sup>1</sup> These words, with the term 'psorospermiosis' changed to 'protozoosis,' I could write again to-day.

It is not my intention to enter into a critical examination of recent work on the pathology of cancer. That, if it should still appear to be necessary, I propose to deal with in the next part of this work. In this connection all I plead for at present is a wider view: that the simpler form of malignant disease, sarcoma, be studied as closely as the more complicated epithelial cancer, and that both be subjected to a more minute ocular analysis than has of late been done; that both be compared closely with syphilitic and variolous lesions; and that the experimental method be no longer narrowed down to one groove of inoculation-experiment, but be made to include also experiments of the ordinary biological kinds.

<sup>1</sup> 'Morbid Growths and Sporozoa,' 1893, p. 91.

## CHAPTER II

### STUDIES OF NON-PARASITIC PROTOZOA

#### *Trichosphærium Sieboldii.*

WE are probably as yet only at the beginning of our knowledge of the parasitic protozoa, and whilst the *Sporozoa* and the parasitic *Flagellata* have been closely examined, many points concerning the *Sarcodina* and the *Ciliata* still remained to be inquired into. It is probable that pathogenic amœbæ, besides that which has been recognised as the cause of amœbic dysentery, and ciliates other than the *Balantidium coli*,<sup>1</sup> await recognition. As a probable explanation of some old observations, and as a preparation for the evolution of possible new discoveries, the following studies are given here.

Among the sarcodina the *Heliozoa* are remarkable for having pseudopodia in the form of slender rays of protoplasm, but apart from this particular subclass there are other sarcodina that are provided with definite slender pseudopodia. One of these, *Trichosphærium* (Fig. 2), was the object of a renewed study by Schaudinn, and its life-history was fully described by him in 1899. Now, although this is one of the non-parasitic forms of amœba, it demands attention, because it is only by making ourselves familiar with the various phases of the higher forms that we can know what to look for in their kindred that are modified by parasitic adaptation. For this reason an outline of the life-history of *Trichosphærium* is given here.

*Trichosphærium* is a marine amœba, and is common in sea-water aquariums. It is marked by great tenacity of life. The full-grown

<sup>1</sup> See Part I. of this work, p. 144.



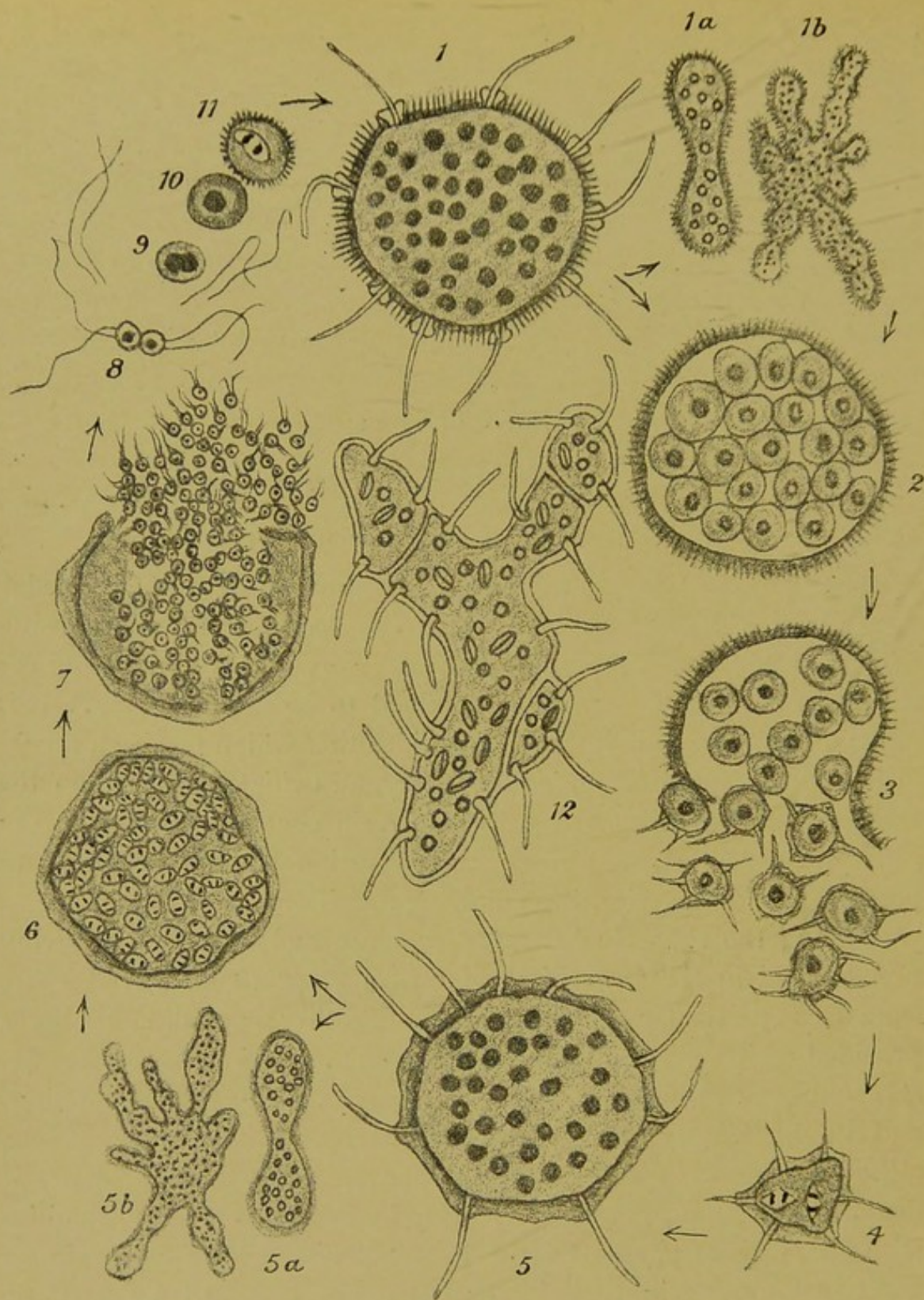


FIG. 2.—TRICHOSPHERIUM SIEBOLDII (SCHAUDINN): SCHEMATIC REPRESENTATION OF THE LIFE-HISTORY. (Modified from A. Lang, after Schaudinn.)

Fully developed amphiont; 1a and 1b, ambulant reproduction by fission (1a, binary; 1b, multiple fission); 2, schizogony (conitomy); 3, escape of spores; 4, young monont; 5, fully developed monont; 5a and 5b, ambulant reproduction; 6, rapid nuclear division by minute mitoses; 7, conitomy and escape of flagellated swarm-spores; 8, conjugation (isogamy); 9, fusion of nuclei and detachment of flagella of copula; 10, complete fusion of nuclei of copula; 11, first nuclear division and appearance of radial rods in sheath; 12, plastogony as seen in the living state.

*lasmatomy* (Dyler),  
*derivation*  
*all nucleoli*  
*abdivis*  
*al*  
*plastotony*



animalcule sometimes attains 2 millimetres in diameter, and it exists in two distinct forms, which are the expression of an alternation of generations. In both forms the body is invested in a gelatinous sheath. In the sexually produced individual, or amphiont (Fig. 2; 1) this sheath is studded with short rods which are composed of magnesium carbonate, and cause this genus, though classed with the naked amœbæ (gymnamœbida), to approach the shelled amœbæ (thecamœbida), such as *Arcella* and *Diffugia*, common in fresh-water ponds.

In the asexually produced individual (monont, Fig. 2; 5), the sheath lacks the rods. Both amphiont and monont are capable of protruding slender processes (pseudo- or lobo-podia) through the sheath, which may present thickenings at the points at which perforations exist. These lobopodia are used for locomotion, which is extremely slow, about 10  $\mu$  to the minute. Food, such as diatoms, and foreign bodies, such as grains of sand, etc., are held by the lobopodia and very slowly incepted.<sup>1</sup> An interesting example of commensalism is also furnished by this organism. When food is plentiful a flagellate (*Cryptomonas Brandti*, Schaudinn) lives in the protoplasm appearing as brown cells. When food is withheld these escape from the *Trichosphærium* as monads, provided each with two flagella. Plastogamy, or the formation of adhesion-colonies (Fig. 2; 12), is observed in this as it is in other amœbæ. The amphiont is capable of two different modes of multiplication: vegetative or ambulant subdivision (Fig. 2; 1a, 1b), and multiple asexual subdivision in a resting state—conitomy or schizogony (Fig. 2; 2). In ambulant subdivision the multinucleated organism, its lobopodia withdrawn, simply divides by constrictions, which include the sheath, into two or more parts. Before conitomy occurs all foreign materials are expelled and the lobopodia are withdrawn; the body subdivides into a number of uninucleated gymnosporos, which escape by rupture of the sheath, which consists of the maternal rod-studded envelope.

<sup>1</sup> This process is described as follows: 'If the organism comes against some foreign body the latter is held between the pseudopodia and the sticky surface of the sheath. The protoplasm of the amœba rolls over the body like a ball of thin paste, into the interior of which the body is pressed.'



Having escaped, the gymnosporos develop a sheath, protrude lobopodia, and, the nucleus multiplying by mitosis, the *monont* thus constituted resembles the *amphiont* (Fig. 2 ; 4) in all details save the absence of the rods from the sheath. The fully developed mononts or sporonts increase vegetatively by constriction (Fig. 2 ; 4a, 4b), in a way similar to that described for the *amphiont*, and multiple subdivision in the resting state also occurs, but in a manner different from that described for the *amphiont*. After food particles have been extruded, the protoplasm becomes vacuolated, and numerous bright protein particles appear. Simultaneously the nuclei subdivide by mitosis (Fig. 2 ; 6), and the body subdivides into larger, and these, again, into smaller, bodies, which move rapidly about, and on the rupture of the sheath show themselves as swarm-spores, each provided with two flagella (Fig. 2 ; 6). These swarm-spores are sexual cells, or gametes, which appear to be unable to unite with gametes arising from the same sporont as themselves, and hence most of them perish ; but if a brood of gametes that have originated from another sporont is near, the individuals of the two broods pair off, forming zygotes by total fusion, the four flagella having been discarded. This process lasts six hours, and twelve hours later nuclear division and the formation of a sheath are begun. After this the lobopodia appear, and the developmental cycle is completed.

The temporary association of amœbæ or plastogamy has been already referred to in Part I. in the diagram illustrating the average life-cycle in the sarcodina ; the phenomenon is common in the shelled amœbæ, such as *Arcella* and *Patella*. The fact that there is a sexual phase in the life-cycle of *Trichosphærium* points to this character being common to the whole group of protozoa.

The importance of the sexual process in protozoan disease is very great. From the fact alone that the virus of yellow fever is intensified by its passage through the gnat, Calkins believes that a sexual phase of the, at present, unknown parasite may be inferred.

Even a cursory study of this amœba *Trichosphærium* suffices to show how difficult it would be to distinguish a degenerate parasitic



amœba akin to this undegenerated free-living form in certain phases from a suctorian. The slender lobopodia only lack the terminal knob to be indistinguishable from the tentacle of a typical suctorian, and though the nuclear structures differ from a typical suctorian, a distributed nucleus may occur in ciliata, as, for instance, in *Trachelocerca*.

Comparison may be made between the ambulatory forms (Fig. 2; 1*a* and 1*b*; and 5*a* and 5*b*), with their multiple minute nuclei and protozoa, in the chromidial state. It is easy to imagine a minute chromidial amœba behaving exactly as do the Guarnieri bodies in the vaccinated cornea.

Large associations of amœbæ in fusion-masses (plasmodium formation or plastogamy) would account for such appearances as the colloid-like contents of the cysts in cystic ureteritis, and multitudes of detached flagella of the gametes might be seen only when stained in some particular way, and thus simulate slender bacteria or, if curved, spirilla. In this way a disease might be thought to be caused by bacteria when the very bodies on which the opinion was based were but one of many phases of a protozoon, the real cause of the disease. It would be easy to mistake forms such as 2, 3, and 4, or 9, 10, and 11, for leucocytes.

The forms breaking up into minute subdivisions, each with its own tiny nucleus, might be explained as 'chromatinorrhesis,' or some other process of disintegration. In addition to this, the involution-forms and dead parasites would probably be considered to be degenerated and necrosed elements of the host's tissues.

#### *Notes on Ciliates—Colpoda Cucullus.*

Among the ciliates one subclass, the *Suctoria*, are especially prone to assume parasitic habits; thus, from their being provided at a certain stage with knobbed tentacles, like those of suctorians, I came to the



conclusion that certain bodies I have described in sarcoma and other pathological tissues probably belonged to this group.

Whatever information there may be with regard to the suctoria proper is not made very prominent in such text-books of biology as I have at hand. I have read that suctorians living within the nucleus of some other protozoon have been mistaken for and described as new and peculiar nuclear structures, and when the mistake has been pointed out, there has been some amusement, but, as far as I am aware, no prominence has been given in biology to the study of the features that distinguish intranuclear suctoria from nucleoli.

The ordinary mode of reproduction in ciliates, as mentioned in Part I., is by mitotic division into two. It was shown by Maupas in 1889 that, after a certain number of such divisions, conjugation with mutual interchange of nuclear elements must occur if senile degeneration and death are to be prevented. This mode of life has been compared to that of the metazoa—a sexual phase followed by a long series of asexual divisions being likened to the impregnation of metazoan ovum, followed by the long series of somatic cell-divisions that build up and maintain the metazoan body. There is one important difference between the life of this protozoon and that of a metazoon. Apart from accidents, there is no necessary death of individual infusorians, whilst in the metazoa individual death is a necessity. This distinction, however, is not absolute, as has been shown by Calkins, who concludes: 'There is a fundamental difference in the protoplasmic elements which go to make up the body of a protozoon, one of which is to be compared with the somatic cells of metazoa, the other with germ-cells: the one connected with vegetative functions of metabolism, the other with reproduction; the one may give out, and so lead to "physiological death" (Hertwig), or it may be restimulated; the other may give out, and so lead to "germinal death" of the race.'<sup>1</sup>

*Encystment.*—Ciliates have also the property of secreting a chitinous envelope in various circumstances, whether as a pre-

<sup>1</sup> G. N. Calkins, 'Studies on the Life-History of Protozoa,' *Journal of Experimental Zoology*, vol. i., No. 3, 1904.



liminary step before dividing, or in order to undergo a period of rest, or, what is more common, in order to shield themselves from desiccation or other injurious influences. In the two former instances the cysts are temporary, but when the adverse conditions last a long time the cysts are of slightly different character, and the term 'duration-cysts' (*dauercysten*) is applied to them. Within these duration-cysts the animalcules, reduced to a minute ball of protoplasm, condensed by loss of water, and now apparently homogeneous in structure, may survive for years. All aerial dust contains such encysted ciliates, which, when they fall into water that is sufficiently pure, escape from their cysts and resume an active life. Thus arose the erroneous idea of spontaneous generation. Bearing in mind that binary division is the sole method of reproduction that has been firmly established for the ciliata, and that the article to be referred to appeared before the work of Maupas was published, it will be none the less interesting, especially as a study of cyst-formation, to peruse a piece of work by a most careful observer and veteran biologist, von Rhumbler, who describes the different forms of cyst that occur in a ciliate (*Colpoda cucullus*) that appears very often in infusions. Those who wish to study the matter practically should read the original article, where ingenious but simple methods for studying the life-processes in this protozoon are given.

The different forms of encystment described by von Rhumbler are well known, but the various appearances described as sporulation of individuals that have formed duration-cysts and development of the mobile individual from such spores are thought by some biologists to be *involution-forms*. This brings us to an important topic in biology, and especially in parasitology. The reader will be already familiar with the idea of involution in bacteriology, and he will find that in protozoology the range of possible involution-forms becomes much greater. Whether all forms described as involuted are really degenerated beyond recall—*i.e.*, are in a phase of death—or whether some now regarded as such are really phases of parasitic adaptation, still remains to be seen. With the reservation that this part of the subject merits reconsideration, we may review the description of the

KOXTIOS  
bottom

KOXTIO

embosom  
based.

folded.



various forms of colpoda, as we have it from von Rhumbler,<sup>1</sup> and regard the forms evolved from the sporocysts provisionally as involution-forms. When watched in a culture in hay-infusion, *Colpoda cucullus*<sup>2</sup> passes through the following changes:

*Encystment before Division.*—The movements are slow, and the animalcules, which are bean-shaped (Fig. 3; 1), become rounder; progression ceases whilst rotation continues; a gelatinous secretion exudes from the surface and hardens to a structureless cyst (Fig. 3; 2), the contractile vacuole continuing to beat at the usual rate, four times a minute, and, in spite of the animalcule rotating within the cyst, the vacuole maintains a position opposite a minute pore in the cyst-wall. Division begins by a constriction of the exterior of the animalcule at right angles to its long axis (Fig. 3; 3); sometimes a second constriction occurs at right angles to the first, resulting in fourfold division (Fig. 3; 4); nuclear division accompanies this protoplasmic constriction.

When the separation of the daughter animalcules is complete, they escape through the opening in the cyst, making many attempts before they finally succeed, owing to the smallness of the pore (Fig. 3; 4). Should conditions not be favourable, the daughter animalcules become re-encysted (Fig. 3; 5, 6) instead of escaping. Darkness appears to favour, want of food to delay, division. The addition of distilled water causes disintegration of the animalcules.

*Duration-cysts* differ from the above in having no pore. Unencysted colpodas die and disintegrate when rapidly dried, but if slowly dried they expel food-stuffs from their body, undergo a rapid rotation, and shed a gelatinous covering, which hardens to a cyst (Fig. 3; 7). The contractile vacuole becomes irregular or disappears, as do the cilia, when the cyst-wall becomes hard (Fig. 3; 8). At this stage the animal will revive after being placed in fresh water for three days. Colpoda appears to survive not longer than three weeks' drying in summer. Division-cysts may be transformed to duration-cysts by secondary encystment (Fig. 3; 9, 10),

<sup>1</sup> L. von Rhumbler, *Zeitschr. für Wiss. Zool.*, 1888.

<sup>2</sup> Colpoda is said (Delage and Hérourard) to subdivide only when encysted.



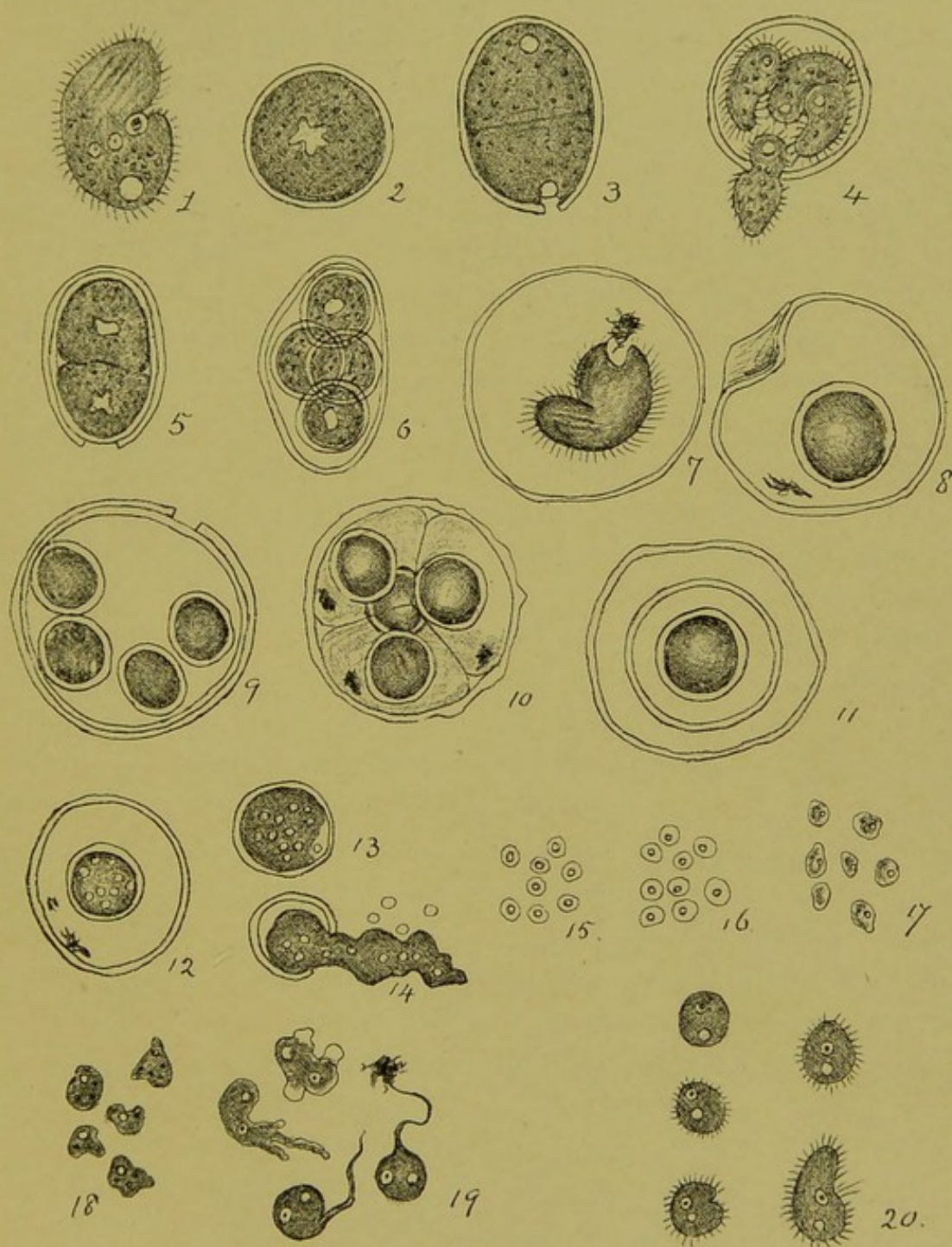


FIG. 3.—STAGES IN THE LIFE OF COLPODA CUCULLUS. (After von Rhumbler.)

1 to 4, Encystment and division within a cyst; 5 and 6, formation of secondary cysts; 7 to 11, formation of duration-cysts; 12 and 13, Rhumbler's view of the formation of sporocysts and spores; 14, escape of spores; and 15 to 20, forms assumed in the production from these of perfect ciliates.



or several cysts may be formed one within another. So far, Rhumbler's account must be accepted as the established mode of encystment; what follows is, as explained above, of great interest, but subject to explanations other than that given by the author, which is briefly as follows:

*Sporocyst Formation.*—A duration-cyst, as described above, having been formed, and the animalcule reduced to a round homogeneous ball of plasm, with a marked opalescent appearance, the outer layer of the animal becomes converted into a second thick cyst-wall, the intervening space being filled with a clear fluid. All distinction between nucleus and plasm is lost, the former having probably become diffused in the plasm. Sporocysts may form within division-cysts in half an hour; complicated cysts thus arise (Fig. 3; 9 and 10).

Such sporocysts placed in nutrient fluid under the microscope became of a clear grey colour, and presented ten to twelve bright bodies like oil-drops (Fig. 3; 12); these doubled in size in two days. At the end of this time some of the cysts burst, and the small bright bodies escaped (Fig. 3; 14). Rhumbler thought at first that they might possibly be synchytrians (vegetable parasites), but he was able to trace them through the various stages (Fig. 3; 15 to 20), which include amœboid and flagellate forms, up to the original ciliate form. If we imagine encystment occurring in parasitic protozoa among the crowded elements of an infected tissue, we should expect the shape of the cysts to be modified by compression, or the formation of a capsule altogether aborted.

The sporocyst state of a colpoda within a duration-cyst, 'a round, homogeneous ball of plasm,' corresponds to many pathological appearances—some, no doubt, real degenerations of tissue-elements, but others, besides the corpuscles of *Molluscum contagiosum*, may be true parasitic protozoa. When molluscum bodies are macerated in water, well-defined capsules that were previously invisible often appear.

W. R. here  
describe the  
chromoidal  
condition?



## CHAPTER III

### NOTES ON CERTAIN PARASITIC PROTOZOA

#### *Spirochætæ : Spirochæta Ziemanni.*

WHAT is a spirochæta? To answer this question we must consider the organisms that were first given this name. The genus *Spirochæta* was founded by Ehrenberg, and the name was first applied by him to the *Spirochæta plicatalis*, since renamed *refringens* by Schaudinn. This is a slender organism with blunt ends and of spiral form, especially when in motion; it has a distinct undulating membrane, but is apparently devoid of flagella. The nuclear structure extends the whole length of the body. Such an organism differs from a spirillum or spiral bacterium in several ways: it is flexible, having no cellulose envelope; in the possession of an undulating membrane, and in the absence of flagella. Until recently the spirochætæ were regarded as being of vegetable nature, but their close similarity to other organisms regarded as belonging to the *Trypanosomatidæ*—e.g., the *Trypanosoma Balbianii*,<sup>1</sup> a parasite of the alimentary tract of the oyster; one which differs from the bacteria in having an undulating membrane and in its mode of division being longitudinal, as in the flagellate protozoa, and not transverse, as in the bacteria, raises this question, What is a spirochæta?—one of the unsolved problems left by the untimely death of Schaudinn. It was first definitely raised by his study of the *Sp. Ziemanni*, a blood parasite of birds. A brief note of Schaudinn's description of this will now be given, in order that the state of our knowledge of spirochætæ may be understood.

<sup>1</sup> A note by W. S. Perrin, Proceedings of Royal Society, August 3, 1905, may be consulted on this subject.



*Spirochæta Ziemanni*.—The *Sp. Ziemanni*, which was discovered by Danilewsky<sup>1</sup> in 1891 in the blood of *Athene noctua*, and later described and figured by Ziemann,<sup>2</sup> preys on both the white corpuscles and the erythroblasts of its warm-blooded host, becoming attached to them by its hinder end, and surrounding them by a thin mantle<sup>3</sup> of its own ectoplasm; erythroblasts<sup>4</sup> thus surrounded are prevented from undergoing their proper development into red corpuscles. When the parasite reaches maturity it casts off its outer envelope, and also the remains of the blood-corpuscle, and, like the *Trypanosoma noctuæ*, then either undergoes subdivision, swimming freely in the blood as a flagellated organism, or, when taken up into the alimentary tract of the gnat, undergoes further development. The changes of the different modifications of *Sp. Ziemanni* in the gnat have been traced by Schaudinn. The female and male forms undergo development similar to that observed in *Plasmodium*, *Proteosoma*, and *T. noctuæ*—that is, the females undergo fertilization by union each with a microgamete. The ookinets thus formed can be distinguished by their nuclear structure and other features into three kinds—asexual, male and female. The course of events in the first of these is represented in Fig. 4. The nuclear changes that accompany these processes are very complex. The resulting small trypanosomes become highly elongated and their flattened bodies spirally twisted, thus assuming a typical spirochæta form. The spirochætæ increase in numbers by longitudinal division, and they have alternating periods of activity and rest. These features are shown in Fig. 5. Schaudinn observed that subdivision proceeded much more rapidly than growth, so that in the end countless very minute organisms, only just visible by the highest powers of the microscope, were present, and he surmised that the same process may lead to invisible organisms that would pass the finest filters, and in this way a particulate virus that is filterable is more than

<sup>1</sup> Danilewsky, abstract in *Cent. für Bakt.*, 1891, p. 120.

<sup>2</sup> Ziemann, 'Ueb. Malaria und andere Blutparasiten,' Jena, 1898.

<sup>3</sup> This mantle contains eight longitudinal bands or 'myonemes.'

<sup>4</sup> The preference shown by *Sp. Ziemanni* for the erythroblasts, or immature red blood-corpuscles, explains their abundance in the bone-marrow and the spleen.



conceivable—even probable. The spirochætæ, when joined end-wise in pairs, can move in the direction of either extremity.

Agglutination occurs when the conditions are unfavourable to the full vitality of the parasites, the hinder—*i.e.*, the non-flagellated ends cohering as shown in Fig 5, *i* and *k*. The same mode of agglutination has been observed in *T. Lewisi* by Mesnil and Laveran (see Part I., Fig. 78). In the *T. noctuæ* it is by cohesion of

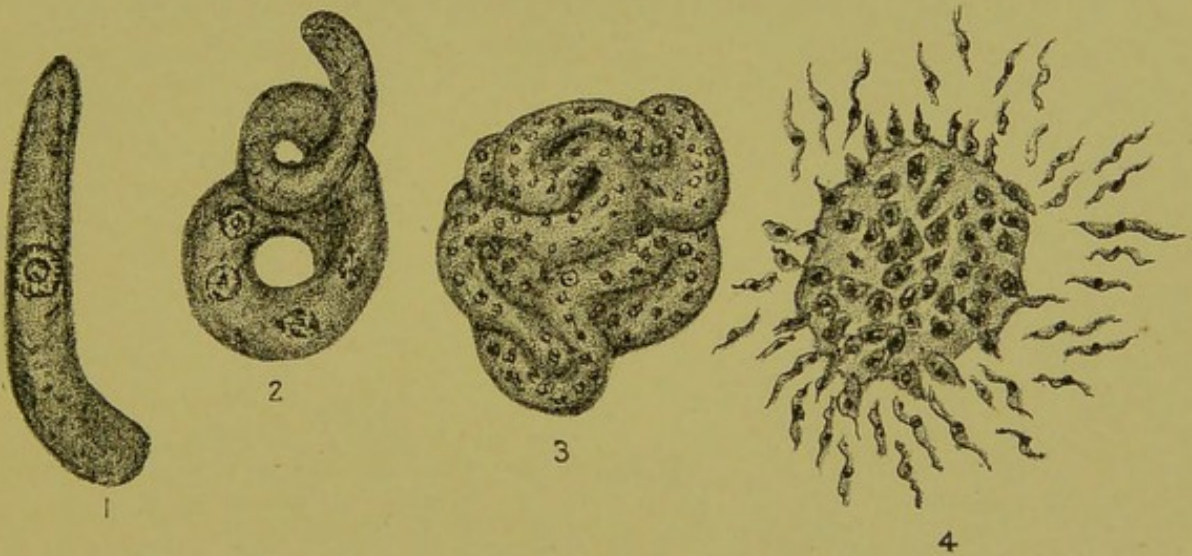


FIG. 4.—SPIROCHÆTA ZIEMANNI. THE GROWTH AND SUBDIVISION OF THE ASEQUAL OOKINET IN THE GNAT'S INTESTINE. (After Schaudinn.)

- 1, The ripe ookinet; the nucleus contains a centrally placed body which is constituted by sixteen chromosomes, in the midst of which is a centrosome. The peripheral chromatin is also composed of sixteen chromosomes. 2, Shows the ookinet elongated in a spiral and with four nuclei, two of which are in process of division; 3, the ookinet greatly elongated and rolled into a multi-nucleated ball; 4, the same ookinet, its coils fused into one body, which is giving off peripheral nucleated buds that are changing into minute flagellates or spirochætæ.

the anterior flagellated ends that the rosette-like clusters are formed.

We must consider with the closest attention Schaudinn's description of the multiplication of these parasites in the body of the gnat. The minute trypanosome, seen more highly magnified in *a*, divides longitudinally, as at *b*; the division may be incomplete for a time, leaving pairs attached end to end as at *c* and *d*. The spirochætæ may



retract and enter the resting stages *g* and *h*, assuming an appearance that recalls the Leishmann bodies of tropical splenomegaly (see Chapter IV. of this volume).

The importance of these observations of Schaudinn's is best realized when we remember that up to the time of the appearance of his paper all spirochætæ were thought to be bacteria like the common spirilla. The training of the eye, as Schaudinn expressed it, that this study afforded, enabled him to discover pale spirochætæ in

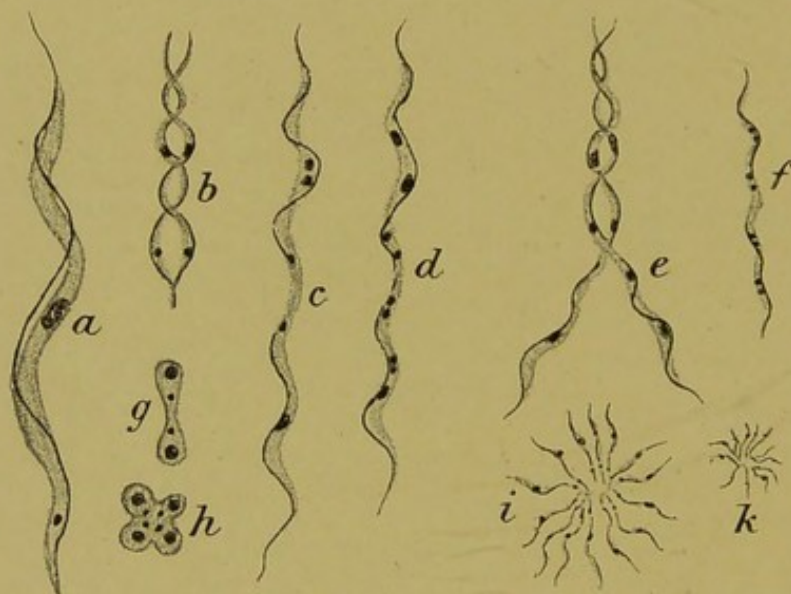


FIG. 5.—DIFFERENT STAGES OF SPIROCHÆTA ZIEMANNI (ASEXUAL MODIFICATION) IN THE BODY OF THE GNAT.

*a*, Isolated spirochæta highly magnified; *b*, spirochæta undergoing binary longitudinal division; *c*, the pair resulting from *b* still attached by their hinder ends; *d*, similar to *c*, but each individual of the adhering pair undergoing division of nucleus and blepharoplast preparatory to further subdivision; *e*, later stage of *d*; *f*, small spirochæta; *g*, resting stage of *f*; *h*, resting stage of *e*; *i* and *k*, agglomeration rosettes of individuals of different sizes.

the juice of syphilitic tissues. It also led him to regard *Spirillum Obermeieri*, the organism of relapsing fever, as a protozoon. This subject is now being examined, and has become greatly extended, all the so-called spirillar diseases, or spirillooses, such as that common in birds, being under review; also some human fevers that follow the bites of certain ticks are suspected of being due to spirochætæ.

This matter is so important that the issue may be thus recapitulated: It is uncertain whether the spiral motile organisms associated



with some diseases of man, other mammals, and birds, are bacteria or protozoa. Amongst them is the *Spirillum Obermeieri* of human relapsing fever. Recent observations appear to suggest that this organism depends upon the common bed-bug for its transference. The parasite of African relapsing fever (or tick-fever) has been found by R. Koch<sup>1</sup> and others to depend for its transference upon a tick. *Ornithodoros moubata*, in which the spirochætæ pass through two generations, the infection being given by larval ticks born of parents that originally fed upon infected blood. Koch found great numbers

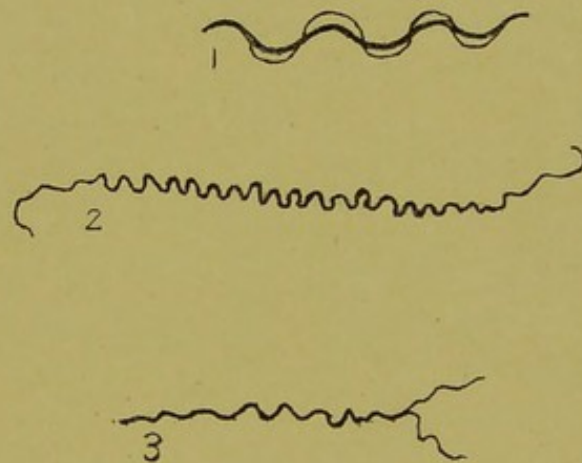


FIG. 6.—SPIROCHÆTA AND SPIRONEMA. (After Schaudinn, from *Deutsch. Med. Woch.*, October 19, 1905.)

1, *Spirochæta refringens*, a common spirochæte ; 2, *Spironema* of syphilis ;  
3, *Spironema* of syphilis (?) dividing.

of spirochætæ in the ovaries of ticks, but he did not detect the developmental stages described by Schaudinn in *Sp. Ziemanni*. The spirilloses of birds are conveyed by ticks belonging to the *Argasidæ* (see Chapter V.). The spiral organism (Fig. 6) discovered in syphilis, and named *Spirochæta pallida* by Schaudinn, differs from a typical spirochæta such as *Sp. refringens* (Fig. 6) in having slender flagellum-like extremities, and on this account its name was subsequently changed to *Spironema luis*. Whether this organism has other developmental stages will be discussed below. Two American observers, Novy and McNeil, regard the organism of tick-fever as a protozoon, and name it *Spirochæta Duttoni* ; the *Spirillum Obermeieri*,

<sup>1</sup> R. Koch, *Deutsch. Med. Woch.*, 1905, No. 47 (quoted by Minchin *loc. supra cit.*).



on the other hand, they regard it as a bacterium. It must, however, be remembered that the disease with which this 'spirillum' is associated is markedly cyclic or paroxysmal in its character, and this fact suggests a protozoan rather than a bacterial cause; moreover, should it be finally proved that the bed-bug is a necessary intermediary in spreading relapsing fever, this again strongly suggests protozoa as the causal agents.

*Trypanosoma Noctuæ*.<sup>1</sup>

The great importance of trypanosome disease makes it necessary for us to consider those of the many brilliant contributions to zoology made by the late Fritz Schaudinn that bear on this subject. No modern investigations have a wider application than those of his that deal with some parasitic flagellates in birds. Certain forms of parasitic protozoa occurring in the red and others in the white blood-corpuscles and erythroblasts of birds had long been familiar under the names of halteridia and leucocytozoa respectively. Schaudinn, working at Rovigno, in Southern Italy, on the blood of the small stone owl, *Athene noctua*, which is common there, found that these parasites constitute but one phase of a varied life-cycle of two different parasites, the *T. noctuæ* and *Sp. Ziemanni*, and that in the case of each of these parasites only part of the life-cycle is passed in the blood or other tissues of the bird, the other and biologically the more important part being completed in the common gnat, *Culex pipiens*. Thus, these parasites, like plasmodium (the hæmatozoon of malaria) and proteosoma, the life-cycle of which was worked out by Ross in birds, require *intermediate hosts* for the completion of their life-cycles. A few of the facts observed in *T. noctuæ* may now be referred to.<sup>2</sup>

<sup>1</sup> In the course of time some modifications of Schaudinn's views are to be expected, but his observations may be taken as giving a correct general impression, and his description of details of structure may be relied upon.

<sup>2</sup> The wide range of forms assumed by the parasites (parasitic adaptation) and the corresponding changes in nuclear structure can only be hinted at here. The original paper must be consulted for details: F. Schaudinn, in *Arbeiten aus dem Kaiserlichen Gesundheitsamte*, Bd. xx., 1903; or H. M. Woodcock's digest of it in the *Quart. Journ. Microsc. Science*, 1906.



*Parthenogenesis*.—An important fact that Schaudinn has observed in *T. noctuæ* is parthenogenesis.<sup>1</sup> This mode of reproduction is most familiar to us in insects such as bees and aphides. He found that the female form of *T. noctuæ* outlasted the males and neuters when infected gnats were starved and kept on ice. Under such circumstances the females pass between the epithelium and the elastico-muscular layer; their flagella disappear, causing these flagellates to

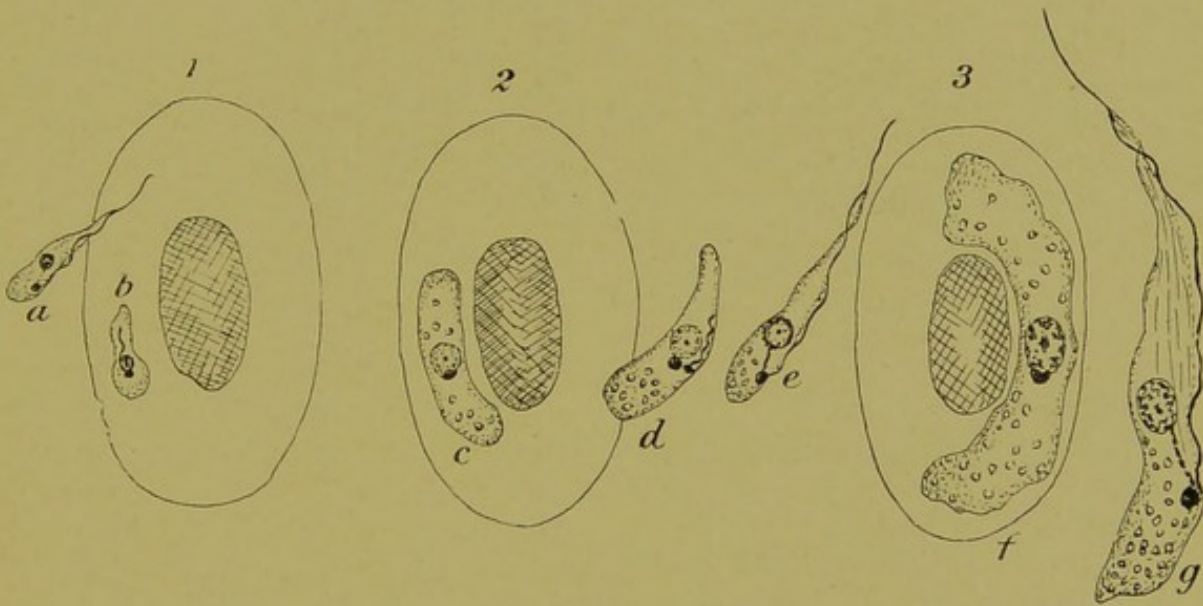


FIG. 7.—THE ASEXUAL OR 'INDIFFERENT' MODIFICATION OF *TRYPANOSOMA NOCTUÆ* IN THE BLOOD OF THE OWL. (After Schaudinn.)

The numerals 1, 2, 3 are placed above outlines representing red blood-corpuscles of the owl. *a*, Marks the youngest stage of an asexual trypanosome adhering to the corpuscle by its anterior end; the parasite *b* has withdrawn its flagellum and come to rest; *c*, a parasite forty-eight hours after the stage *b*; *d*, parasite escaping in a gregarinoid form; *e*, the same parasite as *d* after its flagellum has developed; *f*, resting gregarinoid form adhering to the corpuscle 3, five days after the stage *a*; *g*, full-grown trypanosoma.

resemble gregarines. Infected gnats that have survived the winter contain such parasites. In spring the parasites multiply parthenogenetically, and pass into the gnat's ovary, and the eggs and ensuing generation of gnats are thus infected.

The most prominent symptom of human malaria, the attack of

<sup>1</sup> The occurrence of parthenogenesis in the malarial parasites has been referred to Chapter I., p. 2.



fever, is caused by the rapid asexual multiplication (schizogony) of the parasites within the red corpuscles. In the corresponding phase of infection of birds by *T. noctuæ* the asexual parasites attach themselves to the surface of the red corpuscles, as shown in Fig. 7. The mobile periods occur at night-time, and the flagellated forms are met with chiefly in the spleen and bone-marrow. The periods of attachment and growth, and of free swimming in the plasma, are repeated for six days; and when the parasites have attained their full growth they detach themselves finally, and, swimming freely in the plasma, undergo repeated longitudinal divisions, which result in the blood being charged with small parasites, which then begin to diminish in numbers.<sup>1</sup> The remaining previously asexual forms now become differentiated into males and females, and as such pass into the intestine of any gnat that may suck the bird's blood.

As to those males and small females that entered the owl's blood from the gnat with the asexual forms, whose career has just been traced, the males die off at once, whilst the females enter red corpuscles, losing their flagella, to assume the gregarinoid form already mentioned as occurring in the gnat.

Before leaving this subject we may note the structure of the nucleus in the largest free trypanosome to the right of Fig. 7. We see there the chief nucleus containing chromatin filaments, and at the base of the flagellum a denser and smaller body, the blepharoplast, which is connected by a filament with the chief nucleus. By comparing the living organism with stained preparations, Schaudinn found that what appears in the gregarinoid phases to be a nucleolus becomes amœboid, and its chromatin mixes with that of the nucleus, as the first step in the change to the flagellate phase. The mixed chromatin then divides into two parts, the larger remaining as the principal or trophonucleus, and from the smaller or kinetonucleus, which remains attached by a filament<sup>2</sup> to the

<sup>1</sup> This diminution may be caused either by phagocytosis or from some of the parasites leaving the blood to become gregarinoid in the tissues.

<sup>2</sup> The thickness of this filament is slightly exaggerated in Fig. 7. Among the locomotor organelles are what may be called muscular striæ (myonemes). In



trophonucleus, are developed the locomotor organs—blepharoplast, flagellum, undulating membrane, etc. The nuclei of the male and female and the parthenogenetic modification of the latter have also their own peculiarities of structure.

---

*T. noctuæ* these lie in the undulating membrane, whilst in *Sp. Ziemanni* they are distributed through the whole surface of the parasite.



## CHAPTER IV

### NOTES ON SOME TROPICAL DISEASES

#### *Trypanosomosis<sup>1</sup> in Man : Sleeping Sickness.*

THE first case of this disease that was described in detail was that published in 1902 by the late J. E. Dutton. This case is referred to in Part I. of this work, where a reproduction of his photograph of the organism in the blood of a patient is given. Since that date, as the outcome of systematic inquiry organized by the Royal Society under the direction of Colonel David Bruce, the discoverer of the cause of the tsetse-fly disease in animals, the sleeping sickness of Africa—a disease fatal to man—has been shown to be but one phase of human trypanosomosis; and another tsetse fly, the *Glossina palpalis*, has been found to be the carrier of this disease. The investigations of the Commission were conducted in Uganda,<sup>2</sup> where the disease is prevalent.

The conclusions<sup>3</sup> arrived at are as follows:

I. That sleeping sickness is caused by the entrance into the blood and cerebro-spinal fluid of a species of trypanosome.

<sup>1</sup> This term, which is framed after others, such as tuberculosis, in common use appears to be preferable to 'trypanosomiasis,' which, however, is still employed.

<sup>2</sup> Christy found the disease centred around Lake Victoria Nyanza, and seldom more than ten to fifteen miles from its shores. In the island of Buvuma fully two-thirds of the population had died off at the time of Dr. Christy's visit, and half the remainder were suffering from the disease. The distribution of *Filaria perstans* did not correspond with the disease. The latter accompanied the wearing of clothes and growing of bananas. Low confirmed Christy's observations, and observed that there was no sleeping sickness in British Guiana, where *F. perstans* was very common. The occurrence of both parasites in the same person was thus proved to be a coincidence. Reports of the Sleeping Sickness Commission of the Royal Society, 2nd Fasciculus, December 5, 1902, to August 4, 1903, and *ibid.*, Appendix.

<sup>3</sup> Bruce, Nabarro, and Greig, Reports of the Commission on Sleeping Sickness to the Royal Society, 1903-1905; also *Brit. Med. Journ.*, November 21, 1903.



2. That this species is probably that discovered by Forde and described by Dutton, from the West Coast of Africa, and called by him *Trypanosoma Gambiense*.

3. That the so-called cases of trypanosoma fever described from the West Coast may be, and probably are, cases of sleeping sickness in the earliest stages.

4. That monkeys are susceptible to sleeping sickness and show the same symptoms and run the same course, whether the trypanosomes injected are derived from cases of so-called trypanosoma fever, or from the cerebro-spinal fluid of cases of sleeping sickness.

5. That dogs and rats are partially susceptible, but that guinea-pigs, donkeys, oxen, goats, and sheep, up to the present, have shown themselves absolutely refractory.

6. That the trypanosomes are transmitted from the sick to the healthy by a species of tsetse fly (*Glossina palpalis*), and by it alone.

7. That the distribution of sleeping sickness and *G. palpalis* correspond.

8. That sleeping sickness is, in short, a human tsetse-fly disease.

The actual discovery of trypanosomes was made by Aldo Castellani in cerebro-spinal fluid drawn off by lumbar puncture and centrifuged.

It was the insight gained by the previous investigation of tsetse-fly disease that enabled Bruce to realize the importance of Castellani's discovery. He arranged for further observations to be made, and these resulted in the trypanosome being recognised as the cause of the disease.

The genus *Glossina* (Wiedemann) appears to be limited to Africa. The original tsetse fly (*G. morsitans*) is a good example of the genus (see Part I. of this work).

It may be asked what is found when the tissues of those who have died of sleeping sickness are examined by the usual pathological methods.

We have a report of such a case by G. C. Low and F. W. Mott,<sup>1</sup> in which a diagnosis had been made from the symptoms before death,

<sup>1</sup> G. C. Low and F. W. Mott, *Brit. Med. Journ.*, April 30, 1904.



and by finding living trypanosomes in the blood. The morbid structural changes found in various organs—brain, spinal cord, heart, lymph-glands, etc.—were round-cell-infiltration—*i.e.*, perivascular accumulations of mononuclear leucocytes and clusters of micrococci. The only histological evidence of the presence of protozoa was seen in a hæmorrhage in the heart-muscle, where was found a degenerated trypanosome, which would hardly have been known for such without the previous clinical examination.

Laveran and Mesnil have observed that in dourine<sup>1</sup> and mal de caderas (equine trypanosomoses), as in sleeping sickness, nervous symptoms are marked. In the two former paralysis of the extremities occurs. In these diseases the parasites often appear to be absent from the blood for a period, but if blood apparently free from parasites be injected into another animal (not immune) the disease is thereby communicated.

It is very important that a close watch should be kept on any promise of success in medical treatment in diseases caused by protozoa. Thomas and Breinl,<sup>2</sup> of the Liverpool School of Tropical Medicine, have found that atoxyl, an arsenic compound, slows the progress of the disease, though as yet it has not been found to prevent its fatal issue. Kopke had a similar experience. With improved methods of administration of the drug complete success is not to be despaired of. Meanwhile the British Government are combating the disease by administrative measures based on the above discoveries.

#### *Kala-Azar (Black-Fever) or Tropical Splenomegaly.*

Kala-azar is the epidemic manifestation of a fever endemic in extensive areas of India, which has spread slowly up the Assam Valley as a wave of greatly increased mortality, dying out largely

<sup>1</sup> Dourine and mal de caderas are flagellate diseases of horses met with chiefly in North Africa and South America respectively. Dourine has some resemblance to syphilis, especially in the mode of its propagation. A demonstration of the lesions in dourine was given by J. W. Mott before the Pathological Society on May 29, 1906.

<sup>2</sup> For details see the Harben Lectures by Professor P. Ehrlich, *Journal of the Royal Institute of Public Health*, August, 1907, p. 450.



as it passes, after causing a decrease of population of the affected tracts.'<sup>1</sup> The sporadic form, miscalled 'malarial cachexia,' has been known for centuries, being marked by persistent fever of an alternating, remittent, or intermittent type. It was often mistaken for typhoid in the earlier remittent stages, but subsequently distinguished by the great enlargement of the spleen and later of the liver, with extreme wasting of the rest of the body and chronic illness, ending commonly in some fatal complicating illness.

Our knowledge of the cause of the black-fever begins with the discovery of the 'Leishmann-Donovan' body, first described by W. B. Leishmann<sup>2</sup> as probably an involution form of a human trypanosome. This observation was abundantly confirmed by Manson, Ross, and Christophers, among others.

Soon after, J. H. Wright, of Boston,<sup>3</sup> published an account of quite similar bodies in Delhi boil, a local skin affection, and met with in the Punjab,<sup>4</sup> in India. These bodies are round and oval, 2 to 3 millimetres in diameter, the size of blood-platelets, and containing a nucleus and a smaller body (kinetonucleus). They multiply mainly in the large endothelial cells (macrophages), especially of the spleen and bone-marrow. The host-cells ultimately rupture, and allow the parasites to escape, some of them entering the circulating blood.

The true nature of these bodies has been fully established by the work of L. Rogers.

Rogers obtained by spleen-puncture a little blood containing these bodies, and added to this 1 c.c. of sterile salt solution containing a little citrate of soda,<sup>5</sup> in order to prevent coagulation, and to

<sup>1</sup> L. Rogers, the first Milroy Lecture, 1907, *Brit. Med. Journ.*, February 23, 1907, where the history and symptoms of the disease are given.

<sup>2</sup> Leishmann, 'On the Possibility of the Occurrence of Trypanosomiasis in India,' *Brit. Med. Journ.*, May 30, 1903; also Donovan, *ibid.*, July 11, 1903.

<sup>3</sup> J. Homer Wright, *Journal of Medical Research*, December, 1903.

<sup>4</sup> From the fact that kala-azar is unknown in the Punjab, Rogers points out that the parasites of Delhi boil are probably not identical with those of kala-azar.

<sup>5</sup> Rogers found that acidifying the medium with a trace of citric acid favoured the life of the parasites, increasing the rate of growth and multiplication.



enable him to examine it frequently for the purpose of noting any changes in the parasites. The first observations were made at blood-heat, and produced negative results. Repeating the observations with blood kept in an ice incubator at  $22^{\circ}$  C., Rogers found that not only did the parasites multiply rapidly, but they also increased in size, and developed a protoplasm that stained blue with Leishmann's modification of Romanowsky's stain; after a time a development of actively motile flagellated forms took place. Some of the chief forms described by Rogers are shown in Fig. 8. For further details the original papers<sup>1</sup> should be consulted.

The general effect of the disease on the patient's blood is to produce a pronounced anæmia. Rogers, among other blood changes, has found a great reduction in the number of polynuclear leucocytes, which may fall as low as 500 to each c.cm. So great a reduction he regards as almost diagnostic of kala-azar, so much so, in his opinion, that for diagnostic purposes it may replace spleen-puncture, which is dangerous in extreme anæmia.

The manner in which the disease is spread has not yet been fully worked out. Death is usually preceded by ulceration of the intestines, and many parasites must be voided with the excreta. It is very probable that an intermediary host is necessary, as is the case in other flagellate diseases. Some recent observations<sup>2</sup> tend to show that the common bed-bug may be the intermediate host of the *Leishmannia Donovanii*.

It would thus appear that the protozoa of kala-azar differ from the trypanosomes in that they lack an undulating membrane. In this they resemble the simpler flagellates, such as the herpetomonas of the common house-fly and similar forms that occur in other insects.

<sup>1</sup> L. Rogers, note in *Brit. Med. Journ.*, July 2, 1904, p. 29; Chatterjee and Rogers, *Lancet*, May 15, 1906; Milroy Lectures, *Brit. Med. Journ.*, March 9, 1907. See also L. Rogers, Proceedings of Royal Society, 1906, and the *Quarterly Journal of Microscopical Science*, vol. xlviii., part iii., pp. 367-377.

<sup>2</sup> See a paper by W. S. Patton on 'A Species of *Herpetomonas* found in *Culex pipiens*,' *Brit. Med. Journ.*, July 13, 1907.



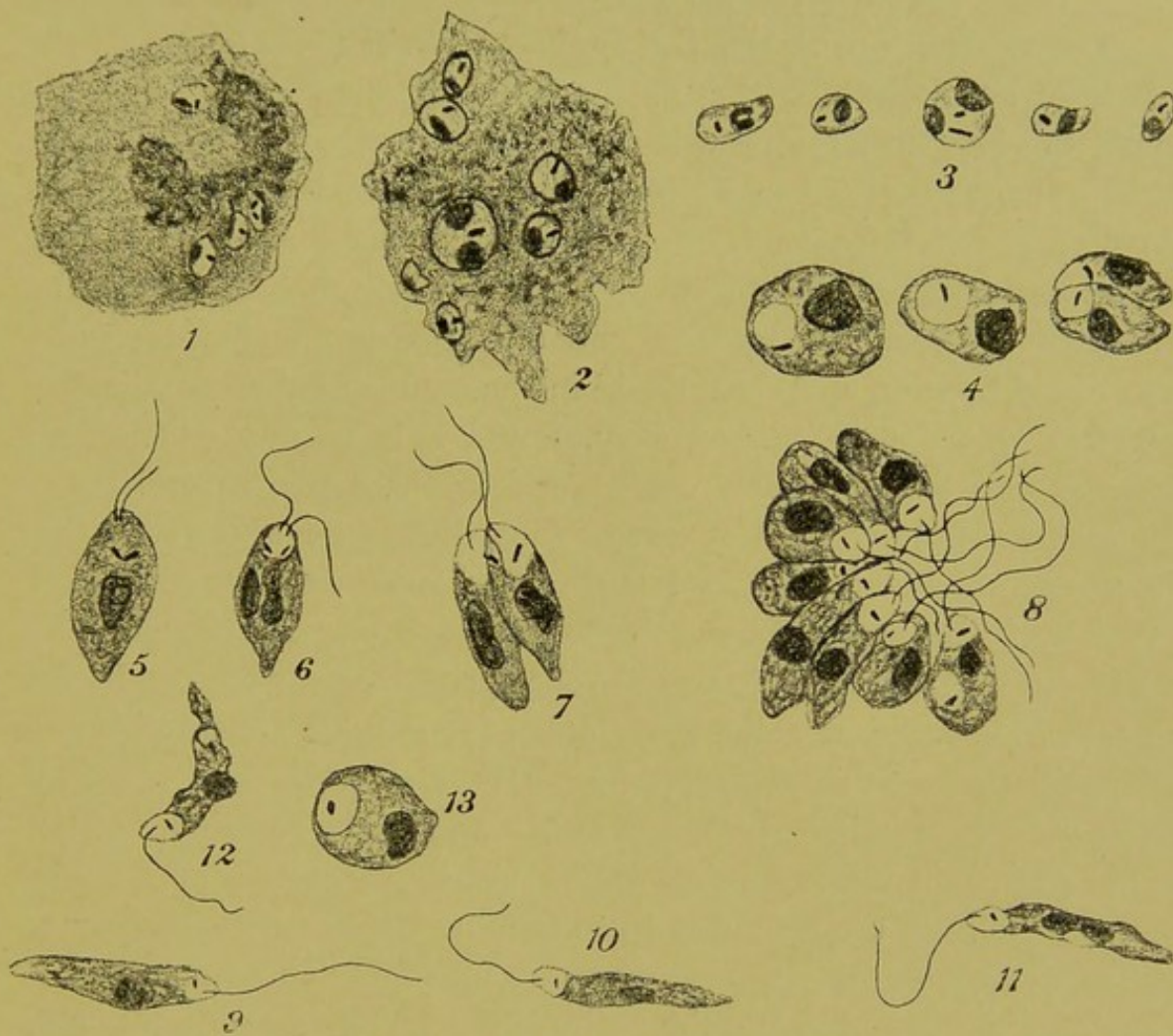


FIG. 8.—*LEISHMANIA DONOVANI*: THE PARASITES OF BLACK-FEVER AND TROPICAL SPLENOMEGALY. (After L. Rogers; selected from the *British Medical Journal*.)

- 1, A leucocyte containing four parasites as seen when freshly taken from the spleen of a living subject; 2, a similar leucocyte after being kept in cooled citrated blood: the parasites have grown, and one is in course of subdivision; 3, other examples of the parasites as found within the human host; 4, three parasites undergoing growth and subdivision: this and the rest were grown under the same conditions as 2; 5, 6, and 7, a later stage: development of flagella and subdivision; 8, an incomplete rosette formed, by repeated longitudinal subdivision; 9, 10, and 11, parasites that have detached themselves from groups such as 8, and are freely moving; 12 and 13, involution-forms, caused by growth of staphylococci in the culture medium.



*Amœbic Dysentery.*

The recognition of the *Entamœba histolytica* (Schaudinn) as the cause of one form of dysentery has made it important to grasp the outlines of recent work on this subject.

First with regard to the disease itself. Amœbic dysentery is to be distinguished from dysentery due to the bacillus discovered by Kruse in Germany and Shiga in Japan. Schaudinn observed that the *B. dysentericæ* was not to be found in cases of amœbic dysentery examined by him, and Castellani,<sup>1</sup> in the course of the examination of twenty-five cases of dysentery, found only two in which liver abscess and amœbæ were present, and in these two cases Kruse's bacillus was not present. A very striking illustration of the condition of the bowel in an advanced stage of amœbic dysentery has been given by L. Rogers.<sup>2</sup> The patient died from peritonitis, caused by perforation of an amœbic ulcer in the vermiform appendix. In the cæcum and ascending colon two-thirds of the mucous membrane was occupied by large sloughing patches separated from each other by narrow areas of inflamed mucous membrane. The remainder of the colon presented ulcers diminishing in size towards the anus. The abscess cavity in the liver was lined with a wash-leather-like slough, and the adjoining liver-tissue was intensely congested.

A. M. Marshall,<sup>3</sup> giving the pathological anatomy of a fatal case, described the wall of a liver abscess as follows: 'Sections from the wall of the abscess showed from within outwards a layer of mucoid necrotic material lining the abscess cavity; in this many amœbæ were found. Next came a reticular layer, also containing amœbæ; deeper came granulation tissue containing connective-tissue cells and swollen fatty liver-cells; and, deeper still, firm fibrous tissue showing compressed liver-cells, distorted bile-ducts, and amœbæ lying both free and in the capillaries.' The same writer emphasizes the

<sup>1</sup> Aldo Castellani, *Journal of the Ceylon Branch of the British Medical Association*.

<sup>2</sup> L. Rogers, 'Amœbic Dysentery in India,' with coloured plate, *Brit. Med. Journ.*, June 6, 1903.

<sup>3</sup> A. M. Marshall, *Brit. Med. Journ.*, June 10, 1899.



importance of the observation quoted from Manson in Part I. of this work, that amœbæ are often absent from the fluid removed by aspiration, and that they are only found later in the discharge in the dressings after the abscess has been opened and drained: 'The size of the amœbæ varied from 10  $\mu$  to 40  $\mu$ , usually 24  $\mu$  to 30  $\mu$ . Their shape is generally circular, but sometimes oval. By careful focussing the surface is seen to be markedly convex when entire. . . . They are not flattened discs, but globular masses. They are bounded by a well-defined capsule or ectosarc, which is often seen to be doubly refractile; this gives them the well-defined outline which renders them easily distinguishable (even under a low power) from most other structures. The interior presents a granular appearance, and in some of the smaller amœbæ this granular material occupies the whole of the space; but some of the larger ones show a well-marked nucleus, while others do not.' This variability as to the presence or absence of a nucleus is important. When the nucleus is absent, protozoa are commonly in what is known as the *chromidial condition*—i.e., the chromatin is diffused as a fine dust throughout the protoplasm. Prowazek<sup>1</sup> has worked out the details of this change from the nucleated to the non-nucleated condition in another amœba—the *Plasmodiophora brassicæ*. By close observation and experiments by feeding cats, Schaudinn<sup>2</sup> found that the *Amœba coli* of Lösch is not the organism that invades the tissues and causes this disease; the organism which does so is the pathogenic amœba he has named *Entamœba histolytica*. In its vegetative stage this protozoon is characterized by having a tough ectoplasm and by the ill-defined character of its nucleus. Vegetative increase is by binary fission and by budding. Cyst-formation occurs when the patient is recovering and the fæces are becoming solid. The parasite then enters into the chromidial state, and buds from 3  $\mu$  to 7  $\mu$  in diameter project from its surface, and, becoming

<sup>1</sup> Prowazek, *Arbeit. aus der Kaiserlich Gesundheitsamte*, vol. xxii., p. 396, 1905.

<sup>2</sup> Schaudinn, *ibid.*, vol. xix., p. 560, 1903. A good account of Schaudinn's paper is given by E. J. McWeeney in a paper on 'Parasitic Protozoa' in the *Transactions of the Epidemiological Society*, 1904-1905, vol. xxiv., new series.



encapsuled as spores which have a brown colour, appear to serve to disseminate the disease.<sup>1</sup>

L. Rogers has suggested that in cases of inflammatory enlargement of the liver—the premonitory stage of liver abscess—large doses of ipecacuanha will prevent the formation of an abscess in that organ.

<sup>1</sup> It is to be regretted that there are no illustrations with Schaudinn's paper ; photographs, such as accompany the paper of Marshall, are very useful, but careful drawings by a competent observer are better still.



## CHAPTER V

### NOTES ON TICKS

THE impression that most of us have of a tick is of a slightly lustrous lead-coloured body, about as big as a pea, lying deep in the coat of a dog or other quadruped. This body is the abdomen of a tick, the beak or rostrum of which (Fig. 9, A) is buried in its host's skin for the purpose of prehension and of sucking blood or lymph. The

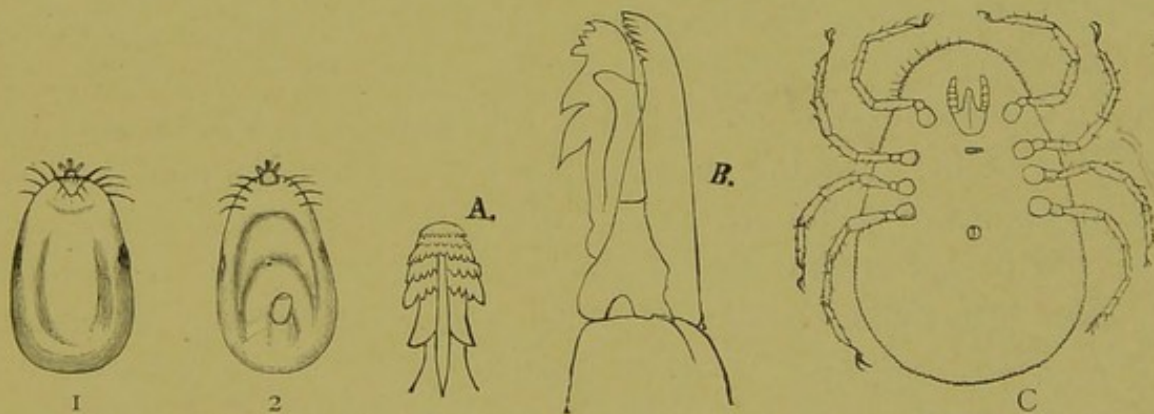


FIG. 9.—TICKS. (From Braun's 'Animal Parasites of Man,' translated by Sambon.)

1 and 2, The dorsal and ventral aspects respectively of the female of *Ixodes ricinus*, a common tick; A, the rostrum; B, the terminal joint of the maxillary palpi of the same; C, the ventral surface of *Argas Persicus*.

common dog-tick, called *Ixodes ricinus* (Fig. 9), from its resemblance to a castor-oil seed, may measure 10 to 11 millimetres in length. It is so tough that it may be seized in a forceps, and if a steady pull is made the parasite comes away, and when released runs off, looking, with its four pairs of legs, not unlike a spider. It is found on many different kinds of quadrupeds as well as on dogs.

S. Dschunkowsky + J. Wrodschevitch  
Trans R. Soc. of Trop. Med. & Hyg. Vol. XVI No. 8.  
11-74



The act of sucking is described as follows by R. Newstead:<sup>1</sup> 'The buccal organs are highly organized in all the members of the ixodoidea, and are composed of four distinct bilateral parts. When about to take food from its host, the animal fastens itself firmly by its legs, depresses its rostrum, and implants the toothed mandibles, and in proportion as these penetrate, the hypostome follows, and the retrograde teeth on the under surface fix this organ in the wound. In this way the hypostome and the mandibles are driven into the wound to their full extent, and so firmly do they become fixed in the derma that it is often impossible to remove the tick without leaving the mouth organs attached to the host, or tearing away a small portion of the skin.'

The spiders and the ticks belong to the same class—the *Arachnida*. This class is subdivided into three orders: the *Acarina* (ticks and mites), the *Araneia* (spiders proper), and the *Scorpionida*. Neumann<sup>2</sup> mentions that there are 1,825 specimens of the tick family in the British Museum. The acarina are the only parasitic order of the class.

Examples of the acarina that are familiar as human parasites in this country are the *Demodex folliculorum*, very commonly found in the plugs of secretion that fill the ducts of the sebaceous glands of the face, constituting 'blackheads'; and the *Acarus scabei*, the parasite that causes itch. Another arachnid, the minute harvest-bug, *Leptus autumnalis*,<sup>3</sup> buries its long proboscis in the skin, and causes an irritating eruption of red spots, erythema, or flat wheals, and in some persons febrile disturbance. Moles, cattle, and horses, as well as man, are attacked by it. In some countries—e.g., the Rocky Mountains and Africa—certain kinds of ticks infest huts, and, like the common bed-bug, attack the inhabitants only in the dark. Severe illness, called tick-fever, may follow, but whether the illness is in all cases caused by protozoal infection is not yet settled,

<sup>1</sup> R. Newstead, 'Pathogenic Ticks,' *Brit. Med. Journ.*, December 30, 1905.

<sup>2</sup> L. G. Neumann, 'Notes sur les Ixodidés,' *Archives de Parasitologie*, May, 1906.

<sup>3</sup> The *Leptus autumnalis* is probably the larval state of one of the *Trombidiidæ*, or running mites.



though in the tick-fever of Africa this is nearly certainly the case. A fowl-tick, *Argas miniatus*, has been found to be intermediary in spreading the spirillosis of fowls, which in some ways resembles relapsing fever in man.

*Ornithodoros moubata* is now known to be the carrier of tick-fever or relapsing fever in man in tropical Africa. In Mexico, Florida, and Texas an allied species, *O. turicata*, is fatal to fowls and harmful to human beings. In Persia the *Argas Persicus* attacks both poultry and human beings, and its bite both in history and at the present time is reputed to be injurious. Whether this is from a specific infection or a common lymphangitis is not known.

The relation of ticks to the piroplasmata will be considered in the ensuing chapter. The tick *Boophilus bovis*, mentioned in Part I. of this work as the carrier of the destructive piroplasmosis of cattle called Texas cattle-fever, has been renamed *Alectorobius* by Pocock.<sup>1</sup> It belongs to the argas family.

Ticks are divided into two distinct families—the *Argasidae* and the *Ixodidae*. The former have no dorsal shield, and the head or capitulum is not seen from the dorsal aspect, being overlapped by the body of the animal (see Fig. 9, C). Ticks differ from insects in having four instead of three pairs of legs, and in the absence of antennæ and the lack of subdivision of the body into somites. The adult females produce a great number—often thousands—of eggs, which they deposit in clefts in the ground. The young ticks hatch out with only three pairs of legs, the fourth pair not then being formed. These young are termed *larvæ*.<sup>2</sup> They crawl upon the stems and leaves of the grass and other vegetation, and, endowed with a remarkable power of fasting, they wait, it may be for months, before a suitable host brushes past or thrusts his muzzle among them; such as find a lodgment lose no time in piercing

<sup>1</sup> R. I. Pocock in Allbutt and Rolleston's 'Medicine,' vol. ii., part ii.

<sup>2</sup> The term 'larva' is thus seen not to be limited to a grub or caterpillar-like creature, as is the case when we speak of insects. Such grubs pass into a chrysalis or *pupa* stage, to emerge as a winged insect or *imago*. This is termed the *metamorphosis*. It is only observed in the higher insecta, and there is no such process in the acarina.



their host's skin and commencing to feed. In some species of ticks, the larvæ, having fed, are said to change into eight-legged nymphs whilst still on their host's skin. More often, after about six days, when they have become engorged, they drop off, and undergo their remodelling on the ground. Here, in the course of a few weeks, they 'moult'—*i.e.*, shed their skin—and are then seen to have changed into nymphs which have four pairs of legs, but no genital apertures. These nymphs require to find a new host to feed upon, and, like the larvæ, when engorged they fall to the ground, and there, in the course of a month, undergo their final change into the sexually mature ticks. The vitality of ticks is very striking. Méguin is said to have had examples of *Argas Persicus* which survived four years' starvation. Nuttall<sup>1</sup> found ticks sent from Africa infected by piroplasmosis were capable of setting up a fatal disease in dogs after being kept without food for seven months in England. The number of eggs laid by the female is said to vary from several to twenty thousand.

In some cases ticks fed on infected mammals can produce a brood capable of carrying the infection of piroplasmosis in all stages—larva, nymph, and adult; in others the tick is infective only in the stage following that in which the infecting meal was taken. In the case of dogs the adult tick alone appears to be capable of conveying piroplasmosis.

<sup>1</sup> G. H. F. Nuttall, 'Ticks and Tick-transmitted Diseases,' Transactions of the Epidemiological Society, 1904-1905, vol. xxiv.



## CHAPTER VI

### PIROPLASMOSIS

PIROPLASMOSIS as a destructive disease affecting cattle in Texas and South America has been already mentioned in Part I. of this work, and since the piroplasmata are growing in importance, it may be well to recall the illustration of the parasites as seen in the red blood-cells of cattle. Then I wrote, 'The history of the parasites whilst contained within the tick has yet to be worked out.' This gap in knowledge has now been filled, S. R. Christophers<sup>1</sup> having traced almost completely the life-history of *Piroplasma canis*; and these important observations are quite in accord with what is known of piroplasmosis in other animals, and may be presumed to be the type for all. This disease in dogs had been observed in Europe and Africa, and Christophers met with the same disease in India. Different species of tick are able to act as intermediate hosts for these parasites. In South Africa, Lonusbury and Nuttall found that called *Hæmaphysalis leachi* (Audouin) was concerned. In India Christophers found the *Rhipicephalus sanguineus* (Latreille) was usually the carrier of the disease, the infected adult female ticks giving rise to an infected progeny. The larvæ from eggs of an infected mother were found not to be capable of transmitting this disease, whilst the nymphs and adults of those same larvæ were. Also previously uninfected larvæ were found to be infective when they reached the adult stage after feeding on infected blood. The chief forms noted in this brief paper are shown in Fig. 10, and may be classified thus:

1. In the gut of nymph or adult fed on infected dogs were many

<sup>1</sup> S. R. Christophers, 'Preliminary Note on the Development of *Piroplasma canis* in the Tick,' *Brit. Med. Journ.*, January 12, 1907.



small free forms similar to those seen in the dog's red blood-corpuscles, and with them others of larger size and more distinct nuclei. Some of these had blunt projections from the surface (Fig. 10; 2 and 3).

2. In the gut, oviducts and ova, and in the salivary glands of

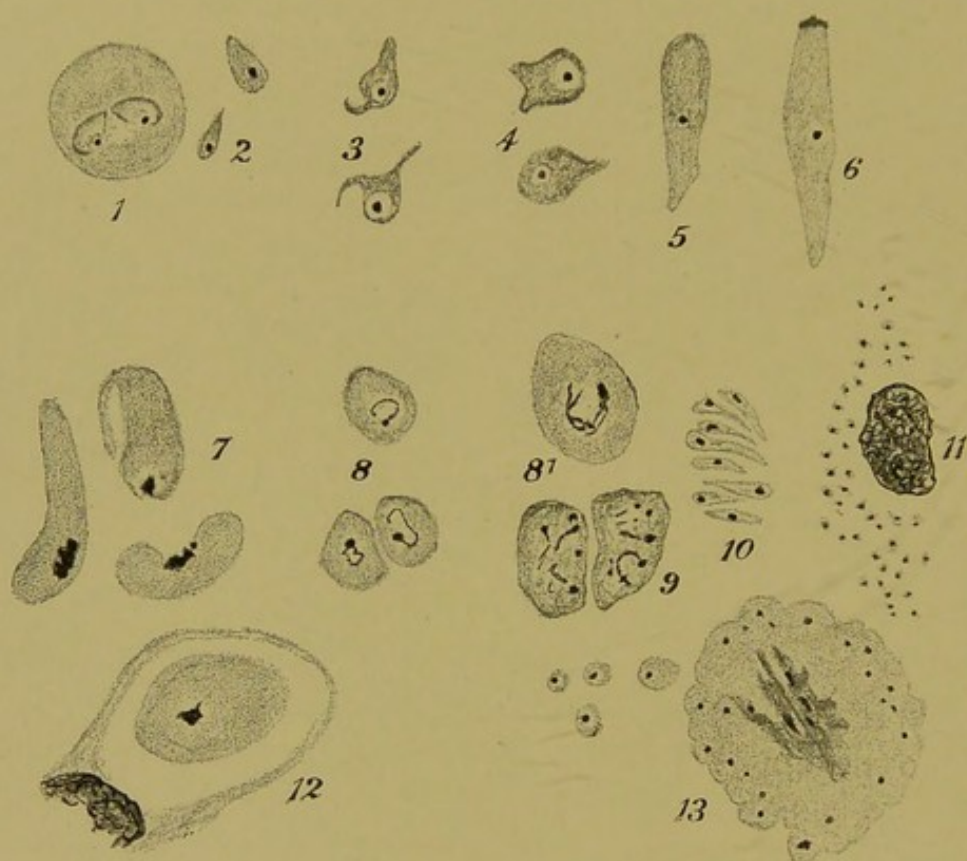

FIG. 10.—DEVELOPMENTAL FORMS OF PIROPLASMA CANIS. (After Christophers; selected from the *British Medical Journal*.)

1, Intraglobular form; 2 to 6, stages of growth and development met with in the gut of the tick; 5 and 6, also occur in the tissues of the tick; 7, club-shaped bodies from the tissues of nymphs of the second generation; 8, 'spiroblasts'—forms found in great numbers in the salivary glands of nymphs; 8¹, shows the chromatin is arranged in a dense point and filamentous streamers; 9, forms from unhatched adult, the chromatin subdivided; 10, group of piroplasma-like bodies resulting from subdivision of 'sporoblast'; 11, cell packed with minute piroplasmata (of the host-cell only the nucleus is shown); 12, coccidium-like intracellular form; 13, sporulation of a form similar to 12. (All  $\times 2,000$  diameters except 11, which is  $\times 300$ .)

nymphs, were large club-shaped bodies, having active creeping and side-to-side movements, and many of them being provided with an anterior organ recalling the 'epimerit' of the higher gregarines (Fig. 10; 5 and 6).



3. In the tissues of unfed nymphs bred from infected mothers were round, oval, or pear-shaped bodies (Fig. 10, 8 and 8<sup>1</sup>), measuring  $4\mu$  in diameter, and having peculiar nuclei consisting of one dense mass from which spreads a looser skein of chromatin. These forms were chiefly aggregated in the cells of the salivary glands, suggesting that they were the final stage in the tick, but this proved not to be the case, although they can probably cause infection in the dog, because nymphs in this stage are highly infective.

4. In squash preparations of unhatched adults<sup>1</sup> bodies occur similar to those last mentioned, but having the nucleus subdivided (Fig. 10; 9), a portion of the looser accompanying each subdivision of the denser part of the nucleus, and side by side with such bodies are groups of from three to ten small piroplasmata, especially in the cells destined to form the salivary glands. Christophers thinks that the paired bodies in the gut may represent true conjugation, the large club-shaped bodies may be the ookinets, the bodies in the salivary glands of the nymph be homologous with sporoblasts of the malarial zygote, and the smaller bodies in the adult equivalent to sporozoites.

<sup>1</sup> To form the adults the tissues of the gorged nymphs are, as it were, first melted down and then recast, the salivary glands becoming unrecognisable as such for a time during the process.



## CHAPTER VII

### SMALL-POX AND VACCINIA

THE modern pathology of variola and its modified form vaccinia began in 1892, when Guarnieri described as protozoa small hyaline bodies that occur in certain stages of the lesions of small-pox and in the epithelial cells of the cornea of rodents after inoculation with active vaccine. These bodies<sup>1</sup> Guarnieri named *Cytoryctes variolæ*, believing them to be protozoa which invade and destroy the cells of their host. He described amœboid movement, and binary and mulberry-like division in the bodies. A photograph of these bodies, as seen in a stained preparation of a rabbit's cornea forty-eight hours after vaccination, is shown in Fig. II. If the simple experiment is done with ordinary skill and care, the appearance of Guarnieri's bodies after inoculation of a rabbit's cornea is certain when active vaccine lymph or the fresh juice of a variolous lesion is used. The latter fact makes the experiment an invaluable one for the diagnosis of doubtful cases of small-pox. Sections may be examined, either unstained, or stained with any good tissue-stain. L. Pfeiffer, who had been at work at the investigation of small-pox and allied subjects for many years, confirmed<sup>2</sup> Guarnieri's account. He described their amœboid move-

<sup>1</sup> Weigert and Renault had previously described the bodies, but without any interpretation of their nature. Before Guarnieri, Grünhagen had described greenish, highly refracting corpuscles, and van der Loeff, in 1887, had described amœboid organisms in variolous and vaccine lymph.

<sup>2</sup> L. Pfeiffer, 'Behandlung und Prophylaxe der Blattern,' 1893. The translation is quoted from an article by myself on 'Recent Contributions to the Pathology of Variola,' etc., *Medical Press and Circular*, July 25, 1894. In that article I mentioned that Dr. Pfeiffer had, at my request, sent me a section of a vaccinated cornea which showed Guarnieri's bodies very clearly. I concluded the same article



ment; translated it is as follows: 'If, after forty-eight hours, a slice of a freshly excised inoculated cornea is placed on the warm stage in aqueous humour faintly tinged with methylene blue, the intracellular parasites are distinctly seen to move within their host-cells. When the parasite dies it contracts to a spherical shape, and then becomes of a blue colour. . . . At this stage there are no leucocytes at the site of inoculation.'

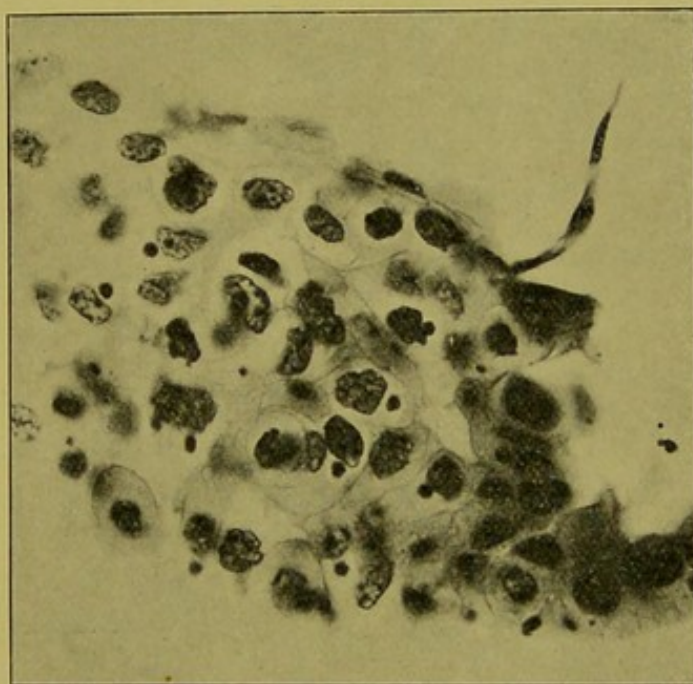


FIG. 11.—A PORTION OF THE EPITHELIUM OF A RABBIT'S CORNEA FORTY-EIGHT HOURS AFTER VACCINATION. (From a photograph of one of the Author's preparations made in 1894. Stain hæma-toxylin and eosin.  $\times 400$  diameters.)

Guarnieri's bodies are seen as roundish dark objects near the nuclei of the epithelial cells.

When I demonstrated these bodies before the Pathological Society of London in October, 1894,<sup>1</sup> I had vaccinated the corneæ

thus: 'The study of an easily inoculable disease like vaccinia affords material for the comparative study of cancer and sarcoma.' The literature relating to Guarnieri's work and its subsequent developments is so large that even where it has been attempted to give it fully serious omissions have been made. I shall only give references to what appear to me to be the salient contributions to the subject.

<sup>1</sup> See the Transactions of the Pathological Society, vol. xlvi., p. 192, 1895, with one plate.



of some six rabbits and several guinea-pigs, and in every case with a positive result. For the study of the growth and development of these bodies, as seen in sections of corneæ taken at different periods after vaccination, I found the guinea-pig's cornea afford the

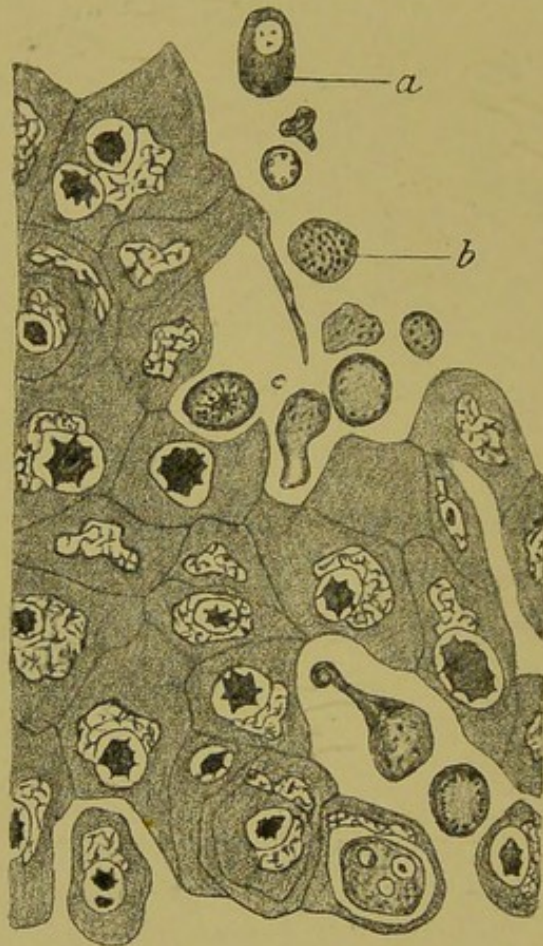


FIG. 12.—PART OF A SECTION OF A GUINEA-PIG'S CORNEA SEVENTY-TWO HOURS AFTER VACCINATION. ( $\times 750$  diameters. From Pathological Society's Transactions, 1895, Plate VIII.)

*Left-* The site of inoculation is to the right. The intracellular bodies are larger and of less regular form than those examined sooner after vaccination. Among the free cells are some, such as *a* and *b*, that contain chromatin in various forms.

more pronounced serial changes, though a similar progress was recognisable also in the rabbit. Fig. 12 is copied from a drawing of one of the specimens of the guinea-pig's cornea that was demonstrated on the occasion referred to. Most of the intracellular bodies are larger than those seen in corneæ examined twenty-four or forty-eight



hours after vaccination. That was, I believe, the first demonstration of Guarnieri's bodies in the amoeboid phase. This same amoeboid phase occurs also at a certain stage of small-pox lesions. They are very clearly shown in a specimen given to me by Professor Calkins in 1903.

Some of the intracellular bodies, and more of those that have escaped into the intercellular spaces—*e.g.*, Fig. 12, *a* and *b*—owing to breaking-down of the host-cells, contained chromatin in various forms. These free bodies, like Guarnieri's corpuscles, were distinguishable from the tissue and other cells of the host by a higher refraction and differences of staining, and by careful comparison I was led to recognise that the series of forms could not well be anything but stages in the life-history of a protozoon.

In order to obtain free bodies, such as those shown in Fig. 12 at *a* and *b*, etc., the greatest care is required, and many sections must be cut. When a suitable specimen has been obtained, there are peculiarities of optical quality and staining reactions that distinguish the Guarnieri bodies from tissue-cells, and the forms I described as parasites, in which chromatin had appeared, are linked to the ordinary Guarnieri bodies by retaining in part those same features which differentiate them from the normal elements of the tissues. In my original article, referred to above, a series of such nucleated forms are represented. They are probably the same bodies subsequently described by Funk and De Korté. The important observations of these authors will be again referred to below. It has been said that the small Guarnieri body has the staining reaction of chromatin. I think this is hardly correct. In well-differentiated preparations stained with acid hæmatoxylin and eosin the nuclear chromatin of the corneal cells show the pure deep blue colour of chromatin, whilst the Guarnieri bodies are of a purplish tint, having apparently retained the two stains about equally.

In 1897 Wasielewski<sup>1</sup> advanced the subject materially. He showed that no kind of injury to the cornea, nor inoculations with

<sup>1</sup> Wasielewski, 'Ueb. die Form und Farbbärkeit der Celleinschlusse bei Vaccineimpfungen,' *Cent. für Bakt.*, xxi., s. 901, and *Zeit. für Hygiene*, xxxviii., s. 212.



other organisms, produced Guarnieri's bodies. They are specific, and may be used as a certain means of diagnosis in doubtful cases of small-pox, and as a reliable test of the activity of any sample of vaccine. They can be inoculated from eye to eye indefinitely. From such vaccinated corneæ typical vaccinations were made in the fifteenth and twenty-fifth generations. From a small quantity of corneal epithelium, rubbed up with bouillon, obtained by scraping a cornea which represented the thirty-sixth generation, six out of seven children were successfully vaccinated, the epithelial scraping having been previously found to be free from bacteria by cultures on agar, blood-serum, and in bouillon.

Wasielewski also found that the cytoryctes increased in size and developed a nucleus. In France F. J. Bosc showed that bodies in many respects similar to cytoryctes are present in sheep-pox, and also that similar forms occur in cancer. Bosc also described the important intranuclear forms almost at the same time as the American observers,<sup>1</sup> Councilman, Magrath, and others, who were aided by Professor G. N. Calkins, whose eminence as a biologist has impressed his fellow-biologists with the importance of the subject. Some of the chief points in the results obtained by the American observers, as digested by the biological knowledge and experience of Calkins, I referred to in opening a discussion at Glasgow in 1904.<sup>2</sup> I then said: 'Calkins believes that in variola these bodies are parasites, and the difference between vaccinia and variola consists in this: that in the former they have only a cytoplasmic habitat and a vegetative (multiplicative) process of reproduction, whilst, in addition to this, in variola there is an intranuclear stage, where, probably, sexual interchange followed by sporing (propagative reproduction) occurs. I have been able to recognise the chief forms that Calkins and his co-workers have described. Some of the various forms figured by Calkins are reproduced in Fig. 13; 1 to 9. They are very abundant in the lesions, and I have been able to identify the

<sup>1</sup> The first description of these appeared in the form of a preliminary note in the *Journal of Medical Research*, 1903. The full account appeared later in the same journal, and is reprinted as a separate volume.

<sup>2</sup> The *Journal of the Royal Sanitary Institute*, part iii., 1904.



later sporing forms with bodies I saw in small-pox tissue ten years ago. The earlier intranuclear forms closely resemble those structures to which in 1895 I drew attention in a sarcoma of the breast, and suggested that both they and the parasites of variola possibly belonged to that subdivision of the protozoa called *Suctorina*, many of which are intranuclear parasites.'

Minchin provisionally places the cytoryctes among the sporozoa *incertæ sedis*.

This view of the pathology of small-pox may now be briefly stated. From some primary point of entrance into the tissues of the body (most probably in the alimentary or respiratory tract, possibly from a flea-bite or some such source) the cytorycte in some minute form (? Doehle's flagellates) enters the blood, and is distributed to all the organs of the body. The chief ocular evidence of this generalized infection is in the skin and fauces, where the organism is found in the papules as the now familiar form of the minute amœbæ in the epithelial cells. In the amœboid cytoplasmic stage the parasites multiply for a time, passing through several generations (Fig. 13; 1 to 5). In vaccinia the process is limited to this stage, but in variola a different stage, the intranuclear, occurs. The intranuclear stage is first recognisable as amœboid structures (Fig. 13; 6). These become rounded off (Fig. 13; 9), and, according to Calkins, male and female forms (male and female gametocytes) are to be distinguished, the end of the process being the formation of minute, highly refracting bodies. I have been able to identify the bodies described by Calkins in preparations that he kindly gave me in 1904. The various bodies require close and leisured attention for their recognition. I am not in a position to criticise the author's view as to the biological cycle of the parasites, but I must observe that I met with bodies exactly resembling some of those he describes as sporoblasts in appearance, but on a much larger scale (and hence more easily studied), in the alveolar sarcoma of the human breast described below (Chapter XII.). A closer study of these showed them to be tentaculiferous, and some portion of their life-history will be described below. It may be ultimately found that the parasites in the intranuclear stage of



variola subdivide into minute spore-like bodies without leaving the nucleus, whilst those in the alveolar sarcoma require to escape.

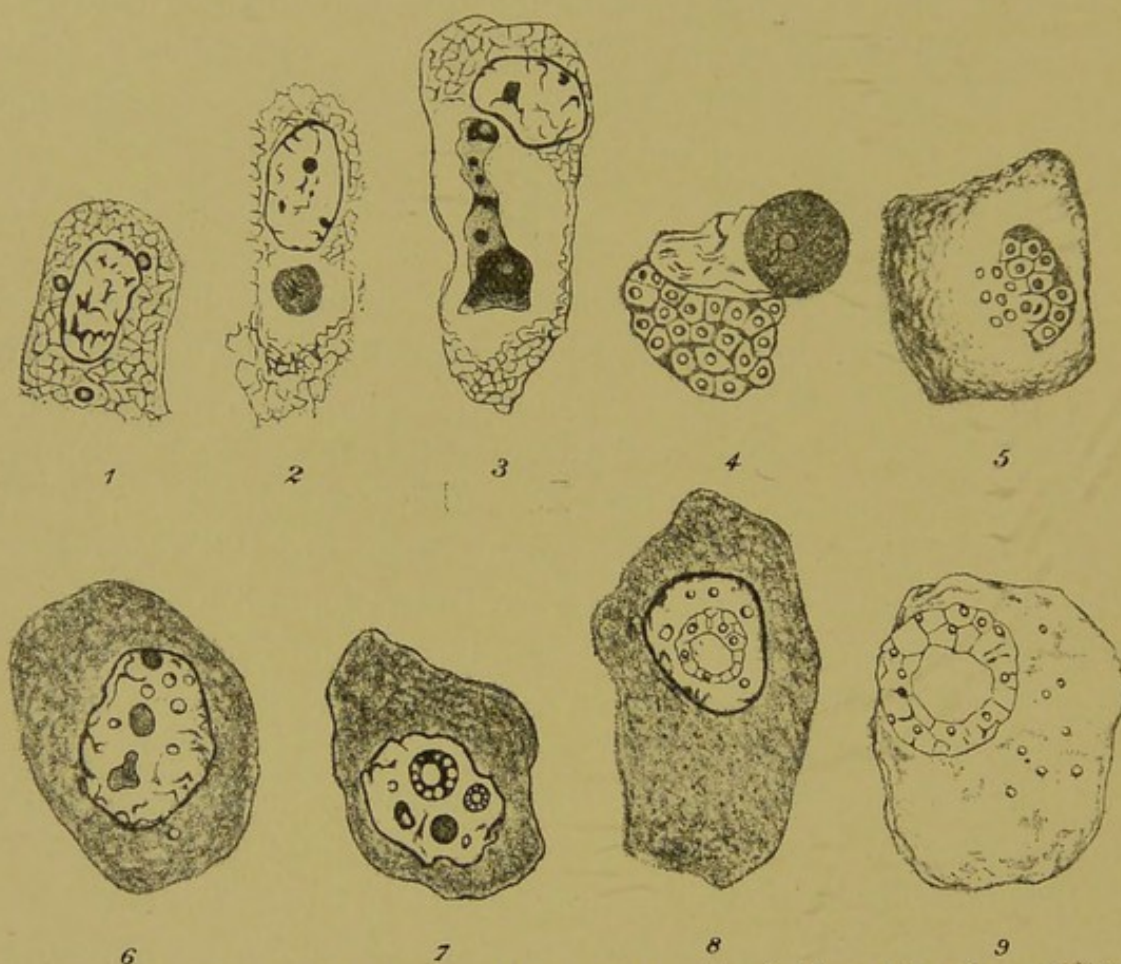

FIG. 13.—CYTORHYNCHUS VARIOLÆ, GUARNIERI. (Copied from the coloured plates illustrating G. N. Calkin's section of 'Studies of the Pathology and on the Etiology of Variola and of Vaccinia,' published in the *Journal of Medical Research*, 1904.)

- 1, A cell from a section of a small-pox lesion: three gemmules are present in the cytoplasm close to the nucleus; 2, a cell containing an older gemmule in the cytoplasm; 3, a cell containing a large amœboid parasite in the cytoplasm; 4, a cell containing an amœboid parasite in process of gemmule-formation, and, above, a round dense body, probably a microgametocyte; 5, a cell containing an amœboid parasite in process of gemmule-formation: some of the gemmules are escaping into the cytoplasm; 6, a cell the nucleus of which contains five spores and three secondary sporoblasts developed from spores: there is one spore in the cytoplasm; 7, a cell the nucleus of which contains secondary sporoblasts; 8, a cell the nucleus of which contains a reticular sporoblast, with spores, some of which have escaped from the meshwork; 9, a cell the nucleus of which has been replaced by a large sporoblast, from which some of the spores have escaped into the cytoplasm.

The results obtained by Bosc<sup>1</sup> agree very closely with those of the American observers.

<sup>1</sup> F. J. Bosc, *Cent. für Bakt.*, 1904, part i., vol. xxxvii., section 1.



Whether we examine a preparation of a small-pox lesion, or of a vaccinated cornea, or a good drawing of such a preparation, everyone must be struck by the degree to which the art of omission has been carried, in framing the figures that represent the same lesions in the ordinary text-books of pathology.

We may now pass to consider briefly the findings of those who have closely examined fresh variolous and vaccine lymph for protozoa. The observations of Funk<sup>1</sup> and De Korté<sup>2</sup> relate to the same bodies, to convey an idea of which I cannot do better than quote from a recent article of the latter observer :

‘ If the vesicular contents of a human vaccine vesicle be examined as a hanging drop with the highest powers of the microscope and suitable adjustment of the light, disregarding any gross cell-element which may be present, the fluid will be seen to contain a vast number of exceedingly small grains, which appear to be motile on a warmed stage ; their shape and size, because of their smallness, is practically indeterminable. These grains, I think, are spores ; they are larger and more distinct in variolous matter, and always normally situated within the cell ; they are motile in calf lymph, immobile in glycerinated calf lymph. The various bodies thus far described will be seen to consist of four elements—spore, sporidium or amœba, encysted parasite, and morula body found in glycerinated calf lymph.’<sup>3</sup>

For the basis of this interpretation, I must refer the reader to Dr. de Korté’s original articles.

Mention of the elements seen in fresh small-pox lymph reminds me of some observations I made in 1894 on some variola lymph taken, by kind permission of Dr. Ricketts, from patients in the hospital ships. Though the lymph drawn, after sterilizing the surface, into a capillary tube from a vesicular or early pustular lesion is usually free from cultivable bacteria, this is not necessarily the case. This was shown to me by the presence of a typical *Acarus scabiei* in lymph drawn from a part of the body where scabies is

<sup>1</sup> M. Funk, *Cent. für. Bakt.*, July 5, 1901.

<sup>2</sup> W. E. de Korté, *Lancet*, vol. xxiv., 1904 ; *Practitioner*, September, 1905.

<sup>3</sup> *Ibid.*, *Brit. Med. Journ.*, December 1, 1906.



rare — *i.e.*, from a pustule of the face of a woman who had a typical thick, discrete eruption eight days old. Such an occurrence is exceptional, and lymph from that particular case was excluded from the observations, one of which I may now relate. This was made on a specimen of variola lymph simply placed on a clean slide, covered with a cover-glass, and sealed with balsam. At the time nothing but the faint outlines of spherical bodies of different sizes were to be seen. The specimen was put away, and not examined for some months. When I re-examined it at the end of this time all the spherical bodies had disappeared, and every part of the specimen showed, as it still shows, only a fine granular matrix,

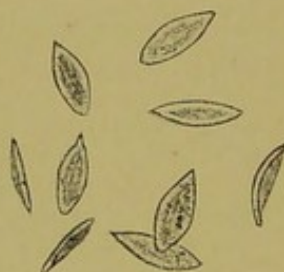

FIG. 14.—BODIES RESEMBLING SPORES OF GREGARINES, FORMED IN VARIOLOUS LYMPH SOME TIME AFTER IT HAD BEEN SEALED UP ON A SLIDE. (Camera drawing  $\times 1,000$  diameters.)

in which are embedded numerous pseudonavicella-like bodies, some of which are sketched in Fig. 14, and which may possibly prove to have some connection with the cytoryctes, and hence I give them a place here, though as yet without any definite claim for them.

One feature of the virus of small-pox and vaccinia is its power of passing under suitable conditions through a Chamberland filter. Siegel,<sup>1</sup> who, among others, has found this to be the case, as shown both by microscopic appearance and inoculation experiments, made at the same time a very careful histological examination of Guarnieri's bodies in the corneæ of rabbits, and concluded that they were parasites. Besides this property of passing filters, another has been recently observed,<sup>2</sup> to the effect that if a rabbit is killed twenty-

<sup>1</sup> J. Siegel, Abstract in *Brit. Med. Journ.*, October 21, 1905, Epitome, p. 64.

<sup>2</sup> Aldershoff and Broers, *Ann. de l'Inst. Pasteur*, September 25, 1906.



four hours after inoculation of its cornea with vaccine lymph, and the juice of this rabbit's kidneys be used to inoculate other rabbits' corneæ, the latter exhibit the same changes as if inoculated with vaccine lymph.

The foregoing account embodies some of the observations and views of those who believe that Guarnieri's bodies and their derivatives are protozoa. It is natural that others have taken the contrary view, or views as it may be more correctly stated, since the critics differ very widely. Thus Ferroni and Massari said that Guarnieri's bodies were derivatives of the nuclei of leucocytes and epithelial cells, and that they could be produced by injury of the cornea. This has been found to be incorrect. Salmon and Borrel regarded them as derived from leucocytes, and that similar bodies occur in sheep-pox. The latter part of their contention has been confirmed, but not the former. One of the best and most careful pieces of work on the negative side is that of Hückel;<sup>1</sup> but to those who have carefully studied Guarnieri's bodies it is evident that he has confused leucocytes and other structures with them. Copeman and Mann<sup>2</sup> do not commit themselves; they recognise Guarnieri's bodies in various vaccine lesions of the calf, and observe that 'Clarke rightly points out that many cells appear similar to those found in cancer.'

More recently Prowazek<sup>3</sup> has advanced the view that Guarnieri's bodies, though specific, are not the virus of the disease, but some part (nucleolus or chromidium) of the host-cell that escapes from the nucleus, invests the true parasites, and grows with them. This view has been framed to account for the fact, referred to above, that the virus will pass a fine filter. It is to my mind more probable that the whole vaccine-body is a parasite in the chromidial condition, and that the disintegration of its body does not necessarily

<sup>1</sup> A. Hückel, 'Vaccine-bodies,' *Beiträge zur Path. Anat.*, xxv., 1898. Supplementary part.

<sup>2</sup> Monckton Copeman and Mann, Twenty-eighth Annual Report of the Local Government Board, 1898-1899, Appendix C.

<sup>3</sup> Prowazek, 'Untersuch. ueb. Vaccinekörper,' *Arbeit. aus der Kaiserl.*, xxii., 1905, p. 535.



involve its death, but that the minutest part—the intimate mixture of nuclear and cytoplasmic matter that such chromidial bodies consist of—has all the potential of a perfect cell.

In conclusion, I may quote what I have written elsewhere of Guarnieri's bodies :

‘1. They are so far specific to variola and vaccinia that their appearance after inoculation of a cornea is the best test of the activity of vaccine lymph; and, an important practical fact, their appearance in an epithelium of a test-animal may be used as an aid to diagnosis in cases suspected of being small-pox.

‘2. They have been cultivated in a long series of corneæ, and from the last a clinically typical vaccination of a child has been done.

‘3. If they were the products of a degeneration peculiar to variola, then the outcome of connected serial observations would be to show that there are products of degeneration which from day to day undergo a regular growth and development, with numerical increase and changes in structure, such changes being, in any number of similar observations (vaccination and examination of tissues at stated periods in sequence), constantly repeated, and at corresponding periods of time. If we imagine a process akin to crystallization to underlie the phenomena, it may be objected that amoeboid movement has been described in them by competent observers, and that no known crystals or crystalloids behave as they do.’



## CHAPTER VIII

### SYPHILIS AND YAWS

ONE of the first to mention protozoa in relation to syphilis was Doehle,<sup>1</sup> who, in 1892, described flagellated bodies in the blood in the febrile stages of vaccinia, variola (early fever), measles, scarlet fever, and syphilis. After this the first description of bodies that resembled protozoa in syphilitic tissues was, I believe, that given by myself in 1894. These bodies are represented in Fig. 15, which is reproduced here because it shows some important features. I have quite recently made a camera drawing (Fig. 16) of the main features of the whole extent of another section of the same piece of tissue, and a careful detailed camera drawing (Fig. 17) of the part of this section which most plainly shows the features to which I wish to draw attention.<sup>2</sup>

The portion of tissue was removed from the edge of a spreading secondary syphilitic ulcer. The part of the section shown in detail in Fig. 17 corresponds to the part marked '2, gregarinoid bodies' in Fig. 16. The part of the ulcer marked '3' contains cavities, only two of which are indicated. These cavities contain massed groups of leucocytes, which are altogether wanting in the part shown in Fig. 17. Without going into any great detail as to the features presented in Fig. 17, one point must be insisted upon—viz., that normal nuclei such as *b*, and nuclei undergoing degeneration,

<sup>1</sup> P. Doehle, 'On the Etiology of Measles, Small-pox, Scarlet Fever, and Syphilis,' *Cent. für Bakt.*, 1892, p. 906.

<sup>2</sup> For permission to use the blocks of Figs. 16 and 17, I am indebted to the Editor of the Transactions of the Royal Medico-Chirurgical Society, where I demonstrated the specimens on January 8, 1907.



such as *c* and *d*, are in the stained section easily distinguished from the bodies *u* to *z*, which I regard as protozoa, by reason of the forms here presented and a comparison of these with similar forms in other pathological conditions. They include hyaline bodies, as at *u*; similar but nucleated bodies, as at *y*; in the space indicated by the

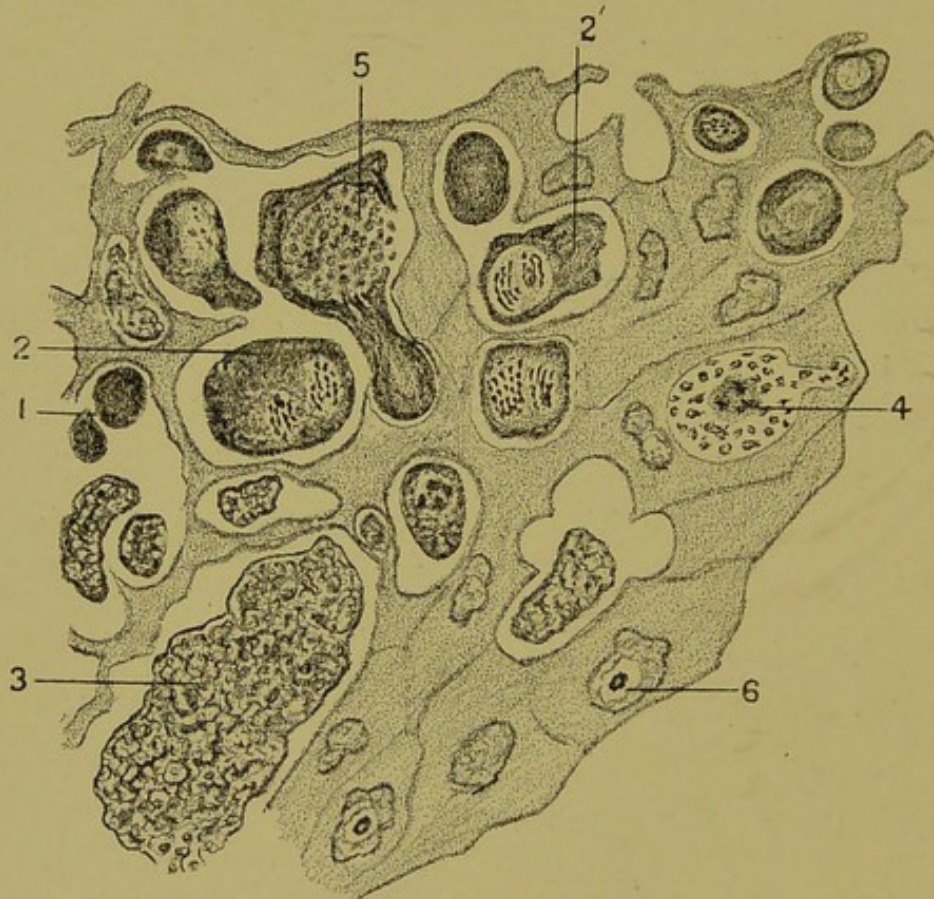

FIG. 15.—A GROUP OF EPIDERMAL CELLS AND PARASITES NEAR THE MARGIN OF A SECONDARY SYPHILITIC ULCER. (Path. Soc. Trans., 1895.)

- 1, Dense parasites devoid of nucleus: the nuclear matter distributed throughout the cell; 2, 2', parasites with nuclear chains of chromatin; 3, large reticular parasitic mass; 4, formation of minute subdivisions in a chromidial state; 5, large club-shaped parasite; 6, (?) intranuclear parasite.

line *w* is a body cut in two parts and having an appearance that I have not seen, except in certain stages of gregarines and other protozoa.

I had for a long time desired to watch these bodies under conditions similar to those that obtain during life, but so great are the obstacles to such work in professional life, and so reluctant is one to



withhold treatment from a patient, and so rapidly in syphilis are lesions usually removed by treatment, that it was not until August 31, 1901, that I was able to do this. Among my out-patients was a man who had some obstinate tertiary syphilitic lesions on the face and in the mouth that resisted full doses of the biniodide of mercury and potassium, which I had given to him by the mouth for several weeks. These lesions were subsequently completely cured by intramuscular injections of sal-alembroth. I arranged for this

*at the N-1  
Lond. Hosp.*

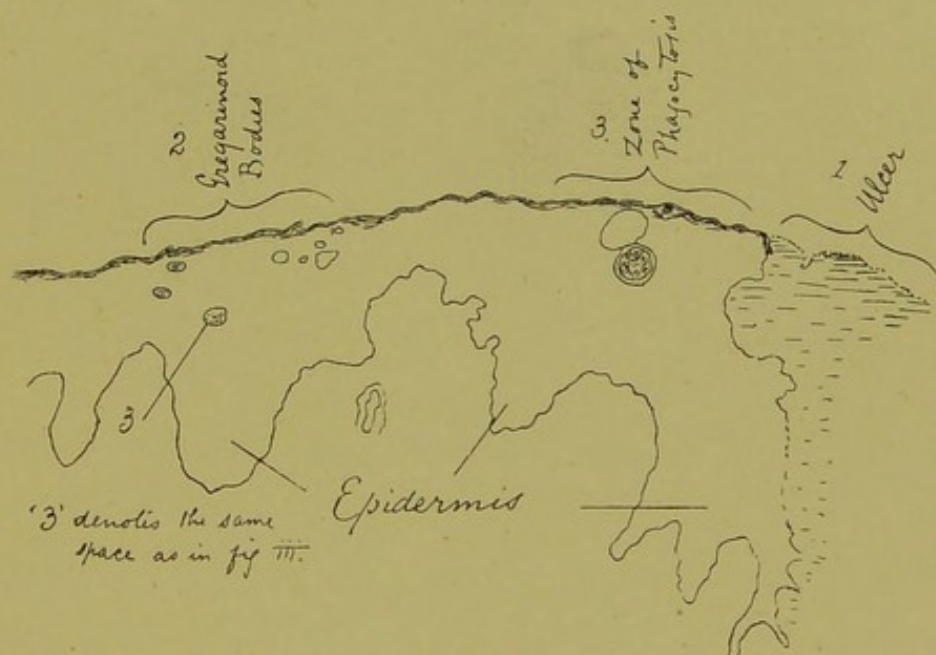


FIG. 16.—SECTION OF SKIN AT THE MARGIN OF A SECONDARY SYPHILITIC ULCER.

Outline drawing of the section from which Fig. 17 was taken, showing the general relations of the parts. The reference to Fig. iii. should be to Fig. 17.

patient to attend at about 7 p.m. on the date mentioned, and after wiping the surface of a warty lesion of the hard palate, I took a scraping with a clean knife, not going sufficiently deeply to cause any bleeding. The material thus obtained I mounted in its own liquid exudation, covered it with a thin cover-glass, and examined it on a Stricker's warm stage. With the objects before me I made the graphic and written notes which are reproduced in Fig. 18 and the accompanying description.

What are the bodies just described and shown in Fig. 18?



They are certainly of kindred nature to those I described in cancers in 1892,<sup>1</sup> but it is to be noted that on the warm stage these bodies from the tertiary lesion exhibited what could only be vital processes. Each group of oscillating granules could only represent a focus where a process equivalent to mitosis was going on. The mass

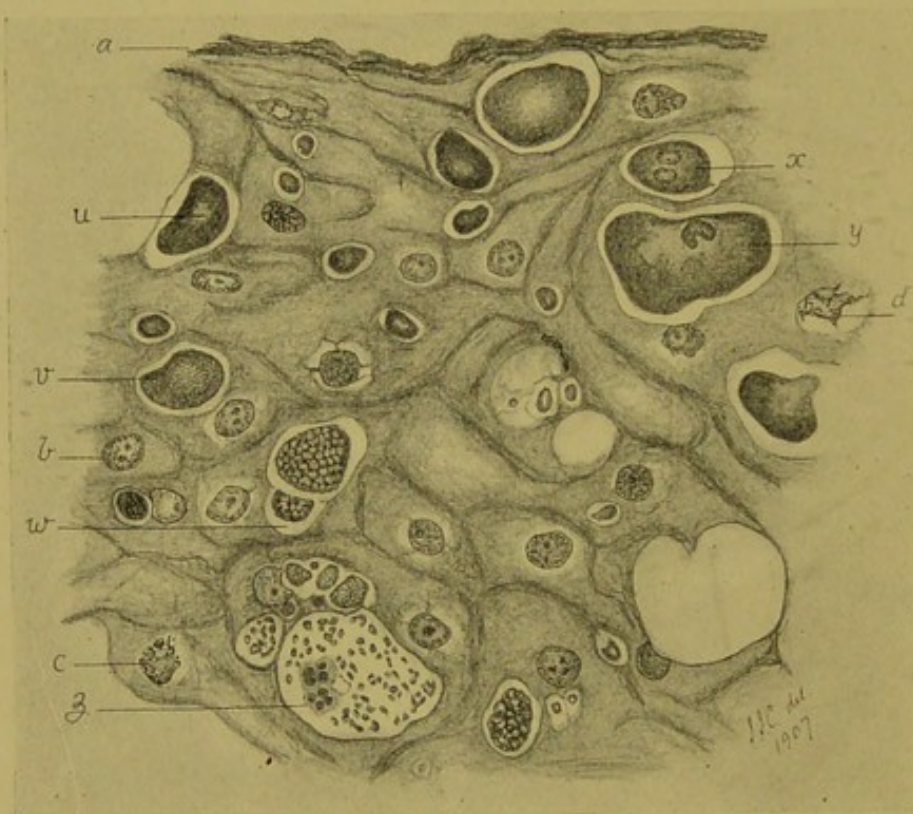


FIG. 17.—PART OF THE EPIDERMIS IN THE SAME SECTION OF A SPREADING SECONDARY SYPHILITIC ULCER. (Reduced from a camera drawing made with Leitz's drawing eye-piece and a  $\frac{1}{12}$ -inch oil-immersion lens.)

*a*, Horny layer; *b*, normal nucleus of epidermal cell; *c* and *d*, nuclei of epidermal cells that are breaking up; *u*, *v*, *w*, *x*, *y* and *z*, various stages of the bodies described as protozoa by the author in 1895. Two bodies resembling leucocytes are present among the minute bodies at *s*.

invading the epithelial cell shown in Fig. 18, 2, contained three typical 'bird's-eye bodies,'<sup>2</sup> and the cluster of granules in violent oscillation at *o'* marked the spot where another bird's-eye body

<sup>1</sup> Pathological Society: 'Cancer of the Septum Nasi caused by Psorosperms,' *Brit. Med. Journ.*, December 24, 1892.

<sup>2</sup> Bird's-eye bodies, known also as 'cancer-bodies,' and 'Plimmer's bodies,' can be obtained by scraping a slice of most cancers. Their definite capsules and



was in process of formation. I had previously concluded from histological study that these bodies are thus formed, and this observation of the living cells confirms my view. Bodies such as 5 and 6 in Fig. 18 are met with in sarcoma and cancer as well as in syphilis. The clear circles within them represent greenish globules, which are formed in the same way as the bird's-eye bodies and the oscillation at *o*, in these two bodies marked I do not doubt the formation of new globules. The two smaller bodies (Fig. 18; 7 and 8), as shown in the sketch, are not unlike leucocytes, but in the living state their absolute identity in physical characters with the larger

---

dense central body, and more or less definite reaction to certain stains, gave them a ready interest among English pathologists, when in 1893 they were demonstrated by Ruffer and Plimmer as the exclusive form of protozoa in cancer of the breast. Here were structures that appeared to be something new—something that could be sought for like tubercle bacilli in a differentially stained preparation. A demand for 'pure cultures' and the satisfaction of 'Koch's postulates' naturally arose in minds long exercised in bacteriological methods. This demand was persisted in, although I pointed out that in no single instance had bacteriological methods then been successfully applied to the study of any of the recognised parasitic protozoa. Sanfelice having described these bodies as *blastomycetes*, Mr. Plimmer isolated from breast cancers a blastomycetic organism which looked like the 'cancer-body.' Pure cultures injected into rats caused granulomata in the lungs, etc. The bird's-eye bodies, as described in the *Practitioner*, 1899, he no longer considers to be protozoa, but blastomycetes. This is a mistake. Mr. Plimmer's research only proves the truth of the view that I have from the first maintained—namely, first, that though I believe the bird's-eye bodies to be protozoa, no one would, from this one phase alone, be justified in forming that opinion; second, that Koch's postulates are not applicable to the study of certain parasitic protozoa; and, third, that cancer of the breast, even when not ulcerated, contains so many different vegetable micro-organisms that it is no better and no worse than other cancers as a material for study. My own view that the bird's-eye bodies are parasitic protozoa is confirmed by the observations recorded in Fig. 18, and so also is my opinion, long ago expressed, that these bodies constitute one link (and that not an essential link) of a chain of forms which includes also some, at least, of Virchow's 'cells of endogenous origin.' In order to prevent misunderstanding, I should like to add that I do not mean to suggest that all cancer is a phase of syphilis, but I do believe that some forms, such as that which supervenes on 'leucoplakia' of the tongue, probably is so. Other cancers may be a phase of measles for aught we know; others, again, some infection possibly dependent on an intermediate host. Such speculations serve to guide inquiry. All we can do at present is to examine the objective evidence, to make such experiments as are necessary, and to think.



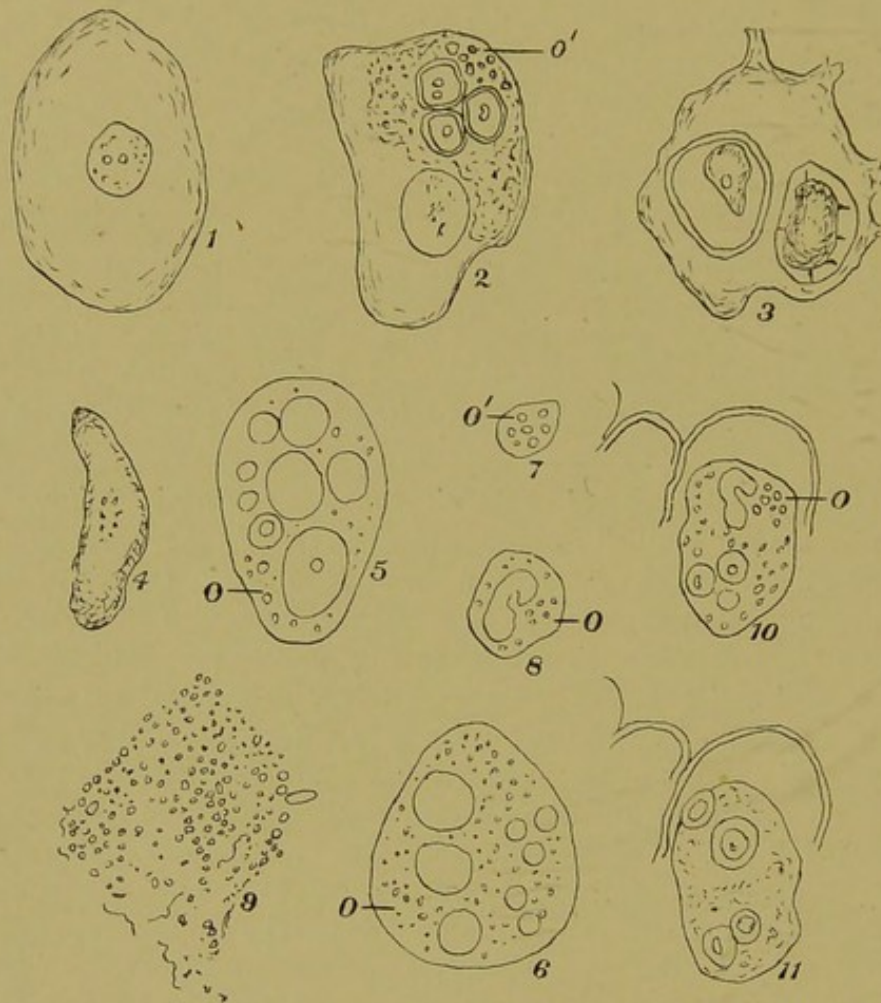


FIG. 18.—BODIES OBSERVED IN A SCRAPING OF A TERTIARY SYPHILITIC LESION. (Examined under a  $\frac{1}{12}$ -inch oil-immersion lens.)

- 1, An ordinary squamous epithelial cell devoid of movement; 2, a similar cell, but containing in optical section a granular mass in which are three typical bird's-eye bodies, and at *o'* a group of granules in lively oscillation; 3, another epithelial cell, the nucleus of which is not seen, and which contains two highly refracting inclusions; 4, a free body of similar optical characters to the inclusions in 3; 5 and 6, structures resembling an epithelial cell in size, but containing large globules of a bright greenish appearance, and at *o* and *o'* groups of smaller globules in oscillation; 7 and 8, small bodies resembling parts of 5 and 6, lively oscillation in one, and oscillation and a greenish nuclear body in the other; 9, a large body, the pale central mass of which is not shown, but globules and granules and a few wavy lines are seen on the surface; 10 and 11 are the same body, 10 as seen at 7.20 p.m., and 11 as seen at 10.45 p.m., when the preparation has cooled down. When first seen, there was a group of oscillating granules, *o*, and a single greenish curved structure to the left of them; later, the preparation having cooled down, the oscillating granules had disappeared, and the body seemed to have divided into two.



bodies and their oscillating granules distinguished them from leucocytes. As to the bodies 10 and 11 in Fig. 18, the partial capsule at their upper end is probably the remains of host-cells, and the evidence detailed in the description strongly supports the view that the curved greenish body near the group of oscillating granules at *o* divided into two parts. The curious body 6 in Fig. 18 looks at first sight something like a zooglœa mass. It was not that, but all the globules, etc., shown in the sketch were on the surface of a dull colourless core. In view of the later work of Schaudinn and

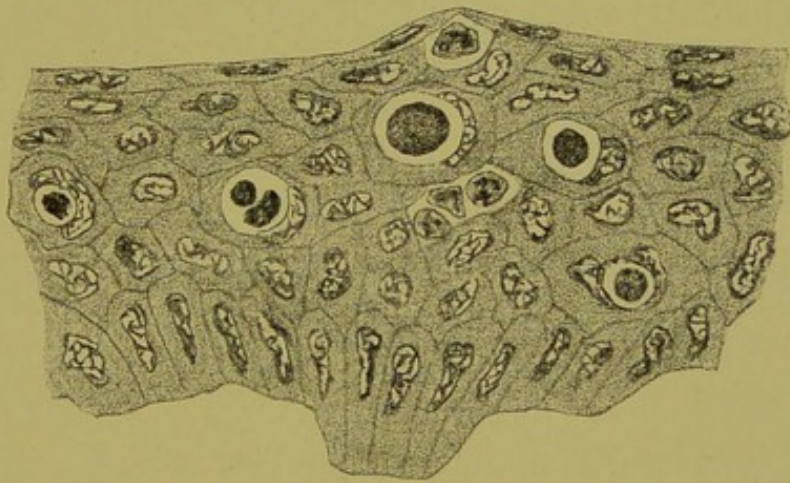


FIG. 19.—PART OF A SECTION THROUGH A RABBIT'S CORNEA SEVENTY-TWO HOURS AFTER INOCULATION WITH SOME MATTER FROM A HARD CHANCRE. ( $\times 500$  diameters.)

It shows hyaline bodies within some of the cells; a few leucocytes are also present.

MacLennan, I think that the various minute bodies are involution-forms of Schaudinn's organism.

The minute bodies, Fig. 15, 4, and Fig. 17, *z*, show traces of chromatin, and I think they may ultimately prove to be a stage in the development of the active spironema, which is only abortively produced in the tertiary lesion. One great interest attaching to the cell-inclusions, etc., in syphilis is that homologous structures occur in cancer, small-pox, and in the later stages of the vaccinated cornea. This latter fact led me to try the effect of inoculating a rabbit's cornea with material from a hard chancre, to compare it with the



vaccinated cornea. Up to that time syphilis had not been successfully transmitted to any animal, but this did not exclude the possibility that some of the stages of the parasite's life might be traced in the rabbit's cells. The result I described in 1895.<sup>1</sup>

In Fig. 19 I reproduce the illustration that accompanied this description. Of these bodies I then wrote that I had not been able to trace such a series of forms as would justify a positive opinion as to their nature, but that their similarity to Guarnieri's bodies was suggestive, adding 'though as yet (1895) no animal has been found which reacts to the virus of syphilis exactly like the human subject; yet it is probable, if sporozoa are present in this disease, that they may be found to live for a time, and even multiply, in some of the lower animals.'

My observations regarding the results of inoculating the rabbit's cornea with syphilis were confirmed by E. Pfeiffer,<sup>2</sup> who found hyaline bodies both in the cells of the cornea and in the subepithelial tissue. Since that time our knowledge of the reaction of animals to syphilis has been greatly augmented, starting from Metchnikoff and Roux's discovery that the chimpanzees and other anthropoid apes are susceptible to syphilis. Since this was established, other apes, dogs, and, to a certain extent, rabbits, have been found suitable media for the reproduction of the spirochæta, as will be further noticed below.

The primary sores that I examined in sections prepared in the same way (fixation in Foa's solution, and acid hæmatoxylin and eosin staining) as the secondary lesion represented in Figs. 15 and 17 showed bodies that I believed to be of the same nature. The sections having been destroyed, I have to trust to my memory, which records them as distinctly smaller but otherwise similar—*i.e.*, hyaline and nucleated bodies which differed in their high refractive power and staining reactions from the leucocytes present in the same sections.

Siegel<sup>3</sup> has described small motile bodies provided with a

<sup>1</sup> *Cent. für Bakt.*, March 15, 1895.

<sup>2</sup> E. Pfeiffer, *ibid.*, Abt. 1, 1895.

<sup>3</sup> J. Siegel, *Münch. Med. Woch.*, Nos. 28 and 29, 1905.



single flagellum, which he has named *Cytoryctes luis*. They attained their maximum number in the second and third weeks; they were seen also in stained sections of primary sores, and were found in apes and rabbits after inoculation. They resemble very closely the bodies described by Doehle. Siegel found that very thin ( $2\ \mu$ ) sections were required. In chancres the larger forms were found inside, the smaller between the connective-tissue cells. Both rabbits and guinea-pigs reacted to inoculation, and motile cytoryctes were found in their blood and tissues.

*Spiroonema Pallida* (Schaudinn).—The discovery of slender motile bodies in syphilitic tissues and fluids was announced in 1905 by Schaudinn and Hoffmann,<sup>1</sup> and since that time the name of this organism, at first called *Spirochæta pallida*, has been changed to *Spiroonema pallida*, because the organism differed in some fundamental respects from other spirochætæ: for instance, Schaudinn was unable to demonstrate an undulating membrane, and there appeared to be a long delicate flagellum at each end. These differences justified the making of a new genus, *Spiroonema*.

The organism was discovered in motion in unstained preparations. In fixed preparations, whether smears or sections, it was found very difficult to stain the spiroonema, but after a time Giemsa's<sup>2</sup> modification of Romanowsky's double stain was found to be best for the purpose; but both Schaudinn and Hoffmann found that the most useful and best way of seeing and appreciating the nature of the organism is to watch it in life. This may be done by adding a little physiological salt solution to a drop of serous secretion, which is then to be simply placed between the slide and the cover-slip, and evaporation is prevented by edging the cover-slip with vaseline. In such preparations the movements of the parasites last a considerable time.<sup>3</sup>

Since, as has been mentioned in Chapter III., the whole question of the biological position of the spirochætæ, etc., is under considera-

<sup>1</sup> Schaudinn and Hoffmann, *Deutsch. Med. Woch.*, April 23, 1905, and *Arbeit. aus der Kais. Gesund.*, 22, 1905.

<sup>2</sup> Giemsa, *Deutsch. Med. Woch.*, No. 26, p. 1026, June 29, 1905.

<sup>3</sup> Hoffmann and Halle, *Münch. Med. Woch.*, July 31, 1906.



tion, it is only necessary to refer to the salient characters of *Spironema luis*. Its slenderness and low power of refracting light, associated with the characteristic form of the spiral, which is narrow, deep, regular, and has usually from ten to twenty-six turns (see Fig. 20), serve to distinguish it from other objects. One great feature is that in the living state the organism exhibits this typical form not only when in motion, but also when at rest. Other spirochætæ become more nearly straight when they come to rest. It is noteworthy that no increase in numbers of the spironema has been obtained in artificial culture media. Schaudinn and Hoffmann<sup>1</sup>

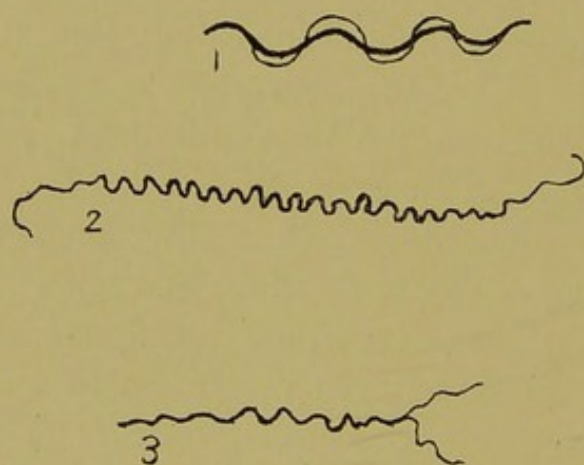


FIG. 20 bis.—SPIROCHÆTÆ. (After Schaudinn.)

1, *Spirochæta refringens*, a common spirochæte; 2, *Sp.* (spironema) *pallida* of syphilis; 3, *Sp. pallida* of syphilis (?) dividing.

found that the addition of glycerine caused various changes in the form of living spironemata. Some remained cork-screw-shaped for from five to ten minutes and then disappeared; others lost their spirals and became straight, then gradually drew themselves together and assumed the shape of a malaria sporozoite, and this in some instances became short and ovoid. Similar bodies were found in cover-glass preparations untreated by glycerine.

So important was the discovery of the *S. luis* that, as recorded in an already voluminous literature, many workers applied themselves to search for the parasites in syphilitic lesions of all

<sup>1</sup> Schaudinn and Hoffmann, *Arbeit. aus der Kais. Gesund.*, 22, 1905.



kinds. The result has been to establish their constant occurrence both in various tissues and organs and in the blood in human syphilis and in experimental syphilis in apes and other animals. They are found in primary and secondary lesions of both acquired and hereditary syphilis, but up to the present they have not been found in tertiary syphilis.<sup>1</sup> A nitrate of silver method of staining introduced by Levatadi demonstrates countless spiral bodies in syphilitic placentas<sup>2</sup> and in the lungs of subjects who have died of hereditary syphilis; but it is not yet quite settled whether all these bodies are the parasites or not.

Among the relatively few writers who have made an attempt to trace the life-history of the parasites are Krzsztalowicz and Siedlecki,<sup>3</sup> who describe trypaniform and sexual stages; but the brief series of forms they depict is too restricted for it to agree with the entire life-cycle of any known trypanosome. Dr. H. M. Woodcock surmises that the spironema has probably been evolved along similar lines to *Trypanosoma equiperdum* (the parasite of *dourine*), although the spironema is probably more modified and almost certainly limited to the human host.

The British author who has paid most attention to this aspect of the problem is Dr. Alex. MacLennan (Glasgow), whose chief published contribution<sup>4</sup> appeared last year. Since then I have seen his preparations at a demonstration.<sup>5</sup> Among other bodies were typical spironemata having a bright globule attached either at one end or near the middle, as well as various minute globular and tailed bodies, clearly shown in preparations from various syphilitic sores, glands, etc. Dr. MacLennan holds the view that the small tailed bodies are the [same] as those described by Siegel (see p. 62), and that they form [with the typical spironemata] part of a life-cycle the remainder of which remains to be determined.

Struck by the difficulty of finding spironemata in the blood of

<sup>1</sup> *I.e.*, not in the spiral form; Schaudinn described them as occurring in tertiary lesions as little granules 'in the characteristic resting state' (*Deutsch. Med. Woch.*, 1905, No. 42, p. 1665).

<sup>2</sup> Marie Wersilowa, *Cent. für Bakt.*, October 29, 1906.

<sup>3</sup> Quoted by H. M. Woodcock, *Quart. Journ. Microsc. Science*, June, 1906.

<sup>4</sup> Alex. MacLennan, *Brit. Med. Journ.*, May 12, 1906.

<sup>5</sup> Royal Medico-Chirurgical Society, January 8, 1907.



persons suffering from secondary syphilis, Dr. W. E. de Korté<sup>1</sup> carefully examined the blood and various lesions for any other bodies, and found some very striking structures in the blood, the chancre, and condyloma, as described by him in 1906. I have had an opportunity of seeing these bodies, and I do not think they can be anything but protozoa. Some of them are very like the structure shown in Fig. 15, 5, of this work, except that a zone of pigment surrounds the central globular space. The fact that many of them are pigmented recalls the structures described in syphilis, cancer, and sarcoma by the late Professor Max Schüller<sup>2</sup> in 1900. The whole subject demands disinterested and broad-minded revision. More care is required on the part of different writers to indicate what relations the bodies they describe have to those previously described by other authors. I have done this as far as possible for my own work, and I have also indicated the bearing of the new on the older pathology of Virchow.

*Experimental Syphilis in Animals.*—In 1904 Metchnikoff and Roux<sup>3</sup> inoculated chimpanzees with syphilis, and found that the disease ran a typical clinical course. Spironemata were found in the lesions, and after the death of one of the animals the lesions were found by Arnal and Salmon to have a structure characteristic of syphilis. In England this observation has been repeated by Grünbaum and Smedley.<sup>4</sup> Only the anthropoid apes, chimpanzee and gibbon, have been found to give the full clinical picture of syphilis, but other apes lower in the scale were made to take the disease in a modified form. More recently, E. Hoffmann and W. Brüning<sup>5</sup> have found that a dog's eye began to react sixteen days after inoculation from a chancre, and a second dog's eye was successfully inoculated from the infected eye of the first dog. After enucleation the eye of the second dog was found to contain typical *Spironemata luis*. The same authors confirm Bertarelli's observation that the rabbit's eye reacts to syphilis in a similar way to that they observed in dogs.

<sup>1</sup> W. E. de Korté, *Practitioner*, June, 1906.

<sup>2</sup> Max Schüller, *Cent. für Bakt.*, 1900, p. 516, and 1904, p. 547.

<sup>3</sup> Metchnikoff and Roux, *Ann. de l'Inst. Pasteur*, 1903-1906, etc.

<sup>4</sup> A. S. Grünbaum and R. D. Smedley, *Brit. Med. Journ.*, March 17, 1906.

<sup>5</sup> E. Hoffmann and W. Brüning, *Deutsch. Med. Woch.*, April 4, 1907.



Neisser<sup>1</sup> has recently summed up the conclusions he has come to in the experimental and practical aspects of recent work on syphilis:

1. The spirochæta is useful in diagnosis.
2. It is impossible to introduce the virus of syphilis except by the formation of a hard chancre.
3. That the spirochæta has not so far been found in tertiary lesions, but the latter, as well as primary and secondary lesions, are contagious, except when they are degenerated.
4. In hereditary syphilis even the nasal mucus is infectious.
5. Neisser has not been able to confirm Metchnikoff's statements as to the destruction of the virus of syphilis by strong mercurial ointment, if applied between one and eighteen hours after inoculation.
6. The rarity of second attacks is probably to be explained by persistence of disease.
7. No attenuated virus has been found; either the virus produced a chancre, or it was dead and inert.

Metchnikoff<sup>2</sup> referring to Neisser's results finds that he did not use a sufficiently strong ointment: from 25 to 30 per cent. of calomel in lanolin is required. Subcutaneous injection of atoxyl proved efficacious in apes as long as fifteen days after inoculation.

#### Yaws.

Yaws, or *Frambæsia tropica*, is a disease which so closely resembles syphilis that the question of their identity has often been discussed. Their likeness has been farther extended by Aldo Castellani,<sup>3</sup> who, in eleven out of fourteen cases, found organisms which closely resemble the *Spirochæta luis*. Castellani thinks that yaws is distinct from syphilis, and proposes the name *Spirochæta pertenuis* for the parasite in yaws. MacLennan has confirmed Castellani's discovery. Castellani found also in the blood of patients suffering from yaws round and oval bodies, which he regards as probably a developmental stage of a protozoon. Experimentally, yaws does not protect an animal against syphilis.

<sup>1</sup> Neisser, 'Bulletin de la Soc. Franç. de Prophylaxie Sanitaire et Morale,' quoted by J. E. Lane, *Practitioner*, October, 1907.

<sup>2</sup> Metchnikoff, *Ann. de l'Inst. Pasteur*, October, 1907.

<sup>3</sup> Aldo Castellani, *Brit. Med. Journ.*, November 18, 1905, and November 23, 1907.



## CHAPTER IX

### CYSTIC DISEASE OF THE URINARY TRACT IN MAN

THE sketch, Fig. 21, repeats the salient anatomical features of a well-characterized instance of this disease. It represents half the left kidney, the ureter, and bladder, removed after death from a woman of sixty years who died from cerebral hæmorrhage, no urinary symptoms being recorded during the brief period that she was in hospital. I have elsewhere<sup>1</sup> described the appearance thus: 'In removing the abdominal viscera the left kidney was noticed to be hydronephrotic, and the ureter was found to contain small elastic-feeling bodies which collapsed on pressure. The same kidney was seen to contain a group of small cysts at its upper end. In the dilated pelvis of the kidney and in the upper half of the ureter there were numerous cysts of a greenish-brown<sup>2</sup> colour, having on an average the size of hemp-seed. There was a moderate amount of hydronephrosis. There were numerous small cysts at the neck of the bladder and at the vesical orifices of the ureters. The contents of the cysts of the ureter in the fresh state showed under the microscope large and small oval and irregular cells, which contained bright globules. Some of the globules were free, and they, like those contained in the cells, stained readily with gentian-violet, logwood, etc.'<sup>3</sup>

<sup>1</sup> Transactions of the Pathological Society of London, 1892, p. 94.

<sup>2</sup> A good coloured illustration of a typical case of this cystic disease of kidney and ureter is given in Morris's 'Surgical Diseases of the Kidney,' first edition, Plate III.

<sup>3</sup> Many similar cases are now on record. The oval bodies were pronounced to be 'psorosperms' by the late T. S. Cobbold. The literature up to the date is



Another part of the same section (Fig. 23) shows other stages of cyst-formation; collections of epithelial cells are indicated at *b* and *c*; the one marked *b* contains a central space. These are two of Brunn's epithelial nests, a possible origin of the ureteral cysts. In the same figure is a small cyst, the contents of which in optical characters and staining reactions are the same as that in Fig. 22, but they are passing, in the form of small granular bodies, at the point *d* into the tissues beyond the cyst.

Still another part of the same section is shown in Fig. 24, where the relation of the cysts to the mucous membrane is seen. The

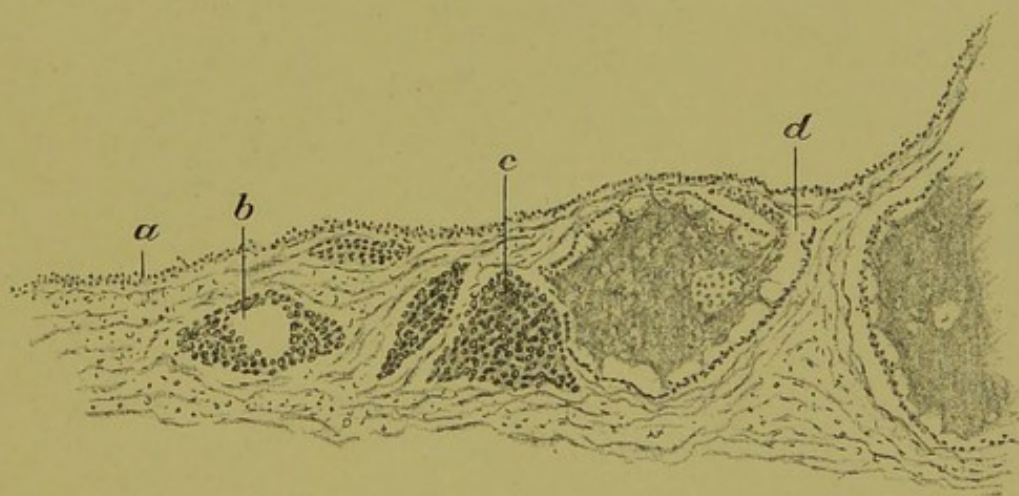


FIG. 23.—CYSTIC DISEASE OF THE URINARY TRACT.

Another part of the same section: *a*, Epithelium of the mucous membrane; *b* and *c*, Brunn's nests, perhaps early stages of cyst-formation; *d*, points to where the contents of a cyst, in the form of amœbæ, are passing into the tissue beyond the cyst. (Low power.)

material contained in some of the cysts—*e.g.*, Fig. 24, *b*—is subdividing into small fragments; these fragments, examined under a higher power, I found to have the same structure as those shown below in Fig. 25, *a*, which represents part of a cover-glass preparation made from the fresh contents of a cyst. The drawing was made carefully with the *camera obscura* under a magnification of 800 diameters.

Returning to the first of the illustrations, we may with advantage examine the cyst containing the oval bodies under a higher power, as shown in Fig. 26. There we see a flattened epithelial lining, *a*, *b*;



within this a hyaline substance, *c*, in which are contained various cellular forms.<sup>1</sup> A few of the largest of these cellular bodies had giant nuclei which stained well with hæmatoxylin; in the majority, however, the central portion did not stain like chromatin, but pre-

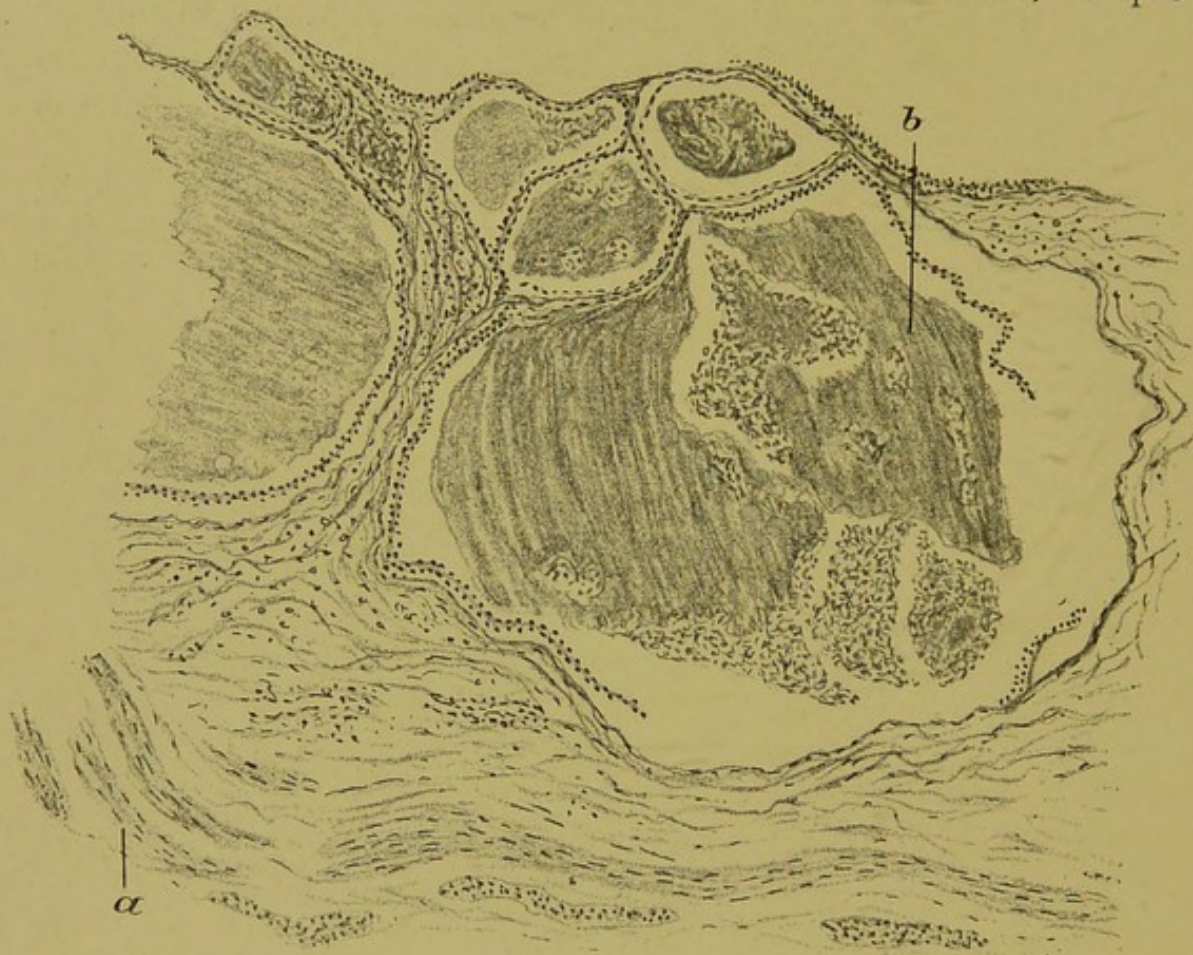


FIG. 24.—CYSTIC DISEASE OF THE URINARY TRACT.

Another part of the same section, showing six cysts: *a*, Muscularis mucosæ; at *b* the contents of the largest cyst are subdividing into amœboid bodies, which are partly dense and partly reticular in structure.

<sup>1</sup> When I first examined this case in 1892, I took the cyst-contents, both cells and intercellular substance, to be due to either hyaline or colloid degeneration. A more critical examination of the large cells, the intercellular substance, and the amœba-like subdivisions into which both of these broke up, brought me to a different conclusion, as stated below. This more critical examination was due to my being asked by a society, through the secretary, to furnish them with an illustrated account of the case, and at the same time I was directed to describe the bodies as 'psorosperms.' At that time our knowledge of the protozoa was very limited, and the word 'psorosperm' was loosely applied to coccidia, myxosporidia, etc. There is now no need to retain it.



Lubarsch<sup>1</sup> has attributed the formation of the cysts to degeneration of these. This hypothesis does not account for the presence in the cysts of the kidney of bodies and material similar to those found in the ureteral cysts, nor does it account for the intense inflammatory action, accompanied by cyst-formation, at the neck of the bladder. The view that the bodies in the cysts of the urinary tract were protozoa appears to have originated with the late T. S. Cobbold, formerly well known as helminthologist to the Middlesex Hospital. Cobbold's view was recorded by the late W. B. Hadden (Trans. Path. Soc., vol. xxxiv., p. 237). The contents of some sub-capsular renal cysts that occurred in a case of multiple sarcoma were submitted to Cobbold, who pronounced them to be 'psorosperms,' and there was in the Society a tradition to the effect that Cobbold regarded certain bodies in the sarcoma-tissue also as psorosperms. I never thought that the oval bodies were coccidia in a strict sense, but I did come to the conclusion that not only the oval and other bodies, but also the albuminous material in which they are embedded, were sporozoa of some kind. The late von Kahlden<sup>2</sup> regarded them as myxosporidia. It must be confessed that the colloid-like basis of the cyst-contents, with the contained bodies, as shown in Figs. 22 and 26, bear a resemblance to some of the myxosporidia. On this supposition the whole contents of a cyst would be one amœboid myxosporidian and the oval bodies pansporoblasts. But the typical spores of the myxosporidia are wanting. Without arguing the matter in further detail, I may say that I still regard the whole of the cyst-contents, together with the oval bodies, as protozoa; and this for many reasons, two of which are—first, the improbability of any process of degeneration being capable of causing both nucleus and cytoplasm of the cells lining the cysts to swell equally to form the large oval bodies; and, second, the evidence that both the oval bodies and the albuminous substance subdivide into smaller amœboid bodies, such as are shown in Fig. 25, *a*. To what class of the protozoa they should

<sup>1</sup> Lubarsch, *Archiv. für Mikroskop. Anat.*, 1893, p. 303.

<sup>2</sup> Von Kahlden, *Zeigler's Beiträge*, 1894.



be referred it is, in the still imperfect state of knowledge, impossible to say.

At one time I based my belief that certain bodies that occur in sarcoma and cancer were protozoa on the ground of their identity with one or other of the forms of these bodies in the disease under consideration. This support is now not required for my view of the bodies in cancer, but rather the converse.



## CHAPTER X

### DEFINITION OF THE TERM 'CANCER,' ETC.

THE term 'cancer' in this book refers to the common forms of malignant disease, whether of the epithelial type (carcinoma proper) or of the connective-tissue type—*i.e.*, sarcoma. These are the instances of disease which have given the word 'cancer' its meaning among the civilized races of mankind. In the present state of knowledge, under the heads of cancer and sarcoma diseases of varied origin and causation are possibly included, and when their causation is more definitely established various distinct groups may require to be made where only one now exists. It is important to examine most closely in every way, clinically, microscopically, and experimentally, the commonest and most typical of the instances of cancer. If it is found that these commoner forms can be grouped together on the ground of their having a similar causation, then it is to this group that the name 'cancer' must be given, and for other rarer forms other names must be sought. Such common examples are the epithelial cancers of the skin, the mouth, the gullet; of the stomach, intestine, and gall-bladder; of the kidney, bladder, and prostate; of the breast and uterus; of the ovary or testis, etc.; and connective-tissue cancers of the fibrous tissue, of various parts of the body, of lymphatic glands, bone, etc.

The first rational step in relation to the investigation of a disease which involves change in the structure of the tissues is to consider the cellular constitution of all living things as established by Schleiden and Schwann about 1838, and to remember that every disease involves a disturbance of the arrangement or condition of



the cells of which the body or part of it is built up, as was established by Virchow in 1847. As applied to cancer, the truth of the main part of Virchow's teaching is incontestable; the bloodvessels of these tumours can be injected from the main artery of the body, showing that they and the cells that constitute them are part of the general vascular system. In primary<sup>1</sup> epithelial cancers many cellular elements<sup>2</sup> besides those of the bloodvessels can also be traced to be in structural continuity with the adjacent normal tissues, and the following pages will show that the same continuity of structure exists in some connective-tissue cancers, not only in the primary, but in all the lesions.<sup>3</sup>

'Virchow and his followers regard all the constituent cells of cancer as lineal descendants of cells which once formed part of the body of the animal in which the tumour grew. The accuracy of Virchow's description of the histological structure of cancer and sarcoma has been proved again and again; the only question with regard to them is one of interpretation.'<sup>4</sup>

In many cancers the structure of the tissue is so changed, and the forms of the cells, their structure and arrangement, are so varied, as to give a bewildering prospect when the tissue is seen in sections under the microscope. Some authors—for instance, Arnold,<sup>5</sup> von Hansemann, and others—have described many varieties of nuclear

<sup>1</sup> By a 'primary' tumour is meant the original tumour; if more than one tumour is present it is possible that two or more of them appeared at the same time. In such a case there would be more than one primary tumour.

<sup>2</sup> That is, the structures readily recognised to be cells under a medium power of the microscope—*i.e.*, ordinary cells, as distinguished from bacteria.

<sup>3</sup> The term 'lesion' or 'damaged part' appears to the writer to be preferable to such names as 'morbid growths,' etc., which involve ideas that require reconsideration.

<sup>4</sup> Virchow's original view of the cells of cancer was that they all belonged to the connective tissue: this error was corrected by Waldeyer. The passage quoted is from the writer's book 'Morbid Growths and Sporozoa,' published in 1893. Further quotations from this work will be made, but, for the sake of simplicity, references will not be made to that work save when necessary.

<sup>5</sup> A short notice of work done up to that date appears in the Transactions of the Pathological Society, 1894, p. 245, as an introduction to an article by myself on cell-forms in a myxosarcoma.



division in the cells of malignant growths. Klebs attempted to find some explanation for the abnormal cell-forms that are seen, and ultimately he arrived at the opinion that leucocytes present within the epithelial cells of cancer exert a spermatogenic property by which they fertilize the epithelial cells, so awakening in them renewed activity of proliferation—conferring on them, in fact, the properties of fertilized ovum-cells. Klebs's theory has recently been revived in this country in a slightly modified form. The following pages will make it clear that as far as cancer of connective tissues is concerned there is no evidence whatever that leucocytes play any such part, and in a subsequent publication I think that I shall be able to show that in epithelial cancer also that theory is equally unnecessary, and devoid of real objective evidence in the cellular elements of the tissues concerned.

All the accepted views of the objective cell-phenomena in malignant disease are based upon the assumption stated above—namely, that all the obvious cells in the tissues implicated in the disease are derived from the sufferer's own body. The term 'metastasis'<sup>1</sup> is based upon the assumption that secondary tumours are transplanted from the primary. Those who have challenged the universal application of this assumption have not as yet received much encouragement. In the present volume I wish to give in a consecutive manner the result of a re-examination of the question as far as it concerns the commoner and better-known of the sarcomas or connective-tissue cancers,<sup>2</sup> they being less complicated in histological structure than the epithelial cancers, reserving publication of the results of a re-examination of the latter for as early a date as opportunity will allow. As a basis for comparing the histology of sarcomas with that of normal granulation tissue, I have taken

<sup>1</sup> By the constant use of such terms in pathological argument attention has been diverted from objective facts and transferred to unproven assumptions.

<sup>2</sup> When I first published my view of the cause of sarcoma it was said, 'What is sarcoma but cancer of connective tissue?' I had arrived at the same conclusion by finding that the same peculiar cells and cell-inclusions which distinguish sarcomas and epithelial cancers from normal tissues were found in sarcomas as well as in epithelial cancers.



developing granulation tissue as I found it growing between the ends of divided tendons in rabbits.<sup>1</sup>

As I mentioned at the time of its publication, this work on the repair of tendons was used as a 'control' for the work on sarcoma that I was then engaged upon.

<sup>1</sup> The original paper appeared in the Transactions of the Pathological Society of London, 1895, p. 218, but the illustrations to which references are made do not appear, and I regret to say that I have been able to find neither them nor the specimens from which they were made, and so I am obliged to fall back on some of the illustrations that appear in my 'Surgical Pathology and Principles,' 1897. These were taken from those that were sent up with the article referred to.



## CHAPTER XI

### GRANULATION TISSUE—THE NORMAL 'GRANULOMA' OF DEFENCE AND REPAIR

*THE formation of granulation tissue from fibrous tissue* is one of the most important defensive processes that occur in the animal body. When the tendon of the heel is divided subcutaneously by a tenotome in a rabbit the divided ends of the tendon separate by a space of nearly  $\frac{3}{4}$  inch. One animal was killed twenty-four hours after this little operation had been done aseptically, and the separated ends of the tendon were found to be already joined by a firm straw-coloured jelly, which filled the tendon sheath in the form of a cylinder, which at its extremities enveloped the divided ends of the tendon. There was but little effused blood, and it was confined to the cut surfaces of the tendon. A tendon similarly divided and removed with the uniting material at the end of forty-eight hours, then fixed in a mixture of saturated perchloride of mercury and 5 per cent. chromate of potassium (Foa's solution), and examined in sections after staining with Ehrlich's haematoxylin and eosin, presents the different features shown in Fig. 27. Another rabbit was killed four days after a tenotomy had been done, and the state of the united medium, now fully formed granulation tissue, is shown in Fig. 28. The series of events thus briefly indicated offers several points for comment. The straw-coloured coagulum that is present at the end of forty-eight hours can only be coagulated plasma from the blood and lymph set free from the divided vessels. That this coagulum, after forty-eight hours, is everywhere traversed by a network of cells testifies to the rapidity of the process



of repair. What is the origin of this network of cells? I could find no evidence that the new cells arose in this instance in any way except by indirect division. The nuclei of the young branched cells everywhere showed signs of activity, and many of them presented mitoses, as seen in Figs. 27 and 28. The new cells were

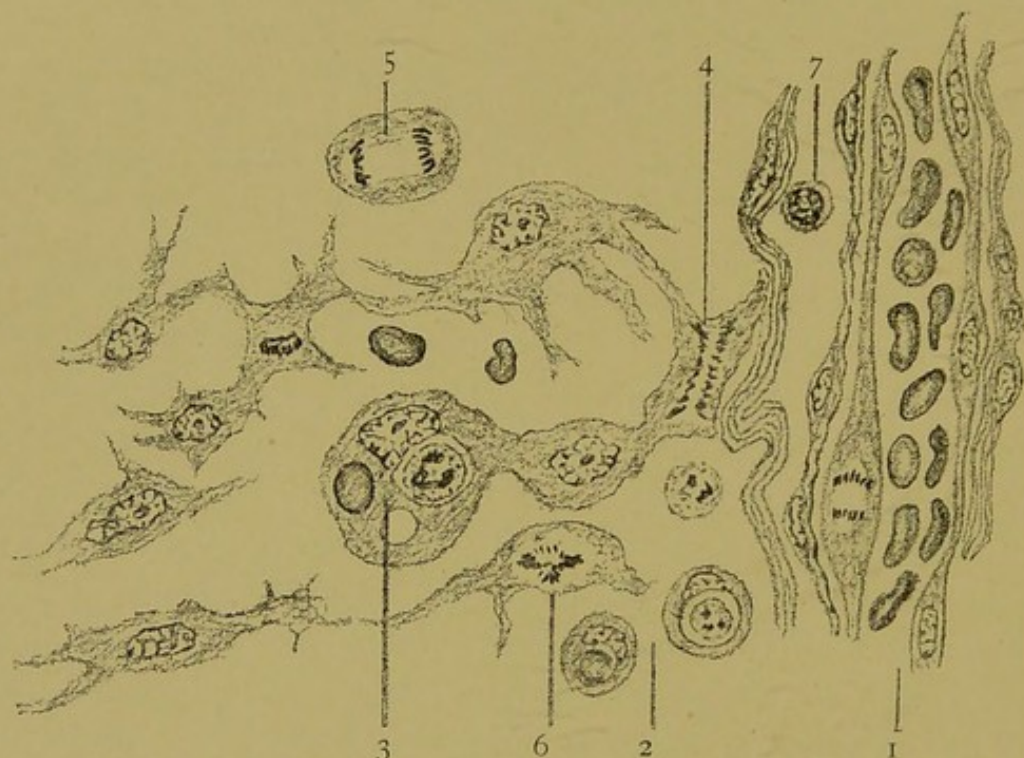


FIG. 27.—PART OF THE TISSUE UNITING THE SEPARATED ENDS OF A TENDON FORTY-EIGHT HOURS AFTER DIVISION. (This figure is composed of several areas selected from a section, drawn to scale.  $\times 1,000$  diameters. From the Author's 'Surgical Pathology and Principles,' 1897.)

- 1, A capillary of the tendon sheath containing red blood-cells: one of its endothelial cells is undergoing subdivision; 2, points between two lymphocytes, one of which contains an ordinary multinuclear leucocyte, the other a red corpuscle; 3, indicates one of the fibroblasts which contains a leucocyte, a red corpuscle, and a vacuole; 4, 5 and 6, connective-tissue cells undergoing mitosis, which is irregular in 6; 7, a lymphocyte.

seen, as evidenced by the presence of mitotic figures, to arise from the fibrous bundles of the tendon sheath, and from its prolongations between the fibres of the tendon bundles. The latter did not appear to take any active part in the process of repair.

Examined on the fourth day, the newly formed tissue was found to have the characters of fully formed granulation tissue—*i.e.*, new



capillary bloodvessels were in process of formation (Fig. 28; 2, 3 and 4), and the outer layers of the cytoplasm of the branched and anastomosing connective-tissue cells were being transformed into fibrous tissue. The transformation of the succulent granulation tissue

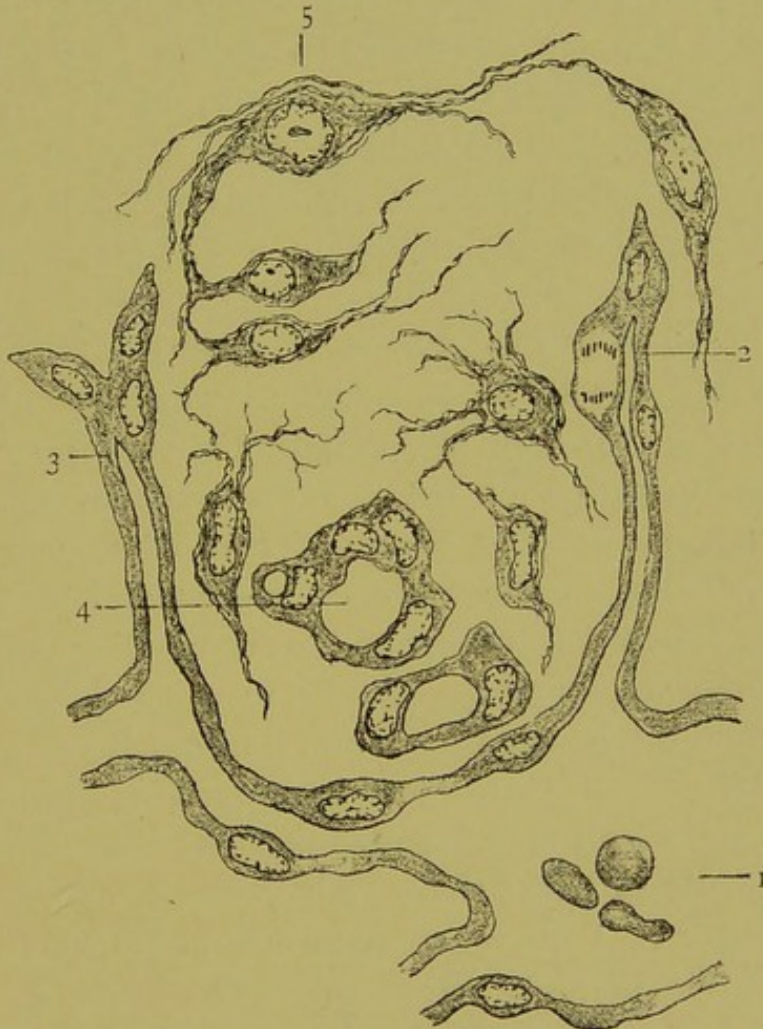

FIG. 28.—A FARTHER STAGE IN THE FORMATION OF SCAR TISSUE FROM GRANULATION TISSUE OF THE RABBIT'S TENDON FOUR DAYS AFTER DIVISION. ( $\times 1,000$  diameters. From the same source as Fig. 27.)

- 1, A dilated capillary of the tendon sheath; 2 and 3, newly formed capillaries; 4, cross-section of a newly formed capillary; 5, one of the young connective-tissue cells: the outer portion of its protoplasm and its branched processes are becoming fibrillated.

into fibrous scar tissue had begun. In another tendon examined on the fourteenth day the scar tissue was already firm and pale. Under the microscope it was easy to see its cells lying flat against bundles of newly formed gelatiniferous fibres.



*What causes Granulation Tissue to form?*—It is worth while to ponder a moment to inquire what the immediate causes of this awakening of the connective-tissue cells into active life may be. The outpoured blood and lymph afford them an abnormally abundant supply of food; and in all probability it is this factor that determines the increase in size and activity of the cells. In repair of rabbits' tendons, as stated above, I was unable to find any evidence of cell reproduction other than by indirect division. Cell multiplication by the simpler process of direct nuclear division may occur when the normal conditions are altered to a less extent; for example, when there is accumulation of lymph about the cells of fibrous tissue, or, in other words, œdema of a part, the supply of food to the cells will not be so abundant as when coagulable plasma escapes with blood from divided vessels, and yet it may be sufficient to cause multiplication of the connective-tissue cells. Such an œdema of the surrounding fibrous tissues will occur where any tumour is growing in the body of any animal. The increased tension exercised by the tumour on the surrounding parts must take effect upon the veins and lymphatics, in which pressure is low or negative, before it tells upon the arteries, in which there is a positive pressure. As a result, there must be around a growing tumour a zone of œdema, which may increase the nourishment of the fibroblasts sufficiently to cause them to increase in numbers and form granulation tissue. To these changes may be added strictly inflammatory ones due to toxic materials, which cause changes in the walls of the bloodvessels and attraction or repulsion of leucocytes (chemiotaxis).

*Nuclear Changes in the Cells of Granulation Tissue.*—In normal connective tissue the nuclei of the cells of the bundles of fibres lie flattened and curved to fit the contour of the bundles. They are very poor in chromatin. When the fibrous bundles become separated by an unusual amount of lymph, the nuclei fill out, assuming ovoid or spherical forms, and, if the condition of œdema persists, the chromatin becomes more abundant, and preparations for cell-division begin.



What I looked for most closely was to see whether the dividing connective-tissue cells assumed appearances like those bodies I had regarded as protozoa in cancerous tissues. This I found not to be the case.

*Nucleoli.*—In studying the granulation tissue I paid close attention to the nucleoli of the connective-tissue cells. Nucleoli were present in many of the cells the nuclei of which were not in mitosis.

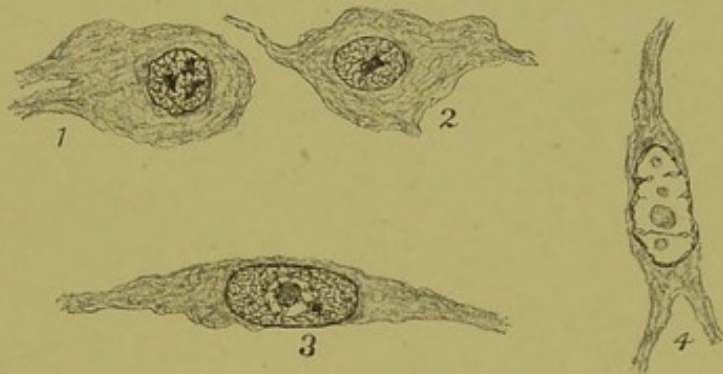


FIG. 29.—TYPES OF NUCLEI IN FIBROBLASTS. (From a Biondi-stained section of rabbit's tendon. Camera drawing.  $\times 800$  diameters.)

1 and 2, Nuclei with fine reticulum of chromatin, in 1 there are three nucleoli and in 2 there is one nucleolus. In this case the nucleoli are net-knots or plasmosomes—*i.e.*, stained like the chromatic network with which they are continuous; 3, near the middle of the nucleus is a nucleolus, the outer part of which was stained by the basic stain like the chromatin network, which it joins at several points, and its central part stained with acid dyes; 4, a nucleus with the chromatic network very little developed, and four oxyphile nucleoli.

These nucleoli appeared as round or oval bodies, which stained chiefly with the acid dyes when mixed stains were used.<sup>1</sup>

Of all the cell-organs the nucleolus is perhaps the least completely known, but in these connective-tissue cells it appears to have what is its commonest constitution and function, undifferentiated protoplasm, from which chromatin is formed before the mitotic change begins. The most rudimentary forms of some protozoa have a quite similar constitution, and experienced biologists have

<sup>1</sup> As stated above, I have not kept the sections on which my description of the change in rabbits is based, and for the past twelve years I have been without the necessary facilities for pursuing practical work in that direction. I have, however, found one of the sections, which I have restained with Biondi, and from this the cells in Fig. 29 were drawn.



erred in describing as peculiar nucleoli protozoa parasitic in nuclei of other protozoa. The high degree of differentiation in structure and function exhibited by the nucleoli of certain cells, such as ovum-cells, nerve-ganglion-, and epithelial cells, accounts for such errors. In the following studies of sarcoma will be given the writer's ground for thinking that a similar mistake has been made by pathologists with regard to intranuclear bodies in some sarcomas. The nucleoli in this granulation tissue of the rabbit do not present the distinguishing features of the bodies to be described below as parasites.

*Phagocytosis in Granulation-Tissue Cells.*—The evidence of phagocytosis I described as follows:

‘In the neighbourhood of the clot, leucocytes of each variety may be found to have engulfed some of the red corpuscles. In the interior of some of the young connective-tissue cells both red and white blood-corpuscles are to be observed. This inception and subsequent digestion of cells and other extraneous particles by living cells is termed phagocytosis.’<sup>1</sup>

Many of the fibroblasts had no nucleolus at all; in others in Biondi-stained sections there was a condensation of chromatin (net-knots) at one or more points in the nucleus (Fig. 29; 1 and 2). In others a central oxyphile body had a marginal part of chromatin which was connected with the general network of the nucleus (Fig. 29; 3). In a few the nucleus was poor in chromatin, and several oxyphile bodies were present (Fig. 29; 4). All these features point to the nucleolus being a structure from which chromatin is differentiated in the passage of the nucleus from a resting to an active stage; as such in its simplest forms it would be indistinguishable from the rudimentary forms of certain protozoa.

<sup>1</sup> The significance of the inception of foreign particles by leucocytes was first pointed out by Haeckel; the bearing of the fact on immunity was indicated by Carl Roser in 1881; and the theory of phagocytosis as we know it was fully worked out by Metchnikoff. See G. Sims Woodhead, Transactions of Pathological Society, 1892, p. 20.



## CHAPTER XII

### ON THE STRUCTURE OF AN ALVEOLAR SARCOMA OF THE HUMAN BREAST AND ITS MEANING

THE tumour, when cut in half and made ready to be placed in a museum,<sup>1</sup> had the appearance shown in Fig. 30. In the catalogue I described it thus: 'Half of a breast, the seat of a large growth, which contains an irregular cavity. The nipple is not retracted. A second mass of growth, as large as a tangerine orange, is present. Its situation suggests that it arose in one of the axillary glands. The microscope showed a typical alveolar sarcoma.' The cavity was the result of a central liquefaction in the tumour, and the opening marked '1' was caused by an exploratory incision made shortly before the tumour was removed by Mr. Owen from a middle-aged woman.

Beneath the breast the pectoral muscle was infiltrated with nodules of the growth.

Sections of this tumour made for the purpose of diagnosis and demonstrations in the laboratory showed the structure characteristic of those sarcomas in which the capillary network, with more or less fibrous tissue, remains to subdivide the cut surface into alveoli, which are filled by small groups of cells. The cells in this tumour accord with Billroth's description of alveolar sarcoma, having 'one or more nuclei with glistening nucleoli.'<sup>2</sup> These average 'good classroom' preparations showed little beyond these points and that the

<sup>1</sup> The preparation was described by me in the catalogue of St. Mary's Hospital Museum, first additional volume, 1897, No. 1,465A. The tumour, with additional details, I described in the *Cent. für Bakt.*, May 10, 1895, and in the *British Medical Journal*, April 6, 1895.

<sup>2</sup> Billroth, 'Surgical Pathology,' English Translation, 1884, p. 719.



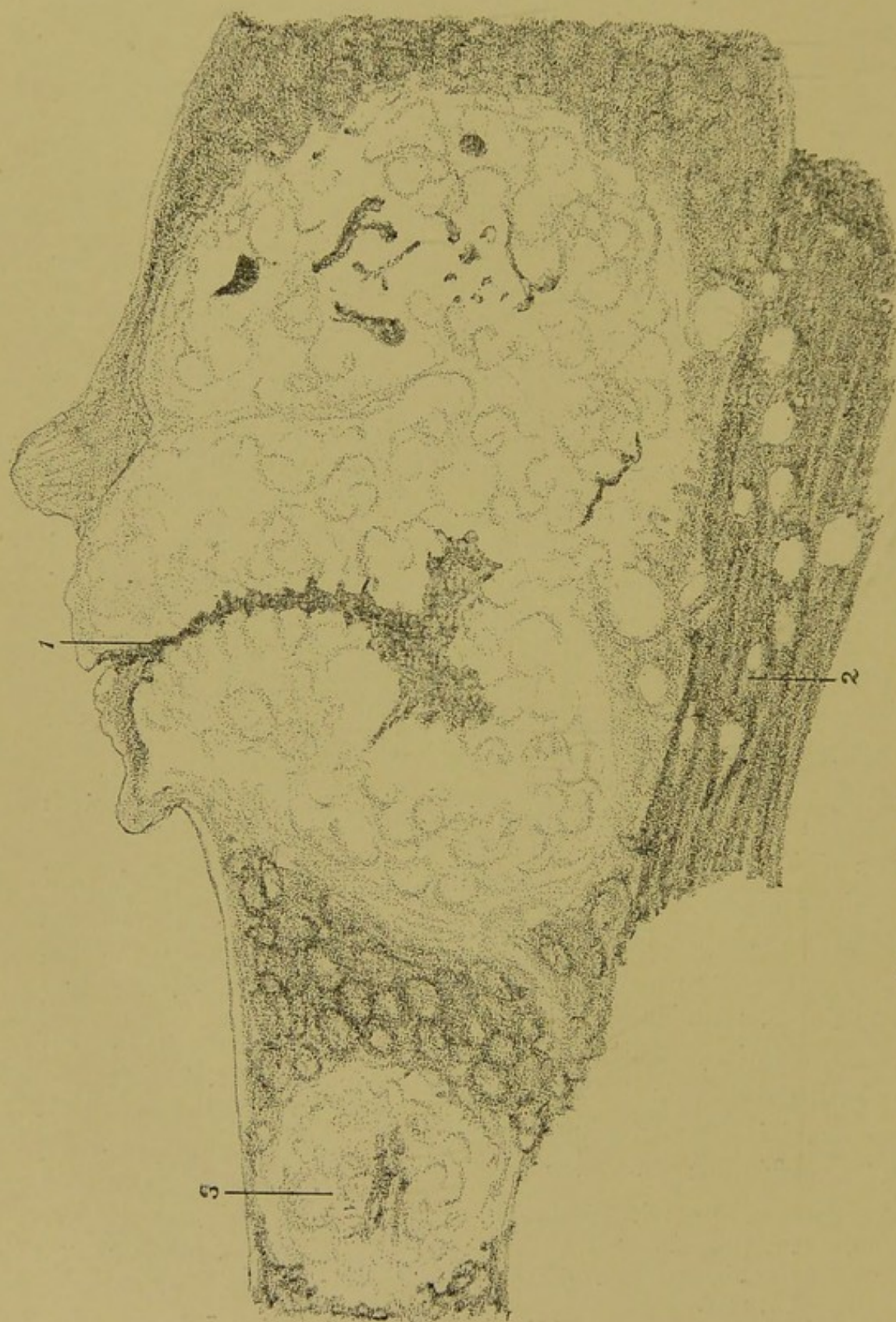


FIG. 30.—ALVEOLAR SARCOMA OF THE BREAST.

A median section of a breast and surrounding parts: The mammary tissue is replaced by a white tumour, which presents an opening on the surface at 1; the growth extends into and infiltrates the pectoralis major muscle, 2; there is a secondary nodule of growth in the axilla at 3.



epithelial part of the breast was simply destroyed by pressure, but other sections more carefully prepared from well-fixed material, cut

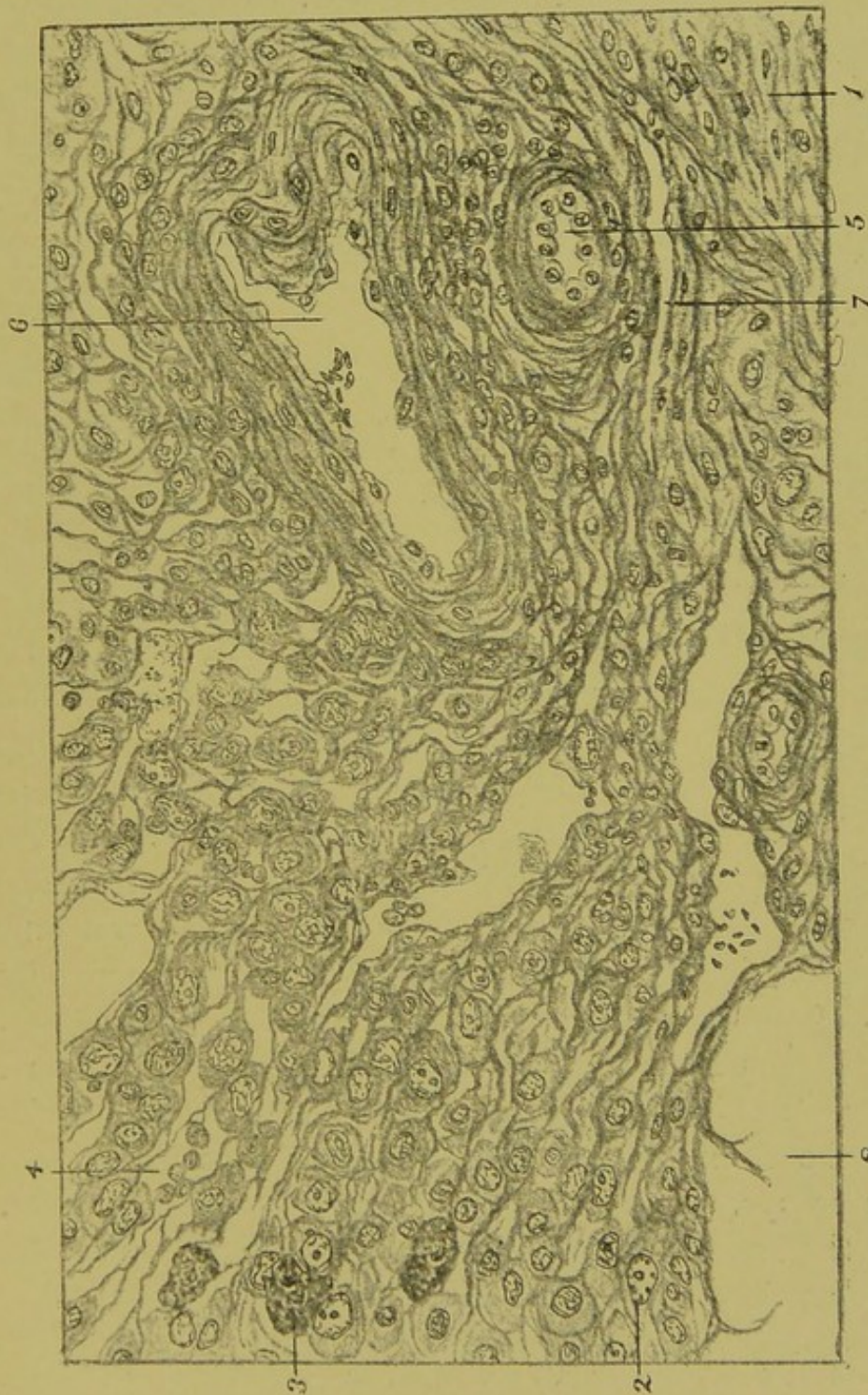


FIG. 31.—ALVEOLAR SARCOMA OF THE BREAST. (Camera drawing.)

A section of a nodule at its junction with the normal tissue: 1, Normal fibrous tissue; 2, nucleus containing a 'glistening nucleolus'; 3, large amoeboid cell with irregular nucleus; 4, mononuclear leucocytes; 5, arteriole; 6, venule containing a few red blood cells; 7, lymph-space; 8, spaces from which fat-cells have been dissolved.

of less than one-cell thickness, and stained so as to give a good differentiation, revealed, when subjected to careful ocular analysis,



most important features, which I will place before the reader as objectively as possible, putting out of mind all definitions of 'cancer'; at the end of the description I will give my interpretation of the phenomena before us. Examining first at many points the peripheral part of the main growth and several of the secondary nodules, I found that in all a gradual continuity of the connective-tissue cells with those of the tumour could be clearly traced, as is shown in Fig. 31.<sup>1</sup>

This fact is of the very greatest importance, and will bear being restated: *The cells that form the basis of this alveolar sarcoma are granulation-tissue cells*—in other words, this alveolar sarcoma is a granuloma.

Inside the marginal zone the structure of the tumour was similar throughout, and an average area examined under a higher power is shown in Fig. 32.

This is drawn from a specimen made twelve years ago, and stained with Ehrlich's hæmatoxylin and eosin, and the colours are still quite definite, almost as much so as when the specimen was first made. The most striking feature is the presence of intranuclear bodies, which recall the nucleoli of nerve ganglion cells or of ova. By tracing the derivation of the tumour-cells, the latter, as has been already pointed out, are seen to be granulation-tissue cells. Are the intranuclear bodies nucleoli? A wider study of this sarcoma is necessary before this question can be answered. Here I will only refer to the description of Fig. 32, where reference to other bodies is also made. Other sections were stained with Biondi's reagent, and from one of such in 1895 I made a coloured drawing, which I have before me. The peripheral processes of the intranuclear bodies were seen in the Biondi-stained sections better than in sections stained in other ways. They are stained a brownish-orange colour, and many of them are seen to possess knobbed 'tentacles' like those of suctorians. In the hæmatoxylin preparations the ends of these

<sup>1</sup> If any illustration in this book—*e.g.*, Figs. 31, 32, etc.—is described as a camera drawing, I shall be pleased to arrange to show the original specimen to anyone who may wish to see it, but I cannot again send specimens by post, having lost several in this way.



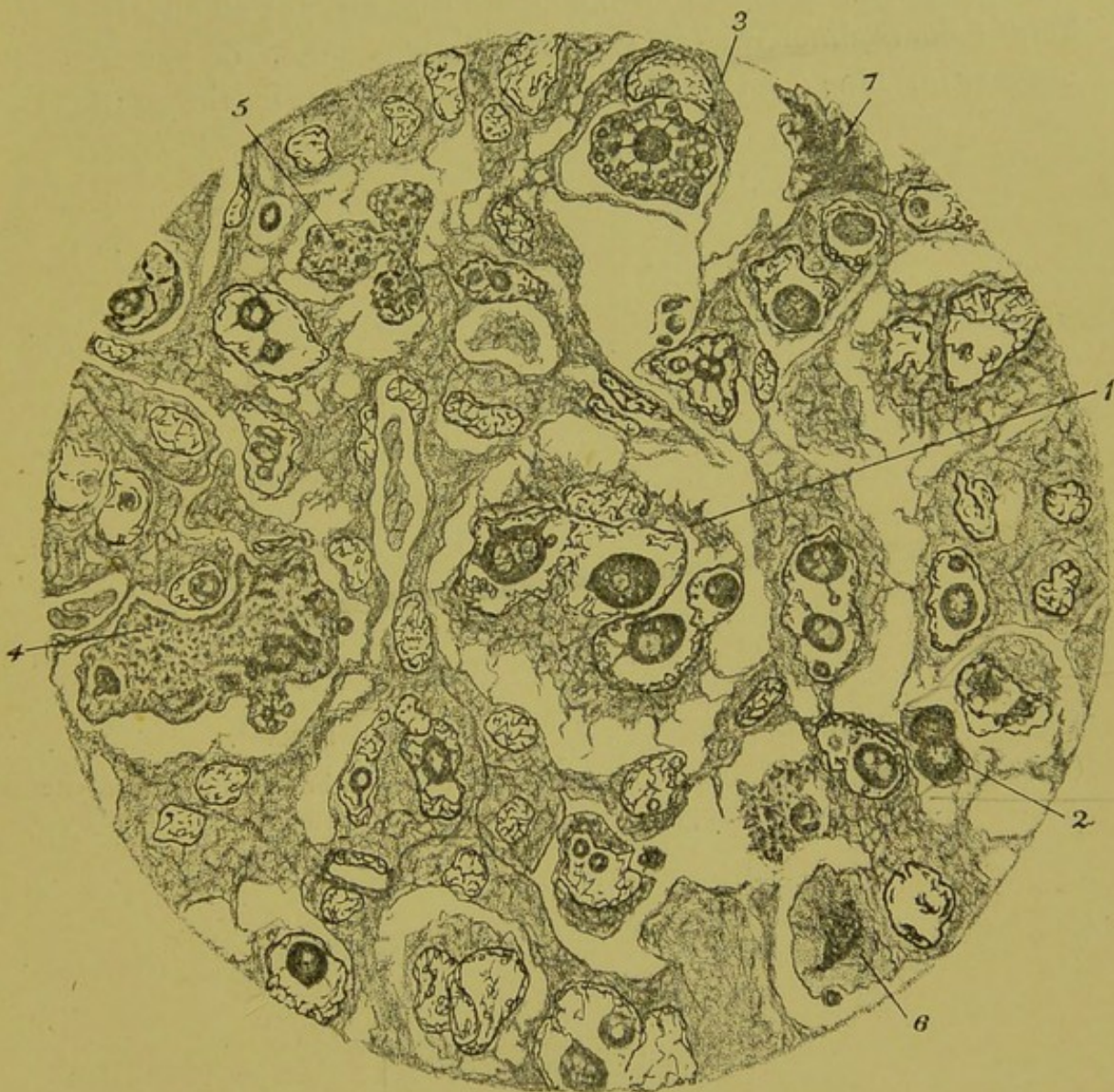

FIG. 32.—ALVEOLAR SARCOMA OF THE BREAST. (Camera drawing—*i.e.*, outlines drawn with Leitz's drawing eye-piece and  $\frac{1}{12}$ -inch oil-immersion.  $\times 800$  diameters.)

A fully developed part of the tumour: 1, In the centre of the field, a large fibroblast with lobed nucleus containing four intranuclear bodies; 2, two bodies similar to those in the interior of the nucleus at 1, free and fusing together with a peripheral extension; 3, a granular intranuclear body with a dense chromatic nucleus sending rays into the periphery and forming chromidial granules by fusion with cytoplasm; 4 and 5, free amœboid bodies containing chromatin and forming granules, the latter similar to those in 3; 6, a free body with a dense chromatic part sending processes into the non-chromatic peripheral part; 7, a body similar to 6, but without differentiation of chromatin.

*Cytoplast*



tentacles, being stained like the chromatin, are not so clearly seen. The colour differentiation—intranuclear bodies, orange-brown; chromatin, blue; and cytoplasm, pale orange—in these Biondi-

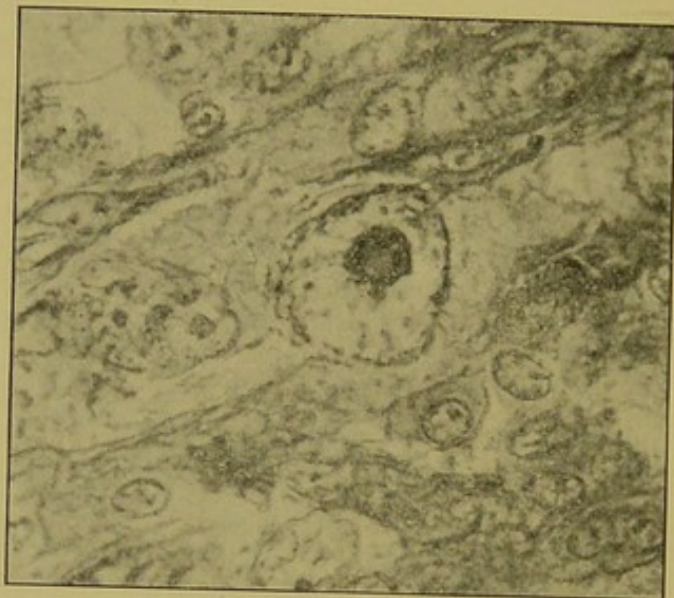

FIG. 33.—ALVEOLAR SARCOMA OF THE BREAST.

(Photograph showing an intranuclear body provided with knobbed tentacles, one of which is spirally shaped.  $\times 800$  diameters.)

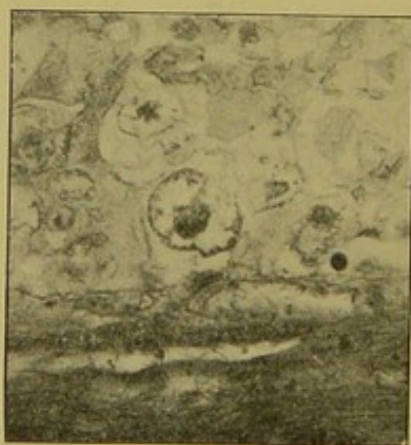


FIG. 34.—ALVEOLAR SARCOMA OF THE BREAST.

(Photograph showing an intranuclear body attached by its shortened tentacles to the nuclear membrane, which is indrawn.  $\times 400$  diameters.)

stained sections was particularly good, but they are now faded, and I have not been able to restain them so successfully; but at the time photographs of these sections were kindly made for me by



Mr. Roughton and the late Dr. Cosens.<sup>1</sup> These photographs are reproduced in Figs. 33, 34, and 35. In the middle of Fig. 33 is one of these intranuclear bodies  $\times 800$  diameters. There is an appearance as of a vacuole in it, and it is seen to be provided with knobbed tentacles, one of which has assumed a spiral form. Fig. 34 shows a similar body. The tentacles at one end are attached to the nuclear membrane, which is indrawn; this feature was better seen in the section than in the photograph. The third photograph (Fig. 35)

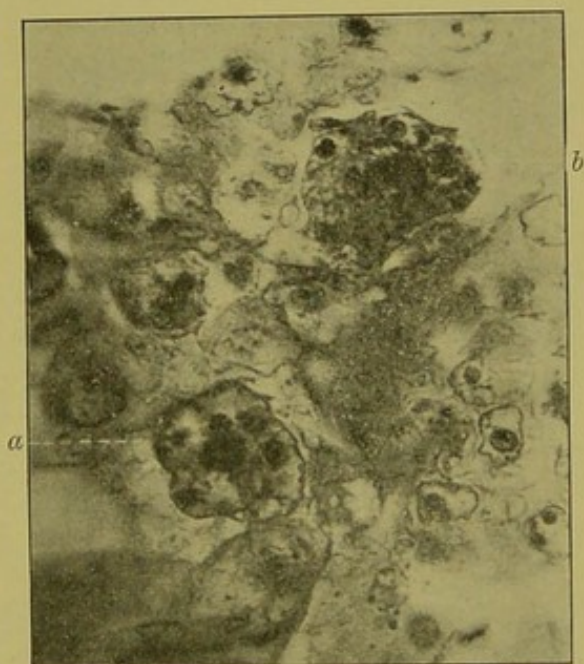


FIG. 35.—ALVEOLAR SARCOMA OF THE BREAST.

(Photograph showing at *a* a nucleus with several intranuclear bodies, and at *b* an amœboid body with 'gemmule' formation.)

shows, first, in optical section at *a* a large nucleus containing one large and four small intranuclear bodies, and at *b* above and to the right of the middle a free amœboid body with the formation of spherical 'gemmules'; some of the latter are seen to have fine peripheral rays attaching them to the rest of the cytoplasm of the cell. Some of the intranuclear bodies seemed to contain a circlet of bright vacuoles, causing them to resemble very closely some of the intra-

<sup>1</sup> These photographs were made at the request of a society, with a view to publication, in 1895, but they were not then published.



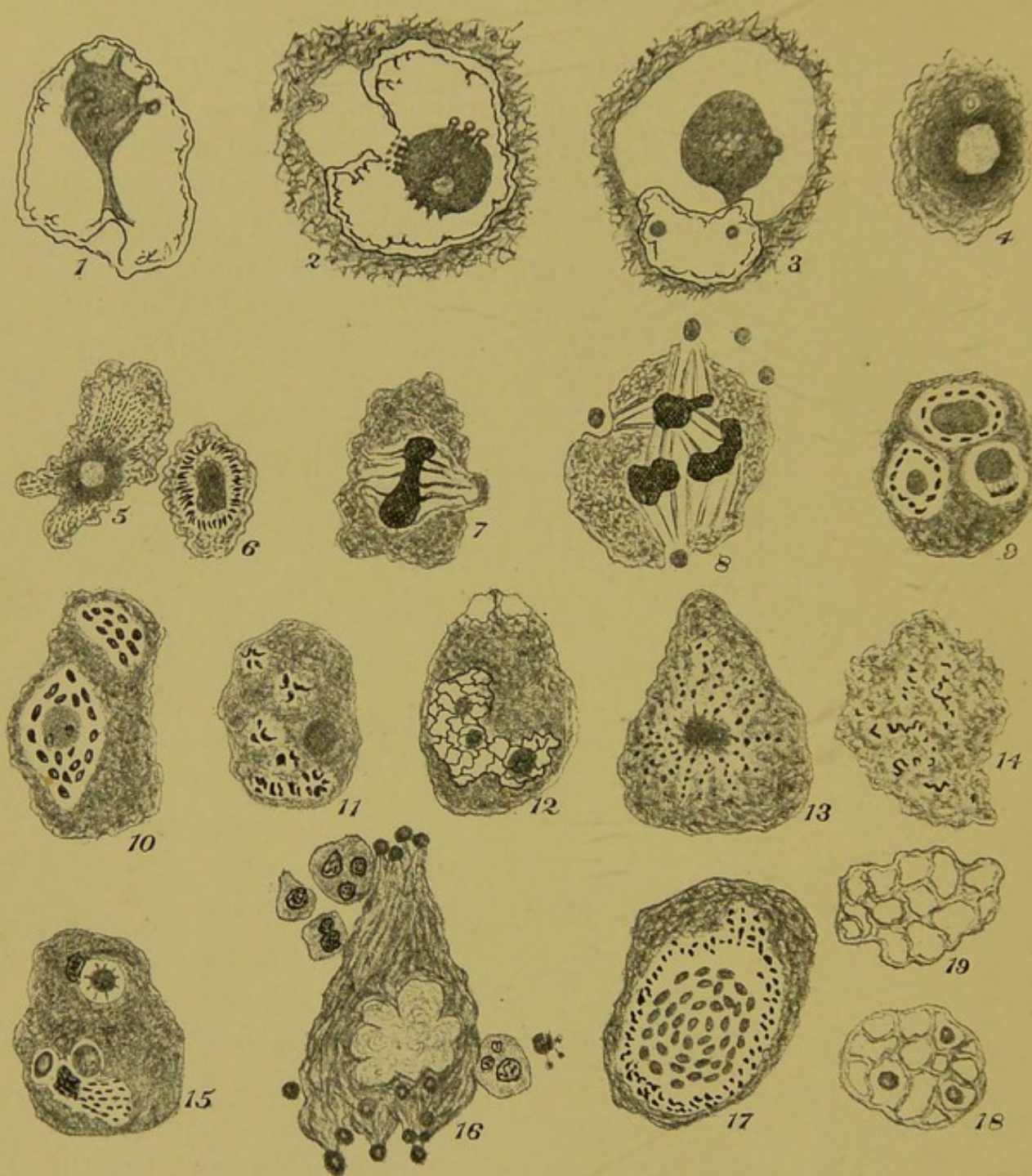


FIG. 36.—ALVEOLAR SARCOMA OF THE BREAST. ( $\times 1,000$  diameters. Nos. 10, 13, 15, and 17 appeared in the *Cent. für Bakt.*, May 10, 1895.)

- 1, Intranuclear parasite attached to the nuclear membrane by a pedicle ; 2, parasite attached to nuclear membrane by a group of short tentacles ; 3, parasite in the cytoplasm of a connective-tissue cell ; 4, a free parasite assuming the amœboid character ; 5, a similar parasite with streaming of chromatin from the chromidial central part ; 6, chromatin appearing as a ring of filaments around a central chromidial mass ; 7, parasite with central mass of chromatin and an irregular spindle—a bud forming to the right ; 8, similar to 7, but with several chromatin masses and peripheral formation of 'gemmules' ; 9, parasite



nuclear bodies described above as occurring in variola—*e.g.*, see p. 50, Fig. 13; 7.

To continue the objective study of this tumour, I will refer to reproductions<sup>1</sup> of various types of cells and bodies that are to be seen in the sections of it, and are represented in Fig. 36. It will be best to consider average examples of cell-forms chosen from many hundreds of carefully studied areas in sections of this sarcoma, such examples being carefully drawn from the actual object. The points for study may be taken in some definite order as follows:

1. *The Fate of the Intranuclear Bodies.*—In some cases the intranuclear body appears to be attached by a pedicle to the nuclear membrane, as in Fig. 36; 1. It has been observed above in connection with Fig. 34 that, previous to its escape from the nucleus, the body appears to become attached to the nuclear membrane in another manner; this is shown also in Fig. 36; 2, where the nuclear membrane is drawn inwards. In many instances bodies in every way similar to those in the nucleus are seen to lie in the cytoplasm or in the spaces between the tumour cells; and in some cases, as in Fig. 36; 3, the body remains attached to the nucleus. In Fig. 32; 2 two such bodies have the appearance of being fused together; they are also assuming a clearer aspect, and spreading outwards at their

<sup>1</sup> Some of these have been already published in the *Cent. für Bakt.*, May 10, 1895, with my article on 'The Biology of an Alveolar Sarcoma'; some were made at the same time, but not published; the remainder have been carefully drawn in moments of leisure since the year 1895. In the description of Fig. 36, for simplicity's sake, the author's interpretations of the various bodies is given, anticipating the conclusions to follow.

with basiphile chromatin in process of formation around oxyphile masses; 10, same as 9 below, and a spindle with ordinary chromatin above; 11, parasite with chromatin in foci somewhat resembling leucocytes; 12, parasite similar to 9, but with basiphile chromatin in a network enclosing three oxyphile bodies: such stages in the parasites simulate nuclei of somatic cells; 13, a parasite with radial moniliform chromatin; 14, parasite with chromatin in a form resembling an irregular spireme—a 'giant mitosis'; 15, a parasite showing below the formation of a 'gemmule' by chromatin streaming into a localized area, and elsewhere stages in gemmule-formation; 16, a parasite with multiple gemmule-formation at the surface: also a free gemmule provided with tentacles, and four leucocytes; 17, a parasite with central gemmule formation; 18, a parasite from which gemmules have been formed, and all but three have escaped; 19, a reticulum from which all the gemmules have escaped.



periphery. This latter change is also shown in Fig. 36; 4, where a body with optical characters otherwise exactly resembling the intranuclear bodies is seen to be opening out at its surface. Thus, close study of many similar forms proves that the intranuclear bodies usually escape from the nucleus and assume the appearance of amœbæ as just described.

The conclusion may be stated thus: These striking intranuclear bodies do not change into chromatin of the nucleus as part of the mitotic process, but they escape from the nucleus, and, some apparently conjugating together, assume the characters of amœboid organisms, and subdivide into minute segments, in some cases after having become nucleated.

*The Bodies that contain Chromatin.*—Apart from the cells that contain resting nuclei, which, except for the large nucleolus-like bodies, are of somatic or of connective-tissue type, such as those provided with a well-marked nuclear membrane—*e.g.*, in Fig. 32; No. 1, and eighteen other nucleated cells, and the others that careful examination shows to be resting nuclei of connective-tissue cells without any intranuclear bodies—apart from these there are a very great variety of bodies which contain structures that give the reaction of chromatin. Many of them it is impossible to derive from a nucleus of any tissue-cell. It is necessary to examine and draw with care a very great number of these chromatin-containing bodies before a series of average examples can be chosen as the basis of an interpretation of their nature. In tracing such a series the eye is guided by a similarity of optical characters and staining reactions which characterizes these bodies and distinguishes them from the cells of the tissues. In granulation tissue those cells that are undergoing mitotic change have a coarser cytoplasmic meshwork and a higher power of refracting light than have the resting connective-tissue cells, but the difference is very slight compared with that seen on comparing the bodies under notice with any form of tissue-cell. Such a series is shown in Fig. 36; 5 to 17 inclusive. In some chromatin can be seen streaming from the central part of a body, which, except for the presence of chromatin, resembles that last



described (Fig. 36; 4). In others the chromatin consists of a single central mass, or several such. Spindles of the ordinary characters are present in some of these cells, and simple binary division of the chromatin mass, with or without formation of definite chromosomes, may occur in them, as in similar cells of other sarcomas; but in this tumour the result of this form of nuclear activity was limited to the formation of the small roundish bodies shown in Fig. 36; 7 and 8. The cells (Fig. 36; 9 to 18) are described with the plate, and need not be further discussed here. A few words as to the formation of the small rounded bodies, which have already been considered as they arise from the flowing of chromatin matter along the spindle. In Fig. 36; 15, is a cell containing two chromatin masses. From the lower one of these a stream of chromatin particles is passing into a limited area of the cytoplasm; and near the same chromatin mass are two rounded bodies. Above is a second chromatin mass adjoining a round body with slender peripheral rays. From long and close study of the cells of this tumour I have no doubt that such round bodies arise from the mixture of a chromatic and a non-chromatic substance, and that they are minute cells<sup>1</sup> which may be termed 'gemmules.' The peripheral rays probably have the same significance as the achromatic strands of 'linin' that make the spindle in cell-division. Another mode of gemmule-formation is that shown in Fig. 36; 16. The lobed chromatin body in this case was translucent, probably from the chromatin being very finely divided; the linin system pervades the whole of the cytoplasm, making lines which converge at the points where gemmules are being formed. Near this cell are a free gemmule and four leucocytes; the latter are quite easily distinguishable, and appear not to have been phagocytic as regards the gemmules, none of which are seen inside them. Other modes of gemmule-formation are seen in Fig. 36.

<sup>1</sup> In anticipation of the conclusions stated below I may here mention that I regard these 'gemmules' as homologous with the endogenous bodies described in Chapter VIII. and shown in Fig. 18, as they occurred in living syphilitic cells—*i.e.*, they are the equivalents of Virchow's 'cells of endogenous origin,' and of the 'bird's-eye' bodies of cancer. See section on Syphilis, p. 60.



A very interesting modification of these gemmule-forming bodies is shown in Fig. 37; 1, which is a more highly magnified

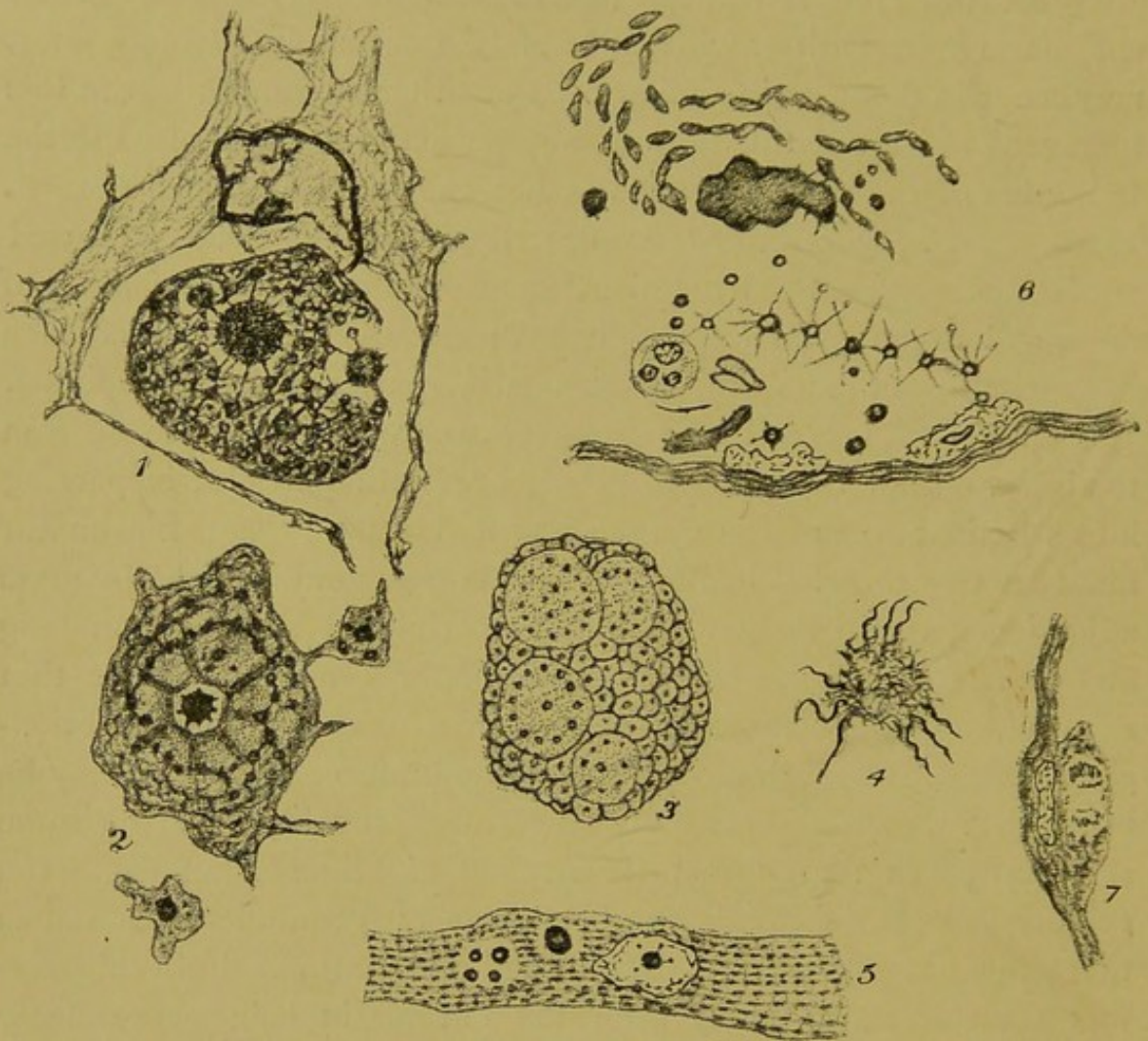


FIG. 37.—ALVEOLAR SARCOMA OF THE BREAST.

- 1, Host-cell and reticular parasite, the latter forming stellate subdivisions ( $\times 1,600$  diameters); 2, *Leydenia gemmipara* of Schaudinn (copied from A. Lang); 3, A parasite subdividing after the manner of bird's-eye bodies—*i.e.*, without the appearance of chromatin as such; 4, (?) microgamete-formation; 5, a portion of a striped muscle-fibre containing six parasites, one of which is in the nucleus; 6, parasite in the interior of a dilated bloodvessel (venule)—a lobed parasitic mass with moniliform segments above, in the middle a chain of acineta-like parasites, and below three gemmules and a larger elongated parasite: a leucocyte and two red corpuscles are present: the capillary wall and two nuclei complete the figure ( $\times 600$ ); 7, an ordinary somatic mitosis from the connective tissue at the margin of the tumour.

image of the body already shown in Fig. 32; 3. The granules are seen to be joined together by a network, which is also connected with

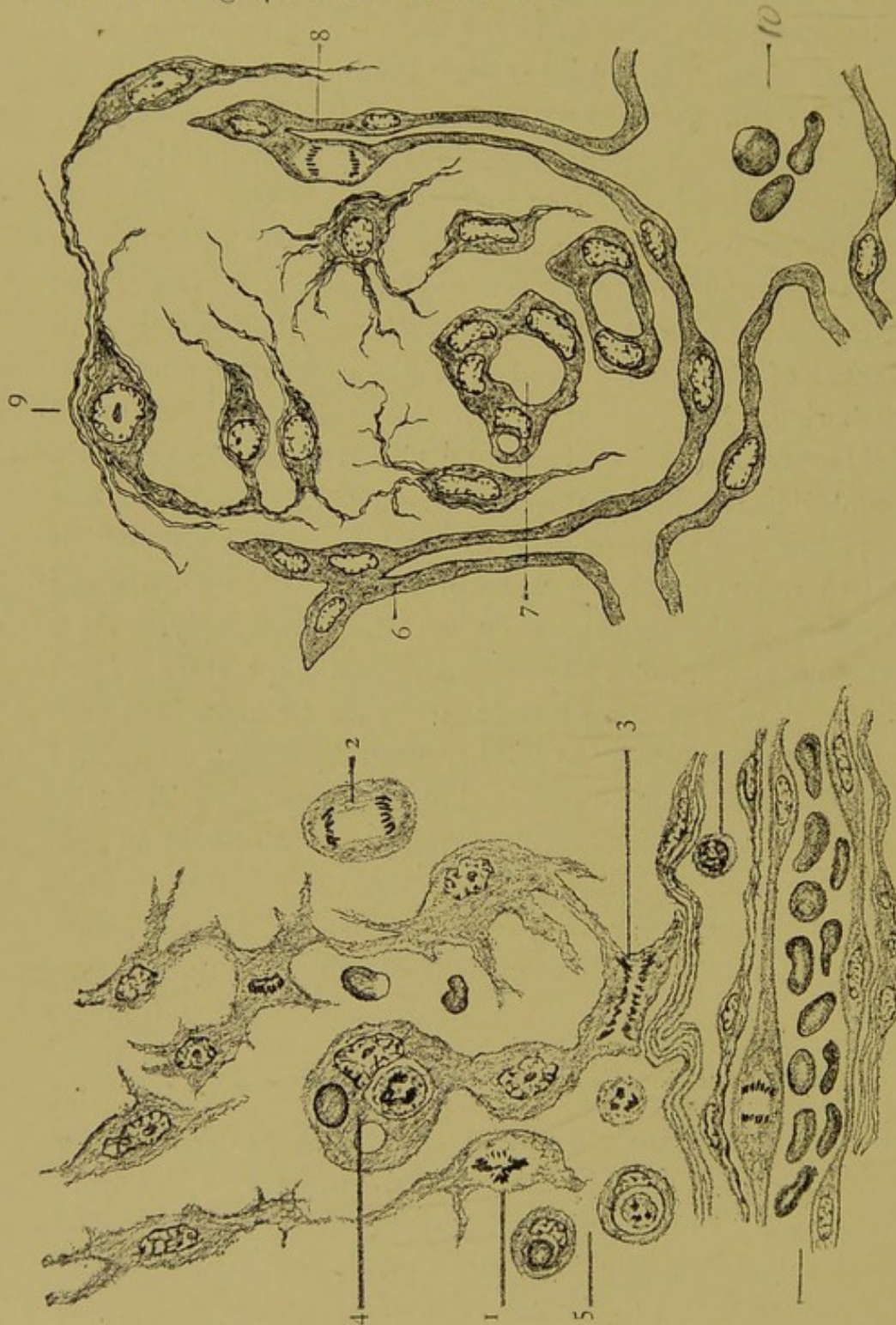


the rays of the central chromatic body, the whole supporting the view that the gemmules are formed by a reunion of the chromatic with the achromatic substance. This body may be compared with those named *Leydenia gemmipara* by Schaudinn, an example of which is given in Fig. 37; 2. The nucleated buds formed by the latter only differ from the gemmules in the former in that the chromatin is condensed in the one and diffused in the other; the main features as to nuclear body, etc., are essentially the same in the two bodies—Fig. 36; 1 and 2 respectively. The bodies described by Leyden and Schaudinn<sup>1</sup> occurred in ascitic fluid—of a man who had cancer of the stomach and of a girl with some peritoneal growth. Lieberkühn had previously seen the bodies and mentioned their amœboid movements. Von Leyden declared them to be parasitic rhizopods, and described them as roundish cells, full of fat-like drops and yellow pigment; usually associated in clusters, which were difficult to separate. They were in lively motion with blunt or pointed pseudopodia, especially on warm days in July. They retained their mobility in fluid which had been kept sterile from three to seven days. Among other features Schaudinn found contractile vacuoles, excretory and other granules. The amœboid bodies incepted both red and white blood-corpuscles, and fused together without fusion of nuclei (plastogamy). Multiplication was by binary fission and budding. Schaudinn was unable to trace fully the causation of the tumour by the parasites, but thought this connection would eventually be made out. I may here state my opinion that some of the bodies described by Schaudinn as *L. gemmipara* are identical with phases of the bodies that I have just described in this alveolar sarcoma. I have not found in the amœboid bodies of this sarcoma any of the evidences of inception of blood-corpuscles mentioned by Schaudinn. In order to express my interpretation of the histological appearances detailed above in the description of this alveolar sarcoma, I cannot do better than direct attention again to the illustrations of granulation tissue

<sup>1</sup> Schaudinn, *Sitzungsbericht d. Berl. Akad. d. Wiss.*, 1896, p. 951.



(Figs. 38 and 39) on the one hand, and of the alveolar sarcoma, as shown in Fig. 40 on the other hand.



FIGS. 38 AND 39 *bis*.—GRANULATION TISSUE FROM A HEALING RABBIT'S TENDON RESPECTIVELY TWO AND FOUR DAYS AFTER DIVISION. ( $\times 1,000$  diameters.)

1, 2, and 3, mitosis; 4 and 5, phagocytosis; 6, 7, and 8, formation of new bloodvessels; 9, formation of fibrous tissue.

In making the comparison, it is to be remembered that Figs. 38 and 39 represent elements in normal granulation tissue of a



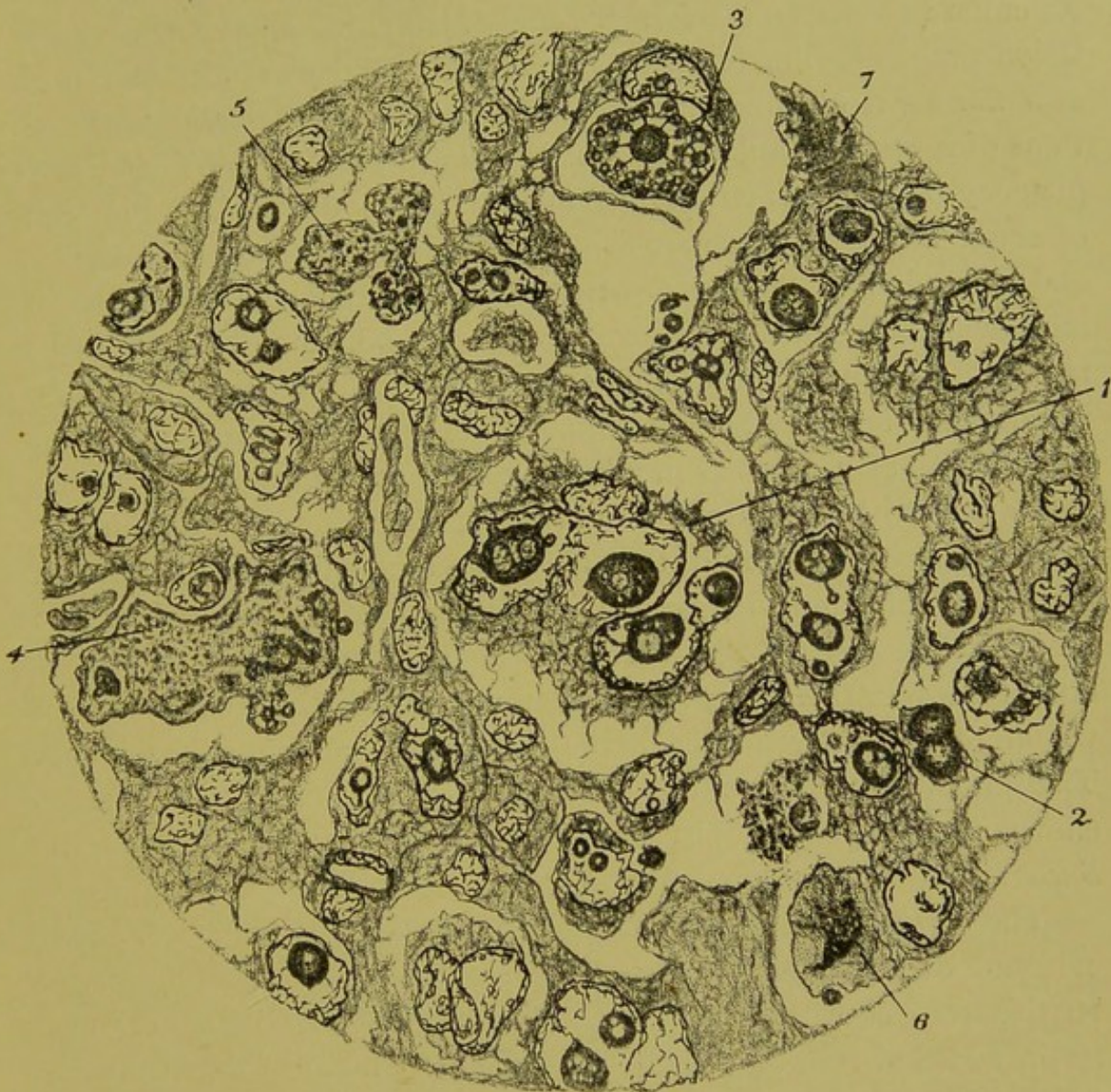

FIG. 40 *bis*.—ALVEOLAR SARCOMA OF THE HUMAN BREAST.

(Camera drawing;  $\times 800$  diameters.)

A fully developed part of the tumour: 1, In the centre of the field, a large fibroblast with lobed nucleus containing four intranuclear bodies; 2, two bodies similar to those in the interior of the nucleus in 1, free and fusing together with a peripheral extension; 3, a granular intracytoplasmic body with a dense chromatic nucleus sending rays into the periphery and forming chromidial granules by fusion with cytoplasm; 4 and 5, free amœboid bodies containing chromatin and granules, the latter similar to those in 3; 6, a free body with a dense chromatic part sending processes into the non-chromatin peripheral part; 7, a body similar to 6, but without differentiation of chromatin.



rabbit, and Fig. 40 is a camera drawing of a portion of a sarcoma of a human breast. In the former some of the chief functions of granulation tissue are illustrated—cell-division, phagocytosis, formation of new fibrous tissue and new bloodvessels; in the latter, these functions of normal granulation tissue have been prevented. There is no phagocytosis, no formation of fibres or new bloodvessels, and instead of somatic mitoses there are evidences of irregular nuclear processes and cell-subdivisions (Fig. 40; 3, 4), resulting in the formation of minute stellate and rounded bodies. The subdividing bodies can be traced in this tumour back through a series of forms to the striking intranuclear bodies. If for a moment we suppose this series of forms to be stages of a protozoon, all the points of structure and function that distinguish this sarcoma from granulation tissue are explained.

I have no doubt that this alveolar sarcoma is an instance of protozoan infection in a person in whom there was no defence on the part of the tissues. To what class should I refer the protozoa? I do not know. In Fig. 37; 6, the forms shown within the small vein would more nearly approach the *Sarcodina* than any other group. The knobbed tentacles of some of the intranuclear bodies, as shown in the photograph (Fig. 33) closely resemble those of the *Suctoria*.

The free parasites in some cases, as shown in Fig. 37; 3, afford evidence of subdivision without the separation of pure chromatin. In this respect they resemble the bird's-eye bodies of cancer and tertiary syphilis. The minute form of the parasites attack muscle-fibres (Fig. 37; 5) as well as connective-tissue cells. I have found evidence in one body (Fig. 37; 4) of sexual elements, as indicated by the presence of slender curved filaments radiating from a reticular mass. The central part of these (?) microgametes stained well with acid hæmatoxylin. One preparation I bleached and restained with Giemsa's stain, but this failed to reveal any spirochæta-like bodies, though it did afford in a striking manner confirmation of my view that in this alveolar sarcoma of the breast the connective-tissue cells perished, whilst the parasites subdivided into a multitude of 'gemmules.'



I have stated above that in this tumour there was no evidence of defence—no evidence of phagocytosis, or any increase in the number of the connective-tissue cells. After many scores of hours spent in minute examination of the sections of this tumour, I have succeeded in finding only one single mitosis in a connective-tissue cell at the margin of the tumour, and in this instance (Fig. 37 ; 7) the mitosis had the ordinary somatic characters.

It may be asked whether the structures described above are to be found in every alveolar sarcoma. About the same time that I examined this sarcoma another typical alveolar sarcoma of the muscles of a man's thigh was sent to me for pathological examination. I used the same methods of fixation, etc., for both, yet the minuter histological features are different in the two tumours. In the alveolar sarcoma of muscle the intranuclear bodies are less definite in form than those of the tumour from the breast. There are evidences, however, in the structure of the muscle-sarcoma that the nucleolus-like bodies escape from the nucleus, enlarge to form highly refracting oval bodies, which are at first devoid of visible nucleus, and subsequently become multinucleated. These features are evidences that the tumour, like that in the breast, was the result of infection by protozoa, that the latter were in a more labile state in the muscle-tumour, and that they would probably have been more satisfactorily studied in the fresh living state at the normal temperature of the body.

What were the opinions expressed by pathologists upon the specimens which form the basis of this study of this tumour of the breast when they were demonstrated by me? Some of my specimens were examined and commented upon by one of the ablest pathologists of our day, the late Professor A. A. Kanthack, and I will quote the report of his remarks, because they reflect the impression made in the year 1895 on minds deeply versed in pathological learning by the work of those who found evidences of protozoan life in certain human diseases; and I may preface this quotation by reminding the reader that in variola and vaccinia the presence and the specific character of the bodies in question are now fully established. The report runs:



Dr. A. A. Kanthack observed that, with respect to Mr. Clarke's statements on vaccinia and variola, Dr. . . . and Dr. . . . had repeated the experiments originally carried out in Germany, and had seen nothing of the protozoa described. He himself, in conjunction with Mr. . . ., had, moreover, found similar bodies to those described in the epithelium raised by blisters in the human subject. The more minute histology of normal tissues had, in fact, not been sufficiently carefully investigated as a check on such statements. In epithelioma cell-fusions were common, and such became infiltrated with leucocytes; various kinds of degenerations ensued, with fragmentation of chromatin, the resulting products staining especially well with acid fuchsin. To draw a life-history from different appearances in a section was not true evidence; what must be done was to trace such a history in its living progress beneath the microscope. If so many diseases as Mr. Clarke had named—carcinoma, sarcoma, vaccinia, variola, syphilis, and others—were due to a similar cause, where did specificity come in, for they had scarcely anything in common? The speaker thought that the different appearances described by Mr. Clarke were degeneration products.<sup>1</sup>

What kind of degeneration it was or in what way it produced so many different appearances was not stated. I think it is extremely improbable that any kind of degeneration could produce the tentaculiferous intranuclear bodies such as that shown in the photograph (Fig. 33). There is only one kind of degeneration—hyaline—that could account for even the homogeneous highly refracting bodies such as those shown in Fig. 32; 2 and 7. I open the first recent text-book on pathology that comes to hand to find the following definition of hyaline material:

'Chemically, hyalin is difficult to characterize, and the substance is even less definite as a chemic body than amyloid and colloid material.'<sup>2</sup> V. Recklinghausen's definition of the same substance was: 'A body of albuminous nature, of homogeneous character and high refractive power. It may be an early stage of amyloid. . . .'

Thus the term 'hyaline degeneration' is so vague that it will very well include certain phases of very vigorous and healthy protozoa. I repeat, with the utmost reverence for one of the greatest of pathologists, my opinion that the pathology of Virchow missed the complete explanation of malignant tumours by attributing all aberrant cell-forms to the tissue-cells of the sufferer, and all

<sup>1</sup> Report of a meeting of the Pathological Society of London, *Brit. Med. Journ.*, April 6, 1895.

<sup>2</sup> Dürck, 'General Pathological Histology.'



apparently structureless bodies to degeneration. And I repeat, with regard to the various structures that I have described as protozoa in the foregoing account of this tumour of the breast, that there is but one interpretation of them which completely explains them and, at the same time, the whole of the phenomena of the tumour in which they occur, and this interpretation is the one I expressed in 1895—viz., that the bodies are protozoa. Further, a close study of the relation of these protozoa to the tissue in which they lie shows that this typical alveolar sarcoma is an infection of connective tissue and muscle cells by this protozoon, which is of amœboid character; also that the structural alveolar character of this particular sarcoma is due to the fact that there is no defence either on the part of the tissues or leucocytes against the protozoa, no proliferation of connective-tissue cells, and no phagocytosis by macrophages or by leucocytes; the tumour is alveolar because the connective-tissue cells of each capillary area swell both by the distending presence of the parasites within them and by the so-called 'hypertrophy' that parasitic protozoa cause in the cells which they infest.



## CHAPTER XIII

### ON THE STRUCTURE OF A ROUND-CELLED SARCOMA OF THE HUMAN TESTIS, WITH ITS INTERPRETATION

THE tumour was removed with the testis of a middle-aged man. It was of oval shape and about 5 inches in its longest diameter, and on section it presented characters common in such growths—an alternation of grey and translucent areas with others opaque and yellow. The translucent substance, before it had been hardened, was of sufficient firmness to allow of fairly thin sections being cut with a razor, and it was streaked with red-and-white lines, where blood-vessels and fibrous septa traversed it. This was the active living part of the tumour. The opaque areas were sharply marked off from the translucent substance, and had all the characters of dead (or necrosed) tissue, both to the naked eye and when placed under the microscope after sections had been made and stained. In this necrosed and degenerated part of the tumour all the elements, cellular and fibrous, that I shall refer to below were alike changed in the way in which they reacted to stains, taking up the acid stains (eosin, fuchsin, etc.) in a diffuse and equal manner, without differentiation, and not staining well with the basic stains (hæmatoxylin, methyl green, etc.). Though all differentiation of nucleus from cytoplasm in stained sections is lost in these necrosed areas, the constituent elements—cells, fibres, etc.—remain perfectly distinguishable by form. Another striking feature of these necrosed areas is that they have a very low refractive power. In both these features the necrosed parts (Fig. 41; 1) contrast with others which I have elsewhere<sup>1</sup> alluded to thus: ‘In sections lightly stained with

<sup>1</sup> ‘Morbid Growths and Sporozoa,’ 1893, p. 71.



picro-carmin, mounted in balsam, and examined with a low-power objective focussed just above the surface, the middle part of each intervascular area was marked out by a bright belt of light.' These areas were thus distinguished by a high power of refracting light, and in this they differed from the necrosed areas. Biondi-

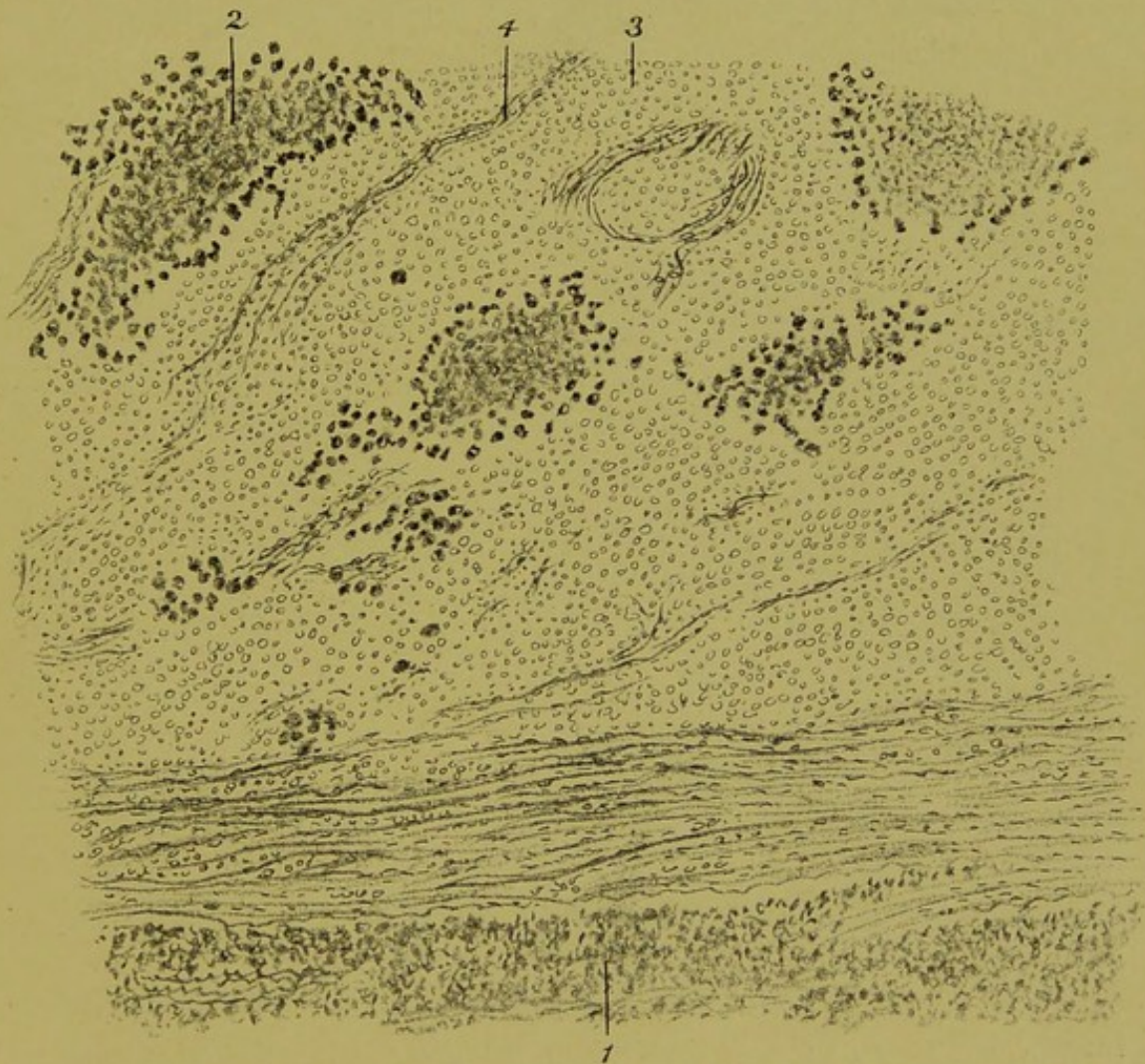

FIG. 41.—SARCOMA OF TESTIS. (Camera drawing;  $\times 60$  diameters.)

1, Necrosed tissue; 2, area occupied by highly-refracting cells; 3, tumour-cells, nuclei only indicated; 4, strand of connective tissue.

stained sections, examined under a low power, have the appearance shown in Fig. 41. The areas last mentioned—*e.g.*, Fig. 41; 2—are marked off from the rest of the tumour by a zone of large cells, the nuclei of which are in a state of activity and stain well with basic stains, and the cytoplasm stain richly with diffuse stains.



Inside this zone of mitosis the chromatin gradually disappears, and highly refracting globes, etc., are alone found. Such areas are the same as those just referred to in the picro-carmin-stained sections, and they contrast with the necrosed areas—*e.g.*, Fig. 41; 1.

The rest of the surface of sections of this tumour is occupied with the round sarcoma-cells (Fig. 41; 3), the clear nuclei of which alone show plainly, and are represented by faint circles. Among these

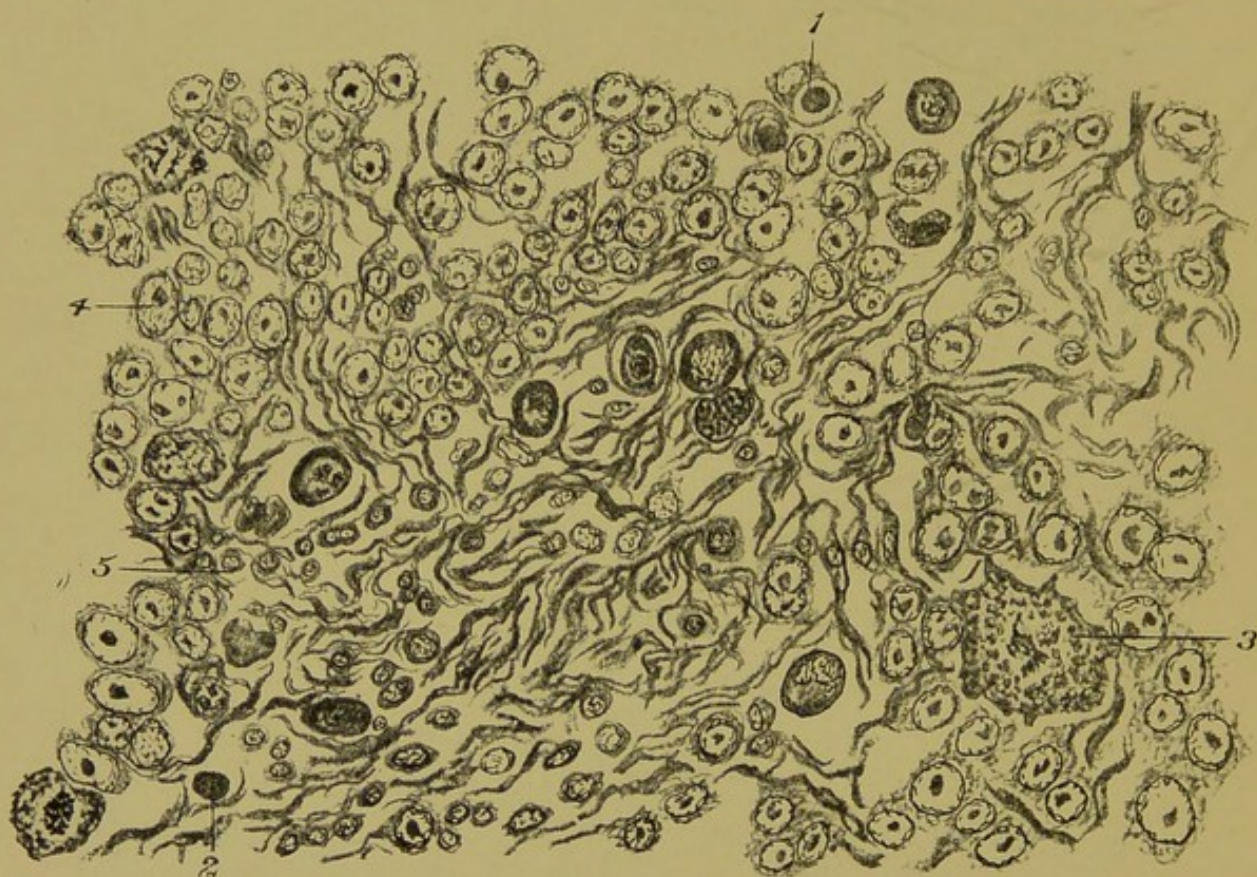


FIG. 42.—SARCOMA OF TESTIS. (Camera drawing;  $\times 800$  diameters.)

1, Intracellular parasite; 2, free parasite; 3, large cell in mitosis; 4, tumour-cells; 5, connective-tissue cells.

areas occur, in groups or singly, cells like those described above as forming the outer zone of the highly refracting areas, and the whole area is intersected by bands of connective-tissue fibres (Fig. 41; 4). Examined under a magnifying power of 800 diameters, the elements of the tumour appear as shown in Fig. 42. The nuclei of the bulk of the cells—those indicated by 3 in Fig. 41 and 4 in Fig. 42—are seen to have a nucleus poor in chromatin, and containing an



intranuclear body of considerable dimensions. These intranuclear bodies stained with the acid stain in mixed stains, such as Biondi, and hæmatoxylin and eosin, the cytoplasm of the tumour-cells being of but slight consistence and small in amount. The connective tissue (Fig. 42; 5) of the tumour had its fibres slightly swollen (mucoid degeneration), but its cells were easily recognisable, and they could be traced in unbroken gradation to the tumour-cells just described. Thus, as in the case of the alveolar sarcoma of the breast described in Chapter XII., the cells forming the basis of this tumour of the testis are connective-tissue or granulation-tissue cells. Amongst these elements were others which could not be traced as having arisen from the normal tissues. Such were dense intracellular bodies (Fig. 42; 1), or similar bodies free, as at 2, and, among other forms, large cells in mitosis, such as 3. In some of these cells the chromatin was massed in an equatorial phase, with a single spindle and without visible division into chromosomes, but more were irregular or multiple mitoses, and many other forms indicating cell-division, as shown in Figs. 42 and 44, were present. A group of cell-forms sketched in one of the areas, such as that marked 2 in Fig. 41, are shown in Fig. 43. Remembering that this drawing was made in 1893, it is interesting to note, among other features, the character of the nucleus of the cell-inclusion at 2. Compared with the nucleus of the ookinet of the *Spirochæta Ziemanni* (see Fig. 4, p. 21) a close similarity will be noted. The dense encapsuled body, 3, with but a trace of the outline of the nucleus remaining, is characteristic of certain encapsuled protozoa in a chromidial condition.

Let us now attempt to reconstruct the cell-life of this tumour—*i.e.*, the sources of the various kinds of cells it contains, or what is sometimes called the histogenesis of the tumour.

Starting from one of the arterioles that are contained in one of the strands of connective tissue such as 4 in Fig. 41, we trace the connective-tissue cells as their nuclei enlarge and the intranuclear bodies appear; then we search minutely for stages of mitosis to connect these swollen connective-tissue cells with the groups such as 2 in Fig. 41, but we find no evidence of such stages. On the



contrary, we note some of the intranuclear bodies escaping into the cytoplasm of the tumour-cells (Fig. 44, 5); and similar intracytoplasmic bodies leading in an unbroken series to the large cells with mitotic processes such as form the margin of groups like Fig. 41, 2. The dense non-nucleated bodies and abnormal cell-

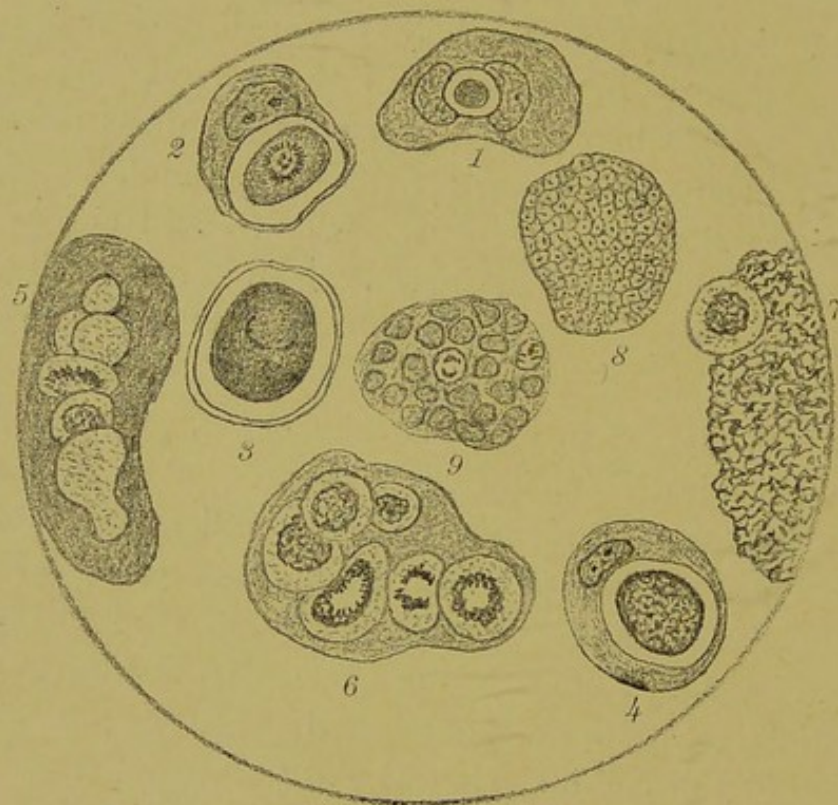

FIG. 43.—SARCOMA OF THE TESTIS. (From 'Morbid Growths and Sporozoa,' 1893.)

1, A sarcoma-cell containing between its two nuclei a dense round body; 2, a sarcoma-cell containing a dense oval body which has a nucleus with radiating chromatin rods and an inner chromatin body; 3, an encapsuled body in a characteristic chromidial condition: a trace of the outline of the nucleus alone remains; 4, a sarcoma-cell containing a reticulated body; 5 and 6, large bodies showing a process of central subdivision, partly chromatic, partly achromatic; 7, a large reticular mass; 8 and 9, probably result from a farther degree of the processes shown in 5 and 6.

forms shown in Fig. 42 are identical with those described in various epithelial cancers as protozoa by various authors, including the writer, and described subsequently by Sanfelice and others as blastomycetes. A more detailed view of some of the peculiar bodies is given in Fig. 43, which first appeared fourteen years ago.



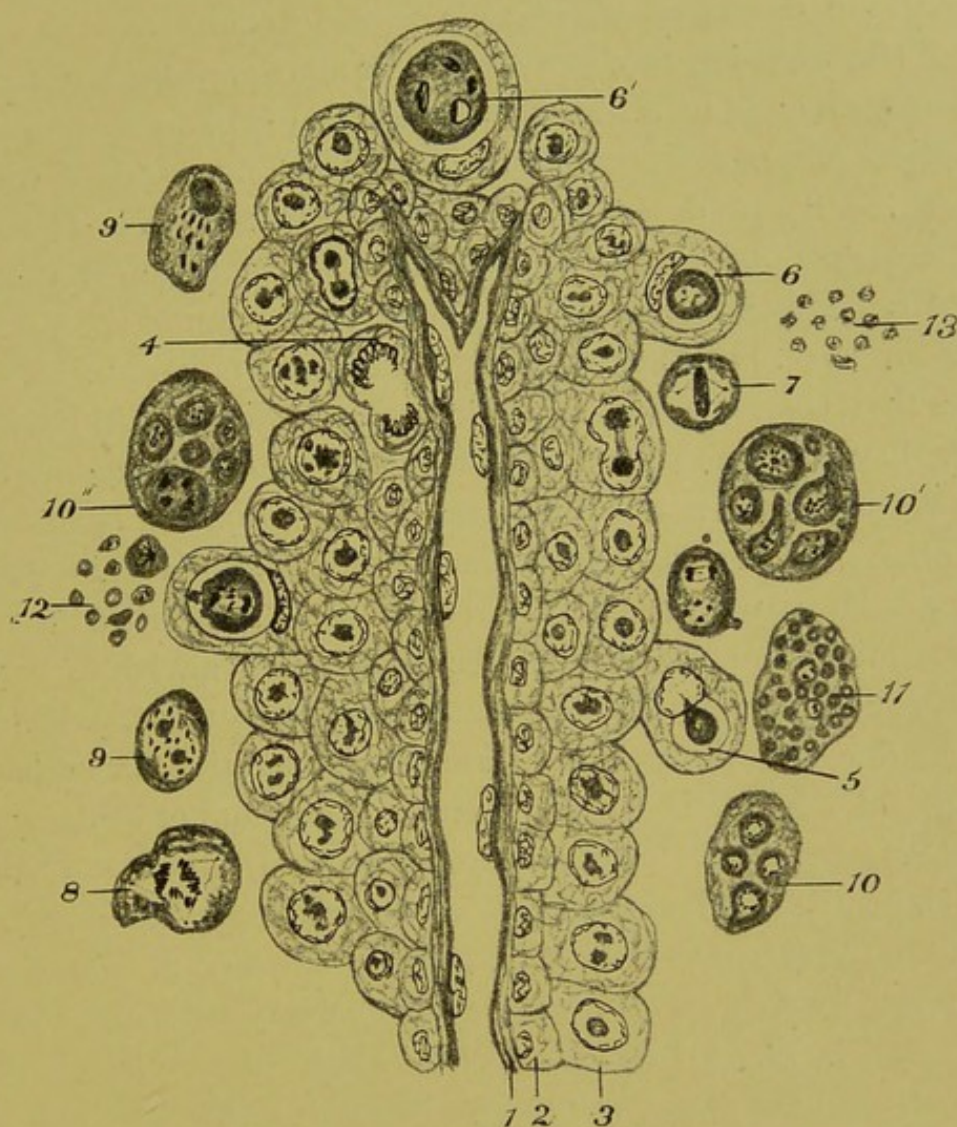


FIG. 44.—SARCOMA OF THE TESTIS.

Schematized representation of a small bloodvessel, with the adjacent cells: 1, Wall of bloodvessel; 2, layer of cells with normal nuclei; 3, layer of hypertrophied cells, the nuclei of which contain parasites which in some cases appear to be dividing into two; 4, mitosis in a tissue-cell; 5, parasite escaping from the nucleus into the cytoplasm; 6 and 6', intracytoplasmic parasites; 7, parasite in equatorial phase of mitosis; 8, free parasite in irregular mitosis; 9, free parasite with irregular cyanophile spindles formed about erythrophile bodies; 9', similar to 9, but the spindle separate from erythrophile body; 10, 10', and 10'', free parasites in course of internal subdivision; 11, free parasites subdivided into small round fuchsinophile 'spores' ('Russell's bodies'), and two clear bodies with cyanophile nuclei; 12, group of bodies, some nucleated, others non-nucleated; 13, group of reticular non-nucleated (?) involution-forms.



Although the tissue of this sarcoma of the testis from which the sections here described were made was not quite so well fixed as that of the alveolar sarcoma described above, yet the details are sufficiently clear to be criticised. There is a general resemblance in the optical characters, staining reactions, and nuclear divisions between the bodies described as protozoa in the alveolar sarcoma and those now under consideration in this round-celled tumour of the testis. The sections of the latter were examined by a committee<sup>1</sup> in 1893, but they declined to express any opinion, on the ground that the structure of the tissue was 'obscured by necrosis.' I think they were mistaken. The areas of necrosis are quite typical and easily recognised, and they have the dull appearance and loss of differential staining characteristic of necrosed tissue. In their striking contrast with the highly refracting areas marked by nuclear figures, reticulation, etc., the necrosed areas afford a basis for comparison, and actually elucidate the other areas, which must either be due to some peculiar form of degeneration, or be parasites passing centrally into involution-forms. They cannot be degenerated tissue-cells, for their form, nuclear structure (when a nucleus is present), or the total absence of a nucleus, show them to be cells other than the sarcoma-cells, which, as explained on p. 109, arise from the connective-tissue cells. It is unnecessary to argue the possibility of their being leucocytes of one sort or another, because a glance at the figures shows this to be out of the question. They can only be parasites of the same nature as those in the alveolar sarcoma. If, then, we reconstruct the life of this tumour as it must have occurred about one of the small bloodvessels, the result is as shown in the diagram (Fig. 44). In this scheme the contrast between the tissue-cells and the foreign parasitic cells is made clear, and in it I have noted my impression that where the infected tumour-cells abut upon the free parasites there is no indication of the prophases of mitosis, as there would be if the parasitic forms were derived from the tumour-cells. Where a connective-tissue cell is found in

<sup>1</sup> Pathological Society of London: Report of the 'Morbid Growths' Committee, *Brit. Med. Journ.*, 1893.



mitosis, as at 4, it has the ordinary characters of a dividing tissue-cell.

On comparing Fig. 42 with Fig. 32 (p. 91), it will be seen that there is no essential difference between this round-celled sarcoma and the alveolar sarcoma; both are based on changes in pre-existing connective-tissue cells. In neither do these cells take any material part in forming the tumour by proliferation; only with great difficulty is a dividing connective-tissue cell to be found, and then it is seen to have the ordinary characters of such a cell. The difference in the two growths consists in the behaviour of the parasites. In the round-celled sarcoma the parasites collect together and form large masses of small bodies, many of which have the appearance of involution-forms, whilst in the alveolar sarcoma the parasites are evenly distributed throughout the tumour, and the products of their subdivision show signs of intense vitality and infecting power.

What accounts for the difference between this tumour and the alveolar sarcoma?

The extent to which molar necrosis is observed in affections of the testis is well known to be in excess of that seen in similar diseases, whether cancer, sarcoma, syphilis, or tuberculosis, of other organs. This fact is easily accounted for by the character of the blood-supply of the organ, which is supplied by long, slender, and tortuous branches of a single artery, itself of great length and subject to temporary, partial, or complete occlusions. The differences observed in the bodies I have described above as protozoa, in the alveolar sarcoma of the breast and the sarcoma of the testis respectively, are evidently due to a slight difference in the vitality of the parasites in the two cases. In the former the parasites were in full vigour and showed no signs of degeneration, but invaded the tissue, destroying it and reducing it to a liquid detritus, as shown by the cavity in Fig. 30; whilst in the sarcoma of the testis the process was a slower one, and the bulk of the parasites congregated in masses (Fig. 40; 2), and their subdivision resulted not so much in the formation of well-defined gemmules and stellate bodies as of granular and reticular involution-forms. I remember that it was on malignant



growths which contain bodies that I regard as protozoa in masses, such as are fairly represented in Fig. 41, that I based my opinion that about one-third of the weight of such growths consists of protozoa. At the time (1893) it was thought that I could not be speaking seriously. I repeat my opinion here, and no words were ever more seriously intended.



## CHAPTER XIV

### VARIOUS HUMAN SARCOMAS

IN 1894 I examined histologically for Dr. Handfield-Jones a large myxosarcoma<sup>1</sup> of the uterus, which had been removed with its annexes. The tumour was soft and elastic, and was not necrosed in any part. The connective-tissue basis of the tumour consisted of cells and bloodvessels. The former were ramified and anastomosed quite like those of granulation tissue.

Among the connective-tissue cells were very numerous other elements which differed from the tissue-cells in their physical

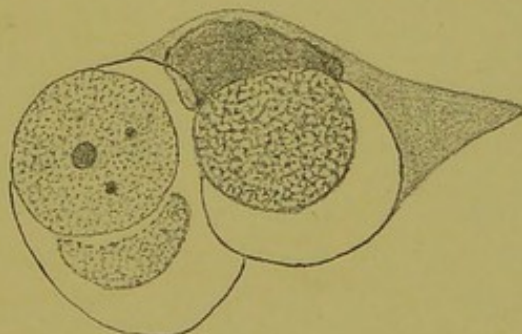


FIG. 45.—CELL AND CELL-INCLUSIONS. (From a periosteal sarcoma.)

Three reticular bodies are contained in the cytoplasm.

characters and other features, and which I have described as follows:

‘Intracellular bodies, some small and dense, with or without nucleus, others larger and reticulated, all alike very highly refracting,

<sup>1</sup> A myxosarcoma is a sarcoma in which the cells assume the branched form characteristic of granulation-tissue cells, the presence of abundant semifluid intercellular substance enabling the offshoots that connect the cells together to be well seen.



are abundant. Free bodies, of which I have been unable to find the homologues in foetal connective tissue, characterized by a protoplasm similar to that of well-known sporozoa—that is to say, of peculiar density and correspondingly high refractive power—occur in great numbers in every part of the growth. In many places they are seen to be dividing by regular mitosis, but for the most part presenting irregular mitotic figures and giving evidence of intense vitality by their simultaneous subdivision into a great number of daughter cells. Some of these bodies are of great size (30 to 40  $\mu$ ), with several central chromatin foci, generally hollow rhomboids with peripheral offshoots, and at the surface clusters of small rounded 2 to 6  $\mu$  particles, some with, some without, nuclei.' The larger bodies referred to in the foregoing paragraph resembled in optical appearance and staining reactions as well as in their wide range of nuclear forms bodies that I described in 1892 as protozoa in a squamous epithelioma of the septum of the nose of a man.

On re-examining the sections of this myxosarcoma, in spite of much fading (they are Biondi-stained), I can still recognise the structures referred to in the above passage. With regard to the bodies that are undoubtedly intracellular, these exactly resemble those that I have figured and described in another sarcoma, and are reproduced in Fig. 45. There is no possibility of mistaking for leucocytes or other wandering cells these highly refracting, coarsely reticulated cell-inclusions, whether nucleated or not; and in a tissue of loose texture, such as a myxosarcoma, there can be no question of invaginated cells simulating cell-inclusions.

Quite recently<sup>1</sup> I have again referred to this case of sarcoma as follows:

'Twelve years ago<sup>2</sup> a paper of mine on the cell-forms in a sarcoma was published; incidentally it dealt with the work of Klebs and von Hanseemann. Unfortunately, no illustrations were published with this paper, but, having kept them, I reproduce three in this place (Fig. 46). Such cells may be "gametoid," but there is no

<sup>1</sup> *Brit. Med. Journ.*, June 2, 1906.

<sup>2</sup> Transactions of the Pathological Society, 1894.



gradation of forms leading up to them from the tissue-cells of the tumour, and many of them are devoid of nucleus—that is, are in the chromidial state common in protozoa.

'Fig. 46; 2, is more like a budding suctorian<sup>1</sup> than any human cell. It is only when cancer or sarcoma tissue is studied broadly

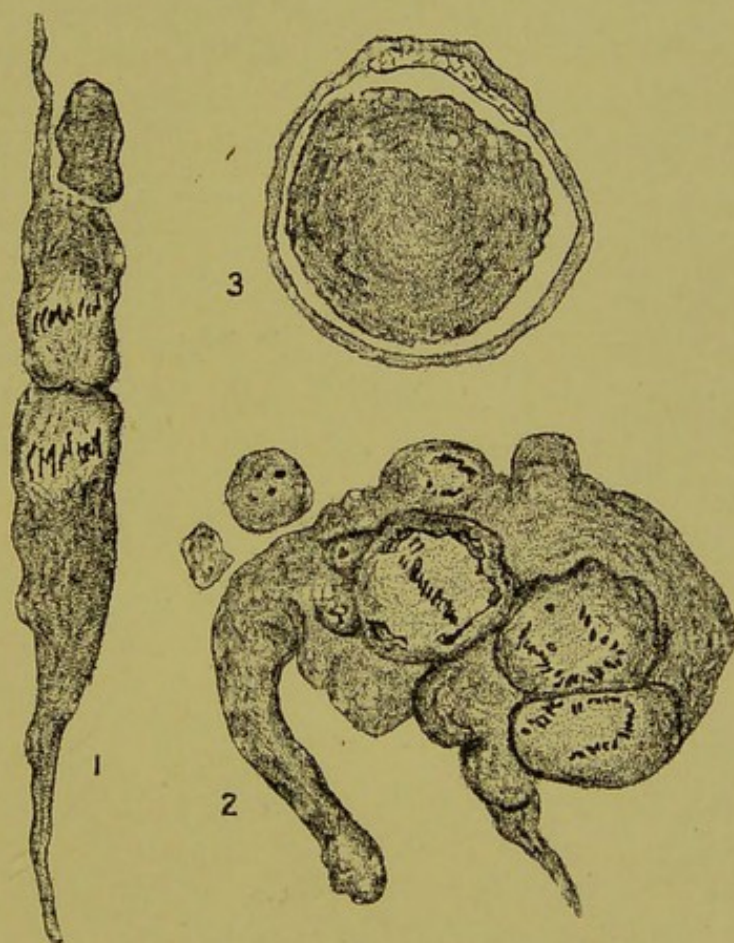


FIG. 46.—MYXOSARCOMA OF THE UTERUS. ( $\times 1,000$  diameters.)

Three cells from a myxosarcoma of the uterus. These cells, according to the author, are protozoa: 1, Large cell undergoing mitotic binary fission; 2, large cell with multiple budding and irregular mitosis; 3, large non-nucleated parasite within a capillary bloodvessel or a connective-tissue cell.

from the point of view of the origin of the tissue elements, and by patient training of the eye by previous study of recognised parasitic

<sup>1</sup> It must not be inferred from this that I deem them to belong to the suctoria. On the contrary, I think we must be prepared to learn that the forms assumed by parasitic protozoa are more protean than has hitherto been thought possible. It should be remembered that spirochaetes have been described in some cancers, and I am prepared to find different kinds of protozoa in different cancers.



diseases in human tissues, that such cell-forms as those depicted in Fig. 46 can be recognised as parasitic. It is now over thirteen years since I first described my view of a cancer of the nasal fossa, being led to it by a case of cystic ureteritis, in which, after careful study, I came to the conclusion that the disease was caused by protozoa. By further study I extended the view to other cancers and sarcomas, and to syphilis, etc. Every time during these past years that I have re-examined my specimens—even when I have tried to take the opposite view—I have been confirmed in my view, which is to the effect that the common forms of cancer and sarcoma are caused by more or less local infections by protozoa, and differ from the infective granulomata only in the more intimate character of the parasitism and the more complicated life-history of the parasites.'

Before deciding that the large free cells, such as those shown in Fig. 46, belong to the same series as the intranuclear bodies that I regard as protozoa, I had duly considered the possibility of their being connective-tissue cells which had become free from the network, their protoplasm having assumed a more highly refracting character than is usual in such cells.

The result of a close examination of all the series of forms and a comparison of them with similar bodies in other tumours led me to the above decision.

When this sarcoma is compared with those of the breast and testis described above, we find that the small parasitic elements that I have mentioned as occurring in the cells of the myxosarcoma were limited to the cytoplasm; and if they had an intranuclear stage comparable to that of the corresponding bodies in two sarcomas of the breast and testis, this stage must have been of very short duration, and the parasites must have been undiscernible as something foreign to the cell by the ordinary microscopic examination. Moreover, the tissue-cells of the tumour are very delicate, being merely the connective-tissue cells separated by a gelatinous intercellular substance; and the parasites being of rapid growth, the latter soon escape from the cells; and so most of them are free. With regard to some of the larger parasites, it is sometimes difficult to



decide whether a parasite is inside a cell or a capillary bloodvessel, but this does not apply to the smaller intracellular bodies. The physical characters, staining reactions, and results of subdivision of these bodies here described as parasites show them to be of the same nature as those in the other two tumours; but whereas in the sarcomas of the breast and testis multiple division into small bodies predominated, in this instance binary fission and multiple budding are the commoner modes of subdivision.

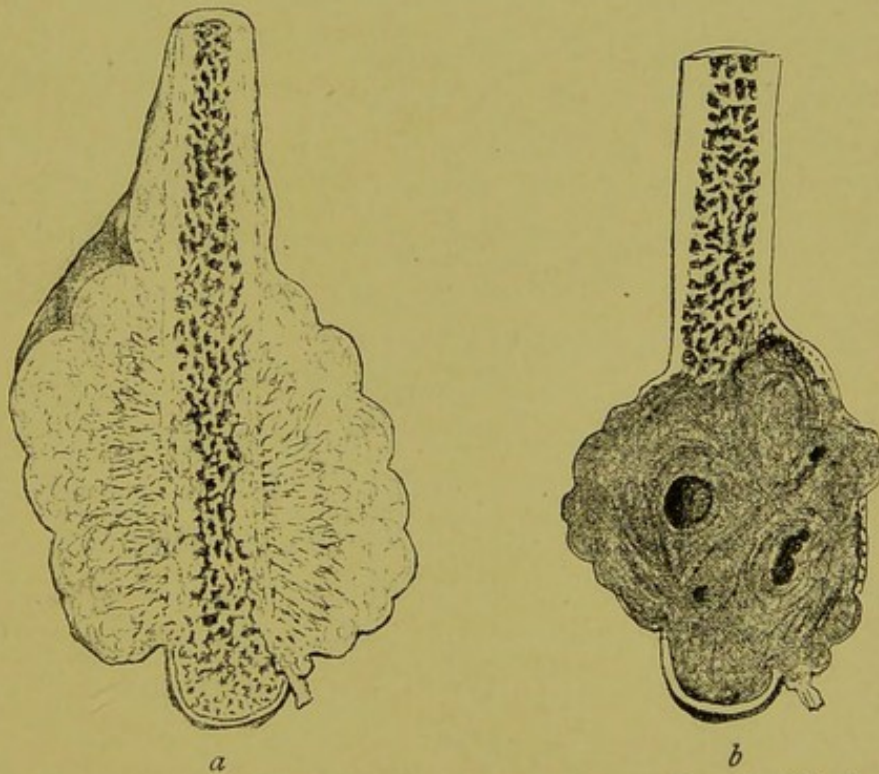


FIG. 47.—SARCOMAS OF BONE. (From the Author's 'Surgical Pathology and Principles,')

*a*, Periosteal sarcoma; *b*, central myeloid sarcoma.

*Sarcoma of Bone.*—Two well-defined types of sarcoma occur in bone, the periosteal and the central, as indicated in Fig. 47; *a* and *b*—one a rapidly growing and very malignant tumour, the other a slow-growing tumour, which usually shows but little malignancy. The former arises, as a rule, on the surface of the bone, in the periosteum; the latter in the central medullary cavity. On these practical clinical features is based a corresponding difference of treatment; the



periosteal sarcoma, when it is possible, calls for amputation far above the disease, whilst a slow-growing central sarcoma is now often treated by scraping away the sarcoma tissue, and allowing the cavity thus produced to fill by granulation. When they are incised also, the tumours differ in naked-eye appearance, the periosteal sarcoma being of a pinkish-white colour at its superficial portion, whilst ossifying spicules project into its substance from the surface of the bone in which it has its origin; the central sarcoma is usually crossed by bands of fibrous tissue, which give it a tougher consistence than has the periosteal sarcoma. It is often covered by a fibrous capsule, and contains cysts which contain serous fluid. This type of tumour is termed a 'myeloid sarcoma.' Histologically both tumours consist chiefly of myeloid tissue, the basis alike of the periosteal and endosteal structure of bone. The multinucleated cells known as myeloplaxes occur in both tumours side by side with uninucleated cells, but the myeloplaxes are more abundant in the 'myeloid' tumour. The ordinary type of marrow-cell in a periosteal sarcoma is shown in Fig. 48—large nuclei rich in chromatin and having a very close nuclear network. Some of the cells in the superficial part of the tumour are in process of subdivision, showing that there is a numerical increase of tissue-cells in this form of sarcoma. The tissue of the more active superficial part of the tumour is traversed by blood-channels, the walls of which are built up of the adjacent marrow-cells. In the periosteal sarcoma the parasites are numerous, and show a striking contrast both to the marrow-cells and to the blood-corpuscles.

The earliest stage of the parasites that I have been able to detect is a small non-nucleated body in the cytoplasm. In the larger forms a nucleus may appear, as in Fig. 48; 1, 2, and 4, but not infrequently the bodies break up whilst still in the chromidial state (Fig. 48; 3). The close similarity of many of these bodies both to the nucleated and the non-nucleated forms of the protozoa of cystic ureteritis is very striking. Some of the cell-inclusions in some of these tumours of bone are coarsely reticulated (Fig. 45).

I need not dwell in great detail on the particular features of



the bodies that I regard as protozoa in this tumour, beyond mentioning that, as in the case of the myxosarcoma, I have not seen them in the nuclei of the cells, and that I interpret the appearance

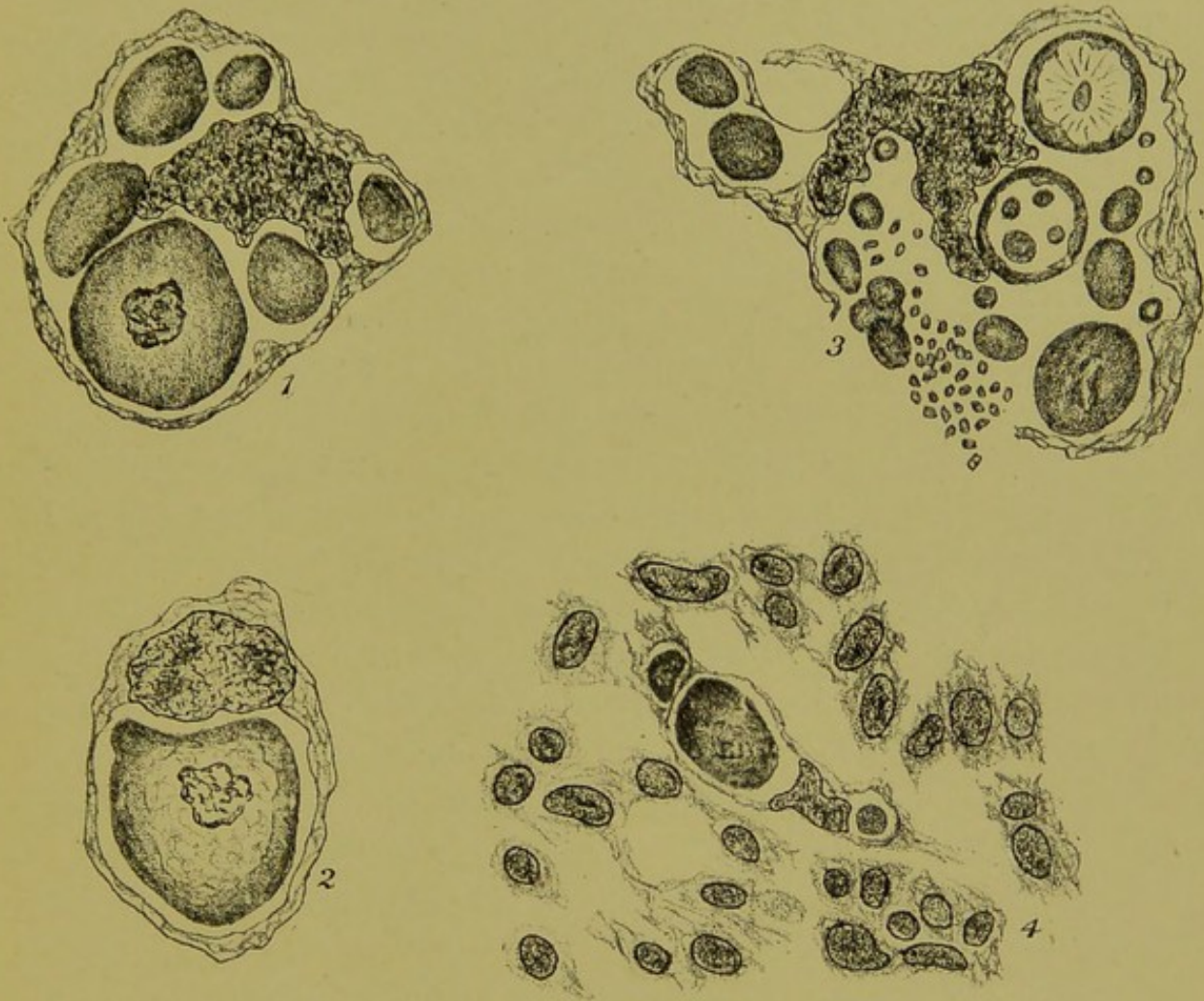


FIG. 48.—PERIOSTEAL SARCOMA. (1, 2, and 3,  $\times 1,000$  diameters ; 4, camera drawing,  $\times 800$  diameters.)

- 1, A tumour-cell containing six parasites, the largest of which contains a nucleus ;
- 2, a sarcoma-cell containing a large nucleated parasite ; the body of the parasite is becoming reticulated around the nucleus ;
- 3, a tumour cell containing many parasites in various stages : at *b*, a cluster of minute bodies resembling the larger ones in texture, etc. ;
- 4, a group of cells of the same tumour : one cell contains one nucleated and two non-nucleated inclusions surrounded by the cells derived from the periosteum.

seen in Fig. 48 ; 3 as a subdivision of the parasites in the chromidial state comparable to that seen in the sarcoma of the breast (Fig. 37 ; 6, p. 98).



In the typical rapidly-growing periosteal sarcomata several parasites are to be seen in every microscopic field, but in the typical central sarcoma, on the other hand, the parasitic inclusions are often very few in number; two or more sections may sometimes be carefully examined before one is found. When they are found their characters are very definite, and make it easy to recognise them at once. They are usually seen within one of the giant-cells (myeloplaxes) as relatively large hyaline bodies surrounded by a space, which is often lined by a doubly refracting capsule.

The cell-inclusions—such as these in this periosteal sarcoma—that first arrested my attention in sarcoma I described as protozoa in 1893.<sup>1</sup> They were subsequently described as blastomycetes by Sanfelice and Roncali,<sup>2</sup> whose work attracted close attention to the pathogenic blastomycetes, and, together with cases of blastomycetic dermatitis described by Drs. Gilchrist and Rixford<sup>3</sup> and others, has resulted in showing how closely some of the blastomycetes resemble certain protozoa, especially the coccidia. It is only when the cell-inclusions and other bodies foreign to the tissues are studied in a series of sarcomas of different kinds, and especially in such a one as the alveolar sarcoma of the breast described above, that the series of forms and the relationship between the tissue-cells and the foreign elements is found to be such that the bodies in question can belong only to the protozoa; so varied are the forms and so intimate the parasitic adaptation.

One feature of great importance is exhibited by the periosteal sarcoma: this is that the secondary growths have the same characters as the primary growths, both as regards the tissue-cells in these secondary growths and the parasitic bodies. This is in contrast with what obtained in the alveolar sarcoma of the breast. In the latter the tumours were the ordinary connective tissue reacting to an invasion of parasites, and secondary growths might arise in any part of the body without actual transference of the

<sup>1</sup> *Brit. Med. Journ.*, January 21, 1893.

<sup>2</sup> Sanfelice and Roncali, *Cent. für Bakt.*, 1895, p. 625.

<sup>3</sup> Gilchrist and Rixford, *Johns Hopkins Hospital Reports*, 1896, vol. i.



tumour-cells. This difference is associated with another—namely, in the alveolar sarcoma the parasites have an intranuclear as well as a cytoplasmic phase, whilst in the periosteal sarcoma they are restricted to the cytoplasmic phase. This difference in the distribution of the parasites corresponds with what obtains in vaccinia and variola, as was first clearly pointed out by Calkins. This difference of habit in the parasites may be associated with another of equally great importance—one that may serve to explain what has hitherto been a difficulty.

Cancer and sarcoma have till now been regarded as extensions from one original focus. This may be true in some, even in the majority, of instances, and not true in others. Thus, in the periosteal sarcoma the multiplication of tissue-cells, as evidenced to the unaided vision by the bone-formation at the base of the tumour (Fig. 47; *a*), and as seen in sections in the marrow-cells under the microscope, may be regarded as a defensive pullulation of cells against the invasion of the parasites. Such a tissue-proliferation would result in a tension of tissue increased out of proportion to that of the surrounding parts, and, combined with an invasion of fresh periosteum by the parasites, would account fully for all the known properties of this form of sarcoma—local extension, formation of secondary growths in the lungs and elsewhere. This view may be stated thus: A specialized infection results in the proliferation of a certain tissue, which spreads, both locally, increasing the size of the original tumours, and by offshoots extending either in continuity with the original tumour inside veins and lymphatics, and thus spreading like an internal papilloma; or the tips of the papillary extensions becoming detached pass as emboli to distant organs, where the combined proliferation of parasites and of cells, descended from those of the periosteum originally attacked, produce secondary lesions which resemble the original one in all important details, including the periosteal type of tissue-cell originally infected. Writing for students ten years ago on this subject, I said:

‘If, as according to present knowledge is believed, it is the cells of the sarcoma that constitute the infection, there is an evident



difference between the infiltration of a tissue by sarcoma and an inflammatory formation such as tubercle.<sup>1</sup>

The facts and comments given above show, I think, that this distinction is not an absolute one. The alveolar sarcoma of the breast is an instance of an infective granuloma caused by protozoa, and it is as simple and direct as any other infective granuloma, a passage of the parasites from one seat of infection to previously healthy connective tissue being all that is required to start a new lesion, or 'secondary growth.'

In the case of the periosteal sarcoma the tumour may be regarded as being the result of a symbiosis of parasites and one special form of connective tissue. But even in the latter case, when later (or secondary) tumours arise in bones other than that first attacked, there is nothing to indicate that parasites alone have not, by finding a suitable nidus, caused a secondary tumour with all the characters of the first.

*Pigmented Sarcomas.*—The commoner of these is the *melanotic sarcoma*, such as arises in the pigmented tissue of the choroid. This type of sarcoma is readily bleached, and may then be examined in the same objective way as any other tissue. When so bleached, I have found in sections of melanotic sarcoma bodies similar to those described above under the head of 'alveolar sarcoma.' I regret that the specimens are missing, so that I am unable to repeat the examination, and to state more exactly the characters of these protozoa-like bodies.

The resemblance between the primary and secondary lesions in melanotic sarcoma is readily explained in the same way as in the periosteal sarcoma mentioned above. As to the melanotic sarcoma that arises in pigmented moles, I have not made any personal observations, and hence I can offer no opinion as to whether I should regard it as being of protozoan causation or not.<sup>2</sup> It happens that one of the commoner forms of sarcoma, the spindle-

<sup>1</sup> 'Surgical Pathology,' p. 94.

<sup>2</sup> I remember examining an ordinary congenital mole. The pigmented cells of such structures are smaller than those of any melanotic sarcoma that has come to my notice, and I have failed to find in these moles any of the forms described above as protozoa. \*



celled, has not been among those I have examined carefully for protozoa. Peculiar forms, such as rhabdomyoma, in which striped muscle in a rudimentary form appears, and other rarer forms of sarcoma, may originate in remains of embryonic tissue. It is not my purpose to discuss such points in the present place, reserving them to a later time.

A form of sarcoma that contrasts sharply with the melanotic in its superficial appearance is the chloroma. Interesting cases have lately been published by Dr. T. H. Butler<sup>1</sup> and the late Dr. F. F. Leighton.<sup>2</sup> In the former the urine had been examined, and found to be loaded with albumin before the sarcomatous growth caused protrusion of the orbits. After death the tumour was found to be diffused widely throughout the body. Dr. Leighton made a careful histological examination, and found that the chloroma masses themselves suggested an 'infiltration' rather than a 'growth.' He farther observed that the blood might be described as myelocytic, with the large hyaline myelocyte predominating.

This latter observation brings us to the question of the relation of the various forms of leucocythæmia to sarcoma. This very attractive subject is one which I have not had opportunities of examining; and such questions, important and interesting though they are, do not affect the results of the close objective study of tumours such as those detailed above.

I venture to repeat the above-mentioned conclusion to the effect that the difference between a pure infection such as I have described as resulting in the alveolar sarcoma of the breast and an infection with proliferation of a special tissue, as in the periosteal sarcoma, is not radical nor does it argue against the periosteal sarcoma being a parasitic disease.

<sup>1</sup> T. H. Butler, *Brit. Med. Journ.*, April 20, 1907.

<sup>2</sup> F. F. Leighton, *Journal of Pathology*, October, 1907.



## CHAPTER XV

### ON THE INFECTIVE GENITAL TUMOURS OF DOGS

THE above name has been given to a kind of tumour that is not uncommon in the genital organs of dogs. The lesions from their histological structure have been variously pronounced to be epithelial cancer,<sup>1</sup> granulation tissue,<sup>2</sup> round-celled sarcoma,<sup>3</sup> lymphosarcoma,<sup>4</sup> blastomycetic tumour,<sup>5</sup> and round-celled sarcoma with 'true metastases'<sup>6</sup> in the testes. These conflicting opinions reflect the perplexing state of thought that prevails at the present time with regard to malignant tumours in general, and on this account this disease merits the closest examination. First, one should consider the more striking points in the natural history of the disease. As far as is known, new cases arise only by sexual contact of a healthy with a previously infected animal. The disease is rare in old dogs, and has not been observed as a natural occurrence in other than sexually mature individuals. *It is easily transmitted experimentally.* The effects of inoculating fragments of the growths into the subcutaneous tissue of other dogs was thus described by the late Dr. Washbourn and Dr. Bellingham Smith:<sup>7</sup>

<sup>1</sup> Geissler, *Verhand. der Deutsch. Gesellsch. für Chirurg.*, 1895.

<sup>2</sup> Duplay and Cazin, Transactions of the International Congress at Rome, 1894; and Bashford and others, Imperial Cancer Research Fund, 1905.

<sup>3</sup> Washbourn and B. Smith, Transactions of the Pathological Society, London, 1897.

<sup>4</sup> Sticker, *Zeit. für Krebsforschung.*, 1904.

<sup>5</sup> Sanfelice, *Riforma Medica*, 1904.

<sup>6</sup> Shattock and Seligman, Reports of the Pathological Society, *Brit. Med. Journ.*, 1907.

<sup>7</sup> Washbourn and Bellingham Smith, *Brit. Med. Journ.*, December 17, 1898.



'For the first few days after inoculation a swelling can be felt, partly due to the fragments of the tumour introduced, and partly to inflammatory exudation. In some cases this swelling completely subsides, so that nothing can be felt until the appearance of a small nodule indicates that inoculation has been successful. In other cases the swelling persists, and it is difficult to decide whether the inoculation has been successful until a definite increase in the size of the swelling has taken place. The usual time at which there is distinct evidence of the first appearance of the growth after inoculation is about three weeks, but it varies between twelve days and a month. . . . The small firm nodules which first appear gradually increase in size, and form rounded lobulated masses. At the commencement they are freely movable beneath the skin, but at a later period the latter become thinned out, of a bluish-red colour, and firmly adherent to the growths. . . . The maximum growth is attained in about three months. A curious regularity obtains in this respect. . . . Having reached this stage, retrograde stages are not long in appearing; the growth becomes soft and flabby, and slowly dwindles until nothing is left to indicate its former presence. . . . In nearly half the cases the subsidence of the tumour was accompanied by ulceration; the thinned-out reddened skin giving way over the growth, which has previously undergone softening, and there results a deep ulcer, from which a thin grumous discharge flows. Even when these retrograde changes are occurring, fresh growths occasionally take place at the periphery of the tumour.'

*The histology of the tumours*<sup>1</sup> must be carefully examined in relation to the mode of evolution of the lesions as quoted above. We must examine first the young tissue at the edge of a growing lesion (Fig. 50), then the more advanced sarcoma-like tissue

<sup>1</sup> This description is based on two sections given to me by the late Dr. Washbourn, and others kindly lent me by Mr. A. G. R. Foulerton. Dr. Washbourn's had been fixed in some osmic acid medium and stained with hæmatoxylin. The osmic acid had prevented a good colour differentiation, a fact that explains the unsatisfactory character of the illustration that appears in his original paper. After bleaching one of the sections in 10-volume solution of peroxide of hydrogen and restaining with acid hæmatoxylin and eosin, I obtained a very fair differentiation.



(Fig. 51), and finally the tissue at the acme of the process—*i.e.*, just at the time at which the central part of the tumour begins to show retrogressive change (Fig. 52). In this way only can a just impression of the whole life of the tumour be traced, in the same way as we trace the inner life of an organism—by studying its structure at different periods of its existence, and as the objective features of the human sarcomas have been given in the preceding chapters of this volume.

The general features of a relatively large lesion are shown in Fig. 49. Camera drawings from parts of this section contained

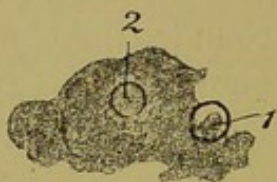


FIG. 49.—INFECTIVE TUMOUR OF DOGS. (Natural size.)

The appearance of a complete section through a relatively large lesion. The circle 1, at the marginal part, marks the area from which Fig. 50 was drawn; and the circle 2 shows the part from which Fig. 52 was taken.

within the circles 1 and 2 are represented in Figs. 50 and 52 respectively.

In the marginal part (Fig. 50) there is a gradual change from normal fibrous tissue below to the more open cellular structure of the tumour in the upper part. When the same area is carefully examined with a higher power this impression is proved to be correct: the cells of the tumour are found to be connective-tissue cells. They are the pre-existing cells which have changed from the flattened and shrunken resting state to the rounded and succulent granulation-tissue state, and increased in numbers. There is no infiltration of leucocytes.

Like the alveolar sarcoma of the human breast and the round-celled sarcoma of the human testis described above, these tumours of dogs are granulomata. There are evidences of multiplication of cells at the margin of the tumour; for although in the area



shown in Fig. 50 only relatively few mitoses are seen, yet there are elongated or biscuit-shaped nuclei, pointing to direct division of the cells.

The more advanced part of the tumour (Fig. 51), when carefully

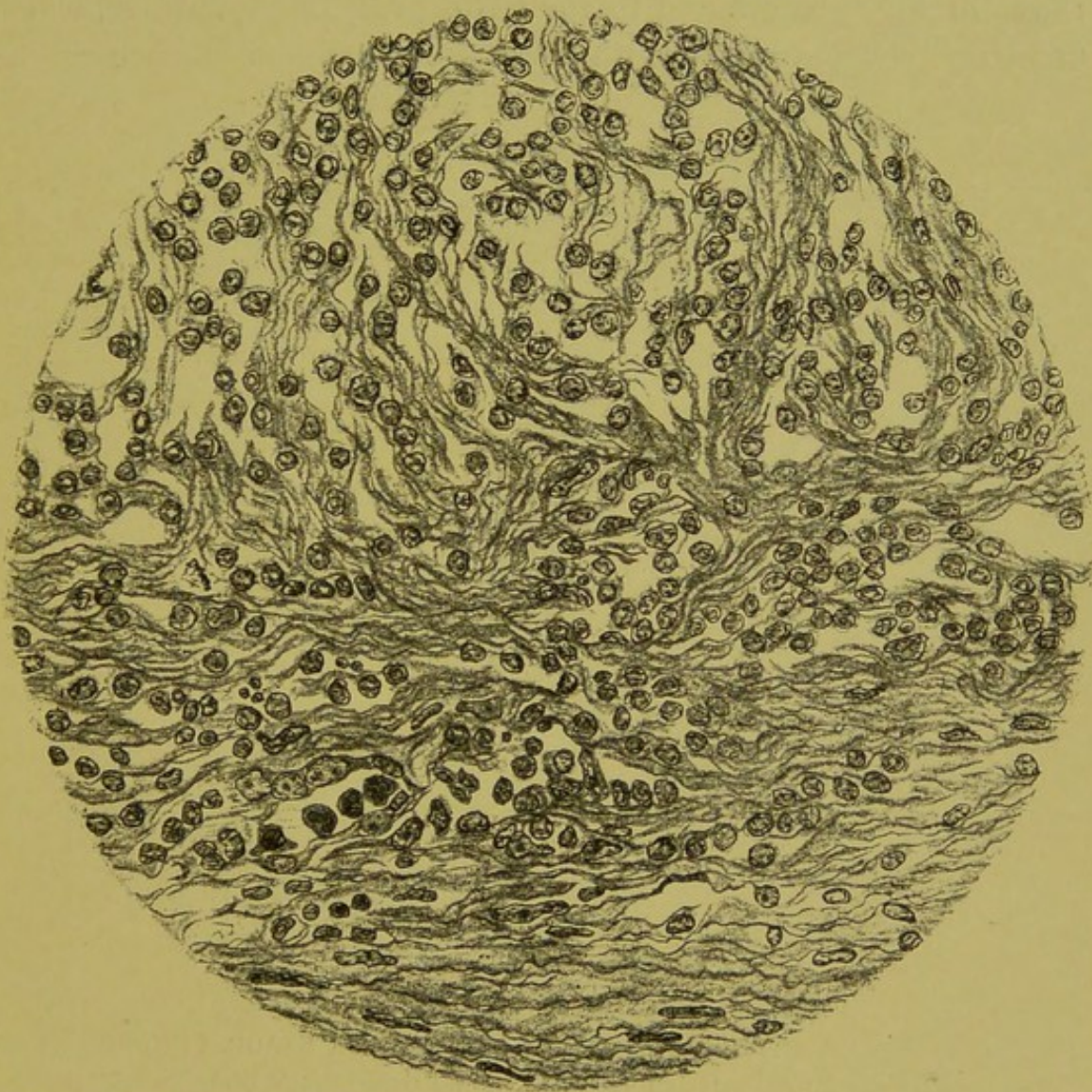

FIG. 50.—INFECTIVE TUMOUR OF DOGS: THE INITIAL STAGE. (Camera drawing, low power.)

A marginal portion of the lesion, Fig. 47; below is the normal fibrous tissue, which gradually merges into the tumour tissue above.

scrutinized under a high power, shows two striking protozoa-like forms: (1) Dense oval or vermicular bodies of hyaline aspect and without nucleus; and (2) highly refracting multinucleated bodies



like the one shown below in Fig. 53; 12, which resembles the plasmodial form of *Scheviakovella*,<sup>1</sup> but without the contractile vacuoles of the latter.

Apart from these forms, there are numerous mitoses, such as those in Fig. 51 at 1 and to the right of 2 and elsewhere, which are tissue-cell mitoses. With these are other bodies, such as the

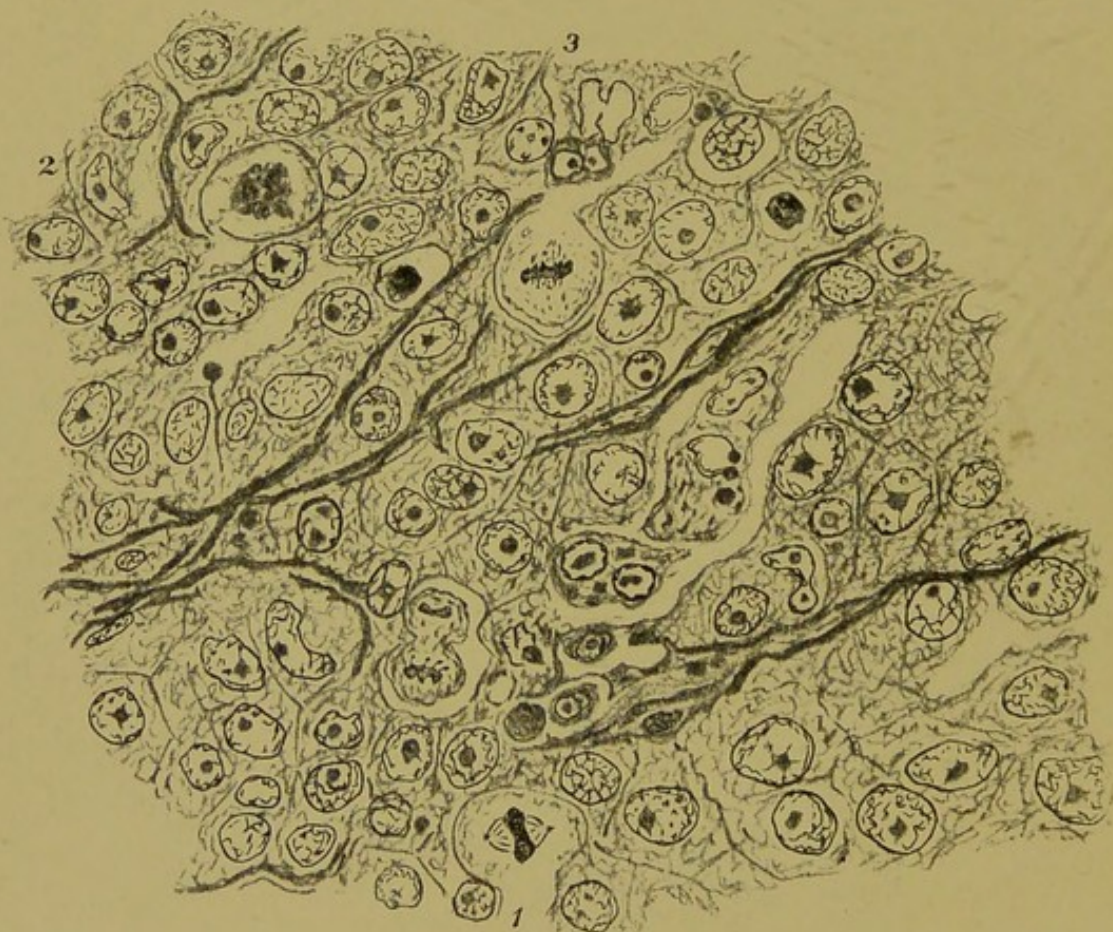


FIG. 51.—INFECTIVE TUMOUR OF DOGS: THE MIDDLE STAGE. (From a section made by the late Dr. Washbourn. Camera drawing;  $\times 800$  diameters.)

The medium stage of development of a lesion in infective sarcoma of dogs: 1 and 2, tissue mitoses; 3, amoeboid body escaped from nucleus. The general appearance is characteristic of sarcoma.

one below 3, which has apparently escaped from the ruptured nucleus above it, and which is probably an early stage of the protozoon-like bodies just referred to. Another striking feature is

<sup>1</sup> One of the Haplosporidia (Caullery and Mesnil).



the prominent intranuclear bodies that are present in about three-fourths of the nuclei. The general appearance of the lesion at this

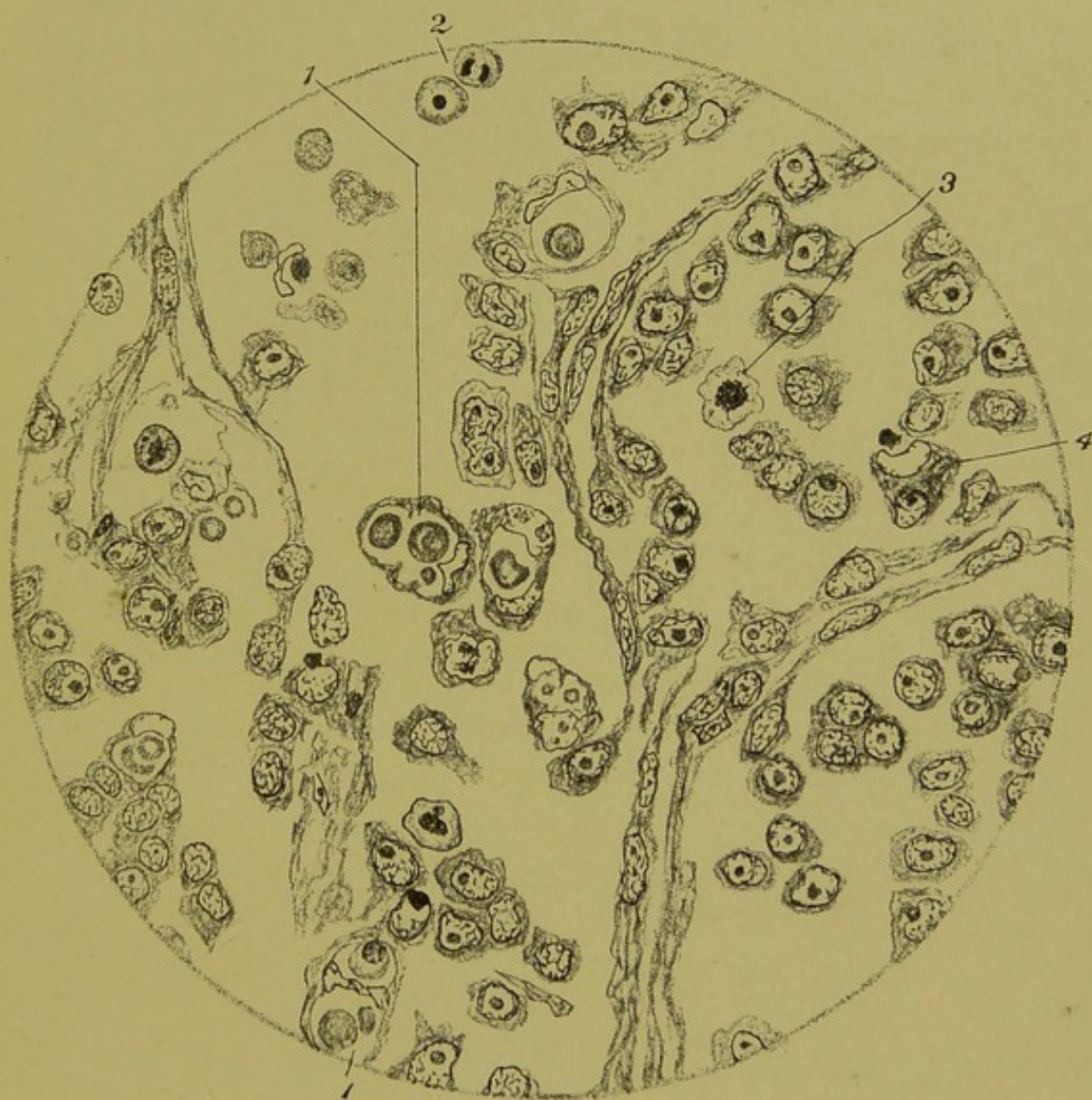


FIG. 52.—INFECTIVE TUMOUR OF DOGS: THE FULLY DEVELOPED STAGE.  
(From the section Fig. 49; 2. Camera drawing;  $\times 800$  diameters.)

The interrupted capillaries will be noted: 1 and 1', cells distended by cell-inclusions; cells with active nuclei, as at 2 and 3; and cells with amœboid bodies close to empty nuclei, as at 4.

stage is typically sarcomatous. It is not the end of the process, and should be regarded, I think, as the middle stage.

The climax of the process is the point at which protozoa, if



present, would attain full development : this I term the *fully developed lesion*.<sup>1</sup>

The fully developed lesion thus defined presents an appearance (Fig. 52) which differs markedly from either of the earlier stages. Even in the naked-eye preparation (Fig. 49 ; 2) the tissue is seen to be less opaque. Under the microscope this translucency is seen to be due to a more open structure ; the intercellular spaces are wider and the capillaries farther apart. Some of the latter are interrupted, as shown in Fig. 52.

There is no crowding of leucocytes within or around the capillary walls ; thus the process is not that of ordinary inflammation. The most striking feature is the presence of cells containing groups of included cells—*e.g.*, Fig. 52 ; 1, and 1<sup>1</sup> ; and Fig. 53 ; 16. Some of these cell-inclusions are nucleated, others not. A close examination shows that they are not the ordinary leucocytes (such as are seen in Fig. 53 ; 17) incepted by the tumour-cells. Some of them are undergoing mitotic subdivision.

The nucleus of the majority of the cells that contain these bodies consists simply of a nuclear membrane ; in a few, however, there is an intranuclear body and network (Fig. 53 ; 26) ; such may be explained by a parasite having entered the cytoplasm from another cell.

As in the earlier stages, so in these fully developed lesions, there are numerous free cells undergoing mitosis. In a few instances these mitoses may belong to granulation tissue cells in mitosis (Fig. 53 ; 18 and 19), but it is not possible to refer the bulk of them to this source. The following points can be definitely established :

1. Some of the cells in this area are surrounded by a definite doubly refracting capsule (Fig. 53 ; 25).

<sup>1</sup> This fully developed stage of the lesion has not, as far as I am aware, been described before. This fact decided me in including some notice of this disease of dogs in this volume. A comparison of Figs. 51 and 52 will serve to show how marked are the objective characters that distinguish the tissue at the moment when retrogressive change sets in ; but no mere drawing can give a full idea of the highly refracting capsules and other peculiar features that this area presents. The appearances are in marked contrast with any that are seen in lesions caused by any bacteria with which I am acquainted.



2. Some of the nuclei have part of their chromatin in the erythrophile, part in the ordinary cyanophile condition (Fig. 53; 22).

3. The great proportion of the nuclei differ in appearance from those of connective-tissue cells. This point is shown in Fig. 53; 28 and 29. Associated with cells of this type are some in mitosis (Fig. 53; 30), which in other respects resemble them.

4. Other cells in mitosis are apparently forming buds—*e.g.*, Fig. 53; 27—some of which are nucleated, resembling, when detached, the small nucleated bodies in 22; but the majority form minute bodies which stain both with hæmatoxylin and with eosin.

These minute bodies resemble minute protozoa in the chromidial condition, and they constitute the most abundant final result of the subdivision of the cells.

Before venturing to form any opinion upon the objects seen in the fully developed lesion, it is necessary to reflect that the fixation in the middle of a large section is necessarily imperfect; and accordingly, before arriving at a conclusion, I have compared the appearances here seen with those described above in the alveolar sarcoma of the breast and other sarcomas referred to above. I wish that I had been able to study also fresh scrapings of these tumours and the process of granulation-tissue formation in the dog, and to complete these observations in other ways; but in spite of the absence of these means of investigation, which have for many years been impossible to me, I have come to the conclusion that these tumours of dogs are in all probability essentially of the same nature as the sarcomas of the breast, testis, bone, etc., described above.

It may be objected that the bodies I regard as parasites are much smaller in this dog's tumour than they are in the human sarcoma, and, in fact, they are in proportion with the size of the cells in each case, and thus would presumably be derived from the cells.

In view of this objection it must be remembered that in infections by coccidia it is a rule that the size of the parasites is in direct proportion with that of the cells of the host, and what is true of coccidia is probably true of other cell-infesting parasitic protozoa.



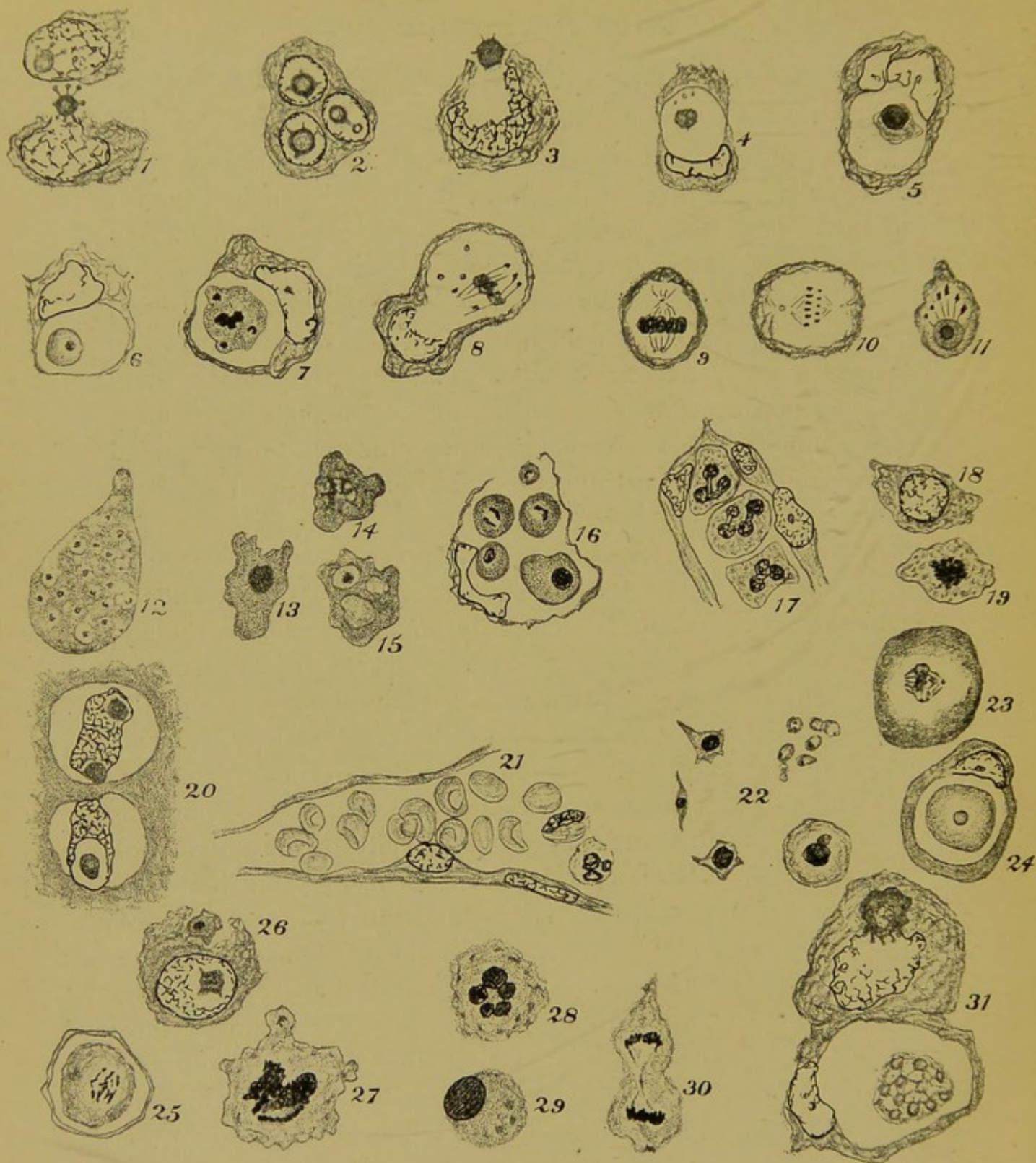


FIG. 53.—VARIOUS CELLS, ETC., OCCURRING CHIEFLY IN THE INFECTIVE SARCOMA OF DOGS.

1, Two adjacent cells in a mature lesion: the upper contains an intranuclear body, in the lower the corresponding body lies external to the nucleus, showing clearly its stellate character and the clublike rays (compare 1 and 2 in Fig. 36, from



I may now state the chief of these conclusions categorically, referring to the objects depicted in Fig. 53.

1. Of the intranuclear bodies, some are doubtless the nucleoli of the granulation-tissue cells, but those with definite radiating 'tentacles,' (7), are probably parasites which escape into the cytoplasm (3 and 4), become nucleated (5 and 6), and there subdivide (7 and 16), either whilst still within the host-cell (7) or after becoming free, as at 27 and 30.

2. Among the free bodies are some of typically protozoan characters (12, 13, 14 and 15).

3. Of the cells in mitosis, the bulk of those in the early and medium stages of the tumour (9 and 10), are connective-tissue cells, whilst the bulk of those in the fully developed lesion (27, 28, 29 and 30), are probably parasites which have become free of the host-cell.

human sarcoma); 2, a cell from a mature lesion containing three nuclei with intranuclear bodies; 3, a similar cell: the stellate body is leaving the nucleus; 4, a cell in which the nucleus contains no intranuclear body and but little chromatin: a non-nucleated body occupies a cavity in the cytoplasm; 5, a similar cell, with a nucleated amœba-like body in the cytoplasmic cavity; 6, a similar cell, with a rounded nucleated body in the cytoplasm; 7, a similar cell, with cytoplasmic cell-inclusion in irregular mitosis; 8, a similar cell, etc., but mitosis is resulting in formation of minute bodies; 9, 10, and 11, three different phases of mitosis, probably tissue-cells; 12, amœboid parasite with multiple nuclei; 13, 14, and 15, three different amœboid parasitic cells; 14, showing transition from stellate to amœboid form; in 15 there are two vacuoles; 16, a cell with empty nucleus and four nucleated cell-inclusions; 17, part of a capillary containing three leucocytes with typical polymorphous nuclei; 18, a connective-tissue cell from the part shown in Fig. 51: the intranuclear body is absent; 19, an adjoining cell in early mitosis: the same as 3 in Fig. 52; 20, two cells of the epidermis covering the tumour (Fig. 49), showing perinuclear space and nucleoli: the latter have not the stellate character of those of the tumour-cells; 21, a capillary of the same tumour with red blood-cells and two leucocytes; 22, a group of bodies of different kinds occurring in the central part of the same tumour: the largest cell has a nucleus consisting of a larger cyanophile and a smaller erythrophile part; 23, mitosis in an epithelial cell in the vaccinated cornea of a rabbit, to show ordinary mitosis in mammalian cell; 24, intracellular nucleated 'vaccine-body' from same preparation as 23; 25, an encapsuled body with nucleus from the middle part of the tumour, as shown in Fig. 49, 2; 26, an amœboid body entering the cytoplasm of a cell which contains an intranuclear body; 27, 28, 29, and 30, various forms of mitosis in the central part of tumour (Fig. 49, 2); 31, two cells from the sarcoma of breast—above showing the intranuclear body escaping, below showing gemmule-formation in cytoplasmic cell-inclusion and empty nucleus.

In this figure the bodies 1, 3, 5, 8, 9, 10, 11, 12, 13, 14, and 15 are from the late Dr. Washbourn's section; the remainder, except where otherwise mentioned, are from Mr. Foulerton's. All are camera drawings; magnification *circa* 1,000 diameters.



4. Many of the 'parasitic' cells are contained within definite capsules (25).

5. The end of the process is the destruction of the granulation-tissue cells and the breaking up of the structural basis of the tumour.

6. The processes described above in the three stages of this tumour occupy the area between the edge and the middle of the section (about  $\frac{3}{8}$  inch in diameter—Fig. 49), whilst in the alveolar sarcoma of the breast the corresponding processes are seen in each capillary mesh, a microscopic area. This difference, as also the greater abundance of tissue-mitoses in the earlier stages of the dog's tumour, is probably associated with a greater rapidity of parasitic invasion in the human sarcoma, and the alveolar character of the latter probably depends upon the same cause.<sup>1</sup>

To repeat, my view is that the course of events in these tumours of dogs may be divided into three stages :

1. The early granulation-tissue stage—*i.e.*, a filling out of the shrunken connective-tissue cells.

2. A stage in which the granulation-tissue cells have assumed the characters of sarcoma-cells. Some of these cells exhibit a mitotic activity comparable to that seen in the earlier stages of invasion of the cells of the cornea by the protozoa of vaccinia in their hyaline or chromidial phase. Among the tumour-cells in this stage are bodies of typical protozoon characters ; and—

3. A final stage in which chromidial parasites escape from the nuclei of the tumour-cells, rapidly enlarge, become nucleated, and subdivide ; this process terminates in the formation of minute bodies, most of which are in the chromidial condition.

<sup>1</sup> In a letter, *Brit. Med. Journ.*, February 2, 1907, I very briefly mentioned the conclusions I had come to as regards the fully developed lesions of this tumour, and in the next issue of the same journal Professor A. E. Mettam wrote to say that he had found spirochaetae among the cells of the lesions, and he kindly sent me, at my request, a preparation in which I saw spiral bodies. Although, from the analogy of syphilis, I think that spiral bodies will probably be found to occur at some stage in the parasite's existence, my experience does not suffice for me to pronounce an opinion as to these particular bodies.



## APPENDIX

### A NOTE ON MOLLUSCUM CONTAGIOSUM

THIS disease has been referred to several times in the foregoing pages. It will have full consideration at a later time. Here I wish to indicate briefly what kind of confirmation I have had of the phenomenon referred to in Chapter I. of this book. Working at different times with material kindly supplied by my friends, Drs. J. H. Stowers, P. Abraham, and Travers-Smith, I have on one occasion observed a streaming movement in the centre of a typical molluscum corpuscle. The appearance was one that I have seen only in living protoplasm. It is a confirmation of the view I hold that these inert and apparently typically degenerated bodies are protozoa. Among other observations of this same affection I will mention only one that I have observed on two occasions. Material kept at a temperature varying from  $30^{\circ}$  to  $37^{\circ}$  C. in tap-water, and examined under  $\frac{1}{12}$ -inch oil-immersion lens, showed considerable numbers of round bodies, varying in size from one-half to twice that of a blood-corpuscle. They showed the same streaming that I have referred to above as having occurred in the molluscum body, but the bodies I refer to now are not fully formed molluscum bodies; moreover slight alterations in shape show them to be in a plastic state. A thin bright seam of protoplasm (ectosarc) is not affected by the streaming movement. These bodies, which could only be protozoa, were not seen after the fourth day. In all probability they represent a stage in the life of the same protozoon as the typical molluscum body. After addition of glycerine and water with 2 per cent. of formalin they remain as bright globes of homogeneous appearance.



## INDEX

- ALVEOLAR sarcoma, intranuclear bodies  
     in, 95  
     of the breast, 87  
 Amœbic dysentery, 34  
*Argas Persicus*, 37  
 Atoxyl, 30  
 Bird's-eye bodies, 58  
 Cancer bodies. See Bird's-eye bodies  
 Cancer, definition of term, 77  
 Cellular pathology, 78  
 Ciliates, encystment of, 14  
*Colpoda cucullus*, 13  
 Cystic disease of the urinary tract, 68  
 Cysts, formation of, in ciliates, 16  
*Cytoryctes Guarnieri*, 44  
     intranuclear forms of, 48  
 Dysentery, amœbic, 34  
*Entamœba histolytica*, 34  
*Frambœsia*. See Yaws  
*Glossina*, 29  
 Granulation tissue, 81  
 Guarnieri's bodies, 45  
     amœboid stage of, 46  
     interpretations of, 53  
 Hyaline degeneration, 104  
 Infective genital tumour, 126  
*Ixodes ricinus*, 37  
*Kala-azar*, 30  
 Klebs's theory of cancer, 79  
 Leishmann-Donovan body, 31  
*Leydenia gemmipara*, 99  
 Molluscum contagiosum, 6, 137  
 Myxosarcoma, 115  
 Negri's corpuscles, 4  
*Neuroryctes*. See Negri's corpuscles  
 Nucleoli in granulation tissue, 85  
 Parthenogenesis, 25  
     in malaria parasites, 2  
 Phagocytosis in granulation tissue, 86  
 Piroplasmosis, 41  
 Plimmer's bodies. See Bird's-eye  
     bodies  
 Sarcoma, 78  
     definition of term, 77  
     of bone, 119  
     round-celled, of testis, 106  
 Small-pox, 44  
*Spirillum Obermeieri*, 22  
 Sleeping sickness, 28  
*Spirochæta*, 19  
*Spirochæta Duttoni*, 23  
     *pallida*, 63  
     *partenvis*, 67  
     *refringens*, 19  
     *Ziemanni*, 20  
*Spironema luis*, 23  
*Stegomeia fasciata*, 3  
 Syphilis, 55  
     in animals, 66  
 Ticks, 37  
 Trachoma, 7  
*Trichosphærium Sieboldii*, 9  
 Tropical splenomegaly, 30  
*Trypanosoma noctuæ*, 24  
 Tsetse-fly, 29  
 Vaccinia, 44  
 Yaws, 67  
 Yellow fever, 3

END OF PART II



BY THE SAME AUTHOR.

# PROTOZOA AND DISEASE,

## PART I.

BAILLIÈRE, TINDALL & COX, LONDON.

“Protozoa and Disease,” by Mr. J. Jackson Clarke, will come as a boon to those whose time is limited, and who are unable to read the many original papers on the subject.’

*British Medical Journal.*

‘The value of the work is greatly enhanced by an excellent series of ninety-one figures, to which, in most instances, are appended luminous descriptions.’

*Medical Press and Circular.*

‘We wish the book every success, and shall look forward with interest to the second part.’

*Lancet.*

‘We look forward with great interest to the publication of the second part of this book.’

*Indian Medical Gazette.*

‘Exceedingly useful introduction to the subject.’

*New York Medical Record.*

# SURGICAL PATHOLOGY AND PRINCIPLES.

LONGMANS, GREEN & CO., LONDON.

‘Should be carefully studied by all men who have any care for pathology, and who know good teaching when they see it.’

*British Medical Journal.*

‘In it is embodied in a concise and accessible form the essence of the teaching, and a good deal of the mode of consecutive thought and reasoning, of one of the best of our modern pathologists and teachers.’

*Intercolonial Medical Journal.*

‘It would be difficult to frame a simpler and more satisfactory account of the process of *repair* than we have in the second chapter.’

*Scottish Medical and Surgical Journal.*

‘He has described from Nature, and has not followed slavishly in the lines of former text-books.’

*Medical Press and Circular.*























