

A report of surgical cases treated in the army of the United States from 1865 to 1871.

Contributors

Otis, George A. 1830-1881.
United States. Surgeon-General's Office.
St. Thomas's Hospital. Medical School. Library
King's College London

Publication/Creation

Washington : Government Printing Office, 1871.

Persistent URL

<https://wellcomecollection.org/works/x9aezkhj>

License and attribution

This material has been provided by King's College London. The original may be consulted at King's College London, where the originals may be consulted.

This work has been identified as being free of known restrictions under copyright law, including all related and neighbouring rights and is being made available under the Creative Commons, Public Domain Mark.


You can copy, modify, distribute and perform the work, even for commercial purposes, without asking permission.

**wellcome
collection**

Wellcome Collection
183 Euston Road
London NW1 2BE UK
T +44 (0)20 7611 8722
E library@wellcomecollection.org
<https://wellcomecollection.org>



5. 5.



St. Thomas's Hospital.
LIBRARY

Q9.

KING'S
College
LONDON

fol. R2205 V6

Library

OT85, GEORGE A.

A REPORT OF JUDICIAL CASES

1871

201003260 5



KING'S COLLEGE LONDON

22. n. 3.
CIRCULAR No. 3.

WAR DEPARTMENT,
SURGEON GENERAL'S OFFICE,

WASHINGTON, AUGUST 17, 1871.

A REPORT

OF

S U R G I C A L C A S E S

TREATED IN THE

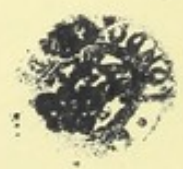ARMY OF THE UNITED STATES

FROM

1865 TO 1871.

WASHINGTON:
GOVERNMENT PRINTING OFFICE.
1871.

100
H13



CIRCULAR No. 3.

WAR DEPARTMENT,

SURGEON GENERAL'S OFFICE,

Washington, August 17, 1871.

The following Report of Surgical Cases treated in the Army during the past five years is published for the information and instruction of Medical Officers.

JOSEPH K. BARNES,

Surgeon General, United States Army.



Digitized by the Internet Archive
in 2015

<https://archive.org/details/b21309929>

A REPORT
OF
SURGICAL CASES

TREATED IN

THE ARMY OF THE UNITED STATES FROM 1865 TO 1871.

By GEORGE A. OTIS,
ASSISTANT SURGEON, UNITED STATES ARMY.

WAR DEPARTMENT,
SURGEON GENERAL'S OFFICE,
DIVISION OF SURGICAL RECORDS,
Washington, August 15, 1871.

GENERAL: In obedience to your instructions, I respectfully submit a report I have compiled from the returns and special reports of medical officers of surgical cases, more particularly of those pertaining to operative surgery, observed in the Army during the past five years.

Although the cases in each category are not sufficiently numerous to warrant any very important generalizations, yet every such contribution must be of value in adding to the mass of facts from which important inferences may be hereafter deduced.

I have endeavored to classify the observations in the shape most convenient for reference, to correct the more obvious errors inseparable from hasty composition, to provide illustrations on wood or stone where requisite, to sum up the inferences and conclusions deducible from the different series of cases, and to be sparing in comment.*

When practicable the language of the reporters has been followed textually; but often it has been necessary to trace the histories of cases through successive monthly statements, and to compile a connected narrative.

*" Je sais que la vérité est dans les choses, et non dans mon esprit qui les juge, et que moins je mets du mien dans les jugements que j'en porte, plus je suis sûr d'approcher de la vérité."—J. J. Rousseau's "EMILE."

GUNSHOT WOUNDS.

The returns of the Army for the past five years present a comparatively large number of gunshot wounds, received either in Indian hostilities, or accidentally, or in brawls, or attempts to evade or escape from arrest. The more important of these cases will be enumerated, as nearly as may be in the order of the anatomical regions in which the wounds were inflicted, with such subdivisions as are most convenient.

GUNSHOT WOUNDS OF THE HEAD.—Few of the cases of this series present peculiarities, yet some of them are not devoid of interest.

I.—*Note on a Case of Gunshot Fracture of the Frontal Bone.* By C. C. BYRNE, Surgeon, U. S. A.

Private Richard Jenkins, Co. B, 82d United States Colored Troops, aged 25 years, was accidentally wounded, at St. Augustine, Florida, on April 26, 1866, by the explosion of a fowling-piece. A fragment of iron perforated both tables of the frontal bone. He was admitted to the post hospital, where the foreign substance was extracted, and cold-water dressings were applied. He was returned to duty May 25, 1866.

II.—*Report of a Gunshot Fracture of the Mastoid Process.* By A. A. WOODHULL, Assistant Surgeon, U. S. A.

At Fort Larned, Kansas, Artificer Charles Andruss, Co. K, 3d United States Infantry, was wounded November 8, 1868, near Fort Gibson, Cherokee Nation, by the accidental discharge of a musket. The case was reported in the Monthly Report of Sick and Wounded, for March last, from which this is an extract. The ball entered the side of the neck, passed across the mastoid process, and through the external ear; the bone was slightly injured, and the external ear nearly destroyed. He was treated in hospital at Fort Gibson, Cherokee Nation, until February 18th, 1868, when he was sent to join his company at this post. The wound has nearly healed, except a little discharge from the ear. There was partial deafness. He was discharged from service June 28, 1869.

III.—*Note of a Case of Gunshot Fracture of the Frontal Bone.* By J. H. PATZKI, Assistant Surgeon, U. S. A.

Corporal John Connor, Co. H, 6th United States Cavalry, aged 25, was wounded in a fight with the Indians, July 12, 1870, by a conoidal ball, which fractured the external table of the frontal bone, over the sinus. He was admitted, on July 14th, to the post hospital at Fort Richardson, Texas. Portions of bone exfoliated, and on August 29th, fragments were removed, and the edges of the wound were freshened and united by metallic sutures. The wound healed readily. The corporal was returned to duty on September 12, 1870.

IV.—*Remarks on a Case of Gunshot Injury of the Head.* By G. MCC. MILLER, Assistant Surgeon, U. S. A.

“Private George Greenland, Co. D, 5th United States Infantry, was wounded, at a fandango, by a pistol ball, on the night of October 10, 1868, near Fort Reynolds, Colorado Territory. The wound was situated on the right side of the head, over the parietal bone, longitudinal in direction,

and one inch and a half long. It was deep, extending down to the pericranium. In accordance with some recent views and results of treatment,* I united the lips of the wound by means of a suture, in order to effect a coalescence by the first intention, or, at least without suppuration, if possible. Cold water dressings were applied. On the fifth day after the injury, I removed the suture; the lips of the wound then gradually separated, until a sloughing sore was produced. The use of the suture, however, seemed to reduce the amount of sloughing. On the 17th, unexpected and alarming symptoms presented themselves. The patient became semi-unconscious—unable to speak—with enormously-dilated pupils, and a wild expression of countenance. These symptoms, however, passed off in an hour, and did not return. The sudden appearance, brief duration, and sudden disappearance of this peculiar condition were quite singular. The wound being foul, I had it washed with a rather strong solution of the sulphate of iron. In twenty-four hours, it showed a healthy granulating surface; it continued to improve, and healed rapidly, and the patient was returned to duty November 2, 1868.”

V.—*Extract from a Report of a Case of Gunshot Fracture of the Mastoid Process.* By DAVID WALKER, Acting Assistant Surgeon.

* * * Private X—, Co. F, 1st Oregon Cavalry, aged 22 years, was wounded September 6, 1865, in an Indian fight on the Little Malheur River, Oregon. He came under treatment on September 12th, at the post hospital at Fort Steilacoom, Washington Territory. It was found that he had a gunshot wound, the ball having entered at the posterior head of the sterno-cleido-mastoid muscle, close to the curved line, ranging outward and a little upward, and lodging in the mastoid process. There was considerable hæmorrhage from the auditory canal, with temporary deafness, and paralysis of part of the *portio dura* of the seventh pair. Ultimately the recovery was complete.

VI.—*Note of a Gunshot Depressed Fracture of the Skull.* By T. S. V. HUTCHINSON, Acting Assistant Surgeon.

Private Romulus Morris, Co. E, 2d United States Infantry, aged 23 years, was wounded at Bowling Green, Kentucky, March 17, 1868, by a rifle ball, which caused a depressed fracture of the left parietal bone, with concussion of the brain. He also received a contused wound of the face. He was taken to the post hospital, where the depressed portion of the bone was elevated and the wound dressed. He recovered, and was returned to duty in the succeeding month.

VII.—*Memorandum of a Case of Gunshot Fracture of the Frontal Bone.* By W. F. SMITH, Assistant Surgeon, U. S. A.

Private J. Geddes, Co. E, 40th United States Infantry, was wounded August 26, 1868, by a small conoidal pistol ball over the right eyebrow. The outer table of the frontal bone was slightly fractured. He was admitted into United States Army post hospital, Goldsboro, North Carolina, August 26th, where the ball was removed and water dressings were applied. The wound healed almost immediately. The patient suffered no inconvenience except a slight headache. Two small pieces of bone came away about a fortnight after the receipt of the injury.

VIII.—*Report of a penetrating Gunshot Fracture of the Skull.* By G. H. GUNN, Assistant Surgeon, U. S. A.

The body of Sergeant Frank Tocker, Co. D, 6th United States Cavalry, was brought to post hospital at Fort Richardson, Texas, at half past seven of the evening of October 15, 1869. The apparent cause of death was a penetrating wound of the skull from a carbine or pistol ball. The pupils were widely dilated, and *rigor mortis* well established, with considerable fetor from the wound. A *post-*

* See American Journal of the Medical Sciences, October, 1868, Vol. LVI, p. 585. Reference to a case reported by W. M. Findley, who quotes Professor Simon, in the British and Foreign Medico-Chirurgical Review, for April, 1867.

mortem examination revealed an extensive fracture of the skull, a transverse section of the entire upper portion of it having been removed. Two openings presented on left side of head. The anterior situated near the coronal suture, some two inches from its junction with the sagittal; the ball evidently entering the brain at this point, and emerging some three and a half inches posteriorly. Various spiculae of bone were found imbedded within the brain, which was broken down and decomposed. Two wounds also on right side of head, one two inches above the ear, the other one inch directly above the former. This man was found dead by the roadside leading to the Government saw-mill near Hog Eye, Texas, October 15, 1869, and was supposed to have been murdered.

IX.—*Report of a Case of Gunshot Fracture of the Skull.* By A. A. YEOMANS, Assistant Surgeon, U. S. A.

Private Frank P. ———, Co. I, 24th United States Infantry, while attempting to escape from the guard-house at the post of Vicksburg, Mississippi, July 20, 1868, was fired upon by the sentinel, at a distance of three hundred and fifteen yards, the missile entering the skull near the posterior border of the left parietal bone, about three-fourths of an inch from the lambdoid suture and

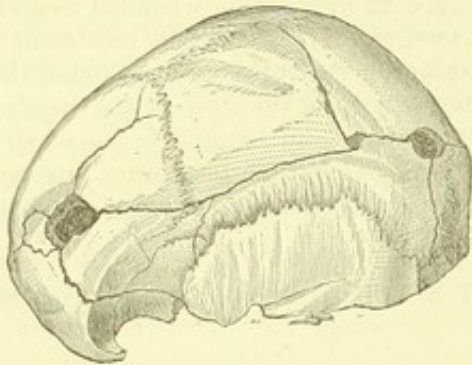


FIG. 1. Perforation of the Skull by a conoidal musket ball. Spec. 5473, Sect. 1, A. M. M.

midway between the sagittal and masto-parietal sutures; passing forward through the frontal bone about two inches above the left orbit. About two ounces of brain came out of the wound on the anterior aspect of the head, and he bled profusely, sinking rapidly, and dying about two hours after the reception of the injury. After death the skull was found to be fractured in nearly every direction from the wounds of entrance and exit, a large number of the bones being involved in the injury, and the left hemisphere of the brain was completely demolished.

The calvaria was forwarded to the Army Medical Museum, and is represented by the adjacent wood-cut, (FIG. 1.). It is remarkable as presenting an example of fracture of the eight cranial bones by a single missile.

X.—*Report of a penetrating Gunshot Wound of the Skull.* By C. T. ALEXANDER, Surgeon, U. S. A.

ON January 9, 1870, Private John Welsh, Co. L, 3d United States Cavalry, was wounded in a drunken row, by a pistol-shot from the hands of some person unknown, at the Placer mines, twenty miles south of Santa Fé, and was received into the hospital at eight on the following morning. The ball entered about one and a half inches behind the right ear, passing inward and forward; death ensuing January 14th, at 7 p. m. *Post mortem* January 15th disclosed that the ball passed in about two inches, lodging at the base of the brain, but not touching it; the man probably died of the shock, as the brain was only very slightly softened, where it rested over the ball, separated by its membrane. He was conscious at the time he entered the hospital, and easily aroused until a short time before death.

XI.—*Report of a Gunshot Fracture of the Skull.* By HENRY LIPPINCOTT, Assistant Surgeon, U. S. A.

“IN Kansas, in October, 1868, Private William Johnston, Co. E, 7th United States Cavalry, while hunting buffalo, on the 2d instant, with a party sent out from this command for that purpose, was shot and killed by Indians; he received two wounds, one entering the head, about the middle of the left parietal bone, and emerging about the middle of the parietal bone of the right side. The skull was extensively fractured, in all probability by a blow dealt by the Indians after the head was pierced by the ball. He was scalped. He was also shot in the right leg, the ball entering about four and a half inches below the knee-joint, on the anterior surface of the leg, passing upward, lodged in the head of the tibia; the bone was much fractured. I am unable to state how long he

lived after receiving the wound, but think that the time was not more than a few minutes. I saw him at the place where he was shot about two and a half hours after."

XII.—*Report of a Perforating Gunshot Wound of the Head.* By J. V. DE HANNE, Assistant Surgeon, U. S. A.

Private Edward Hogan, Co. B, 33d United States Infantry, was shot through the head and killed in the city of Huntsville, February 21, 1869, between 12 and 1 o'clock A. M. His remains were removed to Chattanooga, Tennessee, for interment in the national cemetery, on February 22, 1869. A *post-mortem* examination exhibited a perforating gunshot wound. The ball entered on the left temporal ridge, one and a half inches posterior to the left temporal eminence; exit at the middle of the right lambdoidal suture, one inch posterior and below the right parietal eminence; an extensive fracture of the frontal, left parietal, and occipital bones.

XIII.—*Memorandum of a Case of Gunshot Fracture of the Skull.* By Dr. A. JUDSON GRAY, Acting Assistant Surgeon.

Private Matthew Regan, Co. G, 15th United States Infantry, aged 28 years, was accidentally wounded at Fort Bayard, New Mexico, January 3, 1870, by a conoidal ball, which lacerated the scalp and fractured the cranium. He was admitted to the post hospital, where spiculæ of bone were removed and simple dressing was applied; inflammation of the brain followed, and death occurred on February 16, 1870, forty-four days after the reception of the injury.

XIV.—*Report of a Perforating Gunshot Fracture of the Skull.* By REDFORD SHARPE, M. D., Acting Assistant Surgeon.

At Fort McKavett, Texas, December 22, 1869, Brevet Captain Frederick W. Smith, 9th United States Cavalry, was killed by the accidental discharge of a pistol, in his own hands. The ball entered through the right parietal, and caused a very extended fracture of exit, involving the occipital, left parietal, temporal, and frontal, and making a large aperture, through which over two ounces of brain tissue escaped. The officer survived the injury about seven minutes.

The next four cases are instances of almost immediate death from perforations of the skull by balls:

XV.—*Note of a Case of Perforation of the Brain by a Musket Ball.* By J. H. McMAHON, M. D., Acting Assistant Surgeon.

Private Jeremiah Daniels, Co. I, 9th United States Cavalry, aged 26 years, was accidentally wounded at Fort Davis, Texas, on January 31, 1868, by a conoidal ball, which entered the right orbit, and emerged through the superior posterior portion of the right parietal bone. He died in three minutes from the reception of the injury.

XVI.—*Note of a Case of Perforation of the Skull and Division of the Carotid Artery by a Pistol-Ball.* By Dr. WILLIAM M. AUSTIN, Acting Assistant Surgeon.

Private John Kimball, Co. A, 35th United States Infantry, died at Fort Bliss, Texas, on December 5, 1867, from the effects of a pistol-shot wound, received in an affray at Franklin, Texas. The ball entered midway between the right angle of the lower jaw and the lobe of the right ear, passed forward, inward, and upward and came out immediately above the zygomatic process of the left temporal bone midway between the ear and the external angle of the eye. The internal carotid and jugular veins of the right side were severed.

XVII.—*Memorandum of a Gunshot Perforation of the Brain, fatal almost immediately.* By Dr. W. DEAL, Acting Assistant Surgeon.

Dorrall Nalbrow, a recruit of the 39th United States Infantry, aged 21 years, was killed October 14, 1867, at Greenville, Louisiana, by the accidental discharge of a musket in the hands of a fellow-soldier, the missile striking the right side of the frontal bone and passing through the brain.

XVIII.—*Report of a Case of Gunshot Perforation of the Skull.* By JOHN H. BARTHOLF, Assistant Surgeon, U. S. A.

Private Robert F——, Co. E, 11th United States Infantry, was accidentally killed at Camp Grant, near Richmond, Virginia, on May 11, 1868, by the accidental discharge of a breech-loading musket, in the hands of a comrade, at the distance of six or eight feet. The missile, a conical rifle musket ball, entered the face through the upper lip, three-quarters of an inch to the right of the median line, taking a course directly backward, on a line drawn immediately under the lobe of the ear, emerging from the neck at a point two and three-quarters inches back of the lobe of the ear, and two and a quarter inches in front of the posterior median line. The wound of entrance was small, and stellate in form, having three radiating lines. The wound of exit was very large, half an inch in front of the lobe of the ear. There was a slit made by some of the teeth and fragments of bone forcing an exit there. On dissection, the superior maxillary bone was found torn to small bits, but little more than the nasal process and the inner wall of the antrum remaining *in situ*. The floor of the orbit was broken up; the malar bone was broken, and its body displaced outward; its frontal process, separated from the body, was broken off from the frontal bone; the inferior maxilla was fractured across the body an inch anterior to the angle, and the bone from there to the articulation was completely broken up; the great wing of the sphenoid on the right side was greatly broken; the petrous portion of the temporal bone was broken off and into two pieces, and displaced backward; the mastoid process was to a small extent broken, and a fragment just internal to it, about an inch long and the same in width, entirely detached. Thus the internal and middle ears

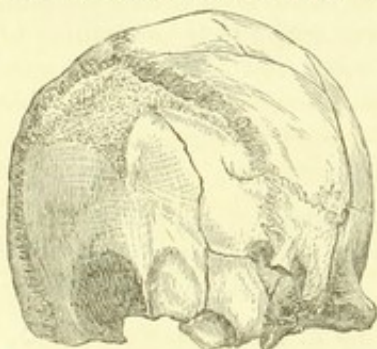

FIG. 2.—Segment of the skull, showing gunshot fractures of the occipital and petrous bones.—*Spec. 5335, Sect. I, A. M. M.*

were quite broken open; the occipital and right parietal bones broken; a fragment two and a quarter inches wide and three inches long, involving these two bones and the posterior inferior corner of the temporal, was driven backward, leaving a fissure along one side three inches long, and more than a sixteenth of an inch wide. A portion of the right transverse process of the atlas was broken off, and the right vertebral artery was cut across. The internal carotid artery was severed at an inch and three-quarters above its origin, and the external carotid at a point a quarter of an inch higher, or just below its bifurcation into its two terminal branches, and all the branches of the last-named vessels below the place indicated, except the superior thyroid and the lingual, were divided. The internal jugular vein was cut off at a point corresponding to the division of the internal carotid artery and the external jugular and its branches. The right pneumogastric nerve was severed opposite the upper part of the ramus of the lower jaw. The brain was not touched by the bullet. The pathological specimens were transmitted to the Army Medical Museum, and are illustrated by the wood-cut.

XIX.—*Memoranda of Three Cases of Fatal Gunshot Perforations of the Skull.*

Private John Miller, Co. H, 6th United States Cavalry, aged 26 years, received gunshot wounds of the skull, right arm, and left hand, in a fight with desperadoes, near Sulphur Springs, Texas, August 14, 1868. He was taken to the post hospital at Sulphur Springs, where he died on August 15, 1868. Acting Assistant Surgeon B. B. Miles reported the case.

Private William Fox, Co. C, 4th United States Cavalry, aged 25 years, was wounded accident-

ally by a Colt's revolver bullet, on May 29, 1869, which entered the left temple, fracturing the occipital bone, then, forcing its way forward in a vertical and slightly downward direction, making its exit on the base of the right temporal bone, immediately above the malar process, killing him almost immediately. The case was reported by Acting Assistant Surgeon Henry Spohn.

Private John E. Renn, Co. D, 16th United States Infantry, aged 21 years, was wounded on July 3, 1868, by a conoidal ball, which entered two inches above the right eye, passed backward, along the center of the right parietal bone, making its exit near the occipito-parietal suture. He was admitted from his quarters to the post hospital at McPherson Barracks, Atlanta, Georgia, on July 3, 1868. He died on the morning of July 4, 1868. The case was reported by Assistant Surgeon J. W. Williams, United States Army.

XX.—*Memorandum of a Case of Fatal Gunshot Injury of the Head.* By G. H. GUNN, Assistant Surgeon, U. S. A.

Private James Osborne, Co. I, 24th United States Infantry, aged 21 years, was wounded on September 17, 1869, by a conoidal bullet, on the left side of the head, during a fracas outside the limits of the garrison. He was admitted into the United States Army post hospital at Fort Richardson, Texas, on September 18th. His treatment consisted of stimulation with a nutritious diet. He died on September 18, 1869.

XXI.—*Report of a Fatal Gunshot Wound of the Brain.* By J. P. WEBB, Acting Assistant Surgeon.

Private John Houle, Co. C, 8th United States Cavalry, wounded by Indians near Collin's Ranch, La Paz route, Arizona Territory, on July 9, 1869, was received into the post hospital at Camp Date Creek, July 11th, after a journey of over sixty miles, under the care of a private physician. Very soon after admission symptoms of pressure appeared, which passed away in the course of twenty-four hours, to be replaced by some indications of cerebral inflammation—pulse ranging from 55 to 60, watering of the eyes, and redness of eyeballs; restlessness and delirium, which lasted a couple of hours of the afternoon, and reappeared about the same time for three days, after which his mind became quite clear, and his speech was unaffected. He exhibited some difficulty in protruding his tongue, which was covered with a dirty white coating for about a week, and then became clean and moist. During the second week, with the exception of the slow pulse, and some restlessness occasionally, there were little or no symptoms to indicate the structural changes taking place within the cranium; in fact, he presented many appearances of convalescence. About the beginning of the third week, he complained of pain in the right side of the head, and paralysis of the left arm made its appearance, gradually extending to the lower extremity. His mind now by degrees became more and more obscured, but without delirium, until a gradually-increasing stupor was merged in complete coma that preceded his death for about twenty-four hours. He died on the 3d of August, having survived the injury twenty-three days. A *post-mortem* examination was made on August 4th. There was a circular perforation of the right parietal bone, just behind the tuberosity, and somewhat in a direction from behind forward. Deeply imbedded in the brain were found the pieces of bone which belonged to the outer table, and seven comminuted fragments of the inner table and cancellated structure. Immediately beneath these was an abscess, perhaps larger than a goose's egg, filled with well-formed pus, and surrounded to the extent of about one inch by brain matter in a soft and pulpified condition. All the ventricles were found filled with fluid, and the membranes were greatly congested over the entire brain. The right cerebral hemisphere was otherwise healthy. The most careful examination failed to discover the ball, which, during life, and almost up to the last moment of fruitless search, I had believed to have lodged in the brain. Having in view the nature of the injury of the cranium, it is to me an entire mystery that I did not find it there. The form of the fracture is shown in the wood-cut. The treatment, which, with the exception of carbolic acid dressings to the wound, was entirely medical, was as follows: The bowels were thoroughly cleansed by purgatives and enemata, and

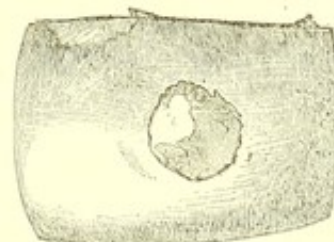


FIG. 3.—Depressed gunshot fracture of right parietal. Spec. 5707, Sect. I, A. M. M.

mild mercurialism established by calomel and opium; the gums were kept just barely touched for about a week, after which the action of the bowels was maintained by purgatives and enemata. A strictly antiphlogistic regimen was enjoined throughout; the entire scalp was shaved, and kept constantly irrigated.

XXII.—*Memorandum of a Fatal Gunshot Wound of the Brain.* By CARLOS CARVALLO, Assistant Surgeon, U. S. A.

Private Walter R. Stone, Co. F, 4th United States Cavalry, aged 22 years, was admitted to the post hospital at Jefferson, Texas, March 4, 1869, with a gunshot wound caused by the accidental discharge of his carbine. The missile entered the left eye, traversed the brain, and escaped through the occipital bone. He died March 4, 1869.

XXIII.—*Note of a Fatal Gunshot Wound of the Brain.* By R. H. WHITE, Assistant Surgeon, U. S. A.

Private William J. Hood, Co. K, 2d United States Infantry, while attempting to escape from a guard, was shot at Mobile, Alabama, March 16, 1870, by order of the officer of the day. He died in a few moments.

XXIV.—*Note of a Fatal Gunshot Wound of the Brain, with Wounds of the Lung and Chest.* By H. G. BATES, M. D., Acting Assistant Surgeon.

Private Ransom Shaw, Co. E, 3d United States Artillery, while attempting to escape from prison at Fort Macon, North Carolina, July 2, 1867, received three gunshot wounds. A conoidal ball entered just above the temporal ridge, on the left side near the coronal suture, and lodged in the brain; another entered the left lateral thoracic region, between the sixth and seventh ribs, passed through and emerged in front between the costal cartilages of the fifth and sixth ribs, near the sternum; there was also a slight flesh wound of the chest in front between the sixth and seventh ribs on the side of and near the sternum. Death resulted instantly.

XXV.—*Memorandum of a Homicide.* By R. M. KIRK, M. D., Acting Assistant Surgeon.

Private James McDonough, Co. B, 6th United States Cavalry, was shot by a corporal of his company on the night of March 14, 1868, at Austin, Texas, the ball, a Remington carbine pattern, passing antero-posteriorly through the brain, killing the soldier instantly.

It is impracticable to learn with precision the nature of the next two cases. Comparison of the different reports would indicate that they were examples of trivial gunshot scalp-wounds.

XXVI.—*Two Cases of Gunshot Injury of the Head.* By JOHN J. CULVER, M. D., Acting Assistant Surgeon.

Private Ole Larssen, Co. A, 35th United States Infantry, aged 35 years, received, on September 6, 1869, a wound of the head, by a pistol ball, in a disturbance with Mexicans, while temporarily at the post, attending a general court-martial. He was admitted into Fort Quitman, Texas, on September 7, 1869. Simple dressings were applied to the wound. He was returned to duty on November 20, 1869.

Private William Weaver, Co. H, 9th United States Cavalry, aged 35 years, was wounded by pistol balls in the right hip and head, on January 16, 1870. On the same day he was admitted into Fort Quitman, Texas, from his company. Simple dressings were applied to his wounds, and he speedily recovered.

On page 16, the remaining gunshot scalp-wounds, seven in number, that have been reported are noted. In battle such wounds are more frequent than fractures of the skull; but at close quarters, when direct aim is taken, the fractures are more frequent.

Eleven cases of suicide by gunshot wounds of the head are reported. Seven of these unfortunates perished almost instantaneously. Two others lived from a half-hour to an hour; a third survived six days; and a fourth long enough for a cerebral abscess to form. In the four instances in which the fatal issue was delayed, the pistol was employed as the implement of self-destruction; in the other seven cases, the regulation rifled musket.

XXVII.—*Report of Two Cases of Suicide.* By CARLOS CARVALLO, Assistant Surgeon, U. S. A.

At Jefferson, Texas, December 31, 1869, Lieutenant E. P. Colby, 11th United States Infantry, aged 24, committed suicide. He used a small Derringer pistol. The ball entered the cranium about an inch above and behind the right ear, and lodged in the brain. A protuberance on the opposite side of the skull rendered it probable that the ball fractured the inner table of the left temporal bone, but did not penetrate it. Lieutenant Colby became instantaneously unconscious, and the wound proved fatal in about a half hour after its infliction. He was *in articulo mortis* when first seen by me, and expired about fifteen minutes thereafter.

Private George Weiss, Co. H, 11th United States Infantry, aged 32 years, shot himself near Fort Jefferson, Texas, on May 28, 1870, with a rifle, from ear to ear. He was found in the woods half a mile from camp, with his brain scattered a distance of several yards from the body. All bones of the cranium and face, except the upper and lower maxillary, were fractured. (See *Specimen 5922*, Sect. I, A. M. M.)

XXVIII.—*Extract from a Report of a Death by Suicide.* By W. F. BROWNE, Acting Assistant Surgeon.

At Petersburg, Virginia, in November, 1868, Private George Kerne, Co. K, 21st United States Infantry, died on the morning of the 24th, by suicide. He fixed a gun-strap on his rifle, so that by putting his foot on the strap he could pull the trigger. He then inserted the muzzle of the gun into his mouth, and discharged the piece. His left jaw was broken, the occipital bone entirely carried away, and the cerebellum driven out. Death, so far as could be ascertained, was instantaneous. The man was probably laboring under temporary insanity.

XXIX.—*Report of a Case of Suicide by a Pistol-Ball through the Head.* By PETER MOFFATT, Assistant Surgeon, U. S. A.

Private James L. Cummings, Co. F, 1st United States Cavalry, died on June 30, 1869, from the effects of a pistol shot, inflicted by himself, with the purpose of committing suicide. The weapon was discharged while the muzzle was inserted in the mouth. The bullet passed upward and forward, carrying away the left eye, upper part of the nose, and the anterior-inferior portion of the base of the skull, and emerged in the vicinity of the frontal sinuses. The anterior-inferior convolutions of the brain could be felt by the fingers introduced into the wound, completely denuded of all covering, to the extent of one inch and a half to two inches; but no laceration of its substance could be detected. Profuse hæmorrhage ensued at the time of the occurrence. After the immediate effects of the injury, the patient remained conscious the greater portion of the time, until within a few hours of death. Had it not been for the injury to the mouth, precluding, almost entirely, the possibility of swallowing, the indications were that the patient might have lived for some time longer. There seemed very little immediate cerebral disturbance. Death occurred on the sixth day. Remorse, resulting from intemperance, was the alleged cause of this act of self-destruction.

XXX.—*Memorandum of a Case of Suicide.* By WILLIAM A. BRADLEY, Assistant Surgeon, U. S. A.

At Point San José, California, on September 23, 1868, Private Octavius E. Daniels committed suicide, by placing the muzzle of his musket against his temple, just anterior to the ear, and pulled the trigger by means of a poker. The ball entered at the lower border of the right temporal bone, on the right side, and emerged on the left side, through the parietal bone, about one-half an inch posterior to the groove for the middle meningeal artery, and about one inch below the track of the longitudinal sinus. Death was almost instantaneous. No autopsy was made.

XXXI.—*Extract from a Report of a Case of Suicide by Shooting in the Head.* By ROBERT BURNS, M. D., Acting Assistant Surgeon.

At Frankford Arsenal, Pennsylvania, November 27, 1869, * * * "Mark E. Richards died from suicide, by shooting in the head. * * * He was about 27 years of age, and enlisted as a private at the Frankford Arsenal, on August 13, 1869. He came under my treatment for secondary syphilis, on the 31st of the same month, and was returned to duty on the 26th of September, cured of the warts, but with orders to continue treatment. He was employed in the office as commissary clerk, about the 12th of November; but, in consequence of intemperate habits, he was reprovved once or more. On the morning of November 27th, he again reported himself sick to his commanding officer, who sent him to quarters to await medical advice. About 9 o'clock A. M. a messenger came to me, stating that Richards was shot. On arriving, I found him lying in the proof-house, in the rear of the barracks, upon his back, his head close by the sill of the building—his right arm flexed over the head, the left slightly out from his body; the head in a pool of blood, cleft from the nasal bone to the occiput, and in numerous places the cranium was fractured in many fragments, particularly the occipital bone, which appeared the point of exit of the ball, the muzzle of the gun being placed at the inner angle of the left eye. The brain had been blown out; the hemispheres being apart, one about three feet from the body, the other about a foot nearer to the body. The Springfield rifled musket was a short distance from him, with the butt toward his person. The coroner, his physician, and jury, came from Philadelphia about 4½ o'clock P. M., and held an inquest, rendering a verdict of 'suicide by shooting.'" Witnesses testified that the man had threatened to commit the deed before, and had left a note declaring his intention, his real name, and the residence of his family.

XXXII.—*Report of a Gunshot Wound of the Brain.* By Z. H. POTTER, M. D., Acting Assistant Surgeon.

At Fort Randall, Dakota Territory, on September 22, 1867, about midnight, I was aroused by the announcement that Lieutenant Robert A. G— had shot himself. I was soon by his side. I found him lying on the floor, in a carotid state, with profuse arterial hæmorrhage from nares, mouth, ears, and wound. The pulse was sixty, and full; breathing, stertorous and labored, twelve per minute. The edges of the wound, which was circular, were blackened, and the skin somewhat discolored by the smoke and heat attending the discharge. The ball had entered at a point just anterior and superior to the tragus of the left ear; passed into the cranium, in a direction nearly perpendicular to the side of the head, but inclining a very little upward and backward; penetrated the cerebrum, for a distance of six inches, and evidently lodged against the internal inferior lateral portion of the right parietal bone. Prognosis, death; accordingly, no effort was made to extract the ball. Twenty minutes past twelve: Pulse full, and eighty; breathing stertorous and labored, twelve per minute. Fifty-five minutes past twelve: Pulse fluctuating, occasionally strong and full, then, fluttering and weak; breathing more labored and stertorous, nine per minute. Death occurred at 1 o'clock A. M. September 23, 1867, from the combined effect of shock, cerebral laceration, and hæmorrhage, either of which, would, of itself, have proved fatal.

XXXIII.—*Memorandum of a Case of Perforating Gunshot Wound of the Head.* By B. E. FRYER, Surgeon, U. S. A.

Private Daniel Kaufman, Co. E, 7th United States Cavalry, aged 23 years, attempted to commit suicide at Fort Harker, Kansas, by shooting himself in the head with a pistol, the missile from which entered over the right frontal sinus and passed out through the left eye, destroying the eye and lacerating the lower lid. The treatment of the case is not recorded. Death supervened on December 21, 1867. At the autopsy the brain was found congested and softened, and an abscess in the anterior lobe of the left hemisphere containing two and a half ounces of pus.

XXXIV.—*Note of a Case of Suicide.* By A. W. GREANLEAF, M. D., Acting Assistant Surgeon.

Private John Flannery, Co. C, 2d United States Infantry, aged 21 years, committed suicide by shooting himself through the head with a conoidal musket ball. He was admitted into the United States Army post hospital at Montgomery, Alabama. He died May 20, 1869.

XXXV.—*Extract relative to a Case of Suicide, from the Chattanooga Post Hospital Report for October, 1866.* By C. E. GODDARD, Assistant Surgeon, U. S. A.

Private Nelson Lowry, Co. D, Second Battalion 16th United States Infantry, aged 25 years, while suffering under mental depression caused by religious melancholy, September 25, 1866, shot himself. The missile, a conical bullet, entered at the inner canthus of the right eye, and passed out at a point midway between the lobe of the right ear and the occipital protuberance, fracturing in its course the lachrymal, frontal, parietal, temporal, and occipital bones. Death was instantaneous.

XXXVI.—*Memorandum of a Case of Suicide.* By R. H. WHITE, Assistant Surgeon, U. S. A.

Private David Wilson, Co. H, United States Infantry, shot himself through the head at St. Augustine, Florida, August 8, 1867, and died instantly. Dr. Hopkins made the autopsy, of which no record is preserved.

Of the many Indian crania contributed to the Army Medical Museum, during the last five years, not a few presented examples of gunshot perforations of the skull, or of depressed or penetrating gunshot fractures. It is very painful to observe that these crania, in many instances, present numerous cleanly-cut perforations, from small projectiles at close range, evidently inflicted after death, and that this senseless vengeance was often wreaked upon the corpses of women and children.

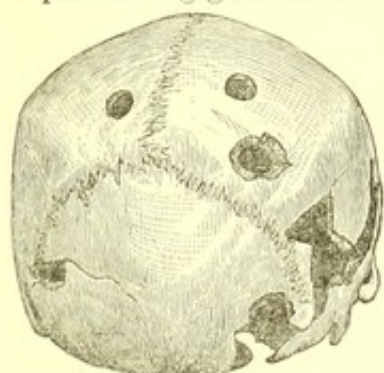


FIG. 4.—Cranium perforated by carbine or pistol balls. Spec. 5695, Sect. I, A. M. M.

Surgeon C. H. Alden, United States Army.

The next figure (FIG. 5) represents the cranium of a Cheyenne warrior, with an extensive fracture of the left upper maxillary region, and a perforation of the frontal by a pistol ball. The missile made its exit through the *foramen magnum*. The preparation was forwarded

The wood-cut adjoining (FIG. 4) illustrates this imitation of the atrocities of the savages. It represents the calvaria of a squaw of the band of Sioux under "Little Bear," killed at Chug Water, Wyoming Territory, in April, 1870. The skull was sent to the Museum by

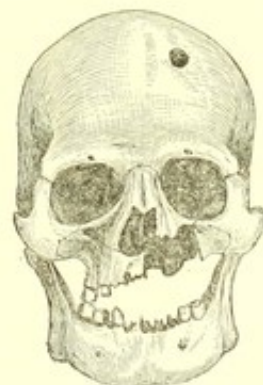

FIG. 5.—Cranium of a Cheyenne, perforated by a pistol-ball. Spec. 5661, Sect. I, A. M. M.

by Assistant Surgeon H. R. Tilton, United States Army. It is a ponderous cranium, weighing nearly two pounds avoirdupois.*

There were a few cases of gunshot scalp-wounds, only noticeable from the promptness with which the men recovered and returned to duty.

Private Robert Davidson, Co. B, 6th Infantry, aged 27 years. Pistol wound of scalp, December 25, 1868. Atlanta. Discharged, December 28, 1868, by reason of expiration of term of service.

Private John Flannaghan, Co. H, 8th Infantry, aged 25 years, near Columbia, January 4, 1869. Flesh wound of the left temple by a round ball. Duty, January 7, 1869.

Private William Morgan, Co. H, 9th Infantry, near Fort D. A. Russell, September 29, 1870. Gunshot wound of the scalp. Duty, September 30, 1870.

Private John Morgan, Co. D, 6th Cavalry, aged 23 years. Near Fort Richardson, July 5, 1869. Contusion of scalp from a pistol-ball. Duty, July 9, 1869.

Unassigned Recruit George McKinney, 6th Cavalry, aged 23 years, near San Antonio, December 6, 1866. Gunshot wound of the scalp. Duty, December 13, 1866.

Commissary Sergeant James O'Brien, 2d Battalion, 16th Infantry, Nashville, January 13, 1866. Gunshot wound of the temple. Duty, January 22, 1866.

Private Henry O'Neal, Co. K, 6th Cavalry, aged 22 years, near Sulphur Springs, Texas, September 12, 1869. Gunshot flesh-wound one inch to right of sagittal suture, over the coronal suture. Duty, September 29, 1869.

Laying aside the gunshot fractures of the Indian crania, regarding the histories of which there are no reliable special data, and the nine gunshot scalp-wounds, which are comparatively unimportant, we have, in the preceding abstracts, memoranda of thirty-eight cases of gunshot fractures of the skull. Five were received in fights with Indians; four in connection with provost duty; eight in brawls; ten accidentally; and eleven by suicide. Of these thirty-eight examples of gunshot fractures of the cranium, there were but seven instances of recoveries.

GUNSHOT WOUNDS OF THE FACE.—This class of injuries has been illustrated by several cases that have furnished interesting pathological contributions to the Museum, and by others that involve delicate points in practice.

XXXVII.—*Note of a Case of Gunshot Wound of the Face.* By H. A. DuBois, Assistant Surgeon, U. S. A.

Corporal Edward Swords, Co. D, 3d United States Cavalry, aged 26 years, was admitted to the post hospital at Fort Union, New Mexico, June 7, 1867, with a gunshot wound of the face. The ball entered the left superior maxilla one inch from its junction with the nasal bone and same distance from the margin of orbit, and passed obliquely backward and a little downward, and lodged behind the posterior fold of the palatine arch. The wound in the face was enlarged, and pieces of bone were removed. The ball, which could be felt in its place of lodgement, was not taken out, but was swallowed by the patient during the following night. On June 30th, the wound had nearly healed, but some necrosed fragments remained. He was discharged the service December 4, 1867.

* Many illustrations of multiple gunshot perforations of Indian crania have been brought to the Museum from Sand Creek, Colorado, the scene of the atrocious massacre of friendly Indians by the troops under Colonel John M. Chivington. *Specimens* 9, 10, 11, 12, Sect. IV; and *Specimens* 4772, 4773, and 5535, Sect. I, are some of the examples. See Mr. Catlin's article in *Trübner's Literary Record*, vol. I, p. 137.—"*Thesaurus Craniorum*," by J. Barnard Davis, M. D., &c., &c. London, 1867; p. 207.—*London Times*, August 8, 1865.—*Report of the Joint Committee on the Conduct of the War, at the second session of the Thirty-eighth Congress*, Washington, 1865, p. 121.

XXXVIII.—*Note of a Case of Gunshot Wound of the Face.* By REESE B. BERKY, Acting Assistant Surgeon.

Sergeant John Howard, Co. K, 16th United States Infantry, was admitted to the post hospital at Corinth, Mississippi, September 18, 1869, with a gunshot wound of the face, received while on duty, making an arrest. The missile, a ball from a Navy revolver, penetrated the left nasal bone and emerged at a point about one inch anterior to, and on a line with, the lowest point of the right ear. Projecting and other loose fragments of bone were removed, the hæmorrhage arrested, and cold-water dressings applied. The patient was returned to duty October, 1869.

XXXIX.—*Extract from the Monthly Sick Report at Fort Macon, North Carolina, March, 1869, describing the peculiar Course of a Musket-Ball.* By ELLIOTT COUES, Assistant Surgeon, U. S. A.

Private Downie, Co. A, 8th United States Infantry, was accidentally shot and instantly killed by a sentinel on guard. The autopsy showed the following singular course of the bullet: The ball entered the mouth from the left side, without touching the lips, and impinged upon the inferior maxilla at about the middle of the right horizontal ramus, shattering the bone into several pieces without breaking or knocking out any teeth. The laceration of the right side of the tongue gave unequivocal evidence that the ball impinged upon the inside of the jaw-bone. It then glanced, or, to speak in all probability more correctly, rebounded, and struck the inside of the alveolar border of the right superior maxilla somewhat above the level of the teeth. Still farther deflected from its original course, it then passed straight upward through the palate and nasal passages into and through the left orbit, close past the inner wall of the latter, struck the orbital plate of the frontal bone into the left anterior lobe of the cerebrum, which was by this means extensively lacerated. It is probable that the ball itself did not enter the brain, its force being by this time expended. It was found curiously furrowed and distorted, lying in the left orbit, upon the eyeball, which had escaped laceration. The battered ball is shown in the wood-cut.

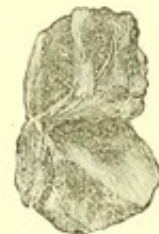

FIG. 6.—Musket ball battered by impact on bones of the face. *Spec. 5564, Sect. I, A. M. M.*

XL.—*Report of a Gunshot Wound of the Face.* By PETER MOFFAT, Assistant Surgeon, U. S. A.

Private B——, Co. H, 23d United States Infantry, was admitted on March 24, 1870, to hospital at Fort Boise, Idaho Territory, with a gunshot wound of the face. The missile entered a little to the left of the median line of chin, almost below the angle of the mouth; ranged almost directly backward, comminuted the lower half of the inferior maxillary bone without destroying the continuity of the arch of the jaw, passed through the soft parts below, and lodged at some point deep in the neck. He fainted from the shock and loss of blood, but reacted and managed to make his way to the hospital. The surgeon enlarged the wound of entrance and removed fragments of comminuted bone. A portion of the leaden missile was extracted; but a channel was found to extend still deeper toward the left side of the cervical spine. It was not deemed safe to pursue the remaining portions of the ball. A tent saturated with carbolic acid was introduced, and simple dressings were applied. The portion of lead extracted was flattened and jagged in form, and weighed thirty grains. A ball of the size of the one by which the wound was inflicted weighed eighty grains, leaving a balance of fifty grains to represent the portion still in the wound. Considerable irritation of the larynx, causing cough and expectoration, supervened. These symptoms improved, and on March 30th the case was progressing favorably. No indication requiring a search for the ball arose, and in May, 1870, the man was returned to duty, the fragment of bullet remaining lodged.

XLI.—*Report of a Gunshot Fracture of the Lower Maxilla.* By EDWARD COWLES, Assistant Surgeon, U. S. A.

CASE.—Private Charles Wicks, Co. C, 26th United States Infantry, aged 20 years, was shot in the face by a Mexican, at Brownsville, Texas, May 5, 1868. The ball entered a little to the left

of the symphysis of the lower jaw, and laid open the lip from its upper border nearly to the lower margin of the chin, causing extensive laceration. A small external wound to the right of the symphysis was probably made by the exit of a fragment of the ball. The body of the lower maxilla, to the distance of about three-quarters of an inch on each side of the symphysis, with the front teeth, was comminuted and carried away. Two large fragments of bone were driven quite deeply under the tongue, and wedged in between the opposite sides of the jaw. The patient was admitted to the post hospital. Hæmorrhage, which had been quite profuse, had nearly ceased. About forty fragments of bone, and a portion of the ball lodged behind the fractured end of the jaw, on the right side, were removed. The two pieces driven under the tongue were allowed to remain. The wound was closed by two harelip sutures, and the jaw supported underneath by pasteboard splint and bandage. Pieces of lint, moistened with a solution of chlorinated soda, were kept in the wound. The wound of the lip closed in nearly its whole extent by first intention, and the harelip sutures were in a few days removed. The cavity of the wound, under the tongue, filled with granulations. The fragments of bone under the tongue united with each other and with the jaw on each side, bridging it across, and giving it its natural firmness, with but little deformity. The man was returned to duty on June 12, 1868.

XLII.—*Memorandum of a Case of Gunshot Fracture of the Upper Maxilla.* By B. C. FRYER, Surgeon, U. S. A.

Sergeant Thomas Logan, Co. A, 10th United States Cavalry, aged 23 years, was shot by an officer for mutinous conduct. He was admitted to the post hospital at Fort Harker, Kansas, January 6, 1869, with a pistol wound of the face. A conoidal ball had entered the left nostril, passed backward, and toward the right, through the vomer, and had lodged, it was believed, under the sterno-cleido-mastoid muscle, near the mastoid process. Simple dressings were applied, and the patient recovered without a bad symptom. He was returned to duty February 2, 1869.

XLIII.—*Report of a Gunshot Fracture of the Lower Maxilla.* By JOSEPH K. CORSON, Assistant Surgeon, U. S. A.

Sergeant Alexander Brown, Co. D, 2d United States Cavalry, aged 26 years, was wounded in a fight with Indians on May 4, 1870, by a conoidal bullet, which fractured the inferior maxilla. He was admitted into the United States Army post hospital, Fort Bridger, Wyoming Territory, from Camp Stambaugh, May 19, 1870. On May 23d the fractured bones, consisting of the inferior maxilla, from the ramus on the left side to the middle of the jaw on the right side, were removed. In September, 1870, he was still under treatment. He was returned to duty in November, 1870.

XLIV.—*Memorandum of a Case of Gunshot Wound of the Lower Maxilla.* By DALLAS BACHE, Surgeon, U. S. A.

Sergeant Washington Coler, Co. C, 9th United States Cavalry (colored troops), aged 24 years, was admitted to the post hospital at San Antonio, Texas, May 2, 1868, with a gunshot wound received May 2, 1868. A pistol-ball fractured the alveolar process of the inferior maxillary, knocking out two left incisors and a canine tooth. Simple dressings were applied. He was returned to duty on May 25, 1868.

XLV.—*Minutes of a Case of Gunshot Fracture of the Lower Jaw.* By WM. M. NOTSON and EDWARD COWLES, Assistant Surgeons, U. S. A.

Private Franklin Grey, Co. F, 41st United States Colored Infantry, aged 23 years, was accidentally wounded near Brownsville on August 26, 1867, by a conoidal musket-ball, which entered the mouth, wounding the tongue, fracturing the body of the lower jaw, comminuting the ramus, passing between the internal and external carotid arteries, and emerged one inch below the right

ear and behind the angle of the jaw. The hæmorrhage was alarming. He was admitted into the post hospital at Fort Brown, Texas, on the same day. The jaw was supported by a pasteboard splint; compresses were applied over the carotid arteries. The mouth was cleansed daily with solution of chlorinated soda. Pieces of bone were removed. Liquid nourishment was given at first by enemata. He was transferred to Fort Concho, Texas, on March 20th, and was discharged for disability October 18, 1869.

XLVI.—*Minute of a Case of Gunshot Fracture of Lower Maxilla.* By H. R. TILTON, Assistant Surgeon, U. S. A.

Private Martin O'Brien, Co. C, 7th United States Cavalry, aged 21 years, was shot at Fort Lyon, Colorado Territory, by the first sergeant, on January 9, 1868, for munitous conduct; a pistol-ball entering left cheek, carrying away the angle of the lower jaw without causing its complete fracture, and lodging against the cervical vertebra. He was admitted to the post hospital at Fort Lyon, Colorado Territory, on January 10, 1868. Simple dressings were applied. On January 27, 1868, an abscess opened in the neck, from which a number of small fragments of bone were removed. On February 14, 1868, the ball was removed. The man deserted from the hospital.

XLVII.—*Report of a Gunshot Wound of the Upper Maxilla.* By CHARLES K. WINNE, Assistant Surgeon, U. S. A.

CASE.—Charles E. M——, first lieutenant and quartermaster 16th United States Infantry, aged 26 years, was wounded May 21, 1868, by a pistol-ball, which entered in left occipital triangle, just behind sterno-cleido-mastoid muscle, at junction of two imaginary lines, one horizontal and parallel with chin, the other vertical and bisecting mastoid process of temporal bone; ball passed inward and upward, then changing direction entered mouth through centre palate process of superior maxillary bone, and finally buried itself in alveolar process of superior maxillary of right side. The internal maxillary artery in its third portion, or one of its large branches, was divided, as hæmorrhage was fearfully profuse from both openings of the wound, and the patient sank exhausted before reaching the barracks. The hæmorrhage was checked by the application of compresses; patient exsanguined and suffering from the intense degree of the shock. He vomited several times, which was followed by the recurrence of hæmorrhage. This immediately ceased upon injection of persulphate of iron; manual pressure applied as far as practicable over track of wound, then a bar-tourniquet substituted and very slight pressure used. As it was impracticable to secure the bleeding vessel, it was determined, upon mature deliberation, to ligate the primitive carotid artery should hæmorrhage again occur. Sulphate of morphia, with small quantity of stimulants, were administered every two hours, and a diet of beef-tea and chicken-soup through a tube. May 22d, patient perfectly comfortable in every way. May 27th, the bar-tourniquet was kept in position for several days, though no pressure was exercised, then it was removed. The wound of entrance is now suppurating freely, considerable swelling in occipital space. Delirium tremens manifested itself, May 30th. Under the free administration of narcotics the attack terminated to-day; during the last twenty-four hours *ext. cann. indicæ* was substituted for the *tinct. opii deodor.*, with the happiest result, though in this case I am inclined to ascribe the effect more to the impression made upon the disease by the opiate primarily, for I pushed it to excess, even, as I considered that a probable hæmorrhage caused by the unconscious and unruly movements of the patient was more dangerous than narcotism. In the majority of instances, I am opposed to such free administration of opium. In addition, the most nourishing food, with weak milk-punch, was given. June 2: patient doing well in every respect. He was returned to duty, July, 1868.

XLVIII.—*Note of a Case of Gunshot Wound of the Face.* By A. A. WOODHULL, Assistant Surgeon, U. S. A.

Private George Bullis, Co. C, 3d United States Infantry, aged 21 years, was wounded on August 11, 1870, by duck-shot, at close range, which shattered parts of the malar bone and superior maxilla, destroyed nearly an inch of the condyle of the inferior maxilla, and chiefly lodged

against the temporal, partly escaping, by suppuration, through the external canal. He was admitted immediately afterward into the post hospital at Fort Larned, Kansas. He had, during September, a slight attack of erysipelas, but is now nearly healed. He was returned to duty October 20, 1870.

XLIX.—*Memorandum of a Case of Fatal Gunshot Wound of the Face.* By HENRY McELDERRY, Assistant Surgeon, U. S. A.

Private Ferdinand Schwindig, Co. I, 6th United States Cavalry, aged 30 years, was wounded on June 11, 1867, by a conoidal bullet, which entered the right submaxillary region, passed upward and inward, making its exit at the root of the nasal bones, fracturing the right superior maxillary, malar, vomer, palate, and nasal bones, and carrying away the right side of the tongue. He was admitted into the United States Army post hospital at Fort Belknap, Texas, on the same day. Stimulants were administered, and local applications of cold water and of persulphate of iron. His death, which took place on June 12, 1867, was probably caused by œdema of the glottis.

The following cases were probably examples of gunshot flesh-wounds only :

Private Peter Alfonze, Co. A, 9th United States Cavalry; aged 24 years; Fort Stockton, Texas, October 24, 1864. Gunshot wound of left eyelid. Duty, November 1, 1868.

Private Jacob Dubois, Co. G, 6th United States Infantry; Little Rock, Arkansas, December 17, 1870. Flesh-wound through left cheek. Duty, January, 1870.

Private Christian Fleming, Co. C, 40th United States Infantry; aged 21 years; Washington, December 10, 1866. Gunshot wound of lip and tongue. Duty, January, 1867.

Private Arthur J. Gregory, Co. D, 25th United States Infantry; aged 21 years; Memphis, Tennessee, July 6, 1868. Gunshot wound of both cheeks. Duty, July 20, 1868.

Corporal Landon Maitlon, Co. H, 128th Colored Troops; aged 40 years; Charleston, South Carolina, August 1, 1866. Gunshot wound of upper lip. Duty, August 10, 1866.

Private Charles Seachrist, Co. I, 37th United States Infantry; aged 20 years; Fort Dodge, Kansas, July 16, 1867. Flesh-wound of right cheek. Duty, July 28, 1867.

Private George W. Young, Co. H, 9th United States Cavalry; aged 27 years; Fort Quitman, Texas, October, 1868. Gunshot wound of face. Duty, November 10, 1868.

Thus, of twenty gunshot face-wounds, two were fatal. Fifteen of the patients were returned to duty, two were discharged, and one deserted. In six of the fractures, the upper maxillary or nasal regions were the principal seats of mischief; in seven, the lower maxillary suffered most.

GUNSHOT WOUNDS OF THE NECK.—A large mortality attended the injuries of this class that have been reported.

L.—*Report of a Case of Gunshot Wound of the Pharynx.* By C. H. ALDEN, Surgeon, U. S. A.

Thomas G—, a teamster in the Quartermaster's Department, was admitted to the post hospital at Fort D. A. Russell, Wyoming Territory, December 20, 1867, having been wounded by another teamster seven days previously, while on the road from one of the posts to the northward. There was a small pistol-ball wound at the point of the chin, discharging pus. The probe could be passed in toward the neck about three-quarters of an inch; but the most careful manipulation failed to discover the further track of the missile. There were no wounds of the mouth, tongue, or any of the tissues in the mouth. The patient could swallow with but very little discomfort or difficulty. His right arm was paralyzed almost completely, the only motion left being partial pronation and

supination of the fore-arm. He was weak, but the symptoms named were the only noticeable ones. Rest was ordered, with beef-tea and milk-punch at regular intervals. A few days after his admission, there was a profuse stringy discharge from the throat; he remained in almost the same condition for a week, with the exception that he gradually grew weaker; deglutition became somewhat more difficult. Death, from seeming exhaustion, resulted December 26, 1867. *Post-mortem* examination revealed a short sinus filled with pus, connected with the external wound; but a careful examination of the parts did not disclose the track of the ball. The neck, toward the right shoulder, was carefully dissected, and no lesion discovered. The parts lying in front of the cervical vertebræ were then removed, down to the œsophagus and pharynx, where an opening was discovered in the posterior wall of the pharynx, and beneath it the ball, embedded in the anterior surface of the body of the fifth vertebra. The pathological specimen is numbered 5584, Section 1, Army Medical Museum, and was contributed, with a history of the case, by Surgeon C. H. Alden, U. S. A.

LI.—*Extract from Monthly Report of Wounded of July, 1869, of Detachment of 7th United States Cavalry.* By HENRY LIPPINCOTT, Assistant Surgeon, U. S. A.

Private John A. Wright, Co. I, 7th United States Cavalry, was accidentally shot on the 17th day of July, 1869, in a scout, near Fort Hays, Kansas. The ball entered the throat at a point corresponding with the fourth ring of the trachea. Passing upward, it destroyed the first, second, and third ring, as well as the fourth. It destroyed, besides the portion of the trachea just named, the thyroid cartilage, and in its ascent fractured the hyoid bone. In addition to these injuries, the inferior maxilla was severely fractured, the ball emerging just in front of the inferior incisors. The shock was terrible. With a view to the arrest of the hæmorrhage, too sudden and great reaction was guarded against; but the shock was not neglected. The wounded tissues were kept apart to favor the exit of accumulating blood. After this a silver tube was inserted, and seemed for a time to afford relief; but despite all attempts to avert the fatal issue, dissolution took place in a few hours.

LII.—*Note of a Case of Fatal Gunshot Wound of the Neck.* By C. L. HEIZMANN, Assistant Surgeon, U. S. A.

Private James Morrissey, Co. B, 34th United States Infantry, was shot through the neck at Grenada, Mississippi, March 28, 1868. The missile entered on the left side, at a point two and a half inches on a line drawn perpendicularly to the clavicle from the lobe of the ear, and emerged about one and a half inches from the spinous process on the right side, on a line drawn from the angle of the jaw to the spinal column. The carotid artery was severed, and death was almost instantaneous.

LIII.—*Remarks on a Gunshot Wound of the Neck.* By ALFRED DELANEY, Assistant Surgeon, U. S. A.

At Fort Gibson, Cherokee Nation, Private John Maybee, Co. C, 10th United States Cavalry, received a gunshot wound in the neck, in a drunken brawl, on the morning of November 19, 1868. He was taken into hospital shortly after the accident, when he presented the following symptoms: Complete paralysis of both superior extremities; respiration gasping and frequent; pulse about 100, and of fair volume and strength; mind clear; he complained of some pain in the hands. On making a critical examination, the ball was found to have penetrated the neck, on the left side, at the anterior border of the trapezius muscle, and about two inches and a half below the mastoid process of the temporal bone; thence passed downward and to the right side, beyond the reach of the bullet probe, fracturing one or more of the vertebræ. A few accessible and loose fragments of bone were removed, but the ball was not discovered. The treatment consisted in placing the patient, supinely, upon a water-bed, and the administration of anodynes to induce sleep and relieve pain. The bladder was relieved by the catheter. The paralysis of the abdominal muscles

allowed an accumulation of gases to take place within the intestines to such an extent as greatly to augment the already existing difficulty of respiration. It was found expedient to introduce an elastic tube, from time to time, through which the gases found vent, when pressure was made, externally, on the abdomen. The paralysis became more profound from day to day; the respiration more difficult, inducing a slow asphyxia, delirium followed by coma; and, finally, death on November 28, 1869, about eight days after the receipt of this injury. The autopsy disclosed the following conditions:—Fracture of the spinous process of the last cervical vertebra; the process had been comminuted, the fragments driven before the ball and lodged in the surrounding soft parts. Secondly, fracture of the laminae of the first dorsal vertebra, at the point where they join to form the spinous process. This fracture opened the medullary canal, and ruptured the sheath of the cord. Several small fragments of bone were found embedded in the substance of the cord, which was found softened and bathed in pus. Thirdly, fracture of the first rib, and the coracoid process of the scapula. The ball was found in the axilla. The lungs were deeply congested, the mucous coat of the bronchi also; and the bronchi themselves filled with a tenacious mucus. In the apex of the right lung was found a cavity filled with pus, and containing a fragment of bone about the size of a pea, probably a piece from the first rib. Death, if not caused by the interference with the respiratory act, and the consequent slow asphyxia, was doubtless hastened by it.

LIV.—*Extract from a Report of a Gunshot Wound involving the Carotid Artery and Spine.* By W. R. BLACKWOOD, Acting Assistant Surgeon.

In December, 1867, at Rome, Georgia, Private John Bowen, Co. G, 33d United States Infantry, was killed by a musket-ball, from a Springfield breech-loading musket, on the morning of the 26th. He was lying down at the time, asleep, having been unwell at the morning sick-call. The piece, which was not known to be loaded, was discharged while in the act of being covered with its flannel case. It was in the hands of George Wood, of Co. H. The ball, after first passing through the left fore-arm, entered the neck, a little to the left of the median line, at the sterno-clavicular articulation, severed the carotid artery, and emerged at the fourth cervical vertebra, fracturing it, and lacerating the spinal cord. Death was instantaneous, the men who were standing around his bunk not being aware that he was struck. One man was sitting beside him on the bed, but believed the ball to have passed beneath the wood-work of it. The accident was not discovered until dinner-time, three hours after its occurrence. No *post-mortem* examination, further than a digital examination, was made.

LV.—*Memorandum of a Fatal Case of Gunshot Wound of the Neck.* By W. F. SMITH, Assistant Surgeon, U. S. A.

Private George Robinson, Co. D, 40th United States Infantry, was shot on August 26, 1868, by the officer of the guard, for mutinous conduct at the United States Army post, Goldsborough, North Carolina, by a Colt's Navy revolver, in the neck, severing the carotid artery. Death from hæmorrhage resulted almost immediately, September 13, 1868.

LVI.—*Note of a Case of Gunshot Fracture of the Spine.* By IRA FERRY, Assistant Surgeon, 9th United States Colored Troops.

Private Gustavus Chase, Co. I, 9th United States Colored Troops, aged 24 years, was shot while walking from Brownsville, Texas, to camp, January 28, 1866. The missile, a conoidal bullet from a Colt's Navy revolver, shattered the spinous processes of the sixth and seventh vertebrae, laid open the canal between the sixth and seventh spinous processes, and lacerated the cord. He was admitted to the post hospital, where fragments of bone were extracted, and simple cold-water dressing applied. There was complete paralysis below the seventh dorsal vertebra, and great pain in the epigastric region. On February 1st the bowels and bladder were completely torpid, the skin hot, the pulse at 140. Death occurred February 4, 1866.

LVII.—*Extract from Quarterly Report of Wounded at Fort Mason, Texas, relative to a Gunshot Wound of the Neck.* By JOHN J. HULSE, Acting Assistant Surgeon.

Major John A. Thompson, 7th United States Cavalry, was wounded by a pistol ball, while engaged in suppressing an affray between a party of soldiers and desperadoes, near Fort Mason, Texas, on November 14, 1867. The missile struck the right malar bone, and emerged below the lobe of the left ear, severing the left carotid artery. He was taken to the post hospital, and died the next day from hæmorrhage.

LVIII.—*Memorandum of a Gunshot Wound of the Neck.* By G. W. B. MINOR, Acting Assistant Surgeon.

Private James Smith, Co. I, 38th United States Infantry, was shot, by the accidental discharge of a Springfield musket in the hands of Private Moses Hunter, while standing in the door of the company quarters. The ball entered the right shoulder behind, and, passing through the scapula, divided the subclavian vessels and fractured the clavicle. It was turned from its course, and ranged backward and upward through the neck, wounding the sheath of the carotid vessels, lacerating the larynx, almost severing the tongue, and making its exit through the left corner of the mouth. The parts near its passage were torn and contused to a very large extent, the calibre of the ball being .50, and death was almost immediate.

LIX.—*Note of a Case of Gunshot Wound of the Neck.* By EDWARD COWLES, Assistant Surgeon, U. S. A.

Private Leon Pinel, Co. I, 1st United States Artillery, aged 35 years, while escaping from patrols on May 23, 1867, was shot, by the officer of the day, with a small bullet from a pistol. The ball entered the middle of the right shoulder, immediately over the supra-scapular notch, passed superficially upward and forward into the neck, wounding the œsophagus posteriorly, at a point opposite the thyroid cartilage, and lodging in the left side of the neck. He had a little hæmorrhage, but had expectorated, and probably swallowed, much blood. He had a constant desire to swallow, which continued several days. He was admitted into the post hospital at Brownsville, Texas, on May 23d, three-fourths of an hour after being wounded. Expectant treatment. Simple dressings to the wound of entrance, which closed by first intention, and in two days there was no remaining tenderness along the track of the wound. The soreness and swelling of the throat gradually increased, with difficult deglutition, and expectoration of mucus, occasionally tinged with blood, until May 27th, when there was great difficulty in swallowing, increased fullness and swelling of the left side of the throat, and expectoration of a great deal of mucus and pus, discolored with a little disorganized blood. There was little dyspnoea, and not much febrile reaction, the pulse, naturally very slow, being 70 per minute. On the 28th the patient was much better, swallowing with more ease, had no fever, pulse about 60 per minute, and continued to improve rapidly to convalescence, with no soreness remaining about the throat. A liberal allowance of milk-punch, beef-essence, eggs, and fresh milk. Gave tincture of sesquichloride of iron three times daily, and used a solution of chlorate of potassa freely as a mouth-wash and gargle; also internally. He was returned to duty on June 10, 1867.

LX.—*Report of a Case of Gunshot Wound of the Neck.* By J. W. WILLIAMS, Assistant Surgeon, U. S. A.

Private James Nixon, Troop C, 5th United States Cavalry, was shot, in a street fight with a policeman, October 24, 1868, by a pistol-ball, which entered the neck, half an inch above, and somewhat external to the greater cornu of the hyoid bone and lodged. He was retained in camp four days, and on the 18th was admitted to the post hospital, McPherson Barracks, Atlanta, Georgia, with complete paralysis of motion and sensation of the lower extremities and the right arm. There was partial paralysis of the left arm, with spasmodic movement when used. The intercostal muscles were paralyzed; there was loss of sensation over the abdominal region, with partial paralysis

of the bowels and complete paralysis of the bladder. His mind was clear, and sensation was normal over the face and upper portion of the chest; respiration abdominal and slow; pulse slow and regular. Although the skin and extremities were hot to the touch, the patient complained of coldness of the surface. The track of the bullet could not be ascertained, as the wound had nearly healed; but from the symptoms described above, which were present immediately after receiving the wound, it was surmised that the spinal cord had been injured. During the first week of his treatment in the hospital there was no perceptible improvement in the paralysis. A large bed-sore formed over the sacrum. Mucus accumulated constantly in the lungs, threatening suffocation, which was averted by the use of stimulant expectorants. The bowels were relieved by injections and purgatives, and the bladder by the catheter; otherwise the treatment was expectant. During the second week there was a partial recovery of motion in the right arm, but none of sensation; the patient could by an effort draw his arm across his breast; œdema of the left leg set in, and was managed by bandaging. During the third week there was no improvement; permanganate of potassa, charcoal, and Peruvian bark poultices were applied to the bed-sore, which was large and sloughy. During the fourth week, on the suggestion of Dr. A. K. Smith, iodide of potassium, and afterward tincture of ergot, were used, and the patient improved perceptibly. The mucus diminished in quantity, expectoration became easy, and the appetite increased. During the first part of the fifth week, improvement was very encouraging. The bed-sores looked healthy, and improved under the alcoholic applications, the appetite remained good, bowels acted readily, and respiration became more normal. On Friday, November 20th, the patient complained of stiff neck, headache, and extreme coldness, and toward night had a slight fever. On Saturday, the 21st, the fever had disappeared, but he still complained of coldness and headache, and I diagnosed that suppuration had set in. On Sunday morning I found the patient comatose, with the left pupil dilated, and the right pupil contracted. A blister was applied to the nape of the neck, purgatives, &c., given, but to no purpose; the patient died at 11.15 P. M. At the autopsy, fifteen hours after death, *post-mortem* rigidity present. On dissection of the muscles of the right side of the neck, it was ascertained that the bullet had passed directly from its point of entrance toward the spinal column, crossing the carotid sheath externally, and just missing it. A probe passed through its course, impinged against the spinal cord, through the third right condyloid foramen of the cervical spine, which was patent, the nerve having been destroyed. Believing that the bullet would be found lodged in the canal between the third and fourth vertebræ, the cervical spine was opened, and, the bullet not being found, the dorsal and lumbar vertebræ were also included in the search, with a like result. Search was then made for the bullet among the muscles of the neck and scapular region, without finding it. The possibility of the bullet having lodged in the body of one of the vertebræ was disproven, by boiling to free them from the soft structure; and a subsequent examination of the brain demonstrated that it had not lodged in that organ. The possibility of its having passed down the canal into the sacrum was not ascertained. The membranes of the cord and left hemisphere of the brain were found extensively disorganized from inflammation. Plastic lymph, forming a continuous layer, was found effused on the visceral surface of the dura mater of the cord throughout its entire length. The sub-arachnoid space was distended with a pyoid serum, by which the cord was compressed and softened opposite the third and fourth cervical vertebræ, and, corresponding with their posterior faces, the dura mater was ecchymosed, and separated from the bone. This was a point of great interest, taken in connection with the supposed course of the bullet. The effusion of plastic lymph had extended into the brain, and, with the exception of the base of that organ, was confined to the left hemisphere. In the left anterior lobe of this hemisphere circumscribed softening was found, presenting the appearance of an abscess. The base of the brain was also the seat of effusion of plastic matter, which extended as far forward as the optic commissure. The gray substance of the left lobe of the brain had evidently been involved in the inflammatory process, being changed in color and consistence. The medullary substance was injected, the lateral ventricles were marked by radiating blood-vessels. The corpora striata and thalami optici were injected.

LXI.—*Memoranda of Five Cases of Gunshot Wound of the Neck. (Condensed from Reports).*

Private John Butler, Co. F, 10th Cavalry; Colorado Territory; January 9, 1869; gunshot flesh-wound of left side of neck. Duty, February 13, 1869.

Private Henry Carr, Co. K, 25th Infantry; aged 21 years; Memphis, Tennessee; February 13, 1868; gunshot wound of the neck on a line with the upper border of the thyroid cartilage. February 28, 1868, doing well. Duty, April, 1868.

Private William Gennigs, Co. K, 38th Infantry; Fort Harker, Kansas; July 15, 1867; gunshot wound of the neck by pistol-ball. Duty, September 19, 1867.

Private Thomas Lee, Co. D, 9th Cavalry; Fort Stockton, Texas; January 17, 1870; gunshot wound of the neck by conoidal ball. Duty, February 21, 1870.

Private Henry Spencer, Co. B, 80th Colored Troops; aged 29 years; Shreveport, Louisiana; October 17, 1866; gunshot wound of the neck by pistol-ball. Duty, November 5, 1866.

The series of sixteen cases of gunshot wounds of the neck above recorded comprises no less than four instances of division of the carotid and one of the subclavian arteries, and five fractures of the vertebræ. In two instances the pharynx was wounded, with fracture of the hyoid bone in one case. In the case in which the œsophagus was wounded, and in five others in which no important organ was implicated, the patients recovered, but more slowly than after gunshot flesh-wounds in other regions. In the cases in which the great vessels were wounded, death was almost instantaneous, except in one, in which there was time to ligate the carotid had surgical assistance been at hand. One of the patients, with fracture of the spine, survived twenty-eight days.

GUNSHOT WOUNDS OF THE CHEST.—These may be subdivided into lesions affecting the walls of the thorax only, penetrating and perforating wounds of the lungs, wounds of the heart and great vessels, and those complicated by fractures of the vertebræ. Cases in which the diaphragm was perforated will be considered in the next section, the wounds of the abdomen being graver than those of the chest. There were eleven cases of recovery after penetrating or perforating gunshot wounds of the lung, as follows:

LXII.—*Report of a Penetrating Wound of the Lung, with Lodgement of a Round Musket-Ball.* By Brevet Lieutenant Colonel J. R. GIBSON, Assistant Surgeon, U. S. A.

Lieutenant Franklin Yeaton, 3d United States Cavalry, was wounded in an encounter with Mes-calero Apaches in the Guadalupe Mountains, December, 1869; arrived at Fort Stanton January 6, 1870; was under the care of Hospital Steward Miller until his arrival at this post. This was a bullet wound, evidently from a small round rifle-bullet, of the left ulna, in immediate vicinity of the wrist-joint, (joint partially involved,) splintering the bone, but not completely fracturing it. The ball entered on the dorsal surface, emerging opposite on the palmar surface and an inch below; then it entered the cavity of the right chest, an inch from the median line of the junction of the cartilages of the seventh, eighth, ninth ribs, making a track which can be probed to the extent of six inches, the probe passing horizontally beneath the ribs, and in a direction toward their angles. The ball lodged, and cannot be detected; no lung symptoms as yet have been manifested.

[This officer spent the winter of 1870-71 in the West Indies, in delicate health. He returned in the spring improved. He was examined by Assistant Surgeons Woodward and Otis, and recommended to appear before the Retiring Board in session in Philadelphia. No alteration of the respiratory murmur or change in the density of the pulmonary tissue was observed. But the general health was impaired.—ED.]

LXIII.—*Note of a Case of Recovery after a Penetrating Gunshot Wound of the Thorax.* By A. C. GIRARD, Assistant Surgeon, U. S. A.

Sergeant James Naylor, Co. M, 9th United States Cavalry, aged 26 years, was wounded on July 4, 1870, in a fight, by a fellow-soldier. A conoidal ball entered the right breast, striking the fifth rib, and penetrating the thoracic cavity, producing severe constitutional shock. The ball was not extracted or found. He was admitted to the post hospital at Fort McKavett, Texas, on July 4, 1870, and was treated by Acting Assistant Surgeon R. Sharpe. Simple dressings were applied. He was returned to duty on September 20, 1870.

LXIV.—*Note of a Case of Recovery after Perforation of the Chest by a Pistol-Ball.* By J. F. WEEDS, Surgeon, U. S. A.

Private Walter R. Oliver, Co. D, 14th United States Infantry, aged 21 years, was wounded on September 11, 1869, by a pistol-ball. The missile entered between the posterior border of the scapula and the vertebræ, two inches above the inferior angle, and escaped two and a half inches below the middle of the clavicle, passing directly above the base of the heart. He was admitted to the post hospital at Nashville, Tennessee, on September 11th, and simple dressings were applied to the wounds. He is still in hospital awaiting discharge on surgeon's certificate of disability.

LXV.—*Report of a Gunshot Wound of the Chest, having a Successful Termination.* By F. MEACHAM, Assistant Surgeon, U. S. A.

Private Thomas Stewart, Co. F, 14th United States Infantry, a prisoner at Omaha Barracks, Nebraska, was shot through the upper lobe of the right lung, while attempting to escape from a sentinel, November 7, 1870. The ball entered near the union of the third rib with its cartilage in front, and emerged between the fifth and sixth ribs, just below the anterior border of the right scapula. When brought to the post hospital, about half an hour after the reception of the injury, he was suffering very severely from pain and shock, the pulse was scarcely perceptible, feet and hands cold, countenance dusky, and the whole body covered with a profuse cold perspiration. Air was escaping from the anterior wound with every expiration. The sputa was streaked with blood, and blood was escaping from the lower opening. The anterior wound was closed with adhesive plaster and the posterior wound covered with lint to allow the escape of blood. Brandy and morphia were freely administered, and hot applications made to the upper and lower extremities. The patient rallied from the shock, and slept well during the night. On the next day the hæmorrhage had entirely ceased, and he was feeling very comfortable. He continued to improve, and, on November 15th, was able to sit up in bed. On November 29th, having absented himself from hospital for several hours without leave, he was returned to the guard-house, where the wound was dressed daily for about four weeks, at the expiration of which time he had entirely recovered and was returned to duty.

LXVI.—*Memorandum of a Case of Recovery from a Penetrating Gunshot Wound of the Chest.* By C. BACON, Assistant Surgeon, U. S. A.

Private Henry Freyer, Co. C, 6th United States Cavalry, aged 20 years, was admitted to regimental hospital near Austin, Texas, on June 2, 1867, with a gunshot penetrating wound of the chest, received June 2, 1867, at the hands of a citizen. He was transferred on the same day to the post hospital. He recovered, and was returned to duty in July, 1867.

LXVII.—*Note of a Case of Gunshot Wound of the Chest.* By W. S. HENDRICKSON, Acting Assistant Surgeon.

Private Holman Doleman, Co. L, 10th United States Colored Cavalry, aged 23 years, was accidentally wounded on March 30, 1870, by a round pistol-ball, which passed below the right nipple, penetrated the pleural cavity, and lodged opposite the articulation of the sixth costal cartilage with the sternum. He was admitted to the post hospital at Fort Arbuckle, Cherokee Nation, on the same day. The treatment consisted in simple dressings. He was returned to duty on May 26, 1870.

LXVIII.—*Report of a Case of Perforating Gunshot Wound of the Chest.* By B. E. FRYER, Surgeon, U. S. A.

CASE.—Private Daniel McDonald, Co. B, 38th United States Infantry, aged 23 years, was admitted to the post hospital at Fort Harker, Kansas, April 28, 1868, with a perforating gunshot wound of the left chest. The ball entered between the second and third ribs, five inches from the sternum, and emerged posteriorly two and a half inches to the left of the spinal column, between the fifth and sixth ribs. Carbolic-acid dressings were applied to the external wound, and the man recovered without any severe constitutional disturbance. The anterior wound closed May 21st, and the posterior, May 29, 1868. He was returned to duty on June 24, 1868.

LXIX.—*Note of a Case of Penetrating Gunshot Wound of the Chest.* By C. S. DE GRAW, Assistant Surgeon, U. S. A.

Corporal James Goodwin, Co. B, 7th United States Cavalry, aged 21 years, was wounded by Indians on September 20, 1868, by a ball which entered to the left of the third dorsal vertebra, passed through the apex of the left lung, and lodged below the first rib. He was admitted into the United States Army post hospital at Fort Dodge, Kansas, on September 3, 1868. Discharged May 15, 1869.

LXX.—*Extract from Case-Book at Fort Hays Hospital.* By W. F. BUCHANAN, Assistant Surgeon, U. S. A.

Private Henry Harvey, Co. E, 38th United States Infantry, aged 20 years, was on August 14, 1867, at Fort Hays, Kansas, accidentally shot while being asleep. The ball, from an Enfield rifle, struck the posterior surface of the chest over the tenth rib, three inches to the right of the spinal column, fractured the rib, passed into the right pleural cavity, and came out between the sixth and seventh ribs, two inches to the right of the spinal column, fracturing the ribs. The air passed freely out and in, through both wounds, at every inspiration and expiration. On August 18th, the patient had a hacking cough, with a pulse at 112; pus was flowing from both wounds. August 25th, the cough continued, and there was dullness in percussion over the posterior part of the right chest, with bronchial respiration. On September 31st, the patient was emaciated and weak. Air no longer passed through the upper wound, but continued to pass through the lower, less frequently, however, than at first. On October 31st, the patient was much improved. Air no longer passed through either of the wounds; but a purulent discharge continued. Several spiculæ of bone were removed. There was a slight dullness on percussion. The patient was regaining strength. On December 22d, the patient was walking about the ward. Purulent discharges from lower wound continued; the upper wound was closed. Spiculæ of bone were removed from week to week during the last two months. February 1, 1868, patient returned to duty. The lower wound had been a long time in healing in consequence of exfoliations from the rib.

LXXI.—*Report of a Case of Rapid Recovery after a Perforating Wound of the Lung.* By J. H. BARTHOLF, Assistant Surgeon, U. S. A.

At Richmond, Virginia, on March 13, 1868, Private William Caldwell, Co. B, 11th United States Infantry, received a penetrating wound of the thorax, by a small rifled pistol-ball, fired at a distance of twenty yards, by accident. The ball entered the back, an inch and a half to the right of the spinous process of the sixth dorsal vertebra, passed upward and very slightly inward, toward the median line. Its track could be followed only an inch and a quarter. Emphysema appeared fifteen minutes after the reception of the wound, and soon became very great throughout the front and side of the neck, a little way over the edge of the lower jaw, and on the chest, two inches down the sternum and an inch below the clavicle. In four hours his respiration became very frequent, short and gasping, and very imperfect; the thoracic walls scarcely moving, and the abdomen not much. Number of respirations, fifty-eight in the minute. This condition of the respiration continued five hours, and then gradually improved. On the next morning his respiration was easy; twenty-two in the minute. Pulse, 70. Ate a little, for the first time. Emphysema

diminished a little in volume, not in extent. Complains only of a soreness of the wound. Has not had hæmoptysis. He continued to improve rapidly. Complained, on the seventh day, of a stitch in his right side, for the first time. The emphysema had disappeared by the seventh day. Respiration continued very feeble and indistinct nearly up to his discharge from hospital. He recovered speedily, and was returned to duty, at his own request, there being nothing in his condition to contraindicate it, on March 31st, eighteen days after the reception of the wound.

What is, further, very noticeable in his case, is the fact that there was no suppuration from or at the wound. There was a slight bleeding from the wound at the time; but a clot dried and closed the wound, and remained there until I removed it, on the morning of his discharge from the hospital, leaving a small, dry, white cicatrix.

LXXII.—*Report of a Case of Gunshot Wound of the Chest, successfully treated by the Method of "Hermetically Sealing."* By H. S. SCHELL, Assistant Surgeon, U. S. A.

Musician George Wolf, Co. I, 18th New York Infantry, was admitted into hospital, September 19, 1867, he having been accidentally wounded by a conical pistol-ball, calibre .22, that morning. The ball passed through the biceps-flexor-cubito muscle of the right arm, and entered the chest between the fifth and sixth ribs, under the axilla. The symptoms, on admission, were great dyspnœa, extreme nervous depression, and intense pain in the right hypochondrium; pulse 85, and very feeble; patient tossing from side to side, anxious expression of countenance; flatness, on percussion, on right side of chest, as high as the fifth rib in front, and anterior border of axilla, from behind forward, with expectoration of blood. Immediately sealed the wound in the parietes of the chest, by means of a dossil of cotton and Richardson's styptic colloid fluid. Administered *morphia*, $\frac{1}{2}$ gr.; *vin. alb.* flʒjss.; this was repeated in half an hour. Chloroform, confined by oil-silk, was applied to the right hypogastrium, and its irritant effects allayed by painting the surface with *tinct. opii*. He became quiet, and slept in the course of an hour. 6 P. M., pulse 95, full. Administered *magn. sulph.* ʒj. September 20th, 8 A. M., pulse 110, hard. Repeat *magn. sulph.* ʒj.; 6 P. M., pulse 115, hard; skin hot; great pain in right hypogastrium, with increased dyspnœa. Applied six cut cups, one ounce of blood extracted from each cup. Administered *ant. et pot. tart.*, gr. $\frac{1}{16}$ every hour. *Pulv. ip. et op.*, gr. xij, at taps. Ten P. M., much relieved from pain, and slept all night. September 21, 8 A. M., pulse 100. Feels somewhat comfortable; continued tartar emetic, and administered an ounce of sulphate of magnesia. At 6 P. M. the epsom salt had operated freely; pulse 110; skin hot, and increased pain in right hypochondrium; applied two cut cups, and abstracted four ounces of blood; continued *ant. et potass.* and repeated Dover's powder. Ten P. M., pulse 95, perfectly comfortable, sleeping. September 22, 8 A. M., feels comfortable, very little pain; expectoration of blood continues. Absolute diet maintained, and *ant. et potass. tart.* continued for one day longer; since which time he has continued to improve, without an unfavorable symptom. Wound in arm nearly healed. Returned to duty October 3, 1867.

The fatal cases of gunshot wounds of the lung reported were, of course, more numerous.

LXXIII.—*Memorandum of a Fatal Penetrating Pistol Wound of the Chest.* By Dr. T. ROCTER, Acting Assistant Surgeon.

Private John Simmons, Co. C, 128th United States Colored Troops, received an accidental pistol-shot wound of the chest, on September 25, 1866. He was admitted to the post hospital at Charleston, South Carolina, on the 25th, and died on the same day, from internal hæmorrhage.

LXXIV.—*Minute of a Penetrating Gunshot Wound of the Chest.* By C. BACON, Assistant Surgeon, U. S. A.

* * * Near Austin, Texas, Private James Donnelly, Co. B, 6th United States Cavalry, aged 24 years, received a gunshot penetrating wound of the left chest, on May 15, 1867, at the hands of the guard. He died the same day, and was taken to the regimental hospital for burial.

GUNSHOT WOUNDS OF THE CHEST.

LXXV.—*Memorandum of a Case of Penetrating Gunshot Wound of the Chest.* By WILLIAM S. ADAMS, Acting Assistant Surgeon.

Corporal William McLaughlin, Co. I, 5th United States Cavalry, aged 23 years, was wounded on September 10, 1867, in a drunken affray, by a conoidal ball, which entered at the junction of the middle and outer thirds of the left clavicle, passed inward, striking its inferior border, and being deflected downward into the cavity of the chest. He was taken to the post hospital at Morgantown, North Carolina, where death resulted one hour after the reception of the injury.

LXXVI.—*Memorandum of a Gunshot Perforation of the Chest.* By JULES LE CARPENTIER, Acting Assistant Surgeon.

* * At Fort Bayard, New Mexico, Private George Stern, Co. A, 38th United States Infantry, aged 25 years, was killed by a round ball, in a riot, which occurred at Central City, near by, on the evening of December 24, 1868. The missile entered the left axilla, and passed out on the right side of the neck.

LXXVII.—*Memorandum of a Fatal Gunshot Wound of the Lung.* By J. R. GIBSON, Assistant Surgeon, U. S. A.

Private Michael Luther, Co. C, Engineer Battalion, aged 26 years, was wounded while trespassing upon private grounds, in the village of Whitestone, Long Island, on February 3, 1867, by a charge of bird-shot, which penetrated the right lung. He was admitted on the following day to the post hospital at Willet's Point, and treated on the expectant plan. He died on February 6, 1867.

LXXVIII.—*Note of a Case of Gunshot Wound of the Lung.* By Brevet Major W. M. NOTSON, Assistant Surgeon, U. S. A.

Private William Leach, Co. H, 4th United States Cavalry, aged 20 years, was admitted to the post hospital at Fort Concho, Texas, on February 4, 1868, with an accidental gunshot wound. The missile perforated the lobes of the left lung. He died on February 6, 1868, from internal hæmorrhage.

LXXIX.—*Note of a Fatal Gunshot Perforation of the Right Lung.* By DONALD JACKSON, Acting Assistant Surgeon.

Private Narcisse Pochet, Co. G, 9th United States Cavalry, aged 24 years, received on March 21, 1870, in a brawl, a wound through the right lung by a carbine-ball, which entered below the clavicle through the second rib, and emerged two inches from the median line. Admitted to post hospital at Fort Clark, Texas, at 5 P. M. He survived two hours.

LXXX.—*Memorandum of a Gunshot Perforation of the Chest.* By D. WEISEL, Assistant Surgeon, U. S. A.

At Fort Davis, Texas, Private David Boyd, Co. K, 9th United States Cavalry, was accidentally shot and instantly killed by a conoidal ball, on March 16, 1870. The missile entered to the left of the sternum between the fourth and fifth ribs, and, passing through the body, issued near the inferior angle of the right scapula.

LXXXI.—*Report of a Case of a Pistol Shot Wound of the Lung Through the Scapula.* By SAMUEL SANTOINE, Acting Assistant Surgeon.

Private Charles Lehmann, Co. B, 35th United States Infantry, aged 21 years, was shot in the street on the night of January 2, 1868. A pistol-ball entered immediately below the spine of the scapula, one inch from its outer end obliquely toward the sternum, and remained in the thoracic cavity.

He was admitted to the post hospital at Indianola, Texas, about one hour after the reception of the injury, in a state of intoxication, walking supported by two men. Profuse hæmorrhage issued from the wound, which rendered it unsafe to counteract the effects of intoxication. Therefore, no attempt was made to bring on reaction. Cold water was applied to the wound and head. He did not recover consciousness until five hours afterward, when he complained of excruciating pain in the left side. Respiration was laborious, and there was complete matity on percussion, and heavy crepitating sound on auscultation. He expectorated about two ounces of coagulated blood. A powder consisting of a fourth of a grain of acetate of lead and an eighth of a grain of sulphate of morphia was given every hour, for four hours, and then discontinued. The pulse was very weak and remained so until death, at six o'clock of the evening of January 3, 1868.

LXXXII.—*Memorandum of a Fatal Gunshot Perforation of the Right Lung.* By JULES LE CARPENTIER, Acting Assistant Surgeon.

At Fort Bayard, New Mexico, Farrier John A. Payne, Co. E, 3d United States Cavalry, aged 21 years, was killed, in a riot, by a patrol, on the night of December 24, 1868, at Central City, New Mexico. He received a gunshot wound of the right chest. The missile entered the back, and passed through the right lung.

LXXXIII.—*Memorandum of a Fatal Case of Gunshot Wound of the Right Lung.* By E. COWLES, Assistant Surgeon, U. S. A.

Second Lieutenant W. S. Alexander, Co. A, 8th United States Infantry, aged 20 years, was wounded at Fort Macon, North Carolina, at midnight, on March 28, 1869, by a conoidal ball, which penetrated the neck and chest, perforating the upper lobe of the right lung, comminuting the scapula and rib, and lacerating the brachial flexus and veins at the base of the neck. He was admitted to the post hospital at Fort Macon, North Carolina, on March 29, 1869. Compresses and styptics were used. There was no reaction after injury. He died at 1 o'clock A. M., on March 30, 1869. Death was apparently hastened by venous hæmorrhage within the cavity of the thorax.

LXXXIV.—*Memorandum of a Fatal Gunshot Wound of the Right Lung.* By F. MEACHAM, Assistant Surgeon, U. S. A.

Private Jonathan J. Johnson, Co. E, 4th United States Infantry, was shot through the right lung on December 2, 1869, by Indians, when about forty miles from Fort Laramie, Wyoming Territory. He was admitted into the post hospital at the fort, in a moribund condition, and died in about one hour after his arrival.

LXXXV.—*Memorandum of a Fatal Case of Gunshot Wound of the Right Lung.* By J. E. SEMPLE, Assistant Surgeon, U. S. A.

Private John Halbert, Co. L, 2d United States Artillery, aged 27 years, was accidentally killed on September 13, 1868, by fine shot, which entered the sternum between the third and fourth ribs, and passed into the right lung.

LXXXVI.—*Note of a Case of Suicide.* By GEORGE A. BENJAMIN, M. D., Acting Assistant Surgeon.

At the island of San Juan, California, November 30, 1870, First Sergeant Louis Miller, Co. F, 23d United States Infantry, shot himself at eight o'clock in the morning. At this hour I was called to see him, and found him lying on his bed, with a gunshot wound one and a quarter inches below and to the left of the left nipple, passing through the lung on that side, ranging upward and inward, passing out at a point about midway of the length of the internal edge of the scapula of the same side. This wound was inflicted by himself with a design of destroying life, as was shown by a written

communication left behind, and addressed to the commanding officer, and also by the position of the gun, lying on the floor, with a string attached to the trigger, suggesting the intention of inflicting the wound. The patient died at half past eight o'clock in the evening. No *post-mortem* examination was made in the case, as it was considered unnecessary.

LXXXVII.—*Remarks on a Case of Gunshot Wound of the Chest.* By J. C. WATKINS, Acting Assistant Surgeon.

Sergeant John Kelly, Co. A, 8th United States Cavalry, aged 29 years, was admitted on April 30, 1868, to the hospital at Camp Winfield Scott, Nevada, with a gunshot wound of the chest. The bullet entered the left lung, just below the first rib, injuring it, and deflected a little downward, lodged under the skin in the dorsal region. The left arm was paralyzed, and pulsation in the radial artery had ceased; but the latter gradually returned, and was nearly normal again on May 4th. A flesh-wound in the outer part of the right thigh was suppurating, but presented a healthy appearance. On June 1st, the patient had repeated cold and hot sweats, with paroxysms of neuralgic pains in the left arm, but he improved again until June 8th, when a commencing aneurism of the left subclavian, or a branch of the superior thoracic artery was observed. The wound in the back commenced to bleed. On June 12th, the patient was doing well, and the wound was healing rapidly. On June 21st, the aneurism, which now appeared to be a false one, was increasing. Slight pressure was applied, with iodide of potash ointment. On June 26th, the aneurismal tumor was still increasing. Opium was given in large doses, and chloroform also was administered. A careful examination of the tumor was made, but the patient was considered too weak for an operation. On July 30th, the condition of the patient was unchanged; the tumor had displaced the clavicle. On July 16th, the patient had not been allowed an operation from the bowels for more than two weeks, attempting Valsalva's method of cure. The patient appears to gain a little strength. July 23d, severe pains in arm and shoulder; the tumor is increasing in size, and appears to be pointing at the old wound. August 13th, during a severe neuralgic attack, the aneurism bursted, and profuse bleeding ensued. Bleeding recurred at intervals, until August 27th, when it ceased. The patient improved until September 17th, when he became slightly delirious. Bleeding occurred again, but the hæmorrhage was checked by plugging the opening with dry lint. Hæmorrhages recurred September 18th, 19th, and 28th, and death occurred at 5 P. M., September 28, 1868. At the autopsy, the left lung was found partially collapsed; one-half ounce of fluid in the pleural sac; the heart, right auricle, and ventricle walls were considerably thickened; the valves, liver, and kidney were normal; the spleen slaty. The bellies of the pectoralis major and minor were infiltrated with blood, and entirely disorganized. The axilla was so much disorganized that it was impossible to discover which had been the bleeding artery. The ball had not penetrated the lung, but had passed above and back of the pleura. At the elbow, the olecranon and the internal condyle of the humerus were necrosed. The wound of the right thigh had entirely healed.

LXXXVIII.—*Minute of a Case of Perforating Gunshot Wound of the Thorax.* By C. MACFARLINE, M. D., Acting Assistant Surgeon.

At Fort Ontario, New York, June 17, 1869, Private Joseph Marks, Co. A, 1st United States Artillery, was shot by a soldier of the same company. The ball, a conical one, entered the right side at a level of the third rib, an inch and a half from the median line, and made exit through the spine of the scapula, near its central portion. Sulphate of morphia, in one-fourth grain doses, was given at intervals of one-half hour until sleep ensued; also extract of ergot with digitalis and tannic acid was given in a mixture, and lemonade was allowed. At indications of sinking, whiskey diluted with water and beef-essence were given frequently. He died fifteen hours after reception of the injury, from internal hæmorrhage.

Five instances are reported of gunshot wounds of both lungs. They were fatal, and, indeed, I know of no authenticated instance of recovery from such a lesion.

LXXXIX.—*Memorandum of a Fatal Perforation of both Lungs by a Musket-Ball.* By J. R. GIBSON, Assistant Surgeon, U. S. A.

On his monthly report from Fort Stanton, August, 1869, Dr. Gibson enters the following statement of Acting Assistant Surgeon Alward White, stationed at Fort Bliss, Texas: "Charles E. Thompson, Co. F, 3d United States Cavalry. The ball presumed to have been discharged from a carbine, entered his chest in front, in the right side, in the second intercostal space, passed diagonally through the upper lobe of the right lung, severing the great vessels at the base of the heart, and thence through the posterior portion of the middle lobe of the left lung, and passed out at the inferior angle of the scapula." The date of the injury is not recorded. It is found that the patient died August 7, 1869.

XC.—*Extract from Remarks on Monthly Report of Sick and Wounded from Fort Stevenson, Dakota Territory.* By C. C. GRAY, Surgeon, U. S. A.

In October, 1867, Private Knowles, Co. B, 31st United States Infantry, was accidentally shot by a comrade. The bullet, from a breech-loading musket, fractured the left humerus, and traversed the apices of both lungs. This wounded man lived about four hours after the reception of the injury.

XCI.—*Memorandum of a Case of Gunshot Wound of both Lungs.* By S. M. HORTON, Assistant Surgeon, U. S. A.

Corporal Peter Donnolly, Co. H, 27th United States Infantry, aged 26 years, received on November 3, 1867, in an attack by Indians, a gunshot penetrating wound of the chest, through both lungs. He was admitted to the post hospital at Fort Philip Kearney, Dakota Territory, on November 4, 1867. Roller-bandages and simple dressings were applied. The patient died on November 4, 1867.

XCII.—*Note of a Case of Suicidal Gunshot Wound of both Lungs.* By CALVIN DE WITT, Assistant Surgeon, U. S. A.

Sergeant Jules Gueree, Co. D, Engineer Battalion, aged 30 years, was admitted to hospital at Willett's Point with a gunshot wound inflicted by himself. The missile entered the left side of the thorax, fracturing the third rib near its articulation with the sternum, passed obliquely near the edge of the left lung, and traversed the upper lobe of the right lung, and emerged midway between the spinal column and the lower angle of the scapula. He died shortly after admission, July 23, 1867.

XCIII.—*Memorandum of a Case of Gunshot Perforation of both Lungs and Aorta.* By W. D. WOLVERTON, Assistant Surgeon, U. S. A.

Private Peter McCabe, Co. B, 1st United States Infantry, aged 29 years, was accidently shot by a guard on June 18, 1868. The missile passed through the lungs and aorta. The man died instantly.

XCIV.—*Memorandum of a Case of Suicide.* By D. C. PETERS, Surgeon, U. S. A.

Private James Finally, Troop D, 3d United States Cavalry, aged 27 years, shot himself on May 19, 1870, while on guard at Fort Union, New Mexico. The ball entered under the last true rib, on the right side, passed upward, wounding the lung and pleura, came out one inch above right nipple, and lodged in the right cheek. It also wounded slightly the right hand and wrist. He was admitted to post hospital, where the missile was excised from the right cheek. Inflammation of pleura and lungs, with internal hæmorrhage, followed, and death occurred on May 21, 1870.

Gunshot Wounds of the Heart.—Fourteen instances of this form of injury were reported. Death followed very promptly in almost every case, though, in one instance of a pistol-ball wound of the right auricle, the patient survived fifty hours. Eight were examples of wounds from musket, and five from pistol balls. One was inflicted by an Indian, two by sentinels, one accidentally, two suicidally, and the eight other cases were murders.

XCV.—*Memorandum of a Case of Gunshot Wound of the Heart.* By CARLOS CARVALLO, Assistant Surgeon, U. S. A.

At Jefferson, Texas, First Sergeant Daniel Murphy, Co. I, 11th United States Infantry, aged 25 years, committed suicide, on September 19, 1870, by shooting himself with a small Derringer pistol, the ball penetrating the left lung and the heart. He lived twenty-seven minutes after being shot.

XCVI.—*Report of a Case of Gunshot Wound of the Lung and Heart.* By A. W. WIGGIN, Assistant Surgeon, U. S. A.

Philip Curry, a citizen, was shot in a drunken row at Pond Creek Stage Station, Kansas, on April 1, 1868. Saw him at midnight and found a penetrating bullet wound of the right side of the thorax; there was no wound of exit. The patient was taken to the post hospital at Fort Wallace, Kansas, a distance of four miles, being able to get into and out of the ambulance without assistance. He seemed quite strong for an hour or two after admission. After a while, however, he began to grow anxious and suffered much pain. He was unable to retain nourishment, and required to be kept in a sitting posture. He was quieted by hypodermic injections of a solution of sulphate of morphia, the only thing attempted in the way of medication. On the morning of April 2d, the right side of the chest was evidently filling up with fluid. The heart beat irregularly and tumultuously. Toward evening he became exhausted; sleep profound, and respiratory efforts only five or six per minute; pulse feeble and fluttering. He died half an hour after midnight April 3, 1868, twenty-six hours after reception of injury. An autopsy, made fifteen hours after death, revealed the course of the ball. It entered three inches inside and one inch above right nipple, passed between the cartilages of third and fourth rib close to the sternum, through anterior margin of the lower lobe of right lung into the pericardium, through the right auricle, and entered again the right pleural cavity, passing through posterior margin of lower lobe of right lung. A conical ball—size of Colt's Navy revolver—was found in the right pleural cavity. The left lung and cavity were perfectly normal; the right lung was engorged and somewhat compressed by coagulated blood in the pleural cavity. Pericardium much distended and containing six or eight ounces of partially coagulated blood. There was a fibrinous clot in the left ventricle.

XCVII.—*Memorandum of a Case of Gunshot Wound of the Heart, probably by Suicide.* By F. MEACHAM, Assistant Surgeon, U. S. A.

Private Rollin Cofcart, Co. G, 4th United States Infantry, left Fort Laramie April 6, 1870, without leave. His body was found April 7th, about twenty miles southeast from the post, under circumstances that led to the belief that he committed suicide. The autopsy was made April 7, 1870, at 5 P. M., time after death unknown—probably twenty-four hours; *rigor mortis* strongly marked; a little blood found on face, about the mouth and nose. The blouse was whole, but a hole was found in both shirts, on the left side of the body. A wound was found about two inches below the left nipple, passing backward and upward, and slightly inward. This wound was surrounded by a margin of burned powder about an inch wide, below the wound, from two to four inches wide above the wound, and to its left. On the back was found a wound situated about two inches to the left of the spine, and on a plane with the spine of the sixth dorsal vertebra. No powder was found about this wound. On opening the thorax it was found that the ball had passed between the fifth and sixth ribs, outside and near the junction of the ribs with the cartilage, then entered the pericar-

dium at its lower end, and on its left side, striking the heart at its apex, carrying away a portion of the left ventricle, opening the cavity—the wound in the heart being two inches long, and one and one-fourth inches wide at its widest part. The part of the left ventricle carried away was the apex—lower and back part. The ball then passed to the left of the spine, fracturing the seventh rib near its junction with the spine. This wound must have caused almost instant death, and the muzzle of the gun, when discharged, must have been in close proximity to the wound. The wound of exit was on a plane seven inches above the wound of entrance.

It is to be regretted that in several other cases of gunshot wounds of the heart that came under treatment the observers have failed to report the duration of life after the reception of the injury, or any particulars of the symptoms.

XCVIII.—*Memorandum of a Gunshot Wound of the Heart.* By C. C. BYRNE, Surgeon, U. S. A.

First Sergeant Frederick Kellner, Co. D, 19th United States Infantry, was wounded on November 9, 1869, by a conoidal pistol-ball, which entered his back, between the fifth and sixth ribs, on the left side, about two inches from spinal column, and passing through the right auricle of heart, lodged under the skin over the lower portion of sternum. He lived long enough to be admitted to the post hospital at Little Rock, Arkansas, and died the same day.

XCIX.—*Note of a Case of Gunshot Wound of the Heart.* By J. A. TONNER, Acting Assistant Surgeon.

Private John Gray, Co. D, 26th United States Infantry, aged 28 years, was shot through the heart, by a pistol-ball, on February 9, 1868. He was admitted into the hospital at Brownsville, Texas, and survived but a short time.

C.—*Mention of a Case of Gunshot Wound of the Heart.* By H. R. TILTON, Assistant Surgeon, U. S. A.

Private John B. Patterson, Co. B, 7th United States Cavalry, while on duty as sentinel, at Fort Lyon, Colorado Territory, April 17, 1870, was wounded by the accidental discharge of his carbine, the ball having entered the right groin, and escaped through the neck on the left side, killing him instantly. The ball passed through the bowels, stomach, left lobe of the liver, right ventricle of heart, upper lobe of the left lung, and carried away a portion of the left clavicle. He breathed three times, and then gasped and expired. No cry of pain escaped his lips.

CI.—*History of a Fatal Gunshot Perforation of the Thorax.* By JOHN B. WHITE, Acting Assistant Surgeon.

Private Louis T——, Co. K, 40th United States Infantry, was mortally wounded, December 15, 1868, and admitted to post hospital at Raleigh, North Carolina, *in articulo mortis*, and died immediately afterward. An autopsy was made one hour after death. The conical ball, from a Springfield breech-loader in the hands of a fellow-soldier, had first passed through the stock of the gun of the deceased; then entering the right thoracic cavity between the second and third ribs, traversed the chest diagonally beneath the ascending aorta, divided the descending vena cava, perforated the superior lobe of the left lung, and, emerging from the chest between the third and fourth ribs, entered the cavity of the axilla, thence into the left arm in its upper third, extensively shattering the left humerus. There was scarcely any hæmorrhage externally. The left thoracic cavity contained a large amount of bloody serum with jelly-like clots. The source of internal hæmorrhage was from the division of the descending vena cava. The missile having traversed

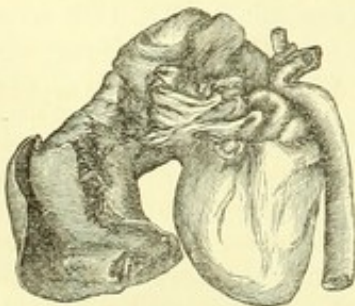


FIG. 7. Heart, great vessels, and portion of lung perforated by a musket ball. Spec. 5567. A. M. M.

a space of some thirteen inches from right to left, from wound of entrance to wound of exit, was found in a shattered condition about thirteen feet from the injured man. The pathological specimens, consisting of the heart, perforated lung, splintered humerus and ball, were forwarded to the Army Medical Museum.

CII.—*Note of a Case of Gunshot Wound of the Aorta.* By W. J. PIPER, M. D., Acting Assistant Surgeon.

At Baton Rouge, Louisiana, December 20, 1867, Private Herman Summers, Co. E, 20th United States Infantry, received an accidental pistol shot wound, the ball entering the arch of the aorta. He was admitted to post hospital immediately after the reception of the injury and died on the same day.

CIII.—*Extract from Remarks on Monthly Report of Sick and Wounded from Fort McKavett, Texas,* By REDFORD SHARPE, Acting Assistant Surgeon.

On February 2, 1870, Corporal Albert Marshall, Co. F, 9th United States Cavalry, was murdered by desperadoes, five miles below Menardville, thirty-five miles below this post, while guarding a prisoner. His remains were brought to the post for interment on the afternoon of the 3d, when a *post-mortem* examination was held at the post hospital. It was conducted by Acting Assistant Surgeon A. De Laffre. The following are the notes in the case: * * The ball, supposed to have been from a Winchester rifle, entered the thoracic cavity on right side, about one inch above the right nipple, passed through the fifth rib at its articulation with the sternum, passing through right ventricle of the heart and through the left fifth rib, and made an exit at left axilla, reentered the left arm, fractured the humerus two inches below the neck, and came out on the other side near the insertion of the deltoid.

CIV.—*Memorandum of a Gunshot Wound of the Chest.* By DONALD JACKSON, M. D., Acting Assistant Surgeon.

At Fort Clark, Texas, on August 1, 1869, Private James Matthews, Co. G, 9th United States Cavalry, aged 20 years, was shot by a sentinel, either intentionally or through gross carelessness. The bullet entered between the third and fourth ribs, above and a little external to the left nipple, passing obliquely through the thorax, and lodging beneath the skin over the right scapula. Death was instantaneous. The heart or great vessels were doubtless wounded. No autopsy is recorded.

CV.—*Memorandum of a Gunshot Wound of the Heart.* By WASHINGTON MATTHEWS, Acting Assistant Surgeon.

Private John T. Vane, Co. I, 22d United States Infantry, was shot by one of a band of hostile Sioux, about four miles from Fort Rice, Dakota Territory, while on duty with a party of woodcutters, and at a short distance from the rest. No others were wounded. His death was instantaneous. An autopsy revealed that the ball had entered the fourth intercostal space near the left nipple, and pierced both ventricles of the heart, about midway between base and apex. It did not effect an exit from the body.

CVI.—*Minute of a Case of Gunshot Wound of the Heart.* By Dr. J. B. PURCELL, Acting Assistant Surgeon.

In August, 1867, James Brown, Co. D, 8th United States Infantry, quartermaster's sergeant of the post at Wilmington, North Carolina, was confined for stealing from the Government, and made his escape from prison. He was overtaken by a patrol, and, not surrendering when commanded to do so several times, was fired upon with fatal effect. The ball entered the right side between the fifth and sixth ribs, traversed the body through both lungs and the heart, passed out at the left side, entered at the bend of the left elbow, destroying the joint, and lodged in the cellular tissue near the external angle, spent.

CVII.—*Minutes of an Autopsy in a Case of Gunshot Wound of the Heart.* By J. H. T. KING, Assistant Surgeon, U. S. A.

On the night of April 30, 1869, John Ahlfeldt, first sergeant of Co. D, 31st United States Infantry, was shot by one of the men belonging to his company, and died instantly. *Sectio cadaveris*, fourteen hours, *post-mortem*. *Rigor mortis* well marked. Externally two gunshot wounds were discovered: one, the largest, anteriorly, at the lower border of the cartilages of the ribs on the left side; one posteriorly immediately below the inferior angle of the right scapula. On opening the chest a large quantity of blood was found in the cavity of the right pleura; tissue of lungs normal; inferior lobe of right lung wounded. The missile had traversed its superior and internal portions horizontally and toward the left side, thus entered the pericardium, and completely lacerated right side of the heart near the right auriculo-ventricular valves, exposing the internal surface of both right auricle and right ventricle, making its exit at the wound on the anterior surface of body before described.

CVIII.—*Report of an Autopsy in a Case of Gunshot Wound of the Heart.* By F. MEACHAM, Assistant Surgeon, U. S. A.

On January 29, 1869, at Camp Douglas, Utah Territory, Hospital Steward Lucius O'Brien, United States Army, was killed in the evening while returning from the city to camp. The autopsy was made twelve hours after death. *Rigor mortis* well marked. The wound was found on a line midway between the left nipple and the sternal end of the right clavicle near the left border of the sternum. On opening the thorax, it was found that a pistol-ball had passed through the cartilage of the third rib, near its junction with the sternum; thence through the right ventricle of the heart, near the origin of the left pulmonary artery, passing through one of the semilunar valves; thence into the left auricle of the heart through the superior lobe of the left lung, and lodged between and behind the posterior ends of the ninth and tenth ribs, from which position the ball was removed. The course of the ball was in a downward direction—that is, the point of lodgement was on a lower plane than the point of entrance. This non-commissioned officer was undoubtedly murdered.

Gunshot Wounds of the Chest involving the Spine.—Eight fatal cases were reported of gunshot chest wounds with injury of the vertebral column.

CIX.—*Memorandum of a Case of Gunshot Wound of the Spine and Chest.* By D. L. MAGRUDER, Surgeon, U. S. A.

Brevet Lieutenant Colonel David H. Buel, Ordnance Corps, was assassinated at the arsenal, near this post (Fort Leavenworth), on the night of the 22d of July, between the hours of ten and eleven P. M. The assassin shot him from behind, with a rifled breech-loading musket, just after his having entered the yard in front of his residence. The ball entered the back, about two inches to the left of the median line, and emerged on the right side of the chest, about four inches to the right of the anterior median line. The spinal column was severed between the sixth and seventh ribs, and the right lung was torn by fragments of both bone and ball. Death resulted immediately.

CX.—*Note of a Case of Gunshot Wound of the Spine and of the Aorta.* By WILLIAM J. WILSON, Assistant Surgeon, U. S. A.

In March, 1870, near Fort Brown, Texas, private Thomas Logan, Co. K, 10th United States Infantry, is reported as having died from a gunshot wound. He had been out in Brownsville, without permission, and when arrested by the patrol attempted to escape from their custody. He was fired at and instantly killed, the ball striking him in the spine, about the sixth dorsal vertebra, passing upward and outward, through the arch of the aorta, and emerging about three inches to the inner side of the left shoulder. He must have been running in a stooping position when fired at.

CXI.—*Extract from Remarks on Monthly Report of Sick and Wounded, from Fort Dodge, Kansas.*
By W. S. TREMAINE, Assistant Surgeon, U. S. A.

Private Thomas K—, Co. A, 3d United States Infantry, deserted from Fort Dodge, Kansas. When twenty-five miles from the post he met a train with citizens, who attempted to capture him. To prevent this he shot himself with a revolver. Was brought into hospital August 6, 1870. The ball entered between the fifth and sixth ribs, one and a half inches below, and a little to the right of the left nipple, and was extracted, together with small fragments of bone, from the sub-cutaneous tissue over the ninth dorsal vertebra, through a small incision. The patient was paralyzed below the middle. He died four days after admission. A *post-mortem* examination was made after ten hours. The track of the ball was found to pass from a point between the fifth and sixth ribs, an inch and a half below and to the right side of the left nipple, grazing the apex of the heart, passing through the lung, and fracturing the transverse process of the ninth dorsal vertebra. There was pericarditis and pneumonitis. There were decolorized fibrinous clots in the heart and great vessels; extensive effusion in cavity of pleura. The missile was a conical pistol-ball of the calibre .44.

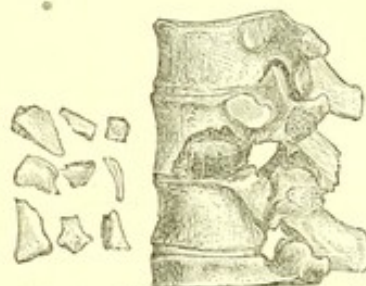

FIG. 8.—Eighth, ninth, tenth, and a portion of the eleventh dorsal vertebrae, with a ball and fragments of bone from the ninth vertebra. *Spec. 5338, Sect. I, A. M. M.*

CXII.—*Note of a Case of Perforating Wound of the Left Lung.* By J. H. PATZKI, Assistant Surgeon, U. S. A.

Private Michael W. Keiley, Co. D, 6th United States Cavalry, aged 22 years, was, on June 19, 1870, wounded and killed by a conoidal bullet, which penetrated the left arm, sixth rib, and perforated the left lung and spine between the sixth and seventh dorsal vertebrae. He was brought into hospital dead June 19, 1870.

CXIII.—*Memoranda of a Case of Gunshot Penetrating Wound of the Lung.* By R. H. WHITE, Assistant Surgeon, U. S. A.

Private Edward Adams, Co. F, 15th United States Infantry, aged 25 years, received a gunshot wound while resisting the guard sent to arrest him, on May 9, 1868. The missile entered the middle of the left arm, producing a compound comminuted fracture of the humerus, and entering the chest between the fifth and sixth ribs posteriorly, traversing the inferior lobe of the left lung, and the spinal column between the sixth and seventh dorsal vertebrae, breaking up the spinal cord, and passing through the inferior lobe of the right lung, lodged itself just beneath the integument of that side. He was admitted to the post hospital at Mobile, on May 9, 1868, and death resulted on the same day.

CXIV.—*Note of a Case of Perforating Gunshot Wound of the Thorax.* By ALFRED DELANY, Assistant Surgeon, U. S. A.

Near Fort Gibson, Indian Territory, Private David McWilliams, Co. H, 6th United States Infantry, was shot by a drunken Cherokee Indian, without any apparent provocation, on the evening of the 11th September, 1869. He was admitted to the hospital soon after, in a profound shock, and died twenty hours afterward, only partial reaction having occurred, notwithstanding the free use of stimuli, warmth, &c. On making a critical examination, *post-mortem*, the ball, supposed to have been from a Navy revolver, was found to have entered the body posteriorly, opposite the sixth dorsal vertebra, passed upward, and to the right, and emerged anteriorly, between the first and second ribs, one and a half inches to the right of the sternum, fracturing the right lamella and the body of the sixth vertebra, the sixth rib, opening the medullary canal, lacerating the cord, and perforating the right lung. Fragments of the vertebra and rib were driven before the ball, and lodged in the lung and pectoral muscles.

CXV.—*Note of a case of gunshot wound of the Chest and Spine.* By IRA PERRY, Assistant Surgeon 9th United States Colored Troops.

Private Gustavus Chase, Co. I, 9th United States Colored Troops, aged 24 years, while walking to camp from Brownsville, Texas, was wounded by a conoidal ball, which shattered the spinous processes of the sixth and seventh vertebrae, laid open the canal, and lacerated the cord. He was admitted to the post hospital at Brownsville, Texas, January 28, 1866. On admission there was an expression of anxiety, complete paralysis below the seventh dorsal vertebra, and great pain in epigastric region. The treatment consisted of the removal of fragments of bone, simple dressings, morphia, catheter, and injections. On February 1st the bowels and bladder were completely torpid; great tympanitis; skin hot; pulse 140. He died on February 4, 1867.

CXVI.—*Memorandum of a Case of Gunshot Wound of the Chest.* By HENRY McELDERRY, Assistant Surgeon, U. S. A.

John J. Baron, citizen, aged 21 years, was wounded on March 14, 1869, at a place about twenty miles from the post. The missile, a conoidal pistol ball, passed through the spinal cord. It entered in the sub-aspect of the left side of thorax, two and a half inches below the lower border of the clavicle, four and one-fourth inches from the median line of the sternum, and passing inward, backward, and diagonally across the trunk, lodged immediately beneath the integument, four inches to the right of median line of the spine, and two inches above the inferior angle of the right scapula. He was admitted to the United States post hospital, at Fort Griffin, Texas, by order of the post commander, on March 14, 1869. He died on March 18, 1869.

A number of instances of gunshot flesh-wounds of the thoracic parietes were reported, but none of them were of special interest, except the following case, in which the wadding from a pistol penetrated the pectoral muscles for several inches.

Private David E. Chase, Co. B, 40th United States Infantry, aged 23 years, was wounded January 15, 1869, in the right breast by hard paper wadding fired from a revolver, the wounded man being but a few feet from the muzzle of the pistol when fired. Wound about four inches in depth, in a course inward and downward. He went to the post hospital, and the wound was dressed. He recovered rapidly, and was sent to duty January 31, 1869. J. T. King, Acting Assistant Surgeon, reported the case.

Private Henry Allison, Co. F, 33d United States Infantry, aged 22 years, Dahlonaga, Georgia, January 1, 1868. Accidental gunshot wound of the left side. Duty January 8, 1868.

Private William Christman, Co. D, 11th United States Infantry, aged 24 years, Jefferson, Texas, May 7, 1869. Gunshot wound of the right buttock, caused by the accidental discharge of a rifle. Duty, May 10, 1869.

Private John Donovan, Co. A, 18th United States Infantry, aged 35 years, near Peno Creek, December 6, 1866. Gunshot wound of back, to left of spine, on a level with the lowest rib, received in an action with Indians. Duty, December 31, 1866.

Private Henry James, Co. F, 22d United States Infantry, aged 22 years, near Fort Randall, Dakota Territory, June 27, 1868. Gunshot wound of the skin and cellular tissues, over the lateral region of the floating ribs of the left side. Duty, July 27, 1868.

Private Alexander Kennedy, Co. F, 7th United States Cavalry, aged 19 years, wounded September 13, 1868, by Indians, near Fort Dodge, Kansas. Gunshot wound of left side, over the eighth rib. The missile made its exit near the umbilicus. Recovered.

Sergeant J. F. Leonard, Co. B, 6th United States Cavalry, aged 29 years, Livingston, Texas, May 7, 1869. Gunshot wound of thoracic parietes. Duty, June 16, 1869.

Private William B. Gallagher, Co. D, 6th United States Cavalry, aged 24 years. Gunshot flesh-wound of the left arm and thoracic parietes by a conoidal ball, received in an action with Indians near north fork of Little Wichita River, Texas, July 12, 1870. Carbolic-acid dressings. Duty, August, 1870.

Corporal Willis Gibbons, Co. A, 117th United States Colored Troops, aged 27 years. Brazos Santiago, Texas, December 17, 1866. Gunshot wound of the left side, over the sixth rib, by a conoidal ball. Duty, January 27, 1867.

Private William Herron, Co. F, 38th United States Infantry, aged 21 years. Fort Quitman, Texas, October 17, 1869. Gunshot wound of the breast. Duty, November 30, 1869.

Private George Lorenzo, Co. F, 6th United States Cavalry, aged 21 years. Fort Richardson Texas, March 18, 1869. Pistol-shot wound of the back. Duty, May 12, 1869.

Sergeant W. W. McCullough, Co. F, 1st United States Cavalry, aged 30 years. Camp Harney, Oregon, May 31, 1868. Gunshot wound of the right side of the chest, near and about the level of the axilla, by a slug. The missile passed out on the posterior aspect of the chest. Duty, June 27, 1868.

Private Alexander McLean, Co. F, 33d United States Infantry, aged 21 years. Dahlongega, Georgia, December 25, 1867. Gunshot wound of the right side. Duty, December 28, 1867.

Private Edward Miller, Co. B, 10th United States Colored Cavalry, aged 26 years. Near Fort Arbuckle, Indian Territory, December 26, 1869. Pistol-shot wound below the left nipple. Missile passed round the chest, and over the spine, whence it was extracted, January 8, 1870. Duty, February 14, 1871.

Private Alexander Newell, Co. A, 114th United States Colored Troops, aged 42 years. Brazos Santiago, Texas, April 3, 1867. Pistol-shot wound over the ensiform appendix. Missile passed upward and lodged one inch to the left of the right nipple. Removal of ball through incision. Duty, April 14, 1867.

Private Winfield Rogers, Co. K, 16th United States Infantry, Corinth, Mississippi, December 8, 1869. A pistol-ball struck the sixth rib, at the point of a line drawn directly downward from the center of the collar-bone, penetrated to the bone, and then glanced off, making a flesh-wound merely. Duty, December 10, 1869.

Private Frederick Weider, Co. A, 16th United States Infantry, aged 25 years. Louisville, Kentucky, March 11, 1871. Gunshot flesh-wound of the chest, by a small pistol-ball. Missile was extracted from under the skin. Recovered.

Private John Webb, Co. B, 1st California Cavalry, aged 38 years. Fort Sumner, New Mexico, July 2, 1866. Gunshot wound of the right chest and right arm. Duty, September 2, 1866.

Private Samuel Wilmore, Co. G, 116th United States Colored Troops, aged 26 years, Brazos Santiago, Texas, July 10, 1866. Wound of trunk between the ninth and tenth ribs. Missile lodged in the intercostal muscles, but was extracted from the wound. Duty, September 26, 1866.

Sergeant William Winterbottom, Co. A, 6th United States Cavalry, aged 25 years. Gunshot flesh-wound of the left side by a conoidal ball, in action with Indians near north fork of Little Wichita River, Texas, July 12, 1870. Carbolic-acid dressings. Duty, August 7, 1870.

GUNSHOT WOUNDS OF THE ABDOMEN.—It will be most convenient to cite first those cases in which the thoracic cavity as well was involved, and then, in their order, those in which the symptoms of lesions of the stomach, liver, spleen, kidneys, small and large intestines, and pelvic viscera were most prominent.

Gunshot Wounds of the Abdominal and Thoracic Cavities.—There are instances of recovery from such injuries, but they are exceptional. An interesting example is recorded in the surgical report in Circular 6, Surgeon General's Office, 1865, page 24. The nine cases here recorded were fatal. One patient survived fifty hours, three others a few hours, and the rest perished in a few minutes, or instantaneously.

CXVII.—*Report of a Gunshot Wound of the Thorax and Abdomen.* By SAMUEL S. JESSOP, Assistant Surgeon, U. S. A.

At Chester, South Carolina, Private George W. Dorman, Co. K, 6th United States Infantry, was shot, November 24, 1867, at 10 in the evening, while resisting arrest, having previously escaped from the sentinel. The missile was a conical ball; the weapon a breech-loading Springfield rifle. The autopsy was made twelve hours after death, and showed the following: The ball entered on the right side, between the eighth and ninth ribs, three and three-quarter inches below the nipple, and five and a half inches posterior to a line drawn from the nipple to the anterior superior spinous process of ilium. It made its exit on the left side, three and a half inches below the nipple, and a half inch in front of a line from the nipple to the anterior superior spinous process, fracturing in its course the eighth rib, at the point of junction with its cartilage. The liver was the only viscus wounded by the shot, which passed almost transversely through it. It presented a very singular appearance. From the point of entrance of the ball, fissures radiated in every direction, looking as if the liver had been exploded. Internally, it was completely disorganized, being merely a pulpy mass, inclosed by thin fissured walls. When uninjured, it was normal; there was no degeneration of tissue. The hæmorrhage from the wound was enormous, and was chiefly external. The diaphragm was cut near the point of exit of the ball, and the left lung was collapsed; the heart and lungs were superficially examined; the latter appeared to be healthy; the former was slightly fatty. About two ounces of fluid were found in the pericardium. After leaving the body the ball entered the left fore-arm at its middle third dorsal surface, fractured the ulna, and came out on palmar surface, then struck a young mulatto man, who was, it is said, about eight feet from Dorman, entering the abdomen about one and a half inches above the pubes, and one inch to the left of the median line, penetrating the ilium, where it lodged. It was extracted about two hours afterward, but the mulatto died twenty-three hours after he was shot. Dorman survived the injury about twenty minutes. The soldier who shot him, and who was the only person who saw the affair, it being a dark night, estimates that he was about eight paces from him when he fired.

CXVIII.—*Note of a Case of Gunshot Wound of the Thorax and Abdomen.* By JOSEPH R. GIBSON, Assistant Surgeon, U. S. A.

CASE.—Private Thomas McCoy, Co. H, 3d United States Cavalry, shot himself by the discharge of his carbine while on duty as sentinel over a party of prisoners; the gun slipped from his hands, and the hammer, catching, exploded. The missile entered about an inch toward the median line, at the junction of the cartilage of the eighth and ninth ribs of the right side, ranged backward and upward, and emerged at the back, near the right scapula, passing through the right lung in its course, and probably through the left border of the liver. Death was instantaneous. Considerable hæmorrhage occurred after death.

CXIX.—*Report of a Gunshot Wound of the Thorax and Abdomen.* By JAMES F. WEEDS, Surgeon, U. S. A.

Private John Ford, Co. G, 45th United States Infantry, was shot in Nashville, Tennessee, on the night of February 11, 1869. The bullet passed through the right arm, four inches above the elbow, entered the side of the thorax, breaking the seventh rib in its middle third, opened the right pleural cavity, but did not wound the lung—penetrated the diaphragm, entered the liver at its right border, traversed this viscus from right to left, impinged on the body of a dorsal vertebra

wounded the left lobe of the liver, and extensively lacerated the spleen, and escaped from the body two and a half inches below, and one inch behind the left nipple, breaking the seventh and eighth ribs. He died in a few minutes after being shot. The contents of the thorax, abdomen, and cranium were examined and found in a normal condition, except as regarded the traumatic lesions.

CXX.—*Report of a Case of Gunshot Wound of the Thorax and Abdomen.* By W. R. STEINMETZ, Assistant Surgeon, U. S. A.

Private Jackson Tolliver, Co. E, 24th United States Infantry, aged 21 years, received on January 23, 1870, at Fort Griffin, Texas, two gunshot wounds. One was an inch below and a quarter of an inch external to the inferior angle of the right scapula; the other in the posterior part of the middle third of the right leg. The patient was admitted to the post hospital, and one missile was extracted from near the ensiform cartilage, and another from the muscles of the inner portion of the calf. The patient recovered from shock four hours after reception of injury, and seemed to be doing well until half past 11 at night, when internal hæmorrhage occurred, and death ensued shortly afterward. At the autopsy, the thoracic cavity was found to contain about one and a half pints of blood. After penetrating the diaphragm, the ball had pierced the upper part of the right lobe of the liver, and, taking an upward course, had buried itself under the skin, near the ensiform cartilage; the lower edge of the seventh rib was fractured, and the lower part of the inferior lobe of the right lung was perforated.

CXXI.—*An Account of a Necropsy after a Gunshot Wound of the Liver.* By W. S. BUCHANAN, Assistant Surgeon, U. S. A.

Private Charles Allen, Co. E, 38th United States Colored Infantry, aged 21 years, was admitted to the post hospital at Fort Hays, Kansas, on December 21, 1867, with a gunshot wound of the abdomen, and died in a few minutes. An autopsy was made nine hours after death. The missile, supposed to be a pistol ball, penetrated the abdominal cavity immediately below the seventh costal cartilage and two inches to the left of the mesial line, entered the left lobe of the liver, traversed that organ nearly its whole length, through the left lobe, crossing the longitudinal fissure, reëntering the under surface of the right lobe, and emerged at its superior surface and near its right extremity; thence it passed through the diaphragm into the right pleural cavity and passed out at the tenth rib, which was completely fractured in its middle. Sixty-four ounces of blood were found in the right pleural cavity, which had passed from the abdomen through the aperture in the diaphragm. About twenty ounces of blood were found in the abdominal cavity.

CXXII.—*Case of Gunshot Wound of the Liver, Spleen, and Diaphragm.* By J. R. SMITH, Surgeon, U. S. A.

Private Richard Sledge, reassigned, 38th United States Infantry, was shot by the sentinel at Jefferson Barracks, Missouri, on the 3d instant, while endeavoring to escape from the guard. The ball entered the body posteriorly, just above the edge of the left ilium, and midway the crest; entered the abdominal cavity, ranging upward and forward, passed through the spleen and the diaphragm, wounding the liver; and then passed out anteriorly, near the left nipple, fracturing the sixth rib. The man lived fifty hours after receiving the wound.

CXXIII.—*Pistol-shot Wound implicating both the Thoracic and Abdominal Cavities.* By J. F. WEEDS, Surgeon, U. S. A.

In October, 1869, at Nashville, Tennessee, Private Frank Gibhart, Co. D, 14th United States Infantry, was accidentally shot by the officer of the day, while the latter was suppressing a disturbance among the prisoners in the guard-house. The deceased was one of the guard. The bullet (a conical ball fired from a 5-inch Smith & Wesson's pistol) entered the back two and a half inches to the left of the fourth dorsal vertebra and lodged the same distance to the right of the xiphoid cartilage, passing through the superior portion of the right lobe of the liver, the diaphragm, and opening the right pleural cavity. He died in a few minutes.

CXXIV.—*Brief Report of a Case of Gunshot Wound involving both the Chest and Abdomen.* By J. A. TONNER, M. D., Acting Assistant Surgeon.

Private Michael O'Callaghan, Co. D, 6th United States Cavalry, was shot by a citizen on February 9, 1867, the missile, a buckshot, inflicting wounds of the chest and abdomen. He was admitted from camp to the regimental field hospital at Austin, Texas, on February 10, 1867. He died on the following day.

CXXV.—*Note of a Gunshot Wound involving the Thorax and Abdomen.* By WILLIAM DEAL, M. D., Acting Assistant Surgeon.

Artificer John Tindolph, Co. K, 1st United States Artillery, aged 21 years, received a gunshot wound of the right side on November 22, 1868, by duck-shot, which entered the right side, fracturing the sixth and seventh ribs, passing downward into the liver, lacerating the lower lobe of the right lung. He was admitted to Sedgwick Barracks post hospital, at New Orleans, on November 22d, and died the same day from hæmorrhage.

The injuries in the cases recorded in the nine foregoing reports were inflicted, in five cases, by musket balls; in two, by pistol balls; in one, by buckshot; in one, by bird shot.

Gunshot Wounds of the Stomach.—It is superfluous to remark on the rarity of recovery from traumatic lesions of the stomach. We have to look back to Dr. Beaumont's report of the case of Alexis St. Martin for a satisfactory published instance, derived from the surgical annals of the Army. But one case of gunshot wound of the stomach, coming under treatment, is reported in the last five years.

CXXVI.—*Report of a Case of Gunshot Wound of the Stomach.* By W. F. BUCHANAN, Assistant Surgeon, U. S. A.

Private James Brennan, Troop F, 7th United States Cavalry, was admitted to hospital at Fort Hays, Kansas, April 18, 1869, for a gunshot wound, from the effects of which he died on the third day after admission. At a *post-mortem* examination, fifteen hours after death, it was found that a large pistol ball had entered the back directly to the left of the spinal column, and had passed just beneath the left renal artery and through the pyloric extremity of the stomach, making its exit to the left and about two and a half inches above the umbilicus. The whole extent of the peritonæum and intestines was congested with an extensive effusion of fibrin. Extensive internal hæmorrhage, most probably from a branch of the gastro-epiploica dextra, had taken place, and was evidently the immediate cause of death. Hæmorrhage from the nose, ears, and mouth took place immediately before death.

Gunshot Wounds of the Small Intestines.—Twenty cases were reported. They were all fatal. Seven were complicated by wounds of large vessels, and the patients died almost immediately. Ten other patients died within forty hours, from internal hæmorrhage mainly. As nearly as can be ascertained most of these died in a very few hours. Three patients survived three, five, and twenty-nine days, respectively, and succumbed to peritonitis.

CXXVII.—*Report of a Case of Perforation of the Duodenum by a Pistol Ball.* By C. H. ALDEN, Surgeon, U. S. A.

Lieutenant George F. Mason, 5th United States Cavalry, was shot in a quarrel with a citizen, near Fort D. A. Russell, Wyoming Territory, on March 1, 1870. The ball was from a Colt's Navy revolver, and entered about two and a half inches above the umbilicus, a little to the right of the median line, ranged downward and backward, perforating the duodenum a short distance below the stomach, dividing the mesenteric vessels in several places, and passed out about two and a half inches to the left of the median line posteriorly and opposite the fourth lumbar vertebra. Internal hæmorrhage was the immediate cause of death, which took place soon after the reception of the injury, March 1, 1870.

CXXVIII.—*Memorandum of a Fatal Case of Gunshot Wound of the Small Intestines.* By JAMES SAUNDERS, M. D., Acting Assistant Surgeon.

Private John Hoffman, Co. A, 6th United States Cavalry, aged 28 years, was wounded in a skirmish at Farmersville, Texas, on November 19, 1868, by a conoidal ball which perforated the jejunum. The treatment consisted of stimulants and anodynes. He died on November 20, 1868.

The skirmish occurred about twenty-five miles from Pilot Grove, Texas, and the case was treated by Dr. Netherby, of that place. His remains were brought to the post, where they were interred.

CXXIX.—*Report of a Fatal Gunshot Wound of the Small Intestines.* By H. H. SMITH, M. D., Acting Assistant Surgeon.

Private Joseph Clark, Co. C, 14th United States Infantry, was shot by Indians four miles from Camp Verde, Arizona Territory, on May 6, 1869. The ball entered just over the anterior superior spinous process of the ilium on the left side, and, passing across and upward, lodged in the right hypochondrium, after perforating the peritonæum and small intestines. He ran or walked half way into camp, and was carried the remainder of the way on a hand-litter. He never recovered from the shock, and his stomach was so irritable that he vomited frequently and could retain nothing. At length, being able to retain a dose of morphia which was administered in a small powder with a few grains of prepared chalk, he slept a considerable portion of the night. Toward morning he took and retained wine and water, and later was able to retain brandy and water; but he could not be induced to take food in any form. He had a passage of fæces and blood. There were slight spots and streaks of blood in the vomited matter. The patient died on the morning of May 7, 1869.

CXXX.—*Minute of a Case of Gunshot Wound of the Ileum and Jejunum.* By WILLIAM A. CANTRELL, M. D., Acting Assistant Surgeon.

Corporal James Dunn, Co. C, 28th United States Infantry, was brought to the post hospital at Little Rock, Arkansas, on the night of March 6, 1868, in an intoxicated condition, having received a wound of the abdomen by the accidental discharge of a small pocket-pistol, in his own hands, while resisting the efforts of a policeman to disarm him. Death resulted on the morning of March 7th. At the autopsy the ball was found to have entered a little above and to the right of the umbilicus, passing backward and to the left through the convolutions of the ileum and jejunum, cutting some of the branches of the superior mesenteric vein, and to have lodged on the left of the spine. The abdominal cavity was filled with clotted blood.

CXXXI.—*Abstract of a Case of Gunshot Wound of the Small Intestines.* By WILLIAM M. NOTSON, Assistant Surgeon, U. S. A.

Private Edward Stuvan, Co. G, 4th United States Cavalry, aged 29 years, was wounded in a drunken scuffle on June 19, 1870, by a conoidal ball, in the abdomen. He was admitted on the same day to the United States post hospital at Fort Concho, Texas. There was no treatment, death being almost instantaneous from internal hæmorrhage.

CXXXII.—*Remarks on a Case of Gunshot Wound of the Jejunum.* By ALBERT NEUMAN, M. D., Acting Assistant Surgeon.

Private Samuel G. Martin, Troop D, 14th Missouri Cavalry, was admitted to hospital at Lawrence, Kansas, June 23d, having received a wound about an hour before by the accidental discharge of a Remington revolver. The ball entered the right side near the lower lumbar vertebrae, and lodged under the skin about an inch above the internal abdominal ring, whence it had been removed by incision before admission. He was suffering great pain, and there was great tenderness of the abdomen. There was a constant and intense desire to urinate with inability to do so, and he begged to have his urine drawn off. An anodyne was administered, and cold-water dressings applied. On the 25th, faecal matter was discharged from the wound in front. On the 26th, he complained of no pain; he became slightly delirious, and vomited; pulse 108. July 4th: Easy; faecal matter discharged from the wound in the back; a dark slough protruded from the wound in front; pulse 96; treated expectantly. July 5th: Suffered much pain in the night; had four discharges *per anum*, and faecal matter discharged from both wounds. July 6th: Symptoms increased, with considerable tenderness over the whole abdomen. July 14th: Patient much prostrated; back and sides of the trunk covered with small, irregular purple spots and lines; lividness of the hands and feet. The symptoms gradually grew worse, and by July 21st the pulse was 104, and small; the lividness had increased, and purple spots covered both legs. Death occurred July 22d. A necroscopic examination, three hours after death, revealed the usual characteristics of peritonitis. The small intestine was completely divided, the lower portion being contracted almost to the size of a goose quill. Communicating with the wounds of exit and of entrance, and surrounding the right psoas muscle, was a cavity of sufficient size to hold a quart, separated by adhesions from the remainder of the abdominal cavity. The upper portion of the small intestine opened into this cavity, which was half full of faecal matter.

CXXXIII.—*Memorandum of a Gunshot Wound of the Abdomen.* By G. A. JAMESON, M. D., Acting Assistant Surgeon.

Private John Hynds, Co. D, 17th Regiment Veteran Reserve Corps, was wounded by an associate at Ekin Barracks, Indianapolis, Indiana, on July 22, 1865; death resulted on July 23d, nine hours after the reception of the injury. At the *post-mortem* examination, the ball was found to have entered the abdomen three inches to the left, and a half inch above the umbilicus; and the adipose tissue around the orifice made by the ball to be infiltrated with blood from one to two inches in every direction. Upon laying back the flaps made by the incision, the peritonæum was found to be more red and swollen than common. In the abdominal cavity were three pints of blood, which must have been effused from the small mesenteric vessels broken by the ball.

CXXXIV.—*Penetrating Gunshot Wound of the Abdomen.* By B. A. CLEMENTS, Surgeon, U. S. A.

Private Michael Ford, Co. E, 19th United States Infantry, received August 9, 1870, a gunshot wound of the abdomen. He was admitted to the post-hospital at Jackson Barracks, Louisiana, on the same day. Simple dressings were applied. He died August 14, from the immediate effects of internal hæmorrhage and peritonitis.

CXXXV.—*Note of a Gunshot Perforation of the Small Intestines.* By JOHN RIDGELY, M. D., Acting Assistant Surgeon.

Private Bernard Curry, Co. B, 6th United States Cavalry, was admitted into the post hospital at Austin, Texas, on August 23, 1868, with a gunshot wound of the abdomen, from the effects of which he died on the same day. At the autopsy, the missile, which was supposed to have been a pistol ball, was found to have entered the cavity of the abdomen about two and a half inches below and to the left of the umbilicus; to have passed transversely through each fold of the intestines, tearing them—in some places destroying the continuity—and to have emerged immediately above the crest of the left ilium.

CXXXVI.—*Memorandum of a Case of Gunshot Wound of the Jejunum.* By H. A. DuBois, Assistant Surgeon, and D. C. PETERS, Surgeon, U. S. A.

Private Antoine Seeberger, Troop F, 3d United States Cavalry, aged 28 years, was admitted to post hospital at Camp Union, New Mexico, June 30, 1867, with a penetrating gunshot wound of the abdomen. The missile, a conoidal ball, entered midway between the umbilicus and the border of the costal cartilages, left side, and emerged two and a half inches on the left side of the spinous process and at the lower margin of the ribs. Hypodermic injections of morphia were tried, but the patient died July 1, 1867. At the *post-mortem* examination the ball was found to have pierced the jejunum in the left lumbar region, and to have grazed the left kidney. The portion of the small intestine above the point of injury contrasted with the portion below, which was contracted and pale.

CXXXVII.—*Note of a Case of Traumatic Peritonitis.* By THEODORE ATWOOD, M. D., Acting Assistant Surgeon.

Private William Linnahan, Co. I, 7th United States Infantry, aged 21 years, received a wound of the abdomen from a slug while on patrol duty February 22, 1869. He was admitted to the post hospital at Jacksonville, Florida, on the same day, and died of traumatic peritonitis, February 25, 1869.

CXXXVIII.—*Remarks on a Case of Gunshot Wound of the Ileum.* By F. W. ELBREY, Assistant Surgeon, U. S. A.

Franklin A. Dennis, Co. I, 5th Cavalry, accidentally shot himself on the 5th of November, while with an expedition to the forks of the Republican River, and died half an hour after the occurrence. The expedition being on its return to Fort McPherson, Nebraska, and distant only one day's march, the body was transported for interment there. The autopsy, which was made at the post hospital, showed that a carbine ball had entered the right iliac region, perforating in its course the ileum two inches from the ileo-cæcal valve, and the external iliac vein near Poupart's ligament. It then struck the body of the pubic bone, which it fractured, and, being thence deflected, took its course along the inner side of the right leg and lodged at the side of the tendo Achilles.

CXXXIX.—*Remarks on a Case of Gunshot Wound of the Abdomen.* By D. WEISEL, Assistant Surgeon, U. S. A.

Private Anderson Merryweather, 9th United States Cavalry Band, was shot by parties unknown on October 14, 1870, at Fort Davis, Texas, from the effects of which he died October 16, 1870. Upon examination, immediately after the receipt of injury, it was found that he had been shot by a small bullet, which had entered the abdomen at and penetrating the posterior part of the crest of the left ilium, passing upward and outward and lodging upon the anterior portion of the ensiform cartilage, from which it was extracted by cutting down upon it. The next day the patient complained of severe pain and soreness of the bowels with the abdomen much swollen, and upon going to stool the pain was intense, with large quantities of blood passing from him. An autopsy upon his body, six hours after death, revealed a large quantity of blood in the cavity of the abdomen, the bowels congested, and the small intestines penetrated by the bullet four times.

CXL.—*Note of a Case of Gunshot Wound of the Abdomen.* By ROBERT McCracken, M. D., Acting Assistant Surgeon.

At Baton Rouge, Louisiana, August 15, 1868, Acting Assistant Surgeon C. B. Braman, aged 27 years, was killed by a pistol ball. The missile entered the back, near the left side of the spine, passed through the body, and lodged in the muscular tissues of the anterior part of the left chest, in its course cutting the ascending cava. Death, consequently, was almost instantaneous.

CXLI.—*Memorandum of a Wound of the Abdomen by a Musket-Ball.* By JOHN RIDGELY, M. D., Acting Assistant Surgeon.

* * At Austin, Texas, April 1, 1868, Private William Burke, Co. B, 6th United States Cavalry, aged 21 years, received a wound of the abdomen from a conoidal bullet. He was admitted to the hospital at Austin, Texas, and died on the same day.

CXLII.—*Note of a Case of Perforation of the Abdomen by a Musket Ball.* By J. C. LAMONT, M. D., Acting Assistant Surgeon.

Private Thomas Baker, Co. K, 24th United States Infantry, aged 25 years, was accidentally wounded on February 20, 1870, by a conoidal ball, which entered midway between the anterior superior spinous process of the right ilium and the linea alba, passed downward, and laterally, traversing the abdominal cavity, and emerged four inches below the crest of the left ilium, and one inch from the junction of the sacrum with the ilium. He was admitted to the United States post hospital at Fort Duncan, Texas, on the same day. He died on February 21, 1870.

CXLIII.—*Minute of a Penetrating Wound of the Abdomen.* By W. M. NOTSON, Assistant Surgeon, U. S. A.

Private John Gourjan, Co. G, 4th United States Cavalry, aged 22 years, was accidentally wounded while on picket, in the abdomen, on June 6, 1868, by a conoidal bullet. He was admitted into the United States Army post hospital at Fort Concho, Texas, on June 7, 1868. Water-dressings were applied to the wound. He died on June 8, 1868.

CXLIV.—*Memorandum of a Perforating Gunshot Wound of Abdomen.* By J. HARVEY, M. D., Acting Assistant Surgeon.

Private Thomas Brown, Co. C, 5th United States Cavalry, was wounded by a conoidal pistol ball, on May 13, 1868, which entered the back near the tenth dorsal vertebra, and emerged through the abdomen just above the umbilicus, causing almost instant death.

CXLV.—*Minute of a Fatal Case of Gunshot Wound of Abdomen.* By J. A. TONNER, M. D., Acting Assistant Surgeon.

Corporal Thomas Casey, Co. M, 6th United States Cavalry, received, near Austin, Texas, a gunshot wound of the abdomen by a conoidal ball. He was admitted from camp to the regimental field hospital on February 7, 1867. He died February 8, 1867.

CXLVI.—*Minutes taken from Monthly Report of Wounded from Fort McKavett, Texas.* By R. SHARPE, M. D., Acting Assistant Surgeon.

At Fort McKavett, February 3, 1870, an autopsy was made on the person of Private Charles Murray, Co. F, 9th United States Cavalry, who was murdered by ruffians while on guard over a man (Jackson) accused of murder. The *post-mortem* notes are as follows: A rifle ball had entered the right side about three inches above the crest of the ilium, perforated the vena cava ascendens, and lodged under the cuticle of the left side about one inch above the anterior superior spinous process of the ilium. This man was wounded on February 2, 1870, and died almost immediately.

Gunshot Flesh Wounds of the Abdomen—Several of the gunshot wounds of the abdominal walls that were reported were of a serious nature.

CXLVII.—*Memorandum of a Case of Gunshot Flesh-Wound of the Abdomen with other Injuries.* By H. J. SMITH, Assistant Surgeon, 5th United States Volunteer Infantry.

Sergeant Little Priest, Co. A, Omaha Scouts, was wounded near Camp Connor, Dakota Territory, in a fight with Sioux Indians, in November, 1865, receiving four gunshot wounds. The first

ball was received in the epigastric region anteriorly, about two inches above the umbilicus and to the right of the median line. As he did not arrive at post until some time after the irritative fever had set in, it was hard to ascertain the direction of said ball, but the best diagnosis that could be made in the case was, that it had passed between the intestines and abdominal walls, passing over the crest of the right ilium, and lodging in the gluteal muscles. The second ball passed in posteriorly to the left of the right scapula, and traveling through the superficial fascia and cellular substance covering that bone, lodged in the substance of the right deltoid muscle. The third ball was a glancing shot, making a lacerated wound of the pectoralis major muscle, near its insertion into the anterior bicipital ridge of the humerus. The fourth ball entered posteriorly the triceps muscle of the left arm. The track and lodgement of this ball are still unknown. At the end of the month the patient was doing well, with good hope of his speedy recovery. [He was returned to duty December, 1865.—ED.]

CXLVIII.—*Note of a Gunshot Flesh-Wound.* By HARVEY E. BROWN, Assistant Surgeon, U. S. A.

Private Daniel McCarthy, Co. D, 24th United States Infantry, aged 22 years, received a gunshot wound from a conoidal pistol bullet, on March 25, 1869. The ball entered one inch below the anterior superior spinous process of the left ilium, and made its exit midway between the crest of the ilium and the tuber ischii. He was admitted to the post hospital at Galveston, Texas, on March 25, 1869. Cold-water dressings were applied. He was returned to duty in April, 1869.

CXLIX.—*Note of a Gunshot Flesh-Wound of the Abdomen.* By REDFORD SHARPE, M. D., Acting Assistant Surgeon.

Private William L. Jones, Co. F, 35th United States Infantry, aged 24 years, received a gunshot wound of the abdomen. He was admitted into the United States Army post hospital at San Antonio, Texas, from field hospital, on December 11, 1866. The treatment consisted of simple dressings. He was returned to duty on December 22, 1866.

CL.—*Note of a Gunshot Flesh-Wound.* By JOHN BROOKE, Assistant Surgeon, U. S. A.

Lieutenant G. A. H. Clements, Co. H, 44th United States Infantry, aged 24 years, received on May 19, 1868, a gunshot wound of the abdomen, by the accidental discharge of his pistol. He was admitted to the post hospital at Washington, D. C., on May 24, 1868. The ball was extracted previous to admission. Simple dressings were applied. He was transferred to quarters on June 8, 1868.

CLI.—*Memorandum of a Gunshot Flesh-Wound.* By F. SUHRING, M. D., Acting Assistant Surgeon.

Private Thomas Marrion, Co. I, 16th United States Infantry, was wounded near McNutt, Mississippi, while assisting the deputy sheriff in making an arrest. The ball entered the lower part of the left iliac region, and, passing to the right, lodged in the lower part of the right iliac region, immediately under the skin. After being wounded, the patient started on horseback for his station, a distance of about thirty-one miles, and on his arrival did not seem to be seriously injured. After some time, however, severe vomiting and great prostration followed, which, after several days' duration, yielded to the administration of counter-irritants and proper diet. Constipation was easily overcome by a few doses of castor oil. The utmost rest, and light, digestible food—as peritonitis had set in—was ordered. The wound was treated first with cold-water dressings; afterwards with warm poultices of slippery elm and hops. The visceral peritonæum, it seems, had been injured to some extent. The patient was convalescent at the date of this report, January, 1870.

Gunshot Wounds of the Large Intestine.—Such injuries are dangerous, but far less so than those of the small intestines.

CLII.—*Memorandum of a Gunshot Wound of the Large Intestine recovering under Simple Treatment.* By W. S. MINEER, M. D., Acting Assistant Surgeon.

Private J. D. Morgan, Co. H, 23d United States Infantry, aged 25 years, was shot by a companion in a dispute on July 15, 1867. A revolver ball entered the abdomen, passing through the colon, and was extracted just above the right ilium. He was admitted to the post hospital at Fort Boise, Indian Territory, on July 15, 1867. Simple dressings were applied. He was returned to duty on September 30, 1867.

CLIII.—*Memorandum of a Gunshot Wound of the Colon.* By S. S. BEACH, M. D., Acting Assistant Surgeon.

Private Octavio Dussett, aged 23 years, was wounded in a quarrel with a comrade, on June 23, 1868, at Atlanta, Georgia. A pistol ball entered above the crest of the right ilium, passed through the transverse colon longitudinally, and made its exit two and a half inches above the left ilium. He was sent to the post hospital at McPherson Barracks. Water-dressings were applied. He died on June 27, 1868, from peritonitis, ninety-six hours after the reception of the injury.

CLIV.—*Report of a Case of Gunshot Wound of the Abdomen with Protrusion of the Omentum.* By S. H. HORNER, Assistant Surgeon, U. S. A.

Private Charles Morris, Co. C, 2d United States Infantry, was admitted to the post hospital at Louisville, Kentucky, August 2, 1866, with a gunshot wound of the abdomen, received in an attempt to escape from arrest. A conoidal ball entered the right side posteriorly, grazing the posterior superior spinous process of the ilium, emerging at a point one inch to the right and above the umbilicus. When admitted he was suffering from great pain, continual vomiting, restlessness, and excessive thirst. His pulse was 70, and very feeble; skin bathed in cold clammy perspiration. About eight inches of the omentum, which protruded through the anterior wound, was washed and returned. The wound was then closed with a suture, and cold-water dressings applied. Stimulants and anodynes were freely given, but the patient continued to sink, and expired at 1 o'clock P. M. on the same day. At the *post-mortem* examination, the ball was found to have traversed the colon in two places, lacerating the omentum; the peritonæum was somewhat thickened and inflamed; the vessels of the omentum and mucous membrane of the colon were highly engorged, and the abdominal cavity contained a considerable quantity of dark bloody fluid mingled with faecal matter.

CLV.—*Remarks on a Case of Gunshot Wound of the Abdomen, followed by Faecal Fistula.* By H. S. SCHELL, Assistant Surgeon, U. S. A.

Private Richard Broad, Co. F, 2d United States Cavalry, was wounded July 3, 1867, at Fort Laramie, Dakota Territory, by a conoidal ball from a Remington revolver, Army pattern. The ball entered on the left side of the abdomen, its lower edge grazing the centre of Poupart's ligament, and ranging backward, inward, and slightly upward, emerged one inch to the left of the spinous processes of the sacrum. He was admitted to the hospital the next morning, put in bed, absolute rest and diet enjoined, and cold-water dressing applied. Opium was given in full doses, to obtain quietude of the bowels, which were disposed to diarrhœa. On July 6th, all the symptoms of peritonitis making their appearance, six cup cups were applied to the abdomen, and ten ounces of blood abstracted. Warm-water dressing and light, hot fomentations were applied, with relief of all untoward symptoms. On July 8th, tea and toast diet was allowed. On July 11th, free discharge of faecal matter from both anterior and posterior wound. This discharge continued for three days, then ceased. More liberal diet was then allowed, and by August 12th, both wounds were entirely healed.

Gunshot Wounds of the Liver, Spleen, and Gall-Bladder.—Wounds of the liver are oftener followed by recovery than is generally supposed. The great fatality of wounds of the spleen must be confessed, and, in presence of gunshot perforations of the gall-bladder, we may admit, with M. Legouest, that the surgeon must lay down his arms. Yet of the cases of gunshot wounds of the liver here recorded, four had a successful issue, and one of these that Dr. Patzki has reported, though not in detail, was a recovery from a wound of the gall-bladder.

CLVI.—*Abstract of a Case of Gunshot Wound of the Liver, treated at the Post Hospital, Cape Disappointment, Washington Territory.* By W. E. WHITEHEAD, Assistant Surgeon, U. S. A.

Francis H. V—s, a citizen, aged 22 years, was wounded by a slug from a pistol, on June 3, 1867. The missile was shot from behind, and entered about four inches from a line drawn from the nipple of the right side to the superior spinous process of the ilium, and about six inches from the right nipple, below and posterior to the nipple. The slug was removed by an incision through the skin, at a point two and a half inches from the median line, and three and a half inches below the left nipple. At the time of injury he bled very freely from the wound of entrance, continuing to lose blood and bile till daylight next morning, when the hæmorrhage ceased, but the flow of bile continued. When seen on June 4th, the patient was quite feeble from loss of blood; his respiration was rapid, with slight spasm of the diaphragm; pulse small and frequent, and 120; tongue coated; skin of a yellowish tinge, and the extremities cold. On June 7th, he was sent a distance of fifteen miles in a boat, and was admitted into the hospital of the post. Upon admission, he was somewhat excited and fatigued; there was pain and tenderness of the abdomen, the contents of the stomach with bile were persistently vomited, and serum passed freely from the wound. An anodyne was prescribed; the wound was dressed with dry lint, and the patient was kept cool and quiet. June 8th, patient more quiet; bowels constipated; urine high-colored. The anodyne was continued every three hours; two grains of calomel with four grains of Dover's powder were given morning and evening, and a light but nutritious diet was allowed. By June 10th, there was considerable improvement, but there occurred from the wound a discharge of blood-clots, bile, and serum. Slight ptialism taking place on the 11th, the calomel was reduced to three-fourths of a grain, and the Dover's powder to five grains, which was directed to be taken daily at bed-time. The patient's feces were clay-colored; his countenance was of an icteroid hue. After his gums were touched, there was an increased discharge of bile from the wound. By June 18th, improvement having taken place, the mercurial was stopped, but the solution of morphia was continued. The patient had so far improved by June 29th, as to be able to sit up several hours daily, and on July 4th was able to walk in the open air once or twice a day. On July 15th, when the patient left the hospital for a farm-house by the sea-shore, the wound was healthy, and discharged less than an ounce and a half during the twenty-four hours. The discharge consisted of free bile, also bile mixed with thick purulent matter. When last heard from, July 27, 1867, the patient was improving finely in flesh and strength. The discharge from the wound was about the same in quantity and quality.—See A. M. M. Photographic Series, Nos. 39 and 40 of Surgical Card Photographs, vol. 2, p. 39.

CLVII.—*Report of a Case of Gunshot Wound of the Liver, terminating in Recovery.* By J. COOPER MCKEE, Surgeon, U. S. A.

Commissary Sergeant Edward Zimmer, 37th United States Infantry, aged 36 years, was wounded at Santa Fé, New Mexico, in a drunken brawl, on March 8, 1868, by a conoidal ball from a Colt's revolver, which entered the centre of the right hypochondriac region three inches from the cartilages of the ribs, and four and one-half inches from, and on the line with, the lower edge of the sternum, between the eighth and ninth ribs, passed through the liver and intermediate interposing tissues, and emerged between the seventh and eighth ribs on the left side, four inches from the interior edge of the sternum in the left hypochondriac region. He was admitted to the post hos-



pital at Santa Fé on the same day. The collapse following the injury was of a very severe kind, lasting nearly all night. Alcoholic stimulants, hot sinapisms, and chloroform were freely used. After reaction he had severe pain in the region of the wound, and dyspnoea. Sulphate of morphia, in one half-grain doses, was given hypodermically, and repeated in two hours. Warm poultices were applied over the wound and abdomen. His condition at this time was unfavorable and discouraging; pulse frequent and feeble. He had great pain on inspiration and an anxious expression of countenance. There was no external hæmorrhage. On March 15th, having had no movement of the bowels, an enema was given, which acted on the next day, after which his condition improved. On the next day, he ate some vegetable soup, by mistake, which brought on a profuse diarrhœa accompanied by intense tenesmus. Considerable blood was found in the last two operations. By March 19th, the diarrhœa was checked, and he again commenced to improve. On the 20th, he complained of great pain over the seat of the left lobe of the liver; there was dullness on percussion, extending as high as the fourth rib, and two inches below the lower boundary of the right hypochondriac region. During the night the wound of entrance discharged two ounces of pus commingled with bile, which was evidently from the right lobe of the liver. The patient was much relieved; pulse 100; respiration 26. On March 28th, the wound commenced discharging daily about two ounces of pus intermingled with bile and shreds of liver. He continued to improve, and on April 13th, was able to sit up two or three hours a day. Nourishing diet and stimulants were continued, and, on April 24th, he returned to his quarters. He recovered, and was returned to duty June 11, 1868.

CLVIII.—*Note relative to a Case of Gunshot Wound of the Liver.* By FREDERICK HASSIG, M. D., Acting Assistant Surgeon.

Private Thomas Riley, Co. E, 25th United States Infantry, aged 26 years, was wounded in an affray near Paducah, Kentucky, on February 29, 1868, by a conoidal ball, which entered between the sixth and seventh ribs, about one and a half inches from the spinal column, passed through the liver, and lodged two inches under the right nipple. There was profuse bleeding from the wound of entrance. The ball was cut out the same day. On March 1st, the patient was sent to Paducah. The wound rapidly healed. He was returned to duty in May, 1868.

CLIX.—*Memorandum of a Case of Recovery after Gunshot Wound of the Gall-Bladder and Liver.* By Assistant Surgeon J. H. PATZKI, U. S. A.

At Fort Richardson, Texas, Private John Murphy, Co. M, 6th United States Cavalry, aged 25 years, received in an affray a gunshot wound of the abdomen, penetrating the right lobe of the liver and the gall-bladder. He was admitted to the post hospital November 27, 1870, one day after the reception of the injury. Water dressings were applied locally, and morphine was given internally. He recovered, and was discharged the service December 27, 1870.

The four following reports relate to fatal gunshot wounds of the liver, and with the preceding reports on the subject, and two reports among *gunshot wounds of the spleen*, furnish a total of fifteen cases of gunshot wound of the liver, with four recoveries:

CLX.—*Report of a Gunshot Wound of the Liver and Colon.* By CALVIN DEWITT, Assistant Surgeon, U. S. A.

Private Joseph Darragh, Co. E, 1st United States Cavalry, aged 21 years, was wounded December 10, 1869, in a personal encounter with an Indian during an attack on a band of Apache—Mojaves met by a scouting party under command of Captain George B. Sanford, 1st United States Cavalry. The ball was shot from a Spencer carbine in the hands of a comrade who attempted to

shoot the Indian in whose embrace Darragh was locked and from whom he was struggling to free himself. The Indian was killed, but it was impossible to determine whether he or his antagonist was first struck, as they were rolling over each other. The ball entered Darragh's body in the right hypochondriac region, just in front of the space between the eleventh and twelfth ribs, passed obliquely downward, backward, and inward, through, it is believed, the anterior edge of the right lobe of the liver, the transverse colon, among the folds of the small intestines, and emerged one inch to the right of the eleventh dorsal vertebra, fracturing the transverse process. There was some paralysis of motion of the right lower extremity and urinary bladder, due, doubtless, to the shock sustained by the spinal cord from the ball striking and fracturing the transverse process of the eleventh dorsal vertebra. But little external, and a small amount of internal, hæmorrhage was evident, and although he grew faint the tendency to collapse was small, as he rallied from the shock in two or three hours, being quite strong and cheerful, notwithstanding he was told the wound would in all probability prove fatal in a few hours. Opium was given to him immediately, and a temporary hand-litter was constructed on which he was carried over a rough country more than half-way to Camp McDowell, Arizona Territory, until the party was met by an ambulance. He arrived at that post on December 11th, twenty-six hours after the occurrence of the injury, and was immediately taken to the post hospital, where he was made as comfortable as possible. His wounds were dressed, and a pint of ammoniacal urine was drawn from his bladder by the catheter, and a small injection of warm water was given to unload the rectum, the patient having been somewhat constipated. Opium was given to relieve the constantly increasing pain, and barley-water ordered as a drink. A more careful examination discovered that general peritonitis had set in, and that though apparently strong he was almost pulseless. Death occurred at 8 o'clock of the evening of December 11, 1869.

CLXI.—*Report of a Gunshot Wound of the Liver.*—By C. W. KNIGHT, M. D., Acting Assistant Surgeon.

Brevet Major William Russell, jr., Second Lieutenant 4th United States Cavalry, was shot by Indians at Mount Adam, Lampasas, Texas, at 2 P. M., on the 14th of May, 1870. He was first seen by the writer at 9.30 P. M., on the day of the shooting, at Grimes's Rancho, about five miles from the scene of action, and some fifteen miles from the post of Lampasas. The ball, from a Remington's revolver, entered just beneath the tenth rib of the right side, and about four inches from the vertebral column. The ball lodged immediately beneath the integument of the epigastrium, from which position a citizen extracted the ball by incision some two hours before the writer arrived upon the spot. There had been extensive hæmorrhage, with much prostration. Major Russell died at midnight, May 15th, and in the line of duty. An autopsy was impracticable; but it is quite certain that the liver was penetrated by the missile. The immediate causes of death seemed to have been the shock of the injury and the hæmorrhage.

CLXII.—*Memorandum of a Case of Gunshot Wound of the Liver.* By F. L. TOWN, Surgeon, U. S. A.

Private Joseph Phelan, Co. K, 13th United States Infantry, aged 22 years, received a gunshot wound of the liver. He was admitted to the United States post hospital at Fort Shaw, Montana Territory, on April 3, 1870. The treatment consisted of simple dressings. He died on April 4, 1870.

CLXIII.—*A Case of Gunshot Wound of the Liver.* By D. L. MAGRUDER, Surgeon, U. S. A.

Private James Stainbrook, 19th Kansas Volunteers, being confined in the guard-house at Fort Leavenworth, Kansas, under a charge of desertion, attempted his escape about 1 o'clock in the afternoon of September 4, 1869. Refusing to halt, he was fired on by the sentinels, and when in the act of crossing a high fence, two hundred yards distant, one of the shots took effect. A ball entered, fracturing the crest of the right ilium, and passed upward and inward, traversing the liver and intestines, making its exit three inches above and a little to the left of the umbilicus. Profuse internal hæmorrhage set in, and the patient died at 6 o'clock the same evening, September 4, 1869.

Gunshot Wounds of the Spleen—One complicated case has been reported on page 41. The three following reports refer to similar injuries. All of the four cases had a fatal result. Wounds of the spleen uncomplicated by lesions of the intestines, or kidneys, or larger arteries, are so uncommon that the symptoms of its injury are almost as obscure as the nature of its functions.

CLXIV.—*Memorandum of a Gunshot Wound of the Spleen.* By F. A. WILLIAMS, M. D., Acting Assistant Surgeon.

Corporal Allen Davis, Co. B, 17th United States Infantry, aged 35 years, was wounded by a round bullet on December 25, 1868. He was admitted to the United States post hospital at Fort Brenham, Texas, on December 26, 1868. The missile entered the left side of the chest near the ninth rib, passed through the front wall, through a portion of the spleen, diaphragm, and pleura, and emerged at the back of the chest. The treatment consisted of simple dressings. He died on December 28, 1868.

CLXV.—*Memorandum of a Case of Gunshot Wound of the Liver and Spleen.* By S. A. DOW, M. D., Acting Assistant Surgeon.

Private Patrick Behn, Co. A, 34th United States Infantry, was instantly killed at Columbus, Mississippi, on the morning of September 6, 1867, by a ball from a musket in the hands of one of his fellow-soldiers. At the autopsy, the missile was found to have entered the body on the left side between the tenth and eleventh ribs, passing through the spleen and liver, and to have lodged in the adipose tissue beneath the lower edge of the seventh rib, just at the right of the ensiform cartilage. The spleen was torn into three pieces, and the right and left lobes of the liver completely separated.

CLXVI.—*Account of an Autopsy following several Gunshot Wounds.* By JOHN RIDGELY, M. D., Acting Assistant Surgeon.

Private Daniel O'Conner, Co. B, 6th United States Cavalry, was admitted into the post hospital at Austin, Texas, August 23, 1868, at 7.30 A. M., in a moribund state from the effects of four gunshot wounds, more particularly described hereafter, of which he died, at 9 o'clock A. M., August 23, 1868.

Wound first: Gunshot, left arm, lower third, flesh-wound.

Wound second: Gunshot, one inch and a half to the right, and above left nipple, entering the thorax between the third and fourth ribs, two inches from sternal articulation; reflected across the pericardium, passing downward, traversing the lower lobe of left lung, and lodging beneath the skin at intercostal space of sixth and seventh ribs. It was extracted by Acting Assistant Surgeon R. Gale, on the morning of the injury, prior to his admission into the post hospital. The missile was a small-sized pistol-ball. The wound was not necessarily mortal.

Wound third: Gunshot, the missile entering the cavity of the abdomen, about three inches to the right and above umbilicus, passed through the right lobe of the liver, thence proceeding transversely, tore the large intestines. The missile was not found, being probably thrown away with intestines after their removal. This wound was necessarily mortal.

Wound fourth: Gunshot, missile entered the cavity of abdomen, three to four inches upward and to the left of umbilicus, passing transversely through the stomach downward, and laterally, through the spleen and the kidney toward the bladder. Time and circumstances caused the examination to be closed at this stage.

GUNSHOT WOUNDS OF THE PELVIS.—Detailed reports of eight grave cases of this class were transmitted, and memoranda of a few slighter cases, which will be noted among the *flesh wounds of the trunk* further on. Seven of the grave cases were fatal.

CLXVII.—*Report of a Case of Gunshot Fracture of the Pelvis.* By J. T. SCOTT, M. D., Acting Assistant Surgeon.

Private Isam Davis, Co. D, 9th United States Cavalry, in a quarrel with a comrade at Fort Stockton, Texas, July 4, 1868, was mortally wounded by a ball from a carbine. The ball entered the iliac region, above Poupart's ligament, ranging downward and backward, striking the ilium on the pectineal line, shattering the acetabulum and the head of the femur, and lodging in the anterior muscles of the thigh. As there was no hope of preserving his life, only palliative treatment was resorted to. He died July 21, 1868, of pyæmia.

CLXVIII.—*Memorandum of a Case of Gunshot Fracture of the Pelvis.* By WILLIAM SHACKLEFORD, M. D., Acting Assistant Surgeon.

Private James Johnson, Co. F, 23d United States Infantry, aged 28 years, was accidentally wounded by the discharge of a carbine, in the hands of a man who was cleaning it, on November 25, 1867. The missile entered to the right of the symphysis pubis, over the right spermatic cord, lacerating the sheath, and bruising the vessels seriously, passed downward and backward, dividing the penis in front of the prostate gland, and passed out through the left nates. At the time of the reception of the injury he was in a thin and anæmic condition. Hæmorrhage was slow at first, owing probably to a greater quantity of blood being caught in the scrotum than passed out of the mouths of the wound. The wound was more lacerated than usual, owing, as was afterward ascertained, to the ball having struck his cartridge box, flattening itself upon another ball before entering the body. The hæmorrhage, though slow, continued some time, until the man was considerably weakened, but finally ceased without any dangerous symptoms arising from this cause. Serious trouble was apprehended from the mass of blood collected in the scrotum, and also from the urine that must empty there. He was admitted into the hospital at Camp Watson, Oregon, on the same day. Stimulants were freely given, collections of clothing taken in by the ball were removed, and sulphate of morphia was given in half-grain doses. After he had recovered and become quiet, a catheter was introduced, and a puncture was made, with a trocar, in the scrotum to remove the blood collected there. There was then forced a stream of warm water into the scrotum, through the catheter in the penis, passing out both through the wounds and scrotum. The morphia was discontinued at night, but whiskey was given freely, and diet *ad libitum* as his appetite returned. 26th: Patient as well as could be expected; passed a tolerably quiet night; scrotum much distended and black. Considerable clotted blood was removed by sucking it into the catheter. Fomentations were applied. His diet consisted of chicken broth, soft-boiled eggs, tea and toast, whiskey in small quantities. 27th: He is in the same condition, excepting a pain in the right iliac region and small of back; treatment continued. 28th: He is in a great deal of pain. The scrotum is very much distended. There has been no movement of bowels or bladder since the day of wound, (before wound.) An injection of warm soap suds was ordered; this produced a free evacuation of the bowels, after which the urine passed off through the scrotum and wound, though none through penis. 29th: He is not so well to-day, discoloration extending up the abdomen, together with swelling and increase of pain, also loss of appetite. Diet continued, but whisky changed for sherry wine. 30th: He is peevish, appearance haggard, scrotum very much swollen and painful, abdomen hard and swollen, urine still passing away through scrotum and wound. One-fourth of a grain of morphia was given every four hours, beef-tea every half hour. December 1st: He is in the same condition as yesterday, with the addition of vomiting. Continued the application of warm water, but administered no medicine to-day. 2d, there are symptoms of peritonitis, the abdomen presenting the appearance of that of a corpse inflated with gas. Singultus set in. He continued to take both stimulants and chicken broth, but retained nothing within the

stomach. Three to five drops of chloroform were given every ten minutes, arresting for a short time the hiccough. The warm applications were continued. 3d: He is gradually sinking; nothing remains in his stomach five minutes at a time. Treatment continued. 4th: He is aware that he cannot recover, and requests particularly that no autopsy shall be made. He died at 11 A. M., on December 5, 1867.

CLXIX.—*Minute of a Fatal Gunshot Wound of the Pelvis.* By JOHN J. HULSE, Acting Assistant Surgeon.

Sergeant John McDougall, Co. H, 4th United States Cavalry, was wounded near Fort Mason, Texas, on November 14, 1867, while endeavouring to suppress an affray between a party of soldiers and desperadoes. The missile, a pistol ball, entered the right ilium, wounding the bladder, and lodged in the pelvis. He was admitted to the United States post hospital at Fort Mason. His death took place from internal hæmorrhage, on November 14, 1867.

CLXX.—*Note of a Case of Gunshot Wound of the Pelvis.* By MILTON A. ROACH, M. D., Acting Assistant Surgeon.

Private Timothy O'Shaughnessy, Co. E, 15th United States Infantry, aged 27 years, was wounded on August 24, 1868, by a pistol ball, which entered the right hip at crest of ilium, passed obliquely downward and lodged. He was admitted from boat while en route with his regiment to Marshall, Texas, on the same day, to the United States Army post hospital at Shreveport, Louisiana. Simple dressings were used, and the ball was removed from seat of lodgement, one inch from the right side of the anus, previously to admission to hospital. He was returned to duty on September 4, 1868.

CLXXI.—*Report of a Gunshot Wound of the Abdomen, in a Patient with Chronic Orchitis.* By H. R. TILTON, Assistant Surgeon, U. S. A.

Private Patrick W—, Troop D, 2d United States Cavalry, while confined in the guard-house at Fort Lyon, Colorado Territory, was wounded February 25, 1868, by the accidental discharge of a Spencer rifle. The missile having passed through the side of the frame guard-house, and the left arm of a prisoner, entered the right thigh of Wogan, six inches below the anterior superior spinous process, passed under Poupart's ligament, two inches from the anterior superior spinous process, and lodged in the left iliacus muscle; he was in a sitting posture at the time of the reception of the injury. He was immediately carried to the hospital, and complained of intense pain in the abdomen, which was partially controlled by morphia in one half-grain doses. In the course of the evening he voided his urine, which was natural in color. He vomited several times. His pulse increased to 100, with tumultuous action of the heart. He passed a very uncomfortable night, having to be frequently propped up in bed to get his breath; pulse scarcely perceptible at wrist.

Heart beating rapidly and with little force. Death resulted at nine o'clock of the morning of February 26, 1868. An autopsy was made six hours subsequently. On opening the abdomen a great quantity of bloody serum escaped; large clots of blood were found in the hypogastric region, and there was general peritonitis. The ball was found in the left iliac fossa, just above the external iliac artery; by tracing its course it was found to have passed four times through the small intestines, making seven openings, three times through the mesentery and once through the mesocolon. Wogan had suffered a long time with gonorrhœal orchitis of the left testicle. The tunica vaginalis was found considerably thickened and adherent to the lower portion of the testicle, while there was hydrocele of the cord. There were also two abscesses in the lower portion of the testicle, a part of which adjacent to the epididymis and to the abscesses having undergone fibroid degeneration. The testicle was forwarded to the Army Medical Museum.

[Its pathological condition is imperfectly represented in the adjoining wood-cut.—Ed.]

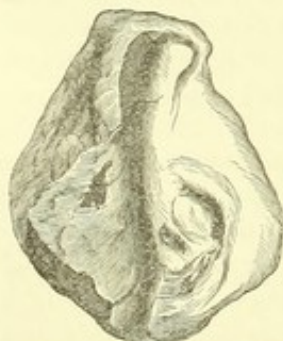


FIG. 9. Testis enlarged and indurated by inflammation. It is laid open to show the cheesy abscesses that have formed. Spec. 5729, Sec. I. A. M. M. [Half the natural size.]

Three examples of division of the external iliac artery were reported. The reader will observe here, as elsewhere, the very large proportion of gunshot wounds of arteries in accidents, assassinations, and suicides, in comparison with those received in battle. In other words, that the great arterial trunks are often divided at very close range by the small projectiles, but very rarely at long range.

CLXXII.—*Note of a Gunshot Wound of the Abdomen, with Lesion of the External Iliac Artery.* By W. H. HOPPER, M. D., Acting Assistant Surgeon.

Private John Gerhardt, Co. K, 2d United States Infantry, aged 22 years, received on January 9, 1869, an accidental gunshot wound of the groin. He was admitted to the regimental hospital at Lebanon, Kentucky, immediately after reception of the injury, and died one hour afterward of hæmorrhage, from a wound of the external iliac artery.

CLXXIII.—*Remarks on a Case of Gunshot Wound of the Large and Small Intestines.* By A. F. FITCH, M. D., Acting Assistant Surgeon.

Corporal Robert Ash, Co. E, 38th United States Infantry, aged 35 years, was admitted to the post hospital at Fort Hays, Kansas, on October 21, 1867, in an intoxicated condition, with a gunshot wound of the abdomen. His pulse was small and feeble, and skin cold. He was very restless, and soon after being put to bed vomited several times. Morphine was administered, and he soon became comparatively quiet. Death resulted at 2 o'clock on the morning of the 22d. At the *post-mortem* examination, thirty-six ounces of fluid, tinged with blood, were found in the abdominal cavity, together with a quantity of coagulated blood and some fecal matter. The ball, on entering the cavity, wounded the small intestines in two places, passed downward and backward through the sigmoid flexure of the colon, severed the external iliac artery completely, and the vein partially, then passed through the ilium immediately below its anterior inferior spinous process, fracturing the acetabulum, and was found lodged in the gluteal muscles.

CLXXIV.—*Mention of a Gunshot Wound of the Abdomen, followed by instant Death.* By B. A. CLEMENTS, Surgeon, U. S. A.

Private Winny Abbott, Co. K, 25th United States Infantry, committed suicide at Jackson Barracks, New Orleans, Louisiana, August 8, 1869, by shooting himself with his own musket. The ball entered the abdomen two inches above the pubis, and one inch to the left of the linea alba, passing through the rectus abdominalis muscle, cutting off the bowel, severing the left external iliac artery, and passing out posteriorly through the os innominatum. He expired immediately after receiving the wound.

CLXXV.—*Memorandum of a Case of Double Gunshot Perforation of the Abdomen, with Recovery.* By L. Y. LORING, Assistant Surgeon, U. S. A.

Private Charles Allen, Battery K, 1st Artillery, received, in a scuffle at Fort Riley, Kansas, August, 1869, two pistol balls in his left side; one entered five and a half inches left of the umbilicus and two inches above crest of ilium, and made its exit two inches above the crest of the ilium on a line with, and two inches from, the fourth lumbar vertebra. The other ball entered four inches below and to the rear of the left nipple, making its exit four inches directly below point of entrance. In their passage these balls did not wound or pass through any of the viscera of the abdomen. With the exception of the traumatic fever, there was no disturbance in the health of the patient. The wounds have now almost healed, and there remains some contraction of the abdominal muscles concerned in the wounds.

GUNSHOT WOUNDS OF THE GENITO-URINARY ORGANS.—The returns refer to two cases of gunshot wounds of the bladder, and to several of the scrotum and testes. One of the cases of wounds of the bladder has been reported with the *gunshot wounds of the pelvis*. (Report CLXIX.) On page 53, a gunshot wound of the penis is noted.

CLXXVI.—*Memorandum of a Case of Gunshot Wound of the Bladder*. By JULES LE CARPENTIER, M. D., Acting Assistant Surgeon.

Private Frank Stewart, Co. D, 38th United States Infantry, aged 24 years, was wounded in a riot, at Central City, December 24, 1868, by a pistol ball which passed through the right thigh and lacerated the bladder. He was admitted into the post hospital at Fort Bayard, New Mexico, on the same day. Simple dressings were applied. He died on December 29, 1868, in consequence of urinary infiltration, producing peritonitis and sloughing.

CLXXVII.—*Report of a Case of Gunshot Wound of the Scrotum*. By S. M. HORTON, Assistant Surgeon, U. S. A.

Private Louis Waffler, Co. E, 18th United States Colored Troops, aged 22 years, was accidentally wounded at Fort Philip Kearney, Dakota Territory, April 14, 1867, by a conoidal ball, which entered the scrotum in front near the middle line. He was admitted to the post hospital. No clew to the course of the ball could be found, the infiltrated loose tissue of the scrotum preventing the probes from entering the channel. There was no tenderness on pressure in any of the adjacent parts. Two weeks after the reception of the injury the missile was excised from its place of lodgment, close behind the trochanter major. The patient recovered, and was returned to duty on May 27, 1867.

CLXXVIII.—*Account of a Gunshot Wound of the Testicles*. By W. N. MCCOY, M. D., Acting Assistant Surgeon.

Private Frank Meyer, Co. E, 14th United States Infantry, aged 24 years, was wounded in a brawl on February 3, 1870, by a pistol bullet which passed through the testicles. He was admitted to the post hospital at Jeffersonville, Indiana, on February 4th. Simple dressings were applied. He was returned to duty on February 21, 1870.

CLXXIX.—*Remarks on a Case of Gunshot Wound of the Testicles*. By L. W. GOLDSBOROUGH, M. D., Acting Assistant Surgeon.

On the monthly report of sick and wounded at Camp Schofield, Lynchburg, occupied by Companies A and I of the 17th United States Infantry, is noted a case in which the patient, whose name is not given, was accidentally wounded by a musket ball which passed through both thighs and both testes, making very ugly wounds, particularly in the left thigh and testicle. The scrotum being much lacerated on both sides, and torn portions of the testicles protruding through the openings, much sloughing was apprehended. The portions of the testicles were, however, returned, and the edges of the wounds of the scrotum were brought together by sutures, leaving space enough for matter to escape. Cold-water dressings were applied for two or three days. When the discharge was beginning to be offensive, a weak solution of carbolic acid was applied, which was continued, either dissolved in water or mixed with flax-seed oil in various proportions, the whole time of the recovery; and so admirably did it answer the purpose, that at no time was there any unpleasant odor scarcely perceptible, and then only when one was immediately at the bedside and the wound exposed. But that was not all; not only did the carbolic acid correct any offensive exhalations, but it certainly contributed to the patient's recovery by preventing sloughing and excessive discharge of matter.

GUNSHOT FLESH-WOUNDS OF THE TRUNK.—The cases reported were not very important and the special reports forwarded not numerous.

CLXXX.—*Note of a Case of Gunshot Flesh-Wound of the Trunk.* By J. P. ARTHUR, Assistant Surgeon 36th United States Colored Troops.

Private Samuel Willmare, Co. G, 116th Colored Troops, aged 26 years, received, on July 10, 1866, an accidental gunshot flesh-wound of the right hypochondriac region. A conoidal ball had entered between the ninth and tenth ribs. He was admitted to the post hospital at Brazos Santiago, Texas, on July 10, 1866. The ball was found lodged in the intercostal muscles, and was extracted. Simple dressings were applied. He was returned to duty on September 26, 1866.

CLXXXI.—*Memorandum of a Case of Gunshot Wound of the Buttock.* By L. W. HAYES, M. D., Acting Assistant Surgeon.

At Camp Winfield Scott, Nevada, April 29, 1868, Lieutenant Pendleton Hunter, 8th Cavalry, was wounded in a fight with Indians. The bullet entered the outer part of the right buttock, and passed in the direction of the pelvic viscera. He also received a slight flesh-wound of the right fore-arm. No serious complications followed, and the officer was returned to duty in March, 1868.

CLXXXII.—*Minute of a Gunshot Flesh-Wound of the Abdomen.* By J. F. KING, M. D., Acting Assistant Surgeon.

Private Hermon W. Seyforth, Co. C, 8th Infantry, aged 28 years, received a gunshot wound of the abdominal walls, on May 6, 1870, from a conoidal revolver bullet. He was admitted from his company on the same day to the post hospital at Spartanburg, South Carolina. Cold-water dressings were applied, and anodynes were administered. He was returned to duty on June 3, 1870.

CLXXXIII.—*Note of a Gunshot Flesh-Wound of the Abdomen.* By J. W. WILLIAMS, Assistant Surgeon, U. S. A.

Private Julius Cooper, Co. A, 21st Colored Troops, aged 20 years, was wounded in a riot at Hilton Head, South Carolina, on April 1, 1866, by a pistol bullet which penetrated the parieties of the abdomen, and lodged. He was admitted into the United States Army general hospital at Hilton Head, on April 2d. Simple dressings were used. He was returned to duty on April 14, 1866.

CLXXXIV.—*Report of a Case of Gunshot Wound of the Pubes.* By S. T. WEIRICK, M. D., Acting Assistant Surgeon.

Private David W. Jones, Co. A, 16th Infantry, aged 27 years, received on March 6, 1869, a gunshot wound immediately above and to the right of the penis, striking the pubis and ranging to the right and downward into the thigh, the parts being very much contused. He was treated at the regimental hospital of a detachment of the 16th Infantry. The surgeon removed fragments of cloth, thread, &c., and applied cold-water dressings. The ball was not found. The wound healed, and the man was returned to duty on March 25, 1869.

CLXXXV.—*Memorandum of a Gunshot Wound of the Lumbar Region.* By SAMUEL S. JESSOP, Assistant Surgeon, U. S. A.

Private Hugh Monaghan, Co. E, 8th Infantry, aged 21 years, was accidentally wounded at Chester, South Carolina, on October 14, 1866, by fragments of a ball which entered the right lumbar region, one piece grazing the posterior crest of the ilium, passing out and perforating the fleshy part of the fore arm on the ulnar side, while the other entered a little below the former and lodged under the integument. He was admitted to the post hospital October 14, 1866, and portions of the ball and pieces of clothing were extracted on the same day.

CLXXXVI.—*Memorandum of a Gunshot Wound of the Lumbar Region.* By M. F. BOWES, M. D., Acting Assistant Surgeon.

Private John Cosgrove, Co. F, 8th Infantry, aged 23 years, was wounded on March 17, 1869. A conoidal bullet entered the right side of the back, near the fifth lumbar vertebra, passed forward and outward, and made its exit immediately over the anterior superior spinous process of the ilium. He was admitted to the post hospital of Columbia, South Carolina, on March 18, 1869. Simple dressings were applied. He was returned to duty in April, 1869.

GUNSHOT WOUNDS OF THE UPPER EXTREMITIES.—The reports are classified according as the lesions involved the scapula, clavicle, humerus, bones of the fore-arm, hand, or principal joints. The reports of cases in which operations were performed are reserved for the next chapter.

Gunshot Wounds of the Shoulder.—Eighteen special reports relate to four cases of fracture of the scapula, one of the clavicle and scapula, one of the clavicle, one fatal from profuse hæmorrhage, ten cases of flesh-wounds, and one wound of the joint with fracture of the humerus.

CLXXXVII.—*Report of a Case of Gunshot Wound of the Shoulder.* By F. DARROW, M. D., Acting Assistant Surgeon.

Private Martin Moulton, Troop E, 8th Cavalry, aged 22 years, was wounded on April 16, 1869, near Camp Willow Grove, Arizona Territory, by a conoidal ball, which entered the right shoulder in front, striking the neck of the scapula immediately under the clavicle, passed downward, backward, and then upward, making seemingly a circuit around the neck of the scapula, and lodged in the infra-spinous fossa close to the glenoid cavity. He was admitted to the post hospital. On April 19th, the wound had become painful, and somewhat inflamed, and the patient was unable to move the right arm or hand. The ball was cut down upon, and removed. On May 8th, the wound was suppurating freely. On May 12th, a rough and shelly piece of lead being discovered in the incised wound, was taken out, and on May 30th, a small piece of necrosed bone came away. On June 20th, the wound had healed, and on June 30th, there was partial use of arm.

CLXXXVIII.—*Mention of a Case of Gunshot Wound of the Scapula.* By A. C. GIRARD, Assistant Surgeon, U. S. A.

Private William H. Goldsborough, Co. D, 24th Infantry, aged 24 years, was wounded on July 4, 1870, by a sentinel on duty. A conoidal bullet passed obliquely through a panel-door, entering the soldier's right shoulder at the upper portion of the deltoid, and passing backward, and slightly upward, fracturing in its progress the acromion process, lodging against the scapula. Ball not found. He was admitted to the post hospital at Fort McKavett, Texas, on July 4, 1870. Simple dressings were applied. He was returned to duty on September 22, 1870. He was treated by R. Sharpe, Acting Assistant Surgeon. This man when returned to duty was detailed on daily duty in the post library. So far he has no use of his right arm.

CLXXXIX.—*Mention of a case of Gunshot Wound of the Scapula.* By S. M. HORTON, Assistant Surgeon, U. S. A.

John Montague, citizen, aged 20 years, was wounded while sitting at a camp-fire, just outside the stockade of the fort, by Indians, on November 2, 1866, by a missile, supposed to be a slug from a shot-gun, which fractured the spine of the left scapula, and wounded the left cheek. He was admitted to the post hospital at Fort Philip Kearney, Dakota Territory, on November 2, 1866. Simple dressings were applied to the wound. He was discharged from hospital, cured, on December 2, 1866.

CXC.—*Memorandum of a Case of Gunshot Fracture of the Acromion Process of the Scapula.* By A. A. YEOMANS, Assistant Surgeon, U. S. A.

Private Henry Allison, Co. I, 16th Infantry, aged 26 years, was wounded July 25, 1870, by a conoidal ball, which entered one inch below the coracoid process of the scapula; the ball passed backward and upward, fractured the acromion process, and made its exit posteriorly. He was at once admitted to the post hospital at Grenada, Mississippi. All foreign substances were removed from the wound, and cold-water dressings applied; the right arm was put in a sling, and the patient kept as quiet as possible. When suppuration ensued, flaxseed poultices were applied, and afterward, resin cerate. He was transferred to Jackson, Mississippi, and returned to duty in December, 1870.

CXCI.—*Mention of a Case of Gunshot Fracture of the Clavicle.* By ELLIOTT COUES, Assistant Surgeon, U. S. A.

Private Daniel Ryan, Co. C, 8th Infantry, aged 21 years, was admitted to the post hospital at Columbia, South Carolina, on November 17, 1868, with a gunshot compound comminuted fracture of the clavicle. The missile, which lodged somewhere in the muscles of the back or side of the neck, could not be found. Excellent results have been obtained by adaptation of bandages to this special case.

CXCII.—*Memorandum of a Case of Gunshot Fracture of the Clavicle and Scapula.* By H. S. SCHELL, Assistant Surgeon, U. S. A.

Private Moses Vetzstine, Co. I, 18th Infantry, aged 20 years, received, in a brawl on August 21, 1867, a gunshot wound by a conoidal ball, which penetrated the right shoulder, fracturing the clavicle and scapula. He was admitted to the post hospital at Fort Laramie, Dakota Territory, on the following day. Splints and bandages were applied. The man was returned to duty January 1, 1868.

CXCIII.—*Memorandum of a Case of Gunshot Wound of the Shoulder.* W. A. CANTRELL, M. D., Acting Assistant Surgeon.

Private John O'Brien, Co. B, 28th Infantry, of a constitution injured by the habitual use of alcoholic stimulants, was wounded July 24, 1868, by buckshot, which entered the left shoulder. He was immediately admitted to the post hospital at Little Rock, Arkansas, prostrated from hemorrhage. The treatment consisted of styptics and simple dressings. He died in a few hours after admission to the hospital.

CXCIV.—*Note of a Case of Gunshot Flesh-Wound of the Shoulder.* By JULIUS H. PATZKI, Assistant Surgeon, U. S. A.

Private Benjamin Amey, Co. H, 6th Cavalry, aged 26 years, received a gunshot flesh-wound of the right shoulder, by a conoidal ball, in action with Indians near the North Fork of the Little Wichita River, Texas, July 12, 1870. He was admitted to the post hospital at Fort Richardson, Texas, on the 14th, where carbolic acid dressings were applied. He was returned to duty on the 18th.

CXCV.—*Note of a Gunshot Wound of the Shoulder.* By J. B. CRANDALL, M. D., Acting Assistant Surgeon.

Private Thomas Nolan, Co. I, 37th Infantry, aged 27, was wounded on September 24, 1867, by a conoidal ball, in the left shoulder. He was admitted from the field on September 25th. Simple dressings were applied to the wound. He was returned to duty in September.

CXCVI.—*Mention of a Gunshot Flesh-Wound of the Shoulder.* By J. W. WILLIAMS, Assistant Surgeon, U. S. A.

Corporal Edward Nolan, Co. C, 5th Cavalry, was admitted to the post hospital at Atlanta, Georgia, on January 9, 1869, with a gunshot wound of the left shoulder, received in a brawl on January 2d. Simple dressings were applied. He was returned to duty on January 28th.

CXCVII.—*Account of a Gunshot Flesh-Wound of the Shoulder.* By J. H. PATZKI, Assistant Surgeon, U. S. A.

Private Samuel Wagoner, Co. A, 6th Cavalry, aged 24 years, received a gunshot flesh-wound of the left shoulder, by a conoidal ball, in action with Indians, near North Fork of Little Wichita River, Texas, July 12, 1870. He was admitted to the post hospital at Fort Richardson, Texas, on the 14th, where simple dressings were applied. He was returned to duty on August 3d.

CXCVIII.—*Report of a Gunshot Flesh-Wound of the Scapular Region.* By EDWARD COWLES, Assistant Surgeon, U. S. A.

Corporal John Pilot, Co. L, 9th Cavalry, aged 26 years, was shot, by a sergeant, on December 27, 1867, by a conoidal carbine bullet which caused a flesh-wound of the right scapular region, and inside of the right arm, below the axilla. He was admitted into the post hospital at Brownsville, Texas, on December 27th. Simple dressings were applied. He was returned to duty in February, 1868.

CXCIX.—*Account of a Gunshot Wound of the Shoulder.* P. MIDDLETON, Assistant Surgeon, U. S. A.

Private William McCulla, Troop E, 1st Cavalry, aged 22 years, was wounded in a drunken row at Prescott, Arizona Territory, December 18, 1867, by a conoidal ball, which entered at the centre of the belly of the biceps muscle, passed upward and inward toward the shoulder-joint, thence beneath the scapula, and lodged under the deep muscles, about two inches from the first dorsal vertebra. He was admitted to post hospital at Camp Whipple, Arizona Territory. On December 26th, I made an incision and removed the ball. Healthy suppuration then followed, and the patient did well. On February 5, 1868, he was transferred to Camp McDowell, where his company was stationed.

CC.—*Report of a Case of Gunshot Flesh-Wound of the Shoulder.* By F. GEISDORFF, M. D., Acting Assistant Surgeon.

Corporal Merritt E. Brown, Co. A, 27th Infantry, aged 22 years, received on August 4, 1868, an accidental gunshot wound. A bullet, ploughing the skin and muscles underneath, caused a wound five inches long, two inches wide, and one inch deep, superior and parallel to the spine of scapula of the left shoulder. He was admitted to the post hospital at Fort Philip Kearney, Dakota Territory, on the same day. Cold-water dressings were applied. He was transferred to the field hospital of a detachment of the 27th United States Infantry, nearly recovered.

CCI.—*Memorandum of a Case of Gunshot Flesh-Wound of the Shoulder.* By J. H. PATZKI, Assistant Surgeon, U. S. A.

Private Albert Ford, Co. H, 6th Cavalry, aged 42 years, received a gunshot flesh-wound of the left shoulder by a conoidal ball, in an action with Indians, near the North Fork of Little Wichita River, Texas, July 12, 1870. He was admitted to the post hospital at Fort Richardson, Texas, on the 14th, and carbolic acid dressings applied. He was returned to duty on August 19th.

CCII.—*Note of a Case of Gunshot Wound of the Shoulder and Thigh.* By R. POWELL, Assistant Surgeon, U. S. A.

At Camp Warner, Oregon, December 3, 1867, Private John Ryan, Co. B, 23d Infantry, aged 20 years, was accidentally wounded by the discharge of his own pistol, while stumbling and falling over rocks. The missile, a conoidal ball, inflicted a wound of the left shoulder and thigh, and remained in the shoulder behind the head of the humerus. He was admitted to the post hospital on the same day, where the ball was excised. Cold-water dressings were applied. He returned to duty January 20, 1868.

CCIII.—*Memorandum of a Case of Gunshot Wound of the Shoulder.* By THOMAS S. TUGGLE, M. D., Acting Assistant Surgeon.

At Columbus, Georgia, January 7, 1868, Private Durant, Co. G, 16th Infantry, received a pistol wound in the fleshy part of the right shoulder by a round ball. He was admitted into the post hospital on the same day, where the ball was excised and simple dressings were applied. He was returned to duty January 19, 1868.

CCIV.—*Abstract of a Report relative to a Gunshot Wound of the Shoulder-Joint.* By B. B. WILSON, M. D., late Surgeon and Brevet Lieutenant Colonel, U. S. V.

Private James Curry, Co. M, 20th Pennsylvania Cavalry, was discharged the service on surgeon's certificate of disability, June 28, 1865. He had been wounded in the late war by a conoidal bullet, which fractured the upper extremity of the humerus, involving the surgical and probably the anatomical neck, and had lodged upon the external margin of the scapula. The missile having been retained in that position for more than three years, and the patient having become exhausted, nervous, and irritable from pain and suppuration, was induced to have the ball removed. On November 27, 1867, he presented himself at the Howard Hospital, Philadelphia. There was complete ankylosis of the shoulder-joint, with enlargement of the upper portion of the humerus; several cicatrices existed in the region of the joint and scapula, and a fistulous orifice at the inferior angle of the scapula discharged tolerably healthy pus. Examination with a Nélaton probe revealed the presence of the ball; the sinuous orifice was enlarged, and the ball, which

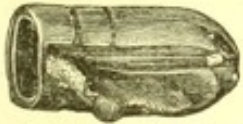

Fig. 10. Conoidal ball grooved by impact upon the humerus. *Spec.* 5257. Sect. I. A. M. M.

clung with tenacity to the edge of the scapula, was extracted. The fistulous orifice closed immediately after the removal of the missile. At the time of this report, April, 1868, the patient had a very useful arm, the great mobility of the scapula seeming to compensate for the ankylosis of the shoulder-joint. The missile, a conoidal ball split by contact with the humerus, and having adherent small portions of bone, is represented in the wood-cut, and was presented to the Army Medical Museum, with the history, by the operator.

Gunshot Wounds of the Arm.—Special reports were received of four cases of gunshot fractures of the humerus.

CCV.—*Mention of a Gunshot Fracture of the Humerus.* By T. M. CHANEY, M. D., Acting Assistant Surgeon.

Private Samuel Bailey, Co. C, 128th Colored Troops, was shot by a sentinel on March 7, 1867, causing a compound comminuted fracture of lower third of the right humerus. The ball entered at the point of the external condyle, traversed the arm, making its exit one inch above the internal condyle. He was admitted to the post hospital at Fort Macon, North Carolina, on March 8, 1867. Simple dressings were applied. He was discharged the service May 21, 1867.

CCVI.—*Report of a Gunshot Fracture of the Neck of the Humerus.* By H. G. TIEDMAN, M. D., Acting Assistant Surgeon.

Private James Sumner, Troop G, 1st Cavalry, was wounded in an action with Apache Indians, in Chilicowley Mountain Pass, Arizona, October 8, 1869. The missile entered under the scapular clavicular articulation, passed through the deltoid downward, shattered the neck of the humerus, barely avoiding the brachial artery, and forced its way out of the triceps muscle. Two pieces of the neck of the humerus were extracted on the field. On October 9th, he was admitted to the hospital at Camp Bowie, Arizona Territory, where another piece of bone was extracted. He was returned to duty in November, 1869.

CCVII.—*Mention of a Gunshot Fracture of the Humerus.* By B. E. FRYER, Assistant Surgeon, U. S. A.

Private Frank Crith, Co. G, 38th Infantry, was accidentally wounded on September 4, 1867, by a conoidal ball which fractured the right humerus at the middle third. He was admitted into the post hospital at Fort Harker, Kansas, on September 5th, from the garrison. Simple dressings were used, and angular splints were applied. He was returned to duty.*

CCVIII.—*Note of a Case of Gunshot Fracture of the Humerus.* By J. V. D. MIDDLETON, Assistant Surgeon, U. S. A.

At Austin, Texas, June 24, 1869, William Bently, a citizen prisoner, aged 38 years, was shot while attempting to escape. The missile, a conoidal ball, fractured the left arm. He was admitted to the post hospital on the same day. Splints and bandages were applied. He was discharged from further treatment on October 17, 1869.

Gunshot Wounds of the Elbow.—Besides reports of cases requiring operations, four special reports were made of gunshot wounds of the elbow, two referring to cases in which the articulation was opened.

CCIX.—*Account of a Case of Gunshot Fracture of the Humerus.* By W. H. HOPPER, Acting Assistant Surgeon.

At Lebanon, Kentucky, August 21, 1869, Private Alexander C. Moore, Co. I, 14th Infantry, aged 23 years, was wounded by a conoidal ball, which passed through the inferior extremity of humerus, splitting off the external condyle, and lodged in the muscular tissue on the anterior surface of the arm. He was admitted to the regimental hospital. Simple dressings were applied and the wound was daily injected with solution of carbolic acid, and covered with lint saturated with the same. September 30th, union of the fractured ends had taken place, and the wound healed with scarcely any suppuration. He was discharged January 21, 1870. There was partial ankylosis of the elbow-joint.

CCX.—*Mention of a Gunshot Wound of the Elbow-Joint.* By J. O. D. CREAGHE, Acting Assistant Surgeon.

Private Willis Graves, Co. F, 19th Infantry, aged 18 years, received on August 29, 1866, at Camden, Arkansas, a penetrating gunshot wound of the left elbow-joint. He was at once admitted to the post hospital. The bullet had passed through the upper part of the articulation, shattered the whole of the external condyle of humerus, and passed out posteriorly. Acting Assistant Surgeon J. O. D. Creaghe enlarged the posterior orifice, and removed all fragments of bone. September 30th, the wound was nearly healed. He was discharged October 30, 1866, his disability being rated one-third.

CCXI.—*Account of a Gunshot Wound of the Elbow-Joint.* By J. O. D. CREAGHE, Acting Assistant Surgeon.

At Camden, Arkansas, December 14, 1866, Private Robert Clarke, Co. B, 28th Infantry, aged 22 years, received a wound from a conoidal pistol ball, which penetrated behind the internal condyle of left humerus, and passing in front of elbow-joint made its exit external to, and a little below, the head of the radius. He was admitted to post hospital December 18, 1866. Simple dressings were applied. He was returned to duty in January, 1867.

* Nearly a year later, in August, 1868, this soldier entered the post hospital at Fort Hays, and underwent an excision of the shaft of the humerus. The further history will be given in the chapter on operations.—Ed.

CCXII.—*Report of a Fatal Case of Gunshot Wound of the Elbow-Joint.* By W. R. RAMSEY, Assistant Surgeon, U. S. A.

Private George Fray, Co. E, 36th Infantry, aged 21 years, was wounded at Fort Sanders, Dakota Territory, February 22, 1868, by the accidental discharge of a musket in the hands of a comrade. The missile passed through the elbow-joint. He was admitted to the hospital in a very feeble condition; there was hæmorrhage from the wound, which it was difficult to control by digital compression, as the artery rolled under the finger on account of the size of the biceps. At 11 P. M. the hæmorrhage ceased by coagulation, and the patient reacted gradually, but continued weak. He remained in the same condition until February 25th, when he, for the first time, asked for something to eat. He seemed restless, and complained of being sick at the stomach and of pain in the arm. On the evening of February 24th, he had a chill and tympanites appeared shortly afterward. He died on February 25th. From the sudden change on the evening of the day previous to his death, and from the prevalence of intermittent fever at the time, the case was supposed to be one of congestive chill. There was no indication of pyæmia.

Gunshot Wounds of the Fore-arm.—Twelve special reports relate to cases of this class. Two of these, resulting from the premature explosion of cannon, terminated fatally; three patients were discharged for disability, and seven returned to duty.

CCXIII.—*Mention of a Gunshot Fracture of the Radius and Ulna.* By O. SMITH, M. D., Acting Assistant Surgeon.

Corporal James Bohan, Co. H, 4th Cavalry, aged 27 years, was shot by a drunken soldier, November 9, 1870. The ball struck the right fore-arm and fractured the radius completely and the ulna partially. He was admitted to the field hospital on the same day, when Acting Assistant Surgeon Orsamus Smith removed all detached pieces of bone, and applied splints. The case progressed favorably, and on November 11, 1870, the patient was transferred to Fort Richardson, Texas. He was sent to his company at Fort Griffin.

CCXIV.—*Mention of a Gunshot Fracture of the Left Radius.* By P. J. A. CLEARY, Assistant Surgeon, U. S. A.

Private Christopher Boats, Co. D, 9th Cavalry, aged 21 years, was wounded by a weapon in the hands of a fellow-soldier. The missile, a conoidal ball, caused a compound comminuted fracture of the radius of the left arm at the middle third, then struck the tenth rib, and passed under the integuments, and lodged two inches to the left of the spine. He was admitted, on June 27, 1870, to the post hospital at Fort Stockton, Texas, where the ball and some small spiculæ of bone were removed; chloride of lime and water dressings were applied to the wounds, and splints to the fore-arm with a view to save the limb. He was returned to duty in September, 1870.

CCXV.—*Mention of a Gunshot Fracture of the Radius.* By G. W. TOWAR, M. D., Acting Assistant Surgeon.

Private Thomas Hubbard, Co. C, 2d Cavalry, aged 22 years, was wounded in a fight with Indians on May 17, 1870, by a rifle bullet, which struck the left fore-arm near the wrist, fracturing the radius. He was admitted from the field on May 17, 1870, to Camp Bingham, Little Blue River, Nebraska. The treatment consisted of simple dressings, with splints. He was transferred to the hospital at Omaha Barracks on June 7, 1870, and returned to duty during the same month.

CCXVI.—*Mention of a Gunshot Fracture of the Radius.* By F. GEISDORFF, M. D., Acting Assistant Surgeon.

Sergeant Edward Oliver, Co. A, 27th Infantry, aged 25 years, received, on August 4, 1868, an accidental gunshot wound. A rifle ball had entered the right fore-arm anteriorly one inch above the wrist-joint, fracturing the radius, and made its exit two inches above the joint. Wound of entrance four lines in diameter; of exit, sixteen lines; area of wound, 12.56, 176 in square lines. He was admitted to the post hospital at Fort Philip Kearney, Dakota Territory, on the same day. Cold-water dressings were applied. He was transferred to the field hospital of a detachment of the 27th Infantry. He was discharged February 27, 1869, for ankylosis of right fore-arm.

CCXVII.—*Note of a Case of Gunshot Fracture of the Ulna.* By J. W. WILLIAMS, Assistant Surgeon, U. S. A.

Private John Tracey, Co. B, 16th Infantry, was admitted to the post hospital at Atlanta, Georgia, on November 28, 1868, with a pistol shot wound of the right fore-arm, fracturing the ulna, received November 27th. He was transferred to his company at Dahlonga, Georgia, on January 28, 1869.

CCXVIII.—*Report of a Gunshot Fracture of the Ulna.* By B. ROCTOR, M. D., Acting Assistant Surgeon.

Private Thomas Trowell, Co. G, 128th Colored Troops, was wounded in a mutiny on Folly Island, South Carolina, July 19, 1866, by a pistol ball, which fractured the ulna of the left arm. He was admitted to the post hospital at Charleston, South Carolina, the same day, and returned to duty August 22d.

CCXIX.—*Report of a Case of Gunshot Wound of the Fore-Arm.* By W. H. SMITH, M. D., Acting Assistant Surgeon.

Private Welcome Joseph, Troop B, 8th Cavalry, aged 18 years, was wounded May 6, 1869, in a fight with Indians near Camp Verde, Arizona Territory. The ball fractured the radius, passing through the left fore-arm between the radius and ulna, diagonally from the end of the elbow in front to the middle of the fore-arm behind. He was admitted to the post hospital, where the fractured bone was set. Small pieces of bone were from time to time removed, and on June 17th, a large piece, grooved by the ball, was cut down upon and taken out. On June 30th, the wound was healing rapidly, the limb promising to be serviceable, and without deformity.

CCXX.—*Mention of a Gunshot Fracture of the Ulna.* By R. TANSZKY, M. D., Acting Assistant Surgeon.

Sergeant George Smith, Troop A, 9th Cavalry, aged 21 years, was wounded at Fort Stockton, Texas, December 26, 1868, by a pistol ball, which fractured the ulna of the left fore-arm. He was admitted to the post hospital, where foreign bodies were removed from the wound, and cold-water lotions were applied. He was returned to duty in February, 1869.

CCXXI.—*Report of a Gunshot Wound of the Fore-Arm.* By F. MEACHAM, Assistant Surgeon, U. S. A.

Private Edward Jones, Co. G, 36th Infantry, aged 22 years, and of scrofulous diathesis, was wounded at Camp Douglas, Utah Territory, on March 4, 1868, by a conoidal ball which entered near the lower third of the right ulna on the inner side, passed through the flexor muscles of the carpus and of the hand, injured the ulnar nerve, and emerged near the internal condyle of the humerus. He was admitted to the post hospital at Camp Douglas, Utah Territory, where water-dressings were applied. The case did well until April 22d, when eczema set in, which gave way to appropriate treatment. On July 27, 1868, he was discharged from service; there was considerable loss of motion in the elbow and wrist-joint, with loss of sensation in the little finger and outside of the ring-finger.

CCXXII.—*Note of a Case of Premature Discharge of a Cannon. Right Fore-Arm carried away.* By WILLIAM CRAIG, M. D., Acting Assistant Surgeon.

Sergeant John Southwood, Co. K, 40th Infantry, aged 39 years, was wounded May 1, 1867, by the premature discharge of a cannon, which carried away the left fore-arm, eight inches below the elbow, and severely contused the left breast and shoulder. He was admitted to the post hospital the same day. Stimulants and tonics were administered, and cooling lotions applied externally. He died May 13th from pneumonia.

CCXXIII.—*Memorandum of a Case in which the Fore-Arm was torn off by a Large Projectile.* By WILLIAM CRAIG, M. D., Acting Assistant Surgeon.

Sergeant Charles H. Peterson, Co. K, 40th Infantry, aged 25 years, was wounded May 1, 1867, by the premature discharge of a cannon, which carried away the right fore-arm, six inches below the elbow, and severely contused the right breast. He was admitted to the post hospital at Fort Caswell, North Carolina, the same day. Stimulants were administered, and olive oil and lime water applied externally. He died May 1st, from the great shock.

CCXXIV.—*Note of a Case of Gunshot Fracture of Radius and Ulna.* By G. H. GUNN, Assistant Surgeon, U. S. A.

Private Thomas Foster, Co. I, 9th Cavalry, aged 24 years, was wounded August 24, 1870, by a conoidal ball, which fractured both bones of the right fore-arm. He was admitted to the post hospital at Fort Quitman, Texas, on the same day. The treatment consisted of splints and simple dressings. On December 16th he was discharged from service on surgeon's certificate of disability.

Gunshot Wounds of the Hand.—Special reports were made of twenty cases. Seventeen patients went to duty, and three were discharged.

CCXXV.—*Note of a Gunshot Wound of the Hand.* By P. MIDDLETON, Assistant Surgeon, U. S. A.

Sergeant F. W. Bryant, Co. G, 14th Infantry, aged 21 years, was wounded at Camp Whipple, Arizona Territory, on December 17, 1868, by the accidental discharge of a pistol; the ball entered to the right of the median line, midway between the metacarpo-phalangeal articulation and the articulation of the first and second phalangeal bones, and emerged directly opposite, fracturing the first phalangeal bone without injuring the tendons. He was admitted to the post hospital, where the finger was placed in a splint and cold-water dressings applied. He recovered and was returned to duty in February, 1869.

CCXXVI.—*Report of a Gunshot Wound of the Hand.* By A. C. GIRARD, Assistant Surgeon, U. S. A.

Private Martin Cramer, Co. A, 19th Infantry, aged 24 years, was accidentally wounded at Baton Rouge, Louisiana, April 23, 1870, by a conoidal ball, which caused a partial fracture of middle finger of left hand. He was admitted to the post hospital, where several small splinters of bone were extracted. The wound suppurated freely, and had healed on May 16, 1870, when the patient was returned to duty.

CCXXVII.—*Mention of a Case of Gunshot Wound of the Hand.* By E. COWLES, Assistant Surgeon, U. S. A.

Private Bernard Cunningham, Co. K, 4th Cavalry, aged 27 years, was accidentally shot on September 15, 1868, at Brownsville, Texas. A ball entered the volar surface of the left hand, and fractured the second and third metacarpal bones. There was considerable hemorrhage

from small vessels, and the wound of exit was considerably lacerated. He was, on September 16th, admitted to post hospital. Several fragments of bone were removed, and cooling lotions applied. October 1st: The hand and fore-arm were much swollen, and almost in a sphacelated condition. The patient was greatly depressed, and suffered from hectic fever and diarrhœa. Liberal diet was given, and a gradual improvement took place. During the first quarter of 1869, the wound remained open, there being necrosis of carpal and metacarpal bones. Sequestra were removed, and on March 31, 1869, the patient was doing well. He was returned to duty in July, 1869.

CCXXVIII.—*Account of a Gunshot Wound of the Hand.* By W. PORTER, M. D., Acting Assistant Surgeon.

Sergeant Thomas Downey, Co. C, 7th Infantry, aged 37 years, received a gunshot wound of the left hand, on February 3, 1868, at Gainesville, Florida, while quieting a riot among civilians. The ball passed into the palm of the hand, and fractured the metacarpal bone of middle finger. The ball was taken out from under the skin at the back of the hand. He was admitted to the post hospital, where chloroform and ether were administered, and several pieces of fractured bone were removed. He was returned to duty February 23, 1868.

CCXXIX.—*Mention of a Gunshot Wound of the Hand.* By C. E. GODDARD, Assistant Surgeon, U. S. A.

Private Martin Flannery, Co. E, 2d Battalion, 16th Infantry, aged 28 years, was wounded (by himself) on December 20, 1866, by a conoidal bullet, which passed between the index and second fingers of the right hand, near their phalangeo-metacarpal articulation, injuring both joints, and the periosteum of the phalangeal bones. He was admitted into post hospital at Chattanooga, Tennessee, on the same day. Simple dressings were applied. He was returned to duty in February, 1867.

CCXXX.—*Report of a Case of Gunshot Fracture of the Metacarpal Bone.* By H. S. SCHELL, Assistant Surgeon, U. S. A.

Private Andrew Likarte, Co. A, 2d Cavalry, aged 20 years, received a perforating gunshot wound of the hand, at Fort Laramie, Dakota Territory, March 1, 1867, by a conoidal ball, which fractured the fourth metacarpal bone. He was admitted to the post hospital March 3d. Lead-water and laudanum dressings were applied. He was returned to duty March 29, 1867.

CCXXXI.—*Note of a Gunshot Wound of the Carpus.* By JAMES P. KIMBALL, Assistant Surgeon, U. S. A.

Private William Lavelle, Co. F, 7th Infantry, aged 21 years, accidentally received on June 7, 1870, a gunshot-wound of the left wrist, the ball passing through the center of the carpus. He was admitted to the post hospital at Fort Buford, Dakota Territory, where fragments of bone were removed from the wound, and the injury was dressed with carbolic acid. He was discharged November 30, 1870.

CCXXXII.—*Account of a Gunshot Wound of the Hand.* By H. McELDERY, Assistant Surgeon, U. S. A.

Private William F. Leete, Co. K, 6th Cavalry, aged 24 years, was accidentally wounded on December 26, 1867, by a conoidal ball, which entered one half inch above the second phalango-metacarpal articulation of the left hand, and emerged on the dorsal surface, comminuting the metacarpal and first phalangeal bone of that finger. He was admitted into the post hospital at Camp Wilson, Texas, on October 27, 1867. The treatment consisted of cold-water dressings, isinglass plaster, solution of muriatic acid, and ointment of subnitrate of bismuth; anodynes and tonics were administered internally. He was discharged March 5, 1868.

CCXXXIII.—*Note of a Gunshot Fracture of the Metacarpus.* By CHARLES C. FURLEY, M. D., Acting Assistant Surgeon.

Private Christopher C. Minnigan, Co. E, 41st Infantry, aged 27 years, accidentally received a gunshot wound of the left hand, by an Enfield rifle ball. He was admitted from his regiment on June 30, 1867, to the post hospital at Brownsville, Texas. At the time of the admission he had nearly recovered. Simple dressings were used. He was returned to duty in July, 1867.

CCXXXIV.—*Report of a Gunshot Wound of the Hand.* A. L. FLINT, M. D., Acting Assistant Surgeon.

Private John Murphy, Co. C, 5th Cavalry, aged 24 years, was wounded October 15, 1868, in a street brawl, by a conoidal ball, which injured the bones of the left hand. He was admitted to Camp Emory, Atlanta, Georgia, on the 16th. Simple dressings were applied. He was returned to duty on the 27th.

CCXXXV.—*Report of a Gunshot Wound of the Hand.* By J. F. BOUGHTON, M. D., Acting Assistant Surgeon.

Private Brice Perkins, Co. D, 22d Infantry, aged 20, was wounded at Fort Dakota, Dakota Territory, on April 5, 1868, by a pistol ball, which entered the outer border of the palmar surface of the index finger of the left hand, and, traversing around more than half the circumference of the second phalanx, made its exit at the inner border of the dorsal surface, near the second joint. Very little hæmorrhage occurred. He was admitted to the post hospital at Fort Dakota, when water-dressings were applied. He was returned to duty on April 30, 1868.

CCXXXVI.—*Report of a Gunshot Wound of the Hand.* By E. C. FOX, M. D., United States Colored Troops.

Private Breboy Reed, Co. G, 128th United States Colored Troops, aged 22 years, was wounded in a mutiny on Folly's Island, South Carolina, July 19, 1866, by a pistol ball, which entered the dorsal aspect of the left hand near the metacarpal bone of the index finger. He was at once admitted to the post hospital, where, on July 31st, the ball was extracted from near the ulnar artery. He was returned to duty October 12, 1866.

CCXXXVII.—*Memorandum of a Case of Gunshot Fracture of the Metacarpal Bone.* By G. H. GUNN, Assistant Surgeon, U. S. A.

Private Felix Ross, Co. H, 9th Cavalry, aged 25 years, was wounded November 16, 1870, by a conoidal ball, which fractured the metacarpal bone of the second finger. He was admitted to the post hospital at Fort Quitman, Texas, on the 18th. Simple dressings were applied. He was returned to duty in February, 1871.

CCXXXVIII.—*Report of a Gunshot Wound of the Hand.* By C. S. DEGRAW, Assistant Surgeon, U. S. A.

Private George Overton, Co. K, 10th Cavalry, was accidentally wounded January 19, 1869, by a conoidal ball, which fractured the second metacarpal bone of the right hand. He was admitted to the post hospital at Fort Dodge, Kansas, on May 18, 1869. Simple dressings were applied. Several small pieces of bone were discharged from the upper wound. He recovered, and was returned to duty in June, 1869.

CCXXXIX.—*Mention of a Gunshot Wound of the Hand.* By REDFORD SHARP, M. D., Acting Assistant Surgeon.

Private Philip Reese, Co. D, 4th Cavalry, aged 19 years, received a gunshot wound of the metacarpal bone of the left hand. He was admitted from field hospital to the post hospital at San Antonio, Texas, on December 18, 1866. Simple dressings were applied to the wound. He was returned to duty in March, 1867.

CCXLI.—*Report of a Case of Pistol-Wound of the Left-Hand.*—By REESE B. BERKEY, M. D., Acting Assistant Surgeon.

At Humboldt, Tennessee, February 5, 1871, Private John Dotzel, Co. G, 16 Infantry, aged 23 years, accidentally shot himself with a pistol in the left-hand. The charge, birdshot, entered the second finger of the left-hand, injuring the first metacarpal bone. He was, on the same day, admitted to the post hospital. The shot and pieces of bone were extracted from the wound, and cold water dressings were applied. The man was returned to duty February 16, 1871.

CCXLI.—*Mention of Four Cases of Gunshot Wounds of the Hand.* By W. T. HENDRICKSON, M. D., Acting Assistant Surgeon.

CASE 1.—Private George Thompson, Co. C, 10th Cavalry, aged 23 years, was accidentally wounded by a conoidal carbine ball which passed through the second phalanx of the middle finger of the left hand, destroying the bone. He was admitted on December 13, 1869, from post hospital Fort Sill, Indian Territory, to the United States Army post hospital at Fort Arbuckle, Cherokee Nation, Indian Territory. Simple dressings were used. He was discharged from the service on June 20, 1870, on surgeon's certificate of disability.

CASE 2.—Private Albert Tasker, Co. M, 10th Cavalry, aged 25 years, was accidentally wounded on July 28, 1869, by a conoidal carbine ball, which destroyed the second, ring, and little fingers of the left hand. He was admitted from company quarters to the post hospital at Fort Arbuckle, Cherokee Nation, Indian Territory, on May 8, 1870. Simple dressings were used. He was returned to duty in May, 1870.

CASE 3.—Private Charles Stanton, Co. M, 10th Cavalry, aged 25 years, was accidentally wounded on February 11, 1870, by a conoidal carbine ball which passed between the second and third phalanges of the middle finger of the left hand. He was admitted from company quarters on the same day to the United States Army post hospital at Fort Arbuckle, Cherokee Nation, Indian Territory. The treatment consisted of cold-water dressings and poultices. He was returned to duty on May 10, 1870.

CASE 4.—Private Lyman Tasker, Co. M, 10th Cavalry, aged 20 years, was accidentally wounded by a conoidal carbine ball between the third and fourth metacarpal bones of the right hand, distal end. He was admitted from post hospital Fort Sill, Indian Territory, on December 13, 1869. Simple dressings were used. He was returned to duty on April 27, 1870.

Gunshot Flesh-Wounds of the Upper Extremities.—Special report of twenty-one cases of this class were made. Twenty of the patients recovered and returned to duty; one recovered and was discharged for disability. Seven were cases of wounds of the arm, five of the fore-arm, and nine of the head.

Private John Connelly, Co. H, 5th Cavalry. Fort McPherson, Nebraska, November 20, 1870. Gunshot flesh-wound of the right arm. Duty, December 22, 1870.

Private Thomas Gavin, Co. I, 37th Infantry, aged 24 years. Near Fort Dodge, Kansas, September 29, 1867. Gunshot flesh-wound of the left arm. Duty, October, 1867.

Private Charles Hall, Co. K, 9th Cavalry. Near Fort Davis, Texas, November 17, 1869. Gunshot flesh-wound of the left arm, near the elbow. Duty, January 20, 1870.

Private Wardlow Irving, Co. D, 9th Cavalry. Gunshot flesh-wound of the arm; received in a fight with Indians, near Fort Stockton, Texas, September 10, 1868. Removal of ball. Duty, November 8, 1868.

Private Benjamin Jones, Co. H, 10th Cavalry. Near Fort Harker, Kansas, August 29, 1867. Gunshot flesh-wound of the right arm. Duty, October 1, 1867.

Private Anthony Lambert, Co. A, 6th Cavalry, aged 49 years. Gunshot flesh-wounds of the arm, hand, and leg by buckshot; received in a skirmish with Indians at Farmersville, Texas, November 19, 1868. Duty, December 17, 1868.

Private Michael Welsh, Co. L, 6th Cavalry, aged 25 years. Gunshot flesh-wound of lower third of the left arm. Fort Richardson, Texas, May 9, 1870. Duty, June 14, 1870.

Private Walter H. Clapp, Co. K, 6th Cavalry, aged 22 years. Fort Belknap, Texas, June 20, 1867. Gunshot flesh-wound of the middle third of the left fore-arm. Discharged February 4, 1868, on account of partial paralysis of hand and finger.

Private Peter Dunn, Co. E, 33d Infantry, aged 21 years. Near Fort Macon, Georgia, March 14, 1868. Gunshot flesh-wound of the right fore-arm by a pistol ball. Duty, April, 1868.

Sergeant James Stevenson, Co. F, 10th Cavalry. Gunshot flesh-wound of the left fore-arm and left thigh. Near Fort Lyon, Colorado Territory, March 10, 1869. Duty, May, 1869.

Private Robert Stuart, Co. H, 6th Cavalry, aged 32 years. Gunshot flesh-wound of right fore-arm; received in an action with Indians near the North Fork of the Little Wichita River, Texas, July 12, 1870. Carbolic-acid dressings. Duty, August 6, 1870.

Private Frederick Smith, Co. E, 19th Infantry, aged 23 years. Camden, Arkansas, September 27, 1866. Gunshot wound of the fore-arm and hand by buckshot. Duty, October, 1866.

Private Alfred Brown, Co. L, 10th Cavalry, aged 20 years. Gunshot flesh-wound of fingers of the left hand. Fort Arbuckle, Cherokee Nation, December 19, 1869. Duty, March 9, 1870.

Private Nathan Dedman, Co. B, 41st Infantry, aged 23 years. Point Isabel, Texas, December 27, 1867. Gunshot flesh-wounds of the third and fourth fingers of the left hand. Duty, January, 1868.

Private James Downs, Co. K, 1st Artillery, aged 38 years. New Orleans, Louisiana, June 11, 1868. Laceration and dislocation of the second phalanx of the left thumb by the premature discharge of a cannon. Duty, August, 1868.

Private Joseph Lather, Co. C, 117th Colored Troops. Brazos Santiago, Texas, January 17, 1867. Gunshot flesh-wound of the left hand. Duty, February 26, 1867.

Private James Mitchell, Co. I, 13th Infantry, aged 24 years. Fort Shaw, Montana Territory, April 3, 1870. Gunshot wound of the right fore-finger. Duty, June 4, 1870.

Sergeant Moses Morris, Co. D, 38th Infantry, aged 21 years. Central City, New Mexico, December 24, 1868. Slight flesh-wound of the finger. Duty, January, 1869.

Corporal M. Reinhold, Co. H, 17th Infantry, aged 23 years. Brenham, Texas, February 26, 1867. Gunshot wound through flexor brevis pollicis muscles. Duty, May 16, 1867.

Private William Thompson, Co. C, 9th Cavalry. Near Fort Davis, Texas, February 18, 1870. Gunshot wound of ring-finger of the left hand. Duty, April, 1870.

Private James Wilson, Co. H, 10th Cavalry. Fort Harker, Kansas, September 17, 1867. Gunshot flesh-wound of the left hand. Duty, October, 1867.

GUNSHOT WOUNDS OF THE LOWER EXTREMITIES.—The reports of many cases will be found in the next chapter. Only those relating to cases treated without operative interference will be recorded here.

Gunshot Fractures of the Femur.—The nine following reports give the particulars of three fatal cases of fracture of the upper third of the femur, one involving the hip-joint—of three cases of fracture of the middle third, with one recovery—and of three fractures of the lower third, all terminating favorably:

CCXLII.—*Report of a Fatal Case of Gunshot Fracture of the Right Femur.* By J. BASIL GIRARD, Assistant Surgeon, U. S. A.

Private Emmet Smith, Co. B, 7th Infantry, aged 23 years, was wounded on May 6, 1870, by a musket ball from a Remington breech-loader. The missile entered the right thigh anteriorly some four or five inches below the anterior superior spinous process on the right side, fractured the femur, and lodged in the limb. The patient, a Frenchman, enlisted under an assumed name, and to all appearances not over 18 or 19 years of age, was conveyed to Fort Steele, a distance of about thirty-eight miles. When admitted to the hospital he was in a state of collapse, and suffered acute and severe pains. Stimulants were given every half hour during the following night, until reaction took place. On May 7th, chloroform was administered. The ball was found under the skin, two or three inches back of the great trochanter, and was removed through a small incision through which I introduced a finger in each wound. The femur was found shattered to a fearful extent. The incision for the extraction of the ball was then enlarged upward and downward, thus making an opening four inches in length, crescentic in shape, with the concavity forward, and the soft tissues were separated from the bone. This opening was intended as part of the incision necessary in extracting the head of the femur, should that operation become necessary, or as a free passage for sloughs and pus during after treatment. The examination disclosed a fracture just below the trochanters and almost horizontal. The upper fragment was tilted forward and a little outward by the action of the flexor and rotator muscles. No fracture, communicating with the joint, could be detected. Accordingly the operation was confined to the removal of foreign materials and loose fragments of bone, a number of which were extracted. No ligation was required. The wound was plugged with lint saturated with a solution of persulphate of iron. After the operation the patient remained for a long time unconscious, cold and almost pulseless, and when reaction set in, he was restless and appeared delirious. Opiates were given, but with little effect. He suffered from intense thirst until the large quantity of water drank brought on vomiting. The wounded limb was disturbed by severe spasms, for which bromide of potassium was given in ten-grain doses every half hour. At ten o'clock P. M. he became quiet, and died on May 9, 1870, at 1 A. M. At the autopsy, a line of fracture was found extending into the hip-joint, but owing to it being only a partial rent, I had failed to discover it at my first examination. Had I been aware of that fact at my first examination, I would have excised the joint, but very probably with the same result, as the patient doubtless died of nervous shock and exhaustion. The fatal issue in the last five months of two such cases, both treated expectantly, as well as the recovery of Private Erne, at Fort Laramie, in whose case excision was performed, suggest in my mind the query whether, when the femur is shattered so near the joint, and the upper fragment with its pointed spicula is thrust among the muscles, nerves, and bloodvessels of the anterior part of the thigh, the patient would not be exposed to local irritation, muscular spasm, and secondary hæmorrhage; in short, whether he would not stand a better chance of recovery if that fragment was extracted. At any rate, should he recover under the expectant treatment, it is very doubtful whether union would be very firm with

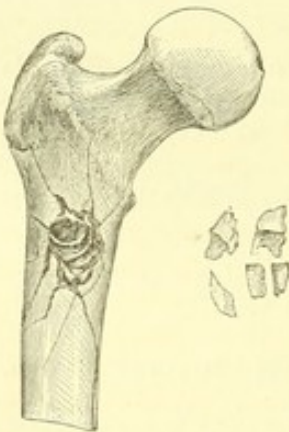


Fig. 11. Upper third of right femur fractured by a conoidal ball. Spec. 5691. Sect. I. A. M. M.

cles, nerves, and bloodvessels of the anterior part of the thigh, the patient would not be exposed to local irritation, muscular spasm, and secondary hæmorrhage; in short, whether he would not stand a better chance of recovery if that fragment was extracted. At any rate, should he recover under the expectant treatment, it is very doubtful whether union would be very firm with

the lower fragment; it would at least, certainly be very tedious, if not imperfect. It seems to me from what little experience I have had in the West, that in this dry and bracing climate where wounds generally do well, excision of the hip-joint in cases like the present, would benefit the patient far more than expectant measures. If another case of this kind comes under my care, I will be strongly tempted to excise. The specimen is figured in the adjoining wood-cut, (FIG. 11.)

CCXLIII.—*Report of a Fatal Case of Gunshot Fracture of the Right Femur.* By Dr. C. C. RADMORE, 114th Regiment of Colored Troops.

Private Henry Jefferson, Co. F, 19th Colored Troops, of a delicate constitution, was admitted, August 30, 1865, to the post hospital at Brownsville, Texas. The patient had accidentally received, two weeks before his admission, a severe gunshot wound, which was found upon examination that the ball had entered about two inches anterior and inferior to the trochanter major, producing a compound comminuted fracture of right femur. The ordinary dressings were applied, and the patient seemed to be doing well during the first two weeks of his stay in the hospital. On September 20th, it was deemed necessary, in consequence of the profuse suppuration and extensive sloughing of the muscular structures of adjoining parts, which had set in a few days previous, to cut down upon, and examine the condition of the wound. A free incision was consequently made, and a few small spiculæ of bone removed, and, after a careful examination of the parts was made, was unable to find the location of the ball, yet nothing presented itself to warrant an unfavorable issue. The same profuse suppuration continued, notwithstanding the free use of tonics and stimulants, together with good nutritious diet. The patient continued to sink, and died November 17, 1865, being two months and eighteen days from receipt of injury. *Sectio cadaveris* 24 hours after death. The body considerably emaciated. On examining the fractured limb, found an oblique fracture to exist extending across the inter-trochanteric line, one-half inch inferior to the trochanter major, with two radiating fractures extending from the main fracture in a superior direction within the capsular ligament. The ball must have fractured itself in two pieces as soon as it came in contact with the bone, as each piece was found to be firmly embedded in each end of the fractured bone, and distant from each other about half an inch, with no prospect of reunion taking place.

CCXLIV.—*Report of a fatal Case of Gunshot Fracture of the Femur.* By WM. M. NOTSON, Assistant Surgeon, U. S. A.

Haller, a citizen, aged about 21 years, had a gunshot fracture of the femur, in the upper part of the middle third, caused by the accidental discharge of a pistol in the hand of a soldier, on the evening of August 25, 1870. The parties were hunting about fifteen miles from Fort Concho, Texas. Upon reception of the injury, he was assisted into the river, and sat in the water all night, for the purpose of keeping off insects, and to relieve the pain. He was brought to the post the next day in a wagon. It was determined, on account of his youth and temperate habits, to make an effort to save the limb. Being wearied from his journey and exposure, he was placed in a comfortable position, and an anodyne administered; the next morning a wire splint was applied, and an examination of the parts made, some spiculæ of bone removed, and an operation determined on; the intervening time was occupied in arranging permanent appliances for the continued use of the anterior splint. August 28th, 11 A. M., an incision was made through the wound, and the loose fragments of bone, and portion of the ball removed, and the extremity of the broken bone cut off with bone forceps, until about two inches had been removed. Opportunity was afforded for free drainage, and carbolized water dressing applied. The next day pointing being noticed in the under portion of the thigh, it was opened, and the remainder of the ball removed. This being a favorable direction, the track of the ball was kept open by a tent until suppuration was freely established. The patient was placed in the ward under the charge of Acting Assistant Surgeon J. A. McCoy, by whom the surgical dressing, treatment, and care of the case was efficiently carried out. On the twenty-sixth day after the operation, some union being evident, on account of much fever of a typhoid character being in the hospital, and the exhausted and debilitated condition of

the patient, he was removed to a bed arranged for him in a wheeled litter, and the leg placed on an inclined plane. On the thirty-fifth day this was changed for a starch bandage. He died on the forty-first day after receiving the injury, from pyæmia. The discharge the day preceding the application of the starch bandage had changed from its healthy hue and consistence to a grumous, fetid character. The *post-mortem* revealed considerable attempt at union, and the limb in nearly the natural position. It is thought more favorable results would have been attained except for the moral, and perhaps physical, effects of the surrounding disease.

CCXLV.—*Report of a Case of Gunshot Fracture of the Femur, with Fatal Result, treated at Fort Fetterman, Wyoming Territory.* By J. BASIL GIRARD, Assistant Surgeon, U. S. A.

Private John W. Keller, Co. H, 4th Infantry, aged 21 years, of temperate habits and fair constitution, was wounded in the left thigh, on December 22, 1869, by the accidental discharge of a Springfield musket in the hands of a comrade. At the time of the accident he was sitting on the edge of his bunk in the company barrack-room, with his right thigh flexed at right angles with the trunk and sustaining the weight of the body, and the left limb stretched and half flexed at the hip joint. The shot was fired from behind, at a distance of about five yards, the ball entering the limb on the outside of the gluteal region, five inches from the anterior superior spinous process of the ilium, and issuing on the front of the thigh, seven inches below the same process, fractured and comminuted the femur in its course. The man was immediately brought to the hospital in a collapsed state, suffering acute pain from the action of the sharp, pointed spiculae of the shattered bone. Upon examination the hæmorrhage was found to have been moderate, but owing to the prostrate condition of the patient further proceedings were postponed until the next day; in the meantime he was put to bed, a sufficient dose of morphia administered to allay suffering, and one ounce of brandy ordered every hour until reaction was brought about. When

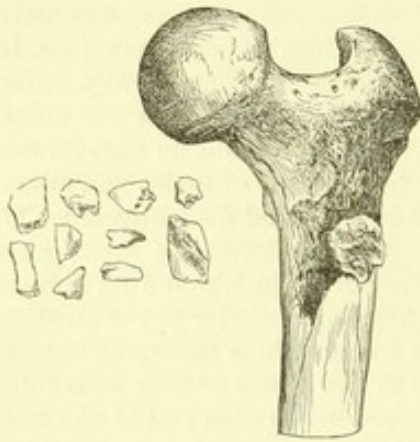


Fig. 12.—Gun-shot fracture of the upper third of the left femur. Spec. 5663, Sect. I, A. M. M.

seen again, late in the afternoon, he had fully reacted, felt quite strong and comfortable, and spoke confidently of his future recovery. He slept well during the night and awoke in excellent condition. On the morning of the 23d an anæsthetic was administered and the wound examined. The orifice of entrance was sufficiently enlarged to allow the passage of the index fingers from each orifice down to the broken bone. The comminution was very great along the track of the ball. The lower fragment presented an oblique line of fracture and moved in accordance with all the motions impressed to the limb, showing that the injury did not extend further downward. The upper fragment was immovable, contained both trochanters, and did not appear to be broken or fissured in any way. Having removed all the loose fragments of bone and foreign substances, among which was a piece of the ball weighing seventy grains, the administration of chloroform was stopped, the patient placed on a bed with an unyielding bottom, and weight and pulley extension applied to the limb, counter-extension being made by raising the foot of the bed four inches. The thigh itself was left free from splints or bandages so as not to interfere with future swelling and discharges. Cold-water dressing was applied to the wound. The patient bore the action of the chloroform well, and was quite comfortable the rest of the day. His condition varied but little until the evening of the 29th, when he complained of great pain in the wounded limb. The wound commenced to discharge fetid pus in large quantity. He was very restless, and disarranged the limb, on account of which his bed was thoroughly cleaned and newly arranged, and a long side splint applied from the lower ribs down to the foot, in order to retain the limb on a line with the body. Brandy and morphia were administered. He slept well during the night, but, on the morning of the 29th, a profuse hæmorrhage occurred, and, before it could be stopped, from two to three pints of blood were lost. Compresses, wet with liquid persulphate of iron, finally arrested the bleeding. Stimulants were given freely, but the patient sank and died in one hour after the occurrence of the

haemorrhage. A *post-mortem* examination was made four hours after death. The body was found in good condition and well nourished, very little emaciation having taken place. An artery, with a diameter of one-sixteenth of an inch, probably a branch of the profunda, if not the profunda itself, was found with its orifice patulous. The hip-joint was totally uninjured. The pathological specimen, consisting of the head and fragments of the femur, is represented in the opposite wood-cut. Fig. 12.

CCXLVI.—*Report of a Case of Compound Comminuted Fracture of the Femur, treated by the Anterior Suspensory Apparatus.* By CARLOS CARVALLO, Assistant Surgeon, U. S. A.

Private William S. Smith, Troop D, 6th Cavalry, aged 31 years, was wounded on March 30, 1868, by a conoidal pistol ball, which entered the anterior internal aspect of right thigh at the lower third, and emerged on the opposite side, not far from the popliteal fold. On admission to hospital, at Fort Richardson, Texas, an examination revealed a compound comminuted fracture, but on account of the swelling it could not be ascertained whether any fragments were detached. Smith's anterior splint was applied, and sulphate of morphia was administered. On the next day, the leg becoming painful, the splint was removed and afterwards reapplied, when the pain ceased. On April 1st the wound was again exposed, and syringed with a solution of carbolic acid. The slightest motion would cause pain, indicating displacement of bony fragments. On April 2d, the wound began to discharge freely, and the patient improved steadily. On May 13th, the splint was removed; the femur had united with only one inch shortening. On the following day a bandage, supported by binders' boards at the fracture, was applied to the limb. On May 20th, a pocket of pus on the inner side of the thigh was discharged from the wound of entrance. On May 21st, the wound was examined, and but one small piece of dead bone could be detected. A few days later the limb began to swell again, but a solution of chlorinated soda was applied, and the swelling readily subsided. On August 10th, the patient was returned to his quarters, able to walk on crutches. November 1st, he was able to walk with a cane; the right knee was still swollen, and became painful in cold or damp weather. The knee could be flexed to an acute angle only, and was turned inward; the right ankle, though pliable, would flex but little; the motions of the hip-joint were normal, but the right hip was lower than the left. The patient suffered from intermittent fever and a bed-sore while under treatment. He was returned to duty (police duty in quarters) on December 16, 1868.

CCXLVII.—*Report of a Gunshot Fracture of the Femur.* By JOHN CAMPBELL, Surgeon, U. S. A.

Private Thomas Toober, Co. H, 42d Infantry, aged 25 years, received a comminuted fracture of the femur above the knee-joint on July 11, 1867, from a conoidal bullet. He was admitted from his company to the Madison Barracks post hospital at Sackett's Harbor, New York, on July 11, 1867. His leg was placed on a double inclined plane. Simple dressings were applied. In September, 1867, union of bone had taken place, but wound was still open; fragments of bone were still being removed therefrom.

CCXLVIII.—*Report of a Case of Gunshot Fracture of the Femur.* By A. B. CAMPBELL, Assistant Surgeon, U. S. A.

Private James Soohen, Co. E, 13th Infantry, aged 23 years, was accidentally shot in the upper portion of middle third of thigh. The femur was fractured and comminuted, the femoral artery ruptured. He was admitted to the post hospital at Camp Cooke, Montana Territory, on November 5, 1868. Brandy, morphine, and tincture of cannabis Indica were administered, and the wound was dressed with creosote water. The patient died comatose on the afternoon of November 7, 1868.

CCXLIX.—*Account of a Gunshot Wound of the Thigh.* By J. W. BREWER, Assistant Surgeon, U. S. A.

Private John Thomas, Co. L, 10th Cavalry, aged 22 years, was accidentally wounded on July 1, 1868, by a conoidal carbine ball, which passed through the lower third of the left femur, implicating

the bone. He was admitted from the post hospital at Fort Sill, Indian Territory, on December 13, 1869. The treatment consisted of simple dressings and poultices, and removal of fragments of bone. He was discharged from service on surgeon's certificate of disability, on March 11, 1870.

CCL.—*Report of a Case of Gunshot Fracture of the Femur.* By G. H. GUNN, Assistant Surgeon, U. S. A.

Private Joseph Phillips, Co. H, 9th Cavalry, aged 26 years, was wounded September 22, 1870, by a conoidal ball, which fractured the left femur, at middle third. He was admitted to the post hospital at Fort Quitman, Texas, soon after the reception of the injury. The limb was placed in a fracture-box, until November 26th, and simple dressings were applied. At the date of this report the case was doing well.

There were twenty-three special reports of gun-shot flesh wounds of the thigh, all the cases resulting favorably, and five reports of grave and fatal lesions of the great vessels or nerves.

CCLI.—*Account of a Gunshot Wound of the Thigh.* By B. E. FRYER, Assistant Surgeon, U. S. A.

Musician William Corin, Co. B, 38th Infantry, accidentally received, on September 17, 1867, a slight gunshot wound of the right thigh from a conoidal ball. He was admitted from the garrison on the same day to the post hospital at Fort Harker, Kansas. The treatment consisted of simple dressings. He was returned to duty on October 1, 1867.

CCLII.—*Account of a Gunshot Flesh-Wound of the Thigh.* By W. E. SAVAGE, M. D., Acting Assistant Surgeon.

Private George Coleman, Co. G, 117th Colored Troops, aged 25 years, was accidentally wounded on August 3, 1867, by a conoidal pistol ball, in the centre of the vastus externus muscle of the right leg. The missile passed upward and backward forty-five degrees, and lodged in the centre of the adductor longus muscle, from which place it was cut out. He was admitted from Brownsville, Texas, to the post hospital at Brazos Santiago, on August 11, 1867. Simple dressings were applied to the wound. He was mustered out of the service on August 14, 1867.

CCLIII.—*Mention of a Case of Gunshot Flesh-Wound of the Thigh.* By JOHN T. KING, M. D., Acting Assistant Surgeon.

Private Elias Simpson, Co. B, 40th Infantry, aged 23 years, received a gunshot wound on February 13, 1869. A small conoidal ball entered the posterior portion of the thigh, passed in a direct course almost entirely through. He was admitted to the post hospital at Goldsborough, North Carolina, on February 13, 1869. Ball extracted through counter opening. He was discharged April 2, 1869.

CCLIV.—*Mention of a Case of Gunshot Wound of the Thigh.* By W. R. STEINMETZ, Assistant Surgeon, U. S. A.

Corporal Henry E. Taylor, Co. E, 24th Infantry, aged 22 years, received a gunshot wound of the lower third of the right thigh, on December 24, 1869. He was admitted from quarters, on December 25th, to the post hospital at Fort Griffin, Texas, and was returned to duty on February 2, 1870.

CCLV.—*Memorandum of a Case of Gunshot Flesh-Wound of the Thigh.* By B. E. FRYER, Assistant Surgeon, U. S. A.

Private Andrew Warner, Co. E, 38th Infantry, on July 10, 1867, was accidentally wounded by a pistol ball in the right thigh. On the same day he was admitted into the post hospital at Fort Harker, Kansas, from the garrison. Simple dressings were applied to the wound. He was returned to duty on July 12, 1867.

CCLVI.—*Report of a Gunshot Flesh-Wound of the Thigh.* By H. R. TILTON, Assistant Surgeon, U. S. A.

Private Anthony Welber, Co. I, 3d Infantry, received an accidental gunshot wound of the right thigh on May 4, 1869. A rifle ball entered the front of the thigh at the middle third externally to the femur, and lodged in the biceps muscle. He was admitted to the post hospital at Fort Lyon, Colorado Territory, on May 6, 1869. On May 8th, the ball was removed by a counter opening, and simple dressings were applied. On May 20, an abscess was opened, and a short time afterward a piece of cloth was removed from the wound. By June 15th, the wounds were entirely healed. He was returned to duty July, 1869.

CCLVII.—*Report of Gunshot Flesh-Wound of the Thigh.* By W. J. WILSON, Assistant Surgeon, U. S. A.

Sergeant John Mullins, Co. K, 4th Cavalry, aged 31 years, received a wound of the thigh from a pistol ball on February 16, 1870. He was admitted from his quarters into hospital on February 17th. Water dressings were used. He was returned to duty on March 14, 1870.

CCLVIII.—*Report of a Case of Gunshot Wound of the Thigh.* By A. C. GIRARD, Assistant Surgeon, U. S. A.

Private James Smith, Co. F, 19th Infantry, aged 29 years, was wounded on February 8, 1870, while leaving a steamboat on his arrival at Baton Rouge, Louisiana. The shot was fired from above, and the weapon was said to be a pistol. The ball entered over the trochanter of the left thigh, took a direct downward course between the aponeurosis and skin, and made its exit ten inches lower. Some part of the underclothes, being carried into the canal, were extracted, and a free suppuration was established. The missile could not be found. During the inflammatory stage, cold applications, with solution of carbolic acid at 57°. After suppuration was established, poultices of linseed, with the same solution, and finally a carbolic cerate. Convalescence was slow. He was admitted to the post hospital at Baton Rouge on February 8, 1870, and was returned to duty on March 20, 1870.

CCLIX.—*Account of a Gunshot Flesh-Wound of the Thigh.* By F. G. H. BRADFORD, M. D., Acting Assistant Surgeon.

Private Charles Osborn, Co. E, 1st California Veteran Volunteers, was wounded at Los Pinos, New Mexico, on June 21, 1866, by a pistol-ball, which entered the left thigh two inches anterior, and a little below the great trochanter, and passed slightly inward, upward, and backward, between the tensor vaginæ femoris, and sartorius muscles. He was at once admitted to the post hospital. The track of the ball could not be traced with a probe beyond three inches. But little pain was experienced by the patient on examination of the limb. Water dressings were applied. Five days after, the ball was found lodged in the gluteal muscle, two inches to the left of the anus, being plainly felt through the skin, and was removed by an incision three-quarters of an inch long. The ball was considerably flattened, having struck the femur in its passage. On June 27th, the patient was doing well, and the wound healing kindly.

CCLX.—*Report of a Gunshot Flesh-Wound of the Thigh.* By JAMES F. WEEDS, Surgeon, U. S. A.

Private Walter R. Oliver, 14th Infantry, aged 21 years, received a gunshot wound on July 15, 1869, from a conoidal ball, which entered at the front of the left thigh, and passed directly through the limb on the inner side of the bone. He was admitted to the post hospital at Nashville, Tennessee, on the same day. Simple dressings were applied. He was returned to duty on August 21, 1869.

CCLXI.—*Report of a Case of Gunshot Flesh-Wound of the Thigh.* By W. S. TREMAINE, Assistant Surgeon, U. S. A.

Private Peter Badamy, Co. D, 25th Infantry, aged 18 years, received in a street fight on February 18, 1868, a slight flesh-wound of the anterior aspect of the left thigh, from a conoidal pistol-ball. He was admitted into the hospital at Memphis, Tennessee, on February 18, 1868. The treatment consisted of simple dressings. He was returned to duty on February 21, 1868.

CCLXII.—*Report of a Case of Gunshot Flesh-Wound of the Thigh.* By J. B. BROOKE, Assistant Surgeon, U. S. A.

Private — Herrarra, Co. B, 1st New Mexican Infantry, was admitted to the post hospital at Fort Sumner, New Mexico, July 18, 1866, with a pistol-shot wound of the right thigh, received accidentally. Simple dressings were applied. He left the post with his company on September 2, 1866.

CCLXIII.—*Report of two Cases of Gunshot Wounds of the Hip.* By W. M. NOTSON, Assistant Surgeon, U. S. A.

CASE 1.—Private Henry Johnson, Co. E, 9th Colored Cavalry, aged 26 years, received a gunshot wound of the left hip, on June 28, 1869, by a conoidal ball. He was admitted from Fort Stockton, Texas, into the post hospital at Fort Concho. The treatment consisted of cold applications. He was returned to duty on August 18, 1869.

CASE 2.—Private James Feaster, Co. F, 41st Infantry, aged 24 years, received a gunshot wound of the left thigh, in a scuffle with a comrade, on July 14, 1869, by a conoidal ball. He was admitted to the post hospital at Fort Concho, Texas. Cold applications were made to the wound. He died on July 16, 1869.

CCLXIV.—*Report of a Case of Gunshot Flesh-Wound of the Thigh.* By J. W. BREWER, Assistant Surgeon, U. S. A.

Private James Shields, Co. M, 10th Cavalry, aged 25 years, was shot on October 15, 1865, through the fleshy part of the middle third of the right thigh, on the mail route between Fort Sill, Indian Territory, and Fort Arbuckle. He was admitted to the post hospital at Fort Arbuckle, Cherokee Nation, Indian Territory, on October 16, 1869. The treatment consisted of cold-water dressings and poultices. He was returned to duty on December 12, 1869.

CCLXV.—*Memorandum of a Case of Gunshot Wound of the Thigh.* By C. S. DE GRAW, Assistant Surgeon, U. S. A.

Private Charles Kennedy, Co. F, 1st Artillery, aged 22 years, was accidentally wounded at Madison Barracks post hospital, New York, May 6, 1870, by a pistol ball, which entered the right thigh, middle third, and lodged. He was admitted to the hospital the same day. Carbolic acid, half an ounce to one pint of water, was applied freely to the wound. He died October 30, 1870, of typhoid fever.

CCLXVI.—*Report of a Case of Gunshot Flesh-Wound of the Thigh.* By J. RIDGELY, M. D., Acting Assistant Surgeon.

Sergeant John Cappings, Co. H, 26th Infantry, aged 27 years, received a wound of the right hip, from a conoidal musket ball, on September 20, 1867. He was admitted from hospital at Waco, Texas, to hospital at Austin, on March 20, 1868. He was returned to duty on May 1, 1868.

CCLXVII.—*Report of Two Cases of Gunshot Flesh Wounds of the Thigh.* By JULES LE CARPENTIER, M. D., Acting Assistant Surgeon.

CASE 1.—Private James Francis, Co. A, 38th Infantry, aged 23 years, while on a scout on September 24, 1868, received a gunshot flesh-wound of the inner and upper portion of the left thigh by a round ball. He was admitted into the post hospital at Fort Bayard, New Mexico, on October 9th. Simple dressings were applied to the wound. He was returned to duty on November 16, 1868.

CASE 2.—Private Logan Goodpastor, Co. A, 38th Infantry, aged 22 years, received a slight gunshot flesh-wound of the thigh from a pistol ball on December 24, 1868, in a riot at Central City. He was admitted into the post hospital at Fort Bayard, New Mexico, on December 25th. Simple dressings were used. He was returned to duty in January, 1869.

CCLXVIII.—*Report of a Case of Gunshot Flesh-Wound of the Thigh.* By L. G. HOLMES, M. D., Acting Assistant Surgeon.

Lieutenant D. W. Walcott, 1st Cavalry, aged 34, was wounded by the accidental discharge of his pocket pistol while riding on horseback near Camp Logan, Oregon, August 16, 1868. The ball entered the thigh on the outside, one inch posterior to, and three inches below, the trochanter major, passed downward and inward and lodged in the belly of the adductor muscles. He was admitted on the same day to the post hospital at Camp Logan, where all foreign substances which could be detected were removed, and an anodyne administered. On the 18th, slight inflammation set in, which increased until the 23d, when some fluctuation was detected on the inside of the thigh. An incision was made over the point of fluctuation, and the ball was found and removed. On August 24th, the leg was greatly inflamed and painful. The pulse was weak and the wound discharged considerable pus. Under the application of cold to the limb and stimulants internally, the patient commenced to improve, and on the 27th, the swelling had somewhat subsided. On September 23d the patient was dropped from the sick report, the wound being completely healed. There was slight lameness from contracted tendons, which was, however, gradually lessening.

CCLXIX.—*Memorandum of a Case of Gunshot Flesh-Wound of the Thigh.* By H. R. TILTON, Assistant Surgeon, U. S. A.

Private Robert Garnet, Co. K, 10th Cavalry, aged 18 years, received October 9, 1868, while on the march, a wound of the left thigh, by a conoidal ball from a pistol in the hands of a sergeant which entered two inches from the great trochanter. He was admitted to the post hospital at Fort Lyon, Colorado Territory, on November 11th, where the ball was extracted from the point of entrance. The patient was returned to duty February 7, 1869.

CCLXX.—*Note of a Case of Gunshot Flesh-Wound of the Thigh.* By JOHN B. WHITE, M. D., Acting Assistant Surgeon.

Private Patrick Burke, Co. B, 17th Infantry, aged 21 years, was wounded at Raleigh, North Carolina, in a street affray between the police of the city and men of the above command, by a conoidal pistol ball, which entered and lodged in the thigh. He was admitted to the post hospital at Raleigh, North Carolina, April 14, 1870. Simple dressings were applied. He was returned to duty on May 10, 1870.

CCLXXI.—*Report of a Case of Gunshot Flesh-Wound of the Thigh.* By H. S. SCHELL, Assistant Surgeon, U. S. A.

Colonel Henry B. Carrington, 18th Infantry, was accidentally wounded, on February 5, 1867, by a conoidal ball, which entered the apex of Scarpa's triangle, and, passing obliquely downward and outward, glanced from the bone and lodged under the skin on the outside of the thigh. He arrived at Fort Laramie, Dakota Territory, on February 9th. The limb was swollen and inflamed, and there was partial loss of sensation in the lower part of the thigh and leg. The patient was feverish and suffered much pain. On February 10th, having administered ether, I made a linear incision, and removed the ball. The inflammation subsided, and the wound of incision healed rapidly. On February 21, 1867, the patient had sufficiently recovered to resume his journey to his station, Fort McPherson.

The three following reports relate to cases of wounds of the great vessels or nerves of the thigh, and two reports that have come to hand while these pages were passing through the press, which should have been placed here, will be found near the close of the chapter.

CCLXXII.—*Report of a Case of Gunshot Flesh-Wound of the Thigh.* By C. R. GREENLEAF, Assistant Surgeon, U. S. A.

Henry C. Clinton, Artificer, Co. C, 2d Infantry, was shot in a street brawl, at Louisville, Kentucky, on October 19, 1868, through the right thigh, by a round pistol ball, which passed obliquely through from behind, severing the femoral artery and vein, at the point where the artery passes through the adductor magnus. Death occurred in a few minutes, from hæmorrhage.

CCLXXIII.—*Report of a Case of Gunshot Wound of the Thigh and Leg.* By S. M. HORTON, Assistant Surgeon, U. S. A.

Thomas Carnovan, citizen, aged 17 years, was wounded by Indians, at night, while sitting by a camp fire, just outside the stockade of Fort Philip Kearney, Dakota Territory. The missiles were supposed to be slugs from a shot-gun. Two of them entered the inner side of the right thigh, in the middle third, two inches apart, and passed through just behind the femur. Two others passed through the calf of the leg of the same side; another comminuted the bones of the second joint of the forefinger of the right hand. He was admitted to the hospital of the post on November 2, 1866. Simple dressings were applied, and liquor of the persulphate of iron was used to arrest venous hæmorrhage. The patient died on November 6th from shock, venous hæmorrhage, and gangrene of the leg. An autopsy revealed laceration of the femoral nerve, and injury to the femoral vein.

CCLXXIV.—*Report of a Case of Gunshot Wound of the Thigh.* By R. SHARPE, M. D., Acting Assistant Surgeon.

Private — Williams, Co. D., 24th Infantry, was accidentally wounded by the discharge of a rifle in the hands of another soldier, March 25, 1870, on the North Llano, Texas, while in the line of duty. The wound was dressed on the spot, and the patient was brought to hospital at McKavett next day. The ball was found to have entered the left thigh, externally, at about the upper third, and, emerging almost opposite, had entered the right thigh, and made its final exit about four inches below the anterior superior spinous process of the ilium, on outer surface of limb, the ball in its passage just grazing both femoral bones. Immediately after the accident he complained of a feeling of numbness of the left leg, and was unable to move it or the foot. The

wound was dressed with a solution of permanganate of potash, and opium was given. The patient was tolerably comfortable till April 1st, when he complained of much pain. He rested badly at night, pulse almost imperceptible; left leg much swollen, and temperature diminished, giving the premonitions of gangrene. Ordered morphine, egg-nog, and beef-tea, and warm applications to leg. Eleven A. M.: Patient, after taking a spoonful of egg-nog, vomited. Twelve M.: Rapidly growing worse, and died at 2 P. M. Autopsy by Dr. De Loffre. Much effusion of serum in areolar tissue of left leg; gangrene of the large muscles around the wounds. Great sciatic nerve much contused by ball; not otherwise injured. All the internal organs healthy. Large clots of blood in the aorta and in the right auricle.

Gun-shot wounds of the Knee-joint.—There are four reports of cases of recovery after gunshot wounds, believed to have involved the knee-joint. The details of evidence will hardly satisfy skeptical military surgeons.

CCLXXV.—*Report of a Case of Gunshot Wound of the Knee-Joint.* By H. R. TILTON, Assistant Surgeon, U. S. A.

Private Thomas Murray, Co. B, 7th Cavalry, who was shot through the knee-joint at Fort Lyons, Colorado Territory, in January, 1867, recovered without an unfavorable symptom. He could move the joint slightly on the 4th of February. February 19th, just four weeks from the date of the injury, he was able to stand on the foot and walk a few steps without crutch or cane. At present, in walking, he has to keep the joint stiff, but eventually there will be very good motion, and little inconvenience from the injury. At the time Murray was shot, January 22, 1867, the only probe which I used was the end of my little finger. I was satisfied that the ball had not passed around the joint. No benefit would have been derived by the patient by making further efforts to determine the exact course of the ball. I was under the impression that it had passed through the head of the tibia. I am satisfied by the result that it could not have done so; but the ball could open the synovial membrane and pass through the joint without injury to either the femur or tibia. The result is remarkable. He was returned to duty on March 4, 1867, but riding caused the knee to swell. He was returned to duty again in March, 1867, able to attend to any duty except riding. I remember a case in the Vicksburg campaign, where the ball struck the patella without fracturing it or opening the joint, and passed up the thigh superficially, escaping four inches above, and yet the man died of inflammation of the knee-joint.

CCLXXVI.—*Report of a Case of Gunshot Wound of the Knee-Joint.* By JOSEPH KUGLER, M. D., Acting Assistant Surgeon.

Private Charles Willis, Troop G, 3d Cavalry, was wounded, October 3, 1866, in an engagement with Ute Indians at Purgatory Creek, Colorado Territory, by a rifle bullet, which entered a little above the external condyle of the right femur, fractured the patella, opened the knee-joint and lodged, it is supposed, in the internal condyle. He was admitted to the post hospital at Fort Garland, Colorado Territory, on October 12th, having been carried in an ambulance from Trinidad, over a very rough mountain road. When admitted he was in such a weak and exhausted condition that it was thought inadvisable to submit him to an operation; his system being very irritable, the wounded part painful, and dreading symptoms of pyæmia, he was put on nutritious diet, with stimulants and narcotics, together with soothing and emollient applications to the knee. Although several abscesses formed, and the discharge was very plentiful, he seemed to be in a much better condition on October 31st than when he entered the hospital. His situation was still very critical, but it was thought he might so far improve as to make it possible to save his life by an operation, even should the limb have to be sacrificed. In December, 1866, Willis was reported as still confined to his bed, and despite the greatest care taken to prevent them, suffered from bed-sores. Some

of the old abscesses were of an erysipelatous character, and formed above and below the knee, discharging a great quantity of purulent matter, which gradually became healthier. He evidently suffered from pyæmia, and an abscess of the right lung was suspected. The treatment consisted of tonics and stimulants. In January, 1867, he was doing well, and was able to sit up several hours each day. During this month the missile, or one and a quarter ounce lead slug, was extracted, after which all the abscesses but one healed kindly. He gained strength daily until attacked with influenza. The ultimate termination of the case does not appear, but he most probably recovered, as he does not appear upon the report of sick and wounded for February, 1867.

CCLXXVII.—*Report of a Case of Gunshot Wound of the Knee-Joint.* By FERDINAND AXT, Assistant Surgeon, U. S. A.

At Rattlesnake Station, Nevada, on September 16, 1867, Sergeant Patrick Corcoran, Co. D, 8th Cavalry, was shot through the upper part of the left knee, the ball entering on the outer side, and passing out on the inner side apparently through the anterior and upper segment of the inner condyle of the femur. He was conveyed to the hospital at Camp McDermit, Nevada, a distance of sixty miles, over a rough road. It was supposed, from the nature of the discharge, that the wound communicated with the knee-joint. The treatment in the case is not recorded. In November, 1868, Corcoran was returned to duty.

CCLXXVIII.—*Memorandum of a Case of Gunshot Wound of the Knee-Joint.* By J. V. D. MIDDLETON, Assistant Surgeon, U. S. A.

At Austin, Texas, March 29, 1869, John Glascock, citizen prisoner, aged 30, shot himself, while being arrested, inflicting a wound of knee, involving the joint; the missile, a conoidal ball, lodged. He was admitted to the post hospital. Cold-water dressings, poultices, carbolic acid and oil were applied. He was discharged from further treatment, October 17, 1869.

Gunshot Wounds of the Leg.—The seven following reports describe gunshot fractures of the tibia in five instances, of the fibula in one, and of the tibia and fibula in one. All of the cases had favorable terminations.

CCLXXIX.—*Report of a Case of Gunshot Wounds of the Thigh and Leg.* Condensed from detailed Reports by Acting Assistant Surgeon IRVING C. ROSSE, M. D.

Major George A. Forsyth, 9th Cavalry, received two severe and dangerous wounds, in a fight with Indians, at Dry Forks, Republican River, Kansas, on September 17, 1868. The first wound was caused by a Henry rifle ball, which entered the left leg posteriorly about the centre, and, passing directly through, fractured and crushed the tibia on the aspect of entrance, transversely fracturing it anteriorly. The second wound was caused by a similar missile, which entered the right thigh at the outer anterior aspect at the juncture of the upper with the middle third, penetrated to the deep fascia, ranged thence upward and inward across the centre of Scarpa's triangle, and lodged deeply on the inner aspect of the thigh, severely contusing the right testicle. The circumstances attending the wounded after this engagement were exceedingly unfavorable. They were not relieved until the evening of the ninth day after the fight; the weather at first was very warm, and the men lay in the sand beside their dead horses, subjected to noisome gases and swarms of flies. Two cold, rainy nights occurred on the 22d and 23d; they were without surgical attendance, dressing, &c., the surgeon having been killed in the fight;* and their only diet was the limited and offensive flesh of their dead animals. The dangerous nature of the wounds mentioned above rendered the drain upon Major Forsyth more severe than on others. He was taken with other wounded to Fort Wallace, distant one hundred and thirty miles, the journey taking nearly four days. On arrival

* John H. Moore, Acting Assistant Surgeon, was mortally wounded at Arickaree Fork of the Republican River, September 17, 1868, and died on the morning of September 20, 1868.—ED.

there every facility in the way of hospital accommodation was afforded by Dr. T. H. Turner, U. S. A. A few days afterward, decided symptoms of septicaemia manifested themselves with the wounded, more especially with Major Forsyth. The symptoms were excessive irritability or nervousness, a hectic form of fever, diffuse abscesses, &c., from which he became rapidly reduced in flesh and strength. An abscess under the scalp, anterior to the vertex, resulted in the death of a small portion of both tables of the skull, which was thrown off by exfoliation. Indications of necrosis of upper part of the lower half of tibia came on in November; but all interference was avoided until January 20, when loose bone being detected, fragments of the tibia, to the extent of nearly three inches, were removed. After this operation the patient improved rapidly, the wound filling up with new material of a cartilaginous nature. About the last of January he was lifted from his bed for the first time in four months, and had his first airing in a Tompkins's wheel-litter. A few days afterward he used crutches, and got about feebly. This case was treated by first placing the leg in a common fracture box; then in a suspension splint of leather and telegraph wire; next in a double inclined plane, made light, and suspended; lastly, in a "Smith's anterior," modified. Quinine and tincture of iron were administered in small doses for some three months, and decided benefit was derived from fifteen-grain doses of hyposulphite of soda. On February 18th he was transferred to Fort Leavenworth, Kansas, 415 miles by rail, where he yet more rapidly gained in flesh and strength, his wounds filling up and the leg acquiring some solidity. On April 8th, he reached Chicago, entering there upon his duty as military secretary to General Sheridan.

Assistant Surgeon J. A. Fitzgerald, U. S. A., who furnished most of the above particulars, stated, under date of August 25, 1869, that it was not until about May 10, 1869, that he first became convinced of a real bony union. In the latter part of April he applied a new splint in the form of long upholsterers' needles, applied as follows: First. Applied two roller bandages from toes to knee, then introduced the long needle interruptedly by catches one or two inches apart, putting alternate needles in the intervals of preceding catches. In this manner were applied three externally and two internally to the leg, over which another roller was closely applied, and lastly a firm elastic stocking. When this was applied there was no discharge whatever, and with it he could get about on crutches with facility. When he left him on May 13, 1869, he walked about five squares twice daily, and to his office in a third story. He could bear considerable weight on the leg without pain at that time. Dr. Fitzgerald also states that he heard from his patient about four weeks previously, and that he expected to be walking by September 1, 1869.*

CCLXXX.—*Mention of a Case in which there was Removal of a Portion of the Fibula after a Gunshot Injury.* By H. R. TILTON, Assistant Surgeon, U. S. A.

Private Thomas Kelly, Co. B, 5th Cavalry, aged 22 years, received an accidental gunshot wound of the left leg, on November 15, 1868. The ball entered the inner side of leg, two and a half inches below the tibia, and passed out at the middle third of the leg, externally, fracturing the fibula. He was admitted to the post hospital at Fort Lyon, Colorado Territory, on April 30, 1869. The patient states that a portion of the fibula was removed by Assistant Surgeon Turner, U. S. A. The wound was nearly healed. The patient was in hospital only two days when the 5th Cavalry left the post. [He was returned to duty on May 2, 1869.—ED.]

CCLXXXI.—*Mention of a Gunshot Wound of the Leg.* By B. E. FRYER, Surgeon, U. S. A.

Private Peter Eustace, Co. H, 5th Infantry, aged 26 years, was accidentally wounded on February 23, 1868, by a small conoidal ball, which fractured the right tibia and fibula at the lower third. He was admitted from Fort Hayes, on April 28, 1868, to the post hospital at Fort Harker, Kansas. The wounds had healed, and the bones had united prior to admission. Some little lameness still exists. There is no shortening or other deformity. He was returned to duty in May, 1868.

* In May, 1871, Major G. A. Forsyth met Assistant Surgeon General Crane, and boasted of the perfection of his cure, speaking in enthusiastic terms of army surgery, and the skill of his attendants, complimenting particularly Drs. Fitzgerald and Asch, with endless grateful expressions toward the former, who had charge of the case at first. There was no apparent shortening of the limb.—ED.

CCLXXXII.—*Report of a Gunshot Wound of the Leg.* By J. M. BEST, M. D., Acting Assistant Surgeon.

Private James Farrall, Co. E, 25th Infantry, was wounded in a street fight, on December 1, 1868. The ball entered the integuments on the anterior and inner part of the upper third of the tibia of left leg, passed out about two inches from the place of entrance, in an almost transverse direction, burying about half the width of a small ball in the substance of the tibia. He was admitted to the post hospital at Von Schrader Barracks, Paducah, Kentucky, on the same day. Simple dressings were applied. He was returned to duty on January 8, 1869.

CCLXXXIII.—*Memorandum of a Case of Gunshot Fracture of Tibia and Ulna.* By W. H. HOPPER, M. D., Acting Assistant Surgeon.

Private John McWilliams, Co. I, 14th Infantry, aged 23 years, received, near Somerset, Kentucky, February 16, 1870, five balls in his body, the first causing a flesh-wound in the right shoulder, the second on the left side, just above the crest of the ilium, the third in the left arm, just below the elbow, the fourth in the right arm below the elbow-joint, fracturing the ulna, and the fifth in the right leg, about four inches below the patella, shattering the tibia. On April 9th he was admitted to post hospital at Lebanon, Kentucky. A ball which had been overlooked was now cut out. The first three wounds had healed before his admission. The fourth healed rapidly, leaving perfect ankylosis of the joint. The fifth wound was still open, and slightly suppurating, June 30, 1870. He was sent to his regiment on October 24, 1870.

CCLXXXIV.—*Memorandum Relative to a Gunshot Wound of the Leg.* By W. M. AUSTIN, Assistant Surgeon, U. S. A.

Private Joseph Shaw, Co. D, 3d Cavalry, was wounded on October 17, 1867, in a fight with Indians, by a ball which caused a wound of the right tibia. He was admitted at Fort Bliss and Camp Concordia, Texas, on October 25, 1867. On February 2, 1868, the necrosed bone was excised. He was returned to duty on March 9, 1868.

CCLXXXV.—*Memorandum of a Case of Gunshot Fracture of the Right Tibia.* By J. F. HAMMOND, Surgeon, U. S. A.

Private Robert Burgi, Co. H, 4th Cavalry, aged 23 years, received a gunshot wound of the right leg by a conoidal ball, June 13, 1870, while on his way to supper, from a soldier who was standing in the door of a tent, ten yards distant, the ball striking the posterior aspect of the limb in the median line, three inches below the knee-joint, passing horizontally through the leg and comminuting the tibia in its transit. He was admitted to the post hospital at Austin, Texas, the same day. Treatment consisted of lead-water, solution of permanganate of potassa, poultices, and solution of carbolic acid. The man was still under treatment January 1, 1871. He was discharged April 30, 1871.

Special reports were made of nineteen gunshot flesh-wounds of the leg. In four instances foreign bodies were extracted. Seventeen patients went to duty; one was discharged and one died of pyæmia.

CCLXXXVI.—*A Case of Gunshot Wound of the Leg.* By FERDINAND AXT, Assistant Surgeon, U. S. A.

Private John Welsh, Co. E, 23d Infantry, aged 34 years, was admitted to the post hospital at Camp McDermit, Nevada, July 23, 1868, with a gunshot wound of the left leg. The ball entered on the inside of the middle of the leg, traversed the cellular tissue posterior to the tendo Achillis, and emerged on a level with the upper end of the malleolus. Chloroform being administered, a large number of minute shreds of clothing were removed from the wound. Ice-water dressings were applied. The patient was discharged from hospital September 13, 1868. The wound had nearly closed and the movement of the foot was not impaired.

CCLXXXVII.—*Report of a Case of Gunshot Flesh-Wound of the Right Leg.* By WILLIAM THOMSON, Assistant Surgeon, U. S. A.

Private John Conroy, Battery D, 4th Artillery, aged 40 years, received at Washington, D. C., July 4, 1866, a gunshot wound of the upper third of the right leg, by the bursting of a rifle. He was admitted to post hospital July 5th. A piece of cast iron, one and a quarter inches long and one-half inch wide, was impacted near the internal surface of the tibia near the insertion of the sartorius muscle. On July 11th, I enlarged the wound by a crucial incision, and extracted the iron with bone forceps; water dressing was then applied to the knee-joint for two days, when the wound was poulticed. September 6th, the wound had healed, and on September 13, 1866, the patient was returned to duty.

CCLXXXVIII.—*Account of a Gunshot Flesh-Wound of the Leg.* By J. B. CRANDALL, M. D., Acting Assistant Surgeon.

Private James Collins, Co. F, 37th Infantry, aged 23 years, received a gunshot flesh-wound of the right leg, in a fight with Indians, on July 19, 1867. He was admitted from the field into the post hospital at Fort Dodge, Kansas, on July 20th. Simple dressings were used. In September the wound had healed, and he was awaiting transportation to his company.

CCLXXXIX.—*Mention of a Case of Gunshot Wound of the Leg.* By G. GWYNTHER, M. D., Acting Assistant Surgeon.

Private Aaron Smith, Co. C, 23d Infantry, aged 25 years, shot himself accidentally at Camp McDermit, Nevada, October 25, 1868. The missile entered on outer aspect of calf of right leg, took a superficial course, and lodged immediately under the skin on the astragalus. He was admitted to the post hospital, where the ball was extracted through a longitudinal incision by Acting Assistant Surgeon George Gwynter. The wound healed rapidly, and the patient was discharged November 9, 1868.

Fifteen other cases of gunshot flesh-wounds of the leg, in which special reports were made, presented no peculiarities of moment, with one exception, in which pyæmia was developed, and the medical officer omitted to make notes of the autopsy.

Private William Barry, Co. G, 6th Cavalry, aged 30. Jefferson, Texas, May 7, 1869. Gunshot flesh-wound of the right leg. Duty, June, 1869.

Private Herman S. Brown, Co. E, 17th Infantry, aged 21. Fort Stephenson, Dakota Territory, July 20, 1870. Gunshot flesh-wound of left leg. Duty, November, 1870.

Corporal James Burnside, Co. F, 114th Colored Troops, aged 26. Accidental, December 25, 1866. Gunshot flesh-wound of right leg. Duty, April, 1867.

Private George Cox, Co. H, 8th Cavalry, aged 36. Fort Union, New Mexico, December 9, 1870. Gunshot flesh-wound of right leg. Missile extracted December 10. Duty, December 31, 1870.

Private James Davis, Co. C, 5th Cavalry, aged 29. Atlanta, October 15, 1868. Gunshot flesh wound of right leg. Duty, October 29, 1868.

Sergeant William Gleason, Co. I, 37th Infantry, aged 29. Fort Dodge, Kansas, September 29, 1867. Gunshot flesh-wounds of right knee, left leg, and scalp. Duty, October, 1867.

Private Martin McMahan, Troop E, 1st Cavalry, aged 27. Prescott, Arizona Territory, December 18, 1867. Gunshot flesh-wound of right leg. Duty, January, 1868.

Private Charles Michael, Co. A, 38th Infantry, aged 23. Central City, New Mexico, December 24, 1868. Gunshot flesh-wound of left leg. Duty, January, 1869.

Sergeant Joseph Myers, Troop L, 3d Cavalry, aged 21. Fort Wingate, New Mexico, May 5, 1868. Gunshot flesh-wound of right leg. Duty, June 6, 1868.

Private John Mann, Troop B, 3d Cavalry, aged 24. Fort Bayard, New Mexico, November 12, 1869. Gunshot flesh-wound of right leg. Duty, February 24, 1870.

Private Isom Paine, Co. H, 24th Infantry, aged 25. Fort Quitman, Texas, November 16, 1869. Gunshot flesh-wound of right leg. Duty, February 13, 1870.

Private Gustavus Smith, Troop H, 6th Cavalry, aged 26. Little Wichita River, Texas, July 12, 1870. Gunshot flesh-wound of the right leg. Duty, August 9, 1870.

Private Robert Smith, Troop L, 10th Colored Cavalry, aged 20, Fort Arbuckle, Indian Territory, February 21, 1870. Duty, April, 1870.

Private John Turner, Co. H, 9th Cavalry, aged 23. Fort Quitman, Texas, August 17, 1870. Gunshot wound of left leg. Died, September 2, 1870, of pyæmia.

Private George W. Youngs, Troop H, 9th Cavalry, aged 27. Fort Quitman, Texas, June 20, 1869. Gunshot flesh-wound of right leg. Duty, October 31, 1869.

Gunshot Wounds of the Foot.—Six special reports were transmitted of cases of fractures belonging to this class. They all resulted favorably under simple treatment.

CCXC.—*Mention of a Case of Gunshot Wound of the Foot.* By A. A. WOODHULL, Assistant Surgeon, U. S. A.

Corporal Patrick Dwyer, Co. K, 3d Infantry, aged 31 years, accidentally discharged his carbine; the missile, a conoidal bullet, passed through the first metatarsal. He was admitted from the field, fifty miles distant, to the post hospital at Fort Larned, Kansas, on September 15, 1870. The treatment consisted of simple dressings. He was returned to duty in October, 1870.

CCXCI.—*Remarks on a Case of Gunshot Wound of the Left Second Toe.* By R. TANSZKY, M. D., Acting Assistant Surgeon.

Private Taliaferro Hall, Co. E, 9th Cavalry, aged 21 years, was accidentally wounded near Fort Stockton, Texas, August 20, 1868, by a conoidal ball, which shattered two phalanges of the second toe of the left foot. He was, on August 30th, admitted to post hospital. The foot was very much swollen, the wounded parts being œdematous with threatening gangrene, and discharging ichorous and fetid pus. On August 31st, Acting Assistant Surgeon R. Tanszky removed the shattered portions of bone, and applied antiseptic lotions. A new phalanx formed. The first joint is ankylosed, but in other respects the toe is in the same condition as before the accident. Hall was returned to duty October 4, 1868.

CCXCII.—*Report of a Case of Gunshot Wound of the Foot.* By C. E. MCCHESENEY, M. D., Acting Assistant Surgeon.

Private Charles Green, Co. D, 7th Infantry, aged 21 years, was admitted, on July 20, 1870, to the post hospital at Fort Buford, Dakota Territory, with a gunshot wound of the left foot. Fragments of bone were removed and carbolic acid dressings applied. He was discharged from service December 18, 1870.

CCXCIII.—*Account of a Gunshot Wound of the Foot.* By D. HERSHEY, M. D., Acting Assistant Surgeon.

Private John Huff, Co. C, 25th Infantry, aged 26 years, accidentally shot himself in the left foot, at Fort St. Philip, Louisiana, on March 30, 1870. The ball entered over superior surface of second joint of great toe, and escaped on under surface, fracturing both phalanges. He was admitted to the post hospital, where spiculæ of bone were removed. He recovered, and was returned to duty in May, 1870.

CCXCIV.—*Mention of a Case of Gunshot Wound of the Foot.* By JOHN T. KING, M. D., Acting Assistant Surgeon.

Private J. H. Lewis, Co. B, 40th Infantry, aged 21 years, received, on January 17, 1869, a gunshot wound of the right foot, from a revolver fired from his own hand, while carelessly handling it. The ball entered the plantar surface of the foot, and became firmly imbedded in one of the tarsal bones. He was admitted to the post hospital at Goldsborough, North Carolina, on January 17, 1869. The ball was permitted to remain. He was returned to duty on March 31, 1869.

CCXCV.—*Report of a Gunshot Wound of the Foot.* By H. R. TILTON, Assistant Surgeon, U. S. A.

Private James Wilmot, Co. M, 5th Cavalry, aged 18 years, received an accidental gunshot wound. A carbine ball passed by the inner side of the right patella, producing a flesh-wound, and then between the great and second toes of the right foot, wounding both, and fracturing the second phalanx of the second toe. He was admitted to the post hospital at Fort Lyon, Colorado, Territory, on January 23, 1869. Simple dressings were applied. He was returned to duty on March 17, 1869.

There were also special reports made of seven cases of flesh-wounds of the foot. The patients returned to duty a few weeks after the reception of the injuries, and their cases presented no particulars of special interest.

Private Henry Clay, Troop M, 10th Colored Cavalry, aged 22 years. Fort Arbuckle, Indian Territory, February 27, 1870. Gunshot flesh-wound. Duty, April, 1870.

Private Alexander Gordon, Co. A, 38th Infantry, aged 22 years. Central City, New Mexico, December 24, 1868. Slight flesh-wound of foot. Duty, January, 1869.

Acting Assistant Surgeon G. W. Hatch, aged 36 years. Little Wichita River, Texas, July 12, 1870. Gunshot flesh-wound of left foot. Furloughed, August 20, 1870.

Private Henry Hight, Troop H, 9th Cavalry, aged 21 years. Fort Quitman, Texas, November 6, 1868. Gunshot flesh-wound of right foot. Duty, January, 1869.

Private Thomas Navin, Co. H, 18th Infantry, aged 19 years. Fort Philip Kearney, Dakota Territory, October 14, 1866. Gunshot flesh-wound of great toe, right foot. Duty, October 23, 1866.

Private William O'Neal, Co. B, 5th Cavalry, aged 21 years. Fort Lyon, Colorado Territory, March 16, 1869. Gunshot flesh-wound of foot. Duty, April, 1869.

Private William Wilson, Co. H, 18th Infantry, aged 23 years. Fort Philip Kearney, Dakota Territory, October 9, 1866. Gunshot flesh-wound of right foot. Duty, October 25, 1866.

There were also two reports of gunshot lesions of the femoral vessels, received too late to be inserted in their proper place after report CCLXII.

CCXCVI.—*Report of a Gunshot Wound of the Femoral Artery and Vein.* By R. TANZKY, M. D., Acting Assistant Surgeon.

Private William Neff, Troop B, 9th Cavalry, was admitted to hospital at Fort Stockton, Texas, in a moribund condition, having nearly bled to death from the effects of a gunshot wound of both thighs. A tourniquet was put over each femoral artery, and carbonate of ammonia, with other stimulants, administered, but the latter were immediately rejected by the stomach. The condition of the patient precluded an operation for ligating the injured vessels. The autopsy showed the femoral artery and vein to be severed.

CCXCVII.—*Report of a Gunshot Wound of the Femoral Vein.* By F. M. HOLLY, M. D., Acting Assistant Surgeon.

Private John Eberhardt, Co. A, 17th Infantry, aged 21 years, was shot, on October 29, 1868, at Belton, Texas, while an attempt was being made by a party of eight men to arrest a desperado. A ball from a Colt's Navy revolver entered the right thigh three inches below Poupart's ligament, internal to sartorius muscle, passed backward and slightly upward, nearly severing the femoral vein, grazed the femur internally at the junction of the shaft and neck, passed through the gluteal muscles, and lodged under the cuticle opposite the great ischiatic notch. The patient, unaware of being wounded, continued walking or running until he fell faint from loss of blood. He was seen some fifteen or twenty minutes after the occurrence, when the ball was removed from its place of lodgement, an efficient compress placed over the wound, and stimulants administered. Reaction never took place. The patient died in about two hours from hæmorrhage.

ANALYTICAL REVIEW.

The two hundred and ninety-seven preceding reports furnish more or less complete data respecting three hundred and eighty-seven patients with gunshot wounds. The results appear in the following statement:

Tabular Statement of the Results of Three Hundred and Eighty-seven Cases of Gunshot Wounds.

Nature of injury.	Cases.	Duty.	Discharged.	Died.
Fractures of the Skull.....	38	6	1	31
Scalp Wounds.....	9	9		
Fractures of Bones of the Face.....	13	8	3	2
Flesh-Wounds of the Face.....	7	7		
Wounds of the Neck.....	16	6		10
Wounds of the Chest.....	75	28	3	44
Wounds of the Chest and Abdomen.....	9			9
Wounds of the Abdominal Cavity.....	37	6	1	30
Flesh-Wounds of the Abdomen.....	5	5		
Wounds of the Pelvis.....	8	1		7
Wounds of the Genito-Urinary Organs.....	4	3		1
Flesh-Wounds of the Trunk.....	7	7		
Fractures of the Upper Extremities.....	45	36	7	2
Flesh-Wounds of the Upper Extremities.....	34	31	2	1
Fractures of the Lower Extremities.....	26	18	3	5
Flesh-Wounds of the Lower Extremities.....	54	43	3	8
Totals.....	387	214	23	150

The mortality rate of the cranial fractures is very large, but the fatal cases were nearly all examples of perforations of the brain, at short range. The large proportion of cases of suicide is noticeable and lamentable. It is interesting to note that, except to remove detached spiculæ, operative interference was not attempted except in a single

case—one of the cases of recovery—where it was necessary to extract a piece of iron that had penetrated the cranial cavity. The two instances of recovery after fracture of the mastoid process are uncommon, and the case reported by Assistant Surgeon Patzki, (III, p. 6), in which the yielding integument of the forehead was pared and approximated by sutures, suggests an expedient which may be of occasional utility.

The fatality of the wounds of the face was unusually small; while, as has been already remarked, the mortality rate in wounds of the neck was excessive.

The reports of wounds of the chest indicate that depletory measures in gunshot injuries of the lung have quite fallen into desuetude in our army practice.

The wounds of the abdomen and pelvis include some remarkable examples of recovery from accidents of the gravest nature; but the general mortality is so very large as to furnish an additional argument in behalf of M. Legouest's proposition to incise the abdominal walls, and explore the track of the projectile, in certain gunshot penetrating or perforating wounds of that cavity. Thus only, in many cases, can the patient exchange the probability of inevitable death for the possibility of recovery, either through the prevention of extravasation by enterorrhaphy, or the bringing of the wounded viscus into apposition with the abdominal walls. For one, I am free to assert that where there is evidence that internal hæmorrhage or fæcal extravasation is going on, what may be termed the "ostrich plan" of giving opium, and "making the patient comfortable," should be abandoned. And I believe that prejudices similar to those that ovariectomy has successfully overcome in the last quarter of a century, will be dispelled by the results of exploratory incisions in gunshot wounds of the abdomen, before many years have elapsed.

The most curious and interesting feature in this series of reports of gunshot wounds is the large proportion of instances of wounds of arteries. Leaving out of view the wounds of the aorta and pulmonary vessels, there were not less than twenty cases of division of the carotids, subclavian, axillary, external iliac, and femoral arteries. Those familiar with field surgery, are aware how rarely such lesions came under the observation of medical officers in campaigns. This is partly explicable by the fact that men may bleed to death in battle before the hospital attendants can reach them. Yet an examination of the dead on battle-fields shows a very small proportion of wounds of the secondary arterial trunks. I believe that the proportionately large number of such cases contained in the reports of garrisons is explained by the fact that the wounds observed are generally inflicted at short range, and by small projectiles, and that a musket or pistol ball, moving with great velocity, will cut or divide an artery, which, at a greater distance, would only be contused, or, by its resiliency, might escape injury altogether.

INCISED AND PUNCTURED WOUNDS AND CONTUSIONS.

The number of incised and punctured wounds, lacerations, and contusions reported is very large in proportion to the mean strength of the Army, as will be apparent from the tabular statement presented further on. The extraordinary proportion of such casualties may be ascribed partly to the fact that the troops were generally posted where the population was most lawless and turbulent, and partly to the laxity of discipline which was generally noticed for several years after the close of hostilities.

A few reports illustrating the different forms of incised, punctured, lacerated, and contused wounds will be cited.

INCISED WOUNDS.—Several reports of remarkable cases are given, and other cases are quoted simply as examples of the accidents likely to be observed in the garrison routine. The total number of incised wounds reported was nearly seven thousand.

CCXCVIII.—*Mention of a Sword Cut of the Skull.* By RICHARD POWELL, Assistant Surgeon, U. S. A.

At Camp Warner, Oregon, December 25, 1867, Private Michael Gillaney, Co. D, 23d Infantry, aged 29 years, received, in a brawl, a sword cut of the cranium, directly over the right frontal protuberance, slightly incising the bone. He was admitted to the post hospital on the same day, and the wound was stitched together. Cold-water dressings were applied. The wound healed promptly, and the man returned to duty January 21, 1868.

CCXCIX.—*Account of a Penetrating Wound of the Occipital Bone.* By W. R. D. BLACKWOOD, M. D., Acting Assistant Surgeon.

Private John O'Niel, Co. I, 2d Infantry, aged 35 years, was wounded December 16, 1870, by a knife which penetrated the occipital bone, severing the left occipital artery. He was admitted to the post hospital at Patona, Alabama, soon after the reception of the injury. The person who was called in neglected to ligate, or to employ any other means than adhesive strips to control the hæmorrhage. No medical officer was present, and the patient lost a large quantity of blood by repeated hæmorrhages. Dr. Burke, of Jacksonville, late Surgeon U. S. V. assisted by Dr. McMahon, of the Selma, Rome and Dalton Railroad, finally stopped the loss of blood by compresses dipped in the persulphate of iron, two days after the reception of the injury. The man was returned to duty January 12, 1871.

CCC.—*Note Relative to an Incised Wound of the Eye.* By D. D. THOMPSON, M. D., Acting Assistant Surgeon.

Private William Hobin, Co. E, 25th Infantry, aged 31 years, received, while intoxicated, February 2, 1869, an incised wound by a knife, resulting in the entire loss of the left eye, cutting through the cornea and iris to the posterior chamber, allowing the escape of the aqueous humor. The wound was obliquely from within out, entirely across the cornea. He was admitted to the post hospital, Von Schrader Barracks, Paducah, on the following day, where simple dressings were applied. The patient recovered, and was returned to duty in April, 1869.

CCCI.—*Mention of an Incised Wound of the Face.* By C. H. ROWE, Assistant Surgeon, U. S. A.

At Galveston, Texas, June 2, 1867, Recruit John Barney, 6th Cavalry, aged 20 years, received an incised wound of the lower lip, which was followed by profuse hæmorrhage, which had continued to the date of his admission to hospital, on June 4, 1867. Solution of persulphate of iron was applied to the wound, and the hæmorrhage being controlled, the parts were brought together, and the patient was returned to duty on the following day.

CCCII.—*Report of an Incised Wound of the Neck.* By J. P. WRIGHT, Surgeon, U. S. A.

Private Patrick Pender, Co. H, 22d Infantry, received a fatal stab in the neck, from a soldier, on the evening of November 15, 1870, at Fort Sully, Dakota Territory. The man was dead when first seen by the post surgeon. The internal margin of the wound was two inches from the median line of the neck. It was rather more than an inch long, the slit in the integument extending in a direction outward and backward. The wound, upon dissection, was found to have passed abruptly backward, downward, and inward, into the thoracic cavity, penetrating in its course the sternocleido-mastoid and the deep cervical fascia and platysma. The deep veins of the neck were found to have been deeply incised at a point corresponding with the junction of the internal jugular and left subclavian vein. Immediately posteriorly, the left subclavian artery was found to have been partially divided in that portion of the vessel interior to the insertion of the scalenus anticus. The left lung was penetrated antero-posteriorly through the apex of the upper lobe. The penetrating instrument was finally arrested by impinging upon the vertebral column, at a point corresponding with the third costo-vertebral articulation, or with the union of the second and the third dorsal vertebrae. The depth of the wound from the surface was four inches, dividing the structures above mentioned, in a direction downward, backward, and inward. The left lung was found to be entirely collapsed and floating in a large quantity of coagulated blood and serum. The greater portion of this fluid was removed, and measured five pints.

CCCIII.—*Note Relative to Incised Wounds of the Neck and of the Arm.* By C. R. GREENLEAF, Assistant Surgeon, U. S. A.

Private John Cogan, Co. F, 2d Infantry, aged 21 years, was admitted to the post hospital at Taylor Barracks, Kentucky, May 26, 1868, with an incised wound four and a half inches long in the posterior cervical region in a direct line between the two mastoid processes. He also received a stab in the lower third of the left arm. The wounds were dressed with interrupted sutures and adhesive plaster. He was returned to duty June 13, 1868.

CCCIV.—*Account of a Self-Inflicted Wound of the Neck.* By J. W. WILLIAMS, Assistant Surgeon, U. S. A.

Private Peter Jennings, Co. G, 6th Infantry, while in a drunken fit, at Raleigh, North Carolina, attempted suicide by stabbing himself with a clasp knife in the region of the neck. The knife entered one inch below the cricoid cartilage, in the median line of the trachea, and took a direction downward and toward the left lung, the apex of which it penetrated. At first the hæmorrhage was very violent, both from the mouth and the wound, inducing prompt syncope, and apparent death, leading the attending surgeon to believe death had actually occurred. The patient slowly revived, however, after a time, under the stimulating effects of strong ammonia. The hæmorrhage was arrested by the prompt action of the steward, who injected a solution of persulphate of iron into the wound and applied a compress over it. Emphysema ensued, and extended over the whole body in spite of careful bandaging. The resulting inflammation of the lung was easily subdued by cyanide of potassium, which had also the effect of arresting a troublesome cough. The emphysema has now completely subsided, except in the scrotum, and the patient is in a fair way of recovery. [He returned to duty June 17, 1868.—Ed.]

CCCV.—*Report of Several Incised Wounds Inflicted with a Razor.* By Dr. C. B. BRAMAN, Acting Assistant Surgeon.

Private McManus, Co. A, 20th Infantry, while a prisoner in the guard-house at Baton Rouge, Louisiana, in May, 1868, was cut in the hip, shoulder, and throat by a razor in the hands of a drunken comrade. The first wound was slight; the second, a deep flesh-wound over the trapezius muscle; the third extended from the right sterno-cleido mastoid, midway upward to the angle of the jaw, and downward to the raphe of the trachea. The external jugular, the thyroid and facial arteries were severed. I did not find it necessary to ligate, but was able to check hæmorrhage by lint and persulphate of iron in powders, with compression. After fourteen hours, I closed the wound. The patient recovered, and was returned to duty May 14, 1868.

CCCVI.—*Report of a Suicide from an Incised Wound of the Throat.* By J. H. BARTHOLF, Assistant Surgeon, U. S. A.

Private John Cody, Co. C, 11th Infantry, committed suicide at Camp Grant, Virginia, on the night of September 3, 1867, at 11 o'clock, by cutting his throat with a razor, half severing the left internal jugular vein, and cutting the larynx through the crico-thyroid to the mucous membrane at the back part of the cartilage. A second cut was made, diverging a little from the middle of the first, and going to the same depth. These two very thorough gashes, made with energy, were the extent of the suicidal effort. Death ensued in a few moments.

CCCVII.—*Remarks on the Monthly Report of Sick and Wounded at Camp Lincoln, California, for February, 1868.* By Dr. F. KNOX, Acting Assistant Surgeon.

The case, entered under the head of convulsions, and resulting in death, was that of Private Gustavus Louiston, Co. G, 9th Infantry. He was relieved in three hours by venesection and sinapisms. After four hours of quiet sleep he appeared perfectly rational and quiet, but with evidence of inflammation of the brain. A ten-grain dose of calomel was administered. About five hours after he got a razor and cut his own throat, completely severing all the integuments to the spinal column. The razor passed through the larynx at the front, but within an inch passed above it. The œsophagus could be plainly seen, entirely divided. He lived ten days. The treatment was solely to alleviate suffering.

CCCVIII.—*Account of an Incised Wound of the Head and Thorax.* By F. A. WILMANS, M. D., Acting Assistant Surgeon.

Private J. W. McClinchey, Co. E, 17th Infantry, aged 21 years, received on August 12, 1868, an incised wound of the head and right side from a knife blade, which penetrated the lung, letting the air escape freely. The wound on the head was three and a half inches long, exposing the right parietal bone. On the following day he was admitted to the post hospital, Brenham, Texas, where sutures and simple dressings were used, and on September 26th, he was returned to duty.

CCCVIX.—*Report relative to Two Incised Wounds.* By DONALD JACKSON, M. D., Acting Assistant Surgeon.

First Sergeant John Jones, Co. C, 24th Infantry, aged 21 years, was wounded June 14, 1870, in a brawl, by a pocket-knife, which entered in front of acromion process, passing directly downward two inches deep. Also an incised wound, three inches below the left axilla, two inches long, penetrating to the ribs. He was admitted to the post hospital at Fort Clark, Texas, on the following day. Dilute carbolic acid dressings were applied. He recovered, and was sent to duty July 7, 1870.

CCCX.—*Report of an Incised Wound of the Heart.* By DALLAS BACHE, Assistant Surgeon, U. S. A.

Artificer Thomas Dardis, Co. F, 10th Infantry, was stabbed with an ordinary jack-knife, in the hands of a comrade, on September 19, 1869, at San Antonio, Texas. Upon being wounded he ran probably thirty yards, with his arms folded across his chest, and then fell. He was instantly removed to the barracks, where respiration ceased in twelve minutes after the reception of the injury. A *post-mortem* examination, made fifteen hours after death, disclosed three wounds upon the anterior parietes of the chest—one superficial over the lower third of the sternum; the second, two and a half inches in length, dividing the cartilage of the sixth rib and penetrating the thoracic cavity, without however wounding the lung; the third and fatal wound, two and a quarter inches in length, two inches below the left nipple, opened the pericardium, and, splitting across the apex of the heart, made an opening in the right ventricle sufficiently large to admit an ordinary silver probe. The clothing on the left side and below the wound was soaked with blood.

CCCXI.—*Report of an Incised Wound of the Sternum and Heart.* By C. S. DE GRAW, Assistant Surgeon, U. S. A.

At Fort Dodge, Kansas, on the night of June 2, 1867, a quarrel arose between two men, one known as Buckskin, in Government employ at the post, the other an employé of the Santa Fé Mail Stage Company. Both men were under the influence of liquor. From words they came to blows, and during the fight Buckskin drew a knife, with which he inflicted several superficial cuts upon the other, who at last succeeded in catching Buckskin, by the wrist of the hand holding the knife, and, turning it upon him still holding it, drove it with great force against his breast. Buckskin fell at once to the ground. Upon being summoned, and reaching the spot a few minutes after, I found Buckskin dead. Upon inquiry, I learned that after falling he had continued to breathe from five to eight minutes. A *post-mortem* examination, held the next morning by Acting Assistant Surgeon J. B. Crandall and myself, demonstrated the wounds as shown by the specimens. The knife is a case-knife such as is in common use among men on the plains. [The specimens, Nos. 4869, 4870, 4871, Section I, A. M. M., are the heart, with an incised wound of the right auricle; the sternum, with an incision obliquely downward from right to left through the gladiolus; and the knife by which the wounds were inflicted.—ED.]

CCCXII.—*Account of a Penetrating Wound of the Thoracic and Abdominal Cavities.* By W. D. WOLVERTON, Assistant Surgeon, U. S. A.

Private Bernhard Kelly, Co. C, 1st Infantry, aged 20 years, received July 23, 1868, a wound by a case-knife in the hands of Private Kennedy, Co. A, 1st Infantry, which penetrated the left side between the seventh and eighth ribs, grazing the left lung, passing through the diaphragm downward into the stomach, causing peritonitis and death, which resulted on the 26th.

CCCXIII.—*Note of a Penetrating Wound of the Abdomen and Thorax.* By C. E. GODDARD, Assistant Surgeon, U. S. A.

Sergeant William Tynes, Co. E, 16th Infantry, aged 21 years, was wounded by a dagger during an encounter with Private Barlow of the same regiment, on November 16, 1866. The weapon penetrated the abdomen and thorax. The patient was admitted to the post hospital at Chattanooga on the same day, and simple dressings were applied. Death resulted on the day of admission.

CCCXIV.—*Report of a Case of Incised Wound of the Stomach, Terminating in Recovery.* By B. A. CLEMENTS, Surgeon, U. S. A.

George Smith, an unassigned recruit, aged 22, a robust German, was stabbed in the abdomen, during an altercation at Jackson Barracks, New Orleans, on the evening of January 2, 1870. He was at once brought to the post hospital. Upon examination, a clean incised wound was found, inflicted with a dirk, the blade of which entered two and a quarter inches to the left of the median

line, on a level with a line drawn transversely two inches above the umbilicus. The wound was one inch in length, its long axis being nearly parallel to the long axis of the body. On inserting the finger into the wound, it was found that the wall of the abdomen was entirely penetrated, beyond which the finger passed without resistance, obliquely through another layer of tissue, into a cavity which was believed to be the left end of the stomach. He complained mainly of pain in the left shoulder, and vomited freely of recently ingested food unmixed with blood, and was somewhat agitated. The wound bled but slightly, and was at once closed by two silver sutures and adhesive plaster, the patient having previously been turned on his abdomen, without any discharge of blood, beyond a few drops, taking place. He was placed in bed, and ordered to have no food or drink. During the night he vomited twice, throwing up in all a pint of dark semi-coagulated blood. His pulse was 84, and small, though he appeared unwilling to take a full inspiration. He complained of a "cramp-like" pain in the fore part of the left shoulder, and also of some pain at the epigastrium, especially about the ensiform cartilage. There was some tumefaction at the seat and in the vicinity of the wound, and a crackling sensation, as well as gurgling, was perceived on palpitation. An incised wound of the stomach, with infiltration of gas or air into the areolar tissue about the wound, was diagnosed. He was allowed to rinse his mouth with water under the supervision of the nurse, and to assume such position in bed as he preferred. On the afternoon of the next day he was quiet and uncomplaining, but the pulse was 120 and wiry, and the face rather pallid. He had not vomited since daylight, but felt nausea all the time, and thought he would feel better could he vomit. He spat up freely, without vomiting, a mucilaginous coffee-colored fluid, evidently altered blood. The abdomen was somewhat tympanitic, and the bowels had not moved. A cathartic enema was given, which operated slightly in the evening. On January 4, the patient lay quietly in bed on his back; his countenance was pale, but not indicative of distress; pulse 112, small, wiry, and feeble; respiration normal, and tongue clean. The whole abdomen was somewhat distended and resonant, and he complained of slight pain at the epigastrium. The emphysema in the vicinity of the wound had not increased, and the gurgling was no longer perceptible. During the night he vomited three times, throwing up in all about one quart of blood, much of which was coagulated and thrown up in mass. The vomiting gave him much relief. An injection of beef essence was given every three hours, and flannel wet with the spirits of turpentine applied to the whole abdomen. In the evening he again vomited a full pint of dark semi-coagulated blood. An anodyne injection was administered, and he rested quietly during the night. He continued to spit up freely, and at times to vomit the same mucilaginous dark-looking fluid, which was evidently blood altered by admixture with the fluids of the stomach. The injection of beef essence was continued until January 7th, when beef tea was given every alternate hour by the mouth. He ceased to spit up the dark fluid, and did not vomit during the night. On the 11th, he complained of pain at the seat of the wound, and that he could feel a swelling there on sitting up. He was examined in a standing posture, but no bulging or protrusion could be felt, but the abdomen had become generally tympanitic, and his bowels did not move. A cathartic was at once ordered, which moved the bowels during the night, and on the next day the tympanitic distension had disappeared. Somewhat above and outward from the wound there was a decided diffused swelling, which was red at one point, and very tender to the touch. He was not allowed to take any food by the mouth, only water by the wineglassful, with an injection of a teacupful of beef essence. On the morning of the 13th, the swelling had plainly diminished, and was not so tender. In consequence of sickness, I did not see him until the 16th, when I found the tumefaction near the seat of the wound was much greater, being as large as half an ordinary-sized orange, very red, and tender to the touch, and seemed resonant on percussion and quite tense. The swelling continued to increase until the morning of the 17th, when a sudden discharge of thin offensive pus took place through the original wound, amounting in all to about eight ounces, that which flowed last being creamy, and streaked with blood. There were some shreds of semi-decomposed coagulated blood passed out with the pus first discharged. The swelling at once greatly diminished; a light broad poultice was applied to the wound without pressure, and he was ordered to lay on his side. During the evening he expressed himself as feeling greatly relieved. On the 19th, his pulse was regular but feeble, and he was quite pale. The swelling had entirely disappeared. There was no discharge from the wound except from the small granulating surface, which had assumed by ulceration a triangular

shape. Meat and soup were ordered for the first time, but no vegetables. He gradually improved, and on the 31st was able to walk about. He complained of being weak, and of having pain in the left shoulder, and also "inside" about the wound when he attempted to lift anything. There was a slight soft painless swelling a little to the left of the wound, but the color of the skin over it was entirely natural. He was retained in hospital until he regained his strength, and was returned to duty in February, 1870.

CCCXV.—*Report of a Case of Incised Wound of the Abdomen with Puncture and Escape of the Intestines, followed by Traumatic Peritonitis.* By W. H. DOUGHTY, M. D.

I was called at midnight of June 11, 1868, in Augusta, Georgia, to see Private James Merchant, Co. I, 16th Infantry, who had just received the following wound, in a street altercation with a negro: As first seen in the street he was laying upon his back, with the abdomen exposed, and covered with the largest mass of protruding intestines that I ever saw, almost the entire region being thus covered. Having been removed to the barracks near by, with the assistance of Dr. John S. Coleman of this city, I proceeded to examine and dress the wound. The intestines were covered with sand and grit, derived from contact with the ground and clothes of the man, and the small intestines (ilium) incised at one point, and scratched by the passing knife at another. This incision, being about an inch in length, was closed with a single stitch of silk thread, and after thorough cleansing the whole mass was with great difficulty returned to the abdominal cavity. In this hernial protrusion we recognized four or five feet of the ilium, the cæcum with its appendix, part of the ascending colon, with corresponding portions of the mesentery, the distribution of the superior mesenteric artery to these several portions made more apparent by its living pulsation, was more beautifully displayed in the series of its successive arches than in any dissection that I ever witnessed. Raising the mass, I found that the wound in the peritonæum, through which it had escaped, was about two and a half inches in length, and tightly embraced its neck; with the hips of the patient raised higher than the chest so as to favor the gravitation of the viscera, it was replaced in the abdomen, whereupon was disclosed an incision commencing two inches below the umbilicus, and two inches to the left of the linea alba, running horizontally above the crest of the ilium, nearly to the spine, fourteen inches long, opening the abdomen near its inner or anterior extremity, and severing the muscular parieties as far back as the thick muscles of the lumbar region. Relaxing the abdominal walls as far as possible, the wound was accurately closed with hare-lip pins, and annealed wire sutures. Suitable compresses were applied and a roller firmly encircling the body. There was also a superficial wound upon the chest, six inches in length, extending obliquely from right to left. The shock from these wounds was very severe indeed, the patient at one time becoming pulseless. We were apparently dressing the wounds of a dying man. Whiskey and laudanum were administered, and next morning the patient was comparatively comfortable, reaction being complete. Perfect quiet and isolation in a dark room were enforced; two grains of powdered opium were administered every four hours; ice was given to quench thirst; poultices of the same were applied to the abdomen, and the left thigh was kept permanently flexed. On June 16th the pulse and temperature being very high, the patient became delirious, and it was necessary to restrain him by force. Bromide of potassium and whiskey were freely administered. Failing to induce sleep they were discontinued, and one-third of a grain of morphine was administered hyperdermically, which caused sleep in half an hour, and deeply narcotized the patient. Next day all the symptoms were much improved; medicine was discontinued, and a stimulating and nutritious diet allowed. The local applications were continued. Hyperdermic medication was again resorted to on the next evening. On the 19th a very decided improvement had taken place; the ice poultices were discontinued, and a more liberal diet, with stimulants, allowed. The wound was subsequently dressed with adhesive strips and a solution of carbolic acid. On June 21st he continued to improve. Muriated tincture of iron was prescribed. By the 23d granulation had begun. Between this date and the 26th the temperature remained normal. At the latter date the patient was doing well, and the wound granulating finely, when he was transferred to Acting Assistant Surgeon Petard.*

* Dr. Felix Petard takes up this case on his June report, and in July, 1868 reports one case of *valvular incision* returned to duty.—Ed.

In connection with the above report, we may be allowed to call attention to the peculiar method employed in the application of cold for the abatement of local inflammation, particularly its applicability to the management of wounds. Without presuming to call the attention of the Department to a subject with which all medical men are more or less familiar, we may yet be pardoned for offering a few reflections prompted by this particular mode. A military experience of more than three years has made us familiar with the great need for improved methods of applying cold for the reduction of inflammation, and with that afforded with the use of ice poultices in this case, we can readily recall occasions where such an application would have been embraced with delight. Cold water, properly employed, is the "*sine qua non*" in inflamed wounds. Its interrupted application, as by cold cloths, frequently changed, is always troublesome where long continued, and more or less partial in its effects, if not judiciously used. It is well known that water dressings may increase local heat by retaining a moist surface in contact with a heated body. Irrigation, when practicable, is a decided improvement upon this, well adapted to wounds of the extremities and head, but not so much so to those of the trunk. Besides this, we have all the inconveniences of a special apparatus for applying it. The flow of water from the irrigated surface must also be provided for as well as other things needless to mention. Again: Ice-bags or bladders are too intense in their effects—always painful upon prolonged contact with the part, and dangerous to its vitality; and when brought in simple proximity to the part, they involve too much inconvenience for permanent and satisfactory use. *Ice poultices*, properly made, combine all of their advantages with none of their disadvantages, being safe, convenient, and producing a permanent uniform reduction of the temperature. They cause no pain, no chillness, no inconvenience from their weight, and admit of easy application to wounds of the trunk as well as the extremities; do not endanger the integrity of the part, do not require removal oftener than two or three hours; do not saturate the clothes of the patient with superfluous water, and require no special arrangement for their employment. Hence, so far as the local abstraction of the heat tends to arrest inflammation, they are, *par excellence*, the remedy. To Maisonneuve we ascribe the credit of their suggestion, from whom the following directions for their manufacture are taken in substance. We saw a notice of them in one of the periodicals of this year, to which, however, we cannot now refer directly: Take of linseed meal a sufficient quantity to form a layer from three-quarters to an inch thick; spread on a cloth of proper size; upon this, at intervals of an inch or more, place lumps of ice of convenient size—of a *big* marble—then sprinkle them over lightly with the meal, cover with another cloth, folding in the edges to prevent the escape of the mass, and apply the thick side to the surface or wound. Closely enveloped with the meal, the exclusion of air retards the melting of the ice, and the thick layer, intervening between it and the surface prevents painful or injurious contact. The linseed meal is better than bran or similar materials, because its mucilaginous properties render it somewhat tenacious and adhesive. Then there you have a uniform abstraction of heat. In the case reported we made special inquiry of the soldier as to the comfort of the application, with a response always favorable; we felt the under surface of the poultice, and found it always cool; we took the temperature with the thermometer, which stood at or about 86 degrees; we continued them seven days without intermission, and firmly believe that the favorable progress of the case was in no small degree attributable to their judicious employment. It is always unsafe to draw inferences for general application from a few cases, and the blind man's rule, "*post hoc, propter hoc*," recurs with this thought; and yet we may not ignore the value of individual cases, and may err by pushing our skepticism to a fallacious extreme. We look to our personal experience with this eligible mode of applying cold for interrupting—perhaps controlling—the inflammatory process, as derived from this case, with peculiar satisfaction, and hopefully await opportunities for its confirmation in other similar ones. Possibly it may occur to some that the non-union in the wound was referable to the application. When we discovered the want of reparative force, we thought of this, but happily the wound upon the chest, to which they had not been applied, set aside the objection, for it also failed to unite, thus clearly indicating where the defect existed, namely, in the general system. The habitual use of alcohol had produced a pathogenetic state of the system; hence the delirium tremens, and the want of reparative power in the wounds.

CCCXVI.—*Account of a Wound of the Abdomen followed by Peritonitis.* By E. A. KOERPER, Assistant Surgeon, U. S. A.

Private John Gill, Co. H, 19th Infantry, aged 21 years, was admitted to the post hospital at Baton Rouge, November 9, 1869, having, a few minutes before admission, received a wound of the abdomen, inflicted with a pocket-knife. The wound was on the median line, on a line between the hypogastric and umbilical regions, and was two and a half inches long in a transverse direction. At each inspiration a copious stream of blood escaped from it. A portion of the omentum protruded. There was no escape of the contents of the stomach or bowels. A cautious examination did not reveal any lesion of the intestines. The omentum was replaced, the wound sewed up externally, ice applied to the abdomen, and opium given. Patient vomited soon after. The pulse, which had been very high and excited, became almost imperceptible, and death was expected to take place. In three hours, however, he rallied and became extremely restless. Peritonitis, with high pulse, set in, and he complained of much pain. Blood continued to escape between the sutures. The ice and opium were kept up, and small pieces of ice were given to allay thirst. The most alarming symptoms gradually subsided, and the colon was emptied after six days by an injection. Encouraged by this, citrate of magnesia was given on the following day, bringing away a great quantity of feces, without blood or any appearance of lesion of the intestines. He continued to improve, and on December 31st he could sit up half an hour at a time, but was very much emaciated and suffered from pain in the abdomen. He was returned to duty in January, 1870.

CCCXVII.—*Account of an Incised Wound of the Abdomen.* By J. P. A. CLEARY, Assistant Surgeon, U. S. A.

George Adams, Co. A, 9th Cavalry, aged 23 years, of healthy constitution, while in a quarrel with another soldier, at Fort Stockton, Texas, in September, 1870, received two cuts with a knife; one extended from the right elbow to within a few inches of the wrist; the other commenced on a line with the sternal end of the ninth rib, and running in a horizontal direction, terminated within half an inch of the linea alba, being, altogether, two and a half inches long. He was wounded about 3 o'clock, on the 4th, and I saw him about ten minutes after. Condition when brought to the hospital, ten minutes after receipt of wound: Almost the entire stomach protruded through the wound, and about 18 inches of the transverse colon, with a considerable amount of omentum. He was in collapse, covered with profuse cold sweat; pulse weak and 130; constant vomiting. Treatment: Endeavored to replace the protruded mass, having first administered an ounce of whiskey. Failing in this, the wound was extended about half an inch toward the linea alba, but the mass could not be returned; frequent vomiting to considerable extent prevented its return, and forced fecal matter into the protruded intestine. The wound was then slightly extended at its other extremity, and by a little manipulation the entire mass was returned and the wound closed by three suture-pins and one common suture at either end of the wound; cold-water dressings were applied. The wound in the arm was treated with five sutures and strips of adhesive plaster and cold water. He was kept under the influence of opium, combined with calomel, from the date of admission to the 7th. He slept well every night, and at no time did he suffer severely with abdominal pain, though he complained frequently of tenderness over right hypogastric region. Sutures removed on 7th; bowels moved once on the 7th, the first time since he was wounded. He convalesced rapidly and was soon able to walk about the camp. He was returned to duty in October, 1870.

CCCXVIII.—*An Incised Wound of the Abdomen, through which protruded a Portion of the Colon, the entire Stomach, and nearly all of the Small Intestines, together with Mesentery and Omentum.* By F. BARNES, Acting Assistant Surgeon.

Edward Brown, colored, aged 25 years, was admitted to the Freedmen's Hospital, New Orleans, May 15, 1868. About 10 o'clock on the night of May 14, I found the patient in a cab, about to be removed from the first district lock-up, and ordered him back that his wound might be dressed. I

found eight inches of the colon, all of the stomach, and nearly the whole of the small intestines, together with the mesentery and omentum protruding through a wound in the left epigastrium. About two and a half feet of the small intestine having a whitish color, appeared filled with food, and had much the characteristic feeling of a sausage. The rest of the small intestines being collapsed, had a dark brown color. The stomach and colon, distended with gas, were leaden colored. The viscera had been out and exposed to the atmosphere for over an hour. Having nothing but cold Mississippi water to wash them with, I preferred returning them without any effort at removing blood and dirt, further than wiping with a cambric handkerchief and trusting to the stripping, if I may so term it, that they would naturally be subjected to while being returned through the wound by which they were tightly packed and almost strangulated. In about ten minutes, I had returned them all, carefully examining inch by inch for a wound or tear in them, but finding none. The first portion returned was the ilium, next the jejunum. The stomach required the gas to be gently pressed out before it was returned, as was the case with the colon, which I presume was the first to escape from, as well as the last to be put back, into the abdomen. The food in the jejunum had also to be partially manipulated out of it before it could be returned. The wound externally was three inches long, and nearly perpendicular. The internal opening was nearly at right angles with it, and allowed easily the introduction of three fingers. The conjoined cartilage at the end of the seventh rib was also divided. The omentum, although frequently returned, could not be made to remain in the cavity of the abdomen, and must still form a plug in the internal wound. The instrument inflicting the wound was said to be a cotton-hook. Three silver sutures through the skin, with long adhesive straps, kept the edges of the wound together. A compress over the wound, and a bandage eight yards long and six inches wide, was tightly applied around the epigastric region. Two persons were ordered to keep watch over the patient, who was not removed from the table upon which his wound was dressed that night. He went to sleep as soon as his wound was dressed, and slept soundly all night, and in the morning was admitted as before stated. During his stay in the hospital he never had a single bad symptom. As a proper precautionary treatment, however, he was allowed no food for four days. Some toast-water, and a moderate quantity of morphine was given him to keep his bowels at rest and allay pain. His food was gradually and cautiously increased after that date, until it appeared that extra diet agreed with him. He had no operation of the bowels until the 22d instant, when he passed a healthy stool without medicine. He was discharged on May 24th, the wound being entirely healed, and no other apparent difference existing from that of a state of health, except that the cartilage of the rib had not reunited. He was directed to wear his bandage and compress for a month.

CCCXIX.—*Account of an Incised Wound in the Hypogastrium.* By SAMUEL W. BLACKWOOD, Surgeon, 81st U. S. Colored Troops.

Sergeant Edward Thompson, Co. A, 81st Colored Troops, received an incised wound in the hypogastric region, at New Orleans, on October 25, 1865. The wound was two and a half inches long, and perforated the small intestines at five points from which its contents escaped. These were closed by the interrupted suture. Upon attempting to return the bowels the abdominal cavity was found to be filled with arterial blood, which issued from a wound in the mesentery, the artery of which was tied. Brandy and opium were exhibited. The wounded man survived twelve hours.

CCCXX.—*Report of an Incised Wound of the Arm.* By W. H. RIPPARD, M. D., Acting Assistant Surgeon.

The incised wound mentioned in this report was a wound of the brachial artery, made by a disreputable practitioner of medicine while in a state of intoxication, in attempting to abstract blood from the median basilic vein. The coats of the artery were not quite cut through, as the artery did not commence to bleed for two hours after, when the patient, while romping in the quarters, noticed the blood oozing through the bandage. His comrades brought him to the dispensary, where the steward proceeded to take off the bandage. Blood immediately gushed out in jets

about as thick as a quill, and spirted to a distance of over two feet. A compress of lint soaked in solution of persulphate of iron was immediately applied to the wound, while an assistant applied the tourniquet. The arm was then bound up very tightly in a roller bandage. About an hour afterwards the tourniquet had to be removed, owing to the intense pain and swelling in the fore-arm and hand. When the tourniquet was removed, the radial pulse was very weak, and continued so for twenty-four hours, after which it gradually increased in strength; there was no after hæmorrhage, and in ten days the bandage was removed, when the wound was found to be entirely healed. Patient is entirely well now, except a slight stiffness of the muscles of the arm, which is being relieved by manipulation and friction. The man was returned to duty in July, 1869.

CCCXXI.—*Account of an Incised Wound of the Fore-Arm.* By C. CAUGHILL, M. D., Acting Assistant Surgeon.

Corporal Gustave Mueller, Co. I, 19th Infantry, was admitted to the post hospital at Dover, Arkansas, April 10, 1868, having been accidentally struck on the back of the fore-arm with an axe, in the hands of a comrade, while in the act of chopping wood. On examination the extensor carpi ulnaris, communis digitorum, carpi radialis brevior, and ossis metacarpi pollicis muscles were found divided, making an incision about three and a half inches long. The posterior interosseous recurrent artery and one of its principal branches were severed. The radius was fractured at its middle in three pieces. The patient was extremely weak and very much exhausted from loss of blood. I immediately proceeded to ligate the severed arteries and extract the loose pieces of bone; the lips of the wound were then brought together by an interrupted silk suture and the two edges of the bone in apposition; splints were applied on the anterior and posterior surfaces of the fore-arm. While the arteries were being ligated and bones brought in apposition, chloroform was administered. At 9 o'clock P. M., the patient was suffering extreme pain. An anodyne was administered and quiet enjoined. He was doing well until midnight of the 12th, when the arm commenced swelling rapidly and he seemed to experience intense pain. On the next day the arm was much inflamed; wound suppurating slowly, and extreme heat extending up to the shoulder-joint. At 12 M. the patient had a chill, attended with little or no fever. His appetite was good. The posterior splint was removed, together with the dressings. The anterior splint was kept under the arm without being bound to it; pulse 90. Cold applications were made, and stimulating diet given, and on April 16th the inflammation had subsided to a great degree. At 6 o'clock P. M. arterial hæmorrhage took place from a branch that had evidently become enlarged from the collateral circulation. I immediately cut down and ligated it, and applied persulphate of iron to the wound to check the capillary bleeding, the arm being very vascular. The patient lost about twelve ounces of blood and was very much weakened. After ligating the artery the arm became considerably engorged, and he experienced intense pain. On April 17th the collateral circulation throughout the arm was thoroughly established. Under the administration of stimulants and nutritious diet his condition improved, the inflammation subsided and healthy granulations sprang up. The wound filled up rapidly, and on May 31st had entirely closed, leaving a very deep scar. He was discharged from service November 16, 1868.

CCCXXII.—*Account of an Incised Wound of the Thigh.* By E. ALEXANDER, M. D., Acting Assistant Surgeon.

Private Joseph B. Smith, Co. G, 25th Infantry, aged 21 years, was admitted to the post hospital at Fort Jackson, Louisiana, on January 18, 1870, with a cut four and a half inches long, inflicted with a razor, about the middle of the thigh, cutting deeply the adductor longus, sartorius, and part of the rectus muscles. There was little hæmorrhage, although some veins seemed to be torn. The lips of the wound were brought together in accurate contact, and secured with sutures, adhesive straps, and roller bandages, interspaces being left for the purpose of drainage. There was little tendency to suppuration, but the discharges were frequently removed with a soft sponge saturated with a solution of carbolic acid. He recovered, and was returned to duty in March, 1870.

CCCXXIII.—*Account of an Incised Wound of the Thigh and Femur.* By J. H. BARTHOLF, Assistant Surgeon, U. S. A.

At Camp Grant, near Richmond, Virginia, on January 4, 1868, Private John Joye, Troop F, 5th Cavalry, aged 22 years, received a blow with an axe, in the hands of a comrade, on the outer aspect of the right thigh, chipping up and nearly severing a portion of the femur an inch and a half in length, an inch and a half wide, and about a quarter of an inch thick, the instrument entering two inches below the tip of the trochanter major. He was at once conveyed to the post hospital. The end of the cut bone protruded from the wound, which gaped very much. The piece of bone adherent at the upper end was pushed back into its place, as nearly as possible, and two sutures were applied, leaving an opening at the most dependent point. On January 17th, two pieces of bone becoming loose were removed from the wound. The patient made a good recovery, and was returned to duty March 1, 1868.

CCCXXIV.—*Remarks on Monthly Report of Sick and Wounded at Fort Abercrombie, Dakota Territory, for May, 1868.* By W. H. GARDNER, Assistant Surgeon, U. S. A.

The incised wound reported in tabular statement was situated over the inner and anterior aspect of the right knee-joint. It was immediately sealed hermetically with fine gauze and collodion, and cold dressings continuously applied, and by the fifth day was entirely healed up. He was allowed to sit up that day for the first time, but abused the privilege, and walked about so much that at night the joint was inflamed and painful, and the next day acute synovitis was declared. The cicatrix opened and pus flowed freely from the cavity of the joint. Treated by absolute rest, nutritious diet, tonics, and the hyposulphite of soda, and is at this date in a fair way to recover, with good motion of the joint. [This man was discharged from service September 21, 1868, for "false ankylosis of the right knee-joint, following acute synovitis." Disability was rated one-half.—Ed.]

CCCXXV.—*Extract from Monthly Report of Sick and Wounded at Fort Gaston, California, May, 1866.* By PETER MOFFATT, Assistant Surgeon, U. S. A.

The case reported as a suicide was one of the most deliberate attempts at self-destruction ever witnessed. The subject, a private of Co. K, 9th Infantry, was returned to duty from the hospital on the morning of May 12, 1866, and at the time was observed to be laboring under dejection of spirits. At evening roll-call he was absent, and it was then noticed by his comrades that he had not been present at either dinner or supper. Between sundown and dark he was found at some distance from the quarters, in a secluded place, among some bushes, cold, almost lifeless, and covered with blood. I was immediately sent for, and upon my arrival at the place found the man lying on the ground in a nicely shaded spot, his coat regularly folded beneath his head, his shirt, vest, and trousers smeared with blood, partially dried and stiffened, the surface of the body cold, the limbs almost rigid, and the pulse imperceptible. On the inner side of each leg, between the knee and ankle, were two transverse gashes through the skin and cellular tissues, so that the muscles lay exposed, and completely severing the superficial veins. The prominent places of the veins had evidently been selected. On each arm the operation was repeated; the lower transverse incision just above the wrists were not sufficiently deep to injure the radial artery, nor the tendons of the flexor muscles; but just below the bend of the elbow, at the point usually selected for venesection, a deep gash was inflicted in each arm, partially severing some of the flexor muscles. I found a razor, covered with dried and hardened blood, lying by the man's side, and a small memorandum book, upon the first leaf of which were a few lines written in lead pencil, and giving reasons for the deed he was about to commit. Upon the administration of brandy and water, and other restoratives, and the application of heat internally, the patient gradually recovered strength. So completely had the system been depleted of blood that the least elevation of the head and shoulders was immediately followed by convulsions. As soon as consciousness was restored the sensations usually experienced in cases of great and sudden depletion were urgent, and the first words were "water, water." The man is still in hospital, but has almost regained his former strength.

CCCXXVI.—*Mention of an Incised Wound of the Foot.* By A. L. BUFFINGTON, M. D., Acting Assistant Surgeon.

Private Fontanice Singleton, Co. D, 20th Infantry, aged 20 years, was admitted to the post hospital at Jefferson, Texas, on December 3, 1867, with an incised wound upon the dorsal surface of the left foot, inflicted with an axe. The parts were retained in apposition by adhesive plaster. He was returned to duty December 11, 1867.

PUNCTURED WOUNDS.—A few of the reports of the more important punctured wounds may be cited. The most interesting injuries of this class were those inflicted by arrows. These will be considered in a separate section.

CCCXXVII.—*Mention of a Bayonet Wound of the Scalp.* By E. ALEXANDER, M. D., Acting Assistant Surgeon.

Corporal Alexander Kay, Co. D, 39th Infantry, aged 28 years, was wounded October 7, 1868, by a bayonet, which entered the scalp between the sagittal suture and the left parietal protuberance, making a wound about two inches long. He was admitted to the post hospital at Fort St. Philip, Louisiana, on the same day. Hæmorrhage occurred to the amount of fifteen or twenty ounces. The wound was carefully explored, but no injury of bone could be detected. The treatment consisted in cold applications to the head and a brisk cathartic. No compresses of any kind were used for several days, but the pus that formed was frequently pressed out. After this a few adhesive straps were applied twice daily, and the wound healed kindly. On November 3, 1868, the patient was returned to duty.

CCCXXVIII.—*Mention of a Sword Wound of the Eye.* By RICHARD POWELL, Assistant Surgeon, U. S. A.

At Camp Warner, Oregon, December 25, 1867, Private John Waltsh, Co. D, 23d Infantry, aged 36 years, received in a brawl a punctured wound of the right eye from a sword, which penetrated the cornea and iris. He was admitted to post hospital December 27, 1867. Cold-water dressings were applied to the eye, cantharides plaster was placed behind the right ear, and saline cathartics were administered. He returned to duty April 12, 1868.

CCCXXIX.—*Note Relative to a Bayonet Wound of the Lower Jaw.* By C. E. GODDARD, Assistant Surgeon, U. S. A.

Private John Fry, Co. E, 16th Infantry, aged 21 years, received a bayonet wound at the hands of the sergeant of the police guard, while resisting arrest, November 23, 1866. The bayonet thrust fractured the lower jaw. The wounded man was admitted to the post hospital at Chattanooga, on the next day, and the fracture was coaptated, and retained in position by splints of binder's boards. [The man was returned to duty in December, 1866.—ED.]

CCCXXX.—*Mention of a Bayonet Wound of the Thorax.* By JOHN B. WHITE, M. D., Acting Assistant Surgeon.

In the case of Private Hilary Herbert, I would state that at the *post-mortem* examination, fourteen hours after death, the autopsy being limited to the cavity of the thorax, there was nothing of additional interest elicited, other than the facts communicated in my report of April 5, 1868, in which I stated "that he received a stab by a bayonet upon the inner or thoracic side of the left

arm, which passed into the cavity of the axilla, and also entered the cavity of the thorax, penetrating the superior lobe of the left lung, and terminating by a small opening into the aorta, a few lines without the pericardial sac." An interesting feature of this case was the rapid cooling of the body, after the stab, to the temperature of the surrounding medium, arising from the rapid and profuse loss of blood, both externally and internally. [This man died April 4, 1868.—ED.]

CCCXXXI.—*Minute of a Bayonet Wound of the Pectoral Muscles.* By J. F. WEEDS, Surgeon, U. S. A.

Private Hugh McClinty, Co. H, 45th Infantry, aged 30 years, was wounded on January 3, 1869, by a bayonet, which entered the left side of the thoracic parieties, one and a half inches, at a point two inches above the nipple, passing upward and outward, and did not enter the thoracic cavity. He was admitted to the post hospital at Nashville, on the same day, and was returned to duty January 6, 1869.

CCCXXXII.—*Mention of a Penetrating Wound of the Lung.* By C. C. BYRNE, Surgeon, U. S. A.

Private John Tobin, Co. C, 19th Infantry, received, April 14, 1870, a penetrating wound of the lung, by a pocket knife. He was admitted to the post hospital at Little Rock, Arkansas, on the following day. Simple dressings were applied. He died on the 18th, from hæmorrhage.

CCCXXXIII.—*Account of a Suicide from Stabbing the left Chest. "Hermetically Sealing" unavailingly employed.* By J. JORGENSEN, M. D., Acting Assistant Surgeon.

Private Ambrose Zepp, Co. I, 21st Infantry, on January 18, 1868, while in an intoxicated condition, attempted to commit suicide at Farmville, Virginia, by stabbing himself with a sharp, long-bladed knife, in the left side of the chest, between the fourth and fifth ribs, about an inch to the left of the nipple, perforating the pleural cavity. There was very little bleeding from the orifice of the wound, and no expectoration of blood. The wound was closed and hermetically sealed; but, in the course of three or four days, it was found necessary, on account of accumulation of pus, to reopen the wound. Until six weeks ago he seemed constantly to improve. The inflammation of the pleura was reduced, and he suffered very little from cough. At that time diarrhœa set in, and he died on July 18th.

CCCXXXIV.—*Report of a Punctured Wound of the Stomach, with other Injuries.* By EDWIN BENTLEY, Assistant Surgeon, U. S. A.

Corporal George Williams, Co. B, 12th Infantry, aged 24 years, a strong and robust man, received a punctured wound of the left side, in an encounter with a comrade, near Russell Barracks, at Washington. A physician applied a roller bandage around the chest, and had the man conveyed to the post hospital twenty minutes after the reception of the injury. He had been eating and drinking freely, and when admitted was suffering the most excruciating agony. He was immediately put under the influence of chloroform and the wound was examined. An incision about three and half inches in length was found between the sixth and seventh ribs, on the anterior portion of the left side. Through this opening nearly a handful of the greater omentum was projecting. In replacing this, two fingers were found to readily pass into the stomach, without enlarging the wound. The anterior portion of the stomach was drawn through the wound, and a portion of its engorged contents was taken out. A branch of the right gastro-epiploic artery was ligated. The incision of one and a half inches in length was closed by the glover's stitch, and the organ, with its omentum, was replaced and the external wound closed by suture and pledgets of lint. A bandage was then applied. He was kept perfectly quiet and sufficiently easy to obtain several hours sleep, by the hypodermic use of a solution of morphia. He was allowed no nourishment but milk, a few teaspoonfuls of which relieved his throat and the inflammation of the stomach very satisfactorily, much better even than ice, pieces of which he was allowed to have con-

tinually in his mouth if he desired. He retained his reason perfectly and lived nearly thirty-six hours after being wounded, death resulting on September 14, 1867. The *post-mortem* examination showed three wounds in the left side of the chest; one in the infra-clavicular region, about half an inch in length and non-penetrating; one in the infra-scapular region, also non-penetrating, and an extensive wound between the sixth and seventh ribs, passing through the lower and anterior portion of the left pleural cavity, perforating the diaphragm, and entering the stomach near the middle and lower side of the anterior surface to the right of the spleen. The wound in the stomach had contracted very much since the injury, as also the organ itself. The left cavity of the chest contained twenty ounces of serum and flocculent lymph, and a deposit of coagulated lymph lined the pulmonic and costal pleuræ. The left lung was partially compressed; all the other organs were healthy, except the spleen, which was enlarged and softened, and contained four masses of cheesy tubercle.

CCCXXXV.—*Report of a Punctured Wound of the Stomach.* By A. J. HOGG, M. D., Acting Assistant Surgeon.

Private Maynard, 9th Infantry, just after eating a hearty dinner, was stabbed on June 7, 1870, near Looking-glass Creek, Nebraska, with a common pocket knife, the blade of which, four inches in length by one-half inch in breadth, cut through the cartilage of the ninth rib of the left side, and penetrated the stomach. The shock lasted about six hours, and was followed by moderate reaction. About four hours after the receipt of the injury, he threw up the contents of his stomach, consisting of what he had eaten for dinner and several ounces of clotted blood. The treatment pursued was very simple; the wound of the integument was closed with an adhesive strip and a compress applied. Nothing was given him for the first forty-eight hours but pounded ice. On the third day he was allowed a small quantity of boiled sago; on the fifth day he was permitted to walk about, and on the thirteenth day after the receipt of the injury was returned to duty.

CCCXXXVI.—*Report of a Punctured Wound of the Abdomen.* By J. H. BARTHOLE, Assistant Surgeon, U. S. A.

Private William Patterson, Co. A, 29th Infantry, aged 23 years, received a punctured wound of the abdomen in a drunken brawl at Lynchburg, Virginia, October 21, 1867. After being wounded he walked a distance of half a mile to camp, when he was admitted to hospital. Upon examination, a wound one-half inch in length, such as would be inflicted by a common clasp-knife, was observed one-half inch from the mesial line and two and one-half inches above the crest of the pubis. A portion of the omentum, about the size of a large walnut, protruded from the wound. This was at once passed within the abdominal walls and the wound brought together and united by three interrupted sutures. Shortly after dressing the wound the bowels moved, followed immediately by vomiting. There was extreme tenderness on pressure over the entire abdomen, particularly over the left iliac region. There was general peritonitis; pulse 120. A narcotic was administered, and he slept during the night. Vomiting occurred during the night of October 23d. He continued to fail and died at 4 o'clock on the morning of October 24, 1867. At the autopsy, on opening the cavity of the abdomen, about one-half gallon of bloody serum was found; the usual characteristics of serous inflammation were observed. An examination of the intestines revealed the fact that the knife inflicting the wound had passed directly through the ilium, causing a double wound.

CCCXXXVII.—*Note of a Punctured Wound of the Abdomen.* By JOHN T. KING, M. D., Acting Assistant Surgeon.

Private William Moller, Co. C, 8th Infantry, aged 24 years, was wounded by a knife, May 15, 1870, which penetrated the abdominal walls, just below the umbilicus. He was admitted to the post hospital at Spartanburgh, South Carolina, the same day. Interrupted sutures and anodynes were used, and on June 3d he was returned to duty.

CCCXXXVIII.—*Note of a Punctured Wound of the Abdomen.* By C. W. YOUNG, M. D., Acting Assistant Surgeon.

Private John Carey, Co. G, 10th Infantry, was wounded in a quarrel, November 26, 1869, by a pocket knife, which entered the left side, penetrating the abdominal cavity. He was admitted to the post hospital at Helena, Texas. Simple dressings were applied, and the man was returned to duty January 16, 1870.

CCCXXXIX.—*Report of a Bayonet Wound in the Hypochondriac Region.* By J. W. WILLIAMS, Assistant Surgeon, U. S. A.

Private William H. Huber, Co. K, 5th Artillery, was stabbed with a bayonet on the night of November 21, 1870, at Fort Sullivan, Maine. The point of the bayonet entered the left hypochondriac region, between the eleventh and twelfth ribs, and from before, backward and below, upward, apparently injuring the spleen. The patient lost about twenty ounces of blood in a few minutes, from which he fainted. Dark-colored blood continued to issue from the wound for two days. The abdomen was considerably distended with blood, but no evident symptoms of peritonitis set in at any time. The patient was kept under full doses of opium. At the date of this writing the patient is convalescent. [He was returned to duty in December, 1870.—ED.]

CCCXL.—*Notes of two Cases of Lance-Wounds.* By J. H. MCMAHON, M. D., Acting Assistant Surgeon.

CASE I.—Private John Foster, Co. K, 9th Cavalry, received a punctured flesh-wound of the right gluteal region, by a lance, September 12, 1868. He was admitted to the post hospital at Fort Davis, Texas, on the 14th. Simple dressings were applied, and he was returned to duty on September 18, 1868.

CASE II.—Private Gilbert Colyer, Troop F, 9th Cavalry, was wounded at the battle of Horse-Head Hills, Texas, September 12, 1868, by a lance which penetrated the thorax, entering on the right side, seven inches from the spine, between the sixth and seventh ribs. The lung was uninjured. Simple dressings were applied to the wound. He recovered and was returned to duty in October, 1868.

CCCXLI.—*Note of Punctured Wounds of the Arm and Shoulder.* By G. H. GUNN, Assistant Surgeon, U. S. A.

Private Samuel Ridley, Co. I, 9th Cavalry, aged 24 years, was wounded, October 22, 1870, by a knife, which entered the superior and inner angle of the scapula and middle of right arm. He was admitted to the post hospital at Fort Quitman, Texas, the same day. Simple dressings were applied. He died on October 30th, from hæmorrhage.

CCCXLII.—*Note of a Punctured Wound of the Thigh.* By AARON ANSELL, M. D., Acting Assistant Surgeon.

At Fort Inge, Texas, August 4, 1867, Lieutenant N. J. McCafferty, Co. K, 4th Cavalry, received a punctured wound of the thigh, penetrating the femoral artery (*sic*). He was admitted to the post hospital, where simple dressings were applied. The hæmorrhage was controlled, and the officer returned to duty, August 17, 1867.

CCCXLIII.—*Report of an Incised and Punctured Wound of the Knee-Joint, having a Fatal Result.* By CALVIN DEWITT, Assistant Surgeon, U. S. A.

Corporal Henry Atley, Co. E, 3d Cavalry, received an incised and punctured wound of the right knee-joint, on April 10, 1870, while on escort duty near Camp McDowell, Arizona Territory; his horse becoming restive, crowded his right leg against the saddle-bags of a comrade, from which a large knife was protruding. The knife entered at the outer side of the popliteal space, passed obliquely upward and inward, struck the head of the tibia, from which it glanced, and entered the

cavity of the knee-joint. The hæmorrhage was very severe, but was finally controlled by cold water. He was admitted on the next day to the hospital at Fort McDowell, where the limb was bandaged, constant applications of cold water ordered, and absolute rest enjoined. On April 12th, the bandage becoming tightened from swelling, was removed. The knee was painful. The wound was dressed with carbolic acid and olive oil, and the limb was placed, slightly bent, in a cradle; the application of cold water was continued, with nourishing diet and opiates at night. No improvement having taken place, on April 16th, the administration of Gross's antimonial and saline mixture was directed, with continuance of the dressings, and application of cold water. Tonics, with beef-tea and wine, were given at regular intervals during the day. Improvement was manifest, and continued until May 23d, when blisters and tincture of iodine were applied, and subsequently iodide of potassium was administered to encourage absorption, which took place slowly. By May 23d, the knee was reduced to its normal size, and almost all evidence of inflammation had disappeared, and the patient's condition was most satisfactory, the wound having healed, except on the surface, over which the new skin was closing rapidly. On the night of May 28th, notwithstanding stringent directions had been given that the leg must not be moved unless permission was given, the patient bent the knee "in order to try it," as he said. The result was manifest the next day; inflammation set in; the knee became hot, swollen, and painful, and in a few days there was effusion in the knee-joint, and constitutional sympathy. He gradually lost his appetite and strength. The wound reopened, and in two weeks suppuration commenced and pus was discharged. Tonics, stimulants, and nourishing diet were given, but without effect. He wasted rapidly until June 12, when a severe diarrhœa set in, which increased in violence until June 23, when he died from exhaustion.

LACERATED AND CONTUSED WOUNDS.—The reports usually contain a rather large proportion of cases of bruises and lacerations. A few instances may be cited, among them two interesting examples of laceration of internal organs without breach of continuity in the integument.

CCCXLIV.—*Note relative to a Wound of the Scalp.* By CARLOS CARVALLO, Assistant Surgeon, U. S. A.

Private George T. Atwood, Co. K, 5th Cavalry, aged 22 years, admitted to hospital at Sedgwick Barracks, Washington, on September 20, 1867, with a triangular lacerated wound of the scalp, received in a fracas with a policeman, in Washington, the previous day. The gaping wound was drawn together with adhesive strips, and on the 21st, proud flesh appearing on the edges of the wound, it was cauterized. The wound healed rapidly, and, on October 6th, the patient was returned to duty.

CCCXLV.—*Note relative to a Wound of the Scalp.* By JAMES F. WEEDS, Surgeon, U. S. A.

At Ash Barracks, Nashville, February 1, 1870, Frank Morton, corporal, Co. K, 14th Infantry, when intoxicated, received, by falling from a railroad tressel-work, on a rough stone, a severe wound on the left side of the head, six inches long, over the parietal and temporal bones. He was admitted to post hospital the next day, and a lotion of a solution of carbolic acid on lint was applied. He recovered and returned to duty February 24, 1870.

CCCXLVI.—*Mention of a Contusion of the Scalp.* By D. McLEAN, M. D., Acting Assistant Surgeon.

Private John Riley, Co. F, 19th Infantry, aged 27 years, received a contusion of the scalp over the left parietal bone, by a fall on a steamer when returning from absence with leave, from New Orleans, on November 9, 1870. He was admitted to the post hospital at Fort Pike, on the same day, and cold-water dressings applied. He was returned to duty on November 14th.

CCCXLVII.—*Note of a Case of Contused Wound of the Forehead.* By DANIEL MCLEAN, M. D., Acting Assistant Surgeon.

Private Eugene Navarra, Co. F, 19th Infantry, aged 33 years, received a lacerated wound over the frontal bone, by a blow of the butt of a musket, in a quarrel in company quarters, on December 13, 1870. He was admitted to the post hospital at Fort Pike, the same day. The edges of the wound were brought together by adhesive strips, compresses, and bandages. He was returned to duty on December 17, 1870.

CCCXLVIII.—*Note of a Lacerated Wound of the Head.* By AARON ANSELL, M. D., Acting Assistant Surgeon.

First Lieutenant N. J. McCafferty, Co. K, 4th Cavalry, aged 27 years, received, by falling from a horse, a lacerated wound of the head, severing the left ear from above to the lobe, at Fort Inge, Texas, on June 2, 1867. He was admitted to the post hospital on the same day. Simple dressings were applied. He rapidly recovered, and returned to duty on June 9, 1867.

CCCXLXI.—*Mention of Scalp Wounds with Laceration.* By W. H. HOPPER, M. D., Acting Assistant Surgeon.

Private Dennis G. Milane, Co. I, 14th Infantry, aged 26 years, received, by a club, lacerated and contused wounds of the scalp, at Lebanon, Kentucky, April 16, 1870. He was admitted to the post hospital on the same day. Simple dressings were applied. He returned to duty on June 20, 1870.

CCCL.—*Remarks on a Case of Wound of the Scalp.* By JOHN B. WHITE, M. D., Acting Assistant Surgeon.

Private Andrew Lewis, Co. B, 40th Infantry, appears, in the report for December, 1868, from the post hospital at Raleigh, as having received a wound of the scalp over the left of the frontal bone, extending from the median line to the centre of the orbital arch, dividing the integument to the bone. The injury was inflicted by a brick, in the hands of one of his comrades. Symptoms of concussion were present from the first. Careful attention was directed to the open wound, the edges of which were secured by sutures and adhesive strips. Irrigation was kept up for about twelve hours. Patient made a good recovery, and was returned to duty in three weeks from the reception of the injury.

CCCLI.—*Report of a Contusion of the Head.* By B. A. CLEMENTS, Surgeon, U. S. A.

Sergeant M. Dougherty, Co. G, 6th Cavalry, aged 28 years, was injured January 31, 1868, at New Orleans. While mounting his horse he received a violent fall upon a stone pavement, in consequence of the parting of the girth, the horse having started at full speed. The scalp was contused and lacerated at the vertex of the cranium, three-quarters of an inch long, but not extending down to the bone; there was also a severe contusion of the forehead. He was stunned by the fall, but did not become insensible. He was at once sent to the post hospital at Jackson Barracks, New Orleans, where he was visited by Surgeon B. A. Clements, United States Army, and Acting Assistant Surgeon Payne, within a few hours after the occurrence of the injury. He was sensible, though somewhat slow in speech; pulse 64, full, but rather weak; respiration unaffected, and skin cool; he vomited at frequent intervals, and complained only of pain in his head, both at the vertex and in the forehead; the pupils were perhaps dilated to a slight extent, but readily contracted on exposure. The case had been considered one of depression, and probable fracture of the skull, but there were no evident signs of such an injury. The next morning the pulse was 56, skin still disposed to be cool, pupils still slightly dilated; had continued to vomit occasionally during the night. In order to determine with accuracy the state

of the cranium at the seat of the wound, and feeling some assurance there was no fracture, Surgeon Clements made an incision at the seat of the wound, and introducing a finger, found no evidence either of fracture or depression; there was no effusion beneath the scalp. Bowels moved freely; there was a purplish ecchymosis at the inner angle of both eye-lids, not extending to the mucous membrane of the eye or eye-lids, and some tumefaction of the skin of forehead. He was quiet and disposed to sleep; patient improved, and by February 15th, the wound of scalp had entirely healed; he complained at times of acute pain at the seat of the wound, otherwise he was quite well. He was returned to duty February 27, 1868, and advised not to ride on horseback for a month, and to be temperate. He still at times had a rather acute pain at the seat of the wound of scalp. One point of interest in this case was the character of the ecchymosis around the eyes, which might have been confounded with that which is seen at times in fracture of the base of the skull, but for its superficial character.

CCCLII.—*Remarks relative to a Case of Contusion.* By P. J. A. CLEARY, Assistant Surgeon, U. S. A.

Private Daniel Sullivan, Co. E, 45th Infantry, was admitted to the post hospital at Chattanooga, November 25, 1867, having, while intoxicated, been engaged in a fight. His face was covered with blood and bruises. On washing away the blood, a flesh-wound was found over the left eye, about an inch in length, and another on the left side of the head, about an inch and a half from the median line, commencing at the coronal suture, and passing downward and inward for two inches. This wound had evidently been made with a blunt weapon, probably brass knuckles. On examination, the lower part of the wound was found to extend to the bone, which was denuded of its periosteum to the extent of about half a square inch, but neither depression or fracture could be detected. He also complained of severe pain in the back from a kick. There was discoloration over the third and fourth lumbar vertebrae, with great tenderness on pressure. The patient was fully conscious, but very restless. Cold applications were made to the head, and Hoffman's anodyne administered. Patient slept well during the night, and the next morning felt much relieved. He continued to improve, and on December 13th was returned to duty.

CCCLIII.—*Note of a Case of Contusion of the Chest.* By W. T. HYSON, M. D., Acting Assistant Surgeon.

Private John Delaney, of Battery F, 5th Artillery, aged 24, while at drill on November 6, 1867, at Camp Williams, near Richmond, Virginia, was knocked down by the wheel of the limber, and immediately run over by the gun-carriage, the wheel passing transversely over his thorax, immediately above the nipples. Incredible to say, he was not killed by the immense weight of the gun (a three-inch Rodman rifle), but was not even hurt seriously. He rode from the drill-ground on the caisson-box. The track of the wheel was distinctly shown by discoloration on the left side and front of the thorax. On the following day, November 7th, he was well, except a slight soreness in the region of the bruise. On the second day he was returned to duty, well, and continued so at the date of this report.

CCCLIV.—*Report of a Case of Contusion followed by Pleuritis and Hepatitis.* By D. MERRITT, Surgeon, 4th Veteran Volunteers.

Lieutenant Daniel K. Springer, 4th Veteran Volunteers, was taken with a severe pain in the right side, in the region of the liver, the symptoms being those of acute inflammation of that organ. He was admitted on August 8, 1865, to the hospital at Camp Chase, Ohio. An abscess soon after formed in the right hypochondriac region, the tumefaction spreading toward the epigastrium, and between the floating ribs and liver. Poultices of flaxseed meal were applied, and the tumor was opened, giving exit to more than two quarts of bloody pus of a very unhealthy character. Gangrene soon after supervened; then extensive sloughing, involving a portion of the rectus abdominis muscle, and causing an opening into the transverse colon, through which fecal matter escaped until, by enemata, it was passed through the natural way. The gangrene was arrested by appli-

cation of nitric acid. Under subsequent applications of lint saturated with a solution of chlorate of potassa, the abscess was doing very well; healthy granulations were being thrown out; fecal matter was discharging by the rectum, and the patient doing well, when an untoward condition set in. He became weaker, notwithstanding the administration of stimulants and nourishing diet, and died October 2, 1865. Throughout the case the patient evinced the utmost heroism. The abscess, as far as could be learned, was the result of injuries received by being knocked down and kicked in Philadelphia while on the way to Camp Chase. The autopsy revealed adhesions between the pleura pulmonalis and pleura costalis. The liver was healthy except on the outward surface, where there was slight evidence of the abscess having burrowed in the hepatic tissue. The kidneys and stomach were normal. The lungs were very much surcharged with dark venous blood. The transverse colon was ulcerated.

CCCLV.—*Report of a Case of Contusion from a Railway Accident.* By G. S. ROSE, Assistant Surgeon, U. S. A.

Private John Holden, Co. C., 29th Infantry, age 23, was injured at Keswick, Virginia, September 28, 1868, by a railroad accident. Being admitted on the next day to the post hospital at Camp Schofield, Lynchburgh, he stated that, while riding on the top of a box-car, and seeing the car in front of him rolling over the embankment, he sprang from the top, but was unable to get away in time, and was struck in the back by the car as it rolled over. He complained of intense pain over the sacrum, extending between the anterior superior spinous process and the right tuber ischii. The parts over the sacrum were exceedingly tender on pressure, the slightest motion or touch causing him to scream with pain. I was unable to elicit crepitus. He could flex the leg on the thigh without pain, but was unable to flex the thigh on the pelvis. The soft parts were much ecchymosed, and he had a dull, moving, continuous pain, extending across the whole front of the pelvis. Anodynes, with nourishing diet, were given. The patient, making a good recovery, was returned to duty November 26, 1868.

CCCLVI.—*Note of a Case of Contusion of the Back.* By A. F. MECHEM, Surgeon, U. S. A.

At Fort Porter, New York, on October 5, 1867, Private Thomas Carroll, Battery L, 1st Artillery, aged 23 years, presented himself at surgeon's call, stating that some time during the previous night he had been struck in the back with the butt end of a musket in the hands of a sentinel. The blow knocked him down, when he was struck twice in the splenic region with the same weapon. On examination, a slight wound, such as might have been made by the percussion hammer of a musket, was found about an inch and a half to the left of the articulation of the twelfth rib with the twelfth dorsal vertebra. About two inches lower, at the same distance from the second lumbar vertebra, was another wound of the same character. He was treated in the post hospital, at Fort Porter, until October 21, 1867, when he was returned to duty entirely cured.

CCCLVII.—*Mention of a Case of Contusion of the Back.* By C. R. GREENLEAF, Assistant Surgeon, U. S. A.

August Burtz, artificer of Co. H, 2d Infantry, aged 38, was admitted to the hospital at Taylor Barracks, Kentucky, on November 7, 1868, having fallen from a ladder to the floor, a distance of fourteen feet. He complained of pain in the bowels and inability to pass water, and suffered considerably from shock. A stimulant and an anodyne were administered. He was improved on the 8th; but, on the 10th, was taken with intermittent fever, which yielded to quinine and iron. He recovered and was returned to duty November 15, 1868.

CCCLVIII.—*Report of Case of Contusion, with Rupture of the Liver and Kidneys.* By G. H. GUNN, Assistant Surgeon, U. S. A.

Private Henry Greene, Co. H, 9th Cavalry, entered hospital at six in the evening of December 15, 1870, at Fort Quitman, Texas, having been run over by a wagon at eight o'clock the morning of the same day, while on his way to Fort Quitman from Eagle Springs. Both wheels of one side

were thought to have passed over him, from the right hip, over the thorax. The patient was suffering, upon admission, from shock and extreme depression, his extremities cold, his wrist almost pulseless. But he was perfectly conscious, the action of the heart was feeble but regular, 104 to the minute; respiration, 44. Any movement was evidently repressed and painful. No rales upon auscultation, some dullness over lower portion of right lung; great tenderness over hepatic region, with nausea and vomiting. Upon percussion over the right hypochondriac region, much pain was experienced. The diagnosis arrived at was, that there was a rupture of the liver. Stimulants and anodynes were ordered, the former continued every hour during the night; hot applications to extremities. Patient rallied a little after a few hours, but no permanent improvement was observed. Death occurred at 7.30 A. M. of the following day, the patient having passed, through the night, a quantity of nearly pure blood from the bladder. A *post-mortem* examination, ten hours after death, revealed a rupture of the liver, through nearly the entire extent of its antero-posterior diameter, following the junction of the right with the left and quadrate lobes, to within one inch of the anterior border of the organ. Also, a fracture of the sternum, at the junction of its upper and middle third, fracture of the eighth rib, two inches in front of its angle. The right lung was engorged, with a small puncture over the anterior aspect of its upper lobe, from the broken end of sternum. A large effusion of blood into the abdominal cavity was found, and a longitudinal rupture of the right kidney, throughout nearly its entire extent. The bladder was normal and empty.

CCCLIX.—*Case of Rupture of the Spleen.* By J. F. WEEDS, Surgeon, U. S. A.

Private Michael —, Co. C, 45th Infantry, while boxing with a comrade in the store of the post-trader at Nashville, Tennessee, July 3, 1869, received a comparatively light blow with the palm of the hand in the left hypogastric region. Ryan turned away, saying nothing, and walked on to the veranda, where, in a few moments, he fainted, and was carried to his company quarters. I visited him eight or ten minutes after the accident, at which time the pulse had ceased to beat at the carotid; the skin was blanched; the pupil fully dilated, and respiration, merely a gasp, repeated three or four times a minute. Death supervened in less than a quarter of an hour after the reception of the blow, with symptoms of shock and hæmorrhage. An autopsy, two hours after death, revealed the abdominal cavity filled with blood. This flowed from extensive fissures in the spleen, which was enlarged and softened, measured five by seven inches in diameter, and was two inches thick, weighing fourteen ounces. All the other abdominal viscera were normal; there were old pleuritic adhesions of the left side; in all other respects, the thoracic viscera was in a healthy condition. The pathological specimen, consisting of the spleen, is number 5600, Section 1, Army Medical Museum, and was forwarded with the history of the case.

CCCLX.—*Remarks on a Case of Contusion of the Abdomen.* By B. E. FRYER, Surgeon, U. S. A.

Private Lewis Metcalf, Co. H, 5th Infantry, on duty as teamster in the Quartermaster's Department, was admitted into the post hospital at Fort Harker, Kansas, August 20, 1870, just after the reception of a kick in the abdomen from a mule. He was bordering on a collapsed state; the pulse was scarcely perceptible at the wrist, and the surface was cold, with a clammy sweat resting on it. No marks of the kick were visible, though the man stated, after reaction had followed on careful use of stimulants, that the blow was received on the abdomen in the left hypochondriac region. He now complained of severe pain, which was promptly relieved by ten-grain doses of chloral hydrate. On the fifth day after the injury the bowels were relieved by an enema, and on August 28th he was able to be about the ward. September 4, 1870: Metcalf was returned to his duty in the Quartermaster's Department, with a request that, for a time, some light work be assigned him. From this period until the date of readmission into the hospital, (42 days' interval,) he was watchman at the quartermaster's stable, which gave him nothing but the lightest duty. On October 15th, the man, complaining of being weak and constipated, was given a mild aperient, marked "sick in quarters," and directed to keep quiet; but, disobeying this injunction, he got permission from his commander to go to the neighboring town, some three miles distant, where he purchased and ate a large quantity of pies, nuts, &c., which, he said, made him vomit. He reported

the next morning at sick-call as "feeling no better," and was readmitted to the hospital. On admission, his pulse was 72, and rather feeble; respiration somewhat labored, but otherwise natural; temperature normal; bowels still constipated; vomited several times; no pain or abdominal tenderness. Half-grain does of calomel, with one grain of opium, soon stopped vomiting. Enemata were given without avail, to move the bowels, though a careful examination of the abdomen showed no great accumulation of fecal matter. Milk and beef essence, with small doses of whiskey, were administered every hour to support strength, which appeared to be rapidly failing, but the man continued, however, to run down in spite of the supporting treatment and faithful nursing, and died early on the morning of October 19th. *Post-mortem* examination, eight hours after death; *rigor mortis* well marked; muscular system well developed; very slight wasting of adipose tissue; thoracic organs healthy; small abscess, about the size of a large hazel-nut, in the lower and posterior portion of the spleen, the pus being of a dirty yellowish-brown hue—the whole organ slightly shrunk, and somewhat hardened. Other abdominal organs, save a slight congestion of the mucous coat of the intestines, normal. No febrile symptoms exhibited themselves after readmission, and no positive indications of the spleen trouble were manifest, though it was feared, by exclusion, that a lesion of the spleen existed.

CCCLXI.—*Report of a Case of Contusion of the Pelvis.* By A. G. SKINNER, M. D., Acting Assistant Surgeon.

Private Thomas Morgan, Co. A, 42d Infantry, aged 34, was admitted to the hospital at Fort Niagara, New York, on October 2, 1867, the wheel of a loaded cart having run over his pelvis on the day previously. There was swelling, with extensive ecchymosis over the upper portion of the sacrum, and he complained of much pain. The patient was unable to walk. A stimulating lotion was applied to the contused parts, and anodynes were administered. A tumor, which formed over the injured part, was several times opened, and its contents evacuated. The patient suffered from chill and fever. By November, his general health had improved under expectant treatment; but the wound was still open. On December 6th, he was permitted to do light duty, the wound being frequently examined. Being returned to hospital on the 27th, the wound was swollen, inflamed, and freely discharging dark, purulent matter. The swelling having subsided by January 13, 1868, and the condition of the wound remaining unchanged, an incision three inches long was made down to the diseased structure, which was found to be a hard, cartilaginous growth, with bony deposit, between which and the periosteum the purulent matter had been lodged, and escaped by means of an opening. On dissecting out this diseased growth, and touching the walls of the remaining cavity with nitrate of silver, the wound was closed with adhesive strip and a compress. But little suppuration followed, and on the 28th, the wound being nearly healed, the patient was returned to duty.

CCCLXII.—*Report of a Case of a Contused Wound of the Perinæum.* By JOHN T. KING, M. D., Acting Assistant Surgeon.

Private Charles May, Co. E, 2d Infantry, aged 25 years, while intoxicated, fell astride of a board as he was descending the steps in the rear of his company quarters, on February 22, 1870. Immediately after the fall there was great swelling and induration of the perinæum, and the calibre of the urethra was encroached upon to such an extent that the patient was unable to micturate. On the next day he complained of severe pain behind the pubes. An attempt was made to introduce the catheter, which failed. On February 27th the bladder had become enormously distended with urine, and every local symptom was aggravated. There was great hyperæsthesia of the entire abdomen, and considerable swelling and slight fluctuation in the perinæum. There was intense thirst, quick pulse, nausea, and headache. A second attempt was made to introduce the catheter, but the great pain, enormous swelling, and spasmodic contraction, complicated with acute gonorrhœa, proved obstacles not readily overcome. Still the effort was persisted in to relieve the bladder in this way rather than resort to either recto-vesical or supra-pubic puncture. After considerable effort the catheter was introduced and about six quarts of fluid drawn, of which it was estimated fully one-half was blood. On March 1st the swelling of the perinæum

had not abated. On attempting to introduce the catheter the urethra contracted spasmodically. Unfortunately, in continuing the effort the wire was thrust through the end of the catheter, which punctured the walls of the urethra and entered an abscess. Whether this puncture with the wire only anticipated what nature would have done, has been a question in my mind. While I believe that any opening into the urethra was of all things to be feared and guarded against, as likely to produce extravasation of urine and urinary fistulæ, yet I believe that the abscess would have pointed there eventually. On March 6th, incisions were made into the perinæum to give vent to the contents of the abscess; the discharge was profuse and offensive; the abdomen was tense, swollen, and very tender; the pulse frequent and feeble; tongue parched with extreme thirst; the appetite impaired, and the bowels constipated. A catheter was retained for several days, through which the bladder was frequently evacuated. Large clots of blood passed, with considerable mucus. Upon the bladder being emptied there would be spasmodic contraction, accompanied by intense pain, which was attributed to the contact between the walls of the bladder and the point of the catheter. The patient was taught to introduce the catheter, which he did with comparative ease. Occasionally the eye of the catheter would become occluded with blood and mucus, so that the contraction of the bladder and the abdominal walls would force the urine by the catheter and discharge it through the fistulous openings in the perinæum. Warm fomentations were applied to the abdomen and stimulants given. Under the treatment adopted there was gradual abatement of the symptoms, and a decided improvement in general health. On March 15th, the hæmaturia had almost disappeared, but the discharge of mucus had become more manifest. The urine was still drawn through the catheter that nature might heal the abnormal outlets. On the 20th, the patient discharged urine with little pain in ordinary amount and with scarcely a trace of mucus. He continued to improve, and on March 31st, two of the fistulous openings had healed, and the only remaining one looked healthy and was contracted very much. The patient had recovered strength, though he still retained the recumbent posture.

CCCLXIII.—*Note of a Case of Contusion of the Thigh.* By CARLOS CARVALLO, Assistant Surgeon, U. S. A.

Private Arthur Calquhoun, Troop K, 5th Cavalry, aged 22 years, was kicked by a horse, September 26, 1867, causing a contusion of the right thigh, just above the knee. On admission to the post hospital at Sedgwick Barracks, Washington, the injured limb was swollen and tender. Plaster of Paris bandage was applied. He recovered, and was returned to duty October 8, 1867.

CCCLXIV.—*Memorandum of a Contusion of the Knee-Joint.* By W. S. ADAMS, M. D., Acting Assistant Surgeon.

Corporal William H. Hoffman, Troop A, 5th Cavalry, aged 25 years, was admitted to the post hospital at Morganton, North Carolina, October 10, 1867, with a contusion of the right knee-joint, caused by the kick of a horse received about October 1st. The joint was found swollen and roughened, with slight redness and much heat. The patella was elevated at least half an inch above the condyles. He complained of but little pain, nor had he any well-marked chill. The limb was placed in a straight splint and a blister applied to the joint, to be followed by tincture of iodine. On October 15th the patient was much improved; effusion apparently absorbed. The splint was removed, but rest enjoined; and on October 25th he was returned to duty, motion nearly perfect.

CCCLXV.—*Note relative to a Contusion of Foot.* By C. R. GREENLEAF, Assistant Surgeon, U. S. A.

Private Albert J. Furay, Co. I, 2d Infantry, aged 32 years, was admitted to the post hospital at Taylor Barracks, Kentucky, July 17, 1868, with a contused wound of the left foot, caused by the falling upon it of an iron safe which he was assisting to move. Warm fomentations were applied, and on July 28th, he returned to duty entirely recovered.

CONCUSSION AND COMPRESSION OF THE BRAIN.—Examples of slight stunning from falls or blows are of course very common in military practice, and the graver cases of concussion, contusion, laceration, and compression of the brain are not infrequent. The Cases of fracture of the skull will be reported in the next section. Some of the instances of concussion and compression may be here recorded:

CCCLXVI.—*Report of a Case of Concussion of the Brain.* By A. G. BATES, M. D., Acting Assistant Surgeon.

Private W. R. Burroughs, Co. I, 40th Infantry, at Fort Macon, July 2, 1867, received two blows from a hammer, in the hands of an escaping prisoner, upon the front and right side of the head, above the temporal ridge, producing severe concussion of the brain. He remained in a comatose state for several hours. After reaction took place he was put upon proper treatment. There being no perceptible fracture of the bones, the flesh-wound was allowed to heal, which it did readily. He suffered from headache, giddiness, loss of memory, impaired vision, confusion of thought, and was very dull of comprehension. To a casual observer his recovery would appear complete, but the injury received had left the brain in such an unstable state that it would be disturbed by the least excitement, and the man was therefore discharged on August 21, 1867.

CCCLXVII.—*Remarks on a Case of Concussion of the Brain.* By H. M. CRONKHITE, Assistant Surgeon, U. S. A.

Sergeant Daniel Isaacs, Co. I, 10th Infantry, while attending a fandango at Rio Grande City, Texas, on the night of December 24, 1869, received a severe blow upon the head with an unknown weapon, supposed to have been a brick, in the hands of a Mexican, from the effect of which he lay insensible until 5 o'clock P. M., December 25, 1869, at which time he died. Upon *post-mortem* examination the following pathological conditions were exhibited: In the cellular tissue of the scalp, over the superior curved line of the occipital bone, on the left side of the occipital protuberance, there was extensive ecchymosis; on removing the skull-cap several ounces of effused, coagulated blood were found between the dura mater, covering all the posterior half of the left hemisphere of the cerebrum. On close examination no fracture of the cranium could be found in either table.

CCCLXVIII.—*Memorandum of a Fatal Case of Compression of the Brain.* By ELLIOTT COUES, Assistant Surgeon, U. S. A.

At Columbia, January 14, 1868, John Kelly, hospital steward, aged 24 years, received, by a fall, a wound of the head, causing compression of the brain. He was admitted to post hospital on the same day. Simple dressings were applied. He died January 16, 1868.

CCCLXIX.—*Remarks on a Case of Severe Concussion of the Brain.* By J. P. FOOT, M. D., Acting Assistant Surgeon.

Private Patrick Eagan, Co. B, 42d Infantry, was brought to hospital at Plattsburg, New York, about 6 o'clock P. M., April 9, 1867, in an unconscious condition, and bleeding profusely from a wound upon the head, the result of a blow which he had received from a musket, in the hands of an intoxicated soldier. On examination, a lacerated wound, one inch in length and one-quarter of an inch in depth, was discovered upon the right orbital ridge; also, a slight tumefaction in right temporal region. Blood was oozing slowly from the nose and mouth; the eyes turned upward and fixed; pupils contracted and insensible to light; pulse feeble; countenance pallid; and the surface of the body cold. The breath was of a decidedly alcoholic character, indicating some degree of inebriation coexisting with concussion of the brain. The case was treated as concussion of the brain. Cold water to the head, hot applications to body and feet, and sinapism to spine. At 11 o'clock P. M., patient exhibited symptoms of a reaction; he replied to questions, but rather con-

fusedly; complained of great pain in the head. He was kept quiet, and the treatment continued. He slept a little during the night, but was restless at intervals. The next morning, April 10th, the patient appeared quite sensible; pulse 76 and stronger; complained of severe frontal headache; skin dry and hot; no appetite and considerable thirst. Continued cold water to the head, and gave four grains of nitrate of potass. every two hours. The febrile symptoms subsided during the day, and patient slept during the night without interruption. From this time the patient rapidly improved, and on April 18, 1867, was dismissed from the hospital and returned to duty.

CCCLXX.—*Note of a Concussion of the Brain.* By JOHN E. TALLON, M. D., Acting Assistant Surgeon.

At Fort Bayard, New Mexico, September 17, 1869, Private John Fracker, Co. B, 3d Cavalry, aged 25, had a fall from his horse, producing a severe concussion of the brain. He was admitted to the post hospital the same day, and was treated by cold-water dressings, with stimulants internally. The patient was gradually recovering at the close of the month, and was returned to duty some time in October.

CCCLXXI.—*Mention of a Case of Concussion of the Brain.* By JOHN VANSANT, Surgeon, U. S. A.

At Little Rock Arsenal, Arkansas, Private Michael Mooney, Co. D, 28th Infantry, aged 19, was admitted to post hospital, December 29, 1866, with concussion of brain. Remained in the hospital; nearly well at the end of the month, and was returned to duty in January, 1867.

CCCLXXII.—*Memorandum of a Fatal Case of Concussion of the Brain following a Blow.* By D. W. BOSLEY, Assistant Surgeon, 3d United States Colored Artillery.

Private Isaiah Williams, 3d Colored Heavy Artillery, was admitted to the regimental hospital, October 31, 1865, suffering from a wound of the scalp over the right parietal bone. The external table of the cranium was not fractured; but, judging from the symptoms which followed, loss of consciousness and convulsions, it was supposed that the internal table was fractured or depressed. Death resulted November 15, 1865.

CCCLXXIII.—*Case of Traumatic Apoplexy.* By L. Y. LORING, Assistant Surgeon, U. S. A.

Private John W. Thomas, Light Battery A, 2d Artillery, aged 23, was brought to the hospital at Fort Riley, Kansas, on the morning of December 20, 1870, having been thrown from his horse to the frozen ground a few minutes before. There was a contusion of the left cheek over the malar bone, from which there was some hæmorrhage; the lid of the left eye was bruised and congested, and a very slight bruise of the skin over the left edge of the frontal protuberance. The most careful examination failed to discover any fracture of the skull or signs of injury other than those mentioned. He was in a semi-conscious condition when admitted, and complained of the cut on his face, which he was constantly picking. He vomited several times. The pupils were contracted, breathing slow and labored, pulse slow and soft. Compression of the brain was diagnosed from fracture of the skull, causing either some pressure of bone upon it or rupturing a blood vessel, causing extravasation, accompanied by some concussion of the brain, from which he was slightly recovering. The prognosis was unfavorable, and operative interference out of the question, as there was nothing at all to indicate the seat of injury. He was covered with warm bed-clothing and warmth applied to the feet, with sinapisms to the abdomen, in order to bring about reaction. He grew rapidly worse, becoming entirely unconscious in the course of twenty minutes; the pupils became dilated and the eyes fixed and insensible. The contents of the bladder were evacuated, but not of the bowels. At 6 P. M. respiration became stertorous and sighing, and he gradually failed, dying at 9 P. M., eleven hours after the reception of the injury. A *post-mortem* examination was made sixteen hours after death. *Rigor mortis* intense; body well nourished and

developed. In dissecting up the scalp, some congestion was found over the temporal muscle, as if it had been contused, but there was nothing whatever to indicate it externally. Upon removing the calvarium a clot of blood weighing three ounces was discovered between the bone and dura mater, over and at the side of the middle lobe of the right hemisphere of the brain; there were also spots of extravasation between the dura mater and arachnoid, at the upper part of both hemispheres over the middle lobes, presenting the appearance as if encysted. The brain at the seat of the large clot presented the appearance of being contused and disorganized by the pressure upon it; with this exception the brain substance appeared normal throughout. There was a fracture of the base of the skull, beginning at the cribriform plate of the ethmoid bone, extending posteriorly to the body of the lesser wing of the sphenoid where it branched, one branch extending to the optic foramen of the left side, and the other taking a course indicated by the optic foramen, the foramen rotundum, and the foramen ovale, and then posterior to the foramen spinosum of the right side, curving around it, and, when at a point one inch external to it, again branched, one branch extending forward through the squamous portion of the temporal bone and across the anterior inferior angle of the parietal into the frontal, ending at a point one inch anterior to the junction of the lower with the middle third of the fronto-parietal suture, the other posteriorly in a line between the squamous and petrous portion of the temporal bone and then into the parietal bone parallel to the occipito-parietal suture and ending at a point two inches anterior to the posterior superior angle of the right parietal. This fracture in its course involved both tables of the skull, and divided the grooves in which run both the anterior and posterior branches of the middle meningeal artery. The large clot formed at the side of the brain was caused by the rupture of the anterior branch. It was moulded and flattened by pressure, and seemed as if covered by a membrane, rendering it tough. The smaller clots appeared to be caused by the rupture of minute veins ramifying in the dura mater. The thoracic and abdominal viscera were healthy throughout, excepting the spleen, which was considerably hypertrophied and somewhat indurated. The intestines were much distended with semi-fluid substances.

CCCLXXIV.—*Report of a Case of Concussion of the Spinal Cord.* By HENRY LIPPINCOTT, Assistant Surgeon, U. S. A.

Surgeon A. F. Mechem, U. S. A., was accidentally injured at Hays City, Kansas, June 21, 1870, by jumping from a railway train while in motion. The fall caused partial concussion of the spinal cord, and violent shock to the sympathetic nervous system. When seen, shortly afterwards, by a medical officer, slight reaction had taken place; but there was extreme hyperæsthesia of the chest, neck, and upper extremities, which were of a cyanotic hue. The cerebral functions were undisturbed. The heart's action, almost suspended when first seen, came up under the influence of stimulants. When reaction had fairly taken place, there was violent arterial action at the wrist, which was unaccompanied by like action in the temporal and carotid arteries; in fact, the action of these vessels coincided neither in force nor frequency with that of the radial and ulnar arteries. Nor was the action of the heart, at any time after the pulsations became normal, other than healthy, although the extraordinary throbbing at the wrist continued several days. Excepting slight paralysis of the bladder, there was no loss of motor power. At first, the terrible hyperæsthesia of the hands and arms inclined me to the belief that there might be a fracture, dislocation, or something of this kind, which, by pressure upon the nerves, might possibly account for the symptoms described. However, a careful examination proved that there was neither fracture nor dislocation, but that the cause of the symptoms was only to be found in the spinal cord and sympathetic nervous system. The effect of the previous medication proving inefficient, morphine was administered hypodermically, and afforded much relief. This was soon repeated, selecting the region of the fourth dorsal vertebra for the operation. The application of cups, with hot applications of lead and laudanum, alternating with fomentations of hops and laudanum to the arms, hands, and thorax, assisted materially in mitigating the pain of the parts implicated. Some three days subsequent to the reception of the injury, the patient was conveyed on a litter to his quarters at Fort Hays. Arriving there, the use of the morphine was in a great measure dispensed with, Indian hemp and hyoscyamus being substituted. The hop fomentations were superseded by local

applications of chloroform and camphor, with sulphate of morphia and simple cerate. Tonics, nourishing diet, and stimulants, contributed much toward recovery. There was a decided tendency to typhoid depression, but this gave way to proper measures. [Surgeon Mechem's health remained delicate. In January, 1871, he availed of a leave of absence of one month, which was extended six months longer, for the benefit of his health. He died at Pleasantville, Maryland, at his father's home, July 14, 1871. The certificate of disability, forwarded to Adjutant General Townsend with the application for extension of leave of absence, was signed by Acting Assistant Surgeon T. B. Chase, at Fort Hays, and clearly traces the shattered condition of Doctor Mechem's health to the accident he had incurred.—ED.]

The foregoing seventy-seven reports afford information regarding twenty-nine cases of incised wounds, eighteen of punctured wounds, twenty-two of lacerated or contused wounds, and nine instances of concussion or compression of the brain. Of the twenty-nine cases of incised wounds, eight were fatal, and two resulted in disabilities incapacitating the men for service. One of these was an interesting instance of a recovery from a wound exposing the cavity of the knee-joint. In three of the eight fatal cases, the great vessels of the neck were divided, in two the heart was wounded, in three the abdominal cavity was penetrated, and in one of the latter the small intestine was divided in five places, and enterorrhaphy was practiced under hopeless conditions, the abdomen being filled with blood from the divided mesenteric artery. Among the nineteen patients who recovered and returned to duty, several survived the protrusion through the abdominal walls of large portions of the viscera.

Of the eighteen reports on punctured wounds, seven refer to fatal cases. One was an example of wound of the aorta, two were stabs in the lungs, three involved the abdominal viscera, and one the knee-joint. There was an interesting instance of recovery after puncture of the stomach. Of the twenty-two cases of contused and lacerated wounds reported, four were fatal. They were examples of lacerations of internal organs without wounds of the integument.

The special reports of concussion or compression of the brain or spinal cord related to nine cases, five of which had a fatal result.

SIMPLE AND COMPOUND FRACTURES AND LUXATIONS.

There were returned, for the period covered by the reports, fifteen hundred and ninety-nine cases of simple and compound fractures, and six hundred and twenty-five cases of luxations. Some cases in which special reports were made are cited here, and others in connection with the reports on operations.

CCCLXXV.—*Report of a Case of Fracture of the Skull.* By J. SIMONS, Surgeon, U. S. A.

Corporal George Adams, Co. E, 4th Artillery, was brought to hospital about two o'clock on the morning of September 1, 1869, by two of his comrades, who stated that he had been assaulted by unknown parties at Locust Point, about a mile from Fort McHenry, Maryland. Upon examination, an incised wound one and a half inches long was found at the back of the head, and a small, lacerated wound on the forehead, above the right eye. The man was questioned as to how and by whom the wounds were inflicted; but he was too much under the influence of drink, and the effects of the injuries he had received, to give intelligible answers. He was placed in bed, and his wounds were dressed with cold applications. During the night he was delirious, and had convulsions, from which he passed into profound coma, with stertorous breathing, in which condition he remained until his death, at half-past ten the following morning. The autopsy made next day by the coroner, in the presence of a jury, revealed an extensive fracture, about three inches long, commencing at the squamous portion of the temporal bone, and running in a semicircular line through the posterior and inferior portion of the parietal bone, and extending also into the occipital. Another small fracture, joining the anterior termination of the first at an acute angle, detaching a small piece of the temporal bone. A thick layer of extravasated blood was found covering a large portion of the right cerebral hemisphere, in the neighborhood of the fractures. It is remarkable that, with such a severe injury of the head, the man was able to walk, with the assistance of his comrades, the distance of a mile from the place where he was wounded.

CCCLXXVI.—*Abstract of a Report of a Fracture of the Base of the Skull and of the Fibula.* By JOHN ASHHURST, Jr., M. D., Surgeon to the Episcopal Hospital.

Joseph K. Alderfer, a discharged soldier, aged 25 years, was thrown from a wagon in Philadelphia, on August 31, 1865, causing a fracture of the sphenoid bone, arising in the left greater wing, passing through the olivary process and right greater wing, and ending in the petrous portion of the right temporal bone. The upper end of the left fibula was also comminuted. He was admitted into the Episcopal hospital about an hour after the injury. There was a great deal of ecchymosis of the left orbit. Blood flowed from the nose and mouth, and a large quantity had been swallowed and afterwards vomited. Pulse, 64; respiration somewhat labored; right pupil slightly contracted. He was restless, but rational. The injured limb was wrapped in pillows, ice applied to the head, and a teacupful of milk ordered every four hours. On the following day he was slightly delirious, pulse 68, arising to 112 on September 2d. Both pupils were contracted. Death resulted on September 3, 1865. At the autopsy, the membranes of the brain were found very much congested, containing about four ounces of reddened serum, and there was slight congestion of the brain and lateral ventricles.*

* This abstract was made by Hospital Steward Sawtelle, U. S. A., from notes by Dr. Bodine. A full account of the case is printed in the *American Journal of the Medical Sciences*, Vol. LII, p. 72.

CCCLXXVII.—*A Condensed Account of a Fracture of the Skull, in which Death occurred Three Years subsequently.* From a report by JOHN TAYLOR, M. D., Acting Assistant Surgeon.

James H. B—, a private of Co. G, 20th Infantry, a robust man, but a confirmed inebriate, was admitted to hospital at New Orleans, Louisiana, on September 12, 1868, in an epileptic fit, which lasted about twenty minutes, and left him in a state of stupor for hours after. From the patient's history, it was ascertained that he had received a blow on the head some three years previously, and had been subject to epilepsy ever since. He was not aware of suffering from other serious disease. Reference to the hospital register of the post showed that he had, at various times, been under treatment. His sufferings, so far as they came under special notice, seemed invariably to have been excited after the excessive use of alcoholic stimulants. For five days after admission, the patient seemed better. The treatment consisted of bromide of potassium and a nourishing diet. On the 18th and 19th, he became slightly feverish and complained of headache. Castor oil and turpentine were administered with good effect, and ice applied to the head. Although free from fever, headache still continued; he looked sulky and dull, and on the 22d there was another epileptic fit. On the following day head symptoms with fever and obstinate constipation became intense. Mercurial purgatives and a terebinthinate enema failing to move the bowels, the negative pole of a battery was applied to the tongue and the positive to the anus with the desired result. Forty ounces of blood was drawn from the arm, lowering the pulse from 120 to 75, and ice was applied to the shaved head. The symptoms becoming worse on the 25th, blood was again taken from the arm and the temples; a mercurial was administered; injections and cold applications were continued, and later in the day a sinapism was applied to the nape of the neck. The patient, gradually growing worse, sunk into a profound coma, and died on the afternoon of the 27th. The antiphlogistic regimen was strictly observed from the 18th to the 25th, but on the last two days beef tea was given, both by the mouth and rectum. At the autopsy, fourteen hours afterward, two old cicatrices were found in the scalp; one over the posterior part of the parietal suture, about half an inch from its occipital termination, measuring about one and a half inches long; the other was over the left parietal eminence, measuring about one inch long; otherwise the scalp seemed whole and perfect. The brain and its membranes seemed to be in a state of general inflammation; the brain, throughout its substance, showed a large number of bloody points; the gray matter was more intensified in its color, and the substance of the brain soft in general. The lateral ventricles contained a small quantity of straw-colored fluid, and the vessels in them were in a state of congestion. That portion of the cerebrum immediately under the first described cicatrix was found closely adherent to the dura mater, and the dura mater itself, at this point, although loosely connected to the skull, was with difficulty removed; in fact the knife had to be used to detach it for about one square inch from the surface of the hemispheres, indicating previous inflammation and adhesion; the Pacchionian bodies were more numerous here, larger, and standing prominently out from the surface; immediately below this point and between the hemispheres, a splinter of bone was found embedded in the falx cerebri; the approximate surfaces of the hemispheres at this spot were redder and the minute vessels more injected. The pituitary body was found to be a little larger than usual and darker in color. From the history of the deceased, and the symptoms during his illness, with the appearance of the brain in general after death, but one conclusion could be arrived at: That he died of general cerebritis, brought on from drink, exposure to the sun, and the irritation which appeared to be set up by the splinter of bone discovered in the falx-cerebri. A portion of the falx cerebri, having a splinter of bone embedded, was forwarded to the Army Medical Museum. It is represented in the wood-cut, (FIG. 13.)

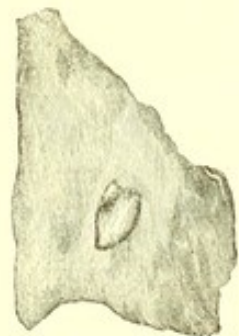

FIG. 13. Osteophyte in the falx cerebri. Spec. 5517, Sec. I, A. M. M.

CCCLXXVIII.—*Note relative to a Fracture of the Skull.* By DALLAS BACHE, Surgeon, U. S. A.

At the Post of San Antonio, Texas, March 16, 1868, private John Bauan, Co. L, 4th Cavalry, aged 23 years, received a blow from a spade, causing a clean fracture in the left occipital region,

about one inch and a half in length, with no depression of the outer table. He was admitted to the post hospital March 17, 1868. Simple dressings were applied. Discharged September 13, 1868. Compound fracture of the skull.

CCCLXXIX.—*Report of a Fracture of the Skull.* By FRANCIS BARNES, M. D., Acting Assistant Surgeon.

Prosper Behan, colored, aged 32 years, was admitted to the Freedmen's hospital, New Orleans, Louisiana, having been beaten into a state of insensibility the night previously, for the purpose of robbing him. There were two wounds of the head, one on the right of the median line, a little over one-half inch, and one over the parietal bone, one inch from its frontal junction. This wound was circular and ragged, and sufficiently open to detect easily that the outer table was depressed, and to allow the passage of a probe to feel the fissure which surrounded it. The next day after admission, the patient had a slight epileptic convulsion, and it was suggested that the trephine should be applied to his head. On the night of May 3d, the patient had a chill, followed by a fever, and the next day the plump appearance of his face was gone, the skin shrunken, and the eyes sunken. The pulse became feeble, and over 100. In the wound a thin sero-pus could be seen welling through the fissure of the fracture every time he breathed. On May 5th, the patient could not lie down, and he had difficulty in swallowing. There was rigidity of the muscles of the neck and abdomen, as well as the chest; the body was thrown slightly backward; pain in right side under point of ribs. Auscultation detected nothing abnormal save the short and hurried movements of the walls of the chest, causing corresponding vermicular murmurs of equal duration with them. There was hernia of the right side, which was reduced and a truss applied, but he tore it off as often as adjusted, saying he wanted room to breathe. Moderate doses of opium were given, which had such prompt effect in relieving the muscular rigidity, that on May 6th, doubt was thrown on the theory that it was due to tetanus. Death resulted May 9, 1868. At the *post-mortem* examination, upon removing the calvarium the outer table was found depressed but not detached, the fissure having an oval form about six-eighths of an inch in the short diameter, and seven-eighths of an inch in the long. The inner table, at a point corresponding, was separated a quarter of an inch greater, and divided into four equal fragments, one of which was completely detached. The opposite parietal bone had a fissured fracture running through the temporal bone, down to the floor of the temporal fossa. This fissure was nearly seven inches long, and extended to and communicated with the first described fracture. The dura mater beneath the depressed fracture had a circle of altered structure, one-fourth of an inch greater than the bony lesion, being thickened to this extent with false membrane, which next the bone was covered with a thin secretion of serous pus. The sinuses were very full of blood, but the other bloodvessels of the dura mater were not unusually congested. Upon removing the dura mater, the pia mater presented three spots of inflammation, manifested by effusion of bloody lymph; one under the depressed fracture, the second corresponding to the fissured fracture, and the third in the posterior part of the two hemispheres of the cerebrum, extending into the fissure between them. The brain itself appeared very firm and healthy. The choroid vessels were pale, and the ventricles had no fluid in them. The heart was healthy, and there was no lesion of the substance of the lungs. The pleurae, however, had thin false membranes over their whole extent, and there was about a pint of thin sero-pus in both cavities. The patient had a reducible inguinal hernia. The organs and peritonæum of the abdominal cavity were healthy. The pathological specimen, consisting of the fissured calvarium, was forwarded to the Army Medical Museum, and numbered 5461, of the Surgical Section.

CCCLXXX.—*Remarks on a Case of Fracture of the Skull.* By E. P. VOLLUM, Surgeon, U. S. A.

Private James Buchanan, Co. I, 42d Infantry, fell over the cliff in front of Madison Barracks, New York, on the night of November 6, 1868, while in a state of intoxication, and struck upon his head. When found the next morning, he was lying near the water's edge—dead. After washing

the body, the integument of the face and neck was of a decidedly bright red color, and a number of cuts and bruises were found on the face and head, evidently produced by falling on loose stones, and blood issued from the right ear. An extensive clot was found under the temporal fascia, and the skull was fractured by a blow on the lower border of the parietal bone, near the posterior inferior angle. The fracture extended posteriorly through the right posterior fossa of the occipital bone, severing the lateral sinus, and anteriorly, through the petrous portion of the temporal, great wing of the sphenoid, near the sella Turcica, and through the right orbital plate. An immense blood-clot covered the dura mater on the right side.

CCCLXXXI.—*Account of a Fracture of the Skull.*—By J. V. D. MIDDLETON, Assistant Surgeon, U. S. A.

Brevet Major James ——, 4th Cavalry, had been drinking hard for several weeks, and was threatened with delirium tremens, when on the night of March 19, 1870, about 10 o'clock, he went to the store of the post trader, at Austin, Texas, and finding three recruits there in a state of noisy intoxication, ordered them to their quarters. They refused to go, when a scuffle ensued, and Lieutenant —— was knocked down. While down one of the men struck him with a cane, the handle probably coming in contact with his head. He was stunned for a few moments, after which he got up and walked to his quarters, two hundred yards distant, and in the absence of the doctor sent for the hospital steward, who examined the injury, and found a wound about an inch long. There was considerable hæmorrhage, which was readily controlled by means of a compress. The wound was brought together by adhesive straps, and cold water applied. He vomited freely immediately after getting back to his quarters. The next morning the doctor saw him, but as there were no symptoms directing his attention to the wound, made no examination of it. His right hand was much swollen from a sprain he received in striking one of the men, and this was all he complained of. The symptoms were those of delirium tremens; and he was treated accordingly. On Sunday, March 20th, he was visited by Assistant Surgeon J. V. D. Middleton, U. S. A., about twenty hours after the reception of the injury. He was extremely restless, and looked upon every one who came near him with suspicion, imagining many absurd things, and wanting to get up and go out. Pulse 130, and full; breathing natural; skin bathed in perspiration; tongue moist and tremulous; eyes injected; pupils dilated, but responding to light; hands tremulous, and constantly picking at imaginary objects. He was ordered a drachm of bromide of potassium and ten grains of capsicum, with a teacupful of beef essence every four hours, alternating so that he took a dose every two hours. His condition remained about the same except that there was a disposition to sleep for a few moments at a time, and the treatment was continued until the morning of March 24th, when he had a chill, followed by fever and profuse sweating, the paroxysm lasting two hours. Two doses of chloroform, one drachm each, were administered in mucilage, one during the day, the other at bed-time, with but little effect. The beef essence was kept up, also cold applications to head. On March 25th, having passed a sleepless night, he was ordered one-half grain of morphia, to be repeated in an hour if sleep was not induced. Before the expiration of the hour he fell into a quiet sleep, which continued until about 3 o'clock, when it assumed a comatose character, which increased until 6.15 P. M., when he expired. Autopsy, eighteen hours after death, revealed a wound over the right parietal eminence; ecchymosis through the temporal muscle; the parietal bone was found fractured and comminuted; an oval piece of the outer table was driven in. On removing the calvaria the inner table was found to be depressed; clots were found in brain under wound, and a large amount of bloody serum beneath the whole of the dura mater and in cavities of brain. The vessels of the brain were enlarged under the wound. The specimen was forwarded to the Army Medical Museum. [It is illustrated by the wood-cut, (FIG. 14). The interior view is still more interesting.—ED.]



FIG. 14. Segment of right parietal and small portions of squamous and occipital bones, with punctured fracture at point of parietal eminence. Spec. 5731, Sect. I, A. M. M.

CCCLXXXII.—*Mention of a Case of Fracture of the Skull.* By A. A. YEOMANS, Assistant Surgeon, U. S. A.

Private Thomas Charleton, Co. F, 16th Infantry, died at the post hospital at Vicksburg, Mississippi, on April 6, 1870, from compression of the brain, with fracture of the base of the skull, the effects of a blow with the stock of a musket. No further particulars are recorded.

CCCLXXXIII.—*Remarks on a case of Fracture of the Skull.* By B. F. POPE, Assistant Surgeon, U. S. A.

George Clapp, artificer of Battery H, 3d Artillery, aged 37 years, went from Fort Adams to Newport, Rhode Island, on November 4, 1867, in company with a comrade, and while there both drank very freely. He was drunk when he started to return to the fort, and while on the way fell in the road; his companion, who was equally intoxicated, attempted to carry him, but failed, and leaving him, dead drunk as he supposed, returned to the fort, but gave no notice of the affair until the next morning. The case was not reported to the surgeon in charge until about 9 A. M. When found Clapp was lying in a stable near the fort; he was comatose, breathing stertorous, pupils dilated, and breath smelling strongly of liquor; countenance natural in color. The head was minutely examined, but no evidence of contusion could be discovered save a slight ecchymosis of the left eye. He was immediately taken to the post hospital at Fort Adams, where cold applications were made to the head and sinapisms to the feet. The pulse was full and slow, and he appeared better than when first seen in the morning. Another minute examination was made, but no injury of the head could be found; the case was diagnosed intense inebriation. The patient died suddenly at 1.30 P. M. without convulsion. An autopsy was made twenty hours after death. The frame was large and muscular; the abdomen and thorax well developed. On removing the integuments with the occipito-frontal and temporal muscles a simple fissured fracture of the left temporal bone was discovered, commencing about one inch above the left ear in the squamous portion of the temporal bone, traversing forward and downward to the base of the cranium, involving the left greater wing of the sphenoid bone. The skull-cap was removed and exposed a large clot of blood, four ounces, occupying the left temporal fossa, extravasated between the cranium and the dura mater. The left hemisphere of the brain was compressed to two-thirds of its original bulk. Detached from the inner table of the temporal bone was found a small spicula of bone, which had wounded some of the small arteries that ramify the dura mater, producing cerebral hæmorrhage and subsequent death. The lungs, liver, and heart were found healthy. The lungs were singularly free from the carbonaceous deposit noticeable in adults, presenting almost the delicate pink color of infancy. The obscurity of the leading symptoms prior to death, complicated as they were by excessive inebriation, and the absence of any marks to lead one to suspect injury of the brain, caused a natural error in diagnosis. In regard to trephining, it is questionable whether (even could the locality of the injury have been discovered) the operation would have relieved the brain from so large a mass of clotted blood, since, even on *post-mortem* examination, the fibrinous coagulation came away with difficulty. [The preparation of the fractured temporal was not forwarded to the Museum.—ED.]

CCCLXXXIV.—*Remarks on a Case of Fracture of the Skull with Recovery.* By JOHN H. BARTHOLF, Assistant Surgeon, U. S. A.

Private Edward Cross, Battery F, 5th Artillery, aged 22 years, was kicked by a horse at Camp Williams, Virginia, on October 22, 1867. The wound was just above the nasal eminence, and was two inches long; there was a fracture of the outer table of the frontal bone with depression, and the margin of the undepressed bone presented a serrated edge. It was not certainly known whether there was also depression of the inner table; but Acting Assistant Surgeon Hysore, who examined the wound at the time of the accident, was of the opinion from the depth of the depression on the surface that the inner table was also driven in. The symptoms were dilated pupils with insensibility for one hour, and so far indicated depression; but there was no

stertor. Cold-water dressings were applied, and when he had improved somewhat, he was conveyed to the hospital at Camp Grant, near Richmond, Virginia. After three hours no cerebral symptoms remained with the exception of a severe headache. On October 23d, a creasote paste was applied to exclude air; a clot filled the wound. The patient continued to improve. On November 6th all cerebral symptoms had ceased, and on the 17th Cross was returned to duty; the wound had healed with an irregular linear cicatrix.

CCCLXXXV.—*Account of a Fatal Fracture of the Skull.* By J. M. BEST, M. D., Acting Assistant Surgeon.

Private J. H. Danney, Co. F, 25th Infantry, aged 21 years, died at Von Schrader Barracks, Paducah, Kentucky, on December 8, 1868, from the effects of a blow upon the head with a club. At the autopsy, a fracture was found extending from the orbit of the left eye, running upward nearly two inches through the frontal bone, then ranging backward in a crescentic shape through the left parietal bone to the occiput; then transversely forward to the orbit, continuing into the floor of the orbit, leaving in this space detached bone nearly two inches in width and four inches long, which was taken out with the fingers. Upon opening the membranes within this space a clot of grumous blood was found, amounting to nearly three ounces. [Specimen not forwarded.]

CCCLXXXVI.—*Report of a Case of Compound Comminuted Fracture of the Skull.* By F. W. ELBREY, Assistant Surgeon, U. S. A.

Private James C. Dixon, Troop H, 5th Cavalry, was injured at Fort McPherson, Nebraska, by the falling of a blacksmith shop, a beam striking him on the forehead in the median line, between the frontal eminences, the blow producing a compound comminuted fracture, which extended down to the nasal eminence. In the upper part of the wound both tables were involved, and the fragments much depressed. In the lower part, the frontal sinus was laid open, but the inner table only fissured and not depressed; the frontal bone was also comminuted at its left external angular process. Notwithstanding the greatness of the injury, neither symptoms of concussion of the brain nor compression occurred. He was at once conveyed to the post hospital, where the loose fragments were removed and the depressed bone elevated. On the fourth day, considerable ecchymosis became manifest near the wound over the left orbital ridge, but no effusion of blood appeared under the conjunctiva of the eye. On the eighth day, a suppurative fever was ushered in by a severe chill, which subsided on the 6th. During its existence, both pupils became dilated and irresponsive to light, but with its subsidence they returned to a normal condition. On the thirty-fourth day, absorption of the ecchymosis had taken place, and this wound, as well as the main one over the forehead, was in a favorable condition for healing, the granulations being healthy, and cicatrization having begun. No symptoms of meningeal or brain lesion had occurred. His treatment consisted in absolute rest, milk diet, cathartics, water dressings for the wounds, and cold compresses for the head. The pathological specimen, consisting of four fragments of cranium removed from over the orbital ridge at the right angular process of the frontal bone, was forwarded to the Army Medical Museum, and is represented by the wood-cut above. (FIG. 15.)

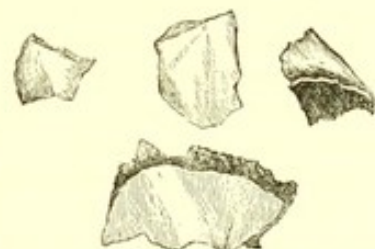

FIG. 15. Fragments from a comminuted fracture of the frontal. Spec. 5582, Sect. I, A. M. M.

CCCLXXXVII.—*Account of a Fracture of the Skull.* By S. S. BOYER, M. D., Acting Assistant Surgeon.

Corporal George Fairbanks, Co. G, 4th Artillery, aged 35 years, was struck with a shovel during an affray, the blow knocking him senseless, and producing a simple fracture of the right parietal bone, with slight depression. He was admitted to the post hospital at Fort Johnson, North Carolina, March 17, 1870. Treatment consisted of cold-water dressings, saline purgatives, and anodynes. He recovered and was discharged July 23, 1870, by reason of expiration of service.

CCCLXXXVIII.—*Notes of a Fatal Head Injury, with Fracture of the Inner Table only.* By A. C. GIRARD, Assistant Surgeon, U. S. A.

Private A. Grevenberg, Co. C, 39th Infantry, was beaten on the head with a club, by a soldier, in a quarrel. The affray took place at Fort Pike, Louisiana, in April, 1868. Although stunned at first, he soon recovered his senses, and remained conscious about an hour. After that time, he commenced to be wandering, and gradually became violently delirious. He had antiphlogistic treatment. After a protracted coma and muttering delirium, he died the next day, thirty hours after injury. The autopsy was made twelve hours after death. There was a large extravasation of blood between the scalp and periosteum. The external lamina of the occipital bone was intact. The internal lamina was splintered at its junction with the parietal bones; one splinter, sharp as a needle, protruding into the torcular Herophili. The dura mater was in a state of hyperæmia. Between the hemispheres, and specially on the right side, there was large extravasation of blood; in the middle fossa, a clot the size of a pigeon's egg. The lateral ventricles were filled with bloody serous fluid; the subarachnoidal interstices contained much serum. The right ventricle of the heart was flabby, the heart filled with dark blood clots. Other organs in a healthy condition. In my opinion, death was the consequence of the opening of the venous sinus by the constant friction of the splinter of bone, referred to, during the pulsation of the brain. [The specimen, unhappily, not forwarded to the Museum.—Ed.]

CCCLXXXIX.—*Account of a Fatal Fracture of the Skull.* By H. S. SCHELL, Assistant Surgeon, U. S. A.

At Savannah, Georgia, September 10, 1866, William Hier, seaman, aged 18 years, received an accidental wound of the head by a fall, fracturing the left temporal bone. He was admitted to the post hospital on the same day. Cold-water dressings were applied, and purgatives given. He died September 21, 1866, from effusion of blood on the dura mater causing meningitis.

CCCXC.—*Remarks on a Case of Fracture of the Skull.* By J. T. AUGUR, M. D., Acting Assistant Surgeon.

Lieutenant Louis M. Hughes, Co. K, 7th Infantry, while in search of a man who had stolen some Government mules, near Camp Miner's Delight, Wyoming Territory, February 13, 1870, was fatally injured by falling down a miner's shaft, thirty-six feet deep, striking upon his head. When taken out he was profoundly insensible; skin pale and cold; pulse feeble and intermittent; and respiration stertorous. There was a transverse wound eight inches long, situated about an inch above the juncture of the sagittal and lambdoid sutures. The right parietal bone was fractured and depressed, and accompanied with alarming hæmorrhage from the ears and nose. There was also a severe cut on the forehead which extended to the frontal bone, and contusion and bruises of the right hip and hand. Death took place at 12.20 o'clock A. M., February 14, 1870.

CCCXCI.—*Memorandum of a Case of Compound Fracture of the Skull.* By J. K. CORSON, Assistant Surgeon, U. S. A.

Private Michael Hurley, Co. F, 30th Infantry, was believed to have been struck by a locomotive on the Union Pacific Railway, near Fort Fred Steele, Wyoming Territory, on October 15, 1868, his body having been found near the railroad, where he had probably been lying since the evening before. His injuries consisted of a compound comminuted fracture of the temporal bone, with depression, the fracture, evidently, extending to the base of the skull. A number of fragments were extracted, and the depressed bone was elevated; the wound was lightly dressed, and the patient was kept lying on the injured side. After pressure was removed, he was able to speak, so far as to ask for water, but would answer no questions. He was entirely pulseless and blanched. He had bled profusely before assistance arrived, but had no hæmorrhage afterward. Stimulants were administered, and every means was used to bring on reaction, but without effect. He died October 18.

CCCXCII.—*Account of a Fatal Injury of the Head.* By H. M. CRONKHITE, Assistant Surgeon, U. S. A.

First Sergeant Daniel Isaacs, Co. I, 10th Infantry, aged 27 years, received December 24, 1869, a contusion, by a club or brick, over the os occipitis. He was admitted to the post hospital at Ringgold Barracks, Texas, on the 25th, in a comatose state, and died the same day. *Post-mortem* examination showed that death was caused by effusion of blood under the dura mater, covering all the posterior half of the left hemisphere of the cerebrum.

CCCXCIII.—*Remarks on a Case of Fracture of the Base of the Skull.* By B. F. POPE, Assistant Surgeon, U. S. A.

Private Thomas M. Johnson, Battery B, 3d Artillery, at Fort Adams, Rhode Island, was discovered, on November 18, 1867, in an insensible condition at the foot of a stairway leading from the outer parapet of the fort into the main ditch. When last seen on the previous evening, he was hurrying through the darkness toward the fort to attend tattoo roll-call. In his haste he undoubtedly mistook his way, and walked off the parapet, falling a distance of some twenty feet. When conveyed to the hospital, he was nearly frozen, having lain in an unfrequented place some eleven hours, with the thermometer 19° above zero. He was in a profound coma; breathing irregular and feeble; thoracic muscles at times convulsed; diaphragm and abdominal muscles apparently paralyzed; pulse 76, feeble and intermittent; blood trickling from the left ear and nose; the right pupil dilated more than the left. The only evidence of contusion that could be discovered on the head was a slight abrasion of the skin covering the frontal region. Fracture at the base of the skull, and probable compression at the origin of the pneumogastric nerve was suspected. The patient was immediately placed in bed. The treatment consisted of warm applications, while vigorous friction was employed to restore circulation in the extremities. A few drops of brandy were administered, but on account of almost complete aphagia, and its embarrassment to the respiratory efforts, the exhibition of stimulants was discontinued. Enemata of brandy, carbonate of ammonia, and milk were equally ineffectual. They could not be retained on account of the complete paralysis of the sphincter ani. In about an hour reaction commenced, the pulse increasing in frequency and volume, but lost nothing of its intermitting character. As reaction continued, the respiration became far more labored, and the face a little darkened. His head was raised to relieve the pressure of blood. The symptoms continued to improve until 1.15 P. M., when he died without convulsion, having survived the injury probably about fifteen hours. An autopsy being held twenty hours after death revealed *rigor mortis* well marked. The left hip and the frontal region were contused. There was no discoloration about the eyes. Blood had trickled from the left ear during the night, and had formed somewhat of a clot upon the table. On removing the integuments and exposing the cranium, a double-fissured fracture, without depression, was discovered, which commenced near the left parietal eminence, and traversed downward and forward through the squamous portion of the temporal bone, to the base of the skull. The contents of the cranium were then exposed. The brain appeared congested, the great longitudinal sinus remarkably so. The brain was removed, and at its base were discovered two ounces of clotted blood. The fissures were traced, one through the greater wing of the sphenoid bone to the foramen lacerum anterius. The other involved the petrous portion of the temporal bone to such an extent as to permit of hemorrhage from the meatus auditorius externus, which was the earliest and most noticeable symptom in the case. The internal table was not splintered or depressed. The blood at the base of the brain, between the dura mater and the skull, accounted for the marked derangement of both the circulatory functions, and also for the sudden death of the patient.

CCCXCIV.—*Account of a Linear Fracture of the Skull.* By J. F. HARTIGAN, M. D., Hospital Steward, U. S. A.

— John, aged 32, was wounded in a *melee* at Washington, July 11, 1869, by being struck on the head with a cobble-stone. The patient lingered about twelve hours. An autopsy, six hours after death, revealed no evidence of any external violence, with the exception of a few slight

scratches on the forehead. Upon removing the scalp, however, there was found a contused appearance of the left temporal muscle, under which was an extensive fissure of the squamous portion of the temporal bone, commencing at the point of junction with the parietal, downward about three-quarters of an inch, and forward and outward two inches, to the temporal surface of the great wing of the sphenoid bone. A smaller fracture, involving only the internal table at its beveled edge, was also detected. Directly under the seat of injury lay a large clot, weighing about six ounces, pressing upon the unruptured dura mater—the result of laceration of one of the branches of the middle meningeal artery. The pathological specimen is numbered 5579, Surgical Section, Army Medical Museum, and is a good example of linear fissure.

CCCXCV.—*Memorandum of an Autopsy of a Pensioner at the Soldiers' Home, who had his Skull Fractured by a Fall.* From data furnished by Hospital Steward E. F. SCHAFHIRT, U. S. A.

Charles L., a pensioner, aged 34 years, suffering from erysipelas and caries of the nasal bones, having committed some misdemeanor while under the influence of liquor, was confined to the guard-house. Being very violent, he was supposed to have the "horrors." On October 29, 1870, he leaped from the window of the guard-house, and, striking on the right side of his head, fractured his skull. He had other internal injuries, and survived the accident but half an hour. On examining the exterior of the head, a great effusion of blood was found under the occipito-frontalis. The orbits were distended with blood. It was thought that a long-fissured fracture extended along the vault of the skull, through the right parietal and temporal bones. Subsequent examination proved this opinion to be correct. On October 30th, Hospital Steward E. F. Schafhirt, U. S. A., by direction of Brevet Lieutenant Colonel C. H. Laub, Surgeon, U. S. A., made an autopsy, and brought the cranium to the Museum. There was an extended linear fissure of the right parietal and temporal, with fracture of the base of the skull, extending through the wing of the sphenoid, and radiating. There was no extravasation of blood between the skull and dura mater; but the sinuses and vessels of the pia mater were gorged with blood. Near the cribriform plate of the ethmoid, the dura mater showed marks of chronic inflammation, having the greenish-yellow fringed processes with adherent curdy pus over a space about an inch and a half in diameter. The skull is specimen 5721; the brain is specimen 5722, and portions of the dura mater 5723.

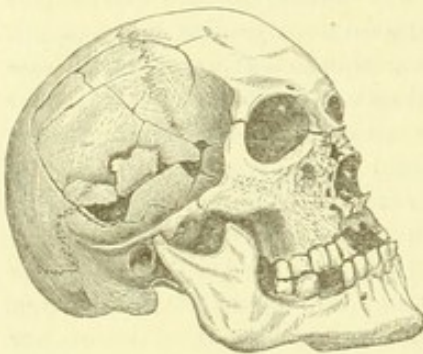


FIG. 16. Simple fissured fracture of the right parietal and temporal. Spec. 5721, Sect. I, A. M. M.

There was no extravasation of blood between the skull and dura mater; but the sinuses and vessels of the pia mater were gorged with blood. Near the cribriform plate of the ethmoid, the dura mater showed marks of chronic inflammation, having the greenish-yellow fringed processes with adherent curdy pus over a space about an inch and a half in diameter. The skull is specimen 5721; the brain is specimen 5722, and portions of the dura mater 5723.

CCCXCVI.—*Account of a Fracture of the Skull by a Dumb-Bell.* By W. H. GEORGE, M. D., Acting Assistant Surgeon.

Private Michael Lawrence, Co. D, 20th Infantry, was accidentally wounded, September 16, 1870, by an iron dumb-bell, which lacerated the forehead and slightly fractured the external plate of the skull over the frontal sinus. He was admitted to the post hospital at Fort Ransom, Dakota Territory, on the following day. Simple dressings were applied. Returned to duty October 9th, cured.

CCCXCVII.—*Account of a Fracture of the Skull.* By D. STEVENS, M. D., Acting Assistant Surgeon.

At Baton Rouge, Louisiana, Sergeant Frank Lightner, Co. C, 65th Colored Troops, aged 22 years, received, by explosion of the steamer City of Memphis, May 31, 1866, a compound comminuted fracture of the outer table of the occipital bone, near the junction of the sagittal and lambdoid sutures. He was admitted to the post hospital July 1, 1866. He returned to duty August 26, 1866.

CCCXCVIII.—*Mention of a Case of Compound Fracture of the Skull.* By J. V. D. MIDDLETON, Assistant Surgeon, U. S. A.

Private William Manahan, Co. M, 3d Cavalry, aged 23 years, received near Prescott, Arizona Territory, May 14, 1870, a compound fracture of the skull, caused by a stone thrown by a comrade. He was admitted to the post hospital at Fort Whipple. The external wound was about two inches in length, and was located immediately over the left frontal eminence. The outer table of the skull was fractured; three days after admission the patient was taken with chills, and suffered for a week with cold sweats, dizziness, headache, and slight fever, with intervals of delirium. June 26th chloroform was administered, and an incision about one and a half inches in length was made over the seat of the fracture, and a piece of the outer table, over one inch in diameter, was removed. On June 30th the patient was still under treatment.

CCCXCIX.—*Remarks on a Case of Contusion with Injury to the Skull and Brain.* By S. M. HORTON, Assistant Surgeon, U. S. A.

Private Charles Miller, musician, 27th Infantry, was reported on sick report of Omaha Barracks, Nebraska, March 11, 1869, as suffering from contusion around both eyes, with partial detachment of the cartilage of the septum, producing flattening of the nose—the result of a blow with the fist. It was reported that a good deal of epistaxis occurred immediately on receiving the injury. By the 17th of March he suffered from headache; bowels were constipated, and the appearance of debility manifested itself. Active treatment was resorted to, and the condition of the patient varied until death, which occurred, apparently suddenly, on the night of the 1st of April, 1869. A *post-mortem* examination, held the same afternoon, revealed, upon removing the skull-cap, a small quantity of pus in the foramen cecum and in the grooves for the bulbs of the olfactory nerves. The crista galli of the ethmoid was found to be broken off at its base, with its upper edge or point toward the left side, and was very easily lifted up by the forceps. Some purulent matter was found in the meshes of the pia mater and between it and the arachnoid membrane, on three-fourths of the entire under surface of the brain. About one-sixteenth inch to the left of the longitudinal fissure, at anterior end of corpus callosum, a longitudinal slit, three-eighths of an inch long, with dark edges, was found in all the three membranes. On detaching the membranes at this point, a sinus was found leading to an abscess in the left anterior lobe, which, when examined, proved to be as large as a hen's egg. It was filled with pus, broken down brain-matter, and, on the outer wall, dark grumous matter. On exploring this abscess, a communication was found between it and the anterior cornu of the left ventricle. On further dissection, I found the left ventricle and the right ventricle, and the third ventricle, through foramen of Monroe, and fourth ventricle through aqueduct of Sylvius, all distended with pus and broken-up cerebral matter with some serum. The lining membrane of the fourth ventricle was of a dusky red color. On pressing up through the nostrils, nearly half an ounce of pus exuded from that part of the cribriform plate of the ethmoid bone from which the crista was broken off, and flowed down over the inner portion of the base of the skull.

CCCC.—*Remarks on a Case of Fracture of the Skull and of the Ribs.* By A. W. WIGGIN, Assistant Surgeon, U. S. A.

Private Samuel D. Robbins, Co. I, 23d Infantry, aged 22 years, was admitted to hospital at Camp Warner, Oregon, on January 10, 1870, at 4 o'clock P. M., suffering from injuries about the head and right side. He stated that while driving a six-mule team, loaded with wood, down a steep declivity, his saddle-mule stumbled and threw him over the pole. One of the mules stepped on his head or kicked him, and two wheels of the wagon passed over his body. An examination revealed a fracture of the ninth and tenth ribs of the right side, about three inches from the vertebral column, with severe contusion of right side, as well as minor contusions about the back and shoulders. Bloody serum was issuing from the right ear and blood from the left ear, as well as from the mouth and nose. The face was much bruised and abraded, and the left eye closed by a flesh-wound, the pupil of the right eye being much dilated and irresponsive to light. The patient was suffering severely from shock, and complaining of sensations of cold; pulse 50, and breathing

labored. When reaction had taken place, some four or five hours after his admission to hospital, the broken ribs were adjusted by applying strips of adhesive plaster and a broad bandage about the chest and abdomen. His pulse at this time had risen to 110, and breathing easier. A small quantity of serum and blood continued to ooze from his ears, and once he vomited four or five ounces of coagulated blood. He complained querulously of the pain in his side. Morphine was cautiously administered during the night, but only partially succeeded in quieting his pain and fretfulness. On the next day he seemed easier, and was fully conscious most of the time; pulse 116, pupils still dilated. There were physical signs of engorgement of the lower lobe of the right lung, and of presence of fluid in the pleural cavity, as also of air in the areolar tissue about the chest and neck. During the day the patient passed blood in small quantities with his urine, and vomited blood twice; in the evening the pulse was 130, and feeble; patient unconscious and breathing labored. At 11 o'clock P. M. the pulse was 150 and fluttering. Death resulted at 1.30 o'clock A. M., on January 12th, about thirty-five hours after the reception of the injury. An autopsy was made fifteen hours after death. On removing the scalp, a fracture which had not been previously noticed was detected, through the squamous portion of the temporal bone without displacement. The dura mater at the base of the brain was considerably lacerated, the openings extending into the ventricles. An extensive fracture was discovered running obliquely across the base of the cranium; starting at the outer edge of left orbit, it passed through the greater wing of the sphenoid and squamous portions of the temporal bone of the left side, and then obliquely through the body and both lesser wings of the sphenoid, and through the whole length of the petrous portion of the temporal bone of the right side. The fracture was considerably comminuted, and six or eight fragments of bone about the left orbit were easily detached with the fingers. The heart was normal; the left lung uninjured and healthy; the lower lobe of the right lung presented a lacerated wound about two inches long, evidently produced by the ragged extremity of one of the broken ribs which had penetrated the pleural cavity; there was about eight ounces of blood in the right pleural cavity, and a lacerated opening existed in the diaphragm. An examination of the abdomen showed the cavity filled with blood, the intestines being bathed in it. Six or eight ounces were removed from the pelvis. The right lobe of the liver was congested and much lacerated; the right kidney presented a slight bruise and a laceration an inch long. The right supra-renal vein was torn across, and the right renal vein wounded but not completely divided. No other abdominal vessels presented lesions. The ninth, tenth, and eleventh ribs were fractured about three inches from the vertebræ.

CCCCI.—*Remarks on a Case of Fracture of the Skull with Concussion of the Brain.* By C. S. DE GRAW, Assistant Surgeon, U. S. A.

Private — Shields, Co. H., 3d Infantry, presented a case of fracture of the zygomatic process of the temporal bone and of the nasal bones, complicated with concussion of the brain, of an aggravated character. He was admitted to the post hospital at Fort Dodge, on November 17, 1868, where it was ascertained that he had been knocked down by another soldier, and severely kicked and trampled upon about the head and face. When brought to the hospital there was complete prostration of all nervous and physical powers. The means taken to bring on reaction, though pursued for an hour or more, seemed of little or no avail. The man remained in the same condition for eight or ten hours, and shortly after midnight, when aroused and spoken to, he answered, but immediately relapsed into his former condition. On the morning of the 18th he seemed somewhat relieved; was more easily aroused, and, when sharply spoken to, would give unintelligible or irrelevant replies. His face was greatly distorted by swelling, his eyes completely closed, and there were several cuts upon his forehead and face. Examination discovered the fractures mentioned above. During the day violent inflammatory symptoms, pointing to brain trouble, set in. He became exceedingly restless, tossing himself about so violently that it became necessary to hold him down in bed; cold applications were made to his head, sinapism applied to the back of the neck, and blisters behind each ear. This condition lasted about five days, when he gradually became calmer, but his mental faculties were much impaired. He improved gradually during December and January, and in March, 1869, he was returned to duty.

CCCCII.—*Remarks on a Case of Fracture of the Skull.* By ELLIOTT COUES, Assistant Surgeon, U. S. A.

Private Emil Shulder fell from the gallery of the church where the troops are quartered, a distance of about eighteen feet, striking his head on the edge of a stair. Profuse hæmorrhage of chiefly venous blood from the left ear, and some from the nose, with instantaneous and complete insensibility. Was conveyed to the hospital, where I saw him fifteen minutes afterward, in condition as follows: Entire insensibility; temperature of blood normal; complete muscular relaxation. Pupils of normal size, insensible to light. No pulse perceptible at wrist or arm, though a feeble, fluttering, irregular, and interrupted motion of the heart could be felt. Respirations about five per minute, labored (but not stertorous), and amounting to little more than gasping. Hæmorrhage of both venous and arterial blood still continued from the ear; a well-marked depression of considerable depth and extent just over the left ear; none others perceptible. A trivial cut over the left eye. Much ecchymosis about the right eye. The patient was in *articulo mortis*, and died in about ten minutes. The pupils, which had been before fixed, dilated to a remarkable degree just before death. Autopsy, twelve hours after death. Skull: On removing the pericranium and left temporal muscle, the squamous portion of the temporal bone was found fractured and depressed for one-third of an inch or more, the posterior edge of the fracture comminuted, and the fragments driven in upon and lacerating the brain. A compound comminuted fracture of the petrous portion of the os temporis, leading into the meatus auditorius externus, through which a probe readily passed, and through which the hæmorrhage had occurred (for the tympanum was intact). A very extensive fracture began at the mastoid portion of the os temporis, and arched over the side of the skull (above, and distinct from the depression of the squamous portion of the os temporis above mentioned), involving parietal and frontal bones to the left orbit, at about its middle, and thence extended into the left orbital plate of the frontal. This was a clean, smooth, fracture, gaping one-twelfth of an inch. The right orbital plate of frontal was also fractured. The cribriform lamella of ethmoid fractured and comminuted. Fracture of left sphenoidal ala. Brain: Anterior lobe of left hemisphere lacerated, from impact of fragments of temporal bone, the dura mater being there ruptured. Several large, firm, black clots about the optic commissure and crura cerebri. The vessels of the pia mater all congested, and numerous minute clots from their rupture among the cerebral and cerebellar convolutions. A little blood in the ventricles, and some clots in the meshes of the choroid plexus, but no great amount of serous effusion. The brain substance was studded more thickly than usual with red points. It was impossible to ascertain the exact amount or origin of the hæmorrhage. It was profuse at first, and continued in a degree until death, and during the autopsy it flowed freely, as soon as the temporal depression was exposed. I believe it originated from either the lateral or superior petrosal sinus, and from one of the meningeal arteries. The internal carotids were intact, as were the superior and inferior longitudinal sinuses, as well as those about the cerebellum. From the indications afforded by the pupils, I presume the patient first suffered chiefly from the concussion, and afterward experienced the full effect of the compression of the brain.

CCCCIII.—*Remarks on a Case of Fracture of the Frontal Bone.*—By GEORGE M. STERNBERG Assistant Surgeon, U. S. A.

Corporal William S—, Co. F, 37th Infantry, was, on March 2, 1867, at work at a pontoon bridge across the Republican River, drawing up a boat with three men with a windlass. The windlass, in some way, escaped from their control, and while revolving rapidly the end of the crank struck him in the forehead. He remained about two hours at the bridge, and then walked to the post hospital at Fort Riley, Kansas. About ten minutes after he came to the hospital, he had a convulsion, and was unconscious from that time until he died, March 7, 1867. Several fragments of bone were removed by Assistant Surgeon W. H. Forwood, U. S. A., soon after the man arrived at the hospital. The specimen is figured in the accompanying wood-cut, (FIG. 17.)

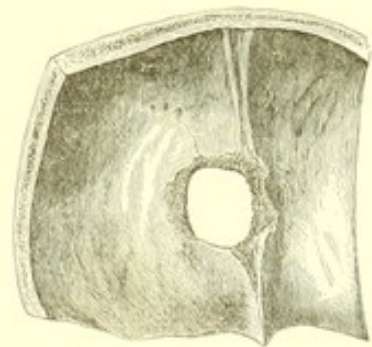


FIG. 17. Segment of frontal bone, giving an interior view of a fracture by a blow from a windlass. Spec. 4861, Sect. I, A. M. M.

CCCCIV.—*Memorandum of a Case of Fracture of the Cranium.* V. B. HUBBARD, Assistant Surgeon, U. S. Army.

Private U——, U. S. Military Academy, detachment of Cavalry, was admitted to the post hospital at 9 o'clock P. M., December 23, 1870, in an unconscious state, bleeding profusely from the left ear. He had fallen down-stairs while intoxicated, receiving the full force of the blow upon his head. There was no laceration, contusion, or swelling of the scalp to indicate the precise locality of the injury. A careful examination of the head revealed nothing. The soldier was so intoxicated as to render it difficult if not impossible to ascertain definitely how much of his comatose condition was attributable to the injury received. Pulse 70, full but compressible, intermitting twice in the minute; respiration 16; temperature 98°; pupils somewhat dilated, though responding to light; his breathing was of the heavy stertorous character usually present in drunkenness. He was extremely restless, requiring two attendants to keep him in bed; muttering incessantly and unintelligibly during the night. The flow of blood from the ear was reduced shortly after being admitted into hospital to an oozing, which continued until his death on the 27th, the fourth day after the receipt of the injury. The blood was chiefly arterial; no serum could be detected. Cold applications were made to the head, and the extremities were kept warm by hot bottles. Saturday, 24th: Patient still remains unconscious; pulse 54, full, compressible, and intermitting as of the previous night; pupils responsive to light; slightly but equally dilated; temperature 98°, respirations 16, their character unchanged; restlessness continues; is constantly making attempts to get out of bed, and is only restrained by close watching and the exercise of a good deal of physical force on the part of his attendants; muttering continuous; bowels moved by enema; movement involuntary; bladder evacuated unconsciously twice during the day; quantity and color of urine normal. Injections of beef tea administered during the day, as the patient was unable to swallow. Sunday, 25th: No perceptible change in the condition of the patient; pulse, respirations, and temperature remain the same as of the day previous; bowels moved and urine voided involuntarily, muttering and restless as before. Upon being slapped quite smartly upon the cheek with the flats of the fingers with the view to rouse him from his comatose condition, he gave utterance to an expression of disgust in a single word—the only evidence of consciousness given by the patient after the receipt of the injury. Injections of beef tea and brandy, largely diluted, every two hours, as the patient was still unable to swallow. Monday, 26th, 6 A. M.: Patient still unconscious; pulse 66; respirations 17; temperature 98°; restlessness continues, patient rolling from side to side, making frequent attempts to get out of bed. 12 M.: Pulse 50; temperature 100°; respirations 16. 4 P. M.: No change worthy of mention in the pulse, respirations, or temperature. At 8 P. M. reaction set in violently, pulse 150; temperature 105°; respirations variable, from 14 to 19. From this hour the patient sank rapidly, pulse running up to 200. Died at 5 A. M., Tuesday, 27th. The decubitus in this case was either dorsal or left lateral; chiefly the latter. The jactitation was the most marked symptom throughout. *Post-mortem*, at 2 P. M., 27th: Removing the scalp, extensive extravasation of blood was found, chiefly on the left side, but no clots. The fracture and depression, their character and extent, are shown in the specimen.* A description of them is therefore omitted. Upon removing the calvarium, a clot, nearly circular in form, two inches and one-half in diameter, and half an inch in thickness at its centre, lying between the dura mater and the skull, was found immediately under the seat of depression. Dark fluid blood mixed with serum, estimated at six ounces, escaped upon removing the skull.

At a point diagonally opposite the seat of injury (the force of the blow evidently coming from behind and being directed forward and upward), immediately under the right frontal protuberance, the surface of the brain was found lacerated and contused, by contre-coup, over a space and to a depth nearly equal in extent with the dimensions of the clot mentioned above.

* The specimen (No. 5919, Sect. I, A. M. M.) is interesting. It is the left side of the cranium, showing a slightly depressed fracture over the parietal eminence, with fissures extending to the petrous bone. At the place of direct impact the outer table is driven into the diploë, and is fissured by two lines, an inch and a half and an inch in length, respectively, crossing at right angles. The inner table is very slightly depressed at this point. Extending from this depression to the auditory canal is a broad fissure which passes through the petrous bone. Wood-cuts of the specimen were prepared, but they were unsatisfactory and were discarded.—ED.

At this stage of the *post-mortem* examination I was called to attend a case of labor, which detained me until the forenoon of the next day, by which time decomposition had set in to such an extent as to render a further examination of the lesions of the brain nugatory. The specimen is No. 5919, Army Medical Museum.

CCCCV.—*Remarks on a Fracture of the Skull from Railway Injury.* By DE WITT C. PETERS, Assistant Surgeon, U. S. A.

The body of an unknown man, aged about 40 years, was brought to the Jarvis Hospital, Baltimore, Maryland, on July 7, 1865, for burial. He had been killed by falling from a railroad car while in motion. The body was much bruised in different places. There was a large and deep wound on the right side of the head above the external auditory meatus, from which blood was escaping. The head, ears, and face were much bruised. Upon removing the calvaria, both tables of the skull were found fractured and driven in upon the brain, compressing it at that point. The fracture commenced on the right side in front of the petrous portion of the temporal bone; the lesser wings of the sphenoid bone and a portion of the orbital plate of the frontal bone were separated from the frontal bone on the right side and extended across to a similar point on the left side. Clots of blood were found effused at the seat of fracture and all through different portions of the brain, and effused blood was found in all the ventricles. The skull was forwarded to the Army Medical Museum, and is represented in the adjoining wood-cut.

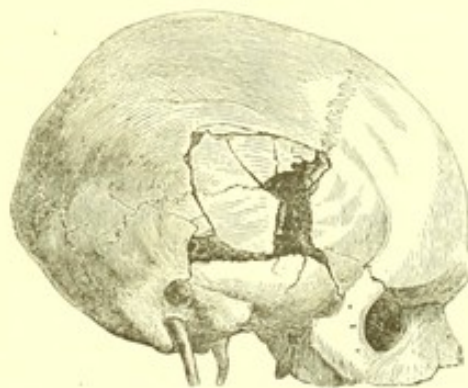

FIG. 18. Skull extensively fractured. There is diastasis of the sutures of the base and right side. *Spec.* 3019. Sect. I. A. M. M.

CCCCVI.—*Remarks on a Case of Fracture of the Skull.* By CHARLES S. MERRILL, M. D., Acting Assistant Surgeon.

At Corinth, Mississippi, on the afternoon of April 9, 1868, Private Edmund H. Wells, Co. K, 34th Infantry, was fatally injured while assisting in loading post-logs upon a wagon, his head being caught laterally between a log already loaded and another which was being thrown upon the wagon. As soon as his head was released he fell unconscious, bleeding from both ears, nose, and mouth. He was brought to hospital with all the symptoms of severe concussion of brain, rapidly followed by those of compression. Hemorrhage continued from ears, nose, and mouth; deep coma, stertorous respiration, and dilated pupils rapidly followed, and continued until April 11, 1868, when death resulted, evidently from compression of the brain, dependent upon extravasation of blood, fracture of base of skull being diagnosticated.

CCCCVII.—*Remarks on a Case of Fracture of the Skull.* By J. H. BARTHOLF, Assistant Surgeon, U. S. A.

Private Charles Williams, Co. F, 5th Cavalry, aged 40 years, was admitted to the post hospital at Camp Grant, near Richmond, Virginia, September 28, 1867, with a compound fracture of the outer table of the skull, inflicted by a blow with the barrel of a pistol in the hands of a drunken sergeant. The flesh-wound was two inches in length over the left parietal region, and the outer table very slightly depressed; the patient had no cerebral symptoms; cold-water dressings were applied, and quiet enjoined. On October 3d, the wound, which had united by soft adhesions, reopened. Simple cerate dressings were ordered. The next day the patient had severe headache at the back of his head and over his left eye; his bowels were regular; the wound gaped open to the skull, discharging a small amount of healthy-looking pus. On October 9th the wound was granulating finely, and discharging but little pus. The patient continued to improve, and was returned to duty November 10, 1867. The wound had entirely healed, but the patient suffered from occasional headache.

Fractures of the Bones of the Face.—Special reports were made of five cases of fractures of the bones of the face. Four of the patients went to duty, and one, with a complicated fracture of the lower jaw, was discharged.

CCCCVIII.—*Account of an Injury of the Head and Face, with Fracture of the Malar Bone.* By JAMES P. KIMBALL, Assistant Surgeon, U. S. A.

Private E. Gibson, Co. F, 31st Infantry, aged 26 years, while at work in a saw-mill, May 5, 1868, 11 o'clock A. M., at Fort Buford, Dakota Territory, was struck by a skid three inches in diameter, suddenly thrown up by a heavy log falling upon one end of it. The blow was received upon the left side of the face and head, fracturing the left malar bone, severely contusing the cheek and scalp, cutting the upper lip against the teeth, and causing concussion of the brain. When first examined, fifteen minutes after the reception of the injury, he was insensible, the pulse was barely perceptible, the pupils were contracted, and the countenance of a deathly pallor. He was immediately carried to the post hospital at Fort Buford, sinapisms were applied to the feet, warmth and friction to the arms and legs, and ammonia held to the nostrils. After a vigorous use of these measures, for nearly half an hour, the patient evinced signs of reanimation, and soon after vomited, and at the expiration of an hour he was able to speak and to move the extremities. The pulse was 96 per minute, soft and weak. Cloths, wet in cold water, were constantly applied to the contused portions of the head and face, and perfect quiet was enjoined. At 5 o'clock P. M. the patient remained sensible, and could move without difficulty. The pulse was 85 per minute, and soft. He had severe pain in the occiput. The left eye was entirely closed by the swollen tissues, which were deeply ecchymosed. On May 6, 1868, at 8 o'clock A. M., the pupils were normal, responding readily to light. The pulse was 80 per minute, soft but stronger. Cloths, wet in a mixture of zinc, camphor, and water, were applied. At 5 o'clock P. M. the pain in the head was very severe. He vomited several times during the day. The pulse was 85, and soft. A sinapism was applied to the pit of the stomach. On May 7, 1868, the pulse was 78, full and moderately strong. He urinated freely. The head and face were kept wet with an evaporating lotion of hydrochlorate of ammonia and water. On May 8th the pulse was 72, and of natural strength. The swelling of the soft parts had diminished. On May 11th the pulse was 72. The tongue was lightly coated. The swelling and ecchymosis had diminished. The cold applications* were discontinued. The patient continued to improve under tonics and nourishing diet, and was able, on May 16th, to sit up. On May 20th the ecchymosis had nearly gone, and the deformity of the cheek was very slight. The patient improved steadily, and on June 2, 1868, was free from pain and vertigo, and, on June 3d, he was returned to duty.

CCCCIX.—*Remarks on a Case of Fracture of the Lower Jaw.* By ELLIOTT COUES, Assistant Surgeon, U. S. A.

Private William Bowers, Co. E, 3d Artillery, aged 24 years, received, on April 20, 1868, a compound comminuted fracture of the lower jaw, left side, by a kick of a horse. On the following day he was admitted to the post hospital at Columbia, South Carolina. The case was complicated by extensive laceration of the soft parts over both the upper and lower jaw, and probable slight fracture of the alveolar process of the superior maxilla. Union was delayed by the successive detachment of spiculæ requiring removal. No proper splint could be adopted to the case, nor was the fitting of one deemed advisable, in view of the condition of the soft parts. A simple bandage was used with good results. [He was returned to duty May 6, 1868.—Ed.]

CCCCX.—*Note on a Fracture of the Lower Jaw.* By J. V. D. MIDDLETON, Assistant Surgeon, U. S. A.

Private Robert Pye, Troop B, 4th Cavalry, aged 27 years, received, on February 6, 1868, at Camp Verde, Texas, a compound fracture of the lower jaw from the kick of a horse. He was admitted to the post hospital, where two pieces of bone were removed. Carbolic acid and linseed oil, with sling bandages, were applied. The man was returned to duty in July, 1868.

CCCCXI.—*Account of a Case of Fracture of the Lower Jaw.* By IRVING C. ROSSE, M. D., Acting Assistant Surgeon.

Private Edward Sheehy, Battery C, 5th Artillery, aged about 30 years, and of fair condition, was admitted to the hospital of the artillery school at Fort Monroe, on October 15, 1870, with a transverse fracture of the body of the inferior maxilla to the right of the symphysis. He stated that he was kicked under the chin, a few hours previously, while in an altercation with another soldier. A suitable splint of pasteboard having been made, and immersed in hot water, was moulded to the chin and jaw. This was retained by a combination of the four-tailed bandage with that of Gibson. That part of the appliance covering the lower jaw was starched, and the bandages were tightened nearly every day. Quiet was enforced, liquid nourishment given, and the patient prohibited from talking. This treatment maintained the parts in steady apposition, and the soldier was returned to duty November 17, 1870.

CCCCXII.—*Note on a Fracture of the Lower Jaw.* By J. H. BAYNE, Acting Assistant Surgeon.

Private Henry Wimsett, Co. I, 4th Artillery, was discharged March 14, 1868, from Fort Foote, Maryland, on account of compound comminuted fracture of the lower maxillary bone, caused by the wheels of a wagon passing over it. The accident was followed by grave inflammation, producing rigidity of the jaw, and such impairment of the power of mastication, that his disability was rated one-half by the pension examining surgeon.

Fractures of the Vertebrae.—Brief mention is made in the reports of some instances of compound fracture of the spine from railway accidents. Of simple fractures details have been given in two instances only.

CCCCXIII.—*Account of a Fracture of the Fourth Cervical Vertebra.* By G. H. GUNN, Assistant Surgeon, U. S. A.

At Waco, Texas, March 5, 1870, Private John Harkey, Co. E, 6th Cavalry, aged 30 years, received, by a fall through an open door on the second floor of a building occupied as barracks, a fracture of the fourth cervical vertebra. Complete paralysis of both motion and sensation of the lower extremities, and most of the trunk and upper extremities immediately ensued. He was admitted to hospital the same day. He died, on the morning of the 7th, of acute myelitis, his intelligence remaining unimpaired throughout. Treatment sedative and stimulant.

CCCCXIV.—*Abridged Account of a Fracture of the Fifth Cervical Vertebra.* From reports furnished by H. R. TILTON, Assistant Surgeon, U. S. A.

Private Emmet J—, Co. A, 5th Infantry, aged 19 years, and of splendid physical organization, was in the habit of bathing in the Arkansas River, at a place near Fort Lyon, Colorado Territory, where the water was ordinarily from six to eight feet deep, and so muddy as to render an object unseen at a depth of six inches. On July 3, 1868, in diving from the bank he struck his head against the bottom, which, being sandy and constantly shifting, was upon this particular occasion only eighteen inches below the surface. Becoming immediately powerless from the effects of the concussion, he would have drowned had not help been given. The legs and arms being paralyzed he was carried on a stretcher to the hospital, lying on his abdomen. Upon admission, at 1 o'clock P. M., the pulse, respiration, and temperature were not counted, nevertheless they appeared normal; the pupils were unaffected; there was priapism. The power soon returned to the arms, although feeble. The extremities were warm, and when touched the sensation was more

acute in the left than in the right leg. The patient complaining of feeling dead below the neck, the spine was carefully examined. No irregularity was found, but there was tenderness over the sixth cervical vertebra. A sinapism was applied to the nape of the neck, and in an hour he requested to be turned over. At 5 o'clock P. M. the pulse was 104; respiration 18; temperature 105°. The patient was directed to hold small pieces of ice in his mouth; the same was applied to the upper portion of the spine, and a saline aperient was prescribed. At 9 o'clock, the pulse was 100; respiration 24; temperature 102°. The urine was drawn off with a catheter, and the patient was placed on a water bed. On the morning of July 4th, the pulse, respiration, and temperature were all diminished. The cold applications to the spine were continued in the form of ice-cold water; a special diet was ordered; and the catheter was used twice during the day. At 5 o'clock the bowels were moved involuntarily. On July 5th, there was considerable diminution of the temperature, sensation was wanting in the lower extremities, and respiration was abdominal. Tonics, nutritious diet, and dry rubbings were prescribed. On the 6th, sensation had partly returned in the left leg, and the breathing was better, there being more movement of the chest. By the 11th, the patient was able to pass his urine without a catheter, but there was no improvement in the sensibility of the right leg. The pulse, respiration, and temperature had diminished. On the morning of the 15th he had a chill, which recurred on the morning of the 17th, and again in the afternoon. After this his countenance became dusky, and there was a rise in the temperature. He had not perspired since the injury. On the morning of the 18th the urine became turbid, the patient complained of his lungs feeling like stone, and his stomach was irritable. By the morning of the 20th, the pulse had become so feeble that it could not be counted, the bowels were loose, the urine was ammoniacal and thick with mucus, and he had an attack of vomiting. These symptoms were followed by increased respiration and a very high temperature, (105°.) The patient, at this time, was again able to pass his urine without the use of a catheter, but on the 21st this instrument was used with difficulty, owing to the formation of clots in the bladder. The patient also suffered from decubitus, and by July 24th his stomach became so irritable as to retain scarcely anything. On the day following his appetite was entirely gone. On the 26th, the temperature was 91.8°. He died at noon on the 28th. At the *post-mortem* the brain was found perfectly healthy, so far as the unaided senses could determine. The spinal cord showed nothing abnormal in the dorsal region, except the fluid which escaped. This was filled with transparent, floating globules resembling volatile oil water. The body of the fifth cervical vertebra was fractured, and it was ascertained that hæmorrhage had compressed the cord at and around the seat of fracture. There was no displacement of the vertebra. The lungs were healthy, except the posterior portions, which were hypostatically congested. The liver was slightly enlarged, the splenic extremity of the stomach congested, and the kidneys were enlarged and gorged with

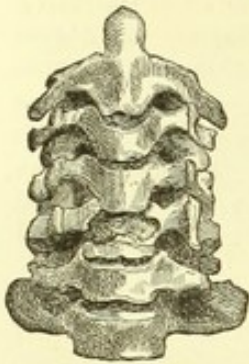

FIG. 19. Fracture of body of fifth cervical vertebra. Spec. 5724. Sect. I, A. M. M.

with transparent, floating globules resembling volatile oil water. The body of the fifth cervical vertebra was fractured, and it was ascertained that hæmorrhage had compressed the cord at and around the seat of fracture. There was no displacement of the vertebra. The lungs were healthy, except the posterior portions, which were hypostatically congested. The liver was slightly enlarged, the splenic extremity of the stomach congested, and the kidneys were enlarged and gorged with

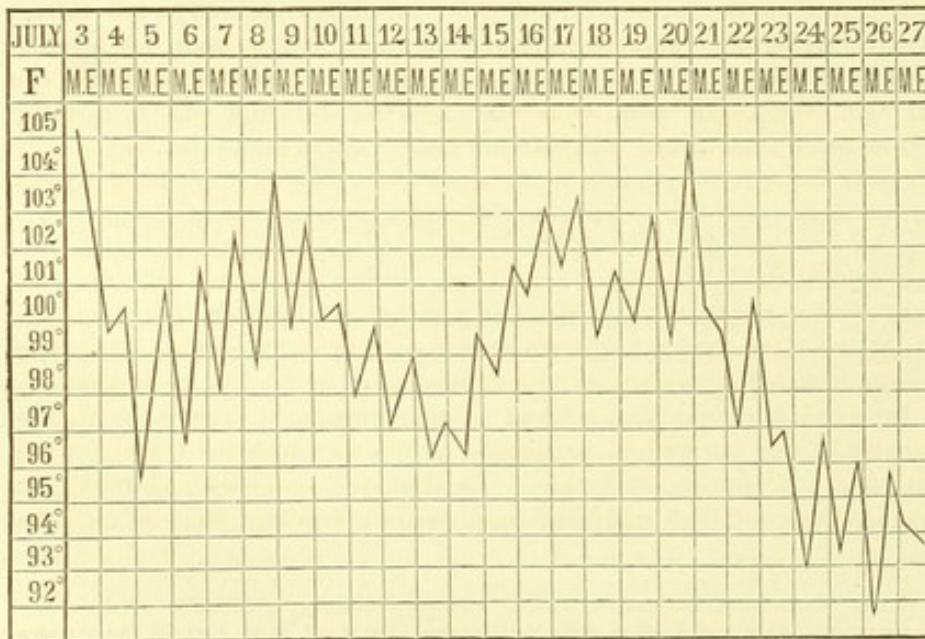


FIG. 20. Thermograph of a fatal case of fracture of the fifth cervical vertebra.

The body of the fifth cervical vertebra was fractured, and it was ascertained that hæmorrhage had compressed the cord at and around the seat of fracture. There was no displacement of the vertebra. The lungs were healthy, except the posterior portions, which were hypostatically congested. The liver was slightly enlarged, the splenic extremity of the stomach congested, and the kidneys were enlarged and gorged with

blood; the pelvis of the left being filled with pus, (?) but upon careful examination no abscess could be found. The ureters were very dark, and one of them contained a clot at the entrance of the bladder. The walls of the bladder were of a dark purple color, inflamed, and thickened; the mucus membrane being absent in patches. The pathological specimens, consisting of the right kidney, the bladder, the urethra, and the cervical vertebrae (Fig. 19), were contributed to the Army Medical Museum, and are numbered 5724, 5725, 5726, 5727 respectively, of the Surgical Section.

FRACTURES OF THE BONES OF THE TRUNK.—But few cases were reported in detail. Fractures of the ribs were not infrequent accidents; while fractures of the spine and pelvis were rare.

Fractures of the Ribs.—Special reports were made of a fatal case, of a case complicated by necrosis, and of a third with fractured clavicle.*

CCCCXV.—*Report of a Case in which the Ribs were Extensively Fractured.* By J. H. FRANTZ, Surgeon, U. S. A.

James B—, a laborer, aged 33 years, was injured at Fort Sanders, Wyoming Territory, April 3, 1870, by the passage over him of the wheel of a heavily laden wagon. Death resulted April 21, 1870. The autopsy revealed twelve fractures of the ribs of the right side; the first to the seventh, both inclusive, were broken, with relation to each other, nearly on a line with the angles of the larger ribs; while the third, fourth, fifth, sixth, and seventh were again broken about four inches nearer their sternal extremities. The cavity of the pleura was found almost obliterated, the visceral and parietal layers of that membrane being adherent to each other. The right lung contained three or four abscesses, having tough-lined membranes, filled with what seemed laudable pus; the remaining portion was broken down, disorganized, and filled with serum darkly covered with blood. [The specimen, presented by Surgeon Frantz, is a ligamentous preparation of the thorax, and is numbered 5692 in the Surgical Section of the Army Medical Museum.—ED.]

CCCCXVI.—*Remarks on a Case of Contusion, with Fracture of the Ribs, followed by Necrosis.* By F. H. BARBARIN, Acting Assistant Surgeon.

Corporal James Kelly, Co. K, 5th Cavalry, aged 25 years, was injured April 2, 1867, while riding. His horse fell, throwing him with his left side upon a railroad track, and falling upon his left leg. He was taken upon sick report for April 3d, and treated for bruise of leg, no mention being made of pain of any kind in the side. On November 10th, Kelly was admitted into the post hospital at Sedgwick Barracks, Washington, on account of the injury to his side. On December 1st, there were two openings, one inch apart, over the anterior portion of the ninth rib, which were discharging pus. The point of a probe introduced, discovered the bone denuded of periosteum for about one inch. An incision was made uniting the two openings, and flax-seed poultices applied, with the hope that, as he was otherwise in perfect health, the portion of necrosed bone would be thrown off. On February 28, 1868, chloroform was administered, and after making an incision of some four inches in the course of the rib, a piece of bone one and a half inches in length was extracted. Exposing the bone in the operation, it was found that in the fall he had received, the rib had been fractured one and a half inches from its sternal extremity, and had become separated from its cartilage. After removing the piece, the end of the remaining portion of the rib was smoothed, and a small portion of the superior portion of the tenth rib found to be diseased was also removed. On November 3d, the patient was in fine condition, and the wound healing kindly. He was returned to duty in April, 1868.

*Almost every variety of fractures of the ribs, either united, with or without deformity, or ununited with attempt at repair, are illustrated by specimens 4917, 5027, 5172, 5173, 5174, 5177, 5178, 5180, 5181, 5504, 5506, of the Surgical Series, A. M. M.—ED.

CCCCXVII.—*Memorandum of Simple Fractures of the Ribs and Clavicle.* By J. P. ARTHUR, M. D., Acting Assistant Surgeon.

Sergeant Joseph I. Allen, Co. C, 4th Cavalry, aged 27 years, received in a fall, December 16, 1870, a fracture of the left ninth and tenth ribs and of the clavicle. He was admitted to the post hospital at Fort McIntosh, Texas, on the same day. Levis's apparatus was applied. He was returned to duty in February, 1871.

FRACTURES OF THE UPPER EXTREMITIES.—Of the numerous injuries of this group, particulars of comparatively few cases were reported. Several reports will be quoted here, and others may be found in the chapter on operations, further on.

Fractures of the Clavicle.—There were five special reports of fractures of the collar bone, besides that on page 131. This accident, common in military as in civil practice, is usually entered on the reports by medical officers without any details. It is desirable that the cause and seat of the fracture, the method of dressing, the duration of treatment, and the degree of deformity left, should be noted on the records.

CCCCXVIII.—*Remarks on a Case of Fracture of the Clavicle.* By P. MIDDLETON, Assistant Surgeon, U. S. A.

Private F. Burnham, Co. D, 14th Infantry, was admitted to the hospital at Camp Whipple, Arizona Territory, February 2, 1868, with a fracture of the middle third of the left clavicle, caused by falling from a mule. The apparatus of Levis* was immediately applied, and continued until February 27th, when the fracture was found to be fairly united, with scarcely any deformity, and the apparatus was removed and a bandage to support the arm was substituted, with instructions to exercise the arm daily. On February 29, 1868, the patient was convalescent.

CCCCXIX.—*Account of a Fracture of the Clavicle.* By A. HEGER, Surgeon, U. S. A.

At Fort Snelling, Minnesota, February 20, 1870, William Gohlke, musician, 20th Infantry, aged 35 years, received, by an accidental fall, a fracture of the left clavicle. He was admitted to the post hospital the same day. Bandages were applied. He returned to duty March 21, 1870.

CCCCXX.—*Remarks on a Case of Fracture of the Clavicle.* By C. R. GREENLEAF, Assistant Surgeon, U. S. A.

Private F. Hofner, Co. A, 25th Infantry, aged 26 years, was admitted to the post hospital at Taylor Barracks, Louisville, Kentucky, July 27, 1868, with a fracture of the outer third of the left clavicle, received by falling a distance of four feet upon his shoulder, while intoxicated. Fox's apparatus was applied, which, although it did not secure complete reduction, kept the shoulder and arm fixed. On July 31st, Fox's apparatus was removed, and a figure-of-eight bandage, with axillary pad and sling used. There was some ecchymosis over the fracture, which was ordered to be rubbed with a stimulating liniment. On August 21st, callus had formed, and the bandages were removed. There was shortening of the arm, but no great deformity. He was returned to duty October 2, 1868.

CCCCXXI.—*Account of a Case of Fracture of the Clavicle.* By IRVING C. ROSSE, M. D., Acting Assistant Surgeon.

Private James Reynolds, of Battery A, 3d Artillery, was taken on sick report at Fort Monroe, Virginia, February 16, 1870, having sustained an oblique fracture near the middle of the left

* Dr. Richard J. Levis described his apparatus for fracture of the clavicle in the *American Journal of the Medical Sciences*, Vol. XXAVI, p. 100. It is also figured and commended in Professor Gross's *System of Surgery*, 4th ed., 1866, Vol. I, p. 900. [The attention of medical officers is invited to Specimen 5302, Surgical Series, A. M. M., which demonstrates the usual modes of distortion and deformity in nine united fractures of the clavicle.—ED.]

clavicle, from indirect violence. There was much displacement, swelling, and suggillation. The indications for keeping the shoulder upward, outward, and backward were fulfilled by placing a wedge-shaped pad in the axilla, which was held in position by strings of tape passing around the shoulder of the opposite side; a triangular bandage was next applied, the initial end being placed on the shoulder of the sound side, and a few turns taken over it and the elbow. The arm was then fixed to the side by several more turns around the elbow and the body, and the fore-arm was placed in a sling. Through the patient's indulgence in frolicking, the fragments, after partial union, were twice misplaced. He recovered, and was returned to duty May 5, 1870.

CCCCXXII.—*Remarks on a Case of Fracture of the Clavicle.* By J. P. KIMBALL, Assistant Surgeon, U. S. A.

Sergeant Samuel Wright, Co. C, 13th Infantry, was admitted to the hospital at Fort Buford, Dakota Territory, October 17, 1869, with a simple fracture of the left clavicle, produced by being thrown from a horse, and falling upon his left shoulder. The fracture was oblique, and situated near the outer end of the middle third of the clavicle. The sternal fragment overlapped the acromial about one inch. The patient stated that when about 10 years of age the same clavicle was broken in the same place by direct violence, but that no subsequent deformity resulted. He does not remember to have received any treatment at that time. The present fracture was treated with Hamilton's apparatus.* Union appeared complete on November 9th, twenty-three days after admission, and the patient was returned to duty November 13th. The limb was shortened one-quarter of an inch, with slight displacement of the outer end of the inner fragment above the inner end of the outer fragment.

Fractures of the Humerus.—Besides the gunshot fractures and the cases referred to in the chapter on operations, special reports of but two cases of fracture of the arm were forwarded. Both were instances of compound and comminuted fractures.

CCCCXXIII.—*Remarks on a Case of Compound Fracture of the Humerus.* By J. P. KIMBALL, Assistant Surgeon, U. S. A.

Private Anthony Welsh, Company H, 13th Infantry, aged 27 years, was injured October 8, 1869, about eight miles from Fort Buford, Dakota Territory, by the passage of a heavy Army wagon over his left arm, producing a compound fracture of the humerus at its middle third. When first seen by the post surgeon, about an hour after the accident, the lower fragment was found protruding through the skin covering the lower portion of the deltoid muscle, having apparently been thrust through after the fracture had taken place by the ill-directed efforts of the persons about him. The arm was temporarily put up in splints made from a cracker-box, and the patient was taken to the post hospital at Fort Buford. The arm was severely bruised, greatly swollen, and the wound bleeding moderately. The next morning the patient was hot and feverish; pulse 105, full and strong; arm still greatly swollen and discolored. On October 12th, the patient was doing well; the febrile excitement had greatly diminished; the swelling and puffiness of the arm were subsiding, and the wound suppurating moderately. The patient continued to do well, and on November 6th the splints were removed; the wound had healed, and the union of the fracture was complete; there was very slight false ankylosis of the elbow. On November 21, 1869, Welsh was returned to duty; the ankylosis of the elbow was completely removed; there was no shortening of the arm.

The next report is interesting as including an instance of rupture of the liver without breach of the integument.

* A figure of "The Author's Apparatus" may be found at page 199 of the third edition of Dr. F. H. Hamilton's *Practical Treatise on Fractures and Dislocations*, Philadelphia, 1866.

CCCCXXIV.—*Account of a Fatal Railway Injury.* By ELLIOTT COUES, Assistant Surgeon, U. S. A.

Private Robert Maternie, Co. H, 6th Infantry, was injured at Columbia, South Carolina, on December 30, 1867, by a railroad accident. The case terminated fatally in about ten hours. The right humerus was fractured a little above the joint, and drawn through the skin. Internal injuries, however, were the immediate cause of death. On examination, the liver was found lacerated in three directions, being completely ruptured into three pieces, which were only held together by the peritoneal investment. A great quantity of coagulated blood lay about the parts. The lungs were much contused, and many of their smaller vessels ruptured. Singularly enough, no ribs were broken.

Fracture of the Radius and Ulna.—Apart from those cases of injuries of the fore-arm which demanded operations, details were given of but two fractures of the radius, and one of the ulna.

CCCCXXV.—*Note of a Fracture of the Radius.* By J. H. BARTHOLF, Assistant Surgeon, U. S. A.

Private Edward Jamison, Co. A, 11th Infantry, aged 24 years, was admitted to the post hospital at Camp Grant, near Richmond, on December 19, 1867, with simple fracture of the left radius at the middle third, caused by falling down a stairway. The fore-arm was placed in a supine position, and straight board splints, somewhat wider than the fore-arm, applied, and held in place by adhesive straps, near the upper and lower extremities of the splints, the sides being left to give a view of the parts. The arm was then put in a sling. On February 10th, the splints were removed. There was good union, and free motion without deformity. A slight callus marked the seat of the fracture. Patient was returned to duty on February 10, 1868.

CCCCXXVI.—*Note of a Fracture of the Radius.* T. F. AZPELL, Assistant Surgeon, U. S. A.

Private W. Chapman, general service, was injured September 24, 1868, by falling about seven feet from the seat of a wagon truck, which caused a simple fracture of the lower extremity of the left radius. He was admitted to the hospital at David's Island, on October 13th; the fractured extremities of the radius being approximated, and the hand kept between pronation and supination, a wooden adaptable splint was placed upon the posterior aspect of the fore-arm; a piece of binder's board of the proper size, well dampened and pliable, was placed upon the anterior portion, and both kept in position by a roller bandage, which was so adapted as to draw the extremity of the fingers downward, so as to produce extension. Patient recovered without any bad symptoms; the motion of the fore-arm and wrist was perfect, without any deformity. Returned to duty.

CCCCXXVII.—*Note of a Simple Fracture of the Ulna.* By C. C. GRAY, Surgeon, U. S. A.

Private H. Hampton, Co. I, 31st Infantry, aged 19 years, presented himself at surgeon's call, at Fort Stevenson, Dakota, on February 10, 1868, with a transverse fracture in the middle of the right ulna, the result of a fall against a box, which he had received a few moments before. Pistol-shaped splints, cut from a shingle and padded, without an interosseous compress were applied. On March 7th, the splints were dispensed with, the limb being still retained in a sling; occasional passive and voluntary motion was prescribed. The patient recovered without any deformity of the limb whatever, and was returned to duty on March 21, 1868.

Fractures of the Carpal Phalanges.—A single case is specially reported.

CCCCXXVIII.—*Minute of a Case of Compound Fracture of a Phalanx.* By E. F. BAKER, M. D., Acting Assistant Surgeon.

Private Eli Hubbard, Co. K, 15th Infantry, aged 19 years, on fatigue duty at Cleburne, Alabama, May 27, 1868, had his hand crushed by a weight, causing compound comminuted fracture of second phalanx of the left middle finger. At the post hospital, the fractured ends of the bone were placed in opposition, the wound was closed with sutures, and kept in position by compresses and roller bandages. The soldier was returned to duty on June 30, 1868.

FRACTURES OF THE LOWER EXTREMITIES.—In regard to the numerous cases of this category, special reports were made in fourteen instances, in addition to the reports of cases in which operations were practiced. Details were given of four examples of fracture of the femur, one of which was believed to be intra-capsular, of one fracture of the patella, and of nine fractures of one or both bones of the leg.

Fractures of the Femur.—Special reports were made of four cases treated by angular splints.

CCCCXXIX.—*Mention of a Fracture of the Femur.* By E. F. BAKER, M. D., Acting Assistant Surgeon.

At Savannah, Georgia, in October, 1868, Private John Carroll, Co. F, 12th Infantry, while laboring under an attack of delirium tremens, leaped from the second story balcony of the post hospital to the ground, causing a slightly oblique fracture of the right femur, a short distance below the great trochanter. The limb was placed in splints, and extension and counter-extension made by means of adhesive strips applied to the leg, and a perineal band. The case progressed favorably, and in January, 1869, Carroll was transferred to Fort Pulaski.

CCCCXXX.—*Remarks on a Case of Fracture of the Femur.* By A. G. SKINNER, M. D., Acting Assistant Surgeon.

Private Thomas McCann, Co. A, 42d Infantry, aged 40 years, was brought to the hospital at Fort Niagara, New York, September 23, 1868, having fallen the earlier part of the preceding night, while intoxicated, and, being unable to assist himself, had lain where he fell until morning. On examination, the left thigh was found fractured near the small trochanter, but the swelling was so immense that the exact condition of the bone could not then be determined. The limb was nearly two inches shorter than its fellow, with no eversion of the toes. The muscles of the upper portion of the thigh were in a state of spasmodic contraction. Two assistants were directed to make extension and counter-extension; as not the slightest effect was produced by this force, two others were directed to aid; for ten minutes this force was continued without effect; two more men were then added to the force, when, after a few minutes steady effort, the bone came to its place with an audible crepitus, resembling the sound heard in reducing luxations. Impaction of fragments had doubtless occurred at the seat of fracture. The limb was placed in an Amesbury splint (the only one within reach), the thigh piece being lengthened to come firmly to the buttock; adaptation splints were applied, and a roller bandage to embrace the whole limb. During the day, the patient recovered from his inebriation, with loss of appetite and sick stomach; but complained of very little pain. The limb continued swollen for about a week, when the swelling abated, and almost entirely disappeared at the end of the second week. The patient did not complain of pain throughout the treatment, except from the occasional chafing of bandages, and being confined in one position. The dressings were removed at the end of seven weeks, at which time the bone

seemed well united at the seat of fracture, and the patient was able to walk on crutches. The limb was shortened from one-half to five-eighths of an inch. McCann was returned to duty in March, 1869.

CCCCXXXI.—*Abstract of a Report of a Simple Fracture of the Upper Third of the Right Femur.* By E. H. BOWMAN, M. D., Acting Assistant Surgeon.

Lieutenant W. E. Sweet, Co. A, 24th Infantry, being thrown from a carriage on April 5, 1870, by a mule team running away, had his right femur fractured at the upper part of the middle third. He was taken to the post hospital at Fort Bliss, Texas, soon after the accident. The treatment consisted in bringing the fractured bones in apposition, securing by splints and bandages, and placing the limb on a double-inclined plane. On the twenty-first day after the injury, I was discharged from attendance on the patient. The limb had less than the usual shortening. Drs. Marsh and White pronounced the shortening only one inch. The case had a favorable issue, and the lieutenant was returned to duty on July 11, 1870.

CCCCXXXII.—*Account of a Fracture of the Femur, supposed to be within the Capsule.* By IRVING C. ROSSE, M. D., Acting Assistant Surgeon.

About July, 1870, my professional attention was called to a female child of six years, an inmate of the laundress's quarters at Fort Monroe, Virginia, whom I at first believed, from the history given by its parents, to be suffering from infantile paralysis. Having the patient stripped, my attention was called by George E. Cooper, Surgeon, U. S. A., to the peculiar everted position of the right foot, and the inability to place it on the floor. Manipulation of the limb was exceedingly painful, and further examination revealing crepitus in the femur, fracture within the capsule was diagnosed. A fracture-bed was at once improvised; the limb was placed on a pillow, and extension produced by means of a weight of several pounds suspended over a pulley by a cord, which was attached to the leg by broad bands of adhesive plaster. This mode of extension not being satisfactory, and productive of much discomfort to the little patient, I was induced to abandon it after a few days and to try the anterior wire splint with suspension. An appropriate one was made and applied, care being taken to bandage it firmly around the body, and to preserve the obliquity of the suspending cord. The remainder of the treatment was conducted on the principles peculiar to fractures in general. Although this case did not get the attention I desired, owing to the carelessness and indifference of the mother, yet recovery, after a reasonable time, was complete. On May 10, 1871, Charles Smart, Assistant Surgeon, U. S. A., writes that he found a perceptible shortening in the limb of one-fourth of an inch, but not enough to give any halt in the gait.

Fractures of the Patella.—A single case was specially reported. The cause of injury was not mentioned, nor was the direction of the fracture described. It is hoped that hereafter medical officers will note such particulars in their reports.*

CCCCXXXIII.—*Report of a Case of Fracture of the Patella.* By W. CRAIG, M. D., Acting Assistant Surgeon.

Private George Johnson, Co. A, 40th Infantry, aged 24 years, received a fracture of the patella of the left leg on April 2, 1867. He was admitted to the post hospital at Fort Caswell, North Carolina, on the 4th. The fragments were retained in close apposition by means of adhesive strips. He was discharged June 17, 1868.

* Officers can consult, in the Army Medical Museum, an excellent series of fractures of the patella united by bony or by ligamentous union. The are numbered 5353, 5354, 5355, 5364, 5413, 5414, 5415, *Surgical Series.*—ED.

Fractures of the Leg.—Nine special reports come under this class. In four cases the tibia and fibula were fractured, in five the tibia only.

CCCCXXXIV.—*Remarks on a Case of Fracture of the Tibia.* By G. S. ROSE, Assistant Surgeon, U. S. A.

Private Ira V. Beam, Co. B, 29th Infantry, aged 26 years, was riding on a box-car on September 28, 1868, when the car rolled over an embankment. His leg was caught under a large box of freight and crushed, causing a compound fracture. He was taken to the post hospital at Camp Schofield, Lynchburg, Virginia. The external wound was not large; the soft parts were not greatly destroyed. The wound was situated just over the spine of the tibia, about its middle and to the inner side. The leg was bandaged and a small splint applied along its outer side, the wound having been left exposed so as to have constant and ready application of carbolic acid, with which the limb was dressed. The patient made a good recovery, and on December 3, 1868, was reported as entirely well, walking without the aid of crutches. The limb was not shortened.

CCCCXXXV.—*Mention of a Case of Fracture of the Tibia.* By F. MEACHAM, Assistant Surgeon, U. S. A.

Private William Janke, Co. K, 9th Infantry, met with a simple oblique fracture in the lower third of the right tibia at Omaha Barracks, Nebraska, on January 15, 1871. The injury was treated with immovable plaster splints. The patient made a good recovery. There was but little deformity, and no perceptible shortening.

CCCCXXXVI.—*Note on a Case of Fracture of the Tibia.* By W. H. ELBRIDGE, M. D., Acting Assistant Surgeon.

Private Thomas Pomfort, Co. H, 5th Cavalry, received on January 7, 1868, a kick from a horse, causing a fracture of the tibia four inches below the knee. He was admitted to the post hospital at Aiken, South Carolina, where a fragment of the tibia, three quarters of an inch in diameter, was removed by Assistant Surgeon A. C. Girard, U. S. A., and Acting Assistant Surgeon T. M. Stuart. On March 20th, Smith's anterior splint was applied to the limb. This man was returned to duty in September, 1868.

CCCCXXXVII.—*Remarks on a Case of Fracture of the Tibia.* By J. J. PURCELL, M. D., Acting Assistant Surgeon.

Private Henry Noyes, Co. H, 1st Artillery, aged 21 years, was admitted to the hospital at Fort Schuyler, New York Harbor, on September 26, 1867, with a simple fracture at the junction of the middle and lower thirds of the right tibia, caused by the falling of a gun-carriage upon it that morning. The fracture was nearly transverse, and was set without difficulty and placed in a fracture-box, the ends remaining in apposition. The case progressed favorably, and on January 21, 1868, he was returned to duty, at which time he had entirely recovered. Upon careful measurement no perceptible shortening could be discovered, and there was but slight deformity at the seat of fracture.

CCCCXXXVIII.—*Note relative to a Case of Fracture of the Tibia and Fibula.* By J. SAUNDERS, M. D., Acting Assistant Surgeon.

Private Thomas Pumphrey, Co. E, 6th Cavalry, aged 21 years, was admitted to the post hospital at Pilot Grove, Texas, December 15, 1868, with a compound fracture of the left tibia and fibula at junction of middle and lower thirds. The tibia projected through the integument and was covered with mud. The limb was placed in a Butcher's box, and carbolic acid lotions were applied. On December 31st the case was progressing finely. He was admitted to the hospital at Greenville, Texas, convalescent, on April 12, 1869; and was discharged the service April 20, 1869, his term of service having expired.

CCCCXXXIX.—*Mention of a Case of Fracture of the Leg.* By W. E. DAY, M. D., Acting Assistant Surgeon.

Private George Scott, Co. M, 3d Artillery, aged 21 years, sustained June 26, 1869, a compound fracture of the tibia and fibula of the right leg, by a blow from a lever of a capstan. He was admitted to the post hospital at Fort Jefferson the same day. Cold water and simple dressings were applied. He was discharged from service March 5, 1870, on surgeon's certificate of disability, "by reason of shortening of the right leg."

CCCCXL.—*Mention of two Cases of Fracture of the Leg, successfully treated by Smith's Anterior Splint.* By IRVING C. ROSSE, M. D., Acting Assistant Surgeon.

CASE 1.—On March 17, 1868, I was requested to see a Mexican *vaquero* who had broken his right leg in attempting to lasso a wild ox near Point Isabel, Texas. The animal had thrown the horse by means of a lariat made fast to the saddle, and both bones of the rider's leg were crushed by the fall. An anterior suspension wire splint was applied a few hours after the reception of the injury. Several days subsequently, the friends of the patient desired to take him to his home, a ranche distant about twelve miles. Without seeking medical advice they caused him to make this journey on a mustang pony, the Rio Grande River being crossed on the route. Strange to say, he suffered but little inconvenience from the ride, and made a good recovery in about six weeks. The patient was a young man accustomed to a diet of beef, beans (*frijoles*), and maize, and possessed the *physique* common to persons of his vocation.

CASE 2.—John Wilson, aged about 50 years, mate of the brig "Peerless," bound to Rio Janiero, had both bones of his right leg broken by getting caught in the cable whilst letting go anchor in Hampton Roads on April 30, 1869. He was brought ashore at Fort Monroe, Virginia, and when seen was much depressed. The fragments of bone were properly adjusted, and Smith's anterior splint was applied to the injured member. Shortly afterward the patient was sent to his home in Baltimore, from which place he advised me of his successful recovery and return to his ordinary avocation.

CCCCXLI.—*Remarks on a Case of Fracture of the Tibia.* By JOHN I. HULSE, M. D., Acting Assistant Surgeon.

Private Louis Wilson, Co. F, 4th Cavalry, on April 16, 1868, while driving a quartermaster's team, on the road to Fort McKavett, Texas, being intoxicated and reeling to one side, was thrown from his seat by a wild mule, both wheels of the wagon going over both legs, bruising the left leg, and producing a compound comminuted fracture of the right tibia, just above the ankle-joint. He was brought to Fort Mason, Texas, a distance of sixteen miles, in an ambulance, and his injuries treated with simple dressings, the fractured leg being placed on a padded board, having a slight elevation. Inflammation soon subsided, and on the 27th instant he was returned to his command, with good prospect of complete recovery, and the following month returned to duty.

Seven of these fractures of the leg were compound, and two were simple. All the patients recovered without much deformity except two, who were discharged for disability. Treatment by some form of suspensory apparatus appears to be generally preferred by the medical officers.

DISLOCATIONS.—Six hundred and twenty-five cases of luxation of joints appear upon the returns for the period covered by this report ; but special histories were forwarded in a few instances only.

Dislocations of the Vertebrae.—Histories of two fatal cases of luxation of the cervical vertebrae were received.

CCCCXLII.—*Memorandum of a Case of Luxation of the Atlas on the Axis.* By J. K. WALSH, M. D., Acting Assistant Surgeon.

Lieutenant Justinian Alman, Troop I, 4th Cavalry, was killed March 17, 1868, in a collision between the boat in which he was returning to town (Jefferson, Texas) and the steamboat J. M. Sharpe. He was struck by the paddles of the wheel and carried under. His body was once thrown to the surface by the eddies of the water, and then sank. Every effort was made to secure his remains, but without avail, until the sixth day after the disaster, when the body, in a very advanced stage of decomposition, rose to the surface. The remains were buried the following day, in the Hebrew Cemetery, in compliance with the wish of his family. An autopsy revealed a dislocation of the atlas upon the second cervical vertebra, with rupture of the transverse ligament, and the odontoid process impinging upon the spinal marrow.

CCCCXLIII.—*Report on a Dislocation of the Fifth Cervical Vertebra.* By C. C. GRAY, Assistant Surgeon, U. S. A.

On the morning of February 10, 1866, I was called to see Private John F—, Co. B, 2d Infantry, who was reported badly hurt by a fall. I found the patient, a muscular, powerful, German, aged 35, laying upon a table in the company kitchen ; face pale, respiration sighing ; pulse slow and full. It appeared that about ten minutes before he had invited the bystanders to witness a gymnastic feat. A few yards away the ground was thickly littered with short straw which had been emptied from bed-sacks. Starting toward this straw he ran a few steps and bounding two or three feet into the air, attempted to throw a somersault without touching hands or head. Although accustomed to perform this exploit, he from some cause failed upon this occasion ; instead of alighting upon his feet, his head struck the earth, and he rolled over upon his side and lay motionless. As he did not arise his comrades approached and found him in the condition before mentioned. Upon examination, I found that sensation and power of motion were alike wanting from the neck downward. The walls of the chest were motionless and respiration was effected by the diaphragm alone. He was unable to raise his head, but moved it freely from side to side. In attempting to examine the neck, it was necessary to lift the head from the table, which movement caused so much distress that I was obliged to desist. I however discovered, as I thought, a slight but unusual depression immediately below the spinous process of the fourth or fifth cervical vertebra. The patient was conveyed to the regimental hospital and placed upon a hard mattress, all pillows having been removed. Assistant Surgeon S. H. Horner, U. S. A., was called in consultation, and we endeavored to ascertain the nature and extent of the injury. By carefully supporting the head, the patient was turned partially upon his side and a clear view of the posterior parts of the neck obtained. The examination was very unsatisfactory, for so thick were the layers of muscle and fat that the usual landmarks, the spinous processes, were confused, and we were unable to arrive at a positive diagnosis. It was clear, however, that there was an abnormal gap or depression between the spinous processes of the fourth and fifth or fifth and sixth cervical vertebrae ; that pressure at this point of depression gave slight pain ; that there was an absence of crepitus, and that the movements of the head upon the atlas, and of the

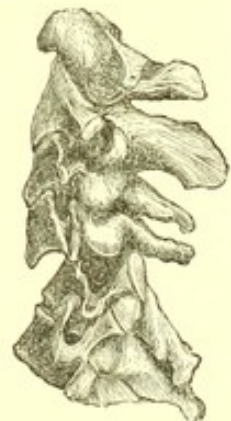

FIG. 21. Luxation of the fifth upon the fourth cervical vertebra. *Spec.* 549, Sect. I, A. M. M.

atlas upon the axis, were such as to prove that these articulations were not involved. Respiration indicated that the lesion, whatever its nature, was below the origin of the phrenic nerve, while the total paralysis of the upper extremities could not be explained upon any other theory than that of injury higher than the origin of the brachial plexus. It was further agreed that we were not likely to benefit the patient by attempting to rectify a distortion concerning the nature of which we were ignorant. From this time forth he was accordingly undisturbed. My function consisted in directing such small attentions as were possible in the case, and in watching the process of dying. He lay perfectly supine, breathing by the diaphragm, suffered no pain, and was able to swallow small quantities of fluids. His pulse, which immediately after the accident had been 78, in two hours had fallen to 72. Respiration 20 per minute. In the evening about three ounces of turbid urine was drawn off by the catheter. He sank gradually, dying at 6 A. M. on February 12, forty-four hours after the reception of the injury. An autopsy was made five hours after death; the *rigor mortis* was imperfectly established; suggillation general over posterior portions of body; ulceration had already commenced over sacrum. The lower and back part of the neck exhibited slight tumefaction, yet sufficient to obliterate the depression which had been felt during life. The whole of the cervical portion of the spinal column was exposed by dissection, revealing a dislocation backward of the fifth vertebra. Both the superior articulating processes of this bone looked directly backward, and its bifid spinous process was astride of, and locked fast upon, the neck of the spinous process of the sixth cervical vertebra. So perfect was this impaction or locking that the spinous processes of the fifth and sixth vertebræ could only be felt as one until after all the soft tissues covering them had been dissected away. The luxation was "symmetrical" in respect to lateral displacement. Of course there was a wide interval, one and a half inches, between the spines of the fourth and fifth vertebræ, which interval contributed the depression felt upon the first examination of the patient. There was no fracture of the body, pedicles or laminae of the displaced bone, but on the right side a portion of the anterior tubercle of the transverse process had snapped off. The tip of the left division of the spinous process of the third cervical vertebra was separated, possibly in the dissection. The subflavian and capsular ligaments between the fourth and fifth vertebræ had given way, as had also the attachment of the ligamentum nuchæ to these bones. The anterior and posterior common ligaments were not ruptured. There was a slight extravasation of blood external to the sheath of the spinal marrow and a considerable quantity between the sheath and the cord. The upper and posterior edge of the fifth cervical vertebra encroached to such an extent upon the spinal canal, that the cord at this point was bent at an abrupt angle, and its antero-posterior diameter reduced more than half. The meninges of the cord were not torn nor was the cord itself lacerated, which may perhaps be accounted for by the fact that the wide separation of the bones allowed it to bulge out posteriorly and thus escape fracture. The lungs were generally congested, the left more than the right. The posterior portions were especially engorged; crepitation was nowhere entirely absent. The heart was slightly hypertrophied and all of its cavities empty. The cervical portion of the spinal column was removed entire; the luxation unreduced. Indeed, I failed in my attempt to reduce it, and that after the bones were removed from the body and were held together by nothing save their ligamentous attachments and the interlocking mentioned before. The specimen, a ligamentous preparation of the first six cervical vertebræ, was forwarded to the Army Medical Museum and is represented in the wood-cut.*

Dislocation of the Clavicle.—One instance of this rare accident is reported:

CCCXLIV.—*Remarks relative to a Subluxation of the Sternal Extremity of the Clavicle.* By G. MCC. MILLER, Assistant Surgeon, U. S. A.

Sergeant William Dow, Co. D, 5th Infantry, was thrown from a mule, while hunting antelope, near Fort Reynolds, Colorado Territory, on January 3, 1869, striking the ground with the point of his right shoulder. On his return to the fort I examined the injury, and found a sublux-

* Dr. Gray has already published this abstract in the *American Journal of the Medical Sciences*, Vol. LI, p. 109.

ation forward of the sternal extremity of the right clavicle, the end of the bone being advanced about the one-sixth of an inch beyond its proper level. He complained of pain at the seat of injury, and there was some tumefaction, as well as tenderness on pressure. I reduced the displaced bone, and applied Fox's apparatus for fractured clavicle. Compresses were also placed over the seat of injury. The apparatus, which was made of stout materials, so long as it was worn and kept moderately tight, maintained the bone in place admirably well, but when it was removed, or became slack, the bone was again displaced. He wore the apparatus until February 28th, a period of two months, when I removed it, and finding that no improvement had taken place, I omitted its further use, believing that if an apparatus does no good for two months after the injury, a reposition of the displaced bone is not to be anticipated. The unsuccessful result of treatment in this case accords with the experience of the best surgeons. Nevertheless, the patient will most probably have a very useful arm, as, according to the best authorities, the functions of the limb in these injuries are but slightly impaired. The ultimate result will be made known at a future time.

Dislocations at the Shoulder.—Since the general adoption of the methods of reduction by manipulations under anæsthesia, cases of this class have seldom presented difficulties, unless complicated by fracture, or unless the attempt to reduce was too long postponed. Though the accident was common enough, especially in the cavalry, the particulars were rarely reported.

CCCCXLV.—*Report of a Case of Irreducible Luxation of the Head of the Humerus.* By W. B. LYON, M. D., Acting Assistant Surgeon.

Private Edward Logan, Co. H, 38th Infantry, was admitted to the post hospital at Fort McRae, New Mexico, on July 31, 1868, having dislocated his right humerus into the axilla, by falling from the tongue of an Army wagon on July 1st; at the same time he received severe flesh wounds on the head and face from mule kicks. No attempt had been made at reduction. On August 2d, he was placed under chloroform, and manipulation and extension employed for two hours without success. Another attempt was made on the 13th with pulleys, and persisted in for two hours, with the same result. He was discharged for disability November 27, 1868.

CCCCXLVI.—*Note relative to a Dislocation at the Shoulder-joint.* By W. S. ADAMS, M. D., Acting Assistant Surgeon.

Private Thomas Ford, 5th Cavalry, aged 27 years, while wrestling with a comrade at Morgantown, North Carolina, on September 15, 1867, had his left arm dislocated, the head of the humerus being thrown downward and forward beneath the pectoral muscles. The dislocation was reduced by manipulation (Reed's method), and the joint was supported by a figure-of-eight bandage. On October 1st the patient was returned to duty, with good use of the limb.

Dislocations at the Elbow.—Of the nine varieties of luxations of the ulna and radius upon the humerus, a special report of one only was given; a case of complete luxation backward of the bones of the fore-arm.

CCCCXLVII.—*Extract from the Monthly Report from Downer's Station, Kansas, for January, 1868.* By L. Y. LORING, Assistant Surgeon, U. S. A.

The case of dislocation entered on the report was that of a soldier of Co. E, 5th Infantry, and was one of displacement of the elbow of the right arm, in which the ulna and radius were thrown backward upon the posterior surface of the humerus, producing a characteristic deformity, easy

of diagnosis. The luxation was caused by a large stick of wood striking the humerus upon its posterior and outer aspect, and thus, in reality, throwing the humerus forward upon the ulna and radius. The patient was placed in a recumbent position upon the floor, and anæsthetized by means of equal parts of chloroform and ether. A guy of strong material, having a loop, was attached just above the wrist of the affected arm, and the loop was passed around my neck and shoulders, thus increasing the power of extension. Counter-extension was produced by placing my heel in the bend of the arm, and thus also furnishing a fulcrum over which the forearm was bent, when the bones began to yield by extension. Reduction by this mode was soon accomplished. Bandages carefully applied over splints, and the usual antiphlogistic remedies and evaporating lotions were resorted to. Passive motion, the swelling having diminished, was also resorted to, in order to prevent ankylosis. The man was returned to duty in February, 1868.

Dislocations at the Wrist.—A single special report on this subject furnishes an additional fact for those surgeons who do not share Dupuytren's incredulity as to luxations at the wrist, without concomitant fracture of the radius.

CCCCXLVIII.—*On a Case of Dislocation of the Wrist.* By D. F. DAMOUR, M. D., Acting Assistant Surgeon.

Private Joseph M. Choate, Troop B, 1st Cavalry, aged 23 years, while acting in the capacity of teamster, was injured by falling from one of the wheel mules while the animals were stampeding, dislocating his left wrist. The carpus was displaced backward, and the lower end of the radius and ulna toward the palmar surface; the pisiform bone was also displaced. He was admitted to the hospital at Camp McGarry, Nevada, and the dislocation reduced at the time, and treated by applying splints and bandages, which were continued to October 1, 1867, without producing the desired result. The carpal bones were displaced on the dorsal surface, on the removal of the splints and roller, the same as before, and the joint remained loose and flabby. The soldier was returned to light duty on October 1st, but, on the 7th, readmitted to hospital, and, on November 17th, the splints and roller were reapplied, with a view of giving support and ease to the injured parts. He was discharged from service March 20, 1868, at which time it was believed he could not regain the use of his left hand.

Dislocations of the Metacarpals.—The rarity of luxations of the last four metacarpals, the cases observed by Bourguet, Blandin, and Roux, being cited by authors as altogether exceptional, adds to the interest of the following abstract:

CCCCXLIX.—*Mention of a Dislocation of the Second Metacarpal Bone.* By J. F. HEAD, Surgeon, U. S. A.

At West Point, New York, in the beginning of April, 1868, Charles Conway, corporal, Ordnance Department, was holding a drill in his right hand for another man to strike, when, suddenly, the hammerhead flew off, and struck a glancing blow on the back of his hand. Although the hand was covered with a thick buckskin mitten, it was rendered helpless by the blow; and on taking off the mitten, he noticed an irregularity in its appearance. I saw him about half an hour after the accident, when there was, already, some swelling, but not sufficient to conceal a marked depression on the back of the hand, over the carpal end of the second metacarpal bone. The bone was felt running down toward the palm, and with its base on a lower level than the next bone. It was fixed in this position, and no crepitus could be detected. As there was, evidently, a dislocation, I attempted to reduce it by making extension from the finger, and at the same time pressing, with my thumb in the palm of the hand, against the base of the metacarpal bone. It almost immediately, and with a snap, returned to its proper place. I then bandaged the hand, with a ball of tow in the palm. The swelling gradually disappeared, and on April 13, 1868, the man was returned to duty.

Dislocations at the Hip.—Of dislocations of the lower extremity, only one case was reported in detail, or by name. This was a case of luxation at the hip, in which the difficulty of reduction was increased by the inevitable delay in procuring surgical aid.

CCCCL.—*Note relative to a Case of Luxation at the Hip.* By L. E. HOLMES, M. D., Acting Assistant Surgeon.

Private Edward Hollen, Co. K, 23d Infantry, aged 24 years, was admitted to the hospital at Camp Logan, Oregon, in February, 1868. His right hip-joint was dislocated upward and backward on the dorsum of the ilium. The injury was received while travelling on snow shoes, from Cañon City to Soda Springs, February 6, 1868, and the patient had been lying six days in a private hospital at Cañon City. The limb became slightly swollen. On February 13th, the dislocation was reduced by pullies, after several unsuccessful attempts by manipulation. A splint was placed upon the outside of the limb, covering the joint, and bandaged closely. Slight inflammation of the joint and ligaments followed. The patient was discharged the service August 17, 1868, on account of lameness of a permanent character.

ARROW WOUNDS.

The illustrious Baron Percy was wont to declare* that military surgery had its origin in the treatment of wounds inflicted by darts and arrows, and used to quote his favorite poet† in behalf of his belief, and to cite Chiron, and Machaon's patients, Menelaus and Philoctetes, and Eurypiles treated by Patroclus. He was even tempted to believe, with Sextus,‡ that the name *ιατρος*, *medicus*, was derived from *ιδε*, which anciently signified *sagitta*, and that the earliest function of our surgical predecessors was the extraction of arrows and darts. An instrument called *belulcum*, from *βελος*, *telum*, a dart, was invented during the long Peloponnesian war (B. C. 431, 405). It was a rude pincers or extracting forceps, and was used by Hippocrates in the many campaigns in which he served. His immediate successor, Diocles, invented a complicated instrument for extracting foreign bodies, called *graphiscos*, and consisting of a canula with hooks.¶ It was not until the wars of Augustus that Heras of Cappadocia designed the famous duck-bill forceps, which, with every conceivable modification, has continued in use to our time. Celsus § instructs us that, in extracting arrow-heads, the entrance wound should be dilated, the barb of the arrow-head crushed by strong pliers, or protected between the grooves of a split reed, and thus withdrawn without laceration of the soft parts. Paulus Ægineta ¶ also treated fully of arrow-wounds, and described an *atracton* used in his day to remove firmly impacted arrows. Albucasis and the Arabian school did little or nothing toward advancing our knowledge of the means of extracting foreign bodies. After the fourteenth century the attention of surgeons was directed to wounds from projectiles impelled by gunpowder. Yet the use of bows and arrows in warfare continued, and we find Paré treating of this class of injuries with the sovereign good sense that characterized all he wrote. As the use of fire-arms became prevalent, the literature of arrow-wounds became meagre, and the subject is now rarely referred to in systematic works. The considerable number of cases reported by our medical officers possess therefore the greater interest.

Multiple Arrow-Wounds.—Dr. Bill, who has printed an interesting essay ** on this subject, remarking upon the rapidity with which the American Indians discharge their arrows, states that it is exceptional to meet with a single wound; that if one arrow takes effect it is immediately followed by two or more others. Of the seven following cases, six were fatal:

CCCCLI.—*Report of a Case of Three Wounds from Arrows.* By C. C. GRAY, Surgeon, U. S. A.

Private William Imbler, Co. H, 31st Infantry, while a few hundred yards from camp, at Fort Stevenson, Dakota Territory, on October 10, 1867, was severely wounded by Indian arrows, one of

* Manuel du Chirurgien d'Armée, p. 4.

† Homer, Iliad, Book XI.

‡ Sextus, Advers. Math., Lib. I, cap. 2.

¶ See Andrea della Croce, Lib. 7, p. 173; Venet. 1574.

§ Celsus, De Medicina, Lib. VII, cap. V.

¶ Paulus Ægineta, De re Medica, Lib. VI, cap. 88.

** Bill, American Journal of the Medical Sciences, Vol. XLIV, p. 365.

which was extracted at the angle of the jaw, after it had entered above the left scapula and transfixed the left posterior triangle of the neck. A second passed through the fleshy portion of the right fore-arm; and a third pierced the ulnar side of the left fore-arm near the elbow-joint, and, becoming twisted and wedged in the interosseous space, severely lacerated the tissues. With some difficulty the distorted head of this arrow was pushed downward and extracted near the wrist. The wounds were treated with simple dressings. Save partial paralysis of the left hand, the patient did well.

CCCCLII.—*Report of Death from Multiple Wounds, most of which were from Arrows.* By W. H. SMITH, M. D., Acting Assistant Surgeon.

Private Robert Nix, Co. G, 14th Infantry, was wounded near Camp Lincoln, Arizona Territory, in October, 1868. He received a gunshot flesh-wound in the upper portion of left arm; a slight cut from an arrow in the left ear; two flesh-wounds from arrows, from one of which the hæmorrhage was profuse; two arrow wounds in the right knee, the synovial membrane having been penetrated, but no bones broken; one gunshot wound in the right elbow, but not through the joint; and another through the metacarpal bone of the third finger of the right hand. During the eight hours following, while being conveyed to camp, he became very weak from loss of blood, and riding part of the time on a horse with a comrade, and the remainder in a Government team. He suddenly died the next morning. Decided symptoms of fatty degeneration, with dilatation and hypertrophy of heart, had been previously observed.

CCCCLIII.—*Note of a Case of Multiple Arrow-Wounds.* By R. B. HITZ, M. D., Acting Assistant Surgeon.

Private Constand Queswelle, Co. E, 13th Infantry, aged 26 years, received May 24, 1868, while on herding duty about half a mile from Camp Reeve, Montana Territory, seven arrow-wounds. One arrow entered the cavity, through the eighth dorsal vertebra, and one through the ninth; three passed through the fore-arm, one between the fifth and sixth ribs on the right side, and one through the palmer surface of the right hand. Death was apparently instantaneous.

CCCCLIV.—*Report of a Case of Death from Arrow-Wounds.* By G. L. PORTER, Assistant Surgeon, U. S. A.

Nat. Crabtree, a citizen, aged 38 years, while looking for his cattle, April 24, 1868, was shot by Indians, receiving nine arrow-wounds; one in the post gluteal region, one in the left lung, one in the abdomen, one penetrating the humerus, one in the hand, one in the testicle, one in the back to the left of the dorsal vertebra, one in the bladder, and a glance-shot five inches long below the ninth rib. He was admitted to the post hospital at Camp Cooke, Montana Territory. Some of the arrows had been removed by his friends, and five, including the one in the gluteal region, which had penetrated ten and a half inches, were taken out at the post. The man died a few hours after admission to hospital.

CCCCLV.—*Report of a Remarkable Case of Arrow-Wounds.* By J. H. PEABODY, M. D., Late Surgeon, U. S. V.

Private George Osborn, of Troop D, 2d Nebraska Cavalry, was wounded by arrows in a skirmish with Indians near Pawnee Reserve, Nebraska, on June 23, 1863. Eight arrows entered at different parts of his body, and were all extracted except the head of one, which had entered at the outer and lower margin of the right scapula, and had passed upward and inward through the upper lobe of the right lung, or trachea. Hæmorrhage at this time was so great that all hope of recovery was abandoned. The patient, however, rallied, but continued to suffer great pain upon swallowing or coughing, and occasionally spit blood. In July, 1866, more than three years subsequent to the receipt of the injury, he called at the office of Dr. J. H. Peabody, to undergo an examination, with a view of applying for a pension, stating that his health was much affected from the presence of the arrow-head. He was much emaciated, and expressed himself tired of life. Upon probing

through a small fistulous opening just above the superior end of the sternum, the point of the arrow was found resting against the bone, about an inch and a half below, the head lying flat against the trachea and œsophagus, with the carotid artery, jugular vein, and nerves overlying. After some little difficulty, the point of the arrow was raised above the sternum, and it was extracted without the loss of an ounce of blood, the edge grating against the sheath of the innominate artery during the operation. The missile measured an inch at the base, and




FIG. 22. Iron arrow-head extracted from the chest. Spec. 5642, Sect. I, A. M. M.

was four inches long, (FIG. 22.) Its form is shown in the annexed wood-cut, nearly, but not accurately, of half the natural size. The patient, appearing highly gratified at the result, rode to his home. His health underwent a remarkable improvement, and in January, 1869, the operator reported him perfectly well.

CCCCLVI.—*Report of a Case in which the Patient received Five Arrow-Wounds, and was Scalped.*
By S. M. HORTON, Assistant Surgeon, U. S. A.

Private Patrick D. Smith, of Co. H, 18th Infantry, was attacked about six miles from Fort Philip Kearney, Dakota Territory, on the evening of September 26, 1866, by three Indians, who inflicted five arrow-wounds, and removed part of his scalp. On the next morning he was seen by two physicians. Two of the arrows still remained in his body—one in the right side below the region of the kidney; the other had pierced the cartilage at the junction of the first rib with the sternum, inflicting a wound three inches in depth. The arrows were extracted, the wound dressed, and the patient supported until 10 o'clock the next morning, September 28th, when he expired. At the autopsy it was found that the wound in his chest had been the cause of death. The arrow had cut the edge of the right lung, and had inflicted a slight wound, one-eighth of an inch in length, in the descending vena cava. The right lung and surrounding tissues were considerably infiltrated with blood, and a large amount of coagulum was found in the cavity of the thorax.

CCCCLVII.—*Account of a Case of Fatal Wounds from Arrows.* By C. S. DE GRAW, Assistant Surgeon, U. S. A.

Private James Spillman, Troop B, 7th Cavalry, aged 22 years, was wounded on the morning of June 12, 1867, about a mile from Fort Dodge, Kansas, by a party of Kiowa Indians, who made a dash upon the herd of horses he was guarding, and inflicted three arrow-wounds: The first in the right shoulder; the second in the right side, the arrow glancing from a rib, and making a wound similar to a stitch, about three inches in length; and the third through the right lumbar region, penetrating the abdominal cavity to a depth of about eight inches or more. The arrow causing the wound in the side was removed by cutting the arrow in two, and then drawing out the parts. The arrow in the lumbar region was removed with great difficulty. The wound being enlarged, two fingers were inserted on either side of the shaft until the base of the iron head was reached, the fingers thus inserted serving as a guide and as a protection to the parts, when, traction being made, the arrow was withdrawn. This latter wound proved mortal, the man dying the next day about 3 o'clock, P. M. His true name was Wise, of Washington. No *post-mortem*. The two arrows removed were contributed to the Army Medical Museum, and are numbered 5651 in the Surgical Section.

Arrow-Wounds of the Head and Neck.—Special reports of eight cases were received, In five, the cranial cavity was penetrated, and four of the patients perished.

CCCCLVIII.—*Report of an Arrow-Wound of the Skull.* By C. C. GRAY, Surgeon, U. S. A.

Private John Krumholz, of Co. H, 22d Infantry, was accidentally wounded at Fort Sully, Dakota, on June 3, 1869, by an arrow, which, entering at the outer canthus of the left eye, penetrated the skull to the extent of two inches, and is supposed to have passed between the

skull and dura mater. Being admitted to hospital on the same day, he was chloroformed, and an operation for extraction was immediately performed. This consisted in sawing nearly through the skull with a Hey's saw, in close proximity to the arrow. The condition of the injured parts was healthy at the time of operation, and the patient's constitutional state was good. The treatment consisted in rest, low diet, elevation of the head, cold applications, and saline cathartics. Recovery was rapid, and he returned to duty on June 7, 1869.

CCCCLIX.—*Extracts from Reports of Sick and Wounded at Fort McDowell, Arizona Territory.* April and May, 1866. By CHARLES SMART, Assistant Surgeon, U. S. A.

Private Andrew Snowdon, Co. B, 3d Battalion, 14th Infantry, was one of a party surprised by Apaches, March 22, 1866, while *en route* from Maricopa Wells to Fort Goodwin. He was struck on the back of the head by an arrow, which penetrated his skull. It is said that he was nine days in traveling to Maricopa Wells from the place where he was wounded. On his arrival there he is stated to have been weak and fatigued, but with his intelligence unimpaired. He believed the arrow-head to be within the cranium, as in pulling on the shaft after the reception of the injury, nothing but the shaft came away. On or about the 10th or 12th of April, he lost his appetite, felt considerable nausea, and appeared to those around somewhat dull and stupid. He rapidly grew worse, so that it was considered advisable to send him to the post for treatment. He was placed on a hay wagon, and made the journey to Salt River on that conveyance—a distance of thirty miles. At this time I was notified concerning the case, and instructed to proceed to Salt River with our ambulance for him. I found him with a full pulse, slow, and somewhat hard; his mental faculties much clouded; hearing distinctly, and giving answer to every question, although the answer seldom contained the information desired. He tried to remember his name, but could not. He was troubled with a very persistent vomiting. On April 19th, he was received into the post hospital; an active cathartic was administered, his head shaved, and cold dressings applied. During the day his stupor increased to such an extent that the sharpest tone failed to make an impression on him. His pulse 50, full and hard; vomiting much abated. On the 20th, the purgative was repeated, as it had as yet been without effect. The scalp was examined, discovering a small tumefaction, in which was an ill defined sense of fluctuation, situated over the parietal side of the left occipito-parietal suture. Pressure exercised upon it caused the issue of a small quantity of serous matter from a point in the cicatrix of the arrow-wound. This was enlarged, and a probe passed into it was made to feel along a fissure in the bone, when it struck upon something metallic. The cranium was laid bare by a crucial incision, and with considerable difficulty a hoop-iron arrow-head, one and three-quarter inches long, and half an inch in breadth, was withdrawn from the brain. About a drachm of pus followed it in its exit. During the procedure the patient lay quiet, except when at times, without any assignable cause, he would burst into a violent scream. After the operation, which was not noticed previous to it, the right side was observed to be paralyzed. April 21st: Pulse as before. Insensibility great. Paralysis of right side more marked; features drawn to wounded side. Has not eaten anything since his admittance, nor for several days previous to that time. Passes his urine when the nurse solicits him, by the application of the urinal. Bowels unmoved, a cathartic enema was administered. 22d: Seems slightly improved. Enema brought away nothing, but during the afternoon of yesterday he had a large involuntary passage. Has eaten nothing; swallows a mouthful of tea occasionally. Pulse 50. 24th: Has eaten nothing—no improvement—pulse less full, and more compressible. 26th: Yesterday, took a few teaspoonfuls of custard. In afternoon, was feverish and delirious. Enema administered. Features sunken and distorted. 27th: Much improved. Has eaten considerably of a farinaceous preparation. Face more regular in expression. Pulse 54, softened. Answers questions readily, but not to the purpose. Cannot remember his name. 30th: Steady improvement. Has eaten well every day since last report. Pulse 68. Hemiplegia unobservable. Has remembered name, and at times take an interest in what is going on in the ward. Wound of operation healing kindly.

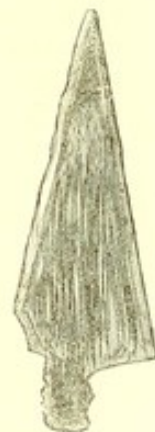

FIG. 23. Iron arrow-head extracted from the brain. Spec. 5654, Sect. I. A. M. M.

During the first week of May he continued to improve; caution concerning diet and an occasional purge being all that was considered necessary. On the 7th, after eating heartily of some soup, which I afterward learned to have been "somewhat greasy," he became slightly feverish, and during the succeeding night did not rest well. On the 8th, skin hot; pulse 65, hard, a little headache, and occasionally sickness at stomach. Cold to head ordered, and an enema administered. From this time he gradually grew worse, complaining much of pain in the head, and stiffness in the back of the neck, while on the 11th and 12th, muscular tremors were the most prominent objective symptom. Unconsciousness set in on the morning of the 13th, and he died quietly about six hours thereafter. *Post-mortem* examination seven hours after death. Body muscular, rigid, not emaciated. A firm cruciform cicatrix on posterior and left side of scalp. The centre of this cicatrix adherent by firm fibres to bone beneath. In the bone almost corresponding in situation with the centre of the cicatrix, was a slit half an inch long, and one-eighth of an inch wide, filled in with recently formed soft tissue, which broke down before the handle of a scalpel. From the upper end of this slit a fissure one inch and a half in length, extended to the inter-parietal suture, while from its other extremity another fissure stretched in curved direction toward the ear two inches. The dura mater was adherent to the margin of the slit in the bone, and to the soft tissue which filled it in; but external to the membrane there was no collection of matter. In the posterior lobe of the left cerebral hemisphere, the track of the arrow-head was followed downward, forward, and inward, communicating with the posterior cornu of the left ventricle. The brain tissue, to the extent of three-quarters of an inch around the track as a centre, was softened and disorganized. The track of the arrow-head was filled with a thick pus, which had extended thence into the ventricle. The right ventricle was also filled, as were the sub-arachnoidean spaces. No other organ examined.

CCCCLX.—*Memorandum relative to the Skull of a Mexican Killed by an Arrow.* By W. M. NORSON, Assistant Surgeon, U. S. A.

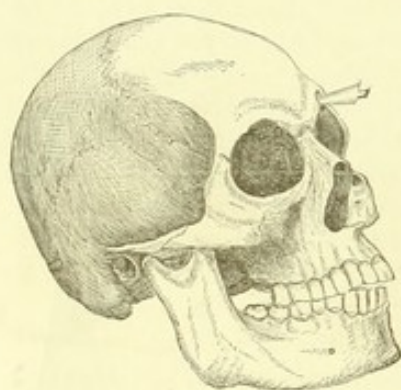

FIG. 24. Cranium penetrated by an arrow through the left superciliary ridge. *Spec.* 5644, Sect. I, A. M. M.

An unknown Mexican was killed by an arrow-wound in an Indian fight, which occurred seventy-five miles northwest of Fort Concho, Texas, on February 22, 1868. The arrow perforated the frontal. When I opened the skull, I found an incision extending clear across the opposite hemisphere, touching the dura mater just above the tentorium. The dura mater was stained, but I could find no mark on the skull. When I made the *post-mortem* I found the arrow-head in the brain. When the Mexican was hit he seized the arrow-shaft with both hands and pulled it out, then dropped and of course remained unconscious until he died, about six hours. The specimen was forwarded to the Army Medical Museum. [It is figured in the adjacent wood-cut, (FIG. 24.) The arrow-head has been removed from the cavity of the skull and fastened at the point of entrance. Apart from the lesion, the skull is a highly interesting specimen.—ED.]

CCCCLXI.—*Memorandum of an Arrow-Wound of the Face.* By P. MIDDLETON, Assistant Surgeon, U. S. A.

Private William Drum, Co. G, 14th Infantry, aged 20 years, was wounded in a fight with Apache Indians on November 11, 1867. One arrow entered over the malar bone of the left side of the face, passed along the lower border of the orbit to within half an inch of the nose. Another arrow entered through the tendon of the latissimus dorsi muscle on the right side, and passed directly backward toward the spine under the deep muscles, penetrating two and a half inches. He was admitted to the post hospital at Fort Whipple, Arizona Territory, on the following day. On November 19th, I cut down upon the arrow-head in the side, and removed it. The parts healed by the first intention, and on December 3, 1867, the patient was returned to duty.

CCCCLXII.—*Account of an Arrow-Wound of the Scalp and of the Leg.* By HENRY McELDERRY, Assistant Surgeon, U. S. A.

Private William Rosback, Troop F, 6th Cavalry, aged 20 years, was wounded during the night of August 29, 1867, in an attack by Indians on Fort Belknap, Texas, by two arrows; one striking the scalp, the other the outer aspect of the left leg three inches below the knee-joint. Missile passed backward and inward, the spike lodging. He was admitted from company quarters on September 1, to hospital at Camp Wilson. Cold-water dressings were applied. The arrow-head was excised posteriorly in the popliteal space. Isinglass plaster and fused nitrate of silver locally. He was returned to duty on November 24, 1867.

CCCCLXIII.—*Report of an Arrow-Wound of the Neck.* By B. SEMIG, Acting Assistant Surgeon.

Private Thomas Dutton, Co. K, 32d Infantry, aged 23 years, was wounded in an attack by Apache Indians upon a wagon train in the lower Senorita Valley, Arizona Territory, on May 8, 1869, by an arrow which caused a flesh wound of the posterior portion of the neck. He was admitted on the next day to the post hospital at Camp Crittenden, Arizona Territory. He recovered, and was returned to duty May 17, 1869.

CCCCLXIV.—*Accounts of Two Fatal Arrow-Wounds of the Skull.* By W. M. NOTSON, Assistant Surgeon, U. S. A.

CASE I.—J. C.—, with two others, were attacked by Indians on September 1, 1870, near the Pecos River, Texas. One man was killed, another escaped, and C— received an arrow-wound of the head, and three gunshot flesh-wounds—one in the arm, another in the breast, and a third in the leg. Seven days afterward he was admitted to the post hospital at Fort Concho, Texas, having traveled part of the distance on foot and the balance by wagon and stage. When admitted his mental condition was good, and as clear and bright as usual. He complained only of weariness from his ride and some slight soreness of the gunshot wounds, and spoke very lightly of the scratch on the side of his head. Water dressings were applied to the wounds and rest enjoined. The gunshot wounds healed kindly. On the fourth day after admission, the indications being something more than irritative fever, special diet was ordered, and aromatic spirits of ammonia was given in small doses. This prescription was afterward replaced by an ordinary fever mixture. On the night of the sixth day the cerebral symptoms becoming more violent, hydrate of chloral was ordered. On the eighth day a saline cathartic was given, and an effort made by Acting Assistant Surgeon C. W. Knight to reopen the wound of the temple. This attempt proved unsuccessful on account of the resistance of the temporal fascia. Doubt as to the cause of the existing symptoms prevented him from making a free incision. The treatment from this up to the fatal termination of the case, September 19, 1870, was with counter-irritants, nutriment, and stimulants. The autopsy revealed the site of the injury of the bone half an inch from the external incision, which, when first seen upon admission, was a clean cut nearly healed. Pus was found in the wound, ventricles, and meninges. The pathological specimen, showing an iron arrow-head lodged in the petrous portion of the right temporal bone, was contributed to the Army Medical Museum, and is figured in the wood-cut FIG. 25. The following thermograph (FIG. 26) exhibits the variations of the temperature, as observed from the seventh to the eighteenth day of disease, inclusive.

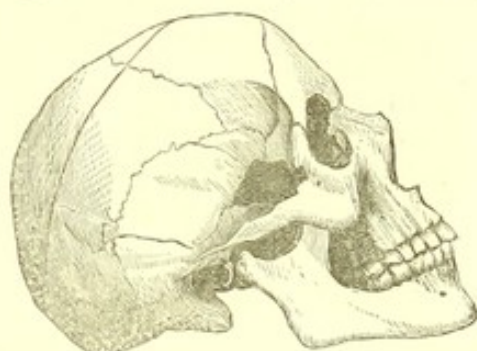

FIG. 25. Cranium with an arrow-head imparted in the right squamous bone. Spec. 5007, Sect. I, A. M. M.

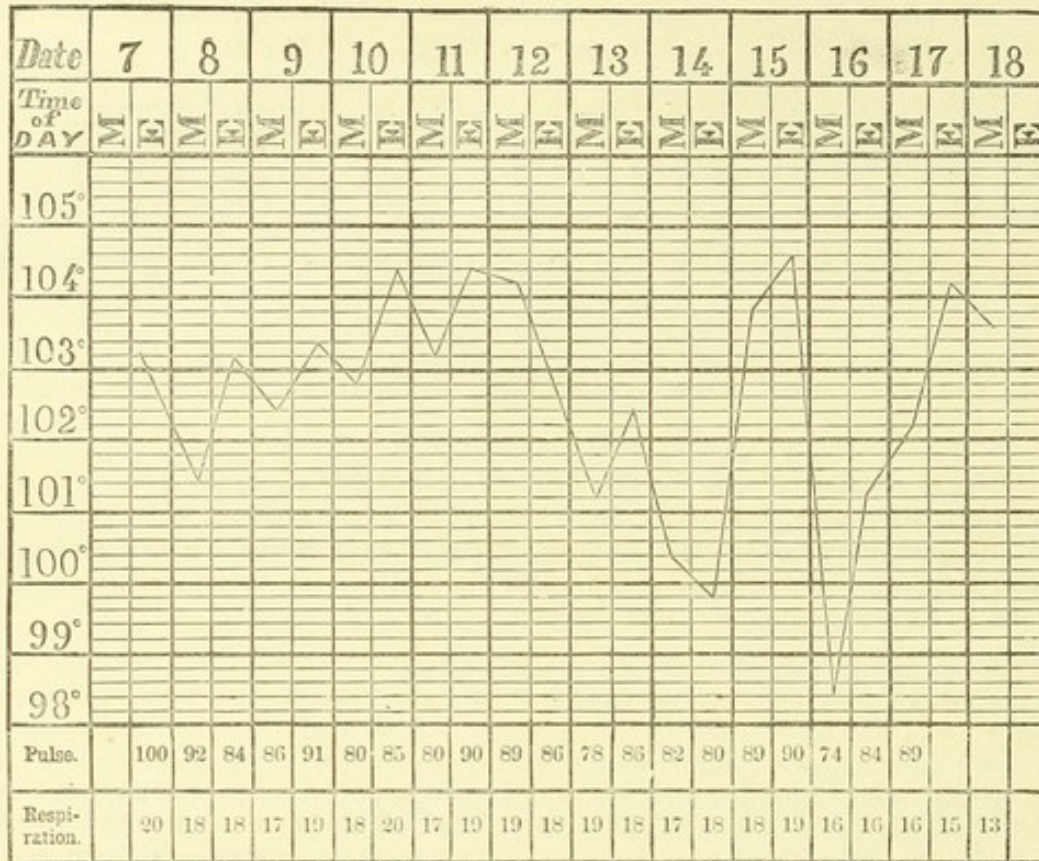


FIG. 26. Thermograph of a Case of Arrow-Wound of Brain from September 7, 1870, to September 18, 1872.

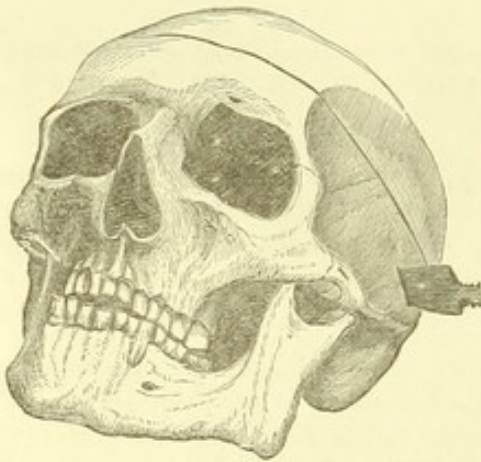


FIG. 27. Cranium with an iron arrow-head impacted in the left temporal bone. Spec. 5008, Sect. I, A. M. M.

CASE 2.—Private Martin W—, Co. E, 4th Cavalry, was killed by Indians, on September 30, 1870, twenty miles from Fort Concho, Texas, while on duty as one of the mail-stage guard from Fort Chadbourne. The escort being attacked by a band of Comanches, this soldier was wounded by an iron-headed arrow, which entered the squamous portion of the left temporal bone, and penetrated the left cerebral hemisphere to a depth of an inch or more, causing intracranial bleeding which was speedily fatal. In the specimen which was forwarded to the Army Medical Museum, and which is represented in the accompanying wood-cut (FIG. 27) the puncture of the thin calvaria, without fissuring, is well indicated. Internally there is no splintering. The vitreous table is as cleanly divided as the outer table.

It was Dr. Bill's belief (*loc. cit.*, p. 375,) that penetrations of the skull by arrows were unusually characterized by a linear puncture of the outer table, corresponding to the size of the arrow-head, with a crack usually extending from either edge, proportionate in length to the momentum of the arrow, while the inner table, struck by the arrow's point at a reduced velocity was splintered and depressed. But such is not the testimony of the specimens in the Army Medical Museum. They show both tables of the calvaria punctured with little or no fissuring externally or internally. In all of the specimens, the

arrow-heads have been literally impacted, the vitreous table being penetrated as cleanly as the outer. This is in such marked contrast to the results of bayonet or sword thrusts or of the impact of gunshot projectiles as to merit notice.

Arrow-Wounds of the Chest.—Seven cases were specially reported. Among them were two remarkable instances of recovery after penetration of the plueral cavity by arrows.

CCCCLXV.—*Note of an Arrow-Wound of the Chest.* By F. DAMOUR, M. D., Acting Assistant Surgeon.

Private George Duggan, Troop K, 8th Cavalry, was wounded near Camp Willow Grove, Arizona Territory, November 8, 1867, by an arrow, which penetrated the posterior side of the right chest. He died December 17, 1867. At the autopsy, the arrow was found to have penetrated the chest a little above the diaphragm, with which the head of the arrow was lying in contact. There was also an abscess containing much purulent matter.

CCCCLXVI.—*Mention of a Fatal Arrow-Wound of the Lung.* By HENRY LIPPINCOTT, Assistant Surgeon, U. S. A.

Private Benjamin McCassey, Troop H, 7th Cavalry, was wounded at the engagement of Washita River, November 27, 1868, by an arrow which entered the left side at the fourth intercostal space, and passed backward and upward into the lung. Stimulants and opiates were administered with cold-water dressings to the wound. The patient expectorated a great deal of blood. Death resulted on November 30, 1868.

CCCCLXVII.—*Account of Two Cases of Arrow-Wounds, compiled from Memoranda on the Monthly Report of Sick and Wounded at Fort C. H. Smith, for September, 1866.* By H. M. MATTHEWS, M. D., Acting Assistant Surgeon.

CASE 1.—Corporal Alvin H. Stables, Co. D, 18th Infantry, received September 20, 1866, two arrow-wounds in addition to a gunshot wound of the head. One arrow entered the left chest posteriorly, and transfixated the thorax, the arrow-point raising the skin above the right nipple; the other arrow passed through the chest to the left of the median line. The soldier was then scalped by the Indians, and killed.

CASE 2.—Private Thomas Fitzpatrick, Co. D, 18th Infantry, in an engagement with Indians in Montana, was killed by numerous arrow, gunshot, and contused wounds. One arrow penetrated the chest through the left axilla; another, entering under the right nipple, penetrated the vertebral column; a third perforated the left elbow-joint; a fourth and fifth had entered the thorax posteriorly above and below the scapula. A musket ball had passed through the heart, and a second through the right knee-joint. The skull was crushed in from behind by a war club, and there was a tomahawk wound of the left temporal region.

CCCCLXVIII.—*Report of an Arrow-Wound of the Lung, resulting in Pleurisy, and followed by Recovery.* By A. MULLER, M. D., Acting Assistant Surgeon.

John Fenske, a civilian, aged 19 years, came to Fort Ridgely, Minnesota, on the night of August 20, 1862, for surgical aid and protection, having been wounded on the previous day by an Indian arrow, which was shot a distance of about twelve feet, and had entered the back horizontally between the third and fourth ribs of the left side, close to the vertebrae. The arrow, a barbed one,

with the head about three inches long, was buried one inch below the surface of the skin, and had penetrated the left lung. On account of the barbs, it became necessary to make a large perpendicular incision in order to remove the arrow-head, which required for its extraction considerable pulling, the sharp edges having been wedged in between the ribs with such force as to bend them over on each side. After its removal, there was a considerable flow of blood for a few minutes, probably from an intercostal artery. The bleeding, however, was entirely arrested by cold-water applications. The wound having been cleansed and its edges brought together by a strip of adhesive plaster, cold-water dressings were ordered and continued for three days. A healthy suppuration then set in, and the wound closed by granulation in thirteen days. It was evident in this case that the arrow had penetrated the left lung through both pleuræ, which diagnosis was fully corroborated by the objective as well as subjective symptoms. The patient complained of severe pleuritic pains (or stitches) through the whole of the left lung at every inspiration. The respiration was greatly accelerated, dyspnoea was often very alarming and palpitations of the heart very severe, obliging the patient to rest in an upright position. Occasional bloody sputæ were observed, and his pulse varied, during the inflammatory process, from 95 to 140. Auscultation and percussion of the thorax revealed an extensive effusion of fluid on the left side, with subsequent hepatization of the upper lobe of the left lung to the extent of the palm of the hand. The treatment was strictly antiphlogistic: Repeated bleeding, (five times in two weeks,)

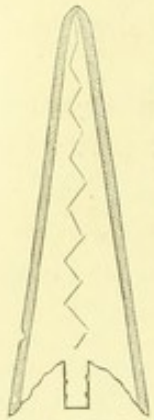


FIG. 28. Barbed Indian arrow-head. From a drawing by Dr. Muller.

cupping intervening, (from six to ten cups each time,) repeated four times in ten days, affording the patient great relief at each repetition; and application of blisters. Internally tartar emetic in progressive doses, nitre and digitalis, were successively administered, under which treatment, aided by low diet, chiefly milk, the effusion gradually disappeared, and all alarming symptoms subsided. On the twelfth day of treatment, his pulse did not exceed eighty, the effusion in the left pleura had entirely disappeared, with the exception of a small accumulation in the lower left lobe. Light vegetable tonics, with iodide of potassium, were now administered, and a full and select diet adopted. The patient left for home on September 30, 1862, forty-two days after receiving the injury, having so far recovered that only an occasional slight dyspnoea remained. The percussion at this time gave a clear tympanitic sound in the vicinity of the wound, followed by a distinct metallic sound to be heard on auscultation of the parts, entirely similar to pneumo-thorax, which, in this case, was believed to exist to a circumscribed extent, adhesions having formed along the posterior surface of the left lung. He was dismissed with advice to use cod-liver oil. Dr. Muller reports lately that he had occasion to meet this patient four years afterward, and that the remaining untoward symptoms, above described, were considerably ameliorated.

CCCCLXIX.—*Abstract from Reports of an Arrow-Wound of the Thorax.* By JOSEPH KUGLER, Acting Assistant Surgeon.

William Livingston, a private of Troop G, 3d Cavalry, was wounded by Indians while herding horses at Fort Stevens, Colorado Territory, on October 6, 1866, an arrow having entered the right side of thorax between the first and second ribs. It was forcibly extracted by the patient, who stated that a great gush of blood followed. After being conveyed in an ambulance over a rough mountain road, he was admitted to hospital at Fort Garland, Colorado Territory, on the 12th, in a very weak condition, and suffering frightfully from dyspnoea. An examination showed effusion of blood into the right pleural cavity, and the lung impervious, owing to the entrance of blood into the bronchii. Hot fomentations were applied to the wound, and stimulants, afterward followed by stimulating expectorants, were administered, under which treatment the patient was gradually improving on the last of October. On the monthly report for November, the patient is borne as convalescent. He was able to walk about, but there was still a collection of serum or pus in right pleural cavity, and the respiration of that side was merely bronchial. The treatment still consisted of stimulating expectorants, with stimulants and generous diet. In December, he is still reported convalescent. The effusion in the right pleural cavity was diminishing, and air entered more freely into the lung. He was daily gaining strength and spirits, and little doubt was entertained of his making a good recovery. He was returned to duty in February, 1867.

CCCCLXX.—*Memorandum of a Case of Arrow-Wounds of the Thorax.* By WILLIAM M. NOTSON, Assistant Surgeon, U. S. A.

"I send to the Army Medical Museum a specimen of an arrow-wound of the spine. It was taken from the body of a white man who was killed by Indians in 1869, at an outpost near Fort Concho, Texas. I found the man dead. There were extracted from his lungs and heart no less than four arrow-heads, and a fifth was impacted at the junction of the rib with the transverse process of the fourth dorsal vertebra. I removed the fourth and fifth vertebrae and portions of the third and sixth, and forwarded them to the Army Medical Museum. The specimen shows the arrow-head impacted in the right transverse process of the fourth dorsal vertebra and posterior extremity of the rib. The wound does not intersect with the vertebral canal. I could learn no particulars of the case. Any one of the wounds of the thorax would have been fatal." (FIG. 29.)

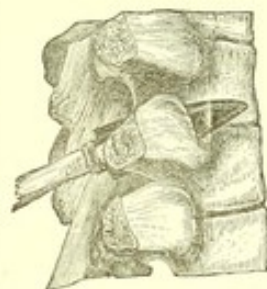

FIG. 29. Arrow impacted in the transverse process of the fourth dorsal vertebra. Spec. 5673, Sect. I, A. M. M.

Arrow-Wound of the Abdomen.—Three instances of penetrating wounds of the abdomen by arrows have been recorded among the cases of multiple wounds in an earlier portion of this section. Special reports were made of six other cases of this class. Of the nine cases seven were fatal, and in the two cases of recovery, there is room for doubt whether the arrow-head penetrated the peritonæal sac. The great fatality of arrow-wounds of the abdomen is well known, so well known to the Indians that, Dr. Bill tells us, they aim always at the umbilicus. Dr. Bill (*loc. cit.*, p. 385) mentions that Mexicans are accustomed, when fighting Indians, to envelope the abdomen as the most vulnerable part in many folds of a blanket.

CCCCLXXI.—*Report of an Arrow-Wound of the Abdomen.* By H. S. KILBOURNE, M. D., Acting Assistant Surgeon.

Private Samuel Brown, Troop F, 10th Cavalry, was wounded near Canadian River, Texas, December 2, 1868, by an arrow, which entered the abdomen in the left hypochondriac region, making a punctured wound three-quarters of an inch in length, through which about eighteen inches of the small intestine protruded. The intestine was cut in four places. The wounds in the intestine were closed by suture, and the protruding portion of the gut returned through the wound, which was enlarged for that purpose. When found, the man had lain out all night, and was in a state of collapse. He was carried along in an ambulance, but died on the second day, not having rallied from the shock of the injury.

CCCCLXXII.—*Note of a Fatal Arrow-Wound involving the Liver, complicated by Gunshot Injuries.* By S. M. HORTON, Assistant Surgeon, U. S. A.

Bugler Edwin L. Train, Troop D, 2d Cavalry, aged 17 years, was wounded at Fort Philip Kearney, Dakota Territory, June 11, 1867, in a fight with Indians. He received a gunshot fracture of the right arm, a gunshot wound in the left side of chest, and an arrow-wound of the liver. He was admitted to the post hospital. Several fragments of bone were removed from the right arm, and the arrow was extracted by forcing it through the body. He died on June 12, 1867.

CCCCLXXIII.—*Mention of an Arrow-Wound by which the Body was Transfixed.* By C. E. GODDARD, Surgeon U. S. A.

John Locke, an employé of the sutler at Fort Rice, Dakota Territory, was accidentally wounded in February, 1868, by an arrow, which entered the back, three inches to the right of the

fifth lumbar vertebra, and emerged about two inches to the right of the ensiform cartilage. During the evening following, the patient lost about eight ounces of blood externally, and a small amount internally. He was confined to his bed some two weeks, suffering from irritative fever and circumscribed peritonitis. In four weeks he was walking about; and by July 1st, was actively employed. The arrow was contributed to the Army Medical Museum.

CCCCLXXIV.—*Account of an Arrow-Wound of the Abdomen.* By J. P. KIMBALL, Assistant Surgeon, U. S. A.

Private James W. Cooper, Co. E, 31st Infantry, aged twenty years, received, in a fight with Indians near Fort Buford, Dakota Territory, August 20, 1868, an arrow-wound of the abdominal parietes. The missile entered over the centre of the eighth rib of the right side, and passed downward and forward, to near umbilicus. He also received an incised wound of the right hip. He was admitted to the post hospital on the day of injury, complaining of excessive pain. Chloroform was administered, and cutting down upon the head of the arrow, immediately above the umbilicus, it was withdrawn through the incision. The patient reacted promptly, and was doing well until September 25th, when he suddenly experienced a severe pain in the right hypochondriac region, and complained of a gurgling sensation. He became faint, and evinced symptoms of internal hæmorrhage. Cold water was applied to the abdomen, and anodynes were administered. On September 30th, he was slowly improving; and on December 31, 1868, he was still under treatment. This man was returned to duty in February, 1869.

CCCCLXXV.—*Report of an Arrow-Wound of the Back and Kidney.* By CALVIN DEWITT, Assistant Surgeon, U. S. A.

Private Conrad Tragesor, Troop I, 8th Cavalry, was wounded in an engagement with Apache Indians, at Sunflower Valley, Arizona Territory, March 9, 1870, by an arrow, which entered the left side, about four inches from the spine, and above the crest of the ileum, from below upward. The kidney evidently was injured, as the patient passed bloody urine in small quantities, and frequently. His face was pale, anxious, and expressive of great pain; pulse weak. He was conveyed in an ambulance to Camp McDowell, Arizona Territory, a distance of thirty miles, over a rough, stony, and hilly road. He died the next day. At the autopsy, it was found that the arrow had trans-fixed the kidney, entering it on the external border, at the juncture of middle and lower thirds emerging from the posterior surface near the internal border, a few lines below the pelvis. A large irregular piece, about one inch long, and half an inch thick, was torn from the posterior border of the kidney at the place of entrance, evidently by the traction made in extracting the arrow, leaving the head behind. The kidney was otherwise normal; the abdomen was filled with blood.

CCCCLXXVI.—*Account of an Arrow-Wound of the Pelvis and Abdomen.* By JAMES P. KIMBALL, Assistant Surgeon, U. S. A.

To-Kah K-ten, or "he that kills his enemy," an Indian scout, in a quarrel with a fellow-scout, at Fort Buford, Dakota Territory, January 3, 1870, received a penetrating arrow-wound of the pelvis and abdomen. The arrow entered midway between the right ischium and the anus. The shaft of the arrow having been withdrawn before he came under surgical observation, the exact direction of the arrow could not be determined, but, as the blood marks on the shaft showed that it had penetrated about twelve inches, and the arrow-head would make at least three inches more, it is supposed that the arrow had passed up through the pelvis into the abdomen. Opiates were administered, and light diet and perfect quiet enjoined. The case apparently progressed favorably for several days, when peritonitis supervened, and death ensued January 18, 1870.

Miscellaneous Arrow-Wounds.—None of the forty-eight cases of arrow-wounds mentioned in the nine following reports proved fatal. With one exception the lesions implicated the soft parts only. The regions injured were the scalp or face, or neck in three instances; the parieties of the chest in six; the long muscles of the back in seven; the abdominal muscles in two; the hip or buttocks in three; the testis in one; the shoulder or arm in thirteen; the fore-arm or hand in six; the thigh or leg in seven. A few cases of extraction of arrow-heads, and an instance of brachial aneurism cured by digital compression are noticeable in this series.

CCCCLXXVII.—*Remarks on an Arrow-Wound of the Back.* By J. P. KIMBALL, Assistant Surgeon, U. S. A.

Corporal Edward Monaghan, Co. C, 31st Infantry, aged 24 years, was wounded in a skirmish with Indians near Fort Buford, Dakota Territory, on November 6, 1867, by an arrow, which entered just below the inferior angle of the right scapula, and, passing around the ribs, came so nearly through in front, that the position of the head could be clearly made out. He was at once admitted to the post hospital. There was no swelling or discoloration, and but little hæmorrhage. He was somewhat excited, having walked nearly two miles after the reception of the injury. An incision one inch in length, and about one inch in depth, was made through the pectoralis major muscle, two inches above and a little to the outside of the right nipple. The arrow-head was then removed through the incision, and the shaft removed through the wound of entrance. Three days later, the anterior wound was healing by first intention; the posterior wound suppurated slightly. On November 26, 1867, both wounds had healed, and the patient was returned to duty.

CCCCLXXVIII.—*Note concerning an Arrow-Wound of the Lumbar Region.* By REDFORD SHARPE, M. D., Acting Assistant Surgeon.

Captain E. M. Heyl, Co. M, 9th Cavalry, aged 26 years, was admitted to the post hospital at Fort McKavett, Texas, on November 28, 1869, with an arrow-wound of the left lumbar region, midway between the spine and umbilicus, received in an engagement with Lipan Indians, at the headwaters of the Llano River, Texas. The wound had a direction oblique and backward. He recovered, and returned to duty December 25, 1869.

CCCCLXXIX.—*Report of an Arrow-Wound of the Arm, followed by Aneurism.* By J. N. McCHANDLESS, M. D., Acting Assistant Surgeon.

Private James Burridge, Co. C, 14th Infantry, aged 22 years, was wounded near Bower's Rancho, Arizona Territory, November 11, 1867, by an arrow, which struck the arm about two inches above the elbow. Traumatic aneurism followed, and on January 3d, digital compression was employed, and continued for twenty-four hours. Before compression, the tumor was about the size of a pigeon's egg, soft and pulsating. One week after the compression, it was reduced to half the size. On January 15th, the compression was repeated for twenty-four hours, and on January 18th, the tumor was almost imperceptible. The patient was returned to duty January 20, 1868.

CCCCLXXX.—*Mention of an Arrow-Wound of the Hand.* By J. B. GIRARD, Assistant Surgeon, U. S. A.

Private Edward M. Detterer, Co. G, 4th Infantry, was wounded at Smoky Hill, Kansas, July, 1867, by an arrow, which split the metacarpal bone of the right thumb down to the trapezium. Amputation at the metacarpal joint was performed, and the radial artery ligated above the wrist on account of hæmorrhage. He was discharged from service August 26, 1867.

CCCCLXXXI.—*Account of Two Cases of Arrow-Wounds occurring near Bower's Rancho, Arizona Territory.* By P. MIDDLETON, Assistant Surgeon, U. S. A.

Private William Hardwick, Co. C, 14th Infantry, aged 45 years, was wounded in an engagement with Indians on November 11, 1867, by arrows, in the left thigh and right arm. One missile penetrated the rectus femoris muscle at the centre, and passed upward and inward to the bone. Another arrow entered through centre of belly of biceps muscle, and penetrated to the bone. I administered chloroform, enlarged the wound of the thigh, and removed the arrow on the field. On the following day, he was admitted to the post hospital at Camp Whipple, Arizona Territory. On December 15th, both wounds had healed, but the patient had only slight use of his leg. He was, however, steadily improving, and on December 28th, was able to walk on crutches. He was returned to duty in January, 1868.

CCCCLXXXII.—*Report of an Arrow Wound of the Thigh.* By B. SEMIG, M. D., Acting Assistant Surgeon.

Private James F. Tompkins, Co. K, 32d Infantry, aged 26 years, was wounded April 20, 1869, in an attack by Apache Indians upon a wagon-train, in the Santa Rita Mountains, by an arrow, which caused a flesh-wound of the anterior portion of the lower third of the left thigh. He was admitted, on the same day, to the post hospital at Camp Crittenden, Arizona Territory. He recovered, and was returned to duty May 22, 1869.

CCCCLXXXIII.—*Note relative to a Case of Recovery after numerous Wounds from Arrows.* By W. S. TREMAINE, Assistant Surgeon, U. S. A.

Sergeant James Murray, Co. B, 3d Infantry, aged 34 years, in an attack by hostile Indians on the Marl Station on Bear Creek, Indian Territory, May 31, 1870, received seven arrow-wounds; two on the anterior surface of the right arm, one in the right axilla, one on the right side of the chest near the border of the axilla, two on the left arm, posterior surface, near the elbow-joint, and one on the left temple. He was admitted on June 1st to the post hospital at Fort Dodge, Kansas. The wound on the right arm, near the deltoid, discharged, and there was slight exfoliation from the humerus. He was treated with simple dressings, and was returned to duty in July, 1870.

CCCCLXXXIV.—*Memorandum relative to an Arrow-Wound of the Testis.* By A. H. SMITH, Assistant Surgeon, U. S. A.

While serving at Fort Bliss, Texas, in 1866, I had occasion to attend a Mexican herdsman,



FIG. 39. Arrow-head of Apache Indians.
Spec. 5641, Sect. I, A. M. M. (Nat. size.)

who had received a wound in the testis from an arrow shot by an Apache Indians. The hoop-iron arrow-head had lodged in the testicle, and the external wound had nearly healed over at the time I saw him, about three months after the reception of the wound. It was not difficult, however, to detect the position of the foreign body and to extract it. Upon its removal the wound cicatrized finely. The specimen was transmitted to the Army Medical Museum. [It is figured in the wood-cut, FIG. 30.—Ed.]

CCCCLXXXV.—*Memoranda of Forty Cases of Arrow-Wounds.* Condensed from reports. By D. C. PETERS, Surgeon, U. S. A.; J. M. DICKSON, M. D., T. H. SNOW, M. D., R. WESTERLING, M. D., J. H. MCMAHON, M. D., B. SEMIG, M. D., Acting Assistant Surgeons; S. M. HORTON, H. McELDERRY, J. P. KIMBALL, H. TURNER, Assistant Surgeons, U. S. A., and Surgeon J. F. WEEDS, U. S. A.

Private John Ahern, Troop L, 8th Cavalry; Camp Willow Grove, Arizona Territory, November 8, 1867; slight arrow-wounds in the back and left shoulder. He had recovered December 9, 1867.

Sergeant George Aldrich, Troop C, 2d Cavalry, aged 33 years; Peno Creek, Dakota Territory, December, 1866; wound in right lumbar region by an iron-headed arrow; treated in post hospital at Fort Philip Kearney, Dakota Territory, and returned to duty December 31, 1866.

Private Joseph A. Arkee, Troop I, 3d Cavalry; engagement with Navajo Indians near Fort Sumner, New Mexico, July 9, 1869; arrow-wound of right shoulder, passing through below the deltoid; recovered.

Pa-yan-za, Indian scout; Rocky Cañon, near Donner and Blitzen Creek, Oregon, March 14, 1868; slight arrow flesh-wound of the arm; transferred to Camp Harney, Oregon; recovered and returned to duty.

Big Mack, Indian scout; Rocky Cañon, near Donner and Blitzen Creek, Oregon, March 14, 1868; slight arrow flesh-wound of the arm; transferred to Camp Harney, Oregon; duty.

Private Frank Burr, Troop D, 3d Cavalry; Sierra Diabola, Texas, in an engagement with Miscallero Apaches, October 18, 1867; arrow-wound of right fore-arm; returned to duty.

Private John Butler, Troop I, 6th Cavalry, aged 26 years; Paint Creek, Texas, March 6, 1868; arrow-wound of upper third of left fore-arm; treated in post hospital at Fort Griffin, Texas, and returned to duty on March 11, 1868.

Private Robert Clinton, Troop I, 3d Cavalry; engagement with Navajo Indians, near Fort Sumner, New Mexico, July 9, 1869; arrow-wound of the back below spine of the scapula; recovered.

Private John Cooley, Troop G, 3d Cavalry; Purgatory Creek, Colorado Territory, October 3, 1866; arrow flesh-wound, a few inches in length, on left side of the thorax; treated in post hospital at Fort Garland, Colorado; recovered; duty.

Private John Craig, Troop L, 8th Cavalry; Camp Willow Grove, Arizona Territory, November 8, 1867; arrow perforating wound of the left hand; transferred to Camp Mojave, Arizona Territory; duty.

Private Bartholomew Creeden, Troop I, 3d Cavalry; engagement with Navajo Indians, near Fort Sumner, New Mexico, July 9, 1869; slight arrow-wound of the left arm; recovered; duty.

Private James Daily, Troop D, 3d Cavalry, Sierra Diabola, Texas, October 17, 1867; arrow flesh-wound through the right thigh above the patella; treated in post hospital at Fort Bliss, Texas, and returned to duty October 26, 1867.

William Fee, a citizen, aged 22 years; Crazy Woman's Fork, Dakota, December 4, 1867; slight arrow-wound of muscles of right side of the abdomen; treated in post hospital at Fort Philip Kearney, and discharged December 8, 1867.

Private Gottlieb Harr, Co. C, 18th Infantry, aged 22 years; Crazy Woman's Fork, Dakota Territory, December 4, 1867; slight arrow flesh-wound of the anterior surface of the left thigh; treated in post hospital at Fort Phil Kearny; doing well; duty.

Sergeant John F. Hilmer, Troop L, 3d Cavalry, aged 24 years; June 24, 1870; arrow-wound penetrating the right arm at the inferior third; treated in post hospital at Camp Verde, Arizona Territory; returned to duty in July, 1870.

Private Charles Hoffman, Troop I, 6th Cavalry, aged 28 years; Paint Creek, Texas, March 6, 1868; arrow-wound in upper third of the left thigh; treated in post hospital at Fort Griffin, Texas, and returned to duty March 31, 1868.

Private George Johnson, Troop L, 8th Cavalry; Camp Willow Grove, Arizona Territory, November 8, 1867; slight arrow-wound in the chest over the shoulder-blade; transferred to Camp Mojave, Arizona Territory; duty.

Rudolph Kinten, citizen, aged 28 years; Pinery, near Fort Philip Kearney, Dakota Territory, December 18, 1867; slight arrow-wounds of the right leg and shoulder; doing well December 20, 1867; recovered.

Sergeant J. R. Ludlow, Troop G, 7th Cavalry; arrow entered immediately behind the junction of the ninth rib with its cartilage and emerged about three inches from the spinal column, same side; discharged from service at Fort Leavenworth, April 8, 1868.

Private Edward Malone, Troop L, 8th Cavalry; near Camp Willow Grove, Arizona Territory, November 8, 1867; slight arrow flesh-wound above the hip; transferred to Camp Mojave, Arizona Territory; duty.

Lieutenant Thomas J. March, 7th Cavalry; Washita River, November 27, 1868; slight arrow-wound of the left hand; recovered; duty.

Trumpeter James Marshall, Troop A, 3d Cavalry, aged 21 years; June 24, 1870; superficial arrow-wound of the right hip; treated in post hospital at Camp Verde, and returned to duty in July, 1870.

Private Joseph Miller, Troop A, 2d Cavalry; Fort Reno, Dakota Territory, July 19, 1868; arrow entered over the external edge of the scapula and protruded through the bicipital portion of the middle third of the arm, from whence it was extracted; returned to duty in August, 1868.

Private Hugh Morgan, Troop I, 7th Cavalry; engagement with Indians, November 27, 1868; arrow flesh-wound of the right arm; treated in post hospital at Fort Dodge, and returned to duty in January, 1869.

Private Clarence G. Morrell, Troop D, 3d Cavalry; Sierra Diabola, Texas, October 17, 1867; arrow-wounds of the right groin, side, and back; treated in post hospital at Fort Bliss, Texas, and returned to duty on November 19, 1867.

Private Daniel Morrison, Troop G, 7th Cavalry; engagement with Indians, November 27, 1868; arrow-wound of the scalp; treated in post hospital at Fort Dodge, Kansas, and returned to duty in January, 1869.

Bugler John Murphy, Troop M, 7th Cavalry; engagement with Indians, November 14, 1868; arrow-wound of the right side; treated in post hospital at Fort Dodge, Kansas, and returned to duty in March, 1869.

Private Charles Murray, Troop F, 10th Cavalry; Beaver Creek, Kansas, August 21, 1867; slight arrow-wound of the left leg; treated in post hospital at Fort Hays, Kansas, and returned to duty.

Corporal Thomas O'Brien, Troop F, 6th Cavalry, aged 21 years; Fort Belknap, Texas, August 29, 1867; slight arrow-wound of the chest, two inches above the nipple; treated in post hospital at Camp Wilson, Texas, and returned to duty September 5, 1867.

Owine, Indian scout, Rocky Cañon, near Donner and Blitzen Creek, Oregon, March 14, 1868; slight arrow flesh wound of the left arm; transferred to Camp Harney, Oregon.

Sergeant Francis Rigby, Troop H, 1st Cavalry; Rocky Cañon, near Donner and Blitzen Creek, Oregon, March 14, 1868; arrow passed through the fore-arm, with cutting edge at right angles to axis of member; treated in post hospital at Camp Harney, Oregon. By some means the arrow-head had been pushed back and became imbedded in the muscles, whence it was extracted; returned to duty in April, 1868.

Private James Ryan, Troop F, 6th Cavalry, aged 29 years; Paint Creek, Texas, March 6, 1868; arrow-wound of lip, treated in post hospital at Fort Griffin, Texas, and returned to duty March 11, 1868.

Lieutenant Gustavus Schreyer, Troop F, 6th Cavalry, aged 29 years; accidental, September 20, 1867; slight arrow-wound of the left thigh; treated in post hospital at Camp Wilson, Texas, and returned to duty October 22, 1867.

Corporal Thomas Sheppard, Troop F, 10th Cavalry; Beaver Creek, Kansas, August 21, 1867; arrow-wound of the neck; treated in post hospital at Fort Hays, Kansas, and returned to duty.

Private George Silence, Troop A, 3d Cavalry, aged 25 years; June 24, 1870; penetrating arrow-wound of the left shoulder; treated in post hospital at Camp Verde, Arizona Territory, and returned to duty in August, 1870.

Private Francis Stall, Troop D, 3d Cavalry; Sierra Diabola, Texas, October 18, 1867; arrow-wound of the right breast; returned to duty.

Private Henry Stockford, Co. G, 31st Infantry, aged 29 years; Fort Buford, Dakota Territory, August 20, 1868; penetrating arrow-wound of internal condyle of the left humerus, requiring the united strength of two men to extract it; returned to duty in October, 1868.

Private William Wagerle, Troop I, 3d Cavalry; engagement with Navajo Indians, July 9, 1869; arrow-wound of the right chest, passing into the pleural cavity; recovered; duty.

Private Lewis White, Troop C, 9th Cavalry; Horse Head Hills, Texas, September 12, 1868; arrow-wound of sixth rib, left side, seven inches from the spine; treated in post hospital at Fort Davis, Texas, and returned to duty September 26, 1868.

Private Michael Zuch, Co. E, 31st Infantry, aged 20 years; Fort Buford, Dakota Territory, August 20, 1868; arrow flesh-wound of the left hip; returned to duty August 23, 1868.

Nearly all of the foregoing instances of arrow-wounds have been copied from "lists of casualties," a few from special reports. The orders which enjoin upon medical officers to forward to the Surgeon General a list of casualties within two or three days after every engagement or skirmish in which they may be on duty, have been generally, but not universally, observed.* It is specially desirable that such returns should be rendered with the utmost regularity and promptness, because many of the wounded in the field do not come under treatment in the post hospitals, and are not accounted for on the monthly and quarterly reports. When casualties occur in small scouting parties, unaccompanied by a medical officer, the medical officer at the nearest post should assume the duty of reporting the killed and wounded by name, with such facts as can be ascertained regarding the nature and seat of injuries. The records of this office prove that he will have, in such cases, the cordial coöperation of line officers; for many reports have been received, signed by lieutenants or captains of infantry or cavalry, enumerating the casualties in their detachments, with the postscript, "I send this as we have no doctor along with us." The two following reports conform to the instructions that have been issued on this subject:

CCCCLXXXVI.—*A Report of Two Fatal Cases of Arrow-Wounds.* By ALFRED D. WILSON, Assistant Surgeon, U. S. A.

A detachment of seven companies of the Fifth Cavalry started from Fort Lyons, Colorado, on May 1, 1869, for Sheridan City, Kansas. On Beaver Creek, Indians were encountered, and a fight ensued. The Indians were pursued towards the Republican River. When they reached Prairie Dog Creek, they dispersed, and it was impossible to follow them further. The command then retraced the route, and then marched in a northwesterly direction to the Platte River, and then westerly to Fort McPherson, Nebraska. There were several casualties from gunshot wounds, and two soldiers were mortally wounded by arrow-wounds penetrating the thorax; viz,

Sergeant John Ford, Troop B, 5th Cavalry.

Private C. A. C. Stone, Troop B, 5th Cavalry.

CCCCLXXXVII.—*Memorandum from a Report of Casualties in an Indian Engagement.* By J. F. WEEDS, Surgeon, U. S. A.

In the engagement of Companies G and I, 3d Cavalry, with a band of Navajoes, near Fort Sumner, New Mexico, July 9, 1869, one soldier died from hæmorrhage from an arrow-wound of the

* See *General Orders*, No. 355, A. G. O., November 4, 1863, *Circular Letter*, S. G. O., March 23, 1864, *Circular Orders* No. 10, S. G. O., October 22, 1867, and Form 55, *Medical Department*.

brachial artery, and four men were wounded so severely that they were dismounted, and, the command being forced to retreat, they were probably at once killed by the Indians, as their bodies were afterward found covered with wounds. These were—

Private John Devine, Co. I, 3d Cavalry, brachial artery severed.

Private James Cook, Co. I, 3d Cavalry, many wounds.

Private William Kerr, Co. I, 3d Cavalry, many wounds.

Private Edward White, Co. I, 3d Cavalry, many wounds.

Private John Lee, Co. G, 3d Cavalry, many wounds.

In this engagement four other soldiers received arrow-wounds of more or less severity, and were taken to Fort Sumner, and treated in the post hospital. All of these cases terminated favorably.

[These four cases are included in the preceding memoranda of forty cases. I have taken the liberty of subdividing the report and classified return made by Dr. Weeds. There was no surgeon with this command; but the wounded, being taken to the nearest post, Dr. Weeds, the post surgeon, offered a good and much needed example, by complying with the spirit as well as the letter of the circular from this office of March 23, 1864, and the instructions on Form 55, *Medical Department*, in forwarding the required Classified Return of Wounds and Injuries and Report of Casualties in the absence of a medical officer attached to the command.—ED.]

The force with which arrows are projected by the Indians is so great that it has been estimated that the initial velocity of the missile nearly equals that of a musket ball. At

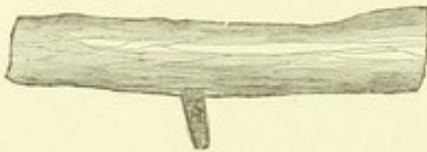

FIG. 31. Section of shaft of seventh right rib of a buffalo with impacted arrow-head. *Spec.* 4735, Sect. I, A. M. M.

a short distance, an arrow will perforate the larger bones without comminuting them, or causing a slight fissure only, resembling the effect of a pistol ball fired



FIG. 32. Section of the eleventh right rib of a buffalo fissured by an arrow. *Spec.* 4736, Sect. I, A. M. M.

through a pane of glass a few yards off. This is well illustrated in two preparations presented to the Army Medical Museum by Professor Joseph Henry, in which the dense laminated portions of the shafts of ribs of the buffalo are transfixed by arrows. These

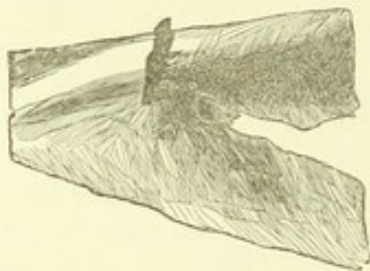


FIG. 33. Section of the left scapula of a buffalo, transfixed by an arrow. *Spec.* 4737, Sect. I, A. M. M.

are represented in the wood-cuts (FIGS. 31, 32) The arrow-points penetrating the bones have not produced the slightest splintering, and in one case not even fissuring. The fissure in the right hand figure is much more conspicuous than in the specimen. I have frequently been informed, by officers who served on the Plains, that it was not infrequent for an Indian to send an arrow fairly through the body of a horse or of a buffalo, provided the missile entered one of the intercostal spaces, and did not impinge on bone on the opposite side. That this statement is well founded is rendered probable by the evidence afforded by a preparation forwarded to the museum by Hospital Steward R. Wall, U. S. A., of a portion of the left scapula of a buffalo, with an arrow-head imbedded in it. The barbed iron head of the arrow has entered the venter of the scapula and the point protrudes from the dorsum, so that the missile must have passed through the thorax. The specimen is from a buffalo killed near Fort Sedgwick, in 1860, by a Cheyenne Indian.

warded to the museum by Hospital Steward R. Wall, U. S. A., of a portion of the left scapula of a buffalo, with an arrow-head imbedded in it. The barbed iron head of the arrow has entered the venter of the scapula and the point protrudes from the dorsum, so that the missile must have passed through the thorax. The specimen is from a buffalo killed near Fort Sedgwick, in 1860, by a Cheyenne Indian.

From the narrative of their explorations by Lewis and Clarke, from Schoolcraft's History, and from the works of Mr. Squier and other writers on North American ethnology, and the reports of the Commissioners on Indian Affairs, many interesting particulars can be gleaned respecting the use of the bow and arrow, but the most important recent contributions to our knowledge of *wounds* by arrows have been made by Surgeon W. F. Edgar, U. S. A.; Dr. T. C. Henry,* Surgeon B. A. Clements,† U. S. A.; Surgeon J. H. Bill,‡ U. S. A.; Assistant Surgeon E. Coues,§ U. S. A.; Professor C. A. Pope,|| Dr. A. Muller,** and the authors of the foregoing reports.

In the foregoing reports of eighty-three cases of arrow-wounds, twenty-six, including nearly all in which the three great cavities, or the larger bones or joints were involved, proved fatal. A greater fatality would be represented had more complete returns been made.†† In hostilities in the Indian country, military and other exigencies sometimes

* GROSS. *A System of Surgery*, 4th ed. Philadelphia, 1866. Vol. I, p. 361.

† CLEMENTS, quoted in *Hamilton's Military Surgery*.

‡ BILL, *American Journal of the Medical Sciences*, N. S. Vol. XLIV, p. 365.

§ COUES, *The Medical and Surgical Reporter*, 1866. Vol. XIV, p. 321.

|| POPE, *St Louis Medical and Surgical Journal*, January, 1864.

** Dr. Muller reports some unpublished facts of historical as well as surgical interest: "Dakota is the vernacular designation of the Sioux Indians, and the whole nation is divided into seven principal tribes viz. I. Mdewakantonwans; (Village of the Spirit Lake), about 2,000 souls. II. Wahpekutes, (Leaf Shooters), about 500 to 600 persons. III. Wahpetonwans, (Village in the Leaves), about 1,000 to 1,200 souls. IV. Sisitonwans, (Village in the Marsh), Sisiton, about 2,500 souls. V. Yanktonwanna, (End Village Band), about 4,000 souls. VI. Yanktonwans, (Village at the End), about 2,400 persons. VII. Tetonwans, (Village of the Prairie), about 12,500 souls. Prior to the great Indian outbreak in Minnesota, in August, 1862, the three first-named bands occupied the country east and south of the Red Wood River, on the Upper Minnesota River, and were, therefore, called Lower Sioux; while the four last-named lived further west, on the Upper Minnesota River, at Lac-qui-parle, at and west of Big Stone Lake, or Lake Travers, to the Upper Missouri River, in Dakota Territory, and called "Upper Sioux," where the "Tetons" still reside; while all the rest of the tribe were driven from the State of Minnesota in 1862, and are now scattered all over the western plains, on both shores of the Missouri River. In their warfare they use all sorts of shot-guns, from an old flint-lock musket to the best kind of Kentucky rifles, the younger and poorer of them being obliged to resort to *bows* and *arrows* for the chase and for battles. The arrow shafts are prepared from hickory, white ash, and a willow which grows in abundance along the banks of all the streams. The arrows of the same tribe are not always made of the same size and material, and are shaped by the savages according to their prevailing fancy; the Tetons, on the Upper Missouri, for instance, using both iron arrow heads and also those made out of flint. No particular difference exists between the war arrow and the arrow for the chase, although most of the Indians are in the habit of painting the shafts of their arrows prior to their going on the war path, with red and other colors. For the chase of smaller birds and other animals, arrows without heads are used, a knob of different size being cut out of the wood the arrow is made of in place of the head. In order also to prevent the easy extraction of the arrow head, the war arrows are often only glued to the shaft, which glue becoming softened from blood, &c., readily detaches the head from the shaft. Burning punk is also often attached to the arrow, for the purpose of setting fire to houses, &c. The iron heads are prepared by the Indians, and also furnished principally by blacksmiths in the Government employ. The Indians make them out of hoop and sheet iron, the shape and sharpness being given by means of a file, according to convenience. No radical difference exists in the arrow heads of different tribes. In the same quiver of an Indian belonging to any one tribe, a great variety of different shaped arrow heads will be found, which proves that the same tribe follows no special type, but fashions them according to any kind of taste. The shallow groove which exists longitudinally down the entire length of each shaft, has, to my knowledge, no particular object, and the feathers used on the arrows are taken from almost any bird, such ones possessing gay colors being preferred, principally by the Upper Sioux (Sisitons) Indians. The various colored bands at the rear end of the arrows are purely ornamental, and have no other significance, so far as I could ascertain.

†† I cannot find on file in the War Department reports of the casualties of the engagement in which Brevet Lieutenant Colonel W. J. Fetterman, Eighteenth Infantry, and forty-nine soldiers, were killed, most of them by arrow-wounds, near Fort Philip Kearney, December 21, 1866; or of General W. S. Hancock's engagement with the Cheyennes, at Pawnee Fork, on April 13, 1867; or of Lieutenant Colonel G. A. Custer's attack on the Black Kettle Band, at Washita, November 27, 1868; or of Major E. A. Carr's affair with the Sioux, at Beaver Creek, October 18, 1868; or of Major A. W. Evans's fight with the Comanches, December 25, 1868; or of the encounter of Major E. A. Baker, with the Piegans, at Mountain Chief, Montana, January 23, 1870. In all of these engagements the newspapers state that arrows, as well as fire-arms, were employed by the Indians.—ED.

preclude the possibility of rendering the returns required of medical officers. For example, in several recent instances, the surgeon's own name would be among those appearing in the list of killed or wounded. But, whenever practicable, it is to be desired that full returns of the casualties in these skirmishes and expeditions should be made, and that medical officers should specify the nature and seat of injuries minutely.*

Reference to the reports here printed, and to the papers that have been cited, will suggest most of the facts we possess in connection with arrow-wounds and their treatment.




FIG. 34. Wire loop for extracting arrow-heads embedded in soft parts. (After a drawing by Dr. Bill.)

when impacted in bone. In an instance in which a Navajoe arrow had penetrated the lung for five inches, Dr. Bill succeeded in removing it by means of a snare, as represented in the preceding wood-cut; (FIG. 34), the arrow-shaft being used as a guide to the wire, and



FIG. 35. Wire-twister recommended by Dr. Bill. It should be twelve inches long. (From Dr. Bill's paper.)

the great danger of detaching the head from the shaft being avoided. Where arrow-heads are lodged in bone and cannot be detached by slight traction, aided by a gentle rocking motion of the shaft, the plan which Dr. Bill advises is to procure a piece of well-annealed iron wire, two and a half feet in length, to pass the ends through the holes in a long suture wire-twister, and secure them to its handle (FIG. 35) leaving a loop at the

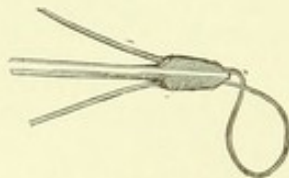


FIG. 36. Wire loop twisted once on itself for snaring impacted arrow heads. (From Dr. Bill's paper.)

distal extremity (FIG. 36). The loop passed over the feathered end of the shaft is to be thrust down to the other extremity and made to snare the arrow-head, and, the wire being tightened, the foreign body and instrument are to be withdrawn together. Dr. Bill suggests that two straightened catheters soldered together would answer in place of the wire-twister, and the ecraseur now supplied with the army field-instrument cases would probably prove a yet more convenient and reliable implement. But, whenever possible, it will be preferable to cut down upon the arrow-head and to remove it with forceps;—for the surgeon should not work in the dark.

The subject of the treatment of arrow-wounds may be passed over with this brief reference to the writings of the medical officers whose observations of such injuries have been most extensive. Further on is an abstract of a case of an arrow-head forming the nucleus of a vesical calculus. In accordance with the plan of this report, it is placed among the operations for lithotomy. The Army Medical Museum possesses also two remarkable specimens of the penetration of bone by stone arrow-heads. Both appear to

* In examining the reports, it is often difficult to decide whether a contused wound that is cited, should be classified with the gunshot, or with other injuries, or to obtain any clue to the cause of an incised or punctured wound. By noting these particulars, medical officers will greatly facilitate the work of consolidating their reports and arranging the statistical information contained in them.

be of great antiquity One was discovered, in looking over a large number of bones

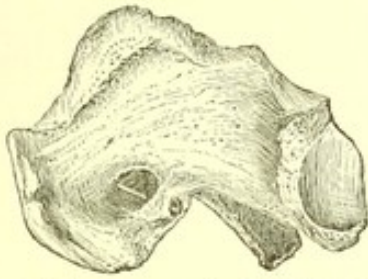


FIG. 37. Stone arrow-head imbedded in the spinous process of a lumbar vertebra. Spec. 5553, Sect. I, A. M. M. [Natural size.]

exhumed by Acting Assistant Surgeon A. T. Comfort, from tumuli near Fort Wadsworth, Dakota, in the course of his interesting explorations of the Indian mounds, in that vicinity, in 1869, and consists of the spinous process of one of the lumbar vertebrae, in which a small quartz arrow-head is encysted. The

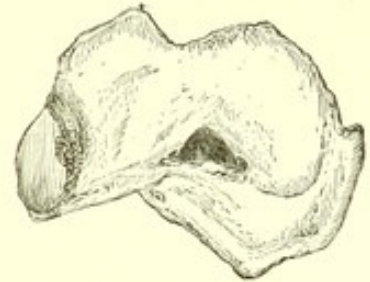


FIG. 38. Reverse view of the foregoing specimen.

missile is so overlaid by new osseous formation, as to prove that the wounded man

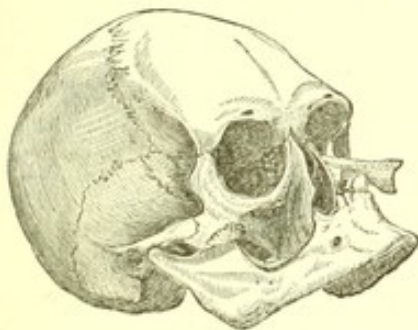


FIG. 39. Cranium with a stone arrow-head in the left orbit. Spec. 5531, Sect. I, A. M. M., Reduced 1.]

survived the injury for many months at least. Two views of the specimen are exhibited in the wood-cuts adjoining, (FIGS. 37 and 38.) The other preparation is a cranium transferred to the Army Medical Museum, by the Smithsonian Institution. It is a skull of an Indian, of advanced age, obtained in Alameda County, California, by Dr. C. Yates. A long flint arrow-head has penetrated the cranial cavity through the left orbit. The lower maxilla is fractured almost vertically to the left of the symphysis. The wood-cut (FIG. 39), shows the form of the cranium and the position in which the flint was found impacted.

Stone arrow-heads are still used by many of the North American Indians*. Many specimens collected in Arizona, California, Utah, and Oregon, have been forwarded to the museum. It was believed by the collectors that these, in many instances, were poisoned arrows. Repeated experiments that I have made of inserting the points beneath the skin of small animals, as frogs, birds, and mice, have had negative results, the punctures healing readily, and the animals surviving. Tho' Indians may dip their arrow-heads in rattlesnake venom, or the decayed livers of animals, as is commonly stated; but it is more than doubtful if the arrows thereby become poisonous.†

Dr. Bill suggests the employment of archers, with regular troops, to pick off sentinals noiselessly; but he remains more strictly in his province as a medical officer in advising a cuirass for soldiers employed in Indian hostilities.

* Lieut. E. G. Beckwith, 3d Artillery (*Reports of Explorations for a Route for the Pacific Railroad*, Vol. II, p. 43, of 2d Report), gives the following description of the manufacture of these stone arrow-heads by the Pitt River Indians of California:

"One of them seated himself near me, and made from a fragment of quartz, with a simple piece of round bone, one end of which was semi-spherical, with a small crease in it (as if worn by a thread) the sixteenth of an inch in depth, an arrow-head, which was very sharp and piercing, and such as they use on all their arrows. The skill and rapidity with which it was made, without a blow, but by simply breaking the sharp edges with the creased bone by the strength of his hands—for the crease merely served to prevent the instrument from slipping, affording no leverage—was remarkable."

† PARÉ, ed. Malgaigne, p. 183, and the Lyon edition of 1652, p. 287. Also BALINGALL, *Outlines of Military Surgery*, 5th ed., Edinburgh, 1855, p. 399; and Professor F. H. HAMILTON, M. D., *Treatise on Military Surgery*, New York, 1865, p. 525. There has always been a wide-spread belief in the poisoning of arrow-heads. Every one will recall the "*Nec venenatis gravidæ sagittas*," in Horace, (*Od. I, 22, viii.*) Pliny relates (*Lib. XVI, cap. 35.*) of the famous Scythian bowmen: "*Sagittæ Sagittas linguæ vipericæ sanie, et humano sanguine, irremediabile id scelus mortem illico offert læci tactu.*" Under the articles "TOXICUM" and "SAGITTA," in the lexicon of Facciolati and Foreellini, many references to similar allusions by classical authors may be found.

POISONED WOUNDS.

The examples of poisoned wounds reported were but few. No instances of glanders, or malignant pustule, or of hydrophobia, or of dissection wounds occurred, and the instances of serious results from the stings or bites of insects, or of venomous serpents were rare. Many specimens of so-called scorpions and tarantulæ and other arachnids were sent by medical officers to the museum, and large scolopendræ, with information that they were considered very venomous at the posts at which the officers were stationed; but without any sufficient evidence that their bites or stings had been attended with any serious results.

SNAKE BITES.—Five examples of poisoned wounds from bites by reptiles were reported. Only one was fatal, and the fatal result in that case was due to secondary complications.

CCCCLXXXVIII.—*Memorandum of a Case of Snake Bite.* By J. V. D. MIDDLETON, Assistant Surgeon, U. S. A.

Private Theodore E. Turner, Troop D, 4th Cavalry, aged 29 years, was bitten by a rattlesnake at Fort Concho, Texas, June 27, 1866. The bite opening the phalangeal joint of the left thumb, caused violent inflammation. Chronic inflammation ensued, which resulted in the destruction of the joint. On January 23, 1869, the patient was admitted to the post hospital at Austin, Texas, at which time the joint was swollen and exquisitely painful on the slightest motion, the anterior and left lateral ligament being destroyed by ulceration. The patient was feverish, unable to sleep from pain, and desirous of having the thumb amputated. On the date of admission the medical officer in charge administered ether, and amputated the thumb above the phalangeal articulation by the circular method. There was very little hæmorrhage and that little was suppressed by torsion of the arteries. The dressing was made with adhesive straps, carbolic acid, and oil. The pain eased, the appetite improved, and the patient slept well. The wound healed by January 30, 1869 and the man was soon afterward returned to duty.

CCCCLXXXIX.—*Memorandum of a Recovery from a Rattlesnake Bite.* By A. B. CAMPBELL, Assistant Surgeon, U. S. A.

A private of the 13th Infantry was bitten in the throat by a rattlesnake of large size. (*Crotalus durissus*, LINN.) near Camp Cooke, Montana Territory, in August, 1868. The wound was immediately sucked by a comrade. The man reported at the post hospital at Camp Cooke, three hours after the accident, which happened some miles from camp. The only noticeable appearance was a slightly wild look about the eyes, although the man did not seem to be the least alarmed. His throat was bound up in olive oil, which was rancid, but the only kind on hand. The region of wound was hard and somewhat painful, probably from being bruised by the teeth of the man sucking the wound, and remained so for about three hours. There were no further bad consequences from the injury, and the patient was soon returned to duty. No internal remedy was administered.

CCCCXC.—*Report of a Case in which a Bite from a Rattlesnake proved Fatal.* By JULES LE CARPENTIER, M. D., Acting Assistant Surgeon.

Private William Robinson, Troop B, 3d Cavalry, aged 37 years, and remarkable for the singularity of his conduct, was known in his company as a snake-charmer, having many times handled poisonous snakes without being injured. On the morning of July 13, 1869, he was detailed as guard with the herd at Fort Cummings, New Mexico, when, in the presence of the herders, he succeeded in catching a rattlesnake, and proving his power as a sorcerer. The performance being over, and the snake killed, he caught sight of another of the same class, and tried to charm this as he had the other. But here his power failed. He was bitten in the middle finger of the right hand. He was immediately admitted to the post hospital, complaining only of a little smarting that might be compared to the pain following the sting of a bee or a wasp. A ligature was applied above the wound; the two injuries made by the fangs were enlarged with a bistoury; ammonia and the actual cautery were applied, and whiskey ordered in large doses frequently repeated. The constitution of the patient being broken down and poor, I had doubts, from the beginning, as to his recovery. Vomiting soon came on, but was stopped without trouble. The swelling of the hand and arm increased gradually, showing the particular livid and yellowish tint following the bites of poisonous snakes. A blister was applied to the bitten finger, tincture of iodine used, and two ounces of whiskey given every two hours until ebriety was induced. The pulse, which was very much reduced, at first gained gradually under the influence of stimulants. Two grains of opium were given at night; the patient slept well, and on the next day complained only of numbness in the arm. The swelling had extended as far as the shoulder-joint, and the blood, which was very fluid, was incessantly running from the wounds. Carbolic acid and cerate were applied to the arm, with stimulants internally. On the 15th, his general condition was good; the swelling had somewhat augmented; there was not so much lividity, but the yellowish hue had increased. On the 16th, he complained of pain in the neck, on the side of the affected limb, but his general condition was good. Examining his genitals, an iron ring six-eighths of an inch in diameter was discovered, imbedded in the soft tissues of the penis, constricting it to such a degree as to have produced an enormous enlargement of the parts. Upon inquiry it seemed probable that the ring had been kept on the parts very long, as a preservative of chastity; but the swelling having come on, under the influence of the snake's venom, and the patient having much difficulty in passing water, was obliged to complain. The ring was filed off with some difficulty. Gangrene destroyed the extremity of the bitten finger. From this date until the 30th, his condition improved somewhat. The progress of the gangrene was stopped, and I disarticulated the injured finger at the metacarpal articulation. Anæsthesia was readily obtained, but the appearance of the second stage was hardly perceptible. I was called early on the next morning, the patient having been observed to be sinking. I found him with stertorous respiration, pulse weak and slow, and only partly conscious. Electricity was applied to the spine, and brandy and bromide of potassium were given; but he died about noon July 16, 1869. A necropsy was made one hour after death. There was general softening of the tissues, particularly on the affected side. The blood was black and very fluid—not coagulable. The ventricles of the brain were filled with a large amount of serum; the brain was somewhat congested. The lungs were healthy, with the exception of a few crude tubercles of recent formation on the left side. The right ventricle of the heart was empty, and the left filled with dark blood which had coagulated. The liver and kidneys were healthy, and the gall-bladder very much distended with bile. The intestines presented a few livid patches on the outside.

CCCCXCI.—*Note relative to Two Poisoned Wounds.* By IRVING C. ROSSE, M. D., Acting Assistant Surgeon.

In May, 1869, Mr. E. C——, a butcher, was stung on the hand by a scorpion, at Point Isabel, Texas. He immediately bound up his hand in a mixture of bruised garlic and common salt, the popular and domestic remedy for these stings among the people of that section of country. When seen a few hours after the reception of the injury, most of the severe symptoms had subsided, and nothing was prescribed. He made a good recovery.

At the same place, and about the same time, a large bull-dog was bitten on the nose by a rattlesnake. A native remedy, probably of no value, was also used in this instance—the dog's nose, at and in the vicinity of the wound, being severely pricked with sharp points of the Spanish bayonet (*yucca*). A ludicrous exaggeration of the animal's features ensued from the swelling of the tissues about the face and head; he seemed surly and ill for several days, but eventually recovered.

CCCCXCII.—*Remarks on Two Cases of Recovery from Bites of the Water Moccasin.* By R. D. BLACKWOOD, M. D., Acting Assistant Surgeon.

Private George Williams, 2d Infantry, was bitten at Patona, Alabama, by a water moccasin, (*Toxicophis piscivorus*, B. & G.) The snake was four feet in length; the wound was on the second phalanx of the left index finger. The finger was constricted above the wound, and free bleeding from it encouraged. Whiskey was freely administered, three quarts (*sic*) being consumed in two hours succeeding the reception of the injury. Although the patient is not addicted to the use of alcoholic stimulants, he was not affected by the large quantity employed. Believing that a sufficient quantity of one poison had been used to neutralize the other, nothing further was done, and, except depression, no ill effect followed. Next day the patient was as well as usual. That the reptile is capable of producing poisonous effects is evidenced by the case of a negro child of five or six years old, in whom serious prostration and stupor followed the bite of a similar snake. The localeffect was more marked than in Williams's case—the swelling greater, and the parts bitten tinged of a green hue, with considerable injection of the conjunctiva. The wound was over the malar bone.

Fatal results from the bites of serpents are comparatively infrequent in this country. We are indebted to Dr. S. Weir Mitchell for dispelling many erroneous views on this subject.* It would appear that only some of the larger crotalidæ are deadly, and even they rarely inflict fatal wounds. The adders and vipers and colubrine snakes are not hurtful. It is probable that only the larger male rattlesnakes, during the rutting season, have sufficient venom to destroy life in the large mammals. Dr. J. T. Fayrer, of Calcutta, has had the kindness to supply me with his work on the *Thanatophidia of India*, soon to be published in London, in which the mortality from snake-bites in Bengal and adjacent provinces, including an area "rather less than half that of the peninsula of Hindostan" was in the year 1869, not less than 11,416,† and it is his belief that the annual mortality in British India from this cause is not less than 20,000. I question whether so many deaths have occurred on this continent, from such cause, within the historical period.

* See Dr. Mitchell's well-known papers in the *Smithsonian Contributions for 1861, North American Medico-Chirurgical Review*, March, 1861, and in the *American Journal of the Medical Sciences*.

† FAYRER. *Indian Medical Gazette*, January, 1870.

‡ See also B. S. BARTON, *Trans. Am. Phil. Society*, Vol. III, p. 110; FONTANA, *Traité Sur la Vénin de la vipère, &c.*, (French trans.,) Florence, 1781; RUSSELL, *Account of Indian Serpents, &c., &c.* PIORRY, *Recue Médicale*, 1826, p. 26; IRELAND, *Med.-Chir. Trans.*, Vol. II, p. 398; HOME, *Phil. Trans.*, 1830, p. 75; BOYER, *Traité des Mal. Chir.*, 5^e ed., T. I, p. 799. CELSUS, *De Medicina*, Edinburgh ed., 1809, Lib. V, cap. 3. REDI, *Obs. Int. alle Vipere*, Firenze, 1664. Charas, Catesby, Barry.

BURNS, SCALDS, AND FROST BITES.

BURNS AND SCALDS.—Under this head two thousand and three cases were reported, nearly all of trivial character, and special reports were not made of any particular cases.

FROST BITES.—Some cases of this class, involving amputations, will be found among the reports of operations. Others, in which special reports were made, are inserted here. Four of these were fatal.

CCCCXIII.—*Account of a Fatal Case of Frost Bite.* By J. B. GIRARD, Assistant Surgeon, U. S. A.

At Fort Fred Steele, Wyoming Territory, December 9, 1870, Private Richard Bowen, Co. A, 13th Infantry, aged 29, an habitual drunkard, was detailed as a member of a wood party ordered to the mountains to procure timber. Previous to starting, he and a comrade secretly procured a quantity of whiskey, of which they partook freely during the day to such an extent as to become considerably intoxicated. Toward evening, owing probably to their condition, they strayed from the wagon-train, and lost their way. They remained during the night near a stream on the bank of which they had built a fire, and Bowen, who during the day had waded through the stream, filling his boots with water, found it impossible to pull them off, the water in them having become frozen. The next morning they returned to the post, marching eight or ten miles, and were both admitted to the post hospital. Bowen's boots having been cut off, his feet were found frozen solidly to the ankle-joints. Two nurses were immediately set to work rubbing the feet with snow, while internal stimulants were administered to prevent collapse. After two hours of vigorous friction and cold water pediluvia, circulation was restored in the skin and motion in the joints of the toes became practicable. The feet were then wrapped in cloths wet with whiskey and surrounded with several layers of cotton wadding secured by bandages. The patient was put to bed and morphia administered. He passed a comfortable night, and the next day, upon removing the dressings, the feet were found in a very satisfactory condition. The toes were all moveable at the patient's will, and the soles alone looked dark and livid. He felt as well as usual, complained of no pain, and enjoyed a moderate appetite. The application of whiskey to the frozen parts was continued, and quinine with tincture of chloride of iron ordered three times daily. He remained in nearly the same condition till the 15th, when the alcoholic lotion was replaced by lime water and olive oil liniment, on account of the removal of the epidermis from some portions of the feet. On the afternoon of the 15th his appetite and strength commenced to fail. When seen on the morning of the 16th he was remarkably weaker and his features wore a typhoid expression. His legs were found œdematous up to the knees, and the feet were less moveable than usual. Milk punch was immediately ordered three times a day, and beef tea at short and regular intervals. He steadily grew worse, and died on the morning of the 17th.

CCCCXCIV.—*Remarks on a Fatal Case of Frost Bite.* By A. A. WOODHULL, Assistant Surgeon, U. S. A.

Sergeant William Earl, Troop G, 7th Cavalry, of robust physique, and usually a temperate man, visited the neighboring town of Las Anima while intoxicated, after tattoo, on the night of

December 21st, 1870. There he grew much more intoxicated, and, it was understood, became involved in a fracas. About or after midnight, he left, or was turned from a saloon, and was found in the morning in a wagon near by, in a badly-frozen condition. The thermometer marked 23° below the zero of Fahrenheit during the period of his exposure, and against this excessive cold he was not specially protected. On admission to the hospital at Fort Lyon, Colorado Territory, about 10 A. M., he was very much prostrated, and both feet and the left hand were frozen. They had been rubbed with snow, and soaked in ice-water before arriving, which treatment was continued for more than two hours in a cold room. When first discovered, both feet were stated to be stiff above the ankle. Moderate reaction having set in, he was provided with food, and his feet and hands were enveloped in lint wet with olive oil and lime-water. There was a slight scalp-wound on the left side, and he complained of severe pain and soreness in the stomach, as if from a blow, and of pain in the left shoulder. An examination of the shoulder could detect no injury. He was much depressed in mind at the extent of his accident and at the circumstances under which it was received, and at no time rallied so as to be either cheerful or sanguine. For the first four days the patient did reasonably well, and in consequence of his usual robust health, no more disastrous result than the partial loss of his hand and feet was anticipated. A little carbolic acid was added to the dressing. About the 24th, although some sensation remained, it was evident he would lose his toes, and a line of demarkation began to show itself the next day, near the tarsus of the right foot, and a little lower on the left. Both heels were also badly vesicated, and amputation was deferred until it could be determined how deeply the slough would descend, and especially the extent of the injury to the heel. No special treatment was adopted, except as to the regulation of his bowels and the use of opiates to subdue nocturnal pains. All this time his comrades noticed his unusual and decided melancholy. On the 27th, perspiration was observed, but it was ascribed to the artificial heat of the ward. On the 28th, his countenance changed, and he rapidly became worse, with some mental aberration. Stimulants were ordered freely. It was then my intention to amputate the next day, if possible. On the 29th both legs, especially the right, were swollen and œdematous, and had an erysipelatous blush, pitting deeply on pressure, and precluding the idea of the knife. Beef essence and strong milk punch were freely and constantly given, and two drachms of the tincture of the sesquichloride of iron were ordered to be taken within twenty-four hours. This was steadily continued night and day throughout the case. The following is from the clinical record, December 29th, 9.30 A. M.: Temp. $101\frac{2}{3}$; 2 o'clock, P. M., 104; pulse 134; respiration 28; 7 P. M.: Temp. 104; pulse 125; respiration 32. December 30th, 7 A. M.: Temp. $102\frac{2}{3}$; pulse 132; respiration 32; 2 P. M.: Temp. $102\frac{2}{3}$; pulse 130; respiration 34; 7 P. M.: Temp. 104; pulse 122; respiration 35. During all this time he was in a typhoid delirium, and he died at 1.10 P. M. December 31st. The right foot was examined three hours after death, with the view of determining how far a Syme's amputation would have been justified. The flesh of the heels was found softened; the ankle was firmer than was anticipated, but a section of the anterior tibial, in the lower part of its course, showed it filled with a purulent-looking fluid. No further examination was considered necessary, the whole course of the symptoms pointing so clearly to blood-poisoning.

CCCCXCV.—*Mention of Two Cases of Frost Bite occurring at Fort Abercrombie, Dakota Territory.*
By W. D. WOLVERTON, Assistant Surgeon, U. S. A.

Private John W. Owens, Co. A, 20th Infantry, aged 24 years, was admitted to the hospital January 28, 1870, with frost bite of the right foot, which was treated with carbolic acid and olive oil. He was discharged from service while in hospital by reason of his term having expired.

Private Alexander Brandt, Co. I, 20th Infantry, aged 21 years, was admitted February 13, 1870, with frost bite of the large toe of the right foot, which was treated with carbolic acid and olive oil. When mortification appeared, poultices were used; after separation of slough, a weak solution of carbolic acid and water. He was discharged from hospital on May 10th, and left with his company for Pembina, the wound being not quite healed.

CCCCXCVI.—*Account of Three Cases of Frost Bite, occurring at Fort Ripley, Minnesota.* By C. K. WINNE, Assistant Surgeon, U. S. A.

On January 11, 1870, Private Thomas Sweeney, Co. G, 20th Infantry, aged 22 years, was admitted to hospital with frost bite of right ear. Simple dressings were applied. He returned to duty the next day.

On January 18, 1870, Private Charles McCombs, Co. G, 20th Infantry, aged 21 years, was admitted with frost bite of right foot. Simple dressings were applied. He returned to duty the next day.

On February 18, 1870, Private George W. Depue, Co. G, 20th Infantry, aged 19 years, was admitted with frost bite of right hand. Simple dressings were applied. He returned to duty next day. He was readmitted March 8th, with frost bite of both feet and legs. Simple dressings were applied. There was excessive constitutional depression, complicated with pneumonia. No operation was justifiable. He died March 20, 1870.

CCCCXCVII.—*Report of Four Cases of Frost Bite, occurring at Fort Snelling, Minnesota.* By A. HEGER, Surgeon, U. S. A.

On January 8, 1870, Private James Smith, Co. E, 20th Infantry, aged 23 years, was admitted to hospital with frost bite of heels and toes of both feet and left ear, which happened when absent, drunk. Ice-water irrigation. He returned to duty January 18, 1870.

On January 20, 1870, Private John Stack, Co. E, 20th Infantry, aged 23 years, was admitted with frost bite of the great toe, left foot. Ice-water irrigation. He returned to duty January 21, 1870.

On January 10, 1870, Private William Hausman, Co. E, 20th Infantry, aged 24 years, was admitted with frost bite of the great toe, right foot. Ice-water irrigation. He returned to duty January 28, 1870.

On January 26, 1870, Private William Flynn, Co. E, 20th Infantry, aged 24 years, was admitted with frost bite of left heel and right great toe. Ice-water irrigation. He returned to duty February 18, 1870.

CCCCXCVIII.—*Note of a Case of Death from Frost Bite.* By P. C. DAVIS, Surgeon, U. S. A.

Private Thomas Kane, Co. D, 13th Infantry, died at Fort Ellis, Montana Territory, on January 20, 1870, from the effects of exposure to the cold on the night of January 16th, while returning from Bozeman, a town three and a half miles distant from Fort Ellis. He was found on the following morning lying on the snow, in a comatose state, and immediately brought to the hospital, where, upon examination, it was found that both feet and legs were badly frozen nearly to the knees, and that his hands and part of his arms were in the same condition. All efforts to rouse him, or procure reaction, proved unavailing. It is supposed he was very much intoxicated. The thermometer, at 7 A. M. on the morning he was found, was 33° F. below zero. The condition of the man, from the time of his admission until death, would not admit of amputation.

SURGICAL OPERATIONS.

The reports for the past five years include minutes of numerous amputations for disease or injury, of many excisions of the larger joints, of a number of ligations, and of other operations, such as trachiotomy, lithotomy, and the extirpation of tumors. The more important abstracts will be recorded in full, and the other reports will be condensed in tabular shape.

AMPUTATIONS.

Two hundred and fifty-one cases of amputations were made the subjects of special report; viz., One hundred and sixty-four of the upper extremity, eighty-six of the lower, and one of both upper and both lower extremities.

AMPUTATIONS IN THE UPPER EXTREMITIES.

Amputations of the Fingers.—Of 114 of these operations, sixty-four were on account of gunshot wounds, ten for frost-bites, eight for incised wounds, two for accidents on railways, and thirty for miscellaneous accidents. All of the patients recovered; sixty-one were returned to duty, thirty-seven were discharged as unfit for military duty, and sixteen recovered, but the ultimate disposition made is not yet ascertained.

Name.	Rank.	Co.	Regiment.	Nature of injury.	Parts removed.	Remarks.
1. Andrew, Cordey	Private....	G.	9th Cavalry	Gunshot wound..	Left index finger.....	Returned to duty Mar. 3, 1871.
2. Appleman, Peter	Private....	D.	23d Infantry	Unknown.....	Distal third of first phalanx of the right index finger.	Deserted May 20, 1870.
3. Auchenpock, Marion....	Private....	I.	37th Infantry	Gunshot wound..	Right forefinger, at junction of first and second phalanges.	Returned to duty September 24, 1867.
4. Banks, Augustus.....	Private....		Ordnance Corps.	Fall	Right thumb, at metacarpal joint.	Returned to duty December 26, 1868.
5. Barclay, James.....	Private....		Ordnance Corps.	Laceration by circular saw.	Third and fourth fingers.....	Discharged January 2, 1868.
6. Bender, Eberhardt.....	Private....	D.	3d Infantry	Gunshot wound..	Left index finger, and head of metacarpal bone.	Returned to duty in March, 1869.
7. Berry, Grippen.....	Private....	C.	24th Infantry	Gunshot wound..	Left thumb, at metacarpo-phalangeal articulation.	Returned to duty December 25, 1869.
8. Bischoff, Franz.....	Private....	I.	37th Infantry	Gunshot wound..	Right index finger, at second joint.	Returned to duty in July, 1867.
9. Borger, Philip.....	Private....	C.	9th Infantry	Gunshot wound..	Left thumb, in continuity of first phalanx.	Returned to duty in August, 1868.
10. Bosworth, Nathaniel C.	Private....	B.	8th Cavalry	Gunshot wound..	Left index finger, at metacarpo-phalangeal joint.	Returned to duty July 9, 1867.
11. Brady, James	Private....	D.	3d Cavalry.....	Bitten by a comrade.	Left forefinger, one inch from metacarpo-phalangeal articulation.	Returned to duty in June, 1869.
12. Brown, Patrick	Private....	G.	4th Artillery....	Incised wound..	Right middle finger, at articulation of second and third phalanges.	Returned to duty September 15, 1870.
13. Burnham, William.....	Private....	C.	10th Cavalry	Gunshot wound..	Second finger of right hand, and two-thirds of the second metacarpal bone.	Discharged January 3, 1868.
14. Bush, Henry	Private....	G.	7th Infantry	Railroad accident.	Three fingers amputated, and portions of carpal and metacarpal bones excised.	Discharged from service August 10, 1867.

Name.	Rank.	Co.	Regiment.	Nature of injury.	Parts removed.	Remarks.
15. Cahil, Patrick.....	Private....	I.	13th Infantry ...	Frost-bite.....	Second and third phalanges of all fingers of left hand.	Discharged from service May 15, 1868.
16. Carter, Monroe.....	Private....	A.	21st U. S. C. T. ...	Gunshot wound..	Right little finger, through metacarpophalangeal articulation.	
17. Clark, Arthur.....	Private....	K.	4th Infantry	Gunshot wound..	Fore and middle fingers, left hand.	Discharged June 27, 1868.
18. Clune, Morris.....	Private....	G.	35th Infantry ...	Incised wound..	Index finger, left hand, at metacarpophalangeal articulation.	Returned to duty September 10, 1868.
19. Cook, Frank.....	Private....	L.	2d Artillery.....	Lacerated wound by circular saw.	All the fingers of left hand.....	Discharged May 12, 1870.
20. Cullen, Martin.....	Private....	M.	2d Cavalry.....	Frost-bite.....	All the fingers of left hand and three first toes of left foot.	Discharged April 9, 1867.
21. Daily, John.....	Unassigned recruit.	9th Colored Cavalry.	Gunshot wound..	Left little finger, at metacarpophalangeal articulation.	Returned to duty August 4, 1868.
22. Day, Barney.....	Private....	Pawnee Scouts..	Gunshot wound..	Right index finger.	
23. De Forester, George.....	Private....	H.	18th Infantry ...	Gunshot wound..	Right index finger, and head of corresponding metacarpal bone.	Discharged June 25, 1870.
24. De Forrest, Frank.....	Private....	H.	4th Artillery....	Crushed by the wheel of a caisson.	Right index finger, at second phalangeal articulation.	Returned to duty in July, 1870.
25. Dempsey, William.....	Private....	D.	22d Infantry	Frost-bite.....	Fourth finger left hand, at metacarpophalangeal articulation.	Secondary hemorrhage; ankylosis of second and third fingers; returned to duty February, 1870.
26. Desmond, Humphrey ..	Private....	D.	15th Infantry ...	Lacerated wound.	Middle finger right hand, at metacarpophalangeal articulation.	Deserted September 26, 1869.
27. De Temple, ———.....	Private....	A.	17th Infantry ...	Bitten by a soldier.	Left little finger.....	Returned to duty May 31, 1868.
28. Dooley, Michael J.....	Private....	L.	18th Infantry ...	Gunshot wound..	Second finger and corresponding metacarpal bone.	Returned to duty in August, 1870.
29. Dowdy, James.....	Private....	A.	42d Infantry	Gunshot wound..	Middle left and ring fingers.....	Returned to duty October 20, 1869.
30. Fisher, Thomas.....	Private....	G.	9th Cavalry.....	Gunshot wound..	Right index finger at first joint.	Returned to duty November 20, 1868.
31. Fletcher, Thomas W. ...	Private....	H.	4th Infantry	Necrosis, following whitlow.	Last phalanx of right thumb....	Transferred to Veteran Reserve Corps.
32. Franklin, A.....	Private....	K.	14th Infantry ...	Bitten by a soldier.	Left thumb.....	Returned to duty August 20, 1870.
33. Gardner, Nelson.....	Citizen.....	Gunshot wound..	Left index finger, and fractured end of metacarpal bone.	Recovered.
34. George, Lewis J.....	Private....	A.	7th Cavalry.....	Gunshot wound..	Index, at metacarpophalangeal articulation.	Recovered.
35. Good, Batton.....	Bagler.....	M.	9th Cavalry.....	Gunshot wound..	Second and third phalanges left index.	Returned to duty November 11, 1870.
36. Hamilton, Frank.....	Private....	G.	9th Cavalry.....	Gunshot wound..	Right index finger, at middle of second phalanx.	Returned to duty September 14, 1868.
37. Hargerty, J.....	Private....	Crushed by wheel of a truck.	Right thumb at first joint, and all the fingers, including the third, fourth, and fifth metacarpal bones.	Discharged June 17, 1868.
38. Harmsing, August.....	Private....	C.	7th Infantry	Gunshot wound..	Right thumb at middle of second phalanx.	Returned to duty September 25, 1870.
39. Hatzel, John.....	Artificer ..	G.	8th Infantry	Gunshot wound..	Three fingers at the second joint, and thumb at carpo-metacarpal articulation.	Discharged from service January 10, 1870.
40. Hennard, Jas. G.....	Private....	E.	17th Infantry ...	Compound fracture.	Right index finger, at middle of second phalanx.	Returned to duty November 22, 1870.
41. Hickey, James.....	Private....	D.	20th Infantry ...	Frost-bite.....	Right index finger.....	Returned to duty March 16, 1869.
42. Hogan, John.....	Private....	D.	42d Infantry	Gunshot wound..	Little finger of right hand, and head of metacarpal bone.	Discharged March 29, 1869.

Name.	Rank.	Co.	Regiment.	Nature of injury.	Parts removed.	Remarks.
43. Hoover, Ephraim	Corporal...	I.	19th Infantry ...	Incised wound...	Left index and second fingers, through the shafts of middle phalanges.	Recovered.
44. Howard, Charles.....	Sergeant ..	D.	5th Infantry....	Incised wound...	Middle, ring, and little fingers of left hand, through middle phalanges.	Recovered.
45. Huntington, Henry	Private.....	G.	4th Infantry	Gunshot wound..	Third and fourth fingers of right hand, at metacarpo-phalangeal articulation.	Discharged February 13, 1869.
46. Hughes, William	6th Cavalry	Supposed to have resulted from injuries received while tied up by the wrist.	Second finger of the left hand...	Discharged September 27, 1867.
47. Ichawgaw	Ind'n scout.....	Incised wound, with fracture.	Fourth finger of right hand, at first joint.	Returned to duty December 23, 1870.
48. Keller, Nicholas.....	Private.....	I.	14th Infantry ...	Gunshot wound..	Right forefinger, through first phalanx.	Discharged December 30, 1870.
49. Kold, John W.....	Private.....	C.	15th Infantry ...	Gunshot wound..	Middle finger of left hand.....	Returned to duty in November, 1868.
50. Leopold, Emil.....	Private.....	F.	26th Infantry ...	Incised wound...	Second finger of left hand, at first phalangeal joint.	Returned to duty August 12, 1868.
51. Lewis, George W.....	Private.....	F.	20th Infantry ...	Frost-bite.....	Fingers of left hand, at distal third of first phalanges.	Returned to duty in May, 1870.
52. Lilly, James.....	Private.....	G.	9th Cavalry	Gunshot wound..	Left hand at carpo-metacarpal articulation, saving the thumb.	Discharged December 16, 1867.
53. McAllister, Alvin M....	Sergeant ..	G.	17th Infantry ...	Gunshot wound..	Right forefinger, at metacarpo-phalangeal articulation.	Returned to duty in May, 1867.
54. McCaffrey, Francis....	Corporal... I.	I.	7th Infantry	Gunshot wound..	Left little and ring fingers with the metacarpals at the carpo-metacarpo-articulations, and middle finger at first joint; also, right little finger.	Returned to duty in September, 1869.
55. McCullar, James.....	Private.....	M.	4th Cavalry.....	Gunshot wound..	Left little finger, in first phalanx.	Returned to duty in August, 1868.
56. McDonald, Matthew ...	Private.....	F.	23d Infantry	Lacerated wound.	First phalanx of right index finger.	Recovered.
57. McPeake, Morris.....	Private.....	A.	15th Infantry ...	Caught by a circular saw.	First phalanx of left thumb, and third phalanges of balance of fingers.	Discharged August 5, 1867.
58. Mathias, John G	Private.....	L.	4th Artillery....	Gunshot wound..	Ring finger at ungual phalanx, and little finger at metacarpal articulation; left hand.	Returned to duty in February, 1871.
59. Miller, William.....	Private.....	D.	15th Infantry ...	Incised wound...	Right index finger, at middle phalanx.	Returned to duty in September, 1870.
60. Minor, H.....	Private.....	F.	17th Infantry ...	Gunshot wound..	Right index finger, through distal extremity of first phalanx, and middle finger near base of second phalanx.	Returned to duty.
61. Mitchel, George.....	Corporal... E.	E.	10th Cavalry ...	Gunshot wound..	Right index finger and head of metacarpal bone.	Returned to duty in February, 1868.
62. Montgomery, Jesse.....	Private.....	M.	10th Cavalry	Gunshot wound..	Right index finger, between first and second phalanges.	Returned to duty August 14, 1870.
63. Moore, John A.....	Private.....	I.	8th Cavalry.....	Lacerated wound.	Left thumb, through first phalanx.	Discharged April 20, 1866.
64. Moore, Walter	Private.....	H.	41st Infantry....	Gunshot wound..	Left little finger, above the second joint.	Recovered.
65. Morris, Patrick.....	Corporal... M.	M.	2d Artillery.....	Gunshot wound..	Left little finger	Returned to duty January 1, 1867.
66. Mowry, Charles.....	Private.....	I.	20th Infantry ...	Gunshot wound..	Two phalanges of left index finger.	Returned to duty November 21, 1868.
67. Murphy, David.....	Private.....	H.	31st Infantry....	Gunshot wound..	Middle finger of left hand.....	Discharged May 5, 1868.
68. Myers, John	Private.....	E.	43d Infantry	Frost-bite.....	Two fingers of left hand	Discharged November 6, 1868.

Name.	Rank.	Co.	Regiment.	Nature of injury.	Parts removed.	Remarks.
69. Nice, Charles	Private....	G.	9th Cavalry	Gunshot wound..	Amputation of thumb; second metacarpal bone of thumb excised.	Returned to duty in January, 1868.
70. Oberfield, Anthony.....	Private....	E.	3d Artillery.....	Lacerated wound.	Ungual phalanx of right middle finger.	Recovered.
71. Paris, Jacob	Private....	C.	36th U. S. C. T. ...	Gunshot wound..	Left thumb, first metacarpal bone and <i>os trapezium</i> ; also, lower end of second metacarpal bone.	Sent home December 4, 1866, and discharged.
72. Parks, Wallace.....	Private....	G.	9th Cavalry	Gunshot wound..	Left index finger, through first third of first phalanx.	Returned to duty in April, 1869.
73. Patterson, Arthur.....	Private....	I.	23d Infantry	Gunshot wound..	Left index finger, at metacarpophalangeal joint.	Returned to duty in April, 1869.
74. Peak, Isaiah	Private....	G.	38th Infantry ...	Railroad accident.	Fourth and fifth fingers right hand at metacarpophalangeal articulation, and middle finger in continuity of second phalangeal bone.	Discharged June 13, 1869.
75. Peterman, August....	Private....	E.	18th Infantry ...	Frost-bite.....	Last phalanges of third and fourth fingers.	Returned to duty March 3, 1867.
76. Platt, Peter.....	Private....	I.	37th Infantry ...	Gunshot wound..	Right forefinger, at junction of first and second phalanges.	Returned to duty September 17, 1867.
77. Post, Peter.....	Private....	B.	45th Infantry ...	Gunshot wound..	Left ring finger, at metacarpophalangeal articulation.	Returned to duty August 6, 1868.
78. Rader, Louis.....	Private....	II.	7th Cavalry	Bitten by a comrade.	Third finger of right hand, at second phalangeal articulation.	
79. Randolph, George C.	E.	9th Infantry	Gunshot wound..	Little, ring, and middle fingers, with their corresponding metacarpal bones; left hand.	Discharged June 9, 1870.
80. Richards, William	Private....	H.	9th Cavalry	Necrosis, following a bite.	Fourth finger of left hand.....	Returned to duty October 25, 1870.
81. Roberts, Theodore	Private....	G.	23d Infantry	Gunshot wound..	First and second fingers of right hand.	Discharged March 23, 1868.
82. Rose, Henry	Private....	C.	35th Infantry ...	Bitten by a dog; necrosis.	First and second phalanges, index finger.	Returned to duty May 19, 1868.
83. Ruff, Michael	Private....	C.	35th Infantry ...	Gunshot wound..	Left little finger, with metacarpal bone.	Returned to duty in June, 1867.
84. Ryan, William	Private....	G.	7th Infantry	Gunshot wound..	Second phalanx of right index finger.	
85. Schoenhard, Gottlieb....	Private.....	Detachment of artillery at West Point.	Laceration by circular saw.	Little finger left hand, at first phalangeal joint, ring finger through first phalanx, and index finger at metacarpophalangeal articulation.	Recovered.
86. Shelton, John W.....	Private....	C.	6th Cavalry	Incised wound...	Right forefinger, at metacarpophalangeal articulation.	Returned to duty March 18, 1868.
87. Simmons, David	Private....	M.	3d Cavalry	Gunshot wound..	Second and third fingers right hand, with the heads of the metacarpal bones.	Recovered.
88. Smith, Charles.....	Private....	F.	27th Infantry ...	Gunshot wound..	Ring finger of right hand, at second joint.	Discharged April 27, 1868.
89. Smith, Charles.....	Corporal...	K.	31st Infantry....	Gunshot wound..	Left index finger, in the continuity of the second metacarpal bone.	Discharged September 29, 1868.
90. Smith, Joseph.....	Private....	G.	3d Infantry	Gunshot wound..	Left index finger and half of corresponding metacarpal bone.	Returned to duty November 7, 1867.
91. Stargratt, John.....	Bugler....	F.	7th Cavalry	Gunshot wound..	Right index finger	Returned to duty in December, 1868.
92. Stowers, Isaac F.....	Private....	F.	11th Infantry ..	Gunshot wound..	First finger of right hand, at articulation of first and second phalanges.	Returned to duty in April, 1870.
93. Sumner, E. V.....	Captain ...	D.	1st Cavalry	Gunshot wound..	Right index finger and first phalanx of left ring finger.	Returned to duty.

Name.	Rank.	Co.	Regiment.	Nature of injury.	Parts removed.	Remarks.
94. Taylor, Joseph A.	Private.	A.	13th Infantry ...	Gunshot wound..	Second and third phalanges, third finger, left hand.	Discharged June 4, 1869.
95. Tolliver, Barnet	Bugler ...	K.	7th Cavalry	Incised wound...	Right thumb, at metacarpo-phalangeal articulation.	Returned to duty March 11, 1867.
96. Turner, Thomas	Private.	A.	9th Cavalry	Gunshot wound..	Returned to duty in September, 1867.
97. Van Doesburgh, Henry.	Private.	Ordnance Corps.	Unknown.....	Second finger of right hand, at carpo-metacarpal articulation.	Recovered.
98. Villhouer, Charles.	Private.	D.	13th Infantry ...	Unknown.....	Right and left index fingers.	Discharged November 11, 1867.
99. Watson, Emanuel.	Private.	K.	25th Infantry ...	Gunshot wound..	Left thumb, at metacarpo-phalangeal articulation.	Returned to duty in January, 1871.
100. Watson, Enos M.	Private.	H.	2d Cavalry	Gunshot wound, followed by caries.	Index finger and part of second metacarpal bone.	Discharged January 26, 1869.
101. Watson, George	Private.	I.	10th Cavalry ...	Gunshot wound..	Middle finger, right hand, with lower fragment of metacarpal bone.	Discharged May 16, 1869.
102. Weber, August.	Private.	D.	20th Infantry ...	Frost-bite.....	First phalanges of ring and middle fingers of right hand, and great toe of right foot.	Discharged July 22, 1870.
103. Welch, Michael	Private.	F.	4th Cavalry	Whitlow.....	Left forefinger.....	Returned to duty April 3, 1869.
104. Wheeler, T. I.	Private.	K.	4th Infantry ...	Frost-bite.....	First phalanx of forefinger.....	Discharged June 3, 1868.
105. White, Alfred.....	Private.	I.	9th Cavalry.....	Gunshot wound..	Right index finger, at phalango-metacarpal joint.	Returned to duty October 4, 1867.
106. Whitman, Daniel	Private.	F.	17th Infantry ...	Gunshot wound..	Last phalanx of the right thumb.	Returned to duty May 10, 1868.
107. Wiley, John.....	Private.	B.	7th Cavalry.....	Gunshot wound..	Middle finger of the right hand.	Returned to duty December 31, 1868.
108. Williams, John	Private.	A.	2d Cavalry	Gunshot wound..	Index and second fingers, left hand.	Discharged March 1, 1869.
109. Williams, Richard ...	Private.	I.	9th Cavalry.....	Bitten by a comrade; necrosis.	First phalanx of the left little finger.	
110. Willis, John H.	Private.	C.	45th Infantry ...	Ulceration following punctured wound.	Left little finger, with its metacarpal bone.	
111. Wilson, Charles H.	Private.	B.	7th Cavalry.....	Gunshot wound..	Little finger, left hand, through second phalanx.	Returned to duty February 27, 1867.
112. Wilson, George	Private.	H.	4th Infantry ...	Lacerated wound by circular saw.	First, second, and third fingers of left hand, through middle of first phalanges.	Discharged September 10, 1868.
113. Wisewell, Adelbert L.	Private.	D.	23d Infantry ...	Lacerated wound by circular saw.	Ring finger, right hand, at metacarpal joint, and little finger at first joint.	Discharged March 31, 1869.
114. Wolf, Albert.....	Private.	M.	2d Cavalry.....	Frost-bite.....	First and second fingers, left hand.	Discharged June 8, 1867.

Amputation at the Wrist.—Special reports of two cases were forwarded, both necessitated by gunshot wounds of the hand.

CCCCXCIX.—*Account of a Primary Amputation at the Wrist-Joint for Gunshot Injury.* By JAMES F. WEEDS, Surgeon, U. S. A.

Private Gaw Jarvis, Co. G, 45th Infantry, aged 28 years, was wounded November 24, 1868, by a conoidal ball, which passed through and shattered the left hand completely. He was at once admitted to the post hospital at Nashville, Tennessee. There was not much swelling. On the same day, Acting Assistant Surgeon R. McGowan administered chloroform, and performed a circular

amputation at the wrist-joint. After two days hospital gangrene ensued. Nitric acid was applied to the gangrenous part, and opiates and stimulants were administered. On December 31, 1868, the case was still under treatment, and progressing very favorably. He was discharged.

D.—*Mention of a Case of Secondary Amputation at the Wrist-Joint.* By H. R. MILLS, M. D., Acting Assistant Surgeon.

Private Reinhold Shulz, Co. B, 43d Infantry, aged 23 years, received May 12, 1867, a gunshot wound of the left hand, caused by the bursting of a fowling-piece. He was at once admitted into the post hospital at Fort Wayne, Michigan. The palmar surface of the hand was much lacerated; the index and middle fingers completely denuded of their soft tissues, and their metacarpal bones fractured near the carpal end; the ball of the thumb was badly lacerated, and its carpo-metacarpal joint opened. Assistant Surgeon B. E. Fryer, United States Army, administered chloroform, and removed the index and middle fingers with their metacarpal bones. One ligature was applied. The patient reacted well, and the wound was dressed with a solution of chloride of zinc, and left open. About three hours after the operation, hæmorrhage occurred, which was arrested by astringent lotions. On June 30, 1867, the parts were nearly well. On September 1, 1867, he was admitted to the hospital at Fort Mackinac, Michigan, with three distinct fistulous openings in the hand, which were discharging sickly-looking pus, more or less freely. Owing to the great desire of the patient to save his hand, it was decided to give the experiment sufficient time, for the satisfaction of all concerned. Alternate healing and reopening of the wound, accompanied by intense pain at times, especially on any sudden change of the weather, and a gradual decline of the general health of the patient comprised the chief symptoms in the case until March 2, 1868, when I decided to remove the hand at the radio-carpal articulation, which was accordingly performed. A small interosseous artery rendered three ligatures necessary. The edges of the flaps were nicely adjusted and united by first intention throughout almost their entire extent. The ligature of the ulnar artery came away the fourth or fifth day. On the 31st of March, the remaining ligatures still remained firmly attached, although traction had been made daily since the first week, with the design of removing them. With this exception, the stump was perfectly sound, and the health of the patient much improved. On examination of the bones of the hand and wrist, the articulating surfaces were found firmly adherent, and the whole a mass of necrosis and caries. This man was discharged the service July 6, 1868.

Amputations of the Fore-arm.—Special reports were made of twenty cases of this nature, of which nineteen were due to gunshot wounds, and one to railroad accident.

DI.—*Note of a Case of Primary Amputation of the Fore-arm for Gunshot Injury.* By H. A. DUBOIS, Assistant Surgeon, U. S. A.

Private Casimiro Alvidrez, Co. H, 1st New Mexico Infantry, was wounded July 4, 1866, at Fort Union, New Mexico, while firing a salute, by the premature explosion of a gun, which greatly shattered the hand and lower third of the fore-arm. The shock was profound. Within a half hour after the receipt of the injury, chloroform was administered and the fore-arm amputated by skin-flap method. The patient rallied in twenty-four hours. Chloroform brought the pulse up, but the reaction, after the operation, was slower than it would have been had the operation been postponed until reaction took place. During the treatment there was hæmorrhage from the medullary cavity. The patient was discharged, with a good stump, September 8, 1866.

DII.—*Report of an Amputation of the Fore-arm and Finger for Gunshot Injury.* By R. H. WHITE, Assistant Surgeon, U. S. A.

Private John Berger, Co. G, 15th Infantry, aged 22 years, was wounded at Mobile, Alabama, on July 4, 1868, while acting as number one in firing a brass field-piece. He had forced

a blank cartridge about one-third home, when the vent was uncovered, causing premature discharge. The receding sponge-staff crushed the right hand, opened the right wrist-joint, severed the muscles of the lower third of the right fore-arm on the anterior aspect, tore away the belly of the deltoid muscle, and lacerated three of its fibres that arise from the acromion process, and fractured the first phalanx of the left index finger. There was also a simple fracture of the left radius, supposed to have been caused by the fall of the patient. The right arm and fore-arm, the right side of face and eye, and the chest, were slightly burned. He was admitted to the post hospital; and having partially recovered from the shock, was chloroformed, and the right fore-arm was amputated at the junction of the lower thirds, and the left index finger at the metacarpo-phalangeal articulation, both by circular operations. The fracture of the left radius being readily reduced, Nélaton's splint was adjusted to the palmar surface of the hand and fore-arm. The stump of the right fore-arm was dressed with dry bandages and oakum, and healed by first intention, except at the inner border, where the ligatures applied to the ulnar and radial arteries required the healing to be by suppuration and granulation. On August 8, 1868, the stump had healed.

DIII.—*Report of a Primary Amputation of the Fore-arm for Gunshot Injury.* By B. A. CLEMENTS, Surgeon, U. S. A.

Private William Blair, Battery K, 1st Artillery, aged 18 years, received, July 8, 1867, by the premature discharge of a six-pound rifled cannon while firing a salute, a compound comminuted fracture of the right fore-arm and hand with extensive laceration of the soft parts. He was, on the same day, admitted to the post hospital, Jackson Barracks, New Orleans, Louisiana, where the fore-arm was amputated at the upper third, one hour and a half after reception of the injury, making oval skin flaps. Parts united in almost their entire extent by first intention. The progress of the case was retarded by an attack of yellow fever. September 11, 1867, perfect union and sufficient stump left to give effective support to an artificial limb. He was discharged November 27, 1868, with a pension of \$15 per month.

DIV.—*Report of a Primary Amputation of the Fore-arm for Railway Injury.* By JOHN T. KING, M. D., Acting Assistant Surgeon.

Private George C. Crawford, Co. C, 40th Infantry, aged 32 years, was injured at Goldsborough, North Carolina, March 29, 1869, by the passage of a railroad car over his right hand, completely crushing it. Assistant Surgeon William F. Smith, United States Army, immediately administered chloroform, and amputated the lower third of the fore-arm by the circular method. Three ligatures were used. On the same day he was admitted to the post hospital, from his company, where, on the 31st of March, the case was reported as progressing favorably. The patient was discharged May 15, 1869, with a pension of \$15 per month.

DV.—*Report of a Double Amputation of the Fore-arm.* By T. H. TURNER, Assistant Surgeon U. S. A.

Private William Greiter, Co. C, 5th United States Infantry, aged 28 years, while firing a salute at Fort Wallace, Kansas, July 19, 1868, was wounded by the premature explosion of a cannon, which badly shattered and burned both hands and fore arms. Immediately after I amputated both fore-arms at the middle third. Both stumps were well on the twenty-fourth day after the operation. He was discharged May 6, 1869, and pensioned at \$25 per month.

DVI.—*Account of an Amputation of both Fore-arms for Gunshot Injury.* By DONALD JACKSON, M. D., Acting Assistant Surgeon.

Private George Grey, Troop M, 9th Cavalry, while firing a national salute on June 29, 1868, at Fort Clark, Texas, was wounded by the sponge-staff of a field piece, which carried away portions

of both hands, tore several tendons from their origin, and superficially injured the arms above the elbow-joints. He was at once admitted to hospital, and on the next day equal parts of ether and chloroform were administered, and both fore-arms amputated by the circular method, the left four inches, and the right one and a half inches above the wrist-joint. The patient, at the time, was powerfully narcotized, opiates having been administered on the previous night to quiet excessive nervous excitement. The pulse was 120 to 150, weak and irregular. The anæsthetic improved the pulse—was better after the operation than at the commencement. He continued under the influence of the opiate, and his condition was rather critical. On July 9th, the right stump had healed and the left was nearly well. On the 11th of July, tetanus occurred, and death on July 15, 1868.

DVII.—*Report of an Amputation of the Fore-arm for Gunshot Injury.* By HENRY SPOHN, M. D., Acting Assistant Surgeon.

Private George E. Hubbell, Troop C, 4th Cavalry, aged 21 years, received on February 7, 1870, a gunshot wound of the left hand and wrist, by the accidental discharge of his carbine. On the same day, he was admitted to the hospital at Fort McIntosh, Texas. The left hand and wrist were very much shattered and torn. Chloroform and ether were administered, and the left fore-arm amputated by the circular operation, four inches above the wrist. Simple dressings were applied. There was very little suppuration. The patient was discharged the service on May 12, 1870.

DVIII.—*On an Amputation of the Fore-arm for Gunshot Injury.* By W. D. WOLVERTON, Assistant Surgeon, U. S. A.

Private Adam Hutton, Battery K, 1st Artillery, aged 24 years, while firing a salute at New Orleans, June 11, 1868, had the greater portion of his right hand blown off. The parts were greatly lacerated, with slight hæmorrhage. He was admitted to the post hospital at Sedgwick Barracks, on the same day, where ether and chloroform were administered and the fore-arm amputated, through the lower third, by the circular method. He gradually recovered, and was discharged the service August 3, 1868, with a stump completely healed. He is a pensioner at \$15 per month.

DIX.—*Account of a Primary Amputation of the Fore-arm for Gunshot Injury.* By E. H. BOWMAN, M. D., Acting Assistant Surgeon.

Private Doctor Johnson, Co. A, 24th Infantry, was wounded at Fort Bliss, Texas, while firing a national salute on July 4, 1870, by the premature discharge of a cannon, which carried away the left hand up to the carpal articulation. On the same day the fore-arm was amputated as close to the wrist-joint as the condition of the parts would admit. The stump was dressed with a solution of carbolic acid, and healed kindly. He was discharged April 30, 1871.

DX.—*Account of a Primary Amputation of the Fore-arm for Gunshot Injury.* By JOHN T. KING, M. D., Acting Assistant Surgeon.

Private Charles D. Jones, Co. H, 8th Infantry, aged 19 years, was accidentally wounded December 9, 1866, by a conoidal ball, which entered the palmar surface of the left hand, and passed directly through, carrying away the fourth, and comminuting the third and fifth metacarpal bones. The tom-pion, as well as the ball, passed through the hand. The soft parts were much lacerated. On the same day he was admitted to the post hospital at Charlotte, North Carolina, and on the 16th chloroform was administered, and the left fore-arm was amputated at the lower third, by the circular method. Simple dressings were used. On January 1, 1867, the patient was doing well, and the stump was nearly healed. [He was discharged on March 4, 1867.]

DXI.—*Account of a Primary Amputation of the Fore-arm.* By S. M. HORTON, Assistant Surgeon, U. S. A.

Private Jesse L. Judd, Co. H, 18th Infantry, aged 36 years, was wounded at Fort Philip Kearney, Dakota Territory, July 24, 1866, by the accidental discharge of a revolver, which fractured the lower end of the left ulna, the ulnar bone, and the third, fourth, and fifth metacarpal bones. He was immediately admitted to the hospital of the fort. He was in a state of drunkenness bordering on delirium tremens, and there was great hæmorrhage from the hand. On the same day equal parts of ether and chloroform were administered, and the fore-arm amputated three inches above the wrist-joint, by the flap operation. Cold-water dressings were applied, and by the 20th of October, 1866, the stump was entirely healed. [The patient was discharged June 6, 1867.]

DXII.—*Remarks on a Primary Amputation of the Fore-arm for Gunshot Injury.* By JAMES SHAW, M. D., Acting Assistant Surgeon.

Private Charles E. Leonard, Co. B, 7th Infantry, aged 22 years, and of good constitution, while firing a national salute July 4, 1868, at Fernandina, Florida, was ramming home a cartridge in a field-piece, when it exploded, and he was thrown some seven or eight yards from its mouth. His right fore-arm was torn off six inches below the elbow-joint, and the soft parts of the arm were burned and lacerated up to the axilla. The thumb of the left hand was also blown off, exposing the end of the carpal bone. Being present at the time, I had him immediately carried into quarters, whereat once, after giving him some brandy and water and administering chloroform, I controlled the circulation, thereby losing very little blood, and amputated the fore-arm three or four inches below the elbow-joint, by the circular method. The soft parts were drawn across the end of the carpal bone left thumb, covering it very neatly. Stimulating and nourishing diet was given, and cataplasms were applied to the superior extremities and stomach, and soothing lotions to the wounds. The nervous shock was so severe, and the vital powers were so entirely prostrated, that all efforts in establishing reaction failed. During the forty-eight hours that he survived, he was only able to speak a few words. He died at 10 A. M., July 6, 1868.

DXIII.—*Remarks on a Primary Amputation of the Fore-arm for Gunshot Injury.* By BURTON RANDALL, Surgeon, U. S. A.

Private Thomas O'Conner, Battery A, 1st Artillery, aged 22 years, while guard-mounting, November 10, 1866, with his left hand over the muzzle of his gun, was wounded by its accidentally slipping and discharging, the ball producing a compound fracture of the metacarpal bones of the first, second and third fingers and thumb, and passing through the bones of the carpus, with great destruction of the bones and soft parts. The parts were much burned and excessively inflamed. He was immediately admitted to the post hospital at Fort Trumbull, Connecticut, where, on the same day, chloroform was administered, and the fore-arm amputated just above the wrist, by the circular method. Simple dressings were applied. The stump healed, and the patient was discharged on March 13, 1867, with a pension of \$15 per month.

DXIV.—*Remarks on an Amputation of the Fore-Arm for Gunshot Injury.* By C. B. WRIGHT, Assistant Surgeon, U. S. A.

Corporal William Pare, Co. D, 57th Infantry, aged 25 years, was wounded at Fort Smith, Arkansas, on February 22, 1866, by the accidental discharge of a cannon, while firing a salute in honor of Washington's birthday. Being, at the time, in the act of loading the piece, the charge took effect in the right hand, completely destroying it and the integuments of the lower third of the fore-arm. On the same day the fore-arm was amputated, by circular operation, at the junction of the upper thirds. Water dressings were applied. Anodynes at night, and a light and nourishing diet, were given. On March 31st the patient was convalescent. He was returned to duty in October, 1866.

DXV.—*Report of an Amputation of the Fore-Arm for Gunshot Injury.* By C. E. GODDARD, Assistant Surgeon, U. S. A.

Private Charles Rhey, Co. H, 31st Infantry, aged 25 years, while firing a salute July 4, 1868, at Fort Stevenson, Dakota Territory, was wounded in the right fore-arm by the premature discharge of a cannon. The skin was burned by powder, and there was more or less contusion. He was at once admitted to the hospital, and on the same day chloroform was administered, and Surgeon C. C. Gray, U. S. A., amputated about the middle of the fore-arm, by the circular method. Simple dressings were applied. The patient recovered slowly but well, and was discharged September 29, 1868, with a pension of \$15 per month.

DXVI.—*Remarks on an Amputation of the Fore-Arm for Gunshot Injury.* By H. A. DU BOIS, Assistant Surgeon, U. S. A.

Private Juan Seis, Co. D, 1st New Mexico Infantry, was wounded while herding, by the discharge of a musket, which took effect in the fore-arm. Forty-eight hours after the reception of the injury, he was admitted to the post hospital, Fort Union, New Mexico. The fore-arm was hanging by tendons. On October 28, 1866, about sixty hours after the receipt of the injury, chloroform was administered, and the fore-arm amputated by the skin-flap method. The patient rallied well; the wound healed, and he was discharged with a good stump November 9, 1866.

DXVII.—*Account of a Primary Amputation of the Fore-Arm for Gunshot Injury.* By J. J. MARSTON, M. D., Acting Assistant Surgeon.

Private Patrick Whalen, Co. D, 3d Infantry, was wounded at Fort Larned, Kansas, April 10, 1867, by the accidental discharge of a Spencer rifle, while in the act of loading the piece. The left hand was badly shattered, the bones being fractured, the arteries, muscles, and tissues lacerated, and the thumb entirely carried away. Three hours after the accident the left fore-arm was amputated at the lower third by the circular method. The tissues of the right hand, between the metacarpal bones of the thumb and fore-finger, were also lacerated, but the bones were uninjured. April 30, 1867: The stump and the wound of the right hand had nearly healed. The patient's condition was good. Discharged May 21, 1867, with a pension of \$15 per month.

DXVIII.—*Account of an Intermediate Amputation of the Fore-Arm for Gunshot Injury.* By H. R. TILTON, Assistant Surgeon, U. S. A.

Private Abraham Wilks, Troop B, 10th Cavalry, aged 23 years, was accidentally wounded November 3, 1868, by a carbine ball, which passed through the left hand, from the palmar to the dorsal aspect, fracturing the second and third metacarpal bones. The third finger was removed on the same day. On November 10, 1868, he was admitted to the post hospital, Fort Lyon, Colorado Territory. There was diffuse suppuration extending above the wrist, and secondary hæmorrhage from the deep palmar arch. The patient was in great alarm, complaining bitterly of his wound, and desiring amputation. On the 11th, chloroform was administered, and the fore-arm amputated through the middle by the circular method. Five ligatures were applied, and simple dressings were used. On November 17th, the first ligature was removed, and on November 29th, the last one came away. The posterior flap sloughed to the extent of half an inch, but by using adhesive straps and weights, the flaps were ample. On December 27th, the stump reopened and discharged freely, but by the 5th of February, 1869, it had entirely healed. He was discharged the service June 18, 1869.

DXIX.—*Account of a Primary Amputation of the Fore-Arm for Gunshot Injury.* By J. C. LAMONT, M. D., Acting Assistant Surgeon.

Private Horace Williams, Troop L, 9th Cavalry, aged 20 years, was wounded December 20, 1869, while firing a salute. In the act of ramming a blank cartridge into a piece of artillery, it accidentally ignited and exploded. The soft tissues of the right hand, wrist, and lower third of

the fore-arm were extensively lacerated, the bones fractured and dissevered, the blood-vessels torn, and his face, neck, and chest very severely burned. His vision was very much injured, if not destroyed. On the same day he was admitted into the post hospital at Fort Duncan, Texas. Ether was administered, and the fore-arm amputated at the junction of the lower and middle thirds, by the circular method. On December 31st, the patient was doing well, and there was a probability of a partial restoration of vision. He was discharged the service April 30, 1870.

DXX.—*Account of an Amputation of the Fore-Arm for Gunshot Injury.* By A. A. YEOMANS, Assistant Surgeon, U. S. A.

Private John Zearambo, Co. I, 24th Infantry, aged 21 years, while firing a salute July 4, 1867, received a compound comminuted fracture of the right fore-arm. He was at once admitted to the post hospital at Vicksburg, Mississippi. The radius and ulna were crushed in the middle and lower thirds, with extensive laceration of the soft parts. The humerus was fractured in the middle third, and there was a severe contusion over the right hypochondrium. The patient was somewhat debilitated from an attack of malarial fever; his pulse was 105, and rather weak. Chloroform was administered, and the fore-arm amputated at the upper third. Hæmorrhage was slight; four ligatures were applied, and the patient reacted promptly. A few days after the operation, the stump became gangrenous. Nitric acid and bromine were applied, and nourishing diet given. In a few days the line of demarcation was formed, and the slough thrown off. Nitro-muriatic acid was applied to the ends of the radius and ulna, which projected from the soft parts after mortification had attacked the stump, but, as their removal by that process seemed tedious, they were subsequently taken off by the saw. Union took place between the fragments of the humerus, and although the patient suffered from a severe attack of tetanus, he was, on September 30, 1867, doing well. Discharged July 22, 1868, and pensioned at \$15 per month.

Amputations of the Arm.—Special reports of twenty-four cases of this class were received; twenty were due to gun-shot wounds, one to railroad accident, two to other injuries, and one to disease. Five cases had a fatal termination.

DXXI.—*Account of an Intermediary Amputation of the Arm.* By W. M. NOTSON, Assistant Surgeon, U. S. A.

Private B. Bowers, Co. E, 11th Infantry, aged 21 years, was wounded on October 13, 1870, by a conoidal musket ball, in the right hand. On the same day, he was admitted to the hospital at Fort Concho, Texas; and on the 14th, the third finger was amputated at the carpo-phalangeal articulation. Immediately succeeding the operation, the patient had an attack of typhoid pneumonia, during which there was much sloughing of the hand and fore-arm, with hæmorrhage. While convalescing from the pulmonary trouble, and a profuse hæmorrhage occurring on November 7th, in consequence of the extent of the diseased tissue, the arm was amputated in the lower third. On March 31, 1871, this man was still under treatment. He was discharged the service May 24, 1871, for loss of arm from gunshot wound received in the line of duty.

DXXII.—*Account of an Amputation of the Arm and Fingers for Gunshot Injury.* By H. A. DuBois, Assistant Surgeon, U. S. A.

Lieutenant George W. Campbell, 3d Cavalry, aged 35 years, was admitted into the post hospital at Fort Union, New Mexico, June 8, 1867, having been wounded by the premature discharge of a cannon which he was loading, in camp on the Cimarron River, fifty miles from Fort Union. The left hand was entirely blown off, the left fore-arm and lower half of arm and the fingers, thumb and palm of the right hand were bruised and shattered; he was also burned in both eyes, head, and face. Carron oil was applied to the burnt parts, and the arm was amputated four inches above the elbow by the circular method, which was followed by a large slough on lower surface of stump. First phalanges of the middle and ring fingers were removed, and a thumb was made by covering the bone with flesh taken from the palm. Returned to duty July 1, 1867; wounds nearly healed; thumb

very useful; loss of vision of left eye. Patient is able to write, and has ridden over one hundred miles in the discharge of his duties as post quartermaster. This officer was retired July 29, 1868.

DXXIII.—Report of an Amputation of the Arm and Fore-Arm for Gunshot Injury. By J. T. GHISELIN, Surgeon, U. S. A.

Private Michael Casey, Battery A, 2d Artillery, aged 23 years, was wounded by the premature discharge of a field piece, October 29, 1866, during review at Presidio of San Francisco, California. Both arms were very much lacerated. There was, also, a lacerated wound of the left breast, and fracture of the sixth rib, caused by a fragment of the sponge-staff. He was admitted to the post hospital Presidio of San Francisco, California, on the same day, not much depressed by his injury, and Assistant Surgeon J. H. Kinsman, U. S. A., immediately administered ether and amputated the right fore-arm at the lower third, and the left arm at the upper third, by the circular method. Cold-water dressings were applied. The patient did well, and on December 31st the stumps had nearly healed. The wound of chest remained open, but was doing well. This man was discharged the service June 29, 1867, for loss of both arms.

DXXIV.—Remarks on a Primary Amputation of the Arm. By W. H. SMITH, M. D., Acting Assistant Surgeon.

Private Patrick Daley, Troop B, 8th Cavalry, aged 24 years, was wounded by Indians while guarding a train, May 6, 1869. The ball entered the left arm from the outside, shattered the humerus from the elbow-joint two-thirds its length upward, and imbedded itself among the fragments. On the same day he was admitted to the post hospital, Camp Verde, Arizona Territory. He rallied from the shock, his pulse was full and soft, and his spirits good. Toward the next morning he became feverish. He preferred amputation to any attempt to save the arm. At 10 o'clock A. M., on the 7th, his arm being considerably swollen and inflamed, chloroform was administered, and it was amputated at the lower border of the upper third of humerus. The brachial artery and the muscular branch were ligated. The flaps were shaped so as best to suit the wounds, and were bathed with cold water for an hour before bringing them together, and securing them with four sutures and adhesive plaster. Nourishing diet, stimulants, tonics, &c., were prescribed, and the case progressed excellently, throughout. Cold-water dressings and poultices were applied as required by the condition of the wound. The ligatures came away on the 18th of May, from the muscular branch, and on the 27th from the brachial artery. The pains felt as if in the lost arm, the nerves having been severed above the level of the end of the bone. He seemed to gain flesh during treatment, and on June 9th, he was seen playing ball outside with the remaining hand. Stump excellent. This man was discharged the service October 5, 1869, for loss of fore-arm.

DXXV.—Report of an Amputation of the Arm and Fore-Arm for Gunshot Injury. By S. M. HORTON, Assistant Surgeon, U. S. A.

Private William Denney, Battery G, 5th Artillery, aged 23 years, while firing a salute on May 2, 1870, was wounded by the premature explosion of a blank cartridge from a twelve-pounder cannon, which shot away and totally destroyed the right hand, leaving a lacerated stump, comminuted the right humerus, involving nearly the entire lower third, and produced a deep flesh wound of right arm in upper part of middle third, involving a portion of the biceps muscle; the left hand and wrist were shattered to pieces, and were hanging to the fore-arm by a few shreds of skin, tendon, and cellular tissue; the lower portion of his face and front portion of the neck were badly scorched by powder. The same day ether and chloroform were administered, and the right arm was amputated in the upper third, near the shoulder. Lateral flaps were made which were retained in apposition by five interrupted sutures and adhesive strips. Dry dressings, except lint, three-fourths inch wide, wrung out of warm water, were applied along the union or junction of flaps. I also amputated the left fore-arm in lower third, making antero-posterior flaps, which were retained in apposition by three interrupted sutures and adhesive strips. Dry dressings, except lint three-fourths inch wide, wrung

out of warm water, were applied along junction of flaps. During the operation, hæmorrhage was controlled by compression with the thumb and fingers of an assistant; on the right side upon the axillary, and on the left side upon the brachial arteries. The patient was very healthy and robust, of cheerful disposition, and bore the loss of his hands and arm with fortitude and patience. After entire reaction from the shock, the constitutional excitement, feverishness, thirst, &c., lasted for three days. He suffered from obstinate constipation and retention of urine, for which cathartics, diuretics, enemata, and hot poultices to abdomen were prescribed. After the first four days' use of the catheter, all retention of urine ceased. He made rapid progress in recovery, the flaps uniting by first intention, or without granulating, except along the tracks of the ligatures, and one point on the upper side of the right stump. The treatment consisted principally of compresses, adhesive straps, supports to the flaps, a saturated solution of carbolic acid and glycerine applied every two or three hours to the edges of the flaps, and creasote used freely on the dressings. *No cold-water dressings* were used at any time. At the end of the first week he was sitting in a chair. On the eighth day after the accident the flaps of the left fore-arm had sufficiently united to allow removal of compress and adhesive straps, and substitution of lint and sweet oil, which was loosely applied to extremity of stump. By the twentieth day, the flaps of right stump were firmly united, except track of ligature on brachial artery, on which day that ligature came away. On the twenty-fourth day the patient walked around out of doors. On June 1st a small boil was opened in right axilla. June 3d, boil entirely healed up, and subsequently did not trouble him. Stimulating and nourishing diet was used. The face and neck have entirely healed without blemish. The stumps are firm with good cushions for artificial limbs, for which application will be made. This man was discharged the service December 14, 1870, on account of loss of both arms.

DXXVI.—*Account of an Amputation of the Arm for Necrosis.* By A. C. GIRARD, Assistant Surgeon, U. S. A.

Private Patrick Ford, Co. G, 19th Infantry, aged 31 years, suffered for eight months from necrosis of radius and ulna of the right arm. There was no attempt at new formation of bone; sequestræ not movable. He was admitted to the post hospital at Baton Rouge, Louisiana, on November 13, 1869. Counter irritants were applied, and alteratives and tonics administered. Scrofula was the source of the disease. On February 8th, with the advice and assistance of E. A. Koerper, Assistant Surgeon, U. S. A., and Dr. W. Reynaud, of Baton Rouge, I attempted exsection of sequestræ by trepanation. I found, however, extensive destruction of both bones, with no attempt at formation of callus. The metaphysis of radius was almost entirely destroyed. The patient commencing to be reduced by pain and suppuration, and amputation above the elbow having been decided on, he was chloroformed, and the limb was amputated by the circular method. Three vessels were ligated, and the wound was closed with the interrupted suture. The patient made a rapid recovery in two weeks, and his general health improved wonderfully. He was discharged the service March 19, 1870.

DXXVII.—*Note on an Amputation of the Arm for Gunshot Injury.* By W. R. RAMSEY, Assistant Surgeon, U. S. A.

Henry Happe, Troop G, 2d Cavalry, was shot in the left arm while on escort duty with Wells, Fargo & Co.'s stage, August 10, 1867. He was conveyed to Fort Sanders, Dakota Territory, where, September 11, 1867, the arm was amputated at the upper third by the flap method. He was discharged on November 1, 1867. On the 20th of November, 1868, he was examined for artificial limb, at which time the stump was in a sound condition. The man is a pensioner at \$15 per month.

DXXVIII.—*Report of an Amputation of the Arm for Gunshot Injury.* By T. ST. V. HUTCHINSON, M. D., Acting Assistant Surgeon.

Private Timothy Houlihan, Co. I, 2d Infantry, aged 29 years, was fired upon by a patrol near the camp of the 2d Infantry, May 27, 1869. The ball entered directly above the head of the

radius, destroyed the outer condyle of the humerus, chipped the coronoid process of the ulna, and splintered the radius down to the upper border of the pronator quadratus muscle. The whole internal structure of the arm, on the radial side, was torn and hanging from a large gaping wound on the anterior surface of the fore-arm. Nerves and vessels were cut and torn. On the same day he was admitted to the post hospital at Huntsville, Alabama, feeble from loss of blood and great pain; pulse about 80. Ether was at once administered, and the arm was amputated at the lower third by the double-flap method. The hæmorrhage was about three ounces. Three ligatures were used. The wound was allowed to glaze before closing the flaps with interrupted sutures. Cerate dressing and a solution of carbolic acid were applied. Reaction was moderate and not delayed. The sutures were removed on the third day. The edges of the wound had united, and had to be opened to give free egress to pus. The patient had no appetite for several days, but it was restored by iron and quinine, and the case progressed favorably. The ligatures came away on the eleventh and thirteenth days. There was strong disposition of the edges of the wound to close, and it was with difficulty that they were kept so as to allow a free discharge. On the 15th of June, the patient was up and about, and on June 30th the wound had closed, with the exception of a small point, at one corner, which had ceased discharging, and was about to heal. The patient was in excellent health. He was returned to duty July 18, 1869.

DXXIX.—*Report of a Primary Amputation of the Arm for Gunshot Injury.* By S. T. WEIRICK, M. D., Acting Assistant Surgeon.

Private William Jackson, Co. E, 16th Infantry, aged 24 years, at Macon, Georgia, June 19, 1868, while firing a salute was wounded, by the premature discharge of a cannon, which blew off his right arm. The right hand and fore-arm were completely gone, and the parts badly contused and burned. On the same day he was admitted to the hospital of the post, and W. F. Bowes, Acting Assistant Surgeon, amputated the arm at the upper third of the humerus, by the circular method. On June 30th the case was progressing favorably. The patient was transferred to hospital at Atlanta, Georgia, August 6th, and was discharged the service October 22, 1869, for loss of right arm.

DXXX.—*Account of an Amputation of the Arm and Fore-Arm.* By W. J. PIPER, M. D., Acting Assistant Surgeon.

Private William Jones, Co. A, 20th Infantry, aged 21 years, while firing a salute February 22, 1868, at Baton Rouge, Louisiana, was wounded by the premature explosion of the charge. The left hand was blown away, the radius and ulna, and the humerus at the middle fractured, and the soft parts contused. The right fore-arm was comminuted above the carpus, and was attached only by a few tendons. The lower maxilla was fractured on both sides anterior to the angle, and the anterior portion of the chest and abdomen burned. He was at once admitted to the post hospital, and one hour after the injury William Thomson, Assistant Surgeon, U. S. A., administered ether and chloroform, with embarrassment on account of oppressed and difficult respiration from displacement of the lower maxilla and bleeding in the mouth, and amputated the left arm at the middle, and the right fore-arm at the lower third, by the double flap method. The patient rallied after the operation, and took liquid food, stimulants, &c. Respiration was sibilant and labored from obstructions at the glottis. He died February 25, 1868, at 7 P. M., from exhaustion, having been very restless and slightly delirious for twenty-four hours. At the *post-mortem* nothing worth mentioning was found. The seats of fracture of the lower maxilla were examined, and the soft parts found infiltrated with blood, with lacerations extending into the buccal cavity.

DXXXI.—*Account of an Amputation of the Arm for Gunshot Injury.* By B. J. D. IRWIN, Surgeon, U. S. A.

First Lieutenant Ransom Kennicott, Co. F, 19th Infantry, aged 28 years, was accidentally wounded, while handling his gun, by a charge of small bird shot, which passed through the left

arm, completely shattering the humerus and tearing the soft structures. Dr. F. Halliday, on November 3, 1866, near Lawrence, Kansas, amputated the arm; internal and external flaps, and four ligatures were applied. On November 11th he was admitted to the post hospital at Fort Leavenworth, Kansas. The wound was without dressing, the flaps everted and insufficient, and the bone protruding. I immediately administered chloroform, and excised one inch of bone, revived the flaps, and applied iron wire sutures. The patient reacted well, and on November 28, 1866, when he left on a leave of absence, his wound was entirely healed up, with the exception of a small space where the principal ligature protruded. This officer was retired November 5, 1868.

DXXXII.—Report of an Amputation of the Arm for Railway Injury. By W. H. RENICK, M. D., Acting Assistant Surgeon.

Private David Linton, Co. B, 7th Cavalry, was run over by railroad cars at or near Willow Springs, Colorado Territory, on the night of August 1, 1870. The wheels passed obliquely across the right arm, completely destroying the elbow-joint. Both bones of the fore-arm were crushed, and a longitudinal fracture extended up the shaft of the humerus, almost to the junction of the upper thirds. One hour after the injury, the patient being chloroformed, the arm was amputated at the junction of the upper thirds, by the circular operation. Cold-water dressings were applied, and occasionally a solution of permanganate of potash. On August 12th the sutures were removed, the patient was allowed the limits of the camp, and on August 17th, he was taken to Fort Lyon. On October 30th, he was sent to the hospital at Fort Leavenworth, Kansas, at which date one ligature yet remained in the stump; his general health was good. He was discharged the service on December 7, 1870.

DXXXIII.—Remarks on a Primary Amputation of the Arm for Gunshot Injury. By W. B. LYON, M. D., Acting Assistant Surgeon.

William McDermith, a gold miner, aged 32 years, on the evening of December 6th, 1870, carelessly grasped the muzzle of a shot-gun, which discharged a large load of number-three shot into his left fore-arm. The charge entered the anterior aspect, four inches above the wrist-joint, severed the belly of the flexor carpi-ulnaris, ranged upward along the course of the ulnar artery, and produced a comminuted fracture of the condyles of the humerus, opening the elbow-joint, and an oblique fracture of the shaft. The soft tissues of the upper fore-arm and lower fourth of the arm, especially on the ulnar side, were so completely disorganized as to be almost unrecognizable. The ulnar artery and nerve were entirely destroyed, and the radial artery was severed near its source. A few shot escaped through a small exit-wound posteriorly, one inch and a half above the upper extremity of the ulna, and three separate exit-wounds from single shot were found three inches above. Copious hæmorrhage occurred immediately after receiving the wound, spontaneously subsiding on the patient's assuming a recumbent position. He was admitted to the hospital at Fort McRae, New Mexico, where, seventeen hours after the reception of the wound, he was chloroformed, and the arm was amputated through the middle third by the circular operation. The stump was dressed with a weak solution of carbolic acid. The wound united mainly by first intention, and progressed favorably throughout. The pathological specimen, with the history, was contributed to the Army Medical Museum, and is numbered 5758 of the Surgical Section.

DXXXIV.—Remarks on an Amputation of the Arm. By J. C. BAILY, Surgeon, U. S. A.

Private Peter McIntyre, Co. K, 23d Infantry, aged 35 years, was wounded while on provost guard duty in San Francisco, California, on October 1, 1870, by a conoidal musket ball, which was fired by a burglar at the distance of a few feet, and which entered the arm anteriorly, two inches above the elbow-joint, fracturing the humerus, and implicating the joint, but left the vessels uninjured. He remained in the city with but little attention until the afternoon of the 3d, when he was sent to the post hospital at the Presidio. On the next day, the patient being feverish and the arm

swollen, inflamed, and very painful, it was decided to operate. The patient having been rendered insensible with chloroform, Assistant Surgeon Edwin Bentley, U. S. A., amputated the arm in the upper third by the antero-posterior-flap operation. There was considerable hæmorrhage; eight ligatures were applied. The patient recovered well from the influence of the anæsthetic. The stump was dressed with a single layer of lint saturated with glycerine and carbolic acid. The wound progressed favorably. On December 31, 1870, the patient remained in hospital, the stump not being yet in a condition to adapt an artificial limb. At this date, there was an occasional discharge of pus, with limited necrosis, which, however, had never been serious, and was improving.

DXXXV.—*Report of an Amputation of the Arm for Gunshot Injury.* By C. CAUGHILL, M. D., Acting Assistant Surgeon.

James Parker, Co. G, 28th Infantry, aged 32 years, was wounded October 10, 1868, at Camden, Arkansas, while in the act of escaping from the guard, by a conoidal ball, which entered the right fore-arm one and a half inches below the elbow-joint, on the anterior surface, comminuted the radius and ulna, ruptured the ulnar, radial, and interosseous arteries, and emerged in a slightly oblique direction upon the opposite side. At 8 o'clock P. M., on the same day, fifteen minutes after the receipt of the wound, he was admitted into the post hospital, having lost a large quantity of blood previous to admission. The wound was very large and jagged, and the muscles very much lacerated. The large number of loose fragments of bone which were removed, necessarily left the fractured ends very widely separated. Stimulants were given freely until reaction was established, and an opiate was given to quiet pain and produce sleep. The next morning, at six o'clock, the parts being immensely swollen, chloroform was administered, and the arm amputated just above the elbow by the circular method. Stimulants, in combination with strong beef tea, were given every hour. The patient died fifteen hours after the operation—evidently from the effect of the loss of blood sustained previous to his admission to the hospital. The ulna and radius were examined after death. Two inches or more from each bone was found missing, and the shafts of both were split.

DXXXVI.—*Remarks on an Amputation of the Arm for Gunshot Injury.* By F. MEACHAM, Assistant Surgeon, U. S. A.

Hospital Steward Lucius O'Brien, United States Army, aged 23 years, was admitted to hospital at Camp Douglas, Utah Territory, on July 5, 1868, having been accidentally shot through the left arm just above the bend of the elbow. The artery was severed an inch and a half above the bifurcation, the lower end of the humerus was extensively comminuted, and the soft parts, about two inches in diameter, on the back of the arm, were completely carried away. The patient had lost considerable blood. Amputation having been decided on, the patient was chloroformed, and the circular operation was done at the lower third about two hours after the accident. The patient was then placed in bed, being allowed tea and a farinaceous diet. Simple cold-water dressings were applied. On the 6th he was doing well, the same treatment being continued. On the 8th there was considerable fever, with scanty urine; the wound looked well, and suppuration was established. The sutures were removed; beef tea was administered as an additional article of diet, and fifteen-grain doses of acetate of potash were administered every four hours, with an anodyne at night. The symptoms of febrile disturbance having disappeared on the following day, the potash was discontinued, and two-grain doses of quinine and iron were substituted. Two of the ligatures were removed on August 1st; the tonic was discontinued, and full diet allowed. On August 24th the last ligature was removed. One day later he was returned to duty, the stump having entirely healed.*

DXXXVII.—*Remarks on an Amputation of the Arm for an Injury.* By W. H. LONGWILL, M. D., Acting Assistant Surgeon.

Private Dionicio Ramires, Troop F, 1st New Mexico Cavalry, was admitted to hospital at Fort Wingate, New Mexico, on May 18, 1866, with asthma, and at the same time suffering from an

* In January, 1869, O'Brien was shot through the heart. See Report CVIII, p. 36.

injury of the left wrist-joint, caused by a log falling upon it. Tincture of iodine was applied to the wrist, and a lotion of lead water and laudanum kept upon the parts. This failing to reduce the inflammation, a poultice of linseed was applied, and openings were made for the exit of pus. Tonics and a generous diet were prescribed; but the patient being of a scrofulous habit, the inflammation extended to the elbow, and pus having formed in the joint, together with bad tendency of the injury to the wrist, it was deemed best to amputate at the lower third of the humerus, which was done on August 13th. Dry dressings were applied, and the stump healed kindly, but the asthma still continued, and the patient subsequently suffered from abscess of the thyroid gland, which, after being opened, continued to discharge until September 1, 1866, when it closed up. On December 23d, another abscess formed in the thyroid gland, leaving an opening in the cirroid cartilage, through which expiration and inspiration took place, and the patient expectorated a great deal of pus. He gradually sank until December 27th, at 3 P. M., when he expired. A *post-mortem* examination, sixteen hours afterward, revealed an abscess in the thyroid gland containing about two ounces of pus; the apices of both lungs were filled with tubercle; the right pleura was adherent around the entire lung, and the heart was hypertrophied.

DXXXVIII.—*Report of an Amputation of the Arm for Gunshot Injury.* By J. F. BOUGHTER, M. D., Acting Assistant Surgeon, U. S. A.

Edward Randall, a trapper, aged 61 years, was accidentally shot in the right arm at Flandreau, on the Big Sioux River, on October 20, 1868. He started alone with a two-horse team, and without assistance reached Fort Dakota, Dakota Territory, on the evening of the 23d, much exhausted, but pulse good. Stimulants were administered and the patient was put to bed, when upon examination of the wound it was found that a round musket ball, weighing an ounce, had entered the middle third of the fore-arm anteriorly, and, having passed obliquely upward and outward, had lodged against the lower extremity of the humerus, producing an extensive comminuted fracture which extended into the elbow-joint and some distance up the shaft. The arm from the hand to the shoulder was much swollen. There were incipient symptoms of traumatic gangrene; blebs, containing dark-colored fluid, covered the hand and fore-arm, a few being scattered on the arm and scapular region; a dark, yellowish blush extended to the shoulder-joint; and the muscles were much infiltrated. It was determined to operate immediately, and, at 1 o'clock the same night, the arm was amputated in the upper third, by the lateral flap operation. The flaps were much infiltrated, and had an unhealthy appearance. Three ligatures were applied, the stump was dressed with cold-water dressings, and an anodyne was administered, and repeated in an hour. The patient rested well, and the next morning breakfasted on light and stimulating diet. A few drops of chlorinated soda were added to the cold-water dressings. He slept well during the next night without an anodyne. The following morning, his bowels not having moved since the injury, cathartics were given. The stump, by this time, was much swollen, and was discharging a bloody serum; the shoulder was also swollen, blush extending over region of scapula. His appetite continued good. On the 27th, one suture was removed. The edges of incision appeared to be healing too rapidly, preventing discharge of pus; a poultice was applied. On the 28th, the remaining sutures were removed, and the stump was dressed with straps and bandages. On the 29th the patient complained of spasmodic twitching of muscles of stump with pain while dozing. On November 1st, the ligatures came away, and the swelling of stump and shoulder was nearly gone. From this time he improved rapidly. On the 17th healthy granulations having sprung up in two places of incision, nitrate of silver was applied; and on December 7th, the stump being entirely healed, excepting a slight sinus at anterior edge of incision, the application was repeated, a small tent was inserted, and the edges brought together with small adhesive straps. On December 14th the arm was entirely healed; it was bandaged, and a pad placed in axilla. On the 15th he left for his home in Canada, which he reached safely on January 6, 1869. At this date, and during the treatment, he complained of some numbness in the arm. His pulse had varied according to the comfort of the stump, it having fallen after dressing on the fourth day, from eighty to sixty-four. The operator says in his report of the case, that "the patient's age, his being over three days without any assistance (being obliged to take care

of his own horse and cook his own food during that period), and the very unfavorable condition of his arm, was very much against his recovery. The difficulty of detecting the extent of the fracture on account of the swollen condition of the arm, and the unhealthy appearance of his shoulder at one time, almost induced me to amputate at the shoulder-joint; and after amputating when I did, I was fearful of the invasion of gangrene. He made a slow but good recovery. Perhaps more of his arm might have been saved, as subsequent dissection showed that the fracture did not extend as high as was suspected. If it had been taken off lower down, I think extensive sloughing would have occurred."

DXXXIX.—Report of an Amputation of the Arm. By T. F. AZPELL, Assistant Surgeon, U. S. A.

Private Ellis B. Robinson, general-service recruit, aged 26 years, was wounded by the premature discharge of a brass cannon at David's Island, New York Harbor, on June 6, 1868, while acting as number one in firing a salute. He was admitted to the post hospital, when, it being found that the right humerus, radius and ulna, and wrist-joint were fractured, and that there was much contusion, with evident laceration of the vessels, he was at once rendered insensible with two parts ether and one chloroform, and the arm was amputated about four inches above the elbow-joint by "the three-quarter lateral flap operation, it being thought advisable not to make the flaps entirely lateral, in order to avoid contused tissue, and give a greater length of stump." Simple dressings were applied. The excessive pain continuing after the operation, an anodyne was given. A nutritious but non-stimulating diet was ordered. The pain did not cease until the next morning, preventing sleep. On June 8th, the bowels not having moved since the injury, an injection was given. On the 9th, the bandages and lint were removed for the first time, and cold-water dressings were applied. About two inches of the posterior portion of the incision had united by first intention; considerable sloughing had commenced on the anterior portion of the flaps, and the severe injury to the skin was evident from the sphacelated appearance of the stump and the discoloration extending to the axilla and chest. Milk punch was now added to his diet. On the 10th, the stump was washed with a diluted solution of chlorinated soda; and on the 11th, the silk sutures apparently increasing the tendency to slough, silver wire was substituted. On the 12th, most of the slough came away on the dressing, showing a healthy granulating surface. On July 1st, the ligature was removed, and nitrate of silver was daily applied, to exuberant granulations, until July 30th, when the stump had entirely healed, with ample covering to the bone. "The sloughing, in this case, appeared to be very materially diminished, and almost suspended, by the use of the chlorinated mixture and wire suture—so much so, that the improvement in the condition of the stump seemed evident in the course of twenty-four hours." In August, 1868, the patient was transferred to another command.

DXL.—Report on an Amputation of the Arm and Fore-Arm. By W. MATTHEWS, M. D., Acting Assistant Surgeon.

Private Jacob Schubach, Co. F, 22d Infantry, while firing a salute, July 4, 1870, at Fort Stevenson, Dakota Territory, was wounded by the premature explosion of the cartridge he was ramming down at the time. The right fore-arm was torn off, and the remainder of the limb was scorched and lacerated in the severest manner up to the axilla. A portion of the left hand was also torn away, and the remainder burned to the wrist. The right side of the face, the right eye, and the entire chest were also badly scorched. On being taken to the hospital and chloroformed, the arm was amputated in the upper third, very close to the shoulder. There was great difficulty in finding sufficient sound flesh to make a stump, and a portion of the scorched tissue in the axilla had to be included in one of the flaps. The left fore-arm was amputated above the wrist. In the right arm suppuration did not commence until after the fifth day, when carbolic-acid lotion was applied, a small portion of the axillary flap having become mortified before that time. The operation was followed by great prostration, and the patient's condition, for seven or eight days, was very doubtful. July 31: He was able to walk around, and in excellent spirits, and the stumps were healing finely. On August 13, 1870, he was transferred to Fort Sully, Dakota Territory, perfectly able to stand the journey.

DXLI.—*Note relative to an Amputation of the Arm.* By C. BACON, JR., Assistant Surgeon, U. S. A.

Private Jean Shields, Troop D, 6th Cavalry, aged 22 years, was admitted into the post hospital at Jacksboro, Texas, December 13, 1866, amputation of the left arm having been performed at the middle third, on account of injury, at Sherman, Texas, October 15, 1866. He was returned to duty January 17, 1867.

DXLII.—*Remarks on a Primary Amputation of the Arm for Gunshot Injury.* By P. MIDDLETON, Assistant Surgeon, U. S. A.

An Indian girl, aged 15 years, received, September 11, 1868, near Dickenson's Rancho, Arizona Territory, a gunshot wound of the right arm. The lower part of the humerus was shattered, and the elbow-joint opened. On the same day, in the field, Private George W. Miller, Company A, 8th Cavalry, acting hospital steward, without administering an anæsthetic, amputated the humerus at the lower third, by the anterior-posterior-flap method. Four ligatures were applied. On the next day, she was brought as a prisoner of war to the post hospital, Camp Whipple, Arizona Territory. Cold-water dressings were applied, and the patient did well. On September 29th, she was convalescent. On the 30th, at midnight, two Indians approached the hospital, and recaptured the prisoner.

DXLIII.—*Note relative to a Primary Amputation of the Arm for Gunshot Injury.* By T. H. TURNER, Assistant Surgeon, U. S. A.

Private George Washington, Troop I, 10th Cavalry, received, January 20, 1869, a gunshot comminuted fracture of the left elbow-joint. He was immediately admitted to the post hospital, Fort Wallace, Kansas, and, on the same day, Assistant Surgeon J. A. Fitzgerald, United States Army, amputated the left arm at the lower third of the humerus. The patient was depressed at the time of the operation. Progress was good until the third week, when he commenced sinking, death supervening on the 8th of February, 1869.

DXLIV.—*Note relative to an Amputation of the Arm.* By T. CUNYNGHAME, M. D., Acting Assistant Surgeon.

Private David White, Co. G, 41st Infantry, aged 23 years, was wounded September 6, 1867, by the accidental discharge of a rifle. The missile, a conoidal ball, caused a compound complicated and comminuted fracture of radius, ulna, and humerus of one arm. He was at once admitted to the post hospital at Ringgold Barracks, Texas, the whole of the elbow-joint being extensively pulpified and lacerated. Patient was suffering with intermittent fever at time of injury. Amputation at middle third of arm was performed September 6, 1867. Death resulted September 9, 1867, from nervous shock.

Amputations at the Shoulder-joint.—Of the four special cases reported one proved fatal. Three were due to gunshot wounds; one to railway accident.

DXLV.—*Report of a Successful Case of Primary Amputation at the Shoulder-Joint for Gunshot Injury.*—By D. L. HUNTINGTON, Assistant Surgeon, U. S. A.

Manuel Chavez, a Mexican, aged 24 years, was wounded near Fort Cummings, New Mexico, on July 3, 1868, by the accidental discharge of an old Springfield musket, while drawing it out of a wagon. The ball entered near the internal edge of the brachialis anticus muscle, about four inches below the head of humerus, fractured the bone badly, and, passing out near the posterior edge of the deltoid, injured the brachial artery and severed the nerve. On July 4th, after riding forty-five miles without water, he was admitted to the hospital at Fort Bayard, New Mexico, the wound being in a high state of inflammation. Morphine was given, and after three hours' rest the patient was rendered insensible with one part chloroform and four parts ether, and the arm was amputated at the shoulder-joint, with a deltoid and inner flap. Little or no blood was lost, and

the patient rallied well from the effects of the anæsthetic. Sedatives were given at bedtime. On July 6th, he had been very restless during the previous night, his skin was dry and hot, the pulse one hundred and ten and feeble, and respiration twenty-eight; there was an offensive sanious discharge from the wound, and great pain. Stimulants and tonics were given, and the wound was washed with a lotion of carbolic acid and water. This treatment (with an injection on the 8th, which caused a good fecal discharge) was continued with great improvement in the condition of the patient; and, on the 12th, three small ligatures came away, leaving only the brachial, and the wound was rapidly closing. On the 18th, the ligature of the brachial came away, and from that time he steadily improved. By August 1st, the cicatrix was complete and firm, and a good stump had formed. He remained in hospital until near the middle of August, when he was sent home. On examination of the humerus after disarticulation, it was found shattered into fragments, with fissures running down the shaft and upward into the cancellated structure of the head of bone.

DXLVI.—Report of a Successful Secondary Amputation at the Shoulder-Joint for Gunshot Injury.
By CHARLES SMART, Assistant Surgeon, U. S. A.

Private James B. Farrington, Co. K, 32d Infantry, aged 36 years, was accidentally wounded April 27, 1867, by the discharge of a fowling piece, six revolver bullets entering the left arm and shoulder, posteriorly fracturing the left humerus and scapula, and severely injuring the soft parts. He was admitted to the post hospital, at Camp Lowell, Arizona Territory, on the same day. The patient became exhausted from excessive suppuration of wound, and the limb entirely useless on account of injury to nerves. On August 27, 1867, an excessive hæmorrhage, supposed to be from the axillary artery, occurred. Several unsuccessful attempts having been made to secure this artery, and taking into consideration the uselessness of the arm, it was decided to amputate at the shoulder-joint, which was accordingly done, after rendering the patient insensible with chloroform. Water dressings, nourishing diet, and stimulants were used. He was returned to duty March 10, 1868.

DXLVII.—Primary Amputation at the Shoulder-Joint for Gunshot Injury, having a Fatal Termination.
By — OWENS, M. D.

John Collins, Co. I, 17th Infantry, was admitted to the hospital at Camp Schofield, Lynchburg, Virginia, about two o'clock on the morning of September 11, 1869, with a gunshot comminuted fracture of the upper third of the right humerus. It is believed that the gun was loaded with ball and buckshot or slugs, as fully one-third of the upper portion of the bone was shattered to its head and the integuments for more than that distance were severely torn, although, strange to say, the main artery was untouched. He had lost a great amount of blood; and this, together with the shock to his nervous system, precluded operative interference until reaction. The patient reacted very slowly; and, at five o'clock in the evening, deeming it inadvisable to wait any longer, I, upon invitation, amputated at the shoulder-joint, by flap operation, with neatness and dispatch. The patient lost but little blood; but, some hours after, his pulse began to fail rapidly, death supervening at half past six o'clock the next morning, thirty hours after being shot. The case is reported by the operator.

DXLVIII.—Report of a Successful Primary Amputation at the Shoulder-Joint for Railway Injury.
By W. F. BUCHANAN, Assistant Surgeon, U. S. A.

Private Alexander Terry, Co. E, 38th Infantry, met with a severe railway injury on the Union Pacific Road, a short distance from Fort Hays, Kansas, for which he was admitted to the hospital, on October 16, 1868. There was a compound comminuted fracture of the left arm, the bone being extensively comminuted with both extremities fractured longitudinally. The soft parts were much lacerated, the little finger was torn off the left hand, and the patient suffered much from the shock of injury. Being comfortably arranged in bed, and precautions having been taken to prevent hæmorrhage during the night, an anodyne was administered, and the patient slept well. On the 17th

he was anæsthetized, when a further examination of the injury led to the conclusion that a prompt removal at the articulation was the best and only chance of saving life. As the subclavian could not be properly compressed, owing to a full development of the chest and shoulders, and the absence of proper assistance, a tourniquet was applied over the axillary artery and retained in situ by an assistant, the screw being placed over the superior border of the scapula and retained in position by a tape passed around the chest. An incision, begun immediately below the acromion process, was carried down through the belly of the deltoid muscle, about three inches; then, making a curve around the external extremity of the humerus to the axilla, a similar flap was made on the inner side, and the bone was disarticulated. The axillary artery was ligated, and after the cessation of a little venous oozing, the flaps were brought together by interrupted sutures and adhesive strips, not more than an ounce of blood having been lost during the operation. The patient reacted promptly, when a stimulant, followed by an anodyne, was administered, and cold-water dressings were applied. He slept well, and on the 18th his condition was fair. The remaining treatment in this case was chiefly expectant. By December 31st the patient had entirely recovered with a good round shoulder. He was discharged April 9, 1867. The specimen, with the history, was contributed to the Army Medical Museum, by the operator, and is No. 5595, Surgical Section.

AMPUTATION IN THE LOWER EXTREMITIES—

Amputations of the Toes.—Special reports of twenty-two cases of this nature were received. Eighteen were due to frost-bites; four to injuries.

Name.	Rank.	Co.	Regiment.	Nature of injury.	Parts removed.	Remark.
Barrago, John.....	Civilian			Frost-bite.....	Second phalanx of right great toe, and outer third of second phalanx of left great toe.	Discharged from hospital April 4, 1868.
Barry, David.....	Private....	B.	7th Cavalry.....	Frost-bite.....	Great toe and first phalanx of second toe of left foot, and first phalanx of great toe of right foot.	Discharged June 22, 1868.
Bell, John.....	Private....	K.	10th Cavalry....	Frost-bite.....	Left great toe at metatarso-phalangeal articulation.	Returned to duty February 25, 1868.
Bovel, John.....	Corporal ..	E.	13th Infantry ...	Frost-bite.....	All the toes of the right foot in the continuity of the metatarso-phalangeal articulation.	Discharged June 19, 1868.
Brown, Samuel.....	Private....	K.	10th Cavalry....	Frost-bite.....	Right great toe and head of metatarsal bone.	Returned to duty March 16, 1869.
Connell, Patrick.....	Private....	D.	20th Infantry....	Frost-bite.....	Great toe and head of first metatarsal bone of left foot, and balance of toes at metatarso-phalangeal articulation.	Transferred to the Soldiers' Home, Washington, D. C., October 8, 1870.
Fisher, John.....	Private....	I.	5th Artillery....	Unknown.....	Second toe of each foot.....	Discharged January 4, 1869.
Gardiner, James A....	Private....	E.	2d Artillery....	Frost-bite.....	Toes at metatarso-phalangeal articulation.	Discharged April 4, 1868.
Gay, Thomas.....	Private....	B.	8th Cavalry.....	Gunshot wound..	Second toe of left foot at metatarso-phalangeal articulation.	Returned to duty April 3, 1868.
Gibben, James.....	Private....	K.	6th Infantry....	Frost-bite.....	Second phalanx of right great toe; also, both thumbs at second phalangeal joints, second and third phalanges of index and middle fingers, and third phalanx of ring finger of right hand, and second and third phalanges of first, second, and ring fingers, and fourth finger at metacarpo-phalangeal joint.	Inmate of the Soldiers' Home, at Dayton, Ohio.
Honig, Charles.....	Private....	C.	13th Infantry....	Frost-bite.....	All the toes of left foot.....	Discharged August 17, 1867.
Hughes, Edward.....	Private....	B.	18th Infantry....	Frost-bite.....	Great toe of right foot in middle of first phalanx, and great toe of left foot at metatarso-phalangeal articulation.	Discharged October 7, 1867.

Name.	Rank.	No.	Regiment.	Nature of injury.	Parts removed.	Remarks.
Jackson, Nicholas B.	Discharg'd soldier.	Frost-bite.....	All the toes of right foot and three toes of left foot through metatarso-phalangeal articulation.	Discharged from hospital March 6, 1871.
Keegan, John	Private....	B.	1st Cavalry	Frost-bite.....	Second and third phalanges of little toe of left foot.	Returned to duty in May, 1868.
McDonald, John	Private....	K.	23d Infantry....	Frost-bite.....	Last phalanx of great toe.....	Returned to duty in April, 1868.
McKee, Alexander....	Private....	D.	33d Infantry....	Incised wound...	Little toe	Returned to duty March 24, 1868.
Murphy, Michael.....	Private....	E.	14th Infantry...	Frost-bite.....	All the toes of both feet and the ends of the metatarsal bones of the right foot.	Returned to duty June 12, 1871.
Nohrton, John	Scout.....	Frost-bite.....	Little toe of the right foot	Returned to duty April 30, 1870.
O'Connor, John	Corporal ..	K.	23d Infantry....	Frost-bite.....	Right great toe and first joint...	Returned to duty in April, 1868.
Phenix, James	Private....	K.	2d Cavalry.....	Frost-bite.....	All toes of both feet	Discharged from service August 11, 1868.
Shanley, Barney	Sergeant ..	F.	1st Artillery....	Lacerated wound	First phalanx of right great toe.	Returned to duty in August, 1866.
Washington, George ..	Private....	H.	10th Cavalry....	Frost-bite.....	Terminal phalanx of left great toe.	Returned to duty March 28, 1868.

Amputations of the Foot.—Six special cases were reported. Three were due to frost-bites, two to gunshot injuries, and one to dislocation.

DXLIX.—Account of a Case in which a Double Operation was Performed on the Feet. By H. S. SCHELL, Assistant Surgeon, U. S. A.

Private William Finn, Troop D, 2d Cavalry, aged 29 years, while on the march from Fort Laramie to Bridger's Ferry, North Platte River, March 26, 1867, was frost-bitten in both feet. He was admitted into the post hospital at Fort Laramie, Dakota Territory, on the same day, the whole of the right foot in front of the ankle-joint and all of the toes of the left foot except the last being gangrenous. On April 12th the patient was slightly feverish, the pulse was 90, and the lower part of right leg and foot had become swollen and congested; there was a distinct line of demarcation extending vertically around the foot, from a point about one-half inch in front of tibio-tarsal articulation, and the cuticle was detached from the plantar region. The left foot was puffy, and there was a line of demarcation a little posterior to commissures of toes. Chloroform was administered, and the right foot amputated by Pirogoff's operation in the manner described by Mr. Spencer Wells, and all the toes of the left foot just behind the heads of the metatarsal bones, dorsal and palmar flaps being made from without inwards. Three ligatures were applied to right foot and two to left. Hæmorrhage three or four ounces. The induction of the anæsthesia was difficult, requiring three-quarters of an hour, but was well borne when induced. Owing to the restlessness of the patient for the first twelve hours after the operation, there was considerable oozing of blood from the right foot, followed by inflammation. The stump and half the leg were wrapped in lint and kept constantly wet with lead-water and laudanum. By April 15th hæmorrhage had ceased. May 13th, both stumps had entirely healed; June 30, 1867, right leg had shortened about three-fourths of an inch. The patient was discharged September 1, 1867. His application for a pension was rejected.

DL.—Note relative to a Partial Amputation of the Foot. By P. MIDDLETON, Assistant Surgeon, U. S. A.

Private George M. Lockwood, Troop C, 3d Cavalry, aged 21 years, was wounded at Fort Whipple, Arizona Territory, May 5, 1870, by the accidental discharge of a Spencer carbine. The

ball at that range shattered the second metatarsal bone of the left foot. The patient was admitted to the hospital of the fort on the same day, and, on May 16th, chloroform was administered and the toe and second metatarsal bone amputated. There was but little hæmorrhage, and no ligatures were applied. At the time of the operation the soft parts near the wound were in a healthy condition. The patient reacted promptly from the anæsthetic, and no bad symptoms followed. On June 30th the patient was still under treatment, convalescent. He was discharged January 21, 1871.

DLI.—*Account of a Partial Amputation of the Foot.* By F. DAMOUR, M. D., Acting Assistant Surgeon.

Private Richard Melitz, Troop B, 1st Cavalry, aged 22 years, while en route to Camp McGarry, Nevada, was frost-bitten in both feet on the 20th of January, 1868. He arrived at his destination, and was admitted to the post hospital on the 25th. On the 31st, ether and chloroform were administered, and a flap amputation of the right foot performed through the second, third, fourth, and fifth metatarsal bones, and through the tarso-metatarsal articulation of the first. The parts amputated were gangrenous. The patient, at the time, was feverish, pulse 110, skin dry, secretion scant, bowels constipated, and appetite not very good. The glands of the right groin were swollen and inflamed; lithic acid was found in the urine. On the 17th of February, part of the left great toe having mortified, an anæsthetic was administered as above, and it was amputated through the first phalanx, with a favorable result. The sutures of the flap of the right foot gave way on account of the great destruction of integument above the amputation, and therefore the healing process was carried on by granulation. A large portion of the soft parts of the heel were also mortified, and sloughed off, exposing a large part of the os calcis. By the 31st of March, 1868, the stump had healed with good cushions. The ulcer in the heel had been filling up by granulation, but was not yet well. Discharged September 26, 1868. Pension, \$15.

DLII.—*Note on a Partial Amputation of the Foot.* By H. R. TILTON, Assistant Surgeon, U. S. A.

Private Frank Reip, Troop B, 7th Cavalry, aged 23 years, while marching from Pueblo to Fort Lyon, Colorado Territory, January 23 to 27, 1867, had his left foot frozen. He was taken to the post hospital at Fort Lyon, Colorado Territory. The injured parts were gangrenous. On February 19th, I administered an anæsthetic composed of chloroform and ether, and amputated the foot through the metatarsal bones. Simple dressings were applied. He recovered, and was discharged.

DLIII.—*Account of an Amputation of the Foot for a Compound Dislocation of the Ankle-Joint.* By W. A. TOMPKINS, M. D., Acting Assistant Surgeon.

Private Leopold Winkleman, Troop K, 7th Cavalry, while suffering from an attack of delirium tremens, leaped from a third story window of the building used as a hospital at Yorkville, South Carolina, falling a distance of about forty feet, and causing a compound, comminuted, complicated fracture of the internal malleolus, os calcis, and astragalus at the posterior part. The weather being extremely warm, and the patient debilitated from excessive debauchery, I decided to amputate as the only means of saving his life, which decision was concurred in by two medical gentlemen who assisted me in the operation. The patient at present is doing well, and will have a serviceable limb. The specimen forwarded to the Army Medical Museum, with the history, is numbered 5928 of the Surgical Section.

DLIV.—*Note Relative to an Amputation of the Foot for Gunshot Injury.* By J. W. WILLIAMS, Assistant Surgeon, U. S. A.

José Antonio Gonzales, a citizen, was wounded at Fort Dodge, Kansas, in July, 1865, by Indians. The ball entered anteriorly, passed backward and downward, carried away the cuboid part of the

os calcis, shattered the astragalus, and involved the joint to such an extent as to render amputation of the foot necessary, which was performed by J. G. Riddler, Assistant Surgeon, 5th U. S. V. The patient became very much reduced in consequence of diarrhœa, which was overcome by the use of turpentine and laudanum in emulsion, all other means failing. On July 31, 1865, the patient was doing well.

Amputations at the Ankle-Joint.—Of the four cases of this class, made subjects of special reports, one proved fatal.

DLV.—*Remarks on a Case of Frost-Bite in which both Feet were removed by Pirogoff's Method.* By JAMES F. WEEDS, Surgeon, U. S. A.

Daniel Ferns, formerly a private of Co. K, 7th Infantry, aged 45 years, started from Santa Fé, New Mexico, about the 15th of January, 1866, at midnight, for Fort Craig, in a state of intoxication, and carrying a canteen of whiskey with him. The night was very cold, the thermometer being below zero. After walking eighteen miles, he lost the road, and lay down, when both his feet were frozen. Being unable to bear transportation, he was treated in a private family at Algodones, New Mexico, twenty-five miles north of Albuquerque. The feet were found sphacelated, the line of demarcation on the right foot being a little above the scapho-cuneiform articulation, and the left at the astragalan-scapoid on the dorsum of the foot, and two lines in front of the calcaneum cuboid on the plantar surface. The parts about the right ankle were much swollen, inflamed, and infiltrated, and the vitality was very low. There was an ulcer over the external malleoli. The parts about the left ankle were but little swollen or inflamed. The patient's constitution was broken by many years of intemperance. The pulse was small and weak, and 120 per minute; surface covered with cold perspiration; bowels were loose, the evacuations being frequent and watery; and the appetite was poor, the patient having an intense desire for whiskey, and constantly calling for it. On January 27th, I amputated at the right ankle-joint by Pirogoff's operation; and, on the 31st, the same operation was performed on the left. The anæsthetic was chloroform one part and ether two parts. After the operations, the constitutional symptoms improved; the pulse fell to eighty-five, and had more volume and force; the cold perspiration ceased, and the appetite improved. The wounds on both feet partly closed by first intention. Inflammation and swelling about the left ankle greatly diminished. He continued to improve until February 10th, when mortification showed itself in both limbs without any previous increase of constitutional symptoms, and spread rapidly toward the body without forming any line of demarcation. From this time he sank rapidly. The treatment prescribed was cold-water dressings, the frequent and free administration of stimulants, nutritious animal diet, and anodynes to relieve pain and secure rest. These directions were not followed; the stimulants were irregularly administered, and the diet was poor and insufficient. To these causes the patient's death, which occurred on February 12, 1866, is attributed. *No post-mortem.*

DLVI.—*Memorandum relative to an Amputation of the Foot by Pirogoff's Method.* By J. E. SEMPLE, Assistant Surgeon, U. S. A.

H. G. Nims, additional paymaster, aged 25 years, was admitted to the post hospital, Fort Vancouver, Washington Territory, December 25, 1866, with a gunshot fracture and comminution of the external and middle cuneiform bones of the right foot, the ball having entered the lower third of tibia externally, passed down, and lodged in the foot. The parts were blackened and bleeding. His general condition was good, with the exception of being exceedingly nervous. On December 28th, ether was administered and the foot amputated at the ankle-joint, after the method of Pirogoff. Water dressings, and a solution of morphia at night, were applied. He recovered, and by the 1st of April, 1867, he had been returned to duty, but was mustered out July 1, 1867.

DLVII.—*Account of an Amputation of the Foot by Syme's Method.* By A. D. WILSON, Assistant Surgeon, U. S. A.

Private Peter Vandel, Co. A, 3d Infantry, aged 31 years, was accidentally wounded, while in quarters, November 5, 1867, by a conoidal musket ball, which entered just below the inner malle-

olus of the left foot, and, escaping beneath the outer malleolus, shattered the os calcis and injured the under surface of the astragalus. He was admitted to post hospital, Fort Dodge, Kansas, on the same day. The parts about the wound were much powder-burned. The patient was of slight frame, anæmic, and suffered considerably from shock of injury. I amputated by Syme's method; both wounds came in the line of the incision for the operation. The flap when put up showed a linear wound one and a quarter inches in extent, caused by wound of exit. A dressing of a weak solution of permanganate of potash was employed. The burnt parts along the wound of entrance sloughed. On November 9th, in attempting to remove a suture, a slight hæmorrhage occurred, which was checked by application of cold, but recurred on the 15th, when the patient lost between two and three pounds of blood. The ligatures would not bear interference until long after the usual period, the last one not being removed until the thirty-first day. Patient was much reduced by the last hæmorrhage. December 31, 1867: Stump bears considerable pressure; there is still a slight discharge from it. [This man was discharged the service September 28, 1868, for amputation of foot.]

DLVIII.—*Report of a Case of Frost-Bite in which both Feet were Removed.* By J. H. PATZKI, Assistant Surgeon, U. S. A.

First Lieutenant Henry B. Mellen, 6th Cavalry, aged 43 years, while travelling from Camp Wichita to Fort Richardson, Texas, on horseback, was overtaken by a severe "norther" on December 20, 1870, during which the mercury fell below zero. Having become wet by his horse falling with him into the west fork of Trinity River, he dismounted, was overcome with the cold, and remained in the timber of the bottom, in a half delirious condition, until found by a hunting party of soldiers on the morning of the 22d, about twelve miles from Fort Richardson. A medical officer was at once sent to his relief with an ambulance, and he was conveyed to the post hospital at Fort Richardson, arriving there at one o'clock on the morning of the 23d. His hands had escaped severe injury, as he had kept them under his clothes in contact with his skin, but both his feet and legs, to about five inches above the ankles, were apparently deprived of vitality, having a white and mottled appearance. He was delirious, and had persistent vomiting and diarrhœa, and was extremely prostrated, the pulse being almost imperceptible at the wrist. His extremities had been rubbed with snow by the soldiers immediately on finding him. In the hospital, friction with the hand was continued until pulsation could be felt over the dorsalis pedis and posterior tibialis, when stimulating lotions and artificial warmth were substituted, but reaction did not extend to the toes of the left nor below the instep of the right foot. The patient remained in a state of profound coma during the greater part of December 25th. The median-basilic vein and anterior temporal artery were opened without obtaining blood; brandy was thrown up the rectum. He finally awoke in a violent delirium, which continued until the 28th. About this time the toes became gangrenous, but the line of demarcation was not fully established until January 4, 1871. It ran on the right foot in a line corresponding to the medio-tarsal articulation, the sole and heel being also destroyed. On the left foot it ran across the dorsum, about one-half inch behind the heads of the metatarsal bones, and across the plantar immediately behind the commissure of the four smaller toes, but when reaching the great toe it curved backward so as to be on a level with its course over the dorsum. Irregular sloughs of varying depths ran along the outer margin of the dorsum, and covered the sole deepest over the bases of the metatarsal bones, the medio-tarsal articulation, and especially over the heel. Stimulants and nourishing diet were administered. On January 13th, in a consultation with Acting Assistant Surgeons R. Gale and B. B. Miles, it was decided that the condition of the patient permitted operative interference. It was resolved to remove the right foot at the ankle-joint, according to Roux's method, the condition of the heel not permitting Syme's or Pirogoff's operation. It was rather embarrassing to determine upon an operation for the left foot, the sloughs having separated except over the heel; the sole was covered with granulations, forming but a thin layer over the bases of the metatarsals and over the heads of the astragalus and calcaneum. This precluded Lisfranc's as well as Chopart's operation. A sufficient flap could be raised from the sole to cover the metatarsal bones with the exception of the first. In consideration of the great usefulness of a portion of one foot, especially after the loss of the other, it was decided to

amputate through the metatarsus, with a view of performing a secondary operation after the soft parts of the foot had sufficiently recovered by cicatrization. Ether having been administered, the right foot was disarticulated by carrying an incision from the insertion of the tendo-Achillis into the os calcis, over the external aspect of the foot immediately below the external malleolus, curving over the instep forward and one inch in front of the tibio-tarsal articulation, then down to and along the internal margin of the foot to the point of departure. This flap included all the healthy tissues on the inside of the foot. The joint was opened from the outside and the os calcis separated from the soft parts, the edge of the scalpel being kept close to the bone. The malleoli and a connecting slice of the tibia were removed with the saw; four arteries were tied and several others twisted; the tendons were trimmed, and sufficient of the posterior tibial nerve to clear the cicatrix. The flap was adjusted with four metallic sutures and adhesive straps, and formed a good cover for the extremities of the bones. The left foot was amputated in the usual manner, through the metatarsus at the junction of the anterior and middle thirds. The flap which was raised from the sole was adjusted by straps and covered the extremities of the metatarsals well, with the exception of the first. Three ligatures were required. The loss of blood was insignificant. The stumps were dressed with carbolated ointment. The patient reacted feebly, but without vomiting or nausea; pulse 125 at 6 o'clock P. M. The stumps being very painful, and to facilitate dressing and cleansing, his limbs were slung in Smith's anterior splint, and suspended from the ceiling, which, in addition to a rope with a handle so suspended as to be in his reach, enabled the patient to shift his position conveniently. The suppuration from the left stump soon became copious; the flap of the right had firmly cicatrized on January 21st, with the exception of three-fourths of an inch at its lower angle. The ligatures came away between the seventh and eleventh days. The patient was doing comparatively well until January 23d, when the granulations of the left foot grew pale, then grayish, as if covered with a delicate film; the pus became scanty and of a grayish color, the flap shrinking and the right stump secreting a small quantity of similar pus. The patient was drowsy, lost his appetite, had rigors in the earlier part of the afternoon and profuse sweats at night. In addition to the chalybeates and quinine which the patient had been taking, he was ordered a solution of chlorinated soda, largely diluted, during the day and morphine followed by hydrate of chloral in the evening, these latter drugs effectively producing sleep and controlling pain, but less so when given separately than when combined. Irrigation was applied to the left foot, with solution of permanganate of potassa, and the body sponged twice a day with aromatic water. Nourishing diet and stimulants were ordered. On February 6th, two small abscesses on the right stump were opened. On the 11th the patient complained of severe pain in the right side of the chest; respiration shallow and frequent; a distinct sound of friction and some subcrepitus perceived over the right lower lobe. The chlorides were almost absent from his urine; patient greatly emaciated and complexion sallow. On February 14th, at 2 o'clock A. M., he had a severe chill lasting one hour; on the 19th the right knee became tender, and on the 22d swollen and exquisitely painful on the slightest touch; this gradually improved under the application of tincture of iodine. The patient was very weak and prostrated, his whole frame being harassed by severe neuralgic pains. He complained of much pain in the right stump, where some healthy pus discharged from the incisions made February 6th, but no necrosed bone could be felt on probing. The slough over the left heel did not separate until February 26th, leaving the heel bone denuded to the extent of a circle three-fourths of an inch in diameter. On March 1st, the stump of the right leg had healed, but was somewhat tender and enlarged; the left foot was covered with healthy granulations, the first metatarsal bone being uncovered to the extent of one-fourth of an inch, and necrosed; the flap over the other metatarsals had cicatrized and formed a good cover. On March 4th pustules and small abscesses formed over the trunk and lower extremities; on March 5th the cicatricial tissue over shaft of fifth metatarsal bone sloughed and separated, on the 13th leaving the external surface of this bone denuded to the extent of one inch. The condition of the patient gradually improved, and on March 28th it was decided to remove the necrosed parts of the heel and first metatarsal bone. The patient having been etherized, a disk of bone corresponding to the point of the heel, of the size and thickness of a silver dollar, was removed with the chisel; a small abscess being discovered in the bone the carious parts were scraped and gouged away. An incision was next made over the external aspect of the first metatarsal bone, and its shaft found to

be carious to the length of about one inch, which was removed with the bone forceps. Patient lost about one and a half ounces of blood; he reacted well, though quite weak. On March 31st the left stump was suppurating profusely, and it was doubtful whether the attempt to save a portion of the foot would be successful. The right stump looked healthy, with a good and firm cushion over the bones, without tenderness, although the abscess opened March 18th still discharged a few drops of healthy pus. His general condition was somewhat better than before the operation, but still critical. In July, 1871, the stump of the right foot had healed, and the condition of the left was favorable.

Amputations of the Leg.—Special reports of twenty-three cases of this class were received, of which nine were due to gun-shot wounds, seven to frost-bites, three to railway accidents, and four to other injuries. Five cases proved fatal.

DLIX.—*Account of an Amputation of the Leg.* By E. A. KOERPER, Assistant Surgeon, U. S. A.

Thomas W. Avens, a musician of the 25th Infantry Band, and a strong, hearty man, was accidentally shot at Fort Clark, Texas, on August 26, 1870, by a musket loaded with duck shot, which carried away the ungual phalanges of the middle and ring fingers of the right hand, shattered the right tibia about three inches below the proximal extremity, wounded the anterior and posterior tibial arteries, and lacerated the soft parts. The patient suffered considerably from pain and arterial hæmorrhage. On being taken to the hospital, chloroform was administered within twenty minutes after the receipt of the injury, when Acting Assistant Surgeon Donald Jackson amputated three inches below the knee by the circular method, ligating the two principal arteries, and applying torsion to the smaller branches. The flaps were closed by five stitches, leaving an opening near the lower angle. Venous hæmorrhage continued a short time afterward. The injured fingers were also properly removed, when the man promptly recovered from the anæsthesia, complaining of pain in the precordial region, which lasted but a short time. After the administration of a stimulant with an anodyne, a good night was passed. On the evening of the 27th, traumatic fever ran high, and the stump became swollen and painful. The treatment in this case, which presented nothing remarkably different from other cases of amputation, consisted in irrigation to the stump, carbolic acid and warm-water dressings, laxatives, and anodynes, when indicated, and a light but nutritious diet. By September 18th, the fingers had entirely healed, and on October 25th, the leg had also healed, leaving an excellent stump. On December 13th, the patient was sent to quarters; and on February 4, 1871, he was discharged the service.

DLX.—*Report of an Amputation of the Leg for Pott's Fracture.* By G. S. ROSE, Assistant Surgeon, U. S. A.

Private John Baker, Co. C, 29th Infantry, aged 22 years, convalescent from intermittent fever, was wounded in a railroad accident which occurred at Keswick Station, Virginia, on September 28, 1868. He was riding on the top of a box-car, when, seeing that it must go over the embankment, he jumped, and alighted on his feet, causing fracture of the left fibula, with displacement of the tibia from the corresponding surface of the astragalus, the fractured extremity of the fibula projecting nearly two inches from the wound. A few moments after the accident, Assistant Surgeon J. H. Patzki, U. S. A., in charge of the detachment, enlarged the wound and replaced the fractured extremities of the bone. On the 29th, he was admitted to the post hospital at Camp Schofield, Lynchburg, Virginia, where, on the same day, the wound was carefully closed and dressed with one part carbolic acid and four parts linseed oil, and a small splint and bandage were adjusted to the outer side of the leg. He was placed on special diet; opiates were given at bedtime, and several days after, quinine and whiskey during the day, on account of his condition prior to the accident. On the 30th, the leg being hot and swelled, the splints and bandages were removed, and the limb was placed in a fracture-box. From October 1st to the 4th, there was a copious discharge of unhealthy pus, and on the latter date, a good deal of irritative fever. On the 5th, a large abscess,

pointing directly over the inner malleolus, was opened; the wound was sloughing, and the joint was entirely open. Amputation being decided on, the patient partook freely of beef tea and milk punch until the night previous to the operation. On the 6th, the directions having been carried out, he was readily brought under the influence of chloroform, and the leg was amputated at the junction of the lower thirds by the half-flap method. There was considerable venous hæmorrhage but by evening he was rallying well. Morphine was given immediately after the operation, and was repeated at night. The stump was dressed with liniment composed of carbolic acid and linseed oil. There was no nausea following the operation, owing, in a great measure, it was believed, to previous abstinence from solid food. Milk punch and beef tea were continued, the appetite improved, and the case was progressing favorably. On the 14th, the whole of the inner half of the wound had closed by first intention; there was, however, considerable suppuration on the outer side of the stump, and pus could be pressed from within two inches of the knee-joint, for which there appeared to be free exit. He did not rest well during the night, and, on the next morning, there was hæmorrhage from the outer side of the stump, probably from the anterior tibial artery, which was controlled by the tourniquet. Persulphate of iron was also applied, the stump was dressed with an iced solution of acetate of lead, a compress and bandage secured over the popliteal artery, and the leg elevated; an opiate was immediately given. An abscess beneath the fascia lata of the thigh was opened, and bandaged. On the morning of the 17th, hæmorrhage recurring, was promptly arrested, and compress over the popliteal reapplied, but, again occurring on the following morning, the patient was chloroformed, and the popliteal artery was ligated at its lower third. Two articular branches were severed during the operation, requiring ligation. The incision was drawn together by four interrupted sutures, and the edges adapted by adhesive plaster. The stump was again dressed with carbolic acid liniment. Stimulants, morphine, and tonic mixtures. On the 21st, the stump began to have a more healthy appearance, and on the 27th, the ligature came away, and the incision was almost healed. The abscess of the thigh continued to discharge several ounces of pus, but it had a more healthy appearance. On November 10th, the stump had nearly healed, the abscess had closed, and the patient was able to sit up. He had a severe chill during the night, followed by diarrhœa; pulse 100; skin hot and dry, and tongue coated. Quinine was given. On the 12th, the thigh was much swollen, and a discharge of watery fluid was pressed from the old opening. On the next day, the swelling had abated, and the patient's appetite was improving. During the month, one or two small pieces of necrosed bone were removed from the stump, which had entirely healed by December 1st, the patient being able to walk around on crutches. Discharged July 21, 1869, and pensioned at \$15 per month.

DLXI.—*Account of a Re-amputation of Both Legs.*—Compiled from various Reports.

Private Jacob Bisbing, Troop C, 2d Cavalry, had both feet frozen while on duty as a mail escort from Fort Laramie to Fort Philip Kearney, January 5, 1867. He was admitted to post hospital at Fort Reno, January 6, 1867, where both feet were amputated January 16, 1867, by E. H. Reed, Acting Assistant Surgeon. Owing to bad hygienic surroundings the wounds healed very slowly, and the patient suffered with conical and painful stumps. On July 21, 1867, both feet were re-amputated by Charles Mackin, jr., Assistant Surgeon, U. S. A. Bisbing was discharged September 28, 1867, and pensioned at \$20 per month.

DLXII.—*Account of Several Amputations, one of which was a Re-amputation of the Leg.*

Private Charles O. F. Clark, Co. G, 1st Oregon Volunteers, had, on December 17, 1865, while on a march between the mouth of the River Owyhee and the Malheur River, Oregon, the lower and upper extremities frozen. He was conveyed to Camp Auburn, where the second and third fingers of the right hand, the left leg, and the right foot were amputated, the latter by Chopart's operation. The end of the second finger of the left hand sloughed off. He was mustered out of service on April 14, 1866. On November 9, 1868, at Bellevue Hospital, New York, Professor Hamilton re-amputated the left leg, five inches below the knee. On April 5, 1870, the patient was

furnished with artificial limbs by D. W. Kolbe, Philadelphia, at which time the stumps were of normal size and perfectly healed. The man is a pensioner at \$20 per month.

DLXIII.—*Account of a Double Amputation of the Legs.* By B. E. FRYER, Surgeon, U. S. A.

Private George Foster, Troop C, 10th Cavalry, having lost his way after a debauch, was exposed to a severe snow-storm on the open prairie, and had both his feet badly frost-bitten. He was admitted to hospital at Fort Zara, Kansas, on December 9, 1868. Before admission, and immediately after discovery, he had been injudiciously taken to a fire. W. H. King, Assistant Surgeon, U. S. A., attempted gradual reduction of temperature, but, mortification ensuing, he administered chloroform, and amputated the right foot just above the ankle, by circular operation, on December 31, 1868. At that time the left foot began to mortify, and was amputated on January 19, 1869, in the same manner as the first. The patient, who had been weak and emaciated, rapidly improved. Carbolic acid, variously diluted, formed almost the only application to the stumps. To reduce the chance of secondary hæmorrhage, as well as to overcome the stretching of the muscles, extension by means of adhesive strips and weight, as in fracture, was employed. On January 31, 1869, the stumps looked well. He was transferred to the hospital at Fort Harker, Kansas, in the latter part of the year, where he stated that he made a good recovery. By December 31, 1869, the stumps had healed, and the patient's health was excellent. [Not on pension rolls.]

DLXIV.—*Report of an Amputation of the Leg.* By J. C. FIELD, M. D., Acting Assistant Surgeon.

Private Samuel Gilbert, Troop A, 3d Cavalry, aged 20 years, was accidentally wounded while on post at Fort Smith, Arkansas, on February 19, 1866. The ball entered the leg at the internal border of the gastrocnemius muscle, severed the posterior tibial artery, fractured the fibula at the middle third, and emerged on the external aspect lower down. On the 22d he was admitted to the hospital of the post. On February 26th, the wound being in a gangrenous state throughout its extent, and the patient in a very low, anæmic condition, I administered ether, and amputated the leg at the upper third, by circular operation. Egg-nog, quinine, iron, and morphine were prescribed, and the best nourishment the hospital afforded was ordered; but death, from exhaustion, occurred the following day. A *post-mortem* examination disclosed extensive sloughing of structure along the entire course of the ball.

DLXV.—*Remarks on an Amputation of the Leg.* By B. J. D. IRWIN, Surgeon, U. S. A.

Private Frederick Hilbrecht, Co. C, 43d Infantry, aged 51 years, was run over December 30, 1867, by a loaded cart, which produced a compound comminuted fracture of the right tibia and fibula in the lower thirds. On the next day he was admitted to the post hospital at Fort Wayne, Michigan. By January 9, 1868, the limb was much swollen to within three inches of the knee, and was gangrenous, with large phlyctænæ. A fragment of bone, denuded of periosteum, protruded through the slough. His health was good, with the exception of a slight cold, which had troubled him some three weeks previously, and which was attended with profuse mucopurulent expectoration, but without evidence of acute inflammatory action. On the latter date I administered chloroform, and amputated the leg at the upper third, by the antero-posterior flap method. On the fourth day after the operation a ligature came away, and another on the fifth. On the ninth day he had a severe attack of intermittent fever. On the eleventh day his bowels were loose, and he had another attack of intermittent fever. On the twelfth day he had involuntary evacuations of urine and fæces, with a slight attack of intermittent fever, and on the thirteenth a severe attack of rheumatism, affecting the whole left side of his body. On the fourteenth day he was very feeble and greatly prostrated. There was profuse expectoration of mucopurulent matter, and evidence of softening of the lungs. The wound was healthy and almost healed, with the exception of slight œdema about the knee-joint. He died of inflammation of the lungs, January 26, 1868.

DLXVI.—*Report of an Amputation of the Leg for Railway Injury.* By B. E. FRYER, Surgeon, U. S. A.

Otho Johnson, a destitute civilian, aged 37 years, of good health and habits, had his left foot crushed, with fracture of the metatarsal bones, by a railroad car. On November 18, 1870, he was admitted to the hospital at Fort Harker, Kansas. An effort to save the foot was made, which seemed to promise success; but, on November 30th, being gangrenous as far as the ankle-joint, the patient was etherized, and the leg was amputated in the lower third, lateral skin flaps being made with the intention of bringing the line of cicatrization between the tibia and fibula. Four ligatures were applied. The patient reacted promptly from influence of anæsthetic. Carbolic acid dressings were applied. Union was immediate, save where ligatures were brought out at flap angles. As soon as the ligatures were removed the stump healed. On December 31, 1870, the stump was full and round, and the line of cicatrix was so situated between the tibia and fibula that it could not be pressed upon by them.

DLXVII.—*Remarks on an Amputation of the Leg for Frost-Bite.* By C. E. MUNN, Assistant Surgeon, U. S. A.

Private Charles Kridenoff, Co. D, 20th Infantry, while with a party marking a railroad, February 11, 1870, was exposed in a storm on the prairie for thirty-six hours, and both of his feet were frost-bitten. He was admitted into the post hospital at Fort Ransom, Dakota Territory, on the next day. The right foot was gangrenous to the ankle-joint. On March 1st I administered ether, and amputated the right leg at the lower third by the antero-posterior flap method. Three ligatures were applied. There was but little hæmorrhage, and the flaps approximated. On March 12th, gangrene having attacked the left foot, I divided the metatarsal bones in the line of demarcation, and partially excised the os calcis. In the operation of separating the sloughing parts the entire plantar surface was removed, no anæsthetic being used. On March 31, 1870, the patient still remained under treatment. The stump of the right leg was nearly cicatrized, two ligatures still being adherent; that of the left was granulating kindly. He was transferred to the post hospital at Fort Abercrombie, Dakota Territory, September 13, 1870, and transferred to the Soldiers' Home, at Washington, October 8, 1870. The man has applied for a pension, and the case is pending.

DLXVIII.—*Report of an Amputation of the Leg on account of an Injury.* By H. FLETCHER, M. D., Acting Assistant Surgeon.

Patrick O'Brien, Co. G, 25th Infantry, aged 21 years, while trimming a tree at or near Humboldt, Tennessee, March 23, 1868, fell twenty feet, his whole weight coming upon his right leg on sloping ground. The fibula was fractured two inches from the lower extremity, several fragments of bone were broken off of each malleolus, and the tibia projected two inches through the flesh, rupturing ligaments and veins and opening the ankle-joint. He was admitted to the post hospital of the above place. There being no instruments at the post, Dr. Thompson, upon my invitation, three hours after the injury, amputated the leg three inches above the ankle-joint, by the circular method. A mixture of chloroform and ether was the anæsthetic used. On the ninth day, the case was progressing finely. He was discharged the service on July 12, 1868, and pensioned, his disability being rated total. In January, 1869, he was furnished with an artificial limb, which proved highly useful. At that date, the stump was less than normal size, but was perfectly healed. He is an inmate of the Soldiers' Home, Dayton, Ohio.

DLXIX.—*Account of an Amputation of the Leg.* From the reports of S. A. STORROW, Assistant Surgeon, U. S. A., and W. E. DAY, M. D., Acting Assistant Surgeon.

Private James Palmer, Battery F, 3d Artillery, aged 22 years, while on guard December 24, 1869, was accidentally wounded by a musket ball, which caused a compound comminuted fracture

of the left tibia and fibula, involving the articulations of the foot, the dorsal region being severely lacerated. He also received a slight bayonet wound in the left leg just below the point where the ball entered. He was admitted to the post hospital at Fort Jefferson, Florida, on the same day. The soft parts were considerably contused and lacerated. Acting Assistant Surgeon W. E. Day, on December 25th, administered ether and amputated the limb at the junction of the middle and lower thirds by a circular operation. At time of operation patient was suffering from primary hæmorrhage and nervous shock. Seventeen hours after operation traumatic tetanus supervened, which was controlled by subcutaneous injections of atropine and morphine. Nourishing diet was allowed. Death resulted January 11, 1870.

DLXX.—*Mention of a Double Amputation of the Legs.* By P. C. DAVIS, Surgeon, U. S. A.

Private David Perigo, Co. D, 13th Infantry, aged 18 years, had both of his feet frost-bitten on the night of December 21, 1869. He was admitted into the post hospital at Fort Ellis, Montana Territory, on the next day. Snow, ice-water, and simple cerate dressings were applied. Gangrene supervened, and on January 1, 1870, Assistant Surgeon Clarence Ewen, U. S. A., administered ether and amputated the left leg at the lower third, and, on the next day, the right leg at the lower third. Stimulants and nourishing diet were given. By March 31, 1870, the patient was convalescent. He was transferred to the Soldiers' Home, Washington, June 1, 1871.

DLXXI.—*Remarks on a Secondary Amputation of the Leg.* By W. R. TOMKINS, M. D., Acting Assistant Surgeon.

Lieutenant W. L. P——, 5th Cavalry, received on February 22, 1868, at Gallatin, Tennessee, a compound comminuted fracture of both bones of the left leg, caused by the bursting of an anvil while firing a national salute. There being no guns, a hole in an anvil had been charged with powder, another anvil placed upon the hole, and the charge ignited by a hot iron. One of the anvils bursted into a number of pieces, one of which, weighing four and three-quarter pounds, struck the lieutenant on the leg, extensively lacerating the soft parts. On the morning of February 23d I excised from six to eight inches of the tibia, and placed the limb in a fracture-box with wheat bran, using extension and counter extension. For some time the case progressed favorably; afterward profuse suppuration set in, with unhealthy granulation and a tendency to gangrene, and the patient became debilitated from profuse discharge of pus. On April 23, 1868, he was again etherized, and Dr. Paul F. Eve amputated the leg by the circular method. He survived the operation nine or ten hours, dying from shock of operation, April 23, 1868.

DLXXII.—*Account of an Amputation of the Leg for Gunshot Injury.* By S. M. HORTON, Assistant Surgeon, U. S. A.

James Scregg, a citizen, aged 29 years, was accidentally wounded July 24, 1866, by the discharge of his rifle, which fractured the bones of the right ankle-joint. On the same day he was fetched a distance of twenty-five miles to the post hospital, at Fort Philip Kearney, Dakota Territory. On admission, his pulse was rapid and weak, his ankle-joint intensely painful and swelled, and gangrene had begun in the foot. I immediately administered equal parts of chloroform and ether, and amputated the leg in the middle third by a flap operation. Cold-water dressings were applied, and stimulants given. The stump healed slowly, the skin refusing to cicatrize entirely on account of scabies. On November 10, 1866, he left for his home, his stump not entirely healed, but very firm.

DLXXIII.—*Remarks on an Amputation of the Leg for Gunshot Injury.* By C. K. WINNE, Assistant Surgeon, U. S. A.

Private Edwin Shears, Co. G, 20th Infantry, aged 23 years, was wounded December 29, 1869, by the accidental discharge of his musket. The ball entered above and behind the internal

malleolus of the left leg; passed inward, downward, and forward through the limb, and extensively comminuted the tibia, and divided the anterior tibial artery. He was admitted the same day to

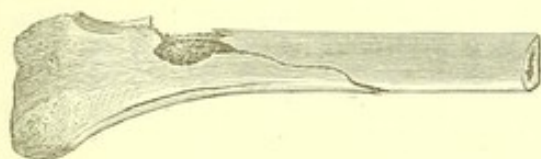

FIG. 40.—Gunshot fracture of the lower third of the left tibia. Spec. 5674, Sect. I, A. M. M.

the post hospital, Fort Ripley, Minnesota. There was constant and profuse hæmorrhage, which was controlled only by the tourniquet. On the next day I administered ether, and amputated the leg, by the double flap method. The patient recovered, and was discharged July 12, 1870. The pathological specimen, with the history, was contributed to the Army Medical Museum, by the operator, and is represented

in the adjoining wood-cut. The man is a pensioner at \$15 per month.

DLXXIV.—*Memorandum Relative to an Amputation of Both Legs for Frost-Bite.* By D. E. HOLMES, Acting Assistant Surgeon.

Private Frederick Silverhorn, Troop F, 8th Cavalry, aged 24 years, while on duty with his team ten miles from Camp Logan, Oregon, December 28, 1867, was frost-bitten in both feet and hands, and was admitted to the hospital of the post the same day. On January 1, 1868, both legs being considerably œdematous, and the feet black and mortified as far as the ankles, I administered ether and chloroform, and amputated both legs four inches above the ankles, the right by the circular method and the left by the flap. The flaps at first appeared to close up rapidly, but afterward opened, slightly sloughed at the margin, and healed from the bottom by granulation. Both stumps had healed by the end of the month. The hands were restored after a few days' treatment. He was discharged the service March 23, 1868, and was pensioned at \$20 per month.

DLXXV.—*Note relative to an Amputation of the Leg for a Sprain.* By H. McL. CRONKHITE, Assistant Surgeon, U. S. A.

Private Albert Smith, Co. E, 26th Infantry, aged 23 years, sprained his right foot, while on drill, on April 28, 1868, and on the next day was admitted to the post hospital, Ringgold Barracks, Texas. Caries, involving all the tarsal bones, resulted. By the 14th of November, 1868, the ankle had been for a long time much swelled and very painful, and there was a fistula which discharged freely. The patient was debilitated from long suffering and profuse suppuration. On the latter date, I administered chloroform and performed an antero-posterior flap amputation of the leg, four inches above the ankle-joint. The wound was closed by ligatures and adhesive straps. On the 31st of December the wound had healed, and his general health was good. He was discharged the service May 27, 1869, and draws a pension of \$15 per month.

DLXXVI.—*Note on an Amputation of Leg for Frost-Bite.* From a Report from the Pension Office.

John Spyri, Troop C, 2d Cavalry, was frost-bitten, while on escort duty between Forts Reno and Kearney, Dakota Territory, in the latter part of January, 1867. Half of the left foot was removed at the time, but the case proving unsuccessful, amputation of the lower third of the leg, by the circular method, was performed May 5, 1867. He was discharged August 26, 1868. A year and seven months after he was examined for an artificial limb, at which time the stump was perfectly healed. He is a pensioner at \$15 per month.

DLXXVII.—*Note on an Amputation of the Leg for Gunshot Injury.* By J. B. GIRARD, Assistant Surgeon, U. S. A.

Corporal James K. Thomas, Troop A, 2d Cavalry, aged 24 years, was accidentally wounded, while scouting after Indians, the ball entering near the middle of the calf of the right leg, and escaping under the malleolus. He was admitted, on April 16, 1870, to the post hospital at Fort

Fred. Steele, Wyoming Territory. The fibula was found to be fractured. Conservative treatment was adopted, but no attempt at reunion followed; the tibia, fibula, and astragalus became necrosed and the ankle-joint ankylosed, until the dorsum of the foot was on a line with the front of the leg. The patient became exhausted by long-continued suppuration, and in January, 1871, amputation became necessary. The operation was performed on January 5, 1871, by removing the leg at the middle third, and taking a single flap from the muscles of the calf. Lotions of carbolic acid were applied. The flap healed by first intention, and on April 14th the patient was strong and healthy and had a good stump. He was discharged June 9, 1871.

DLXXVIII.—*Note on an Amputation of the Leg for Gunshot Injury.* By IRA PERRY, Assistant Surgeon, 9th U. S. C. T.

Private William White, Co. C, 114th Colored Infantry, aged 23 years, was accidentally wounded in camp by a conoidal ball, which entered and fractured the tibia just below the inner tuberosity, and, breaking the fibula, made its exit on the outside of the leg, tearing the muscles and integuments two by four inches. He was admitted to the post hospital at Fort Brown, Texas, on the 20th of February, 1866. The patient was weak from the loss of blood. I amputated just below the attachment of the ligamentum patellæ, by the flap method. The case progressed admirably, the stump healing in good shape. Discharged April 2, 1867. The man is a pensioner at \$15 per month.

DLXXIX.—*Note on an Amputation of the Leg for Gunshot Injury.* By P. C. DAVIS, Surgeon U. S. A.

Private Thomas Wilkinson, Battery C, 3d Artillery, aged 22 years, was admitted to the post hospital, Fort McPherson, Nebraska, July 15, 1867, with a gunshot wound of the left ankle, involving the joint. A musket ball had entered the joint near the external malleolus, and, passing upward, escaped above the internal malleolus. The wound was much swelled, and very painful. The patient suffered from loss of blood and traumatic irritation. On July 19, 1867, I administered ether, and amputated the left leg at the lower third by the flap method. The hæmorrhage was slight, and the patient reacted promptly. The case progressed favorably, no treatment being required but an opiate at night. He was discharged from service September 28, 1867. The stump was completely healed. The man has made application for pension, but the case is still pending.

DLXXX.—*Memorandum relative to an Amputation of the Leg on Account of Compound Dislocation of the Lower End of the Tibia.* By IRA PERRY, Assistant Surgeon, 9th U. S. C. T.

William Wilson, a citizen, aged 30 years, received, May 4, 1866, by the upsetting of a stage-coach, a compound complicated dislocation of the lower end of the left tibia, inward. The internal lateral ligament was ruptured, and the ankle-joint opened; the external malleolus was fractured, and the internal malleolus broken square off, with the end off the tibia. He was sent to the post hospital at Fort Brown, Texas, where the leg and foot were placed in a fracture-box. The patient at first objected to amputation. On the sixth day after the injury, tetanus appeared. On the seventh day, by the advice of the surgeon in charge of the hospital, and of the commanding medical officer of the district of the Rio Grande, I amputated the leg at the upper third. The operation did not appear to benefit. Slight spasms of limbs and some opisthotonus followed; his jaws remained rigid, and deglutition was difficult. Warm poultice to the stump, and hot fomentations to the neck and ears, were applied. Chloroform was the only remedy that had the least effect in relieving spasm. He died the next day, May 12, 1866.

DLXXXI.—*Note on an Amputation of the Leg for Railway Injury.* By J. LUNNEY, M. D., Acting Assistant Surgeon.

Arthur, a freedman, aged 21 years, September 5, 1866, in attempting to get on a freight train while it was in motion, fell and received a compound comminuted fracture of the right leg, a

fracture of the right internal malleolus, with an external wound communicating with the joint, a compound fracture of one of the phalanges of each toe of the right foot, except the great toe, a lacerated wound of the left side of the face, extending from the external angle of the eye to the ear, a lacerated wound of the scalp and of the right ear, and several contusions and abrasions on different parts of the body. On the 6th, he was admitted into a temporary hospital erected for him at the post of Darlington, South Carolina, and on the 8th, chloroform was administered and the limb amputated at the middle third by the antero-posterior flap method. There was but little hæmorrhage, only two ligatures being necessary. At the time of the operation, the limb was swollen and painful; the patient was feverish; pulse 120; and there was concussion of the brain. Simple dressings were applied. The patient reacted promptly. On the 30th of September, the stump was healing finely, and a complete recovery was soon expected.

Amputations at the Knee-joint.—Three successful operations were reported.

DLXXXII.—*Report of Two Cases of Amputation at the Knee-Joint for Gunshot Injury.* By JOHN D. HALL, Assistant Surgeon, U. S. A.

CASE I.—Private Thomas Nipple, Troop F, 3d Cavalry, was shot on March 31, 1870, with a Colt's Army pistol, carrying a conical ball of a calibre four inches. The ball entered the right leg below and very close to the cavity of the knee-joint, passed within the outer hamstring tendon, downward and inward, through the head of the tibia, and made exit upon the inner surface of the tibia. On careful examination, no fracture of the bone could be discovered—a few small pieces and spiculæ of bone near the exit wound, and nothing more. I concluded, also, that the cavity of the knee-joint was not opened. At 9 P. M., nine hours after the accident, the pulse was 60, and the patient comfortable.

Date.	Hour.	Pulse.	Temperature.	Date.	Hour.	Pulse.	Temperature.
April 1st	9 A. M.	76	April 6th	9 A. M.	72	98½
	9 P. M.	92	101½		9 P. M.	80	99½
April 2d	9 A. M.	84	100½	April 7th	9 A. M.	72	99
	9 P. M.	88	100½		9 P. M.	76	99½
April 3d	9 A. M.	96	100½	April 8th	9 A. M.	76	99½
	9 P. M.	92	100		9 P. M.	80	100½
April 4th	9 A. M.	88	100	April 9th	9 A. M.	76	99
	9 P. M.	88	100½		9 P. M.	76	99
April 5th	9 A. M.	84	100½	April 10th	9 A. M.	76	99½
	9 P. M.	84	100½		9 P. M.	84	100

And thus, until April 21st, the case proceeded evenly, with pulse and temperature approaching the normal character. During this time, the wound seemed to be doing well, and there were no symptoms of inflammation in the neighboring joint—neither pain nor swelling. April 21, 9 A. M.: Pulse 76; temperature 98½. 9 P. M.: Pulse 120; temperature 103. Here was a marked change. The patient now complained of pain in the right knee. On the morning of April 22d, his pulse was 108; temperature 101½, and in the evening his pulse rose to 134; temperature 105. The knee was still painful and somewhat swollen. It was evident that the knee-joint had become involved. For several days, local applications were persistently applied, but increased swelling and signs of suppuration within the joint began to appear. Soon after, hectic symptoms began, and the constitution seemed failing. May 3d: I amputated the limb. This was done through the knee-joint, making a long anterior and a short posterior flap, and sawing off about an inch of the condyles, after the manner of Mr. Carden, of Worcester. This operation is also recommended by Martoe, of New York. The anæsthetic used in this case was chloroform. The knee-joint was full of fetid, unhealthy pus, and this extended also above the joint, along the cellular planes of the

thigh. On the after treatment, the flaps were kept partly separated, so as to favor a free exit of pus. There was considerable retraction, and the period of cicatrization was much prolonged. Abscesses forming above the wound, and extending upward between the muscles of the thigh, gave a good deal of trouble. These were met by free incisions and the injection of antiseptic lotions. The patient's system being reduced, and the season hot, careful nursing and supporting treatment were required to carry him through the long period of cicatrization. May 31st (end of first month), 9 A. M.: Pulse 116; temperature $98\frac{1}{2}$; 9 P. M.: Pulse 116; temperature $98\frac{1}{2}$; stump suppurating freely; flaps somewhat sloughy in the last two weeks. Antiseptic lotions and carbon poultices applied; the flaps now look healthier. June 30th (end of second month), 9 A. M.: Pulse 112; temperature 98. 9 P. M.: Pulse 116; temperature 99. The patient has gained strength in the past month; stump healing up; suppuration not more than one ounce per day. July 31, 1870 (end of third month): Pulse and tongue and temperature normal; stump healed over; patient walking about with a long, well-rounded and apparently useful stump. He was transferred on May 15, 1871, to join his command at Tucson, Arizona Territory.

CASE II.—Private Louis Shire, Troop F, 3d Cavalry, was shot by Apache Indians on October 6, 1870. The ball entered the left leg inside of and a little above the patella, passed into the centre of the internal condyle, imbedding itself there and splitting the bone down into the joint. The patient was obliged to ride thirty-five miles on horseback, and did not arrive at the hospital till the next afternoon of October 7th. The knee was then found to be much swollen and very painful. Pulse 112 and quick; skin hot. Exploring the wound carefully, I could not find the ball, but concluded it had entered the joint and lodged within or near it. The patient's condition was much depressed and irritable. He was greatly fatigued by travel and loss of sleep, and the knee was already much inflamed. Hence, I thought best to defer amputation until a more favorable time. On October 8th the pulse was 110, the general condition about the same, only the pain and swelling were increased. October 9th: pulse 112; the patient had slept pretty well; but his condition was still irritable. On October 10th, pulse 100, knee and thigh less swollen, and there was less general irritability. October 11th: pulse 102 and firmer; general condition improved; less complaint of pain; inflammation in knee less acute. Amputation at 11 A. M. The method adopted was by making a long flap anteriorly, and a short one posteriorly. The condyles were sawn off about an inch; the ball was turned out of its bed, and a piece of bone, the size of a hen's egg, which had been split off from the internal condyle, was removed by forceps. The anæsthetic used was sulphuric ether. There was very little hæmorrhage, but considerable shock. At 9 P. M., the pulse beat 136; the reaction was pretty good. October 12th, 9 A. M., pulse 118; 9 P. M., pulse 120; skin hot. In the after treatment no attempt was made to get primary union of the flaps; free outlet was given for suppuration; and antiseptic lotions and dressings were freely used. There was an early tendency to sloughing in the anterior flap; carbon poultices were then applied, and the edges of the daily flap were touched with lunar caustic. After the separation of a large slough, the edges being cauterized, the stump assumed a healthier appearance. An abscess formed among the muscles above the knee, and became the seat of a good deal of suppuration. This was opened and daily injected with antiseptic lotions of chloride of zinc and Labarague's solution of chlorinated soda, and it gradually diminished. On December 1, 1870, about seven weeks after the operation, the stump was almost entirely closed up, and the patient was able to walk about on crutches. He, too, has a stump that will probably serve well for locomotion. On May 15, 1871, the patient was transferred to join his command at Tucson, Arizona.

DLXXXIII.—*Memorandum relative to an Amputation at the Knee-Joint.* From Data furnished by J. R. REILY, M. D., Acting Assistant Surgeon.

Robert Realey, a lad of 10 years, was struck on the right instep by a stone seven weeks previous to the operation below mentioned, when inflammation was at once lighted up, and periostitis rapidly extended up the limb, which was much swollen and very painful ten days after the accident. Fluctuation being detected at the internal malleolus, an incision was made, which gave exit to more

than twelve ounces of pus. Acute necrosis invaded the shaft of the tibia, and a fortnight after the evacuation of the abscess, Doctor Reily held a consultation with Professor Johnson Eliot, who advised an exploratory incision, with a view of ascertaining the extent of the disease of the tibia. On December 24, 1870, the lad was etherized, and the bone being exposed by two incisions on the anterior aspect of the limb, it was found that the bone was diseased to such an extent that no resection, nor even an amputation in the continuity, was practicable. It was therefore determined to amputate at the knee-joint. This operation was performed by Dr. James R. Reily, assisted by Professor J. Eliot and Dr. J. D. Barnes. The integuments were divided circularly, two inches below the knee-joint, and reflected, the patella was removed, and the leg disarticulated. The femoral was completely controlled by a tourniquet, and there was little or no hæmorrhage. The condyles of the femur were then sawn off, a slice half an inch in thickness being removed. The integument was then brought together antero-posteriorly, and united by wire sutures. It was only necessary to ligate the popliteal artery. The patient reacted promptly and progressed favorably. The pathological specimen, with the history, was contributed to the Army Medical Museum by the operator, and is No. 5736, Surgical Section. On January 16, 1871, the wound had entirely healed, and the boy was going about the house. A few weeks subsequently, he called at this office. The stump then presented a very fair appearance, and the boy's health was good.

Amputations of the Thigh.—There were reports of twenty-six cases. Seventeen followed gunshot-wounds; six, accidents; three, diseases. The results were very successful.

DLXXXIV.—*Note on an Amputation of the Thigh for Gunshot Injury.* By CHARLES SMART, Assistant Surgeon, U. S. A.

George W. Albright, a citizen, aged 40 years, received, in a quarrel, August 15, 1866, a gunshot fracture of the right femur, lower third. The femur was splintered, longitudinally, for six inches. On the same day he was admitted to post hospital, Camp McDowell, Arizona Territory, and, on the next day, I administered chloroform, and amputated the thigh by the flap method. The tissues were in a healthy condition. On the 15th of October, the flaps were firmly united, and on November 23, 1866, he was sent away from hospital.

DLXXXV.—*Memorandum relative to a Secondary Amputation of the Thigh.*

Private C. M. Bowen, Co. A, 27th Indiana Volunteers, had his left femur fractured by a musket ball, at the battle of Antietam, on September 17, 1862. He was admitted to Hospital No. 1, Frederick, Maryland, where Buck's apparatus was applied. Five months subsequently, he was removed to Baltimore. There were numerous abscesses, and the patient underwent two operations for the removal of necrosed bone. On September 7, 1863, he was discharged the service, with the limb greatly deformed. He received a pension, and was employed in the Interior Department. Owing to recurrence of abscesses he was admitted to Providence Hospital in the autumn of 1867, and on November 11th, the limb was amputated in the middle third by Dr. D. W. Bliss. The wound healed well, and a photograph was taken at the Army Medical Museum on January 9, 1868, at which time the stump was firm and

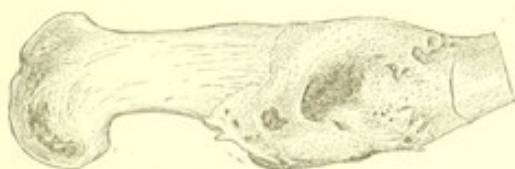

FIG. 41.—Gunshot fracture of the lower third of left femur. Spec. 4914, Sect. I., A. M. M.

healthy. The specimen, with the history, was contributed by the operator to the Army Medical Museum, and is represented in the adjacent wood-cut. The fragments are considerably overlapped, having undergone unusual disturbance, and the amount of callus exceeds what is necessary for complete union. On March 10, 1871, the patient was a clerk in the Pension Office; the stump was healthy, but his general health poor.

DLXXXVI.—*Report of a Secondary Amputation of the Thigh.* By HARVEY E. BROWN, Assistant Surgeon, U. S. A.

Sergeant John Cameron, Co. K, 31st Maine Volunteers, aged 26 years, while on picket before Petersburg, June 18, 1864, was struck by a conoidal musket ball, which produced a flesh-wound about two inches above the right knee. He was sent to City Point, and thence to the De Camp Hospital, New York Harbor, where he arrived on June 26th. Expectant treatment was used. On August 6th, he was sent to the Cony Hospital at Augusta, Maine, and was returned to duty on September 28, 1864. No further record of the case can be found until June 2, 1865, when he was discharged the service at the post hospital at Augusta; but he remained for treatment until July 31, 1866, when the hospital was discontinued. Prior to the latter date, the knee-joint had become very much enlarged from deposit of plastic matter following chronic arthritis. The patient was emaciated, his appetite poor, and general condition bad. On July 5, 1866, being rendered insensible by an anæsthetic composed of one part chloroform and three parts ether, the thigh was amputated at the lower third by the double-flap operation. Water dressings were applied. The incisions healed by first intention; the ligatures came away on the eleventh day. On July 27th the stump had entirely healed, and the patient was walking about on crutches, having gained several pounds since the operation.

DLXXXVII.—*Account of Primary Amputation of the Right Thigh in the Lower Third.* By IRVING C. ROSSE, M. D., Acting Assistant Surgeon.

Frank Cheeseman, a large muscular mulatto man, aged about 30 years, and employed as a laborer in unloading fixed ammunition in one of the small buildings used for pyrotechnic purposes, at Fort Monroe, Virginia, was seriously wounded on the afternoon of August 3, 1870, by several fragments of shell, an explosion having occurred through the carelessness of a fellow-laborer. The patient being taken to hospital on a litter, I found almost the whole of the right leg torn to pieces, and the knee-joint implicated; the fourth and fifth metatarsals of the left foot were broken, a fragment of shell remaining in the muscles of the plantar region, and another fragment was imbedded in the muscles of the right fore-arm. There were besides several superficial wounds on the chest; the patient's hands, neck, and face were badly burned, and he was unable to see. The amount of shock and hæmorrhage was not great considering the gravity of the injuries, and the patient complained more of the smarting from the burns than of his other wounds. The burns were dressed with carbolyzed glycerine; anodynes with stimulants were administered, and proper means were taken to bring about reaction. Amputation having been decided upon, about noon on the following day the usual preliminaries were arranged, and Surgeon George E. Cooper, U. S. A., chloroformed the patient. The induction of anæsthesia was somewhat slow, the pulse meanwhile being intermittent. I amputated the thigh in the lower third, using the circular operation; the arteries were withdrawn from their sheaths and ligated; the cut surfaces of the stump were allowed to glaze, and the wound was closed with silver-wire sutures. Hæmorrhage was very slight. The patient, surviving the operation but a short time, died from the shock.

DXXXVIII.—*Report of an Intermediary Amputation of the Thigh.* By T. H. TURNER, Assistant Surgeon, U. S. A.

Louis Farley, of Major George A. Forsyth's Independant Company of Scouts, received a gunshot fracture of the thigh, at the battle of Dry Forks, on the Republican River, Kansas, September 17, 1868. Amputation was performed on the tenth day. Death resulted four hours afterward.

DXXXIX.—*Mention of a Primary Amputation of the Thigh.* By J. M. DICKSON, M. D., Acting Assistant Surgeon.

Private Charles A. Fonda, Co. D, 23d Infantry, received a severe gunshot wound of the knee-joint in a skirmish near Lake Warner, Oregon, April 29, 1868. Amputation at the lower third of the thigh was performed on the next day. He died under the operation.

DXC.—*Report of a Case in which the Thigh and Leg were Amputated on account of Scorbutus.*

Private Hugh Gleason, Co. A, 140th New York Volunteers, was taken prisoner at Weldon Railroad in August, 1864, and was confined at Salisbury, North Carolina, where, he affirms, on account of exposure and starvation, he contracted scurvy. When released, he received a furlough and went to his home at East Wilson, Niagara County, New York, where he was attacked with typhoid fever. On April 15, 1865, Doctor A. M. Leonard, of Lockport, New York, took charge of the patient. He found him suffering from scurvy, which, resulting in gangrene, necessitated the amputation of the right thigh at the middle third on April 25th, and the left leg at the lower third on June 7, 1865, both by the flap operation. He believes that the disease was caused as above stated. The patient was discharged on August 29, 1865, and was pensioned for total disability. On May 20, 1869, George B. Jewett, who furnished the patient with artificial limbs, reported the stumps sound.

DXCI.—*Report of a Case of an amputation of the Thigh for Gunshot Wound of the Knee-Joint.*
By J. M. LAING, M. D., Acting Assistant Surgeon.

Sergeant David G——, Troop M, 7th Cavalry, aged 25 years, while in command of paymaster's escort proceeding to Fort Larned, Kansas, was accidentally wounded on November 17, 1870, when twelve miles from destination, by a conoidal carbine ball, which entered the right leg between the upper extremities of tibia and fibula, passed through the head of tibia, shattered the patella to pieces, and emerged through the inner condyle of femur. The outer condyle was also completely separated from the shaft, but this is attributed to the explosive force of the powder, the muzzle of the piece having been close to the joint when fired. The carbine was lying in the ambulance, and, being displaced by a jolt, the sergeant stooped over to adjust it when the accident occurred. Eight miles from destination, at 11.30 P. M., he was visited, and the wound dressed with lint, soaked in persulphate of iron, and bandages. On the patient's arrival at the fort the next morning he was chloroformed, and the wounds were examined, when, no fracture of the patella being discovered, and the man being of sound constitution, it was determined to try to save the limb. The wounds were thoroughly syringed out with a solution of carbolic acid, and dressed with successive layers of lint soaked in carbolic oil, and the limb was laid in pillows until the swelling should go down. On November 21st irritative fever had set in; there was a sanious discharge from the wound of entrance; the parts contiguous were in a sloughing condition, and the whole thigh, up to the buttock, was of a brownish color. Amputation in this condition not being deemed advisable, the dressings were removed, and the whole limb was enveloped in a yeast poultice. In a few days the irritative fever was subdued. The gangrenous parts about the wound of entrance having separated, and pus beginning to form in large quantities in the thigh, he was put on liberal diet, and syringing with carbolic acid solution, and carbolic oil dressings were again resorted to. Under this treatment the patient's health improved, and there being no instruments at the post fit for use, a note was dispatched on December 11th to W. S. Tremaine, Assistant Surgeon, U. S. A., at Fort Dodge, requesting him to come over and bring his instruments. On the afternoon of the 13th hæmorrhage set in, but was controlled by a tourniquet. The next morning, Doctor Tremaine having arrived, it was determined, on consultation, that amputation was inadmissible on account of loss of blood, but that an opening should be made toward the back of the thigh for the readier evacuation of the matter. While examining the thigh for this purpose hæmorrhage, evidently from the femoral artery, recurred; and, as a last resource, he was rendered insensible with chloroform, and the thigh was amputated at the junction of the upper thirds by lateral flap operation. The femoral was ligated; bleeding from the other vessels was controlled by torsion. The flaps, after being thoroughly washed with strong solution of carbolic acid, were left open, and a tourniquet was loosely adjusted. The patient nearly died upon the table, and it was only after the employment of artificial respiration and ammonia that he rallied. His pulse never rallied from the shock of the operation, death occurring on December 16th, fifty hours after. The extent of the injury was not discovered until after death. There having been no displace-

ment of the femur, nor of the fragments of the patella, which were held in position by the ligament, the fracture of the outer condyle and of the patella had not been diagnosed. The pathological specimen was contributed, with the history, to the Army Medical Museum by the operator, and is No. 5782 of the surgical section.

DXCII.—*Account of an Amputation of the Thigh for Compound Fracture.* By V. B. HUBBARD, Assistant Surgeon, U. S. A.

Private Maurice C. Hickey, Co. G, 19th Infantry, aged 22 years, received a compound comminuted fracture of the right tibia and fibula, by the falling of a flag-staff upon the leg, while assisting to raise the same, July 3, 1866, at Fort Gibson, Choctaw Nation. On the same day he was admitted to the post hospital. His constitution responded in a very emphatic manner to so powerful a source of irritation. The fever was remittent in type, the febrile exacerbation being vesperal. The evening pulse was 150 to 160, the morning pulse 110 to 120. The exacerbation commenced about 3 P. M., and ended about midnight. By the 23d of July, the parts were intensely inflamed, the inflammation extending to, and in places reaching above, the knee. The limb enlarged to the full capacity of the skin, which was tense and shining, and hot to the touch. The limb was commencing to give out an odor which awakened suspicions of incipient hospital gangrene. On the latter date, chloroform was administered, and the thigh amputated, by the double flap method at the junction of the middle with the lower third. Simple water dressings were applied. The patient rallied well from the effects of the operation. The constitutional irritative fever left him almost simultaneously with the source of irritation. Neuralgic pains, causing severe twitching of the stump, referred to the amputated limb, continued seventy-two hours. The weather, three weeks before and three weeks after the operation, being excessively warm and dry, the thermometer, at noon, indicating 100° F. in the shade, the stitches sloughed out, and the edges of the flaps sloughed away sufficiently to expose the sawn extremity of the femur, on the fourteenth day after the operation. The wound healed, excepting the parts immediately around the bone, the extremity of which necrosed. September 30, 1866, the soldier was awaiting his discharge from the service on surgeon's certificate of disability. A second operation would have been performed for the removal of the dead bone, had the physical condition of the patient been such as to render it justifiable; this, however, together with the extreme heat, contra-indicated further surgical interference.

DXCIII.—*Account of an Amputation of the Thigh for Compound Fracture, by Vermale's Operation.* By J. F. BOUGHTER, M. D., Acting Assistant Surgeon.

John Johnson, a Norwegian, aged 39 years, on January 19, 1869, fell from a rock on the Big Sioux River to the ice, a large rock and the tree he had been cutting rolling after him. He was found a few hours afterward, and was taken to his home, a dirty, unventilated hut, partially under ground. On February 9, 1869, he was admitted for treatment to the hospital at Fort Dakota, Dakota Territory, in a very weak and emaciated condition. His diet had been very meagre. Examination disclosed a compound comminuted fracture of the right tibia and fibula extending to the knee-joint. Portions of the tibia protruded in several places, and, upon pressure with the hand, the bones could be felt crushed to small fragments, some of which had been discharged from the wounds, which were suppurating freely, but were not much swelled. There was, also, a transverse fracture of the left patella, and bed-sores on the hip. Stimulants were administered, and the patient being bathed was put to bed. On the next day, beef essence and milk punch were freely given, the left leg was placed on an inclined plane, and the fractured patella was brought together with adhesive straps. On February 11th, the right thigh was amputated by Vermale's operation (flap) three inches above the knee-joint. The femoral and two other arteries were tied; the flaps were exposed, and cold water was poured over the surface until glazed; then sutures were introduced and the flaps were brought together. Morphine was given, cold-water dressings were applied to the stump, and renewed every five minutes. The left leg was elevated and extended in a swing. On February 12th a tonic and anodyne were given. On the next day,

his bowels not having moved for fifteen days, sulphate of magnesia was given, and being continued until the 18th without effect, castor oil and turpentine were prescribed, which gradually relieved the constipation. On the 16th, the stump being a little swelled and puffy, a chlorinated linseed meal poultice was applied, and on the 20th, warm-water dressings were resorted to. From the latter date to March 2d the patient improved rapidly. A very large quantity of hardened feces, retaining the impress of the sulci of large intestine, was discharged. On the latter date the ligatures from the femoral and from one of the small arteries came away, and the remaining one in a day or two afterward. On March 31st the bandages and compresses were removed, and the patient attempted to walk but was compelled to desist on account of pain in the left knee; soap liniment was applied to the joint. The edges of the patella, which were one-half inch apart, united by ligamentous union. No attention having been given to this wound previous to his admission to hospital, bony union could not be expected. There was no swelling in the joint, and it was thought that ankylosis would not occur. On April 18th he was about to start for home. Dissection of the amputated leg disclosed a stellated fracture of the head of the tibia, extending into the knee-joint, with both bones crushed into about twenty fragments.

DXCIV.—Memorandum Relative to a Secondary Amputation of the Thigh.

Private Jesse M. Jones, Co. K, 21st Indiana Volunteers, aged 29 years, was wounded at




FIG. 42.—Gunshot fracture of right femur at junction of upper and middle thirds. Spec. 5558, sect. I, A. M. M.

Baton Rouge, Louisiana, August 5, 1862, by a musket ball, which fractured the right femur, at the junction of the middle and upper third. He was taken to the regimental hospital the night after, remained a day, and was then sent, by a transport steamer, to New Orleans, the limb meanwhile being supported by bandages and pillows. On arrival, August 7th, he

was admitted to the St. James Hospital, where a long splint was applied, seventeen days after the reception of the wound. The patient was discharged the service April 15, 1863, and was pensioned, his disability being rated total and temporary. From that date till January, 1869, he suffered much pain from frequent exfoliations and abscesses, when he entered Providence Hospital at Washington; and on the 23d, Doctor D. W. Bliss, late Surgeon, U. S. V., amputated the thigh in the upper third, and afterward contributed the pathological specimen to the Army Medical Museum. It is represented in the adjoining wood-cut, showing great deformity with exfoliations on posterior aspect, and a fragment of lead imbedded in the callus. On March 9, 1869, the patient visited the Museum, recovered, and his photograph was taken to accompany the specimen. (A. M. M. Card Photographs, Vol. 1, page 27.)

DXCV.—Account of an Amputation of the Thigh for Gunshot Injury. By A. F. STEIGERS, M. D., Acting Assistant Surgeon.

Private Robert Kinnear, Co. C, 21st Infantry, aged 27 years, received an accidental gunshot fracture of the knee-joint, with extensive laceration of the parts, and was admitted to the hospital at Camp Verde, Arizona Territory, on October 4, 1870, in an exhausted and almost pulseless condition from previous loss of blood. Operation was postponed until the next day for reaction, when, the knee being much swollen, Acting Assistant Surgeon J. T. Pindell, after chloroforming the patient, amputated the thigh just above the knee, by the lateral-flap operation. There was little hæmorrhage; the femoral artery and its branches were ligated; reaction was moderate. Beef-tea and stimulants by enema were ordered. Ninety-nine hours after the reception of the wound, he died of pyæmia.

DXCVI.—Memorandum relative to an Amputation of the Thigh for Synovitis.

Private William H. Long, Co. B, 84th Indiana Volunteers, sprained his left knee joint in the autumn of 1864. He was mustered out of service on June 14, 1865, and pensioned. On May 25,

1866, Pension Examiner John C. Helm reported that there was inflammation of the synovial capsule, which had resulted in suppuration and abscess. There were then five or six points discharging pus; the knee was swollen and enlarged, and there was general œdematous infiltration of the whole limb. The patient was at his home (Eaton, Delaware County, Indiana), unable to leave his bed, and his disability was rated total and permanent. On September 26, 1867, Dr. Helm reported that the leg was about as before described, except that it was worse, and was wearing down the patient's health, and that no relief could be afforded except by amputation. In the latter part of May, 1869, he was fitted with an artificial limb by Hiram A. Kimball, who stated that the thigh had been amputated on February 19, 1868 (amount of limb lost twenty-four inches), by the flap operation. The stump was less than normal size, but was perfectly healed.

DXCVII.—Remarks on an Amputation of the Thigh for Gunshot Injury. By S. M. HORTON, Assistant Surgeon, U. S. A.

Private Joseph McKeever, Co. E, 27th Infantry, aged 28 years, was wounded in an engagement with the Indians near Goose Creek, Dakota Territory, November 4, 1867, by a round ball, which fractured and extensively comminuted the left femur in its lower third. He was admitted to the post hospital, Fort Philip Kearney, Dakota Territory, on the same day. The femur was greatly comminuted for seven inches. Extensive hæmorrhage followed the removal of a large clot while cleansing the wound. The patient seemed to be in good health, and did not appear to suffer much from the wound. On November 6th, I administered equal parts of ether and chloroform, and amputated the thigh at the junction of middle and lower thirds by a large anterior and small posterior-flap method. The patient did well, and partook of stimulants freely until the evening of the 7th, when his pulse became very weak. Death resulted on the morning of November 8, 1867, from nervous prostration. The autopsy revealed a good attempt at the formation of a fibrinous plug above the ligature of the femoral artery.

DXCVIII.—Memorandum relative to an Amputation of the Thigh for Gunshot Injury. By W. H. FORWOOD, Assistant Surgeon, U. S. A.

Private John Martin, Troop H, 7th Cavalry, was wounded in quarters on March 15, 1867, by a missile which entered the left thigh anteriorly at the junction of the upper and middle thirds, passed through the quadratus femoris, semi-membranosus and semi-tendinosus muscles, and, injuring the coats of the femoral vessels, fractured the femur longitudinally six inches. He was admitted to the post hospital, Fort Riley, Kansas, on the same day, the injured parts being much swollen and lacerated, the coats of the femoral vessels torn, and pieces of bone detached and driven into the soft parts. The patient being somewhat intoxicated, was much excited, and suffered great pain. His general health was good; pulse 95. Chloroform was administered, and the left thigh amputated at the junction of the upper and middle thirds by the lateral-flap method. There was but little hæmorrhage; the femoral artery only was tied. Silk sutures, adhesive straps, and cold-water dressings were applied. By March 31, 1867, all symptoms were very favorable, and a good result was anticipated.

DXCIX.—Report of a Primary Amputation of the Thigh for Compound Comminuted Fracture. By B. J. D. IRWIN, Surgeon, U. S. A.

Private James McN——, Company H, 43d Infantry, aged 33 years, received, while intoxicated. April 30, 1868, a compound comminuted fracture of the lower third of the left thigh by being run over by a street car in the city of Detroit, Michigan, some three miles from Fort Wayne. He was temporarily attended by physicians in Detroit, and brought to the post hospital at Fort Wayne, May 1, 1868, about 8 o'clock A. M. The interior side of the thigh, from within three inches of the groin, down to the knee, was much lacerated; the bone was protruding; no arterial hæmorrhage had taken place. There was nausea and vomiting, owing to the presence of liquor, of

which he had partaken freely. On May 1, 1868, at 3 o'clock, P. M., being assisted by Dr. D. O. Farrand, I amputated the thigh through the upper portion of the middle third, while the patient was under the influence of chloroform. The patient was weak, but cheerful. Beef-tea and brandy were given every half hour. Twenty drops of chloroform were given internally one hour before the operation. After the amputation, the patient was quite weak. The muscles and all the small vessels were much bruised and mashed, the femoral artery and deep saphenous vein being the only vessels requiring ligation. The shock of the operation was severe, from which he rallied slowly. The reaction was complete at 7 o'clock P. M.; the pulse was small and feeble—about 120. At 10 o'clock P. M. the patient felt better, took beef-tea and small quantities of brandy and water every half hour; pulse continued weak and feeble, at 120. He complained of much pain in the lost limb. One-fourth of a grain of sulphate of morphia was given. He slept comfortably about two hours, but sank gradually, and died from exhaustion at 4 o'clock A. M., May 2, 1868. The specimen is No. 5447, section I, A. M. M.

DC.—*Remarks on an Amputation of the Thigh for Gunshot Injury.* By JULES LE CARPENTIER, M. D., Acting Assistant Surgeon.

Serrapia Montiel, a Mexican, aged 45 years, and of broken constitution, was fired upon by two drunken soldiers on December 31, 1868, and was wounded by a pistol ball which struck the anterior inner aspect of the right thigh about the middle, passed downward and outward, producing a transverse fracture, with some comminution, at the point of lesion, and a longitudinal fracture extending three and one-half inches up the shaft, and, dividing into about six pieces, scattered and lodged. On the next day he was conveyed to the post hospital at Fort Bayard, New Mexico. The patient had lost much blood, and stimulants were given to produce reaction. At 2 P. M. on January 2d, I chloroformed the patient, who did not exhibit any signs of reaction, but became at once insensible, and amputated the thigh at the junction of the upper thirds by the antero-posterior flap operation. The hæmorrhage was abundant, notwithstanding the measures taken to check it. But three ligatures were required. While the stump was being dressed with alcohol and water the patient suddenly ceased breathing, and the pulse could not be felt. Cold water was dashed into his face, and ammonia was applied to his nose, when the respiration became natural. Stimulants, an anodyne, and beef-tea were given, but, as expected, he died three hours after the operation, of exhaustion.

DCI.—*Report of an Amputation of the Thigh for Gunshot Injury.* By A. J. GRAY, M. D., Acting Assistant Surgeon.

Willis B. Morgan, an indigent civilian, aged 26 years, asthenic from constitutional syphilis and long-continued dissipation, was accidentally wounded on December 27, 1870, by a round musket ball which entered the leg three inches below the knee-joint, passed down between the tibia and fibula, and lodged under the external malleolus, slightly fracturing that process, and opening the ankle-joint. On the next day he was admitted to the hospital at Fort Bayard, New Mexico; and on the 29th, the wound being gangrenous, the patient was rendered insensible with equal parts of ether and chloroform, and the thigh was amputated at the lower fourth by circular operation. The stump was dressed with cold-water dressings, followed by warm fomentation, and wine, beef-tea, and tonics were given. On December 31st the case was progressing favorably.

DCII.—*Memorandum relative to an Amputation of the Thigh for Synovitis.*

Henry Pearce, Assistant Surgeon, 150th New York Volunteers, according to the records of the Pension Office, had been suffering from synovitis of the left knee-joint for some years, when, on October 25, 1863, the disease was aggravated by his horse falling with him. He was treated at the hospital at Tullahoma, Tennessee. His knee grew rapidly worse, and he walked with great difficulty. On April 7, 1864, he was discharged the service, on surgeon's certificate of disability.*

* Resigned April 7, 1864.—*Official Army Register of Volunteers.* Part 2, p. 655.

On November 23, 1868, at Pawling, Dutchess County, New York, the patient's home, Doctor William C. Bennett amputated the left thigh in the lower third by the flap operation. Eight months after, he was furnished with an artificial limb by Monroe and Gardiner. At that date the stump was perfectly healed, but was one-third less than normal size.

DCIII.—*Note on an Amputation of the Thigh.*

Private Reese Furboy, late of Co. C, 98th Ohio Volunteers, underwent amputation of the left thigh in the upper third, by flap operation, for "sickness," at his home in Cadiz, Ohio, on October 9, 1867, by Surgeons Uptegraph and Connelly. On April 28, 1870, he was furnished an artificial limb, by R. Clement, Philadelphia, which gave satisfaction. At that date the stump was sound, but less than normal size.

DCIV.—*Account of a Secondary Amputation of the Thigh for Gunshot Injury.* By S. M. HORTON, Assistant Surgeon, U. S. A.

Alfred Ramey, a citizen, aged 20 years, was fired upon by Indians while sitting, in company with other citizens, by a fire, in a small camp near the stockade at Fort Philip Kearney, Dakota Territory, November 1, 1866, and had his right patella broken into five fragments. He was admitted into the post hospital on the next day, where simple dressings were applied, and two-thirds of the patella were removed, as the fragments loosened by suppuration. By April, 1867, the patient had become greatly emaciated and debilitated from pain, exhaustive suppuration, hectic fever and diarrhoea; there was an ulcerated bed-sore over the sacrum three and a half inches in diameter; sinuses led from the surface into the knee-joint; and there were abscesses in the middle and lower third of the thigh and the leg. The entire limb became erysipelatous, there was muscular ankylosis of the hip-joint, and on the least motion of the knee-joint caused excessive pain. The patient would not consent to an operation until April 25, 1867, when, despairing of his life, he allowed equal parts of ether and chloroform to be administered and the thigh to be amputated in its upper third, by short anterior and long posterior flap method. Light and perfectly dry dressings were afterward applied. The stump healed by first intention at every point, except in the angles of the flaps, in one of which were the ligatures. On the nineteenth day after operation the ligatures came away, the stump was entirely healed, and the patient was able to leave his bed. An examination of the amputated limb showed extensive disorganization of the knee-joint and abscesses in the leg and thigh, which had dissected up the muscles from the bones and from each other throughout the limb. The lower portion of femur and upper half of tibia and fibula showed the entire surface denuded of periosteum, and eroded. There was bony ankylosis of the knee-joint.

DCV.—*Account of an Amputation of the Thigh for Disease of the Knee-Joint.* By W. F. SMITH, Assistant Surgeon, U. S. A.

Private Thomas Ryan, Troop A, 5th Cavalry, aged 24 years, was admitted to the post hospital at Raleigh, North Carolina, on May 26, 1866, with fibro-cellular disease of the lower extremity of the right femur, involving the knee-joint, attributed to a kick by a horse. On August 18, 1866, the knee-joint was enormously enlarged, and the skin was tense and shining. In some spots, fluctuation was perceptible. An immense sac, of what proved to be disintegrated blood, extended as far as the middle of the thigh. The patient was slightly worn from constant pain, but his general health was excellent. On this date, I chloroformed the patient, and amputated, by circular operation, at the junction of the upper thirds of the thigh. The case progressed uninterruptedly well for three weeks, when the patient was attacked by very severe bilious remittent fever, which terminated in death on September 17, 1866. No autopsy.

DCVI.—*Account of an Amputation of the Thigh for Chronic Inflammation of the Knee-Joint.* By A. S. EHLE, M. D., Acting Assistant Surgeon.

Jackson Washington, a freedman, aged 22 years, was admitted to the hospital at Little Rock, Arkansas, on January 5, 1867, with chronic inflammation of the right knee-joint. There was a

constant discharge from two fistulous openings on the outer side of the knee, communicating with the joint, and the patient was much emaciated. Never having received a blow or kick about the knee, the patient could assign no cause for the disease, except that he had been obliged to work in the water a number of days just previous to its commencement, about six weeks before admission to hospital. Iron and quinine were immediately ordered, under which his appetite and general health improved. On February 20th, Surgeon J. R. Smith, U. S. A., amputated the thigh at the junction of the lower thirds by the flap operation. During the first day, the patient was apparently recovering from the shock of the operation, and it was thought he would surely recover until the morning of the 25th, when slight twitchings of the extremities were observed, which increased in violence and frequency, death occurring at 2 o'clock on the afternoon of the same day. The pathological specimen, with history, was contributed to the Army Medical Museum by Acting Assistant Surgeon A. S. Ehle, and is No. 4722, Section I.

DCVII.—*Note relative to an Amputation of the Thigh for Gunshot Injury.* By J. B. CRANDALL, M. D., Acting Assistant Surgeon.

First Lieutenant Ephraim W—, 5th Infantry, aged 30 years, received, in an engagement with Indians, sixty miles west from Fort Dodge, Kansas, September 23, 1867, a gunshot wound of left thigh, extensively fracturing the femur. He was on the next day admitted to post hospital, Fort Dodge, Kansas, much prostrated from shock of wound and transportation. The injured parts were in good condition. On September 25th, Assistant Surgeon H. A. DuBois, U. S. A., administered chloroform, and amputated with anterior and posterior skin flaps at junction of middle and upper thirds. The patient bore the operation very well, and improved rapidly. [This officer was retired April 3, 1869.]

DCVIII.—*Remarks on an Amputation of the Thigh on Account of Injury.* By W. SHACKLEFORD, M. D., Acting Assistant Surgeon.

Private Daniel M. Young, Co. F, 23d Infantry, was run over by the wagon of which he was teamster, February 29, 1868, producing a compound fracture of the middle third of the left tibia and fibula. He was admitted to post hospital, Camp Watson, Oregon. The leg was first put in a fracture-box, and constant application of snow maintained until suppuration and displacement of fractured parts by swelling rendered this useless. By the 12th of March, the soft parts were very much inflamed and painful, and suppuration extended to the knee-joint. The patient was much debilitated from loss of sleep, anorexia, and continued great pain. He was very nervous, and his digestion was much impaired by opium, given to allay pain. On the latter date, chloroform was administered, and the thigh amputated just above the knee-joint, by the circular method. The expended condition of the patient and the considerable evolvment of the knee-joint rendered a more economical course dangerous. The patient immediately began to improve without one untoward symptom; his recovery, however, was delayed by a hæmorrhage from a small artery on the day following the operation, and by a fall, June 31st, the whole weight of his body striking upon the stump. On the 17th of May, 1869, he was examined for an artificial limb, and at that time the stump was perfectly healed.

DCIX.—*Memorandum Relating to a Secondary Amputation of the Thigh, in the Middle Third, for Gunshot Injury.*

Dr. J. A. Freeman, formerly of the U. S. Colored Troops, reports that he was consulted on March 15, 1868, by John H. Echstrand, late a lieutenant of the same organization, relative to a tumor near the left popliteal space. Ascertaining the previous history of the patient, it was found that he had been wounded at Lookout Mountain, November 24, 1863, by a fragment of shell, which entered the left tibia externally, just below the head, causing him to remain off duty only a few days. Again on August 30, 1864, he was wounded by guerrillas, a pistol ball having fractured his

left femur. One-half the ball had been extracted, and the femur had united so that he was able to walk with a cane in six months; but he always had pain in the region of the first-wound, and in September, 1867, the difficulty of locomotion increased. Cutting down upon the tumor it was found to be scirrhous, extending across beneath the anterior ligament, and continuous with the synovial membranes of the joint, which were increased to an inch in thickness. The tumor and the tibia were found to be softening. The patient was unsuccessfully treated until July 17, when amputation of the thigh just above the seat of the fracture was performed. The wound was dressed with carbolic acid and glycerine, and healed by first intention, except at the points of exit of the ligatures. On September 18, 1868, the operator reported his patient to be "well and hearty," and transmitted to the Army Medical Museum the pathological specimens, which are numbered 5479 and 5480, respectively, of the Surgical Section. The first is the lower half of the left femur, showing a well united oblique fracture; the second, the proximal extremity of the tibia, perforated antero-posteriorly, from which the entire cancellous tissue is absent.

Amputations at the Hip-Joint.

DCX.—*Report of a Case of Secondary Amputation at the Hip for Gunshot Injury.** By HENRY A. DUBOIS, Assistant Surgeon U. S. A.

"Antonio Mutieres, a Mexican, aged 33 years, employed by the Quartermaster's Department as a teamster, was received into the post hospital at Fort Union, New Mexico, on May 11, 1867. Early that morning he had had a difficulty with another Mexican, employed in the same train, which resulted in his drawing a pistol on his opponent, who instantly drew his revolver and fired at Mentieres, the ball taking effect in his left hip. I saw the case soon after the patient's admission, at about eleven in the forenoon, and found the wound of entrance about two inches beneath and a little in front of the anterior superior spinous process of the ilium. The man was suffering but little, and there was scarcely any hæmorrhage. I enlarged the wound and introduced my finger, and traced the ball to the neck of the femur, where it was firmly lodged in the anatomical neck of the bone. With a Tiemann's bullet forceps, I, with some trouble, removed the ball and a small piece of wadding. It was an ordinary conical revolver ball, and was fired from a distance not exceeding two or three yards. The man was kept perfectly quiet, a cold-water dressing applied, and he was fed with easily digested and nourishing food. At this time, and for the period of some two weeks, there was no inflammation involving the joint, a smart blow on the heel causing no pain. The patient gradually lost flesh, but suffered little. The discharge from the wound consisted of ill formed pus having little smell, and occasionally streaked with blood. A few small fragments of bone were subsequently exfoliated. The patient slept but little, and perspired much at night; his appetite also diminished, and he was evidently losing strength daily. To these symptoms the following were afterward superadded: Intense pain running up the side and down the thigh to the ankle, much aggravated by the slightest movement or by the least pressure on the part. These symptoms increasing, I proposed the operation afterward performed, but could not gain the patient's consent thereto, he informing my interpreter that he would be up and on his crutches in two weeks. I had, previous to this, made up my mind as to the propriety of amputating at the hip, and felt confident of ultimately obtaining the patient's consent as a relief from the terrible pain suffered in these cases. I had rejected the operation of excision, as in the only case in which I had performed it† it had caused a shock as great to the system as I believed would result from amputation, and though I found any number of authors who recommended excision, in preference to amputation, in this class of cases, I found also that they had, with few exceptions, never tried, or seen it tried, in cases resulting from gunshot injuries. Of the thirty-two cases in which excision was performed during the late war, four only were successful, and how far they succeeded in giving a useful limb is not fully recorded.‡ Surgeon J. C. McKee, who was

* See a Report on Amputations at the Hip-Joint in Military Surgery, Circular No. 7, S. G. O., 1867, p. 46; and American Medical Record, Vol. II, p. 266.

† See a Report on Excisions of the Head of the Femur for Gunshot Injury, Circular No. 2, S. G. O., 1863, Case LVI, p. 49.

‡ See Circular No. 6, S. G. O., 1865, pp. 61-74.

visiting the post at this time, examined the case and advised amputation in preference to excision. Some ten days after I first proposed the operation, I obtained the patient's consent, and as I deemed it advisable, owing to the rapid loss of strength, that the operation should be performed as early as possible, I at once made my arrangements, and on June 22d, having obtained the assistance of Dr. Shout, of Las Vegas, Dr. Simpson, of Moro, and of Hospital Steward Enfield, U. S. A., I proceeded at half past twelve in the afternoon to amputate. I had had previously constructed a rough clamp for compressing the aorta. The patient was quickly put under the influence of a mixture of ether and chloroform, removed to the operating table, and all my assistants having previously been informed of their duties, the operation was quickly and readily performed, the thigh being removed in, I am told, fifteen seconds. The clamp controlled the arterial hæmorrhage well; in fact, so well that it was extremely difficult to find and secure the arteries; but the venous hæmorrhage was more troublesome. Some fifteen ligatures were used in all. Little blood was lost. The acetabulum was found much necrosed, and the tissues a good deal diseased. The diseased structures, as far as practicable, were removed, and a cerate cloth laid between the flaps, and the patient then put to bed. His condition during the operation was on the whole good. The pulse several times became extremely feeble, but it quickly rose again under slight stimulation. The breathing was free. The clamp, which made pressure one inch above and to the left side of the umbilicus, apparently caused no inconvenience, and certainly interfered very little, if any, with his regular breathing. The anterior flap was made long while the posterior one was extremely short. The patient, before taking the anæsthetic, received hypodermically one-half a grain of morphia sulph., and on recovering from their joint influence talked and seemed at perfect ease. He was given small quantities of beef-tea and brandy, and also a little ammonia, as the pulse was feeble and rapid. He complained of great thirst, and craved ice, which was given to him in small quantities. I hoped by these means to bring about reaction and overcome the profound shock under which his system was laboring. His pulse gradually became more feeble, ran up to 160 and 180, and became imperceptible, and yet he was living, talked much, and in every way perfectly sensible. He complained of hunger, said he was as hungry as a dog, and rejected almost immediately everything he took into his stomach. In this condition I resorted to hypodermic injections of tincture of opii, with the effect of bringing up the pulse and quieting to some extent the irritability of the stomach. In this state he lingered about thirty hours, sometimes almost entirely pulseless; but with a warm skin and perspiring profusely; at other times with a quick feeble pulse, sleeping a few moments at a time, until half past five in the evening of the day after the operation, when, taking a piece of ice in his mouth, he said, "I am going," and died almost immediately. A *post-mortem* examination showed the flaps glazed to some extent but not united. Wire sutures, it should have been stated, were used to close the wound, which was done some ten hours after the operation. The acetabulum and head of the femur were both extremely necrosed, and the tissues much diseased. If the operation did not save the life, it at least promoted the happy dying, the Euthanasia which Hippocrates says the physician should have as his second object, considering the saving of life his first."

DCXI.—*Of a Case of Re-amputation at the Hip-Joint.* By GEORGE A. OTIS, Assistant Surgeon, U. S. A.

Private J. Fabry, Co. K, 4th Artillery, aged 38 years, was wounded by shrapnel, August 16, 1864, at Deep Bottom, Virginia, his left leg being shattered, and a portion of the projectile lodged about the knee. His leg was amputated at daybreak the morning following, by Surgeon G. W. Jackson, 53d Pennsylvania Volunteers, and he was sent to the hospital at City Point, and thence to Philadelphia. On August 23d, the stump suppurating and sloughing, an amputation through the knee-joint was done by Acting Assistant Surgeons Atlee and Egan. On August 28th a fuse screw was extracted from the muscles of the thigh by Acting Assistant Surgeon J. B. Roe. The Satterlee Hospital Report for September, 1864, represents the patient as weak, and with a bed-sore over the sacrum; necrosis of the femur, with more pain than large doses of morphia would alleviate. On February 4, 1865, an incision was made to evacuate an abscess that had formed in

the outer part of the thigh. A piece of cloth was removed from the cavity of the abscess. On May 25, 1865, this soldier was sent to regimental headquarters at Fort Washington. Abscesses, which Acting Assistant Surgeon J. H. Bayne endeavored to drain by setons, continued to form within the tissues of the stump. In October, 1865, the patient received an artificial limb, but could not use it without discomfort. During the winter, the stump was irritable and tender. On January 12, 1866, the regiment changing station, Fabry was discharged on surgeon's certificate of disability, and was received at Soldiers' Home, January 31, 1866. The remnant of the femur was affected by osteomyelitis, and Surgeon Laub, U. S. A., had frequent occasion to have the stump poulticed and abscesses opened. October 27, 1866, Assistant Surgeon J. S. Billings, U. S. A., made an exploratory and palliative operation, cutting down on the outer aspect of the thick involucrum, a little below the trochanter major, trephining over one of the cloacæ, and discovering a sequestrum, consisting of the shaft of the femur. Fabry was pensioned, and remained at Soldiers' Home for the next three years, suffering acutely, at times, from suppuration in the stump, and again enjoying intervals of comparative comfort. The general health did not give way materially under the protracted suppuration. The patient was exempt from albuminuria, and the viscera generally were in a normal condition. The nervous system seemed shattered, a result ascribed to the inordinate doses of narcotics which the patient consumed. When suffering from the abscesses in his stump, Fabry would beg that an amputation should be practiced; but, as soon as the pain was mitigated, his resolution would fail. Finally, he made up his mind to undergo the operation, and, on May 15, 1870, I exarticulated at the hip, and removed the stump.*

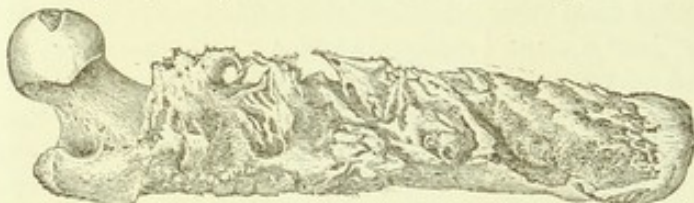

FIG. 43.—An unusually large involucrum, from a case of chronic osteomyelitis. Spec. 5684, Sect. I, A. M. M.


The single anterior-flap procedure was used, only the flap was cut from without inward, because the great masses of foliaceous callus enveloping the upper third of the femur precluded transfixion. The accompanying wood-cut will indicate the extent of these osseous formations. Fabry had a rather rapid convalescence, being about on crutches in twenty-one days. The cicatrix remains at this date, fourteen months and more after the operation, perfectly sound and firm, and Fabry, who remains as a pensioner at Soldiers' Home, enjoys good general health. The lithograph opposite is accurately copied from a photograph of him, made at the Army Medical Museum one year after the operation.

Amputation of all Four Limbs.—One instance of this remarkable surgical undertaking was reported.

DCXII.—*Report of a Case of Recovery after all Four Limbs were Amputated on Account of Frost-Bite.* By ALFRED MULLER, M. D., Acting Assistant Surgeon.

Benjamin Franklin, a private of Troop H, 2d Minnesota Cavalry, aged 26 years, left Fort Wadsworth, Dakota Territory, on December 9, 1865, on furlough to visit his home in Faribault County, Minnesota. After being three days out in the stage from Fort Wadsworth to Fort Ridgely, Minnesota, the party of which he was a member being overtaken by a severe snow-storm, which continued three days, was obliged to leave the stage, on December 13th, in a snow-drift on the prairie, distant about one hundred and ten miles from the place of destination. He wandered over the prairie that day and night, and the following four days, through the storm, freezing his limbs, nose, ears, and cheeks, taking no food or water, until found in a dying condition by Indian scouts, and taken to a station-house on the road, on December 17, 1865. He was sent to hospital at Fort Ridgely, for treatment, where he arrived on the night of the 24th, almost completely exhausted. After slowly thawing the ice from his clothes, stockings, and boots, which had not been removed since December 13th, it was found that both hands and fore-arms were completely mortified by freezing up to middle third, both feet and legs as far as the upper third, both knees over and around the patellæ, and both alæ and the tip of the nose, all presenting a dark, bluish appearance with

* The details of the operation and after-treatment have appeared in the *American Journal of the Medical Sciences*, Vol. LXI, page 141.



Ward, phot.

1871, 1871.

OTISS SUCCESSFUL RE-AMPUTATION AT THE HIP JOINT.

some swelling, and were fairly circumscribed. No evacuation of the bowels having taken place since December 9th, and the patient suffering from singultus and constant pain in epigastric region, a light cathartic was administered, which, in twenty-four hours, gave relief. A mild but nourishing and stimulating diet was given, which, in a week's time, improved his condition. The four frozen limbs were enveloped in cloths moistened with a solution of chloride of zinc. The frozen ears and cheeks healed in due time, and presented nothing remarkable. The gangrenous parts of the nose separated on January 6, 1866, and soon healed, with the loss of the tip of the nose and parts of the alæ, leaving the septum somewhat exposed. On January 10th, the lines of demarcation on all four limbs and the patellæ were distinct and deep. A most offensive smell was emitted, in spite of the liberal use of disinfectants; notwithstanding this the patient obstinately opposed operative interference, being strongly seconded by his wife. On January 13th, the patient, after a little hesitancy, consented to the amputation of the arms. By this time the lines of demarcation had exposed the bones, and as the patient refused the administration of an anæsthetic, and his debilitated condition not admitting the loss of blood, it was determined to carefully dissect as much healthy flesh from the radius and ulna as the line of demarcation would admit without cutting any blood-vessels, and then saw through the bones. This was successfully done on both fore-arms, in middle third, the patient losing very little blood, and complaining of hardly any pain. The great relief afforded by this operation so changed his former aversion to being operated on, that on the next day, he begged to have both legs amputated in the same manner, which was done, three days afterward, and with the same favorable results. In this case, the four stumps could not be covered with sufficient skin, and much had to be left to self-reparation, which took place to an extraordinary extent, keeping even step with the gradual improvement of the unfortunate's condition. The four stumps healed over with healthy granulations, requiring the removal of only two pieces of bone, one from the right tibia, and one from the left ulna, which separated on April 17th and 22d respectively. After applications of diluted nitric acid, the conical stumps soon became covered with a solid cicatrix. Meanwhile, the open sores over the patellæ on both knees, which became as large as the palm of a hand, after the separation of the gangrenous parts, had undergone cicatrization. They, however, reopened in a fistulous manner about the middle of April, and it was found that in both of the patellæ large sequestræ had formed. A longitudinal incision was made over the right patella, and a large portion of the front part of this bone was easily removed. Another portion was also removed from the left patella, but with more difficulty. Both knees readily healed, leaving the patellæ ankylosed. The patient was mustered out of service with his company on April 28, 1866; but remained under treatment until June 19, 1866, when he left for his home, perfectly recovered. The same year, Congress passed a special act pensioning him for total disability. The pathological specimens, with history, were contributed to the Army Medical Museum by the operator, and are numbered 4711, Surgical Section and consists of four exfoliations. Dr. Muller expresses the belief that the patient can never make use of artificial limbs.

Of the two hundred and fifty-one cases of amputations cited in the foregoing reports, twenty-five resulted fatally; one hundred and forty-three were due to gunshot wounds; eight to railway accidents; nine to incised wounds; forty-five to other injuries; forty-one to frost-bites; and five to diseases. Setting aside the one hundred and thirty-six successful operations on the fingers and toes, there remain one hundred and fifteen major amputations, with a mortality rate of 21.7—a very favorable exhibit. Sixty-three of these major amputations were primary, twenty-seven were intermediary, and twenty-five were secondary. The death rate in these classes was, for once, almost uniform, being primary 22.2, intermediary 22.2, secondary 20. This circumstance is explained partly by the small number of cases analysed, and partly by the proportion of severe cases included in the primary class. Among the major amputations not less than seventeen were multiple amputations: of fore-arms, 2; of arm and fore-arm, 4; of feet, 3; of legs, 4; of leg and foot, 2; of thigh and leg, 1; of four extremities, 1; with three fatal results only.

TABULAR STATEMENT OF CCL AMPUTATIONS.

Results of One hundred and Sixty-four Amputations in the Upper Extremities.

REGION.	Cases.	Primary.	Intermediary.	Secondary.	Date of operation unknown.	Successful.	Fatal.	Result undetermined.	Ratio of mortality.
Amputations of Fingers	114	75	17	6	16	114
Amputations at Wrist.....	2	2	2
Amputations of Fore-arm.....	20	19	1	18	2	10.0
Amputations of Arm.....	24	18	3	3	19	5	20.8
Amputations at Shoulder-joint.....	4	3	1	3	1	25.0
Total.....	164	117	21	10	16	156	8	4.9

Results of Eighty-six Amputations in the Lower Extremities.

REGION.	Cases.	Primary.	Intermediary.	Secondary.	Date of operation unknown.	Successful.	Fatal.	Result undetermined.	Ratio of mortality.
Amputations of Toes.....	22	4	5	9	4	22
Amputations of Foot.....	6	2	3	1	6
Amputations at Ankle-joint.....	4	1	3	3	1	25.0
Amputations of Leg.....	23	8	11	4	18	5	21.7
Amputations at Knee-joint.....	3	1	2	3
Amputations of Thigh.....	26	10	5	11	16	10	38.5
Amputations at Hip-joint.....	2	2	1	1	50.0
Total.....	86	25	28	29	4	69	17	19.8

To these two hundred and fifty cases must be added the instance of amputation of the four extremities (p. 216). As has been already remarked, the mortality rate was unusually small. In looking over the reports, it is impossible to avoid the conviction that the medical officers greatly profited by the experience of the War, and performed their operations with little regard for the narrow rules laid down in the text-books, preferring to adapt their incisions to the exigencies of particular cases. The method of making flaps of the skin and subcutaneous tissue, reflecting them, and dividing the muscles circularly, which had many advocates during the War, remains in favor.

EXCISIONS.

Twenty-nine special reports of cases of excision were made; five were excisions of the bones of the head; sixteen of the upper extremities, and eight of the lower extremities. Among excisions I include operations for trephining, and for removal of parts of the bones of the face. This classification must, I think, be hereafter adopted, although systematic authors have heretofore generally restricted the term "excisions" to the removal of the articular extremities, or of portions of the shafts of the long bones.

EXCISIONS OF THE BONES OF THE HEAD.

Trephining.—Two successful cases of this nature were reported.

DCXIII.—*Report of a Compound Fracture of the Skull, treated successfully by Trephining.* By A. C. GIRARD, Assistant Surgeon, U. S. A.

Private John Higgins, Co. I, 20th Infantry, aged 23 years, was admitted to the post hospital at Baton Rouge, Louisiana, March 9, 1869, with a compound fracture of the skull from a brick-bat. At the junction of the left parietal and frontal bones, near the sagittal suture, was a slight depression of bone, of the size of a five-dollar gold piece; the wound of the scalp was two inches long, and the periosteum was destroyed. The wound was cleaned, and light diet ordered. On March 10th, fever set in with violent headache, and the pupils became dilated. Chloroform was administered, a transverse incision elongating the wound was made. The bone was found depressed in a triangular shape, the deepest depression being toward the forehead; the skull was then perforated with the largest of drills, expecting by breaking through the communication between the crack and the hole with a chisel to have sufficient room for elevation. The elevator was then introduced, but failed to raise the depression. The smaller trepan was then applied, using the drill hole for the point of the trepan, and three-fourths of the depression were removed, exposing the dura mater. The ragged edges of the hole were pared down, a few splinters removed, the wound well cleaned, and the edges of the scalp united by suture and ichthyocolla plaster. The patient bore up well under the operation, the latter part of which was performed after his return to consciousness, as he had shown some alarming signs while being put a second time under the influence of chloroform. Ice was applied to the head, and calomel in small doses was given. On March 11th the patient felt tolerably well, but still suffered some headache; on the following day there was erysipelatos swelling of the left eye; no headache. March 14th the patient complained of want of rest, and shooting pain through left eye. There was a little discharge from the wound, and the incision began to fill with granulations. Thence steady improvement took place, and on March 30th the wound had nearly closed. This man was returned to duty in May, 1869.

DCXIV.—*Report of a Case of Fracture of the Skull treated by Trephining.*—By IRA PERRY, Assistant Surgeon, 9th Colored Troops.

Jesus Soldaco, a Mexican, while at a drunken revel in Brownsville, Texas, June 1, 1866, was struck with the stock of a gun, which caused extensive contusion and fracture of the skull from the external angle of the orbit of left eye toward the occiput. The fracture could be traced through the scalp a distance of six inches. About one inch from the orbital angle was a portion of bone one and a half by three-quarters of an inch, which was depressed one-fourth of an inch, and was loose. The patient was admitted to the post hospital totally unconscious, with pulse slow and very feeble. The case being considered hopeless, water dressings only were applied; on the third day, the patient being still alive, the trephine was applied, and fragments of bone elevated; three days

later the patient was slightly conscious; hernia cerebri appeared. Until the tenth day the patient had taken nothing but cold water, but now was given some flour gruel; bowels were opened for the first time with lavement of soap and water. On June 15th the protruding brain began to slough and gradually became less prominent. On June 21st copious hæmorrhage, apparently from middle meningeal artery, occurred, and continuing for two hours, was controlled by pressure. The patient became unconscious, with stertorous breathing, and signs of compression, but on June 25th consciousness returned, and a gradual improvement took place. July 17th the wound was almost healed, and the patient was removed from the hospital by his friends.

Excisions of the Bones of the Face.—Three special reports were received; another case will be found among the operations for tumors.

DCXV.—*Abstract of a Case in which Portions of the Superior and Inferior Maxilla were Removed.*
From a report by JULES LE CARPENTIER, M. D., Acting Assistant Surgeon.

Private John Francis, Troop E, 3d Cavalry, after escaping from the guard-house at Fort Bayard, New Mexico (where he had been confined by the civil authorities and was awaiting trial for murder), went to Hot Springs, where, on April 12, 1868, upon the approach of an escort, he shot himself under the mouth with a rifle. The patient denied all attempts at suicide, and alleged the shooting to be accidental. Soon after the occurrence he was conveyed to Rio Membros for better attendance, being very much exhausted and in a doubtful condition. The chin and most of the inferior maxillary were carried away, the superior maxillaries were fractured, and the soft parts, including the tongue, were badly lacerated and burned. The loss of voice was complete; and the whole buccal cavity, being exposed, presented a hideous appearance. The wound was carefully washed, and numerous small fragments of bone, impacted in the soft tissues, were removed. Simple dressings were applied, anodynes and stimulants were prescribed, and a nourishing liquid diet was administered by means of a syringe, owing to the patient's inability to swallow. On the 14th the patient was sent to the post hospital at Fort Cummings, New Mexico. An operation was delayed "for fear of extensive suppuration, sloughing of some unseen fragments of bone, &c., which would interfere very much with cicatrization." On the night of the 16th the patient suffered severe pain. The stimulants, anodynes, and nourishing diet were continued, and the wound was frequently cleansed with a weak solution of carbolic acid. On the 19th several fragments of bone were removed, after which the pain abated. On the 20th three of the upper incisors fell out. On the 25th an operation was resolved upon, when the patient was, with difficulty, rendered insensible by chloroform, his tongue having first been secured by a thread passed through the tip. The stages in the operation were as follow: 1st. Removal by dissection of two large pieces of the superior maxillaries. 2d. Removal by dissection of a large piece of the inferior maxillary, fractured on the right side, to a level with the coronoid process. 3d. On the left side, incision extending from the posterior part of the coronoid process to the labial commissure, and excision of the bone by saw and pliers to a level with that process. (This procedure was preferably adopted to entire disarticulation of the bone, in order to leave some support to the soft parts.) 4th. Paring the edges of the wound and keeping them approximated by interrupted suture, after which the deformity of the face was not very considerable. The patient was kept two and a half hours under the influence of chloroform, and seemed to stand it very well. His efforts to speak were somewhat intelligible. His general condition was good, but he suffered a good deal from pain in the morning, attended with fever which exacerbated toward the afternoon. The details of the treatment up to May 15th, at which time he was able to walk round the ward, are unimportant, except that the sutures gave way entirely, and that sticking plaster and appropriate bandages were substituted. Attempting to escape on the night of the 23d, he was confined in the guard-house; but on the 25th was taken back to hospital, where, on the 27th, a small fragment of bone was removed during the dressing. His condition was good; but great difficulty was experienced in feeding him. After this ineffectual attempt to escape he declined rapidly, owing, no doubt, to a complete absence of any hope whatever for escaping trial, and he died on June 2, 1868, of exhaustion.

DCXVI.—*Report of a Case in which a Portion of the Maxilla was Removed.* By P. MIDDLETON, Assistant Surgeon, U. S. A.

Private Joseph Smith, Troop I, 8th Cavalry, was shot by a comrade at Camp Whipple, Arizona Territory, November 17, 1867. The missile, a conoidal ball, entered over the bridge of the nose, and taking an oblique direction, fractured the maxillary bone of the right side. He was admitted to post hospital in a state of syncope. The excessive hæmorrhage was controlled by plugging the wound with lint saturated with liquor of the persulphate of iron. The patient grew weak from loss of blood, the face became puffy and swollen, and part of the fractured bone projected into the mouth, preventing the mastication of food. On November 28th a part of the maxillary bone of the right side, containing molar and bicuspid teeth, was removed. The missile could not be found. Hæmorrhage was controlled by plugging. The patient did well until December 3d, when he complained of pain in the joints and back, also of slight numbness of feet and hands. These symptoms increased until December 10th, when the anæsthesia in both feet and legs up to the knee was complete. There was also partial loss of sensation in both hands; the wound was nearly healed, appetite good, and secretions normal. Under a magneto-electric treatment, with iron, quinine, strychnia, and iodide of potassium he gradually improved, being able to walk on December 20, 1867. Sensations were almost normal again.

DCXVII.—*Note of a Case in which Fragments of the Upper Jaw were Excised.* By W. H. KING, Assistant Surgeon, U. S. A.

Private Samuel Walker, Co. D, 3d Infantry, aged 28 years, was wounded on November 13, 1868, by a conoidal ball in the right side of the face. On the same day he was admitted to the hospital at Fort Zara, Kansas, where fragments of the upper jaw were excised. He was returned to duty in December, 1868.

EXCISIONS OF THE BONES OF THE UPPER EXTREMITIES.

Excisions of the Bones of the Hand.—Six cases were reported.

DCXVIII.—*Account of an Excision of Metacarpal Bones, having a Fatal Result.* By P. H. BROWN, M. D., Acting Assistant Surgeon.

Private Jerry Hewes, Co. A, 9th Colored Troops, aged 24 years, was wounded on September 1, 1867, in the right hand. He was admitted to the regimental hospital at Fort Stockton, Texas, where an excision of metacarpal bones, was performed. Pyæmia supervened, and death occurred September 15, 1867.

DCXIX.—*Memorandum of a Case in which a Portion of the Metacarpal Bone and Phalanx were Excised.* By E. H. BOWMAN, M. D., Acting Assistant Surgeon.

Private Thomas H. Whipper, Co. A, 24th Infantry, was accidentally wounded in the left hand at Fort Bliss, Texas, March 19, 1870. The missile passed through the anterior portion of the hand, destroying the articulation of the middle finger, and shattering the metacarpal bone for one and a half inches above the joint. He was admitted to post hospital. The injury was powder-burned, but free from swelling. Chloroform was administered, and one inch and a half of metacarpal bone and a portion of the first phalanx, making two inches in all, were excised. Simple dressings, with application of carbolic acid, were used. The patient recovered rapidly, and was returned to duty on May 16, 1870.

DCXX.—*Account of an Operation for Paronychia.* By BENJAMIN JAMES, Hospital Steward, U. S. A.

Sergeant Charles Krouse, Co. G, 32d Infantry, aged 34 years, was admitted to the hospital at Camp Goodman, Arizona Territory, on January 1, 1869, with a whitlow on the left thumb. The

last phalanx, being found diseased, was removed through an incision one inch in length. The patient recovered, and was returned to duty on February 10, 1869.

DCXXI.—*Note Relative to an Excision of a Metacarpal Bone.* By H. F. LIVINGSTON, M. D., Acting Assistant Surgeon.

Private Thomas Barrett, Co. I, 22d Infantry, was admitted to hospital at camp near Crow Creek Agency, Dakota Territory, on September 22, 1870. Lacerated wound of fore-finger of right hand. Excision of metacarpal bone. Simple dressings were applied. He recovered and was returned to duty November 12, 1870.

DCXXII.—*Minute of a Case in which a Portion of the Metacarpal Bone was excised.* By S. M. HORTON, Assistant Surgeon, U. S. A.

Private George W. Smith, Co. A, 27th Infantry, aged 18 years, on March 1, 1868, at Fort Philip Kearney, Dakota Territory, had the ring finger of the left hand, between the first and second joints, sawed off by a circular saw. The distal end of the metacarpal bone of the same finger was also injured, and there was considerable laceration. Assistant Surgeon S. M. Horton excised the distal half of the metacarpal bone of the ring finger of the left hand. No anæsthetic was used; cold-water and laudanum dressings were applied, and the parts united by granulation in ten days. The man was discharged from service May 3, 1868, on account of expiration of term of service, but he remained in hospital. March 31st: The hand is nearly healed.

DCXXIII.—*Remarks on an Excision of a Finger-Joint.* By DONALD JACKSON, M. D., Acting Assistant Surgeon.

Private Frank Castle, Co. C, 41st Infantry, aged 21 years, while in a brawl with other enlisted men in quarters at Fort Clark, Texas, on the night of September 8, 1868, was wounded by a small pistol ball, which entered the volar aspect of the left index finger, and, passing through the inner side, slightly injured the first phalanx near its phalangeal articulation. Upon being admitted to the hospital, simple dressings were applied until it became evident that the articular extremities were diseased, when, on October 5th, equal parts of ether and chloroform were administered, and the joint was excised after making an incision on the inner side of the finger. The wound being well cleansed, was brought together by a narrow bandage. On the 8th the bandage was removed, and simple dressings were applied. By the 28th the wound had entirely healed, leaving the finger shortened one-half inch, and with a false joint, in which there was ample motion. On November 3, 1868, the patient was returned to duty.

Excision of the Bones of the Fore-arm.—Only one case of this nature was reported.

DCXXIV.—*Abstract of a Case of Excision of the Radius.* From the Report of F. REYNOLDS, Assistant Surgeon, U. S. A.

Charles Arnold, artificer of Battery C, 2d Artillery, aged 30 years, and of excellent constitution and usually temperate habits, was wounded at Fort Stevens, Oregon, on November 6, 1870, by the accidental discharge of his musket, the tompon and a conoidal ball having passed through the upper third of the left fore-arm, producing a comminuted fracture of the radius, severing probably the radial and interosseous arteries, and causing extensive laceration and loss of tissue. A large vessel was also supposed to have been displaced. On admission to the hospital, there was no pulse at the wrist, but the temperature was normal. At first, it was determined to remove the limb; but the temperature of the hand having undergone no perceptible change, and hoping that the collateral vessels would prove sufficient for its support, the idea was abandoned. Accordingly, on the same

day (the patient being very fully alcoholized), the wound was enlarged two inches, the head of the radius excised, and splinters and the rough extremity of the remainder of the bone removed. No anæsthetic was considered necessary, and it is believed by the operator that its non-administration was greatly in the patient's favor. After applying carbolized oil dressings, the arm was placed in a splint. Chloral was given at night, and was continued as long as necessary. On December 31st, the wound had almost healed, leaving a large and very deep cicatrix. The elbow was semi-flexed, and the motions of the fingers, wrist, and elbow were impaired, but rapidly improving. The dressings and anodyne fulfilled all that could be desired. The patient was discharged April 6, 1871. Dr. Reynolds, in his report, makes note of "the very slight constitutional sympathy accompanying so severe a wound." He regards this as a case for amputation in an ordinary subject, and thinks that the favorable result is, in a great measure, owing to the man's good habits and exceptionally good constitution. [He forwards the interesting specimen in the case, consisting of the shattered upper third of the radius, the battered musket-ball, and the tom-pion. These are mounted together in the Museum as Specimen 5877, Sect. I.]

Excisions in the Shaft of the Humerus.—Seven successful cases of excisions of the shaft of the humerus for gunshot-wounds were reported.

DCXXV.—*Memorandum relative to an Excision of a Portion of the Humerus.*

Private John Haire, Troop B, 2d Cavalry, was wounded in the left arm at Fort McPherson, Nebraska Territory, on March 5, 1867, by a rifle ball, which fractured and comminuted the humerus at the middle third, necessitating excision of the bone to the extent of about four inches. The operation was done by a linear incision forty-eight hours after the receipt of the injury, in the hospital of the post, by Surgeon P. C. Davis, U. S. A. The patient was discharged August 5, 1867. On September 29, 1869, Dr. E. D. Hudson, who furnished the patient with an apparatus, reports the arm shortened two and a half inches, and somewhat atrophied, but well healed and healthy. The functions of the fore-arm and hand were normal, but the flexion of the limb was somewhat impeded by concretions in the elbow-joint, which could be easily broken. The arm was unreliable, owing to want of leverage. The incipient usefulness of the apparatus, which was applied two years and seven months after the injury, is reported to be highly gratifying and efficacious.

DCXXVI.—*Minute relative to an Excision of a Portion of the Humerus.* By H. R. TILTON, Assistant Surgeon, U. S. A.

Private Edward McCarthy, Co. E, 5th Infantry, aged 18 years, was accidentally shot by a guard at Fort Lyon, Colorado Territory. The missile, a Spencer rifle ball, entered the left shoulder posteriorly at the outer edge of the deltoid, three inches from the head of the humerus, passed downward, fracturing and comminuting the shaft of the humerus into about twenty-five pieces, and escaped three inches above the condyles at the outer edge of the biceps. He was sent to the post hospital; chloroform was administered; an incision made from the lower wound upward five inches in length, and four inches of the shaft of the humerus was excised. Four stitches were introduced and a felt bandage applied. April 24th the wound had healed; there was only one inch and a half shortening. The periosteum remaining after operation had entirely renewed the bone, and on June 30, 1868, union between the upper and lower end of humerus was complete. The musculo-spiral nerve being destroyed, there is paralysis of extensor muscles. He can pick up any object with his fingers, and will soon be able to carry his hand to his head. He was discharged on August 7, 1868.

DCXXVII.—*Account of a Partial Excision of the Humerus.* Abstract from Report of DONALD JACKSON, M. D., Acting Assistant Surgeon.

Private Charles Mitchell, Troop C, 4th Cavalry, aged 31 years, of good constitution and regular habits, was accidentally wounded in the line of duty at Fort Clark, Texas, on June 2, 1867, by the explosion of his carbine, the bullet causing four different wounds; the first entered the left thigh

posteriorly, in the lower third, and, passing through the soft parts, produced a slight wound of the left little finger; next entered the left fore-arm on the ulnar side, one inch above the wrist-joint, and, passing upward and outward, emerged three inches above; finally entering the left arm three inches below the axilla and just in front of the brachial artery, it passed through the bone upward, outward, and backward, causing extensive comminution, and lodged in the body of the infra-spinatus muscle. After having sufficiently recovered from the shock of injury, the patient was rendered insensible by equal parts of ether and chloroform, when a V-shaped flap was made having the apex at the insertion of the deltoid. The anterior incision was carried to the acromion; the posterior, three inches upward and backward from the vertex. Another incision, one inch and a half downward, was also made. The soft parts were greatly lacerated and there was considerable oozing of blood. No important artery was cut. One-half of the bone being removed, the wound was filled with cotton and tightly bandaged to arrest bleeding. A few hours subsequently an anodyne was administered, and the patient rested well. Irrigation was applied to the wounds, the discharge from which was profuse, and his strength was sustained by generous diet. By the middle of July, all the wounds had healed favorably, except a small sinus through the anterior incision communicating with inferior border and the spine of the scapula, portions of which subsequently exfoliated, and which finally healed up completely by October 12th. The last phalanx of the little finger was extruded through the wound, after which it healed, leaving a small cicatrix. The flexor tendons became involved in the cicatrix of the wound of the fore-arm, causing impaired usefulness of the hand. The patient was discharged the service on July 1, 1867, by reason of expiration of enlistment, no certificate of disability being furnished him. He was finally discharged from hospital on November 10, 1867, and on January 12, 1868, was a watchman of Government property at San Antonio, Texas. [In June, 1868, Mitchell was furnished with an artificial apparatus by Doctor E. D. Hudson. At that date there was no command of arm or fore-arm, and the hand was partially paralyzed. He made an application for pension, but the case is still pending. Ed.]

DCXXVIII.—*Account of an Excision of a Portion of the Humerus.* By H. K. DURRANT, M. D., Acting Assistant Surgeon.

Baranga Nepomoceno, a Mexican, was wounded in an attack made by Apache Indians on a Government freight train, which he was driving, on December 18, 1870, by a ball which shattered the left humerus in the upper third. He was admitted to hospital at Camp Lowell, Arizona Territory, where, on the 26th, the parts being painful and very much swollen, he was chloroformed, and four inches of the shaft of the humerus, immediately below the head, was excised. His general condition at the time of the operation was very good. Cold water and a solution of permanganate of potash were applied to the wound, which healed rapidly. The patient experienced very little constitutional disturbance. On January 21, 1871, the patient was about to leave the hospital with a very useful arm. The excised bone, with the history of the case, was contributed to the Army Medical Museum by the operator, and is No. 5756, Surgical Section.

DCXXIX.—*Remarks on a Case of Excision of the Shaft of the Right Humerus.* By S. M. HORTON, Assistant Surgeon, U. S. A.

James Navity, a citizen, aged 30 years, was wounded in an attack by Indians at Crazy Woman's Fork, Dakota Territory, December 2, 1867, by a conoidal ball, which entered in front and lodged in back part of right arm. He was, on December 7th, admitted to post hospital at Fort Philip Kearney. Copious suppuration from wounds of entrance and exit ensued, and the arm became swollen from shoulder to elbow. On February 6, 1868, I administered equal parts of ether and chloroform; made an incision six inches long over the seat of fracture, and excised six fragments of the humerus, the largest one inch and a half long by one-fourth of an inch thick. The ball, very much flattened, was found imbedded in the shaft of the humerus, three inches above the fracture, and was also removed. The fragments, as also the contiguous ends of the broken humerus, were found denuded of periosteum.

The wound progressed favorably, healthy callus formed, and the bone united in four weeks. On March 31, 1868, the external wounds still suppurated slightly, but the parts around the fracture had become indurated.

DCXXX.—*Account of an Excision of a Portion of the Humerus and the Olecranon Process of Ulna.*
By H. A. BUBOIS, Assistant Surgeon, U. S. A.

Sergeant Charles Brunett, Co. D, 3d Cavalry, aged 26 years, was admitted to hospital at Fort Union, New Mexico, June 7, 1867, with a gunshot wound of the arm. The ball passed from behind, forward, and upward, through the olecranon process, shattering the condyles of the humerus and the shaft for a distance of three and a half inches. On June 10th, the shattered portion of the humerus and olecranon process were excised, and the wound was closed with wire sutures. The patient recovered, and was discharged from service September 21, 1867.

DCXXXI.—*Account of an Excision of a Portion of the Humerus.* By W. F. BUCHANAN,
Assistant Surgeon, U. S. A.



FIG. 44.—Portion of shaft of left humerus, excised for gunshot wound. Spec. 5594, Sect. I, A. M. M.

Private Frank Crith, Co. G, 38th Infantry, aged 22 years, was admitted to the hospital at Fort Hays, Kansas, August 24, 1868, for caries of the humerus. Having been accidentally shot nearly one year previously, by a conoidal musket ball, which formed a compound fracture of the right humerus in the middle third.* Subsequent to the reception of the injury he was attended by the post surgeon at Fort Harker, Kansas, who, patient states, removed several pieces of bone, adjusted the fracture and applied splints. Pieces of bone were at times removed while under treatment at Fort Harker. The patient's general health was good, notwithstanding the occasional exfoliation of bone and a discharge of sanious fetid character, with slight pain. On August 27, the patient was anesthetized, and the parts were thoroughly examined. Two or three small sinuses were found leading to the bone, which appeared to be firmly united at the seat of fracture, but roughened on its surface. An incision down to the bone showed it to be entirely denuded of periosteum in its entire circumference. Excision being determined upon the bone was sawn through by means of a chain saw, and a portion of the shaft, three and one-eighth inches in length, was removed. Very little venous hemorrhage attended the operation; no arteries were cut. The parts were well washed, and the incision united by the interrupted suture. The patient was removed to his bed and the arm carefully placed in position on small pillows, with fore-arm flexed on the chest, and cold-water dressing instituted. A narrow strip of lint had been left in between the sutures to prevent discharge during suppuration. August 29th, the arm was swollen, red, and painful, with appearances threatening erysipelas. There was a bloody, dark-colored discharge, with considerable nervous irritability, and the appetite was poor. Patient was given a nourishing diet, with milk and brandy punch occasionally throughout the day; the pus was well pressed from the arm by the fingers on each side from below upward, a solution of chlorinated soda was applied three times daily, and the water dressing continued. On September 7th, the condition of the arm was much improved. Healthy granulations and suppuration, with extensive formation of callus, appeared. The arm was adjusted in angular splints made of binder's boards, the fore-arm being flexed, the whole bandaged firmly, apertures being made through the dressing for the exit of the products of suppuration, the splint applied to anterior and internal surface of arm reaching close up in the axilla; thus arranged there was a moderate degree of extension kept up by the angle of the splints on the fore-arm and the internal splint in the axilla. September 28th, callus had been formed to the entire extent of the excision, bony union had taken place, and the temporary callus was being absorbed. On October 7th the discharge had ceased. The splints were removed, and on October 28th the patient had entirely recovered. The arm was of natural size, and the functions of hand and arm were well performed. He could lift eight or ten pounds, and the arm was still becoming stronger. No atrophy. He was discharged June 11, 1869. The specimen is represented in the adjoining wood-cut.

* See Case CCVII, p. 62.

Excisions of the Head of the Humerus.—Two successful operations of this nature were made the subject of special reports.

DCXXXII.—*Account of an Excision of the Head of the Humerus.* By DONALD JACKSON, M. D., Acting Assistant Surgeon.

Private Joseph Quimby, Troop L, 9th Cavalry, aged 27 years, was, in April, 1869, while fighting the Indians, (Pension Report,) accidentally wounded by a carbine ball, which entered the right shoulder below the acromion, passed obliquely downward and inward, shattered the upper third of the humerus, and lodged beneath the teres major. He was admitted to post hospital at Fort Clark, Texas, on June 26, 1869, being very much exhausted from the effects of inflammation, which had existed in the whole limb. On admission the active stage of inflammation had subsided; the wound suppurated freely, and a large abscess, caused by lodgement of bullet, had formed below the axilla. On June 27th, chloroform was administered, and a vertical incision made, commencing at the wound below the acromion, through the deltoid to its insertion. The upper portion of the humerus, four and a half inches in length, was then removed. The patient reacted promptly, but the shock of operation was great, and for four hours after operation life was with difficulty sustained by constant use of stimulants. He recovered, and on November 13, 1869, was sent to his company at Fort Duncan, Texas, to be discharged. Eight months after injury an apparatus, which was very useful to command the arm, was furnished by Doctor E. D. Hudson. At that time the arm was not shortened, but little reduced in size, very healthy, and the wound well cicatrized; the functions of the arm and fore-arm were normal, except lack of leverage. The man has made application for pension, but the case is pending.

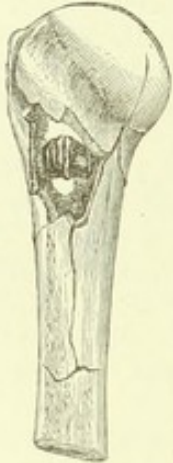


FIG. 45.—Upper portion of right humerus, excised for gunshot wound. Spec. 5638, Sect. I, A. M. M.

DCXXXIII.—*Account of an Excision of a Portion of the Humerus.* By S. S. JESSOP, Assistant Surgeon, U. S. A.

Ordnance Sergeant James T. Skillin, aged 50 years, while engaged in the line of his duty at Castle Pinckney, Charleston Harbor, South Carolina, July 31, 1869, was shot by a drunken soldier, at a distance of about five feet. The missile, a conoidal musket ball, fractured the first and second phalanges of the left fore-finger, then entered about an inch below the right clavicle, passed backward and outward through the humerus, close to the capsule, emerging at the posterior and outer aspect of the arm. He was admitted into the post hospital of that place on the next day. The orifices of entrance and exit were very large—the first about three inches in diameter, the latter somewhat smaller, and irregular in shape. In the track of the ball anterior to the humerus, were fragments of clothing; posterior to it, comminuted fragments of bone. The patient, a man of unusually fine physique and very temperate habits, had rallied well from a copious venous hæmorrhage. Pulse 75, and tolerably full. Eighteen hours after the reception of the injury, I

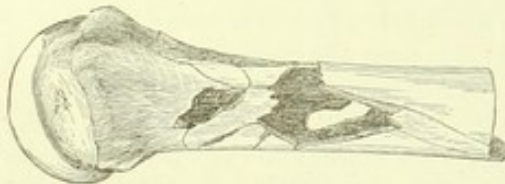

FIG. 46.—Head and portion of shaft of humerus excised for gunshot wound. Spec. 5588, Sect. I, A. M. M.

administered chloroform, and excised the head and about three and a half inches of the shaft of the humerus, and amputated the left fore-finger at the metacarpophalangeal articulation. Recovery was rapid. On September 30, 1869, there was a very slight discharge from the opening of the entrance, and from the middle of the cut made by the operation. On the latter date, he had good use of the fore-arm and hand, but none of the arm. Passive motion was daily employed. The wounds, during most of the treatment, had been washed and dressed

with a solution of crude carbolic acid, twenty drops to the pint. He was returned to duty November 10, 1869. The specimens, with the history, were contributed to the Army Medical Museum by the operator, and are numbered 5588 and 5589, Surgical Section.

EXCISIONS OF THE BONES OF THE LOWER EXTREMITIES.

Excisions of the Bones of the Foot.—Two examples were reported.

DCXXXIV.—*Account of an Excision of a Portion of the Os Calcis.* By W. B. DGDS, M. D., Acting Assistant Surgeon.

Private Charles Lorenzel, Co. A, 1st Cavalry, aged 20 years, was accidentally wounded at Camp Bidwell, California, November 3, 1866, by a Spencer carbine ball, which penetrated the heel, and glanced off from the calcaneum. He was admitted to the post hospital. Caries of the heel-portion of the calcaneum supervened, and on February 26, 1867, the superior portion of the calcaneum was excised through an incision three inches in length. Simple dressings were applied, and on March 30, 1867, the wound was perfectly healed.

DCXXXV.—*Memorandum relative to an Excision of Portions of the Bones of the Foot.* By G. M. STERNBERG, Assistant Surgeon, U. S. A.

Private Julius Edwards, Troop F, 10th Cavalry, aged 21 years, was accidentally wounded by a Spencer carbine ball, at Fort Riley, Kansas, January 21, 1868. The missile passed through the metatarso-phalangeal articulation of the left great toe, extensively comminuting the bones. He was admitted to the post hospital, and on March 1, 1868, was rendered insensible by one part of chloroform and two of ether, when the phalanx and head of the metatarsal bone of the great toe were excised by a straight incision along the dorsum, and the toe-nail was removed. The periosteum was preserved as far as possible, for the reproduction of bone. About half of the wound united by first intention; the remaining portion healed slowly, with profuse suppuration. An abscess which formed at the seat of the original wound, was opened March 25th, and March 31, 1868, the wound was nearly healed. The patient was returned to duty in April, 1868.

Excisions in the Bones of the Leg.—Reports of two cases were furnished.

DCXXXVI.—*Account of an Excision of a Portion of the Fibula.* By JULES LE CARPENTIER, M. D., Acting Assistant Surgeon.

Private Waddie Hostler, Co. D, 38th Infantry, aged 19 years, being apprehended as a deserter at Fort Bayard, New Mexico, on July 10, 1868, was shot in the left leg, a conoidal ball taking effect in the middle third, fracturing the fibula, splitting thereon, and making its exit by two tracks. Being admitted to the hospital in a state of collapse, four hours after the injury, about an hour was allowed for reaction to take place, when insensibility was produced by ether and chloroform, and the wound thoroughly examined. It was found necessary to excise about three and a half inches of the fibula, which was badly comminuted. The peroneal artery, which was found injured in several places by splinters, was tied above and below the wound. Little blood was lost during the operation, and the patient recovered well from the anæsthesia. An anodyne was administered, and he passed a good night. During the day of the 11th, he was restless and somewhat strange in conduct, refusing to take food toward the evening, when the anodyne was repeated, and a quiet night was passed. On the 12th, pus appeared upon the lips of the wound; he again refused food, and had a vacant look. About noon, a peculiar choking noise drew the attention of the nurse, who found him dead. At the autopsy, twenty-two hours after death, *rigor mortis* was well marked; decomposition was going on rapidly, and the abdomen was distended with flatus. An examination of the chest showed the pericardium distended and thickened, adherent in places to ventricles and auricles, and containing about ten fluid-ounces of bloody serum; heart rather large (weighing eleven ounces), heavily coated with fat, walls hypertrophied, and very soft and flaccid, particularly those of the right ventricle; fatty degeneration well marked of chordæ tendinæ, and the upper part of the right ventricle, and adherent to the serous membrane of the right ventricle, among the chordæ tendinæ, was a large fibrinous clot, weighing nearly six drachms, attached to which was an irregular rope-like yellow cord, three-eighths of an inch wide and one-eighth of an inch thick, extending into the pulmonary artery about six inches; the

auriculæ, ventriculæ and semi-lunar valves of the right side were somewhat thickened ; the walls of the left ventricle showed fatty degeneration, and were very soft, but the valves were in good order, and the auricles healthy, but pale ; lungs healthy, but marks of old pleuritic adhesions existed on the interior lobes of each side.

DCXXXVII.—*Minute of a Case of Excision of a Portion of the Tibia.* By W. M. AUSTIN, Assistant Surgeon, U. S. A.

Private Joseph Shaw, Troop D, 3d Cavalry, was admitted to hospital at Fort Bliss and Camp Concordia, Texas, on October 25, 1867, with a gunshot wound of the right tibia, which was received in a fight with Indians, October 17, 1867. The bone became necrosed, and on February 2, 1868, the necrosed portion was excised. He recovered, and was returned to duty on March 9, 1868.

Excisions at the Hip-joint.—It is very gratifying to record two successes in the three excisions for gun-shot injury of the upper extremity of the femur, that have been performed in the army since the War. The two men referred too not only recovered, but retained very useful limbs. Through the kindness of the chief of the medical staff of the navy, I am enabled also to record a memorandum* of a successful case occurring in the practice of Surgeon W. E. Taylor, of the navy. Photograph 271, Surgical Series, A. M. M., contributed by Dr. Grimm, the Director General of the medical staff of the Prussian army, represents a very successful result of this operation, in a soldier wounded in the Austro-Prussian seven-weeks war. These instances must place excision at the hip for gun-shot injury among the established operations of surgery.

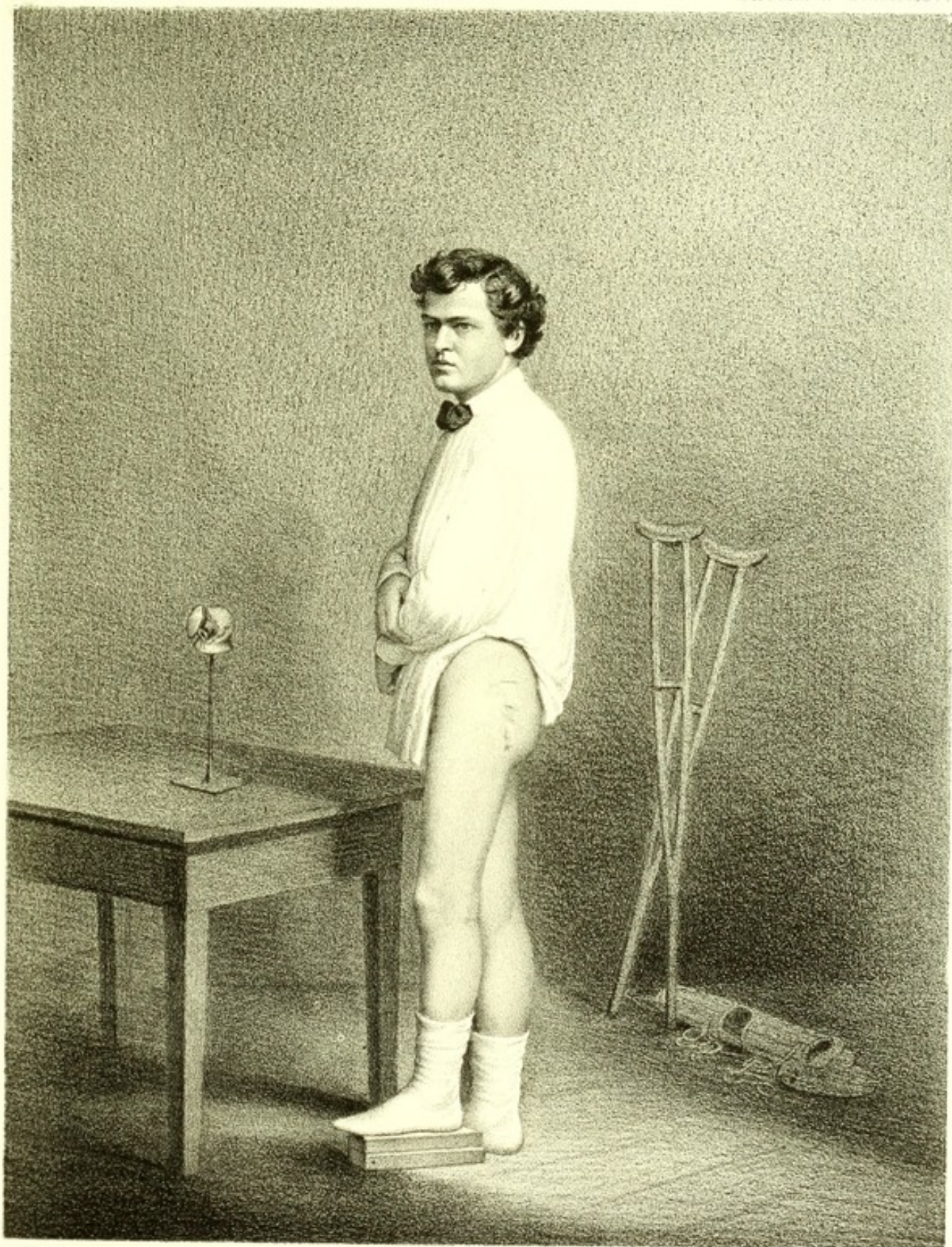
DCXXXVIII.—*Account of a Successful Case of Excision of the Hip-Joint for Gunshot Injury.* From detailed reports.

Private Charles F. Read, Co. I, 37th Infantry, while in a stooping posture, and distant about one hundred feet, was shot by a sentinel at Missouri Bottom, New Mexico, on June 6, 1868. The ball struck about the middle of the posterior aspect of the left thigh, causing an injury to the bone, the nature of which is shown in the accompanying wood-cut, illustrating the specimen contributed to the Army Medical Museum by the operator, J. R. Gibson, Assistant Surgeon, U. S. A., (FIG. 47.) The case being fully detailed in *Circular No. 2, S. G. O., 1869, page 117*, reference will only be made to the more salient points, and to information received since the publication of that report. After weeks of temporization, during which the patient, a young man in the prime of life, had become much exhausted from numerous and futile searches after the missile, from bed-sores, profuse suppuration, an irritable diarrhœa, and pain so intense as to require the administration of an anæsthetic previous to dressing the wound, the choice lay between a lingering death or excision of the head of the femur, or the more fearful and precarious alternative of amputation at the joint. On August 14th the patient expressed willingness to submit to any operation that would afford relief, when he was anæsthetized for the purpose of again freely examining the parts, and performing such operation as should be considered necessary. Upon explorations of the wound with the probe and finger, the ball was discovered in the head of the femur, a T-shaped incision was made over the joint, the head of the bone was turned out of the acetabulum, and was sawn through the neck, just within the great trochanter. The incisions were closed with metallic sutures, and the limb was temporarily placed between splints, with a

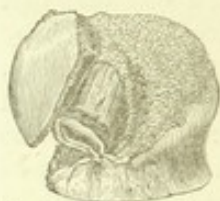

FIG. 47.—Excised carious head of left femur with an impacted musket ball. Spec. 5576, Sect. I, A. M. M.

* Surgeon Taylor, besides contributing to the Museum his specimen of excised head, neck, and trochanters of the left femur, with a conoidal musket-ball, lodged in the head, (Spec. 5884, Sect. I, A. M. M.), forwarded a most interesting and detailed history of the case, which I would gladly reproduce in full, did not Surgeon General Wood, U. S. N., prefer that it should be inserted in a volume of communications from medical officers of the Navy, which he purposes publishing from his Bureau.



B. phot.

Bien. lith.

GIBSON'S SUCCESSFUL EXCISION AT THE HIP.

pillow under the knee. A Smith's anterior splint not being on hand, nor the material procurable for making one, a long external splint, made in two parts, and connected by iron braces, was devised and put in course of construction. The after treatment consisted in carbolized dressings to the wound, the administration of antiperiodics to control a fever of a remittent type (at one time supposed to be the precursor of erysipelas or pyæmia), and a plain nutritious diet. Notwithstanding frequent displacement of the limb from occasional attacks of diarrhœa, and the absence of a proper apparatus to secure immobility, the performance of this formidable operation seemed to have imparted a new tenure of life. By November 20th the patient was able to walk about the hospital, and the further progress of the case was as rapid as it was favorable. On May 16, 1869, this soldier was discharged the service, and pensioned for total and permanent disability, the injured member being shortened one inch and three-quarters. He came across the Plains by the next train, and in September, 1869, reported at the Surgeon General's Office, where a photograph was taken. At that time, the patient's general health was excellent; the cicatrix was perfectly firm and sound, and the strength of the ligamentous attachments and the amount of control over the movements of the limb were very remarkable. He could bear much weight on the limb. He was supplied with a protective apparatus and advised not to use it straightway, but to continue exercising the limb continuously for some months, thereby increasing the strength of the muscles and ligamentous attachments, and the freedom of the newly-formed joint. The next week Read went to New York, where the proposed apparatus was ingeniously applied by Dr. E. D. Hudson. In the summer of 1870, it was reported that this man could walk very comfortably with a cane either with or without apparatus. The appearance of the patient is shown in the accompanying plate. In June, 1871, three years after the operation, the man was in very good health, and could walk almost as well as ever.

DCXXXIX.—*An Intermediary Excision at the Hip, performed in 1867.* By GLOVER PERIN, Surgeon, U. S. A.

Private Francis Ahearn, general service, aged 30 years, was wounded at Newport Barracks, Louisville, Kentucky, on July 31, 1867. He was a prisoner in the guardhouse, and was shot by a sentinel while attempting to escape.

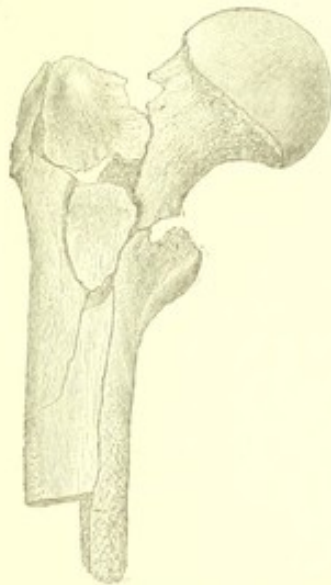

FIG. 48.—Shattered upper extremity of the right femur, excised for caries following gunshot fracture. Spec. 5489, Sect. I, A. M. M.

The ball entered behind and below the prominence of the right trochanter major, and passed inward and upward, emerging on the anterior part of the thigh, two inches below Poupart's ligament, a little to the outside of the course of the femoral artery, having shattered the upper part of the femur, the fissures extending within the joint. The wounded man was immediately taken to the post hospital, and was examined by Doctor Perin, the surgeon in charge. The patient had been an habitual drunkard for years, and had *mania a potu* when shot. The shock of the injury was so great that an operation was not considered advisable. It was determined to adopt a supporting treatment, and to endeavor to build up the general health, with the view of operating at the first favorable moment when a good result could be reasonably anticipated. On August 26, 1867, the patient was in better condition than at any time subsequent to the reception of the injury. The pulse was at 90; there had been troublesome diarrhœa, but it was somewhat abated; the injured limb was much wasted, except at the upper part of the thigh where it was greatly swollen; the discharge from the wound was very copious, and there was extreme pain on the slightest movement. There were abscesses about the joint communicating with its cavity. Excision having been decided upon, I proceeded with the operation, assisted by T. E. Wilcox, Assistant Surgeon, U. S. A. The patient being rendered insensible by a mixture of chloroform and ether, the entrance wound was enlarged by a straight incision downward, three inches in length. The head of the bone was disarticulated, and

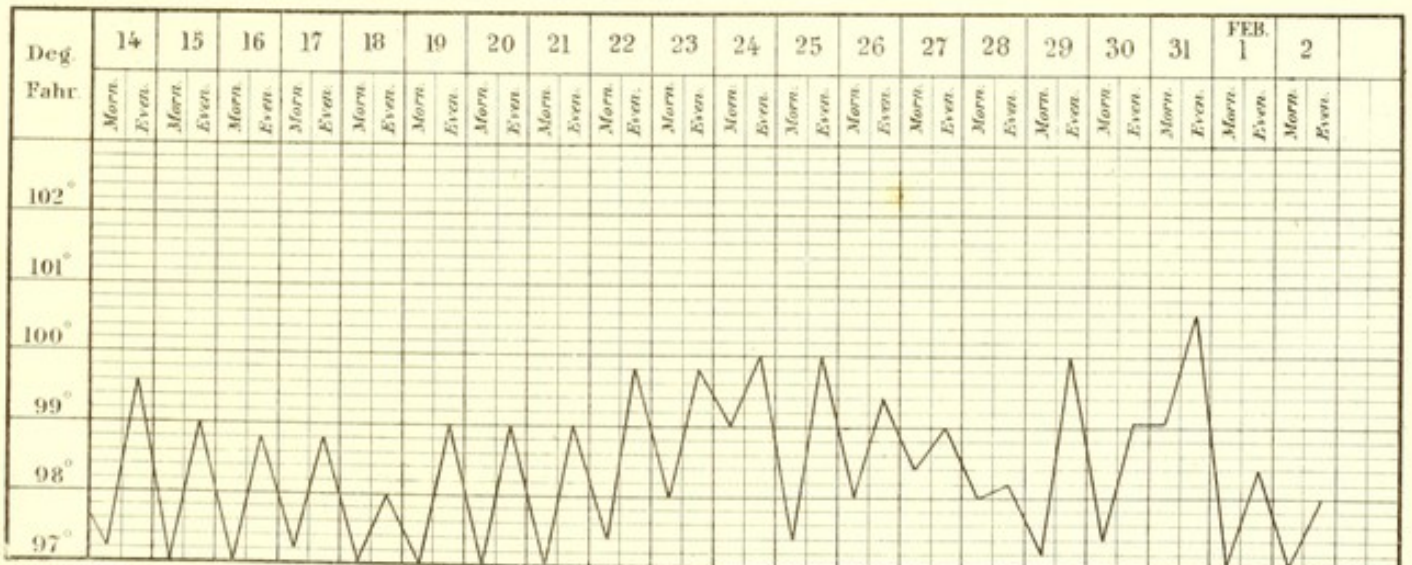
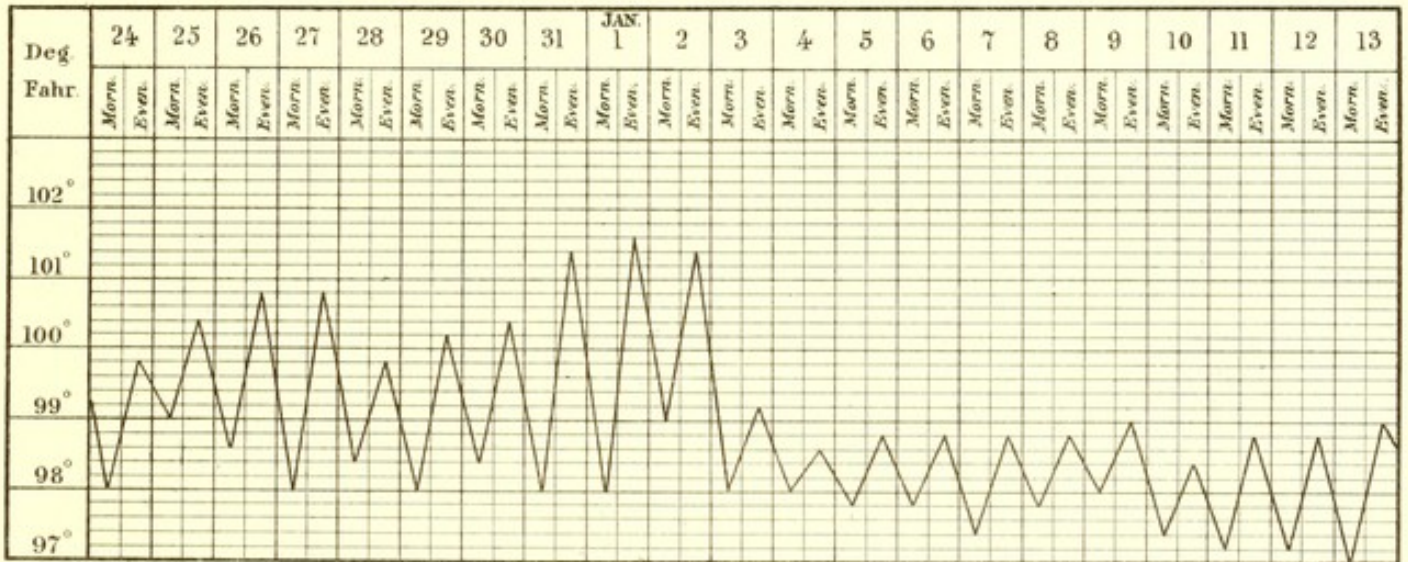
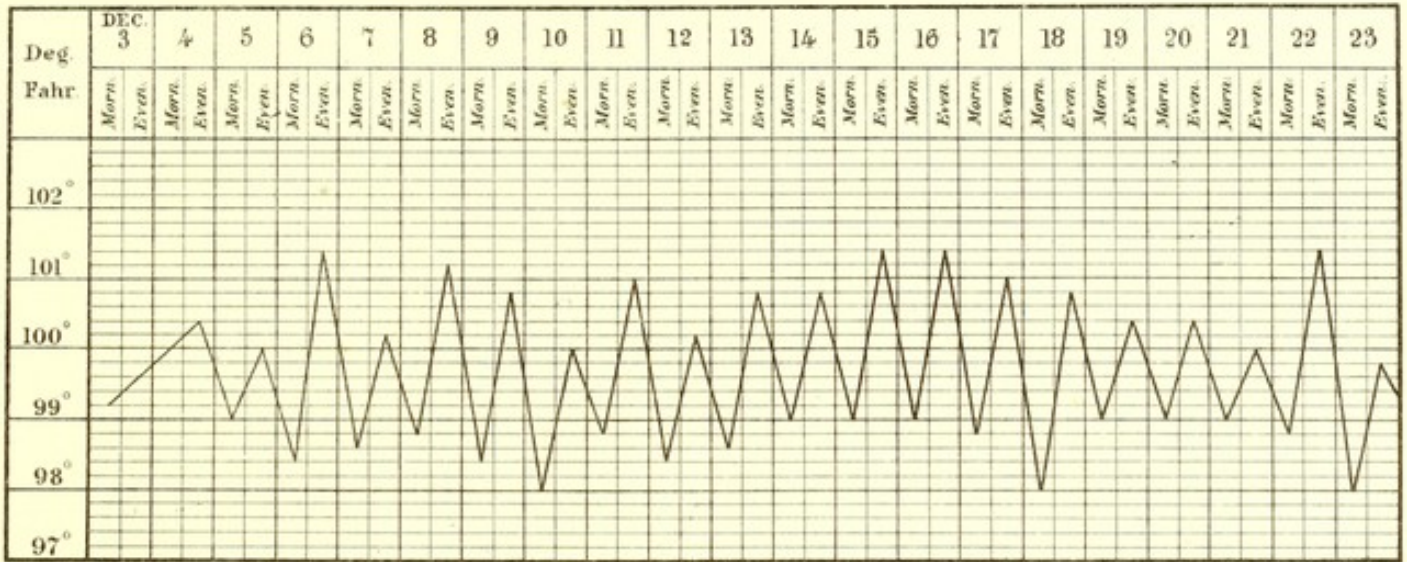
the shaft was sawn several inches below the lesser trochanter. The wound was then cleansed and approximated. Scarcely any hæmorrhage took place, no ligatures being required. On recovering from the anæsthetic, the patient complained of great pain and nausea. Brandy was administered and half a grain of sulphate of morphia; but there was such irritability of stomach that everything was rejected. A quarter of a grain of sulphate of morphia was then administered hypodermically, and this relieved the pain. But there was no decided reaction, and, sinking gradually, the patient died from the shock of the operation, twenty hours after its completion. No autopsy was made. The shattered excised bones were sent to the Army Medical Museum, and are represented in the preceding wood-cut, (FIG. 48.) Many of the fragments were carious.*

DCXL.—*Account of a Case of Excision of the Hip-Joint for Gunshot Injury.* Condensed from Detailed Reports.

Private Hubert Erne, Co. D, 4th Infantry, aged 48 years, while acting as one of a corporal's guard escorting the mail wagon from Fort Laramie to Fort Fetterman, was wounded in an attack on the party by a band of Indians December 2, 1869. He was struck in the left hip by a musket ball, and fell to the ground. His comrades placed him in the mail wagon and returned as rapidly as circumstances would permit to Fort Laramie, from which they were distant about thirty-two miles. The wound was received at two in the afternoon, and the patient was placed in bed in the hospital by half past seven. He had been driven over a very rough road, and was much exhausted. He had lost considerable blood, and his feet and hands were cold, and circulation feeble, the pulse being almost imperceptible, while his face was pale and covered with a clammy perspiration. There was shortening of the left lower extremity, with eversion of the foot, and the thigh was arched with an anterior convexity. The aperture of entrance of the ball was one and a half inches behind and slightly above the trochanter major. The aperture of exit was near the centre and just below Poupart's ligament, directly over the femoral artery. The diagnosis was fracture of the shaft, neck, and trochanters of the left femur. As he had not rallied from the shock, it was thought best to defer surgical interference until morning, and the limb was placed in a comfortable position, and the patient was ordered to take a half ounce of brandy every half hour, and external applications of heat were made by hot blankets, heated sad-irons, and bottles of hot water. The circulation was gradually restored. At midnight the patient had reacted, but complained of great pain in the middle of the thigh, and a fourth of a grain of morphia was ordered, to be repeated every two hours, if needed; the stimulant was continued. At half past seven in the morning of December 3, it was found that the patient had fully recovered from the shock, and was comfortable, with a good pulse at 90. He had no appetite, and had slept but little during the night. There was pain of the thigh below the wound, but it was not excessive. The temperature in the axilla was 99.2. Cold-water dressings were applied to the wound, and milk punch was given freely, with an eighth of a grain of sulphate of morphia every two hours. At 1 o'clock, December 3d, Post Surgeon F. Meacham, Assistant Surgeon, U. S. A., assisted by Assistant Surgeon J. B. Girard, U. S. A., who was visiting him, made a thorough exploration of the injury, placing the patient under chloroform, and enlarging the entrance wound to admit the finger. It was ascertained that the neck and trochanters were shattered, and the shaft of the femur was splintered for a short distance below. No important vessels or nerves were injured. The patient was an old soldier; he had been a hard drinker, and during the late war had been several times wounded, having on one occasion suffered a gunshot fracture of the lower jaw. After a careful consideration of all the circumstances, local and constitutional, it was decided that excision of the upper extremity of the femur would afford the patient the best chance of life, and Assistant Surgeon Meacham immediately proceeded with the operation. He made a curvilinear incision seven inches in length, commencing an inch and a half above the trochanter, through the wound of entrance, and then vertically parallel to the shaft. Exposing the bone by a rapid dissection, the fragments of the shaft and trochanters were first removed, and the sharp extremity of the shaft was taken off

* See Circular No. 2 S. G. O., 1869, p. 60.

Diagram shewing the Variations of Temperature after an Excision at the Hip.



by a chain saw. Then, with some difficulty the head of the femur was exarticulated, and the operation was completed. The exploratory incisions and operation altogether occupied about an hour. Very little blood was lost, and the patient rallied very promptly after the operation. He seemed to suffer very little from shock. The upper portion of the wound was closed by sutures and adhesive strips. The patient was placed in bed with the limb in an extended position, cold-water dressings being applied to the wound, and a weight of four pounds being attached by Buck's method to the foot to keep up extension. The patient was ordered an ounce of brandy every hour while awake, and a quarter of a grain of sulphate of morphia every two hours. On December 4th the patient, after a comfortable night, having slept well, complained only of thirst. His tongue was dry, his pulse at 90 and full. During the day he had nutritious diet, a half ounce of brandy every hour when awake, and two grains of quinine and one-eighth of a grain of sulphate of morphia every four hours. The fragments of bone excised were cleaned and put together, and transmitted to the

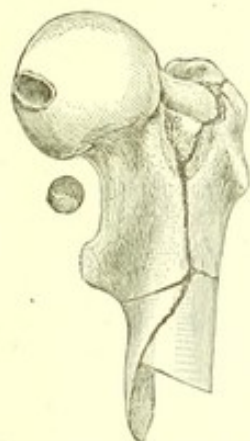


FIG. 49.—Excised head of left femur shattered by a musket ball. *Spec. 5658, Sect. I, A. M. M.*

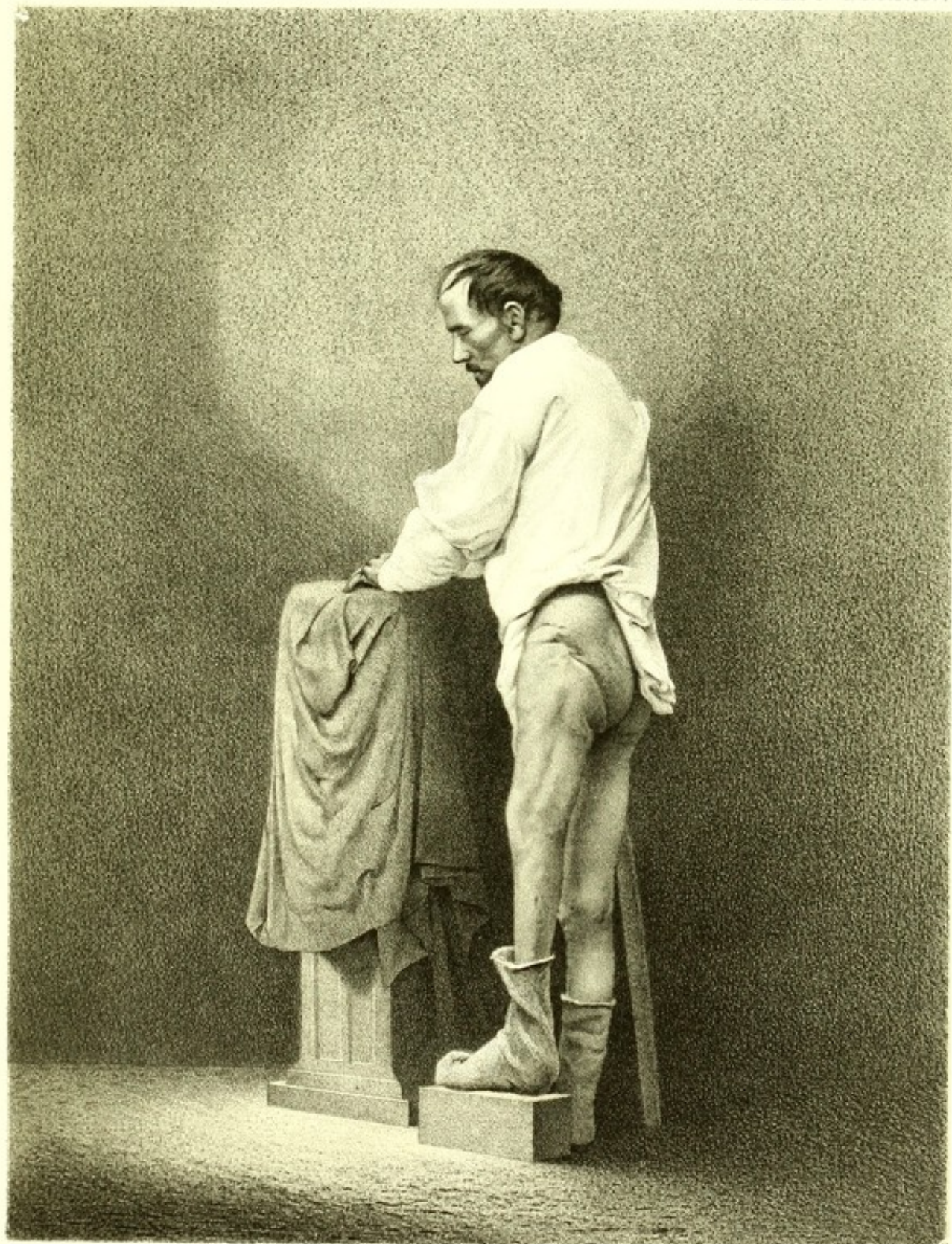Army Medical Museum. They are represented in the adjoining wood-cut. On December 5th, in the early morning, there was little change in the constitutional symptoms. The patient had slept four hours during the night. He was troubled with hiccough. He had partaken freely of freshly prepared essence of beef. At the surgeon's morning visit, at half past seven, twenty-grain doses of bromide of potassium were substituted for the morphia, and the other treatment and diet were continued with the addition of canned oyster soup. At the evening visit, at nine, the hiccough had nearly ceased, the wound had begun to suppurate, the pulse was 100, the tongue was moist, and the thirst diminished. The dose of bromide of potassium was reduced one half; the other treatment was continued. On the morning of December 6th, he was found to have passed a restless night, annoyed by hiccough when awake. He complained of the extension, and the weight attached to his foot was diminished one half. Whiskey was substituted for the brandy, which he disliked, and a tincture of sesquichloride of iron was given in twenty-drop doses, with two grains of sulphate of quinia every four hours. One-fourth of a grain of sulphate of morphia was ordered to be given when the pain demanded it. The patient was removed to a water bed. On December 7th, the

patient was more comfortable, and had slept well. He was annoyed by flatulence, the bowels not having moved since the reception of the injury. He was ordered a tablespoonful of castor oil, and twenty drops of turpentine, and an enema of soap and water. The suppuration from the wound was quite copious. On the following day it was practicable to omit the anodyne, and the patient had a free evacuation of the bowels, with great relief. The patient was allowed a small piece of beefsteak for his breakfast, and chicken for dinner. The discharge from the wound was profuse, and the integument over the hips and nates was somewhat abraded from heat and moisture. The weight attached to the foot was removed altogether. The patient was transferred from the water bed to a mattress, in the middle of which was a movable portion corresponding with the pelvic region. This arrangement greatly facilitated the application of dressings and the use of a bed-pan. The patient was ordered three ounces of beef essence thrice daily, and as much milk as he should relish. On the 9th, he was found to have slept well without taking an anodyne. The suppuration was profuse. The pulse was at 100. The appetite was abundant. Hiccough was again quite troublesome. The bowels had not been moved since the 7th, and an enemata of castile soap and warm water were ordered to be given daily, unless there should be an alvine evacuation before nine in the morning. During the next fortnight there were no symptoms of especial interest. The wound continued to suppurate, but less copiously, and was rapidly filling up with granulations. On December 22d, the patient passed a very restless night. The surface was hot, and pulse at 100; the appetite was gone; the abdomen was tympanitic. On December 23d, he had several dejections, and had slept soundly during the previous night, and was in every respect much better. On January 1, 1870, his bowels were again obstinately constipated. Cicatrization of the wound was rapidly going on. Citrate of iron and quinine was substituted for the sesquichloride of iron. Laxative enemata were required daily, and whiskey was still given. The obstinate hiccough ceased about the middle of January, at which date the pulse had fallen to an average of 90, and the

wound had far advanced toward healing. For the next six weeks there was very little change in the daily record. The patient's convalescence progressed favorably, and by February 28 the wound was open at two points only. Constipation was still a troublesome complication; the patient being annoyed by injections, he was ordered to take a three-grain compound cathartic pill nightly. By the end of March the patient was able to sit up. There were still two fistulous sinuses leading toward the cotyloid cavity. About an ounce of pus was discharged daily. The limb was about five inches shorter than the other. On the 10th of April, the patient got on crutches, but could not walk far without fatigue. For the next twenty days he seemed disinclined to exert himself, but was taken out every fair day in a wheeled litter. One of the sinuses had closed. By July 8th, the patient had gained in flesh and strength, and the purulent discharge had diminished to a few drops daily. The limb was swollen considerably, and there was an erysipelatous blush extending below the knee. At this date Dr. Meacham was ordered to Omaha, and the patient passed into the hands of Acting Assistant Surgeon L. S. Tesson, who, on July 29, wrote to Dr. Meacham that quite a large abscess formed in the muscles of the thigh. On August 9th, Dr. Tesson again wrote that it had been necessary twice to make incisions to evacuate abscesses in the thigh. Again, on March 9, 1871, Acting Assistant Surgeon A. J. Hogg writes that the man is entirely well, the cicatrix being perfectly sound; but the man persisted in lying in bed. On April 1, 1871, Dr. Meacham reports that he had succeeded in getting his patient again under his personal observation, previous to which he had borne transportation in an ambulance for ninety miles, and appeared in better spirits at the end of the journey than when he set out. The wound had entirely healed, leaving a firm and sound cicatrix three inches in length. The patient was able to walk comfortably on crutches and had slight control over the limb, which admitted of a to-and-fro motion, with rotation inward. The upper end of the femur rested on the dorsum of the ilium about one inch above the acetabulum, and was movable in that position. There was six and a half inches shortening. The patient was somewhat hypochondriacal, being greatly troubled with indigestion and irregular bowels. By an order dated A. G. O., June 9, 1871, it was provided that Private Erne should be sent to the Soldiers' Home. A communication from Dr. Meacham, dated June 14, 1871, states that this man is much better, and will soon be able to comply with the provisions of the above order. [Private Erne was discharged the service on surgeon's certificate of disability, May 18, 1871. The lithograph opposite (Plate III) is copied from a photograph taken at Omaha, March 30, 1871, No. 303, Surg. Series, A. M. M.—ED.]

DCXLI.—*Account of a Successful Case of Excision of the Hip-Joint for Gunshot Injury.* Condensed from a Report of W. E. TAYLOR, Surgeon, U. S. Navy.

Charles B. Scott, a seaman of the United States Navy, aged 34 years, of fair general health, was wounded in the line of duty while an attack was being made on a piratical vessel in Tecapan River, west coast of Mexico, June 17, 1870. A conoidal musket ball, entering the left nates midway between the great trochanter and point of coccyx, fractured and comminuted the head and neck of the femur, and lodged nearly in the centre of its head. The weapon inflicting the wound was fired from shore, a distance of about eighty yards, the patient being at the time in a stooping posture in one of the cutters. After a long sea voyage of eleven days, he was admitted, on July 12, 1870, from the United States ship *Mohican* to the naval hospital, Mare Island, California. Cold-water dressings had been applied to the wound, and anodynes administered when required. His general condition was decidedly below par. The least movement in the injured joint caused severe pain; he did not sleep well, and his appetite was poor. Full diet with milk, and an anodyne at night, were ordered. On July 14, an examination of the wound was made. No anæsthetic was used, and the result was unsatisfactory. However, appearances led to the belief that the head and neck of the femur were extensively fractured. Nothing was felt that was supposed to be the ball. The joint was not swollen, but was very sensitive, and there was a scanty, sanious, and fœtid discharge from the wound. The patient's condition was much better than could be expected after such a serious injury. His appetite improved; there was no hectic; he slept tolerably well, and his bowels were regular. Circumstances indicating beyond a doubt the necessity of operative interference, it was desirable to get the patient in as good condition as possible, whereupon a tonic mixture, with



G. phot.

Bien. lith.

MEACHAM'S SUCCESSFUL EXCISION AT THE HIP.

nutritious diet, and an anodyne, when required, were ordered, and the wound was dressed with oakum. On July 25, the patient seemed to be slowly sinking, and there being evidently no prospect of recovery if treated on the expectant plan, the operation of the excision of the injured parts was decided upon, as giving him the best chance of life, especially as there was no injury to the large vessels and nerves, and very little damage to the soft parts. The patient, cheerfully consenting to the operation, was chloroformed by Assistant Surgeon A. M. Owen, U. S. N. The limb being straightened, a well-marked crepitus was elicited. A straight and deep incision was then made, commencing about two inches above the great trochanter, and carried downward over its centre and along the outer side of the thigh for about eight inches. On exposing the joint, the thigh was well adducted and pushed upward, that the trochanter might be prominent; the muscular attachments were then carefully divided close to the bone, which, being well cleared, was pushed through the wound and sawn off just below the trochanter minor, with an ordinary amputating saw; after which the fragments of the neck and head, some twelve in number, with the ball, were easily removed. Very little blood was lost, two small arteries only requiring to be secured. After syringing the wound with a weak solution of permanganate of potash, it was partially approximated by four sutures, and the limb was placed in an ordinary fracture-box, and dressed with oakum. The operation was well borne, and reaction prompt. Stimulants, with nutritious diet, were ordered, and rigid cleanliness was enforced. On the 27th, the patient began to suffer from decubitus. On the evening of the 29th, he became delirious; pulse 130 and irritable. Hydrate of chloral being substituted for morphia, he went to sleep in a few minutes, and next morning awoke refreshed and natural, and feeling better than at any time since the accident. The pulse fell to 100. On the 31st, the sutures were removed. The good effect of the chloral was very marked, but by August 6th it seemed to have lost some of its effect, whereupon morphia was combined with the usual dose, and he slept well. The discharge from the wound was small in quantity, and laudable. On August 8th, some extension of the limb was made, but was badly borne. By the 14th, the patient was doing well in every respect. On the 21st, all dressings being removed from the limb, it was thoroughly bathed and rubbed, after which it was replaced in the fracture-box, when extension and counter-extension were made by means of the ordinary perineal band and a screw. This was discontinued on the 26th, owing to enlargement of the inguinal glands and the general *malaise* and discomfort experienced by the patient. On the 30th, the use of anodynes was discontinued, as he could sleep without them. September 1st found the patient improving, the discharge from the wound being moderate, with an entire absence of inguinal trouble, bed-sores, and excoriations. Slight passive motion was commenced in the limb, and it was allowed to rest lightly on a pillow for several hours. On the 7th, he was able, for the first time, with assistance, to leave his bed. After this, he continued to sit up several hours daily, and, gaining in flesh, &c., was able, by the 18th, to walk on crutches. He continued to take daily a moderate amount of out-door exercise, the limb meanwhile being supported and steadied by means of a wire splint, and his general condition became excellent. He continued steadily to improve, and on December 27th went by steamer to San Francisco, a distance of fifty miles. He returned in the evening, having borne the journey well. By January 1, 1871, the patient was doing well in all respects. On the 20th, a protective apparatus was adjusted to the limb, which, at the beginning, proved highly useful. Photographs of the patient, both with and without the apparatus, were taken on the 30th. On February 1st, the patient was transferred to the new Naval Hospital. At this time, his general health was excellent. The left buttock was somewhat flattened, and there was a small opening about the centre of the line of incision, which discharged a small quantity of pus; the limb was about three and a half inches shorter than its fellow, the knee being quite stiff, and foot everted. The patient had gained about thirty pounds since the operation of excision, and there was a probability of his being able, in time, to walk quite well without the aid of crutches. The above "general reference" to a very fully detailed case is concluded by a quotation of Surgeon Taylor's remarks: "This report terminates my official connection with the case, and, inasmuch as the result cannot yet be positively known, it would perhaps be premature to make any comments, or draw any conclusions. There is one point, however, worthy of mention, viz, that prior to the operation, the patient complained of severe and constant pain, which ceased immediately upon the removal of

the injured parts. This relief was so marked that even had the case terminated fatally, I think operative interference was warranted with a view to euthanasia. It will also be noticed that treatment by extension and counter-extension was abandoned after a trial of a few days, and I feel quite certain that this particular case did better without it. The case was admirably suited for the operation of excision; a better one could not well have been selected. There was no injury to the vessels or nerves, and none to the soft parts, save the small wound of entrance; the pelvic walls were not injured; there were no abscesses, and but little swelling about the joint. The neck and head of the femur alone bore the brunt of the injury."

The four cases above enumerated, the sixty-three operations done during the American War, the twelve operations prior to that war, and eight more cases recently published, make an aggregate of eighty-seven excisions at the hip for injury, with eight recoveries, a mortality rate of 91.9.

But we have the great satisfaction of knowing that of the survivors of this operation, four can walk comparatively well, without assistance. It has occurred to me to examine many patients recovered from excisions at the hip for coxalja, but none of them had regained the use of their limbs to such an extent as Hugh Wright,* for whom Dr. Mursick excised the head and trochanters of the femur, shattered by a ball. The recovery of Dr. Gibson's patient was yet more perfect, and fully verified the prediction of Mr. Blenkins,† that inutility of the limb would not prove to be inevitably the result of such operations.

* MURSICK, *New York Medical Journal*, Vol. I, p. 424.

† BLENKINS, l. c. Additions to Cooper, 8th ed., Vol. I, p. 838. London, 1870.

LIGATIONS.

LIGATIONS.—Abstracts of twenty-seven instances of ligations of the larger vessels were furnished. The operations were required in four cases of punctured, seven incised, and four lacerated wounds, in twelve cases of gunshot wounds, and in two cases of aneurism. Seven cases resulted fatally.

Ligations of Arteries of the Head and Neck.—Special reports were made of six examples of ligations of these vessels; viz., three of the temporal, one of the facial, one—a fatal case—of ligation of the thyroid, and a successful ligation of the common carotid.

DCXLII.—*Note on a Ligation of the Temporal Artery.* By H. S. SCHELL, Assistant Surgeon, U. S. A.

Private Patrick Toole, Troop H, 2d Cavalry, aged 35, was kicked by a horse at Fort Laramie, Dakota Territory, on November 16, 1867, the effect of which was a lacerated wound of the scalp with punctured fracture of the frontal bone. He was taken to the post hospital, where both ends of the temporal artery were ligated. He recovered, and was returned to duty in December, 1867.

DCXLIII.—*Minute of a Case of Ligation of the Temporal Artery.* By J. F. WEEDS, Assistant Surgeon, U. S. A.

Jacob Wall, a teamster of the Quartermaster's Department, aged 32, was admitted to the post hospital at Albuquerque, New Mexico, January 3, 1866, with a lacerated wound in the anterior temporal region, caused by a blow from the butt-end of a Colt's revolver. The temporal artery was severed and the pericranium exposed. On the same day I ligated both ends of the artery and closed the wound with sutures. The patient recovered rapidly, and was returned to duty January 16, 1866.

DCXLIV.—*Note relative to a Ligation of the Transverse Facial Artery.* By HARVEY E. BROWN, Assistant Surgeon, U. S. A.

Corporal Frank Sachse, Co. F., 17th Infantry, aged 27 years, received a lacerated wound of the right cheek, at Galveston, Texas, on November 20, 1868, for which he was admitted to the post hospital. The wound extended from angle of mouth transversely across the cheek two inches, the transverse facial artery being severed. The artery was ligated. On November 26th the ligature came away; the wound was closed by silver sutures, and healed by first intention. The final result of this operation was favorable, and the patient was returned to duty on November 29, 1868.

DCXLV.—*Minute of a Case in which Hemorrhage from the Temporal Artery was controlled by Ligation.* By J. F. M. FORWOOD, Acting Assistant Surgeon.

Hospital Steward Charles Rivers, Co. B, 20th Infantry, aged 22, received, on March 1, 1868, at Alexandria, Louisiana, accidentally, a lacerated wound of the head, and was admitted to the

post hospital. On March 6th, profuse hæmorrhage from the temporal artery occurred. Styptics and pressure failed to control it; acupuncture needles were then inserted, but only checked the hæmorrhage for twenty-four hours; at the end of that time an incision was made, and the bleeding vessel tied. The wound then healed rapidly, and the patient returned to duty in April, 1868.

DCLXVI.—*Minute of a Case in which the Thyroid Artery was ligated.* By HARVEY E. BROWN, Assistant Surgeon, U. S. A.

Private Joseph Hamley, Co. K, 1st Infantry, aged 27 years, cut his throat with a razor, at Jackson Barracks, Louisiana, November 3, 1866. The larynx was opened, and the superior thyroid artery severed, the incision extending from one angle of the jaw to the other. When admitted to post hospital he was nearly pulseless. I at once ligated the divided ends of the thyroid. The patient did very well, and seemed to improve until the evening of November 5th, when he had a choking fit, and died a few minutes later of asphyxia.

DCXLVII.—*Report of a Successful Case of Ligation of the Common Carotid Artery.* By G. McC. MILLER, Assistant Surgeon, U. S. A.

Private Patrick Jordan, Co. A, 16th Infantry, aged 28, was wounded at Savannah, Georgia, November 27, 1866, by a conoidal ball, which entered the mouth, and, knocking out four teeth in the left superior maxilla (two incisors, one cuspidate, and one bicuspid), passed obliquely over the tongue, grooving it slightly, fractured the right ramus of the inferior maxilla at the angle, then passed into the neck and lodged under the upper portion of the right sterno-mastoid muscle, rather deeply, taking a position just behind the external carotid artery. There was little primary hæmorrhage. He was admitted to post hospital at Savannah; the neck was moderately swollen, and pus discharged from the mouth, but the jaw apparently was not much comminuted. On December 6th, profuse hæmorrhage occurred through the mouth, probably from the right external carotid artery near its origin. The ball was excised through an incision in the direction of fibres of the sterno-mastoid muscles, and liquor of the persulphate of iron was introduced into the opening. The patient became very weak, but the case progressed favorably, until the evening of December 10th, when hæmorrhage to the amount of eight ounces recurred from the mouth, and also from the wound of incision. On December 11th, I administered equal parts of ether and chloroform, and ligated the right common carotid artery. Owing to the depth of the artery, from tumefaction and infiltration of tissues, it was deemed expedient to divide the omo-hyoid muscle, and the ligature was applied to the part of the artery which lies behind the muscle. December 26th, fifteen days after the operation, the ligature came away; on December 31st the wound made in the operation of ligating the artery was nearly healed, but the incision for removal of the ball was still discharging. A large amount of callus had formed about the seat of fracture, and the prospect for recovery was excellent. The case progressed favorably, and the patient was returned to duty in January, 1867.

Ligation of Arteries of the Upper Extremity.—Nine special reports were made; one relating to a ligation of the brachial, five to ligations of the radial, and three to ligations of the interosseous or of the arteries of the hand. Two other cases have been already recorded in the chapter on wounds; a ligation of the interosseous (p. 97), and a ligation of the radial, (p. 155.)

DCXLVIII.—*Minute of a Case in which the Brachial Artery was ligated.* By R. A. CHRISTIAN, M. D., Acting Assistant Surgeon.

Private James McMahon, Co. F, 8th Infantry, aged 25 years, was accidentally wounded while on guard, July 23, 1867, at New Berne, North Carolina. The missile entered at the commencement of the upper third of the fore-arm, passed obliquely through the muscles, and out over the radius. Upon

being admitted to hospital the arm was much swollen, and there was considerable hæmorrhage. Secondary hæmorrhage occurred from perhaps both radial and ulnar artery, on July 31st, when the brachial artery was ligated in the lower third, while the patient was under the influence of chloroform. Recurring hæmorrhage was controlled by compresses, which were removed on the third day after the operation. The ligature came away on August 12th, and on August 19, 1867, the patient was doing well. He was returned to duty in September, 1867.

DCXLIX.—*Minute of a Case in which a Branch of the Radial Artery was ligated.* By E. P. VOLLUM, Surgeon, U. S. A.

Private Frank Henrietta, Battery F, 1st Artillery, aged 18 years, was accidentally wounded at Madison Barracks, Sackett's Harbor, New York, October 27, 1869, by the discharge of a shotgun. The left hand was over the muzzle; the load passed into the palm and carried away a portion of the metacarpal bones of the little and ring fingers. He was at once admitted to the post hospital, where fragments of the metacarpal bone of the little finger were removed from the wound, and a branch of the radial artery was ligated by Hospital Steward John S. Perkins. The edges of the wound were brought together by sutures, and dry lint was applied. On December 30, 1869, the wound had nearly closed. The patient was returned to duty in March, 1870.

DCL.—*Minute of a Case of Ligation of the Radial Artery.* By E. T. BAKER, M. D., Acting Assistant Surgeon.

Private William McBride, Co. F, 12th Infantry, aged 24 years, received, on September 22, 1868, an incised wound on the dorsal surface of the right hand, severing the radial artery. He was admitted to hospital at Oglethorpe Barracks, Savannah, Georgia, where both extremities of the artery were ligated. On September 30, 1868, the patient was doing well. He was returned to duty in October, 1868.

DCLI.—*Minute of a Case of Ligation of the Radial Artery.* By J. F. HEAD, Surgeon, U. S. A.

Private James Quinan, of the cavalry detachment at West Point, struck his fist through a window pane, and severed the radial artery, May 31, 1868. Assistant Surgeon E. J. Marsh enlarged the wound of incision and tied both ends of the artery with silk ligatures. Considerable swelling followed, but the wound healed with slight suppuration. On June 9th, the ligatures were removed, and on June 18th, the patient was returned to duty.

DCLII.—*Minute of a Case in which the Radial Artery was ligated.* By E. T. BAKER, M. D., Acting Assistant Surgeon.

Private C. P. Ray, Co. I, 16th Infantry, aged 21 years, was wounded on January 6, 1868, near Atlanta, Georgia. The ball passed between the thumb and index finger of the right hand and severed the radial artery. He was admitted to the post hospital. A tourniquet applied to the artery to control the hæmorrhage, caused considerable tumefaction, and the patient became debilitated. Secondary hæmorrhage occurred, and on January 27th, the radial artery was ligated in its lower third, while the patient was under the influence of chloroform. The wound healed in about a week; the hand remained weak and partially paralyzed for some time, but eventually recovered entirely. The patient returned to duty in March, 1868.

DCLIII.—*Note on a Ligation of the Radial Artery.* By JOHN M. DICKSON, Assistant Surgeon, U. S. A.

Private Alonzo Youngman, Co. D, 23d Infantry, received a severe gun-shot wound of the wrist-joint, in a skirmish with Indians, at Lake Warner, Oregon, April 29, 1868. The radial artery being

lacerated was ligated above and below the seat of injury, and water dressings were applied to the wound. The patient returned to duty in July, 1868.

DCLIV.—*Account of a Wound of the Arm necessitating Ligation of the Interosseous Artery.* By G. M. STERNBERG, Assistant Surgeon, U. S. A.

Private Wesley Jess, Troop M, 7th Cavalry, received, on November 21, 1868, while on picket at Camp Supply, Indian Territory, a gun-shot wound of middle of right fore-arm. The ball passed between the radius and ulna without fracturing either. He was admitted to post hospital on November 23d. No hæmorrhage occurred until the fifth day after the reception of injury; afterward, hæmorrhage occurred about every twenty-four hours, generally at night, from a few ounces to a pint at a time. When the dressings were removed the hæmorrhage would cease; an operation was consequently delayed from day to day, in the hope that it would become unnecessary. The arm began to swell, became painful, tense and glossy, and above the elbow to the shoulder swollen and œdematous. On December 5th a sharp pointed bistoury was introduced into the wound, and a deep incision about four inches long was made in the long axis of the limb. A large quantity of clotted blood was thrown out from between the muscles, which had been dissected up by it in every direction; the interosseous artery was severed at the point from which the blood escaped, and tied at both ends. The pain was immediately relieved, the swelling of the limb rapidly disappeared, and healthy granulation set in. On December 31st, the wound had nearly closed, and there had been no hæmorrhage since the operation. The patient was returned to duty in January, 1869.

DCLV.—*Note on a Ligation of the Superficialis Volæ Artery.* By H. S. SCHELL, Assistant Surgeon, U. S. A.

Corporal Cyrus Reed, Co. E, 4th Infantry, aged 20 years, at Fort Laramie, Dakota Territory, September 26, 1867, accidentally cut his left wrist, severing the superficialis volæ artery. He was admitted to the post hospital, where both ends of the artery were tied, and three iron wire sutures were applied. On September 30th, the patient was doing well. He returned to duty in December, 1867.

DCLVI.—*Memorandum of a Case in which the Superficial Palmar Arch was ligated.* By CHRISTIAN RAUSHENBERG, Acting Assistant Surgeon.

John Stanridge, a private of Co. B, 16th Infantry, accidentally wounded himself with a shot-gun at Albany, Georgia, on February 14, 1868. The wound extended from the middle of the palm of left hand, seven inches above the wrist. The soft parts between the ulna and radius were lacerated and destroyed, the wrist-joint was opened, the superficial palmar arch and branches of the ulnar and interosseous arteries were wounded, and several carpal bones were fractured. Considerable hæmorrhage was arrested by ligation of the former and torsion of several branches of the latter arteries; five pieces of carpal bones of different sizes were removed, and the edges of the wound about the wrist were brought as close together as possible by a twisted suture. In consideration of the age and condition of the patient, the importance of the limb and its great capacity for recovery, and the fact that two large arteries of the fore-arm were not wounded, it was determined, after consultation with another physician, not to resort to primary amputation, but to make an effort to save the limb. Cold applications, opiates, and saline purgatives constituted the principal treatment from the 14th to the 19th of the month. By the latter date inflammation had reached a fearful degree. A large and deep incision was made, and warm cataplasms were resorted to, when the hand, on the evening of that day, became cold and lifeless. The change in the condition during the night was very great. The next morning his pulse was soft and small, skin cool and jaundiced, and the wounded arm had become gangrenous. The state of the pulse precluding the idea of amputation, local and internal stimulants were promptly but unsuccessfully used, death occurring on the evening of the 20th.

Ligations of the Great Vessels of the Trunk.—Reports of four cases come under this head:

DCLVII.—*Ligation of the Abdominal Aorta for Aneurism.* Compiled from reports by D. R. BROWN, M. D., Acting Assistant Surgeon, J. H. JANEWAY, Assistant Surgeon, U. S. A., and Professor H. MCGUIRE, M. D.

Wilson F——, a negro of thirty years, a wood-chopper, was admitted to the Howard Grove Hospital, at Richmond, Virginia, March 20, 1868. He stated that a week before, while pursuing his ordinary avocation, he felt something give way in the lower part of his abdomen, a sensation followed by nausea and great pain. On admission the tumor was small, but it rapidly increased and soon its aneurismal nature became unmistakable. Drs. Janeway and McGuire were invited to examine the case. No pulsation could be discovered in the left femoral; but no change in the temperature or size of the left leg was observed. His general health was good. The patient said that the tumor gradually increased in size and was daily growing worse. Rest in bed, with digitalis, iron, acetate of lead, and opiates, seemed to alleviate the pain and to diminish the size of the tumor; but the relief was but temporary. On March 26th, compression of the aorta was resorted to, but had to be discontinued because of the tenderness of the tumor. On March 30th, at 1 P. M., Dr. McGuire, after consultation with Drs. Brown and Janeway, Professors Joynes, Wellford, and others, determined to cut down and to ligate the common iliac above the aneurism. When the aneurism was exposed it was found to involve the whole of the common iliac, and the aorta near its bifurcation. The sac was very thin. Dr. McGuire now determined to tie the aorta, when the sac suddenly ruptured, although it had been handled with the utmost delicacy, and a profuse discharge of blood took place. The aorta was instantly compressed by the finger an inch above the tumor, and surrounded by an assistant with a ligature and tied. About a pint of blood was removed from the cavity of the abdomen. The lips of the wound were brought together. Sutures and bandages were applied. A stimulating enema was given. The patient was put to bed, and the lower extremities were surrounded by warm applications. In a few moments the effects of chloroform passed off, and slight reaction took place. He complained much of numbness of the lower extremities. The temperature of the axilla never rose above 96. He died half an hour after midnight, eleven and a half hours after the operation. At the autopsy, the ligature was found to embrace the aorta at the origin of the inferior mesentery and included the left ureter. The rent in the sac was just over the bifurcation of the aorta. The specimen, figured by the wood-cut (FIG. 50) was contributed to the Museum at Washington.* It is still better represented by Photograph 222, of the Surgical Series of Photographs, Vol. V., p. 22.†

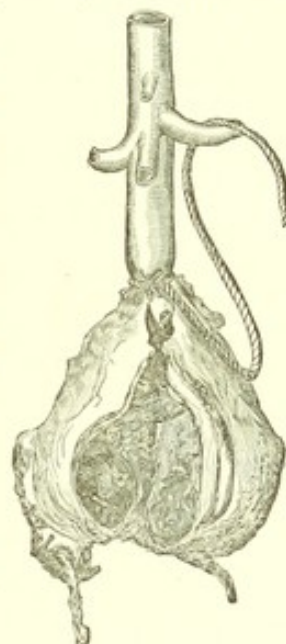


FIG. 50.—Aorta ligated for iliac aneurism. Spec. 5256, Sect. I., A. M. M.

DCLVIII.—*Minute of Case of Ligation of the External Iliac.* By B. E. FRYER, Assistant Surgeon U. S. A.

Sergeant Patrick Fitzpatrick, Co. B, 4th Infantry, was admitted to post hospital at Fort Wayne, Michigan, on May 21, 1867, with a large aneurism of external iliac and femoral arteries. The tumor extended from about two inches above Poupart's ligament to eight inches below. The thigh was nearly thirty-six inches in circumference. The man had been intemperate, and had been confined to his bed for nearly three months before his admission to hospital. On May 24th, ether having been administered, an incision was made seven inches in length, beginning an inch above the external

* A detailed account of this case may be found in the *American Journal of the Medical Sciences*, Vol. LVI, p. 415, Oct., 1868.

† Sir Astley Cooper's famous case of ligation of the aorta is recorded in the *Surgical Essays of Cooper and Travers*, London, 1818, p. 113.

abdominal ring, outward, upward, and inward, toward and nearly on a line with the umbilicus. The ligature was passed from within out, about three inches above Poupart's ligament, and one inch above the tumor. Thirty-six hours after operation the stomach became excessively irritable, and remained so for three days. The patient vomited whatever he ate. The tumor decreased until June 19th, when hæmorrhage to the amount of twenty-four ounces occurred. On the 22d hæmorrhage recurred, about three ounces of blood being lost, and death ensued June 25, 1867, from exhaustion. At the autopsy, the external iliac was found divided by the ligature about three-fourths of an inch below its origin, the cardiac extremity closed by a firm plug as far up as internal iliac; distal end remaining open. The sac of the tumor was filled with a dark fluid and coagula.

DCLXIX.—*Curtailed Account of a Traumatic Aneurism, Succesfully Treated by Ligation of the External Iliac Artery.* By J. B. WHITE, Acting Assistant Surgeon.

Corporal Wm. A. Johnson, Co. B, 8th Infantry, aged 22 years, was wounded at Goldsborough, North Carolina, October 23, 1869, by a conoidal ball, which entered right thigh on outer aspect of junction of upper and middle third, and lodged beneath the skin two inches higher up on inner side. He was admitted to the post hospital at Goldsborough, where the missile was extracted through a counter opening. On November 1st, he was transferred to the post hospital at Raleigh. The wound had entirely healed, but an aneurismal swelling could be perceived to pulsate very strongly, and on auscultation a blowing or sawing sound could be heard. The thigh became swollen and œdematous, the circumference of the affected limb being six inches in excess of its fellow, and the patient was emaciated from extreme pain and disquietude. On December 16th, ether having been administered, an incision was made, commencing on a line one inch on the inner side of the anterior superior spinous process of the ilium, running downward one and a half inches above and parallel with Poupart's ligament, terminating a little without the inner margin of the abdominal ring. The parts were found slightly infiltrated with a light yellowish serum. The sheath of the artery was reached without injury to the peritoneum, and without the division of any vessel of importance. The armed aneurismal needle was passed on the inner side of the artery between it and the vein, and the artery tied at least one inch above the epigastric and circumflex artery. The muscular and integumental lips were tacked together, and adhesive strips applied. The patient rallied promptly, but the pulsation in the limb was entirely gone. Warmth was applied to foot and limb, and stimulants given. On December 18th there was slight oozing from wound of operation, but the patient slept well, and the size of the leg was rapidly diminishing. On December 28th; the ligature came away, pus was laudable. December 30th: the wound was granulating finely, and the patient in excellent spirits. Early in February, 1870, the patient was placed upon crutches, and gradually regained the use of the affected limb, which was slightly ankylosed from long disuse. He was returned to his company in April, 1870. In May, 1870, Doctor White reports his patient to have entirely recovered.

DCLX.—*Report relative to a Case in which the External Iliac Artery was ligated.* By FRANCIS BARNES, M. D., Acting Assistant Surgeon.

Alfred Sullivan, aged 26 years, was admitted to the Freedmen's Hospital, at New Orleans, Louisiana, on January 16, 1868, suffering from two gunshot wounds, one about two inches below Poupart's ligament, the other about one inch below the first wound. Both were external to the rectus femoris. The ball which caused the lower wound passed to the inside of the femur, and emerged at a point opposite its entrance; the other ball lodged. When I took charge of the ward, the patient was much emaciated, pulse 100, appetite feeble, tongue coated, and skin dry. He had no pain, save when his position was disturbed. All the wounds healed except the upper one. A non-fluctuating tumefaction extended from the middle third of the thigh to Poupart's ligament, and to the gluteal muscles. But one position of the limb could be borne, that of flexing the leg upon the thigh at right angles, and flexing the thigh upon the pelvis, with the limb rotated outward. The upper wound would open every few days, and discharge a quantity of grumous black blood,

or thin serum. These hæmorrhages were undoubtedly venous, and it also appeared as if the blood were effused some hours into the tissues of the thigh, before its debris escaped from the wound. The hæmorrhages were not alarming until a day or two before March 22d, when they became more copious, and the patient sinking from their effects, it was determined to lay open the parts and search for the wounded vessel, which was believed to be the femoral vein. On March 22d, a number of medical gentlemen being present, the patient was ordered upon the operating table. In bringing him from his bed to the table, on a stretcher, a most profuse arterial hæmorrhage occurred, evidencing that the femoral artery had given way. I compressed the artery, below Poupart's ligament, with my thumb, while Dr. Schuppert ligated the external iliac artery just above Poupart's ligament. This measure arrested the hæmorrhage instantly, and it did not recur. After the ligation, a free incision was made from the wound upward, in the direction of the crest of the ilium, and the finger being used to explore the cavity, passed upward to the crest of the ilium, under the tensor vaginæ muscle. The finger could also be passed in front of the femur and around it, through openings in the adductor muscle, so as to ascertain the presence of a large cavity filled with coagula and serum, all of which were washed out with a syringe. Death resulted in a short time. The *post-mortem* examination revealed a cavity of the capacity of a pint, occasioned by the tearing up of the connected tissues of the muscles of the thigh from the middle third to gluteal and Poupart's ligament. The same cavity was continuous with one made by separating the peritoneum from the back part of the pelvis in right side, as far as the bifurcation of the iliac. The external iliac had a perfectly formed thrombus, extending to the bifurcation. The most interesting result of the examination was the demonstration that the ball must have entered while the thigh was flexed upon the pelvis, passed in such direction as to open the hip-joint and knock off a fragment of the cotyloid rim, on its inner and lower side; it then passed through the thyroid opening and lodged just behind the acetabulum. The cartilages of the head of the femur and of the cotyloid cavity had entirely disappeared, leaving the bones denuded and rough. The ligamentum teres had disappeared. From the direction of the balls either could have wounded the femoral vessels, or rather injured them so that a subsequent slough caused them to give away; the femoral vein first by a small opening and the artery afterward.

Ligations of the Arteries of the Lower Extremity.—Eight special reports relate: four to the femoral, one to the external, and one to the posterior circumflex, one to the tibial and peroneal, and one to the *arteria dorsalis pedis*.

DCLXI.—*Account of a Ligation of the Femoral Artery.* By W. B. BUTCHER, Acting Assistant Surgeon.

Corporal Henry Cheesely, Co. I, 114th Colored Troops, aged 29, was accidentally wounded at Fort McIntosh, Texas, December 18, 1866, by a conoidal pistol ball, which entered two inches below Poupart's ligament, and passing inward, downward and backward, emerged upon the inner part of the thigh, three inches below point of entrance, injuring the femoral artery one-half inch below the profunda. Upon being admitted to hospital he was very faint from excessive loss of blood. Four hours after the reception of injury the wound of entrance was enlarged by incision, while the patient was under the influence of ether; the tourniquet was applied and the femoral artery ligated, above and below the seat of injury. The wound of exit was then enlarged to favor drainage. December 31, 1866: the patient was doing well, and was returned to duty February 28, 1867.

DCLXII.—*Note relative to a Ligation of the Femoral Artery.* By Surgeon LEONARD F. RUSSELL, 4th U. S. Veteran Volunteers.

Private David Jones, Co. E, 4th Infantry, was wounded at Fort Sully, Dakota Territory, on March 7, 1866, by a soldier who made a thrust with a large bread knife, which entered the thigh transversely about three inches above the inner condyle of the femur, and passing almost through, severed the popliteal artery and vein, and nerve. Hæmorrhage was controlled by compression,

and it was then deemed best not to open the wound and attempt to ligate. On the fourth day, some arterial hæmorrhage occurring, it was thought unsafe to delay, and I ligated the femoral at the middle third. There had been no warmth or circulation below the wound since the injury, and, at the time of operation, there were strong indications of gangrene. The patient died on March 16, 1866.

DCLXIII.—*Account of a Ligation of the Femoral Artery.* By E. McCLELLAN, Assistant Surgeon, U. S. A.

Private George Hastings, Co. K, 37th Infantry, was admitted to the hospital at Fort Garland, Colorado Territory, July 30, 1868, having been accidentally stabbed the same day, in the upper portion of the thigh, with a long, narrow hunting-knife, which had been made exceedingly sharp, and which, passing the femoral artery, partially divided the profunda femoris below the origin of the external circumflex. The hæmorrhage was excessive. Some few moments only elapsed after the accident, before complete syncope ensued with all the characteristic symptoms. Pressure on the femoral arrested the hæmorrhage, but the extreme prostration prohibited surgical interference at the time, and stimulants and nourishments were administered. At 10 o'clock P. M. hæmorrhage again occurring, now from the lower extremity of the artery, the wound was enlarged and the artery secured. The patient was kept for several days under the influence of morphine. Slight pressure continued on the femoral, although not sufficient at any time greatly to impede the circulation in the limb. At no time after the operation was the circulation arrested. On the nineteenth day the upper ligature was removed, but the lower one did not come away until the thirty-fourth, although steady and continual traction upon it was made. The patient was returned to duty in October, 1868.

DCLXIV.—*Memorandum relative to a Ligation of the Femoral Artery.* By A. JUDSON GRAY, M. D., Acting Assistant Surgeon.

Private John Neun, Troop B, 3d Cavalry, aged 26 years, was wounded in a drunken altercation at Fort Bayard, New Mexico, November 12, 1869, by a pistol ball, which entered the outer aspect of right leg, three inches below the knee, passed obliquely downward and inward, between tibia and fibula, and emerged from inner aspect of leg, six inches above the ankle-joint. He was admitted to the post hospital on November 13, 1867. The leg became inflamed, and the foot and ankle œdematous. The discharge was thin and bloody. Hæmorrhage occurred on December 5th, and again on December 8th, but was easily controlled by pressure. The patient became anæmic from loss of blood, and was anxious and desponding. On December 10th, ether was administered, and an incision four inches long was made, commencing five inches below Poupart's ligament, and extending parallel to, and a little to the outside of, the inner border of the sartorius muscle. The femoral artery was then ligated. The patient reacted promptly. Three days after the operation a slough three by five inches, formed under the leg just above the ankle, but suppurated healthily. The inflammation in the leg subsided, the ligature came away on the 27th, and on December 30th the upper wound had entirely healed, while the others were closing satisfactorily. He was returned to duty on February 24, 1870.

DCLXV.—*Minute of a Case in which the External Circumflex Artery was ligated.* By DONALD JACKSON, M. D., Acting Assistant Surgeon.

Private John Davis, Co. C, 41st Infantry, aged 22 years, received on March 13, 1869, at Fort Clark, Texas, a punctured wound of thigh. He was admitted to the post hospital, where the wound was enlarged and the internal circumflex artery ligated, while the patient was under the influence of ether. Five days later the ligature was removed, and the wound was filling with healthy granulations. He was returned to duty May 12, 1869.

DCLXVI.—*Note relative to a Ligation of the Posterior Circumflex Artery.* By B. B. MILES, M. D., Acting Assistant Surgeon.

Private Thomas Quigley, Co. G, 17th Infantry, aged 21 years, received at Sulphur Springs, Texas, December 24, 1868, an incised wound of left shoulder, eight inches in length from shoulder downwards. He was admitted to the post hospital. The patient had fainted from loss of blood, and the pulse was almost imperceptible. I ligated the posterior circumflex artery, and brought the edges of the wound together with silk and adhesive plaster. The wound healed rapidly, and was doing well December 31, 1868. The patient was returned to duty in February, 1869.

DCLXVII.—*Note relative to a Ligation of the Peroneal and Tibial Arteries.* By H. A. DuBois, Assistant Surgeon, U. S. A.,

Corporal Peter Stone, Troop C, 3d Cavalry, aged 24 years, was admitted to the post hospital at Fort Union, New Mexico, June 29, 1867, with a gunshot wound in the leg. The missile, a conoidal ball, entered three inches below the head of tibia, passed through the gastrocnemius and soleus muscles, descended the tibialis posticus to two inches below the outer malleolus, and injured in its course the peroneal, and probably the posterior tibial artery. An incision through the gastrocnemius and soleus muscles was made, and the peroneal and tibial arteries and all bleeding branches were ligated. The patient never rallied from the shock, and died July 1, 1867, fifty-two hours after the operation. At the *post-mortem* examination the kidneys were found inflamed, and the unlooked-for termination of the case was explained by the fact that the patient had been on a debauch at the time of his admission, and for some weeks previously.

DCLXVIII.—*Minute of a Case in which the Dorsalis Pedis Artery was ligated.* By E. Y. CHASE, M. D., Acting Assistant Surgeon.

Private James Lasby, Co. G, 23d Infantry, aged 33 years, while, on December 15, 1868, chopping wood at Fort Colville, Washington Territory, cut his right foot with a sharp axe. The flexor tendons of the foot, dorsalis pedis artery, and the metatarsal bone of big toe were divided, causing a gaping wound four inches in length. He was admitted to the post hospital, where the dorsalis pedis artery was ligated, and the wound closed by interrupted suture. The wound failed to unite by first intention, and on December 20, 1868, the ligature was removed. The patient was returned to duty in March, 1869.

VARIOUS OPERATIONS.

Reports were made of a few operations on the eye and ear and air passages, and of examples of lithotomy and of the removal of tumors.

OPERATIONS ON THE EYE OR ITS APPENDAGES.—A case of extraction for cataract, one of staphyloma, one of ectropion, and one of extraction of a foreign body, were specially reported.

DCLXIX.—*Account of an Operation for Ectropion.* By A. C. GIRARD, Assistant Surgeon, U. S. A.

Private William Brown, Co. E, 20th Infantry, was admitted to the hospital at Baton Rouge, Louisiana, February 22, 1869, with ectropion of the right eye. The conjunctiva of the lower eyelid was largely everted and considerably swelled in consequence of a burn, involving the whole right cheek and part of the temporal region. There was chronic conjunctivitis oculi and palpebrarum. A V-shaped piece was excised from the external angle of the eye, and the edges united with twisted suture; the thickened conjunctiva was excised with curved scissors, and parallel to lower eyelid an incision, one and a half inches in length, was made, to relieve tension. Simple dressings were applied, and occasionally cauterization, to insure even granulation. The patient was discharged March 13, 1869, at which date the wound had not entirely healed.

DCLXX.—*Account of an Extirpation of the Eye-ball for Staphyloma.* By G. M. STERNBERG, Assistant, Surgeon U. S. A.

Private Lewis Johnson, Co. D, 38th Infantry, aged 29, was admitted on June 24, 1867, to the post hospital at Fort Riley, Kansas. For six months prior to admission the patient had noticed that his right eye was becoming prominent, and that he could not see with it. On admission there was staphyloma of the sclerotic, near the cornea. The whole eye continued to enlarge slowly in all its diameters, and ulceration at the apex of the staphyloma ensued. The patient suffered from pain in the head and eye, and had frequent attacks of temporary paralysis of the extremities, lasting from one to three hours. On December 18th, an anæsthetic of one part chloroform and two parts ether, was administered, and the globe of the right eye was removed. A circular cut was made through the conjunctiva with scissors, hooking up and cutting the muscles close to their insertion in the globe; the globe was dislocated, and the optic nerve severed with long scissors. A plug of picked lint soaked in alum water was then inserted in place of the globe. On the third day suppuration was established, and the plug of lint removed. The pain in the head and the attacks of paralysis ceased, and the patient made an excellent recovery. He was discharged April 8, 1868.

DCLXXI.—*Report of a Case of Traumatic Cataract.* By HARVEY E. BROWN, Assistant Surgeon, U. S. A.

Private John Ehlman, Battery A, First Artillery, was admitted to the post hospital at Fort Ontario, on June 30, 1870, on account of a severe contusion of the right eye, which had produced so much ecchymosis and effusion in the lids that it was impracticable to ascertain the condition of the globe until July 3d. It was then found that there was a luxation of the crystalline lens, with extravasation of blood into the anterior chamber, and total loss of sight from traumatic cataract.

As the tension was very great, on consultation with Dr. E. M. Curtis, of Oswego, it was decided to operate as soon as possible. Accordingly, on the 16th of July, the linear operation was performed by Dr. Curtis, with my assistance, the patient being under the influence of chloric ether. It was found, on operating, that the iris was extensively injured; so much so as to give but little hope of an entirely favorable result. The lens extracted was completely disorganized. After the operation the sight decidedly improved, though the patient had to undergo quite a severe attack of irido-choroiditis after the operation. This soldier was discharged on October 10, 1870, on surgeon's certificate of disability, for loss of sight. The accident occurred from a blow received in a drunken brawl.

DCLXXII.—*A Case of Extraction of a Foreign Body from the Anterior Chamber of the Right Eye.*
By F. MEACHAM, Assistant Surgeon, U. S. A.

Private Patrick Sheridan, Co. D, 36th Infantry, appeared at sick-call at Camp Douglas, Utah Territory, January 14, 1869, complaining of an injury of the right eye. A foreign substance was found deeply imbedded in the cornea. An attempt to remove it failed, as it had passed entirely through, and was suspended in the anterior chamber of the eye. Chloroform was administered, the wound of entrance was enlarged, and a piece of steel one-sixteenth of an inch in length, one-forty-eighth of an inch in width, and one-ninety-sixty of an inch in thickness was removed from the anterior surface of the iris. Prolapse of the iris occurred when iridectomy was performed. January 31st the wound of the cornea had entirely healed, with a slight leucoma, which somewhat interfered with the vision. The patient was mustered out January 22, 1869, on account of expiration of term of service.

OPERATIONS ON THE EAR.—A single special report on this subject was received.

DCLXXIII.—*Account of an Operation for the Removal of an Aural Polypus.* By J. M. DICKSON, Assistant Surgeon, U. S. A.

Private John Jeffcott, Co. B, 9th Infantry, of strumous diathesis, was admitted to hospital at Fort Sedgwick, Colorado Territory, on July 10, 1870, with deafness of both ears, accompanied by discharge, a small polypus existing in the meatus of the right ear. By July 24th the walls of the meatus, &c., were so thickened that a small speculum could with difficulty be introduced but a short distance. The Eustachian tubes were pervious. On that date the polypus was removed, by torsion, with forceps, the remaining portions by the application of nitrate of silver. The ensuing treatment consisted of astringent injections, the occasional application of a blister over the mastoid portion of the occipital bone. Tonics and alteratives were administered. On September 2, 1870, he was transferred to hospital at Fort Russell, Wyoming Territory, accompanying his company. At that date his hearing was much improved.

OPERATIONS ON THE MOUTH AND ITS DEPENDENCIES.—Interesting instances have been reported of operations for ranula, polypus, and salivary calculus.

DCLXXIV.—*Remarks on a Case of Ranula.* By IRVING C. ROSSE, M. D., Acting Assistant Surgeon.

Private Magenthaler, Battery G, 1st Artillery, presented himself at sick-call at Fort Monroe, Virginia, on December 16, 1869, having for some time had a troublesome tumor, involving the right side of the floor of the mouth. It forced the tongue upward and backward, and interfered with swallowing and pronunciation. There was no perceptible derangement of the general health. Making a small puncture in the cyst, a glairy, ropy fluid escaped; but it was not ascertained whether this was an accumulation in the salivary ducts or a collection in an enlarged follicle. The cyst was thought to constitute that form of atheroma known as cholesteatoma, or, more commonly, ranula. A seton was passed through its walls, and a saturated solution of chlorate of potash was

directed to be used as a mouth-wash. The seton was several times renewed in the course of treatment. The patient was returned to duty December 29, 1869.*

DCLXXV.—*Note relative to the Removal of a Polypus from the Tonsil.* By G. M. STERNBERG, Assistant Surgeon, U. S. A.

Private David Young, Troop K, 10th Cavalry, aged 22 years, was admitted on December 22, 1867, to the post hospital at Fort Riley, Kansas, complaining of difficulty in swallowing. An examination of the pharynx disclosed a fibrous polypus, about one and a half inches long, attached to the right tonsil. The polypus was removed by first seizing it with toothed-forceps, and then severing it from its attachments with a blunt-pointed bistoury. Very little hæmorrhage occurred, and, up to December 31st, no return of polypus was noticed. He was returned to duty in January, 1868.

DCLXXVI.—*Note relative to a Salivary Calculus.* By CLINTON WAGNER, M. D., late Surgeon, U. S. A.

I transmit to the address of the Surgeon General a salivary calculus, which I hope will be, on account of its extraordinary size, an acceptable offering to the collections of the Army Medical Museum. I removed the stone in December, 1870, from the sublingual gland of a laboring man. It blocked up the orifice of the duct of Bartholine at its junction with the Whartonian duct. From the man's statement I inferred that the concretion had been about three years in forming. The man lived in Boise City, Idaho. The calculus weighs about eight grains, or little less. The groove was made by scraping with my knife. The powder scraped off did not effervesce with hydrochloric acid. With solution of molybdate of ammonia it gave the characteristic reaction of phosphoric acid, and a white precipitate with oxalate of ammonia. The concretion would seem to be composed mainly of phosphate of lime and of organic matter. It is figured of the natural size in the wood-cut. (FIG. 51.)

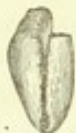

FIG. 51.—Salivary Calculus. Spec. 5735. Sect. I. A. M. M.

DCLXXVII.—*Account of a Plastic Operation.* By L. E. HOLMES, Acting Assistant Surgeon.

Private Andrew Mussell, Troop F, 8th Cavalry, aged 22 years, was admitted to the post hospital at Camp Logan, Oregon, on March 7, 1868. He had lost a portion of his nose, which had been injured two or three years previously. A part of the left wing of the vomer was destroyed, leaving a fistulous opening through the middle third of the organ. On March 7th I performed the rhinoplastic operation, Indian method. Considerable swelling of the flap and the lids of both eyes followed the operation. This was treated with cold water-dressings. On the fourth day the stitches were removed, and the root of the flap was cut on the thirtieth day. The flap was well located, and appeared satisfactory. The patient was returned to duty on April 1, 1868.

OPERATIONS ON THE AIR PASSAGES.—Reports were furnished of five cases of bronchotomy, and one of paracentesis of the thorax.

DCLXXVIII.—*Report of Two Operations of Tracheotomy, with Remarks on some Details of the Operation and After-treatment.* By BASIL NORRIS, Surgeon, U. S. A.

A child, 3½ years old, son of Mr. Paulson, in general service at the War Department, was seen in consultation November 9, 1869. It had been suffering five days from membranous croup; was extremely restless, with sharp, ringing, croupy cough, livid lips, and laborious respiration. In the afternoon, at two o'clock, it was put under the influence of chloroform, which was sprinkled on a handkerchief caught loosely in the hand and held before the face; it was then placed upon a table, the shoulders being raised on a pillow, and the head allowed to fall back. An incision was

* This man was drowned at Fort Monroe, November 14, 1870.

made one and a half inches long, "exactly in the median line," through the skin and superficial tissues; the cervical fascia was next pinched up with a pair of forceps and divided on a grooved director; this being done the knife was laid aside and the point of a strong steel director used to separate the sterno-hyoid muscles, and clear a way to the windpipe; the lips of the wound were held apart by blunt hooks; the trachea, thus exposed, was kept steady by a tenaculum in the hands of an assistant, and opened with a small scalpel, inserted with the point toward the cricoid cartilage and the edge upward. By the aid of Trousseau's dilator, a double canula was quickly introduced, and the operation completed. The patient soon awoke, breathing easily; it looked about more calmly, and bore on its face a sense of relief and comfort; it lay at rest on a bed, taking nourishment and water, until two o'clock in the morning, when it again began to breathe with difficulty, and died at 5 o'clock A. M.

A child, — years old, son of Mr. Page, of Frederick, Maryland, was seized with symptoms of membranous croup, January 2, 1870, while on a visit to an officer of the Army stationed in Washington. It was six days under treatment by the usual remedies, and, in addition, was treated with lime water atomized by the "hand apparatus;" the patient, possessed of more intelligence than is common to children of that age, willingly inhaled through the mouth-piece whenever it was presented. Tracheotomy, earlier advised, was not performed until literally the last moment; the face and lips were congested, the hands and feet cold, and the breathing slow and gasping. While in this condition, chloroform was administered, and the operation was begun; but before the trachea could be reached, it was remarked that the heart's action had ceased; the operation was, nevertheless, continued, and the child revived under artificial respiration, maintained by pressure on the abdomen with the hand, firmly and repeatedly applied. It lived two days and eight hours; was able to take beef-tea, water, and milk-punch, and preferred to help itself to ice from a saucer placed at the bedside. It finally succumbed to the constitutional effect of the disease.

In both these cases, some hæmorrhage occurred from a vein, which is unavoidable in dividing the cervical fascia, crossing, as it does, the line of incision, midway between the cricoid cartilage and the sternum; though very small, it was seen and examined in the second case, as it lay immediately upon the fascia when raised on a grooved director. Hæmorrhage from this source soon ceased, and was of so little consequence, that I would not think it worth while to allude to it, had I not found it practicable, with this exception, to go through all the steps of the operation without the loss of more blood than is caused by the first incision through the skin. Keeping the canula clean, and removing exudation from the trachea below the artificial opening, we ascertained to be a very important part of the nurse's duty. In the first case, which lived fifteen hours, a feather, cut off at the end, was used to cleanse the canula. In the second case, which lived fifty-eight hours, a tube cleaner, belonging to "Mawson's nursing bottle," was discovered to be the "ne plus ultra" for this purpose, and for clearing the trachea below the tube. It was dipped in water, shaken, and introduced as far as it would go, even beyond the bifurcation of the trachea; it was withdrawn loaded with thick mucus, and often with partial casts of false membrane. The use of this instrument was frequently necessary to relieve the breathing, and it was introduced as many times as in the judgment of the attendant the emergency required.

DCLXXIX.—*Report of a Successful Case of Tracheotomy.* By WILLIAM M. NOTSON, Assistant Surgeon, U. S. A.

Patrick McMahon, a private of Co. H, 11th Infantry, aged 23, was admitted to hospital at Fort Concho, Texas, on September 12, 1870, with a longitudinal fracture at the angle of the lower jaw, supposed to have been caused by a kick received in a general fight in the guard-house. On the 18th, the patient being moribund, with the throat, neck, and head much swollen, it was decided to perform tracheotomy, which was done, at midnight, by Assistant Surgeon William M. Notson, U. S. A., assisted by Acting Assistant Surgeons J. A. McCoy and C. W. Knight. The incision was made below the isthmus of the thyroid gland. The constitutional state of the patient was favorable from age, but unfavorable from the fact that he had been on a debauch. The tube remained in the opening ten days. Light, liquid diet was allowed, and soup enemata were adminis-

tered. Cold-water dressings were used. The result was entirely successful, the patient having left the hospital cured, on the expiration of his term of enlistment, November 29, 1870.

DCLXXX.—*Report of a Fatal Case of Laryngotomy.* By A. C. GIRARD, Assistant Surgeon, U. S. A.

Philip Haxel, a private of Co. H, 19th Infantry, reported sick at Baton Rouge, Louisiana, on March 7, 1870, and stated that he was beaten on the left temple with a club some days previously whilst in an altercation with another soldier. A cold-water dressing was applied to reduce the swelling, but erysipelatous inflammation appearing on the 9th, he was admitted to hospital. The left cheek and temple were considerably swelled. The general health and appearance of the patient were good. An examination with a probe revealed a comminuted fracture of the zygoma, with probable lesion of the skull. The pupils were natural, pulse 72, bowels confined, and tongue somewhat coated. Absolute rest in bed was enjoined, with a nourishing diet, and cold applications of carbolic acid in solution. The administration of aperients, followed by a solution of quinine and iron, with the application of a poultice to the wound, constituted the remainder of the treatment. He did well until the evening of the 14th, when symptoms of tetanus set in. After consultation, one-third of a grain of the extract of Calabar bean, in solution of eighteen minims of water, was injected in the region of the left deltoid muscle, and an enema of four ounces of brandy was administered. This treatment was steadily adhered to until the evening of the 15th, when the patient was in immediate danger of suffocation. The spasms had become more violent, there was terrible orthopnoea with cyanosis, and small but frequent pulse. Having decided upon laryngotomy as the only means of saving life in this instance, the patient was laid on a bed and held by six men, chloroform being inadmissible, when Assistant Surgeon A. C. Girard opened the thyroid membrane, after having stopped bleeding from some small veins. Immediately on opening a large stream of whipped blood issued with great force from the opening, apparently coming from the lungs, and continued to gush forth at each attempt at respiration for full fifteen minutes. Upon the introduction of the tube the air commenced to pass too and fro with great force, but the expectoration of blood continued for one hour. When it abated breathing became fairly established, and the patient felt greatly relieved. The Calabar bean and the stimulating enemata were repeated, together with hypodermic injections of atropine, and of morphia with Calabar bean, but the patient got lower and lower, and died at noon on the 17th. At the autopsy the body was somewhat emaciated, there was considerable suggillation of the temporal muscle, and the zygomatic bone was fractured in two places, the fragments being loose but undetached. The meninges on the left temple were somewhat congested. The brain was normal, and the temporal bone intact. The larynx was normal. The lungs were in a high state of congestion and œdematous. No ruptured blood-vessel of any size was discovered. The heart and intestines were normal.

DCLXXXI.—*Report of a Fatal Case of Laryngotomy.* By E. P. VOLLUM, Surgeon U. S. A.

Patrick O'Callaghan, a private of Co. B, 13th Infantry, aged 25, was admitted to the post hospital at Camp Douglas, Utah Territory, on December 10, 1870, suffering from œdema of the glottis and tonsillitis. On the next day the patient becoming cyanosed, and symptoms of suffocation setting in about mid-day, the larynx was opened and a tube inserted by Surgeon E. P. Vollum, U. S. A. No anæsthetic was used. After the admission of air through the tube, the patient revived a little, and lived about three-quarters of an hour. At the autopsy, the cutaneous surface was of a bluish color; the tonsils were so tumefied as to completely overlap the rima glottidis, and the sub-mucous tissue of the epiglottis and that surrounding the brim of the rima glottidis, as well as that covering the base of the tonsils and the membranous fold about the base of the tongue, were boggy, with œdematous effusion. No abscess or pus was found in the vicinity of the tonsils or fauces. The sub-maxillary glands were greatly enlarged, and the areolar tissue of the neck was distended by serous effusion.

DCLXXXII.—*Report of a Case of Thoracentesis.* By D. BACHE, Surgeon, U. S. A.

At San Antonio, Texas, May 6, 1869, Richard Elliott, private, Co. H, 9th Cavalry, aged 24, received an incised and punctured wound of the left breast by a knife. He was admitted to hospital from camp on May 7th. Paracentesis thoracis on the left side, was performed for empyema on June 12th. He was discharged from service March 24, 1870, because of empyema, partial collapse of the lung, and great impairment of respiratory power.

OPERATIONS ON THE CHEST.—Instances of removal of fragments of ribs and of "hermetically sealing" wounds, after gunshot injuries of the thorax, have been detailed on pp. 27, 28, *ante*, and a case of excision of a necrosed portion of rib is described on p. 131. Reports were received of two other cases which may be placed in this category.

DCLXXXIII.—*Note of a Case in which Fragments of the Ribs were removed, with Remarks on the After Treatment.* By G. C. DOUGLAS, M. D. Acting Assistant Surgeon.

George Christopher, a private of Troop L, 9th Cavalry, was maliciously shot by another soldier at Fort Duncan, Texas, on September 19, 1870. The missile causing the injury was a conoidal ball, which fractured and comminuted the fourth, fifth, and sixth ribs of the right side, and, in its course, destroyed a portion of the pleura costalis. On being admitted to the hospital, numerous small fragments of the ribs, amounting in all to quite a handful, were removed; the wound was dressed with a weak solution of carbolic acid and alcohol, and adhesive strips were applied in order to control the movements of the thorax, but were constantly loosened by the effusion from the wound. The injury did well until October 16th, and had nearly closed, permitting the patient to move about the ward without inconvenience; his general health was excellent. But at that date a rain and wind storm prevailed, and he evidently took cold, which resulted in an attack of pleurisy of the wounded side, extending to substance of lung, accompanied with profuse hemoptysis and effusion into the pleural cavity, causing the wound to reopen when dependent, or when the patient was in the horizontal position. On the 18th he commenced to respire through the wound, the air passing freely both in and out. The discharge and expectoration were exceedingly offensive. The patient sank rapidly, being almost moribund by October 20th. Stimulants, beef-tea, and other articles of extra diet suitable to his condition were administered. In addition to this, he commenced taking, on the 20th, in as large quantities as his appetite craved, the raw, clear muscle of fresh beef, pounded to a soft pulp and seasoned to suit his taste. Relishing the beef, he ate freely of it during the twenty-four hours of the day. The liquid portion pressed out after pounding was also given as a change. The injured side of thorax was protected with a large plaster of simple cerate having an opening over the wound. This was covered with oakum, which was kept constantly saturated with a strong solution of carbolic acid, with a view to impregnate the air entering the cavity containing the effused liquid, and to effuse the surface with the antiseptic. The offensive odor speedily disappeared, the effusion rapidly diminished, and, by the 24th there was no disagreeable odor to the discharge. On the 27th, the discharge through the wound had ceased, the wound was rapidly closing, the remaining effusion into the pleural cavity was gradually absorbing and the patient was well enough to walk around the ward. The effect of the raw beef and its essence was as immediate and marked as a full dose of alcoholic stimulant, and had the advantage of being more permanent. To this and the introduction of the antiseptic into the pleural cavity, the patient's recovery is attributed.

DCLXXXIV.—*Account of a Gunshot Wound of the Chest, Treated by the Method of "Hermetically Sealing."* By P. MIDDLETON, Assistant Surgeon, U. S. A.

Private John Lee, Troop B, 8th Cavalry, aged 24, was shot in the left breast at Camp Whipple, Arizona Territory, November 19, 1867. The ball entered below the left clavicle, two inches from the sternum, and, passing through the chest and scapula, emerged over the infraspinatus muscle, just below the spine of the scapula. He was sent to the post hospital in a state of syncope. Six hours after admission, venous hemorrhage occurred until the patient fainted. The wound was

then hermetically sealed. The patient reacted, and continued to do well until December 2d, when pyæmia supervened, and death occurred December 8, 1867.

OPERATIONS ON THE ABDOMEN.—A number of cases of paracentesis are mentioned in the reports and several operations for hernia, but without names or details. The reader has not overlooked the cases of gunshot wounds of the abdomen in which balls were removed (pp. 44, 49 *ante*), nor the remarkable instances of recovery after the protrusions of the intestines from incised wounds (pp. 93, 95). The remaining reports coming under this head relate to a successful removal of a mass of omentum, operations for fistula, for imperforate anus, and for hæmorrhoids.

DCLXXXV.—*Account of a Case in which a Portion of Omentum was successfully removed.* By G. M. STERNBERG, Assistant Surgeon, U. S. A.

Brevet Lieutenant Colonel Albert Barnitz, captain 7th Cavalry, aged 33, was wounded on November 27, 1868, at the battle of Wichita, Indian Territory, by a ball from a Lancaster rifle, which entered the left side of the abdomen, just below the free margin of the false ribs, four and one-half inches to the left of the umbilicus, and emerged behind, three and one-half inches to the left of the central line of the vertebral column. The colonel was mounted when wounded, and killed the Indian who shot him at the same instant that he received his wound. The Indian was only about fifteen feet from him when they exchanged shots. After receiving the wound the colonel rode about two hundred yards, dismounted and laid down, holding his horse until some of his company came to him. About half an hour afterward he was examined by Assistant Surgeon Lippincott, U. S. A., who found a mass of omentum protruding from the anterior wound, about the size of a man's fist. The doctor supposed, from the position of the wound, that the intestine must be wounded, and that the injury must necessarily prove fatal. The colonel was brought to Camp Supply in an ambulance, the distance being about one hundred miles, and the country exceedingly rough. He arrived at this place on December 1st, at which time I took charge of his case. He was not able to take any food or stimulus on the way in, on account of the irritability of his stomach, which rejected everything except a little water. I found him very much fatigued by the journey, but having a good pulse and presenting no bad symptoms. The mass of omentum protruded from the anterior wound as at first, completely closing it, and preventing any air from entering or fluid from escaping. I think that adhesion had already taken place to a certain extent between the constricted portion of the omentum and the sides of the wound. From the posterior wound there was a very free discharge of bloody serum, which from day to day decreased in quantity, and gradually changed to a discharge of healthy pus. In a day or two after his arrival the protruding mass of omentum became covered with florid granulations bathed with thick pus. Small quantities of beef-tea and wine were retained the day of his arrival and larger amounts

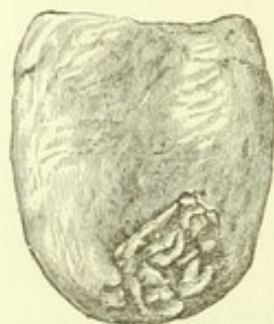

FIG. 52. Portion of excised omentum. Spec. 5524, Sect. I, A. M. M.

were given from day to day without any return of the vomiting. No medicine has been administered to this date, except one grain of quinine three times a day, as a tonic, and two quarter-grain doses of morphine, the first two nights after his arrival, to procure sleep. There was no movement of the bowels from date of injury until December 7th, when two copious and natural passages occurred. On the 8th I removed the protruding mass of omentum. I commenced the operation with a wire ecraseur, but before it was completed the loop of wire broke and I severed a small portion, which was not yet cut through, with scissors. A small artery in the portion cut by the scissors bled for a few moments, but the hæmorrhage was stopped by the simple application of cold water. December 12th: the colonel is able to sit up an hour or two at a time, has a good appetite, sleeps well, and may be considered out of all danger. There has not been a bad symptom in the case since the first shock was recovered from, except the irritability of the stomach while on the way in. [The specimen was contributed to the Army Medical

Museum by the operator. It is figured of half the natural size in the foregoing wood-cut, (Fig. 52).]

DCLXXXVI.—*Minute of an Operation for Imperforate Rectum.* By IRVING C. ROSSE, M. D., Acting Assistant Surgeon.

At Fort Monroe, Virginia, in August, 1870, an operation for the removal of a membranous obstruction in the rectum of a newly-born male child was performed by George E. Cooper, Surgeon, U. S. A. An opening was maintained by the daily introduction of a bougie. The natural passages were restored, and rapid recovery ensued.

DCLXXXVII.—*Abstracts of Reports of Operations for Fistula in Ano.* By J. F. WEEDS, Surgeon U. S. A.; F. A. DAVIS and E. H. BOWMAN, Acting Assistant Surgeons; and A. C. GIRARD, Assistant Surgeon, U. S. A.

CASE 1.—Private Andrew Clifford, Co. B, 17th Infantry, aged 26 years, was admitted to the post hospital at Cheyenne Agency, Dakota Territory, December 2, 1870, with an anal fistula of two years' standing. The external orifice was three and a half inches from the margin of the anus the internal orifice being just above the sphincter. The fistulous track was very tortuous and sacculated, it being necessary to enlarge the external opening in order to pass a probe through its whole extent. On December 5th, the whole of the superimposed structure was divided on a grooved director, previously passed along the fistulous track. No anæsthetic was used, and there was but moderate hæmorrhage. Poultices of linseed meal and a solution of carbolic acid were applied, and on January 16, 1871, the patient was returned to duty.

CASE 2.—Private George Rogers, Co. D, 16th Infantry, aged 24 years, was admitted to post hospital at Nashville, December 20, 1870, with fistula in ano. The general condition was favorable. Inflammation had subsided. The sphincter was divided on the 21st and kept open by tents saturated with glycerine and carbolic acid. The wound healed rapidly, and the man was soon returned to duty.

CASE 3.—Private John A. Graves, Co. A, 24th Infantry, was admitted to the hospital at Fort Bliss, Texas, November 2, 1870, with a fistula in ano of long standing. A thickened indurated canal opened into the rectum above the sphincter, and externally near the tuberosity of the left ischium. On November 4, 1870, the sphincter ani was divided, and tents of lint saturated with liquor of the persulphate of iron were introduced. The patient recovered rapidly, and was discharged on account of expiration of term of service.

CASE 4.—Private Timothy Soleven, Co. H, 19th Infantry, aged 21 years, was admitted to the post hospital at Baton Rouge, Louisiana, June 9, 1869, with fistula in ano. There was extensive suppuration from the perineal tissues. On June 24th, an inductor was introduced through the fistula into the rectum and the bridge divided with a curved bistouri. A tent, soaked in glycerine, was introduced, and the bowels were kept inactive by opium. Subsequently the bowels were cleaned every morning by injection. On June 30th, the wound had almost entirely healed.

DCLXXXVIII.—*Operation for Removal of Hæmorrhoids.* By JOHN H. BARTHOLOF, Assistant Surgeon, U. S. A.

Private James S. Kehan, Co. H, 11th Infantry, aged 30 years, was admitted to the post hospital at Camp Grant, near Richmond, on August 15, 1867, with an aggravated form of internal piles, which he had suffered from for two months prior to admission. The mass protruding was of a size equal to twice the bulk of a black walnut, and bled profusely at every stool, of which he had two or

three daily, not from a diarrhoea, but apparently from the desire to defecate being excited by the condition of the parts. He had been treated in quarters with astringent injections and suppositories, but without benefit. The protrusion, which almost amounted to a prolapsus of the rectum, was returned with difficulty. Shortly afterward I placed three silk ligatures well up around three of the most prominent projections, the gut being first caused to protrude as much as possible by the patient sitting for some time over a vessel of hot water in a squatting posture and using straining and expulsive efforts. The ligatures came away on the tenth day. He made a good recovery, having been kept quiet on his back, and opiates administered; in two weeks he was employed as a helper in the dispensary, and was returned to duty with his company on October 2, 1867.

DCLXXXIX.—*Minute of an Operation for the Removal of Hæmorrhoids.* By J. F. BOUGHTER, M. D., Acting Assistant Surgeon.

Private James McNally, Co. D, 22d Infantry, aged 36 years, was admitted to the post hospital at Fort Dakota, with internal hæmorrhoids, on July 3, 1868. On July 7th, ligatures were applied to two large and vascular tumors, which were congested and sensitive to the touch. Recovery being rapid, the patient was returned to duty July 18th, and was mustered out of service August 4, 1868, the hæmorrhoids not having returned.

OPERATIONS ON THE GENITO-URINARY ORGANS.—Several successful and highly interesting operations for lithotomy were reported, and a number of operations for stricture, and one of supra-pubic puncture of the bladder for retention of urine. The prevalence of venereal affections, unhappily not less common in our own than in other armies, caused circumcision or other operations for phimosis to be not infrequent.

DCXC.—*Memoranda of Fourteen Cases of Phimosis in which Operations were performed.* By B. A. CLEMENTS, Surgeon, U. S. A.; C. SMART, C. R. GREENLEAF, C. B. WHITE, and HARVEY E. BROWN, Assistant Surgeons, U. S. A.; and E. WOODRUFF, M. D., B. F. SLAUGHTER, M. D., A. ANSELL, M. D., and R. MCCRAKEN, M. D., Acting Assistant Surgeons.

CASE 1.—Private John Anderson, Co. E, 32d Infantry, aged 22 years, was admitted to the hospital at Camp Lowell, Tucson, Arizona Territory, September 27, 1868, suffering from congenital phimosis. On September 28th Assistant Surgeon Charles Smart, U. S. A., removed the prepuce. The patient had recovered October 10, 1868.

CASE 2.—Private Henry Hoffman, Co. C, 2d Infantry, aged 23 years, was admitted to the hospital at Taylor Barracks, Louisville, Kentucky, November 6, 1868, with phimosis, and a large mass of venereal warts on the inner side of prepuce. On November 7th, Assistant Surgeon Charles R. Greenleaf removed the prepuce. December 2, 1868, the patient had entirely recovered.

CASE 3.—Private Isaac Taylor, Co. I, 2d Infantry, aged 22 years, was admitted to the hospital at Taylor Barracks, Louisville, Kentucky, November 6, 1868, with gonorrhœa and phimosis. Acting Assistant Surgeon Ezra Woodruff removed the prepuce, December 2, 1868. On December 31st the patient had entirely recovered.

CASE 4.—Private Edward Burke, Co. G, 16th Infantry, was admitted to the hospital at Humboldt, Tennessee, with balanitis and phimosis. On August 20, 1870, Acting Assistant Surgeon B. F. Slaughter divided the prepuce from the corona glandis outward. Cold-water dressings were applied, and on September 3, 1870, the patient was returned to duty.

CASE 5.—Private John T. Talbot, Co. G, 25th Infantry, was admitted to Jackson Barracks Hospital, New Orleans, June 25, 1869, with congenital phimosis, aggravated by gonorrhœa. On July 25th, Surgeon B. A. Clements operated by circumcision. Owing to the contact of irritating discharge, the parts healed slowly by granulation. The patient made an excellent recovery, the

line of union being less marked than would have been anticipated from the slow healing. He was returned to duty August 30, 1869.

CASE 6.—Private John Harling, Co. G, 25th Infantry, was admitted to the Jackson Barracks Hospital, New Orleans, May 20, 1869, with congenital phimosis, aggravated by recent gonorrhœa. On June 26th, Surgeon B. A. Clements performed circumcision, with slitting up of mucous membrane. Silver wire sutures and cold-water dressings were applied, and the wound healed by first intention except at one small point. The patient was doing well June 30, 1869.

CASE 7.—Private Edward P. Hacketts, Co. F, 1st Infantry, aged 24 years, was admitted to the Jackson Barracks Hospital, New Orleans, January 11, 1869, with congenital phimosis, aggravated by gonorrhœa. On January 15th, Surgeon B. A. Clements performed circumcision. The patient recovered entirely by March 4, 1869.

CASE 8.—Private Michael Leadthan, Co. K, 1st Infantry, aged 24 years, was admitted to the hospital at Jackson Barracks, Louisiana, February 26, 1867, with phimosis following venereal disease. On March 14th, Assistant Surgeon Harvey E. Brown, U. S. A., performed circumcision, and divided the stricture along the dorsum of the penis. The wound healed promptly by granulation, and the patient soon returned to duty.

CASE 9.—Private James Clements, Co. E, 1st Infantry, was admitted to hospital at Jackson Barracks, Louisiana, February 27, 1867, with phimosis, the result of venereal disease. Circumcision was performed on March 14th, by Assistant Surgeon C. B. White, U. S. A. The patient recovered.

CASE 10.—Private Wesley Thomas, Troop G, 9th Cavalry, aged 19 years, was admitted to the hospital at Fort Inge, Texas, June 3, 1867, with phimosis following syphilis. On June 24th, Acting Assistant Surgeon Aaron Ansell removed the prepuce. The patient was returned to duty August 11, 1867.

CASE 11.—Private William Maunsell, Co. F, 1st Infantry, was admitted to the Jackson Barracks Hospital, New Orleans, Louisiana, with phimosis aggravated by gonorrhœa. On August 19, 1867, Surgeon B. A. Clements, U. S. A., removed the prepuce. The patient recovered rapidly.

CASE 12.—Private Wilson Dennis, Co. C, 39th Infantry, aged 21 years, was admitted to the hospital at Fort Pike, Louisiana, February 19, 1869, with phimosis. On the same day Acting Assistant Surgeon Robert McCracken slit up the prepuce along the dorsum of the penis. The patient had recovered April 1, 1869.

CASE 13.—Private William Jackson, Co. K, 39th Infantry, aged 27 years, was admitted to the hospital at Fort Pike, Louisiana, February 22, 1869, with primary syphilis. Phimosis followed, and on March 20th, Acting Assistant Surgeon Robert McCracken, slit up the prepuce along the dorsum of the penis. The man was returned to duty March 25, 1869, almost well.

CASE 14.—Private John Rice, Co. A, 39th Infantry, aged 21 years, was admitted to the hospital at Fort Pike, Louisiana, March 9, 1869, with primary syphilis. Phimosis supervened, and on March 25th, Acting Assistant Surgeon Robert McCracken cut the prepuce along the dorsum of the penis. On April 1st, the man had nearly recovered.

DCXCI.—*Memoranda relative to Two Cases in which the Penis was amputated.* By W. A. TOMPKINS, Acting Assistant Surgeon, and S. M. HORTON, Assistant Surgeon, U. S. A.

CASE 1.—Private Julius Citius, Co. H, 8th Infantry, was admitted from the guard-house to hospital at Columbia, on October 12, 1870, for primary syphilis complicated with phimosis, sloughing, and gangrene of the penis. The condition of the injured parts having grown worse, and several copious hemorrhages occurring, chloroform was administered on the 18th, and the glans and two

inches of the body of penis were removed. The mucous membrane was then stitched at four different points to the edges of the cutaneous portion of the wound. No contraction of the urinary canal followed, and very little blood was lost. The dorsal artery was ligated. The patient's constitutional condition at the time of the operation was fair, a generous diet and tonics having rapidly removed the cachexy present at the date of his admission. The after treatment consisted in the use of a catheter, which was retained four days by tape straps, carbolized dressings, tonics, stimulants, and a nourishing diet. The wound healed rapidly, and the patient gained twenty-four pounds while in the hospital. He passed his urine without difficulty, and, being convalescent, joined his regiment on December 26, 1870. The pathological specimen, with the above particulars, was contributed to the Army Medical Museum by the operator, and is No. 5737 of the Surgical Section.

CASE 2.—Private R. Vögler, Co. B, 27th Infantry, aged 22 years, was admitted to the hospital at Fort Philip Kearny, Dakota Territory, July 15, 1867, with a very large warty growth, which discharged an ichorous, fetid pus, and involved the glans penis, the prepuce, and the anterior third of the entire body of that organ. On July 16th the penis was amputated at the junction of the middle and posterior third, while the patient was under the influence of equal parts of ether and chloroform. The mucous membrane of the urethra was tacked by thread to the skin at four points. The stump healed without a bad symptom, and the patient was returned to duty on August 22, 1867. Since then he has complained of partial closure of the external orifice, which was relieved by gradual dilatation, repeated every three hours for one day.

DCXCII.—*Memorandum relative to an Operation for the Relief of Stricture.*—By JOHN H. BARTHOLF, Assistant Surgeon, U. S. A.

Private Hugh Donohue, Troop F, 5th Cavalry, was admitted to the post hospital at Camp Grant, Richmond, with an impermeable stricture of the urethra, of fourteen months standing, following gonorrhœa. It was situated half an inch behind the root of the scrotum. The urine came away in a very small stream, and often in drops. The smallest instrument was absolutely impassable. A No. 7 catheter was passed down to the stricture and cut down upon; the incision was then continued into the bladder, and the catheter passed directly afterward into the bladder, where it was secured. The patient recovered, and was returned to duty in May, 1868.

DCXCIII.—*Report of an Operation for the Relief of Stricture.*—By F. L. TOWN, Surgeon, U. S. A.

Private Timothy Quill, Co. I, 13th Infantry, aged 30 years, was admitted to the hospital at Fort Shaw, Montana Territory, May 25, 1868, with a stricture of the spongy part of urethra, of long standing. It was situated just anterior to the scrotum, and was apparently not of great thickness; a No. 2 catheter could with difficulty be passed. On May 25th chloroform was administered, and the stricture was divided by the urethrotome. A full-sized catheter was then inserted, and allowed to remain. The incision healed rapidly, and with apparently very little contraction at the seat of stricture. The patient was returned to duty, but the stricture contracted again, and on March 11, 1869, he was readmitted to the hospital, and the stricture again divided by the urethrotome. The same treatment was observed as above, and on March 31st the patient was able to urinate freely.

DCXCIV.—*Memorandum relative to an Operation for the Relief of Stricture.*—By SAMUEL S. JESSOP, Assistant Surgeon, U. S. A.

Private J. E. Smith, Ordinance Corps, aged 31 years, was admitted to the hospital at Charleston, April 17, 1869, with stricture of the urethra, the result of gonorrhœa, contracted about seven years previously. Stricture occurred in two places, one about two and a half inches behind the external meatus, the other near the bulb. Several fistulæ existed; there had been urinary infiltration, and the scrotum, with the skin of the abdomen, had sloughed. The patient was feeble, and suffered much pain from the slightest movement. On May 15th the sloughs had separated, and the wounds

were granulating finely. Chloroform being administered, the anterior stricture was divided by urethrotomy, and the posterior by Syme's perineal section. A catheter was introduced, and nourishing diet ordered. All the fistulae were closed and the patient recovered rapidly.

DCXCV.—*Account of an Operation for the Relief of Stricture.* By E. P. VOLLUM, Surgeon, U. S. A.

Private John White, Co. H, 42d Infantry, aged 32 years, was admitted to the hospital at Madison Barracks, Sackett's Harbor, New York, March 25, 1868, with strictures of the urethra. The first stricture extended from the bulb to near the prostate gland, and the second was at a point about three inches from the head of the penis; both were impassable to the smallest bougie. The patient had been twice injured, each injury being followed by bloody urine. On April 10th, ether was administered and the upper stricture divided by the urethrotome. On the following day equal parts of chloroform and ether were administered, and the lower stricture was divided by perineal section. The patient, who had been prior to the operation cachectic and debilitated, sank gradually, and died on April 14, 1868, from the effects of the operation. At the autopsy, pus and black ecchymosis were found at the site of the divided strictures. The prostate gland was much enlarged, hardened, and contained two small abscesses. The bladder was thickened to about half an inch, and its mucous lining eroded, excepting some small patches at the base, and for about an inch around the neck; the ureters were irregularly dilated in some places to three times the natural size; pelvis was dilated and contained a little pus; fat in the pyramids. The kidneys were white, measured five and three-eighths by three and a half inches, and weighed ten ounces.

DCXCVI.—*Report of a Case in which a Foreign Substance was removed from the Urethra by Urethrotomy.* By J. H. BARTHOLF, Assistant Surgeon, U. S. A.

Private John Kline, Co. C, 11th Infantry, aged 33 years, was admitted to the post hospital at Camp Grant, near Richmond, on October 24, 1868. He had for several days previously had considerable difficulty in urinating, the stream being small and attended with straining efforts to pass it. At 9 A. M., on the 24th, as he could not pass water at all, he undertook to remedy the trouble by passing a broom straw seven or eight inches into the urethra, and on withdrawing it a portion was broken off and remained. One hour and a half after the occurrence I removed it by cutting down upon it, opening the urethra an eighth of an inch in front of the anterior border of the scrotum, where the external or anterior end of the wisp was situated and could be felt. Making an opening into the urethra of the necessary size, the end of the stem was made to protrude and was withdrawn. Its length was three and a half inches, and its inner end must therefore have been well on toward the bladder. No anæsthetic was used. On the next day, being unable to evacuate his bladder, a No. 1 flexible catheter, without the wire, was inserted, and the urine drawn off. The condition of the patient varied until December 21st, when he was detailed as hospital attendant. Up to December 26th the bladder had been evacuated by the aid of catheters, but the patient being rather ill at that date their use was discontinued. On December 31st, he is reported as being well as regards his genito-urinary organs. The piece of broom removed was forwarded to the Army Medical Museum, and is numbered 5527 of the Surgical Section.

DCXCVII.—*Report of a Case of Supra-Pubic Puncture of the Bladder for Retention of Urine produced by Chronic Enlargement of the Prostate.* By A. W. WIGGIN, Assistant Surgeon, U. S. A.

Patrick Quohn, aged 59 years, a policeman in the cadets' barracks at the Military Academy, West Point, New York, had been suffering for several years from chronic enlargement of the prostate gland, with irritable stricture at the neck of the bladder, which required him to void his urine as frequently as once in two hours, and occasionally, as a result of a debauch, necessitating the introduction of a catheter. On August 5, 1869, having been drinking whiskey the evening previous, he applied to an irregular practitioner, who endeavored for two or three hours to introduce a very small-sized catheter. I saw him at 3 A. M., August 5th. There had evidently been considerable hæmorrhage from the urethra, and, on the gentle passage of a No. 7 catheter, a good deal of soreness and tumefaction were discovered, and blood flowed very readily. After trying with much

care and gentleness to introduce the instrument, I placed the patient in a hot bath, afterward making another ineffectual attempt with the catheter. Hot baths, with enemata of hot water, were continued during the forenoon, with occasional attempts on the part of Surgeon T. A. McParlin, U. S. A., and myself to introduce catheters of different sizes and curves, both metallic and flexible, but without success. At 3 P. M., the pain and anxiety of the patient had become extreme; pulse 120, irregular and intermittent. He had passed no water for twenty-four hours, a condition of great extremity for him. In view of these facts, and the additional circumstance of the chronic diseased condition at the neck of the bladder and consequent danger of rupture, it was decided that the only recourse was to puncture. The only operation practicable was the supra-pubic, which was performed by Surgeon McParlin, the puncture being made in the median line about an inch above the os pubis. Twenty-six ounces of urine was withdrawn, and a canula left in the wound, retained *in situ* by a T bandage and tapes. Morphine was freely given to allay pain and insure perfect quietude. On the next day the canula had partially slipped out, and could not be restored to its original position. The urine was oozing; the patient was feeble; pulse frequent, irregular, and intermittent. At five A. M. of the 7th, I found the canula entirely out of the wound, an accident doubtless attributable to the patient himself. There was some evidence of absorption of urea; pulse quick, feeble, and irregular; respiration frequent; partial coma. The bladder was nearly as full as before, and no urine escaping by the puncture. Another puncture was made by Surgeon McParlin as near the same spot as possible, the canula being retained by adhesive plaster and tape. Anodynes and nourishing diet were administered. On August 8th, the urine escaped freely by the canula. There was no sign of extravasation, and the symptoms of uræmia had passed away; pulse 130, feeble and irregular. Warm soap suds and sweet oil were injected into the urethra, which discharged pus slightly. The patient slowly improved in appetite and general health, the scrotum became slightly excoriated, but this gave way under the application of a carbolic lotion. The same general treatment was pursued until August 13th, when a gum-elastic catheter was introduced for the first time since the operation. This was withdrawn on the next day, as was also the canula, and a No. 7 silver catheter inserted and fastened in the urethra by a metallic ring around the penis with tapes attached. This was found to be unendurable, and unless pushed so far into the bladder as to defeat its object, the point was liable to slip out of the bladder into the urethra, particularly during a fit of coughing. The urine continued to flow through the wound without extravasation, a perfect fistula having become established by adhesion of the walls of the bladder to the abdominal parietes. From August 17th to 23d, no attempt was made to retain a catheter in the urethra, the urine being withdrawn by the frequent introduction of a gum-elastic catheter, while the passage of the urine by the fistula was not restricted. In a few days the patient acquired the habit of passing his urine naturally; the fistula gradually closed, and on August 24th the wound had nearly healed, the urine only passing through it in small quantities at the commencement of an effort to urinate. He continued to improve, and, on September 25th, was walking about apparently as well as before the operation.

DCXCVIII.—*Account of a Successful Lithotomy Operation by the Lateral Method, with a Description of the Specimen.* By H. A. DuBois, Assistant Surgeon, U. S. A.

* * * On August 3, 1866, I removed from the person of Henry McJ., a citizen of Mora, New Mexico, by the ordinary lateral operation, a large vesical calculus. The wound healed in a short time, and the patient recovered without any incident of interest during the after-treatment. I met him a year subsequently and obtained from him the concretion. Its weight, after removal



FIG. 53.—External view of a vesical calculus. Spec. 4903, Sect I, A. M. M.

and drying, had been three hundred grains, but after being carried about in the patient's pocket for a year it weighed only one hundred and seventy grains. I made no complete analysis of the specimen owing to want of time, but found the external lamina soluble in hydrochloric acid, and effervescing in the cold and precipitated with carbonate of soda. The specimen will be forwarded

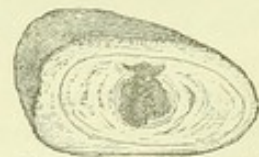

FIG. 54.—Section of the calculus.

to the Army Medical Museum. [Its size and exterior surface is represented in the adjoining wood-

cut, (FIG. 53,) and the appearance of the section through the short axis is shown in the opposite wood-cut, (FIG. 54). [It is of a yellowish white color, and measures one inch and a half in length, one in breadth, and five eighths in depth. It is compressed laterally; is irregularly ovoid in shape, and is soft and friable. Its structure, as seen by the microscope, is amorphous. After exposure to heat it emitted the smell of burnt feathers. The nucleus, of a brownish-red color, consists of urate of lime, and is of firmer consistence than the body or crust, both of which are made up of ammonio-magnesian phosphate and organic matter.—ED.]

DCXCIX.—*Memorandum relative to a Vesical Calculus successfully removed by Lithotomy.* By JOSEPH R. SMITH, Surgeon, U. S. A.

The specimen numbered 5575 of the Surgical Section was presented to the Army Medical Museum, by Surgeon Joseph R. Smith, U. S. A., who removed it, by the lateral operation, from a boy of seven years, at Little Rock, Arkansas. On March 20, 1871, Surgeon Smith writes: "There was no hæmorrhage; the incision in the prostate was enlarged by the finger, and the stone extracted only with considerable traction. No catheter was used after the operation, and in a short time the urine passed by the natural channel. The patient passed from under my observation in a few months, cured.

[This stone, weighing five hundred and sixty-one grains, and of a dull white color, is generally ovoid in shape, being compressed laterally, and is smooth. It is one inch and three-quarters in length,

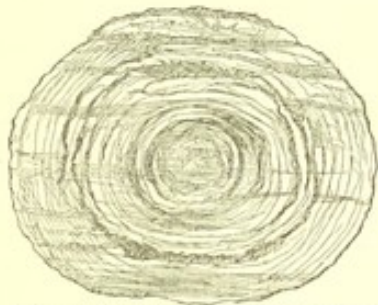

FIG. 55.—Section of a urinary calculus. Spec. 5575, Sect. I, A. M. M. [Nat. size.]

one and three-eighths in breadth, and one in depth. A section shows a number of concentric layers around a nucleus. It is compact, firm, and brittle. The microscope shows its minute structure to be amorphous, and it emitted the smell of burnt feathers when subjected to heat. It consists probably of ammonio-magnesian phosphates, with large quantity of organic matter. The dimensions of the concretion



FIG. 56.—Exterior view of the calculus.

and its general appearance externally and in section are shown in the wood-cuts. FIGS. 55, 56.—ED.]

DCC.—*Report of a Successful Case of Lithotomy.* By R. J. JENNINGS, M. D., Acting Assistant Surgeon.

Leroy Johnson, a mulatto boy, aged about 19 years, and weighing only eighty pounds, was admitted to the Freedmen's Hospital at Little Rock, on August 26, 1867, with vesical calculus, having been previously treated for the ordinary remittent fever of the country by Dr. E. V. Denell, who discovered a concretion in the bladder, and sent him to the hospital. Upon admission, he stated that he had of late suffered extreme pain in passing his urine, and that fits frequently occurred during the effort. A day or so subsequently an opportunity offered for the post surgeon to observe one of these paroxysms, which was intensely severe, and when it subsided left the patient much prostrated, and bathed in a profuse perspiration like that of the sweating stage of intermittent fever. An examination with a sound was made in the presence of several medical men, which established, beyond a doubt, the existence of calculus. One of the physicians present remembered having prescribed for this patient, ten years previously, for incontinence of urine. On September 3d, eight days after admission, the patient was chloroformed, and the bi-lateral operation of lithotomy was performed, removing a stone weighing three and one-eighth ounces. Some difficulty was experienced in the extraction, which was overcome by enlarging the primary incision. The after-treatment in this case consisted of rest—the patient lying supine, with a fold of blanket drawn under his hips—and cold-water dressings to the wound. On the ninth day after the oper-

ation urine was twice passed through the urethra; then followed an interval of five days, during which it was passed through the wound. After this it passed almost continuously by the urethra, and the patient was able to be up and about on the twenty-fifth day. Several times after this, however, there occurred, at distinct intervals of from two to three weeks, a slight watery or sanguineous discharge from the wound, generally accompanied by more or less gastric disturbance and slight

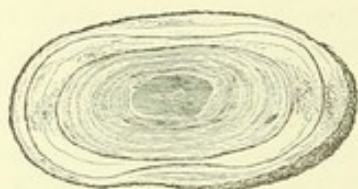

FIG. 57.—Vesical calculus. Section through the long diameter. Spec. 5572, Sect. I, A. M. M.

fever, the correction of which, with absolute rest, usually caused this discharge to disappear. After about six months, everything of this character ceased. Two years subsequently the patient reported himself as enjoying excellent health, never having since experienced the slightest inconvenience. His physical appearance had greatly improved. He had increased in strength and energy, and weighed one hundred and nineteen pounds. The specimen

was contributed to the Army Medical Museum, and is figured in the adjacent wood-cuts, (FIGS. 57, 58). It weighs two ounces and twenty-seven grains, troy; but before it was sawn, it weighed three and one-eighth ounces.

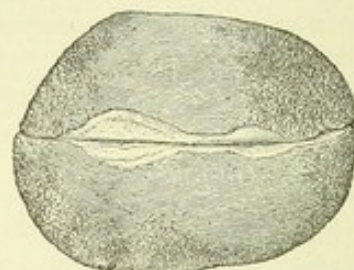

FIG. 58.—Phosphatic urinary calculus. Spec. 5572, Sect. I, A. M. M.

DCCL.—*Minute of a Successful Case of Lithotomy.* By W. F. SMITH, Assistant Surgeon, U. S. A.

Henry Morris, a mulatto, aged twenty-three years, had a large vesical calculus removed by lithotomy at Raleigh, North Carolina, about the middle of December, 1867. The operation was delayed for some time, owing to the impossibility of passing a staff into the urethra, which contracted violently at every attempt to introduce one. After this excitability had been overcome by a course of training, which rendered the passage of any instrument easy, the patient was chloroformed, and the stone was removed by the lateral operation, both lobes of the prostate gland being divided in consequence of its great size. It was partly attached to the bladder, and this caused some trouble. The hæmorrhage, did not



FIG. 59.—Vesical calculus, exterior view. Spec. 4762, Sect. I, A. M. M.

exceed six ounces. The wound granulated finely, and by January 23, 1868, the patient was entirely well and attending to his ordinary avocation. The stone, weighing two hundred and fifty-three grains, is represented in the adjoining wood-cuts, (FIGS. 59, 60,) and was contributed by the operator.

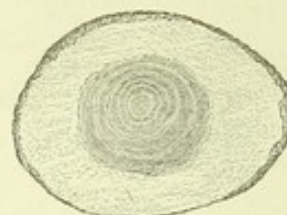

FIG. 60.—Sectional view of the calculus.

DCCII.—*Guns hot Wound of Bladder and Rectum, and subsequent Operation for Stone in the Bladder* By DR. HUNTER MCGUIRE.*

Mr. H., aged 23 years, was wounded at the battle of McDowell, May 8, 1862. The ball struck him on the horizontal ramus of the left pubic bone, about an inch from the symphysis, passed through the bladder and rectum, and came out just below the right sacro-sciatic notch, near the edge of the sacrum. The day after the battle he was sent to the general hospital at Staunton, where he remained under treatment for four months. For the first month urine passed freely through the wounds, made by the entrance and exit of the ball, and was generally mixed with blood and pus. Faecal matter was frequently discharged through the posterior wound. Some time during the third week he passed several small pieces of bone from the rectum. At the end of the fifth week the wound of exit healed, and for the first time since his injury urine was discharged through

* See *Richmond Medical Journal*, April, 1863, vol. V, p. 279.

the urethra. The water continued to be discharged through the urethra and wound of entrance for five months, when the latter gradually closed. It opened again, however, in a few weeks, and continued alternately to close and open at varying intervals until September, 1865, when he came to me. For two months after being wounded he was confined to the bed; after this he was able to go about with the aid of crutches. At the end of four months he could walk slowly without assistance, and was for a long time engaged as clerk for the post quartermaster at Staunton. In September, 1865, he applied to me with symptoms of stone in the bladder. On sounding him, the stone was readily discovered, being against the posterior wall of the bladder, and apparently fixed in that situation. His general health was very bad, in consequence of the pain and continued irritation he suffered, and the fistulous opening in front still remained discharging urine and pus. After some days of careful preparatory treatment, I performed the lateral operation, and found the stone attached to the mucous membrane, over and around the old wound in the posterior wall of the bladder. He recovered without any untoward symptoms; the fistulous opening closing at the same time that the wound in the perinæum was healed, and he was out of bed on the fifteenth day. I heard from him a few days ago, and learned that the fistulous track had never reopened, and that his health and strength were excellent. The calculus, which was presented to the Army Medical

Museum by Dr. H. McGuire, is represented in woodcut Nos. 61 and 62, and consists principally of the triple phosphates of lime and magnesia, and weighed, immediately after its removal, two and a quarter ounces; it has for




FIG. 61.—Exterior view of a urinary calculus. Spec. 5041, Sect. I, A. M. M.

its nucleus a piece of bone about half an inch long.

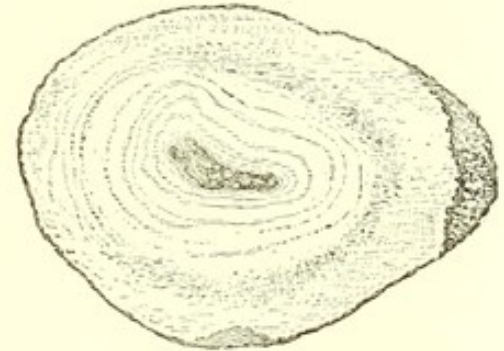

FIG. 62.—Sectional view of the calculus.

DCCIII.—*Account of an Operation for Lithotomy, in which a Ball with a Phosphatic Incrustation was Successfully Removed.* By J. L. FORWOOD, M. D.

Thomas Lindsey, of Co. F, 69th Pennsylvania Volunteers, aged 43 years, was wounded at Gettysburg, on July 2, 1863, while in a kneeling posture, by a ball which, after passing through his canteen, entered the thigh. On January 18, 1864, he was discharged the service at the Newton University Hospital, in Baltimore. On his return home to Chester, Pennsylvania, he suffered many of the symptoms of stone in the bladder, for which he was treated from time to time, until February, 1866, when an operation for strangulated hernia, the result of dyspnoea, became necessary. On April 12, 1866, the operation of lithotomy was performed upon the patient, when, most unexpectedly, an irregularly shaped ball, coated with a phosphatic deposit, was removed from the bladder, weighing 768 grains. The operation was successful, and at last accounts the patient was well, and living in the vicinity.

DCCIV.—*Memorandum relative to a Vesical Calculus, the Nucleus of which was an Iron Ball.* Condensed from Reports by A. N. DOUGHERTY, M. D., late Medical Director of the Second Army Corps.

William Cockcroft, late a private of Co. D, 199th Pennsylvania Volunteers, aged 42 years, was admitted to the New Jersey Home for Disabled Soldiers, on May 30, 1867, to be treated for "shingles" (herpes zoster). A week afterward he was discharged cured, without having complained of any urinary disorder. In the fall the patient returned to be treated for painful micturition, and stated

that he had been wounded at Petersburg, on April 2, 1865, by a ball, the cicatrix of which was visible just above the pubis. A normal and painless evacuation occurred from both the bladder and the bowels half an hour after the reception of the wound. Some days subsequently he was taken to the Hampton Hospital, at Fort Monroe, where frequent and unavailing efforts were made to find the ball. No urine ever passed through the wound, but eight pieces of bone (probably of the pubic bone) were removed at various times. At this visit to the "Home" his wound had healed, difficult micturition having occurred simultaneously. A sound failed to reveal the presence of any extraneous substance in the bladder. In a few weeks he returned to say that the wound had reopened, and that in consequence he had experienced entire relief. Nothing more was heard from him until July 13, 1868, when he was readmitted, the wound having closed and his old symptoms having grown worse. A foreign body was now readily detected by physical exploration, and the urine was heavily loaded with pus, and at times was bloody. On August 31st, the patient was cut for stone, and a vesical calculus removed, the nucleus of which was an iron ball. The incrustations consisted of uric acid and tripple phosphates, and the specimen, when recent, weighed one ounce and twenty-three grains, avoirdupois. The ball was part of a shrapnel,* and the incrustations were chiefly on one side, giving it the shape of a cock's comb. The operation used was the one lately recommended by Sir William Fergusson, and consisted in making a superficial cut, as in Dupuytren's bi-lateral method, viz, semicircular, the convexity forward half an inch in front of the anus, with the extremities of the wings equidistant between the anus and the ischium. When, in the dissection, the membranous portion of the urethra was reached, the cut was made as in the lateral. The incision described above is said to afford more ample room for the fingers than the usual lateral cut. The only untoward feature of this case was, that although the urine began to flow wholly by the urethra as early as the fifteenth day, there was, and still was at the date of this report (December 20, 1868), a fistulous track leading toward the bladder, but from which no urine came. The patient was healthy-looking, although he stated that there was still some pus in his urine. He had neither incontinence of urine nor irritable bladder, and was able to retain his urine for four or five hours. At the above date, he had left the "Home" in order to pursue his ordinary avocation. The specimen, which is represented in this wood-cut, (FIG. 63,) was contributed by the operator.



FIG. 63.—Vesical calculus, of which an iron ball is the nucleus. Spec. 5529, Sect. I, A. M. M.

DCCV.—*Remarks on the Removal of a Vesical Calculus, the Nucleus of which was an Iron Arrow-Head.* By W. H. FORWOOD, Assistant Surgeon, U. S. A.

Litimore, a wild Indian, chief of the Kiowas, aged 42 years, applied to me at Fort Sill, Indian Territory, August, 1869, with symptoms of stone in the bladder. The following history was elicited: In the fall of 1862 he led a band of Kiowas against the Pawnee Indians, and was wounded in a fight near Fort Larned, Kansas. Being mounted and leaning over his horse, a Pawnee on foot and within a few paces drove an arrow deep into his right buttock. The stick was withdrawn by his companions, but the iron point remained in his body. He passed bloody urine immediately after the injury, but the wound soon healed, and in a few weeks he was able to hunt the buffalo without inconvenience. For more than six years he continued at the head of his band, and traveled on horseback from camp to camp, over hundreds of miles every summer. A long time after the injury he began to feel distress in micturating, which steadily increased until he was

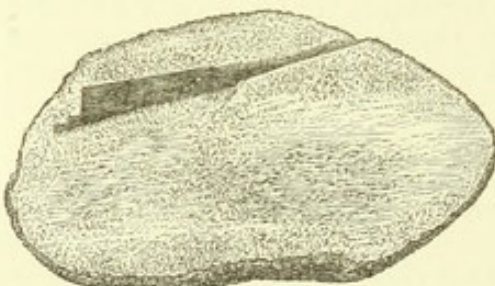


FIG. 64.—Vesical calculus of which an arrow-head is the nucleus. Spec. 5931, I. A. M. M.

*The projectile known as shrapnel is a spherical case-shot containing lead balls. The missile in question is similar to one of the small iron balls of a canister-shot for a howitzer.

forced to reveal this sacred secret, as it is regarded by these Indians, and to apply for medical aid. His urine had often been stopped for many hours, at which time he had learned to obtain relief by elevating the hips, or lying in different positions. The urine was loaded with blood and mucus, with a few pus globules, and the introduction of a sound indicated a large hard calculus in the bladder. The Indians advised me of the depth approximately to which the shaft had penetrated and the direction it took, and judging from the situation of the cicatrix and all the circumstances it was apparent that the arrow-head had passed through the glutei muscles and the obturator foramen and entered the cavity of the bladder, where it remained and formed the nucleus of the stone. Stone in the bladder is extremely rare among the wild Indians, owing no doubt to their almost exclusive meat diet, and the very healthy condition of their digestive organs, and this fact, in connection with the age of the patient, and the unobstructed condition of his urethra, went very far to sustain this conclusion. On August 23d I removed the stone without difficulty by the lateral operation through the perinæum. The lobe of the prostate was enlarged, which seemed to favor the extent of the incision beyond what would otherwise have been safe. The perinæum was deep and the tuberosities of the ischii unnaturally approximated. The calculus, of the mixed ammoniaco-magnesian variety, was egg-shaped, and weighed nineteen drachms. The arrow-point was completely covered and imbedded near the centre of the stone. It was of iron, and had been originally about two and one-half inches long, by seven-eighths of an inch at its widest part, somewhat reduced at the point and edges by oxidation. The removal of the stone was facilitated by the use of two pairs of forceps, one with broad blades by which I succeeded in bringing the small end of the stone to the opening in the prostate, while the other, long and narrow, seized and held it until the former were withdrawn. In this way the forceps did not occupy a part of the opening while the large end of the stone was passing through it. The capacity of the bladder was reduced and its inner walls were in a state of chronic inflammation. The patient quickly recovered from the effects of the chloroform, and felt great relief both in body and mind after the operation, and up to the eighth day the case did not present a single unfavorable symptom. The urine began to pass by the natural channel on the third day, and continued more or less until on the seventh it had nearly ceased to flow at the wound. But the restless spirit of the patient's friends could no longer be restrained. Open hostility with the whites was expected to begin at every moment, and they insisted on his removal. He needed purgative medicine on the eighth day, which they refused to allow him to take. They assumed entire charge of the case, and the following day started with him to their camps sixty miles away. Nineteen days after he is reported to have died. But his immediate relatives have since assured me that his wound was well, and that no trouble arose from it. They described his symptoms as those of bilious remitting fever, a severe epidemic of which was prevailing at the time, and from which several white men and many Indians died in that vicinity. The calculus was contributed to the Museum at Washington. A section is represented in the wood-cut (FIG. 64) of natural size. [The weight of the concretion is eight hundred and fifteen grains, and it consists of an almost uniform deposit of triple phosphates about the nucleus.—ED.]

DCCVI.—*Report of a Case in which a Conoidal Musket Ball was Successfully Removed from the Bladder by Lithotomy.* By J. L. FORWOOD, M. D.

Edwin T. Mason, a private of Co. K, 198th Pennsylvania Volunteers, aged 49 years, was wounded near Hatcher's Run, Virginia, on March 31, 1865. He was sent to Lincoln Hospital at Washington, from which he was discharged per general order on June 9, 1865. His wound remained open, but did not require medical aid. He returned home, and followed his ordinary occupation up to February, 1869. At this date the wound healed up and the patient thought himself well; but on February, 1870, vesical trouble, bloody urine, &c., appeared. On April 16th the operation of lithotomy was performed, and there was removed a conoidal musket ball weighing one ounce and a quarter, and having two small pieces of phosphatic deposit attached. On May 30th the patient was up and about, but the wound had not entirely healed. There were no symptoms of calculus until six weeks before the operation, notwithstanding there seems but little doubt of the ball having been in the bladder previous to that time.

REMOVAL OF TUMORS.—Several instances of the removal of important tumors, malignant or non-malignant were reported :

DCCVII.—*Memorandum of a Case of Scirrhus.* By JAMES P. KIMBALL, Assistant Surgeon, U. S. A.

Private William Wallace, Co. B, 31st Infantry, aged 19 years, was admitted, on February 4, 1868, to the post hospital at Fort Buford, Dakota Territory, with a scirrhus in the skin and subcutaneous cellular tissue immediately above the centre of the forehead. The patient was slightly cachectic, nervous, and debilitated from pain and want of sleep. On February 5th, I made a crucial incision one and one-fourth inches in length, through the skin over the centre of the tumor, reflected back the flaps and dissected out the tumor, which was of the size of a hickory nut. No anæsthetic was used. The outer portion of each incision united by first intention, the centre filling up by granulation. The patient was returned to duty March 5, 1868. A large scar remained unavoidably, in consequence of the skin over the centre of the tumor having been involved in the disease.

DCCVIII.—*Note of a Case of Extirpation of a Fatty Tumor.* By A. C. GIRARD, Assistant Surgeon, U. S. A.

Private Nicholas Daly, Co. I, 20th Infantry, was admitted to the hospital at Baton Rouge, February 22, 1869, with a lipoma over the left zygomatic arch. The tumor was removed through an incision, running obliquely from the corner of the eye to the ear. Erysipelas of the face and neck supervened, but yielded to treatment. The wound of incision healed by granulation, and on March 9, 1869, the patient was returned to duty.

DCCIX.—*Note of a Fibrous Tumor of the Back.* By EDWARD COWLES, Assistant Surgeon, U. S. A.

Private Isaac Spencer, Co. H, 117th Colored Troops, aged 56 years, was admitted to the post hospital at Brownsville, Texas, April 13, 1867, with a tumor, four or five inches in diameter, on the left shoulder, over the spine of the scapula. On May 24th, ether being administered, an incision, five inches, was made, and the tumor was removed. It did not present the appearance of a malignant growth, but was closely adherent to the adjacent parts. Hæmorrhage was copious. The incision was closed by sutures and healed rapidly. The patient had recovered, and was reported for duty on June 24, 1867.

DCCX.—*Memorandum relative to a Morbid Growth on the Lip requiring Surgical Interference.* By BASIL NORRIS, Surgeon, U. S. A.

A canceroid tumor on the lip of General H— was removed very satisfactorily to him and myself, by seizing it with a pair of forceps, and enucleating the mass with a thin, sharp thumb lancet, which passed around and beneath it as cleanly as a razor. By this means, in the language of Professor Gross, "the operation is best done," when the skin is not involved. The nest left by the tumor was covered over with a piece of wet tissue paper, which was moistened by the tongue of the patient, as often as was necessary to keep it in place. With this dressing only, the wound nearly filled with plastic lymph in twenty-four hours, and was well in a week. I inclose extracts of a letter as a part of the report:

* * * * *

"NOVEMBER 21, 1870.

"MY DEAR DOCTOR: In reply to your note of the 17th, I have the pleasure to report that my lip is doing very well—seems perfectly healthful—although, of course, the circulation has been interrupted by the cuts it has had, and occasionally it looks a little blue and feels benumbed. You performed the operation on the 30th of March, 1870. My trouble commenced as early as the spring of 1865, when I first noticed the skin of the lip broken as from a blister. Two such spots appeared, producing no other inconvenience than soreness to the touch and extreme sensitiveness to salt, &c. As they did not heal, I got a physician to touch one with caustic, but without good effect. I

then commenced, upon advice of different physicians and surgeons, to apply different remedies, caustic or emollient, acid or alkaline, until, I think, the whole round of acids, alkalies, metalloids, and antiseptics had each a chance. In the spring of 1868, I determined to have a surgical operation tried, and after advice from two sources, one in favor of a strong caustic, and the other of the knife. This required cutting through the lip down to the external mark, and removing quite a large piece of what was thought to be diseased membrane. At that time the smaller place in front and centre of the lip, which you afterward removed, was supposed to be curable, * * * in March, 1870, I showed it to you, determined to have it out if you so advised, I am glad to say that you did advise it." * * *

DCCXI.—*Report of a Case of Medullary Cancer at the Angle of the Lower Jaw.* By J. R. REILY, M. D., Acting Assistant Surgeon.

Private Michael Keilly, Ordnance Detachment, Washington Arsenal, aged 27 years, was admitted into the hospital on February 5, 1870. A large medullary carcinoma involved the articulation of the lower maxilla on the right side, and had dislocated the condyle in its growth, and had extended inward above the palatine arches, pushing down the soft palate, and almost filling the fauces. The patient's pulse, skin, and secretions were normal, at the time of the operation to be described. His appetite was good; but he was unable to masticate or swallow solid food. On March 31, 1870, the patient having been placed under the anæsthetic influence of sulphuric ether, an exploratory incision, three inches in length, was made, beginning immediately in front of the lobe of the right ear, and passing downward in the direction of the sterno-mastoid muscle. It was now found necessary to make a second incision, from the angle of the jaw to the angle of the mouth, the excision of the right ramus of the inferior maxillary being necessary to remove the tumor. The operators were Assistant Surgeon J. S. Billings, U. S. A.; Assistant Surgeon G. A. Otis, U. S. A.; and Surgeon Basil Norris, U. S. A. The patient continued in comfortable condition during the evening, taking liquid nourishment freely, and continued in good condition until about four o'clock on April 1st, when symptoms of tetanus set in, and, in spite of the usual remedies, he sank rapidly, and died at eight o'clock in the evening, April 1, 1870.

[Assistant Surgeon Billings wrote out a more extended account of this operation, and yet a third report of the case was received. Dr. Reilly's official statement gives the main facts and dates.

Dr. J. J. Woodward had the kindness to make the drawings represented by the woodcuts (FIGS. 65, 66), and to furnish the following memorandum of the microscopical appearances:

"Some rather large fragments of the tumor removed from Private Keilly having been brought to the Army Medical Museum, on the day of the operation, were examined by me while fresh, and subsequently sections stained with carmine were prepared by Dr. E. M. Schaffer, and mounted in Canada balsam. These are preserved in the microscopical section of the museum, (Nos. 3500 to 3512 inclusive). The tumor was chiefly composed of a stroma of connective tissue, with large meshes, which were filled with masses of small, loosely adherent, nucleated cells. In the permanently mounted sections the position and arrangement of the cells is indicated by that of the oval nuclei, which measure from $\frac{1}{30000}$ to $\frac{1}{50000}$ of an inch in long diameter. In the fresh preparation the nuclei appeared rather larger, and each was seen to be contained in a delicate young cell.

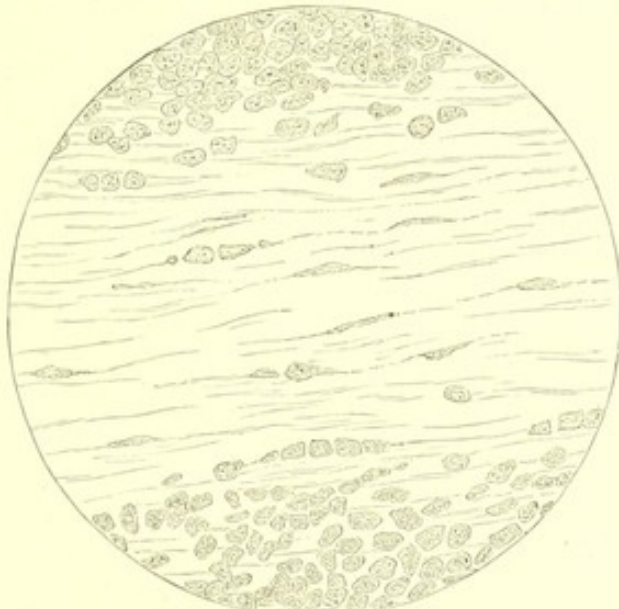


FIG. 65.—Portion of section of medullary carcinoma, showing connective tissue stroma with the nuclei of the cell masses on either side. *Spec.* 3500, Sect. III, A. M. M., 740.

In the permanently mounted sections the position and arrangement of the cells is indicated by that of the oval nuclei, which measure from $\frac{1}{30000}$ to $\frac{1}{50000}$ of an inch in long diameter. In the fresh preparation the nuclei appeared rather larger, and each was seen to be contained in a delicate young cell.

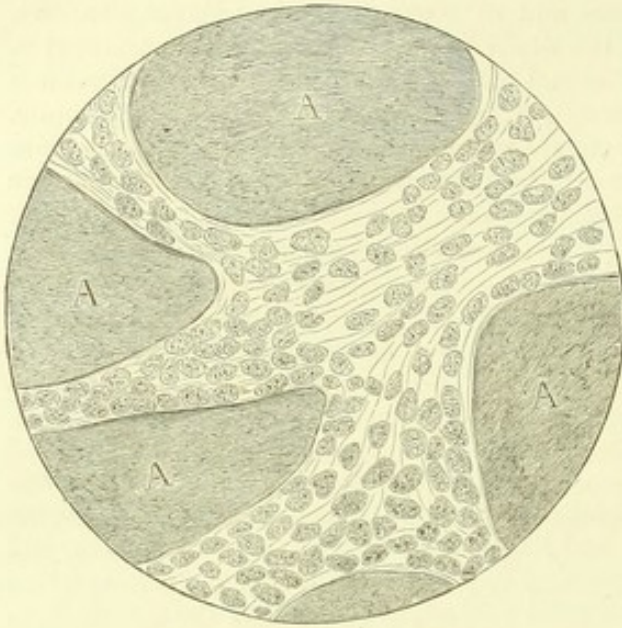


FIG. 66.—Portion of same specimen, showing portion of five muscular fibres, with nuclei of cancer cells in the intervening connective tissue. Spec. 3500, Sect. III, A. M. M.

Some of the fragments yielded sections, in which the structure of the parotid gland could be distinctly made out, the ultimate lobules of the gland being pushed apart by a soft fibrillated connective tissue, in which numerous small cells similar to those of the rest of the growth abounded. The same sections passed through portions of the masseter muscle, the connective tissue of which was similarly infiltrated, the bundles of fibres, and, in some instances, the individual fibres being pushed apart by the new formation. Nos. 3501 and 3502 show this condition of the parotid and muscle very well. In places the parotid lobules are perfectly normal, and their epithelium well shown in the preparations, but pushed apart by the medullary infiltration; in other parts the tissue of the parotid is obscured by the new growth, and appears to pass gradually into it. The tumor is to be regarded as a rapidly developing medullary carcinoma, involving the parotid and the adjacent parts.”]

DCCXII.—*Account of an Encephaloid Tumor at the Angle of the Jaw.* From information furnished by C. H. LAUB, Surgeon, U. S. A.

In December, 1864, William P——, aged sixty-two years, thirty of which were passed in the Army of the United States, an inmate of the Soldiers' Home, at Washington, complained of a small indolent swelling under the left angle of the lower jaw. The tumor was painted with tincture of iodine for about three weeks, but its growth was not arrested. The patient then left the asylum to return after an absence of three months. During this period the tumor increased rapidly in bulk. In October, 1865, its attachments extended from the mastoid process of the left temporal backward to within half an inch of the spinous process of the upper cervical vertebrae, upward over the occipital bones and the ramus of the inferior maxilla, and downward along the sterno-cleido-mastoideus to within two inches of the middle of the clavicle, deflecting the trachea and oesophagus to the right. The tumor was regarded as a malignant one, and in view of the great danger that its extirpation would involve and the probability of its recurrence, operative interference was decided against. The tumor enlarged rapidly, greatly impeding respiration and deglutition, and there was grave constitutional disturbance. On October 22, 1865, the patient died. The tumor was removed *post-mortem*, by Assistant Surgeon J. S. Billings, U. S. A. A microscopical examination of the growth, by Doctors Billings and Curtis, proved it to be of a cancerous nature. It is preserved in the Surgical Section of the Army Medical Museum as No. 4961. Photograph 102, Surgical Series A. M. M., represents the appearance of the tumor a few weeks before the fatal termination.

DCCXIII.—*On a Case of Scirrhus of the Mamma, treated by Ablation, and Internally by the Decoction of Cundurango.* By BASIL NORRIS, Surgeon, U. S. A.

The specimen of scirrhus of the mamma, which I sent to the Medical Museum, was removed September 14, 1869, from the breast of a servant woman, 42 years of age. Four years previously she requested me to examine a small tumor in the right mamma, near the nipple. It was not then larger than a filbert. An elliptical incision made to include the morbid growth embraced one-half of the gland, and a portion of skin in the direction of the axilla. In the endeavor to remove “every trace of the disease,” it was necessary to dissect off the fascia from a small space covering

the body of the pectoralis major, and some fibres of the muscle. The wound was well sponged with cold water, closed with silver sutures, and left to heal, as it did very rapidly, and almost entirely by first intention. Relieved in mind and body, she continued well and cheerful until the following February, 1870, when the disease returned. A small, hard tumor beneath the cicatrix first attracted her attention, and increased until May 21st, when, having attained its former size, with indications of approaching ulceration, it was again removed. Three months afterward it reappeared at several points along the course of the scar. She next treated the tumor herself, five weeks—under the advice of friends and with my consent—with poultices of crushed cranberries, which produced a peculiar pustular eruption, but with neither appreciable harm nor benefit. More recently I prescribed, and am still using in this case, with good effect in relieving pain, bromide of potassium and acetic acid, an external remedy, recommended by Mr. Henry Osborne, of Southampton, in a communication to the *British Times and Medical Gazette*, republished in the October number of the *Practitioner* of 1870. He says: "I have not had an opportunity of trying the bromide of potassium and acetic acid in many cases of cancer. I nevertheless am able to state that those who have given it a trial during the last twelve months have derived the greatest relief from its use. The proportion of bromide of potassium and acetic acid should be in accordance with the severity of the pain. In one case I ordered it to the extent of three drachms of bromide of potassium to one ounce of acetic acid and five ounces of water, to be used warm and kept constantly applied to the breast by saturating a piece of lint and covering it with oil silk. If abrasion of the cuticle or a cicatrix has formed, the lotion may be more readily absorbed, or especially if ulceration has taken place; in that case the lotion should be diluted accordingly.

[Subsequently Surgeon Norris made the following further report of this case.]

WASHINGTON, D. C., June, 1871.

GENERAL: I have the honor to report as follows on the treatment of cancer by cundurango, as prescribed in the case of Isabella G—, aged 43 years. She had been my patient twenty-one months, suffering from scirrhus of the right mamma. I removed the tumor on the 5th of September, 1869, and again on the 14th of May, 1870. It reappeared in July following, and on the 24th of April, 1871, the day on which she began to use the remedy, it occupied a remaining small portion of the mammary gland, and extended over its original situation as far as the axilla. The axillary glands were involved, the arm and hand swollen, and the skin ulcerated, forming three circular sores, which discharged a thin offensive pus peculiar to sloughing of this variety of cancer. She complained of pain and irritable stomach, and was too feeble to leave her apartment. Observing, as nearly as possible, directions laid down by Dr. Casares, of Ecuador, and contained in a pamphlet published for information by the Department of State, I prepared a decoction by putting half an ounce of crushed cundurango with twelve ounces of water, and boiling it down to six fluid ounces. Of this, one ounce was taken, morning and evening, until the 11th of May—eighteen days—when the dose was reduced to half an ounce, and continued to the 29th of May. Whether as coincident, or in consequence of this treatment, the tumor completely sloughed out, leaving the integument sound and a surface granulating beneath. Irritability of the stomach, with pain in swallowing and on pressure upon the epigastrium, increased, and the patient, much emaciated, died on the 6th of June. *Post-mortem* examination revealed cancer of the stomach and spleen; a hard flat tumor, leaf shaped, starting from the point of entrance of the œsophagus, embraced a portion of the spleen, which could only be separated from the stomach by tearing the morbid growth common to both organs. I am indebted to Dr. J. J. Woodward, U. S. A., for microscopical examinations of the tumor and specimen, and for his note appended to this report.

Very respectfully, your obedient servant,

BASIL NORRIS,
Surgeon, U. S. A.

General J. K. BARNES,
Surgeon General, U. S. Army, Washington, D. C.

ARMY MEDICAL MUSEUM, *Washington, D. C., July 21, 1871.*

SIR: In accordance with your request, I have made a microscopical examination of the several morbid growths in the case of Isabella G—, with the general conclusion that the case was undoubtedly one of scirrhus carcinoma.

The specimens preserved at the Museum are as follows:

No. 5598, Surgical Section. The tumor first removed by Surgeon Norris is an oval mass, about five inches long by three broad, with a portion of skin attached externally. The greater portion of the piece is occupied by a firm irregular scirrhus growth, which, after being several months in alcohol, still yielded, on scraping, a creamy juice containing cells and nuclei; on the edges of the mass is some normal adipose tissue.

No. 5921, Surgical Section. The tumor removed by Surgeon Norris at the second operation is a smaller mass, containing a similar but somewhat softer growth. In the skin, adherent externally, a portion of the cicatrix of the first operation can be recognized, and from this an irregular soft nodule, the size of a walnut, protrudes.

No. 1083, Medical Section, is a portion of the stomach and the spleen of the same patient. In the greater curvature of the stomach, and not far from the cardiac orifice, is a carcinomatous thickening of the coats of the organ, about half an inch in thickness, occupying an area about four inches in diameter. Externally the thickened patch was closely connected with the hilus of the very small spleen by a soft carcinomatous tumor, about the size of a hen's egg.

Sections of the first and second tumors removed from the breast, of the stomach, and the spleen, were prepared in the Microscopical Section of the Museum, by Acting Assistant Surgeon E. M. Schaeffer, and having been stained with carmine and mounted in Canada balsam, now form a part of the microscopical collection.

Nos. 3513 to 3519, Microscopical Section, are from the tumor first removed from the breast, and show it to consist of an areolar stroma of soft connective tissue, the interspaces of which are stuffed with masses of loosely adherent, nucleated cells; the nuclei of these cells are oval, and measure from three to six ten-thousandths of an inch in long diameter;

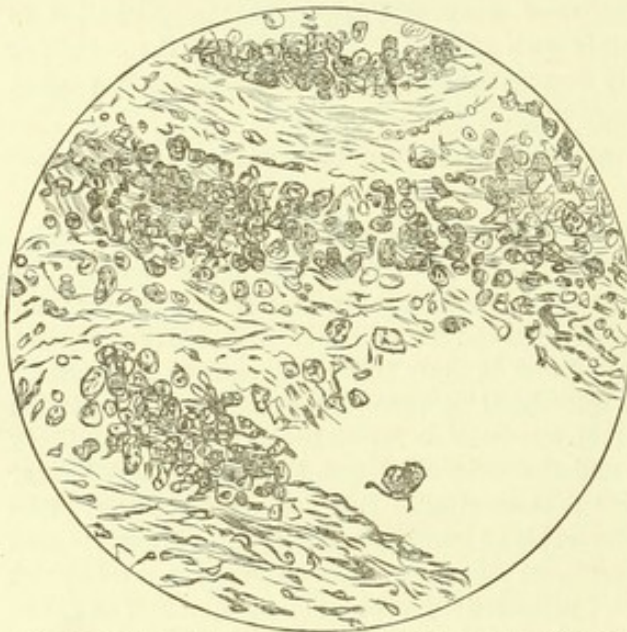

FIG. 67.—Section of scirrhus, magnified 400 diameters. *Spec. 3513, Sect. III., A. M. M.* [Drawn by Dr. Schaeffer.]

they contain generally one or two shining nucleoli. The cells themselves are of an irregular form, and various sizes, the smaller ones predominating. The connective tissue stroma contained an abundance of small nucleated, connective tissue corpuscles, resembling those found in most new formations of connective tissue.

Nos. 3673 to 3676, Microscopical Section, are from the second breast tumor, and are very similar to those from the first; in many places, however, the cell masses are more voluminous and the connective tissue stroma is less prominent.

Nos. 3663 to 3672, Microscopical Section, are sections cut perpendicularly to the surface, through the indurated portion of the stomach. In most places the mucous membrane and the tubular glands are in a condition not far from normal; but the submucous connective tissue, the muscular and peritoneal coats, are transformed into a carcinomatous mass, consisting of groups of cells with large nuclei imbedded in a connective tissue stroma, the general character of the neoplasm closely approximating those of the breast tumors.

Nos. 3656 to 3662, Microscopical Section, are sections of tumor between the spleen and the stomach; they present the same general characteristics, but this tumor was much softer than the other growths, and in the section the stroma appears less pronounced, and the cell masses are more voluminous. In this case, as in others of multiple carcinoma, examined in the Microscopical Section

of the Museum, the general similarity of the structural details of the several growths found, in very different organs, deserves attention.

The tumor between the stomach and the spleen was evidently of recent origin and rapidly growing. Its relation to its chief blood-vessels probably accounts for the manifest atrophy of the spleen, which was only three inches long by two and a half broad.

Very respectfully, your obedient servant,

J. J. WOODWARD,
Assistant Surgeon U. S. A.

Surgeon BASIL NORRIS, U. S. A.

DCCXIV.—*Remarks on the Removal of a Fibroid Growth from the Left Breast.* By HENRY McELDERRY, Assistant Surgeon U. S. A.

James Johnston, Sergeant Co. C, 15th Infantry, was admitted to hospital, August 12, 1868, with a fibroid tumor of the left breast. The patient, a large and a well-developed man of the sanguine temperament, stated that the tumor first made its appearance during September, 1865, while he was working at his trade, boot and shoe making. His attention was first called to the enlargement by a burning pain in the left chest; and he then, on examination, noticed the growth. From that time until the present, the tumor has gradually increased in size. He does not experience pain in the growth, except when the chest becomes constricted from any cause. Has not been able to wear his suspender on the left side, nor to carry his knapsack on this account. Has a sister, who, when about eight or nine years old, had a hard tumor on the right eyebrow, which was removed by a surgeon, and has not since returned. The remainder of the family are all healthy, and have never had any tumors of any kind.

August 12, 1868. The tumor is movable and rather flat; measuring two inches and one quarter, in length, and two inches in width; lying immediately beneath the left nipple, superficial to the pectoralis major muscle; its diameter corresponding with the direction of the fibres of that muscle; complains of pain when the surface beneath the nipple is pinched; pinching the base or sides of the tumor gives no pain or uneasiness. There is no retraction of the nipple, nor lymphatic involvement; no enlargement of the subcutaneous veins; general health of the patient excellent. As the patient was anxious to have the tumor removed, its excision was performed August 12th, parts brought together with interrupted silken sutures, and ichthiocola plaster. One grain of morphine was given hypodermically, after operation. August 13th, slept well during night, and complains of no pain. Three compound cathartic pills were prescribed. Did well until August 15th, when the wound began to assume a gangrenous appearance, and a small quantity of fetid, reddish, purulent fluid was discharged. Sutures were removed, and the parts well touched with liquor of permanganate of potash, no adhesion having taken place. The solution of permanganate salts was applied twice daily, until August 18th, when the gangrenous appearance had entirely disappeared. The edges of the wound were then brought together by isinglass plaster. The parts rapidly healed, and the patient was returned to duty September 28th, having no pain in or about the cicatrices.

Microscopical appearance of the juice of the growth, immediately after the operation; numerous round uninnucleated cells, about the size of blood cells, with fat and blood cells, and occasionally fragments of fibrous tissue, were the only elements observed in the field of the microscope. The growth appeared, on section, of a whitish color, tough and gristly feel, and had all the appearance of condensed fibrous tissue. Weight, fifteen drachms. It has been preserved in proof spirit, for transmission to the Army Medical Museum.

DCCXV.—*Report of an Encysted Tumor of the Back.* By H. S. SCHELL, Assistant Surgeon, U. S. A.

John A. Batt, a private of Troop I, 2d Cavalry, aged 54 years, was being treated in quarters at Fort Laramie, Dakota Territory, for a cystic sebaceous tumor situated between the scapulae. This

tumor had been opened on April 10th, and the contents discharged. It had filled, ulcerated, and discharged three times previously, at intervals of six months; but at the time of second operation, it was a large, inflamed, and painful cyst, five inches in diameter. On April 27, 1867, the patient's constitutional state warranting an operation for removal, he took chloroform, and a crucial incision was made, and the encysted mass was dissected from the surrounding tissues. One ligature was applied; the edges of the incisions were approximated by iron wire sutures and adhesive strips. The edges of the wound not uniting, the dressing was removed and the wound allowed to heal by granulation. By May 30, 1867, the wound had healed.

DCCXVI.—*Memorandum relative to a Morbid Growth removed from the Back of the left Forearm.* By B. J. D. IRWIN, Surgeon U. S. A.

Specimen 5561 of the Surgical Section of the Museum is a cystic tumor, which was removed at Fort Wayne, Michigan, from the dorsal aspect of the left wrist and fore-arm of a woman, aged about 46 years, who had never borne children, and whose usual occupation was that of a seamstress. The operator, who contributed the specimen, states under date of February 22, 1869, that some four years previously Professor Van Buren had removed from this patient a morbid growth from the same position. The disease having subsequently returned, the woman was advised to submit to amputation of the fore-arm. Upon consultation with two medical men, it was decided to make an exploratory incision with a view to excision of the radius. The incision showed the bone to be healthy, and it was deemed advisable to confine the operation to the complete removal of the diseased tissues. The tumor extended about half an inch over the carpal bones, and about two inches along the extensor tendons of the radius. [A microscopical examination of the tumor was made by Assistant Surgeon J. J. Woodward, U. S. A., who furnishes the following memorandum: [*Hygroma p.roliferum*, of Virchow (*Die Krankhaften; Geschwülste*, Band I, S. 206).] Ganglion containing fibrinous bodies. The walls of the lobulated cyst are composed of tough connective tissue, containing, however, many spindle-shaped elements imbedded. The little fibrinous bodies of granular matter are arranged in layers.]

DCCXVII.—*Account of a Morbid Growth on the Leg, requiring Surgical Interference.* By A. C. SCHWARTZWELDER, late Surgeon U. S. V.

Private Philip ———, Co. C, 13th Colored Infantry, aged about 25 years, fell through a cow-catcher, on a railroad track and injured his left thigh. The accident put him in the hospital for two or three weeks, during which time cups were applied above the knee. He was mustered out of service in January, 1866. In December, 1866, the patient first noticed the appearance of a hard, painless tumor, on the anterior aspect of the left fibula, near the middle third. The tumor was first examined in April, 1867, at Nashville, Tennessee. It then occupied the greater part of the shaft of the fibula, to which it seemed firmly attached, and from which it seemed to originate. Its contour was even and smooth, and the skin adherent. Its most striking characters were extreme hardness, density, and weight. Anteriorly, and just below the head of the fibula, was a soft, fluctuating spot, of small extent. On thrusting a grooved needle into it, nothing escaped but thick, black blood. A heteroplastic growth was diagnosed, of scarcely questionable malignity. The patient was placed under close observation. The growth increased rapidly. In two months it doubled its size. An exploring needle introduced into several places revealed osseous (osteoid) tissue, the hardness and apparent density of which was remarkable. The perimeter of the calf, including the tumor, measured twenty-one inches and a quarter; of the sound leg, fourteen. The day after the measurement, June 26, 1867, the removal of the limb having been decided on, it was amputated by Dr. Schwartzfelder, just above the knee-joint. The skin was still adherent. The gastrocnemius and soleus muscles were spread out, and, with the other muscles of the leg, formed a membranous-like

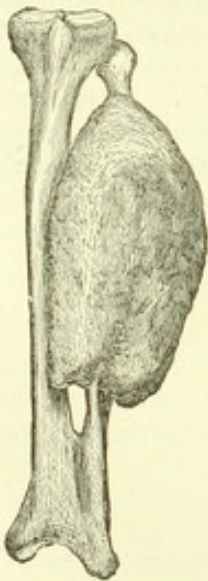


FIG. 68.—Osteocephaloma of the left fibula. Spec. 4747, Sect. I., A. M. M.

covering for the tumor. Near the union of the two former with their common tendon, the muscular tissue was destroyed or converted into a gelatinous-like substance. In front, and just below the upper tibio-fibular joint, a small sac was found, containing less than an ounce of dark, grumous blood. The whole growth was seen to be constituted of osseous spicula, (osteoid tissue?) and gelatinous and cartilaginous tissue, the latter greatly predominating. On subjecting the growth to the microscope, the bone corpuscles were clearly defined, and also others which it was inclined to range with cartilage cells. Its great succulency, and the fact that the inguinal glands of the left side were enlarged, looked toward its heteroplastic and malignant essence. On July 9th the patient was doing well, and had every prospect of recovering from the operation. He could ascribe no cause whatever for the appearance of the tumor, except the above-mentioned injury to the thigh. The marks occasioned by the cupping were still visible at the time of operation. The specimen, with the history, was contributed to the Army Medical Museum by the operator, and some idea of the growth can be gathered from the wood-cut FIG. 68.

TETANUS.—Six special reports were made of cases of alleged tetanus, with the surprising result of four recoveries and two deaths.

DCCXVIII.—*Information relative to a Fatal Case of Traumatic Tetanus.* By W. H. LONGWILL, M. D., Acting Assistant Surgeon.

Edward Waterfield, a private of Co. C, 5th Infantry, was admitted to hospital at Fort Wingate, New Mexico, on November 24, 1866, having been accidentally wounded by a musket ball, which entered the right wrist anteriorly, and passing through, emerged directly opposite, after comminuting the os magnum and the second and third metacarpal bones. A number of fragments of bones being removed, persulphate of iron was applied to stanch the hæmorrhage. Dry dressings were used until November 27th, when a linseed poultice was applied in order to remove the crust formed by the styptic. On November 30th, the crust was removed, and the cataplasm was continued; the wound discharging freely looked well, and the patient was in good condition. On the morning of December 1st, tetanus set in. Tincture of opium, in doses of sixty drops to be taken every two hours, was prescribed, and a blister was applied along the spine. At 7 P. M., a drastic purgative was administered. On December 2d, the patient's bowels were freely moved, and the blister had become very painful, but no relief was afforded. He experienced great difficulty in swallowing. The tincture of opium was continued, but, at 9 P. M., opisthotonos occurred, when chloroform was administered through the remainder of the night with slight relief. The patient died at 3 P. M., on December 3d. At the autopsy, the median nerve was found swollen and inflamed at the seat of the wound, and five or six inches along its course.

DCCXIX.—*Remarks on a Case of Tetanus following a Burn.* By A. A. YEOMANS, M. D., Acting Assistant Surgeon. ☞

Private D. A. McCrum, Co. B, 24th Infantry, was severely burned by the accidental ignition of a quantity of gun-powder, at one of the magazines at Vicksburg, on December 8, 1867. January 6th he was attacked by premonitory symptoms of tetanus. His jaws were firmly closed and he was unable to separate them, neither could they be opened more than half an inch by the attendants, with the aid of various appliances. Pulse 85 and rather weak. Prescribed half an ounce of castor oil, to be followed by one ounce of wine with a raw egg, three times a day; beef-essence and brandy, every hour, and a grain dose of morphine at bed-time. On the 7th, there was increased immobility of the jaws, and occasional light spasms. The treatment was continued; and in addition, an enema of soap, water, and castor-oil was administered. A blister was applied over the whole length of the spine, and a drachm of bromide of potassium was given every fourth hour. On the 11th the patient had severe spasms, which, increasing in frequency and violence, assumed the form known as opisthotonos, and were produced by the least movement on the part of the patient, or by a current of cold air. As the bowels had not been moved for two days, another enema was ordered, and the bromide of potassium was increased to half an ounce four times a day.

The morphia, wine and raw egg, brandy, and beef-essence were continued. 15th: Spasms continue unchanged in severity; muscles of extremities rigid; pulse 95, and diminished in volume. Treatment continued; beef-essence and brandy given at shorter intervals. 18th: Patient improving; spasms not so severe; and there is less rigidity of muscle. For the last three days, he has had paroxysms of spasms, commencing at 11 o'clock A. M. Four grains of quinine were ordered to be given twice daily, in addition to previous treatment. 21st: Patient continues to improve. He is now able to separate his jaws about an inch, and enjoys his food, still given in a liquid form. Pulse 87 and increased in volume. Spasms became less frequent, and ceased entirely February 3d, since which date has had no symptoms of tetanus. 23d: He was attacked by epilepsy, of a very severe grade, to which he has been subject several years. The convulsions continued, at intervals over half a day, when finally checked by chloroform. February 29th: Is now doing well, although his hands are still very sore from the effects of the burn. This man was discharged the service June 11, 1868, at Vicksburg, Mississippi, for burns.

DCCXX.—*Report of a Case of Tetanus treated with Calabar Bean.* By CHARLES SMART, Assistant Surgeon, U. S. A.

Hugh Nugent, bugler Troop K, 5th Cavalry, on November 8, 1869, at Washington, injured his left fore-arm by a fall from his horse on the curbstone, causing a lacerated and slightly contused wound about an inch and a half below the inner condyle of humerus. The joint was uninjured. Cold-water dressings and simple ointment were applied until November 17th, when the patient complained of stiffness in the muscles of the injured fore-arm and the back of the neck, and that he could not separate his jaws as usual, which symptoms he ascribed to a cold. He was admitted to the Sedgwick Barracks Hospital, when a hot-air bath was given, the wound dressed with bread and milk poultice, and Dover's powder administered. Excepting the stiffness of neck and inability to separate the jaws he felt comfortable, but had no desire for food. Several attempts to swallow a teaspoonful of wine occasioned violent choking feelings, and spasms of the muscles of neck. At 7 P. M., however, the stiffness of muscles of neck was continuous, and the muscles of the spine were implicated. Every ten minutes an exacerbation took place lasting a few seconds, during which the abdomen and chest were thrown forward and the head back, while the face became flushed, and brows corrugated and the teeth clenched and exposed by the parted lips; pulse 100, increasing during and after exacerbation to 120. One-third of a grain of extract of Calabar bean was given in the form of a pill. At 8 o'clock, as no change was perceptible, the dose was repeated, and again at 9 P. M. At 10.30 one-third of a grain of the extract was injected under the skin of the right fore-arm, and one-half grain one hour later. The only result was the fall of the pulse from 100 to 80, while the patient was quiet. Although he complained of pain and stiffness in the neck and back, no marked rigidity of the muscles in those regions was observed. At 1.30 A. M., on November 18th, sulphate of morphia was given, but without manifest effect. At 9 A. M., during an exacerbation, spasm of the diaphragm was indicated, more particularly at the attachments to the ribs on the right side. At 9.30 A. M., half a grain of the extract was given *per orem*, and repeated at 11. No benefit was derived from the administration; on the contrary, his condition became worse, the diaphragmatic spasms being continuous, pulse 100 to 140, skin hot but moist, and forehead beaded. Four ounces of chicken-tea and three ounces of wine were administered by feeding bottle with a rubber teat. At 4 P. M., two grains of the grated kernel of the Calabar bean in a drachm of water were given by a quill, and this was repeated at 5.30. At 7 P. M. the dose was increased to three grains and repeated at 9 o'clock, with the effect of producing marked contraction of the pupils. No change for the better could be discovered. The spasms continued, and the patient showed signs of exhaustion. At 11 P. M. four grains of the grated kernel, with one grain of sulphate of morphia, were given, which ameliorated the sufferings of the patient, who fell into a dose, which lasted till 3 A. M., November 19th. During his sleep, however, the paroxysms would occasionally return. On awakening, his face was cadaveric, his pupils contracted to one-sixteenth of an inch, but he declared that he felt good. Wine being given, spasms were induced, which lasted about thirty seconds. The possibility of introducing nutritives by enemata precluded by

spasms following any attempt to lie on the side. Wine and milk were, however, cautiously continued, but the further exhibition of the Calabar bean was discontinued until the pupils should show a tendency toward enlargement. The patient suffered no pain either in right side, back, or neck, yet every few minutes his head was thrown back, and his chest and abdomen forward by the action of the muscles, while his right hand clutched at the epigastrium. The pupils showed no enlargement. He gradually failed, and died at 10 A. M., November 19, 1869.

DCCXXI.—*Report of a Case of Traumatic Tetanus thought to have been treated successfully with Calabar Bean.* By DAVID HERSHEY, Acting Assistant Surgeon.

Charles Holker, colored, aged 20 years, by occupation a deck-hand, was admitted to the Freedmen's Hospital, New Orleans, Louisiana, on May 24, 1868, having about a week previous to his admission thrust a sliver of wood into the sole of his foot. It was immediately removed and the wound healed readily, no unpleasant symptoms occurring until the 24th. When admitted, spasms were occurring every twenty minutes; the jaws were firmly locked, and the muscles of the neck, chest, and abdomen were very rigid, with considerable opisthotonos. His bowels had not moved for five days. A terebinthinate enema was given with the desired result. Opium was administered in grain doses every two hours. He passed a restless night, the spasms recurring with but very slight intermission; and on the 25th the pulse was 120. Tincture of Calabar bean was given in the dose of five drops every half hour, which was finally increased to twenty-five drops. Very little change took place until the 30th, when all the symptoms became less severe; beef-tea was given freely. He continued to improve, and on June 5th the pulse was 52, full and regular, and the spasms occurred but twice during the day. Opisthotonos was less marked. On the 16th, having had no spasms for four days, the use of the bean was discontinued. On June 20th he had completely recovered. The quantity of extract of Calabar bean taken during the case was three hundred and forty-two grains.

DCCXXII.—*Report of a Case of Traumatic Tetanus believed to have been treated successfully by Large Doses of Opium and the Inhalation of Ether.* By W. D. JAMAISON, M. D. Acting Assistant Surgeon.

Charles Wilson, a private of Co. B, 11th Infantry, aged 21 years, came under notice for medical treatment at Charlottesville, Virginia, on February 25, 1866, having chancres and bubo. The bubo had suppurated and was opened, giving exit to a copious quantity of pus. He was doing well until March 3d, when, coming in violent contact with the end of a board, which struck him over the seat of the bubo, he gave a scream, fell prostrate on the ground, and immediately became convulsed. Upon being seen within twenty minutes from the attack, he vomited the contents of his stomach, mingled with blood. From this time, 4.30 P. M., till 2 A. M. next morning, the convulsions followed each other in rapid succession, with intervals varying from five to ten minutes. Opisthotonos was marked in its fullest intensity; his speech was voluble but incoherent, changing at times to a loud and boisterous tone. The pulse at no time exceeded 86; the pupils were dilated, and did not respond to the action of light, or when an object was suddenly brought near the eye; the countenance during the paroxysms, was almost purple, the superficial vessels of the face and neck being much distended; the muscles of deglutition were unaffected throughout, and the surface of the body and the extremities were much below the natural temperature. The treatment in this case consisted of sinapisms to the hands, feet, and stomach, followed by drachm doses of laudanum every hour, and the free inhalation of ether on the recurrence of spasms. No abatement of the spasms was perceptible until the next day at 2 P. M., a period of ten hours, during which time two and a half ounces of laudanum and fourteen ounces of ether had been expended. Being unable to make water, warm fomentations were applied over the region of the bladder, and bottles of hot water to the feet and perineum, which had the desired effect an hour or so afterward, the patient experiencing no further trouble in that respect. He slept well and soundly at night, but evinced no desire to sleep in the day-time. On the fourth day the patient was walking about, taking no medicine except tincture of iron, and expressed himself feeling "very well."

DCCXXIII.—*Report of a Case of Traumatic Tetanus believed to have been treated successfully with Hydrate of Chloral.* By D. BACHE, Surgeon, U. S. A.

George Deems, a private of Troop A, 4th Cavalry, aged 24 years, was admitted to the post hospital at San Antonio, Texas, July 4, 1870, with a contused wound of the scalp. He had been carousing the previous evening, and while intoxicated had been thrown from the top of a carriage which he was in the act of mounting. Simple dressings were applied to the wound. He ate his breakfast as usual, but in half an hour afterward complained of increasing stiffness about the lower jaw, and in two hours it had become firmly closed and general convulsions had set in, each lasting from three to five minutes. Hydrate of chloral in twenty-grain doses was administered every hour. Pulse 102, temperature in axilla 100, pupils natural. Spasms occurred upon the slightest touch, or upon blowing the breath upon the face. On the next day the pulse was 64, respiration 24, temperature 98. The bowels moved and urine passed freely. The pupils were somewhat dilated equal and sensitive to light. There was some rigidity of the masseter muscles, which were painful upon touch, and hyperæsthesia over the entire length of the spine; greatest in the cervical region. The case progressed very favorably until July 13th, the patient complaining only of occasional headache. He had been moved during the day to an adjoining bed; at 10 P. M. he had a general convulsion, and two within the next hour; the jaws closed firmly, the pupils became widely dilated and fixed. Pulse full, intellect much confused after the convulsion. Thirty grains of hydrate of chloral were given. From this time convalescence was steadily progressive, the patient only requiring attention to his diet and secretions, and all exposure to the sun being prohibited. He was discharged from the hospital August 9, 1870, and had no return of convulsion or any form of cerebro-spinal disturbance.

DEATH FROM CHLOROFORM.—Although anæsthetics were employed almost invariably in the surgical operations performed in the Army during the quinquennial period considered in this report, as well as in the reduction of luxations and fractures, and to a limited extent in obstetrical practice, there is only a single instance reported in which a fatal result is attributed to the use of chloroform. With what justice the allegation was made the reader can infer from this report.

DCCXXIV.—*Report of a Death ascribed to the Effects of Chloroform.* By IRA PERRY, Assistant Surgeon, 9th U. S. Colored Troops.

Henry Jefferson, a private of Co. E, 19th Colored Troops, aged 20 years, was accidentally wounded by a comrade at Brownsville, Texas, on August 30, 1865. Two fragments of a conoidal musket ball entered the outer aspect of thigh, two inches below the trochanter major and, fractured the femur. He was admitted to post hospital, where spiculæ of bone were removed. About September 15th, extension with pulley and weight was used, and the limb, which was easily kept in place, was apparently doing well. The wound was kept open and discharged an ounce of healthy pus daily, until October 16th, when pus was rusty; no bony union had taken place. On November 17th, Acting Assistant Surgeon Raphael administered chloroform and ether for the purpose of excising the ends of the bone. The patient inhaled two minutes, then began to sink; pulse failed; spasms occurred; the head was drawn back, and hands and feet were in a tremor. The sponge was removed and the patient rallied, but as soon as the sponge was reapplied the spasms returned, the pulse stopped, and death supervened. At the autopsy, the fragments of bullet were found imbedded in the bone even with the surface. No ossific deposit was in the fracture or close to it, but some above and below its edge.

VARIOUS SURGICAL AFFECTIONS.—The reports are too few for classification.

DCCXXV.—*Account of a Case in which Transfusion was employed.* By C. B. BRAMAN, M. D., Acting Assistant Surgeon.

James Smith, a private of Co. D, 12th Infantry, was admitted to post hospital at Petersburg, Virginia, on November 7, 1866, suffering from thoracic aneurism, caused by a strain experienced

on November 1st, while throwing heavy weights backward over his head. He had been a stout, robust man, but on admission was completely pulseless from the loss of blood by repeated emesis, sufficient to fill a common water bucket once and a half. I transfused blood to the amount of two and a half ounces into the median basilic vein; opium and morphine were administered by the mouth, cutis, and rectum every hour for over three days, in order to subdue the cough, which brought an renewed hæmorrhages. An equivalent to sixty-four grains of opium was administered within the first twenty-four hours. Nourishment was given by enemata of whiskey, quinine, beef-juice, and laudanum. The patient gradually recovered under this treatment, although for several days the result was extremely doubtful. He was discharged in the latter part of the month; he could sleep only in a chair, not being able to breathe in the horizontal posture. There was constant cough and gnawing pain in sternum near third right rib, and some hepatization of right lung. Aneurismal fremitus was occasionally perceptible to the ear; nevertheless the patient was gradually gaining strength.

DCCXXVI.—*Report of a Case of Lumbar Abscess.* By J. F. HEAD, Surgeon, U. S. A.

Charles O——, a private of Battery H, 3d Artillery, aged 33 years, and unmarried, served in the field during the rebellion with 1st or 2d Connecticut Heavy Artillery, and reënlisted as a veteran volunteer in 1863. In 1864 he suffered from typhoid fever, for which he was sent to general hospital at Baltimore, Maryland, where he was very ill for some time. During convalescence he felt pain in back, accompanied by swelling, which he attributed to long lying on his back. An abscess was opened in right lumbar region, and a quantity of pus, estimated by himself at "more than a quart," was evacuated. The abscess healed rapidly, and, returning to his regiment, the man was mustered out in 1865. In February, 1866, he enlisted in the 3d United States Artillery. He was not reported sick, except three days' diarrhœa in August, 1867, until November 28, 1867, when he complained of pain in the lumbar region, and was treated for rheumatism, with counter-irritants, salts of potassa, and electricity, and returned to duty December 24, 1867. After five days duty returned to hospital, and was treated much as before for rheumatism. Returned to duty January 11, 1868. Readmitted March 21st with same symptoms. Treated by tincture of iodine externally, dry cups, and tonics. The disease was recognized as lumbar abscess. On April 22d, an incision, about midway between third lumbar vertebra and crest of right ilium, gave exit to less than an ounce of apparently healthy pus. The opening healed, and he again returned to duty on June 21st. On the 28th of April, it is recorded that his weight has decreased from 145 to 121 pounds. On July 4, 1868, he reëntered hospital, which he never left until his death. The abscess had reopened, and on July 8th is recorded as discharging about two ounces in twenty-four hours. Nourishing diet, wine, and quinine were prescribed. The case first came under my observation about July 16, 1868. The patient appeared to be gradually failing, the amount of discharge varying, pus never offensive, nor could any denuded bone be detected by the probe. There was never any tenderness upon strong pressure or percussion over the spinous processes of vertebræ, nor did the nervous power of the lower extremities ever seem impaired during the course of the disease. The thighs were flexed upon the trunk, and attempts to extend them caused pain, which was referred chiefly to the hip-joint and back. Emaciation was marked; countenance sunken and sallow; tongue moist and florid; appetite capricious; bowels generally regular, about one dejection in forty-eight hours; occasionally required a simple cathartic. The case progressed without noteworthy incident or variation until about the middle of October, when some swelling, accompanied by pain, was observed in left lumbar region. Tincture of iodine applied. Swelling increased, decided fluctuation observed, and on November 2d an incision, under cover of a rag soaked in carbolic acid and linseed oil one part to seven, evacuated about twenty ounces of abominably fetid pus. The opening was covered with "antiseptic putty," after Lister's method. The discharge soon lost entirely its offensive smell, the quantity daily evacuated decreased from eight ounces to two, the original opening on the right side nearly closed, and ceased to furnish any discharge. For a time the patient seemed to rally somewhat. At about the same time with the appearance of last named swelling, œdema of the feet was observed, which afterward extended to the thighs, and

even to the loins, and increased pretty steadily to the time of his death. On November 23d began to expectorate bloody sputa, somewhat darker than in ordinary pneumonia. At first but little dyspnœa and almost no pain in chest. On 24th complained of slight "stitch" in lower right chest. On auscultation considerable coarse rale in both fronts; no fine crepitus; back not examined on account of difficulty of moving in bed. On 28th and 29th dyspnœa much increased. On the 30th, he was evidently moribund at 8 A. M., and died at 1.30 P. M.

The treatment during the last four months, in addition to the local means already mentioned, may be briefly summed up as consisting of a generous diet—eggs, milk, fresh meat, &c., *ad libitum* with strong beef-tea, regularly administered when the appetite did not induce him to take sufficient nourishment otherwise; tonics, as quinine, citrate of quinine, and iron, compound tincture of cinchonæ, &c., brandy or whiskey, from four ounces to twelve ounces daily, and opiates, when needed, to relieve pain and procure sleep.

Autopsy nineteen hours after death.—Body greatly emaciated, considerable œdema of lower extremities. Cadaveric rigidity marked. Chest decidedly resonant on percussion in both upper fronts, somewhat less so at sides. Abdomen sunken.

Thorax.—Lungs do not fully collapse on opening chest. Left pleura contains about fourteen ounces of straw-colored serum. Recent adhesion at left middle front (region of nipple), where pleura costalis shows patch of arborescent redness and blotches as of ecchymosis, slight old adhesions at apex. Left lung, lower lobe completely hepatized. On incision of lower part of upper lobe, free exudation of muddy, sanguineo-purulent fluids; upper half of this lobe crepitant. Right pleura, some old adhesions at base (diaphragmatic portion), otherwise normal. Right lung, upper and middle lobes, generally crepitant. On section abundant issue of frothy serum. Lower lobe hepatized, friable, particularly toward base, where it resembles softened spleen. At anterior lower margin apparently a clot of blood effused in pulmonary textures, but its margin not well defined from the splenified tissues surround. Pericardium normal. Heart not examined.

Abdomen.—Peritonæum smooth, moist, no effusion or adhesions, no enlargement of mesenteric glands. Intestines externally pale, glossy; alimentary canal not opened. Liver, spleen, and left kidney normal. Right kidney not examined. A large abscess occupies most of situation of left psoas magnus communicating with external opening that made on November 2d, and with the denuded bodies of second, third, and fourth lumbar vertebræ. Posterior crest of ilium denuded. On right side a section through pelvic fascia unexpectedly opened a cavity with no apparent opening, containing eight or ten ounces of thick, healthy, pus, communicating with space between last lumbar vertebra and sacrum, from which the intervertebral substance had entirely disappeared, the opposing surfaces of bone eroded and separated. Traces were found of another sinus, independent of the last named abscess, communicating with the old, opening in right lumbar region. The parts were so degenerated, however, that the anatomical boundaries could not well be made out. [A section showing three lower vertebræ, sacrum, and parts of ilia in situ, was forwarded to the Army Medical Museum with this report, and is numbered 5526 of the Surgical Section.]

DCCXXVII.—*Report of a Case of Caries of the Pubis, treated in the Post Hospital at Fort D. A. Russell, Wyoming Territory.* By J. BASIL GIRARD, Assistant Surgeon, U. S. A.

John K——, buglar Troop F, 2d Cavalry, aged 22 years, reported at sick-call in the latter part of August, 1868, complaining of pain on pressure and motion about the region of the right groin. Inspection of the part showed no swelling, heat, redness, or other visible pathological change, and the case being considered as a sprain of the adductor muscles, caused by horse-back exercise, the patient was dismissed with some anodyne liniment to rub the painful part. A few days after he came again, stating the pain to be worse, and judging from his sickly and worn-out look that the affection might be serious, he was admitted to the hospital on August 31st. On admission, the symptoms were great pain in the groin, especially over Scarpa's triangle, and emaciation. His appetite was good, pulse regular, and no fever present. The painful part was for a few days painted with iodine, and an anodyne given at night to produce sleep. Ordinary diet with beef-tea was prescribed. No effect being produced by the tincture of iodine, it was replaced by warm linseed-meal poultices, which in their turn were dispensed with, and a lotion of

lead-water and opium used. The anodyne liniment was also used at times, and these several remedies were alternately employed till the patient's death, but with only partial alleviation of the local pain. The bowels were irregular during the whole length of the disease, being sometimes confined, but much oftener very loose. In fact the diarrhœa became so violent that during the last two weeks the evacuations were repeated and involuntary. It was treated at first by small doses of chalk and Dover's powder, tincture of catechu, opium, and acetate of lead, and when it became excessive, tannic acid was given by mouth, injection, and suppository, while the patient at the same time was taking large quantities of tincture of iron and quinine. Another complication of the disease was bronchitis and pain over the chest, which annoyed the patient for a long time, and were treated by cough mixture and the local application of mustard-plasters or linseed poultices. A few light chills and some increase in the rapidity of the pulse were noticed at times, caused probably by the formation of pus. The emaciation progressed steadily, although the patient's appetite continued good to the last, and beef-tea and milk-punch were freely administered from an early period. He became completely bed-ridden, and an indolent ulcer opened itself over the right knee, which resisted all means of treatment. Bed-sores threatened to form upon the sacrum, but were prevented by the early application of washes of alcohol and tannin. One week before death an abscess showed itself in the perinæum, and having opened under the action of poultices, a large quantity of unhealthy-looking pus issued from it, and continued to flow for several days. Death occurred on October 26th, from exhaustion. During the last three days fœcal evacuations had been almost incessant. The patient was conscious to the last. At an autopsy, five hours after death, the body was very rigid, exceedingly emaciated, and of a strangely dark hue. Nothing abnormal was found in the thoracic and abdominal organs except some hypostatic congestion in the lungs. On cutting down over the symphysis pubis, a vast and diffuse abscess was opened, full of a sanious, unhealthy pus. The soft parts around the pubis and about the perinæum were all infiltrated with that fluid, which must have amounted at least to a pint. The adductor muscles and femoral vessels and nerves of the right thigh were destitute of connective tissue and bathed in pus, which had burrowed down to the lower third of the thigh. The right pubis was extensively carious, the bony particles being so disintegrated that, on making the attempt to divide the symphysis, the knife missed the joint and cut through the bone without difficulty. The disease had not proceeded beyond the pubis, the hip-joint, to all appearances, being healthy. The left os innominatum was also found in a healthy condition. [The pathological specimen, consisting of the right os innominatum, showing caries of the pubic portion, was forwarded to the Army Medical Museum, and is numbered 5583 of the Surgical Section.]

DCCXXVIII.—*Report of the Removal of a Bunion.* By WILLIAM J. WILSON, Assistant Surgeon, U. S. A.

Michael McCormick, a corporal of Co. C, 34th Infantry, was admitted to the hospital at Holly Springs, Mississippi, in March, 1868, with a large bunion on the outside of the first metatarso-phalangeal articulation, with which he had been suffering for a long time; the toe was drawn inward and across and beneath the toes. The tendon of the adductor pollicis and the inner head of the flexor brevis pollicis were divided subcutaneously, and the toe straightened on a splint. On March 31, 1868, the toe was much straighter and not drawn across the toes as before the operation. The bunion itself was not much reduced in size. The case is reported by the operator.

LIGHTNING-STROKE.—A report of two cases of recovery of soldiers struck simultaneously by lightning, and also a report of a very interesting fatal case were received.

DCCXXIX.—*Report of Two Cases of Lightning-Stroke.* By A. K. SMITH, Surgeon, U. S. A.

CASE 1.—Henry Ward, a private of Co. D, 18th Infantry, aged 27 years, was struck by lightning July 12, 1870. He was admitted to hospital at McPherson Barracks, Atlanta, Georgia, on the following day. Stimulating liniments and electricity were applied. He was returned to duty July 31, 1870.

CASE 2.—Charles Zeichler, a private of Co. D, 18th Infantry, aged 22 years, was struck by lightning July 12, 1870. He was admitted to hospital at McPherson Barracks, Atlanta, Georgia, on the following day. Stimulating liniments and electricity were applied. He was returned to duty September 16, 1870.

DCCXXX.—*Report of a Case of Lightning-Stroke.* By C. H. ALDEN, Surgeon, U. S. A.

Elias W——, a quartermaster's employé, aged about 60 years, was struck by lightning, near Fort D. A. Russell, Wyoming Territory, on June 24, 1869. At the time of this occurrence he was on horseback, herding Government mules, about a mile east of the post, and was exposed to a violent thunder storm. The horse was instantly killed, but no wound could be discovered. The rider was shortly afterward found lying insensible by his side, and in about fifteen minutes was brought to hospital. On admission he was still insensible, and could not be aroused by loud calling; his eyes were closed, he was restless, and, tossing about his limbs, resisted efforts to remove his clothes, which were very wet. The surface and extremities were cold; the pulse small. There was a superficial wound of the scalp, about two inches and a half long, just above and behind the right ear, ranging upward and backward, but nearly vertical, and having the appearance of being made by the point of some sharp instrument. A chain or series of large, irregular vesicated spots extended from below the right ear to the front of the neck, and down the chest and abdomen to the penis. There was a similar spot on the upper and inner surface of left thigh, with slight superficial wounds like abrasion on the outer and middle surfaces of both thighs. His felt hat was very much torn on the right side, the leather lining inside being burned. His shirt was somewhat torn in front, and the pantaloons were torn in positions corresponding to wounds on the thighs. On applying heat to the extremities the patient was wrapt in blankets, and a small quantity of whiskey administered, which was swallowed without difficulty. In the afternoon the pulse grew somewhat fuller and the surface warmer, when slight vomiting occurred. In the evening he became more restless; got up from his bed and muttered a few inarticulate words; passed water in a close stool. During the night he lay for the most part quietly, but had occasional attacks of restlessness, and passed his feces and urine in bed. On June 25th his condition was much the same as on the previous evening; he was generally quiet, but occasionally grew restless; pulse was somewhat fuller, and surface warmer than when admitted, but reaction not very decided; passed his urine involuntarily, and a little watery fluid oozed from the right ear. Weak milk-punch and beef-tea were ordered every two hours. Toward noon respiration became somewhat blowing, and no change was apparent in the pulse or otherwise. There was occasional restlessness. Dry cups were ordered to the back of the neck and sinapisms to the extremities. In the afternoon he opened his eyes, looking around somewhat intelligently for a few moments, but did not speak, and again became entirely unconscious. At 7.30 P. M. the pulse was 72; respiration 30; temperature 97. At midnight he began to swallow with difficulty. On June 26th, at 7 A. M., his condition was apparently unchanged from the last evening; pulse 90; respiration 30. The dry cups to the nape of the neck were ordered to be repeated. He remained in the same condition until he died at 12 M. At a *post-mortem*, eight hours afterward, *rigor mortis* was complete, having come on about 5 o'clock. The wounds were found as described on admission, the scalp wound being very superficial, scarcely extending through the skin, and the underlying muscles somewhat infiltrated with blood, but not decided. The periosteum and cranium were apparently intact. On removing the calvaria there appeared to be a very slight fissure on the inner surface corresponding in position to the external wound, but so slight that its existence was almost doubtful. Between the bone and dura mater was a hard, black, circular clot, about one-fourth of an inch in thickness and two inches in diameter. Opposite the centre of the clot was a minute orifice in the membrane. The brain under this clot was broken up and mixed with blood for about two inches in diameter, and extending into the lateral ventricles. The pia mater was injected, and the ventricles filled with bloody serum. There was no fracture at the base of brain. The thoracic and abdominal viscera exhibited nothing abnormal, excepting the heart, which was loaded externally with fat, its cavities being quite empty. [A pathological specimen, which is numbered 5585 of the Surgical Section, showing a portion of the brain, temporal bone, and dura mater, was contributed to the Army Medical Museum along with this report.]

DCCXXXI.—*Extract from Reports suggesting a Modification in the Methods of Amputation, by preserving the Periosteum to cover the Ends of the Bone, together with Remarks on Amputations at the Knee.* By GEORGE M. MCGILL, late Assistant Surgeon, U. S. A.

In the winter of 1862-'63, while on duty at Lincoln General Hospital, Washington, I conceived that the adoption of a periosteal flap in amputations, such as would cover the severed end of the bone and possibly unite with and nourish the surfaces recently cut, would be of the greatest utility and of easy performance. The idea was a new one to me at that time, and to all to whom I presented it. But recently I have observed the process noted as an old one, and have been verbally informed to the same effect by an eminent and learned gentleman, Surgeon J. H. Lidell, U. S. V. I have practiced this operation in all ordinary amputations with excellent results, and with facility from the time I conceived it until the present, and by my advice it was frequently adopted in primary operations upon soldiers of the cavalry corps of the army of the Potomac, and by such eminent and worthy men as Surgeon W. H. Rulison, 9th New York Cavalry, afterward unhappily killed while serving in the Shenandoah Valley. In these primary operations and in a secondary operation performed in the middle of the leg, by lateral flaps, upon Lieutenant ————, at Gettysburg, July 8, 1863, and more recently in tertiary operations, this procedure in the leg, so far as I am able to ascertain, has been accompanied by favorable results; neither sequestra nor exfoliations having formed, and the spine of the tibia never having ulcerated through. The operation supposes no such shock as destroys the vitality of the osseous tissue involved, by the molecular disturbance that gives rise to inflammatory necrosis or by nuclear paralysis and subsequent separation and rejection, such as occurs, as seems probable to me after much observation, when the diaphysis of a bone is jarred in addition to being broken by a missile of large size, or by one moving with high velocity and striking obliquely so as to furnish a modified resultant force of injury in addition to the immediate destroying one. The operation is performed upon the hypothesis that the osseous structure at the point of division is healthy. After forming the flaps and reaching the bone and clearing away and retracting the muscles, without touching the knife to the periosteum, taking half or more of the circumference of severance as the base, I form by a firm, smooth cut with a heavy-bladed knife, a long anterior flap sufficient at least to cover the medullary substance. This flap is then carefully raised by a periosteum knife, the operator running the blade of this instrument firmly and whetting it, as it were, against the bone, so that the membrane is raised intact. It will be found that periosteum retracts more than skin; this flap, for instance, retracting greatly upon and within itself. The section of bone should then be made carefully, accurately, and by no means too rapidly, as the aim is to preserve the life of osseous particles to be touched by the periosteal flap's internal surface. The flap is then allowed to fall of itself. I have never formed double flaps, nor fixed the periosteal flaps in any manner—proceedings extremely easy, however. I found the flaps I made to fall readily, and to adhere to the roughened cut surface of the bone. Of course, the number of cases I have had will not justify generalization, but as these cases number three in which the result was eminently good, I have ventured to present a theory of the availability of a periosteal flap in amputations, especially of the leg, in which so much inconvenience has arisen from the spine of the tibia even when this spine has been cut away in part. Why does not the substance of bone require its natural cover, viz., periosteum, to live properly, as much as muscles and other tissues require the skin?

[This paper was dated Baltimore, October 30, 1865. Dr. McGill's next paper relates to knee-joint operations, and is dated January 19, 1866.]

I submit the following remarks upon three cases of amputation through the knee-joint, in all of which the patella was left, and the proximal joint surfaces interfered with as little as possible. On May 6, 1864, near Todd's Tavern, Virginia, in the brigade of the first division of cavalry, commanded by General Custer, the first sergeant of an independent New York battery, I think the 6th, was struck by a cannon ball in the left leg. Both bones were broken, and the soft parts were extensively

lacerated. The soldier was removed to the field hospital of the brigade, located five hundred yards in rear of the line of battle, at which hospital, very shortly after reception of injury, I performed amputation through the knee-joint. The steps of this operation were substantially those taken in the second case. The patient rallied well, and was carried to the rear very shortly. Since then I have not heard of him. Owing to the press of my duties at the time I could make no notes, and these statements are made from memory, twenty months after the operation. The battery to which this sergeant was attached was commanded by Captain Martin.

[William H. Turner, 1st sergeant, 6th New York Independent Battery, died of pyæmia May 27, 1864, and is doubtless the patient referred to.—ED.]

On August 18, 1864, in one of our forts in front of Petersburg, Private Kelly, Co. A, Battalion of U. S. Engineers, Headquarters, Army of the Potomac, was wounded in the left knee by a sharpshooter. The ball entered somewhat to the left of the median line, near the tuberosity of the tibia, and passing upward and backward lodged in the face of the external condyle, partially imbedding itself crosswise. On consultation the same day the man was wounded, with Surgeon Ghiselin, U. S. A., Assistant Surgeon J. R. Gibson, U. S. A., and Acting Assistant Surgeon Goodrich, who had charge of the case, it was decided to amputate through the knee-joint. After the usual preliminaries, having taken a scalpel of medium size, taking position on the right side of the limb, I introduced it opposite the termination of the external condyle, and outlined an anterior flap, the lowermost portion of which was two inches below the terminal insertion of the quadriceps extensor, with a firm cut that divided the skin and superficial fascia, terminating the primary incision of the anterior flap opposite a point of the internal condyle corresponding to the point of the external condyle opposite which the scalpel had been introduced. From this termination the scalpel was reversed, and the inner half of the posterior flap formed, the depth of my incision being such as insured section of the superficial fascia as well as skin proper. The knife was then removed and reinserted near the original point of entrance, from which the outer half of the posterior flap was formed. This posterior flap was very long, extending fully half way down the leg. The angles of union of the anterior and lines of incision were made very acute, so that retraction would not tend to separate the angles posterior of the stump by drawing the sac of the stump tightly over the large extent of bone substance left. The anterior flap was now raised, and I took care in raising it to dissect so as to inflict as little injury as possible upon superficial fascia. The ligament of the patella was incised closely above the tuberosity of the tibia, and the patella, with its connections, left untouched so far as practicable. The ligaments remaining were then divided at their insertion, and so cut through that the semilunar cartilages remained in the stump. All the ligaments binding the head of the tibia being thus severed with a large operating knife, I cleared the posterior flap, cutting in the plane of the retracted posterior skin flap outlined as described above. This procedure afforded a base of flesh to what was essentially a skin-flap. But in addition, by the method adopted, I found that the fleshy part of the posterior-flap had been so formed as to expose the anterior surface of the deep posterior layer of crural fascia, and expose so much of this surface that it was found that a fibrous sheet fitted upon the synovial surfaces exposed by removal of the tibia. I now cut away all points and strips of cartilage or fibrous tissue accidentally made in operating. The ball was elevated from its bed in the face of the external condyle and this bed cleared. Nothing unusual took place in the subsequent steps of the operation. Unfortunately, however, the silk ligature threads were rotten. There was a ball hole in the anterior flap, besides the wound in the face of the external condyle to complicate the case. The latter was oozing blood from its sides when last observed. Throughout the operation injury to what was left of the synovial sac was avoided. September 9, 1864; Kelly is doing very well. The ligatures have none of them come away yet, and gentle traction met with firm resistance this morning. He is afflicted with pains of a darting lancinating character, which shift location. The wound of entrance in the outer border of the anterior flap has healed rapidly by granulation. To a great extent the flaps have united. A sinus, the mouth of which is to the right of the middle of the cicatricial line, communicates with the bed of the ball. So little discharge takes place through this sinus that it is thought that the bed of the ball has already been filled with callus. A peculiar "leaden" feeling has been observed by Kelly about his patella. He is not able to move this bone, but moves the left thigh without pain. On September 14th Kelly

is doing finely, one of the inside ligatures, that of an articular artery, has broken off short. The popliteal ligature has not yet separated. September 22d: the patient has steadily improved. The tumor of the stump has subsided, and the line of cicatrix is somewhat depressed. There is still discharge from where the ligature is broken off. It is probable that the knot of this ligature will remain in the stump for some time. The main ligature has not yet come away. I dread pulling, be it ever so gentle, for the ligature thread is fine and very rotten. The patella is freely movable, up and down, to the right and left. The capsule of the joint, as a whole, has adhered strongly to the condyloid surfaces of the femur, and affords a sufficient stay to the connected muscles. September 27th: Kelly was sent away to West Point, New York, this afternoon able to walk on crutches. The only regret is that knots of all the ligatures remain in the stump. I have considered it inexpedient to search for them. On his way to West Point, Kelly was, as I was informed by a letter from him, attacked with what he termed "gangrene." Some operation became necessary, and was, I believe, performed at West Point. From what he wrote I understand that this second "operation" did not extend to interference with bones or the remains of the synovial sac.

In addition to the foregoing remarks, I subjoin a history of Private David D. Cole, wounded in the left leg at Amelia Court-House, April 5, 1865, and operated upon by myself on August 1, 1865, at this general hospital. The leg was much swollen, and there was a great deal of dead bone in it. Patient was greatly weakened by discharge, and prostrated by sympathetic irritation. When the operation was performed it was evident that there was no other way to save life. In operating—yielding to the opinion of a gentleman present that the tumid and discolored tissues about certain fistulous orifices, that gave vent posteriorly to discharge from about the dead bone, was not capable of living as part of a flap—I made a very long anterior flap. The angles of union of the anterior and posterior flap were too obtuse, so made in consequence of miscalculating the effects of retraction upon the anterior flap. In operating, moreover, I removed the semilunar cartilages, and thus freed the lower part of the capsule of the joint, which was immediately drawn up; and to this removal is due in great part the extreme retraction presented. There being, however, an abundance of skin-flap to cover the condyles, I closed the stump in the usual manner. At the first dressing, three days later, I removed the sutures at the inner angle and along the centre of the line of coaptation wherever there was strain. The stump had an indolent and weak look. Removal of sutures at the inner angle of the stump disclosed a pearly surface of the internal condyle and bright red surface of the lateral ligament. The anterior flap exhibited a decided tendency to slough. In a few days this slough formed, all the sutures were removed, and the flaps carefully supported with adhesive strips. The angles opened widely after a slough (terminal) of an inch separated. But I relied on the vitality of the yet abundant integumentary tissue in the middle line of the stump. Without further bad symptoms the case progressed favorably, with a copious formation of pus, however, until the third week, when a great abscess was developed under the fascia lata. I do not think this abscess was in any manner connected with the ascending anterior pouch of the synovial sac. After this, as the abscess gradually healed, so did the stump, the general phenomena presented by the patient being favorable, *pari passu*. In November the patient was discharged from hospital perfectly well. At that time the patella was drawn upon the supercondyloid anterior space and fixed there, and the synovial sac appeared wholly obliterated. The integumentary tissue covering the faces of the condyles was well nourished, firmly attached, and capable of sustaining pressure with comfort to the patient. There were no irregular nervous sensations. The patient was fat, and the muscles of his left thigh were well developed. I have received a letter from him since, in which he informs me that he has received a proper artificial leg (supplied, I believe, by Dr. Hudson, of New York), and has nothing to regret in the manner in which the operation was performed.

DCCXXXII.—*Second Paper on Periosteal Flaps.* By the late George M. McGill, Assistant Surgeon, U. S. A.

I have the honor to transmit (April 12, 1866) casts of the stumps of Private Josiah Gamble, Co. C, 13th Virginia Infantry; private Church Lewis, Co. B, 116th U. S. C. T., and Private John

H. Allison, Co. I, 21st Pennsylvania Cavalry. Those of Gamble and Lewis, are of amputations of the right leg, and that of Allison of an amputation of the left thigh, lower third. In the operations performed on these men, the method of operation with periosteal flaps to cover the cut ends of the bones, to which I called attention by a paper acknowledged by Surgeon George A. Otis, U. S. V., December 20, 1865, was duly tried. It has succeeded very well. Subjoined is a detailed history of each case, also of the case of Private Leonard Babb, Co. B, 5th New Hampshire Volunteers.

CASE 1.—Leonard Babb, Private Co. B, 5th New Hampshire Volunteers, aged 43 years, was wounded April 7, 1865, at Farmville, Virginia, in the right foot, a conoidal ball entering the heel, and making exit in the instep, breaking up the tarsal bones. He was treated expectantly until August 12, 1865, when, no improvement being manifest, and much dead bone, abscesses, and light general cachexy being observed, and more feared, at the man's desire amputation was performed in the lower part of the middle third of the leg, by the operation of Lenoir. Operating myself, I was careful to raise a long and thick periosteum flap, being particular in so grating the knife on the compact substances of the tibia as to leave all the transitional tissue possible attached to the periosteum. His recovery was rapid and perfect; the stump was painless on pressure and admirably suited for an artificial limb. He was discharged on October 5, 1865. There was no tenderness over the sharp cut end of the tibia during the cure.

CASE 2.—Specimen 455 A. M. M., Private Josiah Gamble, Co. C, 13th West Virginia Volunteers, aged 23 years, was wounded on July 24, 1864, at Winchester, Virginia, in the right ankle. There being no prospect of recovery, and the case becoming worse daily, with dead bone, abscesses, and sympathetic irritation, on October 12, 1865, I performed amputation in junction of lower and middle thirds of leg, operating by lateral flaps, and making a circular incisions of soft tissues. I raised a flap of periosteum, as in case one, with the greatest ease. The man recovered quickly and well, but in removing the ligatures one of the knots was broken off in the stump; I believe that of the ligature of the anterior tibial, drawn downward and inward. After it was perfectly healed the cicatrix opened near its anterior extremity, and from this opening there has been an intermittent discharge until the present time (April, 1866). Repeated efforts have been made to find dead bone without success; and I think that the knot of silk is the cause of the discharge, and that this knot will finally be cast out. Gamble was transported to Fort McHenry post hospital, on February 20, 1866. The end of the tibia is well rounded. The stump is not in the least tender nor tumid, and the man's general health is good.

CASE 3.—Specimen 450 A. M. M., Private Church Lewis, Co. B, 116th U. S. C. T., aged 22 years, of tuberculous diathesis. Patient sprained his ankle in July, 1864, while drilling, and there was extensive disease of a low type of the bones and connective tissues generally of the right ankle. I made antero-posterior flaps. The posterior flap was formed in the soft tissues, after being outlined by the scalpel in the skin and superficial fascia, by cutting from within outward in the plane of the border of the retracted outlined skin-flap. In this case I made periosteal flaps for both tibia and fibula. The periosteum was lifted with the greatest ease, and, after the operation, was even more than sufficient to cover the ends of the bones. I found it necessary to be careful not to cut the bones below the folds of periosteum. These bones were very easily cut by the saw. Before this operation there was extensive irritability, the patient screaming when the foot was touched. After it he complained of great pain for several days. The fourth day after the operation, I was compelled to open the stump in the night and religate the peroneal artery, for profuse hæmorrhage, preceded, during the day, by vomiting and straining. The first ligature had apparently cut through the fibrous coat. Later there was a large abscess in the superficial fascia on the outer side of the leg. After the seventh day his recovery was rapid, and he was transferred on February 20, 1866, to Fort McHenry post hospital, perfectly well. His tibia was markedly rounded and the end of the stump well suited to bear strain.

CASE 4.—Specimen 403 A. M. M., is a cast of the stump. John H. Allison, Farrier, Co. I, 21st Pennsylvania Cavalry, aged 19 years, was wounded on April 5, 1865, at Amelia Court-House, Vir-

ginia, by a conoidal ball. The popliteal artery near its beginning was completely severed, the missile bruising the femur about the inferior termination of the diaphysis. There was hæmorrhage to syncope on the field, and secondary hæmorrhage, and when any one meddled with the wound there was apt to be hæmorrhage. Inflammation of the knee-joint, (treated by free incisions), gangrene, abscesses of the leg and thigh, ankylosis of the knee-joint, with the leg bent at right angles, erysipelas repeated and associated with great constitutional disturbance, emaciation, pallor, leucocythæmia, and fatty degeneration, interstitial and proper, of the leg and thigh, were severally declared. At last irritative fever was decidedly formed, and incurable ulcers on the heel and leg. By my direction Dr. H. McElderry, Acting Assistant Surgeon, U. S. A., performed amputation in the lower third through the diaphysis; forming an ample anterior flap, and a short and somewhat thick posterior one, and raising a very long and wide periosteum flap. This periosteal flap was raised with the greatest ease, too easily in fact, and after the operation was completed, was folded over every part of the cut surface of bone, as were the flaps in the case of Lewis (Case 3). Great prostration followed the operation; from this he reacted rather slowly, a kind of fever appearing the third day. He was kept under the influence of morphia. After the fourth day he improved steadily and speedily. At first when the stump was being dressed he complained a great deal. It was dressed first the third day. His blood presented remarkable phenomena of change of the white into red corpuscles (as Dr. McElderry and myself thought), during his cure, which will be fully described in a more detailed report of the case. He was discharged the service, at his own request, perfectly well, with the exception of a surface granulating in the cicatrix. On March 14, 1866, he was able to sit all day in a chair and help himself. The end of bone in this case was beautifully rounded.*

When a bone is cut in amputations, two conditions, I believe, must result from the action of its distal living bone tissues. First, metamorphosis into such transitional forms as will connect with ordinary fibrous tissue. Second, change of medullary tissue into such transitional tissue and into bone proper. If, then, we adapt living transitional tissue we substitute the mere action of union the cohesion of homologous formed material, the easiest in nature apparently, for the action of change that reproduces bone out of medullary tissue and forms a connective tissue, certainly by means of the germinal matter that lives in fully formed bone, and that has already performed the work of development and growth. Again it might be reasoned, *a priori*, that in changes one and two, made, of course, feebly by substance of exhausted (?) formative energy, the least injury of the general health and the most trifling local injury are calculated to kill or set the germinal matter free (in the form of pus), and so throw the labor of formation, and, it may be, an added one of separation, upon more proximal forms. Thus we have sequestra, thus often osteomyelitis and pyæmia. With periosteum over the cut end of a bone, we have a tissue there whose office is to form, to connect, and to resist. So promising have the results of amputations with a periosteal flap been in my hands, that I am constrained, most respectfully, to call your attention again to the subject.

This paper was dated Baltimore, April 12, 1866. The suggestions it contains were communicated to several medical officers; but there appear to have been no further experiments on the subject, and, indeed, the whole matter of sub-periosteal operations has received little attention in the Army.



FIG. 69.—Ruginé for sub-periosteal operations. [After Ollier.]

figured in the second volume of his work.

Dr. McGill used and recommended, for the separation of the periosteum, a ruginé similar to that employed by M. Ollier, and

* See Catalogue of the Surgical Section of the Army Medical Museum, p. 555.

† OLLIER, *Traité Expérimental et Clinique de la Régénération des Os*. Paris, 1867, T. II, p. 83.

REVIEW AND CONCLUSION.

The one thousand and thirty-seven cases recorded in the foregoing pages, with more or less detail, are but a small portion of those entered under the head of Class V on the monthly reports of sick and wounded for the period embraced by this report. The casualties thus entered numbered over sixty thousand.* The following consolidation from the numerical reports indicates the relative frequency of the different classes of wounds, accidents, and injuries: †

Abstract of Wounds, Accidents, and Injuries reported on the Monthly Reports of Sick and Wounded of the United States Army for the Period commencing July 1, 1865, and ending December 31, 1870.

Burns and scalds.	Contusions.	Concussion of brain.	Drowning.	Sprains.	Dislocations.	Simple fractures.	Compound fractures.	Gunshot wounds.	Incised wounds.	Lacerated wounds.	Punctured wounds.	Poisoning.	Other accidents and injuries.	Homicide.	Suicide.	Hanging.
2,003	23,651	152	198	13,731	635	1,380	219	3,213	6,774	3,038	1,591	683	3,683	68	84	2

It was proposed to publish only a selection from the histories of the more interesting cases entered in Class V of the monthly reports of sick and wounded, but ultimately it was deemed expedient to print condensed abstracts at least of each case of which a special report had been forwarded. All of the evidence being thus presented to them, it was thought that medical officers would hereafter be enabled to determine precisely what cases it would be advisable to make the subject of special reports, and the extent and form in which said reports should be made. Many letters of inquiry on these points have been received by this Division of the Office, and it has been difficult sometimes to answer them definitely. The gravest wounds are occasionally devoid of interest because of their immediate or inevitable fatality; while the most trivial accidents may be followed by formidable complications, demanding the most careful study, and yielding the most instructive illustrations.

It is very desirable that the name and military description should be noted in all cases entered under Class V on the monthly report of sick and wounded, and that the patient should appear, by name, on the report of the following months, until he is finally accounted for. Thus, it will become practicable to identify always such patients, and when they are moved from one post to another to trace their histories. The memoranda of grave cases can hardly be too minute, or of trivial cases too concise, provided means of identification of the patient are afforded. It is hardly necessary to insist on the

* The exact number is 61,105.

† The period covered by the consolidation does not precisely correspond with that considered in the Report; but the ratios are the same. At the beginning of the period the Army numbered over 150,000; but it was rapidly reduced to 80,000; then to 54,000, and finally to 30,000, its present nominal strength.

importance of the fullest description of autopsies and of pathological specimens forwarded to the Army Medical Museum. Some medical officers have performed creditable surgical operations on citizens, but have excluded such cases from their reports. Such additions to the surgical data of the Army should be forwarded in supplementary reports, otherwise the records of the office will imperfectly represent the work accomplished by the medical staff.

On page 86, the results of the gunshot wounds that were not subjected to operations are summed up, and, on page 113, a summary is given of the results of the incised, punctured, lacerated, and contused wounds, comprising some remarkable recoveries after visceral protrusions and punctures of the alimentary canal. Summaries of the results of simple and compound fractures and of dislocations have been given in connection with the abstracts of cases of those injuries (pp. 114, 143). Matters of interest respecting arrow-wounds are comprised in the reports from pages 144 to 163. A few abstracts of cases of poisoned wounds, and of burns and frost-bites, close this chapter.

The chapter on surgical operations, commencing (p. 170) with a tabular statement of the minor amputations, concludes (p. 218) with a favorable exhibit of the results of the major operations. Those at the shoulder and knee-joint had a larger measure of success than usually rewards the efforts of surgeons, and the small ratio of mortality in the thigh amputations (38.5) is exceptional. Two of the amputations in the thigh were of special interest as performed for the consequences of gunshot fractures of the femur, inflicted five and seven years previously. The pathological specimens furnished from these cases, very imperfectly represented by the wood-cuts (Figs. 41, 42), are very instructive. There was a successful case of amputation of the fore-arms and of the legs in one patient, and one of the two exarticulations at the hip had a successful issue.*

The results of the amputations, according as they were performed for injury or disease, or in the primary, intermediary, or secondary stages, are summed up on p. 217.

Under the head of excisions are included two examples of successful trephining in depressed fractures of the skull, for symptoms of compression, following on the second and third days, respectively, the reception of blows. An excision of portions of the upper and lower maxillaries resulted fatally. Two other operations on the facial bones, recorded in this section, appear to have been extractions of splinters from gunshot fractures rather

* In a letter to Assistant Surgeon General C. H. Crane, Dr. J. Fayrer, of Calcutta, had the goodness to furnish abstracts of eight cases of amputations at the hip occurring in his practice, kindly hoping they might be of service in the further investigation into this important subject by this office. Five of the cases have already been published. (Clinical Surgery in India, pp. 630, 609, 666, and Medical Times and Gazette, 1867, p. 270, 1868, p. 657.) The series is as follows:

1. Burman, aged 30, primary amputation for gunshot injury. Death from tetanus.
2. Ashgur, aged 16, re-amputation. Recovery.
3. Hadji, aged 36, re-amputation. Death in four days.
4. Hindoo, aged 25, amputation at the hip-joint for cancer at the knee. Death in 13 days.
5. Hindoo, aged 21, thigh-amputation for injury, re-amputation at the hip. Death in 26 days.
6. Hindoo, aged 55, primary amputation at the hip for shark-bite. Death in six hours.
7. Bupeer, aged 20, cancer of right thigh, amputation at the hip. Death in five days.
8. Lieutenant H., aged 21, secondary amputation for gunshot wound. Death in a few hours.

Dr. P. F. Eve records (Richmond and Louisville Medical Journal, Vol. XII, p. 370) an amputation at the hip for caries and anchylosis, terminating fatally in twenty-five hours.

Dr. N. S. Lincoln has recently performed a successful re-amputation at the hip, at Providence Hospital, Washington, in the case of W. Cotter, aged 32, for necrosis following primary amputation for gunshot fracture performed seven years ago.

than formal excisions. Of six operations on the bones of the hand, one terminated fatally on account of pyæmia. These cases were reported as excisions; but would probably be more suitably described as extractions of diseased phalanges, resections of the ends of the metacarpals—a finger being shot off—or extraction of splinters of metacarpals or phalanges. These abstracts are followed by an interesting report of a successful intermediary excision of the upper portion of the radius for gunshot fracture, and this by seven cases of excision in the continuity of the humerus, three primary, two intermediary, and two secondary, all performed on account of gunshot fractures and all terminating successfully. Two men recovered from excisions of head and upper extremity of the humerus, after gunshot fracture involving the shoulder-joint, with the excellent results that frequently follow this excellent operation. The excisions in the lower extremities were fewer in number, but of greater importance. They were all performed for gunshot injury; one on the calcaneum, one on the first metatarsal, one on the tibia, one on the fibula, and four on the hip-joint. Every reader must be impressed and gratified by the successful issue of the excisions of the head and trochanter of the femur. Three of the four cases were eminently successful, and the fourth and fatal case was practiced on a patient broken down by disease and intemperate habits, and unlikely to bear even a trivial operation satisfactorily.

The twenty-seven reports of ligations of the larger arterial trunks (see summary on p. 235) include one in which the common carotid was successfully tied for secondary hæmorrhage following a gunshot-wound of the face and neck, supposed to involve the external carotid near its origin. That there should not have been recurrent hæmorrhage from the distal orifice in the vessel is surprising. A compulsory ligation of the aorta for rupture of an aneurism of the common iliac is reported from one of the freedmen hospitals. One of three ligations of the external iliac proved successful. Three of the four ligations of the femoral resulted happily. The fatal case was one in which Anel's operation was performed, neither experience nor theory having convinced the operator that tying the femoral in its middle third would not preclude the fatal consequences of recurrent hæmorrhage from a wound of the popliteal. It is almost incredible, but there are still many surgeons who think it unnecessary to place two ligations on wounded arteries, but are satisfied in securing the proximal extremity or in tying the main trunk at a distance. The reports indicate that acupressure was not employed to any great extent. Styptics and tourniquets were sometimes too freely substituted for more effective hæmostatics. An interesting case of brachial aneurism successfully treated by compression is recorded on p. 155.

The reports under the head of "Various Operations" comprise accounts of four operations on the eye, and one on the ear; of four operations on the face, including one of rhinoplasty and one of extraction of a large salivary calculus; and five cases of bronchotomy, in three of which the opening was made in the trachea and in two in the larynx. One of the two cases in which the operation was done for traumatic inflammatory swelling occluding the air-passages was successful. Three other cases, one of œdema of the glottis and two of membranous croup, terminated fatally; yet the observation of the two latter convinced the experienced surgeon in charge of them of the propriety of tracheotomy in all hopeless cases of croup.

The only reported case of much interest among the operations on the abdomen is one

of successful excision of a large portion of extruded omentum (p. 250); but the numerical returns indicate that there were some important operations for hernia and for imperforate rectum; but no details were reported. The rarity of strangulated hernia in the Army bears creditable testimony to the fidelity with which the physical examination of recruits has been conducted.

The reports of operations on the genito-urinary organs commence with accounts of fourteen cases of phymosis. These show that many of the medical officers are of M. Ricord's opinion regarding the inutility of the prepuce, and prefer circumcision to the dorsal incision. After notes of two cases in which it was deemed expedient to amputate the penis on account of the syphilitic complications of the unhappy patients, are four reports on the surgical treatment of stricture. Four cases were treated by urethrotomy, with a single fatal result. Reports of successful removal of a foreign body of the urethra, and of suprapubic puncture of the bladder for retention, are followed by nine operations for lithotomy reported (pp. 256, 261), which presented some very interesting features. The pleasantest was that all resulted successfully. Four were performed by the usual lateral method for the removal of uric acid or phosphatic calculi of large size. Five were for the extraction of vesical concretions having foreign bodies as nuclei, the foreign bodies being a fragment of the pubic bone, a cast-iron ball, two leaden musket-balls, and an iron arrow-head. The latter instance is perhaps unique, and all constitute valuable additions to the remarkable series in the museum,* of vesical concretions found around foreign bodies. Median lithotomy seems not to have been practiced as yet in the army.

The eleven reports on tumors comprise notes of one lipoma, one sebaceous and two fibroid tumors, one hygroma, one epithelioma, two examples of scirrhus, and three of encephaloma. There were eight recoveries from the operations, with the prospect of recurrence in several cases. The reports of Surgeon B. Norris of the treatment of a case of undoubted medullary cancer by the drug called cundurango, forwarded by the minister resident at Ecuador, does not encourage a belief in any specific therapeutic property in this new agent.†

The six reports on tetanus refer to two fatal cases and four examples of recovery under the use of the Calabar bean, ether-inhalation with opium, and hydrate of chloral. It must be reluctantly admitted that the evidence regarding the curative efficacy of these drugs, and also to the accuracy of the diagnoses, is altogether insufficient. Dr. Smart's

* Specimens 88, 1687, 2567, 4712, and 5,019, Section I, A. M. M., are vesical concretions, induced by gunshot injuries of the bladder. Besides casts and hemp-seed calculi, and other small secretions passed through the urethra, the Army Medical Museum possesses one hundred and ninety-five vesical calculi removed by lithotomy. As the erroneous impression that the museum only receives donations from medical officers, and only such as pertain to military medicine and surgery, are not entirely dispelled, it may be well to reiterate that valuable pathological preparations, from whatever source, are welcomed, the preparations carefully mounted and preserved, the histories duly registered and catalogued, the names of the donors being always recorded.

†The correspondence of the minister, Mr. E. Rumsay Wing, with the State Department, relative to this drug, is printed in the *National Medical Journal*, May, 1871, p. 28, and also in pamphlet form. Mr. Wing furnishes recommendations of the drug by Drs. Casaras and Eguiguren, and it is noticeable that the latter speaks of this agent as one "which I alone possessed in Quito." Mr. Wing writes to Mr. Fish that cundurango cures not only cancer, but syphilis, and he judges from analogy that it will also cure "scrofula and ulcerous affections of different types." There are now on file at the State Department three reports on the use of this agent in soft cancer, and other evidence will soon be forthcoming. If the verdict is that anticipated by pathologists whose powers of analogical reasoning do not permit them to discern the pathological affinities of cancer, syphilis, scrofula, and indolent ulcers, every one who has aided in augmenting the misery of incurables in the interest of commercial speculation will occupy an unenviable position.

carefully observed case (p. 270) was instructive in relation to the therapeutic powers of the Calabar bean. In the earlier stages, he used the extract and tincture without any marked effect on the pupil or upon the severity of the paroxysms. He then procured a parcel of the beans from the museum, and used an infusion of the grated kernels, with the uniform effect of contracting the pupil and reducing the frequency and severity of the spasms. He assured me that he believed that he might have saved his patient if he could have employed this remedy earlier. In the past few years, I have had the opportunity of examining the brain and spinal cord after tetanus in three instances only, twice in the human subject and once in the horse. Only hyperæmia of the membranes was observed. The proliferation of connective tissue in the cord and medulla, proposed as the constant anatomical lesion of tetanus⁷ by some German pathologists, was nowhere detected.

The reports on a death from chloroform and on a successful transfusion in thoracic aneurism leave much to be desired in details of diagnosis. Several reports on surgical diseases are followed by accounts of three instances of lightning-stroke, an interesting autopsy having been made in the fatal case. Dr. McGill's essay on osteoplastic amputations concludes the series of papers.

I have appended to the report an index of contributors, an index of patients, and a table of contents, as readers of some of the former surgical reports have justly complained of the want of facilities for reference in documents of such length. The compilation and discussion of the surgical annals and statistics of the war of the rebellion have engrossed the time and attention of this Division to such an extent as to preclude the possibility of compiling the report with the closest care; yet it may be hoped that the value of the facts brought together, and the interest of many of the abstracts of cases, will compensate for all faults in the report.

I am, General, very respectfully, your obedient servant,

GEORGE A. OTIS,
Assistant Surgeon, U. S. A.

Brigadier General J. K. BARNES,
Surgeon General, U. S. Army.

ERRATA ET CORRIGENDA.

On page 18, 17th line, for *B. C. Fryer*, read *B. E. Fryer*.
On page 22, 38th line, for *Terry*, read *Perry*.
On page 39, 39th line, for 186, read 1866.
On page 58, 16th line, for *Darrou*, read *Damour*.
On page 93, 44th line, for *hyperdermic*, read *hypodermic*.
On page 143, 11th line, for *pullies*, read *pulleys*.
On page 147, last line but one, for *take*, read *takes*.
On page 148, 26th line, for *secenty*, read *twenty*.
On page 149, in note under wood-cut, for *impacted*, read *impacted*.

On page 163, 33d line, for *sentinals*, read *sentinels*.
On page 234, 15th line, for *coxalpia*, read *coxalgia*.
On page 234, 16th line, for *extrent*, read *extent*.
On page 254, 12th line, for *Kearny*, read *Kearney*.
On page 266, 14th line, for *tripple*, read *triple*.
On page 267, 30th line, for *ichthiocolla*, read *ichthyocolla*.
On page 268, 23d line, omit semicolon after *Krankhaften*.
On page 270, last line, after *enemata*, insert *was*.
On page 271, 7th line, for *Tetanus's*, read *Tetanus*.
On page 271, 25th line, for *belieaed*, read *believed*.

INDEX OF REPORTERS.

- ADAMS, W. S., pp. 29, 109, 141.
 ALDEN, C. H., pp. 20, 43, 276.
 ALEXANDER, E., pp. 97, 99.
 ALEXANDER, T. C., p. 8.
 ANSEL, A., pp. 102, 104, 252.
 ARTHUR, J. P., pp. 57, 132.
 ASHHURST, J., jr., p. 114.
 ATWOOD, T., p. 45.
 AUGER, J. T., p. 120.
 AUSTIN, W. M., pp. 9, 82, 228.
 AXT, F., pp. 80, 82.
 AZPELL, T. F., pp. 134, 187.

 BACON, C., pp. 26, 28, 188.
 BACHE, D., pp. 18, 91, 115, 249, 272.
 BAILEY, J. C., p. 184.
 BAKER, E. T., pp. 135, 237.
 BARTHOLF, J. H., pp. 10, 27, 90, 98, 101, 118, 127, 134, 251, 254, 255.
 BARNES, F., pp. 95, 116, 240.
 BARBARIN, F. H., p. 131.
 BAYNE, J. H., p. 129.
 BATES, H. G., pp. 12, 110.
 BEACH, S. S., p. 48.
 BENTLY, E., p. 100.
 BERKY, R. B., pp. 17, 68.
 BENJAMIN, G. A., p. 30.
 BEST, J. M., pp. 82, 119.
 BLACKWOOD, S. W., p. 96.
 BLACKWOOD, W. R. D., pp. 22, 88, 166.
 BOSLEY, D. W., p. 111.
 BOUGHTER, J. F., pp. 67, 186, 208, 252.
 BOWMAN, E. H., pp. 136, 177, 221, 251.
 BOWES, M. F., p. 58.
 BOYER, S. S., p. 119.
 BRADFORD, F. G. H., p. 75.
 BRAMAN, C. B., p. 90, 273.
 BRADLEY, W. A., p. 14.
 BREWER, J. W., pp. 73, 76.
 BROWN, H. E., pp. 47, 206, 235, 236, 244, 252.
 BROWN, P. H., p. 221.
 BROWN, W. F., p. 13.
 BROWN, D. R., p. 239.
 BROOKE, J., pp. 47, 76.
 BUCHANAN, W. F., pp. 27, 41, 42, 189, 225.
 BURNS, R., p. 14.
 BUFFINGTON, A. L., p. 99.
 BUTCHER, W. B., p. 241.
 BYRNE, C. C., pp. 6, 34, 100.

 CAMPBELL, A. B., pp. 73, 164.
 CAMPBELL, J., p. 73.
 CANTRELL, W. A., pp. 43, 59.
 CARVALLO, C., pp. 12, 13, 33, 73, 103, 109.
 CHRISTIAN, R. B., p. 236.
 CHANEY, T. M., p. 61.
 CHASE, E. Y., p. 243.

 CLEARY, P. J. A., pp. 63, 95, 105.
 CLEMENTS, B. A., pp. 44, 55, 91, 104, 176, 252.
 COUES, E., pp. 17, 59, 110, 125, 128, 134.
 CAUGHILL, C., pp. 97, 185.
 CORSON, J. K., pp. 18, 120.
 COWLES, E., pp. 17, 18, 23, 30, 60, 65, 202.
 CRAIG, W., pp. 65, 136.
 CRANDALL, J. B., pp. 59, 83, 213.
 CREAGHE, J. O. D., p. 62.
 CRONKHITE, H. M., pp. 110, 121, 201.
 CULVER, J. J., p. 12.
 CUNYNGHAME, T., p. 188.

 DAVIS, F. A., p. 251.
 DAVIS, P. C., pp. 169, 200, 202, 223.
 DAMOUR, F., pp. 58, 142, 151, 192.
 DAY, W. E., pp. 138, 199.
 DEAL, W., pp. 10, 42.
 DELANY, A., pp. 21, 37.
 DEGRAW, C. S., pp. 27, 67, 76, 91, 124, 146.
 DE HANNE, J. V., p. 9.
 DE WITT, C., pp. 32, 50, 102, 154.
 DICKSON, J. M., pp. 156, 206, 237, 245.
 DOUGHERTY, A. N., p. 259.
 DOUGHTY, W. H., p. 93.
 DOUGLAS, G. C., p. 249.
 DODS, W. B., p. 227.
 DOW, S. A., p. 52.
 DUBOIS, H. A., pp. 16, 45, 175, 179, 180, 214, 225, 243, 256.
 DURRANT, H. K., p. 224.

 EHLE, A. S., p. 212.
 ELBREY, F. W., pp. 45, 119.
 ELBRIDGE, W. H., p. 137.

 FIELD, J. C., p. 198.
 FITCH, A. F., p. 55.
 FLETCHER, H., p. 199.
 FLINT, A. L., p. 67.
 FOOTE, J. P., p. 110.
 FORWOOD, J. L., pp. 259, 261.
 FORWOOD, J. F. M., p. 235.
 FORWOOD, W. H., p. 210, 260.
 FOX, E. C., p. 67.
 FRANTZ, J. H., p. 131.
 FRYER, B. E., pp. 15, 18, 27, 62, 74, 75, 81, 107, 198, 199, 239.
 FURLEY, C. C., p. 67.

 GARDNER, W. H., p. 98.
 GEORGE, W. H., p. 122.
 GEISDORFF, F., pp. 60, 64.
 GIBSON, J. R., pp. 25, 29, 32, 40, 228.
 GIRARD, A. C., pp. 26, 58, 65, 75, 120, 182, 219, 244, 248, 251, 262.
 GIRARD, J. B., pp. 70, 72, 101, 155, 167, 201, 274.
 GHESELIN, J. T., p. 181.
 GODDARD, C. E., pp. 15, 66, 91, 99, 153, 179.
 GOLDSBOROUGH, L. W., p. 56.

- GRAY, A. J., pp. 9, 211, 242.
 GRAY, C. C., pp. 32, 134, 139, 144, 146.
 GREANLEAF, A. W., p. 15.
 GREENLEAF, C. R., pp. 78, 89, 106, 109, 132, 252.
 GWYNTHYER, G., p. 83.
 GUNN, G. H., pp. 7, 11, 65, 67, 74, 102, 106, 129.

 HALL, J. D., pp. 203, 204.
 HAMILTON, F. H., p. 197.
 HAMMOND, J. F., p. 82.
 HARTIGAN, J. F., p. 121.
 HARVEY, J., p. 46.
 HASSIG, F., p. 50.
 HAYES, L. W., p. 57.
 HEAD, J. F., pp. 142, 237, 273.
 HEGER, A., pp. 132, 169.
 HEIZMANN, C. L., p. 21.
 HENDRICKSON, W. T., pp. 26, 68.
 HERSHEY, D., pp. 84, 271.
 HITZ, R. B., p. 145.
 HOGG, A. J., p. 101.
 HOLLY, F. M., p. 86.
 HOLMES, L. E., pp. 77, 143, 201, 246.
 HORNER, S. H., p. 48.
 HOPPER, W. H., pp. 55, 62, 82, 104.
 HORTON, S. M., pp. 32, 56, 58, 78, 123, 146, 153, 156, 178,
 181, 200, 210, 212, 222, 224, 253.
 HUBBARD, V. B., pp. 126, 208.
 HULSE, J. L., pp. 23, 54, 138.
 HUTCHINSON, T. S. V., pp. 7, 182.
 HUNTINGTON, D. L., p. 188.
 HYSON, W. T., p. 105.

 IRWIN, B. J. D., pp. 183, 210, 198, 268.

 JACKSON, D., pp. 29, 35, 90, 176, 222, 223, 226, 242.
 JAMAISON, W. D., p. 271.
 JANEWAY, J. H., p. 239.
 JAMES, B., p. 221.
 JAMESON, G. A., p. 44.
 JENNINGS, R. J., p. 257.
 JESSOP, S. S., pp. 40, 57, 226, 254.
 JORGENSEN, J., p. 100.

 KILBOURNE, H. S., p. 153.
 KIMBALL, J. P., pp. 66, 128, 133, 154, 155, 156, 262.
 KING, J. H. T., p. 36.
 KING, J. T., pp. 38, 57, 74, 85, 101, 108, 176, 177.
 KING, W. H., p. 221.
 KIRK, R. M., p. 12.
 KNIGHT, C. W., p. 51.
 KNOX, F., p. 90.
 KOERFER, E. A., pp. 95, 196.
 KUGLER, J., pp. 79, 152.

 LAING, J. M., p. 207.
 LAMONT, J. C., pp. 46, 179.
 LAUB, C. H., p. 264.
 LE CARPENTIER, J., pp. 29, 30, 56, 77, 165, 211, 220, 227.
 LIPPINCOTT, H., pp. 8, 21, 112, 151.
 LIVINGSTON, H. F., p. 222.
 LONGWILL, W. H., pp. 185, 269.
 LORING, L. Y., pp. 55, 111, 141.
 LUNNEY, J., p. 202.
 LYON, W. B., pp. 141, 184.

 MAGRUDER, D. L., pp. 36, 51.

 MACKIN, C. J., p. 197.
 MACFARLINE, C., p. 31.
 MARSTON, J. J., p. 179.
 MATHEWS, W., pp. 35, 187.
 MATHEWS, H. M., p. 151.
 MCCHANDLESS, J. M., p. 155.
 MCCHESENEY, C. E., p. 84.
 MCCRACKEN, R., p. 45, 252.
 MCCOY, W. M., p. 56.
 MCCLELLAN, E., p. 242.
 McELDERRY, H., pp. 20, 38, 66, 149, 156, 267.
 MCGILL, G. M., p. 277.
 MCGUIRE, H., p. 239, 258.
 MCKEE, J. C., p. 49.
 McLEAN, D., pp. 103, 104.
 McMAHON, J. H., pp. 9, 102, 156.
 MEACHAM, F., pp. 26, 30, 33, 36, 64, 137, 185, 245.
 MECHEM, A. F., p. 106.
 MERRILL, C. S., p. 127.
 MERRITT, D., p. 105.
 MILES, B. B., pp. 10, 243.
 MILLER, G. McC., pp. 6, 140, 236.
 MILLS, H. R., p. 175.
 MIDDLETON, P., pp. 60, 65, 132, 148, 156, 188, 191, 221, 249.
 MIDDLETON, J. V. D., pp. 62, 80, 117, 123, 128, 164.
 MINEER, W. S., p. 48.
 MINOR, G. W. B., p. 23.
 MOFFATT, P., pp. 13, 17, 98.
 MULLER, A., pp. 151, 216.
 MUNN, C. E., p. 199.

 NEUMAN, A., p. 44.
 NOTSON, W. M., pp. 18, 29, 43, 46, 71, 76, 148, 149, 150, 153,
 180, 247.
 NORRIS, B., pp. 246, 262, 265.

 OTIS, G. A., p. 215.
 OWENS, p. 189.

 PATZKI, J. H., pp. 6, 37, 50, 59, 60, 194.
 PEABODY, J. H., p. 145.
 PERIN, G., p. 229.
 PERRY, I., pp. 22, 38, 202, 219, 272.
 PETERS, D. C., pp. 32, 127, 156.
 PIPER, W. J., pp. 35, 183.
 POPE, B. F., pp. 118, 121.
 PORTER, G. L., p. 145.
 PORTER, W., p. 66.
 POTTER, Z. H., p. 14.
 POWELL, R., pp. 60, 88, 99.
 PURCELL, J. B., pp. 35, 137.

 RADMORE, C. C., p. 71.
 RAMSEY, W. R., pp. 63, 182.
 RANDALL, B., p. 178.
 RAUSHENBERG, C., p. 238.
 RECTOR, P., pp. 28, 64.
 REILY, J. R., p. 204, 263.
 RENICK, W. H., p. 184.
 REYNOLDS, F., p. 222.
 RIDGELY, J., pp. 44, 46, 52, 77.
 RIPPARD, W. H., p. 96.
 ROACH, M. A., p. 54.
 ROSE, G. S., pp. 106, 137, 196.
 ROSSE, I. C., pp. 80, 129, 132, 136, 138, 165, 206, 245, 251.
 ROWE, C. H., p. 89.
 RUSSELL, L. F., p. 241.

- SANTOINE, S., p. 29.
 SAVAGE, W. E., p. 74.
 SAUNDERS, J., pp. 43, 137.
 SCHELL, H. S., pp. 28, 48, 59, 66, 78, 120, 191, 235, 238, 268.
 SCHWARTZWELDER, A. C., p. 268.
 SCOTT, J. F., p. 53.
 SEMPLE, J. E., pp. 30, 193.
 SEMIG, B., pp. 149, 156.
 SHACKLEFORD, W., pp. 53, 213.
 SCHAFFHIRT, E. F., p. 122.
 SHARPE, R., pp. 9, 35, 46, 47, 68, 78, 155.
 SHAW, J., p. 178.
 SIMONS, J., p. 114.
 SKINNER, A. G., pp. 108, 135.
 SLAUGHTER, B. F., p. 252.
 SMART, C., pp. 147, 189, 205, 252, 270.
 SMITH, A. H., p. 156.
 SMITH, A. K., p. 275.
 SMITH, H. H., p. 43.
 SMITH, H. J., p. 46.
 SMITH, J. R., p. 41, 257.
 SMITH O., p. 63.
 SMITH, W. F., pp. 7, 22, 212, 258.
 SMITH, W. H., pp. 64, 145, 181.
 SNOW, T. H., p. 156.
 SPOHN, H., p. 177.
 STEIGERS, A. F., p. 209.
 STEINMETZ, W. R., pp. 41, 74.
 STERNBERG, G. M., pp. 125, 227, 238, 244, 246, 250.
 STEVENS, D., p. 122.
 STORROW, S. A., p. 199.
 SUBRING, F., p. 47.
- TALLEN, J. E., p. 111.
 TANSZKY, R., pp. 64, 84, 85.
 TAYLOR, W. E., p. 232.
 TAYLOR, J., p. 115.
 THOMPSON, D. D., p. 88.
 THOMSON, W., p. 83.
 TIEDMAN, H. G., p. 61.
 TILTON, H. R., pp. 19, 34, 54, 75, 77, 79, 81, 85, 129, 179,
 192, 223.
- TOMKINS, W. R., p. 200.
 TOMPKINS, W. A., p. 192, 253.
 TONNER, J. A., pp. 34, 42, 46.
 TOWAR, G. W., p. 63.
 TOWN, F. L., p. 51, 254.
 TREMAINE, W. S., pp. 37, 76, 156.
 TUGGLE, T. S., p. 61.
 TURNER, H. T., pp. 156, 176, 188, 206.
- VANSANT, J., p. 111.
 VOLLUM, E. P., pp. 116, 237, 248, 255.
- WAGNER, C., p. 246.
 WALKER, D., p. 7.
 WALSH, J. K., p. 139.
 WATKINS, J. C., p. 31.
 WEBB, J. P., p. 11.
 WEEDS, J. F., pp. 26, 40, 41, 76, 100, 103, 107, 156, 159,
 174, 193, 235, 251.
 WEIRICK, S. T., pp. 57, 183.
 WEISEL, D., pp. 29, 45.
 WESTERLING, R., p. 156.
 WHITE, C. B., p. 252.
 WHITE, J. B., pp. 34, 77, 99, 104, 240.
 WHITE, R. H., pp. 12, 15, 37, 175.
 WHITEHEAD, W. E., p. 49.
 WIGGIN, A. W., pp. 33, 123, 255.
 WILLIAMS, J. W., pp. 23, 57, 59, 64, 89, 102, 192.
 WILLIAMS, F. A., pp. 52, 90.
 WILSON, A. D., pp. 159, 193.
 WILSON, B. B., p. 61.
 WILSON, W. J., pp. 36, 75, 375.
 WINNE, C. K., pp. 19, 169, 200.
 WOLVERTON, W. D., pp. 32, 91, 168, 177.
 WOODRUFF, E., p. 252.
 WOODHULL, A. A., pp. 6, 19, 84, 167.
 WOODWARD, J. J., pp., 263, 265.
 WRIGHT, C. B., p. 178.
 WRIGHT, J. P., p. 89.
- YEOMANS, H. H., pp. 8, 59, 118, 180, 269.
 YOUNG, C. W., p. 102.

INDEX OF PATIENTS.

Name.	Regiment.	Page	Name.	Regiment.	Page.	Name.	Regiment.	Page.
Abbott, W.	25th Infantry	55	Bohan, J.	4th Cavalry	63	Chase, G.	9th Col. Troops	22, 38
Adams, E.	15th Infantry	37	Boats, C.	9th Cavalry	63	Chase, D. E.	40th Infantry	38
Adams, G.	9th Cavalry	95	Bowers, W.	3d Artillery	128	Christman, W.	11th Infantry	38
Adams, G.	4th Artillery	114	Bosworth, N. C.	8th Cavalry	170	Charlton, T.	16th Infantry	118
Ahlfeld, J.	31st Infantry	36	Bowen, R.	13th Infantry	167	Chapman, W.	Gen'l service	134
Ahearn, J.	8th Cavalry	156	Bowers, B.	11th Infantry	180	Choate, J. M.	1st Cavalry	142
Ahearn, F.	General service	229	Bowen, C. M.	27th Indiana	205	Chavez, M.	Civilian	188
Allen, C.	38th Col. Troops	41	Brown, J.	8th Infantry	35	Cheeseman, F.	Civilian	206
Alfonz, P.	9th Cavalry	20	Brown, A.	2d Cavalry	18	Church, L.	116th Col. Troops	280
Alexander, W. S.	9th Infantry	30	Baron, J. J.	Civilian	38	Cheeseley, H.	114th Col. Troops	241
Allison, H.	33d Infantry	38	Brannan, J.	7th Cavalry	42	Christopher, G.	9th Cavalry	249
Allison, J. H.	21st Pa. Cavalry	280	Braman, C. B.	Act. Ass't Surg	45	Clark, J.	14th Infantry	43
Allen, C.	1st Artillery	55	Brown, T.	5th Cavalry	46	Clements, G. A. H.	44th Infantry	47
Allison, H.	16th Infantry	59	Broad, R.	2d Cavalry	48	Clarke, R.	28th Infantry	62
Alderfer, J. K.	Dis. soldier	114	Brown, M. E.	27th Infantry	60	Clapp, W. H.	6th Cavalry	69
Allen, J. I.	4th Cavalry	132	Bryant, F. W.	14th Infantry	65	Clinton, H. C.	2d Infantry	78
Alman, J.	4th Cavalry	139	Brown, A.	10th Cavalry	69	Clay, H.	16th Cavalry	85
Aldrich, G.	2d Cavalry	156	Brown, H. S.	17th Infantry	83	Clapp, G.	3d Artillery	118
Alvidrez, C.	1st New Mexico	175	Brown, E.	Civilian	95	Clifford, A.	17th Infantry	251
Allbright, G. W.	Civilian	205	Brown, S.	10th Cavalry	153	Clinton, R.	3d Cavalry	157
Aney, B.	6th Cavalry	59	Brown, P.	4th Artillery	170	Clark, A.	4th Infantry	171
Andruss, C.	3d Infantry	6	Brady, J.	3d Cavalry	170	Clements, J.	1st Infantry	253
Andrew, C.	9th Cavalry	170	Brown, S.	10th Cavalry	190	Clune, M.	35th Infantry	171
Anderson, J.	33d Infantry	252	Brunett, C.	3d Cavalry	225	Clark, C. O. F.	1st Oregon	197
Appleman, P.	23d Infantry	170	Brown, W.	20th Infantry	244	Colby, E. P.	2d Infantry	13
Arkee, J. A.	3d Cavalry	157	Bullis, G.	3d Infantry	19	Connor, J.	6th Infantry	6
Arthur	Freedman	202	Butler, J.	10th Cavalry	24	Coler, W.	9th Cavalry	18
Arnold, C.	2d Artillery	222	Buel, D. H.	Ordnance Corps	36	Cooper, J.	21st Col. Troops	57
Ash, R.	38th Infantry	55	Burke, W.	6th Cavalry	46	Cosgrove, J.	8th Infantry	58
Atley, H.	3d Cavalry	102	Burke, E.	16th Infantry	252	Connelly, J.	5th Cavalry	68
Atwood, G. T.	5th Cavalry	103	Burke, P.	17th Infantry	77	Corin, W.	38th Infantry	74
Auchenpock, M.	37th Infantry	170	Burgi, R.	4th Cavalry	82	Coleman, G.	117th Col. Troops	74
Avens, T. W.	25th Infantry	196	Burnside, J.	114th Col. Troops	83	Cole, D. D.		279
Baker, T.	24th Infantry	46	Buckskin	Gov't employe	91	Coreoran, P.	8th Cavalry	80
Bailey, S.	128th Col. Troops	61	Burtz, A.	2d Infantry	106	Conroy, J.	4th Artillery	83
Badamy, P.	25th Infantry	76	Burr, F.	3d Cavalry	157	Collins, J.	37th Infantry	83
Barry, W.	6th Cavalry	83	Butler, J.	6th Cavalry	157	Cox, G.	8th Cavalry	83
Barney, J.	6th Cavalry	89	Burnham, W.	10th Cavalry	170	Cogan, J.	2d Infantry	89
Barnitz, A.	7th Cavalry	250	Bush, H.	7th Infantry	170	Cody, J.	11th Infantry	90
Banan, J.	4th Cavalry	115	B——	23d Infantry	17	Colyer, G.	9th Cavalry	102
Banks, A.	Ordnance Corps	170	B——, J. H.	20th Infantry	115	Conway, C.	Ordnance Corps	142
Barclay, J.	Ordnance Corps	170	B——, J.	Laborer	131	Cooper, J. W.	31st Infantry	154
Barrago, J.	Civilian	190	Carr, H.	25th Infantry	25	Cooley, J.	3d Cavalry	157
Barry, D.	7th Cavalry	190	Caldwell, W.	11th Infantry	27	Cook, J.	3d Cavalry	160
Baker, J.	29th Infantry	196	Casey, T.	6th Cavalry	46	Cook, F.	2d Artillery	171
Barrett, T.	23d Infantry	222	Cappings, J.	26th Infantry	77	Collins, J.	17th Infantry	189
Batt, J. A.	2d Cavalry	268	Carrington, H. B.	18th Infantry	78	Connell, P.	20th Infantry	190
Babb, L.	5th N. Hampsh'e	280	Carnovan, T.	Civilian	78	Cockcroft, W.	199th Pa.	259
Behn, P.	34th Infantry	52	Carey, J.	10th Infantry	102	Crith, F.	38th Infantry	62, 225
Bently, W.	Civilian	62	Carroll, T.	1st Artillery	106	Cramer, M.	19th Infantry	65
Behan, P.	Civilian	116	Calquhoun, A.	5th Cavalry	109	Cross, E.	5th Artillery	118
Beam, I. V.	29th Infantry	137	Carroll, J.	12th Infantry	135	Crabtree, N.	Civilian	145
Bender, E.	3d Infantry	170	Cahil, P.	13th Infantry	171	Craig, J.	8th Cavalry	157
Berry, G.	24th Infantry	170	Carter, M.	21st Col. Troops	171	Creeden, B.	3d Cavalry	157
Berger, P.	9th Infantry	170	Campbell, G. W.	3d Cavalry	180	Crawford, G. C.	40th Infantry	176
Berger, J.	15th Infantry	175	Casey, M.	2d Artillery	181	Cummings, J. L.	1st Cavalry	13
Bell, J.	10th Cavalry	190	Cameron, J.	31st Maine	206	Curry, P.	Civilian	33
Bischoff, F.	37th Infantry	170	Castle, F.	41st Infantry	222	Curry, B.	6th Cavalry	44
Bisbing, J.	2d Cavalry	197				Curry, J.	20th Pa. Cavalry	61
Blair, W.	1st Artillery	176				Cunningham, B.	4th Cavalry	65
Bowen, J.	33d Infantry	22				Callen, M.	2d Cavalry	171
Boyd, D.	9th Cavalry	29				C——, J.	4th Cavalry	117

Name.	Regiment.	Page.	Name.	Regiment.	Page.	Name.	Regiment.	Page.
C——, J.		149	Ferns, D.	7th Infantry	193	Grey, G.	3d Cavalry	176
C——, E.	Civilian	165	Finally, J.	3d Cavalry	32	Gueree, J.	Engineer Batt'n.	32
Daniels, J.	9th Cavalry	9	Fitzpatrick, T.	18th Infantry	151	G——, R. A.		14
Daniels, O. E.		14	Fisher, T.	9th Cavalry	171	G——, T.	Teamster	20
Davidson, R.	6th Infantry	16	Fisher, J.	5th Artillery	190	G——, Isabella	Servant	265
Davis, A.	17th Infantry	52	Finn, W.	2d Cavalry	191	G——, Philip	13th Col. Troops	268
Davis, I.	9th Cavalry	53	Fitzpatrick, P.	4th Infantry	239	Harling, J.	25th Infantry	253
Davis, J.	5th Cavalry	83	Flannagan, J.	8th Infantry	16	Hacketts, E. P.	1st Infantry	253
Darragh, J.	1st Cavalry	50	Flammery, J.	2d Infantry	15	Harvey, H.	38th Infantry	27
Dardis, T.	10th Infantry	91	Flemming, C.	40th Infantry	20	Halbert, P.	2d Artillery	30
Danney, J. H.	25th Infantry	119	Flannery, M.	16th Infantry	66	Hall, C.	9th Cavalry	69
Daily, J.	3d Cavalry	157	Flynn, W.	20th Infantry	169	Hallet	Civilian	71
Daily, J.	24th Col. Cavalry	171	Fletcher, T. W.	4th Infantry	171	Hall, T.	9th Cavalry	84
Day, B.	Pawnee scout.	171	Ford, J.	45th Infantry	40	Hatch, G. W.	Act. Ass't Surg.	85
Daly, W.	20th Infantry	262	Ford, M.	19th Infantry	44	Harkey, J.	6th Cavalry	129
Daley, P.	8th Cavalry	181	Ford, A.	6th Cavalry	60	Hampton, H.	31st Infantry	134
Davis, J.	41st Infantry	242	Foster, T.	9th Cavalry	65	Hardwick, W.	14th Infantry	156
Dennis, F. A.	5th Cavalry	45	Forsyth, G. A.	9th Cavalry	80	Harr, G.	18th Infantry	157
Dennis, W.	39th Infantry	253	Foster, J.	9th Cavalry	102	Hausman, W.	20th Infantry	169
Dodman, N.	41st Infantry	69	Ford, T.	5th Cavalry	141	Hamilton, F.	9th Cavalry	171
Delaney, J.	5th Artillery	105	Ford, J.	5th Cavalry	159	Hargarty, J.		171
Detterer, E. M.	4th Infantry	155	Ford, P.	19th Infantry	182	Harmering, A.	7th Infantry	171
Devine, J.	3d Cavalry	160	Fonda, C. A.	2d Infantry	206	Hatzel, J.	8th Infantry	171
Depue, G. W.	20th Infantry	169	Freyer, H.	6th Cavalry	26	Happe, H.	2d Cavalry	182
De Forrester, G.	18th Infantry	171	Frey, G.	36th Infantry	63	Haire, J.	2d Cavalry	223
De Forrest, F.	4th Artillery	171	Francis, J.	38th Infantry	77	Hamley, J.	1st Infantry	236
Dempsy, W.	23d Infantry	171	Fry, J.	16th Infantry	99	Hastings, G.	37th Infantry	242
Desmond, H.	15th Infantry	171	Fracker, J.	3d Cavalry	111	Haxel, P.	19th Infantry	248
Dotemple	17th Infantry	171	Frank, J.	2d Infantry	139	Herron, W.	38th Infantry	39
Denney, W.	5th Artillery	181	Franklin, A.	14th Infantry	171	Herrarra	1st N. M. Inf'try.	76
Deems, G.	4th Cavalry	272	Franklin, B.	2d Minn. Cavalry	216	Herbert, H.		99
Dixon, J. C.	5th Cavalry	119	Francis, J.	3d Cavalry	220	Heyl, E.	9th Cavalry	155
Downie	8th Infantry	17	Furay, A. J.	2d Infantry	109	Hennard, J. G.	17th Infantry	171
Doleman, H.	10th Cavalry	26	Furboj, R.	98th Ohio	212	Hewes, J.	9th Col. Troops	221
Donnelly, J.	6th Cavalry	28	F——, R.	11th Infantry	10	Henrietta, F.	1st Artillery	237
Donnelly, P.	27th Infantry	32	Gamble, J.	13th West Va.	280	Hight, H.	9th Cavalry	85
Donovan, J.	18th Infantry	38	Gallagher, W. B.	6th Cavalry	39	Hier, W.	Seaman	120
Dorman, G. W.	6th Infantry	40	Gavin, T.	37th Infantry	68	Hilmer, J. F.	3d Cavalry	157
Downey, T.	7th Infantry	66	Garnet, R.	10th Cavalry	77	Hickey, J.	20th Infantry	171
Dotzel, J.	16th Infantry	48	Gardner, N.	Civilian	171	Hickey, M. C.	19th Infantry	208
Downs, J.	1st Artillery	69	Gardiner, J. A.	2d Artillery	190	Higgins, J.	20th Infantry	219
Dougherty, M.	6th Cavalry	104	Gay, T.	8th Cavalry	190	Hogan, E.	33d Infantry	9
Dow, W.	5th Infantry	149	Geddes, J.	40th Infantry	7	Howard, J.	16th Infantry	17
Dowdy, J.	42d Infantry	171	Gemigs, W.	38th Infantry	25	Houle, J.	8th Cavalry	11
Dooley, M. J.	18th Infantry	171	Gerhardt, J.	2d Infantry	55	Hood, W. J.	2d Infantry	12
Donohue, H.	5th Cavalry	254	George, L. J.	7th Cavalry	171	Hoffman, J.	6th Cavalry	43
Drum, W.	14th Infantry	148	Gibbons, W.	117th Col. Troops	39	Hobin, W.	25th Infantry	88
Dubois, J.	6th Infantry	20	Gibhart, F.	14th Infantry	41	Holden, J.	29th Infantry	196
Dunn, J.	28th Infantry	43	Gillanej, M.	23d Infantry	86	Hoffman, H.	2d Infantry	252
Dussett, O.		48	Gill, J.	19th Infantry	95	Hoffman, W. H.	5th Cavalry	109
Durant	16th Infantry	61	Gibson, E.	31st Infantry	128	Hofnar, F.	25th Infantry	132
Dunn, P.	33d Infantry	69	Gibben, J.	6th Infantry	190	Hollan, E.	23d Infantry	143
Dutton, T.	32d Infantry	149	Glascok, J.	Civilian	80	Hoffman, C.	6th Cavalry	157
Duggan, G.	8th Cavalry	151	Gleason, W.	37th Infantry	83	Holker, C.	Colored	271
Dwyer, P.	3d Infantry	84	Gleason, H.	140th New York	207	Hogan, J.	42d Infantry	171
Eagan, P.	42d Infantry	110	Goodwin, J.	7th Cavalry	27	Hoover, E.	19th Infantry	172
Earl, W.	7th Cavalry	167	Gourjan, J.	4th Cavalry	46	Howard, C.	5th Infantry	172
Eberhardt, J.	17th Infantry	86	Goldsborough, W. H.	24th Infantry	58	Houliban, T.	2d Infantry	182
Echstrand, J. H.		213	Goodpaster, L.	38th Infantry	77	Honig, C.	13th Infantry	190
Edwards, J.	10th Cavalry	227	Gordon, A.	38th Infantry	85	Hostler, W.	38th Infantry	227
Ehlman, J.	1st Artillery	214	Gohlke, W.	20th Infantry	132	Hunter, P.	8th Cavalry	57
Elliott, R.	9th Cavalry		Good, B.	9th Cavalry	171	Hubbard, T.	2d Cavalry	63
Erne, H.	4th Infantry	230	Gordon, D.	7th Cavalry	297	Huff, J.	25th Infantry	84
Eustace, P.	5th Infantry	81	Greenland, G.	5th Infantry	6	Huber, W. H.	5th Artillery	192
Farley, L.	Scouts	206	Grey, F.	41st Col. Troops	18	Hughes, L. M.	7th Infantry	120
Farrell, J.	25th Infantry	82	Gregory, A. J.	25th Infantry	20	Hurley, M.	30th Infantry	120
Fairbanks, G.	4th Artillery	119	Gray, J.	26th Infantry	34	Hubbard, E.	15th Infantry	135
Farrington, J. B.	32d Infantry	189	Graves, W.	19th Infantry	62	Huntington, H.	4th Infantry	172
Fabry, J.	4th Artillery	215	Graves, J. A.	24th Infantry	251	Hughes, W.	6th Cavalry	172
F——, W.	Civilian	239	Green, C.	7th Infantry	81	Hubbell, G. E.	4th Cavalry	177
Feaster, J.	41st Infantry	76	Greene, H.	9th Cavalry	106	Hutton, A.	1st Artillery	177
Fenske, J.	Civilian	151	Grevenberg, A.	39th Infantry	120	Hynds, J.	17th V. R. C.	44
Fee, W.	Civilian	157	Greiter, W.	5th Infantry	176	H——	Citizen	258

Name.	Regiment.	Page.	Name.	Regiment.	Page.	Name.	Regiment.	Page.
H —	General	262	Krouse, C.	32d Infantry	222	McCarthy, D.	24th Infantry	47
Ichawgaw	Indian Scout	172	K——, T.	3d Infantry	37	McDougall, J.	4th Cavalry	54
Imbler, W.	31st Infantry	144	K——, J.	2d Cavalry	274	McCulla, W.	1st Cavalry	60
Irving, W.	9th Cavalry	69	Larssen, O.	35th Infantry	12	McWilliams, J.	14th Infantry	82
Isaacs, D.	10th Infantry	110	Lavelle, W.	7th Infantry	66	McMahon, M.	1st Cavalry	83
Jackson, W.	39th Infantry	253	Lambert, A.	6th Cavalry	69	McManus	20th Infantry	90
James, H.	22d Infantry	38	Lather, J.	117th Col. Troops	69	McClinchey, J. W.	17th Infantry	90
Jamison, E.	11th Infantry	134	Lawrence, M.	20th Infantry	122	McClinty, H.	45th Infantry	100
Janke, W.	9th Infantry	137	Lasby, J.	23d Infantry	243	McCafferty, N. J.	4th Cavalry	102 104
Jarvis, G.	45th Infantry	174	Lee, T.	9th Cavalry	25	McCann, T.	42d Infantry	135
Jackson, W.	16th Infantry	183	Lee, J.	8th Cavalry	249	McCasey, B.	7th Cavalry	151
Jackson, N. B.	Civilian	191	Leach, W.	4th Cavalry	29	McCombs, C.	20th Infantry	169
Jenkins, R.	82d Col. Troops	6	Lehmann, C.	35th Infantry	29	McAllister, A.	17th Infantry	172
Jefferson, H.	19th Col. Troops	71	Leonard, J. F.	6th Cavalry	39	McCaffrey, F.	7th Infantry	172
Jennings, P.	6th Infantry	89	Leete, W. F.	6th Cavalry	66	McGrum, D. A.	24th Infantry	269
Jess, W.	7th Cavalry	238	Lewis, J. H.	40th Infantry	85	McCormick, M.	34th Infantry	275
Jeffcott, J.	9th Infantry	245	Lewis, A.	40th Infantry	104	McT——, H.	Citizen	256
Jefferson, H.	19th Col. Troops	272	Lee, J.	3d Cavalry	160	McCuller, J.	4th Cavalry	172
Johnston, W.	7th Cavalry	8	Leopold, E.	26th Infantry	172	McDonald, M.	23d Infantry	172
Johnson, J. J.	4th Infantry	30	Lewis, G. W.	20th Infantry	172	McPeake, M.	15th Infantry	172
Jones, W. L.	35th Infantry	47	Leadtham, C.	1st Infantry	223	McDermith, W.	Civilian	184
Johnson, J.	23d Infantry	53	Leonard, C. E.	7th Infantry	178	McIntyre, P.	23d Infantry	184
Jones, D. W.	16th Infantry	57	Linnahan, W.	7th Infantry	45	McDonald, J.	23d Infantry	191
Joseph W.	8th Cavalry	64	Lindsey, T.	69th Pa.	259	McKee, A.	33d Infantry	191
Jones, E.	36th Infantry	64	Lillimore	Indian Chief	260	McKeever, J.	27th Infantry	210
Jones, B.	10th Cavalry	69	Likarte, A.	2d Cavalry	66	McM——, J.	43d Infantry	210
Johnson, H.	9th Cavalry	76	Lightner, F.	65th Col. Troops	122	McCarthy, E.	5th Infantry	223
Johnson, L.	Colored	252	Livingston, W.	3d Cavalry	152	McMahon, J.	8th Infantry	226
Johnston, J.	15th Infantry	267	Lilly, J.	9th Cavalry	172	McBride, W.	12th Infantry	237
Jones, J.	24th Infantry	90	Linton, D.	7th Cavalry	184	McMahon, P.	11th Infantry	247
Joyce, J.	5th Cavalry	98	Logan, T.	10th Cavalry	18	McNalley, J.	22d Infantry	252
Johnson, T. M.	3d Artillery	121	Logan, T.	10th Infantry	36	Merryweather, A.	9th Cavalry	45
John		121	Lowry, N.	16th Infantry	15	Meyer, F.	14th Infantry	56
Johnson, G.	40th Infantry	136	Louiston, G.	6th Cavalry	39	Merchant, J.	16th Infantry	93
Johnson, G.	8th Cavalry	157	Logan, E.	9th Infantry	90	Metcalf, L.	5th Infantry	107
Johnson, D.	24th Infantry	177	Locke, J.	38th Infantry	141	Mechem, A. F.	Surgeon U. S. A.	112
Jones, C. D.	8th Infantry	177	Lockwood, G. M.	Civilian	153	Melitz, R.	1st Cavalry	192
Jones, W.	20th Infantry	183	Long, W. H.	3d Cavalry	191	Mellan, H. B.	6th Cavalry	194
Johnson, J.	Civilian	208	Lorenzel, C.	84th Indiana	209	Mentieres, A.	Civilian	214
Jones, J. M.	21st Indiana	209	Luther, M.	1st Cavalry	227	Miller, J.	6th Cavalry	10
Jordan, P.	16th Infantry	236	Ludlow, J. R.	Eng. Battalion	29	Miller, L.	23d Infantry	39
Johnson, W. A.	8th Infantry	240	L——, C.	7th Cavalry	157	Miller, E.	10th Cavalry	39
Jones, D.	4th Infantry	241	Maitton, L.	Pensioner	122	Minnigan, C. C.	41st Infantry	67
Johnson, L.	38th Infantry	244	Maybee, J.	128th Col. Troops	20	Mitchell, J.	13th Infantry	69
Judd, J. L.	18th Infantry	178	Marks, J.	40th Cavalry	21	Michael, C.	38th Infantry	83
J——, E.	5th Infantry	129	Marshall, A.	1st Artillery	31	Milane, D. G.	14th Infantry	104
Kaufman, D.	7th Cavalry	15	Mathews, J.	9th Cavalry	35	Miller, C.	27th Infantry	123
Kay, A.	39th Infantry	99	Mason, G. F.	9th Cavalry	43	Miller, J.	2d Cavalry	158
Kane, T.	13th Infantry	169	Martin, S. G.	5th Cavalry	35	Miller, W.	154th Infantry	172
Kerne, G.	21st Infantry	13	Marrison, T.	14th Mo. Cav.	44	Miner, H.	17th Infantry	172
Kelly, J.	8th Cavalry	31	Mann, J.	16th Infantry	47	Mitchel, G.	10th Cavalry	172
Kelly —	U. S. Engineers	278	Mannard.	3d Cavalry	84	Mitchell, C.	4th Cavalry	223
Keilly, M.	Ordnance Corps	263	May, C.	9th Infantry	101	Morris, R.	2d Infantry	7
Kellner, F.	19th Infantry	34	Manahan, W.	2d Infantry	108	Morris, H.	Colored	258
Keiley, M. W.	6th Cavalry	37	Materne, R.	3d Cavalry	123	Morgan, W.	9th Infantry	16
Kennedy, A.	7th Cavalry	38	Mack, Big	6th Infantry	134	Morrissey, J.	34th Infantry	21
Keller, J. W.	4th Infantry	72	Malone, E.	Scout	157	Morgan, J. D.	23d Infantry	48
Kennedy, C.	1st Artillery	76	March, T. J.	8th Cavalry	158	Morris, C.	2d Infantry	48
Kelly, T.	5th Cavalry	81	Marshall, J.	7th Cavalry	158	Monaghan, H.	8th Infantry	57
Kelly, B.	1st Infantry	91	Mathias, J. G.	3d Cavalry	158	Moulton, M.	8th Cavalry	58
Kelly, J.	Hosp'l Steward	110	Martin, J.	4th Artillery	172	Montague, J.	Civilian	58
Kelly, J.	5th Cavalry	131	Magenthaler	7th Cavalry	210	Moore, A. C.	14th Infantry	62
Kerr, W.	3d Cavalry	160	Mannell, W.	1st Artillery	245	Morris, M.	38th Infantry	69
Keller, N.	14th Infantry	172	Mason, E. T.	1st Infantry	253	Moller, W.	8th Infantry	101
Kennicott, R.	19th Infantry	183	McKinney, G.	198th Pa.	261	Morton, F.	14th Infantry	103
Keegan, J.	1st Cavalry	191	McDowell, D.	6th Cavalry	16	Morgan, T.	42d Infantry	108
Kimball, J.	35th Infantry	9	McWilliams, D.	38th Infantry	27	Mooney, M.	28th Infantry	111
King, T.	3d Infantry		McCoy, T.	6th Infantry	37	Monaghan, E.	31st Infantry	155
Kinten, R.	Civilian	157	McDonough, J.	3d Cavalry	40	Morgan, H.	7th Cavalry	158
Kinnear, R.	21st Infantry	209	McLaughlin, W.	6th Cavalry	12	Morrell, C.	3d Cavalry	158
Kline, J.	11th Infantry	255	McCabe, P.	5th Cavalry	29	Morrison, D.	7th Cavalry	158
Knowles	31st Infantry	32	McCullough, W. W.	1st Infantry	32	Montgomery, J.	10th Cavalry	172
Kold, J. W.	15th Infantry	172	McLean, A.	1st Cavalry	39	Moore, J. A.	8th Cavalry	172
Krumholz, J.	22d Infantry	146		33d Infantry	39			

INDEX OF PATIENTS.

293

Name.	Regiment.	Page.	Name.	Regiment.	Page.	Name.	Regiment.	Page.
Moore, W.	41st Infantry	172	Pare, W.	57th Infantry	178	Sachse, F.	17th Infantry	235
Morris, P.	2d Artillery	172	Parker, J.	28th Infantry	185	Schwindig, F.	6th Cavalry	20
Mowry, C.	20th Infantry	172	Paulson.	Civilian	246	Scott, George	3d Artillery	138
Montiel, S.	Mexican	211	Page	Civilian	Schonard, G.	Det. Artillery	173
Morgan, W. B.	Civilian	211	Peterson, C. H.	40th Infantry	65	Schuback, J.	22d Infantry	187
Murphy, D.	11th Infantry	33	Perkins, B.	22d Infantry	67	Scrogg, J.	Civilian	200
Murray, C.	9th Cavalry	46	Pender, P.	23d Infantry	89	Scott, C. B.	Seaman	232
Murphy, J.	6th Cavalry	50	Peak, I.	38th Infantry	173	Seachrist, C.	37th Infantry	20
Murphy, J.	5th Cavalry	67	Peterman, A.	18th Infantry	173	Seeberger, A.	3d Cavalry	45
Mullins, J.	4th Cavalry	75	Perigo, D.	13th Infantry	200	Seyforth, H. W.	8th Infantry	57
Murray, T.	7th Cavalry	79	Pearce, H.	Assist't Surgeon 150th N. Y.	211	Seis, J.	1st N. M.	179
Mueller, G.	19th Infantry	97	Phelan, J.	13th Infantry	51	Shaw, R.	3d Artillery	12
Murray, J.	3d Infantry	156	Phillips, J.	9th Cavalry	74	Shields, J.	10th Cavalry	76
Murphy, J.	7th Cavalry	158	Phenix, J.	2d Cavalry	191	Shaw, J.	3d Cavalry	82
Murray, C.	10th Cavalry	158	Pinal, L.	1st Artillery	23	Shields, J.	3d Infantry	124
Murphy, D.	31st Infantry	172	Pilot, J.	9th Cavalry	60	Sheehy, E.	5th Artillery	129
Murphy, M.	14th Infantry	191	Platt, P.	37th Infantry	173	Shulder, E.	125
Mussell, A.	8th Cavalry	246	Pochet, N.	9th Cavalry	29	Sheppard, T.	10th Cavalry	158
Myers, J.	3d Cavalry	83	Pomfort, N.	5th Cavalry	137	Shelton, J. W.	6th Cavalry	173
Myers, J.	43d Infantry	172	Post, P.	45th Infantry	173	Shultz, R.	43d Infantry	175
M——, C. E.	16th Infantry	19	Priest, "Little"	Omaha Scouts	46	Shields, J.	6th Cavalry	188
Nabrow, D.	39th Infantry	10	Pumphrey, T.	6th Cavalry	137	Shanley, B.	1st Artillery	191
Naylor, J.	9th Cavalry	26	Pye, R.	4th Cavalry	128	Shears, E.	20th Infantry	200
Navio, T.	18th Infantry	85	P——, F.	24th Infantry	8	Shire, L.	3d Cavalry	204
Navarra, E.	19th Infantry	104	P——, W. L.	5th Cavalry	200	Shaw, J.	3d Cavalry	228
Navity, J.	Civilian	224	Queswelle, C.	13th Infantry	145	Sheridan, P.	36th Infantry	245
Newell, A.	114th Col. Troops	39	Quigley, T.	17th Infantry	243	Simmons, J.	128th Col. Troops	28
Neff, W.	9th Cavalry	85	Quimby, J.	9th Cavalry	226	Simpson, E.	40th Infantry	74
Nepomoceno, B.	Mexican	224	Quinan, J.	Cav. Detachm't.	237	Singleton, F.	20th Infantry	99
Nenn, J.	3d Cavalry	242	Quill, T.	13th Infantry	254	Silence, G.	3d Cavalry	158
Nixon, J.	5th Cavalry	23	Quohn, P.	Policeman	255	Simmons, D.	2d Cavalry	173
Nix, R.	14th Infantry	145	Rader, L.	7th Cavalry	173	Silverhorn, F.	8th Cavalry	201
Nice, C.	9th Cavalry	173	Randolph, G. C.	9th Infantry	173	Skillin, J. T.	Ordnance Corps	226
Nims, H. G.	Add'l Paymaster	193	Ramires, D.	1st N. M. Cavalry	185	Skelan, J.	11th Infantry	251
Nipple, T.	3d Cavalry	202	Randall, E.	Trapper	186	Sledge, R.	38th Infantry	41
Nolan, T.	37th Infantry	59	Ramey, A.	Civilian	212	Smith, F. W.	9th Cavalry	9
Nolan, E.	5th Cavalry	59	Ray, C. P.	16th Infantry	237	Smith, J.	38th Infantry	23
Noyes, H.	1st Artillery	137	Regan, M.	15th Infantry	9	Smith, F.	9th Cavalry	64
Nohrton, J.	Scout	191	Reed, B.	128th Col. Troops	67	Smith, E.	7th Infantry	70
Nugent, H.	5th Cavalry	270	Reese, P.	4th Cavalry	68	Smith, W. S.	6th Cavalry	73
O'Brien, J.	16th Infantry	16	Reinhold, M.	17th Infantry	69	Smith, J.	19th Infantry	75
O'Brien, M.	7th Cavalry	19	Reynolds, J.	3d Artillery	132	Smith, A.	23d Infantry	83
O'Brien, L.	Hosp'l Steward	36	Reip, F.	7th Cavalry	192	Smith, G.	6th Cavalry	84
O'Brien, J.	28th Infantry	59	Realey, R.	Civilian	204	Smith, R.	10th Cavalry	84
O'Brien, T.	6th Cavalry	158	Reed, C.	4th Infantry	238	Smith, G.	Recruit	91
O'Brien, L.	U. S. A.	185	Reed, C. F.	37th Infantry	228	Smith, J. B.	25th Infantry	97
Oberfield, A.	3d Artillery	173	Rhey, C.	31st Infantry	179	Smith, P. D.	18th Infantry	146
O'Callaghan, M.	6th Cavalry	42	Rice, J.	39th Infantry	253	Smith, J.	20th Infantry	169
O'Connor, D.	6th Cavalry	52	Richards, M. E.	14	Smith, C.	27th Infantry	173
O'Connor, T.	1st Artillery	178	Riley, T.	25th Infantry	50	Smith, C.	31st Infantry	173
O'Connor, J.	2d Infantry	191	Ridley, S.	9th Cavalry	102	Smith, J.	3d Infantry	173
O'Callaghan, P.	13th Infantry	248	Riley, J.	19th Infantry	103	Smith, A.	26th Infantry	201
Oliver, W. R.	14th Infantry	26	Rigby, F.	1st Cavalry	158	Smith, J. E.	Ordnance Corps	254
Oliver, E.	27th Infantry	64	Richards, W.	9th Cavalry	173	Smith, J.	8th Cavalry	224
Oliver, W. R.	14th Infantry	76	Rivers, C.	20th Infantry	235	Smith, G. W.	27th Infantry	222
O'Neil, H.	6th Cavalry	16	Robinson, G.	40th Infantry	22	Snowden, A.	14th Infantry	147
O'Neal, W.	5th Cavalry	85	Rodgers, W.	16th Infantry	39	Southwood, J.	40th Infantry	65
O'Neil, J.	2d Infantry	88	Rogers, G.	16th Infantry	251	Soleven, T.	19th Infantry	251
Osborne, J.	24th Infantry	11	Ross, F.	9th Cavalry	67	Soohen, J.	13th Infantry	73
Osborne, C.	1st Cal. Vet. Vols.	75	Robbins, S. D.	23d Infantry	123	Soldado, J.	Mexican	219
Osborne, G.	2d Neb. Cavalry	145	Rosback, W.	6th Cavalry	149	Spencer, H.	80th Col. Troops	25
O'Shaughnessy, T.	15th Infantry	54	Roberts, T.	22d Infantry	173	Spencer, I.	117th Col. Troops	262
Overton, G.	10th Cavalry	67	Rose, H.	35th Infantry	173	Springer, D. K.	4th Veteran Vol.	105
Owine	Indian Scout	158	Robinson, W.	3d Cavalry	165	Spillman, J.	7th Cavalry	146
Owens, J. W.	20th Infantry	168	Russell, W.	4th Cavalry	51	Spyri, J.	2d Cavalry	201
O——, C.	3d Artillery	273	Ruff, M.	35th Infantry	173	Stainbrook, J.	19th Kansas	54
Payne, J. A.	3d Cavalry	39	Ryan, D.	8th Infantry	59	Stone, W. R.	4th Cavalry	12
Patterson, J. B.	7th Cavalry	34	Ryan, J.	23d Infantry	60	Stewart, T.	14th Infantry	26
Paine, I.	24th Infantry	84	Ryan, M.	45th Infantry	107	Stern, G.	38th Infantry	29
Patterson, W.	20th Infantry	101	Ryan, J.	6th Cavalry	168	Stuvan, E.	4th Cavalry	43
Pa-yan-za.	Indian Scout	157	Ryan, W.	7th Infantry	173	Stewart, F.	38th Infantry	26
Paris, J.	36th Col. Troops	173	Ryan, T.	5th Cavalry	212	Stanton, C.	10th Cavalry	68
Parks, W.	9th Cavalry	173						
Patterson, A.	23d Infantry	173						

INDEX OF PATIENTS.

Name.	Regiment.	Page.	Name.	Regiment.	Page.	Name.	Regiment.	Page.
Stevenson, J.	10th Cavalry	69	Unknown		96	Whalen, P.	3d Infantry	179
Stuart, R.	6th Cavalry	69	Unknown		98	White, D.	41st Infantry	188
Stables, A. H.	18th Infantry	151	Unknown		98	White, W.	114th Col. Troops.	202
Stall, F.	3d Cavalry	159	Unknown	45th Infantry	107	White, J.	42d Infantry	255
Stockford, H.	31st Infantry	159	U	U. S. Mil. Acad'y	126	Whipper, T. H.	24th Infantry	221
Stone, C. A. C.	5th Cavalry	159	Unknown		127	Wicks, C.	26th Infantry	17
Stack, J.	29th Infantry	169	Unknown	Female child	136	Wilson, D.	U. S. Infantry	15
Stargratt, J.	7th Cavalry	173	Unknown	Mexican	138	Wilmare, S.	116th Col. Troops.	39
Stowers, I. F.	11th Infantry	173	Unknown	5th Infantry	141	Winterbottom, W.	6th Cavalry	39
Stanridge, J.	16th Infantry	238	Unknown	Mexican	148	Wilmare, S.	116th Col. Troops.	57
Stone, P.	3d Cavalry	243	Unknown		153	Wilson, J.	10th Cavalry	69
Sumners, H.	29th Infantry	35	Unknown	Mex'n herdsman	156	Williams	24th Infantry	78
Sumner, J.	1st Cavalry	61	Unknown	3d Cavalry	159	Willis, C.	3d Cavalry	79
Sullivan, D.	45th Infantry	105	Unknown	13th Infantry	164	Wilson, C.	11th Infantry	271
Summer, E. V.	1st Cavalry	173	Unknown Indian		188	Wilmot, J.	5th Cavalry	85
Sullivan, A.	Freedman	240	Unknown			Wilson, William	18th Infantry	85
Swords, E.	3d Cavalry	16	Vandel, P.	3d Infantry	193	Williams, G.	12th Infantry	100
Sweet, W. E.	24th Infantry	136	Van Doesburgh, H.	Ordnance Corps.	174	Williams, I.	3d Col. H. Art.	111
Sweeney, T.	29th Infantry	196	Vane, J. T.	22d Infantry	35	Williams, C.	5th Cavalry	127
S—, W.	37th Infantry	125	Vetzstine, M.	18th Infantry	59	Wimsett, H.	4th Artillery	129
Talbot, J. T.	25th Infantry	252	Villhouer, C.	13th Infantry	174	Wilson, J.	Seaman	138
Tasker, A.	10th Cavalry	68	V—, F. H.	Civilian	49	Wilson, L.	4th Cavalry	138
Tasker, L.	10th Cavalry	68	Vogler, R.	27th Infantry	254	Wiley, J.	7th Cavalry	174
Taylor, H. E.	24th Infantry	74	Waffler, L.	18th Col. Troops.	56	Williams, J.	2d Cavalry	174
Taylor, I.	24 Infantry	252	Wagoner, S.	6th Cavalry	60	Williams, R.	9th Cavalry	174
Taylor, J. A.	13th Infantry	174	Warner, A.	38th Infantry	75	Willis, J. H.	45th Infantry	174
Terry, A.	38th Infantry	189	Wallace, W.	31st Infantry	262	Wilson, C. H.	7th Cavalry	174
Thompson, J. A.	7th Cavalry	23	Waterfield, E.	5th Infantry	269	Wilson, G.	4th Infantry	174
Thompson, C. E.	3d Cavalry	32	Ward, H.	18th Infantry	275	Wisewell, A. L.	23d Infantry	174
Thompson, G.	10th Cavalry	68	Walcott, D. W.	1st Cavalry	77	Williams, G.	2d Infantry	166
Thompson, W.	9th Cavalry	69	Waltsh, J.	23d Infantry	99	Wilks, A.	10th Cavalry	179
Thomas, J.	10th Cavalry	73	Wagerle, W.	3d Cavalry	159	Williams, H.	9th Cavalry	179
Thompson, E.	84th Col. Troops.	96	Watson, E.	25th Infantry	174	Winkleman, L.	7th Cavalry	192
Thomas, W.	9th Cavalry	253	Watson, E. M.	2d Cavalry	174	Wilkinson, T.	3d Artillery	202
Thomas, J. W.	2d Artillery	111	Watson, G.	10th Cavalry	174	Wilson, W.	Civilian	202
Thomas, J. K.	2d Cavalry	201	Washington, G.	9th Cavalry	188	Wolf, G.	18th Infantry	28
Tindolph, J.	1st Artillery	42	Washington, J.	Civilian	212	Wolf, A.	2d Cavalry	174
Tocker, F.	6th Cavalry	7	Walker, S.	3d Infantry	221	Wright, J. A.	7th Cavalry	21
Tolliver, J.	24th Infantry	41	Wall, J.	Teamster	235	Wright, S.	13th Infantry	133
Toober, T.	42d Infantry	73	Welch, J.	3d Cavalry	8	W—, P.	2d Cavalry	54
Tobin, J.	19th Infantry	100	Weaver, W.	9th Cavalry	12	W—, M.	4th Cavalry	150
To-kah-k-ten	Indian Scout	154	Weiss, G.	11th Infantry	13	W—, E.	5th Infantry	213
Tompkins, J. F.	32d Infantry	156	Weider, F.	16th Infantry	39	W—, E.	Civilian	276
Tolliver, B.	7th Cavalry	174	Webb, J.	1st Cal. Cavalry	39	X.	1st Oreg. Cavalry	7
Toole, P.	2d Cavalry	235	Welsh, M.	6th Cavalry	69	Yeaton, F.	3d Cavalry	25
Tracey, J.	16th Infantry	64	Welber, A.	3d Infantry	75	Young, G. W.	9th Cavalry	20, 84
Trowell, T.	128th Col. Troops	64	Welsh, J.	23d Infantry	82	Young, D. M.	23d Infantry	213
Train, E. L.	2d Cavalry	153	Wells, E. H.	34th Infantry	127	Young, D.	10th Cavalry	246
Tragesor, C.	8th Cavalry	154	Welsh, A.	13th Infantry	133	Youngman, A.	23d Infantry	237
Turner, J.	9th Cavalry	84	Weber, A.	29th Infantry	174	Zeichler, C.	18th Infantry	276
Turner, W. H.	6th N.Y. Battery	278	Welch, M.	4th Cavalry	174	Zepp, A.	21st Infantry	100
Turner, T.	4th Cavalry	164	White, L.	9th Cavalry	159	Zearambc, J.	24th Infantry	180
Turner, T.	9th Cavalry	174	White, E.	3d Cavalry	160	Zimmer, E.	37th Infantry	49
Tynes, W.	16th Infantry	91	Wheeler, T. J.	4th Infantry	174	Zuch, M.	31st Infantry	159
T—Louis	40th Infantry	34	White, A.	9th Cavalry	174			
Unknown		56	Whitman, D.	17th Infantry	174			

TABLE OF CONTENTS.

	Page.
Circular No. 3, Surgeon General's Office, 1871	3
Preliminary observations	5
Gunshot wounds of the head	6
Gunshot wounds of the face	16
Gunshot wounds of the neck	20
Gunshot wounds of the chest	25
Gunshot wounds of the chest involving spine	36
Gunshot wounds of the abdomen	39
Gunshot wounds involving thorax and abdomen	40
Gunshot wounds of the stomach	42
Gunshot wounds of the small intestine	42
Gunshot flesh-wounds of the abdomen	46
Gunshot wounds of the large intestine	48
Gunshot wounds of the liver, spleen, and gall-bladder	49
Gunshot wounds of the pelvis	53
Gunshot wounds of the genito-urinary organs	56
Gunshot wounds of the trunk	57
Gunshot wounds of the upper extremities	58
Gunshot wounds of the arm	61
Gunshot wounds of the elbow	62
Gunshot wounds of the fore-arm	63
Gunshot wounds of the hand	65
Gunshot flesh-wounds of the upper extremities	68
Gunshot wounds of the lower extremities	70
Gunshot flesh-wounds of the lower extremities	74
Gunshot wounds of the knee-joint	79
Gunshot wounds of the leg	80
Gunshot wounds of the foot	84
Analytical review of cases of gunshot wounds	86
Incised and punctured wounds and contusions	88
Punctured wounds	99
Lacerated and contused wounds	103
Concussion and compression of the brain	110
Simple and compound fractures and luxations	114
Fractures of the skull	114
Fractures of the bones of the face	128
Fractures of the vertebræ	129
Fractures of the bones of the trunk	131
Fractures of the upper extremities	132
Fractures of the humerus	133
Fractures of the radius and ulna	134
Fractures of the lower extremities	135
Fractures of the patella	136

	Page.
Fractures of the leg.....	137
Dislocations.....	139
Dislocations at the clavicle.....	140
Dislocations at the shoulder-joint.....	141
Dislocations at the elbow-joint.....	141
Dislocations at the wrist-joint.....	142
Dislocations at the hip-joint.....	142
Arrow wounds.....	144
Arrow wounds of the head and neck.....	146
Arrow wounds of the chest.....	151
Arrow wounds of the abdomen.....	153
Poisoned wounds.....	164
Burns, scalds, and frost-bites.....	167
Amputations in the upper extremities.....	170
Amputations in the lower extremities.....	190
Excisions.....	219
Ligations.....	235
Various operations.....	244
Operations on the eye, ear, and mouth.....	245
Operations on the chest.....	249
Operations on the abdomen.....	250
Operations on the genito-urinary organs.....	252
Cases of lithotomy.....	256
Removal of tumors.....	262
McGill on osteoplastic amputations.....	277
Concluding observations.....	282
Index of reporters.....	287
Index of patients.....	290



