

**A course of operative surgery / with plates drawn from nature by M. Léveillé and coloured by hand under his direction ; by Christopher Heath.**

**Contributors**

Heath, Christopher, 1835-1905.

**Publication/Creation**

London : J. & A. Churchill, 1877.

**Persistent URL**

<https://wellcomecollection.org/works/pudtwxgz>

**License and attribution**

This work has been identified as being free of known restrictions under copyright law, including all related and neighbouring rights and is being made available under the Creative Commons, Public Domain Mark.

You can copy, modify, distribute and perform the work, even for commercial purposes, without asking permission.



Wellcome Collection  
183 Euston Road  
London NW1 2BE UK  
T +44 (0)20 7611 8722  
E [library@wellcomecollection.org](mailto:library@wellcomecollection.org)  
<https://wellcomecollection.org>







Presented by the Council  
OF  
King's College, London  
TO

Bertram Herbert Stevens

as a Prize for Obstetric Medicine  
and diseases of Women & Children

Medical Department

Summer Session 1881

Tanner Prize

King's Collection.



Sl/6 6/5 207

**KING'S**  
*College*  
**LONDON**

---

KCSMD POL. 0030 MRA

*Library*

HEATH, CHRISTOPHER  
A COURSE OF OPERATIVE  
SURGERY  
1877



Digitized by the Internet Archive  
in 2015

<https://archive.org/details/b21302935>







A COURSE OF  
OPERATIVE SURGERY

WITH

Plates Drawn from Nature by M. Lebeillé

*AND COLOURED BY HAND UNDER HIS DIRECTION*

BY

CHRISTOPHER HEATH, F.R.C.S.

SURGEON TO UNIVERSITY COLLEGE HOSPITAL, AND HOLME PROFESSOR OF CLINICAL SURGERY  
IN UNIVERSITY COLLEGE, CONSULTING SURGEON TO THE DENTAL HOSPITAL OF LONDON,  
HONORARY FELLOW OF KING'S COLLEGE



LONDON

J. & A. CHURCHILL, NEW BURLINGTON STREET

—  
1877



5201

CSMD



16660(K)

71.172

Donation

King's Collection.



## PREFACE.

---

HAVING ceased to teach surgical operations on the dead subject, I have in this "Course of Operative Surgery" embodied the experience gained during twenty years of such teaching, combined with some considerable practice in operating upon the living body. The work makes no pretension to be a "System of Surgery," or an exhaustive treatise on the subject of "Operative Surgery," but comprises all the operations which may be conveniently practised on the subject, and will be required in ordinary surgical practice. I have selected for illustration and description those methods which have appeared to me to give the best results in practice, without, however, ignoring entirely those which may be preferred by other surgeons, and have indicated my preferences and the reasons for them, which must be taken *quantum valeant*. In describing the operations, I have also mentioned the errors most likely to occur in their performance, and the best methods of avoiding them.

Not possessing the skilful pencil of Sir Charles Bell, whose "Great Operations of Surgery" show the artist no less than the surgeon, I consider myself fortunate in having secured the co-operation of M. J. B. Lévillé, the well-known anatomical artist of Paris, who has faithfully represented the operations performed by myself on the dead body.

In the case of the arteries, the first incisions were drawn one-third, and the deeper dissection of each vessel one-half the natural size. The *same* limb was then dissected by myself, and the exact anatomy delineated. The student will thus have brought before him the parts involved in the operations and their surroundings with an accuracy which will, it is hoped, prove serviceable. The descriptions of the operations have been made as brief as was compatible with the object of the work, viz., to furnish a reliable guide to the student when practising, and to the surgeon when about to undertake important operations.

CHRISTOPHER HEATH.

36, CAVENDISH SQUARE,

June, 1877.



# CONTENTS.

---

## PLATE I.

	PAGE
OPERATIONS ON THE LACHRYMAL APPARATUS, STRABISMUS, EXTRACTION OF LENS, AND EXTIRPATION OF GLOBE . . . . .	1

## PLATE II.

LIGATURE OF RADIAL AND ULNAR ARTERIES, AND OF THE BRACHIAL AT THE ELBOW; ANATOMY OF FORE-ARM AND HAND . . . . .	9
--	---

## PLATE III.

LIGATURE OF BRACHIAL AND AXILLARY ARTERIES; ANATOMY OF UPPER ARM. . . . .	17
---	----

## PLATE IV.

LIGATURE OF AXILLARY AND SUBCLAVIAN ARTERIES; AMPUTATION OF BREAST; ANATOMY OF AXILLA AND SHOULDER . . . . .	21
---	----

## PLATE V.

LIGATURE OF CAROTID, INNOMINATE, LINGUAL AND FACIAL ARTERIES; ANATOMY OF SIDE OF NECK . . . . .	27
--	----

## PLATE VI.

LIGATURE OF ILLIAC AND COMMON FEMORAL ARTERIES; HERNIA; ANATOMY OF ILLIAC ARTERIES AND HERNIA . . . . .	33
--	----

## PLATE VII.

LIGATURE OF FEMORAL AND POPLITEAL ARTERIES; ANATOMY OF THIGH . . . . .	39
--	----

## PLATE VIII.

LIGATURE OF POSTERIOR TIBIAL ARTERY; TENOTOMY; ANATOMY OF BACK OF LEG AND ANKLE . . . . .	43
--	----

PLATE IX.		PAGE
LIGATURE OF ANTERIOR TIBIAL ARTERY; ANATOMY OF FRONT OF LEG . . . . .		47
PLATE X.		
LARYNGOTOMY, TRACHEOTOMY, REMOVAL OF TONGUE; ANATOMY OF FRONT OF NECK . . . . .		51
PLATE XI.		
REMOVAL OF JAWS; TREPHINING . . . . .		57
PLATE XII.		
LITHOTOMY AND COLOTOMY . . . . .		65
PLATE XIII.		
LITHOTRITY; CIRCUMCISION; AMPUTATION OF PENIS; CASTRATION . . . . .		73
PLATE XIV.		
AMPUTATION OF FINGERS, THUMB AND HAND, AND EXCISION OF WRIST . . . . .		79
PLATE XV.		
EXCISION OF ELBOW; AMPUTATIONS OF FORE-ARM AND UPPER-ARM . . . . .		93
PLATE XVI.		
EXCISION OF HEAD OF HUMERUS; AMPUTATION AT THE SHOULDER-JOINT. . . . .		101
PLATE XVII.		
AMPUTATIONS OF TOES AND FOOT . . . . .		105
PLATE XVIII.		
EXCISIONS OF ANKLE AND KNEE; AMPUTATIONS AT AND ABOVE THE ANKLE . . . . .		111
PLATE XIX.		
AMPUTATIONS OF LEG, KNEE, AND THIGH . . . . .		119
PLATE XX.		
EXCISION OF HEAD OF THIGH-BONE; AMPUTATION AT THE HIP-JOINT . . . . .		125





Fig 2

Fig 1

Fig 3

Fig 6

Fig 5

Fig 4

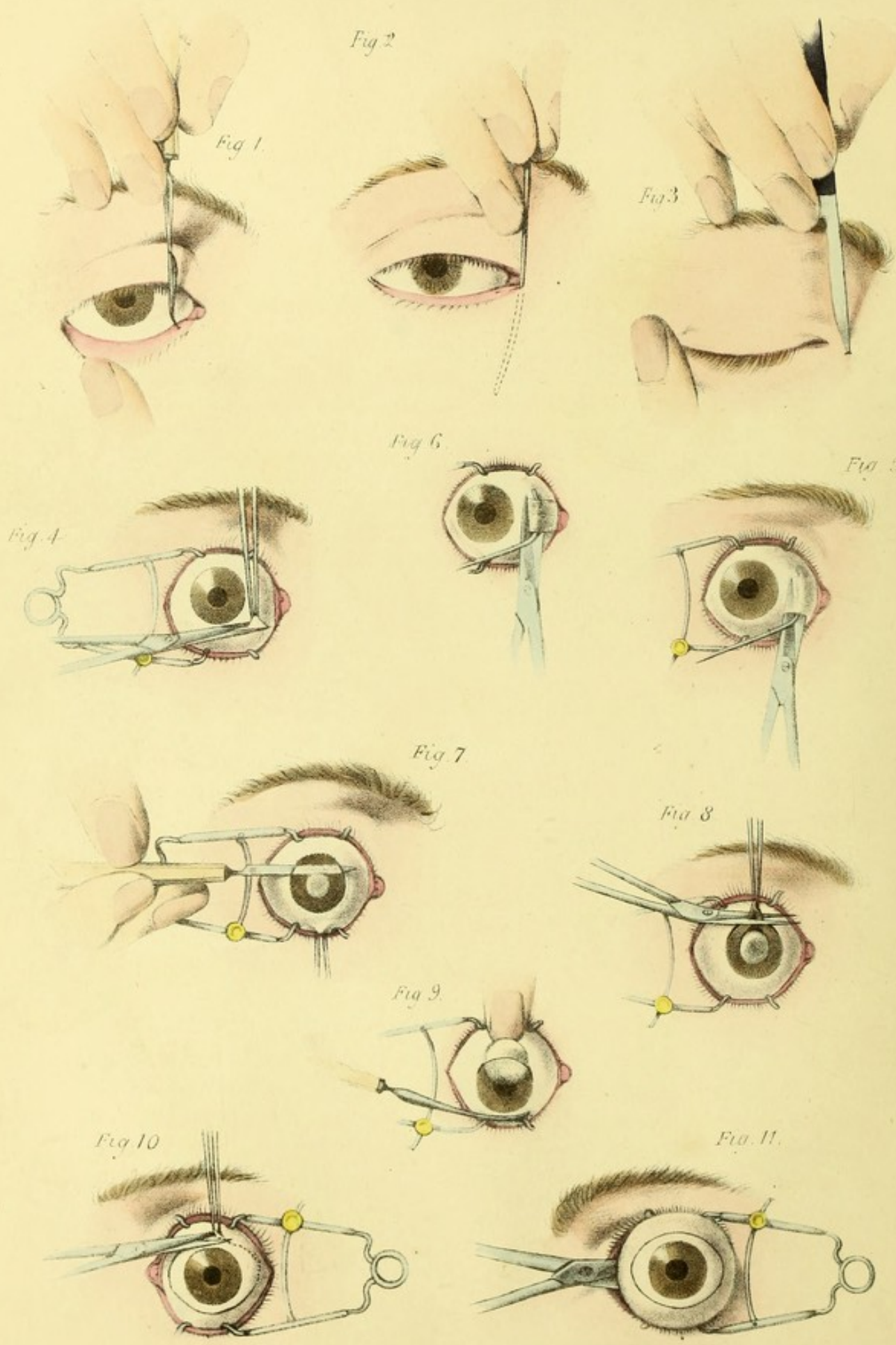
Fig 7

Fig 8

Fig 9

Fig 10

Fig 11



## PLATE I.

---

- FIG. 1.* Introduction of Weber's canaliculus-knife into the punctum lachrymale.  
*FIG. 2.* Probe introduced into lachrymal sac.  
*FIG. 3.* Bistoury in lachrymal sac.  
*FIG. 4.* Operation for Strabismus, 1st stage—division of conjunctiva and fascia.  
*FIG. 5.* Operation for Strabismus, 2nd stage—sub-conjunctival division of tendon.  
*FIG. 6.* Position of Strabismus hook and scissors shown by removal of conjunctiva.  
*FIG. 7.* Extraction of lens, 1st stage—section of cornea with Graefe's knife.  
*FIG. 8.* Extraction of lens, 2nd stage—iridectomy.  
*FIG. 9.* Extraction of lens, 4th stage—evacuation of lens.  
*FIG. 10.* Extirpation of globe, 1st stage—division of conjunctiva.  
*FIG. 11.* Extirpation of globe, 3rd stage—division of optic nerve.
- 

## OPERATIONS ON THE EYE.

THE following operations on the eye and its appendages have been selected for illustration as those with which every surgeon ought to be acquainted, although he may not care to perform all of them. They are all easily practised on the dead body without causing any disfigurement, and nothing but considerable practice will give the skill necessary for their satisfactory performance.

### LACHRYMAL APPARATUS.

*Epiphora*, or overflow of the tears from displacement of the punctum or obstruction of some part of the lachrymal canal, is best treated by laying open the lower canaliculus, so as to convert the tube into an open trough into which the tears readily pass. Weber's canaliculus-knife, consisting of a fine blade with a probe-point set at an angle, may be conveniently used alone, or Critchett's small director may be employed in combination with any slender-bladed knife. Whether the



probe-knife or the director be used, the mode of introduction is the same (Fig. 1). The operator, standing behind the patient, draws down and slightly everts the lower eye-lid with the thumb of one hand, and with the opposite hand (right or left, according to the side operated on), holds the instrument vertically to the surface of the lid, and seeks the minute opening of the punctum, which is on the papilla lachrymalis or angle of the lid external to the caruncle. This aperture is not always easy to find, and the mistake is often made of looking for it too near the caruncle, and not sufficiently on the margin of the lid. If any force is used, it is easy to make false passages beneath the conjunctiva; but by rotating the instrument gently between the forefinger and thumb, the probe-end will be pretty readily introduced into the punctum, when the handle must be lowered to the horizontal position so that the probe-point may glide along the canaliculus. The cutting edge must then be slightly turned, so as to divide the upper wall of the canal slightly forwards and in front of the caruncle. If the director and knife be used, it will be necessary to hold the director with the fingers of the hand which makes traction on the eye-lid while the knife is run along the groove in it. The whole extent of the canaliculus should be divided, and care taken that no bands are left. The subsequent passage of a probe (once or twice), at intervals of one or two days, to prevent re-union of the divided edges, will be necessary to ensure the success of the operation.

*To probe the lachrymal sac* (Fig. 2) is comparatively easy when the canaliculus has been laid open, unless a tight stricture exists. One of Bowman's lachrymal probes may be selected, and the divided canaliculus being again put on the stretch, the probe is to be introduced horizontally, and pushed steadily on into the lachrymal sac and against the lachrymal bone. The lid being now released, the probe can be brought up over the forehead, and a little beyond the vertical line, when the point may generally be pushed steadily downwards and outwards along the nasal duct to the floor of the nose. In the case of a very over-hanging brow, it will be necessary to bend the probe slightly before attempting to introduce it.

If an obstruction should exist at the junction of the canaliculus with the sac, it will be necessary to introduce a fine sharp-pointed knife to make an opening for the probe. The difficulty often encountered at this stage is more generally due to a failure to enter the sac fairly before the probe is raised, or to the point becoming entangled, owing to its not being carefully kept fixed during the rotation of the probe, which is then



forced in the wrong direction, and very probably perforates the lachrymal or ethmoid bone, giving rise to a crackling sound.

*Abscess in the lachrymal sac* points below the tendo oculi, and can be opened by a superficial incision, but it is always necessary to carry a knife into the sac as shown in Fig. 3. A small narrow bistoury should be employed, and the lid being drawn forcibly outwards, the knife is to be entered flat, and with the edge away from the nose, immediately below the tendo oculi, which will have become prominent. The bistoury is to be directed from before backwards while entering the skin, so as to pass with certainty behind the margin of the orbit, and being then brought flat on to the forehead, may be pushed downwards and outwards into the sac. The space between the tendo oculi and the margin of the orbit varies much in different subjects, and without care the blade may pass altogether in front of the orbit, and among the facial muscles. On the subject, the knife being withdrawn, a probe may be readily passed into the sac and nasal duct, or, if preferred, the probe may be introduced along the back of the knife. In the living body this should not be done, but after a few days, when the swelling has subsided, the canaliculus should be laid open and the probe passed from it.

#### STRABISMUS.

*Division of the internal rectus* (Fig. 4) for convergent strabismus may be best performed sub-conjunctivally, by which the unsightly sinking-in of the caruncle is avoided. In this and the subsequent operations, it will be necessary to employ a spring-speculum to keep the eye-lids open, and this is conveniently furnished with a screw-stop, as shown in the illustrations.

*To introduce the speculum*, the operator may either stand behind, or, more conveniently, at the right side of the patient, and closing the speculum with the forefinger and thumb of one hand, he raises the upper lid with the fingers of the other hand, and slips the branch of the speculum beneath its edge; the lower lid is then drawn down and the other branch slipped beneath it, when, the spring being released, the instrument will keep its place, and the amount of separation of the lids can be regulated with the stop. This little operation is often mismanaged, owing to the speculum being improperly held, and not sufficiently closed during introduction, or from the branches being inadvertently allowed to pass entirely beneath the lids, instead of supporting their margins. The speculum having been



introduced and fixed, the operator standing at the side of the patient, grasps the conjunctiva and sub-conjunctival tissue immediately below the level of the internal rectus (*i.e.* at the level of the lower border of the cornea) with a pair of finely serrated or hooked forceps. A vertical fold of conjunctiva, thus held with the left hand, can be readily divided horizontally with a pair of blunt-pointed scissors in the right, and the incision prolonged if necessary. In old subjects, the conjunctiva is very thin and apt to tear; in younger ones, the conjunctiva is thicker, and there is more sub-conjunctival tissue, which will require division until the white sclerotic is fairly seen. The strabismus-hook is next passed through the opening and beneath the tendon, which can be readily done if the point of the hook is kept close to the sclerotic while it is slipped behind the line of insertion of the muscle. On bringing the hook forward, the resistance of the tendon will be felt, and it will be seen beneath the conjunctiva raised upon the hook, the point of which will be prominent beyond it. The tendon may be missed altogether if the hook is not carried sufficiently far back, and the point may be entangled in the muscle if it is brought forward too abruptly.

The scissors are now introduced by the side of the hook, in order to divide the tendon close to its insertion into the sclerotic (Fig. 5). This is the most difficult part of the operation, it being necessary to pass one blade above the tendon without injuring the conjunctiva, and the other blade beneath the tendon without pushing it off the hook. The position of the hook and blades is shown with the conjunctiva removed in Fig. 6, where it will be seen that when the blades are open, the hook and the tendon are between the two. The tendon is divided by a series of snips until the hook is felt to be free, and it should then be passed again to make sure that no bands of fascia are left undivided, the best proof of which is, that the hook can be brought up to the margin of the cornea beneath the conjunctiva. The same operation may be practised on the external rectus, but it must be borne in mind that the insertion of the muscle is farther from the cornea than on the inner side.

#### CATARACT.

*Extraction of the lens* for hard cataract is an operation which has been completely revolutionized of late years. The large section of the cornea with a triangular knife has given way to a smaller section of the cornea or



sclerotic with a narrow knife, and the fear of injuring the iris has been replaced by a systematic removal of a piece of that curtain, with the best results. In the modern operation (Fig. 7) the stop-speculum is introduced as in the operation for strabismus, and the operator being behind the recumbent patient, seizes a fold of conjunctiva and subjacent tissue with the forceps, immediately below the centre of the cornea. The eye being thus steadied and drawn down, a narrow knife, held lightly between the thumb and the first and second fingers, is entered at the outer border of the cornea (or behind the cornea, as preferred by some), at the level of the junction of its upper and middle thirds; the knife being directed slightly from before backwards, until it has entered the anterior chamber, so as to avoid splitting up the substance of the cornea, and also obliquely downwards so as to divide the inner co-extensively with the outer surface of the cornea. The entry into the anterior chamber will be known by the loss of resistance, and in the living or recent eye the point can be clearly seen. The knife is then to be brought horizontal, and to be steadily pushed on, so that the point may emerge at the corresponding spot on the opposite side, and having done so, is to be made to cut a corneal (or corneo-sclerotic) flap with a steady sawing movement. The next step is to excise a portion of the iris (iridectomy, Fig. 8), and for this purpose the forceps steadying the eye should be transferred to the charge of an assistant. With one hand the operator then lays the open blades of a pair of delicate angular scissors on each side of the wound already made, and with the other introduces a fine pair of iris-forceps by which the upper border of the pupil is grasped and drawn out between the blades, by the closure of which its separation is effected.

The third step is the laceration of the capsule of the lens, which is done with the "pricker," usually mounted on the same handle as the curette. In using this instrument, it should be especially noted that the point of it is always turned the reverse way to that of the curette, and it should be introduced and withdrawn so that the point may not become entangled in the section or iris. Held horizontally, the pricker is introduced through the wound with the back downwards; it is then rotated, so as to bring the point against the capsule, which it is made to tear both vertically and across; after which, by another half turn, the back will be brought upwards, and the instrument can be withdrawn. In lacerating the capsule, the operator has no sensation of resistance to guide him, and must be careful not to push the pricker too deeply, and so dislocate the lens with its capsule.



The last step (Fig. 9) is the extrusion of the lens by pressure with the curette beneath the globe. The forefinger of the left hand being gently applied to the eyeball immediately behind the section so as to steady it, the curette is passed well beneath the eyeball and made to press gently upwards, when the lens will be dislocated forwards through the ruptured capsule into the anterior chamber, and will appear at the wound, through which it may be gently pushed by following its movements along the cornea with the curette. The mistake commonly made at this stage is, in placing the curette much too high at first, by which the lens is tilted backwards into the vitreous instead of being lifted forwards. Instead of employing the forefinger as above, the eye may be fixed and drawn down with the forceps as in the previous stages. For the left eye, the operator must employ his left hand to make the section and lacerate the capsule; or, if this is not practicable, may use his right hand while standing on the patient's right side. The operation described supposes an "upper section" of the cornea, but if for any reason a "lower section" is preferred, the whole of the proceedings will be the same in order but reversed in direction.

*Iridectomy* for the treatment of acute glaucoma is performed exactly as in the preceding operation, except that a smaller wound is usually made in the sclerotic, about a line from the margin of the cornea, and with a lance-shaped knife set at an angle with its handle. When the anterior chamber is very shallow, as is frequently the case in glaucoma, the incision should be made with a Graefe's knife as in extraction.

#### EXCISION OF EYE-BALL.

*Excision of the eye-ball* (Fig. 10) is the ophthalmic operation of greatest importance to the general surgeon, since cases of ruptured eye-ball, with or without the lodgment of foreign bodies, are sufficiently common, and the secondary changes, likely to arise in the sound eye from the irritating presence of a damaged globe, frequently necessitate the removal of a shrunken and withered eye-ball.

The stop-speculum having been introduced beneath the lids, the operator picks up a fold of conjunctiva near the margin of the cornea, and divides that membrane around the upper segment of the cornea, using one blade of the scissors as a director to raise the conjunctiva previous to division. Beginning at the same point as before the lower segment is divided



in the same way, and the division of the tendons of the several muscles is then effected with the strabismus hook and scissors. In this operation, however, it will be found convenient to make the scissors meet the hook instead of following it as in strabismus, for the tendons are thus more readily divided. The obliqui are usually divided with the recti without being specially recognized by the operator, who must be prepared for well-marked adhesions between the eye-ball and the surrounding structures in cases of long-standing disease. If the eye-ball has been ruptured by a blow (or the lens previously extracted) it will be somewhat collapsed, and it will be necessary to draw it forward with forceps, in order to reach the optic nerve. When the eye-ball is tense on the other hand, it can be fairly lifted out of the socket by introducing a pair of curved scissors, half opened, along the inner wall of the orbit, and the optic nerve being thus rendered tense, can be readily divided by closing the scissor blades (Fig. 11). The hæmorrhage after the operation is extremely slight, none but the small ciliary branches being divided. The eye-lids being kept apart a little ice-cold water is allowed to trickle between the lids for a few minutes, after which they are closed with a compress and bandage. In cases where, after excising the globe, it is necessary to remove the contents of the orbit, the operation is obviously much more severe, and it may be advisable to plug the orbit in order to check the hæmorrhage.

1875

1. The first part of the document is a letter from the Secretary of the Board of Education to the President of the Board of Trustees of the University of the State of New York. The letter is dated January 1, 1875, and is addressed to the President of the Board of Trustees of the University of the State of New York.

2. The second part of the document is a report from the Secretary of the Board of Education to the President of the Board of Trustees of the University of the State of New York. The report is dated January 1, 1875, and is addressed to the President of the Board of Trustees of the University of the State of New York.

3. The third part of the document is a report from the Secretary of the Board of Education to the President of the Board of Trustees of the University of the State of New York. The report is dated January 1, 1875, and is addressed to the President of the Board of Trustees of the University of the State of New York.

4. The fourth part of the document is a report from the Secretary of the Board of Education to the President of the Board of Trustees of the University of the State of New York. The report is dated January 1, 1875, and is addressed to the President of the Board of Trustees of the University of the State of New York.

5. The fifth part of the document is a report from the Secretary of the Board of Education to the President of the Board of Trustees of the University of the State of New York. The report is dated January 1, 1875, and is addressed to the President of the Board of Trustees of the University of the State of New York.

6. The sixth part of the document is a report from the Secretary of the Board of Education to the President of the Board of Trustees of the University of the State of New York. The report is dated January 1, 1875, and is addressed to the President of the Board of Trustees of the University of the State of New York.

7. The seventh part of the document is a report from the Secretary of the Board of Education to the President of the Board of Trustees of the University of the State of New York. The report is dated January 1, 1875, and is addressed to the President of the Board of Trustees of the University of the State of New York.

8. The eighth part of the document is a report from the Secretary of the Board of Education to the President of the Board of Trustees of the University of the State of New York. The report is dated January 1, 1875, and is addressed to the President of the Board of Trustees of the University of the State of New York.

9. The ninth part of the document is a report from the Secretary of the Board of Education to the President of the Board of Trustees of the University of the State of New York. The report is dated January 1, 1875, and is addressed to the President of the Board of Trustees of the University of the State of New York.

10. The tenth part of the document is a report from the Secretary of the Board of Education to the President of the Board of Trustees of the University of the State of New York. The report is dated January 1, 1875, and is addressed to the President of the Board of Trustees of the University of the State of New York.





Fig. 1.

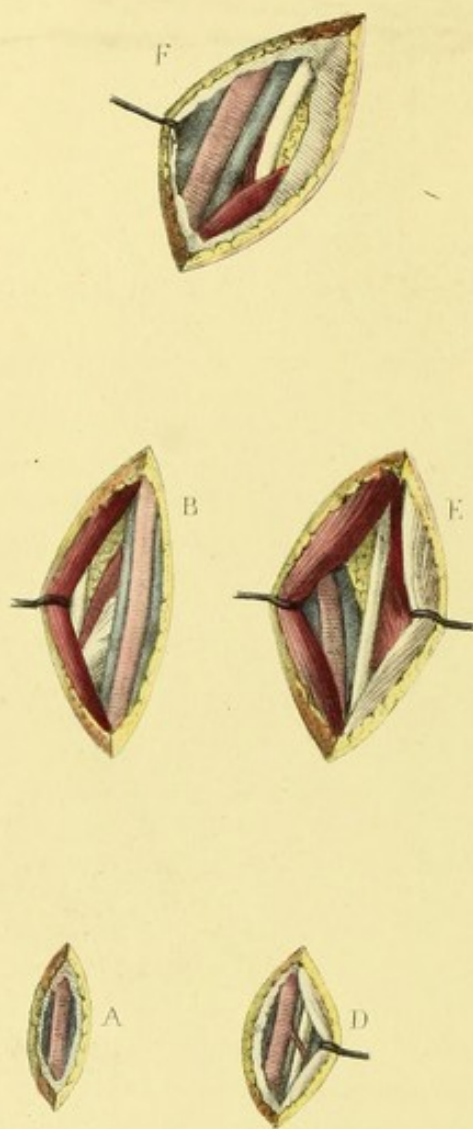
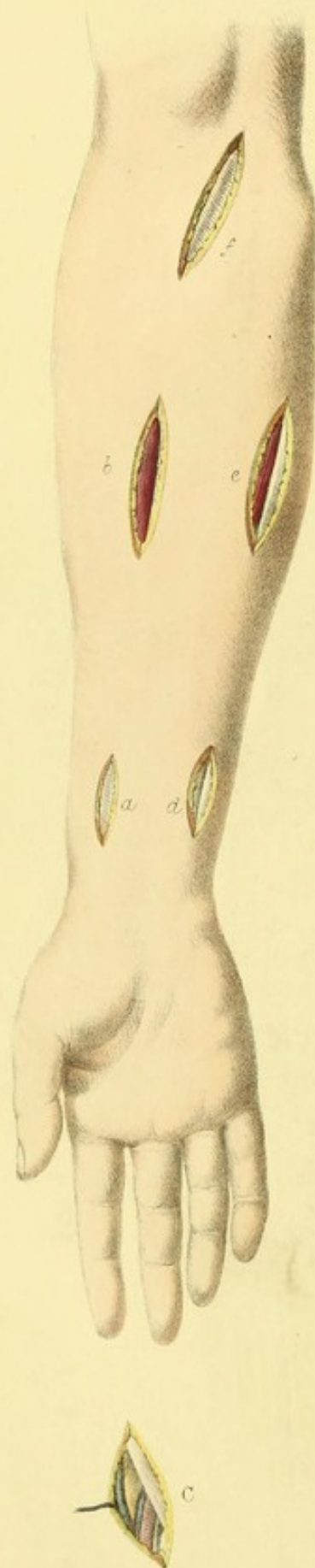

Fig. 2.

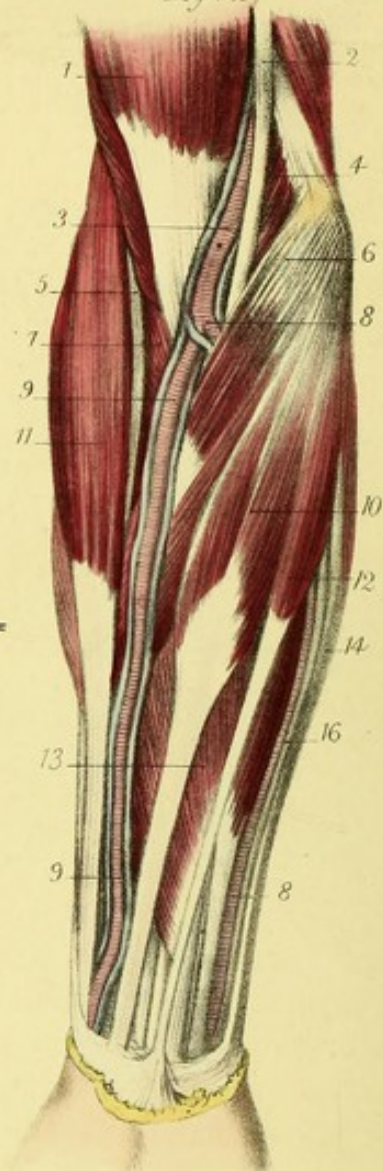
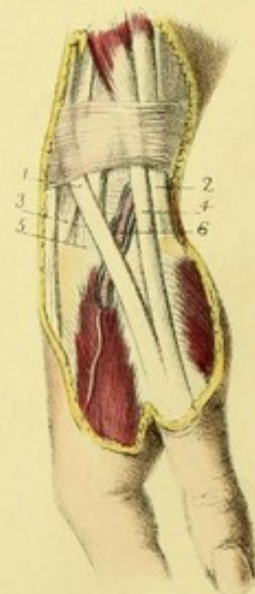


Fig. 3.

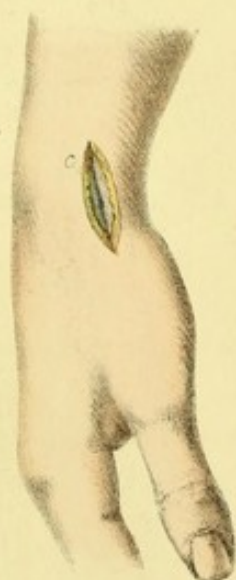

Fig. 4.





## P L A T E   I I.

---

FIG. 1.

<i>a.</i>	Incision for ligature of Radial artery at wrist.
<i>b.</i>	„ „ Radial artery in forearm.
<i>d, d.</i>	„ „ Ulnar artery at wrist.
<i>e.</i>	„ „ Ulnar artery in forearm.
<i>f.</i>	„ „ Brachial artery at elbow.
	A. Deep dissection of <i>a.</i>
	B. „ „ <i>b.</i>
	D. „ „ <i>d.</i>
	E. „ „ <i>e.</i>
	F. „ „ <i>f.</i>

FIG. 2. Anatomy of Radial and Ulnar arteries in forearm.

1. Biceps.	9, 9. Radial artery.
2. Median nerve.	10. Flexor carpi radialis.
3. Brachial artery.	11. Supinator longus.
4. Brachialis anticus.	12. Palmaris longus.
5. Radial nerve.	13. Flexor sublimis digitorum.
6. Pronator teres.	14. Flexor carpi ulnaris.
7. Supinator brevis.	16. Ulnar nerve.
8, 8. Ulnar artery.	

FIG. 3. Incision for ligature of Radial artery at root of thumb.—C. Deep dissection of *c.*

FIG. 4. Anatomy of Radial artery at root of thumb.

1. Extensor secundi internodii pollicis.	4. Extensor primi internodii pollicis.
2. Extensor ossis metacarpi pollicis.	5. Extensor carpi radialis longior.
3. Extensor carpi radialis brevior.	6. Radial artery.

---

### THE DELIGATION OF ARTERIES.

THE application of a ligature in the continuity of an artery may be required for the arrest of hæmorrhage, or the treatment of aneurism. In either case it is essential that the vessel should be exposed with as little disturbance of the tissues as possible, and efficiently tied with a round hempen ligature, unless the cat-gut ligature with antiseptic dressings is preferred. The incision through the integuments should be made exactly in the right place with one steady sweep of the scalpel, which may be most conveniently held for the purpose beneath



the hand. The skin should be steadied with the finger and thumb of the left hand, but must on no account be drawn out of its natural position. The point of the knife should be entered perpendicularly to the surface, and should resume that position as it finishes the incision, so as not to leave unsightly "tails" to the wound. In the deeper dissection, the scalpel may be conveniently held like a pen, but when in the immediate neighbourhood of the artery, the blade should be reversed, so as to have the back next the vessel.

A steel director is useful in one or two operations, especially when vessels and nerves are imbedded in a quantity of loose cellular tissue; but a director should not be ordinarily employed to strip an artery for the passage of the aneurism-needle, since thereby much bruising may be inflicted on the adjacent veins. The scalpel and forceps are the best instruments for opening the sheath and exposing the artery, and the aneurism-needle itself will be the best for completing any separation not readily effected with the knife.\* All the larger arteries have a distinct cellular sheath in which the *vasa vasorum* ramify, and although too extensive separation of this connection is on that account to be avoided, it must necessarily be divided with the scalpel until, in the words of Syme, "the surface of the artery appears perfectly white and distinct."

The needle is passed ready threaded, and the loop having been caught by the forceps the needle is withdrawn and the ligature tied with a close reef-knot, without pulling the artery out of its bed. If a hempen ligature is used, one end is cut short, and the other left hanging out of the wound. If the cat-gut ligature is employed, both ends are cut close to the knot.

In passing the aneurism-needle, it is well to grasp the tissue by the side of the artery (not the artery itself) with the forceps, in order to steady it, and then to pass the needle from the forceps. If some piece of tissue becomes caught on the end of the needle, it should be carefully inspected to see that the point is not driven through the coats of the artery itself, but if it is merely cellular tissue, it may be conveniently torn through with the nail. When an artery has a single vein it is better, as a rule, to pass the needle between the vein and artery; but when there are two veins, the position of the nerve will settle the side *from* which the needle ought to be passed.

In the living body, before tying a ligature upon a main artery, the

\* "He must be insufferably clumsy who cannot open the sheath of an artery without piercing the proper coats of that artery."—*Sir Charles Bell*.



operator should, by holding the vessel in the loop of thread and compressing it with the finger, ascertain that the current of blood is controlled, and pulsation below that point arrested. Otherwise, he may possibly tie a nerve instead of the artery, and have great difficulty in subsequently removing the ligature.

The principal differences between the appearances of the arteries in the dead and living subject are the following:—

In the dead body, uninjected, the small arteries contain a little blood, and, therefore, very closely resemble veins, but the coats being thicker, the arteries have a blue, and the veins a purple, appearance. When the blood is driven out of the smaller arteries they have a white appearance, like the larger arteries. The large arteries are white and collapsed, and may be distinguished from the nerves by their contour, and by the absence of longitudinal markings always to be seen in large nerves.

In the living body, the arteries have a pink appearance, partly from the contained blood, and partly from the blood necessarily shed in the first incision, and then wiped away. The pulsation of the living artery serves at once to distinguish it, but is liable to be propagated to other tissues lying close upon it, *e.g.*, the median nerve may thus be mistaken for the brachial artery. It is important to remember that the manipulation which an artery undergoes in an operation, is often enough to cause it to contract and cease to pulsate temporarily. Again, in cases of hæmorrhage, it may be necessary to apply a ligature below the tourniquet, in which case pulsation will of course be wanting.

The length of incision required will vary with the artery and the individual. The deeper the artery, the longer the incision required, and, therefore, in a fat subject, the incision will be longer than in a thin one. The incision in the skin should be made sufficiently freely to obviate all difficulty in reaching the deeper parts, and the fascia of the limb divided to the same extent. It will be found, as a rule, most convenient to make the incision from above downwards on the right, and from below upwards on the left side of the body, the operator standing on the side to be operated upon. For convenience, the descriptions of the operations refer to the right side, and the direction of the incision would be reversed on the left side, unless special directions to the contrary are given. The wound should be drawn open, but not displaced, by an assistant, who may use a blunt hook or spatula, and it must be borne in mind, that muscles which are flaccid in the dead, will contract forcibly in the living body, and



require to be drawn firmly aside. Bleeding vessels should be twisted or tied, so that the wound may be sponged out dry before the deeper and more important dissection is undertaken.

#### THE RADIAL ARTERY.

*The Radial Artery* (Plate II.) may be tied in three places, at the wrist, in the forearm, and at the root of the thumb.

*At the wrist* (Fig. 1, *a*).—An incision,  $1\frac{1}{2}$  to 2 inches in length, is to be placed midway between the tendons of the flexor carpi radialis and the supinator longus and parallel to them, immediately above the annular ligament. The first incision must divide only the skin and sub-cutaneous tissue, and expose the fascia of the arm, beneath which the artery with its two veins can generally be seen. The fascia being carefully held up with the forceps and opened, the artery will be seen and the veins must be separated from it. There is no nerve in relation with the artery at this point, and it is a matter of indifference which way the needle is passed (A).

*Anatomy* (Fig. 2).—The artery is placed quite superficially between the tendons of the flexor carpi radialis and supinator longus, and lies upon the pronator quadratus.

*Fallacies*.—The first incision, if carried too deeply, may divide the artery longitudinally, or one of the veins. If placed to one side, the pronator quadratus may be reached without the artery being recognized.

*In the forearm* (Fig. 1, *b*).—A line drawn from the middle of the bend of the elbow to the base of the metacarpal bone of the thumb, will mark the position of the artery, and an incision at any part of the line would reach it. An incision, 2 to  $2\frac{1}{2}$  inches in length, may be most conveniently made in the middle of the forearm, and should be carried at once through the deep fascia. In a thin subject, this incision will expose the border of the supinator longus, but in a fleshy arm that muscle will overlap the artery considerably, and the border must be sought nearer the median line of the arm. The edge of the supinator is to be turned outwards, and the artery with its two veins will be found in the cellular interval between it and the pronator teres. The radial nerve is deeper than, and to the outer side of, the artery, and the needle should therefore be passed from the outer side (B).



*Anatomy* (Fig. 2).—The radial artery in the forearm lies beneath the supinator longus, and upon the supinator brevis, insertion of pronator teres, radial origin of flexor sublimis digitorum, and flexor longus pollicis. The radial nerve is at a distance in the upper and lower parts, but in the middle third is in close relation to the outer side.

*Fallacies*.—If the first incision is not made through the fascia, it is difficult to find the edge of the supinator. In reflecting this muscle, it is easy to miss the artery, and expose the nerve to its outer side.

*At the root of the thumb* (Fig. 3, c).—In the space between the extensors of the thumb, the radial artery may be reached by an incision,  $1\frac{1}{2}$  inch in length, from the lower end of the radius to the base of the metacarpal bone of the thumb, and slightly overlapping each bone. A large and very regular superficial vein will be found to lie parallel to this incision, and must not be divided. The incision being carefully deepened at the lower end, the artery, with its two veins, will be found passing obliquely across the incision, and beneath the extensors of the thumb, and may be secured close to the base of the metacarpal bone (C).

*Anatomy* (Fig. 4).—The radial artery winds from the front to the back of the wrist, beneath the extensors of the metacarpal bone and first phalanx of the thumb, and upon the external lateral ligament. It is then crossed by the extensor of the second phalanx, and passes between the first and second metacarpal bones to the palm.

*Fallacies*.—The superficial vein may be mistaken for the artery, which is much deeper and very regular as to its course, though uncertain as to its branches. The operation is not one of any practical utility, it being much easier to secure the artery at the wrist.

#### THE ULNAR ARTERY.

*The Ulnar Artery* (Plate II.) may be tied in two places, at the wrist and in the forearm.

*At the wrist* (Fig. 1, d).—An incision,  $1\frac{1}{2}$  to 2 inches in length, is to be made along the radial border of the flexor carpi ulnaris immediately above the annular ligament. The first incision is to go through the fascia of the forearm, and expose the white border of the tendon. This being drawn inwards with a hook, another process of fascia will be seen binding down the ulnar artery, veins, and nerve to the flexors of the fingers. This fascia is to be picked up and opened directly over the artery, and the veins



having been separated, the needle is passed from the nerve, which is to the ulnar side of the vessels (D).

*Anatomy* (Fig. 2).—The artery lies beneath the tendon of the flexor carpi ulnaris, which is attached to the pisiform bone, and upon the flexor sublimis digitorum. The ulnar nerve is to the ulnar side of the artery, and gives off its dorsal branch at this point. A dorsal branch is often given by the artery to accompany the dorsal nerve, and the ligature should not be applied too near to it.

*Fallacies*.—The position of the pisiform bone in front of the wrist is often misapprehended, and the incision made too far to the ulnar side, exposing the ulnar border of the tendon, which can be recognized by the muscular fibres attached along it. If the deep process of fascia is not opened, the artery cannot be found.

*In the forearm* (Fig. 1, *e*)—A line from the prominent internal condyle to the pisiform bone will mark the course of the ulnar artery in the middle and lower thirds. An incision,  $2\frac{1}{2}$  to 3 inches long, in the middle third of this line should be made to expose the deep fascia of the limb, through which the white tendinous margin of the flexor carpi ulnaris can be perceived. An incision carried along this will allow the handle of the scalpel to separate the flexor ulnaris from the palmaris longus, or the flexor sublimis digitorum, until the ulnar nerve is exposed at the bottom of the wound. To the radial border of the ulnar nerve the ulnar artery will be found with its two veins. The needle should be passed from the nerve (E).

*Anatomy* (Fig. 2).—The ulnar artery in the upper third of the forearm takes an oblique course from the middle to the inner side of the arm beneath the superficial muscles and the median nerve, and lies upon the flexor profundus digitorum. It usually meets the ulnar nerve, which comes direct from the internal condyle, at the junction of the upper with the middle third of the forearm, and lies to its radial border for the rest of its course. The development of the palmaris longus varies considerably, and it may be absent.

*Fallacies*.—If the incision is made too much in front, the interval between the palmaris longus and flexor sublimis digitorum may be selected in error. If the incision is too high, the artery will not be in relation with the nerve.



## THE BRACHIAL ARTERY.

The *Brachial Artery*, at the bend of the elbow (Plate II., Fig. 1, *f*).—The position of the median-basilic vein having been ascertained if possible, a 2-inch incision, beginning at the level of the internal condyle, is to be placed parallel to, and usually above, the vein on the inner side of the tendon of the biceps, which is always to be readily felt, if not seen. The incision may be conveniently made from above downwards on both sides of the body, the operator being between the arm and the trunk on the *left* side. The bicipital fascia, varying much in thickness, will be exposed by the first incision, and on dividing it with the knife and forceps, or, if preferred, upon a director slipped beneath it, the artery with its two veins will be found between the median nerve and the tendon of the biceps. The needle to be passed from the nerve (F).

*Anatomy* (Fig. 2).—The space at the end of the elbow is bounded externally by the supinator longus, internally by the pronator teres, and its floor is formed by the brachialis anticus and supinator brevis. The median nerve, brachial artery, and tendon of the biceps lie in that order from the inner side, but the nerve may be at some distance from the artery. The bicipital fascia varies both in extent and thickness, according to the development of the muscle itself.

*Fallacy*.—In the case of a high division of the brachial artery, there may be two arteries side by side, or one may pass superficially over the bicipital fascia.



4





Fig. 1.

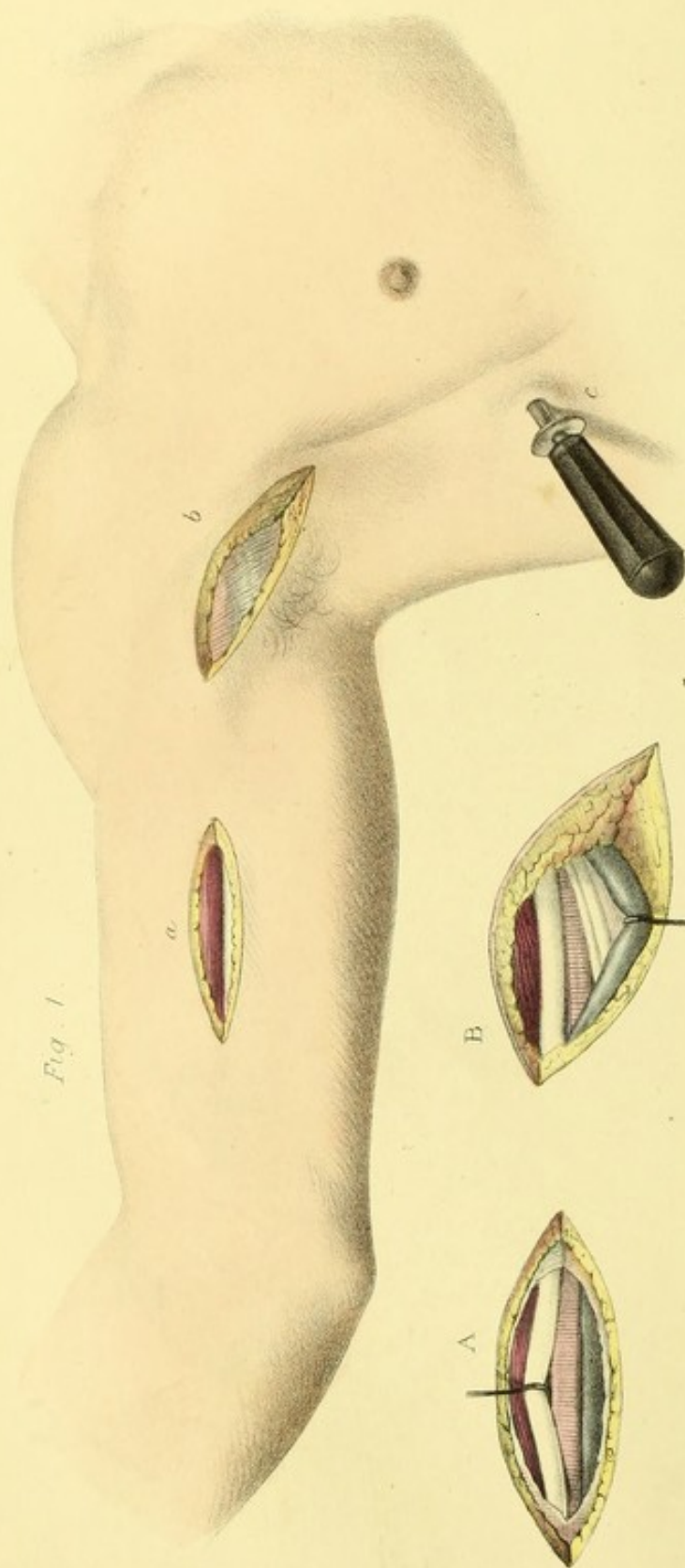
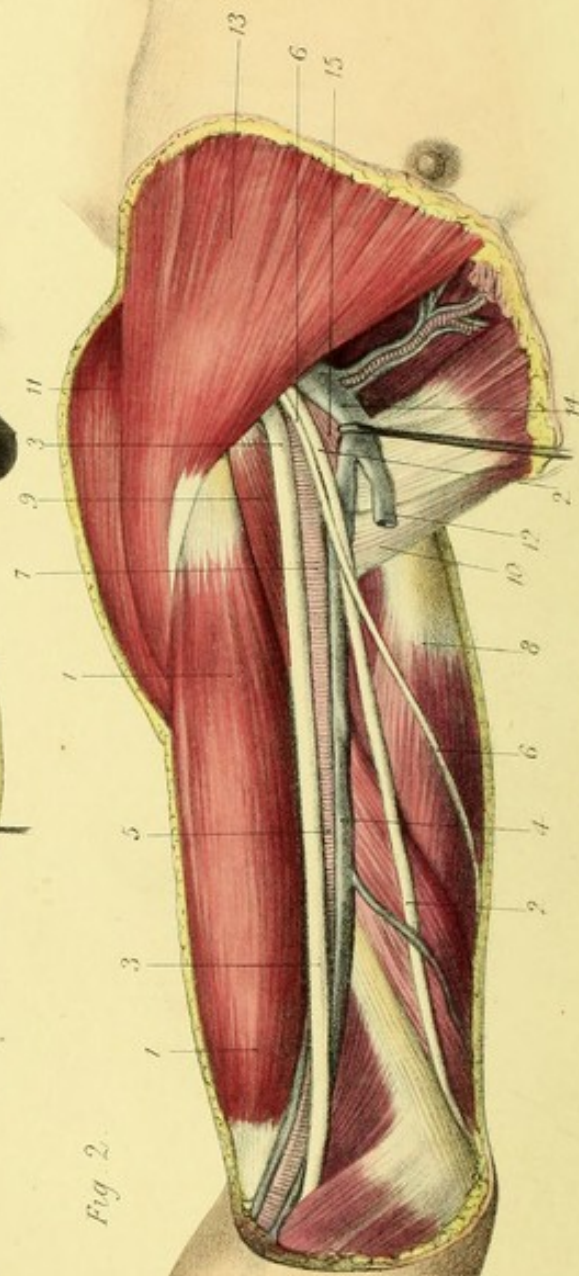


Fig. 2.



# PLATE III.

FIG. 1.

- a. Incision for ligature of the Brachial artery.
- b. " " " " third part of the Axillary artery.
- c. Paracentesis thoracis.
- A. Deep dissection of a.
- B. " " " b.

FIG. 2. Anatomy of the Brachial and Axillary arteries.

- |                                 |                                       |
|---------------------------------|---------------------------------------|
| 1, 1. Biceps muscle.            | 9. Coraco-brachialis.                 |
| 2, 2. Ulnar nerve.              | 10. Latissimus dorsi and teres major. |
| 3, 3. Median nerve.             | 11. Deltoid muscle.                   |
| 4. Brachial veins.              | 12. Basilic vein (cut).               |
| 5. Brachial artery.             | 13. Pectoralis major.                 |
| 6, 6. Internal cutaneous nerve. | 14. Axillary vein.                    |
| 7. Axillary artery.             | 15. Musculo-spiral nerve.             |
| 8. Triceps muscle.              |                                       |



## PLATE III.

---

### THE BRACHIAL ARTERY.

*The Brachial Artery* (Fig. 1, *a*) is best tied in the middle of the arm, at the inner border of the biceps muscle. The arm is most conveniently held by an assistant at right angles to the body without resting upon any support, which, if employed, is apt to push up the triceps muscle and displace the vessel. On the *right* side, the operator will most conveniently stand behind the arm, and look over it to make his incision from above downwards; on the *left* side, he will be similarly placed, but make his incision from below upwards, or may be seated between the arms and the trunk and begin his incision above.

Feeling the inner border of the biceps with his left hand, the operator makes an incision,  $2\frac{1}{2}$  to 3 inches long, upon the edge of the muscle in the middle of the arm. The incision should divide the deep fascia of the limb and expose the fibres of the biceps without dividing them. The deep fascia being drawn inwards, a dissection is made along the edge of the biceps to expose the median nerve, which is to be drawn outwards with a blunt hook by an assistant, in order to expose the brachial artery and veins beneath it (A). It may be more convenient to draw the nerve inwards if it has crossed the artery higher than usual, but in either case the aneurism-needle should be passed *from* the nerve. Occasionally the brachial artery lies superficially to the nerve, in which case the vessel will be found next to the biceps.

*Anatomy* (Fig. 2).—The brachial is the direct continuation of the axillary artery, beginning at the lower border of the teres major, and ending at its point of bifurcation. It lies along the inner border of the biceps and is usually crossed by, but may go over, the median nerve about the middle of the arm, and it rests upon the inner head of the triceps, the coracobrachialis, and the brachialis anticus. A high division, or a high additional trunk (generally the ulnar) is not very unfrequent, in either of which cases two vessels of similar calibre may lie side by side, and it may be necessary to ligature both.



*Fallacies.*—If the arm is allowed to rest on the table the triceps may be pushed up and be mistaken for the biceps. A more common error is to endeavour to cut upon the artery or median nerve (which last is often prominent), without exposing the biceps. The incision is then made too much to the inner side, the basilic vein may be exposed and be mistaken for the artery, or the ulnar nerve may be reached and be mistaken for the median. The transmission of pulsation to the median nerve causes it closely to resemble the artery in the living body.

#### THE AXILLARY ARTERY.

*The Axillary Artery* (Fig. 1, *b*) in its third part, may be readily reached when the arm is at right angles to the body. The operator should sit between the arm and the trunk, and may most conveniently make his incision from below on the *right*, and from above on the *left* side.

The anterior and posterior boundaries of the axilla are easily seen, and an incision 3 to 3½ inches long is to be placed parallel to the anterior border (pectoralis major) at the junction of the anterior with the middle third of the space, *i.e.*, one-third of the whole width of the axilla behind its anterior border. Carried through the deep fascia, this will expose the axillary vein, which is to be drawn down by an assistant (B). The great cords of the brachial nerves will then be seen, and a little separation of these will expose the large axillary artery between them. The needle should be passed from the inner side, or away from the vein, and the ligature must not be applied close to a branch.

*Anatomy* (Fig. 2).—The axilla is bounded by the pectoralis major in front, and by the latissimus dorsi, teres major, and subscapularis behind. The axillary vessels and nerves pass through the space, lying nearer the anterior than the posterior border. In the lower part, the axillary artery has the median and musculo-cutaneous nerves to its outer side, the ulnar and internal cutaneous nerves with the vein to its inner side, and the musculo-spiral nerve with the latissimus dorsi and teres muscles behind. The arrangement of the veins varies, for instead of one large axillary vein, the basilic vein may take its place, there being two *venæ comites* in close relation with the artery. Occasionally the artery may be quite superficial to the nerves at the lower part of the axilla, and in this case the brachial artery usually crosses the median nerve.

*Fallacies.*—If the incision is made in the middle of the axilla, the vein



will be to its outer side, and in great danger, and it will be difficult to expose the artery. The relation of the artery to the nerves being uncertain, it is easy to miss the vessel, or to mistake one of the cords for it. If the ligature were applied too close to the large sub-scapular branch, secondary hæmorrhage would be likely to occur.

#### PARACENTESIS THORACIS.

*Paracentesis Thoracis* (Plate III. Fig. 1, *c*) is best performed between the sixth and seventh ribs, midway between the anterior and posterior boundaries of the axilla. The intercostal vessels run along the lower border of each rib, and therefore the trochar should be entered at the upper border, the skin being drawn up so that the wound may be valvular. If an ordinary trochar be employed it is convenient to make a small incision in the skin so that it may not be punctured, but if the small needle of an aspirator be used, this may be pushed through the skin in an upward direction. When it becomes necessary to make a free incision to relieve empyema, this may be safely done along the upper border of the sixth or seventh rib.





Fig. 1

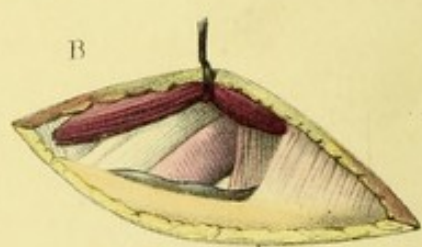
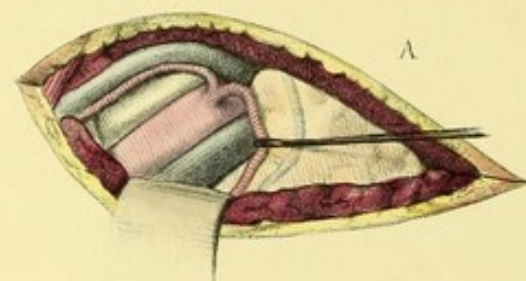
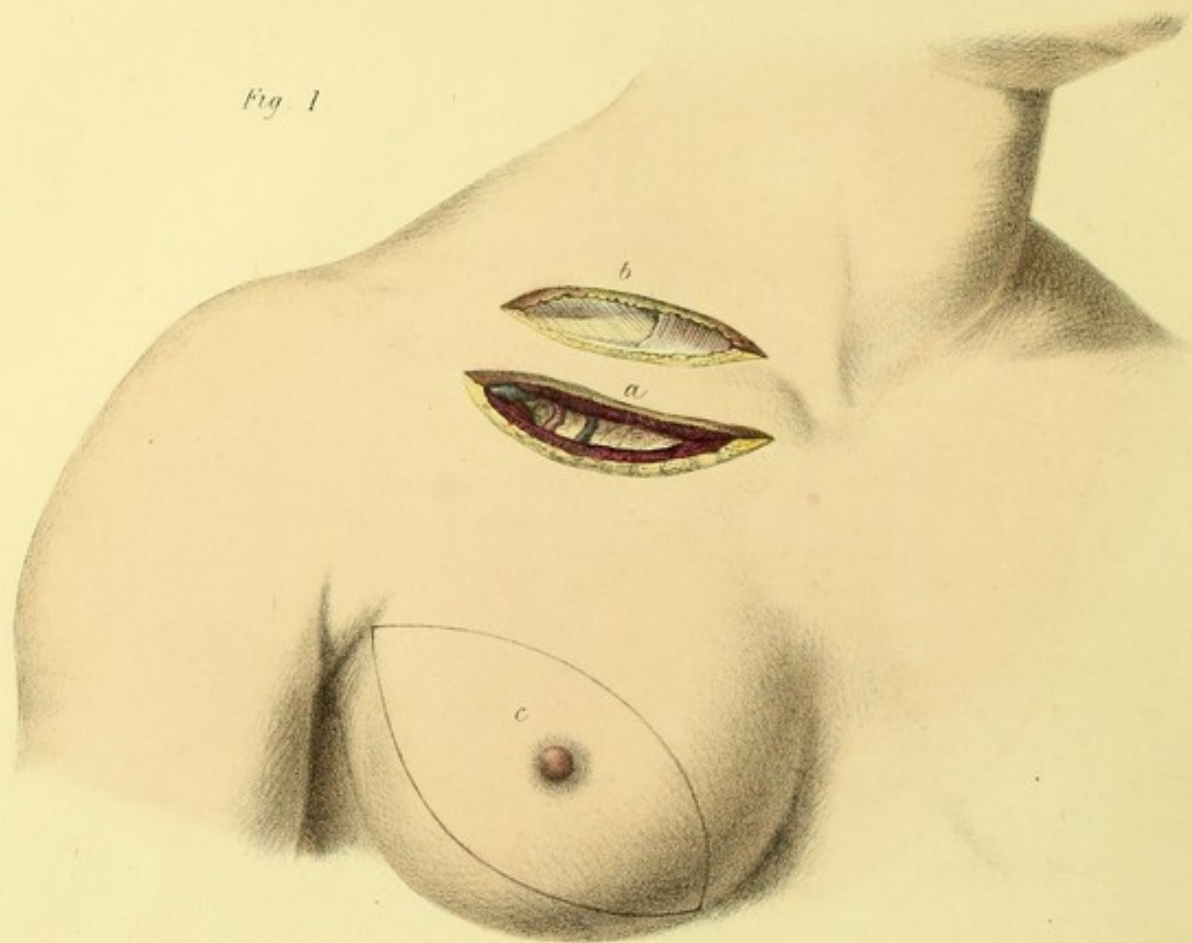


Fig. 2

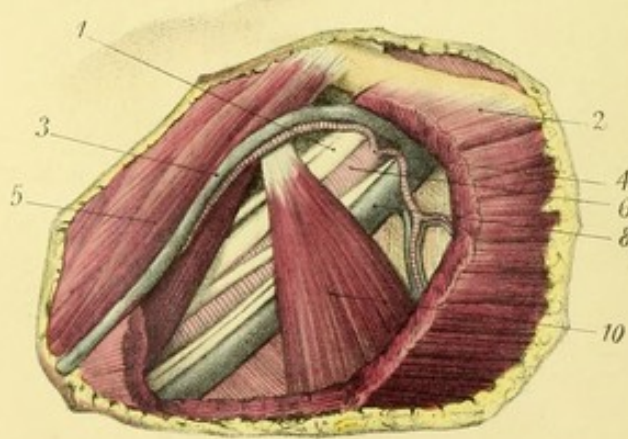
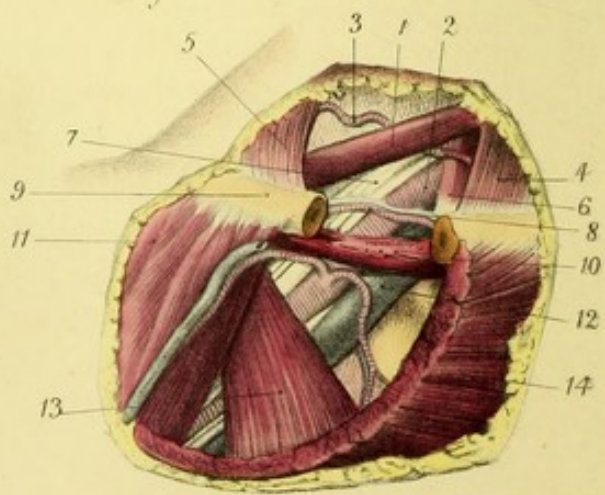


Fig. 3



## P L A T E I V.

---

- FIG. 1.*    *a.* Incision for ligature of the first part of the Axillary artery.  
              *b.*        "        "        "        third part of the Subclavian artery.  
              *c.* Incisions for Amputation of Breast.  
              *A.* Deep dissection of *a.*  
              *B.* Deep dissection of *b.*

- FIG. 2.* Anatomy of the first part of the Axillary artery.
- |   |   |
|---|---|
| <ol style="list-style-type: none"> <li>1. Brachial plexus.</li> <li>2. Pectoralis major.</li> <li>3. Cephalic vein.</li> <li>4. Acromio-thoracic artery.</li> </ol> | <ol style="list-style-type: none"> <li>5. Deltoid muscle.</li> <li>6. Axillary artery.</li> <li>8. Axillary vein.</li> <li>10. Pectoralis minor.</li> </ol> |
|---|---|

- FIG. 3.* Anatomy of the third part of the Subclavian artery.
- |  |   |
|--|---|
| <ol style="list-style-type: none"> <li>1. Omo-hyoid muscle.</li> <li>2. Subclavian artery.</li> <li>3. Transversalis colli artery.</li> <li>4. Sterno-mastoid muscle.</li> <li>5. Trapezius muscle.</li> <li>6. Scalenus anticus muscle.</li> <li>7. Brachial plexus.</li> </ol> | <ol style="list-style-type: none"> <li>8. Transversalis humeri vessels.</li> <li>9. Clavicle (cut).</li> <li>10. Subclavius muscle.</li> <li>11. Deltoid muscle.</li> <li>12. Subclavian vein.</li> <li>13. Pectoralis minor.</li> <li>14. Pectoralis major.</li> </ol> |
|--|---|

### THE AXILLARY ARTERY.

*The Axillary Artery* (Fig. 1, *a*) may be tied in the first part on the dead body, but the operation would be extremely difficult and dangerous on the living subject. A curved incision from the coracoid process to the sterno-clavicular joint will expose the clavicular fibres of the pectoralis major, which must be divided to the same extent, care being taken to preserve the cephalic vein, which lies at the outer angle of the wound between the pectoralis major and deltoid. In the cellular tissue beneath the pectoralis major will be seen one or two vessels which lie upon the costo-coracoid membrane, and the forefinger is to be thrust through the membrane to the outer side of these. The membrane being torn through (or divided if necessary), the pectoralis minor can be drawn down with a spatula, and the space in which the artery lies will be exposed (*A*). A steel director or other blunt instrument should be employed to define the



artery, which will be found between the trunks of the brachial plexus on the outer, and the axillary vein on the inner, side. The needle is to be passed from the vein.

*Anatomy* (Fig. 2).—The clavicular fibres of the pectoralis major must be divided, as it would be impossible to reach the vessel satisfactorily through the small interval between the clavicular and sternal fibres of that muscle. The vessels seen beneath the pectoralis major are from the acromio-thoracic (thoracic axis) branch of the axillary, and if drawn outwards, would greatly embarrass the operator. The cephalic vein passes up the arm between the pectoralis major and deltoid, and crosses the axillary artery to open into the vein close to the clavicle, and usually too high to be inconvenient. The costo-coracoid membrane, seen above the pectoralis minor, varies in thickness, but must be divided in order to reach the upper border of the pectoralis minor, the fibres of which pass obliquely to the coracoid process. The axillary artery in its first part lies upon the first intercostal space and digitation of the serratus magnus, with the vein to its inner, and the great cords of the plexus to its outer, side. Some variation in the relation of the nerves is not uncommon, but the vein is constant in its relation. The size of the acromio-thoracic artery varies, and one of its branches may be conveniently used as a guide to the main artery should it not be readily found.

*Fallacies*.—The pectoralis major has occasionally a cellular interval between two planes of muscle, and this may be mistaken for the space beneath it. If the incision is put too low, it will be difficult to reach the upper border of the pectoralis minor. The axillary vessels are placed at a great depth in a stout subject, and any incautious use of sharp instruments might easily open the axillary vein and destroy the patient by hæmorrhage.

#### THE SUBCLAVIAN ARTERY.

*The Subclavian Artery* (Fig. 1, *b*) in its third part, may be tied either for axillary aneurism, or for aneurism of the innominate or aorta. In the former case, the operation will be more difficult than in the latter, owing to the elevation of the shoulder and clavicle by the axillary tumour. In order to reach the vessel, the arm should be drawn down, and the head turned towards the opposite side, so as to bring the posterior triangle thoroughly into view. Standing at the shoulder of the patient, the



operator draws the skin down upon the clavicle with the left hand, and makes a curved incision upon the bone, reaching from the sterno-mastoid to the trapezius. This incision should divide the skin, platysma, and fascia down to the bone, and with them the descending branches of the superficial cervical plexus, and possibly a branch of vein which may pass superficially from the cephalic, and which should be tied at once if it bleeds. The skin being now allowed to resume its natural position, the incision will be about half an inch above the clavicle, and must be deepened by cutting carefully with knife and forceps through the deep fascia thus exposed.

The position of the external jugular vein should have been previously ascertained, if possible, and it should be carefully exposed. If it is close to the sterno-mastoid, so that it can be conveniently held out of the way with a hook, it should be preserved, but if it is in the middle of the incision, it should be tied in two places, and divided between them. The posterior belly of the omo-hyoid may or may not be seen, and it is of no importance, but if seen, the dissection should be kept below it.

The finger introduced at the inner part of the wound, and behind the clavicle, will be able to recognize the edge of the anterior scalenus, and the first rib with its tubercle, and possibly the artery and the cords of the brachial plexus (B). With the steel director and forceps a cautious dissection is to be made in the direction of the artery, the finger being applied from time to time to ascertain its exact position, until by tearing through a process of fascia continuous with the scalenus, the vessel is exposed. The needle may be most conveniently passed from above downwards, *i.e.*, between the last cord of the brachial plexus and the artery, rather than from below between the vein and artery as usually directed. There is much greater risk of including the nerve in the ligature by the latter proceeding, than there is of injuring the vein (always at some distance) by the former, which is therefore recommended.

*Anatomy* (Fig. 3).—The incision corresponds to the base of the posterior triangle of the neck, which is bounded in front by the sterno-mastoid, and behind by the trapezius. The extent of attachment to the clavicle of both these muscles varies, and in a muscular subject it will be necessary to divide some of the clavicular fibres of the sterno-mastoid in order to reach the artery.

The size and position of the external jugular vein vary greatly as already mentioned, and the transversalis colli and transversalis humeri veins may join it so as to cover the artery, and greatly complicate the operation.



Ordinarily, the transversalis colli artery is well above the incision, and the transversalis humeri artery close behind the clavicle and out of danger, but one or both may be exposed. The posterior belly of the omo-hyoid always crosses the posterior triangle obliquely, but at a very variable height. It is practically of no assistance as a guide to the artery, and has simply to be avoided.

The third part of the subclavian artery reaches from the outer border of the scalenus anticus to the lower border of the first rib. It is covered by a process of fascia attached to the scalenus, and may be crossed by the external jugular vein. It lies against the scalenus medius, the last cord of the brachial plexus, and the first rib; the rest of the plexus being immediately above, and the subclavian vein below the artery. Usually the subclavian artery gives off no branch, but the transversalis colli or transversalis humeri (or even both), may arise from it instead of from the thyroid axis, in which case the branch would be in danger of division, and the difficulty of tying the subclavian satisfactorily would be much increased.

*Fallacies.*—The great risk of the operation is venous hæmorrhage, which is to be guarded against most carefully. In the male subject, the scalene tubercle in the first rib, and the edge of the scalenus are readily recognized with the finger pushed downwards and inwards behind the sterno-mastoid, but in the female, these points are not as readily distinguished, though the artery lying on the rib may be felt. In the dead body, it is quite possible to thrust the finger in front of the scalenus and reach the trachea, if undue violence is employed.

It occurred to the author on one occasion, to be obliged to abandon the operation, owing to the artery being completely overlapped by the sac of the aneurism (aortic), which had forced its way into the neck.

The last cord of the brachial plexus has been tied, instead of, or with, the artery on more than one occasion.

#### REMOVAL OF THE BREAST.

The incisions for removal of the breast (Fig. 1, *c*) must vary according to the size of the tumour, and the amount of skin involved. Two elliptical incisions carried above and below the nipple suffice for the great majority of cases, and they may be most conveniently placed as shown in the illustration, so that when the patient is recumbent, the outer end of the wound may be most dependent. This extremity of the wound may also be



prolonged into the axilla very readily, when, as often happens, enlarged glands require removal.

In order to avoid loss of blood, the lower incision should be made first, and the skin be reflected from the breast before the upper incision is begun. In thin subjects, great care will be necessary to avoid making "button-holes" in the skin, or dissecting the skin so thoroughly as to cause it to slough. In fat subjects, the skin and sub-cutaneous fat can be readily reflected with very little employment of the knife, by a free use of the fingers, and this method has the advantage of causing very little hæmorrhage. Great care should be taken to expose the thin border of the gland effectually, so that none of it is left behind, and the edge being then forcibly raised, a few touches of the knife will free the under surface of the breast from its cellular bed upon the pectoral muscle. If, as often happens, the disease has involved the pectoral muscle, the fibres drawn up with the breast should be divided and removed with it, and in severe cases, it may be necessary to remove nearly the entire muscle.

When diseased axillary glands exist in connection with mammary disease, they are close beneath the pectoral muscle, and not in the neighbourhood of the axillary vessels, unless the disease is very extensive. They may be most conveniently enucleated with the finger, any vessel supplying a gland being ligatured before the gland is separated. In this way the axilla may be thoroughly cleared out, if necessary, with very little hæmorrhage or risk to the patient.









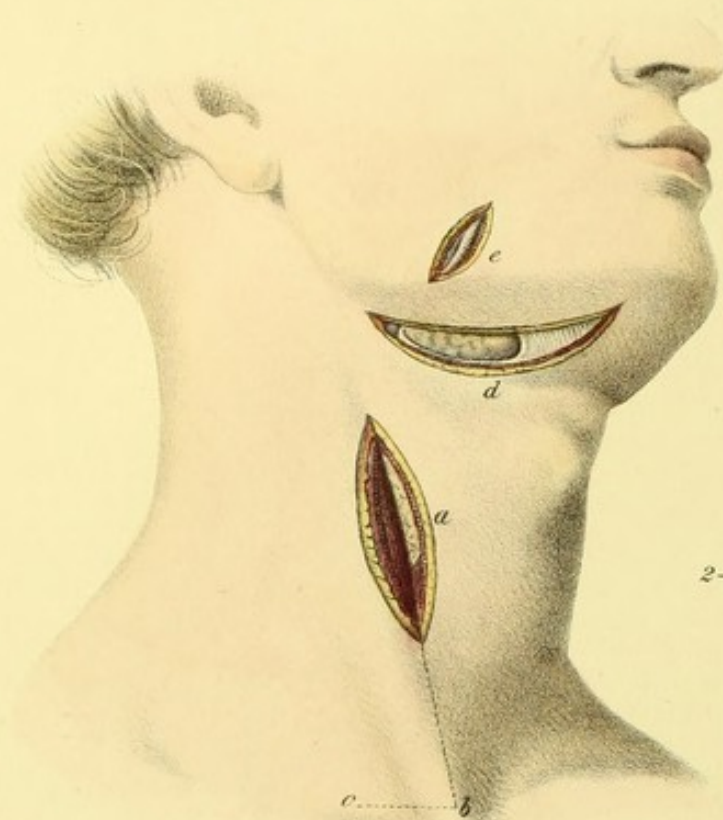

Fig. 1.

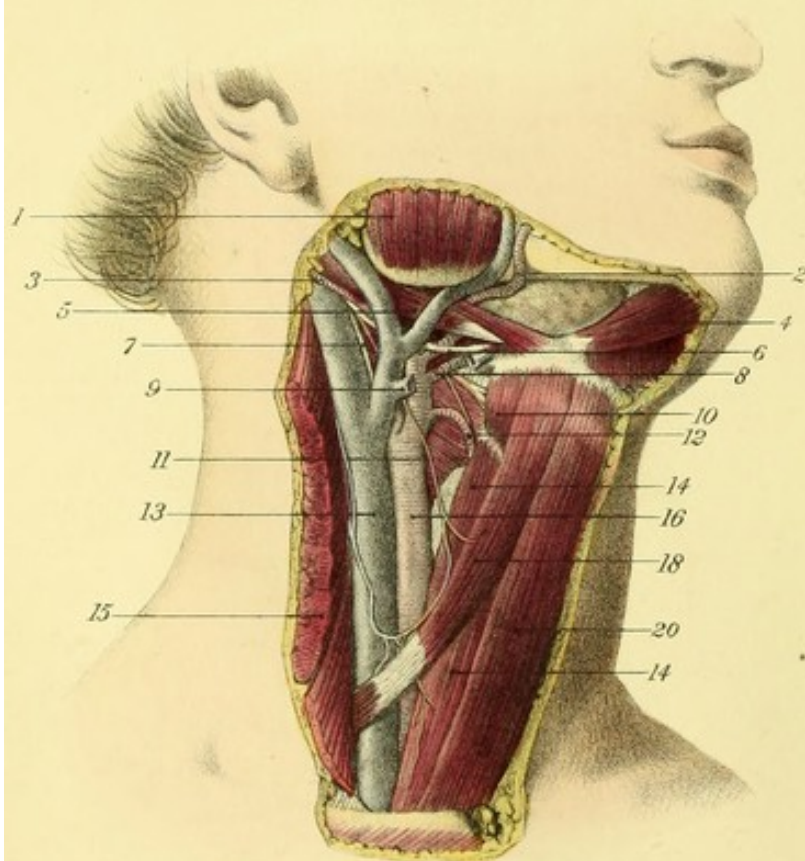
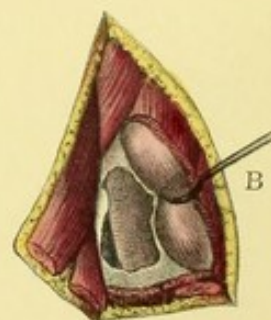
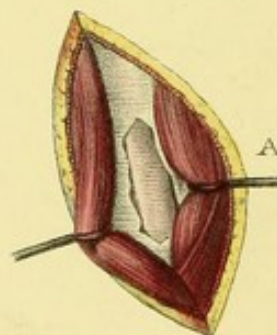
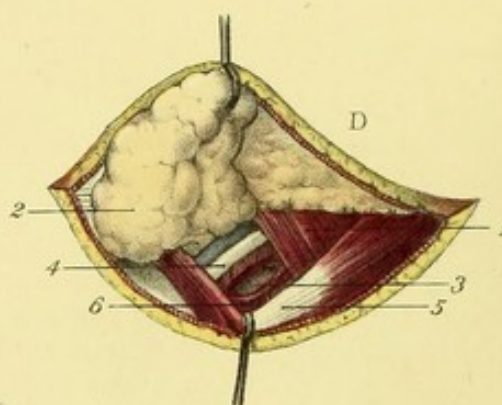
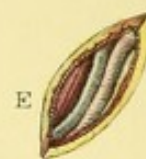

Fig. 2.

## PLATE V.

FIG. 1.

- a. Incision for ligature of Common Carotid artery above omo-hyoid.
- a, b. " " " " " below omo-hyoid.
- b, c. Additional incision for ligature of Innominate artery.
- d. Incision for ligature of Lingual artery.
- e. " " " " " Facial artery.
- A. Deep dissection of a.
- B. " " " b.
- D. " " " d.
- 1. Mylo-hyoideus.
- 2. Sub-maxillary gland.
- 3. Lingual artery.
- 4. Hypo-glossal nerve with vein.
- 5. Digastricus.
- 6. Hyo-glossus (cut).
- E. Deep dissection of e.

FIG. 2. Anatomy of Common Carotid artery and its branches.

- |                                      |   |
|--------------------------------------|---|
| 1. Masseter.                         | 10. Thyro-hyoideus.                     |
| 2. Facial artery and vein.           | 11. Descendens noni nerve.              |
| 3. Occipital artery.                 | 12. Superior thyroid artery.            |
| 4. Anterior belly of digastricus.    | 13. Internal jugular vein.              |
| 5. Posterior " " and stylo-hyoideus. | 14, 14. Sterno-thyroideus.              |
| 6. Hypo-glossal nerve.               | 15. Sterno-mastoid (cut and reflected). |
| 7. Pneumo-gastric nerve.             | 16. Common carotid artery.              |
| 8. Lingual artery.                   | 18. Omo-hyoideus.                       |
| 9. Lingual vein (cut).               | 20. Sterno-hyoideus.                    |

### THE COMMON CAROTID ARTERY.

*The Common Carotid Artery* (Fig. 1) may be tied in two places, above or below the omo-hyoid muscle, the former being the easier and preferable operation in most cases. The head being turned with the chin towards the side opposite to that on which the operation is to be performed, the edge of the sterno-mastoid muscle is to be defined, and this, even in very muscular subjects, will be found to be perfectly straight below the level of the hyoid bone.

*Above the omo-hyoid (a).*—An incision,  $2\frac{1}{2}$  to 3 inches in length, is to be placed exactly on the anterior oblique border of the sterno-mastoid muscle



immediately opposite the larynx, so that the middle of the incision may correspond to the level of the cricoid cartilage. The incision should be carried at once through the platysma, superficial cervical nerve, and fascia, to expose the muscular fibres of the sterno-mastoid, unless the external jugular vein should happen to cross the line of incision, in which case it must be secured with two ligatures before being divided. The anterior edge of the sterno-mastoid is to be carefully turned back until the angle formed between it and the omo-hyoid at the lower part of the wound is clearly defined. The sterno-mastoid is then to be held back by an assistant while the operator dissects forward the outer edge of the omo-hyoid, which is then to be held with a hook, so as to increase the space between the two muscles. In doing this, a large anterior jugular vein may be seen, and must be carefully preserved. The forefinger, introduced into the lower part of the wound, will now recognize the artery, enclosed in its sheath, by its pulsation and by its slipping beneath the finger across the vertebræ behind. The exact position of the artery being thus ascertained, the fibrous sheath is to be opened with knife and forceps directly over it, and the surface of the vessel fully exposed by carefully dissecting the cellular sheath without injuring the descendens noni nerve if it should happen to be seen. The outer side of the sheath being grasped with the forceps, the needle is to be passed close to the artery from without inwards, and will readily surround it (A).

*Below the omo-hyoid (a—b).*—An incision, 3 inches in length, along the anterior border of the lower third of the sterno-mastoid muscle will allow that muscle to be reflected outwards (with or without division of its sternal attachment), until the muscles passing upwards to the hyoid bone (with, in some cases, an anterior jugular vein) are exposed. The outermost muscle is the omo-hyoid, and this is to be separated from the sterno-hyoid, when the broad sterno-thyroid will be seen beneath them, pushed up by thyroid gland. The finger carried between the omo-hyoid and sterno-thyroid, both of which are to be held aside with hooks, will distinguish the carotid in its sheath lying against the vertebræ, and the space must be cautiously enlarged so as to bring the sheath into view. The sheath is to be opened with knife and forceps, and the artery fully exposed, without injuring the descendens noni nerve, when the needle may be passed from without inwards, as in the former operation. In muscular subjects it may be necessary to divide the sterno-thyroid muscle in order to reach the artery (B).

*Anatomy (Fig. 2).*—The relations of the common carotid artery are the



same on both sides of the neck, each artery bifurcating ordinarily at the level of the upper border of the thyroid cartilage, but the left artery is considerably longer than the right, arising from the arch of the aorta within the thorax; hence the left carotid may be safely tied nearer the sterno-clavicular articulation than the right, which arises from the innominate at that spot. The common carotid lies beneath the sterno-mastoid muscle in all its cervical portion, and also beneath the sterno-hyoid and sterno-thyroid muscles in the lower half of its course, being crossed by the omo-hyoid about the middle. It is enclosed in a fibrous sheath derived from the deep cervical fascia, upon or within which the descendens noni nerve forms loops with its communicating branches. Within the sheath and to the outer side of the artery is the large internal jugular vein, and between and behind the two is the pneumo-gastric or vagus nerve. On the left side of the neck the jugular vein tends to overlap the artery somewhat, especially at the lower part, but in the operation the vein should be seldom seen, and the vagus nerve never. The carotid sheath lies against the vertebræ and prevertebral muscles with the sympathetic cord, and the inferior thyroid artery crosses behind it at the lower part. The larynx, trachea, thyroid gland, and œsophagus are to the inner side of the artery, and the thyroid, if enlarged, may overlap or even displace the great vessels.

*Fallacies.*—If the first incision is not made exactly upon the margin of the sterno-mastoid there will be difficulty in reflecting it. When the sheath is exposed it should be opened directly over the artery, *i.e.*, to the inner side; if opened to the outer side the vein will be exposed, and in the subject, when empty, may readily be opened by mistake for the sheath. The pneumo-gastric may be tied in the ligature if the needle is not carried close round the artery.

#### THE INNOMINATE ARTERY.

*The Innominate Artery* (Fig. 1, *a b c*) has never been successfully tied, and its ligature is generally regarded as unjustifiable. It can be reached on the dead body by an incision similar to that for the lower ligature of the carotid, joined by another incision along the clavicle, so as to allow of free division and reflection of the sterno-mastoid. The sterno-hyoid and sterno-thyroid muscles must then be cut across close to the sternum, behind which bone a cautious dissection is to be made with the steel director and



finger in order to reach the innominate artery, the best guide to which will be the common carotid, which can be traced down to its origin. The needle should be passed from right to left.

*Anatomy.*—The innominate artery is crossed by the left brachio-cephalic vein, and has in front of it the remains of the thymus gland, the sternum, and the origins of the sterno-hyoid and sterno-thyroid muscles. The right inferior thyroid vein crosses it obliquely, and must not be interfered with. The pneumo-gastric and phrenic nerves with the innominate vein are to the right of the artery and in close relation to it, and the pleura is immediately behind it at the point where it would be tied.

### THE LINGUAL ARTERY.

*The Lingual Artery* (Fig. 1, *d*) may be most certainly tied at the apex of the digastric triangle beneath the hyo-glossus, as follows: A curved incision, beginning to the right of the symphysis menti, is to be carried to the level of the hyoid bone, and then nearly up to the angle of the jaw. This should divide the platysma and expose the sub-maxillary gland without injuring it. The lower border of the gland is then to be turned up and held with a hook, when a little dissection will expose the two bellies and intervening tendon of the digastric, forming two sides of a triangle, of which the 9th or hypo-glossal nerve is the base. The nerve will be seen to pass beneath the posterior border of the mylo-hyoid which should be defined, and is usually accompanied by a branch of the lingual vein. Both these are to be dissected up a little, so as to bring the hyo-glossus muscle, on which they lie, fully into view, and the hyo-glossus is then to be divided transversely about one-eighth of an inch above the great cornu of the hyoid bone, when the lingual artery with its *venæ comites* will be seen. The needle should be passed from above downwards (D).

*Anatomy.*—The lingual artery arises from the external carotid either alone or in common with the facial artery. In the latter case it descends to the level of the hyoid bone, and does not pass along the whole length of the greater cornu, and would not be found if the incision were made at its extremity. It passes beneath the hyo-glossus, and upon the middle constrictor and the fibrous bag of the pharynx, and there gives off a dorsal branch which, however, is seldom seen in the operation.

*Fallacies.*—If the incision is carried up to or beyond the angle of the jaw, the large facial vein may be divided, and will require two ligatures.

In dividing the hyo-glossus, if the incision is made too deeply it will open the pharynx. This part of the operation is easier on the living than the dead body, since the muscular fibres contract when divided, and the artery protrudes by its own elasticity.

#### THE FACIAL ARTERY.

*The Facial Artery* (Fig. 1, *e*) may be tied immediately in front of the masseter, on the margin of the lower jaw, by an incision, one inch in length, parallel to the fibres of the masseter. The artery lies upon the bone immediately beneath the platysma, and the vein is to its outer side. The artery is often tortuous, and is more easily found in the living than the dead subject, owing to the pulsation (E).









Fig. 1.

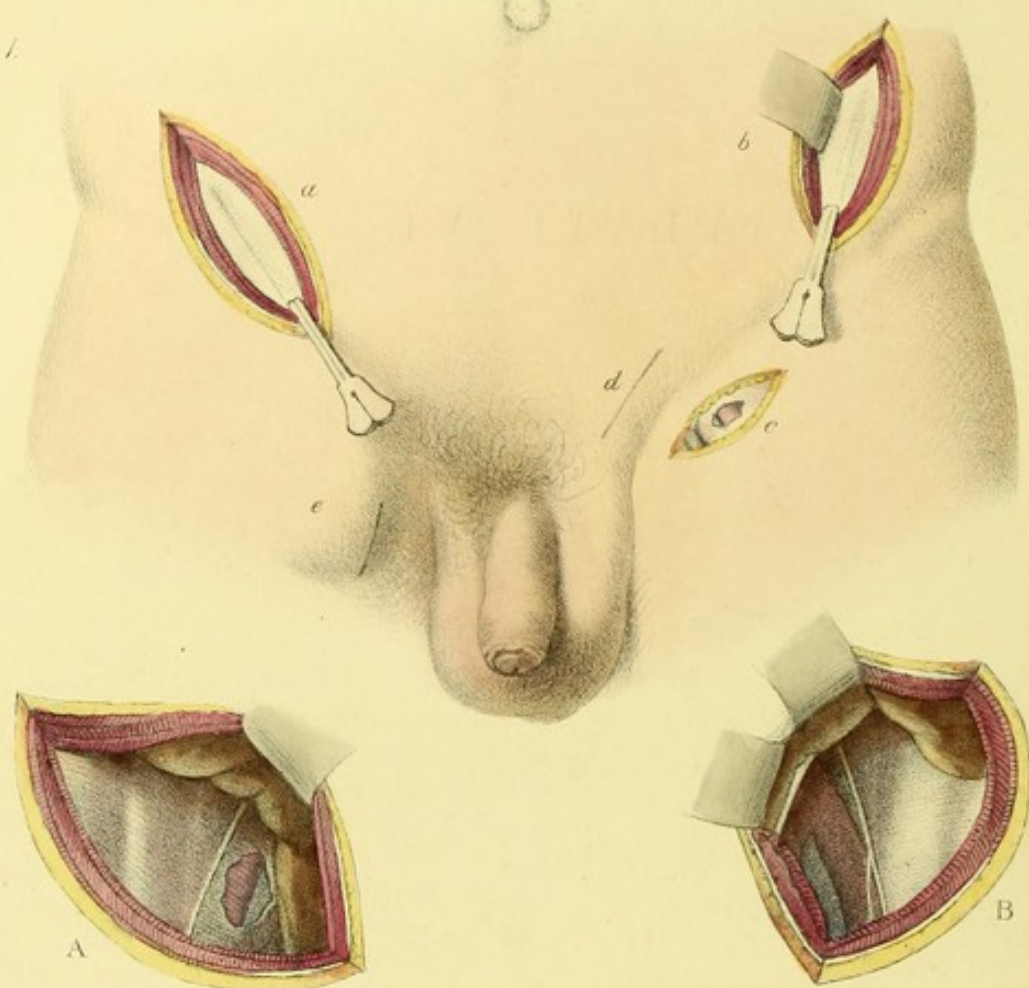
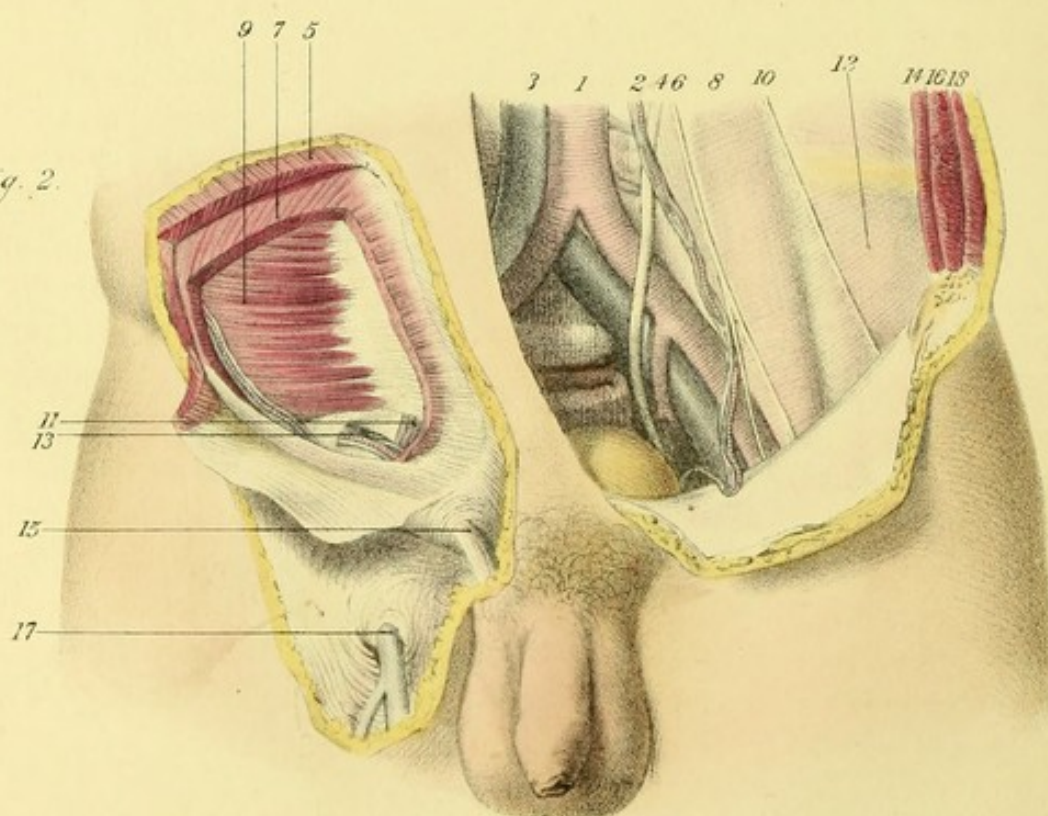


Fig. 2.



## PLATE VI.

FIG. 1.

- |    |   |  |
|----|---|--|
| a. | Incision for ligature of External Iliac artery. |  |
| b. | Common Iliac artery                             |  |
| c. | Common Femoral artery.                          |  |
| d. | strangulated Inguinal Hernia.                   |  |
| e. | Femoral Hernia.                                 |  |
|    | A. Deep dissection of a.                        |  |
|    | B. " " b.                                       |  |

FIG 2. Anatomy of Iliac arteries and Hernia.

- |   |  |  |
|---|--|--|
| 1. Abdominal aorta.<br>2. Spermatic vessels.<br>3. Inferior vena cava.<br>4. Ureter.<br>5. Obliquus externus.<br>6. Genito-crural nerve.<br>7. Obliquus internus.<br>8. Psoas magnus.<br>9. Transversalis.<br>10. External cutaneous nerve. |  | 11. Epigastric vessels.<br>12. Iliacus internus.<br>13. Spermatic cord passing through internal abdominal ring.<br>14. Section of transversalis.<br>15. External abdominal ring.<br>16. Section of obliquus internus.<br>17. Saphenous opening.<br>18. Section of obliquus externus. |
|---|--|--|

### THE ILIAC ARTERIES.

*The External Iliac Artery* (Fig. 1, a) may be tied by a curved incision, 4 to 5 inches long, through the abdominal muscles. It will be found convenient to begin the incision below on both sides of the body, at a point an inch to the outer side of the middle of Poupart's ligament and an inch above its level, and to prolong it to a point an inch above the anterior superior iliac spine. The first incision should expose the tendon of the external oblique, and may divide the superficial epigastric artery, which in the living body should be secured at once. The tendon is then to be divided to the same extent, the blade of the knife being held with its edge perpendicular to the surface in the whole length of the incision, and the muscular fibres of the internal oblique will be exposed. These are to be divided in the same



way, the original curve of the incision being carefully preserved, until the transversalis is exposed. The muscular fibres of the transversalis are then to be divided in the original curve and by the same method, or, if preferred, a portion of the muscle may be taken up with forceps and divided with the blade held horizontally until the transversalis fascia is brought into view, when a director may be slipped beneath the remainder of the muscle, and the knife run along it. The transversalis fascia, which will now be exposed in the whole length of the incision, will be found to vary much in the quantity of fat it contains, being sometimes thin and transparent, and at others thick and well developed. It is to be picked up with forceps, and carefully opened with the blade held horizontally, and, the director being inserted, it is to be divided. The outside of the peritoneum will now be exposed. It is of a bluish appearance, and the bowels can be indistinctly seen through it with, in the dead body, some fluid.

The assistant has hitherto only kept the abdominal wall tense with his hand and made slight traction upon the muscles as they are divided, but he must now be prepared with a broad bent spatula to draw up and hold the peritoneum out of the way.

The operator with his forefinger carefully strips up the peritoneum from the iliac fossa towards the median line as far as the inner border of the psoas, taking care neither to tear up the psoas by forcing his finger through its sheath at the outer border, nor to tear the iliac vessels away from the inner border of the muscle. The external iliac artery and vein will be found lying parallel to the inner border of the psoas in a distinct sheath of fascia, which must be opened with knife and forceps in order to expose the artery. The vein lies to the inner side of the artery, and the genito-crural nerve to its outer side; the needle should be passed from within outwards (A).

*Anatomy* (Fig. 2).—The external iliac artery has the same relations on both sides of the body. It extends from the bifurcation of the common iliac artery to Poupart's ligament, lying along the inner border of the psoas in the whole of its course, and enclosed with the vein in a separate sheath of fascia. The genital branch of the genito-crural nerve lies upon the outer side of the artery, and close to Poupart's ligament it is crossed by the vas deferens. The spermatic vessels lie upon the artery at its lower part, but will in the operation be turned forward, and may be seen with the vas deferens at the internal abdominal ring. Close to Poupart's ligament the artery gives off the deep epigastric and circumflexa ilii branches, and the ligature must not be applied too near these.



*Fallacies.*—If the incision is placed too near the middle line there will be risk of opening up the external abdominal ring or the sheath of the rectus, and of dividing the epigastric artery. If the incision is put too low, it will interfere with the inguinal canal and spermatic cord in front, and, behind, the trunk of the circumflexa ilii, running between the internal oblique and transversalis, will be divided. The curve and length of the incision must be carefully preserved or it will be difficult to reach the artery, and each muscle should be finished before the deeper one is interfered with. With practice and a steady hand it is possible to divide all the tissues down to the peritoneum without having recourse to the director, but it is safer to use the director for the fascia transversalis. In using the director great care must be taken not to force it through deeper structures unawares, but by moving it horizontally to make it clear its way at the intended level. When dividing the structures upon the director the knife should not be run up to the extremity of the groove, lest the peritoneum should have become folded over the end of the instrument and thus be divided. The outside of the peritoneum is *not* glistening and smooth, but slightly roughened from the separation of its attachments. A wound of the peritoneum is not necessarily fatal in the living body, and in the dead is only inconvenient by letting out the contained fluid.

The tendon of the psoas parvus may be mistaken for the artery, particularly in old subjects, in whom the artery is tortuous and does not run along the brim of the pelvis, but, making one or more bends, emerges from the pelvis close to Poupart's ligament. In such a case (which is hardly likely to occur in an operation on the living subject) the artery must be hooked up out of the pelvis with the finger before being separated from the vein.

*The Common Iliac Artery* (Fig. 1, *b*) may be tied through an incision resembling that for the external but more extensive, or it may be reached by enlarging that incision. Beginning at the level of the anterior superior iliac spine, and about  $1\frac{1}{2}$  inch nearer the median line than that point of bone, a semi-lunar incision, 5 to  $5\frac{1}{2}$  inches long, is to reach well back over the ilium and up towards the last rib. The external oblique, internal oblique, and transversalis are to be successively divided, and the peritoneum exposed by dividing the fascia transversalis on a director. The peritoneum is then to be stripped up and turned forward as in the preceding operation, but two spatulas will be required to exercise the necessary traction. The spermatic vessels and ureter are turned forward with the peritoneum, to which they adhere, and the operator feels for the promontory of the



sacrum, and with the steel director tears through the cellular tissue surrounding the artery, immediately above this bone. The needle must be passed from right to left on both sides of the body, the vein being to the right side in both cases (B).

*Anatomy* (Fig. 2).—The common iliac artery extends from the bifurcation of the aorta on the left side of the fourth lumbar vertebra to, usually, the sacro-iliac synchondrosis, but it may bifurcate earlier. The artery is crossed by the ureter, and, on the left side, by the rectum, and is covered by the peritoneum. The relation of the veins differs on the two sides. On the left side, the vein lies internally to the artery and crosses beneath the right artery to the vena cava; on the right side, the vein is at first behind, and then to the outer side of the artery to join the vena cava, which is also to the right side. Thus both veins are to the right of their respective arteries.

*Fallacies*.—In addition to the points referred to under the external iliac, there is the possibility of mistaking the enlarged ureter for the vessel, and of tying the upper part of the external iliac artery instead of the common iliac. The operation has not been a successful one, and is now practically abandoned.

The Internal Iliac Artery, or the Abdominal Aorta might be reached by the incision here described, but the operations are not of practical utility.

#### THE COMMON FEMORAL ARTERY.

*The Common Femoral Artery* (Fig. 1, c) may be tied without any difficulty half an inch to an inch below Poupart's ligament, by a  $2\frac{1}{2}$  inch incision parallel to the ligament. The artery lies midway between the anterior superior iliac spine and the symphysis pubis, and can be readily felt in the living or dead body. The incision is to be carried through the fascia lata, and any small bleeding vessels being secured, the exact position of the femoral artery is to be ascertained with the finger. The femoral sheath being then picked up with the forceps is to be opened vertically directly over the artery, when the needle can be passed from within outwards.

*Anatomy*.—The common femoral artery lies in the femoral sheath with the femoral vein to its inner side, and is covered only by the fascia lata and integuments. It gives off three or four small branches, which may be in the way.



*Fallacy.*—The only fallacy is that the common femoral artery may be so short, that unless the ligature is applied close to Poupart's ligament, the vessel tied may prove to be the superficial femoral.

### THE OPERATION FOR STRANGULATED HERNIA.

THE incision for the relief of a strangulated *Inguinal Hernia* (Fig. 1, *d*) should be made over the external abdominal ring in the axis of the swelling. A transverse fold of skin being picked up, the scalpel is made to transfix it with the back towards the hernia, and by dividing it makes an incision averaging  $1\frac{1}{2}$  to 2 inches long, which may be readily enlarged if necessary. In doing this, the superior external pudic artery will probably be divided and require a ligature. The amount of tissue between the skin and the hernial sac will vary very much. If slight and fatty it may be most conveniently torn through with the nails of the forefingers, but if too tough for this, it should be picked up with forceps and divided with the knife held horizontally, when, a hole being thus made, a director may be slipped beneath, and the scalpel run along the groove. The cremaster is the only structure likely to be recognized in an operation for hernia, and the operator should not attempt to make several layers of fascia, but dissect steadily down to the peritoneal sac, which will be recognized by its bluish appearance, and the presence of intestine and fluid within it, as in the operation for tying the iliac arteries. The sac being reached, the finger can be readily carried along it into the inguinal canal to seek for the point of constriction, and if this is found, it should be divided directly upward with a hernia knife, slipped along the finger and guided by the nail beneath the constriction. Failing to find a constriction, or failing to return the bowel after dividing it, the operator must open the sac. The sac is to be opened by picking it up with forceps and dividing it horizontally close to them. It is generally thicker than anticipated, and will be known to have been opened by the escape of fluid from the interior, except in the rare case of adhesion to the hernial contents. The director is then to be slipped in and the sac opened to the extent of an inch and a half, so as to allow of the introduction of the finger without permitting the escape of the intestines. The finger is then to pass upwards in search of the stricture, which, being found, is to be divided with the hernia knife guided by the finger-nail as before. It can seldom be

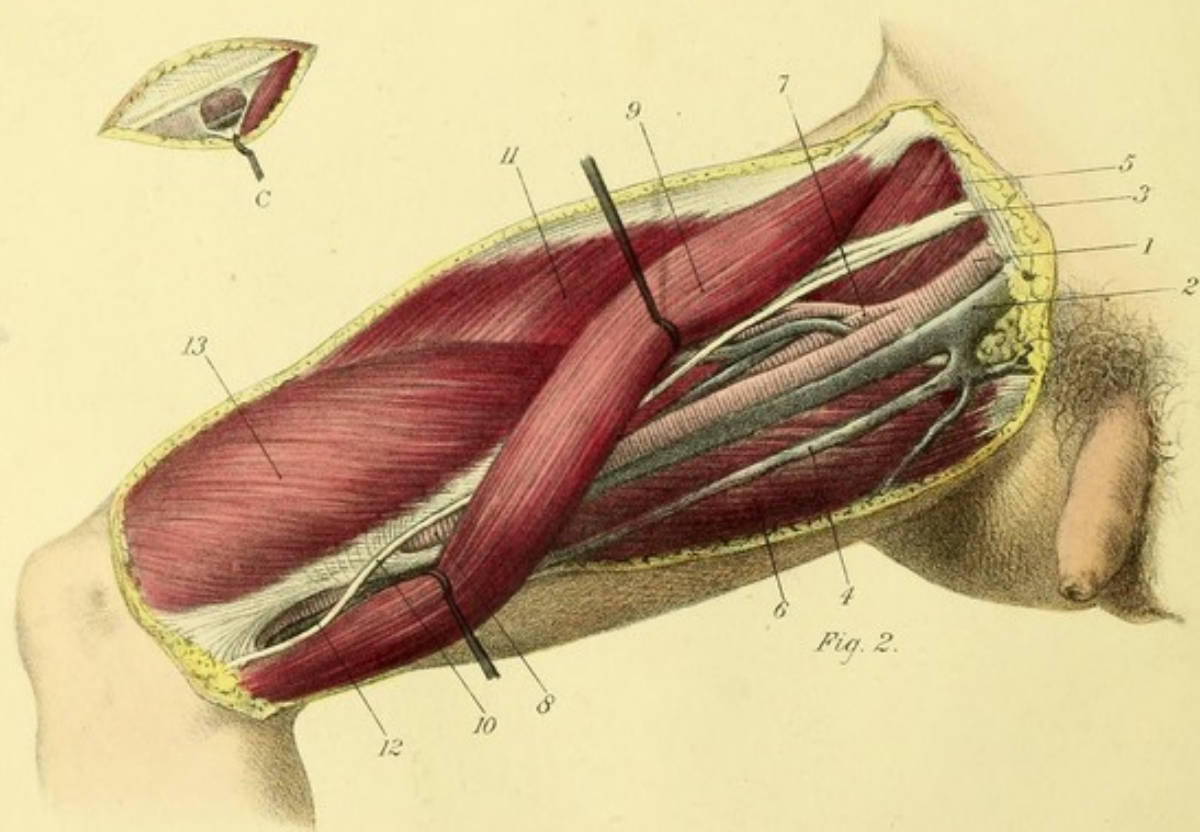
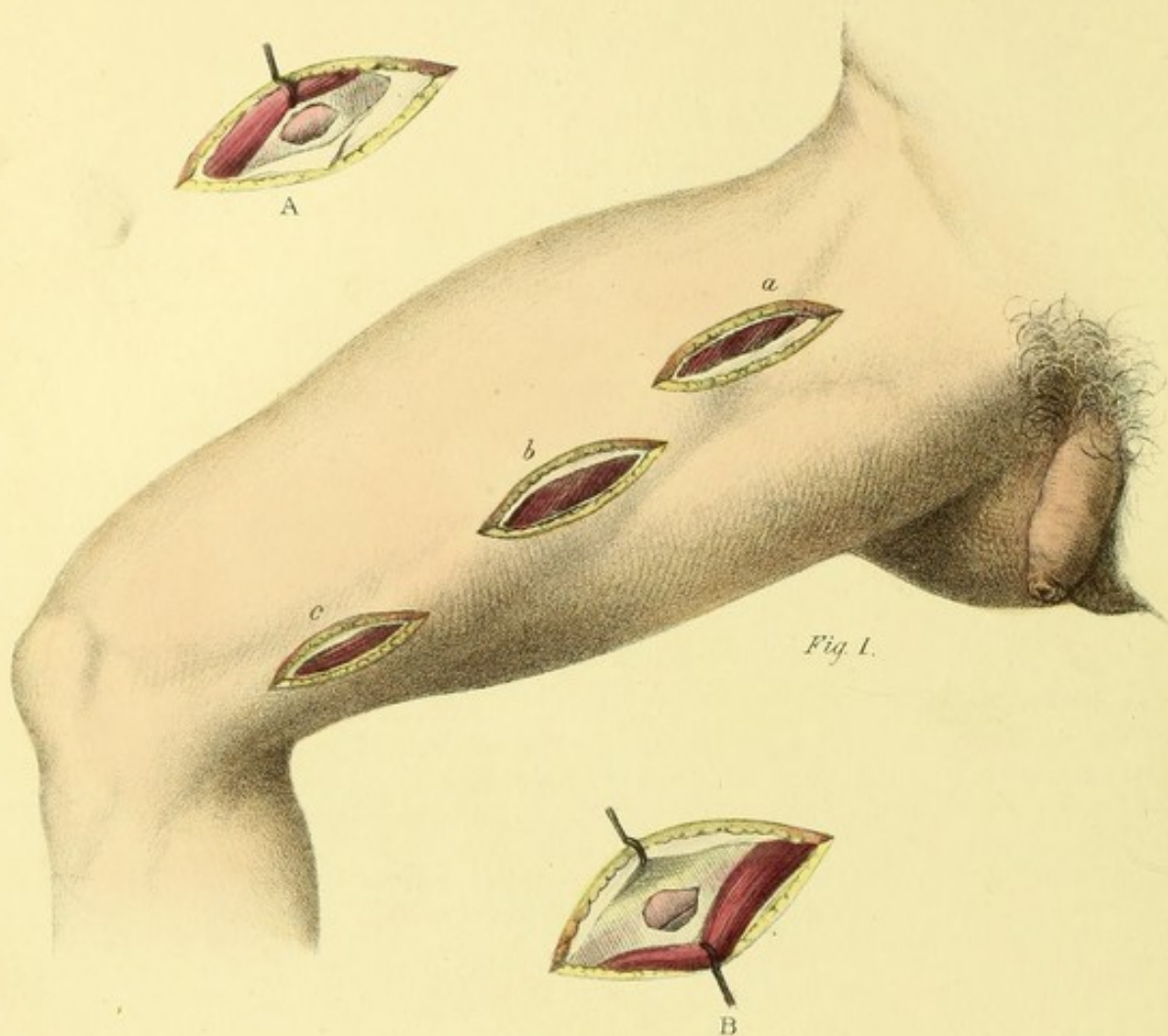

necessary to use a director to divide the stricture, and there is always a danger of doing mischief with its point.

The incision for the relief of a strangulated *Femoral Hernia* (Fig. 1, *e*) may be most conveniently made close to the inner side of the sac, by pinching upon a transverse fold of skin and dividing it as in the previous operation. The subcutaneous tissues can be readily torn through with the finger-nail and the sac reached, when the finger can be at once passed along its inner side to the constriction, which will probably be at the femoral ring. The hernia-knife, guided by the finger-nail, should be slipped beneath Gimbernat's ligament and made to divide a few fibres, cutting towards the median line. If it becomes necessary to open the sac, the original incision may be enlarged, or another at right-angles to it made. The sac is to be picked up and opened on a director sufficiently to admit the finger, as in the preceding operation, and the constriction in the neck of the sac is then to be divided directly inwards in the same way. The existence of an abnormal obturator artery cannot be diagnosed, and with ordinary care it is not likely to be divided.







## P L A T E   V I I .

---

FIG. 1.

- |           |   |  |
|-----------|---|--|
| <i>a.</i> | Incision for ligature of Femoral artery in Scarpa's triangle.               |  |
| <i>b.</i> | ,,                   ,,                   Femoral artery in Hunter's canal. |  |
| <i>c.</i> | ,,                   ,,                   Popliteal artery.                 |  |
|           | A. Deep dissection of <i>a.</i>   |  |
|           | B.   ,,                   ,, <i>b.</i>                                      |  |
|           | C.   ,,                   ,, <i>c.</i>                                      |  |

FIG. 2. Anatomy of Thigh.

- |  |  |  |
|--|--|--|
| 1. Femoral artery.<br>2. Femoral vein.<br>3. Anterior crural nerve.<br>4. Internal saphenous vein.<br>5. Psoas and Iliacus.<br>6. Gracilis.<br>7. Profunda femoris artery. |  | 8. Femoral artery in Hunter's canal.<br>9. Sartorius.<br>10. Internal saphenous nerve.<br>11. Rectus femoris.<br>12. Popliteal artery.<br>13. Vastus internus. |
|--|--|--|

---

### THE FEMORAL ARTERY.

*The Femoral Artery* (superficial) may be tied in two places, at the apex of Scarpa's triangle, and in Hunter's canal, the former being the preferable and more usual operation.

*To tie the femoral artery in Scarpa's triangle* (Fig. 1, *a*) the thigh is to be slightly flexed and abducted, the knee being bent, and in this position of the limb a line drawn from about the middle of Poupart's ligament to the inner condyle of the femur will mark the position of the upper part of the artery. An incision begun two inches below the groin and in the centre of the thigh, should be prolonged for three to four inches, and be carried through the fascia lata so as to expose the sartorius crossing the lower part of the incision. A blunt hook being inserted at the inner edge of the fascia lata by an assistant, the operator seeks the inner border of the sartorius, and turns the whole muscle outwards with his finger, when it is to be held aside with a spatula by an assistant. Any small bleeding branch



is now to be secured, and the wound wiped out, when, if the incision has been properly made, and it is not pulled out of position, the sheath of the artery will be readily seen at its lower part. The femoral sheath is to be carefully opened with knife and forceps, and especial pains taken to dissect well down to the true arterial coat on both the inner and outer sides of the vessel. There will then be no difficulty in passing the aneurism needle from within outwards without any danger to the femoral vein or the saphenous nerve (A).

*Anatomy* (Fig. 2).—The femoral artery lies superficially in Scarpa's triangle in the upper third of the thigh, but is best tied beneath the sartorius, or just at the apex of the triangle. In the dissected limb there appears to be plenty of room above the sartorius for the safe application of a ligature, but in the living body the muscle overlaps the artery so considerably, that an attempt to reach the vessel without displacing the muscle would bring the ligature into dangerous proximity with the profunda branch, the point of origin of which is uncertain. Scarpa's triangle is bounded above by Poupart's ligament, to the outer side by the sartorius, to the inner side by the adductor longus, and below by the junction of the two muscles. The femoral artery lies upon the psoas, the pectineus (the profunda vessels and femoral vein intervening) and the adductor longus. The femoral vein is to the inner side above, but is behind the artery below. The anterior crural nerve is at first separated from the femoral artery by a portion of the psoas muscle, but below its branches are in closer relation with the artery, one branch, the internal saphenous nerve, lying close to the outer side of the artery.

*Fallacies*.—If the limb is not flexed and abducted the incision will be made too much to the outer side, or, if with the idea of more easily reaching the edge of the sartorius, the incision is put too near the inner side, there will be great risk of wounding the saphenous vein, and difficulty in reaching the artery. If the incision is too small it is very difficult to displace the sartorius sufficiently. The sheath being exposed must be opened with the knife, for no blunt instrument would do this without bruising the femoral vein which lies in close proximity to the vessel. No attempt should be made to pass the needle until the artery is thoroughly cleared, or the vein may be perforated. Should such an accident occur, the hæmorrhage being controlled by pressure with the finger below the wound, the needle should be withdrawn, and separation of the vessels effected higher up, when the artery being carefully tied, the hæmorrhage from the vein will not recur.



*To tie the Femoral artery in Hunter's canal* (Fig. 1, *b*) the thigh is to be flexed and abducted, as in the previous operation. An incision, 3 to 4 inches in length, is to be made in the middle third of the thigh, parallel to the inner border of the limb, and about an inch from the margin of the gracilis. This incision may expose the saphenous vein, which is to be avoided, and the fascia lata is to be divided so as to expose the sartorius, which will be recognized by the direction of its fibres. The outer edge of the divided fascia being held with a hook, the operator seeks the outer border of the sartorius, and turns the whole muscle inwards with his finger, when it is to be held aside with a spatula by an assistant. The tendinous expansion thrown across the vessels from the adductors to the vastus internus must now be opened over the artery, which can generally be seen through it, and the artery carefully isolated, when the needle should be passed from without inwards, avoiding the saphenous nerve (B).

*Anatomy* (Fig. 2).—Hunter's canal is formed by a tendinous expansion derived from the adductors longus and magnus and the vastus internus, which encloses the femoral vessels and long saphenous nerve in the middle third of the thigh, and is covered by the sartorius in its whole length. The vein is behind and to the outer side of the artery. The saphenous nerve, at first to the outer side of the artery, crosses it at the lower part to pierce the sheath and become subcutaneous.

*Fallacies*.—If the incision is put below the middle third of the thigh the canal will not be exposed, but the popliteal space will be opened. If the incision is put too far from the inner border of the thigh the vastus internus will be exposed, and may be mistaken for the sartorius, but its fibres are coarser, and run in the opposite direction. When the tendinous canal is exposed, the white tendon of the adductor magnus might be mistaken for the artery, which is always to its outer side.

*The Popliteal Artery* (Fig. 1, *c*) may be reached in the upper part through an incision in the lower third of thigh, between the vastus internus and hamstring tendons. The sartorius and hamstrings being held aside with a spatula, the round tendon of the adductor magnus will be seen with the vastus internus, and immediately behind this a cautious use of the steel director will expose the popliteal artery in its upper part, with the vein behind and to the outer side. This is not an operation of practical utility, and is only described to illustrate the fallacy of seeking the femoral too low (C).









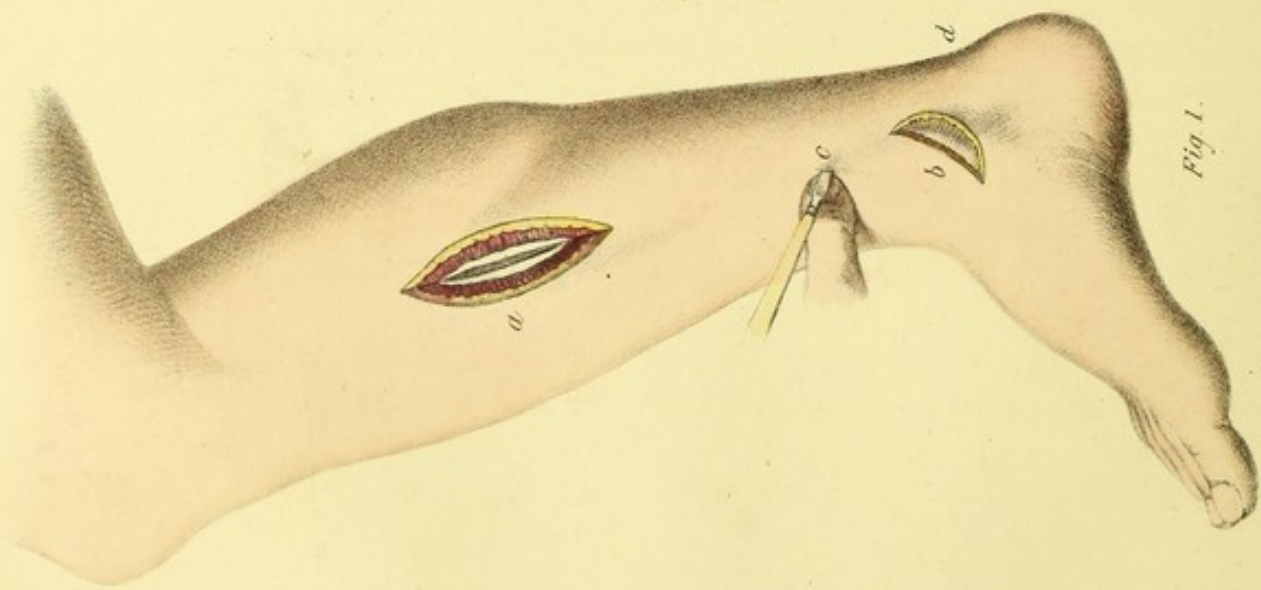


Fig. 1.

C. Heath prep.

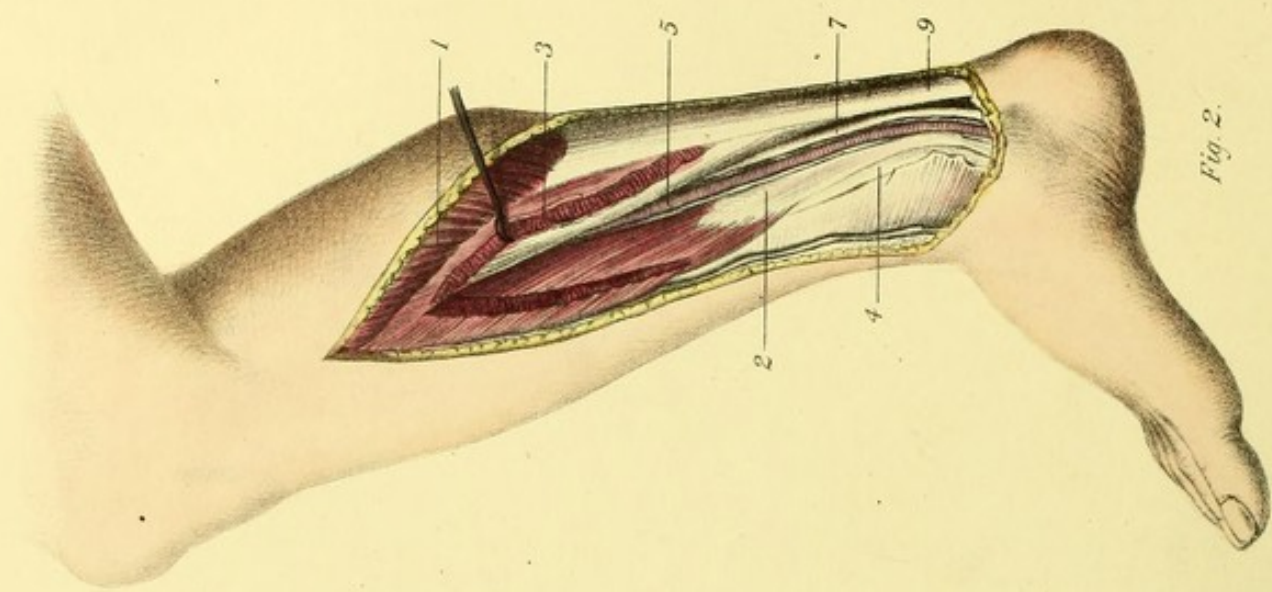


Fig. 2.

J.B. Léveillé del. et nat. 1875.

Hanhart lith.





being opened with the knife, the *venæ comites* should be separated from the artery with a steel director, and the needle passed from without inwards, *i.e.*, from the nerve, which is usually to the fibular side of the vessels (A).

*Anatomy* (Fig. 2).—The posterior tibial artery is beneath the soleus, and lies upon the tibialis posticus and flexor longus digitorum. The posterior tibial nerve is at first to the inner side of the artery, and then crosses it to the outer side, along which it runs to the ankle. The peroneal artery arises from the posterior tibial in the upper part, and may be larger than that vessel, or take its place, in which case it might be reached by following out the wound to the fibula, against which bone the artery lies.

*Fallacies*.—If the incision is put too far from the tibia the gastrocnemius will be found, and may be mistaken for the soleus. In dividing the soleus if the knife is turned away from, instead of towards the tibia, a much more extensive division of muscular fibre will result. A tendinous intersection occasionally met with may be mistaken for the deep tendon of the soleus, which has very rarely a few muscular fibres on its deep surface. If the incision be made close to the border of the tibia it is difficult to distinguish the soleus, and there is great risk of getting beneath the deep muscles and down to the interosseous membrane.

*At the ankle* (Fig. 1, *b*) the posterior tibial artery may be tied through a 2-inch semi-lunar incision, placed half an inch behind the internal malleolus. The edge of the scalpel is to be directed towards the tibia, and the incision carried down to the internal annular ligament. In the dead body the colour of the artery (usually containing a little blood) and veins will be seen through the annular ligament, which should be opened immediately over them. The nerve lies in the same division of the ligament, and to the outer side, unless it should have divided higher up, in which case a nerve may lie on each side of the artery. The needle should be passed from without inwards (B).

*Anatomy* (Fig. 2).—The order of structures behind the inner malleolus from within outwards is, the tendons of the tibialis posticus and flexor digitorum longus; the posterior tibial artery, veins and nerve; the tendon of the flexor longus pollicis, more deeply placed.

*Fallacies*.—If the incision is made too near the tibia, the sheath of the tendons will be opened. The artery may have divided into the two plantar arteries, in which case ligatures should be applied to both those vessels.



## TENOTOMY.

The *Achilles Tendon* (Fig. 1, *d*) is to be divided from the inner side, the patient lying on his back with the knee well bent, or, more conveniently with children, being turned on the face with the foot projecting over the end of the table, and the foot being held by an assistant, who should make the tendon tense. The operator feels the inner edge of the tendon with his left thumb-nail and slips the tenotome held flat beneath it, and the edge of the knife being then turned against the tendon, it is divided by a steady sawing movement, the finger guarding the skin over the point of the knife to prevent puncture. The assistant should forcibly extend the foot until the tendon yields and should then promptly let go, and the operator should at the same moment turn his knife ready for withdrawal as soon as a piece of lint can be applied over the puncture.

*Fallacies.*—The tendo Achillis may be easily transfixed without care, and then only a portion of it will be divided. If the puncture were made from the outer side, it would be possible to injure the tibial vessels with the point of the knife.

*The Tibialis Posticus* (Fig. 1, *c*) may be most satisfactorily divided immediately above the inner malleolus. The leg being flexed and abducted, the operator is to define the inner border of the malleolus with his left thumb-nail, and will find a minute tubercle just at the junction of the malleolus and tibia. Immediately above this tubercle the sharp-pointed tenotome, or a very small scalpel, is to be carried vertically over the thumb-nail and between the bone and the tendon, and will, if properly inserted, remain fixed without any support from the hand. Without enlarging the skin-wound the knife is to be moved up and down slightly, so as to make a sufficient opening in the sheath, and is then to be withdrawn. A blunt-pointed tenotome having been introduced in precisely the same direction, is then to be turned so as to bring the edge against the tendon, which is to be divided with a sawing movement whilst the foot is everted by an assistant. If desirable the flexor longus digitorum is readily divided at the same time as the tibial tendon, and in fact it is often so divided unconsciously.

*Anatomy.*—The tendon is next to the bone, and the point at which it is to be divided is immediately above the annular ligament and close to the attachment of the muscular fibres. If divided lower the cut ends of the tendon are apt to become adherent to the fibrous sheath, and the muscle is rendered useless. In the healthy foot there is room to divide the tendon



between the annular ligament and the scaphoid bone, but in talipes varus, and especially in children, the space would be too small.

*Fallacies.*—The common mistake is to slip the knife, particularly the blunt-pointed one, between the tendons instead of between the bone and the tibial tendon. The knife must be kept nearly vertical in the whole of the operation, for it is quite possible, if the point of the tenotome is introduced too deeply and then raised, that it should wound or divide the tibial vessels.

*The Tibialis Anticus* seldom requires division, but may be safely cut at any point below the annular ligament by slipping a tenotome beneath it.

*The Hamstring Tendons* are not readily divided on the dead body, owing to the difficulty of making them tense. The knife should be passed beneath them near their insertions, especial care being taken to define the border of the biceps, on account of the close proximity of the peroneal nerve.





Fig 1.

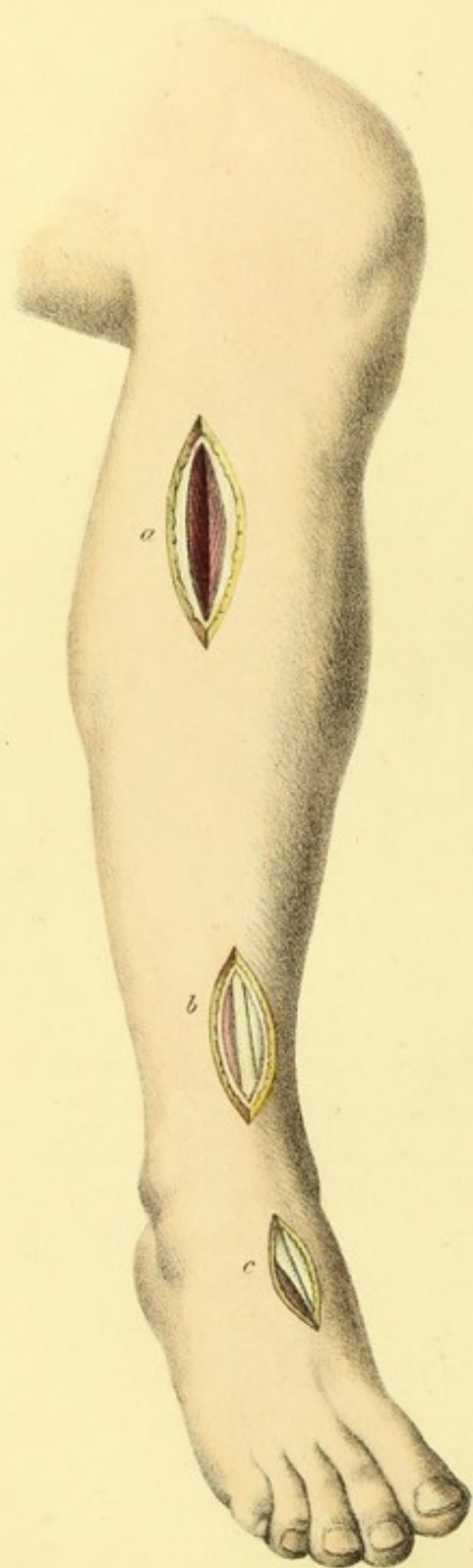
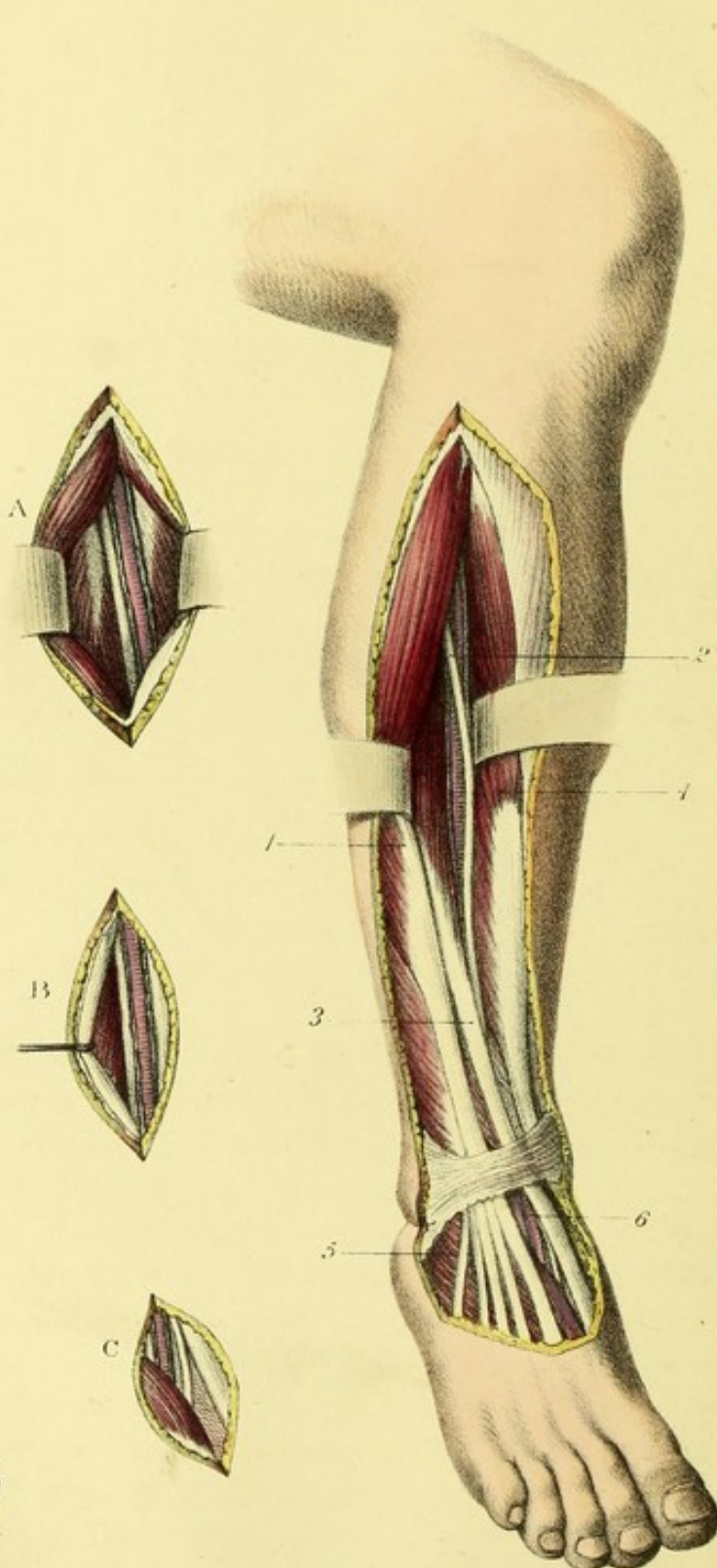


Fig 2.



## P L A T E   I X.

---

FIG. 1.

- |                                 |  |
|---------------------------------|--|
| <i>a.</i>                       | Incision for ligature of Anterior Tibial artery. |
| <i>b.</i>                       | " " " "  |
| <i>c.</i>                       | " " Dorsalis Pedis artery.                       |
| A. Deep dissection of <i>a.</i> |  |
| B.                              | " " <i>b.</i>                                    |
| C.                              | " " <i>c.</i>                                    |

FIG. 2. Anatomy of the Front of the Leg.

- |                                       |                               |
|---------------------------------------|-------------------------------|
| 1. Extensor longus digitorum.         | 4. Tibialis anticus.          |
| 2. Anterior Tibial vessels and nerve. | 5. Extensor brevis digitorum. |
| 3. Extensor proprius pollicis.        | 6. Dorsal artery of the foot. |
- 

### THE ANTERIOR TIBIAL ARTERY.

*The Anterior Tibial Artery* may be tied in the upper or lower third of the leg.

*In the Upper Third* (Fig. 1, *a*).—The limb being supported under the knee so that the foot may have the sole flat on the table, an incision begun at a point midway between the external tuberosity of the head of the tibia and the head of the fibula, and an inch below them, is to pass obliquely downwards and inwards from 3 to 3½ inches. The deep fascia of the leg is to be divided to the same extent without injuring the muscles beneath and then with the forefinger and handle of the knife the cellular interval between the tibialis anticus and extensor longus digitorum is to be sought, and the two muscles carefully separated. This interval can be more easily recognized with the finger than by the eye, but when opened up a muscular branch of the artery will usually be seen between the two muscles. Two broad spatulas must be employed to separate the muscles down to the interosseous membrane, and it is convenient to hitch the outer one over the border of the fibula. The anterior tibial artery and veins will then be



seen lying on the interosseous membrane, with the nerve to the outer side, and the needle should be passed from the nerve (A).

*Anatomy* (Fig. 2).—The artery with its *venæ comites* lies upon the interosseous membrane between the tibialis anticus and the extensor longus digitorum in the upper third, and between the tibialis anticus and the extensor proprius pollicis in the middle third of the leg, but the extent of attachment of the last muscle varies somewhat in different subjects. The anterior tibial nerve lies at first to the outer side of the artery, but lower down it may cross the vessel.

*Fallacies*.—It is commonly supposed that a "white line" marks the outer border of the tibialis anticus, and that an intermuscular septum passes between that muscle and the extensor digitorum. The intermuscular septum in reality lies between the extensor digitorum and the peronei muscles, and if found leads the operator to the wrong side of the extensor. In muscular subjects the fascial origin of the tibialis is sometimes so developed as to be mistaken for a septum; but the muscular must not be separated from the tendinous fibres. In using the finger to find the intermuscular space it should be directed towards the tibia rather than the fibula.

*In the Lower Third* (Fig. 1, *b*).—The tendon of the tibialis anticus can be readily felt through the skin, lying next to the anterior border of the tibia immediately above the ankle-joint. An incision 2 to 2½ inches long on the outer border of the tendon of the tibialis anticus and immediately above the anterior annular ligament, is to be carried through the deep fascia so as to expose the tendon. To its outer side will be seen the tendon of the extensor proprius pollicis, which is to be drawn outwards with a hook, when, in the interval between the two, the anterior tibial vessels and nerve will be seen lying upon the tibia. The relation of the nerve is irregular, but most commonly it is to the outer side of the artery at this point, and the needle should be passed from it (B).

*Anatomy* (Fig. 2).—The anterior tibial artery in its lower third lies between the tibialis anticus and the extensor longus digitorum upon the tibia, becoming quite superficial at the ankle-joint. Muscular fibres are attached to both tendons close down to the annular ligament, and the artery if tied high will be found between muscular fibres only. The relation of the anterior tibial nerve to the artery varies in this part of its course.

*Fallacies*.—The tendon of the extensor pollicis may be mistaken for that of the tibialis anticus, in which case the extensor digitorum will be



drawn aside, and the operator will be on the wrong side of the extensor proprius pollicis. The muscular fibres of the tibialis are sometimes dissected from the tendon, being mistaken for those of the extensor proprius pollicis.

# THE DORSAL ARTERY OF THE FOOT.

*The Dorsalis Pedis* (Fig. 1, *c*) is the direct continuation of the anterior tibial artery, and may be reached, immediately below the anterior annular ligament, by an incision  $1\frac{1}{2}$  inches long upon the outer border of the tendon of the extensor proprius pollicis. With a little dissection the artery will then be found lying upon the tarsus between the extensor proprius pollicis and the inner tendon of the extensor longus digitorum, immediately above the extensor brevis digitorum (C).

*Anatomy* (Fig. 2).—The dorsal artery of the foot lies between the tendon of the extensor proprius pollicis and the innermost tendon of the extensor longus digitorum, and is crossed by the innermost slip of the extensor brevis digitorum. The anterior tibial nerve is in uncertain relation. This artery is often irregular in its course, and may go at once to the outer side of the foot, or it may be wanting, its place being supplied by the anterior peroneal.



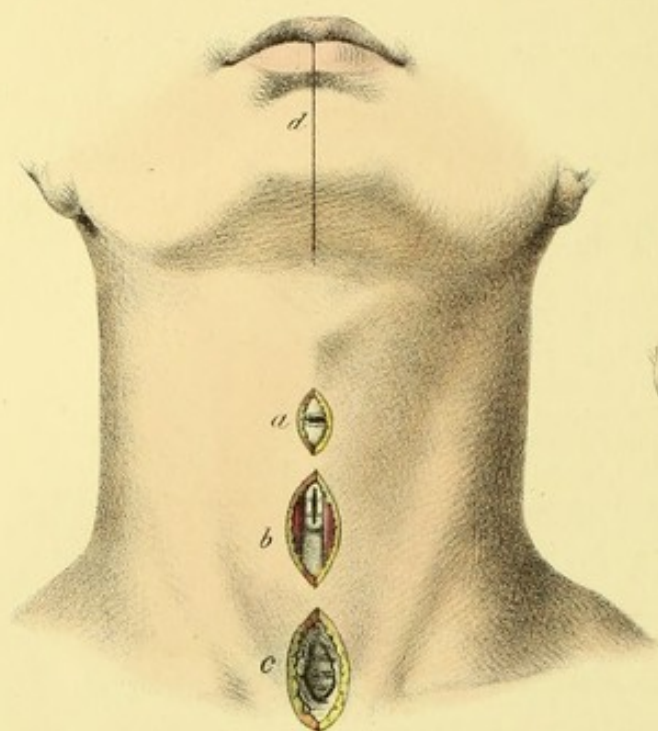




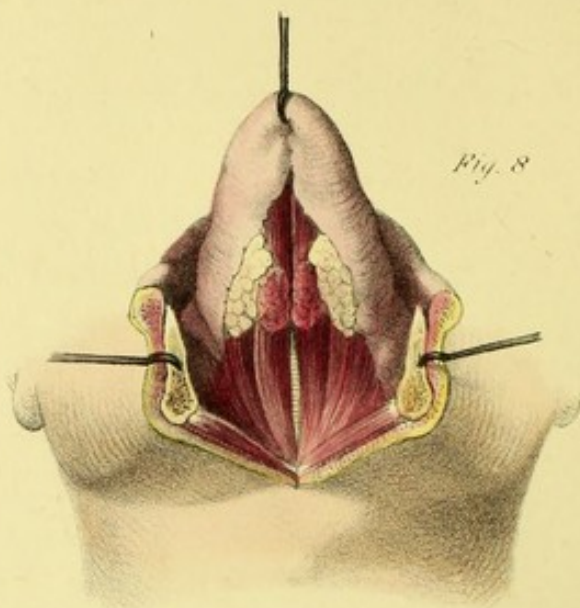




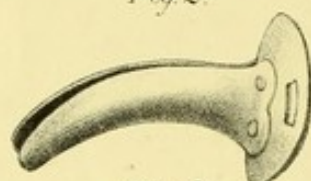*Fig. 1.*



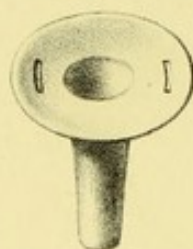
*Fig. 8.*



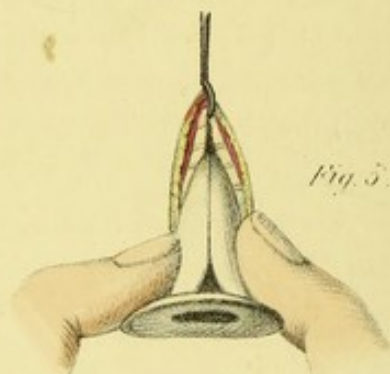
*Fig. 2.*



*Fig. 4.*



*Fig. 5.*

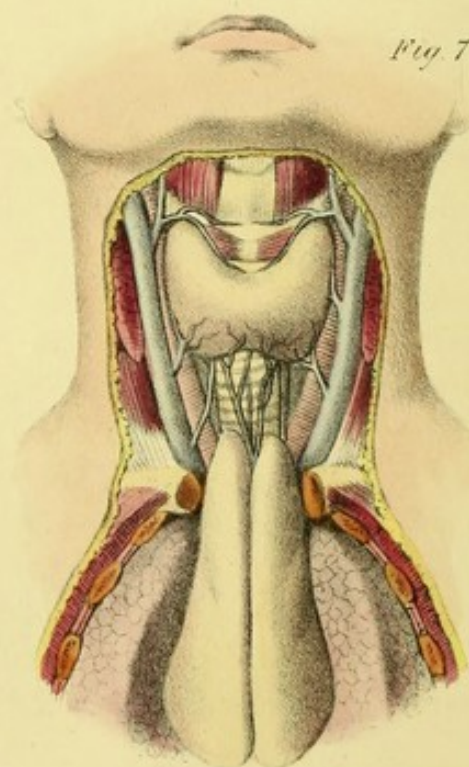
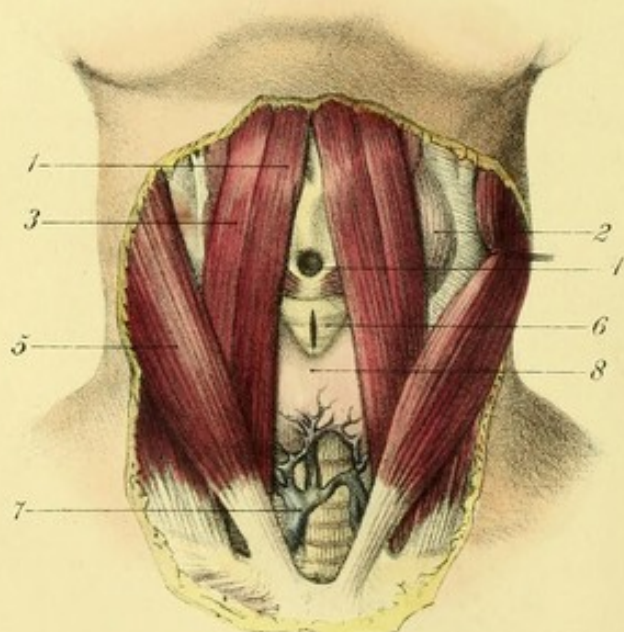


*Fig. 3.*



*Fig. 6.*

*Fig. 7.*





## PLATE X.

---

FIG. 1.

- |           |   |  |
|-----------|---|--|
| <i>a.</i> | Incision for Laryngotomy.                 |  |
| <i>b.</i> | ,, Tracheotomy above the thyroid isthmus. |  |
| <i>c.</i> | ,, below ,,                               |  |
| <i>d.</i> | ,, Removal of the tongue.                 |  |

FIG. 2. Bivalve tracheotomy tube.

FIG. 3. Internal cylindrical tube.

FIG. 4. External cylindrical tracheotomy tube.

FIG. 5. Method of introducing the bivalve tube in tracheotomy.

FIG. 6. Anatomy of the neck in the adult.

- |  |  |  |
|--|--|--|
| 1. Sterno-hyoideus.<br>2. Foreign body in œsophagus.<br>3. Omo-hyoideus.<br>4. Crico-thyroid membrane. |  | 5. Sterno-mastoideus.<br>6. Trachea.<br>7. Inferior thyroid veins.<br>8. Thyroid body. |
|--|--|--|

FIG. 7. Anatomy of the neck in the child, to show relations of thyroid and thymus.

FIG. 8. Removal of the tongue by section of the symphysis menti.

---

### LARYNGOTOMY.

*Laryngotomy* (Fig. 1, *a*) is performed in the crico-thyroid membrane, between the ring of the cricoid and the lower border of the thyroid cartilage. The head being, if possible, thrown back, so as to expose the front of the throat, the operator feels for the firm ring of the cricoid cartilage, which is always to be recognized, even in women and children. The larynx being fixed with the forefinger and thumb of the left hand an incision from  $\frac{3}{4}$  to 1 inch in length is made over the membrane in the median line, and the knife then passed horizontally through the gaping wound into the larynx, dividing the membrane to the extent of half an inch. A laryngotomy tube or small tracheal tube is then introduced (with the end downwards) and fastened with tapes round the neck. In cases of great urgency a transverse incision may be made at once into the larynx without any superficial incision, and, failing a tube, the two cartilages can, if necessary, be held asunder with a blunt pair of scissors.



*Anatomy* (Fig. 6).—The crico-thyroid membrane is bounded on each side by the crico-thyroid muscle, and is crossed by the small crico-thyroid arteries, which, however, lie so near the cricoid cartilage as ordinarily to escape injury, or if divided are so small as to be of no consequence.

*Fallacies*.—It is possible to mistake the thyro-hyoid for the crico-thyroid membrane by confounding the upper border of the thyroid with the ring of the cricoid cartilage. The mistake of turning the laryngeal tube upwards instead of downwards is one occasionally committed on the subject.

### TRACHEOTOMY.

*Tracheotomy* may be performed above or below the isthmus of the thyroid body.

*Above the Isthmus* (Fig. 1, *b*) is the easier and more satisfactory operation. Standing on the right of the patient, who should have his head thrown back, the operator makes an incision in the median line from the upper border of the cricoid cartilage downwards for  $1\frac{1}{2}$  inches, or more if the neck is swollen. A careful dissection is then made through the fascia in the median line, the tissues being pushed aside with the nail or a steel director until the rings of the trachea are reached. The space between the cricoid cartilage and the isthmus of the thyroid body can now be materially increased by forcibly drawing down the isthmus with the finger, and, if necessary, holding it with a blunt hook, which is to be entrusted to an assistant. The wound being sponged out, the operator fixes the trachea by inserting a sharp hook or tenaculum immediately below the cricoid cartilage, and draws it up with his left hand, whilst with the right he plunges the scalpel (with the back downwards) into the trachea at the lowest point exposed, and cuts up to the hook. Maintaining his hold on the hook the operator compresses the bivalve tube with his forefinger and thumb (Fig. 5), and slips it into the opening below the hook, and then inserts the inner tube. The hook may now be removed and the tube secured with tapes round the neck. When the space between the isthmus and cricoid cartilage is very small it may be necessary to extend the incision through the ring of the cricoid cartilage, thus converting the operation into *laryngo-tracheotomy*.

*Anatomy* (Fig. 6).—The sterno-hyoid muscles are separated by only a small median interval which it is important to find, since division



of the muscular fibres would give rise to hæmorrhage. The space between the cricoid cartilage and the isthmus of the thyroid is very small in infants, but increases with age, so that in adults there is no difficulty in exposing the three upper rings of the trachea. Ordinarily there is no vessel upon this part of the trachea, but there may be a loop between the two superior thyroid veins, which might be divided without great risk.

*Fallacies.*—In infants with fat necks and an undeveloped thyroid cartilage it is easy to wander from the median line and get to the side of the trachea, or even to miss it altogether, and dissect down to the vertebræ. If the trachea is not fixed with a sharp hook the operator may puncture the trachea, but fail to make a sufficient opening for the tube, and then be embarrassed by emphysema. Arterial hæmorrhage, if any, having been arrested by ligature or torsion, it is useless to wait for the cessation of congestive venous hæmorrhage, which will cease directly air is admitted to the lungs.

*Below the Isthmus* (Fig. 1, *c*), Tracheotomy is more difficult and dangerous, owing to the vessels in the neighbourhood. A median incision begun over the isthmus of the thyroid is to be carried down to the sternum, and the interval between the sternal muscles carefully maintained. A cross-branch between the anterior jugulars will, if it exist, be necessarily divided, and may require two ligatures. The dissection is to be carefully continued, and principally with the nail of the forefinger and handle of the scalpel, until the rings of the trachea are thoroughly recognized by the finger. The wound being held open with blunt-hooks, the trachea is then to be fixed at the upper part with a sharp hook by the operator's left hand, and opened from below upwards to the extent of three rings by one steady plunge of the knife with the back towards the sternum. The tube having been inserted, a stitch may be put in the top and bottom of the incision.

*Anatomy* (Fig. 6).—The trachea is deeper at its lower than its upper part, and the length below the isthmus varies considerably. The space between the sterno-thyroid muscles is filled by a firm fascia which requires division, and beneath it is a quantity of fat in which the inferior thyroid veins run. These are usually a little to each side of the median line, and may be still further displaced during the operation, so as to be out of danger, but cross-branches must necessarily be divided. Should the trunk of one of the inferior thyroid veins be divided the hæmorrhage will be severe, owing to the proximity to the innominate vein. An artery (*thyroidea ima*) is occasionally found passing up the front of the trachea



from the aorta to the thyroid body. The common carotid arteries are in close relation to the sides of the trachea, and the innominate artery lies against the right side of the tube as high as the sterno-clavicular joint, and may in exceptional cases reach higher, so as to be in danger. The left innominate vein crosses the trachea below the top of the sternum in the adult, but in the child is usually higher, and would when the neck is stretched be in considerable danger. The thymus gland varies very much at different ages, and in different individuals. In infants it usually reaches above the sternum in the median line, and considerably higher at the sides of the trachea, occasionally touching the thyroid body (Fig. 7). In children the thymus usually dwindles down with advancing years, but occasionally the gland remains largely developed up to or near puberty, and might be found in the way of the lower operation of tracheotomy.

*Fallacies.*—Without a free superficial incision it is impossible to perform the operation satisfactorily, but this renders it easier to wander from the median line, and even miss the trachea altogether than in the operation above the isthmus. In cases where the thyroid is itself the cause of the dyspnœa by the pressure exerted upon the trachea, that tube may be either displaced or so compressed from side to side as to present an angle instead of the ordinary convex rings. If the trachea is insufficiently exposed and opened the tracheal tube may be thrust down behind the sternum and in front of the trachea, upon which it may exert fatal pressure. It is, of course, possible to open the œsophagus by thrusting the knife through the membranous back of the trachea in opening that tube, if the operation is rashly done.

#### ŒSOPHAGOTOMY.

The operation of *Œsophagotomy* may be required for the extraction of a foreign body impacted in the gullet. It is usually performed on the left side, the œsophagus tending to that side, and the incision is similar to that for ligature of the common carotid artery. A 3-inch incision with the centre opposite the cricoid cartilage is to be made along the edge of the sterno-mastoid, and a careful dissection carried down by the side of the trachea and larynx to the inner side of the carotid sheath. The projecting foreign body will serve as a guide, or if it is not obvious the gullet may be rendered prominent by introducing a pair of œsophagus forceps or a



curved sound from the mouth. This was done in the preparation from which Fig. 6 was drawn, and the projection is there seen. The œsophagus having been opened, and the foreign body carefully extracted, the opening may be advantageously closed with carbolized catgut sutures.

#### REMOVAL OF THE TONGUE.

*Removal of portions of the Tongue* may be effected with the knife, or better, on account of the absence of hæmorrhage, with the galvanic *écraseur*. When, as usually happens, the cancerous disease involves one side of the tongue, the operation may be satisfactorily performed as follows:—

The patient being secured in an arm-chair, the mouth is to be gagged, and with a needle set in a handle a thread is to be passed through the tip of the sound side, so as to enable the whole organ to be drawn forwards. Two or three needles in handles are then to be made to transfix the whole thickness of the tongue well beyond the disease, and the galvanic wire passed around them, so as to encircle the entire growth. The galvanic circuit being then completed, the *écraseur* is to be slowly screwed up, and the heated wire will steadily cut through the tissues without giving rise to any hæmorrhage, the needles being loosened in order as the loop of wire passes them. It is well to leave the thread in the tongue for a few hours in case of the occurrence of hæmorrhage, and as an extra precaution to brush the cauterized surface over with liquor ferri persulphatis.

*Removal of the entire Tongue* (Fig. 1, *d*) may be most satisfactorily performed by dividing the lower jaw so as to allow of the application of the galvanic *écraseur* close to the hyoid bone. An incision in the median line of the lower lip prolonged to the hyoid bone will allow of the dissection of the lip from the jaw for about a quarter of an inch on each side. With a drill the bone can then be perforated on each side of the median line, and about midway in the depth of the jaw, so as to admit of the two halves being subsequently drawn together with wire. The jaw is then to be divided exactly in the median line with a fine saw, which may advantageously have its handle raised above the level of the blade, so as to be out of the way of the patient's chest. The section need not be completed with the saw, but the bone-forceps may be used for the purpose, the slight irregularity often resulting being advantageous in maintaining the parts in apposition. The halves of the bone should be held asunder with hooks



while the operator cuts the *genio-hyo-glossi* muscles from the jaw with a pair of scissors, leaving the attachment of the *genio-hyoid* muscles (Fig. 8). With the forefinger and scissors the tongue can then be dissected from the floor of the mouth with the sublingual glands and mucous membrane, until the hyoid bone is reached, firm traction being made with a stout string passed through the tip. The tongue being then drawn down the *palato-glossi* muscles will be put on the stretch, and must be divided with scissors, after which a handled needle should be passed through the tongue close to the hyoid bone, around which the galvanic wire should be passed. The battery should not be too powerful in its action, and the screw of the *écraseur* should be worked very slowly or hæmorrhage may occur, and would be difficult to arrest, since both lingual arteries are probably divided at the same time.

The operator should be prepared with a handled needle and stout thread to transfix and hold the small remnant of tissue left attached to the hyoid bone should the breathing be embarrassed by the epiglottis and base of the tongue falling back. In the author's experience this is much more likely to happen when a considerable portion of tongue is left than when the section is made far back, and the difficulty seems to arise from the weight of the piece left forcing back the epiglottis when the sublingual muscles have been divided.

All hæmorrhage having been checked, the two halves of the jaw are to be brought together with a piece of stout silver wire. This may be passed from before backwards readily enough through the hole in one side of the jaw, but it is not easy to pass it back again on the opposite side unless a loop of thin wire be passed from before backwards through the hole already made, into which the end of the wire can be bent, and thus drawn forward. The two halves of the jaw should be brought into close and correct apposition, and the ends of the wire twisted and brought up beneath the lip. The lip is then to be brought together with hare-lip pins and a fine silk stitch in the mucous membrane, but care should be taken to leave the lower part of the incision open, so that there may be a free drain for the saliva and discharges from the mouth.

In removing the wire from the jaw at the end of three weeks or more, it will be found convenient to cut the wire close to the jaw on each side, and then with a blunt hook to pull out the loop from behind.





Fig. 1.

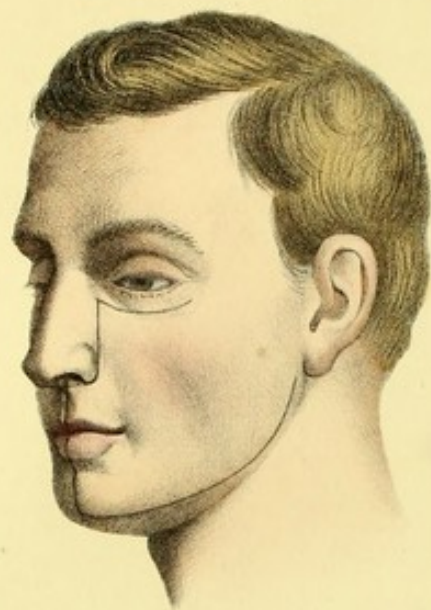

Fig. 2.

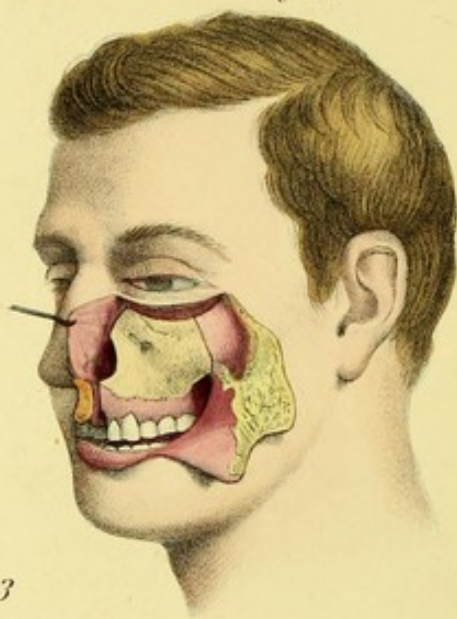

Fig. 3.

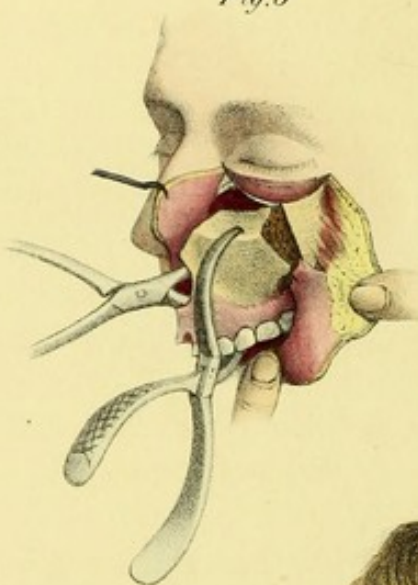


Fig. 6.

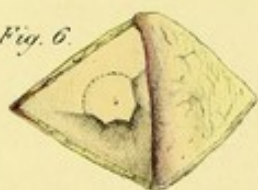


Fig. 7.

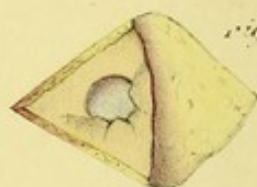


Fig. 5.

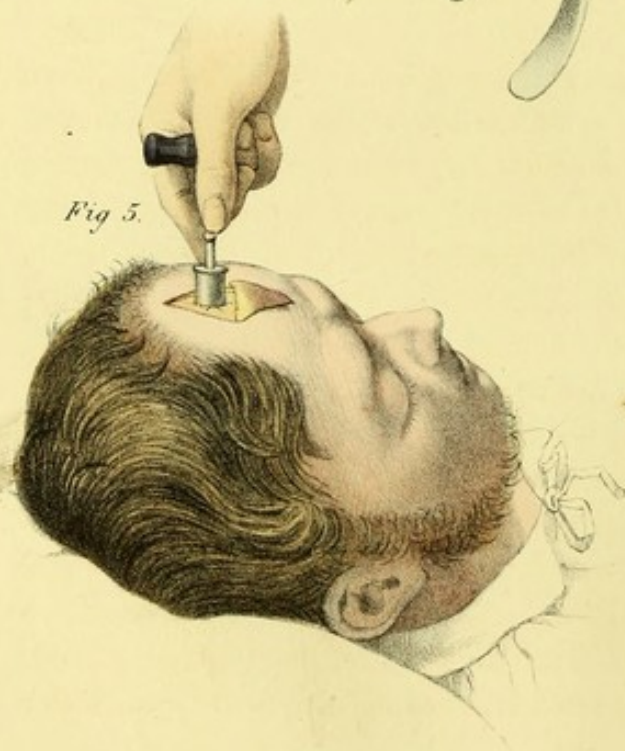
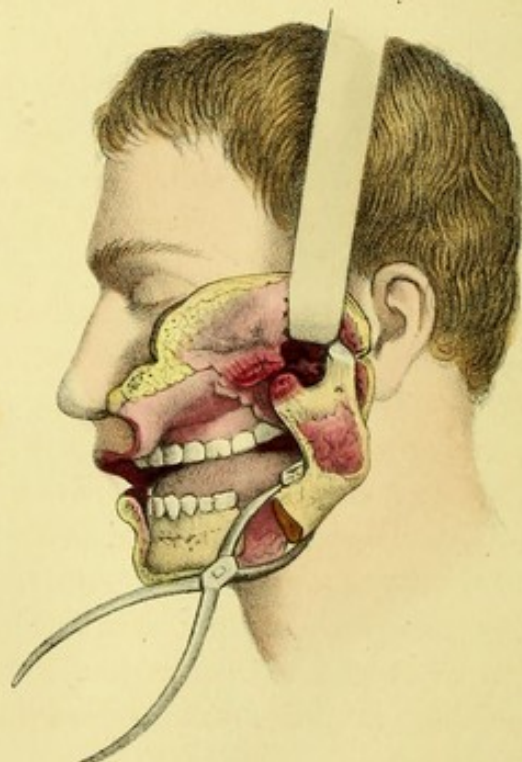


Fig. 4.





## PLATE XI.

---

*FIG. 1.* Incisions for removal of Upper and Lower Jaws.

*FIG. 2.* Removal of Upper Jaw. Flap of skin reflected; sections of palate, nasal process of maxilla, and malar bone shown.

*FIG. 3.* Disarticulation of Upper Jaw with the lion-forceps and a pair of bone-forceps introduced into the nostril.

*FIG. 4.* Disarticulation of one side of the Lower Jaw.

*FIG. 5.* Trephining.

*FIG. 6.* Diagram to show application of trephine for removal of overlapping edge of bone in depressed fracture.

*FIG. 7.* Diagram showing removal of the crown of bone exposing the dura mater.

---

### REMOVAL OF THE UPPER JAW.

Partial or complete removal of the upper jaw may be required for disease, and the minor may be readily converted into the major operation as follows :

A straight incision carried through the median line of the upper lip and then prolonged on one side of the *columna nasi* into the posterior extremity of the nostril of the affected side will allow the tissues of the face to be readily dissected up off the jaw, so as to expose completely the front wall of the antrum. This may then be removed with bone forceps for the extraction of a solid tumour from the cavity, but if the contents are fluid the front wall of the antrum has usually become membranous by absorption of the bone, and can be efficiently opened from beneath the lip without making any incision through it (Fig. 1).

In a case of more extensive disease, in addition to the incision already made, one should be begun near the inner angle of the orbit, and be carried down by the side of the nose and around the ala into the nostril. This will allow of further reflection of the soft tissues, and more complete exposure of the bone, so that it would be easy to cut away large portions of the jaw with suitable bone-forceps, or a small saw could be readily



carried horizontally from the nostril at any level desirable, so as to preserve either the palatine or orbital plate (Fig. 1).

For removal of the entire upper jaw it will be advisable to make an additional incision below the orbit from the inner angle to the malar bone, following the natural curve of the skin-markings of the part. This incision may be prolonged on to the malar bone as far as may be necessary, and may be met, at its extremity by another at right angles to it in very extensive disease of that bone. The flap of skin is now to be reflected outwards, and this method has the great advantage of preserving the facial nerve, and of dividing only small branches of the facial artery (Fig. 1).

Division of the bone will be required at three points—(1) the palate, (2) the nasal process of the maxilla, and (3) the malar bone, and these sections may be made with the saw or bone-forceps, or more conveniently with both. A narrow saw, with moveable back, is to be passed into the nostril, and the hard palate divided with the alveolus, from which a central incisor tooth should have been previously extracted. The saw should be kept horizontal in the nostril, and there need be no fear of damaging the pharynx with its extremity. The moveable back allows the blade of the saw to pass through the bone into the mouth, thus dividing the whole of the hard palate without the splintering which usually follows division with bone-forceps. The soft palate escapes injury from the saw, and any attempt to dissect off and preserve the soft covering of the hard palate is futile. The nasal process of the maxilla may be conveniently notched or completely divided with a small saw; and the saw is next to be applied to the malar bone parallel to and immediately in front of the masseter muscle. This cut will then run into the speno-maxillary fissure, and the prominence of the cheek will be preserved, but in cases of very extensive involvement of the malar bone it will be necessary to remove the whole of it by dividing the zygomatic process, and the frontal process at its junction with the frontal bone (Fig. 2).

Before dislocating the bone it is well to divide the soft palate transversely close to its attachment to the hard palate, which can be readily done from the mouth. With a pair of angular bone-forceps the three cuts made with the saw should then be thoroughly cleared, and it is convenient to take them in the reverse order, viz., malar bone, nasal process, palate. The bone-forceps, when dividing the palatine attachments, may be conveniently used to tilt the whole jaw forward, and the lion-forceps should then be employed to grasp it, and forcibly depress the mass (Fig. 3), while the scalpel is used to divide the infra-orbital nerve behind the bone



so as to prevent its being stretched, and also any soft tissues which may remain attached to the jaw.

In the living body the amount of bone brought away will vary according to the nature of the disease, and it will often be necessary to remove further portions with forceps or scissors, and to apply the actual cautery to arrest hæmorrhage. In the subject, the maxilla usually brings away with it the lower part of the palate bone, including part of the pterygoid fossa and internal pterygoid muscle. In old subjects the jaw is apt to break down under the lion-forceps, leaving the posterior wall of the antrum behind.

#### REMOVAL OF THE LOWER JAW.

In removing portions of the lower jaw the incision should as far as possible be placed below its border, so that the cicatrix may be hidden. An incision from the median line to the angle thus placed will divide the facial artery immediately in front of the masseter muscle (Plate V., *e*), and both ends should be at once secured with a ligature. The tissues of the face can now be dissected up, and the cavity of the mouth opened by dividing the mucous membrane close to the gums, when any part of the body of the jaw can be removed by making a section with the saw on each side of it. In making these sections it is better not to complete one before the other is begun, because of the loss of resistance consequent upon breaking the continuity of the bone; but each cut being carried nearly through the bone with the saw may be conveniently finished with the bone-forceps. Should it be necessary to prolong the incision beyond the median line and to remove the symphysis, care must be taken in the living body to guard against the falling back of the tongue by having a stout thread passed through it, upon which traction may be made. The mylo-hyoid muscle and mucous membrane inside the bone can then be divided and the piece removed, but whenever possible the alveolus alone should be divided and the border of the jaw preserved. For removal of one half of the lower jaw it will be advisable to divide the lower lip in the median line; for though it is possible, on the subject especially, to perform the operation without this, yet if the disease is at all serious it unnecessarily complicates the operation to save the lip, which reunites readily enough. The incision should then be carried at right angles to that in the lip along the lower border of the bone as far as the angle, and then upwards to near the lobule of the ear. This will necessarily divide the facial artery, but no important branches of



the facial nerve, unless prolonged into the parotid gland (Fig. 1). The tissues of the face and the masseter being dissected up off the bone or tumour, the jaw is to be divided at a convenient point, a tooth having been previously extracted. The scalpel is then to be carried closely along the inner surface of the jaw to divide the tissues forming the floor of the mouth, and care must be taken not to detach or damage the sub-lingual gland. The cut end of the jaw being grasped with the lion-forceps can now be everted so as to bring the internal pterygoid muscle into view, and this must be dissected from the bone. Should the disease be of a non-malignant character and not involve the articulation, the ramus of the jaw should be sawn across in preference to disarticulating, and even when the tumour encroaches very closely upon the joint, it may be possible to divide the neck of the condyle and the coronoid process separately with bone-forceps.

In order to disarticulate the condyle (Fig. 4), the soft tissues should be held out of the way with spatulas, and the jaw being firmly grasped with the lion-forceps, is to be depressed so as to bring the coronoid process forward and allow of division of the insertion of the temporal muscle. This is sometimes rendered difficult by an unusual length of the process, or by its being jammed against the malar bone by the bulk of the tumour. In this case it may be necessary to cut off the coronoid process with bone-forceps or to break it by force. The coronoid process having being cleared, the depression of the jaw from before backwards is to be continued, in order to throw the condyle forward, but great care must be taken not to rotate the jaw outwards, or the internal maxillary artery will be stretched around the neck of the bone and be either torn or divided, when the hæmorrhage would be severe and difficult to arrest. The condyle being made prominent the knife is to be carefully applied over it, when the bone will start forward, tearing through and bringing away with it a portion of the external pterygoid muscle. The knife must not be used to divide the muscular fibres, which bleed less if torn, but may be employed to divide the inferior dental nerve, so as to save it from being pulled out of the bony canal, as usually happens in the subject.

Any bleeding vessels should be secured with ligatures, the lip united with hare-lip pins and the wound with sutures, care being taken to leave a dependent opening for the discharges.



## TREPHINING.

The actual operation of trephining is sufficiently easy, but the selection of appropriate cases is more difficult. In most cases of punctured fracture of the skull the trephine should be applied, and also in cases of depressed fracture with symptoms of compression, where the bone cannot be elevated by other means.

On the living body, the wound probably already existing may be enlarged as far as may be necessary; on the subject a V-shaped incision may be conveniently made over the frontal bone with the base of the triangle downwards, so as to avoid cutting across the supra-orbital vessels and nerves. In making this incision the knife should divide the periosteum as well as the pericranial aponeurosis, and the handle of the scalpel be employed to reflect the triangular flap, so as to leave the surface of the bone bare and to preserve the periosteum. It is unnecessary to use the old-fashioned "rasparatory" for the purpose of clearing the bone, and the trephine may now be applied to the bone, or better, a fracture may be produced with a hammer, so as to resemble more closely the condition of parts in the living body.

In a case of depressed fracture, the object of the surgeon is to raise the depressed bone without injuring the dura mater. Any loose pieces should therefore be carefully drawn away with forceps, and thus very probably room may be found for the introduction of the elevator beneath the depressed fragment, which should then be raised to the level of the healthy bone. Should the depressed portion be held down by a projecting angle of bone, this latter may be sawn off with a Hey's saw, but if it is a firm margin, or if there is no opening for the elevator, it will probably be necessary to use the trephine. A trephine of suitable size should be selected, and the central pin should be made to project and be fixed by its screw-nut. The point for its application should be chosen, so that the pin may be on the margin of the sound bone, and the major part of the circle of the trephine will necessarily be on that part also (Fig. 6). The trephine being grasped by the hand, the thumb should press against the screw-nut so as to prevent its rising when the pin is entering the bone, and the instrument should be gently rotated to right and left alternately, so as to make the pin gradually enter the bone (Fig. 5). As this is done, the circle of the trephine will gradually cut into the bone if the movements are lightly made without



undue pressure. When the groove for the crown of the trephine, or that part of it which is on the sound bone, is sufficiently deep for the instrument to maintain its position, the pin should be withdrawn by unscrewing the nut. The trephine is then re-applied and worked steadily and evenly, so that one side should not go deeper than another. It is well to use a probe or cut quill to clear out the groove and ascertain that the depth is regular all round, but as it is impossible to tell beforehand the thickness of the individual's skull, but little information is given to the operator by mere measurements. When the diploe is reached (if any exists), the sawdust will be discoloured with blood even in the dead body, but it must be borne in mind that the thickness of the diploe varies very much in different parts of the skull, and that it is absent in young persons. Having cautiously deepened the cut by a few steady turns of the hand after reaching the diploe, it is well to apply the elevator in order to raise the circle of bone; but if this is not practicable the trephine must be again applied for a few turns, and then moved sharply from side to side so as to break out the piece of bone contained in it. The elevator must then be again applied and the piece of bone removed (Fig. 7).

It is quite possible to wound or even cut out a piece of the dura mater by want of caution in using the trephine; or, in the dead body where the brain is shrunken, to drive the trephine with the circle of bone in upon the brain by undue pressure of the hand.

In trephining for punctured fracture or the evacuation of blood or pus, the operation will be completed when once the crown of bone is removed, unless it be necessary to remove any spicula or blood-clot with forceps. In the case of a depressed fracture, it will be necessary, in addition, to apply the elevator in order to raise the depressed bone, and any loose fragments should be removed with forceps.

The "lenticular" is an instrument seldom employed in modern times, but its use is in smoothing off any rough projecting portions of the inner table which may have been left by the trephine.

The trephine may be applied in the temporal fossa for the relief of hæmorrhage from the middle meningeal artery lacerated by the extension of a fracture from the base of the skull. The injury will be on the same side as that of a paralyzed facial nerve, and opposite to that of paralyzed limbs, and an incision should be made across the fibres of the temporal muscle parallel to and about an inch above the zygoma. The muscular fibres with the periosteum being scraped from the bone, a search is to be made for the line of fracture, and failing this, the crown of a large trephine may



be applied about three-quarters of an inch from the external angular process of the frontal bone. The bone is here very thin and has no diploe. Any clot exposed should be withdrawn, and hæmorrhage arrested by plugging the bony canal in which the artery lies.

In employing a small trephine to perforate the mastoid cells, the instrument should be directed forwards or toward the meatus. It is only necessary to remove the outer plate of bone with the trephine, and a tooth-elevator may then be used to perforate the cells in the direction of the meatus. If a trephine were applied at right angles to the side of the head, and were driven sufficiently deeply, it might easily open the lateral sinus.

In trephining over the frontal sinus in the adult, a large crown should be taken out of the outer plate in order to allow of the easy application of a small trephine upon the inner plate, should that also be fractured and depressed.



The first of these is the fact that the  
the second is the fact that the  
the third is the fact that the  
the fourth is the fact that the  
the fifth is the fact that the  
the sixth is the fact that the  
the seventh is the fact that the  
the eighth is the fact that the  
the ninth is the fact that the  
the tenth is the fact that the







Fig. 1.

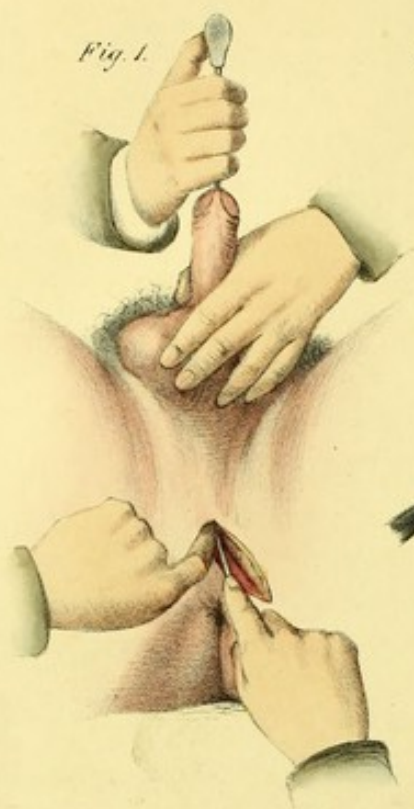

Fig. 2.

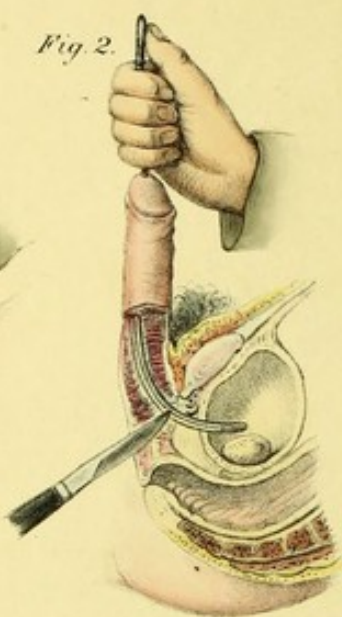


Fig. 3.

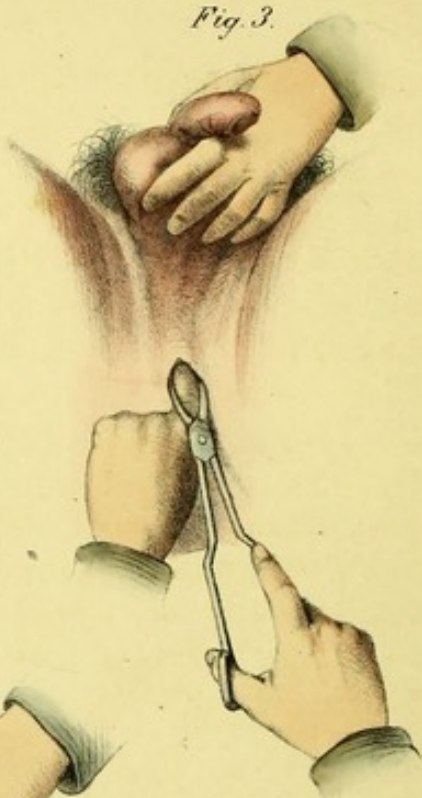


Fig. 4.

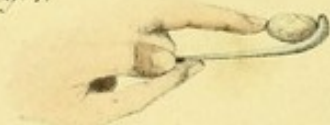

Fig. 6.

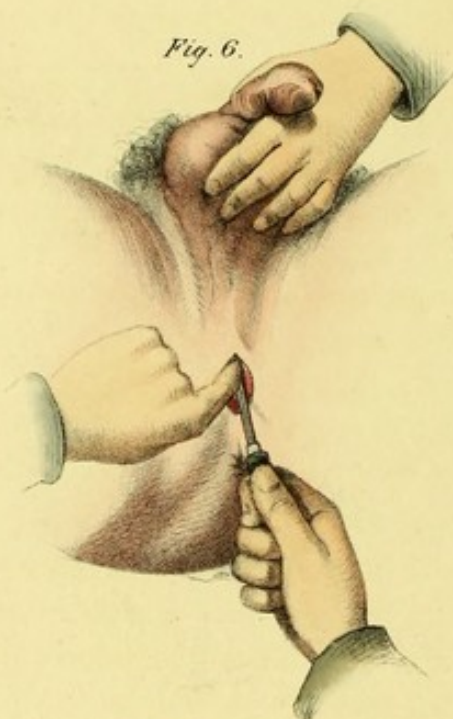


Fig. 9.

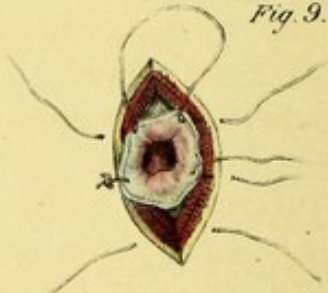


Fig. 5.

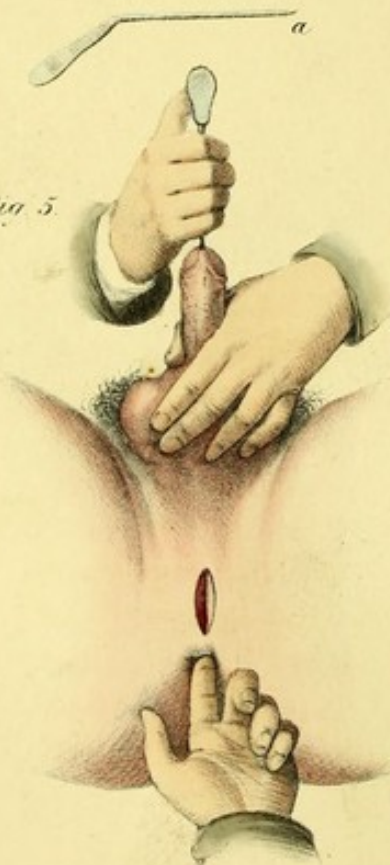

Fig. 8.

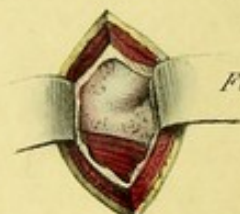
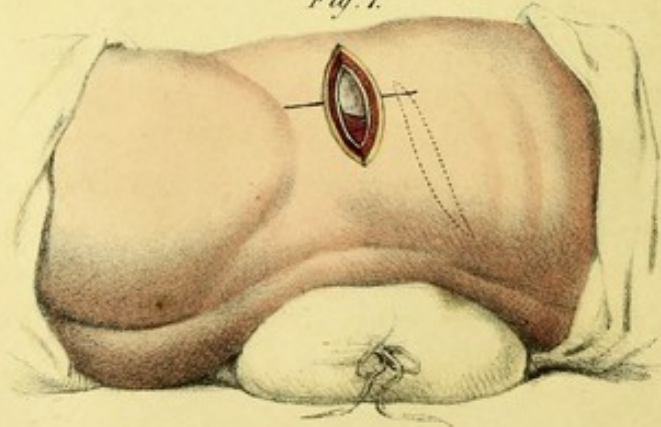


Fig. 7.





## PLATE XII.

---

- FIG. 1.* Lateral Lithotomy; the knife being guided by the left fore-finger into the groove in the staff.
- FIG. 2.* Lateral Lithotomy; side view to show the anatomy of the parts.
- FIG. 3.* The lithotomy-forceps being introduced over the left fore-finger.
- FIG. 4.* Mode of fixing a calculus with the fore-finger during its removal with the lithotomy-scoop.
- FIG. 5.* Median Lithotomy; showing the incision made from below, with the left fore-finger in the rectum.
- FIG. 6.* The left fore-finger being introduced along the handled director (*a*), which was passed into the bladder before the withdrawal of the staff.
- FIG. 7.* Incision for Lumbar Colotomy, with guide-mark between the crista ilii and last rib.
- FIG. 8.* Enlarged view of lumbar wound, showing relation of colon to quadratus lumborum muscle.
- FIG. 9.* The methods of applying sutures to the colon and skin in lumbar colotomy.
- 

### COLOTOMY.

*Colotomy* (Fig. 7) is performed by preference on the descending colon in the left loin, but the steps of the operation are precisely the same if it becomes necessary to open the ascending colon on the right side.

It is advisable that the loin should be made prominent by placing a pillow beneath the opposite side, and the operator may most conveniently stand behind the patient. With a measuring tape, the distance between the anterior and posterior superior iliac spines is to be ascertained, and a vertical line drawn with ink from the ilium to the last rib at the mid-point. This will mark accurately enough the position of the bowel to be opened.

A transverse or slightly oblique incision, four inches in length, is to be made parallel to the last rib and midway between it and the crista ilii, half the incision being on each side of the inked line. The skin and subcutaneous fat having been divided, the fibres of the obliquus externus and latissimus



dorsi will be seen and are to be divided, bringing into view the obliquus internus, which is also to be thoroughly divided for the whole length of the incision. The white posterior tendon of the transversalis, or *fascia lumborum*, will then be exposed and may be conveniently divided on a director. At the posterior part of the incision the quadratus lumborum will now be seen, and in front of it a quantity of loose fat in which the kidney and colon lie. The edges of the incision should be drawn up and down with broad spatulæ, whilst the fat is carefully displaced with the finger, when the colon, if distended, will present at the wound covered only by fascia transversalis (Fig. 8). Should the bowel be empty, the fascia transversalis is to be carefully torn through with the finger-nails immediately in front of the quadratus lumborum, and the fore-finger, being passed forward below the kidney (which may be readily recognized), will feel the empty intestine and hook it forward. This proceeding will be much facilitated by rolling the patient over so as to make the wound dependent, when the colon will fall upon the finger and be readily recognized.

The colon having been brought into the wound, it is a safe precaution to roll it round slightly so as to bring the posterior or renal surface into view and thus avoid all risk to the peritoneum. A large curved needle carrying stout silk is then to be passed through the skin to one side of the ink mark, across the bowel and through the skin at a corresponding point on the other side of the mark, and the entire proceeding is to be repeated at the other end of the incision. The colon is thus fixed before being opened, and is held in place by the threads which are grasped by assistants. It only remains now to open the intestine, and this is best done midway between the two threads by a small transverse incision, which may be cautiously enlarged so as to be about  $1\frac{1}{2}$  inch in length. The finger passed into the bowel can now draw out each loop of thread by which it is transfixed, and these being divided will give four threads already passed through skin and intestine, and only requiring to be tied. The anterior and posterior extremities of the wound should afterwards be drawn together with two stitches and the operation is completed (Fig. 9).

*Anatomy.*—The back of both ascending and descending colon is ordinarily uncovered by the peritoneum, which is reflected only over the anterior surface of the bowel; but occasionally the peritoneum completely surrounds the bowel forming a meso-colon, and under these circumstances it is impossible to avoid opening the peritoneum. The relation of the colon to the front of the kidney is very constant. The point at which the colon is usually opened is just at the junction of the transverse with the



descending colon, so that of the two openings separated by a ridge seen in Fig. 9 the upper one leads into the transverse, and the lower into the descending, colon.

*Fallacies.*—The incision is apt to be made too far back, in which case the quadratus lumborum and erector spinæ muscles are exposed, and the former has to be divided in part. The fascia transversalis varies in thickness, and is often mistaken for the peritoneum, the intestine being seen to glide beneath it. The operation is facilitated if the bowel is distended, but with care there is no difficulty in drawing forward and opening satisfactorily an empty intestine. Should the peritoneum be opened, the operation should be completed, and the opening in the serous membrane closed with one or two fine stitches, the complication not being necessarily fatal.

## OPERATIONS ON THE GENITO-URINARY ORGANS.

### LITHOTOMY.

*The Lateral Operation* is that most generally practised, and may be conveniently divided into three parts: 1, the introduction and holding of the staff; 2, the incisions; 3, the extraction of the calculi.

Presuming the operator to be right-handed, the staff should be grooved to the left of the patient, and the reverse if the operator is left-handed. The staff selected must be suitable to the size of the urethra of the patient, but if the meatus urinarius is contracted it should be divided so as to allow of the introduction of an instrument large enough to fill the urethra. To introduce the staff, the operator stands on the left of the patient, and having well oiled the instrument, introduces it over the left groin, letting it find its way by its own weight, and gradually bringing the handle to the median line. The point may be arrested at the bulb, when the left hand should draw up the penis slightly and make a little pressure in the perinæum, the point of the staff being gently raised at the same time by the right hand. The staff will then probably glide on into the bladder, and should be made if possible to touch the calculus, the presence of which has been previously ascertained with the sound. It is desirable that the staff should strike the calculus, but it is possible that in cases of enlarged prostate, the curve of the instrument may prevent its touching a stone lodged behind the gland, and in this case the finger should be introduced into the rectum both to



ascertain that the staff is properly introduced, and also to lift up the calculus and bring it if possible into contact with the staff. It is so easy in children to force the staff through the urethra, that in them the operator would not be justified in proceeding with the operation unless he felt the stone with the staff.

In the dead subject it is more difficult to introduce the staff than in the living body, owing to the absence of the ordinary mucus of the urethra, and the staff should therefore have its groove filled with oil, or some oil should be injected with a syringe. The complete relaxation of all the tissues also makes it necessary to use more care in the introduction of instruments lest the urethra should be torn. The bladder may be firmly contracted, and care must be taken not to force the point of the staff through it when depressing the handle in order to reach its apex above the pubes and introduce some stones. This is best done by cutting into the peritoneal cavity immediately above the pubes, and grasping the coats of the bladder with a pair of dissecting forceps on each side of the end of the staff, which is pushed up by an assistant. The bladder is then incised between the forceps, and stones of various sizes introduced, after which a string should be tied round the opening and beyond the forceps to prevent the escape of the stones into the peritoneal cavity.

The assistant who is to hold the staff during the operation, must be careful that it does not slip out of the bladder whilst the patient is being brought into the ordinary "lithotomy position" at the edge of the table by two other assistants, who either tie or hold the thighs flexed and the knees separated. The assistant holding the staff must be to the left of the patient and close behind the assistant holding the left knee, who should stand out of his way as much as possible. The staff must be firmly grasped by the fingers, the thumb pressing against the handle (Fig. 2), and the elbow may be conveniently rested upon the thorax. The operator should see that the staff is central in the perinæum and well hooked up under the pubes, and the assistant must maintain the exact position desired. He should grasp both scrotum and penis with his left hand so as to keep the former out of the operator's way, and to stretch the latter upon the staff, which is important, since thereby the bulb is drawn up and is less likely to be wounded, and also to prevent the escape of urine during the involuntary straining of the patient (Fig. 1).

The operator, before sitting down, should arrange his instruments on a convenient table so that they may be easily within his reach, and should then ascertain that the staff is held perpendicularly to the pelvis and



beneath the pubes in the centre of the perinæum. He should note the distance between the tubera ischii, which varies considerably even in males, and may pass his finger into the rectum to ensure its being empty, and to note the development of the prostate. Steadying the skin of the perinæum with his left hand, the surgeon holds the knife firmly in the hand with the fore-finger on the back and enters it one inch in front of the anus, either in the central raphé or a little to the left of it, and pushes it in the direction of the staff which may often thus be touched. He then cuts with a sawing motion downwards towards the tuber ischii, letting the wound become gradually superficial by slowly withdrawing the knife. The left fore-finger introduced into the upper part of the wound (Fig. 1) will now readily feel the staff, which may be completely exposed, but if not, the knife must be introduced again by the side of the finger to divide the structures covering the staff. The nail of the fore-finger is to be fixed upon the edge of the groove in the staff, and the knife passed over it so that the point may fairly enter the groove (Fig. 2). The handle of the knife should now be raised and the blade turned with the edge slightly towards the patient's left, when the blade can be pushed along the curved groove, the hand of the operator being gradually brought down and finishing below the level of the wound. The knife being carried as deeply as may be judged necessary, is to be withdrawn in a downward direction so as to enlarge the deep part of the wound as it comes out.

The fore-finger, which has been kept in contact with the staff, is now to be insinuated along and carefully in contact with it until it reaches the bladder, which will be recognized by the sudden cessation of resistance and the presence of the calculus in a cavity, and as soon as this is reached the staff should be withdrawn. The fore-finger should be rotated to enlarge the opening, and be used to ascertain the size and position of the calculus. If lying with its long diameter transversely it should be turned so as to bring it into the axis of the pelvis, and if much larger than anticipated the wound should be enlarged by introducing a blunt-pointed bistoury along the finger before any attempt at withdrawal of the stone is made.

A pair of forceps, of a size suited to the calculus and the patient, being selected, should be grasped with the thumb in the ring, and the fingers in the hook, and the blades separated so as to embrace the fore-finger (Fig. 3), upon which, as their guide, they are to glide into the bladder. The handles of the forceps are best held above the finger, which is to be gradually withdrawn, and when the forceps have fairly entered the bladder the blades are to be separated, and made to sweep over the floor of the



cavity by a rotatory movement of the wrist. In this way a calculus is almost certainly caught in the first gush of urine, and is then to be withdrawn by slow steady traction downwards in the axis of the pelvis. If a second stone is suspected, or detected with a sound, the forceps must be re-introduced, and again swept over the floor of the bladder, and in the dead body this manœuvre should be frequently practised.

If a stone is grasped in its long diameter it is possible to turn it with the finger by slightly relaxing the forceps, but without quitting hold altogether, or, in cases of large stones, it will be advisable to pass a blunt-pointed bistoury along the forceps, and to divide the soft structures on one or both sides sufficiently to allow of the ready withdrawal of the calculus without lacerating the tissues. In the case of an extremely large stone it will be better to break it with suitable screw-forceps introduced through the wound, and extract it piece-meal.

The scoop may be advantageously used for small or irregularly-shaped stones, being passed beneath and behind the calculus, which is to be fixed with the fore-finger of the opposite hand while the instrument is withdrawn (Fig. 4).

Any spouting vessel should be secured at once with a ligature, and the risk of secondary hæmorrhage may be best combated by the use of the "*tube en chemise*" introduced at the time of the operation.

*Anatomy* (Fig. 2).—The membranous urethra is the portion of the canal which has to be reached in lithotomy, and this is situated behind the triangular ligament or deep perineal fascia, and in front of the capsule of the prostate formed by the pelvic fascia. The membranous urethra is surrounded by muscular fibres forming the *compressor urethræ*, which must necessarily be divided on the left side. The artery to the bulb crosses behind the triangular ligament at a variable level, and is often divided, probably always by those surgeons who carry their incision far forward. The bulb of the urethra lies in front of the triangular ligament, and is covered by the *accelerator urinæ* muscle. It is least likely to be injured if the urethra and penis are well drawn up by the assistant. The crus penis with the *erector penis* lie against the ramus of the pubes, and the *transversus perinæi* crosses at the level of the tuberosity. The pudic vessels and nerve lie behind the margin of the rami of the pubes and ischium, and are out of danger.

The capsule of the prostate is derived from the pelvic fascia, and is necessarily divided in lateral lithotomy. The fear of extravasation of urine from free division of this capsule is groundless, but great danger



would follow a splitting of the prostate and its capsule by forcible extraction of too large a stone.

*Fallacies.*—Tumours of the bladder or prostate or incrustations with phosphatic matter have been mistaken for calculi, and it is undoubtedly possible to strike the pelvis through the thin bladder of a child so as to elicit a "click" resembling that of a stone. The staff may be forced out of the urethra, or may enter an old false passage—in either case failing to reach the bladder—or, in the dead body, may be made to transfix the bladder.

In the first incision the bulb may be wounded by carrying the knife too far forward, or the rectum, if the incision is made too vertical. In the adult it is hardly possible to miss the staff, but in children it is easy to mistake the sharp ramus of the pubes for the edge of the staff. The point of the knife having been safely fixed in the groove of the staff must not be allowed to leave it during the deep incision, and this is best accomplished by raising the handle of the knife slightly so as to enable the blade to follow the curve of the staff. The young operator may, as an extra precaution, slip the finger below the blade (blunted at the heel for the purpose), and press the knife into the groove so as to ensure its safety.

The most difficult part of the operation is the introduction of the finger into the bladder. In children, especially, the small size of the parts makes it difficult to get the point of the finger between the staff and the urethra, and there is undoubtedly danger of tearing the urethra across and of pushing the bladder before the finger, as laid down by Sir W. Fergusson. In practice one is often obliged to take the upper or concave border of the staff as the guide, and to insinuate the finger between it and the upper or fixed wall of the urethra, and it appears to the author that this part of the operation would be greatly simplified by adopting the practice of median lithotomy, viz., to pass a probe or director along the staff into the bladder, and then to withdraw the staff, using the handled director to draw down the urethra, and thus allow the finger to be introduced more readily and safely.

If the forceps are taken up the wrong way, *i.e.*, with the thumb in the hook instead of the ring, they slip out of the operator's hand when opened in the bladder, and he is apt to resort to the dangerous practice of grasping the handles with both hands, and using undue violence in opening and closing the blades. If properly held, the forceps can be opened with the thumb and fingers of the right hand widely enough to grasp any stone which can be extracted by the perinæum.



## MEDIAN LITHOTOMY.

*In Median Lithotomy* the staff used has a central groove, but is introduced and held with the same precautions as in the lateral operation.

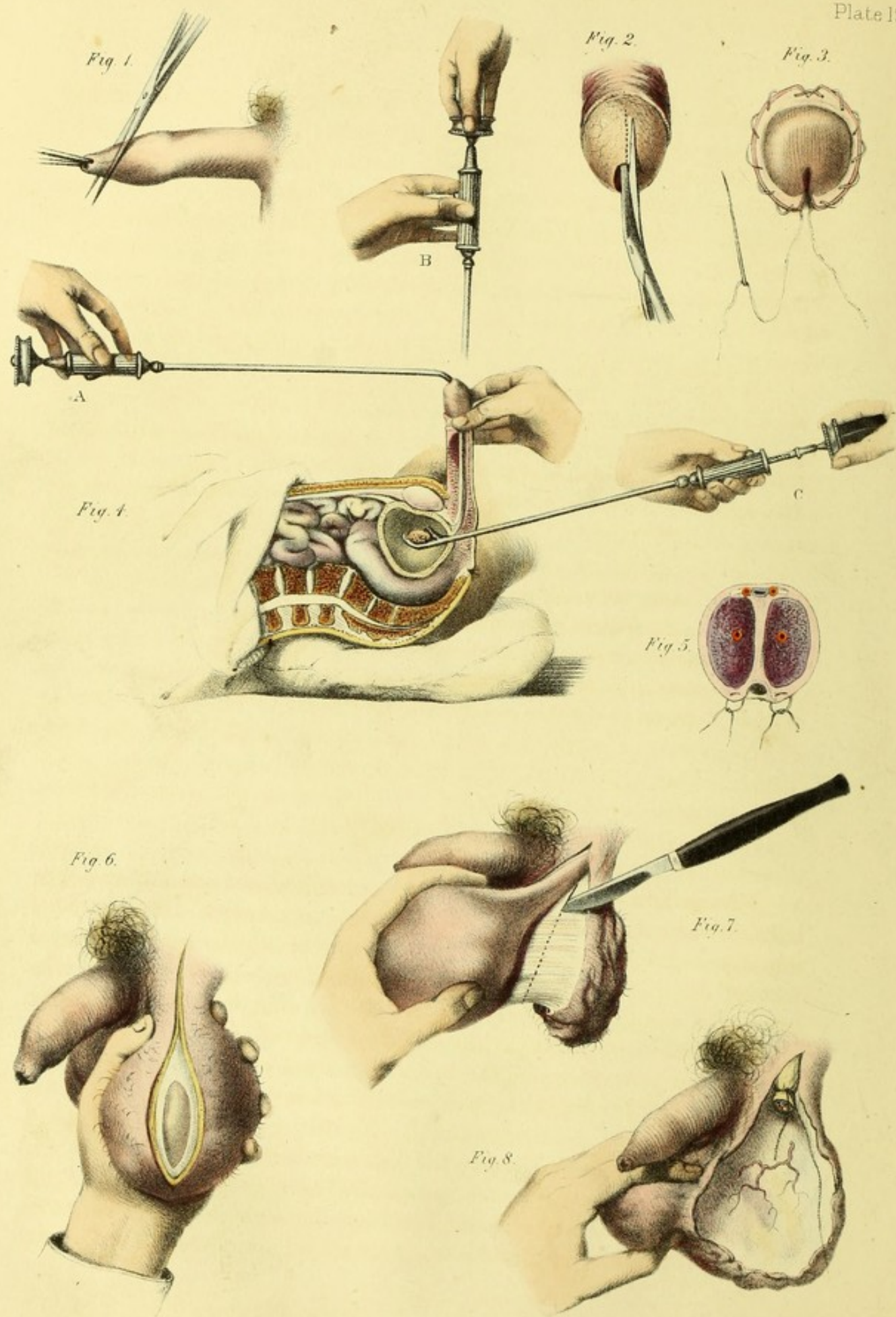
*The Incision* (Fig. 5) is ordinarily made from below upwards, the object being to open up the membranous urethra without interfering with the prostate. The operator passes his left fore-finger into the rectum, and feels for the apex or front of the prostate and the staff in the membranous urethra; he then enters a broad bistoury with the back downwards in the median raphé of the perinæum immediately in front of the anus, and, guided by the finger in the rectum, makes the blade enter the groove in the staff as near the prostate as possible. With a steady sawing movement the knife is then made to open the whole length of the membranous urethra, and to divide the skin for about  $1\frac{1}{2}$  inch as it is withdrawn. A large probe, or, better, a steel director, with a handle set at an angle (Fig. 4, *a*) is then introduced into the wound, and made to reach the staff, along which it is conducted to the bladder by raising the handle, and allowing it to slip along the groove, and the staff is then withdrawn by the assistant. Drawing the director down with his right hand the operator then insinuates his left fore-finger along the urethra between the instrument and the pubes, and by steady dilatation, combined in most cases with some degree of laceration of the prostate, at last enters the bladder (Fig. 6).

The forceps are introduced over the fore-finger as in lateral lithotomy, and the stone extracted with the same precautions, but the space is so much smaller that it is impossible to extract so large a stone as in lateral lithotomy, except by conversion of the median into a bi-lateral incision with a bistoury, or, if preferred, with the *bistouri caché*.

*Fallacies.*—It is hardly possible to miss the staff in the membranous urethra, but the opening may be made insufficiently large. In completing the incision upwards the bulb is in great danger, and is certain to be cut if the assistant does not forcibly draw up the penis and urethra. The only difficulty in the operation is the extraction of the stone should its size prove larger than anticipated.









## PLATE XIII.

---

- FIG. 1.* Circumcision; the prepuce drawn forward and cut obliquely with straight scissors.
- FIG. 2.* Circumcision; the mucous lining of the prepuce exposed, and being divided up to the corona glandis with angular scissors.
- FIG. 3.* Circumcision; the glans penis exposed by reflecting the mucous lining of the prepuce, which is attached to the skin by a continuous suture.
- FIG. 4.* Lithotrity. A, the left hand of the operator introducing the lithotrite into the urethra, which is stretched by his right hand; B, the lithotrite brought into the vertical position, is grasped by the right hand of the operator; C, the lithotrite introduced into the bladder is held by the left hand while the right hand works the screw.
- FIG. 5.* Amputation of the penis; section with urethra stitched back.
- FIG. 6.* Castration; incision into tunica vaginalis.
- FIG. 7.* Castration; division of mesorchium.
- FIG. 8.* Castration; cord tied *en masse*; artery of septum scroti shown.
- 

### LITHOTRITY.

The modern operation of Lithotrity necessitates the use of the modern light instruments of either English or French manufacture. The operator standing to the right side of his patient, who should be recumbent on a table of convenient height with a pillow placed so as to elevate the pelvis, grasps the penis with the right hand, and drawing it up introduces the closed blades of the lithotrite (previously warmed and oiled) into the urethra with the left hand, directing the instrument along the patient's right groin (Fig. 4, A). The lithotrite will now be horizontal, and the left hand holding the handle lightly beneath it. By its own weight slightly aided by the left hand of the operator the lithotrite will find its way along the urethra as far as the bulb, the instrument being gradually raised to the vertical position by the left hand, the fingers of which slide on the handle allowing it to rotate, so that the wheel passes between the thumb and fore-



finger. The lithotrite will now be vertical and the left hand to its side (Fig. 4, B). The right hand of the operator now grasps the wheel at the extremity of the instrument, and steadily but gently brings the lithotrite down between the patient's thighs, at the same time letting it glide along the urethra into the bladder. The left hand now again grasps the handle of the lithotrite, the thumb being uppermost to act upon the button disconnecting the screw, and the right hand retains its hold upon the wheel, which is the extremity of the male blade, and can withdraw it as may be necessary (Fig. 4, C). The blades of the lithotrite being fairly in the bladder, which may be known by the loss of resistance and the ease with which the instrument can be turned round, the button is to be drawn down with the thumb of the left hand, so as to release the male blade, which is then to be withdrawn and closed once or twice, when a stone may probably be grasped. Failing this, the instrument is to be rotated with the left hand first to one side and then to the other of the bladder, the male blade being withdrawn and closed once or twice in each position. Lastly, the blades should be turned downwards (the button being beneath and the handle depressed between the thighs) in case a stone should be lodged behind a large prostate. In whatever position of the lithotrite a stone is grasped between the blades, the button should be immediately pushed up so as to lock them, and then, before any screw power is applied, the handle should be rotated so as to bring the button uppermost and the blades as they were when first introduced (C). The left hand is now to play the part of a vice and hold the lithotrite absolutely firm while the screw is worked by the right hand. In order to do this effectually, it is necessary to bring the left elbow to the side and firmly grasp the handle of the lithotrite, since the force necessarily used in the first crushing of a hard calculus is sometimes very great. The frequency with which a stone should be crushed at one sitting must vary with the nature of the case and the judgment of the operator.

Some surgeons prefer to introduce the lithotrite with the right hand throughout, but this necessitates a somewhat awkward crossing of the hands; others prefer to stand to the left of the patient during the introduction of the lithotrite, and to change their position for the manipulation, but this is undesirable.

*Fallacies.*—The bladder may not be reached owing to the handle of the lithotrite not being sufficiently depressed to pass over a prominent middle lobe of an enlarged prostate. Under these circumstances it is sometimes possible to separate the blades to a limited extent, which fact misleads



the inexperienced operator. A stone of very small size may of course be missed in any bladder, but most probably in cases complicated by enlargement of the prostate or pouches in the wall—a condition possibly more common than is generally believed. It would be extremely difficult with well-made modern instruments to nip the coats of the bladder, and attention to the rule of always bringing the stone to the centre of the bladder before crushing it gives an additional safeguard against inflicting injury upon the viscus itself.

#### CIRCUMCISION.

*Circumcision* may be performed in various ways and with instruments more or less complicated, but the following operation gives very satisfactory results in cases of simple phimosis, whether congenital or acquired.

The fore-skin is to be firmly held with a pair of sharp forceps, which should be inserted at the margin of the preputial orifice exactly at the junction of the skin with the mucous membrane. Being then drawn well forward beyond the glans penis, the fore-skin may be removed with either straight scissors or knife, either instrument being applied obliquely so as to cut off more of the upper than the under part of the prepuce (Fig. 1). The elastic skin of the penis at once retracts, leaving the constricted mucous lining of the prepuce still covering the glans, and this is to be divided along the upper surface as far as the *corona glandis* with scissors, the angular ones being most convenient for the purpose (Fig. 2). The mucous-membrane thus divided is readily reflected when no adhesions exist between it and the glans penis; but adhesions in this situation are extremely common, and they must be either torn through or divided until the whole of the glans is exposed, when probably a quantity of inspissated *smegma preputii* will be found around the *corona glandis*. In some cases where the *frænum* is abnormally short it may be necessary to divide it, but as a rule this is better avoided on account of an artery contained in it, which is apt to give rise to troublesome bleeding.

The reflected mucous-membrane does not require trimming, but should be secured to the margin of the skin with fine silk sutures, or, better, by a continuous suture (Fig. 3). Beginning on the cutaneous surface close to the left of the *frænum*, and leaving a loose end, the operator should steadily "hem" the mucous and skin edges neatly together, until he arrives at the right side of the *frænum*, when the needle is brought last



through the skin, and the two ends of the thread are tied together and then cut off long. The great advantage of this method of proceeding is that when on the third day it is desirable to remove the suture, it is only necessary to draw upon the loose ends so as to bring the knot into view, when division of the thread at either side of the knot will allow of the withdrawal of the entire thread by a steady pull. If interrupted sutures are employed it is both difficult and painful to divide each separate suture, owing to the swelling of the parts.

Phimosis depending upon disease is best treated by slitting up the whole thickness of the prepuce along the upper surface as far as the corona. This may be satisfactorily done by slipping a director between the prepuce and glans to serve as a guide for a sharp-pointed curved bistoury, the point of which is to be brought out opposite the corona, and the division effected by one rapid sweep. If thought advisable, the redundant flaps of fore-skin may be trimmed with scissors, but usually in these cases the swelling is too great to allow of the introduction of sutures.

*Fallacies.*—In performing circumcision, unless care is taken to fix the forceps at the line of junction of the skin and mucous membrane, it is easy to draw forward the very elastic skin of the penis, the true fore-skin being left upon the glans. Under these circumstances the operator will remove a circle of skin from the middle of the penis, the prepuce being *in statu quo antea*. Should this misadventure occur, the orifice of the prepuce should be freely divided on its upper margin, so as to allow the fore-skin to be retracted from the glans, when the divided skin of the penis should be carefully re-united to that of the prepuce by sutures, a good result being much favoured by the elasticity of the part. If a knife is employed care must be taken not to slice the glans, and as a precaution a pair of dressing-forceps may be made to grasp the prepuce in front of the glans; also in introducing either scissors or a director beneath the fore-skin care must be taken to avoid entering the urethra by mistake.

#### AMPUTATION OF THE PENIS.

In order to obviate hæmorrhage in this operation it is advisable to tie a tape around the root of the penis if there is room, or Clover's clamp may be advantageously employed. Simple division of the organ with a bistoury yields very good results if care be taken not to leave superabundant skin, and to treat the urethral orifice in the following manner.



The two dorsal arteries and the arteries of the corpora cavernosa having been secured, the floor of the urethra with its surrounding skin is to be divided for half an inch with either scissors or bistoury, and a stitch inserted on each side so as to keep the urethra patent, and prevent the contraction otherwise certain to occur. The same thing should be done if it is preferred to remove the penis with the galvanic *écraseur*, a method which has the advantage of being bloodless.

Another method is to cut the urethra with its surrounding corpus spongiosum half an inch longer than the body of the penis, so as to form a spout for the urine. This is readily accomplished by turning the knife forward when the corpora cavernosa have been divided, or, if preferred, by transfixing the penis above the corpus spongiosum, and severing it from the body of the penis for the requisite distance first.

#### CASTRATION.

Having ascertained the non-existence of a hernia on the side to be operated on, the surgeon should grasp the testicle with the left hand and make an incision from the external abdominal ring to the bottom of the scrotum. In cases in which the skin is adherent to the testicle or involved by a protruding fungus, two elliptical incisions should be made well beyond the disease and meeting above and below. The first incision should open the tunica vaginalis or its remains, so as to expose the testis (Fig. 6); this is then to be grasped by the left hand and drawn out of the scrotum, which may be stripped off with the right. The tunica vaginalis, or what remains of it, will be readily separated from the scrotum, but a firm fibrous structure (mesorchium) extending between the back of the testicle and the scrotum will require division with the scalpel (Fig. 7).

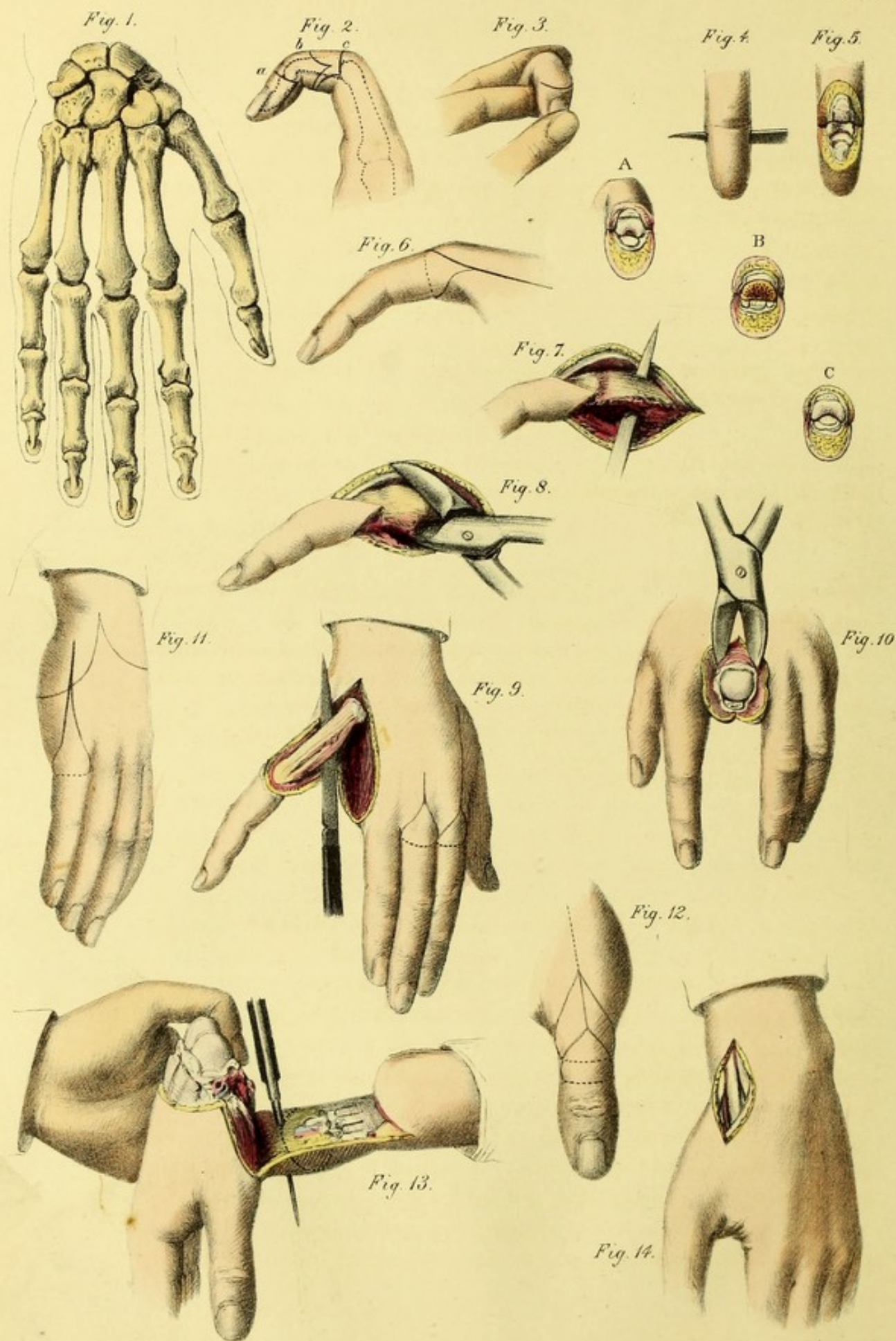
The spermatic cord being isolated as high as may be necessary is to be firmly tied *en masse* with a whip-cord ligature, the ends of which should be left long, so as to be held by an assistant. The cord having been divided at least half an inch below the ligature, the vessels of the cord (spermatic, deferential, and cremasteric) should be twisted with torsion-forceps, so as to obviate hæmorrhage in case of the ligature becoming loosened. The artery of the septum scroti should then be secured, and the edges of the wound brought together with sutures, the ends of the ligature being brought out at the bottom of the scrotum so as to maintain effectual drainage (Fig. 8).



Some surgeons prefer not to open the tunica vaginalis, under the idea that it is more easily separated from its scrotal attachments when entire, but on the other hand the bulk of the tumour is often much reduced by emptying the tunica vaginalis, and it is just possible that an old hæmatocele may be mistaken for a solid tumour of the testis—an error thus cleared up before it is too late. For similar reasons it is recommended to attack the testicle before the cord, since any mistake in diagnosis is irremediable if the cord is already divided. In treating the spermatic cord it may be preferred for an assistant to grasp it firmly with serrated forceps above the point at which it is to be divided, the vessels of the cord being then separately ligatured; but there is a risk (in the case of large tumours when the cord has been much stretched) of its becoming retracted into the inguinal canal and abdomen, when a dangerous dissection will be requisite to secure the vessels. An improvement on this method is, in addition to the forceps grasped by an assistant, for the operator to divide only a part of the cord at one time, thus securing the spermatic vessels before severing the *vas deferens* with its artery.









## PLATE XIV.

---

- FIG. 1.* Skeleton of hand.
- FIG. 2.* *a.* Amputation of terminal phalanx.  
*b.* Amputation through second phalanx.  
*c.* Amputation of second phalanx.  
     *A.* Stump of amputation at *a.*  
     *B.* „ „ „ at *b.*  
     *C.* „ „ „ at *c.*
- FIG. 3.* First mode of amputating a phalanx.
- FIG. 4.* Second mode „ „
- FIG. 5.* „ „ „ „ with flap reflected.
- FIG. 6.* Oval amputation of fore-finger.
- FIG. 7.* „ „ knife passed behind metacarpal bone.
- FIG. 8.* „ „ application of bone-forceps.
- FIG. 9.* Oval amputation of fore-finger; ditto middle-finger; flap-amputation of little finger.
- FIG. 10.* Flap amputation of middle finger, and removal of head of metacarpal bone.
- FIG. 11.* Oval amputation of little finger; flap amputation of wrist-joint.
- FIG. 12.* Oval amputation of first phalanx of thumb; ditto of metacarpal bone of thumb.
- FIG. 13.* Amputation at wrist-joint.
- FIG. 14.* Excision of wrist-joint.
- 

## AMPUTATIONS AND EXCISIONS.

THE method of amputating selected by each surgeon must necessarily vary both with the situation of the operation and the predilection of the operator. The objects to be attained are: 1. To remove as little of the healthy body as possible; 2. To obtain a good skin covering for the bone; 3. To place the cicatrix out of the way of injurious pressure.

The old-fashioned method of dividing the tissues by a series of *circular* incisions, had the advantage of cutting the main vessels and nerves transversely and shorter than the soft tissues, but gave a short, badly covered stump, the cicatrix of which was usually adherent to the bone. It was also a tedious operation and excessively painful before the introduction



of anæsthesia. It may still, however, be performed in suitable cases and in a limb with a single bone.

The *flap method* was advocated by Liston specially for the sake of the rapid execution to be attained by double transfixion and the formation of two fleshy flaps. The flap method had the advantage of providing better coverings for the bone (though this often proved illusory), but the cicatrix was still generally adherent to the bone, and there was the drawback that the vessels were apt to be sliced and the nerves cut long, thus giving rise to painful stumps.

In order to obviate the numerous objections to large fleshy flaps, *skin flaps with a circular division of the deep structures* have been introduced with advantage, and are applicable to most parts of the limbs.

The *long anterior and short posterior flaps* of Teale and their modifications, have the great advantage of placing the cicatrix entirely behind the bone and out of the line of pressure, and this method yields most satisfactory results.

The *oval method* is especially applicable to the amputations about the hand and foot, since it leaves but a single line of cicatrix, and it may be adopted in a few other positions.

In the formation of all skin-flaps, especial care is necessary not to interfere with their vitality by destroying the subcutaneous fat with the vessels ramifying in it. The young operator is apt to reflect the skin as cleanly as if he were dissecting, with the infallible result of causing the skin to slough. It is essential to reflect with the skin the whole of the superficial fascia and fat down to the level of the deep fascia of the limb, and this is best done by keeping the edge of the knife vertical and altogether away from the skin, which is to be drawn forcibly up by the left hand of the operator. In cutting flaps from without inwards by transfixion, care must be taken to have the skin left longer than the soft tissues, and therefore not to bring the knife out too abruptly.

The best position for the operator in amputating a limb is, as a rule, to stand on the right side of the limb to be removed, which should be entrusted to an assistant to hold. In forming skin-flaps, this position enables the operator to use his left hand efficiently in combination with the right, and also gives him thorough command of the part when using the saw. The limb being removed, the operator is thus also in the best position for taking up the vessels, and is able, should occasion occur, to compress the main trunk with his left hand.

In amputating at a joint, either in the upper extremity or the foot, it



will be found most convenient for the operator to stand in front of the limb, grasping the part to be removed with the left hand, and leaving the flaps to an assistant. This method secures that co-operation of the two hands which is necessary for the dexterous performance of joint-amputations. In the case of the knee and hip-joints it would be impossible for the operator to manipulate the limb with one hand, and it should therefore be entrusted to an assistant, the operator standing at the side most convenient.

The knife selected for each operation will vary somewhat with the taste of the operator; but whatever it may be, it should be held beneath the hand, and not like a pen. It is to be borne in mind that every knife is a saw in miniature, and that, however sharp, it cannot be made to cut satisfactorily by sheer force, but must be drawn backwards and forwards lightly in order to divide the structures evenly. Before using the saw, care should be taken to clear the bone effectually with the knife, when the heel of the saw should be applied, and the blade drawn lightly from heel to toe until a groove is made, and the saw is then to be worked sharply but lightly to and fro until the bone is nearly divided; the few remaining strokes should then be slowly and steadily made so as not to splinter the bone. In applying the saw it is convenient to place the nail of the left thumb upon the bone at the point of section, so that the blade may rest against the terminal phalanx of the bent thumb whilst forming the groove. The satisfactory sawing of the bone will depend very much upon the assistant holding the limb, who by raising the limb may effectually lock the saw, or by depressing it, may break off an awkward splinter. The assistant should be instructed to hold the limb horizontally, and to draw it away from the trunk, by which means it will be held steadily. Should any projecting edge of bone be left, it should be removed with the bone-forceps.

In the following pages the several methods of amputating will be illustrated and the preferences of the author for each indicated; but circumstances may necessitate the substitution of one operation for another in any given case.

It is presumed that the ordinary methods of obviating hæmorrhage will be adopted by the operator on the living body, and a drawing of the face of each stump will serve to indicate the positions of the main vessels in each instance.

The excisions are most conveniently taken with the amputations on the dead body, and will be described in their order; but it would be impossible to combine all of them with all the amputations in one subject.



## AMPUTATIONS OF THE FINGERS.

*To amputate a terminal phalanx; first method (Fig. 3).* The hand being pronated, and the neighbouring fingers held apart by an assistant, the operator grasps the terminal phalanx with the fore-finger and thumb of the left hand and flexes it to a right angle with the second phalanx. It is convenient but not essential to steady the part by slipping the second finger behind it, as shown in the illustration. A narrow scalpel or finger-bistoury is then to be drawn from heel to toe horizontally across the front of the joint, which will always be found below the prominence of the knuckle, and about midway in the thickness of the phalanx above (Fig. 2, *a*). The joint being opened, the knife is carried behind the base of the phalanx, and made to cut a sufficient flap from the palmar surface (A). The small digital vessels cannot be identified on the dead body, and seldom require a ligature on the living subject.

*Fallacies.*—If the phalanx is not well flexed the knife will probably go too high and miss the joint. If the knife be held horizontally as if to split the second phalanx, it will certainly open the joint unless the spur at the base of the terminal phalanx should happen to be exaggerated, in which case it is necessary to go a trifle higher. A narrow knife will pass readily where a broad-bladed scalpel would be locked.

*To amputate a second phalanx (Fig. 2, c).* The operation is precisely like the preceding, the second phalanx being bent to a right angle with the first, and the knife drawn across the joint midway in the thickness of the phalanx above. The knife is to be carried round the base of the phalanx and a flap made on the palmar surface (C).

An objection is made to this amputation that it leaves, as a rule, an immovable first phalanx, owing to the want of attachment of the long tendons. Although this is not invariably the case, it is better where possible to leave the base of the second phalanx by amputating in its continuity.

*Amputation of terminal phalanx; second method (Fig. 4).* The hand being supinated, a narrow knife is passed transversely in front of the bones immediately below the crease in the skin corresponding to the joint, and a flap is cut from the palmar aspect. This being reflected, the joint will be found a line nearer the tip of the finger (Fig. 5), and the knife being passed through it can form a small dorsal flap.

*Fallacy.*—The head of the second is liable to be mistaken for the base



of the terminal phalanx, and if the knife is placed too close to the reflected flap it will slip behind this prominent head.

*Amputation through second phalanx* (Fig. 2, *b*). The hand being pronated and the neighbouring fingers held asunder by an assistant, the operator grasps the end of the finger with the left hand, and makes a semi-lunar sweep over the back of the phalanx with a narrow knife. Transfixing at the base of the incision, the knife is passed in front of the phalanx to cut a corresponding palmar flap. The dorsal skin is then slightly reflected and the bone cleared, when it is to be divided with bone-forceps (B).

The bone-forceps may be straight or angular. In all cases it should be applied so that the flat surface of the blades may be towards the body, since otherwise the bone would be crushed.

*Amputation of first phalanx* (Fig. 10).—This may be conveniently done by lateral flaps as follows. The hand being pronated and the fingers separated, the finger to be removed is held straight by the left hand, and the point of a finger-knife, held vertically, is entered immediately above the head of the metacarpal bone. A lateral flap of skin is then marked out by the heel of the knife being brought down, and the flap is dissected up until the joint is reached, the finger being drawn aside by the left hand. Passing across the joint a corresponding lateral flap is then cut on the opposite side from within outwards (as shown in the metacarpal bone of the little finger in Fig. 9), and the head of the bone may subsequently be removed with bone-forceps or not as preferred.

*Fallacies*.—It is possible to pass beyond the base of the phalanx and head of the metacarpal bone if the finger is not drawn well over. It is essential for this operation that the knife, when the heel has been brought down, should be kept vertical with the point up during the rest of the operation. It is impossible to avoid a little notching of the palmar junction of the flaps, which is of no consequence so long as a single line of cicatrix is secured on the dorsum. The flap operation is applicable to the middle or ring fingers, but the oval method is preferable for the fore and little fingers and the thumb.

#### METACARPO-PHALANGEAL AMPUTATIONS.

The *Oval Method* is specially applicable to amputations at the metacarpo-phalangeal joints, with or without removal of the head of the metacarpal bone. It consists in an incision beginning above the part to be removed



and carried straight down the finger for a variable distance ; the knife is then carried in an oval sweep around the finger and back to the straight part of the incision. The skin requires to be reflected until the joint or the point of section of the bone is reached, and upon removal of the part, the sides of the wound will be found to fall together and fit accurately, leaving a single line of cicatrix.

In order to perform the operation satisfactorily, the bistoury must be held firmly in the hand, but must be used lightly and with a series of sawing movements. The part to be removed is to be firmly grasped and manipulated with the left hand, and an assistant must draw back the skin as it is reflected. Beginning the incision with the point of the knife, the operator gradually lays on the blade as he makes the sweep beneath the finger, bringing up the heel of the knife on the opposite side as far as convenient. It is useless, however, to attempt to complete the oval thus, and the knife should be withdrawn and re-applied to complete the small portion of the oval incision still wanting on the dorsal aspect. (The lines of incision and the method of making them may be conveniently practised on the living body with a pen and ink.) In reflecting the skin and soft tissues the knife must at first be kept parallel to the metacarpal bone, but when some progress has been made the knife may be pushed behind the metacarpal bone (Fig. 7), and made to cut its way out through the original incision—thus saving time.

The *Fore-finger* (Fig. 9) may be most conveniently removed with a part of the metacarpal bone, unless it is desired to leave a broad hand, in which case care must be taken to bring the incision far enough on the first phalanx to secure a good covering for the head of the metacarpal bone.

The straight incision being placed well to the radial side of the finger so that the scar may be hidden (Fig. 6), is to be begun about half-way down the metacarpal bone and prolonged to the head, where an oblique cut is to be carried forward to beyond the web of the finger, and then circularly as far as convenient for the hand of the operator, who is to complete the oval by prolonging the incision obliquely on the opposite side. In the fore and little fingers the natural crease in the skin marks sufficiently accurately the line of incision when the head of the metacarpal bone is to be removed. In the middle and ring fingers the incision should extend beyond the crease.

The bone may be completely cleared (without opening the joint) by carrying the knife around and parallel to it, but it will save time, when some dexterity has been acquired by practice, if the knife is made to transfix



the tissues between the metacarpal bones and cut its way out (Fig. 7). The bone-forceps must be applied obliquely (Fig. 8), so that no unsightly projection shall be left, and the bleeding digital arteries having been secured, the flaps are brought together to form a single line of cicatrix.

If the head of the metacarpal bone is to be left, the incision need not be begun so far up the metacarpal bone, but must be brought lower on the phalanx. When the bone has been cleared and the joint exposed, the finger should be flexed to facilitate opening the articulation.

*Fallacies.*—The two mistakes to be guarded against in all the oval amputations of the fingers are: First, not allowing sufficient covering for the bone; and second, cutting into the web of the fingers, thus leaving a gap which can only be filled up by tedious granulation.

The *Middle or Ring Finger* (Fig. 9) with the head of the metacarpal bone may be conveniently removed by the oval method. The operation is the same as that for the fore-finger, but the straight part of the incision is necessarily in the back of the hand, and care must be taken not to damage the web on either side of the finger. The bone-forceps is to be applied from above as in the flap operation (Fig. 10), and care must be taken to remove the entire head of the metacarpal bone, or the adjacent fingers will not come together as closely as they should.

The *Little Finger* (Fig. 11) is to be removed exactly like the fore-finger, the incision being placed at the ulnar side.

The *Thumb* (Fig. 12) being the most important member of the hand should be preserved as long as possible, and each of its bones being provided with distinct muscles, it is possible to excise any one bone and yet leave a useful member. In amputating the first phalanx by the oval method, the head of the metacarpal bone should never be removed, and due allowance for its large size must be made by bringing the incision well forward on the phalanx.

In the case of a crushed hand, it may be necessary to remove portions of two or more metacarpal bones, and this may be readily effected either with bone-forceps or a metacarpal saw, a covering being taken from the front or back of the hand, or both, as circumstances may permit.

#### CARPO-METACARPAL AMPUTATIONS.

These may be performed by both the "oval" and "flap" methods, but they are seldom resorted to, since, in the case of the fingers, the



operation necessarily opens the large synovial membrane of the wrist, and often leads to destruction of the joint.

*Oval method.*—In the *fore-finger* (Fig. 9) or the *little finger* (Fig. 11), it is only necessary to prolong the straight incision up to or a little beyond the joint; in the *thumb* (Fig. 12), the incision should be begun at the base of the metacarpal bone and need not be prolonged beyond its head, as the tissues are amply sufficient.

*Flap method.*—This may be practised on the little finger, and though more rapid than the oval method has the great drawback of leaving a scar on both the dorsal and palmar aspects. The finger being drawn away from the hand, the knife held at right angles to the finger and with the point upwards is made to cut through the web of the finger and interosseous space until it reaches the base of the metacarpal bone. This is somewhat expanded, and the knife must be turned outwards slightly to open the joint, when forcible traction of the finger will dislocate it. The knife is then passed round the base of the metacarpal bone and brought out with the edge forwards, cutting a flap from the ulnar side of the finger rather longer than the exposed surface, in order to allow for shrinking.

The flap operation may be applied to the fore-finger and thumb, but is not to be recommended.

#### EXCISION OF THE WRIST.

Excision of the wrist-joint by Lister's method (Fig. 14) is more difficult of accomplishment on the dead than on the living body, since in cases of disease of the articulation the ligaments are softened and the bones loosened. The accompanying woodcuts from Erichsen's "Science and Art of Surgery" will serve to illustrate the anatomy of the tendons of the back of the wrist and the relations of the synovial membranes, which must be carefully borne in mind throughout the operation.

The following is Mr. Lister's description of his own operation (*Lancet*, 1st April, 1865):—

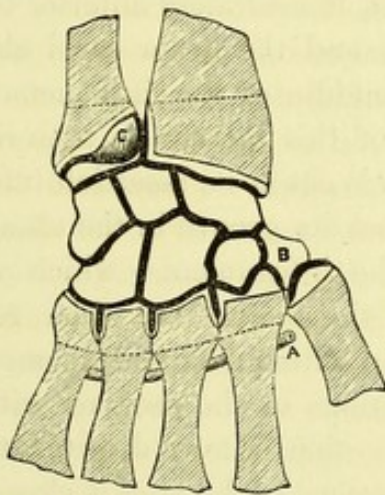
"Before the operation is commenced, any adhesions of the tendons are thoroughly broken down by freely moving all the articulations of the hand. The radial incision is then made in the situation indicated by the thick line (L L) in the accompanying diagram of the anatomy of the back of the hand (Woodcut 2). This incision is planned so as to avoid the



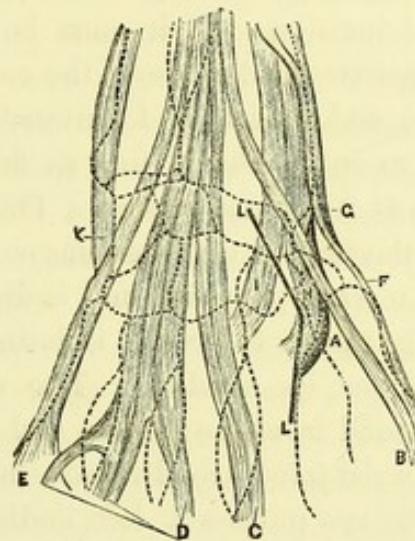
radial artery, and also the tendons of the extensor secundi internodii pollicis and indicator. It commences above at the middle of the dorsal aspect of the radius, on a level with the styloid process, this being as close to the angle where the tendons meet as it is safe to go. Thence it is at first directed towards the inner side of the metacarpo-phalangeal articulation of the thumb, running parallel in this course to the extensor secundi internodii; but on reaching the line of the radial border of the second metacarpal bone it is carried downwards longitudinally for half the length

Woodcut 2. *Tendons of Back of Wrist.*

Woodcut 1. *Diagram of Wrist-joint.*



- A. Deep palmar arch.
- B. Trapezium.
- C. Articular surface of ulna, over which radius moves (Lister).



- A. Radial artery. B. Tendon of extensor secundi internodii pollicis. C. Indicator. D. Extensor communis digitorum. E. Extensor minimi digiti. F. Extensor primi internodii pollicis. G. Extensor ossis metacarpi pollicis. H. Extensor carpi radialis longior. I. Extensor carpi radialis brevior. K. Extensor carpi ulnaris. L L. Line of radial incision (Lister).

of the bone, the radial artery being thus avoided, as it is somewhat further to the outer side of the hand. The soft parts at the radial side of the incision are next detached from the bones with the knife guided by the thumb-nail, so as to divide the tendon of the extensor carpi radialis longior at its insertion into the base of the second metacarpal bone, and raise it, along with that of the extensor carpi radialis brevior previously cut across, and the extensor secundi internodii, while the radial artery is thrust somewhat outwards. This prepares the way for the next



step, which is the separation of the trapezium from the rest of the carpus, by means of cutting forceps applied in a line with the longitudinal part of the incision—a procedure which, as experience shows, does not endanger the radial artery. The removal of the trapezium is reserved till the rest of the carpus has been taken away, when it can be dissected out without any considerable difficulty; whereas its intimate relations with the radial artery and its secure connections with neighbouring parts would cause a great deal of trouble at an earlier stage of the operation. The soft parts on the ulnar side of the incision are now dissected up from the carpus as far as is convenient, the hand being bent back to relax the extensor tendons of the fingers. The separation of these is, however, best effected from the ulnar incision, which must be made very free. The knife is entered at least two inches above the end of the ulna, immediately anterior to the bone, and is carried downwards between it and the flexor carpi ulnaris, and on in a straight line as far as to the middle of the fifth metacarpal bone at its palmar aspect. The dorsal lip of this incision is then raised, and the tendon of the extensor carpi ulnaris is cut at its insertion into the fifth metacarpal bone, and is dissected up from its groove in the ulna, care being taken to avoid isolating it from the integuments, which would endanger its vitality. The extensors of the fingers are then readily separated from the carpus, and the dorsal and internal lateral ligaments of the wrist-joint are divided; but the connections of the tendons with the radius are purposely left undisturbed. Attention is now directed to the palmar side of the incision. The anterior surface of the ulna is cleared by cutting towards the bone so as to avoid the artery and nerve; the articulation of the pisiform bone is opened, if that has not been already done in making the incision, and the flexor tendons are separated from the carpus, the hand being depressed to relax them. While this is being done, the knife is arrested by the process of the unciform bone, which is clipped through at its base with pliers. Care is taken to avoid carrying the knife further down the hand than the bases of the metacarpal bones; for this, besides inflicting unnecessary injury, would involve risk of cutting the deep palmar arch, the position of which is shown in Woodcut 1. The anterior ligament of the wrist-joint is also divided, after which the junction between the carpus and metacarpus is severed with cutting pliers, and the carpus is extracted by seizing it from the ulnar incision with a serviceable pair of sequestrum forceps, and touching with the knife any ligamentous connections that may remain undivided. The hand being now forcibly everted, the articular ends of the radius and ulna will protrude at the ulnar



incision, and are carefully examined and treated according to their condition. If they appear sound or very superficially affected, the articular surfaces only are removed. The ulna is divided obliquely with a small saw, so as to take away the cartilage-covered rounded part over which the radius sweeps, while the base of the styloid process is retained. The ulna is thus left of the same length as the radius, and this greatly promotes the symmetry and steadiness of the hand, the angular interval between the bones being soon filled up by fresh ossific deposit. The end of the radius is then cleared sufficiently to permit a thin slice to be sawn off parallel to the general direction of the inferior articular surface. For this purpose it is scarcely needful to disturb the tendons in their grooves on the back of the bone, the bevelled ungrooved part being enough to remove, and thus the extensor secundi internodii pollicis may never appear at all. This may seem a refinement; but the freedom with which the thumb and fingers can be extended, even within a day or two of the operation, when this point is attended to, shows that it is important. The articular facet on the ulnar side of the bone is then clipped away with bone-forceps applied longitudinally. The metacarpal bones of the fingers are next dealt with on the same principle, each being in its turn closely investigated, the second and third being most readily reached from the radial incision, the fourth and fifth from the ulnar side. If they seem sound, the articular surfaces only are clipped off, the little facets by which they articulate with one another being removed by the longitudinal application of the pliers, as is indicated in Woodcut 1.

“The trapezium is next seized with a strong efficient pair of forceps, and dissected out so as to avoid cutting the tendon of the flexor carpi radialis, which is firmly bound into the groove on its palmar aspect, the knife being also kept close to the bone elsewhere to preserve the radial artery. The thumb being then pushed up longitudinally by an assistant, the articular end of its metacarpal bone is cleared and removed. This may seem a superfluity, as this bone articulates with the trapezium by a separate joint. But besides the possibility of its being affected through its immediate vicinity to the other articulations, the symmetry of the hand is promoted by reducing it to the same level as the other metacarpal bones. Lastly, the articular surface of the pisiform bone is clipped off, the rest of the bone being left, if sound, as it gives insertion to the flexor carpi ulnaris, and affords attachment to the anterior annular ligament, and may serve other useful purposes in the palm. But if there is any suspicion of its unsoundness, it must be dissected out completely. The same applies to



the process of the unciform. It may be observed that the extensors of the carpus are the only tendons divided; for the flexor carpi radialis is connected with the second metacarpal bone below its base, and so escapes. But if it should be cut, there is no doubt that, like the extensors, it would acquire new and secure attachments."

#### AMPUTATION AT THE WRIST-JOINT.

This operation is one seldom performed, since in cases of disease of the articulation it is necessary to remove the articular extremities of the radius and ulna, and even in cases of injury the higher operation yields better results.

The hand being pronated and the wrist-joint flexed by the left hand of the operator, a dorsal flap is marked out (Fig. 11) by entering the point of a large bistoury at the styloid process of one side and making a sweep across to the other. This flap is to be retracted by an assistant and dissected up, and is to include the tendons of the back of the hand. The ends of the radius and ulna being exposed, the wrist-joint is to be opened, and it is to be borne in mind that the joint is the reverse of the flap in shape, *i.e.*, the convexity is upwards. The point of the knife is to free the styloid processes, but should inflict no damage upon the palmar structures.

It is impossible to form the palmar flap by transfixion on account of the arch of the hand, and a deep incision parallel to the metacarpus should therefore be made first on one side and then on the other, when the intervening tendons will be brought into view, and should be divided with the median nerve, the ulnar artery and nerve being left in the flap. The thumb of the left hand being slipped over the articulation (Fig. 13) will much facilitate the latter steps, and will allow the flap to be thoroughly dissected down. It should be longer than afterwards required, and the operator may most conveniently shape a well rounded flap by passing the knife vertically through the middle of the palm, and cutting outwards first to one side and then to the other.

The radial artery will be cut close to the radius, and the ulnar artery will be formed in the palmar flap. It is of course open to the operator to saw off the articular ends of the radius and ulna if diseased, or to remove the styloid processes with bone-forceps.

*Fallacies.*—In opening the articulation, the space between the two rows of carpal bones may be mistaken for the wrist-joint proper. In this

case the small and rounded head of the os magnum and the unciform bone will be seen instead of the broad convexities of the scaphoid and semilunar bones, and the operator should go half an inch higher.

In forming the palmar flap care must be taken not to make "button-holes" in it, particularly in dissecting round the pisiform bone, nor to score it so as to damage its vitality. Unless more flap is cut than is afterwards required, it will be found impossible to avoid making a jagged and uneven edge to the palmar flap.

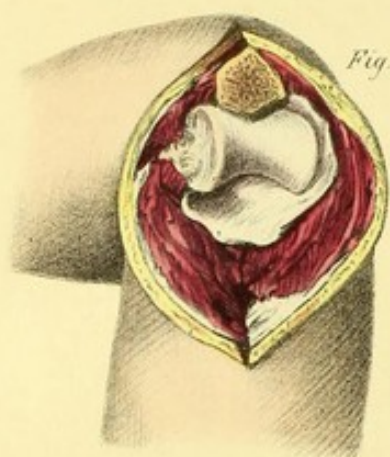
Another mode of performing the operation is to mark out the palmar flap first on the supinated hand, and then proceeding as before.



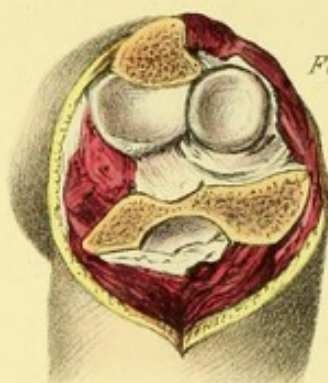




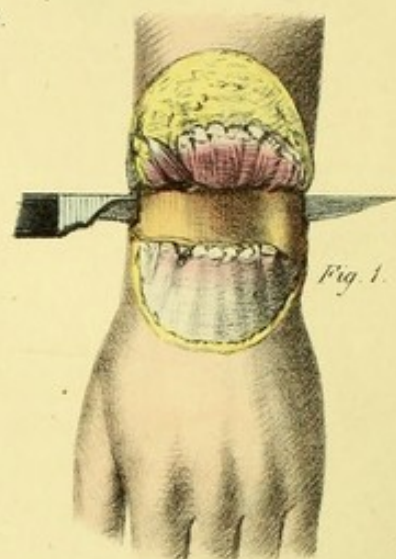




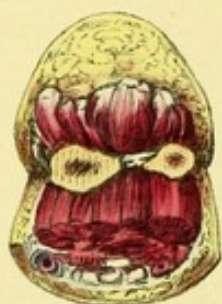*Fig. 3.*



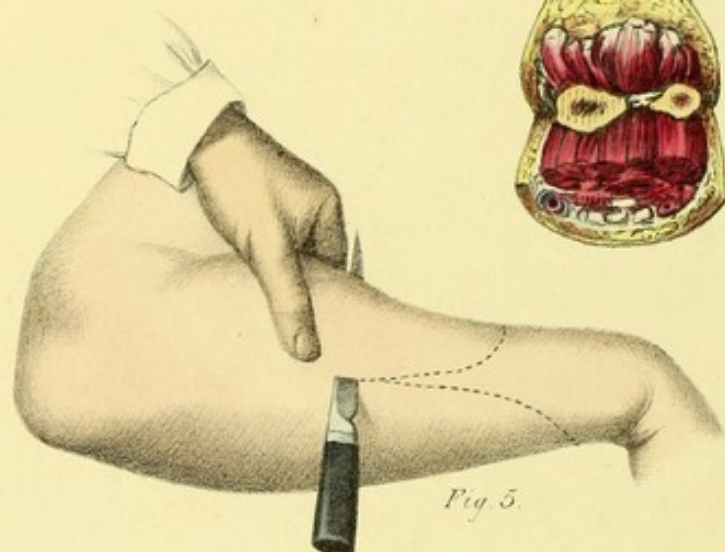
*Fig. 4.*



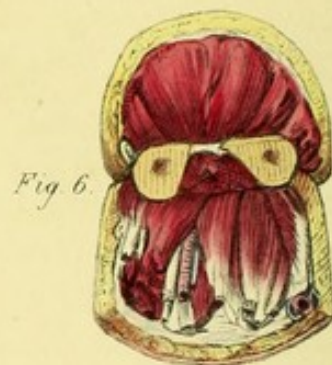
*Fig. 1.*



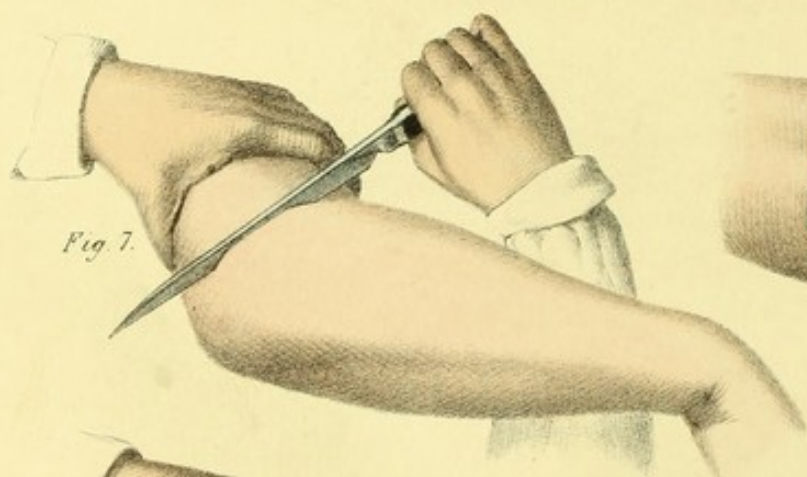
*Fig. 2.*



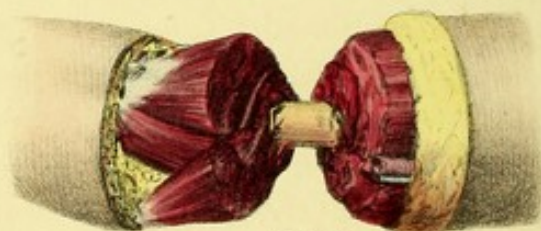*Fig. 5.*



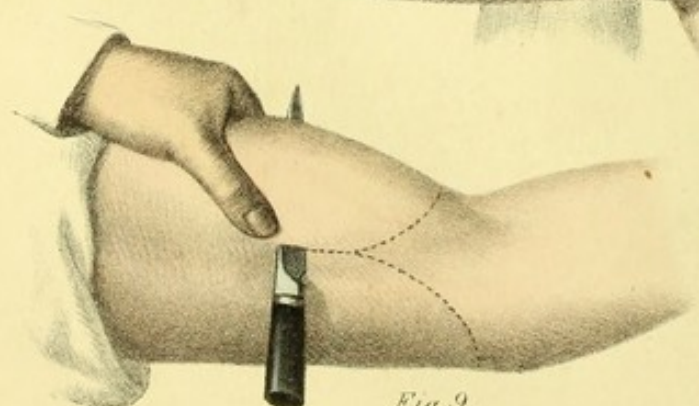
*Fig. 6.*



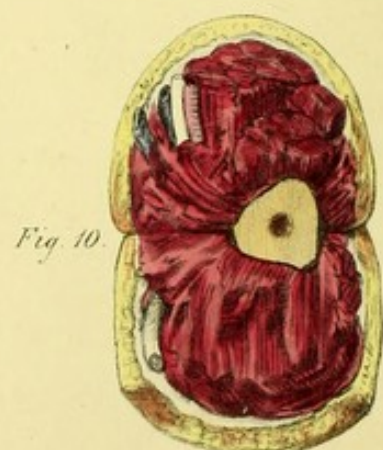
*Fig. 7.*



*Fig. 8.*



*Fig. 9.*



*Fig. 10.*



## PLATE XV.

---

- FIG. 1.* Amputation by long and short flaps immediately above the wrist-joint.  
*FIG. 2.* Stump of ditto.  
*FIG. 3.* Excision of left elbow-joint; removal of olecranon process.  
*FIG. 4.* „ „ „ removal of articular end of humerus.  
*FIG. 5.* Amputation of the right fore-arm by double flaps.  
*FIG. 6.* Stump of ditto.  
*FIG. 7.* Circular amputation of right upper arm, first stage.  
*FIG. 8.* Circular amputation of right upper arm, second stage. The limb is now viewed from the inner side, that the position of the brachial artery and median nerve may be seen.  
*FIG. 9.* Amputation of left upper arm by flaps.  
*FIG. 10.* Stump of ditto.
- 

### AMPUTATION OF THE FORE-ARM ABOVE WRIST.

*Amputation immediately above the wrist-joint* (Fig. 1) may be most conveniently performed by a long dorsal and short palmar flap. The hand being pronated and held by an assistant, the operator stands to the right of the limb, and with a short amputating-knife or catlin marks out a flap on the back of the hand, the incision beginning and ending above the styloid processes on either side, and coming half-way down the metacarpus. This flap may be convex or rectangular, according to the fancy of the operator, but should only include the skin and subcutaneous fascia until the level of upper border of the posterior annular ligament is reached, when the knife should be carried down to the bones through the tendons, which should then be reflected. The knife then transfixes the limb in front of the bones, and a flap about one-third of the length of the dorsal one is cut by a steady sawing movement, the knife being brought out rather sharply at the end, so as to make the flap more or less rectangular (Fig. 2).

The radial and ulnar arteries will be found divided at the edge of



the anterior flap, and probably one or two muscular branches will bleed. The palmar flap will be found to retract somewhat, and the dorsal flap will fall over its end, the skin edges fitting exactly.

*Fallacies.*—If, following strictly Mr. Teale's directions, the knife is carried down to the bone in making the first incision, and the tendons are reflected with the flap, it will be found impossible to dislocate them from the grooves in the end of the radius without damaging them, and it is more convenient therefore to divide the muscles above the annular ligament. The operator must draw the flap up with his left hand, and carefully keep the edge of the knife against the deep structures, or he may cause the skin-flap to slough.

#### EXCISION OF THE ELBOW-JOINT.

*Excision of the Elbow* (Fig. 3) is best performed through a single straight incision, but under certain circumstances it may be advisable to adopt the T or H incisions. The arm may be most conveniently held extended by an assistant standing at the patient's shoulder and grasping the upper and fore-arm with his hands. The operator thus has the back of the joint fully exposed to his view, and should clearly fix in his mind the side on which the ulnar nerve is lying. (In the illustration the *left* elbow is represented, and the nerve is to the operator's *left* hand, although not seen in the operation.)

A straight incision, four inches long, is to be made in the middle line of the limb, with its mid-point opposite the olecranon. The upper two inches will expose the subcutaneous ulna, but the lower two should be carried at once through the whole thickness of the triceps down to the humerus. The left thumb of the operator inserted in the lower part of the wound will obtain a firm hold of the tissues, which are to be carefully peeled off the ulna and humerus, the knife being used cautiously and parallel to the ulnar nerve, and with the edge against the bone. One side of the olecranon and the corresponding condyle being cleared, the operation is to be repeated on the opposite side, the left hand being brought round so as to exercise traction on the flap. The elbow being now bent and the flaps on each side held back with blunt hooks, the olecranon process is to be grasped with the lion-forceps and sawn off transversely, or, in young subjects, cut off with bone-forceps. This opens up the interior of the joint most satisfactorily, and saves the trouble of dislocating the ulna.



The condyles of the humerus are next to be cleared, the close proximity of the ulnar nerve to the internal condyle being always borne in mind. It will be found most convenient to clear the outer condyle first, and after the flap of skin and muscle is reflected, it is necessary to pass the knife between the condyle and the head of the radius to divide the strong external lateral ligament. This loosens the connection of the bones effectually, and allows the internal condyle to be cleared without difficulty. The lower end of the humerus is to be grasped with the lion-forceps and removed with the saw, which may be applied to the back or front of the bone as preferred. The line of section should be exactly parallel to the condyles, and close above the articular surface, so as to pass through the fossæ immediately above the trochlear surfaces (Fig. 4).

The coronoid process and upper end of the ulna are now to be cleared by the division of a few fibres of the insertion of the brachialis anticus and the orbicular ligament of the radius, and the ends of the two bones can then be thrust out from the soft tissues for section. The ulna should be grasped with the lion-forceps and the two bones sawn together, the line of section including the lesser sigmoid cavity of the ulna and the head of the radius.

*Fallacies.*—If the incision is too small there is great difficulty in exposing the joint satisfactorily, particularly when, in the living body, the synovial membrane is much thickened. Too great care cannot be exercised in keeping the knife parallel to the axis of the limb, so as to avoid injury to the soft tissues, and especially the ulnar nerve. If the triceps is cut across at some distance from its insertion, instead of being “peeled” off the bone, so as to be continuous with the anconeus as far as possible, there will be great loss of power afterwards. In sawing the humerus it is most important that a broad surface should be left, and an increase of half an inch in the height of the section will make all the difference in the usefulness of the limb. In cases of disease the bone may be roughened, or in those of accident the bone may be fissured for some distance above the coronoid and olecranon fossæ, but the bone should never be cut higher if it can possibly be avoided. The ulnar nerve should not be actually exposed, but may generally be seen through the surrounding cellular tissue in the dead body. It is more in danger of being cut with the saw when the ulna is divided than when the section of the humerus is made, it being more difficult to clear the former bone. The whole insertion of the brachialis anticus never requires division, still less the tendon of the biceps.



## AMPUTATION OF THE FORE-ARM.

The operation by long and short flaps (Fig. 1) may be performed with advantage at any point in the fore-arm, or amputation by two nearly equal flaps (Fig. 5) may be selected. In a thin arm the flaps may be conveniently made by transfixion, thus including the greater part of the muscles; but in a large muscular arm it would be better to cut the flaps from without inwards and containing only a part of the muscular fibres, or to dissect up two skin-flaps and to divide the muscles and vessels circularly.

In the *Double-flap operation by transfixion* (Fig. 5) it is essential that the operator should be quite clear as to the position of the bones of the fore-arm, lest he pass the knife between them. The position of *pronation* appears to be the best for the arm to be held in by an assistant, and the operator then grasps the dorsal tissues with his left hand, feeling with his thumb the border of the ulna in the left and the radius in the right limb. Entering the point of a small amputating-knife or catlin slightly upwards, he then passes it across the bones and depresses the point at the opposite side, at the same time drawing up the tissues with the fingers. In this way a broad flap may be raised on the knife, which should saw steadily down the limb for two to three inches, when it is to be brought out so as to cut the skin longer than the soft tissues. The knife entering at the original spot is then passed beneath the bones, and the left hand of the operator is able to keep the first flap back, and to ensure the exit of the point at the proper spot. The under flap is cut slightly longer than the upper by a steady sawing movement, and the knife should be brought out rather sharply, so as to cut it somewhat square, and to divide the flexor tendons with the vessels and nerves at one sweep. Both flaps being retracted by the left hand of the operator (aided when necessary by an assistant), the knife is to be swept around the bones close to the flaps, and to be passed between them so as to divide the interosseous tissues. The double-edged catlin is convenient but not essential for this part of the operation, since it is unnecessary to withdraw it in order to reverse the blade. The bones being sufficiently bared are to be sawn through together, and of the same length. The radial and ulnar arteries will be found in the under flap (Fig. 6), the radial being more superficial than the ulnar, which lies close to its nerve. An interosseous and some muscular branches will probably require ligatures, and should the median or ulnar nerve have been left too long, it should be at once shortened.



*Fallacies.*—In this, as in all transfixion operations, it is possible for a careless operator to have the edge of his knife towards the body instead of towards the limb to be removed, and in both the fore-arm and leg it is not difficult to thrust the knife between the bones. In either case the knife must be completely withdrawn and re-entered, or great mischief will be done to the soft tissues. In bringing the knife out at the end of either flap care must be taken not to turn the edge too vertically when dividing the skin, or it will be found to retract and be shorter than the muscle. In all flaps the skin must be the longest structure.

#### AMPUTATIONS OF THE UPPER ARM.

The *Upper Arm* is a good position for practising the circular method and its modifications, but most surgeons would prefer the easier operation by double flaps.

The *Circular Amputation* (Fig. 7) demands for its proper performance a perfectly sound condition of the skin from two to three inches below the point at which it is intended to saw the bone; hence in cases of injury it becomes necessary either to go very high up, thus leaving a very short stump, or to modify the operation by turning back flaps of the skin, shaped as circumstances may dictate, and dividing the remaining structures circularly.

The limb being held by an assistant, the operator should stand so that his left hand may grasp the upper arm and draw up the skin. Then bending the right knee and steadying himself by throwing his left foot behind him, the operator passes his right arm beneath the limb and brings the point of the knife as far round as convenient (Fig. 7). The old-fashioned curved amputating knife with a blunt point is more convenient than the modern straight one, the point of which is apt to catch in the tissues as they are dissected up. The knife should be firmly grasped by the fingers, and held between them and the thumb as shown, and not awkwardly in the fist. The whole thickness of the skin is to be divided by the first circular sweep, which should take the entire circumference of the limb, and this is not easily accomplished unless the assistant is directed to rotate the limb slightly, so as to meet the knife as the heel is brought up. The skin with all the subcutaneous structures down to the muscles is now to be reflected for about  $1\frac{1}{2}$  inches, and turned back like the cuff of a coat, being grasped by the left hand whilst the edge of the knife is applied vertically



with the right (Fig. 8). Another circular sweep is now to be made close to the reflected skin, and this may go completely down to the bone, or, better, may be made to divide the biceps and triceps only, and leave the main vessels and nerves uncut. The muscles being then retracted, the vessels and nerves should be divided last and shortest of all. A two-tailed retractor may now be advantageously used by an assistant to draw up the soft tissues on the bone, which is to be sawn through as high as possible.

The brachial artery (Fig. 8) will be found close to the median nerve, and cut short and square. The superior profunda artery accompanies the musculo-spiral nerve on the outer, and the inferior profunda artery the ulnar nerve on the inner side.

*Fallacies.*—The skin being the most important covering, must be carefully preserved both in length and thickness, so as to effectually cover the bones. If the first sweep of the knife goes deeply into the muscles it is more difficult to reflect the skin and fascia, and if any of the subcutaneous fat is left behind, the vitality of the skin will be impaired. The number of times that the knife is applied circularly is a matter of little importance, so long as the tissues are thoroughly dissected up from the bone for a sufficient distance.

The *Flap Amputation* (Fig. 9) in the upper arm is most conveniently done by double transfixion, though the flaps may be cut from without inwards without difficulty. The limb being held away from the trunk by an assistant, the operator grasps the biceps with the brachial vessels and nerves, and entering the point of the knife upwards close below his thumb, passes it in front of the humerus, depressing the point as it appears on the opposite side close to the operator's fingers. With a steady sawing movement, a flap from two to three inches long is cut, with the skin left longer than the muscles. Drawing up the flap with his fingers, the operator passes the knife behind the bone, and cuts a slightly larger flap behind, bringing out the knife abruptly at the last. Both flaps being gently retracted, the knife is swept round the bone, which is then sawn steadily through, the thumb and fingers of the left hand protecting the soft tissues.

The brachial artery (Fig. 10) will be found in the anterior flap with the median nerve, and the ulnar nerve will be a little posterior. The artery if cut too long may be conveniently shortened, and the nerves should always be drawn out and cut short by an inch or so, since if left they are apt to become entangled in the cicatrix. The inferior profunda artery

will be found in company with the ulnar nerve, and the superior profunda with the musculo-spiral nerve in the posterior flap.

*Fallacies.*—The only mistake possible in performing this operation is to transfix the artery with the point of the knife. This is best avoided by drawing the vessels and nerves well up with the biceps, and should the accident happen, care must be taken to place the ligature well above the divided portion of the vessel, and to cut off the split ends.

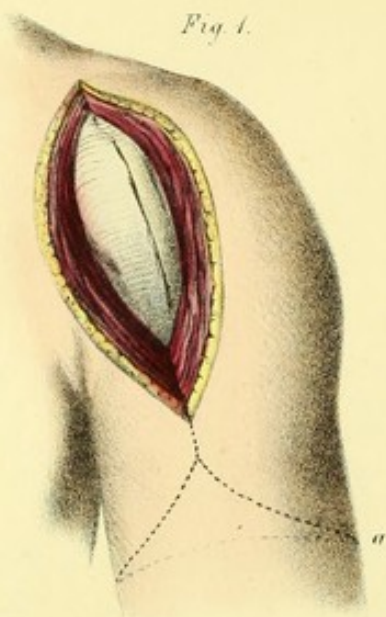




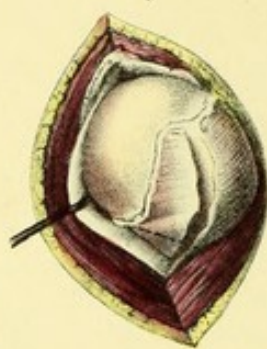




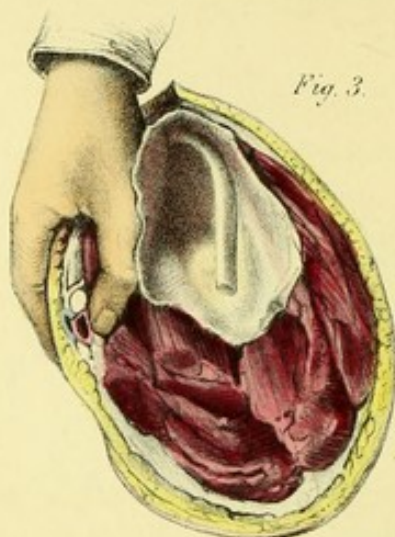
*Fig. 1.*



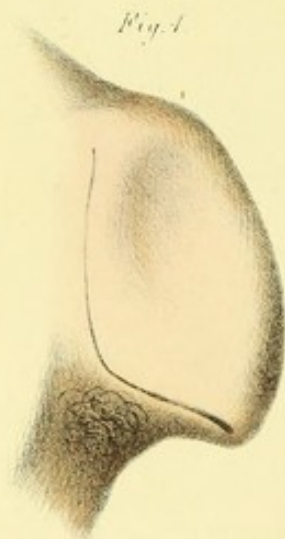*Fig. 2.*



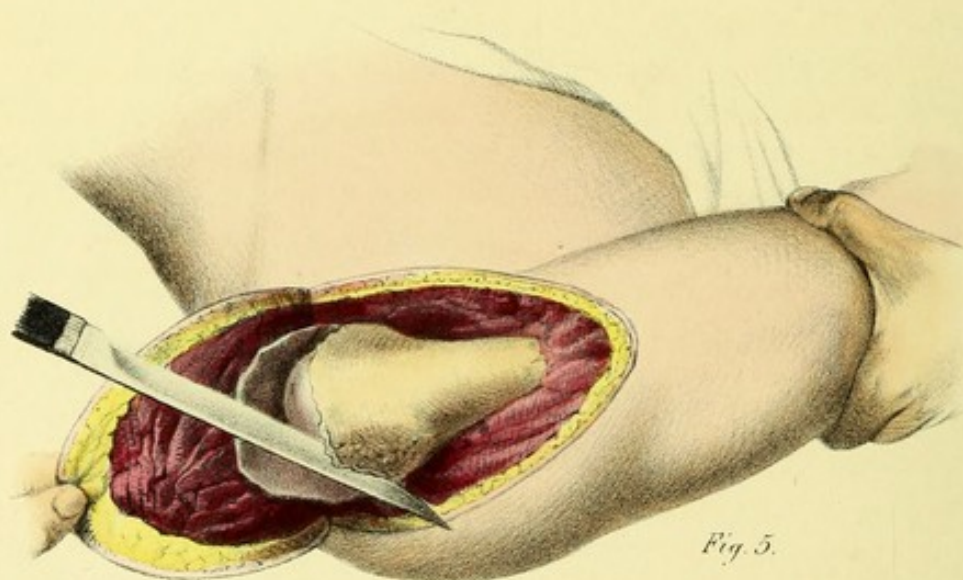
*Fig. 3.*



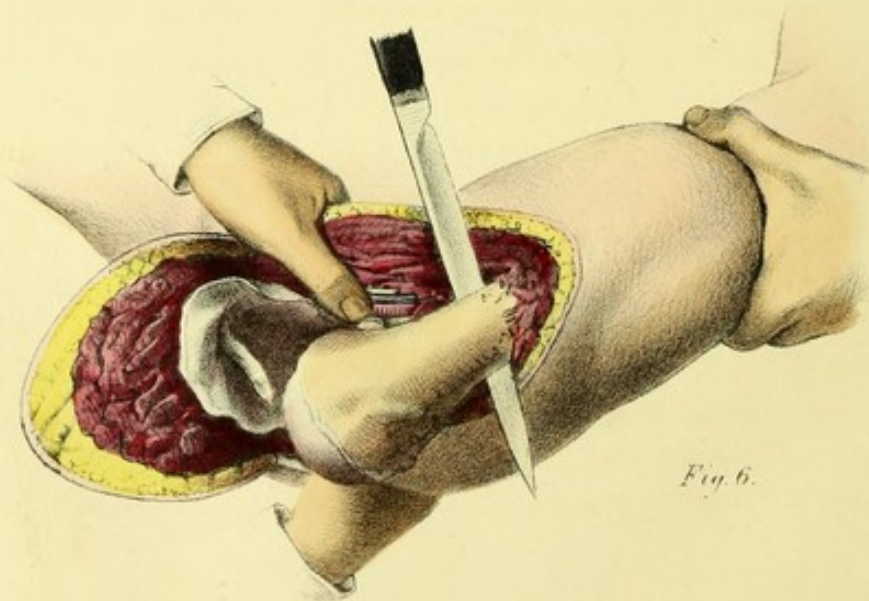
*Fig. 4.*



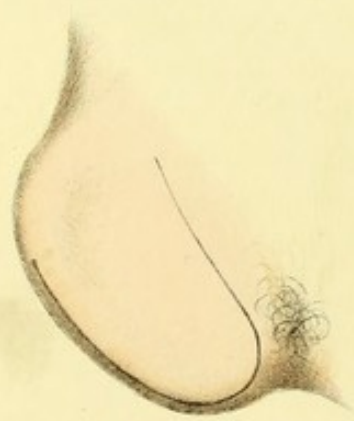*Fig. 5.*



*Fig. 6.*



*Fig. 7.*





## PLATE XVI.

---

*FIG. 1.* Excision of the head of the left humerus by a straight incision.

*a. a.* Line of oval amputation at the shoulder joint.

*FIG. 2.* Excision of the head of the left humerus; tendon of biceps held aside; capsule divided, and head of bone thrust out.

*FIG. 3.* Oval amputation at the left shoulder joint; axillary artery held by assistant.

*FIG. 4.* " " " flaps brought together.

*FIG. 5.* Flap amputation at the right shoulder joint; deltoid flap reflected, capsule opened.

*FIG. 6.* " " " formation of axillary flap; assistant grasping the vessels behind the knife before they are divided in the completion of the flap.

*FIG. 7.* " " " flaps brought together.

---

### EXCISION OF THE HEAD OF THE HUMERUS.

*Excision of the Head of the Humerus* (Fig. 1) is best performed by a single straight incision, though in cases of great splintering of the bone by gun-shot injury it may be necessary to reflect a deltoid flap (Fig. 5).

The straight incision is best placed immediately to the outer side of the coracoid process, and, beginning at the clavicle, should be four inches in length. The fibres of the deltoid being divided should be retracted with spatulas, and the arm rotated slightly outwards so as to bring the bicipital groove into the line of the incision. In the dead body, and in some cases of injury, it may be possible to preserve the long tendon of the biceps, which should be at once dissected out and held aside with a blunt hook, but in cases of disease the tendon is invariably destroyed or adherent to the bone and cannot be preserved. The capsule is now to be divided, and in order to bring the attachment into view, the humerus must be rotated by an assistant, who should endeavour to thrust



the head out of the wound as soon as it is sufficiently cleared (Fig. 2). In this part of the proceeding the operator may either employ the knife with which the first incision was made, or, on the living body when the parts are infiltrated and thickened, may advantageously use a straight blunt-pointed bistoury when once the capsule has been opened. The head of the humerus being thrust out of the wound is to be sawn off transversely close to the articular surface, either with a small saw with moveable back, or with "Butcher's saw," the blade of which has been reversed. The head being removed, any disease of the glenoid cavity can be readily reached, and if necessary removed with gouge or bone-forceps. In rare cases of extensive adhesions of the head to the glenoid cavity, it may be advisable to saw the neck of the bone first, and then by grasping the head with the "lion-forceps" to twist it out of the socket. No large artery is wounded, but a muscular branch or two may require ligatures. The cephalic vein occasionally crosses the lower part of the line of incision, and if divided had better be secured.

*Fallacies.*—If the incision is placed too near the tip of the shoulder, or is made too small, the difficulty of the operation is much increased. The operation by a deltoid flap is easier than that by a single incision, but has the drawbacks of giving rise to greater hæmorrhage, and of leaving a much less useful area. It is not advisable to remove simply the articular surface of the humerus by an oblique incision, but the whole head must be removed by section at the surgical neck of the bone.

#### AMPUTATION AT THE SHOULDER-JOINT.

The *Oval Method* (Fig. 1, *a*) may be readily practised on a subject in which excision of the head of the humerus has already been performed, or may be undertaken independently. The straight incision is to be four inches long, and placed to the outer side of the coracoid process, and is to be carried down to the bone. The operator grasping the limb firmly with the left hand, then carries the heel of his amputating knife round the back of the arm as far as he conveniently can, and completes the oval incision from the front with the point. The incision on the outer side of the limb should go to the bone, but on the inner side the skin only should be divided, so that the vessels and nerves may be preserved to the last. The deltoid muscle being drawn back by an assistant, who should stand at



the shoulder of the patient, the capsular ligament is to be exposed and divided close to the anatomical neck of the humerus by a semi-circular sweep of the knife (Fig. 5), the arm being rotated so as to bring the several parts successively into view. The humerus being now dislocated from its socket, the knife can be passed round it and carried down the inner side of the bone followed by the thumbs of the assistant, which should grasp the vessels before they are divided. Lastly, the knife is brought out through the original oval incision on the inner side, dividing the great vessels and nerves at the last moment, and leaving them grasped by the assistant (Fig. 3).

The axillary artery should be secured at once, and probably the vein will require a ligature also. One or two branches of the circumflex artery will bleed in the deltoid muscle, and unnamed muscular branches in the divided fibres. The flaps when brought together will present the appearance shown in Fig. 4, the vertical cicatrix being well forward out of the way of pressure, and drainage being effectually obtained at the lower part.

*Fallacies.*—If the vertical incision is made too short, the oval sweep will not include the whole of the deltoid, and the flap will be too small. The same thing will occur if the heel of the knife is allowed to go up instead of down the limb in making the oval sweep. The deltoid flap must not be touched with the knife on its inner surface, or the large posterior circumflex artery will be divided and bleed freely.

The *Flap Method* (Fig. 5) may be performed either by transfixion or by cutting from without inwards, and the latter method gives a larger and more satisfactory flap. The operator grasping the limb with his left hand brings it across the chest, and leaning over, enters the point of an amputating knife at the most prominent point or angle of the acromion process. With a sawing movement he marks out a flap of skin and deltoid muscle, taking nearly the entire muscle down to its insertion, and bringing the incision up to the coracoid process, at the same time drawing the arm away from the side. An assistant grasping the flap draws it up so as to expose the shoulder joint, which is to be opened by one semi-circular sweep of the knife laid on close to the anatomical neck of the humerus, the bone being rotated by the left hand of the operator, so as to bring the several parts of the capsule into view successively. The tendon of the biceps is divided with the capsule, and the head of the bone is then readily dislocated so as to allow the blade of the knife to be passed behind it to form an inner flap. The assistant is now to follow the knife with his thumbs, having his



fingers in the axilla so as to compress the vessels before they are divided (Fig. 6), and the operator is then to cut the remaining tissues opposite the point of the deltoid flap.

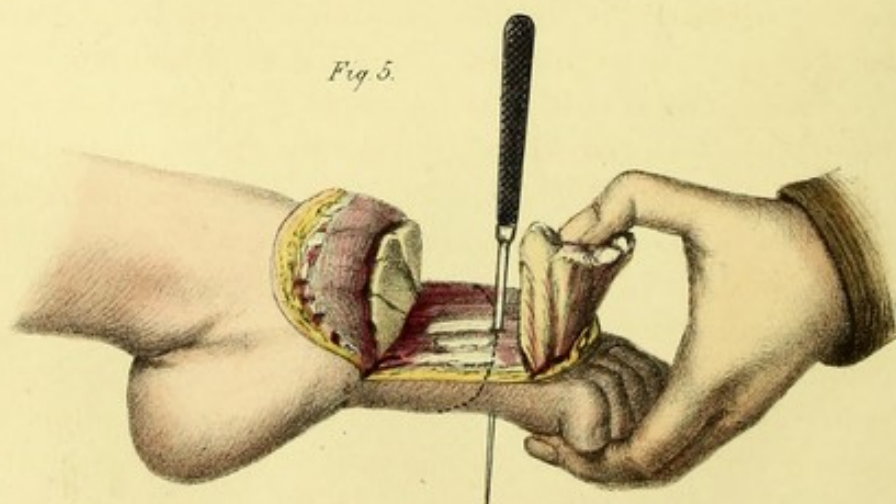
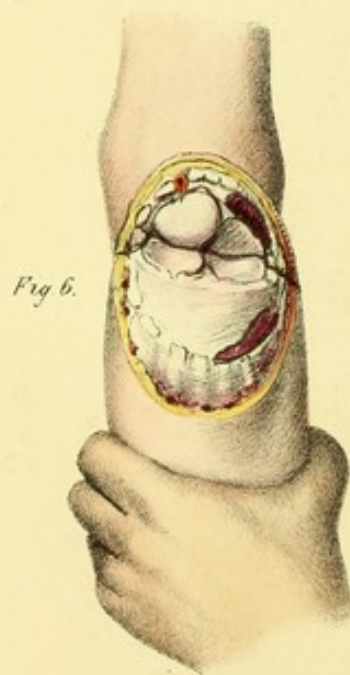
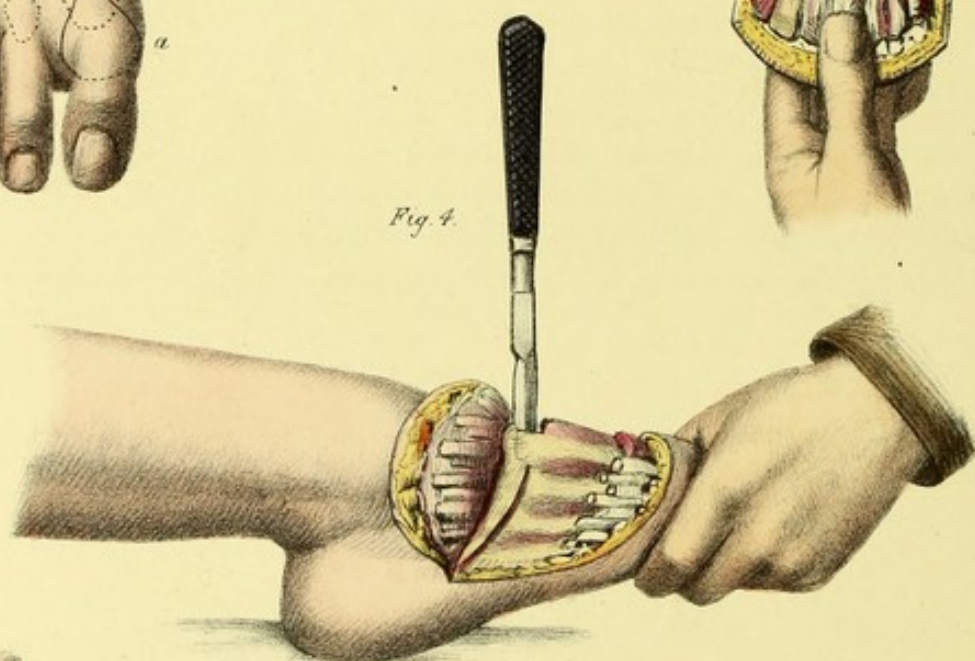
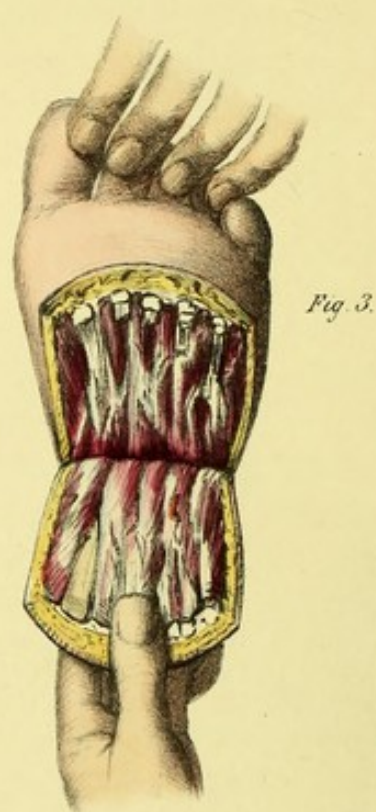
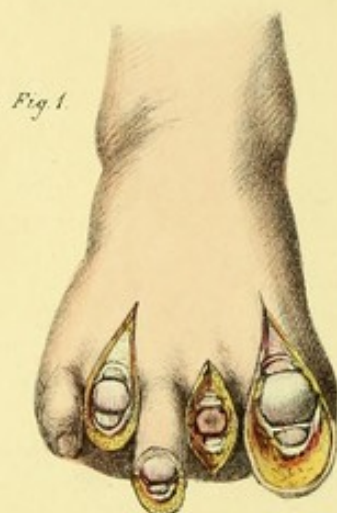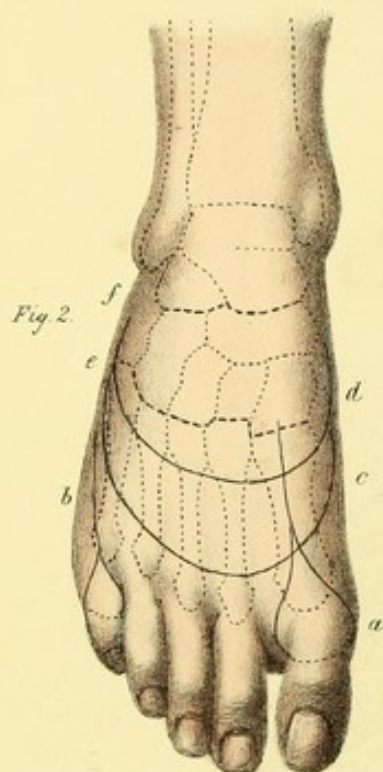
The axillary artery, and probably the vein, will require ligatures, and the posterior circumflex artery will probably have been cut near the junction of the two flaps on the outer side, though it is possible to avoid cutting its trunk with care. A few muscular branches will also bleed. The flaps when brought together are superior and inferior, as in Fig. 7.

On the left side the operation will be the same, but with the proceedings reversed; thus the arm will be drawn away from the side whilst the incision is begun at the coracoid process, and be brought across the chest as the knife reaches the acromion. The sweep of the knife in dividing the capsule will of course be from within outwards on the left side.

*Fallacies.*—In the living body, when the arm is entire, it is possible that the operator may find a difficulty in manipulating a heavy muscular limb with his left hand unless he is aided by an assistant, who should support the hand and fore-arm, and follow without impeding the movements of the operator. Some surgeons prefer to entrust the limb altogether to an assistant, and in that case the operator should stand at the shoulder of the patient, and, reversing the directions for the right and left sides given above, will draw up his own deltoid flap, and with his left hand grasp the axillary flap before it is completed. The real difficulty in the operation is the division of the capsular ligament, and this can only be satisfactorily done by cutting upon the head of the humerus near the anatomical neck in a semi-circular sweep. If the point of the knife is thrust among the muscles attached to the capsule and bone, hæmorrhage will be caused, and the capsule will not be satisfactorily divided.







## P L A T E   X V I I .

---

- FIG. 1.* Great toe; oval amputation of first phalanx.  
 Second toe; lateral flap amputation through first phalanx.  
 Third toe; flap amputation of terminal phalanx.  
 Fourth toe; oval amputation of first phalanx.
- FIG. 2.* *a.* Incision for amputation of first metatarsal bone.  
*b.* Incision for amputation of fifth metatarsal bone.  
*c.* Incision for Lisfranc's amputation.  
*d.* Incision for Chopart's amputation.  
*e.* Line of disarticulation in Lisfranc's amputation.  
*f.* Line of disarticulation in Chopart's amputation.
- FIG. 3.* Chopart's amputation on the left foot; the sole flap formed first.
- FIG. 4.* Lisfranc's amputation on the right foot; the three outer and the innermost tarso-metatarsal joints opened, and the knife passed between the internal cuneiform and second metatarsal bones.
- FIG. 5.* Lisfranc's amputation; formation of the sole flap after disarticulation.
- FIG. 6.* Chopart's amputation on the left foot; opening the transverse joint of the tarsus.
- 

### AMPUTATIONS OF THE TOES.

The *terminal* and *second phalanges* of the smaller toes seldom require removal, but may be readily amputated by a small dorsal and larger plantar flap, as in the fingers. An assistant should hold the adjacent toes and separate them with narrow tapes, and the operator grasping the phalanx to be removed, bends it to as near a right angle with the phalanx above as possible, and cuts with a narrow scalpel or bistoury across the back of the joint and through it, making a flap below as shown on the third toe in Fig. 1.

*Amputation through the first phalanx* may be conveniently performed in the not uncommon cases where a contracted second toe is a constant source of annoyance. It is best done with two small lateral flaps made by transfixion with a narrow bistoury, and the bone-forceps should then be



employed to divide the bone as shown on the second toe in Fig. 1. This method has the great advantage of not opening up the tissues of the sole.

*Amputation of the first phalanx* is best performed by the oval method on all the toes. It is important to bear in mind that the metatarso-phalangeal joints of the smaller toes are more deeply placed than is generally supposed (Fig. 2), and also that the base of the first phalanx is considerably expanded.

The adjacent toes being separated by an assistant, the operator grasps the toe to be removed, and entering the point of a bistoury an inch above the web of the toes, makes a straight incision down the centre of the toe nearly to the web. Then carrying the knife round he completes the oval sweep as in the case of the fingers, without cutting the web on either side of the toe. The knife may now be conveniently thrust in parallel to the phalanx and made to clear away the tissues around it, when the toe should be forcibly drawn up, and the joint opened from below with the point of the knife. The head of the metatarsal bone will be left deeply bedded in the soft tissues as shown on the fourth toe in Fig. 1.

In the *great toe*, it must be borne in mind that the head of the metatarsal bone is very large and prominent, and it will be necessary to bring the oval incision well on to the first phalanx in order to leave sufficient tissue to cover the head, which should never be removed unless diseased. The oval flap having been dissected back, the great toe should be flexed and the joint opened from above, the sesamoid bones being left untouched.

The hæmorrhage in all these operations is extremely small, the great toe alone probably requiring a ligature.

*Fallacies.*—In the smaller toes it is easy to miss the metatarso-phalangeal joint either by cutting against the expanded base of the phalanx, or by going beyond the joint and cutting against the head and neck of the metatarsal bone. In the great toe, the only risk is in not preserving sufficient covering for the head of the metatarsal bone, thus necessitating its removal with permanent damage to the foot.

*Amputation of the Metatarsal Bone of the Great Toe* (Fig. 2, *a*) may be best performed by the oval method, the incision being begun just above the base of the bone and carried nearly to the base of the first phalanx before the oval sweep is made, care being taken to preserve the web of the toe. In clearing the bone, the integuments only should be preserved, the short muscles of the toe with the sesamoid bones being for the most part removed with the bones. In opening the joint, the operator should



forcibly draw the great toe away from the others (which should be firmly held by an assistant) and pass the point of the knife between the metatarsal bones close to the great toe, so as to avoid injuring the communicating branch of the *dorsalis pedis* artery which passes between the metatarsal bones.

The same operation may be performed on the little toe (Fig. 2, *b*), but has the disadvantage of opening a synovial membrane common to the fourth and fifth metatarsal bones.

*Excision of a Metatarsal Bone* may be performed in the rare cases in which the disease is confined to a single bone, by making an incision over the bone and removing it with bone-forceps, but the results are not generally satisfactory.

#### AMPUTATION THROUGH THE METATARSUS (HEY).

This is an admirable operation in cases of crush of the front part of the foot, and consists in simply reflecting as much dorsal and plantar flap as may be available, and then applying the saw at the most convenient point. The line of section may even be carried into the tarsus with advantage, in cases of severe injury, in preference to having recourse to either of the following operations.

#### TARSO-METATARSAL DISARTICULATION (LISFRANC).

The irregular line of the tarso-metatarsal articulations (Fig. 2, *e*) should be thoroughly studied before this operation is undertaken, and it should be especially remembered that a strong interosseous ligament binds the second metatarsal to the internal cuneiform bone.

In performing both Lisfranc's and Chopart's amputations, there are two methods for selection according to the taste of the operator. By one, the dorsal flap is formed first, and the sole flap cut after disarticulation; by the other, the flap is first cut from the sole, then the dorsal flap is formed, and the operation completed by disarticulation. The first method will be given with Lisfranc's, and the second with Chopart's operation.

*Lisfranc's Amputation* (Fig. 2, *c*).—Having ascertained the positions of the bases of the first and fifth metatarsal bones, the operator grasps the fore



part of the foot with the left hand, and makes a curved incision from one point to the other across the foot, bringing the dorsal incision down nearly to the heads of the metatarsal bones. This flap being grasped by an assistant is to be dissected up, the edge of the knife being carefully kept against the metatarsal bones, until the whole extent of the flap is reflected. The knife is next to be drawn across the articulations, and in the right foot (Fig. 4) it will be found most convenient to open first the three outer tarso-metatarsal joints which run obliquely from behind forwards, then that of the great toe which is below the others, and lastly, to insert the point of the bistoury between the base of the second bone and the internal cuneiform bone, to divide the strong interosseous ligament already referred to. When this has been done, the second tarso-metatarsal joint will be readily found and opened if the foot is forcibly depressed with the left hand. (On the left foot the order will be reversed, the first metatarsal bone being first disarticulated, then the third, fourth, and fifth, and lastly, the second.) The metatarsal bones being thoroughly dislocated, a sole flap is to be made either by passing the knife across, or by cutting from the side so as to include its whole thickness, and this is to be carried as far as the roots of the toes. The metatarsus being now raised with the thumb of the left hand, which still grasps the toes, the operator can cut off a neatly rounded flap to fit the face of the tarsus, which is deeper on the inner than on the outer side. The flap should be cut so that the integuments are slightly longer than the tissues beneath, and this can be most conveniently done by puncturing the extended flap at its centre, and cutting both halves of the flap from within outwards, giving the necessary slope to the blade of the knife (Fig. 5).

The dorsal artery of the foot and both plantar arteries will require ligatures, and the flaps will be found to fit easily together, the large dorsal flap shrinking considerably, but being long enough to fall over the plantar and prevent all strain upon the stitches.

If the proceeding is reversed, the incision in the sole must be brought nearer the roots of the toes than that given for Chopart's amputation (Fig. 3), and the flap having been dissected back, the dorsal flap is to be formed and the joints opened as described above.

*Fallacies.*—The most common error is to make the dorsal flap too small, and not to dissect it back far enough. Consequently the knife is brought against the bases of the metatarsal bones instead of opening the articulations. It is possible, however, to go too far up the foot and to open the articulation between the scaphoid and cuneiform bones, in which



case it would be necessary to divide the cuboid bone with a saw in order to complete the operation. If the interosseous ligament binding the second metatarsal to the inner cuneiform bone is not properly divided, and the disarticulation attempted by main force, it is possible to tear away the internal cuneiform bone from its attachments.

#### CHOPART'S AMPUTATION.

*Chopart's Amputation* (Fig. 2, *f*) is a disarticulation at the transverse tarsal joint, the guides to which are the prominent tuberosity of the scaphoid bone on the inner side, and a point midway between the tip of the external malleolus and the base of the fifth metatarsal bone on the outer side.

The toes being grasped by an assistant, and the sole brought into view, the operator fixes the two points given above with his fore-finger and thumb of the left hand, and carries the incision from one to the other, marking out a sole flap slightly convex forwards, and reaching as far as the heads of the metatarsal bones, *i.e.*, to the "tread" of the foot (Fig. 3). This flap is to include the whole thickness of the sole, and is to be reflected with the knife kept steadily against the metatarsal bones and deep structures. The toes being now grasped by the operator, the foot is to be brought down and a convex dorsal flap (Fig. 2, *d*) marked out, extending from the back of the scaphoid and cuboid bones well forward on to the bases of the metatarsal bones. This being dissected up, and including the muscles and vessels, the transverse tarsal joint is to be opened by forcibly depressing the foot and drawing the knife across the joints (Fig. 6). The division of a few remaining fibres in the sole will then complete the operation. The dorsal artery of the foot and both plantar arteries will require ligatures.

The proceeding may be reversed; the dorsal flap being first formed, the joints opened, and the sole flap cut last as in Fig. 5.

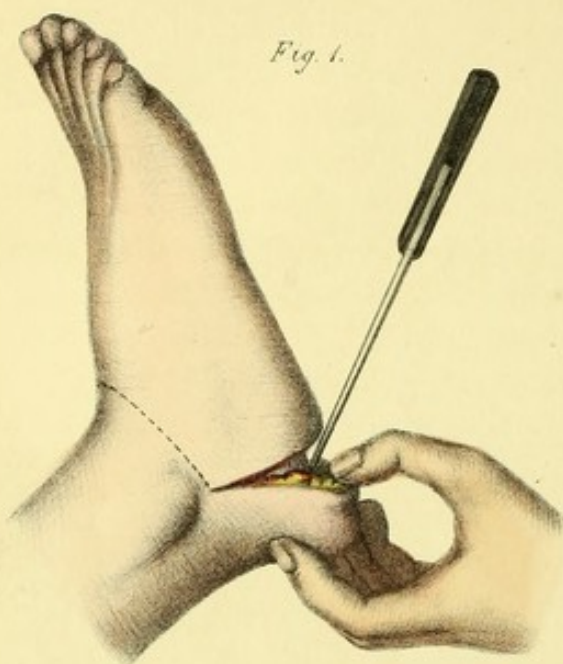*Fallacies.*—A common mistake is to dispense with a dorsal flap, the dorsal incision being taken nearly straight across from one side to the other. It will then be found that however long the plantar flap may be, it will be inconvenient on account of its thickness to bring it up over the prominent astragalus, whereas a dorsal flap fits neatly over and brings the cicatrix out of the line of pressure. If the dorsal flap is not sufficiently dissected up, it is easy to open the wrong joint, *viz.*, that between the



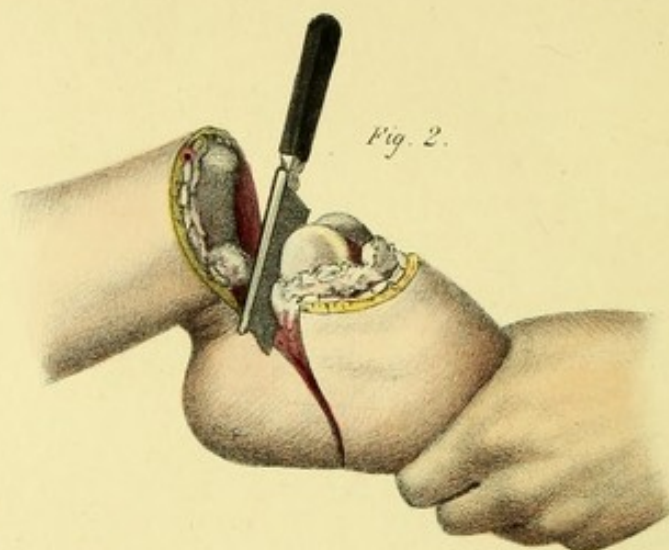
scaphoid and cuneiform bones, which will be at once recognized by the three cuneiform articular surfaces. Under these circumstances, all pressure with the left hand should be taken off until the proper joint three-quarters of an inch further back has been thoroughly opened with the knife. In cases of old-standing disease of the foot, the transverse tarsal joint may be wholly or partly ankylosed, and require a saw for its division; or, as preferred by some surgeons, the saw may be applied at the most suitable point without reference to the articulations.



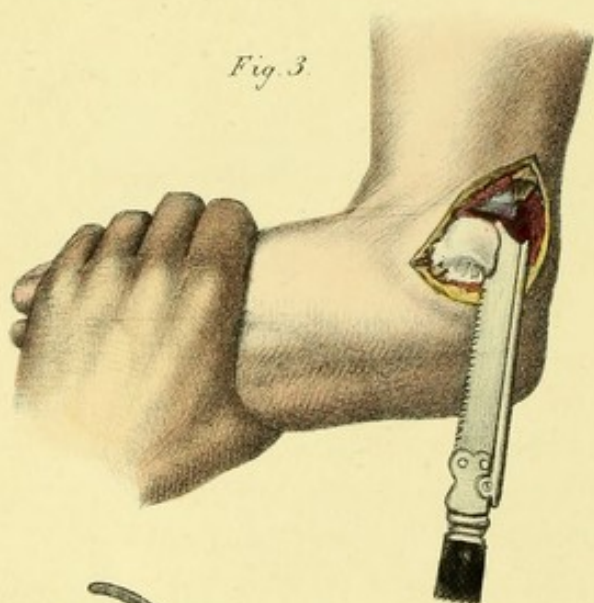




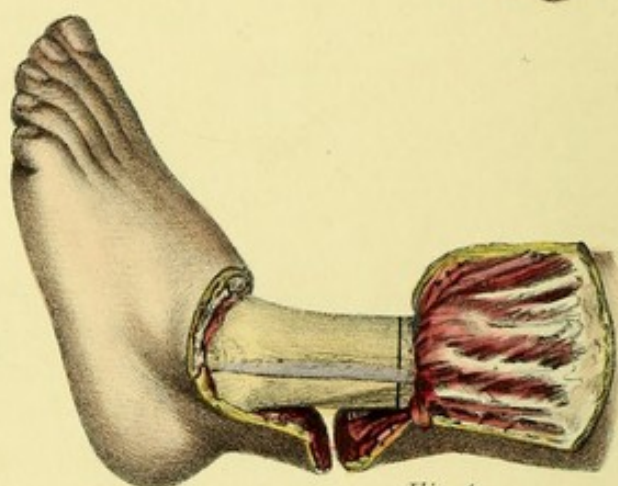
*Fig. 1.*



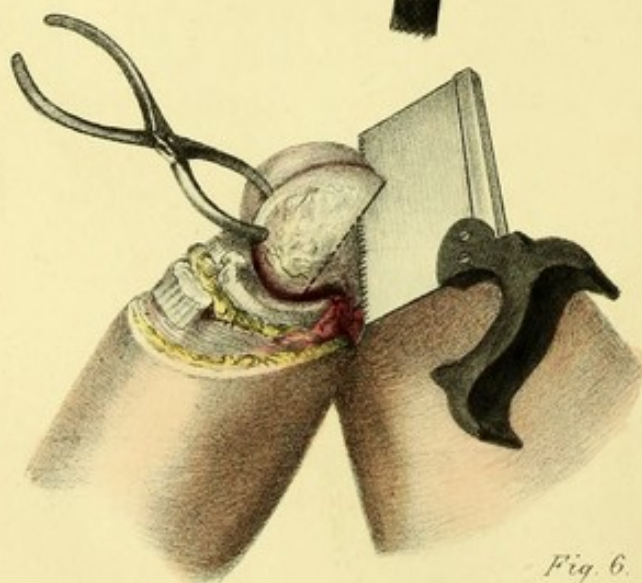
*Fig. 2.*



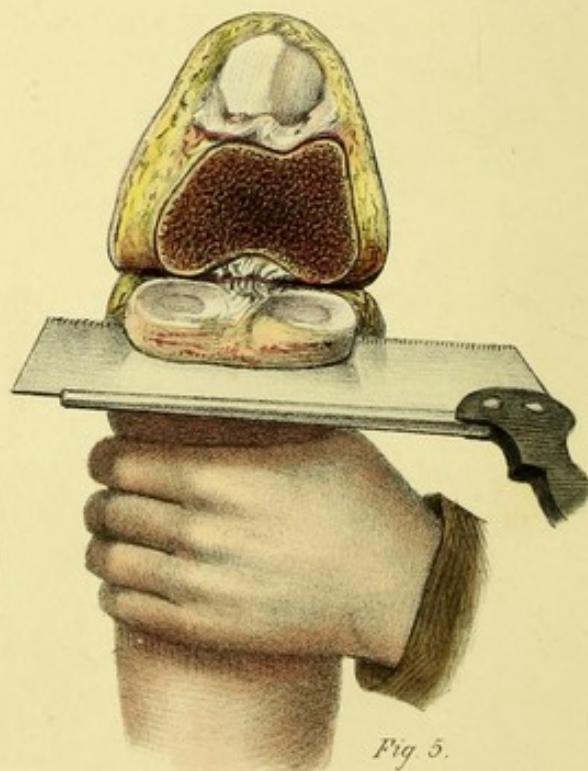*Fig. 3.*



*Fig. 4.*



*Fig. 6.*



*Fig. 5.*



## P L A T E   X V I I I .

---

*FIG. 1.* Syme's amputation at the ankle-joint.

*FIG. 2.* Pirogoff's amputation; division of the calcaneum with the saw.

*FIG. 3.* Excision of the ankle-joint; trochlea of astragalus dislocated outwards for removal.

*FIG. 4.* Teale's amputation in the lower third of the leg.

*FIG. 5.* Excision of the knee-joint; removal of the articular surface of the tibia.

*FIG. 6.*     "     "     "     removal of the condyles of the femur.

---

### SYME'S AMPUTATION AT THE ANKLE.

Before beginning any operation at the ankle-joint, the operator should ascertain the exact relations of the two malleoli, and notice especially that the external malleolus is longer than the internal and posterior to it. An incision across the heel in order to be strictly symmetrical and at right angles with the axis of the foot, must therefore extend from half an inch behind and below the internal malleolus to the tip of the external malleolus.

*Syme's Amputation* (Fig. 1) requires that the tissues of the heel should be sound. The foot being held at right angles to the leg, and raised to a convenient height so as to expose the sole, an incision is to be made from a point half an inch behind and below the internal malleolus to the tip of the external malleolus, or *vice versâ*, passing vertically to the sole in most cases, but a little backward if the heel is very prominent. This cut is to go thoroughly to the bone, and the operator then using his left thumb to draw the flap down is carefully to peel all the tissues from the calcaneum and the plantar fascia. In doing this, the edge of the knife guided by the thumb nail is to be kept most carefully against the bone, so as to avoid any "scoring" of the flap. The flap being reflected until the insertion of the *tendo Achillis* is exposed, this may, if preferred, be at once divided transversely. The foot being now grasped by the left hand of the operator is to be brought down, and an incision made across the front of the ankle at right angles



to the former one, and meeting its extremities. This incision is to divide all the tendons with the vessels and nerves, and the flap being drawn slightly upwards by the assistant, the joint is to be opened. In opening the ankle-joint, the mortise-like shape of the articulation, and the strength of the lateral ligaments is to be borne in mind. The thin anterior ligament having been divided, and the broad trochlear surface of the astragalus exposed, the point of the knife is to be thrust between the astragalus and the malleolus on each side so as to divide the lateral ligaments effectually. The foot can now be dislocated forwards, and the tissues at the back carefully divided close to the calcaneum, including, lastly, the *tendo Achillis* if this has not been cut before.

The foot being removed, the tissues are to be carefully dissected up from the malleoli, which are to be removed, together with the articular cartilage from the end of the tibia, by a transverse cut with the saw. In doing this, the saw should be parallel to the lower end of the tibia, and about a quarter of an inch from it, since the surface is concave and some of it will be left if the slice taken is too thin.

The anterior tibial artery in front, and the posterior tibial behind the inner malleolus will require ligatures. The anterior flap should fit neatly over the flap from the heel, which should have a uniform smooth surface of finely granular fat and no "button-holes."

*Fallacies.*—The most common error is to make the heel flap too large, the incision being brought so far forward that it is in front of the tuberosities of the calcaneum. The attempt to preserve any of the muscular fibres of the sole of the foot must lead to great difficulty in reflecting the heel flap. Provided the edge of the knife is kept against the bone, the flap will not be "scored," and its vitality therefore not interfered with; it is a mistake to suppose that it is possible to preserve the plantar arteries to the end of the flap. In opening the ankle-joint, the mistake of cutting outside instead of inside the malleoli is very common.

The operation may be performed from the front altogether, the flap being formed after disarticulation, but by this method the heel flap is much more liable to injury.

#### PIROGOFF'S AMPUTATION AT THE ANKLE.

*Pirogoff's Amputation* (Fig. 2) requires a healthy condition of the calcaneum, and is therefore more adapted to cases of injury than of disease of the foot. The foot being held at right angles to the leg, an incision is



to be made from a point half an inch behind and below the inner malleolus to the centre of the external malleolus, or *vice versâ*, passing forwards to the sole so as to reach the middle of the calcaneum, and going down to the bone. The foot being then brought down, a straight cut is to be made across the front of the ankle to join the extremities of the former incision. The ankle-joint is next to be opened and the lateral ligaments divided by passing the knife between the astragalus and the malleoli, when the foot can be dislocated and the upper surface of the back of the calcaneum exposed. The fat beneath the *tendo Achillis* having been divided, the knife should be carried round the incision first made, so as to reflect slightly the soft tissues and clear the way for the saw. The foot being drawn well down by the operator, and the heel grasped by an assistant, a small saw with moveable back is to be applied nearly vertically to the calcaneum midway between the astragalus and the *tendo Achillis*, and the bone divided in the line of the first incision. Owing to the position in which the foot is held, this vertical cut will really divide the calcaneum obliquely, leaving more of the lower than of the upper surface.

The malleoli being cleared are to be removed together with a slice of the tibia, and here the direction of the cut is to be the reverse of that in the calcaneum, the saw being applied parallel to and a quarter of an inch from the lower end of the tibia in front, but sloping upwards so as to remove more of the posterior than of the anterior surface of the bone.

The anterior and posterior tibial arteries will require ligatures, and the bones, if properly cut, will fit well together without any tension upon the *tendo Achillis*, which, however, may be divided if necessary.

*Fallacies.*—The piece of calcaneum should not be too large, and where the heel is prominent the incision should be less oblique than that given. If too little of the tibia is removed, the posterior angle is apt to prevent the heel flap being brought up so as to fit accurately.

Pirogoff's amputation may be performed like Syme's, the heel flap being formed first by applying the saw from below before opening the ankle-joint, but this method is rather more difficult of execution, and there is a danger of applying the saw too far forward.

Both Syme's and Pirogoff's operations may be performed without opening the ankle-joint, by at once reflecting the front flap and sawing through the tibia and fibula above the malleoli.



## EXCISION OF THE ANKLE-JOINT.

*Excision of the Ankle* (Fig. 3) is ordinarily performed through lateral incisions, by which injury to the tendons and main vessels and nerves is avoided. A straight incision is to be made along the posterior border of the fibula in its lower two inches, and this is to be prolonged round the malleolus, and obliquely down the side of the foot for another inch. The fascia being opened close to the bone, the two peronei tendons are to be carefully separated from the malleolus and held aside, when the external lateral ligament is to be divided and the malleolus cleared. The fibula is next to be divided with bone-forceps at the upper end of the incision so as to include the whole of its articular surface, and the malleolus being grasped with the lion-forceps is to be twisted out. The limb being now turned on its outer side, a corresponding incision is to be made on the inner side, close to the margin of the tibia. The fascia is to be opened, and the tibial and flexor tendons together with the posterior tibial vessels and nerves carefully isolated from the bone. The internal lateral ligament is next to be carefully divided, or, as preferred by some surgeons, the internal malleolus sawn off. By the application of some force to the foot, and more easily in the diseased than in the healthy subject, the articular surface of the astragalus may now be dislocated outwards so as to present in the outer incision (Fig. 3). The entire articular surface may now be readily removed horizontally with a small saw, unless the bone should be so disorganized as to justify its entire excision, which may be readily effected by grasping it with the lion-forceps, and twisting it out of its bed.

The lower end of the tibia is lastly to be cleared and sawn off, either by passing a narrow saw across from the inner to the outer side, while the tissues are held asunder with spatulas, or by dislocating the lower end of the tibia through the outer wound.

It is possible to perform the operation through an external incision only, but the proceeding is difficult, and the risk to the soft parts is increased.

## AMPUTATION ABOVE THE ANKLE.

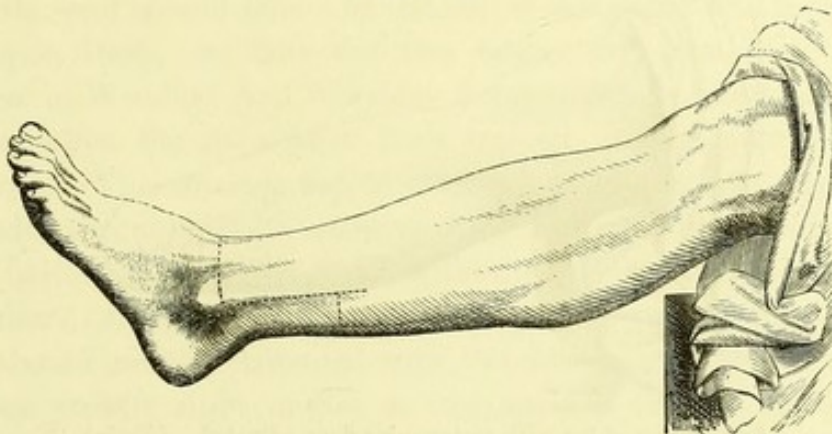
The lower third of the leg is a particularly favourable position for the practice of amputation by Teale's method (Fig. 4).

*Teale's Amputation* consists in the formation of a long anterior and a



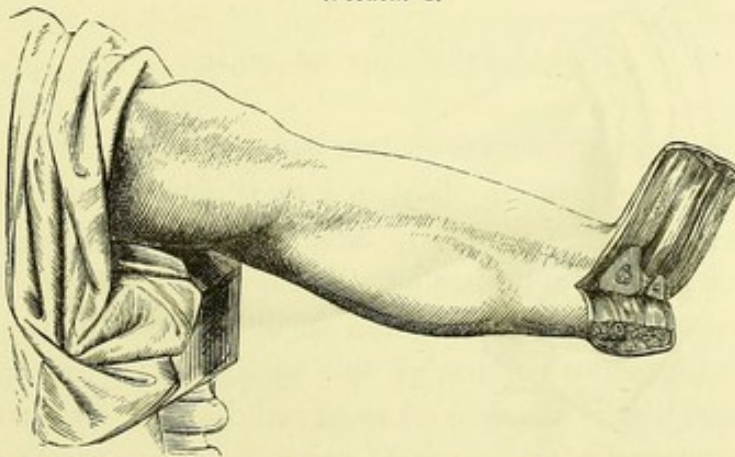
short posterior flap, both of which are rectangular. The advantages of it are that the stump is well covered with soft tissues which do not adhere to the cut ends of the bones, and that the cicatrix is well behind, and therefore not exposed to pressure. The vessels and nerves are cut square, and in limbs where there is but one main vessel, this is cut short in the posterior flap, thus diminishing risk of secondary hæmorrhage. The drawbacks to the method are the great extent of healthy tissue required on one aspect of the limb, and consequently the high level at which

Woodcut 3.



Lines of incision for Teale's amputation. (Teale.)

Woodcut 4.



Long anterior and short posterior rectangular flaps reflected. (Teale.)

division of the bone must be effected, thus diminishing the usefulness of the stump, and increasing the risk of the operation.

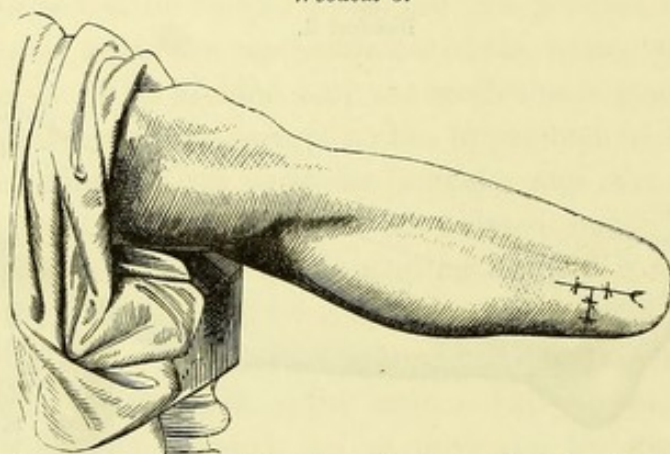
The point at which a Teale's amputation is to be performed having been selected, the circumference of the limb is to be measured with a tape, and one half this measurement will give the length and breadth of the anterior flap, which may be conveniently marked on the limb with dots



of ink (Woodcut 3). The posterior flap should, according to Teale, be one quarter the length of the anterior flap, and include the remaining half of the circumference of the limb, but it will be found in practice better to make the posterior flap one third the length of the anterior.

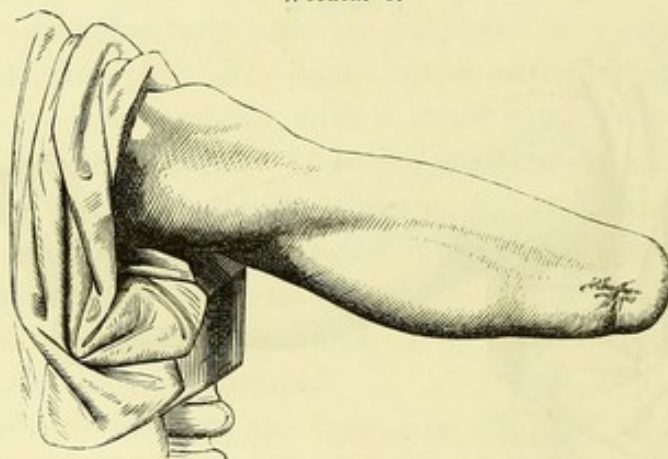
In the lower third of the leg (Fig. 4) it is convenient to take part of the anterior flap from the back of the foot, so as to bring the line of section of the bones as low as possible, but at whatever point the flap is made it

Woodcut 5.



Amputation of leg with rectangular flaps adjusted. (Teale.)

Woodcut 6.



Stump of amputation by long and short rectangular flaps. (Teale.)

should include the whole of the soft tissues. The lateral incisions running along the edges of the tibia and fibula, the deep fascia of the leg is to be similarly divided, and the whole of the muscles with the anterior tibial vessels and nerve stripped up from the bones and interosseous membrane with the thumb-nail or the handle of a scalpel. In this way a much more uniform and complete flap can be made than by using the



knife. The posterior flap is best made by cutting from the skin to the bones, and the same precautions as regards the deep structures must be observed so that the deep vessels and nerve may be uninjured. The interosseous membrane is to be divided, and the bones sawn together at the point previously determined, though the flaps may for convenience be reflected a trifle further (Woodcut 4).

The anterior tibial artery in the anterior flap, and the posterior tibial and peroneal arteries in the posterior flap will require ligatures. The anterior flap will fall over and fit upon the face of the posterior flap very conveniently, and should either be left so, or according to Teale, should be doubled upon itself, so that the two edges may come in contact as represented in Woodcut 5. Woodcut 6 represents a stump after Teale's amputation when the flaps have been treated in this manner.

*Fallacies.*—The anterior flap in all Teale's amputations must be of the same breadth throughout. Owing to the fact that all the limbs narrow in the lower part, it is easy by following the line of the limb to make the flap narrow below. In raising the anterior flap it is most important that its nutrition should not be damaged with the knife. Whether the angles of the flaps are strictly right angles or not appears to be a matter of small moment, since they become rounded by the contraction of healing.

#### EXCISION OF THE KNEE-JOINT.

*Excision of the Knee* (Figs. 5 and 6) may be performed by a straight or slightly lunated incision from the back of one condyle to the back of the other, reaching down to the head of the tibia. The *ligamentum patellæ* being divided and the joint opened, the patella is to be turned up with the anterior flap, when the knee is to be flexed by the assistants holding the leg and thigh so as to expose the ligaments thoroughly. The lateral ligaments should be divided first so as to allow of slight separation of the bones, which facilitates the division of the crucial ligaments. In dividing these last the knife must on no account be thrust through the back of the joint, lest the popliteal vessels should be wounded.

The condyles are now to be removed with the saw, and the success of the operation in securing a useful limb depends very much upon this part of the proceeding. The inner condyle is naturally longer than the outer; and as nature cannot be improved by art, the section must be parallel to the surfaces of the condyles, or the patient will be either knock-kneed or bow-



legged. The joint being usually held semi-flexed as shown in Fig. 6, it is most important also that the section should be at right angles to the shaft of the femur, and the necessary slope must therefore be given to the blade of the saw. In order to get over this difficulty the thigh may be laid upon the table and the leg allowed to hang over the edge if preferred; but whatever the position of the limb, the section must be "parallel to the condyles and perpendicular to the shaft." The amount of bone to be removed will vary somewhat with the amount of disease present, but it is better not to include the whole of the trochlear surface on the front of the condyles, so that a broad basis of support may be insured as shown in Fig. 5. In young subjects the whole of the epiphysis should never be removed.

The femur being supported by an assistant, the tibia is to be drawn in front of it and supported in the upright position, and the operator grasping the leg with his left hand will readily remove a thin slice from the head, holding the saw horizontally. This slice, so long as it includes the whole of the articular cartilage of the tibia cannot be too thin, especially in young subjects in whom the epiphysis is shallow. The cut surface of the tibia should fit accurately to the corresponding surface of the femur, the limb being perfectly straight.

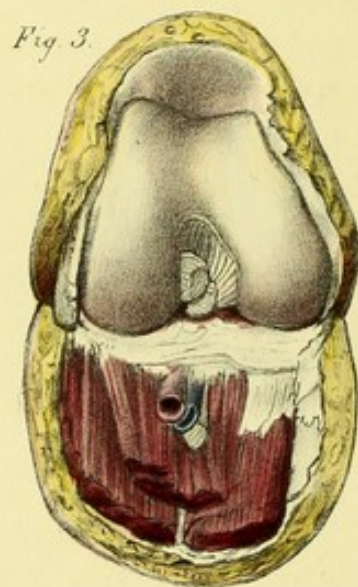
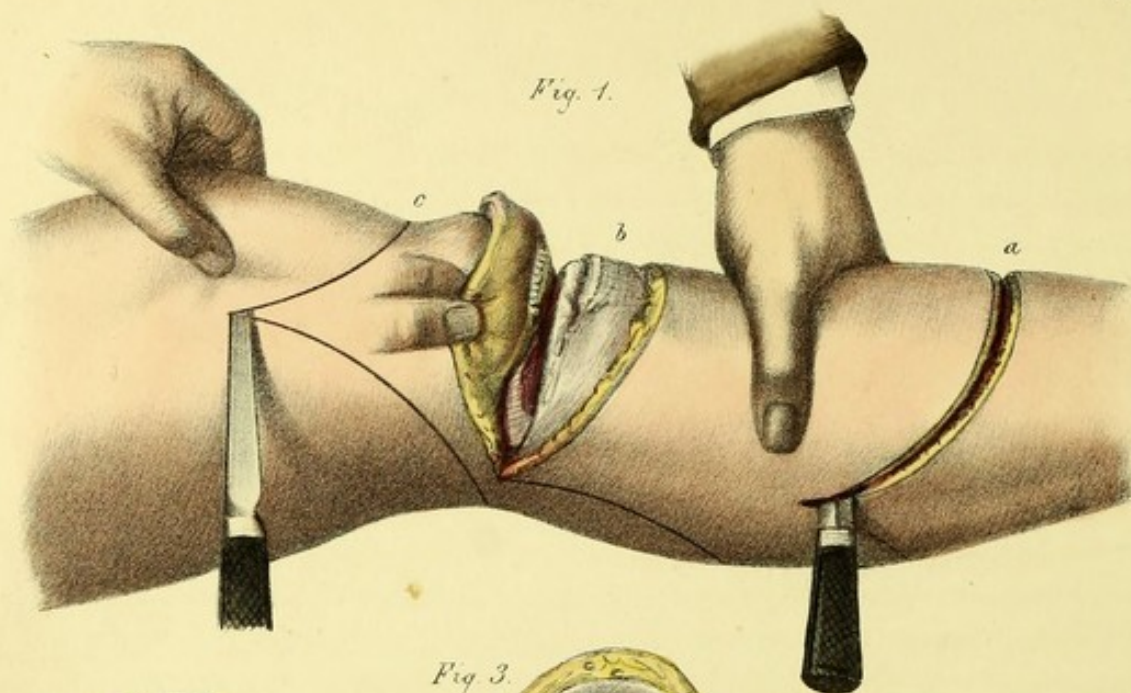
The patella is to be removed by grasping it with the lion-forceps and dissecting it out of the flap, which is then to be laid down without any curtailment, since any apparent superabundance will shortly disappear by shrinkage. No vessel ordinarily requires a ligature, but one or more of the articular arteries may do so.

*Fallacies.*—In dividing the crucial ligaments it would be possible to wound the popliteal artery were it not that the fibrous posterior ligament intervenes, but a careless use of the saw when dividing the tibia might endanger it. In dividing the femur, if the saw is held perpendicularly to the table instead of to the limb, the section will probably be very oblique, and the limb will either have to be put up semi-flexed or a second slice removed. In cutting the tibia the section should never be low enough to interfere with the head of the fibula.

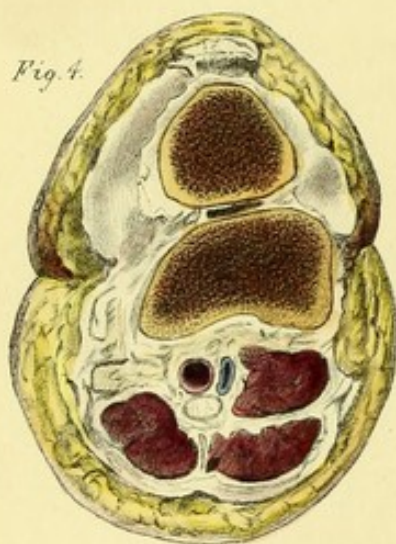
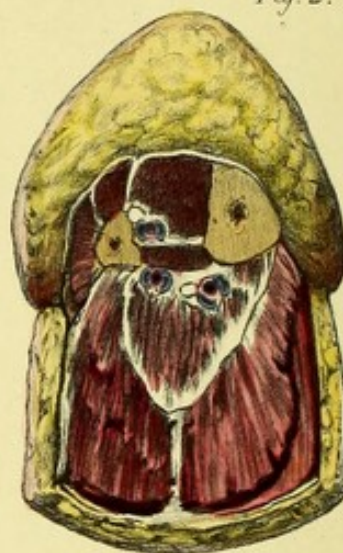For the above operation an ordinary saw, at least  $2\frac{1}{2}$  inches deep in the blade, is recommended in preference to Butcher's saw, because in unpractised hands the latter instrument is apt to cut an uneven surface, whereas the ordinary saw can hardly go wrong if the correct line is once taken. If Butcher's saw is employed the sections can be made from behind forwards with the blade reversed if preferred.



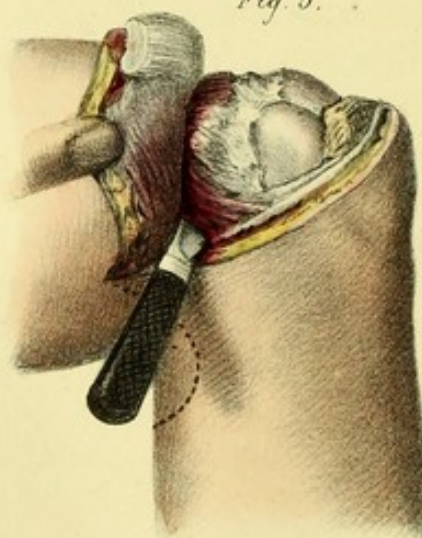




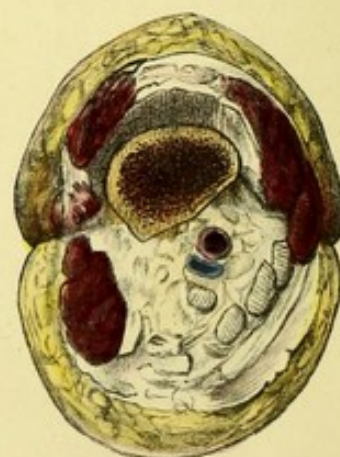
*Fig. 2.*



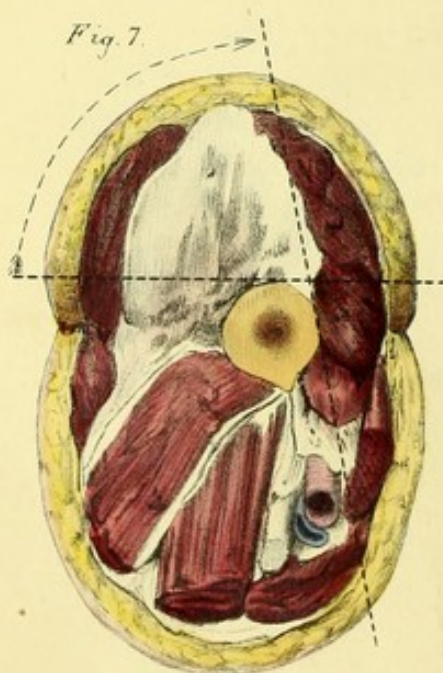
*Fig. 5.*



*Fig. 6.*



*Fig. 7.*





## P L A T E   X I X.

---

- FIG. 1.*   *a.* Flap amputation of the right leg.  
               *b.* Amputation through the knee-joint.  
               *c.* Flap amputation in the thigh.
- FIG. 2.* Stump of amputation of the right leg.
- FIG. 3.* Stump of amputation through the right knee, with patella left.
- FIG. 4.* Stump of amputation through the knee, with the condyles and articular surface of the patella removed.
- FIG. 5.* Amputation through the condyles of the right thigh.
- FIG. 6.* Stump of ditto.
- FIG. 7.* Stump of antero-posterior flap amputation of right thigh.
- 

### AMPUTATION OF THE LEG.

*Amputation of the Leg* (Fig. 1, *a*) may be performed at any point in the limb, the old-fashioned "point of election" being a hand's-breadth below the knee-joint. The operator should stand to the right side of the limb, which is to be firmly held by an assistant. Placing his left hand on the limb at the point selected for the amputation, the operator should thoroughly ascertain the position of the fibula, which is considerably posterior to the tibia. In the case of the right limb, the thumb should mark the fibula and the fingers the tibia, and the reverse in the left limb, and there will then be little risk of the knife passing between the bones.

Making a semi-lunar sweep from behind the fingers to the thumb of his left hand, so as to mark out a broad skin-flap from the front of the leg, the operator at once transfixes the limb close behind the fibula, but not so near the tibia, making the knife pass through the angles of the former incision. (In order to do this neatly, it will be necessary to raise the point of the knife slightly on the right leg and to depress it on the left leg



when transfixing.) A short posterior flap of about half the length of the anterior is then to be cut from the calf, which if very muscular should be flattened out as it is cut by slipping the fingers of the left hand beneath it.

Returning to the anterior flap, the operator now draws it up forcibly with his finger and thumb, using the knife merely to sever the connections with the deep fascia, against which its edge should be carefully kept. The skin-flap being reversed to the level required, the left hand grasps the posterior flap and draws it back, whilst the knife is swept circularly round the limb close to the two flaps. The knife is then to be passed from before backwards between the bones, so as to divide the interosseous structures transversely by a single cut from one bone to the other. Lastly, the saw is to be applied to the tibia, and when about half its thickness is cut through, the blade should be depressed so as to reach the fibula and complete the section of the two bones together. The anterior prominent border of the tibia should then be rounded off with the saw or bone-forceps.

The arteries (Fig. 2) to be tied will be the anterior tibial close in front of the interosseous membrane, and the posterior tibial and peroneal between the superficial and deep muscles of the calf, with some muscular branches. The internal and external saphenous veins sometimes bleed and require ligatures.

The large anterior flap falls over the small posterior one, the cicatrix being entirely behind, and the vessels being divided circularly we have in this amputation a combination of the advantages of both the flap and circular methods.

*Fallacies.*—If the anterior flap is cut small and the posterior large, the cicatrix is in front and there is often great difficulty in managing the large muscular flap from the calf. In any case where there is superabundant muscle, it is best to strip it up from the flap and cut it off at the time of the operation. The danger of passing the knife between the bones in transfixing is always to be remembered, though the accident ought not to occur with the precautions given above. In subsequently passing the knife between the bones, it is important to make only one transverse cut so as to avoid injury to the vessels. If the prominent spine of the tibia is not removed, it is apt to protrude through the flap.



## AMPUTATIONS AT THE KNEE-JOINT.

*Amputation at the Knee-joint* (Fig. 1, *b*) may be variously modified by leaving or removing the condyles and patella. A large anterior skin flap is to be marked out by carrying an oval incision from one condyle to the other and as low as the tubercle of the tibia. This being dissected up for a short distance, the *ligamentum patellæ* and capsule of the knee are to be divided and the joint thoroughly opened. The knee being now flexed by one assistant and the thigh supported by another, the operator cuts the lateral and crucial ligaments, in that order, and passes the knife backwards horizontally between the bones. Turning the blade behind the tibia as soon as possible, he then cuts a flap of corresponding length from the back of the limb and the operation is completed.

The popliteal artery (Fig. 3), and probably the vein will require ligatures and will be readily found in the posterior flap; the external saphenous vein also sometimes bleeds. The patella can be drawn down into the inter-condyloid notch with the anterior flap to meet the posterior flap, from which the muscular fibres of the calf should be removed if they are redundant, but the bone will be generally drawn up again in front of the condyles in the process of healing.

A better stump will in most cases be formed by removing the patella, and this may be done either by cutting above it when opening the joint so as to leave it attached to the tibia, or, better, by carefully dissecting it out of the flap when the amputation has been completed.

Another modification (Gritti) is shown in Fig. 4, where the condyles and the articular surface of the patella have been removed with the saw, and the cut surfaces will come in contact when the anterior flap is brought down.

In removing the articular surface of the patella, it will be found convenient to grasp the flap firmly with the left hand, and to press the bone down upon the femur whilst the saw is applied vertically; an assistant should hold the patella with the lion-forceps applied transversely until a groove for the saw has been made.

If this operation is selected, the posterior flap need not be so large as in the former amputation, but the patella does not commonly unite, being drawn up in front of the femur, where it gives a very useful attachment to the extensors of the thigh.

*Fallacies.*—In all these operations a long broad skin flap in front is essential, and it is most important that the vitality of the skin should not



be interfered with by the knife. In opening the joint, it will be found impossible to divide the crucial ligaments satisfactorily until the lateral ligaments have been cut so as to allow the femur and tibia to drop asunder, and there is the liability to break the point of the knife against the spine of the tibia, or to perforate the popliteal vessels.

#### AMPUTATIONS THROUGH THE CONDYLES OF THE FEMUR.

*Carden's Amputation* consists in making a single rounded flap from the front of the knee-joint, consisting of integument only, which is to be reflected to the level of the condyles, at which point the whole of the tissues at the back of the thigh and the muscles on the front are to be divided by a circular sweep, the saw being applied at the junction of the condyles with the shaft of the femur. The objection to this method is that the single flap being composed of skin only, is liable to slough if at all injured either by preceding violence or during the operation, and it has accordingly been modified by Mr. Spence, who retains the muscles in the anterior flap and retracts the soft parts so as to divide the shaft of the femur, which is a less satisfactory point of section.

*Lister's Amputation* consists in making a transverse cut across the leg at the level of the tubercle of the tibia, the extremities of the incision being prolonged obliquely downwards for half an inch so as to obviate subsequent notching. The knife is then passed beneath the limb, and a slightly convex short skin-flap marked out by joining the two oblique cuts. The limb being now raised, this posterior flap is to be reflected together with the integument of the knee as in a circular amputation, until the hamstring tendons are exposed, when they are to be divided by a circular sweep passing also above the patella and through the muscles on the front of the thigh. The saw is to be applied immediately above the articular cartilage of the knee and the condyles divided.

*Fallacies.*—The objection to this method is, that in cases of disease of the knee it will be difficult to reflect the skin sufficiently and particularly, that when the knee is permanently flexed it is impossible to form a posterior flap first.

*Amputation through the Condyles* (Fig. 5) may be conveniently performed as follows. The knee being bent to a right angle, an oval sweep is to be made from one condyle to the other, at the lower border of the patella, and a flap reflected consisting of skin and the superficial



muscular fibres. The limb being transfixed above the condyles, a short posterior flap is to be cut from the ham, and both flaps being retracted, a circular sweep is to divide the remaining muscles with the popliteal vessels and nerves. The saw is applied to the condyles, and thus a broad surface of cancellated bone is preserved. Any muscular fibres of the gastrocnemius which may be in the posterior flap should be dissected out at once, and the fibres of the popliteus shortened if necessary.

The popliteal artery, and possibly the vein, will require a ligature, and the artery will be close to the femur (Fig. 6). The anterior flap when drawn down forms an admirable covering, and the cicatrix is entirely behind.

#### AMPUTATION OF THE THIGH.

*Amputation through the Shaft of the Femur* (Fig. 1, *c*) by antero-posterior flaps may be satisfactorily performed at any point by double transfixion. Grasping the tissues of the front of the thigh with his left hand, the operator raises them so as to have as large a flap as possible in front; and this will be much increased by entering the knife as far back as possible, and sloping it upwards over the bone at its entry and downwards at its exit. A rounded anterior flap having been cut as long as convenient by a steady sawing motion, it is drawn up while the knife passes behind the bone to form a posterior flap slightly longer than the anterior. Both flaps being retracted, the knife is swept circularly round the bone as close to the flaps as possible and the saw applied. In sawing the femur the position of the thick ridge (*linea aspera*) at its posterior aspect is to be remembered, and the saw, at first horizontal, must be brought nearly vertical (Fig. 7), so soon as a groove is cut, in order that the *linea aspera* may be divided early and not left to break and form a projecting spike.

The position of the main vessel will vary according to the seat of the amputation. In the lower third of the thigh, it will be posterior to the bone (Fig. 7), in the middle third it will be to the inner side of the bone, and in the upper third in front of the bone. Numerous muscular branches will require ligatures.

*Fallacies.*—The possibility of splitting the femoral vessels with the knife in transfixing the middle of the thigh is to be remembered, and the danger is best avoided by not going too close to the femur on the inner side, thus leaving the vessels to be divided by the circular incision.



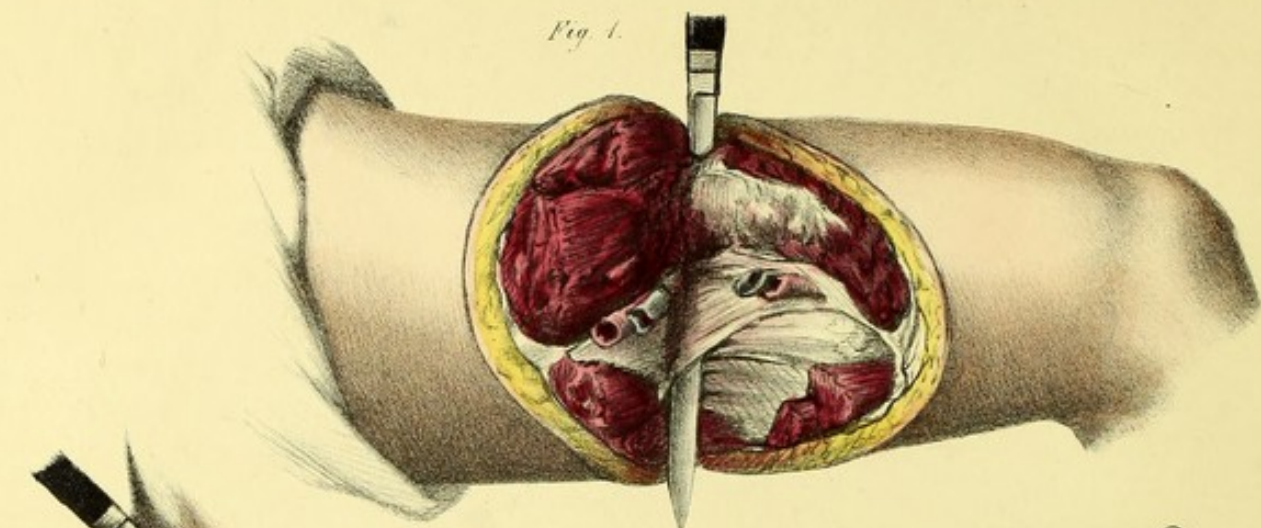




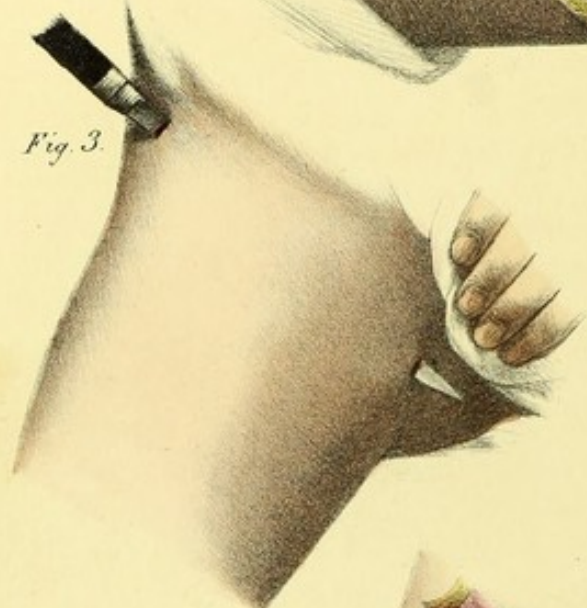




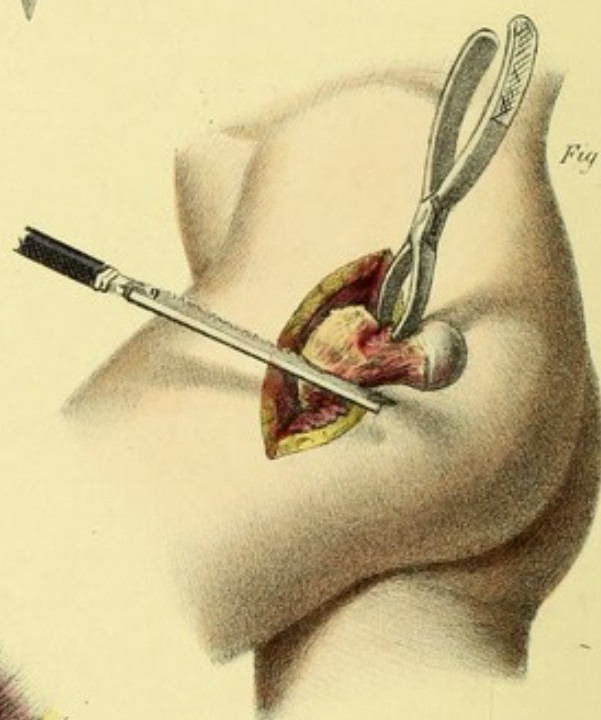
*Fig. 1.*



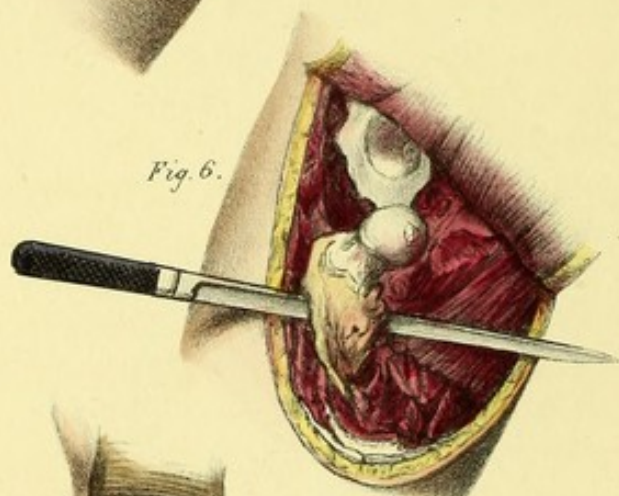
*Fig. 3.*



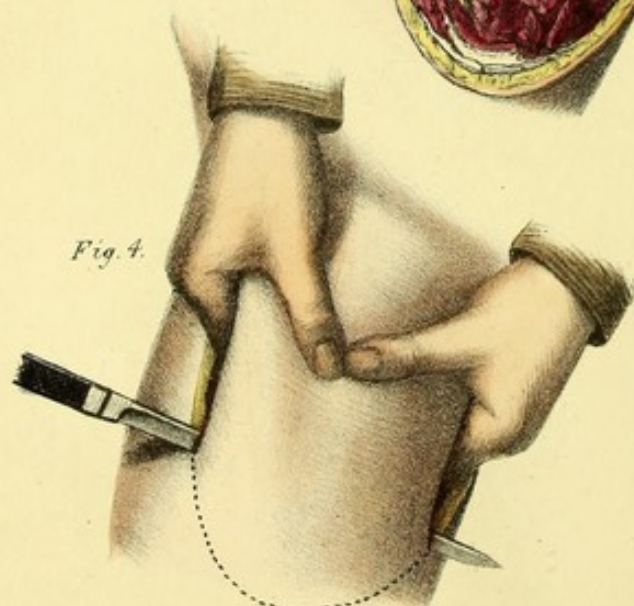
*Fig. 2.*



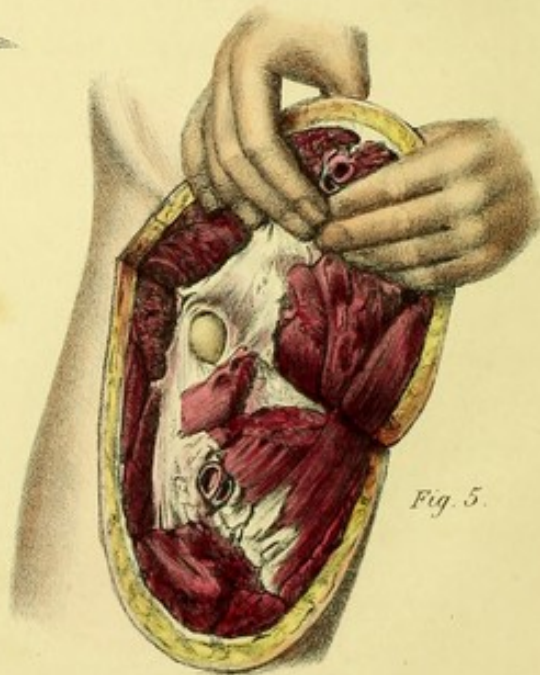
*Fig. 6.*



*Fig. 4.*



*Fig. 5.*





## PLATE XX.

---

FIG. 1. Amputation of the left thigh by lateral flaps.

FIG. 2. Excision of the head of the femur.

FIG. 3. Amputation at the hip-joint. Transfixion.

FIG. 4.       "       "       "       Formation of anterior flap.

FIG. 5.       "       "       "       Anterior flap reversed to show the hip-joint opened.

FIG. 6.       "       "       "       Dislocation of the head of the femur, and formation  
of posterior flap.

---

### AMPUTATION OF THE THIGH BY LATERAL FLAPS.

*Amputation of the Thigh by lateral flaps* (Fig. 1) is an operation which does not yield such good results as that by antero-posterior flaps. It is most conveniently done by transfixion of the inner flap first, the operator standing on the outer side of the limb in all cases. Grasping the tissues on the inner side with the left hand, and drawing them forward, the operator enters the amputating knife vertically close to the inner side of the femur and, transfixing the limb, cuts a short broad flap from the inner side of the thigh. This flap being drawn back by an assistant, the operator grasps the tissues on the outer side of the limb and passes the knife on the outer side of the femur, looking over to see that the point emerges in the former wound. A flap corresponding to that on the inner side is then cut, and being retracted, the bone is cleared with a circular sweep and sawn through with the precautions respecting the *linea aspera* mentioned above.

This operation being only adapted to the middle or lower third of the thigh, the main vessels will be in the inner flap close to the bone (Fig. 1), and there is considerable risk of splitting them with the knife. The patient being recumbent, the limb becomes rotated outwards, so that the



lateral flaps in a few days appear to be antero-posterior, but the cicatrix will be across the face of the stump.

*A modification of the lateral flap method* may occasionally be found useful in cases of injury of the knee and front of the thigh. Two lateral skin flaps, the inner if possible larger than the outer, being dissected up carefully, a circular division through the muscles will allow of sufficient retraction to make a well-shaped stump with ample skin covering, and without the unwieldy flaps of the preceding operation.

#### EXCISION OF THE HEAD OF THE THIGH-BONE.

*Excision of the Head of the Thigh-bone* (Fig. 2) is an operation very difficult of accomplishment on the dead body in which the ligaments are healthy, but comparatively easy in cases of hip-disease or gunshot injury of the joint. Existing sinuses may be advantageously laid open when conveniently situated for the exposure of the head of the bone, but failing these, a straight incision four or five inches long is to be made in the axis of the femur along the posterior border of the great trochanter. The aponeurosis of the gluteus maximus being divided, and the trochanter cleared, the finger can examine the capsule of the joint, the posterior aspect of which will probably have been already opened by abscess. If not, an opening must be made in it, and a blunt-pointed bistoury, guided by the finger, employed to divide it as far as may be necessary to allow of dislocation of the head of the thigh-bone from the acetabulum. In order to accomplish this, an assistant should flex the thigh and rotate it forcibly inwards, when the head will be thrust out of the wound as in Fig. 2. The head being grasped with the lion-forceps should be removed with a small saw, which should be applied immediately below the great trochanter so as to include in the section the entire neck of the bone.

The acetabulum, if diseased, can now be readily reached with the gouge, and any loose sequestrum can be removed with forceps. In cases of perforation of the floor of the acetabulum it would be possible also to evacuate an intra-pelvic abscess or to saw out any diseased bone.

*Fallacies.*—An oblique incision across the buttock, though facilitating the dislocation of the bone, inflicts greater injury on the soft parts than that over the trochanter, and has the disadvantage of being subject to pressure when the patient is recumbent. The trochanter must be thoroughly cleared, and the posterior aspect of the capsule divided before the



limb is flexed or unnecessary violence will have to be employed, at the risk of breaking the femur. In cases of long standing disease it is possible that the head of the bone may be so firmly fixed to the pelvis by adhesions that it will require to be forcibly detached with an elevator, and this may be done either before or after the application of the saw as may be most convenient.

#### AMPUTATION AT THE HIP-JOINT.

*Amputation at the Hip-joint* may be performed by various methods, but that by a long anterior and a shorter posterior flap appears to give the most satisfactory results. The anterior flap is most conveniently formed by transfixion, but in exceptional cases, where a tumour involves the front of the upper part of the thigh, it may be cut from without inwards and be formed of the integuments only.

Three well-trained assistants are essential for the rapid and satisfactory performance of amputation at the hip-joint. No. 1 should take charge of the abdominal tourniquet applied to the abdominal aorta a little below and to the left side of the umbilicus. No. 2 should stand on the opposite side to the operator and be prepared to grasp the anterior flap and compress the femoral vessels. No. 3 should grasp the limb firmly, and be prepared to move it as required during the operation.

It will be found most convenient for the operator to stand on the *outer* side of the limb to be removed, whether right or left, the buttocks of the patient being brought to the edge of the table, and the opposite leg being secured to it by a bandage.

The limb being slightly flexed upon the pelvis so as to relax the tissues in front of the hip-joint, the operator enters a long amputating knife one inch behind and below the anterior superior iliac spine, and passing it parallel to Poupart's ligament, makes the point go deeply to the capsule of the joint, which should be opened by slightly raising the knife so as to pass over the neck of the femur before dipping deeply through the adductors to emerge on the inner aspect of the thigh (Fig. 3). With a steady sawing movement of the knife a long and broad anterior flap is then to be cut from the front of the thigh, assistant No. 2 slipping the fingers of both hands beneath the flap behind the knife, and grasping the femoral vessels before they are divided (Fig. 4). Drawing up the anterior flap the assistant will expose the front of the hip-joint, which should have



been opened or at least thoroughly exposed. Assistant No. 3 now forcibly depresses the thigh so as to throw the head of the bone forward, and the operator divides the remains of the capsule when the head will start forward, tearing the *ligamentum teres*, though this may require division in some cases. The tissues attached to the great trochanter should now be divided, the bone being rotated inwards by the assistant so as to bring that process forward, and the knife can then be passed behind the neck of the bone to form the posterior flap (Fig. 6). This should be shorter than the anterior, and may be cut from within outwards altogether, or, better, may be rounded off by bringing the knife down and sweeping round the flap from the outer side to the perinæum, when sufficient length has been obtained.

The femoral vessels being thoroughly under the control of the assistant the operator may conveniently place ligatures on the branches of the gluteal and sciatic arteries in the posterior flap first if they are bleeding. If the anterior flap should be formed of integument only, the femoral artery must necessarily be divided close below Poupart's ligament, and should be compressed against the pubes until secured.

*Fallacies.*—It is possible to break the knife against the femur in transfixing, but the more common error is to go wide of the hip-joint, leaving much soft tissue over it to be divided. If the knife is not kept parallel to Poupart's ligament, but allowed to glide down the thigh in transfixing, it will be difficult to retract the anterior flap sufficiently to expose the head of the femur satisfactorily. With the leverage of the thigh-bone in the hands of a good assistant there should be no difficulty in dislocating the bone provided the ilio-femoral ligament is thoroughly divided. If it should be necessary to apply the knife to the *ligamentum teres* the limb must be rotated forcibly outwards to bring it into view. A broken or shortened thigh-bone should be grasped with the lion-forceps in order to increase the leverage.

Some operators prefer to transfix the *right* thigh from within outwards, standing between the patient's legs. The objections to this method are that in transfixing, it is possible for an unpractised operator to drive his knife through the obturator hole into the pelvis, and that the operator must either himself manipulate the limb or be very much in the way of the assistant. Again, the operator being in front of the patient during the entire operation, would be liable to be incommoded by any accidental hæmorrhage, and would certainly much intercept the view of any by-standers.



## INDEX.

---

- Amputations, 79  
 ankle, at, 111  
   ,, above, 114  
 arm, 97  
 Carden's, 122  
 carpo-metacarpal, 85  
 Chopart's, 109  
 condyles of femur, 122  
 fingers, 82  
 fore-arm, 96  
 Gritti's, 121  
 Hey's, 107  
 hip-joint, at, 127  
 knee-joint, at, 121  
 leg, 119  
 Lisfranc's, 107  
 Lister's, 122  
 metacarpo-phalangeal, 83  
 metatarso-phalangeal, 106  
 metatarsus, through, 107  
 penis, 76  
 phalanges, 82  
   ,, toes, 105  
 Pirogoff's, 112  
 Syme's, 111  
 shoulder, at, 102  
 tarso-metatarsal, 107  
 Teale's, 114  
 thigh, 123, 125  
 toes, 105  
 upper-arm, 97  
 wrist-joint, above, 93  
   ,, at, 90  
 Ankle, amputations at, 111  
   ,, above, 114  
   excision of, 114  
 Arm, fore, amputation of, 96  
   upper, ,, 97  
 Arteries, deligation of, 9  
 Artery, axillary, 19, 21  
   brachial, 15, 18  
   carotid, 27  
   dorsal of foot, 49  
   facial, 31  
   femoral, 39  
     ,, common, 36  
   iliac, external, 33  
     ,, internal, 36  
     ,, common, 35  
   innominate, 29  
   lingual, 30  
   popliteal, 41  
   radial, 12  
   subclavian, 22  
   tibial, anterior, 47  
     ,, posterior, 43  
   ulnar, 13  
 Axillary artery, 19, 21  
 Brachial artery, 15, 18  
 Breast, removal of, 24  
 Carden's amputation, 122  
 Carotid artery, 27  
 Carpo-metacarpal amputations, 85  
 Castration, 77  
 Cataract, 4  
 Chopart's amputation, 109  
 Circumcision, 75  
 Colotomy, 65  
 Condyles of femur, amputation through, 122  
 Deligation of arteries, 9  
 Dorsal artery of foot, 49  
 Epiphora, 1  
 Excisions, 79  
 Excision, ankle, 114  
   elbow, 94  
   hip, 126  
   knee, 117  
   shoulder, 101  
   wrist, 86



- Excision of eye-ball, 6  
 Extraction of lens, 4  
 Eye, operations on, 1
- Facial artery, 31  
 Femoral artery, 39  
 „ „ common, 36  
 Fingers, amputation of, 82  
 Fore-arm „ 96
- Genito-urinary organs, 67  
 Gritti's amputation, 121
- Head of femur, excision, 126  
 „ humerus, excision, 101  
 Hernia, femoral, 38  
 „ inguinal, 37  
 Hey's amputation, 107  
 Hip-joint, amputation at, 127  
 „ excision of, 126
- Iliac artery, common, 35  
 „ „ external, 33  
 „ „ internal, 36  
 Innominate artery, 29  
 Iridectomy, 6
- Jaw, upper, removal of, 57  
 „ lower, removal of, 59
- Knee, amputation at, 121  
 „ excision of, 117
- Lachrymal apparatus, 1  
 „ sac, to probe, 2  
 „ „ abscess in, 3  
 Laryngotomy, 51  
 Leg, amputation of, 119  
 Lingual artery, 30  
 Lisfranc's amputation, 107  
 Lister's „ 122  
 Lithotomy, lateral, 67  
 „ median, 72  
 Lithotrity, 73
- Metacarpo-phalangeal amputations, 83  
 Metatarso-phalangeal amputations, 106  
 Metatarsus, amputation through, 107
- Oesophagotomy, 54
- Paracentesis thoracis, 20  
 Penis, amputation of, 76  
 Phalanges, amputation of, 82  
 „ „ toes, 105  
 Pirogoff's amputation, 112  
 Popliteal artery, 41
- Radial artery, 12
- Shoulder, amputation at, 102  
 „ excision of, 101  
 Speculum oculi, 3  
 Strabismus, 3  
 Subclavian artery, 22  
 Syme's amputation, 111
- Tarso-metatarsal amputation, 107  
 Teale's amputation, 114  
 Tendo Achillis, 45  
 Tenotomy, 45  
 Thigh, amputation of, 123, 125  
 Tibial artery, anterior, 47  
 „ „ posterior, 43  
 Tibialis anticus tendon, 46  
 „ posticus tendon, 45  
 Toes, amputation of, 105  
 Tongue, removal of, 55  
 Tracheotomy, 52  
 Trephining, 61
- Ulnar artery, 13  
 Upper-arm, amputation of, 97
- Wrist, amputation above, 93  
 „ „ at, 90  
 „ excision of, 86

















