A manual of human anatomy : descriptive, practical, and general / by Robert Knox.

Contributors

Knox, Robert, 1791-1862.
Westmacott, Richard, 1775-1859.
Phillips, John, Sir, 1855-1928
Blandford, G. Fielding 1829-1911
King's College London

Publication/Creation

London : Renshaw, 1853.

Persistent URL

https://wellcomecollection.org/works/mxars3m7

License and attribution

This material has been provided by This material has been provided by King’s College London. The original may be consulted at King’s College London. where the originals may be consulted.
This work has been identified as being free of known restrictions under copyright law, including all related and neighbouring rights and is being made available under the Creative Commons, Public Domain Mark.

You can copy, modify, distribute and perform the work, even for commercial purposes, without asking permission.

Wellcome Collection
183 Euston Road
London NW1 2BE UK
T +44 (0)20 7611 8722
E library@wellcomecollection.org
https://wellcomecollection.org

RENSHAW'S MANUALS.

King's College Hospital
Medical School
(UNIVERSITY OF LONDON).

Presented by

Sir John Phillips
M.A., M.D., F.R.C.P.
Emeritus Professor
of
Obstetric Medicine

May. 1921.

SIR ASTLEY COOPER'S LECTURES ON SURGERY. Fcap. Price 7*s.*

CAZENAVE'S MANUAL OF DISEASES OF THE SKIN, translated by Dr. Burgess. Fcap. Price 7*s.*

WARD'S OUTLINES OF HUMAN OSTEOLOGY. 32mo. cloth. Price 5*s.*

HENRY RENSHAW'S PUBLICATIONS.

THE MOST COMPLETE SYSTEM of SURGERY EVER PUBLISHED.

2 vols. 8vo. cloth, £3 0 0.

CHELIUS' SYSTEM OF SURGERY, translated from the German, and accompanied with additional Notes and Observations, by John F. South, late Professor of Surgery to the Royal College of Surgeons of England, and Surgeon to St. Thomas's Hospital.

"This System of Surgery is most extensive and comprehensive, and should be patronized by the Profession."—*Lancet.*

"The most learned and complete systematic treatise now extant. The descriptions of surgical diseases, and indeed the whole of the pathological department, are most valuable."—*Edinburgh Medical Journal.*

"This work supplies a desideratum long wanted in the profession."—*Medical Times.*

"We earnestly recommend this work as the best and most comprehensive system of modern surgery."—*British and Foreign Review.*

SIMON'S PATHOLOGY.

Crown 8vo. cloth, 7*s.* 6*d.*

GENERAL PATHOLOGY, as conducive to the establishment of rational principles for the Diagnosis and Treatment of Disease. By John Simon, F.R.S., one of the Surgeons of St. Thomas's Hospital.

Contents:—Diseases of the Blood—Inflammation and its Products—Tumours—Cancer—Scrofula—Nervous Diseases—Evacuative Medicines in Relation to Humaral Pathology—Infective Diseases.

"Mr. Simon's Lectures are elegantly written, and will be perused with advantage.'—*Edinburgh Monthly Journal.*

"We strongly advise our readers to peruse this work for themselves."—*London Journal of Medicine.*

ANDRAL'S CLINIQUE.

8vo. cloth, 25*s.*

THE CLINIQUE MEDICALE; or Reports of Medical Cases by G. Andral: translated, with Observations from the Writings of the most distinguished Medical Authors, by D. Spillan, M.D., Fellow of the College of Physicians in Ireland.

"We strongly recommend all our young friends who wish to know what is most excellent in the modern pathology of France to lose no time in adding this translation to their stock of Medical authorities."—*British and Foreign Medical Review.*

"We recommend Dr. Spillan's translation to our readers."—*Lancet.*

KING'S College LONDON

Knox Library
A manual of human anatomy...
1853
KCSMD QM23.KNO

200826471 2
KING'S COLLEGE LONDON

Geo: Fielding Blandford
M. Surgeon - 1853.

A MANUAL

OF

HUMAN ANATOMY.

LONDON :
PRINTED BY WILLIAM CLOWES AND SONS,
STAMFORD STREET.

KING'S COLLEGE HOSP
LIBRARY
MEDICAL SCHOOL

A MANUAL

OF

HUMAN ANATOMY:

DESCRIPTIVE, PRACTICAL, AND GENERAL.

By ROBERT KNOX, M.D., F.R.S.E.,

LECTURER ON ANATOMY, AND CORRESPONDING MEMBER OF THE NATIONAL ACADEMY OF MEDICINE OF FRANCE.

ILLUSTRATED BY 250 HIGHLY FINISHED WOOD ENGRAVINGS, FROM DRAWINGS BY DR. WESTMACOTT.

LONDON:

HENRY RENSHAW, 356, STRAND.

1853.

573795 KCSMD QM23.KND

5717



TO MY STUDENTS.

GENTLEMEN,

I dedicate to you this my latest work on Anatomy, written I hope in the spirit with which I lectured and taught, and I trust improved by all those advantages which a matured experience alone can bestow.

Daily occurrences in your professional career must long since have convinced you how treacherous the memory is, even of the most gifted and best educated, especially in respect of anatomical details, and how necessary it is from time to time to refresh it by an appeal to Anatomical Works. I claim on this ground from you, for this Manual, a continuance of the patronage you so liberally bestowed on my Lectures.

I am naturally reminded of your numbers,* of the high position many of you hold in medicine, in surgery, and in general science, and of the influence which still for many years you must of necessity exercise over the studies of those who are to follow. Many will be guided by you in the choice of an elementary work on that branch of education which they will soon discover to be the basis of their future profession. Now express to them respecting this Manual but a tithe of the encomiums you have so oft and on so many occasions bestowed on my oral Lectures, and the success of the work cannot be doubtful.

I have the honour to be,

Gentlemen,

Your much obliged and most obedient servant,

R. KNOX.

London, October 4, 1852.

* About 5000.

Digitized by the Internet Archive
in 2015

https://archive.org/details/b21302133

COLLEGE HOSP. LIBRARY MEDICAL SCHOOL

PREFACE.

THE useful arts of Medicine and Surgery are only entitled to the name and dignity of professions when based on descriptive Anatomy. It is to the labours of the anatomy of adult forms that Medicine, Zoology, and Geology owe their present position, whatever that may be. For the Medicine which appeals not to Anatomy is empiricism; and the Zoology not based thereon is not a science. That profound instinctive tact guided by genius may do much unaided by Anatomy, I am free to admit: Hippocrates was an able surgeon and a skilful physician, though no anatomist; Linné an admirable zoologist, though ignorant of the structure of "the kingdoms" he so skilfully arranged: both trusted to the observation of what Nature presented to them; for them that was sufficient; genius did the rest. But Bichat followed the one, and Cuvier the other; and they introduced — the former into Medicine and Surgery, the latter into Zoology—descriptive Anatomy. With them the era of "pure observation" terminated, and that of "scientific analysis" commenced: they first minutely described adult forms in their *entière*, with a view to distinguish, to discriminate, and to compare. They added a new element of thought to the human mind—a new instrument of research. They trusted not to that divine genius with which they were gifted: the safer course is to follow their example.

Other forms of Anatomy or methods of studying Anatomy

have their value — general Anatomy, for example, surgical, pathological, and microscopic; but of this be assured (I speak from a large experience), the pathological researches of physicians unacquainted with minute descriptive Anatomy are unworthy the slightest attention; equally so is their Physiology—a tissue of idle speculations and of words to which no useful meaning can be attached. Surgery in such hands is a hap-hazard game, full of danger to human life.

The student's first step then ought to be the acquisition of the exact anatomical knowledge of man's structure, if his views be directed towards Medicine and Surgery. Should his aim be Science, then the minute descriptive Anatomy of one at least of all the great genera of animals, vertebrate and avertebrate, will be required. Distrust your genius, and follow the example of Bichat and Cuvier.

The neglecting, or even the delaying to a future period of your studies, this preliminary step, is sure to entail on you innumerable anxieties, vexations, and losses, which, as a rule, neither natural tact, sound judgment, nor courage can altogether overcome. Exceptions to this rule, no doubt, exist, but these must not be mistaken for the rule.

To many it may seem an easy matter minutely to describe the organs and textures of the adult animal, and surprise, no doubt, will be expressed that a branch of knowledge so clearly essential to correct science should for so many ages have remained imperfect—incomplete. But the history of Anatomy proves that in this as in other sciences the difficulty lies in the first conception of the idea, which, being once discovered and announced, seems to the world so facile of comprehension and performance. A child can now describe to you that circulation of the blood which it required a Harvey to discover.

That rational Medicine and Surgery can only be based on minute descriptive Anatomy, and that Zoology can have no

other foundation, is a fact now admitted I believe by all; but ages rolled on before two men appeared equal to the right conception of this idea and its execution—these men were Xavier Bichat and George Cuvier.

From the era of Vesalius, or rather from the times of Leonardo da Vinci and Della Torre, who preceded Vesalius, and who no doubt were the earliest descriptive and iconographic anatomists, to the period alluded to, many illustrious men had written admirable monographs on Anatomy; but it was reserved for Bichat to demonstrate that Medicine and Surgery cannot or ought not to be based on fragments. With the telescopic eye of genius, universal when true, he separated the descriptive from all other kinds of Anatomy, putting each in its place. To the descriptive he assigned the foremost rank, proved by its being his latest study; since his time it has formed the broad portal stone of that doorway by which all must enter who purpose exercising conscientiously the arts of Medicine and of Surgery. Scarpa and Hunter, John Bell and Dupuytren entered by this gate: you will find it the safest and the best.

What Bichat did for Medicine and Surgery, John Hunter for comparative Physiology, Cuvier, a fellow-labourer in the same field, effected for Zoology. They were all descriptive anatomists of the highest order. This was the instrument they employed in their vast inquiries. Each wielded it with different views; Cuvier was the most fortunate of his great contemporaries. The publication of the 'Ossemens Fossiles' roused the thinking world from a slumbering lethargy which had endured for ages. But the names of John Hunter and Bichat, though less known, must also be imperishable.

A few words must suffice in respect of the arrangements of this work. Its object is to carry out the views of Bichat; those views which I believe I first introduced into Britain,

and which since then have been all but universally adopted. It is a work intended for the class-room, the private study, the dissecting-room. I have done my best to make it at once practical, systematic, minute. Study deeply the osteology and myology; compare the descriptions you will find in this work with nature, and your future anatomical studies will prove a pleasant recreation rather than a painful and it may be an unsatisfactory pursuit. To the question frequently put as to the utility of minute anatomy, I reply that this invaluable knowledge will enable you to reject many idle speculations in physiology and pathology daily offered you; by it you may at least check, if not destroy, empiricism, and combat rash Surgery, come from whom it may. It is, in brief, the only torch which Medicine possesses to guide her on the obscure, experimental, conjectural course she seems doomed to follow.

In the Iconographic portion of the work, it will be found that no pains have been spared by Dr. Westmacott to render the Manual as useful as possible. To Professor Partridge, of King's College, I owe the valuable recommendation to use the drawings of Herschfeldt in the section on the Organs of Sense, in preference to every other. This advice, which Dr. Westmacott and I unhesitatingly adopted, came with double force from a gentleman at once the minute anatomist and excellent artist.

ILLUSTRATIONS.

FIG.		PAGE
	BONES.	
1.	Male skeleton, profile	2
2.	Female skeleton	3
3.	A lumbar vertebra	4
4.	Male skeleton, front	5
6.	Cervical vertebra, upper surface	6
7.	Same, lower surface	6
8.	Atlas, upper surface	7
9.	Same, viewed from below	7
10.	Axis, or vertebra dentata	8
11.	Vertebra dentata, upper surface	8
12.	Vertebra proeminens, from above	9
13.	Same, from below	9
14.	Same, in profile	9
15.	Dorsal vertebra, from above	10
16.	Same, from below	10
17.	Same, in profile	10
18.	Lumbar vertebra, upper surface	11
19.	Lumbar vertebra, inferior surface	11
20.	Sacrum; its right margin	11
21.	Sacral vertebræ, or sacrum	12
22.	Dorsum of the sacrum	12
23.	Coccyx, or coccygeal vertebræ, front view	13
24.	Coccyx, back view	13
25.	Portion of base of skull and lower jaw	14
26.	Vertebral column, profile	17
27.	Same, behind	17
28.	Same, front	17
29.	Same, vertical section	20
30.	Occipital bone, external surface	22
31.	Occipital bone, cerebral aspect	22
32.	Sphenoid bone, cerebral aspect	26
33.	Sphenoidal bone, orbito-nasal aspect	26
34.	Left parietal bone, cerebral aspect	27
35.	Temporal bone, right side, cerebral aspect	28
36.	Frontal bone, cerebral aspect	31
37.	Ethmoid bone, lower surface	34
38.	Same, right side	34
39.	Superior maxillary bone	39
40.	Right maxillary bone	39
41.	Palate bone, external aspect	41
42.	Right palate bone	41
43.	Right malar bone	43
44.	Os unguis	43
45.	Same bone, inner aspect	43
46.	Nasal bone	44
47.	Inferior turbinated bone	44
48.	Right turbinated bone	44
49.	The vomer, in profile	45
50.	Vomer, from above	45
51.	Lower maxillary bone	46
52.	Bones of the cranium and face	50
53.	Base of the skull	56
54.	Same, viewed from within	57
55.	Vertical section of cranium	65
56.	Lingual or hyoid bones	66
57.	Skeleton of the torso	67
58.	Same, front view	68
59.	Sternum	69
60.	Ribs	71
61.	Same, male and female, to show their curvatures	72
62.	Right os innominatum	73
63.	Left os innominatum	73
64.	Introitus	76
65.	Perineal exit of the pelvis.	77
66.	Section of the pelvis	77
67.	Collar-bones	79
68.	Right scapula, posterior surface	80
69.	Same, costal surface	80
70.	Same, viewed anteriorly	80
72.	Bones of the humerus	83
73.	Bones of the radius	85

FIG.		PAGE
74.	Right hand, palmar surface	91
75.	Same, dorsal aspect	91
76.	Adult thigh-bone	94
77. 78.	Bones of the tibia and fibula	98
79.	Right foot; upper surface	100
80.	Same, lower surface	100
81.	Calcaneum and astragalus	101
82.	Patella or rotula, outer surface	104
83.	Skeleton of the child	106
84.	Adult artificial skeleton	107
	ARTICULATIONS.	
85.	Vertical section of spinal column	112
86.	Anterior common ligament of vertebræ	113
87.	Posterior ditto	114
88.	Section of vertebral column	115
89.	Articulations, vertebral column	116
90.	Portion of base of skull	117
91.	Base of skull, lower jaw, &c.	118
92.	Vertical section of base of skull	118
93.	Anterior tubercle of atlas	119
94.	Costo-sternal articulations	122
95.	Same, anterior surface	122
96.	Sternum and collar-bone	124
97.	Bodies of two dorsal vertebræ	124
98.	Section of a dorsal vertebra	125
99.	Ligaments of clavicle and scapula	134
100.	Shoulder-joint, left side	134
101.	Section of shoulder-joint	135
102.	Elbow-joint, &c.	136
103.	Ligaments of the hand	136
104.	Section of hip-joint	142
105.	Capsular ligament of ditto	142
106.	Vertical section of knee-joint	145
107.	The knee-joint laid open from the front	147
108.	Crucial ligaments of knee-joint	147
109.	Ligaments of sole of foot	151
	MUSCLES.	
109.	Muscles of the torso	156
110.	Trapezius, back view	158
111.	Same, front view	159
112.	Levator of scapula	163
113.	Serratus posticus superior	164
114.	Same, inferior	164
115.	Sacro-lumbalis	167
116.	Trachelo-mastoideus	169
118. 119.	Muscles of the right shoulder	174
120.	Muscles of superior extremity, front	176
121.	Same, back view	176
122. 123.	Muscles of the left shoulder	178
124.	Abductor pollicis	197
125.	A deeper dissection	197
126. 127.	Flexor brevis minimi digiti	199
128.	The diaphragm	206
129.	Muscles of the perineum	210
130.	Female perineum	213
131.	Transverse muscle of the urethra	215
132.	Muscles of outer side of left thigh	218
133.	Muscles of thigh, left side	218
134.	Muscles of left thigh, inner side	219
135.	Front of left thigh	219
136. 137.	Deeper dissection of ditto	222
138.	Left leg, external side	226
139.	Same, inner side	226
140.	Muscles of thigh, left side	228
140*a*.	Adductor magnus muscle	229
140*b*.	Muscles of haunch and thigh	229
141.	Dorsum of the foot	232
142. 143.	Sole of the foot	236
144. 145.	Muscles of the foot	240
146.	Muscles of the head	242
147. 148.	Muscles of the jaws	257
149.	Section of head and neck	259
150.	Muscles of the pharynx	260
151.	Palatal muscles	262
152.	Muscles of both orbits	268
153.	Muscles of eyeball	269
154.	Serratus magnus muscle	274
	THORAX, ETC.	
157.	Heart, anterior surface	305
158.	Left ventricle and aorta	311
159.	Heart, prepared to show the arrangement of its fibres	315
160.	Arch of the aorta	316
161.	A. Heart, ventral aspect B. Same, back view	317
162.	Vessels of ditto	318
163.	Fœtal circulation	319
164.	Trachea and lungs, posterior	324
165.	Same, anterior	325
166.	Thymus gland in fœtus	328

FIG.		PAGE
167.	Larynx, trachea, and bronchi	329
168.	Cartilages of the larynx	329
169.	Larynx, right side	330
	ARTERIES.	
170.	Aorta and other arteries	336
171.	Common and external carotid arteries	340
172.	Communicating artery of Willis	351
173.	Vertebral artery	354
174.	Arteries of superior extremity	362
175.	Branches of cœliac axis	376
176.	Superior mesenteric artery	380
177.	Inferior mesenteric artery	381
178.	Internal iliac artery	386
179.	Femoral artery and branches	392
180.	Popliteal art. and branches	397
181.	Anterior tibial artery	397
182.	Plantar arteries	400
	VEINS.	
183.	Posterior saphena vein	411
184.	Superficial veins of the thigh	411
185.	Formation of the vena portarum	416
186.	Sinuses of the dura mater	418
187.	Sinuses at base of cranium	419
188.	Facial veins	420
189.	Superficial veins at bend of elbow	421
190.	System of the vena azygos	424
191.	Sinuses of the vertebræ	425
	ABSORBENTS.	
192.	Formation of thoracic duct	431
	ORGANS OF DIGESTION, ETC.	
193.	Molar tooth with fangs	437
194.	Incisor and other teeth	438
195.	Section of lower jaw	441
196.	Surface of the abdomen	450
197.	Alimentary canal	466
198.	Ileo-cæcal valve	467
199.	The pancreas	476
200.	The spleen	477
201.	The liver	481
202.	Right kidney	487
203.	Section of the kidney	487
204.	Bladder, prostate gland, and penis	491
205.	Section of testis	496
206.	The uterus	504
207.	The placenta	506
208.	Section of female pelvis	507
209.	Mammary gland	515
	NERVOUS SYSTEM.	
210.	Medulla spinalis	521
211.	Portion of ditto	522
212.	Base of the brain	523
213.	Interior of brain	538
214.	Surfaces of the pons	542
215.	Mesial parts of the brain	543
216.	Encephalon	546
217.	Nerves of the face	552
218.	Cervical and brachial plexuses	554
219.	Musculo-spiral nerve	563
220.	Cutaneous and other nerves	563
221.	Lumbo-sacral plexus	570
222.	Great sciatic nerve	574
223.	Nervus peroneus	575
224.	Nervus tibialis	577
225.	Plantar nerves	579
226.	Great sympathetic nerve	602
	ORGANS OF SENSE.	
227.	Cartilages of the nose	607
228.	Ditto, lateral view	609
229.	Olfactory nerve	610
230.	The tongue	612
231.	Meatus auditorius externus	615
232.	A. Membrana tympani and ossicula auditus B. Distribution of the portio mollis	616
233.	A. Osseous labyrinth B. The cochlea	618
234.	The Meibomian glands	622
235.	Lachrymal apparatus	625
236.	Section of the eyeball	626
237.	Ciliary nerves	629
238.	Foramen centrale of Sœmmering	630
239.	Distribution of the fifth pair of nerves	631
240.	The skin	634
241.	The animal tissues	637

GLOSSARY.

A.

A. The Greek α, used as a prefix in compound words, has a privative or negative force, as *a-sternal*, having no sternal attachment.

Acoustic. (Ακουω, I hear.) Belonging to the ear, or to sound.

Acromion. (Ακρον, the top or extremity, and ωμος, the shoulder.)

Amnios, *ii.* n. (Αμνος, a lamb.)

Amphiarthrosis, *is.* f. (Αμφι, both, and αρθρον, an articulation.) A movement of bones, partaking of *Diarthrosis* and *Synarthrosis*, as in the tarsal and carpal bones, and the *vertebræ*.

Anastomosis, *is.* f. (Ανα, by, στομα, a mouth.)

Anatomy. (Ανα, through, among, and τεμνω, I cut.)

Anchylosis, *is.* f. (Αγκυλαι, plur. of Αγκυλη, a contraction of the nerves or sinews; being often caused by the contraction of the flexor muscles.) The morbid consolidation of the articulating extremities of two or more bones which previously formed a natural joint; a stiff-joint.

Ancon, *onis.* f. (Αγκων, the elbow.) The triangular surface of the olecranon process of the ulna; being the part on which we rest when said to lean on the elbow.

Antihelix, *icis.* m. (Αντι, against, and *helix*; because opposed to it.)

Antitragus, *i.* m. (Αντι, against, and *tragus*; because opposed to it.)

Aorta, *æ.* f.

Aponeurosis, *is.* f. (Απο, by, and νευρον, a nerve; because formerly supposed to be the expansion of a nerve.)

Apophysis, *is.* f. (Αποφύω, to grow from.)

Arachnoid Membrane. (Αραχνη, a spider's web, and ειδος, resemblance.)

Artery. (Αηρ, the air, and τηρεω, to keep; because, being found empty after death, the ancients supposed they contained air.)

Arthrodia, *æ.* f. (Αρθρόω, to fasten by joints.) An articulation admitting of motion on all sides.

Arthrosis, *is.* f. (Αρθρόω, to fasten by joints.)

Arytænoideus, *a, um.* (Αρυταινα, a funnel, and ειδος, resemblance.)
Astragalus, *i.* m. (Αστραγαλος, a die shaped like the anklebone.)
Atrophy. (A, priv. and τρεφω, to nourish.)
Acoustic. (Ακουω, I hear.)
Azygos. (A, priv. and ζυγὸς, a yoke.)

B.

Basilaris, *is. e.* (Βασιλεὺς, a king.) Applied to certain bones, arteries, veins, processes, &c., from the importance of their situation, or being near the brain.
Basis, *is.* f. (Βαίνω, to rest upon.)
Brachium, *ii.* n. (Βραχιων, the arm.)
Bronchia, *orum.* n. pl. (Βρόγχος, the windpipe.)
Buccinator, *oris.* m. (Βυγανάω, to sound a trumpet; because it chiefly is used in doing so.)

C.

Calcaneum, *i.* n. (*Calx*, the heel. Σελις, the heel.)
Canthus, *i.* m. (Κανθὸς, the angle, or corner, formed by the junction of the eyelids; the internal being the greater and the external the lesser canthus.)
Cardia, *æ.* f. (Καρδία.) The heart.
Carpus, *i.* m. (Καρπος.) The wrist.
Cephale. (Κεφαλη.) The head.
Cerebrum, *i.* n. (Κάρα, the head.) The brain, situated within the cranium.
Cholæus, or Cholœus, *a, um.* (Χολη, bile.) Belonging to bile; biliary.
Chole, *es.* f. (Χολη.) *Path.* The bile: chole.
Choledochus, *a, um.* (Χολη, bile, and δέχομαι, to receive.) Receiving bile or gall.
Chondrology. (Χονδρος, a cartilage, and λογος, a discourse.) A dissertation or discourse on cartilages. *Chondrologia, æ.* f.
Chorion. (Χωρεω, to contain.) The second, or most external membrane involving the fœtus.
Choroid. (Χοριον, and ειδος.) A membrane of the eye. Derived from a fancied resemblance to the chorion.
Chyle. (Χυλὸς, juice extracted by decoction.) The milk-like liquor, separated by digestion from the chyme, from which the blood is formed; it occupies the lacteals (hence their name) and thoracic duct. *Chylus, i.* m.
Chyme. (Χυμος, juice.) The pulpy mass formed by the food when it has undergone its first great change in the process of digestion, and passed from the stomach into the duodenum. *Chymus, i.* m.
Cleido. (Κλεις, the clavicle.)

Clinoid. (Κλίνη, a bed, and εἶδος, resemblance.) Resembling a bed. *Clinoides, is.* f.; also used adj.

Clitoris, *idis.* f. (Κλειω, to shut up; because it is shut up by the *labia pudendi.*)

Coccyx, *cygis.* f. (Κοκκυξ, the cuckoo, whose bill it is supposed to resemble.)

Cochlea, *æ.* f. (Κοχλιας, a winding staircase.)

Cœliac. (Κοιλια, the belly.)

Colon, *i.* n. (Κοῖλος, hollow; because generally empty in the dead subject; or Κωλυω, prohibeo.)

Condyle. (Κόνδυλος, a tubercle.) A round eminence of a bone in a joint. *Condylus, i.* m.

Cor. (Κηρ, καρδια.) The heart.

Coracoid. (Κοραξ, a raven, and εἶδος, resemblance.) Shaped like a crow's beak. *Coracoideus, a, um.*

Coronoid. (Κορώνη, a crow, and εἶδος, resemblance.) Applied to processes of bones that are curved, or in any way like a crow's beak. *Coronoideus. a, um.*

Cotyloid. (Κοτύλη, a small drinking-cup, εἶδος, likeness.) Resembling an ancient drinking-cup. *Cotyloides, is.* f., also used adj.

Cranium. (Κρανιον, calvaria of the Latins.)

Cremaster, *eris.* m. (Κρεμάω, to suspend.)

Cricoid. (Κρίκος, a ring, and εἶδος, resemblance.)

Crista, *æ.* f. (As if *carista*, from καρα, the head.) A crest; anything like the comb of a cock. *Crista Galli.*

Crystalline. (Κρυσταλλος, crystallus.)

Cuboid. (Κυβος, a cube, or solid square body, and εἶδος, resemblance.) Like a cube. *Cuboides, is.* f.; also used adj.

Cystis, *is.* f. (Κυστις, a bag.) A bladder. The membranous bag in which any morbid substance is contained: a cyst; hence cystic.

D.

Dartos, *i.* m. (Δερας, a skin.)

Deltoid. (Δελτα, and εἶδος, resemblance.) Shaped like the Greek letter Δ. Applied to a triangular muscle on the shoulder.

Dermis. (Δερμα.) The skin. See *Cutis.*

Diaphanosus, *a, um.* (Δια, through, and φαινω, to shine.) Transparent: diaphanous.

Diaphragm. (Δια, and φραττω, to shut in.)

Diarthrosis, *is.* f. (Δια, through, and ἄρθρον, a joint.) A moveable articulation of bones.

Diastole, *es.* f. (Διαστελλω, to dilate.) The dilatation of the heart, by which, with its alternate contraction (*systole*), the circulation is carried on.

Digastricus, *a, um.* (Δις, twice, and γαστηρ, a belly.)

Dislocation. (Δις, out of, and *locus,* a place.)

E.

Elytroides. (Ελυτρον, vagina: tegumentum.) A tunic of the scrotum. The cremaster was also called the erythroid membrane.

Enarthrosis, *is.* f. (Εν, in, and αρθρον, a joint.) The ball-and-socket joint; a variety of the class *Diarthrosis.*

Encanthis, *is.* f. (Εν, in, and κανθος, the angle of the eye.)

Encephalon. (Εν, in, and κεφαλη, the head.)

Entero. (Εντερον, an intestine.)

Epicranial. (Επι, upon, and κρανιον, the cranium.)

Epicranium, *ii.* n. (Επι, upon, and κρανιον, the cranium.)

Epidermis, *idis.* f. (Επι, upon, and δερμα, the skin.)

Epididymis, *is.* m. (Επι, upon, and διδυμος, a testicle.)

Epigastric. (Επι, upon, and γαστηρ, the stomach.)

Epiglottis, *idis*, or *is.* f. (Επι, upon, and γλωττις, the aperture of the windpipe.)

Epiphysis, *is.* f. (Επι, upon, and φυω, to grow.)

Epiploic. (Επιπλοον, the omentum.) Belonging to the epiploon, or omentum. *Epiploicus, a, um.*

Epiploon, *i.* n. (Επιπλυω, to sail upon; because it, as it were, floats on the intestines.)

Ethmoid, or Æthmoid. (Ηθμος, a sieve, and ειδος, resemblance.)

G.

Ganglion, *ii.* n. (Γαγγλιον, a knot.) An enlargement in the course of a nerve, resembling a knot.

Gastric. (Γαστηρ, the stomach.) Belonging to the stomach. *Gastricus, a, um.*

Gastrocnemius. (Γαστηρ, the belly, and κνημη, crus, the leg.)

Generation. (Γεινομαι, to beget.)

Genio. (Γενειον, the chin.)

Ginglymus, *i.* m. (Γιγγλυμος, a hinge.) The hinge-like joint; a variety of the class *Diarthrosis.*

Glenoid. (Γληνη, a cavity, and ειδος, resemblance.) Having a cavity for articulation with another bone. *Glenoides, is.* f.: also used adj.

Glosso. (Γλωσσα, the tongue.)

Glottis, *idis.* f. (Γλωττις, the aperture of the windpipe.)

Gluteal. (Γλουτος, the buttock.)

Gomphosis, *is.* f. (Γομφοω, to drive in a nail.) A variety of the class *Synarthrosis*, in which one bone is fixed in another like a nail in wood, as the teeth in their sockets.

H

Halo, *onis.* m. (Αλως, a circle.) The brownish circle around the female nipple.

Hæmorrhoidal.

Harmonia, *æ.* f. (Αρω, to adapt.) Harmony; a variety of the class *Synarthrosis*, denoting such bones as are simply joined together, as the nasal and other bones of the face.

Hemisphere. (Ἡμισυς, half, and σφαίρα, a globe.)

Hepar. (Ηπαρ.) Jecur, the liver.

Hippocampus, *i.* m. (Ἱππόκαμπος, a sea insect, with a head like that of a horse.) The sea-horse.

Humerus, *i.* m. (Ωμος, the shoulder.) The arm: the shoulder: also the long bone of the arm, *os humeri*, or *os brachii*. BRACHIUM.

Hyaloid. (Ὑαλος, glass, and ειδος, resemblance.) Resembling glass: transparent. *Hyaloides, is.* f.; also used adj.

Hymen. (Υμην, a membrane.)

Hyoides, *is.* f. (Υ, and ειδος, resemblance.) Like the Greek letter υ: hyloid.

Hypoglossal. (Υπο, under, and γλωσσα, the tongue.)

I.

Ileum, *i.* n. (Ειλεω, to turn about: from its convolutions.)

Ilium. (A portion of the os innominatum.)

Ischium, *ii.* n. (Ισχις, the loin; from its proximity to the loin; also Ισχιον, coxa.)

L.

Lachryma, *æ.* f. (Λακρυμα.)

Lambdoidal. (Λ, and ειδος, resemblance.)

Lamina, *æ.* f. (Ελαω, to beat out.) A plate of metal.

Larynx, *gis.* f. (Λαρυγξ.) The windpipe.

M.

Mamma, *æ.* f. (Μαμμα, the instinctive cry of an infant for the breast.)

Masseter, *eris.* m. (Μασσάω, to chew; because it is employed in chewing.)

Mastoid. (Μαστος, the breast, and ειδος, resemblance.)

Matrix, *icis.* f. (Ματηρ.) The womb, or uterus.

Maxilla, *æ.* f. (Μασσάω, to chew.) The upper, or lower jaw.

Meninx, *gis.* f. (Μανὸς, thin.)

Mesentery. (Μεσος, the middle, and εντερος, the intestine.)

Mesocæcum, *i.* n. (Μεσος, the middle, and *cæcum*, the blind-gut.)

Mesocephalon, *i.* m. (Μεσος, the middle, and κεφαλη, the head; because situated below the centre of the brain.)

Mesocolon, *i.* m. (Μεσος, the middle, and κωλον, the colon.)

Metacarpus, *i.* m. (Μετα, after, and καρπος, the wrist.)
Metatarsus, *i.* m. (Μετα, after, and ταρσος, the tarsus.)
Mylo. (Μυλη, a mill; in allusion to the *grinding* teeth.)
Myology. (Μυς, a muscle, and λογος, a discourse.) The doctrine of the muscles. *Myologia*, *æ.* f.
Myotomy. (Μυς, a muscle, and τεμνω, to cut.) Dissection of the muscles. *Myotomia*, *æ.* f.

N.

Nasus, the nose. (Ρις of the Greeks.)
Neurilemma, *atis.* n. (Νευρον, a nerve; and λεμμα, a covering.)

O.

Odontoid. (Οδους, a tooth, and ειδος, resemblance.) Resembling a tooth in shape. *Odontoides*, *is.* f. also used adj.
Œsophagæus, *a*, *um.* (Οισοφαγος, the gullet.)
Œsophagus, *i.* m. (Οιω, to carry, and φαγω, to eat; because it conveys what is eaten to the stomach.)
Olecranon. (Ολενη, *cubitus*, and κρανος, *galea.*)
Omo. (Ομος, the shoulder.)
Ophthalmic, from Οφθαλμος.
Optic. (Οπτομαι, to see.) Relating to the eye. *Opticus*, *a*, *um.*
Os, *oris.* n. (Οσσα, the voice.) The mouth. Applied to the openings of parts.
Osteogeny. (Οστεον, a bone, γενεια, generation.) The growth of bones. *Osteogenia*, *æ.* f.
Osteography. (Οστεον, a bone, and γραφω, to describe.) The description of the bones. *Osteographia*, *æ.* f.
Osteology. (Οστεον, a bone, and λογος, a discourse.) The doctrine of the bones. *Osteologia*, *æ.* f.

P.

Palma, *æ.* f. (Πάλλω, to wield.) The palm of the hand.
Pancreas, *atis.* n. (Παν, all, and κρέας, flesh; from its flesh-like substance.)
Parenchyma, *atis.* n. (Παρεγχοω, to strain through.)
Parotid. (Παρα, before, and ους, ωτος, the ear.)
Pelvis, *is.* f. (Πελλὶς, a bowl; from its shape.)
Pericardium, *ii.* n. (Περὶ, about, and καρδια, the heart.)
Perichondrium. (Περὶ, *circa*, around, and χονδρος, a cartilage.)
Pericranium, *ii.* n. (Περὶ, about, and κρανιον, the cranium.)
Perinæum, *i.* n. (Περινέω, to flow around; because it is generally moist.)
Periosteum, *i.* n. (Περὶ, about, and οστεον, a bone.)

Peristaphyline. (Περὶ, around, and σταφυλη, the uvula.)
Peritonæum, *i.* n. (Περιτεἰνω, to stretch all over.)
Perone. (Περονη, fibula, from πειρω, to traverse; because it passes through or traverses the leg.)
Phalanges. (Φαλαγγες, from Φαλαγξ. Pl. of *Phalanx*, *gis.* f. a battalion of foot.)
Pharynx, *gis.* f. (Φερω, to conduct; because it leads the food into the œsophagus.)
Phrenic. (Φρένες, the diaphragm; being the plural of φρὴν, the mind, which the ancients supposed to exist in the diaphragm and parts immediately above it.) Belonging to the diaphragm. *Phrenicus*, *a*, *um.*
Placenta, *æ.* f. (Πλακους, a cake; from its resemblance.)
Platysma-Myoides. (Πλατὺς, broad, μυς, a muscle, and ειδος, resemblance.)
Pneumonic; pneumo-gastric, &c. (Πνευμονες, the lungs.)
Pleura, *æ.* f. (Πλευρα, the side.)
Prostate. (Προ, before, and ἱστημι, to stand; because situated before the urinary bladder.)
Psoæ. (Φοαι, the loins.) The loins: also applied to two pairs of muscles of the loins.
Pterygoid. (Πτέρυξ, a wing, and ειδος, resemblance.) Resembling a wing. *Pterygoideus*, *a*, *um.* ALÆFORMIS.
Pulmo, *onis.* m. (Πλεύμων, for πνεύμων, the lungs.) The lung.
Pylorus, *i.* m. (Πυλη, an entrance, and ουρος, a guard; guarding, as it were, the entrance of the bowels.)

R.

Rachis, *eos.* f. (Ῥάχις, the spine.)
Raphe, *es.* f. (Ραφὴ, a seam, or suture.)
Ren, renes; the kidneys (in Greek, Νεφροι).

S.

Sacrum, *i.* n. (*Sacer*, sacred; because it was formerly offered in sacrifices. The Greeks used the word ιερον.)
Saphena, *æ.* f. (Σαφὴς, manifest.)
Scalenus, *a*, *um.* (Σκαληνος, irregular.)
Scaphoid. (Σκάφη, a little boat, and εἶδος, resemblance.)
Sceletos, *i.* m. (Σκελλω, to dry.) A skeleton.
Schindylesis, *is.* f. (Σχινδυλέω, to split into small pieces.) A variety of the class *Synarthrosis*, in which one bone is received into a slit in another, as the vomer into the sphenoid bone.
Sclerotic. (Σκληρόω, to harden.) Hard: tough. *Scleroticus*, *a*, *um.*
Sesamoid. (Σήσαμον, a grain of Indian corn, and εἶδος, resemblance.) Resembling a grain of Indian corn. *Sesamoideus*, *a*, *um.*

Sigmoid. (Σ, and εἶδος, likeness.) Resembling the Greek letter Σ. *Sigmoides, is.* f.; also used adj.

Sphenoid. (Σφην, a wedge, and ειδος, resemblance.) The sphenoid bone does not resemble a wedge, but serves the purpose of a clamp.

Splanchnic. (Σπλάγχνον, an entrail, or viscus.) Belonging to the entrails, or viscera. *Splanchnicus, a, um.*

Spleen. (Σπλὴν, a purple, or livid-coloured, oval viscus in the left hypochondrium, whose function is not yet ascertained. *Splen, enis.* f.

Splenius, *ii.* m. (Σπλὴν, the spleen; because like its shape.) A muscle of the neck.

Staphyline. (Σταφυλὴ, a grape.) Like a grape. *Staphylinus, a, um.*

Sternum, *i.* n. (Στέρνον.) The oblong, flat bone at the fore-part of the thorax, consisting, in the young subject, of several pieces united by cartilages; in the adult of three, of only two, and in the old subject often of one entire bone: the breast-bone. Os Pectoris.

Stomach. (Στόμα, the mouth, and χεύω, to pour; the food passing into it from the mouth and œsophagus.)

Styloid. (Στύλος, a pillar, εἶδος, likeness.) Like a stake, or pillar: styliform. *Styloideus, a, um.*

Symmetry. (Σὺν, together, and μέτρον, a measure.) The due and exact proportion of one thing to another, in respect of the whole. *Symmetria, æ.* f.

Sympathy. (Συμπαθέω, to suffer with.)

Symphysis, *is.* f. (Σὺν, together, and φύω, to produce.) A natural union of bones, by means of an intervening substance; a variety of the class *Synarthrosis.*

Synarthrosis, *is.* f. (Σὺν, together, and ἄρθρον, a joint.) An immoveable joint; a class of articulations having three varieties, *Sutura, Gomphosis, Symphysis.*

Synchondrosis, *is.* f. (Σὺν, together, and χόνδρος, a cartilage.) A union of bones by means of an intervening cartilage; a species of *symphysis*, as of the pubes.

Syneurosis, *is.* f. (Σὺν, together, and νεῦρον, a nerve; the term nerve formerly including ligaments, membranes, and tendons.) Union of bones by means of an intervening membrane; a species of *symphysis.*

Syssarcosis, *is.* f. (Σὺν, together, and σὰρξ, flesh.) Union of bones by means of a kind of connecting muscle, as the *os hyoides* to the sternum.

Systole, *es.* f. (Συστέλλω, to draw together.)

T.

Tarsus, *i.* m. (Ταρσὸς.)

Thalamus, *i.* m. (Θάλαμος.) A bed.

Thorax, *acis.* f. (Θώραξ, a coat of mail; because it incases the viscera of the chest.)
Thymus (gland). Θυμος.
Thyroid. (Θυρεὸς, a shield, and εἶδος, resemblance.) Resembling a shield. *Thyroideus, a, um.* SCUTIFORM.
Trachea, *æ.* f. (Τραχὺς, rough; from the inequalities of its cartilages. The Latins also called the trachea the aspera arteria, being merely a translation of the Greek name Τραχεια αρτηρια.)
Tragus, *i.* m. (Τράγος, a goat; from the short hairs that grow on it in advanced life.)
Trapezium, *ii.* n. (Τραπέζιον, a four-sided geometrical figure; from its shape.)
Trapezoides, os. (Τραπέζιον, the trapezium, and εἶδος, resemblance.)
Trigonus, *a, um.* (Τρεῖς, three, and γωνία, a corner.) Three-cornered: trigonial; the trigon or trigonal space.
Trochanter, *ri.* m. (Τρέχω, to run; from the use of the muscles attached to it; or from τροχος, a wheel: hence τροχαντηρ μεγας, the greater trochanter.)
Trochlea, *æ.* f. (Τρέχω, to run.) A pulley.
Tympanum, *i.* n. (Τύμπανον, a drum.)

U.

Ulna, *æ.* f. (Ωλένη, the ulna, or cubit.)
Unguis, *is.* m. (Ονυξ, a claw, or talon.)
Urachus, *i.* m. (Οὖρον, urine, and ἐχω, to contain.)
Ureter, *eris.* m. (Οὖρον, urine.)
Urethra. (Ουρηθρα.)
Urine. (Ὀρούω, to rush forward.)
Uterus, *i.* m. (Ὑστέρα.)

V.

Vein. (In Greek, Φλεψ.)

X.

Xiphoid. (Ξιφος, a sword, εἶδος, resemblance.) Sword-shaped, *Xiphoides, is.* f.; also used adj. ENSIFORMIS.

Z.

Zygoma, *atis.* n. (Ζυγὸς, a yoke.)

ERRATA.

Page 38, *after* the syllable at the end of the fifth line *insert* noid.
Pages 74 and 75, *for* ischion *read* ischium.
Page 93, line 28, *for* larger *read* shaft.
„ 99, last line, *for* tibia *read* fibula.
„ 103, line 34, *for* small *read* long.

COLLEGE HOSPITAL
LIBRARY
MEDICAL SCHOOL

MANUAL OF ANATOMY.

OSTEOLOGY.

THE SKELETON.

By the term skeleton is meant the assemblage of bones constituting as it were the frame-work of the body. The word is derived from *sceletum*, and that, no doubt, from σκέλλω, to dry. To the Greeks, who knew but little of anatomy, we owe most of our anatomical terms. The bones, as first shown to the student, are hard, solid organs, of various forms: they ought to be prepared with great care, by maceration in water of a certain temperature, and cleaned without the aid of any hard instruments. The object of this is to exhibit them in a perfect state. It is to the adult skeleton and the bones composing it that the student must first devote his attention—to the skeleton articulated artificially, or connected by means of wires. He will afterwards examine the natural skeleton, or that in which the bones are left connected by their own ligaments: the skeleton of the fœtus is usually so articulated. By its solidity and hardness the skeleton affords support to the soft parts. Some adhere to it, as the muscles and ligaments; others it partially or fully protects. Moreover, being composed of levers, it forms a portion of the system of organs of locomotion—passive organs of locomotion, acted on by the living muscles.

FUNDAMENTAL PART OF THE SKELETON.

The vertebral column is the fundamental part of the skeleton; 1st, as existing in all animals which have a true skeleton, and thus bestowing a name on a whole division of the animal kingdom, namely, the vertebrate animals; 2nd, as being obviously the centre of the osseous system. Philosophical anatomy becoming daily more practical, has all but demonstrated that the vertebral column ought to include the head, and that all the other bones of the body are merely its appendages.

But the practical student must ever view the vertebral column as composed of a series of bones extending from the head to the extremity of the column. I scarcely think it necessary to allude to the

Fig. 1.*

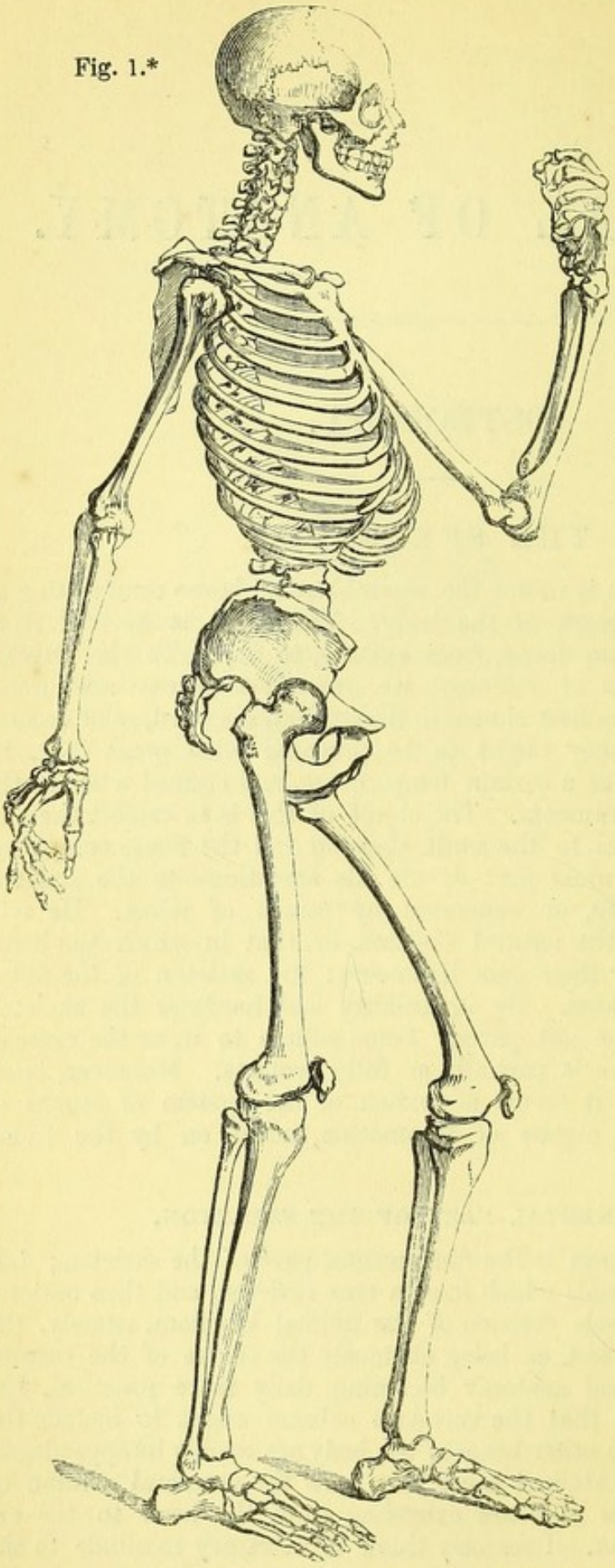

old division of the skeleton into head, trunk, and extremities. As regards the skeleton, such divisions are calculated to mislead; they have a reference more to the soft parts. The essential element of the skeleton is the vertebral column (see *Figs.* 26, 27, 28, p. 17), and this ought to include the cranial bones; but the number of vertebræ composing the cranium has not yet been determined, and therefore I shall describe the column (*columna vertebralis, rachis, spina,*) as being composed of a series of bones, thirty-three in number, strongly connected together by means of ligaments, to be hereafter described. When clothed with all its soft parts, it is strong, firm, elastic—qualities which are not to be observed when examined as we now consider it.

The bones composing it are called Vertebræ. Those

* Fig. 1.—Male skeleton, viewed in profile.

Fig. 2.*

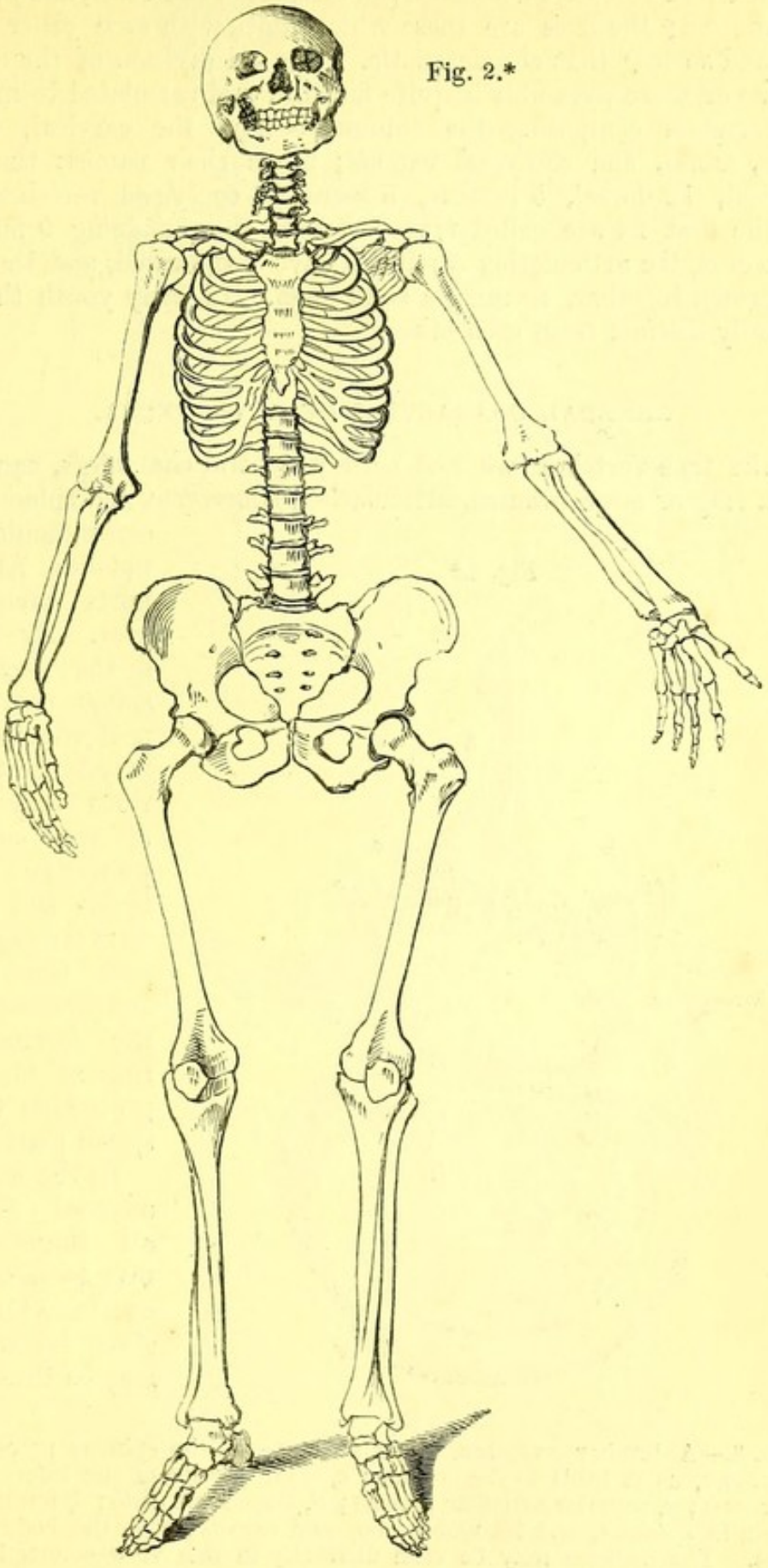

* Fig. 2.—Female Skeleton.

are called true vertebræ which remain distinct in the adult, and preserve their motion; the false are those which unite with each other into a mass, and so lose that characteristic. The old division of the column into two or more pyramids is quite fanciful, and calculated to mislead. The vertebræ composing the column occupy the cervical, dorsal, lumbar, sacral, and coccygeal regions; hence their names: there are 7 cervical, 12 dorsal, 5 lumbar, 5 sacral, 4 coccygeal vertebræ. Of these the first 24 are called true vertebræ, the remaining 9 false; in other words, the articulating cartilages have disappeared, and the bones have grown together, forming a solid mass. In early youth they are all equally distinct from each other.

GENERAL CHARACTERS OF A VERTEBRA.

In the true vertebræ we find certain general characters, namely, a body, a ring or large foramen, articulating, transverse, and spinous processes, laminæ and notches. All these parts have their uses. By means of the notches the spinal nerves are protected from injury during the various movements of the column; powerful ligaments and fibro-cartilages connect the bodies and processes; and the foramen or ring affords some protection to the spinal marrow.

Fig. 3.*

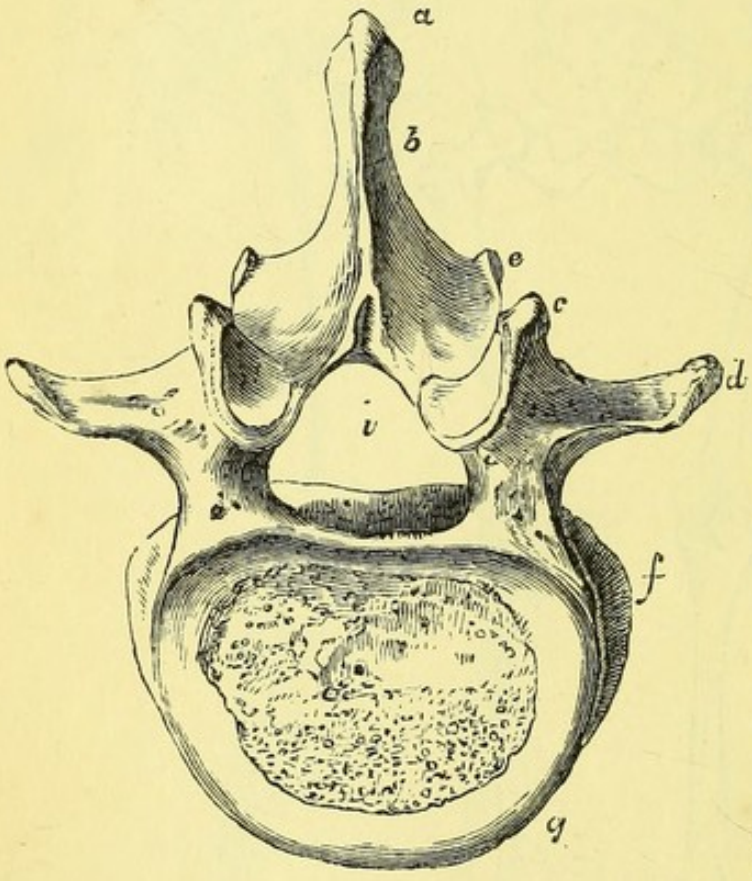

In the woodcut annexed (*Fig.* 3) all these parts may be seen; the explanation is given below. It may be thus sum-

* Fig. 3.—A lumbar vertebra, upper surface.—*a*, the spinous process; *b*, same process, as it leads to the laminæ; *e*, small portion of the inferior articular process; *c*, superior articular process; *d*, transverse ditto; *i*, foramen for the *medulla spinalis*, and its membranes and nerves; *g*, *f*, the body of the vertebra. The pedicles may be seen distinctly in this view connecting the processes to the body.

Fig. 4.*

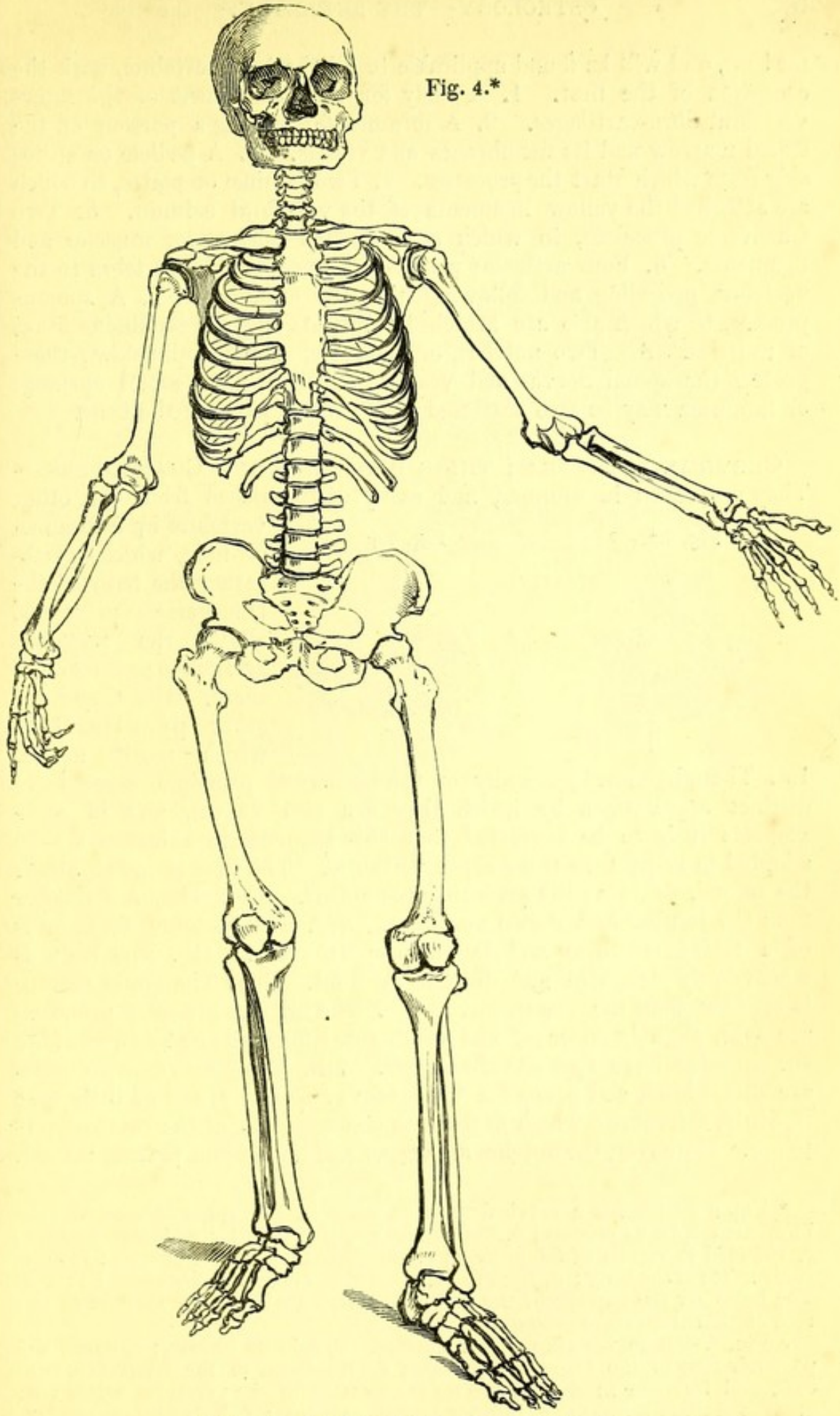

* Fig. 4.—Male Skeleton, viewed in front.

med up, and will be found applicable to all the true vertebræ, with the exception of the first. 1. A body for the attachment of the inter-vertebral fibro-cartilages. 2. A foramen for lodging a portion of the spinal marrow and its membranes and vessels. 3. A pedicle on either side from which start the processes. 4. Two laminæ or plates, to which are attached the yellow ligaments of the vertebral column. 5. Two transverse processes, to which are attached tendons of muscles and ligaments. 6. Four articular processes connecting the vertebra to the vertebræ preceding and following the one examined. 7. A spinous process, to which also are attached ligaments and the tendinous fibres of muscles. 8. Two notches, or incisuræ, above and below; these protect the spinal nerves and vessels. 9. Numerous small openings or foramina may be seen scattered over various parts of the bone.

CERVICAL VERTEBRÆ; THEIR DISTINGUISHING CHARACTERS.—They are seven in number, and easily distinguished from the other vertebræ by a foramen or hole, which, perforating the base of the transverse processes, allows the vertebral arteries to pass through them. But they have other peculiarities which merit notice. 1st. Though named generally on the numerical principle, some have distinct appellations by which they are also known, and in some respects it is to be regretted that this nomenclature had not been adopted in respect to these seven vertebræ. The first is called atlas; the second, dentata; the seventh, proeminens. 2nd. They are smaller than the lumbar and dorsal vertebræ. 3rd. The vertebral foramen is of a triangular form and larger proportionally. 4th. The body is transversely elongated and deepest in front. 5th. The upper surface is broader than the lower one. 6th. The inferior articular processes are oval, slightly concave, and are directed forwards and downwards; the superior have opposite characters. 7th. The transverse processes are short, bifid, and present a deep groove superiorly, and at their base is, 8thly, a foramen, which is the true characteristic of the cervical vertebræ. Moreover, the notches are deeper and the spinous process is bifid.

Fig. 6.*

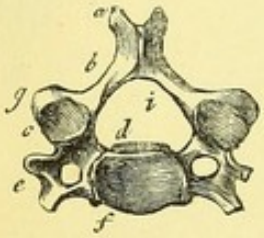

Fig. 7.†

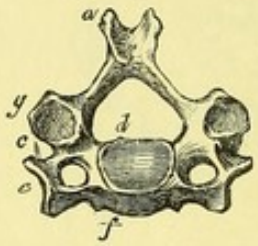

* Fig. 6 represents a cervical vertebra seen on the upper surface.—*a*, the bifurcated spinous process; *b*, the laminæ; *c*, the superior articular process; *g*, rounded extremity of the process; *e*, bifurcated transverse process; *f*, anterior surface of the body; *d*, posterior surface of the body; *i*, vertebral foramen. The holes for the passage of the vertebral artery are distinctly marked at the root of each transverse process.

† Fig. 7.—Same vertebra, lower surface.—*a*, spinous process; *c*, notch and posterior root of the transverse process; *e*, bifurcation of the transverse process, and foramen in the process for the passage of the vertebral artery; *d*, great medullary foramen; *g*, inferior articular process; *f*, body of the vertebra.

Meckel compares the posterior root of the transverse process of the cervical vertebræ to the transverse processes of the dorsal vertebræ; and the anterior root to the ribs, which in the cervical vertebræ are rudimentary. But though followed in this by many good anatomists,* I have demonstrated the opinion to be an erroneous one. *The anterior root of the transverse processes of the cervical vertebræ is composed of two distinct osseous elements*, of which the anterior one alone *is the rudimentary rib.*

PECULIAR CERVICAL VERTEBRÆ.—Every vertebra differs in some respects from all the others; but descriptive anatomists think it sufficient to attend to a certain number only in each region. In the cervical region we find three which have been so described; namely, 1, the first, or atlas; 2, the second, or dentata; 3, the seventh, or proeminens.

THE ATLAS.—This bone is so called from its supporting the head. It cannot well be mistaken for any other vertebra. In form it resembles a somewhat irregularly shaped ring, the narrower and smaller portion of the ring or circle being in front. A ligament running transversely across from one side to the other, divides the ring into two unequal parts; the one in front of the ligament is intended for the reception of the processus dentatus of the axis or 2nd cervical vertebra; through the larger circle, behind the ligament, passes the medulla spinalis, its membranes and vessels, together with the spinal accessory nerves.

Fig. 8.†

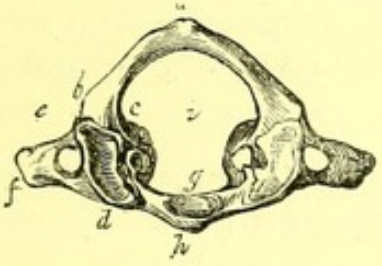

Fig. 9.‡

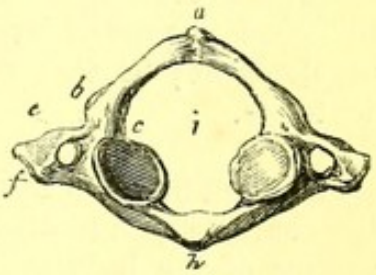

When we examine the vertebra in detail and endeavour to recognise in it the structures it may have in common with the other vertebræ, and the modifications these may have undergone to fit the bone for its place and functions, we find, 1st, that it has no body properly speaking, the processus dentatus occupying its place; 2nd, on the posterior

* Quain, 5th edition by Sharpey and Quain, p. 7.

† Fig. 8.—Atlas; upper surface.—*h*, anterior margin of the ring of the atlas; *g*, articular surface for the play of the odontoid process of the second vertebra or axis; *d*, superior articular process, right side; *f*, transverse process, in its base may be seen the foramen for the passage of the vertebral artery; *c*, points to the tubercles to which the transverse ligament is attached; *e*, points to the groove connecting the notch and vertebral foramen; *b*, the commencement of the posterior part of the ring of the atlas; *i* is placed in the anterior part of the foramen for the spinal marrow, and a short way behind the situation of the ligament. (See the illustrations of the ligaments.)

‡ Fig. 9.—Atlas viewed from below.—*a*, tubercle, representing the spinous process. The other letters indicate the corresponding or similar structures as in the preceding figure.

part of the anterior portion of the osseous ring is an articular facette, on which plays the fore part of the odontoid process. The superior articular processes are large, concave, oval, and inclined inwards, and adapted to receive in their concavities the occipital condyles and to admit readily of the movements of the head forwards and backwards. On their inner side are two tubercles to which the transverse ligament is firmly attached. The inferior articular processes are, on the contrary, nearly plain, corresponding to similar articular surfaces on the axis. Between these takes place the rotatory motion of the head around its axis. The transverse processes are long and thick, and terminate in an obtuse point. The foramen in their base (for the passage of the vertebral artery) is larger than in the other cervical vertebræ. The notches in which lie the vertebral arteries and first pair of spinal nerves, are situated behind the articular processes; in the other cervical vertebræ the notches are anterior to the articular processes.

Lastly, there are no well marked laminæ; but in their place the posterior part of the osseous ring completing the circle of the vertebra. A tubercle at the back marks the position of the spinous process of which it is a vestige. The physiological unimportance of this part of the bone is proved by the comparative frequency of its incomplete development; in this respect resembling the last lumbar and sacral vertebræ.

Axis, or Second Cervical Vertebra.—Also called *dentata* from the characteristic tooth-like process (odontoid), rising from the upper surface of the body of the vertebra. The following peculiarities characterize the bone: The body is higher than it is broad, and presents mesially and anteriorly a central ridge and two hollows, to which are attached the longi colli muscles. The odontoid process (ὀδούς ὀδόντος, a tooth) is a strong vertical osseous projection, strongly united to the upper surface of the body of the vertebra. On its anterior surface is a small articular facette by means of which it plays on a corresponding smooth surface on the back of the anterior part of the ring of the atlas: posteriorly there is a similar articular facette

Fig. 10.*

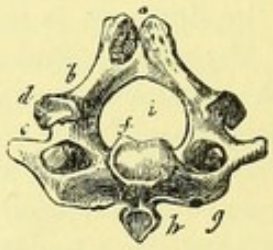

Fig. 11.†

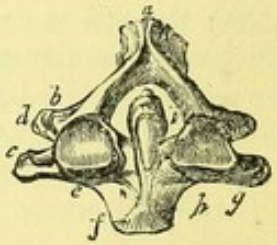

* Fig. 10.—Axis, or vertebra dentata.—*a*, lower surface, spinous process; *b*, lamina; *c*, notch; *d*, inferior articular process; *i*, foramen medullare; *f*, the body; *h*, processus dentatus; *g*, root of the transverse process.

† Fig. 11.—Vertebra dentata, upper surface.—*a*, spinous process; *b*, lamina; *c*, anterior root of the transverse process; *d*, posterior root of the transverse process; *e*, superior articular process; *f*, the body, from which springs the processus dentatus; *g*, anterior root of the transverse process; *h*, surface conducting to the notch; *i*, foramen medullare.

corresponding to the anterior surface of the transverse ligament; the ligament in fact which retains the process in its place. Close to the summit, but at the sides, are attached two ligaments whose course is obliquely transverse, and by means of which the odontoid process is strongly attached to the inner side of the condyles of the occipital bone. These ligaments are called the check ligaments, inasmuch as they check the rotatory motion of the head, limiting it to half a circle; nevertheless the rotatory motion of the head, as far as it goes, is, in the language of the natural philosopher, universal. The spinous process of this vertebra is very large and deeply grooved inferiorly. The upper notches are placed much further back than the lower. The superior articular processes are nearly horizontal and somewhat convex; they are broader than the inferior, which are turned forwards and downwards. The transverse processes are short, and are neither bifurcated nor grooved. The foramen for the passage of the vertebral artery passing through their base, more resembles a short canal than a mere foramen; its direction is obliquely outwards. The laminæ are thick and strong, and the foramen medullare is heart-shaped.

SEVENTH CERVICAL VERTEBRA.—The last of the region, and physiologically the most remarkable. Its large and projecting spinous process, well known to artists; its irregularly formed transverse processes, carrying anteriorly a rudimentary rib, that is, the vestige of a rib, which though developed in other animals is not so in man; its close resemblance to the succeeding vertebra, the first dorsal, distinguish this vertebra from all the others. Its spinous process is not bifur-

Fig. 12.* Fig. 13.† Fig. 14.‡

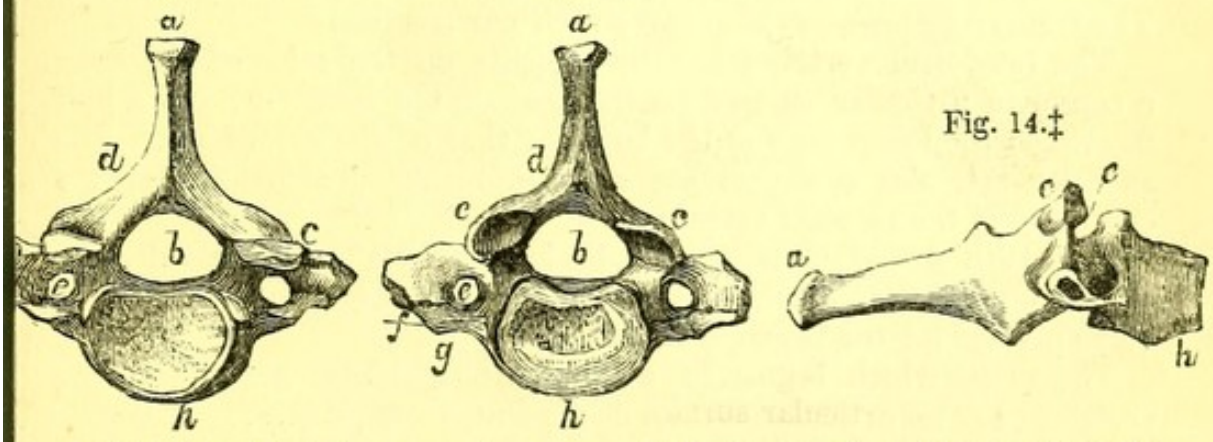

* Fig. 12.—Vertebra proeminens seen from above.—*d*, the lamina; *e*, hole for the vertebral artery, which, however, never passes through it; *f* points to the germ of the rudimentary rib; *c*, articular process and notch; *h*, body of the vertebra.

† Fig. 13.—Same vertebra, seen from below.—*a*, spinous process; *b*, vertebral foramen; *c*, articular process; *d*, lamina; *e*, hole for the v. artery and vein; *f*, germ or nucleus of the accessory rib; *g*, the supernumerary rib itself, separated from the anterior root of the transverse process by a distinct foramen; *h*, body of the vertebra.

‡ Fig. 14.—Same vertebra as seen in profile.—*a*, spinous process; *c*, *e*, superior articular process and notch, or incisura; *h*, body of the vertebra.

cated; and although it has foramina in the base of the transverse processes, the vertebral arteries seldom pass through them. The vertebra is one of transition.

This being one of the transition vertebræ, partakes of the character of the series it terminates and of that which is immediately to follow it, namely, the dorsal. In the very young it always carries a rudimentary rib, distinct from the anterior root of the transverse process, and in many other respects resembles a dorsal vertebra. I have seen it on one side strictly resembling a dorsal vertebra and on the other a cervical. The preparation showing this was formerly in my own museum; it is now in that of the University of Edinburgh.

Dorsal Vertebræ.—These vertebræ are twelve in number; what they have in common has been already mentioned. A dorsal vertebra

Fig. 15.* Fig. 16.† Fig. 17.‡

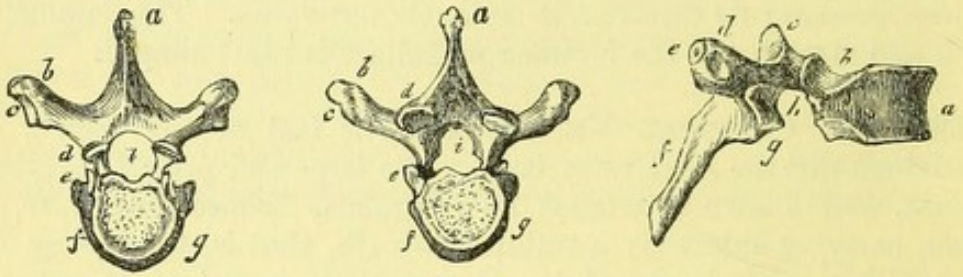

may be known at once by the absence of the foramina for the vertebral arteries and by the presence of smooth articular facettes or surfaces, originally encrusted with cartilages on some part of the sides of the body. On these facettes are articulated the heads of the ribs. The transverse processes also carry articular facettes.

The 1st dorsal vertebra usually presents on the sides of the body a complete articular surface for the head of the first rib; and a half facette on the lower edge of the body for that of the second rib. The superior articular processes are oblique, retaining something of the character of the cervical vertebræ.

The 10th dorsal vertebra may be known by a complete articular surface on each side of the body, together with a facette on the transverse process for the tubercle of the rib.

The 11th, which begins to assume the character of the lumbar vertebræ, has no articular surface on its transverse process.

* Fig. 15.—A dorsal vertebra, viewed from above.—*a*, spinous process; *b*, transverse ditto; *c*, articular facette for the reception of the tubercle of the rib; *d*, *e*, point to the s. articular process and notch; *f*, *g*, the body; *i*, foramen medullare.

† Fig. 16.—The same vertebra seen from below. The lettering of the preceding figure applies to this.

‡ Fig. 17.—The same vertebra viewed in profile.—*a*, the body; *b*, the semifacette for the articulation of the head of the rib; *c*, superior articular process; *g*, inferior ditto; *d*, *e*, transverse process and facette; *f*, spinous process; *h*, notch.

The 12th, a transition vertebra, can only be distinguished from the 11th by its still greater resemblance to the lumbar vertebræ, especially as regards the form and direction of the lower articular processes.

THE LUMBAR VERTEBRÆ.—Of these *five* vertebræ, the fifth only merits particular notice. The body is deeper anteriorly than posteriorly, and the transverse processes are thick and short. The vertebra is a *transition* vertebra, being the last of its series, and begins to resemble the first sacral.

Fig. 18.*

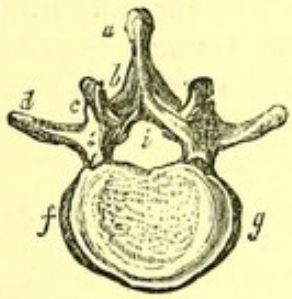

Fig. 19.†

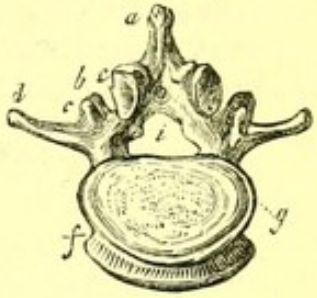

SACRAL VERTEBRÆ, OR SACRUM.—The next vertebræ are called false, because, in the adult state, they are united to each other by bone, thus forming one osseous mass. To these bones so united the name of sacrum has been given. They form a portion of the pelvis.

Fig. 20.‡



The sacrum is composed, then, of five vertebræ, usually described as one bone.

The last lumbar vertebra is articulated with it above, and the first coccygeal below. It is concave internally, and convex externally. With the last lumbar vertebræ it forms an angle, called the sacro-vertebral. Anteriorly may be seen four transverse ridges, marking the position of the intervertebral cartilages which once existed here. On this surface, also, called pelvic, may be seen eight foramina; through these pass the anterior sacral nerves; grooves in the bone lead from these foramina.

External to the foramina is the surface for the attachment of the pyramidal muscle. On the posterior or dorsal aspect of the bone (see *Fig.* 22) may be seen, first, a series of elevations, usually forming a ridge; these correspond to, and form the spinous processes of, four of the sacral vertebræ. The fifth is wanting, and in its place we have

* Fig. 18.—A lumbar vertebra, upper surface.—*a*, spinous process; *b*, lamina; *c*, superior articular process; *d*, transverse process; *f*, *g*, body of the vertebra; *l*, foramen for the spinal marrow and its membranes.

† Fig. 19.—A lumbar vertebra, inferior surface.—*e*, inferior articular process. The other letters point to the same parts as in the preceding figure.

‡ Fig. 20.—Sacrum; its right margin.—*a*, superior articular process; *b*, sacro-vertebral angle; *c*, facies auricularis; *h*, spinous processes, or crest; *d*, termination of the canal of the sacrum, and cornua sacralia; *f*, apex.

an opening leading into the canal of the sacrum. This canal of the sacrum is simply the successive rings or foramina of the sacral vertebræ for lodging the spinal nerves and membranes. The tubercles on the margins of this opening are called cornua; the lower ones articulate with those of the first coccygeal vertebræ: these cornua correspond to the articular processes of the true vertebræ. External to the mesian line or ridge (spinous processes) will be found eight foramina, corresponding, and including those in front, to the incisuræ of the true vertebræ; and on each side of these foramina are processes which also represent the articular and transverse processes of the true vertebræ. The groove on each side the mesian line corresponds to the vertebral

Fig. 21.*

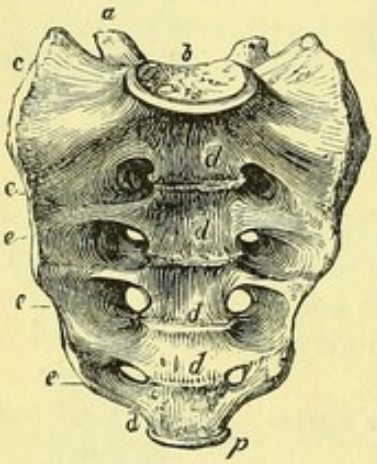

Fig. 22.†

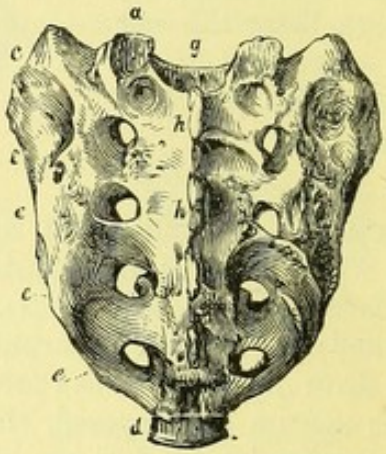

grooves above, the basis of which was the *laminæ vertebrarum*. Thus we find on these vertebræ all the corresponding parts of the true vertebræ merely modified. The *foramina sacralia*, anteriora as well as posteriora, communicating directly with the sacral canals, are simply the sacral intervertebral foramina. The borders or margins present two distinct surfaces; one, the superior, broad, articular, smooth; the other, the lower, irregular and thin. The large articular surface is often called the *facies auricularis* of the sacrum, from its supposed resemblance in shape to the external ear. By this surface the sacrum, or rather its three uppermost vertebræ, are articulated with the iliac bones. The sacro-sciatic ligament is attached to the lower, thin, irregular part of the margin.

On the base, or upper part of the sacrum, will be found, 1st. The disc corresponding to the upper surface of the body of this vertebra.

* Fig. 21.—The sacral vertebræ, or sacrum; pelvic, or anterior surface.—*a*, superior articular process; *b*, disc, upper surface of the body of the first sacral vertebra; *c*, right margin of the bone; *d*, anterior surface of the bodies of the sacral vertebræ; *e*, grooves leading to the anterior sacral foramina; *p*, apex, formed by the body of the last sacral vertebra.

† Fig. 22.—Dorsum of the sacrum.—*a*, superior articular process; *g*, superior opening leading to the canal of the sacrum; *c*, *e*, *e*, *c*, point to the margin of the bone and the grooves leading to the posterior sacral foramina; *h h*, crest or spinous processes of the sacrum; *d*, cornua sacralia.

2nd. Behind it the foramen medullare of the vertebra, leading into what is usually called the sacral canal. 3rd. The superior articular processes connecting it, also, to the lumbar vertebræ, and, at the sides, two large masses, formed, probably, by transverse processes, and rudimentary ribs.

The *apex*, or inferior extremity of the bone, is merely the lower surface of the body of the last sacral vertebra. This vertebra is exceedingly imperfect, having neither laminæ nor spinous process, a deficiency which I have seen extend, even in the adult, to all the sacral vertebræ.

In structure, the sacrum resembles the true vertebræ, being composed of loose, spongy bone. It presents many peculiarities, chiefly sexual and infantile, and of race, to which I shall refer when speaking of the skeleton generally. The last sacral vertebra, as in the other regions, is a transition vertebra.

THE COCCYX: COCCYGEAL VERTEBRÆ.—In young persons, there are four coccygeal vertebræ, which unite into one or more pieces with age. The first resembles the last sacral; it has horns (cornua), rudiments or vestiges of the articular processes, and projections at the sides, corresponding to transverse processes. The remaining three coccygeal vertebræ are composed merely of irregularly formed bodies of vertebræ, all processes and other parts having disappeared. The little process at the side, belonging to the first coccygeal bone, sometimes unites with the last sacral vertebræ, and thus gives rise to another pair of foramina. The vertebræ of this region (coccygeal) also present sexual and other peculiarities, which will fall to be noticed when speaking of the skeleton as a system of organs.

Fig. 23.*



Fig. 24.†



OF THE MINUTE ANATOMY AND OSSIFICATION OF THE VERTEBRAL COLUMN.

There are many important considerations, connected with a history of the skeleton, which I have thought might be given appropriately in this place, it being presumed that the student has made himself intimately and familiarly acquainted with all the separate or distinct bones —their processes, foramina, position, shapes, connexions, &c. This chapter is not especially addressed to the first year's student, but he cannot too soon make himself master of it.

* Fig. 23.—Coccyx, or coccygeal vertebræ, front or pelvic view.—*a*, upper surface of the first coccygeal vertebra; *b*, cornua coccygis; that is, the superior articular processes; *c*, remains of a transverse process; *d*, margin of the four bones.

† Fig. 24.—Coccyx, back view. The lettering corresponds with that of Fig. 23.

I have already remarked that the bones examined for the first time by the student must be prepared with the greatest care, cleansed merely by means of water, no hard instruments being employed for this purpose. When I first taught anatomy, skeletons and separate bones were put into students' hands which had been scraped and polished! I need not say what this leads to.

The human skeleton, as exhibited to the student (see *Figs.* 1, 2, 4), is generally articulated by means of wires, so as to admit of some of those motions which, during life, it performs by means of the muscles, acted on through the nerves; but some of the most important cannot be so imitated. The spine, for example, artificially articulated, is made to represent an unyielding column; the scapulæ and collar-bones are, of necessity, firmly attached to the trunk in these artificial skeletons, and the motions of the thorax cannot be imitated.

Fig. 25.*

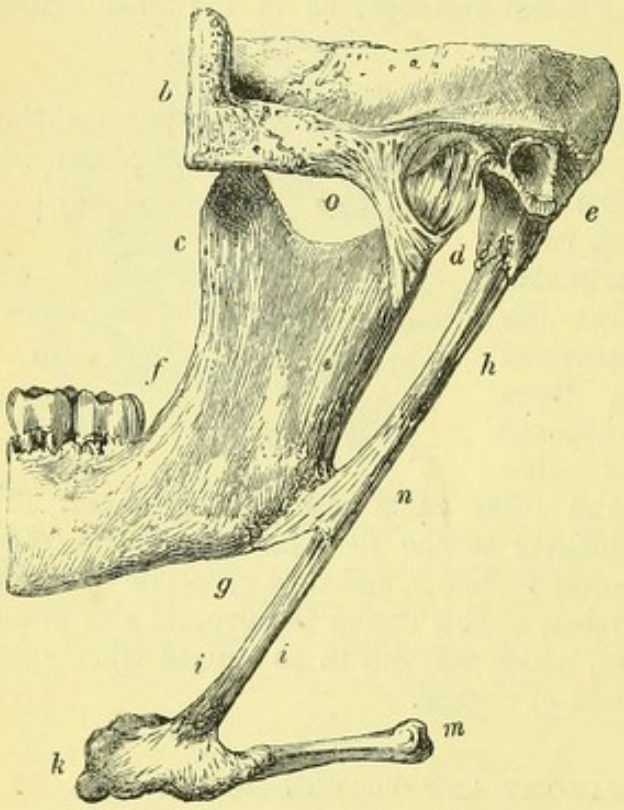

Of the hard, or seemingly osseous parts, found in the body, and in the skeleton as set up in schools, some are true bones, and some are not. The teeth, for example, are not strictly bones, and their development is more connected with the digestive system of organs than with the skeleton. The lingual bones are not usually articulated with the skeleton, their connexion with the tongue and larynx being considered as more intimate; the sesamoid bones (osteids), which are not developed like the ordinary bones, but belong to another system, the fibro-cartilaginous, are usually attached to their place in the skeleton by means of wires,

* Fig. 25.—A portion of the base of the skull and of the lower jaw, with the lingual or hyoid bones *in situ*, and connected to the jaw and base of the cranium (styloid process of the temporal bone) by their natural ligaments.—*a*, portion of the base of the skull; *b*, zygomatic arch; *c*, coronoid process of the lower jaw; *d*, condyloid process; *e*, meatus auditorius externus; *f*, ramus of the lower jaw bone; *g*, angle of the same; *h*, styloid process of the temporal bone; *i*, stylo-hyoid ligament; *k*, body of the hyoid or lingual bones; *l*, smaller horn of the hyoid bones, called styloid cornu by Cuvier, to distinguish it from, *m*, the larger, inferior, or laryngeal horn; *n*, stylo-maxillary ligament; *o*, external lateral ligament of the temporo-maxillary articulation.

but naturally they are quite moveable. The *ossicula auditus* are not enumerated with the bones of the skeleton, whilst the true nature of the supernumerary bones (*ossa Wormiana*) has never yet been determined. Thus no two persons agree as to the precise number of the bones composing the human skeleton. They may, however, be thus enumerated, as seen in the adult, or person of mature age:—

Skeleton of the Head . . .	Cranial Bones . .	8		
	Facial	14		
		—		22
Skeleton of the Neck . . .	Cervical Vertebræ .			7
Ditto Thorax . .	Dorsal Vertebræ .	12		
	Ribs	24		
	Sternum	1		
		—		37
Skeleton of the Loins & Abdomen;	Lumbar Vertebræ .			5
Ditto Pelvis . . .	Sacrum	1		
	Coccyx	1		
	Ossa innominata .	2		
		—		4

Skeleton of the Upper Extremities—each:

Shoulder	2		
Arm	1		
Fore Arm	2		
Hand	27		
	—	32	=64

Skeleton of the Lower Extremities—each:

Thigh	1		
Leg	2		
Foot	26		
	—	29	=58
Total			197

The hard parts not enumerated above are, first,

The osteids or sesamoid bones—(uncertain)—usual number	12
Ossicula auditus	8
Supernumerary bones	uncertain
Hyoid, or lingual bones	5
Teeth (adult)	32

But in youth, or before ossification is complete, there are many more. To this I shall presently advert.

The really essential part of the skeleton is the cerebro-spinal, or vertebral column. In it we find—

1. Cranial	Vertebræ	3 (?)
2. Cervical	Do.	7
3. Dorsal	Do.	12
4. Lumbar	Do.	5
5. Sacral	Do.	5
6. Coccygeal	Do.	4

These are all vertebræ, however much they may differ in shape or size; some being merely rudimentary, as the coccygeal; others more fully developed, as the cranial or encephalic.

The skeleton also forms, as it were, two great cavities; these, with reference to their contents, may be called nervous and splanchnic; the former being the cranio-spinal cavity; the latter the thoraco-abdominal.

VERTEBRÆ AND VERTEBRAL COLUMN—PROPERLY SO CALLED.

The vertebral column determines the length of the trunk; its regions vary much in their absolute and relative lengths in different persons: it is the centre of all the movements of the body, and ought naturally to be perfectly straight, when viewed anteriorly, and from behind. Its profile presents a series of curves, which the student ought carefully to study. Its average length is about 2 feet 2 or 3 inches; and, in general, it may be said that the relative height of individuals depends more on the length of their limbs than of the trunk or column; but to this there are many exceptions.

The *form* varies much in different individuals, and even, perhaps, in different races of men. Its division into two cones, or pyramids, has always appeared to me fanciful, and a straining after something which does not really exist. The column is narrowest, and perhaps weakest, at the fourth and fifth dorsal vertebræ; viewed in profile it shows four curves; these are alternately forwards and backwards, and, when finally formed, give to the human figure, and especially to woman when young, in good health and condition, her matchless grace, as shown in every attitude.

A lateral bend or curvature is unnatural, and, however slight it may be, is still a deformity. In civilised countries, such curvatures are exceedingly common. There is no truth whatever in Bichat's theory of such curvatures; he ascribed them to a more frequent use of the right arm. They depend on an unequal development of the segments, of which the bodies of the vertebræ are composed in infancy. The same want of symmetry may be seen in the bones of the cranium and face, the two sides of which are, in many persons, unequally developed.

A detailed examination of the articulated column merits the student's careful attention. It may be gone over in this way—

Fig. 26.* Fig. 27.* Fig. 28.*

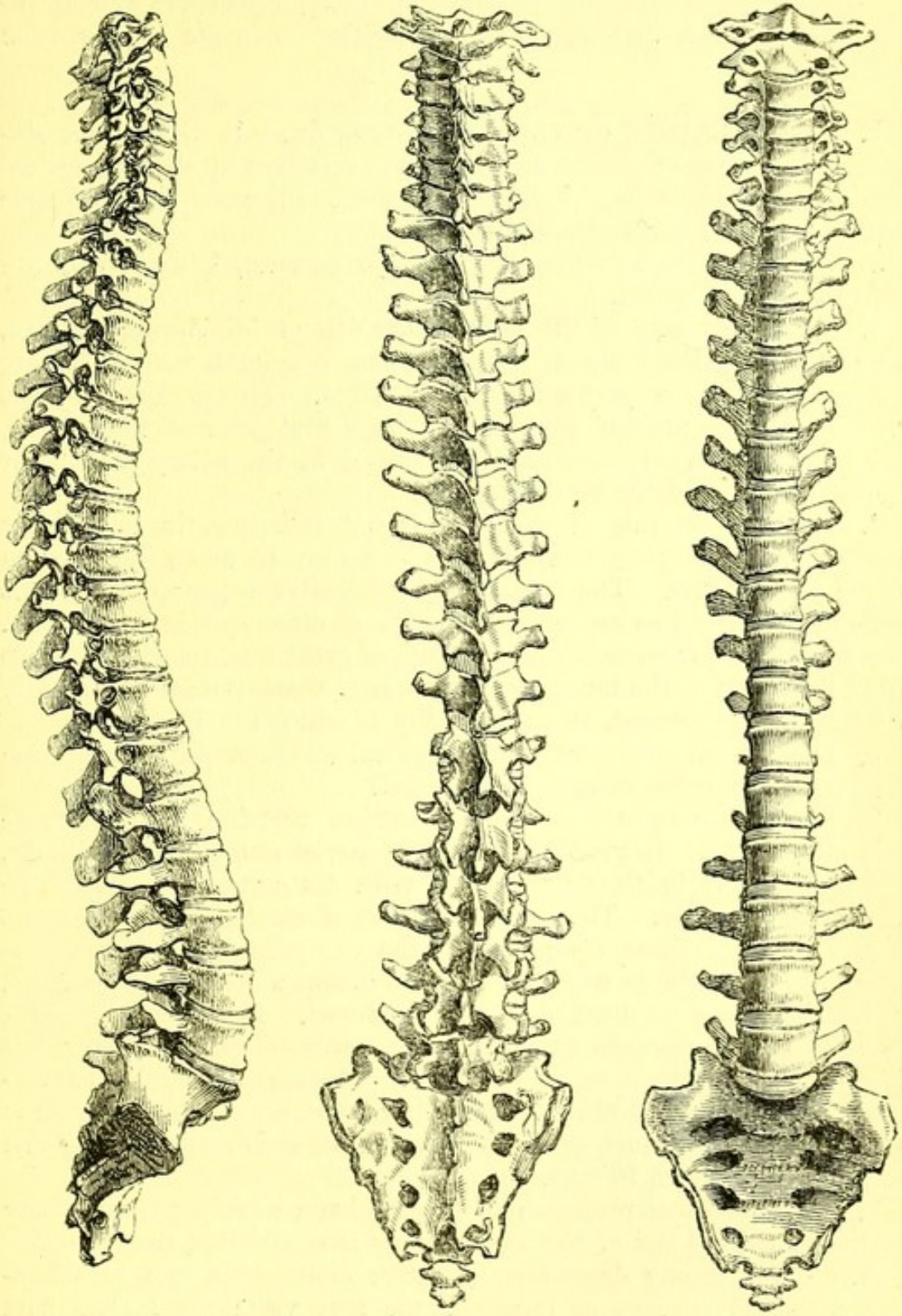

* Adult vertebral column, viewed—1st, in profile, Fig. 26; 2nd, from behind, Fig. 27; 3rd, from the front, Fig. 28. These figures require no descriptions. They show the forms and curves of the column under its various aspects, but they do not and cannot explain its functions. To understand these, the column must be dissected and examined practically.

Before considering more minutely the history of the sacral and coccygeal portions of the column, I shall complete this view of the true vertebræ by considering, first, some minute points in the descriptive anatomy of these vertebræ, their ossification or mode of formation and growth.

I. Nomenclature of the Vertebræ, &c.—1. Although anatomists still continue to count and name the vertebræ by their numerical standing or position in the different regions, it is more than probable that this method is essentially defective.

2. The transition vertebræ are, the 7th cervical, 12th dorsal, 5th lumbar, and 5th sacral.

3. On the left side of the body of the 4th or 5th dorsal vertebra, anteriorly, will be found in some persons, a smooth surface, having the appearance of a part acted on by friction. This is caused by the extremity of the arch of the aorta, where it first touches the column, and by the continual impetus of the blood in the artery pressing it against the body of the vertebra.

4. The arch or ring of the atlas is not unfrequently imperfectly formed, or not fully ossified. It does not seem to affect the strength of the osseous ring. The occurrence of defective organization here is sufficiently curious as repeating what we so often find in the sacrum. The transverse processes of the atlas are of great size, relatively. Two small tubercles on the inner side of the arch mark the attachments of the transverse ligament, on the integrity of which life depends.

5. The spinous processes of the cervical vertebræ do not approach the surface, with the exception of the last.

6. The minute history of the 7th cervical vertebra interests more than all the rest. In youth it uniformly carries two rudimentary ribs, which disappear in time by uniting with the anterior roots of the transverse processes. The line of direction of the transverse processes of this vertebra differs from that of the one preceding and that following. The vertebra would seem to represent a system of vertebræ, of which in man we have only one developed. It was long thought that in all the mammalia there were only seven cervical vertebræ; but this was at last shown to be incorrect. The normal number of vertebræ or type which Nature has given to vertebrate animals, cannot be determined, inasmuch as the anatomy of all such animals, fossil and recent, is not known to man.

7. The transverse processes of the lumbar vertebræ present many varieties; and the last of this region many irregularities, as regards its arch. These chiefly depend on defective ossification, to a consideration of which process, as it affects the true vertebræ, I shall next proceed.

II. Ossification of the true Vertebræ.—In the early fœtus the skeleton is cartilaginous. At different periods even of its intra-

uterine life, the process of ossification commences in different bones. It begins by centres of osseous deposits, which are called germs or nuclei: on a question of this kind it may be readily comprehended that an approximation only to the truth is all that at present can be expected.

Each vertebra is formed at first of three principal pieces; to which ultimately five others, which may be called epiphyses, are added. Of the three principal pieces *one* forms the body; the other *two* form the arch and the processes. About the eighth week or second month, bone may be seen forming in these three portions; in the arch and in the body; in the arch generally first. The osseous granules of the arch appear first at the root of the transverse processes, or in other words at the pedicles. From these points the osseous granules spread in all directions. The nodule of bone which ultimately forms the body of the vertebra, appears first in the centre of the cartilaginous body.* At birth these three primary pieces are still distinct. In about a year they unite with each other to form the arch, posteriorly: about the third year the three portions unite, each assisting somewhat towards the formation of the body.

The germs or nuclei afterwards superadded to these have been called epiphyses. There are two for the body, which may be shown just before puberty, on its upper and lower surface; two for the extremities of the transverse processes; one for the extremity of the spinous process; two at least for the lower articular processes; in all seven. Thus a vertebra may be considered as composed of ten bones originally, but in all probability of many more; nor is it until about the age of thirty-six that the ossification may be considered as complete.

Of the vertebræ requiring special notice may be mentioned, first, the atlas. At birth the anterior arch is altogether cartilaginous; soon after birth an osseous nucleus appears in the arch; but sometimes there are two and even three have been observed.

In the axis there is a distinct nucleus of ossification for the odontoid process. Of the 7th cervical vertebra I have already observed, that anatomists have mistaken the nucleus or germ, which here forms a short cervical rib, for the anterior root of the transverse process. They are quite distinct. This incorrect observation has led them into several other mistakes. They confound the anterior root of the transverse process with the ribs, and they give to the 7th cervical vertebra, as a vertebra, a centre of ossification more than it has. I have reason to believe that most of the cervical vertebræ have minute germs representing rudimentary ribs in very early fœtal life; but these germs either do not pass into bone, or rapidly disappear.

In the lumbar vertebræ additional germs of ossification are seen in the

* I feel disposed to think that *two* germs, not *one*, form the body of each vertebra.

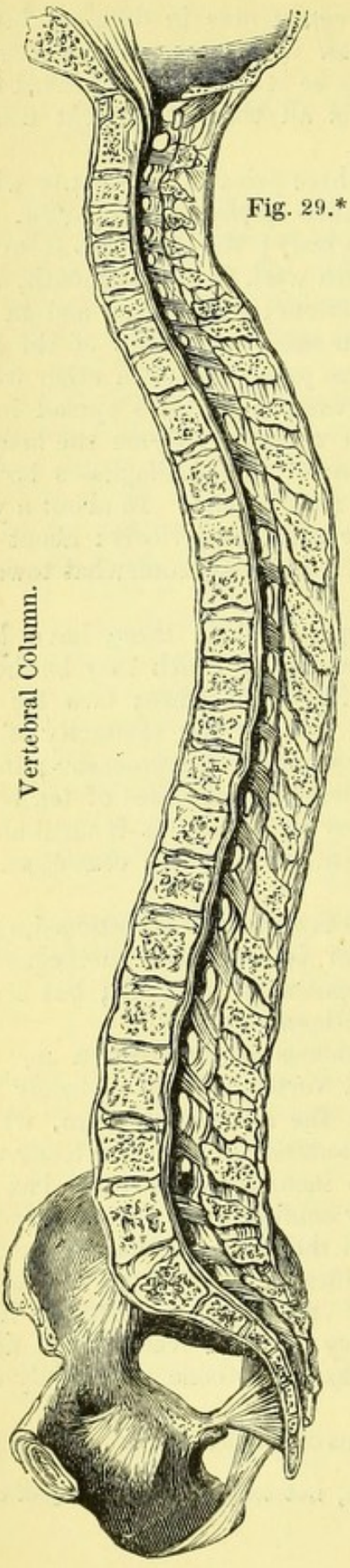

Fig. 29.*

articular processes, but there is no reason to suppose them peculiar to these vertebræ, although they cannot be demonstrated in the others. The history of the accidental appearance of lumbar ribs is not well understood.

To complete the history of the vertebral column we have next to consider that of the false vertebræ, sacral and coccygeal.

ADULT SACRUM,
its Peculiarities and Ossification.

1. The adult sacrum presents many individual peculiarities. There are sometimes four or six vertebræ instead of five. The cartilage between the first and second of the sacral vertebræ may remain distinct in the adult, or the laminæ and spinous processes being imperfectly developed, may leave the whole of the sacral canal open posteriorly.

Sexual differences affect the curve and size. In woman the sacrum is smoother and broader, and, perhaps, more curved; but this cannot always be depended on as characteristic of the female sacrum. It is comparatively shorter.

2. The five vertebræ composing the sacrum resemble, in their ossification, in most respects the preceding vertebræ. That which is peculiar in them is the appearance of osseous germs or nuclei in the first three vertebræ laterally and anteriorly. The real nature of these additional germs has not been determined. They for a time form distinct bones, as may be seen in

* Fig. 29.—Vertical and mesial section of the Vertebral Column, with the ligaments and fibro-cartilages. On these depend its elasticity and strength.

the sacrum of children. Their history has, I think, been misunderstood.

It is sufficiently remarkable, as having some relation to the speculations of transcendental anatomists, that the consolidation of the sacral vertebræ takes place from below upwards.

COCCYX—COCCYGEAL VERTEBRÆ.

These bones present numerous varieties, which need not be here insisted on. They ossify from a single centre, but two granules are often found, corroborating what I have said above, as to the double germs or nuclei of the bodies of all the vertebræ. In the fœtus it has been asserted that at first the coccygeal vertebræ are five in number, being reduced afterwards to four. The last, or fourth, presents merely the vestige of a vertebral body; it usually consolidates with the third. Besides the ischio-coccygeus muscle attached to this bone, there is generally found a sacro-coccygeus, but not always very distinctly marked: it is a rudimentary muscle in man.

BONES OF THE SKULL.

The skeleton of the head is divided into two parts. 1. The bones of the cranium properly so called. 2. The bones of the face: the former eight in number, the latter fourteen.

Arrangement and Names.

Cranium.		*Face.*	
Occipital bone	1	Upper maxillary	2
Parietal	2	Malar	2
Frontal	1	Nasal	2
Temporal	2	Palatal	2
Sphenoidal	1	Lachrymal	2
Ethmoidal	1	Lower turbinated	2
	—	Vomer	1
	8	Lower jaw	1
			—
			14

THE OCCIPITAL BONE.—The occipital bone (*Fig.* 30), *os occipitalis*, occipital vertebra of the cranium, is situated at the base and posterior part of the cranium. Its resemblance to a vertebra was first observed by the celebrated Goëthe, and has since been recognised by all anatomists. Some, with Meckel, describe the bone along with the sphenoidal, under the conjoined name of spheno-occipital, and for this

reason, that these two bones are always consolidated in the adult. Still it is convenient, by reason of the complexity of both portions, to describe each as distinct, which in a sense they really are; the first composing the occipital vertebra of the cranium; the second the spheno-parietal.

The occipital bone (*Fig.* 31) is situated at the posterior part of the base of the skull. Its natural position in the head is easily determined by placing the condyles of the bone on a horizontal and flat surface, so that the large foramen in the bone may look directly downwards.

Fig. 30.*

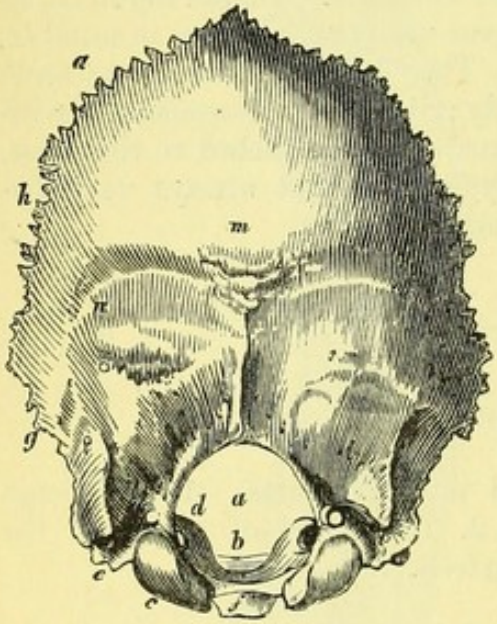

Fig. 31.†

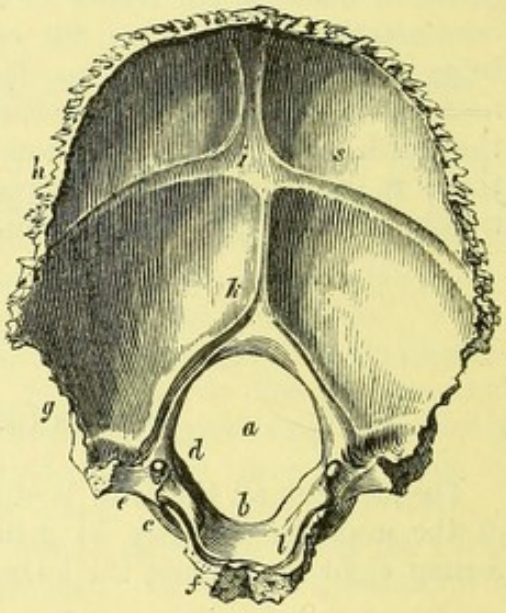

The resemblance of the bone to a vertebra cannot be overlooked. It is usual to describe it as composed of two surfaces and a margin extending all round the bone.

External surface.—Begin at the summit of the squamous plate of the bone which Loder mistook for the body. There is, 1st, the superior angle; 2nd, the convex surface of the larger part of the bone which follows; 3rd, the external occipital protuberance, and extending obliquely from this protuberance the superior curved line; a little lower down is the inferior curved line; between these are many rough

* Fig 30.—Occipital bone, external surface.—*a*, placed near the superior angle; *h*, lateral angle; *m*, near the external occipital protuberance; *n*, superior curved line of the bone; *o*, inferior curved line; *a*, *d*, *b*, foramen magnum; *g*, mastoid edges; *c*, transverse process and jugular eminence; *e*, condyle; *f*, basilar process.

† Fig. 31.—Occipital bone, cerebral and cerebellar aspect.—*h*, serrated edge of the bone; the letter points also to the superior occipital fossa; *i*, internal occipital protuberance; *s*, superior occipital fossa of the left side; *k*, lower portion of the vertical crest near to where it bifurcates; *a*, foramen magnum occipitale; *b*, commencement of the basilar process; *f*, *l*, basilar process; *e*, jugular process; *c*, anterior condyloid foramen; *d*, edge of the foramen magnum.

depressions. These curved lines are crossed by a vertical line called the external occipital crest or spine, extending from the protuberance to the edge of the foramen magnum occipitale.

The foramen magnum is the large oval opening in the bone, corresponding to a similar aperture in all the vertebræ. In front is the body or basis of the bone; the margins correspond to the laminæ vertebrarum, and the condyles to articular processes, which in fact they are. The position and form of these condyles merits particular attention. Oblique and convex, they are received into corresponding hollow articular facettes on the upper surface of the atlas. On their inner side, anteriorly, are rough hollow surfaces to which the check ligaments are attached. In front of the condyles are the anterior condyloid foveæ and foramina; behind these the posterior condyloid foveæ and foramina. Through the anterior pass the hypoglossal nerves; through the posterior, which however are not always present, pass a small artery and vein. External to either condyle is a rough surface, somewhat projecting, running transversely outwards; it should be called the transverse process of the bone: to it is attached the rectus capitis lateralis muscle.

On the *internal* or cerebral aspect of the bone may be seen, 1st, two crucial lines or ridges; the vertical one extends from the upper angle of the bone to the foramen magnum; the transverse one from one lateral angle to the other. At the point of their intersection is the internal occipital protuberance. These crests divide the bone into four fossæ, two superior and two inferior. The superior lodge a portion of the posterior lobes of the brain; in the inferior rest the hemispheres of the cerebellum. The upper half and the transverse crests are double, and enclose grooves corresponding to the superior longitudinal and lateral sinuses. The lower half of the vertical spine bifurcates near the foramen magnum; to it is attached the falx cerebelli, a process of the dura mater: the tentorium, another process of the same membrane, is attached to the transverse crests. Anterior to the foramen magnum, on the internal aspect of the bone, is the basilar groove, being in fact the upper surface of the body (basilar process) of the occipital vertebra: it supports the medulla oblongata. Close to the margin of the foramen magnum are the inner openings of the anterior condyloid foramina; and external to it are two fossæ, in which are placed the termination of the lateral sinuses.

Two shallow grooves mark the edges of the basilar process; these correspond to the inferior petrosal sinuses.

The borders or margin.—Notched and serrated they frequently present specimens of the *ossa Wormiana* or supernumerary bones of the cranium. Traced from above downwards on either side are, 1st, the superior angle; 2nd, the lateral angles; 3rd, the jugular process and notch; and 4th, the fovea juglandica. This notch forms the foramen lacerum when the temporal bone is in its place.

The occipital bone varies much in strength and thickness; thinnest in the fossæ, thickest in the basilar process and at the protuberance.

It articulates with six bones, namely, the two parietal; the two temporal; the sphenoid, and atlas.

The muscles attached to it are, 1, the trapezius; 2, occipito-frontal; 3, sterno-mastoid; 4, complexus; 5, splenius capitis; 6, recti postici majores, minores, and lateralis; 7, obliquus superior; 8, recti antici major and minores; 9, superior constrictor of the pharynx.

THE SPHENOID BONE.—An idea prevails with students that the sphenoid bone (*Fig.* 32) is difficult to be understood and described; but this notion is wholly incorrect. Only those who are destitute of memory, or of any power of fixing their attention for a short time on any subject whatever, can ever experience the smallest difficulty in comprehending the anatomy of this bone.

The sphenoid bone, placed transversely in the base of the skull, and so named from its resembling a wedge (*σφὴν*, a wedge; *εἶδος*, like) in its position as regards the other cranial bones, has also been compared to a bat, to which it bears some slight resemblance. To place it in its natural position hold it by the ends of the supposed legs of the bat: the great divisions of the bone should first be considered.

I. These are, 1, the mesial portion or body; 2, the pterygoid processes; 3, the larger wings, or alæ; 4, the smaller wings, so called, of Ingrassias; 5, the cerebral aspect and pituitary fossa; 6, the orbito-nasal aspect; 7, the open space, bounded by the pterygoid processes, measuring the extent of the posterior nostrils and bounding them; 8, the sphenoidal sinuses.

II. Attend next to the foramina passing directly through the bone: 1, the optic; 2, the foramina lacera anteriora (sphenoidal); 3, the vidian foramina and canal; 4, the foramina rotunda; 5, ovalia; 6, spinosa.

III. Observe the margins and sutures, foramina and cavities, formed alone or with the aid of other bones: 1. It assists in forming a portion of the cavity of the cranium. In the cavities hollowed out on the upper surface of the greater wings (*alæ majores*) rest the middle lobes of the brain; the wings of Ingrassias occupy the fissure separating the middle from the anterior lobes of the brain; the pituitary substance occupies the pituitary fossa; at the sides are the cavernous sinuses. 2. Examining the bone anteriorly and laterally, we find the orbitar plates, the union of the bone with the ethmoid and frontal. 3. Inferiorly and mesially is the process called rostrum, by means of which the bone articulates with the vomer, the *septum* dividing the sphenoidal sinuses from each other, and continuous inferiorly with the rostrum, and in front, the crest, articulating with the vertical or central plate (*lamella*) of the ethmoid bone. The *cornets*, or sphenoidal, spongy, or turbinated bones, two bones distinct in youth, unite here to complete the anterior and lateral wall of the sphenoidal sinuses, shutting up their cavities, but leaving two rounded apertures, by means of which they communicate with the posterior ethmoidal cells. The minor processes less observable on these surfaces are,—the ethmoid spine,

the processus olivaris, clinoid processes, the rostrum, hamular, and spinous processes. The position of these is best made out by a systematic examination of all the parts of the bone.

I have already spoken of the sphenoidal fissure, also called the foramen lacerum orbitale. At the root of each pterygoid process there is a canal, with two apertures leading to it: it is the vidian.

The bone articulates with the occipital, the ethmoid, the frontal, parietal, temporal, vomer, malar, and palate bones. By its union and proximity to some of these bones, fissures and cavities are formed which fall to be described when speaking of the cranium as a whole.

To complete the study of the bone, examine it carefully with reference to its aspects, naming the objects they contain in succession, and in detail.

Guttural or lower aspect.—Mesially is the rostrum, or azygous process, united with the vomer below, and continuous with the septum of the sinuses above. On each side a small groove for receiving a plate of the vomer, and in the bottom a small vascular opening, distinct in young persons. Another small groove, assisting in forming the pterygo-palatine, a vascular canal. A process of the palate bone is required to complete this canal. Next the pterygoid process (πτέρυξ, *ala*; εἶδος, *forma*), single above; inferiorly dividing into two laminæ or plates. The inner surface of the inner plate is lined by the pituitary membrane, and measures the breadth of the nostrils; the outer side of the external plate is hollow, and gives attachment to the external pterygoid muscle; this surface belongs to the zygomatic fossa. Anteriorly and beneath, the process joins the palate bones; above it is smooth, and also forms a portion of the zygomatic fossa. Posteriorly is the pterygoid fossa; this can be seen only by turning the bone round and looking at it from the occipital aspect. In the upper part of this fossa is the scaphoid depression, to which the external peristaphyline muscle is attached. The internal peristaphyline is attached to the pterygoid fossa. Still higher, and at the root of the pterygoid process, on either side, is the vidian canal, for transmitting the vidian nerves and vessels. In the bifurcation of the process inferiorly is inserted the tuberosity of the palate bones. At the extremity or lower end of the inner plate is the hamular process, around which plays the tendon of the external peristaphyline muscle, or circumflex muscle of the palate.

Cerebral aspect.—In connexion with the membranes of the brain; uneven. Examined from behind, forwards there are, 1, the basilar surface, grooved; 2, the posterior clynoid processes; 3, the pituitary fossa; 4, the anterior clinoid processes; 5, the olivary process; 6, a transverse groove, on which rests the commissure of the optic nerves; 7, a smooth surface, leading to two slightly marked longitudinal depressions, on which rest the olfactory nerves.

At the sides, and from behind forwards.—On this aspect are found, 1, the foramen spinosum; through this passes the middle meningeal artery: 2, some small vascular apertures; 3, the foramen ovale, for

the passage of the third division of the fifth pair of nerves; 4, the foramen rotundum, through which passes the second division of the fifth pair of nerves; 5, a broad groove for lodging the cavernous sinus and internal carotid artery, and branches of the sympathetic system of nerves. Anteriorly is a small prominence, to which is attached the common origin of the outer, inner, and upper recti muscles of the eyeball; 6, the orbitar processes, or wings of Ingrassias; and below these the sphenoidal fissures, through which pass the third, fourth, first division of the fifth, and sixth pair of nerves; 7, the anterior clinoid processes; 8, the optic foramina; the ophthalmic artery passes with the nerve; the vein leaves the orbit by the sphenoidal fissure.

Fig. 32.*

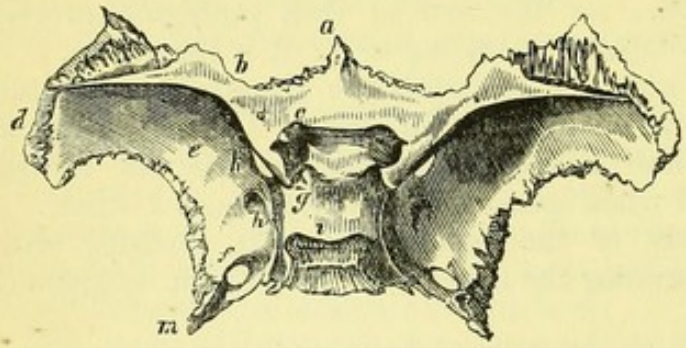

Occipital or posterior aspect.—Rough, uneven, quadrilateral. The bone unites here with the basilar process of the occipital, so as, in the adult state, to form but one. Lower down are objects already described when speaking of the guttural aspect.

Orbito-nasal—anterior aspect.—In this view there are, the apertures leading to the sphenoidal sinuses (which do not exist in young children); the sphenoidal fissure is seen in this view; also, the part of the bone assisting in forming the spheno-maxillary fissure; likewise the anterior aperture of the foramen rotundum.

Fig. 33.†

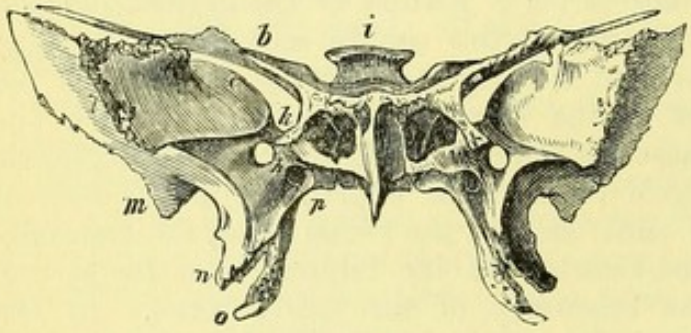

External or Zygomato-temporal aspect.—Divided into two portions by a transverse ridge, to which are attached a deep portion of the

* Fig. 32.—Sphenoid bone, cerebral aspect.—*a*, the crest; *b*, smaller wings, or wings of Ingrassias; *d*, *e*, larger wings; *c*, optic foramen; *k*, foramen lacerum sphenoidale; *g*, corresponds to the position of the cavernous sinus; *i*, the sella turcica, or pituitary fossa; *h*, foramen rotundum; foramen ovale; *m*, spine and foramen spinosum. The figures have been placed only on one side of the bone and on the mesial portion.

† Fig. 33.—Sphenoidal bone, orbito-nasal aspect.—*i*, clinoid processes; *b*, smaller wings; foramen lacerum sphenoidale; *e*, orbitar plates, or processes placed between the, *h*, foramen rotundum and anterior opening of the vidian canal; *p*, the rostrum; *l*, *m*, portions of the larger wings; *n*, outer lamina, *o*, inner lamina of the pterygoid process of the right side.

temporal muscle; above the ridge, the bone forms a portion of the temporal fossa; beneath, of the zygomatic fossa.

The bone further presents edges or margins, the frontal, temporal, parietal, occipital. These will be best understood by considering them as assisting in forming the articulations of the bones.

OF THE PARIETAL BONES—*Ossa Parietalia, Os Bregmatis.*

Double, and unsymmetrical, each representing, however, the other.

Irregularly square in form, convex externally, concave internally; it presents two surfaces, a cerebral and dermoid, or cutaneous; four margins or edges, a temporal, parietal or sagittal, frontal or coronal, and an occipital; as many angles, called the upper or frontal angle, the inferior and anterior, or sphenoidal angle; the inferior and posterior, or mastoid; the posterior and superior, or occipital.

The bone, like the other cranial bones, is composed of two plates, or laminæ, an outer and inner, and of an interposed diploe. It is articulated with that of the opposite side, by the proper parietal suture; with the frontal by the coronal; and with the occipital and temporal bones by the lambdoidal, mastoidian, and squamous sutures. The bone presents few objects requiring special notice. Externally, the bone is smooth, and is covered by the epicranial aponeurosis; a small and unimportant vascular foramen traverses the bone generally, close to the sagittal suture, and about an inch from the posterior and superior angle. About the middle of this external aspect is the parietal protuberance (tuber), and a little lower a curved line, which can scarcely be called a crest, though partaking of the nature of a crest. This curved line (parietal crest) is continuous with the crest or ridge of the frontal bone, and extends to the upper root of the zygomatic process. The temporal aponeurosis is attached to this crest.

Fig. 34.*

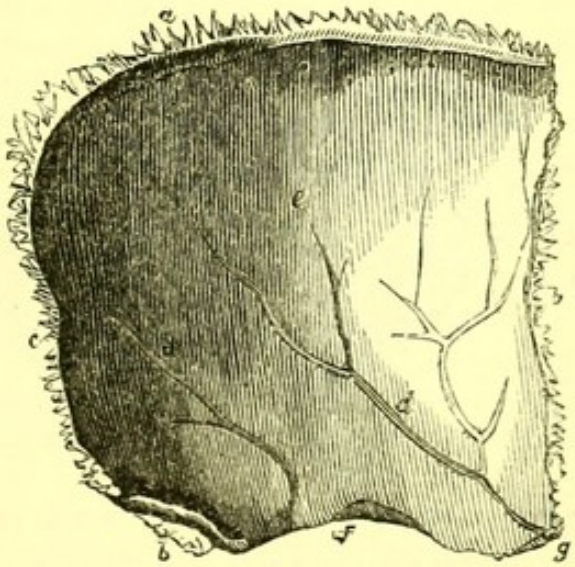

On the cerebral aspect are the elevations and depressions corresponding to the convolutions and anfractuosities of the brain; also the

* Fig. 34.—Left parietal bone, cerebral surface or aspect.—*a*, superior or parietal margin; *b*, anterior, or frontal; *c*, posterior, or occipital; *b*, *f*, temporal; *g*, sphenoidal; *d*, *d*, *e*, grooves for lodging branches of the middle meningeal arteries.

depression called the parietal fossa and the sulci meningei. A half groove runs along the parietal edge, contributing, with that of the other side, to form a longitudinal depression, in which is lodged partially the superior longitudinal sinus. Near this are several depressions of varying size, mostly found in the adult and aged skull, for lodging the glands of *Pacchioni*.

The frontal angle is truncated in children, from the want of the full development of the bones; and it is here that the anterior fontanelle exists, through which the pulsations of the brain may be felt. Near the inferior and anterior angle, internally, is the commencement of the chief groove for lodging the middle meningeal artery; the vein passes close to this, but through the diploe. Internally, the mastoid angle is grooved for a short space, continuous with others found on the occipital and temporal bones, for lodging the lateral sinus of the dura mater.

THE TEMPORAL BONES—*Ossa Temporum*

Occupy the lateral and inferior parts of the cranium, and contain within them the essential structures of the organ of hearing. The description of one applies, *mutatis mutandis*, to both. The relation they hold to the cranial vertebræ has not been determined by philosophic anatomists.

Fig. 35.*

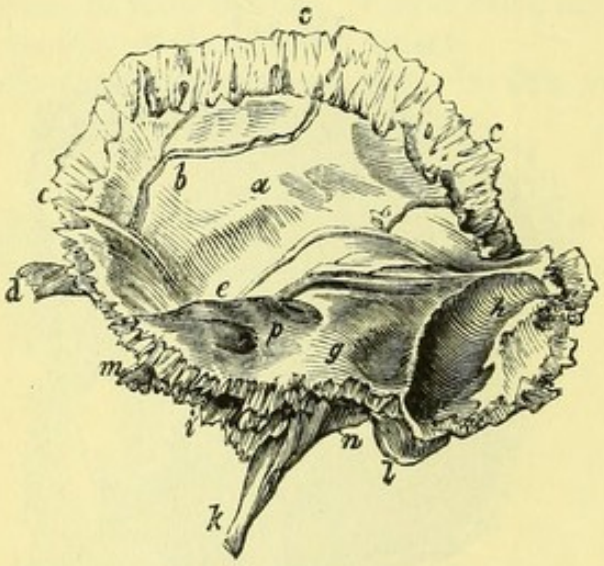

In each temporal bone we have the following principal parts: — 1. The squamous portion. 2. The pars petrosa, called also os petrosum. 3. The mastoidian portion, including its process. 4. The zygomatic. 5. The styloid. All these parts can readily be made out, and the bone easily put in its place. Besides these, there are two leading aspects, a cerebral and external, to which a third may be added, the basial, or inferior. The margins of the bone are irregular, and vary in thickness; the squamous portion thin; the mastoid thick; the squamous dense and hard. Like the frontal, sphenoid, ethmoid, and upper maxillary bone, the temporal has cells, into which the external air is admitted.

* Fig. 35.—Temporal bone, right side, cerebral aspect; *c*, *c*, squamous suture and upper margin of the squamous plate; *a*, *b*, *e*, inner surface of the plate; sulci for arteries are spread over it at some points; *d*, zygomatic process; *e*, petrous portion of the bone; *p*, meatus internus; aquæducts of Cotunnius; *h*, groove for the lateral sinus; *n*, vaginal process; *k*, styloid process.

Its processes are—the zygomatic, mastoid (as distinct from the mastoidian portion of the bone), auditorius, petrous, styloid, vaginal (around the root of the styloid). The foramina canals, and hollows or grooves, are,—1. The meatus auditorius externus, being the entrance of the osseous canal, so called. 2. The meatus auditorius internus, by which the seventh pair of nerves, the portio dura and portio mollis, pass into the interior of the bone. 3. The upper and lower apertures of the carotid canal, and the canal itself, by which the internal carotid artery passes through the basis of the skull, to reach the interior of the head. 4. The foramen stylo-mastoidea. 5. The foramen and sometimes the foramina mastoidea. 6. A groove for a portion of the lateral sinus. 7. The opening leading to the osseous portion of the Eustachian canal. 8. The canal for the tensor tympani muscle. 9 and 10. The opening leading to the aquæducts of Cotunnius. 11. The meatus of Fallopio. 12. Various elevations and depressions corresponding to the cerebral surface. 13. The grooves for the superior and inferior petrosal sinuses.

To know how to point out all these parts, and to explain their various uses, is to know the descriptive anatomy of the bone; but it is proper, also, to examine so interesting a bone systematically, and in detail.

Auricular or external aspect.—On this surface, which is slightly convex, are seen grooves for lodging branches of the deep temporal arteries. This surface forms a portion of the temporal fossa, and gives attachment to the temporal muscle. It is on this surface that we find the zygomatic process, strong, projecting from the surface of the bone, to form an union with the malar. The process starts, as it were, from two roots, which merit particular notice. One of these roots (the *tuber articulare*) is covered with cartilage, concave from within outwards, convex from before backwards, serves for the articulation of the lower jaw; the other root, superior and longitudinal, divides into two. The upper, curved, gains the circumference of the bone; the lower descends and terminates at the outer extremity of a very narrow fissure, which opens into the cavity of the tympanum; this is the fissure of Glasser (*scissura Glasseri*): through this fissure pass the tendon of the external muscle of the malleus, some vessels, and a nerve called corda tympani.

Next is the glenoid cavity, divided into two parts by this fissure; the anterior part of the cavity is covered with cartilage; it also forms a part of the articulation with the lower jaw-bone; the posterior part is merely covered with periosteum, and forms no part of the joint.

The meatus auditorius externus is the external opening of an osseous canal leading to the cavity of the tympanum; the canal is a little curved downwards, proceeds from behind forwards, and is narrower about the middle than at either extremity. In the fœtus it was merely an incomplete osseous ring; in philosophic anatomy the ring and the lower part and side of the meatus which it ultimately forms, is called the tympanic bone. To the edges of this meatus externus is

attached the fibrous tube of the ear, thus connecting the external ear to the cranium.

Beyond the meatus is the mastoid process, which is flat and small in young persons, large and rounded in the aged; the sterno-mastoid muscle is attached to it and to the adjoining part of the bone: on it, or near it, is the foramen mastoideum, through which passes a vein communicating with the lateral sinus; a small artery also passes through. This foramen varies in position and number, and is occasionally absent. Behind the mastoid process is the digastric groove, and further back another; to these grooves are attached the digastric muscle and trachelo-mastoideus.

Cerebral aspect, internal.—Chiefly remarkable for the presence of the rocky or petrous portion of the bone. This process, the petrous, is pyramidal, having the summit directed upwards and inwards towards the sphenoid bone; in or on it may be distinguished an upper surface, on which is a small irregular aperture, the meatus Fallopii; this leads into the aqueduct of Fallopius, and by it there passes into that canal a small nerve, from the spheno-palatine ganglion, and an artery. In front of this is a hollow which lodges the nerve and artery; behind it a prominence marking the position of the superior semi-circular canal; cerebral impressions cover the surface. The pars petrosa has, 2nd, a posterior surface; on this are seen the aperture called the meatus auditorius internus. This opening is the commencement of a short canal, at the bottom of which may be seen a cribriform plate with several apertures. One of these is the commencement of the aqueduct or canal of Fallopius, by which the portio dura traverses the rocky part of the temporal bone, escaping by the inferior aperture of the aqueduct, called the foramen stylo-mastoideum. The osseous canal then is a nerve-duct, not an aqueduct. By the other openings seen at the bottom of the short internal auditory passage, pass filaments of the portio mollis (auditory nerve) to the internal ear.

Behind the aperture of the meatus internus is an irregular cavity and small foramen. In the fœtus a process of the brain and a prolongation of the dura mater passed in here; these are vestiges of fœtal structures. Behind this is a narrow slit leading into the aqueduct of the vestibule; from this slit there descends a groove towards the jugular fossa. The groove for the superior petrosal sinus runs along the upper margin of this portion of the bone.

3rd. The *inferior aspect* of the petrous portion of the bone is rough and complex. Of the objects seen here the most remarkable are, 1st, the inferior aperture of the carotid canal, already spoken of; 2nd, the jugular fossa, in which is the commencement or bulb of the jugular vein; it is here that the lateral sinus terminates in it. Behind the fossa is a small square surface, covered with cartilage in the recent state; this surface articulates with the jugular process of the occipital bone. Close to this is the foramen stylo-mastoideum by which the facial nerve (portio dura) passes out of the cranium; and

immediately adjoining is the styloid process, giving attachment to the muscles called styloid,* and to the stylo-maxillary and stylo-hyoid ligaments.

At the root of this process is the vaginal, deficient internally.

The groove for the inferior petrosal sinus is partly formed by this part of the bone, partly by the occipital. A triangular opening on the margin of the petrous process leads to the aqueduct of the cochlea.

The summit of the petrous process is irregular and obliquely truncated. The internal and upper orifice of the carotid canal is seen here. Tracing the circumference of the bone, we find at the angle which receives the spine of the sphenoid bone, two apertures, separated by a bony lamina, and placed one above the other. The superior contains the inner muscle of the malleus; the lower is the commencement of the osseous portion of the Eustachian tube.

The structure of the bone will be spoken of when describing its mode of ossification; its articulations are with the parietal, occipital, malar, sphenoid, and lower jaw. By dividing the bone with a saw judiciously, the mastoid cells may be exposed, and the cavity of the tympanum and labyrinth; but the description of these parts belongs to the history of the organ of hearing, of which they form a part.

THE FRONTAL BONE—*Os Frontis.*

A symmetrical bone, originally composed of two, divided mesially by a suture which occasionally remains in part to the adult condition; it is convex externally, concave internally, uneven and complex below. It may at once be divided into an external, internal, and orbito-nasal aspect.

Fig. 36.†

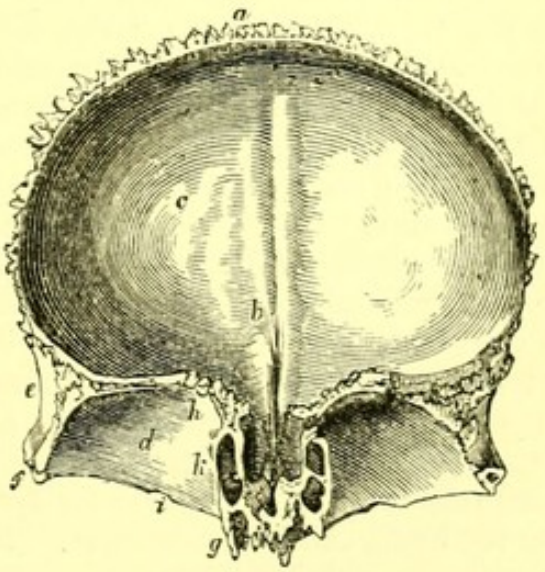

Orbito-nasal, or Ethmoidal Aspect. — Uneven and turned downwards. Mesially, there is, first, the ethmoidal notch (*incisura ethmoidalis*); anteriorly the nasal spine (*spina*

* Stylo-hyoideus; stylo-glossus; stylo-pharyngeus.

† Fig. 36.—Frontal bone, cerebral aspect.—*a*, denticulations of the coronal suture; *b*, groove for the commencement of the superior longitudinal sinus; *c*, depressions corresponding to the frontal protuberances; *e*, *f*, crest and external angular process of the frontal bone; *d*, orbitar plates, or processes; *g*, points to the ethmoidal aspect of the bone, the nasal spine, and apertures leading to the frontal sinuses.

nasalis); anteriorly and laterally, the nasal orifices of the frontal sinuses and small plates of bone, uniting with the anterior ethmoid cells, and serving to complete them.

Beyond the notch, laterally, are the plates called orbitar processes, forming the vault of the orbits. Here the bone is remarkably thin. Just within the external angular process of the bone, limiting these orbitar plates externally, is a digital impression, or cavity, in which is partially received the lachrymal gland. Opposite to this, internally, is a slight depression, and inequality or elevation, to which is attached a cartilaginous staple, through which plays the tendon of the superior oblique muscle, called, therefore, Trochlearis.

Frontal or interior aspect.—In the middle, there is a longitudinal line, generally not very distinct, marking the line of the proper frontal suture, but not caused by it. At the lower part of this line is the nasal protuberance, notch, and spine, which articulates anteriorly to the nasal bones, posteriorly to the vertical plate of the ethmoid; there are two grooves, one on each side of this nasal spine; they form a part of the roof of the nasal fossæ. The nasal, or frontal processes of the superior maxillary bones, articulate with the notch of the frontal, externally, to each nasal bone.

Returning to the surface superiorly, we find, 1st, The frontal protuberances, most distinct in children. 2nd, The superciliary arches, on which rest the eyebrows. 3rd, The orbitar margin on each side, *margo orbitalis*, or *supra orbitalis*, in which is a notch, sometimes a foramen; the supra orbitar notch, over which pass vessels of the supra orbitar branch of the first division of the fifth pair of nerves, or trigemini. The external and internal angular processes bound the orbitar margins.

From the external angular process, on either side, runs the crest. This limits superiorly a small hollow surface, forming a portion of the temporal fossa. The crest is continuous with the parietal crest.

Internal or Cerebral aspect.—On its cerebral aspect, the frontal is divided into two distinct portions—1st, The concave hollow surface, looking backwards. 2nd, A horizontal unequal surface, passing backwards at right angles to the vertical portion of the bone, and being, in fact, the cerebral and upper surface of the orbital plates or processes already described.

The more remarkable features of these two surfaces are, 1st, The large square notch for the reception of the ethmoidal bone separating the orbitar plates from each other. 2nd, The mamillary eminences and digital impressions. 3rd, Grooves for arteries. 4th, The fossæ corresponding to the frontal protuberances. 5th, The groove (*sulcus longitudinalis*), for receiving the commencement of the superior longitudinal sinus. 6th, The foramen cæcum of Morgagni, seen near the commencement of the groove. Lastly, the margins of the groove united below, and forming the inner frontal crest.

Of the margins of the bone itself little need be said. The superior is bevelled or cut obliquely, at the expense of the inner table above, and outer table below. This strengthens greatly the fronto-parietal

articulations. The other articulations are with the ethmoid, sphenoid, nasal, maxillary, lachrymal, and malar.

Density, &c.—The bone is of great strength towards the external angular processes, but so thin in the orbitar plates as to be translucent. The history of the frontal sinuses is as obscure as that of all the others. They are not found in children, but are large in old persons. I think them frequently absent, or at least very small, in women. Their uses are quite unknown. The notion that they are constantly absent in certain races of men, the Tasmanian and Papuan for example, is wholly without foundation. For my own part, I have always been disposed to view the osseous sinuses here spoken of, as well as the others existing in other cranial and facial bones, as merely the bony coverings of mucous prolongations or sacs, connected by and communicating with the nasal and guttural mucous cavities and membranes, of which, in fact, they are the continuations and appendages; they are of vast extent in some animals. Philosophic anatomy can alone explain their nature and functions.

OF THE ETHMOID BONE.

Rightly to understand the anatomy of this bone, it must be viewed, first, as composed, 1, of a vertical plate of compact tissue, dividing it into two nearly equal parts. 2, of two lateral masses, composed on each side of two turbinated bones, and two sets of cells. 3, of two thin plates of compact bone (*pars plana*), shutting in these cells towards the orbits. 4, of cerebral, nasal, orbitar surfaces, and two extremities.

The objects connected with these various surfaces are—

On the cerebral surface, 1st, Posteriorly there is a small notch, sometimes a process, articulating with the sphenoid bone. 2nd. A crest, the crista galli; to the summit of this crest the greater falx of the dura mater is attached. On either side is the cribriform plate of the bone, and the foramina of three forms, for the transmission of the olfactory and nasal branch of the fifth pair of nerves; also vessels and processes of the dura mater. The foramina just described lead to short canals, in which these parts are contained. More externally are, 1st, A square surface, with incomplete cells; these are completed by the frontal bone generally; and still further out, at the edge of the bone, are the foramina orbitaria interna, anterior and posterior.

The nasal aspect, covered throughout by the pituitary membrane, presents, mesially, 1st, The vertical plate (lamina perpendicularis). This forms a portion of the septum narium; below, it articulates with the vomer and cartilaginous septum; anteriorly with the nasal spine of the frontal and nasal bones; posteriorly, by a margin, which is thin and sharp, with the septum of the sphenoidal sinuses.

On each side of the perpendicular plate there is a deep narrow groove;* on the outer side of this groove is, 1st, The superior concha, or upper

* To demonstrate this aspect of the bone it must be divided vertically with a saw.

turbinated bone; behind it the middle turbinated bone. These, in fact, are not separate bones, but merely processes of the ethmoid, and were so named, in ignorance of their real nature, by the older anatomists. Between these conchæ is the superior meatus of the nasal fossæ, so named, although there is an appearance of a short and imperfect one a little higher up, posteriorly. The channel or meatus occupies only about a half of the whole length of the bone. Into it open the posterior ethmoid cells. The inferior concha of the ethmoid assists in forming the upper meatus above, and the middle one below; this middle meatus is placed between the concha I now speak of and the true turbinated bone. The anterior ethmoidal cells open into it. These cells, which are larger than the posterior, do not communicate with them. One of the largest is called *infundibulum:* it communicates superiorly with the frontal sinus. The inner surface of the turbinated processes is rough, with grooves and canals, for nerves and vessels. The outer is smooth.

Fig. 37.*

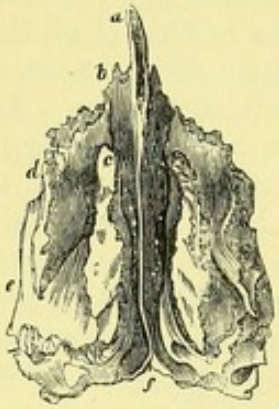

Fig. 38.†

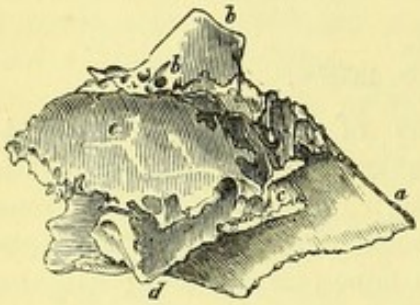

Sphenoidal or posterior aspect.—Presents no difficult or complex surfaces; the naso-maxillary is also of small extent, and merely shows structures already described.

The two Orbital or lateral aspects.—The compact plate of bone shelling in the surface on each side was called by the ancients the *os planum.* They were constantly mistaking parts of bones for distinct bones, and *vice versâ*, in consequence of their ignorance of embryology, and of the principles of true descriptive anatomy. The os planum of the ancients is the orbital plate of modern anatomists. It shuts in, but incompletely, the ethmoidal cells towards the orbits, leaving them open anteriorly and posteriorly, to be completed by other bones. Moreover, it forms the inner wall of the orbit. It is smooth and polished; articulated above with the frontal bone, anteriorly with the lachrymal; inferiorly with the superior maxillary and palate

* Fig. 37.—Ethmoid bone, lower surface.—*a*, vertical or perpendicular plate; *b*, points to the anterior ethmoidal cells; *c*, the rolled portion of the ethmoid, called usually the middle turbinated bone; *d*, superior turbinated bone; *e*, small portion of the pars plana, or orbitar plate.

† Fig. 38.—Ethmoid bone, profile, right side.—*a*, anterior edge; *d*, posterior edge of the perpendicular plate; *e*, pars plana, or orbitar plate; *b*, *b*, crista galli; *c*, lower and outer edge of the middle turbinated bone, or process.

bones; behind with the sphenoid. On the upper edge are low notches, and these concur in forming the internal orbitar foramina.

In structure the ethmoid is almost wholly composed of cells; it is extremely light and fragile, and hence can scarcely be shown in a perfect state. It assists in forming a portion of the base of the cranium, of the nostrils and orbits.

Sphenoidal Turbinated Bones. — These small, triangular-shaped bones were first described by Bertin. They always unite before the age of twenty with the sphenoid or ethmoid bones, or with both. They scarcely merit a minute separate description, although their importance in philosophic anatomy is of course admitted. The spheno-palatine foramen, which in young persons does not belong to the sphenoid bone, is bounded by these bones and by the palate bones. The apex of the bone is situated in a groove near the base of the pterygoid process.

OF THE SUPERNUMERARY BONES OF THE CRANIUM: *Ossa Wormiana.*

The nature of these bones is not yet understood. They are not confined to any particular suture, but occur most frequently in the lambdoidal. They vary exceedingly in size, situation, form, number, and other circumstances. These bones are generally of the same thickness as the other bones of the cranium, and are composed of an outer and inner table, and diplöe interposed. They unite with the other bones and with each other by denticulated edges.

In hydrocephalic crania the supernumerary bones are sometimes remarkably numerous: many specimens of this may be seen in the museums.

MINUTE ANATOMY AND OSSIFICATION OF THE BONES COMPOSING THE SKELETON OF THE HEAD.

CRANIAL BONES.

The osteology of the head must be viewed, like every other part of the body, in a variety of ways; for it is not enough to have studied the individual adult bones; their ossification must be understood, and their relation to each other when united together by their natural articulations. This can only be accomplished by a variety of sections and preparations.

Occipital Bone.—1. A rough surface external to the condyles, on the outer aspect of the bone, corresponds to the transverse processes of the vertebræ, and is in fact the transverse process of the occipital.

2. The condyles are not formed of single germs, but partly of two;

and this leaves a slight indented line across the condyle, observable even in the adult.

3. The basilar part of the bone is the body of this vertebra; it unites in the adult before with the body of the sphenoid. Hence many anatomists, as Meckel, have described the occipital and sphenoidal bones as one, under the name of spheno-occipital; and for this they have the same reason as descriptive anatomists have for describing the sacral vertebræ as one bone. It is sufficiently remarkable that the anterior and posterior terminations of the vertebral column should thus resemble each other in their early consolidation into a single bone. The sphenoid, ethmoid, and occipital, unite into one in the adult. The mesial parts of these bones correspond to the bodies of the vertebræ.

4. Internally, the grooves for the lateral sinuses vary much in different bones, and the groove on one side has been found exceedingly small or seemingly deficient. This indicates corresponding varieties in the calibre and arrangement of the lateral sinuses.

5. *Ossification of the occipital bone.* For some time before and after birth this bone is composed of four pieces: 1, the basilar portion; 2, the two lateral, or condyloid; 3, the posterior, occipital, proral, or squamous plate. These distinct germs or nuclei meet around the foramen magnum; this opening is simply the vertebral ring of the bone. But in the squamous plate there are also four separate nuclei or germs. I have seen many varieties in respect of these four germs or nuclei, especially as regards their growth and future consolidation into one.

PARIETAL BONES.—These bones present few varieties worthy of notice here. The crests already indicated are at times sufficiently remarkable. The history of these crests is to be explained only by comparative anatomy; they belong to zoological science.

Ossification.—By two germs, or nuclei, commencing in the parietal protuberances. In each, for some time after birth, the anterior and superior angles of these bones are not ossified; the space thus left unprotected by bone is called the *Bregma*, or *fontanelle*, and through it may be felt the pulsations of the brain.

Future researches may show that the parietal bones originate in four germs or nuclei; and this was Meckel's opinion. The superior germs would correspond to the interparietal bones of other animals.

FRONTAL BONE.—This bone presents numerous varieties in form; it constitutes the great intellectual feature of the head. Its ossification commences before that of the vertebræ, by two osseous points at the orbital arches. After a time the bone is found to be composed of two distinct bones; the vertical suture which afterwards unites them remains occasionally distinct for life.

TEMPORAL BONES.—If the mere descriptive anatomy of these bones

be, as we have already seen, confessedly difficult, their minute and philosophic anatomy is still more so. Much of it remains still to be determined. Their correspondence with vertebræ cannot be shown; the analogies are lost. They contain within them one of the organs of sense, the organ of hearing. The rocky part, *pars petrosa*, has a somewhat peculiar character, differing in density, at least, from mere bone; the external air passes deeply into the interior of these bones, and they contain within them a system of bones which, although distinct in man, is not so in some other animals.

Ossification.—This proceeds from several nuclei: 1, one for the zigoma; 2, one for the squamous plate; 3, a distinct and remarkable nucleus called the tympanic bone; 4, one for the petrous and mastoid portions; 5, the styloid process. Others exist within the bone for the ossicula auditus; and independent nuclei have been found in the mastoidian portion of the bone. The styloid process occasionally remains distinct throughout life. At birth the temporal bone is composed of three pieces. The temporal bones continue to undergo changes throughout the whole of life.

Sphenoid Bone.—Much importance is attached to this bone as a consequence of its complexity, the numerous relations it has with nerves of great physiological interest, and with the mesial parts of the brain itself. The latest researches * mark its history in the formation of the vertebral column as quite peculiar.

In the adult all the germs or nuclei originally composing this bone have united into one mass, and this mass with the occipital bone. This fact induced Meckel to describe both bones as one, under the name of the spheno-occipital bone. Sœmmering extends this view still farther, and considers the entire cranium as composed of a single cartilage originally, and therefore of a single bone ultimately; but, however philosophic these views may be, they do not affect the view we must take here; and adhering to the observations of others as well as of ourselves, we may thus describe the usual ossification of the bone.

The fleeting anatomy of the embryo and the more permanent arrangement in the lower adult animals, shows that there exists a period when the sphenoid is distinctly divided into two bones—an anterior sphenoid and a posterior; the tendency of the first in the lower animals is to unite with the ethmoid, of the second with the occipital.†

In the posterior, or spheno-occipital, section of the bone the first nuclei are deposited, one on each side the foramen rotundum; from this point it spreads into the great wings, and downwards into the external pterygoid process. The internal pterygoid processes are formed from distinct centres, and in many of the lower animals they form distinct bones, even in the adult.

In the body two nuclei appear beneath the sella turcica; they become

* Agassiz and Voght.

† I have seen some good veterinary anatomists baffled in comprehending this arrangement in the cranium of the horse.

one about the fourth month. During the whole term of fœtal life these germs, or parts just spoken of, remain distinct, with the exception of the internal pterygoid processes.

The germs composing the anterior sphenoid are, 1st, one near the optic foramen; 2ndly, an appearance of a central nucleus: the sphe-crest may also be considered as of independent formation.

The two sphenoids run together a little before birth; at this time the sphenoid consists of three large pieces, namely, the great wing and pterygoid process of each side; and 2nd, the body. Engravings to explain such facts seem unnecessary.

In describing the supernumerary bones of the cranium I shall advert more in detail to the remarkable series of bones occasionally found in the spheno-parietal and spheno-frontal sutures; and in the chapter on the Brain, the peculiarities of the sella turcica, and its relations to the peculiar structure it supports (the pituitary body), will also be alluded to; the history of the sphenoidal sinuses has been already considered with the ethmoid, frontal, and other cranial sinuses.

The ethmoid bone is at first composed of a solid cartilage. Between the fourth and fifth months bone begins to appear in the pars plana, and soon after in the spongy bones; but the vertical plate remains cartilaginous until after birth. At birth the ethmoid consists of two lateral masses; at last the cribriform and vertical plates ossify, and the bone becomes one. With years the bone enlarges; the cells unfold themselves, receiving within them prolongations of the mucous membrane of the nose.

SUPERNUMERARY BONES—*Ossa Triquetra.*

These supernumerary bones, also called the bones of Olaus Wormius, are found occasionally in the lambdoidal, sagittal, and coronal sutures; they occur also in the spheno-parietal. Their true nature is not understood, but it seems certain that they form by independent germs in the cartilage of the skull, uniting in time with the contiguous bones. They have serrated edges, which do not extend, however, to the inner table, and they are composed of two tables and a diplöe like other bones of the skull.

OF THE BONES OF THE FACE.

The skeleton of the face is divided into two regions; the upper and lower jaw. In the former there are eleven bones; in the latter, one.

BONES OF THE UPPER JAW.

Superior Maxillary Bones.—The anatomy of the superior maxillary

bones is the key to the anatomy of the face; they are two in number, symmetrical and somewhat complex. In each of these ought to be noticed, first, the more distinguishing characteristics: these are, 1, the frontal, or ascending process; 2, the orbitar; 3, the malar; 4, the alveolar; 5, the maxillary protuberance; 6, the alveoli; 7, the antrum maxillare, occupying the interior of the bone and the wide irregular opening leading to it from the cavity of the nostrils; 8, the infra-orbitar canal and opening; 9, the lachrymal groove; 10, lastly, the palatal arch or process. When these parts have been carefully examined and their extent, connexions, and uses considered, the student will find no difficulty in completing the history of the bone, it being always understood that as he reads the description a perfect specimen of the bone is in his hand.

Fig. 39.*

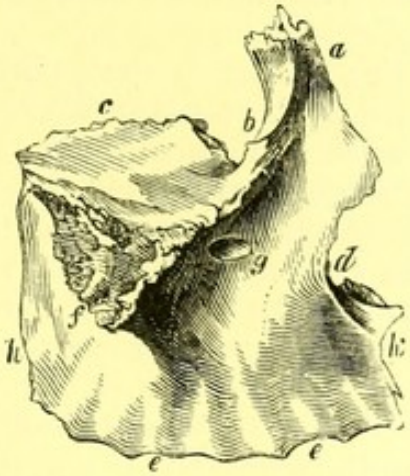

Fig. 40.†

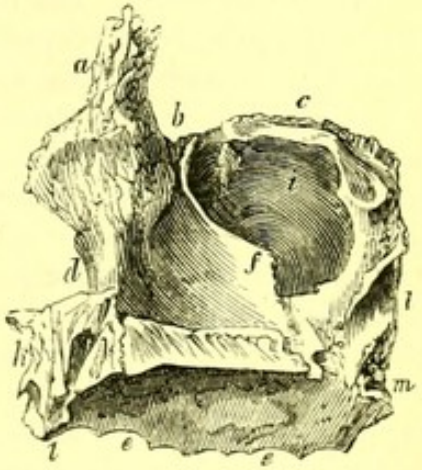

To hold the bone as if in its place in the head, turn the alveolar process downwards, the nasal spine and notch forwards, and the malar process outwards; the palatal process will then be horizontal.

Examined in detail the bone presents the following circumstances worthy of notice:—

Orbito-facial aspect.—The nasal process; also called frontal and ascending, of varying breadth in different individuals and races, and very strong. Above, this process articulates with the frontal bone, laterally with the corresponding nasal, posteriorly with the os unguis. To the anterior surface of this process several muscles are attached;

* Fig. 39.—Superior maxillary bone, right side, external surface.—*a*, frontal process; *b*, lachrymal groove; *c*, orbitar process, or plate; *d*, nasal notch; *e*, *e*, alveolar process and border; *f*, malar process; *g*, infra-orbitar foramen; *h*, maxillary tuberosity; *k*, nasal spine.

† Fig. 40.—Right maxillary bone, nasal or internal aspect.—*a*, frontal or ascending process; *b*, lachrymal groove; *c*, margin of the orbitar process; *d*, edge of the nostrils, incisura nasalis; *e*, *e*, alveolar border and process; *f*, edge of the antrum, to which the inferior turbinated bone is suspended; *i*, maxillary tuberosity; *k*, nasal spine, anterior palatine groove and foramen; *m*, rough surface with which the corresponding palate bone is articulated.

behind, it assists in forming the lachrymal groove. Vascular openings perforate this portion of the bone.

External to this process is the orbitar process—*facies orbitalis*, forming a part of the floor of the orbit. The channel seen on its upper surface at the back is soon changed into a canal which terminates below the orbit by the infra-orbitar opening. This groove and channel give passage to the infra-orbital vessels and nerves. As this canal proceeds forward it sends off a descending branch called the superior and anterior dentar canal in the anterior wall of the maxillary antrum; vessels and nerves having the same name descend in it. The inner edge of this facies orbitalis is articulated with the os unguis and pars plana of the ethmoid; quite at the back with the palate bone.

External to this is the processus malaris, articulated with the cheek bone. A sort of ridge extends from this process, dividing the surface of the bone into two: anteriorly the suborbitar fossa; posteriorly the maxillary tuberosity. The myrtiform fossa is an indistinct impression close to the suborbitar fossa.

Inner or naso-palatine aspect. — On this surface is the palatine process, dividing the nose from the mouth; it is shorter than the bone itself, leaving posteriorly a gap in the osseous palate filled up by a smaller palatal plate belonging to the palate bone. This process unites, by a very strong surface, with the corresponding process of the opposite maxillary, and anteriorly also by this union is formed the anterior palatine canal. The palatal process of the maxillary bone is rough below, where it forms the ceiling of the mouth; and smooth above, where it assists in forming the floor of the nostrils and of the inferior meatus; a little above this is a large irregular opening leading into the antrum maxillare, or maxillary sinus.

The orifice of the sinus is articulated above with the ethmoid; below and before with the inferior turbinated; behind with the palate bone; and by these bones and by the presence of the pituitary membrane, which passing in from the nostrils lines the sinus throughout, the aperture is much contracted in the fresh state. Behind the antrum is the uneven surface articulated with the palate bone and the groove contributing to form the posterior palatine canal.

The maxillary protuberance is more prominent in the young than in the old, in consequence of the presence of the wisdom tooth, lodged in the alveolar border of the bone. The posterior dentar canals are seen on this surface; nerves of the same name pass through them. The nasal spine has been already noticed. The alveolar process is strong, vascular, and composed of two plates, an outer and inner. Between these are the alveoli, or cavities for lodging the roots of the teeth. The uses of the antrum are unknown, nor has the true nature of the anterior palatine canal been fully made out. Vestiges of structure are seen here, the true nature of which neither human nor comparative anatomy as yet explains. What has been made out in respect of its osteology is this:—A comparatively large opening, by some called incisor, as being immediately behind the incisor teeth, leads to a short

canal, the anterior palatine canal. On looking into this canal, or rather fossa, four openings are observed, two at the sides and two mesially, one behind the other. Those at the sides are called the foramina of Steno; by some they are called incisor foramina. The mesial ones are placed in the suture, and are thus formed by both maxillary bones, or rather by the rudimentary intermaxillary bones which once existed here. Through these mesial apertures pass the naso-palatine nerves, described by Scarpa, the nerve of the right side by the posterior, and that of the left side by the anterior foramen.

OF THE PALATE BONES.

These bones, two in number, were long confounded by anatomists with the upper maxillary bones, of which they are, as it were, the complement. To place the bone in its natural position, and to determine to which side it belongs, observe that it is composed of three portions; 1, a pyramidal process; 2, a palatal, which is horizontal; and, 3, a vertical, upright portion of greater extent than the others. Place the palatal process horizontally, with the pyramidal portion backwards, and the smooth edge of the palatal process in the same direction; the rough and strong articular surface of the same process inwards to meet the corresponding part of the other palate bone.

Fig. 41.*

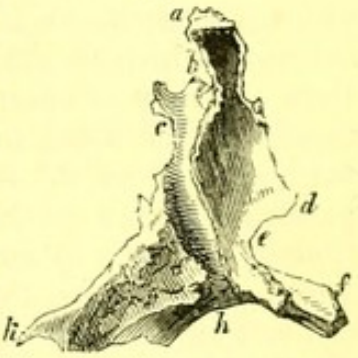

To facilitate the examination of a bone admitted to be extremely complex, it is usual to examine each of its great divisions separately.

Fig. 42.†

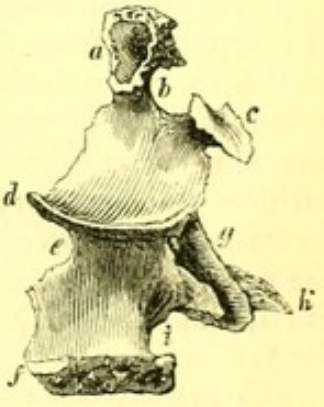

1. *Palatine or horizontal process.*—This looks like a continuation of the palatine process of the upper maxillary bone. Its upper surface, facing the nostrils, is smooth and concave; the lower surface (facing the mouth) is rough, but not so much so as the palatine process of the maxillary. On this surface is seen the inferior orifice of the posterior palatine canal; anteriorly the process articulates with the palatine process of the maxillary bone; internally with the opposite bone; posteriorly the edge is sharp but smooth, the pendulous palate is

* Fig. 41.—Palate bone of the right side, external aspect.—*a*, orbital process; *b*, pellicle and spheno-palatine foramen; *c*, sphenoidal process; *d*, anterior edge of the vertical portion of the bone; *e*, angle of junction with, *f*, the palatal process; *h*, *k*, the pyramidal process.

† Fig. 42.—Right palate bone, inner or nasal aspect.—*a*, orbital process; *b*, pedicle and spheno-palatine foramen; *c*, sphenoidal process; *d*, crista turbinalis inferior; *e*, the angle of junction between the vertical plate and the horizontal; *f*, palatal process, palatal edge; *i*, guttural edge of this process; *g*, *k*, pyramidal process marked by three grooves.

attached to it. This edge is called the guttural; the nasal spine is formed by the union of the two palatine plates.

Vertical or ascending portion.—Broad and thin. It rests on the upper maxillary bone. On its inner side are two concave surfaces separated by a crest; *crista turbinalis inferior.* Superiorly to this the bone contributes to form the middle meatus of the nostrils; below is the inferior meatus. A portion of the vertical plate lies over the orifice of the antrum, and assists in diminishing the extent of the orifice.

The pyramidal process fills up the notch or deficiency between the two plates of the pterygoid process inferiorly. Grooves may be observed on the bone where it unites with the sphenoid; one of the grooves completes the pterygoid fossa. The posterior palatine canals have been already mentioned.

Superiorly this vertical plate of the palate bone is surmounted by two eminences, the anterior of which is larger than the other. This anterior eminence is named the *orbitar process;* is supported by a pedicle or neck, on the inner side of which is the crista turbinalis superior, which is articulated with the ethmoidal turbinated bone. Here also may be observed a small channel belonging to the superior meatus of the nasal fossæ. The orbitar process presents five distinct surfaces. 1, an interior, articulated with the maxillary bone; 2, a posterior, united to the sphenoid bone; a small cell exists here continuous with the sphenoid sinus; 3, an outer smooth surface, forming a part of the zygomatic fossa; 4, an inner, frequently hollowed by a cell and united with the ethmoid bone; 5, an upper, forming the innermost part of the floor of the orbit, and contributing to form a part of the spheno-maxillary fissure.

The other eminence of this edge is called the *sphenoidal process.* It is separated from the orbitar by a notch, sometimes a foramen. This is the spheno-palatine notch or foramen, when completed by the sphenoid bone, in which is placed the spheno-palatine ganglion. The foramen is occasionally formed solely by the palatine. The spheno-turbinated bones very generally assist in converting the notch into a foramen. This process, the sphenoidal, enters into the composition of the nasal fossa; internally it assists in forming the pterygo-palatine canal, and externally it enters into the composition of the zygomatic fossa.

The articulations of this complex bone are numerous. With the sphenoid, the ethmoid, the upper maxillary, the opposite palate bones, the vomer, the lower turbinated, and sphenoidal turbinated bones.

OF THE MALAR OR CHEEK-BONES.

These bones, two in number, are easily understood; they are of a square form, and present an external, an internal, and upper aspect, and four ridges, with as many angles.

On the outer surface are several small holes, the malar; through these pass vessels and nerves; they lead to canals in the bone.

The upper aspect constitutes a part of the orbit; the posterior opening of one of the malar foramina is seen on it. Its edge, posteriorly, articulates with the frontal and sphenoid bones, and below with the upper maxillary bone; but there is a smooth rounded portion of this edge which assists in forming the spheno-maxillary fissure.

Fig. 43.*



The posterior aspect of the bone is concave; smooth behind, where it forms a part of the temporal fossa, but rough where it articulates, by a broad triangular surface, with the malar process of the upper maxillary bone. A small malar foramen may also be seen here.

Of the four edges, two are anterior and two posterior. The anterior surface of the bone is covered, to a certain extent, by the orbicularis palpebrarum, and the following muscles are attached to it: the zygomatic, major and minor, and masseter. Its articulations are with the frontal, temporal, sphenoid, and upper maxillary bones.

LACHRYMAL BONES.—*Ossa Unguis—Ossa Lachrymalia*—two in number, are the smallest bones of the face; they form a portion of the inner wall of the orbit, and assist in completing the nasal canal. One muscle is attached to each of them, namely, the tensor tarsi.

Fig. 44.† Fig. 45.‡

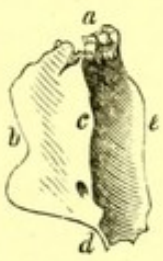



Each bone presents an external surface or orbital, and an internal or nasal.

A vertical ridge, occasionally not very distinct, divides the orbitar aspect into two unequal parts. That behind the ridge is smooth, and gives origin to the tensor tarsi muscle; that before the ridge is somewhat cribriform, and is hollowed out so as to assist in completing the osseous part of the lachrymal canal. The lachrymal sac is placed on this portion.

On the inner aspect a groove, corresponding to the ridge seen on its orbitar surface, in like manner divides the bone into two unequal parts, an anterior and a posterior. The anterior belongs to the middle meatus of the nasal fossa; this surface corresponds also with the anterior ethmoidal cells.

* Fig. 43.—Right malar bone, internal aspect.—*a*, frontal angle; *b*, orbitar process, or aspect; *c*, *c*, malar foramina; *d*, maxillary process; *h*, external edge; *f*, zygomatic angle and process, where it joins the zygomatic process of the temporal bone; *g*, posterior concave smooth surface; *e*, lower edge of the bone.

† Fig. 44.—Os unguis, or lachrymal bone, right side; orbitar or outer aspect.—*a*, upper margin; *b*, posterior margin; *c*, vertical ridge; *d*, inferior margin; *e*, anterior margin.

‡ Fig. 45.—Same bone, nasal, or inner aspect; *a*, *b*, *e*, *d*, designate the same margins as in the preceding figure. The position of the vertical groove may readily be recognised.

This bone, moreover, has four edges—an upper, lower, anterior, and posterior. By its upper edge the bone is articulated with the internal angular process of the frontal bone; by its lower edge, anteriorly with the lower turbinated bone; posteriorly, with the superior maxillary. The posterior edge is very thin: it articulates with the orbitar process of the ethmoid; the anterior articulates with the edge of the nasal process of the upper maxillary bone.

The lachrymal bone is extremely thin, translucent, and composed of compact tissue.

Of the Nasal Bones—*Ossa Nasi.*—Two in number, presenting each two surfaces, and four edges or margins. These bones are thick and strong superiorly, but much thinner inferiorly; they are articulated above with the frontal, internally with each other; externally with the ascending process of the superior maxillary bone; the inferior border has attached to it the lateral cartilage of the nose.

Fig. 46.*



A minute vascular foramen is seen upon the anterior surface of each; a branch of the nasal nerve passes immediately behind the posterior surface. The nasal spine of the frontal bone and the perpendicular plate of the ethmoid assist in supporting these bones. The internal nasal nerve passes through the notch in the inferior border of the bone.

The pyramidales and compressores nasi muscles are attached to them. In some races of men they are small and extremely narrow, superiorly.

The inferior Turbinated Bones.—These bones, two in number, are situated within the nostrils. Each is applied to the upper

Fig. 47.†



Fig. 48.‡



maxillary bone by its outer aspect, which is concave; they diminish the aperture leading into the maxillary antrum, which in the separate bone is large, but small when the turbinated bone is in its place. They also touch the lower crest of the palate bones, as if continuous with it.

* Fig. 46.—Nasal bone, right side, inner aspect.—*a*, superior, *b*, inferior, *c*, external, *d*, internal, borders.

† Fig. 47.—Inferior or true turbinated bone, right side, inner side, facing the nasal septum.—*a*, posterior angle; *b*, anterior; *c*, lachrymal process; *d*, maxillary and upper edge of the bone; *e*, inferior or turbinated edge of the bone.

‡ Fig. 48.—Right turbinated bone, maxillary or external aspect.—*a*, posterior; *b*, anterior angles of the bone; *c*, lachrymal process; *d*, maxillary; *e*, inferior margin; *g*, curved portion (hook-like process) of the maxillary process.

On the inner aspect they are convex and uneven. They have no foramina or canals for the olfactory nerves, but are marked by two grooves for other nerves. Anteriorly, its superior border articulates with the ascending process of the superior maxillary bone; next with the os unguis; and lastly, and posteriorly, with the palate bone. By means of a hooked process, it is articulated with the edge of the antrum. The lower edge is free, and slightly convoluted.

THE VOMER.

This is a single or azygous bone placed in the mesial plane of the head; it is so called from its resemblance to a ploughshare. It is placed vertically between the nasal fossæ, contributing to form a portion of the nasal septum. It presents two surfaces and four edges or borders. The surfaces are covered by the pituitary membrane. The borders or edges are, 1, the inferior or palatal, by which the bone rests on the mesial suture of the palatal processes of the upper maxillary and true palate bones.

Fig. 49.*



Fig. 50.†



2. The posterior or guttural; this is smooth and easily recognized.

3. The superior, which is thick and deeply grooved for receiving the rostrum of the sphenoid. The margins of this groove expand, and are articulated with two small lamellæ at the roots of the pterygoid processes of the sphenoid.

4. The anterior border is also grooved, and into this groove superiorly is inserted the descending or vertical plate of the ethmoid; lower down the cartilaginous septum of the nose.

INFERIOR MAXILLARY BONE—*Mandibula—Lower Jaw Bone.*

This is the thickest and strongest bone of the face. Its anatomy is comparatively simple; nevertheless, it merits the most careful study on the part of the student. Its position in the body cannot be mistaken.

The bone is essentially composed of a middle portion, the body and two branches, rami. The body is horizontal; the rami vertical.

* Fig. 49.—The vomer, in profile.—*a*, *b*, superior; *c*, anterior; *d*, inferior edges of the bone; *f*, lateral surface.

† Fig. 50.—Vomer, viewed from above.—*a*, *b*, upper surface grooved to receive the sphenoid crest; *c*, *d*, anterior margin of the bone.

Besides these are two surfaces, an external and internal; two margins or borders; a condyloid and coronoid process on either side; an incisura, or notch, separating these processes from each other; the symphysis or union of the two sides of the bone in the middle, where originally there existed a cartilaginous junction; four foramina, two on the external surface and two on the internal, leading to so many canals for vessels and nerves; lastly, the base, angles, and alveolar processes.

Fig. 51.*

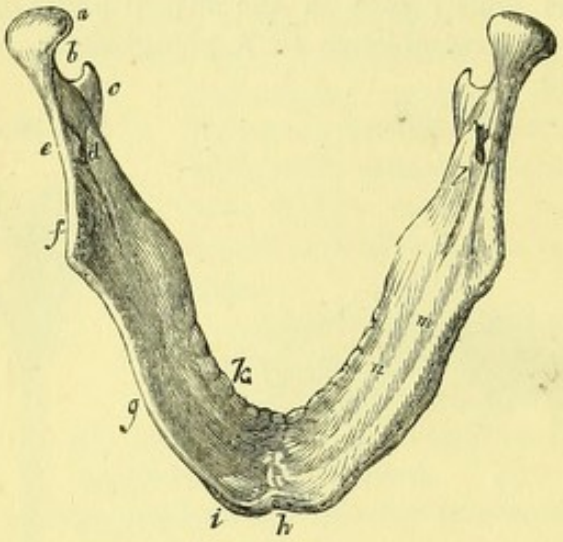

Examined in detail, the bone presents, besides the points already mentioned, others requiring notice. The condyles are obliquely transverse in respect of the rami; they are hollowed out on their inner surface, and to this depression is attached the external pterygoid muscle. Externally the condyle presents a small tubercle, to which is attached the lateral ligament of this joint. Beneath the condyle the bone is somewhat contracted, forming a sort of pedicle. From this the ramus extends downwards to the angle and base of the bone. The posterior edge of this ramus is called the parotid margin of the bone, from the proximity of the parotid gland to it. Anteriorly to the notch is the coronoid process, to which the tendon of the temporal muscle is attached: the masseter covers a great portion of the outer surface of the ramus, as far as the angle and the base; this surface is furrowed and irregular. On the inner side of the ramus may also be observed the foramen leading to a canal, in which are lodged the dentar vessels and nerves. This canal passes quite forward to the symphysis beneath the alveolar cavities, but it also communicates with the outer surface of the bone by openings called foramina menti.

The outer surface of the body is irregularly convex. Tracing it from the mesial line, called the symphysis, we find a superficial depression (incisor fossa), to which is attached the levator menti muscle. External to this is the *foramen mentale*, already spoken of; this

* Fig. 51.—Lower maxillary bone, viewed from below.—*a*, left condyle; *b*, incisura sigmoidea; *c*, left coronoid process; *e*, parotid margin; *f*, the angle; *d*, inner and posterior opening of the inferior dentar canal; *g*, the base, inferior margin; *h*, symphysis menti; *i*, the spines, called genoid, are a little above the letters *i* and *h*; *k*, the alveolar process; *n*, *m*, inner surface of the right side of the body of the bone; *l*, the posterior opening of the superior dentar canal of the right side.

foramen looks somewhat outwards; whilst farther on there is the external oblique line, extending from near the symphysis to the anterior border of the ramus. Before turning the bone to examine its deep surface, note the form of the base; its angle, and the smooth and sometimes slightly grooved part over which runs the facial artery; lastly the chin, called mentum—γενειον.

On the inner side or surface there is a hollow just within the symphysis, and four spines (*spinæ mentales*), more or less distinct, placed in pairs, one above the other. To the uppermost of these spines the genio-glossal muscles are attached, to the inferior pair the genio-hyoidei; beneath are two slight depressions for the digastric. The line running from within, outwards and upwards, is the internal oblique line dividing the surface of the bone into two parts. To this line or ridge, called also mylo-hyoidean, the mylo-hyoideus muscle is attached, which, with its fellow of the opposite side, are an important pair of muscles, inasmuch as they form the floor of the mouth. Above the line is a depression more or less hollowed out, for the sub-lingual gland, and below it a better marked depression for the sub-maxillary gland.

In the alveolar border are the alveoli, or cavities for containing the roots of the teeth; the exterior surface of this dentar edge is marked by notches and elevations corresponding to these alveoli, and to partitions separating them from each other.

In the adult the rami form nearly a right angle with the base; in infancy and extreme old age the angle is obtuse. Beneath the interior dentar foramen, seen on the inner side of the ramus, is a groove for lodging the mylo-hyoid nerve and accompanying artery and vein. The notch between the condyle and coronoid process is called the incisura sigmoidea.

The history of the bone cannot be completed until that of the teeth be also given, for these organs greatly influence by their presence and absence the form of the body of the bone. The alveolar process is very vascular. The muscles attached to it are—

To the coronoid process—the temporal.

To the neck or pedicle—the internal pterygoid.

To the outer surface of the ramus—the masseter.

To the inner surface of the ramus—the inner pterygoid.

To the inner oblique line—the mylo-hyoideus, the buccinator, and a small portion of the superior constrictor of the pharynx.

To the outer oblique line and adjoining surface—the depressor labii inferioris, depressor anguli oris, and a portion of the latissimus colli.

To the incisor fossa—the levator menti.

To the upper tubercles inside the symphysis—the genio-hyo-glossi.

To the lower tubercles—the genio-hyoidei.

To the depression beneath these tubercles—the digastric.

When the teeth are lost, and in extreme old age, the alveolar process disappears.

BONES OF THE FACE—MINUTE ANATOMY AND OSSIFICATION.

SUPERIOR MAXILLARY BONE.

Ossification and Peculiarities.—Few bones in respect of their ossification have excited more interest than the superior maxillary; but the inquiry is not as yet satisfactorily terminated. The following facts seem to have been tolerably well made out. As regards their ossification and the number of germs or nuclei which compose the bone ultimately, there are, 1, a palatal nucleus or germ; 2, an orbitar and malar, or at least a division is seen in this direction; 3, a nasal and facial; 4, an incisor. This latter germ is the most remarkable; it involves a question agitated for ages—the question, namely, whether or not, in accordance with the law of unity of the organization, man has intermaxillary bones as an embryo at least. All the facts and reasonings of philosophic anatomy are in favour of the opinion that the fissures seen in the young bone on either side of the incisor canal of the palate, mark the presence of germs which were once distinct, and which therefore correspond strictly, however small, to the intermaxillary bones of the lower animals.

The superior maxillary bones present many varieties, individual, and of race.

The Malar Bones.—Remarkable for the varieties they present in different races of men, their ossification need not, however, detain us; a single ossific point suffices for each.

Nasal Bones.—Their history in the different races of men is still to write. Their development is from a single germ or osseous centre.

Lachrymal Bones (*Ossa Unguis*).—*Ossification.*—From a single osseous centre. These bones, though small, give attachment to a distinct muscle first described by De Verney; the tensor tarsi.

Palate Bones.—*Ossification.*—From a single centre, at the angle of union of the different parts of the bone. The adult bones merit a careful study, separately and *in situ.*

The Vomer.—In this bone ossification proceeds by two laminæ or plates, which unite inferiorly. The adult bone presents numerous varieties in direction and form; these have an influence over the nasal cavities.

Inferior Turbinated Bones.—Ossification proceeds from a single point. To the anterior extremity of this bone is attached a small cartilage, which, though vestigiary, is of remarkable import in

the history of the nasal cavities; we shall return to it when describing the organs of the senses.

INFERIOR MAXILLARY BONE.—Varies much in form, as well in individuals as in races of men. Its ossification has been found, contrary to the expectations of comparative anatomists, remarkably simple, that is, in so far as it has been made out; it is the earliest of all the bones in ossifying, excepting the collar-bone. At the time of birth it consists of two equal lateral parts, united together mesially by a cartilage; this afterwards ossifies: thus two osseous points or centres are alone admitted; but the correctness of this view is extremely questionable.

In consequence of the presence of the teeth this bone, like the superior maxillary, undergoes many changes in form throughout life. The alveolar portion disappears, is absorbed, or rather ceases to be nourished, and the teeth fall out, no longer supported by an alveolar cavity; or if a tooth be extracted prematurely, the alveolar cavity disappears, and thus the depth of the jaw greatly diminishes. The rami also in old age change their direction as regards the body of the bone; and the very aged and very young bones come at last to resemble each other.

HYOID BONES.—The hyoid bones have been deeply studied by the philosophic anatomist; they vary but little in different persons; they are formed originally, and really consist, of different bones; their philosophic anatomy would be misplaced here. It is generally admitted that they represent, and are in fact the homologues of a portion at least of the branchial arches of fishes; this is borne out by the anatomy of the human embryo.

For other peculiarities in respect of the bones of the cranium and face, the student is referred to the section on the sutures, and to that on the skeleton of the head, viewed as a segment of the skeleton, and a continuation of the vertebral column.

THE CRANIUM IN GENERAL.

OF THE CONFORMATION OF THE CRANIUM.

Outer surface of the Cranium.—Viewed from without, the cranium in general presents the form of a pretty regular ovoid, of which the small extremity is anterior, and, in the adult, commonly bears the same proportion to the large extremity as thirty to thirty-one; it is flattened on the sides in the region of the temples, and below, towards its base; over the rest of it it is convex. Its whole outer surface is pretty smooth at the upper part, but below it is uneven, and perforated with a great number of holes. It is also observed that on the outside the skull is always more symmetrical than on the inside.

It is more particularly on the outside that the mode of junction of the bones of the cranium may be observed, where they form lines, more or less irregular, to which the name of *sutures* is given, these lines being much less distinct on the inside of the skull, where they merely present the form of superficial marks without indentation, at least in adults. When they exist between bones of no great thickness, they penetrate directly into the cranium; but when the contrary is the

Fig. 52.*

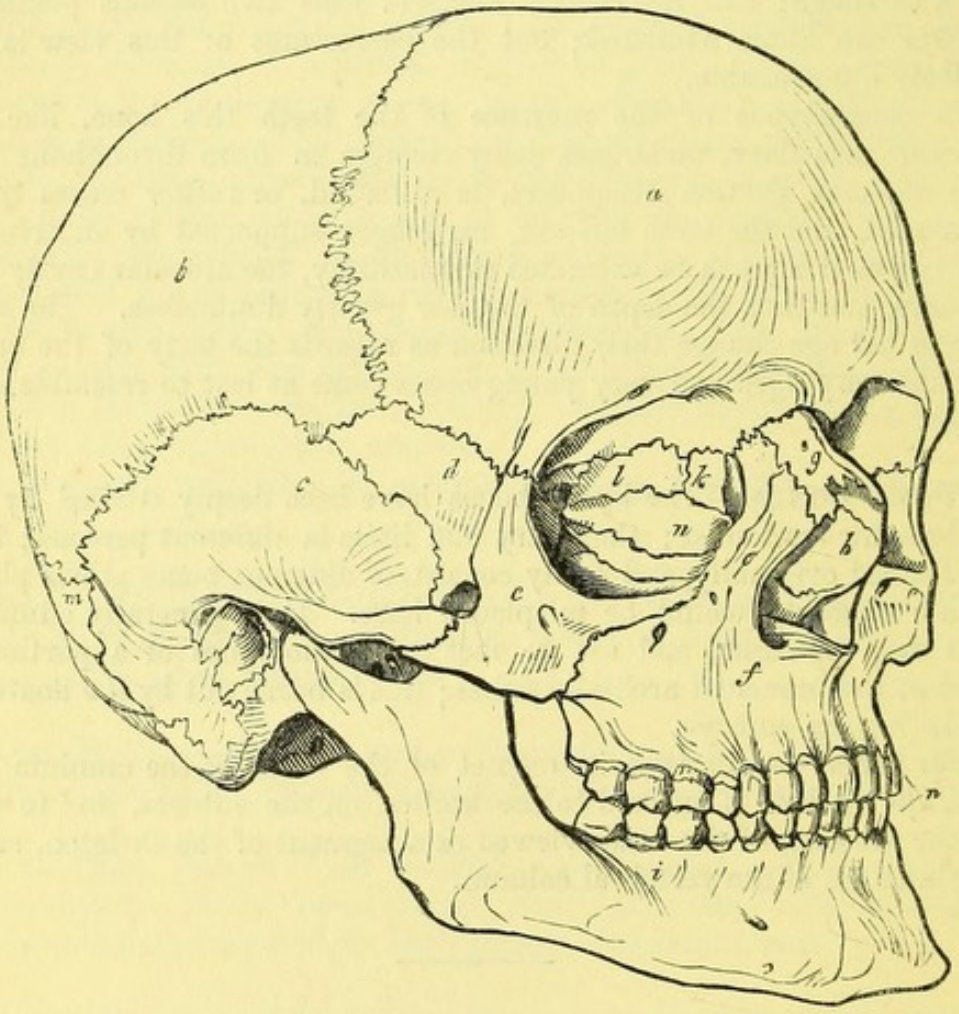

case they follow an oblique direction, the edges of the bones being then shaped in such a manner as to overlap each other. All these sutures seem to proceed from various points of the circumference of the sphenoid bone.

Thus, from the anterior of that bone may be seen, proceeding to the right and to the left, a curved line, concave anteriorly, which results internally from the junction of the sphenoid bone with the ethmoid,

* Fig. 52.—Bones of the cranium and face.—*a*, frontal bone; *b*, parietal; *c*, temporal; *d*, sphenoidal; *e*, malar; *f*, superior maxillary; *g*, nasal; *h*, septum, vertical plate of the ethmoid; *i*, lower jaw bone; *k*, lachrymal bone; *l*, pars plana of the ethmoid; *m*, supernumerary bone; *n*, incisor teeth.

and with the sphenoidal turbinated bones, and externally from the articulation of the first of these bones with the frontal. It traverses the upper wall of the orbit, and when it has arrived at the external orbital process of the frontal bone, it directs itself backwards, towards the anterior and inferior angle of the parietal bone. It there presents more distinct dentations, and a greater thickness than in the rest of its extent, where the edges of the bones of which it is formed are extremely thin, and are merely placed together, without interlocking by means of denticulations. This is the sphenoidal suture (*sutura sphenoidalis*).

Behind the sphenoid bone there is another transverse suture, which is short, and disappears with age; it is formed by that bone itself, and the basilar process of the occipital bone; it is named the basilar suture (*sutura basilaris*). So long as it exists, it is filled up by a cartilaginous plate lying between the bones.

On its lateral parts the sphenoid bone is limited by a curved line, concave posteriorly, arising from the junction of that bone with the squamous portion of the temporal: this is the spheno-temporal suture (*sutura spheno-temporalis*). It presents denticulations, although the surfaces of which it is formed are cut very obliquely; it terminates below, towards the glenoid fissure, forming an acute angle with another suture named the petro-sphenoidal (*sutura petro-sphenoidalis*), which is produced by the anterior edge of the petrous process, and the posterior edge of the sphenoid bone; and it unites above with the sphenoidal suture by a short longitudinal line, slightly curved, which results from the junction of the extremity of the great wings of the sphenoid bone with the anterior and inferior angles of the parietal bone; this may be named the spheno-parietal suture (*sutura spheno-parietalis*).*

From the anterior angle of the latter proceeds the fronto-parietal or coronal suture (*sutura coronalis*), which cuts the upper part of the cranium almost vertically, and terminates at the corresponding point of the other side. It points out the separation of the frontal and two parietal bones, and is so disposed that the former of these bones rests upon each parietal bone superiorly, while it supports them below. It presents denticulations at its upper part, which, however, are not very distinct, and it is but rare that Wormian bones occur in it, which is also the case with the sutures already mentioned.

From the opposite angle there arises the squamous suture (*sutura squamosa*), which describes about a third of the circumference of a circle proceeding backwards and downwards. It separates the temporal bone from the lower edge of the parietal, and is formed by an overlapping of these bones, the latter sustaining the other, which frequently projects outwards. A little before it terminates it changes its direction, forming an obtuse and retiring angle, and proceeds backwards to meet the occipital bone. The last mentioned part of the suture is not squamous; it results from the junction of the posterior and inferior

* In some crania this suture is not present; but this conformation is not peculiar to any particular race of men.

angle of the parietal bone with the mastoid portion of the temporal. It is always formed by very irregular and very distinct indentations, and almost always contains supernumerary bones, which are not often met with in the squamous portion, properly so called.

From each extremity of the basilar suture there is seen arising a line which separates the petrous process of the temporal bone, and the side of the basilar process of the occipital, and afterwards the latter bone from the temporal. From being at first concave, and directed outwards, and forwards, this line becomes afterwards straight, and proceeds directly backwards when it has arrived at the middle part of each condyle of the occipital bone. The first point of this line is named the petro-occipital suture (*sutura petro-occipitalis*), while the name of mastoid suture (*sutura mastoidea*) is applied to the second portion, which slightly arises to meet the extremity of the squamous suture, and which, in general, presents neither distinct indentations nor supernumerary bones.

The petro-occipital suture is a true groove, deep, and pretty wide, in which the bones are not in immediate contact, but present an intervening thin layer of cartilage.

From the angle formed by the union of the mastoid and squamous sutures, there arises another suture, with very distinct denticulations, which separates the occipital from the parietal bones, and which is named the occipito-parietal, or lambdoid suture (*sutura lambdoidalis*). It ends at the corresponding point of the opposite side, and gives rise, in its middle part, to an acute angle projecting forwards so as to form the two sides of a triangle, having its base directed downwards. In general there are numerous Wormian bones in this suture; and of all the sutures of the cranium this has its denticulations most distinctly marked.

Another longitudinal suture, which separates the two parietal bones, and is named the sagittal (*sutura sagittalis*), arises from the angle formed by the last described; it presents distinct indentations, and is sometimes traversed posteriorly by the parietal hole. It falls upon the middle of the coronal suture, and is then continued, sometimes in adults and always in children, into another longitudinal suture, which divides the frontal bone into two equal parts. A large Wormian bone of a quadrilateral form frequently occupies the place of this union.

The last-mentioned suture, designated by the name of the median or frontal (*sutura frontalis*), is generally indistinct, and occurs much more frequently in children than in adults: it ends at the nasal spine of the frontal bone, when it is continued on each side into a line formed by the ethmoidal notch of that bone as it joins the ethmoid, and which afterwards terminates at a right angle in the sphenoidal suture, under the name of ethmoidal suture (*sutura ethmoidalis*); it is in it that the internal orbitar foramina occur.

The sutures, which as we have said are formed by the mutual connexion of the bones of the cranium, present considerable varieties. In some the sutures are partially obliterated, and in a few they all but

disappear; this indeed is their natural tendency as age progresses. The supernumerary bones in the lambdoidal suture present many varieties.

The *outer surface* of the cranium may be conveniently, though not rigorously, divided into four regions, namely, upper, lower, and right and left lateral.

Upper region.—Extending from the nasal spine to the external occipital protuberance, and laterally to the curved line of the frontal and parietal bones. In this region we have anteriorly the proper frontal suture, or a slight crest resulting from its union; the frontal protuberances; the proper parietal suture; the parietal foramina and protuberances; the crest of the frontal and parietal bones; the upper angle of the occipital, and the comparatively smooth part of the bone itself, extending as far as the external occipital protuberance and the superior curved lines. The occipito-frontalis muscle, and its tendinous expansion, covers nearly the whole of this region, which besides is smooth, though in some marked by indentations which seem congenital. The more remarkable of these is the overlapping of the frontal and parietal bones, and a general broad depression extending quite across the cranium, and situated towards the anterior part of the parietal bones. These varieties in form have been mistaken by practical men* for accidental deformities, or the result of accidents; but they are congenital, innate, and obey certain laws which philosophic anatomy alone explains.

Inferior region.—Free posteriorly, but being articulated with the bones of the face, it is seldom or ever seen by the student, and from the preparations shown the student in Britain, as "*the base of the cranium*," I have sometimes thought that English practitioners may never have seen "the base of the cranium." To prepare it, remove from the nearly adult cranium all the bones of the face, leaving the bones of the skull properly so called. When this is done the following parts come into view:—The region extends longitudinally from the nasal notch to the external occipital protuberance, and may be considered as limited above by an undulating line extending from that prominence forwards, to the external angular process. The objects comprised in this region are very numerous; but they have been distinctly enumerated in the description of the occipital, sphenoidal, ethmoidal, and temporal bones, with the exception of certain foramina completed by the apposition of two or more bones. Commencing at the occipital protuberance there are, 1, on either side, the upper curved line, the vertical crest, and the lower curved lines follow; the impressions between them for the complexus splenius and recti muscles, and superior oblique muscles of the head; next, the great foramen medullare and condyles; the transverse crest or process for the attachment of the rectus capitis lateralis; the jugular and mastoid processes; the groove of the same name; the foramen stylo-mastoideum, and anterior and posterior condyloid foramina; 3, the basilar surface follows, with its inequalities for the attachment of the recti-capitis antici majores et

* Foville.

minores; anteriorly in the young the so-called basilar suture; laterally, the petro-occipital suture, terminated behind by the fossa juglandica, formed by the occipital and temporal bones. This cavity lodges the bulb of the jugular vein, that is to say, its commencement; for here the lateral sinus terminates and the internal jugular vein commences. The foramen by which the vessel passes through is generally largest on the right side, but occasionally on the left; seldom quite equal; and I think I have seen it once absent, or nearly so, on the left side. It measures the calibre of the vessel which is to pass through it, also the size of the grooves for lodging the lateral sinuses within the cranium. The rectus capitis lateralis is immediately behind the bulb of the vein, and separates it from the vertebral artery of that side. The fossa in fact terminates superiorly in the foramen lacerum posterius, of which it forms, as it were, a part. Through this foramen then, which is in fact the suture, pass the lateral sinus posteriorly; anteriorly the eighth pair of cerebral nerves; a partition, partly osseous, divides the anterior portion of the foramen from the posterior. In the base of the skull, anteriorly to the foramen just described, is another, of little or no importance; it is the foramen lacerum medium, filled up with cartilage in the recent state.

Laterally and from behind forwards there are, next, the lower orifices of the carotid canal, the styloid and vaginal processes, the sphenoidal spine, the glenoid cavity of the temporal bone, the transverse root of the zygomatic process; lastly, the spinous and oval foramina.

Anteriorly and mesially the sphenoidal crest; the grooves for the wings of the vomer. Outwards are the pterygoid processes and the posterior orifices of the vidian canal, the scaphoid depression, the pterygoid fossa, the bifurcation, and the hamular process of these pterygoid plates or processes.

Anterior to these may be seen the anterior orifice of the vidian canal, the foramen rotundum, and the openings leading into the sphenoidal sinuses, the sphenoidal turbinated bones, and their junction with the ethmoid. The perpendicular plate of the ethmoid bone comes next; laterally the deep fissures between this plate and the lateral masses of the ethmoid, and in the bottom of these fissures the foramina of the cribriform plate of the ethmoid bone. Anteriorly, the vertical plate of the ethmoid touches the nasal spine of the frontal bone; laterally are, the anterior angular processes of the frontal, and the orifices leading into the anterior ethmoidal cells and frontal sinuses.

The orbital vaults of the frontal bones (and *foramina optica*) may be included in this view, as they look forwards and downwards, and complete the basis of the cranium anteriorly, as a part distinct from the face.

But the objects also, seen on the inferior surface of the orbitar plates of the frontal, and those found on the pars plana of the ethmoid, might be enumerated here if necessary; for they also are seen on the basis of the cranium.

The *lateral regions* require no minute description here, still they

ought to be attended to by the student, in order that nothing may escape him in his view of this important osseous cavity. These regions may be viewed as extending from the external angular process of the frontal bone to the lambdoidal suture; and, vertically, from the crest of the parietal to the base of the zygomatic process. Each may be divided into two portions; the anterior forms the temporal fossa; the posterior includes the mastoid process and mastoidian portion of the temporal.

INNER SURFACE OF THE CRANIUM.—To display this surface the cranium must be divided with a saw, removing the skull-cap, as is usual when it is intended to remove the brain.

It is invested throughout by the dura mater. I speak of it here as an osseous cavity, divested of all soft structures.

The cavity of the cranium is continuous inferiorly with the vertebral canal; it presents but one surface naturally; divided with a saw, horizontally it presents two for description, namely, the vault and the base.

On the inner surface of the vault of the cranium are found numerous cerebral depressions; a groove for the superior longitudinal sinus; the irregular cavities for lodging the glands of Pacchioni and the inner orifices of the foramina parietalia; grooves for branches of the meningeal arteries; and the parietal foveæ.

The base requires especial study. It is divided as it were into three distinct cavities or surfaces on either side, and a mesial portion. These planes or surfaces are limited by the wings of Ingrassias and petrous portions of the temporal, and by the walls of the cranium. On the anterior plane rest the anterior lobes of the brain; in the middle cavities the middle lobes; whilst in the still deeper cavities behind are contained the hemispheres of the cerebellum. On the surface of the first or anterior plane may be observed, proceeding from before backwards, and in succession, the foramen cæcum of Morgagni, the union of the frontal and ethmoidal bones, the crista galli, the olfactory grooves and cribriform plate, the orbito-sphenoidal suture, and the deep or internal orifices of the internal orbitar foramina.

Next come the smaller wings of the sphenoid, the optic foramina, and the anterior clinoid processes.

In the second plane are, the *sella turcica*, the posterior clinoid processes, and the cavities corresponding to the cavernous sinuses and the orifices of the carotid canal. Laterally a concave surface of some extent, extending from the sphenoidal fissure to the upper edge of the pars petrosa; and besides sutures, the sphenoidal fissures, the foramina rotunda, ovalia and spinosa, and the hiatus of Fallopius, on each side; mamillary eminences, and the foramen lacerum medium; lastly, arterial furrows, as on the adjoining bones.

In the third plane we have the foramen magnum occipitale, the basilar groove and suture, the grooves laterally for lodging the inferior petrous sinuses, the occipital ridges and grooves for the superior longi-

tudinal and transverse sinuses, the anterior and posterior condyloid foramina; lastly, the foramen lacerum posterius. The sutures seen here have been already described.

Fig. 53.*

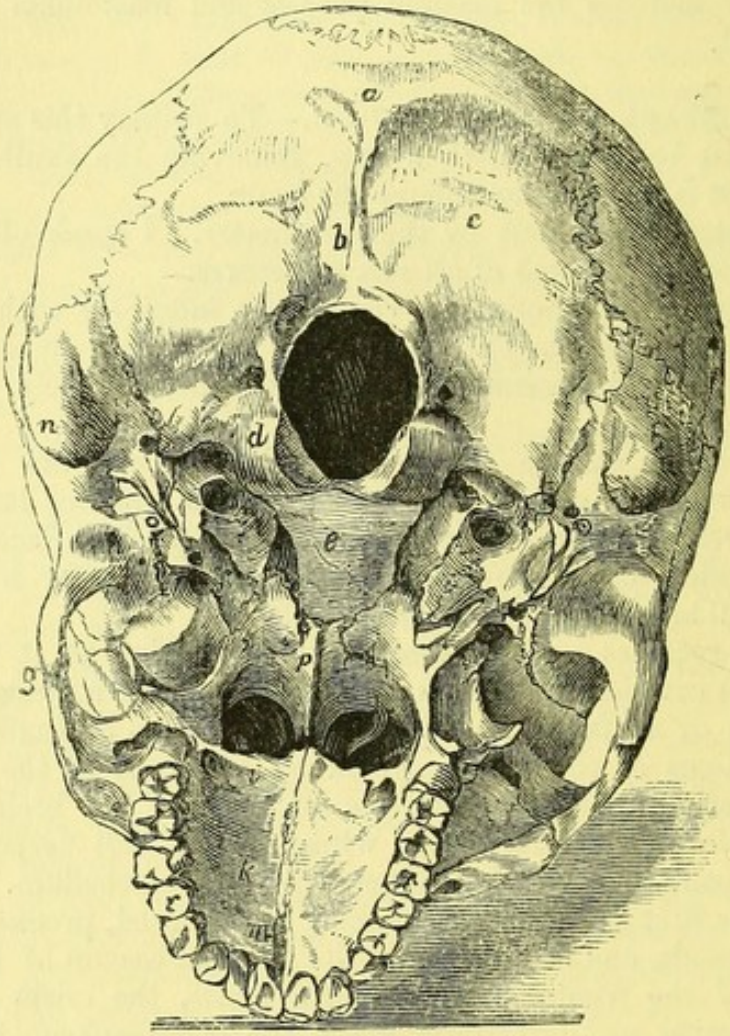

These planes, forming the basis of the cranium on its inner side, present a very different appearance when the dura mater and its various processes are present. The foramina of exit for the nerves seem much closer to each other, and the middle plane is extended quite to the transverse ridges of the occipital bone by the *tentorium cerebello super extensum.*

* Fig. 53.—Base of the skull, with the bones of the upper jaw *in situ.*—*a*, external occipital protuberance; *b*, external vertical crest of the occipital bone; *c*, inferior curved line of this bone, left side; *d*, left condyle of the occipital bone; *e*, basilar process of the occipital; *f* is placed on the roots of the pterygoid processes; *g*, zygomatic arch; *h*, glenoid cavity of the temporal bone; *i*, palatal processes of the palate bones; *k*, palatal processes of the maxillary bones; *l*, inferior opening of the posterior palatine canal; *m*, anterior palatine canal and foramen incisivum; *n*, mastoid process; *o*, styloid process of the temporal bone.

DIMENSIONS OF THE CRANIUM.

The capacity of the cranium varies in almost every individual and race. It measures pretty accurately the size, weight, and form of the brain, not merely in man, but in most mammals. Certain cetacea we shall find form a remarkable exception to this.

Fig. 54.*

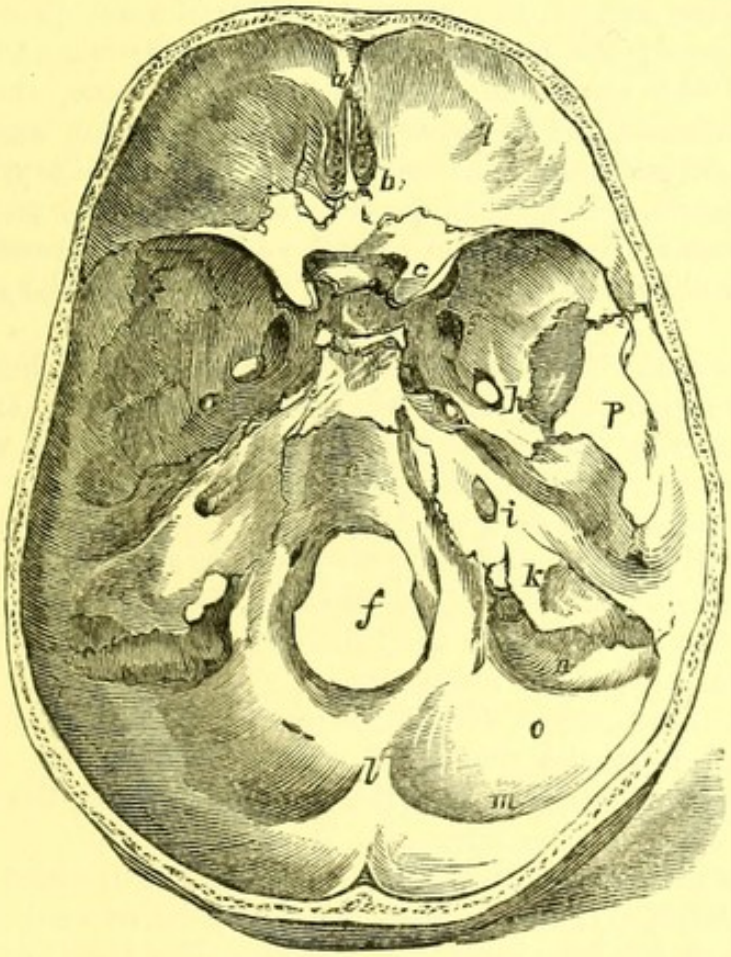

The diameters usually spoken of are the longitudinal, transverse, and vertical. The female head or cranium is usually narrower in front, and less elevated than in the male head; it is also less capacious.

In some married women, osseous deposits form on the inner surface of the frontal bone; these are no doubt pathological, yet the sympathies of the frontal bone with the organs of generation are sufficiently re-

* Fig. 54.—Base of the skull viewed from within.—*a*, crista galli; *b*, cribriform plate; *c*, anterior clinoid process; *d*, sella turcica; *e*, basilar process; *f*, foramen magnum; *g*, foramen rotundum; *h*, foramen ovale; *i*, foramen auditorium internum; *k*, points to the foramen lacerum posterius; *l*, internal occipital protuberance; *m*, groove for the right lateral sinus; *n*, mastoidian portion of the same groove; *o*, inferior occipital fovea; *p*, inner surface of the temporal bone.

markable. The vitreous table then has its sympathies; its relations to the vascular surface or layer of the dura mater are most intimate; in very young children the membrane can scarcely be torn from the bone.

OF THE FACE IN GENERAL.

With anatomists the face extends anteriorly from the upper edge of the nasal bones to the symphysis of the chin. Anteriorly and mesially there are, 1, the nasal bones and nasal processes of the maxillary bones; the proper nasal suture is mesial. Laterally, the openings of the orbits, the prominent cheek bones, the suborbitar fossa and foramen, and the canina fossa. Under the nasal bones are seen the anterior nares, the nasal spine, the maxillary suture, and alveolar process. Next the aperture of the mouth, and the teeth; the symphysis of the chin and mental eminence and mental foramina; the external oblique line, and a portion of the base of the jaw.

Posterior or Guttural Region.—This region extends from the parotidean margin of one jaw to the other transversely, and vertically from the posterior nasal spine to the upper edge of the vomer. The objects most worthy attention here are in the middle, the posterior edge of the vomer and its articulation with the palate bones and sphenoid; laterally, and on each side, the posterior aperture of the nostrils; *apertura narium posterior*. The upper portion of the pterygo-palatine canal may also be seen here; the tuberosity of the palate bone; lastly, the parotideal edge of the lower jaw.

Although these osseous structures seem to be so deeply placed as to remove them from the sphere of medical observation and surgical operation, experience shows that this is far from being the case.

Inferior or Palatine Region.—In this region, which in the skeleton is open inferiorly, there occur, 1st, The palatine vault, the composition of which has been already explained. The vault, or roof of the mouth as it has been correctly called in common language, extends longitudinally from the posterior nasal spine, and posterior edge or margin of the palatal processes of the true palate bones (to which is attached the pendulous palate), to the anterior palatine canal. Looking into this orifice, four apertures may usually be seen. According to some, the foramina incisiva are two small apertures, existing in the posterior lip of the anterior part of the alveolar process, in front of the anterior palatine canal. They seem to be merely short vascular canals, opening into the alveoli of the incisive teeth.

The vertical portion of this region is bounded by the inner surface of the alveolar processes, by the teeth, and by the inner surface of the inferior maxilla. The lower orifices of the posterior palatine canals may readily be made out on the vault; so also the posterior orifices of the inferior dentar canal. The genial or genioid processes on the inner

side of the symphysis menti; the mylohyoidian line; the fossæ for the sublingual and submaxillary glands, &c.

LATERAL OR ZYGOMATIC REGIONS. — Each of these regions has been divided into an external and internal; the latter can only be examined by removing the ramus of the lower jaw-bone. The surface called the maxillary tuberosity forms the greater part of this region. Above the tuberosity is the pterygo-maxillary fissure; behind the fissure is a vertical suture; in this suture is the upper orifice of the posterior palatine canal. The large oblique surface still higher up forms a part of the orbit.

DIMENSIONS OF THE FACE.—By placing before him at one and the same time the skeleton of the face, apart from the cranium, the student will readily remark the superior size of the latter over the former. The subject has more of a physiological and psychological interest than an anatomical one, and need not be pursued farther in this work.

OF THE HEAD IN GENERAL.

The skeleton of the head, when entire, presents several circumstances resulting from a union of parts, which, although already described in detail, present other views when combined.

OF THE ORBITS.

The orbits (*orbitæ*), which are situated on each side, and in the upper part of the anterior region of the head, and are perfectly similar to each other, have the form of a pyramid with the base turned forwards, but whose axis, being directed obliquely inwards, causes the summit to incline in that direction. Their walls represent four triangular surfaces, which unite so as to form laterally retiring angles.

The *upper wall*, or vault of the orbit, is slightly inclined backwards; it is concave, and formed anteriorly by the frontal bone, posteriorly by the process of Ingrassias. Near its summit, and to the inside, it presents the optic hole, which is directed obliquely backwards and inwards, so that, were its axis prolonged, it would intersect the one on the other side at the pituitary fossa. Before, it is a portion of the sphenoidal suture of the cranium; and altogether, anteriorly, there are observed, to the outside, the small fossa which lodges the lachrymal gland; and internally, the inequalities to which the cartilaginous pulley of the obliquus superior muscle of the eye is attached.

The *lower wall*, or the floor of the orbit, is nearly plain, and inclined outwards and downwards. It is formed at its fore part by the cheek-bone; in the middle by the orbitar surface of the upper maxillary bone; posteriorly and inwards by one of the small surfaces of the

anterior process of the upper edge of the palate bone; and it is intersected, at the point where these three bones meet, by two sutures, whose denticulations are not very distinct, and of which the posterior is of very small extent. At its posterior and external part is seen the infra-orbitar groove, to which succeeds the canal of the same name.

The *outer wall* is plain, and is formed, in two posterior thirds, by the sphenoid bone, and in the anterior third by the malar. A vertical suture, with large serratures, marks the place where these two bones unite; and at its fore part are observed the internal orifices of the malar holes.

The *inner wall* is of much smaller extent than the others; it is smooth, and perfectly plain. Three bones enter into its composition—the lachrymal before, the ethmoid in the middle, and the sphenoid behind. Two vertical sutures result from the juxta-position of these bones, and present themselves under the appearance of two slightly uneven and very narrow slits.

The *upper wall*, in uniting with the inner and outer, forms two retiring angles. The first of these angles contains, anteriorly, the suture which results from the articulation of the frontal and lachrymal bones, and a little behind this the ethmoidal suture of the cranium, in which are seen the internal orbitar foramina, to the number of two or three. The second presents, posteriorly, the sphenoidal fissure; in the middle, a part of the sphenoidal suture of the cranium; and, anteriorly, the articulation of the frontal to the malar bone.

The *lower wall* also forms two retiring angles where it joins the inner and outer walls. The first presents the suture which results from the articulation of the upper maxillary and palate bones to the lachrymal and ethmoid. The second is perforated posteriorly by the spheno-maxillary or inferior orbitar fissure. This fissure is formed at its upper part by the sphenoid bone, below by the upper maxillary bone, anteriorly by the malar bone, and posteriorly by the palate bone. It is less wide in the middle than at its extremities, is closed up by fat in the recent state, and gives passage merely to a few vascular and nervous ramifications.

The circumference of the orbit, or its base, is irregularly quadrilateral, wider externally than internally, directed obliquely downwards and outwards, and presents, at its upper part, the orbitar arch and superciliary hole; and at its lower, the articulation of the malar tuberosity with the cheek bone. It presents externally a short denticulated suture, formed by the cheek bone and the external orbitar process of the frontal bone; and internally the lachrymal groove, formed by the os unguis and the nasal process of the upper maxillary bone, and consequently divided into two portions by a longitudinal suture. This groove, which lodges the lachrymal sac, terminates below in the nasal canal. The circumference of the orbit gives attachment particularly to the orbicularis palpebrarum.

The axis of the orbit, which forms a slight angle with that of the

optic foramen, is however, like it, placed so obliquely that it would meet posteriorly that of the opposite side, but at a point behind the intersection of the axis of the optic foramina. The inner wall alone proceeds directly backwards, parallel to that of the other orbit. The three others are inclined.

From what has been said, it is seen that the bones which enter into the composition of the orbit are, the sphenoid, ethmoid, frontal, upper maxillary, palatine, lachrymal, and malar bones.

OF THE NASAL FOSSÆ—*Cavum nasi ; nares internæ.*

These cavities are of an angular form, which however is nearly that of a parallelopiped; they are broader below than above, but longer in the latter direction, higher in the middle than before and behind, and present several appendages, which are formed by the different sinuses that exist in the bones of the head, and of which we have already spoken. They are not exactly similar, the right to the left; they are separated from each other by an intermediate septum (*septum narium*), formed by the perpendicular plate of the ethmoid bone above and the vomer below, and at the back part, and occupy the space situated beneath the anterior part of the bone of the cranium, above the mouth, between the orbits, the canine, temporal, and zygomatic fossæ, and before the guttural cavity. Their walls, which are four in number, terminate anteriorly at the nose, and posteriorly at the throat.

The *upper wall* or vault of the nasal fossæ is disposed in three different directions; anteriorly, where it is formed by the bones of the nose, it looks backwards and downwards; in the middle, where there is seen the cribriform plate of the ethmoidal bone, it is horizontal; posteriorly, where it belongs to the body of the sphenoid bone, it is turned forwards and downwards. In the first portion is observed the inner surface of the nose, much narrower than the outer, surmounted by a crest towards the middle line, concave transversely, straight from above downwards, marked with a furrow for the internal nasal nerve, and perforated with one or two small vascular apertures. It presents externally the suture, which joins the nasal process of the upper maxillary bone to the nasal.

At the union of the interior with the middle portion there is observed a somewhat indistinct suture, formed by the nasal notch of the frontal bone and the bones of the nose; then a small concave longitudinal surface, marked on the sides of the nasal spine of the frontal bone, and applied posteriorly upon the cribriform plate, the foramina and small fissures of which are perceived farther back. This part of the vault is very thin and narrow.

Posteriorly, the cribriform plate forms a suture with the sphenoid bone and its turbinated bone. It is there that the third portion commences, in which are observed the lower and inner surfaces of the sphenoidal turbinated bone, and the orifice of the sphenoidal sinuses, which they concur to form, and which is sometimes wanting, as has

been observed by Ingrassias, Reiningen, Schneider, and some others. Very different from what it appears in a sphenoid bone separated from the others, here this aperture is narrow and regularly rounded, and it always occupies the upper region of the sinus. Lastly, beneath this latter, is the articulation of the vomer with the sphenoid bone. This region of the nasal fossæ is extremely thick, and of much greater extent than it seems at first sight to be, on account of the existence of the sinus, which prolongs it behind, and thus augments its surface.

The *lower wall*, or floor of the nasal fossæ, is rectilinear, and does not vary its direction like the vault. It is concave transversely, and slightly inclined backwards. Behind the superior orifice of the anterior palatine canal it descends a little forwards, after being raised for a moment; and anteriorly it is prolonged a little more on the inner side than on the outer, on account of the anterior nasal spine. There is observed upon it the orifice of which we have just made mention; and just at the point of junction of the vomer with the maxillary bone is seen the entrance of the small canal for the naso-palatine nerve, which is pretty constantly preceded by an arterial groove. Towards the posterior third of this wall, there is a kind of squamous suture, formed by the palatine and upper maxillary bones, and which is here much less distinct than it is on the palatine arch. Posteriorly, it is terminated by a notched edge, which is somewhat raised, and by the posterior nasal spine.

The *inner wall* of the nasal fossæ is the least complicated, and is formed by one of the surfaces of the septum which separates these cavities. Sometimes this septum is deflected to the one side, which is most commonly the right, as Haller has observed; it is then observed that the inner wall of one of the nasal fossæ is concave, and the other convex. In other circumstances, on account of the vertical plate of the ethmoid bone being laterally united to the anterior edge of the vomer, there occurs on one side a prominent oblique line, and on the other a corresponding groove; or there may also be observed an aperture of greater or less size.

This septum is composed of the vomer, the perpendicular plate of the ethmoid bone, a crest of the frontal bone, another of the nasal bones, and a third formed by the upper maxillary and palate bones.

It is marked by numerous vascular and nervous furrows; presents at its upper part the lower orifices of the internal olfactory canals; is cut anteriorly by a large triangular notch; and is terminated behind by the guttural edge of the vomer.

The *outer wall* of the nasal fossæ is that which presents the most important object of examination. At its upper and fore part there is observed the union of some transparent and irregular lamellæ of the ethmoid bone with the frontal bone, and the nasal process of the upper maxillary bone, of which the internal surface is seen a little beneath, where it forms part of the middle meatus. A little farther back is a rugose and quadrilateral surface of the ethmoid bone, perforated by a great number of olfactory canals, shaped like the point of a pen, more

or less long and oblique. This surface becomes convex posteriorly, and directs itself outwards to unite with the sphenoidal turbinated bone, and with the sphenoid bone itself. From this arrangement there results a vertical channel between the body of the sphenoid bone and the lateral masses of the ethmoid, which ends above at the orifice of the sphenoidal sinus, and below at the superior meatus. This same surface is prolonged forwards over the middle turbinated bone; but, posteriorly, it is suddenly limited by the *superior turbinated bone,* which is formed by a thin plate of the ethmoid bone, inclined downwards and backwards, convex internally, concave outwards, limited anteriorly by a cul-de-sac, gradually terminated behind towards the vertical channel, and below, determining the form and extent of the *superior meatus.*

This meatus is a kind of horizontal channel, occupying only the posterior part of the wall which we are describing; perforated anteriorly by one or two apertures, which lead into the posterior cells of the ethmoid bone, and posteriorly by the spheno-palatine foramen, which is formed by the palate bone, the sphenoid bone, and frequently by its turbinated bone, which is sometimes double, and which always perforates directly the outer wall of the nasal fossæ from within outwards. This hole gives passage to the nerves and vessels of the same name, and opens into the spheno-maxillary fossa.

Beneath the superior meatus is the *middle or ethmoidal turbinated bone*, larger and more curved than the upper; thin above and thick below; convex inwards, and concave externally; its surface is wrinkled, and sometimes the small olfactory channels are prolonged as far as its lower edge. It belongs to the ethmoid bone, and is terminated behind by five inequalities. It occupies only about the middle third of the outer wall of the nasal fossæ, and principally forms their *middle meatus.*

This meatus is of much greater extent than the upper, and presents from before backwards, 1, a portion of the inner surface of the nasal process of the upper maxillary bone; 2, a suture, which it forms with the lachrymal bone; 3, the anterior part of the inner surface of the latter bone, the pores with which it is perforated, and its union with the ethmoid bone; 4, a portion of this latter, which has a lacerated appearance, and is articulated to the upper maxillary bone; 5, the *infundibulum*, which leads into the anterior of the ethmoid cells and frontal sinus; 6, the entrance of the maxillary sinus, which is contracted by the ethmoid bone, the inferior turbinated bone, and the palate bone, and situated toward the posterior third of the wall, always above the floor of the sinus. This aperture is sometimes double, and is further contracted, in the recent state, by a glandular organ, lodged in the substance of the pituitary membrane.

Beneath the middle meatus is the *inferior turbinated bone*, which presents the greatest number of variations, and seems suspended by its cruciform process, which penetrates into the maxillary sinus. Bertin, Cheselden, and Haller, are of opinion that it is most com-

monly an appendage of the ethmoid bone. Whether it be so or not, it lies over the *inferior meatus*, which consists of a horizontal channel, concave from above downwards, and straight from before backwards, formed above by the inferior turbinated bone, anteriorly, where it is broader, by the upper maxillary bone, and posteriorly, where it is contracted, by the palate bone.

The only thing remarkable that this meatus presents is, the inferior orifice of the *nasal canal*, which is situated anteriorly, and concealed by the lower turbinated bone. This aperture is inclined a little obliquely backwards, and varies much as to its position with respect to the entrance of the nostrils, being sometimes but a line or two distant from it, and sometimes upwards of a finger's breadth. The *nasal canal* itself is formed by the upper maxillary bone, sometimes by itself, but more commonly united with the lower turbinated bone and the lachrymal bone. It ascends towards the lachrymal canal by describing a slight curve, the convexity of which is turned forwards and outwards; it is narrower at the middle than at the extremities; its diameters are not all equal, it being a little compressed; it is lined by the mucous membrane.

We have already spoken of the anterior and posterior apertures of the nasal fossæ; the very numerous bones of which these cavities are composed are, the sphenoid and ethmoid bones, the sphenoidal turbinated bones, the frontal bone, the upper maxillary palate and nasal bones, the inferior turbinated bones, and the vomer.

OF THE SUTURES FORMED BY THE UNION OF THE CRANIUM AND FACE.

These sutures have most of them distinct denticulations. They may be traced from the naso-frontal laterally and named systematically; thus, naso-frontal, lachrymo-frontal, ethmoido-frontal, spheno-frontal, malo-frontal, zygomato-malar, palato-pterygoid.

OF THE TEMPORAL, ZYGOMATIC, AND SPHENO-MAXILLARY FOSSÆ.

The temporal fossa has been already in part described. The position, form, and connexions of the zygoma form its principal features; the large hollow within is filled up by the temporal muscle. The suture which the zygomatic process of the temporal forms with the malar is denticulated, and so arranged that the temporal portion rests on the malar.

ZYGOMATIC FOSSA.—This name is given to the space between the external surface of the outer pterygoid plate and the ridge descending from the maxillary tuberosity. Between the tuberosity and the pterygoid process is a fissure, called pterygo-maxillary; this fissure unites above, nearly at right angles with the spheno-maxillary fissure. The pterygo-maxillary fissure leads into the spheno-maxillary fossa. It is important that the student rightly understand the mechanism of

this fossa and the anatomy of the apertures leading to or from it; for this purpose he will require to examine several different sections of the cranium and face. 1, the pterygo-maxillary, sphenoidal, and spheno-maxillary fissures open into it; 2, five apertures are found on its surfaces; these are, 1, the posterior orifices of the foramen rotundum, vidian, and pterygo-palatine canals; 2, the spheno-palatine foramen; and 3, inferiorly, the upper orifice of the posterior palatine canal.

Fig 55.*

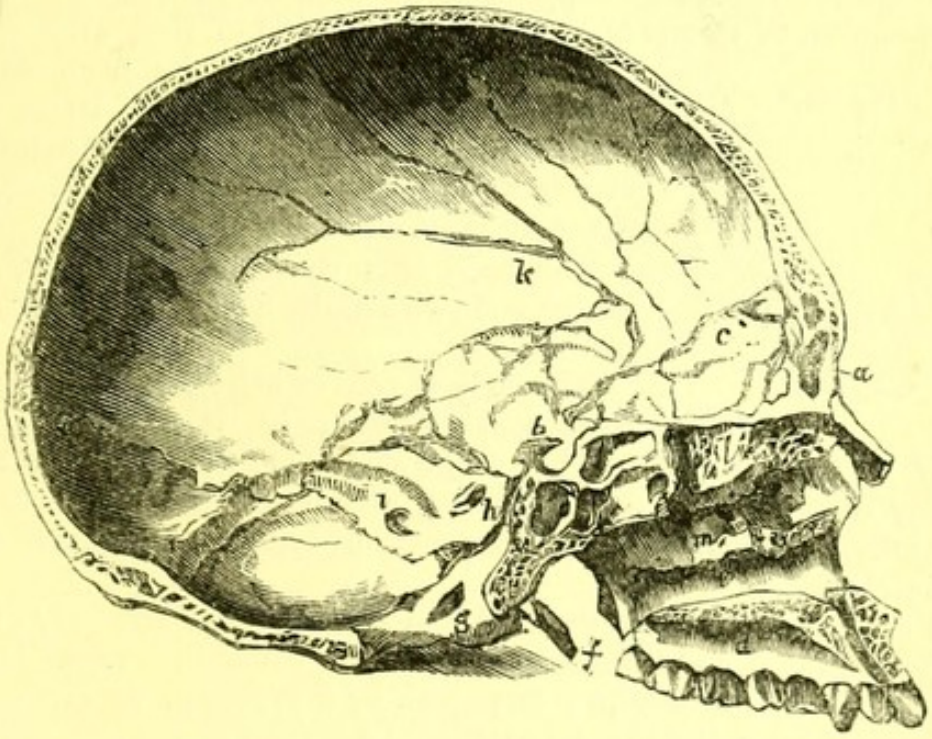

RESPECTIVE DIMENSIONS OF THE CRANIUM AND FACE.

This is a psychological question not as yet decided on. Attempts have been made in various ways to arrive at some approximation as to the mere facts, independent of all theory, but even these have not been very successful. The first proposed was the method of Camper, hence called Camper's facial angle; a mere artistic view, leading to no important results. Next followed the vertical view of Blumenbach;

* Fig. 55.—Vertical section of the cranium and upper jaw, left side; seen from within. Besides showing the anatomical details of these extensive and complex osseous surfaces, the section is a valuable one, physiologically: it enables the student to compare the area of the cerebral and cerebellar cavities with the area of the face, or at least of the upper jaw; the relation therefore which the encephalon has to the organs of sense. It displays also the position of the brain to the face, pharynx, and vertebral column, although these last are not present in the figure.—*d*, the osseous palate; *e*, inferior meatus of the nostrils; *m*, middle meatus; *l*, a portion of the perpendicular lamina of the ethmoid; *a*, points to the frontal sinuses; *c*, crista galli; *k*, grooves for the branches of the middle meningeal artery; *b*, posterior clinoid processes; *h*, foramen ovale; *i*, groove for the left lateral sinus; *s*, is placed near the section of the foramen magnum; *f*, styloid process of the temporal bone.

then the basial; lastly the vertical, proposed by Cuvier, in which the cranium and face are divided vertically with a saw into two equal parts. Gerdy has shown that Camper's views have been wholly mistaken by nearly all subsequent writers. These are physiological questions, connected more with philosophic and transcendental anatomy than with the descriptive anatomy of adult man, the main object of this work.

OS HYOIDES: OS LINGUÆ—*Lingual or Hyoid Bones.*

The osseous apparatus supporting the basis of the tongue, though usually spoken of as one bone, is really composed of five, all more or less distinct in young persons: from bearing some resemblance to the Greek letter υ it has been called hyoid. Its character in human anatomy is quite simple, but in philosophic anatomy most difficult and complex.

Fig. 56.*

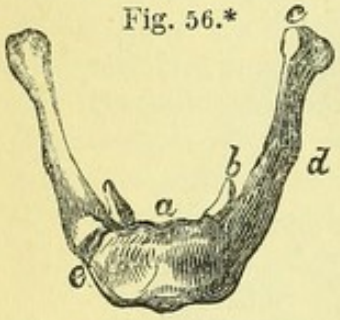

The apparatus consists of a body, two larger, and two smaller horns; these are called cornua.

The body is convex externally, and somewhat concave internally; it is subcutaneous, or may be felt immediately below the skin. On the external surface the body is marked by a vertical line and irregular depressions, to which muscles are attached. The posterior surface corresponds with the epiglottis.

The cornua majora spring from the extremities of the body; they project backwards and terminate by rounded surfaces. These larger horns are also called inferior; laryngeal, or thyroidean, as expressing the connexion with the thyroid cartilage (a portion of the larynx), is a much more appropriate term for them.

The small horns are situated immediately above the larger, and continue moveable often to an advanced age, long after the larger have become consolidated with the body. These smaller horns should be called styloid by reason of their connexion with the styloid processes of the temporal bone.

The thyro-hyoid ligament connects the laryngeal horns to the thyroid cartilage, and the stylo-hyoid ligament connects the styloidian horns to the styloid process of the temporal. The muscles which are attached to the hyoid apparatus are very numerous. The stylo-hyoid, sterno-hyoid, and digastric muscles are attached to the anterior surface of the body; the mylo-hyoid, genio-hyoid, genio-hyo-glossus, hyo-glossus, and superior constrictor of the pharynx are attached to the superior border, extending of course to a large portion of the thyroid horns; to the lower border are attached the omo-hyoid and thyro-hyoid.

Five distinct germs or nuclei compose the hyoid apparatus of bones,

* Fig. 56 represents the lingual or hyoid bones, seen from the front.—*a*, body of the hyoid; *b*, smaller or styloidian cornua; *c*, *d*, larger, inferior, or laryngeal cornua; *e*, junction of the body and larger horn of the right side.

being one for each of its parts. By most philosophic anatomists the hyoid bones are considered the homologues of the branchial arches of fishes, but this opinion, though extremely probable, has not been made out to the satisfaction of all anatomists.

SKELETON OF THE TORSO, OR TRUNK.

It is usual to speak of the trunk as being composed of the neck, chest, or thorax, abdomen, and pelvis. The skeleton of the neck consists of seven bones—the cervical vertebræ; these have been already described. In the loins, forming the lumbar region, there are five bones—the lumbar vertebræ; these have also been described. There remain only the thorax, or chest, and the pelvis; and of this latter a portion (the sacral and coccygeal vertebræ) has been described, as a part of the vertebral column.

THE THORAX.

Twelve dorsal vertebræ, twenty-four ribs, and their cartilages of prolongation, and the sternum, compose the skeleton, or framework of the chest. Of these bones the twelve dorsal vertebræ have been already described. There remain only the sternum and ribs.

THE STERNUM—*Os Pectoris Xiphoides.*

This bone, or rather chain of bones—for it really is so—occupies the mesial or median line of the chest: it is flat, and of unequal breadth

Fig. 57.*

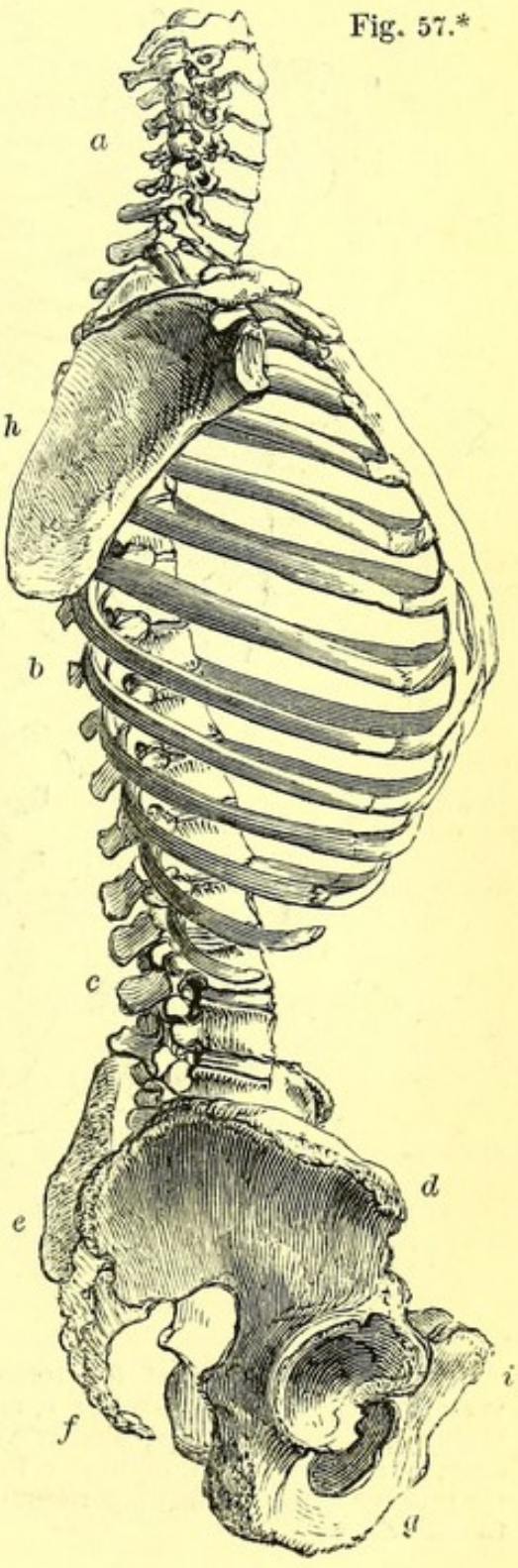

* Fig. 57.—Skeleton of the torso; seen in profile.—*a*, cervical portion of the column; *b*, dorsal; *c*, lumbar; *e*, sacral; *f*, coccygeal; *d*, pelvis; *g*, tuberosity of the ischium; *h*, right scapula; *i*, symphysis of the pubes.

Fig. 58.*

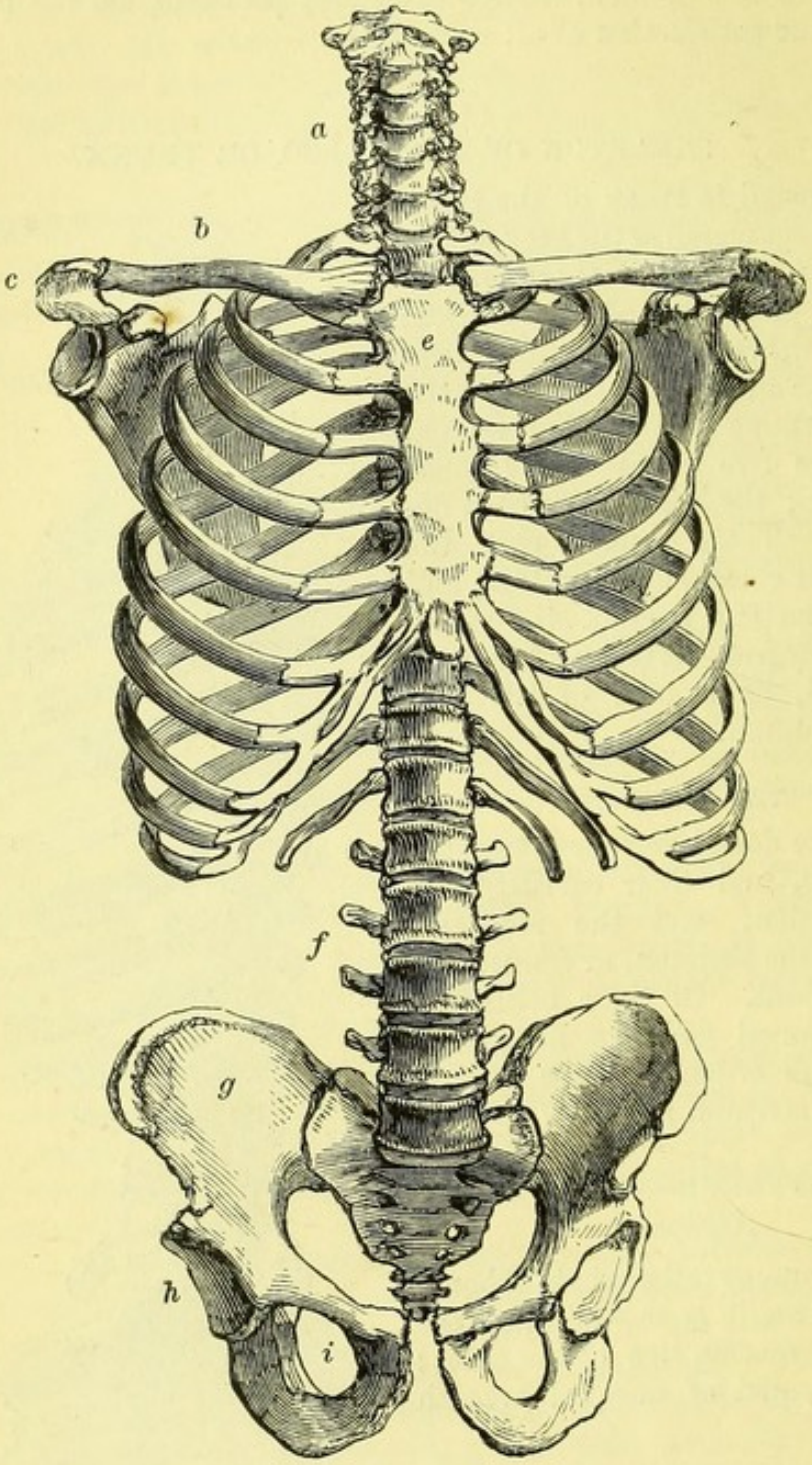

* Fig. 58.—Skeleton of the torso: front view.—*a*, points to the cervical vertebræ; *b*, right collar-bone; *c*, acromion scapulæ; *d*, ribs and their cartilages; *e*, the sternum; *f*, lumbar vertebræ; *g*, os innominatum of the right side; *h*, acetabulum; *i*, obturator foramen. The figure is intended to show the relative situation and proportions of certain parts or segments of the skeleton to each other.

and thickness. Its direction is from above, downwards, and from before, backwards; and it is usual to speak of it as composed of three portions —the handle, or manubrium, the body, and the ensiform cartilage or process, as the case may be, this depending on the state of its ossification. These three parts may either be distinct from each other or consolidated into one piece.

Fig. 59.*

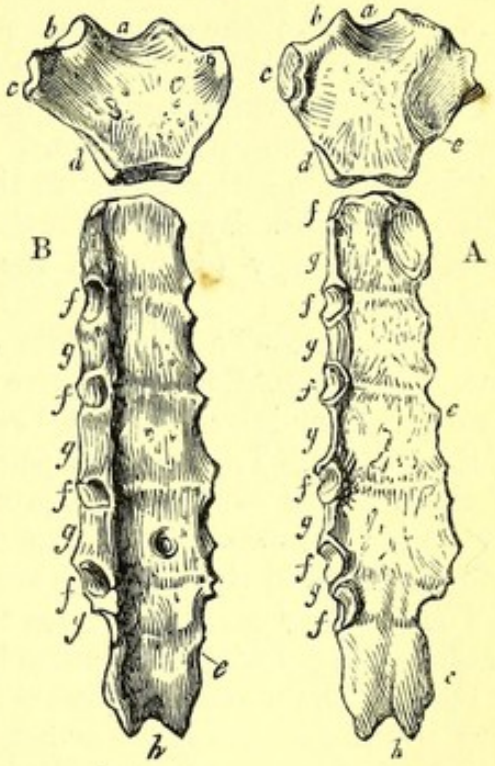

The sternum, viewed as one bone, presents for consideration two surfaces, two margins, and two extremities.

The *anterior* surface, slightly convex and partly subcutaneous, is marked by four transverse lines, indicating its original division into five pieces. The first of these transverse lines, namely, that between the manubrium and the body, often remains cartilaginous for life.

The *posterior* surface is slightly concave, and faces the vertebral column. It corresponds to a space left between the pleuræ, called *anterior mediastinum.*

The borders or edges of the bone are marked on each side by seven angular depressions, or cavities, to receive the cartilages of the true ribs; this gives them a notched or serrated appearance. These little cavities are each hollowed out of what was at one time two distinct bones, thus repeating in a remarkable manner the disposition which exists in respect of the articulation of the heads of the ribs with the dorsal vertebra; the heads of most of the ribs resting on two vertebræ and on the intervening fibro cartilage.†

The manubrium, or upper part, besides these surfaces and edges, to which the cartilages of the first ribs are attached, has an incisura semilunaris or notch, on its upper margin, and an articular cavity on each

* Fig. 59.—Sternum. A. anterior; B. posterior surface.—*a*, incisura semilunaris; *b*, facette for the articulation of the sternal end of the collar-bone; *c*, notch where the first rib is attached; *f*, *f*, *f*, *f*, four cavities into which are inserted the costal cartilages of the 3rd, 4th, 5th, and 6th ribs; *d*, *f*, mark the junction of the second ribs with the manubrium of the sternum above and the body of the sternum inferiorly. The 7th rib is connected in a similar way between the body of the sternum and the ensiform cartilage or process, *c*, in both figures; *h*, marks the bifurcation of the ensiform process; *g*, *g*, slight cavities or incisuræ on the sides of the body of the sternum between each of the cavities for the reception of the cartilages of the ribs.

† This, with other considerations, no doubt induced De Blainville to call the sternum the "sternebræ." Meckel and others had already compared the breast bone to the back bone. The true signification of the sternum in the history of the skeleton has not yet been determined.

side of this notch for the articulation of the collar bones. The inferior or abdominal extremity of the sternum is called the ensiform cartilage or process. It varies exceedingly in form; is often in whole or in part cartilaginous; perforated, twisted, bifurcated, or turned forwards; but it is precisely of the same nature as the rest of the sternum, and not a distinct part. When the eighth rib sends a cartilage to the sternum, which happens sometimes, the little cavity for its reception is on the border of the ensiform process.

The sternum articulates with the collar bones and with the cartilages of fourteen ribs. By sawing it through transversely, or longitudinally, the loose, spongy texture of the bone is displayed, and its lightness explained.

Ossification.—To the middle of fœtal life the sternum is wholly cartilaginous. After a time five ossific germs or nuclei appear in the manubrium and body of the bone. These in fact may be viewed as distinct bones. They form in pairs, but not always. The arrangement of these germs explains the occasional occurrence of a longitudinal division in the mesial line of the sternum; also the occurrence of holes or deficiencies in the bone at various points.

The ensiform cartilage begins to ossify soon after birth, but in most instances its ossification remains imperfect.

Perhaps the most remarkable circumstance in the physiological history of the sternum is the occasional presence of two additional bones, called epi-sternal, and articulated with the upper border of the manubrium. They are of rare occurrence, and their real nature has not been determined. The subject belongs to philosophic anatomy.

THE RIBS AND THEIR CARTILAGES.

The ribs, twenty-four in number, twelve on either side, are the osseous arches enclosing the chest. The seven superior, having cartilaginous prolongations to the sternum, are called true ribs; sterno-vertebral; the remaining five on either side, the cartilaginous prolongations of which do not extend to the sternum, are called *false* ribs, or *asternal*. The ribs are not uniform but irregular arches; they increase in length from the first to the eighth, decreasing from this to the last. Their breadth decreases from the first to the last. They vary also much in their direction, as regards the vertebral column, and they are mostly twisted on themselves.

In the ribs we describe two surfaces, two borders, and two extremities. The external surface is convex; the internal concave; both are smooth. The superior border or margin is rounded and smooth; the inferior is comparatively sharp, and on its inner side is marked by a groove (*sulcus costalis*), in which, or near to which, lie the intercostal vessels.

At the vertebral extremity of the rib, there is, 1, the head (*capitulum costæ*); 2, the rounded neck; 3, the tuberosity or tubercle. Two articular facettes, divided from each other by a ridge, are found on the heads of most of the ribs; the exceptions will be mentioned

presently. The outer surface of the tubercle is divided into two parts; one articular, for receiving on it the corresponding articular surface of the transverse process of a dorsal vertebra; to the other, a non-articular part is attached to the costo-transverse ligament.

Between the tubercle and the most convex part of the body of the rib is a rough line called the angle. The distance between the tubercle and angle increases from the second to the eleventh: in the first they run together; in the last, the angle is not distinct.

Fig. 60.*

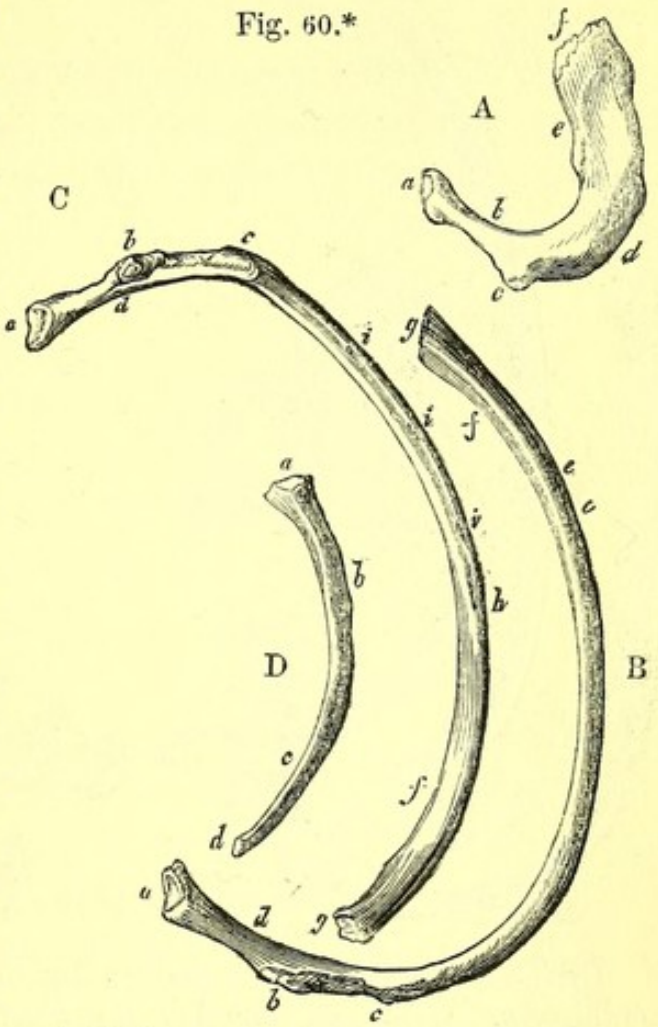

The first and last ribs are peculiar; the eleventh also merits further notice.

The first rib is broad and short, and nearly horizontal. Two slight grooves are readily seen on its upper surface, and between them is a rough part, to which the scalenus is attached.† On the grooves rest the subclavian vessels, the vein in front of the little rough surface, and the artery behind. The tubercle of the rib is strong; there is no angle properly speaking. The neck is slender; the sternal end of the rib broad; and the head presents a single articular surface, undivided by a ridge.

The *second* rib may also be readily distinguished from the others.

The *eleventh*. The head has an undivided facette; it has no sulcus. The angle is scarcely perceptible, and its cartilage is said to float; that is, is unconnected with the preceding one.

The *twelfth* cannot be mistaken for any other. It has no angle, tubercle, nor groove; the anterior extremity is rounded, the cartilage short and floating.

* Fig. 60.—A. First rib, right side, upper surface.—*a*, the head; *b*, the neck; *c*, the tubercle; *d*, the lower margin of the rib; *e*, the groove for lodging the subclavian artery; *f*, the irregular looking sternal end of the rib.—B. *a*, the head; *d*, the neck; *b*, the tubercle; *c*, the angle; *e*, *e*, convex surface; *f*, concave surface; *g*, sternal end of the rib.—C. and D. the 8th and 12th ribs: *a*, the head; *d*, the neck; *b*, the tubercle; *c*, the angle; *i*, *i*, *h*, convex or outer surface of the rib; *f*, concave surface; *g*, sternal end of the rib.—D. Last rib: *a*, the head; *c*, convex surface; *c*, concave ditto; *d*, sternal end.

† The precise nature of this projecting part of the rib has not yet been well determined.

Fig. 61.*

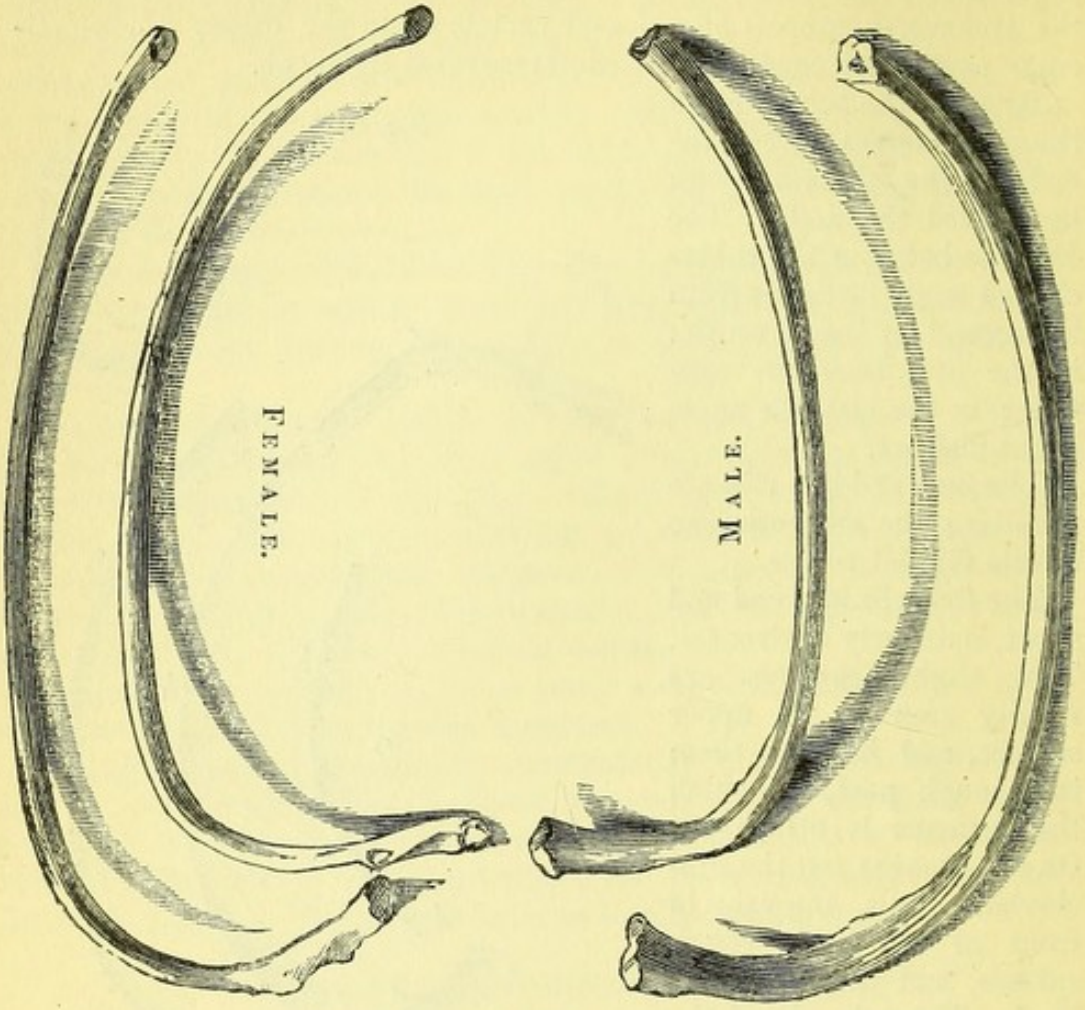

Ossification.—Each rib ossifies by one principal piece and two epiphyses. Of these, one belongs to the head; the other to the tubercle.

COSTAL CARTILAGES.—Each rib has a cartilage of prolongation. Like the ribs they vary in direction, breadth, &c. These cartilages are of great strength, and eminently elastic. By their means the seven true ribs on each side are connected directly to the sternum. The cartilages of the eighth, ninth, and tenth ribs are connected with each other merely, and with the seventh; the two last remain apart. The cartilages just described are apt to ossify in old age, especially in men. The first is most frequently found ossified.

Attachment of Muscles.—Numerous muscles are attached to the walls of the chest, just described. The intercostals fill the spaces between the ribs; attached to the first and second there are the scaleni; to the cartilage of the first the subclavius; to the cartilages of the true ribs, except the first, the pectoralis major; to the bodies of the third, fourth, and fifth, the pectoralis minor. In addition there are the recti

* Figs. 61.—Male and female ribs, to show the difference in their curves.

of the abdomen and serratus magnus; oblique muscles of the abdomen; diaphragm; the sacro lumbalis to the angles of all the ribs; the latissimus dorsi; serratus posticus, superior and inferior; levatores costarum. To the sternum several muscles are attached; the sterno thyroid, sterno hyoid, &c.

OF THE OS INNOMINATUM AND PELVIS.

At the lower extremity of the trunk is situated the pelvis, an osseous cavity, containing and giving support to many most important organs.

Fig. 62.*

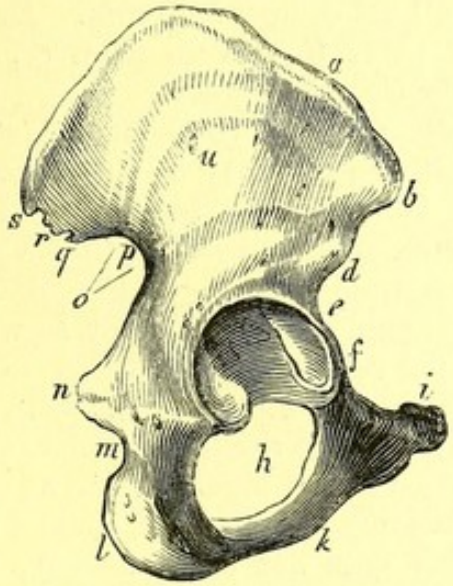

Fig. 63.†

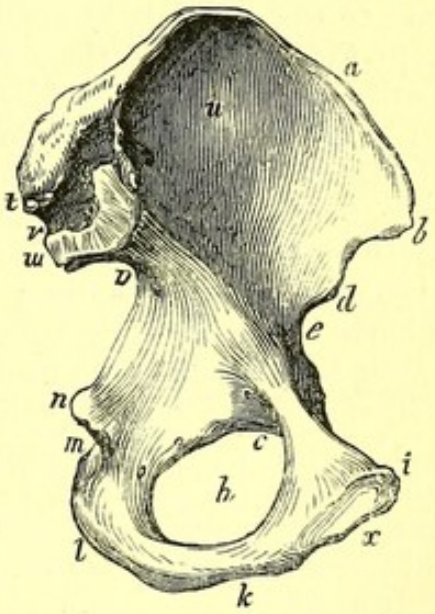

Of the bones composing the pelvis, the posterior wall, comprising the sacral and coccygeal vertebræ, have been already described. These bones are merely the continuation of the vertebral column. There remain but the great haunch bones, the *ossa innominata*, requiring a detailed description.

* Fig. 62.—Right os innominatum.—*a*, crest of the ilium; *b*, anterior superior spinous process of the ilium; *d*, anterior and inferior ditto; *e*, incisura or notch over which passes the psoas muscle; *f*, ileo-pubic spine, and horizontal ramus; *i*, angle of the pubes; *k*, descending ramus of that bone, where it joins the ascending ramus of the ischion; *l*, tuberosity of the ischion; *h*, thyroid, or obturator foramen; *m*, smaller sciatic notch; *n*, spine of the ischion; *o*, *p*, greater sciatic notch; *s*, tuberosity of the ilium and superior and posterior spinous process; *q*, posterior and inferior spinous process of the ilium; *r*, irregular intervening surface; *u*, dorsum of the ilium. The cotyloid cavity, with its incisura, or notch, is also seen in this view.

† Fig. 63.—Left os innominatum; pelvic or deep surface.—*a*, crest of the ilium; *b*, anterior and superior spinous process; *d*, anterior and inferior spinous process; *e*, incisura, or notch, over which passes the psoas muscle. The eminentia ileo-pectinea is immediately below it; *i*, angle of the pubes; *x*, situation of the symphysis; *k*, descending ramus of the pubes; *h*, thyroid foramen; *c*, groove below the horizontal ramus of the pubes; *l*, tuberosity of the ischion; *m*, smaller sciatic notch; *n*, spine of the ischion; *p*, greater sciatic notch; *t*, tuberosity of the ilium and superior and posterior spinous process; *v*, incisura; *w*, posterior and inferior spinous process of the ilium; *u*, concavity of the ilium.

OSSA INNOMINATA—*The nameless bones,*

So called since the time of Galen, from the irregularity of their shape, forbidding a comparison with any known object, are placed at the sides and in front, forming together a large portion of the walls of the pelvis. On each we have the following parts meriting notice.

The ancient anatomists, whether that they mistook the history of the bone, or were at a loss how to describe so complex a structure, speak of it as if it were composed of three bones—the ilium, ischion, and pubes; that is to say, they mistook the anatomy of the child for the adult, and so described the bone when in an imperfect state, and prior to the complete consolidation of all its component parts. Even as to the number of these component parts they were in error, as we shall find, when describing the *ossification* of the bone.

But as the names given to these three parts of the bone are still retained in all descriptions of the adult bone, it may be well for the student that he be first shown the bone in this imperfect state (skeleton of a person about fifteen), in order to understand that what was at one time the os ilium becomes in time the iliac portion of the os innominatum. A drawing of the young bone would not so well answer the purpose as an inspection of the young bone itself.

Having thus a clear apprehension of what is meant by os ilium, os ischion, and os pubis, all these becoming in time the iliac, ischiac, and pubic portions of the bone, I shall describe the os innominatum as one bone, which it really is in the adult, avoiding the error of those who still persist in speaking of that which does not exist, namely, an adult os ilium.

THE ADULT OS INNOMINATUM.—Broad, flat, and exceedingly irregular in form and thickness. On the *external surface* we find, 1, the dorsum of the ilium; 2, the superior and inferior curved lines dividing the bone into different spaces, to which strong muscles (the glutei) are attached; 3, the tuberosity of the ilium. A little lower down is the brim of the acetabulum, and the acetabulum itself, a remarkably round cavity for the reception of the head of the femur. In the bottom of this cavity is a fovea or depression; somewhat anteriorly, the foramen obturatorium or thyroideum; and still lower the external surface of the pubic and ischiadic portions of the bone; of the parts of each called the bodies, and rami of the pubis and ischion; the horizontal ramus; the ascending and descending; lastly, the external surface of the tuberosity of the ischion, on which the trunk rests whilst sitting.

Many of these parts are likewise seen on the inner surface, to which we may next advert.

INTERNAL OR ABDOMINAL AND PELVIC ASPECT OF THE OS INNOMINATUM.—1. The iliac fossa. 2. The linea ileo-pectinea. 3. The smooth surface of the pubic and ischiadic portions of the bone.

Margins.—Connected with these is nearly all the difficult anatomy of the bone.

Commencing at the crest of the ilium, there is,—1, the outer and inner margins of this crest, and the intermediate surface; 2, the anterior and posterior superior spinous processes of the ilium; 3, the notches following these; 4, the anterior and posterior inferior spinous processes of the ilium. Posteriorly, the tuberosity of the ilium is best seen in this view.

Following the margin anteriorly, we next come to the eminentia ileo-pectinea; the misnamed horizontal ramus of the pubis; the crest, angle, and symphysis of the same portion of bone.

Continuing the examination of the bone from the symphysis, there is the sharp edge of the descending ramus of the pubes, the ascending ramus of the ischion, the tuberosity of the ischion, the lesser sciatic notch, the spine of the ischion, the greater sciatic notch, the inferior and posterior spinous process of the ilium, which has been already adverted to, and which completes this brief sketch of the margins of the bone.

What remains to be said of this bone may conveniently be arranged under three heads: 1, what regards the articulations of the bone; 2, its minute anatomy and ossification; 3, when viewed in connexion with its fellow of the other side and with the sacrum.

1. *Articulations.*—On the portion of the bone adjoining the sacrum there is an extensive surface, partly smooth, partly rough. The smooth is the articular surface, and is called the *facies auricularis*; it corresponds to a similar surface already described on the sacrum. Further, the os innominatum is joined to the corresponding bone of the other side by the symphysis pubis, and this gives rise to the triangular space below, which in the male pelvis is called the angle of the pubes, and in the female the arch.

2. *As regards the minute anatomy of the bone and its ossification.*—By their upper portion the bones form the walls of the false pelvis; by their lower they assist in forming the true pelvis. The crest of the ilium forms an epiphysis in young persons which is long in adhering to the rest of the bone.

The iliac portion of the bone enters into the composition of the acetabulum, contributing, with the *bodies* of the other two portions (ischion and pubes), to form the acetabulum. To the eminentia ileo pectinea is attached the tendon of the psoas parvus, when that muscle is present.

The summit of the symphysis is sometimes called the angle of the pubes, and the part adjoining, running outwards, is called the *crest.* This latter may be divided into two parts: 1, that nearest the angle, to which is attached the rectus muscle, and over which passes the round ligament of the uterus in woman and the spermatic vessels and cremaster in man; 2, the sharp continuous edge to which is attached the ligament of Gimbernat. This sharp edge running outwards,

gradually becomes a portion of the linea ileo-pectinea, forming the brim of the pelvis.

The tuberosity, or spine of the pubes, is a small elevation, more remarkable in woman than in man, in which terminates outwards the *rounded* portion of the crest of the pubes. It has been much attended to by the philosophic anatomist from its supposed connexion with the marsupial bones, found developed only in certain animals.* To it is attached the external pillar of the ring.

The body of the ischion forms about two-fifths of the acetabulum. Its tuberosity is of great strength. Between the spine and the tuberosity the obturator internus muscle glides.

The acetabulum is also called the cotyloid cavity. It presents two surfaces, one encrusted with cartilage, and one not. Its supercilium, or margin, is unequal, and it presents a deep notch in front.

To conclude. The os innominatum is formed originally of three larger centres of ossification and of a smaller one developed in the bottom of the acetabulum at a certain age, and of four epiphyses, which show themselves about the age of puberty:

1. One forming the crest of the ilium.
2. A second, not always present, forming the anterior and inferior spine of the ilium.
3. The tuberosity of the ischion.
4. The inner margin of the pubes.

THE PELVIS.

The pelvis, formed of the bones just described, and of the sacrum and coccyx, merits the most careful examination on the part of the student. Let him enumerate every part of the anatomy visible; here we may attend only to certain forms resulting from the union of all the bones.

Fig. 64.†

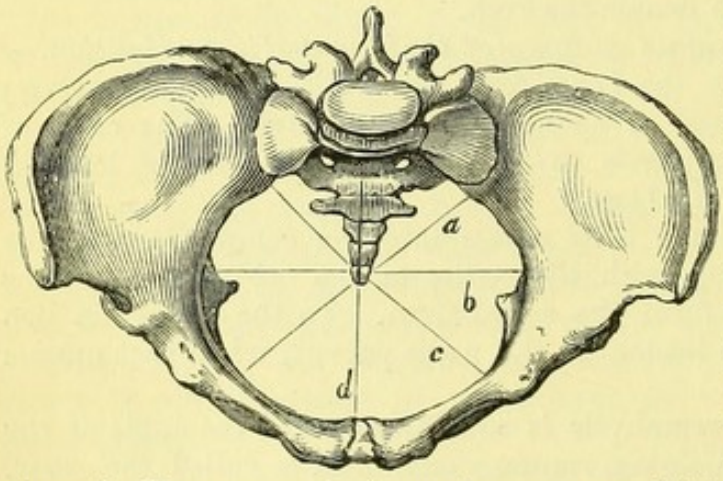

1. The symphysis of the pubis, its form and varieties, 2. The angle or arch (subpubic arch) beneath it. 3. The form and position of the foramina obturatoria. 4. The sacro-sciatic notches converted into holes by the presence of the sacro-sciatic ligaments.

* Ornithorhynchus, wombat, kangaroo, &c.

† Fig. 64.—Introitus or abdominal entrance of the true pelvis.—The lines *a*, *b*, *c*, *d*, mark the antero-posterior, oblique, and transverse diameters of the abdominal entrance or introitus.

Internally, the division of the cavity into two parts by the linea ileo-pectinea, the crest and symphysis of the pubes, and the anterior and superior margin of the base of the sacrum (*promontory*); this line so formed divides the pelvis into two cavities; the upper, called false, the lower, the true pelvis; the passage between is the introitus or abdominal entrance, by which the head of the child must pass into the cavum or excavation below.

Fig. 65.*

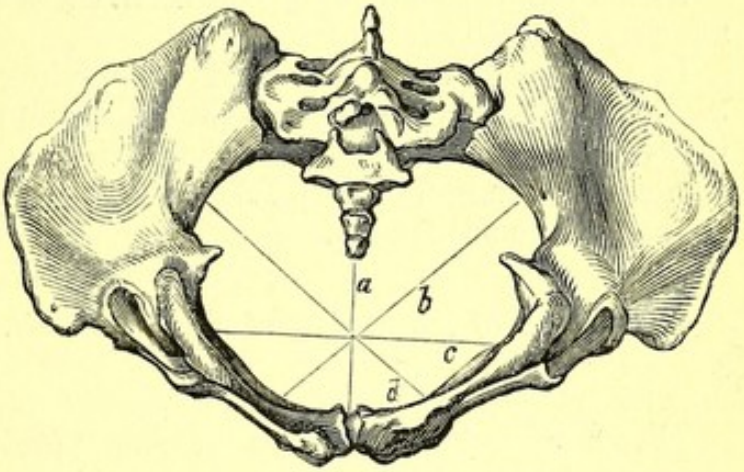

The pelvis, when entire, presents a deep notch in front, filled up by the abdominal muscles, and two at the back, between the lumbar vertebræ and the more elevated parts of the crest of the ilium. Inferiorly there is the outlet or inferior circumference; and here the pelvis presents three bony projections and three deep notches. The osseous projections are formed by the tuberosities of the ischion and the coccygeal bones; the notches are the pubic arch, and the sacro-sciatic.

Fig. 66.†

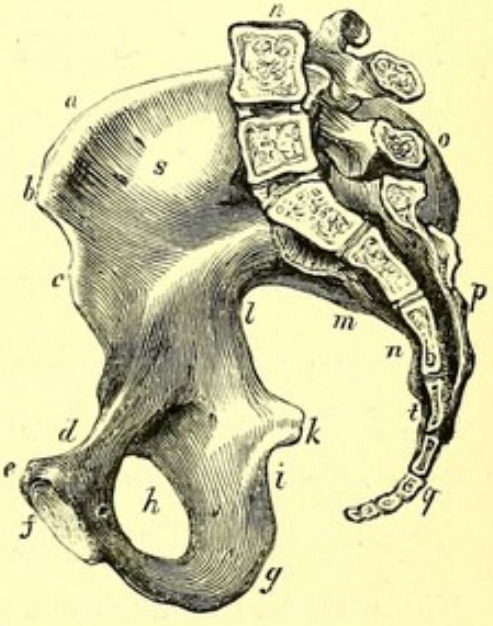

The pelvis is placed obliquely on the trunk, and the true angle which it forms has been but lately determined. For its exact position, see the figures of the entire skeleton. The annexed figure shows this obliquity; it also gives a view of the interior of the osseous pelvis, of the right side.

By this oblique position of the pelvis the crest of the symphysis comes to be placed much lower (3 inches and 9 or 10 lines) than the promontory of the sacrum; and the introitus of the pelvis is directed forwards, the exit backwards. The obliquity of the pelvis is greatest in the very young.

* Fig. 65.—Perineal exit of the pelvis, female.—The ideal lines *a*, *b*, *c*, *d*, mark the antero-posterior, oblique, and transverse diameters of the outlet of the pelvis, looking towards the perinæum.

† Fig. 66.—Section of the pelvis, right side, seen from within.—*o*, portion of the crest of the ilium; *p*, crest or spinous ridge of the sacrum; *q*, coccygeal bones divided like the sacrum, mesially and longitudinally; *n*, *n*, bodies of the 4th and 5th lumbar vertebræ, and of the five sacral, divided mesially; *m*, points

Axis of the cavity of the true pelvis.—By this is meant an ideal line transmitted through the false pelvis, equidistant from all its walls, and passing through the centre of the entrance and outlet; but such is the form and direction of the walls, that the upper and lower portions of the cavity of necessity have a different axis—one for the outlet and lower portion, another for the inlet and upper portion. By the mobility of the coccyx the axis of the outlet shifts backwards and forwards, or varies.

In the natural and living condition there are other circumstances affecting this important cavity.

In most women the soft parts composimg the articulations relax before and during delivery, and thus facilitate birth. Such a condition materially facilitates the birth of the child, and affects the measurements of the interior of the pelvis, with which it is right, however, that the student be acquainted.

Dimensions of the Male and Female Pelvis, according to Meckel.

		Male. In.	line.	Female. In.	line.
From one anterior and superior spinous process to the other		7	8	8	6
Between the middle of the crest of the iliac		8	3	9	4
Transverse diameter	inlet	4	6	5	0
Oblique	inlet	4	5	4	5
Antero posterior	inlet	4	0	4	4
Transverse	cavity	4	0	4	8
Oblique	cavity	5	0	5	4
Antero posterior	cavity	5	0	4	8
Transverse	outlet	3	0	4	5
Antero posterior	outlet	3	3	4	4

BONES OF THE SUPERIOR OR THORACIC EXTREMITIES.

The upper extremities are composed of the following regions: the shoulder, arm, fore-arm, and hand.

BONES OF THE SHOULDER.

These are two in number in each limb, the scapula and clavicle, or collar-bone.

to the sacro-iliac articulation; *a*, anterior part of the crest of the ilium; *b*, anterior and superior spinous process of the ilium; *c*, anterior and inferior spinous process; *s*, concavity of the ilium; *d*, horizontal ramus of the pubes; *e*, angle of the pubes; *f*, cartilaginous disc forming with the opposing bone the symphysis; *h*, obturator foramen; also called thyroid; *g*, tuberosity of the ischion; *i*, smaller sciatic notch; *k*, spine of the ischion; *l*, greater sciatic notch.

Fig. 67.*

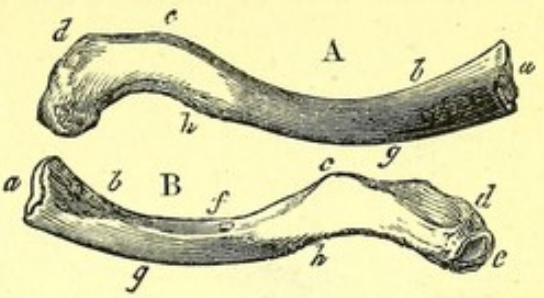

Of the Clavicle—*Clavicula os juguli.*—The position of the clavicle between the acromion of the scapula and the manubrium of the sternum, with both of which it articulates, is readily understood. It may be described as a long bone, that is, as composed of body or middle part, and two extremities. It presents sexual differences, being generally slenderer in woman. To put the bone in a right position, and to determine to which shoulder it belongs, hold it horizontally, placing the larger extremity outwards, and the smooth rounded surface superiorly.

Body, or middle part.—Its upper surface is rounded at the inner, and broader and flatter towards the outer part. The trapezius and clavicular portion of the sterno-cleido-mastoideus muscle are attached to this surface of the bone, leaving an interval between them. On the lower surface of this middle portion of the bone, near the sternal extremity, is a rough impression for the attachment of the costo-clavicular ligament; in the middle a longitudinal groove; also a foramen for the passage of the artery of the medulla; in the groove are received the fibres of the subclavius muscle; externally a prominent ridge, to which are attached the coraco-clavicular ligaments. The *anterior edge* of the middle part is broad and convex internally, narrow and concave externally; to the former is attached the pectoral muscle, to the latter the deltoid. The posterior edge is thick, rounded, concave, and smooth.

Sternal or internal extremity.—Thicker than the rest of the bone, and, in the fresh state, encrusted with cartilage. Ligaments are attached nearly all round this extremity. The lower and posterior angle is much more prominent than the others.

Acromial, external, or scapular extremity—is articulated with the acromion process by a narrow articular surface. Numerous small vascular apertures may be observed upon it.

Structure.—The body is composed of a thick layer of compact tissue externally and of a spongy and areolar tissue internally. There is no medullary canal. The extremities are composed of areolar tissue, covered by a thin plate of compact tissue.

Development.—By three germs or nuclei, one for the body and two for the extremities, ossification appears very early in this bone. The

* Fig. 67.—A. Right collar-bone, upper surface.—*a*, sternal extremity of the bone, articular facette; *b*, *c*, shaft of the bone, inner edge; *h*, *g*, shaft, outer edge; *d*, acromial extremity.—B. Same collar-bone, lower surface.—*a*, sternal end; *b*, shaft; *h*, *g*, outer rounded surface or edge; *c*, tuberosity for the attachment of the conoid and trapezoid ligament; *f*, opening to admit the nourishing artery of the bone; *d*, acromial end; *e*, articular facette, connecting the bone with the scapula.

epiphyses are late in forming, and more resemble osseous crusts; it articulates with the sternum and scapula.

Fig. 68.* Fig. 69.† Fig. 70.‡

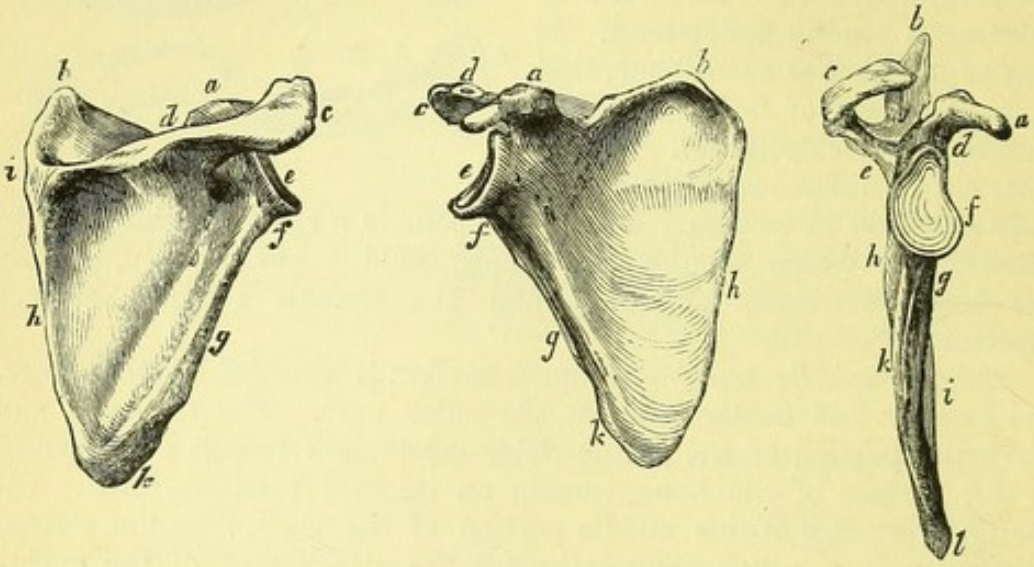

Of the Scapula.—This, the more important bone of the shoulder, is situated at the upper and back part of the chest; it extends from the first to about the seventh rib, and is loosely connected by muscles to the head, the ribs, and spinal column. Triangular, flat, and thin, it presents two aspects, external and internal; three angles, anterior, superior, and posterior, and so many margins, cervical, spinal, and axillary. To determine to which shoulder it belongs, place the concave surface towards the chest, and the articular surface (glenoid cavity) externally.

On the posterior or dorsal aspect are seen, 1st, the spine (*spina scapulæ*); this commences by a smooth triangular surface, near the spinal margin or costa of the scapula. Externally, the spine terminates in the acromion process, on which may be seen a small articular facette.

To the spine are attached, superiorly, the trapezius; inferiorly, the deltoid. It divides this surface of the scapula into two unequal parts; that above the spine is called fossa supra-spinata; that below it the fossa infra-spinata. These are filled respectively by the supra and infra-spinatus muscles.

* Fig. 68.—Right scapula, posterior surface.—*a*, anterior angle and cervical margin; *b*, superior and posterior angle; *i*, triangular smooth surface at the base of the spine; *c*, the spine of the scapula; *d* points also to the notch in the cervical margin of the bone; *e*, glenoid surface or cavity; *f*, cervix or neck; *g*, axillary margin; *h*, spinal or vertebral margin; *k*, inferior angle.

† Fig. 69.—Right scapula, costal surface.—*a*, coracoid process; *b*, superior and posterior angle; *c*, acromion; *d*, articular facette; *e*, glenoid cavity; *f*, cervix; *g*, axillary margin; *k*, inferior angle; *h*, vertebral margin.

‡ Fig. 70.—Right scapula, viewed anteriorly.—*a*, coracoid process; *b*, superior angle; *c*, acromion and spine; *d*, cervix; *e*, *f*, glenoid cavity; *h*, *g*, squamous plate and axillary margin; *k*, *i*, crests and grooves for the attachment of muscles; *l*, inferior angle.

On the surface called fossa infra-spinata is seen a ridge, to which an aponeurosis is attached, common to the infra-spinatus, teres major, and teres minor muscles. Between this ridge and the axillary margin of the bone is a long surface, divided into two by another ridge, descending from that edge, and joining the preceding at an acute angle. The upper and narrow portion of this surface gives attachment to the teres minor; the lower and broader to the teres major.

Internal or *costal aspect.*—Concave, and inclined forwards, it forms the subscapular fossa. Ridges, more or less prominent, divide this surface into several broad and superficial grooves, occupied by the fasciculi of the subscapular muscle. Two plain surfaces may be seen behind the subscapular fossa, above and below, to which the serratus magnus muscle is attached.

Cervical edge, or *costa.*—In this edge, which is shorter than the others, is a notch, converted into a foramen by a ligament. The supra-scapular nerve passes through the notch below the ligament, and the supra-scapular artery above it. The omo-hyoideus is attached partly to this ligament, partly to the adjoining portion of the margin. The *coracoid* process terminates the margin anteriorly. To this process are attached the coraco-clavicular ligaments, superiorly; the lower surface is smooth and concave. The pectoralis minor muscle is attached to the anterior edge of the process; the acromio coracoid ligaments to its posterior edge; the short head of the biceps and coraco-brachialis muscle to its extremity or summit.

Vertebral or *spinal edge*, or *costa.*—This edge is also named the *base*, is turned towards the vertebral column, and hence its name; the rhomboid muscles are more immediately attached to it; the levator anguli scapulæ terminates in the superior angle.

Axillary margin or edge—is much thicker than the others; it looks towards the axilla. To a groove near the upper part is attached the scapular head of the triceps extensor muscle; the teres minor is connected to this edge posteriorly. The inferior angle, where this edge meets the spinal, is thick and rounded; the teres major embraces it, and some fibres of the latissimus dorsi overlap it: occasionally this muscle is strengthened by some fibres attached to this portion of the scapula.

A notch is occasionally found on this edge in which passes the dorsal branch of the subscapular artery; a short ligament protects the artery.

The *glenoid* cavity is the articular surface on which plays the head of the humerus; its circumference, like that of the cotyloid cavity, is surrounded in the fresh state by a fibro-cartilaginous rim, into which runs at the upper part the long tendon of the biceps. The glenoid cavity is supported by the cervixcollum, or neck of the scapula; to this is attached the fibrous capsule of the articulation.

Structure.—The scapula varies much in thickness. In the middle of the supra and infra spinous fossæ it is entirely compact, thin, and transparent. On the neck and anterior angle generally the bone is

thick and strong, and abounds with areolar tissue. Vascular openings are seen on various surfaces of the scapula.

Development.—This takes place by six or seven points of ossification; 1, one for the body of the bone; 2, one for the glenoid cavity; 3, one for the summit of the coracoid process; 4, one for the upper surface and summit of the acromion; 5, one for the spinal margin; 6, one for the lower angle; 7, one for the base of the coracoid process.

The coracoid process is viewed by the philosophic or transcendental anatomist as a rudimentary clavicle; he calls it in the skeleton of the bird, for example (where it extends to the sternum), the coracoid clavicle.

SKELETON OF THE UPPER EXTREMITIES.

BONES OF THE ARM.

THE HUMERUS (*Os humeri, os brachii*).—This bone is the largest of the upper extremities. Placed between the scapula, and the radius and ulna, it articulates with these three bones. Long and irregularly cylindrical, twisted on itself, it is easiest described as composed of a body and two extremities, upper and lower.

The body, rounded above, somewhat triangular below, is divided into an anterior and posterior surface by two lines, an external and an internal; these are also somewhat anterior and posterior. Trace these lines from the inner and outer condyles of the bone, where they seem to commence, or at least where they are well marked; for as they ascend upwards they gradually become effaced. Intermuscular aponeuroses are attached to these lines or ridges. The external ridge is interrupted about the middle by a groove or oblique depression, in which runs the musculo-spinal nerve and superior profunda artery.

The internal and posterior line or ridge.—Tracing this line from the inner condyle, we find about an inch above the condyle a small osseous eminence or process, the supra-condyloid process, varying much in size, but seldom altogether absent. It is this process much enlarged, which in the carnivorous animals unites with the inner condyle, forming an aperture through which run, from behind forwards, the median nerve and humeral artery. I have once seen this arrangement in man; the process was of unusual length, and was united to the inner condyle by a short ligament: the great artery and nerve, deviating from their usual course, followed that which we find to prevail in the *carnivora*.

Posterior surface of the body of the bone.—Rounded superiorly, broad and flat inferiorly, it is covered throughout nearly its whole extent by the triceps extensor muscle; the medullary vessels pass into the anterior by a small aperture near the inner edge or line at the point of attachment for the coraco-brachialis muscle.

Anterior surface.—The groove seen superiorly is the bicipital for lodging the tendon of the biceps; the groove presents two lips or edges: to the outer is attached the tendon of the pectoralis major muscle; to the inner, and especially to the bottom of the groove, the

tendons of the latissimus dorsi and teres major muscles. Farther on the shaft, about the middle, is the rough surface or impression for the attachment of the deltoid.

Upper or scapular end of the bone.—Here we have, 1, the head of the bone, when fresh encrusted with cartilage, articulating with the glenoid cavity of the scapula; this is followed by a slightly contracted part called the anatomical neck of the humerus; beneath this follow two eminences, the larger and smaller tuberosities. To the larger, which is marked externally by three flat surfaces, are attached the supra and infra spinatus and teres minor muscles: to the smaller tuberosity is attached the subscapularis. The bicipital groove already spoken of separates these tuberosities.

Fig. 72.*

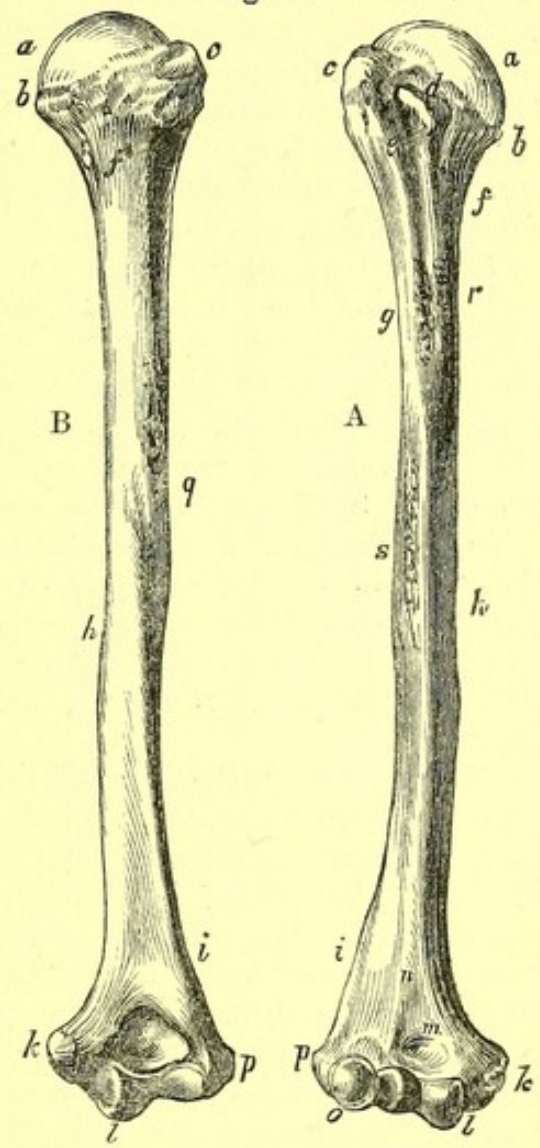

The lower extremity is the most complex part of the bone. There are, 1, the inner condyle; 2, the outer condyle: these projections are in no shape condyles, and ought to have been differently named. The external is also sometimes called the extensor condyle, from the circumstance that the extensor muscles are mostly attached to it: the inner for the same reason is called the flexor condyle. The external and internal lateral ligaments are attached to these condyles; 3, a

* Fig. 72.—A. Right humerus, anterior surface.—*a*, head of the bone; *b*, anatomical neck of the humerus; *c*, greater tuberosity; *d*, smaller tuberosity; *e*, bicipital groove; *f*, *r*, *g*, *s*, *h*, *r*, shaft, external and internal edges; *i*, crest running to the outer condyle of the humerus; *p*, outer condyle; *o*, smaller head; *l*, inner edge of the trochlea; *k*, inner condyle; *m*, anterior and internal fovea, for lodging the coracoid process of the ulna during violent flexion of the fore-arm.—B. Right humerus, as seen posteriorly.—*a*, head of the bone; *b*, anatomical neck; *c*, larger tuberosity; *f*, shaft; *g*, *h*, twisted form of the shaft and groove for the passage of a branch of the radial or musculo spiral nerve and artery; *i*, crest running to *p*, the external condyles; *k*, *i*, inner condyle; *l*, trochlea or pulley. About an inch above the inner condyle; *k*, there exists in nearly every humerus a vestige of the supra-condyloid process. (See the text.)

rounded eminence, the capitulum, or smaller head of the humerus: on this plays the disc of the radius; it is an articular surface, and placed rather on the anterior aspect of the bone; this is followed by the trochlea or pulley, on which plays the larger sigmoid cavity of the ulna. These articular surfaces merit the peculiar attention of the student. The pulley (trochlea) is placed obliquely from before backwards; it extends to the posterior aspect of the bone, which is not the case with the articular surface called the capitulum.

Above the trochlea is a fovea, or depression, and another above the capitulum. Above the trochlea, on the posterior surface of the bone, is a much deeper fossa, or depression, for receiving into it during the extension of the fore arm, the ancon process of the ulna: the coronoid process of the same bone is received partly, during flexion, into the anterior supra trochlear fovea.

The muscles attached to the bone, reckoning from above downwards, are, posteriorly, the triceps; anteriorly, externally, and internally, the deltoid, coraco brachialis, biceps, brachialis flexor, pectoralis major, latissimus dorsi, teres major, supra spinatus, infra spinatus, teres minor. To the external ridge, or border, and condyle, are attached the supinator radii longus, extensor carpi radialis longior, extensor brevior, extensor communis, extensor carpi ulnaris, anconeus, supinator brevis; to the inner condyle chiefly the flexors, pronator radii teres, flexor carpi radialis, palmaris longus, flexor ulnaris, and flexor digitorum sublimis.

Ossification.—At birth the shaft of the humerus is ossified nearly throughout its whole length, but the ends are cartilaginous. At various periods osseous points or germs appear, namely, 1, in the head of the bone; 2, in the tuberosities; 3, these unite after a time, and form one large epiphysis, which does not unite with the shaft until about the age of twenty. In the lower end of the bone there is a nucleus for the small head, a second for the inner condyle. About twelve years a third appears in the inner side of the articulating surface, and at thirteen or fourteen, in the external condyle, an ossific germ appears. At sixteen or seventeen years the external condyle and the two germs, now united, forming the articular surfaces, unite with the shaft; the inner condyle unites at eighteen. This happens at the lower extremity of the bone, whilst the epiphysis at the upper continues disunited until about the twentieth year.

Of the Radius.—Of the two bones composing the skeleton of the fore arm, the radius is esteemed to be the more important. It is with it that the hand is chiefly articulated, and on its integrity depend the movement of pronation and supination, which characterize so remarkably the human hand. The axis of the bones of the fore arm differs from that of the humerus, a fact pre-indicated by the direction of the trochlea or pulley of the humerus.

The radius bone is shorter than the ulna by nearly the length of the ancon process, called also olecranon of the cubit. It is stronger

and broader at the carpal than at the humeral end, the reverse therefore of the ulna, which, strong superiorly, becomes styliform inferiorly. It has been divided, for the sake of description, into a body and two extremities.

Fig. 73.*

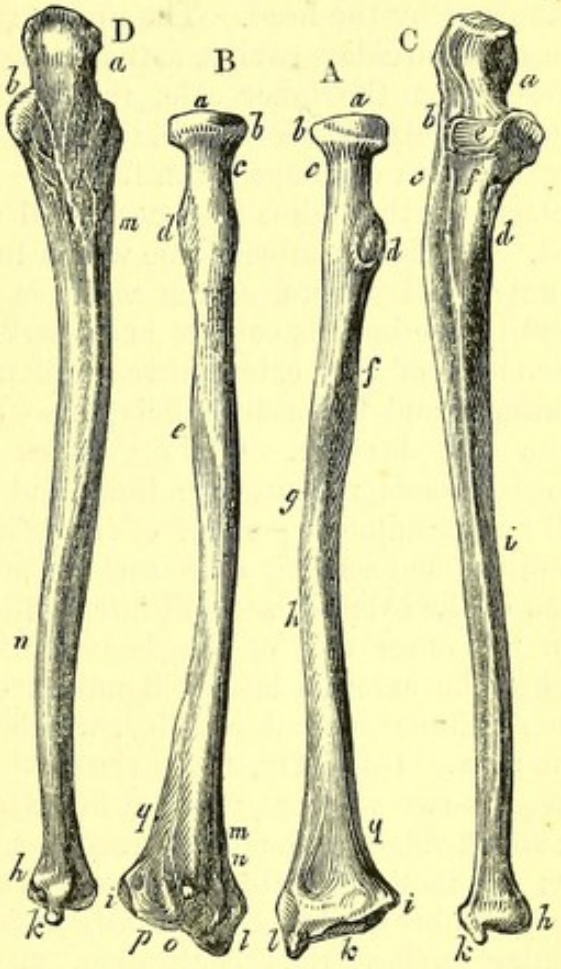

In the body we have three surfaces bounded by three margins. On the anterior surface is a longitudinal groove for lodging the flexor pollicis longus. On this surface may be seen, superiorly, the foramen for the medullary vessels, and inferiorly, the flat surface, to which is attached the pronator quadratus muscle.

The posterior surface is convex, and grooved about the middle for the attachment of the extensors of the thumb; the external surface is round and convex; a rough impression about the middle points out the attachment of the tendon of the pronator teres muscle. In respect of the margins, the posterior is not very distinct; the external, round and smooth, disappears also inferiorly; the internal margin, on the contrary, is a sharp, distinct edge. To this the interosseal ligament is attached.

* Fig. 73.—A. Radius, anteriorly.—*a*, *b*, head of the bone; *c*, the neck; *d*, bicipital tuberosity; *f*, shaft, and hole for the transmission of the nourishing artery; *g*, *h*, external rounded edge; *q*, *i*, crest running to the lower part of the bone; *k*, articular surface opposed to the scaphoid and semi-lunar carpal bones; *l*, styloid process of the radius.—B. Radius, posterior surface.—*a*, *b*, *c*, *d*, correspond to the same parts as in Fig. 68; *e*, inner sharp crest or ridge, to which is attached the interosseal ligaments; this inner ridge runs to *i*, the articular surface which plays on the smaller head of the ulna; *p*, *o*, grooves on the back of the radius for the play of tendons; *m*, *n*, external ridge running to *l*, the styloid process of the radius.—C. Right ulna, anterior surface.—*a*, greater sigmoid cavity, an articular surface for receiving the pulley of the humerus; *b*, lower part of the ancon process; *c*, triangular smooth surface below the ancon; *e*, articular facette for the head of the radius; *f*, triangular surface below; *d*, *i*, shaft; *h*, small head of the ulna; *k*, styloid process of this bone.—D. Right ulna, posterior.—*a*, *b*, point to the ancon process; *d*, smooth subcutaneous surface, and crest for the attachment of the anconeus muscle; *n*, shaft, lower part; *h*, *k*, styloid process, and part of the smaller head of the bone.

A rough prominence, the *tuber radii*, bicipital tuberosity of the radius, terminates the body superiorly, giving attachment by its inner and back part to the tendon of the biceps muscle. A bursa protects the tendon and bone. Above the tuberosity is the neck of the bone, surmounted by the head. The upper surface of the head is hollowed out into a circular cavity, articulating with the smaller head of the humerus; on the inner side, the head of the radius rotates in an articular cavity (lesser sigmoid cavity) of the ulna; both surfaces are encrusted with cartilage when fresh.

Inferiorly, the radius becomes broad and thick; anteriorly, flat and broad. To the prominent line which limits the bone in this direction, the anterior ligament of the wrist is attached. Posteriorly at this extremity the bone is convex and marked with grooves, in which run the tendons of the extensor secundi internodii pollicis, the extensor communis, and extensor indicis; also of the extensor carpi radialis, longior and brevior. Other grooves exist for the tendons of the extensores ossis metacarpi pollicis and primi internodii. There is a small but prominent portion of the bone dividing these grooves from each other, and serving as a sort of pulley, around which plays the tendon of the extensor secundi internodii pollicis.

On the outer side of the bone is the styloid process, to which is attached the external lateral ligament of the wrist; on the inner side is the semilunar articular cavity, which receives the rounded extremity of the ulna. Inferiorly, the surface of the radius is wholly articular; it presents two surfaces, unequal in extent, and divided from each other by a slight ridge. The outer rests on and articulates with the scaphoid bone; the inner with the semilunar. The triangular ligament of Weitbrecht (a fibro-cartilage) is firmly attached to the inner edge of this articular surface, thus continuing, as it were, by being interposed between the multangular bone and ulna, the level of the carpal articulation of the bones of the fore arm; a beautiful mechanism, on which depends much of the motion of the hand. By means, also, of this triangular ligament, the radius and ulna are firmly connected inferiorly.

Attachment of muscles.—The biceps flexor is attached to the bicipital tuberosity; the pronator radii teres, supinator brevis, and flexor sublimis, to the oblique line leading from the bicipital tuberosity; the pronator quadratus to the inferior fifth of the bone anteriorly; the extensores pollicis to the posterior surface; the pronator teres to a rough surface on the external margin; to the lower end, a little above the styloid process, is the attachment of the supinator longus. The radius articulates with the humerus, the ulna, the scaphoid, and semilunar bones.

Ossification.—It grows from three points, one for the shaft, and one for each of the extremities; these form the epiphyses which ultimately unite with the shaft.

THE ULNA.—The ulna occupies the inner side of the arm. Long and irregular, it is much more difficult of description than the sphenoid.

The body or shaft has three surfaces and three lines, sufficiently prominent. These surfaces decrease from above downwards. The anterior surface is grooved deeply for the attachment of the flexor profundus; but inferiorly the bone becomes round and subcutaneous. On this surface is the foramen for the passage of the medullary artery. The flexor profundus also covers a large portion of the inner surface. The posterior surface is somewhat rough, and divided by a line into two portions; to the upper or smaller is attached the anconeus; to the lower, extending to the lower end of the bone, is connected the extensor of the thumb.

At the upper extremity there is, 1st, the olecranon or ancon process; 2d, the coronoid. These bound the cavity by which the ulna articulates with the trochlea of the humerus. To the rough tuberosity near the summit of the olecranon is attached the tendon of the triceps muscle. To the anterior surface of the coronoid process, which is rough, is attached the tendon of the brachialis flexor.

The greater sigmoid cavity is the articular hollow of the ulna, adapted to the trochlea or pulley of the humerus; the smaller sigmoid cavity, the smooth depression at the outer side, though continuous with the greater, on which the head of the radius rotates during pronation and supination of the hand.

The inferior end of the bone is slender compared with the upper. On it are situated two eminences, namely, the head of the ulna and the styloid process. The head is an articular surface, is encrusted with cartilage, and presents two surfaces; the inferior corresponding to the fibro-cartilage of Weitbrecht; the external to the semilunar notch of the radius. The styloid process projects downwards; to it is attached the internal lateral ligament of the wrist-joint.

The muscles attached to this bone are the flexor digitorum profundus; the pronator quadratus; the anconeus; the extensor carpi ulnaris, supinator radii brevis; extensores pollicis, and extensor indicis; an aponeurosis, common to the flexor carpi ulnaris, flexor profundus, and extensor ulnaris, attaches these muscles to the posterior line. The triceps is attached to the olecranon, and the brachialis to the anterior rough surface of the coronoid process. The pronator teres has a second origin from the inner side of the coronoid process.

Articulations.—Above with the humerus and radius; below with the radius. It does not come into contact with any of the carpal bones, the triangular fibro-cartilage of Weitbrecht being interposed between the head of the ulna and the multangular bone.

Ossification and development.—At a certain period of youth, the ulna is composed of three portions, a shaft and two epiphyses. These unite together, or consolidate, and the bone is completed about the twentieth year.

BONES OF THE HAND.—*Ossa carpi.*

The carpal bones (Καρπὸς of the Greeks) are eight in number, and form two rows.

First Row—Of the Scaphoid Bone.—The scaphoid bone (*os scaphoides, os naviculare*, Σκάφη, navicula; εἶδος, figura), situated at the upper and outer part of the carpus, is the largest of those that occur in the first row. Elongated, convex on the side next the foramen, concave in the other direction, and inclined downwards and outwards. *Upper* surface, triangular, smooth, and cartilaginous, articulated to the radius. *Inferior* surface, directed a little outwards and backwards; is also triangular and smooth, convex, covered with cartilage, and is articulated to the trapezium and trapezoides. The *posterior* surface is very narrow, and marked in its whole length by a groove, into which ligaments are inserted. The *anterior*, which is also narrow, is concave at the upper and outer part, and presents a pretty distinct eminence for the insertion of ligaments. The *outer* surface is narrow and tubercular, and receives the insertion of the external lateral ligament of the radio-carpal articulation. The *inner* presents two concave and cartilaginous spaces; the upper, which is narrower, is articulated to the semilunar bone; the lower, which is broader, is inclined downwards, forwards, and inwards, and is united to the head of the os magnum.

Of the Semilunar Bone.*—The semilunar bone (*os lunatum*) is smaller, and less elongated than the scaphoid. Its *upper* surface is convex and smooth, and is articulated to the radius. The *lower*, which is of greater extent from behind forwards than in the transverse direction, presents a concave space, which is connected with the head of the os magnum, and with the unciform bone; this articulating surface is sometimes double. The *anterior* and *posterior* surfaces, uneven and rough, give attachment to ligaments; the former of these is the larger. The *outer* surface, which is a little concave, smooth, covered with cartilage, slightly inclined upwards, and of a semicircular form, is articulated to the scaphoid bone. The *inner* surface is directed a little downwards, and presents a broader, somewhat convex, and nearly quadrilateral facet, which rests upon the cuneiform bone.

Of the Cuneiform Bone.—The cuneiform or pyramidal bone (*os triquetrum*) is a little smaller than the semilunar, and is situated on the inside of that bone, and a little beneath it. Its form is that of a wedge, whose base is directed outwards and upwards, and the summit downwards and inwards. Its upper surface is convex and smooth, and is contiguous to the triangular fibro cartilage, which separates it from the head of the ulna. The *inferior* surface is

* So named because the surface by which it is articulated to the scaphoid bone is of the form of a crescent.

inclined outwards, a little concave and smooth, and rests upon the unciform bone. The *posterior* surface is uneven, and gives attachment to ligaments. The *anterior* presents internally a plain and circular surface, covered with cartilage, which articulates with the pisiform bone, and is limited externally by ligamentous impressions. The *outer* surface, which is quadrilateral, convex, smooth, and inclined a little upwards, is articulated to the semilunar bone. The *inner* is marked with an uneven depression, for the insertion of ligaments.

Of the Pisiform Bone.—This is the smallest bone of the carpus, of which it occupies the inner and upper part. It is of a rounded form, whence its name; and is placed in a plane anterior to the other bones of the carpus. Posteriorly it presents a circular surface, which unites with the anterior surface of the cuneiform bone. All the rest of its surface is convex, rough, and uneven. It gives attachment above to the flexor carpi ulnaris; below to the abductor of the little finger; anteriorly, to the anterior annular ligament of the wrist.

Second Row—Of the Trapezium.—The trapezium (*os multangulum majus*) is situated at the outer and lower parts of the carpus, a little before the other bones, and seems to have an oblique direction. Its *upper* surface is concave and cartilaginous, and articulates with the scaphoid bone. The *lower* surface, which is convex from behind forwards and concave transversely, is connected with the first metacarpal bone. The *posterior* and *outer* present insertions of ligaments. The *anterior*, which is narrow and uneven, is marked above with a groove, in which lies the tendon of the flexor carpi radialis, and of which the outer edge forms an eminence for the attachment of the anterior annular ligament of the wrist, and the abductor and opponens pollicis muscles. The *inner* surface is inclined downward, and articulates with the os trapezoides by a broad and concave space, and with the second metacarpal bone by another narrow and plain surface, situated beneath the preceding.

Of the Os Trapezoides.—The trapezoides (*os multangulum minus*) is smaller than the trapezium, more extended from behind forwards than in any other direction, and thicker behind than before. Its *upper* surface, which is concave, smooth, narrow, and quadrilateral, is articulated with the scaphoid bone; the *lower* is divided by a prominent line passing from before backwards, into two parts, of which the inner is broader and somewhat concave, and unites with the second metacarpal bone. The *posterior* surface is convex and rough, for the attachment of ligaments; the *anterior* is of a similar description, but is narrower. The *outer* is convex, and articulates with the trapezium; the *inner*, which is narrower and concave anteriorly to be articulated to the os magnum, receives the insertions of ligaments behind.

Of the Os Magnum.—The os magnum (*os capitulum*) is the

largest of the carpal bones. It is thick and cubical below, rounded and hemispherical above, and its height is greater than any of its other dimensions. Its *upper* surface, which is named its *head*, has the greatest part of its convexity turned backwards and outwards; it is supported by a contracted neck, in the form of a groove, and is received into a cavity presented by the scaphoid and semilunar bones together. Its *inferior* surface is divided into three portions, the external of which, inclined outwards, concave and smooth, is articulated with the second metacarpal bone; while the middle portion, which is broader than the rest, horizontal, and turned a little obliquely upwards at its posterior part, rests upon the third metacarpal bone; and the *inner*, which is very small, plain, and also horizontal, is joined to the fourth. Its *posterior* surface is broad and convex below, a little concave above, and gives attachment to ligaments, as does the *anterior*, which is narrower. The *outer* surface is plain, and is articulated to the trapezoides. The *inner* surface presents, posteriorly and above, a large concave space, which is connected with the unciform bone; the remaining part is rough, and gives attachment to ligaments.

Of the Os Unciforme.—Next to the os magnum, this is the largest of the bones of the carpus, of which it occupies the inner and lower part; it is somewhat of the form of a wedge, with the base directed downwards. Its *upper* surface, which is extremely narrow, is rounded and smooth, and is articulated to the semilunar bone. The *lower* surface is divided into two facets, which rest upon the fourth and fifth metacarpal bones. The *posterior* is triangular and uneven, and gives attachment to ligaments. The *anterior* bears internally and below a large eminence, curved outwards, which affords attachment to the annular ligament of the wrist and some of the muscles of the little finger. The *outer* is smooth above and behind, to be articulated with the os magnum; uneven before and below, where it gives insertion to ligaments. The *inner*, which is very oblique, is concave downwards and backwards, convex above and before, and is articulated to the cuneiform bone.

Structure and development.—All the bones of the carpus are formed of a loose and spongy tissue, which in the recent state is filled with a great quantity of fluid; a very thin layer of compact tissue invests their surface. They are each developed by a single point of ossification, excepting the os unciform, which has two. The pisiform bone does not begin to ossify until about the age of twelve.

These bones form an arch of great strength. When carious, operations performed on them for their removal require to be done with great care; they cannot be attempted on the palmar side.

Though the number be 8 in man, it is probable that this is not the type applicable to all mammals; in some the number is greater.

The part in the fore leg of the horse usually called "the knee" is in reality the wrist, or carpus: its elevation above the ground is caused by the length of the metacarpal (cannon bone) and digital bones in that animal.

THE METACARPUS.

In this region there are five bones, according to some, and four according to others, the metacarpal bone of the thumb by some being considered as a digital bone. These bones are named numerically, beginning with the thumb; they are parallel; nearly on the same plane, excepting the first, which forms an opposing finger to the rest.

Fig. 74.*

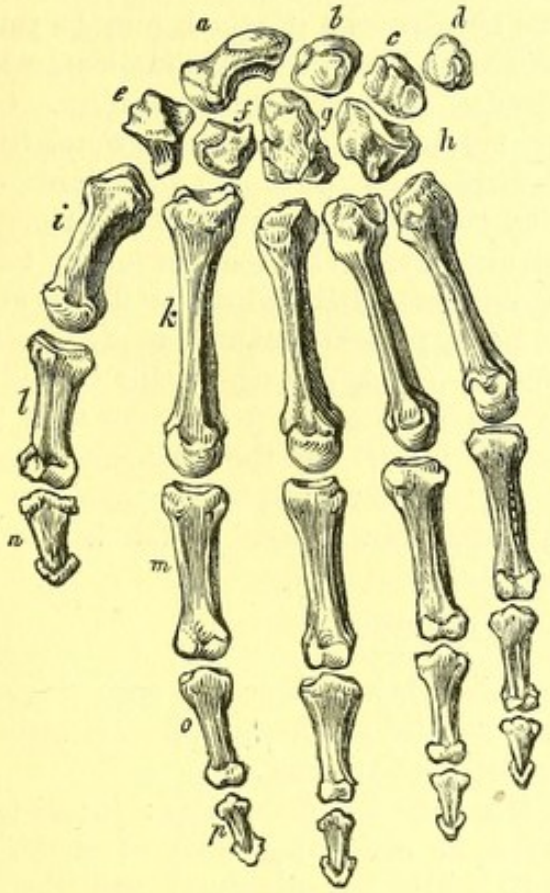

Fig. 75.†

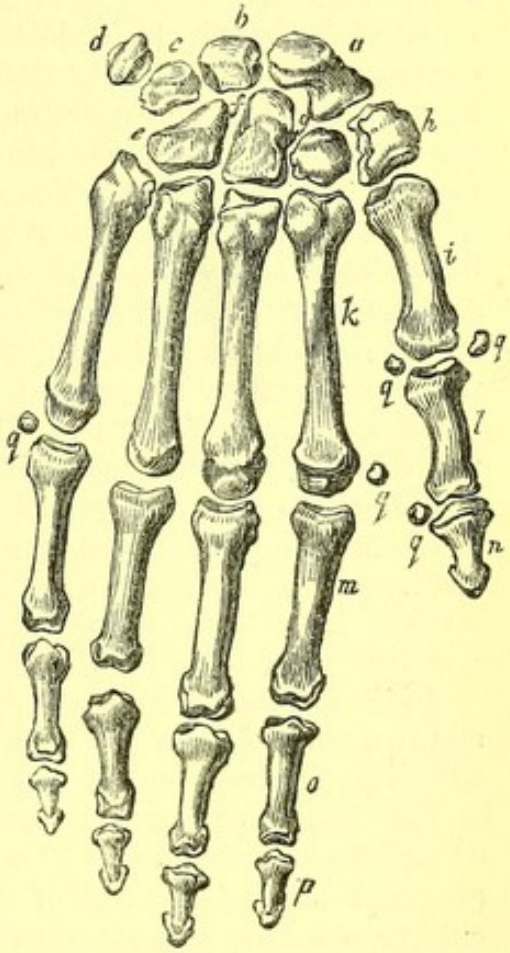

These bones vary in size; the 1st is thicker and shorter, the 2d and 3d are larger than, the rest: the 5th is the shortest. They are slightly concave on the palmar side, convex on the dorsal; larger at the extremities than in the shaft. They terminate all in a similar way, by articular surfaces at both extremities; the proximal adapted to the

* Fig. 74.—Right hand, palmar surface.—*a*, scaphoid bone; *b*, semi-lunar; *c*, pyramidal; *d*, pisiform; *e*, trapezium; *f*, trapezoides; *g*, magnum; *h*, unciform; *i*, metacarpal bone of the thumb, by some viewed as a phalanx; *l*, *n*, first and second phalanges of the thumb; *k*, metacarpal bones of the fingers; *m*, proximal phalanges; *o*, middle ditto; *p*, distal ditto, or nail bones.

† Fig. 75.—Right hand, dorsal aspect.—*a*, scaphoid; *b*, semi-lunar; *c*, multangular; *d*, pisiform; *e*, unciform; *f*, magnum; *g*, trapezoides; *h*, trapezium; *i*, metacarpal bone of the thumb; *k*, ditto of the index finger; *q*, *q*, *q*, *q*, *q*, sesamoid bones in connexion with the thumb, forefinger, and little finger; *l*, proximal phalanx; *n*, distal phalanx of the thumb; *m*, *o*, *p*, proximal middle and distal phalanges of the fingers.

varying surfaces of the second row of carpal bones; the digital by rounded heads, encrusted when fresh with cartilages, resting on the cup-like hollows of the proximal phalanges of the fingers.

The bodies or shafts of all these bones are triangular, presenting three surfaces and three borders. The spaces between them are occupied by the interosseal muscles, and are called interosseal.

To discriminate one from another is not difficult. Begin with the 1st and 5th: these cannot be confounded with any of the rest. A sharp ridge on the dorsum of the 5th distinguishes it from all. There remain but the 2d, 3d, and 4th, the peculiarities of which may be thus enumerated. The 2d articulates with the bone called trapezoides, and, by a small articular surface on its radial side, with the trapezium. On the 3d, besides the plane articular surface for the os magnum, this metacarpal bone has an articular facette on its radial and ulnar sides, or three in all. The 4th is recognised by two articular surfaces superiorly, by which it articulates with the os magnum and unciform bone; two articular facettes on the radial side, and one on the ulnar, or five in all.

The digital extremities of these bones present but one mode of termination, namely, by rounded articular heads, resting on the cup-like hollows of the first digital. These heads form the projections seen in the emaciated or the coarsely-formed hand. In the beautiful hand they form dimples or depressions. The most prominent of these heads of the metacarpal bones is the 3d, which shows itself a little in every hand.

BONES OF THE FINGERS.

Digital Bones.—Fourteen in number, being three for each finger, and two for the thumb. They are also called phalanges and internodia; they vary in shape and in length in different persons.

The 1st, or proximal, is longer than the 2d, or middle: the distal or nail bone is the least. They have in common a body or shaft, a proximal extremity, and a distal. All the proximal and distal extremities show articular surfaces, with the exception of the distal or nail bones, which present articular surfaces only at their proximal extremities.

The bodies have a dorsal and a palmar aspect, or surface, and margins bound these surfaces. In the 1st row the proximal extremity presents hollows, or cup-like articular cavities, for receiving the rounded extremities of the metacarpal bones. The distal extremity, smaller than the proximal, terminates in two small condyles, with a groove between them, to correspond with the proximal extremities of the middle phalanges, which present two small cup-like cavities, and a ridge between them. In this way, independent of size, or of any other character, the bones of the 1st and 2d rows may easily be distinguished from each other. The rough surfaces at the sides of these articulations are for the attachment of ligaments.

The 2d row consists of only four bones, that of the thumb being wanting. The *anterior* extremity of each has two lateral convex

surfaces, with a groove between them: these will be found to correspond to the articular surfaces of the last phalanges or nail bones, which resemble, in their form, that of the proximal or corresponding extremity of the middle phalanges.

The muscles attached to the metacarpal bones and phalanges are—To the metacarpal bones, the extensor ossis, metacarpi pollicis, opponens pollicis, and to a part of the abductor indicis; these are connected with the 1st metacarpal bone; to the 2d, the tendon of the flexor carpi radialis, extensor carpi radialis longior, two dorsal interossei, and one palmar; to the 3d, the extensor carpi radialis, brevior adductor pollicis, and two dorsal interossei; to the 4th, two dorsal interossei, and one palmar; to the 5th, the extensor carpi ulnaris, and the adductor, or opponens minimi digiti, one dorsal and one palmar interosseal. The muscles attached to the bones of the fingers are, the common extensors of the fingers and flexors, superficial and deep. The interossei are indirectly connected by means of the extensor tendons. As regards the thumb, to the 1st phalanx is attached the extensor primi internodii, flexor brevis adductor and abductor; to the last, extensor secundi internodii, and flexor longus.

OSSIFICATION OF THE METACARPAL AND DIGITAL BONES.

Metacarpal Bones.—Each metacarpal bone is formed of two parts; one representing as it were the shaft of the bone; the other its epiphysis. This epiphysis, which is at the digital end of the bone, joins the shaft or principal piece about twenty years of age. The bone of the thumb, usually called metacarpal, has the epiphysis at the proximal end, in this respect, as in its form, resembling the digital bones.

Digital Bones—Bones of the Fingers.—These bones are also formed of two portions, a larger and an epiphysis; these consolidate about the twentieth year. The epiphyses are placed at the proximal end of each bone.

SESAMOID BONES.—Of these, two are constant; they are situated under the metacarpo-phalangeal joint of the thumb, developed in fibro-cartilages, embedded in the tendons of the flexor brevis pollicis; they are secured in their place by these tendons, and by powerful ligaments. They greatly resemble two we shall afterwards find in the corresponding joints of the foot, under the ball of the great toe.

SKELETON OF THE LOWER EXTREMITIES.

Anatomists divide the lower, or pelvic, or abdominal limbs, into three regions; the thigh, the leg, the foot. In the skeleton of the adult thigh there is one bone, the femur; in the leg there are two, the tibia and fibula; in the foot there are 26, arranged in three regions. tarsus, 7; metatarsus, 5; digital, 14. In addition to these we always find, in

the normal limb, one large sesamoid bone, the patella, and two smaller, in each limb, at the first metatarso-phalangeal articulation. But these sesamoid bones do not form an integral part of the skeleton of the limbs.

BONE OF THE THIGH.

Fig. 76.*

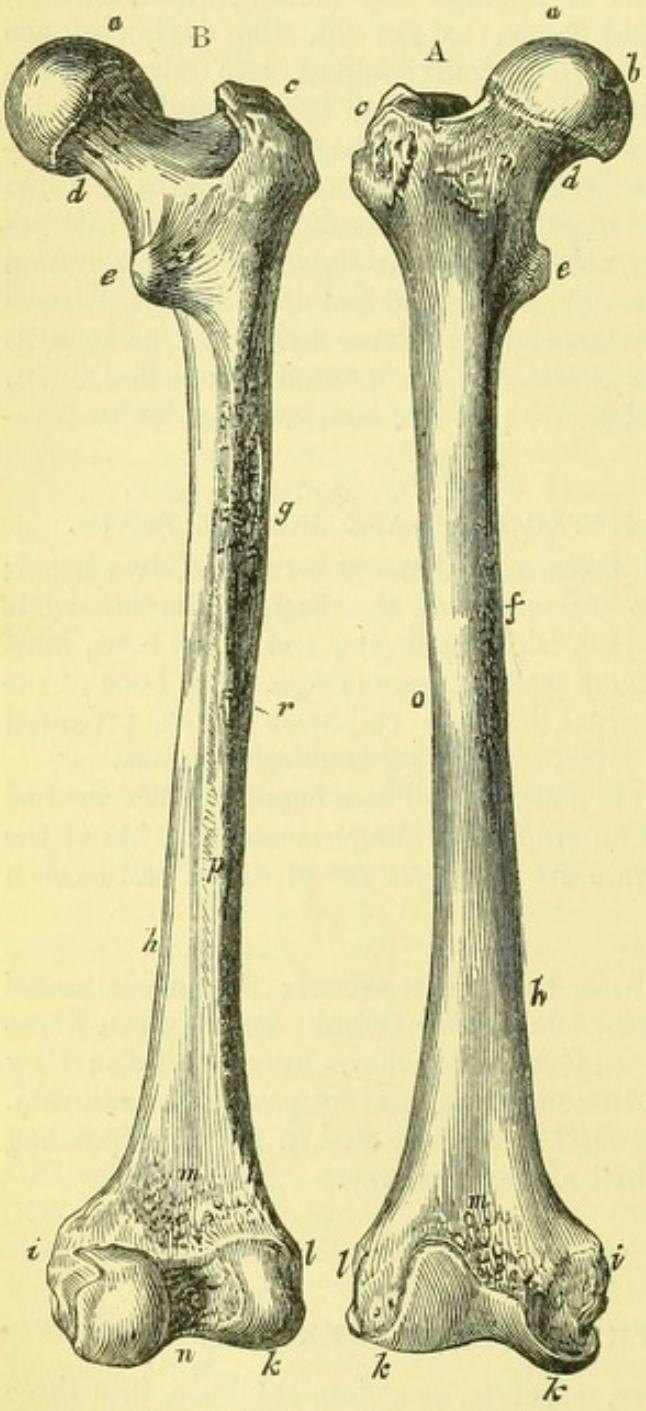

The Femur. — The femur, or thigh-bone, the longest and largest bone of the skeleton, is articulated above with the os innominatum; below, directly with the tibia. In the erect position of the body, the direction of the femur is not vertical; widely separated from each other above, by the whole breadth of the pelvis, these bones slope inwards inferiorly, and in woman nearly meet. The angle of the inclination varies much in different individuals.

In describing the femur, anatomists, as is usual with all the long bones, divide the bone into a body, shaft, and extremities. The shaft or body is compressed; at the centre nearly cylindrical, convex, or arched forwards, remarkably so in woman. The anterior surface is smooth, convex; both lateral surfaces compressed and flattened; these surfaces give attachments to the vasti muscles. At the union of these lateral surfaces, behind, is a

* Fig. 76 A.—Adult thigh-bone, anteriorly.—*a*, *b*, head of the femur; *b*, points to the depression or fovea, to which is attached the inter-articular ligament, the round ligament of the hip-joint; *c*, the trochanter major; *d*, the neck, cervix; *e*, the trochanter minor; *f*, *o*, the shaft; *h*, points to the situation of a groove in the bone, corresponding to the femoral artery at the point where it becomes popliteal; *l*, external tuberosity; *i*, internal tuberosity; *k*, *k*, lower surface of

rough and prominent line or crest, called *linea aspera,* to which are attached several muscles.

This crest or linea aspera is composed of two margins and a rough interstice. Above and below it is bifurcated; the two superior divisions proceed towards the trochanters, the inferior towards the condyles, enclosing between them a smooth triangular surface, corresponding with the popliteal vessels. In the upper part of the linea aspera will be found the opening by which the nourishing artery of the medulla passes into the interior of the bone.

The *superior extremity* (pelvic) includes, 1st, the head of the femur; on it the fovea, or pit, for the attachment of the interarticular or round ligament. 2d, the neck, forming an obtuse angle with the body or shaft. 3d, the greater and lesser trochanters.

The head of the femur, with the exception of the fovea, is encrusted with cartilage. To the great trochanter are attached the gluteus, medius, and minimus muscles; to the lesser trochanter the united tendons of the iliacus and psoas magnus muscles. To the inner side of the greater trochanter is the *fovea trochanterica,* or *digital,* to which are attached the rotator muscles; the pyriformis, obturator internus, gemelli, obturator externus.

At the junction of the neck (*cervix*) with the shaft are the two intertrochanteric lines; the *anterior* somewhat rough; the *posterior* smooth.

Inferior extremity of the bone.—Thicker and broader than the superior. In it we observe the condyles, external and internal, and the deep depression posteriorly, called *fovea intercondyloidea.* Connected with these condyles are, 1st, the external and internal tuberosities; 2d, the articular surfaces of the condyles; 3d, the pit and groove below the external tuberosity for the tendon of the popliteus muscle.

The articulating surface of the outer condyle is broader than that of the inner, and ascends higher anteriorly. The apparent increased length of the inner condyle, and its descent lower down, is more apparent than real. When placed on the upper surface of the tibia, on which they naturally rest, both condyles are nearly on a level. Anteriorly the articular surfaces of the condyles together form a pulley, on which the rotula glides or plays during flexion and extension of the leg on the thigh, and *vice versâ.*

Articulations.—Above with the acetabulum; below with the tibia; indirectly with the rotula and the fibula.

the outer and inner condyles; *m*, a smooth non-articular part of the shaft, immediately above the trochlea or pulley, on which the rotula plays.—B. Thigh-bone viewed posteriorly.—*a*, head; *d*, neck; *c*, trochanter major; *e*, trochanter minor; *g*, *r*, shaft; *r*, points to the hole for the passage of the nourishing artery of the shaft; *p*, linea aspera; *h*, smooth surface or groove for the femoral artery; *m*, popliteal portion of the shaft, the bone is here cribriform to a certain extent; *l*, external tuberosity; *i*, internal tuberosity; *k*, external condyle; *n*, fovea inter-condyloidea. The crucial ligaments are attached to this depression, which also protects and lodges them.

Muscles attached.—The crureus and sub-crureus to the shaft anteriorly; vasti to the lateral surfaces and linea aspera; adductors and short head of the biceps to the centre of that crest; the gluteus medius to the outer surface of the trochanter major; the gluteus minimus to the anterior part of the inner border of that process; to the fovea trochanterica the rotators outwards; the united tendon of the psoas magnus and iliacus to the trochanter minor, and to a portion of the shaft below the process just named; the quadratus femoris to the line descending from the great trochanter, posteriorly; to the line below the lesser trochanter is attached the pectineus; to the rough impression below the great trochanter is attached the gluteus maximus; above the inner and outer condyles posteriorly are the attachments of the gastrocnemius; above the external condyle the plantaris; and to the fore part of the groove below the external tuberosity is attached the tendon of the popliteus.

Ossification begins in the femur before it commences in the vertebræ. The earliest ossific point is in the shaft; an osseous ring forms which extends towards either extremity involving ultimately the shaft and neck. By-and-bye distinct centres of ossification appear which form the epiphyses—one in the lower extremity of the bone; this ultimately includes both condyles, which remain long quite distinct from the shaft; 2d, a nucleus appears which forms the head; a 3d and 4th for the trochanters. Ossification does not commence until about the twelfth or thirteenth year. Thus at fifteen, and even much later, the femur is composed of five distinct osseous parts; gradually the epiphyses unite with the shaft, consolidating into one bone about the twentieth year. The epiphyses forming the condyles is the last to unite with the shaft.

Age affects the shape of the femur as of the other bones. The angle which the neck forms with the shaft is greatly altered, becoming almost a right angle. On the inner surface of the shaft, from the smaller trochanter downwards, there is a remarkable smooth surface, extending downwards for a couple of inches or more; it is of no great breadth. To this surface there are no muscular fibres attached; near to the junction of the middle and to the lower third of the bone there will often be found a groove corresponding to the course of the femoral artery.

TIBIA AND FIBULA.

The Tibia.—The tibia, the next in length and strength to the femur, receives through the femur the entire weight of the body, communicating it to the foot. As usual it has been divided into a body and two extremities.

The *femoral* or *upper* extremity is much broader than any other part of the bone: it presents, 1st, in front the tubercle, smooth above and rough below. On the smooth portion rests a deep bursa; to the rougher inferior portion is attached the so-called ligament of the patella.

2d. At the sides are the two rounded masses called tuberosities

on the external of which is the facette for the articulation of the fibula. To these are attached the lateral ligaments of the knee-joint.

3d. The superior concave surfaces of the bone are called *condyles*, outer and inner; between these hollow surfaces is the superior spine of the bone; to the irregular depressions behind and before this spine are attached the crucial ligaments.

The inferior or tarsal end of the bone is much smaller than the upper or femoral: it is nearly quadrilateral, convex, and smooth anteriorly, posteriorly flat. Anteriorly there is a slightly rough surface, to which is attached the anterior tibio-tarsal ligament; posteriorly the bone is slightly marked by a groove for the flexor longus pollicis muscle. Externally this extremity of the bone is slightly concave and rough superiorly, for the attachment of the transverse ligament, but smooth below, to receive the extremity of the fibula inferiorly, and internally projecting downwards is the malleolus internus, convex internally, where sub-cutaneous merely; smooth externally, where it articulates with the astragalus. Posteriorly, in connexion with this part of the bone are two grooves for the tendons of the tibialis posticus and flexor longus digitorum; and to the apex or lowest part of the process is attached the deltoid or internal lateral ligament.

Inferiorly, where the bone faces the astragalus, it is wholly articular. It is composed of a horizontal and vertical portion, both encrusted with cartilage when complete, and forming, with the astragalus and the lower extremity of the fibula, the ankle-joint.

The *shaft* or body of the tibia, triangular, and diminishing gradually from above downwards for about two-thirds of its length, when it again enlarges a little. It presents three surfaces, an internal, external, and posterior; also three borders, an anterior, inner, and outer. The internal surface is slightly convex, and to a great extent subcutaneous; the external, hollowed above, convex below: the posterior surface is placed at a great depth; it is divided into two parts by an oblique line extending across the bone; this line bounds inferiorly a triangular surface, giving attachment to the popliteus muscle: from the line itself comes the soleus; below are the attachments of the tibialis posticus and flexor digitorum. Near the line is the largest foramen of the kind, called medullary; the arteria nutritia tibiæ passes through it towards the centre of the bone; its direction is from above downwards.

The anterior border or crest is sometimes called the spine or crest of the tibia; the inner border is thick and rounded; it gives attachment to the soleus and flexor longus digitorum: the external, somewhat sharp, bifurcates inferiorly. It gives attachment to the interosseous ligament.

The body of the bone, like the other long bones, is twisted on itself. The axis of the bone differs from that of the femur. The tibia *articulates* with the femur, fibula, and astragalus.

Attachments of muscles.—To the external surface and tuberosity, the tibialis anticus; to the triangular space above the oblique line,

seen on the posterior surface, the popliteus; to that line itself the soleus; to the posterior surface below the oblique line, the tibialis posticus and flexor longus digitorum.

Fig. 77.*

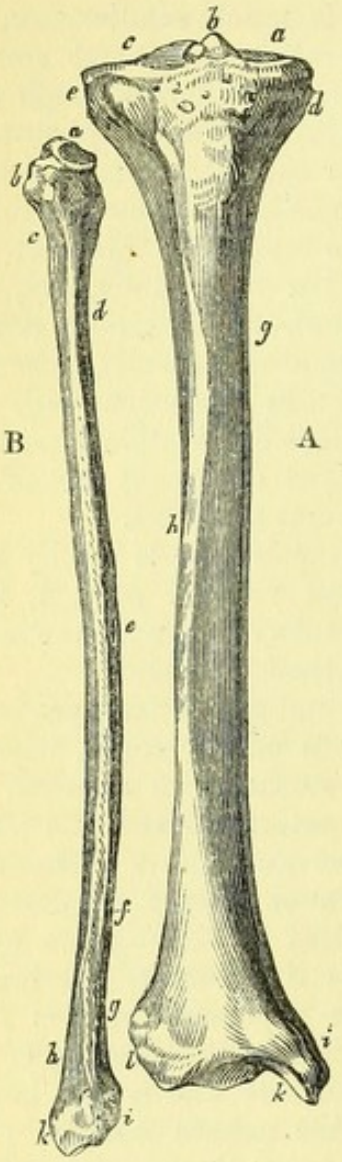

Fig. 78.†

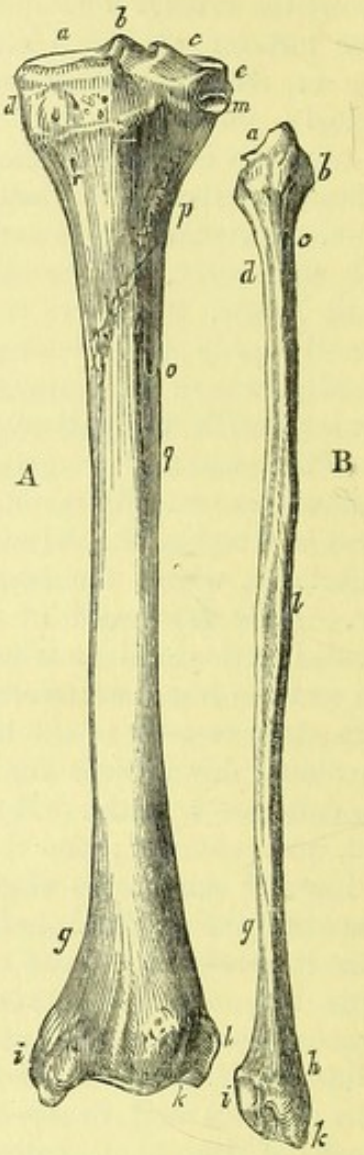

* Fig. 77.—A. Right tibia and fibula, anteriorly.—*a*, *c*, articular facettes, called condyles of the tibia; *b*, superior spine, to which the crucial ligaments are attached; *g*, shaft, smooth, anterior and somewhat internal aspect; *h*, spine or crest; *i*, malleolus internus; *k*, articular surface receiving the head or pulley of the astragalus; *l*, triangular articular hollow, on which rests the fibula.—B. The fibula.—*a*, articular facette of the head of the bone; *b*, spine or tuberosity for the attachment of the tendon of the biceps; *c*, neck and smooth surface, the external popliteal nerve rests on this surface; *d*, shaft of the bone; *e*, foramen for the entrance of the nourishing artery of the shaft of the fibula; *f*, *g*, spines or crests of the bone, defining grooves for muscles and tendons; *h*, crest running to *k*, the malleolus externus.

† Fig. 78.—A. Right tibia, posterior surface.—*a*, upper surface, inner condyle; *c*, upper surface, outer condyle; *b*, superior spine; *d*, *e*, inner and outer

Ossification.—The tibia ossifies from a centre, corresponding to the shaft; and two epiphyses, an upper and lower.

Prior to the 18th year the bone then is composed of three distinct parts; soon after they unite into one, forming the adult bone. The centres of ossification vary somewhat in number; the epiphyses include the articular surfaces.

From 2 to $2\frac{1}{2}$ inches above the malleolus internus is the part of the shaft considered as the weakest, by reason of its being so frequently the seat of the fracture called "Pott's Fracture."

THE FIBULA, *or peronè, from peron, a clasp.*—Slenderer than the tibia, which it nearly equals in length; it is situated on the outer side of the leg. In its natural position it extends lower than the tibia, which goes beyond it superiorly; it carries no part of the weight of the body.

The shaft or body, irregularly triangular; presenting three prominent lines, bounding as many surfaces. The anterior bifurcates inferiorly, enclosing a slight concave triangular surface; this is subcutaneous: the line also gives attachment to the muscles. To the internal line is attached inferiorly the interosseous ligament and muscles. The three lines bound so many surfaces, to which muscles are attached. On the posterior surface, towards the middle, is the foramen for the passage of the medullary artery.

The upper extremity of the bone is called the head; it is smaller than the inferior one, called malleolus externus; it is here we find a small oval facette, by which the bone is articulated to the external tuberosity of the tibia. To the external and upper portion of the head is attached the tendon of the biceps and the external lateral ligament of the knee joint, and those connecting the bone to the tibia. The inferior, or tarsal extremity (called malleolus externus), has posteriorly a shallow groove for lodging the tendons of the peronei muscles. Externally, the malleolus is convex and subcutaneous; internally, triangular and articular; encrusted with cartilage when entire, and resting against the astragalus. Posteriorly there is a rough depression, to which is attached the transverse ligament of the ankle joint, whilst to the apex is attached the external lateral ligament.

Articulations.—At both extremities with the tibia, and inferiorly with the astragalus.

Attachment of muscles.—The extensor communis, proprius and peroneus tertius, are attached to the internal surface of the tibia; the

tuberosities; *g*, shaft; *o*, hole for the entrance of the nourishing artery of the tibia; *i*, malleolus internus; *k*, articular surface on which plays the astragalus; *l*, triangular surface connected with the fibula; *p*, oblique line bounding the triangular surface.—B. Right fibula; posterior surface.—*a*, articular facette; *b*, spine or tubercle; *c*, groove and neck; *d*, shaft and crests; *l*, opening for the passage of the nourishing artery of the fibula; *l*, *g*, *h*, crests and grooves described in the text; *k*, malleolus externus; *i*, articular surface, on which plays a corresponding cartilaginous surface of the astragalus.

tibialis posticus to the depression on its posterior surface; the peronei are attached to its external surface, and the soleus and flexor longus to its posterior surface; the tendon of the biceps flexor cruris to its head.

Its *ossification* proceeds from three centres; one for the shaft, one for the upper, and one for the lower extremity. The epiphyses which the extremities form are late in uniting with the shaft, so that entire consolidation may not take place until the twenty-fifth year.

BONES OF THE FOOT.

The foot, the analogue of the hand, is composed of three parts; tarsus, metatarsus, and toes. In the tarsus are seven bones; the calcaneum, astragalus, scaphoid, cuboid, and three cuneiform.

Fig. 79.*

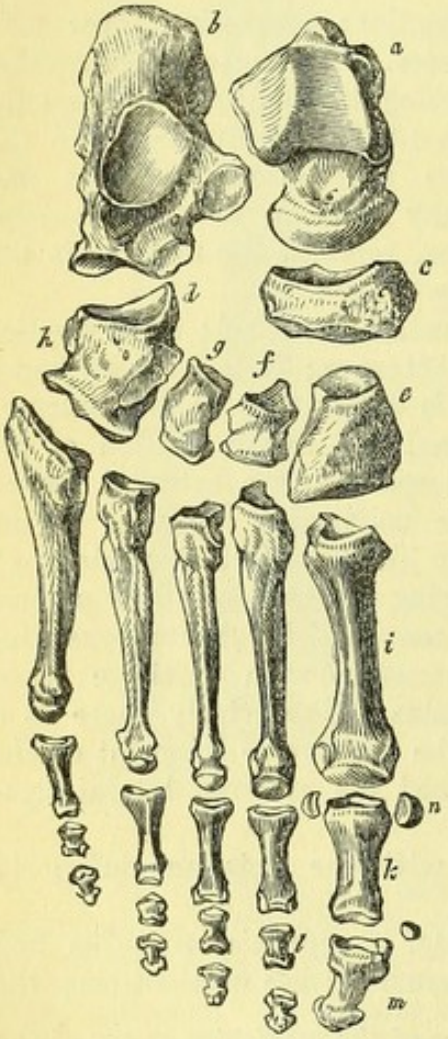

Fig. 80.†

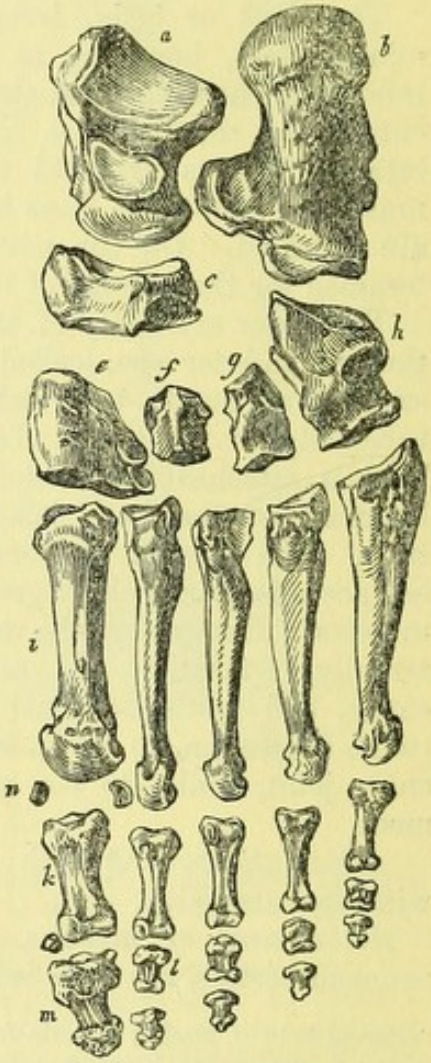

* Fig. 79.—Skeleton of the right foot; upper surface.—*a*, astragalus; *b*, calcaneum, os calcis; *c*, scaphoid or navicular; *d*, cuboid; *h*, groove for the tendon of the peroneus longus muscle; *e*, *f*, *g*, internal, middle, and external cuneiform bones; *i*, first metatarsal; the other four follow in succession; *k*, proximal phalanx of the great toe; *l*, middle phalanx of the second toe; the

Os Calcis; *Calcaneum.*—The largest of the bones of the foot. Examined superiorly, there is, 1, a concave portion intervening between the tendon of Achilles and the articular surface, on which rests the astragalus; 2, this articular surface; 3, a rough depression, into which is inserted the interosseous ligament; 4, another articular surface for the astragalus.

Inferior surface of the bone.—1, two tubercles, to which are attached the plantar aponeurosis and superficial plantar muscles. A depression between these ligaments gives attachment to the long plantar ligament, whilst to an eminence in front is attached the calceo scaphoid ligament.

Fig. 81.*

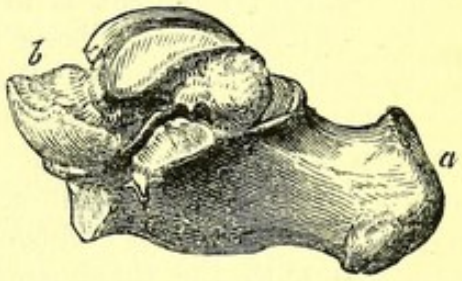

Anterior surface. — Articulates with the cuboid bone.

The Posterior surface.—Convex, forms a rough projecting tuberosity (tuber calcis) for the attachment of the tendo Achillis. A synovial bursa separates the upper part of this tuberosity (posterior surface) from the tendo Achillis.

External surface of the bone.—Mostly subcutaneous, but presenting anteriorly superficial grooves for the tendons of the peronei muscles.

Inner surface.—Deeply concave, corresponds to the plantar vessels, nerves, and tendons of the flexor muscles. The process at the upper part of this surface is grooved for the tendon of the flexor longus pollicis; the process itself presents an articular surface above, to sustain the fore part of the astragalus, and hence the process itself has been called *sustentaculum tali.*

The bone articulates with the astragalus and cuboid bones.

The Astragalus (*Talus*).—This bone, as forming in a great measure the ankle joint, is the most important bone of the foot.

Upper surface.—1, a large cartilaginous surface, articular; 2, a rough and slightly elevated part for the attachment of ligaments. On the outer and inner sides are two smooth articular surfaces of unequal depth; they are continuous, with the articular surface on the tibial aspect of the bone. These outer and inner articular surfaces articulate with the malleoli. The astragalus presents inferiorly, two

rest follow in succession; *m*, distal phalanx, or nail bone of the great toe; *n*, sesamoid bones, developed in the tendons of the flexor brevis pollicis.

† Fig. 80. Right foot, lower or plantar surface.—*a*, astragalus; *b*, os calcis; *c*, scaphoid; *h*, cuboid; *e*, *f*, *g*, inner, middle, and outer cuneiform bones; *l*, metatarsal bones; *n*, *n*, sesamoid bones; *k*, proximal phalanges of the toes; *l*, middle phalanges of the four external toes; *m*, distal phalanges or nail bones of all the toes.

* Fig. 81.—Calcaneum and astragalus, *in situ*, right and inner side.—*a*, tuberosity of the calcaneum. In the young this forms a distinct epiphysis, becoming a process of the bone in the adult. *b*, head of the astragalus.

articular surfaces, separated by a groove, into which is inserted the interosseous ligament, binding it to the os calcis. Both these articular surfaces rest on the calcaneum.

THE CUBOID BONE (*Os cuboides: cuboideum*).—Situated on the outer side of the foot. *Upper* surface: rough, for the attachment of ligaments.—*Plantar* surface: a tuberosity, a rough surface, and a groove for receiving the tendon of the peroneus longus muscle. The calcaneo-cuboid ligament is attached to the irregular parts of this surface. Anteriorly, the bone is smooth, and divided into two parts; by this surface, so divided, the bone articulates with the fourth and fifth metatarsal bones. Posteriorly, the bone has an articular surface, by which it meets the os calcis. Externally, there is a groove continuous with that of the inferior or plantar surface; in this groove plays the tendon of the peroneus longus muscle. Internally, the bone articulates with the third cuneiform bone, and occasionally with the scaphoid, and for this purpose has one or two corresponding articular surfaces.

THE SCAPHOID BONE (*Navicula*).—Situated on the inner side of the foot, between the astragalus and the three cuneiform bones. This bone is best understood by considering its articular and non-articular surfaces. Its superior inner and lower surface are uneven; they are in fact non-articular, and give attachment to ligaments. Anteriorly, the bone presents a convex articular surface, on which rest the three cuneiform bones; posteriorly, a concave articular surface, corresponding to the head of the astragalus. Inferiorly there is a tubercle, to which is connected the tendon of the tibialis posticus muscle; and occasionally we find, externally, a small articular surface connecting it with the cuboid.

THE CUNEIFORM (*wedge-shaped*) BONES.—These bones are well named. They are like the preceding, best understood by considering their articular and non-articular surfaces.

The first, or most internal, is the largest; the second, in point of position, reckoning from within outwards, is the smallest; the third is of an intermediate size. They articulate, 1, with each other; 2, with the first, second, and third metatarsal bones; 3, with the scaphoid and cuboid bones. The first articulates with the first metatarsal bone and with the scaphoid; it presents then two articular surfaces for this purpose. But it also articulates with the second cuneiform bone; hence the necessity for another articular surface. The first and third cuneiform bones, by projecting beyond the middle one, come in contact with the sides of the second metatarsal bone, and this gives rise to additional small articular facettes in both these bones. On the external side of the third cuneiform bone there is a smooth surface, by which it articulates with the cuboid bone.

The other surfaces are non-articular, unequal, and give attachment to ligaments.

Attachment of muscles.—The muscles in connexion with the tarsal bones are, 1, the extensor brevis digitorum communis to the dorsum of the os calcis, and the tendo Achillis and the tendon of the plantaris to the tuberosity of the same bone. Inferiorly, the following muscles are attached to the os calcis; the flexor accessorius, a part of the abductor pollicis, the abductor minimi digiti, and the flexor brevis digitorum. 2. To the cuboid bone is attached a portion of the abductor pollicis and the flexor brevis pollicis. 3. To the scaphoid a portion of the tendon of the tibialis posticus. 4. To the cuneiform bones a portion of the tendons of the tibialis anticus and posticus muscles is attached to the first; to the second and third a part of the flexor brevis pollicis.

METATARSAL BONES.—In the metatarsal region there are five bones, named numerically, beginning with the one nearest the mesial plane of the body. Posteriorly they are in contact, but separated from each other throughout the rest of their course. The interosseous spaces between these bones are also named numerically.

These bones have *common* and *special*, or individual characters. The 1st and 5th may be recognised at a glance; the projecting tubercle at the outer side of the base of the fifth being peculiar to it. The first, short and strong, articulates with the great toe and with two sesamoid bones, by smooth pulley-shaped surfaces, seen upon the inferior surface of the digital end of the bone. The *second* metatarsal is distinguished from the others by its being the longest of the five. It has, moreover, articular surfaces, placing it in connexion with the first cuneiform bone and with the 1st and 2d metatarsal bones. The 3d metatarsal bone is with more difficulty to be distinguished from the 4th; the 3d is somewhat longer. When placed together the 4th projects further backwards, and generally the 4th has a small additional articular facette, connecting it with the 3rd cuneiform bone. Besides its remarkable form, the 5th has only one lateral articular facette.

In respect of common characteristics, these bones have all a shaft and two extremities; they are, as it were, small bones in miniature. Anteriorly (digital end), they have rounded articular heads, supporting the proximal phalanges of the toes. That of the first metatarsal bone forms what is called the ball of the great toe.

PHALANGES OF THE TOES.—These correspond in number and form with those of the fingers; they do not require any minute description. It is in their comparative smallness (with the exception of the large toe) that they differ most from the phalanges of the fingers, already described. The middle phalanges are remarkably short. In the aged the middle and distal phalanges of the little toe are often found consolidated.

Attachments of muscles.—The metatarsal bones give attachment to the following muscles:—To the 1st, are attached the tendon of the

peroneus longus and the first dorsal interosseal; to the 2d, the transversalis pedis, and the first and second dorsal interossei; to the 3d, a part of the adductor pollicis, three interossei, and part of the transversalis pedis; to the 4th, three interossei and part of the transversalis pedis; to the 5th, the peroneus brevis and tertius, the transversalis pedis, part of the flexor brevis minimi digiti, also the fourth dorsal and third plantar interosseal muscle.

To the proximal phalanx of the great toe are attached the tendons of the extensor brevis digitorum, the abductor flexor brevis, and adductor pollicis; to the second, the tendons of the extensor proprius pollicis and flexor pollicis longus. To the middle phalanges of the other toes proceed the tendons of the flexor sublimis and of the extensors; and to the third or distal, the tendons of the flexor profundis and the common extensors.

Sesamoid Bones.—In each of the lower extremities there are at least three sesamoid bones; one, the patella or rotula, in connexion with the knee-joint; and two, much smaller but equally constant, holding a similar relation to the metatarsal phalangeal articulation of the great toe.

Of the Patella.—The patella, rotula or knee-pan, is placed in front of the knee-joint. Like the other sesamoid bones it is developed in a fibro cartilage, imbedded in the tendon of a muscle. By means of this tendon, called generally the ligament of the patella, the bone is firmly connected to the tibia. The patella has two surfaces; an external, uneven, and non-articular. This is the cutaneous surface; the bone is here protected by a synovial bursa, and by an expansion of the femoral aponeurosis and extensor tendons. The other surface faces the joint, and plays on the pulley of the femur; its upper part is encrusted with cartilage in the fresh state. The upper part of the bone is called the base; the lower the apex. The lateral borders are convex, the external being thinner than the internal. A vertical and somewhat elevated line divides the articular surface into two unequal parts, the external being the broader; by this the patellæ may be distinguished from each other. It ossifies about the third year, from a single centre.

Fig. 82.*

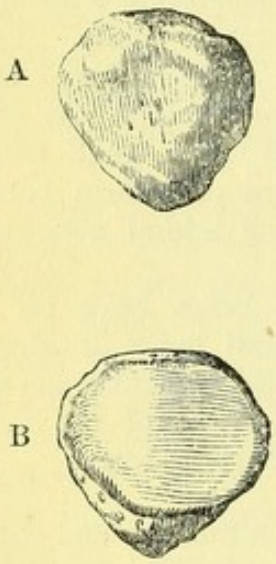

Other Sesamoid Bones.—Of these the two placed below the ball

* Fig. 82.—A. The patella or rotula, outer surface.—B. The same osteïd, as seen on its articular or inner surface.

of the great toe are never absent; they resemble the patellæ in their relation to the joint and to the tendon of the flexor brevis pollicis. In all respects they resemble the sesamoid bones already noticed in describing the hand.

Sesamoid bones are occasionally found in connexion with the tendons of the tibialis posticus and peroneus longus; and two occasionally behind the condyles of the femur.

Accidental ossifications, strongly resembling sesamoid bones (osteïds), are occasionally found imbedded in tendons and muscles; they are, however, pathological appearances.

OF THE SKELETON OF THE FOOT GENERALLY.

No part of the skeleton merits more the attention of the student: its physiology also is interesting. In the finely-formed foot the second toe is the longest, and the first interosseal metatarsal space considerably larger than the others.

The foot and hand are strictly analogous structures, but they are not homologous, properly speaking, but merely represent each other; they belong to different segments of the skeleton.

OSSIFICATION OF THE TARSAL, METATARSAL, AND DIGITAL BONES.

Tarsal bones.—The os calcis grows from two centres of ossification, one for the body of the bone, the other for the tubercle: this continues as an epiphysis to near puberty. The other bones of the tarsus have single centres of ossification.

Metatarsal bones.—These bones have each two centres of ossification, one for the shaft and a second for the head or digital end: this latter forms the epiphysis; but in the metatarsal bone of the great toe, like that of the thumb, the epiphysis is at the proximal end of the bone, showing an analogy in this as well as in shape with the digital bones.

The phalanges of the toes resemble in their ossification those of the fingers. Each is formed of two parts, a principal one and an epiphysis: the latter is found at the prominent end of each bone.

SKELETON OF THE INFANT COMPARED WITH THE ADULT.

Although Ruysch, Kirkringius, Albinus, and other exact descriptive anatomists knew well the history of the young skeleton, in so far as regards the progress of ossification, the number of the germs or nuclei, the vascularity of the periosteum, and the bones themselves, they were yet ignorant of the meaning of those infantile forms revealed to us by the discovery of transcendental or philosophic anatomy. Bichat himself was ignorant of this new element of research, and this circumstance much affected his otherwise great discoveries.

I have caused, therefore, to be reproduced here a woodcut originally

executed for another work,* not altogether as a substitute for the skeleton itself, which it can never be, but with a view to the calling the attention of the student to those singular forms and disproportions which the infantile skeleton presents. These peculiarities and disproportions gradually give way with years, being succeeded by the *adult forms*, the specific attributes of the individual. When this does not take place the infantile forms remain, at least to a certain extent; they are of course *anormal* as regards the adult individual; they are, in fact, *deformities* as regards the human adult form, but they are *normal* as regards the infant and the inferior animals of creation, recent and fossil.

Fig. 83.†

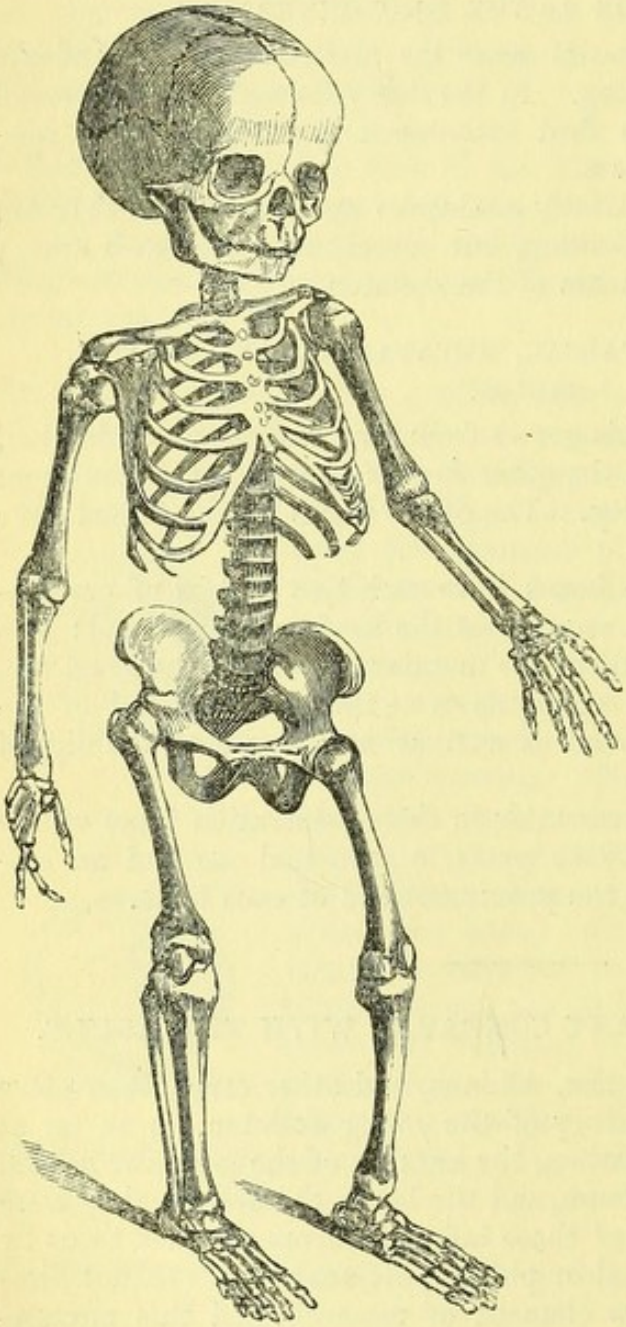

It were foreign to the object of this work to do more than point out a few of these peculiarities:—The great bulk of the head, compared with the trunk and limbs; and, more especially, the disproportion between the cranium and face, and, as a consequence, between the brain and the organs of sense. The jaws are small; the neck short; the thorax slender, and without form; the shoulders narrow; spinal column much less curved than it afterwards becomes; pectoral extremities long as compared with the lower, and with the torso generally. In the pelvic or inferior extremities the thigh-bones are short and straight, and with the legs and feet recall strongly to the mind the forms of the oran and chimpanzee, the two animals hitherto found which approach nearest to man's structure.

The skeleton of the feet are elongated and narrow;

* "A Manual of Artistic Anatomy."

† Fig. 83.—Natural Skeleton of the child about 2 years old.

Fig. 84.*

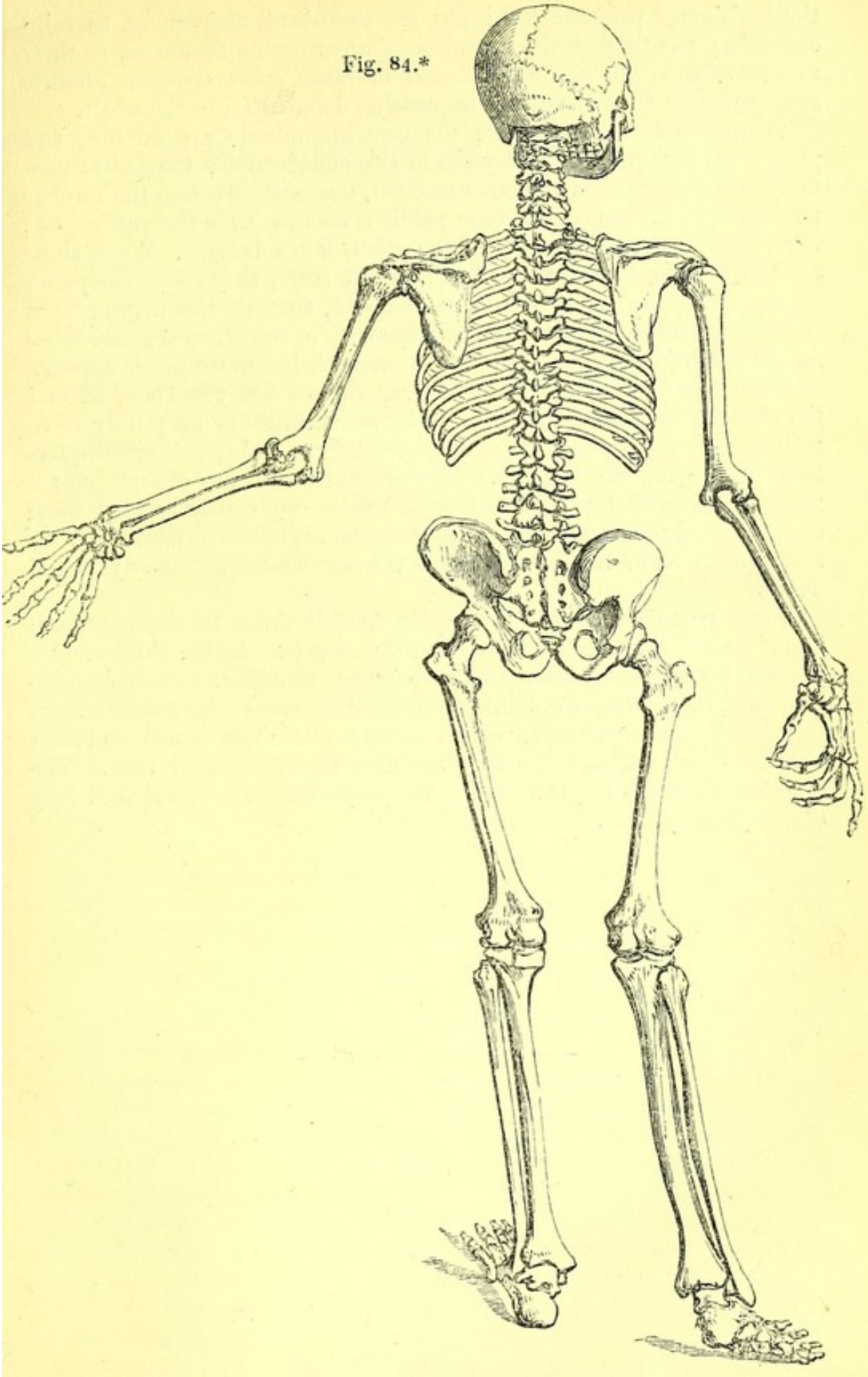

* Fig. 84.—The Adult artificial Skeleton; back view.

the heel-bones project; the limbs are semi-bent, and cannot be fully extended; the thigh-bones are wide apart at both extremities, or their axis is vertical like the thigh-bones of birds. When these infantile shapes remain they constitute unpleasing deformities in the adult.

The pelvis also is peculiar; the ossa innominata are narrow, and placed nearly upright as they are in the chimpanzee; the sacral vertebræ are narrow, and resemble in form, size, and direction the lumbar portion of the column; the false pelvis is narrow, as in the quadruped; the antero-posterior diameter of the pelvis is the longest. When these forms continue, more or less, to the adult state, they cause the pelvis of the European woman to resemble,—1, that of the negro; 2, if more aggravated, that of the chimpanzee, or quadruped; and those forms which give to the European woman all her grace never appear.

Reflections and inferences like these, which a few years ago, when I first taught anatomy, were viewed by the profession as purely theoretical, are now found to bear on physiological and pathological questions of the highest interest. The formation of the obliquely-oval pelvis discovered by Negele, though made empirically by that most distinguished of accoucheurs, could only be explained satisfactorily by the application of the principles of transcendental anatomy just laid down.

These peculiarities of form apply in full force to the new-born infant generally; hence artists avoid drawing it. In the child of two years old the deformities and disproportions, though not overcome, are concealed by the improved integumentary covering and subcutaneous cellulo-adipose membrane, which covers all. The hands and feet become beautiful, and the face acquires an intellectual look. The skeleton continues to grow, and other proportions are established long before puberty.

LIBRARY

ARTICULATIONS, OR LIGAMENTS.

THE bones composing the skeleton are connected together by articulations, of which some are *moveable* and some fixed.

Until Bichat appeared, the various structures entering into the composition of the articulations were usually confounded with each other. He ought, perhaps, to have gone farther than he did, and boldly discarded the language of the older anatomists, who were learned merely in words.

The *moveable* articulations have been subdivided into two great subdivisions, those, namely, in which the surfaces of the bones forming the articulation are said to be continuous, though not strictly so, as in the case of the bodies of the vertebræ, and those in which the osseous surfaces are merely contiguous; but even here the classification is faulty, for, in the articulation of the lower jaw, knee, and clavicles, the bones are not contiguous, even in this sense.

Certain of the immoveable articulations have been already described; the sutures and harmoniæ of the bones of the head; others remain to be spoken of. This class of joints has, moreover, been arranged in four divisions, 1st, where the bones are placed merely in juxta-position, as at the base of the skull; 2d, where they are interlocked, as in the sutures; 3d, where there exists *implantation*, as in the teeth and alveoli.

Systematic writers still present their readers with a tabular account of the articulations, employing Greek terms, invented by those who knew little or nothing of the true nature of the joints.

MOVEABLE ARTICULATIONS, OR DIARTHROSES.

Surfaces united: amphiarthroses. Ex. Junction of the bodies of the vertebræ with each other.

Surfaces not united, and permitting of circumduction: 1st, orbicular diarthroses. Ex. hip-joint. 2d, or only permitting of limited motion: Ginglymus. Ex. The elbow-joint.

The articulation of the lower jaw is called an arthrodia, and the term amphiarthrosis has been applied to the carpal articulations.

The immoveable articulations, called also synarthroses, have been subdivided into: 1st, sutures: dovetail. Ex. Sagittal, &c.; squamous; temporal. 2d, harmonia. Ex. Nasal, maxillary. 3d, gomphosis. Ex. Teeth in the alveoli. 4th, schindylesis. Ex. Vomer and rostrum of the sphenoid bone.

Anatomists still employ the term symphysis to express, when

applied to the lower jaw, a firm bony union; and when used in reference to the pelvis, to designate a joint having a complex apparatus of soft structures.

The terms synchondrosis and syndesmosis are still applied to the sacro-iliac articulations.

STRUCTURES COMPOSING THE ARTICULATIONS.

A much more important inquiry is the nature and character of the structures which enter into the composition of the joints.—These are, in addition to the osseous surfaces, 1st, synovial capsules; 2d, cartilages called articular; 3d, ligaments; 4th, fibro-cartilages.

The *Synovial capsules*, or membranes, have a strong resemblance to serous membranes in form, structure, and functions. They occur in all the moveable articulations without exception, and form shut sacs; transparent, and applied over all the parts, entering into the composition of the joints without including any of them. Their internal surface is free, contiguous to itself, smooth, polished, and often furnished with villosities and fimbriated prolongations, and continually lubricated by an albuminous fluid, similar to that bedewing the surfaces of the serous membranes. Their external surface is cellular, and is attached to the neighbouring organs.

These articular capsules, mistaken by the older anatomists for ligaments, vary much in size and complexity. The miscroscopic history of these capsules will be found in the section on general anatomy, towards the close of this work. Their functions are to protect the surfaces over which they are spread, and this they effect chiefly by means of the synovia, or joint-oil, they secrete by their deep surfaces. This fluid is chiefly composed of water and albumen.*

2d. *Articular cartilages.*—The surfaces of the bones where they form moveable articulations are covered with cartilages of a pearly white colour, remarkably hard and elastic. Their mode of union with the osseous surface has not been very clearly made out; nevertheless it is extremely firm. Their opposing or smooth surfaces, called also the free surface, is probably invested continuously with a layer of synovial membrane. This, however, has been denied.

These cartilages are generally thickest in the centre, becoming thinner towards their edges. Their physical and vital properties have been considered in the section on general anatomy, to which such inquiries more appropriately belong.

3d. *Ligaments.*—The ligaments are dense fibrous bundles, or fasciculi of ligamentous tissue. They are interlaced at their extremities with the periosteum, and thus may readily be distinguished from tendons; their use is to connect the bones to each other. A loose cellular tissue connects the ligamentous fibres to each other. Ligaments are non-elastic, and thus differ from fibro-cartilages, with which they have often

* See the section, General Anatomy.

been confounded. Some have divided them into cordiform or rope-shaped, and orbicular or capsular. The division is of little moment.

4. *Fibro-cartilages—articular.*—These substances are now admitted to be distinct from ligaments; they are of great strength, and elastic. They vary much in form, and are subject to few pathological affections. At times, as between the bodies of the vertebræ, they form the whole articular apparatus, or nearly so; at others they merely form appendages placed within the joints.

OF THE ARTICULATIONS IN PARTICULAR.

It was formerly the practice of the medical student cursorily to examine a few only of the joints, and chiefly, if not exclusively, those which he fancied to be of *practical* importance. This pernicious mode of study has, it is hoped, been finally abandoned. The articulations of the body ought each to be examined attentively, after having been carefully dissected. The joints may be examined in any order the student may think fit. The osteological arrangement of, 1st, the articulations of the trunk; 2d, those of the extremities, has been adopted here. In well-conducted practical classes, the student ought not to meet with any impediment in carrying out this arrangement.

VERTEBRAL ARTICULATIONS, OR COMMON ARTICULATIONS OF THE VERTEBRÆ.—Each vertebra, from the third cervical to the last lumbar inclusive, is placed in contact with that which precedes or follows it, by its body and articular processes; the laminæ and spinous processes of all the vertebræ being moreover connected by ligaments. There results from this, that the common articulations of the vertebræ present themselves under the appearance of an amphiarthrosis for their bodies, and of a plain arthrodia with obscure motions for their articular processes, and that they are further strengthened by accessory ligaments capable of great resistance. We also observe that each vertebra has, on the one hand, isolated and peculiar means of union, as the ligamenta flava and the fibro-cartilages; and on the other, participates in the use of common organs, which extend at once over the whole vertebral column, or at least the greater part of it, such as the anterior and posterior vertebral ligaments. Any portion of the vertebral column may be selected by the dissector for his examination of these ligaments; but perhaps the four last dorsal and two first lumbar will show him all the ligaments to best advantage.

The *great anterior vertebral ligament* (*Fig.* 85), or longitudinal facia, occupies the anterior part of the vertebral column, from the axis to the upper part of the sacrum. It is membraniform, and of a glistening appearance, and presents very distinct longitudinal striæ, which separate so many bundles of fibres, between which there exist small intervals, irregular as to form and position, for the passage of blood-vessels and cellular tissue. This membrane is very narrow in the neck, broader in the back, still broader in the lumbar region, and so disposed as to cover the greater part of the bodies of the vertebræ. The

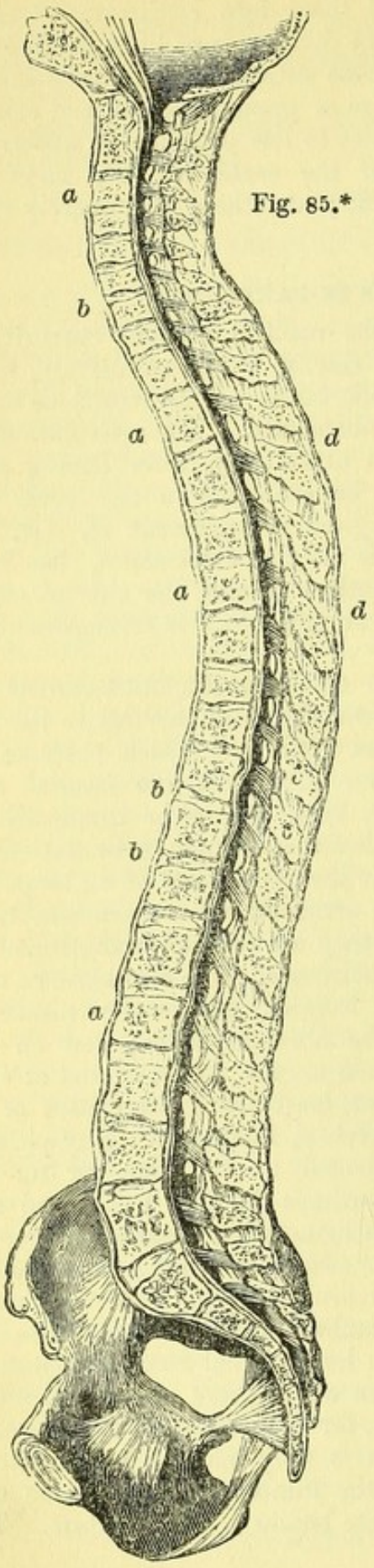

Fig. 85.*

fibres which constitute this membrane do not occupy its whole length; they even have not all the same dimensions. The superficial fibres cover the bodies of four or five vertebræ; those which are intermediate are lost beyond the third vertebra below that from which they have risen; the deepest are still shorter, and only go from one vertebra to that which is immediately below it. It is also to be observed, that in general these fibres arise in much greater numbers from the fibro-cartilages than from the vertebræ themselves.

The student will now, with a small Hay's-saw, or bone-nippers, cut across all the pedicles or roots of the processes, and thus remove the posterior part of the spinal canal in a mass. On the posterior aspect of the bodies of the vertebræ thus exposed, he will observe the *great posterior vertebral ligament* (*Fig.* 85), or *longitudinal facia*. It extends at the back part of the bodies of the vertebræ, from that of the axis to the sacrum. It is broader in the neck and back than in the lumbar region, where it is so narrow as not to be more than two lines broad in all parts of its course; it is broader opposite each intervertebral substance than on the bodies of the vertebræ themselves, which gives it the form of a long band con-

* Fig. 85.—Vertical section of the spinal column, right side.—*a*, bodies of the vertebra; *b*. intervertebral fibro-cartilages; *c*, spinous processes; *d*, interspinal ligament (ligament of the apices of the spinous processes). The interior of the vertebral canal is also seen, the intervertebral foramina and a portion of the inner surface of the yellow ligaments of the right side. *a* points also to the great anterior ligament, as seen in profile. The posterior common ligament is behind the bodies of the vertebræ.

Fig. 86.*

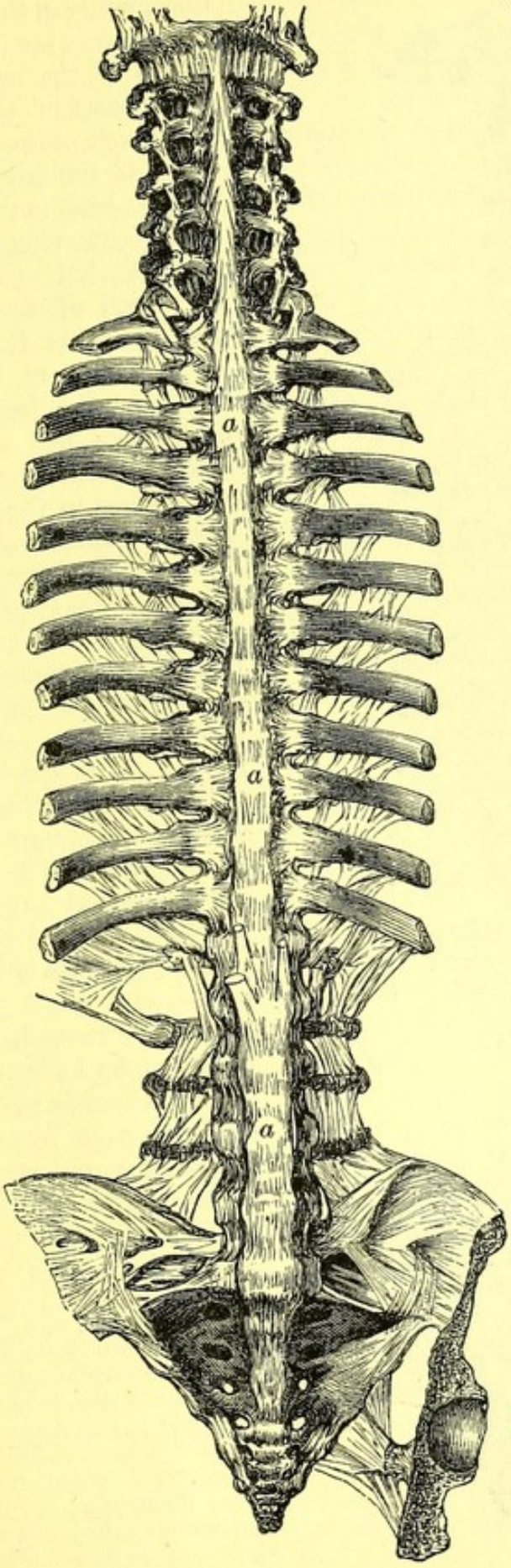

tracted at intervals. It is smooth and of a very shining pearly-white. It is in general denser and more compact than the anterior facia, rather thin in the lumbar and cervical regions, and thickest in the back. This membrane, like the anterior, is composed of superficial fibres, occupying the interval of four or five vertebræ or fibro-cartilages, and of deep fibres, extending over two vertebræ only, or even over a single vertebra and its fibro-cartilage.

Next, remove entirely these membraniform ligaments, and thus bring into view the *inter-vertebral fibro-cartilages*. These organs resemble sections of cylinders, of a whitish colour, firm, and possessed of great flexibility; they are situated between the bodies of the vertebræ, from the interval which separates the second and third, to that which exists between the last lumbar vertebra and the sacrum. Their form corresponds to that of the bodies of the vertebræ, with which they are connected, being

* Fig. 86.—Section, showing the anterior common ligament of the vertebræ throughout its whole extent.—*a*, *a*, *a*. The ligament extends along the front of the vertebral column from the atlas to the sacrum.

Fig. 87.*

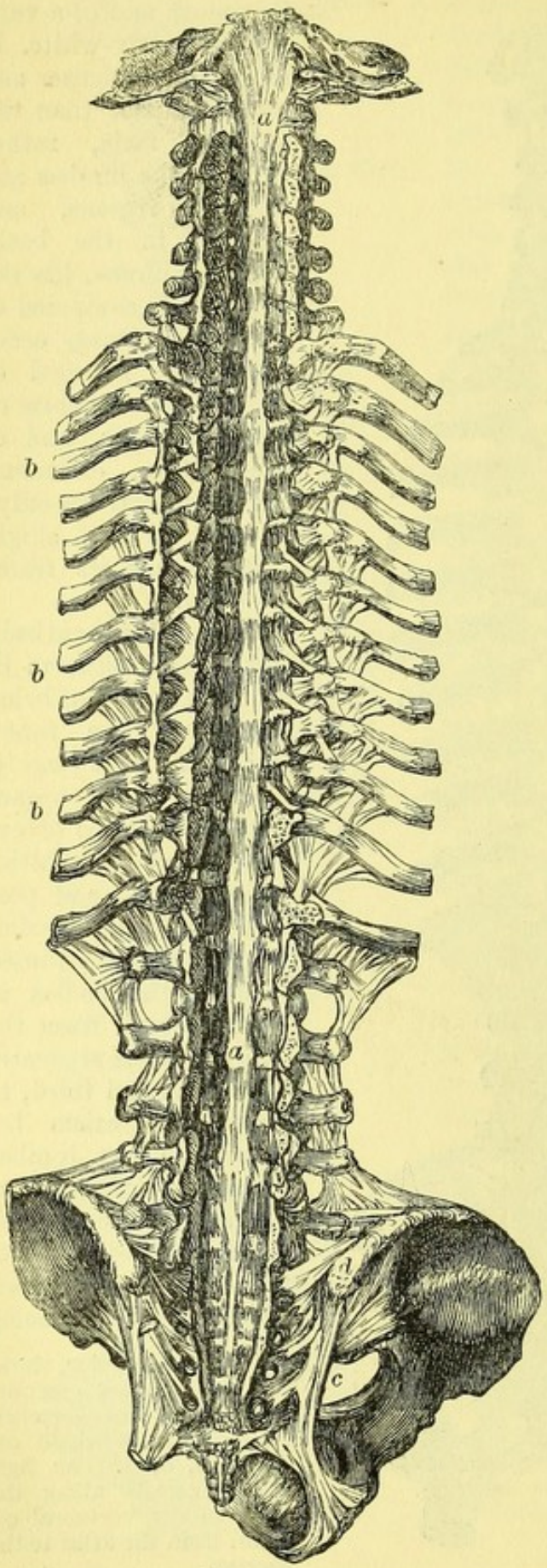

oval in the neck and loins, while in the dorsal regions they are circular. Those of the neck and upper part of the back are much thinner than those of the lower part of the back and loins, the latter having a thickness of half an inch. But each of them has not an equal thickness in all parts of its extent; in the loins and neck they are thinner behind than before, and the reverse in the dorsal region, which constitutes one of the principal causes of the triple curvature of the spine. (*Fig.* 57.) By their *upper* and *under surfaces* the fibro-cartilages closely adhere above and below to the corresponding surfaces of the vertebræ. In subjects which have not exceeded twenty years, they are united to the epiphyses of these bones, with which they are easily removed. The intervertebral fibro-cartilages are formed in their circumference by very close fibres and laminæ of the nature of ligaments; the fibres never direct themselves per-

* Fig. 87.—*a*, *a*, *a*, Posterior common ligament of the vertebral column. The spinal canal has been laid open, and the medulla and its membranes removed; *b*, posterior costo transverse ligaments; *c*, posterior sacro-sciatic ligament; *d*, posterior sacro-iliac ligaments.

Fig. 88.*

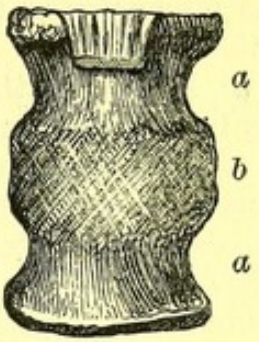

pendicularly from one vertebra to another; but the outermost ascend from right to left, and cover a layer which has an opposite direction, and which is itself applied against other layers having a different direction. The laminæ, which are concentric, are numerous anteriorly and laterally, but in less number at the back part; they intersect each other, diminish in thickness, and leave between them wider intervals, in proportion as they approach the centre of each fibro-cartilage. Their vacuities are filled with a soft, pulpy, homogeneous viscid substance, of a greyish colour, and at the centre itself there is only a very soft, spongy, elastic, areolar tissue, plentifully supplied with the substance in question. This disposition is much more apparent in the lumbar region than in any other part of the vertebral column. In children this substance is whitish, transparent, and much less abundant than in adults, in whom it has more consistence, and is of a yellowish colour. In old people it diminishes still more in quantity, and the fibro-cartilages lose much of their thickness. These bodies, when soaked in water, swell and increase very much in their vertical extent, frequently acquiring a whole inch in thickness; but it is especially towards the centre that the increase is effected, and if one of them is cut horizontally between two vertebræ, each portion rises in the form of a cone, having its base towards its external laminæ of the fibro-cartilage, which acquires a red colour on remaining some time in water. By desiccation, on the contrary, these organs are rendered much thinner, especially in the middle part, which is then reduced to a line of thickness. In the recent state the elasticity of these fibro-cartilages is extremely remarkable, and restores to its direction the vertebral column after it has been variously bent in a dead state. If a vertical section is made of several vertebræ, the tissue of this body expands and surpasses the level of the osseous surfaces. Their tenacity, or power of cohesion, is also very great, and even exceeds that of the bones with which they are connected.

The posterior segment of the spinal canal, which was directed to be removed in order to see the great posterior vertebral ligament, may now be examined. On the internal aspect, most conveniently and almost without dissection, is observed the ligamenta subflava. These occupy the interlaminar spaces of the vertebræ, from that which exists between the second and third to that which separates the last from the sacrum, and complete the vertebral canal behind; they are formed of a strong, firm, and elastic tissue, of a yellowish colour, and composed of vertical fibres. Each of these is divided into two portions, the one right the other left, angularly united toward the base of the spinous process, but in such a manner as to leave between them a

* Fig. 88.—Section of the vertebral column, to show the relation of the intervertebral substance to the bodies of the vertebræ.—*a*, *a*, bodies of two of the vertebræ; *b*, intervertebral fibro-cartilage uniting these firmly to each other.

small fissure, which is closed by a cellular tissue. At the upper part of the neck they are thin and narrow; they become thicker and broader in proportion as they descend, and in the loins acquire very considerable dimensions. Their *upper* edge is attached to the inner surface of the laminæ of the vertebra, which is situated above; the *lower* edge is fixed to the very margin of the vertebral lamina beneath.

The spinous processes of the dorsal and lumbar vertebræ are connected together by two sets of ligaments, those by which the spines of the spinous processes are connected, *supraspinal* and the *interspinal ligaments* which occupy the intervals of the spinous processes. The interspinal ligaments are *lateral*, and correspond on either of the median lines, to the erector muscles of the spine. One of their *edges* is attached *above* to the lower edge of the upper process, and another *below*, to the upper edge of that situated beneath. Posteriorly they are connected with the ligament by which the apices of the spinous processes are connected, and anteriorly with the yellow ligament. They are composed of regular bundles of fibres, which follow different directions, but generally proceed obliquely, and in an opposite direction to the inferior process and the next ligament, so as to cross each other. Lastly, each vertebra has two superior and two inferior oblique articular processes, the inferior of one vertebra articulating with the superior of the other. These surfaces are incrusted with a very thin layer of cartilage, each being provided with a synovial capsule, and in many instances with strengthening bundles of ligamentous fibres.

ARTICULATIONS OF THE 1ST AND 2D VERTEBRÆ WITH EACH OTHER AND WITH THE HEAD.—In description these articulations cannot well be separated from each other. It seems advantageous to allude to those of the head first.

Fig. 89.*

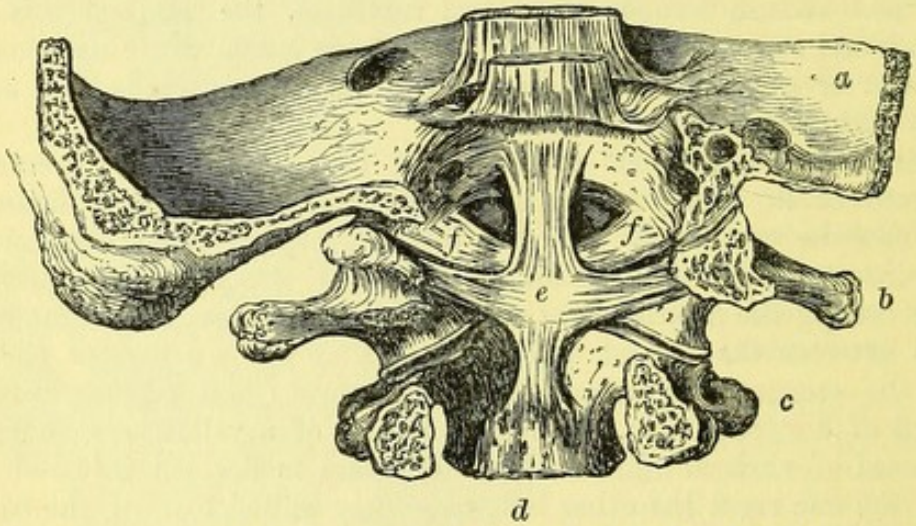

* Fig. 89.—Section displaying the articulations of the head with the vertebral column; with the 1st and 2d cervical vertebræ.—*a*, base of the skull; *b*, transverse process of the atlas; *c*, transverse process of the vertebra dentata; *d*, body of the second vertebra; *e*, transverse or cruciform ligament; *f*, *f*, odontoid or cheek ligaments.

The articulations of the bones of the cranium and face have been already spoken of in the Osteology. They are motionless or fixed, excepting that of the lower jaw.

ARTICULATION OF THE LOWER JAW.—The osseous surfaces are, 1, the glenoid cavity of the temporal bone on either side; 2, the condyles of the temporal bone. These surfaces are encrusted with a thin cartilage, the former only partially. The ligaments are,—

1. The external lateral ligament. 2. The internal lateral ligament. 3. The stylo-maxillary ligament; and, in addition to these, a somewhat complex synovial membrane, and an interarticular fibro-cartilage.

1. *The external lateral ligament* is in fact the true ligament of the joint. Its upper attachment is to the rough surface which separates the commencement of the roots of the zygomatic process, from which, descending backwards, it is attached by its inferior extremity to the outer side of the neck of the inferior maxillary bone. The skin and parotid gland cover the ligament externally; its inner surface touches the synovial membrane and the interarticular fibro-cartilage.

Fig. 90.*

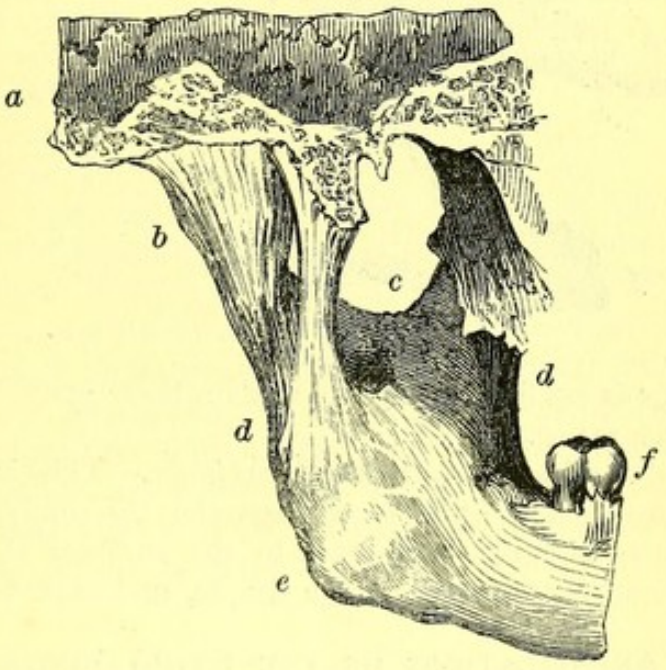

2. *The internal lateral ligament.*—Thinner and longer than the last described; attached superiorly to the spinous process of the sphenoid and the parts in its vicinity, it descends obliquely forwards, becoming broad and membranous, to be fixed to the inner and anterior part of the edge of the commencement of the inferior dental canal.

The internal maxillary artery passes between it and the neck of the condyle; the inferior dentar vessels separate it from the ramus, lower down. The ligament moreover separates the two pterygoid muscles from each other.

3. *Stylo-maxillary ligament.*—This is a mere aponeurotic cord, attached above to the styloid process of the temporal bone; inferiorly, to the angle of the jaw. The ligament gives attachment to numerous

* Fig. 90.—*a*, portion of the base of the skull; *b*, position of the joint; *c*, internal lateral ligament of the joint; *d*, ramus of the jaw; *e*, angle; *f*, last molar tooth of the left side.

Fig. 91.*

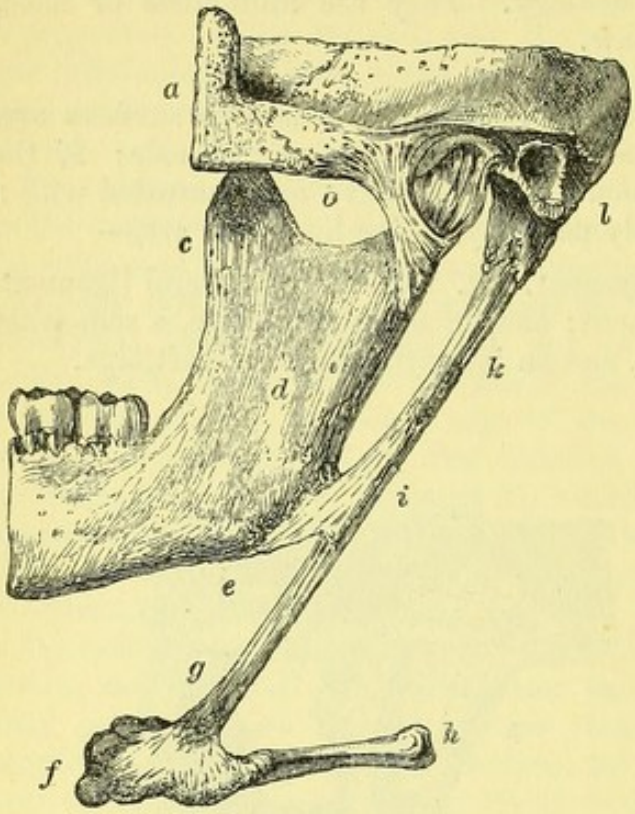

fibres of the stylo-glossus muscles.

The ligament called *intermaxillary* is not properly a ligament. Its structure and important relations to the buccinator, and superior constrictor of the pharynx, will be particularly noticed when describing these muscles.

4. *The Synovial capsule.* — Generally, but not always, two in number. The upper is expanded over the glenoid surface and the superior surface of the fibro-cartilage; the lower invests the inferior surface of this cartilage and the condyle of the lower jaw. When the fibro-cartilage is perforated in the centre, these synovial sacs communicate with each other.

5. *Interarticular fibro-cartilage.*—This is a thin lamina or disc of fibro-cartilage interposed between the condyle and the glenoid cavity. Its form is accommodated to the surfaces it covers. Its relations to the surrounding parts are simple, and cannot well be mistaken.

Articulations of the Hyoid Bones.—It may be as well to describe here, though somewhat out of place, the articulations of the chain of bones called lingual, or hyoid.

Fig. 92.†

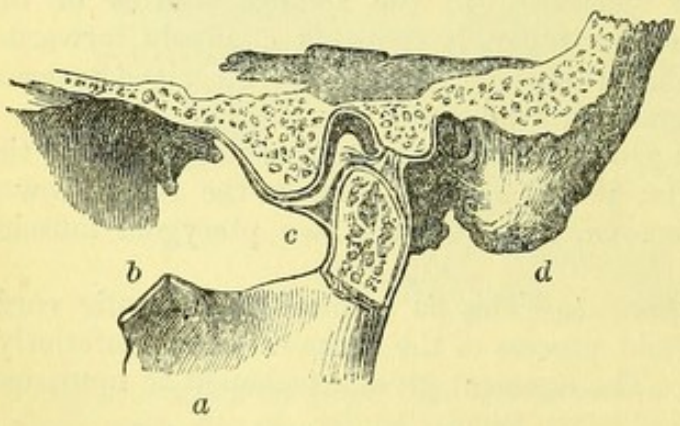

The connexions of the hyoid bones are indirect; by means of the stylo-hyoid ligaments these bones are connected to the base of the cranium.

The stylo-hyoid ligament (one on each side) is a slender, elongated,

* Fig. 91.—Base of the skull, lower jaw, lingual bones, and stylo-hyoid ligament of the left side.—*a*, section of the skull; *b*, external lateral ligament; *c*,

fibrous fasciculus; it is not a true ligament. It is attached superiorly to the styloid process of the temporal bone; inferiorly to the lesser or styloid horn of the hyoid bones. In its place we sometimes find a muscle, sometimes an elongated bone.

ARTICULATION OF THE HEAD WITH THE VERTEBRAL COLUMN (*Occipito-atlantal articulation*).—This articulation is a very close double arthrodia, formed by the condyles of the occipital bone and the superior articular cavities of the atlas; the surface of both these parts is invested with a pretty thick cartilage, which is interrupted in several points of its circumference by inequalities, in which are lodged small masses of reddish cellular tissue. A *synovial* membrane, which exists on each side, covers the articular surfaces, being reflected from the one to the other. It is very loose anteriorly, because on this side it comprehends in its circuit a part of the surface of the occipital bone, while in the rest of its extent it is confined to the circumference of the condyle. *Anteriorly*, it covers the anterior occipito-atlantal ligament; *posteriorly* and *externally*, it is in connexion with much cellular tissue; *internally*, it covers the extremity of the transverse ligament, a part of the corresponding odontoid ligament, and small masses of adipose cellular tissue, which have been taken for synovial glands. This articulation is further strengthened by two ligaments, the one before, the other behind, besides a great number of small irregular ligamentous fibres.

Fig. 93.*

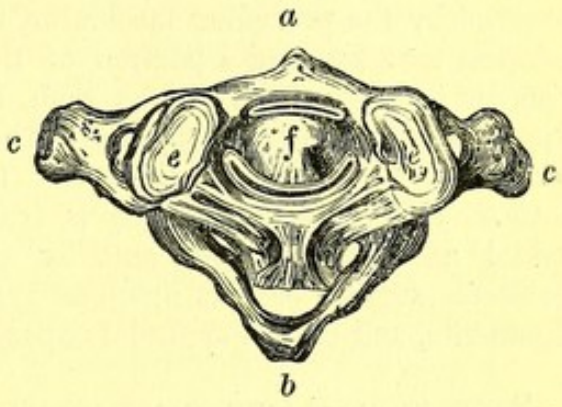

ANTERIOR OCCIPITO-ATLANTAL LIGAMENT (*Membrana annuli anterior v. primæ*).—It is situated between the anterior arch of the atlas and the corresponding part of the margin of the occipital foramen,

coronoid process of the lower jaw; *d*, ramus; *e*, angle; *f*, body of the hyoid bones; *g*, smaller or styloid horn; *h*, larger, thyroid or laryngeal horn; *i*, stylo-hyoid ligament (a slip may be seen detached to the angle of the jaw); *k*, styloid process of the temporal; *l*, vaginal process.

† Fig. 92.—Vertical section of the base of the skull and lower jaw, to show the arrangement of the articulation of the lower jaw with the temporal bone.—*a*, ramus of the jaw; *b*, root of the coronoid process; *c*, condyle of the lower jaw; *d*, mastoid process of the temporal bone. The situation of the inter-articular fibro-cartilage, and the disposition of the synovial membrane, may readily be made out.

* Fig. 93.—*a*, anterior tubercle of the atlas; *b*, posterior; *c*, *c*, transverse processes; *e*, *e*, articular cavities for receiving the condyles of the occipital bone; *f*, summit of the odontoid process *in situ*. The synovial capsules before and behind this process are well seen in this section; likewise the position of the transverse ligament immediately behind the odontoid process.

and is composed of two distinct fasciculi. One of these, which is narrow, round, thick, superficial, and formed of vertical fibres, parallel to each other, has been named the anterior cervical ligament; it descends from the basilar process to the tubercle of the anterior arch of the atlas. The other, which is much thinner, broad, and membranous, extends transversely from the outer extremity of one of the occipito-atlantal articulations, to the corresponding point on the opposite side; its tissue is dense and compact, and the fibres of which it is composed are with difficulty distinguished; its *anterior* surface is covered by the preceding fasciculus, the recti capitis antici majores and minores muscles, and a portion of the recti capitis laterales. It gives rise, by its sides, to a fibrous arch, the concavity of which is directed upwards, and which is attached to the fore part of the occipital condyle on the one hand, and on the other to the jugular surface of the same bone. This ligamentous arch is traversed by the pneumo-gastric and spinal accessory nerves, and by the internal jugular vein. The *posterior* surface of this ligament rests upon the odontoid process, its ligaments, and on the synovial capsules of the articulations itself.

Posterior Occipito-atlantal Ligament (*Membrana annuli post. vert. primæ*).—This is broader than the last; it is formed of two laminæ placed the one before the other, which proceed together from the posterior part of the circumference of the occipital foramen, between the condyles, separating as they descend. The anterior, which is thick, and presents very distinct vertical fibres, is interlaced with the dura mater of the vertebral canal; while the other, which is of a looser and apparently cellular tissue, is attached to the great arch of the atlas. Between these two laminæ there is a slight layer of cellular tissue, traversed by a great number of nervous filaments and vascular twigs, which pass through small holes formed in the midst of the fibres. The *anterior* surface of this ligament corresponds to the dura mater; the posterior to the recti capitis postici majores and minores, and the obliquus superior. Its *extremities* form, with the upper notches of the vertebra, two apertures, through which pass the vertebral arteries and sub-occipital nerves.

Articulation of the Occiput with the Axis or 2d Cervical Vertebra.—The osseous surfaces do not touch each other in this joint. The union is effected by the odontoid ligaments, and an additional ligamentous slip, denied by Weitbrecht.

The odontoid ligaments, usually called the cheek ligaments of the head, from the important functions they perform of limiting the movements of rotation of the head, are two very powerful ligamentous cords, connecting the summit and sides of the odontoid process of the vertebra dentata to two irregular depressions, situated on the inner side of the condyles of the occipital bone. Their direction is diverging, or obliquely outwards.

A ligamentous band of great strength passes across from one condyle

to the other, intermingling part of its fibres with the preceding ligaments.

A suspensory ligament passing from the anterior margin of the occipital bone to the summit of the odontoid process, lies anteriorly to the superior portion of the cruciform, or transverse ligament, so as readily to be confounded with it.

ARTICULATIONS OF THE FIRST AND SECOND VERTEBRÆ WITH EACH OTHER.—This articulation takes place by several points at once, namely, by the tooth-like process of the second vertebra with the anterior arch of the atlas, and by the lateral articular surfaces or processes of these vertebræ, which are horizontal, and much larger than those which succeed.

Odontoid articulation—Synovial membranes.—Two in number, one anterior, between the odontoid process and the posterior surface of the anterior arch of the atlas; the other posterior, between the odontoid process and the transverse ligament. The opposing osseous surfaces are encrusted with cartilages.

TRANSVERSE OR CRUCIFORM LIGAMENT.

Physiologically the most important ligament in the body. This ligament, which is thick and strong, extends from the inner side of one of the lateral masses of the atlas to a corresponding point on the opposite side, passing behind the odontoid process. It thus forms, with the arch of the atlas, a ring, in which the processus dentatus turns, or which turns upon it. It secures the process in its place, and protects the spinal marrow. A small fasciculus of fibres descends from its lower edge to the posterior part of the body of the axis, and a second, ascending from its upper edge, to be attached to the basilar surface of the occipital bone, a short way anterior to the foramen magnum. Hence the ligament has been called cruciform.

On removing the recti capitis antici majores muscles, another ligament is displayed. It is the *anterior atlanto axoidal ligament.* It is attached inferiorly to the base of the odontoid process and body of the axis, and superiorly to the anterior arch of the atlas.

The posterior atlanto axoidal ligament resembles a membrane; it connects the posterior arch of the atlas to the upper edge of the lamin of the axis on each side.

The inferior oblique muscles of the head cover it posteriorly; anteriorly, it corresponds to some yellowish fibres strengthening it, and to the dura mater of the vertebral canal.

Articular process—Synovial membrane.—The articular surfaces by which the atlas and axis meet, differ from all the others in form and extent. Those of the axis are the larger; a thin cartilage invests them, on which are placed the synovial capsules. The capsules are comparatively large, apparently to accommodate them to the extent of motion going on in these joints.

ARTICULATIONS OF THE THORAX.

STERNO-COSTAL ARTICULATIONS.—The cartilages of the first seven ribs are directly articulated with the sternum, and thus the articulations of the ribs may be subdivided into two, namely, 1st, articulations of the true ribs; 2d, those of the false.

Fig. 94.*

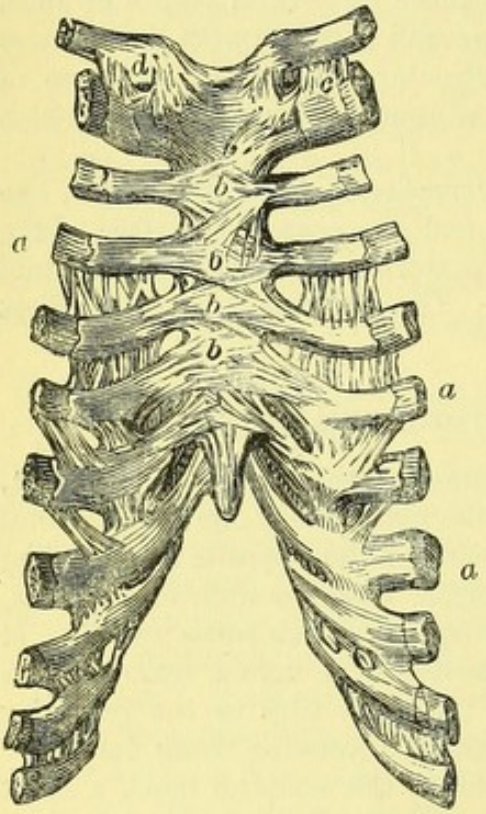

Fig. 95.†

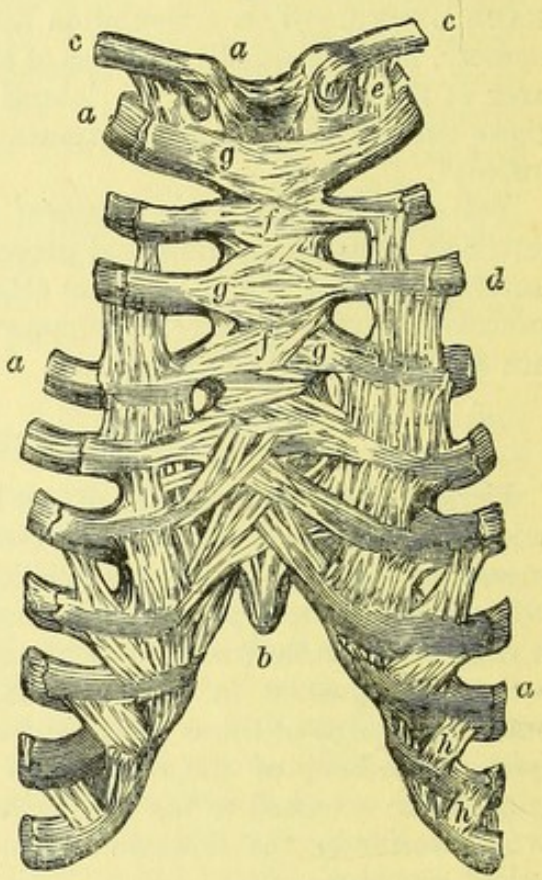

ARTICULATIONS OF THE CARTILAGES OF THE TRUE RIBS WITH THE STERNUM.

The inner extremity of each of these cartilages presents a surface which is lodged in one of the small cavities placed upon the lateral edges of the sternum, and which, like those edges, is invested with a slight layer of cartilage, the surface of which is not very smooth. Two radiated ligaments, the one *anterior*, the other *posterior*, strengthen this species of arthrodia. A very close, and extremely thin, synovial

* Fig. 94.—Costo-sternal articulations. The ligaments represented here are —*a*, *a*, the posterior costo sternal ligament, and *b*, *b*, the membrana-sterni posterior; *c*, the rhomboid, and *d*, the posterior portion of the sterno-clavicular ligament.

† Fig. 95.—Costo-sternal articulations; anterior surface.—*a*, manubrium of the sternum; *b*, ensiform process or cartilage; *c*, *c*, clavicles; *d*, *d*, ribs cut across; *e*, costo-clavicular ligament, left side; *f*, membrana-sterni anterior; *g*, anterior costo-sternal ligaments; *h*, *h*, ligaments uniting the cartilages of the false ribs to each other.

membrane, furnished with but little synovia, covers the articular surfaces; it is not, in general, so easily perceived, but is a little more distinct in the two or three upper articulations than in those which follow, excepting, however, the first, in which there is an absolute continuity of substance between the costal cartilage and the sternum. This capsule is connected before and behind with the anterior and posterior ligaments of the articulation, and is, moreover, strengthened above and below by some irregular fibres.

There almost always occurs, in the articulation of the second of these cartilages, a fibrous fasciculus, which proceeds from its projecting angle to the retiring angle of the sternal cavity, and which divides this articulation into two parts, thus rendering two synovial membranes necessary.

Anterior Ligament.—This ligament is broad, thin, membranous, triangular, and composed of fibres, which proceed in a radiating manner from the inner extremity of the cartilage, to be expanded over the anterior surface of the sternum, where they are interlaced with those of the ligaments of the opposite side, and of those situated immediately above and beneath, with the periosteum of the bone, and with aponeurotic fibres of the pectoralis major. The direction of the fibres of this ligament is such, that the upper fibres pass obliquely upwards, the lower obliquely downwards, and the middle fibres horizontally; they are not all of the same length, the superficial being longer than the deep-seated, which are shorter the nearer they are to the joint. From the mutual interlacing of the fibres of all the anterior ligaments, there results a membrane of considerable thickness (*membrana sterni anterior*), which entirely covers the sternum, and which is much more apparent at its lower part than above; in some subjects, it even forms at the lower part a kind of triangular plane, separate and distinct. The anterior ligament is covered anteriorly by the pectoralis major.

Posterior Ligament.—It is not so thick as the preceding, and its fibres are not so apparent, although their disposition is absolutely the same. By their mutual interlacing they form, on the mediastinal surface of the sternum, a membrane (*membrana sterni posterior*) as thick as that formed by the anterior ligaments, but smooth, polished, without distinct fibrous fasciculi, unless it be merely a few, which extend over its whole length, seeming to indicate that it does not entirely originate from the posterior ligaments. It is traversed by a considerable number of small blood-vessels.

Ligament of the Ensiform Cartilage, or Costo-xiphoid Ligament (*Ligamentum cartilaginis ensiformis*).—Besides having the same ligaments as those of the other cartilages of the true ribs, the cartilage of the seventh is connected with the ensiform cartilage by a particular ligament, whose dimensions vary much in different subjects. This ligament generally presents itself in the form of a small elongated and very thin fasciculus, which, arising from the lower edge of the cartilage, descends obliquely inwards, and expands over the anterior

surface of the sternal appendage, uniting with that of the opposite side. It is covered by the rectus abdominis.

ARTICULATIONS OF THE CARTILAGES OF THE FALSE RIBS WITH EACH OTHER.

We have already pointed out the manner in which the sixth, seventh, and eighth sterno-costal cartilages meet each other by their contiguous edges, by means of small oblong surfaces. These articular surfaces vary much as to form and extent, and are also frequently observed between the eighth and ninth cartilages. Each of these articulations is furnished with a small synovial bursa, much looser and more apparent than that which exists at the junction of the preceding cartilages with the sternum; each is also strengthened anteriorly and posteriorly by

Fig. 96.*

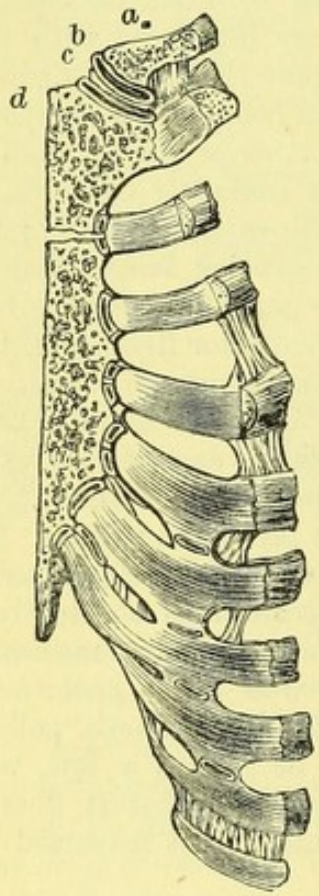

Fig. 97.†

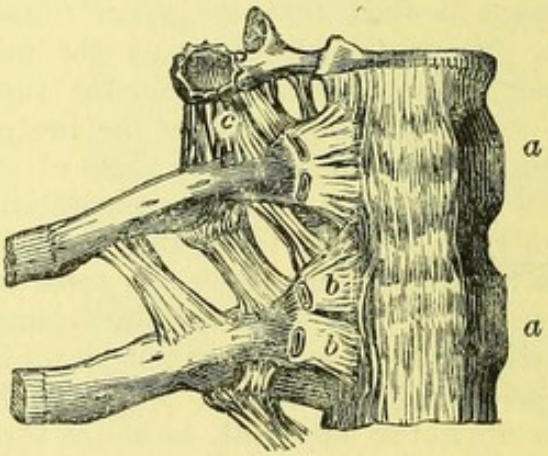

* Fig. 96.—Double section of the sternum and collar-bone; the object is to show the loose and spongy character of the sternum, and more especially the double joint and inner-articular fibro-cartilage at the sterno-clavicular articulation.—*a*, clavicle; *b*, superior synovial membrane; *d*, inferior ditto; *c*, the fibro-cartilage.

† Fig. 97.—Shows the bodies of two of the dorsal vertebræ, with the corresponding ribs *in situ*.—*a*, *a*, bodies of the vertebræ covered by the anterior common ligament of the vertebræ; *b*, *b*, anterior or radiated costo-vertebral ligaments (*Ligamentum capituli costarum*); *c*, *c*, anterior costo-transverse ligaments.

oblique and irregular fibres, which proceed from one cartilage to the other, much more distinct in the former than in the latter direction, and are confounded with the perichondrium. Moreover, the inner extremities of the first three or four abdominal ribs are connected, by a kind of small ligamentous cord, with the lower edge of the next cartilage above. The corresponding extremity of the cartilages of the two last ribs in general, and of the last rib always, are connected solely with the abdominal muscles.*

ARTICULATIONS OF THE RIBS WITH THE BODIES OF THE VERTEBRÆ.

These articulations, which belong to the order of angular ginglymi, and which are extremely close, result from the junction of the heads of the ribs, invested with a thin cartilaginous lamina, with the cavities formed on the bodies of the dorsal vertebræ. These cavities, as we

Fig. 98.†

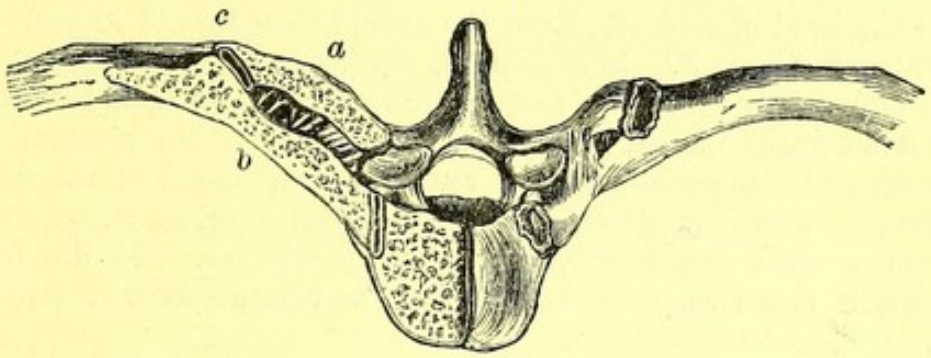

have already shown, belong to one vertebra only for the first, eleventh, and twelfth ribs, but for all the others they are formed on the bodies of two contiguous vertebræ, and on the fibro-cartilage which connects them; they are all covered with a thin layer of cartilage, which is destitute of the polished appearance commonly remarked in organs of this nature. There is also observed in each of them a small mass of the reddish cellular tissue which has been taken for synovial glands, together with the following ligaments:—

ANTERIOR OR RADIATED LIGAMENT (*Ligamentum capituli costarum*).—It is not the same in all the articulations of the ribs, on account of the peculiarity which we have expressed in the preceding paragraph. In the nine which follow the first it is formed of three flat and thin fibrous fasciculi, which are fixed separately to the two vertebræ and the fibro-cartilage, which concur to form the articular

* The outer extremity of the sterno-costal cartilages is intimately united to that of the ribs, but there is no ligament of any kind to retain those surfaces (which do not admit of any motion) in connexion.

† Fig. 98.—Section of the body of a dorsal vertebra and of a rib *in situ*, to show the interosseous or middle costo-transverse ligament.—*a*, transverse process; *b*, neck of the rib; the middle costo-transverse ligament connects these parts together in a line with the letters; *c*, tubercle of the rib resting on the extremity of the transverse process.

cavity, and which, converging, attach themselves all round the anterior part of the head of the rib; they constitute an irregular quadrilateral fasciculus, with radiating fibres, of which the superficial are longer than the deep-seated. The small middle fasciculus, which comes horizontally from the fibro-cartilage, is the least distinct.

The radiated ligaments of the first, eleventh, and twelfth ribs, which are not thus divided, do not, however, present only a single order of fibres; part of that of the first is attached to the last cervical vertebra, and those of the two others also extend to the neighbouring vertebræ.

The *anterior surface* of these radiated ligaments is covered by the branches of the thoracic ganglia of the great sympathetic, by the pleura, and, on the right side only, by the vena azygos. The *posterior surface* is applied against the articulation, for which it forms a sort of fibrous capsule, in conjunction with the middle costo-transverse ligament.

Inter-articular ligament.—It exists in the interior of the articulation of the head of each rib, from the second to the tenth inclusive, and is wanting in the rest. It is a small, fibrous fasciculus, slightly tinged with yellow, of a very close texture, more or less thick, flattened from above downwards, short, fixed on the one hand to the prominent line which separates the two articular surfaces of the head of the rib, and on the other to the angle of the cavity, which receives it, where it is continuous with the intervertebral fibro-cartilage. It divides the articulation into two parts, which have no communication with each other.

Synovial membranes.—It will readily be perceived that there must be two in the articulations in which the last-mentioned ligament occurs, which naturally separates from each other, and only permits them to be expanded over the upper or lower half of the articular surfaces; while in the other articulations these membranes are simple, and cover the whole extent of the articular surfaces, being reflected from the one to the other. These capsules are always indistinct, and contain but a very small quantity of synovia; in some cases they even seem to be wanting, on account of the great thickness of the inter-articular ligaments.

ARTICULATIONS OF THE RIBS WITH THE TRANSVERSE PROCESSES.

These articulations are formed between the tuberosity of the ribs and the summit of the transverse process of the corresponding vertebræ. All the ribs are thus articulated, excepting the two last. Each of the parts mentioned presents a surface covered with a thin cartilage, and invested with a small synovial bursa, looser and more distinct than that of the preceding articulation; the presence of the synovia is also more manifest in it. The ligaments which concur to keep the parts in their respective situations are named as follows:—

Posterior Costo-transverse Ligament (*Ligamentum transversum externum costarum*).—This ligament is of a quadrilateral

form, and flat, about two lines broad, with close and parallel fibres, which are a little longer below than above; it arises from the summit of each of the transverse processes of the dorsal vertebræ, and proceeds nearly transversely outwards towards the non-articular portion of the tuberosity of the corresponding rib. Its deep-seated fibres are shorter than the others; it is shorter and more oblique in the upper ribs than in the lower, in fact, the last descends a little forwards; that which precedes it is nearly horizontal, and the rest are ascending. It corresponds *anteriorly* to the articulation, and *posteriorly* to the muscles of the vertebral grooves.

MIDDLE COSTO-TRANSVERSE LIGAMENT (*Ligamentum cervicis costæ externum*).—This ligament is only seen when the rib is forcibly separated from the transverse process, and its fibres torn asunder, or when a horizontal section of these two parts is made, while they are still in their natural place. It seems formed of a cellular substance, in which there are perceived some irregular fasciculi of fibres of a reddish colour, which occupy the interval situated between the rib and the anterior surface of the corresponding transverse process.

ANTERIOR COSTO-TRANSVERSE LIGAMENT (*Ligamentum transversum internum costarum, seu ligamentum cervicis costæ internum*).—The first and last ribs are destitute of this ligament; and, in the others, it does not really belong to their articulation, since it does not proceed from the transverse process to be attached to the corresponding rib. It presents the appearances of a fasciculus composed of long diverging fibres, narrower above than below, broader and thinner in the lower ribs than in the upper, and always more distinct anteriorly than posteriorly; it is attached to the lower edge of each transverse process, and descends from thence inwards, to be inserted broader into the upper edge of the rib beneath, near its articulation with the body of the vertebra. In most subjects it seems composed of two fasciculi, one of which, smaller than the preceding, crosses its direction; the latter arises immediately from the base of the process, and is attached to the head of the rib beneath. The anterior costo-transverse ligament corresponds *anteriorly* to the intercostal nerve and vessels; *posteriorly*, to the longissimus dorsi. *Externally*, it is continuous with a thin aponeurosis of the intercostal muscles, and serves *internally* to complete an aperture, filled with cellular tissue, and traversed by the posterior branch of the corresponding intercostal nerve.

PELVIC ARTICULATIONS.

The left os innominatum is commonly, and indeed must always be, removed during the dissection of the soft parts, in order to obtain the lateral view of the pelvic viscera. The joint ought not to be cut into, but the left os pubis sawn through vertically, about three-fourths of an inch from the symphysis pubis, or midway between it and the foramen obturatorium. The articulation of the sacrum, with the fifth

lumbar vertebra, is in general perfectly similar to those of the preceding vertebræ, and takes place by three different points; namely, by the oval surface which is at the middle of the base of the sacrum, and which is connected with the inferior surface of the body of the last vertebra, forming an amphiarthrosis; and by the two articular surfaces, seen behind the entrance of the sacral canal, which constitute a double arthrodia with the inferior articular surfaces of the last lumbar vertebra. The means of union which are met with here are also the same as in the vertebral column, the sacro-vertebral ligament being the only ligament not equally observable in the vertebral column. It is a very short and strong fasciculus of fibres, which, arising from the anterior and inferior part of the transverse process of the last vertebra, descends obliquely outwards towards the base of the sacrum, where it attaches itself, intermixing with irregular fibres placed before the sacro-iliac articulation. Some minute anatomists have shown ligaments existing between the transverse processes of the vertebræ, and this sacro-vertebral seems to be one of those on a large scale.*

The coccygeal vertebræ, four in number, become more and more rudimentary. In respect of ligaments, we have a continuation of the great anterior and posterior longitudinal facia or common ligaments, and intervertebral fibro-cartilages; the arches not being developed, the spinal canal would have been open posteriorly and inferiorly, were it not for the presence of a membrane called the posterior sacro-coccygeal ligament. This arises from the margin of the inferior orifice of the sacral canal, and descends over the posterior surface of the coccyx, into which it is inserted. An *anterior sacro-coccygeal ligament* is also described; it is simply a repetition of the great common vertebral ligament, but from the rectum lying upon it, deserves particular attention from the student.

The *ossa innominata* are connected with the lumbar, sacral, and coccygeal vertebræ in a very powerful manner. Of the three portions, which compose each *os innominatum*, two, namely, the iliac and sciatic, are directly connected with the spinal column, and the ligaments have received names accordingly.

The *ilio-lumbar ligament* arises from the summit of the transverse process of the fifth lumbar vertebra, and passing transversely outwards, is inserted into the posterior third of the crest of the ilium. A few irregular aponeurotic fibres will be observed running from the sides of the sacrum to the ilium anteriorly, or on the visceral aspect of the pelvis, seemingly continuous with the periosteum, and have received no particular name, so that the dissector should proceed to examine the ligaments on the external aspect of this important region. The long posterior sacro-iliac ligament (*Ligamentum sacro-iliacum*) is attached to the posterior and superior spine of the ilium, and to the lateral, posterior, and inferior half of the sacrum. It consists of a very strong, long, flat, nearly vertical fasciculus, broader above than below; the superficial fibres being longer than those placed

* Or it may represent the anterior costo-transverse ligaments, described above.

deeper. The short posterior sacro-iliac ligament* is very irregular, very short, and occupies posteriorly the space which the sacrum and ossa innominata leave between them, before the mass of the muscles of the vertebral grooves. The fibres which constitute it are much shorter before, near the articulation, than behind; they cross each other in a number of different directions, and are very close, and possessed of great firmness; they are attached, on the one hand, to the first two eminences of the posterior aspect of the sacrum, and to the sides of that bone at its upper part; and on the other, to the internal surface of the iliac tuberosity. Such is their adhesion to these parts, that if the sacrum and os innominatum be forcibly separated, the surface of one or other of these bones is detached along with them, without their being ruptured.

The articular and non-articular surfaces which these ligaments bind together, are, first, the semilunar, notched, slightly convex, and uneven surfaces, particularly pointed out in describing the lateral surfaces of the sacrum, and the internal surfaces of the ossa innominata. The true articular surfaces present the appearance of the human ear, and are hence called the *facies auriculares*; these are each invested by a thin cartilaginous lamina, which however does not come into immediate contact, there being placed between them a soft yellowish substance, disseminated in insulated flakes, very different from synovia, although performing its functions. The dissector will best understand this structure, by examining the left side of the sacrum, from which the left os innominatum has been torn off in his previous dissection of the pelvic viscera.

The sacrum is connected with the sciatic portions of the ossa innominata, by two powerful ligaments on each side. These ligaments may be said to complete the inferior aperture of the pelvis, and include much of the anatomy of this region. I am of opinion, indeed, that it is the want of a clear view of these ligaments (in themselves very simple), which causes this whole region of the body to assume so much complexity to the student. The *great sacro-sciatic ligament* is placed at the posterior and inferior part of the pelvis; it is of a triangular form, thin, flat, narrower in the middle than at its extremities. It arises by a broad base from the posterior and inferior iliac spine, the long sacro-iliac ligament, the last posterior tubercles of the sacrum, the lower part of the lateral surface of that bone, and the edge of the coccyx, and directs itself obliquely outwards, downwards, and a little forwards. As it advances it loses much of its breadth, but its thickness increases in the same proportion; it is at length attached to the tuberosity of the ischium, becoming broader a second time, and intermingling with tendinous fibres of the biceps femoris and semi-tendinosus muscles. Here there is detached a small fibrous prolongation, named by some anatomists the *falciform ligament*, which winds around the inner part of the tuberosity, attaches itself above it by its convex

* M. J. Cloquet, in his plates, includes the long and short sacro-iliac ligaments under one name (posterior sacro-iliac).

edge, and with its concave edge covers in part the obturator internus muscle, for which it forms a sort of channel, as it ascends along the ramus of the ischium. The *posterior surface* of this ligament gives attachment, in its whole extent, to fibres of the glutæus maximus: the *anterior* is united internally to the small sacro-sciatic ligament, and is separated from it externally by a triangular interval, through which the tendon of the obturator internus passes, and the pubic vessels and nerve. Its fibres, which converge from the sacrum towards the os innominatum, and are more oblique as they ascend, are so disposed that at the middle of their length the inner cross the outer; they form several planes, separated from each other by cellular tissue, between which pass pretty considerable branches of the sciatic artery. The *small sacro-sciatic ligament* is smaller than the preceding, before which it is situated, and therefore must be dissected and examined from the internal aspect of the pelvis; internally it is broad, fixed to the sides of the sacrum, and to a small portion of the edge of the coccyx; from this it proceeds outwards and forwards towards the spinous process of the ischium, to which it is attached, contracting and becoming thinner as it approaches its insertion. These ligaments divide the great sciatic notch, as seen in the fully macerated skeleton, into two holes; the upper and larger of which is traversed by the pyriformis muscle, the gluteal vessels and nerve, and the sciatic vessels and nerves, while the lower and smaller gives passage to the obturator internus, and to the pubic vessels and nerve. These two ligaments, while they serve to connect the sacrum and the os innominatum, also contribute to the formation of the walls of the pelvis; their inner edge sends towards the anus an aponeurotic expansion which supports the levator ani muscle.

The pubic portions of the two ossa innominata are articulated with each other mesially; the articular convex, oval surfaces, particularly alluded to in describing the pubes, under the term symphysis, form this articulation; the term symphysis is more strictly applicable, however, to the articulation: we find the *interpubic fibro-cartilage* placed between them analogous to that between the bodies of the vertebræ; it is thick anteriorly, and posteriorly forms a prominence, very distinct in the female, and greatly increased in some diseases of the osseous texture. Two ligaments strengthen this articulation—1, the anterior pubic ligament, is an irregular fibrous expansion, partly intermingled with the aponeurosis of the abdominal muscles, partly with the periosteum of the bones of the pubis; it appears to be formed of several superimposed layers, which all pass before the articulation; the most superficial of these layers proceeds from the upper part of the symphysis, expanding and separating into fasciculi, to the fore part of the rami of the pubic arch; the deep fibres are transverse, and unite in their passage with the laminæ of the fibro-cartilage. 2, the sub-pubic ligament is much stronger than the preceding; it is a thick and triangular bundle, occupying the upper part of the arch of the pubis, to the upper and inner part of the rami of which it is attached on either

side; its fibres, which are of a yellowish colour, very close, transverse, and a little curved so as to present their concavity below, are very short above, and are continuous with the laminæ of the symphysis (interpubic-fibro cartilage); they become longer in proportion as they are lower.

The *obturator membrane* (misnamed ligament) almost entirely closes the obturator foramen, to the circumference of which it is attached, excepting at the upper part, where there is a more or less distinct notch for the passage of the obturator vessels and nerve; its fibres are interlaced in various directions, and are always more marked toward the notch; its *anterior surface* corresponds to the obturator externus muscle, and the *posterior* to the obturator internus, both of which are in part attached to it.

ARTICULATIONS OF THE BONES OF THE SUPERIOR EXTREMITIES.

STERNO-CLAVICULAR ARTICULATION.

The osseous surfaces are, 1, the sternal end of the clavicle; 2, the notch or cavity in the side or margin of the manubrium of the sternum. Each osseous surface is encrusted with cartilage of considerable thickness. The articular surfaces do not correspond in extent, that of the clavicle being so much larger than the sternal cavity for its reception. There exists also an inter-articular fibro-cartilage.

LIGAMENTS.

ANTERIOR STERNO-CLAVICULAR LIGAMENT.—This is a broad fasciculus consisting of diverging fibres, attached by one extremity to the fore part of the head of the clavicle, and by the other to the fore part of the articular cavity of the sternum. Its relations are simple, and easily understood. *Posteriorly*, it covers the two synovial membranes, and adheres strongly to the interarticular cartilage; *anteriorly*, it corresponds to the sterno-mastoid muscle and to the integuments.

POSTERIOR STERNO-CLAVICULAR LIGAMENT.—Narrower, and not so strong as the preceding. It is situated at the back of the joint, and connects both bones together, similarly to the anterior. It is in relation to the sterno-hyoid and sterno-thyroid muscles.

INTER-CLAVICULAR LIGAMENT.—This name is given to a distinct fasciculus, placed transversely above the upper extremity of the sternum, between the heads of the two clavicles. This ligament varies much in its strength and other arrangements, such as its connexion with the sternum. The integuments cover it anteriorly.

COSTO-CLAVICULAR LIGAMENT.—This ligament, sometimes called rhomboid, from its being of a rhomboidal form, is short, flat, and very

strong, with dense, compact, oblique fibres. It connects the cartilage of the first rib to a prominence on the lower surface of the clavicle. The subclavius muscle covers this ligament anteriorly, and its external edge is in relation to the subclavian vein. Internally it corresponds to the articulation.

INTER-ARTICULAR FIBRO-CARTILAGE.—This is a circular plate or disc, sometimes perforated in the centre, and placed between the two osseous surfaces. Its structure, functions, and relations, resemble those of the fibro-cartilage of the lower jaw and knee joint.

The synovial membranes of this joint are two in number; they may or may not communicate. One belongs to the clavicle, the other to the sternum. The fibro-cartilage separates them from each other.

SCAPULO-CLAVICULAR ARTICULATION.—Those fond of Greek terms call this joint a plain arthrodia. The *osseous* surfaces are the external extremity of the clavicle and a portion of the edge of the acromion scapulæ. Where these bones meet there are two small articular surfaces encrusted with cartilage; a synovial membrane, and two ligaments, complete the joint. In addition to these, there exist two other ligaments, passing from the coracoid process to the clavicle; these will be immediately described.

1. The *superior* ligament of the joint.—This is a broad and thick fasciculus placed over the joint, connecting the extremity of the clavicle to the acromion process of the scapula. The tendinous fibres of the deltoid and trapezius muscles are in relation to it.

2. The *inferior* ligament—Resembles the superior in form. Anteriorly, it is continuous with the ligament just described.

3. The synovial capsule is occasionally double, in which case there will be found a thin fibro-cartilaginous plate.

OF THE CORACO-CLAVICULAR LIGAMENT.—Connecting the base of the coracoid process to the clavicle, this ligament is usually considered as composed of two—the conoid and trapezoid.

1. The *posterior* and *inner*, or conoid ligament, has the form of a reversed cone. The base is attached to a tuberosity which the clavicle presents here, and its summit to the broadest part of the coracoid process.

2. The *anterior* and *external* fasciculus is also called trapezoid. This ligament is placed at about an inch from the shoulder joint; it connects the coracoid process to the oblique line which runs on the lower surface of the clavicle from the tuberosity mentioned above to the extremity of the collar bone.

PROPER LIGAMENTS OF THE SCAPULA.

The proper ligaments of the scapula are fibrous structures which extend only from one part of the scapula to another. They are three

in number, but of these, perhaps, the first only should be described as a ligament.

THE CORACO-ACROMIAL LIGAMENT.—Triangular, broad, thin, and flat, this ligament extends from the whole extent of the outer edge of the coracoid process, in two fasciculi, to the summit of the acromion, into which it is inserted. The upper surface of this ligament is covered by the clavicle and by the deltoid muscle; inferiorly it covers the supra-spinatus muscle. Its anterior edge is continuous with a dense cellular lamina subjacent to the deltoid muscle, and applied over the tendons of the supra-spinatus and infra-spinatus muscles. The ligament completes the vault formed by the acromion and coracoid process above the head of the humerus.

It is questionable if the remaining two proper ligaments of the scapula are really ligaments. One is called coracoid; it shuts in the notch or the cervical margin of the scapula, converting it into a foramen. It is often osseous. Beneath it passes the supra-scapular nerve; above it the vessels.

The third fibrous structure alluded to as a ligament is a fibrous membrane extending from the fore and under part of the spine of the scapula downwards to the neck of the bone. It has been called the ligament of the neck of the scapula. It serves the purpose of an interosseal membrane, separating the supra-spinatus and infra-spinatus muscles at this point from each other; between it and the bone anastomosing arteries pass, connecting the supra-scapular and infra-scapular arteries.

SHOULDER-JOINT.

Scapulo-humeral Articulation.

Osseous surfaces.—The head of the humerus and glenoid cavity of the scapula. Both are covered with diarthrodial cartilages.

CAPSULAR LIGAMENT.—Attached around the edge of the glenoid cavity, it forms a hollow conoid; its inferior attachment is to the neck of the humerus. Longer and looser than seems necessary, it varies also in strength at different points. Its outer surface is covered by the coraco-humeral ligament and deltoid muscle; by the tendons of the supra and infra-spinati and teres minor muscles; the tendon of the subscapularis muscle interrupts it, and mingles its fibres with it. Internally, it is lined by the synovial membrane. This ligament is formed of fibres, which, running in all directions, are thicker above than anywhere else. The tendon of the biceps passes into its interior.

CORACO-HUMERAL OR ACCESSORY LIGAMENT — Is formed by a very dense fasciculus, which runs from the outer edge of the coracoid process to the anterior part of the great tuberosity of the humerus, mixing its fibres with those of the tendon of the supra-spinatus muscle.

Fig. 99.*

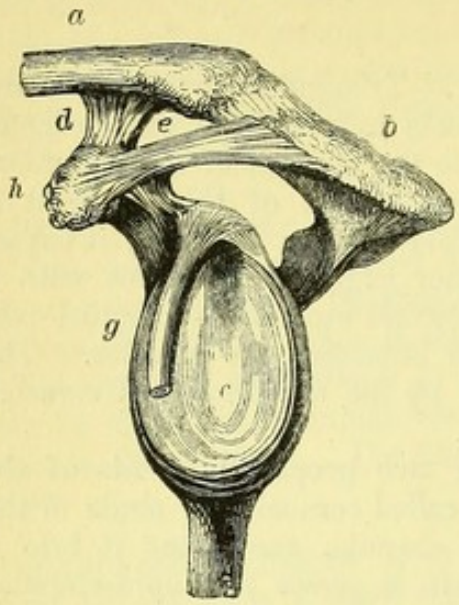

Fig. 100.†

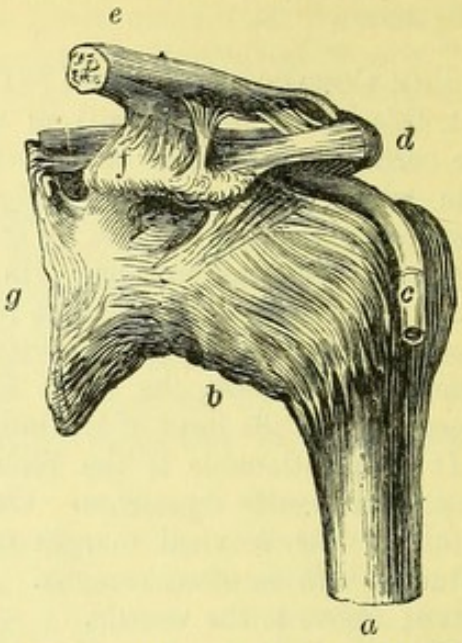

GLENOID LIGAMENT.—This is a fibro-cartilaginous rim attached to and surrounding the glenoid cavity of the scapula. The tendon of the biceps bifurcating near its insertion into the glenoid edge contributes to form this ligament. It is partially covered by the synovial membrane.

SYNOVIAL CAPSULE.—As in other joints, this membrane lines the inner surface, forming a shut sac at all points. It transmits a process along the bicipital groove, investing the tendon of the biceps on all sides. The tendon, though interarticular, is still exterior to the synovial capsule, a fact explicable only by an examination of the joint in the fœtus.

Superiorly, a large bursa lies on the capsular ligament, between it and the coracoid and acromion processes, and coraco-acromial ligament; it belongs to the system of the deep bursæ. No joint is liable to so many accidents as the shoulder-joint.

Dislocations are especially frequent, and fractures in the anatomical neck of the humerus, close to the articulation, have led to dangerous errors in diagnosis. I have seen a disease of the bursa mistaken for a disease of the joint itself; excision of the head and neck of the humerus, followed by death, was the sad result of this error.

* Fig. 99.—Ligaments of the clavicle and scapula; the shoulder-joint has been opened and the humerus removed.—*a*, the collar-bone, left side; *b*, the acromion process of the scapula; *c*, glenoid cavity of the scapula; *d*, coraco-clavicular ligaments; *e*, points to the superior ligament of the articulation between the clavicle and scapula; *f*, the coraco-acromial ligament; *g*, long tendon of the biceps cut across; *h*, summit of the coracoid process.

† Fig. 100.—Shoulder-joint, left side, viewed anteriorly.—*a*, the shaft of the humerus; *b*, the capsular ligament; *c*, tendon of the biceps; *d*, coraco-acromial ligament; *e*, collar-bone; *f*, coraco-clavicular ligaments; *g*, section of the scapula.

The strength of the joint depends no doubt on the capsular muscles and their tendons. Dislocation is possible in every direction but upwards. The reason why the long head of the biceps passes into the joint to be attached to the scapula has not yet been discovered. Its section in the dead body gives rise to no perceptible change in the joint.

Fig. 101.*

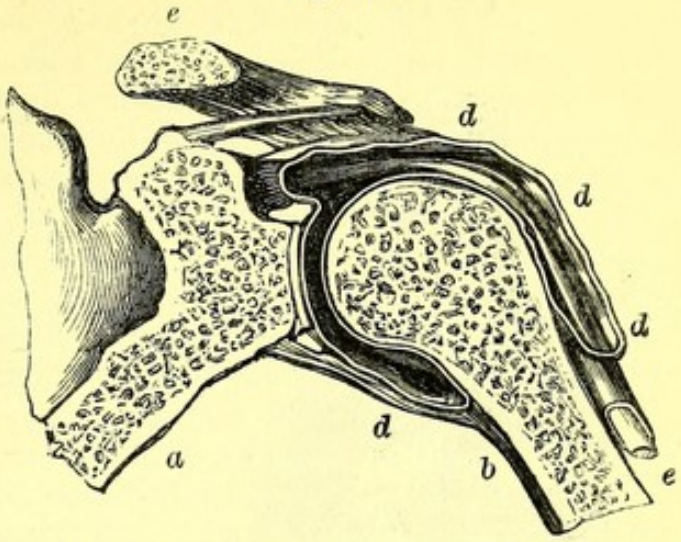

The student ought to avail himself of every opportunity of carefully dissecting diseased and injured joints, and more especially the one I have just described. He should also, when practicable, preserve the pathological specimens for future comparison with others. After becoming well acquainted with the anatomy and physiology of the joint, the inspection of the specimens in a well arranged Pathological Museum will prove advantageous.

ELBOW-JOINT.

One of the most complex joints in the body.

Osseous surfaces.—Lower end of the humerus; head of the radius; greater sigmoid cavity of the ulna. It is a perfect angular gynglimus. The articular surfaces are, as usual, encrusted with cartilages; there are, moreover, ligaments chiefly laterally, and in consequence of the movements necessitated by the functions of the hand the joint is still further complicated by the radio-cubital articulation, into which the synovial membrane of the elbow-joint penetrates, and of which it forms a complex appendage.

The cartilage of the great sigmoid cavity is prolonged over the smaller cavity. All these points should be examined after the ligaments have been dissected and studied.

1. *External lateral ligament.* — Almost confounded with the tendinous fibres of the supinator brevis; this short fibrous fasciculus connects the external tuberosity of the humerus to the annular ligament of the radius, bifurcating so as to be divided equally between it and the anterior and posterior parts of the annular ligament; a few fibres, however, mingling with the posterior ligament, are also attached to the outer edge of the ulna.

* Fig. 101.—Vertical section of the shoulder-joint, to show the course of the synovial capsule and inter-articular tendon.—*a*, the scapula; *b*, the humerus; *c*, the tendon of the biceps; *d*, *d*, *d*, the capsular ligament and the synovial capsule at various points of reflexion; *e*, the divided clavicle.

Fig. 102.*

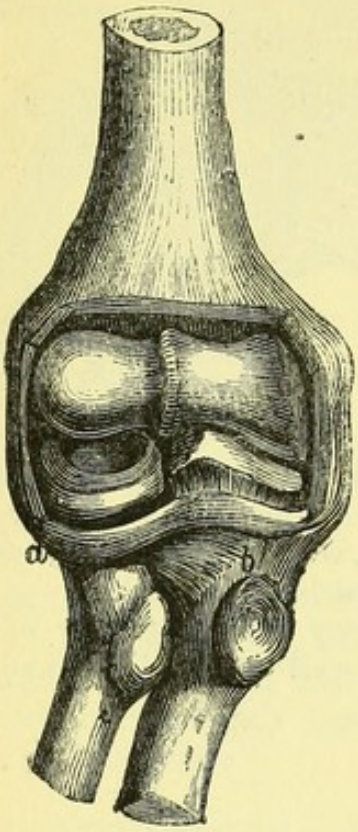

Fig. 103.†

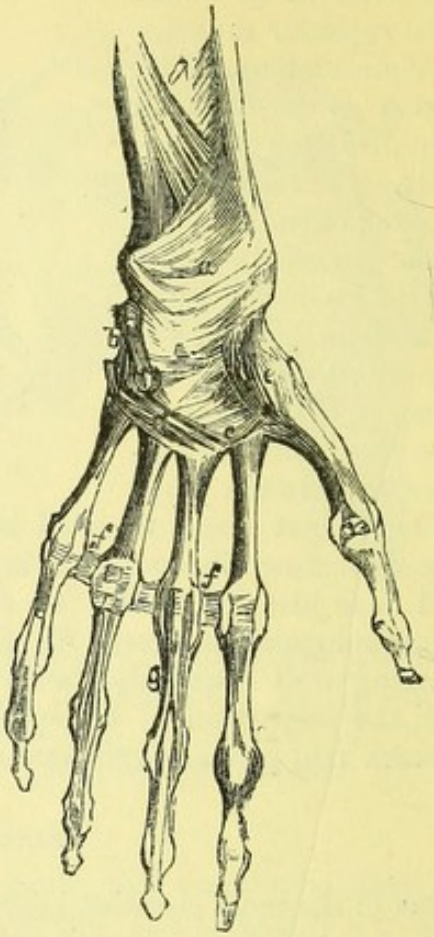

2. *Internal lateral ligament.*—Longer, broader, and stronger than the preceding. It is of a triangular form, and is composed of two distinct bundles; the anterior connects the internal tuberosity of the humerus to the inside of the coronoid process of the ulna; the other, which is posterior, descending also from the inner tuberosity, is attached to the inner part of the olecranon. It is connected with the tendinous origins of the flexor carpi ulnaris and the ulnar nerve, which it assists in protecting.

3. *Anterior ligament.*—A thin irregular membrane, composed of oblique fibres, and placed in front of the joint. The fibres cross each other, the superficial ones proceeding from the inner tuberosity of the humerus to the annular ligament of the radius; the middle are vertical; the deep are also vertical; and, descending from the coronoid fovea of the humerus, they gradually disappear on the synovial mem-

* Fig. 102.—The elbow-joint, together with the radio-humeral and superior radio-cubital articulations, laid open to display the course of the synovial membrane or capsule.—*a*, *b*, point to the cut edges of the inferior portion of the synovial capsules.

† Fig. 103.—Ligaments of the hand; palmar aspect.—*a*, anterior radio-carpal ligaments; *b*, ligament connecting the pisiform bone to the unciform process of the unciform bone; *c*, *d*, *e*, anterior carpo-metacarpal ligaments; *f*, transverse metacarpal ligament; *g*, fibrous sheaths enclosing the flexor tendons of the fingers.

brane. The tendon of the brachialis flexor covers the surface of this ligament; the posterior lies on the synovial membrane.

4. *Posterior ligament.*—This is much weaker than the anterior; to be seen, the fore arm requires to be bent on the arm. Formed of two separate fasciculi, one descends from the summit of the olecranon to the humerus; the other fasciculus is external, and runs between the two tuberosities of the humerus. The tendons of the triceps and anconeus cover this ligament.

Synovial capsule.—This may now be laid open and examined. Its chief peculiarity is the mode in which it invests the head of the radius, the annular ligament, and the smaller sigmoid cavity of the ulna; further than this, there is nothing peculiar in the anatomy of this capsule. The entire joint is extremely close, admitting of no lateral movement. The joint, though well protected, is yet subject to serious accidents, and to many pathological conditions, of which the more common is scrofulous caries of the extremities of the bones.

ARTICULATIONS OF THE ULNA WITH THE RADIUS.

The systematic anatomists of the Continent have divided these articulations into three: the superior, middle, and inferior radio-cubital articulations.

1. SUPERIOR RADIO-CUBITAL ARTICULATION.—This joint is formed by the inner side of the circumference of the head of the radius, received into the smaller sigmoid cavity of the ulna. These surfaces are invested with cartilage, continuous with that covering the head of the radius on one hand, and with that investing the larger sigmoid cavity on the other. The synovial membrane is merely an appendage of that belonging to the joint. The joint has but one ligament.

ANNULAR LIGAMENT. — *Ligamentum annulare, seu orbiculare radii.*—This is a fibrous band, of great strength, attached to the two edges of the smaller sigmoid cavity, and embracing the head of the radius, which it thus permits to rotate freely. On this rotation of the head of the radius depend the movements of pronation and supination of the hand. It completes, with the smaller sigmoid cavity, the ring in which the head of the radius rotates. The ligament forms about three-fourths of the ring. The external lateral ligament of the joint is connected to it, and the synovial membrane invests its free surfaces internally.

2. MIDDLE RADIO-CUBITAL ARTICULATION—*Interosseous ligament*, or *membrane.* — Thin, aponeurotic, resplendent; it connects the inner edge of the radius to the outer edge of the ulna. This membrane extends from below the bicipital tuberosity to the lower ends of the bones, filling up the spaces between them. Small vessels and nerves pass through the ligament; through the deficiency above, the posterior

interosseal vessels pass. Anteriorly, the ligament is covered superiorly by the flexor profundus and flexor proprius pollicis; inferiorly, by the pronator quadratus; posteriorly, it is covered by the extensor muscles proceeding to the hand; inferiorly, the anterior interosseal vessels and nerves also pass through it.

Round ligament—Corda transversalis cubiti. — This is a round fibrous cord, of a very small size, situated on a plane anterior to that of the interosseal ligament, running in an opposite direction, and separating the flexor sublimis from the supinator brevis. Above it is attached to the ulna beneath the attachment of the brachialis flexor, and descending parallel to the tendon of the biceps, it is attached to the radius immediately below the bicipital tuberosity.

3. Lower Radio-cubital Articulation.—The osseous surfaces in this joint are the head of the ulna, and a cavity for its reception, on the outer side of the lower extremity of the radius. These surfaces are encrusted with a thin cartilage. A somewhat complex synovial capsule exists (*membrana capsularis sacciformis*), and a remarkable ligament, the triangular fibro-cartilage; it has been carefully described by Weitbrecht.

This fibro-cartilage, serving the purpose of a ligament, is attached by its apex to the groove between the head of the ulna and the root of the styloid process, and by its base to the inner edge or margin of the lower end of the radius. The fibro-cartilage is thin, particularly towards its base. The upper surface is in contact with the head of the ulna; the lower with the cuneiform bone. Interposed, in fact, between the ulna and the cuneiform bone, it extends the articular surface in the plane of the carpus and of the radius, and compensates for the shortness of the ulna at this point. The synovial capsule of the joint, remarkably loose (hence its name, sacciform), covers the surfaces of the fibro-cartilage.

WRIST-JOINT.

Osseous and other surfaces.—The hand is mainly articulated to the radius, and follows all its movements. On the integrity of the radius the movements of pronation and supination of the hand depend.

The surfaces forming the joint are, above, the radius and fibro-cartilage; below, the scaphoid, lunatum, and cuneiform bones. There is a synovial capsule which invests all the cartilaginous surfaces, as well as the peculiar substance connecting the carpal bones (first row) to each other. In addition, there are four ligaments strengthening the joint. The so called anterior annular ligament of the carpus, though composed of ligamentous fibres, is not, properly speaking, a ligament, but belongs to the system of the retinacula. These vill be described with the tendons of the muscles.

External lateral ligament—extends from the summit of the styloid process of the radius to the outer part of the scaphoidbone. Its fibres are divergent.

Internal lateral ligament—extends from the summit of the styloid process of the ulna, inwards and forwards, to the inner side of the cuneiform bone, to which it is attached.

Anterior ligament.—To reach this ligament, a deep dissection is required, by cutting through the annular ligament of the carpus, and all the flexor muscles and their tendons. The ligament extends from the fore part of the lower extremities of the radius and ulna to the fore part of the scaphoid, lunar, and cuneiform bones.

Posterior ligament—extends from the posterior part of the inner extremity of the radius; descends obliquely inwards, and is attached to the posterior part of the semilunar and cuneiform bones.

ARTICULATIONS OF THE CARPAL BONES.

I. Of the first row. II. Of the second row. III. Of the first and second row with each other.

I. The osseous surfaces by which these bones meet each other need not be again enumerated. The points by which they come in contact are covered with cartilage. All that is required here is to speak of their ligaments.

Interosseous ligaments.—They are two very narrow layers of a fibro-cartilaginous substance, dense and compact, which occur at the upper part of the interval left between the scaphoid and semilunar bones on the one hand, and between the semilunar and cuneiform on the other. These ligaments are very short.

Dorsal or *posterior ligaments.*—Two in number, and placed transversely behind the bones of the first row of the carpus, connecting the scaphoid and semilunar to each other; also the semilunar and cuneiform.

Palmar or *anterior ligaments.*—These are placed very deeply under the radio-carpal ligament. They resemble in all respects the corresponding dorsal.

The pisiform bone has its peculiar form of articulation. A synovial capsule, strengthened by irregular ligamentous fibres, is all we find here.

II. The second row of carpal bones, like the first, have their dorsal, palmar, and interosseous ligaments similarly disposed. Of the interosseous ligaments, however, there are only two; one between the trapezoides and os magnum, the other between the os magnum and unciforme.

III. The two rows of the carpal bones are articulated with each other by means of the apparatus of a moveable joint, although the joint be all but immoveable.

The ligaments are an *external* and an *internal* lateral; anterior and posterior. These ligaments are very short, and are continuous with the radio-carpal. A strong fasciculus connects the scaphoid and trapezium; another connects the cuneiform to the unciform.

The *anterior ligament* consists of several oblique fasciculi, con-

necting the first bones of the carpus to those of the other bone. The *posterior* ligament varies in size and direction. In other respects it resembles the anterior.

The synovial capsule covers the osseous surfaces by which the two rows of carpal bones touch each other. It also sends processes, two upwards and three downwards, between the carpal bones themselves. These prolongations terminate of course in culs de sac. One synovial capsule then is common to all the carpal joints, with the exception of that of the pisiform bone. This bone has two strong ligaments peculiar to itself; the one connects the pisiform to the unciform process of the bone of the same name, the other connects the pisiform bone to the fifth metacarpal.

CARPO-METACARPAL BONES.—Of these articulations, with the exception of the first, little need be said. Their osseous surfaces have been already described. These are encrusted with cartilages, and they have synovial capsules. Two ligaments are found here, an *anterior* and *posterior*. The dorsal or posterior ligaments descend from the posterior surface of the bones of the second carpal bone to the four last metacarpal. An additional ligament is sent from the trapezium to the second metacarpal bone.

Palmar or *anterior ligaments*.—Less distinct than the dorsal, which, however, they entirely resemble in their arrangement.

The articulation of the metacarpal bone of the thumb with the trapezium is so far peculiar that its ligamentous capsule is nearly orbicular.

ARTICULATION OF THE METACARPAL BONES WITH EACH OTHER.—These articulations have synovial capsules and dorsal and palmar ligaments. Some are strengthened by interosseal ligaments. These remarks do not apply to the first metacarpal, which is isolated.

Transverse and inferior metacarpal ligament.—This is a remarkable fibrous band, connecting transversely the phalangeal extremities of the metacarpal bones (the last four only) to each other. Superiorly, it is in relation to the metacarpo-phalangeal articulations; inferiorly, the tendons of the flexor muscles rest upon it in grooves. It resembles in its nature the anterior ligament of the fingers. It probably represents, in the hand, a muscle we find in the foot called the transversus pedis.

METACARPO-PHALANGEAL ARTICULATIONS.—*Osseous surfaces*.—These have been already described. The surfaces are covered with cartilages. The ligaments are, an anterior and two lateral ligaments; there is a synovial membrane of course for each.

The anterior ligament, first described by Bichât, is a kind of fibrous half ring, embracing the anterior part of each articulation. On each side it is attached to the metacarpal bone before the lateral ligaments; and anteriorly it partly confounds its fibres with those of the transverse

and inferior metacarpal ligament and with those of the sheath of the tendon of the flexor muscles of the finger. From this disposition there are formed two curved planes meeting each other by their convexity, one of which corresponds to the tendon, and the other to the articulation. It is in the substance of this ligament that in the thumb the two sesamoid bones, between which passes the tendon of the flexor longus pollicis, are developed.

Lateral ligaments.—They arise from the lateral parts of the head of each metacarpal bone, behind the preceding in a small special depression, and extend obliquely forward to be attached to the two sides of the proximal end of the phalanx. They are thick, rounded, and strong. They correspond externally to the collateral vessels and nerves, internally to the synovial membrane.

The synovial membrane requires no special description.

ARTICULATIONS OF THE PHALANGES.—All these articulations resemble each other. They are angular gynglimi, with cartilages of incrustation, synovial capsules, and anterior and lateral ligaments.

The anterior (palmar) ligament, as well as the external and internal lateral ligaments, so strongly resemble those already described (metacarpo-phalangeal articulations), as to require no separate description. The so-called anterior ligament merits especially the attention of the student.

ARTICULATIONS OF THE LOWER EXTREMITIES.

HIP-JOINT.

Ilio-femoral Articulation.

1. *Osseous surfaces.*—The head of the femur and the cotyloid cavity or acetabulum. It is a true ball and socket joint. 2. The cartilages of incrustation are, that investing the cotyloid cavity, and a second, encrusting the head of the femur. 3. The ligaments, which might be assumed *à priori* from the form of the osseous surfaces, are, 1, a capsular, including within its cavity the neck of the femur; 2, a supplementary ligamentous band called ileo-femoral.

In addition to these structures essentially forming the joint, we find, 1, a fibro-cartilaginous rim or border, surrounding the margin of the acetabulum; 2, an interarticular ligament, the ligamentum teres. An extended synovial capsule, and a little fatty cushion placed in the fovea at the bottom of the cotyloid cavity, complete the enumeration of the structures connected with this joint, the strength of which depends mainly, after all, on the powerful muscles and their tendons, which surround it.*

When these structures are dissected and examined in detail, and

* As the joint is perfectly air tight, the pressure of the external atmosphere may contribute towards its security.

Fig. 104.* Fig. 105.†

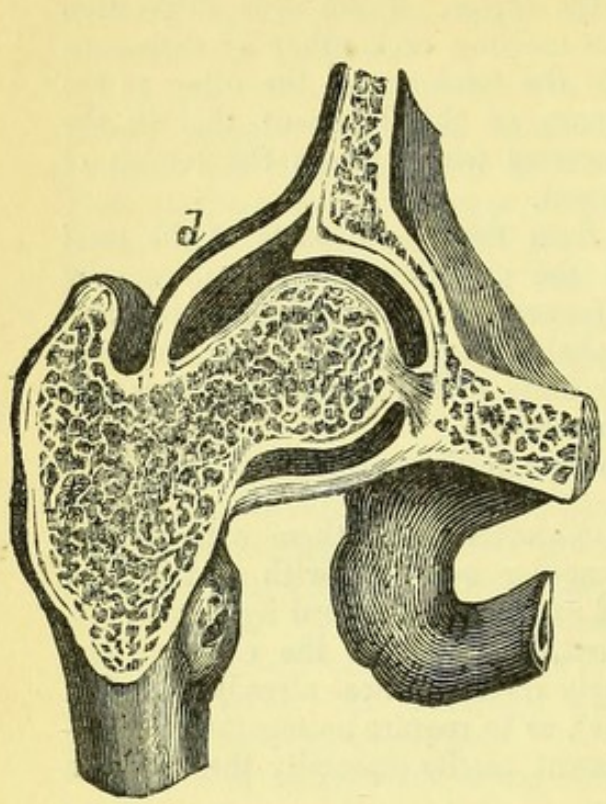

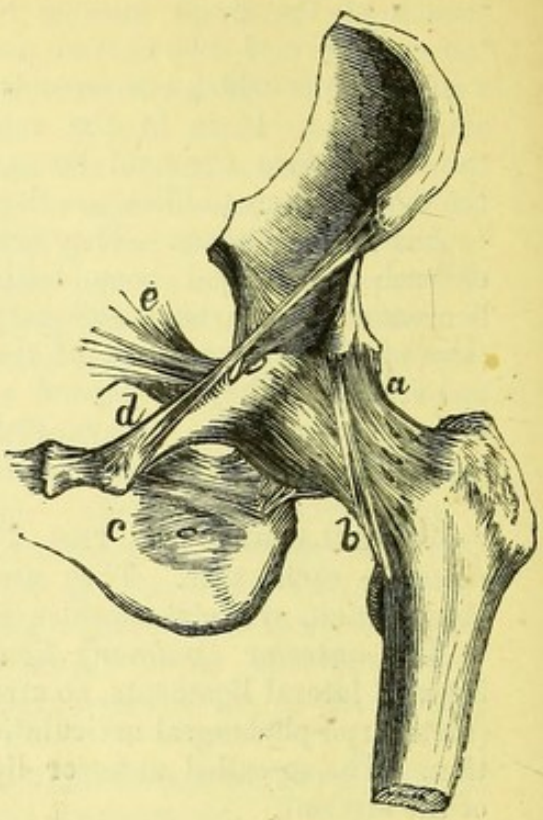

this ought to be proceeded with the instant the surrounding muscles have been dissected and removed, it will be found, 1, that the capsular ligament has a dense and firm structure, varying in strength at different points; strongest externally and above, weakest within and below, where the fibres are not unfrequently wholly deficient. Anteriorly also, beneath the psoas and iliacus muscles, the fibres of the capsule are frequently deficient; it is at this point that the synovial capsule of the joint communicates with a large synovial bursa, which always exists in this situation. This communication happens quite as frequently in the young as in the old.

The capsular ligament is attached at its upper extremity to the os innominatum, around the osseous margin of the cotyloid cavity. Inferiorly, where this osseous rim is notched and deficient, the capsule is attached to the transverse ligament, which converts this notch into a foramen. Inferiorly, and in front, the capsule is attached to the oblique line leading from one trochanter to the other; superiorly, and behind, the capsule is attached to the neck of the bone, close to the trochanteric line and fossa.

* Fig. 104.—This instructive section of the hip-joint requires little or no explanation.—*d* points to the superior part of the capsular ligament.

† Fig. 105.—Capsular ligament of the hip-joint; also Poupart's ligament.—*a*, the capsular ligament; *b*, the oblique, or accessory ligament of the joint; *d*, attachment of the external pillar of Poupart's ligament to the tubercle of the pubis; *e*, deep structures immediately behind that portion of Poupart's ligament, called the ligament of Gimbernat; *c*, ligamentum obturatorium.

The *accessory*, or *ilio-femoral* ligament, is a firm band of fibres which extends obliquely downward, crossing the front of the capsule, from the anterior and superior spinous process of the ilium, downwards and inwards to near the smaller trochanter. The synovial capsule of the joint invests the interior of the capsular ligament. Though not separable by dissection, they must not be confounded with each other. The ligament is rough and fibrous externally; smooth internally; this is due to the synovial membrane, which closely invests it.

When surgeons speak of "fractures within the capsule" (a common occurrence in old age), they do not strictly mean the fibrous capsule, but also include the synovial.

The fibro-cartilaginous ring or border surrounding the cotyloid cavity, and strongly attached to its border, has been called the *cotyloid ligament*. By means of this fibro-cartilaginous ring the cavity is deepened and strengthened; by inclining inwards at its free margin it seems also to embrace somewhat the head of the femur, rendering the joint air-tight. The free edge of the cotyloid ligament is thinner than the fixed edge or base; the free edge is covered on both sides by the synovial membrane, and thus the outer surface of the fibro-cartilage is in contact with the synovial membrane, covering the fibrous capsule, whilst its inner side lies on the surface of the head of the femur. At the cotyloid notch the fibres of the cotyloid ligament pass across from one side to the other, crossing each other so as to make the ring complete. This portion has been called the transverse ligament. Beneath it, as below an arch, pass the vessels which proceed by the round ligament to reach the head of the bone.

The interarticular ligament (*Ligamentum teres*) is a thick and dense fasciculus of fibres, implanted, by its rounded extremity, in the fovea or pit seen on the head of the femur. At the other extremity, by which it is attached to the margins of the cotyloid notch, intermingling with the fibres of the cotyloid ligament, the so-called round ligament is broad, flat, and bifid, or, at least, triangular.

A tubular process of the synovial membrane invests this ligament throughout its length; the mechanism of this can be explained only by the anatomy of the embryo. The ligament varies in strength and thickness, and is said even occasionally to be wanting; such an occurrence, although possibly it may have been congenital, was more probably pathological.*

The synovial membrane invests the interior of the capsular ligament, and the exterior of the round ligament. It covers, no doubt, the cartilages of incrustation, the cotyloid ligament, and the neck of the femur. On the neck of the femur it is separated from the bone by a fibrous structure only, serving the purpose of a periosteum. Like other synovial membranes, it is smooth and lubricated on its inner surface by the synovia. The student should trace it over all its

* I have observed it once absent in a middle aged man. There was also atrophy of the cartilages of incrustation.

surfaces, observing carefully its various points of reflexion. This can only be done after the joint has been laid open. For a thorough examination and demonstration of this joint, as of most, several dissections and preparations are required.

In the fovea of the cotyloid cavity, and near the root of the round ligament, is a large packet of fat; fringes also of the synovial membrane exist here. The nature of these has been already alluded to.

The capsular ligament is traversed by a number of blood-vessels, and nerves have been traced to it. The functions of the round ligament have not been satisfactorily determined. It is absent in the strongest of all animals—the elephant.

KNEE-JOINT.

A thorough examination of this joint requires several preparations and dissections. Dried preparations of this or of any other moveable joint are sure to mislead the junior student. See that all the structures examined be as fresh as possible; maceration in water destroys the appearance of ligamentous structures.

The knee-joint is a gynglimus or hinge-joint. Under particular circumstances, which will be explained afterwards, it rotates, though very slightly. It may be looked on, for all practical purposes, as a hinge-joint, the most complex in the body.

Osseous surfaces.—1, The condyles of the femur and of the tibia; the patella is supernumerary or accessory; 2, cartilages of incrustation; 3, two interarticular ligaments, called semilunar cartilages; 4, an internal lateral ligament; 5, an external lateral ligament; 6, the crucial ligaments; 7, the transverse; 8, the posterior ligament of Winslow. In addition to these there are the synovial capsule and its adipose and semilunar ligaments; a thin fibrous capsule, continuous with the periosteum, exterior to the synovial capsule; and even a sort of interarticular tendon, for a part at least of the tendon of the popliteus is invested on three sides by the synovial capsule of the joint.

To examine these various structures, clean the joint, by dissection, of everything extraneous, leaving, however, at first, the tendons of all the muscles attached around or near to the joint, and especially the united tendons of the triceps extensor, the so-called ligament of the patella, and the tendon of the semimembranosus. Remove the aponeurosis with the greatest care: the synovial capsule lies at no great distance from the surface, and may be laid open unexpectedly; and proceed to examine the precise attachments of the biceps extensor cruris and semimembranosus muscles.

The tendon of the semimembranosus muscle forms one of the inner hamstrings; it will be found at the back of the joint. This tendon, as will be more minutely described in the description of the muscle, is attached inferiorly by two tendinous attachments to the tibia; a third expands into the posterior ligament of Winslow, which passing across and behind the joint, from within outwards, and obliquely upwards, is

finally attached to the femur a little above the external condyle. The ligament receives some additional fibres from other sources. The middle articular artery and vein pass through it. The posterior ligament of Winslow assists in supporting the limb when the attitude is that of "standing at ease."

Fig. 106.*

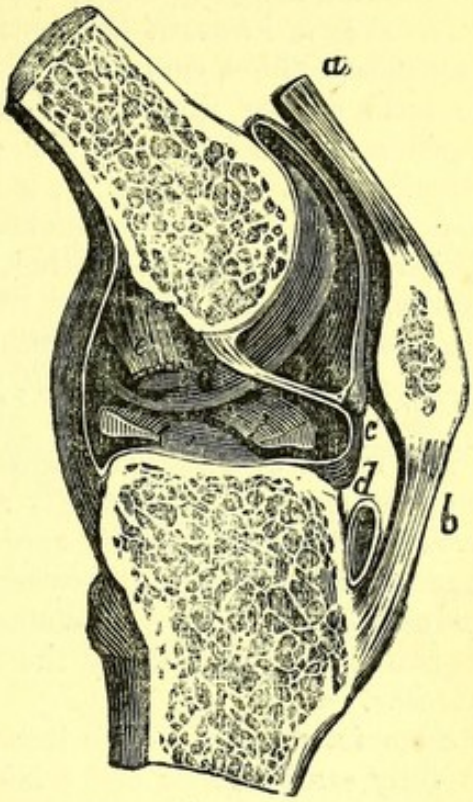

LIGAMENTUM PATELLÆ.—Next, examine the so-called ligamentum patellæ. A careful dissection will show that this ligament is merely the terminating tendon of the triceps extensor cruris, by which the patella is firmly secured to the tuberosity of the tibia.

Dissect carefully the united tendons of the triceps, or quadriceps extensor, as they expand over the surface of the knee-joint; insulate cautiously from the expansions of the vasti, the stronger portion called ligamentum patellæ; raise it cautiously up from the subjacent parts, and examine it first in its continuity and with a reference to its functions. It may afterwards be divided transversely, in order to study its relation to the synovial capsule, the bursa interposed between its lower part and the upper smooth portion of the tuberosity of the tibia, and generally to the joint. When thus prepared the ligamentum patellæ may be described as a strong band of tendinous fibres, connecting the patella to the lower part of the tuberosity of the tibia, and thus connecting the quadriceps extensor muscle to the tibia. Inferiorly it is firmly connected with the apex of the patella; but its fibres also ascend over the surface of the bone, showing their continuity with the tendon of the rectus. Some adipose substance separates it superiorly from the synovial membrane and a bursa already alluded to, from the spine of the tibia.

The internal lateral ligament connects the internal tuberosity of the femur with the inner surface of the upper extremity of the tibia; it is broad, flat, and distinct. The tendons of the sartorius, gracilis and semitendinosus muscles, with a synovial bursa interposing, cover the ligament inferiorly; internally it corresponds to the synovial membrane

* Fig. 106.—Vertical section of the knee-joint, displaying the relation of all the structures to each other. The figure requires few explanatory letters.—*a*, tendon of the extensor muscles of the leg; *b*, ligament of the patella: between them may be seen the patella, divided vertically and mesially; *c*, points to the anterior attachment of the ligamentum adiposum; *d*, to the bursa interposed between the ligamentum patellæ and the tibia.

for a short space, and is attached to the internal semilunar cartilage. The internal articular artery lies between the ligament and the bone.

The external lateral ligament is a rounded or cordlike fasciculus of ligamentous fibres connecting the external tuberosity of the femur to the head of the fibula. Its course is vertical. Internally it corresponds to the tendon of the popliteus muscle and to the external articular artery; externally, it is covered by the tendon of the biceps flexor cruris and the tendinous expansion of the extensor muscles. Behind this ligament is another, parallel with it, and called the short external lateral ligament; but the arrangement of this ligament varies. It connects the femur to the fibula.

The external lateral ligament passes between the bifurcated extremity of the biceps flexor cruris.

The name of capsular membrane has been given to a thin aponeurotic expansion, seemingly a continuation of the periosteum, and investing immediately the synovial capsule. Whilst passing beneath the attachments of the gastrocnemius muscle, two small sesamoid bones are occasionally found in connexion with this capsule. The capsule is greatly strengthened by the tendinous expansion of the quadriceps extensor.

Synovial capsule.—This important and complex membrane can only be fully examined by being laid open, carefully traced over the cartilages of incrustation and other structures, and its points of reflexion attended to in an especial manner: by dividing the capsule immediately above the patella, the general synovial capsule will seem to extend higher up than is at first imagined; this is owing to the presence of a large synovial bursa placed beneath the tendon of the crureus. This bursa very generally communicates with the synovial capsule by a very wide opening, but sometimes it is perfectly distinct and no orifice of communication exists.

The Crucial Ligaments.—These ligaments are placed at the back of the joint and external to the synovial membrane; they cross or decussate each other, hence their name; they are two in number and very strong. The anterior is attached inferiorly to a depression in front of the spines of the tibia; it is here connected with the anterior course of the inner semilunar cartilage; from this, proceeding upwards and backwards, it terminates by being attached to the inner side of the external condyle of the femur. The posterior crucial ligament connects the depression behind the spines of the tibia to the side of the inner condyle. Inferiorly this ligament is connected to the posterior bone of the external semilunar cartilage. These ligaments connect the condyles of the femur strongly to the tibia, but their precise functions are not well understood.

The semilunar cartilages.—These are two crescent-shaped interarticular fibro-cartilages, on which no doubt much of the security of the joint depends. Interposed between the condyles of the femur and the hollow articular surfaces surmounting the tibia, they are named

Fig. 107.*

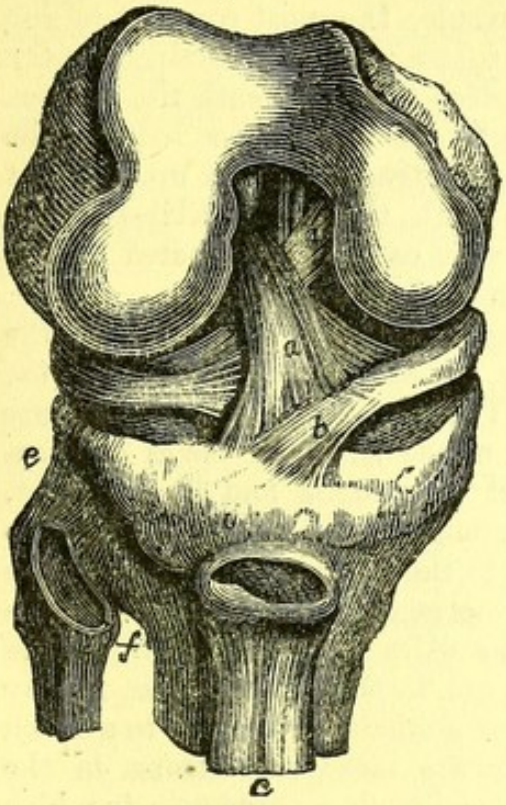

Fig. 108.†

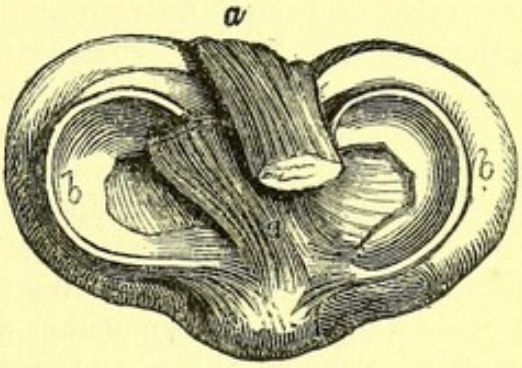

accordingly, internal and external. The outer edge or circumference of each is thick and convex; the inner thin and concave; in the centre is a circular space where the cartilaginous surfaces of the femur and tibia come into contact. The anterior horn of the internal semilunar cartilage is connected to the anterior crucial ligament, and is itself attached to the fovea before the spine of the tibia: the posterior horn is attached behind the spine and is connected to the posterior crucial ligament. The thin edge is free in both; the external thick edge has relations to the synovial capsule and to the external ligaments of the joint, easily understood by an inspection of the structures.

The external semilunar cartilage has relations similar to the internal. Its outer edge is connected to the tendon of the popliteus muscle and external lateral ligament. The synovial capsule of the joint invests both semilunar cartilages on their upper and lower surfaces and inner margins.

Transverse ligament.—A transverse band of no great strength, and variable, connects the convex borders of the semilunar cartilages to each other anteriorly.

* Fig. 107.—The knee-joint laid open from the front.—*a*, *a*, crucial ligaments; *b*, ligament connecting the internal semilunar cartilage to the tibia; *c*, ligament of the patella, cut across and laid down on the tibia; *d* points to the bursa placed between this ligament and the tibia; *e*, *f*, articulation of the head of the fibula to the tibia.

† Fig. 108.—Section to show the crucial ligaments and semilunar cartilages of the knee-joint.—*a*, *a*, the crucial ligaments cut across, but left attached to the tibia; *b*, *b*, the semilunar fibro-cartilages.

Lastly, there remains to be spoken of certain appendages of the synovial capsule which are curious and interesting as completing the history of the joint. The synovial capsule, the most complex in the body, is, like all the others, a shut sac. It communicates very generally, but not always, with, 1, the deep bursa, beneath the crureus muscle; 2, it sends a prolongation into the groove for lodging the popliteus muscle, and partially invests the tendon of that muscle. It has been said also to communicate with the upper tibio-peroneal articulation; but after repeated and very carefully conducted dissections of the structures, I have not found this to be the case.

Traversing the joint, and extending from the anterior part of the intercondyloid fovea to a little below the apex of the patella, is the ligamentum mucosum or adiposum. The disposition of this structure may be best seen by a vertical section of the joint and bones composing it, made upon the inner margin of the patella and its ligament. The so-called adipose ligament is a prolongation of the synovial membrane, of a funnel shape, and belongs to the same category as do the ligamenta alaria, two semilunar or crescent-shaped folds of the membrane running outwards from the sides of the patella. These three processes of the synovial capsule are, in the human knee, merely the *vestiges* of structures which in other animals are carried to a much higher degree of development. They are large and strong in the horse; still more complete in the Ornithorhynchus paradoxus, in which animals the ligamenta alaria, being connected to the condyles of the femur by their concave edge, divide the knee-joint into two distinct cavities or joints—a superior and an inferior; the articular surfaces in the superior are the upper half of the condyles of the femur and the patella; in the lower joint, the opposing surfaces are the tibia and the inferior half of the condyles of the femur.

In some specimens of the femur a slight transverse groove or indentation may be traced along the surface of the condyles in the direction I now speak of, indicating a structural arrangement which existed no doubt in the embryonic state.

PERONEO-TIBIAL ARTICULATIONS.

These articulations resemble, to a great extent, the corresponding articulation of the bones of the fore arm; they may be divided into a superior, middle, and inferior.

THE SUPERIOR PERONEO-TIBIAL ARTICULATION.—The osseous surfaces are, the oval articular surface of the head of the fibula and a corresponding one on the inferior surface of the external tuberosity of the tibia; 2, a synovial capsule; 3, two ligaments, an *anterior* and *posterior*.

Anterior ligament. — Connecting the fore part of the external tuberosity of the tibia to the fore part of the head of the fibula. It is flat and broad. It is composed of several distinct bundles of fibres, and is strengthened by the tendon of the biceps.

Posterior ligament.—Much weaker than the anterior, but composed of closer fibres. It is covered by the popliteus, and sometimes, as has been said, the synovial capsule of the knee-joint extends to it.

Synovial capsule.—This requires no special notice; the joint is all but immoveable.

THE MIDDLE PERONEO-TIBIAL ARTICULATION.—This is formed by the interosseous ligament (*ligamentum interosseum*, *membrana interossea*), a thin aponeurotic membrane, or lamina, filling up the space between the two bones, and attached extensively to both. It is partly composed of oblique fibres, which pass from the outer edge of the tibia to a ridge running along the inner surface of the fibula. Anteriorly, the interosseous membrane is covered by the tibialis anticus, extensor longus digitorum, extensor proprius pollicis, by the muscle called peroneus tertius when present, and by the anterior tibial vessels; the muscles, also, are attached to it by many fleshy fibres; it is an aponeurosis, in fact of origin, whatever other functions it may perform. Its posterior surface corresponds to the tibialis posticus and flexor longus proprius pollicis, which are also in part attached to it.

At the upper and outer part there exists a pretty large aperture, close to the neck of the fibula, by which the anterior tibial vessels pass through from behind forwards; but the corresponding nerve passes outside the fibula, and thus this bone is interposed between the anterior tibial vessels and nerve at this particular point. Inferiorly, the membrane or ligament is continuous with the interosseous ligament of the inferior peroneo-tibial articulation. At various points small vessels pass through this membrane, and inferiorly there is an aperture for the passage of a branch of the fibular artery.

INFERIOR PERONEO-TIBIAL ARTICULATION.—This is a close and firm articulation, and is somewhat continuous with that of the ankle-joint, from which it borrows its synovial membrane. The osseous surfaces are part of the inferior extremities of the fibula and tibia. These are connected, 1st, by a peculiar interosseous ligament of considerable strength, and which can be seen only as the bones are being forcibly separated from each other; 2d, by three other ligaments, an *anterior* and *posterior*, and *posterior inferior*.

The anterior ligament is triangular, broader below than above, and composed of separate fasciculi. The base is attached to the fibula, the summit to the tibia.

The posterior ligament resembles the preceding, but is smaller. It is attached by one extremity behind the tarsal extremity of the fibula, and by the other to the neighbouring part of the tibia. The peronei muscles cover it.

The *posterior* and *inferior* ligament is continuous with the preceding. Attached to the fibula, behind the malleolus externus, it proceeds transversely to the malleolus of the tibia, and thus deepens the cavity into which is received the articular pulley of the ankle-joint.

The inferior interosseous ligament has been already in part described. It is a dense tissue, intermingled with adipose flakes. The synovial membrane is of very small extent, and is merely a prolongation of that belonging to the ankle-joint.

ANKLE-JOINT.

Osseous surfaces.—The nature of this joint, which is a perfect angular gynglimus, may readily be understood by looking at the osseous surfaces. These are the lower surface of the inferior extremity of the tibia, the articular surface of the malleoli, and the pulley of the astragalus. All these are covered with arthrodial cartilages; that which invests the pulley of the astragalus extends to the sides of the pulley, but unequally. A synovial membrane, lax and extensive, covers all these articular surfaces.

The ligaments of this joint are—two lateral, two posterior, and one anterior.

Internal lateral ligament.—Broad, quadrilateral; composed of numerous fibres, which, descending obliquely backwards from the summit of the malleolus internus and its depression, attach themselves to the inner part of the astragalus and calcaneum. On one side it is in relation to the tendon of the tibialis posticus; on the other it is invested by the synovial membrane.

External lateral ligament.—This ligament is round, narrow, very strong, and of considerable length. It descends vertically from the summit of the malleolus externus to the upper and middle part of the outer surface of the calcaneum. It is covered by the tendon of the peroneus longus, and covers a part of the synovial membrane.

Anterior peroneo-tarsal ligament.—Attached to the fore part, and near the summit of the malleolus externus, it passes forwards obliquely, to be attached to the anterior edge of the external articular surface of the astragalus.

Posterior peroneo-tarsal ligament.—Attached to the depression behind the malleolus externus, it descends to the posterior part of the astragalus, near the outer edge of the groove for the tendon of the flexor longus pollicis pedis. Its fibres are numerous.

Tibio-tarsal ligament.—This ligament, by no means distinct, is composed of fibres, descending from the anterior part of the tarsal extremity of the tibia to the fore part of the articular pulley of the astragalus.

The synovial membrane requires no particular description. It should be laid open and carefully examined. It abounds with synovia.

ARTICULATIONS OF THE TARSAL BONES WITH EACH OTHER—*Articulation of the astragalus with the calcaneum.*—The inferior surface of the astragalus is articulated with the calcaneum by arthrodia in two places. Between them is an irregular rough depression, non-articular, for the attachment of the interosseal ligaments. These

articular surfaces have the usual cartilages and synovial membranes common to all moveable joints. Three ligaments exist here, to strengthen the joint: these are, 1, the interosseal; 2, the posterior; 3, the external.

Fig. 109.*



1. The *Interosseal* is composed of a great number of fibres, very dense and close, but concealed in a mass of adipose tissue. The ligament extends from the non-articular grooves of the os calcis and astragalus, already described.

2. The *Posterior ligament.*—The tendon of the flexor longus pollicis pedis conceals and covers it, and the sheath of this tendon is somewhat incorporated with the ligament. The ligament connects the posterior part of the astragalus to the neighbouring part of the calcaneum.

3. *External ligament.* — Descends from the base of the external articular surface of the astragalus to the outer surface of the calcaneum.

The synovial membrane, besides covering these articular surfaces, approaches the tendo Achillis, from which, however, it is separated by a great quantity of fat.

ARTICULATION OF THE CALCANEUM AND SCAPHOID BONE.

These bones do not touch each other; they are merely connected together by two very powerful ligaments, called calceo-scaphoid; inferior and external.

The inferior calceo-scaphoid ligament more resembles a fibro-cartilage, which I believe it in reality to be. It extends from the anterior part of the small tuberosity of the calcaneum to the inferior surface of the scaphoid bone. Weitbrecht divided it into two; the *ligamentum planum* and *ligamentum teres*. Its position and functions are important. Inferiorly it is situated over the tendon of the tibialis posticus; superiorly it forms with the calcaneum and scaphoid bone a cavity in which rests the head of the astragalus. On this ligament depends the

* Fig. 109.—Ligaments of the sole of the foot.—*a*, ligamentum longum plantæ; *b*, groove for the tendons of the flexor muscles; *c*, *c*, tendon of the peroneus longus muscle; *d*, expanded insertion of the tibialis anticus muscle; *g*, transverse metatarsal ligament, with the anterior metatarso-phalangeal ligaments; *h*, *i*, fibrous sheaths of the toes.

phenomenon of the elongation of the feet when sustaining the weight of the body.

The external calceo-scaphoid ligament is a very short fasciculus, with numerous fibres; it assists the preceding in forming the cavity just spoken of.

ARTICULATION OF THE SCAPHOID BONE WITH THE ASTRAGALUS.

This articulation is an enarthrosis, formed by the head of the astragalus being received into a hollow cavity of the scaphoid bone. The osseous surfaces are as usual covered with cartilages, and there is a synovial membrane. A single ligament belongs to this joint.

Ligament between the scaphoid bone and the astragalus.—Extending from the upper part of the neck of the astragalus to the upper part of the scaphoid bone. It is broad and thin with parallel fibres. The synovial membrane requires no special description.

CALCEO-CUBOID ARTICULATION.—The osseous surfaces covered with cartilage have been described. There is a synovial capsule and two ligaments.

1. *Superior calceo-cuboid ligament.*—Broad, thin, divided into fasciculi, and formed of several superimposed planes. The fibres originate in the upper and fore part of the calcaneum, and are inserted into the corresponding part of the os cuboides. This ligament is on the dorsum of the foot.

2. *The inferior calceo-cuboid ligament* (Ligamentum longum plantæ).—The longest and strongest of the ligaments of the foot. It arises from the inferior and posterior part of the calcaneum, and, passing directly forwards, terminates partly in the oblique tuberosity of the os cuboides. The remaining portion of the ligament continues outwards, passing below the sheath of the peroneus longus, and divides into several bundles which proceed to, and are attached to, the posterior extremities of the 3d and 4th metatarsal bones.

Inferior and deep calceo-cuboid ligament.—This ligament is shorter and is situated above the one just described. It proceeds from the os calcis, and is inserted wholly into the tuberosity of the os cuboides.

The synovial capsule of this joint requires no special description.

ARTICULATION OF THE SCAPHOID WITH THE CUBOID.—There is here a sort of interosseous ligament, which is strong and firm; also an inferior ligament, extending inferiorly between the two bones.

These two bones occasionally touch each other; and when this happens there will be found a small synovial capsule and a dorsal ligament.

ARTICULATION OF THE EXTERNAL CUNEIFORM BONE WITH THE CUBOID.—Where these bones meet there exist cartilaginous surfaces and a synovial capsule. In addition, the joint is strengthened by a dorsal and plantar ligament. A sort of interosseal ligament also exists.

ARTICULATIONS OF THE CUNEIFORM BONES WITH THE SCAPHOID.—Anteriorly the scaphoid bone is articulated with the three cuneiform bones by surfaces covered with cartilage, a synovial membrane, and 6 ligaments.

Dorsal ligaments. — 3 in number, viz. an internal, middle, and external. Attached posteriorly to the scaphoid, they diverge as they proceed to their attachments to the cuneiform bones.

Plantar ligaments.—These are also 3 in number. They are less distinct than the preceding; one synovial membrane suffices for all these articular surfaces.

ARTICULATIONS OF THE CUNEIFORM BONES WITH EACH OTHER.—These bones are mutually articulated by surfaces covered with cartilage; the synovial membrane is the same as the preceding articulation. Two ligaments, which may be called dorsal from their position, pass transversely from one to the other, connecting these bones together; two others, plantar, in a similar way connect them together in the plantar aspect of the foot.

TARSO-METATARSAL ARTICULATIONS.

The osseous surfaces are, the anterior articular facettes of the three cuneiform and cuboid bones on the one hand; and on the other, the proximal or tarsal extremities of the 5 metatarsal bones. These surfaces are invested with cartilages and synovial capsules arranged in this way. Between the 1st metatarsal bone and the internal cuneiform there is a distinct and separate capsule; a second is common to the 2d metatarsal bone, the 2d and 3d cuneiform bones, and is common to the articulation between the first two of the cuneiform bones with each other; a third capsule belongs to the third metatarsal bone and the 3d cuneiform; but this also sends prolongations between the surfaces of the two adjoining metatarsal bones. The 4th synovial capsule serves for the articulation of the two last metatarsal bones with each other and with the cuboid.

The ligaments strengthening these articulations are dorsal and plantar.

Dorsal ligaments.—Each of the metatarsal bones receives a ligament from each of the tarsal bones with which it is articulated. All these ligaments are covered by the extensor muscles of the toes and correspond to the synovial capsules.

Plantar ligaments.—These are equal in number to the dorsal, and disposed nearly in the same manner. The sheaths of the tendons in the sole of the foot, and especially that of the peroneus longus, greatly strengthen all these ligaments.

ARTICULATIONS OF THE METATARSAL BONES WITH EACH OTHER.

These joints resemble those of the metacarpus. The first metatarsal bone is not immediately articulated with the next posteriorly, but anteriorly; and unlike the hand in this respect, the transverse liga-

ment of the toes extends to it. The other four are directly articulated with each other posteriorly, by surfaces encrusted with cartilages, and lined by prolongations of the synovial membranes of the preceding articulations. In addition there are dorsal and plantar ligaments similar to each other and to those of the metacarpus. They extend transversely in each region from the 2d to the 3d, from the 3d to the 4th, and from the 4th to the 5th metatarsal bones. Some interosseous fibres extend between the points of the non-articular surfaces.

METATARSO-PHALANGEAL ARTICULATIONS.

These articulations constitute arthrodiæ, and resemble in nearly all respects the corresponding joints in the hand, between the metacarpus and phalanges of the fingers.

ARTICULATIONS OF THE PHALANGES OF THE TOES.

Their surfaces, ligaments, and synovial membranes are, in all respects, similar to those of the fingers, but smaller, corresponding to the diminished size of the phalanges of the toes.

To be useful to the surgeon, ligamentous preparations must be prepared by himself and kept in spirits. In their dried state they serve only to mislead.

MYOLOGY,

OR

DESCRIPTIVE ANATOMY OF THE MUSCLES.

MUSCLES OF THE TRUNK.

THE muscles are the active organs of locomotion. They form by far the greater part of the solid bulk of the body, and compose what is commonly called the flesh. They are attached in a variety of ways to the bones, sometimes by long, sometimes by short tendons, or by tendinous expansions, to which, unfortunately I think, the name of aponeuroses has been given. By the terms *origin* and *insertion*, words of frequent use in describing the muscles, is merely meant their attachments to the bones or other structures. The word *origin* is usually applied, but not necessarily, to the fixed or less moveable attachment; that of *insertion*, to that extremity of the muscle which is attached to the more moveable bone or part. Thus the *origin* of the trapezius is said to be from the spinal column and head, and its attachment to the shoulder bones is called its *insertion*; but such terms are quite conventional, and have no special meaning, excepting in so far as they merely mean attachments.

The muscles are composed of fibres arranged in fasciculi, whose intimate nature, in so far as this is understood, will be explained in the section on General Anatomy. These fasciculi are enclosed in cellular sheaths, and the entire muscle in a cellular covering, which may be called the fascia propria of the muscle. Beyond these there are other fasciæ, described in the special section following this chapter.

The muscles are disposed in layers; the meaning of their varied shapes is quite unknown. One system or plan prevails throughout all the mammalia, man included. The anatomist speaks of them as occupying certain regions, but this is not to be understood rigorously, either in a physiological or anatomical sense; very few muscles occupy merely a single region, and, in respect of their action on the parts, the language used is apt to mislead the beginner. Thus the deltoid is called a muscle of the shoulder, but its action is mainly on the arm. The muscles of the fore arm act chiefly on the fingers; the so-called muscles of the arm act on the fore arm, &c. The right understanding of the anatomy of the muscles is the great aim of the student's labour, sensible that without a competent knowledge of these he never can become an anatomist in any sense of the term. It is therefore recommended to him to neglect every other structure during his first

Fig. 109.*

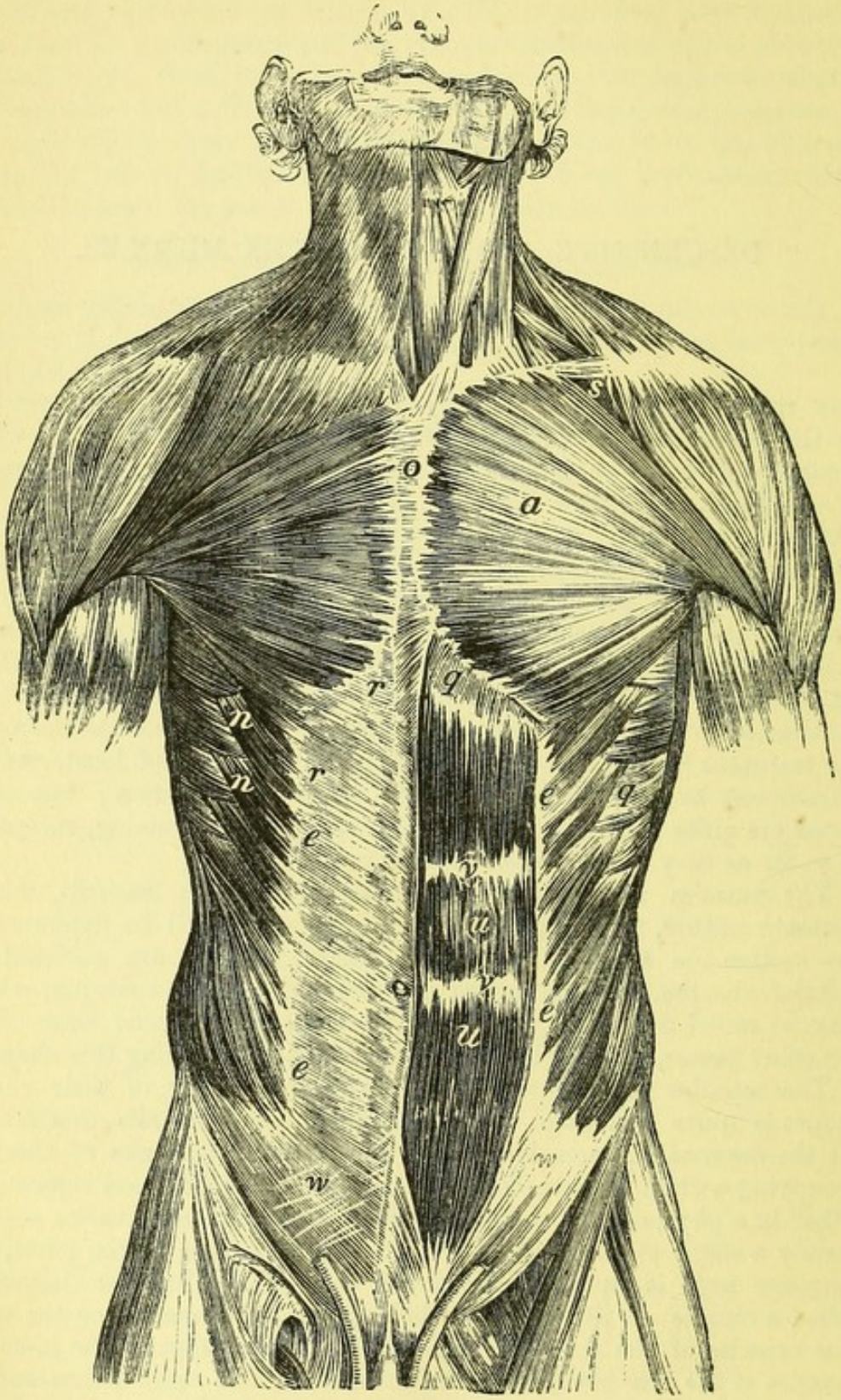

* Fig. 109.—Muscles of the torso, front view.—*a*, sternum; *s*, triangular hollow bounded by the collar-bone, pectoral muscle, and deltoid; *r*, rectus abdominis, covered by the aponeurosis; *q*, *u*, *v*, *u*, *v*, rectus exposed by dissection; *e*, *e*, external oblique muscle of the abdomen; *q*, some attachments of the

dissection of the muscles, and to look to their anatomy solely. It is not of any moment with what region he commences his dissections.

MUSCLES OF THE BACK.

Mode of dissection.—The body being placed in a suitable position, and supported by blocks of wood placed under the chest and abdomen, so as to put the muscles of the back on the stretch, commence the dissection by an incision carried through the integuments along the mesial line, from the external occipital protuberance to the coccyx. A transverse incision is to be carried outwards from this longitudinal one to the mastoid process; another from the spinous process of the seventh cervical vertebra to the summit of the acromion scapulæ, and a third from the termination of the longitudinal one around the crest of the ilium to the extent which the position of the body admits of. Commence raising the flaps, very cautiously at first, as the muscles are thin and tendinous where attached to the spine and ligamentum nuchæ, proceeding more boldly when the muscular fibres have been reached. Clean the muscles about to be exposed thoroughly, by removing from them in the usual way, that is, in the direction of the fibres, the integuments, superficial fascia, and proper investing fascia of each muscle. The muscles and other structures thus exposed, presuming the dissection to be confined to one side, are,—1, the trapezius; 2, the latissimus dorsi; 3, the surface of the ligamentum nuchæ; 4, the so-called cervical aponeurosis; 5, the so-called lumbar aponeurosis.

THE TRAPEZIUS.—Thin and triangular. Attached to the inner third of the superior curved line of the occipital bone, to the whole length of the ligamentum nuchæ, the spinous processes of the seventh cervical, and of all the dorsal vertebræ, as well as to the interspinal ligaments, or ligaments of the *apices*. These origins take place by thin tendinous layers often called aponeuroses; that attached to the occipital bone is thin and broad, and is often removed by the incautious dissector mistaking it for cellular tissue. Along the ligamentum nuchæ the fibres of origin are short, but from the sixth cervical to the third dorsal vertebræ they again lengthen, and, with those of the opposite muscle, form an elliptic or oval figure, which anatomists have sometimes called, though improperly, the posterior cervical fascia or aponeurosis. It is neither a fascia nor an aponeurosis, but simply the tendinous origin of the trapezius.

The aponeurotic fibres in which the muscle originates again shorten, to elongate once more towards the lower part of the back, where they form a triangular-shaped tendon; thin, and sometimes descending lower in the right muscle than in the left. To these tendinous fibres

serratus magnus muscle; *e*, *e*, *n*, tendon of the external oblique muscle of the abdomen, sometimes called the abdominal aponeurosis; *n*, *n*, origins of the external oblique muscle of the abdomen; *w* points to the abdominal rings, or cremasteric openings.

Fig. 110.*

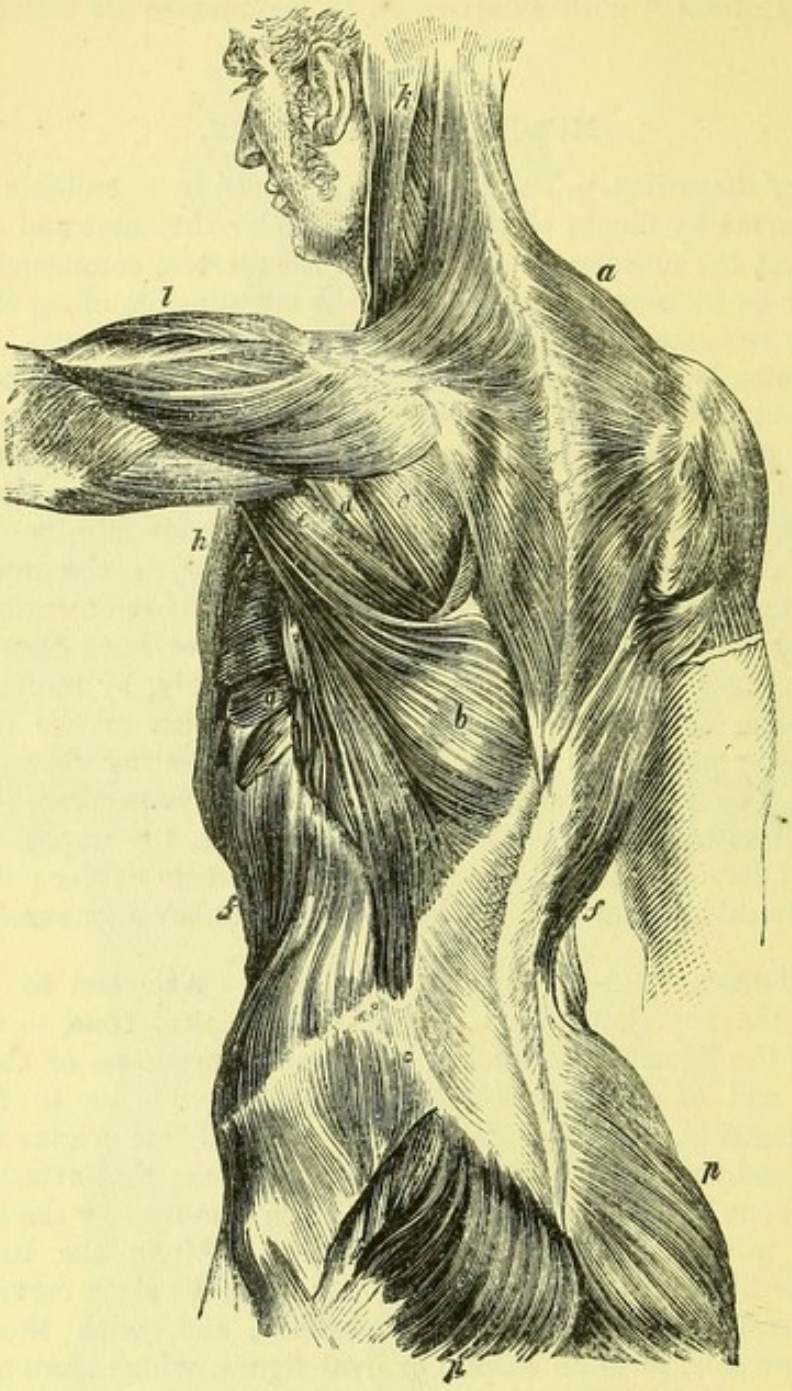

succeed the fleshy fibres, constituting the living contractile part of the muscle; those which come from the occipital bone and ligamentum nuchæ descend obliquely outwards and forwards; those from the last cervical and superior dorsal vertebræ pass transversely towards the shoulder; the remaining fibres ascend. The mode of attachment or the insertion of all these muscular fibres to the bones of the shoulder is by tendinous fibres of considerable but varying length, attached to

* Fig. 110.—*k*, sterno-mastoid; *a*, trapezius; *l*, deltoid; *c*, infra-spinatus; *d*, teres minor; *e*, teres major; *b*, latissimus dorsi; *h*, pectoralis major; *g*, serratus magnus; *f*, external oblique muscle of the abdomen; *p*, gluteus maximus.

Fig. 111.*

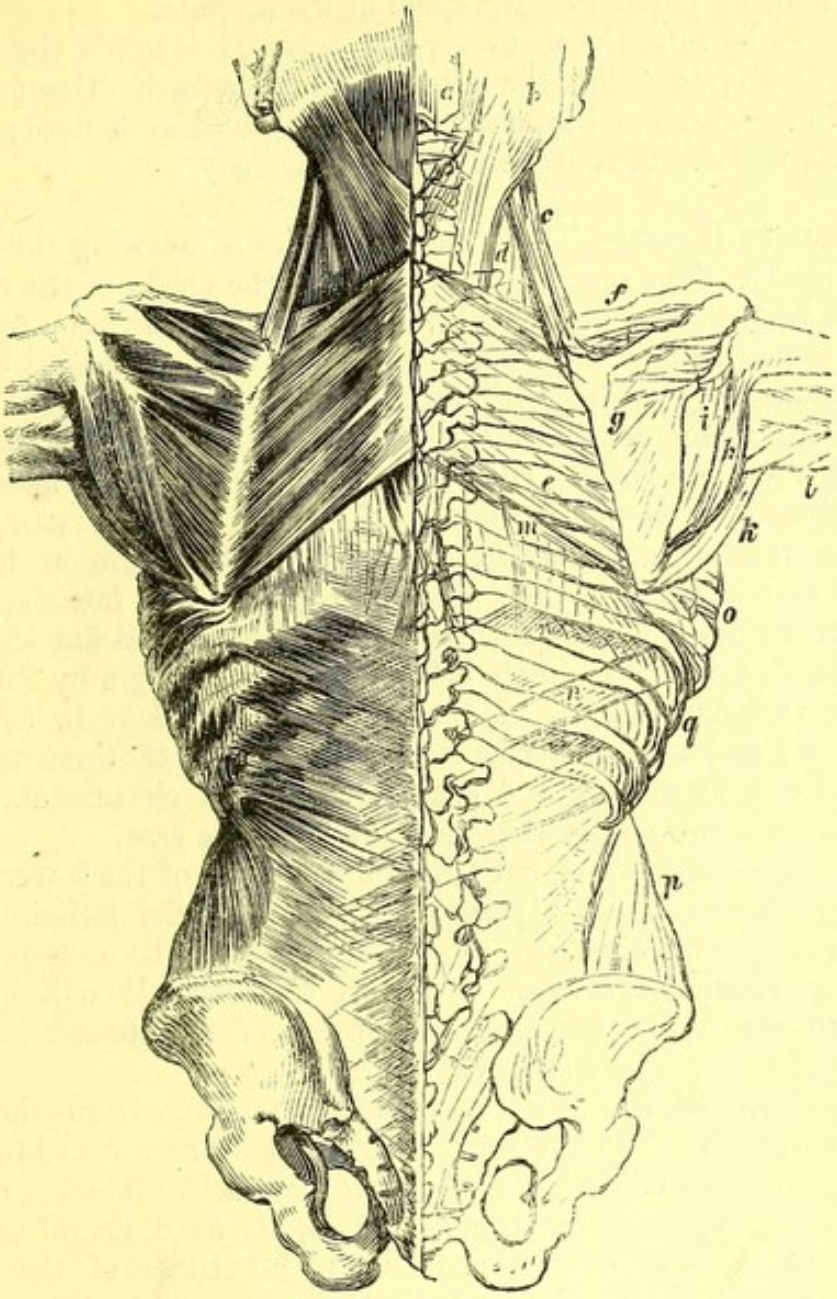

the outer third of the posterior edge of the clavicle, to the acromion, the acromio-clavicular ligament, and the spine of the scapula. A loose cellular substance, probably a rudimentary bursa, enables the lower part of the tendinous expansion to play freely over the triangular, smooth, osseous surface which the spine presents where it commences near the vertebral costa of the scapula.

Relations.—The muscle is covered posteriorly by the integuments and superficial fascia; anteriorly, it rests on the complexus, splenius, levator anguli scapulæ, and serratus posticus superior. It covers also more or less the supra-spinatus, infra-spinatus, rhomboideus, a small

* Fig. 111.—*a*, complexus; *b*, splenius capitis; *d*, scaleni; *f*, supra-spinatus; *g*, infra spinatus; *e*, rhomboideus, major and minor; *i*, *h*, teres minor; *k*, teres major; *l*, triceps; *o*, serratus magnus; *n*, serratus posticus inferior; *q*, intercostal muscles; *p*, obliquus internus.

portion of the latissimus dorsi, sacro-lumbalis, and longissimus dorsi muscles; also a portion of the spine of the scapula.

Action.—To raise the shoulder, and carry it towards the head and spinal column; to bring the scapulæ towards each other; to carry the head backwards and laterally when the shoulder is fixed; directly backwards when both muscles act simultaneously.

LATISSIMUS DORSI.—There are two modes of viewing the anatomy of this muscle. The one consists in tracing the origin of the muscle in the usual way, from a broad and thin tendinous membrane connecting it to the spinal column and pelvis; but this thin expanded tendon is all but inseparably united with other tendons lying beneath it. This fact has led many continental anatomists to describe the muscle as originating on the outer edge of a common lumbar aponeurosis. To the student it is not a matter of the slightest moment how he views the lumbar aponeurosis, whether as the common tendinous origin of several muscles, and, amongst these, of the latissimus dorsi, or as a strong tendinous expansion composed of several flat tendons all but inseparably united to each other, and giving origin by its various layers to various muscles. I recommend the student to adopt this latter view, and shall describe these muscles as if these tendinous origins were really distinct and easily separable, a circumstance which the student will find in his dissection not to be the case.

Dissection.—Raise up or cut through a portion of the lower margin of the trapezius so as to display that portion of the latissimus dorsi which it covers and conceals. Put the fibres of the muscle on the stretch and clean them in so far as is possible. It will be found difficult to expose the humeral attachment of the muscle until the dissection of the arm be well advanced.

Description.—Broad, thin, and flat, extending from the spinal column and pelvis to the humerus. Commencing by a broad tendinous origin, incorporated with that of the serratus posticus inferior, attached to the spinous processes of the last 5, 6, 7, or 8 dorsal vertebræ, according to the size of the muscle; to all those of the lumbar and sacral vertebræ; to the interspinal ligaments; to the asperities of the sacral grooves; to the tuberosity of the ilium and posterior part of the iliac crest, where it is continuous with aponeurotic fibres of the gluteus maximus and sacro-spinalis. In addition to these spinal and pelvic origins, the muscle has others, namely, three or four fleshy digitations, which are at first also aponeurotic from the last three or four ribs. These digitations are interlaced with those of the external oblique muscle of the abdomen, and are laid in some measure over each other. The fleshy fibres thus originating converge, the muscle becoming narrower and thicker as it approaches its attachment to the humerus.

The superior margin of the muscle crosses the inferior angle of the scapula, from which it sometimes receives an additional slip. When near the humerus it forms a tendon about three inches in length and

an inch broad. This tendon, twisted partly on itself, is turned from below upwards, and from behind forwards, over the lower edge of the teres major. The lower part of the tendon of insertion receives the fibres belonging to the upper part of the muscle; and *vice versâ*, those belonging to the lower part of the muscle go to the upper part of the tendon.

The tendon at first is contiguous with the tendon of the teres major; next separated from it by cellular tissue, afterwards by a small synovial bursa. It soon unites with it, to be inserted at the same time into the posterior or inner margin of the bicipital groove of the humerus.

These tendons are, moreover, strengthened by an aponeurotic band, descending from the smaller tuberosity of the humerus; and they send out from their lower margin a similar band, which spreads out into the brachial aponeurosis, together with some fibrous bundles which line the bicipital groove, in conjunction with the tendon of the pectoralis major.

The *posterior* surface of the muscle is everywhere subcutaneous, excepting the triangular portion covered by the trapezius. *Anteriorly*, the muscle covers the oblique muscles of the abdomen, the serratus posticus inferior, sacro-spinalis, levatores costarum, inferior intercostals, serratus magnus, rhomboideus, teres major, infra-spinatus, the lower ribs, and the inferior angle of the scapula.

The *anterior* surface of the tendon, united with that of the teres major, is in connexion with the axillary vessels, the brachial plexus, and coraco-brachialis. A thin synovial capsule, interposed between the posterior surface of the tendon and the bone, facilitates their respective motions.

Action.—To carry the arms backwards until the hands meet behind the trunk; it brings the arms strongly against the walls of the chest, and, in this action, coincides with the pectoral muscle, of which, under other circumstances, it is the direct antagonist. When the arm is fixed, it pulls the trunk towards it, and, at the same time, by its costal attachments, it is a respiratory muscle, by assisting in fixing the ribs.

LIGAMENTUM NUCHÆ.—During the dissection of these muscles, the structure called ligamentum nuchæ comes partly into view. This is a fibrous lamina, extending from the external occipital protuberance to the spinous processes of the lowest cervical and first dorsal vertebræ, analogous to the pax-wax, a much stronger ligament present in large quadrupeds, and obviously a continuation of the system of ligaments called supra-spinous. It forms a septum, dividing the neck mesially into two symmetrical halves; it gives attachment to several muscles, and slightly supports the head. In man, it is to a certain extent a rudimentary structure; in the elephant and horse it is of vast strength, extending nearly to the extremity of the trunk.

CERVICAL REGION.—Other muscles and structures approach the

surface, which the trapezius and latissimus dorsi do not cover. These are, 1st, in the cervical region, the upper part of the sterno-mastoid muscle; 2d, in the dorsal region, a portion of the base or vertebral margin of the scapula; a small part of the rhomboideus major; two or three tendons of the sacro-lumbalis; a portion of the vertebral aponeurosis; and lastly, a triangular space, mesial to the base of the scapula, below the rhomboideus and trapezius, and above the margin of the latissimus dorsi, in which space will be found, subcutaneous merely, portions of the 7th, 8th, and 9th ribs, and of their corresponding intercostal muscles.

This exposed space of the chest may be enlarged by throwing the arms forward across the chest, and contracted by the opposite action of bringing the scapulæ towards each other, and towards the spine.

LUMBAR REGION.—During the same dissection, there will be exposed, in the lumbar region, the posterior margin of the external oblique muscle of the abdomen. The relation of this margin to the outer edge of the latissimus dorsi will be touched on when describing the muscles of the abdomen.

RHOMBOIDEUS—(*Musculi rhomboidei; major et minor*).

Dissection.—Cut through the trapezius where thickest, and reflect the flaps, one towards the spine, the other towards the shoulder. Clean the fibres at once, whilst removing the trapezius; these must be placed and kept on the stretch.

The rhomboideus is a broad flat muscle, nearly square, occupying the upper part of the back and lower part of the neck. It is divided by a cellular line into two portions, which have been considered as distinct muscles; of these, the upper is smaller, the lower larger. It arises by aponeurotic fibres, longer below than above; from the lower part of the ligamentum nuchæ, the spinous process of the last cervical, and the first four or five dorsal vertebræ, and from the corresponding supra-spinal ligaments. The fleshy fibres, which are all parallel, descend a little outwards to the spinal edge of the scapula, where they are attached superiorly and inferiorly; but in the middle they are inserted along an aponeurotic arch, vertical, and parallel to the edge of the scapula, with which it is only connected by its two extremities, being separated from it in the rest of its extent by cellular tissue, traversed by vessels.

The *posterior* surface of the rhomboideus is in a great part covered by the trapezius; inferiorly, it is covered by the latissimus dorsi, and, between these two muscles, it is in contact with the skin. The *anterior* surface covers the serratus posticus superior, the splenius, sacro-spinalis, and part of the intercostalis exterior; it is also applied over some of the ribs. Its *appendage* is covered, in nearly its whole extent, by the levator anguli scapulæ.

The rhomboideus, in action, brings the scapula toward the trunk, and in this way the rhomboid muscles of the opposite sides draw the

shoulders forcibly towards each other; it also lowers the tip of the shoulders, by bringing the lower angle of the scapula toward the vertebral column.

These muscles may now be detached from the spine and ligamentum nuchæ. Great caution must be used here, otherwise the dissector will most certainly also raise a muscle which lies below it, viz. the serratus posticus superior.

LEVATOR ANGULI SCAPULÆ; long and thick, situated at the lateral and posterior part of the neck. It is attached to the posterior tubercles of the transverse processes of the first three, four, or five cervical vertebræ, by as many small tendons, frequently united with the splenius and scalenus posticus. Each of these tendons gives rise to a fleshy bundle; that of the atlas is the longest and thickest; the others become more slender, as they are more inferior. They are at first isolated, but unite below into a single bundle, which descends obliquely backwards and outwards, to be inserted by short tendinous fibres into the posterior angle of the scapula, and the inner part of its upper edge.

* Fig. 112.

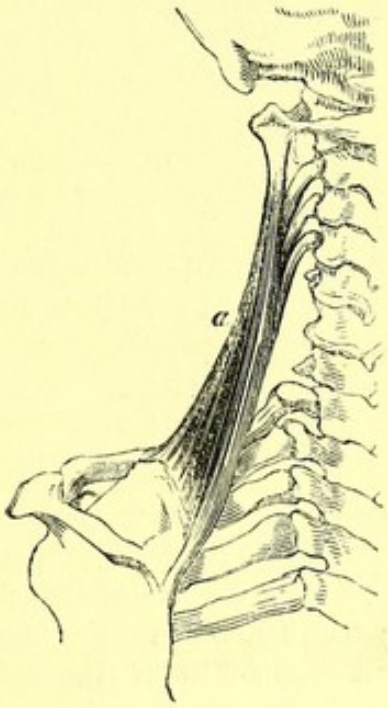

Its *outer* surface is covered at its upper part by the sterno-cleido-mastoideus, in the middle by the skin, and below by the trapezius.

The *inner* is applied upon the serratus posticus superior, sacro-lumbalis, transversalis colli, and splenius Its *posterior* edge covers a portion of the upper edge of the rhomboideus.

This muscle, in action, raises the posterior angle of the scapula, at the same time it depresses the shoulder. When it acts in concert with the trapezius, the shoulder is directly raised. It may also incline the neck to its side, or fix it in the erect position, when it acts in conjunction with its fellow.

SERRATUS POSTICUS SUPERIOR.—Of an irregularly quadrilateral form, flat, and very thin. It is attached to the lower part of the ligamentum nuchæ, to the spinous processes of the last cervical, and of two or three of the upper dorsal vertebræ, by a very delicate aponeurosis, extending to the half of its length. The fibres of this aponeurosis are parallel, and directed obliquely from above downwards, and from within outwards; the fleshy fibres follow the same direction, and separate into four or five digitations, which are attached to the

* Fig. 112.—*a*, levator of the angle of the scapula.

Fig. 113.*

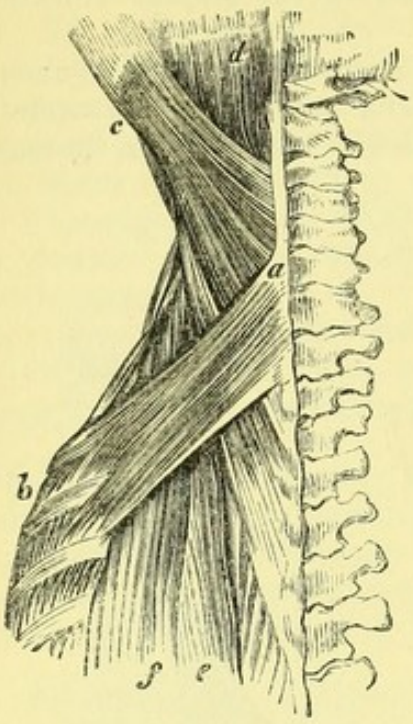

Fig. 114.*

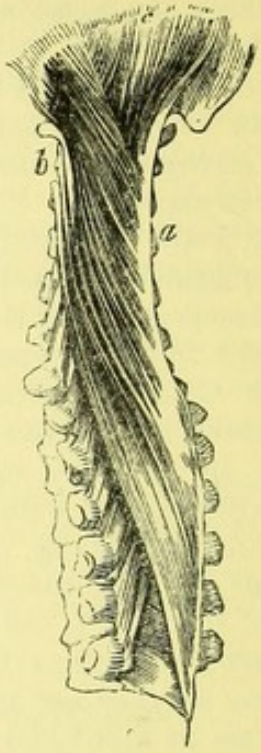

outer surface and upper edge of the second, third, fourth, and fifth ribs, outside their angles.

The *posterior* surface of this muscle is in connexion with the rhomboideus, angularis scapulæ, serratus magnus, and trapezius. The *anterior* is applied upon the splenius, longissimus dorsi, transversalis colli, sacro-lumbalis, the ribs, and external intercostal muscles.

It raises the ribs to which it is attached, and is, consequently, subservient to inspiration. It also keeps down, in some measure, the vertebral muscles over which it passes.

Serratus Posticus Inferior.—This muscle is exposed by reflecting the inferior segment of the latissimus dorsi towards the spine. It is broader, but equally thin, and has nearly the same form, as the serratus posticus superior. It is situated at the lower part of the back, and in the lumbar region. Arising from the last two spinous processes of the back, and the first three of the loins, as well as from the corresponding supra-spinal ligament, by a broad aponeurosis, with parallel fibres directed obliquely upwards and outwards, which is intimately connected with that of the latissimus dorsi, or fascia lumborum; it divides, after a short passage, into four or five distinct muscular bundles. The first, which is broad, is attached to the outer lip of the

* Fig. 113.—*a*, ligamentum nuchæ; *b*, external intercostals—these letters also point to the two extremities of the serratus posticus superior; *c*, splenius capitis; *d*, complexus major; *f*, sacro-lumbalis; *e*, longissimus dorsi.

Fig. 114.—*a*, ligamentum nuchæ; *b*, splenius capitis and colli; *c*, top of the complexus major.

lower edge of the second floating rib, over an extent of four or five inches, and, by its lower border, covers the upper edge of the third. The other three, which become successively narrower and shorter, are attached in the same manner, but are directed upon the ribs, further from the angle than the first, so that the fourth is attached not only to the bony part, but also to the cartilage of the last rib. Their edges also overlap each other, presenting (to use a botanical phrase) the appearance of *imbrication*.

The *superior* surface is covered by the latissimus dorsi. The *anterior* rests upon the three last ribs, the corresponding external intercostal muscles, and the posterior lamina of the aponeurosis of the transversalis abdominis, which separates it from the sacro-lumbalis, longissimus dorsi, and transverse spinal muscles.

This muscle in action lowers those ribs to which it is attached, and thus contributes to increase the capacity of the chest.

The VERTEBRAL APONEUROSIS connects the inferior margin of the serratus superior with the upper margin of the serratus inferior. This aponeurosis varies much in strength, and sometimes resembles a continuation of the muscles themselves, composed however merely of aponeurotic fibres. It extends laterally from the spinous processes of the vertebræ to the angles of the ribs, and thus binds down the great erector muscles of the spine.

SPLENIUS (*Musculi splenii capitis, et colli*). This muscle is exposed by reflecting towards the shoulder the whole of the trapezius, and that portion of the sterno-mastoid which is attached to the superior curved line of the occipital bone. The dissector must be careful here not to encroach too much on the lateral aspects of the neck, otherwise the important dissection of the anterior aspect of this region will be destroyed. The *splenius* is an elongated, flat, but thick muscle, broader above than below, situated obliquely at the back of the neck and upper part of the back. It arises by aponeurotic fibres, which are longer below than above, from the spinous processes of the first five or six dorsal vertebræ, from their interspinal ligaments, from the spinous process of the last cervical vertebra, and from the ligamentum nuchæ as far as the third cervical vertebra. From these different points of attachment the fleshy fibres arise, which form a bundle whose thickness and breadth continue to increase as it recedes from them. It ascends outwards, leaving between it and its fellow a triangular interval, in which the complexi are seen. At the middle part of the neck it separates into two portions. The lower and outer of these (*splenius cervicis*) is narrower, and is itself divided into three small bundles, which are attached by an equal number of thin and slender tendons, longer internally than externally, to the transverse processes of the three upper cervical vertebræ. The other portion, which is superior and internal, is called the *splenius capitis;* it is larger, continues to ascend, and terminates, by short aponeurotic fibres, at the outer half of the rough impression between the two

curved lines of the occipital bone, at the mastoid portion, and the whole outer edge of the mastoid process of the temporal bone, below the insertion of the sterno-cleido-mastoideus.

The *posterior* surface lies upon the complexus, longissimus dorsi, trachelo-mastoideus, and transversalis colli.

In action it extends the head, inclining it laterally; if only one muscle act, say the right, it will turn the face to the right shoulder. When the two muscles act together they raise the head directly.

The muscles filling the vertebral grooves may now be examined; the various accounts given of them by a variety of anatomists, from Winslow to Portal, and even later, have greatly tended to confuse this part of the subject, so that most anatomists give them up in despair, and few surgeons understand them: this neglect has greatly influenced the surgical treatment of spinal disease and spinal curvature, reducing it to a deplorable empiricism. The student will do well not to neglect these muscles: upon a good anatomical basis he can alone found a correct physiology, and this again is the only secure basis for the practice of physic and surgery.

Raise the splenius by cutting across its spinal attachments, not too close, and reflecting it outwards. In the lumbar region divide the united tendons of the latissimus dorsi, serratus posticus inferior (*lumbar fascia*), by a longitudinal incision carried within half an inch of the vertebral column. By reflecting the outer part, it will be seen that the lumbar fascia is really composed of the united tendons of the muscles already described, and is formed of three layers, the most superficial of which is the broad tendon of the latissimus dorsi; the next, the tendinous origin of the serratus posticus inferior; and the 3d, a layer derived from the tendinous origin of the transversalis abdominis muscle. The relation of this deepest layer of the so-called lumbar fascia will be described more minutely when speaking of the transversalis muscle.

The muscles now exposed by this section of the lumbar aponeurosis extend throughout nearly the whole length of the spine; they form the third layer of the muscles of the back. Some delicate cellular tissue invests them; this is to be removed by dissection, together with numerous vessels and nerves, and the entire range of muscles may be viewed as composed of three divisions, a cervical portion, a dorsal, and a lumbo-sacral. The spinous processes of the vertebral column and the ligamentum nuchæ divide them mesially from those of the other side. Proceed with the dissection of the muscles. It is quite a mistake to suppose that this can be performed satisfactorily in a coarse manner; it is also an error to suppose that many of the muscles now to be described are so connected with each other as to render their description impracticable.

The muscles to be first examined, and the order in which this should take place, are, 1, the sacro-lumbalis, musculi accessorii, and cervicalis descendens; these form one system: 2, the longissimus dorsi and transversalis colli: 3, spinalis dorsi. On a right understanding of these

muscles depends the facility of the dissection of all the muscles which follow in this region.

Fig. 115.*

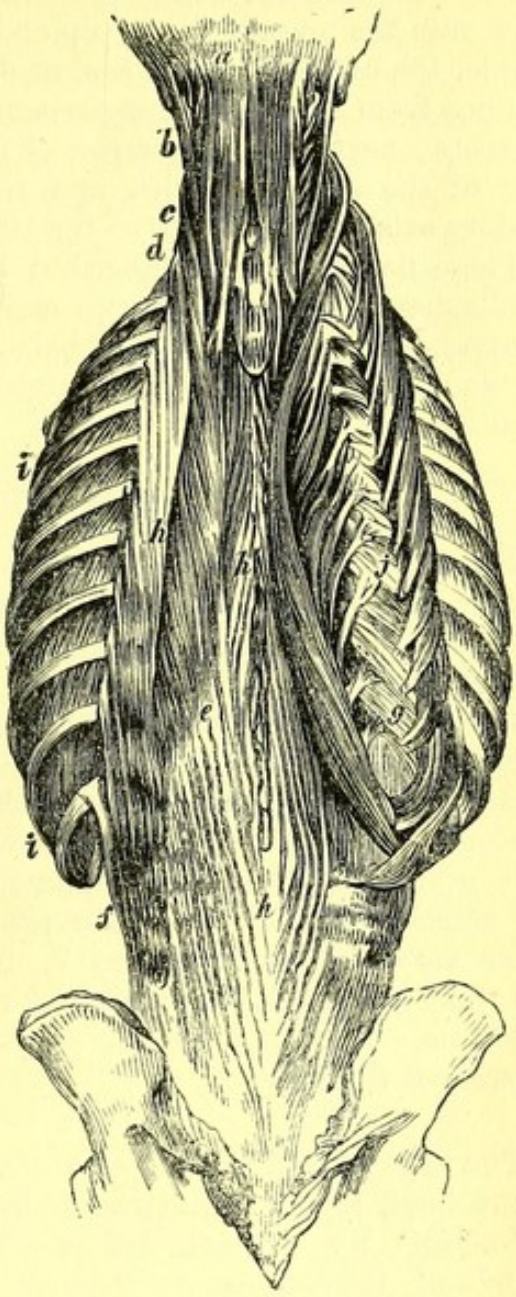

SACRO-LUMBALIS—Arises in common with the longissimus dorsi by a broad, strong, dense, and thick aponeurosis, white and glistening, formed of fibres interlaced, but separated from space to space by openings traversed by blood-vessels. The large fleshy mass lying beneath this aponeurosis, though viewed by some continental anatomists as a part of the muscle I now describe, does not belong to it; its fibres run in another direction.

This tendinous or aponeurotic origin is attached to the posterior part of the iliac crest, the sides of the notch terminating the sacral canal, the whole middle ridge of the sacrum, and to the spinous processes of the lumbar vertebræ, more particularly to the three inferior ones.

From both surfaces of this aponeurosis there arises a fleshy mass, which afterwards divides into the sacro-lumbalis and longissimus dorsi. These muscles, then, are single at first. The separation takes place nearly opposite to the last rib; the fleshy fibres constituting the sacro-lumbalis proceed upwards, nearly vertically, but a little outwards, and terminate by 12 flat tendons, which are attached to the ribs below their angles. Some anatomists view the superior 5 tendons as belonging to the musculi accessorii, but this seems, to a certain extent, incorrect; and practically it is preferable to view all these external and costal attachments of these tendons as pertaining to one muscle.

* Fig. 115.—*a*, complexus major; *b*, trachelo-mastoideus; *c*, top of the longissimus dorsi and transversalis cervicalis; *d*, top of the sacro-lumbalis and cervicalis descendens; *i*, external intercostals; *f*, sacro-lumbalis, outer edge; *e*, longissimus dorsi; *h*, *h*, spinalis dorsi; *g*, levatores costarum; *j*, costal attachments of the longissimus dorsi.

These tendons, by being connected with each other, form superiorly a thin tendinous aponeurosis of unequal and varying strength. If we now raise the muscle gently up and trace it on its inner side where it is free, the *cervicalis* ascendens or descendens next appears, arising by tendons from the transverse processes of 4 or 5 of the lower cervical vertebræ, next forming a series of fleshy bundles situated on the inner side of the sacro-lumbalis, and terminating by a series of slender tendons attached to 7 or 8 of the ribs above their angles.

These fleshy bundles, described by the older anatomists as the cervicalis descendens and musculi accessorii, are best viewed practically as appendages of the sacro-lumbalis. Mechanically at least, if not also physiologically, they serve to extend the sacro-lumbalis into the cervical region.

LONGISSIMUS DORSI AND TRANSVERSALIS COLLI.

These muscles should be examined together. On the back of the sacrum the longissimus dorsi, like the sacro-lumbalis, is tendinous; they have in fact a common origin, which has been already described.

The longissimus dorsi, becoming free nearly opposite to the last rib, proceeds vertically upwards, between the sacro-lumbalis and spinalis dorsi. It divides, as it ascends, into a great number of fleshy tongues, terminating in tendons; these tendons form two distinct rows, one external on the side of the sacro-lumbalis, the other internal along the edge of the spinalis dorsi. The innermost tendons, 12 in number, are attached to the transverse processes of the dorsal vertebræ; the outer vary in number, being 7, 8, or more; they are attached to the ribs between the tubercles and the angles.

Action.—Similar to the sacro-lumbalis. These are the great erector muscles of the spine.

Transversalis Colli.—Situated on the inner side of the longissimus dorsi, higher up, extending into the neck.

Origin.—By 6 small tendons from the 8th to the 3d dorsal vertebræ; terminating by tendons attached to the 2d, 3d, 4th, 5th, and sometimes 6th cervical vertebræ. The muscle is flat and thin, and requires a careful dissection. Internally to it are placed the trachelo-mastoideus, the complexus major, and semi-spinalis colli: its occasional intimate union with the trachelo-mastoideus renders the dissection of these two muscles difficult. Before dissecting the trachelo-mastoideus return to the

Spinalis Dorsi.—Imperfectly seen in aged persons.

Situated between the longissimus dorsi and the spinal column, and close to the spine.

Attached, by tendons, to three or four of the spinous processes of the dorsal vertebræ, from the second or third downwards, and also by tendons to the uppermost of the spinous processes of the lumbar verte-

bræ. Its inferior margin is not unfrequently inseparably united to the tendinous origin of the longissimus dorsi and sacro-lumbalis.

Remarks.—1st. In aged persons this muscle is mostly tendinous, and very small. 2d. The inferior part of the muscle, being inseparably connected to the tendinous origin of the longissimus dorsi, must be separated from it by the knife, before the spinalis dorsi can be shown as a distinct muscle. 3d. About the centre of the muscle there is a fleshy and tendinous slip, sent from the longissimus dorsi to the spinalis dorsi. The presence of this fleshy slip, which is all but constant, and which, after being examined, should be cut through, tends, also, to embarrass the student in the dissection of this muscle. It has scarcely been noticed by anatomical writers.

TRACHELO-MASTOIDEUS.—This and the following muscle (complexus) are placed beneath the splenius, which has already been dissected, and detached from the head and spine.

The trachelo-mastoideus, by some called complexus minor, is long, slender, and flattened.

Fig. 116.*

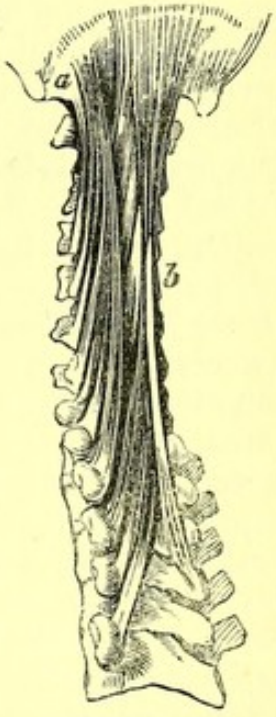

Situation.—Between the transversalis colli and complexus.

Attached by small tendons to the last four transverse processes of the neck, and to two or three of the back; superiorly to the groove behind the mastoid process. The muscle is frequently intersected by a transverse aponeurosis; superiorly, it covers the posterior extremity of the digastric, and occipital artery.

Action.—It inclines the head a little without rotation, or reverses it slightly when both muscles act.

COMPLEXUS.—The complexus, thick, elongated, situated under the splenius, but not entirely covered by it. It arises from the transverse and articular processes of the last four or five cervical, and from the transverse processes of the first four or five dorsal vertebræ; by as many small tendons, whose fibres are strongly interlaced with the fleshy fibres, and more distinct below than above. To all these tendons succeed the fleshy fibres, which, from being at first disposed in isolated fasciculi, are soon intimately incorporated. Those which come from the third, fourth, and fifth transverse processes of the back, form a separate band, which ascends obliquely inwards, and terminates anteriorly by a small tendon, broader at its extremities than in the middle,

* Fig. 116.—*a*, complexus minor muscle, or trachelo-mastoideus; *b* points to the ligamentum nuchæ, and complexus major.

which occupies the middle third of the inner edge of the muscle, and sends from its upper part other fleshy fibres, which ascend to the occipital bone. The fleshy fibres which proceed from the transverse processes of the neck, and the two first of the back, ascend less obliquely, and have an aponeurotic intersection in the form of the letter V, more distinct internally than externally, and directed transversely, occurring about the middle of the muscle, and occupying its whole breadth. From the upper edge of this intersection proceed other fleshy fibres, which ascend a little inwards, and are attached to the inner part of the impression which is observed between the two curved lines of the occipital bone, by aponeuroses, prolonged very far among the fleshy fibres.

The complexus, when both right and left act, draw the head forcibly backwards, but when only one acts, say the right, it will turn the face towards the left shoulder, and thus, in rather an unexpected manner, oppose the splenii muscles. In removing the latter inferiorly, the knife must be carried cautiously through the strong tendinous origin connecting it to the spinous processes of the lumbar and sacral vertebræ. In doing this, the student will observe a powerful fleshy mass, occupying the vertebral and sacral grooves, which most anatomists have considered as a portion of the longissimus dorsi; but this opinion is evidently erroneous. The muscular fibres we speak of are separated only, it is true, by cellular tissue, from the strong tendon of the longissimus dorsi and sacro-lumbalis, but the muscular fibres run in a quite different direction, and evidently belong to the following system of muscles: semi-spinalis colli, semi-spinalis dorsi, semi-spinalis lumborum.

Dissection.—Detach the complexus from the head, and reflect it outwards; remove entirely the spinalis dorsi and longissimus dorsi.

An extended chain of muscular fasciculi will now be exposed, varying in strength: strongest in the neck and loins; commencing at the spinous process of the axis, and terminating on the posterior surface of the sacrum. These muscles, or muscular fasciculi, as they may be viewed, occupy the deepest part of the vertebral grooves, close to the bones. The French anatomists, generally systematic and clear, have given to them the name of *transverse épineux*, meaning, thereby, muscles which run between the spinous processes of the vertebræ and the transverse processes of the same bones. But prior to this name being introduced, the superior fasciculi had been long known to anatomists by the name of semi-spinalis colli and semi-spinalis dorsi; to the lumbar portion the name of multifidus spinæ had been given, extending it upwards, however, to a series of deep muscular fibres lying beneath the semi-spinales colli and dorsi. These deep fasciculi have always seemed to me to belong simply to the class of muscles which I have grouped under the names just given, namely, semi-spinalis colli, semi-spinalis dorsi, and semi-spinalis lumborum, constituting the great transverse spinal muscle.

The cervical portion is very strong. It arises from the spinous processes of the second, third, and fourth, and sometimes fifth, cervical

vertebræ, and, proceeding downwards and outwards, is attached to the transverse processes of the five or six superior dorsal vertebræ. Beneath them lie a series of muscular fasciculi, described by Steno and Winslow as distinct muscles (*multifidus spinæ*), but scarcely meriting a separate description and name.

SEMI-SPINALIS DORSI arises from the spinous processes of the sixth and seventh cervical vertebræ, and from those of three or four superior dorsal, and, descending obliquely outwards and downwards, is attached to the transverse processes of the sixth, seventh, eighth, ninth, and tenth dorsal vertebræ.

The LUMBAR PORTION (*semi-spinalis lumborum*) arises from the spinous processes of most of the lumbar and sacral vertebræ, and, descending obliquely, is attached to the articular processes of the lumbar vertebræ, and into the tubercles of the sacrum corresponding to these articular processes; also, into the posterior portion of the crest of the ilium.

INTERSPINALES CERVICIS.—Twelve in number: in two rows, occupying the spaces between the spinous processes of the cervical vertebræ, from the second downwards to the first dorsal. A little cellular tissue separates them from each other.

Action.—To approximate the cervical spinous processes to each other.

Vestiges or traces of similar muscles may be seen in the back, but more especially in the loins.

INTER-TRANSVERSALES COLLI.—Placed between the transverse processes of the cervical vertebræ, two and two, excepting between the first and second, where there exists but one.

The *Anterior* are six in number; the posterior five; the anterior branches of the cervical nerves pass between them. The rectus capitis anticus major covers them anteriorly; the splenius, transversalis colli, and sacro-lumbalis posteriorly.

INTER-TRANSVERSALES LUMBORUM.—Ten in number, five on each side; resemble the preceding, but they are much less distinct; their name points out their attachments and position.

Anteriorly, they correspond to the quadratus lumborum; posteriorly, to the sacro-lumbalis.

RECTUS CAPITIS POSTICUS MAJOR.—*Attached* to the tubercle of the spinous process of the axis, and to the occipital bone in the space below the inferior curved line.

Corresponds anteriorly to the occipital bone, posterior arch of the atlas, posterior atlanto-axoidal ligament, rectus minor muscle, and vertebral artery; *posteriorly*, to the complexus and obliquus superior.

Rectus Capitis Posticus Minor.—Detach the preceding muscle from the occipital bone. This exposes the rectus minor, which, however, is sometimes wanting.

Attached *inferiorly* to the tubercle of the posterior arch of the atlas; superiorly, to the occipital bone, not far from the crest, and close to the occipital foramen.

Posteriorly, it corresponds to the rectus major and complexus, separated, however, from them, by much fat. Anteriorly, it covers the occipital bone, the vertebral artery, and the posterior occipito-atlantal ligament.

These muscles strengthen the articulations, and incline the head backwards.

Obliquus Capitis Inferior.—Attached *inferiorly* to the tubercle of the spinous process of the axis; superiorly, to the lower and back part of the transverse process of the atlas.

Posteriorly, covered by the complexus and trachelo-mastoideus.

Anteriorly, it corresponds to the lamina of the second vertebra, the posterior axoido-atlantal ligament, and the vertebral artery.

Assists in rotating the head.

Obliquus Capitis Superior.—Attached *inferiorly* to the summit of the transverse process of the atlas; *superiorly*, to the occipital bone, beneath the outer part of the superior curved line, and sometimes to the mastoid process of the temporal, between the splenius and rectus capitis posticus major.

Posteriorly, it is covered by the complexus, trachelo-mastoideus, and splenius; *anteriorly*, it rests on the occipital bone, the vertebral artery, and the attachment of the rectus capitis posticus major.

Assists in rotating the head.

In concluding the history of the extensive series of muscles occupying the back of what artists call the torso, it may be useful to remark to the student how my attention was first directed to them. It had been with me a frequent observation, that, when the dissections were commenced on the front of the body, the muscles of the back were seldom or never dissected on that subject. The result was, that the student remained ignorant of all the great moving powers of the spine, of its shape and physical properties; and when called on to offer a medical or surgical opinion in respect to existing or suspected disease or injury, he was wholly unable to do so from a want of that knowledge which anatomy alone can give.

It was easy also to observe, that, by neglecting the anatomy of these muscles, the relation of the more important muscles and nerves on the front and sides of the neck could not readily be understood; the movements of the head, the position of the scapulæ to the thorax and spine, the lumbar portions of the great muscles of the abdomen, were necessarily left undissected and misunderstood.

MUSCLES OF THE SUPERIOR EXTREMITIES.

To dissect the muscles of these extremities with advantage and ease, the limb should be removed from the body so soon as the large muscles connecting it to the trunk have been dissected and well examined. These muscles were, the pectoralis, major and minor; serratus magnus; latissimus dorsi; trapezius; levator anguli scapulæ; and rhomboideus, major and minor. The attachments of these muscles to the bones of the shoulder and humerus should not be hastily cut away, but, on the contrary, carefully cleaned, minutely examined, and left for some time adhering to the bones. So soon as this has been done, place the arm in such a way as to proceed with the dissection of its muscles.

Immediately beneath the integuments the student will find the superficial fascia or subcutaneous cellular membrane investing the whole limb. Imbedded in it are the superficial nerves and veins, and certain bursæ mucosæ. Beneath this fascia or cellular envelope (a description of which will be found in the chapter on the Fasciæ) lies the aponeurosis of the superior extremity. This also invests the whole limb; it is in many places distinctly aponeurotic, in others less so. Besides giving to all the muscles a general covering, it transmits septa or partitions between them, dividing them singly or in groups; in the arm it is called the brachial aponeurosis, in the fore arm the anti-brachial, in the hand the palmar and dorsal; it does not extend to the fingers.

In addition to these fasciæ there will be met with, in the course of the dissection, the retinacula called annular ligaments of the carpus anterior and posterior; the fibrous sheaths of the tendons, and the deep bursæ found in connexion with these, or placed between certain tendons and the bones. For a full history of the aponeuroses and retinacula, see the chapter on Fasciæ and Aponeuroses.

DELTOID MUSCLE.

Dissection.—Place the fibres of the muscle on the stretch; carry a vertical incision from the top of the shoulder to the anconeus process; another, extending along the spine of the scapula and clavicle, will enable the student to remove the integument, and with it, if so desired, the superficial fascia and aponeurosis, which is here thin and cellular, exposing the muscular fibres at once. Clean them in the usual manner, dissecting in the course of the fibres.

Description.—The deltoid muscle is thick, flat, triangular, broader above than below, curved upon itself to embrace the shoulder joint, whence it descends to the outer side of the arm, as far as its middle. It is composed of seven fleshy bundles, separated by grooves more or less deep, and divided into two orders. Those of the first order, to the number of four, are broad and fleshy above, contracted below, and terminate by strong tendons. One of them, strengthened behind by a transverse fibrous band, which unites the acromio-coracoid ligament to the pectoralis major, arises from the outer third of the anterior

Fig. 118.*

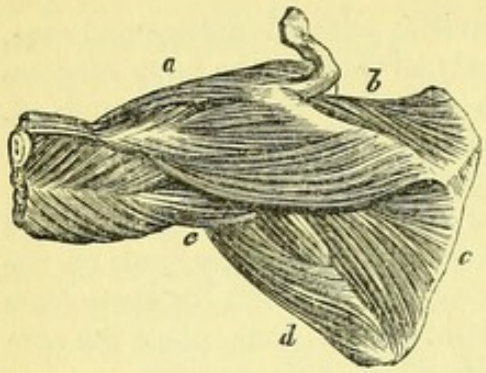

Fig. 119.†

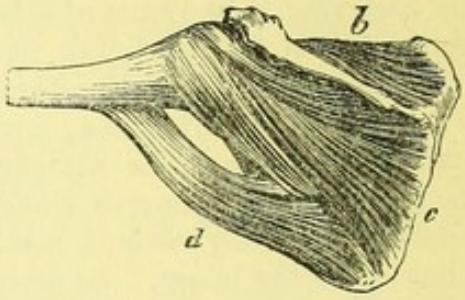

edge of the clavicle, by small aponeuroses, and descends obliquely outwards. Another is inserted externally into the acromion by various aponeurotic fasciculi, which are more or less prolonged in or over the fleshy fibres; it descends vertically. The two last proceed from the posterior edge of the spine of the scapula, where they are attached by means of an aponeurosis, which unites with those of the trapezius and infra-spinatus, and are directed obliquely downwards and forwards. The bundles of the second order, to the number of three, are placed in the intervals of these latter, between which they seem to ascend, to terminate in a point at the commencing aponeurosis. All these different bundles, which are themselves formed of fleshy fibres disposed in secondary bundles, are united below into a very strong triangular tendon, broad and thick, little apparent externally, but prolonged to a great length upon the inner surface of the muscle, where each bundle furnishes a portion to it; this tendon is attached to the deltoid impression of the humerus, over an extent of about an inch and a half. At its termination it is embraced by a bifurcation of the brachialis muscle.

The *outer* surface of the deltoid is convex, and covered by the skin and platysma myoides above. The *inner* surface is concave, and covers, in whole or in part, the infra-spinatus, teres minor, and triceps extensor muscles, the tendon of the supra-spinatus, acromio-coracoid ligament, subscapularis, pectoralis minor, biceps, and coraco-brachialis muscles, coracoid process, capsule of the joint, upper third of the outer surface of the humerus, circumflex nerve and vessels, and tendon of the pectoralis major.

The *posterior* edge of the muscle is thin; anteriorly it is separated from the pectoralis major, by a cellular interval occupied by the cephalic vein, and below it is parallel to the outer edge of the biceps.

Action.—The deltoid raises the arm directly, or carries it at the

* Fig. 118.—Muscles of the shoulder.—*a*, the deltoid; *b*, the supra-spinatus; *c*, spinal margin of the scapula, and origins of the infra-spinatus; *d*, teres major; *e*, scapular head of the triceps extensor of the fore-arm.

† Fig. 119.—Muscles of the shoulder.—*b*, supra-spinatus muscle; *c*, spinal margin of the scapula, and origins of the infra-spinatus and teres minor muscles; *d*, teres major. This latter muscle belongs to the system of the latissimus dorsi. The deltoid must be removed to display these muscles.

same time forwards or backwards, according to the direction of the bundles which act. When the arm is raised, its posterior fibres can lower it. If the arm be fixed, it depresses the shoulder. In removing the deltoid it ought to be cut directly through, about an inch below its origin, and the upper and lower portions raised from the adjacent parts.

Dissection.—Cut through the deltoid from its scapular and clavicular attachments. Divide with a saw the acromion process, forcibly remove the clavicular portion in connexion with the clavicle and coraco-acromial ligament, and proceed with the dissection of the

SUPRA-SPINATUS. — Long, thick, triangular, pyramidal, broader within than without, and kept in position by a thin aponeurosis, which, arising from the whole length of the upper lip of the spine of the scapula, is attached behind the upper edge of that bone, and to the upper part of its inner edge. The fleshy fibres arise from the posterior part of this aponeurosis, and from the two inner thirds of the fossa supra-spinata, by short tendinous fibres. They proceed outwards, converge towards each other, and are inserted obliquely round a broad aponeurosis, which, after being concealed among them, contracts, becomes thicker, and entirely emerges from them, passing under the coraco-acromial ligament. It forms a strong tendon, which, curving over the shoulder joint, becomes identified with its capsular ligament, and is attached also to the upper surface of the large tuberosity of the humerus.

The *posterior* surface is covered by the trapezius and deltoid, and by the coraco-acromial ligament.

The *anterior* is applied upon the fossa supra-spinata (from which it is separated, in its outer third, by cellular tissue, and the supra-scapular vessels and nerve), and the capsular ligament.

Action.—It assists the deltoid muscle in raising the arm. If the arm be fixed, it acts upon the scapula.

INFRA-SPINATUS.—Broad internally, narrow externally, thick and triangular. It is covered posteriorly by a thin aponeurosis, but strong. Some of the fleshy fibres come from this aponeurosis internally, but the greater number arise from the two inner thirds of the fossa infra-spinata. Of these the upper proceed outwards, and the rest ascend more, and are longer, the lower their position is. They go to a broad aponeurosis concealed beneath them, situated nearer the posterior surface of the muscle than the anterior, which, towards the humerus, becomes a strong and thick tendon, attached to the middle surface of the large tuberosity of that bone, after being identified with the fibrous capsule of the articulation, and in part incorporated with those of the supra-spinatus and teres minor.

The *posterior* surface is covered externally by the deltoid muscle, internally by the trapezius, below by the latissimus dorsi, in the middle by the integuments.

Fig. 120.*

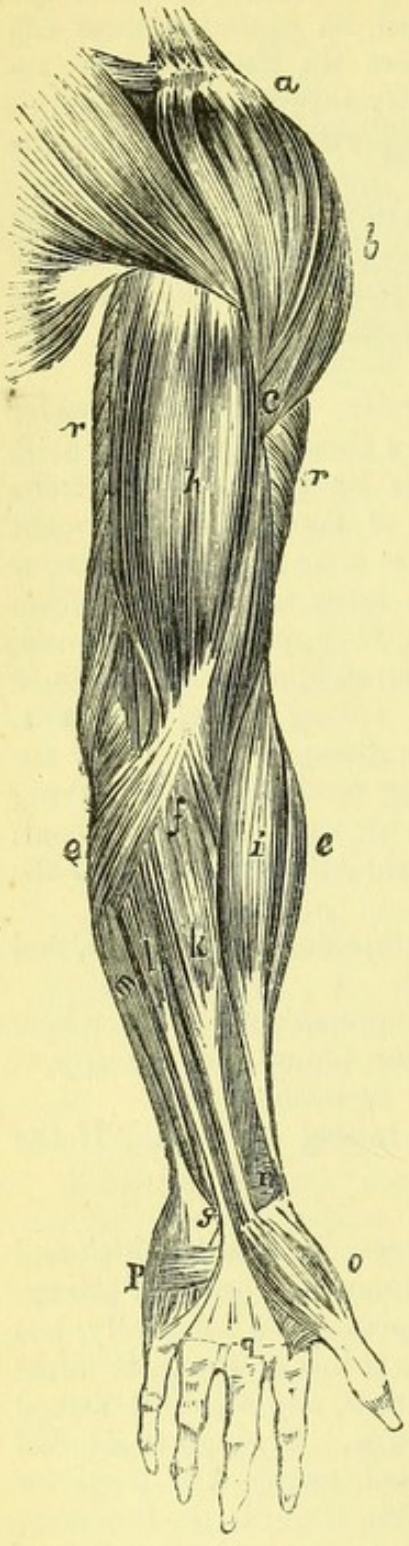

Fig. 121.†

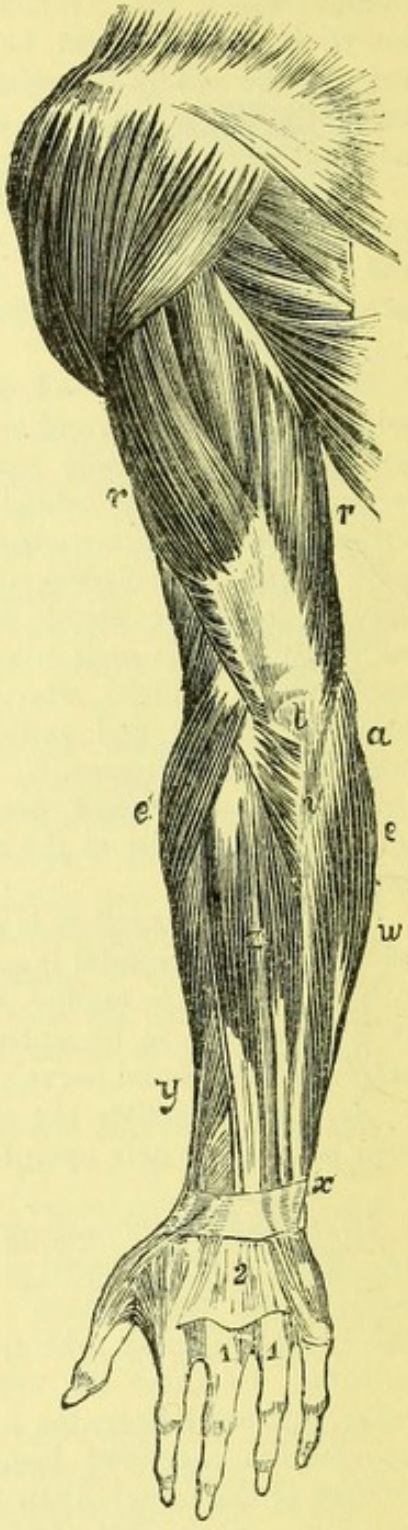

* Fig. 120.—Muscles of the superior extremity, anterior aspect.—*a*, the scapula and collar-bone; *b*, the deltoid; *c*, attachment of the deltoid to the humerus; *e*, *e*, origins of the extensors and flexors, supinators and pronators of the fore-arm and hand; *f*, *k*, flexor radialis; *i*, supinator longus; *l*, palmaris longus; *m*, flexor ulnaris; *n*, portion of the radius; *s*, portion of the retinaculum; *p* points to the abductor minimi digiti and palmaris brevis; *o*, abductor pollicis; *q*, divisions of the palmar aponeurosis proceeding to the fingers.

† Fig. 121.—Muscles of the upper extremity, back view.—*r*, *r*, triceps extensor

The *anterior* surface covers the fossa infra-spinata, from which it is separated, in its outer third, by much cellular tissue, and by the superior scapular nerves and vessels. It is also applied upon the capsular ligament of the shoulder-joint. The muscle, when the arm is lowered, turns it outward by rotation; when raised, it draws it backwards.

TERES MINOR.—An elongated narrow muscle, flattened from above downwards in its inner half, and from behind forwards in the outer. It is situated beneath the preceding, and arises from a rough triangular surface, which limits the fossa infra-spinata near the axillary edge of the scapula, and from two aponeurotic laminæ which separate it from the teres major and infra-spinatus. Thence it ascends obliquely outwards, in company with the infra-spinatus, to which it is often united. Its fleshy fibres terminate, near the humerus, on the anterior surface of a flat tendon, which commences by an aponeurosis on the posterior surface of the muscle, and is inserted into the inferior surface of the great tuberosity, where it is united with the capsule of the joint. Some of the lower fibres are directly attached to the humerus, beneath the great tuberosity.

Its *posterior* side is covered by the deltoid muscle and the skin.

The *anterior* covers the dorsal scapular artery, a portion of the long head of the triceps, the fibrous capsule of the joint, and a small part of the scapula.

TERES MAJOR.—Flat, broader than the preceding; arises by short aponeurotic fibres from a quadrilateral surface, which terminates the fossa infra-spinata inferiorly, and from fibrous partitions that are met with between it and the subscapularis on the one hand, and the infra-spinatus and teres minor on the other. Thence its fleshy fibres, which are all parallel, proceed obliquely outwards, running alongside of the teres minor; then, twisting upon themselves, separate from that muscle, and give rise to a broad and flat tendon, more distinct below than above, and before than behind. This tendon, which is about an inch broad, follows the direction of the muscle, is applied by its anterior surface upon that of the latissimus dorsi, unites with it, and is attached to the posterior edge of the bicipital groove of the humerus.

Its *posterior* surface is covered, internally, by the latissimus dorsi, and in the middle by the skin. Externally, it corresponds to the humerus and the long portion of the triceps.

The *anterior* surface is in connexion with the subscapularis, latissimus dorsi, coraco-brachialis, and biceps muscles, and with the axillary vessels and brachial plexus.

Its *lower* edge, which is covered by the integuments, forms with the latissimus dorsi the posterior edge of the hollow of the axilla.

of the fore-arm; *t*, ancon process and anconeus muscle; *e*, *a*, *e*, origins of the muscles proceeding to the fore-arm and hand; *z*, extensor communis; *w*, extensor ulnaris; *x*, posterior annular ligament; 2, dorsal aponeurosis of the hand; 1, 1, extensor tendons of the fingers.

Fig. 122.*

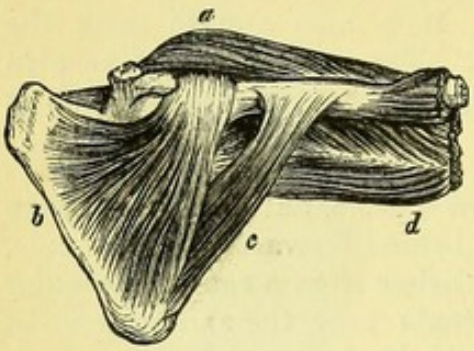

Fig. 123.†

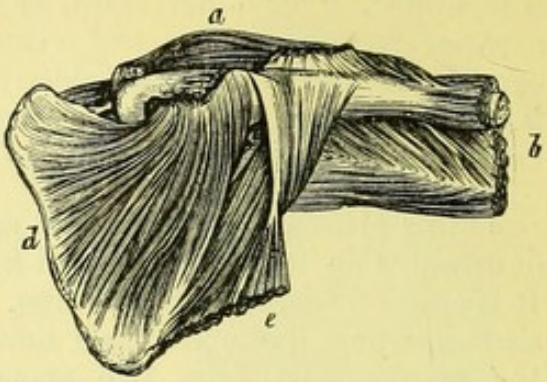

The *upper* edge, which is united to the teres minor internally, but separated from it in the middle by the long portion of the triceps, corresponds externally with the subscapularis muscle and the circumflex vessels and nerve. This muscle rotates the humerus inwards. When its action is combined with that of the latissimus dorsi and pectoralis major, it applies the arm against the thorax.

THE SUBSCAPULARIS is thick, triangular, occupying the whole of the subscapular fossa, from the inferior three-fourths of which it arises, both from its periosteum and from three or four aponeurotic partitions between the fleshy fibres, which are themselves attached to the oblique bony ridges presented by the scapula at this place. The fleshy fibres are disposed into five or six distinct bundles, which converge together, and, proceeding outwards, are attached to the two surfaces of a broad and flat tendon, which, contracting and becoming thicker, terminates at the small tuberosity of the humerus by embracing it, and extends a short way on the shaft of the bone. It adheres strongly to the capsule of the joint.

The *anterior* surface is separated from the serratus magnus, with which it forms the hollow of the axilla, by a very thick layer of cellular tissue. Its outer part corresponds to the brachial plexus, axillary artery, and coraco-brachialis, biceps and deltoid muscles. When the arm is abducted from the body, the subscapularis draws it toward it, or adducts it; it can also turn the arm inwards, and, when raised, depresses it: it also strengthens the shoulder-joint. The arm should now be placed on the anterior (flexor) aspect, and the muscles of the *arm* dissected.

A low and narrow block under the axilla will enable the student to dissect most of the muscles in the region of the shoulder and arm.

The TRICEPS EXTENSOR is divided superiorly into three portions or heads, viz., a scapular or long head, and two shorter or humeral

* Fig. 122.—Muscles of the left shoulder.—*a*, deltoid; *b*, subscapularis; *c*, teres major; *d*, triceps.

† Fig. 123.—Muscles of the left shoulder.—*a*, portion of the deltoid; *b*, triceps cut across; *d*, subscapularis; *e*, latissimus dorsi and teres major proceeding to their insertion in the inner margin of the bicipital groove of the humerus.

heads; the scapular is also called the middle head; the second, as to length, is external and posterior; the third, as to length, is internal and somewhat anterior. The scapular head arises from the highest part of the axillary margin of the scapula by a flat tendon, which separates into two aponeuroses,—an outer, short; and an inner, which extends much farther downwards. The fleshy fibres of this portion of the muscle, arising from the outer and back part of the tendon just mentioned, form a bundle, which descends vertically between the teres major and teres minor, behind the shoulder-joint, then increases in size, and is united to the *outer* portion about the upper third of the arm, and to the *inner* about its middle.

The *outer* portion (*caput externum*) arises, by a pointed extremity, from the upper part of the outer edge of the humerus, beneath the great tuberosity of that bone, and almost immediately below the insertion of the teres minor muscle. Its fleshy fibres shorten as they descend, and come from the outer edge of the humerus over a larger extent, and from the *external intermuscular* partition or ligament, common to them with those of the deltoid muscle and brachialis.

The *inner* portion (*caput breve*) commences under the tendon of the teres major and latissimus dorsi, by a pointed extremity, which is attached to the inner edge of the humerus, and receives additions in succession from an aponeurosis which covers it above, from the posterior surface of the humerus, and from the *internal inter-muscular ligament*. After their union, these three portions form a thick and broad bundle, terminating by a strong, broad, and thick tendon, attached to the posterior and upper part of the olecranon process of the ulna. Besides the fleshy fibres furnished to the tendon by each of the three portions, the common bundle receives a number of others, which arise along the lower third of the posterior surface of the humerus, to near the olecranal cavity, and descend obliquely backwards upon the anterior surface of the tendon.

The *outer* side of the tendon, and of its aponeurotic origins, serves for the insertion of several others, which come from about the lower fourth of the outer edge of the humerus, where they leave between them a small aperture for the passage of the musculo-spiral nerve and its accompanying vessels.

The *posterior* surface of the muscle is covered above by the teres minor and deltoid, and in the rest of its extent by the brachial aponeurosis and the skin.

The *anterior* surface covers superiorly and in part the subscapularis, teres major, latissimus dorsi, and fibrous capsule of the shoulder-joint; inferiorly, the posterior surface of the elbow-joint. In action the muscle extends the fore-arm upon the arm, and in certain circumstances the arm upon the fore-arm. When the fore-arm is extended, its long portion carries the arm backwards. It may also sometimes move the scapula upon the humerus.

Place the arm on its posterior (extensor) aspect, and dissect the flexor muscles.

The CORACO-BRACHIALIS is long, thin, flat, and narrow, especially at its extremities, and is situated at the upper and inner part of the arm. It arises from the summit of the coracoid process, between the short head of the biceps and the pectoralis minor, with which it is united; this origin takes place by means of an aponeurosis, which also belongs to the short portion of the biceps, is extended before their common fibres, then interposed between the two muscles, and separates into two portions, one for each of them. It is from the posterior surface of this aponeurosis that the fleshy fibres arise. In their upper third they are incorporated with those of the biceps, afterwards separate, and form a bundle which increases in size to its middle part. Near the humerus they terminate in an aponeurosis, which is fixed to the middle of the inner surface and edge of the humerus, between the brachialis and triceps. The muscle is generally traversed at its middle part by the external cutaneous nerve, the perforans Casserii.

Its *anterior* surface is covered by the deltoid, pectoralis major, and biceps.

The *posterior* is applied upon the subscapularis muscle, the united tendons of the latissimus dorsi and teres major, the axillary artery, the external cutaneous and median nerves, and the brachial artery. In action it raises the arm and carries it forwards and inwards.

The BICEPS FLEXOR CUBITI is situated on the fore and inner part of the arm, long, broad, and thick at its middle part, and divided above into two portions.

The *outer* is long, arises from the upper part of the edge of the glenoid cavity of the scapula, by a long flattened tendon, continuous with the glenoid ligament. This tendon turns over the head of the humerus, crosses the articulation obliquely inwards, and advances to the interval between the two tuberosities of the humerus, surmounted by a sheath which is furnished by the synovial capsule; it then becomes rounded, contracts, and enters the bicipital groove, still accompanied by the synovial membrane, and kept down by a prolongation of the fibrous capsule; emerging from this groove, it continues to descend vertically, expands, and gives rise to fleshy fibres.

The *inner* portion is short, attached to the summit of the coracoid process, descends, approaching the others, and becomes fleshy sooner than it. These two fleshy bundles approach each other as they descend, and are at length intimately incorporated toward the lower third of the arm. The bundle which results from this junction continues to descend, contracting, and near the elbow-joint forms a tendon, appearing sooner on the outside than internally; at first broad and thin, it is in a great measure concealed by the fleshy fibres. When fairly emerged from them, it becomes narrower and rounded, turns obliquely outwards, and then sinks between the supinator longus and pronator teres, and, on arriving beneath the elbow, twists upon itself to terminate by embracing the bicipital tuberosity of the radius, at its back part.

The *anterior* surface of the biceps is covered superiorly by the

deltoid and pectoralis major; in the rest of its extent, by the brachial aponeurosis and the integuments.

The *posterior* surface rests upon the humerus, the coraco-brachialis muscles, and the external cutaneous nerve.

Its *inner* edge is united above with the coraco-brachialis; in the middle and below it is accompanied by the brachial artery, median nerve, and venæ comites, or deep humeral veins. A thin loose bursa invests the fore part of the bicipital process and neck of the radius, and no doubt contributes to facilitate the motions of the fore-arm. In action the biceps bends the fore-arm on the arm, supinates the hand when it is prone, or bends the arm upon the fore-arm when the latter is fixed. It may bring the humerus and scapula closer together, and strengthens the shoulder-joint by means of the tendon of its long portion.

The BRACHIALIS FLEXOR is deeply seated at the lower and fore part of the arm, before the elbow-joint, flat, broader in the middle and at the upper part than below. It arises from the anterior aspect of the humerus, over a space extending from the deltoid impression to near the elbow-joint, and also along the inner edge of that bone, and from the aponeurotic inter-muscular partitions. From these origins it descends, increasing to its middle part, then becomes a little thinner, passes obliquely inwards over the elbow-joint, and terminates at the rough impression beneath the coracoid process of the ulna, by a broad and thick tendon, which commences by several portions at a considerable distance above the joint, in the substance of the muscle, especially on the outer side.

Its *anterior* surface is covered above by the brachial aponeurosis and the skin; below and externally by the supinator longus, which is lodged in a depression which it presents; at the middle by the biceps muscle and the external cutaneous nerve; internally by the brachial artery, the median nerve, and the pronator teres.

The *posterior* surface covers the lower part of the humerus and elbow-joint.

Its *upper* extremity presents a notch which embraces the tendon of the deltoid muscle. It bends the fore-arm upon the arm, or the latter upon the former.

SURGICAL ANATOMY OF THE ARTERIES AND NERVES IN CONNEXION WITH THE MUSCLES OF THE ARM.

THE AXILLARY ARTERY,* met with in this dissection, passes in front of the tendon of the latissimus dorsi muscle; it here changes its name for *humeral* or *brachial*, and, proceeding downwards as far as the bend of the elbow, divides into two branches, the *radial* and *ulnar*. In its course, the humeral artery is enclosed in a

* During the dissection of these muscles it may be as well for the student to take a surgical view of the arteries and nerves in connexion with them. Their systematic history comes afterwards. Their enumeration here will give him an idea of what is meant by surgical anatomy.

sheath of loose cellular substance, along with the median nerve and the *deep* humeral veins (*venæ comites*), which frequently anastomose with each other, both in front of and behind the artery. In the upper part of the arm the great artery is placed upon the inner margin of the coraco-brachialis, and inferiorly upon that of the biceps; it passes below that portion of the fascia which is sent from the tendon of the biceps across the pronator teres muscle, and, rapidly sinking deeper at this spot, soon after divides into its radial and ulnar branches. The vessel in its course through the arm is subjacent to the aponeurosis; the ulnar nerve runs somewhat parallel to it, but not quite so, and gradually recedes from it, passing more inwards towards the internal condyle of the humerus, whilst the humeral artery preserves more the direction or axis of the centre of the arm. It is placed superiorly upon a small part of the triceps, but inferiorly chiefly upon the brachialis flexor. Its branches are,—

1st. Those which proceed from the external side of the artery have no particular names; they are muscular branches supplying the adjacent muscles.

2nd. Those from the internal side of the artery are, the profunda humeri superior, profunda inferior, and arteria anastomotica magna.

Finally, a small artery proceeding also from the humeral, somewhat below the middle of the arm, which, after perforating the tendon of the coraco-brachialis, enters the osseous canal leading to the medullary cavity of the humerus: this is the *arteria nutritia humeri.*

The *nerves* found in the arm arise from the brachial plexus.

1st. The *musculo-spiral*, or radial nerve, passes between the humeral heads of the triceps; winds round the humerus in a groove which the bone presents, and will be found between the upper part of the supinator longus and brachialis flexor; from this it may be traced on the radial side of the fore-arm to the fingers.

2d. The *median*, which has been already mentioned, and traced as far as the bend of the elbow, into which it passes a little to the inner side of the humeral artery.

3d. The *ulnar*, descending on the triceps and brachialis as far as the inner condyle, behind which it passes to the fore-arm; a small artery generally accompanies it.

4th. The *circumflex*, or axillary, which more properly belongs to the description of the axilla and shoulder. It passes between the long head of the triceps and the surgical neck of the humerus, accompanied by the internal circumflex artery and vein.

5th. The external cutaneous, or *perforans Casserii*, which will be found passing through the coraco-brachialis muscle, or closely connected with it.

6th. The internal cutaneous, already spoken of in describing the axilla and superficial veins of the arm. There is a second or smaller internal cutaneous, and two intercosto-humeral nerves, some of whose branches are met with in this dissection, but their minute history belongs rather to that of the *nervous* system.

MUSCLES OF THE FORE-ARM AND HAND.

Dissection.—The dissection of the extensor muscles should precede that of the flexors. Make an incision through the integuments from the elbow to the roots of the fingers, reflect the skin to the right and left, and with it the subcutaneous cellular tissue, in which will be found embedded some superficial veins and nerves; next dissect the antibrachial aponeurosis, already spoken of. On the posterior aspect of the fore-arm it is strong, and extends as far as the roots of the fingers; the fibres run in several directions, but chiefly in two. Connected superiorly to the condyles of the humerus, and receiving a strong tendinous expansion from the triceps, it descends, investing the muscles generally and particularly, sending partitions between most of them, which, proceeding deep, are attached to the bones of the fore-arm.*

The POSTERIOR annular ligament of the carpus (*retinaculum tendinum musculorum*), binding down the extensor tendons, is connected to the styloid process of the ulna, and, passing across from one bone to the other, is equally attached to the styloid process of the radius. The aponeurosis of the fore-arm seems to pass over this annular ligament, and to form a very thin covering on the back of the hand, but as it proceeds over the ligament it is intimately connected with it.

This RETINACULUM, which looks like a single, strong band of ligamentous fibres, externally presents quite a different appearance on the side which touches the tendons; it sends partitions inwards, so as to enclose in *separate sheaths* the following tendons:—

1st. The tendon of the extensor carpi ulnaris.

2d. The tendon of the extensor minimi digiti.

3d. The tendons of the extensor communis digitorum and extensor indicis.

4th. The tendon of the extensor secundi internodii pollicis.

5th. Those of the extensores carpi radiales.

6th. The tendons of the extensor ossis metacarpi pollicis and primi internodii pollicis; even these two are partially separated from each other by a partition. All these sheaths formed by the annular ligament have bursæ within them to favour the action of the muscles and tendons to prevent friction, but they will be better examined at a later period of the dissection. The bodies of the muscles themselves are also enclosed in separate sheaths, as the student will observe in the process of cleaning them. Having carefully surveyed this aspect of the antibrachial aponeurosis, proceed to raise it from the muscles.

ANCONEUS, short, thick, triangular, and placed behind the elbow-joint. Arises tendinous from the outer condyle of the humerus, and descending becomes fleshy, the fibres following different directions. The upper are short, continuous with those of the triceps, nearly trans-

* See the chapter on the Fasciæ.

verse, and terminate by short aponeuroses at the outside of the olecranon. The lower, longer, and the more oblique the lower their position is, are inserted, also by short aponeuroses, into the upper fourth of the posterior edge of the ulna, forming a sharp point below. The anconeus is applied upon the articulation of the fore-arm, annular ligament of the radius, supinator brevis, and the ulna. It assists the triceps extensor muscle, and may be considered a continuation of it.

Extensor Carpi Ulnaris is long, fusiform, arises from the outer condyle of the humerus, by a common tendon, from the aponeurotic septum placed externally between it and the extensor minimi digiti, from the aponeurosis of the fore-arm, and from about the middle third of the posterior edge of the ulna, below the anconeus muscle. Thence it descends at first obliquely inwards, and then vertically behind the ulna, and, becoming tendinous sooner apparent behind than before, gets engaged in a particular groove, under the posterior annular ligament, near the lower extremity of the ulna. It passes behind the cuneiform bone, in a sort of fibrous canal attached to that bone, the pisiform bone, the os unciforme, and the styloid process of the ulna. It passes under the abductor minimi digiti, enlarges a little, and terminates at the inner and back part of the upper extremity of the fifth metacarpal bone, whence it sends some aponeurotic fibres over the opponens minimi digiti.

The *posterior* surface of this muscle is covered by the aponeurosis of the fore-arm, to which it adheres above.

The *anterior* is applied upon the supinator brevis, extensor ossis metacarpi, and extensor secundi internodii pollicis, and extensor proprius indicis muscles, and upon the ulna.

Its *outer edge* is united above to the extensor proprius minimi digiti: the *inner* is contiguous at its upper part to the anconeus. It extends the hand upon the fore-arm, inclining it a little upon the ulna.

Extensor Minimi Digiti, situated to the outside of the extensor communis, long but slender. It arises from the outer condyle, by a common tendon, the aponeurotic septum which separates it from the preceding muscle, that which is placed, internally, between it and the extensor carpi ulnaris, and from the aponeurosis of the fore-arm. Its fleshy fibres form a small bundle, which descends and passes very obliquely to within a short distance of the carpus, on the anterior surface of a tendon at first concealed in their substance, and entirely free near the posterior annular ligament, which presents a fibrous canal for it, opposite the lower radio-cubital articulation; this canal is directed obliquely downwards and inwards, lined by a synovial capsule, and is about 2 inches in length. Before passing into this canal, the tendon of the muscle divides into two portions, which remain contiguous and connected by cellular tissue; but towards the upper part of the metacarpus it again becomes single and enlarges. It then arrives at the little finger, to the phalanges of which it is attached. This muscle covers the supinator brevis, extensores pollicis, and extensor indicis.

Its *outer* edge is united above to the extensor digitorum communis; the *inner* to the extensor carpi ulnaris. It extends the little finger.

EXTENSOR COMMUNIS DIGITORUM. — Long, round, fleshy, and simple at its upper part, terminating below in four tendons; arises, superiorly, from the outer condyle, by a tendon common to it and the three other preceding muscles; internally, from a long aponeurotic partition sent off from that tendon, which separates it from the extensor proprius minimi digiti; externally, from a shorter partition, placed between it and the extensor carpi radialis brevior; posteriorly, from the aponeurosis of the fore-arm. From these different origins, its fleshy fibres, proceeding obliquely, form a bundle, which divides into four portions, at first united by cellular tissue, and terminated each by a tendon, at first concealed by their substance, and accompanied by the fleshy fibres to near the wrist, particularly in those of the ring and little fingers. These tendons vary in size: that of the ring finger is strongest and thickest; the next is that of the middle finger, and the little finger has the smallest. They pass along with the tendon of the extensor indicis, in a groove formed behind the carpal extremity of the radius, where they are kept down by the posterior annular ligament. Beneath this ligament the tendons diverge, become broader, and proceed to the base of the metacarpal bones. The last three are commonly split longitudinally, and send small aponeurotic bands, varying in size, and more or less oblique, to each other. Opposite the articulations of the metacarpal bones with the phalanges, they contract and become thicker; they then become broad again, and receive the tendons of the lumbricales and interossei, forming with them an aponeurosis, which covers the whole surface of the fingers. Towards their extremity they divide into three portions, the middle of which passes behind the articulation of the proximal and middle phalanges, to be inserted into the posterior surface of the latter; while the two lateral pass over the sides of the same articulation, contracting, and separating from each other; they then approach and re-unite, forming a flat tendon, which is attached to the posterior and upper part of the distal phalanx. The muscle is covered posteriorly by the aponeurosis of the fore-arm, with which it is intimately united; anteriorly, it covers the supinator brevis, extensores pollicis, extensor indicis, the wrist-joint, the posterior surface of the carpus, metacarpus, and fingers, and the interossei dorsales muscles.

Between its *outer* edge and the extensor carpi radialis brevior, is an interval, in which the extensor ossis metacarpi, and extensor primi internodii pollicis, are seen. The tendons, as they pass under the annular ligament, are embraced by a synovial membrane. This muscle extends the phalanges of the last four fingers upon each other, and upon the metacarpal bones, the hand upon the fore-arm, or the fore-arm upon the hand.

Divide the extensor communis and extensor minimi digiti about the middle of the fore-arm, reflect the inferior tendinous portions towards their attachment, and proceed to examine the deep layer of muscles.

Extensor Indicis Proprius — (*Indicator*) — Arises, by short aponeuroses, from the posterior surface of the ulna, and from the interosseous ligament, forming a tendon enclosed in its substance, which becomes free towards the posterior annular ligament of the wrist, unites with those of the extensor communis digitorum by means of a membraniform cellular tissue, passes into the same groove with it, is embraced by the same bursa, and, on arriving at the back of the hand, is situated to the outside of that which the extensor communis sends to the fore-finger. It is incorporated with it behind the articulation of the second metacarpal bone, with the first phalanx of the fore-finger, to terminate in the manner indicated. This muscle lies on the ulna, the interosseous ligament, the extensor secundi internodii pollicis, the inferior extremity of the radius, and the back of the hand. It arises in common with the extensor secundi internodii pollicis. In action, it extends the three phalanges of the fore-finger.

Extensor Secundi Internodii Pollicis—Arises from about the middle third of the posterior surface of the ulna, and from a small portion of the interosseous ligament. It descends outwards, and terminates in a tendon, which first appears behind, and is isolated near the lower extremity of the radius, where it passes under the posterior annular ligament, in a spiral osseous groove, cut much deeper than the general groove of the tendons of the extensor communis, and, to a certain extent, distinct from it; its outer edge presents a short elevated ridge, calculated to retain the tendon in its situation, and to act as a staple. When the tendon has arrived at the back of the hand, it passes over the tendons of the radial extensors, crosses their direction, descends at the posterior and inner part of the first metacarpal bone, joins the tendon of the extensor primi internodii pollicis, near the articulation of that bone with the first phalanx, receives, in the same place, two aponeurotic expansions from the abductor and flexor brevis pollicis, and is inserted at the back part of the phalanx of the thumb. The muscle lies upon the extensor ossis, metacarpi pollicis, and extensor primi internodii pollicis; the two bones of the fore-arm, the interosseous ligament, the wrist-joint, the tendons of the radial extensors, the first metacarpal bone, and the phalanges of the thumb. In action, it extends the last phalanx of the thumb upon the first.

Extensor Primi Internodii Pollicis—Arises from a small portion of the ulna, from the interosseous ligament, and more especially from the posterior surface of the radius. It becomes, on the outer side of the fore-arm, a slender tendon, more apparent externally than internally, which passes into a groove on the outer side of the distal extremity of the radius, and in which the tendon of the extensor ossis metacarpi is also lodged. On issuing from this groove, it separates from the extensor ossis metacarpi pollicis, descends behind the first metacarpal bone, and is inserted at the upper and back part of the first phalanx of the thumb. In its course this muscle adheres so closely to

the extensor ossis metacarpi pollicis, that the student is apt to overlook it. The muscle covers a small portion of the ulna, the interosseous ligament, and the posterior outer surface of the radius, the first metacarpal bone, and its articulation with the thumb.

In action, it extends the first phalanx of the thumb, and also assists in supination.

EXTENSOR OSSIS METACARPI POLLICIS.—Long and flat, broader in the middle than at its extremities. It arises, by a pointed extremity, from the posterior surface of the ulna, beneath and in common with the supinator brevis; then, by short aponeurotic fibres, from a ridge on its posterior surface, and also from a line directed obliquely downwards and outwards, and from the interosseous ligament. Its fleshy fibres form a fusiform bundle, which descends obliquely outwards behind the fore-arm, and terminates upon the posterior surface of a tendon, at first concealed among its fibres, which they accompany to the inferior extremity of the radius; there the tendon passes into a groove on the outer side of the radius, which is common to it and the extensor internodii pollicis. On issuing from this groove, the tendon divides into two or three portions, and goes to be inserted into the outer part of the superior extremity of the first metacarpal bone, also into the trapezium, occasionally sending a small prolongation to the abductor pollicis. This muscle, at its lowest part, is in connexion with the aponeurosis of the fore-arm. It covers a small portion of the ulna above, the interosseous ligament, and the posterior and outer surface of the radius, the tendons of the radial extensors, the radial artery, and the wrist-joint below.

In action, it carries the thumb outwards and backwards, and contributes to supination.

Place the arm on its internal or ulnar margin, secure it by means of hooks, and examine the muscles on the radial margin.

SUPINATOR LONGUS.—Elongated, fusiform, flattened from before backwards in its upper fourth, and transversely in the rest of its extent. Arises by short tendinous fibres, and covers an extent of about two inches, from the external ridge of the humerus, between the brachialis and triceps, and from its external intermuscular septum, terminating by a flat tendon, which, at first lying upon its anterior surface, becomes free about the middle of the fore-arm. This tendon is thin and broad above, becomes thick and narrow as it descends, runs along the outer edge of the radius, and is inserted near the base of the styloid process, sending off a fibrous elongation, which lines the groove in which the extensor ossis metacarpi, and extensor primi internodii pollicis, glide.

The *anterior* side of this muscle is covered by the skin and aponeurosis of the fore-arm.

The *posterior* covers the supinator brevis, extensor carpi radialis longior, pronator teres, flexor carpi radialis, flexor sublimis digitorum, flexor longus pollicis, and the radial artery and nerve.

The *inner* side is applied above, upon the brachialis flexor and the

radial nerve. Upon the ulnar side of its tendon may be found the radial artery in the lower third of the arm.

In action this muscle supinates the hand, and assists in bending the fore-arm upon the arm. Reflect the supinator longus by dividing it in the middle of its fleshy belly, and thereby expose the *long radial extensor muscle.*

Extensor Carpi Radialis Longior.—Nearly of the same form as the supinator longus, beneath which it is situated, arises further down, from the same ridge of the humerus, and from its intermuscular septum; it also receives some fibres from the upper part of the outer condyle. It forms a bundle at first flat, then larger and rounded, descends vertically on the outside of the fore-arm, and terminates in a tendon at first thin and broad, becoming narrow and thick, which, turning backwards, passes beneath the extensor ossis metacarpi and extensor primi internodii pollicis, and covers the tendon of the extensor carpi radialis brevior, both entering a particular groove formed behind the lower extremity of the radius, where they are fixed by the posterior annular ligament of the carpus. On emerging from this groove the two tendons separate. That of the extensor carpi radialis longior passes over the wrist-joint, and is inserted at the posterior and outer part of the upper extremity of the second metacarpal bone.

The *anterior* surface of this muscle is covered by the aponeurosis of the fore-arm, the supinator longus, extensor ossis metacarpi, and extensor primi internodii pollicis.

The *posterior* covers the elbow-joint, the supinator brevis, and extensor carpi radialis brevior muscles. Divide this muscle, and expose the

Extensor Carpi Radialis Brevior.—Precisely similar to the preceding, behind which it is placed. It arises from the outer condyle by means of a common tendon, which sends an aponeurotic prolongation over its inner surface, and an aponeurotic partition between it and the extensor communis digitorum. It descends in the same direction as the extensor carpi radialis longior, forms a tendon of the same length and form, which passes into the same groove, and is attached to the posterior and outer part of the upper extremity of the third metacarpal bone. In action it extends the hand upon the fore-arm. The student must have observed, that, although these muscles are called *carpal*, they really send their tendons to the metacarpal bones, but at the same time they act principally on the wrist-joint and carpal articulation. Divide this muscle, and expose the

Supinator Brevis.—Broad, thin, and triangular, embracing the head of the radius; arising from the outer condyle of the humerus by a broad thick tendon, from the external lateral ligament of the elbow-joint, from the annular ligament of the radius, and by distinct aponeurotic fibres from a longitudinal ridge observed upon the posterior

surface of the ulna. Its commencing tendon expands over the outer surface of the fleshy fibres, which are short and nearly vertical before, long and more oblique the more posterior they are, and all twisted round the radius, to the fore, outer, and back part of which they are attached by distinct aponeuroses, deeply concealed in their substance. It covers the outer part of the elbow-joint and the superior radio-cubital articulation.

Its *posterior* edge covers the upper part of the extensor ossis metacarpi and extensor secundi internodii pollicis.

The *anterior* is notched above for the passage of the tendons of the biceps flexor, and is covered below by the pronator teres. These two edges unite, forming an acute angle, which is attached to the outer side of the radius, above the insertion of the latter muscle. In action it turns the radius upon its axis from before outwards, and brings the hand into supination.

The *dissection* of the flexor muscles of the hand falls next to be examined. They cannot be considered in an insulated way, as has been almost uniformly the practice heretofore, for most of the structures in the anterior part of the fore-arm terminate in the hand.

Reflect the integuments from off the entire surface, as far as the extremities of the fingers, and thus expose the superficial fascia, imbedded in which will be found many superficial veins, the origins of those already alluded to, and the branches of the external and internal cutaneous nerves. After removing these the aponeurosis of the fore-arm and of the hand will be exposed. On the fore-arm the aponeurosis is strong, and the fibres run in various directions. As it passes over the wrist-joint, it is intimately united to the anterior annular ligament (*Retinaculum tendinum musculorum*), but does not form it. It then proceeds into the hand, where it forms the palmar aponeurosis. Of this *palmar aponeurosis* very minute descriptions have been given by surgical anatomists. It may be divided into three portions, a middle, external, and internal. Of these the middle is by much the strongest, and composed of very strong glistening fibres, continuous with the aponeurosis of the fore-arm and with the expanded fibres of the palmaris longus when present. This portion is of a triangular shape, and occupies the hollow of the hand. Narrow at its commencement, it gradually spreads out, and a short way from the roots of the fingers divides into four fasciculi, each of which again bifurcates, to be finally attached to the sheaths of the tendons of the flexor muscles. These fasciculi are crossed by strong aponeurotic fibres posteriorly, and, moreover, they are attached to the metacarpal bones and interosseal muscles. Their importance has only been rightly appreciated since the discovery of M. Dupuytren that their contraction occasionally gives rise to permanent flexion of the fingers.*

This splitting of the central portion of the palmar aponeurosis into

* See the chapter on the Fasciæ and Aponeuroses.

fasciculi is supposed to be necessary, to allow the tendons of the flexor muscles, and the digital arteries and nerves, to proceed to the fingers. The external portion of the palmar aponeurosis is thin, and covers the muscles of the ball of the thumb; the internal portion is also thin; it covers the muscles connected with the little finger.

PALMARIS BREVIS arises from the inner edge of the middle portion of the palmar aponeurosis, and from the annular ligament beneath it, and terminates in the integuments and subjacent cellular substance. It is usually composed of three or more small fleshy bundles, but sometimes fewer than these. They cross the abductor and flexor muscles of the little finger. There is no analogous muscle in the foot. The ulnar artery and nerve lie beneath it.

RETINACULUM TENDINUM MUSCULORUM (*Ligamentum annulare anterius*) is usually considered as a continuation of the aponeurosis of the fore-arm, but it is evidently not so. This is a strong and broad fibrous band, of a quadrilateral form, broader transversely than from above downwards, extended at the fore part of the carpus, and converting into a canal the groove which that part presents. It is attached externally to the fore part of the trapezius and scaphoides, and furnishes insertions to the abductor, opponens, and flexor brevis of the thumb. Laterally it is attached to the pisiform bone, the process of the os unciforme, and a ligament which descends from the one to the other. It affords some points of origin to the opponens minimi digiti, and receives a prolongation of the tendon of the flexor carpi ulnaris.

Its *upper* edge and anterior surface are connected with the aponeurosis of the fore-arm; the *lower* with the palmar aponeurosis. Its *anterior* surface is also covered by the tendon of the palmaris longus, which is intimately united to it, by the palmaris brevis muscle, the skin, and the ulnar nerve and vessels.

The *posterior* surface contributes to the formation of a canal, in which the tendons of the two common flexors, and of the flexor longus pollicis, and the median nerve pass. The fibres of this tendinous band are numerous, transverse, and close upon each other. Beneath this ligament is a most extensive and highly complicated bursa, in which there form not unfrequently those small, rounded, foreign bodies which Laennec and others have called acephalocysts. Proceed next with the muscles.

PRONATOR TERES.—Extended obliquely at the upper and anterior part of the fore-arm. Short, broad at its commencement, arising from the inner condyle of the humerus by a tendon common to it with the flexor carpi radialis, palmaris longus, flexor carpi ulnaris, and flexor digitorum sublimis; from the coronoid process by another small distinct tendon; the median nerve passes between it and the first; from an aponeurotic septum, which separates it internally from

the flexor carpi radialis; from a similar partition placed between it and the flexor sublimis, and lastly, from the aponeurosis of the fore-arm. Its fleshy fibres, which are all parallel, descend obliquely outwards to the middle of the outer surface of the radius, where they are attached by a broad and thick tendon, at first concealed in their substance, and afterwards expanded in the form of a membrane over their anterior surface. Covered anteriorly in its two upper thirds by the aponeurosis of the fore-arm and by the skin; in the lower third by the supinator longus, the radial nerve and vessels, and the radial extensor muscles.

Posteriorly it covers the brachialis flexor and flexor sublimis muscles, the median nerve and ulnar artery.

Its *outer* edge is separated above from the supinator longus by a triangular space, in which are lodged the tendons of the biceps, the brachial artery, and the median nerve, thus forming the inner boundary of the hollow at the bend of the elbow; inferiorly, it is parallel to the anterior edge of the supinator brevis, which it covers a little. In action it turns the radius upon the ulna from without inwards, and thus pronates the hand.

FLEXOR CARPI RADIALIS is long, fusiform, thick, fleshy above, thin and tendinous below, situated internally to the pronator teres. It arises above from the inner condyle of the humerus by a common tendon; anteriorly, from the aponeurosis of the fore-arm; posteriorly, from an aponeurotic septum, separating it from the flexor sublimis, and which afterwards descends some way upon its posterior surface; externally and internally, from two similar partitions which separate it, in those two directions, from the pronator teres and palmaris longus. Its fibres form a bundle, large in the middle and slender at its extremities; they descend outwards, and near the upper third of the fore-arm, form a tendon, which descends in the original direction of the muscle, passes over the wrist, enters, behind the abductor and opponens pollicis, a groove of the trapezium, in which it is retained by a ligamentous sheath and by a small prolongation of its own fibres, and is attached to the fore-part of the upper extremity of the second metacarpal bone. The tendon cannot be fully traced to its termination until the muscles of the hand have been dissected.

The *anterior* surface of the flexor carpi radialis is covered, externally by the supinator longus, and in the rest of its extent by the aponeurosis of the fore-arm.

The *posterior* is applied upon the flexor digitorum perforatus, flexor longus pollicis muscles, and the wrist-joint. Its two edges are connected above with the pronator teres and palmaris longus. In the lower third of the arm the radial artery will be found between the tendon of this muscle and that of the supinator longus. In action it bends the hand upon the fore-arm, turning it a little inwards.

PALMARIS LONGUS—Placed internally to the preceding, arises

above from the inner condyle by the common tendon; behind, externally and internally, from aponeurotic partitions which that tendon sends between it and the flexor perforatus and flexor carpi radialis; anteriorly, from the aponeurosis of the fore-arm. The fleshy fibres descend vertically, and terminate by a thin, flat, slender tendon, which loses itself in the upper part of the palmar aponeurosis, often sending some fibres to the anterior annular ligament of the wrist. Its two edges are united above, the one with the flexor carpi radialis, the other with the flexor perforatus, which muscle it also covers. In action it stretches the palmar aponeurosis, and bends the hand on the fore-arm.

Flexor Carpi Ulnaris.—Situated internally to the preceding muscles, at the fore part of the inner edge of the fore-arm, long, thin, flat, semi-penniform, broader above than below, arises from the inner condyle of the humerus by the common tendon, and from the inner side of the olecranon; between these two origins the ulnar nerve passes, covered by an aponeurosis, which goes from the one to the other. It also takes origin, externally, from a short aponeurotic septum, which separates it from the flexor perforatus; internally, from the aponeurosis of the fore-arm, which presents for this attachment very distinct and strong fibres, proceeding to the posterior edge of the ulna, and there fix the muscle over a great extent. From these different points the fleshy fibres descend, the outer nearly vertically, the inner obliquely forwards and outwards. The first terminate at the upper extremity, the others along the whole posterior surface of a long tendon, which, however, only becomes free from muscular fibres at the lowest part of the fore-arm, and is inserted into the pisiform bone. At its termination some fibres are detached from it, of which one set descends before the abductor and flexor minimi digiti, while the others pass over the ulnar artery and nerve, to be continued into the upper part of the anterior annular ligament of the wrist. This muscle covers the flexor perforatus, the ulnar artery and nerve, and the pronator quadratus.

Its *outer* edge is united above with the flexor perforatus, from which it is separated below by an interval, where the ulnar nerve and vessels are seen, and thus the tendon forms a guide to ascertain the position of the artery.

In action it bends the hand upon the fore-arm, inclining it a little towards the ulna.

Divide the last three muscles described, reflect their tendons towards their insertion, and proceed with the dissection of the

Flexor Digitorum Sublimis or Perforatus.—Elongated, thick, and flattened. Simple above, separating into four tendons below; arising from the inner condyle by the common tendon, from the internal lateral ligament of the elbow-joint, from the coronoid process of the ulna, from two aponeurotic partitions which exist between it and the flexor carpi ulnaris internally, and the pronator teres, palmaris

longus, and flexor carpi radialis anteriorly. From these different points there proceeds a rather thin, fleshy bundle, which descends a little obliquely outwards, and receives another broad, thin, and flat muscular plane, which comes from the anterior edge of the radius, where it is attached by distinct aponeurotic fibres, between the supinator brevis and flexor longus pollicis. The muscle then increases in breadth and thickness, and is frequently further augmented by another portion. Arising separately from the inner condyle, it descends vertically, and soon divides into four portions, which proceed one to each of the last four fingers. Two are anterior, united to each other by their edges, and belong to the middle and ring fingers; two posterior, one for the fore-finger, the other for the little finger; the latter is the smallest, while that of the middle finger is the broadest and thickest. They are all terminated by tendons porportioned to their size, which are connected together, and with those of the flexor perforans, by loose cellular tissue. These four tendons pass into the concavity presented by the anterior aspect of the carpus, and are there kept down by the annular ligament, beneath which they separate from each other to descend into the palm, behind the palmar aponeurosis, and before the tendons of the flexor perforans and the lumbricales. They then enlarge a little, are enveloped by a loose cellular sheath, and engaged towards the heads of the metacarpal bones, between partitions formed by the palmar aponeurosis, and are lodged in a groove which the anterior surface of the phalanges presents, where they are retained by a peculiar fibrous sheath, only one of which should be opened at this stage of the dissection. Before arriving at these sheaths, the tendons exhibit the appearance of a middle longitudinal division, and present posteriorly a sort of concave channel, which receives the corresponding tendons of the flexor profundus; but, towards the lower part of the first phalanges, they split in the middle to afford a passage to these latter, and divide into two portions, which separate at first, then turn and approach each other, so as to form anteriorly a second channel, which is filled by the tendon of one of the portions of the flexor profundus. These two portions unite towards the articulation of the proximal and middle phalanges, and send off to each other small fibrous bands which decussate. Lastly, they separate again, contract, and terminate on the sides of the anterior surface of the middle phalanx, near its centre. At their first separation these portions are attached to the anterior surface of the proximal phalanges by one or two long and slender ligamentous bridles. This muscle covers the flexor profundus, flexor longus pollicis, the median nerve, the ulnar artery, the lumbricales muscles, and the phalanges of the fingers. In action it bends the middle phalanges upon the proximal, and the latter upon the metacarpal bones, and, lastly, the hand upon the fore-arm.

The fibrous sheaths of the fingers form, with the anterior surface of the phalanges, a true canal, half bony and half fibrous, which lodges portions of each of the tendons of the two flexor muscles.

They commence beneath the inferior metacarpal ligament, from which several fibres are sent off to join them, and terminate at the distal phalanx, by interlacing with the expansion of the tendon of the flexor profundus, being in their whole extent attached along the edges of the phalanges.

The *anterior* surface is covered by the skin and collateral vessels of the fingers; the *posterior* is smooth, and lined by a synovial bursa. The tissue of these sheaths is compact; they are formed of interlaced transverse fibres, of a pearly colour, and very thick at the middle of the proximal and middle phalanges, but, opposite their articulation, disappear entirely, so as to leave the synovial bursa exposed. The latter proceeds from the wall of the sheaths over the tendons, forming above and below very distinct *culs de sac*, and, having enveloped these tendons, is reflected posteriorly to the anterior surface of the phalanges by a triangular fold, formed by two laminæ placed back to back. The separation which exists between the two terminal slips of the tendons of the flexor perforatus is filled by prolongations of the bursæ. Divide the flexor sublimis about its middle, and make a careful section mesially, in the axis of the arm, of the anterior retinaculum. The fibrous sheaths of all the fingers may now be slit up.

Flexor Digitorum Profundus, or Perforans, is a thick, flattened, elongated muscle, simple and fleshy above, separated into four tendons below. It arises from the upper three-fourths of the anterior surface of the ulna, and from the interosseous membrane below the coronoid process, where it bifurcates so as to surround the insertion of the brachialis, sending, at the same time, a prolongation over the sides of the olecranon; it also arises from the aponeurosis which goes from the flexor carpi ulnaris to the ulna, and from the upper third of the inner surface of that bone.

From these different origins, which are all aponeurotic, the muscle, thin at first, thicker in the middle, and becoming thin again, descends vertically, and divides into four portions, the three inner of which are not very distinct. Each of these portions is terminated by a broad tendon, separated into several slips concealed in the substance of the fleshy fibres, and appearing upon their anterior surface, toward the middle of the fore-arm. These tendons become free near the anterior retinaculum, under which they pass, along with those of the flexor sublimis, into the palm, where they descend, separating from each other. At first round, and giving rise to the lumbricales, they become broader towards the articulations of the proximal phalanges with the metacarpal bones, present traces of a longitudinal division, pass into the fibrous sheaths of the fingers, through the fissure in the tendons of the flexor perforatus, lodged in the channels which limit it above and below, and are at length inserted, previously becoming flat, into the fore part of the distal phalanges of the fingers. It covers the fore and inner surfaces of the ulna, the interosseous ligament, the pronator quadratus, the wrist-joint, the fore part of the metacarpus, the flexor brevis, and abductor pollicis, and the last two palmar interossei muscles.

Its *outer* edge corresponds above to the inferior interosseous artery. In action, it bends the distal phalanges upon the middle, the latter upon the proximal, and these upon the metacarpus, and the hand upon the fore-arm.

The accessory muscles of the deep flexors are called *lumbricales*. These muscles occupy the middle palmar region, but had better be described here.

The lumbricales are four small, slender, elongated, fusiform, fleshy bundles, situated in the palm of the hand, and distinguished into first, second, third, and fourth, according to their relative position, counting from the radial to the ulnar side of the arm; they diminish in size in the same order. They arise towards the upper part of the hand; the first from the fore and outer part of the tendon of the flexor profundus, which goes to the fore finger; the three following from the separation of the other tendons of the same muscle, so as to be attached to two of them at once. Thence they descend, following different directions; the middle two vertically, the outer outwards, and the inner inwards; and having arrived at the outer side of the articulation of the metacarpal bones with the proximal phalanges of the fingers, they become very thin, and terminate by flattened tendons, which proceed behind the three phalanges, become broader, join the tendons of the corresponding interossei, and go along with them to be inserted into the outer edge of the tendons of the extensor digitorum communis. These tendons vary very much in their dispositions; they frequently divide into two, and one of their branches is attached to the phalanx; covered anteriorly by the tendons of the flexor digitorum sublimis, by the palmar aponeurosis, and by the collateral vessels and nerves of the fingers.

The *posterior* surface lies upon the interossei, the inferior transverse metacarpal ligament, and the phalanges. In action they bend the fingers upon the metacarpus, carry them a little outwards, and fix the tendons of the extensor communis digitorum. The tendons of the flexor sublimis and profundus, and the lumbricales, separate the superficial palmar from the deep palmar arch.

The FLEXOR LONGUS POLLICIS MANUS is elongated, thin, flattened, thicker internally than externally, situated upon the radius, from the upper three-fourths of the anterior upper surface of which it arises by short aponeurotic fibres, as well as from the neighbouring portion of the interosseous membrane, and even frequently from the coronoid process of the ulna, by a particular prolongation, fleshy in the middle, and tendinous at its extremities. The fleshy fibres, which are all oblique, and about an inch long, form a bundle, which descends vertically, and is inserted at the back part of a tendon, which it accompanies until opposite the pronator quadratus. This tendon then becomes free and rounded, and passes before the carpus, under the annular ligament, with the tendons of the two common flexor muscles. It then descends obliquely outwards, between the two portions of the flexor brevis pollicis, passing between the two sesamoid bones. It now passes into

the fibrous sheath of the thumb, and terminates by being expanded over the anterior surface of the distal phalanx of the thumb.

The *anterior* surface is covered by the flexor digitorum sublimis, flexor carpi radialis, and supinator longus muscles, the radial artery, and the anterior retinaculum.

The *posterior* surface lies upon the radius, part of the interosseous membrane, the pronator quadratus, the wrist-joint, the fore part of the carpus, and the flexor brevis pollicis.

The *inner* edge lies upon the flexor digitorum profundus. In action it bends the distal phalanx of the thumb upon the proximal, and that upon the corresponding metacarpal bone, and the latter upon the carpus. This muscle and the preceding may now be cut across, which, with a little dissection, will expose the

PRONATOR QUADRATUS, of a quadrilateral form, thin, and flat. It lies upon the lower part of the fore-arm, and arises by a very thin aponeurosis expanded over its inner third, from the lower fourth of the anterior surface and inner edge of the ulna, passes transversely outwards, and terminates at the fore part of the lower fourth of the radius by an indistinct aponeurosis.

Its *anterior* surface is covered by the flexor digitorum profundus, flexor longus pollicis, flexor carpi radialis, and flexor carpi ulnaris muscles, and by the radial and ulnar arteries.

The *posterior* surface covers the two bones of the fore-arm, and the lower part of the interosseous membrane. In action it turns the radius upon its axis from without inwards, and thus pronates the hand.

The remaining muscles on the flexor aspect are mostly confined to the palm of the hand, and are generally esteemed difficult. I have seldom seen the student in his first year make much of them.

ABDUCTOR POLLICIS.—Short, triangular; arises externally by short aponeurotic fibres, from the anterior surface of the os scaphoides; internally, from the anterior retinaculum. Thence it descends obliquely outwards; its fibres converge towards each other, and terminate by a short and flat tendon, concealed at first in their substance, afterwards receiving a portion of the flexor brevis pollicis, and inserted at the outer edge of the upper extremity of the proximal phalanx of the thumb, over the back of which it transmits some aponeurotic fibres to the tendon of the extensor secundi internodii pollicis. *Anteriorly* covered by a portion of the palmar aponeurosis, and by the skin; *posteriorly* it covers the opponens and flexor brevis pollicis. In action it abducts the thumb. Divide the abductor about the middle, and reflect the two portions: this will expose—

OPPONENS or FLEXOR OSSIS METACARPI POLLICIS.—Triangular, arising internally from the fore part of the anterior retinaculum, by long aponeurotic fibres; externally from the outer edge of the groove

Fig. 124.*

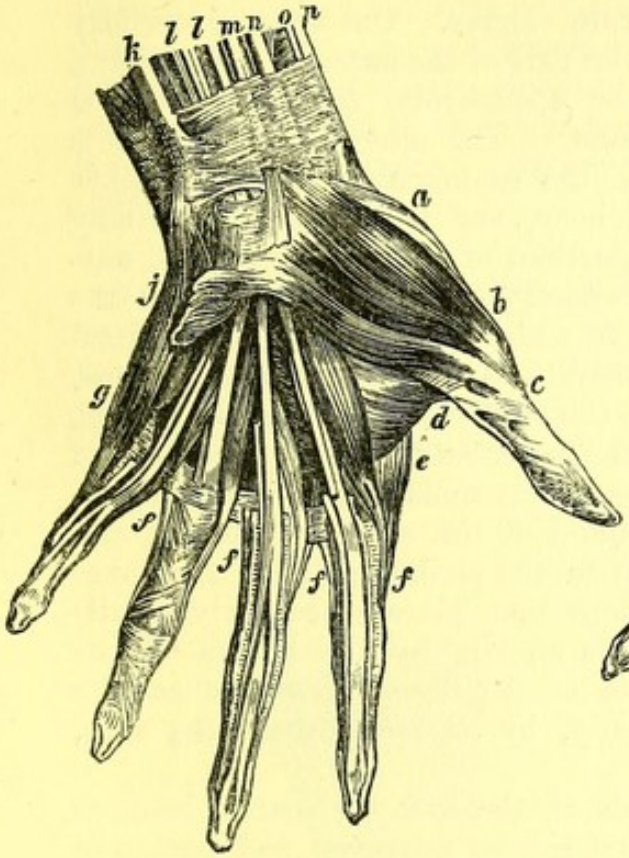

Fig. 125.†

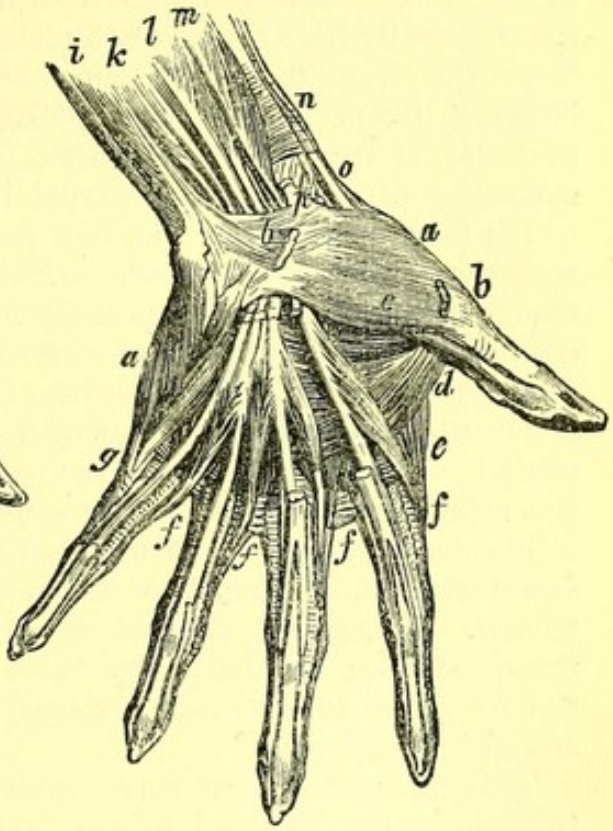

in the trapezium; and posteriorly from an aponeurotic septum, interposed between it and the flexor brevis pollicis. From these different places the fleshy fibres, which are so much the longer and more oblique the lower they are, proceed downwards and outwards, and terminate by short aponeuroses all along the outer edge of the first metacarpal bone, and sometimes partially on the tendon of the extensor ossis metacarpi pollicis; *anteriorly*, partly covered by the preceding muscle, and by the skin; *posteriorly*, applied upon the anterior retinaculum, the articulation of the trapezium with the first metacarpal bone, part of the anterior surface of the latter bone, and the flexor brevis pollicis muscle; it opposes the thumb to the fingers. The inner edge of this muscle is almost uniformly inseparably connected with the outer portion of the flexor brevis pollicis. Their separation, therefore, is quite artificial.

* Fig. 124.—*a*, *b*, abductor pollicis; *c*, opponens; *d*, adductor; *e*, abductor indicis; *f*, first palmar interosseal; *f*, *f*, *f*, 2d, 3d, and 4th ditto; *g*, abductor minimi digiti; *i* points to the palmaris brevis—the broad extremity of the muscle is loose, being detached from the skin, to show the subjacent muscles; *k*, flexor carpi ulnaris; *l*, *l*, flexor sublimis; *m*, palmaris longus; *n*, flexor radialis; *o*, *p*, supinator longus and flexor ossis metacarpi pollicis.

† Fig. 125.—A deeper dissection of the palm of the hand.—*i*, *k*, *l*, *m*, flexor muscles of the fore arm cut across; *n*, *o*, extensors of the thumb; *a*, *b*, opponens pollicis; *c*, outer head of the flexor brevis; *d*, adductor pollicis; *e*, *f*, first dorsal and palmar interossei; *f*, *f*, *f*, *f*, tendons of the flexor profundus and lumbricales; *g*, flexor brevis minimi digiti and adductor.

Flexor Brevis Pollicis.—Within and beneath the two preceding muscles, short, of an irregular form, and bifurcated at its two extremities, this muscle has two separate origins. One arises anteriorly and externally from the fore and under part of the anterior retinaculum, from the trapezium, and from an aponeurotic septum interposed between it and the opponens pollicis. The other origin, which is posterior, is from the lower part of the os magnum, from the upper extremity of the third metacarpal bone, and from the ligaments by which they are united. The two portions of the muscle descend outwards, separated at first from each other, but soon united behind the tendon of the flexor longus pollicis, to which they afford a longitudinal channel. Arrived at the lower extremity of the first metacarpal bone, they separate anew; the outer joins the tendon of the abductor pollicis, and is attached to the fore part of the upper extremity of the proximal phalanx of the thumb, and to the outer sesamoid bone of its articulation; the inner is united to the summit of the adductor pollicis, and in like manner goes to be attached to the phalanx and to the inner sesamoid bone. These two insertions take place by a pretty strong tendon. Anteriorly, covered at the middle by the tendon of the flexor pollicis; internally, by those of the flexor profundus and by the first two lumbricales; externally, by an aponeurosis, the skin, and abductor pollicis.

The *posterior* surface corresponds to the first metacarpal bone, to the first two dorsal, and to the first palmar interossei and tendon of the flexor carpi radialis.

Its *outer* edge joins the opponens pollicis, and the *inner* the adductor. In action it bends the proximal phalanx of the thumb upon the first metacarpal bone, and the latter upon the trapezium.

Adductor Pollicis, broad, thin, and triangular, is still more deeply seated than the flexor brevis. It arises from the inferior three fourths of the anterior surface of the third metacarpal bone, between two of the interosseous muscles, by short aponeuroses, to which the fleshy fibres succeed, which descend outwards converging, and terminate in a tendon united to that of the preceding muscle, and attached, along with it, to the inner and upper part of the proximal phalanx of the thumb. It often sends a fibrous prolongation to the tendon of the extensor secundi internodii pollicis; *anteriorly*, covered by the tendons of the flexor profundus, the first two lumbricales, and the skin; *posteriorly*, corresponding to the first three interossei, and also to the skin. In action it carries the thumb inwards, and brings it near the other fingers.

Adductor (*Abductor*) Minimi Digiti, flat, broader at its middle part than at the extremities; arises from the anterior and inferior parts of the os pisiforme, by aponeurotic fibres, continuous with the tendons of the flexor carpi ulnaris. Thence it descends along the inner edge of the fifth metacarpal bone, and is attached to the inner side of

the upper extremity of the proximal phalanx of the little finger, by a tendon, which is united to that of the flexor brevis, and sends some fibres to join the inner edge of the tendon of its extensors: *anteriorly*, covered by the palmaris brevis, a very thin aponeurosis, and the integuments: *posteriorly*, covering the opponens minimi digiti. In action it carries the little finger inwards and forwards, and separates it from the other fingers. Detach this muscle from the pisiform bone, and reflect it.

FLEXOR BREVIS MINIMI DIGITI, thin and narrow, arising by aponeuroses from the anterior retinaculum, and anterior edge of the process of the os unciforme, descends outwards, unites to the outer part of the tendon of the preceding muscle, and terminates along with it. In action it bends the first phalanx of the little finger. Detach this muscle also.

Fig. 126.*

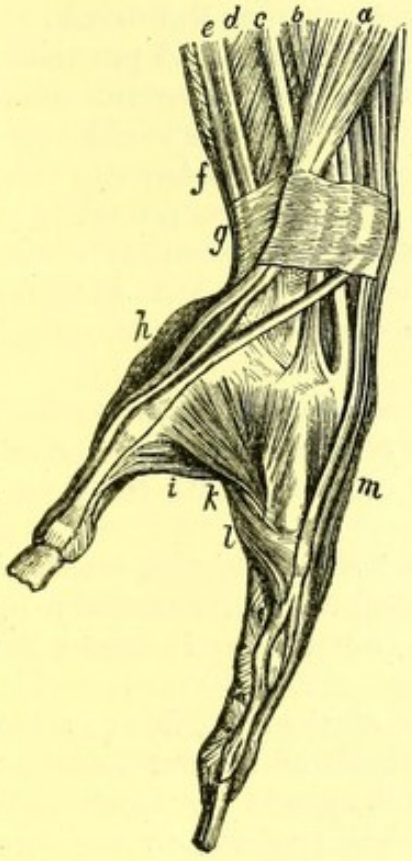

Fig. 127.†

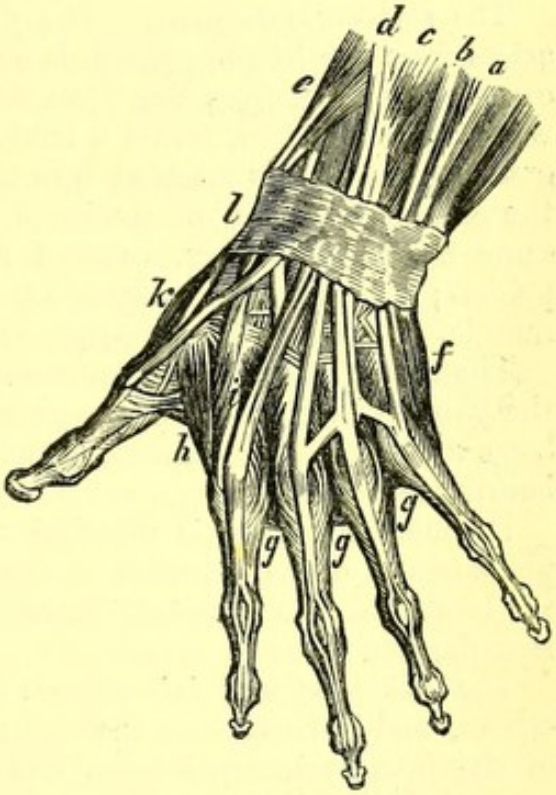

* Fig. 126.—*a*, Extensores ossis metacarpi and primi internodii pollicis; *d*, *c*, *b*, long and short radial extensors; *e*, *f*, supinator longus; *g*, posterior annular ligament of the carpus; *h*, abductor pollicis; *i*, *k*, *l*, adductor pollicis and abductor indicis; *m*, tendons of common extensor and extensor indicis.

† Fig. 127.—*a*, extensor carpi ulnaris; *b*, *c*, *d*, extensor sublimis; *e*, extensors of the thumb; *l*, posterior annular ligament of the carpus; *k*, abductor pollicis; *f*, abductor minimi digiti; *g*, *g*, *g*, dorsal interosseal and their tendons; *h*, *i*, the abductor indicis, which is also an interosseous muscle.

OPPONENS MINIMI DIGITI (*Adductor ossis metacarpi* of Cloquet) has nearly the same form and disposition as the opponens pollicis. Having the same origins as the preceding muscle, its fleshy fibres, so much longer and more oblique the lower they are, descend inwards, and terminate along the inner edge of the fifth metacarpal bone, by distinct aponeurotic fibres.

Its *anterior* surface corresponds to the adductor and flexor brevis of the little finger, and an aponeurotic expansion sent off by the tendon of the extensor carpi ulnaris.

The *posterior* surface is applied upon the last interosseous muscle, the fifth metacarpal bone, and the tendon of the flexor sublimis. In action it carries the fifth metacarpal bone forwards and outwards, thus augmenting the cavity of the palm of the hand. Most of the soft parts may now be so far removed as to expose the *interossei* muscles; but previous to this, the student, if advanced in his studies, may re-examine the arteries and nerves of the *arm*, *fore-arm*, and *hand*.

INTEROSSEI.—These muscles occupy the intervals between the metacarpal bones, and are divided into two sets, palmar and dorsal.

The *Palmar interossei*.—The *first palmar* is thin and prismatic, arises from the two upper thirds of the inner side of the second metacarpal bone, and, from the ligaments by which that bone is connected with the trapezoides, forms a tendon, appearing sooner internally than externally, which is inserted into the inside of the upper extremity of the proximal phalanx of the index, and to the extensor tendon of the same finger; anteriorly, covered by the flexor brevis and adductor pollicis; internally, corresponding to the second dorsal interosseous muscle. It carries the fore-finger inwards.

The *second palmar interosseous muscle* is also prismatic, arises from the two anterior thirds of the outer surface of the fourth metacarpal bone, and from the ligaments by which it is connected with the neighbouring bones.

Its inferior tendon is attached to the outer side of the proximal phalanx and extensor tendon of the ring-finger; covered anteriorly by the lumbricales and the tendons of the flexor profundus. It carries the ring-finger outwards.

The *third palmar interosseous muscle* is of the same form as the others, and inserted into the two anterior thirds of the outer surface of the fifth metacarpal bone, and into the ligaments by which it is connected with the os unciforme. Its tendon is attached to the outside of the upper extremity of the proximal phalanx, and of the extensor tendon of the little finger.

Its *anterior* surface is covered by the opponens minimi digiti; the *outer* corresponds to the fourth dorsal interosseous muscle. It carries the little finger outwards.

The *Dorsal interossei* are four in number:—

The *first* is the largest of the interossei, and is sometimes called the *abductor indicis*. It is of a triangular form, thin and flat, and arises

along the outer edge of the second metacarpal bone, and from the upper half only of the inner edge of the first, as well as from the ligaments which connect those bones with the trapezium. Between these two origins there exists, superiorly, an interval through which the radial artery passes, forming a remarkable analogy with what takes place in the foot. The two fasciculi which arise from them unite, and terminate in a tendon partly attached to the outside of the upper extremity of the proximal phalanx, partly to the extensor tendon of the index.

Its *posterior* surface is covered by the skin; the *anterior* by the first lumbricalis, the flexor brevis, and abductor pollicis, and by the skin. It draws the fore-finger outwards and the first metacarpal bone forwards.

The *second dorsal interosseous muscle* has the form of a triangular prism, arising from the inner side of the second metacarpal bone, behind the origins of the first palmar interosseous muscle (separated by a thin cellular line), from the outer side of the third metacarpal bone, and from the ligaments which connect these bones with each other and with the neighbouring bones.

Its *upper* extremity is perforated for the passage of an artery.

The *lower* is terminated by a tendon, which, like the preceding, is attached to the outer side of the proximal phalanx of the middle finger and of its extensor tendon.

Its *posterior* surface is covered by the skin and the tendons of the extensor muscles of the fore-finger, as well as by an aponeurosis which passes from the second metacarpal bone to the third.

The *anterior* surface is narrow and concealed under the flexor brevis and adductor pollicis. It carries the middle finger forwards.

The *third dorsal interosseous muscle* has the same form as the preceding. It arises from the inner side of the third metacarpal bone, from the posterior part of the outer side of the fourth, and the ligaments by which they are connected. At its upper part it is bifurcated for the passage of an artery. Below, it terminates, like the others, in a tendon which is attached to the inner side of the upper extremity of the proximal phalanx, and of the extensor tendon of the middle finger.

Its *posterior* surface is covered by the skin and tendons of the common extensor of the fingers. It carries the middle finger inwards.

The *fourth dorsal interosseous muscle* is triangular and prismatic, and arises from the whole inner side of the fourth metacarpal bone, and from the posterior part of the outer edge of the fifth, as well as from the ligaments by which they are connected.

Its *upper* extremity is traversed by an artery; the lower terminates in a tendon which is attached by the inner side of the ring-finger.

Its *posterior* surface is covered by an aponeurosis which goes from the fourth to the fifth metacarpal bone, by the extensor tendons of the little finger, and by the skin; the *anterior* is concealed above, beneath the interosseous muscle of the little finger, and appears below, between it and the second palmar interosseous muscle. In action it carries the

ring-finger inwards. Thus all the palmar interossei have single, and all the dorsal have double origins. From their connexions with the tendons of the extensors of the fingers, the interossei and lumbricales may contribute to extend the fingers.

MUSCLES OF THE ABDOMEN AND PELVIS.

DISSECTION OF THE MUSCULAR WALLS OF THESE CAVITIES.

These cavities form but one internally, as may be seen by inspecting the skeleton; and to be understood they must be dissected as one as well in the male as female. It is usual to divide the structures to be now examined into containing and contained parts. The first form the osseous and muscular parietes or walls; the second, the organs of digestion, urine, and generation contained within the cavities. The osseous walls have been already described; in the present section the muscular parietes fall to be considered.

MUSCLES OF THE ABDOMEN.

Dissection. — Place a block below the loins so as to put the abdominal muscles on the stretch. Make an incision through the integuments mesially, from the ensiform cartilage to the pubes; a second from the middle of this one obliquely upwards in the direction of the first false rib: dissect the flaps, the superior upwards, the inferior downwards.

The part which first presents itself is the superficial fascia, a full history of which is reserved for the article "Fasciæ and Aponeuroses." On removing this fascia a second is met with, viz. the fascia propria of the muscles and their tendons. This ought to be removed along with the superficial, in order that the muscles and their tendons be properly displayed. When the surface has been cleared of these fasciæ the external oblique muscle of the abdomen and its tendon are brought into view. But this tendon has been described in two ways, tending greatly to embarrass the student in his first dissection. By some the tendon of the external oblique muscle is viewed merely as a portion of an extensive aponeurosis (the abdominal aponeurosis), from which spring the fleshy fibres of the external and internal oblique and transverse muscles of the abdomen: by others the aponeurosis is viewed merely as a structure composed of three layers of expanded tendons belonging respectively to these muscles.

Both views are in part correct, or at least each possesses certain advantages over the other. To view the whole as an aponeurosis is, perhaps, the simpler view, but not the more systematic. As the region requires being dissected frequently and with different views, I shall here describe the aponeurosis in question as composed of the expanded tendons of certain muscles.

Obliquus Abdominis Externus.—Commence with the fleshy

fibres. These arise from the lower edge of the 5th and 6th ribs, and from the outer surface of the 7th, 8th, and 9th ribs, and from the lower edge of the 10th, 11th, and 12th, by digitations or fleshy bundles; they proceed from these attachments downwards and forwards, first, to the two anterior thirds of the outer edge of the crest of the ilium; secondly, to terminate in a broad tendon covering the anterior part of the abdominal cavity, and forming the anterior layer of the so-called abdominal aponeurosis.

This tendon is inseparably united to the subjacent tendon, and unites with its fellow of the opposite side and with those below it in the mesial plane of the abdomen. The line of union is called the linea alba, and extends from the ensiform cartilage to the pubes. The umbilicus is situated in this line. Laterally there are two other lines formed in a similar way, called lineæ semilunares: the lineæ transversæ will be afterwards noticed.

Inferiorly, the tendon stretches across the groin from the anterior and superior spinous process to the pubes: it is to this portion of the tendon that so much attention has been given by surgical writers.

The inferior edge of the tendon is called Poupart's ligament. There it unites for at least two-thirds of its extent with the femoral aponeurosis. Internally, or towards the pubes, the tendon divides into two portions; the external and inferior is attached to the tubercle or tuberosity of the pubes, sending a prolongation outwards along the crest called the ligament of Gimbernat; the upper and inner to the crest or upper margin of the body of the pubic bone. These separate attachments leave between them a truncated triangular aperture or ring, through which pass in the male the spermatic cord and cremaster muscle; in the female, the round ligament of the uterus. The "ring," or aperture, has also been called the *external* abdominal ring or aperture, to distinguish it from another, deeper and placed further outwards. The portions of the tendon forming the ring are called the outer and inner pillars of the ring: on three sides the aperture is bounded by the tendon; on the fourth by the pubes. Many small vascular openings are scattered throughout the tendon.

The larger aperture just described leads into the inguinal canal; a part which will be hereafter described minutely.*

Action.—The external oblique, besides supporting and compressing the abdominal viscera, acts as a muscle of expiration antagonistic of the diaphragm.

Obliquus Abdominis Internus.—*Dissection.*—To expose this muscle, cut through the external oblique where it lies on the ribs; raise up the posterior edge and detach the muscle also from the crest of the ilium. Carry an incision across the tendon towards the linea alba, sufficiently high up to the abdominal ring and pillars: leaving them entire, reflect this lower portion for the present downwards towards the thigh. Clear the fibres of the internal oblique from behind

* See the Chapter on the Digestive Organs.

forwards and from below upwards. Remove the tendon of the external oblique as far as the union with that of the internal will admit of.

Arises, fleshy and tendinous, from a small portion of the lumbar fascia; from the anterior three-fourths of the middle of the crest of the ilium; and from the inner side of Poupart's ligament, or lower part of the tendon of the external oblique.

From these origins the muscle proceeds in three directions—upwards, inwards, and downwards. It terminates, 1st, by fleshy fibres in the lower edge of the cartilage of the last rib, and of the 11th, 10th, and 9th; 2d, by a broad tendon, through means of which the muscle is attached to the linea alba and pubes.

The muscle lies between the external oblique, and transversus abdominis. In the male the cremaster muscle and spermatic cord will be found passing on its lower margin from within outwards, and from above downwards, and from without inwards, the spermatic cord coming out, as it were, beneath the lower edge of the internal oblique.

If it be desired to examine more carefully the position of the tendon situated immediately behind the cord, ring, and pillars of the ring, detach carefully the inner pillar of the ring from the pubis, and reflect it towards the thigh; by pulling the cord and cremaster downwards the posterior wall of the inguinal canal may be examined, and the share which the tendon of the internal oblique has in forming it ascertained.

Lastly, the broad tendon of the internal oblique divides at the linea semilunaris into two layers, of which the anterior passes in front of the rectus, and the posterior behind that muscle; inferiorly, however, this posterior layer is deficient, or the tendon is said to pass wholly in front of the rectus.

Use.—Similar to the external oblique.

Transversalis Abdominis.—*Dissection.*—Detach the internal oblique from the crest of the ilium and from the inferior ribs, and clear the transversalis which lies immediately beneath it, from behind forwards.

Arises, 1st, from an aponeurosis which may be traced to the spinal column, after dividing into three layers, or laminæ, of which the posterior passes to the spinous processes of the lumbar vertebræ; the middle to the summits of the transverse processes, and the anterior to the base of the same processes, passing in front of the quadratus lumborum muscle. 2d, the transverse arises from the inner lip of the crest of the ilium and from the outer two-thirds of the crural arch, or Poupart's ligament; 3d, from the lower edge of the cartilage of the 11th and 12th ribs, and from the inner surface of the 6th, 7th, 8th, 9th, and 10th.

From these various origins the fibres proceed forwards to terminate at last in a tendon which passes behind all the others to unite with that of the opposite side in the linea alba.

Inferiorly, for about a hand's breadth above the pubes, the tendon is deficient. Use—strongly to contract the abdominal cavity.

Beneath the transversalis muscle lies the fascia transversalis, which may now be carefully examined. Raise up cautiously the transversalis muscle; a fine layer of cellular substance connects the muscle to the fascia. In the fascia, about midway between the pubes and anterior spinous process of the ilium, will be found the opening called the deep ring, through which passes the spermatic cord in the male, and the round ligament of the uterus in the female. Beneath the fascia is the peritoneum. For a full history of all these structures see the chapter on the fasciæ and that on the digestive organs.

RECTUS ABDOMINIS.—*Dissection.*—Cut through longitudinally the tendinous sheath enclosing the muscle, and reflect the flaps. The rectus arises by two tendons attached to the symphysis of the pubes, and adjoining part of the bone; these soon become fleshy. The muscle, proceeding upwards, terminates by being attached in three portions to, 1, the costo-xiphoid ligament, and to the lower and fore part of the cartilage of the 7th rib; 2, to the lower edge and anterior surface of the cartilage of the 6th rib; 3, to the lower edge of the cartilage of the 5th rib.

Action.—To bend the chest or the pelvis, or *vice versâ*.

In its course the muscle presents anteriorly certain tendinous intersections, which vary in number and in extent. There are usually from three to five; anteriorly, they unite strongly with the inner layer of the tendinous sheath of the muscle, but they do not generally extend quite through the whole thickness of the muscular fibres. They are usually considered as the vestiges of abdominal ribs, but this theory has not been proved. The linea alba separates the recti from each other. Inferiorly, the sheath of the recti being deficient, the muscles rest on a thin expansion of the fascia transversalis, which separates them from the peritoneum.

The PYRAMIDALES.—These muscles vary in number, and are occasionally absent. They arise from the symphysis of the pubes in front of the recti on each side, and, proceeding upwards, terminate, after a short course, in the linea alba. They are situated within the sheath of the rectus, yet separated from that muscle by a thin lamina detached from the stronger tendinous surface.

THE DIAPHRAGM.

Dissection.—This muscle cannot be seen until the abdomen has been opened and the abdominal viscera removed. The thorax, if possible, should be entire or unopened. Remove the peritoneum and close cellular layer investing its concave or abdominal surface; leave portions of the large vessels and gullet passing through it; study its relations carefully. Although placed in the mesial line of the body, the two sides of the muscle are not symmetrical.

It is usual to speak of the diaphragm as composed of two, the greater and smaller muscles of the diaphragm. To a certain extent this division is artificial. The fleshy fibres forming the greater muscle

Fig. 128.*

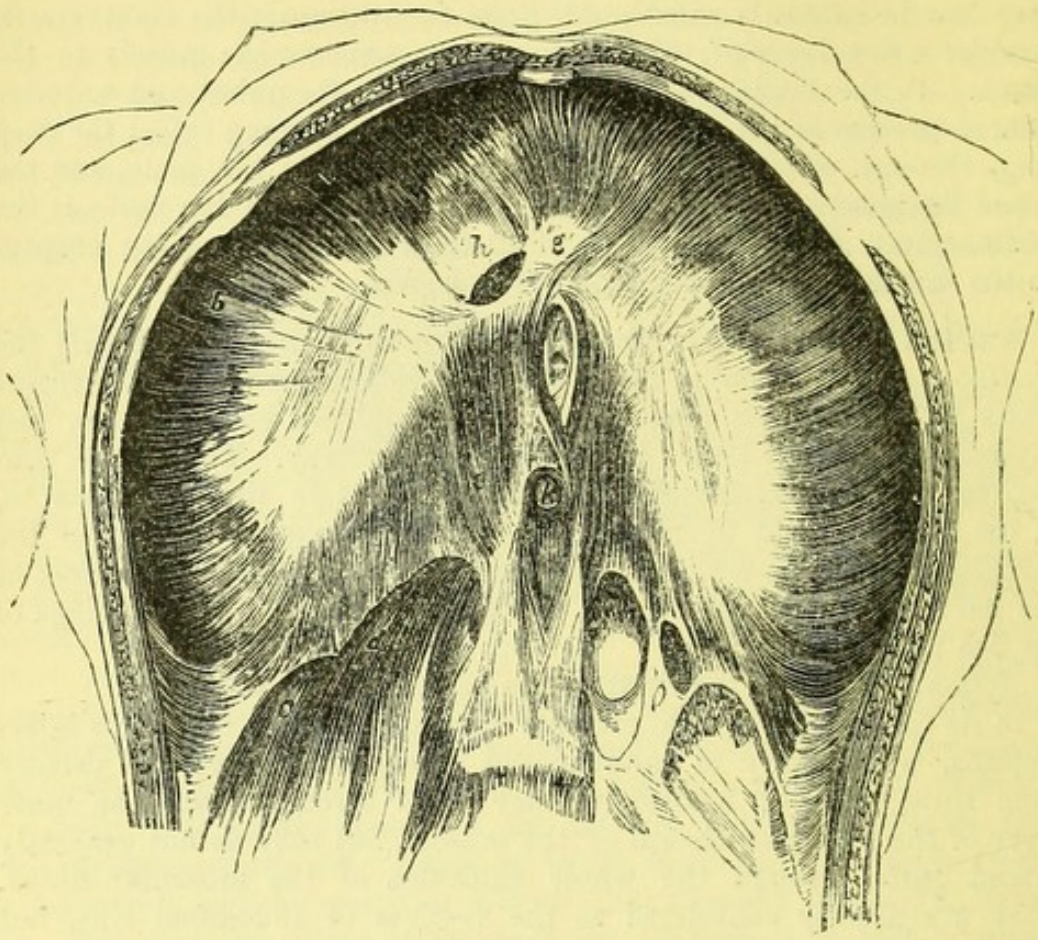

of the diaphragm arise, 1st, from the inner surface of the last six ribs, on both sides, and the ensiform cartilage; 2d, from a tendinous edge (the inferior margin of the aponeurosis connected with the transversalis abdominis) stretched between the last rib and the base of the transverse process of the first lumbar vertebra. The quadratus lumborum passes upwards behind this ligamentum arcuatum to be attached to the last rib; 3d, from a shorter ligamentum arcuatum, extending from the base of the transverse process of the first lumbar vertebra to the body of the second, thus passing over the upper extremity of the psoas magnus. From these origins the fleshy fibres proceed, to terminate in a central tendon, which will be presently described.

The smaller muscle of the diaphragm, also called the crura, arises—the tendinous *right crus*, which is the longer, from the bodies, anteriorly, of the four first lumbar vertebræ; the left, which is smaller and narrower, from the bodies of the three first lumbar vertebræ.

* Fig. 128.—Septum transversum, diaphragm, or midriff; the great muscle of inspiration.—*a*, cordiform tendon, right side; *b*, fleshy fibres of the great muscle of the diaphragm; *c*, *d*, ligamenta arcuata, right side; *e*, fleshy fibres of the right crus; *f*, decussation of the crura; *k*, section of the aorta as it passes between the crura and behind the diaphragm, and upon the vertebral column; *l*, esophageal opening of the diaphragm; *h*, aperture for the passage of the vena cava inferior; *g*, central portion of the cordiform tendon.

From these tendinous origins the crura soon become fleshy, and terminate in the central tendon; but before this happens they decussate, or at least transmit from each a fleshy bundle, which is interlaced with that of the opposite side, that which ascends from the right crus to the left being the larger, and also the anterior.

Lastly, the central tendon (cordiform tendon of the diaphragm), to which all the fleshy fibres proceed, and in the margins of which they terminate anteriorly, is three-lobed and posteriorly notched, to correspond with the vertebral column. The fibres composing this tendon are strong and lustrous; they run in various directions.

Certain points in the anatomy of the diaphragm require especial notice. First, in the cordiform tendon, towards the right side, is a square-shaped aperture, or short canal, for the passage of the vena cava inferior; a second in front of the decussation of the crura, and between the fleshy portions of these crura, for the passage of the gullet; and a third behind and between the tendons of the crura, completed posteriorly by the vertebral column; in this semi-canal lie the aorta, vena azygos, and thoracic duct.

The fleshy fibres springing from the ligamentum arcuatum externum are pale and scant, leaving at times a triangular space, in which no muscular fibres exist.

The splanchnic nerves pass through the diaphragm, and the communicating filament, connecting the last thoracic ganglion of the sympathetic to the first lumbar, passes behind it, protected from pressure by a cellular arch stretched over it.

The thoracic surface of the diaphragm is convex. Its middle portion (cordiform tendon chiefly) is strongly connected to the fibrous layer of the pericardium, but not inseparably so, the connexion being strongest at the circumference. The pleuræ cover a large portion of its upper surface, and thus the muscle supports the lungs. *Inferiorly* the muscle is invested by the peritoneum, and is in relation to the liver, spleen, stomach, &c. On this surface the muscle at the sides is remarkably concave.

This important muscle separates the thorax from the abdomen, and is the great muscle of respiration. By contracting, the concavity towards the abdomen is much diminished, and the capacity of the chest enlarged. It is the antagonist of the broad abdominal muscles, and of the levatores ani.

It is also important to observe, that on the right side, the diaphragm, during forcible respiration, extends nearly as high as the fourth rib.

QUADRATUS LUMBORUM.

Placed between the last rib and the pelvis, and enclosed by two laminæ of the aponeurosis belonging to the transversalis abdominis, this muscle, easiest of dissection in woman, is attached below by aponeurotic fibres, over an extent of about an inch, to the middle and posterior part of the crest of the ilium, to the ileo-lumbar ligament, and to the transverse process of the fifth lumbar vertebra. Superiorly

the muscle is attached to nearly the whole inferior margin of the last rib, and by aponeurotic slips to the fore part of the base of the first four transverse processes of the loins.

Anteriorly the muscle is covered superiorly by the diaphragm, and for the rest of its extent by the anterior layer of the aponeurosis of the transversalis abdominis; *posteriorly* it is separated from the sacro-spinalis by the middle layer of the same aponeurosis.

It inclines the thorax to one side, and fixes the last rib. It is probably the antagonist of the scaleni.

Psoas Parvus.—This muscle is frequently absent; when present, it is placed on the psoas magnus. It arises from the lower part of the body of the last dorsal vertebra, and from the fibro-cartilage connecting that vertebra to the first lumbar. Inserted by a long, flat tendon into the ileo-pectineal eminence and neighbouring portion of the pelvis, sending an expansion into the fascia iliaca.

Superiorly the muscle is covered, first, by the diaphragm (*ligamentum arcuatum internum*), afterwards by the renal vessels and nerves and by the peritoneum, below by the external iliac artery. Posteriorly the muscle is united to the psoas magnus throughout its whole extent by cellular tissue.

To bend the pelvis on the thorax, and *vice versâ*.

PSOAS MAGNUS AND ILIACUS.

These muscles really form but one—a bicipital muscle, in fact. Their dissection is easy.

Psoas Magnus.—Arises from the lateral and inferior part of the body of the last dorsal vertebra; from a small portion of the posterior extremity of the last rib; from the side of the bodies of the first, second, third, and fourth lumbar vertebræ; from the fibro-cartilages uniting these vertebræ to each other, and from the base of the corresponding transverse processes. These complex origins explain many important facts in the history of psoas and lumbar abscess. The branches of the nerves forming the lumbo-sacral plexus pass between these origins.

After forming a large fleshy belly, the muscle descends along the brim of the true pelvis, forming in its descent a strong tendon, concealed at first by the fleshy fibres of the muscle. Before passing under the crural arch it receives upon its outer side the fleshy fibres of the iliacus. The tendon thus strengthened passes out of the pelvis by the notch external to the ileo-pectineal eminence, descending into the thigh over the capsular ligament of the hip-joint, and terminates by being attached to the inner and back part of the trochanter minor.

The *external* surface of the psoas may be divided into three parts; that, namely, which is covered by the ligamentum arcuatum internum and diaphragm; this is the dorsal portion; 2, an abdominal and pelvic part, invested by a layer of the iliac fascia, and in relation anteriorly

to the kidney, psoas minor, and great vessels and nerves; 3, the portion which, passing under the crural arch, terminates at the trochanter minor; over this lie the crural arch, and the crural or femoral artery and vein.

The *inner* edge or surface of the muscle is applied upon the sides of the bodies of the last dorsal and first four lumbar vertebræ and their intervertebral cartilages, but is yet partially separated from them by the lumbar nerves and vessels. This surface is also in relation to the iliac vessels, more especially to the external; inferiorly the internal circumflex vessels separate it from the pectineus.

The *posterior* surface of the muscle is applied above to the quadratus lumborum, lumbar nerves, and to the anterior lamina of the aponeurosis of the transversalis abdominis; farther down to the os innominatum and capsular ligament of the hip-joint, from which the muscle is separated by a large synovial bursa, occasionally communicating with the joint.

Action.—To bend the thigh on the trunk and the trunk on the thigh. It rotates the thigh a little outwards.

The ILIACUS is merely a second head of the psoas. It occupies the iliac fossa on each side.

Origin.—By very small aponeuroses from about the upper three-fourths of the iliac fossa, the inner lip of the two anterior spinous processes of the ilium and of the two anterior thirds of the inner lip of the crest; lastly, from the ilio-lumbar ligament.

From these origins the muscular fibres converge towards the crural arch, underneath which they pass; all the fibres being successively inserted into the outer edge of the tendon of the psoas, by means of which the muscle is attached to the trochanter minor and to the adjoining part of the femur.

Anteriorly, the iliac portion of the muscle is in relation to the fascia iliaca, the peritoneum, and viscera; to the cœcum on the right side, and sigmoid flexure of the colon on the left. The portion below the crural arch touches the sartorius, pectineus, crural vessels and nerves, and the fold of the groin. Its action is similar to that of the psoas, of which it forms a part.

The iliac fascia (*see* Fasciæ and Aponeuroses), which plays so important a part in the history of the surgical and medical anatomy of these regions, holds an intermediate place between an aponeurosis, properly so called, and a cellular fascia. The fascia transversalis, already described, seems, in some measure, a continuation of the fascia iliaca; at all events they are perfectly continuous with each other along nearly the whole line of Poupart's ligament. The surgical relations of these fasciæ to the great vessels and nerves, and to the abdominal and pelvic viscera, will be fully described in the chapters on the Fasciæ and Vascular System.

MUSCLES OF THE PELVIS.

Dissection.—It is usual at this stage of the dissection of the trunk to proceed with the examination of the muscles of the pelvis: these may be divided into two classes; 1st, those of the perineum, which are dissected without any section of the pelvis being required; 2d, those which necessitate, before being fully seen, one or more sections of the osseous pelvis.

MUSCLES OF THE MALE PERINEUM.

Dissection.—Place the subject in the same position as for lithotomy. Distend the lower part of the rectum with baked hair, introduce a staff by the urethra into the bladder, and draw the scrotum and penis for-

Fig. 129.*

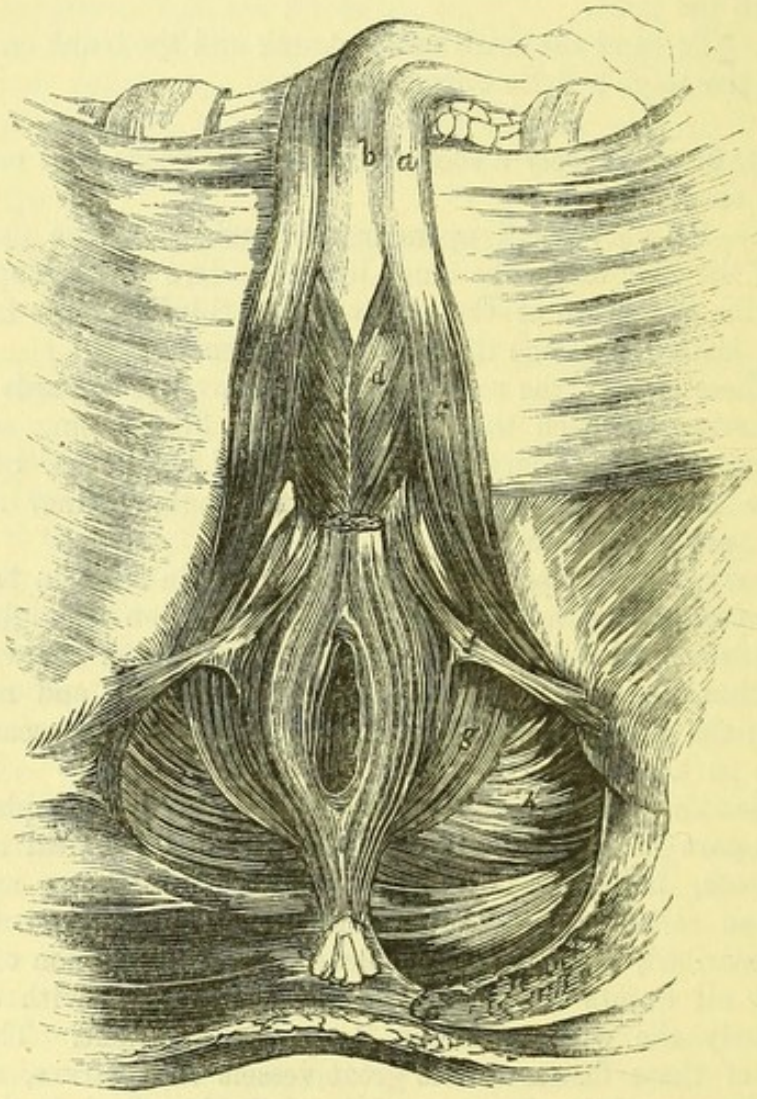

* Fig. 129.—Muscles of the perineum.—*a*, crus of the penis; *b*, corpus spongiosum urethræ; *d*, acceleratores urinæ; *c*, erectores penis; *e*, sphincter-muscle of the rectum; *f*, transversus perinei muscle; *g*, deep sphincter of the rectum; *h*, levator ani, left side.

ward and upwards; then make an incision through the integuments along the raphe, from the posterior part of the scrotum to the anterior part of the anus; continue the incision around the anus, and carry one on each side from the anterior part of the anus to the tuberosity of the ischium. The parts first met with on removing the integument is the superficial fascia, extending upwards into the scrotum, and outwards and downwards towards the hips and thighs. This fascia varies in thickness in different persons; it has a tolerably firm connexion with the rami of the pubes and ischium on each side.

Divide the fascia so as to lay it off to the right and left; a layer of cellular substance closely enveloping the muscles will next show itself. By some French writers on surgical anatomy this layer has been called the deep, by others the middle perineal fascia; but it were better, if it merit a name, to call it simply what it is, namely the fascia propria or envelope of the perineal muscles. Clear this away in the direction of the fibres of the various muscles, commencing with the

SPHINCTER ANI.—This muscle surrounds the anus: it is composed of two portions, a superficial and a deep. The superficial lies immediately beneath the integuments, and is composed of small muscular fasciculi, some of which decussate in front of the anus. The fibres are concentric and elliptic, and form acute angles where they interlace with each other. Anteriorly they are connected with the *central point* of the perineum; posteriorly by a cellular cord to the extremity of the coccygeal bones. Some of the fibres expand in the cellular tissue: above this and within, may readily be exposed the deep sphincter or ring, surrounding more completely the extremity of the bowel, and formed of circular fibres which do not decussate nor proceed to any other termination.

Its function is to close the rectum: a similar muscle exists in woman; and in both male and female the muscle is intimately united with the levatores ani: this will be best seen whilst examining these muscles.

ERECTOR PENIS (*Ischio-cavernosus*).—Dissect these muscles on both sides of the perineum. Attached to the inner side of the sciatic tuberosity, it ascends forward and upwards, to terminate in an aponeurosis identifying itself with the fibrous membrane of the corpus cavernosum of the penis. The name is supposed to express its function.

ACCELERATORES URINÆ; BULBO-CAVERNOSI.

These two muscles arise from a central raphe occupying the mesial plane of the bulb and of the urethra; by this raphe they are intimately connected with the bulb and corpus spongiosum urethræ over a considerable space. From this origin, which also is united by cellular tissue to the central point of the perineum, the two muscles proceed forward, diverging in their course, to terminate in the sides and upper

part (dorsal) of the crura of the corpus cavernosum penis on each side. The two names given to them sufficiently express their relations and supposed functions. On dividing one of these muscles towards its attachment to the crus of the penis, and reflecting the flap so formed towards the muscle of the opposite side, the exterior of the bulb will be exposed, and the slight adhesion of the acceleratores to the sides of the bulb explained. The adhesion is strong only in the mesial line.

TRANSVERSUS PERINEI.

These muscles vary much in form and strength, but they are readily found. Arises from the inner part of the tuberosity and ramus of the ischium; it passes transversely, and at the same time somewhat obliquely, across the perineum, to terminate in the *central point* of this region, being in part confounded with the accelerator urinæ and sphincter ani muscles; and in the female, when present, with the constrictor vaginæ.

With the levator ani it assists in supporting the perineum and viscera within the pelvis.

MUSCLES OF THE FEMALE PERINEUM.

The muscles called ischio-cavernosi become, in woman, the erectores clitoridis; they represent in miniature the erector muscles of the penis.

CONSTRICTOR VAGINÆ.—Formed of two planes of fleshy fibres: descending by the sides of the vagina, are attached superiorly to the proper tissue of the vagina; inferiorly to the cellular substance of the perineum, between the perineum and tuberosity of the ischium. Beneath them lie the vascular organs called semi-bulbs, and certain glands which no doubt represent the glands of Cowper in the male.

Superiorly these muscles are attached to the cavernous bodies, or crura, of the clitoris. They represent probably the acceleratores urinæ of the male.

DEEP MUSCLES OF THE PELVIS.

At this stage of the dissection the student, should he think fit, may proceed with the dissection of the levatores ani by the perineum; but the view he thus obtains of these muscles is necessarily imperfect though important.

Dissection of the Levatores Ani by the Perineum.—To distend the perineum and thereby bring the levatores more within the reach of the dissector, press a towel into the cavity of the pelvis, firmly, so as to force the viscera downwards towards the perineal exit of the pelvis. Next remove the perineal muscles, already described, cautiously: leave the sphincter ani in its place, also the organs of generation, bulb, &c. Draw the anus to one side and clear the ischio-rectal space on each side the rectum, removing the abundant cellular tissue generally found

Fig. 130.*

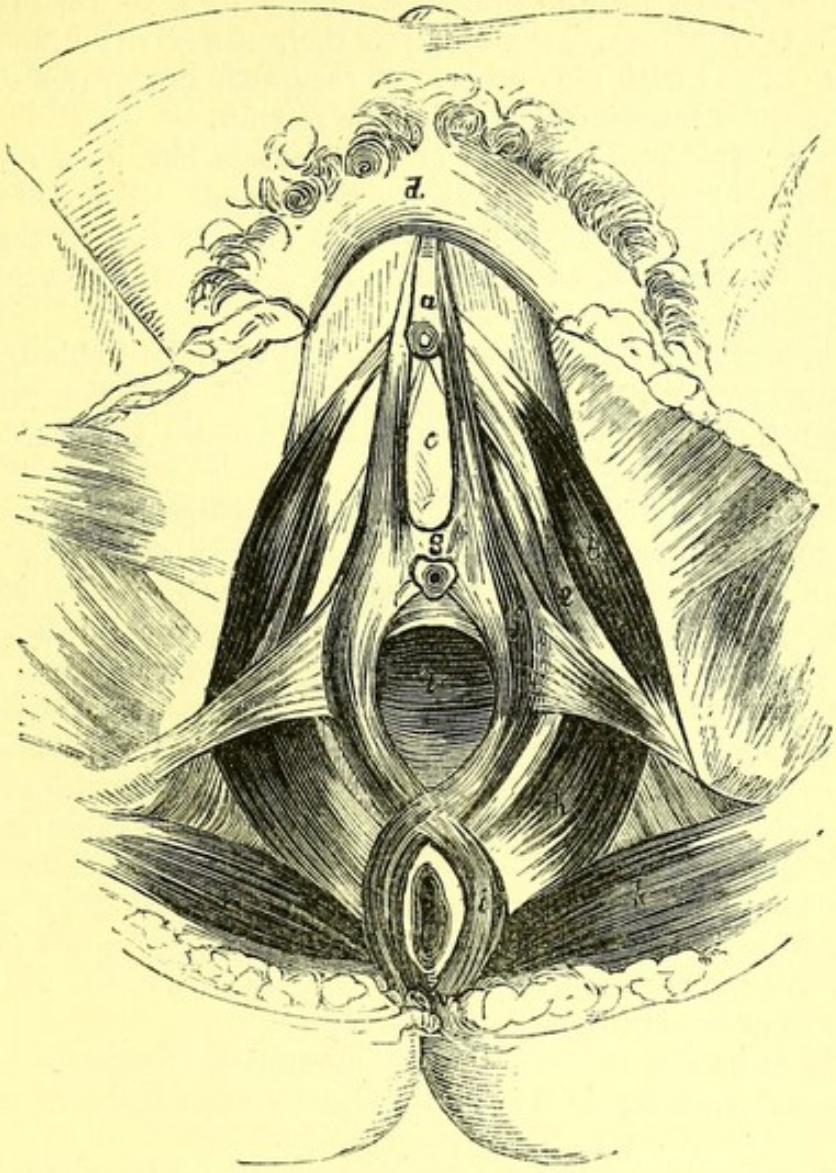

there; this will expose the layer of the pelvic fascia investing the exterior or convex surface of the levatores; clear the fibres, and thus expose the exterior surface of both muscles. The origin of these muscles cannot be shown by this dissection, but by another, to be described immediately.

The LEVATOR ANI muscle arises within the pelvis, on each side, by short aponeurotic fibres, from the posterior and inferior part of the symphysis of the pubes, from the ilium, from above the upper region of the obturator internus, from the spine of the ischium, and from the pelvic fascia. Its fleshy fibres do not cover the inner surface of the obturator internus.

* Fig. 130.—Muscles of the female perineum.—*a*, glans clitoridis; *b*, erector clitoridis; *c*, vestibule; *d*, mons veneris and sub-mucous surface of the greater labia; *e*, left crus clitoridis; *f*, constrictor vaginæ; *g*, meatus urinarius; *h*, portion of the levator ani; *i*, sphincter ani; *k*, gluteus maximus; *l*, orifice and upper wall of the vagina.

From these origins these muscles descend, presenting a concavity towards the pelvis, until they meet behind the lower part of the rectum, to which they adhere, intermingling their fibres with those of the sphincter ani and with each other. A tendinous line or raphe connects the two muscles immediately behind the rectum.

The *outer* (perineal) surface of the muscle has been already described. Its *inner* surface, that we now speak of, is immediately lined by a layer of the pelvic fascia, and is in relation with the urinary bladder, prostate gland, and rectum. Its posterior edge is continuous with the ischio-coccygeus muscle.

These muscles, the levatores ani, together with the ischio-coccygeus, form the true muscular walls of the pelvis. They support the viscera at the great outlet of the trunk, and antagonize the action of the diaphragm.

Dissection of the Levatores Ani from the inside.—Divide with a saw the body and ramus of the pubis and ischium a short way from the symphysis on the left side; likewise the sacro-iliac joint of the left side; some prefer dividing the sacrum and coccygeal bones mesially and longitudinally; both sections have their advantages. Remove cautiously the portion of osseous pelvis of the left side thus divided, leaving at first every soft part. On the exposed surface clear the exterior of the left levator ani, and, laying it down, examine its relation attentively to the rectum, bladder, prostate gland, and urethra. Next withdraw the viscera of the pelvis towards the left side, and, having first ascertained the course and connexions of the pelvic fascia, strip it carefully from off the concave side of the right levator ani and coccygeus. Leave the part of the fascia running from the back of the pubes to the spine of the ischium.

By raising up the rectum, the raphe uniting the levators together at the posterior surface of that bowel will be made distinct.

Ischio-coccygeus.—Of a triangular shape. Attached by its apex to the spine of the ischium, and by its base to the margins of the coccygeal bones, these muscles support indirectly the pelvic viscera by acting on the coccygeal bones. It is sometimes connected with the lower edge of the sacrum.

Posteriorly it is covered by the sacro-sciatic ligaments; anteriorly it corresponds to the rectum.

Coccygeus.—There is sometimes found a small muscle descending in front from the fore part of the last sacral vertebra to the bodies of the coccygeal. It has been called the curvator coccygis. The muscle in man is a rudimentary one.

MUSCULAR FIBRES OF THE URETHRA.

The portion of the urethra which surgeons call "membranous," but which was aptly designated by Cuvier "muscular," a name much more exact, philosophical, and expressive of its true character, is sup-

ported in its passage under the arch of the pubis by ligamentous structures of an elastic nature, and occasionally, in those persons in whom the muscles are highly developed, by muscles, or at least by fasciculi of muscular fibres, which for obvious reasons are not always present. These muscular fibres were well known and admirably described by Santorini, Morgagni, and the anatomists of their day. I have frequently seen them fully developed; but they are more generally obscure or imperfect, and their place taken and their office fulfilled by a yellow elastic tissue, a tissue which not unfrequently performs the duty of muscular fibres. When perfect they have the appearance described by Santorini.

Fig. 131.*

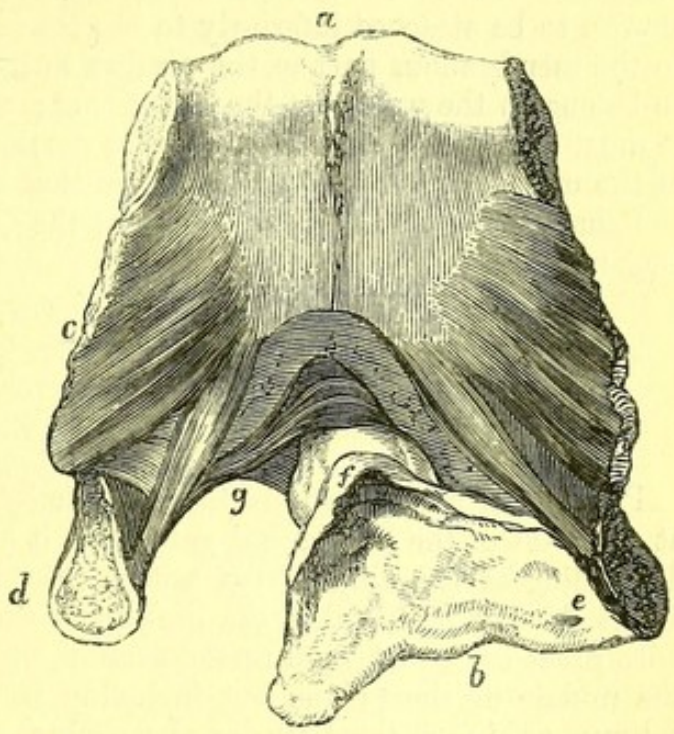

COMPRESSOR AND LEVATOR OF THE URETHRA.

The compressor of the urethra is composed of two layers, of which one passes above the membranous part of the urethra, the other beneath it. They are both attached on each side to the ramus of the pubis close under the arch; at the middle of their course they are connected by close cellular tissue to the urethra, on which they spread out so as to cover its whole length. Cowper's glands lie beneath the lower fasciculus, and occasionally, as they pass over and under the urethra, a tendinous raphe is said to have been observed. The same structures prevail in the female.

The existence of the muscles described by Mr. Wilson, who taught anatomy as the partner of Sir Charles Bell, is still disputed; the facts seem to be these:—When the bladder is drawn backwards with care from the posterior surface of the pubes, a muscular slip of a trian-

* Fig. 131.—Intended to show the transverse muscle of the urethra—a muscle well known to Santorini, whose anatomical descriptions, like those of De Graaff and Morgagni, are generally more accurate than those of succeeding anatomists; *a* is placed over the symphysis of the pubes; *b*, a portion of the bladder laid open; *e*, mucous surface of the bladder; *f*, commencement of the prostatic portion of the urethra; *g* points to the transverse muscle of the urethra, a portion only of the lower one seen, passing beneath the urethra, and concealed by it; *d*, section of the ramus of the pubes; *c*, a portion of the obturator internus.

gular shape may be seen in some subjects, but by no means in all, descending from the posterior surface of the body of the pubis. If this be carefully traced on either side, it will be found to follow the anterior margin of the levator ani, separated, however, from it by cellular substance, to be attached inferiorly to the fascia covering the prostate and to the membranous part of the urethra in front of it. It seems to me to belong to the system of the levator ani; nevertheless, when present, it must support the prostate and that portion of the membranous part of the urethra immediately in front of that gland.

I shall return to these structures in the Chapters on the Fasciæ and Organs of Generation.

MUSCLES OF THE LOWER EXTREMITIES.

Posteriorly and externally this is a well-defined region, commencing at the crest of the ilium; but anteriorly it is not so. Certain muscles descending to the thigh from within the abdominal region embarrass the student at first, unless the limb has been removed from the trunk with great care, and by a mesial section, extending not merely through the middle of the pelvis, but including in the section, the vertebral column, as high as the 10th dorsal vertebra. By this section the student is enabled (the abdominal viscera having been removed) to trace from their origins to their terminations the psoas parvus, psoas magnus, and iliacus muscles, but not otherwise. As these muscles have been already described as muscles of the trunk, and more especially of its abdominal region, I shall not return to them here, but recommend the student, in whatever way the limb has been removed from the trunk, which in the dissecting-room is generally done in a disadvantageous way to him, to commence his dissection of the muscles of the lower extremity on its posterior region.

Dissection.—Place the limb on its anterior surface; carry a section around the crest of the ilium, and extend it to the extremity of the coccyx; make another incision through the integuments only, commencing near the iliac tuberosity and terminating below the great trochanter; a third transversely across the thigh beneath the one last made. By these incisions there will result two flaps, exposing a distinct region.

Beneath the skin the structure first met with is the superficial fascia (see the chapter on Fasciæ and Aponeuroses) continuous with that of the trunk and thigh. Remove this fascia in a similar manner as the integuments, and expose the femoral aponeurosis. (See Fasciæ and Aponeuroses.) The portion of the aponeurosis covering the gluteus medius is strong, that covering the gluteus maximus is comparatively thin and cellular. Carry an incision through the thin portion from above downwards, and from behind forwards, dissecting it from the gluteus maximus, and at the same time cleaning the fibres of the muscle, by removing with the aponeurosis the fascia propria of the muscle.

GLUTEUS MAXIMUS.

Large, square, and composed of coarse-looking fibres and fasciculi. This muscle is attached superiorly to the posterior part of the crest of the ilium; to the surface of the same bone above and behind the superior curved line; to the aponeurosis of the latissimus dorsi; to the posterior sacro-iliac ligament; to the rough surface on the back of the sacrum; to the circumference of the notch terminating the sacral canal; and to the lateral parts of the coccyx, as far as the summit of the bone; externally and inferiorly to the sacro-sciatic ligament.

The fleshy fasciculi run parallel to each other, from above downwards and from behind forwards, descending towards the great trochanter. The tendon in which they terminate is so incorporated with the fascia lata (femoral aponeurosis) that it cannot be separated from it. Thus the muscle may be said to terminate inferiorly in two ways,—1st, by a strong tendon strongly and extensively attached, for a space of 3 inches, to the rough impression proceeding from the great trochanter to the linea aspera of the femur; 2d, by expansion into the back and outer part of the femoral aponeurosis.

A thick layer of adipose substance, especially in woman, occupies the superficial fascia corresponding to the external surface of the muscle. The anterior margin of the muscle is connected to the gluteus medius by the aponeurosis, which here divides into two layers, of which one passes behind the muscle, the other in front of it. The inferior edge of the muscle is free.

Use.—To extend the limb; also, to raise the trunk upon the limb. Its great size in man has a reference, no doubt, to his upright position.

Deep Synovial Bursa.—On dividing the muscle transversely, and reflecting the lower portion, a large bursa will be found interposed between the tendon of the muscle and the outer surface of the trochanter major. It protects also a portion of the vastus externus.

GLUTEUS MEDIUS.

This muscle is partly covered by the preceding muscle. Its attachments are superiorly, 1, to the inner surface of the aponeurosis, from which its fleshy fibres cannot be separated; 2, from the anterior three fourths of the iliac crest; 3, from the surface between the two curved lines of the dorsum of the ilium, and from the inferior curved line itself.

From these different points the fibres descend converging, to terminate at last in a tendon, by which the muscle adheres to the whole of the upper edge of the trochanter major.

Externally and anteriorly it is covered by the fascia lata femoris; posteriorly by the gluteus maximus, from which it is separated by a very thin layer of the same aponeurosis. The *deep surface* is in relation to the os innominatum, the gluteus minimus, the pyriformis, and

Fig. 132.*

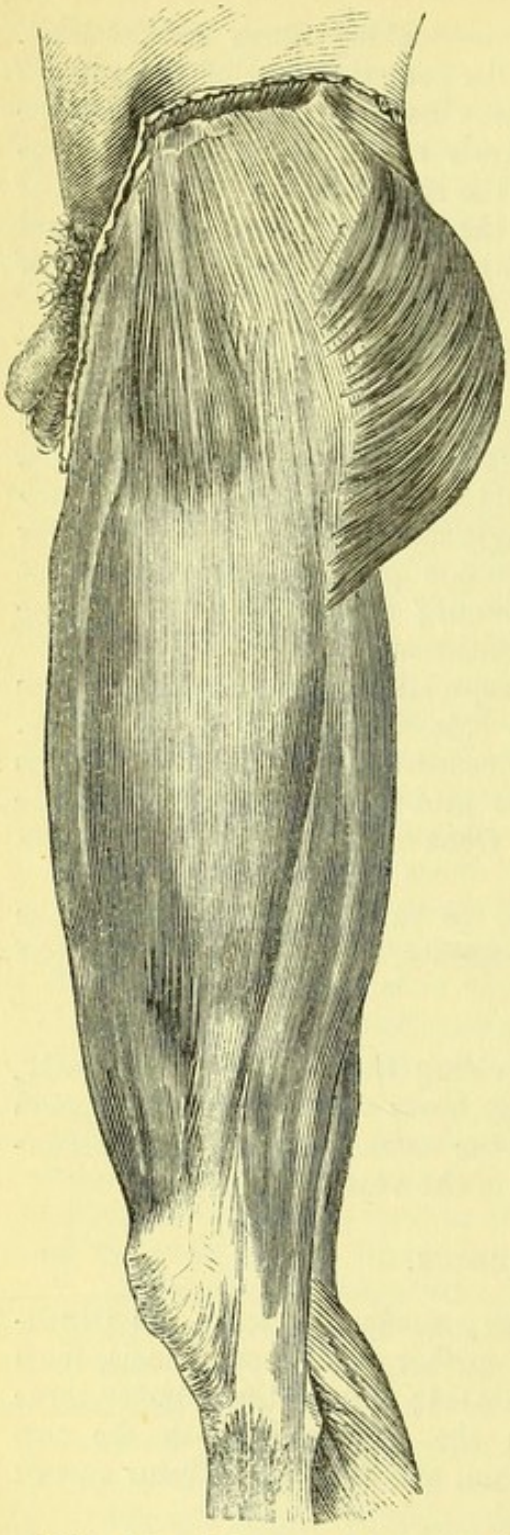

Fig. 133.†

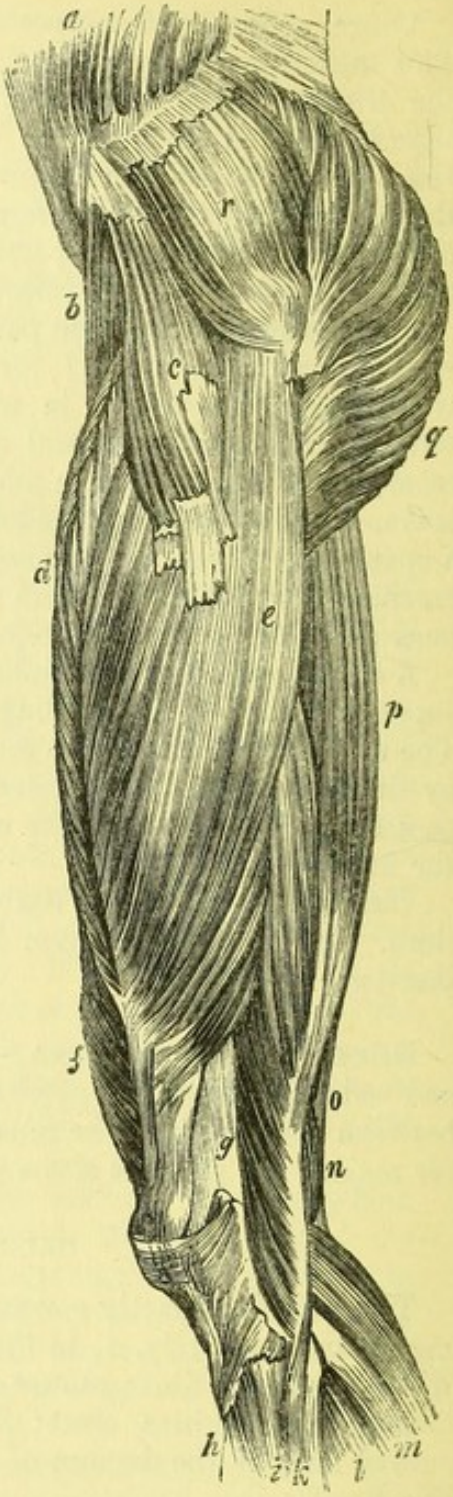

* Fig. 132.—Muscles of the outer side of the left thigh. The femoral aponeurosis is mostly present. The only muscle fully dissected on this view is the gluteus maximus. The muscles whose outlines are seen here are the same as those described in the next figure.

† Fig. 133.—Muscles of the thigh, left side, external aspect.—*a*, external oblique muscle of the abdomen; *b*, sartorius; *c*, tensor fasciæ latæ; *r*, gluteus medius; *q*, g, maximus; *e*, vastus externus; *d*, rectus; *f*, vastus internus; *g*, short head of the biceps; *p*, long head of the biceps; *o*, *n*, inner hamstring muscles; *h*, crest of the tibia; *i*, tibialis anticus; *k*, extensor longus; *l*, *m*, gastrocnemius and soleus.

Fig. 134.*

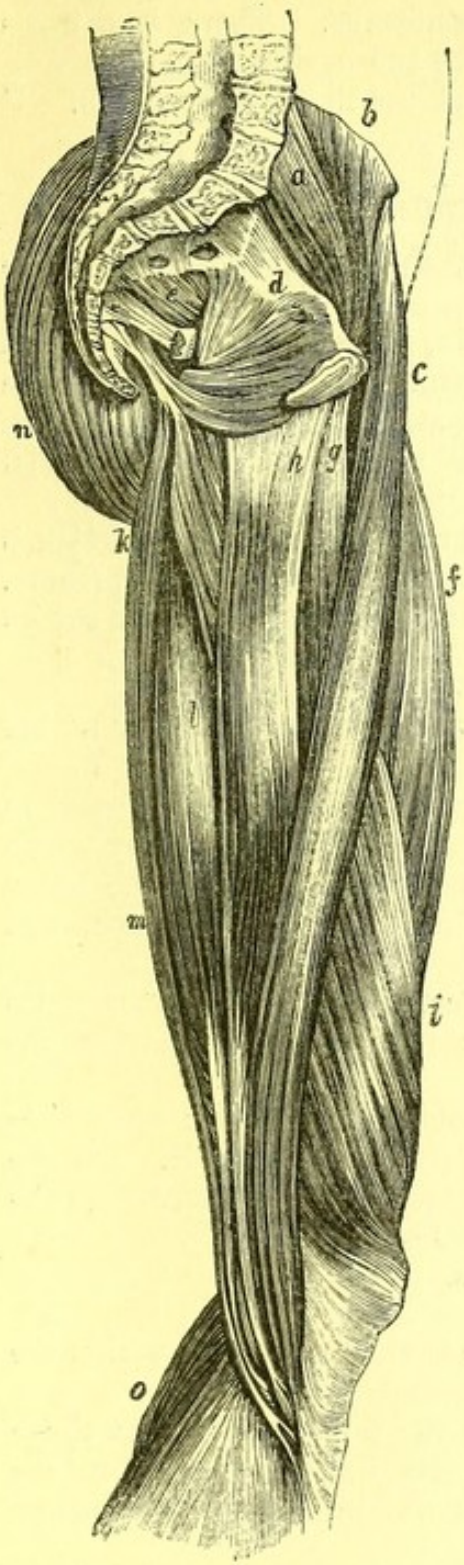

Fig. 135.†

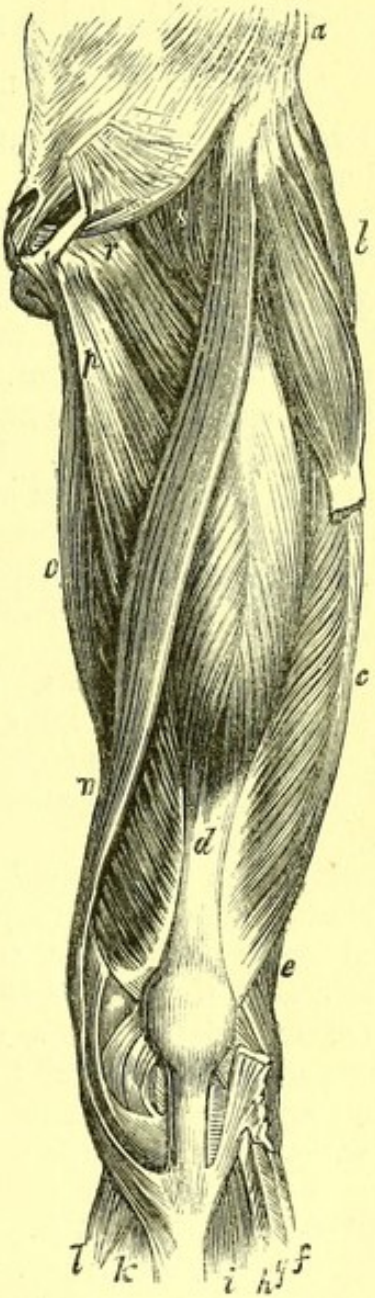

* Fig. 134.—Muscles of the inner side of the left thigh: the pelvis has been divided mesially, and the viscera removed.—*a*, psoas magnus; *b*, iliacus; *d* points to the obturator internus; *e*, pyriformis or pyramidalis; *f*, rectus; *i*, vastus internus; *g*, adductor longus; *h*, gracilis; *l*, *m*, semi-tendinosus and semi-membranosus muscles; *o*, gastrocnemius; *n*, gluteus maximus.

† Fig. 135.—Front of the left thigh.—*a*, superior and anterior spinous process of the ilium; *b*, tensor and fore part of the gluteus medius; *d*, rectus; *n*, sartorius; *o*, gracilis; *p*, adductor longus; *r*, pectineus; *s*, united mass of the psoas magnus and iliacus; *e*, biceps flexor cruris; *l*, *k*, gastrocnemius; *i*, *h*, *g*, *f*, heads of the tibialis anticus and extensors cut across.

the gluteal artery. Its anterior edge is connected with the tensor fasciæ latæ; the posterior with the pyriformis. There is a bursa between the tendons of the gluteus medius and pyriformis.

Use.—To rotate the femur and extend the limb on the trunk. It also acts in standing and in progression.

GLUTEUS MINIMUS.

Detach the medius cautiously from the bone, and expose the minimus.

Arises from the dorsum of the ilium, between the anterior and inferior curved line and the capsular ligament of the hip-joint. The fleshy fibres converge and descend, to be attached by a strong tendon to the anterior part of the trochanter major. A small synovial capsule favours its motions.

This muscle lies more immediately over the hip-joint: its action is similar to the preceding. In dislocation of the head of the femur, upwards or on the dorsum of the ilium, it is this muscle which suffers the most.

PYRIFORMIS.—The origins of this muscle must be sought for within the pelvis.

It arises, by digitations, from the anterior surface of the sacrum to the outside of the anterior sacral foramina, and in the spaces by which they are separated from each other. It is attached also to the lower part of the great sacro-sciatic ligament, and a little to the upper and back part of the ilium.

Issuing from the pelvis, by the great sacro-sciatic notch, it assumes a pyriform shape, and terminates by a tendon in the upper part of the digital cavity of the great trochanter.

Posteriorly the muscle lies on the capsule of the joint: *anteriorly* the rectum, sciatic plexus, and hypogastric vessels cover it. On the upper edge will be found the gluteal artery; on the lower edge the sciatic nerve separates it from the gemellus superior.

Use.—A rotator of the thigh outwards.

OBTURATOR INTERNUS.—This muscle is chiefly situated within the pelvis, and can only be seen by examining that cavity.

Origin.—From the posterior surface of the pubes, within and above the obturator foramen; from the obturator ligament, and from the bony surface separating the obturator foramen from the sciatic notch.

From these points the fibres converge, and leave the pelvis by the smaller sciatic notch, over which they pass as over a pulley. The bony surface on which the muscle plays is encrusted with a thin plate of fibro-cartilage: an extensive, well-marked bursa is developed here, and the muscle is tendinous on the side facing the bone.

Having left the cavity of the pelvis, the tendon in which the muscle terminates proceeds horizontally over the capsular ligament united with

the tendons of the gemelli, between which it runs, to be inserted along with these into the digital cavity behind the trochanter.

Use.—To rotate the thigh, and so turn the toes outwards.

GEMELLI, SUPERIOR AND INFERIOR.—These two muscles may be viewed as appendages of the obturator internus; they also are capsular and rotator muscles.

The *superior* arises from the spine of the ischium, and, after uniting with the tendon of the obturator internus, it terminates with it in the digital cavity.

The *inferior* has a similar form and connexions. It arises from the upper and back part of the tuber ischii, and terminates in the digital cavity.

These muscles form, as it were, a muscular sheath for lodging the tendon of the obturator internus. The sciatic nerve passes behind all three muscles.

QUADRATUS FEMORIS.—When this muscle is small the gemellus inferior is large, and it is said to be occasionally wanting; but this I have not observed. It partakes of the character of the adductor magnus, a muscle to be presently described.

Arising from the outer side of the sciatic tuberosity in front of the semi-membranosus, it proceeds horizontally, and terminates in the lower part of the posterior edge of the great trochanter, in a line with the attachments of the adductor magnus; it does not follow the inter-trochanteric line, but slightly crosses it.

The muscle is situated between the gemellus superior and adductor magnus. In use it resembles the gemelli.

POSTERIOR PART OF THE THIGH.

Dissection.—Make an incision directly along the back of the thigh as far as the upper part of the calf of the leg; another transversely across the limb inferiorly. The superficial fascia will be exposed; and inferiorly, the upper part of the shorter saphena vein, a bursa called the popliteal, and some nervous filaments. On removing this by a longitudinal incision and reflexion of its portions, the femoral aponeurosis is exposed; dissect and remove this to the same extent as was done with the superficial fascia, opening the sheaths it gives to the muscles. Clean these carefully.

BICEPS FEMORIS, or FLEXOR CRURIS.—*Arises* by two heads, as its name implies,—the longer from the outer and upper part of the tuber ischii, by a tendon common to it and to the semi-tendinosus; the shorter, by short aponeuroses to a large part of the outer lip of the linea aspera between the adductor magnus and vastus externus, from which it is separated by a lamina or partition of the femoral aponeurosis.

Fig. 136.*

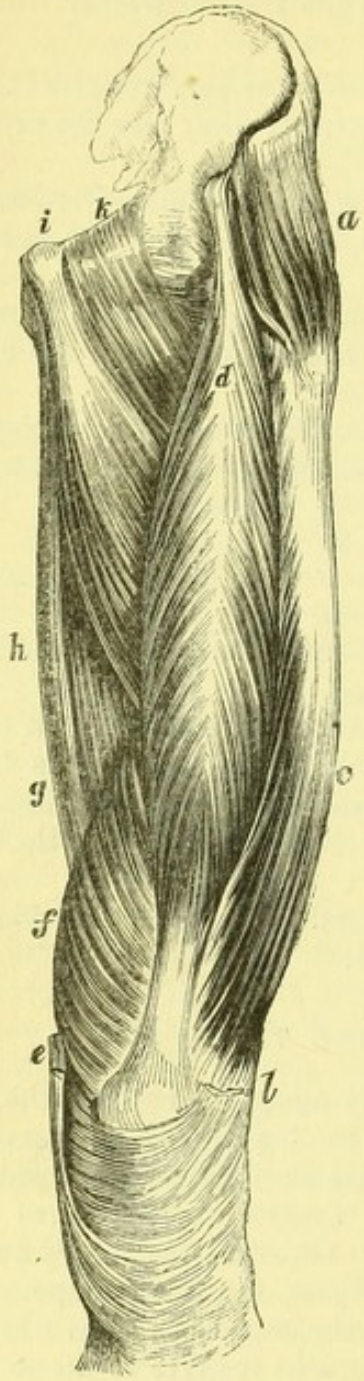

Fig. 137.†

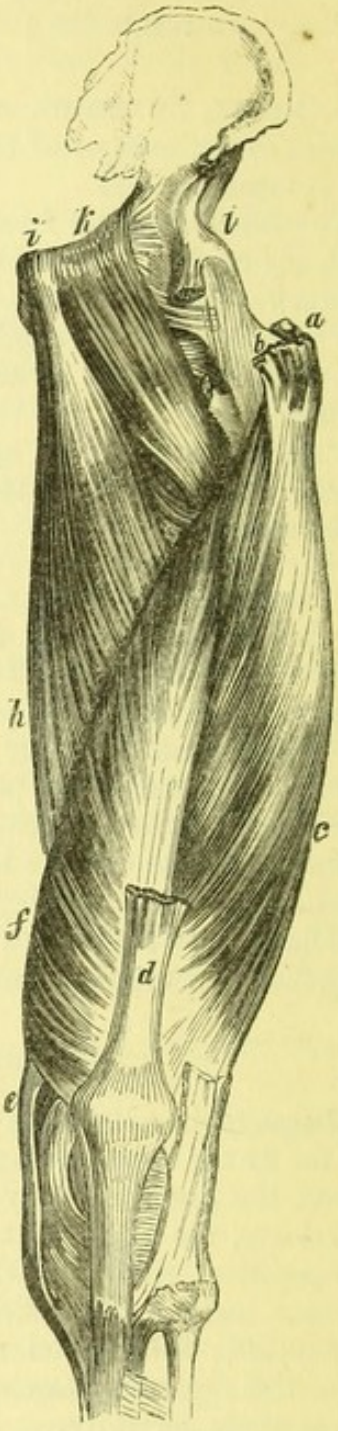

* Fig. 136.—Muscles of the left thigh, deeper dissection.—*k*, pectineus; *i*, adductor longus; *h*, *g*, gracilis; *f*, vastus internus; *e*, tendon of the sartorius cut across; *d*, rectus; *a*, tensor fasciæ; *c*, vastus externus; *l*, portion of the aponeurosis left covering the knee-joint.

† Fig. 137.—Deeper dissection of the muscles of the left thigh.—*l*, bifurcated origin of the rectus muscle; *k*, pectineus: *i*, adductor longus; *h*, gracilis; *f*, vastus internus; *e*, position of the internal lateral ligament of the knee-joint; *d*, tendon of the rectus; *c*, vastus externus; *a*, *b*, attachments of the gluteus medius and minimus.

Uniting below, these two heads form a tendon, terminating, after bifurcating, in the head of the fibula: the bifurcation embraces the external lateral ligament of the knee-joint. The tendon sends a prolongation to the aponeurosis of the leg.

The inner edge of the muscle and its tendon form the outer hamstring; it assists in forming the outer boundary of the popliteal space. The sciatic nerve lies in front of it, and its external branch runs close to the tendon of the muscle.

SEMI-TENDINOSUS.—*Arises* from the tuberosity of the ischium, behind the membranosus, and in common with the biceps. *Attached* below to the inner surface of the upper part of the tibia, along with the tendons of the gracilis and sartorius.

Use.—To bend the leg on the thigh; it acts also on the pelvis and trunk. Its tendon forms one of the inner hamstrings. About the middle of the thigh the fleshy belly is often traversed by a tendinous intersection.

A bursa placed between it and the membranosus protects the tendon above; and another inferiorly between its tendon and the internal lateral ligament of the knee-joint. The same bursa protects the tendons of the gracilis and sartorius.

SEMI-MEMBRANOSUS.—Situated in front of the preceding muscle. Arises from the tuber ischii, behind the quadratus, by a flat tendon. *Attached*, inferiorly, in a complex manner, to, 1st, the back part of the internal tuberosity of the tibia and adjoining surface of the bone; 2, by an aponeurotic expansion spread over the popliteus; 3, by a thin and narrow portion crossing the joint and terminating above the external condyle of the femur. This is the ligament, so called, of Winslow.

Use.—To bend the leg and thigh. It forms one of the inner hamstrings, and contributes to define the popliteal space.

MUSCLES OF THE FRONT OF THE THIGH.

Dissection.—Place the limb on its posterior surface; carry an incision from the anterior and superior spinous process of the ilium to the pubes; a second, beginning at the same process, downwards to a little below the knee. Carry a transverse incision from the lower extremity of the last to the inner side of the leg, and dissect off the integuments carefully, from without inwards. This will expose the superficial fascia, lymphatic glands of the groin, Poupart's ligament, and long saphena vein. Trace these structures so as to understand their position and relation to the parts beneath; next remove the superficial fascia by incisions similar in direction to those by which the integuments were raised, and expose and clean the femoral aponeurosis or fascia lata. (*See* Chapter on Fasciæ and Aponeuroses.) Open the sheath with which the aponeurosis invests the TENSOR muscle by an incision carried directly down about the middle of the muscle through-

out its whole course, and follow the same plan with all the muscles to be described. As each sheath is being opened anteriorly, clean the surface of the muscle and examine carefully the relations of the sheath to the adjoining aponeurotic partitions and to the sheaths of the other muscles; avoid above all things the removing the aponeurosis as if it were a fascia, merely enclosing the muscles in a general envelope.

The TENSOR FASCIÆ LATÆ, or VAGINÆ FEMORIS, *arises* from the anterior and superior spinous process of the ilium between the sartorius and gluteus medius, terminating about 3 inches below the great trochanter by being attached to the aponeurotic laminæ forming its sheath. Some tendinous fibres may be traced downwards as far as the head of the fibula, but this dissection is artificial.

Use.—To rotate the thigh inwards; it acts also on the pelvis. It stretches the aponeurosis of the thigh.

Cut the muscle across about the middle in order to examine its relations to the posterior wall of its sheath and to the surrounding muscles.

The SARTORIUS.—*Dissection.*—Follow, in the dissection of this and of most of the succeeding muscles of the limb, the directions given above for the dissection of the tensor; that is, lay open the sheath of the muscle about the middle, from one extremity of its course to the other, reflecting the flap and cleaning the anterior surface of the muscle before raising it up or in any way disturbing its edges. When fully examined the edges may be raised up, and the muscle divided or removed according to circumstances.

The sartorius is the longest muscle of the body. It arises from the anterior and superior iliac spine, and, after following an oblique course across the front of the thigh, terminates in a tendon attached to the upper and inner part of the tibia. The tendon forms an aponeurosis which passes over the tendons of the gracilis and semi-tendinosus, uniting with them.

The surgical relations of this muscle are important and require to be carefully studied. The upper third, by its inner margin, forms with the adductor longus a triangular space, in the lower part of which are found the superficial femoral artery and vein. The middle third of the muscle covers these vessels, crossing them; the lower third runs towards the inner side of the knee-joint. In action it bends the leg on the thigh and is much used by tailors, hence its name; but it is also an adductor of the limb. It acts also on the pelvis.

QUADRICEPS EXTENSOR CRURIS OR FEMORIS; RECTUS, CRUREUS, VASTUS INTERNUS AND EXTERNUS.

These muscles form but one, a four-headed extensor of the leg; nevertheless it is convenient to describe them as four.

RECTUS FEMORIS.—*Origin.*—By two tendons from the ilium; of these, one is horizontal and is attached to the bone close to the upper edge of the cotyloid cavity. The other descends from the anterior and

inferior iliac spine. The fleshy belly which succeeds these tendons descends nearly straight towards the knee-joint, terminating in a tendon which, after uniting with that of the crureus and those of the vasti, is strongly attached to the patella, covering its anterior surface, and proceeding ultimately to be incorporated with that part of the tendon which, connecting the patella to the tubercle of the tibia, gets usually the name of the ligament of the patella. Thus the real attachment of the rectus is to the tibia.

Use.—To extend the leg on the thigh; it acts also on the pelvis. Remove the muscle from its position by cutting it across, and examine the

CRUREUS.—So intimately is this muscle connected with the vasti, that it has been proposed to view them as one muscle, calling them the triceps extensor of the leg. But these names lead only to confusion, for the four muscles really form but one.

The crureus arises from the fore part of the base of the neck of the femur along the oblique ridge proceeding from the great to the small trochanter, and from the upper three-fourths of the anterior surface of the body of the femur.

The muscle so formed is at first distinct, but in its descent it soon becomes inseparably united with the vasti. Its mode of termination in the patella will be presently described.

VASTUS EXTERNUS.—Attached to the base and fore part of the great trochanter, to the outer lip of the linea aspera, and to the ridge connecting it to the great trochanter by a broad aponeurosis expanded over the outer surface of the muscle. The fleshy fibres arise extensively from the inner surface of this tendon or aponeurosis, and from the outer surface of the femur. The last fibres of the muscle take their origin from that portion of the linea aspera which runs towards the external condyle of the femur.

The mass thus formed is at first separated from the crureus by a thin layer of cellular tissue, which extends but a short way, and the two muscles proceed downwards as one, to terminate in the common tendon.

VASTUS INTERNUS.—Separated above from the crureus by cellular tissue and blood-vessels. It is shorter and smaller than the preceding muscle, and is attached to the anterior and inferior part of the smaller trochanter and to the inner lip of the linea aspera; also from the inner surface of the femur,* and from the upper two thirds of the ridge which descends from the linea aspera to the inner condyle. The fleshy fibres descend inward and forwards, forming one with the crureus.

* There exists here a long and narrow strip of the bone to which no muscular fibres are attached.

Fig. 138.*

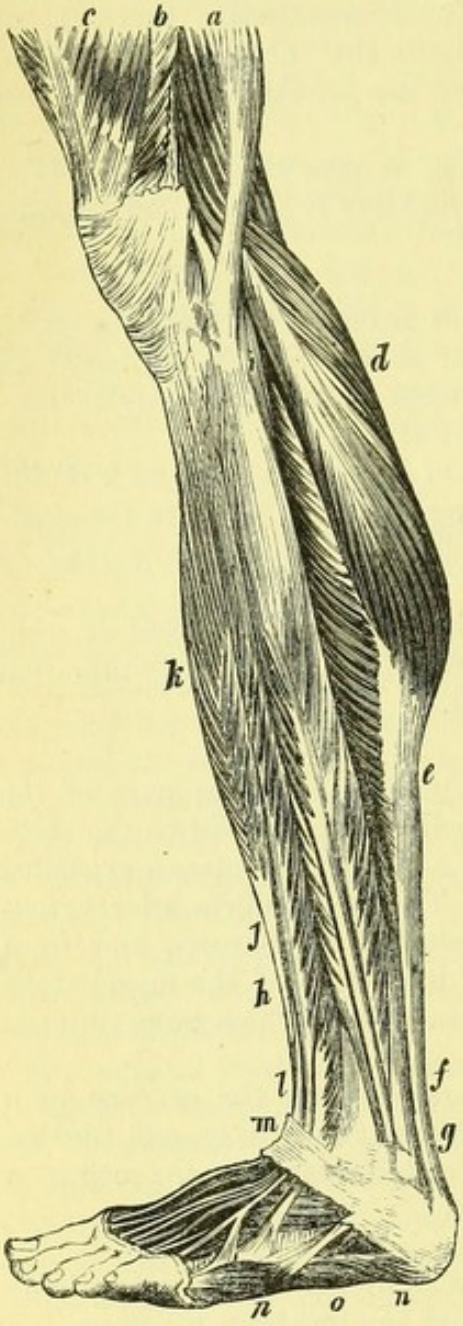

Fig. 139.†

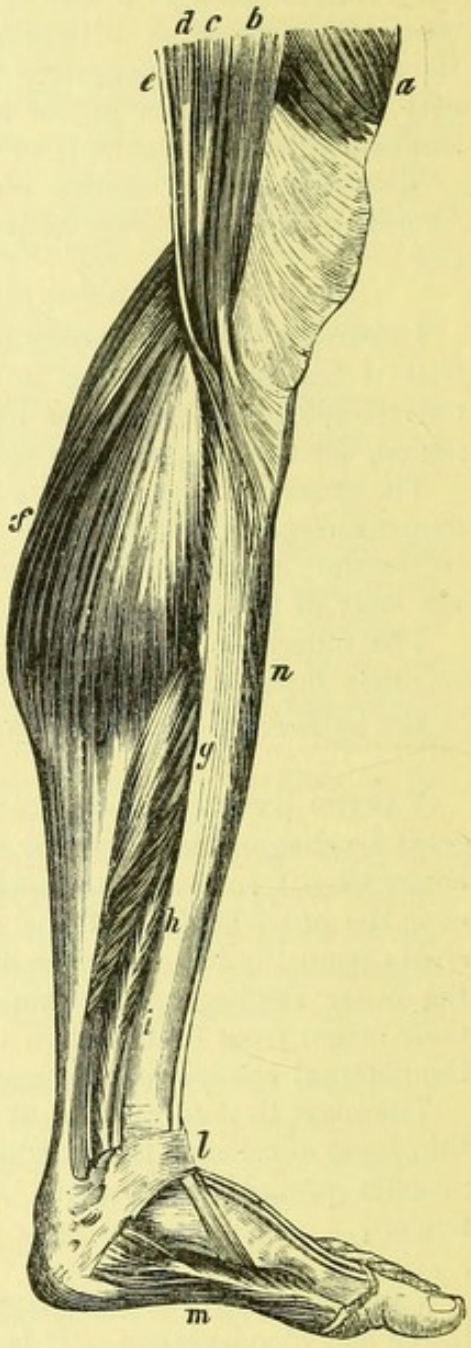

* Fig. 138.—Left leg, external side.—*a*, biceps; *b*, *c*, vastus externus; *d*, *e*, *f*, *g*, gastrocnemius and tendo Achillis; *k*, *i*, *h*, *l*, point to the tibialis anticus, extensor proprius pollicis, extensor communis, peroneus tertius, and peroneus brevis, seen in succession, commencing at the crest of the tibia, and proceeding outwards to the fibula; *p*, *o*, *n*, external side of the foot and portion of the abductor minimi digiti.

† Fig. 139.—Muscles of the left leg, inner side.—*a*, vastus internus; *b*, *c*, *d*, *e*, muscles of the inner hamstrings; *f*, gastrocnemius, inner head; *g*, *h*, *i*, inner surface of the tibia; *n*, tibialis anticus; *l*, anterior annular ligament; *m*, muscles in the sole of the foot; abductor pollicis.

TERMINATION OF THESE THREE MUSCLES.

The vasti and the crureus, being, inferiorly, but one muscle, at last form a tendon inferiorly, which soon unites inseparably with the tendon of the rectus. The united tendon is inserted into the base of the patella (sending fibres, however, over it), sending off lateral expansions, which embrace that bone, and are ultimately attached to the tuberosities of the tibia, along with portions of the fascia lata. The united action of all the four muscles is to extend the leg on the thigh.

Beneath the tendon of the crureus is an extensive bursa, which, though sometimes distinct, more generally opens into the synovial capsule of the joint.

SUB-CRUREUS.—Beneath the crureus there arise, from the anterior surface of the shaft of the femur, several distinct fleshy fasciculi, which, descending over the synovial capsule of the knee-joint, terminate on its outer surface. The use of these muscular fasciculi has not been determined.

OF THE GRACILIS.—*Origin.*—From the anterior surface of the body of the pubes, close to the symphysis, from the ramus of that bone and of the ischium. The French call it rectus internus, which expresses its straight course. It terminates by a slender round tendon, which, uniting inferiorly with the tendon of the semi-tendinosus, is attached to the tibia behind that of the sartorius.

It is a superficial muscle, and an adductor.

OF THE PECTINEUS.—The surgical relations of this muscle are important. It is easily dissected, but occasionally care is required to distinguish it from the adductor longus, with which at times it is inseparably connected at its origin. When the pectineus is small, the head of the adductor longus is broader and larger than usual, and *vice versâ*, the deficiency in the one being made up for by the increased strength of the other.

The pectineus, called by the older anatomists musculus lividus, arises, by extremely short aponeuroses, from the upper edge of the pubes, between the spine of the bone and the eminentia ileo-pectinea, and immediately outside the crest, to a portion of which the ligament of Gimbernat is attached. Thence it descends obliquely, and is attached inferiorly by a flat tendon to the ridge which descends from the trochanter minor to the linea aspera, immediately beneath the insertion of the psoas magnus and iliacus.

Anteriorly covered by the femoral aponeurosis, crural vessels, and nerves; *posteriorly* it lies on the horizontal ramus of the pubes, the hip-joint, the obturator externus and adductor brevis muscles; also, on the obturator vessels and nerve. The inner edge is a little covered by the adductor longus; the outer runs parallel with the psoas.

It is an adductor.

OF THE ADDUCTORS.

ADDUCTOR LONGUS.—This muscle, which has been already alluded to, is the first of the adductors met with in the dissection of the thigh.

Fig. 140.*

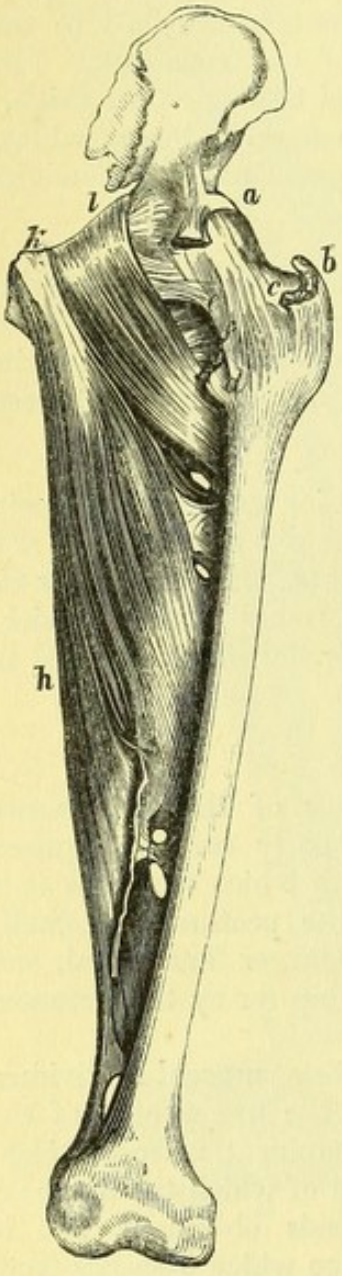

Origin.—By a narrow but strong tendon from the spine or tubercle, from the anterior surface, and from the symphysis of the pubes.

From this commencement, easily made out in the living body, the muscle descends outwards and backwards, becoming at first broader and thicker, but afterwards terminating in a thin, flat tendon, attached to the middle part of the interstice of the linea aspera, over a space of about 3 inches, and between the vastus internus and adductor magnus.

The sartorius and crural artery and vein lie upon the anterior surface of the muscle. The name describes its action, but, although called "*longus*," it is not the longest of the adductors.

ADDUCTOR BREVIS.—*Dissection.*—Detach the ad. longus, gracilis, and pectineus from the pubes, and clean carefully the surface of the muscle.

Arises from almost the whole space which separates the symphysis of the pubes from the obturator foramen.

Attached for a space of about 3 inches (to the middle part of the linea aspera) from the small trochanter downwards.

It is an adductor of the thigh.

ADDUCTOR MAGNUS. — This muscle should be examined on both sides; to be seen clearly, the preceding muscles must be detached from their origins and reflected.

It commences by a broad and thick tendon attached to the base of the tuberosity of the ischium, and, by short aponeuroses, from the ramus of the same bone. The fleshy fibres from these origins spread out like

* Fig. 140.—Deep dissection of the muscles of the thigh, left side.—*a*, tendinous origin of the rectus; *l*, pectineus; *k*, adductor longus; *h*, adductor magnus; *b*, tendinous attachment of the gluteus medius; *c*, *e*, *f*, capsular ligament; a portion of the obturator externus is seen here; *d*, attachment of the iliacus and psoas magnus to the smaller trochanter.

Fig. 140 *a*.*

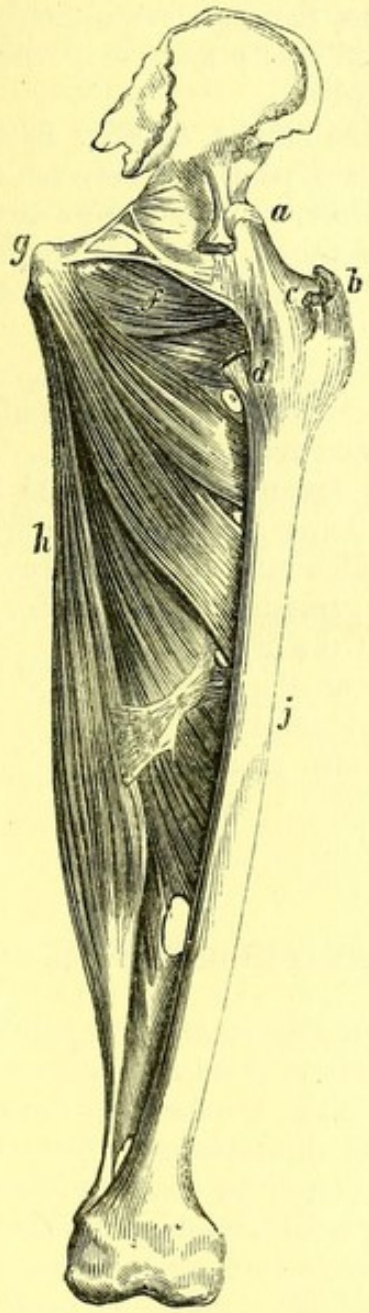

Fig. 140 *b*.†

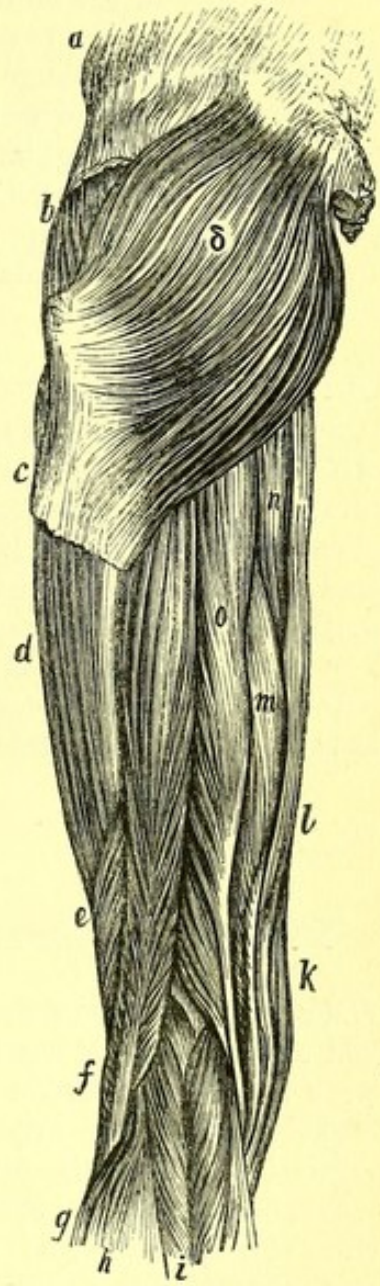

* Fig. 140 *a*.—Intended to show the precise form and attachments of the adductor magnus muscle, left side.—*a*, bifurcated tendon of the rectus, the muscle having been removed; *b*, trochanter major; *c*, capsular ligament of the hip-joint; *d*, trochanter minor; *f*, obturator externus; *g*, symphysis and crest of the pubes. The pectineus has been removed to show *h*, the three adductors; *i*, shaft of the femur.

† Fig. 140 *b*.—Muscles of the posterior region of the haunch and thigh.—*a*, external abdominal oblique; *b*, portion of the gluteus medius; δ, gluteus maximus; *c*, attachment of this muscle to the aponeurosis, which has been cut through and removed; *d*, vastus externus; *e*, *f*, biceps flexor cruris; *o*, semi-membranosus; *m*, semi-tendinosus; *n*, *l*, *k*, gracilis and sartorius; *g*, *h*, *i*, heads of the gastrocnemii muscles.

a fan, and terminate, 1st, in the linea aspera of the femur, from the great trochanter downwards to its termination at the edge of the slight groove against which rest the femoral artery and vein; 2d, the lower portion of the muscle terminates in a tendon which is attached to the inner tuberosity of the femur. Between these two portions a triangular space is left for the passage of the femoral artery and vein, which, on passing through, change their name to popliteal.

The adductor just described is one of the largest muscles in the body. It is of a triangular shape, and forms a partition between the extensors and adductors on the front of the limb, and the flexors on its opposite surface. Its upper part often resembles a muscle distinct from the lower; a cellular space divides its upper edge from the quadratus femoris.

OBTURATOR EXTERNUS.—This muscle can only be dissected after all those just described have been examined and removed.

Attached to the bony surface of the os innominatum around the obturator foramen, anteriorly, and from the inner part of the anterior surface of the ligament. Is inserted by a tendon into the digital cavity behind the trochanter beneath the inferior gemellus. The tendon is strongly attached to the capsular ligament of the hip-joint.

The obturator nerve and vessels pass over the upper edge of the muscle; the lower edge corresponds to the adductor magnus.

It is a rotator of the thigh outwards, and also an adductor.

MUSCLES OF THE LEG AND FOOT, ANTERIOR REGION.

Dissection.—Make an incision through the integument in the anterior region of the leg and dorsum of the foot, midway between both margins; a transverse incision above, and a second at the instep, from one side of the foot to the other, will enable the dissector to expose the superficial fascia of this region. Remove this fascia by incisions similar to the above, and the aponeurosis and anterior retinaculum of the tendons (anterior annular ligament) come next into view, extending from the crest of the tibia to the fibula, and enveloping the muscles now to be described. It also furnishes them with separate, but superficial sheaths.

Divide the aponeurosis by an incision carried from the knee to the extremity of the toes, leaving the annular ligament or retinaculum, and clean the subjacent muscles.

TIBIALIS ANTICUS.—Nearest to the crest and external surface of the tibia. *Arises* from the external tuberosity and upper half of the outer surface of the tibia, from the upper and fore part of the interosseous ligament, from the aponeurotic partition (a slip of the

crural aponeurosis) separating it from the extensor digitorum, and from the inner surface of the upper part of the aponeurosis of the leg.

Descending from these origins, it is attached by a strong tendon to the inner side of the internal cuneiform bone, and to the posterior extremity of the first metatarsal bone.

In passing under the annular ligament it is furnished with a sheath distinct from the other tendons, and a bursa protects it near its termination. Between it and the extensor proprius pollicis will be found, close to the interosseal ligament, the anterior tibial artery, veins, and nerve.

Action.—To bend the foot on the leg, and the leg on the foot.

EXTENSOR PROPRIUS POLLICIS.—The proper extensor of the great toe.

This muscle is situated between the tibialis anticus and extensor communis. It commences, superiorly, by attachments to the fore part of the inner surface of the fibula, over an extent of 5 or 6 inches, proceeding from the lower part of its upper third, and from the neighbouring region of the interosseous ligament.

The tendon in which this muscle terminates, after passing in a particular groove or sheath furnished it by the retinaculum, is attached to the last phalanx of the great toe.

As might be anticipated, the tendon is provided with a synovial bursa, whilst passing under the retinaculum.

Its name denotes its use.

EXTENSOR LONGUS COMMUNIS DIGITORUM PEDIS.—External to the preceding.

Arises from the external tuberosity of the tibia, between the tibialis anticus and peroneus longus, from the two aponeurotic partitions which separate it from these muscles, from the anterior ligament of the superior tibio-peroneal articulation, from the interosseous ligament, from the inner surface of the aponeurosis of the leg, and, lastly (its principal origin), from the fore part of the fibula, over a space of 5 or 6 inches.

Thus originating, the muscle descends towards the dorsum of the foot, and, prior to passing under the annular ligament, subdivides into three contiguous portions. These pass under the ligament in a groove, common, also, to the peroneus tertius, when that muscle is present. Soon after passing, the inner portion subdivides, and thus four tendons are formed, which, passing over the extensor brevis, are inserted into the last phalanges of the four outer toes, in precisely the same manner as are the tendons of the extensor of the fingers.

These tendons, strengthened by prolongations of the tendons of the lumbricales and interossei, form a kind of aponeurotic covering to the upper surface of the toes.

PERONEUS TERTIUS, OR ALTER.—This muscle has been unhappily named peroneal. It is an adjunct merely, when present, of the extensor communis. It arises from the lower third of the fore part of the fibula, and, after passing under the annular ligament along with the tendons of the extensor communis, is attached to the outer edge of the posterior extremity of the 5th metatarsal bone.

It has the same action as the peroneal muscles, and in this respect resembles them.

DORSAL REGION OF THE FOOT.

EXTENSOR BREVIS COMMUNIS.—On the back of the foot there is, properly speaking, but one muscle, the extensor brevis digitorum pedis. To expose it, cut through all the tendons of the muscles just described, removing also the aponeurosis.

Fig. 141.*

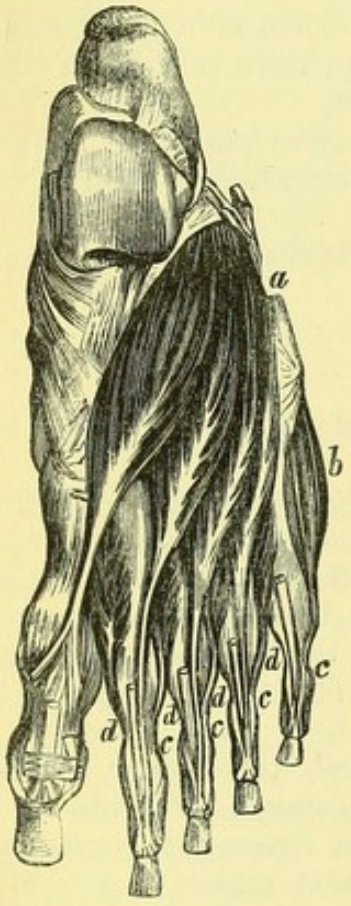

Origin.—From the upper surface of the calcaneum before the groove for the tendon of the peroneus brevis, from the external ligament of the calcaneum and astragalus, and from the retinaculum or annular ligament. Proceeding forwards it soon divides into four portions, each of which terminates by a thin and flat tendon, which passing under those of the extensor longus, proceeds to the dorsum of the toes. The first is attached to the upper part of the posterior extremity of the first phalanx of the great toe; the others, after passing over the first phalanges of the 2d, 3d, and 4th toes, join the outer edge of the tendons of the extensor longus muscle.

EXTERNAL OR DORSAL INTEROSSEI.—These muscles occupy the spaces between the metatarsal bones. The first is the largest and most important; it is attached to the whole of the inner side of the 2d metatarsal bone, and to a part of the outer side of the 1st; an interval separates these origins, through which passes the terminating branch of the anterior tibial artery (*arteria pediosa*). The tendon in which they terminate is partly inserted into the inner side of the base of the first phalanx of the second toe, and partly into the corresponding extensor tendon.

* Fig. 141.—Deep dissection of the dorsum of the foot.—*a*, extensor brevis communis; *b*, abductor minimi digiti; *d*, *d*, *c*, *c*, tendinous attachments of the dorsal and plantar interosseal muscles.

The second arises from the whole of the outer side of the second metatarsal bone, and from the upper part of the inner side of the third. It terminates by a tendon which has the same insertion on the outer side of the second toe as the 1st interosseal on the inner.

The third has its origin from the whole outer side of the 3d metatarsal bone, and from the upper part of the inner side of the 4th, and from the ligaments by which they are united, terminating by a tendon similar to the preceding, in connexion with the 3d toe.

The fourth arises from the inner edge of the 5th metatarsal bone, and from the whole outer surface of the 4th; it terminates in the outer side of the 4th toe.

Their uses are not well understood.

PERONEAL REGION.

In this region of the leg there are two muscles, the peroneus longus and brevis. The former cannot be fully dissected and examined until after the muscles of the sole of the foot have been examined and removed.

PERONEUS LONGUS.—*Arises* from the upper part of the aponeurosis of the leg, the upper third of the outer surface of the fibula, a small part of the tibia, two aponeurotic partitions placed between it and the soleus and flexor longus pollicis on the one hand and the extensor communis digitorum pedis on the other. The tendon in which it terminates runs along the fibula behind the malleolus externus, in a groove provided for it; bound down along with the tendon of the peroneus brevis by the retinaculum placed over them, and further secured by a vaginiform bursa, protecting them from injury by friction.

Beneath the malleolus it quits the other tendon and passes into a groove on the outer surface of the calcaneum, where it is again kept down by a special retinaculum, but lined by the same synovial bursa, which extends towards the os cuboides. The tendon next turns over that bone lodged in the deep groove it presents, bound down by another retinaculum and protected by a synovial bursa. Passing from this point forwards and inwards, it is inserted into the lower and outer part of the posterior extremity of the 1st metatarsal bone.

Whilst in the groove of the os cuboides, a sesamoid bone is often found in the substance of the tendon, and it is probable that a fibro-cartilage always exists whether the bone be present or not.

The relations of the muscle are easily understood. Its terminating tendon is situated above all the other soft parts in the sole of the foot, and can only be seen after these have been dissected and removed.

Use.—To extend the foot on the leg, raising its outer edge. It also acts upon the leg.

PERONEUS BREVIS.—Resembles in many points the preceding, but is shorter. It arises from the lower half of the outer surface of the fibula, and from two aponeurotic partitions separating it anteriorly

from the extensor communis and peroneus tertius when present, and posteriorly from the flexor longus digitorum. The tendon in which it terminates passes under the retinaculum along with the tendon of the peroneus longus, but, separating from it, passes above it over the outer surface of the calcaneum, and is inserted finally into the posterior extremity of the 5th metatarsal bone. It frequently sends a prolongation to the extensor tendon of the little toe.

Action.—Similar to the peroneus longus.

POSTERIOR AND SUPERFICIAL REGION OF THE LEG.

PLANTAR REGION OF THE FOOT.—The muscles occupying these two regions must be dissected together. Place the limb on its anterior surface and make an incision through the integuments merely, in the middle of the limb, commencing in the popliteal space and terminating at the extremity of the middle toe. Two or more transverse incisions will enable the student, by raising up the integuments, to expose the superficial fascia throughout the whole of this extent.

In the superficial fascia of the back of the leg the student will meet with the posterior saphena vein and some remarkable nervous filaments; also the popliteal bursa. Next remove the superficial fascia and expose the aponeurosis. This is naturally divided into two parts; that belonging to the leg and the plantar fascia. The first not only gives a general covering to the muscles of this region, but transmits a layer between the two sets of muscles, the superficial and the deep. This will be best seen during the course of the dissection.

In the foot, the plantar fascia, as it is called, is of great strength, shutting in all the muscles, and furnishing partitions penetrating deeply to the bones themselves.

Remove both cautiously by an incision carried through their structure, and following the direction of the incisions made through the integuments and superficial fascia. The first muscles met with are the gastrocnemius or gemellus and soleus.

These muscles have been occasionally viewed as three, sometimes as two muscles; they are essentially one, constituting a triceps extensor of the foot. The division called gastrocnemius arises by two heads, of which the inner is the longer. These are attached superiorly to the back part of the femur, immediately above the condyles, and close to the synovial capsule of the knee-joint. These two heads unite inferiorly, and terminate in a broad and thin tendon, which proceeding downwards becomes incorporated with the tendon of the portion called soleus.

The origins just described contribute to form the boundaries of the popliteal space.

SOLEUS.—Detach cautiously the heads of the preceding muscle, dividing them a short way from the bone; on reflecting the mass of the gastrocnemius, the plantaris, when present, is the first muscle met with, next the soleus; attend first to the soleus.

Arising by three distinct aponeuroses; the 1st, broad and thin, is attached to the upper extremity of the fibula; the 2d is a fibrous arch, stretched across the popliteal vessels and nerves, uniting the preceding origin to the 3d, and thus passing from the fibula to the tibia. The 3d origin is in the posterior oblique line of the tibia and the middle third of the inner edge of that bone.

From these origins the fleshy fibres descend, ultimately forming a broad aponeurosis, uniting with that of the gastrocnemius. From these proceeds the strong tendon called tendo Achillis, by means of which the three portions of muscle just described are strongly attached to the lower portion of the tuberosity of the calcaneum.

A small bursa protects the anterior surface of the lower part of the tendon, as it slides over the superior portion of the tuberosity of the os calcis. The deep layer of the aponeurosis separates the soleus from the deeper layer of muscles.

The united muscle extends the foot upon the leg and the leg on the foot. It is the great instrument of progression.

Before detaching the soleus examine the plantaris and popliteus.

PLANTARIS MUSCLE.—This muscle, which is not always present, arises by a small tendon from above the outer condyle of the femur, from the posterior ligament of the knee-joint, and from the tendon of the outer head of the gastrocnemius muscle. It next descends obliquely inwards to terminate by a tendon of remarkable length. By means of this tendon the muscle is attached inferiorly, partly to the calcaneum and partly to the plantar aponeurosis. The muscle crosses the limb diagonally from the outer to the inner side, so that its tendon will be found adhering to the inner side of the tendo Achillis, and not unfrequently escapes notice from that circumstance.

An imperfectly developed bursa is interposed between the middle of the tendon and the soleus and gastrocnemius.

It is probably in man merely a vestigiary or rudimentary muscle, more fully developed in some other animals. In man it is scarcely entitled to the name of plantar.

The POPLITEUS arises, by a thick and strong tendon, from the anterior part of a depression situated close to, and partly below, the tuberosity of the outer condyle of the femur, and beneath the attachment of the external lateral ligament of the knee-joint, the ligament serving to retain the tendon in its place.

Crossing the back of the joint, the muscle, now become broad and fleshy, though mingled with tendinous fibres, terminates by being attached to the posterior and superior triangular surface of the tibia, to the inner edge of that bone, and to a thin aponeurosis detached from the tendon of the semi-membranosus.

The anterior surface of the muscle lies close to the articulation; behind it lie the popliteal vessels and the posterior tibial nerve.

To this muscle has been ascribed the function of bending the leg on

the thigh, and the thigh on the leg, but it is manifest that it can perform no such function; for the tendon by which it is attached to the femur, being free, and lined by a prolongation of the synovial capsule of the joint, must be in motion, sliding over the edge of the condyle during all the time the leg is bending on the thigh, or the thigh on the leg. When the flexion has been completed, the popliteus, if then called into action, will simply rotate the knee-joint,—a remarkable function, and possible only when the flexion of the leg on the thigh has been carried as far as is possible.

Before dissecting the posterior and deep region of the leg, it will be found advantageous to dissect and examine the superficial muscles of the sole of the foot.

SOLE OF THE FOOT—FIRST LAYER OF MUSCLES.

Abductor Pollicis Pedis.—*Dissection.*—Remove the aponeurosis by an incision carried in the direction of the muscle, and clean the surface of the muscle, making out its edges distinctly.

Fig. 142.*

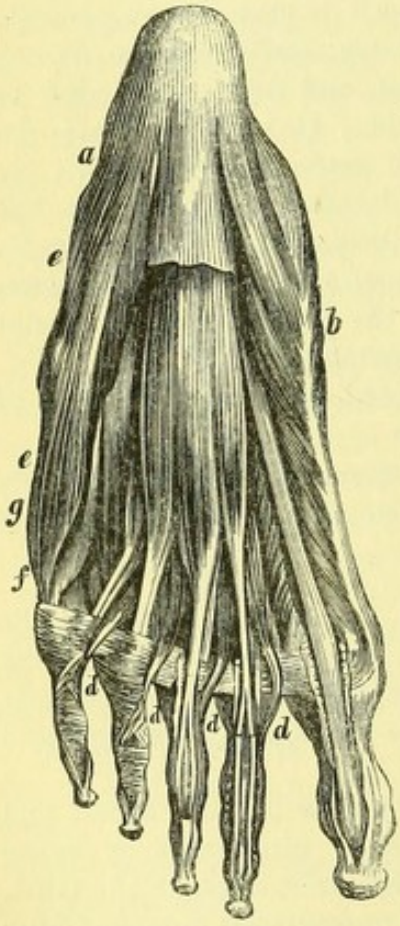

Fig. 143.†

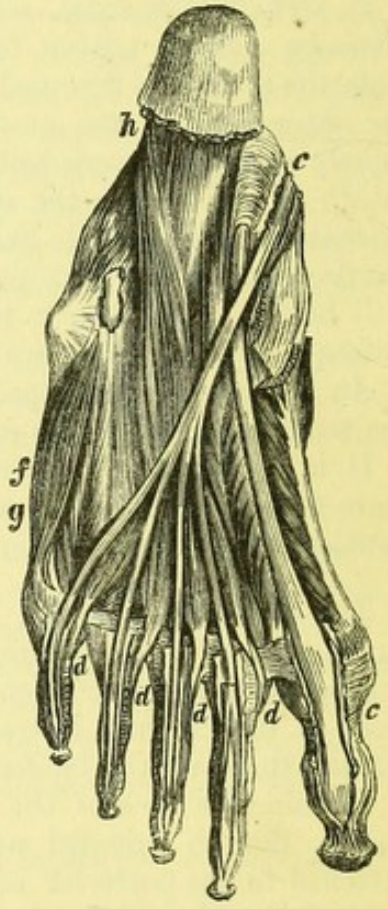

* Fig. 142.—*a*, tendinous commencement of the abductor minimi digiti; *b*, adductor or abductor pollicis pedis; *d*, *d*, tendons of the interosseal muscles; *e*, *e*, *g*, *f*, point to the course of the abductor minimi digiti.

† Fig. 143.—*c*, flexor longus digitorum; *h*, flexor accessorius; *e*, flexor longus pollicis; *f*, *g*, flexor brevis minimi digiti; *d*, *d*, tendons of the plantar interosseal.

Arises from the posterior, internal, and inferior part of the calcaneum, from the aponeurotic partition separating it from the flexor brevis communis, from the internal annular ligament or retinaculum, and from the deep surface of the plantar aponeurosis.

Proceeding forwards, on the inner side of the foot, to be attached by a tendon to the lower and inner part of the base of the first phalanx of the great toe, adhering strongly to the ligament by which it is connected to the first metatarsal bone.

It carries the great toe inwards, or adducts it towards the middle plane of the body.

FLEXOR BREVIS DIGITORUM PEDIS.—Occupies the centre of the sole of the foot, or middle plantar region.

Arises from the posterior and inferior part of the calcaneum, between the abductor pollicis and abductor minimi digiti, from which it is separated by aponeurotic partitions, portions of the plantar aponeurosis. From these partitions, and from the upper surface of the plantar aponeurosis, many fibres also originate.

Proceeding directly forwards in the middle plantar region, the muscle divides into four distinct bundles, each terminated by a tendon.

These tendons advance beneath the heads of the metatarsal bones, passing between the slips of the aponeurosis. They then split, as in the corresponding muscle of the hand, become enclosed in the fibrous sheath on the plantar side of the toes, and, finally, terminate by being attached by two slips upon the sides of the second phalanx of each of the last four toes.

It bends the second phalanges of the toes upon the first, and these upon the metatarsal bones.

ABDUCTOR MINIMI DIGITI PEDIS.—Occupying the external plantar region. Attached, posteriorly, to the outer surface of the calcaneum, to a fibrous partition separating it from the flexor perforatus, to the plantar aponeurosis, and to the posterior extremity of the fifth metatarsal bone, by a tendon continuous with the aponeurosis itself.

It terminates by a tendon, which is inserted into the outside of the corresponding extremity of the first phalanx of the little toe.

Use.—To abduct the little toe from the others.

Detach these three muscles cautiously from their origins, but without wholly removing them, so that they may be replaced at will, and return to the dissection of the

DEEP MUSCLES OF THE POSTERIOR REGION OF THE LEG.

FLEXOR PERFORANS.—This muscle is the common flexor of the toes; the term "perforans" expressing that circumstance in its structure by which it is best characterized.

Arises from the posterior surface of the tibia, extending from its

upper oblique line to its lower fourth, and from an aponeurotic partition common to it with the tibialis posticus and flexor longus pollicis, these being the three muscles composing the deeper layer in this region. After forming a tendon, it passes behind the malleolus internus, in a groove or sheath completed by a strong retinaculum, and lined by a synovial capsule.

Under the same retinaculum, and invested in like manner with a synovial bursa, runs the tendon of the tibialis posticus, separated, however, from the one we now describe by a fibrous partition.

Open the sheath to examine these facts, and the relative position of the tendons. Now trace the tendon into the sole of the foot, the superficial layer of muscles in that region having been dissected and reflected for that purpose.

The tendon crosses the tendon of the flexor longus pollicis passing beneath it, generally receiving from it a slip of tendon more or less strong. The tendon thus strengthened divides into four, and receives at this point the fibres of the "massa carnea," or accessory muscle.

ACCESSORY MUSCLE.—This is an accessory or appendage of the flexor longus communis, and ought to be described, not as a distinct muscle of the foot, but as a portion of the flexor longus. It has been added to it, seemingly, to correct the obliquity in action of the flexor communis.

This small muscle arises, by two distinct bundles, from the lower and inner surface of the calcaneum, and is attached to the outer and upper part of the tendon of the flexor longus, near to the point where it divides.

In action it corrects the obliquity of the long flexor.

The tendons of the long flexor thus strengthened proceed forwards towards the roots of the toes, where, being enclosed in the fibrous sheath common to them and to the short common flexor, they, after passing through the tendons of the latter, terminate by being attached to the last phalanges of the four smaller toes.

Whilst passing through the sole of the foot, the tendons now described give attachment to four small muscles, which may also be deemed appendages of the flexor perforans; they are called lumbricales, and ought to be described along with the flexors.

LUMBRICALES.—Four in number. The first is the longest and largest. It arises from the inner edge and upper surface of the flexor tendon of the second toe; the other three arise from the interval which the four tendons of the flexor leave between them at their separation. They terminate each by a tendon, which is at length attached to the inner and lower part of the base of the first phalanx of each of the last four toes. As in the hand, they send a thin aponeurosis to the extensor tendons of each of these toes.

Their precise functions are not well understood.

FLEXOR LONGUS POLLICIS PEDIS.—This muscle *arises* from the lower two-thirds of the posterior surface of the fibula, from the interosseous ligament, and from two aponeurotic partitions which separate it from the flexor perforans and tibialis posticus. It descends vertically behind the fibula, forming a strong tendon, which, becoming nearly horizontal, enters a groove formed behind the inferior extremity of the tibia and the posterior surface of the astragalus. A strong fibrous retinaculum binds it down there, and a synovial bursa protects the tendon from the effects of friction. The tendon next passes under the arch of the calcaneum in a particular depression, enters the sole of the foot, crosses the tendon of the flexor perforans, passing above it, divides into two slips, of which one proceeds to join the tendon of the flexor, the other, placing itself between the heads of the flexor brevis pollicis, passes between, but also below, the sesamoid bones, and terminates finally in the last phalanx of the great toe. The fibrous sheath, synovial capsule, relation to the sesamoid bones and to the flexor brevis, resemble, in most points, what has been already minutely described in reference to the anatomy of the hand.

Its union, by means of a tendon, with the flexor perforans, explains why the power of the muscle is not lost, even after the loss of the great toe.

TIBIALIS POSTICUS.—Bifurcated at its upper part. Through the opening resulting from this bifurcation the anterior tibial vessels pass to the anterior surface of the interosseous ligament, which is also deficient at this point.

Arises from the inner and back part of the fibula by one portion; by the other from the oblique line of the tibia, and from the interosseous ligament. The muscle descends at first nearly vertically, afterwards somewhat inwards. It here receives fibres from the aponeurotic partition separating it from the flexor perforans and flexor proprius pollicis.

The tendon in which it terminates passes in the groove behind the malleolus internus, bound down by the retinaculum, and protected by a synovial bursa in the same manner as has been already described with reference to the flexor communis.

The tendon is finally attached to the lower and inner part of the os scaphoides and by a prolongation into the base of the internal cuneiform bone.

Action.—The antagonist of the peronei muscles. It raises upwards the inner side of the foot.

The remaining muscles belong exclusively to the sole of the foot. They are, 1, the flexor brevis pollicis; 2, adductor pollicis; 3, transversus pedis; they form a group. The adductor minimi digiti and flexor brevis minimi digiti constitute a second; the plantar interossei a third.

1. FLEXOR BREVIS POLLICIS PEDIS.—*Arises* from the anterior

and inferior part of the calcaneum, and from the last two cuneiform bones and their ligaments. An aponeurotic partition separates it from the abductor pollicis. The fleshy mass thus resulting presents a groove inferiorly, in which is lodged the tendon of the flexor longus pollicis. It divides anteriorly into two portions; the inner unites with the tendon of the abductor pollicis, and terminates along with it at the first phalanx of the great toe, besides being attached to the inner sesamoid bone of the articulation. The outer, which is thinner, is confounded with the adductor pollicis (called by some the oblique abductor), and is inserted along with it into the lower and outer part of the base of the first phalanx of the great toe, and into the corresponding sesamoid bone.

Its name sufficiently expresses its functions.

Fig. 144.*

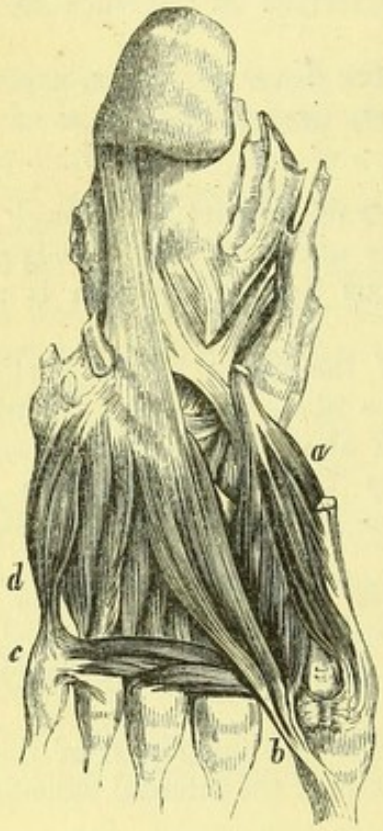

Fig. 145.†

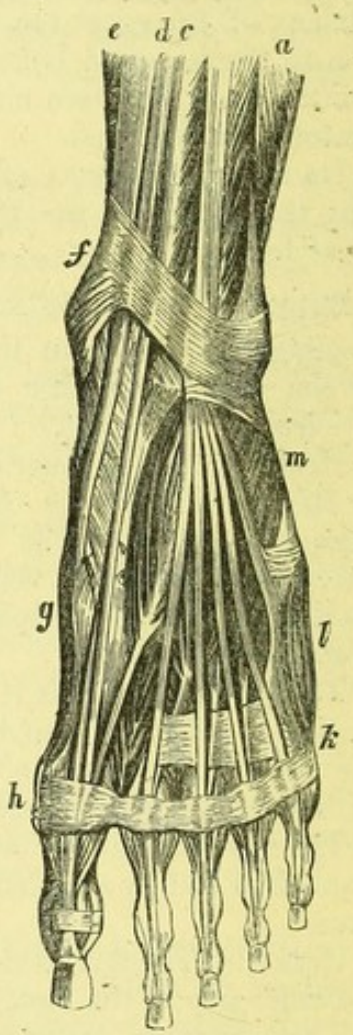

* Fig. 144.—*a*, flexor brevis pollicis; *b*, tendon of the adductor pollicis (oblique); *c*, transversus pedis; *d*, flexor brevis minimi digiti.

† Fig. 145.—Dorsum of the foot, left side.—*a*, peroneus; *d*, tibialis anticus; *e*, extensor pollicis; *g*, *h*, small portion of the abductor pollicis; *m*, origin of the extensor brevis; *h*, aponeurotic sheaths binding down the extensor tendons; *l*, *k*, a portion of the abductor minimi digiti.

2. ADDUCTOR POLLICIS (by some called the Oblique Abductor).—It arises from the inferior surface of the os cuboides, from the ligamentous sheath of the peroneus longus, and from the posterior extremity of the 3d and 4th metatarsal bones, as well as from the ligaments by which they are connected. Confounded with the outer edge of the preceding muscle, and a little further on with the transversus pedis, it is attached along with them to the outer and under part of the first phalanx of the great toe and to the outer sesamoid bone.

3. TRANSVERSUS PEDIS (called by some the Transverse Abductor).—This muscle, peculiar to the foot, arises by distinct fasciculated aponeurotic fibres from the ligaments of the last four metatarso-phalangeal articulations; the four slips thus originating unite together to be attached along with the abductor pollicis to the outer edge of the base of the first phalanx of the great toe.

It contributes to strengthen the articulations and to keep the metatarsal bones together.

The second group of muscles which remains to be described comprise, 1, the abductor minimi digiti, and 2, the flexor brevis minimi digiti. Of these the first has been already described.

2. FLEXOR BREVIS MINIMI DIGITI.—*Arises* from the under part of the proximate end of the 5th metatarsal bone and from the ligamentous sheath of the tendon of the peroneus longus.

Inserted into the lower and outer part of the base of the 1st phalanx of the little toe.

Use.—To bend the first phalanx of this toe.

OF THE PLANTAR INTEROSSEI.

Three in number. The 1st arises from the lower two-thirds of the whole of the inner surface of the 3d metatarsal bone and from the adjoining ligaments. Inserted at the inner side of the third toe.

The second plantar interosseal muscle arises from the lower part of the inner surface of the 4th metatarsal bone and from the adjoining ligaments; its tendon is attached to the inner side of the 4th toe.

The third of these interosseal muscles arises partly from the fibrous sheath of the peroneus longus, and partly from the inferior two-thirds of the inner surface of the 5th metatarsal bone, and terminates by a tendon on the inner surface of the 5th toe.

On completing the dissection of the muscles of the sole of the foot, the student will have an opportunity of tracing the remarkable course of the tendon of the peroneus longus, its fibrous sheath and synovial bursa, and its termination in the metatarsal bone of the great toe.

MUSCLES OF THE HEAD AND NECK.

MUSCLES OF THE CRANIUM—EPICRANIAL APONEUROSIS.

Dissection.—The dissection of the head and neck is generally considered to be the most difficult in the body. This opinion is borne out by the number of the muscles found in these regions, the important organs connected with them, the great number and complexity of the arteries, veins, and nerves; lastly, the presence of the cavity of the cranium and its contents, and of the cervical portion of the medulla spinalis. For these reasons it is, in general, the region last examined by the student, preparatory to his engaging in the dissection of the cerebro-spinal axis and nervous system: with these he completes his anatomical studies.

Fig. 146.*

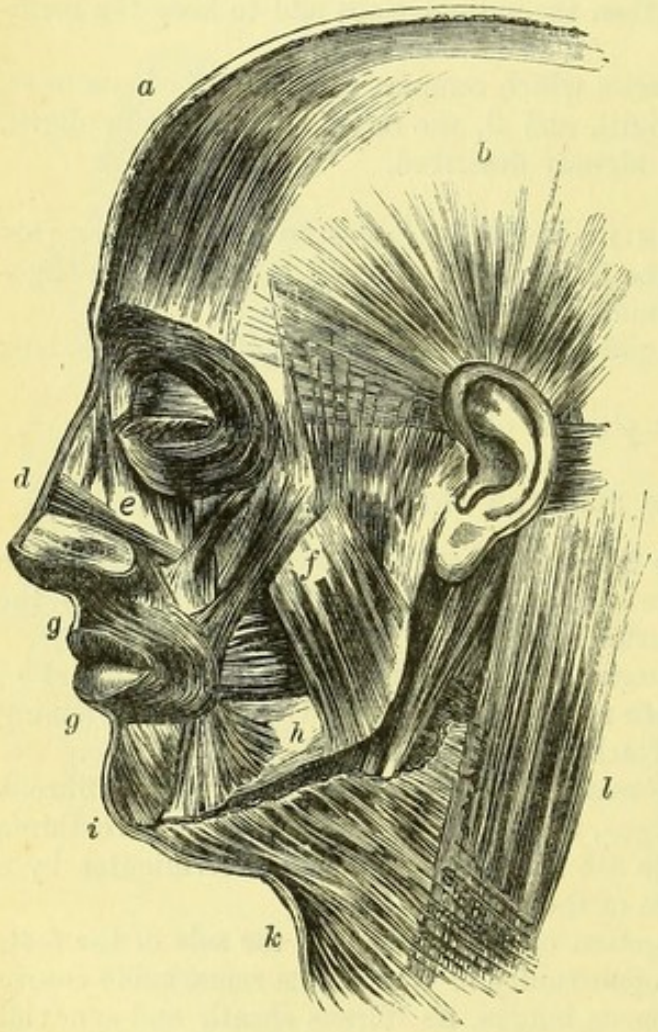

In his first, perhaps even in his second dissection, it were better that he confine himself strictly to the muscles and larger organs, such as the parotid, thyroid gland, &c.; this will enable him to study with advantage, afterwards, the arteries and nerves; and by these repeated examinations he will become master of the surgical anatomy of these regions.

Begin with the soft parts situated over the calvarium.

The hair having been closely removed, make an incision through the integuments merely, commencing at the external occipital protuberance and terminating at the extremity of the nose, carrying it along the dorsum; a second incision, between the extremity of the first and

* Fig 146.—*a*, the frontalis muscle; *b*, attollens auriculam; *c* points to the orbicularis palpebrarum; *d*, compressor nasi; *e*, levator communis; *f*, masseter; *g*, *g*, orbicularis oris; *h*, depressor anguli oris; *i*, quadratus, or depressor labii inferioris; *k*, latissimus colli; *l*, outline of the sterno-cleido-mastoideus.

the back part of the cartilage of the ear; a third incision, from the vertex or top of the head to the root of the zygomatic arch; and a fourth, from the root of the nose along the superciliary ridges, in a semicircular direction towards the external angular process of the frontal bone, and a short way above the eyebrow. The greatest care must be used in dissecting off these flaps of integument; the cellular substance connecting them to the subjacent muscles and tendons being extremely dense, close, and granular, similar in some respects to what is found over the palmar and plantar aponeuroses. Having removed the integuments carefully, the student will find them of great thickness and extremely vascular, it being in this part of the body, more than in any other, that arteries of considerable magnitude approach the surface for the purpose of supplying the integuments; this is obviously caused by the peculiarities of the hairy scalp, and the necessity of an ample supply for the nourishment of the hair. The bulbs of the hair may be seen mostly in the subcutaneous cellular substance, and their presence, together with that of numerous sebaceous follicles, contributes, no doubt, to give to the hairy scalp its peculiarities both of structure and disease. That the hairy scalp moves either by the action of its own muscles or by the hand, is dependent on the looseness of a cellular tissue between the epicranial aponeurosis and the pericranium; thus the epicranial muscles and aponeurosis move along with the hairy scalp. Now proceed to clean the following muscles:—

Occipito-Frontalis.—Although this muscle is usually described as one, it is in fact composed of four, viz. two occipital and two frontal, with a common central aponeurosis—the epicranial aponeurosis; the whole might with propriety be called the musculus epicranius. Clean the muscles, as usual in the direction of their fibres, and commence with the occipital portion. The occipitalis is situated at the posterior part of the cranium, behind the mastoid process, and above the upper curved line of the occipital bone; it is attached by short aponeurotic fibres to the outer part of that line, and to the neighbouring region of the temporal bone, above the splenius and sterno-cleido-mastoideus; it terminates above, after a short course, in the epicranial aponeurosis. The integuments and some nervous filaments cover it, together with a thin layer of the epicranial aponeurosis: beneath it we find a similar layer of the same part; secondly, the pericranium; and lastly, the occipital and temporal bones. Its action is to stretch the aponeuroses and to alternate with the frontalis muscle. Next clean the frontalis. This muscle covers the forehead: it is thin, square-shaped, adheres strongly to the skin; superiorly it terminates in the epicranial aponeurosis, inferiorly the fibres unite with the pyramidalis nasi, orbicularis palpebrarum, and corrugator supercilii; thus it is the antagonist of these muscles. It moves the scalp freely, and by its action produces the transverse wrinkles of the forehead; it is also enclosed by a thin sheath or splitting of the epicranial aponeurosis. The integuments cover it anteriorly; its deep

surface covers the supra-orbitar vessels and nerves. The *epicranial aponeurosis* is the broad tendinous expansion which connects these four muscles to each other; it adheres strongly to the scalp, but very loosely to the parts beneath it: anteriorly the frontal muscles are inserted into it; posteriorly, the occipital; laterally, the superior muscles of the ear: upon the temples it degenerates into common cellular membrane, and, becoming thinner and thinner, is lost upon the face. The six arteries supplying the scalp lie above it, together with the integuments; beneath it is a quantity of lax cellular substance containing no fat, and connecting it loosely to the pericranium and to the temporal aponeurosis; the fibres composing it are white and parallel posteriorly, but in other parts interwoven and indistinct; the intervals which occur between the bundles of its fibres contribute to render its dissection difficult; lastly, as we have seen, it furnishes thin sheaths for the muscles just described. The next muscles to be dissected are the extrinsic muscles of the ear, so named, as they proceed from other parts towards the ear itself.

The SUPERIOR AURIS, or *Attollens auriculam*, is situated on the temple, above the ear. Thin, membranous, and angular, attached by its summit to the fore and inner part of the fibro-cartilage of the ear, on the convexity which is formed by the upper part of the concha, it ascends thence, in a radiating manner, to the epicranial aponeurosis, where it terminates. The *outer* surface is covered by the skin, the *inner* covers the aponeurosis of the temporal muscle. Its action is to raise the ear.

ANTERIOR AURIS (*Prior auriculæ*) is of the same form as the preceding muscle, but less apparent, and is situated on the temple, before the ear. Its summit is attached to the fore part of the helix, and from this point its fibres proceed, to terminate on the outside of the epicranial aponeurosis, near the frontal muscle. Its external surface is covered by the skin; the *inner* is applied upon the temporal muscle and artery. Its *upper* edge is confounded with the preceding muscle, while the *lower* is lost in the cellular tissue above the zygomatic arch. It carries the ear forwards and upwards.

The POSTERIOR AURIS (*Musculi retrahentes auriculam*).—This muscle consists of one or more small bundles of fleshy fibres, thin, flat, or fusiform, rather irregular, and situated behind the ear; attached by short aponeuroses to the mastoid process, whence they proceed horizontally forwards to terminate at the lower part of the convexity formed by the concha of the ear by aponeurotic fibres or small tendons. They are covered by the integuments, and are separated from the temporal bone by cellular tissue. This muscle, which has no connexion with the epicranial aponeurosis, carries the ear backwards. To dissect this muscle, the student will require to draw the external ear forward

with hooks. The intrinsic muscles of the ear, viz. those which pass from one cartilage to another, will be described along with the organ of hearing, as being interesting only in a physiological point of view. The vessels and nerves, which supply the region of which we have just examined the muscles, are chiefly the temporal, posterior, auricular, and occipital arteries; the branches of these vessels proceed mostly to the hairy scalp; veins having the same names accompany them: the nerves are derived from the portio dura (7th), ophthalmic division of the 5th, and the occipital branches of the cervico-spinal nerves.

Removal of the brain and dissection of the face.—If the student be desirous of examining the brain of the subject he is dissecting, he must, at this stage of the dissection, take off the skull-cap, and in the usual way remove the brain. He will, however, in doing so, destroy the temporal muscle and its aponeuroses, which should therefore, if possible, be rapidly cleaned and examined. Having removed the brain, it ought to be preserved in alcohol of sufficient strength, until such time as he can return to its examination with advantage; he may now proceed with the dissection of the face.

Commence the dissection by an incision round either orbit; a *second* around the mouth, which cavity must be filled with baked hair or some such substance, and neatly stitched up; a *third* incision is to be carried from the angle of the mouth to the temple, and a *fourth* to the angle of the jaw. Remove cautiously the integuments from these surfaces, and commence by the dissection of the orbicularis palpebrarum.

MUSCLES OF THE FACE.

ORBICULARIS PALPEBRARUM.

Broad, thin, and circular; is slit transversely in the middle, for the aperture of the eyelids. It arises by three distinct points of origin: 1, from the ascending process of the superior maxillary bone and internal orbitar process of the frontal; 2, from the anterior edge of the lachrymal groove and the neighbouring part of the base of the orbit; 3, on the two sides and fore part of a small tendon (*tendo palpebrarum*) easily rendered distinct by stretching the eyelids outwards. This tendon connects both tarsal cartilages to the bone at the anterior edge of the lachrymal groove. Posteriorly the tendon adheres to a thin aponeurosis covering the lachrymal sac.

From these various origins the fleshy fibres proceed above and below, following the curve of the orbit, forming a layer of the eyelids, and spreading out upon the cheeks; they unite on the temporal region.*

All these fibres describe concentric circles.

The outer surface of the muscle is covered by the skin; posteriorly it is applied upon the corrugator supercilii, to which it adheres; lower

* At their junction I have only once seen a distinct tendinous raphe.

down, upon the ligamentum latum and fibro-cartilage of the upper eyelid; externally, upon the external angular process of the frontal bone and the temporal aponeurosis; below, upon the cheek-bone, the zygomatic muscles, the levatores labii superioris proprius and communis (from which it is separated by the facial vein), and upon the ligament and fibro-cartilage of the lower eyelid; internally, upon the ascending process of the superior maxillary bone and the lachrymal sac. The circular margin of the muscle is to a great extent free.

Action.—It acts especially on the eyelids; it is the antagonist of the levator palpebræ superioris.

The muscle called tensor tarsi might not inappropriately be viewed as an appendage or separate origin of the orbicularis. I have described it, however, as a muscle of the face, although it cannot be well seen until the roof of the orbit has been removed.

Corrugator Supercilii.—*Dissection.*—Remove the superior portion of the orbicularis cautiously from within outwards, and from below upwards, and thus expose the muscle.

This is a short and thin muscle, following in its curve the superciliary arch of the frontal bone on which it lies. Attached internally, towards the nasal prominence of the frontal, by one or more slips; externally it terminates in a pointed form, mingling its fibres with the frontal and orbicularis palpebrarum.

Relations.—*Anteriorly*, it is covered by these two muscles; *posteriorly*, it covers the frontal bone, superciliary artery, and frontal branch of the ophthalmic nerve.

Action.—To corrugate the eyebrows.

Tensor Tarsi.—*Dissection.*—Cut through both eyelids about the middle, and reflect the inner portion towards the nose. Dissect, from off the inner canthus, the mucous membrane of the eyeball; this done, and a little cellular membrane removed, the muscle is exposed.

It arises, broad, square, and fleshy, from the *os unguis*, near its junction with the orbitar plate of the ethmoid bone, and, after a curved course, divides into two fasciculi. These run along the edge of the tarsal cartilages until they are lost by uniting with the fibres of the orbicularis muscle.

Use.—The muscle is supposed to assist in bringing the puncta lachrymalia in close contact with the surface of the eyeball, and to compress the lachrymal sac. It more probably serves to strengthen the edges of the eyelids, and keep them in their place. When morbidly affected it may cause inversion of the eyelids.

Pyramidales Nasi.—Viewed by many anatomists as appendages of the frontal muscles. Single above, but bifurcated lower down; they terminate, after diverging, in a membranous tissue occupying the sides and dorsum of the nose. Externally, they are united with the orbiculares palpebrarum; superiorly, they cover the frontal bones.

Use.—They give to the frontales a fixed point, and contribute a little to the movements of the nose.

TRIANGULARIS NASI.—*Dissection.*—Raise up cautiously the inner edge of the levator communis: it ought not to be cut away at this stage of the dissection.

Thin, flat, and triangular. *Origin:* from the inner edge of the fossa canina (superior maxillary bone) by a short and narrow aponeurosis; from this the fleshy fibres diverge; they terminate in a thin aponeurotic expansion covering the dorsum of the nose, continuous with that of the opposite side. One of its portions is attached to the fibro-cartilage of the wing of the nose. *Anteriorly*, covered by the skin and levator communis: *posteriorly*, applied to the superior maxillary bone and lateral cartilage of the nose.

Use.—To dilate the nostrils.

LEVATOR LABII SUPERIORIS ALÆQUE NASI: LEVATOR COMMUNIS.—Cautiously remove the integument of this part of the face, raising up the lower margin of the orbicularis palpebrarum. Dissect from above downwards, in the course of the fibres.

Attached above to the outer surface of the ascending process of the superior maxillary bone, beneath the tendo oculi, to the anterior edge of the lachrymal groove, and lower part of the base of the orbit; *inferiorly*, to the integuments of the upper lip, and to the fibro-cartilage and integuments of the wing of the nostrils.

Anteriorly, it is covered by the skin, a portion of the orbicularis, and labial vein; *posteriorly*, it rests on the preceding muscle.

LEVATOR PROPRIUS (*L. labii superioris*).—Arises from the malar and upper maxillary bones, beneath the edge of the orbit, and over the infra-orbitar foramen; from this, descending somewhat inwards, it mingles inferiorly with the orbicularis oris and integuments of the upper lip.

Action.—To raise the upper lip.

LEVATOR ANGULI ORIS.—To display this muscle raise the outer edge of the preceding muscle; expose the infra-orbitar vessels and nerves, and remove these also; clean the muscle, by putting its fibres on the stretch.

Small and elongated. Attached superiorly to the bone beneath the infra-orbitar foramen; *inferiorly*, to the commissure of the lips, mingling its fibres with the orbicularis oris, zygomatic, buccinator, and even the depressor anguli oris.

Use.—To raise the angles of the mouth.

The *posterior* surface of the muscle covers the fossa canina, the mucous membrane of the mouth, and a portion of the buccinator.

ZYGOMATICUS MAJOR.—Attached superiorly to the outer surface of

the malar bone; inferiorly, to the commissure of the lips, mingling its fibres with the orbicularis oris, and with those of the muscles immediately preceding.

Occasionally, much fat separates the muscle anteriorly from the skin; posteriorly, it touches the buccinator and masseter muscles, or is at least in relation to them.

It acts principally in laughing.

ZYGOMATICUS MINOR.—Not always present. It lies anterior to the last-described muscle, which it resembles in its origin, course, and termination; occasionally, it looks as if detached from the orbicularis palpebrarum.

It has a similar action to the preceding muscle.

DEPRESSOR LABII SUPERIORIS ALÆQUE NASI.—To display this muscle, evert the upper lip, and remove the mucous membrane on either side the frenum.

Attached by a short aponeurosis, near the anterior nasal spine, to a small fossa on the surface of the superior maxillary bone. From this it ascends, to terminate partly in the posterior region of the cartilaginous wing of the nose, and partly by being confounded with the levator communis and orbicularis oris.

Action.—To depress the wing of the nose.

DEPRESSOR ANGULI ORIS (*Triangularis labiorum*).—The base of this muscle is attached to the outer surface of the lower jaw, between the masseter muscle and the anterior opening of the inferior dental canal. The fibres ascend, to terminate at the commissure of the lips, mingling with the zygomaticus, orbicularis, and levator anguli oris.

The name expresses its action.

DEPRESSOR LABII SUPERIORIS.—*Dissection.*—Detach the preceding muscle.

Origin.—From the external oblique line of the lower jaw-bone.

The muscle ascends to the lower lip, where its fibres mingle with the orbicularis oris. Its fibres unite intimately with those of the opposite side, and with those of the levator menti.

The posterior surface of the muscle is applied upon the lower jaw, the inferior dental nerves and vessels, and the orbicularis oris and levator menti.

LEVATOR LABII INFERIORIS, LEVATOR MENTI.—To display the muscle, evert the lower lip, and remove the mucous membrane.

Short, thick, and conical. It is attached by its summit to the fossa, which may be seen at the side of the symphysis of the chin, under the alveoli of the incisors. Its fibres diverge from this point, and are inserted into the skin of the chin, to which they strongly adhere.

The name expresses the action of these muscles. They have been supposed to be the cause of the dimples not unfrequently found on the surface of the chin, but this opinion is probably incorrect.

For the dissection and history of the parotid gland, see the chapter on the Digestive Organs.

MASSETER MUSCLE.— *Arises* from the two anterior and outer thirds of the inferior edge of the zygomatic arch, and from the posterior part of the same edge; from the inner surface of the arch, and from the internal aponeurosis of the temporal muscle. The fleshy fibres which come from these different origins follow different directions, but they all descend to be attached to the outer side of the ramus of the lower jaw, from the base of the coronoid process to the angle and base of the jaw.

Externally, the muscle is covered posteriorly by the parotid gland; below, by the platysma myoides; in the middle, by the duct of the parotid, the facial nerve, and transverse facial artery; anteriorly and above, by the orbicularis palpebrarum and zygomaticus major; it also in some parts approaches the skin. The internal surface covers the ramus of the jaw, the tendon of the temporal, and the buccinator.

The masseter is a powerful muscle of mastication.

TEMPORAL OR CROTAPHITE MUSCLE.

The TEMPORAL APONEUROSIS, by some considered as a portion of the epicranial, conceals the temporal muscle from view, until dissected and removed. The aponeurosis, thin above, strong and double below, is attached superiorly to the crests of the frontal and parietal bones; inferiorly to the zygomatic arch. At this point it is composed of two layers, between which there exist some adipose matter, and some small vessels.

Remove the aponeurosis by a vertical incision; divide the zygomatic arch with a saw, in such a way as to expose fully the coronoid process of the lower jaw, to which the tendon of the temporal muscle is attached.

The fleshy fibres of the muscle take their origin from the whole extent of the inner surface of the aponeurosis, from the periosteum of the temporal fossa, and from the ridge separating the temporal from the zygomatic fossa. The muscle has a central tendon or aponeurosis, to which all the fleshy fibres proceed.

Opposite the zygomatic arch this central aponeurosis becomes a powerful tendon, by which the muscle is firmly attached to the coronoid process of the inferior maxillary bone, which it embraces nearly in its whole extent.

The relations of the muscle and its functions are easily understood; it is the chief masticatory muscle.

BUCCINATOR MUSCLE.— *Dissection.*—To clean this muscle the mouth must be moderately distended with baked hair, or some similar

substance, and the lips sewed up. By these means the fibres of the buccinator will be put on the stretch, and can be readily cleaned. The coronoid process of the lower jaw must be removed.

The buccinator especially forms the cheek. Flat, thin, and square, it is situated between the upper and lower jaw-bones, filling up the space between them, laterally.

Attached above to the posterior part of the upper alveolar border, from the last tooth to the second small grinder; below, to the same part of the lower alveolar border; in the middle, to an aponeurosis which descends from the summit of the inner wing of the pterygoid process to the inner surface of the ramus of the jaw, and which, on its posterior edge, gives origin to the fibres of the superior constrictor of the pharynx.

From these different origins the fleshy fibres proceed forwards, converging towards the angle of the mouth, where they meet at the commissure, mingling with the fibres of the orbicularis and adjacent muscles; the fibres from the lower part of the buccinator passing to the upper lip, and *vice versâ*.

An extremely thick layer of fat covers the muscle externally, and is interposed between it and the integuments of the cheek. Anteriorly, it is partially covered by the zygomatic, levator anguli oris, triangularis, and platysma myoides. It is invested externally by a firm fascia of cellular tissue, by which the buccal glands are separated from it posteriorly; whilst opposite the third molar tooth it is obliquely traversed by the parotid duct.

It is a muscle of mastication, and of the expression of the passions; it is much used by glassblowers, and by those who play on wind instruments.

PTERYGOID MUSCLES.

These muscles are difficult to be displayed and understood. They may be most easily dissected from within, but this can only be accomplished after the dissection of the muscles of the neck, and the vertical division, by the saw, of the cranium and face. At this stage of the dissection they may, however, be exposed sufficiently to understand their position and action; and a second view may be taken of them after the dissection of the head and neck has been completed.

PTERYGOIDEUS INTERNUS.—*Dissection.*—The zygomatic arch and coronoid process being already removed, and the temporal and masseter muscles drawn aside or cut through, the external lateral ligament must next be divided, so as to admit of the partial dislocation and rotation of the lower jaw. Next divide the lower jaw-bone with a saw, in front of the attachment of the masseter, and evert the posterior segment, turning it outwards and backwards. Unless this be done with great care it will affect, or even destroy, the dissection of the upper part of the neck, and it is on this account that I recommend the student rather to study these muscles at a future stage of this dissection of the head and neck.

Place before you the cranium and lower jaw, artificially articulated.

The INNER PTERYGOID arises from the whole pterygoid fossa, and from the inner surface of the summit of the outer wing of the pterygoid process.

It descends and terminates on the inside the ramus of the lower jaw, as low as the angle to which it is attached, on the surface opposite to that occupied by the masseter. The ramus of the jaw, in fact, separates these two muscles.

Its inner surface covers, at its upper part, the circumflexus palati and superior constrictor of the pharynx; inferiorly, the sub-maxillary gland. The outer surface is separated from the jaw by an interval, in which are found the lingual and dental nerves, the inferior dental artery, and internal lateral ligament of the joint.

It is whilst studying the relation of this and of the following muscle to the ramus of the jaw that the course of the internal maxillary artery should be particularly attended to.

When the two muscles act together they raise the jaw upwards, as in mastication. If only one contracts, the jaw is carried obliquely forwards, towards the opposite side.

PTERYGOIDEUS EXTERNUS.—This muscle is situated in the zygomatic fossa.

It has two origins—one from the outer surface of the pterygoid process, and from the palatine tuberosity; the other from the lower part of the zygomatico-temporal aspect of the sphenoid bone. The internal maxillary artery often passes between these two origins.

The muscle thus formed proceeds outwards and backwards, and is inserted into a small fossa at the anterior surface of the neck of the condyle of the lower jaw, and into the fore part of the circumference of the interarticular fibro-cartilage.

The relations of this muscle, like those of the preceding one, are exceedingly complex. Its outer surface is in contact with the temporal muscle, and most commonly with the internal maxillary artery; the inner corresponds to the pterygoideus internus.

These pterygoid muscles are in an especial manner intended to move the jaws forwards and backwards, and from side to side. The muscle called internal is, on the whole, vertical; the external is horizontal.

ANTERIOR AND LATERAL REGIONS.

Dissection of the anterior and lateral regions of the neck.—During the first and second dissections of these important regions, the attention of the student should be directed solely to the anatomy of the muscles. In future dissections he will attend to the history of the great nerves and arteries, the various organs found here, and the fasciæ, the arrangements of which modify the relations of surgical diseases.

A block being placed under the shoulders so as to expose the surface

of the neck as much as possible, and the face turned to the opposite side to that on which the dissection is to be made, an incision is to be carried through the integuments from the symphysis of the chin to the sternum; a second along the line of the clavicle, as far as the shoulder; and a third, if required, from the symphysis of the chin to the mastoid process of the temporal bone. Commence the removal of the integuments with great care, at the angle nearest to the manubrium of the sternum, looking carefully for the anterior margin of the latissimus colli. When this has been found, dissect the muscle, cleaning it from below upwards, or from above downwards.

The first dissection will expose the platysma myoides, or latissimus colli, of one side, together with portions of the cervical fascia. This is an extensive cellular membranous apparatus, covering and enclosing in sheaths, not merely the muscles of the neck, but also blood-vessels, nerves, and other organs. The student may safely neglect its anatomy during his first dissection, opening up the sheaths with which the fascia furnishes the muscles, and giving his exclusive attention to these organs.

For a full account of the relations of the cervical fascia, see, 1, the Chapter on the Fasciæ and Aponeuroses; 2, that on the blood-vessels of the neck.

Latissimus Colli (*Platysma myoides*).—This is a thin fleshy membrane, varying much in strength and extent, spread over the surface of the neck, and essentially an appendage of the skin. It seems to be the remains of the panniculus carnosus enveloping the trunk of the horse and other large animals. In man this system of muscles is confined to the neck.*

The muscle commences inferiorly in the cellular tissue covering the thin aponeurosis of the deltoid and in the cellular fascia covering the pectoralis major muscle. The fibres are at first scattered in separate fasciculi, but they collect together as they ascend, forming a muscular plane on the neck, and ascending to the base of the jaw, over which they pass. The termination of the muscle superiorly is by intermingling its fibres with those of the opposite muscle just beneath the symphysis; 2, in the integuments of the chin, in the external oblique line and base of the lower jaw; 3, some fibres mingle with the depressor anguli oris and extend to the commissure of the lips. The muscle then, properly speaking, is a thoraco-maxillary muscle.

Occasionally the fibres ascend to the orbicularis palpebrarum, and are strengthened by a layer described by Santorini (*Musculus risorius*) running from the cellular envelope of the parotid or masseter to the commissure of the lips.

Externally there is interposed between the platysma myoides and the integuments a thin layer of cellular substance, the fascia propria, in fact, of the muscle.

* Although it is usual to call the panniculus carnosus in animals, and the platysma in man, cutaneous muscles, it is yet to be observed that they are not strictly so, if by this be meant that they have no connexion with the skeleton.

Internally there exists a thin layer of the same substance, separating the muscle from the cervical fascia which here invests the muscles about to be described. The external jugular vein is situated beneath the platysma myoides.

Action, not well determined. It raises in strings the integuments of the neck.

STERNO-CLEIDO-MASTOIDEUS.—*Dissection.*—Cut through the preceding muscle transversely, and reflect the flaps upwards and downwards; this will expose the cervical fascia. Open the sheath which the fascia furnishes to the sterno-mastoid and other muscles of the neck, along the centre of the muscle, longitudinally, from the mastoid process of the temporal bone to the sternum, following the curve of the muscle; reflect the sheath inwards and outwards so as to expose the surface of the muscle throughout its whole length, but do not as yet disturb or interfere with the margins of the muscle. Clean the surface of the muscular fibres whilst reflecting the anterior layer of the sheath furnished by the fascia, removing along with the sheath a fine layer of cellular substance forming the fascia propria of this and of nearly every other muscle: by means of this cellular texture, as was seen in the dissection of the arms and limbs, the muscle is retained in its place, and in vital as well as mechanical connexion with the sheath and the surrounding structures.

Having exposed and cleaned the anterior surface, proceed to examine it carefully before disturbing its margins in the slightest degree. After this the muscle may be cut across a little below the middle; but before doing so, raise up somewhat the anterior edge of the muscle, and, passing the handle of the knife behind it, the muscle may thus be detached from the sheath at this part, and a view obtained of the posterior layer of the sheath on which the muscle lies, of the splitting of the sheath into two layers so as to enclose the muscle, and of the connexion of the sheath with the deeper partitions and prolongations it sends inwards to embrace the vessels and to seek attachments to the vertebral column itself.

Follow the same plan and mode of dissection with all the other muscles of the neck; the distribution of the cervical fascia being, as regards these muscles, quite similar to that of the aponeuroses of the extremities. The terms superficial and deep layers of the *fascia*, being incorrect, ought to be laid aside; the fascia is single wherever it does not split to enclose muscles and vessels. Though not an aponeurosis strictly, it resembles in its arrangements and functions the true aponeuroses of the extremities.

STERNO-CLEIDO-MASTOID.—Commencing by a broad and thin aponeurosis attached to the outside of the upper curved line of the occipital bone, and by a stronger to the mastoid process of the temporal, the muscle in its descent along the side of the neck bifurcates or divides into two portions—one proceeding to be attached to the manu-

brium of the sternum, the other to the inner and upper part of the collar-bone. A triangular cellular space exists between these two attachments; the clavicular insertion varies in extent. The muscle then is attached to two bones above and to two below.

It is traversed by the spinal accessory nerve, and presents many other important points for consideration. These have a reference chiefly to its surgical relations.

On its *outer* surface may be observed the latissimus colli, a small portion of the parotid, the external jugular vein, and some nervous filaments of the superficial cervical plexus.

Its *inner* surface crosses the great vessels and nerves of the neck and most of the muscles presently to be described. The sternal origins of the muscle are separated inferiorly by about the breadth of the finger; in the mastoid and occipital regions by the whole width of the head.

In action it carries the head forward directly when both muscles act together, but turns the face to the opposite side when one muscle only acts.

Raise up the muscle from the posterior layer of the sheath on which it rests, and proceed with the dissection of the omo-hyoideus muscles and all the others of the neck, as with the sterno-mastoideus; that is by first opening the anterior layer of the sheath they receive from the cervical fascia; cleaning the anterior surface of the muscle; examining it carefully in situ; detach the edges of the muscle from the sides of the sheath; cut the muscle across so as to examine the posterior layer of the sheath; study the relations of the edges of the sheath to the surrounding parts, whether muscular, vascular, or osseous, and proceed with the dissection of the next muscle.

These directions need not be repeated, for they apply as well to all the muscles of the region I now describe, as to the aponeuroses and muscles of the extremities.

OMO-HYOIDEUS.—To expose this muscle fully, the trapezius and sterno-mastoideus muscles must have been first dissected and cut through.

Attachments.—Superiorly, by very short aponeuroses to the sides of the lower edge of the body of the hyoid bone; *inferiorly*, to the cervical margin of the scapula behind the notch, and most frequently somewhat to the coracoid ligament.

It presents some varieties, and especially as to its occasional connexion with the collar-bone by means of an aponeurosis.

Action.—Whatever be its action on the scapula, I have ascertained it to be, at least in some persons, a muscle of speech.

In its course from the hyoid bone downwards it alters its course, being at first somewhat vertical, afterwards horizontal. It is a bicipital muscle, being composed of a double head and central tendon. This tendon occupies the part of the muscle which passes behind the sterno-mastoid, and is at this point protected by a loose synovial

apparatus of a simple form.* The surgical relations of the muscle are most important, as it crosses in its course the great vessels and nerves of the neck.

STERNO-HYOIDEUS.—Its name happily implies its attachments, which are, superiorly, to the lower edge of the body of the hyoid bone; inferiorly, from the posterior sterno-clavicular ligament, and sometimes from the cartilage of the first rib.

Relations. — *Anteriorly*, the clavicle and sternum, sterno-mastoideus, omo-hyoideus, latissimus colli, skin. *Posteriorly*, sterno-thyroideus, thyro-hyoideus, crico-thyroideus, thyroid body, thyro-hyoid membrane, and superior thyroid vessels.

Action.—To depress the hyoid bone, and consequently the larynx. It may also act on the sternum, and influence the movements of the lower jaw.

A tendinous intersection crosses the muscle at a varying height, often existing only on its inner side.

STERNO-THYROIDEUS.—Its name implies its course, attachments, and functions.

Inferiorly, to the upper part of the inner surface of the sternum, opposite the cartilage of the second rib.

Superiorly, to the oblique ridge of the thyroid cartilage.

Anteriorly, in relation to the preceding three muscles.

Posteriorly, it covers the subclavian and internal jugular veins, the trunk of the carotid artery, the trachea, thyroid body and its vessels, the crico-thyroid muscle, and a portion of the inferior constrictor of the pharynx.

THYRO-HYOIDEUS.—Its name implies its attachments, position, and functions.

Attached, inferiorly, to the oblique ridge of the thyroid cartilage; *superiorly*, to the lower edge of the body of the hyoid bone, and to the anterior half of the outer edge of its laryngeal horn.

Anteriorly, covered by the sterno-hyoid, omo-hyoid, and platysma myoides; *posteriorly*, it lies on the thyroid cartilage and thyro-hyoid membrane.

DIGASTRICUS; BIVENTER MAXILLÆ.—Dissect the muscle by an incision carried from the symphysis of the chin to the hyoid bone, and thence to the mastoid muscle, through the fascia, which forms the sheath of the digastric.

Origin.—From the mastoidal groove of the mastoid process of the temporal bone. After forming a thick fleshy belly the muscle becomes tendinous, and again fleshy (anterior belly), to be inserted into a fossa situated at the side of the symphysis of the chin. Its fibres meet here those of the opposite side, and are sometimes interlaced.

The tendon forming the centre of the muscle is about 2 inches long,

* A synovial bursa of a primitive or fœtal character.

and passes through the stylo-hyoid muscle. A broad and thin aponeurosis, detached from the lower edge of the tendon, connects the tendon to the hyoid bone. A small synovial bursa placed here protects the tendon from friction during the varied and frequent action of the muscle; it protects, also, the aponeurotic ring connected with the hyoid bone, through which the tendon of the digastric more immediately plays.*

Relations.—Posteriorly, to the trachelo-mastoid, sterno-mastoid, and splenius, which cover it; in the middle, and just below the jaw, in a triangular space formed by the jaw and muscle, lies the sub-maxillary gland; *anteriorly*, the platysma myoides covers it in part. *Internally*, its deep surface is in relation to the stylo-hyoid, stylo-glossus, and stylo-pharyngeus muscles; to the external and internal carotid, the facial and lingual arteries, the internal jugular vein, the hypo-glossal nerve, the hyo-glossus and mylo-hyoideus muscles.

Use.—To depress the lower jaw, or raise the hyoid apparatus, the jaw being fixed.

MYLO-HYOIDEUS.—This muscle assists in forming the floor of the mouth, and, as well from this as from its important surgical relations, should be dissected and examined with the greatest care.

Dissection.—Separate the attachment of the digastric to the lower jaw. Dissect and display the sub-maxillary gland, which lies above it. Its duct runs above the mylo-hyoid, passing over and above the posterior edge of the muscle. Clean the fibres of the muscle from above downwards, from the posterior edge forwards, to the mesial plane of the throat.

Of a truncated triangular form; it is *attached*, *superiorly*, to the internal oblique line of the lower jaw; internally, to the tendinous raphe connecting the muscles to each other, to the jaw above, and to the hyoid bones below; lastly, to the lower and fore part of the body of the hyoid bone.

The *outer* surface should be called the *inferior*; it inclines downwards and forwards; its relations are to the digastric, platysma myoides, and sub-maxillary gland. The *inner*, which is the upper surface, conceals the genio-hyoid, genio-glossal, and hyo-glossal muscles, the sub-lingual gland, the duct of the sub-maxillary gland, a prolongation of the gland, and the lingual nerve.

The two muscles should, if possible, be dissected together, in order to enable the student fully to comprehend the importance of a right understanding of the relations of these muscles to the surrounding structures.

Action.—To raise the hyoid bone, or depress the lower jaw.

GENIO-HYOIDEUS.—*Dissection.*—Divide the mylo-hyoideus muscle on either side; the genio-hyoideus lies directly above it.

* The pulley, however, is not complete.

Fig. 147.*

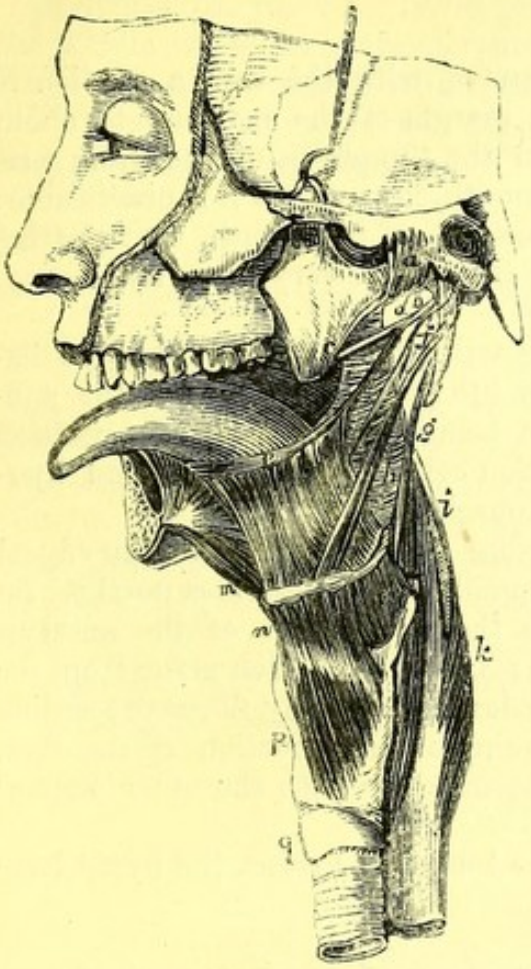

Fig. 148.†

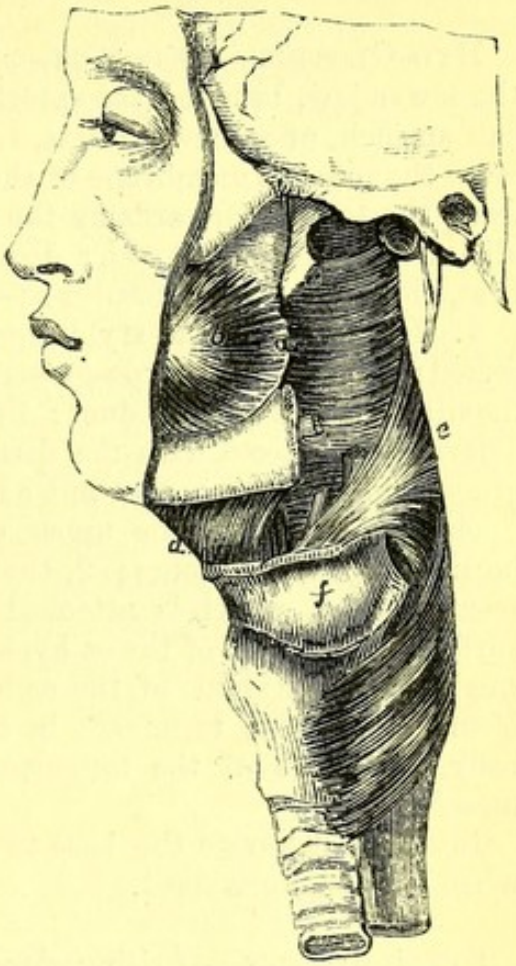

Attached, *superiorly*, to the inferior genoid processes of the lower jaw; *inferiorly*, to the middle of the anterior surface of the body of the os hyoides. Its name explains its course and functions. A little cellular substance separates it from its fellow of the opposite side.

The STYLOID MUSCLES.—There are three styloid muscles on either side: 1, the stylo-hyoideus; 2, the stylo-glossus; 3, the stylo-pharyngeus. They cannot be all dissected together; at present I shall only describe the "stylo-hyoideus."

Long and slender. Attached superiorly to the styloid process near its base; inferiorly, to the sides of the body of the hyoid bones. It splits, to allow the tendon of the digastricus to pass through it.

* Fig. 147.—*a*, external lateral ligament of the lower jaw; *c*, ramus and angle of the jaw; *b*, *d*, stylo-maxillary ligament; *e*, stylo-glossus muscle; *f* is placed between the stylo-hyoid ligament in front and stylo-hyoideus muscle behind; *h*, superior constrictor of the pharynx; *i*, *k*, inferior constrictor; *l*, genio-glossus muscle; *m*, genio-hyoideus; *n*, hyo-thyroideus; *o*, portion of the thyro-hyoid ligament; *p*, thyroid cartilage; *k*, cricoid cartilage.

† Fig. 148.—*a*, inter-maxillary ligament, or aponeurosis; *b*, buccinator; *c*, superior constrictor of the pharynx; *d*, mylo-hyoideus; *e*, middle constrictor of the pharynx; the lower constrictor has not been lettered; it follows immediately the middle constrictor; *f*, thyro-hyoid ligament.

Its surgical relations are important. The name characterises its course and functions.

HYO-GLOSSUS.—*Dissection.*—Remove, with the saw, a portion of the lower jaw, between the anterior margin of the masseter to about half an inch, or somewhat less, from the symphysis of the chin; preserve the mucous membrane of the mouth, in as far as it is practicable; draw the tongue forwards by the apex out of the mouth, thus putting all the fibres on the stretch; dissect the surface very carefully, noting, first, the following structures:—

1. The fusion of the stylo-glossus with the muscle about to be dissected; 2, the great hypo-glossal or 9th pair of nerves; 3, the submaxillary gland and its duct: these being cleaned and their position determined, proceed with the dissection of the stylo-glossus and hyo-glossus, these being in fact but one muscle.

Attached, 1st, to the upper surface of the great horn (laryngeal horn) of the hyoid bones; 2, the lingual artery separates portion 1st from this one, which is attached to the upper part of the anterior surface of the body of the os hyoides; 3, a third portion arises from the smaller horn (styloid) of the os hyoides. The fleshy fibres proceeding from these origins terminate in forming a large portion of the face, body, and sides of the tongue, intermingled with the other lingual muscles.

In action it lowers the base of the tongue, or raises the hyoid bone when the tongue is fixed.

STYLO-GLOSSUS.—Arising from the lower half of the styloid process of the temporal bone and from the stylo-maxillary ligament; inferiorly, dividing into two or three bundles, it passes on to the tongue, intermingled with the lingualis, hyo-glossus, and genio-glossus muscles.

The external carotid artery separates the stylo-hyoid from the other styloid muscles.

LINGUALIS.—A small and somewhat irregular bundle of muscular fibres, usually described here, but forming rather one of the intrinsic muscles of the tongue. The fibres forming it run on the sides of the tongue from the base to the apex, between the hyo- and stylo-glossal muscles on one side and the genio-glossus on the other.

Action.—It shortens the tongue; perhaps depresses its point.

GENIO-GLOSSUS.—The deepest muscle in this region; it is sometimes called the genio-hyo-glossus: remove the hyo-glossus by cutting it through and whatever lies in the way of exposing the muscle.

Attached inferiorly to the superior genoid processes, its fibres form a fan-shaped powerful muscle, terminating superiorly in the tongue, from the apex to the base. The muscle represents, in fact, a triangle, the base being in the tongue and the apex at the genoid processes.

Its deep surface is in contact with its fellow of the opposite side.

In action, the posterior fibres protrude the tongue from the mouth; the middle fibres form the dorsum into a hollow, whilst the anterior fibres replace the tongue within the cavity of the mouth.

The stylo-pharyngeus will be best understood if dissected along with the pharyngeal muscles.

MUSCLES OF THE PHARYNX, PALATE, AND LARYNX.

1. MUSCLES OF THE PHARYNX.—*Dissection.*—The skull-cap and brain having been removed, cut through the œsophagus and trachea nearly on a level with the upper edge of the sternum; raise them cautiously upwards from the front of the vertebral column and deep muscles of the neck, to which they are loosely connected by cellular tissue; and, placing the skull downwards, divide with a saw the anterior part of the skull, including the face, from the posterior part and cervical vertebræ. By this section the entire back wall of the pharynx is exposed. Fill the œsophagus and pharynx with baked hair, so as moderately to distend the cavities. Clean the posterior wall of the

Fig. 149.*

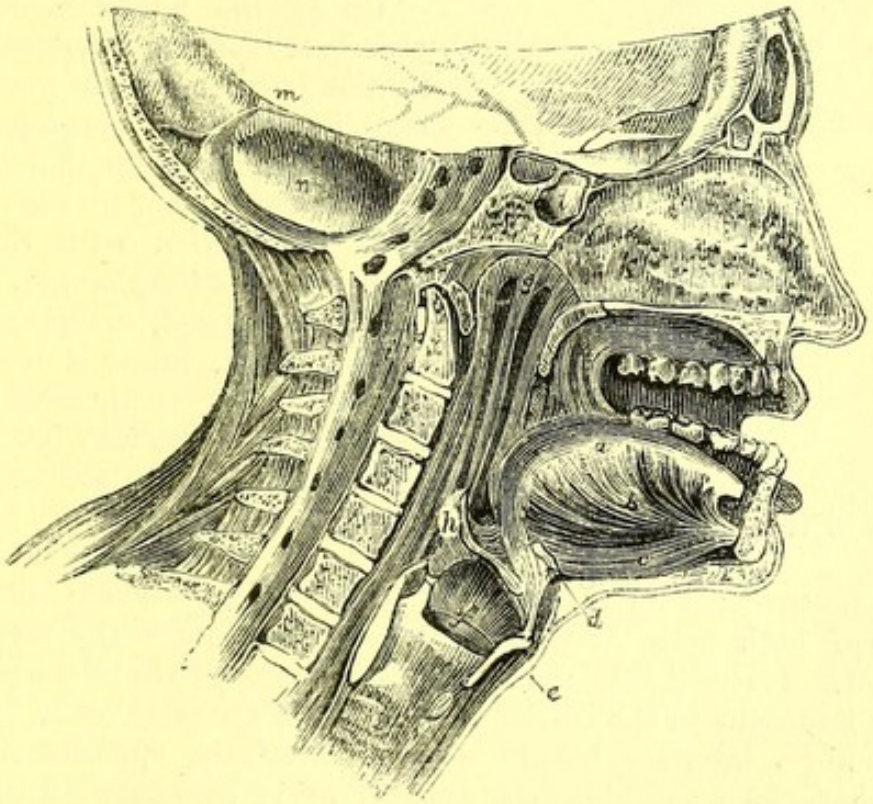

* Fig. 149.—Vertical section of the head and neck.—*a*, *b*, *c*, genio-hyo-glossus muscle; *d*, mesial section of the body of the hyoid bones; *e*, corresponding section of the thyroid cartilage; *f*, rima of the glottis and left ventricle of the larynx; *g*, vertical section of the epiglottis; *h*, superior part of the pharynx; *k*, nasal cavity; *l*, sphenoidal sinus; *m*, interior of the cranium; *n*, inferior occipital fossa.

pharynx and gullet by carefully removing the pharyngeal fascia, connecting the cavities to the basilar process of the occipital bone. In making the section of the skull, it will be found best to carry the saw clear of the styloid processes, leaving them entire, and encroaching rather on the mastoid processes. Nothing is injured but the tops of the recti antici muscles.

Begin the examination with the

CONSTRICTOR PHARYNGIS INFERIOR.—*Attachments.*—1, to the 1st ring of the trachea and outer part of the cricoid cartilage; 2, to the small horn and oblique line of the thyroid cartilage: from these points of attachment its fibres proceed backwards, inwards, and upwards to the raphe occupying the median line at the back of the pharynx.

Fig. 150.*

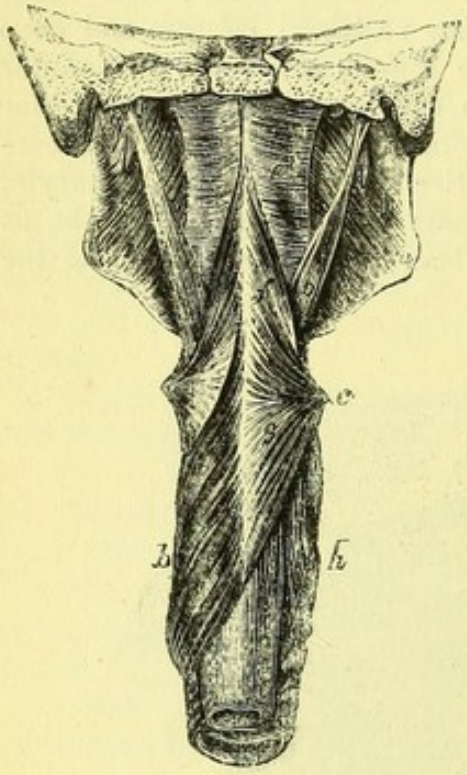

Relations. — Externally, the sterno-thyroideus, thyroid body, trunk of the carotid artery; posteriorly it is connected with the rectus capitis major and longus colli muscles and anterior vertebral ligament.

Under the lower edge of the muscle the inferior laryngeal branch of the pneumo-gastric passes; the superior laryngeal nerve passes between the upper edge of this muscle and the constrictor medius.

In conjunction with the other constrictors of the pharynx, it raises the pharynx, and, compressing the bolus of food, forces it downwards into the gullet, or upwards into the mouth as the case may be.

The inferior constrictor posteriorly ascends nearly to the basilar process of the occipital bone.

CONSTRICTOR PHARYNGIS MEDIUS.—*Origin.*—From the whole extent of both horns of the hyoid bones and from the stylo-hyoid ligament. Inserted into the mesial raphe on the back of the pharynx, and by its means to the basilar process of the occipital bone.

The fibres interlace behind with those of the opposite side: the stylo-pharyngeus and glosso-pharyngeal nerve pass between the upper edge of this muscle and the next.

* Fig. 150.—Section to show the constrictor muscles of the pharynx; *a*, angle of the lower jaw; *b*, stylo-pharyngeus muscle; *c*, greater or laryngeal horn of the hyoid bones; *f*, *g*, middle constrictor of the pharynx; *h*, thyroid cartilage of the larynx; *b*, *b*, inferior constrictor of the pharynx; *e*, superior constrictor.

CONSTRICTOR PHARYNGIS SUPERIOR.—*Arises*, 1, from the lower half of the edge of the inner wing of the pterygoid process; 2, from the so-called intermaxillary ligament common to it and the buccinator; 3, from the extremity of the myloidian line of the lower jaw; 4, from the side of the base of the tongue between the stylo-glossus and hyo-glossus muscles. The fleshy fibres from these different origins proceed backwards to meet each other in the mesial raphe, and to be attached to the basilar process of the occipital, leaving between the upper margin of the muscle and the basis of the cranium a semicircular space where the mucous membrane of the pharynx is not protected by any muscular fibres. These semicircular spaces have been called the sinuses of Morgagni.

Action the same as that of the other constrictors.

From this description it will be gathered that these muscles are placed partially over each other, and are lined by the mucous membrane of the pharynx. The superior, from the nature of its origins, is maxillo-pharyngeal; the middle, hyo-pharyngeal; and the inferior, laryngo-pharyngeal.

Intimately connected with them is the

STYLO-PHARYNGEUS.—*Arising* from the styloid process of the temporal bone near its base, descends, passing under the constrictor medius, between it and the superior, and mingling its fibres with these muscles, it is attached inferiorly to the thyroid cartilage and hyoid bone.

The muscle shortens the pharynx and raises the larynx: its superior attachments are more distinct than is usually supposed.

MUSCLES OF THE PALATE.

Dissection.—Slit up the bag of the pharynx, along the mesial line, posteriorly, and detach it superiorly, to a certain extent, from the occipital bone. Clean the surface thus exposed and remove the mucous membrane from the posterior surface of the velum palati; this will expose the azygos uvulæ; next from the posterior part of the pterygoid processes to reach the circumflexus palati and levator palati muscles; the hamular process of the inner plate of the pterygoid will point out the position of the tendon of the circumflex. Lastly, the mucous membrane being removed from the pillars of the fauces, the palato-pharyngeus and constrictor isthmi faucium come into view.

It is usual for the student at this stage of the dissection to attempt a full examination of the mucous membrane of the pharynx, mouth, and nostrils, and of the various apertures leading into the pharynx. I do not recommend him to try this at present, but, should he feel so disposed, he will find a full description of all these structures in the Chapter on the Organs of Digestion; article, Pharynx.

Circumflexus Palati (*External Peristaphyline*).—*Arises* from the scaphoid fossa of the pterygoid process, from the great wing of the sphenoid as far as its spine, and from the fore and outer part of the fibro-cartilage of the Eustachian tube. From these origins it descends, slender when the levator is large and *vice versâ*, until it reaches the hamular process of the sphenoid; around this it turns as in a staple, to terminate by expanding into the soft or pendulous palate.

Fig. 151.*

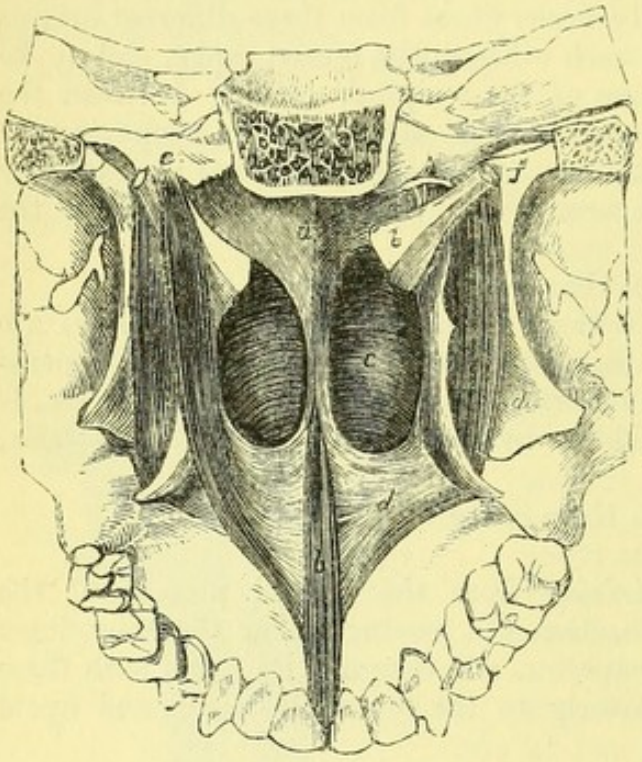

A small synovial capsule facilitates its motion around the hamular process, and a ligament retains it in its place.

It runs parallel, or nearly so, with the levator palati mollis; its relations cannot well be misunderstood.

Action.—To raise up and stretch horizontally the velum palati and assist the next muscle.

Levator Palati Mollis.—Arising from the under surface of the petrous process of the temporal bone, anterior to the external orifice of the carotid canal, and from the neighbouring part of the Eustachian tube. Descending somewhat obliquely, it terminates at the middle part of the velum palati, its fibres being confounded with those of the adjoining muscles.

Action.—To raise the velum so as to protect the nostrils during deglutition. It is probable that, when so raised, the velum forms a partition between the upper and lower portions of the pharynx. I have not unfrequently seen this division of the cavity into two parts become permanent by disease. These muscles are the chief obstacles to the success of the operation for cleft palate.

Levator Uvulæ (*Azygos uvulæ*).—This is a small elongated

* Fig. 151.—Palatal muscles of the velum pendulum palati, dissected and viewed from behind.—*a*, septum of the nostrils; *b*, muscle called azygos uvulæ; some view it as composed of two; *c*, aperture of the right nostril; *d*, *d*, circumflex muscle of the palate; *e*, levator palati mollis; *b*, *f*, point to the Eustachian tube of the right side.

fasciculus occupying the substance of the uvula, sometimes single but generally double: it descends from the guttural spine, to which it is attached, to the tip of the uvula.

The name of the muscle expresses its functions.

MUSCLES OF THE ISTHMUS FAUCIUM.

In the folds of mucous membranes which limit on each side the isthmus of the fauces, before and behind the tonsils, will be found four muscles, two on either side. The posterior is the

PALATO-PHARYNGEUS.—This muscle may be divided into three portions, which have been described as so many muscles:—

1. The portion which has been called peristaphylo-pharyngeus.

Attached superiorly to the posterior edge of the palatine vault; this descends posteriorly in the velum palati.

2. The portion called pharyngo-staphyline occupies the posterior pillar of the isthmus faucium, but does not descend far, seeming rather to form an arch over the tonsils.

The 3d is the proper pharyngeal portion. This descends from the palate vertically on the sides of the pharynx, intermingling with the stylo-pharyngeus and constrictors, and sending fibres as far as the thyroid cartilage.

Action.—To raise and shorten the pharynx.

CONSTRICTOR ISTHMI FAUCIUM.—A small fleshy cord, thin, but sufficiently distinct, occupying the anterior pillar of the fauces, in front of the tonsil. It descends on each side from the velum palati to the base of the tongue, which it raises up, so as to assist in deglutition, and in cutting off occasionally all communication between the buccal and pharyngeal cavities.

The importance of the organs just described requires, in an especial manner, that they be carefully studied by the student. The course of the mucous membrane, the anatomy of the tonsils, pharynx, &c., ought to be examined in another subject, distinct from that dissected for the muscles.

Mem.—Proceed next with the muscles left on the section, including the back of the cranium and cervical vertebræ; that is to say, with the examination of the deep muscles of the front of the neck.

DEEP MUSCLES OF THE NECK.

Dissection.—It is a common mistake, on the part of the student, to imagine that the anatomy of the deep muscles of the neck has no practical importance, and to confine, in consequence, his view of these muscles to an imperfect inspection of the lower ends of the scaleni, where they are attached to the first rib. The scaleni, like all other

parts, can only be understood by a clear and comprehensive dissection and survey of all the structures directly or indirectly connected with them.

The pharynx, larynx, &c., having been removed in the mode already described, and the clavicles sawn through or removed, the following muscles are readily exposed by a little careful dissection.

LONGI COLLI MUSCLES.

The LONGUS COLLI.—To expose these muscles fully, the chest will require to be opened, and the viscera removed from its upper part.

Flat, narrow, elongated, these muscles extend from the anterior tubercle of the atlas to the body of the third dorsal vertebra. Each is divided, as it were, into two portions, a superior and an inferior. The superior arises from the tubercle of the atlas, and terminates by being attached to the transverse processes of the third, fourth, and fifth cervical vertebræ. The lower portion is attached superiorly to the bodies of the second, third, and fourth cervical vertebræ; inferiorly, to the bodies of the lower cervical vertebræ and three first dorsal.

Important parts lie on it anteriorly, such as the rectus major, pharynx, carotid artery, pneumo-gastric nerve, communicating cords of the cervical ganglia and the gullet. Posteriorly, it covers the bodies of the vertebræ and their fibro-cartilages; on the outer edge of the muscle is the vertebral artery.

It acts feebly on the cervical and dorsal vertebræ, as the antagonist of much more powerful muscles placed on the back of the column.

RECTUS CAPITIS ANTICUS MAJOR.—*Arises*, by tendons, from the anterior tubercles of the third, fourth, fifth, and sixth transverse processes of the cervical vertebræ; occasionally a fleshy slip joins them from the longus colli. Inserted tendinous into the basilar surface of the occipital bone, near the occipital foramen, and into the posterior surface of an aponeurosis attached to the basilar surface, and extending downwards on the surface of the muscle.

Anteriorly, the muscle is in relation with the carotid artery, internal jugular vein, pneumo-gastric nerve, superior cervical ganglion, and the pharynx. *Posteriorly*, it covers the longus colli, rectus minor, and adjoining articulations. The outer edge is free; the inner united by cellular tissue to the longus colli.

Action.—It bends the head on the neck; in standing on the head it may act on the vertebral column.

RECTUS CAPITIS ANTICUS MINOR.—Situated behind the preceding muscle, and close to the joint. *Arises* from the fore part of the lateral mass and transverse process of the atlas; is attached superiorly to the anterior margin of the occipital foramen, and to the cartilaginous substance uniting the basilar process to the petrous portion of the temporal bone.

Its action resembles that of the rectus major; its relations are chiefly with the joint.

RECTUS CAPITIS LATERALIS.—This muscle appears to be analogous to the inter-transversales cervicis already described, and, in fact, is the first of them.

Attached inferiorly by a small tendon to the upper and anterior part of the transverse process of the atlas; superiorly, to an impression in the occipital bone, behind the jugular fossa. The part to which it is attached superiorly may be viewed as the transverse process of the occipital vertebra.

The muscle separates the internal jugular vein from the vertebral artery. The former lies in front of the muscle, the latter behind it.

It inclines the head laterally and forward.

SCALENI MUSCLES.

The scaleni vary in number, and have been variously described by different anatomists. The practical anatomist and surgeon views them uniformly as two on each side, the scalenus anticus and posticus; but there are generally more, and almost always three on each side. Nevertheless, in consequence of the importance of the surgical anatomy of this region, and the relation these muscles have to the subclavian vein, and artery, and the brachial plexus of nerves, it is, upon the whole, the safest method to describe the scaleni as two on each side—a scalenus anticus and posticus.

SCALENUS ANTICUS.—Attached inferiorly, by a tendon, to the outer surface and upper edge of the first rib.* The muscle ascends somewhat obliquely inwards and backwards, and dividing into four fleshy slips, these ending in so many tendons, is by this means attached to the anterior tubercles of the transverse processes of the sixth, fifth, fourth, and third cervical vertebræ.

The relations of the muscle are of the highest surgical importance. Anteriorly and inferiorly the subclavian vein crosses it; higher up the phrenic nerve crosses it diagonally from above downwards, and from without inwards; here also are found, anteriorly, the transverse and ascending cervical arteries, and the omo-hyoid and sterno-mastoid muscles.

Posteriorly, the muscle forms with the s. posticus and first rib a triangular space, in which are lodged, inferiorly, the subclavian artery, close to the rib, and, superiorly, the branches of the cervical

* Occasionally there exists a tubercle on this edge of the rib, which however is not always present, nor even frequently so. This tubercle is the vestige of the cartilage of the cervical rib, occasionally found developed in connexion with the last cervical vertebra. Nothing therefore can be more incorrect than to say that this accidental tubercle is "for the attachment of the scalenus anticus." Equally incorrect is the advice given to the surgeon to feel for this tubercle when seeking for the subclavian artery.

nerves, which form the brachial plexus. The vertebral artery and vein occupy a small triangular space between the inner edge of the muscle and the longus colli.

It is a muscle of inspiration.

SCALENUS POSTICUS.—There is usually a rough impression on the outer surface and lower edge of the first rib, and not unfrequently another on the second. From these rough impressions the scalenus posticus, by some called medius, arises by aponeurotic fibres. The origin from the second rib is sometimes wanting. The muscle ascends vertically, either as two or one, but more commonly united into one, inwards and forwards, terminating at last by six small tendons, attached to the posterior tubercles of the last six transverse processes of the cervical vertebræ. It sometimes sends a tendon to the atlas.

The SCALENUS MINIMUS of Soemmering, when present, is a small muscle, ascending from the first rib to the transverse process of the sixth or sixth and seventh cervical vertebræ, between the two scaleni just described.

Anteriorly, as has been already mentioned, the subclavian artery and cervical nerves separate this muscle from the s. anticus; *posteriorly*, it is in relation with the sacro-lumbalis, transversalis colli, splenius, and levator anguli scapulæ. These relations are unimportant, surgically.

The muscle has the same uses as the scalenus anticus.

MUSCLES OF THE LARYNX.

At this stage of the dissection of the muscles of the neck the student has an opportunity of examining those of the larynx. If his object be the acquiring a knowledge of the anatomy of the larynx as an organ of voice and respiration, he will find the requisite details in the Chapter on the Organs of Respiration: in this section the muscles merely are described with little reference to the important structures connected with them.

CRICO-THYROIDEUS.—The crico-thyroidei (for there are two) arise from the side and fore part of the cricoid cartilage. They ascend obliquely, diverging from each other, to terminate in the lateral part of the lower edge of the thyroid cartilage, and at the anterior edge of the inferior base of the cartilage. Between them they leave an interval, in which the crico-thyroid ligament is seen.

CRICO-ARYTENOIDEI POSTICI.—These muscles are easily found. Situated at the back part of the larynx, they arise from the longi-

tudinal depression observed on either side the prominent line (mesial) of the cricoid cartilage, and are attached superiorly and externally to the base of the arytenoid cartilages.

CRICO-ARYTENOIDEUS LATERALIS.—Each of these muscles occupies the side of the larynx. To expose either of them, divide partially one wing of the thyroid cartilage and reflect it from off the cricoid.

They arise from the side of the upper circumference of the cricoid cartilage, and terminate in the outer and fore part of the base of the arytenoid cartilages, where they are confounded with the thyro-arytenoidei. The mucous membrane of the larynx lines the interior of these muscles.

THYRO-ARYTENOIDEI.—These muscles arise from the middle and lower part of the thyroid cartilage, whence they proceed backwards and outwards to be attached to the outer part of the base of the arytenoid cartilages, immediately above the preceding muscles.

Internally they are closed by the mucous membrane of the larynx.

The ARYTENOIDEUS.—This remarkable muscle crosses the mesial plane of the body; it is a single muscle, but of an irregular form. Of the fibres composing it some are oblique, others transverse. Some of the oblique ascend from the base of the right arytenoid cartilage towards the summit of the left; others follow the opposite direction; whilst some proceed transversely across the mesial plane from one cartilage to the other.

ARYTENO-EPIGLOTTIDEI.—Some delicate muscular fibres run from the arytenoid cartilages to the epiglottis; they will be more fully noticed in the Chapter on the Larynx.

MUSCLES OF THE ORBIT.

Dissection.—The horizontal section of the cranium having been already made in order to remove the brain, all that is now necessary is to remove with a saw, chisel, and mallet, or strong cutting pliers, the ceiling of the orbit. The part adjoining the internal angular process of the frontal bone must be left, likewise a small portion of the bone surrounding more immediately the optic nerve. Attend to the muscles only (leaving the optic nerve *in situ*) during the first dissection; in subsequent ones the course of the nerves will be better understood. On cautiously removing the bony plate forming the ceiling of the orbit, the first soft structures met with are the periosteum and the frontal branch of the ophthalmic nerve: what next presents itself is the levator palpebræ superioris.

LEVATOR PALPEBRÆ SUPERIORIS.—*Attachments.*—Posteriorly to the meningeal sheath of the optic nerve, and to the lower surface of the small wing near the optic foramen. Passing forwards, it curves downwards, spreading out, to terminate finally in the fibro-cartilage of the upper eyelid. *Action,* to raise the upper eyelid.

Fig. 152.*

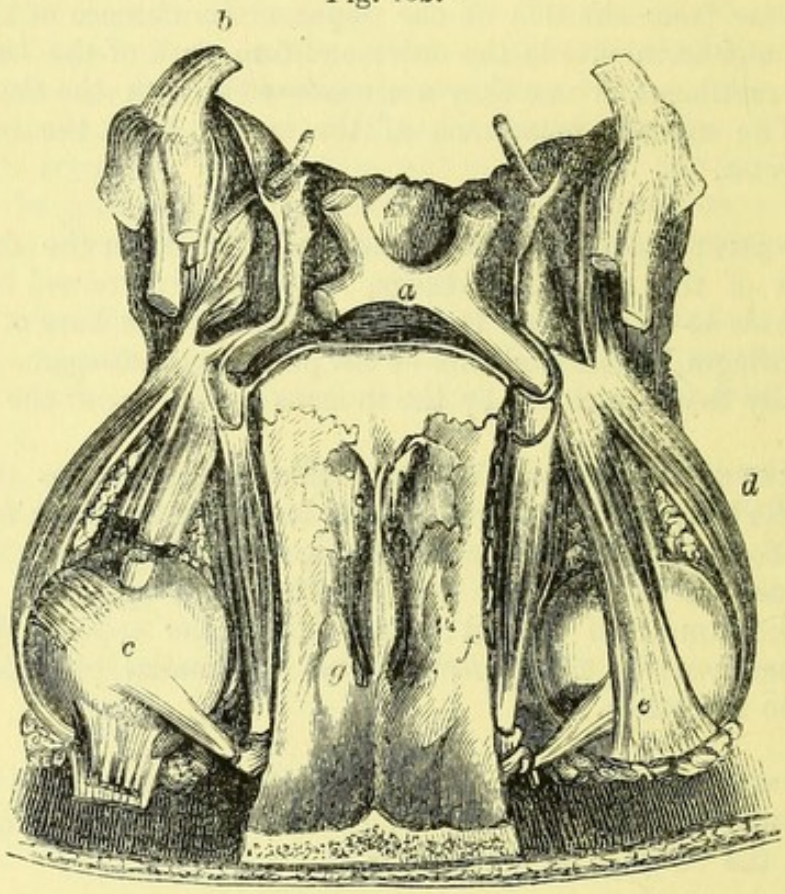

RECTUS OCULI SUPERIOR (ATTOLLENS).—*Dissection.*—Cut through the preceding muscle and reflect the divided portions; the superior rectus will come into view.

Attachments.—Posteriorly, near the optic foramen, to the process of Ingrassias and to the fibrous sheath of the optic nerve.

Anteriorly, becoming thin and aponeurotic, it is attached to the upper part of the eyeball. This aponeurosis, like those of the other recti, is attached to the tunica sclerotica of the eyeball, from which it is separated in a part of its course by an indistinct synovial

* Fig. 152.—Muscles of both orbits.—*a*, optic nerves and commissure; *b*, fifth pair of nerves; *c*, ball of the eye; the letter is placed between the attachments of the superior and inferior oblique muscles of the eye; *d*, rectus externus; *e*, rectus superior; *f*, trochlearis muscle; *g* points to the crista galli, and is placed immediately in front of it. The drawing illustrates the proper mode of dissecting and displaying the muscles acting on the eyeball.

capsule. Although called recti, these muscles are not straight but curved.

Relations.—Superiorly to the levator palpebræ superioris and tunica conjunctiva. Inferiorly, the muscle rests on the optic nerve, the ophthalmic artery, and nasal branch of the ophthalmic nerve, and on the eyeball itself.

Action.—To raise the eyeball upwards.

RECTUS INTERNUS.—On the inner side of the orbit. It has been also called adductor oculi; this name expresses its action.

Arises near the margin of the optic foramen; terminates by an aponeurosis attached to the eyeball like the preceding and following recti.

Fig. 153.*

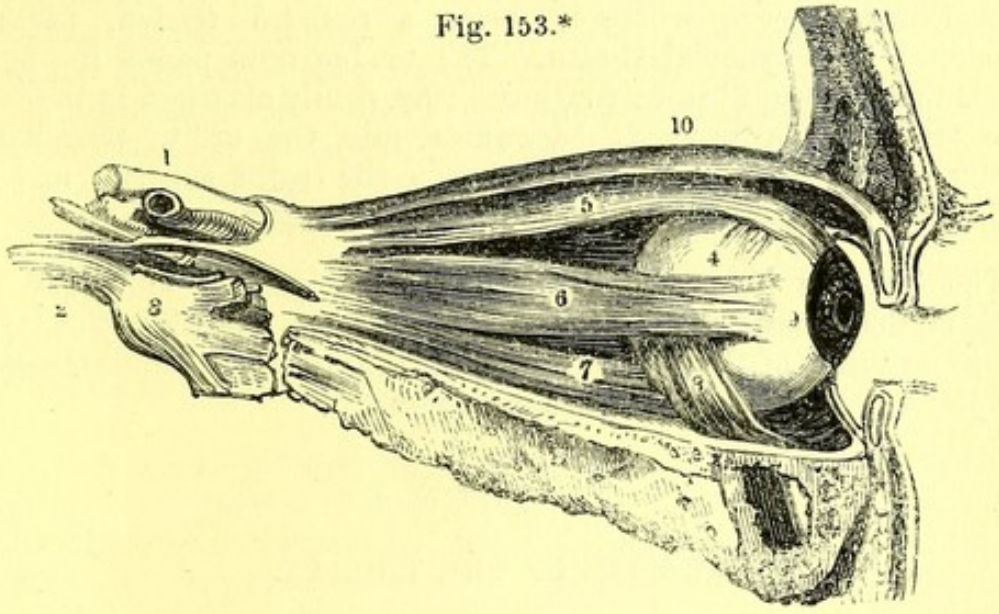

RECTUS EXTERNUS.—The antagonist of the last described muscle, called also abductor oculi.

Arises from the outer part of the circumference of the optic foramen, and from a tendon common to it and to the internal and inferior recti. Between these two origins pass the 3d and 6th pair of nerves; also the nasal branch of the ophthalmic. In its mode of connexion with the sclerotic it resembles the other recti.

RECTUS INFERIOR.—Resembles in *attachments* the preceding recti. To dissect the muscle and show it distinctly, the lower eyelid must be detached from the margin of the orbit. The muscle is also called depressor oculi, which expresses its function. Its origin is from the

* Fig. 153.—Muscles of the eyeball.—1, the optic nerve; 2, fifth pair of nerves; 3, ganglion of the fifth pair, semi-lunar ganglion; 4, superior oblique muscle; 5, rectus superior; 6, rectus externus; 7, rectus inferior; 8, inferior oblique; 9, ball of the eye; 10, levator palpebræ.

tendon common to it with the internal and external recti, and its termination in the sclerotic.

OBLIQUUS INFERIOR.—*Dissection.*—Raise the eyeball upwards; cut through the rectus externus; dissect from within outwards.

Arises from the inner and fore part of the orbitar surface of the superior maxillary bone, outside the lachrymal groove; terminates in an aponeurosis attached to the sclerotic, close to the entrance of the optic nerve into the eyeball. Its relations are simple; not so its functions, which, like those of the succeeding muscle, have never been clearly determined.

OBLIQUUS OCULI SUPERIOR, or TROCHLEARIS.—*Arises*, by short aponeuroses, near the optic foramen; proceeds horizontally to near the interorbitar process, where it forms a rounded tendon, partially enveloped in a synovial sheath. The tendon now passes through a staple formed by a fibro-cartilaginous ring, firmly attached to the bone. The tendon then proceeds backwards into the orbit, terminating finally in the tunica sclerotica, between the rectus superior and the ball of the eye, near the entrance of the optic nerve.

The TENSOR TARSI muscle (lachrymo-palpebral; Duverney and Rosenmuller) may be examined at this stage of the dissection, for it is also a muscle of the orbit. For a description of the muscle see the Chapter on the Eyeball and its appendages.

MUSCLES OF THE THORAX.

Dissection.—The muscles of the thorax, properly speaking, are, 1st, the intercostales and triangularis sterni; these belong entirely to the chest; 2d, muscles which also have relations to the cavity as a respiratory apparatus, viz. the scaleni and the serratus magnus; 3d, those which have but remote relations to the thorax as a respiratory cavity, namely, the pectoralis major and minor, and the subclavius. The diaphragm, the most important muscle of the chest, is usually described as a muscle of the abdomen, in consequence of its being dissected from the abdomen.

PECTORALIS MAJOR.—*Dissection.*—Before commencing the dissection of this muscle, place a block under the shoulders of the subject, and extend the arm; this will place the muscular fibres on the stretch.

To display the muscles of the thorax the upper extremities must be removed. In doing this, certain muscles are met with which may as well be described here, although they do not really belong to the thorax, and certain other structures (the mammæ): the systematic description, as well as physiological arrangement, require to be considered else-

where. What may be readily understood of these organs will be stated here, their systematic description being reserved.

These muscles connect each pectoral extremity to the trunk. Of these, five are met with on the back, and have been already described. The remaining four are the pectorales major and minor, the serratus magnus, and subclavius.

Having extended the arm nearly to a right angle with the body, make an incision in the mesial line the full length of the sternum; a second from the middle of this one, obliquely outwards to the upper and fore part of the arm. Two flaps are thus formed, which ought to be dissected, the upper one from below upwards, the lower from above downwards. These incisions must be made with great care.

If it be the object merely to expose the pectoralis major muscle, these incisions ought to be carried deep enough to expose the muscular fibres, and the entire muscle should be cleaned at once. This is the course the beginner should adopt. If, on the other hand, it be his second dissection of the region, and other structures are now to be examined, the incisions should be carried no deeper than the superficial fascia, and the relations of this fascia examined.

1. On the inner side of the upper flap of integuments he will find some of the terminating fibres of the platysma myoides or latissimus colli, a muscle already described. These fibres have descended from the sides of the neck, crossed the clavicle, and, spreading themselves out towards the shoulder, seem attached to the surrounding cellular tissue.

2. In the hollow between the deltoid and pectoralis muscle will be found the upper portion of the cephalic vein.

3. A little lower down, and met with whilst reflecting the lower integumentary flap, lies the mammary gland in the female; in the male this gland is merely rudimentary.

Proceed with the dissection of the muscle, reserving the gland, when entirely removed, for a future examination, cleaning the muscle fully as you proceed.

PECTORALIS MAJOR.—Large, flat, and triangular.

Attachments.—1st, to the inner half of the clavicle; 2d, to the anterior surface of the sternum; 3d, to the cartilages of the second, third, and fourth ribs, and to a small part of the osseous portion of the fifth rib; 4th, and lastly, to an aponeurosis continuous with that of the abdomen. Inferiorly, the attachments of the muscle are intermingled with those of the external oblique and rectus of the abdomen.

From these various origins or attachments, clavicular, sternal, costal, and aponeurotic, the muscular fibres proceed, converging, to cross the axilla, of which they form the anterior wall, and ultimately to form a tendon attached to the anterior or external margin of the bicipital groove of the humerus.

The clavicular portion is generally separated from the rest by a cellular line. The tendon of attachment to the humerus is twisted

on itself, as also the fleshy belly of the muscle; the tendon, moreover, is composed of two laminæ, placed one before the other, separated above, but united below.

From the tendon, superiorly, there runs an aponeurotic slip, ascending before the bicipital groove, to unite with the tendon of the supraspinatus muscle; it also sends into the groove a fibrous lamina, continuous with that detached from the tendons of the teres major and latissimus dorsi.

Anteriorly, the muscle has relations with the platysma myoides, the mamma, and the integuments; *posteriorly*, with the pectoralis minor, and many other important structures—such as, a part of the anterior surface of the sternum; the cartilages of certain of the ribs, and a portion of their bony structure; the thoracic vessels and nerves; the subclavius; intercostales externi; serratus magnus; rectus abdominis; obliquus abdominis externus; numerous lymphatic glands; and axillary vessels and nerves, embedded in an abundant lax cellular tissue. Lastly, it passes before the coraco-brachialis and biceps flexor cubiti.

It is important to trace the relations of the edges of this large muscle. Its *inner*, or *sternal edge*, is interlaced with that of the opposite side; its *upper* edge is continuous with that of the deltoid, from which, however, it is separated by a cellular triangular space, broader above than below. A portion of the cephalic vein, and some branches of the acromio-thoracic artery, are met with in this space. The inferior edge is free, and forms the anterior margins of the hollow of the axilla.

Action.—The muscle is essentially a muscle of the arm, which it moves in various directions. It is of vast size in athletic men. It can also act on the trunk when the arms are fixed. It is the antagonist, to a certain extent, of the latissimus dorsi, but their actions are frequently combined.

Pectoralis Minor.—*Dissection.*—Raise the pectoralis major by a semicircular incision through the whole thickness of the muscle, at the distance of about 1½ inch from its clavicular and sternal origins; reflect the divided portions, and thus expose, with other parts, the pectoralis minor.

Thin and triangular. *Attached*, by its base, to the third, fourth, and fifth ribs, by so many thin, aponeurotic laminæ or digitations. From these the muscular fibres ascend convergingly, upwards and outwards, to be attached by a tendon to the anterior part of the coracoid process of the scapula, as far as its summit, where it unites with the coraco-brachialis and biceps.

Anteriorly, the muscle is covered by the pectoralis major; *posteriorly*, it is in relation to the ribs, the external intercostal muscles, the serratus magnus, the axillary vessels and nerves, and several lymphatic glands. The upper and lower edges are free.

The muscle is properly a muscle of the shoulder. In action it draws the shoulder forward; but it may act also on the ribs when the shoulders are fixed.

SUBCLAVIUS.—*Dissection.*—A thin aponeurosis, called subclavian which some anatomists consider as a ligament, conceals this muscle from view. The aponeurosis in question extends from the first rib, outwards and upwards, to the clavicle and coracoid process. Its lower edge is generally strong. Remove this aponeurosis, and clean the surface of the muscle.

The *subclavius* is extended obliquely between the cartilage of the first rib and the clavicle, to both of which it is attached. Its origin lies in front of the costo-clavicular ligament.

The muscle is lodged in the groove observed on the lower surface of the clavicle, and its clavicular attachment extends to the coraco-clavicular ligament.

The muscle rests, *posteriorly*, upon the axillary vessels, brachial plexus, and nerves. Its lower edge is free, and separated from the first rib by the axillary artery, vein, and nerves, over which, with the aponeurosis, it forms an arch.

In action the subclavius lowers and carries forward the clavicle, and with it the shoulder.

Dissection of the axilla.—It is at this stage of the dissection of these muscles that the axillary cavity is met with; but the student, desirous of laying a solid foundation for his future anatomical knowledge, should on no account attempt the dissection of the axilla until he has thoroughly mastered the difficulties of the muscular system. I refer the advanced student to the Chapter on the Vascular System for an account of the mode of dissecting the axilla, and proceed with the systematic history, and the method of exposing the remaining muscles belonging in whole or in part to the thorax.

SERRATUS MAGNUS.—*Dissection.*—Saw through the clavicle about the centre; cut across the axillary artery, vein, and axillary nerves, about an inch below the edge of the subclavius muscle; divide the subclavius itself. Extend the arm as far as possible from the trunk, and clean the muscle in the direction of its fibres.

The *serratus* muscle is one of the largest in the body. It arises, by eight or nine fleshy slips, from the superior ribs, commencing with the first.

These fasciculi proceed outwards, converging, to terminate finally along the inner edge of the vertebral margin of the scapula.

The muscle is obviously composed of three parts—a superior, middle, and inferior; all these have their distinct characters. The superior is thick, short, and strong; the middle thin, and sometimes wholly deficient about its centre; the lowest is large, broad, and fleshy. A great quantity of loose cellular substance connects the muscle to the sides of the chest, and to the subscapular muscle, to facilitate, no

doubt, the sliding motion of the shoulder over the thoracic walls, effected chiefly by means of this muscle. Besides carrying the whole shoulder forward, and consequently the arm itself, it becomes, under certain circumstances, a powerful muscle of inspiration and effort.

Fig. 154.*

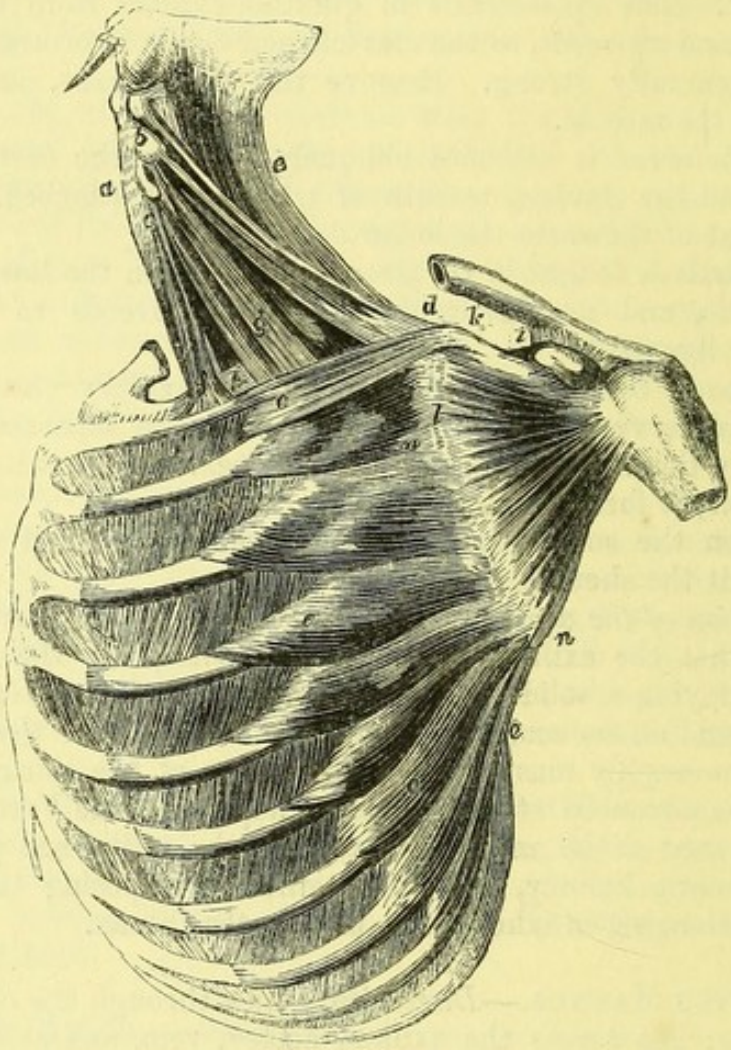

INTERCOSTALES EXTERNI.—Eleven in number, and situated in the intercostal spaces. Their dissection requires no particular directions.

Attached to the outer lip of the lower edge of the rib above, and to the upper edge of the rib below; also, in part, to the transverse pro-

* Fig. 154.—This figure is intended to give a clear and comprehensive view of the serratus magnus muscle; such a view, in short, as it is not easy to persuade the student to take on the subject in consequence of the depth of the dissection, and the necessity there is for cutting away so many important organs which lie in the way.—*a*, front of the cervical vertebræ; *b*, transverse process of the second cervical vertebra; *c*, *f*, scalenus anticus muscle; *h*, portion of the first rib; *g*, scalenus medius and scalenus posticus; *e*, ligamentum nuchæ; *d*, levator anguli scapulæ; *k*, collar-bone; *i*, coraco-clavicular ligaments; *l*, scapular attachment of the subscapularis muscle; *n*, lower margin of the muscle; *o*, *o*, *o*, costal origins of the serratus magnus; *e*, lower margin of the muscle; *m*, scapular attachment, upper portion.

cess carrying the lower rib; the course of these fibres is from above downwards, and from behind forwards. Tendinous bundles are prolonged between them. A delicate aponeurosis continues the muscle as far as the sternum, but the muscular fibres themselves do not extend so far.

Externally, they are in relation to the muscles just described, including the deeper layer of those of the back; internally, they correspond to the pleura of that side, from the tubercle to the angle of the rib, and from this point to their termination forwards they are in relation to the internal intercostal muscles, separated from these, however, by the intercostal vessels and nerves, and by a layer of cellular substance passing from rib to rib.

INTERCOSTALES INTERNI.—*Dissection.*—To expose these, remove the external intercostals.

Eleven in number. Those occupying the intercostal spaces of the true ribs extend outwards from the sternum to the angles of the ribs; those lower down, from the extremities of the cartilages of prolongation to the same point. Their fleshy fibres are intermingled with aponeuroses, and their attachments above and below are similar to the external intercostals; but their fibres run in an opposite direction, that is to say, from before backwards, a fact which has caused much speculation amongst physiologists from Galen to the present day.

Externally covered, in part, by the preceding muscles, they are lined internally by the pleuræ.

The action of both sets of intercostals is the same; they fix the ribs, and, by so doing, expand the chest, enabling the diaphragm to act upon it.

LEVATORES COSTARUM.—These muscles are easily found on the back of the chest.

A small, flat, triangular, fleshy, and tendinous slip descends obliquely from above downwards, from behind forwards, from the summit of each transverse process to the upper edge of the rib below, and occasionally to the one lower down. The first arises from the last cervical vertebra. Their action, no doubt, is to raise the ribs.

TRIANGULARIS STERNI.—*Dissection.*—Before this muscle can be examined, the thorax requires to be opened. If the object be merely to examine the muscle (one on each side), this is best done by dividing, with a saw, the ribs on either side, at the distance of about 3 or 4 inches from the margins of the sternum; detach the abdominal parietes from the edges of the thorax, and raise the flap thus made. The portion raised will include the sternum and both triangular muscles; these require merely to be cleaned.

Arising from the edge of the ensiform cartilage and sternum, as high as the articulation of that bone with the cartilage of the fourth rib; thence ascending outwards, the muscle is attached, by so many digita-

tions, to the edges and inner surface of the cartilages of the third, fourth, fifth, and sixth ribs.

Relations.—Anteriorly, the muscle is covered by the cartilages of the last four true ribs, the internal intercostal muscles, and the internal mammary arteries and veins; the posterior surface rests upon the pleura, and, in a small part of its extent, on the diaphragm. It is supposed to be a muscle of expiration.

INFRA-COSTALES.—In various places on the inner side of the thorax there may be seen, on stripping off the pleuræ, small planes of muscles, varying much in respect of size, number, and situation. They descend obliquely backwards from one rib to that which follows it, sometimes, however, passing over a rib. Their real history is not well known, but they no doubt form vestiges of a structure more highly developed in other animals.

For the anatomy of the contents of the thorax, and for the method of displaying these contents, see the Chapter on the Organs of Respiration and Circulation.

TABULAR VIEW OF THE MUSCLES.

The student who has dissected the muscular system just described will have learned by this time that these many-shaped organs cannot be distinctly arranged either in layers or regions, or grouped by function. Most muscles extend into several regions; the latissimus colli, for example, is found on the face, the neck, the chest, and shoulder; its precise functions are unknown; and although called and always considered to be a strictly cutaneous muscle, the vestige in man of a more extended, in some respects, and more highly developed system in other animals, it yet unquestionably has relations to the skeleton.

The defects, then, in every tabular arrangement of organs so constructed, are inherent in the nature of the thing itself; their nomenclature is still barbarous and incorrect. I disapprove, therefore, of the use of tabular views, but, aware that there are some who require to arrange the facts before them in some order or another, I have subjoined a brief table of the muscles, with no further pretensions than to assist those who have defective memories.

I. MUSCLES OF THE HEAD AND NECK.

I. EPICRANIAL REGION.

I.

1. Right frontal.
2. Left frontal.
3. Right occipital.
4. Left occipital; usually called occipito-frontalis.

II.

Epicranial Aponeurosis.

II. AURICULAR REGION.

EXTRINSIC MUSCLES OF THE EAR.

1. Attollens aurem.
2. Retrahens aurem.
3. Attrahens aurem.

INTRINSIC MUSCLES OF THE EXTERNAL EAR.

1. Musculus tragicus.
2. „ anti-tragicus.
3. Musculus helicis major.
4. „ „ minor.
5. Musculus transversus auriculæ.

DEEP MUSCLES OF THE MIDDLE EAR.

1. Tensor tympani.
2. Laxator tympani.
3. Stapedius.

II. MUSCLES OF THE EYELIDS AND ORBIT.

PALPEBRAL AND ORBITAR REGIONS.

1. Orbicularis palpebrarum.
2. Corrugator supercilii.
3. Levator palpebræ superioris.
4. Tensor tarsi.

---

1. Rectus superior.
2. ,, inferior.
3. ,, internus.
4. Rectus externus.
5. Obliquus superior; trochlearis.
6. ,, inferior.

Within the eyeball are structures, considered by some as muscular:—

1. The iris.
2. The annulus albus.

III. MUSCLES OF THE FACE.

NASAL REGION.

1. Pyramidalis nasi.
2. Compressor narium.
3. Levator communis.
4. Depressor alæ nasi.
5. Levator proprius alæ nasi posterior.
6. ,, ,, ,, anterior.

SUPERIOR MAXILLARY REGION.

1. Levator labii proprius.
2. ,, anguli oris.
3. Zygomaticus major.
4. ,, minor.

INFERIOR MAXILLARY REGION.

1. Triangularis oris.
2. Depressor labii inferioris.
3. Levator labii inferioris.

INTERMAXILLARY REGION.

1. Buccinator.
2. Risorius (when present).
3. Orbicularis.

TEMPORO-MAXILLARY REGION.

1. Masseter.
2. Temporalis.

PTERYGO-MAXILLARY REGION.

1. Pterygoideus externus.
2. Pterygoideus internus.

IV. MUSCLES OF THE NECK.

The numerous and rather complex muscles occupying this extensive section of the trunk cannot well be arranged in regions; they are best examined and enumerated merely in the order of their dissection. The *triangular spaces* of surgical writers are poor inventions to supply the want of a sound anatomical knowledge.

1. Latissimus colli.
2. Sterno-cleido mastoideus.
3. Sterno-hyoideus.
4. Sterno-thyroideus.
5. Omo-hyoideus.
6. Thyro-hyoideus.
7. Crico-thyroideus.

8. Digastricus.
9. Stylo-hyoideus.
10. Stylo-glossus.
11. Stylo-pharyngeus.

12. Mylo-hyoideus.
13. Genio-hyoideus.
14. Hyo-glossus.
15. Genio-hyo-glossus.
16. Lingualis.

17. The intrinsic muscles of the tongue.

PHARYNGEAL, PALATAL, AND LARYNGEAL REGIONS.

18. Constrictor pharyngis inferior
19. ,, ,, medius.
20. ,, ,, superior.
21. Levator palati mollis.
22. Circumflexus palati.
23. Azygos uvulæ.
24. Palato-glossus.
25. Palato-pharyngeus.

Laryngeal.

26. Crico-arytenoideus posticus.
27. ,, ,, lateralis.
28. Thyro-arytenoideus.
29. Arytenoideus.
30. Aryteno-epiglottideus.
31. Thyro-epiglottideus.
32. Levator glandulæ thyroideæ.

Return to the muscles of the trunk, and examine the system of the deep muscles lying close to the spine.

SCALENI, RECTI, LONGI COLLI.

1. Scalenus anticus.
2. ,, medius.
3. ,, posticus.

(Soëmmering describes five scaleni on each side, which no doubt are occasionally present).

4. Rectus capitis anticus major.
5. ,, ,, minor.
6. ,, ,, lateralis.
7. Longus colli.

V. MUSCLES OF THE TRUNK.

BACK.

1. Trapezius.
2. Latissimus dorsi.
3. Rhomboideus major.
4. ,, minor.
5. Serratus posticus superior.
6. ,, ,, inferior.
7. Levator anguli scapulæ.
8. Splenius capitis.
9. Splenius colli.
10. Sacro-lumbalis.
11. Musculi accessorii.
12. Longissimus dorsi.
13. Transversalis colli.
14. Complexus minor; trachelo-mastoideus.
15. ,, major.

16. Spinalis dorsi.
17. Semi-spinalis colli. „ „ dorsi. „ „ lumborum.
18. Inter-spinales.
19. Inter-transversales.
20. Levatores costarum.
21. Rectus capitis posticus major.
22. „ „ minor.
23. Obliquus capitis superior.
24. „ „ inferior.
* 25. Rotatores spinæ of Theile.
* 26. Extensor coccygis of Gunther and Mulde.

* These are rudimentary or vestigiary muscles, which are only occasionally present.

FRONT AND SIDES.—1. *Thoracic Portion.*

1. Pectoralis major.
2. „ minor.
3. Subclavius.
4. Serratus magnus.
5. Intercostales externi
6. „ interni.

Seen only when the chest has been opened.

Infra-costales. Triangulares sterni.

ABDOMINAL AND PERINEAL REGIONS.

ABDOMINAL.

1. Obliquus abdominis externus.
2. „ „ internus.
3. Transversalis abdominis.
4. Rectus.
5. Pyramidalis.
6. Cremaster.

On opening the Abdomen—

IN MAN.

1. Diaphragm.
2. Quadratus lumborum.
3. Psoas parvus.
4. „ magnus.
5. Iliacus.

PERINEAL.

Externally.

1. Sphincter ani.
2. Erector penis.
3. Accelerator urinæ.
4. Transversus perinei.

Within the Pelvis.

5. Levator ani.
6. Ischio-coccygeus.
7. Coccygeus.

Connected with the Urethra.

Compressor urethræ.
Levator muscles of Wilson.

IN WOMAN.

1. Erector clitoridis.
2. Constrictor vaginæ.

These exist under other names in man.

VI. MUSCLES OF THE SUPERIOR EXTREMITIES.

SHOULDER.

1. Deltoid.
2. Supra-spinatus.
3. Infra-spinatus.
4. Teres minor.
5. „ major.
6. Subscapularis.

EXTENSOR SIDE OF THE ARM.

1. Triceps extensor. 2. Anconeus.

FLEXOR SIDE OF THE ARM.

1. Biceps. 2. Coraco-brachialis.
3. Brachialis flexor.

EXTENSOR SIDE OF THE FORE-ARM AND HAND.

1. Extensor ulnaris.
2. ,, communis.
3. ,, proprius indicis.
4. ,, ossis metacarpi pollicis.
5. Extensor primi internodii pollicis.
6. ,, secundi pollicis.
7. ,, minimi digiti.
8. Dorsal interossei.

RADIAL SIDE.

1. Supinator longus.
2. Extensor carpi radialis longus.
3. Extensor carpi radialis brevis.
4. Supinator brevis.

ANTERIOR AND ULNAR SIDE—FORE-ARM AND HAND.

1. Pronator teres.
2. Flexor carpi radialis.
3. Palmaris longus.
4. Flexor carpi ulnaris.
5. Flexor sublimis.
6 & 7. Flexor profundus; lumbricales.
8. Flexor pollicis longus.
9. Pronator quadratus.

THE HAND; IN ADDITION TO THE MUSCLES ALREADY MENTIONED.

1. Palmaris brevis.
2. Abductor pollicis.
3. Opponens ,,
4. Flexor brevis pollicis.
5. Adductor pollicis.
6. Abductor minimi digiti.
7. Flexor brevis ,,
8. Adductor ,,
9. Palmar interossei.

The lumbricales have been already mentioned; they are appendages of the deep common flexor of the fingers.

VII. MUSCLES OF THE LOWER EXTREMITIES.

POSTERIOR REGION—HAUNCH.

1. Gluteus maximus.
2. ,, medius.
3. ,, minimus.
4. Pyriformis.

* 5. Gemellus superior.
* 6. Obturator internus.
* 7. Gemellus inferior.

* These form a kind of three-headed muscle.

8. Quadratus femoris. 9. Obturator externus.

POSTERIOR REGION—THIGH.

1. Biceps flexor. 2. Semi-tendinosus.
3. Semi-membranosus.

ANTERIOR REGION—THIGH.

1. Tensor vaginæ femoris.
2. Sartorius.
3. Gracilis.
4. Adductor longus.
5. Pectineus.
6. Adductor brevis.
7. Adductor magnus.
8. Quadriceps extensor cruris.
   - *a*. Rectus.
   - *b*. Crureus; and sub-crureus.
   - *c*. Vastus internus.
   - *d*. „ externus.

LEG AND FOOT—ANTERIOR SURFACE.

1. Tibialis anticus.
2. Extensor communis longus.
3. Peroneus alter (when present).
3. Extensor proprius pollicis longus.
4. Extensor communis brevis.
5. Dorsal interossei.

POSTERIOR AND PLANTAR REGIONS.

1. Gastrocnemius.
2. Plantaris.
3. Soleus.
4. Popliteus.
5. Tibialis posticus.
6. Flexor longus pollicis.
7. Flexor communis perforans.

   Appendages of the Flexor Perforans:—
   - *a*. Massa carnea, or flexor accessorius.
   - *b*. Lumbricales.

These can only be traced in the foot after the superficial layer of muscles of the plantar region has been dissected and removed.

FOOT—PLANTAR REGION.

1. Abductor pollicis.
2. Flexor brevis digitorum.
3. Abductor minimi digiti.

The flexor accessorius and lumbricales have been already enumerated as appendages of the long flexor.

4. Flexor brevis pollicis.
5. Adductor pollicis.
6. Flexor brevis minimi digiti.
7. Transversus pedis.
8. Plantar interossei.

FIBULAR REGION.

In this region of the leg we find two muscles, namely,—

1. The peroneus longus.
2. The peroneus brevis.

The tendon of the long peroneus can only be traced to its termination when all the other parts in the sole of the foot have been dissected.

FASCIÆ AND APONEUROSES.

BURSÆ MUCOSÆ AND RETINACULA, OR ANNULAR LIGAMENTS.

During the dissection of the muscles, the student will have met with, and partially examined in detail, all the structures I am now about to describe. Should circumstances permit, these structures, of much importance in a surgical point of view, merit a careful and systematic examination and revisal as a system.

The term fascia may be taken as expressing, *generally*, three distinct forms of sheaths, enclosing the muscles, tendons, &c., securing them in their situations, and yet offering no obstruction to their varied natural movements. It is a *generic* term, therefore, applicable to fasciæ properly so called, as well as to those sheaths which Continental and exact writers have termed aponeuroses.

The sheaths and enveloping membranes of muscles, generally speaking, are not exclusively formed of one kind of tissue; hence it is difficult rigorously to define what is an aponeurosis and what a cellular sheath; and it is merely for the sake of description, and of rendering the matter clear, in a practical sense, at least, that I venture to speak of the whole system as composed of—1, aponeuroses, properly so called; in these the tendinous fibres predominate; 2, elastic fasciæ, with a slight admixture of the yellow tissue; 3, cellular sheaths or fasciæ, which may be divided into the superficial and the deep. The aponeuroses of the extremities form the best example of the first; the fascia transversalis is an example of the second; mere cellular sheaths abound everywhere; the fasciæ of the neck, of the muscles of the trunk, &c., may be cited as examples of the third class of fasciæ; lastly, the most extended of all the fasciæ, the cellular envelope placed beneath the integuments is intended, no doubt, to facilitate motion and to protect the skin.

I. OF THE SUPERFICIAL AND OTHER CELLULAR FASCIÆ.

On removing what is usually called the integument from almost any part of the body, a cellular layer is met with, varying in thickness and density in different regions, as well as in the abundance or absence of the adipose tissue of which, in youth, it is the peculiar seat. Attached to the skin, on one hand, of which it seems almost to form a constituent layer, it unites by its inner surface with the great cellular structure or *trame*, which everywhere invests the organs of the body, and in which they are, as it were, embedded. This general envelope is in every region of the body called the superficial fascia, and is that

which requires first to be studied; in it are developed the entire system of the superficial or subcutaneous bursæ mucosæ.

The superficial fascia is intimately connected, not merely by cellular tissue, with the integuments above, and with the deeper structures beneath it, but also by means of numerous vessels and nerves which pass through it on their way to the surface of the body; hence its extensive separation from the integuments necessarily causes the death of the latter, unless speedily remedied by surgical means.

In some places, as in the palm of the hand and sole of the foot, it is so extremely dense and fine that its presence has been doubted; it is also very thin under the scalp.

The fascia is lax and abundant at the bending of the great joints of the hip and axilla; the adipose deposition it generally presents varies also greatly at different periods of life, in different persons, and in different places. Fat is never deposited in this fascia beneath the integuments of the eyelids, nor under that of the scrotum. On the other hand, it abounds over the gluteus maximus, especially in the yellow race of men,* and generally persists longest in women. Lastly, in many parts of the body it is divisible into several layers superimposed, but this, to a certain extent, is artificial.

By means of this fascia the skin slides freely over the surrounding parts; when destroyed it adheres to them, and the sliding motion ceases. To facilitate and extend this kind of motion still further, superficial bursæ are placed in it, congenitally, at various points: these I shall now consider.

II. OF THE SUPERFICIAL BURSÆ.

These bursæ or synovial capsules are developed wherever the integument is exposed habitually to much motion and pressure from within and from without. Accordingly, we find them situated—1, over the patella; 2, over the olecranon process; 3, over each external malleolus. These are the more constant ones; but there exist numerous others, smaller and less constant, very generally present over the joints of the fingers and toes. Lastly, numerous others, less perfectly formed, exist in the popliteal space, and in the superficial fascia of the groin and axilla. Some of these do not form complete capsules, but merely imperfect vesicles, opening into the general cellular tissue; and this was at first, that is in the fœtus, the character of them all, prior to their full development.

The fully developed bursæ are frequently double, or even more numerous; and this explains the re-appearance of a second bursa after the destruction of the first by a surgical operation, or otherwise. They are all congenital. The idea entertained by some surgeons that they are, or may be, produced accidentally, is unquestionably erroneous. For the intimate nature of these bursæ and their microscopic characters the reader is referred to the Section on General Anatomy.

* Bosjeman; Hottentot.

III. OF THE SUPERFICIAL FASCIA AS IT COVERS CERTAIN REGIONS.

1. OF THE SUPERFICIAL FASCIA OF THE HEAD AND NECK.—Although the fascia I now speak of scarcely admits of demonstration over the upper and fore part of the cranium, it no doubt exists. It is continuous with that covering the back of the neck; on the face the continuity of the superficial fascia is frequently interrupted by the cutaneous attachments of muscles; in the neck it is found investing the platysma myoides, and forming for that cutaneous muscle an investing sheath; but its chief layer is no doubt beneath the muscle, where we find the external jugular vein and some superficial nerves embedded in it. It is internally connected with the deep cellular fascia; this fascia I shall examine in the second section.

2. SUPERFICIAL FASCIA OF THE THORAX.—Continuous with that covering the rest of the body and limbs, this portion of the great cellular envelope of the body is loose and distinct over the greater part of the chest. The mamma on each side is enclosed between two layers of the fascia; or rather the gland lies embedded in its layers. By its union with the integument around the nipple, it contributes to support the gland and maintain it in its place. In the mesial line of the front of the chest the superficial fascia adheres more closely to the integument and to the deeper structures.

3. The same fascia is found all over the dorsal region of the torso, adhering more closely in the mesial (vertebral) line than elsewhere; it adheres, also, closely to the ligamentum nuchæ, and to the tendinous structures in the loins; also over the sacrum and coccygeal bones.

It is on the abdomen and in the region of the groins that the superficial fascia acquires a really surgical importance. It is for this reason that writers on surgical anatomy have divided and subdivided this fascia, some viewing it as composed of one layer, others as of two, and some as of three distinct layers. The difficulty consists mainly in their not having defined what layers they mean to include in their term of superficial fascia; whether they confine their view to that portion whose natural relations are with the skin, or extend it to that deeper layer which forms the proper investing cellular sheath of the muscles and their tendons. To examine and understand this fascia correctly, dissect the integuments downwards for about two inches, from off the abdomen and upper surface of the thigh. If the subject be a male, extend the incision through the integuments nearly to the extremity of the penis, carrying another downwards quite to the bottom of the scrotum.

By these incisions the relations and structure of the superficial fascia may readily be made out. These have a reference chiefly to the position of the superficial vessels imbedded in it; its close connexion inferiorly with Poupart's ligament; its descent upon the penis, where, devoid of fat, it forms the sheath of the penis and superficial suspensory

ligament; its descent into the scrotum, of which it forms one of the layers; lastly, its attachment to the rami of the pubes and ischium, and its passage across the perineum, of which it forms the superficial fascia.

Practically, the superficial abdominal fascia just described may be viewed merely as one layer; but occasionally, in pathological investigations especially, it may be advantageously viewed as composed of two layers. In such inquiries it ought not to be confounded with the third cellulo-membranous covering, investing more immediately the muscles and their tendons.

It remains to say a few words respecting the superficial fascia as it is found in the perineum. Continuous with that of the abdomen and thighs, it nevertheless is attached to the rami of the pubes and ischium. It has been described as composed of two distinct laminæ,—1, a subcutaneous layer, thick and cellular, containing fat, and more adherent to the skin, of which no doubt it forms a constituent part; 2, a deeper layer, attached firmly to the periosteum and closely adherent to the muscles. It is clear that this layer of the fascia is merely the proper cellular fascia of the muscles, strengthened at the pleasure of the dissector by an artificial dissection of the superficial layer.

SUPERFICIAL FASCIA OF THE LOWER EXTREMITIES.

In the lower limbs the superficial fascia holds of course the same relations to the integuments and to the deeper structures which it does in other parts of the body. It connects the integuments everywhere with the aponeurosis of the lower extremity. On the sole of the foot, as in the palm of the hand, it is so thin that its presence has been questioned. In the groin it has important surgical relations. The superficial vessels and nerves, and especially the large subcutaneous veins, are imbedded in it; the superficial lymphatic glands also, and lymphatic vessels. It is intimately united to Poupart's ligament. The thin *cribriform* cellular layer extending from the saphenic opening upwards, and shutting in the vessel at this point, has been by some considered as a portion of the superficial fascia now described, but others have taken an entirely different view of its nature. For the surgical and pathological view of the relation of the superficial fascia to inguinal and crural hernia see the account of hernia in the section on the abdomen.

The subcutaneous synovial bursæ found in the superficial fascia of the lower limbs are,—1, that over the patella; 2, one over each malleolus; 3, one in the popliteal space; 4, several imperfectly developed bursæ in the groins; 5, several in connexion with the toes, and more especially one on the inner side of the metatarso-phalangeal articulation of the great toe.

SUPERFICIAL FASCIA OF THE ARM.

This fascia, though simple in its anatomy, should be carefully dissected and examined. It invests the whole limb, and has the same relation to the integuments over it, and to the aponeurosis under it, which we have seen in respect of the same fascia in the lower limbs.

The superficial veins lie imbedded in its deepest layer; also the superficial arteries, lymphatics, glands, and nerves. In the palm of the hand it is extremely thin; the superficial bursæ mucosæ over the anconeus process, acromion, inferior head of the ulna, and fingers, are imbedded in this fascia.

OF CERTAIN DEEP FASCIÆ MORE IMMEDIATELY CONNECTED WITH THE VISCERA.

These fasciæ belong to the trunk, and the order of their consideration is of little moment. The view taken here is a systematic one merely in this, that it describes parts in a single chapter which naturally have no connexion with each other. The practical and surgical view of each will be found in the chapters on the various muscles, vessels, and viscera with which they are more immediately connected.

HEAD AND NECK.

In this region of the body we have several fasciæ more or less deep and complicated.

1. The *temporal fascia* has been described along with the temporal muscle. Superiorly it is formed of a single lamina; inferiorly of two, which are attached to the outer and inner margins of the zygomatic arch. A layer of fat and some small arteries lie between the layers.

Parotid fascia.—A strong layer of condensed cellular tissue, forming a fascia, descends from the zygomatic arch, covering the parotid gland. The attachments of this cellular sheath of the parotid are,—superiorly to the zygoma, inferiorly to the deep cervical fascia, posteriorly to the cartilaginous portion of the external meatus of the ear, mastoid process, and upper portion of the sterno-mastoid muscle; anteriorly, it sends a thin covering over the masseter muscle, still partaking of some strength. The posterior surface of the parotid has also its investing fascia, which unites at the margins with the one just described.

THE DEEP CERVICAL FASCIA.

This fascia is met with on removing the latissimus colli and trapezius muscles. Its attachments are posteriorly, where thinnest, to the spinous processes of the cervical vertebræ and to the ligamentum nuchæ. Proceeding from this forwards over the splenius and levator

anguli scapulæ, it first meets the sterno-mastoid, on the external margin of which it divides into two layers, enclosing the muscle and re-uniting at its anterior margin. The layer thus become again single, may be traced to the mesial plane of the neck, where it unites with that of the opposite side. It may be traced upwards to the lower jaw, and downwards behind the collar-bone and sternum as far as the pericardium, to the fibrous layer of which it is connected. In the mean time a portion of the same fascia passes over the collar-bone as far as the pectoral muscle. It is through this layer that the internal jugular vein passes from without inwards on its way to join the deeper veins. A deep layer, in its arrangements similar to that which we have seen happen in respect of the sterno-mastoid muscle, furnishes sheaths for all the other muscles of this region, sheaths for the vessels, and a covering for the thyroid body. A process from this deep layer is attached to the styloid process of the temporal bone and angle of the lower jaw; it has been called the stylo-maxillary ligament. A portion of the fascia secures the inferior belly of the omo-hyoid to the clavicle, and is connected with the subclavian aponeurosis. The method of dissecting and studying the relations of this fascia has been already given.

The *prevertebral fascia* is a layer of condensed cellular membrane interposed between the larynx and the muscles lying in front of the vertebral column. It is attached to the basilar process of the occipital bone, and on each side to the anterior tubercles of the transverse processes of the cervical vertebræ. Deep abscesses sometimes form under this fascia, requiring to be punctured through the mouth and pharynx.

DEEP PECTORAL FASCIA.

Beneath the pectoralis major muscle, and in connexion with the costo-coracoid ligament, is a layer of cellular membrane, which may be viewed as a fascia. Superiorly, it gives rise to the subclavian aponeurosis or fascia, and is stretched over the vessels; inferiorly, it expands over the pectoralis minor, gradually degenerating into mere cellular tissue.

INTERCOSTAL FASCIÆ are thin, cellulo-fibrous layers of membrane, extending from the inferior margin of one rib to the superior margin of the rib below.

The *vertebral aponeurosis* has been described when speaking of the serrati muscles. It connects the margins of these muscles to each other, and forms a covering for the long muscles of the back, occupying in this region the vertebral grooves.

DEEP FASCIÆ OF THE ABDOMEN.

FASCIA TRANSVERSALIS.—The method of dissecting and demonstrating this fascia belongs, properly speaking, to the history of the muscles and viscera; in both these sections it will be found that this fascia has been particularly adverted to. The anatomical relations and the nature of the fascia may be thus briefly summed up:—

Of a firm and dense, and perhaps elastic character in some places, and where strongest of a slightly yellow colour, this important fascia is interposed between the transversales muscles and the peritoneum. A thin layer of adipose cellular tissue separates it from the peritoneum, and the posterior surface of the transversalis muscle has its own investing covering of cellular tissue. Thus, the fascia transversalis is a distinct organic part, not derivable from any adjoining cellular fascia or layer. It is usual to expose it first in the inguinal region, where it is strongest, but it may be traced upwards to the diaphragm and uninterruptedly across to the other side of the abdomen. It is extremely thin mesially and superiorly. Inferiorly it unites firmly with the lower margin of Poupart's ligament, and externally to the inner lip of the crest of the ilium throughout nearly its whole length. When looked at along this line of junction, externally, it might be supposed to terminate here by firmly adhering to the periosteum, but on being divided and reflected it will be found continuous on its inner surface with the fascia iliaca, so that these two fasciæ, though differing considerably in structure, may yet be considered as a continuation of the same system.

As the great vessels pass from the trunk to the limbs under Poupart's ligament, they are generally considered as invested in a sheath derived from the outer surface of the fascia transversalis, aided no doubt by the cellular sheath they bring with them from the abdomen.

About half way between the spine of the ilium and the pubes, at a short distance above the level of Poupart's ligament, is an irregular aperture in the fascia transversalis, through which passes the round ligament in the female and the spermatic cord in the male. The opening is not distinct until dissected and cleaned, being shut in by a fine layer of cellular membrane, which these structures bring with them from the outer surface of the peritoneum; and perhaps from the margins of the deep ring itself, although this is not so clear. This delicate membrane, however formed, invests immediately the cord and round ligament, forming their *proper* covering whilst occupying the inguinal canal.

The opening I have just described is the deep abdominal ring through which the bowels pass in indirect inguinal hernia, pushing the peritoneum before them. The epigastric artery lies on its inner pillar, or margin, connected to it by cellular membrane.

FASCIA ILIACA.

The origin of this fascia, as a continuation of the fascia transversalis, along the inner margin of the crest of the ilium, has been already alluded to. Its anatomical relations and structure are as follows:— 1, it crosses the iliacus and psoas muscles, and receives tendinous or aponeurotic fibres from the psoas parvus, when that muscle is present. 2, it encloses between two layers the psoas magnus, and, again subdividing, it furnishes a sheath for the external iliac vessels, and, once more uniting into a single lamina, it passes over the brim of the pelvis, adhering to the periosteum. Descending into the pelvis, it becomes, or at least is continuous with, the pelvic fascia. Superiorly the fascia extends upwards as high as the ligamentum arcuatum.

PELVIC FASCIA.

The relations of this fascia are best understood and demonstrated whilst dissecting the pelvic viscera. Several views require to be taken of it; perhaps the best is that which may be had when, after the dissection of the *lateral section* of the pelvis, the viscera can be drawn outwards towards the left side, and the pelvic fascia viewed on the inner surface of the right side of the pelvis. But it requires also to be examined from the perineum, and a good view may be had of the fascia by removing the sacrum.

The pelvic fascia, continuous with the fascia iliaca, adheres to the brim of the pelvis, along the ileo-pectineal line. From this origin it descends into the pelvis, first covering the concave or inner surface of the levator ani and obturator internus muscles on each side. Between the inner surface of the pubes and spine of the ischium, it forms an aponeurotic arch, and at this point divides into two laminæ, one of which, descending on the convex or external side of the levator ani, proceeds to the cellular substance around the sphincter. Prior to this, however, this outer lamina has again subdivided into two layers, of which the more external proceeds outwards to be attached to the tuberosity and ramus of the ischium. The space between these two laminæ of the pelvic fascia is called the ischio-rectal space, and can be examined only from the perineum. Returning to the innermost layer of the pelvic fascia, we find it passing uninterruptedly downwards into the pelvis until it meets the bladder, prostate gland, and rectum. Over these it is reflected, giving to each of them, more especially to the bladder, a covering more or less complete.

Passing from the fore part of the bladder to the back part of the symphysis of the pubes, it forms the anterior ligaments of the bladder, whilst laterally it forms the most important and secure connexion the bladder has with the walls of the pelvis. Thus arise the prostatic, vesical, and rectal fasciæ, all emanating from one, the pelvic.

It is the examining this fascia as so many unconnected laminæ, and under a variety of names, which has hitherto rendered its description

unintelligible to the student. But in the absence of a good *section* of the pelvis, it cannot be comprehended from any mere description.

THE PERINEAL FASCIÆ.

Under this name some surgical anatomists comprise the superficial fascia, already described, and an interosseal ligament filling up the triangular space below the pubes and perforated for the passage of the urethra. This ligament is very firm above the urethra, but weak below it. Above, it is connected with the subpubic ligament. The lower margin of the stronger, or superior portion, sends a layer forwards, which becomes continuous with the coverings of the bulb and the corpus spongiosum urethræ; another backwards towards the fibrous tunic of the prostate. The lower edge of the lower portion also divides into two layers; one joins the superficial fascia, the other spreads out upon the surface of the levator ani.

The glands of Cowper and the compressor muscle of Santorini are usually described as lying between the layers of the triangular ligament of the pubes.

APONEUROSES AND RETINACULA, OR ANNULAR LIGAMENTS.

There are, properly speaking, but four true aponeuroses in the body, namely, those investing the upper and lower limbs.

APONEUROSIS OF THE UPPER EXTREMITY.

This extensive fascia or aponeurotic investing-sheath is fibrous only in certain parts; where thin, it resembles condensed cellular tissue. It descends from the clavicle and spine of the scapula, to which it is attached, downwards, to the fingers, investing the arm, fore-arm, and hand with a general investing fascia, and, by separating into layers, it encloses many of the muscles and their tendons in distinct fibrous sheaths. It adheres, by partitions called intermuscular septa, to the external and internal fibrous layers; these run from the condyles of the humerus, upwards; it also receives a tendinous layer from the biceps. In the palm of the hand, where it is called the palmar aponeurosis, it forms three distinct portions of varying strength; it covers the back of the hand, but not the fingers.

RETINACULA OF THE TENDONS CONNECTED WITH THIS APONEUROSIS.

It is usual to describe the retinacula or annular ligaments as portions merely of the general investing aponeuroses of the limbs, but minute dissection demonstrates that they are not strictly so. That they are intimately united with them may be admitted.

1. Anterior annular ligament of the carpus. This retinaculum of the tendons of the flexor muscles extends transversely from the scaphoid and trapezium on the outer side, to the unciform and pisiform bones on the inner side. It thus forms a bridge, below which run the flexor tendons and median nerve into the palm of the hand. The deeper surface is invested by the vaginiform bursa of the tendons.

2. The posterior annular ligament of the carpus extends from the outer margin of the radius on one side, to the pisiform bone and palmar fascia on the other. It forms various sheaths for the different extensor tendons, by partitions sent down to the bones, thus forming fibro-osseous grooves, lined by synovial membranes, in which the tendons play.

The fibrous sheaths, or retinacula, retaining the flexor tendons in their places on the palmar side of the digital bones, have been already described; they are also lined by synovial sheaths.

APONEUROSIS OF THE LOWER LIMBS.

The lower extremities have their investing aponeurotic fascia, remarkable for its strength. It invests the entire limb, with the exception of the toes, and gives, besides, numerous sheaths for muscles and tendons, sometimes singly or in groups. In the thigh it is called the fascia lata; in the leg, the aponeurosis of the leg; in the foot, the dorsal and plantar aponeurosis: it is one membrane throughout. The tendons of some muscles are attached to it, such as the tensor and gluteus; it transmits many partitions to the bones between the muscles, gives origin to numerous muscular fibres, and strengthens the cellular sheaths of the vessels.

Superiorly, it is attached to Poupart's ligament, but it divides into two layers external to the vessels, and in this way is formed the crescentic margin or duplicature, and the layer passing behind the vessels to join the inferior edge of the fasciæ transversalis and iliaca. Some view the cribriform fascia as a continuation of the outer layer.

At many points, as at the crest of the ilium, tuberosity of the ischium, &c., it is directly connected with the periosteum. Like the aponeurosis of the upper limb, it forms intermuscular septa or partitions. The sheath it gives to each of the muscles should be examined separately, as has been already explained.

On the *dorsum* of the foot the aponeurosis of the limb is distinct, but thin, as in the hand. The *plantar fascia* is, on the contrary, of great strength, and divided, as in the hand, into three portions, a middle, external, and internal. It is the middle or centre one which shows such remarkable strength. Between these portions intermuscular partitions are sent upwards towards the bones, dividing the muscles from each other by sheaths of greater or less strength.

Opposite the middle of the metatarsal bones, the central portion of the fascia divides into five portions, which, diverging, and further subdividing, leave space for the passage of the tendons, vessels, and nerves. Each of these processes proceeds to one of the toes, and terminates by

being attached to the proximal end of the nearest phalanx, to which they are attached by the dorsal termination in which each ends. Strong transverse fibres are superadded, binding these processes to each other.

OF THE RETINACULA CONNECTED WITH THE CRURAL APONEUROSIS.

These retinacula are—1, the so-called anterior annular ligament of the tarsus; 2, the internal annular ligament; 3, the external.

By means of the first of these, the tendons of the tibialis anticus, extensor proprius pollicis, extensor communis, and peroneus tertius, when present, are bound down in passing from the leg to the foot. The bridge-shaped ligament is formed of two bands; the upper extends from the lower end of the fibula to the lower end of the tibia, to both of which bones it is attached. The *lower band* extends from the lower end of the tibia to the upper surface of the calcaneum, thus assisting in binding down the same tendons.

These bands, by splitting into two portions, form sheaths, lined by synovial membranes. Thus the tendons pass in separate compartments of the ligament. The anterior tibial vessels and nerves pass under the same ligament, towards the dorsum of the foot.

The internal annular ligament is the *retinaculum* of the tendons of the tibialis posticus, flexor longus digitorum, and flexor proprius longus pollicis. The posterior tibial vessels and nerves also pass under the ligament, on their way to become plantar.

It is attached to the inner malleolus and to the calcaneum, between which osseous points it forms a bridge.

Nearest the malleolus pass the tendons of the tibialis posticus and long common flexor: these pass in one groove, afterwards subdivided. Behind them pass the vessels and nerves, and, at a certain distance behind, the tendon of the flexor longus pollicis. The tendons have synovial bursæ developed on them in common with the deep surface of the ligament.

The external annular ligament is the strong fibrous band which retains in their place the tendons of the peroneus longus and p. brevis muscles, as they pass behind the malleolus externus, towards the foot. It is stretched over these tendons, from the malleolus externus to the outer surface of the calcaneum, to both of which it is attached. A synovial bursa, as usual, protects the tendons of the ligament.

The fibrous sheaths binding down the tendons of the flexor muscles proceeding to the toes differ from those found in the fingers only in size. These structures require merely to be examined in order to be perfectly understood. They are crisp, and of great strength, and are protected, as well as the tendons they enclose, by vaginiform bursæ, quite analogous to those existing in the fingers.

ORGANS
OF
RESPIRATION AND CIRCULATION.

THE HEART, LUNGS, AND THEIR APPENDAGES.

EXAMINATION OF THE CAVITY OF THE THORAX AND ITS CONTENTS.

THE food, after being partially digested in the stomach, passes from that cavity into the small intestines, where its nourishing portion is converted into a highly animalised liquid, termed chyle. This liquid is absorbed, or taken up in a way not yet well understood, by numerous very delicate vessels or tubes provided with perfect valves. These vessels are called lacteals; they form a portion or section of a large system of vessels, to which the general name of the lymphatic or absorbent system of vessels has been given. The use of the lacteals is obvious, but not so that of the general lymphatics or absorbents. Be this however as it may, they unite at last into one vessel of no great size, called from its situation the thoracic duct. By means of this duct, the chyle, and whatever is contained in the lymphatic system, is poured into the general torrent of the blood.

The circulation of the blood itself is carried on by two sets of vessels, veins, and arteries, and by the heart. The heart is the centre of the circulation; it is placed in the thorax, which will be described immediately.

But it is a law of life that the blood requires to be purified by being exposed in a peculiar way to the action of the atmosphere, and hence the necessity for the organs of respiration, the lungs. These also are placed within the thorax, and may be most advantageously examined at the same time with the heart.

To render the history of the thoracic viscera at once practical and systematic, I shall first describe the mode of exposing and dissecting the contents of the thorax, adding to this the systematic anatomy of the heart, the lungs, and their appendages, including the larynx or organ of the voice.

THE THORAX, VIEWED EXTERNALLY.

The interior of the thorax is not so extensive as its external dimensions would lead one to suppose; this is owing to the ribs shutting in as it were, and forming, or assisting to form, the hypochondria, and thus contributing (though indirectly) to form a part of the abdominal parietes likewise. The cavity itself extends from the lower part of

the neck to the abdomen, and contains, 1, the lungs; 2, the pleuræ, two in number; 3, the heart and pericardium; 4, a considerable number of arteries, veins, lymphatics, and nerves, either belonging to the chest itself and its contained organs, or passing through it in an upward or downward direction; thus portions of very important organs are found within it, such as the greater part of the gullet or œsophagus, of the aorta, of the thoracic duct, &c.

The boundaries are as follows:—*Anteriorly,* the sternum and costal cartilages; *laterally* and *posteriorly,* the ribs, intercostal muscles, and dorsal portion of the spinal column; *inferiorly,* the diaphragm; *superiorly,* the cavity of the thorax would open into the lower part of the neck, were it not for the pleuræ, the scaleni, and other muscles, and the passage of the trachea, gullet, and large vessels filling up the rather contracted passage called the superior aperture of the chest. Upon the whole, now that the extremities are removed, the thorax will be found to resemble a cone, somewhat truncated above, flattened behind, expanded below, with an extremely sloping basis (the diaphragm) towards the abdomen. Through the *superior aperture* of the thorax, whose boundaries are the first ribs, and their cartilages, the sternum and inter-clavicular ligament, there pass the following parts: the sterno-hyoid and thyroid muscles, the venæ innominatæ, the phrenic and eighth pairs of nerves, the sympathetic system of nerves, the anterior branch of the first dorso-spinal nerve; the brachio-cephalic, left carotid, and left subclavian arteries; and the superior intercostal vessels, the trachea, the gullet, the thoracic duct, the longi colli muscles, and the anterior common ligament of the vertebral column. Occasionally also may be seen ascending the middle thyroid vessels. Through the *inferior or base,* the vena cava inferior, and the gullet, the aorta, the thoracic duct, and azygos vein pass from the thorax into the abdomen, but behind the diaphragm. The boundaries of the circumference of the basis or inferior aperture of the thorax are anteriorly and laterally the xiphoid process of the sternum, the cartilages of the seventh, eighth, ninth, tenth, eleventh, and twelfth ribs, and behind, the spinal column.

METHOD OF OPENING THE THORAX.

The thorax requires to be opened systematically, and the following method is recommended:—Divide the cartilages of the second, third, fourth, fifth, and sixth ribs on each side, close to their connexion with the ribs; likewise the intercostal muscles and pleuræ in the same line of incision: introduce the fingers cautiously into the opening so made, in order to protect the diaphragm inferiorly, and carefully tear through any adhesions which may exist between the contained organs and the walls of the thorax. Divide the first pair of intercostal muscles on each side till within about two or three inches of the spine; next saw the ribs a little anterior to their angles so as to allow the removal of a large portion of the walls of the chest; by this means the student exposes the interior of the chest most favourably for forming a correct

idea of the mechanism of the interior, the position of the lungs, and the nature of the partition which divides the chest into two cavities having no communication with each other. As soon as he has thus removed a sufficiently large portion of each side of the walls of the chest, leaving the first and last two ribs untouched, the student may proceed to examine the pleuræ, and the form and position of the lungs themselves.

THE PLEURÆ.

The pleuræ (two in number) are serous membranes investing the interior of the chest, and giving a partial covering to the lungs and to other organs situated within the cavity. A pretty firm cellular substance connects their external surface to the intercostal muscles, the ribs, the lungs, the pericardium, or whatever parts they invest; on their inner surface they are uniformly smooth, thin, and as it were polished, and further bedewed with a serosity, as all serous membranes are. Each pleura, if dissected from every part it covers, would present an empty sac without an opening into it; this was proved by Mr. Hunter. The older anatomists, not understanding this mechanism, called that part of each pleura covering a great part of the lungs the *pleura pulmonalis*, and the portion connected with the ribs *pleura costalis*; these terms, as conveying inaccurate ideas, ought to be discontinued. The pleuræ vary in thickness at different parts, as the student will observe on dissection.

It will be proper for the student to trace each pleura in the following manner:—Proceeding from the sternum, the pleuræ direct themselves outwards, line the inner surface of the ribs, their cartilages, and the muscles which occupy their intervals, separated, however, from the latter by the intercostal vessels and nerves, and by adipose cellular tissue. They thus advance as far as the vertebral column, and are reflected inferiorly over the diaphragm where, connecting the inferior lobe of each lung to that muscle, there is a process of pleura called the *ligamentum latum pulmonis*; they cover the thoracic surface of the diaphragm, and superiorly pass under the upper ribs, behind and above which they form a cul-de-sac for lodging the summits of the lungs. Towards the articulations of the ribs with the vertebræ they are applied upon the thoracic nervous ganglia and their branches, and then direct themselves over the lateral parts of the bodies of the vertebræ. There the pleura of the right side approaches to that of the left, but there remains between them a narrow and irregular triangular space, named the *posterior* mediastinum. Anterior to this space, the pleuræ, though very close to each other, do not yet come into contact, but pass to the sides of the pericardium, cover it at first over a small extent, and are reflected over the posterior part of the pulmonary vessels and over the lungs themselves, covering at first their convex surface, their summit and base, diving deeply into the interlobular fissures. Thence they return upon their plane surface, the anterior part of the pulmonary vessels, and the other portion of the sides of the pericardium, at the fore part of which they again

approach each other. They then gain the posterior surface of the sternum, and the point whence we have considered them as setting out, intercepting between them a space not parallel to the sternum, but inclined from above downwards and from right to left, broader below than above, very narrow at its middle part, named the *anterior mediastinum*. The pleuræ are easily detached from the sternum, ribs, intercostal muscles, and sides of the vertebral column, but are united in a more intimate manner to the surface of the lungs, although there exists between them and the parenchyma of the organ a rather dense membrane composed of cellular tissue. They are connected in a loose manner with the anterior and posterior parts of the lateral surfaces of the pericardium, but on their middle region, and opposite the pulmonary vessels, they adhere with extreme firmness.

The *inner surface* of the pleuræ is smooth, polished, moistened by a serous fluid, and free of all adhesion in the natural state. By boiling they lose their transparency, and acquire an opaque opaline tint. On the sides of the diaphragm they present small adipose appendages (appendices epiploicæ of the pleuræ), similar to those described as occurring on the large intestine, and they are a little thicker at the posterior surface of the chest than at the anterior. By inflammation, adhesions may take place anywhere betwixt the smooth surfaces of the parietal and visceral portions of the pleuræ, so as even to obliterate the cavity of the pleura. Such adhesions affect the consequences of penetrating wounds of the chest, favourably in some cases; but quite the reverse in others. The arteries of the pleuræ come from the intercostal, internal mammary, phrenic, inferior thyroid, thymic, pericardiac, and bronchial arteries. The veins correspond to the arteries. A prodigious quantity of lymphatics is perceived in these membranes, but no nervous filaments have yet been traced in them. The student will by this time have remarked that there must exist a space between the right and left pleuræ, extending from the internal surface of the sternum to the front of the dorsal vertebræ; this space contains the pericardium, heart, &c., and is generally called *mediastinum*, or mediastina, for there are two, and according to some, three. The best mode of examining these cavities intermediate of the pleuræ, and which form by their walls a partition of varying breadth across the centre of the chest from before backwards, is as follows:—

Mediastina.—The mediastina are three in number: 1, the *anterior*, lying behind the sternum and before the pericardium; 2, the *middle*, containing the pericardium and heart, and bounded before by the anterior mediastinum, behind by the posterior one; 3, the *posterior*, lying in front of the vertebral column. But the walls of these cavities are simply formed by the pleuræ passing backwards from the sternum to the spine.

The *anterior mediastinum.*—Saw the sternum across in the lower part of its body, a little above the ensiform process, and begin to raise it up, the cartilages at the ribs having been already cut through. As this is being done, the pleuræ forming the right and left walls of the

anterior mediastinum must be cut cautiously, and the student, looking in below the sternum as he raises it up, will see a cavity gradually unfold itself; this is the cavity of the anterior mediastinum. The sternum may then be removed in this way altogether, and, the region being fully exposed, its form may be examined. It does not exactly follow the axis or direction of the sternum, but inclines to the left side, owing to the position of the heart and pericardium (the right wall being nearly straight, and the left descending rather to the left side); broad above, behind the manubrium, narrow in the middle, where the pleuræ all but touch each other, and broader again below, immediately above the diaphragm. It almost forms two triangular spaces, the base of the one being above, that of the other below, and the common apex in the centre. It has been very incorrectly compared to the letter X, whereas it is precisely of this shape)(. On the inner side of the manubrium of the sternum just removed the student will find the attachments of the sterno-hyoidei and sterno-thyroidei muscles, and some remains of the thymus gland lie in this part of the mediastinum; likewise a few lymphatic glands, and much cellular substance: laterally and close to the sternum, the internal mammary vessels and triangulares sterni muscles.

[Triangularis Sterni.*—Arising from the edge of the ensiform cartilage and sternum, up to the articulation of that bone with the fourth cartilage, by means of aponeurotic fibres which are prolonged among the fleshy fibres; thence ascending outwards to be attached by so many digitations to the edges and inner surface of the cartilages of the third, fourth, fifth, and sixth ribs. Covered anteriorly by the cartilages of the four last true ribs, the inner intercostal muscles, and the internal mammary vessels; the *posterior surface* rests upon the pleura, and in a small part of its extent upon the diaphragm; its *inferior* edge or base is contiguous to the transversalis abdominis. In action it draws the cartilages of the ribs, to which it is attached, backwards, inwards, and downwards, and assists expiration.]

The cautious dissection of each pleura from the pericardium, as far back as the root of the lungs, should now be made, and the close adhesion of these two membranes at certain points (towards the middle), and the laxity above and below, cannot fail to be noticed. It is here that the pleuræ are thinnest.

Middle mediastinum.—This cavity is easily understood; it contains the pericardium, heart, and a portion of the large vessels, on its outer side. The phrenic nerves and *arteria comes nervi phrenici* may be seen lying betwixt the pleuræ and pericardium.

The posterior mediastinum extends from about the third dorsal vertebra to the tenth, behind the pericardium and in front of the spine. It ought to be examined in three ways: 1, from the right side, by drawing the right lung upwards and forwards out of its cavity; 2, from the left side, by drawing up in like manner the left lung;

* I have preferred repeating the anatomical description of these muscles to referring the student to their history, already given in the section Myology.

3, after the examination of the heart *in situ*. The student, having removed that organ altogether, may then examine the posterior mediastinum, by cutting through the back part of the pericardium, and dissecting it from the front backwards towards the spine. He thus cannot fail to understand the mechanism of this cavity. Its walls are formed by the pleuræ; *posteriorly* it is bounded by the bodies of the dorsal vertebræ; *anteriorly*, by the back of the pericardium. In it there lie the œsophagus, the descending portion of the thoracic aorta, the eighth pair of nerves, the thoracic duct, the venæ azygos of the right and left sides, the splanchnic nerves towards the lower part; several lymphatic glands; the division of the trachea inferiorly, and the commencement of the bronchial tubes. The course of these important parts, and their connexion with each other, will be best understood after the dissection of the heart and pericardium; but the student may, previously to the complete examination of the contents of the posterior mediastinum, dissect and examine that cavity on both sides.

First, on the right side; draw the right lung out of its cavity, and lay it over towards the left side; make an incision through the right pleura, close to the root of the lungs, and reflect it towards the ribs; clear away a little cellular substance and expose the following parts:— The *œsophagus;* this lies close to the front and mesial part of the column; it enters the thorax from the neck behind the trachea, and to its left side, passes under and behind the arch of the aorta, finally reaching the diaphragm, through which it passes to enter the stomach. The orifice in the diaphragm through which it passes is called the *œsophageal orifice*, and is formed anteriorly by the cordiform tendon, laterally by the pillars of the diaphragm: posteriorly the decussating fibres separate it from the aorta. Whilst in this course the eighth pair of nerves, the œsophageal plexus, and cords (portions of the eighth pair), are united with it by cellular substance; inferiorly it dilates somewhat before joining the stomach. The student should distend the gullet with air to have a good view of it. The eighth pair of nerves are also proceeding towards the stomach, and pass through the diaphragm by the same opening with the gullet, the left nerve anteriorly, the right more posteriorly.

The *thoracic duct* is placed to the right of the gullet, embedded in cellular and adipose membrane, and so close to the pleura as to be very often removed along with it by the incautious dissector. Behind it lie the right intercostal arteries and some of the left intercostal veins, more especially a small portion of the left vena azygos; the right azygos vein lies close to it, but towards the right side. Although the full description of this vessel properly belongs to the absorbent system, where the student will find its systematic anatomy, it may not be amiss to offer a brief account of it here. The thoracic duct is the great terminating vessel of nearly the whole of the absorbent system of vessels, including lacteals and lymphatics. It commences in the abdomen on the second or third lumbar vertebra, and behind the aorta, by a dilatation called *receptaculum chyli;* contracting in calibre to

about the size of a crow-quill, it passes from the abdomen into the thorax by the aortic opening of the diaphragm, gets into the posterior mediastinum to the right side of the aorta; it then ascends between the aorta and the vena azygos, embedded in fat, but anterior to the intercostal vessels, as already mentioned. Opposite to about the fifth dorsal vertebra it passes obliquely behind the gullet and arch of the aorta, and ascends in the neck, behind the left jugular vein and left carotid artery, as high as the sixth cervical vertebra, thus passing from the right side of the thorax to the left side of the neck; it next bends downwards, and enters the left subclavian vein, near the point of its junction with the corresponding jugular vein. The thoracic duct abounds with strong valves, allowing the contents to pass only in one way, that is, from below upwards; by opening it low down in the thorax, the student may distend it with air blowing from below upwards; its tunics are nearly transparent, although they have, by some, been supposed to be muscular.

The right vena azygos (*vena sine pari; Eust.*) is also found in the posterior mediastinum on the right side. It commences in the abdomen by a branch or two from some one of the superior lumbar veins, or from the inferior cava or right common iliac vein, enters the thorax behind the diaphragm by its aortic opening, covered by the right pleura, and, running up parallel with the thoracic duct, it arches forward opposite the third or fourth dorsal vertebra, over the root of the right lung and right bronchus, and opens into the superior vena cava just as that vessel is about to pass through the fibrous pericardium. In this course the right vena azygos, like most of the deep veins of the trunk, has no valves, and may be injected with air from above downwards, in order to show its course, and the branches or veins which pour their blood into it. These are the bronchial, œsophageal, and many of the intercostal veins, and a vein, or sometimes two, which come from the left side, opposite to about the sixth dorsal vertebra, viz. the left azygos; this passes behind the aorta to join that of the right side.

The splanchnic nerves lie somewhat in the posterior mediastinum, towards its lower extremity. These *nerves* are merely filaments of communication between the thoracic ganglia of the sympathetic system of nerves and the great abdominal semilunar ganglion and solar plexus. They commence by four or five filaments from the fifth, sixth, seventh, and eighth of the thoracic ganglia; these unite to form a single trunk, which passes through the diaphragm at varying points, enters the abdomen, and there joins the semilunar ganglion. A smaller splanchnic generally arises from the tenth and eleventh thoracic ganglia; its course resembles that of the greater splanchnic, but it usually joins the renal plexus.

The thoracic ganglia and sympathetic system of nerves.—These ganglia will be found external to the posterior mediastinum and pleura. There is usually a ganglion opposite to the head of each rib, and a filament of communication with the one preceding and the other following, thus connecting all these ganglia invariably with each other, and the

first one with the last cervical ganglion of the same system of nerves. This last thoracic ganglion, sending a communicating filament through into the abdomen, behind the diaphragm, connects the last thoracic ganglion with the first lumbar. I have found this connexion *invariable*. Contrary to the opinions of Bichat and Haller, the sympathetic system of nerves thus enters the thorax from the neck, close to the cervix of the first rib, and quits it by passing behind or through the diaphragm, but usually behind the internal ligamentum arcuatum, close to the inner margin of the psoas, as has been described. The right bronchial tube and the division of the trachea had better be examined whilst examining the lungs, after the dissection of the pericardium and heart. Besides the organs already described, the student will find, on the right side of the chest, the corresponding aortic intercostal arteries; between the intercostal spaces, also, the dorso-spinal nerves; and in the upper part of the chest, descending over the neck of the first rib, the subclavian intercostal artery. This vessel supplies two or more of the superior intercostal spaces. The anterior branch of the first pair of dorso-spinal nerves ascends upwards over the same rib to join the brachial plexus.

In order to examine the posterior mediastinum on the *left* side of the thorax, raise up the left lung, drawing it over towards the right side; remove the pleura, and look for the following structures:—1, the descending portion of the thoracic aorta; 2, the left vena azygos; 3, the splanchnic nerves; 4, the thoracic ganglia of the sympathetic and their communicating filaments; 5, the left dorso-spinal nerves; 6, the left intercostal arteries and veins. The description of all these parts (excepting the aorta and left vena azygos) resembles, with but trifling differences, that of the analogous parts on the right side, and need not, therefore, be repeated. The aorta and left vena azygos require a separate brief description at this stage of the dissection. The descending portion of the thoracic aorta enters the posterior mediastinum about the left side of the third, sometimes the fourth, or even the fifth dorsal vertebra, on the body of which bone it not unfrequently makes a distinct impression, and descends along the left side of the bodies of the remaining dorsal vertebræ; on the eleventh and twelfth it passes betwixt the crura of the diaphragm into the abdomen, of course altogether behind the muscle, and, losing its name, is called, from this point downwards, the abdominal aorta. In this course there arise the following arteries from it:—1, the bronchial arteries; 2, the œsophageal; 3, the aortic intercostals. These vessels will be carefully described in the Section on the Arteries.

The *left vena azygos* arises in the abdomen from some one or other of the lumbar veins; like those of the right side, it has no valves. The lower intercostal veins generally contribute to form it; and there is sometimes a *descending* azygos of this side collecting the upper intercostal veins; they then cross behind the aorta to the right side, and enter the right vena azygos about the middle of the chest. It has been already remarked that before the student can complete his

view of the posterior mediastinum and its contents, the pericardium and heart must be dissected and examined. In this examination there are two stages: 1, the examination of each part *in situ*; 2, the removal of the heart from the pericardium, by carefully cutting through its great vessels just as they are about to pass through the pericardium.*

The PERICARDIUM.—The pericardium, or fibro-serous envelope of the heart, is a membranous bag, composed of two laminæ, an *outer* or fibrous, an *inner* or serous, which envelopes the heart and the arterial and venous trunks which issue from or enter it. It is lodged in the middle mediastinum, above the central aponeurosis of the diaphragm, to which it is strongly united. Its external form is, at first sight, that of a cone, with the base directed downwards, backwards, and to the right; but when freed of the fat in which it is, as it were, immersed, it is found to be exactly moulded upon the heart.

Anteriorly, the pericardium is covered by the pleura, excepting in its middle part, where it corresponds to the anterior mediastinum and to the thymus gland, and by intervention to the sternum and cartilages of the last sterno-costal ribs of the left side, from which it is separated laterally by the fore part of the lungs. *Posteriorly*, it is of very small extent, and rests upon the bronchi, œsophagus, and descending aorta.

To the right and left it is connected by cellular substance with the pleuræ, the phrenic nerves, and the internal surfaces of the lungs.

Inferiorly, it corresponds to the aponeurotic centre, and, a little to the left, to the fleshy fibres of the diaphragm.

The *outer*, or *fibrous membrane*, is intimately united below, and more especially around its circumference with the aponeurosis of the diaphragm: it ascends around the heart, which it embraces as far as its base, and there it is continued to a greater or less extent upon the great trunks of the vessels, dividing into several distinct sheaths, which accompany them to a certain distance. The pericardium, therefore, is in one sense not perforated to allow these vessels to pass, as many anatomists have alleged; but its fibrous lamina loses itself insensibly on their walls, and even seems to be united with them. These sheaths are eight in number; one, which is very short, for the vena cava superior; four, still shorter, for the pulmonary veins; one, which is indefinitely prolonged, for the aorta; two for each branch of the pulmonary artery. The vena cava inferior penetrates the diaphragm, and immediately enters the right auricle of the heart, and has thus no fibrous sheath. This membrane presents the greatest resemblance to the dura mater in its structure, only it is not so thick. Its colour is pearly and aponeurotic. Its

* Although, in accordance with the usual description of authors, I have spoken of the anterior and posterior mediastinum as extending up as high nearly as the level of the upper part of the manubrium of the sternum, yet, in point of fact, there is no natural division of the cavity lying immediately behind the manubrium of the sternum; or, in other terms, it is the pericardium and heart which, properly speaking, separate the anterior from the posterior mediastinum: above this the division is perfectly artificial or ideal.

fibres are sometimes isolated, often collected in distinct bundles, of variable thickness and breadth, irregularly disposed, and cross each other in all directions. The greater number, however, ascend vertically and parallel to the axis of the pericardium.

To examine the *inner* or *serous* membrane of the pericardium, the bag must be laid open extensively on its anterior surface; in this way the student opens the cavity of the pericardium, by cutting through both its layers, and is enabled to examine and trace its serous layer. The *serous membrane* has a much more extended course than the fibrous membrane, as, after lining its inner surface, it is reflected over the heart and covers it entirely, without, however, containing it in its interior, in which respect it is similar to the other serous membranes existing in joints, and the pleuræ in the thorax. It has always appeared to me that the fibrous layer is interposed between the serous layer and the diaphragm.*

Lining the parietes of the fibrous membrane to the place where the latter is prolonged upon the great vessels of the base of the heart, it is reflected upon the aorta, above its first curve; to the left, upon the pulmonary artery, before its bifurcation; to the right, upon the vena cava superior, about an inch above its entrance into the auricle, and on the right pulmonary veins, immediately after their issuing from the lung. It covers the surface of all these vessels, penetrates into their intervals to a greater or less distance, and invests the aorta and pulmonary artery in their whole circumference, excepting the place where they are in immediate contact. It also covers, between them, the ductus arteriosus, or the ligament by which it is substituted. In the place where this membrane is reflected the separation of the two laminæ of the pericardium may be very distinctly seen, a perceptible triangular space existing between them. Having arrived at the base of the heart, the serous membrane proceeds directly from the pulmonary artery over the ventricles, and from the vena cava over the right auricle. On leaving the aorta it is prolonged into the depression which exists between that artery and the right auricle, whence it also directs itself towards the ventricles. From the summit and edges of the heart it goes to its posterior surface and covers it, ascends again to its base, embraces it to the right and below the vena cava inferior, to the left and above the left pulmonary veins, and is reflected over the posterior part of the fibrous membrane. This membrane dives into all the irregularities which the heart presents at its surface, where it is so thin and transparent, especially upon the ventricles, that it becomes very difficult to demonstrate its existence, excepting in the places where it is separated from the fleshy fibres by adipose tissue. It adheres intimately to the fibrous membrane, and can only be detached from it in points of small extent, or at the place of its reflection. It has very little attachment to the vessels, and can easily be raised from their surface. The inner surface of this mem-

* M. H. Cloquet thinks that the serous membrane is applied directly, and in a very close manner, upon the aponeurosis of the diaphragm: to me the fibrous membrane of the pericardium appears complete at this point.

brane, which is everywhere in contact with itself, is smooth and polished, and continually moistened by a serous fluid, the liquor pericardii. This liquor may amount to several ounces, and yet not constitute the hydrops pericardii. The arteries of the pericardium are very small, and arise from the thymic, phrenic, bronchial, and œsophageal arteries, the coronary arteries of the heart, the internal mammary arteries, and the aorta itself. Its veins correspond to the arteries, and partly terminate in the vena azygos. Its lymphatic vessels go to the glands which surround the vena cava superior, and the origin of the aorta. Nervous filaments have not yet been traced into the substance of its laminæ.

THE HEART.

The heart (*cor*) should first be examined *in situ*, all its parts named, and its relative position, direction, form, &c., carefully noted. The following description may be read over before the student commences cutting into any part of it. The heart is the centre of circulation; it is a hollow muscular organ of an irregular conical or pyramidal form, placed obliquely between the lungs, inclined forwards, downwards, outwards, and from right to left; flat posteriorly and inferiorly, convex anteriorly and superiorly, and lodged in the pericardium. Its volume varies much in different individuals. Its mass, compared with that of the body, is very small; but in general it is so much the greater the younger the subject is. Although it is retained in its position by the pericardium, the mediastinum, and large vessels, its situation changes every moment during life, because its weight drags it in different directions, according to the position that is assumed; and it must also be slightly affected by the motions of the diaphragm and the different states of inspiration and expiration.

Its *anterior* surface, which is turned a little upwards, is convex, and presents in its middle a groove which traverses it obliquely from above downwards, and from left to right, and in which are lodged the anterior coronary artery and vein, in the midst of a considerable quantity of adipose tissue. The portion of this surface which is situated to the right of the groove, is much broader than that to the left. This groove marks the position of the septum ventriculorum.

Its *posterior* surface is directed downwards, and is nearly horizontal. It is flat, and rests upon the aponeurotic centre of the diaphragm, from which it is separated by the pericardium; but, according to Cloquet, by its serous membrane only. It is traversed nearly vertically by a groove which receives the posterior coronary artery and vein, and which joins the preceding at the apex of the heart. The portion of the posterior surface of the heart which is to the left of the groove is much broader than that which occupies its right side.

The *right* margin of the heart is at the same time inferior. It is thin and sharp, longer than the left, and rests upon the diaphragm.

The *left* margin is directed backwards and upwards; it is obtuse,

rounded, very thick; the posterior coronary artery may be seen on it.

Fig. 157.*

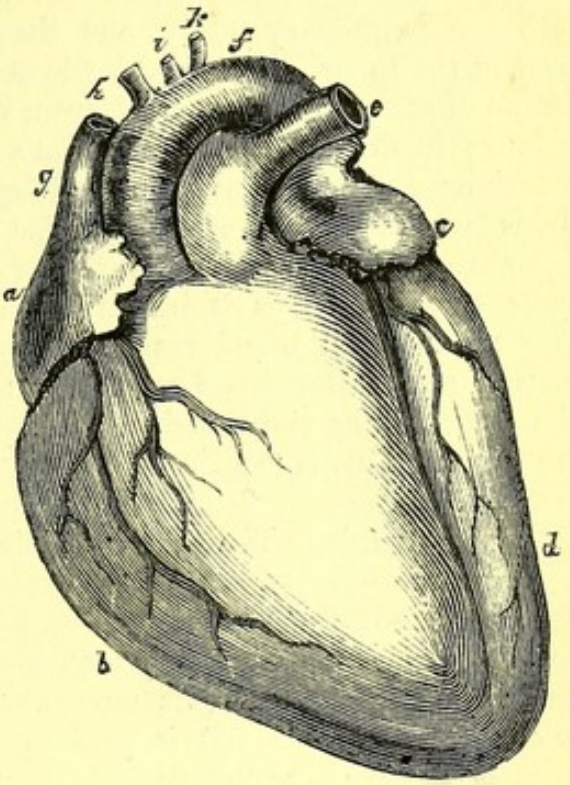

The *base of the heart*, which is situated above, behind, and to the right, slightly inclined from above downwards, and from left to right, is separated from the vertebral column by the aorta and œsophagus, and is connected with the pericardium through the medium of arteries which issue from, and of veins which go to it. There is observed upon it an oblique groove, which indicates the junction of the auricles and ventricles.

The *summit* or apex, which looks forwards, downwards, and to the left, is lodged in a notch of the lung of that side, and corresponds to the interval of the cartilages of the fifth and sixth ribs, under which the pulsations of the heart may be easiest felt. Close to the apex, but always rather to the right side, is a depression, in which terminate the sulci, or grooves, seen upon the anterior and posterior surfaces of the heart. Thus the apex of the heart is to a certain extent bifid, more so in some individuals than in others, but much less so in man than in certain of the lower animals, as in the dugong. The heart consists of four cavities, named *ventricles* and *auricles*. The two auricles occupy its base, or its superior and posterior region, the two ventricles its inferior part. An auricle and a ventricle are placed to the right, and to the left the same disposition is observed. On each side the auricle communicates with the corresponding ventricle, but the right cavities seldom communicate directly with the left in the natural state after birth. In the right cavities there is found black blood, which is to be submitted to the action of the air in the lungs. In the left there is found red blood, which has already undergone this action. The circulation of the blood through the heart may readily be traced by the student in this manner. Before laying open any of the cavities of the heart, blow air into the superior vena cava, and compress the inferior cava as it passes through the diaphragm.

* Fig. 157 represents the heart, anterior surface.—*a*, right auricle; *b*, right ventricle; *g*, vena cava superior; *f*, summit of the arch of the aorta; *h*, origin of the brachio-cephalic artery; *i*, the left common carotid; *k*, the left subclavian; *e*, pulmonary artery, left branch; *c*, left auricle; *d*, left ventricle.

He will thus distend these veins, the right auricle, the right ventricle, the pulmonary artery, and its right and left branches proceeding to the lungs, and thus prove that the dark blood, proceeding from the body into the right auricle of the heart by the two venæ cavæ, passes readily from the auricle into the ventricle, and from the ventricle into the pulmonary artery, and through its ramifications into every part of the lungs. It (the blood) is then altered by exposure to the action of atmospheric air, and, from being dark, becomes of a florid red colour; in short, from being venous blood, it becomes arterial, or is arterialized. It returns from the lungs by the right and left pulmonary veins (which the student will notice at the root of the lungs) to the left auricle, is poured by it into the left ventricle, which again, by its violent action, drives it into the aorta and its branches; and in this way the arterial blood reaches every part requiring nourishment, to return, again altered and wasted by the processes of nutrition, through the veins, to the right auricle of the heart, from which we have just traced it. This is the double circulation of the blood discovered by Harvey.

Right auricle.—The right auricle (*Auricula dextra seu anterior*) occupies the inferior, right, and anterior part of the base of the heart, and rests upon the diaphragm; its form is very irregular and difficult to be described; transversely elongated, it presents its greatest breadth to the right and behind, its narrowest part before and to the left, in which latter direction it is prolonged by a flattened loose appendage (*proper auricle*), terminating in a point, irregularly dentated on its edges, and placed transversely between the aorta and the right ventricle. It is in general wider than the left auricle.

Its *outer* surface is free externally, but internally it is united with the left auricle, below with the right ventricle, and behind with the orifices of the two venæ cavæ. Anteriorly it is surmounted by the appendage mentioned above. Lay open its interior by an incision in its long axis, cautiously avoiding coming too near the orifice of the inferior cava.

Its *inner* surface presents, *posteriorly*, at its upper part, the orifice of the vena cava superior, directed obliquely forwards and downwards, and furnished with a rounded, thick, and fleshy projecting edge, more distinct and stronger posteriorly than anteriorly. This orifice is narrower than that of the vena cava inferior, which is situated below and more behind it, and which is directed obliquely upwards and inwards. These two apertures are very close to each other, and are even continuous, by a portion of their circumference. In this common portion there is sometimes observed a more or less distinct tubercle (*tuberculum Loweri*), which is merely a prominence formed by fat, or by a fleshy bundle. Near the orifice of the vena cava inferior, and to the left side, is the Eustachian valve. The breadth of this valve varies much in the adult, but it can never entirely close the aperture of the vein; its dimensions are more considerable in children, and especially in fœtuses, and it becomes gradually obliterated with age, so as to be very indistinct in

old persons; its position is nearly vertical, and its form semilunar. Its *posterior surface*, which is directed backwards, to the right, and upwards, corresponds to the cavity of the vena cava inferior; the *anterior*, which has an opposite direction, corresponds to the cavity of the auricle; its *free edge*, which looks upwards and backwards, is sometimes reticular; it is more or less concave, but is always very thin; its *right extremity* is connected with the circumference of the vena cava inferior, while the *left* is prolonged upon the inner wall of the auricle, and is continuous with the anterior pillar of the fossa ovalis, of which we shall presently speak. Under the Eustachian valve, and above the entrance of the ventricle, is the common aperture of the coronary veins, which is also furnished with a semilunar valve, the valve of Thebesius, broad enough to cover it entirely, the free edge of which is directed downward.

2. *Anteriorly*, at its upper part, is the small cavity of the appendage, remarkable for the prominences which are formed in it by a multitude of fleshy columns (*musculi pectinati*) crossing each other; and, inferiorly, the wide aperture by which the two right cavities of the heart communicate (right auriculo-ventricular opening). This aperture is circular when the heart is full, elliptical when it is empty. A cartilaginous ring surrounds this orifice.

3. The *outer* side presents nothing remarkable but a great number of irregular prominences, formed by muscular bundles, which leave between them spaces of various dimensions, and of which the principal are in general directed from behind forwards. These prominences are commonly less numerous than in the appendage.

4. *Internally*, there is a septum separating the right auricle from the left (*septum auricularum*). In the adult it presents, under its middle part, a depression (*fossa ovalis S. vestigium foraminis ovalis*) which is more distinct above than below, where it disappears insensibly, becoming continuous with the vena cava inferior. The surface of this depression is sometimes smooth, sometimes uneven and reticulated. It does not appear to have any fixed limit behind, but, anteriorly, it presents a kind of very thick semilunar valve, or annulus, of which the inferior extremity is continuous with the Eustachian valve. By its inner surface, this valve corresponds to another valve, which projects in the left auricle, and forms of itself the bottom of the fossa ovalis. On pushing from behind forwards the handle of a scalpel or a fine probe between these two valves, a passage is, for the most part, easily obtained from the right auricle into the left. In the space occupied in the adult by the fossa ovalis there is, in the fœtus, an aperture, the *foramen ovale* (foramen of Botal), which sometimes remains open after birth. Its use is to transmit, before the period of birth, the blood of the vena cava inferior directly into the left auricle. There are observed, moreover, in the whole extent of the inner surface of the right auricle, a great number of small orifices, not furnished with valves (*foramina Thebesii*), which are supposed to belong to the veins of the walls of the heart.

The right ventricle (*ventriculus dexter seu anterior*), wider and broader, but less extended in length than the left, at the right and anterior part of which it is situated, has a considerable resemblance to a triangular pyramid, of which the base is turned upwards and backwards, and is confounded with the corresponding auricle; it has more extent on the anterior surface of the heart than on the posterior.

Open this ventricle on its anterior surface, about an inch below the origin of the pulmonary artery, introducing the fingers of the left hand, and continue the incision through the walls of the ventricle, so as to do the least injury possible to the fleshy columns and tendinous chords which are felt in the interior of the ventricle.

Its *anterior and outer wall* is rather thin, and very concave; the *posterior and inner* is formed by a septum, which equally belongs to the left ventricle. Their thickness is unequal in the different parts of their extent; both are pretty smooth towards their base, but in the rest of their extent they present a great number of muscular bundles (*columnæ carneæ*), which vary much as to size, length, and direction; their disposition is in general rather irregular, some directing themselves vertically from the summit to the base, while others cross them in all directions, forming with them a confused net-work. Of these columns, from three to eight or nine are much larger than the others; they are rounded, and differ so much in length that some of them resemble mere tubercles, while others have an extent of nearly an inch. All arise from some point of the walls of the ventricle, direct themselves, becoming larger, from its summit towards its base, and terminate abruptly, each by several small tendons (*chordæ tendineæ*) which are inserted into the tricuspid valve, diverging sensibly from, and sometimes anastomosing, as it were, with each other; some of these tendons are bifurcated, and most of them enlarged at their termination. Other fleshy columns of the right ventricle, more numerous than the preceding, are attached to its walls by their two extremities, but are free in their circumference. Others, again, are attached to the walls in their whole extent, and in the manner of pilasters. These are the most numerous and the thinnest. They pass in all directions, and are interlaced with each other, so as to represent a net-work, leaving between them depressions differing in form and dimensions.

The *base* of the right ventricle is perforated by two apertures; one of these, the right auriculo-ventricular orifice, which is situated posteriorly, is separated from the other by an interval of about an inch, communicates with the auricle, and is furnished with a membranous fold, named the *tricuspid valve*. One of the surfaces of this valve is turned towards the walls of the ventricle, and the other towards the cavity of the auricle; its adherent edge is attached to the circumference of the orifice, and surrounds it without interruption; its free edge is connected with the chordæ tendineæ; it is very irregular, and presents variable intersections, among which, however, there are always remarked three of larger size than the rest. One of these, which is triangular, longer and broader than the others, and directed upwards

and forwards, exactly closes, when laid down, the entrance of the pulmonary artery. This valve, which is thin and transparent in its whole extent, becomes decidedly thicker at its free edge, for the attachment of the small tendons of which we have spoken. The other aperture of the base of the ventricle is of smaller size than the preceding, and leads to the pulmonary artery.

The PULMONARY ARTERY.—The pulmonary artery (*Art. pulmonaris*), carrying into the lungs the blood to be submitted to the action of respiration, arises from the upper and left part of the right ventricle, within which its orifice is surrounded by a cartilaginous ring, marking the limit of the fleshy fibres of the heart; but, externally, these fibres descend upon the artery, over an extent of about half a line. In this orifice are the *sigmoid or semilunar valves*, three membranous folds, adhering to the artery by their whole convex and inferior surface, and presenting above a free, horizontal, and straight edge, on the middle of which there is a small, prominent tubercle, of a fibro-cartilaginous consistence (*Corpusculum Arantii*). They are in contact at their extremities, and are thin and transparent. When let down they completely close the artery and prevent the blood which it contains from returning into the ventricle. To expose these valves, and likewise the anterior part of the artery, the student has only to continue the incision he previously made into the ventricle, upwards through the walls of the artery as high as its division.

The pulmonary artery, slightly dilated at first (*Sinuses of Valsalva*), directs itself obliquely upwards and to the left, crossing the course of the aorta, anterior to which it is at first placed, and to which it is united by an adipose cellular tissue. It then places itself to the left of the aorta, and at the end of a course of two inches, at the height of the second dorsal vertebra, it divides into two trunks, one for each lung.

These trunks separate from each other almost transversely, and at the point of separation there ascends from the pulmonary artery, to be attached to the concave side of the aorta, a rounded cord of cellular tissue. This is the remains of the *ductus arteriosus*, or ascending middle branch of the pulmonary artery, in the fœtus, by which branch the blood in the fœtus is diverted from passing into the lungs, but, being transmitted directly into the aorta, is thus sent through the body. The cord is now called the ligamentum arteriosum.

The left recurrent nerve (*Nervus laryngeus inferior*), a branch of the eighth pair, will be found passing around the arch of the aorta, close to the left side of the ligamentum arteriosum. The right pulmonary trunk, which is longer and smaller than the left, passes transversely behind the aorta and vena cava superior, forms an arch which embraces anteriorly the corresponding bronchus, reaches the lung, towards the upper part, and divides into three principal branches. The left pulmonary branch passes obliquely before the aorta and below its arch, embraces the bronchus of its side, and entering the upper part of the root of the lung, divides into two branches only,

one for each lobe of the lung. Once entered into the lungs, the first divisions and the successive ramifications of the pulmonary artery accompany the bronchi to their last extremities, multiplying like them, so that there is no part of the organ, however small, which does not receive twigs from them. At their termination these minute twigs are supposed to anastomose with the roots of the pulmonary veins, and with the bronchial arteries and veins. The pulmonary artery has the same structure as the aorta, but its walls are weaker, and it partly collapses when empty.

The pulmonary veins (*Venæ pulmonares*) are supposed to arise from the extremities of the pulmonary arteries, and are collected into small twigs and branches, becoming successively larger, which accompany the divisions of the bronchi, and those of the arteries, it being observed that in general the venous twig is placed beneath, and the arterial above, the bronchial twig. At length all the branches of the pulmonary veins unite into four trunks, which leave each lung, two and two, at the middle of its internal surface, and penetrate into the pericardium.

The *superior right pulmonary vein* emerges under the bronchus, directs itself obliquely downwards, and opens into the upper and right part of the left auricle of the heart.

The *inferior* comes from the lower lobe of the lung, and ascends obliquely towards the inferior and right part of the same auricle. They are both difficult to be exposed, being concealed by the vena cava superior and the neighbouring part of the right auricle.

The two *left pulmonary veins* follow a similar course, and are merely a little nearer each other. The pulmonary veins have the same structure as the other veins of the body, from which they differ in the circumstance that during life they contain red blood. A few fleshy fibres may be seen on their outer surface derived from the left auricle. These veins are easily found, seeing that their orifices terminate in the left auricle.

The left auricle (*Auricula sinistra seu superior*), situated at the upper, posterior, and left part of the heart, is almost entirely concealed by the great vessels at the base of that organ, so that, at first sight, there is nothing perceived but its appendage (proper auricle), near the left side of the pulmonary artery. Its form is somewhat cubical, while that of the right auricle may be in some measure compared to a segment of an ovoid. Its capacity is about a fifth less than that of the latter.

Posteriorly, it rests upon the vertebral column, from which it is separated by the pericardium; *anteriorly* and internally it is united to the rest of the heart. From its inner and upper part there is seen rising an appendage similar to that of the right auricle, but smaller and directed to the right; its edges are equal, but its form is triangular. It may be laid open and its interior examined by an incision commencing in the proper auricle and extending through the whole of the division called sinus venosus.

Its *inner* surface presents four walls or sides for examination:—

1. The *posterior*, which is smooth, receiving the right pulmonary veins above.

2. The *anterior* presents, below, a wide aperture leading into the left ventricle, and, above, the cavity of the appendage, containing much fewer *musculi pectinati* than that of the right appendage.

3. The *right* is smooth and formed by the interauricular septum. There is here a semilunar valve forming the bottom of the fossa ovalis.

4. The *left* is perforated by the two corresponding pulmonary veins, the orifices of which are very near each other, and even sometimes joined.

The LEFT VENTRICLE (*Ventriculus sinister seu posterior*), is a little narrower but longer than the right, and thus forms the apex of the organ. Its shape is that of a pyramid a little flattened; but, as its walls are very thick, it never presents the same falling in as the opposite ventricle. It should be laid open much in the same way as the right, by making an incision into its fleshy walls sufficient to allow the introduction of a finger or two, and cutting cautiously on these, avoiding any incisions into the mitral valve. Internally, there are columnæ carneæ, similar to those of the right ventricle, but less numerous and less irregularly disposed. Two of these fleshy bundles, which are larger than the others, and free at their circumference, arise, the one before, the other behind, and a little beneath the middle part of the walls of the ventricle, by several distinct and smaller bundles, ascend obliquely towards the base of the heart, and terminate by a rounded or bifurcated extremity, from the summit of which pro-

Fig. 158.*

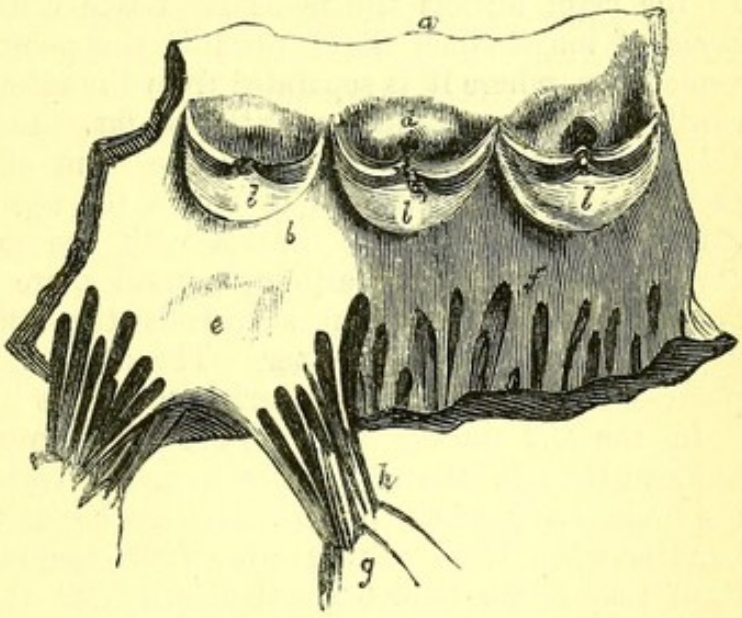

* Fig. 158 represents a portion of the left ventricle, and of the aorta laid open to show the disposition of the semilunar valves at the entrance of the aorta; *e*, *b*, portion of the mitral valve; *g*, *h*, fleshy and tendinous columns cut across; they connect the valve to the walls of the ventricle; *f*, fleshy portion of the ventricle; *l*, semilunar valves; *g* is placed near the corpuscles of Arantius, one of which may be observed about the middle of the free edge of each valve; *d* is placed on the inner surface of a portion of the aorta, beyond the valves; it points to the orifice of one of the coronary arteries.

ceed a multitude of very slender divergent tendons, frequently crossing each other, which attach themselves to the free edge of the mitral valve. In the base of the left ventricle there are two apertures; one of these, the *left auriculo-ventricular orifice*, which is posterior and larger, leads into the auricle, and is nearly elliptical. Like that of the right side, it is surrounded with a cartilaginous zone, and furnished with a membranous fold, called the mitral valve, because its free edge is divided into two slips, to which are attached the chordæ tendineæ; one of these slips is applied upon the mouth of the aorta, which it almost entirely closes when the ventricle is dilated. This valve is thicker than the tricuspid valve, and frequently contains small hard fibro-cartilaginous tubercles, and sometimes even bony plates. The other aperture, to the right and anteriorly of the latter, leads into the aorta; here there are three *semilunar valves,* similar to those at the entrance of the pulmonary artery. Above their free edge the orifices of the two coronary arteries of the heart are seen. This orifice of the aorta is surrounded with a cartilaginous ring, forming the true boundary between the tissue of the heart and that of the artery. Outside the semilunar valves the walls of the aorta are dilated, forming three prominences (sinuses of Valsalva) externally.

Organisation of the heart.—1st. Muscular tissue of the auricles. The walls of the auricles are much thinner than those of the ventricles. In the right auricle the muscular tissue constitutes a pretty thick layer of longitudinal fibres towards the point of union of the two venæ cavæ, where it is separated from the serous laminæ of the pericardium by a considerable quantity of fat. In the rest of the auricle this tissue only presents itself in the form of thin bundles crossing each other, in the intervals of which the serous lamina of the pericardium is in immediate contact with the inner membrane of the cavity. These bundles, although smaller, are more numerous in the appendage. One of them surrounds the orifice of the vena cava superior in a circular manner. The disposition which we have just pointed out causes the right auricle to appear transparent.

In the *left auricle* the fleshy layer is much thicker and more uniform than in the right; the muscular fibres seem to come from the pulmonary veins, on which they begin to appear by parallel bundles when these vessels issue from the lungs. On the auricle itself they retain their original direction at the surface, and form a transverse plane; but more deeply they cross each other irregularly, without, however, being disposed in isolated bundles, as in the right auricle. Between the two auricles the muscular tissue forms a thicker and more uniform layer, from which results the inter-auricular septum.

2d. Muscular tissue of the ventricles. The walls of the *right ventricle* are rather thin; a uniform fleshy layer invests it externally. More deeply, the muscular tissue collects into bundles disposed like those of the auricles, but stronger and more numerous; several of these, detached from the walls of the cavity, give rise to the columnæ carneæ.

The *left ventricle* has much thicker walls than the right; its super-

ficial fibres seem directed longitudinally from the base to the summit; the middle fibres are intermingled in an inextricable manner; the deeper contribute to the formation of the columnæ carneæ.

3d. In the septum the muscular fibres of the right ventricle are interlaced with those of the left, forming very acute angles. They may be separated, however, so as to divide the heart into two portions, the one right and the other left.

4th. The muscular fibres of the heart are extremely numerous and very close upon each other; their red colour is less florid and darker than that of the muscles of locomotion; their direction is very difficult to be determined; they intermingle with each other without any cellular tissue being interposed, as happens in the other muscles, to form distinct bundles. But although not very distinctly arranged in fasciculi, there is a sufficiency of very fine cellular tissue amongst the fibres generally. They are fleshy in their whole length, the internal columnæ alone being terminated by tendons.

5th. The membrane of the cavities of the heart, *endo-cardium*, is considered by the German anatomists as composed of two layers, the deeper elastic one not extending into the ventricles. This is evidently continuous with the membrane which lines the vessels destined for the circulation of the black blood. On leaving the venæ cavæ it lines the whole extent of the auricle, being applied upon the muscular bundles, and, in their intervals, against the serous lamina of the pericardium, to which it is united by a dense but spare cellular tissue. Beneath the vena cava inferior it is folded upon itself to form the Eustachian valve, and afterwards that of the coronary vein of the heart. At the circumference of the auriculo-ventricular orifice it is separated from the muscular tissue by a layer of thin and semi-fluid fat, which constitutes the white zone of which we have spoken. There, also, it is folded upon itself, on leaving the walls of the organ, to give rise to the tricuspid valves; after which it lines the whole ventricle, becoming excessively thin, introduces itself into the pulmonary artery, forms at its origin the three semilunar valves, and is continued to the last ramifications of that vessel.

6th. Membrane of the left cavities of the heart. It forms part of that which lines the walls of the vessels that carry red blood. It commences at the extremities of the pulmonary veins, lines them in their whole extent, and the whole cavity of the auricle, without presenting any fold, and penetrates into the ventricle. At the entrance of the latter its thickness increases a little, and it is folded upon itself to form the mitral valves, but afterwards becomes very thin. It leaves that part to proceed into the aorta, and thence into all the arteries of the body. It is of it that the three semilunar valves are formed which are found in that vessel near its origin.

The arteries of the heart are two in number, rising immediately from the aorta, and are called coronary. The coronary vein enters the right auricle. The orifices of the veins of Thebesius are seen in the interior of the heart, but these have not been very satisfactorily demonstrated.

The coronary veins of the heart have valves, but they are rudimentary and very imperfect. Its lymphatics are numerous and go to the lymphatic glands, situated before the arch of the aorta and left bronchus.

The *cardiac nerves* are small with reference to the size of the organ; they come from two sources:—1st, from the cervical ganglions of the sympathetic; 2d, the cardiac filaments of the pneumo-gastric. Lastly, a portion of the serous lamina of the pericardium may be considered as entering into the composition of the heart, its outer surface being invested by it in its whole extent. Some further remarks respecting this important organ may be useful to the student.

Volume.—A healthy heart should, according to Laennec, be about the size of the closed fist of the individual; and this, though a coarse approximation, is tolerably just. If enlarged by dilatation, the disease is called aneurism; if enlarged by thickening, it is called hypertrophy; if much diminished, it is said to be atrophied.

Weight.—The medium weight of the empty heart is about 11 ozs. in man and 9 ozs. in woman; the atrophied heart is sometimes so low as 2 ozs.; and the hypertrophied may occasionally weigh 22 ozs.

Measurements.—The height or length of the ventricles, measured anteriorly, is about 3 inches 3 lines; the posterior only 2 inches 3 lines. Its circumference at the base, when moderately injected, is about 10 inches.

Fibrous zones of the heart.—These zones are four in number,—1st, auriculo-ventricular; 2d, arterial.

Each *auriculo-ventricular* zone is a kind of circle, surrounding the orifice of communication between the auricles and ventricles. It is a very peculiar structure, but was well understood by the most ancient anatomists. In the left auriculo-ventricular zone, in certain of the lower animals, there is frequently a bone developed, as in the ox, deer, &c., but not in the horse. Galen knew these facts perfectly, and his successors ventured to apply them to the anatomy of the human heart, but in this they committed a great error. The presence of the bone in the auriculo-ventricular zone of the heart in ruminating animals is a *specific structure*, and not a pathological phenomenon, as M. Cruveilhier supposes. It is present in the calf, fawn, &c. As it is absent in the horse, it is evident that its presence or absence is not caused by any necessity for strengthening the part in the larger animals, else it would be present in all. From each of the circles they form there proceeds an expansion of the same nature, occupying the thickness of the tricuspid and mitral valves; and into these fibrous circles proceed, directly or indirectly, most of the cordæ tendineæ of the ventricles.

2d. *Arterial zones.*—These are two fibrous circles somewhat less than the orifice of the arteries which they surround at their junction with the heart. From these zones proceed,—1st, three very thin but strong prolongations, filling the angular intervals of the festoons which the aorta and pulmonary arteries have at their origins; 2d, three other prolongations to the sigmoid valves of these vessels. The pos-

terior half of the aortic circle is intimately united to both auriculo-ventricular zones. All these parts may readily be seen by laying open the orifices of the great arteries at their connexion with the heart.

Fig. 159.*

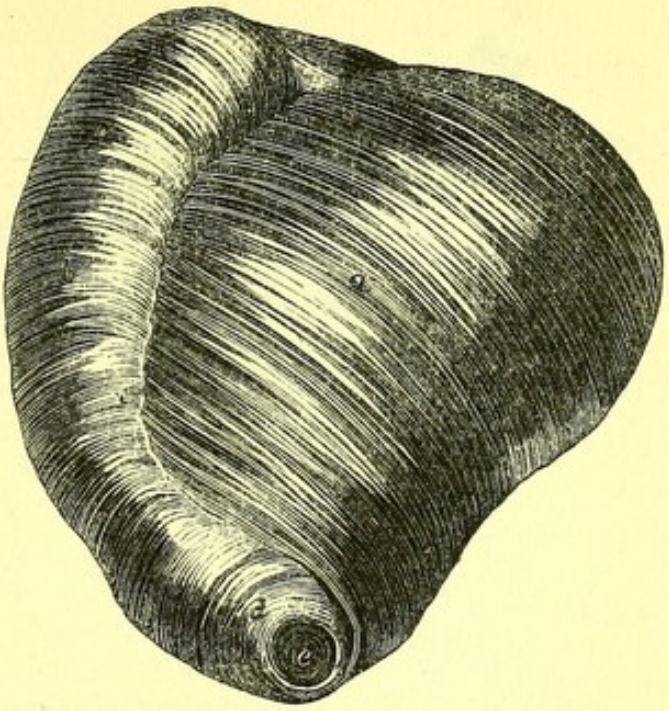

It is difficult to describe to the elementary student the course of the muscular fibres of the heart. The only way, perhaps, to understand them is to follow the fibres, layer by layer, in an ox's heart, after it has been boiled for several hours. The following statement has been given by M. Cruveilhier as an approximation to the truth :—

The heart is formed of two muscular sacs contained in a *third, common to both ventricles.*

All the muscular fibres of the heart arise from the fibrous zones, and all terminate in these zones. The muscular fasciculi are of great length, ascending and descending; they are disposed in successive layers, and the fibres cross each other at right angles; they may also be divided into common and proper. All the superficial fibres are common to both ventricles; they are oblique and spiral towards the point.

The *cause* of the sounds of the heart has been much disputed; it is a purely physiological question.

The AORTA.—The student is now prepared to take a practical view of the course of the aorta through the chest. At its origin from the left ventricle of the heart, it is covered for a considerable extent by the pulmonary artery; it ascends obliquely forwards, and to the right side, to a level with the cartilage of the second rib. Opposite to about the second dorsal vertebra it leaves the pericardium, and shortly after proceeds transversely backwards; it next descends, until about the level of the fourth dorsal vertebra, from which point it follows, as has been already described, the course of the vertebral column, but rather towards the left side. The portion of the aorta, from its commencement to the

* Fig. 159.—The heart, after it has been long boiled, to show the arrangement of the fleshy fibres, chiefly of the left ventricle.—*a*, the left ventricle; *b*, the right ventricle; *c*, position of the septum ventriculorum; *d*, the muscular fibres turning in a spiral manner around *e*, the apex and vortex.

Fig. 160.*

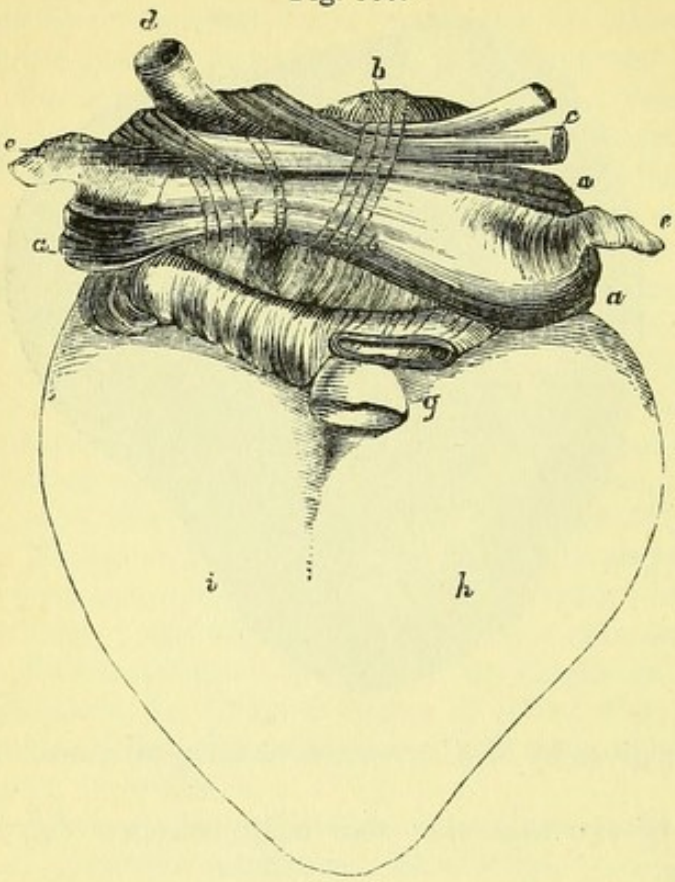

level of the fourth dorsal vertebra, is called the *arch of the aorta*, and is subdivided into three portions, viz.—1, an ascending; 2, transverse; 3, a descending portion. The first portion is the longest, and can be best seen by cutting away the pulmonary artery and carefully cleaning the aorta. It lies chiefly within the pericardium, and is but little covered by the serous layer of that membrane. It is here that the aorta is very liable to ulceration, and consequent rupture and sudden death, caused by the filling of the pericardium with blood.

In this position, also, the student will observe its calibre greater than in the other parts; the orifices of the coronary arteries; the sinuses of Valsalva, or Morgagni, lying exterior to the semilunar valves.

The second, or *transverse* portion of the arch, is chiefly external to the pericardium; above it, and in front of the trachea, it gives origin to the arteria brachio-cephalica, the left common carotid and left subclavian arteries. If another artery be found arising from this part of the arch, it will usually happen to be the left vertebral.

The third, or *descending* portion of the arch, is remarkable for occasionally presenting a slight contraction; and it is here that the aorta has been known to become spontaneously obliterated. To the commencement of this portion, but on its concave side, the ligamentum arteriosum is usually attached. Passing through below the arch of the aorta, the student will find the right branch of the pulmonary artery, the left bronchus, and the left recurrent nerve. For a more particular account of the branches of the aorta, the student may, at this stage of the dissection, consult the account of the Vascular System.

* Fig. 160.—*a*, *a*, *b*, the superficial or transverse fibres, forming an incomplete layer, more numerous near the base of the auricles *a*, *a*, *a*, and opening to embrace the veins *d*, *e*, and the auricular appendages *e*, *e*; *f*, *b*, deeper layer or looped fibres of the left auricle; *d*, vena cava superior; *c*, pulmonary veins; *g*, arterial orifices of pulmonary artery and aorta; *i*, *h*, right and left ventricles.

DEVELOPMENT OF THE HEART AND GREAT BLOOD-VESSELS.

In the embryo the heart first appears as an elongated sac or tube, having two veins connected with it behind, and one arterial trunk proceeding from it in front. The tube soon bends, or becomes curved on itself.

Fig. 161.*

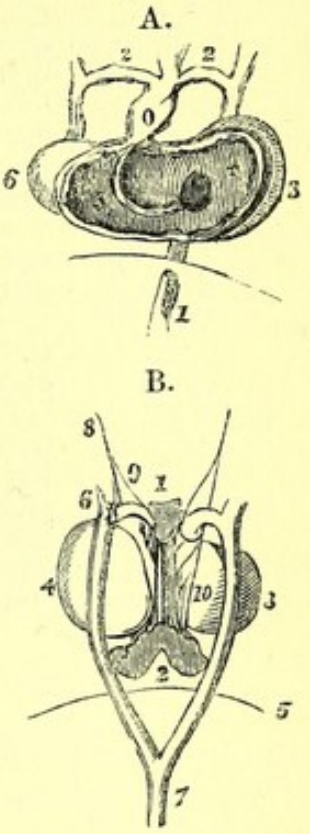

The heart gradually assumes more and more the form of the heart of the fish; the tube becomes divided into three compartments, auricular, ventricular, and the arterial bulb. From the arterial bulb five vessels arise on each side; they proceed around the pharyngeal cavity, meet in front of the vertebræ, and unite into a single vessel. This is the future thoracic segment of the aorta. At this period the heart and vessels represent the structure of fishes; the bulb is permanent in the fish, together with the vessels it gives off; these are, in fact, the branchial vessels proceeding to the gills. In man all is altered.

As the development proceeds, these branchial arches rapidly disappear.

The next metamorphosis is the subdivision of these three cavities into six, thus forming two auricles, two ventricles, and two arteries, the pulmonary and the aorta,—that is to say, the septa of the auricles and of the ventricles are formed, and the bulb divides into two. The mode of formation of the pulmonary vein has not as yet been carefully determined, nor the part which certain of these arches play in respect of the structures present in the fœtus, at a period shortly before or just before birth; these I may here describe.

The vascular arches and branchial fissures of the fœtus, corresponding to, and representing, at that stage of its existence, the branchial arches and opercular fissures in fishes, are amongst the most remarkable of all animal structures. Even alone they prove the great theory of unity of organization; but they also go far to prove unity of composition in all animals. In man they are temporary and fugacious; in fishes they are permanent.

Their *vestiges* may occasionally be discovered on the adult neck in the shape of small mucous openings leading to tubes secreting a limpid fluid. These tubes may or may not communicate with the larynx, or trachea, as the case may be. They close, re-opening from time to time so soon as the liquid has accumulated in sufficient quantity to burst the thin epidermic covering, showing by this that

---

* Fig. 161.—A. Heart seen on the ventral aspect, and laid open. Heart of the human embryo, fifth week—*Baer*. 0, bulbus arteriosus; 2, arterial canal on each side, uniting behind to form the aorta; 3, auricular portion of the heart; 4, opening leading from the single auricular cavity, 3, to the single ventricular cavity, 6; 5, septum of the ventricles commencing; 1, vena cava inferior.—B. Back view of the same heart; 1, larynx and trachea; 2, lungs; 3, ventricular, and 4, auricular part of the heart; 5, diaphragm; 7, descending aorta formed by the union of a right and left aortic arch; 8, 9, 10, trunk and branches of the pneumo-gastric nerves.

mucous tubes, or canals, never become completely obliterated: attempts made to obliterate these canals have generally failed. It is sufficiently curious that this peculiarity of structure seems to be hereditary.

Fig. 162.*

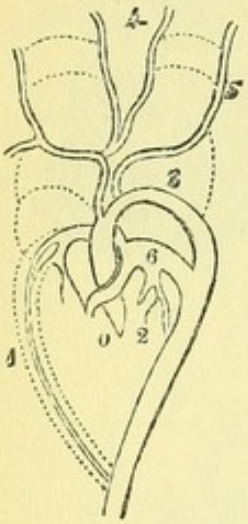

When M. Geoffroy (St. Hilaire) published, in 1821, his Theory of the Philosophic Anatomy of the Respiratory Organs, in which the metamorphoses of the structures played a prominent part, I objected to the theory on grounds based partly on his own views, pointing out to him that the *plan* or *type* of nature in the construction of the respiratory apparatus of all animals was evidently double; viz. aquatic and aerial; and that, sooner or later, as in the generative system, it would be proved that in the fœtus, whether of man or animals, the respiratory organs were double; that is, composed of lungs and branchiæ; and that the only interchange which took place in respect of these organs was merely the *suppression of the one or the other*, according as the animal was intended to breathe air in water or as air—*aquatic* or *aerial*, or the retention of both sets of organs, as in the amphibia.†

The branchial and opercular apparatus, then, is not a purely ichthyological structure, created solely for the fish, but a set of organs, which it has in common with all other animals, man included. In man and mammals it remains rudimentary, or wholly disappears in the adult state; in fishes, on the contrary, it is fully developed, the other apparatus (lungs, trachea, etc.) remaining in them rudimentary.

FŒTAL CIRCULATION.

Until the fourth month the heart of the fœtus is situated mesially and vertically in the chest. At this time the apex begins to move towards the left side.

1. For a time, nearly until birth, the walls of the ventricles are of equal thickness. On opening the right auricle, it will be found that this cavity communicates directly with the left by the *foramen ovale*, and that the Eustachian valve is large and perfect. The result is, to direct by far the greater part, if not the whole, of the blood which enters the right auricle of the fœtus, towards the left auricle, instead of passing into the right ventricle as in the adult.

2. The pulmonary artery of the fœtus divides into three distinct branches, instead of two as in the adult. The third branch is the one it sends directly into the aorta, the remains of which I have already described as the ligamentum arteriosum. The ductus arteriosus joins the aorta on the concave side of the termination of the arch, and immediately after it has given off the left subclavian artery. It is a remarkably strong and large vessel, with thick fibrous walls resembling the bulbus arteriosus of fishes.

3. The common iliac arteries send off in the fœtus two large vessels,

* Fig. 162.—0, two tubes resulting from the division of the arterial bulb; 3, Fourth, arch of the left side remaining as an arch of the aorta; 4, 5, great vessels arising from it; 1, 2, fifth, pair of arches sending branches into the lungs, and forming the right and left divisions of the pulmonary artery; 6, Corresponding part of left arch, forming the ductus arteriosus.

† Proteus, etc.

the hypogastric or umbilical. These, passing upwards by the sides of the bladder, leave the body of the fœtus through the umbilicus; they form the umbilical arteries of the placental cord, and are supposed to terminate in the placental tufts which float in the great venous sinuses of the uterus of the parent. In these tufts commence the vessels which ultimately form the umbilical vein. The vessel so formed enters into the composition of the umbilical cord, and enters the body of the fœtus by the umbilicus. Here it changes its direction, or rather leaves the accompanying arteries, and, proceeding upwards towards the liver of the fœtus, joins the vena portæ, contributing to form the sinus of the porta. From this sinus, immediately opposite to the entrance of the umbilical vein, a large vessel, the ductus venosus, proceeds to join the vena cava inferior, direct. Thus the larger portion of the blood entering the sinus of the porta may reach, by the vena cava, the right auricle of the heart, without passing through the liver of the fœtus. At birth, so soon as the child breathes, this complex circulation ceases. The ductus venosus and ligamentum arteriosum degenerate into cellular cords, and the ductus arteriosus and umbilical vein are known in the adult by the names of the ligamentum teres, hepatis, and ligamentum arteriosum, already described, but the foramen ovale does not always close completely, and I have seen it as distinctly open in an adult of forty years, and the Eustachian valve as perfect, as in the fœtus at the time of birth. The umbilical arteries shrink, and are reduced to cellular cords; they figure in the adult as ligaments of the bladder.

Fig. 163.*

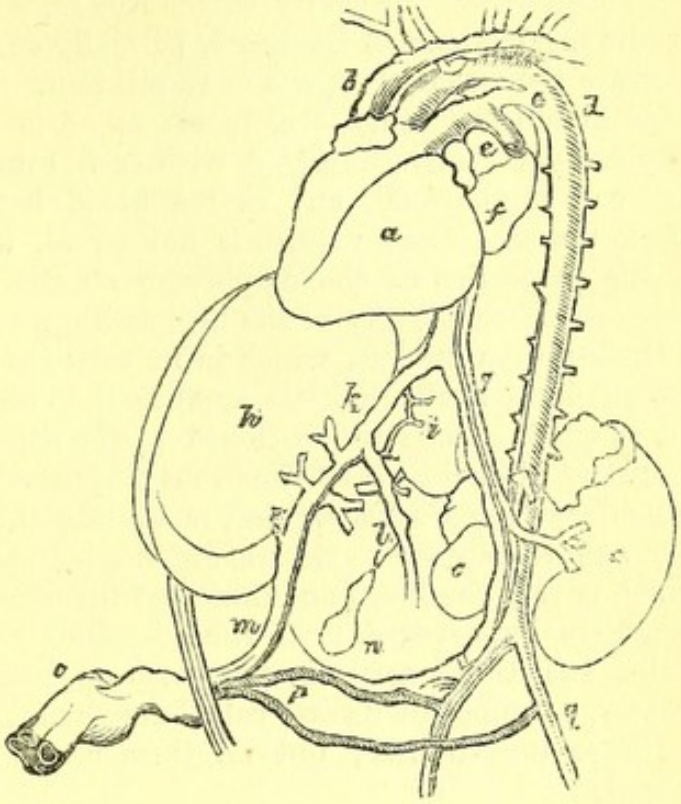

* Fig. 163 represents the fœtal circulation.—*a*, left ventricle; *b*, vena cava superior; *e*, *f*, left auricle; *c* is placed on the aorta, close to the entrance of the ductus arteriosus; *d*, the aorta; *q*, the iliacs giving off the umbilical arteries; *p*, right umbilical artery; *o*, the umbilical cord cut through a short way exterior to the umbilicus; *m*, the umbilical vein; *h*, lower surface of the right lobe of the liver; *k*, ductus venosus; *i*, lobulus spigelii; *l*, vena portæ; *n*, gall-bladder; *g*, vena cava inferior; *c*, *c*, kidneys and supra-renal capsules.

THE LUNGS AND THEIR APPENDAGES.

The lungs (*pulmones*) are two spongy, cellular, expansible organs, contained within the cavity of the thorax, separated from each other by the mediastina and the heart, partially surrounded by the pleuræ; they are the essential organs of respiration.

Although the lungs are, to all appearance, separate and distinct, they are yet really connected with each other, since they receive the air by a single canal, and as the blood is transmitted to them by a single vessel. Their volume is not equal, however, but on account of the projection of the diaphragm on the right side caused by the liver, and the obliquity of the mediastinum to the left, the right lung is thicker than the left, which in its turn has a greater vertical extent; the left lung is also a little smaller than the right. The volume of the lungs is exactly proportioned to the capacity of the cavity of the thorax. They follow the motions impressed upon its walls, against which they are always applied, and dilate and contract like them; nor does any vacuity ever exist during life between that part of the pleura which covers the lungs and that part investing the walls of the chest. It is here, however, *i. e.* in the so-named cavity of the pleuræ, that water sometimes accumulates, forming hydro-thorax; and purulent matter, forming the disease called empyema; and sometimes even air, as in pneumo-thorax; but all these are diseased conditions of the organs.

The lungs are proportionally much lighter than the other organs; they never sink in water so long as they are in their natural state, and this lightness depends upon the air which penetrates their whole tissue. In infants which have never breathed the lungs generally sink in water. But the absolute weight of the lungs varies much in different individuals, which may depend upon the greater or less quantity of blood that remains in them at the moment of death, or upon a larger development. It is also to be observed that, in children which have not breathed, the lungs are, with respect to the total weight of the body, in the variable relation of 55 or 70 to 1; whereas the proportion is as 28 or 35 to 1 when respiration has taken place. The act of respiration, therefore, diminishes their gravity in a great degree, a circumstance which it is of importance to know with reference to medical jurisprudence. The colour of the lungs in the healthy and adult state is a pale yellowish red, more or less approaching to white or gray. The younger the subject the redder will be the lungs. This tint is equally observed in the interior and at the exterior of the organ. But if the blood happen to be too much accumulated in its parenchyma, the colour is a dark-red or purple, uniformly diffused, or only dispersed in patches, which produces a marbled appearance. It is for this reason that the lungs are always more coloured on the side on which a dead body has lain. The reddish or greyish colour of the lungs is interrupted by small black and brown spots, irregularly dispersed on their surface, and more or less nume-

rous: they are exactly defined, and in general affect a linear form; they are seldom isolated from each other; some are entirely superficial, others penetrate more or less deeply into the tissue of the lungs, and there are some which seem limited to the pleura or membrane which immediately envelops these organs, in the substance of which they also occur. Buisson considers them as analogous to the lymphatic glands of the bronchi. Of the solid organs of the body, the lungs are those which have the smallest density; they may be compressed with the greatest ease, and only resume their original state imperfectly. Although flexible and soft, however, they have a tissue which is not easily torn. The form of the lungs is not very easy to be described; it may, however, in a general manner, be likened to that of a cone, having its base directed downwards and its summit upwards, and flattened internally. The right lung is divided into three unequal lobes, by two oblique fissures; the left presents only a single fissure, and consequently has but two lobes.

Their *outer* surface, which is convex, especially behind, and nearly plain anteriorly, is free *in its whole extent*, and corresponds to the walls of the thorax, from which it is separated by the costal layer of the pleuræ. It is smooth and polished, and constantly bedewed with a serous fluid. On the left lung it presents a fissure which descends obliquely from the posterior to the anterior edge, and divides the organ into two lobes, a superior and anterior, which is smaller, and a posterior and inferior, which is larger: this fissure nearly penetrates through the whole thickness of the organ. A similar fissure is observed on the right lung; but in it the upper lobe is divided into two portions by a secondary fissure running obliquely downwards and outwards, and consequently in a direction the reverse of the great fissure, and which varies much as to depth and extent. In the two lungs, the upper lobes, which are large above, terminate below in a point, while the contrary takes place in the lower lobes, which are always the larger. In the right lung the middle lobe is triangular, presenting its summit outwards, and its base inwards, and it is smaller than the other two.

The *internal* surface (roots) of the lungs, which is plane or slightly concave, to accommodate itself to the shape of the heart, corresponds, posteriorly, to the mediastinum and the vertebral column. About the middle of its height is seen the insertion of the bronchi and pulmonary vessels. Its anterior two-thirds are contiguous to the pericardium and thymus gland. Anteriorly to the roots lie the phrenic nerves, and a few filaments of the eighth pair; posteriorly, the pulmonary plexus of the same pair of nerves. The dissection of the roots of the lungs, a little anteriorly or posteriorly, consists merely in stripping off the pleura and removing a little cellular substance; when this has been done, the branch of the pulmonary artery proceeding to each lung will be found superiorly and posteriorly; the pulmonary veins below, but anteriorly the bronchial tubes lie superior to these, more especially the right one.

The *anterior* edge of the lungs is thin, sharp, especially below, oblique, sinuous, more or less uneven, directed obliquely downwards and forwards, and notched on the left side only, to receive the point of the heart.

Their *posterior* edge is thick, rounded, nearly vertical, and lodged in a groove which the ribs form on the sides of the vertebral column.

Their *base*, which is slightly concave, rests upon the upper surface of the diaphragm, and is inclined a little downwards and outwards on each side. It is circumscribed by a sharp and sinuous edge, which is lodged between the ribs and the insertions of the diaphragm, and on which there occurs the end of the interlobular fissure.

Lastly, their *summit*, which is narrow, obtuse, and a little bulged, is situated generally in the neck, a little above the level of the anterior part of the first rib.

ORGANIZATION OF THE LUNGS.

The tissue of the lungs is very complicated. It seems essentially composed of prolongations and successive ramifications of the bronchi, and pulmonary arteries and veins, which stick together in all their divisions, and are sustained by a very fine cellular tissue, so as to constitute a series of lobules, covered and united by the pleuræ, and interspersed with nerves, vessels, and lymphatic glands. Reseissen thought that the bronchial tubes terminate in air-cells.

PROPER TISSUE OF THE LUNGS.—We have already, to a certain degree, an idea of the intimate structure of the lungs, as we know several of the organs which enter into its composition. But when we come to consider it with some attention, without reference to its constituent parts, we find that it is divided into several lobules distinct even at the exterior, and separated from each other by small whitish grooves. They are especially very well seen on tearing the tissue of the organ after it has been boiled. They vary much as to volume and form. They present, in general, a number of small surfaces, bounded by prominent angles, and present in their intervals a loose, filamentous cellular tissue, destitute of fat, very extensible, and capable of becoming emphysematous with the greatest ease, either during life, by a rupture of a division of the bronchus, or after death, by insufflation. Each of these lobules is divided into smaller, without its being possible to discover the precise termination of this division. The intimate structure of these last lobules is unknown. Willis asserted that they have a racemiform arrangement around the ramifications of the bronchi, which, however, does not appear to be the case. It is only very probable that they are formed by the union of the last extremities of the bronchi, vessels and nerves which are distributed throughout the lungs. At this stage of the dissection the student should get permission from those who may be dissecting the neck to examine the anatomy of the *trachea* throughout its whole course. Let him first remove the great blood-vessels placed over its lower part, and clean it carefully

downwards to its division into the bronchi; dissect these carefully towards each lung, preserving as well as he can the bronchial glands, the bronchial arteries, and pulmonary plexus and nerves.

The TRACHEA.—The trachea (*Arteria aspera;* windpipe) is a cylindrical, cartilaginous, and membranous tube, a little flattened posteriorly, placed before the vertebral column, extending from the lower part of the larynx to opposite the second or third dorsal vertebra, in the posterior mediastinum. Running along the median line of the body, symmetrical and regular in its whole extent, slightly mobile and extensible, the trachea has a uniform diameter of about 8 or 10 lines, which varies only according to the age and certain individual peculiarities.

The *anterior* side of the trachea is convex, and covered above by the thyroid gland, inferior thyroid veins, and sterno-hyoidei and sterno-thyroidei muscles, from which it is separated by a layer of loose cellular tissue. Inferiorly, it corresponds to the thymus gland, the left vena innominata, the arteria innominata, and the arch of the aorta. Its *posterior* side is flattened, covers the œsophagus, and a little to the right the bodies of the vertebræ, owing to the obliquity of the œsophagus. *Laterally*, it is continuous to the common carotid arteries, the internal jugular veins, the pneumo-gastric nerves, and the communicating twigs of the cervical ganglia, which are separated from it by a mass of adipose cellular tissue. *Inferiorly*, the trachea bifurcates, dividing into the two bronchi, which are distinguished into right and left, and which separate from each other, directing themselves downwards and outwards at nearly a right angle.

The *right bronchus* is wider, shorter, and more horizontal than the left, and is a little anterior to it. It penetrates into the lung opposite the fourth dorsal vertebra, is embraced in its course by the curve of the vena azygos, and by the arch which the right branch of the pulmonary artery forms.

The *left bronchus*, which is a little smaller, but longer and more oblique, is embraced by the aorta and left branch of the pulmonary artery. The bronchi enter the lungs by their internal surface, and divide into two branches, which, after a very short course, subdivide, and thus give out branches becoming gradually smaller, which take all kinds of directions. These ramifications seem to divide the whole tissue of the organ into lobules, separated from each other by cellular tissue, and absolutely exist in all points. It is extremely difficult to trace them to their termination. Malpighi thought that they end by rounded and membranous vesicles, which, according to Willis, are pedicellate. Senac imagines the lobules of the lungs to be composed of polyhedral vesicles, the sixth of a line in diameter, into each of which a twig of the bronchi opens. But it appears demonstrated, on the contrary, that the divisions of the bronchi ultimately terminate by a small undilated cul de sac, and that it is from the union of several of these minute twigs, kept together by the cellular

Fig. 164.*

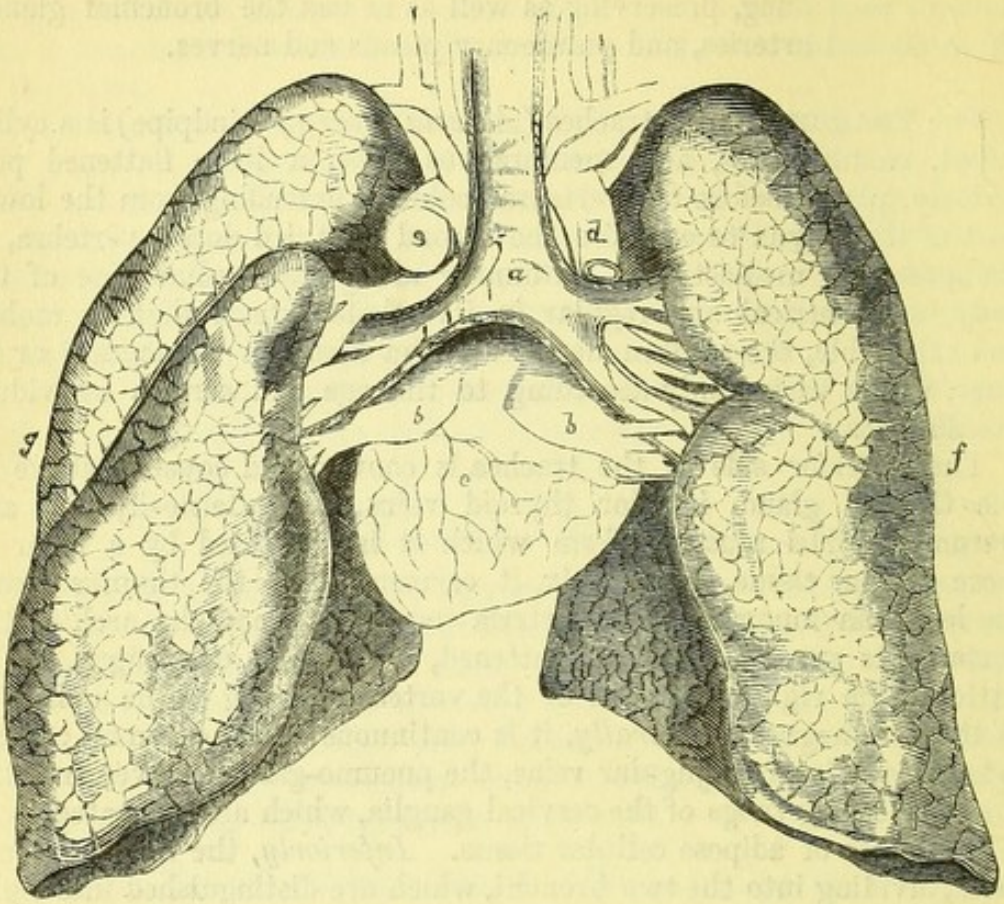

tissue in which they are immersed, that what is called the pulmonary lobule results.

The TRACHEA and BRONCHI are composed of,—1st, cartilaginous rings; 2d, membranes; 3d, arterial and venous vessels; 4th, lymphatics; 5th, nerves; 6th, mucous follicles; 7th, bronchial glands.

1st. The *Cartilaginous rings* are from sixteen to twenty in number: they are not complete rings in man, being interrupted in their posterior third. They are placed horizontally above each other, and separated by narrow membranous intervals; curved upon themselves, and flattened in the plane of their direction, they have all the same length, but vary as to breadth; their form approaches that of a very elongated right-angled triangle when they are stretched out; they are commonly thicker at their middle part than at their extremities, which are sometimes bifurcated. By their convex surface they correspond to a fibrous membrane, and by the concave are in connexion with a mucous membrane. Their rounded edges give attachment to the first of these membranes, and project a little more on the inner than on the outer surface of the canal; sometimes, also, several of them are seen to unite. The first is commonly very broad, and sometimes joins the

* Fig. 164.—Posterior surface of the trachea and lungs.—*a*, posterior surface of the trachea; *b*, *b*, pulmonary veins; *c*, the heart, posterior surface; *d*, *e*, arch of the aorta; *f*, *g*, posterior convex surface of the lungs.

Fig. 165.*

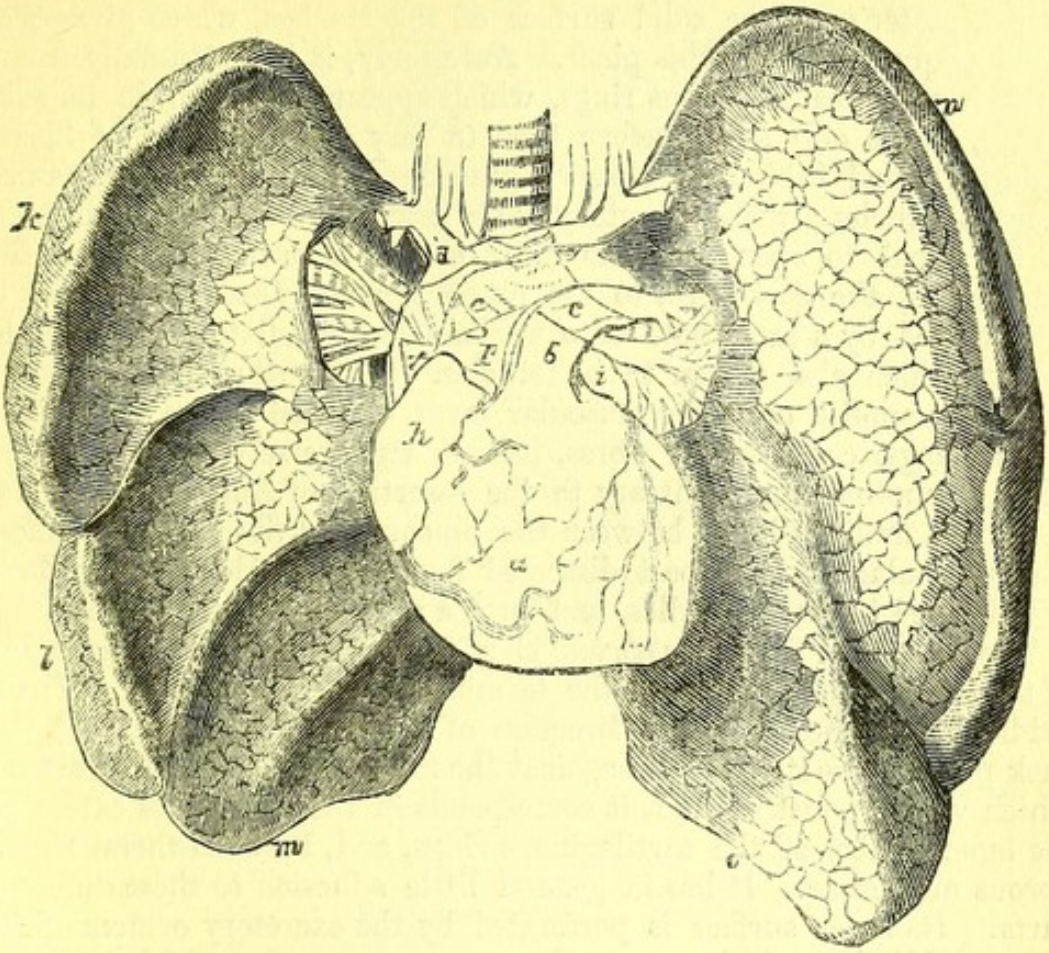

cricoid cartilage; the last is still broader, and very different from the others. It is triangular, and its middle part is prolonged inferiorly, bending a little backwards, to accommodate itself to the origin of the bronchi. In the first ramifications of the bronchi the cartilaginous rings are entirely similar to those of the trachea, only thinner, smaller, and sometimes formed of several pieces; but in the secondary ramifications they are merely small, irregular grains, varying in form, united or separate, which gradually diminish, so as to disappear entirely in the ultimate divisions of these canals. The colour and consistence of the cartilages of the trachea and bronchi are the same as in those of the ear, the apertures of the nose, &c. Their elasticity is very remarkable. They seldom ossify, even in the most advanced old age.

2d. The *fibrous* or *outer membrane* comes from the inferior circumference of the cricoid cartilage, and is prolonged to the last extremities of the bronchi, becoming gradually thinner to an excessive degree. It is formed of longitudinal and parallel fibres, of which the

* Fig. 165 represents the anterior surface of the lungs with the heart *in situ*. —*a*, the heart, right ventricle; *h*, right auricle; *b*, pulmonary artery; *p*, aorta; *c*, left bronchus; *d*, junction of the venæ innominatæ; *i*, pulmonary veins; *k*, right lung, upper lobe; *l*, middle lobe; *m*, inferior lobe; *n*, left lung, upper lobe; *o*, inferior lobe.

more superficial are reddish, the deeper white. This membrane alone forms, posteriorly, the solid surface of the trachea, which gives that canal a square form in this place. Anteriorly, it is continually interrupted by the cartilaginous rings, which appear developed in its substance, and it only sends before them a very small number of fibres. Externally and behind we observe granules, varying in figure, named mucous follicles; their excretory ducts traverse the whole substance of the canal to open upon its inner surface internally, and in the intervals of the cartilages, to the mucous membrane, from which it is separated by a multitude of other smaller granulations, varying in colour, which also appear to be follicles. But posteriorly, it is immediately applied upon the muscular layer attached to the extremities of the rings, composed of fibres, passing transversely from one cartilage to another, but, contrary to the assertion of Andral and others, it forms a uniform layer between the mucous and fibrous membranes. This muscular layer is best dissected from the inside. These fibres are disposed in small bundles, and form a perfectly distinct plane.

The *mucous* or *inner membrane* is a continuation of the membrane of the larynx, and extends to the termination of the bronchi. Firm, reddish, and plicate in the direction of its length, especially at the back part, where it is applied against the fibres of muscular appearance which we have just noticed, it corresponds in the rest of its extent to the inner surface of the cartilaginous rings, and, between them, to the fibrous membrane. It has in general little adhesion to these different parts. Its inner surface is perforated by the excretory orifices of its mucous follicles, which constantly pour out a rather thick and not very plentiful fluid. Its organization presents nothing remarkable. To examine it, the trachea must be cut open longitudinally and anteriorly from near its commencement, quite to its division into the bronchi, and these also should be laid open in the same direction.

3d. The vessels of the trachea come from the superior and inferior thyroid. Its nerves are furnished by the pneumo-gastric nerves and cervical ganglia. The bronchi have arteries which bear their name, and which arise immediately from the aorta; they are commonly two in number, a right and a left. They have corresponding veins, which empty their contents, the right into the vena azygos, the left into the superior intercostal vein. Their nerves are supplied by the two pulmonary plexuses.

The thyroid body (*glandula thyroidea*) is an organ respecting the uses of which we are totally ignorant, and which anatomists usually describe after the larynx, on account of its situation; for it covers the lower and anterior parts of that organ, as well as the first rings of the trachea. This body exhibits great differences in its size in different individuals, and at different ages in the same individual, without our being able to assign any reason for such differences; but, in general, it is larger in the child than in the adult, and in the female than in the male; it is also more constant in its form. It is composed of two oval lobes, flattened from before backwards, thicker below than

above, and has a more or less oblique direction in different individuals. These two lobes are sometimes united in a great part of their extent, but in general are separated, and only connected with each other by a transverse cord, more or less broad and thick, named the isthmus or middle lobe of the thyroid gland. From the middle lobe there ascends not unfrequently a narrow portion, called the pyramidal lobe; this ascends upwards on the surface of the thyroid cartilage, following the course of the muscle named the levator glandulæ thyroideæ. This lobe is rarely wanting, and varies in almost every subject.

The *anterior* surface of the thyroid body is covered in the middle by the sterno-thyroidei muscles, and on the sides by the latissimi colli, omo-hyoidei, and sterno-cleido-mastoidei.

Its *posterior* surface, which is concave, is connected, by a filamentous cellular tissue, with the larynx and the first rings of the trachea; it also covers the crico-thyroidei, thyro-hyoidei, and constrictores pharyngis inferiores.

Its posterior and lateral edges rest upon the trunks of the carotid arteries, the internal jugular veins, the pneumo-gastric and recurrent nerves, the communicating cords of the cervical ganglia, and that of the left side only on the œsophagus. The superior thyroid arteries run along its *upper* edge, which is deeply notched in the middle.

The *lower* edge, which is convex, is in like manner accompanied by arteries, and gives rise to large veins.

The *upper* extremities of its lateral lobes are lodged between the thyroid cartilage and the trunks of the carotid arteries; the *lower* between these arteries and the trachea.

The thyroid body is not contained in any capsule. The cellular tissue by which it is immediately surrounded seems alone to supply it with an envelope, which is somewhat dense, and never contains fat.

The proper tissue of the thyroid body is soft and spongy. Its arteries come from the external carotid and subclavian arteries; frequently the arch of the aorta sends a separate branch to it. Its veins are numerous, and accompany the arteries, or issue from its lower edge; its nerves come from the pneumo-gastric nerves and sympathetic; its lymphatics lose themselves in the jugular glands. It is this body or gland which, becoming enlarged, forms bronchocele, one of the synonymes of goître. The number of large vessels proceeding to it, whilst they seem to warrant a conclusion in regard to its physiological use in the system, contribute to render its extirpation in disease a hazardous operation. Bronchocele is more frequent in Britain than has been supposed, and abounds particularly in Newark and Wolverhampton, and in Derbyshire, in England, and in some parts of Roxburghshire, in Scotland. In Derbyshire it is so common that the disease is called the "Derbyshire neck."

4th. The *sympathetic glands* are very numerous, and are situated before the bifurcation of the trachea, around the bronchi, and even in the interior of the lungs, where they are irregularly disseminated. Their form presents numerous variations, being sometimes oval or

rounded, sometimes lobular, and varying much as to size; the larger are lodged above the trachea, the smaller in the intervals of the bronchi. Their colour is black or of a dark brown in the adult, reddish in children. Their tissue has in general but little consistence; when crushed under the fingers they stain them deeply; when cut directly across, the trachea remains always open.

The THYMUS.—The thymus is an organ whose uses are unknown. Its description, however, naturally enough, comes to be considered in this place. No excretory duct has ever been discovered in it.

Fig. 166.*

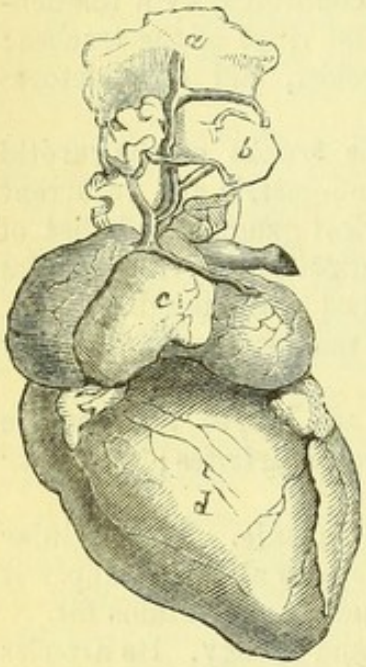

In the fœtus this organ extends nearly from the thyroid body to the vicinity of the diaphragm, and thus occupies the greater part of the anterior mediastinum. Gradually diminishing with age, whilst the other textures increase, it can scarcely be seen in the adult.

Behind it are situated the trachea, the great blood-vessels, and the pericardium; *before* it, the manubrium of the sternum and lower part of the sterno-thyroidei muscles; by its edges it touches the pleuræ below.

It is notched and grooved anteriorly. A thin *cellular capsule* proceeds into its interior, separating it into lobules, and these again show vesicles filled with a milky and slightly viscous fluid; these cavities seem to communicate with each other. Its arteries arise from the inferior thyroid, internal mammary, bronchial, mediastinal, and pericardiac arteries, and are pretty numerous, that is, in the young person, before the age of ten or twelve. A few nervous filaments proceed to it from the eighth pair, the phrenic and inferior cervical ganglia.

The LARYNX.—The larynx cannot be understood merely by a dissection of that larynx which appertains to the head and neck, that the student has just dissected. He must apply to his anatomical teacher for the following preparations,—the os hyoides; a dried larynx, with the upper part of the trachea; separate specimens (recently prepared and preserved in weak alcohol) of the individual cartilages entering into the composition of the larynx. With these, and a careful dissection of the larynx belonging to the head and neck he has just dissected, he will readily make himself master of this organ, which no existing manual of practical anatomy, aided by the dissection of a

* Fig. 166 shows the position and relative size of the thymus gland in the fœtus.—*a*, *b*, larynx and thyroid gland; *c*, the thymus; *d*, the right ventricle of the heart.

single larynx, would ever enable him to accomplish. Having put these preparations before him, and cautiously cleaned the larynx, attached to which he must have the tongue and hyoid bone, let him commence by re-examining the anatomy of the hyoid bones.

Fig. 167.*

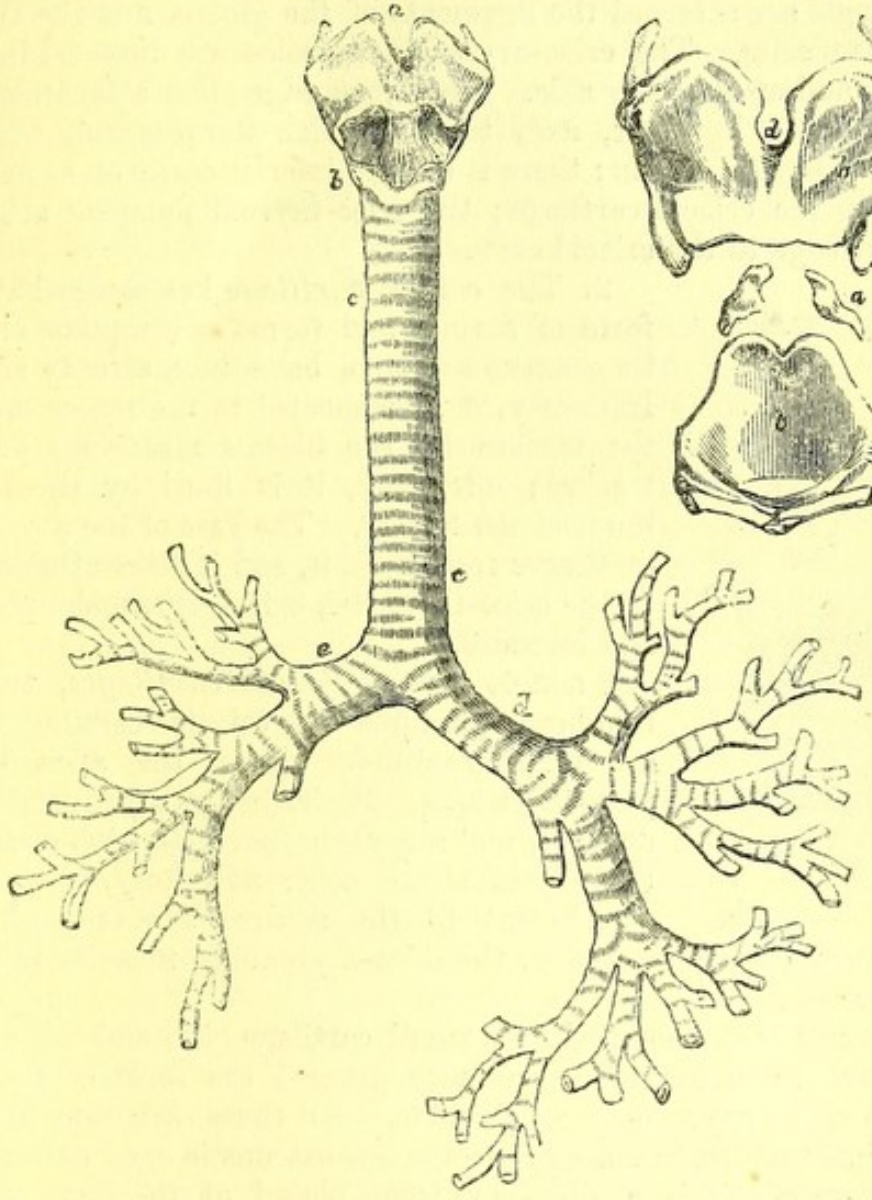

Fig. 168.†

The *larynx* communicates superiorly with the pharynx; inferiorly, with the trachea. The pharynx separates it from the vertebral column. It gives passage to the air in the act of respiration, and is the organ of the voice.

The cartilages of the larynx are nine in number.

* Fig. 167 represents the larynx, trachea, and bronchi.—*a*, thyroid cartilage; *b*, cricoid cartilage; *c*, *c*, trachea; *d*, left bronchus; *e*, right bronchus.

† Fig. 168.—A, cartilages of the larynx.—*a*, thyroid cartilage, superior horn; *b*, same cartilage, left side of the body; *c*, inferior or descending horn; *d*, incisura, or notch.—B, *a*, arytenoid cartilages.—C, *b*, cricoid cartilage.

1. The *thyroid cartilage*, composed of two broad laminæ, having thus something of the form of a shield; hence, also, called scutiform. These laminæ give rise to a projecting angle anteriorly, readily felt under the integuments; posteriorly, the thyroid cartilage is quite open, being defective here; the sterno-thyroid, sterno-hyoid, and inferior constrictor of the pharynx are attached to it. In the hollow of the retiring angle are attached the ligaments of the glottis and the thyro-arytenoid muscles. The crico-arytenoid muscles are inserted into it inferiorly, and on its outer side. The upper edge gives attachment to the thyro-hyoid ligament, and, together with the posterior margin, forms the ascending *cornu;* there is also an inferior cornu on each side, overtopping the cricoid cartilage; the crico-thyroid ligament attaches its inferior edge to the cricoid cartilage.

Fig. 169.*

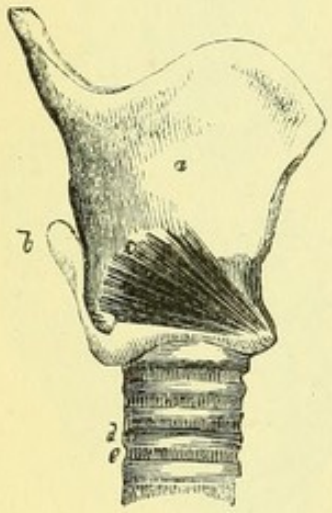

2. The *cricoid cartilage* has somewhat the form of a ring, and forms a complete circle; its connexions above have been already stated. Inferiorly, it is connected to the upper ring of the trachea by the fibrous membrane of the trachea; internally, it is lined by the membrane of the larynx. The base of the arytenoid cartilages rests upon it, and it gives attachment to the crico-thyroidei, crico-arytenoidei postici, and laterales.

3 and 4. The *arytenoid cartilages*, two in number, rest upon the cricoid cartilage, and are of a pyramidal shape, the apex being placed upwards. Posteriorly, they give attachment to, and are connected with each other by the arytenoid muscles; anteriorly, they give attachment to the ligaments of the glottis, or true vocal cords; moreover, the crico-arytenoidei muscles are attached to them.

The summit is surmounted by a small cartilage (5th and 6th *cornicula laryngis*), and from their summits proceed the folds of mucous membrane called aryteno-epiglottic folds. All these cartilages have a homogeneous texture, and are apt to become osseous in aged persons.

7. The *epiglottis* is a fibro-cartilage, placed at the base of the tongue, with which it is connected by folds of a mucous membrane; *frenula epiglottidis*. Its tissue is elastic, the base superiorly, apex inferiorly. The glands of the epiglottis lie in front of it. In general its position is vertical, but it changes and becomes horizontal during deglutition; it serves, therefore, to cover and protect the superior aperture of the larynx during the deglutition of solid and liquid aliment. It has two surfaces, a lingual and a laryngeal.

8 and 9. The *cuneiform cartilages* are two small cartilages, of a tri-

* Fig. 169.—The larynx, right side.—*a*, thyroid cartilage; *b*, cricoid cartilage; *c*, crico-thyroid muscle; *d*, *e*, cartilaginous rings of the trachea and their connecting fibrous membrane.

angular form, with the base superiorly and apex inferiorly, situated in the aryteno-epiglottidean folds; their use is to support these folds. They are always present, but are easier felt than demonstrated.

The ligaments of the larynx are—

1. The *thyro-hyoid* and the fibro-cartilaginous ligament of the great horn.

2. The *crico-thyroid membrane*. It is this ligament which is opened in laryngotomy: there are also ligaments which attach the small horns of the thyroid cartilage to the cricoid, and a synovial bursa to facilitate motion, and others which attach the arytenoid cartilages to the cricoid.

3. The *thyro-arytenoid* ligaments, which can only be seen upon the deeply dissected larynx, are called the inferior or true vocal cords; also, the inferior ligaments of the glottis.

The muscles of the larynx are easily dissected, requiring no particular directions. Clean first the crico-thyroid, next the crico-arytenoidei postici, by removing the mucous membrane of the pharynx; also the arytenoidei; cut through vertically one of the wings of the thyroid cartilage, but in such a way as to avoid injuring the salient angle; this will expose the crico-arytenoideus lateralis and thyro-arytenoideus of one side. The crico-thyroidei have already been described. Each arises from the side and fore part of the cricoid cartilage, and, ascending obliquely upwards and outwards, is inserted into the lower and outer surface of the thyroid cartilage, leaving between it and its fellow an interval occupied by the crico-thyroid membrane.

Use.—To approximate these cartilages to each other: these muscles are further remarkable in being supplied by branches of the superior laryngeal nerves.

The crico-arytenoidei postici are also two in number; they are of a triangular shape, and, arising extensively from the cricoid cartilage, are inserted into the base of the arytenoid cartilage.

The crico-arytenoideus lateralis; each arises from the side of the upper circumference of the cricoid cartilage, and is inserted into the outer and fore part of the base of the arytenoid cartilage.

The *arytenoideus* is a single and very remarkable muscle, inasmuch as it crosses the middle plane of the body. It is formed of several planes of fibres having different directions, hence the names of oblique and transverse given to different portions of it. They connect the arytenoid cartilages to each other. Finally, this muscle is invested anteriorly and posteriorly by a mucous membrane.

The glands of the larynx are, 1, the periglottis, situated anteriorly to the epiglottis; and 2, the arytenoid glands, lodged in the aryteno-epiglottei folds: all these glands are extremely small.

The mucous membrane of the larynx may be studied, 1, upon the entire larynx; 2, upon the larynx divided posteriorly by cutting through the cricoid cartilage and the arytenoid muscles and mucous membrane. This membrane is obviously continuous superiorly with that of the mouth, and inferiorly with that of the trachea and lungs.

After forming the glosso-epiglottic folds, it invests a portion of the epiglottis and penetrates into the larynx, forming superiorly, between the epiglottis and summits of the arytenoid cartilages, the arytenoepiglottic folds. These folds, together with the epiglottis in front, and the arytenoid cartilages and muscles behind, constitute the *superior aperture* of the larynx. A short way beneath this, within the larynx, are the false vocal cords, or superior ligaments of the glottis, formed merely of mucous folds, and covering a part of the thyro-arytenoidei muscles. A little lower down, within the larynx, are two other folds; these are the two vocal cords, or inferior ligaments of the glottis, and are formed of the thyro-arytenoid ligaments covered by the mucous membrane. The space between these ligaments is called the glottis, or *rima of the glottis*, and is the narrowest part of all the air-tubes. It is of a triangular shape, and liable to vary, and may sometimes, no doubt, be completely closed at the will of the individual. On each side of the larynx, bounded above by the false vocal cords, and below by the true ones, is a depression or cavity; these are the ventricles or sinuses of the larynx.*

The mucous membrane lining the larynx is soft, spongy, continually moistened, and of a rose colour. The arteries of the larynx are furnished by the superior and inferior thyroid; the nerves are the superior and inferior laryngeal nerves on each side, branches of the pneumo-gastric.

THE ŒSOPHAGUS.

The œsophagus, although properly belonging to the digestive organs, will be best described in this place. It is a musculo-membranous canal, extending from the lower part of the pharynx to the cardiac or superior orifice of the stomach. It commences opposite to the fifth cervical vertebra (at the back part of the cricoid cartilage, which may be felt in the living body), and terminates between the crura of the diaphragm, and consequently in the abdomen. At first it is mesial, but gradually inclines to the left side a little lower down; but in entering the thorax it becomes again mesial about the upper and back part of the bronchi, and continues so until it leaves the thorax. Whilst passing into the abdomen, it once more inclines a little to the left and terminates in the stomach. A loose cellular tissue connects it to the surrounding parts; excepting where covered by peritoneum, it is very firmly fixed to the diaphragm: this cellular tissue contains some lymphatic glands. The gullet may be subdivided, for the sake of its more careful examination, into two portions, viz. a *cervical* and

* An attempt has been lately made to establish a distinction between the terms *glottis* and *rima* of the glottis; the *superior aperture of the larynx* they call the glottis. But there can arise nothing good from such a distinction, and the superior aperture of the larynx should simply be allowed to retain its name. The same persons seem to think that the rima of the glottis and the inferior aperture of the larynx are synonymous: it is rather difficult to imagine how a practical anatomist could have confounded them with each other.

thoracic; the third portion, or *abdominal*, being too short to merit attention in this way.

The *cervical portion* has relations anteriorly, to a certain extent, with the lower part of the larynx, the left half of the trachea, the left inferior thyroid vessels, and the sterno-thyroidei muscles; and, posteriorly, with the great anterior vertebral ligament and the left longus colli muscle; laterally it is in relation, at first, with the common carotid arteries and internal jugular veins; and afterwards, on the right side, to the trachea, and on the left, to the recurrent nerve and carotid artery of that side.

The *thoracic portion* of the gullet is entirely contained within the posterior mediastinum; in front, it touches the trachea and left bronchus, the posterior part of the pericardium; posteriorly, it touches the vertebral column, the curve of the vena azygos, the thoracic duct, and at its lower part the aorta. In diameter it is somewhat less than an inch. It is composed, according to some, of two tunics; according to others, of four. The indisputable ones are the muscular tunic, and the mucous or inner membrane; the two less certain are, the nervous or cellular, and the epidermic. To examine the gullet carefully, the student may remove two or three inches of its thoracic portion, and distend it with air, having first secured it with ligatures. The muscular tunic is external; there are two layers of fibres, viz., the longitudinal, which are seen first, and the circular, which can only be exposed by removing the others. They are well marked, the gullet being much more muscular than any other part of the digestive tube, excepting the rectum. The redness of the muscular fibres of the gullet diminishes gradually as we descend towards the stomach. On the stomach the longitudinal fibres of the gullet expand and spread out in a remarkable way, but the circular fibres soon cease. A layer of condensed cellular tissue lies between the muscular and the mucous tunic; this is analogous to the lamina nervosa, cellulosa, or vasculosa of the intestines. To see the *mucous membrane*, it is necessary to lay open the gullet longitudinally. It is soft, spongy, delicate, continuous above with that of the pharynx, below with that of the stomach. Several longitudinal folds may be observed upon it, and mucous follicles (œsophageal glands), which lie exterior to the membrane. It is lined throughout, as far as the cardiac orifice of the stomach, with an epidermis. The arteries are not large; in the neck they come from the inferior thyroid arteries; in the thorax from the bronchial, and directly from the aorta; in the abdomen from the sub-diaphragmatic, and from the coronary of the stomach. The veins terminate in the thyroid, the superior cava, the internal mammary, the vena azygos, the bronchial, phrenic, and coronary veins of the stomach. Its lymphatic vessels go to the adjoining glands; the nerves are furnished chiefly by the eighth pair and their recurrent branches. These nerves form a plexus around it. By bending the head backwards the student will find that a straight and unyielding instrument may be introduced from the mouth directly down to the stomach; in

this position the gullet, mouth, and pharynx must be nearly in a straight line, as was proved by the Indian jugglers, who exhibited in this country a few years ago the very singular feat of passing a sword directly down into the stomach of a living person. Under the microscope it would seem that the muscular coat of the upper end of the gullet is red, and consists of striped muscular fibres; but lower down it becomes paler, and is principally composed of plain muscular fibres. A few striped fibres, however, are found mixed with the others, and have been traced throughout its whole length. However this may be, there is a pathological observation of which I am certain, which goes far to decide the physiological properties at least of the muscular fibres of the gullet and of the constrictors of the pharynx respectively. The minute vibrio which occasionally infests the human muscles, the natural history of which is still to write, is never found in the œsophageal fibres, being strictly limited to the constrictors. Indeed, throughout the body, the vibrio is found only in the muscles called voluntary.

Orifices of the Thorax.—The superior orifice of the thorax presents many important anatomical relations. Immediately above the manubrium of the sternum is the cervical fascia, beneath it the sterno-hyoid and sterno-thyroid muscles, ascending through the aperture; behind these a quantity of cellular substance, and a little lower down the remains of the thymus; then the venæ innominatæ, the right being short and straight in its course, the latter crossing over from the left to the right side, to join with the right, and thus form the vena cava superior. The union of these two veins (venæ innominatæ) corresponds to the cartilage of the second rib on the right side. Behind these veins the phrenic nerves and parvagum enter the thorax, but anterior to the subclavian arteries, thus passing between the veins and arteries, the phrenic more external, the nervi vagi more internal. The course of the phrenic nerves to the diaphragm, between the pleura and pericardium, and anterior to the root of the lungs, may be noted; likewise the course of the nervi vagi, behind the root of the lungs, and ultimately terminating in the stomach. Behind these veins and nerves lie the three great arteries arising from the aorta, viz., 1st, the brachio-cephalic,or innominata, more anteriorly than the others; 2d, the left common carotid; 3d, deeper and farther back the left subclavian. Behind these lie the trachea, entering the thorax, and its bronchi lower down. To the left of the gullet, in the situation we now advert to, will be found the thoracic duct, ascending from the thorax to the neck, between the left carotid and subclavian arteries. On either side lie the recurrent nerves. External to this nerve also, on each side, will be found the sympathetic nerves; from the inferior cervical ganglion, filaments pass in front and behind to each subclavian artery. Posterior to the gullet are the longi colli muscles, also the anterior common ligament of the vertebræ; and to the right and left, the superior intercostal arteries, and anterior branch of the first pair of dorso-spinal nerves. They ascend to join the axillary plexus.

THE

VASCULAR SYSTEM.

THE ARTERIES.

WOUNDS of the great arteries are justly reckoned amongst the most serious accidents which can happen to man. For this reason even surgeons, who generally neglect the minute anatomy of most parts of the body, devote an earnest attention to that of the arteries.

After much consideration, I have introduced their history into this part of the present work, so as immediately to follow the history of the heart and lungs, the organs with which they are most directly connected, though well aware that, until the student shall have made himself acquainted with the anatomy of all the organs of the body, he can never hope to dissect the arteries with any advantage. In a purely practical work, then, the anatomy of the arteries and vessels generally ought to come last; but something is due to system or method, so essential to right education; and on this ground, cautioning the student not to attempt their dissection until he has mastered the anatomy of the bones, muscles, and viscera, I have thought it right not to separate, by too great an interval, the anatomy of the aorta and its branches from that of the heart; the anatomy of the pulmonary artery and veins from that of the lungs.

The term artery is derived from the Greek Αρτηριαι, and that from Αηρ, *air*, and Τηρειν, to *carry*; the ancient physicians foolishly imagining them to be aëriferous tubes. This silly hypothesis was refuted by Galen, who first introduced experiment into physiology.

There are, properly speaking, but two arteries in the body; the pulmonary artery, which has been already described together with the pulmonary veins, and the aorta. This great trunk, the largest in the body, is the systemic artery. It conveys the arterial blood into nearly every texture of the system; its many branches are also described as arteries, and special names and descriptions are given of all these branches above a certain size.

The AORTA.—The aorta commences at the base of the left ventricle of the heart, and terminates opposite to the anterior surface of the body of the fourth or fifth lumbar vertebra. At its origin, the aorta is concealed by the pulmonary artery, which artery must be cut across and reflected, in order to expose that portion of the aorta which it conceals. At first, as has been already remarked, the aorta ascends rather obliquely forwards than vertically, and to the right

Fig. 170.*

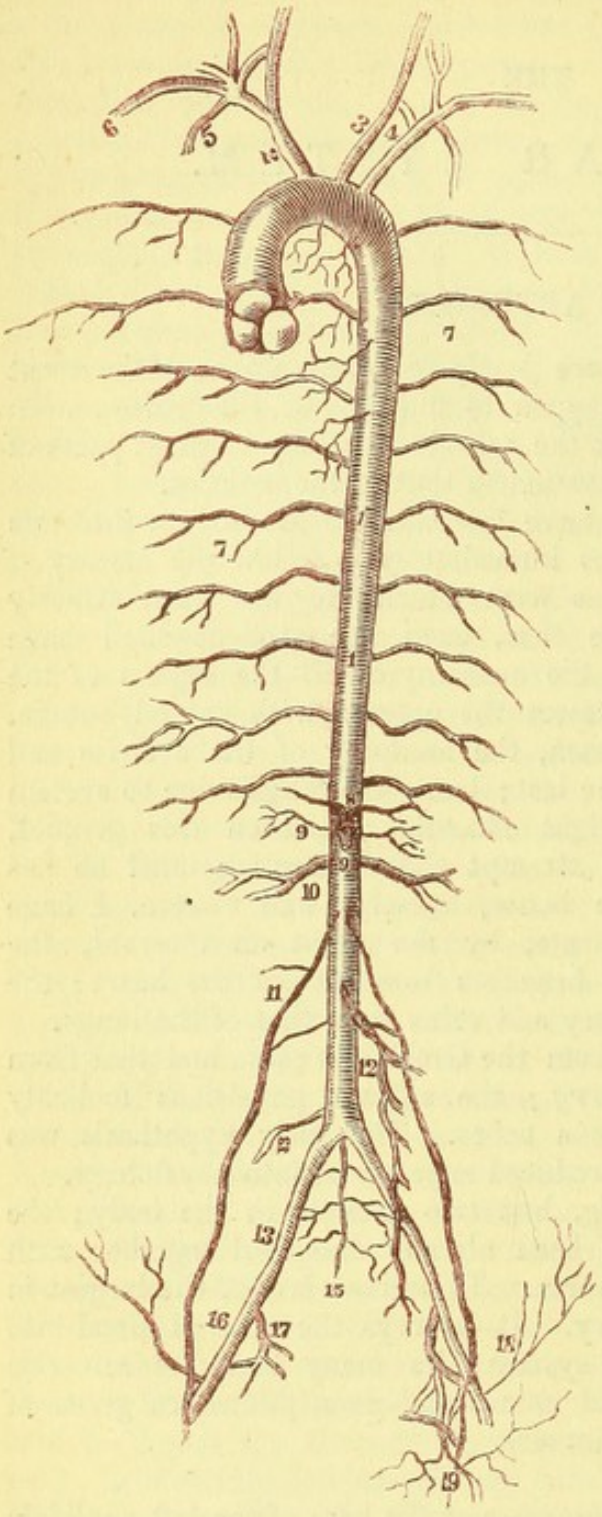

side, until it gains the level of the cartilage of the second rib. Opposite to about the second dorsal vertebra it leaves the pericardium by an opening particularly described by Haller, and shortly thereafter proceeds transversely backwards. It now descends until about the level of the fourth dorsal vertebra, from which point it follows pretty exactly the course of the vertebral column, though not quite mesially, but rather to the left side.

The portion of the aorta just described, commencing at the heart and terminating on the left side of the fourth dorsal vertebra, is usually called the arch of the aorta, though some restrict this name to the summit or transverse portion only. It may be divided in description with advantage to the memory into three portions, — 1st, an ascending; 2d, a transverse; 3d, a descending portion.

The first is the longest, and lies chiefly within the pericardium. It is remarkable for its greater calibre, for the origins of the coronary arteries, and for the sinuses of Valsalva or Morgagni marking the position of the semilunar valves.

The second or transverse part of the arch lies exterior to the pericardium, above it,

* Fig. 170.—The aorta and the arteries which arise from it.—1, 1, the aorta; 1*a*, 1*b*, the coronary arteries; 2, the brachio-cephalic, or innominata; 3, left carotid; 4, left subclavian; 5, internal mammary; 6, right subclavian; 7, aortic intercostals; 8, cœliac axis; 9, superior mesenteric; 10, right emulgent; 11, spermatic; 12, inferior mesenteric; 13, right common iliac; 16, external iliac; 17, internal iliac; 15, ar. sacri media; 18, epigastric; 19, obturator.—The figure is intended merely as a diagram.

and in front of the trachea; from it spring the brachio-cephalic, the left carotid and left subclavian arteries. Should another vessel arise from this portion of the arch, it will be the left vertebral.

The third or descending portion of the arch is remarkable for occasionally presenting a slight contraction (connected with fœtal structures); it is here that the aorta has been known to become spontaneously obliterated. Attached to the concave side of the aorta, at the commencement of this portion, is the ligamentum arteriosum, the remains of the ductus arteriosus.

The portion of the aorta immediately following the arch is called the thoracic. It descends through the chest, in the posterior mediastinum in front of the vertebral column to the left side, but gradually as it descends becoming more mesial until it passes from the thorax into the abdomen, behind the diaphragm and between its crura. The thoracic duct and vena azygos pass with it. It is now called the abdominal aorta, and it retains this name until it terminates by dividing into the common iliac arteries. Whilst in the abdomen the artery lies behind all the viscera, yet it is not far removed from the anterior abdominal walls, and may be felt pulsating in thin persons.

The arteries which are given off by the aorta from its commencement in the left ventricle of the heart to its termination on the 4th or 5th lumbar vertebra are,—

I. Arteries springing from the arch of the aorta:—

1. The coronary arteries 2
2. The innominata or brachio-cephalic 1
3. The left carotid 1
4. The left subclavian 1

II. Those arising from the thoracic aorta are,—

Anteriorly—

1. The bronchial 2
2. The œsophageal . . . . . variable in number.
3. The posterior mediastinal . . . . . variable in number.

Laterally—

4. The aortic intercostals . . . . . variable in number.

III. Those arising from the abdominal aorta are,—

Anteriorly—

1. The inferior phrenic 2
2. The cœliac axis 1
3. The superior mesenteric 1
4. The inferior mesenteric 1

Laterally—

5. The middle capsular 2
6. The renal or emulgent 2
7. The spermatic 2
8. The lumbar . . . . . variable in number.

Near the termination of the abdominal aorta, a little before its division into the common iliacs, it sends off a comparatively small vessel, called art. sacri media, which, descending into the pelvis, in front of the sacral vertebræ, must be held to be the pelvic continuation of the aorta itself.

To trace the arteries minutely and carefully, it is necessary that they be filled with some coloured injected material to distinguish them from other structures; but all the important vessels ought to be afterwards examined, *in situ*, and not injected. Further, in dissecting the arteries, clean carefully the margins at least of all the muscles met with, and so arrange the viscera as best to display the course and distribution of the great vessels supplying them with blood. To do this well clearly requires an intimate knowledge of the muscles and viscera.

Right (posterior) Coronary Artery of the Heart (*Arteria coronaria cordis dextra*).—It arises from the aorta, immediately above the free edge of one of the semilunar valves, to the right side of the pulmonary artery, and opposite the base of the right ventricle. It presently proceeds from within outwards, in the groove which separates the right auricle from the corresponding ventricle, the aorta, and pulmonary artery. It describes several flexuosities, winds over the base of the heart, arrives at its free edge, changes its direction, and gains the groove on the posterior surface of that organ. There it divides into two considerable branches, of which the larger follows the same groove as far as the summit of the heart, while the other directs itself transversely between the left auricle and ventricle, and descends upon the thick edge of the heart to its extremity.

In this course the artery just described sends branches to the aorta, to the right auricle and ventricle, to the commencement of the pulmonary artery, to the venæ cavæ and inter-auricular septum. One of its largest branches follows the other margin of the heart. The artery also sends branches to the left ventricle and to the inter-ventricular septum. It anastomoses freely with the left coronary.

Left Coronary Artery of the Heart (*Arteria coronaria cordis sinistra*).—Much smaller than the preceding, and a little higher, it arises like it from the commencement of the aorta, but to the left side of the pulmonary artery. It immediately directs itself downwards, and a little to the left and forwards, between the pulmonary artery and the left auricle, by the appendage of which it is at first entirely concealed. It then enters the groove of the anterior surface of the heart, and runs along its whole extent to the summit of that organ.

The left coronary supplies in its course branches to the walls of the aorta and pulmonary artery, to the thick margin of the heart, and to the septum; whilst in the anterior groove of the heart it distributes branches to the anterior wall of both ventricles, especially the left. It anastomoses freely with the other coronary.

ARTERIA INNOMINATA.—The arteria innominata ascends obliquely to the right, on the side of the trachea, and after a course of an inch divides into two trunks, one of which is the *right carotid*, the other the *subclavian* of the same side. It is covered by the left subclavian vein, the sternum, and the sterno-thyroidei muscles, and corresponds posteriorly to the trachea and longus colli muscle of the right side.

The left carotid artery forms a right angle with the aorta at its origin, and the subclavian of the same side comes off obliquely, as does also the arteria innominata.

COMMON CAROTID ARTERIES (*Carotides communes*).—The left is longer than the right by nearly the whole extent of the arteria innominata. Their size is precisely the same. They ascend a little obliquely outwards on each side of the neck, to the upper part of the larynx, where they divide into the *external* and *internal carotid arteries.*

Inferiorly, the right carotid is a little anterior to the left, but as it ascends it places itself in the same plane. The interval which these two arteries leave between them is filled below by the trachea and œsophagus, and above by the larynx.

Anteriorly, the left carotid is covered in its lower part by the left vena innominata, the thymus gland, and the clavicle.

In the lower part of the neck both carotids are covered by the sterno-mastoidei, sterno-hyoidei, sterno-thyroidei, and platysma myoides muscles, but higher up in the neck, after having ascended behind the omo-hyoidei, they are directly covered by the platysma myoides only.

Posteriorly, the common carotids are applied upon the vertebral column, and more immediately upon the inferior thyroid arteries, and the longi colli and recti capitis antici majores muscles.

Internally, they correspond to the trachea, the thyroid body, which advances a little upon them, the larynx, and the pharynx. That of the left side is, moreover, in relation with the œsophagus.

Externally, they correspond to the internal jugular veins, the pneumo-gastric nerves, and the communicating cords of the superior and middle cervical ganglia. All these parts are connected by a filamentous cellular tissue, which, together with a portion of the cervical fascia, forms the sheath of the vessels.

In their whole course, the common carotid arteries preserve the same calibre. In fact, they give off no branch, excepting some very slender ramifications, which lose themselves in their own walls or in the neighbouring muscles.

EXTERNAL CAROTID ARTERY (*Carotis externa*).—This artery is particularly destined for the face and the exterior of the head. Its size is equal to that of the internal carotid, excepting in children, in whom the latter is larger, on account of the greater proportional or comparative development of the brain and organs of sense.

The external carotid artery extends from the upper part of the

Fig. 171.*

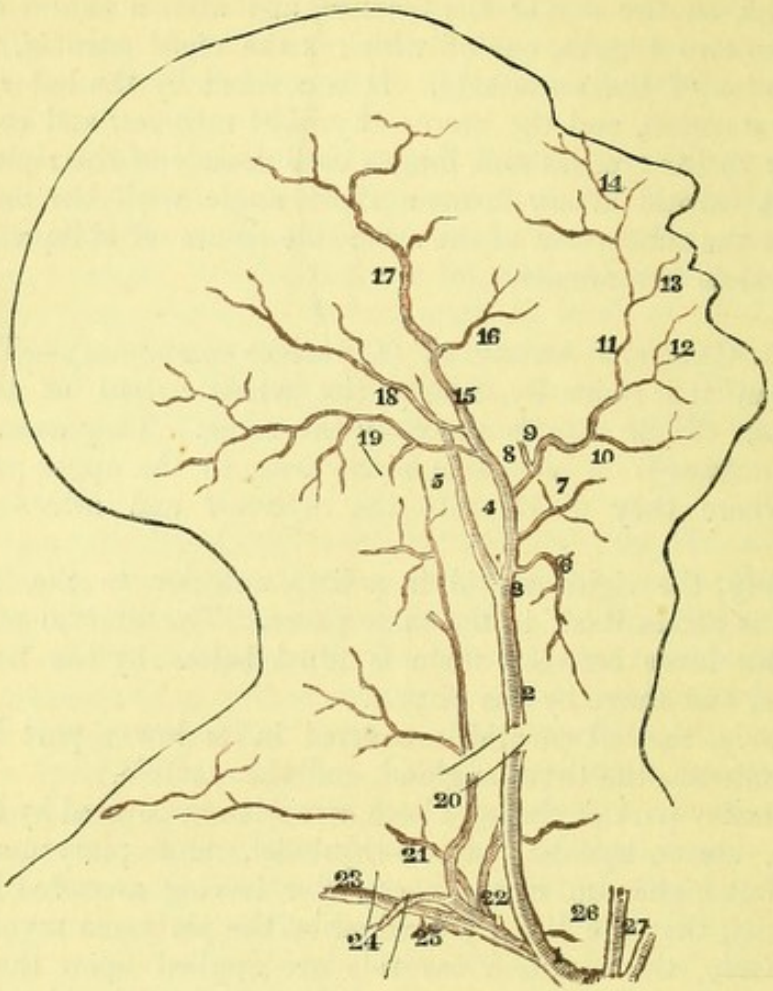

larynx to the neck of the condyle of the lower jaw. Placed near the internal carotid at its commencement, and even situated internally and anteriorly to it, it ascends parallel to it, until under the digastric muscle, where it crosses its direction, winding outwards and backwards to gain the angle of the jaw and become more superficial. It then proceeds between the ear and the posterior edge of the lower jaw, concealed by the parotid gland, and divides into two branches, the temporal and internal maxillary arteries.

Inferiorly, the external carotid is only covered by the platysma myoides and the skin; but it presently sinks under the hypoglossal nerve and the digastricus and stylo-hyoideus muscles, and lastly under

* Fig. 171.—Diagram of the common carotid and external carotid arteries of the right side.—1, the arteria innominata; 2, common carotid, where it is crossed by the omo-hyoideus muscle; 3, bifurcation of the common carotid into the external and internal carotids; 4, external carotid; 5, internal carotid; 6, superior thyroid; 7, lingual; 8, 9, external maxillary, or facial; 10, submental branch; 11, continuation of the facial towards the mouth and nose; 12, 13, upper and lower coronary arteries; 14, nasal or angular branch; 15, continuation of the external carotid, now called the common trunk of the temporal and internal maxillary; 16, internal maxillary; 17, temporal; 18, posterior auricular; 19, occipital.

the parotid gland. *Internally*, it is in relation, below, with the internal carotid artery, at the middle with the stylo-pharyngeus and stylo-glossus muscles, and above with the styloid process of the temporal bone.

The branches which this artery furnishes may be distinguished into those which arise from its anterior part, three in number, viz. the superior thyroid, lingual, and facial arteries; those which come from its posterior region, two in number, viz. the occipital and auricular arteries; the inferior pharyngeal artery issuing from its inner side; lastly, those by which it terminates, viz. the temporal and the internal maxillary arteries. A branch which it very generally furnishes to the sterno-mastoid muscle has been called the arteria sterno-mastoidea.

SUPERIOR THYROID ARTERY.

(*Art. Thyroidea Superior.*)

It arises from the fore-part of the external carotid, very near its origin, and even sometimes opposite to it, then descends inwards and forwards towards the side of the larynx, where it changes its direction, and proceeds almost vertically downwards towards the summit of the corresponding lobe of the thyroid body, where it arrives after describing different sinuosities, which vary in different subjects. In this course it is covered from without inwards by the platysma myoides, omo-hyoideus and sterno-thyroideus muscles, to which it gives some small ramifications; others go to the skin and neighbouring muscles, the sterno-cleido mastoideus, sterno-hyoideus, thyro-hyoideus, and constrictor pharyngis medius.

Laryngeal branch.—Towards the upper part of the larynx, the superior thyroid artery furnishes this branch, which directs itself transversely behind the thyro-hyoideus muscle over the thyroid membrane, gives the latter, and the muscles of the hyoid bone, some small twigs, which anastomose with those of the opposite side, and traverses it in company with the internal laryngeal nerve of the pneumo-gastric. On entering the larynx this twig bifurcates. One of its branches throws itself into the crico-arytenoideus lateralis and crico-thyroideus muscles; the other winds round the base of the arytenoid cartilage, and loses itself in the crico-arytenoideus posticus muscle. Both unite with those of the opposite side, and send a great number of ramifications over the epiglottis and to the mucous membrane of the larynx.

Crico-thyroid branch.—A little smaller than the preceding, it descends obliquely inwards over the thyroid cartilage, gives twigs to the thyro-hyoideus muscle, and passes transversely over the crico-thyroid membrane, at the middle of which it anastomoses with that of the opposite side, after furnishing ramifications to the crico-thyroideus muscle.

When the superior thyroid artery has reached the thyroid body,

it separates into three branches; one of these dives between the thyroid body and the walls of the larynx; another, which is larger, proceeds along its outer edge; the third follows its inner edge, and in front of the cricoid-cartilage unites by a reversed arch with the branch of the opposite superior thyroid artery, while the first two anastomose with the twigs of the inferior thyroid artery of the same side. They are all distributed, by a great number of divisions, in the parenchyma of the thyroid body.

Lingual Artery (*Arteria lingualis*).—The next artery given off from the external carotid is the *lingual*, which sometimes arises by a common trunk with the facial artery. It ascends at first a little, winding and directing itself inwards and forwards; it then enters between the hyo-glossus muscle, near its inferior attachment, and the constrictor pharyngis medius; after which, bending upwards, it ascends between the hyo-glossus and genio-glossus muscles, and between the latter and the sublingual gland, above the great horn of the hyoid bone, as far as the root of the tongue; there it becomes horizontal, and, under the name of *ranine artery*, advances, accompanied by the lingual nerve, between the genio-glossus and lingualis muscles, to the point of the tongue, where it anastomoses with that of the other side by an arch.

This artery is consequently nearly horizontal from its commencement, until it bends back towards the anterior edge of the hyo-glossus muscle; it is vertical during its course along the genio-glossus muscle, and horizontal again from the base to the point of the tongue.

This disposition allows it to be distinguished into three portions.

In its course the lingual furnishes branches to the hyo-glossal and genio-glossal muscles; also to the digastric, constrictor pharyngis medius, and thyro-hyoid.

The branch called the *dorsal artery of the tongue* directs itself towards the base of that organ and the epiglottis, sending branches to the tonsils and velum palati. It is not a constant branch.

The *sublingual branch* passes forward between the genio-glossus and mylo-hyoideus, above the sublingual gland.

Under the tip of the tongue the two ranine (lingual arteries) anastomose.

Facial Artery (*Art. labialis vel maxillaris vel angularis externa*).—It arises from the fore part of the external carotid, above the lingual artery, and behind the digastric muscle. Its size is considerable. Immediately after its origin it directs itself almost transversely inwards and forwards; and, after describing several flexuosities, gains the inner part of the angle of the lower jaw, covered in this part of its course by the hypo-glossal nerve, the digastric, stylo-hyoid muscles and sub-maxillary gland. It then turns between that gland and the base of the inferior maxillary bone, changes its direction, ascends very obliquely towards the commissure of the lips, between

the triangularis and masseter muscles, forms a great number of flexuosities, and is covered by the skin and the platysma myoides. Near the free edge of the upper lip it enters under the union of the levator anguli oris and triangularis muscles, and ascends upon the side of the nose, as far as the inner angle of the eye, where it terminates, either by anastomosing with the nasal twig of the ophthalmic artery, or with the infra-orbitar, or by spreading out its twigs in the neighbouring parts.

In the second part of its course the facial artery is separated from the skin by a greater or less quantity of fat, and corresponds successively and posteriorly to the inferior maxillary bone, the buccinator muscle (from which it is separated by a mass of adipose tissue, of which we have already repeatedly spoken), the orbicularis oris, levator labii superioris proprius, and levator labii superioris alæque nasi.

Branches which the facial artery gives off under the jaw.—It is an interesting and useful dissection for the student to follow carefully and to name the branches of the facial artery, although their diminutive size renders many of them unimportant in a surgical point of view. The anatomical student, however, is expected to know them systematically.

Under the jaw the facial gives off—1, *the inferior palatine*, which places itself against the lateral and posterior wall of the pharynx, reaches the tonsils and pillars of the velum palati and Eustachian tube.

2. *Submental branch.*—This is a larger branch. It runs along the inferior surface of the mylo-hyoideus, supplying that muscle with muscular twigs, and anastomosing with the sublingual. It may be traced to the chin, anastomosing with that of the opposite side, beneath the digastric muscle. The facial, in this part of its course, sends off several small and nameless branches to the neighbouring organs.

The facial artery gives off in the face the following branches:—

1. *External.*—Numerous, but small.
2. *Internal.*—Muscular twigs to the nearest muscles.
3. *Inferior coronary or labial.*—Arising from the facial at a considerable distance from the commissure of the lips, it advances tortuously in the substance of the free edge of the under lip, on the middle of which it joins the opposite coronary branch, after supplying with twigs the mucous membrane and muscles around. Near the commissure it is placed just outside the mucous membrane.
4. *Superior coronary.*—Arising above but near the commissure, it proceeds inwards in the substance of the edge of the upper lip. Of its twigs, some supply the mucous membrane, others the orbicularis and other muscles; some go to the gums.
5. *Dorsal branches to the nose* (nasal).—These vary much in number and disposition; sometimes they terminate the facial artery, but they always supply the soft parts forming the organ, and anastomose with those of the other side.

Occipital Artery (*Arteria occipitalis*).—It arises from the pos-

terior part of the external carotid, under the parotid gland and opposite the lingual artery. It ascends, at first obliquely backwards, beneath the sterno-cleido mastoideus muscle, along the posterior belly of the digastric and the hypo-glossal nerve. It then passes horizontally between the transverse process of the atlas and the mastoid process, after crossing the internal jugular vein and pneumo-gastric nerve, above which it is situated. It then bends back upon the occipital bone, covered by the splenius muscle, under the inner edge of which it emerges to become subcutaneous, and ascends in a tortuous manner upon the back part of the head, where it terminates.

The artery thus described sends branches—1, from its deep portion; 2, from its subcutaneous.

Those from the deep portion are distributed to the digastric, sterno-mastoid, and stylo-hyoid muscles. A branch called the posterior mastoid enters the cranium by the mastoid foramen. The splenius and trachelo-mastoid muscles also receive branches from this portion of the occipital.

The branches of the subcutaneous portion are very numerous, but have not received names. They supply the back part of the scalp and the occipitales muscles, and anastomose freely with the posterior auricular and opposite occipital arteries.

Posterior Auricular Artery (*Art. auricularis posterior*).—This is one of the smallest branches of the external carotid artery, from which it separates in the substance of the parotid gland, above the digastric muscle, to extend to the inner surface of the auricle, and over the side of the head. It ascends at first backwards, covered by the gland, between the mastoid process and auditory canal. On arriving at the lower part of the auricle it bifurcates; one of its branches, placed before the other, expands over the inner surface of the auricle, between the skin and the cartilage; the other, which is posterior, passes over the mastoid process, and divides into a multitude of twigs, which belong to the temporalis and retrahens auriculam muscles, the epicranial aponeurosis, the cellular tissue and integuments of the lateral part of the head.

Before the bifurcation the artery sends off the stylo-mastoid artery, a small but remarkable branch, which, entering by the stylo-mastoid foramen, supplies the middle ear and labyrinth with blood-vessels, anastomosing with a branch of the middle meningeal artery.

Inferior Pharyngeal Artery (*Arteria pharyngea*).—This branch is smaller than the posterior auricular artery, and is more deeply situated than the other branches of the external carotid, from which it arises at the same level as the facial. It ascends at first vertically along the lateral and posterior part of the pharynx, between the external and internal carotids, covered below by the stylo-pharyngeus muscle, and above by the constrictor superior.

After a short course, and after furnishing some irregular twigs,

which descend obliquely behind the pharynx and in its constrictor muscles, this artery divides into two branches of equal size.

Pharyngeal branch. — Lying transversely upon the constrictor pharyngis superior, it divides into two or three twigs, of which one is distributed to that muscle, ascending in its substance; the others, proceeding obliquely downwards, lose themselves in the two corresponding middle and inferior constrictors. Its last divisions anastomose with some twigs of the superior thyroid and lingual arteries.

Meningeal branch.—It ascends between the internal carotid, the pneumo-gastric nerve, and the internal jugular vein; gives ramifications to these different parts,—to the superior cervical ganglion, the Eustachian tube, rectus capitis anticus major, rectus anticus minor, and longus colli muscles, and at length enters the cranium by the foramen lacerum posterius, to ramify upon the dura mater. Some of its twigs penetrate separately into that cavity, and have the same destination; one in particular passes through the fibro-cartilage of the foramen lacerum medium; another passes through the anterior condyloid foramen.

TEMPORAL ARTERY (*Art. temporalis*).—Not so large as the internal maxillary artery, from which it separates opposite the neck of the condyle of the jaw, and following the original direction of the external carotid, this artery ascends at first a little obliquely outwards, between the ramus of the jaw, the auditory canal, and the parotid gland, which covers it as far as the zygomatic arch; but above the latter it glides in a tortuous manner under the anterior and superior muscles of the ear, and becomes subcutaneous. Arrived at the middle of the temporal region, it divides into two branches, an anterior and a posterior.

Anterior branches.—The temporal artery gives off a certain number of branches, which direct themselves forwards towards the masseter and the articulation of the lower jaw. Among these there is to be distinguished the *transverse artery of the face*, which arises from the temporal immediately after its origin, varies much in size, passes over the neck of the condyle of the jaw, gives off a twig, which is distributed in the masseter, and there anastomoses with a division of the internal maxillary artery, crosses the direction of that muscle, proceeding above Steno's duct, and terminates opposite its anterior edge, ramifying on that duct, in the parotid, in the two zygomatic and the orbicularis palpebrarum muscles, as well as in the integuments. Several of its twigs anastomose, in the substance of the cheek, with those of the facial, buccal, and infra-orbitar arteries.

Posterior branches.—These are of considerable size, and vary in their number; they are called the *anterior auricular arteries*, and are distributed to the external auditory canal, and to the auricle.

INTERNAL TWIG, OR MIDDLE TEMPORAL ARTERY.— It comes from the temporal artery, immediately above, but sometimes under,

the zygomatic arch. It almost immediately perforates the aponeurosis of the temporal muscle, into which it passes, and where it separates into a great number of ramifications, of which several are seen to communicate with the deep temporal arteries.

Of the two branches in which the temporal artery terminates, the anterior ascends in a serpentine manner towards the forehead, and subdivides into a great number of twigs, which run in all directions, and diffuse themselves in the frontalis and orbicularis palpebrarum muscles, and in the integuments. Of these twigs, some, which are transverse, anastomose with the frontal and superciliary arteries, while the others bend towards the top of the head, where they meet those of the opposite side.

The posterior branch ascends obliquely over the parietal and occipital bones, describes there a great number of sinuosities, and gives off many twigs, which are uniformly spread out in all directions—in the integuments, the aponeurosis of the temporal muscle, the attollens auriculam, and the pericranium; they communicate with those of the anterior branch, and of the opposite temporal, occipital, and posterior auricular arteries.

Internal Maxillary Artery (*Art. maxillaris interna*).—This is larger than the temporal, with which it forms the termination of the external carotid; it is remarkable for its complex course, and for the great number of important branches which it gives off to the deep parts of the face.

Immediately after its origin it passes behind the neck of the condyle of the jaw, bending inwards and downwards, then advances directly inwards, between the dentar and lingual nerves, and arrives in the interval which separates the two pterygoidei, where it changes its direction a little, to proceed forwards to the maxillary tuberosity. It then bends, becomes vertical, glides between the two fixed insertions of the pterygoideus externus muscle, and ascends in the bottom of the zygomatic fossa between it and the temporal muscle.

Finally, arriving near the floor of the orbit, it again takes a horizontal and transverse direction, enters the spheno-maxillary fossa, and divides into several branches in the middle of the adipose cellular tissue which fills that cavity.

The internal maxillary artery is consequently horizontal near its origin and termination, and vertical in the middle of its course. It describes, moreover, several very distinct sinuosities, which vary in different subjects.

Branches which arise from the Internal Maxillary Artery, behind the neck of the Condyle of the Jaw.

The internal maxillary artery sends off, 1, *the middle meningeal artery*. This is its largest branch: after giving off some small extra cranial twigs, the artery enters the cranium by the foramen spinosum of the sphenoid bone, placing itself in the osseous groove intended for

its reception, exterior to the dura mater, to which, however, it closely adheres. In this groove the artery divides into two principal branches, an anterior and a posterior. The *anterior* ascends in a deep groove marked for it in the inner table of the parietal bone; it supplies innumerable twigs to the bone itself as well as to the dura mater.

The *posterior* branch ascends in a similar way upon the inner table of the squamous plate of the temporal and parietal bones. Both sets of branches proceed as high as the superior longitudinal sinus.

2. The *inferior dentar* is a branch of the internal maxillary: descending along the inner surface of the ramus of the jaw, external to the pterygoideus externus and behind the inferior dentar nerve, it reaches the posterior aperture of the inferior dentar canal, traversing it throughout its whole extent. It has already given off several branches before it enters the canal. As it passes below the alveoli, it sends off twigs into these cavities, which proceed to the pulps of the teeth. A branch emerges at the foramen menti.

3. The *posterior deep temporal artery* ascends beneath the temporal muscle vertically, spreading a number of ramifications over the temporal fossa to the periosteum and muscle.

4. The *masseteric*, a muscular branch passing outwards over the incisura or notch of the bone, and, thus reaching the muscle, is distributed mainly to it.

5. The *pterygoid arteries* are muscular branches sent by the internal maxillary to supply the muscles so named. They do not, however, always arise directly from the main artery.

6. The *buccal artery* is occasionally wanting, or arises from other vessels. Flexuous and inconsiderable in size, it descends obliquely forwards near the buccal nerve between the pterygoid muscle and the ramus of the jaw, and thus, advancing towards the cheek, reaches the buccinator and zygomatic muscles, integuments, mucous membrane, and mucous glands of the mouth.

7. *Anterior deep temporal artery:* ascends in the anterior part of the deep temporal fossa. It sends a twig to the orbit, and supplies many branches to the temporal muscle.

8. *Alveolar artery:* arises from the internal maxillary opposite to the maxillary tuberosity on which it descends from behind forwards. Its course is flexuous. Its first branches pass through the alveolar process to penetrate the posterior alveoli, and so reach the pulps of the teeth. But the main branch proceeds forwards along the gums, to which it gives branches. It further sends twigs to the periosteum of the maxillary bone and to the cellular tissue of the cheeks.

9. The *infra-orbitar artery;* considered by some as the terminating branch of the internal maxillary artery. It enters the infra-orbitar canal along with the nerve of the same name, by the posterior aperture or fissure, and, traversing the canal, reaches the cheek by the infra-orbital foramen. In its course it supplies twigs to the periosteum and to the fat of the orbit, others which penetrate the walls of the

canal; these supply the rectus inferior, orbicularis, and the lachrymal sac. It sends branches to the pulps of the canine and incisor teeth and the membrane of the maxillary sinuses. On the face it supplies many twigs to the upper lip and lower part of the nose, which anastomose freely with other arteries. To comprehend clearly the course of the remaining branches of the internal maxillary, it is only necessary to be well acquainted with the osseous canals which they traverse.

10. The *vidian* is a small artery which, entering the vidian canal along with the nerve, runs throughout its whole length, to be distributed at last to the Eustachian tube and vault of the pharynx.

11. *Pterygo-palatine, or superior pharyngeal artery.*—Enters the canal so named, and proceeding backwards terminates in the pharynx.

12. *Superior palatine.*—This artery descends vertically in the pterygo-maxillary fissure, and enters the posterior palatine canal. After leaving the canal it is reflected from behind forwards between the membrane and vault of the palate, and is lodged in a groove of the bone. It is here very flexuous, and supplies with many twigs the mucous membrane and follicles of the palate. One of its twigs ascends to the nasal fossæ by the anterior palatine foramen.

13. *Spheno-palatine artery;* by most considered as the terminating branch of the internal maxillary. This artery proceeds through the spheno-palatine foramen to the posterior part of the superior meatus of the nasal fossæ beneath the pituitary membrane. Its twigs are distributed to the septum of the nasal fossæ, and generally to the mucous membrane of the outer wall of the nasal cavities, and to the mucous membrane of the anterior and posterior ethmoid cells. They supply in brief the greater part of the pituitary membrane.

Internal Carotid Artery (*Carotis interna seu cerebralis*).—It separates from the external behind the digastric muscle, enters the space which exists between the ramus of the inferior maxilla and the pharynx, and ascends a little inwards before the vertebral column, becoming deeper and deeper as it approaches the skull, into which it enters by the carotid canal. It is accompanied externally by the internal jugular vein, internally by the pneumo-gastric nerve, the superior cervical ganglion, and the twig by which it communicates with the middle cervical ganglion. It is connected with these different parts by a loose and filamentous cellular tissue. It forms at first a curve whose convexity rests upon the vertebral column; near the skull it presents another, having its convexity directed downwards; and sometimes a third, whose convexity is outwards. These flexuosities are extremely variable, and are rarely the same in two subjects. In all this part of its course the internal carotid artery furnishes no branch.

In passing through the carotid canal it accommodates itself to the different directions which it follows, so that, from being at first vertical, it afterwards directs itself a little obliquely forwards and upwards. This portion of the internal carotid artery is surrounded by the ascend-

ing filaments of the superior cervical ganglion and the lamina of the dura mater which lines the canal. Before emerging it gives off a small branch, which penetrates by a particular aperture into the cavity of the tympanum, to be distributed to its mucous membrane and to the promontory, on which it anastomoses with a twig of the middle meningeal artery. Frequently also it furnishes another, which enters the vidian canal from behind forwards, and there anastomoses with the artery of the same name.

On emerging from the carotid canal the internal carotid artery directs itself upwards and a little forwards, enters the cavernous sinus of the dura mater, and follows anteriorly its lower wall, on the sides of the body of the sphenoid bone, to above the anterior clinoid process, enveloped by the inner membrane of the sinus and accompanied by the sixth nerve and cavernous ganglion. In this course the artery forms two curves, which pretty exactly resemble those of a Roman S. The convexity of the first is turned backwards and upwards, and that of the second forwards and downwards. While contained in the cavernous sinus, the internal carotid artery sends two or three twigs to the dura mater, the pituitary body, the membrane of the sphenoidal sinuses, and the trunks of the third, fourth, fifth, and sixth pairs of nerves.

Arrived under the anterior clinoid process, it curves vertically upwards, then directs itself a little backwards, is embraced by the dura mater and arachnoid membrane, and enters into the cranium a little externally and posteriorly to the optic nerve. It is afterwards enveloped with a sheath, which is furnished to it by the arachnoid membrane, ascends obliquely backwards and outwards, and separates into several branches opposite the fissura Sylvii, where it terminates. But before this, whilst ascending along the anterior clinoid process, the internal carotid artery furnishes a very remarkable branch, which is the following.

OPHTHALMIC ARTERY.—The ophthalmic artery (*Art. ophthalmica*) is not large. Immediately after its commencement it enters into a small canal which the dura mater presents to it, places itself on the outer and lower part of the optic nerve, passes along with it through the optic foramen, and enters the orbit between the nerve of the sixth pair and the rectus externus muscle of the eye. It then ascends on the outer side of the optic nerve, passes above it, crossing its direction obliquely from without inwards, being covered by the rectus superior oculi muscle, and becomes horizontal a second time to pass forwards, along the inner edge of the nerve, between the obliquus superior and rectus internus muscles of the eye, as far as the internal angle of the orbit, where it ends dividing into two branches.

Branches of the Ophthalmic Artery.

1. The *lachrymal artery* is one of the largest branches of the ophthalmic. Besides supplying the lachrymal gland it sends branches to the rectus superior, inferior, abducens, and levator palpebræ muscles;

a twig passes through the malar bone and reaches the temporal fossa. It terminates ultimately in the eyelids and tunica conjunctiva oculi.

Central artery of the retina.—This very slender artery perforates obliquely the envelopes of the optic nerve, places itself in its centre and accompanies it into the eye. It sends a multitude of twigs to the tunica vasculosa retinæ, and in the child a branch, which traversing the vitreous humor, terminates by many fine twigs on the back of the capsule of the lens; with age this twig is obliterated.

The *supra-orbitar artery* passes under the superior wall of the orbit above the levator palpebræ, and leaving that cavity by the supra-orbitar notch or foramen, terminates in the frontalis muscle and integuments of the forehead.

The *posterior* or *short ciliary arteries* are occasionally 30 or 40 in number. They do not all come directly from the ophthalmic artery. They are to be found mostly in the fat surrounding the optic nerve. On reaching the posterior part of the ball of the eye, they penetrate the sclerotic near the entrance of the optic nerve. The greater number of the branches proceed to the external surface of the choroid and to the iris and ciliary processes.

The *long ciliary arteries* are generally two in number. They pass through the sclerotica more forward than the short ciliary branches, and so reach the ciliary body. They ultimately form the vascular circle of the iris. In the fœtus they supply the membrana pupillaris.

The *superior* and *inferior muscular branches* assist by their branches in supplying the muscles of the orbit, and send off the anterior ciliary twigs which enter the eyeball.

The *posterior ethmoidal* is occasionally absent. It enters the posterior internal orbitar foramen, and, so reaching the posterior ethmoidal cells, it enters the skull to be distributed upon the dura mater.

The *anterior ethmoidal artery* enters the anterior internal orbitar foramen along with the internal nasal nerve. It next enters the skull, and supplies with small twigs the pituitary membrane and falx cerebri.

The *inferior and superior palpebral arteries* are branches whose names indicate their course and distribution.

The *nasal artery* is usually considered as the terminating branch of the ophthalmic. It leaves the orbit above the tendon of the orbicularis palpebrarum, passes over the side of the root of the nose, gives some twigs to the lachrymal sac and neighbouring muscles, and anastomoses with the facial artery.

The *frontal branch* is smaller than the nasal. It ascends upon the forehead between the bone and the orbicularis, and becomes subcutaneous.

Anatomy of the Internal Carotid Artery continued.

After giving off the ophthalmic artery, the internal carotid produces in the interior of the cranium several branches distinguished into posterior and anterior.

The first are *the communicating* and *choroidal arteries:* the others, the *anterior* and *middle cerebral arteries.*

COMMUNICATING ARTERY OF WILLIS.—It directs itself obliquely backwards and a little inwards, passes over the side of the infundibulum and mammillary eminences, above the arachnoid membrane, and internally to the thickened edge of the middle lobe of the brain, opening into the posterior cerebral artery, a branch of the basilar. Its size, which is in general rather moderate, frequently varies, however, and is not always the same on both sides.

In its course it sends very slender ramifications to the optic thalami and nerves, the mammillary eminences, the *tuber cinereum*, the infundibulum, the choroid plexus, and the crura of the brain. Frequently the twig which belongs to the optic thalamus is much larger than the others.

Fig. 172.*

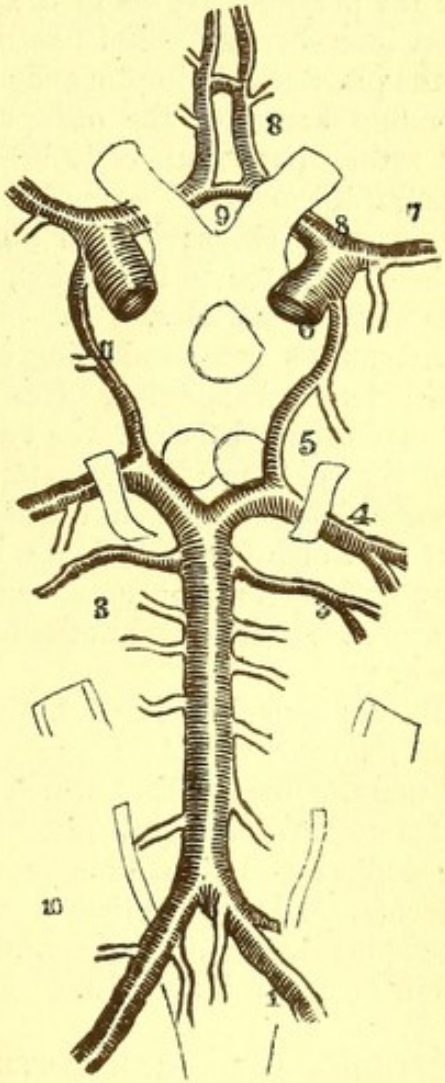

ARTERY OF THE CHOROID PLEXUS.—Always less than the preceding; it arises above it, and proceeds obliquely backwards and outwards towards the crus cerebri, close to which it enters into the corresponding lateral ventricle by its inferior fissure, to lose itself by subdividing in the choroid plexus. But before this it gives a great number of twigs to the thalami nervorum opticorum.

The arterial circle first described by Willis is remarkable chiefly on account of its connexion with the brain. Occasionally the communicating arteries are small, or one may be absent, or rather obliterated; but I have never seen this happen to both. Nevertheless, such an

* Fig. 172.—Showing the distribution of the vertebral arteries, the formation of the basilar artery, and the circle of Willis.—1, 1, vertebral arteries; 2, basilar artery; 3, 3, anterior cerebellar arteries; 4, posterior cerebral arteries; 5, 5, communicating arteries of Willis; 6, 6, internal carotids; 7, middle cerebral artery of one side; 8, 8, anterior cerebral arteries; 9, anterior communicating artery (sometimes double) connecting the two anterior cerebral arteries to each other, and thus completing the circle of Willis; 10, 10, optic nerves; E, pituitary body; 12, corpora albicantia.

arrangement might occur, in which case the ligature of both carotids, at the same time, would probably prove fatal. Some experiments made by Cooper seem to support this view.

ANTERIOR CEREBRAL ARTERY.—The *anterior cerebral artery* directs itself obliquely forwards and inwards, between the optic nerve and the posterior region of the anterior lobe of the brain, as far as the great inter-hemispherical fissure. There, after furnishing small twigs to the pia mater and optic and olfactory nerves, it approaches the corresponding artery of the other side, and unites with it by a very short but rather large transverse branch, which is named the *anterior communicating artery*. Sometimes this branch is substituted by three or four parallel twigs; but in all cases it sends one or more small twigs to be distributed to the fornix, the anterior commissure, and the septum of the ventricles.

After thus communicating with each other, the two anterior cerebral arteries change their direction, proceed forwards, and dive, parallel to each other, between the two anterior lobes of the brain, turning over the corresponding extremity of the corpus callosum. They then proceed from before backwards over its upper surface, at the posterior part of which they terminate by subdividing, so as to embrace that body entirely in an arch which exactly represents its form. It is to this arch that the name of artery of the corpus callosum is commonly given.

In this second part of its course the anterior cerebral artery sends from its concave side a great number of small twigs to the corpus callosum, while, by that which is convex, it furnishes somewhat larger twigs to the plane surface of the cerebral hemispheres. These twigs are lodged and subdivide in the anfractuosities which this surface presents, and are prolonged as far as the convex part of the same hemispheres, where they communicate with those of the middle and posterior cerebral arteries.

MIDDLE CEREBRAL ARTERY.—The *middle cerebral artery* is much larger than the anterior; it seems to be truly the terminating branch of the internal carotid. Directed outwards and backwards, it gives at first a great number of twigs to the lower part of the brain, to the pia mater which covers the crura cerebri, and to the choroid plexus; it then enters the fissura Sylvii, and divides into two branches, the one to the anterior, the other to the middle, lobe of the brain. These branches bend backwards, following deeply the fissure, and end towards the posterior part of the brain, where they subdivide into a great number of twigs. In their course they also furnish some, and all enter together into the cerebral anfractuosities, forming many windings, and ramifying in the pia mater to such a degree as to convert that membrane into an extremely fine and close vascular network, from which issue the arteries which are distributed to the substance of the brain. It is only in some particular places, which I

have already made known, that this organ receives trunks of any size, as in the optic thalmus, near the medullary roots of the olfactory nerves, &c.*

SUBCLAVIAN ARTERIES (*Arteriæ Subclaviæ*).—They are situated upon the upper part of the thorax and lateral and inferior parts of the neck. At their origin they present some differences on the right and left, which it is of importance to observe.

The right, which is generally a little larger than the left, arises upon the corresponding side of the trachea, from the arteria innominata. The left separates from the aorta at the end of its arch. Both extend as far as the upper part of the first rib, in the interval of the scaleni muscles; but the right is obviously shorter than the left.

They also differ in their position, direction, and relations, to the neighbouring organs.

Thus the right subclavian is more superficial than the left, which appears to depend especially upon the direction of the arch of the aorta. The right directs itself obliquely outwards and upwards, as far as the interval of the scaleni muscles; the left ascends vertically to near them, and suddenly turns outwards to pass into their interval.

Thus the *anterior* side of the right subclavian is covered from within outwards by the clavicle, the sterno-hyoidei, and sterno-thyroidei muscles, the corresponding subclavian vein, and the right pneumo-gastric and phrenic nerves, which cross its direction. Its *posterior* side is separated from the vertebral column and longus colli muscle by a pretty large interval. Its *outer* side comes somewhat near the top of the lung, and the *inner* leaves a triangular space between it and the right common carotid artery.

The *anterior* side of the left subclavian is covered at first by the lung and vena innominata, then by the pneumo-gastric nerve, which, instead of crossing its direction, runs parallel to it. Lastly, the first rib, the clavicle, and the sterno-thyroideus muscle, are applied upon it in a distant manner. Its *posterior* side rests immediately upon the vertebral column and longus colli muscle. Its *outer* side lies upon the pleura, which separates it from the lung; the *inner* corresponds to the common carotid artery.

The subclavian arteries traverse a considerable space without furnishing any branch; but, in the vicinity of the first rib, before passing between the scaleni muscles, they give off a pretty large number, of which the vertebral and inferior thyroid come off from its upper side; the internal mammary and superior intercostal from its lower, and the transverse cervical, supra-scapular, and deep cervical from the outer.

VERTEBRAL ARTERY (*Art. vertebralis*).—The vertebral artery is

* It is necessary to study the arteries which are furnished to the brain by the vertebral arteries of the subclavian at the same time with those which the internal carotids transmit to it.

the largest branch of the subclavian, almost equalling the axillary artery in size. It is especially destined for the cerebrum, cerebellum, and spinal marrow. It arises deeply from the upper and back part of the subclavian, near the place where the latter changes its direction. To the right it forms a very obtuse angle with it, while on the left side it seems to continue it in the same direction.

Fig. 173.*

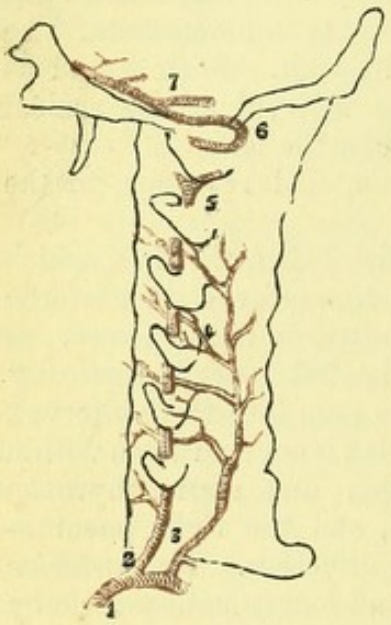

On both sides, immediately after its commencement, the vertebral artery proceeds directly upwards, behind the inferior thyroid artery, upon the vertebral column, between the longus colli and scalenus anticus muscles.

At the end of a more or less short course it enters the foramen with which the base of the transverse process of the sixth cervical vertebra is perforated, and sometimes that of the fifth, without having given rise to any branch; in other rarer cases it enters these foramina only at the fourth or third vertebra; it then ascends in the canal which results from the aggregate of all those holes with which the transverse process of the cervical vertebræ are perforated, and which is completed by the intertransversales muscles. In this part of its extent it passes before the trunks of the cervical nerves. It thus arrives at the axis, having only described very slight flexuosities; but it then leaves the canal, directs itself backwards under the trachelo-mastoideus, and forms between the two first vertebræ a vertical curve, the convexity of which is directed backwards, upwards, and inwards. It then proceeds upwards and outwards, as far as the transverse process of the atlas, of which it perforates the base directly upwards; under the obliquus capitis, after which it passes backwards and inwards, and describes, between that vertebra and the occipital bone, in the triangular space of the recti postici and obliqui capitis muscles, a second transverse curve, whose convexity, also directed backwards, is covered by the complexus and rectus capitis posticus major muscles, while its concavity embraces the side of the posterior occipito-atlantal ligament.

Lastly, the two vertebral arteries pass through the apertures of the two extremities of the same ligament, and through the dura mater, and enter the cranium by the occipital foramen, on the

* Fig. 173.—Showing the course of the vertebral artery—1, the subclavian; 2, anterior surface of the vertebral column; 3, left vertebral artery; 4, anastomosing branches with the cervical arteries; 5, the artery as it is about to pass into the foramen in the transverse process of the atlas; 6, the last turn the artery makes as it is passing into the cranium through the foramen magnum of the occipital bone.

sides of the spinal marrow. They then converge and ascend in a tortuous manner inwards and forwards, between the corpora-pyramidalia and olivaria and the basilar groove, on which they unite angularly, to give rise to the basilar artery.

In the canal of the transverse processes the vertebral artery sends off several *branches* in all directions, of which the external, anterior, and posterior, emerge between these processes, go to the intertransversales, scaleni, rectus capitis anticus major, trachelo-mastoideus, and splenius muscles, and communicate with the neighbouring arteries, while the internal penetrate into the vertebral canal by the intervertebral foramina, to expand upon the spinal marrow and dura mater, anastomosing with those of the opposite side.

In its vertical curve the vertebral artery sends, internally and inferiorly of the obliquus capitis inferior, a small branch, which bifurcates as it descends. One of its twigs is distributed to the semi-spinalis colli and multifidus spinæ, and the other (*Art. meningea posterior*) ascends under the posterior arch of the atlas, to be distributed to the dura mater. Moreover, there also separate from it some twigs for the obliquus capitis inferior and trachelo-mastoideus.

In its transverse curve it sends a considerable number of twigs to the recti postici and obliqui capitis muscles. One of them, larger than the others, is transverse, directs itself inwards, and presently divides into two branches, one of which, anastomosing with that of the opposite side, constitutes a kind of arch between the complexi and recti capitis postici majores muscles, while the other, descending obliquely, is distributed to the latter, and to the rectus posticus minor.

Posterior Spinal Artery (*Art. spinalis posterior*).—It arises from the vertebral artery, near the corpora-pyramidalia, and sometimes from the inferior cerebellar artery. It directs itself downwards and a little obliquely inwards, passes behind the spinal marrow, and continues to descend, parallel to that of the opposite side, as far as the second lumbar vertebra. It is extremely slender; all its twigs are transverse, and anastomose with those of the opposite side, or lose themselves upon the proper membrane of the spinal marrow, sending only some absolutely capillary ramifications to the pulpy substance of the latter.

Anterior Spinal Artery (*Art. spinalis anterior*).—It is a little larger than the preceding, and arises, internally, near the termination of the vertebral artery; it even sometimes comes from the inferior cerebellar or basilar artery. It descends in a tortuous manner upon the anterior surface of the upper extremity of the spinal marrow, gives some ramifications to it, and unites angularly with that of the opposite side, opposite the occipital foramen. There results from this union a very flexuous common trunk, which descends as far as the lower extremity of the spinal marrow, giving off, to the right and left, twigs similar to those of the posterior spinal arteries, and which is after-

wards prolonged, without dividing in the midst of the nervous filaments forming the cauda equina, as far as the articulation of the sacrum with the coccyx, where it terminates by anastomosing with the twigs of the lateral sacral arteries.

INFERIOR CEREBELLAR ARTERY (*Art. inferior cerebelli*).—It arises, externally, from the end of the vertebral, or even from the basilar trunk. Its size is very variable, although almost always pretty considerable. It directs itself transversely outwards, crossing the corpus pyramidale, passes between the origins of the corresponding pneumo-gastric and spinal accessory nerves, and advances in a serpentine manner upon the inferior surface of the cerebellum. Its first twigs, which are very small, are distributed to the superior extremity of the spinal marrow, the origins of the pneumo-gastric and hypoglossal nerves, and the walls of the fourth ventricle; but the last, which are much larger, creep under the hemisphere of the cerebellum, as far as its circumference, where they communicate with those of the superior cerebellar artery. There are only some which penetrate into the anfractuosities; the rest subdivide at the surface, and form a very fine network in the pia mater.

BASILAR ARTERY (*Arteria basilaris*).—The basilar artery results from the union of the two vertebral arteries. Larger than either of them individually, it has yet a smaller calibre than that of the two together. It commences posteriorly towards the groove which separates the cerebral protuberance from the medulla oblongata, ascends, describing some flexuosities, in the groove which runs along the middle part of the protuberance, and ends anteriorly in the interval which separates the crura of the brain. It therefore corresponds above to a groove of the protuberance, and rests below upon the basilar groove.

In its short course, the basilar artery gives off on each side a great number of small, irregular, and flexuous twigs, which are distributed to the protuberance, the cerebellum, the corpora olivaria and pyramidalia, and the acoustic, facial, and trifacial nerves. But there also separate from it two somewhat more remarkable branches, which are the superior cerebellar.

SUPERIOR CEREBELLAR ARTERY (*Art. cerebelli superior*).—Arising from the basilar artery, near its termination, it directs itself outwards and backwards under the protuberance and crus of the brain, around which it turns to ascend upon the upper surface of the cerebellum, opposite the tubercula quadrigemina, and after sending a great number of twigs over the protuberance, the crura cerebri and cerebelli, the tubercula quadrigemina, and pineal gland, the choroid plexus, and the valvule of Vieussens, it divides into a great number of branches, some of which ascend in a very flexuous manner upon the posterior lobe of the cerebrum, whilst others descend upon

the upper surface of the cerebellum, where they are distributed like those of the inferior cerebellar artery.

The basilar artery terminates by separating into two branches, which are the posterior cerebral arteries.

POSTERIOR CEREBRAL ARTERY.—The posterior cerebral artery (*Art. cerebri profunda*) is much larger than the superior cerebellar, from which it is separated at its commencement by the nerve of the third pair. It proceeds at first forwards and outwards, then presently directs itself backwards, turning over the corresponding crus of the brain, whence it gains the lower part of the posterior lobe of that organ. Immediately after its commencement it furnishes several small twigs to the mammillary tubercles, and to the crura of the brain: it sends a pretty large one into the third ventricle for the thalamus of the optic nerve, the tuber cinereum, and the anterior pillars of the fornix. Precisely in the place where it is in contact with the nerve of the third pair, it receives the communicating artery of Willis, which comes from the internal carotid.

Afterwards there still proceed from it a considerable number of twigs to the cerebral protuberance, the crus of the brain, the choroid plexus, the thalamus of the optic nerve, the cornu Ammonis, the corpus striatum, the pineal gland, and the tubercula quadrigemina.

The branches which this artery sends over the brain dive into the anfractuosities of its posterior lobe, and subdivide in the pia mater like those of the other cerebral arteries, with which their ramifications anastomose.

The posterior cerebral arteries, the communicating arteries of Willis, the anterior cerebral, and the anterior communicating artery, form a sort of polygon, in the area of which are situated the mammillary eminences, the tuber cinereum, the pituitary body, and the infundibulum.

It is also to be observed that the principal trunks of the arteries of the brain occupy the base of that organ, and are placed between it and the bony surfaces, so that the motions of the arterial circulation are communicated to the brain, as was first distinctly proved by Duverney. This impulse is transmitted to it in a uniform manner, on account of the extensive anastomoses of these different trunks. The principal branches of these same trunks are lodged in the fissures and anfractuosities. The twigs subdivide to infinity in the pia mater, and it is in reality only the capillary extremities of the vessels that penetrate into the pulp of the organ.

INFERIOR THYROID ARTERY (*Art. thyroidea inferior*).—Proportionally larger in children than in adults, it is of much smaller size than the vertebral artery, and is more superficial. It arises from the upper part of the subclavian, almost opposite the internal mammary, and a little externally of the vertebral. It ascends at first vertically upon the scalenus anticus, and, on arriving before the fifth vertebra,

suddenly bends inwards, passes transversely behind the common carotid artery, and goes in a tortuous manner to the thyroid body.

In its course the inferior thyroid artery sends off the following branches:—1, internal; to the œsophagus and trachea: 2, external; the most remarkable of which is the artery called *Art. cervicalis ascendens*. This branch ascends upon the scalenus anticus and longus colli muscles on each side, as far as the rectus capitis anticus major. It anastomoses with the vertebral posterior, cervical and occipital arteries.

Arrived at the lower and outer part of the corresponding lobe of the thyroid body, the inferior thyroid artery divides into two large branches which separate from each other, pass behind the organ, and send it numerous twigs which subdivide in its substance, anastomosing with the opposite inferior thyroid artery and with the two superior thyroids. It also sends some very small twigs to the mucous membrane of the trachea.

Internal Mammary Artery (*Art. mammaria interna*).—The internal mammary artery arises from the subclavian at the same level as the inferior thyroid. It descends at first a little inwards before the scalenus anticus muscle, and externally of the phrenic nerve. It then enters the thorax, where it is situated on the outside of the pleura, along the posterior surface of the sterno-costal cartilages, and internal intercostal muscles, whose direction it crosses. In descending it gradually approaches the sternum, places itself between the triangularis sterni and the walls of the thorax, and, towards the xiphoid cartilage, divides into two branches (*musculo-phrenic* and *superior epigastric*), which are prolonged to a greater or less distance into the walls of the abdomen.

Near its origin the internal mammary artery sends a great number of branches to the thymus gland, the sterno-hyoidei, and sterno-thyroidei muscles, and the neighbouring lymphatic ganglia. The branches which the internal mammary gives off in its course are,

1. The *anterior mediastinal*, supplying with twigs a portion of the pericardium, and pleuræ, thymus, and substernal lymphatic glands.

2. *Superior phrenic artery*; constant, though of very small size. It accompanies the phrenic nerve and supplies branches to the muscular fibres of the diaphragm.

3. *Anterior intercostal arteries.*—They equal in number the intercostal spaces and increase in size from above downwards. They arise opposite the inferior edge of each cartilage, follow it for some extent, and descend afterwards upon the intercostal muscles. They sometimes divide into two branches, one following the inferior edge of the cartilage, the other the superior.

4. *Internal branches.*—The superior are the largest; and they gradually decrease in size, the reverse of the preceding vessels. In number they are the same. After sending off some twigs they pass through the intercostal spaces, and, bending on themselves, supply with

branches the pectoralis major, rectus abdominis, obliquus externus, and internal intercostal muscles.

SUPERIOR INTERCOSTAL ARTERY (*Art. intercostalis superior*).—Its volume and length vary much. Arising from the lower and back part of the subclavian, opposite the deep cervical artery, it descends before the neck of the first rib, externally of the inferior cervical ganglion, and forms some flexuosities. Opposite the lower edge of that rib it gives off two twigs, the one posterior, the other external, and sometimes terminates there. But most commonly it passes before the neck of the second rib, and on arriving at the second intercostal space furnishes two other twigs. In some subjects it proceeds still lower. In the whole of this course the superior intercostal artery is covered by the pleura.

Before the first rib it frequently sends a pretty large twig to the lower part of the scalenus anticus muscle.

The *posterior branch* which it furnishes in the first intercostal space is very small; and, after throwing some small twigs over the spinal marrow, by the intervertebral foramen, it emerges posteriorly between the transverse processes and goes to lose itself in the muscles of the back. The *external branch*, which comes off from it at the same point, is distributed to the two intercostal muscles, after furnishing some ramifications to the periosteum of the vertebræ, the œsophagus, and bronchi.

In the second intercostal space the artery terminates by dividing into two branches, which follow precisely the same course as the preceding, are lost in the muscles, and anastomose widely with the first aortic intercostal artery.

TRANSVERSE CERVICAL ARTERY (*Art. transversalis colli*).—Next to the vertebral, inferior thyroid, and mammary arteries, this is the largest branch of the subclavian. It sometimes arises from the inferior thyroid. Directing itself transversely outwards, it winds along the scaleni muscles, above the nerves which form the brachial plexus, in the triangular space which exists between the sterno-cleido mastoideus and trapezius muscles and the clavicle, where it is covered by the first of these muscles. It then curves and descends obliquely backwards under the trapezius and levator anguli scapulæ muscles, changes its direction again, and descends vertically under the rhomboideus muscle, along the posterior edge of the scapula, where it gets the name of posterior scapular (*Art. scapularis posterior*), to terminate by subdividing near its inferior angle.

Near its origin this artery gives off several branches to the scaleni muscles, which ascend vertically, and another larger and more superficial branch (superficial cervical artery), which proceeds in a tortuous manner from within backwards, and goes to be distributed to the splenius and trapezius muscles, the cellular tissue and skin of the inferior and lateral region of the neck. In passing under the levator

anguli scapulæ, it sends upwards a pretty large branch to this muscle and the trapezius, and downwards several branches, which descend under the latter muscle as far as the supra-spinatus, and are equally distributed among them, communicating with several branches of the supra-scapular artery.

Opposite the rhomboideus muscle the transverse cervical artery separates into two equal branches, one of which follows the posterior edge of the scapula, and spreads out in the subscapularis, serratus magnus, rhomboideus, serratus posticus superior, latissimus dorsi, and trapezius muscle, as well as in the integuments of the back, while the other proceeds outwards, under the scapula, and is destined for the serratus magnus and subscapularis alone.

In some subjects the transverse cervical artery comes from the axillary, and then, instead of passing above the nerves of the brachial plexus, it glides in one of the intervals which they leave between them.

Supra-scapular Artery (*Art. scapularis superior seu transversalis humeri*).—Less voluminous than the preceding, it more commonly comes off from the inferior thyroid than from the subclavian itself; sometimes it has a trunk common to it and the transverse cervical or internal mammary artery. In all cases it proceeds in a tortuous manner from within outwards, behind the clavicle, covered by the sterno-cleido mastoideus, platysma-myoides, and trapezius muscles, and arrives at the upper edge of the scapula, following exactly the course of the supra-scapular nerve. On arriving near the supra-spinatus muscle, it passes above the coracoid ligament, dives between the supra-spinatus muscle and the fossa of the same name, directs itself outwards under the arch formed by the clavicle and acromion process united, winds over the edge of the spine of the scapula, and enters into the fossa infra-spinata, between the bone and the infra-spinatus muscle.

In the first part of its course this artery furnishes several twigs to the subclavius and platysma myoides muscles, to the clavicle, the cellular tissue, and lympathic ganglia of the lower part of the neck. Before passing over the coracoid ligament it sends to the supra-spinatus muscle a pretty large superficial branch, which gives twigs to the trapezius muscle and acromio-clavicular articulation; they anastomose with the transverse cervical artery. Lastly, in the fossa infra-spinata the supra-scapular artery anastomoses with the subscapular, which comes from the axillary artery, and divides into two principal branches, of which one follows the anterior edge of the scapula and belongs to the teres major and latissimus dorsi muscles, while the other proceeds transversely backwards under the spine of the scapula, and throws a multitude of twigs into the infra-spinatus muscle.

Deep Cervical Artery (*Art. cervicalis profunda*).—The deep cervical artery arises from the posterior and deep part of the sub-

clavian, externally of the inferior thyroid, behind the scalenus anticus muscle, and immediately before the transverse process. It has been seen to come from the inferior thyroid or vertebral artery, or to have a common trunk with the superior intercostal. Immediately after its origin it ascends obliquely outwards, passes between the two last transverse processes of the neck, after giving small twigs to the scaleni, longus colli, and rectus capitis anticus major muscles, directs itself backwards, upwards, and inwards, between the complexus and semi-spinalis colli muscles, becomes vertical, and ends by anastomosing, towards the head, with the vertebral and occipital arteries, sending numerous ramifications into the muscles and integuments of the back part of the neck.

AXILLARY * ARTERY (*Arteria axillaris*)—Is the direct continuation of the subclavian. Situated at the superior lateral part of the thorax, and in the axilla. It directs itself obliquely downwards and outwards, as far as the level of the inferior edge of the latissimus dorsi muscle, where it is then called brachial. In this course it describes a curve, of which the convexity is directed outwards and upwards, and the concavity inwards and downwards. This great trunk receives the name of axillary so soon as it reaches the surface of the first rib.

The *anterior* side of the axillary artery is at first covered by the platysma myoides, in a small triangular space which is formed by the scalenus anticus muscle, the nerves of the brachial plexus, and the clavicle. It is then in relation with the clavicle itself, whose direction it crosses, and with the subclavian muscle. Still lower, the pectoralis major muscle, then the pectoralis minor, and lastly, the tendon of the pectoralis major and the coraco-brachialis and biceps muscles, are applied upon it. From the clavicle to the lower part of the axilla, the axillary vein lies upon the artery of the same name.

Its *posterior* side rests internally upon the brachial plexus. At the middle it corresponds to the cellular interval which separates the serratus magnus and subscapularis muscles. Externally it lies upon the teres major and latissimus dorsi.

Its *under* or *inner* side is at first lodged in a more or less deep groove, which the upper surface of the first rib presents for it; it then corresponds to the first intercostal muscle, the second rib, and the upper digitation of the serratus magnus, from which it is afterwards more or less separated by the brachial plexus, or by cellular tissue and lymphatic ganglia.

Its *upper* or *outer* side is at first covered by the skin, the platysma myoides, and a layer of adipose tissue; afterwards by the clavicle and subclavius muscle, and, lastly, by the capsule of the shoulder-joint, the subscapularis muscle, and the tendon of the teres major and latissimus dorsi, which separates it from the upper part of the humerus.

The axillary vein is always placed before the artery, as I have

* Axilla—the arm-pit.

Fig. 174.*

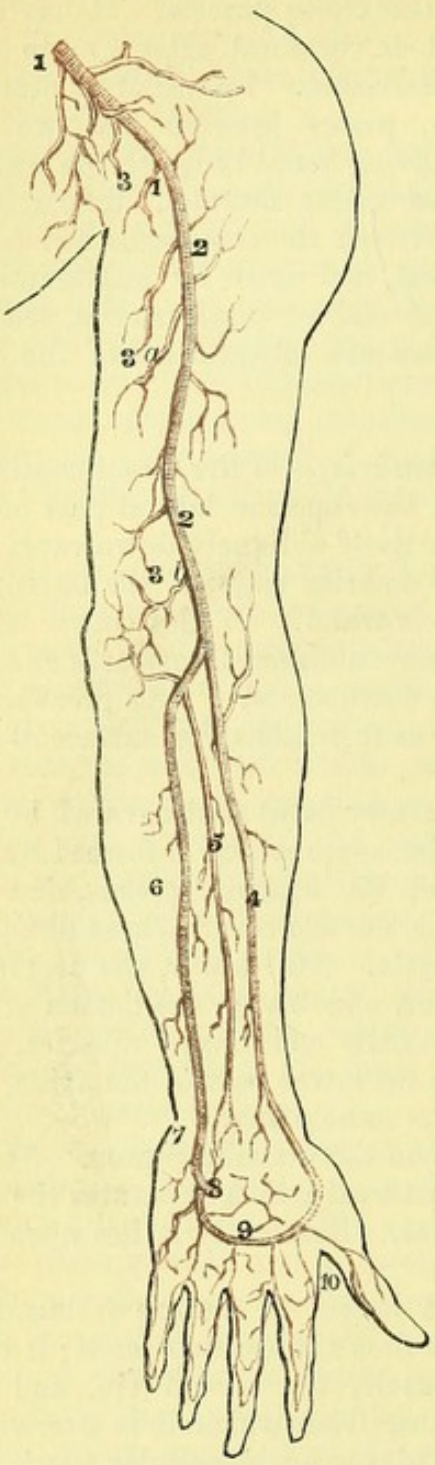

already said. The brachial plexus is situated behind the latter until near the lower edge of the subscapularis muscle, where the principal branches of this plexus embrace the artery and form for it a kind of sheath.

Branches which the Axillary Artery gives off opposite the Thorax.

The *acromial thoracic artery.*—It is of considerable size, and comes off from the fore part of the axillary artery, opposite the upper edge of the pectoralis minor, and frequently by a trunk common to it and the superior thoracic. Concealed at its commencement by the pectoralis major, it descends obliquely outwards towards the deltoid muscle, throwing some small twigs into the subclavius, serratus magnus, and first intercostal muscle. Arrived at the narrow interval which separates the deltoid from the pectoralis major, it divides into two branches, a superior and an inferior.

The *superior branch* ascends in a tortuous manner in the interval which we have just mentioned, and arrives at the clavicle. There it gives off a transverse twig, which is distributed to the skin of the top of the shoulder and upon the deltoid muscle. It then dives under that muscle, and still divides into two twigs, one of which follows the edge of the clavicle to its acromial

* Fig. 174.—Sketch of the distribution of the arteries of the superior extremity.—1, 1, the axillary artery; 2, 2, its continuation, called humeral, or brachial; 3, branches called thoracic; 3*a*, superior and inferior deep humeral arteries; 3*b*, anastomoticus magnus; 4, radial artery; 6, the ulnar artery; 5, the interosseal, the largest branch of the ulnar; 7, the ulnar passing into the palm of the hand to form the superficial palmar arch; 8, superficial palmar arch, cut across and removed, to show, 9, the deep palmar arch formed by the radial, uniting, near 8, with the ulnar; the uniting branch is called the ramus communicans.

articulation, while the other, which is larger, forms a network upon the fibrous capsule of the shoulder-joint. It anastomoses with the superior scapular artery.

The *inferior branch* follows the course of the cephalic vein between the deltoid and pectoralis major muscles, and divides into two twigs, which are distributed to each of them, anastomosing with the thoracic and circumflex arteries.

The *superior thoracic artery*.—Most commonly it arises along with the acromial. Its size is variable. It descends obliquely forwards between the pectoralis major and pectoralis minor muscles, to which it is distributed by a great number of twigs, some of which run superficially as far as the mamma. It anastomoses with the intercostal arteries and the internal mammary. In some subjects there are two or three superior thoracic arteries.

The *long thoracic* or *external mammary artery*.—It sometimes arises along with the superior, but more commonly it comes off from the axillary, a little lower than it. It descends at first almost vertically, and only a little from behind forwards, on the lateral part of the thorax, between the lower edge of the pectoralis major, which covers it, and the serratus magnus, on which it lies. It then bends inwards, becomes subcutaneous, and divides into several branches, which embrace the mamma.

This artery gives numerous twigs to the pectoralis major, serratus magnus, and intercostales muscles, the lymphatic ganglia of the axilla, the integuments, and mamma. It anastomoses with the intercostal, internal mammary, and superior thoracic arteries.

Branches which the Axillary Artery gives off in the Axilla and upper part of the arm.

Subscapular artery (*Art. infra-scapularis*).—The subscapular artery is of considerable size, and comes off from the lower part of the axillary artery, opposite the lower edge of the tendon of the subscapularis muscle, and behind the brachial plexus. Immediately after its origin it gives off three or four pretty large branches, which proceed transversely, either to the lymphatic ganglia of the axilla or to the subscapularis muscle. It then descends obliquely along the lower edge of that muscle, and presently divides into two considerable branches, an inferior and smaller, and a superior and larger.

Inferior branch.—It descends upon the subscapularis muscle, and along the anterior edge of the scapula, as far as the lower third of the latter, between the latissimus dorsi and serratus magnus muscles, and in the midst of cellular tissue. It divides into a very great number of twigs, all of large size, which are expanded partly in the middle and inferior portions of the serratus magnus, and partly in the latissimus dorsi and integuments of the back. Some of them run along the edge of the scapula and turn over its inferior angle, to anastomose posteriorly with twigs of the superior branch, and of the transverse cervical artery.

Superior branch (*Art. dorsalis scapulæ*). — It runs horizontally from before backwards, first between the latissimus dorsi and subscapularis, teres major and minor, and then between the triceps extensor and subscapularis muscles, to turn over the anterior edge of the scapula. At its commencement it gives a remarkable twig to the latissimus dorsi, near its tendon, and throws some small twigs into the subscapularis, teres major, and teres minor muscles. After turning over the edge of the scapula, it enters into the fossa infra-spinata, where it divides into two twigs. One of these twigs, which is superficial and smaller, glides between the skin and aponeurosis of the infra-spinatus muscle; while the other, which is deep and much larger, passes under the teres minor and infra-spinatus muscles, and is distributed in their substance by three or four large secondary twigs. One of them ascends under the acromion to enter into the fossa supra-spinata, anastomosing with a branch of the supra-scapular artery.

Circumflex Arteries of the Humerus.—The *posterior circumflex artery*, less voluminous than the preceding, arises from the posterior part of the axillary artery, and passes backwards round the upper part of the shaft of the humerus, between the subscapularis and teres major muscles, and before the long portion of the triceps extensor. It gives them some twigs, then dives under the deltoid, and arrives at the fore and outer part of the humerus. There then come off from it *superior twigs*, which ascend to be distributed to the capsule of the shoulder-joint, and to the teres minor and infra-spinatus muscles, as well as to the fleshy fibres of the deltoid, between which it anastomoses with the acromial artery; and *inferior twigs*, which descend in the substance of the deltoid as far as its tendon. The artery itself is distributed to that muscle, and there communicates with the anterior circumflex artery.

The *anterior circumflex artery* is very small, and frequently furnished by the preceding. It directs itself horizontally forwards and outwards, under the coraco-brachialis muscle, and under the short portion of the biceps flexor, running along the upper edge of the tendon of the latissimus dorsi and teres major muscles. It then turns over the upper part of the humerus, runs between that bone and the deltoid as far as the bicipital groove, passes under the tendon of the long portion of the biceps, and dives into the substance of the deltoid, where it loses itself. This artery is always immediately applied upon the bone, and adheres to it in a decided manner. It gives but very few twigs to the deltoid muscle until its termination, but it sends a great number upon the fibrous capsule of the shoulder-joint, and upon the subscapularis muscle, near its attachment.

Pretty frequently, instead of losing itself in the deltoid, the anterior circumflex artery ascends in the bicipital groove, and is expanded over the capsule.

Brachial or Humeral Artery (*Arteria brachialis seu hume-*

rarıa).—Placed at the inner and fore part of the arm, from the axilla to a finger's breadth beneath the bend of the elbow; it forms the true continuation of the subclavian and axillary arteries.

Pretty deep, and altogether internal above, it becomes more superficial and anterior as it descends.

Anteriorly, the brachial artery is successively covered, from above downwards, by the coraco-brachialis muscle, which is separated from it by a considerable thickness of cellular tissue, the brachial aponeurosis, and the skin along the inner edge of the biceps muscle; and, lastly, at the bend of the elbow, by the inferior aponeurosis of the biceps, the median basilic vein, and the skin, from which it is separated by a pretty thick layer of cellular tissue.

Posteriorly, it is free in its upper third, which is separated from the triceps extensor muscle by a great quantity of fat, but in the rest of its extent it is applied upon the brachialis internus muscle.

Internally, it is accompanied by the brachial vein and median nerve, and covered by the integuments.

Externally, it is applied, in its upper third, upon the inner surface of the humerus, from which it is only separated by the lower extremity of the coraco-brachialis muscle. Farther down it is lodged in the groove between the triceps and brachialis internus muscles, and, at its lowest part, corresponds to the tendon of the biceps.

The *brachial artery* gives off a great number of branches, which are distinguished into anterior, posterior, internal, and external. Inferiorly, it divides into the radial and ulnar arteries.

Anterior Branches of the Brachial Artery.

Of these branches a few only have received distinct names, but, with or without names, they should all be dissected and examined.

1st. The *anterior branches* are distributed to the biceps and integuments.

2d. The *posterior branches* are short and slender, and irregular as to number; they proceed chiefly to the brachialis muscle.

3d. The *external branches of the humeral* artery are small, and few in number; they go to the coraco-brachialis and integuments.

4th, and lastly. The *internal branches* may be divided into the superficial and superior internal: these proceed to the pectoralis major, deltoid, and axilla. A branch occasionally accompanies the ulnar nerve into the fore arm, where it anastomoses with the artery called anastomotica magna.

Lastly. The deep humeral (*Art. profunda humeri*) is given off from this aspect of the humeral. This vessel is of considerable size, and is often described as distinct from a second branch given off lower down; when both are present they are distinguished into a *superior* and *inferior*. The student must be prepared to meet with many varieties in the coming off of these arteries.

The *Art. profunda humeri* is of considerable size, but does not always come from the brachial artery, being sometimes given off by the pos-

terior circumflex, sometimes by the subscapular. When it is furnished by the brachial artery it separates from it above the inner portion of the triceps extensor muscle, opposite the groove of the humerus, in which the musculo-spiral or radial nerve winds, and follows the course of that nerve exactly, being placed above it. It therefore passes at first between the triceps extensor and the humerus, directing itself backwards and downwards, and, when it has arrived at the middle of the posterior surface of the arm, enters between the triceps extensor and brachialis flexor, emerges through the interval which separates them, and becomes superficial. It then descends vertically, and, at a greater or less distance from the elbow-joint, separates into two branches.

Near its origin the deep humeral artery gives off *posterior twigs*, which descend to a greater or less distance in the triceps extensor muscle, and of which one follows its inner portion to near the olecranon. At the same point there also separate from it *external branches* which go to the outer portion of the muscle, the brachialis internus, and over the periosteum of the humerus. One of them (*Art. nutritia humeri*) enters the nutritious canal of that bone, and is distributed to its medullary membrane.

Two branches terminate this artery; one of them follows its original direction and loses itself in the triceps extensor muscle, near its insertion into the olecranon; the other directs itself between the brachialis internus and the integuments, and gives a great number of ramifications to them as well as to the upper part of the supinator longus.

In many cases the trunk itself of the deep humeral artery anastomoses a little above the outer condyle with a branch given off farther down (*Art. profunda humeri inferior*), and with which it forms a transverse arch, which embraces the humerus externally. The twigs which issue from this arch are diffused over the elbow-joint and the origins of the extensor muscles of the hand.

Ramus anastomoticus. — It arises from the brachial, very near the inner condyle, and directs itself transversely inwards, before the brachialis internus muscle and behind the median nerve, whose direction it crosses. It passes through the aponeurosis placed between the brachialis internus and the inner edge of the triceps extensor, and there divides into two twigs. One of them follows the edge of the humerus as far as the inner condyle, on which it subdivides, and where it communicates with the anterior ulnar recurrent artery. It sends off a secondary twig, which descends upon the fore-arm, between the olecranon and inner condyle, and accompanies the ulnar nerve to a certain distance. The other passes backwards into the olecranal cavity, subdivides and throws itself into the lower part of the triceps muscle; it anastomoses with the posterior ulnar recurrent artery. The ramus anastomoticus magnus moreover furnishes many small twigs to the brachialis internus and pronator teres muscles, the elbow-joint, the integuments, and the ulnar nerve.

A second anastomosing artery is frequently met with.

Branches by which the Brachial Artery terminates.

They are two in number, the ulnar artery and the radial artery, and separate from each other at an acute angle, under the bend of the arm, and at the place where the tendon of the biceps flexor dives between the anterior muscles of the fore-arm. This division of the brachial artery is not always situated at the same point, and not unfrequently takes place about the middle of the arm, and even sometimes in the axilla. Before furnishing the radial and ulnar arteries, this trunk sends, in all cases, some isolated and small twigs into the bundle of muscles which are attached to the inner condyle.

Radial artery (*Arteria radialis*).—More superficial and smaller than the ulnar, it follows the original direction of the brachial artery, and extends at the fore and outer part of the fore-arm, from the bend of the elbow to the wrist-joint, where it winds outwards, and dives under the tendons of the extensor muscles of the thumb, to place itself in the interval of the first and second metacarpal bones. From thence it descends between the second of these bones and the abductor indicis, and passes into the palm of the hand, where it constitutes the deep palmar arch.

Of the radial artery in the fore-arm.—Before the radial artery arrives at the wrist, it has the following relations to the neighbouring parts:—

1st. *Posteriorly*, it is applied upon the anterior surface of the radius, from which it is separated above by fat and by the supinator brevis, in the middle by the pronator teres, farther down by the flexor longus pollicis, and still lower by the pronator quadratus muscle, below which it rests immediately upon the bone.

2d. *Antèriorly*, it is covered by the radial vein in its whole extent, and in its upper third by much adipose tissue, and by the supinator radii longus; but below, it becomes subcutaneous, and its pulsations may be distinctly felt through the skin during life.

3d. *Internally*, it is applied against the pronator teres above, the flexor carpi radialis at the middle, and flexor digitorum sublimis below.

4th. *Externally*, it corresponds only to the supinator longus and the radial nerve.

The branches which the radial artery gives to the fore-arm are distinguished into anterior, posterior, external, and internal.

Anterior branches.—Their number is as uncertain as their disposition. They pass through the aponeurosis and are distributed to the integuments of the fore-arm.

Posterior branches.—They are very slender, and descend obliquely towards the flexor longus pollicis and pronatus quadratus, in which they are lost.

External branches.—The largest of these branches separates from the radial artery at its commencement. It is named the radial recurrent (*Art. recurrens radialis*). Directing itself at first transversely towards the supinator longus, it presently bends to ascend

between it, the supinator brevis and brachialis internus muscles, to the neighbourhood of the olecranon. It thus forms a kind of arch, from the convexity of which proceed several twigs, which descend between the two supinator muscles, to which they are distributed, as well as to the two extensores carpi radiales, the extensor digitorum communis, and the extensor muscles of the thumb. In terminating, this artery divides into several other twigs, which anastomose with those of the deep humeral artery.

The other external branches are numerous, but their occurrence is not always regular. They descend obliquely in the supinator longus and extensores carpi radialis, as well as in the extensor ossis metacarpi pollicis.

Internal branches.—Very numerous, but irregular, they are distributed in the muscles of the anterior and superficial layer of the fore-arm. Two of them, however, are constant, and arise from the radial artery, close to the wrist. The first, which is very small and deep, directs itself transversely inwards, along the inferior edge of the pronator quadratus muscle, and anastomoses with a similar branch of the ulnar artery, forming an arch which furnishes twigs above for the pronator quadratus, and below for the ligaments of the wrist.

The second branch (*superficialis volæ*) is superficial, and varies much as to size. It descends obliquely before the anterior annular ligament of the wrist, and gains the palm of the hand after passing through the upper extremity of the abductor pollicis. It anastomoses with the extremity of the superficial palmar arch, formed by the ulnar artery, and sends a great number of twigs to the muscles and integuments of the external palmar region.

Of the radial artery behind the wrist.—It is only covered, in this region, by the tendons of the extensores pollicis and by the integuments. It is applied upon the ligaments of the carpus, and upon the upper part of the first metacarpal bone. The branches which here come off from it are distinguished into internal and external.

External branches.—They are three in number, and are distributed to the thumb. The first descends under the tendons of the extensor ossis metacarpi and extensor primi internodii pollicis, and goes to the attachment of the abductor pollicis, where it loses itself. The second, which arises a little lower, is called the dorsal artery of the thumb (*Art. dorsalis pollicis*). It descends obliquely outwards, behind the first metacarpal bone, and over the first phalanx of the thumb, and terminates by anastomosing with its external collateral artery, after distributing some very small twigs to the periosteum, the integuments, and the abductor muscle of the thumb. The third descends, along with the tendon of the extensor secundi internodii pollicis, upon the inner edge of the first metacarpal bone. It gives ramifications to the periosteum and abductor muscle of the forefinger.

Internal branches.—They are two in number. One belongs to the carpus, the other to the metacarpus.

1. *Dorsal artery of the carpus* (*Art. dorsalis carpi radialis*).—It arises opposite the outer edge of the tendon of the extensor carpi radialis longior, and directs itself transversely inwards over the posterior surface of the second row of carpal bones, covered by the tendons of the extensores carpi radiales and extensores digitorum, and terminates by anastomosing with a similar branch of the ulnar artery, or by dividing into several twigs. But, in its course, it gives off very short *superior twigs*, which lose themselves upon the ligaments of the radio-carpal articulation, communicating with those of the anterior interosseous artery, and the longer *inferior twigs*, in indeterminate numbers, which descend towards the superior extremities of the metacarpal bones, where they anastomose with the perforating arteries of the deep palmar arch. They then proceed behind the interossei muscles, and lose themselves in their substance and in the integuments of the back of the hand.

2. *Dorsal artery of the metacarpus.*—It comes off from the radial artery where it is about to enter into the upper extremity of the abductor indicis muscle. It passes immediately over the second metacarpal bone, along which it descends obliquely to the middle of the back of the hand. Sometimes it is prolonged as far as the index. Its twigs are distributed to the abductor indicis and the integuments; some of these communicate with the artery of the wrist.

Before entering into the palm of the hand, the radial artery gives off a branch which descends between the flexor brevis pollicis and abductor indicis muscles, and divides into two twigs, one of which follows the inner edge of the thumb, the other the outer edge of the forefinger, at the extremities of which they anastomose with the collateral vessels; these two branches sometimes come off separately from the radial.

Radial Artery in the Palm of the Hand.—On entering the palm of the hand the radial artery gives off the *arteria magna pollicis*, which proceeds downwards towards the lower extremity of the first metacarpal bone, and divides into two branches, which run, one along the radial side, and the other along the ulnar side, of the anterior surface of the thumb.

Deep palmar arch (*Arcus palmaris profundus*).—It is formed by the continuation of the radial artery, which passes transversely to near the ring-finger, describing a slight curve having its convexity directed downwards. It is covered by the abductor pollicis, the tendons of the two flexor muscles of the fingers and the lumbricales, and rests upon the extremities of the metacarpal bones and upon the interossei muscles.

The twigs which it furnishes are the superior, inferior, anterior, and posterior.

Superior twigs.—They are very slender and not numerous. They ascend before the carpus, and are distributed to its ligaments and to the abductor, flexor brevis, and opponens pollicis muscles.

Inferior twigs (*Rami interossei volares*).—More voluminous and longer, they are generally five in number. The first is usually larger than the others, and proceeds along the whole length of the forefinger, forming its digito-radial branch. The next three descend in the interosseous spaces, from the second to the fourth, and, at the articulation of the metacarpal bones with the phalanges, divide into small twigs which go to the fingers. The fifth is a little inclined downwards, and passes between the flexor brevis and opponens minimi digiti, in which it loses itself.

Anterior twigs.—Very short and small; they are entirely destined for the lumbricales muscles.

Posterior twigs or *perforating arteries* (*Art. perforantes*).—They are three in number. At their commencement they pass through the corresponding interossei muscles, and go to anastomose on the back of the hand, with the twigs of the dorsal artery of the wrist.

The deep palmar arch terminates, toward the inner edge of the hand, by anastomosing with a branch of the ulnar artery, under the flexor brevis and opponens pollicis muscles.

Ulnar Artery (*Arteria ulnaris seu cubitalis*).—The ulnar artery is larger than the radial, and descends at the anterior and inner part of the fore-arm, from the bend of the arm to the palm of the hand. It is at first directed a little obliquely inwards, and enters between two layers of the anterior muscles of the fore-arm, whose direction it slightly crosses. At the middle part of the fore-arm it becomes vertical, and emerges from beneath the muscles, in the place where the flexor digitorum sublimis muscle separates from the flexor carpi ulnaris. It preserves its direction as far as the pisiform bone, where it is nearly as superficial as the radial artery. It then bends outwards, passes over the anterior annular ligament of the wrist, and forms in the palm of the hand the superficial palmar arch.

The ulnar artery, in this course, is somewhat flexuous. Its upper part describes a slight curve, of which the convexity is directed inwards and backwards.

Its *anterior* side is covered above, at first by the median nerve, afterwards by the pronator teres, flexor carpi radialis, palmaris longus, flexor digitorum sublimis, and flexor carpi ulnaris muscles. Inferiorly it is in relation with the aponeuroses and skin, from which it is separated only by the lateral projections of the flexor sublimis and flexor carpi ulnaris. In the hand it is entirely concealed beneath the palmaris brevis and palmar aponeurosis.

Its *posterior* side is applied, from above downwards, upon the brachialis internus, flexor digitorum sublimis, and pronator quadratus muscles, the anterior annular ligament of the wrist, and the tendons of the two flexor muscles of the fingers.

Its *inner* side is accompanied by the ulnar nerve and flexor carpi ulnaris muscle. It corresponds below to the pisiform bone.

Its *outer* side is applied upon the flexor digitorum sublimis.

Anterior ulnar recurrent artery (*Art. recurrens ulnaris anterior*). —It arises from the inner side of the ulnar artery, at its commencement, and descends at first a little outwards between the brachialis internus and pronator teres and flexor carpi radialis muscles. It then ascends towards the fore part of the inner condyle, where it anastomoses with the ramus anastomoticus. It is of small size, and gives twigs to the pronator teres, flexor carpi radialis, and flexor digitorum sublimis muscles, the periosteum of the humerus and the integuments.

In the fore-arm, the ulnar artery gives off branches which are distinguished into internal, external, and anterior.

Internal branches.—The largest and most constant is the posterior ulnar recurrent artery (*Art. recurrens ulnaris posterior*), which much exceeds the anterior in size, and comes off from the ulnar artery generally a little below, though sometimes along with it. It descends at first inwards, behind the pronator teres, flexor carpi radialis, and flexor digitorum sublimis, and before the flexor digitorum profundus. It then ascends behind the inner condyle, between that eminence and the olecranon, beside the ulnar nerve, passes between the two origins of the flexor carpi ulnaris, and anastomoses with the deep humeral and the ramus anastomoticus. It gives off a great number of twigs, which are distributed to the flexor muscles of the fingers, flexor carpi ulnaris, and triceps extensor muscles, to the ligaments of the elbow-joint, and to the ulnar nerve and integuments.

Nothing can be less regular as to number and disposition than the other internal branches. One of them, however, which is somewhat larger than the rest, separates from the ulnar artery at its lowest part, and goes to unite with the dorsal artery of the carpus, or to lose itself upon the corresponding edge of the hand.

External branches.—Very numerous and small; they almost all throw themselves into the flexor digitorum sublimis and flexor carpi ulnaris. One of them, however, is constant in its occurrence; it follows the inferior edge of the pronator quadratus, and goes to communicate with a similar branch of the radial artery.

Anterior branches.—They are very numerous, and are all distributed to the superficial and anterior muscles of the fore-arm. One of them only, which is longer and larger than the others, and sometimes arises from the interosseal artery, descends behind the median nerve, as far as the lower part of the fore-arm, and gives off laterally a great number of small twigs to the flexor digitorum sublimis.

INTEROSSEAL ARTERY (*Arteria interossea*). — The interosseal artery comes from the posterior part of the ulnar, a little beneath the bicipital tuberosity of the radius, and is always of considerable size. It directs itself horizontally backwards, and almost immediately divides into two branches, which are named the anterior and posterior interosseal.

Anterior interosseal artery.—It descends vertically before the interosseous ligament, between the flexor longus pollicis and flexor

digitorum profundus muscles, which conceal it by their approximation. Arrived at the upper edge of the pronator quadratus muscle, where its size is already sensibly diminished, it passes behind it, perforates the interosseous ligament near the inferior radio-cubital articulation, descends in the groove which lodges the tendons of the extensor digitorum communis muscle, passes over the carpus, and then divides, anastomosing with the dorsal artery of that part.

In its course the anterior interosseal artery gives off the nutritious arteries of the radius and ulna; also numerous muscular twigs to the deep muscles. A few pass through the interosseal ligament.

Posterior interosseal artery.—It passes above the interosseous ligament, and appears at the posterior and upper part of the fore-arm, under the anconeus muscle, where it divides into two branches of nearly equal size.

1. One of these, named the interosseal recurrent artery (*arteria recurrens interossea*), ascends between the anconeus and extensor carpi ulnaris muscles, as far as the back part of the outer condyle, where it anastomoses with the twigs of the deep humeral artery and radial recurrent. It distributes its divisions to the extensor carpi ulnaris, anconeus, and triceps extensor muscles, the elbow-joint, and to the periosteum of the humerus and bones of the fore-arm.

2. The other branch, or posterior interosseal artery, properly so called, descends vertically between the supinator brevis and extensor ossis metacarpi pollicis muscles, and afterwards between the two layers of the posterior muscles of the fore-arm, as far as the posterior surface of the carpus, where it anastomoses with the anterior interosseal. It becomes much smaller inferiorly, and gives a great number of ramifications to the extensor carpi ulnaris, extensor proprius minimi digiti, extensor digitorum communis, extensores carpi radiales, supinator brevis, extensor ossis metacarpi pollicis, extensor primi internodii, extensor secundi internodii pollicis, and extensor indicis. One of its twigs, which is much larger than the rest, passes between the extensor ossis metacarpi pollicis and extensor primi internodii pollicis, gains the inferior extremity of the radius, and loses itself separately at the posterior and external part of the carpus.

The Ulnar Artery in the Palm of the Hand.—Superficial palmar arch (*arcus superficialis volæ*).—When the ulnar artery has passed the pisiform bone it descends, at first vertically, before the anterior annular ligament of the wrist, and then bends outwards in the palm of the hand to form this arch, of which the convexity is directed downwards. Towards the upper extremity of the fourth metacarpal bone it communicates with a branch of the radial artery.

The concavity of this arch gives off but very few twigs, which are distributed to the lumbricales muscles and annular ligament; but its convexity generally furnishes four larger branches, which are called the digital arteries.

The first of these digital arteries descends obliquely inwards upon

the muscles of the little finger, to which it gives ramifications, and whose direction it crosses at right angles. It is afterwards placed upon the inner edge of the little finger, and reaches as far as its extremity.

The other three branches descend in the interosseous spaces to the heads of the metacarpal bones, where they each divide into twigs; the *second* into the digito-radial artery of the little finger and the digito-ulnar of the ring-finger; the *third* into the digito-radial of the ring-finger and the digito-ulnar of the middle finger; and the *fourth* into the digito-radial of the middle finger and the digito-ulnar of the fore-finger.*

They anastomose, by an arch, with each other in the substance of the pulp of the fingers, and give off in their course a great number of twigs, which are distributed to the tendons and sheaths of the flexor muscles, the periosteum of the phalanges, the ligaments by which they are united, and especially to the integuments.

OF THE ARTERIES WHICH ARISE FROM THE THORACIC AORTA.

They are distinguished into those which come from its anterior part and those which issue from its sides.

Branches which the Thoracic Aorta gives off anteriorly.

Bronchial Arteries (*Art. bronchiales*).—There are commonly two, a right and a left. The *right* arises from the aorta itself, or, which is more common, from the first intercostal artery. Sometimes it is the internal mammary artery that furnishes it. At its commencement it throws off some twigs over the œsophagus. It then advances in a tortuous manner along the posterior part of the bronchus of its side, and sends some slight ramifications over the pleura, pericardium, and bronchial lymphatic ganglia.

The *left bronchial artery* arises from the aorta at the same level as the right, gives small twigs to the same parts, proceeds behind the left bronchus, and arrives at the corresponding lung.

The bronchial arteries were discovered by Ruysch. They vary much in number and in origin. They plunge into the parenchyma of the organ accompanying the bronchi. They communicate with the other vessels which enter into the composition of the lungs.

Œsophageal Arteries.—Their number varies from two to five or six, and their size equals that of the bronchial. They arise from the fore part of the aorta, and give off, at first, some twigs to the pleuræ, to the walls of the aorta and thoracic duct, and to the cellular tissue of the posterior mediastinum.

Almost immediately after their commencement they bend to the right and downwards, and ramify in the substance of the walls of the

* There is sometimes another artery, which divides into a digito-radial branch for the fore-finger, and a digito-ulnar for the thumb.

œsophagus. The lowest anastomoses with branches of the coronary artery of the stomach.

POSTERIOR MEDIASTINAL ARTERIES.—They are extremely numerous and very slender. They come from the fore part of the aorta, and from the œsophageal and intercostal arteries, and are distributed to the cellular tissue of the posterior mediastinum and to the walls of the aorta; some of them anastomose, by an arch, with the thymic twigs of the internal mammary artery.

Branches which the Thoracic Aorta gives off laterally.

AORTIC INTERCOSTAL ARTERIES.—Their number is commonly nine, but sometimes eight or ten, on each side, according to that of the intercostal spaces to which the superior intercostal artery gives twigs. They arise from the lateral and posterior part of the aorta, at a slightly acute angle, and immediately ascend obliquely outwards before the vertebral column. This inclination upwards is always much greater in the upper than in the lower intercostals.

The right intercostal arteries are longer than the left by the whole breadth of the œsophagus, under which they pass; in other respects, however, they are precisely the same on both sides. The first are lodged in the groove which each body of the vertebræ presents, as far as the articulation of the rib with the spine, and are covered by the œsophagus and vena azygos, the direction of which they cross. The second are in relation with the vertebræ, in a much smaller space, and are only covered in this the first part of their course by the pleura and thoracic ganglia.

Near the articulation of the vertebræ with the ribs, on entering the space to which it is to belong, each intercostal artery divides into two branches.

Dorsal branch.—It directs itself backwards between the transverse processes of the corresponding vertebræ, internally to the anterior costo-transverse ligament. It furnishes, at first, some small twigs to the periosteum of the vertebræ, together with small branches which anastomose, by an arch, upwards and downwards, with the nearest intercostals. Then, through the intervertebral foramen, it sends off another twig, which is distributed to the spinal marrow and its envelopes.

Lastly, it traverses the fleshy bundles of the multifidus spinæ* muscle, descends between it and the longissimus dorsi, and loses itself in the latter and the sacro-lumbalis muscle, sending some twigs to the skin.

Intercostal branch (properly so called).—This, which is much larger than the preceding, may be considered as the continuation of the artery itself. It proceeds, winding a little, to the middle of the intercostal space, between the pleura and the external intercostal muscles, and in the midst of much adipose cellular tissue. Immediately after, it divides into two twigs, which enter between the two planes of the intercostal muscles.

* Deepest layer of the transverse spinal or semi-spinalis dorsi.

Inferior twig.—It is of rather small size, and follows, at first, for some time, the upper edge of the rib which is beneath, and then directs itself upon its outer surface, to subdivide in the periosteum.

Superior twig.—It is much larger, and runs along the lower edge of the rib which is above, situated in or near the groove which that edge presents. Towards the anterior third of the rib it leaves that groove and the bone, and directs itself to the middle of the intercostal space. There, as in the rest of its course, it gives numerous twigs to the intercostal muscles, the periosteum of the ribs, and the pleura. Some of them pass to the superficial muscles on the outside of the thorax, while others anastomose with the divisions of the inferior twig. Lastly, the branch itself terminates towards the fore part of the thorax, by anastomosing with the branches of the internal mammary artery, if it belong to one of the intervals which separate the true ribs; if, on the contrary, it occur in the region of the false ribs, it disperses itself in the muscles of the abdomen, where it anastomoses with ramifications of the internal mammary, epigastric, and circumflex iliac arteries.

The last intercostal artery is concealed at its origin by the corresponding crus of the diaphragm, which receives some twigs from it. After giving off its dorsal branch it continues its course along the inferior edge of the rib, which is above, and, arriving at its middle part, divides into two or three branches. One of them passes transversely into the abdominal muscles; the others descend vertically, between the two oblique muscles of the abdomen, as far as the iliac crest, where they anastomose with the lumbar arteries, or with the circumflex iliac artery.

Of the Arteries which arise from the Abdominal Aorta.

They are distinguished into anterior, lateral, and inferior.

Branches given off anteriorly by the Abdominal Aorta.

Inferior Phrenic Arteries.

Right phrenic artery.—It generally comes off from the aorta by itself, sometimes along with the left. It also occasionally comes from the cœliac artery. In the first case it has its origin immediately beneath the interlacing of the fleshy fibres which go from one crus of the diaphragm to that of the opposite side. It immediately ascends a little outwards, along the free edge of the right crus of that muscle, to which it gives several twigs, as well as to the supra-renal capsule, the pancreas, and the liver. It then divides into two branches.

The *anterior branch* sends twigs to the œsophagus, passes through the coronary ligament of the liver, sends ramifications through the diaphragm, which reach the pericardium; other twigs enter the liver, but by far the greater number pass to the muscular fibres of the diaphragm.

External branch.—This is directed transversely outwards above the liver and behind the right lobe of the cordiform tendon of the

muscle. Its branches go chiefly to the muscle itself; a few reach the supra-renal capsule.

The left phrenic artery corresponds in its general distribution to the right; like it it, subdivides into two branches, whose ultimate distribution resembles that of the opposite side.

THE CŒLIAC* ARTERY.—The cœliac artery (*Art. cœliaca*) is the shortest of the arteries which the abdominal aorta furnishes. It comes off at a right angle, between the crura of the diaphragm, opposite the union of the last vertebra of the back with the first of the loins. It is directed horizontally forwards and to the right, in the posterior separation of the two laminæ of the hepato-gastric omentum. It corresponds, *above*, to the left side of the small lobe of the liver; *below*, to the upper edge of the pancreas, on which it rests; *to the left*, to the cardia; *to the right*, to a considerable space separating it from the pylorus.

Fig. 175.†

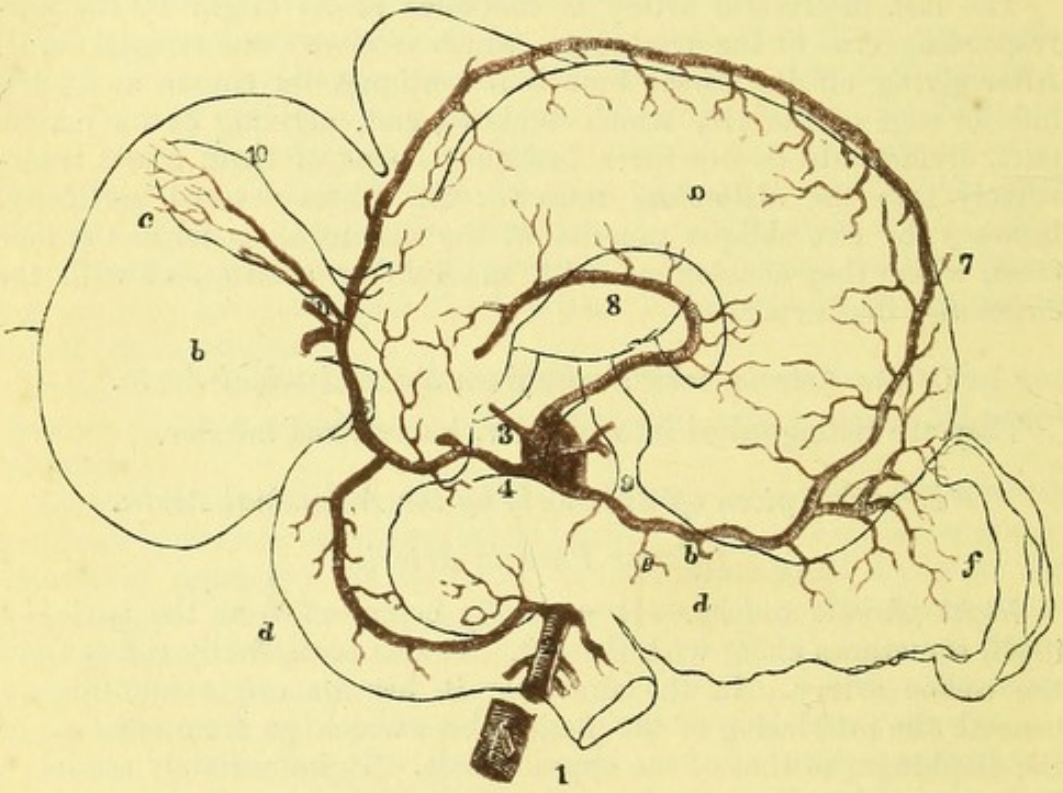

* Κοιλια, venter, ventriculus. Κοιλος, hollow.

† Fig. 175.—Showing the distribution of the three great branches of the cœliac axis.—1, the aorta; 2, the superior mesenteric artery; 3, the hepatic artery coming off from the cœliac axis; 8 points to the arteria gastrica, or coronaria ventriculi; 9, the splenic artery; 7, the gastro-epiploica sinistra, a branch of the splenic; *f*, proper splenic branches going to the spleen; *a*, the stomach reversed, or so turned upwards as to show its vertebral surface; *e*, *b*, *d*, the body of the pancreas, with branches entering it from the splenic artery; 4, head of the pancreas; 5, gastro epiploica dextra; 11, neck of the gall-bladder and proper hepatic artery; 10, lobulus quadratus; *c*, gall-bladder; *d*, duodenum. *b*, *b*, under surface of the right lobe of the liver.

This artery sometimes furnishes the capsular or the inferior phrenic. But it always separates, after a course of about half an inch, into three branches of unequal size, which are named the *coronary artery of the stomach*, the *hepatic artery*, and the *splenic artery*.

Coronary Artery of the Stomach (*Art. coronaria ventriculi*).—This is the smallest of the three which arise from the cœliac trunk. It directs itself upwards, forwards, and to the left, approaching the cardia, over the right side of which it bends downwards to follow the small curve of the stomach, near to the pylorus, where it anastomoses with the pyloric artery. In this second part of its course it occupies the interval which the two laminæ of the hepato-gastric omentum leave between them when they are reflected over the stomach. The branches which it gives off may be distinguished into œsophageal and gastric.

The *œsophageal branches* vary in number, and are either vertical or transverse. They also penetrate into the posterior mediastinum.

The gastric branches come off along the small curvature of the stomach, passing over both surfaces of that organ. They anastomose with the gastro-epiploic arteries.

Hepatic Artery (*Arteria hepatica*).—Much larger than the preceding; it directs itself transversely to the right and forwards under the small lobe of the liver near to the pylorus, whence it slightly ascends towards the neck of the gall-bladder, and the transverse fissure of the liver. In this course it furnishes only two branches, the pyloric and the right gastro-epiploic.

Pyloric artery (*Art. pylorica*).—It arises from the anterior part of the hepatic, on the right side of the pylorus, whence it ascends, from right to left, along the small curvature of the stomach, to anastomose with the termination of the coronary artery of the stomach, after a course of a greater or less length. It gives to the two surfaces of the stomach, and to the pylorus, twigs, which inosculate with those of the right gastro-epiploic artery.

Right gastro-epiploic artery (*Art. gastro-epiploica dextra*), called by some *gastro-duodenalis*.—It arises to the right of the pylorus and beneath it, from the lower part of the hepatic. Its size is considerable. It descends at first vertically behind the stomach as far as its great curvature, applied posteriorly upon the second portion of the duodenum, and covered to the left by the pancreas. It then proceeds from right to left along the great curvature of the stomach, between the layers of the anterior lamina of the great omentum, as far as the middle part of that curvature, where it inosculates with the left gastro-epiploic artery.

In its *vertical portion* this artery gives off twigs of indeterminate number and inconsiderable size (*Art. pancreatico-duodenales*), which are distributed to the walls of the duodenum and the posterior surface of the pancreas.

In its *horizontal portion*, along the great curvature of the stomach,

it gives off, superiorly, numerous twigs, which ascend in a flexuous manner over the two surfaces of that viscus, and anastomose with those of the pyloric artery and the coronary artery of the stomach. Inferiorly, it sends off some which descend vertically between the laminæ of the great omentum, and gain, by being reflected in the posterior lamina, the edge of the arch of the colon, where they inosculate with the colic arteries.

After the hepatic artery has furnished these two arteries, it ascends, before the vena portæ, and on the left of the hepatic duct, to the right side of the lobulus Spigelii of the liver, and in the transverse fissure of the liver divides into two considerable branches, a right and a left.

Right branch (*Art. hepatica dextra*).—Directed upwards and outwards, it crosses the direction of the hepatic duct, beyond which it furnishes the cystic artery (*Art. cystica*), which gains the neck of the gall-bladder, and spreads out in the lower part of the walls of that reservoir, where it winds for some time between its serous and mucous membranes. The cystic artery, moreover, sends a very considerable twig between the liver and gall-bladder, to be distributed in the substance of each.

After the origin of the cystic artery, the right branch of the hepatic artery dives into the transverse fissure of the liver, and loses itself by ramifying in its right lobe.

Left branch (*Art. hepatica sinistra*).—Proceeding obliquely upwards and inwards, it enters the transverse fissure and loses itself in the left lobe and in the lobulus Spigelii of the liver, accompanying, like the preceding, the divisions of the vena portæ.

Splenic Artery (*Arteria splenica*).—In the adult it is larger than the hepatic; the reverse of what happens in the child. At its commencement it passes from right to left in a very tortuous manner along the upper part of the pancreas, which lodges it in a particular groove. It thus arrives at the fissure of the spleen, after furnishing several branches, which are the following:—

1. *Pancreatic branches* (*Art. pancreaticæ mediæ et sinistræ*): irregular in number; they plunge into the substance of the pancreas.

2. *Art. gastro-epiploica sinistra.*—In size this artery equals often the right gastro-epiploic, and occasionally looks like the continuation of the splenic itself. It descends along the great curvature of the stomach, sending branches to both surfaces, and finally terminates by anastomosing with the right gastro-epiploic about the middle of the great curvature.

3. The *vasa brevia arteriosa* are three or four large but short twigs, which the splenic sends to the large curvature of the stomach.

At some distance from the spleen the splenic artery divides into two or three branches, which again subdivide into seven or eight twigs; these plunge into the substance of the organ.

Superior Mesenteric Artery (*Art. mesaraica superior*).—It

arises from the anterior and right side of the aorta, a little below the cœliac, which it almost equals in size but greatly exceeds in length. It immediately ascends somewhat to the left and forwards, behind the pancreas and before the third portion of the duodenum, and, passing behind the left part of the transverse mesocolon, goes to the upper extremity of the mesentery, between the two folds of which it enters, directing itself downwards and to the right, and describing a very elongated curve, the convexity of which is turned to the left and forwards, approaching so much nearer the intestine the lower it is examined. Towards the end of the ileum, the superior mesenteric artery, now become very slender, anastomoses with the inferior branch of the inferior right colic artery.

Near its origin it gives off some very small branches, which go to the duodenum and pancreas, and communicate with twigs of the splenic and hepatic arteries. But, in the mesentery, it furnishes a great many large branches, which may be distinguished into those which arise from its convexity and those from its concavity.

Branches which the Superior Mesenteric Artery gives off from its convexity.

1. The branches which arise from the convexity of the artery are variable in number; from fifteen to twenty are usually reckoned. The uppermost are large, the inferior ones mere twigs. They all proceed between the layers of the mesentery towards the small intestine, including the lower third of the duodenum; these bowels they supply with blood. In dividing and subdividing they form arches, from the convexities of which branches arise.

Branches which arise from the concavity of the Superior Mesenteric Artery.

2. The branches which arise from the concavity of the superior mesenteric artery are—

a. The superior or middle colic.

b. The colica dextra; also called middle right colic.

c. The ileo-colic, or inferior right colic.

These three arteries, when all are present, are easily found and named. They proceed between the folds of the right mesocolon to supply with blood the cœcum, the ascending colon and about one-half the transverse arch of the colon. The highest (*colica media*) anastomoses freely with the left colic (a branch of the inferior mesenteric) and with the colica dextra; this again with the middle colic and with the ileo-colic; and this with the colica dextra media, and with the terminating branch of the superior mesenteric. These anastomoses form very wide and remarkable arches.

Inferior Mesenteric Artery (*Arteria mesaraica inferior*).—Somewhat smaller than the superior, it arises much lower down from the anterior and left part of the aorta, at the distance of an inch and a

Fig. 176.*

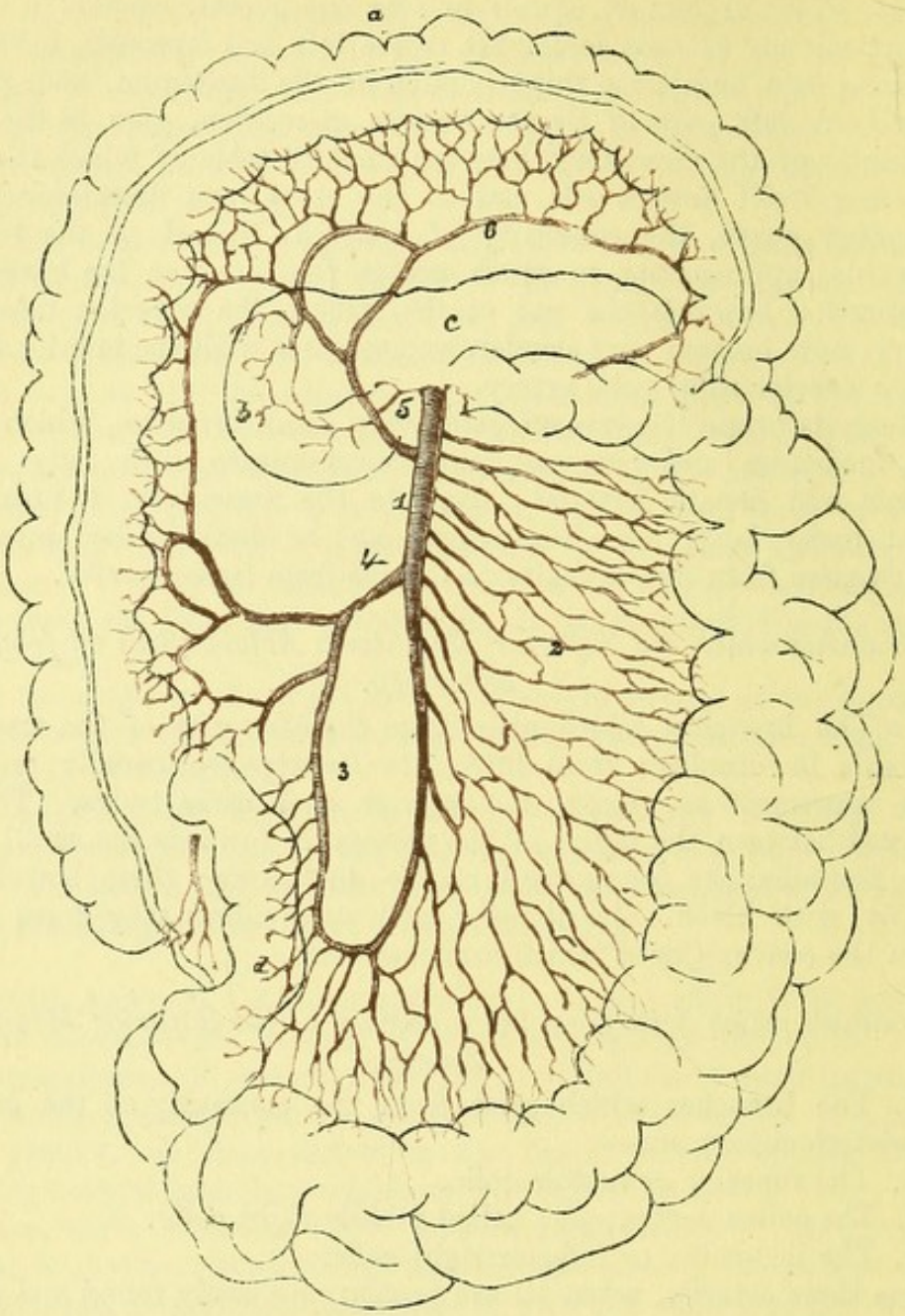

half from its termination. It descends at first a little to the left, behind the lamina of the peritoneum, which goes to form the corresponding lamina of the mesentery; then, bending to the right, it enters between the laminæ of the mesocolon, forming a much less extended curve than that of the superior mesenteric artery, and whose

* Fig. 176.—Showing the course of the superior mesenteric artery and its branches.—1, the superior mesenteric artery; 2, branches which arise from the artery on its convex side; 4, right middle colic; 3, right inferior colic anastomosing with the terminating branch of the superior mesenteric artery; 5, superior right colic, by some called the middle colic; 6, anastomosis of this artery with the superior left; *c*, *b*, outline of the pancreas; *a*, transverse arch of the colon; *d*, termination of the small intestine.

Fig. 177.*

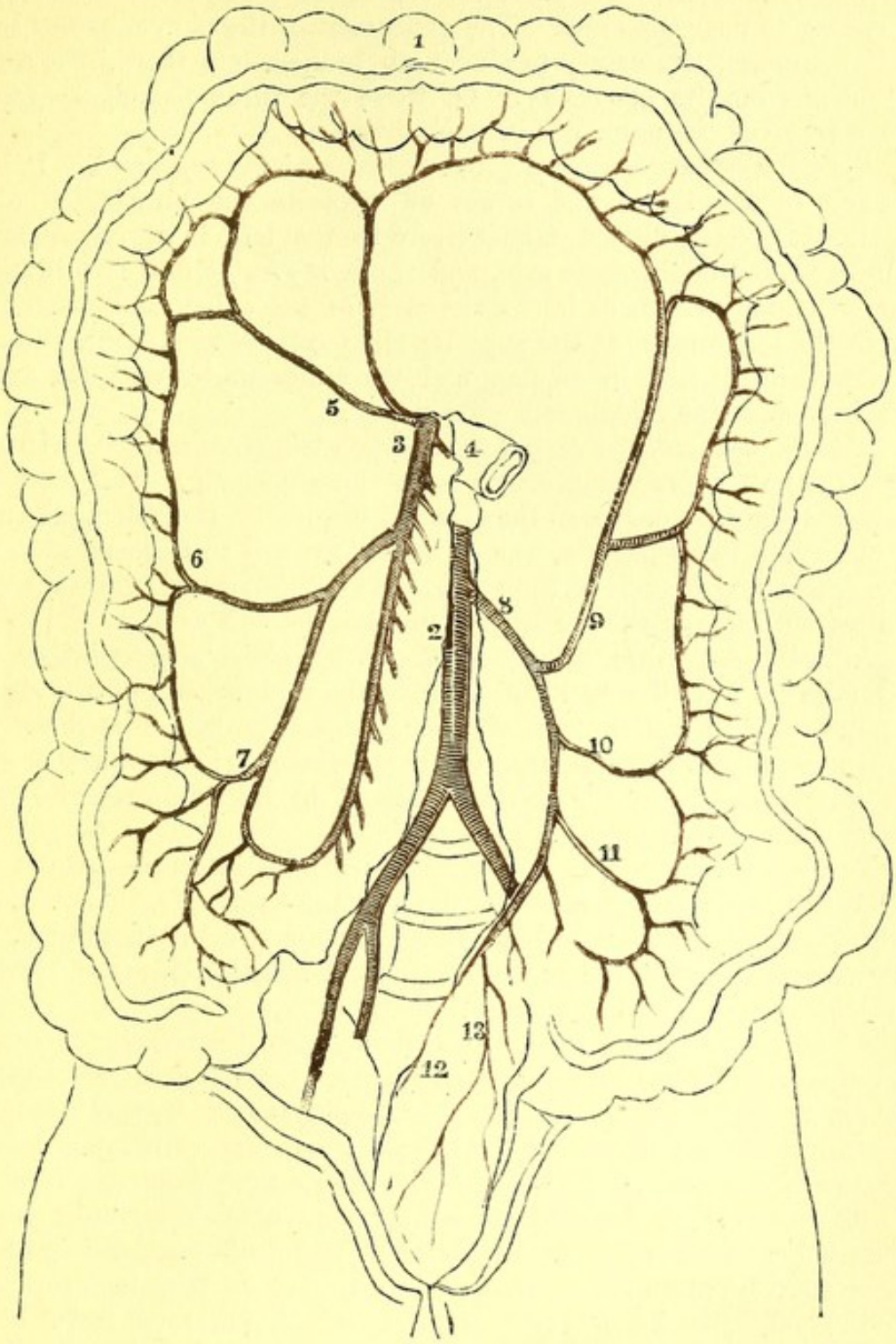

* Fig. 177.—Inferior mesenteric artery; system of the right and left colic arteries.—1, large intestine; 2, aorta; 3, superior mesenteric artery; 4, small intestine cut across; 5, right superior colic; 6, arcade taking the place of the right middle colic; 7, right inferior colic; 8, inferior mesenterie artery; 9, superior left colic, by some called colica sinistra; 10, middle and inferior left colic, the inferior being occasionally called arteria sigmoidea; 12 and 13, superior hemorrhoidal arteries.

convexity also looks to the left. Arrived at the brim of the pelvis, it prolongs itself into the posterior separation of the meso-rectum, descending to near the anus. The concavity of the curve formed by the inferior mesenteric artery produces no branch, but there issue a great number from its convexity. Of these the three principal branches have received the name of *left colic arteries.*

Superior left colic artery (*Art. colica sinistra superior*). It is the largest of the three, and comes off opposite the bifurcation of the aorta. Directed almost transversely to the left, it arrives near the lumbar colon of the same side, and there separates into two branches, one of which ascends as far as the arch of the colon, and anastomoses with the left branch of the superior right colic artery, while the other descends in the iliac mesocolon, and there inosculates with the ascending branch of the middle left colic artery.

Middle left colic artery (*Art. colica sinistra media*). It often arises from the preceding, and is sometimes wanting. It directs itself towards the first curve of the sigmoid flexure of the colon, and there divides into two branches, one of which ascends to form an arch with the descending branch of the superior left colic artery, while the other unites with one of the branches of the inferior left colic.

Inferior left colic artery (*Art. colica sinistra inferior* or *Art. sigmoidea*). It directs itself towards the middle part of the sigmoid flexure of the colon, and also separates into two branches. The upper ascends to form an arch with the preceding; the lower descends to unite with one of the twigs furnished to the meso-rectum by the inferior mesenteric artery.

These left colic arteries, on arriving at the intestine, exhibit precisely the same arrangement as those of the right side, that is to say, after forming arches to which succeed some areolæ, they send, over the two surfaces of the colon, twigs at first parallel, and afterwards divided a great number of times.

After furnishing the three left colic arteries, the inferior mesenteric gives off some small, and, in all respects, very irregular arteries, and presently after divides into two branches, which descend along the posterior surface of the rectum, and which are called the *superior hæmorrhoidal arteries* (*Art. hæmorrhoidales superiores seu internæ*). These two arteries, from being at first superficial, soon after conceal themselves in the layer of longitudinal fleshy fibres of the intestine, progressively diminish in size, and end by very minute twigs, after giving off laterally a great number which embrace from behind forwards the circumference of the rectum, and anastomose on its fore-part with each other, and with the middle and inferior hæmorrhoidal arteries. Some of them communicate with the lateral sacral arteries.

Branches which are given off laterally by the Abdominal Aorta.

MIDDLE OR PROPER CAPSULAR ARTERIES (*Art. capsulares mediæ.*) —These arteries, which are two in number, one on each side, are called middle, to distinguish them from those which the phrenic above, and

the renal below, send to the supra-renal capsules. Their size is very inconsiderable, and they come off from the lateral parts of the aorta, a little above the renal arteries. Sometimes they are produced by the cœliac trunk. Directed transversely over the sides of the vertebral column, they gain the anterior edge of the capsules, and divide into several branches, which spread out upon the two surfaces of these organs and ramify in their substance. Before arriving at the supra-renal capsules, they frequently send several small twigs to the crura of the diaphragm, and to the mass of adipose cellular tissue which envelopes the kidneys. The left, moreover, gives some twigs to the colon and spleen; the right to the duodenum and liver.

Renal or Emulgent Arteries (*Art. renales seu emulgentes*).—Of large size and very short, and generally two in number, one on each side; they come off below the capsular arteries and the superior mesenteric, forming with the aorta an angle approaching more or less to a right one. The left is commonly a little more anterior and higher than the right. Immersed in a very abundant adipose cellular tissue, directed transversely over the sides of the bodies of the vertebræ, covered by the renal vein and peritoneum on both sides, and, on the right only, by the vena cava inferior, they arrive, after a short course, at the fissure of the kidneys, where they each divide into two, three, or four large branches.

Before arriving at the kidney they give off only some slender twigs, which ascend towards the supra-renal capsules, or lose themselves, under the name of *adipose arteries*, in the surrounding fat. They also, however, frequently furnish the spermatic arteries.

The three or four branches which terminate each renal artery separate from each other and enter the kidney, between the pelvis, which is behind and below, and the roots of the renal vein, which are before. They presently divide into a considerable number of twigs, which pass between the walls of the pelvis and parenchyma of the kidney, and subdivide round the calyces into a number of small twigs. They pass round each of the bundles of tubes which are to form one of the mammillæ of the kidney, and anastomose with each other so as to constitute a distinct arch, the convexity of which is turned towards the cortical substance, which receives a great number of ramifications from it.

In some subjects there are three or four renal arteries on each side, but this arrangement is not of frequent occurrence.

Spermatic Arteries (*Art. spermaticæ*).—One on each side, very slender and of great length: they come off from the anterior or lateral parts of the aorta, and sometimes from the renal arteries. They do not always both come off from the aorta at the same level, but pretty frequently one of them is higher than the other. In all cases, however, forming with it a very acute angle below, they descend almost vertically, but a little outwards, over the sides of the vertebral

column, before the psoas muscles and ureters (whose direction they cross), and behind the peritoneum. The right passes, moreover, backwards, before the vena cava inferior. Their course is extremely flexuous. They presently after join the spermatic veins, to be afterwards distributed in the male to the testes, and in the female to the ovaria, previously giving off, in either sex, very small twigs to the fat and lymphatic ganglia of the surrounding parts, as well as to the walls of the ureters and to the peritoneum.

In the male, the spermatic artery, placed beside the vas deferens, issues by the inguinal rings, and is distributed to the testicles, giving off, by the way, ramifications to the different parts which constitute the spermatic cord. At its termination it divides into two bundles of twigs, one of which goes to the epididymis, the other to the testicle. The first penetrates by the head of the epididymis, and is expanded in that body, giving some ramifications to the tunica albuginea and to the substance of the testicle. The others penetrate into the testicle by its upper edge, and give to the tunica albuginea a great quantity of ramifications, which afterwards lose themselves upon the fibrous septa lying between the masses of the spermatic ducts.

In the female, after crossing the edge of the psoas muscle, the spermatic artery dives into the pelvis and goes to the ovary. Most of its twigs lose themselves in the tissue of that organ; the others are distributed in the Fallopian tube, the round ligament, and on the sides of the uterus, where they anastomose with the uterine arteries.

Lumbar Arteries (*Art. lumbales*).—They are commonly four on each side; five, however, are not unfrequently met with, and sometimes only three. Their size is always greater than that of the intercostal arteries. They come off as much from the posterior part as from the sides of the aorta, and direct themselves more or less transversely outwards, over the middle of the bodies of the four first lumbar vertebræ, being covered by the psoas magnus or by the crura of the diaphragm. At the base of the transverse processes they divide into a dorsal or posterior branch, and an anterior or lumbar branch, properly so called, after sometimes giving a few small twigs to the bodies of the vertebræ, the cellular tissue, and the lymphatic ganglia of the loins, the crura of the diaphragm, and the psoas muscles.

The dorsal branches of the four lumbar arteries are very slender. They send, at first, into the vertebral canal a twig, which is distributed to the spinal marrow and its envelopes, and then dive into the substance of the fleshy mass of the sacro-lumbalis and longissimus dorsi muscles, where they lose themselves, sending some ramifications into the inter-transversales and multifidus spinæ muscles, and into the integuments. They anastomose with each other.

Anterior Branches of the Lumbar Arteries.

First lumbar artery.—It directs itself outwards, under the lower edge of the twelfth rib, following exactly the attachment of the

diaphragm. It then bends downwards, and descends almost vertically between the peritoneum and transversus abdominis muscle, in which latter it loses itself.

Second lumbar artery.—Its anterior branch, which is of small size, descends in the substance of the quadratus lumborum, and ramifies there.

Third lumbar artery.—Its anterior branch, which is very large, dives between the quadratus lumborum and transversus abdominis muscles, bends towards the iliac crest, and divides towards the posterior third of the latter, into two large twigs, which pass through the broad muscles of the abdomen, near their origins, and descend backwards into the glutei muscles, where they communicate with the twigs of the gluteal artery.

Fourth lumbar artery.—Its anterior branch, which is still larger than that of the preceding, directs itself transversely between the psoas magnus and quadratus lumborum, along the inferior attachment of the latter, gives large twigs to the iliacus muscle, passes above the iliac crest, and is equally dispersed in the glutei muscles.

ARTERIES WHICH TERMINATE THE AORTA BELOW.

Middle Sacral Artery.

The middle sacral artery (*Arteria sacri media*) arises from the posterior part of the aorta, a little above its bifurcation, before the fourth lumbar vertebra. Its size is about the same as that of the lumbar arteries, but it is frequently much less. It descends vertically, and in a flexuous manner, over the sacro-vertebral articulation, and upon the anterior surface of the sacrum, placed, in the median line of the body, behind the rectum, the superior hæmorrhoidal vessels, and the nerves of the hypogastric plexus. It is very slender when it arrives at the coccyx, and terminates towards the summit of that bone, anastomosing, by two arches, with the lateral sacral arteries, and sending small twigs into the fat which surrounds the rectum, and into the ischio-coccygeus muscle.

The middle sacral artery furnishes a great number of lateral branches. The first frequently takes the place of one of the inferior lumbar arteries. They are generally very small and irregular, and communicate with the ilio-lumbar arteries. The others, which are larger, come off to the right and left, at the middle of each false vertebra of the sacrum; they direct themselves transversely outwards, and unite, near the anterior sacral foramina, with the branches of the lateral sacral arteries. Sometimes they pass through these foramina, and are distributed upon the last vertebral nerves. In their course they furnish many ramifications to the periosteum of the sacrum.

COMMON ILIAC ARTERIES.—If the student be well acquainted with the myology of the lower extremities and pelvis, no directions need be given him for the dissection of the arteries; if he be not, he had better not proceed with the arteries until he has mastered the myology.

Opposite the body of the fourth lumbar vertebra, or upon the fibro-cartilage uniting that body to the fifth, the aorta divides or bifurcates into two great trunks; these are the common iliac arteries. They are of nearly equal size, and descend, diverging at an acute angle, wider in the female than in the male, as far as the sacro-iliac synchondrosis, where they each subdivide into two large arteries, the external and internal iliac arteries; this latter is also called hypogastric.

The right common iliac artery passes before the vein of the same name, and covers in a great part the vena cava inferior.

The left, accompanied by the left common iliac vein, is only covered by the peritoneum. The ureters cross both these arteries at right angles. In their course they give off no branch, but send a few slender twigs to the walls of the iliac veins, the peritoneum, lumbar lymphatic ganglia, and the ureters.

Hypogastric or Internal Iliac Arteries.—The hypogastric artery is smaller than the external iliac. It is in an especial manner the artery of the pelvis, and its walls and viscera; on the other hand, the external iliac or crural supplies the inferior extremity.

Fig. 178.*

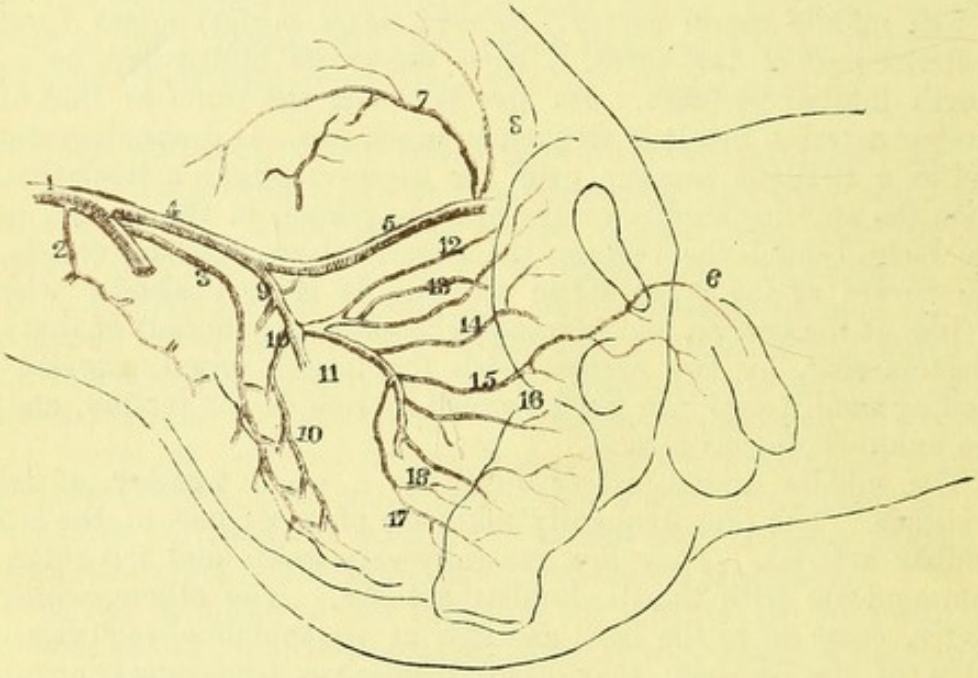

The artery, soon after coming off from the common iliac, descends almost immediately into the excavation of the pelvis, in front of the sacro-

* Fig. 178.—Sketch of the hypogastric or internal iliac artery and the distribution of its branches.—1, the aorta; 2, one of the superior lumbar arteries; 3, art. sacri media; 4, common iliac artery, left side; 5, external iliac; 6, portion of the ilio-lumbar; 7, circumflex artery of the ilium; 8, epigastric artery; 9, internal iliac, or hypogastric; 10, lateral sacral; 11, gluteal, leaving the interior of the pelvis; 12, obturator artery; 13, remains of the umbilical; 14, vesical branches; 15, common pudic; 16, hæmorrhoidal; 17, ischiatic.

iliac symphysis, forming a slight curve, the convexity of which is posterior. At the end of a very short course it separates into a great number of branches, which arise, sometimes separately, sometimes by common trunks; they are as follow:—

Posterior Branches of the Internal Iliac Artery.

1. *The ilio-lumbar artery.*—It arises from the main trunk opposite the base of the sacrum, or it may come from the gluteal. It varies much in size. Its course is outwards and backwards before the lumbo-sacral nerve, and behind the psoas magnus muscle. Towards the anterior edge of the base of the sacrum it divides into two branches, the ascending and the transverse.

The *ascending branch* terminates by anastomosing with the fourth or fifth lumbar artery. It sends branches to the psoas, iliacus, and quadratus, and even to the dura mater within the vertebral canal.

The *transverse branch* passes between the psoas and iliacus. It supplies these muscles, the periosteum of the iliac bone sending a branch into the interior of the bone itself.

2. *Sacro-lateral artery.*—Sometimes there is but one, frequently, however, two or three on each side. They do not always come directly from the hypogastric, but occasionally from the ilio-lumbar or gluteal. When single or otherwise, it descends before the anterior sacral foramina, and reaches the summit of the coccyx, where it anastomoses with the middle sacral.

In its course it gives off,—1, *external* or *posterior* twigs, which enter the sacral canal by the sacral foramina, supplying the dura mater and nerves; 2, *internal* twigs, which supply the sacral nerves and pyriformis muscle.

Gluteal Artery.—One of the largest branches of the internal iliac. Soon after it comes off from the main trunk it leaves the pelvis by the upper part of the great sciatic notch above the pyriform muscle. Having reached the exterior of the pelvis it is covered by the gluteus maximus muscle, and there divides into two branches, a superficial and a deep.

1. *Superficial branch.*—Passing between the gluteus maximus and g. medius muscles, it supplies these chiefly with branches.

2. *Deep branch.*—Passes between the gluteus medius and g. minimus, supplies a nourishing artery to the bone, and branches to the muscles themselves, and sends twigs as far as the tensor vaginæ femoris, where they anastomose with branches of the femoral artery.

Anterior Branches of the Hypogastric.

Umbilical artery.—The history of this artery belongs more especially to the anatomy of the fœtus. Long prior to the adult state, the artery may be said to be obliterated, being converted into a sort of ligament, which, proceeding along the sides of the bladder, may be

traced to the umbilicus. Nevertheless, even in the adult, it is occasionally pervious as far as the bladder, but its walls are thick. In the fœtus it was the true continuation of the hypogastric, formed a portion of the umbilical cord, and, passing through the umbilicus, terminated in the placenta.

In the adult it furnishes a few slender twigs to the bladder.

Vesical arteries.—Very various as to number and origin: three or four come from the umbilical; others come from the middle hæmorrhoidal, obturator and internal pudic; and one somewhat larger comes from the internal iliac. This sends twigs to the fundus of the bladder, the prostate gland, the vesiculæ seminales, and vas deferens.

Obturator artery.—An artery interesting to the surgeon chiefly in its varieties, and more especially when it, or a large branch joining it, arises from the epigastric, instead of coming from the internal iliac. When it arises from the latter trunk it proceeds at first forwards and outwards, then turns horizontally into the cavity of the pelvis, over the obturator internus muscle, and under the nerve of the same name, along with which it emerges from the pelvis by the deficiency in the obturator membrane. In this course it gives off the following branches:—1st, a pretty large branch to the iliacus internus muscle; 2d, several smaller to the obturator internus muscle; and, 3d, a remarkable branch which passes behind the symphysis pubis, and anastomoses with that of the opposite side.

At its exit from the pelvis, on the upper edge of the obturator muscle, the artery sends a branch to each obturator muscle; some twigs from this reach the capsular ligament of the hip-joint. A small but remarkable branch penetrates into the cotyloid cavity by the notch, and thus reaches the round ligament and the head of the femur.

An *anterior branch* of the obturator artery descends between the long and short adductors, giving twigs to these muscles and to the adductor magnus, pectineus, gracilis, and obturator externus. It anastomoses with the internal circumflex.

Middle Hæmorrhoidal Artery.—Sometimes wanting; it is more constant in the female than in the male. It varies much in size and origin. It will be found over the anterior part of the rectum, behind the fundus of the bladder in the male, and the vagina in the female. It separates into a great number of twigs.

Uterine Artery.—Its volume depends on the condition of the uterus; when unimpregnated it is comparatively small; towards the end of gestation it is the reverse. Its origin is various. Its course is between the upper part of the vagina and the bladder, sending twigs to both these organs. It next ascends between the layers of the ligamentum latum, upon the sides of the uterus, and is here extremely flexuous; its ultimate distribution is to the walls of the uterus, the Fallopian tube, and round ligament. It anastomoses with branches of the ovarian artery.

VAGINAL ARTERY.—It exists only in the female. It is not constant as a distinct branch of the hypogastric, its place being supplied by others. When present it will be found to descend by the side of the vagina, giving numerous branches to it, and reaching as far as its orifice.

ISCHIATIC ARTERY.—It may arise separately or in common with the gluteal. Though smaller than the gluteal, it looks as if it were the true continuation of the internal iliac. Passing almost vertically downwards between the rectum and the walls of the pelvis, below the pyriformis muscle, it issues by the lower part of the sciatic notch, between the inferior edge of that muscle and the short or anterior sacro-sciatic ligament, having behind it the great sciatic nerve.

In the pelvis this artery furnishes a few unimportant twigs to the rectum, bladder, uterus, &c.; but it occasionally gives off important arteries, such as the pudic, obturator, and middle hæmorrhoidal. On leaving the pelvis it separates into several large branches. One follows the edge of the gluteus maximus muscle which covers it, and proceeds towards the coccyx, where it gives branches to the ischio-coccygeus and levator ani muscles; another branch goes to the gluteus maximus; the third, which is the continuation of the artery itself, accompanies the sciatic nerve as far as the inferior part of the thigh posteriorly, giving branches to the rotator muscles of the hip-joint, and to the flexors of the thigh and leg.

INTERNAL OR COMMON PUDIC ARTERY.—Is smaller than the ischiatic, from which it sometimes arises. Its course is complex, and one of its varieties especially peculiarly embarrassing to the litho-tomist. After coming off from the internal iliac or one of its branches, as the case may be, it leaves the pelvis by the lower sciatic notch, separated from the ischiatic artery by a layer of fat, and between the pyriformis muscle and the edge of the levator ani. It now passes behind the spine of the ischium and re-enters the pelvis by the smaller sciatic notch, passing between the two sciatic ligaments. It is next found on the inner side of the ischium, between the obturator internus and levator ani muscles, and running horizontally forwards to near the common origin of the erector penis and transversus perinei muscles; it here divides into two branches, a superficial and deep, differently distributed in the male and female. Whilst in the pelvis, in the first part of its course, this artery gives off branches to the bladder, the vesiculæ seminales, prostate gland, commencement of the urethra and rectum; and in the female to the upper part of the vagina. Further on it sends branches to the levator ani and obturator internus muscles, and to the fat of the perineum. In the perineum, where it chiefly interests the surgeon, it gives off,—

1. *The superficial perineal artery.* — This artery runs superficially in the adipose cellular tissue, filling the triangular space between the erector penis and accelerator urinæ muscles. It ap-

proaches the raphe, gives off the *arteria transversalis perinei*, and supplies the surrounding muscles with branches. Some of these *inferior* or *external hæmorrhoidal branches* reach the rectum.

The artery itself terminates in the scrotum, the dartos, and integuments of the penis.

2. *Deep branch.*—Arteria penis. Ascends along the ascending ramus of the pubes, somewhat covered by it. Concealed by the erector penis, it reaches the triangular space which separates the two roots of the corpus cavernosum before the symphysis of the pubes. Here it divides into two arteries,—1st, the dorsal artery of the penis; 2d, the artery of the corpus cavernosum penis. Before this it has given off the

ARTERY OF THE BULB OF THE URETHRA.

Situated almost immediately above the transverse muscle of the perineum, it directs itself inwards and forwards as far as the bulb of the urethra, into which it dives, subdividing into many branches.

Artery of the corpus cavernosum penis.—This artery penetrates into the corresponding side of either crus of the corpus cavernosum, and presently subdivides into branches whose mode of termination has not yet been satisfactorily demonstrated.

These are the arteries on which the erection of the penis depends.

Dorsal artery of the penis.—It passes through the suspensory ligament of the penis, running along the dorsal aspect of the organ parallel with that of the opposite side. Its course is very flexuous, and it gives numerous twigs to the fibrous membrane of the corpus cavernosum and to the skin. Near the glans it subdivides, and ultimately supplies that part of the penis.

In the female, the *superficial* branch of the common pudic artery, after sending twigs to the transversus perinei, sphincter ani, and constrictor vaginæ muscles, terminates in the substance of the labium.

The deep branch, *arteria clitoridis*, ascends, as in the male, along the inner surface of the ramus of the ischium and pubes, as far as the interval between the crura clitoridis; sends a twig to the retiform plexus (corresponding, no doubt, to the artery of the bulb in the male), which partly surrounds the orifice of the vagina, and separates before the symphysis of the pubes into two secondary branches, one of which penetrates the corpus cavernosum clitoridis; the other becomes the dorsal artery of that rudimentary organ.

External Iliac Artery.—It may be considered as the continuation of the common iliac, as the femoral is of this artery. It retains the name of external iliac until it passes under the crural arch, where it is called femoral. The distinction is purely arbitrary. It descends obliquely outwards along the inner edge of the psoas magnus, applied posteriorly and internally upon the external iliac vein, enclosed in a cellular sheath and braced down to the muscle by a

layer of the fascia iliaca, which divides to enclose it: finally it is covered by the peritoneum.

In this course the external iliac gives off two considerable branches; these are the epigastric and circumflex iliac arteries.

1. *Epigastric.*—Arises from the external iliac artery, on the inner side, a short way above the crural arch, and below the reflexion of the peritoneum. It proceeds inwards and forwards, crosses the direction of the spermatic cord, which conceals its origin, and ascends vertically to the inner side of it, and of the internal or deep inguinal ring. In this part of its course the artery lies immediately behind the inner pillar of the ring, between the peritoneum and fascia transversalis. Its course is towards the umbilicus, at first upon the outer edge of the rectus muscle, but, presently passing behind it, it proceeds as far as the umbilicus, where it terminates by communicating with branches of the internal mammary artery.

Near its origin the obturator, or a strong branch uniting with the obturator, not unfrequently arises from it. Its more constant branches are, 1, a branch to the spermatic cord, which enters the inguinal canal and is distributed to the cremaster muscle and skin of the scrotum; 2, many lateral branches to the rectus and broad muscles of the abdomen.

Circumflex Iliac Artery.—Arises from the outer part of the external iliac artery, generally opposite to, and equal in size to the preceding. It ascends obliquely outwards, curving a little along the outer edge of the iliacus muscle until, above the anterior and superior iliac spine, it directs itself backwards, separating here into two branches. These will be found between the internal oblique and transversalis muscles, which muscles they chiefly supply. Their extreme branches anastomose with the internal mammary, the lumbar and inferior intercostal arteries.

Femoral or Crural Artery.—This great trunk is simply the continuation of the external iliac. On passing beneath the crural arch it receives its name, which it maintains until, reaching the popliteal space, it is called popliteal.

When passing under the crural arch it is comparatively superficial. It is situated about midway between the anterior superior spine of the ilium and the spine of the pubis.

Its relations in the upper part of the thigh are, anteriorly, with the crural aponeurosis and inguinal lymphatic glands; posteriorly it rests upon the horizontal ramus and body of the pubes, from which it is separated by the pectineus muscle and its aponeurotic covering; a little lower down it rests upon the muscle itself, and still lower upon the short and long adductors; here it is crossed by the sartorius muscle.

At a little distance *externally* is the crural nerve; then the tendon of the psoas and iliacus. Lower down will be found the inner edge of

Fig. 179.*

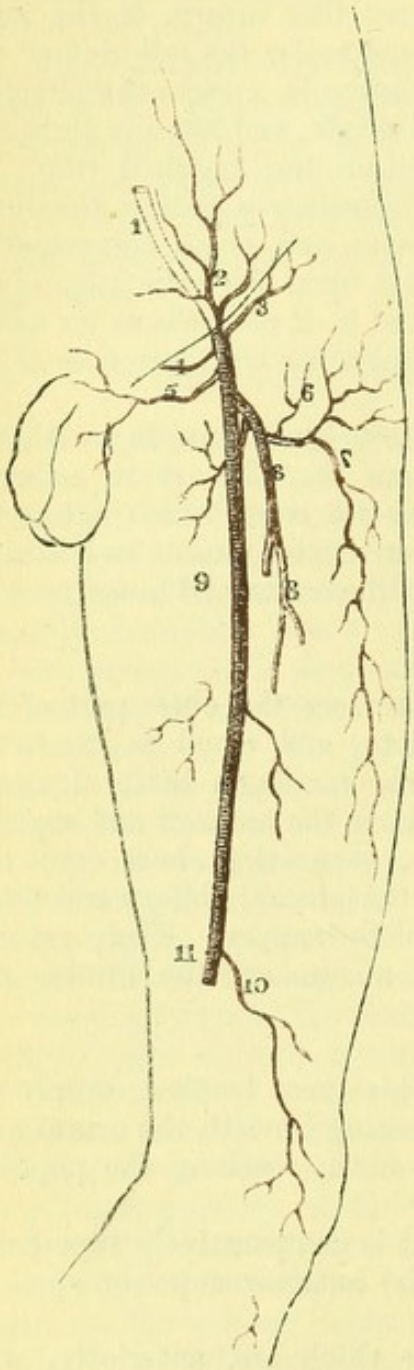

the sartorius, whilst below this the vastus internus separates it from the shaft of the femur.

Internally the artery is in relation to the common femoral vein, with which it is enclosed in a strong sheath; somewhat lower its relation is with the pectineus, and lastly with the adductor longus, on which muscle it rests. The sartorius having crossed it, the artery will be found at this part of the thigh under the external margin of that muscle. Thus the margins of the sartorius are, to a certain extent, the guides to the artery.

The branches of the femoral have been divided by systematic anatomists into internal and external, anterior and posterior; but so methodical an arrangement is scarcely necessary. They may readily be enumerated in a more simple manner, and their course and comparative size, and consequently importance, be fixed in the recollection by repeated careful dissections. In exposing these and other arteries, the dissector should at first avoid disturbing the relations of the principal vessels, looking at them attentively *in situ;* afterwards, cleaning the muscles very carefully, he may minutely examine the systematic anatomy of each important vessel.

1. External pudic arteries.

2. Superficial circumflex and epigastric.

3. Arteria profunda femoris; deep femoral.

Its branches are—1, external circumflex; 2, internal circumflex; 3, upper perforating; 4, middle perforating; 5, lower perforating.

* Fig. 179.—Diagram to show the femoral artery and its branches.—1, external iliac in outline; 2, superficial epigastric; 3, superficial circumflex of the ilium; 4, superficial pudic and inguinal branches; 8, 8, deep femoral, with some of its branches; 9, superficial femoral artery; 11, point where the artery gets the name of popliteal; 10, arter. anastomotica mag.

After giving off the deep femoral the crural artery is called the superficial femoral. From this arises,

4. The ramus anastomoticus.

The superficial femoral, now passing through the opening in the adductor magnus, acquires the name of popliteal.

A glance at this table shows that the superficial femoral is, properly speaking, the artery of the leg; and the deep femoral, the artery of the thigh.

1. *External pudic arteries.*—These small arteries arise from the common femoral. They are either *superficial* or *deep*. The *superficial* is a vessel which, arising from the main trunk a short way below the crural arch, directs itself towards the genital organs, sending twigs to the pubes and integuments of the abdomen, to the scrotum and skin of the penis, and in the female to the corresponding labium pudendi.

The deeper branches, besides supplying the inguinal glands, have a similar course to the superficial.

These arteries vary much in number and in origin. Some supply twigs to the head of the gracilis and adductor longus.

2. *Of the superficial circumflex and superficial epigastric arteries.*—These arteries are so far remarkable that they imitate in their course the deep arteries of the same name.

The *superficial epigastric* is never absent, nor its accompanying veins. Arising from the common femoral immediately below the crural arch, it ascends obliquely between the abdominal aponeurosis and integuments, imbedded in the superficial fascia towards the umbilicus. It is an integumentary artery. It anastomoses with the epigastric (*deep*) and internal mammary arteries.

The *superficial circumflex iliac artery* may come from the deep femoral. Its course is upwards and outwards between the sartorius and rectus femoris; next between the iliacus, sartorius, and tensor. To these muscles and to the gluteus medius it is distributed.

3. The ARTERIA PROFUNDA FEMORIS, or DEEP FEMORAL ARTERY.—This is, properly speaking, the artery of the thigh, and is extremely difficult of dissection.

It arises from the back part of the femoral artery, at a point varying from an inch to two below the crural arch, opposite the middle space between the pubes and small trochanter, and is of large size, nearly equalling that of the *superficial femoral*, the name which the main trunk assumes on giving off the deep femoral.

It descends obliquely backwards as far as the origin of the crureus, then inwards, proceeding between the femur and the long and short adductors to the middle part of the thigh. It now diminishes rapidly in size, passes through the aponeurosis of the adductor longus, gains the posterior surface of the thigh, and here divides into two branches, one of which enters into the short head of the biceps, the other into the semi-membranosus.

In this course the deep femoral artery gives off—

1. The external circumflex; 2, the internal circumflex; 3, superior perforating; 4, middle perforating; 5, inferior perforating.

1. *The external circumflex artery.*—Arises from the outer side of the profunda. , In size it sometimes equals that of the trunk; a circumstance of which the surgeon should be on his guard. Proceeding transversely outwards, it passes behind the sartorius and rectus, presently dividing into two branches, the *transverse* and the *descending*.

The *transverse* crosses the upper part of the femur, supplying with branches the rectus, tensor, gluteus medius and minimus, and capsular ligament of the hip-joint.

The *descending*, a large branch, descends along the fore part of the thigh between the crureus and rectus femoris, which muscles it supplies with branches. Some of its twigs may be traced as far as the patella, where they anastomose with the superior articular arteries.

2. *Internal circumflex.*—Generally larger than the preceding; arises from the inner and back part of the profunda, close to the origin of the latter artery. It almost immediately passes between the pectineus and the united tendons of the psoas and iliacus muscles (and thus is really a perforating artery), turns over the inner part of the neck of the femur, running along the obturator externus muscle, under the adductor brevis and adductor magnus. After giving branches to these muscles it divides behind the neck of the femur into two branches. The *ascending* proceeds towards the digital cavity behind the trochanter, where it distributes branches to the rotatory muscles; the *transverse* passes between the quadratus and the femur, and so reaches the top of the flexor muscle on the back of the thigh. The vessel passing between the inferior edge of the quadratus and upper margin of the adductor magnus is a branch of this artery.

3. *Upper perforating artery.*—It is the largest of the perforating arteries. Its course is backwards through the tendons of the adductor longus and brevis, to which muscles it supplies twigs, and so reaches the back of the femur. It terminates by supplying branches to the gluteus maximus, long head of the biceps, vastus externus, semi-membranosus, and sciatic nerve.

4. *Middle perforating artery.*—Comes off lower than the preceding, and passes through the tendon of the long and great adductors, reaching the back of the thigh. It supplies with blood portions of the same muscles as the upper perforating artery.

5. *Inferior perforating.*—The smallest of the three perforating. It comes off much lower down than the others, and passes through the aponeurosis of the adductor longus, close to the trunk of the profunda itself. In distribution it resembles the other two.

Return to the Superficial Femoral Artery.

Ramus Anastomoticus.—This is the last branch given off by the superficial femoral before it alters its name for popliteal. It is a remarkable branch, being in the direct line of the great trunk, as if it were its true continuation.

It descends towards the inner condyle, in front of the tendon of the adductor magnus, and anastomoses with the internal articular artery.

POPLITEAL ARTERY.—This is the direct continuation of the superficial femoral. It receives its name at the point where the artery has passed through the opening in the adductor magnus, and retains it until it divides into the posterior tibial and fibular. This takes place at or near the inferior edge of the popliteus muscle.

Although surgeons are now seldom called upon to place a ligature on the popliteal artery, since the genius of John Hunter pointed out an easier and more successful operation, the surgical anatomy of the popliteal space can never lose its importance. Whilst passing through the popliteal space, the artery, which is at first situated on the inner side of the femur, along with the vein, enclosed in a sheath of cellular substance corresponding to the groove in the bone, but always separated from it by a slip of the adductor magnus, gradually advances towards the middle of the space, partially covered by the vein. Here it is joined by the sciatic nerve, whose course from this point is, for a short space, the same as that of the artery.

Its relations in the popliteal space are, *posteriorly*, to the sciatic nerve and popliteal vein; to the semi-membranosus above; farther down a great quantity of fat separates it from the aponeurosis and integuments; and still lower it is protected by the gastrocnemii, plantaris, gracilis, and soleus.

Anteriorly, it corresponds superiorly to the femur, separated from it, however, by adipose cellular tissue; in the middle it rests upon the posterior surface of the joint; lower down upon the popliteus and tibialis posticus muscles.

Its *outer* side corresponds to the biceps, the outer condyle of the femur, and the external head of the gastrocnemius, the plantaris, and soleus.

Its *inner* side is near the semi-membranosus muscle, which retires from it as it descends; it afterwards corresponds to the internal popliteal nerve and inner head of the gastrocnemius muscle.

Branches which the Popliteal Artery gives off before it divides into the Posterior Tibial, and Fibular Arteries.

I. The articular:—1, the internal superior; 2, the external superior; 3, the middle articular; 4, the internal inferior; 5, the external inferior.

II. Sural arteries:—The branches which supply the gastrocnemii muscles.

1. The *internal superior articular artery* passes under the tendon of the adductor magnus, and turns forward over the inner part of the femur, above the corresponding condyle. Its ultimate branches supply that muscle, and proceed as far as the knee-joint, furnish-

ing it with twigs, and anastomosing with the external superior articular.

2. The *external superior articular* arises from the popliteal, immediately above the outer condyle, and winds round the shaft of the bone beneath the biceps muscle. It supplies branches to the vastus externus, and ultimately terminates over the patella.

The *middle articular artery* is much smaller than the preceding. It passes from behind forwards through the posterior ligament of the knee-joint; it thus reaches the crucial ligaments and gives twigs to all the parts of the joint.

4. *Internal inferior articular artery.*—This vessel descends obliquely inwards, under the sciatic nerve and internal head of the gastrocnemius muscle, winding over the corresponding head of the tibia, between the lateral ligament and the bone. It ascends along the inner margin of the ligament of the patella to the lower part of that bone, anastomosing with the internal superior articular and external inferior.

5. *External inferior articular.*—It arises from the popliteal, lower down than the preceding, concealed at its origin by the plantaris muscle and under the outer condyle of the femur. It descends obliquely outwards above the soleus, and enters behind the tendon of the biceps and the external lateral ligament of the knee-joint. It gives twigs to the adjoining muscles; then winds over the edge of the external semilunar fibro-cartilage, and advances as far as the lower part of the patella. It supplies twigs to the joint and anastomoses with the opposite artery.

6. *Sural arteries.*—These arteries, two in number, supply the heads of the gastrocnemii muscles. The sciatic nerves separate them as they come off from the popliteal. They supply some twigs to the plantaris and soleus, and are the branches first met with by the student in his dissection of the popliteal space. The last branch given off by the popliteal is the

Anterior Tibial Artery.—This large artery, soon after leaving the popliteal, passes through the upper extremity of the tibialis posticus, and through the interosseous ligament, close to the neck of the fibula. The external popliteal nerve, proceeding in the same direction as the artery, passes on the outer side of the neck of the bone, and thus the fibula separates the artery from the nerve. The artery thus at once places itself on the anterior surface of the interosseus ligament, and occupies a position in the anterior region of the leg.

Its course may now be easily traced. It descends obliquely, first between the extensor longus digitorum pedis and the tibialis anticus; then between the tibialis and extensor proprius pollicis, gradually approaching the tibia, over which at last it passes. It then slips under the anterior annular ligament of the tarsus, between the tendons of the extensor communis digitorum pedis and extensor proprius pollicis. Here the anterior tibial acquires the name of the dorsal artery of the foot.

Fig. 180.*

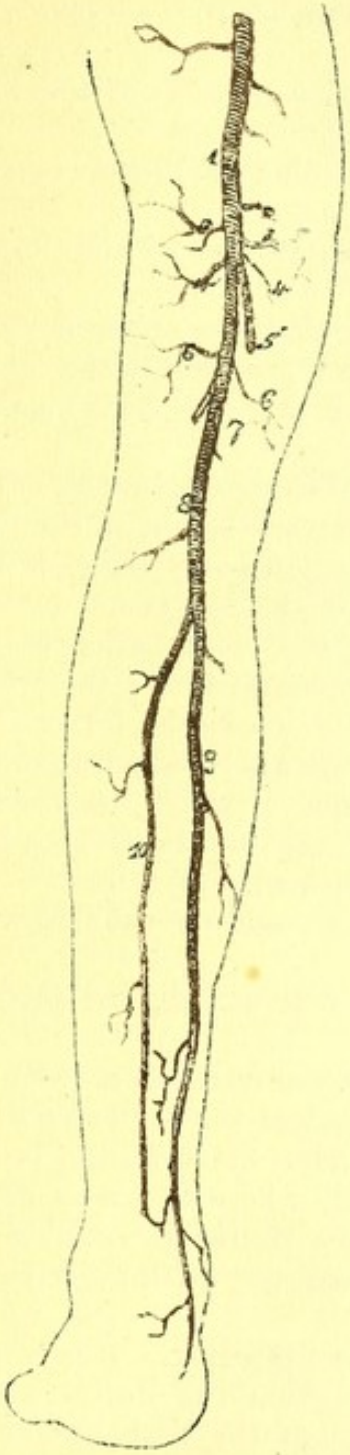

Fig. 181.†

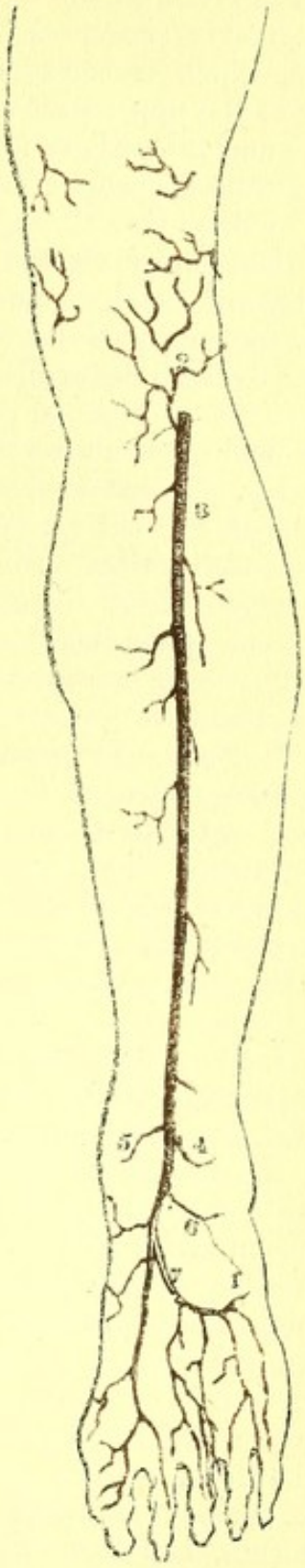

* Fig. 180.—Diagram, to show the course of the popliteal artery, its subdivision and branches.—1, the popliteal; 2, 3, 3, 4, origin of the superior articular arteries; 5, muscular or sural arteries; 6, 6, inferior articular; 7, is placed near the origin of the anterior tibial; 8, common trunk of the posterior tibial and fibular; 9, posterior tibial; 10, fibular.

† Fig. 181.—Diagram, showing the course of the anterior tibial artery.—

Dorsal Artery of the Foot.—Prior to this point the anterior tibial has given off the following branches :—

1. *Arteria recurrens*—the recurrent artery of the knee.—This branch, which is considerable, ascends obliquely inwards in the substance of the upper part of the tibialis anticus muscle. It supplies the muscle and proceeds as far as the knee-joint.

2. Numerous small branches to the anterior muscles of the leg. Some of these pass through the interosseous ligament.

3. Near the ankle the anterior tibial gives off two branches—the *internal* and *external malleolar* arteries.

The *internal* passes transversely behind the tendon of the tibialis anticus to the inner malleolus.

The *outer* or external passes behind the tendon of the extensor communis and peroneus tertius, when present, and proceeds to the outer malleolus. It anastomoses with the peroneal artery, the dorsal artery of the foot, and the external plantar.

The anterior tibial artery, under the name of the *dorsal artery of the foot*, extends from the ankle-joint, over the tarsal bones, to the first interosseal space, which it traverses, passing vertically through the first interosseal muscle, at its base. Here it divides into two branches; one unites with the external plantar artery, the continuation of the posterior tibial—this contributes to form the plantar arch; the other, continuing rather in the course of the artery outwards, follows the interval of the first two metatarsal bones between the adductor pollicis and flexor brevis, to which it gives twigs, one of which reaches the extremity of the great toe. This branch ultimately subdivides, and supplies a small artery to the edges of the first and second toes.

In this course the dorsal artery of the foot sends off the following branches :—

1. *Internal branches.*—They are small but numerous, and proceed to the corresponding edge of the foot.

2. *External branches.*—Of these two have received names :—

a. Arteria tarsea.—Arises opposite the head of the navicular bone, proceeds outwards and a little forwards under the extensor brevis digitorum as far as the outer edge of the foot, where it passes under the tendon of the peroneus longus. In this course it supplies all the neighbouring soft parts, ultimately anastomosing with the external plantar artery.

b. Arteria metatarsea.—Smaller than the preceding. I have seen these arteries come off as one. It arises from the dorsal artery of the foot, a little before it passes through the first interosseal space, passes forwards and outwards under the extensor brevis digitorum, and from its convexity gives off the *three dorsal interosseous arteries.* As these vessels proceed along the second, third, and fourth interosseous spaces, they give twigs to the dorsal inter-

3, the anterior tibial artery; 2, the tibial recurrent; 4, 5, internal and external malleolar branches; 6, arteria tarsea; 7, arteria metatarsea; 1, anastomoses with the malleolar and plantar arteries on the outer side of the foot.

osseal muscles, and between the extremities of the metatarsal bones they anastomose with the posterior perforating arteries, branches of the external plantar. Other twigs communicate with the anterior perforating arteries coming from the sole of the foot. At the same time each sends off small branches, which follow the corresponding sides of the toes.

The last branch given off by the dorsal artery of the foot, before passing into the sole of the foot, is,—

c. The arteria dorsalis hallucis.—This artery runs on the outer side of the first metatarsal bone, as far as the articulation with the great toe; here it divides into two branches, one of which runs along the outer edge of the great toe, the other follows the inner edge of the second.

The terminating branches of the popliteal artery are,—

I. The peroneal or fibular. II. The posterior tibial.

I. The *fibular artery.*—Smaller than the posterior tibial, this artery is seated very deeply at the back of the leg. It follows the course of the fibula, parallel to the inner edge of its internal surface. Posteriorly it is covered by the soleus and flexor longus pollicis. Above it rests upon the tibialis posticus, but inferiorly it passes through its fibres, and is placed at length on the interosseal ligament. Near the malleolus externus posteriorly, it divides into two branches, called the posterior and anterior fibular. But prior to this the common fibular has given off numerous twigs to the adjacent muscles.

Posterior fibular branch.—This branch follows the original course of the artery, descends behind the inferior articulation of the fibula, and passes over the outer side of the calcaneum. It gives numerous twigs to the muscles and integuments; one of them passes under the outer malleolus.

Anterior fibular branch.—Occasionally wanting. It perforates the inferior extremity of the interosseous ligament, passes under the peroneus tertius, to which it gives twigs, descends upon the inferior tibio-fibular articulation, and anastomoses with the anterior tibial. The twigs from the arch so formed pass to the neighbouring soft parts.

II. *Posterior tibial artery.*—This great artery follows the course of the popliteal, descending in the back of the leg, between two planes of muscles, as far as under the arch of the calcaneum, where it subdivides into two branches, called the plantar arteries. A line drawn from the middle of the ham to behind the malleolus internus gives the course of the artery.

In its upper two-thirds it is covered by the soleus and gastrocnemius. In its lower third it is placed along the inner side of the tendo Achillis, and here it is not covered by any muscle, but by the integuments, the superficial fascia, and a double layer of the aponeurosis of the leg. It is accompanied by its corresponding veins and by the posterior tibial nerve, which is placed at its outer side. Behind the malleolus it has a sheath distinct from the tendons, passing in the

Fig. 182.*

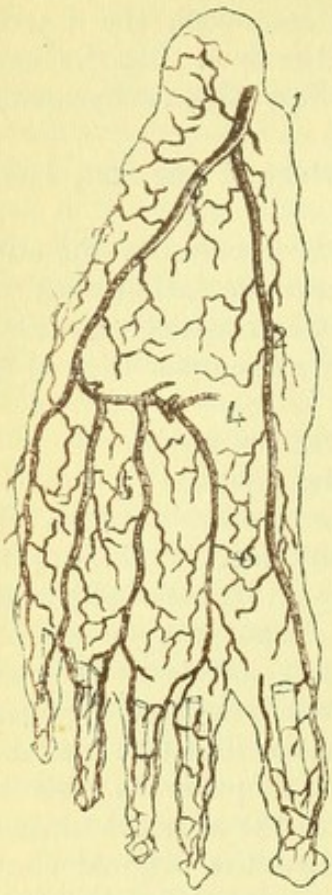

same direction; here it is bound down by the retinaculum or internal annular ligament. It now divides into the two plantar arteries; the nerve has already separated into the plantar nerves.

In its course the posterior tibial artery furnishes many twigs to the adjacent muscles, but it gives off no branch which has received a distinct name, excepting the

Arteria Nutritia Tibiæ.—This is the largest of the arteries of this kind. It descends upon the posterior surface of the bone in a groove, and penetrates into the interior of the tibia by the foramen destined for it. It proceeds to the medullary canal.

External Plantar Artery.—In respect of size this may be esteemed as the continuation of the posterior tibial. Concealed at its commencement by the internal annular ligament of the tarsus, it directs itself downwards in the groove of the calcaneum, and passes between the flexor brevis communis and flexor accessorius. It next proceeds forwards in the interval between the flexor brevis and abductor minimi digiti, after which it bends inwards towards the posterior extremity of the fifth metatarsal bone, and in this part of its course it is most exposed, being nearest to the surface. It now passes between the adductor pollicis and the interossei, and the posterior extremities of the metatarsal bones, describing a curve (plantar arch), which brings it near the first metatarsal bone, under which it anastomoses with the dorsal artery of the foot. Thus is formed the plantar arch, the concavity of which looks backward.

In this course the external plantar artery gives off,—1st, the superior branches, three in number; these pass through the interosseal spaces, and are called *posterior perforating arteries*. They anastomose with the metatarsal arteries. 2d, posterior and inferior branches. They are very small, and pass to the interossei and lumbricales. 3d, *anterior branches*. These are the largest, and are commonly four in number. They mostly follow the interosseal spaces, giving twigs to the muscles filling these spaces. Near their anterior extremities these arteries pass above the transversalis pedis, sending from each, to the

* Fig. 182.—Diagram, showing the course of the plantar arteries.—1, posterior tibial artery; 2, internal plantar; 3, external plantar artery; 4, extremity of the plantar arch, where it unites with the anterior tibial; 5, metatarsal and digital branches.

dorsum of the foot, an anterior perforating branch, communicating with branches of the metatarsal artery.

Lastly, they separate at the roots of the toes each into two large twigs, which are distributed to the corresponding edges of all the toes with the exception of the great toe and the inner side of the second, resembling in this the distribution of the collateral arteries of the fingers.

INTERNAL PLANTAR ARTERY.—It is much smaller than the external. Like it, concealed at first by the retinaculum, it passes horizontally forwards along the inner part of the sole of the foot, above the abductor pollicis; it then turns a little inwards towards the middle of the foot, passes under the flexor brevis pollicis, and ends by anastomosing with the first digital artery. It supplies with twigs the adjacent muscles as it passes along. It also sends branches to the integuments, and anastomoses with branches of the dorsal artery.

The minute dissection of the smallest branches of the arteries is a useful exercise for the student, although it leads to no practical results.

TABULAR VIEW OF THE PRINCIPAL ARTERIES OF THE BODY.

Two great arteries spring from the heart: one from its right ventricle—the pulmonary artery; another from its left ventricle—the aorta.

A. PULMONARY ARTERY.

This artery subdivides into—

a. Right branch. *b.* Left branch.

These vessels proceed to the lungs for a special purpose. They convey all the venous blood of the body to the lungs in order that it may be converted from venous to arterial blood.

B. THE AORTA.

The branches which arise from the aorta, before it terminates in the common iliac arteries, are as follows:—

1. ARTERIES which spring from the ARCH of the AORTA.

a. Right coronary of the heart.
b. Left coronary of the heart.
c. Arteria innominata, or brachio-cephalic.
d. Left carotid.
e. Left subclavian.

---

2. ARTERIES arising from the THORACIC PORTION of the AORTA.

f. Arteriæ bronchiales; usually two.
g. Œsophageal arteries; varying from two to five or six.
h. Posterior mediastinal arteries; extremely numerous and slender.
i. Aortic intercostal arteries; nine or more on each side.

---

3. ARTERIES which arise from the ABDOMINAL PORTION of the AORTA.

Azygos Arteries.

1. Cœliac artery or axis.
2. Superior mesenteric artery.
3. Inferior mesenteric artery.

In Pairs.

k. Right and left phrenic arteries.
o. Middle capsular arteries.
p. Art. renales.
q. Art. spermaticæ.
r. Lumbar arteries; usually four on each side.
s. Middle sacral artery.
t. Common iliacs.

The arteries just named proceed to the organs and textures of the body, in which they divide and subdivide *ad infinitum*. Of their branches some are of sufficient importance, whether from calibre or peculiarity in distribution, to merit distinct names.

The following tabular view of each vessel and its branches may assist the student in recollecting the names of such arteries and their branches:—

A. Coronary arteries. Their branches have received no distinct names.

B. Arteria innominata; divides into—

a. Right carotid; and *b*. Right subclavian.

Right common carotid; subdivides into—

1. Right external carotid. 2. Right internal carotid.

---

1. RIGHT EXTERNAL CAROTID ARTERY gives off—

1. Superior thyroid.
2. Lingual.
3. Facial.
4. Occipital.
5. Auricular.
6. Inferior pharyngeal.

Lastly subdividing into—

7. The temporal. 8. The internal maxillary.

To these some add—

9. Art. sterno-mastoidea.

---

2. The INTERNAL CAROTID ARTERY gives off—

1. The ophthalmic.
2. The communicating artery of Willis.
3. Artery of the choroid plexus.
4. The anterior cerebral artery.
5. The middle cerebral artery.

The distribution of the left common carotid is similar to the right.

SUBCLAVIAN ARTERY and its Branches.

It is the great trunk which supplies the pectoral extremity, and in its course receives in succession the names of subclavian, axillary, brachial, or humeral. These are but one artery. The right subclavian artery arises from the brachio-cephalic, the left from the aorta. Each gives off the following branches:—

1. Those from the SUBCLAVIAN PORTION of the VESSEL are—

1. The vertebral.
2. The internal mammary.
3. The inferior thyroid artery or axis.
4. The superior intercostal.
5. The art. transversalis colli.
6. Art. supra-scapularis.
7. Art. cerv. profunda.

---

2. Those from the AXILLARY PORTION of the TRUNK are—

1. The acromial thoracic.
2. The superior ,,
3. The long ,,
4. The alar ,,
5. The subscapular.
6. and 7. The posterior and anterior circumflex arteries.

3. Branches given off by the BRACHIAL or HUMERAL PORTION of the TRUNK (Humeral Artery).

1. Art. profunda humeri superior.
2. Art. prof. hum. inferior.
3. Ramus anastomoticus magnus.

The trunk supplying the pectoral extremity with arterial blood, after having received the name of humeral or brachial, subdivides into two great branches; these are—

1. The radial.
2. The ulnar.

---

1. The RADIAL ARTERY gives off the following branches which have names:—

1. The radial recurrent.
2. Art. superficialis volæ.
3. Dorsal artery of the thumb.
4. Dorsal artery of the carpus.
5. Dorsal artery of the metacarpus.
6. Art. magna pollicis.
7. Deep palmar arch.
8. Art. interosseæ volares.
9. Art. perforantes.

---

2. The ULNAR, a branch of the brachial, gives off the following branches which have names:—

1. Anterior ulnar recurrent.
2. Posterior ,, ,,
3. Interosseal—subdividing into anterior and posterior interosseal.
4. Superficial palmar arch.

Returning to the primitive arteries springing from the aorta which in their course give off branches having names, the next we find to be—

l. The cœliac artery or axis; its branches are as follows:—

1. Art. coronaria ventriculi.
2. Art. hepatica.
3. Art. splenica.

---

m. The superior mesenteric gives off—

1. Superior right colic; also called the middle colic.
2. Middle right colic.
3. Inferior right colic; also called the ilio-cæcal.

---

n. The inferior mesenteric artery gives off—

1. The superior left colic.
2. The middle left colic.
3. The inferior left colic; also called art. sigmoidea.
4. Superior hæmorrhoidal.

The common iliacs, by which the aorta terminates inferiorly, are the two great trunks supplying the pelvis and lower extremities with blood. The description of one applies to both.

Common iliac or crural artery: subdivides into—

1. Internal iliac.
2. External iliac.

1. The INTERNAL ILIAC ARTERY gives off—

1. Art. ilio-lumbalis.
2. Art. sacri lateralis.
3. Art. glutea.
4. Art. umbilicalis.
5. Art. vesicalis.
6. Art. obturatoria.
7. Art. hæmorrhoidea med.
8. Art. uterina.
9. Art. vaginalis.
10. Art. ischiatica.
11. Art. pudend. communis.

---

2. The EXTERNAL ILIAC ARTERY (called in succession—1, External Iliac; 2, Common Femoral; 3, External Femoral; 4, Popliteal) gives off by its iliac portion—

1. Art. epigastrica.
2. Art. circumflexa ilii.

---

3. From its COMMON FEMORAL PORTION there arise—

1. The external pudic arteries.
2. The superficial circumflex.
3. The superficial epigastric.

---

4. The ARTERIA PROFUNDA FEMORIS. This gives origin to the

a. External circumflex.
b. Internal circumflex.
c. Sup. perforating art.
d. Middle do. do.
e. Lower perforating art.

From the SUPERFICIAL FEMORAL,

1. Muscular Branches.
2. Art. Anastomotica magna.

---

5. Lastly, from its POPLITEAL PORTION it gives off—

1. The superior articular; internal and external.
2. The middle articular.
3. The inferior articular; internal and external.
4. Art. surales.
5. The anterior tibial.

The POPLITEAL then subdivides into two great branches;—

1. The fibular.
2. The posterior tibial.

---

1. The FIBULAR ARTERY divides into—

1. The anterior fibular.
2. The posterior fibular.

---

2. The POSTERIOR TIBIAL gives off the following branches which have names—

1. The art. nutritia tibiæ.
2. The internal plantar.
3. The external plantar.

It is right to call the attention of the student to a circumstance he must have frequently observed in the course of his dissections, that many large and important branches sent off from still larger arteries, have received no names, and therefore are not included in the above

tabular view. Take, for example, the artery last named—the posterior tibial, which in its course down the limb supplies with blood all the adjoining muscles; but such muscular branches, however large, are seldom named.

TABULAR VIEW OF SOME MINOR OR SECONDARY ARTERIES AND THEIR BRANCHES.

There are certain arteries of secondary importance as to calibre or other circumstances, but which, notwithstanding, have been minutely described by anatomical writers, and many of their branches have received distinct names which the student is expected to know and to recollect. To avoid confusion, or mingling them up with the history of the *primary* arteries, springing directly from the aorta, I have superadded the following tabular views of the more important of these vessels.

1. The SUPERIOR THYROID ARTERY gives off—

a. Ramus thyroideus. Ramus superficialis.
Ramus laryngeus.

---

2. The LINGUAL ARTERY gives off—

a. Ramus hyoideus. Ramus sublingualis.
„ dorsalis linguæ. „ raninus.

---

3. The FACIAL ARTERY gives off the following branches:—

1. The inferior palatine.
2. Art. tonsillaris.
3. Glandular branches.
4. Submental.*
5. Inferior labial.
6. Inferior coronary.
7. Masseteric.
8. Superior coronary.
9. Lateral nasal.
10. Angular.

Few of these branches are of much consequence in a surgical point of view.

---

4. The INTERNAL MAXILLARY ARTERY gives off the following branches:—

1. Middle meningeal.
2. Inferior dental.
3. Pterygoid branches.
4. Deep temporal.
5. Masseteric.
6. Buccal.
7. Superior dentar.
8. Infra-orbitar.
9. Descending palatine.

---

* Often divided in operations below the jaw.

4. The OPHTHALMIC ARTERY, a branch of the internal carotid, gives off the following branches:—

1. Lachrymal.
2. Art. centralis retinæ.*
3. R. supra-orbitalis.
4. R. ciliares; long, middle, and short.
5. R. Musculares.
6. R. ethmoidalis.
7. R. palpebrales superior and inferior.
8. R. Nasalis.
9. R. Frontalis.

---

4. The THYROID AXIS is a branch of the subclavian; it gives off several branches, which are as follows:—

1. The inferior thyroid.
2. Cervicalis ascendens.
3. Supra-scapular, or transversalis humeri.
4. Posterior scapular, or transversalis colli.
5. Cervicalis superficialis.
6. Cervicalis profunda.
7. Intercostalis superior.

---

5. The INTERNAL or COMMON PUDIC ARTERY, a branch of the hypogastric or internal iliac, gives off the following branches:—

1. The external hæmorrhoidal.
2. Art. of the perineum.
3. Transversalis perinei.
4. Art. of the bulb.
5. Art. of the corpus cavernosum of the penis.
6. Dorsal art. of the penis.

It was clearly shown by the illustrious Scarpa, though well understood before his time by practical men, that even after the ligature of the largest trunks the supply of blood to the parts thus temporarily cut off from communication with the heart, is, by means of frequent anastomoses, fully equal to maintaining the life and integrity of these parts.

A distinction, in order to avoid grave errors and disappointment, must always be made between *wounded* arteries and aneurisms. In both *pressure* is a valuable means of obliterating the vessel, but some arteries do not admit of pressure being applied, and in those the ligature must be resorted to.

The study of the *varieties* in the course and origin of various arteries is interesting surgically, pathologically, and physiologically: it is best followed by the student's observing carefully in the practical rooms whatever varieties may occur in his own dissections or in those of others; he may then advantageously compare the knowledge so acquired with that which has been accumulated by others.

* This disappears at a certain age, not yet determined. It is distributed to the posterior surface of the capsule of the lens.

OF THE VEINS.

During the dissection of the muscles and viscera, the student will have become familiar with all the great venous trunks, and, indeed, with most of the veins of the body. Whilst dissecting, for example, the upper extremity, he will have met with the superficial veins at the bend of the elbow, and may probably have dissected them with a view to their surgical anatomy,—that is, to the making out distinctly the relation of the veins of that region to the superficial fascia, to the aponeurosis, and to the nerves and arteries.

In the dissection of the axilla, the axillary vein and the veins forming that great vessel must have been especially noted, whilst the surgical anatomy of the subclavian and carotid arteries and the deep dissection of the neck will have forced on his attention all the great veins to be found in those important regions.

Thus it is with most other regions of the body, during the dissection of which every vein of any consequence must have been brought before the student's notice. It is for this reason, no doubt, that the veins are seldom or never dissected and examined as a system, which, however, they in reality constitute—a system liable to fewer varieties than the arteries; but still they require to be studied systematically, and it is to enable the student to do so that I have superadded to the practical views of the veins already given in various chapters of this work the following

SYSTEMATIC ANATOMY OF THE VEINS.

The veins, with the exception of the pulmonary veins, are vessels carrying dark or venous blood.

Their form is cylindrical, and their parietes or walls are composed essentially of two tunics, to which, however, of late, a third, cellular and external, has been added.*

The inner tunic is thin and smooth, forming, by being folded as it were, upon itself inward, a vast number of semicircular valves, arranged in pairs, and at uncertain distances. These valves abound in the veins of the limbs, but they are not present, with a few exceptions, in those of the trunk or torso. Hence arises a difference in the mode of injecting these veins for the purposes of demonstration or preparation; for whilst those of the torso may be injected from trunk to branches, it is the reverse in the veins of the limbs, which must, by reason of the presence of these valves, be injected from branches to trunk.

* See Chapter on General Anatomy.

When valves exist in the deep-seated veins, as in the coronary of the heart, they are imperfect, and do not perform their office as valves.

The tissue now spoken of, namely, the inner tunic of the veins, seems continuous with the endocardium or lining membrane of the right auricle of the heart, and with the sinuses of the dura mater.

The middle tunic, by some called the outer, is loose, extensile, composed of longitudinal fibres, but not elastic, or but little so. Its vital properties differ essentially from the corresponding arterial tunic, with which it must not be confounded, whatever may be the determinations of the microscope. Exteriorly it is surrounded with a sheath of fine, dense cellular membrane, which some consider as a third tunic.

The coats of the veins have, of course, their vasa vasorum. A few nervous filaments have been traced to them, chiefly, however, in the tunics of the vena portæ.

The course of the blood towards the heart is proved, 1st, by the anatomical structure of the valves; 2d, by injections made into them after death; 3d, by the application of a ligature above the elbow or foot. The obstruction it causes to the course of the blood in the superficial veins of these regions demonstrates the actual course of the blood during life.

The knotted appearance of the veins when dilated is due to the presence of the valves. These exist and are very numerous in the deep veins of the limbs (*venæ comites arteriarum*), contrary to what has been asserted.

Two great venous trunks enter the right auricle of the heart, conveying into this cavity the entire blood of the body, with the exception of the blood from the tissue of the heart itself. This is discharged into the auricle by the coronary vein or sinus. The composition, then, of these vessels, and of the branches, which, by uniting, ultimately form them, constitute the history of the venous system. To trace them systematically from trunk to branches, or the reverse, is the object of the student, and it is a matter of indifference which method he adopts. The more natural one seems to be to trace the veins from their commencement in the organs onwards towards the heart, thus following the course of the blood. As three venous trunks enter the heart, the system divides itself into three sections—1, the anatomy of the vena cava superior, and of the branches giving rise to it; 2, the vena cava inferior and its formative branches; 3, the coronary vein. To these I have added, in separate sections, a brief account of systems of veins presenting several remarkable peculiarities: these are—1, the system of the vena portæ; 2, the sinuses of the dura mater;* 3, the sinuses and venous circulation of the spinal marrow, its membranes, and column; and, 4, the system of the vena azygos.

I. CORONARY SINUS.

1. The GREAT RIGHT CORONARY VEIN commences towards the summit of the heart by several twigs or branches, which anastomose

* See the Section on the Nervous System.

freely with those of the small right coronary. It lies in the adipose groove of the thick margin of the heart, turns over this margin, and passes into the groove between the auricles and ventricles, becoming horizontal, and directing itself to the right.

2. The SMALL RIGHT CORONARY VEIN, arising like the preceding, passes in the groove of the posterior surface of the heart, receiving the veins of that surface and of the septum, ascends vertically on the wall of the septum, and unites with the preceding.

3. The LEFT CORONARY VEINS are much smaller than the right; they occupy mostly the convex surface of the organ in two or three branches. Collecting into a single trunk, they join the others, terminating in the right auricle of the heart.

These veins for description might be advantageously considered as one. Its mode of termination has been already described.

OF THE VENA CAVA INFERIOR, AND OF THE VEINS WHICH UNITE TO FORM IT.

The veins of the lower extremities may be divided into two sets—the superficial and the deep-seated.

1. Superficial.—EXTERNAL OR SHORT SAPHENA VEIN.—This vein is situated on the back of the leg, embedded in the superficial fascia. It commences by several roots expanded on the back of the foot, upon its outer side, and by others situated around the external malleolus; these unite into a single trunk, which, proceeding vertically upwards towards the heads of the gastrocnemii muscles, gradually pass through the aponeurosis, so as at last to join the popliteal vein in the popliteal space. A nerve accompanies it for a part of its course, and it is frequently joined by superficial veins descending from the back of the thigh.

2. INTERNAL or LONG SAPHENA VEIN.—This is also a superficial vein, embedded in the superficial fascia. Its roots commence on the inner side of the foot, edge of the great toe, and back of the foot, where it anastomoses with the short saphena. All these roots united ascend before the malleolus internus, over the ankle-joint, and form a trunk, which is further augmented, as it proceeds upwards towards the groin, by many branches. The trunk ascends at first vertically, and afterwards obliquely forwards, and passes behind the inner condyle of the femur. It again proceeds vertically upwards on the inner side of the thigh, receiving many superficial branches, one of which is much larger than the rest, until within a short space of the crural arch, where, passing through the saphenic opening of the fascia lata, it joins the common femoral vein. Several superficial, inguinal, and abdominal veins join the saphena before passing through the aponeurosis.

Fig. 183.*

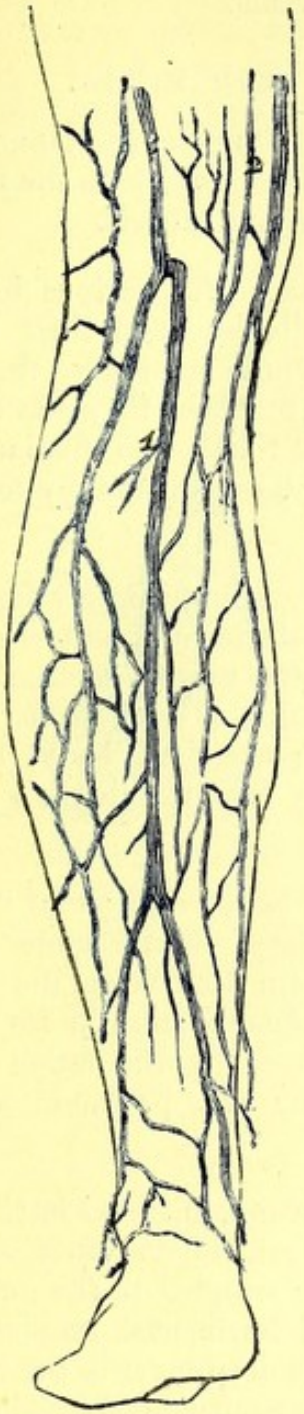

Fig .184.†

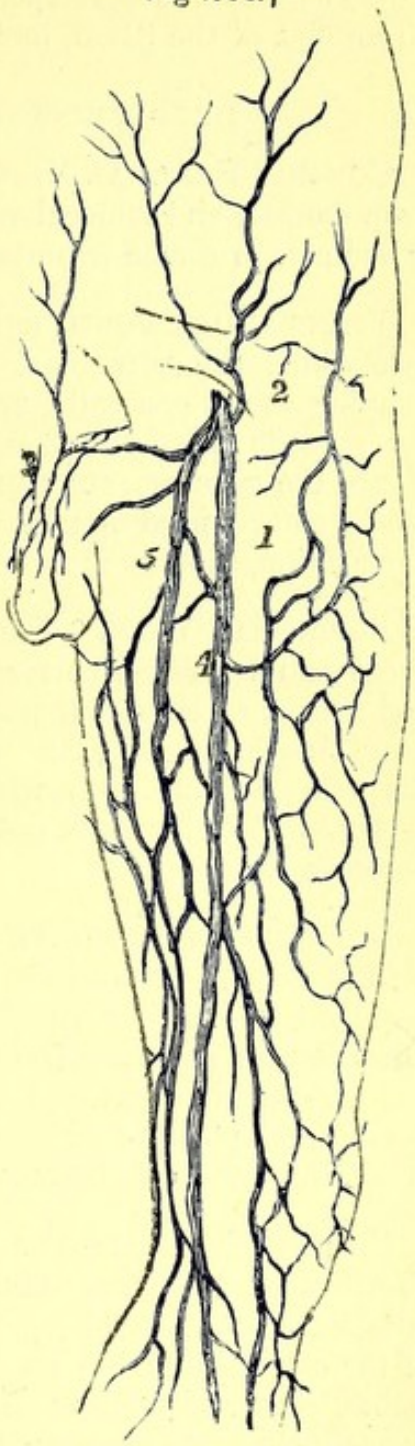

* Fig. 183.—Sketch to show the short or posterior saphena vein, left leg.—1, the short saphena as it is about to pass through the popliteal portion of the aponeurosis of the lower extremity to join the deep or popliteal veins; it is not unusual to find several superficial veins descending from the back of the thigh to join the short saphena as it is passing through the aponeurosis; 2, branches of the long saphena, of which some are anastomosing with the branches of the short saphena.

† Fig. 184.—Sketch of the superficial veins of the thigh.—2, long saphena vein at the point where it traverses the fascia lata femoris to join the femoral vein.—1, external superficial veins on the anterior part of the thigh; 4, trunk of the long saphena; many superficial veins may be seen joining it from the inner side of the thigh, and from the external organs of generation; 5, a large vein collecting many branches joining the long saphena.

These small veins correspond to the superficial epigastric, superficial circumflex of the ilium, and external pudic veins.

DEEP VEINS OF THE LOWER EXTREMITIES.

COMMON FEMORAL VEIN.—This vein results from the union of the deep femoral and femoral veins, the veins corresponding to the arteries called art. profunda femoris and art. superficialis femoris.

VEINS WHICH FORM THE FEMORAL VEIN.—The various branches into which the superficial femoral artery divides have their accompanying veins, generally two in number, whose anatomy, therefore, corresponds strictly to that of the arterial branches they accompany. Hence the plantar, anterior tibial, posterior tibial, and fibular veins, whose course need not be dwelt on here. They ultimately form, by their union, the

POPLITEAL VEIN.—The vessels which more immediately form this great vein are three, corresponding to the anterior and posterior tibial and fibular arteries. It is situated close to the artery, enclosed in the same sheath, on its outer side, and has tunics of such strength that the vein remains open when cut across in the dead body, like an artery. It follows the course of the artery into the thigh, where it becomes the

SUPERFICIAL FEMORAL VEIN.—Though called *superficial* it is not so, but deep. It ascends close to the artery, in the same sheath, requiring to be very carefully separated from that vessel during the operation for aneurism, receives many branches of veins in its course, and chiefly the vena profunda femoris, formed by the union of the veins corresponding to the branches of the art. profunda femoris, after which the vein becomes the

COMMON FEMORAL VEIN.—This short trunk, enclosed in the same sheath with the artery, and covered by the cribriform fascia, speedily passes under Poupart's ligament. It is here situated to the inner side of the artery, and lies on the pectineus and horizontal ramus of the pubes, separated from them, however, by the deep layer of the femoral aponeurosis. As soon as it gets within the cavity of the abdomen it changes its name for

EXTERNAL ILIAC VEIN.—This large trunk follows the course of the external iliac artery, on the inner side of which it is situated. It receives the epigastric and circumflex veins and the veins which enter by the inguinal canal.

Near the sacro-iliac synchondrosis this vein is joined by the hypogastric vein. The trunk formed by the union of these two vessels is called the

COMMON ILIAC VEIN.—These veins are of very large size; they

ascend from opposite to the sacro-iliac synchondrosis, converging obliquely inwards to the articulation of the bodies of the fourth and fifth lumbar vertebræ, where they unite to give rise to the vena cava inferior. They differ somewhat from each other in their course; the left is the longer; it passes successively behind the left common iliac artery, then before the last vertebra, and, lastly, behind the right common iliac artery. At this spot the vena cava inferior commences. Before describing the course of this great vein and the branches it receives, let us return for an instant to the hypogastric, whose branches remain to be described.

OF THE VEINS WHICH FORM THE HYPOGASTRIC OR INTERNAL ILIAC.

This large vein is placed in the excavatiou of the pelvis, behind the artery of the same name, and is composed of a number of branches corresponding to those of the artery, and similarly named. There are certain exceptions, which I shall now notice.

Vesical Veins.—They are very numerous, and of large size; they exhibit sexual differences.

In the male they commence on the glans penis, where they form a complete network of fine vessels. They may be filled with quicksilver through the dorsal vein of the penis. They unite into two large trunks, the dorsal veins of the penis, which run upon the back of the organ, accompanying the dorsal arteries. After dividing and subdividing, and uniting with other veins proceeding to them from the scrotum, they pass through the sub-pubic ligament and under the arch of the pubes, and thus reach the sides of the bladder. After this they unite with other venous branches expanded over the prostate and the walls of the bladder, forming, by their anastomoses, a very extensive plexus, the veins of which, at last, terminate in a few trunks, which open into the internal iliac vein, near the obturator vein, receiving, as they proceed, some veins from the rectum and seminal vesicles.

In woman the vesical veins commence by the dorsal veins of the clitoris, and by a great number of roots spread out in the skin and cellular tissue of the labia. They unite around the vulva, and communicate with the internal and external pudic veins. Several come from the constrictor vaginæ, and others communicate with that remarkable venous plexus called the semi-bulb, situated underneath the constrictors. At the sides of the bladder these veins receive others from the bladder and rectum.

Sacro-lateral Veins.—Within the sacral canal their branches communicate with the vertebral sinuses. In general their branches follow the course of the arteries so named, and they terminate ultimately in the hypogastric.

VENA CAVA INFERIOR.—This is a much larger and longer vein than the superior cava. It extends from the fourth and fifth lumbar vertebræ to the right auricle of the heart, at the inferior and posterior part of which it opens, assisting in forming the sinus venosus of the auricle.

It ascends at first vertically on the right lateral part of the bodies of the lumbar vertebræ to beneath the liver, covered at first by the right common iliac artery, then by the peritoneum and duodenum, and placed to the right of the aorta. It varies in its calibre whilst opposite to the liver; behind that organ it curves slightly, and is lodged in the notch or canal (as it may be) formed between its right lobe and that of Spigelius. Soon after, it passes through a wide aperture in the cordiform tendon of the diaphragm, to the edges of which it is well secured by cellular tissue, and immediately thereafter, passing through the fibrous layer of the pericardium, it reaches the right auricle of the heart. At the entrance is placed the Eustachian valve.

The branches which the inferior cava receives in its course correspond very closely with the arteries given off by the abdominal aorta, and are named after these arteries, whose course they usually follow. Thus we have

1. The MIDDLE SACRAL VEIN.

2. The LUMBAR VEINS, four in number; of these the left, as they have to pass behind the aorta to reach the vena cava, are longer than the right.

3. The SPERMATIC VEINS.—Somewhat longer than the corresponding arteries; they also have sexual differences.

In the *male* they commence from the spermatic plexus of the testicles, leaving it before the head of the epididymus. The plexus afterwards ascends, enveloping the vas deferens, its vessels anastomosing frequently with each other. They thus form a portion of the spermatic cord, which enters the abdomen by the inguinal rings and canal. On passing through the deep inguinal ring the cord breaks up into two divisions; one, the vas deferens, dips rapidly into the pelvis to proceed to the urethra; while the spermatic vein, now a single trunk, ascends vertically in the abdomen, running along the psoas muscle as far as the brim of the pelvis. Beneath the kidney it forms another plexus, and is increased by some adipose veins from the mass surrounding that organ. Forming once more a single trunk, it ascends between the peritoneum and psoas, and opens—the right one into the vena cava, under the renal vein—the left into the renal vein of that side.

In *woman* the spermatic veins derive their origins from the ovarian plexus; they anastomose freely with the uterine veins. In leaving the pelvis they pass over the external iliac artery. Their course afterwards is much as in the male.

4. The RENAL or EMULGENT VEINS are of great size. The

left renal vein is commonly larger and longer than the right; they leave the kidney at the fissure by which the artery enters; they correspond strictly to the arteries.

5. CAPSULAR VEINS, corresponding to the arteries of that name. They sometimes open into the renal veins.

6. HEPATIC VEINS.—These arise, as will be more minutely described in a future chapter, in the substance of the liver, where they are enveloped by a sheath of the fibrous capsule of the organ or a prolongation at least of the capsule of Glisson. Some of small size enter the cava separately; but the larger, called *venæ cavæ hepaticæ*, to the number of two or three, and distinguished into *right* and *left*, enter the cava just as it is about to pass through the diaphragm.

7. The INFERIOR PHRENIC VEINS, two in number, resemble in their distribution the course of the arteries to which they correspond.

SYSTEM OF THE VENA PORTÆ.

Origin of the Porta.

This remarkable system of vessels is situated within the abdomen. It is destitute of valves. The veins ultimately composing it in the adult derive their origin from all the organs contained within the cavity of the abdomen, with the exception of the kidneys and bladder in the male, and in woman the kidneys, bladder, and uterus. The innumerable branches arising from surfaces so extensive unite at last to form two large trunks, which again, by their union, form the vena portæ. These trunks are the splenic and superior mesenteric veins.

The SPLENIC VEIN follows pretty nearly the course of the artery, passing transversely, however, from left to right. Formed at first by the proper splenic branches, it receives in its course the veins of the vasa brevia, the right and left gastro-epiploic veins, the duodenal and pancreatic, the coronary vein of the stomach, and the small meseraic. In this way it returns the blood which has circulated in the intestines, even as low as the rectum. This blood we shall find goes to the liver.

SUPERIOR MESENTERIC VEIN.—The branches which form this vein follow in an inverse order the arteries of the same name. They collect at last into a large trunk, which, passing behind the pancreas and in front of the vertebral column, near the second lumbar vertebra, unites with the splenic, and thus forms the vena portæ.

VENA PORTÆ.

To expose the course of this vein dissect for the pancreas; clear the lower edge of this viscus, underneath which the superior mesenteric

Fig. 185.*

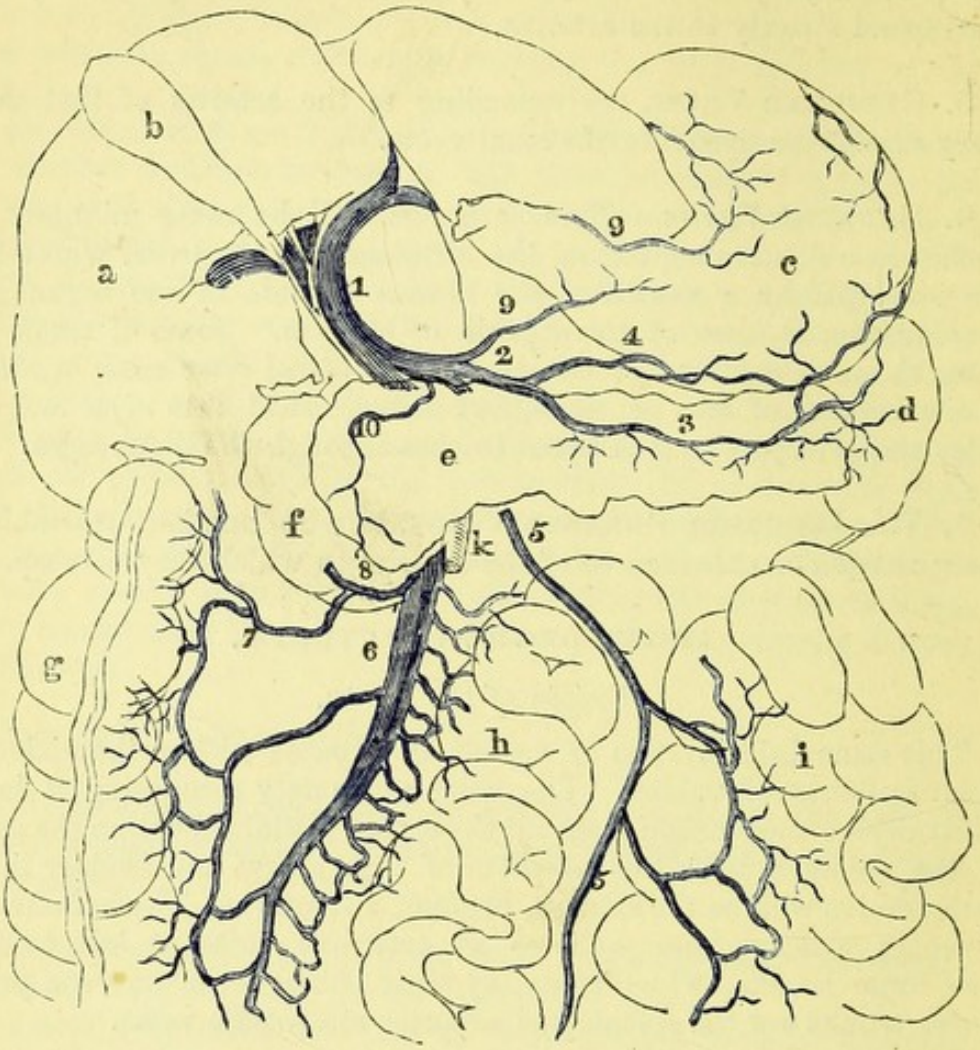

artery and vein will be found; divide the pancreas and reflect the segments; next raise up the liver and remove the pyloric portion of the stomach cautiously; finally, remove the external layer of the small omentum and trace the vein to the liver.

The vena portæ, thus formed and situated, ascends obliquely to the right and backwards for about four inches, and terminates in the portal groove of the liver. It lies at first under the smaller extremity of the pancreas, then behind the second portion of the duodenum, covered by the hepatic artery, cystic and hepatic ducts, surrounded by many nervous filaments and lymphatics, all enclosed by the capsule of

* Fig. 185.—Intended to show the formation of the vena portarum, or portæ.—1, the vena portæ; 2, 3, 4, the splenic and its branches; 5, 5, the inferior mesenteric vein; 6, the superior mesenteric vein; 7, 8, superior right colic veins; 9, 9, placed on branches and portions of the coronary vein of the stomach; *a*, lower surface of the right lobe of the liver; *b*, gall-bladder; *c*, stomach; *d*, spleen; *e*, the pancreas; *f*, *f*, portion of the duodenum; *g*, ascending colon; *h*, small intestines, drawn over towards the right side, in order to show the inferior mesenteric vein; *i*, sigmoid flexure of the colon; *k*, the superior mesenteric artery cut across.

Glisson. Near the right extremity of the transverse groove of the liver the vein bifurcates; one branch proceeds to the right lobe, the other to the left. These branches together form a horizontal canal, usually called the sinus of the vena portæ. The right branch is shorter and larger than the left, and proceeds to ramify in the right lobe of the liver: the left proceeds horizontally as far as the groove permits it, and then sends branches to the left lobe and the lobulus Spigelii. The remains of the sinus venosus, and of the umbilical vein, will be found in connexion with this branch.

Thus the vena portæ ramifies like an artery through the liver; the blood it carries there is collected by the hepatic veins, and through them is discharged into the inferior vena cava.

VENA CAVA SUPERIOR.

Of the Branches which form the Vena Cava Superior.

Internal maxillary vein.—Formed of branches corresponding to the artery of the same name (the middle meningeal is considered as an exception), this vein collects also some of the veins of the diploë and some of the emissary veins of Santorini. The trunk of the vein thus formed will be found close to the artery behind the neck of the condyle of the lower jaw, where it unites with the superficial temporal vein.

The *superficial temporal vein*, besides receiving the vein just described, is formed by branches corresponding to those of the temporal artery. The trunk formed by those branches plunges into the parotid gland. From this gland it emerges, receives the posterior auricular vein and other small branches, and is now called the *external jugular vein.*

The course of the *external jugular* has been already carefully referred to in the description of the surgical anatomy of the neck. It descends vertically and towards the supra-clavicular space to terminate in the upper part of the subclavian vein of each side, a little external to the termination of the internal jugular in the same vein. In its course through the neck it is placed between the platysma myoides and the sterno-cleido-mastoid muscle. Inferiorly it passes deeper and gets beneath the inferior portion of the omo-hyoid. In this course it is joined by the cervico-cutaneous and trachelo-scapular veins; it sometimes bifurcates and presents other varieties in calibre and in position.

INTERNAL JUGULAR VEIN.

These two large veins collect the blood chiefly of the brain and face; they commence as it were by the

Superior Cerebral Veins, which are spread over the convex surface of the two hemispheres of the brain, from the substance of which they issue by many fine radicles. Their course when formed is towards the great fissure of the hemispheres, uniting into trunks, of which the largest are behind. These trunks are joined near the

main line by others from the plain surface of the hemispheres, and next, receiving envelopes from the arachnoid and sub-arachnoid cellular tissue, they enter the superior longitudinal sinus obliquely.

The VEINS OF THE CORPORA STRIATA and adjacent parts of the brain unite with the vein of the choroid plexus, the roots of which are formed in the velum interpositum and in the veins which form the velum. These veins, passing backwards through the great cerebral fissure of Bichat, give rise to the veins of Galen. These veins issue from the interior of the brain by the above fissure, and immediately enter the *straight sinus*. They cross each other before terminating.

SUPERIOR AND INFERIOR CEREBELLAR VEINS; arising from the substance of the cerebellum, they open into the nearest sinuses; the former into the straight sinus, the latter into the left lateral.

LATERAL AND INFERIOR CEREBRAL VEINS.—They are as numerous as the superior cerebral, though not so much noticed. On leaving the brain as three or four pretty large trunks on each side, they proceed obliquely forwards, and terminate in the corresponding lateral sinuses at their upper part.

OPHTHALMIC VEIN.—It arises from all the parts within the orbit, the pituitary membrane, palpebræ, &c., and in brief by branches corresponding to all those of the ophthalmic artery. The venous branches are similarly named; as lachrymal, ciliary, muscular, &c. The trunk thus formed leaves the orbit by the inner part of the sphenoidal fissure and enters the cavernous sinus.

The SINUSES OF THE DURA MATER, minutely described in the Chapter on the Brain and its membranes, thus become charged with all the blood of the encephalon, and with a part of the blood circulating in the organs of sense, terminate on either side of the base of the cranium, at the foramina lacera posteriora. Here the internal jugular veins commence by a dilatation or sinus lodged in the fossa juglandica. The vein

Fig. 186.*

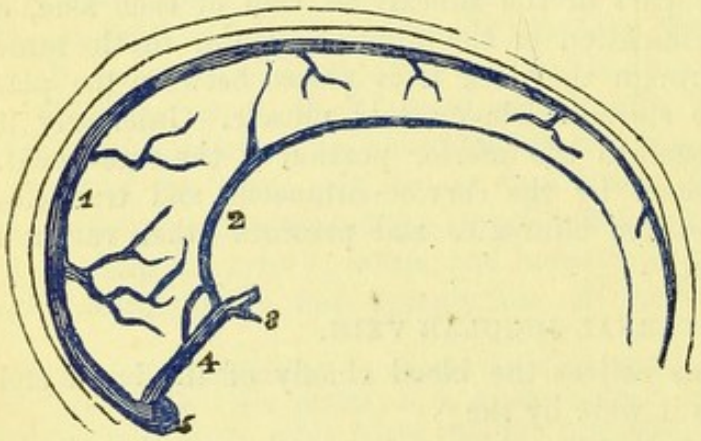

* Fig. 186.—Sinuses of the dura mater.—1, the superior longitudinal sinus; the figure is placed on the falx cerebri; 2, the inferior longitudinal sinus; 4, the veins of Galen (cut across) as they are proceeding to join, 3, the straight sinus; 5, torcular of Herophilus.

descends along with the internal carotid artery, covered by the styloid process of the temporal bone, and by the muscles which are attached to it. At this point it receives a branch from the external jugular, and a little before reaching the level of the larynx, it is joined by the *facial vein.*

The FACIAL VEIN commences on the top of the head and on the forehead by numerous branches. The large subcutaneous branch often seen to descend on the middle of the forehead is called the *vena preparata.* When this vein reaches the side of the nose it becomes the *angular vein.* Here, properly speaking, the *facial vein* commences; descending from this point under the integuments and superficial muscles, it passes beneath the zygomaticus major at some distance from the commissure of the lips, and therefore apart from the artery, and finally reaches the base of the jaw, over which it passes with its corresponding artery. In this part of its course it receives the dorsal veins of the nose, the superior and inferior coronary, buccal, and masseteric branches.

After passing over the basis of the jaw, it next descends obliquely downwards, backwards, and outwards, between the platysma myoides and the submaxillary gland, and thus arrives at the internal jugular vein, after being joined by the ranine, submental, and inferior palatine.

After receiving the facial, the internal jugular is further strengthened by the lingual, pharyngeal, superior thyroid, and occipital veins.

None of these veins require any special description; they accompany their corresponding arteries. The veins of the diploë, which ramify through the cancelli of the cranium, join

Fig. 187.*

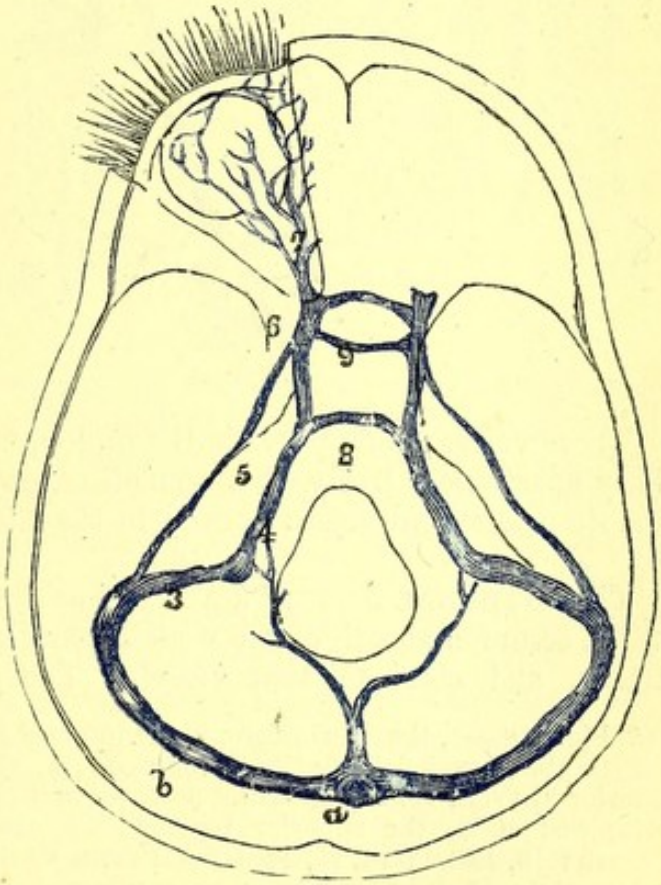

* Fig. 187.—Sinuses at the base of the cranium.—*a*, opening of the superior longitudinal sinus into the torcular; *b*, horizontal portion of the left lateral sinus; 4, gulf of the jugular vein; 5, superior petrosal sinus; 6, cavernous sinus; 8, transverse sinus; 9, coronary sinus; 7, ophthalmic vein.

these veins at various points, and thus contribute to form the internal jugular vein.

Fig. 188.*

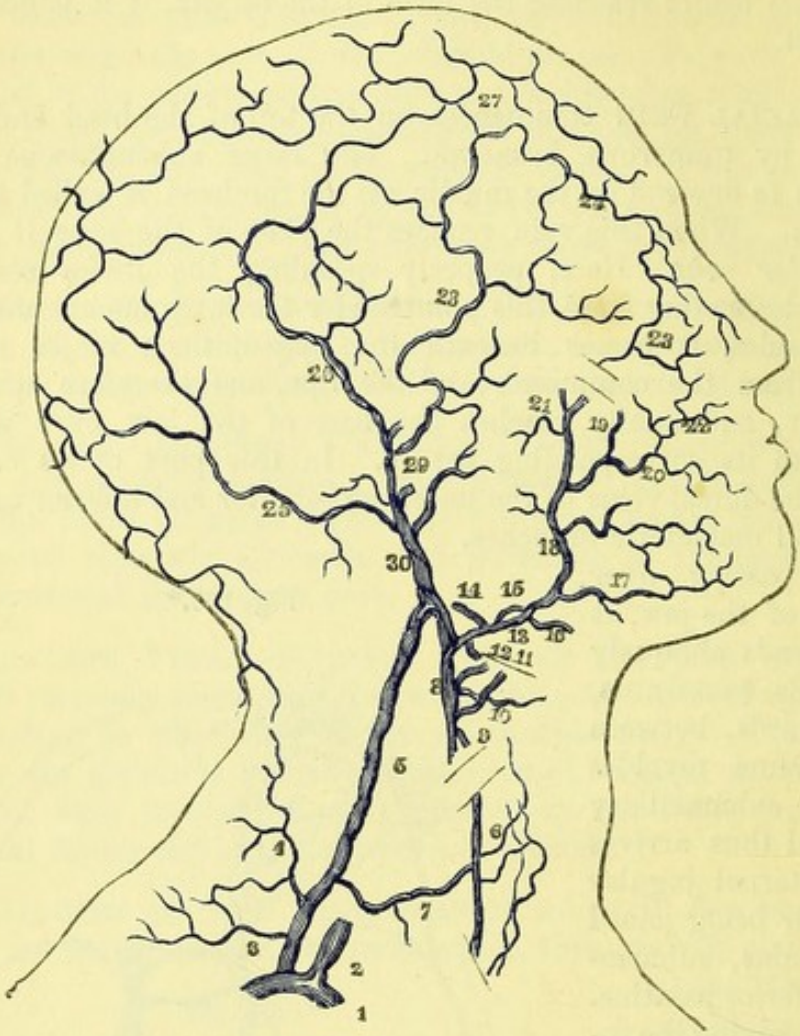

These veins, which pervade the diploë, were known to Hippocrates. They anastomose freely with each other, and join the frontal, occipital, and deep temporal veins: some join the lateral sinuses.

The Internal Jugular Vein thus formed descends in the neck, in the common sheath of the vessels, parallel with the common carotid artery, and close to that vessel. The pneumo-gastric nerve lies

* Fig. 188.—1, the subclavian; 2, the internal jugular; 3, 4, veins corresponding to the superficial arteries of the neck; 5, the external jugular vein; 6, 7, inferior thyroid veins; 8, trunk proceeding to join the internal jugular, and composed of, 9, the superior thyroid; 10, the lingual; 11, 12, a muscular branch; 13, facial; 14, 15, superficial veins joining the facial from above; 16, submental; 17, inferior labial; 18, continuation of the facial or external maxillary vein; 19, 20, 22, upper and lower coronary veins; 21, transverse vein of the face; 23, continuation of the vein towards the side and root of the nose; 24 anastomoses with the orbital veins; 25, occipital vein; 26, 27, temporal vein; 28, 29, anterior branches of the temporal; 30, trunk of the temporal descending branch, uniting with the external and internal jugular veins.

between them, and behind. The vein has the same anatomical relations as the artery. By joining inferiorly the subclavian vein the *vena innominata* is formed.

SUBCLAVIAN VEIN.—Certain superficial veins situated in the bend of the elbow, being those usually selected for phlebotomy, have received more attention than much larger vessels, owing, no doubt, to their practical importance.

Fig. 189.*

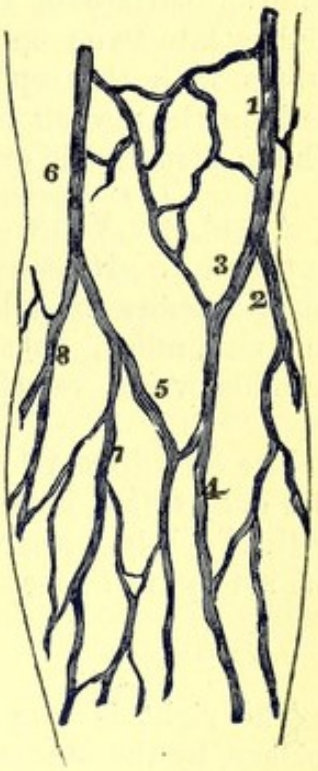

The VEINS OF THE THORACIC EXTREMITIES may be divided into two sets, the superficial and the deep. Commencing with the extremities of the fingers, we shall find that the deep veins follow very regularly the course of the arteries, and receive their names accordingly—as radial, ulnar, interosseal, &c. These unite at the bend of the elbow into two vessels (venæ comites, or satellites), which follow the course of the humeral artery, and anastomose, by cross branches, with each other. Finally, they unite into one, becoming the axillary vein, the surgical anatomy of which has been already described with the artery. The same vein continued upwards gets the name of subclavian, forming one of the great divisions on either side of the venæ innominatæ, from the union of which the vena cava superior is formed.

2. The superficial veins of the limb are thus arranged; they lie embedded in the superficial fascia.

CEPHALIC VEIN.—Commences by a number of fine twigs, disposed in the form of a network on the back of the hand and muscles of the thumb. These unite into a single trunk. This trunk ascends along the anterior and external part of the fore-arm, and is here called the superficial radial vein. Numerous branches join it in this region; on arriving at the bend of the elbow, it receives the median-cephalic, a branch larger, generally, than the so-called radial. These two, uniting, form the trunk of the cephalic, properly so called. This vessel ascends vertically at the outer and fore part of the arm, along the external edge of the biceps muscle, at first subcutaneous, afterwards dipping into the triangular cellular space separating the pectoralis major and the deltoid. Thus bending inwards under the clavicle, it opens into the axillary vein, not unfrequently communicating, by a twig, with the external jugular.

* Fig. 189.—Sketch to illustrate the superficial veins at the bend of the elbow; left arm.—1, cephalic vein; 6, basilic vein; 3, median cephalic; 2, superficial radial veins; 5, median basilic; 7, 8, anterior and posterior cubital; 4, common median veins.

BASILIC VEIN.—This vein is formed by the superficial veins of the fore-arm, called the *posterior ulnar* and *anterior ulnar*. These uniting form the *basilic* vein. After receiving the *median basilic* the basilic vein ascends along the inner part of the arm before the ulnar nerve, anastomosing with the cephalic. It gradually passes through the deep fascia or aponeurosis, and joins the axillary.

The MEDIAN VEIN, irregular in its arrangements, like those just described, is formed of a number of superficial veins expanded over the anterior surface of the fore-arm. About the bend of the elbow it divides into two; one joins the basilic, the median basilic; the other unites with the cephalic, the median cephalic. Of all these veins perhaps the median cephalic is the only safe vein for the phlebotomist. The median basilic ought uniformly to be avoided.

AXILLARY VEIN.—This vein is the result of all those just examined in the arm. It ascends in front of the artery, until reaching the first rib it becomes the subclavian. In this part of its course it receives the circumflex, subscapular, long thoracic, superior thoracic, and acromial veins, vessels named from their corresponding arteries.

The SUBCLAVIAN VEIN extends from the lower margin of the first rib, over which it passes to its junction with the internal jugular, with which it forms the vena innominata. It is situated in front of the artery, and is separated from it by the scalenus anticus muscle.

VENÆ INNOMINATÆ.

The right is very short. It is covered by the sterno-cleido mastoideus, by the sterno-clavicular articulation, by the cartilage of the first rib, and by a small portion of the sternum. Externally and posteriorly it is in relation to the right lamina of the mediastinum, the pneumo-gastric nerve, the right subclavian artery, and the scalenus anticus muscle. Internally it corresponds to the aorta. It is shorter than the left.

The left vena innominata is longer than the right, and more nearly horizontal. Its relations are in some respects similar to those of the right, but in addition, as it comes over from the left to the right side, it is covered by nearly the whole breadth of the sternum, and lies on the arch of the *aorta* and *arteria innominata*.

The venæ innominatæ receive each of them the vertebral and the superior intercostal veins. The left is joined by two others—the left internal mammary and the left inferior thyroid.

1. The VERTEBRAL VEINS commence in the muscles of the superior and external occipital and cervical regions, by a great number of roots, which collect into a single trunk towards the foramen magnum occipitale. This trunk proceeds forwards to the superior surface of the atlas, enters the foramen at the base of the transverse process, and,

descending through the foramina of the cervical vertebræ, emerges at the sixth or seventh, passes before the subclavian artery on the left side, and behind it on the right, and opens posteriorly and inferiorly into the vena innominata.

In this course it receives several branches, and anastomoses with the vertebral sinuses by the foramina intervertebralia.

2. The RIGHT SUPERIOR INTERCOSTAL VEIN collects the branches coming from the two superior intercostal spaces into a single trunk, which joins the innominata posteriorly, near the vertebral.

The LEFT SUPERIOR INTERCOSTAL VEIN is larger than the right. It collects into a single trunk the branches coming from the left intercostal spaces, as low, sometimes, as the seventh or eighth, anastomosing, as it proceeds upwards, with the vena azygos and the semi-azygos. It ascends vertically behind the pleura on the side of the bodies of the vertebræ: it then passes behind the lung and aorta, and there receives the left bronchial. After this it leaves the thorax by the superior aperture, and joins the left *vena innominata*.

3. The LEFT INTERNAL MAMMARY VEIN.—This vein corresponds strictly to the artery of the same name. It is strengthened by the superior phrenic, left mediastinal, and thymic veins. It enters the left vena innominata.

4. The LEFT INFERIOR THYROID VEIN, with the vein of the opposite side, forms a plexus, from which the single trunk arises; this opens inferiorly and posteriorly into the left vena innominata.

The VENA CAVA SUPERIOR.—The trunk of this vein, formed as we have seen, is much longer than the thoracic portion of the inferior cava. It commences opposite the cartilage of the first rib, a little above the arch of the aorta, descends to the left and forwards as far as the base of the pericardium, from which it receives a fibrous sheath. It next enters the sac of the pericardium, descends vertically, and to the right of the aorta, and finally opens into the right auricle of the heart.

Posteriorly the vena cava superior is in relation to the superior right pulmonary vein and artery.

The trunk of the cava receives the following veins:—

1. The RIGHT INTERNAL MAMMARY VEIN.—This requires no special description.

2. RIGHT INFERIOR THYROID.—In most respects similar to the left.

3. SEVERAL THYMIC, mediastinal, pericardiac, and superior phrenic branches, all from the right side.

4. The VENA AZYGOS.—This important vein connects the systems

Fig. 190.*

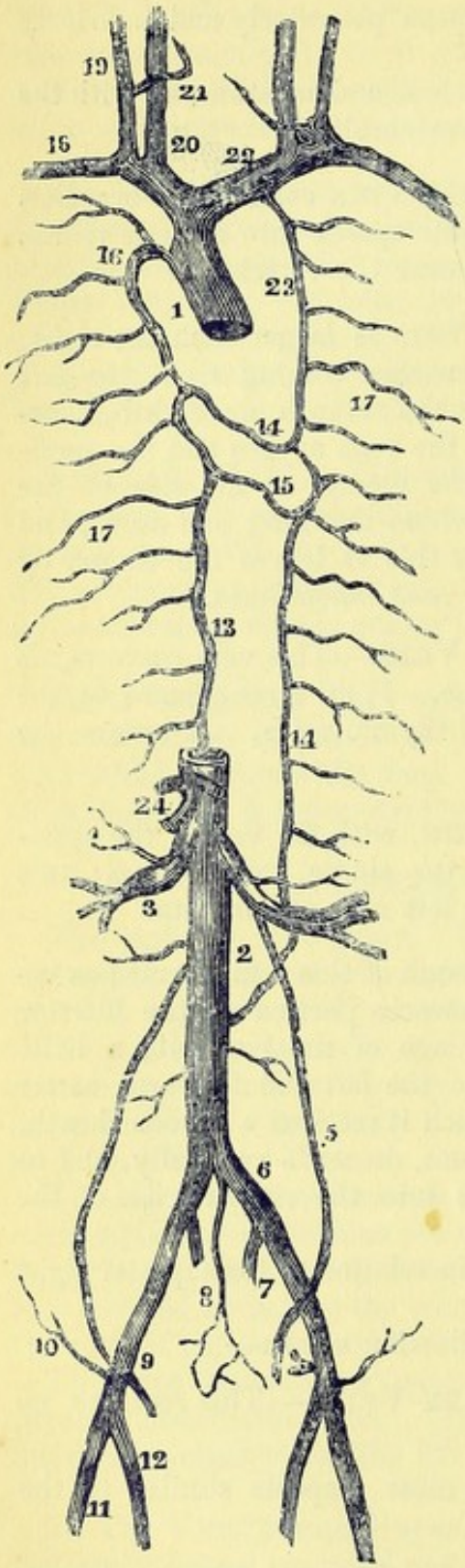

of the two cavæ. It commences in the abdomen, either directly from the inferior cava itself, or indirectly from one of the lumbar veins. As it ascends it passes, with the aorta and thoracic duct, behind the diaphragm into the thorax; here it is placed to the right of both these vessels, and before the intercostal arteries. In the chest it collects the right intercostal veins corresponding to the arteries of the same name, at each of the intercostal spaces, with the exception of those of the first and second (right side), which join the vena innominata. At about the seventh dorsal vertebra the azygos vein receives the left or semi-azygos. This is a considerable but variable vein, which commences by a branch from the renal vein or the first lumbar, passes through the diaphragm by a special aperture, and, proceeding through the chest parallel with the aorta, collects the inferior left intercostal veins, and then passes behind the aorta and œsophagus, to join the azygos of the right side. These veins are subject to many varieties.

OF THE VERTEBRAL VENOUS SINUSES AND VEINS OF THE MEDULLA SPINALIS.

Two great venous canals, quite different from the sinuses of the dura mater, extend behind the bodies of the vertebræ, the whole length of the vertebral column.

Opposite the anterior condyloid foramina these sinuses communicate with the internal jugular vein, but they have no communication with the sinuses within the cranium.

* Fig. 190.—Showing the system of the vena azygos.—1, vena cava superior; 2, vena cava inferior; 3, right renal vein; 4, capsular vein; 5, left spermatic; 6, left common iliac vein; 7, hypogastric vein of this side; 8, vena sacri

The sinuses of each side communicate by a transverse sinus behind the body of each vertebra. These transverse sinuses pass between the ligament and the bone, and receive the veins which, coming from the osseous structure, are analogous to the veins of the diploë.

In the interval of the transverse processes these vertebral sinuses communicate with the vertebral, intercostal, and lumbar veins.

In the sacral canal these sinuses become diminished, and alter in character; they more resemble veins, and have no adhesion to the soft parts.

Fig. 191.*

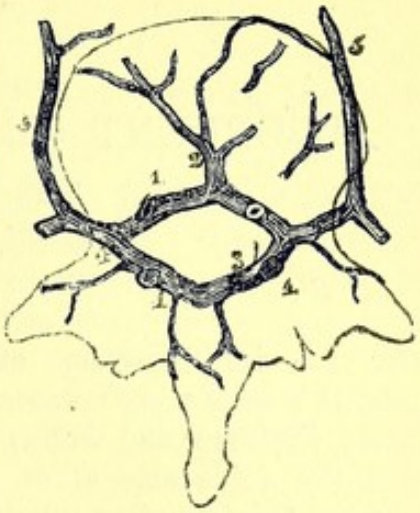

The veins of the spinal marrow have the same disposition as the arteries of that organ. They accompany them, and open into the inferior cerebellar veins.

media; 9, right iliac vein; 10, circumflex iliac vein; 11, superficial femoral; 12, deep femoral; 13, *vena sine pari*, right azygos vein; 14, left azygos; 15, junction of the left azygos with the right; 16, right azygos; 17, the left intercostal veins; 18, right subclavian; 19, right external jugular; 20 points to the right vena innominata; 21, right internal jugular; 22, left innominata; 23, superior left intercostal, collecting as it descends a certain number of the superior intercostal veins; 24, hepatic veins.

* Fig. 191.—Sinuses of the vertebræ.—1, 1, 1, 1, longitudinal sinuses, laid open; 2, anterior transverse sinus, into which there enters a sinus of the body of the vertebra; 3, posterior transverse sinus; 4, 4, lateral transverse sinuses; 5, 5, external veins communicating with the vertebral sinuses.

ABSORBENT OR LYMPHATIC SYSTEM OF VESSELS.

PRIOR to the discovery of the lacteals, lymphatics, and their glands, the veins were considered as the only absorbing vessels. The Hunters, William and John, and the school they gave rise to, discarded the veins altogether from their office of absorbing vessels, bestowing this function wholly and exclusively on the lymphatics, or absorbent vessels properly so called. Lately, physiologists have made efforts to restore at least a portion of the office to the veins.

But be this as it may, it is undoubted that to this system of vessels belongs mainly the function of absorbing,—1st, by means of the lacteals, the fluid called chyle, the product of digestion; as this fluid resembles milk, at least in colour and general appearance, the vessels conveying it from the intestinal tube have been called lacteals; 2d, of taking up or absorbing from nearly all the tissues of the body a fluid called lymph; hence the name lymphatics, or carriers of lymph.

These two sets of vessels strongly resemble each other anatomically, though differing probably physiologically. The lacteals arise from the mucous membrane of the small intestines, and their mode of origin has not been clearly made out; but one thing is certain, they proceed in great numbers to pass through certain bodies called lacteal glands (mesenteric, as being placed in the mesentery), on leaving which they terminate in the thoracic duct, the termination of which is near the junction of the left subclavian and left jugular veins. Thus the chyle is poured into the veins, where it mingles with the venous blood.

But it is into the thoracic duct that by far the greater part of the common lymphatics or absorbents, arising in all the textures of the body, also pour their contents. The fluid circulating or flowing in the thoracic duct is then of a mixed character, and, at least after digestion, must be held to be composed of two opposite and distinct substances; that, namely, which is proceeding towards the heart to restore the losses of the body, and that refuse portion of the organs which has already served the purposes of nutrition.

As this system of vessels was discovered by piecemeal or fragments, so is it usually investigated by the student. One portion of it he sees at one time and during one dissection, another at another. He never attempts, nor is it incumbent on him to do so, to dissect the

absorbent system systematically and continuously; but it is right that a systematic description of the system be placed before him. This is the object of the present brief chapter.

DISSECTION AND DISPLAY OF THE LYMPHATICS, AND LACTEALS, AND THEIR GLANDS.

These vessels, being all but transparent, are difficult of detection; nevertheless, by a little practice this can be effected. The instruments required are a fine glass tube, with stopcock and steel pipes; the glass tube to be filled with mercury. The mesentery is next spread out, and one layer of the serous membrane cautiously removed. Fine vessels may be seen, if looked for with a good light, imbedded in the cellular membrane, along with the mesenteric or meseraic vessels; their coats are not quite transparent. One must be cautiously punctured in its axis with a sharp-pointed lancet, and the nozzle of the pipe introduced for some distance. Herein lies the only difficulty. The pipe is apt to tear the inner tunic of the vessel from off the outer, and effectually obstruct the flow of the mercury. Great care also must be taken that the mesentery be not stretched or compressed by any obstructing body, between the artificial opening made in the vessel and the mesenteric glands. These precautions having been attended to, the mercury will flow from the glass tube into the lacteal, directly towards the mesenteric glands, showing the course the lacteals are taking. Into these glands all the lacteals enter, and, after ramifying throughout the glands, they quit them to proceed at last to the thoracic duct.

Whilst proceeding to the glands they are called *vasa inferentia;* when leaving them for the thoracic duct they are denominated *vasa efferentia;* but they are the same vessels.

By the same method the lymphatics may be shown in any other part of the body. They will be readily found in the subcutaneous cellular tissue, &c.

The lymphatic or absorbent system, then, is composed of vessels and glands, or at least of bodies which are called so. The vessels are long, extremely delicate, and almost pellucid tubes, presenting when full, at short intervals, dilatations, giving to them a knotted appearance. This is due to the presence of valves, placed in the interior of these tubes, whose arrangement and functions altogether resemble what has been shown to prevail in the veins.

As a necessary result of the presence and strength of these valves, the lymph and chyle can only flow in one direction, that is, from branch to trunk; hence the difficulty of their dissection and injection. The motor power is not known, but the fact is certain.

The absorbents are extremely numerous, and have been demonstrated in most organs of the body; their presence, however, in the brain, spinal cord, their membranous envelopes, the eye and ear, has not been satisfactorily demonstrated.

These vessels are arranged in two distinct planes, a superficial and a deep seated.

The *superficial* are found on the periphery of the body, in the subcutaneous cellular tissue; the *deep seated*, arising also in the cellular tissue, collect in bundles around the great blood-vessels, whose direction they follow; but these two planes unite freely and form plexuses. Occasionally a great number of twigs collect into a single trunk; this trunk again subdivides and afterwards re-unites.

The largest, but not the only terminating trunk of the whole system, is the thoraic duct, a vessel already described in the anatomy of the thorax. In this trunk terminate directly or indirectly,—

1. The lymphatics of the lower extremities. 2. Those of the abdomen, including the lacteals. 3. Those of the left side of the thorax and left upper extremity. 4. Those of the left side of the head and neck.

The lymphatics of the right side of the head and neck, right upper extremity and right side of the thorax, terminate in a short trunk situated on the right side of the superior dorsal vertebræ. This trunk joins the venous system at the junction of the right subclavian and right jugular veins.

The *Lymphatic conglobate glands* occur in the course of these vessels. Through these glands the vessels pass seemingly uninterruptedly, that is, without losing their character of vessels. Nothing is known of the functions of these glands. They vary in diameter from the twentieth part of an inch to an inch. Their colour is reddish, changing to grey, and they are enveloped by a compact capsule of cellular tissue. Though occasionally isolated, they are more generally collected into groups, and abound in the abdomen.

The groups of mesenteric glands may amount to a hundred; they abound also around the vena portæ, splenic artery, aorta, between the laminæ of the mesocolon (mesocolic), along the two curvatures of the stomach (gastro-epiploic). A variable number may be seen in front of the lumbar vertebræ; others in the line of the iliac vessels. Lastly, they abound in the groins, the axillæ, and the neck.

The names given them are generally derived from their position, as cranial, cervical, sacral, hypogastric, inguinal, deep, or superficial.

In the neck the superficial are found chiefly below the platysma myoides; the deep-seated (glandulæ concatenatæ) near the internal jugular vein and carotid artery. They here form a chain extending from the mastoid process to the superior orifice of the thorax, prolonged backwards between the pharynx and vertebral column.

In the superior extremity the lymphatic glands (as do the vessels) follow closely the line of the great blood-vessels, from the elbow to the axilla. A lymphatic gland is generally found immediately above the inner condyle of the humerus; in the axilla they abound, and are of great size.

In the inferior extremities, one of the glands we now describe is very uniformly found on the lower extremity of the interosseous

ligament; it has been called anterior tibial. In the popliteal space, where they are called popliteal, they are somewhat numerous but small; in the inguinal region (inguinal glands) they are large and numerous, and have been divided into two layers, a superficial and deep. The superficial, varying from six to twelve in number, surround the saphena vein, imbedded chiefly in the cribriform fascia. The deep inguinal, four or five in number, embrace chiefly the femoral artery.

Although I have examined the thoracic duct very carefully many hundreds of times, I have never found it in any way injured or diseased, nor have its contents presented anything remarkable. Twice I have seen the gastro-epiploic lymphatics filled with a matter resembling scrofulous purulent fluid; in these cases the conglobate glands were filled with the same matter. The lymphatic glands throughout the body are liable to constitutional disease. Though slow to inflame, inflammation of the lymphatics, when it does occur, is extremely rapid and fatal, as exemplified by puerperal fever and by poisoned wounds of the fingers, occurring in dissection. When inflamed, they enlarge to a great size, and become filled with pus. The functions of the system are, upon the whole, still but little understood.

THE LYMPHATIC VESSELS OF THE INFERIOR EXTREMITIES.

Commencing in the cellular tissue, the superficial follow the course of the saphenæ veins, the deep that of the great blood-vessels. The lymphatics of the haunches join the superficial inguinal glands, as do those of the loins the lower half of the walls of the abdomen, those of the perineum, scrotum, and penis.

In the female the lymphatics of the labia pudendi and clitoris have the same termination.

The deep obturator, ischiatic, and genital lymphatic vessels accompany their respective arteries, terminating in the hypogastric or the lumbar glands.

The lymphatics of the uterus are of large size at the period of gestation, but diminish and become microscopic in the unimpregnated condition of the organ. They unite with those from the vagina, and terminate in the hypogastric glands.

The vessels arising from the ovaria, and those found in the course of the broad ligaments, form plexuses which ascend along the spermatic vessels and pass into the lumbar glands.

The renal, capsular, and vesical lymphatics follow very closely the course of the blood-vessels connected with these organs, and communicate with the lumbar glands.

The lymphatic vessels of the abdominal and pelvic walls are also very numerous; they accompany the arteries, giving rise to plexuses called the external iliac, hypogastric, lumbar, aortic, &c.

The lymphatic and lacteal vessels of the stomach and intestines are important. They may be subdivided into two sets,—1, lacteals, pro-

perly so called; 2, common absorbents. I believe these vessels to be physiologically distinct.

1. The lacteals are readily found on carefully inspecting the mesentery and cautiously removing one of its layers. They are very numerous. I have already spoken of these vessels. They are found only in the mesentery, and are the more numerous the higher up they are examined. The functions of these vessels have been tolerably well made out; but this cannot be said of those lymphatics which arise from the mucous membrane of the stomach and of the large intestine. The fluids they contain have not been analysed. Numerous lymphatics arise from the cellular surface of the peritoneum, others from the spleen, pancreas, and liver. But however originating, they all terminate directly or indirectly, after having passed through various absorbent glands, in the thoracic duct.

DUCTUS THORACICUS SINISTER.

This important vessel, which however is not larger than a crow's quill, commences on the body of the third lumbar vertebra, by the successive union of five or six large trunks, resulting from the assemblage of nearly all the lymphatic vessels and plexuses I have just enumerated.

At its commencement the duct generally presents a dilatation (*receptaculum chyli* *), which gradually passes behind the aorta, at the anterior and left part of the second lumbar vertebra. The duct, contracting, ascends into the chest, between the crura of the diaphragm, with the aorta on its left side and the vena azygos on the right. As it ascends through the chest, imbedded in the loose cellular tissue of the posterior mediastinum, it continues to contract as far as the sixth dorsal vertebra; after which it gradually dilates, ascends behind the aorta to the left subclavian artery, on the inner side of which it is placed, resting on the longus colli muscle. It then reaches the seventh cervical vertebra, bends inwards and downwards, passes behind the left thyroid artery and internal jugular vein, and here enters the left subclavian vein.

Two valves are found at its entrance into the vein, the functions of which may be to prevent the blood circulating in the vein passing into the duct.

The course of the duct through the chest is commonly straight, but sometimes flexuous; and in some cases it has been observed to divide into branches, which again reunited before it reached the subclavian vein.

The lymphatics of the lungs and heart are superficial and deep. They pass through the bronchial glands, from which different vessels proceed to the right or imperfect thoracic duct; but the greater number join the left or thoracic duct, properly so called.

* The receptaculum is not intended solely for the reception of the chyle: all the lymph collected in the sub-diaphragmatic half of the body of necessity passes through it.

The general disposition of the lymphatics of the superior extremities resembles that which obtains in the lower.

The epicranial lymphatics descend and pass through the conglobate lymphatic glands of the neck on their way to the right and left thoracic ducts. Disease or a wound of the scalp may give rise to an enlargement of the lymphatic glands of the neck, which must not be confounded with constitutional disease, properly so called.

Some rare occasions have occurred in which the valves of the lymphatics happened to be imperfect, at least in so far as not to perform their functions; in such cases the absorbents could be injected from trunk to branches.

Fig. 192.*

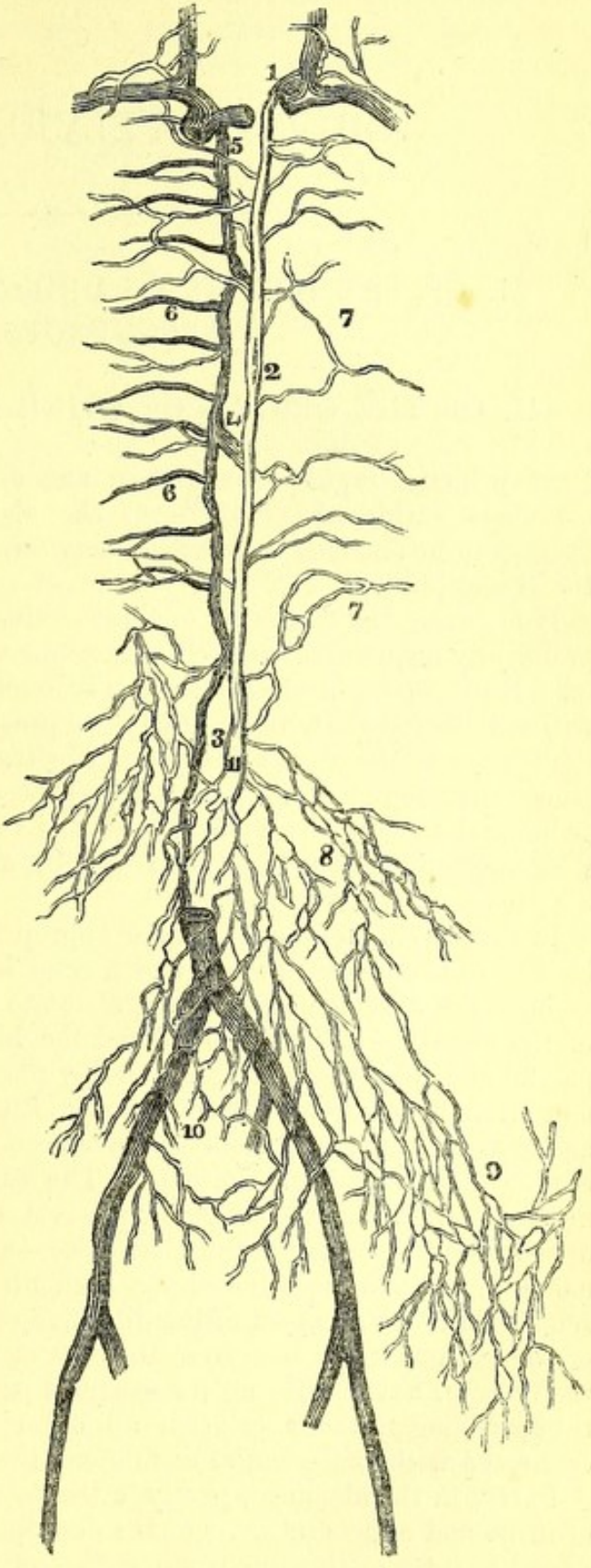

* Fig. 192.—To show the formation and course of the thoracic duct.—1, termination of the thoracic duct; 2, splitting into two ducts, which again unite; 3, lower end of the duct, near the receptaculum chyli; 4, left azygos vein, crossing behind the duct to join the right azygos; 5, right azygos, or *vena sine pari*; 6, intercostal veins entering the right azygos; 7, 8, 9, 10, these numbers are placed on numerous lacteals and lymphatics, proceeding to join the thoracic duct from the abdominal cavity and its contents.

ABDOMINO-PELVIC CAVITY.

I. OF THE ORGANS OF DIGESTION AND THEIR APPENDAGES.

II. OF THE ORGANS OF URINE AND GENERATION.

THE principal organs of digestion and of urine and generation are contained within the cavities of the abdomen and pelvis. These cavities form but one, the division between them being merely conventional and ideal.

It is during the dissection of these cavities that the student becomes practically acquainted with the numerous viscera I am about to speak of. But keeping in view, also, the systematic character of this work, without interfering with its utility in a practical sense, I shall introduce the history of the organs of digestion by tracing them from the mouth, where they commence. I shall then proceed with the contents of the abdominal and pelvic cavities, expose the various methods of dissecting these segments of the trunk, and describe, as I proceed, systematically, the organs successively exposed.

In former chapters, and in their appropriate place, will be found the history of the larger muscles which come in contact with and exercise an influence over the organs I am about to speak of. In the myology of the head and neck will be found the history of the muscles of the palate and pharynx; even the fleshy fibres of the gullet, although not strictly belonging to the system of voluntary muscles (muscles acting with our consciousness), have been alluded to in the dissection of the thorax and its contents. The osseous, muscular, and ligamentous walls of the abdomino-pelvic cavity have been already described; the perineal muscles, also—all, at least, entitled to the name of distinct muscles—have been already pointed out. What remains, then, in respect of the digestive organs, is to trace the course of the mucous membrane from the edge of the lips to the extremity of the rectum, as constituting the essential portion of the great digestive tube; adding to the description all other structures and appendages connected with the essential membrane, the mucous.

Partly in the abdomen, partly in the pelvis, will be found the organs of urine and of generation, and the description of these will occupy the second chapter of this important section of the work.

ORGANS OF DIGESTION.

The great digestive canal commences on the face. The due performance of all its functions requires, in man, the following organs, each having distinct functions:—

1. Organs of prehension: the mouth and lips.
2. Organs of mastication: the teeth.
3. Organs of insalivation: salivary glands.
4. Organs of deglutition: the pharynx and gullet.
5. Organs of digestion (including defecation): the stomach and the small and large intestines.
6. Organs of secretion, or appendages of the intestinal canal: liver, spleen, and pancreas.

The mouth or buccal cavity.—The common integuments of the face, as they approach the margins of the lips and nostrils, begin to lay aside their character of integument or external envelope, and to assume that of mucous membrane or internal integument. It has already been shown how the portion lining the interior of the nostrils, proceeding backwards, becomes, or is continuous with, that investing the pharynx and gullet; the same happens with that lining the buccal cavity, which, at the *isthmus faucium*, is also continuous with that of the pharynx. But here the membrane divides into two great portions, one, namely, which, passing into the larynx, becomes the lining membrane of the organs of respiration, which has been already described; the other, descending into the stomach by the gullet, may be traced continuously to the anus.

It is the latter of these divisions which now remains to be examined.

I.—ORGANS OF PREHENSION.

MOUTH AND LIPS.

The mouth, which varies so much in different individuals, is a nearly oval cavity, placed horizontally, comprised between the two jaws, bounded laterally by the cheeks, anteriorly by the lips, posteriorly by the velum palati and the pharynx; above by the arch of the palate, and below by the tongue. The mucous membrane may be traced on the free edge of the under lip, the posterior surface of which it lines, to be afterwards reflected upon the body of the maxillary bone; there it forms, opposite the symphysis of the chin, a fold, more developed below than above, named the *frænum of the under lip*, which is lost insensibly upon the lip. The membrane then sends into each alveolus a prolongation which strengthens the insertion of the roots of the teeth, and is continuous with a membranous lamina lining these cavities. Thence it proceeds over the posterior surface of the

frænum of the tongue, covers that organ, gains the epiglottis, and is continued into the mucous membrane of the larynx and pharynx.

Superiorly it commences on the free edge of the upper lip, forms between it and the superior maxillary bones a *frænum*, gains the upper alveolar arch, sends prolongations into the corresponding alveoli, passes to the vault of the palate, of which it closes the anterior and the two posterior foramina, receives the nerves and vessels which pass through them, and is reflected over the fore part of the velum palati, on the free edge of which it is continuous with the pituitary membrane. On either side this membrane, proceeding from the commissure of the lips, lines the cheeks, and proceeds over the rami of the inferior maxillary bone, forming a vertical fold opposite their anterior edge. At the backmost part it turns over the constrictor isthmi faucium and palato-pharyngeus muscles, to form the pillars of the velum palati, between which it covers the tonsils. Beyond this it is continuous with the membrane of the pharynx. The mucous membrane of the mouth varies in structure, and is covered by a distinct epithelium. At this stage of the dissection the student may examine the structure of the lips. At the back of the mouth he will observe the velum pendulum palati, descending from which are the two anterior pillars of the fauces, one on either side.

To examine these minutely, cut through the cheek on one side, and also through both pillars of the fauces and the tonsil of the same side. The side which remains entire, and is thus fully brought into view, will give an exact notion of the relative position of the fauces, and of the tonsils lying between them.

The tonsils (*amygdalæ*) are bodies lodged between the pillars of the velum palati.

They represent an ovoid, of which the *large extremity*, directed upwards, corresponds to the point at which the pillars meet, while the *small extremity*, which looks downwards, rests upon the base of the tongue.

Their *external surface* adheres to the constrictor pharyngis superior muscle; the *internal*, convex and free, projects, and constitutes the sides of the isthmus of the fauces; their *anterior edge* touches the constrictor isthmi faucium muscle; the *posterior* touches the palato-pharyngeus. They are divided into several lobes, have a greyish colour, and appear formed by a pulpy tissue resembling that of those follicles. They are filled internally by cellules, open on their inner surface, whose orifices are large; the mucous membrane of the mouth lines their wall. In their bottom, excretory ducts are observed to open from a mass of follicles, forming the substance of the tonsil externally. The arteries of the tonsils come from the lingual, inferior palatine, and internal maxillary arteries; their nerves from the lingual and glosso-pharyngeal.

The tongue is very moveable, and extends from the hyoid bone to behind the incisor teeth; it is used in sucking, mastication, deglutition, speaking, &c.: it has two surfaces, two edges, and two extremities.

The upper surface is entirely free and flat, covered by the mucous membrane of the mouth, with a groove running along the middle, and dividing it into two equal lateral portions. Towards the back part of this surface there is a depression called the foramen cœcum; from this point two lines formed of papillæ proceed forward, diverging from each other. All this surface of the tongue is rough with nervous papillæ. The fore part of the tongue is called the apex, the central part the body, the posterior part the base. The apex is free inferiorly: the body and base are fixed by numerous and powerful muscles to the inferior maxilla and hyoid bone: the edges are also free. The mucous membrane covering the upper surface of the tongue passes from it uninterruptedly upon the epiglottis. Three folds may be observed here, one mesial and two lateral; these are called the ligaments of the epiglottis. The tongue is very thick at the level of the foramen cœcum, but it becomes thinner as it approaches the hyoid bone: its apex, inferiorly, is fixed to the inferior maxilla by the *frænum linguæ*, a fold of mucous membrane.

The *fleshy or muscular portion* forms the greater part of the organ, and is composed of fibres of the stylo-glossi, hyo-glossi, and genio-glossi muscles; their fleshy fibres interlace in an inextricable manner, and form, at the upper region of the tongue, a layer in which it is impossible to discern them, and in which there is interspersed a multitude of small globules filled with an almost fluid fat, placed very close upon each other, which gives them a flattened form; they become paler in colour the nearer they approach to the back of the organ. On the sides of the tongue may be distinguished an inferior longitudinal muscular plane, formed by the linguales and stylo-glossi muscles; and another plane lying above the latter, with transverse fibres, formed by the genio-glossi, and surrounded by the proper tissue of the tongue. These interlaced fibres have been described, lately, by Gerdy and others, as distinct muscles, under the names of superficial lingual, vertical lingual, and transverse lingual. At the centre of this fleshy tissue, and in the direction of the median line, there occurs a *fibro-cartilaginous lamina or septum*, of a whitish colour, stronger behind than before, having *its upper edge* concealed in the substance of the organ, at a considerable distance from the mucous membrane; and the *lower* free, in the interval of the genio-glossi muscles. This septum is continued posteriorly as far as the body of the hyoid bone, and, by its two lateral surfaces, gives attachment to muscular fibres. To exhibit this elastic septum the tongue may be cut across about the middle, or the septum exposed at the base, or vertically.

The *papillæ* on the upper surface of the tongue are of three kinds—*lenticular*, from nine to fifteen in number, arranged in the form of a triangle without a base; *fungiform*, placed near the edges at the point of the tongue; lastly, *conical*,—these are most numerous, and are spread generally over the surface.

The nerves of the tongue are furnished by the inferior maxillary, glosso-pharyngeal, and hypoglossal. The filaments of the latter

belong especially to its muscles, those of the glosso-pharyngeal chiefly to certain papillæ and to the mucous surface. The first is distributed to the mucous membrane, and to the conical papillæ. The arteries come from the lingual, palatine, and tonsillar twigs of the labial. Its veins are the superficial lingual, ranine, lingual, and sub-mental; they open into those of the pharynx and larynx. Its lymphatic vessels go to the gland on the edge of the hyo-glossi muscles.

II.—ORGANS OF MASTICATION.

THE TEETH.

In the course of life man has two sets of teeth—1st, the temporary, deciduous, or milk teeth; 2d, the permanent.

The temporary are 20 in number; the permanent 32. Each jaw carries the same number. Deficiencies are not unfrequent, and supernumerary teeth have also been observed.

General characters.—The human teeth differ in this from those of all other recent animals, that, although comprising three different kinds, their summits are yet on a level.* Each tooth has its own peculiarities, but still there are structures and circumstances common to all. Each, for example, has a *corona* projecting above or beyond the gum; a narrow constricted part follows it, called the neck; and a third, the radix, root, or fang, is implanted in the alveolus intended to receive it.

Each alveolus is invested by a vascular periosteum, which is reflected over the fang as high as the neck. This covering seems to contribute in an unknown way to the vitality of the tooth.

The *permanent teeth*, 32 in number, 16 in each jaw, are divided (above and below) into four incisors, two canine, four bicuspids or small molars, and six true molar teeth. Among the temporary teeth there are no bicuspids.

The incisors are chisel-shaped, and have a sharp horizontal cutting edge; this becomes beveiled off and worn away by trituration during life. Before the wearing away takes place the edge is slightly serrated or notched; for it must be borne in mind that the instant a tooth cuts the gum it begins to lose its original form. The fang of the incisor is single, long, and conical. The upper and lower incisors differ in form.

The *canine teeth*, four in number, follow the incisors: they are larger and stronger, and have been called cuspidati. The fang is single, conical, and strong. A slight groove is seen on its sides.

The *small molars* (bicuspidati) are four in number in each jaw: they follow the canine. The corona is surmounted by two tubercles or cusps, and the fang has a tendency to divide into two. The

* In the *extinct* anaplotherium this peculiarity also existed.

apex of the fang is bifid. The upper bicuspids are larger than the lower.

Fig. 193.*



The *true or large molar teeth*, or *multicuspidati*, are 12 in number, three on each side in both jaws. The first is the largest; the third the smallest. This is called the wisdom tooth. It often appears late in life. The upper molars have, on the corona, four cusps; the lower ones five. The fangs are multiple, being two or three.

The *milk teeth* should be carefully looked at whilst entire and in the jaws; they are smaller than those which follow. The last molar is the largest of these teeth, and the corona exceeds in size the permanent bicuspid which is to follow it. Moreover, the milk molar teeth are not bicuspids, but resemble, by their coronal surface, the permanent multicuspidati.

Structure.†—When a tooth is divided vertically it is found to be hollow in the centre. This hollow occupies the interior of the corona, and extends as a canal to the apex of the fang, where it opens on the surface. This central cavity is called the pulp cavity, being filled with the dental pulp (dentar vitrine), a vascular and highly sensitive pulpy substance. The vessels and nerves reach the pulp by the canal and aperture in the fang.

The solid portion of the corona of the tooth is composed of three distinct substances, namely, 1st, the ivory; 2d, the enamel; 3d, the crusta petrosa, or cement. Of these the first, or ivory of the tooth, lies deepest, and forms by far the larger portion of the tooth; the second, or enamel, covers the corona and tubercles, or free surfaces; the third is a thin layer of a peculiar substance investing the ivory of the fang.

The ivory is dense and compact, resembling compact bone, but it is not identical in structure. It is composed of 28 parts of animal matter (gelatine) and 72 of phosphate of lime, with traces of fluoride of calcium, carbonate of lime, phosphate of magnesia, and other salts.

When examined under the microscope the ivory structure of the tooth is found to be composed of innumerable fine tubes, passing through a matrix or dense intermediate or intertubular tissue.

The *dental tubuli* were discovered by Leeuwenhoek, and again described by Purkinje and Retzius.

The tubes or tubercles open into the central cavity of the tooth, and pass in a radiated manner to the periphery of the ivory. From these

* Fig. 193.—To show the formation of a molar tooth with two fangs.—1, the caps of dentine, at first distinct, but which afterwards unite; 2, a bridge of dentine beginning to stretch across the base of the tooth-pulp; when complete the pulp is henceforth double; 3, the tooth fully formed.

† The true history of human dentition was discovered by Hunter; that of other mammals by Cuvier: their intimate structure by Leeuwenhoek and Retzius.

Fig. 194.*

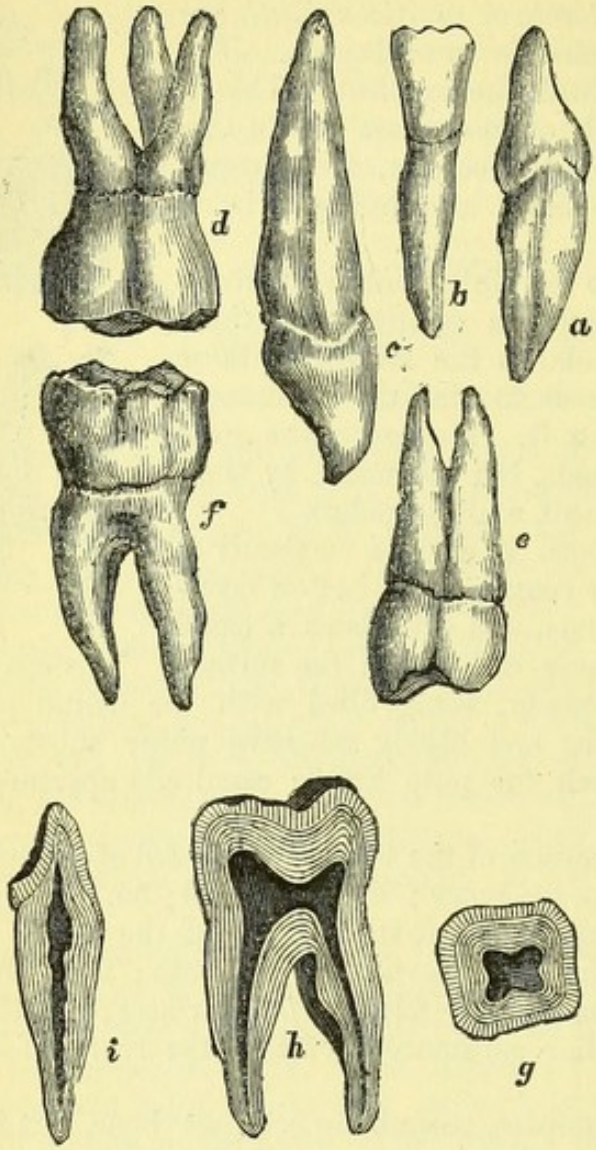

primary tubes, as they may be called, spring branches of inconceivable fineness, which penetrate the intertubular tissue; they are supposed to end in minute cells; the tubes themselves also divide and subdivide before they reach the periphery; they are generally considered, also, as passing into the cement.

The *intertubular* substance is translucent and finely granular: its precise nature is still doubtful.

The *enamel* is the hard white substance encrusting the crown of the tooth. Though extremely hard, it becomes worn by trituration. When the tooth is charred the dentine blackens, but the enamel remains white. It has 96·5 per cent. of earthy constituents; the remaining 3·5 of animal substance. It is made up of very hard and dense microscopic fibres or prisms, arranged closely together side by side (Retzius).

The crevices observed in the enamel, running so deep as sometimes to reach the ivory of the tooth, are supposed by some to contribute to the formation of caries or decay. The prisms composing the enamel are conjectured to be originally formed in cells, the membranous walls of which gradually disappear.

The *crusta petrosa* is best seen on the molar teeth of the elephant. In man it forms an extremely thin covering, investing the fang, but pro-

* Fig. 194.—*a*, the middle incisor seen in profile; *b*, a lower incisor, front view, showing the serrated form of the cutting edge before being brought into use; *c*, a canine tooth, showing the lateral groove; *d*, the first molar, upper jaw; *e*, one of the small molar teeth, *bicuspidati*; *f*, first molar, lower jaw; *g*, *h*, *i*, transverse and longitudinal sections of the teeth, to show the form and extent of the pulp cavity.

bably at first extending over the corona and neck. It contains cells and canaliculi, and its structure more resembles bone than does that of the ivory of the tooth. It is now considered as a layer of true bone, distinct from the other component parts of the tooth in this respect. Towards the lower end of the fang it becomes thicker, and at last occasionally closes the orifice at the apex leading to the central cavity.

Fourth substance in teeth.—With age the central cavity diminishes, by the growth of a substance viewed by Cuvier as a further ossification of the pulp; but a careful examination of this substance in the teeth of the cachalot and some other animals led me, many years ago, to view this substance as a fourth component part of a mammal's tooth. It is probably a modification of the bony structure, and forms, in all probability, the greater part of the structure of the teeth in fishes and serpents, and reptiles generally.

Development of the teeth.—Their origin and growth; the order in which they appear; the mode of formation of the tissues; the ivory, enamel, cement, and central bony tissue.

The teeth were long ago said by De Blainville to resemble the bulbs of the hair; this comparison is correct, and contains the whole philosophy of their development.*

At first the jaws present no appearance of alveoli. After a time a wide groove appears along the edge of each jaw; this gradually deepens, and is at last divided by bony partitions into a series of four-sided cells. This happens about the *fifth month of fœtal life.*

As regards the mucous membrane in which the teeth are developed, about the sixth week of embryonic life a groove appears in the mucous membrane of the gum — the *primitive dental groove.* A series of ten papillæ grow from the bottom of this groove in each jaw; these constitute the pulps or germs of the milk-teeth. By the tenth week all these papillæ are completely formed. This has been called the *papillary stage.* A second follows, called *follicular*, in which the papillæ grow rapidly, assume individual forms, and project from the groove. This stage is completed about the fourteenth week. A third stage follows, to be completed about the end of the fifteenth week. In this stage the groove is gradually obliterated, and the follicles are converted into closed sacs.

The *dental sacs* thus formed continue to enlarge. The walls of the sacs consist of an outer fibro-cellular layer and an inner vascular. The dental pulps adhere, by a broad base, to the bottom of the sac; and, now resembling strictly the crowns of the future teeth, the hard substance begins to form in them. By the end of the fourth month thin cusps or shells are formed on all the pulps of the milk-teeth, presumed to be the ivory substance. This continues to increase in thickness, constricting the pulp, and seemingly growing at its expense.

* Goodsir.

In the mean time the enamel is being formed and deposited on the ivory by the parietes of the sac adapted to the outer side of the pulp. Sooner or later the part of the crown so encrusted with enamel appears through the gum, the other processes going on until the fang is also formed. These facts, and many others connected with the formation of the teeth, were first clearly demonstrated by Cuvier on the teeth of the young elephant, and applied analogically to the human teeth.

Formation of the hard tissues of the teeth: theories.—It was at first supposed that the ivory was formed by a process of ossification similar to that which takes place in bone. This theory gave way to the Cuvierian, which viewed the ivory as a secretion in layers from the surface of the pulp, the enamel being deposited over it by the inner side of the enveloping capsule. The former or first opinion has been revived by Schwann, Purkinje, and Raschkow; they view the ivory merely as an ossified pulp. The whole theory is still doubtful. There is one thing which I think certain, namely, that a delicate membrane encloses the pulp, which, perhaps, is the first to ossify; but even this is doubtful; for it has always appeared to me that the cap of ivory forms exterior to the investing membrane of the pulp. Thus the nature of the tubuli and of the intertubular matrix is not well understood.

The enamel.—A peculiar organ is developed in the outer wall of the dentar sac, by which the enamel is secreted. Hunter described this perfectly. Whilst the enamel is being formed it is soft and chalky, and easily broken down. The examination of this peculiar organ forming the enamel, even under the most powerful microscopes, has totally failed in detecting its intimate nature.

The cement.—This layer, secreted probably by the periodontoid portion of the periosteal covering of the alveolus, forms simultaneously with the ivory. The coronal cement is supposed to be formed by the same membrane that secretes the enamel.

First dentition.—This commences at about the seventh month, and is completed about the second year. The central incisors of the lower jaw appear first, next those of the upper. As the tooth is about to cut the gum this latter alters its appearance. The nature of the small white bodies with which the mucous membrane is studded just before the eruption of the tooth has not been ascertained.

Second dentition.—The teeth of this dentition grow in the same way as those of the first.

The sacs and pulps of the ten anterior permanent teeth are formed behind those of the first set, before birth. The sac of the permanent tooth adheres to that of the corresponding deciduous one. They are at length separated from each other by a bony partition, each thus having its own alveolus. A solid membranous pedicle connects the sac with the gum, then passes through an opening in the bone. As the permanent tooth rises through the gum it presses on the bony partition separating it from the milk-tooth, and assists in

destroying it. Thus the milk tooth loses its support; it becomes loosened and falls out or is removed, the permanent tooth taking its place.

The large permanent molar teeth, six in each jaw, are not preceded by any deciduous teeth. But their mode of formation from a papilla and sac does not seem to me materially to differ in other respects from those in front of them.

The papilla, which is to form the anterior large molar tooth, appears about the 16th week of fœtal life; at the 7th month after birth the papilla of the 2d large molar appears; and about the sixth year appear the rudiments of the sac and papilla of the wisdom-tooth.

Second or permanent Dentition.

First molar	6th year.
Incisors—central	7th „
„ lateral	8th „
Bicuspid—anterior	9th „
„ posterior	10th „
Canine	11th to 12th „
Molars—second	12th to 13th „
„ third, or wisdom tooth .	17th to 25th „

In consequence of these changes in the number of the teeth the jaws undergo remarkable alterations in form; the alveolar arch alters its form, but the segment of the arch which it forms anteriorly seems almost as large in the child as in the adult. The angle of the lower jaw is obtuse in the child and in the very aged person; it approaches a right angle in the adult.

Fig. 195.*

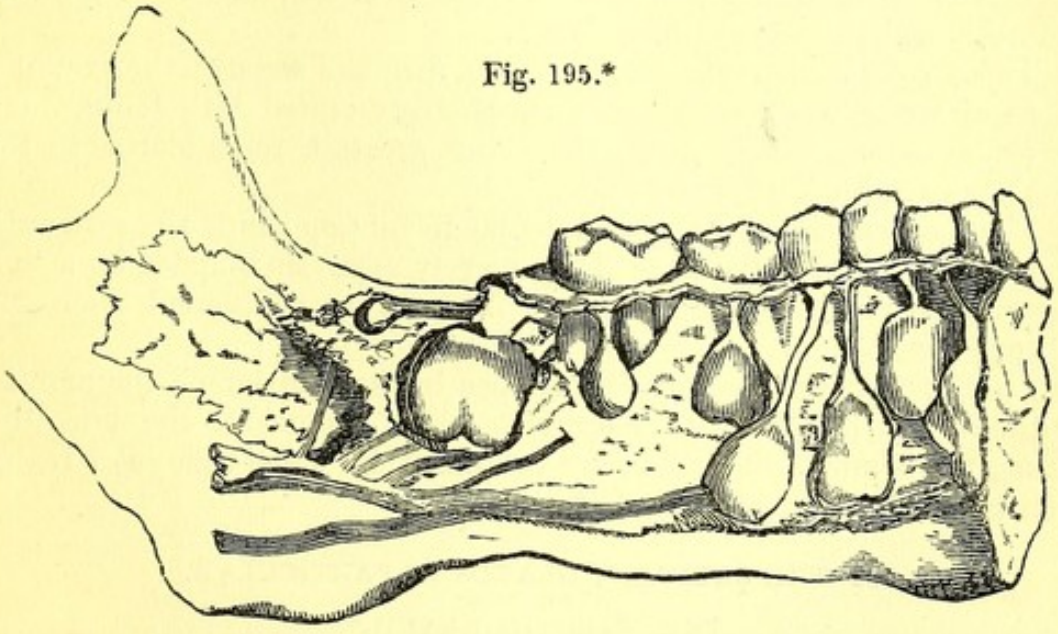

* Fig. 195.—Showing one half the lower jaw of a child, with the alveolar cavities containing both sets of teeth, exposed: the sacs and pedicles of the permanent teeth have been exposed, also the inferior dentar nerve.

The question as to the presence of blood-vessels in the hard substance of the teeth is still somewhat undecided; the evidence, however, is against the extension of blood-vessels into any portion of the ivory. In this respect it resembles the lens of the eye.

It is possible that in very young animals blood-vessels which afterwards become obliterated extend a short way into the ivory, but this has never been proved.

The results of the latest microscopic inquiries tend to establish certain analogies between teeth and bone. But the comparisons hitherto made are coarse and have not a sufficiently extended base; that base must be sought for in philosophic anatomy. The nature of the tartar which grows on the human teeth has not yet been determined.

III.—ORGANS OF INSALIVATION AND OTHER MUCOUS GLANDS.

The *salivary glands* are symmetrically placed, to the number of three on each side of the face, behind and beneath the lower jaw. Their form is in general very irregular, and their extent varies much in different subjects. Sometimes they are perfectly distinct and isolated; at other times they seem to be confounded with each other. But they all present characters which are common to them, and which serve to distinguish them from the other glands of the body.

Thus their vessels penetrate on all sides, and are already much ramified before arriving in their parenchyma; while the liver, the spleen, and the kidneys receive theirs by a determinate point, in the form of more or less voluminous trunks.

They are supplied with a considerable number of nervous filaments from the encephalic system; while the liver has but a very small number, and the kidneys none at all.

Their colour is greyish, their tissue firm and strong; the granulations of which they consist are successively united into lobules and irregular lobes, which gives them the greatest resemblance to the pancreas and the lachrymal gland.

They are enveloped by no particular membrane, as is the case with the liver, the kidneys, &c. They merely seem surrounded by a thin layer of cellular tissue, destitute of fat, and very different from the fibrous membranes.

Lastly, their excretory ducts all open in the interior of the mouth, without any intermediate reservoir, while the tears, the bile, the urine, the seminal fluid, &c., are contained for some time in a reservoir before arriving at their destination.

OF THE SALIVARY GLANDS IN PARTICULAR.

THE PAROTID GLAND.*

The *parotid gland* is the largest of the salivary glands. It is situated partly in front of and partly beneath the external ear, filling up the

* Παρα, *juxta*; ους, ωτος, *auris*.

deep excavation on the sides of the face, between the posterior edge of the ramus of the lower jaw, the meatus auditorius externus, and the mastoid process of the temporal bone. It extends vertically from the zygomatic arch to the angle of the jaw. Its form is that of a very irregular pyramid, with an oval base directed outwards.

Its *outer* surface, which is broad, flat, oval, slightly convex, and has no precise limits, extends more or less upon the face. It is covered by some fibres of the platysma myoides, and by the skin, under which creep some nervous filaments. Its circumference is prolonged anteriorly over the masseter muscle, and superiorly over the articulation of the jaw. At the under part of this circumference, from which Steno's duct takes its rise, the branches of the facial nerve are seen emerging.

The *anterior* surface corresponds above to the articulation of the lower jaw, externally to the posterior edge of the same bone, and internally to the pterygoideus internus muscle. It is moulded upon these different parts, and penetrates into their intervals.

Its *posterior* surface is connected by pretty dense cellular tissue with the meatus auditorius externus, the mastoid process, the anterior edge of the sterno-cleido-mastoideus, the posterior belly of the digastric muscle, the styloid process, and the muscles which arise from it. It is coated internally by the internal carotid artery, and by the internal jugular vein. The external carotid artery, at its termination, and especially the superficial temporal artery, are also in connexion with this surface of the parotid gland. They are even generally enveloped by its parenchyma, especially the latter, which traverses it from below upwards; while the facial nerve, which is also placed in the gland during part of its course, passes transversely through it. The parotid gland furnishes, by each of the granulations of which it is composed, a very slender excretory duct, which unites with those in its vicinity, in the manner of veins, to form somewhat larger twigs, then branches, and lastly a considerable trunk named the parotid duct, or Steno's duct (*Ductus Stenonianus*). This duct emerges from the fore and outer part of the gland, a little above the middle of the height of the masseter muscle, over which it proceeds horizontally, from behind forwards, to turn over its anterior edge, and sink into the adipose cellular tissue of the cheek. Having arrived upon the buccinator muscle, it passes through an aperture formed in the midst of its fibres, and terminates in the mouth, opposite the second molar tooth of the upper jaw, at the distance of about three lines from the meeting of the cheek with the corresponding gums.

The parotid duct does not pass through the buccinator obliquely, but perforates it perpendicularly, and forms an angle as it passes through the mucous membrane of the mouth, proceeding a little forwards. Its orifice is, besides, very contracted, and furnished with a small fold of the mucous membrane, so that it is not easily perceived.

It very frequently receives, about the middle of its length, another

duct from a granular body placed in its vicinity, which appears to be an accessory gland to the parotid. This body is, in fact, placed in front of the masseter muscle, either above or beneath the duct, sometimes even in its course. Its surface is commonly smoother than that of the gland itself.

Steno's duct is but loosely connected with the neighbouring parts. It is accompanied by several branches of the facial nerve, and by some arteries which furnish ramifications to its walls. Placed immediately under the skin, it is only separated from it internally by some fibres of the platysma myoides, and by the zygomaticus major, which cross its direction obliquely.

The parotid duct is about a line in diameter, but its cavity is very narrow. Its walls are composed of two distinct membranous layers. The *outer* is firm, strong, and thick, of a whitish colour, and fibro-cartilaginous appearance; it acquires still greater density towards the end of the duct, which, without increasing in capacity, becomes conical; near the buccinator muscle it gives rise superficially to a thin aponeurosis which covers its fleshy fibres, while it also gives attachment to some of the fibres of that muscle as it passes into the aperture of which we have spoken above, by which these fibres are actually interrupted and not merely separated. The other membranous layer of the duct is *internal;* it is essentially mucous, and very delicate; it appears to be continuous with the membrane which lines the cheeks, differing from it only in whiteness.

There are always found, in the substance of the parotid gland, a great number of branches of the facial nerve, the transverse artery of the face, the posterior auricular artery, and the vein which forms a communication between the internal and external jugular veins. It thus receives the greater part of its vessels and nerves; but a branch of the inferior maxillary nerve, and one of the ascending branches of the cervical plexus, furnish it with a few additional nerves. Its lymphatic vessels are pretty numerous, and pass into the ganglia situated at its surface or behind the angle of the jaw. Its parenchyma differs in nothing from that of the other salivary glands.

SUBMAXILLARY GLAND.

This gland is smaller than the parotid, and is situated at the inner side of the ramus and body of the inferior maxillary bone, in the triangular space which the two bellies of the digastric muscle leave between them. Irregularly ovoidal and flattened on its surface, frequently bifurcated at its fore part, it is prolonged externally as far as the angle of the jaw, and is sometimes confounded in this direction with the parotid gland.

Internally the superficial portion of its anterior extremity advances towards the digastric muscle, and the deep portion, which is engaged behind the mylo-hyoideus muscle, touches the sublingual gland. In the same direction it is separated from its fellow by the anterior belly of the digastric muscles and the genio-hyoidei.

Anteriorly, it is covered by the inferior maxillary bone, and *posteriorly*, is in connexion with the lingual nerve, the stylo-glossus and hyo-glossus muscles, and the facial artery, which it embraces.

Inferiorly, it rests upon the platysma myoides and the integuments.

Superiorly, it is prolonged more or less between the pterygoideus internus and mylo-hyoideus. It is, moreover, surrounded by a rather considerable, although variable, number of lymphatic ganglia.

The excretory duct of the submaxillary gland is commonly designated by the name of Wharton's duct (*Ductus Whartonianus*). It is much smaller than Steno's duct, and has much thinner walls, which are transparent and more elastic. Arising in the same manner by very slender radicles in the lobules of the gland, it issues from its deepest portion, passes between the stylo-hyoideus and hyo-glossus muscles, and proceeds nearly horizontally from without inwards, and a little forwards, between the genio-glossus and the sublingual gland, from which it often receives several excretory ducts. When it has arrived upon the side of the frænum linguæ, it places itself beneath the mucous membrane of the mouth, and terminates in this place by a very narrow orifice, situated in the middle of a slightly prominent tubercle. It is accompanied, in its whole extent, by the lingual nerve, and lined in its interior by a prolongation of the mucous membrane of the mouth: perhaps it is entirely formed by the latter.

The arteries of the submaxillary gland are numerous, but of small size. They are furnished by the trunk of the facial and the branches of the lingual arteries. Its veins correspond exactly to the arteries. Its nerves come from the lingual nerve, the mylo-hyoid branch of the inferior dentar nerve, and the submaxillary ganglion.

The cellular envelope of the submaxillary gland is proportionally much thinner than that of the parotid gland. The structure of the two organs is precisely similar.

SUBLINGUAL GLAND.

The *sublingual gland* is placed in the substance of the inferior wall of the mouth, under the fore-part of the tongue, and seems in general to be merely a sort of appendage to the submaxillary gland. Its position is nearly horizontal, and its direction parallel to that of the opposite side. It is smaller than the submaxillary gland, of an oblong form, with its greatest diameter from behind forwards, transversely flattened; it is nearly of the shape of an almond. It rests upon the mylo-hyoideus muscle, which separates it from the preceding gland, and is covered by the mucous membrane of the mouth, beneath which it forms a prominence. It is, moreover, in connexion, *internally*, with the genio-glossus muscle; *anteriorly*, with the body of the jaw; *posteriorly*, with the deepest extremity of the submaxillary gland, with which it often appears confounded between the hyo-glossus and mylo-hyoideus muscles.

This gland has several excretory ducts, whose disposition is liable to much variation. They are always very slender. Six or eight

proceed from its upper part to open upon the sides of the frænum linguæ, while five or six others issue from its lateral parts, and perforate singly the mucous membrane of the floor of the mouth. Two, or three, or even a greater number, are also seen to end in the submaxillary duct; these latter are very short, and frequently unite into a single trunk before terminating. All these ducts appear to have the same structure as that of the submaxillary duct, and, like it, are thin and transparent.

The arteries of the sublingual glands come from the facial and sublingual; their nerves are furnished by the lingual and hypoglossal.

IV.—ORGANS OF DEGLUTITION.

PHARYNX AND GULLET.

Method of dissecting and of exposing these Cavities.

Divide the trachea, œsophagus, and great vessels and nerves, about an inch above the sternum; raise them up, cutting through the loose cellular substance connecting them with the anterior part of the cervical vertebræ; draw them well forward, and, introducing a saw close to the vertebræ, divide the *basis cranii* on each side, between the styloid and mastoid processes, but always behind the styloid. These two sections should meet each other in the basilar portion of the occipital bone, in front of the foramen magnum. We thus leave the superior part of the spine, its connexion with the occipital bone, and consequently all its important ligaments, for after dissection. Under particular circumstances, the student may wish to preserve the head entire, in which case, making up his mind to sacrifice the ligaments, he cuts through all connexion between the occiput and spine, and thus gets a view of the pharynx, &c., similar to the first, but not so manageable. The pharynx and mouth must now be fully distended with baked hair; place the preparation on its anterior aspect, and proceed to examine the posterior, or that part which lies immediately on the bodies of the cervical vertebræ.

The pharynx is a muscular and membranous bag, placed in the median line of the body, and somewhat funnel-shaped; it extends from the base of the cranium, in front of the vertebral column, to about the fourth or fifth cervical vertebra. Limited *above* by the basilar process of the occipital bone, continuous *below* with the œsophagus, *anteriorly* with the nasal fossæ, mouth, and cavity of the larynx, and posterior surface of the velum palati; *posteriorly*, it rests upon the vertebral column, longi colli and recti capitis antici muscles.

On *its sides* it is in contact with the common and internal carotid arteries, internal jugular veins, and pneumo-gastric nerves, and at its

uppermost part with a small portion of the internal pterygoid muscles.

Superiorly, the pharynx is attached in a solid manner to the basilar process by the cephalo-pharyngeal aponeurosis, to which are attached some of the fibres of the superior constrictors of the pharynx. Stronger and denser at the middle than on the sides, it there constitutes of itself the fixed part of the organ.

Inferiorly, the termination of the pharynx in the œsophagus is indicated by a sudden contraction at the exterior, and rendered very remarkable by a change in the direction of its muscular fibres. In a general way, therefore, the pharynx may be described as a bag, placed between the mouth and larynx, which are in front, and the cervical region of the spine, which is behind, and into which bag pass the air, whether breathed by the nose or mouth, and the food solid or liquid, which passes directly from the mouth into the pharynx, over the surface of the tongue, by an aperture which the student may examine at this stage of his dissection, simply by opening the mouth. The aperture by which the mouth communicates with the pharynx is called the isthmus faucium. Depress the tongue and look through the isthmus faucium into the pharynx, and observe the superior aperture of the pharynx, which also leads into the larynx. Thus the air, which ultimately passes into the lungs by the larynx and trachea, can reach the tube only through the pharynx. Next proceed with the dissection of the constrictor muscles of the pharynx, by removing carefully, and in the direction of the fibres, the pharyngeal aponeurosis which covers them, preserving at the same time whatever lateral parts may still remain.*

Open the bag of the pharynx by an incision made along the mesial line, extending from the basilar process of the occipital bone to the commencement of the œsophagus; it may also be convenient to cut the pharynx laterally for a short way in the situation of the sinus of Morgagni, at least on one side. Looking into the pharynx, which has thus been laid open, the following apertures may be observed: the posterior apertures of the nostrils and anterior openings of the Eustachian tubes; suspended beneath these is the velum pendulum palati, and mesially the uvula; beneath is the isthmus faucium or opening from the mouth, bounded by the base of the tongue inferiorly, the *velum* and uvula above, and laterally by the pillars of the fauces with the tonsils. Connected with the base of the tongue is the epiglottis, immediately beneath which is the superior aperture of the larynx; lastly, inferiorly the student will find the opening leading directly to the gullet; thus there are seven openings leading to or from the pharynx. The boundaries of the other apertures may be easily understood. All the surfaces here mentioned are covered by a continuous mucous membrane, lining not only the interior of the pharynx, but passing along the various tubes already mentioned, to

* For the anatomy of the constrictor and palatal muscles, see the Myology.

the nostrils, ears, larynx, trachea, and lungs, and by the gullet towards the stomach; the student must carefully observe the form of these different openings. The openings of the nostrils being bounded by hard parts do not vary; those of the Eustachian tubes look forward and are composed of an extremely thick and dense fibro-cartilage; they will be examined afterwards in relation to the cavity of the tympanum, to which the tube leads. The opening into the larynx is protected by the epiglottis, which follows the movements of the tongue, and is bounded laterally and posteriorly by the aryteno-epiglottic folds, arytenoid muscles, and cartilages. These, however, cannot be seen until the mucous membrane has been removed, which must not be done at this stage of the dissection.

The palate is the upper wall of the mouth, limited anteriorly by the adhering edge of the upper lip, posteriorly by the base of the velum palati, and laterally by the cheeks. A white line, slightly depressed, traverses it mesially. At the anterior extremity of this line, between the two middle incisors of the upper jaw, is a small tubercle which corresponds to the inferior orifice of the anterior palatine canal.

The *bony portion of the palate* is formed by the upper alveolar arch, the inferior surface of the palatine processes of the superior maxillary bones, and the horizontal portions of the palate bones. On the vault of the palate the mucous membrane is denser, thicker, and less red than in the other parts of the mouth.

At its anterior part it presents transverse rugosities, varying in number and extent; elsewhere it is smooth, and presents the orifices of mucous follicles, situated between it and the bony arch of the palate, which become more numerous near *the velum*. The gums are formed of a firm and compact reddish tissue, covering the two sides of each alveolar arch, and filling the intervals which remain between the teeth, the necks of which they closely surround. They appear composed of two layers, a pulpy and a fibrous, covered by the mucous membrane, united to the periosteum. The mucous membrane, which enters into their constitution, is prolonged into the alveoli, and from the bottom of these cavities sends into the cavity of each of the teeth a bulbous prolongation which exactly fills it, and which has been named the *pulp* or *nucleus* of the tooth. The arteries of the palate and gums come from the palatine, alveolar, infra-orbitar, facial, and buccal branches, and, for the lower gums in particular, from the submental and mental. The veins correspond to the arteries. The nerves are furnished by the palatine, facial, infra-orbitar, superior and inferior dentar nerves, and by the naso-palatine ganglion.

The *velum palati* is a soft, broad, thick, mobile partition, appended to the extremity of the vault of the palate, and separating the mouth from the pharynx. Its form is nearly quadrilateral. Its two surfaces, the *anterior* and *posterior*, are smooth.

Its *upper edge* is very thick, and fixed to the vault of the palate; the *lower edge* is free, and floating above the base of the tongue. It

presents at its middle part an appendage or prolongation named the *uvula*. The uvula is cone-shaped, forming the inferior edge of the velum palati into a double arch, terminated on each side by two pillars, which are continuous with the tongue and the pharynx. These pillars are placed the one before the other, separated by a triangular space, in which are lodged the tonsils; they are united above, but diverge below. The anterior is oblique, and contains in its substance the constrictor isthmi faucium muscle. The posterior is nearly vertical, and is formed internally by a portion of the palato-pharyngeus muscle.

The mucous layer of the velum palati contains the muscular, and is continued anteriorly into the membrane of the mouth, and posteriorly into that of the nasal fossæ, so that the palatine and pituitary membranes unite upon the free edge of the velum palati. The anterior lamina of this layer is less red than the posterior, and covers many mucous follicles, extending over the fore part of the muscles: they are so close as to be in contact with each other; they form of themselves nearly the whole thickness of the uvula; they are rounded and compressed. Beneath the velum pendulum palati is the posterior or pharyngeal aperture of the mouth, the form and limits of which we have already described; its size is in no case equal to that of the anterior aperture; it varies, however, but only from above downwards, for on the sides it is limited by the pterygoid processes, which of course are perfectly fixed.

STOMACH AND INTESTINES.

Abdomino-pelvic cavity.—Dissection.—The dissection of the contents of the abdomen and of the pelvis is one of great difficulty to the student. He will require at first the constant assistance of an experienced demonstrator. The muscular walls have been already described (*see the Myology*); what we have now to consider is the contents of these cavities.

Cavity of the abdomen.—Carry an incision through the walls of this great cavity, commencing at the ensiform process of the sternum, to about the umbilicus; a second and third from this point to the anterior and superior spines of the ilium; reflect the flaps, and display the organs, which occupy the cavity thus laid open. To facilitate description, anatomical writers for many hundred years have divided the cavity of the abdomen into regions, by ideal lines drawn across it in the following directions:—two lines are drawn transversely between the extremities of the cartilages of the ninth ribs and anterior spinous processes of the ilium; these divide the whole surface into three great regions, viz. the epigastric, umbilical, and the hypogastric. Two vertical lines drawn from the cartilages of these ribs to the anterior spines of the ilium, will, with the mesial line, subdivide each of the larger into three smaller regions, viz., superiorly, the right and

Fig. 196.*

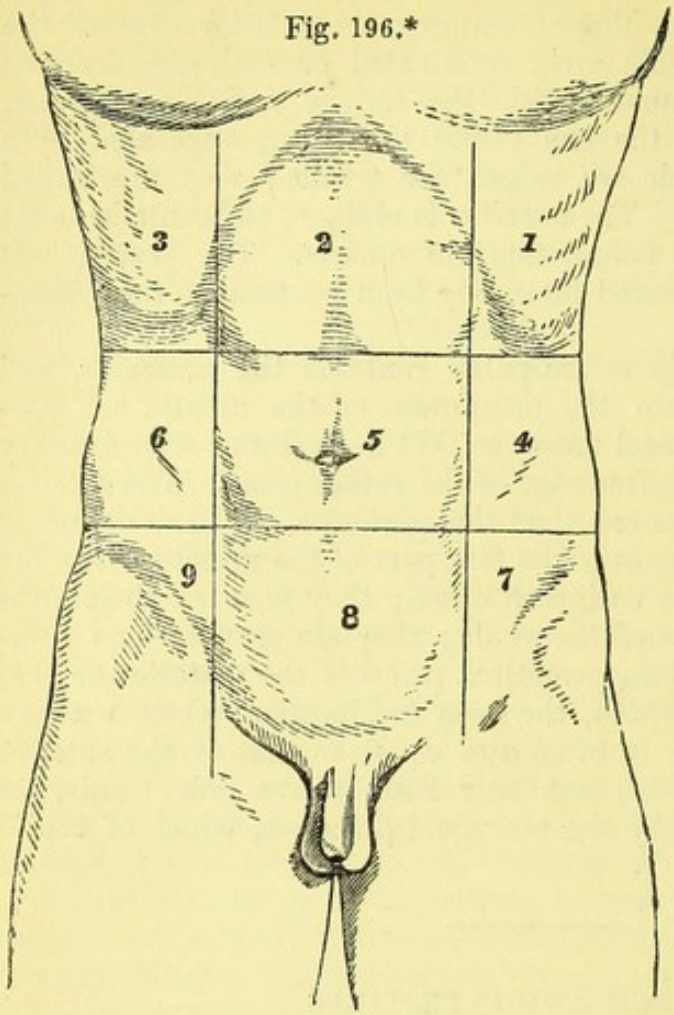

left hypochondria and the proper epigastrium; in the middle, the umbilical, and laterally the lumbar regions; inferiorly, in the middle, the hypogastrium proper; laterally the iliac regions.

Many of these regions may be still farther subdivided, and this has been done to a very great, and perhaps unnecessary extent, by systematic writers on surgical anatomy.

Previous to proceeding further with the inspection of the contents of the abdomen, replace the lower flap in its natural position, and, after distending the urinary bladder by blowing air into it through the urethra, dissect the remaining portions of muscles from off the outer surface of the two lower flaps: this will expose the external surface of a portion of the peritoneum (its fixed or cellular surface), and upon it three cords, viz. two lateral and one mesial. The lateral cords are the remains of the obliterated umbilical arteries, the mesial is the obliterated urachus; all these structures have a reference to the original fœtal condition of the individual. If the flap be now laid down again, it will be seen that, in some subjects particularly, the cords just described project inwards, although placed on the external surface of the peritoneum, and by their projections, and the weakness of the abdominal walls, they cause the formation in many subjects of two pouches on each side. Of these pouches, one will be found to correspond to that weak point in the abdominal walls (the abdominal ring), and the other will correspond to the superior

* Fig. 196.—Imaginary lines drawn on the surface of the abdomen, dividing it into regions. They were devised, no doubt, in consequence of the absence on this extensive surface of any characteristic eminences or depressions, chiefly attributable to the absence of any skeleton, cartilaginous or osseous.—1, left hypochondriac region; 2, epigastric; 3, right hypochondriac; 4, left lumbar; 5, umbilical; 6, right lumbar; 7, left iliac; 8, hypogastric; 9, right iliac.

aperture of the crural canal, situated just below Poupart's ligament, to the outside of Gimbernat's ligament. These pouches, by their depth, not unfrequently resemble peritoneal sacs. A third pouch may sometimes be observed corresponding to the situation of the direct or ventro-inguinal hernia.

When a penetrating opening, whether large or small, has been made through the walls of the abdomen, and the finger or hand passed in between the walls and the viscera, it enters not only the cavity of the abdomen, but also that of the peritoneum. It is in this space, which the student now sees fully laid open, that fluids collect in dropsies (ascites), &c. The peritoneum, a smooth shining serous membrane of great extent, not only invests the walls of the abdomen but covers more or less most of the viscera, which are to be seen shining through it. With the hand the student may now examine the boundaries of the abdominal cavity, which are anteriorly and laterally the abdominal muscles just described, and superiorly the diaphragm, while the cavity inferiorly is continuous with the pelvis; posteriorly large muscles, together with the spine, shut it in; these will be seen after the viscera have been removed.

The viscera to be seen *in situ* are portions of the liver and its suspensory ligament, the stomach, large omentum, small omentum, large intestines, small intestines, and bladder if distended. The abdomen contains many more parts, but they cannot be seen at present.

PERITONEUM.—I strongly recommend the student to delay, if practicable, the examination of the peritoneum until he has dissected all the abdominal and pelvic viscera. For this, however, he would require a fresh subject, which at the time may not be at his command.

The peritoneum is a shut sac in the male; there are two openings in it in the female. It is thin and translucid, has a very complicated course, invests the inner surface of the walls of the abdomen, forms several more or less marked folds in that cavity, and is prolonged, under the form of an envelope, over most of the viscera contained in the abdomen and pelvis, and which belong to the organs of digestion, of secretion, and generation. It is not unusual to call that part of the peritoneum lining the walls of the abdomen its *parietal*, and that investing the *viscera* its *visceral portion*, but the distinction is not practical, and of little importance.

In the male, the peritoneum represents, like all serous membranes, a shut sac, whose internal surface is, to appearance, smooth, but in reality it is covered with very fine villosities, moistened with serous fluid, and is everywhere in contact with itself. In the female it is perforated with an aperture corresponding to the fimbriated extremity of each Fallopian tube, with the mucous membrane of which it seems to be continuous. Trace with the hand the peritoneum as it invests the umbilical portion of the abdominal cavity and its viscera. It lines the posterior part of the linea alba, closes the posterior

orifice of the umbilicus, and adheres around that aperture to the abdominal aponeurosis. Thence the peritoneum directs itself horizontally to the right and left, behind the broad muscles of the abdomen; in the first direction it meets the ascending colon, in the other the descending colon; it forms around these intestines two folds, named the lumbar mesocola, which serve to attach them to the posterior wall of the abdomen. At the same time it passes before the kidneys, from which it is separated by a thick layer of cellular tissue; then, covering the ureters, the spermatic and renal vessels, the vena cava and the aorta, it advances on each side towards the vertebral column, before which it is reflected from behind forwards, lying upon itself, in order to form the *mesentery*. The mesentery is thus a process of peritoneum supporting the small intestines, extending at its base from about opposite to the second lumbar vertebra obliquely downwards to the right iliac fossa. In the hypogastric region the peritoneum, tracing it *mesially*, descends from the umbilicus towards the pubes, covering the urachus and the two umbilical arteries, which raise it a little, causing it to form three folds projecting backwards, confounded together at the umbilical ring, but separated inferiorly. It is then applied against the posterior surface of the recti muscles, and arrives at the upper edge of the ossa pubis, whence it is directed over the summit and posterior region of the bladder; there it presents differences, according as it is examined in the male or in the female. In the former it invests the base of the vesiculæ seminales, and is reflected over the rectum, forming two semilunar folds, separated by a cul de sac, and called the *posterior ligaments of the bladder*.

Opposite these folds and their separation, the peritoneum is applied superiorly upon the anterior surface of the rectum; but above, it also covers its lateral surfaces, and constitutes behind it the *mesorectum*, the upper extremity of which is continuous with the *iliac mesocolon*.

In the female, the peritoneum passes from the bladder over the vagina, before which it forms two semilunar folds and an intermediate cul de sac, similar to those which in the male occur between the rectum and bladder, but less distinct. It then invests the anterior surface, the upper edge and posterior surface of the uterus, and a portion of the corresponding wall of the vagina, prolonging itself to the right and left to form the *broad ligaments*. Thence it gains the rectum, and presents the same disposition as in the male. The peritoneum then ascends before the sacro-vertebral articulation, and unites with the lamina which forms the mesentery.

Laterally the peritoneum is at first seen reflecting itself from the walls of the abdomen over each iliac fossa, covering part of the iliacus and psoas muscles, embracing to the left the sigmoid flexure of the colon by means of the iliac mesocolon, and to the right the cœcum and its appendages by means of the mesocœcum—a process of peritoneum which varies in length, thus giving to the cœcum very different relations in different subjects. Thence it ascends forwards behind

Poupart's ligament, forming two depressions on each side, called the inguinal fossæ; these are distinguished into *internal* and *external*. These fossæ are separated from each other by the fold of the membrane which the umbilical artery supports. At the bottom of its summit, which is directed downwards and inwards, the peritoneum is seen to dive a little into the internal orifice of the inguinal canal. Posteriorly the peritoneum, which has invested the iliac fossæ, ascends and is continuous with the lumbar mesocola.

The epigastric portion of the peritoneum is of great extent and very complex.

1. *To the left*, it invests a portion of the diaphragm, and sinks into the most retired region of the hypochondrium as far as the vertebral column, whence it is successively reflected over the posterior surface of the splenic vessels, the posterior half of the inner surface of the spleen, its outer surface, its whole circumference, and the anterior half of its inner surface. There it meets the splenic vessels a second time near the fissure of the spleen, passes over the anterior part, gains the cardiac extremity of the stomach, and is continued into the anterior lamina of the great omentum. These laminæ of the peritoneum of which we have just been speaking, and which are comprised between the spleen and the stomach, are called *gastro-splenic omenta* by many authors.

2. *In the middle*, the peritoneum leaves the diaphragm before its œsophageal aperture, arrives upon the anterior surface of the stomach, passes between the gastro-epiploic vessels, descends to near the cavity of the pelvis, and is reflected from below upwards as far as the convex edge of the arch of the colon, thus contributing to the formation of the great omentum. It then invests the inferior surface of the arch of the colon, glides beneath the pancreas and duodenum, forming the inferior lamina of the transverse mesocolon, and is finally continued into one of the laminæ of the mesentery.

3. *To the right*, the peritoneum covers a less extent of the inferior surface of the diaphragm. Arrived upon the posterior edge of the liver, it is reflected upon that organ, forming a fold which has been inappropriately named its *coronary ligament* (*ligamentum hepatis coronarium*). It covers its whole upper surface, at the middle of which it gives rise to another triangular fold, which is its *suspensory ligament* (*ligamentum hepatis suspensorium*). This fold divides the upper surface of the liver into two unequal parts, corresponds on the other hand to the diaphragm, and is continued inferiorly into another fold, named *the falx of the umbilical vein*. This fold, in fact, contains that vein in its substance, and descends anteriorly and to the left as far as the umbilicus. The right lamina of the so-called suspensory ligament of the liver is then reflected under the concave surface of the great lobe, unites with the rest of the peritoneum along its sharp edge, covers the gall-bladder, and partially forms on the extreme right a small fold which gains the diaphragm; this fold is called the right lateral or triangular ligament of the liver (*ligamentum hepatis triangulare dextrum*). This same lamina leaves the gall-bladder posteriorly, and

slips before the duodenum to proceed over the colon. The left lamina is in like manner reflected under the inferior surface of the left lobe, unites upon its sharp edge with that which covers the upper surface of the liver, and bends, near its posterior edge, to form the *left lateral or triangular ligament* of the liver (*ligamentum hepatis triangulare sinistrum*), and the anterior lamina of the *hepato-gastric omentum*, and also to expand over the anterior surface of the stomach.

The entrance to the *posterior cavity of the omentum* lies immediately under the neck of the gall-bladder, where a triangular aperture, the *foramen or hiatus of Winslow*, will be found, into which two fingers may easily be made to penetrate. Through this aperture there is seen to dive, superiorly, the lamina of the peritoneum, which has formed the anterior lamina of the hepato-gastric omentum; thus applied upon itself, it contains in its duplicature the cystic and hepatic ducts and ductus communis choledochus, the vena portæ, the hepatic and pyloric arteries, and the capsule of Glisson, and, nearer to the cardia, the coronary artery of the stomach. The lamina then directs itself over the whole posterior surface of the stomach, descends behind the gastro-epiploic vessels, applies itself upon the portion of the peritoneum which has embraced the spleen and the anterior surface of the stomach, arrives along with it as far as the inferior edge of the great omentum, and afterwards ascends towards the convex edge of the arch of the colon. It then leaves this first lamina, covers the upper surface of the colon, forming the upper lamina of the *transverse mesocolon*, and passes above the pancreas and duodenum, the base of the crura of the diaphragm, the vena cava, and lobulus Spigelii. At length it passes through the foramen of Winslow, and is continued over the concave surface of the right lobe of the liver. In following this course the lamina of the peritoneum of which we have been speaking forms the walls of a large ovoidal cavity, the *posterior cavity of the omentum*.

This cavity, which has no other issue than the foramen of Winslow, is formed anteriorly from above downwards by the hepato-gastric omentum, the posterior surface of the stomach, and the two lamellæ of the anterior lamina of the great omentum.* Posteriorly, and from beneath upwards, it is formed by the two lamellæ of the posterior lamina of the great omentum, the upper surface of the arch of the colon, the upper lamina of the transverse mesocolon, and its prolongation towards the lobulus Spigelii. To prove these facts, insert the nozzle of a bellows into the foramen of Winslow, and distend the great bag of the omentum; this will generally succeed in a healthy abdomen, where the omentum has not been handled;—or, make an incision through the anterior lamina of the great omentum coming from the great curvature of the stomach, and, pushing the hand into the great bag of the omentum thus laid open, the student may satisfy himself of the existence of that layer of the peritoneum investing the posterior surface of the stomach, and likewise examine the course of the superior lamina of the transverse mesocolon.

* Each lamina of the great omentum is of course double.

The organisation and general relations of the peritoneum.— The peritoneum has precisely the same structure as the other serous membranes which we have already examined. It is in general very thin, although not equally so in all its parts. Its thickness is greater in the loins and behind the anterior wall of the abdomen than anywhere else. Upon the liver, spleen, stomach, and intestines, and especially in the omenta, the thinness of this membrane is extreme. Nor is its adhesion to the organs which it invests uniform in all parts. It is very decided upon the liver, spleen, and intestines, with the exception of the duodenum, but is much less so upon the pancreas, bladder, uterus, and vagina, as well as upon the diaphragm and the walls of the abdomen; this is especially remarkable in the lumbar regions and before the kidneys. In general, at the level of these different parts, in the excavation of the pelvis, the peritoneum has beneath it a great quantity of adipose cellular tissue. It also contains much of that substance in the different folds which it forms, as in the mesentery, mesocolon, &c.

The student may now examine more carefully the various processes which the peritoneum forms.

The *hepato-gastric omentum* (*omentum minus*) is a fold of the peritoneum, extending transversely from the right side of the cardia to the corresponding extremity of the transverse fissure of the liver, and, from above downwards, from the inferior surface of the diaphragm to the pylorus and duodenum. It is under it that the foramen of Winslow occurs, and between its two laminæ that the biliary and hepatic vessels are lodged. It contains, in general, but little fat.

The great omentum (*omentum majus*) is a very large fold, free and floating upon the convolutions of the intestine. It is irregularly quadrilateral, and commonly longer on the left side than on the right. Its base is attached anteriorly to the great curvature of the stomach, and posteriorly to the arch of the colon. Its edges are continuous above, the one with the colic omentum, the other with the gastro-splenic omentum, and, further down, with the neighbouring portions of the lumbar mesocolon. It is formed of two laminæ, each composed of two lamellæ, four in all, the one superficial, the other deep. The two lamellæ of the anterior lamina leave between them and the great curvature of the stomach a triangular space, between which are situated the gastro-epiploic arteries and veins, also the long epiploic arteries and their veins, but they are afterwards confounded, proceed downwards, and then, turning upwards, ascend together to form the posterior lamina. At the upper part of this latter they separate again, to embrace the arch of the colon, and to form the transverse mesocolon. The one joins the mesentery, the other ascends towards the foramen of Winslow. There is found in the substance of the great omentum a large quantity of vessels (art. epiploicæ and their accompanying veins) and fat, the latter being generally dispersed in flakes.

Colic omentum.—This is a fold of the peritoneum which exists only on the right side, and is placed behind the great omentum; it nearly

fills the angle formed by the union of the right and transverse portions of the colon; sometimes it extends as far as the cœcum, or towards the spleen; its two laminæ are separated by the colic arteries and veins.

The gastro-splenic omentum is formed by the peritoneum, which, from the edges of the fissure of the spleen, proceeds over the cardiac extremity of the stomach. It contains in its substance the splenic vessels and the vasa breviora.

Besides the omenta the peritoneum forms other folds, such as the mesentery, the mesocola, the mesorectum, the mesocœcum, the broad ligaments of the uterus, the suspensory ligaments of the liver, the adipose appendages of the large intestine, &c.

It may be useful for the student to dissect most of these processes of the peritoneum, and thus, besides acquiring a knowledge of their general course, extent, and connexions, ascertain in a practical way what is contained between their folds. Commence with the dissection of the *mesentery*. The removal of one layer of this extensive process, and of the fat which may be present, exposes the superior mesenteric artery and its branches, the corresponding veins, the mesenteric or lacteal glands, the lacteal vessels, and the superior mesenteric plexus of nerves: these parts will be described afterwards. Next dissect the transverse *mesocolon*. By laying up the transverse arch of the colon over the edges of the thorax, it will be seen that the transverse mesocolon, together with that portion of the large intestine it encloses, forms a sort of partition across the abdomen, above which will be found the stomach, liver, and spleen, and below it the small intestines, &c. Dissect off the inferior layer of the transverse mesocolon, and expose the pancreas, which is situated between its layers and across the spine. The ascending layer of the transverse mesocolon may be seen either by raising up the stomach after the bag of the omentum has been opened into, or by tearing through the smaller omentum. The course of these layers has been already particularly described. Finally, upon the edges of the large intestines there are numerous small processes of thin peritoneal tunic: these are called *appendices epiploicæ*. These appendices are probably analogous to the omenta, whose uses are unknown. They generally contain a good deal of fat.

The further dissection of the abdomen may be proceeded with in two ways—

1. If the dissector be already acquainted with the viscera, he ought next to proceed with the dissection of the arteries and nerves of the abdomen; but, 2d, if this be not the case, and particularly if it be his first dissection of the abdomen, his attention should be exclusively devoted to the viscera. These organs are—

1. The stomach, duodenum, jejunum, ileum, appendix vermiformis, cœcum, ascending or right colon, transverse arch, and descending or left colon, sigmoid flexure of the colon, proper rectum, and pouch of the rectum: these last are pelvic viscera.

2. Liver, pancreas, spleen.

3. Supra-renal capsules, kidneys, and ureters.

4. Diaphragm, psoas magnus, psoas parvus, quadratus lumborum, iliacus internus.

5. The arteries, veins, and absorbent vessels within this cavity.

Lastly, the nerves of the walls and of the viscera, including the anatomy of crural and inguinal hernia.

As it is evident that a great multiplicity of important parts cannot be dissected upon one subject, I shall first consider the anatomy of those organs and muscles the consideration of which must precede the others, and without a correct knowledge of which the student can never hope to become master of the anatomy of the arterial and nervous systems, nor of the surgical anatomy of these regions.

Lay up the transverse arch of the colon over the edges of the thorax, and at the root of the mesentery will be found the termination of the duodenum and the commencement of the jejunum. Place ligatures above and below the section of the gut, and, cutting through the mesentery at about an inch from the intestine, detach the jejunum and ileum from the mesentery, leaving, however, about three or four inches of the lower end of the ileum in connexion with the colon and cœcum.

The most convenient way of exposing and dissecting the alimentary canal (abdominal portion) is to commence with the small intestines; but if the thorax has been already opened there will be no difficulty in commencing with the stomach. For the sake of system I shall here describe the stomach.

The STOMACH (*ventriculus*) is a conical, elongated, musculo-membranous reservoir, curved from before backwards and from below upwards in the direction of its length, slightly depressed on two opposite sides, continuous on the one hand with the œsophagus, on the other with the duodenum, situated beneath the diaphragm, between the liver and the spleen, behind the left asternal ribs, occupying, at the upper part of the abdomen, the epigastrium and a portion of the left hypochondrium. Its greatest diameter is transverse; the small diameter is vertical, gradually diminishing in proceeding from the œsophagus towards the duodenum. Its two orifices are considerably contracted, and are directed upwards and backwards. Its direction is nearly transverse, but inclined slightly downwards, to the right, and forwards, so that its right extremity is anterior and inferior to the left. When the viscus is filled with food this obliquity is increased, and the stomach approaches the vertical direction.

There are to be distinguished in the stomach,—1st, an external or outer surface; 2d, two curvatures; 3d, two extremities, each having two orifices, a larger to the left, and a smaller to the right; and lastly, an internal mucous surface.

1st. The *external surface* is more convex anteriorly than posteriorly, turned a little upwards in the state of repletion, corresponds from right to left to the left lobe of the liver, to the diaphragm, and to the false ribs, and in the state of distention only to the anterior wall of

the abdomen, over a greater or less extent. It is always inclined downwards and forwards.

Posteriorly flat, oblique like the preceding, but of less extent than it, and directed downwards when the organ is full, this surface is always entirely concealed in the posterior cavity of the omenta, and is in connexion with the transverse mesocolon; sometimes even with the arch of the colon and the duodenum. These two surfaces are of a whitish colour; smooth and polished, continually moistened, and traversed by a great number of blood-vessels.

2d. The *great curvature* is that margin where the two surfaces of the stomach meet externally downwards and forwards. The edge here produced is convex, and extends from the one orifice to the other. In the vicinity of the spleen, and to the left, its convexity is greater than elsewhere. It corresponds to the transverse mesocolon and to the arch of the colon. It is, as it were, lodged in a separation of the lamellæ of the anterior lamina of the great omentum, so that, in the empty state, the peritoneum is not exactly applied upon it. It is to this space that the right and left gastro-epiploic arteries, and a certain number of lymphatic glands correspond. To the right, the great curvature of the stomach forms a bend, which corresponds to an internal depression, named the small cul de sac. To the left it presents a considerable prominence, named the *tuberosity, or great cul de sac of the stomach*, which, placed beneath the œsophageal orifice, is prolonged into the hypochondrium, and diverges from the general direction of the viscus. It increases its length in a decided manner, and corresponds to the anterior half of the internal surface of the spleen, with which it is connected by a fold of the peritoneum, lodging the vasa brevia. The *small curvature* is concave, and unites the two surfaces of the stomach above and behind. It corresponds to the aorta, the great fissure and lobulus Spigelii of the liver, and extends from the one orifice to the other, without presenting either dilatation or cul de sac, on which account its dimensions are smaller than those of the great curvature. But, like it also, it is not immediately invested by the peritoneum, for it sinks between the two laminæ of the hepato-gastric omentum; the coronary artery of the stomach courses along this margin.

3d. The cardia (*cardiac, left, or œsophageal extremity and orifice*) separates the two curvatures on the left side, and is placed beneath the diaphragm and above the large extremity of the stomach, at the union of the right two-thirds and the left third of that viscus. It is there that the œsophagus terminates. It is surrounded by a circle formed by the coronary artery and vein, and by the extremities of the œsophageal cords of the pneumo-gastric nerves. It is also in relation with a part of the left lobe and lobulus Spigelii of the liver, and with the corresponding anterior side of the vertebral column.

The pylorus (*pyloric, right, or intestinal extremity and orifice*) is situated in the epigastrium, lower and more anteriorly than the cardiac orifice; it terminates the stomach to the right, forming the summit

of the cone represented by that viscus; here the stomach communicates with the duodenum. Placed in the direction of the two curves at once, it commences by a funnel-shaped expansion, and terminates abruptly by a circular contraction. It generally ascends backwards and a little to the right, as far as the union of the two fissures of the liver. It corresponds above and in front to the liver, below and behind to the pancreas, posteriorly directly to the right gastro-epiploic artery, and on the right side to the neck of the gall-bladder. It is often coloured by the transudation of the bile through the walls of that reservoir, and is surrounded by a number of vascular twigs and nervous filaments.

The *internal* (mucous) surface of the stomach is of a reddish white colour, having a marbled appearance; it is lined by mucous membrane, and numerous and irregular wrinkles are observed upon it in its empty condition. The walls of the stomach are formed by three superimposed membranes—a serous, a muscular, and a mucous. There also enter into their composition cellular tissue, vessels, and nerves.

The *serous membrane or coat* is formed by the peritoneum, and does not exist along the curvatures when the stomach is empty, as has been already said. There results from this disposition, that the stomach in the state of vacuity is no longer covered by the same portions of peritoneum which were in connexion with it during its distention, for it is then prolonged between the laminæ of the omenta. Its peritoneal tunic is white, transparent, smooth, and lubricated externally by a serous fluid; united to the muscular membrane by a cellular tissue, loose on the edges of the stomach, but dense in the middle part of its two surfaces, where there is an intimate adhesion.

The *muscular membrane or coat* is thin, and differs essentially in this respect from the muscular coat of the pharynx and œsophagus. It is composed of fasciculi of soft whitish fibres, never red, placed beside each other, and running in three different directions.

1st. Some of these fibres, which are more superficial, are *longitudinal*. Less numerous and less uniformly diffused than the others, they form the continuation of the external muscular layer of the œsophagus; the principal fasciculi form a bundle which runs along the small curvature as far as the pylorus; another bundle descends on the great cul de sac, and is prolonged in the direction of the great curvature; those which are expanded over the two surfaces of the stomach are shorter and irregularly disposed; some of these latter collect into two small bands, the one before, the other behind, which arrive at the pylorus after a course of about an inch.

2d. The fibres of the second kind, lying immediately under the former, are *circular*, and belong peculiarly to the stomach; they appear to have no connexion with those of the œsophagus. Less numerous at the cardia than on the rest of the stomach, especially at the middle, and running parallel to each other, they never entirely encircle the stomach.

3d. The fibres of the third kind are *oblique;* constitute two broad bands, one extending from the left side of the cardia over the two

surfaces of the stomach, the other prolonged from the right side of the cardia over the great extremity, where it seems to replace the circular fibres, which occur there only in small numbers.

A layer of dense and close filamentous cellular tissue unites the muscular to the mucous membrane; this the older writers improperly named the *nervous coat*. Cuvier called it the vascular.

The *mucous membrane or coat* is soft, spongy, of a reddish white colour, having a marbled appearance, continually moistened with an abundant inodorous viscid fluid; it presents numerous and purely accidental irregular wrinkles when the stomach is empty. When examined with a lens, especially at some distance from the orifices, it is found to be perforated with a multitude of holes disposed pretty regularly in quincuncial order, not more than a fifth of a line in diameter, separated from one another by partitions, thus constituting a kind of reticular warp, the tissue of which recurs between the folds of the mucous membrane of the duodenum and around Peyer's glands or follicles. It does not at first sight appear to be a continuation of the inner membrane of the œsophagus, there being an apparent line of demarcation perceived between the two membranes, caused by the seemingly abrupt termination of the epithelium or epidermis of the mucous membrane of the œsophagus. Microscopic observers, however, are now generally agreed that a fine epithelium invests the interior of the stomach at all points. The reticular surface just described has long been known. By the application of higher glasses it would appear that this appearance is connected with little depressions or cells of a polygonal figure; at the bottom of these cells or pits there are appearances of a number of minute tubes opening upon the surface of the stomach. If such tubes exist, they represent, on a small scale, the distinctly visible layer of tubes perpendicular to the cellular tunic they rest on, described by me in 1821–22 in the stomach of the cetacea, more especially in that of the porpoise. This layer had been noticed by Camper and Cuvier; but the latter anatomist considered it to be muscular. Dr. Brewster, who examined this tubular structure at my request, confirmed the view I had adopted respecting the nature of this layer.* The use of this layer has not been determined; it is probably a secreting organ. The longitudinal folds which the mucous layer of the œsophagus forms terminate at the cardia by so many mamillæ or tubercles. The mucous membrane of the stomach is thicker than that of the œsophagus, neither having villosities. Between the muscular and mucous coats of the stomach, and along the two curvatures only, are observed mucous follicles of small size, opening on the inside of the viscus by sunk, and not very apparent orifices. They are commonly called *Brunner's glands*, from the name of the anatomist who first described them. At the place where the pylorus presents the least width, there occurs internally a circular rim, flattened and perpendicular to the walls of the orifice; it has

* See Transactions of the Royal Society of Edinburgh. My opinion was, that it was a tubular, glandular layer; not muscular.

been improperly called the *valve of the pylorus;* it is merely a replication of the muscular and mucous coats of the stomach, corresponding by one of its surfaces to the cavity of that viscus, and by the other to that of the duodenum, the small circumference of which is thin, free, and floating, so as to circumscribe a narrow aperture by which the contents of the stomach pass into the intestines. But its great circumference is formed by a particular fibrous ring, of a solid texture and white colour, placed between the two forementioned membranes. This ring is the pyloric muscle of some authors.

The arteries of the stomach are numerous and large, compared with the volume of the organ and the thickness of its walls. They come from the two gastro-epiploic, the pyloric, the coronary, and the splenic arteries. They creep at first in the cellular tissue between the peritoneal and muscular coats, but their secondary divisions pass through the latter, and their ultimate ramifications form a very delicate network in the substance of the mucous membrane. These arteries are extremely flexuous, on account of the changes of volume to which the stomach is exposed. The veins of the stomach bear the same name and follow the same course as the arteries. They pour their blood into the trunk of the vena portæ, or into one of its principal branches. Like the arteries, they anastomose with each other a great number of times. The lymphatic vessels of the stomach arise from its inner and outer surfaces, and present for the most part their principal trunks under the peritoneum; they may be referred to three orders; they go particularly to the glands placed along the two curvatures. The nerves of the stomach come from the pneumo-gastric nerves and from the three divisions of the cœliac plexus.

The DUODENUM (*Ventriculus succenturiatus*) immediately succeeds to the stomach. It is less voluminous than that organ, but has a greater diameter than the small intestine, properly so called, and is susceptible of great dilatation. It occupies the deep middle part of the abdomen, where it is concealed by the transverse mesocolon or by the stomach. The direction of the duodenum is such that it may be divided into three portions.

The *first*, which is about two inches long, commences at the valve of the pylorus, proceeds horizontally backwards and to the right, and ends near the neck of the gall-bladder, uniting angularly with the *second*, which has a variable length, and which descends vertically and a little to the left, as far as the third lumbar vertebra.

The *third* portion is directly continuous with the second, with which it does not form an angle; it proceeds transversely to the left, before the vertebral column, and ends by being directed upwards and forwards toward the upper extremity of the mesentery, above the superior mesenteric vessels, which cross its direction, and are embraced by curve which it forms for them.

The *first* portion is covered, in the greater part of its extent, by the peritoneum, and is in connexion with the hepato-gastric omentum.

The *second* has no other connexion with the peritoneum than that of being covered by the upper lamina of the transverse mesocolon.

The *third* is contained between the two laminæ of that fold. From this disposition the duodenum forms a semicircle, which circumscribes the head of the pancreas, and has its concavity to the left and its convexity to the right; it only appears to be kept in a fixed position in its inferior two-thirds. The relations of the duodenum to the neighbouring organs are the following:—*Above*, it corresponds to the liver and part of the neck of the gall-bladder; *below*, it is limited by the inferior lamina of the transverse mesocolon; *anteriorly*, it is covered by the superior lamina of this fold inferiorly, and by the stomach and right extremity of the arch of the colon above; *posteriorly*, it is applied upon the anterior and right side of the vertebral column, the right kidney, the vena cava inferior, the aorta, and the right pillar of the diaphragm. By its whole inner side it embraces the pancreas, from which it is separated below by the superior mesenteric vessels. Its outer side is immersed in the sub-peritoneal cellular tissue, between the right kidney and the ascending portion of the colon.

The *inner surface* of the duodenum is mucous like that of the stomach. There is seen upon it a multitude of circular folds, which differ in their configuration and are close to each other; these are the *valvulæ conniventes;* they are formed by the mucous membrane, and their existence is constant in all states of the duodenum; they project three or four lines into its cavity; some of them are oblique and cross each other, or run into those next them; their length is not the same in all: they never form entire circles, only representing arches which embrace the half, two-thirds, or three-fourths of the intestine; their pointed extremities advance unequally beyond each other; their breadth varies as much as their length. The use assigned to them is that of retarding the progress of the alimentary substances for the purpose of favouring the absorption of the chyle. The reticular tissue which we pointed out on the inner surface of the stomach, shows itself in the bottom of the grooves by which they are separated. There is also observed in the interior of the duodenum, at the point of union of the second and third curvatures, a small tubercle, at the summit of which are seen the united or isolated orifices of the biliary and pancreatic ducts. At its lower part the duodenum is continuous with the small intestine, without any very distinct line of demarcation being observed. The duodenum is not, like the stomach, invested with a serous membrane, the peritoneum being only applied upon it in a small portion of its extent; it is to this deficiency of the peritoneal coat that the intestine owes the faculty of dilating, under certain circumstances, to such a degree as almost to equal the stomach.

The *muscular membrane or coat* is thick; all its fibres are transverse or circular, and have a great similarity to those of the stomach.

The *mucous membrane or coat* is reddish, soft, spongy, villous, and as if downy; the valvulæ conniventes are formed from its reduplication; it possesses all the characters of the internal membrane of

the stomach and is truly continuous with it. Between it and the preceding coat there is observed a quantity of flattened mucous follicles, the orifices of which are more visible than in the stomach. The arteries of the duodenum are very numerous, and come from the superior mesenteric, pyloric, pancreatic, and gastro-epiploic arteries. Its veins correspond to the arteries. Its lacteals and lymphatics go to the glands situated above the pancreas. Its nerves come from the solar plexus.

The SMALL INTESTINE.—The small intestine (*Intestinum tenue*), in which the duodenum terminates, is the longest portion of the digestive canal. It forms a general great curve, of which the concavity is connected with the mesentery, while the convexity is free and floating: and it is moreover folded upon itself in different directions a great number of times, producing the *convolutions*. All these convolutions, of which the convexity is directed forwards, and whose concavity faces backwards towards the vertebral column, are placed close together, and constitute a considerable mass, occupying, in the abdomen, the umbilical and hypogastric regions, a portion of the lumbar and iliac regions, as well as of the excavation of the pelvis. This mass is circumscribed on all sides by the large intestines, that is to say, superiorly, by the transverse mesocolon and arch of the colon, which separate it from the stomach, the pancreas, the liver, and the spleen; to the right, by the cœcum and ascending colon; to the left, by the descending colon and the sigmoid flexure. The small intestine commences under the superior mesenteric vessels, on the left side of the transverse mesocolon, and terminates in the right iliac region, where it opens into the large intestine. There results from this that its general direction is inclined from above downwards and from left to right. Its length is about four times the length of the body: anatomists have divided it into two portions, although they have failed to assign fixed and distinct limits to each of them. The upper is named *jejunum*, on account of its being commonly found empty; the other is called the *ileum*.

The jejunum occupies the upper two-fifths of the small intestine, and the ileum the rest of its extent. The division is arbitrary, and has no sufficient foundation. A projection called a *diverticulum*, composed of the same tunics as the intestine, and communicating with it, is occasionally found upon the small intestine: it has been supposed by M. Meckel to be the remains of the vesicula umbilicalis of the fœtus, and by its presence marks a distinction in the canal above and below it; I concur in this opinion.

This intestine has a smaller calibre than that of the other parts of the digestive canal; it is wider above than below. Its *outer surface* is smooth, excepting on its posterior edge, where it is destitute of peritoneum, and lodged between the two laminæ of the mesentery; its *inner surface* has the same appearance as the duodenum. There are seen upon it numerous villosities disposed in the form of more or less prominent fringes, and extremely large val-

vulæ conniventes. But the latter are more numerous the nearer the intestine is to the duodenum, and diminish progressively towards the cœcum. To display this *inner surface*, or mucous membrane, requires merely that a few inches of the intestine be laid open at each end in order to contrast the appearance. The peritoneum covers the entire external surface of the small intestine, excepting at the posterior edge, where it is reflected to be prolonged backwards by two laminæ constituting the mesentery, which leave between them and the intestine, at the moment of their coming together, a triangular space similar to that prevailing along the curvatures of the stomach; in this space the intestine does not adhere to the peritoneum, a circumstance favourable to its dilatation. To display the anatomy of the peritoneal tunic of the intestine, it is only necessary to distend the gut with air.

The *muscular membrane or coat* is shown by stripping the peritoneal from off a portion of the intestine previously distended with air; the superficial fibres are longitudinal, thin, not numerous, and collected especially along the convex edge of the intestine; they do not run along its whole extent, but are interrupted from space to space, and seem composed of shorter fibres whose extremities are interlaced with each other: the deep fibres form a more distinct layer; they are curved in the transverse direction of the intestine; but some of them pass entirely round it, being interrupted like the longitudinal. The muscular membrane is connected with the peritoneum by means of a layer of cellular tissue, thin, and loose on the side next the mesentery. It is separated from the mucous membrane by another layer of more dense and compact cellular tissue, the *nervous coat* of the older anatomists.

The *nervous*, cellular, or vascular tunic may be examined either from within or from without. If from without, scrape off the peritoneal and muscular tunics; this will show the density and strength of the cellular tunic: if from within, evert a portion of the small intestine, turning it inside out, enclose it in ligatures, and distend it with air, so that the cellular tunic may be entirely filled with it. If this portion of the intestine be thus dried, and afterwards cut across, it will give a very good idea of the cellular tunic.

The *mucous membrane or coat* is whitish and thicker than that of the stomach. It is covered everywhere with a thin epithelium of the columnar or cylindrical kind. The valvulvæ conniventes are formed by the mucous layer being folded upon itself. These crescent-shaped folds of the mucous membrane commence about an inch beyond the pylorus, and, after being very numerous in the duodenum and jejunum, become rarer in the ileum; they finally disappear before that bowel terminates. Its villosities are thin, flexible, and collected into pellets. On examining them with the microscope, it has been thought that each terminates by an oval ampulla perforated by a small hole, which Lieberkuhn considers as the entrance of a lacteal vessel; but later observers deny that any lacteal or other apertures exist. The

crypts of Lieberkuhn are the smallest of the glandular structures; they are found in every part of the small intestine.

The glandulæ solitariæ have been carefully examined by Boehm; they resemble Peyer's glands, but are not disposed in clusters. They exist in all parts of the small intestine.

The walls of this ampulla are lined with a net-work of arteries and veins; intervals which exist between these villosities are furnished with mucous follicles, designated by the name of glands of Brunn, which form slight prominences on the inside of the intestine; they are more numerous on the side next the mesentery than anywhere else; their form is round or oval. In addition to these mucous follicles, which Brunn considered as most abundant in the duodenum, other small glandular-looking bodies are found upon the mucous surface in various parts of the small and even of the large intestine. They were perhaps first described by Peyer, and, as they are collected in considerable numbers, and have a distinct oval shape, they have of late been known by the name of *Peyer's Patches*. They are in general easily found by holding up the intestine between the eye and the light. In many animals they are much more extended than in man, as in the kangaroo, &c. The arteries of the small intestine come from the convexity of the terminating branch of the superior mesenteric artery. Its veins join the vena portæ. Its lacteals, which are more numerous above than below, end in the glands of the mesentery. Besides the lacteals it has numerous absorbent vessels connected especially with its serous coat. Its nerves arise from the superior mesenteric plexus.

The large intestines (*Intestinum crassum*).—Having thus examined the anatomy of the small intestines, proceed with the larger. Remove them cautiously from the body, in the same way as the small, cutting through, close to the intestine, the various mesocola connecting them to the walls of the abdomen and to the stomach, &c.; throw a ligature around the top of the rectum, and leave it in the pelvis for future examination. The portion of intestine thus removed consists of—1st, a small part of the ileum; 2d, the appendix vermiformis; 3d, the cœcum; 4th, the ascending colon; 5th, the transverse arch; 6th, the descending colon; 7th, the sigmoid flexure of the colon. The mode of examining the large intestine is generally similar to what has been recommended for the investigation of the small. The following are most of the anatomical facts:—The small intestine, after diminishing in calibre, enters the large intestine upon its left side; the peritoneal tunic binds down this gut in a remarkable way to the large intestine, and it is this chiefly which gives rise to a valve (ileo-colic and ileo-cœcal valve), to be afterwards described. To satisfy himself of this, let the dissector cut through the peritoneal tunic above and below the entrance of the small into the large intestine, and cautiously dissect through the close cellular substance connecting the termination of the small intestine to the cœcum and colon. If this dissection be continued far enough, the valve will afterwards be found nearly destroyed, thus proving the mechanism of

Fig. 197.*

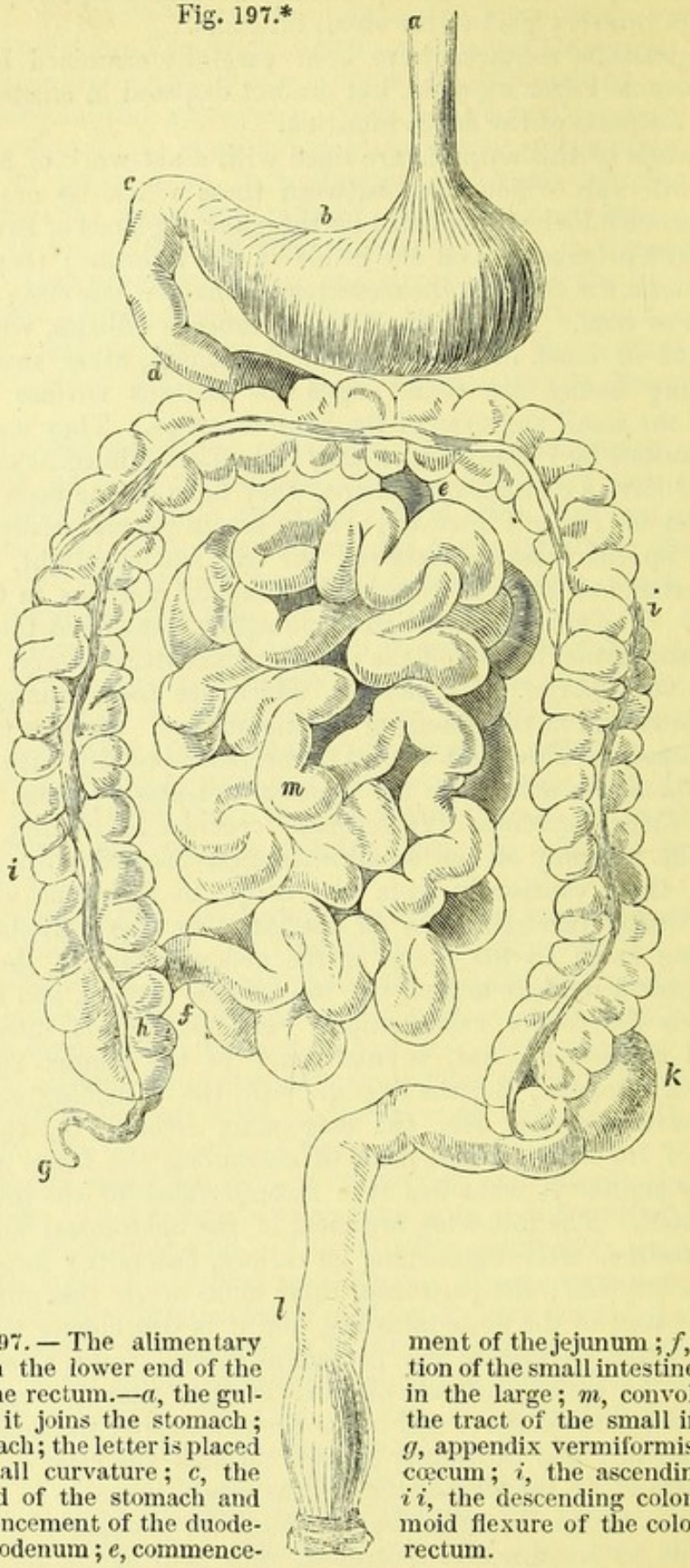

* Fig. 197. — The alimentary canal from the lower end of the gullet to the rectum.—*a*, the gullet where it joins the stomach; *b*, the stomach; the letter is placed on the small curvature; *c*, the pyloric end of the stomach and the commencement of the duodenum; *d*, duodenum; *e*, commencement of the jejunum; *f*, termination of the small intestine (ileum) in the large; *m*, convolutions of the tract of the small intestine; *g*, appendix vermiformis; *h*, the cœcum; *i*, the ascending colon; *i i*, the descending colon; *k*, sigmoid flexure of the colon; *l*, the rectum.

its formation. Distend the large intestine with air, enclosing various parts with ligatures, and commence with the *appendix vermiformis*. This appendix is the smallest part of the large intestine, and is the commencement of it; it is present in man, and in only a few animals. Even Morgagni mistook the *cœcum* of the dog for the *appendix vermiformis*, an organ which that animal has not.

The appendix vermiformis is similar to the rest of the cœcum in its structure; its fleshy coat is thick, and formed of longitudinal fibres. Three bands of the intestine seem to come from it, of which we shall speak presently; it communicates with the cœcum by an orifice which allows air readily to enter, but not to escape so easily. The mucous membrane, at its orifice, forms a sort of valvule. The appendix is sometimes wanting.

The CŒCUM is placed between the end of the appendix vermiformis and the colon, in the right iliac fossa. Its volume is often triple that of the small intestine, and surpasses that of the colon or rectum. Its length is about three or four finger-breadths, and no other limits can be assigned to it, to distinguish it from the colon, than the termination of the small intestine.

Its *outer surface* presents very large bulgings irregularly disposed, and interrupted in three places by longitudinal depressions formed by the union of the longitudinal muscular fibres. One of these depressions is anterior, the other two are posterior, but one is turned to the right, and the other to the left. In its interior the cœcum is lined by a mucous membrane, which we shall afterwards describe. It presents three longitudinal prominences, which correspond to the three external depressions mentioned above, and cellules occupying their intervals, separated by transverse folds, and forming externally prominences which we have also mentioned. Inferiorly and posteriorly is seen the entrance of the appendix vermiformis, which is always free and open, and a little widened. To the left are the orifice of the small intestine, and the *ileo-colic valve or valvule of Bauhin*. This valve, which prevents

Fig. 198.*

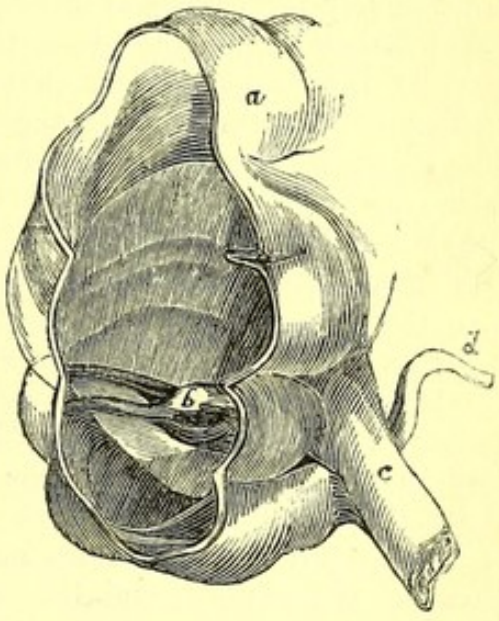

* Fig. 198.—To show the ileo-cœcal valve, the colon and cœcum have been laid open, exposing the interior of the bowel and the valve of Bauhin, or ileo-cœcal.—*a*, the colon; *b*, the colic portion of the valve,—the aperture between the two portions of the valve is immediately below the letter, and beneath it the cœcal portion of the valve; *c*, the termination of the small intestine; *d*, the appendix vermiformis.

the return of the excrementitious matters from the cœcum into the small intestine, is elliptical, broad, soft, thick, without support, and directed transversely. In the direction of its great diameter it is divided by a slit which separates it into two lips united at their extremities, adhering to the intestine by their convex edge, and floating in its cavity by their concave edge. Of these two lips, the upper, which is narrower, corresponds above to the colon, and below to the small intestine; while the lower, which is broader, faces the small intestine above, and the cœcum below. Their extremities unite and form a prominent line on each side, which terminates insensibly in the straight part of the cœcum. These rugæ were called by Morgagni *the frœna of the valvule of Bauhin.* The peritoneum wholly covers the inferior portion of the cœcum, and invests the greater part of it above, forming its *serous coat.* It passes upon the walls of the abdomen without in general forming any fold. Sometimes, however, a more or less distinct fold is observed, to which the name *meso-cœcum* is given.

The *muscular membrane or coat* is composed of longitudinal and circular fibres: the longitudinal fibres are united into three distinct bands, and are shorter than the intestine itself, causing it to present the prominences of which we have already made mention. These fasciculi seem to arise from the appendix vermiformis, and on cutting them transversely the cœcum is immediately seen to elongate, and the transverse folds and prominences which it presented entirely disappear. The circular layer forms a very thin coat of fibres spread over the general surface of the intestine. In the rectum they are continuous and strong. The layer of cellular tissue which connects this membrane with the following is thicker than in the small intestines, but in other respects presents nothing remarkable.

The *mucous membrane or coat* presents villosities much less apparent than those of the small intestine, and no valvulæ conniventes; it contains a greater quantity of mucous follicles, but they are isolated from each other. Though continuous above with that of the small intestine, it presents many peculiarities. It is pale, but redder in the rectum than elsewhere. It has no valvulæ conniventes, and no villi. According to Boehm, who has examined it with great care, its surface is marked all over with the orifices of numerous tubuli resembling those of the stomach and the crypts of the small intestines. Besides these are found scattered over the surface of the whole of the large intestine numerous rounded whitish glandular bodies. These are follicular recesses or crypts, simple in their structure. They are most abundant in the cœcum and its appendage. The epithelium of the large intestine is columnar.

The *ileo-colic* valve is formed by the mucous coat of the small intestine and the cellular coat which lines it, folded upon itself in such a manner as to project into the cœcum before being continued into the same membranes of that intestine and of the colon. There results from this that it is formed of four mucous laminæ, two for each of its lips, and that in their interval there occurs cellular tissue. But,

moreover, there is observed in the lower lip a layer of strong muscular fibres, of a whitish colour, which are continuous with those of the small intestine.

The COLON extends from the right iliac region to the left, between the cœcum and the rectum, with which it is continuous, and describes various turns which have caused it to be divided into four portions.

1. The *ascending colon* commences at the cœcum, and ascends in the right lumbar region, vertically and a little backwards, to near the edge of the corresponding false ribs, lying upon the quadratus lumborum and kidney of the right side: *internally*, connected with the inferior lamina of the transverse mesocolon and the right lamina of the mesentery; *externally*, applied against the walls of the abdomen. Its volume does not much exceed that of the small intestine. Its mobility is not great, on account of its being connected with the kidney and quadratus lumborum by a great quantity of adipose cellular tissue. Sometimes, however, the peritoneum forms for it, posteriorly, a more or less loose fold which is named the *right lumbar mesocolon*.

2. *The arch of the colon*, or transverse colon, occupies the anterior and inferior region of the epigastrium, beneath the stomach, above the small intestine, behind the great omentum, and before the transverse mesocolon.

Its *upper surface* is free and smooth, corresponding to the liver and the great curvature of the stomach, which advances more or less upon it, and at its left end is in relation with the spleen.

Its *lower surface*, which is also smooth and polished, rests upon the mass of the small intestine.

Its *anterior edge*, which is convex, gives attachment to the great omentum, and is in contact with the walls of the abdomen; the *posterior* is concave, and embraced by a fold of the peritoneum named the *transverse mesocolon*.

3. The *descending, or left lumbar colon*, commences under the spleen; it is placed behind the small intestine, and before the left kidney and quadratus lumborum, with which it is connected by cellular tissue, or by a fold of the peritoneum named the *left lumbar mesocolon*.

4. The *sigmoid flexure of the colon* is very mobile, occupies the deeper part of the left iliac fossa, where it describes a double curve in the form of the letter S, whence its name. It commences at the end of the left lumbar region, and terminates at the upper strait of the pelvis, near the articulation of the last lumbar vertebra with the sacrum. It is surrounded in nearly its whole circumference by the peritoneum, which fixes it above and behind, by means of a loose fold, directed obliquely from left to right, named *iliac mesocolon*. The colon thus describes in the abdomen a circle which measures nearly its whole circumference, and which contains the convolutions of the small intestine. In its whole extent, the colon, like the cœcum, presents interrupted bulgings, produced by three longitudinal muscular bands; but these prominences, which are not so large as in the cœcum, are

almost obliterated in the sigmoid flexure. It also presents a very great number of fatty appendages, owing to a particular fold of the peritoneum, so multiplied in its ascending and descending portions, that they seem to envelop it with a continuous layer; there are fewer upon the arch, and scarcely any upon the sigmoid flexure, where they are also much less voluminous. In its interior the colon presents the same disposition as the cœcum.

The peritoneum forms its *serous coat*, after having enveloped the intestine, fixing it to the neighbouring parts by different folds, which take their name from the portion to which they belong; the largest of these folds is the *transverse mesocolon*, which proceeds from the concave edge of the arch of the colon which it supports, and forms a horizontal and moveable partition, which separates the epigastric region from the umbilical, and the stomach, liver, and spleen from the small intestine. It is broader at the middle than at its two extremities, and has a nearly semicircular form. It is composed of two laminæ, an inferior and a superior; the former is continuous with the mesentery; the other is prolonged into the posterior cavity of the peritoneum, and covers a part of the duodenum. In the interval of these two laminæ are found the vessels and nerves destined for the arch of the colon, together with a great number of lymphatic glands. Between them and the concave edge of the intestine there is observed an empty triangular space, similar to those we have already described in the stomach and small intestine. These two laminæ, after uniting upon the colon, give rise to the posterior lamina of the great omentum.

The *iliac mesocolon* varies much with respect to its extent, and is similar to the other folds of the same kind; it is broader at the middle than its extremities; it is continuous above with the descending mesocolon, or terminates in a point behind the colon, and inferiorly is united to the meso-rectum; it also contains vessels, nerves, and some lymphatic glands.

The *muscular* and *mucous membranes* are the same in the colon as in the cœcum. The arteries of the cœcum, of the ascending colon, and of the right half of the arch of the colon, are furnished by the superior mesenteric artery. Those of the other parts of the colon come from the inferior mesenteric. The veins of these two intestines form the two meseraic veins, and open into the vena portæ. It is doubtful if any lacteals exist in the mesocolon. Its nerves are furnished by the two mesenteric plexuses. The total length of the large intestine is about seven feet in a man of ordinary size. It forms about a fifth of that of the small intestine. In conclusion: the structure of the large intestine resembles the structure of the small intestine, being composed of four tunics, viz. the serous, muscular, cellular, and mucous.

THE RECTUM.

The rectum succeeds the sigmoid flexure of the colon, and extends from the left side of the sacro-vertebral articulation to the summit of the coccyx, where it opens externally. It is a little inclined from

right to left at its commencement, but afterwards follows the median line of the body nearly vertically, but accommodates itself to the curve of the sacrum.

As it descends, it expands to form the pouch of the rectum, which in aged persons presents a considerable dilatation. At times it is susceptible of great dilatation. Less voluminous than the cœcum or colon, it does not present those irregular bulgings and distinct muscular bands, which form so remarkable a feature in the colon and cœcum.

Fixed in its place by the mesorectum, its relations in the male are with the prostate, seminal vesicles, and bladder; in the female, with the vagina and uterus. The connecting medium is called the recto-vaginal septum. Anteriorly and superiorly, it is covered by the peritoneum in both sexes.

Inferiorly, it is in contact with, and supported by, the levatores ani on each side. Much cellular substance surrounds the rectum, which moreover receives a distinct covering from the pelvic fascia.

Organisation of the rectum.—1. The serous coat is partial and does not extend to the pouch of the rectum; thus the lower portion of the gut is entirely free from any connexion with the peritoneum.

2. Muscular tunic. This is stronger than in the other intestines, and in this the rectum resembles the gullet. It is composed of two planes of fibres, a superficial and a deep, of which the former are longitudinal, the latter circular. Inferiorly, these fleshy fibres form a distinct sphincter, usually called the deep sphincter of the anus.

3. Mucous coat or membrane. This is continuous above with the mucous membrane of the sigmoid flexure of the colon; inferiorly it passes into the integuments around the anus. It is thicker, redder, and more vascular than the mucous membrane of the colon, and more abundantly supplied with mucosities.

No intestine receives so many blood-vessels as the rectum in proportion to its volume. These come from the inferior mesenteric, hypogastric, and internal pudic arteries; they are called the superior, middle, and inferior hæmorrhoidal arteries. Its veins proceed partly to the hypogastric, partly to the inferior meseraic. The nerves come from the sciatic and hypogastric plexuses.

Lastly; in the interior of the rectum there exist always two or more folds (shelf-like projections of the mucous membrane), projecting inwards towards the interior or axis of the bowel. The first, which, however, is not very constant, occurs at about the distance of an inch or less from the anus; the second and third higher up, at from $2\frac{1}{2}$ to 3 inches from the same aperture. They slightly overlap each other, and serve to insulate, as it were, the cavity of the pouch below from that of the true rectum above.

DEVELOPMENT OF THE ALIMENTARY CANAL.

The development of the alimentary canal in man has been described chiefly from what has been observed to prevail in the chick. This method of investigation is not a safe one; and thus the statement that

"in mammalia and man the origin of the alimentary canal is precisely similar" must be received with due caution and reservation. That they are extremely similar may be freely admitted.

The alimentary canal commences in the mucous layer of the blastoderm, in the form of a groove, which soon becomes a tube at each end, but remains open in the middle on the ventral aspect, communicating by means of a tube (omphalo-enteric or vitelline duct) with the vitelline sac. This duct is soon obliterated, and the vitelline sac is then called the umbilical vesicle, connected with the embryo by a slender pedicle containing the omphalo-mesenteric vessels; these structures are finally atrophied.

The alimentary canal is at first a straight tube closed at each end, placed along the front of the vertebral column, to which it is attached above and below, and in the middle by the rudiment of the mesentery. It soon thereafter forms a bend towards the middle, but remains straight at its upper and lower ends. The apex of the bend advances to the umbilicus, where it is connected with the umbilical vesicle by the pedicle and by the omphalo-mesenteric vessels.

A slight dilatation marks the place of the future stomach; this divides the tube into an upper and lower portion. From the upper are gradually developed the mouth, tongue, salivary glands, pharynx, larynx, trachea and lungs, and œsophagus. This tube is closed superiorly. A fissure at length appears. It is not the mouth properly so called, but the part out of which the mouth and lips are ultimately to be formed.

At first the stomach, as in some animals, is vertical; by-and-bye this alters, assuming first an oblique, and next a transverse direction. The liver, pancreas, and spleen, seem attached to the duodenum as appendages.

The portion below the stomach becomes the intestinal canal. As the small intestine grows, a portion protrudes into the part which is afterwards to become the umbilical cord, for the abdominal parietes are open: it usually retires again within the abdomen. The diverticulum, so generally found at one point of the intestine, is considered as the remains of the vitelline duct; but diverticula are found, though clearly differing much from this one, at other points of the canal. The large intestine is at first the smaller. The various segments of the intestine gradually assume their places, so that about the fifth or sixth month they occupy pretty nearly the positions they do in the adult. The anus does not exist at first, but appears some time after the oral opening.

At first the intestinal walls seem composed of two layers only; the serous is formed afterwards. The folds found in the intestine of the fœtus disappear, and are replaced by others. A layer of epithelium is easily perceptible.

INGUINAL AND CRURAL HERNIÆ.

1. Anatomy of the Inguinal Canal.—A portion of the bowels just described occasionally quit the cavity of the abdomen by apertures

which are either accidental or natural. The disease thus occasioned is called hernia, or rupture. At times it gives rise to operations requiring for their safe performance a due acquaintance with the anatomy of the structures through which the protruded part has passed.

Of the various kinds of hernia the most frequent, unquestionably, are the inguinal and the crural; and I shall confine my remarks to these—or rather to the anatomy of the openings by which the bowels escape from within the abdomen in these two kinds of hernia.

1. Anatomy of the inguinal canal. If the abdominal muscles and fascia transversalis be dissected in the mode already described, it will be easy for the student to examine the relations of the inguinal canal and its occasional contents.

The course of the canal is from above downwards, and from within outwards; its limits are the internal and external abdominal rings; its boundaries are, anteriorly, the tendon of the external oblique muscle; inferiorly, Poupart's ligament and its junction with the fascia transversalis; posteriorly, the fascia transversalis and a small part of the conjoined tendons of the internal oblique and transversalis muscles; superiorly, the inferior margins of these same muscles, shut in by their cellular attachment to the inner surface of the tendon of the external oblique. The obliquity of the canal and the want of coincidence between the abdominal rings contribute, no doubt, to render hernia less frequent than it otherwise would be.

As the abdominal rings are larger in man than in woman, inguinal hernia is the more frequent disease in the male; crural hernia in the female.

When inguinal hernia takes place the bowel may leave the abdomen by passing through the deep ring, pushing a portion of the peritoneum before it (this forms the hernial sac), and so entering the inguinal canal. This sort of hernia is called the *indirect* inguinal. When in the canal it may either remain there, or may, according to circumstances, descend in it, and escape by the external abdominal ring, and so descend, with the cord, into the scrotum.

Or, the bowel may enter the inguinal canal by an *accidental* opening or weak point in the walls of the abdomen, nearer to the mesial plane of the body; it is then called *direct* inguinal hernia.

As the epigastric artery is situated immediately behind the inner pillar of the deep ring, the relation it holds to the bowel of necessity alters, according as the hernia is direct or indirect. If indirect, the artery lies on the *inner* side of the neck of the sac containing the bowel, as it emerges through the deep ring. If the hernia be, on the contrary, direct, the artery in question is situated on the outer side of the neck of the sac, and on the outer margin of the accidental opening, through which, in this case, the bowel has passed.

The necessity for this minute anatomy and careful discrimination of the kind of hernia to be operated on arises from this circumstance. When hernia appears it cannot always be replaced by the hand; it may become strangulated, and thus necessitate an operation. During

this operation the surgeon's aim is to relieve the strangulated bowel by cutting through the strangulating part, whatever that may be. This first incision through the integuments and superficial fascia exposes the tendon of the external oblique and the external abdominal ring. By dividing a portion of this ring, upwards and outwards, he may at once relieve the bowel and replace it in the abdomen without even opening the sac; but if he cannot succeed at this stage of the operation, the sac must be opened, and the inguinal canal explored, to ascertain where the stricture on the bowel is situated; or, in other words, he must divide a portion of the *deep ring*, if the case be one of indirect inguinal hernia, or a portion of the deep *accidental ring* if the hernia be *direct*. To avoid the artery, it has been recommended, in both cases, to cut directly upwards; the minute anatomy of the artery proves the advice to be sound.

A few other points in the history of the inguinal canal may be noticed here, although the subject belongs more properly to surgical works.

In the inguinal canal the spermatic vessels and vas deferens are situated behind the hernial sac and its contents; the cremaster, on the other hand, is spread out over them.

When the bowel has passed through the external abdominal ring, and descended towards the scrotum, the coverings of the *hernial sac* are—1, the integuments; 2, the superficial fascia; 3, the intercolumnar fascia; 4, the cremaster; 5, the fascia propria,—all these require to be divided before the external surface of the sac be reached.

In *direct*, or ventro-inguinal hernia, the cremaster does not usually cover the sac, but a very thin expansion of the *conjoined tendons* of the internal oblique and transversalis may have been pushed before the bowel on its passing through the abdominal walls.

2. Of Crural Hernia.—In woman especially the bowels are apt to protrude from their natural cavity by a small aperture or weak point in the containing walls situated under Poupart's ligament, bounded, anteriorly and superiorly, by Poupart's ligament; internally, by the ligament of Gimbernat; externally, by the sheath of the great vessels; posteriorly and inferiorly, by the horizontal ramus of the pubes.

The parts connected with crural hernia require to be dissected from without and from within; the latter method gives the most satisfactory view.

Having divided the walls of the abdomen so as to expose the contents, examine carefully the peritoneum where it corresponds to Poupart's ligament and groin. A slight depression may be observed under Poupart's ligament towards its pubic extremity. On pushing the finger against this part it will readily pass a short distance under the ligament towards the groin: this is the situation of crural hernia, which the finger now imitates, having passed into the superior aperture of the crural canal.

Cautiously strip the peritoneum from off this and a small portion of the adjoining surfaces: an exceedingly delicate layer of cellular tissue will next be found; it seems to come from the fascia transversalis: outside this is a second layer of cellular membrane, which the French anatomists call the septum crurale: it is often indistinct. On removing these the finger may now be pushed downwards through the opening thus made into a short canal, whose walls are, externally, the sheath of the femoral vein; anteriorly, the cribriform fascia; internally, the union of this fascia with the femoral aponeurosis; posteriorly, the portion of the aponeurosis covering the pectineus muscle. It is into this canal that the bowels first descend in the crural hernia; they may remain here and distend the canal, or they may escape by the opening through which the saphena passes, on its way to join the femoral vein.

When crural hernia has become strangulated so as to require an operation, the strictured part will be found to be in the upper opening of the canal; and the part which may be divided with safety is the concave edge of the ligament of Gimbernat. The neck of the sac must also be divided. Timid surgeons cut upwards instead of inwards; they divide the lower margin of Poupart's ligament; in woman this leads to no bad results. The section of Gimbernat's ligament must be made with the utmost caution, for it not unfrequently happens that the obturator artery, or, at least, a large branch proceeding to join it, arises from the epigastric, and, placing itself upon the semilunar edge of Gimbernat's ligament, comes to be directly in the way of the surgeon's knife. I have examined a case of omental hernia (crural) in which the obturator artery was found so firmly united to the margin of Gimbernat's ligament, that, had an operation been required, the artery must of necessity have been divided. Mr. Liston, to whom I showed the dissection, readily admitted that this must have happened in any hands.

Occasionally the ligament of Gimbernat seems double, probably due to a strengthening of that portion of the cellular membrane interposed between the peritoneum and the tendinous terminations of the muscles.

OF THE PANCREAS.

The pancreas, though situated in the abdomen, is now generally admitted to be analogous to the salivary glands already described.

It is of a greyish white colour, inclining to red, of a rather irregular form, and has no special capsule enclosing it. It lies across the vertebral column, and is curved naturally to meet this position, although it be usual to describe it as straight, an error arising no doubt from its having been generally described and drawn after it has been removed from the body.

It is situated between the three curvatures of the duodenum, behind the stomach, and to the right of the spleen, which it approaches by

its left extremity. The superior mesenteric artery and vein pass under its lower edge at the part where the organ is narrowest.

Fig. 199.*

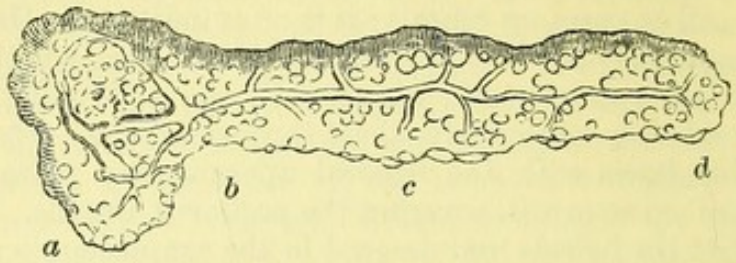

It is most easily displayed by the dissector by laying up the transverse arch of the colon and dividing transversely the inferior layer of the mesocolon, immediately above which it will be found.

The right extremity is larger than the left. The splenic vessels lie in a groove behind its upper and posterior margin, and the commencement of the vena portæ will be found behind its narrowest part. The cœliac axis is close to the upper margin, and the superior mesenteric vessels in passing into the mesentery separate the pancreas from the duodenum.

The left extremity is called the *tail;* the right the *head;* the intermediate portion the *body*. Connected with the head is an accessory part of the gland, usually called the *small pancreas*.

The parenchyma is firm, and appears composed of lobes and granular bodies, connected together by cellular substance. From these granulations and lobules proceed the small ducts, which, uniting in the manner of veins, form at last the duct of the pancreas—duct of Warsung.

This duct may be traced from near the tail until it passes into the second portion of the duodenum. It is usually single, but other smaller ducts often run parallel to it; it is said to be in the fœtus uniformly double.

Placed in the substance of the organ, a little nearer its lower than its upper margin, directed from left to right, and progressively

* Fig. 199.—The pancreas. Represents the pancreas when removed from its natural position in the abdomen, and detached from all the surrounding organs. This, and I believe all previous drawings of the pancreas, are copies of that engraved in Santorini's posthumous work: there is a drawing also of the pancreas in De Graaff's work, which no doubt was taken from the original.—*a*, head of the pancreas, or smaller pancreas. It is this portion of the organ which is not covered by peritoneum, and which adheres closely to the muscular tunic of the second portion (descending turn) of the duodenum. The ducts originating in this part of the pancreas present numerous varieties, more especially as to the mode in which they terminate. *b*, the narrow part, or neck of the pancreas. Under this portion pass the superior mesenteric artery and vein, and the third turn of the duodenum separates it from the vertebral column. *c*, the body, and *d*, the tail, of the pancreas; the duct, which requires to be exposed by dissection, runs from the tail towards the head, collecting in its passage the smaller ducts of the glandular substance: it may be exposed by dissection on either surface of the gland.

increasing in size from the numerous branches it receives in its course, the duct proceeds in a serpentine direction towards the duodenum; quits the gland and becomes free behind the second portion of the duodenum. As it is about to enter the gut it receives the duct of the smaller pancreas. It now adheres to the ductus communis choledochus, with which it unites; or it enters the duodenum apart and singly; sometimes near the ductus choledochus, sometimes considerably removed from it.

The pancreas, besides resembling the salivary glands in many other particulars, resembles them also in this, that it has no special artery sent to it from the aorta, but is supplied from several sources.

Its nerves are from the sympathetic. It is not often found the seat of disease.

OF THE SPLEEN.—*Lien.*

The spleen is a solid, vascular organ, situated in the left hypochondrium, beneath the diaphragm, above the descending colon, and between the cardiac extremity of the stomach and the cartilages of the false ribs, before the left supra-renal capsule and kidney. The posterior portion of the inner surface is applied to the left side of the vertebral column. Folds of the peritoneum attach it to the surrounding organs. Its volume varies much, and, having no excretory duct, its probable functions in the economy cannot be determined.

The *outer* surface of the spleen is convex, and corrresponds to the 9th, 10th, and 11th ribs; its *inner* surface, which faces the stomach, is divided into two parts by a depression—the *fissure of the spleen*. By this fissure, which never extends throughout the whole length of the spleen, the vessels enter and leave it.

Fig. 200.*

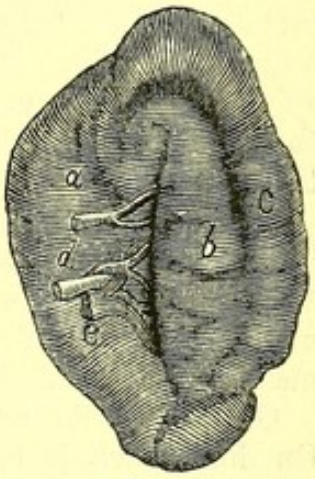

On the circumference of the spleen anteriorly, the edge is notched; small supernumerary spleens are occasionally found below the other.

Tunics.—The first of these is the serous, derived from the peritoneum. Within this is the fibrous, which sends a great number of delicate prolongations into the interior of the organ.† It furnishes prolongations, supporting the vessels which pass

* Fig. 200.—The spleen. The figure represents the concave surface looking towards and resting on the cardiac end of the stomach; the convex or diaphragmatic surface presents nothing remarkable.—*a*, *b*, between these letters is the *hilus* of the spleen, or fissure by which the splenic artery enters, and the vein quits the spleen; *d*, one of the larger branches of the splenic artery entering the spleen; *e*, the splenic vein. The artery comes from the cœliac axis, and the vein unites with the superior mesenteric vein to form the vena portæ.

† Muscular fibres, or something resembling them, have been seen in the interior of the spleen of some animals by Kolliker, in connexion with the fibrous envelope.

into the spleen by the fissure. This envelope seems to be of elastic tissue.

Vessels.—Its supply of blood is comparatively large. The principal artery sent to it is the continuation of the splenic; but it also receives branches from the capsular, phrenic, first lumbar, and spermatic of the left side. The veins are not larger than the arteries, and are remarkable for the thinness of their walls. *They communicate directly with the arteries.* They are without valves, and form a trunk, which constitutes one of the two large vessels giving rise to the vena portæ. Its nerves come from the solar plexus; the lymphatics are numerous, and unite with those of the liver.

Little or nothing is known of the intimate nature of the parenchyma of this organ, and nothing whatever of its functions.

OF THE LIVER.—*Hepar.*

Dissection.—Trace carefully, whilst *in situ*, the hepatic artery and vena portæ, the ductus cysticus, hepaticus, and communis choledochus; examine the capsule of Glisson and folds of the small omentum; dissect the organ from the diaphragm by cutting through the coronary ligament; trace the termination of the hepatic veins into the inferior cava, immediately below the diaphragm; and having dissected and examined all these structures, their course, situation, and connexion, divide them so as to remove the liver from the abdominal cavity.

The liver is the largest gland in the body. Besides performing, no doubt, other functions, it secretes the bile. It is a single unsymmetrical organ, dense, of a deep brown colour, and readily torn. It occupies the whole of the right hypochondrium and a portion of the epigastric region, extending downwards for a very short way below the margins of the ribs. Its weight in the adult varies from two to five pounds.

The liver is convex on its *upper* surface, and divided into two lobes of unequal size by the suspensory ligament. This ligament is a process of the peritoneum, containing within it, anteriorly, the remains of the umbilical vein of the fœtus, now called the round ligament of the liver. These lobes are called the right and left.

On the inferior or lower surface the liver is much more complex. On this, which is concave, we find,—1, the right lobe; 2, the left; 3, the lobulus quadratus, placed anteriorly between the gall-bladder and left lobe; 4, the lobule of Spigel, immediately opposite to the l. quadratus, but separated from it by the transverse sulcus of the liver; 5, the lobulus caudatus, connecting the right lobe to the lobulus Spigelii.

Between the right lobe and lobulus quadratus is a fossa for lodging the gall-bladder; and between the lobulus quadratus and left lobe is a groove or hollow in which the round ligament or remains of the umbilical vein will be found. Between the lobulus quadratus and the lobulus Spigelii runs the transverse sulcus, in which are placed the vena portæ, the terminating branches of the hepatic artery, the

ductus cysticus, and d. hepaticus; and in the sulcus, between the lobulus Spigelii and left lobe, run the remains of the vessel called ductus venosus. Between the lobe of Spigel and the great lobe is the sulcus for the vena cava inferior.

The *tunics* of the liver are two; one imperfect, furnished to it by the peritoneum; an inner, fibrous and complete. It sends no prolongations inwards into the substance of the organ.

Trace the hepatic artery into the transverse fissure, and observe its subdivision into two branches of unequal size; one to the right lobe, the other to the left. Follow in like manner the vena portæ, noting the sheath it receives, along with the other vessels, from the capsule of Glisson; and how, whilst in the sulcus, it forms a transverse sinus, from which branches proceed in all directions. To this sinus the student may trace the remains of the umbilical vein and ductus venosus, vessels which at one time opened into the sinus of the porta, nearly opposite to each other.

The ligaments of the liver are the coronary, the suspensory, the round, and the right and left lateral ligaments. With the exception of the round ligament, they are all processes of the peritoneum.

Superficial depressions on the concave surface of the right and left lobes are caused seemingly by the proximity of the right kidney, the arch of the colon, and stomach, on which the liver rests.

The grooves for the round ligament and ductus venosus are sometimes bridged over by a portion of the liver. The margins of the lobulus quadratus and lobe of Spigel, which bound the transverse sulcus, are sometimes called the anterior and posterior eminences of the porta.

EXCRETORY APPARATUS OF THE BILE.

The radicles or roots of the hepatic ducts commence in the parenchyma of the liver, and, uniting, give rise to larger branches. These at last form two trunks, one for the left lobe, the other for the right, which leave the substance of the liver and pass into the transverse sulcus; these, uniting, form the hepatic duct. The duct is about one and a half inch in length, and about a line and a half in diameter. It has two tunics, an inner mucous, and an outer fibrous, and, perhaps, muscular. It unites at length with the cystic duct at an acute angle, thus forming the ductus communis choledochus. The common duct, thus formed, descends behind the second portion of the duodenum, through the coats of which it passes obliquely, entering the bowel at a variable distance from the pylorus, but usually along with the duct of the pancreas, at the end of the second portion of the duodenum. It is from three to three and a half inches long; its fibrous tunic is distinctly muscular; the fibres run obliquely and longitudinally; its duodenal opening is provided with a membranous fold or semi-valve of the mucous membrane of the intestine; its mucous tunic is continuous with that of the intestine and gall-bladder.

Of the gall-bladder and cystic duct.—The gall-bladder is a mem-

branous pyriform reservoir for a certain amount of bile which paases into it and returns to the cystic duct, there being no hepato-cystic duct in man. It is fixed in a hollow, excavated on the concave side of the liver, between the great lobe and the lobulus quadratus, which it separates. The peritoneum passes over it, giving it a partial covering, which of course is deficient over all that portion of the gall-bladder which is more immediately in contact with the liver. The descriptive anatomist divides the gall-bladder into a body, a fundus, and a cervix. The fundus is rounded, and entirely covered by peritoneum, and passes beyond the sharp edge of the liver; the body adheres to the liver by cellular substance and blood-vessels. The cervix is continued into the cystic duct.

Tunics.—Besides the peritoneal, the gall-bladder has, 1st, a cellulo-fibrous, and, 2d, a mucous coat. The cellulo-fibrous presents nothing remarkable in its structure. The mucous is rough, reticulated, and plicate. In the vicinity of the neck of the gall-bladder, and especially in the cystic duct, there are five or six imperfect valves; they allow a probe, or air, to pass readily into the gall-bladder from the cystic duct, but impede their return from the bladder to the duct. Its arteries arise from the hepatic, its nerves from the *hepatic* plexus. Whilst enclosed in the smaller omentum, and surrounded by the capsule of Glisson, the ductus communis choledochus is situated to the right, the hepatic artery to the left, and the vena portæ between and behind these vessels.

STRUCTURE OF THE LIVER.

Notwithstanding the efforts made of late years to unfold the structure of the liver, microscopic observers are not yet agreed as to its intimate nature. The view most generally adopted is that of Mr. Kiernan.

1. It is admitted that the liver has two tunics—a serous incomplete, a cellular complete. The course of the serous has been described; also the parts mentioned where it is deficient. It adheres closely to the proper capsule of the liver.

2. The cellular, also called fibrous, invests the whole gland. Internally it seems to be continuous with the delicate cellular tissue passing into the interior of the gland.

3. The proper substance of the liver, or the parenchyma, is compact but not firm. Hence its liability to be torn during life. It seems composed of lobules varying from half a line to nearly a line in diameter. They are, in short, about the size of a pin's head; connected to each other by fine cellular tissue and by the blood-vessels. But even here observers do not agree; some imagining the lobules to be isolated, others viewing them as connected or continuous at various points. I lean to the opinion, merely from analogy however, that they are essentially isolated. Each lobule is said to rest by a smooth surface or base upon a branch of the hepatic vein, connected with it by a small venous trunk which arises in the centre of the lobule, and passes out from the middle of its base to end in the larger subjacent vessels. To the small

Fig. 201.*

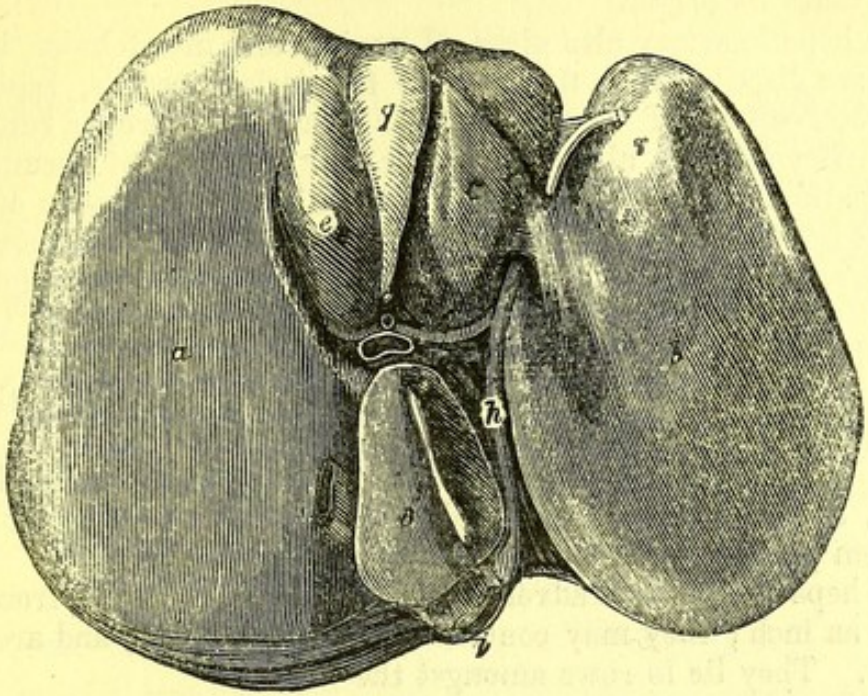

vein the name of intralobular has been given. The branch of the hepatic vein with which it communicates has been called sublobular.

The sublobular veins so formed, uniting into larger and larger vessels, end at length in another kind of vessels (hepatic venous trunks) which receive no intralobular veins. These terminate in the vena cava on the convex and blunt edge of the liver.

The other vessels which *enter* and *quit* the liver have a totally different arrangement: they are the portal vein, the hepatic artery, and the biliary ducts. Within the liver the branches of these vessels lie together in canals, called *portal;* these commence at the transverse fissure and branch upwards in all directions. Glisson's capsule enters with them and encloses them. A transverse section of one of these portal canals proves this, showing the open orifices of branches of the portal vein, hepatic artery, and biliary duct, enclosed together by a cellular sheath. The ultimate branches of the portal vein proceed to ramify on the lobules: from the network which these form in the

* Fig. 201.—Intended to show the concave surface of the liver, the surface which rests on the stomach and colon.—*a*, right lobe; *b*, left lobe; *c*, lobulus quadratus. This lobe, or lobule, separates the gall-bladder, *g*, from the obliterated umbilical vein, *r*, which, after birth, becomes the round ligament of the liver. *d*, lobe or lobule of Spigel. This separates the fossa for receiving the vena cava inferior, and the vein itself, *i*, as it passes behind the liver and through the diaphragm, from the fossa, in which is lodged the obliterated ductus venosus. *e* is placed a little too high up; it is intended to point to the lobulus caudatus, a small portion of the liver connecting the great lobe to the lobule of Spigel; *f*, the hepatic artery dividing into its right and left branches; close to it is the vena portæ, cut across. The sulcus, into which these vessels are passing, is the transverse hepatic sulcus or sinus of the porta, and the lobes bounding it receive also the names of anterior and posterior portal eminences; *r*, the remains of the umbilical vein; *h*, the remains of the ductus venosus.

lobules, the interlobular vein, that is, the commencement of the hepatic veins, takes its origin.

The hepatic artery also gives off vaginal and interlobular branches. These are distributed to the coats of the various vessels, especially to the ducts, capsule of Glisson, cellular tissue, and proper tunic of the liver. Beyond this all is conjecture, for the mode of termination of the hepatic artery, and its connexion with the other system of vessels, has not been demonstrated. Mr. Kiernan infers that the blood of the hepatic artery reaches the hepatic veins only indirectly through the intervention of the vena portæ. This was Ferrein's opinion; it is now supported by Thiele.

The hepatic ducts, after leaving the lobules, collect in the portal canals, to reunite in the ductus hepaticus.

The biliary ducts at their commencement contain a peculiar substance, supposed to be composed of numerous nucleated corpuscles. On them probably depends the secretion of the bile.

The hepatic cells just adverted to are said to measure from $\frac{1}{840}$ to $\frac{1}{1000}$ of an inch; they may contain one or more nuclei, and are slightly yellow. They lie in rows amongst the vessels.

Aberrant biliary ducts, without lobules, but accompanied by branches of the vena portæ, hepatic artery, and hepatic vein, are occasionally found in the duplicature of the peritoneum forming the left lateral ligament of the liver; also in the two fibrous bands, converting the fossa lodging the vena cava and the fissure containing the umbilical vein into canals.

Development.—The liver begins to be formed very early in fœtal life. At the third or fourth week it is said to constitute nearly one-half the weight of the whole body. This ratio gradually decreases as development advances; at birth it is as 1 to 18. At first the right and left lobes are nearly of equal size; the position of the organ is more symmetrical, and it occupies a large portion of the cavity of the abdomen.

Up to the moment of birth all the blood circulating in the umbilical vein passes through the substance of the liver, with the exception of what reaches the vena cava by the ductus venosus. In point of fact the *sinus* of the porta is chiefly formed by the umbilical vein, the *vena* portæ being at this time a comparatively small vessel. Before entering the sinus of the porta, the umbilical vein sends some branches to the square lobe and lobule of Spigel. The ductus venosus of the fœtus is not a branch of the umbilical vein; it arises from the sinus of the porta, opposite to the entrance of the umbilical vein.

At birth the supply of blood to the liver by the umbilical vein is at once cut off; the vein itself and the ductus venosus contract and degenerate into cellular cords, and the liver diminishes in size until its ratio to that of the body be as 1 to 36. This ratio it attains about the sixth year.

A small accessory liver has been seen on the left side, and the organ is liable to many congenital deviations from the ordinary or normal form.

II. ORGANS OF URINE AND GENERATION IN THE MALE AND FEMALE.

THE organs about to be described are situated partly in the abdomen and partly in the pelvis. Systematic anatomy and sound physiology forbid the consideration of these cavities, and especially of their contents, as distinct from each other. To expose the pelvic viscera, including the rectum already described * systematically as a portion of the intestinal canal, requires several careful sections and dissections. Practical instructions must of necessity be commingled with the systematic history of organs so situated, at the risk of occasional repetitions; otherwise, an anatomical work, whatever its value may be in other respects, ceases to be of use to the student. The chapter has been subdivided into suitable heads, with a view to the convenience of the dissector.

SUPRA-RENAL CAPSULES.

These are two small organs placed above the kidneys, the upper extremities of which they embrace. Their uses are wholly unknown; nor is much known of their intimate structure beyond the mechanical tracing of arteries carrying red blood to them, and veins returning venous blood from them to the venous system; yet they are never absent, and are very large in the fœtus. It is this circumstance which has induced physiologists to view them as being, in some way or other, subservient to fœtal life.

These capsules are of a yellowish-brown colour. *Posteriorly* they rest on, or correspond to, the diaphragm and upper part of the psoas; *anteriorly* they are covered, the right by the vena cava inferior, the duodenum, and the liver; the left by the spleen and pancreas: the *inferior* surface is concave, and is applied to the summit of the corresponding kidney.

Each supra-renal capsule is, in fact, a small bag with thick parenchymatous walls, of but little consistence, formed of small granulations collected into lobules. In the interior is a triangular cavity with no known orifice. The capsules have no excretory duct. The fluid contained in the capsules changes colour with age; they receive arteries from the aorta, inferior phrenic, and renal arteries; the veins of the right capsule enter the vena cava; those of the left open into the renal vein. Their lymphatics join the emulgent and inferior diaphragmatic plexuses; their nerves come from the renal plexus. I have examined them in every mammal without obtaining any useful information from the inquiry.

THE KIDNEYS (*Renes*)

Are the secreting organs of the urine: they are abdominal organs, easily found, and easily dissected. Attend first to their position.

* See page 470.

They are situated in the lumbar region, on the sides of the vertebral column, opposite to the last two dorsal and the first two lumbar vertebræ—one to the right, the other to the left—and are enveloped on all sides by a thick mass of fat; the left is higher than the right, and generally larger; in the male the average weight is from 4½ to 6 ounces, and in the female from 4 to 5½.

Their colour is a dark red, inclining to brown, and their form that of a kidney-bean.

The anterior surface is convex, and occasionally completely covered by peritoneum; at other times it is more or less in connexion, to the right side, with the vertical portion of the duodenum, the liver and the ascending colon, and, to the left, with the spleen and the descending colon. The posterior surface, resting upon a cushion of fat (*tunica adiposa*), is in relation to the diaphragm and the aponeurosis of the transversus abdominis muscle. On their circumference anatomists have noticed, 1st, the thick and rounded superior extremity embraced by the corresponding renal capsule; 2d, inferiorly a thin and elongated portion, approaching somewhat the iliac spine; 3d, an extremely thick convex edge looking backwards; 4th, internally a deep notch (fissure or hilus of the kidney), more distinct anteriorly than posteriorly.

The renal arteries are large, and generally single, but sometimes there are two or more to each kidney; they arise from the aorta. The renal veins, which are also large, join the vena cava inferior; the left is the longer, having to cross the spine. A nervous plexus accompanies these vessels, derived from the semilunar ganglion and solar plexus of the sympathetic; a plexus of lymphatic vessels also exists. The parenchyma of the kidney is firmer than that of the other glands; it is composed of two distinct substances, an external or *cortical*, and an internal or mammillary, also called tubular.

1. The external or cortical, besides forming an external layer one or two lines thick, of a dark or reddish bay colour, adhering to the capsule, furnishes prolongations, which, extending inwards, form septa, between which are placed the cones of the tubular or mammillary structure. This cortical substance tears with ease; it seems to be the essential part of the gland on which the secretion of the urine depends.

2. The internal, tubular, or mammillary part of the kidney is arranged into a certain number of cones, marking the original divisions in the fœtal kidney. These cones are enveloped on all sides by the cortical substance, excepting towards their truncated extremities, where they project into the calices,—that is, into the membranous tubes which by ultimately coalescing form the pelvis of the ureter. By these tubes the urine secreted by the parenchyma of the kidney is conveyed into the pelvis of the ureter, and by the ureter into the urinary bladder, from which it is discharged through the urethra.

The colour of this tubular part of the kidney is a pale red; it is dense, firm, and tenacious; it is formed of tubes, whose nature will be described immediately. The mammillæ projecting into the calices are

the summits of these tubular cones. Each cone, with its membranous tube (calyx) and its surrounding cortical portion, represents one of the small kidneys of which the fœtal kidney is composed. Their number varies from 12 to 18. Cellular and adipose tissue, not, however, in great abundance, separates them from each other.

The membranous envelope or capsule of the kidneys is double; it covers their entire circumference and dips into the fissure or hilus, where it is traversed by the renal vessels, and expands upon the walls of the pelvis of the ureter. Numerous delicate filaments and fine blood-vessels connect it to the parenchyma of the organ. The morbid serous cysts so frequently occurring in these organs grow between the layers of the capsule, which they separate from each other. In texture it is celluloso-fibrous.

The calices, infundibula (supposing these to be distinct), the pelvis, and the ureter, form together one continuous canal, by which the urine escaping from the mammillary portion of the kidney passes at last into the urinary bladder. The short tubes forming the commencement of this system are the calices; they embrace the summits of the mammillæ, and are, on the other hand, continuous with the pelvis of the ureter; those of the upper half of the kidney generally unite into one short trunk; those of the lower form a similar one; the term infundibula has been given to these short trunks. By their union the infundibula form the pelvis, which terminates inferiorly in the ureter. It sometimes happens that these two short tubes do not unite, and then the pelvis and ureter remain double to near the entrance of the latter into the bladder.

The pelvis so formed is a dilated portion of the urinary passages, placed behind the vessels, and occupying the back part of the hilus or fissure of the kidney. The ureter is the long membranous canal (from 16 to 18 inches) descending from the pelvis of the kidney to the inferior fundus of the urinary bladder, into which it enters, passing obliquely through its tunics. Its course is first towards the sacro-iliac synchondrosis; from this, descending rapidly into the pelvis, it crosses the iliac vessels and psoas muscles; anteriorly it is covered by the peritoneum; the spermatic artery and vas deferens cross it in the male. These tubes, the calices, pelvis, and ureters, seem to have but one organization; their walls are composed of two membranes,—the outer, thick, of an opaque white colour, strengthened superiorly by the fibrous capsule of the kidney; the inner is a mucous membrane continuous with that of the urinary bladder; it may even pass into the tubuli uriniferi.

It is in the cortical part of the kidney that the pathological condition called "Bright's disease of the kidney" occurs. It first destroys the granular or cortical substance, and thus arrests the secretion of the urine. The exact nature of the *cystic* disease of the kidney mentioned above has not yet been determined. When calculi become impacted in the ureter the flow of urine is gradually arrested; it accumulates above the point of obstruction; the pelvis, infundibula, and

calices gradually enlarge, or become dilated. The accumulated urine, incompressible as being a liquid, accomplishes, in time, the entire destruction of the parenchyma of the organ; the kidney, in the mean time, may become of large size, but, on being cut into, is found to be composed merely of the system of the membranous tubes, viz. calices, infundibula, and pelvis, enclosed by the general fibrous capsule of the organ, which yields in part, yet is sufficiently resisting to destroy the parenchyma of the organ.

When the substance of the organ is destroyed by the cystic disease, which sometimes happens, there is no dilatation of the system of the calices and pelvis. The cyst or cysts, for they are occasionally very numerous, slowly or rapidly enlarge; the outer layer of the capsule resists more strongly in these cases than the inner; this yields, and the parenchyma, being exposed to mechanical pressure, is absorbed and destroyed.

When one kidney has been destroyed by disease, the remaining one, if sound, enlarges, becomes more vascular, and performs the duties of both.

The structure of the kidneys is not affected by the disease called diabetes.

Calculi form, generally, first in the kidneys, and then descend by the pelves and ureters to the urinary bladder. To this, however, there are exceptions, of which the most obvious is when the calculus forms upon a foreign body, accidentally introduced into the bladder.

Structure of the Kidneys.—The tubuli uriniferi, composing the greater part of the mammillary eminences, open upon the surface of these eminences, and by this means pour the urine into the calices. These tubuli, after bifurcating again and again, finally reach the cortical part of the kidney; here they become convoluted in the most intricate manner. The tubes of the straight portion are called the tubes of Bellini; those of the convoluted portions, the tubes of Ferrein. The blood-vessels are ramified on the walls of these tubes; a spheroidal epithelial covering lines their interior. Nothing for certain is known as to the mode in which the tubuli uriniferi commence.

Malpighian Corpuscles.—These small bodies lie embedded in the cortical substance of the kidneys. They were discovered by Ruysch to be formed of blood-vessels forming small tufts. The true relation of these vascular tufts to the uriniferous tubes is said to be this: the uriniferous tube forms at its commencement, a capsule, into which one of the vascular tufts projects, so as to be entirely enclosed within it; but these vascular tufts, occasionally, also pierce the sides of the uriniferous tubes,—that is, they may be lateral or terminal. It has also been asserted that the lining epithelium of the tubuli is not reflected over these tufts; but this has been denied by good observers.

A network of capillary veins may be seen near the surface of the kidney; they gradually unite to form a single vein, the renal.

Fig. 202.*

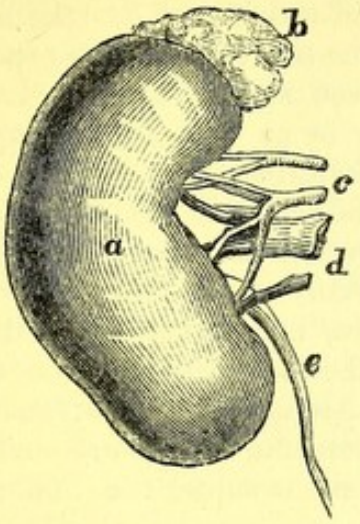

Fig. 203.†

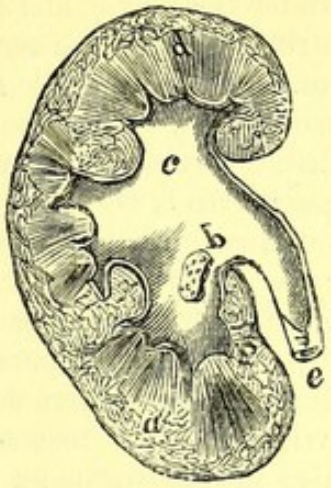

Lastly, an interlobular cellular structure has been described as lying between the vessels and the tubuli, the nature of which is entirely unknown.

THE URINARY BLADDER.

Dissection.—Distend the bladder, if entire, with air or water introduced into it by the ureter or urethra, and examine the varying position of its body and fundus, before any further steps be taken.‡ But the anatomy of this important organ; its relations to the surrounding viscera; its intimate connexion with the prostate and male organs of generation, cannot be understood nor even attempted until a section of the pelvis has been made.

This section may be either *lateral, anterior*, or *posterior;* the lateral section may be either mesial or to one side; and the mesial section may be confined to the walls of the pelvis or may extend to all the organs met with in the line of the section. This latter is the preferable one in *the female;* or at least should always be made, sooner or later, by the student, whatever other views he may previously have taken.

Although each section possesses certain advantages peculiar to itself, yet for all practical purposes the one I am about to describe is generally preferred.

* Fig. 202 represents the right kidney and corresponding supra-renal capsule, anterior surface.—*a*, the kidney; *b*, the supra-renal capsule; *c*, the chief branch of the renal artery; in this instance the renal artery seems to have entered the fissure of the kidney by three branches, as represented in the figure; *d*, the renal or emulgent vein; *e*, the ureter. The direction of the duct, called ureter, and the position of its pelvis or dilated origin, properly attended to, will always enable the student to distinguish one kidney from the other, though removed from all their connexions. The pelvis of the ureter is placed behind the other vessels.

† Fig. 203 represents a vertical section of the kidney.—*a*, the cortical substance; *c*, *b*, the interior or mucous surface of the calices, infundibula, and pelvis of the ureter, all these tubes having been laid open by the section; *e*, the ureter cut across; *d*, *d*, *d*, the mammillary substance, and the eminences in which they terminate.

‡ If accidentally opened it may be filled with baked hair.

1. Place the subject as in the operation for lithotomy; a thin block is put under the pelvis, and a grooved staff introduced into the bladder by the urethra and there secured; raise the scrotum, and so expose the perineum. Although this region has been already alluded to more than once and partially described, it may be as well to sum up here the principal structures seen during its dissection.

The *perineum* is bounded in front by the scrotum, behind and at the sides by the coccyx and sacro-sciatic ligaments and tuberosities of the ischium; laterally and forward, by the rami of the pubes and of the ischium. The integuments are tense, thin, and stretched, as it were, across this triangular space, and, like the scrotum, are of a darker colour than in other parts of the body. Along the mesial plane is the raphe, which extends forward over the scrotum and lower surface of the penis; in the fœtus an extensive fissure occupies the line of this raphe.

Dissect the integuments by two flaps; reflect these outwards towards the thighs and tuberosities of the ischium, and thus expose the *superficial perineal fascia.** After again and again examining the relation of this fascia to all the surrounding structures, its varying depth and strength, and its influence over the course of abscesses, urinary or otherwise, which may occur here, reflect it also and expose the muscles. These have been already described.† The cellular sheath investing these surfaces has been by some called the middle perineal fascia. Re-dissect these parts with care, for the perineum cannot be too often examined, and next proceed with the section which is to expose the contents of the pelvis, and to put them in a position for a minute examination of their surgical, systematic, and general anatomy.

The object then of the steps to be next adopted by the student is so to expose the viscera of the pelvis as to enable him to examine them, 1st, *in situ;* 2d, systematically, when removed from the cavity. To accomplish this he is required to make a lateral or other section of the pelvis; the object being to remove, with the least injury to the contained organs, a side or other wall of the pelvis. The left wall, for obvious reasons, is always selected for removal in the lateral section.

LATERAL SECTION OF THE MALE PELVIS.

Dissection.—Divide the left pubis with a saw at the distance of about three-fourths of an inch from the symphysis, and detach the remains of the left os innominatum by opening the left sacro-iliac articulation; leave all the soft parts belonging to the left side in the pelvis, and consequently in connexion with the deep organs and with those of the other side; distend the bladder and rectum, clean the surfaces, and preserve every important part.

Trace the peritoneum over the bladder, and mark the points of its reflexions; how it leaves the abdominal walls, passes over the bladder, and is reflected upon the rectum; note the fold which forms the meso-

* See chapter on the Fasciæ. † See Muscles of the Perineum.

rectum, and how much of these organs, the bladder, and rectum, is wholly free of a peritoneal covering.

Now examine the pelvic fascia, or at least what is left of it, of the *left side;* to be re-examined afterwards with more advantage on the right side.

By examining carefully the fascia of the left side, now detached from the iliac fascia and from all connexion with the left wall of the pelvis, it will be seen that, after lining the inner surface of the obturator internus and levator ani muscles of this side, it is reflected inferiorly from the walls of the pelvis upon the viscera nearly on a level with the upper surface of the prostate gland, transmits a lamina (vesical fascia) over the surface of the bladder, and by means of laminæ sent from its outer surface encloses the prostate, bladder, and rectum. These laminæ detached from the outer surface of the pelvic fascia have been named, in reference to the organs they enclose, the vesical, prostatic, and rectal fasciæ.

Dissect from off the bladder a small portion of the fascia to test its nature, its strength, and its attachments; lay open the *rectal* fascia by a longitudinal incision, and clean the external longitudinal fibres of the muscular tunic of the rectum; clean the ureter and vas deferens, tracing the former to the bladder, the latter to the prostate gland; dissect between the prostate, bladder, and rectum, and, drawing the former upwards, expose the vesiculæ seminales and the inferior fundus of the bladder, at the point where the bladder is opened when punctured through the rectum, marking in an especial manner the line where the peritoneum leaves the bladder to be reflected on the anterior surface of the rectum.

Examine practically the prostate gland *in situ;* observe how it surrounds and strengthens the neck of the bladder and the commencement of the urethra, and mark the consequent impropriety of dividing its base in lithotomy.

At this stage of the dissection the precise anatomy and surgical anatomy of the inferior portion of the left levator ani and ischio-coccygeus muscles may be readily studied; the covering the prostate receives from the subpubic ligament; and the anatomy of the muscles of Santorini and Wilson already described.

In front of the prostate are the glands of Cowper and membranous part of the urethra, which shall be described immediately.

Prior, however, to the systematic account of these organs, it will be proper to take a view of the surgical anatomy of the pelvic fascia of the right side.

Examination of the pelvic fascia of the right side.—It is on the right side of the pelvis, as yet untouched, that the clearest view of the disposition of the fascia may be obtained.

The peritoneum having been stripped off and the loose cellular substance removed, clean and afterwards divide the remains of the right umbilical artery; draw the rectum and bladder towards the left side clear of the cavity of the pelvis, but taking care to injure none of their attachments; in this way will be displayed the pelvic

fascia, descending from the linea ilio-pectinea, and covering the obturator internus muscle and concave surface of the levator ani of the right side. After descending to a level with the prostate, it is reflected upwards upon the sides and front of the urinary bladder, becoming thus the vesical fascia. A kind of tendinous arch, strengthening the fascia, extends from the back of the symphysis to the spine of the ischium. This tendinous arch may be considered as the principal origin of the levator of the anus; above and behind the arch the fibres of the obturator muscle may be seen through the fascia; below and in front those of the levator ani. Posteriorly the fascia degenerates into common cellular tissue.

At the tendinous arch just described the pelvic fascia divides into two layers; one, the internal, descends on the concave side of the levator; the other, the external, passes on its outer or convex side. But this latter again subdivides into two layers; one, the internal, proceeding with the muscle as its investing sheath towards the anus and perineum; the other, the external, descending more outwardly to be attached to the tuberosity and ramus of the ischium. It shuts in the obturator muscle and common pubic artery. The space between these laminæ has been called the ischio-rectal space.

OF THE LIGAMENTS OF THE URINARY BLADDER.

A subject in itself simple has been made to appear complex by the laboured descriptions of surgical anatomists.

When empty the bladder sinks down into the cavity of the pelvis; as it fills with urine it ascends above the pubes into the cavity of the abdomen. In young persons the bladder is more of an abdominal than a pelvic viscus, and when full, occupies, in them especially, a large share of the hypogastric region.

The bladder is secured in its position chiefly by two kinds of ligaments. The first, derived from the peritoneum, have been called *false* ligaments; the second, derived from the pelvic fascia and other structures, are called the true ligaments.

The so-called false ligaments derived from the peritoneum are five in number; they are the reflexions in fact of the peritoneum, from the walls of the abdomen and pelvis to the bladder, the superior false ligament being the portion reflected from the recti muscles upon the anterior and superior surface of the bladder: on the outer surface of this reflected portion are the remains of the umbilical arteries laterally, and in the centre, the urachus. When the structure is made tense, they project slightly inwards as cords, and give rise to two pouches, one on each side the urachus.

The false lateral ligaments are merely the folds of peritoneum extending from the iliac fossæ to the sides of the bladder. Anteriorly, these form a duplicature, in which will be found the vas deferens in the male and the round ligament of the uterus in the female.

The *posterior* false ligaments, formed, as the preceding, of peritoneal reflexions, extend from the back of the bladder to the sides of

the rectum: they also give rise to duplicatures or folds, in which are the obliterated umbilical arteries and ureters. A deep cul de sac exists between the bladder and rectum, the lowest part of which marks the extreme limit of the descent of the peritoneum into the cavity of the pelvis.

The bladder has four true ligaments; namely, two anterior and two lateral. These are formed chiefly by the pelvic fascia, and arise out of the connexion of the fascia to the bladder at the point of its reflexion upon the organ from the walls of the pelvis. The anterior of these ligaments pass backwards from the inferior margin of the pubes near the symphysis, and expand upon the neck of the bladder and prostate gland; the dorsal veins of the penis pass between them on their way to join the iliac veins. These ligaments are firm and of considerable strength. Muscular fibres have been seen here occasionally, connecting the bladder to the pubes.

Fig. 204.*

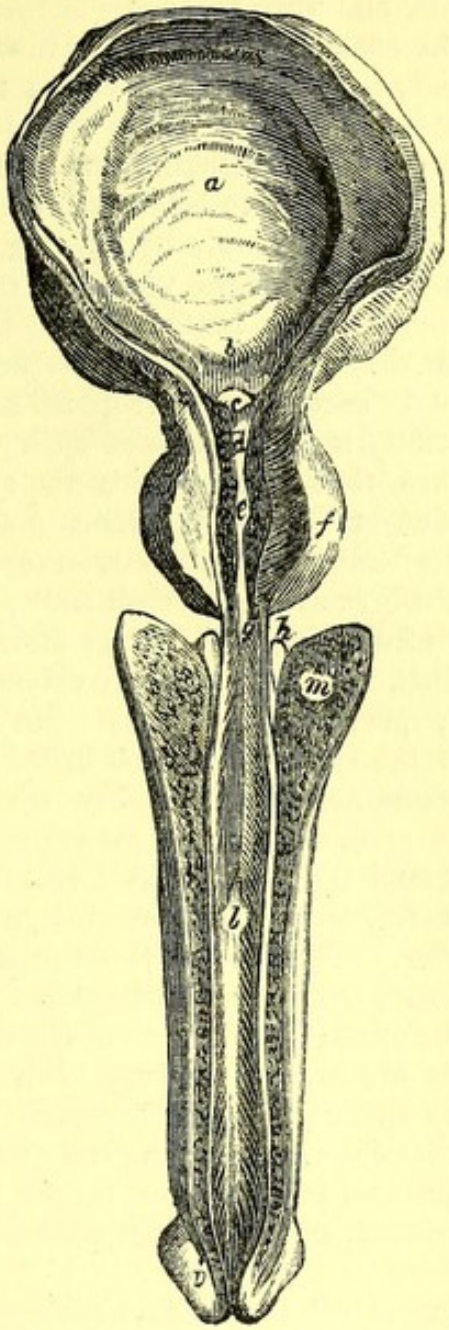

STRUCTURE OF THE URINARY BLADDER.

The form, situation, connexions, and intimate structure of the urinary bladder, must next engage the attention of the student.

It has been divided into a *superior fundus*, partially covered by peritoneum; an *inferior fundus*, resting on the rectum; a *body*, and *cervix*.

Its regions are—the *superior* and *inferior*, the *anterior* and *posterior*, and the *lateral*. These must be studied with reference to their con-

* Fig. 204 represents the bladder, prostate gland, and penis, removed from the body, and laid open on the anterior and superior surface. In this section the corpus cavernosum of the penis is divided mesially throughout its whole length, in the line of the septum or partition.—*a*, interior of the bladder; *b*, the slight eminence called uvula; *c*, neck of the bladder; *d*, *e*, verumontanum or caput gallinaginis, and sinus pocularis; *f*, prostate gland, divided; *g*, membranous or muscular portion of the urethra; *h*, gland of Cowper; *l*, canal of the urethra laid open to show its mucous surface; *i*, glans penis; *m*, section of the bulb of the corpus spongiosum urethræ.

nexions with the peritoneum, with the fascia, with the surrounding organs, and with the walls of the pelvis.

The coats or tunics of the bladder, dissected from without inwards, are—1, a peritoneal or serous tunic; this is only partial. 2, a *cellular tunic* derived from the pelvic fascia; this invests its entire surface. 3, a muscular tunic, composed of pale, muscular, unstriped fibres, running in different directions, irregularly. 4, A mucous membrane, seen only by opening the bladder.

In some places the muscular tunic is extremely thin, permitting the mucous or inner tunic to touch the cellular layer; in others the layer I now describe is strong and fleshy, especially in young persons. It is apt to become hypertrophied under various circumstances, but more especially in those affected with enlarged prostate or stricture of the urethra, thus giving rise to the appearance seen in the interior of the bladder, called, by the French anatomists, *vessie à colonnes*. The neck of the bladder is not surrounded by any particular sphincter or muscular fibres arranged circularly; but at this point the fibres approach each other, and are further strengthened by the presence of a layer of whitish, firm, elastic, and extensile tissue, having a fibrous appearance, prolonged as far as the *trigonal space*, and contributing to orm the slight projection called uvula vesicæ—structures which will be examined more readily when the bladder has been laid open. Some anatomists view the cellular layer, situated between the muscular and the mucous, as a fourth tunic or coat.

Lastly, the mucous or internal tunic, forming the interior of the bladder. To examine this tunic, lay open the bladder, anteriorly and mesially, from the upper fundus to the prostate.

The mucous membrane of the bladder is thin, and continuous with that of the urethra and ureters. It is said to have no villosities. The nature of its epithelial membrane and the character of its intimate structure will be described in the general anatomy at the end of this work. In the natural state neither crypts nor mucous follicles have as yet been discovered, but in certain pathological conditions they manifest themselves.

The arteries of the bladder come from the hypogastric, mostly indirectly,—that is, they arise from branches of the hypogastric. Its veins, which are numerous, and form plexuses, join the hypogastric venous plexus. Its nerves come from the sciatic and hypogastric plexuses; its lymphatics proceed to the hypogastric glands.

When empty the bladder falls into folds, which disappear when distended.

The name of *trigon*, or trigonal space, has long been given to a triangular surface seen in the interior of the bladder, in the centre of its inferior fundus, where the mucous membrane has no rugæ. The two posterior angles of this triangular space correspond to the mouths of the ureters, and the anterior, or apex of the triangle, to the internal orifice of the urethra. The base is an ideal line drawn between the openings of the ureters.

At the apex of this triangle there arises, occasionally, in cases of disease of the prostate gland, an elevated tubercle, which seriously obstructs the entrance to the urethra; it forms, in fact, a uvula, or nipple-like projection; but this is, under all circumstances, whether large or small, a pathological appearance. What really exists here is a whitish-looking structure, seen immediately exterior to the mucous membrane, and between it and the prostate; situated elsewhere it would scarcely merit notice.

OF THE URETHRA.

Dissection.—The relations of the urethra to the surrounding structures, and more especially to the sub-pubic ligament and muscles of Santorini and Wilson, having been examined with care, remove the bladder and penis altogether from the body; prolong the incision already made into the anterior surface of the bladder quite to the extremity of the penis, thus laying open the urethra throughout its whole extent.

The urethra is the tube or duct by which the urine and seminal fluid are discharged from the body. It is then an excretory duct of variable length; its average may be stated at 9 or 10 inches. It is naturally nearly straight, but not quite so; it receives in its course the ductus ejaculatorii, the ducts of the prostate, and those of Cowper's glands. A number also of mucous follicles open upon its inner surface.

The urethra was divided by Cuvier into three parts—a prostatic or glandular, a muscular, and a vascular. This is the view which ought to be adopted by surgeons. They have generally preferred another, namely, a prostatic, membranous, and a spongy. These names are without any meaning, excepting the first.

1. The prostatic portion of the urethra means that portion of the tube which is surrounded on all sides by the prostate. It varies from 15 to 18 lines in length; it passes somewhat obliquely through the prostate gland.

In this portion of the urethra and on its inferior surface, mesially, enter the ductus ejaculatorii and ducts of the prostate. The mucous membrane presents a longitudinal elevation, in which there is posteriorly a large lacuna. The oblong rounded prominence is called the *verumontanum* or *caput gallinaginis*. The ductus ejaculatorii enter on its sides, and those of the prostate on its surface. The ducts of Cowper's glands enter the urethra further forward, in the vascular portion of the urethra.

2. The portion of the urethra which Cuvier called the *muscular*, and modern surgeons the *membranous*, is about $\frac{3}{4}$ of an inch in length; it follows the prostatic and is succeeded by the spongy or vascular. This is usually considered as the narrowest part of the urethra, and is frequently the seat of stricture. It is the portion of the urethra first opened by the surgeon in lithotomy, and as it has been so frequently divided in this operation, together with a portion at least of the prostatic portion of the urethra, it seems the more surprising that surgeons

should so long have hesitated in incising other parts of the urethra in cases of what are called impermeable strictures.

3. The spongy or vascular portion of the urethra is by much the longest. It commences close to the anus (to which it is partly attached), by a bulging called the *bulb* of the urethra. The situation of this bulb in the perineum immediately in front of the anus is readily found. The vascular or spongy body surrounding the urethra from the bulb to the glans inclusive is called the *corpus spongiosum urethræ*. It forms the glans or balanus. The urethra within the glans is increased in diameter; it has been called the fossa navicularis.

Organization of the Urethra.—From its commencement in the prostate to its termination in the extremity of the glans penis, the urethra is lined throughout by a mucous membrane, continuous anteriorly with the margins of the orificium externum urethræ; posteriorly with that of the bladder, and with the membranes lining the various ducts entering it. Its colour varies; of a bright red near its orifice, it is pale and whitish throughout the rest of its extent. Mucous ducts (sinuses of Morgagni) open upon its surface, some of them of considerable size.

This membrane is delicate, and covered by a fine epithelium throughout its whole extent. The urethra, like other mucous canals, never perhaps becomes wholly obliterated. A layer of cellular membrane supports this mucous tissue, in which a layer of longitudinal muscular fibres may be detected with the microscope.

The spongy tissue surrounding the urethra (the corpus spongiosum urethræ) will be described with the anatomy of the penis.

ORGANS OF GENERATION IN THE MALE.

The minuteness of some of their structures is the only difficulty the student will experience in the dissection of these organs. The systematic method is upon the whole the best.

1. THE SCROTUM, DARTOS, AND CREMASTER;

the external envelopes of the Testes.

These envelopes are generally viewed as five in number:—

1. The integuments.
2. The dartos.
3. The cremaster muscle.
4. The fibrous tunic.
5. The serous or tunica vaginalis testis.

These superincumbent layers form the scrotum; an internal septum divides this into two portions.

The connexions of the scrotum do not require to be pointed out. It varies much as to laxity and contraction, being much influenced by cold, age, &c. On the left side the scrotum descends lower than on the right; this has not escaped the attention of artists, painters and sculptors.

1. The *skin of the scrotum* is remarkable for its delicacy and dark colour, for its rugosities, and for the number of sebaceous follicles it contains; for its *raphe*, and for the long hairs which grow in it.

2. The *dartos* are two cellulo-fibrous and occasionally muscular tunics, destitute of fat, of a reddish tint, and attached to the ossa pubis and ischii, where they descend towards the raphe, to which they closely adhere. Internally they form a septum, which terminates above at the lower part of the urethra, thus separating the testes from each other. Externally they correspond to the integuments; internally to the fibrous tunic and cremaster.

3. The *cremaster muscle*.—On each side there descends through the inguinal canal a bundle of fleshy fibres called cremasters. Its origin commences at the lower edge of the internal oblique and transversalis muscles, and they may even derive fibres from the inner side of Poupart's ligament; from these origins the fibres descend in the inguinal canal, on the anterior and inferior surface of the spermatic cord, to the external ring, through which they pass with the cord.

The fibres now change their direction, passing downwards into the scrotum, where they form in many cases concentric circles, returning by one extremity to the pubes. In the scrotum, the fasciculi composing the cremaster are spread out apart from each other.*

Action.—To raise the testes and to give them a rolling motion.

4. The *fibrous* or *cellular tunic* supports the cremaster, which is, indeed, spread out upon it. This fibrous tunic forms, as it were, a bag for each testis: it is thin, transparent, and intimately connected to the serous or vaginal tunic which immediately follows it.

5. The *tunica vaginalis* of the testes was, at one time, a process of the peritoneum. Its origin and nature then cannot be doubted. It forms a closed sac without an aperture, and, like all other serous membranes, furnishes a portion to line the walls of the cavity containing the organ, the *parietal* portion; and another, the *visceral* portion, affording to the testes a more or less complete covering; this, for obvious reasons, is never complete; a serous fluid bedews its surface: when dropsical it constitutes the disease called hydrocele.

In the fœtus, and for a short time after birth, it communicates with the peritoneum; this explains the true nature of the hernia called congenital; but it closes, or ought to close, soon after birth, its remains degenerating into cellular membrane, forming a part of the spermatic cord.

It is the pathology of hernia chiefly which gives an interest to the structures just described. But they are connected also with some interesting anatomical and physiological facts in the history of the fœtus.

Some view the *dartos* merely as a continuation of the superficial abdominal fascia, extended into the scrotum.

* I have observed this peculiar arrangement of the muscular fibres in the powerful levator which raises the cartilages protecting the nostrils of the whale.

2. THE TESTES, SPERMATIC CORD, VAS DEFERENS, VESICULÆ SEMINALES, AND DUCTUS EJACULATORII.

The TESTES are the essential organs of generation in the male.

The weight of a healthy testicle and epididymis is about an ounce. The serous tunic is a partial one, derived from the tunica vaginalis testis, covering and supporting the testes in the same way that the peritoneum does the liver, or the pleuræ the lungs, the mechanism being precisely the same.

Fig. 205.*

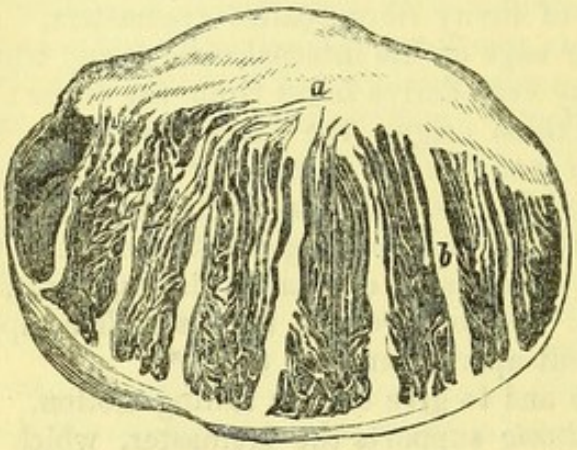

The proper tunic of the testis is the tunica albuginea, situated beneath the serous coat, and intimately united with it. Besides being complete, this tunic sends a process, called *mediastinum* testis, into the interior of the organ. From this inverted portion numerous ligamentous cords arise, of which some are attached to the inner surface of the tunica albuginea; others form pouches or purses containing and supporting the glandular lobes of the testis.

The tunica albuginea itself seems divisible into two. layers—an external or fibrous, and an internal or vascular.

From the glandular substance of the organ arise the tubuli seminiferi which compose the greater mass of the testis. These tubuli are disposed in numerous pyriform tubes, of two kinds, a larger and a smaller.

By the term *rete* testis is meant a set of canals which receive the semen from the tubuli; the canals are situated within the mediastinum, at the posterior edge of the testis, opposite the epididymis. From the *rete* to the epididymis there pass vessels called *vasa efferentia;* they vary in number, but are usually 13 or 15; they arise singly from the rete, and terminate in the epididymis in such a way as to leave it a single tube.

The upper and lower ends of this convoluted tube are called the globus major and g. minor: the vasa efferentia assist in forming the globus major, and the globus minor or tail of the epididymis terminates by becoming the *vas deferens.* The body of the epididymis is entirely composed of this single seminal vessel, the *vas deferens.*

* Fig. 205.—Vertical section of the testis.—*a*, the posterior margin where the blood-vessels enter, passing through the tunica albuginea, but avoiding the serous membrane; the seminal vessels also leave the testis by this margin; *b*, the septa or partitions formed by the tunica albuginea; these support the seminal tubes and the blood-vessels placed in the intervals between the septa.

Proceeding upwards, it gradually recedes from the body of the testicle to form a portion of the spermatic cord.

The SPERMATIC CORD (*Funiculus spermaticus*).—The spermatic cord, of which the vas deferens constitutes the most important vessel, commences at the back of the testicle, becoming comparatively free when it reaches the level of its upper edge. From this point it ascends almost vertically until it reaches the external abdominal ring or aperture. On entering this ring it alters its course, ascending upwards and outwards as far as the deep abdominal ring (opening in the fascia transversalis), which it also passes through and thus enters the cavity of the abdomen: here its component parts separate; the vas deferens dips into the pelvis to reach the prostate gland, and ultimately, though under another name, the urethra; the blood-vessels, lymphatics, and nerves, on the other hand, may be traced to the sources whence they came.

By reversing the description and dissection, the student will have a clearer idea of how the spermatic cord is formed. Just within the deep abdominal ring, between the peritoneum and the fascia transversalis, the spermatic artery, vein, lymphatics, and nerves join the vas deferens, ascending from within the pelvis. They receive a cellular sheath from the outer surface of the peritoneum, and on passing through the fascia transversalis, a second from the edges of the ring; the cord thus formed is joined, in the inguinal canal, by the fibres of the cremaster. Thus descending, and considerably enlarged by cellular substance and additional fine blood-vessels, it leaves the abdomen by the external ring, where it is further strengthened by a cellular sheath.

It now descends vertically into the scrotum, proceeding to the posterior edge of the testicle.

A small artery accompanies the vas deferens in this part of its course. The spermatic nerves cannot be traced into the substance of the testicle. The *fibrous coat*, considered as a continuation of the superficial abdominal fascia, also embraces the spermatic cord; and occasionally the remains of that portion of the tunica vaginalis which connected it with the peritoneum are distinctly visible.

VAS DEFERENS.—The nature and course of this vessel has been already repeatedly alluded to. It is in fact the continuation of the epididymis; it begins to recede from that body at the lower end or *tail*, and ascends in the spermatic cord behind the vessels and nerves. Having entered the abdomen in the way already described (*see* Spermatic Cord), it descends in the pelvis backwards and inwards, attached to the sides of the bladder. It crosses, in this part of its course, the iliac vessels, passing behind the umbilical artery and before the ureter.

Gradually approaching each other, the vasa deferentia reach the inferior fundus of the bladder, proceeding horizontally forwards

to the base of the prostate, where they touch. They are situated on the inner side of the vesiculæ seminales, from which each receives a canal, being the termination of the vesiculæ themselves. The seminal ducts now enter the prostate gland, in which, to their termination in the urethra, they receive the name of ductus ejaculatorii.

The vasa deferentia are firm tubes, of a dull white colour, with thick walls, and easily recognisable by the touch. They are composed of two tunics, a mucous and a fibrous, which latter some have thought to be muscular.

Their calibre is exceedingly fine: from their commencement in the tail of the epididymis to the deep abdominal ring, they are scarcely capable of admitting a hair; but being without valves, they may be filled with mercury, and in that way the minute structure of the testes has been investigated.

VESICULÆ SEMINALES.—Two small membranous tubes so convoluted as to resemble vesicles or bags. When carefully dissected, the vesicles are found to be merely elongated tubes, with short diverticula at various points.

Placed under the bladder, before the insertion of the ureters, above the rectum, behind the prostate gland, and externally to the vasa deferentia, they are immersed in a mass of adipose cellular tissue. They have no communication with each other.

Posteriorly, they terminate in a rounded cul-de-sac; anteriorly, they end each in a short canal, uniting with its corresponding vas deferens.

These vesicles are merely flexuous canals, with numerous lateral diverticula opening into them. In structure they resemble the vasa deferentia.

EJACULATORY DUCTS.—These, two in number, are formed by the junction of the vasa deferentia and seminal vesicles of either side. They are of a conical shape, and about an inch in length. They proceed forwards, parallel to each other, passing through the substance of the prostate, and finally terminate in the urethra by two small oblong orifices, situated upon the lateral and anterior parts of the verumontanum.

To expose their course, pass bristles into them, and lay open the ducts to near their termination.

OF THE PROSTATE.

The prostate gland, the anatomical relations of which have been already carefully described,* is a solid glandular body about the size of a small walnut, and is liable to enlargement in old age. It is formed by an assemblage of mucous follicles. Of the form of a truncated cone, with the apex forwards, it surrounds the neck of the bladder and commencement of the urethra.

The intimate texture of the gland is peculiar, and is especially remarkable for a physical property long known to lithotomists dis-

* See anatomy of the bladder, pelvis, fascia, etc.

tinguished for their success and skill—its *elasticity*. Their method of operating, on which their success depended, was based on the knowledge of this physical property of the gland. The secret was ultimately revealed by the distinguished Scarpa.

It is owing to this property of cohesion, tenacity, and elasticity, that a small incision made through the anterior part of the gland, the base being left entire, may be dilated by the introduction of the finger of the surgeon, passed through it into the bladder, to such an extent as to admit of the ready and safe extraction of all but the very largest calculi.

The old surgeons who invented and used the apparatus major were aware of this property of the prostate, but they attempted the dilatation by means of hard instruments instead of the finger of the surgeon himself.

On a knowledge of this fact, which, though he was Rau's assistant, Albinus never discovered, was based, no doubt, the *secret* of that most distinguished of lithotomists. It consists in this—as I ascertained by a post-mortem examination of two men operated on by Mr. Liston, and who died, the one of fever and sloughing, the other of pelvic abscess—*not to extend the incision of the prostate beyond two-thirds of its entire length; leave the base entire*; dilate skilfully with the forefinger of the left hand, giving to it *a rotatory motion;* touch the calculus, if possible, before withdrawing the finger from the bladder; introduce the forceps cautiously; grasp the stone with the least possible violence, and remove it slowly and firmly from the bladder.

To Scarpa we owe the first published account of the method practised without a doubt by Rau, Cheselden, Martineau, Crichton, and by all good lithotomists.

The *upper* surface of the prostate is covered by the anterior ligaments of the bladder; the *lower* surface, smooth and plain, rests upon the rectum, to which it is connected by cellular tissue. A layer of the pelvic fascia passes, in fact, between them. Its sides are rounded and smooth; they correspond to the levatores ani. The base surrounds the neck of the bladder, and the summit, gradually becoming thinner, encircles the commencement of the *membranous* part of the urethra. The canal of the urethra and the ejaculatory ducts thus pass through it.

Of its intimate texture but little is known. When cut into a number of small follicles may be seen in it, containing a viscid, ropy fluid of a whitish colour. From these arise excretory ducts, ten or fifteen in number, which open into the urethra by the sides and at the surface of the verumontanum.

Surgical anatomists and pathologists have found it convenient to divide the prostate into three lobes; two lateral, and one mesial. The latter connects the two lateral together.

Two kinds of calculi, white and dark brown, or black, form in the prostate; hypertrophy of the gland goes by the improper name of scirrhus.

COWPER'S GLANDS.—*Accessory Glands.*

These glands seem to have been discovered by Cowper, an English surgeon, notorious for his plagiarisms of the writings of the Dutch anatomists.

They are two small, granulated, oblong, or rounded glandular bodies, placed parallel to each other, before the prostate, on the sides of the urethra, and above the acceleratores urinæ muscles. They vary in size, but are generally as large as a pea, of a reddish colour and glandular tissue. Though occasionally wanting, or single, they are probably not unimportant glands, and seem to exercise, expecially in woman (for they are as large in the female as in the male), a marked influence over sexual desire.

Their excretory duct, about six lines in length, creeps obliquely inwards and forwards in the spongy tissue of the urethra, and opens before the verumontanum.

In man, these glands may upon the whole be viewed as rudimentary parts of a system, multiplied and increased both in size and number in some other animals.

THE PENIS.

The penis is the preparatory male organ. In woman the same organ, in a rudimentary state, is called the clitoris. With certain differences the history of the anatomy of the one applies to the other.

The penis is composed of the following parts:—

1. The common integuments of the body cover the greater part of the penis, terminating by a prepuce or free part, whose dimensions vary in different individuals. These integuments are fine and delicate. No adipose tissue is ever found in the cellular membrane connecting the skin to the superficial fascia beneath. A number of follicles at the base of the prepuce, on its inner side, secrete a fœtid whitish substance, called smegma.

2. The superficial fascia, descending from the abdomen, passes over the pubes, furnishing the penis with a tolerably firm and elastic sheath. This is connected by loose cellular tissue to the integuments above, and to the fibrous covering of the corpora cavernosa and corpus spongiosum urethræ beneath. It forms the superficial suspensory ligament of the penis. Abscesses forming beneath this fascia require the immediate attention of the surgeon, to prevent sloughing of the organ.

3. The corpus cavernosum of the penis forms about two-thirds of its volume. It is essentially composed of a slightly elastic, thick, and strong fibrous membrane, traversed in many places by vascular ramifications. Its general colour is an opaque white.

The fibrous membrane just described is not confined to the surface of the organ, but extends into its interior, dividing it incompletely into two cylinders, whose *crura*, or roots, are attached to the rami of the

ischium and pubes. The septum is called *septum pectiniforme;* it is incomplete, especially anteriorly. It seems, however, to support the vascular tissue forming the essential part of the organ, by sending filaments in all directions to the inner surface of the enveloping fibrous membrane. In the penis of the whale I found these structures to be of great strength; their office is mechanical.

The corpus cavernosum of the penis does not extend into the glans. Its muscles have been already described. Its anterior extremity, when the glans has been removed, represents a truncated cone, united to the base of the glans, and perforated by several vessels. On its upper surface, mesially, is a groove, in which run the dorsal arteries and veins of the penis; posteriorly it is connected to the symphysis of the pubes by a fibrous suspensory ligament of considerable strength; inferiorly the crura adhere firmly to the rami of the pubes and ischium. On its inferior aspect is a broad groove, deeper than the superior one, in which is lodged the urethra, surrounded by the *corpus spongiosum urethræ.*

The interior of the fibrous cylinders thus forming the crura and body of the corpus cavernosum is filled with blood-vessels, but how arranged has not yet been determined. All that we know is confined to a mechanical tracing of the arteries and veins, and even this stops short of their extremities.

Their arteries come from the deep branch of the internal pudic, and occupy the centre of its lateral portions. They anastomose freely with each other, and communicate (as shown, at least, by injections made after death) with the arteries of the glans and corpus spongiosum urethræ.

Nervous filaments accompany these arteries. The accompanying veins are not well understood; they seem to be more connected with the structure next to be described—the corpus spongiosum urethræ.

Two arteries, the dorsal arteries of the penis, and two veins, also called dorsal, run along the groove in the upper surface of the corpora cavernosa of the penis. The distribution of these vessels has a reference more to the corpus spongiosum urethræ and glans than to the structures I now describe.

CORPUS SPONGIOSUM URETHRÆ AND GLANS PENIS.

This is a structure analogous to, but not identical with, the vascular tissue of the corpus cavernosum penis; they are both erectile, and similarly disposed as to their component parts,—that is, the corpus spongiosum is fibrous and vascular, but yet sufficiently peculiar to require a separate description.

The corpus spongiosum urethræ surrounds the urethra from the membranous portion to its termination at the orifice of the glans. The vascular structure commences in the bulb, which it forms, and terminates by expanding into the glans or balanus. The fibrous envelope more immediately surrounding it is a portion of, or, at least,

intimately connected with, that belonging to the corpus cavernosum; its vascular tissue, wherever examined, seems to differ; it is, in fact, mostly venous: a network of short veins freely communicating with each other, ultimately terminating in the dorsal veins of the penis.

Two arteries (arteries of the bulb) of moderate size enter the bulb immediately above the transverse muscle of the perineum; they proceed through the centre of the corpus spongiosum urethræ, giving off numerous branches: but how they terminate is not known for certain.

A network of veins and another of lymphatics cover the surface of the *glans*, which is continuous with the corpus spongiosum urethræ, and forms its terminating portion; it is circumscribed by a prominent edge, the corona glandis, behind which the inner margin of the prepuce forms a cul-de-sac by being reflected.

Beneath the urethra the corona glandis is interrupted by a small groove extending to the orifice of that canal, occupied by the frænum preputii.

The glans is invested by the submucous covering of the prepuce, which, over it, assumes another character. It is here covered by a delicate epidermis, and has no mucous crypts. Its tissue is similar to that of the corpus spongiosum urethræ.

THE ORGANS OF GENERATION IN THE FEMALE.

In a systematic description of these organs the ovaria claim the first attention.

THE OVARIA AND FALLOPIAN TUBES.

The OVARIA, formerly called the female testes, are the essential organs of generation in woman. They are remarkable in having *interrupted ducts*, by means of which they at times communicate with the interior of these ducts, whilst at other times there exists complete separation of the gland and its ducts. It was this curious circumstance in their history which misled even Fallopius, the discoverer of these oviducts, which, in his honour, are called the "Fallopian tubes."

The recent improvements in the anatomical history of the female organs do not originate in any recent discoveries, but in the revival, by modern anatomists, of the superior descriptions of the older anatomists—of De Graaff, for example, Bartholin, Santorini, Morgagni, Ruysch—descriptions which had been overlooked for at least a century, their place having been occupied by those made by hasty and inaccurate observers.

I. The ovaria are two egg-shaped bodies, placed between the layers of the broad ligaments, on either side; they are of a pale red colour; they lie transversely, as it were, in respect of the pelvis. Their inner extremity is attached to the uterus by a ligament—the *proper ligament of the ovary;* the external extremity of each is

connected to the extremity of the corresponding Fallopian tube by a filament detached from the extremity of the tube itself; thus retaining the duct and gland near each other.

As no duct could be discovered in *direct* communication with the ovarium, the ancient anatomists asserted that the true ligament of the ovarium was a duct. This was easily refuted by cutting the ligament across, and showing that it was solid. But the physiologists of those days, clinging to the Hippocratic theory of seminal fluids secreted by both sexes, and commingling in the uterus, maintained that, although the cord was solid, fluids might pass along its surface. At last the Fallopian tube was discovered; its grasping of the ovarium during coition was at first guessed at and afterwards proved. The ovary theory was finally established by De Graaff, and the ovaria ceased to be called *testes*.

The ovaria, besides having a partial covering from the peritoneum, are enveloped by a dense cellulo-filamentous membrane, from the inner surface of which a number of prolongations are transmitted into the solid structure of the organ. The real nature of the parenchyma is quite unknown; it is soft and spongy, and, when torn, seems composed of cellular and vascular lobules abounding with vessels. Amongst these may be observed from 15 to 20 small vesicles, first observed by De Graaff, and from him called the Graaffian vesicles; they are translucent, and contain a fluid. These are now admitted to be the seat of the ova—to be intimately connected with the history of the ovum, and of generation. When ruptured they give rise to the *corpus luteum*, and this may be either true or false.

It is not true that De Graaff mistook the vesicles which bear his name for *ova*. De Graaff was the first who discovered the true ovum in the Fallopian tube on its way to the uterus.

The FALLOPIAN TUBES—*Oviducts*.—These are two canals placed within the duplicature of the broad ligaments and along the upper edge, connected by one extremity to the uterus, into which they open, and terminating at the other in a free extremity, wide, floating, and fringed, the fimbriated extremity* of the tube. Amongst these fimbriæ, one larger than the rest is attached to the external pole of the corresponding ovarium.

The canal which each tube forms commences at the upper angle of the cavity of the uterus by an opening so fine as merely to admit a large bristle. The tube, which is tortuous, gradually widens and opens at the surface of the fimbriated extremity, and here the serous and mucous membranes touch each other. The opening thus formed is the peritoneal or abdominal opening of the tube. It is here that the surface of the serous membrane communicates with the exterior. The inner aperture is the uterine.

The Fallopian tubes are lined by a mucous membrane of a peculiar character, plicated nearly throughout: the folds run in the long

* Morsus diaboli.

axis of the tube. The fimbriated extremity is at times very vascular, and seems composed of erectile tissue. A rather strong fibrous tunic completes the exterior of the tube.

It is now a generally received opinion that during coition the Fallopian tube grasps the ovarium by its fimbriated extremity, thus becoming an uninterrupted oviduct for the moment. If the coition be fruitful a Graaffian vesicle bursts, the peritoneal and fibrous tunics of the ovarium give way at the point corresponding to the vesicle, and an ovum is discharged, which ultimately finds its way into the uterus by the Fallopian tube. The smallness of the ovum when it first reaches the uterus may be best understood by reflecting on the narrow opening by which the tube communicates with the uterus.

Ruysch denied the bursting of the coverings of the ovarium, necessary for the escape of the ovum from the vesicle of De Graaff; he imagined that the investing tunics were merely reflected inwards, forming little culs-de-sac communicating with the parenchyma of the organ. I consider De Graaff's view as the more correct one, and all but demonstrated. The ovarian arteries and veins have been already described; their nerves come from the sympathetic.

THE UTERUS—*Matrix.*

The uterus is a hollow symmetrical organ of the shape of a truncated cone, placed in the middle of the pelvis, between the bladder and the rectum, above the vagina and beneath the convolutions of the small intestines. It is flattened from before backwards and is nearly an inch in thickness. About two inches broad superiorly, it becomes much narrower below.

Fig. 207.*

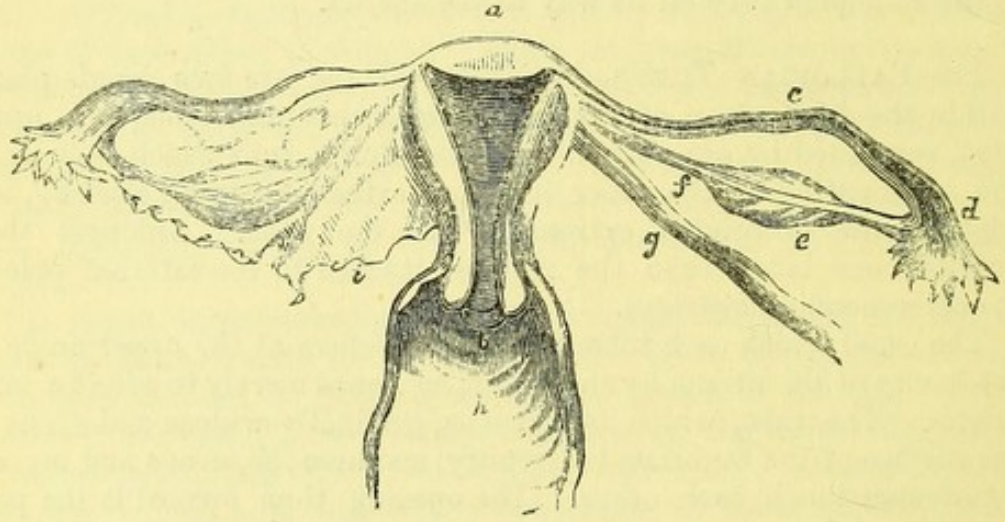

* Fig. 207.—Showing the uterus, ovaria, and Fallopian tubes: the uterus has been laid open anteriorly and mesially.—*a*, the fundus of the uterus; *b*, the os tincæ; *c*, left Fallopian tube laid open; *d*, fimbriated extremity of the Fallopian tube; *e*, the left ovarium; *f*, the proper ligament of the ovarium; *g*, the round ligament of the uterus; *h*, a portion of the vagina, laid open; *i*, a portion of the peritoneum.

In the history of the uterus are observed—1, its ligaments; 2, its division into body and neck; 3, its intimate structure.

1. The ligaments of the uterus are—

a. The broad ligaments—ligamenta lata.

b. The round ligaments—ligamenta rotunda.

c. The ligaments of Douglas.

a and *c*. The ligamenta lata uteri and the ligaments of Douglas are simply folds of the peritoneum, which attach the uterus to the walls of the pelvis, and to the sides of the rectum and front of the sacrum.

Within the broad ligaments are situated the ovaria, the Fallopian tubes, the proper ligaments of the ovaria, and the round ligaments of the uterus. These folds of peritoneum, moreover, form, together with the uterus, a sort of septum quite across the pelvis, dividing it as it were into two parts: in the anterior is situated the urinary bladder; in the posterior, the rectum. I have seen muscular fibres between the folds of the broad ligaments.

The folds of peritoneum running towards the rectum, called the ligaments of Douglas, need not be described.

b. The round ligaments arise from the lateral, superior, and anterior part of the uterus, beneath and before the insertion of the tubes. From this they proceed towards the deep abdominal ring, pass through it into the inguinal canal, and, leaving it by the inferior abdominal aperture, terminate by expanding in the cellular tissue of the groin. It was long ago observed that these ligaments have a fibrous character under certain circumstances, and are somewhat muscular. They have blood-vessels and cellular tissue, but their real nature and functions are unknown. They may represent the remains of the vas deferens in the male, but this is improbable.

2. The uterus is composed of a body and neck. It has three orifices: two superiorly, the terminations of the Fallopian tubes; one inferiorly, by which the organ opens into the vagina. It is called the os tincæ or os uteri.

The peritoneum invests a great part of the surface of the organ, chiefly anteriorly and posteriorly: the sides are comparatively free for the passage of the blood-vessels, nerves, tubes, and ligaments. Its upper edge is rounded; it is called the fundus, and is covered anteriorly and posteriorly by the peritoneum; so also is the body of the uterus, with which it is confounded. The neck of the uterus, continuous with the body, is from ten to twelve lines in length: the neck projects into the vagina so as to be embraced by it for some extent. This varies in different women. The os tincæ is transverse, and provided with two lips, an anterior and a posterior. Both ought to be smooth and rounded, but a fissured appearance does not imply ulceration and disease. The peritoneum, on leaving the bladder posteriorly, is reflected at first on the upper part of the anterior wall of the vagina, a small part of which it inverts. Having passed over the uterus, it again covers a portion of the posterior wall of the vagina, before being reflected on to the rectum. See Fig. 208.

The interior of the uterus is lined by a mucous membrane, continuous inferiorly with that of the vagina, superiorly with that of the Fallopian tubes. It has also an epithelial membrane.

Mucous crypts may be seen on the surface of the mucous membrane and rugæ, placed transversely in the neck or cervix; two vertical lines may, moreover, be seen upon this portion of the uterus.

Although the cavities of the fundus or body and cervix do not differ much from each other in respect of size, yet it is necessary to speak of them as being quite distinct: hence in the cervix are recognised two orifices; one leading into the vagina (the os tincæ), the other into the body of the uterus (*os cervicis internum*).

3. Between the serous and mucous tunics of the uterus is the tissue of which the organ is chiefly composed. Its thickness in the unimpregnated condition (the only view taken here), amounts to five or six lines: it is dense, close, fibrous, and vascular, and, in the impregnated condition, is distinctly muscular. It is abundantly supplied with vessels and nerves, which increase, especially the former, to a great extent in the impregnated state. The arteries come from the hypogastric and spermatic; they are flexuous, and anastomose freely with each other; its veins follow the same course, but are still more flexuous. In the impregnated uterus they form large sinuses, filled with the blood of the mother, possessing at that time, no doubt, peculiar qualities. It is in these sinuses that the placental tufts, discovered by Weber, float.

Its nerves come from the sciatic and hypogastric plexuses. The lymphatics are numerous, and during gestation are greatly enlarged.

Fig. 206.*

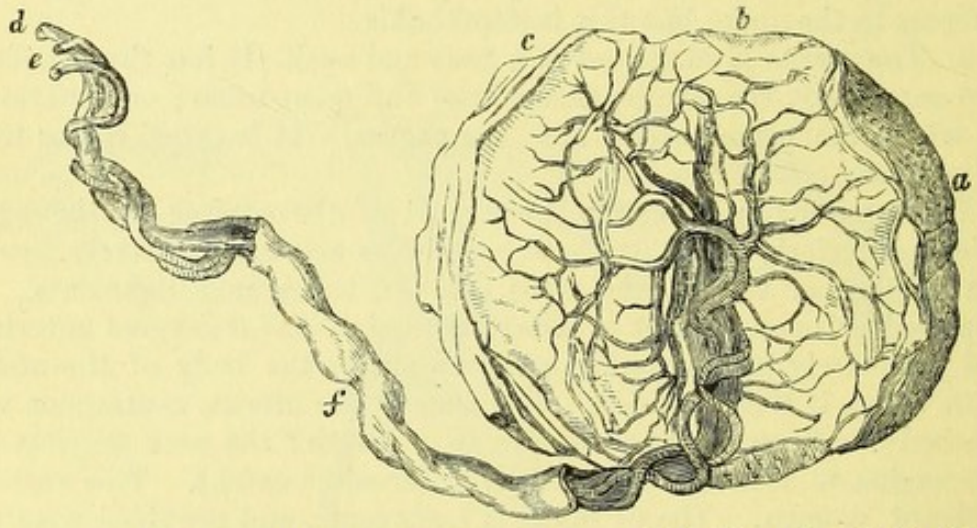

* Fig. 206.—Representing a portion of the umbilical cord and the fœtal surface of the human placenta; the organ is of the normal shape.—*d*, the umbilical vein, conveying the blood which has circulated in the placenta to the fœtus: the placental tufts which float in the uterine sinuses or veins of the mother are chiefly, if not wholly, composed of the roots of this vein. *e*, *e*, the umbilical arteries, conveying a great part of the blood of the fœtus to the placenta; they may be readily traced in the woodcut to the surface of the placenta, where they anastomose and ramify: how they terminate is not precisely known. *f*, a portion of the umbilical cord covered by its membranous sheath; it has

THE VAGINA, AND THE EXTERNAL ORGANS OF GENERATION IN WOMAN.

Of these organs the essential is the vagina; all the others are appendages having reference to the anatomy of the embryo, to the law of unity of the organization, or to the law of specialization regulating human forms.

The MONS VENERIS.—This is a rounded eminence, more or less prominent in different persons, situated in front of the pubes, and formed of a mass of fat immediately covered by the integuments. It is external to all the organs of generation.

It is generally large in young persons.

Fig. 208.*

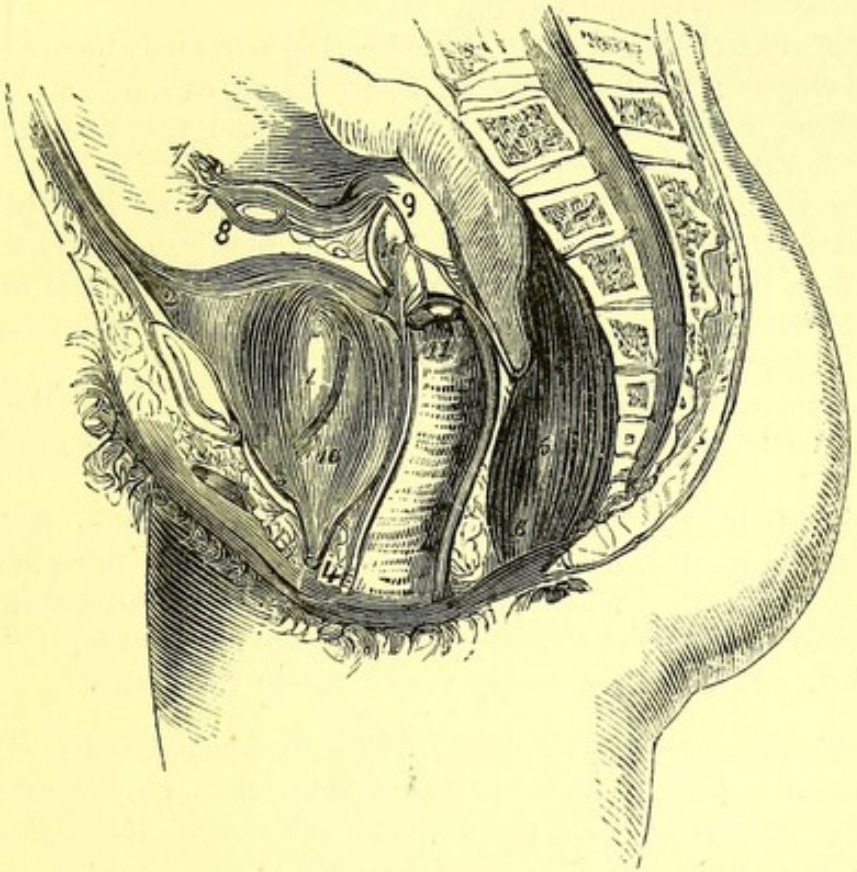

been stripped from off the rest of the cord to expose the arteries and umbilical vein. *c*, *b*, circumference or margin of the placenta, with the amnion and chorion left adhering: the amnion is the more superficial, the chorion is the deeper: the liquor in which the fœtus floats is contained within the amnion.

* Fig. 208.—Lateral view and section of the female pelvis, right side: the bladder, rectum, and uterus are represented as entire; the vagina is laid open longitudinally to show the os uteri externum, or os tincæ.—1, the urinary bladder; 2, the remains of the urachus; 3 points to the clitoris; 4, the urethra; 5, the pouch of the rectum where it has no peritoneal covering; 6 is placed a short way above the sphincter; 7, the fimbriated extremity of the right Fallopian tube; 8, the right ovarium; 9, the fundus of the uterus; 10, one of the round ligaments; 11, mucous surface of the vagina: the figures are placed close to the os tincæ, or *os uteri externum*.

The GREATER LABIA.—These are two integumentary and sub-mucous folds, which in finely formed young and healthy women shut in and conceal all the other structures.* They are thick above, gradually becoming thinner as they descend, and their size in some measure depends on the *embonpoint* of the individual. Their *outer* surface is integumentary, their *inner* sub-mucous. Inferiorly they do not exactly meet or run together, but terminate apart in front of the perineum.

The term *vulva* should be restricted to the space extending from the edges of the greater labia to the entrance of the vagina, and to the great external opening or fissure communicating with the interior.

It is bounded superiorly and anteriorly by the prominence called mons veneris; at the sides by the edges of the labia; posteriorly, where these cease, by the integuments forming the fore part of the perineum. This in woman is about an inch in length, and measures the greatest depth of the recto-vaginal septum.

On separating the great labia the following parts may be observed:—

1, the clitoris; 2, the nymphæ; 3, the meatus urinarius, leading to the urethra; 4, the entrance to the vagina and the hymen; 5, the vagina; 6, the fourchette and fossa navicularis.

1. The CLITORIS.—Between the clitoris and the margin of the greater labia there is a space which does not require any special notice. Neither does the space between the clitoris and the meatus urinarius, which, however, has been called the vestibule, and is spoken of by surgical writers.

A mucous membrane, varying in character, covers all the parts I am about to describe. It is continuous with that of the urethra and vagina.

The clitoris is simply the penis in miniature; it is in fact a rudimentary and imperforate penis. There are the vestiges of a glans and of a corpus cavernosum, with its crura attached, as in the male; muscles are attached to it (the erectores), and, like the male penis, it is capable of erection. It is comparatively very large in the fœtus.

2. The NYMPHÆ: *labia minora*.—These are two erectile, elongated, membranous ridges, thicker at the middle than at the extremities, descending from the lateral parts of the prepuce of the clitoris; they separate from each other as they descend, leaving between them the meatus urinarius and the entrance to the vagina; they vary much in length, and one is not unfrequently absent: they vary, also, much in thickness; they are wholly vascular, and are supposed to represent the bulb of the urethra in the male; their uses are unknown.

Before proceeding with the examination of the urethra and vagina the following dissection should be made:—

Remove the integuments from one or both sides, between the greater labia and the thigh; this will expose the *constrictor vaginæ* muscle. On cutting this across, and reflecting the divided portions upwards and

* The nude figure, *when finely formed*, exposes no mucous surface.

downwards, two structures of some interest are exposed—1, a vascular and erectile tissue called the semi-bulb, composed of a plexus of vessels, and seemingly connected with the labia minora. 2, inferiorly, a small but distinct glandular body, corresponding to the glands of Cowper in the male. These glands exist generally on both sides, but they are occasionally single, or to be found only on one side. The duct, which is several lines in length, opens upon the surface of the vulva, immediately outside the ridge of the vagina, where the orifice may always be detected on careful inspection. The fluid contained in the duct is of a clear, light-brown colour, the secretion, no doubt, of the gland.

Numerous careful dissections of these glands have shown me that they are small in the young and the very aged—largest in the healthy adult; their functions are unknown; they seem to be connected with sexual desire.

3. The MEATUS URINARIUS AND URETHRA.—The urethra in woman is short (about an inch in length) and straight, or but slightly curved, and admits of considerable dilatation artificially. The external orifice is situated in the vulva, immediately above the entrance to the vagina, along the superior wall of which it runs on its way to the urinary bladder. The mucous membrane investing it abounds with mucous lacunæ, and it is surrounded, when entering the bladder, by a glandular-looking body, which no doubt is a vestigiary or rudimentary prostate.

4. ENTRANCE OF THE VAGINA—THE HYMEN.—At the entrance to the vagina, in the virgin, will generally, but not always, be found a semilunar, or even almost circular, fold of mucous membrane called the hymen. It varies much in form and strength; neither its presence nor absence is a proof of virginity or of the reverse. When destroyed it produces the small reddish tubercles called *carunculæ myrtiformes*. In number they vary from two to five or six: their colour also varies, from a variety of circumstances.

5. The VAGINA is a membranous cylindrical canal, compressed from before backwards, placed within the pelvis, between the urethra, bladder, and rectum, opening inferiorly about the middle of the vulva, and superiorly embracing the neck of the uterus. It varies in its dimensions in almost every individual; its average length is from three to four or four and a half inches; but it is shorter than this in some women, and longer in others. It is slightly curved upon itself, and its anterior wall is shorter than the posterior.

Outer surface.—Anteriorly the peritoneum adheres to it for a short space superiorly; inferiorly and anteriorly it is in contact with the bladder and urethra; posteriorly it rests on the rectum, from which it is separated by the recto-vaginal septum. The upper portion of the posterior wall is covered by the peritoneum before its reflexion on to the rectum.

Inner surface.—The walls of the vagina are usually in contact with each other. The mucous membrane, continuous with that of the vulva, and, extending upwards into the uterus, lines it throughout. Mucous follicles abound in this membrane.

Anteriorly, on this surface, there runs, longitudinally and in the middle, an elevated ridge; a similar ridge exists on the posterior wall, together with many transverse wrinkles or folds, most prominent near the vulva. These rugæ are intersected at right angles by the two longitudinal ridges just mentioned. These ridges indicate a tendency to a bifid form of the vagina, a phenomenon which sometimes exists, extending, also, to the uterus itself.

Exterior to the mucous membrane is a celluloso-vascular membrane, continuous with the texture of the uterus above. It seems slightly fibrous, and is firm and elastic, returning readily, after dilatation, to nearly its original dimensions. Inferiorly it is partially surrounded by an erectile tissue (*plexus retiformis*) already spoken of under the name of semi-bulb.

Its nerves come from the sciatic plexus; and it receives an artery on each side from the hypogastric.

In front of the vagina, in women who have not borne children, are—6, a fold of integument called the FOURCHETTE, and a small cavity called the fossa navicularis: these must not be confounded with the entrance to the vagina, which lies deeper.

GENITO-URINARY ORGANS.

Development.—It is generally admitted, since the researches of Wolff, that two temporary glands or bodies precede the development of the genito-urinary organs. From their discoverer they have been called corpora Wolffiana. They are observable only in very young fœtuses, and their history has not been fully made out. At first they resemble two slight ridges of blastema placed on each side of the line of attachment of the intestinal canal to the vertebral column. About the fifth week of embryonic life they seem to have reached their full size, and they then resemble two oblong reddish masses. They are vascular, and seemingly glandular, composed chiefly of cæcal tubes. The course of their ducts is still disputed, some supposing that they spring from the lower ends of the bodies; others maintain that they run along the outer edge throughout their whole length. They terminate by opening into the allantois; they have been named primitive or primordial kidneys, from its being conjectured that they perform the office of these organs. As development advances the Wolffian bodies rapidly shrink and disappear; nor do they seem to take any part in the formation of the supra-renal glands, kidneys, testes, or ovaria.

This, at least, is the more usually received opinion. Nevertheless, I feel disposed to doubt it, at least as regards the testes and ovaria. Vestiges remain even in the child at birth, and perhaps throughout life. The whole subject merits deeper inquiry.

THE KIDNEYS AND URETERS.

The kidneys first appear about the seventh week; about the tenth week they are lobulated. The separate lobules gradually coalesce, and the kidneys become smooth some time after birth. It is not unusual, however, for the kidneys to show traces of their primitive lobular form throughout life.

The tubuli uriniferi grow out of numerous club-shaped bodies, which soon show themselves all over the organ; they form the cortical part first, and afterwards the mammillary.

The ureters commence after the kidneys, and then connect themselves with the hilus; they terminate inferiorly in that portion of the allantois which afterwards becomes the bladder.

Of the true nature of the supra-renal capsules nothing positive is known.

ALLANTOIS, URINARY BLADDER, AND URACHUS.

The urinary bladder in the early fœtus communicates by means of a duct called *urachus*, with a small extra-abdominal bag. To this bag the name of *allantois* is usually given. This, to a certain extent, is a rudimentary structure in man; it is in the bird that its full development is to be observed.

The allantoid *apparatus* communicates below with the intestinal canal of the fœtus, and receives into it the excretory ducts of the Wolffian bodies, the ureters, and the Fallopian tubes or vasa deferentia.

The mode of development of this apparatus has not been determined. Its extra-abdominal portion soon shrinks, and the urachus degenerates into a cord passing from the fundus of the bladder to the umbilicus.

At first the bladder and rectum freely communicate, and when they become opened externally the whole structure resembles the cloaca of the bird. After a time a separation takes place, and the genito-urinary and intestinal openings become distinct.

ORGANS OF GENERATION IN THE FŒTUS.

It is usual to repeat, after Meckel, that all embryos are at first of no sex. A rudimentary or primitive organ at first appears on each side, below the Wolffian bodies; out of these are ultimately formed ovaria or testes, as the case may be.

As development advances (if ovaria are to be the result) the organs remain unconnected with the Fallopian tubes; both descend, but the ovaria remain within the pelvis; the testes ultimately quit the abdomen to occupy the scrotum.

To Valentin and Bischoff we owe the results of some patient and careful inquiries into this difficult subject. They are as yet contradictory.

The ovum, which may ultimately become an embryo, begins to form in the Graaffian vesicle in the ovarium of the fœtus soon after birth, so early do these important organs assume their distinctive sexual peculiarities. The development of new Graaffian vesicles seems to go on as long as the procreative faculty persists.

Fallopian tubes and vasa deferentia.—The difficulty in respect of these ducts is to ascertain what relation they have to the Wolffian bodies and their ducts. This has not yet been satisfactorily made out. It is a question which simple or direct observation or intuitive inspection must ever find it extremely difficult to solve.

Müller is of opinion that no part of the Wolffian bodies (including, I presume, their ducts) is converted into the generative organs in either sex.

As the fœtus becomes more and more developed, passing through those temporary forms which prove the unity of organization in all animals, the testes pass from the abdominal cavity into the scrotum. Whilst in the abdomen, in addition to their proper envelope (*T. albuginea*), they have a covering from the peritoneum adhering closely to it. This covering is naturally deficient behind, where the blood-vessels, nerves, and vas deferens pass to or from the testis; a slight opaque cord may be seen passing from the lower end of the testis to the inguinal region. The Wolffian bodies have now disappeared, or are, at least, no longer recognizable as such, and the testicle, moving lower down, is evidently supported by a duplicature of peritoneum similar to that which we have seen in the case of the intestines, &c. There is, in fact, a *mesorchium*.

The opaque cord, extending through the inguinal canal, enlarges; it now reaches the pubes and scrotum, and is called the *gubernaculum testis*. This happens about the fifth or sixth month. The gubernaculum now contracts or shortens; a small process or pouch of peritoneum precedes the testicle, which passes into the inguinal canal, entering the scrotum in advance of the gland. Usually by the end of the eighth month the testis is in the scrotum; the process of peritoneum it has brought with it soon becomes an independent part, the aperture by which it communicated with the abdomen having closed. It is now called the tunica vaginalis testis. When these processes are interrupted the testes may remain in the inguinal canal, or the tunica vaginalis may continue to be in direct communication with the general peritoneal cavity. The history of such imperfect developments explains many important pathological conditions.

The formation of the cremaster has been explained by supposing that some of the lowermost fibres of the internal oblique, or transversalis, or both, are carried downwards before the testis into the scrotum. I should think the opinion an erroneous one. The precise office and structure of the gubernaculum have not been accurately made out.

In the female embryo the cord, occupying the position of the gubernaculum in the male, becomes ultimately the round ligament of the uterus.

The metamorphoses of the urino-genital organs in the male and female embryo present objects of much interest. The first which takes place is the separation of the lower part of the allantois (bladder) from the intestinal canal, the sinus thus becoming distinct from the anus. Into this urino-genital sinus, two canals enter on each side in either sex, namely the ureters and the Fallopian tubes, or vasa deferentia, as the case may be.

In the male embryo the urinary part of the sinus becomes a short canal, representing the neck of the bladder and the prostatic portion of the urethra. The mode by which the vasa deferentia or seminal vesicles and vessels coalesce with this passage has not been fully made out. Meckel's researches are obviously based on the supposition that at first all embryos are similar, or of no sex, and that *the part* which in the female ultimately forms the lower part of the uterus, constitutes in the *male* the sinus pocularis and verumontanum. The theory is a plausible one, but it has not as yet been demonstrated satisfactorily by intuitive inspection. I was led early to adopt another view, namely, that the embryo is at first hermaphrodite.

In the *female* embryo the common genito-urinary passage becomes divided at the bottom into a *pars urinaria* and a *pars genitalis*. The former receives the ureters, and ultimately forms the urethra and bladder; the latter is metamorphosed into a vagina, and receives the Fallopian tubes. These coalesce inferiorly, and so form the uterus, which for some time continues to be bifid like the uterus of many mammals (sheep, cows, &c.); this peculiar shape may remain throughout life.

Tiedemann has carefully described the development of the external organs of generation.

At the fifth week there exist neither anus nor genito-urinary openings. At the sixth there is a common opening, leading in fact to a cloaca. In front of this simple opening, resembling that which exists in the adult bird, a small curved projecting body appears; it is the clitoris, or the penis, as the case may be; the glans is soon developed. A groove, with margins extending backwards, may readily be traced along the lower surface of this organ, whether it be clitoris or penis. About the tenth or eleventh week a transverse band, the perineum, appears; the clitoris or the penis protrudes; they are then of nearly equal size, and might be mistaken for each other. This state continues to the fourteenth week, when the sexes greatly resemble each other.

In the female the two lateral folds of integument enlarge so as to partially cover the clitoris; these form the labia majora; two other margins or folds form the nymphæ. The groove becomes less distinct and at last disappears; the hymen shows itself about the fifth month, and the urethra becomes distinct from the vagina. The clitoris does not extend.

In the male, on the other hand, the penis enlarges, though slowly; the edges of the groove close in to form an elongated urethra, running throughout the whole extent of the penis. This is effected about the fifteenth week. It is the incompleteness of this union which forms the congenital deformity called hypospadias.

Lastly, the scrotum is formed by the closing in of the lateral cutaneous folds, thus forming the raphe.

The imperfect development of the structures just described gives rise to the various forms of hermaphrodism.

MAMMARY GLANDS.

The skin covering the mammæ is smooth, soft, and semitransparent; in the healthy state no wrinkles or folds can be noticed in it. Towards the central part of each mamma the skin abruptly changes its colour to a rosy tint in young girls, or a reddish-brown one in women who have suckled several children. This circle, when the skin is remarkable for its extreme tenuity, presents a wrinkled appearance, owing to the presence of sebaceous glands, and is called the *areola* of the *nipple*. The glands, varying from four to ten, are disseminated over the whole areola, or form a regular circle near its circumference. They present near their summit two, three, or four small apertures, the orifices of their excretory ducts. They furnish an unctuous fluid calculated to protect the nipple against the action of the saliva of the child. In the middle of the areola is the nipple (papilla), a conical eminence of a rosy tint, susceptible of a kind of erection during life, on the surface of which the lactiferous vessels open. The skin which covers the nipple is wrinkled, reticulate, and furnished with a great number of fine papillæ. The orifices of the lactiferous ducts, which are observed on its surface, are surrounded by excessively minute hairs.

The *mammary gland* lies in a layer of adipose tissue, before and near the inferior margin of the pectoralis major muscle; it is of an oval form, an irregularly circumscribed base, convex anteriorly, concave towards the chest; its anterior surface is uneven, and there are observed upon it prominences in the form of ridges, more or less voluminous, and depressions in which are lodged pellets of adipose cellular tissue. The tissue of the gland results from the assemblage of several lobes or lobules varying in size, and closely connected with each other by dense cellular membrane. These lobes are near each other, and more numerous towards the centre than at its circumference. Each of them is composed of several lobules, which are formed of rounded granulations of a rosy-white colour, of the size of a poppy-seed. The microscope shows that these organs, themselves so small, are formed by the union of a number of smaller vesicles. These glandular grains give rise to the radicles of the *lactiferous ducts*, which, uniting, form twigs and trunks gradually becoming larger. They collect towards the centre of the gland; they are flexuous, very extensile, and semitransparent. Those of the different lobes do not

communicate with each other, so that there are as many series of vessels as lobes in the gland. They all terminate in *sinuses*, placed near the base of the nipple, which are commonly from fifteen to eighteen in number. These sinuses have not all the same capacity; the largest are two or three lines in breadth, while others are not much larger than the trunks which form them. They are short, of a conical form, and connected with each other by cellular tissue. From their summits proceeds a bundle of other canals which occupy the centre of the nipple, do not communicate together, and open separately at its surface. All these vessels are destitute of valves; Bichat thought they were lined by a particular mucous membrane. The arteries of the mammæ come from the thoracic, axillary, intercostal, and internal mammary. The deep veins accompany the arteries: others are subcutaneous, and follow a different course. Their nerves are furnished by the intercostal nerves and the brachial plexus. Their lymphatics are numerous and form two layers; they communicate with those of the abdomen and thorax, and go to the axillary glands. The cellular tissue, penetrating and enveloping the mammæ, becomes in most cases impregnated with fat, and increases the size of the organ very much.

Fig. 209.*

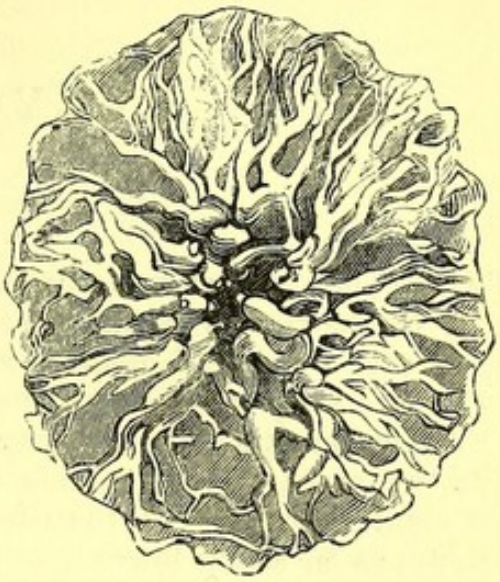

* Fig. 209 represents the ducts of the mammary gland after the integuments and superficial fascia have been removed, more especially when the lactiferous ducts happen to be filled with milk. The glandular tissue has not been represented by the artist: it is composed of rounded granulations grouped into lobules; from these the ducts arise. In describing the lactiferous ducts it is usual to speak of them as composed of—1, the radicles or smaller ducts; 2, the sinuses; 3, the system of tubes which terminate on the nipple; all these however are continuous ducts.

THE NERVOUS SYSTEM.

THIS important system is composed of two great divisions:—

1. Of the central organs, the encephalon and medulla spinalis, named by Meckel "the cerebro-spinal axis."

2. Of a peripheral portion, composed of the nerves and ganglions.

The cerebro-spinal axis, chiefly for the sake of description, is divided into two parts,—1, the portion called encephalon, as contained within the cranium or head; 2, the portion partially occupying the vertebral column as far as the lower margin of the first lumbar vertebra or the commencement of the second; this has received the name of spinal marrow—*medulla spinalis*.

Of the nerves, the peripheral portion of the nervous system, a certain number are called cranial or cerebral, being seemingly in more direct communication with the brain; others are called spinal, with reference to their communication with the spinal marrow; others are called sympathetic. The connexion of this system of nerves with the brain or spinal marrow is evidently less direct.

Lastly. Of the ganglions or enlargements found in the course of the nerves, some are placed on the cerebral and spinal nerves, others on the sympathetic. The use of the ganglions is wholly unknown.

The nerves are still further subdivided into nerves of motion and nerves of sensation; nerves of the special senses, nerves serving for nutrition; respiratory nerves, nerves of reflex action, &c. These terms are derived from obvious mechanical relations, or from physiological experiments and views, for the most part as yet imperfect.

It was an ingenious idea on the part of Meckel to commence the description of the nervous system of man with the sympathetic and its ganglions; the communicating branches of this system with the spinal and cerebral nerves led him to these nerves themselves and to the centres from which they come and go; but experience has taught me that the safest course for the student to follow is, to dissect the centres first, and from these centres, whatever be his physiological views, to trace the nerves to all parts of the body.

As he traces the nerves he will necessarily meet with the ganglions, to whatever system of nerves they may belong.

By tracing the nervous system from man downwards to the lowest of the avertebrate kingdom of animals, the ascidia for example, we arrive at last at the lowest element of a nervous system; the simplest expression, if I may so say, of Nature's plan in constructing a system

of organs to which all animals owe their animal nature. This elementary or fundamental form proves to be a small, albuminous, soft, and somewhat rounded body, from which, or to which, proceed at least two white cords, connecting the central part of the rudimentary nervous system with the tissue and organs of the animal. This small, rounded body is the central organ of the nervous system in this animal, reduced to its simplest element; the cords are the nerves.

Respecting the nature of the peripheral organs, the nerves, in such a system as this, there can be no doubt; but it is not so with the central organ. It has been called by most writers on comparative anatomy a *ganglion*, and so it is, no doubt, in some sense; but it were hasty and unphilosophic to imagine it to represent a human sympathetic ganglion or a spinal ganglion, for it may represent a rudimentary spinal marrow and brain. And accordingly this view was adopted by De Blainville, by myself (in early life), and no doubt by many others. De Blainville considered the spinal marrow and brain of the vertebrate animals as composed of a double series of ganglions, united to each other by longitudinal and transverse commissures; this view is still, I believe, the one most generally received.

But whatever physiological views the student may ultimately adopt in respect to the development of the nervous system, and its general and particular functions, it is strongly recommended to him carefully to examine for himself the anatomy of the organs, setting aside, in as far as he can, all preconceived theories, and taking nothing for granted but that which can fairly be demonstrated.

CEREBRO-SPINAL AXIS.

Dissection.—The cerebro-spinal axis is composed of,

1. The cerebrum.
2. The cerebellum.
3. The medulla oblongata.
4. The medulla spinalis.

These are strictly continuous, and seem but one organ, although, as respecting its functions, it must be regarded as composed of many.

Dissection.—Place the subject on its face, and lay open with the saw, chisel, and mallet, the spinal canal, taking care not to injure the parts within. This is best done by placing an elevated block below the middle of the chest and upper part of the abdomen, so as to cause it to arch backwards, and, applying a saw obliquely inwards to the laminæ of five or six of the dorsal vertebræ, remove these laminæ, together with their spinous processes. As soon as this has been done, proceed to lay open the entire canal, from the extremity of the sacrum to the head, removing also the posterior part of the occipital bone. This section will expose the spinal marrow enclosed by its membranes.

MEMBRANES OF THE SPINAL MARROW.

The SPINAL DURA MATER.—The spinal portion of the dura mater is a long, fibrous, cylindrical prolongation of that portion of the dura mater which is within the cranium, extending from the foramen magnum of the occipital bone to the termination of the canal of the sacrum.

The *capacity* of the spinal portion of the dura mater is much larger than is required by the organ it contains. This may be shown by injecting a fluid into it, which, by distension, shows a considerable enlargement in the cervical region, and another in the lumbar region. It terminates inferiorly by subdividing into several sheaths, enclosing the sacral nerves. The reason assigned by Cotunni for the great capacity of the spinal portion of the dura mater is, that, in addition to the spinal marrow, it contains a "serous liquid."* This is called the liquor of Cotunni, respecting the nature of which many interesting experiments were made a few years ago by M. Magendie.

The *external* surface of the spinal portion of the dura mater posteriorly, scarcely adheres to the osseous and ligamentous surfaces: a network of veins surrounds it, preventing contact with the inside of the laminæ vertebrarum and with the yellow ligaments. The spaces are filled with a fluid reddish fat, intermingled with small veins, and infiltrated with serosity. This fat resembles the marrow of the long bones. On each side the dura mater furnishes short sheaths for the spinal nerves, passing with them through the foramina conjugalia, and then mingling with the surrounding cellular substance and periosteum.

Anteriorly, the dura mater adheres more firmly to the posterior common ligament of the vertebræ by fibrous prolongations; this can only be seen towards the close of the dissection, when the student proposes removing the spinal *marrow and its membranes from out its osseous case*. But before doing this, lay open the dura mater by an incision from the upper quite to its lower part.

The *internal* surface is smooth and humid, owing to the layer of the arachnoid membrane investing closely its inner surface. They cannot be separated to any extent by dissection. On each side may be seen the double orifices of the fibrous canals, giving passage to the anterior and posterior roots of the spinal nerves. The edges of these openings are quite smooth, as the arachnoid passes in a short way along with the nerves.

Inferiorly, the dura mater extends quite to the extremity of the sacral canal, and consequently much beyond the extent of the spinal marrow.

Superiorly, it is intimately united to the bone around the edge of

* Quidquid autem spatii est inter vaginam duræ matris et medullam spinalem, id omne plenum etiam semper est; non medulla quidem ipsa in viventibus turgidiori, non nube vaporosa, sed aqua, etc., p. 11.

the foramen magnum, and is there continued into the interior of the cranium, where it becomes the cerebral dura mater. The vessels of the spinal dura mater come from the adjoining ones; no nerves have yet been traced to it; it is insensible under the knife in living animals, but it is said by M. Cruveilhier to be sensible when torn.

SPINAL ARACHNOID.—This, like the spinal dura mater, is a continuation of that within the cranium. It is composed of two portions, a *parietal* and a *visceral*. The parietal layer invests intimately the inner surface of the dura-matral sheath just described. It is continuous with the visceral portion by the sheaths which the latter furnishes to the spinal nerves. The visceral layer is an extremely delicate serous sheath, much more capacious than the spinal marrow it envelopes. It is also prolonged around the cauda equina, and furnishes to each pair of nerves a funnel-shaped sac, terminating on a level with the foramina conjugalia, and is there reflected upon the dura mater; and thus the visceral and parietal layers of the arachnoid are continuous, as is the case with all serous membranes.

Between the spinal marrow and its visceral layer there exists posteriorly a considerable interval, or at least a large space may be formed by blowing air between them, or by the injection of a liquid. In this respect the spinal arachnoid differs much from the cranial; it is in this sub-arachnoid space that the liquor Cotunnii is found. The visceral layer, however, has certain connexions with the proper membrane of the spinal marrow by means of long filaments of a seemingly fibrous nature. Anteriorly its connexion is much more intimate, especially in the mesial line or fissure of the medulla spinalis, or, in other words, air, blown in with the blowpipe, does not detach the arachnoid anteriorly from the pia mater so extensively as it does posteriorly. This mode of connexion takes place also at some points of the cerebral arachnoid, but not generally so. It may also be observed, that the two layers of the spinal arachnoid adhere occasionally by a number of points to each other; these are not found in the cerebral arachnoid.

The sub-arachnoid liquid fills the space between the visceral layer of the arachnoid and the pia mater; it is found as well within the cranium as within the spinal canal. The existence of this liquid was known to Haller, but most clearly demonstrated by Cotunni: many interesting experiments have been made on it by M. Magendie. By opening the dura mater in the lumbar region, from four to five ounces of a clear limpid fluid may sometimes be collected. There can be little doubt that the cerebral sub-arachnoid liquid communicates with that in the spine; but a question has arisen, Does the liquid of the ventricles of the brain mingle with the spinal sub-arachnoid liquid at the bottom of the fourth ventricle or elsewhere? I have always been of the opinion that there exists no communication between them. Tiedemann also, I believe, denies this communication.

The *uses* of the arachnoid membrane resemble those of other serous membranes.

The *uses* of the sub-arachnoid liquid are not well known; when evacuated in the living animal by opening the spinal canal, it appears for a time as if stupified or intoxicated; but it soon recovers.*

Spinal Pia Mater.—This is a continuation of the cerebral *pia mater*, but it differs from it in some respects. It has been named by some the *neurilemma* of the spinal marrow. It is easily examined, but it is difficult of demonstration, in consequence of its firm adhesion to the spinal marrow, and the softness of the organ to which it adheres. In order to effect this the spinal marrow ought to be quite fresh; but this the student cannot expect, if he have already taken time to dissect the muscles of the back. In newly-born children the membrane we now speak of is more easily demonstrated.

The proper or investing membrane of the medulla spinalis is usually considered to be a fibrous membrane of some resistance supporting the medulla, as the neurilemma does the nerves. The external surface is surrounded by a vascular network, remarkable for its flexuosities; it penetrates into the thickness of the membrane. In other respects the membrane is of a dull yellowish colour, and even a few black points may occasionally be seen upon it. Its outer surface posteriorly adheres by a few fibrous points to the visceral layer of the arachnoid; anteriorly its connexion is much more intimate with the arachnoid; with the medulla its connexion is cellular and vascular. In the line of the anterior median fissure it forms a duplicature which penetrates to a considerable depth; a single prolongation of extreme tenuity passes into the posterior median fissure.

The terminating *cord* or *filament* of the spinal marrow is generally considered merely as a prolongation of the proper membrane. It is strong and habitually tense, and seems intended to keep the spinal marrow in its proper position.

Next examine the ligamentum dentatum. This is so named from its functions and from its toothed appearance. It is a delicate fibrous lamina extending through the whole length of the medulla spinalis, adhering by its base to the proper membrane of that organ, and sending out from its free margin tooth-shaped processes which adhere by their summits to the inner side of the dura-matral covering of the spinal marrow. The first of these may be seen at the sides of the foramen magnum occipitis, between the vertebral artery and the hypoglossal nerve; the last, which is the twentieth or twenty-first, is the termination of the ligament and corresponds to the termination of the medulla. It separates the roots of the spinal nerves from each other, and retains the medulla in its place.

* The notion taken up by some anatomists, that there exists a series of short sacs between the visceral layer of the arachnoid and the spinal pia mater, the uppermost of which communicates with the fourth ventricle, is easily refuted by the correct descriptive anatomy of the part. Equally incorrect is the idea that the arachnoid passes into the interior of the ventricles of the brain. It requires no appeal to the microscope to prove this.

THE MEDULLA SPINALIS.

The medulla spinalis (spinal marrow, *μυελος ραχιτης*) is a white symmetrical cylinder of nervous matter, situated in the spinal canal, and occupying its superior portion chiefly; it is continuous with the encephalic portion of the nervous system. The limits superiorly are the bulb, usually called the *medulla oblongata:* inferiorly, it descends as low as the middle or inferior margin of the first lumbar vertebra, or the middle of the second. Its dimensions vary in the adult from fifteen to eighteen inches; its absolute bulk has been supposed by some to be in the direct ratio of the vital activity of the animal; this idea, however, is extremely vague. In respect to the discussions regarding the comparative importance of the spinal marrow and brain, and the relation they hold to each other, these may be cut short by the remark that neither organ produces the other, and thus in respect to their growth they are strictly independent.

Proportionally to the weight of the body, Man is supposed to have the largest spinal marrow. It differs also in volume in different parts of its course, being somewhat larger in the cervical region, on a level with the third cervical vertebra, and as far as the second dorsal; it here contracts considerably, and thus continues as far as the eleventh dorsal, where it once more enlarges, but, again suddenly contracting, it forms a cone, which terminates by a fine cord, concealed amongst the nerves constituting the *cauda equina*. This cord is semi-transparent, elastic, fibrous, and firm; a vein constantly accompanies it. The cord may be followed as far as the first coccygeal bone.†

Viewed *anteriorly*, the medulla presents the *anterior median fissure; posteriorly*, a similar one, but scarcely

Fig. 210.*

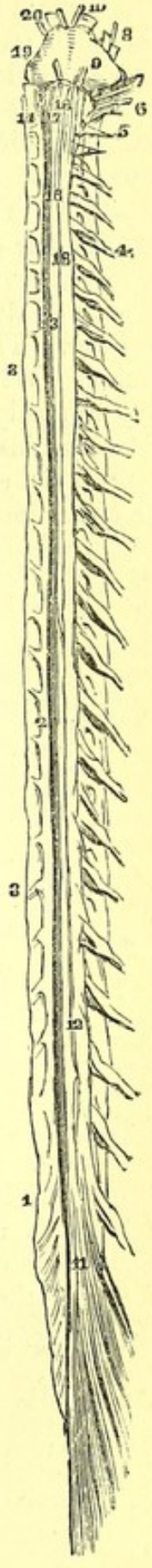

* Fig. 210.—Showing the medulla spinalis, medulla oblongata, and pons, anterior surface.—11, cauda equina; 12, enlarged portion of the medulla corresponding to the lumbar and sacral nerves; 3, 3, ligamentum dentatum, right side; 13, enlarged portion of the medulla, corresponding to the lower cervical nerves; 18, anterior median fissure; 16 is placed a little below the decussation of the anterior columns; 17, 18 point to the corpora pyramidalia and corpora olivaria; 14, top of the ligamentum dentatum; 5, 6, 7, the eighth pair of cranial nerves; 9, the sixth pair; 19, crus ad cerebellum; 8, the fifth pair; the fourth is seen a little in front; 10, the third pair; in front of these is the second, or optic, not fully represented.

† M. Cruveilhier says, "On le suit jusqu'à la base de sacrum, où on le voit se confondre avec la dure mère," 566. But the above remark is decidedly erroneous.

so distinct, although some assert it to be deeper than the anterior. On each side these fissures are seen the roots of the anterior and posterior spinal nerves. By pulling out a few of these roots of the nerves, Chaussier endeavoured to show lateral fissures; there are *no lateral fissures*. The immediate investing membrane of the spinal marrow has been already described; it differs somewhat in structure from the cerebral pia mater, in having a fibrous appearance. The investing membrane must now be carefully stripped off (the roots of the nerves coming with it), which can only be done in very fresh subjects. Next examine the *anterior commissure;* this is at the bottom of the *anterior median fissure*, and is cribriform; the perforations are caused by the passage of numerous blood-vessels proceeding into the interior of the medulla. The commissure is generally considered merely a medullary lamina. When anatomists say that originally there are two medullæ, they can only use the language in the same sense as they would speak of two brains. The *posterior median fissure* is deeper than the anterior; it is extremely narrow, and in the bottom of it may be seen the cineritious substance of the medulla spinalis.

Fig. 211.*

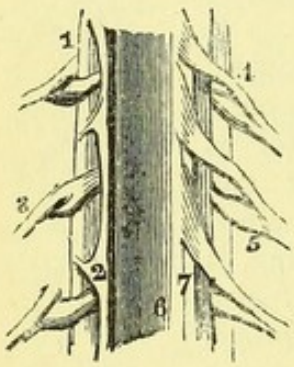

The following cords have been admitted as composing the spinal marrow: two posterior median, excessively narrow, traced on either side of the posterior median fissure; two posterior lateral, compressed between these and the roots of the posterior nerves; two anterior lateral, comprising all the remaining parts of the medulla, as far as the anterior fissure.

Are there any strictly lateral cords or fasciculi situated between the anterior and posterior roots of the spinal nerves? This is very doubtful.

Interior structure.—It results from a careful inspection of the structure of the medulla spinalis, that it is composed of two large lateral cylinders of the white nervous matter enclosing the grey or cineritious. The mark)(represents tolerably well the arrangement of the interior when cut across. Little is known further than this of the precise structure of the spinal marrow: many consider it as fibrous and laminated, each fibre and each lamina being independent of each other, and extending throughout the whole length; but these descriptions are far from being distinct. Previous to the fourth month in utero, there is a cavity in the centre of the medulla spinalis, *but this usually disappears before birth.*

* Fig. 211.—A portion of the medulla spinalis, to show the anterior and posterior roots of the spinal nerves.—1, posterior root; 2, the ligamentum dentatum; on this side the anterior roots have been cut across and removed; 4, the anterior roots; 5, a posterior root, on which the ganglion may be seen; 6, the anterior surface of the medulla; 7, supposed lateral groove.

THE BRAIN AND ITS MEMBRANES.

When the student has made up his mind to dissect the brain and its membranes, he ought to proceed as early as possible to open the head by a vertical incision carried from the root of the nose, over the vertex, to the external occipital protuberance, through the soft parts. Reflect these flaps, and next divide all the soft parts quite to the bone circularly around the skull-cap, a little above the zygomatic arch. Saw through the skull-cap cautiously, and remove it. This will expose the outer surface of the dura mater. Or the skull-cap may be removed in fragments, by repeated blows of a sharp-pointed hammer, without injury to the dura mater or brain, as was first shown by Bichat.

Fig. 212.*

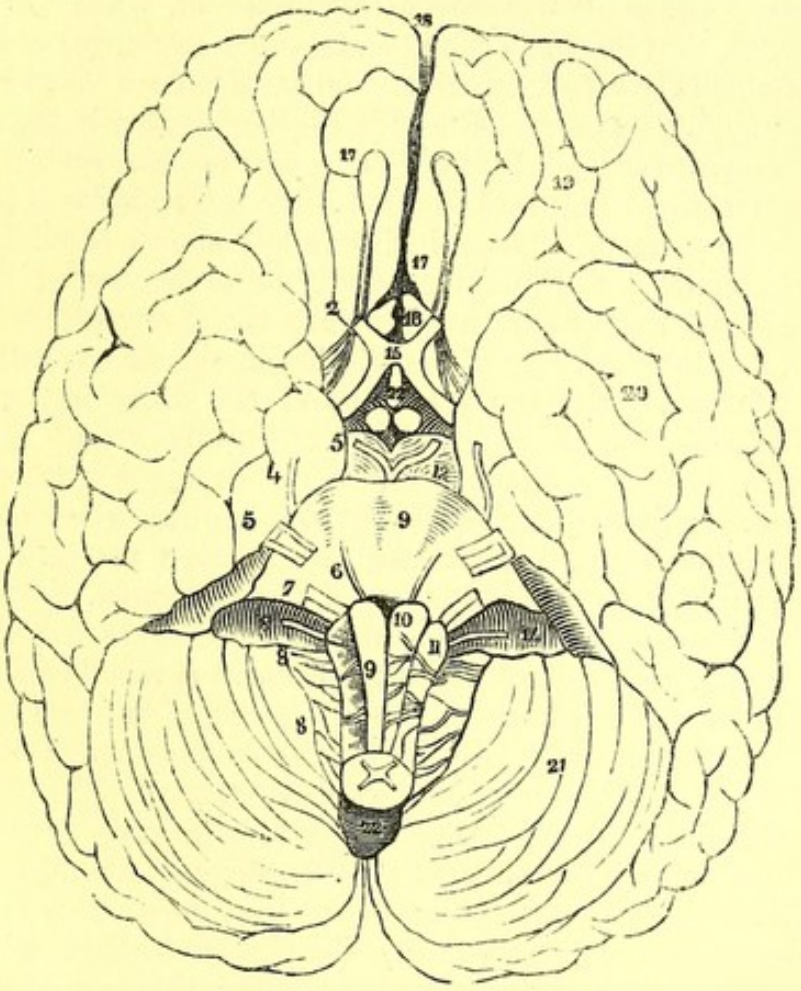

* Fig. 212.—The brain, its base.—18, inter-hemispherical fissure; 19, inferior surface of the anterior lobe, left hemisphere; 17, 17, olfactory nerves and bulbs; 16, portion of the brain connected with the corpus callosum; 2, optic nerves; 15, commissure of the optic nerves; 22, infundibulum and corpora albicantia; 5, 12, third pair of nerves and crura cerebri; 4, the fourth pair of nerves; 9, the pons; 6, the sixth pair of nerves; 7, the seventh pair; 8, the eighth pair; 9, the ninth pair: the figure is placed on the corpus pyramidale of that side. 10, 11, the olivary and pyramidal bodies of the left side; 14, glosso-pharyngeal nerve, left side; 21, cerebellum; 20, middle lobe of the cerebrum.

The cranial dura mater is a dense fibrous sac enclosing the brain, which it further supports by processes or partitions; it serves also as an internal periosteum to the cranium. The external surface comes, of course, first into view. It exactly invests the interior of the cranium, to which it adheres more or less strongly, both by means of numerous blood-vessels, and likewise by many small fibrous prolongations. Upon this outer surface of the dura mater may be seen the branches of the middle meningeal artery, and some of the branches of its veins, adhering internally to the membrane. These are the vessels which nourish the skull. The adhesion of the dura mater to the skull differs in different regions and in different subjects. It adheres very strongly to the upper margin of the *pars petrosa*, around the great occipital foramen, and to the base of the skull generally; also in the line of the sutures. In extreme old age, and in extreme youth, the union is most intimate. At the base of the skull we shall afterwards find, when the brain has been removed, that it sends some remarkable prolongations through it; one particularly into the orbit. Open the dura mater with the scissors, beginning just above the edge of the divided bone, and carry the incision forwards and backwards as far as convenient. Make a similar incision through the dura mater on the opposite side, and lay up the flaps so formed. These incisions will expose the inner surface of the dura mater and the external surface of the brain; but anatomically speaking, these incisions open into the cavity of the arachnoid membrane, and into the seat of the effusion in the disease called hydrocephalus externus. The inner surface of the dura mater, where it faces the brain, is smooth and polished. This is owing to its being invested with a layer of the arachnoid. This inner surface ought to be free from all adhesions, excepting at those points where the cerebral veins proceed to open into the sinuses of the dura mater. It closely touches the visceral or cerebral layer of the arachnoid, there being no space between them but what is sufficient to contain the lubricating serosity common to the arachnoid with all serous membranes.

From the internal surface of the dura mater proceed three processes or partitions which divide the brain into subdivisions, and the interior of the cranium into compartments. These prolongations are the *falx cerebri*, *tentorium cerebelli*, and *falx cerebelli*. The first two can readily be seen at this stage of the dissection, but not the falx cerebelli. These processes can be very well examined upon a preparation, which will enable the student, in this his first dissection of the brain, to avoid disturbing that organ, so as to endanger its after-dissection. They may, however, be examined in this way. Cut through the cerebral veins entering the superior longitudinal sinus on each side, and gently draw outwards the hemispheres of the brain, so as to widen the inter-hemispherical fissure; on looking down into this fissure, the whole extent of the falx cerebri may be seen.

Again, by raising up the posterior lobes of the cerebrum on each side, the tentorium cerebelli may be seen, but not very well examined.

Indeed, to examine these processes of the dura mater, it would be necessary to dissect the brain *in situ*, or to sacrifice it altogether; this would not be advisable, because the mechanical arrangement of all the processes can be well seen on a dried preparation.

The falx cerebri, however examined, is a median fibrous lamina, having the shape of a scythe; it is tense, and stretched between the crista galli and the tentorium cerebelli. The point is forwards, dips into the foramen cœcum of Morgagni, and envelopes the crista galli of the ethmoid. Its base is behind, and falls perpendicularly upon the tentorium cerebelli. Where these two processes meet is the straight sinus. In the upper or convex margin will be found the superior longitudinal sinus. This should be laid open and examined at the present stage of the dissection, because it will in part be afterwards destroyed. Its inferior edge looking towards the corpus callosum, contains the inferior longitudinal sinus. The course of these sinuses will be more fully explained afterwards. The uses of the falx cerebri are not well known. It is sometimes slightly cribriform, and one or two instances are recorded of its total absence.

The *tentorium cerebelli* is an incomplete, horizontal septum, separating the posterior lobes of the brain from the cerebellum. It is in a state of continual tension.

The *external circumference* of the tentorium corresponds behind to the posterior half of the lateral grooves of the occipital bone, for lodging the lateral sinuses which are formed or lodged within this portion of the dura mater. Anteriorly it adheres to the upper margin of the pars petrosa; here the superior petrosal sinuses are to be found.

The *internal circumference* intercepts a small space, filled by the pons Varolii or tuber annulare. The extremities or points of these margins, or circumferences, cross each other like the letter X. The extremity of the external edge or base is fixed to the posterior clinoid process, thus forming, towards the summit of the petrous portion of the temporal bone, a bridge under which passes the trifacial nerve. The point or extremity of the inner margin or circumference of the tentorium cerebelli proceeds to be attached to the anterior clinoid process. These prolongations of the tentorium will be better seen when the brain has been removed; they complete the sides of the sella turcica or pituitary fossa, and enclose the cavernous sinuses within their thickness.

The *falx cerebelli* cannot be seen at this stage of the dissection. It is a small, vertical, median, scythe-shaped process of the dura mater, extending from the internal occipital protuberance to the edge of the foramen magnum occipitis; it slightly separates the hemispheres of the cerebellum from each other. Its base is fixed to the lower surface of the middle of the tentorium, the summit is bifurcated at the sides of the occipital foramen. Its posterior edge corresponds to the internal occipital crest, its anterior to the median fissure of the cerebellum. The occipital sinuses are formed in it.

In *structure* the dura mater is remarkably strong. It has been usually divided into two layers, a fibrous and serous. The serous is internal, the fibrous external. The internal or serous is merely the reflected lamina of the cerebral arachnoid; the fibrous or external may be further subdivided into two layers, a periosteal or vascular layer, and a fibrous, properly so called. The separation between these layers is best seen where the sinuses are formed in the thickness of the dura mater.

The *glands of Pacchioni*, which are met with at this stage of the dissection, are certain small bodies of a whitish or yellowish colour, sometimes isolated, sometimes collected together in the form of a bunch of grapes, which receive vessels, but are destitute of nerves, and of whose intimate texture and uses we are entirely ignorant. They are not met with in children nor in all subjects. The superior longitudinal sinus contains a remarkable quantity of them, particularly at its middle and posterior parts. They were formerly designated by the name of glands of Pacchioni, although they are very different from glandular organs. These granulations generally occupy in this sinus the circumference of the orifices of the veins, where they form a more or less distinct prominence between the internal bundles. Very few of them are isolated, almost all being agglomerated into small masses, and intimately connected with each other. They are covered by the internal membrane of the sinus. In the torcular Herophili very few of them are observed, but there are some at the mouths of the veins in the occipital portion of the lateral sinuses. In the straight sinuses some are occasionally found at the orifices of the venæ Galeni; all the other sinuses are destitute of them. In the external pia mater graniform bodies, resembling those of the sinuses, are also met with. They are especially observed along and to the outside of the superior longitudinal sinus, around the cerebral veins. Here they are enveloped by the arachnoid membrane, and their size is so much the larger the nearer they are to the sinus. Some of them are engaged in the separations of the fibres of the dura mater, which give passage to the veins, and are in some measure continuous with the granulations of the sinus itself. At the base of the brain, and around the other sinuses, no similar disposition is observed. The internal pia mater also presents some of these granulations. They are observed in the choroid plexus, where they are of a reddish grey colour, and rather soft. There are also some beneath the velum interpositum, at the fore-part of the pineal gland, where they are disposed in two rows, which unite so as to form a triangle. Lastly, they are equally met with in the choroid plexus of the fourth ventricle.

I have already spoken of the arteries and veins of the dura mater; the presence of nerves in it has been much disputed, as it is quite insensible during life while in a healthy state. M. Cruveilhier says that its nerves are derived from the fifth pair. The dura mater extends into the spinal canal.

Dissection.—Remove the brain from its case; cut through the

anterior part of the falx cerebri, and draw it upwards; next divide the veins of Galen, which enter the straight sinus at the fore-part of the tentorium cerebelli; then cut through the tentorium on each side, and commence raising the brain from before backwards, cutting through in succession all the nerves and blood-vessels proceeding to or from it. Having reached the back part, with a long and sharp scalpel cut the spinal marrow across as low down as possible—that is, if the brain is to be removed independent of the medulla spinalis. The entire mass may then be withdrawn from the cavity, and laid in pure water for an hour, and immediately afterwards immersed in spirits, or in a solution of corrosive sublimate. By this means it may be preserved until the student has examined all the parts left on the base of the cranium, which he will find fully exposed by the removal of that organ.

The whole interior of the base of the cranium will be seen covered with the dura mater, smooth and shining, owing to the presence of the arachnoid layer investing it. This surface the student should examine with the greatest care. At the base of the cranium the external surface of the dura mater is very complex in its disposition, on account of the great number of holes aud inequalities which are observed in that region. It sinks into the foramen cœcum, where it contracts somewhat intimate adhesions by several prolongations. It embraces the summit of the crista galli of the ethmoid bone, whence it descends on each side into the ethmoid grooves: then, at each hole of the cribriform plate it furnishes for each branch of the olfactory nerves a small fibrous canal, which terminates on the outer layer of the pituitary membrane. More laterally similar canals penetrate into the internal orbitar canals, to accompany the nerves and vessels which they contain, and are continued into the periosteum of the orbit. Lastly, altogether, on the sides, the dura mater adheres but little to the orbitar arches, even at the place of the sphenoidal suture. More posteriorly it adheres in a decided manner to the groove, to the fore-part of the sella turcica, and penetrates into the optic foramina, forming an envelope for the optic nerves. When it arrives at the posterior insertion of the recti muscles of the eye, the outer lamina (which is rather thin) of this cylindrical envelope expands into the periosteum of the orbit; the inner, which is whiter, denser, thicker, and immediately applied on the nerve, accompanies it to the ball of the eye, and is continued into the sclerotic membrane. Behind the optic foramen the dura mater presents a circular aperture, which embraces the internal carotid artery as it issues from the cavernous sinus; some fibres arising from the circumference of this aperture seem to throw themselves into the walls of the artery. At its anterior part there occurs the orifice of a small canal, formed inferiorly between the two laminæ of the envelope of the optic nerve; it transmits the ophthalmic artery into the orbit. The dura mater then lines the sella turcica, where it is covered by the pituitary body, which separates it from the arachnoid membrane at this place; it then passes over the sides of the body of the sphenoid bone, where it divides into two laminæ to form the

cavernous sinuses. The innermost of these laminæ is thin, and immediately covers the cavernous groove; the outer, which is free, forms the opposite wall of the sinus. On the free edge of the processes of Ingrassias the dura mater forms a small fold, which enters into the *fissura Sylvii;* then, descending thence vertically, it closes the sphenoidal fissure, and sends through it a prolongation, thicker on the inner side, which proceeds into the orbit, and is continuous with the periosteum of that cavity. This prolongation presents several apertures for the passage of vessels and nerves which enter the orbit. The membrane then extends into the middle lateral fossæ at the base of the cranium, to which it adheres but feebly; but, on approaching the sides of the body of the sphenoid bone, it furnishes first an envelope to the superior and inferior maxillary nerves in the bony canals by which they pass out of the cranium; it also gives one to the middle meningeal artery, and concurs to form the cavernous sinus and various canals. One of the latter is for the third pair; it commences a little before the posterior clinoid process; it is fibrous in its whole circumference, and invested by the arachnoid coat at the commencement of its course; but the latter afterwards leaves it to be reflected over the nerve, and there is no longer perceived a complete fibrous canal, but the lamina of the dura mater alone, which forms the outer wall of the cavernous sinus, is seen externally; internally the nerve is separated from the sinus itself only by a thin and apparently cellular membrane. Another canal belongs to the nerve of the fourth pair; it is a little higher than the preceding, and much narrower, and, like it, is fibrous, and lined by the arachnoid membrane in the first part of its course; afterwards it is in like manner only formed by a single lamina of the dura mater applied externally upon the nerve, which is separated from the rest of the sinus by a thin and transparent membrane. Lastly, a little farther back, and opposite the upper edge of the petrous process, the dura mater forms a canal for the nerve of the fifth pair, consisting of two laminæ; the upper of these laminæ is attached to the posterior clinoid process, and is continued over the upper edge of the petrous process; the other is placed between the nerve and the cavernous sinus, and becomes so thin as to be converted into a cellular lamella, which is prolonged internally to the ophthalmic branch. As it advances, the nerves of the third pair, fourth pair, and ophthalmic branch of the fifth, are each engaged in a new portion of entirely fibrous canal, which is afforded them by a prolongation of the dura mater passing from the sphenoidal fissure into the orbit. On the middle of the upper surface of the petrous process the dura mater covers the superior filament of the vidian nerve, and may easily be detached from it. It then adheres rather strongly to the upper edge of the petrous process, and to the quadrilateral plate of the sphenoid bone; it descends thence into the basilar groove, and is intimately attached to the occipital bone over the whole circumference of the foramen magnum. A little laterally it presents, for the nerve of the sixth pair, a foramen, which is not succeeded by a canal, and which, conse-

quently, transmits it into the cavernous sinus. The arachnoid membrane descends in it as far as that sinus, which it closes, and is then reflected upon the nerve. Farther on, and upon the posterior surface of the petrous process, the dura mater penetrates into the meatus auditorius internus, seems to enter the aqueduct of Fallopius, but cannot be followed into the foramina, which are traversed by the filaments of the portio mollis of the seventh pair. Farther down, at the foramen lacerum posterius, it envelopes the glosso-pharyngeal, the pneumo-gastric, and spinal accessory nerves, and is continued into the periosteum of the outer part of the base of the skull. A thinner lamina surrounds the internal jugular vein; it also sends into the anterior condyloid foramen a fibrous canal, which is in like manner continuous with the periosteum.

PRACTICAL EXAMINATION OF THE SINUSES OF THE DURA MATER.

Next examine the sinuses. These may very generally be detected by the dark blood they contain, and should all be laid open. The following description will point out their position, course, and terminations.

The *sinuses* are of variable dimensions, and disposed in a symmetrical and regular manner; they have walls formed externally by the dura mater, and lined internally by a smooth and polished membrane of a serous aspect, such as is met with in the interior of all the veins. Being constantly stretched in all points of their extent, they can neither change place nor can they even contract upon themselves; their cavity presents, at intervals, bridles, passing irregularly from one wall to the other; they are generally formed by fibrous bundles of the dura mater. It is into the sinuses that all the veins of this membrane, and all those of the brain, empty themselves.

Torcular Herophili.—This is a smooth and polished cavity of irregular form, placed at the union of the three great folds of the dura mater, on the fore part of the internal occipital protuberance. It is lined by the internal membrane of the veins, and presents six apertures—a superior, of a triangular form, belonging to the superior longitudinal sinus; two inferior, of variable form and breadth, corresponding to the occipital sinuses; an anterior, rounded, belonging to the straight sinus; lastly, two lateral, broader, but generally of different sizes, transversely oval, furnished with a thick rim in their contour, and leading into the lateral sinuses. The two last always, and sometimes the two inferior, transmit to the interior of the cranium the blood which is poured into them by the others.

Superior longitudinal sinus (*sinus falciformis superior*).—This is a long triangular canal, convex above, presenting its acute angle below, and occupying the whole upper edge of the falx cerebri; narrow before,

broader behind; commencing by a sort of cul-de-sac at the fore part of the crista galli of the ethmoid bone, and corresponding to the frontal ridge, the sagittal suture, and the vertical groove of the occipital bone. In its interior it is smooth and polished throughout its whole extent, and presents a number of the bridles (chordæ Willisii) mentioned above; these are invested, like it, by the internal membrane of the veins. This sinus communicates above with the frontal veins by a certain number of little veins, which pass through the sagittal suture; it also receives, in the same direction, veins which come from the diploë of the bones of the upper part of the skull; it communicates, by means of a small branch which passes through the parietal foramen, with the veins on the outside of the head; lastly, it receives some trunks from those of the dura mater, and all those which are expanded over the convex and plane surfaces of the two cerebral hemispheres; they almost all open into its interior, obliquely forwards. In general the mouths of the veins are covered in a great measure by membranous folds, in the form of valvules, the free and concave edge of which is turned forwards. All these folds are formed by the internal membrane of the veins applied upon itself, and are, in general, much less visible in the anterior region of the sinus than in the posterior. It is also probable that, by its anterior extremity, the superior longitudinal sinus communicates with a vein of the nose, which passes through the foramen cœcum.

Inferior longitudinal sinus (*sinus falciformis inferior*).—Much narrower than the preceding, occupying the lower edge of the cerebral falx, from its anterior third to the tentorium cerebelli, it seems to result from the union of several small veins of the falx itself, and generally terminates by two branches in the straight sinus. Of these branches one is directly continuous with it above the aperture of the venæ Galeni; the other ascends in the substance of the falx for some time, curves backwards and downwards, and penetrates obliquely into the straight sinus towards the middle of its length; the latter only is furnished with a valvular fold.

Straight sinus (*sinus quartus*, *s. perpendicularis*).—Triangular in its whole extent, broad behind, contracted before, passing a little obliquely downwards and backwards, it prevails all along the base of the falx, above the tentorium cerebelli, from the termination of the inferior longitudinal sinus to the torcular Herophili. In its interior it presents the same appearance as the superior longitudinal sinus,—that is to say, upon its walls a great quantity of fibrous bundles, closer to each other before than behind, form remarkable prominences beneath the delicate membrane which covers them. It receives the inferior longitudinal sinus; the veins of the cerebral ventricles, or the venæ Galeni, also empty themselves into its anterior and inferior part, where there is a valvular fold. Towards the middle of its length, and inferiorly, the straight sinus still receives the blood of the superior veins of the cerebellum, through a rounded separation of the fibres of the dura mater.

Occipital sinuses (*sinus occipitales, dexter et sinister*).—These sinuses commence on the sides of the foramen magnum, not far from the termination of the lateral sinuses, with which they sometimes communicate, and ascend, becoming broader, and drawing nearer each other, in the substance of the falx cerebelli, where they pretty frequently unite altogether; they open, each by itself, into the lower part of the torcular Herophili; they receive the veins of the falx cerebelli, of the dura mater which lines the inferior occipital fossæ, and those of the posterior part of the cerebellum.

Lateral sinuses (*sinus transversi*).—They carry the blood from the torcular Herophili to the foramen lacerum posterius, into the sinus of the jugular vein; their course is marked by a groove which exists on each side of the interior of the cranium. A difference of capacity is almost always observed between them, the sinus of the right side being generally the larger. From the torcular Herophili to the upper edge of the petrous process they have a triangular form; in the rest of their course their section is elliptical. Their interior, which is everywhere smooth and polished, presents none of the bridles of which we have made mention in speaking of the other sinuses; they receive some veins from the cerebellum, the posterior extremity of the cerebral hemispheres, the tentorium cerebelli, and the cavity of the tympanum; they also present, in the second part of their course, the orifices of the superior and inferior petrous sinuses, which carry the blood from all the other sinuses of the base of the skull. By the mastoid and posterior condyloid foramina they communicate, moreover, with the occipital veins on the outside of the cranium.

Coronary sinus (*sinus circularis*).—It surrounds, in a more or less regular manner, the sella turcica and pituitary body, passing behind the channel of the optic nerves, and before or above the quadrilateral lamina of the sphenoid bone. It is very narrow in its whole course; it receives the small veins of these different parts, and those of the neighbouring portion of the dura mater, and opens to the right and left into the cavernous sinuses.

Cavernous sinuses (*sinus cavernosi*).—These sinuses are much more complicated than all the rest; they commence beneath the anterior clinoid processes, behind the inner third of the sphenoidal fissure, proceed thence horizontally backwards upon the sides of the sella turcica, whence they descend into the place which separates the summit of the petrous process from the quadrilateral plate of the sphenoid bone; there they terminate by emptying themselves into the superior and inferior petrous sinuses. Their breadth is considerable, and they are lodged in the lateral grooves of the body of the sphenoid bone, between two laminæ of the dura mater. Of these two laminæ, by an arrangement already partly described, the inner immediately lines the bony surface, and is prolonged into the sphenoidal fissure; while the other, which is much thicker, forms the outer wall of the sinus, which contains in its substance the nerves of the third and fourth pairs, and the ophthalmic branch of the fifth, and closes the two outer

thirds of the sphenoidal fissure, becoming confounded above with the extremities of the tentorium cerebelli, which close the sinus in that direction. Altogether, internally, the latter lamina is united with the first. The cavity of the cavernous sinuses generally presents a great number of soft reddish filaments, interlaced, and, as it were, reticulated. The intimate nature of this kind of cellular structure is very difficult to be determined. It appears to be formed by nervous filaments of the superior cervical and cavernous ganglions, the fibres of the dura mater, and the folds of the internal membrane of the veins. There are, moreover, met with in the interior of these same sinuses, the internal carotid artery, and the nerve of the sixth pair, placed against their inner wall, and immersed in the blood, from which they are only separated by the delicate internal membrane of the veins which envelopes them. The cavernous sinuses receive a great number of meningeal veins; the ophthalmic veins, whose roots originate in the interior of the eye and orbit; several emissary veins, which traverse the sphenoid bone; and the two coronary sinuses. Beneath the pituitary body the two cavernous sinuses have a very distinct communication (sinus transversalis, sellæ equinæ, Haller).

Superior petrous sinuses (*sinus petrosi superiores*).—They seem to arise from the termination of the preceding sinuses, towards the summit of the petrous process, whose upper edge they follow, lodged in a somewhat distinct groove, and in a part of the great circumference of the tentorium cerebelli; they pass above the fifth pair of nerves, where they leave for a moment the groove of the temporal bone; they are less broad, but longer, than the inferior; they open into the lateral sinuses, towards the point where the latter experience a curvature; they are triangular in their interior, and present but a very few transverse bridles.

Inferior petrous sinuses (*sinus petrosi inferiores*).—They arise from the cavernous sinuses at the same point as the preceding, with which they communicate at their commencement, descend behind and to the outside, between the inferior edge of the petrous and basilar processes, and terminate in the lateral sinuses, opposite the sinus of the internal jugular vein; they are broader at their extremities than at their middle part, and present the same structure as the superior petrous sinuses; their inner wall, that which is immediately applied upon the bones, appears to be formed only of the internal membrane of the veins, no lamina of the dura mater being perceived upon it. The two petrous sinuses receive veins of no great importance, all of which come from the dura mater. Some of them traverse the bones, and communicate with the outside of the skull.

Transverse sinus (*sinus occipitalis anterior*).—Placed transversely at the upper part of the basilar process, it forms a communication between the union of the two petrous sinuses and the cavernous sinus of the one side with that of the other. It varies in breadth, but is always of large size, and is lodged between two laminæ of the dura mater, in a superficial depression of the bone. In its interior it

presents a very distinct cavernous tissue. It receives several veins from the labyrinth. It is by no means rare to see two or three other transverse sinuses placed between the latter and the occipital foramen. Should the student be disposed to trace the nerves, of which he will have carefully examined the position in connexion with the dura mater, he may turn to the systematic description of the cerebral nerves; but I recommend him to proceed with the dissection of the brain and its remaining membranes.

CEREBRAL ARACHNOID.—The layer of this membrane, investing the inner surface of the dura mater, has been already described: the visceral layer invests the brain. On the convexity of the cerebrum it invests the convolutions without penetrating into the anfractuosities by which they are separated, and gives to each vein going to the longitudinal sinus a sheath which is reflected over the dura mater. Descending on each side in the great longitudinal fissure, it lines the corpus callosum, passing over the arteries which cover it, and furnishes the veins of the inferior longitudinal sinus with envelopes which are afterwards continued on the falx cerebri. Posteriorly, the arachnoid membrane is prolonged over the posterior lobes, envelopes some of the veins of the lateral sinuses, is reflected over the upper surface of the cerebellum, surrounds the veins of the straight sinus and part of those of the lateral sinuses, then covers the circumference and inferior surface of the cerebellum, between the two hemispheres of which it is isolated by its two surfaces over a greater or less extent. Anteriorly, the arachnoid membrane descends over the anterior lobes, and passes immediately from the one to the other inferiorly, near the commissure of the optic nerves, without penetrating into the fissure which separates them. It equally covers the inferior surface of the olfactory nerves, for which it forms a small sheath near their extremity. It also furnishes one to each of the optic nerves; but this sheath is conical, accompanies them to a great distance, and is only reflected upon their fibrous envelope in the orbit. It descends farther around the infundibulum, and is expanded over the pituitary body, which separates it from the dura mater. It embraces the internal carotid arteries at their exit from the cavernous sinuses; it then passes under the cerebral protuberance, being separated from the pia mater in all the space that exists between that protuberance and the commissure of the optic nerves, which is also separated from it, but by a less marked interval, opposite the protuberance and the grooves which limit the anterior prolongations laterally. It also gives sheaths to the third, fourth, fifth, sixth, and seventh pairs of nerves. Lastly, it directs itself over the lateral parts of the cerebellum, the posterior prolongations, the pneumogastric, spinal accessory, hypoglossal, and first cervical nerves, the vertebral arteries, and the spinal marrow itself, with which it is only connected by a small number of cellular filaments, easily torn, and which in general scarcely exist, so that it may very easily be detached by insufflation.

On the sides of the spinal marrow the arachnoid membrane furnishes envelopes to each nerve, and to each serra of the ligamentum dentatum, which are reflected upon the dura mater when the nerve penetrates it, and when the ligamentum dentatum is inserted upon it. It also furnishes an envelope to the vessels which creep upon its anterior and posterior surfaces. These have been already described. Lastly, on arriving at the lower extremity of the spinal marrow, it terminates by a sort of narrow and very long canal, of a cylindrical form, which descends vertically in the middle of the bundles of the lumbar nerves to the extremity of the sacral canal, where it is reflected upon the dura mater. It is by means of this canal, and of all the envelopes of the nerves and vessels, that it may be conceived how the arachnoid membrane covers in its whole extent the inner surface of the dura mater, and gives it the smooth and polished appearance which it presents. It is difficult to separate these two membranes from each other by the scalpel, except in the fœtus, or in very young children.

I have always maintained that the arachnoid membrane, although it penetrates a short way towards the interior of the third ventricle, beneath the corpus callosum and the fornix, does not line the interior of any of the ventricles. The membrane is here reflected around the veins of Galen; it is the pia mater which proceeds inwards into the interior of the ventricles of the brain.

Beneath the membrane just described, and closely investing the brain, is situated the *pia mater*. In the interval between them is the sub-arachnoid space, filled with cellular tissue; in this space is found the liquor of Cotunni.

The Cerebral Pia Mater (*Meninx interior*) may be divided into two parts, an external and internal. It covers the brain on all sides, is prolonged into its internal cavities, and dips down into the anfractuosities and depressions which are observed on its surface. Properly speaking, it is not a true membrane analogous to the organs known under that name. It is a cellular, loose, transparent web, without consistence, in which there ramify and cross each other in a thousand different directions a multitude of blood-vessels, more or less delicate, and more or less tortuous, and is only attached to the surface of the brain by the ramuscules of these vessels which penetrate into the substance of the latter organ.

External Pia Mater.—Above, the pia mater covers on each side the convex surface of the two hemispheres of the brain, sinks into their anfractuosities, is reflected in the great longitudinal fissure, prolongs itself over the upper surface of the corpus callosum, and descends upon its anterior extremity. Opposite the posterior extremity, it also bends downwards, and enters the third ventricle. Inferiorly, the pia mater covers on each side the anterior, middle, and posterior lobes of the brain, sinks into the fissura Sylvii, is reflected over the commissure of the optic nerves, after covering the membrane

which closes the third ventricle anteriorly, passes over the layer of grey substance which forms its floor, envelopes the infundibulum, invests the inferior surface of the cerebral protuberance, is engaged in the groove which separates it from the spinal marrow, on which it alters its nature in an insensible manner, to be carried over the lower surface of the cerebellum, and thence over the upper, as far as the posterior central fissure, by which it enters into the third ventricle. It sinks between the lobes of the cerebellum, and is engaged in all the anfractuosities which separate its concentric laminæ. By its *outer* surface the pia mater is in contact with and adheres to the arachnoid membrane, upon all the cerebral prominences, but is entirely isolated from it opposite the depressions into which it alone penetrates. They are even frequently separated by a rather large vacant interval, as may be easily seen in the fissura Sylvii, in the spaces which exist between the lobes of the cerebellum; also between the brain and the cerebral protuberance. These spaces are filled by the liquor of Cotunnius.

Its *inner* surface corresponds everywhere to the cerebral substance.

The internal pia mater will be best understood, and can only be seen, when the ventricles have been laid open during the dissection of the brain.

As the pia mater passes from one convolution to another, it adheres firmly to the free edge of each convolution by blood-vessels and filamentous tissue. At the margin of each it transmits a delicate membrane which invests the nervous surfaces; but in addition, it gives off a vascular fold or plexus, which, but for its vascular connexions with the brain, would be considered free. These descend into the bottom of all the anfractuosities or cavities, and may readily be drawn out entire. They are analogous to those larger folds which we shall afterwards find the pia mater transmits into the interior of the ventricles of the brain.

The internal portion of the cerebral pia mater.—To understand the arrangement of the portions of the pia mater which proceed into the ventricles of the brain, it is necessary to examine carefully the passage of the membrane into the interior by the great horizontal fissure leading into the lateral and third ventricles and the margins of the opening leading posteriorly into the fourth ventricle. When the pia mater approaches the margins of these openings, to which it adheres somewhat more firmly than elsewhere, it transmits a sufficiently dense membrane across the opening in both cases. By this means the lateral ventricles have no communication with the exterior of the brain, or with the sub-arachnoid space; and the same remark applies precisely to the posterior opening of the fourth ventricle. This is proved by what takes place in hydrocephalus internus, the effused fluid being strictly limited to the ventricles.

The membrane next transmits a delicate investing membrane inwards; this is the lining membrane of the ventricles; but in addition it sends in a process, to a certain extent free, which becomes the choroid plexuses and velum interpositum of the ventricles.

The tela choroidea, also called velum interpositum, is that portion of the pia mater transmitted into the third and into the lateral ventricles by the great cerebral fissure. Its form is that of a truncated triangle. On its margins are the choroid plexuses, which are but a portion of the same structure; mere vascular prolongations of that portion of the pia mater which passes between the thalami and the fimbriated bodies.

These plexuses are seen immediately on laying open the lateral ventricles; but to trace their connexion with the velum interpositum, and to display the manner in which the velum connects the plexuses to each other, the fornix must be cut across and reflected.

It will then be seen that the choroid plexuses and velum interpositum are but parts of one structure; that they receive numerous veins from the surrounding cerebral substance; and that they terminate anteriorly immediately below the anterior pillars of the fornix, in that place where, by thrusting a probe through from one lateral ventricle to the other, they may be made to communicate without destroying any cerebral structure. A few blood-vessels generally intercept the passage, which, however, is free in other respects.

The plexuses themselves are merely folds of the pia mater, similar to those I have already shown to pass into the bottom of the anfractuosities of the cerebrum. The veins which abound in them proceed to join the vena magna Galeni, which opens into the straight sinus.

A vascular membranous process, analogous to these choroid plexuses, is transmitted for a short way into the interior of the fourth ventricle.

APPARENT ORIGIN OF THE CRANIAL NERVES.

The student may now remove the vessels and membranes at the base of the brain, and examine the coming out of the roots of the cranial nerves or their *apparent origins*. These, examined from before backwards, are, 1st, the olfactory, whose apparent origin will be found about the commencement of the fissure of Sylvius; 2d, the optic; a considerable part of the tractus opticus is seen without dissection, also the chiasma or commissure, and the divided extremities of the nerves themselves; the 3d pair seem to come from the inner side and back part of the crura cerebri; the 4th may be traced upwards towards the deep parts of the brain; it comes from the valvule of Vieussens, which cannot be seen at present; the 5th comes out from the sides of the pons Varolii; the 6th, from the fore part of the medulla oblongata; the 7th (*portio mollis* and *portio dura*) seems to arise from the top of the corpora restiformia and floor of the fourth ventricle; the filaments or roots of the 8th (glosso-pharyngeal, nervus vagus, and spinal accessory) may be seen coming from the medulla oblongata between the corpora restiformia and olivaria, and the divi-

sion called spinal accessory, from the sides of the spinal marrow; the 9th, or hypo-glossal, from between the corpora pyramidalia and olivaria. The filaments by which these nerves communicate with the brain will be examined afterwards.

The BRAIN, *viewed from above*.—The brain may now be examined, either from above downwards or from below upwards; the first method will best suit the student during his first examination of this organ. Place the brain upon its base as situated in the body, and remove as much as possible the membranes from its convexity. This displays the *convolutions*. In the mixed races of Europe these convolutions are not symmetrical, but they probably are so in the Bosjesman (yellow-skinned African race), and even in the negro. It is possible that the same remark may apply to many *pure races* of men whether white or black, but it certainly does not apply to the now existing European family of men, which, to a certain extent, is a *mixed race*. A transverse section of the upper surface of the brain, made so as to take off about an inch of its substance, displays the two kinds of matter composing it, viz. the cortical, grey, or cineritious, and the white or medullary. The grey is probably the seat of the intelligence; the white or medullary, of motion. The grey is very vascular and not fibrous; the medullary or white substance is distinctly fibrous. A section a little above the level of the corpus callosum displays the *great hemispherical medullary centre;* a section on a level with the corpus callosum shows the *centrum ovale* of Vieussens.

The *corpus callosum* is a powerful transverse commissure connecting the hemispheres of the cerebrum to each other. In length it is about three and a half inches in the adult brain, which it is presumed the student first examines: this body presents a *superior surface*, an *inferior*, and two *extremities*. Upon the superior surface are observed the *raphe* and the arteries of the corpus callosum, which in the progress of dissection may have been removed. The inferior surface of the corpus callosum contributes to form the ceiling of the ventricles at the sides, but in the median line it is situated immediately above the *septum lucidum* and the *fornix*. These will be examined afterwards. Next lay open the lateral ventricles by cautiously scraping through the sides of the corpus callosum, and, having penetrated into them on each side, display them with the handle of a scalpel throughout their whole length.

The *lateral ventricles* thus shown are two in number, a right and a left; they communicate with each other below the fornix and through the *third ventricle;* but there is one point where the *lateral ventricles* communicate with each other beneath the fornix more directly than at any other part; this is towards the fore part of the ventricles, near the point where the corpora striata join the thalami nervorum opticorum; here the communication is very direct, and, as the fornix is narrow, it led the second Dr. Monro into the opinion, somewhat erroneous, that the *lateral ventricles* of the brain com-

municate *directly* with each other, whereas they only communicate *through* the third.

Fig. 213.*

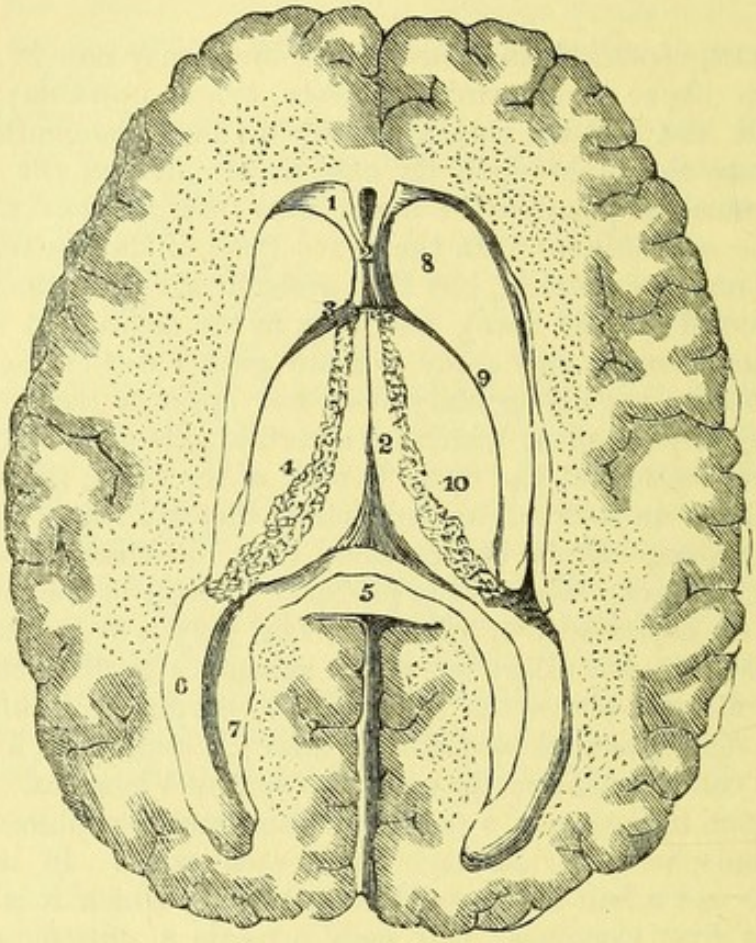

Next attend to the objects seen in each of the lateral ventricles: 1, the anterior horn (*cornu anterior*); 2, the corpus striatum; 3, the tenia semicircularis of Haller; 4, the thalamus nervi optici; 5, the posterior horn, digital or ancyroid cavity; 6, the hippocampus minor; 7, the choroid plexus. Now make an incision through the lateral mass of the hemisphere, following the fornix down towards the base of the brain: this will display, 8, the inferior horn of the ventricle; 9, the cornu Ammonis; and, 10, the fimbria, corpus fimbriatum or tenia hippocampi. He may now return to examine more at leisure some of the parts thus named.

Between the fornix and the corpora striata is the septum lucidum, forming here a partition between the ventricles; and upon the base of the ventricle may be seen the commencement of the veins of Galen.

* Fig. 213.—Interior of the brain, lateral venticles laid open.—1, a portion of the fornix; 2, septum lucidum; its ventricle has been laid open; 3, tenia semicircularis of Haller; 4, thalamus nervi optici, left side; 1—3, fornix, upper surface: it conceals in its present position the velum interpositum; 10, choroid plexus, right side; 6, 7, hippocampus and descending horn of the lateral ventricles; 8, corpus striatum; 9, tenia semicircularis, right side.

The hippocampus minor varies much in appearance and size; it is sometimes double, and occasionally absent. The choroid plexuses, which are seen as soon as the lateral ventricles have been sufficiently laid open, cannot be well understood until the corpus callosum and fornix have been cut through and raised up. These bodies are vascular, and have a granular appearance, but their uses are unknown. They are intimately connected with each other by the tela choroidea or velum interpositum situated beneath the fornix; and as they are continuous with the pia mater covering the external surface of the brain, they have been called the *internal pia mater*.

Next return to the median parts which lie between and over the ventricles; cut through the corpus callosum cautiously, and raise its anterior part from the septum lucidum; this usually tears off the upper part of the septum lucidum, and exposes its ventricle, also named the *fifth ventricle*. The upper margin of the septum lucidum is connected with the corpus callosum, the posterior with the fornix and its anterior pillars. It is formed of two lamellæ and a ventricle between them: the walls of this fifth ventricle are smooth and glossy, as in the other ventricles, but it does not communicate with them in the adult.

The removal of the corpus callosum exposes the fornix. This body is continuous above with the corpus callosum; it is of a triangular shape, and has four pillars, two anterior and two posterior. Below it is placed the velum interpositum or tela choroidea. Cut through the fornix about the middle, and reflect the divided portions anteriorly and posteriorly. This shows the inferior surface of the fornix, called *lyra, psalterium;* also the anterior and posterior pillars. The anterior pillars of the fornix may be traced downwards to the *corpora candicantia* in the base of the brain; the anterior commissure of the brain runs in front of these pillars. The *posterior pillars* of the fornix proceed backwards and downwards, to terminate by chiefly forming the medullary layer investing the cornu Ammonis and the corpus fimbriatum. Immediately below the fornix will be found the tela choroidea, a vascular membrane uniting the choroid plexuses to each other. If a probe be pushed backwards below the fornix, it will be found to pass to the exterior surface of the brain by an extended fissure (the great cerebral fissure); it is by this fissure that the pia mater enters so as to form the velum and the choroid plexuses. This fissure extends quite down to the base of the brain between the posterior pillars of the fornix and the thalami nervorum opticorum. Next cut through the back part of the fornix and corpus callosum mesially, and, separating the parts from each other, trace the velum interpositum and veins of Galen through the fissure to the exterior brain. The *velum* or *tela* is of a triangular shape; it lies in the third ventricle; its edges are continuous with the choroid plexuses, its anterior extremity is bifid, and it terminates below the narrowest part of the fornix. Posteriorly it is continuous with the external pia mater, and encloses partially within it the *conarium* or pineal gland. Raise up

the velum after dissecting the pineal gland, and, removing a good part of the membrane, expose the greater part of the *third ventricle* more fully.

This ventricle is placed upon the middle plane of the brain; it is a very narrow, oblong cavity, or rather fissure. In it we observe,—1st, the commissura mollis, connecting the two sides of the thalami nervorum opticorum together. This commissure varies much in shape and strength, &c., but I have only observed it to be once absent in many hundred brains examined with more or less care. The openings in front and behind the commissura mollis used to be called the anus and vulva. Anteriorly, this ventricle leads towards the infundibulum and tuber cinereum, which here contribute to form the floor of the ventricle. At the sides are the thalami nervorum opticorum; behind, the pineal gland, its peduncles, the corpora quadrigemina, posterior commissure of the brain; and beneath it, the aqueduct of Sylvius: this passage leads from the third to the fourth ventricle; it is, as it were, hollowed out of the substance of the isthmus, above which it is placed. We have already mentioned the pineal gland, its situation and pedicles; in it are usually found a few gritty particles or concretions.

The parts which next require examination are the *valvule* of Vieussens and the fourth ventricle. To examine these with advantage, push back cautiously the median part of the cerebellum as far as possible; this will display the valvule of Vieussens, which assists in forming the ceiling of the fourth ventricle. Cut through the median part of the cerebellum, and thus expose the posterior opening of the aqueduct of Sylvius and the cavity of the fourth ventricle: connected with it may be seen the calamus scriptorius; the posterior median fissure of the medulla oblongata; the origins of the portio mollis; the *crura cerebelli a medulla* (corpora restiformia); the *crura cerebelli a tuberculis*. The valvule of Vieussens connects these crura to each other, and extends from the posterior tubercles to the median part of the cerebellum. From its appearance it seems to belong to the peculiar formation of the cerebellum,—that is, its structure is more analogous to it than to the cerebrum. Finally, in the fourth ventricle are small choroid plexuses, and the ventricle is shut up at the back by the arachnoid membrane and pia mater, so that there is no communication between its cavity and the arachnoid and sub-arachnoid cavities of the spinal column.

The BRAIN, *viewed from below*.—The brain may now be turned upon its upper surface, and the parts seen at its base examined carefully. The *Rachidian bulb*, usually called in this country the *medulla oblongata*, terminates superiorly the spinal marrow, with which it is strictly continuous. It lies in the basilar fossa of the occipital bone, and unites the medulla spinalis to the cerebrum and cerebellum; its limits are well defined anteriorly, but posteriorly they are conventional; it is usual to fix its posterior limits where the decussation of its fibres takes place; anteriorly the transverse fibres of the isthmus

sufficiently point it out. It is thought that the position of the bulb varies a little during flexion and extension of the head. On the anterior surface of the bulb are—1st, the median fissure and *decussation of the fibres*, and to the right and left of this decussation and fissure are the *anterior pyramids*. Outside these pyramids are the *corpora olivaria*; these are shorter than the pyramids; thus they do not reach the isthmus anteriorly; whilst posteriorly a series of fibres (*arch-formed fibres*) limit them. Those of the arch-formed fibres which proceed along with the corpora restiformia to the cerebellum have been considered by Mr. Solly as proving the passage of motor fibres from the anterior columns of the spinal cord to the cerebellum. The filaments of the hypo-glossal nerves come out between the c. olivaria and pyramidalia; a deep fissure separates them from the corpora restiformia. When cut into, the corpora olivaria display an appearance called *corpus rhomboideum*. The posterior surface of the bulb has been already examined when speaking of the fourth ventricle. It is formed by the *corpora restiformia*, which are also called *inferior peduncles* of the *cerebellum;* but many divide the corpora restiformia into two parts on each side; to the cords which run up on each side of the posterior median fissure they give the name of *posterior pyramids*, or *posterior median columns*, and to the large lateral portions, proceeding chiefly to the cerebellum, the name of corpora restiformia is reserved. The lateral surfaces of the bulbs are chiefly remarkable for the *arch-formed* fibres so well described by Santorini and Rolando. I have seen them in one or two brains remarkably large and distinct, but they are also extremely irregular in number, &c.; they seem, as it were, to arise from near the anterior median fissure, and, ascending, divide into two bundles, one of which proceeds to join the anterior pyramids; the other joins the corpora restiformia; and probably in this way reach the cerebellum.

Whatever be the physiological views adopted in respect of the structure of the bulb, the following anatomical facts merit attention, at least until they be refuted by more careful examination.

The anterior *pyramids* are not formed out of the anterior columns of the medulla spinalis. The posterior fasciculi of the medulla separate into two divisions on a level with the bulb. The medullary fibres of the spinal marrow, having reached the bulb, divide into two bundles: the one *anterior*—this passes into, or becomes, the anterior pyramid, and proceeds ultimately to the cerebrum; the other *posterior*, the restiform body, proceeds almost entirely to the cerebellum. The fibres composing the anterior or cerebral fasciculi come chiefly from the deepest part of the medulla; those composing the cerebellar fasciculi come chiefly from the anterior fibres of the medulla.* A fasciculus innominatus has been lately described as commencing in the bulb; it is so situated as to form the anterior wall of the fourth ventricle, close to the median fissure, and it terminates in the *thalamus* and

* Thus there is a double decussation in the bulb. The fact bears on Mr. Walker's view of the functions of the columns.

restiform body. The existence of *olivary fasciculi* has always appeared to me extremely doubtful.

Next examine the *pons, isthmus*, or annular protuberance. Its limits are well defined. In volume its development follows that of the lateral lobes of the cerebellum. As the pons is usually, or at least at first, examined from below upwards, or commencing by its inferior surface, we shall follow this method here.

The inferior surface of the pons is composed of firm transverse medullary fibres, which go chiefly to form the crura cerebelli; whilst from the anterior part of the pons proceed the crura cerebri. These crura cerebri follow in their development the ratio of the cerebral hemispheres; their course is oblique and diverging, leaving a triangular space between them, filled by the substantia perforata, the mammillary eminences, and the tuber cinereum. We have already examined the superior peduncles of the cerebellum, the valvule of Vieussens, the aqueduct of Sylvius, and the tubercula quadrigemina; but as these parts in some measure belong to the system of the pons, the student should again, at this stage of the dissection, examine their relations with it and with each other. The *tubercles* are situated on the superior surface of the crura cerebri; from the anterior proceed fibres to the tractus opticus. The *corpora geniculata* (externum et internum) may now be best seen upon the posterior and inferior surface of the thalamus nervi optici.

Fig. 214.*

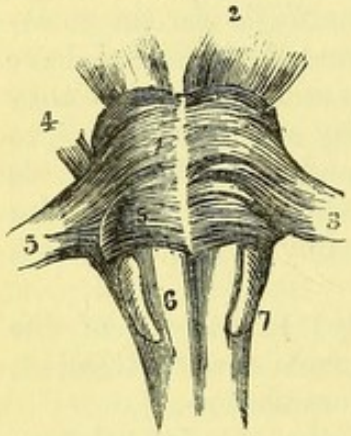

The *pons or protuberance*, when dissected, exhibits the following parts:—

1. The superficial layer of transverse fibres proceeding across to the hemispheres of the cerebellum. 2. Above these, but not in any very regular order, a series of *antero-posterior* fibres, which are the continuation of the anterior pyramids of the bulb, and which, traversing the pons from behind forwards, proceed into the crura cerebri. In the centre, also, of the isthmus, may be traced the fasciculus of the origin of the fifth pair of nerves. It is usual to divide the layers composing the pons into three stages or planes, which may readily be made out either by vertical or transverse sections of the pons and bulb.

The cerebellum, into which the dissector will by this time have traced the passage of its crura on each side, may now be considered more minutely. In respect to volume it is larger in man than in any other animal; its ratio to the cerebrum is as one to seven. On its

* Fig. 214.—Anterior and inferior surface of the pons.—1, the pons; 2, the left crus of the cerebrum, leaving the pons for the thalamus; 3, the crus of the cerebellum, left side; the *crus a ponte* ad cerebellum; 4 and 5 point to portions of the crus on the right side, and to the apparent origin of the seventh and fifth pairs of cranial nerves; 6, corpus pyramidale, right side; 7, olivary body, left side.

Fig. 215.*

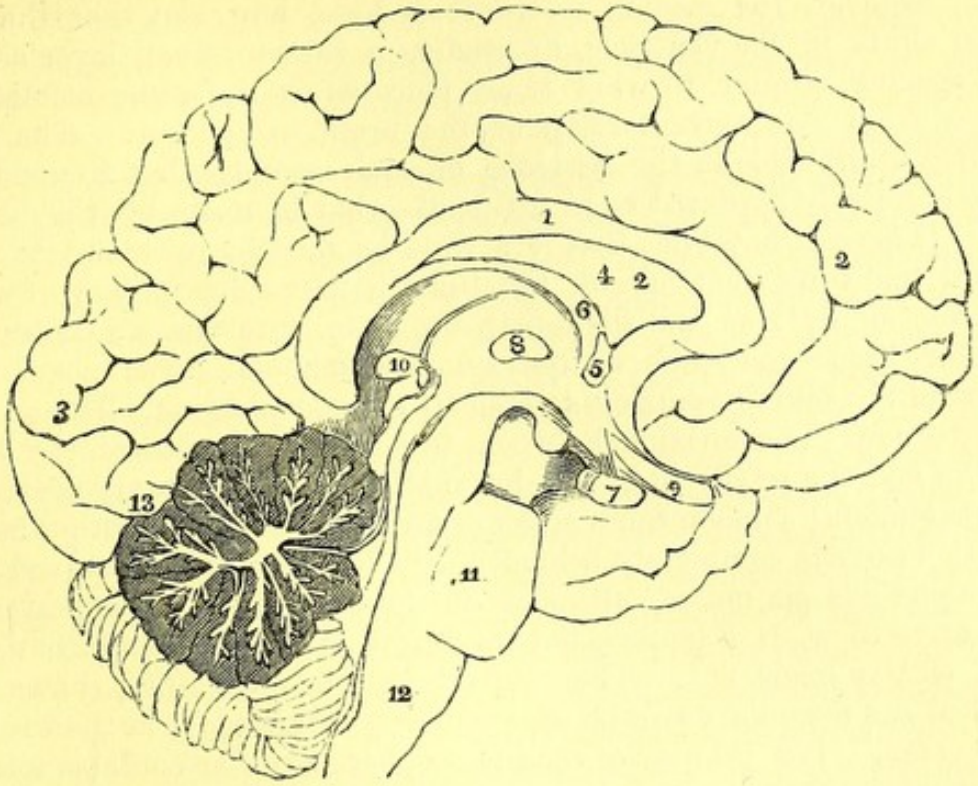

superior surface is the *vermis superior*, which is merely the superior surface of the median lobe of the cerebellum. There is also to be remarked the inter-hemispherical fissure, the hemispheres themselves, and, inferiorly, the *inferior vermis*. Externally the cerebellum has a very different appearance from the cerebrum; it presents fissures and laminæ; and about the middle of each hemisphere is the *sulcus horizontalis*, which penetrates very deeply into the interior of the organ. The laminæ composing the cerebellum are situated upon each other like the leaves of a book; but within these are lamellæ, which go from one lamina to another. Besides these parts, some anatomists, as Meckel, speak of lobes, or lobules, to be seen upon the surface of the cerebellum, and of a *lobule* of the *pneumo-gastric* nerve (flocculus), situated behind the pneumo-gastric nerve, but under the facial and auditory nerves.

The *fourth ventricle*, sometimes called the ventricle of the cerebellum, has been already examined. This ventricle is shut in behind by the arachnoid and pia mater, so as to cut off all communication between the cavity of the ventricle and the general *arachnoid* cavity (serous cavity) of the head and spinal column. M. Magendie thinks, however, that the fluid contained in the fourth ventricle may find its way into the sub-arachnoid space of the spinal cord, by two openings,

* Fig. 215.—Vertical section of the mesial parts of the brain, cerebellum, and pons.—1, the corpus callosum; 2, inner surface of the anterior lobe of the left hemisphere; 3, posterior lobe of the same hemisphere; 4, 2, septum lucidum; 6, 5, fornix; 8, soft commissure and cavity of the third ventricle; 10, pineal gland and corpora quadrigemina; 13, arbor vitæ of the cerebellum; 11, 12, pons and medulla oblongata; 7, 9, infundibulum and corpus albicans of that side.

which he states to exist between the inferior cerebellar arteries, and upon, or near, the median line. It is here, however, that the pia mater shuts in the ventricle, by sending a rather strong layer across the opening, similar to what takes place when the same membrane passes from one anfractuosity of the brain to another. There is nothing improbable in the existence of such openings, but to me they have uniformly appeared to be artificial—that is, made by the dissector. It is said, however, that if a fluid be forcibly injected into the lateral and third ventricles of the brain it will make its way, by the aqueduct of Sylvius and the fourth ventricle, into the sub-arachnoid cellular tissue and space of the spinal arachnoid. The pia mater forms in the fourth ventricle two small choroid plexuses. The precise structure of the connexion between the inferior vermis of the cerebellum and the restiform bodies has not been as yet clearly made out by anatomists; some authors speak of a fibrous lamella shutting in the fourth ventricle completely behind. I have only as yet observed the arachnoid and pia mater, although at the sides there are appearances indicative of such a lamina, but its limits and connexions have never been clearly made out. The cerebellum, when cut into, shows the cortical and medullary substances peculiarly arranged, so as to form the *arbor vitæ*. The interior of each hemisphere likewise contains a large *corpus rhomboideum*.

In conclusion, the dissector may re-examine with more care the encephalic division of the cerebro-spinal axis. It is undoubtedly a remarkable feature in the human organization; and although it be not true that the intellect in its most extended sense is in a direct ratio to the cerebral mass, yet below a certain standard as to bulk there is no intellect. The cerebral hemispheres, then, are remarkably large in man, and in all the races of men equally so; thus, if the different races *differ* in the degree of intelligence possessed by each, it is not owing to any inferiority as to volume of *brain*, but must be dependent on some other specific qualities of texture. The male brain is heavier than the female; it is also larger; it varies from a little less than two pounds to nearly four pounds; the average is under three pounds.

A few points upon the inferior surface of the encephalon still merit attention. Each hemisphere of the cerebrum inferiorly is divided into three lobes, an anterior, middle, and posterior; there is often a great want of symmetry between the hemispheres, and an obliquity in the great superior median fissure, but this does not necessarily imply an *obliquity* in judgment. The base of the brain must be examined very carefully after being cleared of its vessels and membranes. We have already spoken of most of the parts seen here; they are placed in the following order; the enumeration applies only to the base:—1, lower surface of the anterior lobe and great median fissure; 2, fissures of Sylvius; 3, behind these the inferior angles of the great central fissure. In the middle, the commissure of the optic nerves, the infundibulum and tuber cinereum, the corpora candicantia, the interpeduncular space or substantia perforata, the crura cerebri, annular protuberance, &c.

A horizontal section of the commissure of the optic nerves shows a distinct decussation of its fibres. The tuber cinereum, infundibulum, and the pituitary body seem to belong to the same system of parts; their uses are entirely unknown.

A tolerably accurate idea of the structure of the brain may be obtained by following the anterior pyramids as they pass from the bulb, through the protuberance, crura cerebri, thalami nervorum opticorum, and corpora striata, finally expanding into the cerebral hemispheres and their convolutions. The fasciculus innominatus of the bulb may be traced above the cerebral protuberance into the corresponding optic thalamus. From all the external parts of the thalami, fibres proceed in a radiating manner into the convolutions (corona radiata of Rei); most of the white fibres of the corpora striata proceed from the thalami. A difference of opinion exists as to the mode of connexion between the radiating fibres from the thalami and the corpora striata and those forming the corpus callosum, some supposing that they are continuous; they have generally appeared to me to be interrupted by grey matter. The brain of the young child is extremely soft; and previous to birth the distinction of its texture into grey and medullary is scarcely apparent. According to some, the brain attains its full weight and size as early as the fourth year. The texture of the brain of the negro has always appeared to me different from that of the European.

DEVELOPMENT OF THE BRAIN AND SPINAL CORD.

The parts which first begin to assume a form in the human embryo are the brain and spinal cord, usually called the cerebro-spinal axis. It commences in the germinal membrane in the form of a groove, dilated at one extremity and bounded by two ridges (laminæ dorsales); these unite at first in the middle, and thus give rise to a canal. The enlarged end is the cephalic, which afterwards divides into three vesicles; these form the cranial cavity, in which the encephalon is developed; the remaining part ultimately contains the spinal cord.

The spinal cord is then first a groove and next a canal. By the deposition first of the grey matter in this cord or canal, the groove is obliterated throughout its whole extent in the human species; but not so in many other animals.

The fissures on the surface of the spinal marrow and the cervical and lumbar enlargements appear very early. At first the cord occupies the whole length of the vertebral canal so that there is no cauda equina. But the vertebræ grow faster than the cord, and the cauda equina begins at the fourth month to show itself. At the ninth month the lower end of the cord coincides with the third lumbar vertebra; in the adult, with the upper part of the body of the second.

Fig. 216.*

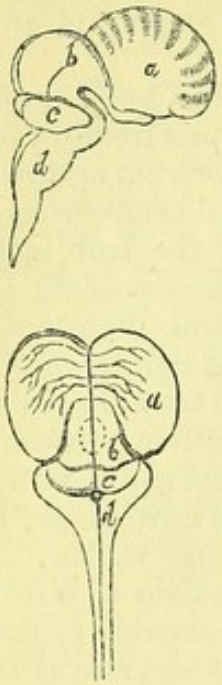

ENCEPHALON.

The three cephalic dilatations just mentioned contain three hollow vesicles of nervous matter; out of these is formed the encephalon. The anterior forms the principal mass of the hemispheres and corpora striata; the posterior part becomes the thalami and third ventricle. The second vesicle, or middle one of the three, forms the corpora quadrigemina above and the crura cerebri below; the aqueduct of Sylvius is the vestige of the cavity of the vesicle. The third vesicle forms, by its anterior portion, the cerebellum above and the pons Varolii below. Its posterior part continues open above; beneath it forms the medulla oblongata and the fourth ventricle.

By degrees the anterior vesicle preponderates and gradually overlays the others. The history of congenital malformations supports these views.

Two nervous tracts, proceeding from the spinal cord, spread out upon the floor of these cephalic vesicles. They probably represent the rudiments of the crura cerebri and the corresponding columns of the medulla oblongata.

About the third month the three elements of the medulla oblongata begin to be distinguishable; namely, the corpora restiformia, pyramidalia, and olivaria.

At first the corpora quadrigemina are comparatively very large; that is, the human encephalon at this time resembles in structure that of animals lower in the scale. These, together with the thalami, are then at first sacs of nervous matter which gradually fill up so as to become solid, leaving clefts between them. The commissura mollis makes its appearance about the ninth month; I never saw it absent in the adult but once. The infundibulum shows itself very early; its nature is not yet understood. At the end of the third month the pituitary body is comparatively a large soft mass; its nature is not at all understood. It seems to terminate anteriorly the primitive medullary tube.

As the hemispheres of the cerebrum extend they gradually approach each other superiorly and thus form the lateral ventricles. About the fourth month the convolutions and sulci appear. These hemispheres come at last to conceal, by their growth, the corpora striata, thalami, &c.; in the fissure which always separates them appears the corpus callosum about the end of the third month. The formation of the fornix is similar; they both commence in front and extend backwards.

* Fig. 216.—Figures to show the form of the brain in the early human embryo, twelfth week, side view.—A. *a*, cerebrum; *b*, corpora quadrigemina; *c*, cerebellum; *d*, medulla oblongata. The same letters apply to Fig. B.

The grey and white matter of the brain may be distinguished from each other very early, but not wholly by their colour. The membranes are distinguishable at a very early period.

The mode of development described above, in addition to its being based on direct inspection, is further supported by comparative anatomy and by teratology, or the examination of abnormal brains, whether human or otherwise.

The male adult brain has an average weight of 49½ ounces; the female, of 44 ounces. The maximum has been stated for the male at 65 ounces: for the female, 56 ounces: the minimum for the former at 34 ounces; for the latter at 31 ounces. These weights have a reference, it is to be presumed, solely to those whose intelligence during life was at least sufficiently good. This difference between the male and female brain holds good at all ages, even at birth; they differ also in form at a very early period of life.

The brain is thought by many to reach its maximum weight at seven years of age; but it is more than probable that in most it continues to increase in weight until near puberty.

The brain of the illustrious Cuvier weighed 64 ounces; that of Dr. Abercrombie 63 ounces. Idiots' brains are usually very small, weighing only 19, 22, or 25 ounces. But the size of the brain bears no constant relation to the *genius* of the person.

DEVELOPMENT OF THE MEDULLA SPINALIS.

In the very early condition of the fœtus, the medulla spinalis occupies as such the entire length of the vertebral column or nearly so. But as the vertebræ grow faster than the medulla, they lose this relation to each other, and speedily, by this arrangement, the cauda equina is formed; that is to say, the inferior spinal nerves have to descend within the canal for a considerable distance to reach the intervertebral foramina, whether lumbar or sacral, by which they have to pass outwards. These nerves so collected, together with the terminating membranous filament of the medulla spinalis, constitute what the older anatomists called the cauda equina. The term should be discarded from anatomical works.

The adult medulla spinalis measures from 15 to 18 inches. The enlargements seen upon it correspond to the origins of the nerves supplying the upper and lower extremities.

The central cord is not a nerve, but a kind of ligament; a small vein very generally accompanies it.

THE SPINAL NERVES.

Comparatively speaking, the anatomy of these nerves is less complex than that of the cranial, and may be studied before the others

with advantage. Indeed, during his dissection of the muscles, the student must have met with most of them; and he may therefore think that he knows them practically; but this he will find to be a mistake, for, until these nerves shall have been dissected and examined systematically, their study in fragments, however practical, will never avail him in *practice*.

The spinal nerves have double roots, a *motor* and a *sentient*. The posterior root is now almost universally admitted to be the *sentient*;* the anterior is held to be the *motor*. On the posterior roots of all these nerves there is a ganglion, a structure not known to exist on any purely motor nerve.† The anterior roots have no such ganglions, and from this circumstance alone it might have been conjectured, independent of all experiment, that the anterior roots of the spinal nerves must be motor, and the posterior sentient.

There are 31 pairs of spinal nerves, namely, 8 cervical, 12 dorsal, 5 lumbar, and 6 sacral.‡ They all leave the vertebral canal by the foramina conjugalia, or by openings corresponding to these. They arise from or terminate in the spinal marrow by a double linear series of roots or filaments—the anterior or motor; the posterior, ganglionar, or sentient. Beyond the ganglions, that is, peripherally, the anterior and posterior roots unite inseparably, mingling their fibres in such a manner that a motor filament can no longer be recognised from a sentient; and the nervous trunk resulting from this union thus combines all the filaments from both roots, mechanically at least.

From this trunk (I speak now of what is common to all, the spinal nerves) there usually proceed three sets of branches,—

1. A posterior spinal. 2. An anterior spinal. 3. Branches to join the ganglions of the great sympathetic. §

These characters are common to all the spinal nerves, the sub-occipital or first pair seldom offering any exception.

On it the ganglion is said to be frequently wanting; but in every careful dissection I have made in order to determine this question, I have always found the ganglion present.

Spinal Nerves.—*Descriptive anatomy.*—To those who have dissected and studied the muscles, no directions need be given to enable them to dissect and display the following system of nerves.

With reference to *regions*, the peculiarities of the spinal nerves are,—In the *cervical* spinal nerves the volume of the *posterior* roots is to the anterior as three to one: they increase generally from the first pair to the fifth, and maintain that increase to the eighth. The first pair has the posterior roots fewer than the anterior.

* Mr. Walker, I believe, still doubts this. † Johnson.

‡ Or 5 sacral and 1 coccygeal.

§ In 1820-21, and subsequently, I made great efforts to ascertain to which of the roots these branches could be traced. They seemed to me to arise from or to join both.

The dorsal pairs of spinal nerves, with the exception of the first (which ascend to join the brachial plexus), are nearly equal in volume: the roots are slender.

The lumbar and sacral nerves exhibit a great number of roots or central filaments of communication with the spinal marrow. The length of them within the vertebral and sacral canals is also remarkable; these roots form the cauda equina. It has even been said that some filaments of the anterior roots pass through the corresponding spinal ganglions, but I have not been able distinctly to verify this by dissection.

I. SPINAL NERVES, *posterior branches*.—These branches are to be met with on the posterior regions of the trunk.

1. The posterior branches of the cervico-spinal nerves are met with chiefly between the complexus and semi-spinalis colli, but their cutaneous branches occur, of course, first. The posterior branch of the first, leaving the column by the space between the occipital bone and atlas, close to the vertebral artery, and under the rectus capitis posticus major, ultimately supplies with branches the rectus major and minor, obliquus superior and inferior, and by a ramus anastomoticus assists in forming a sort of plexus—*the posterior cervical plexus*. It sends no branch to the complexus major.

Second pair of cervico-spinal nerves; posterior branch.—This, the largest of all the posterior branches of the cervical nerves, passes under the margin of the inferior oblique, and proceeds upwards to the occipital region and the scalp. It traverses the great complexus and trapezius, and follows partly the course of the occipital artery. It supplies branches to the great oblique, complexus major, splenius, trapezius, and finally to the hairy scalp of the occipital region. The occipital muscle is said not to receive any branches from this nerve, but to be supplied by the facial.

Third cervical pair.—The posterior branch of this pair of nerves leaves the canal between the transverse processes of the second and of the third cervical vertebræ, and proceeds transversely inwards between the complexus and semi-spinalis colli.

Near the inner margin of the complexus it divides into two cutaneous branches, one ascending, the other horizontal.

Thus the first, second, and third pairs of cervical nerves, by their posterior branches, form occasionally a wide plexus, already alluded to, situated under the complexus, close to its external attachment; but this plexus is neither remarkable nor of constant occurrence.

The *posterior branches* of the fourth, fifth, sixth, seventh, and eighth cervical pairs are much smaller than the preceding, and decrease from the fourth to the seventh. They send branches to the semi-spinales colli, and dorsi, and to the integuments.

DORSO-SPINAL NERVES, *posterior branches*.—Those of the first pair have much the same distribution as those of the last cervical;

the posterior branches of the second, third, fourth, fifth, sixth, seventh, and eighth pairs greatly resemble each other. They all leave their respective foramina conjugalia, external to the semi-spinales muscles, and there divide each into two branches—one, external and muscular, to the sacro-lumbalis and longissimus dorsi; the other, musculo-cutaneous, which, after reaching the integuments close to the spinous processes, ascend towards the scapular region.

The *posterior* branches of the ninth, tenth, eleventh, and twelfth dorso-spinal nerves precisely resemble those of the loins. They have no musculo-cutaneous branch like the preceding; they supply the abdominal walls in this region.

The *posterior* branches of the *lumbar* spinal nerves diminish gradually from above downwards, the last being very small; they supply the adjoining soft parts.

Sacro-spinal Nerves.—The *posterior* branches of these nerves are extremely small, bearing no proportion to the size of the posterior sacral foramina. They decrease also in size, and supply the semi-spinales lumborum muscles and adjoining integuments.

II. Spinal Nerves, *anterior branches*.—These branches are the true continuation of the nerves, and supply,—

1. The lateral and anterior parts of the trunk. 2. The pectoral and pelvic extremities.

Besides, these nerves form two great plexuses, namely, the cervico-brachial and lumbo-sacral.

Some view these as composing four plexuses, viz., cervical, brachial, lumbar, sacral. This arrangement, though rather artificial, is convenient for description.

*Cervical plexus.**—The *anterior* branch of the first cervical pair joins that of the second, which subdivides into two branches—an ascending, to join the preceding one; and a descending, which unites with the anterior branch of the third cervical pair. This is much larger than the preceding, and chiefly forms the cervical plexus.

The situation of the plexus so formed is behind the upper part of the sterno-mastoid muscle, corresponding to the *foramina conjugalia*, between the second cervical vertebra and the third. It divides into an ascending and a descending branch. Its ascending branch bifurcates on the posterior margin of the sterno-mastoid muscle, and, anastomosing by one or two filaments with the second cervical pair, forms the mastoid nerve and the superficial cervical and auricular nerves.

The anterior branch of the fourth cervical pair, besides furnishing the phrenic, anastomoses, but not directly, with the third cervical pair; and thus these four, by their anastomosing, form the cervical plexus. Generally, also, the fourth pair unites by a small branch with the fifth.

This plexus is situated on the lateral and anterior part of the first four cervical vertebræ, under the posterior margin of the sterno-

* See Fig. 218, p. 554.

mastoid muscle, external to the internal jugular vein, between the rectus capitis anticus muscle and the cervical insertion of the splenius and levator anguli scapulæ.

A deep layer of the cervical fascia invests it closely. The branches arising from it are as follows:—

1. *Anterior*	The superficial cervical.
2. *Ascending*	The great mastoid.
	The small mastoid.
	The auricular.
3. *Descending*.	Superficial.
	Supra-clavicular.
	Supra-acromial.
4. *Profound Accessory of Willis.*	The inner descending branch.
	The phrenic.
	Anastomotic branch to the spinal.
	Branch to the trapezius.
	,, rhomboid.
	,, levator anguli.

This last comes as often from the brachial plexus.

The SUPERFICIAL CERVICAL (*Superficialis colli*) crosses the external surface of the sterno-mastoid, beneath the latissimus colli and external jugular vein. It supplies the integuments of the chin and of the space immediately beneath the lower jaw, and sends an anastomosing branch or two to the facial.

The *great mastoid*, the small mastoid, and the auricular branches of the cervical plexus, are cutaneous nerves. Their names suggest their course.

The *supra-clavicular* and *supra-acromial* branches are also essentially cutaneous nerves; they supply the integuments of the shoulder and upper part of the chest. Inferiorly, near to their destination, they are superficial, and cross the clavicles; but superiorly, they, of course, are situated deeper, beneath the cervical fascia and between the omo-hyoidei and scaleni muscles.

The *inner descending branch* is usually not much attended to, but is yet a remarkable branch. There are not unfrequently two inner descending branches; but whether single or double, they form, with the *descendens noni* (an offset of the ninth cranial pair of nerves), a *plexus—plexus* of the *descendens noni*. From the convexity of this plexus, filaments arise, supplying the sterno-hyoidei, omo-hyoidei, and sterno-thyroidei muscles. The plexus crosses in front of the deep jugular vein.

The second deep branch arising from the *cervical plexus* is the phrenic.

The *phrenic* is considered by many as the terminating branch of the cervical plexus. It receives its principal filament from the anterior branch of the fourth cervical pair of nerves; a slender branch joins it from the third; two or three minute branches from

Fig. 217.*

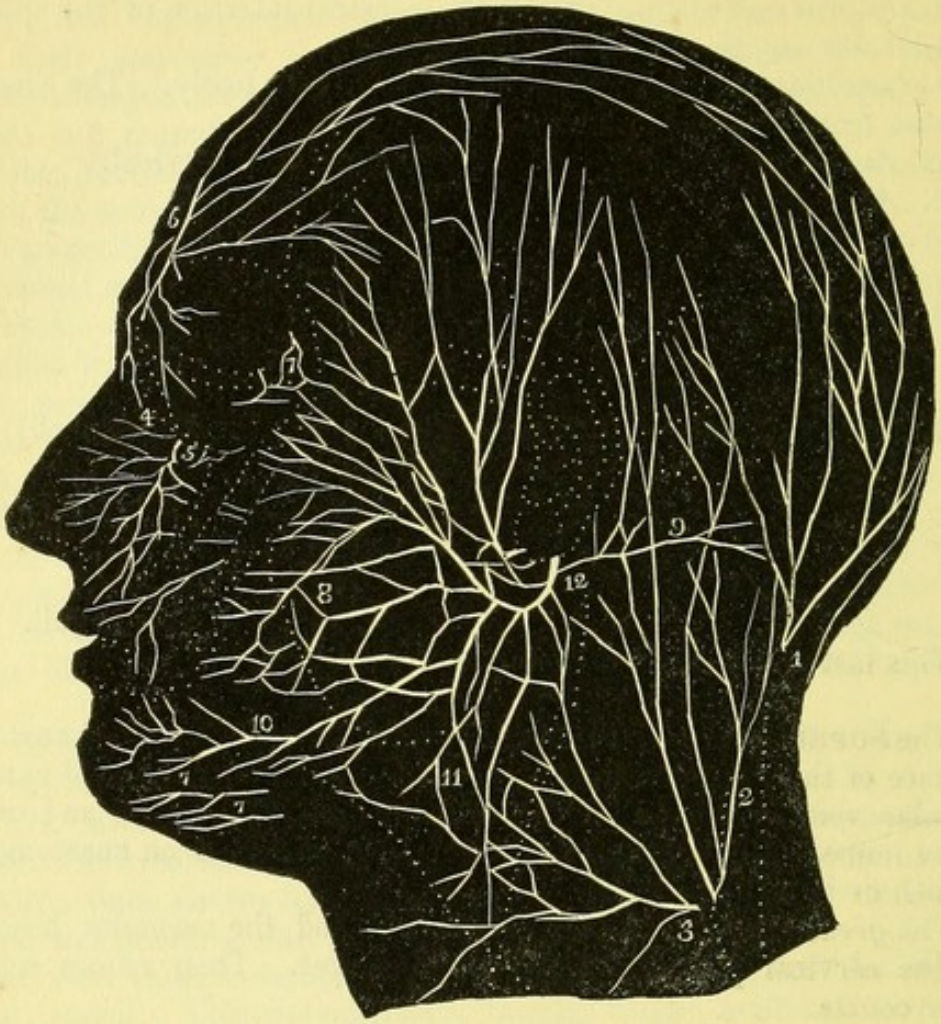

the brachial plexus join it lower down, at the lower part of the neck, or even in the thorax. Sometimes its volume is augmented by a twig of the descendens noni, or of the plexus which terminates it, and by a filament of the superior cervical ganglion.

Thus formed in a more or less variable manner, difficult to describe with precision in the inextricable interlacement which forms the plexus, the phrenic nerve descends along the fore and lateral part of the neck, between the rectus capitis anticus major and scalenus anticus, then over the anterior edge of the latter, giving off some

* Fig. 217.—I. Nerves of the face; terminating branches of the portio dura and of the fifth pair of nerves.—1, 2, 3, posterior branches of the second, third, and fourth pairs of cervical nerves distributed to the muscles and integuments of the back of the neck and head; they anastomose with branches of the facial nerve. II. Fifth pair.—4, 5, infra-orbitar branches of the superior maxillary; 6, supra-orbitar branches of the ophthalmic or first division of the fifth; 7, terminating cutaneous filaments of the third division of the fifth, the inferior maxillary branch; 12, the *facial nerve* passing through the parotid; 9, a branch anastomosing with the posterior cervical nerves; 8, 10, 11, motor branches of the portio dura, supplying the muscles of expression; but some filaments run to the integuments of the scalp, and many anastomose on the face with the infra-orbital branches of the fifth; others with branches of the inferior maxillary.

delicate filaments to them. Crossing diagonally the scalenus anticus from the outer to the inner side, it communicates at the lower part of the neck with the inferior cervical ganglion by one or two other filaments, then penetrates into the thorax, between the subclavian artery, which is behind, and the subclavian vein, which is in front, and, proceeding inwards, forwards, and downwards, crosses the internal mammary artery and enters the anterior mediastinum; there it sends ramifications to the thymus gland. It then passes over the trunks of the pulmonary vessels, and, gliding in front of the root of the lung, descends as far as the diaphragm, between the pleura and the lateral parts of the pericardium, to which it is closely attached, without, however, supplying any filament either to it or to the lung.

The phrenic nerve of the right side, which is more vertical and placed more anteriorly than the left, divides, before entering the diaphragm, into six or seven filaments, which separate from each other and communicate frequently together. They first spread out ramifications upon the upper surface of the muscle; then the inner filaments, closely connected with the vena cava inferior, pass by the aperture which gives passage to that vessel, to its inferior surface, to which they are partly distributed, partly also losing themselves in the cœliac plexus. The other filaments, which are longer and directed forwards, backwards, and inwards, perforate the aponeurosis of the diaphragm, accompany the diaphragmatic arteries and veins, and send several filaments to anastomose with the cœliac plexus and the stomachic filaments of the pneumo-gastric nerve.

The left phrenic nerve, which is posterior to the preceding, turning over the apex of the heart, and consequently longer also than it, furnishes ramifications to the convex surface of the diaphragm, perforates it after being divided into several filaments, is partly expanded over its concave surface, partly over the œsophagus, and gives anastomosing filaments to the solar and cœliac plexuses. It also furnishes filaments to the crura of the diaphragm, and to the supra-renal capsules, and sends some to anastomose with those of the opposite nerve.

It is not uncommon to see the terminating twigs of the phrenic nerves presenting more or less numerous enlargements resembling ganglia.

Finally, the cervical plexus transmits deep muscular branches to the trapezius, levator anguli scapulæ, and rhomboidei muscles. These anastomose with the spinal accessory of Willis.

Brachial Plexus (*Plexus nervorum brachii*). — The anterior branches of the fifth, sixth, seventh, and eighth pairs of cervical nerves, together with the larger portion of the anterior branch of the first pair of dorso-spinal nerves, compose the brachial plexus. All these nerves are of large size.

Thus formed, the plexus extends from the lateral and inferior part of the neck to the axilla.

Fig. 218.*

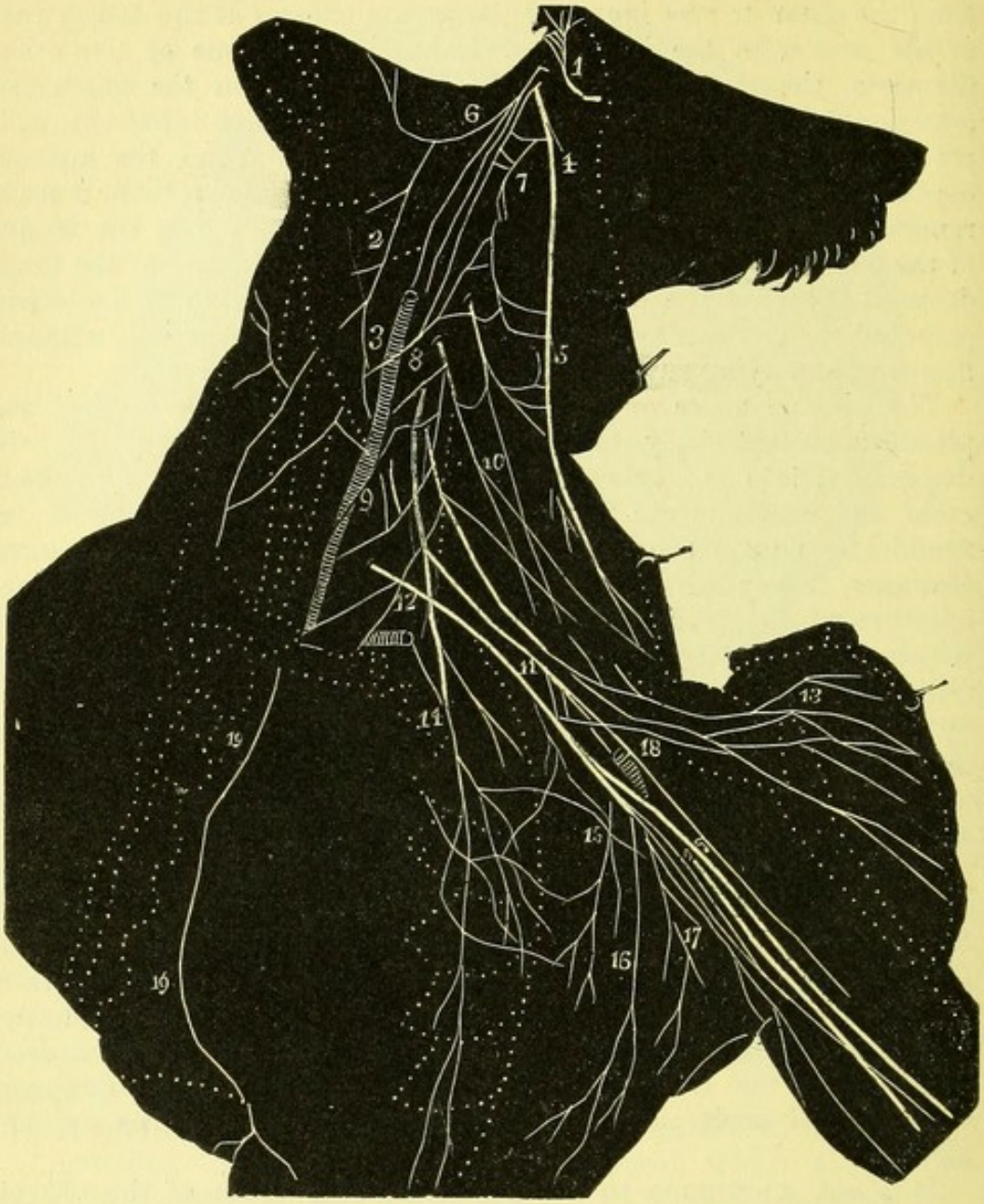

Formed by the union and interlacement of the anterior branches of the last four cervical nerves and first dorsal, the brachial plexus extends from the lateral and inferior part of the neck to the axilla,

* Fig. 218.—Diagram showing the position and formation of the cervical and brachial plexuses of nerves.—1, a portion of the portio dura; 6, ninth pair or hypoglossal; 2, 3, 8, descendens noni, showing the plexus it forms with branches of the cervical nerves; 4, 5, spinal accessory; 7, communicating branches with the ninth; 8, 9, anterior branches of the fifth, sixth, seventh, and eighth pairs of cervical nerves, forming, with a part of the first dorsal, the brachial plexus; 10, superficial branches of the brachial plexus; 11, 18, 13, nerves to the pectoral and subclavian muscles, also to the integuments; 15, 16, 17, subscapular nerves; these and the preceding come from the brachial plexus; 12, 14, nerve of the serratus magnus; 19, phrenic nerve, left side; a portion of the common carotid, subclavian, and axillary arteries, are laid down in the diagram.

where it divides into several branches, which are distributed to the arm. In forming it, the anterior branches of the above-mentioned nerves proceed in the following manner: those of the fifth and sixth cervical nerves descend obliquely outwards, and, after a course of about an inch and a half, unite into a single trunk, which preserves the same direction. Those of the eighth cervical and first dorsal nerves also unite and form a trunk, which becomes nearly horizontal. Lastly, that of the seventh cervical nerve proceeds for a long time between these two trunks in an isolated manner; but, opposite the first rib, it unites to both.

Thus, the brachial plexus, divided into three distinct portions at its origin, afterwards forms a large flat bundle. in which the nervous filaments are mingled and interlaced in an inextricable manner.

The brachial plexus is situated at its commencement between the scaleni muscles, the anticus lying upon it so as to cover it below over a considerable extent, and leaving it almost bare above. It is then immersed in the subclavicular adipose tissue, passes between the subclavius muscle and the first rib, is applied upon the upper portion of the serratus magnus, and is lodged in the upper part of the axilla. Until it reaches the latter place it remains situated behind the axillary artery and vein; but then the different branches which terminate it surround the artery on all sides, and form a sort of sheath for it; while the vein, which had always been more superficial, retains its position.

The branches furnished by the brachial plexus have been arranged into—1, thoracic; 2, supra-scapular; 3, infra-scapular; 4, brachial.

The following offers a more minute arrangement of the nerves sent off by the brachial plexus.

I. Those which the Plexus furnishes above the Clavicle.

1. A branch to the subclavius: this branch anastomoses with the phrenic.
2. Branch to the levator anguli scapulæ: this comes especially from the cervical plexus.
3. Branch to the rhomboid.
4. The posterior external thoracic to the serratus magnus (external respiratory nerve of Charles Bell).
5. The supra-scapular to the supra- and infra-spinati muscles.
6. The superior subscapular branch.

II. Branches which the Plexus furnishes on a line with the Clavicle.

The external anterior thoracic nerves.—1, great pectoral; 2, small pectoral.

III. Those which the Plexus sends off in the Axilla.

1. The circumflex or axillary, distributed to the deltoid.
2. The subscapular branches, comprising—

a. Branch to the latissimus dorsi.

b. Branch to the teres major.

3. The inferior subscapular nerve is the only branch which proceeds from the front of the plexus.

IV. The terminating Branches are five in number.

1. Internal cutaneous and its accessory.
2. Musculo-cutaneous, or perforans Casserii.
3. Median.
4. Musculo-spiral, or radial.
5. Ulnar.

First Division.—1. *The nerve of the subclavius muscle* is a small but constant nerve, arising at the upper part of the plexus (fifth cervical), passing in front of the subclavian artery, and entering the subclavian muscle at an angle perpendicular to the course of the muscle: it furnishes a small branch to the phrenic.

2. *Branch to the levator anguli scapulæ.*—This arises as often from the fourth cervical as from the fifth, thus belonging ultimately to either plexus. Passing behind the posterior scalenus, it enters the muscle by its deep aspect; it passes through the muscle, and reaches the surface of the rhomboid.

3. *Branch to the rhomboid.*—Arising also from the fifth, occasionally, in common with the nerve of the serratus magnus, it passes between the posterior scalenus and levator anguli scapulæ, then under the levator, and thus reaches the rhomboid. One of its filaments traverses this muscle, and proceeds to the trapezius.

4. *The nerve of the serratus magnus* is remarkable for its length, but not for any physiological properties. It comes from the fifth and sixth cervical pairs, proceeds vertically downwards behind the brachial plexus and axillary vessels, in front of the scalenus posticus, and thus reaches the top of the serratus muscle to which it is distributed.

5. *Supra-scapular branch:* nerve of the supra- and infra-spinati muscles.—This nerve reaches its destination by passing beneath the trapezius and omo-hyoideus, whose direction it follows, reaching the notch in the cervical margin of the scapula, and, passing through it beneath the ligament (the artery and vein passing over it), enters the supra-spinatus muscle; it gains the fossa infra-spinata, and corresponding muscle, by passing in front of and close to the spine of the scapula, being here protected by a fibrous band sometimes called the ligament of the neck of the scapula.

6. *The superior subscapular nerve* is very small: it enters the superior margin of the subscapular muscle.

Second Division.—The anterior thoracic nerves are two in number:—

1. *Branch to the great pectoral muscle.*—This nerve reaches the muscle by passing between the subclavius muscle and vein.

2. *The branch to the pectoralis minor* requires merely to be mentioned. It is situated behind the axillary artery, and, besides supply-

ing branches to the small pectoral muscle, it also sends some to the larger muscle of that name.

THIRD DIVISION of the nerves given off by the axillary plexus, comprising—

1. *The axillary or circumflex.*—This is a large nerve detached from the back of the plexus. The subscapular muscle separates it from the articulation. It winds suddenly around the surgical neck of the humerus, and, being reflected from below, upwards, enters the deltoid by its concave aspect: it is distributed chiefly to that muscle. I have seen the nerve partially torn through in some cases of dislocation of the shoulder.

2. *Subscapular nerves*, divided into—1, nerve to the latissimus dorsi; 2, nerve to the teres major; 3, inferior subscapular nerve.

These nerves are situated chiefly on the subscapular muscle; they require no particular description, though important in surgical anatomy.

The FOURTH DIVISION contains the terminal or brachial nerves.

I. INTERNAL CUTANEOUS NERVE.

(*Nervus cutaneus medius.*)

It is the smallest of the six branches which terminate the brachial plexus, from the inner and lower part of which it comes, being furnished almost exclusively by the first dorsal nerve and the last cervical. It descends vertically under the brachial aponeurosis, along the inner surface of the arm, near the basilic vein, which is sometimes placed before, sometimes behind it, and sometimes on its side.

At first deeply concealed in the cellular tissue of the axilla, between the median and ulnar nerves, it becomes more superficial as it descends; but it only gives off some very slender filaments, which lose themselves in the cellular tissue and skin, and of which one directs itself towards the inner condyle. It is near this tuberosity, and sometimes sooner, that the trunk of the nerve itself divides into two branches, an external and internal.

External branch.—Smaller than the other, it runs along the edge of the biceps muscle, almost immediately pierces the brachial aponeurosis, and directs itself obliquely downwards and forwards, placed above the median nerve, which it accompanies as far as the lower part of the biceps muscle; then, traversing the middle of the bend of the arm, it remains on the surface of the aponeurosis of the fore-arm until near the wrist, where it terminates by twigs, which are distributed to the integuments, but which cannot be traced beyond the annular ligament of the wrist. In passing over the fore-arm it gives off, on either side, filaments, which may be distinguished into *radial* and *ulnar*, and which proceed obliquely downwards, to be distributed to the integuments of this part of the upper extremity, anastomosing, on the one hand, with the twigs of the external cutaneous nerve, and, on the

other, with those of the internal branch of the internal cutaneous nerve itself.

Internal branch.—This may be regarded as a continuation of the trunk; it continues to descend upon the brachialis internus muscle, accompanied by the basilic vein. Near the inner condyle it divides into two twigs: of these the *anterior* directs itself obliquely over the anterior muscles of the fore-arm, passing sometimes behind, sometimes before, the median basilic vein, and then furnishes, especially from its inner side, several filaments, which descend very far behind the fore-arm and ramify in its integuments; some of them extend as far as the inner edge of the hand. The *posterior* turns backwards under the condyle, descends along the ulna, and terminates by a great number of filaments, which may be followed in the integuments as far as the back of the hand, and to near the little finger.

II. EXTERNAL CUTANEOUS NERVE.

(*Nervus perforans Casserii, seu musculo-cutaneus.*)

A little larger than the preceding, but smaller than the other brachial nerves. It arises from the outer part of the plexus, and comes in particular from the fifth and sixth cervical nerves, which, after forming a single trunk as far as the common origin of the biceps and coraco-brachialis, divide anew into two divergent cords, the inner of which passes in front of the axillary artery to contribute to the formation of the median nerve, while the outer constitutes the nerve of which we here speak.

This nerve descends at first obliquely outwards behind the coraco-brachialis muscle, then passes through it, after supplying it with a very slender filament, which may be traced until its insertion into the humerus. After this it descends along the inner and fore part of the arm, between the brachialis internus and biceps muscles, giving off several small twigs to them. One of these twigs, which is larger than the others, descends inwards, divides into two filaments, and proceeds as far as the lower extremity of the brachialis internus. Another follows the same direction, and communicates with the median nerve towards the lower part of the arm. The external cutaneous nerve then disengages itself on the outside of the tendon of the biceps, traverses the middle of the bend of the arm under the median cephalic vein, and descends along the fore and outer part of the fore-arm, between the aponeurosis and the skin. When it has arrived near the wrist it divides into two branches, an outer and an inner, and so terminates.

The *outer branch*, which is larger than the other, sends a twig over the back of the hand, which is more or less prolonged upon the fingers. It then descends behind the thumb, and upon its outer side, giving some filaments to the fore-finger. Several of its ramifications anastomose with those of the radial nerve.

The *inner branch* descends upon the muscles of the thumb, in the

palm of the hand, and there subdivides into a multitude of filaments, which may be traced upon the fingers.

MEDIAN NERVE.

(*Nervus medianus.*)

This is the largest nerve of the brachial plexus, from which it arises, behind the internal cutaneous nerve, and between the ulnar and external cutaneous nerves. The seventh and eighth cervical nerves, united to the first dorsal, form its principal origin, to which is joined a branch of the common trunk of the fifth and sixth cervical nerves, which forms, with all the other roots, a kind of nervous interlacement around the axillary artery.

After thus originating, the median nerve descends a little outwards, behind the inner edge of the biceps and internally to the brachial artery. It arrives at the bend of the arm without giving off any ramifications, and traverses it in its middle part, internally to the biceps and under the median vein. It then sinks behind the anti-brachial aponeurosis, between the brachialis internus and pronator teres, passes between the two origins of the latter muscle, and proceeds along the fore-arm, between the flexor digitorum sublimis and flexor profundus, between whose tendons it becomes apparent below. Lastly, it passes along with them under the anterior annular ligament of the carpus, adheres to them by a very delicate membranous cellular tissue, becomes broader and thicker than it was before, and, on arriving in the palm of the hand towards the upper part of the metacarpal bones, divides into several twigs, which are distributed to the fingers, and which are distinguished numerically, counting from without inwards.

As it proceeds between the brachialis internus and pronator teres, the median nerve gives off its first twigs to the pronator teres, flexor carpi radialis, palmaris longus, flexor carpi ulnaris, flexores digitorum sublimis and profundus, and flexor longus pollicis. They penetrate by the inner surface of most of these muscles, and are lost in their fleshy fibres.

Interosseous twig.—Larger than the preceding, and arising under them, this twig separates from the median nerve at a very acute angle, and gives off, at its origin, a filament, which goes to the flexor sublimis, in which it loses itself.

The interosseous nerve then passes between the two flexor muscles of the fingers, gains the anterior surface of the interosseous ligament accompanying the artery of this name, and gives off, laterally, several filaments, which are destined for the flexor digitorum profundus and flexor longus pollicis. Arrived at the upper edge of the pronator quadratus, it dives under it, giving it some filaments, and then emerges by the inferior aperture of the interosseous ligament to be expanded over the back of the hand, where it furnishes a great number of ramifications, which become superficial, but do not extend as far as those of the interosseous artery which they accompany.

After giving rise to the interosseous twig, the median nerve not unfrequently furnishes another, which descends inwards, follows the course of the ulnar artery, and anastomoses with the ulnar nerve. It then sends some irregular filaments to the flexors of the fingers and the flexor carpi radialis; but, at the lower part of the fore-arm, there separates from it the *cutaneous palmar twig*, which is of considerable size, issues between the tendons of the flexor sublimis, and loses itself in the integuments of the palm of the hand after a short course.

First digital twig.—Directed obliquely outwards, it immediately gives off several filaments to the abductor, opponens, and flexor brevis pollicis, descends along the latter, to which it gives off a ramification, and, following the radial edge of the thumb, arrives at its extremity. Opposite the first phalanx it throws backwards, into the integuments of the posterior surface of the thumb, a filament, which also ascends outwards. Frequently, also, the first filaments, which escape from it to be distributed among the muscles of the ball of the thumb, form an entirely distinct twig.

Second digital twig.—It follows at first the direction of the preceding twig, but separates from it as it descends, to proceed over the ulnar edge of the first bone of the metacarpus and of the thumb, giving a filament to the flexor brevis, and several other ramifications to the integuments of the posterior surface of that finger.

Third digital twig.—Placed upon the first of the lumbricales muscles, it furnishes it at first with a filament, then descends along the radial edge of the second metacarpal bone and fore-finger to the extremity of the latter, where, after giving off one or two posterior filaments, it expands, and anastomoses with one of the branches of the next twig.

Fourth digital twig.—Descending between the second and third metacarpal bones, it gives a filament to the second of the lumbricales muscles, and bifurcates opposite the separation of the fore and middle fingers, and sometimes sooner. One of these secondary twigs follows the ulnar edge of the first, the other the radial edge of the second of these fingers. They both furnish filaments posteriorly to the integuments, opposite the first phalanges, and are expanded upon the summits of the fingers.

Fifth digital twig.—It follows the original direction of the median nerve, in the interval of the third and fourth metacarpal bones. After giving a filament to the third lumbricalis it divides into two secondary twigs, which descend upon the ulnar edge of the middle finger and radial edge of the ring finger. The latter receives a filament from the ulnar nerve, but both send posterior filaments into the integuments of these fingers, and terminate by anastomosing in their pulp. All the digital twigs furnished by the median nerve accompany the arteries of the fingers, and give off, on all sides, slender filaments to the skin.

ULNAR NERVE.

(*Nervus Cubitalis.*)

Arising from the inner and back part of the brachial plexus, and, in particular, from the last two branches which enter into its formation, this nerve descends almost vertically, only inclining a little backwards along the inner edge of the biceps extensor muscle, to which it is rather closely attached by cellular tissue. Not far from the elbow it gives off some long and slender filaments, which go to the integuments of the upper and back part of the fore-arm. It then passes between the inner condyle and the olecranon, traverses the upper extremity of the flexor carpi ulnaris muscle, and directs itself obliquely downwards and forwards along the anterior and inner part of the fore-arm, between the flexor carpi ulnaris and the flexor digitorum profundus, internally to the ulnar artery: its volume gradually diminishes as it descends. Towards the lower region of the fore-arm, a little above the wrist, it divides into two branches, one of which proceeds over the back of the hand, while the other goes to the palm.

Before dividing, and after passing through the substance of the flexor carpi ulnaris, the ulnar nerve commonly gives off from four to six filaments to the neighbouring muscles, especially to the flexor carpi ulnaris and flexor digitorum profundus. One of them accompanies the ulnar artery for a considerable space, and loses itself in the two flexors of the fingers, near the wrist.

Palmar branch.—Larger than the dorsal, and appearing to be the true continuation of the trunk, it emerges from behind the tendon of the flexor carpi ulnaris, proceeds along its outer edge, passes between the annular ligament and the integuments, beside the pisiform bone, and, before arriving at the palm of the hand, divides into two twigs, a *deep* and a *superficial*.

The *deep twig* passes behind the upper extremity of the opponens minimi digiti, dives behind the bundle formed by the tendons of the flexors of the fingers and of the lumbricales, and then bends outwards, so as to form a kind of arch, the concavity of which is above; its convexity furnishes some filaments. Of these, the first two are distributed to the muscles of the little finger; four or five others dive into the substance of the interossei muscles, and lose themselves towards the back of the hand, while those which terminate the twig are expended in the abductor pollicis and abductor indicis muscles.

The *superficial twig* gives a filament to the muscles of the little finger, beneath the pisiform bone, and presently divides into two secondary twigs, an outer and an inner.

The *outer* is the larger. It descends vertically beneath the palmar aponeurosis, gives off a filament which anastomoses with the last digital twig of the median nerve, furnishes another to the fourth lumbricalis, and bifurcates in such a manner that one of its ramifications descends along the ulnar side of the ring-finger, and the other

along the radial side of the little finger, being in other respects distributed precisely in the same manner as that of the median nerve.

The *inner* directs itself obliquely inwards, gives at first filaments to the muscles of the internal palmar region, before which it passes and gains the ulnar edge of the little finger, at the extremity of which it anastomoses by an arch with the preceding.

Dorsal branch. — Much smaller than the palmar, and winding between the inferior part of the ulnar and the tendon of the flexor carpi ulnaris, it gains the inner part of the back of the hand, where, after giving one or two filaments to the integuments, it separates into two twigs, an *inner* and an *outer*.

The *inner* descends along the ulnar edge of the fifth metacarpal bone, gives a great number of filaments to the abductor minimi digiti and to the integuments, and loses itself on the dorsal surface of the little finger.

The *outer* passes between the fourth and fifth metacarpal bones, and divides at a greater or less height into two filaments, one of which descends backwards over the radial side of the little finger and the ulnar side of the ring-finger, while the other is distributed on the radial side of the latter, and the ulnar side of the middle finger. These ramifications distribute a great number of filaments to the skin of the back of the fingers, and anastomose at their extremities with themselves, or, on that of the middle finger, with the radial nerve.

Radial or Musculo-spiral Nerve (*Nervus radialis*).— It arises from the inner and back part of the brachial plexus, where it is especially formed by the sixth, seventh, and eighth cervical nerves, and the first dorsal. Its volume equals that of the median nerve, and even sometimes exceeds it. It descends at first obliquely from before backwards, between the three portions of the triceps extensor and the inner part of the humerus. It then turns from within outwards, and from above downwards, in the groove which the outer surface of that bone presents; and lastly, on arriving at the anterior, external, and inferior part of the arm, between the brachialis internus and supinator longus, it proceeds over the elbow-joint, and there divides into two branches, an anterior and posterior.

But before dividing, this nerve gives off a considerable number of twigs. Thus it gives off two or three, opposite the united tendons of the latissimus dorsi and teres major, to the triceps extensor muscle. Farther down it sends several twigs into the same muscle. One of them traverses its inferior and external portion, and loses itself in the brachialis internus. Another descends under its large portion, ramifies there, and transmits a very long and remarkable filament to the anconeus muscle. Still lower, the radial nerve gives off a rather large branch to the integuments of the fore-arm; sometimes it is double. It perforates the brachialis internus, emerges between it and the supinator longus, passes behind the outside of the elbow, and descends along the outer and back part of the fore-arm and hand as

Fig. 219.*



Fig. 220.†



* Fig. 219.—Diagram to show the course of the musculo-spiral nerve.—1, passage of the nerve in the groove of the humerus as it passes from the inner aspect of the arm to the posterior surface of that extremity; 2, posterior branch of the same nerve supplying the extensor muscles and sending a branch under the annular ligament of the carpus to the back of the hand.

† Fig. 220.—Diagram to show the terminating branches of the external and internal cutaneous, the musculo-spiral or radial, the ulnar, and the median

far as the thumb, giving a great number of filaments to the skin and cellular tissue. Lastly, as it passes between the brachialis internus and the supinator longus, the radial nerve sends some filaments still to the latter and to the extensor carpi radialis longior.

Anterior branch.—Smaller than the other, it descends along the anterior and outer part of the fore-arm, between the two supinator muscles, on the outside of the radial artery. Towards the lower third of the fore-arm it winds a little outwards, passes under the tendons of the supinator longus and extensor carpi radialis longior, and descends between the integuments and the tendons of the extensor ossis metacarpi and extensor primi internodii pollicis. Presently after, it divides into two twigs, an *outer*, which is smaller, and an *inner*, larger. The *outer* descends upon the dorsal surface of the thumb, and divides into two filaments, one of which ramifies along its radial edge, while the other bifurcates to be distributed to its ulnar side, and to the radial side of the fore-finger. The *inner* proceeds over the back of the hand, and divides into two filaments, one of which belongs to the ulnar side of the fore-finger, the other to the radial side of the middle finger. All these filaments, before terminating at the extremities of the fingers, furnish many ramifications to the interossei muscles, the integuments, and the parts about the first metacarpo-phalangeal articulations.

Posterior branch.—It directs itself obliquely outwards, passes under the supinator longus and extensores carpi radiales muscles, gives off several filaments to them as well as to the anconeus, enters between the fleshy fibres of the supinator brevis, furnishes it with several filaments, passes through it in the longitudinal direction, winding obliquely downwards over the superior extremity of the radius, and arrives at the posterior surface of the fore-arm, divided into several twigs varying as to their number and origin. Some of these, the *posterior*, lose themselves by being more or less prolonged downwards in the supinator brevis, extensor carpi ulnaris, and extensor muscles of the fingers and index. The *anterior* belong to the muscles of the deep and posterior layer of the fore-arm. One of them, which is larger and longer than the others, descends behind the interosseous ligament, gives some ramifications to the neighbouring muscles, passes over the wrist-joint, under the posterior annular ligament of the carpus, and divides on the back of the hand into a great number of filaments, which lose themselves in the interossei muscles and cellular tissue.

CIRCUMFLEX NERVE (*Nervus axillaris*).—Arising from the inner and back part of the brachial plexus, in certain subjects it appears to

nerves.—5, 9, external and internal branches of the internal cutaneous nerve; the external branch may be traced to near the wrist-joint; the internal branch may be traced sending branches behind and in front of the condyle. 3, the ulnar artery; 6, the ulnar or cubital nerve; 11, 12, 13, palmar branches of the ulnar nerve; 11, 11, median nerve; 7, 8, palmar branches of the median; 4, 10, 15 point to branches of the musculo-spiral or radial nerve.

be but a branch of the radial nerve, but in general it is principally produced by the last two cervical nerves and the first dorsal. Immediately after its origin it descends before the subscapularis muscle, which receives a considerable twig from it, then dives between the two teretes muscles, turns from before backwards and from within outwards between the capsule of the shoulder-joint and the long portion of the triceps extensor, and at length gains the posterior edge of the inner surface of the deltoid muscle, after giving some filaments to the teres minor.

Opposite the triceps extensor muscle this nerve divides into two branches. The *upper*, which is shorter, sends a twig into the infraspinatus, and then loses itself in the deltoid muscle, after running for some extent upon its external surface. The other, or *inferior*, entirely loses itself in the deltoid muscle, and terminates near its anterior edge and insertion into the humerus.

DORSO-SPINAL NERVES.

Anterior Branches.

The cutaneous branches of these nerves are somewhat difficult of dissection, but the larger branches are easily found during the examination of the interior of the thorax.

They are twelve in number, and are chiefly destined to supply the muscular walls of the thorax and of a portion of the abdomen with nerves. Other nerves reach these parts from the brachial plexus and lumbar nerves.

The nerves I now speak of may also be subdivided practically into muscular and cutaneous.

The anterior cutaneous (perforating) branches are extremely small; they escape by the sides of the sternum and of the upper portion of the linea alba. There are also middle and posterior perforating cutaneous.

The anterior branches of the dorso-spinal nerves, to which these cutaneous branches belong, greatly resemble each other in their anatomy. Separated from the posterior branches by the superior costo-transverse ligament, they reach the middle part of each intercostal space; here they are situated between the pleura and an aponeurosis extending from the termination of the internal intercostal muscles to the spine. They next pass forwards between the intercostal muscles themselves, situated always below the corresponding intercostal artery. But about midway between the vertebral column and the sternum they all divide into two branches, one cutaneous or perforating (already spoken of), the other muscular or the proper intercostal. The latter follows the original course of the nerve.

The anterior branch of the first pair of dorso-spinal nerves differs, as we have already seen, from the others in this,—that by far the largest portion of its fibres proceed upwards in front of the neck of the

first rib, to join that of the last cervical, and with it assist in forming the brachial plexus. Its proper intercostal branch is very small.

The second intercostal is remarkable for the great size of its perforating or cutaneous branch, which crosses the axilla to supply the integuments of the arm.

It anastomoses with the accessory of the internal cutaneous, and generally receives the name of the superior intercosto-humeral nerve.

The third is also remarkable for the size of its cutaneous or perforating branch, which also proceeds to the integuments of the arm, and is called the inferior intercosto-humeral. It escapes from the thorax between the third and fourth ribs.

Of the inferior intercostals it may be said that they are almost as much abdominal as intercostal or thoracic. They supply the integuments and muscular walls of the abdomen, sending branches to the recti, oblique, and transversales muscles.

No rational theory has ever yet been offered respecting the functions of the intercostal nerves.

LUMBO-SPINAL NERVES.

Anterior Branches.

The lumbar plexus is formed by the anterior branches of the five pairs of lumbar nerves. The plexus is situated by the side of the lumbar vertebræ between the transverse processes, and buried amongst the fasciculi of the psoas muscle, through which its terminating branches pass. The anterior branch of the first pair is the smallest of the five: it divides, on leaving the foramen conjugale, into three branches, two of which are the ilio-scrotal nerves; the third is the anastomotic, which joins the second to assist in forming the plexus. The second pair (anterior branch), as large again as the preceding, gives off two branches, the genito-crural and inguino-cutaneous; the nerve now flattens out, and after furnishing numerous fine filaments to the psoas it joins the third.

Anterior branch of the third.—As large again as the preceding; it descends, after receiving the second, in the psoas muscle. The trunk so formed subdivides into two branches of unequal size; these join with two branches of the fourth to form the *crural* and *obturator* nerves.

Anterior branch of the fourth.—Somewhat larger than the third; it divides after a short course into three branches, of which one joins the bifurcation of the third, to assist in forming the crural nerve; a second joins the other bifurcation of the same pair (the third), to form the *obturator;* and an internal branch, called anastomotic, which unites with the anterior branch of the fifth.

Anterior branch of the fifth pair of lumbar nerves.—Somewhat larger than that of the fourth, it receives the internal branch sent from the fourth, and, forming with it a large trunk, descends into the pelvis and

joins the first sacral. The trunk just alluded to was first named by Bichat the lumbo-sacral.

The branches or nerves given off by this plexus, whilst buried in the psoas muscle, are, 1, the crural; 2, the obturator; 3, the lumbo-sacral. These have been called the terminating nerves of the plexus. Those termed *collateral* are, 1, superior musculo-cutaneous; 2, the middle musculo-cutaneous; 3, inferior musculo-cutaneous (inguino-cutaneous); 4, genito-crural or sub-pubic.

The musculo-cutaneous nerves present numerous varieties, and have been variously named by different anatomists.

1. *Superior musculo-cutaneous nerve of Bichat* (*ilio-scrotal*).—This nerve arises from the anterior branch of the first pair of lumbar nerves, of which it seems the continuation, traverses immediately the psoas, becomes subperitoneal, crosses anteriorly the quadratus lumborum obliquely, and at last reaches the crest of the ilium: here it traverses the aponeurotic attachments of the transversalis muscle, places itself between the transversalis and the smaller oblique, follows the course of the crest of the ilium, and ultimately divides into two branches, of which one, the abdominal, following the course of the last dorsal, is distributed in a similar manner; the other, the *pubic* branch, continues in the original course of the nerve, proceeds parallel with the crural arch but somewhat superiorly, meets the spermatic cord in man, and the round ligament of the uterus in woman, escapes by the external abdominal ring, is reflected from within outwards on the superior angle of the orifice, and terminates in filaments which proceed to the integuments of the pubes and of the groin.

2. *The middle musculo-cutaneous of Bichat* may be viewed as merely a dependence of the preceding. It crosses obliquely the quadratus lumborum, next the iliacus, and proceeds either to join the abdominal branch of the preceding or to gain the level of the middle portion of the crural arch, where it anastomoses by a filament with the pubic branch already described, subsequently terminating in a similar manner in the integuments of the pubes.

3. *Inferior musculo-cutaneous of Bichat;* inguino-cutaneous of Chaussier. This branch is exclusively destined to the integuments of the external and posterior regions of the thigh. Arising from the upper part of the plexus (second or second and third lumbar nerves), it traverses obliquely the posterior part of the psoas, crosses the iliacus, next reaches the superior and anterior iliac spine, underneath which it quits the abdomen, passing behind the femoral arch.

Immediately below the iliac spine this nerve is sub-aponeurotic, or rather occupies a fibrous sheath at the expense of the deep layers of the femoral aponeurosis; it divides here into two branches, both superficial, a femoral and an iliac. The latter, after crossing the tensor fasciæ latæ, is distributed to the integuments at the back of the thigh; the *anterior* is distributed to the integuments in the front of the thigh. The filaments of these branches proceed to the integuments.

4. *Genito-crural branch.*—This nerve descends from the second

lumbar pair of nerves, traverses the psoas directly from behind forwards, quits the muscle at the side of the bodies of the lumbar vertebræ, and descending, connected to the surface of the psoas by a very thin aponeurotic lamella, divides, as it approaches the crural arch, into two branches, the one *internal* or *scrotal*, the other *external* or *cutaneous femoral*.

In its passage the genito-crural is crossed by the ureter and covered by the spermatic vessels.

The *scrotal branch* crosses the femoral artery, reaches the deep orifice of the inguinal canal (deep abdominal ring), crosses the epigastric artery, and here sends a few fibres to the transversalis and oblique muscles. The scrotal branch itself at this point is situated under the spermatic cord, from which it is altogether distinct, but whose course it follows until it reaches the level of the external pillar of the outer ring; here it is reflected and proceeds directly downwards behind the cord to terminate in the integuments of the scrotum in the male, and in the great labium in woman.

2. The *cutaneous femoral branch* of the genito-crural reaches the *crural ring;* but before entering it, it furnishes a great number of filaments to the psoas, iliacus and transversalis; after this it traverses the *crural canal* applied against the external angle of the ring, and crosses the circumflex artery at its origin. Becoming sub-aponeurotic after having passed through the crural canal, it soon becomes subcutaneous, anastomoses with a cutaneous branch of the crural arch, and may be followed as far as the middle of the thigh.

TERMINAL BRANCHES OF THE LUMBAR PLEXUS.

The three terminating branches of the lumbar plexus are, 1, the crural or anterior crural; 2, the obturator; 3, the lumbo-sacral.

THE CRURAL NERVE.

The crural, or anterior crural, arises from the anterior branches of the first four lumbar nerves, and forms the outermost of the three cords which terminate the plexus. At first situated under the psoas muscle, it separates from it opposite the fourth lumbar vertebra, proceeds outwards along its outer edge in front of the psoas and iliacus muscles, gives them many fine filaments, which, before penetrating the muscles at the distance of about half an inch, form a sort of network at their surface, and issues from the abdomen behind the crural arch, along with the crural artery, externally to which it is situated at the distance of about half an inch.

Immediately after issuing from the abdomen the crural nerve divides into a variable number of twigs, but always of considerable size. Sometimes this division takes place before its passage under the crural arch; but they may always be distinguished into superficial and deep.

Superficial twigs.—Less voluminous than the others, they vary in number from two to six; the distribution of their filaments is constant and uniform. They creep for some time under the crural

aponeurosis, and perforate it more or less high, to become subcutaneous. The foramina through which they pass are very distinct. Presently after they separate into a multitude of filaments, which expand upon the inner and fore part of the thigh, and are distributed to the integuments; several of them descend as far as the upper part of the leg, accompanying the vena saphena.

External deep twigs.—They vary much in number and size; but in general they are always larger than the preceding. They descend outwards between the iliacus, sartorius, and rectus femoris, and separate into filaments, which are distributed to the neighbouring muscles.

Internal deep twigs.—They are less numerous than the external, and are especially distributed to the vastus internus and to the pectineus and sartorius muscles. One of them accompanies the crural artery, being placed at first before it, and afterwards on its inner side, but separates from it below to glide under the inner edge of the sartorius, to which it gives some filaments, and then descends to the knee, where it is expanded. But the largest of all these twigs is the one which is called the *internal saphenus nerve*, which accompanies the vena saphena. It descends at first internally of the crural artery, receives a twig of the obturator nerve, passes under the sartorius muscle in the channel which the abductor magnus forms, gives several filaments to these muscles, emerges on the inside of the knee between the tendons of the abductor magnus and vastus internus, sends small twigs to the integuments, then, united to the inner vena saphena, ramifies like it, accompanying it in all its subdivisions, and descends as far as the first toe, after furnishing many cutaneous filaments.

THE OBTURATOR NERVE.

(*Nervus obturatorius.*)

It comes principally from the second and third lumbar nerves, and sometimes from the fourth. Smaller than the crural nerve, it descends at first almost vertically between the inner edge of the psoas magnus and the body of the fifth lumbar vertebra. It then follows the lateral and superior part of the excavation of the pelvis, running a little below the line of the upper strait, accompanied by the obturator artery and vein, and placed under the former and above the latter. On arriving at the upper part of the obturator foramen, it gives off a twig which loses itself in the two obturator muscles; it then passes through the foramen, and arrives at the upper and inner part of the thigh, concealed by the pectineus and abductor longus; there it divides into two branches, an anterior and posterior.

The *anterior* descends between the abductor brevis and abductor longus, and separates into two twigs, of which the *inner* gives filaments to the first of these muscles, and loses itself in the upper part of the gracilis, while the *outer* belongs entirely to the latter muscle. Both also give off cutaneous ramifications, and furnish one or two anastomoses to the inner saphenus nerve.

The *posterior* directs itself between the abductor brevis and abductor magnus, and loses itself in the latter after giving filaments to the abductor externus muscle.

THE LUMBO-SACRAL NERVE.

This nerve is double the size of the anterior crural, and is formed by the anterior branch of the fifth lumbar nerve, to which is united a large twig of the fourth. It descends into the pelvis before the sacrum, near the sacro-iliac symphysis, and unites with the sciatic plexus. In its course it furnishes a single branch, which is the gluteal.

Fig. 221*



GLUTEAL NERVE.

(*Nervus gluteus superior.*)

It derives some roots from the sciatic plexus, issues by the sciatic notch above the pyriformis muscle, and divides into a number of twigs, some of which enter the gluteus minimus, and others the gluteus medius.

THE SACRAL NERVES.

(*Nervi sacrales.*)

The sacral nerves are commonly six on each side, often five, and rarely only four. The first issues by the upper sacral foramina, and the last by the notches which are observed at the upper part of the coccyx, or, when there are only five, it escapes between that bone and the sacrum. Their size diminishes successively, so that the two last are very slender.

These nerves arise from the lower part of the bulging which terminates the spinal marrow, by a double cord of filaments, as is the case with the vertebral nerves in general. These different cords descend vertically in the vertebral and sacral canals, form with those of the last lumbar parts the bundle known by the name of *cauda equina*, and in other respects are precisely similar to the other nerves which arise from the sides of the spinal marrow; only the ganglions of the

* Fig. 221.—Lumbo-sacral plexus, generally viewed as two—the lumbar and the sacral. 1, 2, trunk of the great sympathetic; 3, anterior branches of the sacral nerves; 4, anterior branches of the lumbar nerves forming the lumbar plexus; 5, 6, the musculo-cutaneous branches arising from the plexus; 8, crural nerve; 9, obturator nerve; 10, lumbo-sacral: this is not properly speaking a nerve, but rather a great anastomosing branch sent from the last lumbar to join the first sacral, thus contributing to form the sacral plexus.

posterior root, in place of occurring at the outer part of the foramen from which they are transmitted, occupy the bony canal of the sacrum. The last three are even considerably distant from the inferior sacral hole, so that the common trunk which results from the union of the two cords runs a certain course before entering them.

The sacral nerves transmit, through the anterior foramina of the sacrum, branches which diminish in volume from above downwards, while on the contrary the posterior branches increase to the fourth and then diminish.

The FIRST SACRAL NERVE.—*Anterior branch.*—It is about the same size as that of the fifth lumbar nerve. On issuing from the first anterior sacral foramen, it communicates, by two filaments, with the sacral ganglia, then descends outwards along the upper edge of the pyriformis muscle, and joins, above, the lumbo-sacral nerve, and below, the second sacral nerve, thus contributing to the formation of the sciatic plexus.

The SECOND SACRAL NERVE.—*Anterior branch.*—It issues by the second anterior sacral foramen, between the two upper slips of the pyriformis muscle, communicates with the sacral ganglia, descends outwards, and throws itself into the sciatic plexus, uniting with the anterior branches of the preceding and following nerves.

The THIRD SACRAL NERVE.—*Anterior branch.*—Smaller than that of the first two pairs, it communicates with the sacral ganglia, throws filaments into the hypogastric plexus, descends outwards, and, uniting with the two neighbouring nerves, enters into the sciatic plexus.

The FOURTH SACRAL NERVE.—The two branches of this nerve are precisely similar to those of the preceding nerves, and do not require to be particularly described. The anterior enters into the formation of the sciatic plexus.

The FIFTH and SIXTH SACRAL NERVES.—*Anterior branches.*—That of the fifth passes between the sacrum and coccyx, and that of the sixth escapes through the lateral and superior notch of the latter bone. They communicate with each other, and with the fourth, but contribute very little to the sciatic plexus. They are distributed to the ischio-coccygeus, levator ani, and sphincter ani muscles.

SCIATIC or SACRAL PLEXUS.—It is particularly formed, as we have already said, by the anterior branch of the fifth lumbar nerve, and by those of the first four sacral nerves. It occupies the lateral and posterior part of the excavation of the pelvis, and lies upon the pyriformis muscle, behind the hypogastric vessels, the rectum and bladder, the uterus, and a great quantity of adipose tissue. Its breadth

is much greater internally, where it is limited by the anterior sacral foramina, than externally, where it is continuous with the sciatic nerve; and its structure is different from that of the other plexuses which we have hitherto had occasion to examine. In place of forming a kind of network, by sending twigs to each other, the branches of which it is formed join immediately, so as to give rise to a thick nerve flattened from before backwards.

The branches and twigs which it furnishes may be distinguished into anterior and posterior. The former, which arise especially from the third and fourth sacral nerves, and whose number is variable, are the hæmorrhoidal, vesical, vaginal, and uterine nerves.

Brief summary of the Anatomy of these Nerves.

To expose them, the section required is that usually made of the pelvis when it is intended to examine the relation of the viscera of that cavity and of the pelvic fascia. With caution, the nerves just enumerated may very readily be discovered.

The following visceral nerves do not come, properly speaking, from the sacral plexus, but rather from the fourth and fifth pairs of sacral nerves; they form frequent anastomoses with the sympathetic.

1. The nerves of the *levator ani* are two or three in number: the lowermost proceeds towards the sides of the prostate in man, and of the vagina in woman.

2. The nerve of the *obturator internus* comes from the anterior part of the top of the plexus; it passes immediately behind the spine of the ischium, where, dividing into three branches, it enters the muscle. To expose this nerve the smaller sciatic ligament ought to be removed.

3. *Hæmorrhoidal* or *anal nerve.*—This nerve supplies the sphincter and the skin around the anus. In its course it passes between the two sacro-sciatic ligaments, next, in front of the lower portion of the gluteus maximus, communicates with the superficial branch of the perineal, reaches the sides of the rectum and the superior part of the sphincter, where it divides into a great number of branches. Of these some are *anterior*, others *middle*, others *posterior*. It has been remarked that, occasionally, this nerve is distributed exclusively to the integuments around the anus.

4. *Internal pudic.*—To expose this nerve fully is a troublesome, and rather difficult dissection; it follows nearly the course of the common or internal pudic artery. It divides in the perineum, close to the artery, into two principal branches.

a. The inferior or perineal.—This branch, which is the true continuation of the nerve, corresponds to the trunk, and to all the branches of the pudic artery, with the exception of the dorsal branches. In its course this perineal branch of the pudic nerve gives off—1st, the external or superficial perineal; this proceeds ultimately to the dartos

and scrotum in man, and to the greater labia in woman: it presents many varieties; 2d, a second branch, also called superficial perineal, following the course of the superficial perineal artery; and a 3d, the bulbo-urethral branch, which supplies the bulbo-cavernosus muscle and enters the bulb itself.

b. The deep branch of the pudic nerve is also called the dorsal nerve of the penis. It corresponds to the course of the dorsal arteries of the penis, which it accompanies. On the dorsum of the penis the nerves are more superficial than the arteries; they ultimately divide, each, into a branch for the *glans*, and an external or cutaneous. The filaments of the former may be traced almost to the papillæ; those of the latter belong to the integuments and prepuce; but none seem to penetrate into the centre of the corpus cavernosum of the penis.

In woman the nerve to the clitoris, corresponding to the dorsal nerve of the penis in man, is very small. The other branches correspond; but the pudic nerve in woman is not half so large as it is in man.

5. *Nervus gluteus superior.*—This nerve supplies branches to the gluteus medius, minimus, and tensor fasciæ muscles; it quits the pelvis at the upper part of the great sciatic notch.

6. *Nerve of the pyramidalis.*—This is a small nerve, easily found, supplying the pyramidalis muscle.

7. *Nervus gluteus inferior.*—Sometimes called the small sciatic nerve. It leaves the pelvis by the notch, passing out under the pyramidalis muscle along with the great sciatic nerve, and soon divides into two sets of branches—muscular and cutaneous. The muscular branches proceed exclusively to the gluteus maximus; the cutaneous may be traced to the scrotum, to the back of the haunches and thigh, and to the leg. A large branch it sends to the scrotum is called *nervus pudendalis longus*. The terminating branches in the popliteal space are—one which continues on the surface; another, which, passing through the aponeurosis, reaches the short saphena vein, and anastomoses with the external saphenus nerve.

8. *Nerves of the quadratus femoris and gemelli muscles.*—The gemellus superior has a special nerve sent to it; the gemellus inferior is supplied by a branch from the nerve which proceeds to the quadratus femoris. This latter nerve, besides its muscular branches, transmits filaments to the tuberosity of the ischium, and to the fibrous capsule of the joint.

TERMINATING BRANCH OF THE SACRAL PLEXUS.

The great sciatic nerve is, in fact, the termination of the sacral plexus. It is the thickest and longest of all the nerves of the body, and terminates the plexus of the same name, all the roots of which contribute to form it. It descends at first before the pyriformis muscle, gives it some filaments, issues from the pelvis, between it and

Fig. 222.*



the gemellus superior, by the sciatic notch, and enters between the great trochanter and the tuber ischii. It then descends a little obliquely outwards along the posterior part of the thigh, as far as the ham, where it divides into two principal trunks, of which one is the external, the other the internal popliteal nerve, and which are sometimes distinct from the upper part of the limb.

By its *anterior* side the sciatic nerve is successively applied, from above downwards, upon the two gemelli muscles, the tendon of the obturator internus, the quadratus femoris and abductor magnus.

Its *posterior* side is covered above by the gluteus maximus, inferiorly by the long portion of the biceps flexor, and a little by the semi-tendinosus. Lastly, altogether inferiorly, it is placed in the ham in the midst of fat, under the crural aponeurosis and skin, and between the biceps and semi-membranosus muscles.

On emerging from the pelvis, the sciatic nerve

* Fig. 222.—To show the course and distribution of the great sciatic nerve. — 1, 2, superior and inferior gluteal nerves; 3, 3, 3, the great sciatic. In this part of its course this great nerve supplies branches to the flexor muscles forming the ham-strings, which are generally overlooked by the student.

gives off some twigs to the gemelli, obturator internus, and quadratus muscles. The gluteus maximus, also, generally receives several, unless when the twigs of the inferior gluteal nerve are very large, in which case the sciatic nerve sends none to it. Two or three twigs go to the long portion of the biceps muscle; one of them accompanies it as far as the knee, and sometimes becomes cutaneous; another is destined for a short portion of the same muscle. The last twigs are expanded in the semi-tendinosus, semi-membranosus, and abductor magnus muscles. Among these twigs there are many which extend as far as the skin, in which they terminate, whether on the thigh or on the leg.

Fig. 223.*



EXTERNAL POPLITEAL OR FEMORAL NERVE.

(*Nervus peroneus.*)

The *peroneal nerve*, which is smaller than the tibial, descends obliquely outwards along the inferior extremity of the biceps muscle, behind the outer condyle of the femur and the tendon of the corresponding head of the gastrocnemius; then, bending a little forwards and inwards, passes between the upper part of the fibula and the peroneus longus muscle, and there divides into two branches, the musculo-cutaneous and the anterior tibial.

At its origin, and sometimes even a little before, this nerve gives off a long and slender filament, which glides between the femur and the inferior extremity of the biceps, gives some ramifications to the latter muscle, and then expands upon the fore and outer part of the knee-joint and the upper articulation of the tibia and fibula. Before arriving at the condyles of the femur it gives off another twig of remarkable size (peroneo-cutaneous), which sends a great

* Fig. 223.—Showing the terminating branches of the smaller division of the great sciatic, usually called the fibular or peroneal. In the ham this branch is sometimes called the external popliteal.—1, anterior tibial branch and artery; 6, its passage along with the artery beneath the anterior annular ligament, or retinaculum; 2, external musculo-cutaneous branches of the fibular; they supply the muscles and integuments on the external and anterior aspects of the leg and foot; 7, filaments seen passing from the peroneal.

number of filaments to the outer head of the gastrocnemius, over which it descends, keeps along the outer and back part of the leg, beneath the aponeurosis, and separates into many other filaments, which lose themselves in the integuments; one of them, however, which is larger than the others, and frequently arises separately, unites at the outer edge of the tendo Achillis with a twig of the tibial nerve, to form the external saphenus nerve.

Musculo-cutaneous branch (*nervus peroneus externus*).—It descends at first a little obliquely inwards and forwards, between the peroneus longus and the extensor communis digitorum pedis, then between the latter and the peroneus tertius.

Towards the middle of the leg this nerve becomes more superficial, and is situated under the aponeurosis, behind which it creeps for some time. It perforates it about two-thirds down, sends outwards some filaments into the integuments which cover the lower extremity of the fibula, and divides into two twigs, which direct themselves superficially over the back of the foot, diverging from each other, the internal one being the larger.

Internal and superficial twig of the back of the foot.—It directs itself inwards, and gives at first several filaments to the integuments which communicate with those of the internal saphenus nerve. When it has arrived at the foot, it bifurcates, and produces two divergent secondary twigs. The *inner* follows the corresponding edge of the foot, furnishes several filaments to the cellular tissue, the integuments, and the muscles of the great toe, and runs along the first metatarsal bone and great toe, reaching almost to its extremity. The *outer* runs between the first two metatarsal bones, and sends its ramifications over the upper and outer part of the second.

External and superficial twig of the back of the foot.—It runs along the middle part of the upper surface of the foot, between the tendons of the extensor muscles of the toes and the integuments, after sending some filaments over the outer malleolus. Towards the posterior extremity of the metatarsus it separates into three secondary twigs. The *inner* is prolonged between the second and third metatarsal bones, and spreads its divisions over the outer side of the second toe and the inner side of the third. The *middle twig*, passing between the third and fourth metatarsal bones, is distributed in the same manner to the third and fourth toes. Lastly, the *outer* runs in the interval between the fourth and fifth metatarsal bones, and loses itself on the corresponding toes. Frequently this twig is replaced by one of the twigs of the outer saphenus nerve, but it always, at least, communicates with it.

Anterior tibial branch (*Nervus tibialis anterior*).—It traverses the upper extremity of the peroneus longus and extensor digitorum communis, descends at first obliquely inwards between the fibula and these two muscles, gives them several filaments, then directs itself

before the interosseous ligament and along the anterior tibial artery, which is placed internally to it, above, and externally, below. After passing under the annular ligament of the tarsus, along with the tendon of the extensor pollicis muscle, this nerve separates on the back of the foot into two twigs, an inner and an outer, both deeply seated.

The largest of the twigs of this nerve, before its division, arises near its origin. It traverses horizontally the upper extremity of the extensor communis digitorum, and divides into several filaments, the inferior of which are distributed to that muscle and to the tibialis anticus, while the upper ascend under the origin of the latter, and lose themselves around the knee-joint. It also sends lower down a considerable twig to the extensor digitorum cummunis, and two or three others to the extensor proprius pollicis and tibialis anticus.

Internal and deep twig of the back of the foot.—It runs along the inner edge of the extensor brevis digitorum pedis, to which it gives some filaments, passes under the portion of it destined for the great toe, places itself between the first two metatarsal bones, sends ramifications to the first dorsal interosseous muscle and to the integuments, and at length divides into two filaments, which spread out, the one on the outer side of the first toe, the other on the inner side of the second, communicating with the superficial filaments already indicated.

External and deep twig of the back of the foot.—It passes outwards and forwards under the posterior part of the extensor brevis digitorum, and then divides into a great number of filaments, which are distributed to that muscle and to the interossei.

Fig. 224.*



INTERNAL, POPLITEAL OR TIBIAL NERVE.

(*Nervus tibialis.*)

The *tibial nerve* is larger than the preceding, and seems to be the true continuation of the sciatic nerve. It descends at first nearly vertically into the ham, along the outer edge of the semi-membranosus muscle, between the crural aponeurosis and the popliteal vessels, from which it is commonly separated by much adipose tissue. Then entering between the two heads of the gastrocnemius, it passes behind

* Fig. 224.—To show the distribution of the nervus tibialis, the larger division of the great sciatic nerve.—1, the tibial or posterior tibial nerve, following the course of the corresponding artery and deep veins: before passing into the sole of the foot it subdivides into the external and internal plantar nerves corresponding to the arteries. 2, a portion of the external saphenus nerve, seen as it winds around the outer ankle: some of the branches of this nerve may be seen in fig. 223, on the outer side of the foot.

the knee-joint and the popliteus muscle, then between the latter and the upper extremity of the soleus; it there passes through the arched aperture which that muscle presents. It then descends along the leg, between the soleus muscle, which is behind it, and the tibialis posticus and flexor longus digitorum, which are in front of, and externally to the posterior tibial artery, with which it is closely connected. Towards the lower part of the leg it becomes superficial, places itself on the inner side of the tendo Achillis, dives under the arch of the calcaneum, above the origin of the abductor pollicis, and divides into two branches, one of which is the internal, the other the external, plantar nerve.

External saphenal branch (*Communicans tibiæ*).—Arises from the tibial nerve, about an inch above the corresponding condyle of the femur, descends with the external saphena vein along the back part of the leg, in the interval which separates the two heads of the gastrocnemius muscle above. It then places itself behind their union, gains the outer side of the tendo Achillis, sends several filaments to the integuments, and joins a branch of the peroneal nerve. There results a rather large trunk, the external saphenus nerve, which descends on the outer side of the leg, behind the peroneus longus, and under the aponeurosis. There then proceed from it a great number of filaments, which almost all enter beneath the tendo Achillis, and are spread out to a distance upon the sheath which is anterior to it. It then winds behind the outer malleolus, gains the outer and upper extremity of the foot, reaches the posterior extremity of the fifth metatarsal bone, and there divides into two secondary twigs, after sending several filaments to the abductor minimi digiti and the surrounding cellular tissue. Of these two twigs, the inner, which is above the extensor brevis digitorum, follows the fourth metatarsal bone, and loses itself on the corresponding sides of the last two toes; while the outer runs along the outer edge of the foot and little toe, and distributes a certain number of filaments. In the hollow of the ham itself, the tibial nerve sends one or two distinct twigs to the upper part of each head of the gastrocnemius muscle. It gives off another, which divides in the soleus muscle after a considerable course. It also furnishes some to the popliteus and plantaris muscles, and to the knee-joint; while a last twig winds under the lower edge of the popliteus muscle, sends off a long filament, which follows the course of the posterior tibial artery, gives some others to the tibialis posticus muscle, passes through the superior aperture of the interosseous ligament, and is expanded in the upper part of the anterior muscles of the leg, anastomosing with the filaments of the anterior tibial nerve.

After passing through the arch of the soleus muscle, the tibial nerve furnishes several long and slender filaments, which descend around the posterior tibial artery, and anastomose frequently with each other. They there lose themselves in the lower part of the

soleus and of the muscles which occupy the posterior and deep region of the leg. Farther down are detached some filaments which go to the integuments; but towards the inner malleolus there arises another, which, uniting with one of the preceding, goes to the integuments of the sole of the foot.

The *internal plantar* nerve is thicker than the outer, which forms an acute angle with it at its separation; it proceeds directly and horizontally forwards above the abductor pollicis, beside the tendon of the flexor longus pollicis, to the posterior extremity of the first metatarsal bone, and in its passage gives ramifications to the abductor pollicis, flexor brevis digitorum, and accessorius muscles. But there it separates in a variable manner into four twigs, which may be designated by their numerical names, counting from within outwards. The first, which is smaller than the others, follows the inferior surface of the flexor brevis pollicis, which receives some filaments from it, proceeds along the lower and inner part of the great toe, and loses itself upon it, sending some filaments upwards. The second, which is directed horizontally forwards, between the first two metatarsal bones, at first above and then below the flexor brevis digitorum, which receives several filaments from it, as does also the first lumbricalis muscle, separates opposite the first metatarso-phalangeal articulation, into two secondary twigs, one of which is distributed on the outer side of the first toe, while the other is spread out on the inner side of the second, sending upwards some filaments which anastomose with those of the internal and deep nerve of the back of the foot, and which themselves anastomose by arches in the pulp of the toes. The third, which is placed between the second and third metatarsal bones, gives filaments to the second lumbricalis muscle, and is distributed between the second and third toes, precisely in the same manner as the preceding twig. Lastly, the fourth advances between the third and fourth metatarsal bones, and is distributed to the corresponding toes.

Fig. 225.*



The *external plantar* nerve proceeds obliquely forwards and outwards, between the flexor brevis digitorum and accessorius muscles, to which it gives filaments, in the groove situated near the large tuberosity of the calcaneum. Arrived at the posterior extremity of the fifth metatarsal bone, it divides into two branches, a superficial and deep. Before this it generally sends a pretty large twig to the abductor minimi digiti. The superficial branch advances under

* Fig. 225.—Diagram to show the distribution of the plantar nerves.—1, the posterior tibial nerve, bifurcating into, 2, the internal plantar nerve, and, 3, the external plantar nerve.

the outer edge of the foot, and divides into two twigs; an outer, which gives a filament to the flexor minimi digiti, and loses itself on the corresponding edge of the little toe; and an inner, which directs itself between the last two metatarsal bones, gives a filament to the fourth lumbricalis, communicates with the preceding twig, and subdivides on the contiguous sides of the fourth and fifth toes.

The deep branch at its commencement furnishes a filament to the flexor brevis minimi digiti, and ascends inwards and forwards between the interossei muscles and adductor pollicis pedis, forming a kind of arch, the posterior side of which does not give off filaments, while the anterior sends some to the interossei and transversus pedis.

CRANIAL, OR ENCEPHALIC NERVES.

These nerves pass through the foramina at the base of the cranium, generally admitted to correspond to the foramina intervertebralia.

The OLFACTORY NERVES are prismatic in form, and situated on the inferior surface of the anterior lobes of the brain. They gradually approach each other, and form on the cribriform plate of the ethmoid a *bulb* (olfactory bulb) which is much more developed in some of the vertebrata, and is termed the olfactory lobe.

It arises by three roots, the external and internal being composed of white nervous matter, the middle of grey. The *external* is the longest; is directed outwards and backwards, concealed partly by the fissure of Sylvius, and can be traced into the middle lobe of the brain. The *internal* is shorter but broader; it appears to arise from the substantia perforata. The middle grey root is situated between the two others, and arises from the anterior lobe. Its branches proceed from the inferior surface of the bulb, and pass through the foramina in the cribriform plate of the ethmoid bone, and are divided into internal, external, and middle. The internal are softer and spread out on the septum. The external are of a whiter appearance, and are distributed to the membrane lining the two upper turbinated bones. The *middle* lose themselves in the membrane that lines the vault when they reach the nasal fossæ.

The olfactory nerves, as far as the bulbs, resemble rather prolongations of the brain than nerves; and this seems to have been Mr. Hunter's opinion.

SECOND PAIR.—The OPTIC NERVES are said to arise by two roots; they arise chiefly from the *nates* of the corpora quadrigemina; which part is the chief seat of vision, as proved by modern physiological experiments; the nerve, however, although arising from the nates, turns over the outer edge of the optic thalamus and joins itself closely to the corpus geniculatum externum, which is termed its other origin. Before they reach the crura cerebri they are flattened, but when they

get beyond it they become rounded. They unite at the fore part of the sella turcica and form the optic commissure, which is manifestly connected posteriorly with the tuber cinereum. It rests on the olivary process of the sphenoid bone. The optic nerves separate again and pass through the optic foramina with the ophthalmic arteries, which are situated externally to the nerves. Ultimately they pierce the tunicæ sclerotica and choroidea, to be connected with, or perhaps to expand, into the retina.

The *tractus nervorum opticorum* (the portions of these nerves between the cerebral attachments and the commissure) look more like prolongations of the brain than nerves. In the commissure many nervous filaments decussate, but others, more especially those on the external sides of the commissure, proceed onwards without decussation.

As the nerve enters the orbit it receives a firm fibrous sheath from the dura mater; this accompanies the nerve to the sclerotic. As happens in most of the other nerves, the dura mater divides at the optic foramen into two layers; one uniting itself to the periosteum of the orbit; the other forming the investing sheath of the nerve.

An artery pierces the nerve as it is about to enter the sclerotic, and passes with it into the interior of the eyeball. It is the *art. centralis retinæ*, whose branches are distributed to the tunica vasculosa retinæ.

As the optic nerve is passing through the rounded opening in the sclerotic, by which it is admitted into the interior of the eyeball, the nerve is contracted considerably in size, but it passes as one. Through the choroid, on the other hand, it passes by a number of small openings, each admitting a nervous filament.

The arrangement of the optic nerve whilst enclosed in the sheath by the dura mater is peculiar. The sheath is canaliculated; each of the small canals composing it communicate frequently with each other, and by these openings nervous filaments pass, giving rise to an appearance of numerous anastomoses and interchanges of nervous filaments. This arrangement led the celebrated Bichat into an erroneous opinion respecting the discontinuity of nervous filaments.

The nerves just described have been always considered as nerves of special sensation, whose functions are largely connected with intelligence. To these have naturally been added the seventh pair, or rather the auditory portion of that pair, the portio mollis. But although this be a correct view in some respects, there is a difficulty in respect of the portio mollis, which in its structure and in the arrangement of its fibres resembles merely the common nerves of the body.

Taste, moreover, is as special a sensation as sight or hearing; yet this function is performed by a branch of the fifth pair, a nerve which may be looked on as the type of the spinal nerves. I shall proceed, therefore, with the cranial nerves, in their numerical order.

The THIRD PAIR of encephalic nerves is evidently a nerve of motion; but sensitive fibres may be wrapped up in it along with the motory.

These nerves, also called motores oculi, arise from the inner side of

the crura cerebri, near the pons of Verolius. Traced into the nervous centres they seem to commence in the grey substance of the crus cerebri, the superior fibres of the crus, and into the motor branch or anterior pyramids of the medulla oblongata.

When formed they present a remarkable twisting; pass forward between the superior cerebellar and posterior cerebral arteries; pierce the dura mater in front of the posterior clinoid process; pass along the outer wall of the cavernous sinus, into which, however, they do not enter; divide into two branches, which enter the orbit by the sphenoidal fissure between the two origins of the rectus externus muscle.

1. The superior branch ascends, and supplies with branches the levator palpebræ superioris and rectus oculi superior.

2. The inferior branch gives branches to the rectus inferior, the rectus internus, and the inferior oblique; from this branch a short and comparatively thick branch proceeds to the lenticular ganglion, forming its inferior root or connecting central filament. The ganglion has another root, of which I shall speak presently.

In passing over the cavernous sinus it receives one or two filaments from the cavernous plexus and one from the ophthalmic, a branch of the fifth.

FOURTH PAIR, also called PATHETIC and TROCHLEARIS, from its supplying the inferior oblique or trochlearis muscle. It is the smallest of the so-called cerebral nerves. Its apparent commencement may very readily be seen upon the upper surface of the valve of Vieussens; but it may also be traced to the corpora quadrigemina (testes). In its lengthened course forwards towards the orbit it passes around the crus cerebri, is enclosed within the outer wall of the cavernous sinus, and finally enters the orbit by the sphenoidal fissure. It is placed at first beneath the third, but becomes afterwards the highest of the nerves entering the orbit.

1. Whilst passing through the wall of the sinus the fourth gives off a recurrent branch; this is distributed to the lining membrane of the lateral sinus.

2. Some filaments of communication to the ophthalmic nerve.

3. A branch to the lachrymal. Its sympathies, therefore, are extensive.

The nerve itself is ultimately distributed to the trochlearis muscle.

FIFTH PAIR—TRIFACIAL: closely resembling the spinal nerves in its mode of origin by double roots (the posterior being provided with a ganglion), motor and sentient, it yet differs from them in some important points.

Cerebral termination or origin.—There is a tract of yellowish-white matter in front of the floor of the fourth ventricle, behind the crus cerebelli. This spot may be traced downwards by two fasciculi, placing it in relation with the anterior and posterior columns of the spinal marrow.

From this tract come the roots of the fifth pair by two distinct bundles of fibres, issuing from the encephalon upon the anterior part of the *crus cerebelli à ponte*. At this point they form two distinct bundles, one much larger than the other. The filaments composing them may be seventy or eighty in number. Passing over the anterior border of the pars petrosa, they are covered by a fibrous bridge of dura mater; immediately thereafter the larger bundle of filaments enters the Casserian or semi-lunar ganglion; the smaller, or what may be called the anterior, as corresponding to the anterior roots of the spinal nerves, passes beyond the ganglion without entering it. In this situation the larger or posterior root and the ganglion conceal the motor or anterior root.

They now proceed together through the foramen ovale of the sphenoid bone: the mass of nervous filaments coming from the Casserian ganglion subdivides into three great divisions, called, 1, the ophthalmic; 2, the superior maxillary; 3, the inferior maxillary. The motor part of the nerve, already described as passing beyond the ganglion without entering into its composition, joins the third division of the fifth.

1. The OPHTHALMIC NERVE, the first division of the trifacial, is a short trunk. Its destination is chiefly the parts within the orbit. As it passes forwards through the outer wall of the cavernous sinus, enclosed by a fibrous sheath and situated externally to the other nerves, it subdivides into three branches, namely, 1, the frontal; 2, the lachrymal; 3, the nasal. Prior to this division the nerve receives some twigs from the carotid plexus of the sympathetic, and transmits a recurrent branch towards the tentorium.

1. The *frontal* branch of the ophthalmic is the first part seen on removing the vault of the orbit. It rests on the levator palpebræ superioris muscle. After dividing into two branches, the larger leaves the orbit by the supra-orbitar notch or foramen, to be distributed to the integuments of the forehead; it no doubt also sends branches to the muscles and other soft parts. This branch is sometimes called the external frontal.

The *internal frontal nerve*, also called supra-trochlearis, a branch of the ophthalmic, runs towards the cartilaginous pully of the obliquus superior oculi, and issues from the orbit between the pully and the supra-orbitar foramen, ascends beneath the corrugator supercilii to be distributed to the soft parts around, nearly as far as the top of the head.

In this course it furnishes several twigs: one joins the lachrymal; several are distributed to the upper eyelid; some to the anterior surface of the corrugator and frontalis muscles; and a fine filament to the frontal sinus.

2. The *lachrymal* branch of the ophthalmic is the smallest of its branches. After entering the orbit it proceeds along its outer wall,

between the periosteum and the rectus externus, as far as the lachrymal gland and upper eyelid. In this course it gives off a posterior or *spheno-maxillary* filament, anastomosing with a branch of the superior maxillary; also a *malar* filament, which, entering a canal in the malar bone, passes through it, emerges on the cheek, communicating with the facial nerve. Occasionally these filaments traverse the lachrymal gland before leaving the orbit.

To the gland itself the lachrymal nerve furnishes three or four filaments, which are partly distributed to its tissue, partly to the tunica conjunctiva oculi. Lastly, the nerve terminates by sending a great number of filaments to the upper eyelid. It is to the lachrymal nerve that the fourth pair transmits a filament.

3. The *nasal nerve*.—This branch of the ophthalmic, which frequently receives a branch from the superior cervical ganglion, penetrates into the orbit to the inner side of the third pair and above the sixth. It is smaller than the frontal, but larger than the lachrymal. Ascending between the optic nerve and the rectus superior, it soon gains the inner wall of the orbit, under the trochlearis muscle, and here it subdivides into two secondary twigs: but prior to this the nerve has generally received a branch from the sympathetic, and always sends a long filament to the ophthalmic ganglion, together with two or three *ciliary filaments*, to be distributed to the ball of the eye.

The two twigs or branches which terminate the nerve are called, 1, the nervus nasalis, or internal nasal; 2, nervus infra-trochlearis, or external nasal.

1. The *internal nasal*, accompanied by a small artery, enters the anterior internal orbitar foramen, passes through the osseous canal to which the foramen leads, and enters the cranium, close to the side of the crista galli. Here it enters a small fissure at the anterior part of the ethmoidal groove, thus reaches the vault of the nasal fossæ, and terminates by subdividing into two filaments, of which one descends upon the pituitary membrane, opposite the edge of the septum; a filament of this leaves the nostrils, between the ossa nasi and lateral cartilages of the nose, to be finally distributed to the integuments of the lobe of the nose. The other branch of the nasal nerve enters a bony canal behind the nasal bone, or on the nasal spine; it ultimately passes through one of the small apertures observed on these bones, to be distributed to the integuments.

2. The *external nasal* branch of the proper nasal nerve proceeds in the direction of the original trunk, along the inner wall of the orbit, and, on arriving behind the cartilaginous pully of the obliquus superior, anastomoses with a filament of the internal frontal nerve, issuing finally from the orbit, to be distributed to all the soft parts around.

It is a remarkable feature in the history of the fifth pair of cerebral nerves, that, in addition to having the Casserian ganglion upon that division of the nerve corresponding to the posterior roots of the spinal nerves, it should also be in the most intimate relation with other ganglia, whose functions are altogether unknown. These ganglia, by some

(Cloquet and others) arranged with the sympathetic system of nerves, are—1, the ophthalmic; 2, the ganglion of Meckel; 3, the submaxillary.

I shall here describe the ciliary or ophthalmic as being evidently a portion of the system of the ophthalmic nerves.

1. The OPHTHALMIC GANGLION.—*Dissection.*—The ophthalmic ganglion may be reached in a variety of ways—1st, by a little tact and care it may be at once detected close to the external side of the optic nerve, a few lines in front of the optic foramen, where it lies embedded in fat, between the rectus externus and the optic nerve; or, 2d, the branch from the third may be traced to it; or, 3d, the branch from the nasal may be traced to it; 4th, any of the ciliary nerves arising from it, by being followed backwards, will lead directly to the ganglion.

The ophthalmic ganglion is also called ciliary and lenticular; it is a small, lenticular, greyish body, situated as above described; varying in different persons, but never absent, and of much interest physiologically. By its posterior and superior angle it receives, from the nasal branch of the fifth, a long and slender fasciculus, which leaves the nerve whilst still engaged in the walls of the cavernous sinus; occasionally there are two such filaments, but whether single or double they constitute the *long root* of the ganglion. The *short root* of the ganglion comes from the branch of the third, which supplies the small oblique muscle. By its anterior angle the ganglion furnishes two small bundles of nerves known by the name of ciliary. Finally, the ganglion has a sympathetic root or filament communicating with the superior cervical ganglion; this root comes from the cavernous plexus, and joins either the ganglion itself, or the long nasal root which the ganglion receives from the nasal nerve.

The *ciliary nerves* are extremely remarkable. The superior bundle is composed of four filaments, the inferior of five or six. They do not anastomose with each other before arriving at the globe of the eye, with the exception, however, of the ciliary nerve coming directly from the nasal, which anastomoses with an inferior ganglionic ciliary nerve. On reaching the globe of the eye they pass through the sclerotic obliquely, around the entrance of the optic nerve, with the exception of two or three, which enter the eyeball more anteriorly, and close to the attachments of the recti muscles. Having passed through the sclerotic, they become flat like ribbons. Placed between the tunica sclerotica and the choroid, they proceed forwards, to terminate by fine filaments, chiefly in the annulus albus or ciliary ligament, some few proceeding to the iris.

After examining these structures with the greatest care in the eyes of most vertebrate animals, I have not been able to detect any resemblance between the ciliary ligament and a nervous ganglion.

The ciliary nerves, coming directly from the nasal (fifth pair), have been already alluded to.

SUPERIOR MAXILLARY NERVE.—This great branch of the fifth pair is called the superior maxillary. It leaves the cranium by the foramen rotundum, immediately enters the spheno-maxillary fossa, arrives at the posterior opening of the sub-orbitar canal, and, passing out by the anterior opening of this canal, bends from above downwards to spread out upon the cheek. The nerve is at first plexiform in its structure, but afterwards fasciculated.

The branches it gives off in this course are,—

1. The orbitar branch.

2. The nerves from the main trunk joining the ganglion of Meckel.

3. The nerves arising from the ganglion:—*a.* the palatine; *b.* the spheno-palatine; *c.* the vidian or pterygoidian.

4. The posterior, and

5. Anterior alveolo-dentar.

6. Sub-orbitar or terminating branch.

1. The *orbitar branch* traverses the spheno-orbitar fissure, and so enters the orbit. It traverses the lachrymal gland from below upwards, and anastomoses with the lachrymal branch of the ophthalmic division of the fifth. Its ultimate filaments traverse the malar bone, and so reach the surface of the malar region of the face and the deep temporal region, where they anastomose with the anterior deep temporal nerve.

2. *Nerves from the main trunk joining the ganglion of Meckel.*—Having given off the orbitar, the superior maxillary furnishes a thick branch or two by its inferior edge, from which proceed immediately, in various directions, several nerves, whose course I shall now describe; but at the point of their divergence is a small rounded body, which the elder Meckel first described as a ganglion, and which, since his time, has borne his name.

Ganglion of Meckel.—This ganglion is often exceedingly indistinct; nevertheless, it is usual to describe it as being always present, and as transmitting from it the following nerves, many of which seem to come more directly from the superior maxillary itself than from the ganglion, so called, of Meckel. I have seen the ganglion adhere to the edge of the trunk itself, but this may not affect its true character. The grey substance which ought to be present in every true ganglion is, with difficulty, to be made out occasionally.

3. *Nerves from the ganglion.—a.* The palatine nerves may be described as anterior, posterior, and intermediate. The anterior is the *great palatine* nerve, which descends through the posterior palatine canal to the soft palate, and is there distributed. In its course it furnishes branches, 1, to the pituitary membrane of the middle meatus and of the middle and inferior turbinated bones; 2, several small

branches which traverse the inner wall of the antrum and proceed to the last molar teeth of the upper jaw; 3, branches to the pendulous palate, and especially to the soft palate, in which these nerves terminate.

The *posterior palatine* is distributed to the mucous membrane of the nasal aspect of the soft palate.

b. Spheno-palatine, or *posterior nasal*.—These are very delicate nerves which enter the nasal fossæ by the spheno-palatine foramina, and are expanded, between the periosteum and the pituitary membrane, upon the membrane of the septum, and next investing the exterior wall of the nasal fossæ. Having reached the superior orifice of the anterior palatine canal, they enter each a special orifice leading to a canal distant from the anterior palatine. At this point their further course is a matter of difficulty. According to M. Cloquet these two nerves terminate in a ganglion (naso-palatine), without reaching the mouth. I have occasionally seen a small rounded body in this situation without being able to determine its real nature. The structures connected with these canals, with the anterior palatine and intermaxillary bones, are probably merely rudimentary in man, vestiges of structures more highly developed in some hitherto unexplored class of animals, recent or fossil.

One thing is certain,—filaments of these nerves may be traced to the prominence of the mucous membrane immediately behind the incisive teeth.

These nerves, together with the external branches of the nerve I now describe, are best seen by stripping the pituitary membrane and periosteum from off the osseous surfaces.

c. Vidian or *pterygoidean*.—Different views have been taken of the course and connexions of this nerve; I shall notice only the more generally received opinions.

Arising from, or terminating in, the ganglion of Meckel, the vidian nerve penetrates almost immediately into the canal of Vidus Vidius (pterygoidean); on leaving this it crosses diagonally the cartilaginous substance filling the *foramen lacerum medium* (by some called anterius), and divides into two filaments; 1, a *superior*, *cranial*, or *superficial petrosal*; 2, a *deep* or *carotid* branch. This division may take place in the ganglion of Meckel itself.

1. The *superior* or *petrosal*, *entering the cranium*, is lodged in a groove of the pars petrosa of the temporal bone; this leads to the hiatus of Fallopius, into which the nerve penetrates. By the hiatus the nerve enters the canal of Fallopius, containing the portio dura of the seventh pair of nerves; and here the vidian has always seemed to me to terminate by anastomosing with the portio dura. By this I do not mean that the nervous fibres of the vidian are merged in those of the portio dura, but merely that the vidian cannot be traced further as a *distinct* nerve. This question has nothing to do with the ultimate course of its filaments. My meaning is simply this. There is a fusion

of the two nerves at this point, and not a mere juxta-position. But according to others the union is merely apparent, and the vidian, continuing its course along with the facial, quits it whilst descending behind the tympanum, by an aperture leading into that cavity, traverses the tympanum, getting the name of corda tympani, and, leaving it by a fissure near that of Glasser, places itself upon the inferior edge of the lingual branch of the inferior maxillary division of the fifth: coursing along the inferior margin of the nerve, the vidian, now called corda tympani, leaves the lingual to connect itself with the submaxillary ganglion.

A great part of this anatomy is true and easily proved; a part is at least doubtful.

2. *The descending or carotid branch of the vidian* is larger than the cranial or superior portion of the continuation of the trunk. It rests against the internal carotid artery, where it concurs in forming the carotid plexus, and here it anastomoses with the nerves which connect the superior cervical ganglion to the sixth pair of cranial nerves. There is a small ganglion at the junction of these nerves. I have frequently seen two distinct carotid branches (nervi molles) ascending from the superior cervical ganglion; one, *the vidian*, proceeding to the ganglion of Meckel; the other to the sixth, apparently.*

Anatomists are not yet agreed as to the true nature of the vidian: at the point of union with the facial I have seen a bluish-grey appearance, indicative of a change in character. Neither is it clear to what description of nerves the vidian belongs.

Finally, it has always appeared to me that the cranial branch of the vidian resembles the cranio-rachidian nerves, and the carotid filament the sympathetic. If this view be adopted, the inferior branch of the vidian would form the ramus communicans between the superior cervical ganglia and that of Meckel, which in this case would belong to the system of the sympathetic nerves; whilst the superior branch of the vidian would be the anastomosing branch connecting the sympathies of the facial and superior maxillary.

The corda tympani in this view would be merely a branch of the inferior maxillary detached to join the sub-maxillary ganglion. But the physiology of these intricate nerves is as yet purely conjectural.

4. *Posterior alveolo-dentar nerves.* — These nerves are detached close to the ganglion of Meckel from the superior maxillary; their name indicates their nature and course: applied against the maxillary tuberosity, they enter, after giving off a few filaments, the osseous canals hollowed out in the substance of the tuberosity, and here divide into two sets of branches, of which the inferior, forming numerous remarkable areolæ in the thickness of the bone, terminate at last in many delicate filaments, which, entering the alveoli, proceed to the

* In the horse, this nerve, as it approaches the sixth, divides, passes the sixth, and reunites beyond it. It joins the fifth.

pulps of the wisdom and small molar teeth. No bone receives so many nerves as the superior maxillary.

5. *Anterior alveolo-dentar nerve.*—This is the only branch which the superior maxillary nerve sends off whilst passing through the sub-orbitar canal. It is so large a branch that it might almost be viewed as a bifurcation of the great terminal branch of the superior maxillary.

It enters a special canal in the superior maxillary bone, and remains contained in the substance of the bone. Having descended to the level of the floor of the nasal fossæ, it subdivides into a great number of filaments which proceed to the pulps of the incisive, canine, and first molar teeth. A great number of filaments go to the maxillary bone itself.

6. *Sub-orbitar nerve.*—Terminating branch of the superior maxillary nerve.

Whilst in the infra or sub-orbital canal, the filaments of this nerve are placed merely in juxta-position. At the infra-orbitar opening they pass outwards upon the face, diverging immediately on escaping from the canal. Some pass upwards to the integuments of the lower eyelid; others inwards towards the nose; a third set proceeds in great numbers to the integuments of the upper lip. The nerve then is the nerve of sensation of all these surfaces.

Below the orbit it is intricately interlaced with the facial, forming here the *sub-orbital plexus.*

Inferior maxillary nerve. — Third division of the fifth pair.— This division of the nerve, like the preceding, requires to be examined internally and externally. The osseous parts with which it is connected must also, as in the case of the superior maxillary, be frequently referred to.

After a very short course, the nerve I now describe, the larger division of the fifth pair, leaves the cranium by the foramen ovale. It is accompanied by the nerves of Palletta, that is to say, by the motor division of the fifth, which, avoiding the Casserian ganglion, joins this division only. It is this division, then, and not the entire fifth, which so strictly resembles the ordinary spinal nerves.

From the nerve thus formed, of a sentient and motor portion, intimately united, seven branches arise as follows:—

1. The deep temporal. 2. The masseteric. 3. The buccal. 4. The internal pterygoid. 5. The auriculo-temporal. 6. The lingual. 7. The inferior dentar.

1. *The deep temporal nerve*, situated in the zygomatic fossa, enters the deepest layers of the temporal muscle, to which it is distributed.

2. *Nerve to the masseter muscle.*—This is a nerve of some size. It passes over the incisura sigmoidea of the lower jaw-bone, and enters the masseter muscle by its deep aspect.

3. *The buccal*, also called labio-buccal, is a still larger and more remarkable nerve. It arises by two or three roots; traverses

the external pterygoid muscle; descends between the coronoid process and the maxillary tuberosity; gives filaments to the pterygoideus externus, some filaments to the temporal, and terminates at last by a great number of filaments in the buccinator muscle.

But the nerve anastomoses freely with branches of the facial, and sends many branches to the integuments of the cheek.

4. *Nerve to the internal pterygoid muscle.*—This is a very slender nerve. It is in close contact with the otic ganglion. It is distributed to the above-mentioned muscle.

5. *Auriculo-temporal.*—This is a large branch of the inferior maxillary. Arising sometimes by a great number of roots, it passes behind the neck of the condyle of the lower jaw, and divides into two branches. The *ascending* or *temporal* passes upwards between the articulation and the external auditory canal. It soon reaches the integuments of the temporal region, to which it is distributed.

As it proceeds in its course it gives off a strong anastomotic branch to the facial, which almost resembles an additional root to that nerve, for it is sensibly increased after the anastomotic branch joins it. Physiologically, this communicating branch is of considerable importance. The temporal branch I now describe furnishes a plexus, which follows the course of the temporal artery.

The *inferior* or *descending* branch of the auriculo-temporal nerve forms a plexus behind the condyle around the internal maxillary artery, in which occasionally may be found a few ganglions, and divides into a number of branches, of which some pierce the parotid and proceed to the lobe of the ear: others anastomose with filaments of the cervical plexus; one joins the dentar nerve as it is about to enter the dentar canal.

6. *Lingual nerve.*—The course of this remarkable branch of the superior maxillary nerve has been in a great measure already described whilst describing the muscles.

It is situated at first between the two pterygoids, then between the internal pterygoid and the branch of the lower jaw, passing from this forward along the upper margin of the sub-maxillary gland, which it crosses in order to reach the corresponding margin of the tongue, in the substance of which it expands. The canal of Warton is placed on its inner side, and crosses it at an acute angle. Whilst passing between the pterygoids this nerve receives, at an acute angle, the *corda tympani*. This branch of the *facial*, or, as some consider it, of the *vidian*, runs along the lower margin of the lingual, becoming at last incorporated with it. Some view it as one of the roots of the lingual. The lingual, now increased by the division of the corda tympani and by a branch from the dentar, not constant, however, gives, as it passes towards the tongue, a certain number of filaments to the tonsils, to the mucous membrane of the mouth, and to the gums.

When on a level with the sub-maxillary gland, the lingual transmits nerves to a ganglion situated close to it. This is the *sub-*

maxillary ganglion. Always distinct and present, this ganglion receives branches from the lower edge of the lingual, of which some proceed from behind forwards, others from before backwards. The branches which join it from behind forwards have been viewed as the *corda tympani* detached from the inferior edge of the lingual. This anatomy is, to a certain extent, theoretical. From the ganglion arise a great number of filaments, the greater number of which enter the sub-maxillary gland.

In the tongue, the lingual is at first placed on the margin above the hypoglossal, with which it communicates by an anastomosing branch. Traversing the lingual muscles, its filaments proceed to the nervous papillæ as far as the point of the tongue.

7. *Inferior dentar nerve.* — This nerve exceeds the preceding in size. It descends with it at first between the two pterygoids, then between the inner pterygoid and the ramus of the jaw. The aponeurotic lamina, called internal lateral ligament, retains it near the bone, and separates it from the lingual nerve and inner pterygoid muscle. It now enters the posterior opening of the inferior dentar canal, which it traverses throughout its whole extent. A fibrous sheath protects it whilst in the canal. As it passes along it furnishes filaments to the large and small molar teeth, and, arriving at the anterior opening, it divides into two branches; the one *mental* or integumentary, the other dentar or deep.

Before entering the inferior dentar canal, a remarkable branch is detached from the dentar nerve; it is the mylo-hyoidean, which proceeds, along with the artery, to the mylo-hyoideus muscle.

The *mental* branch, which escapes by the *foramen menti* (anterior opening of the inferior dentar canal), is distributed to the integuments of the chin and lips. It forms a plexus with the facial.

Its *dentar or incisive* branch, very slender, continues within the substance of the lower jaw, beneath the incisive teeth, the pulps of which it supplies with filaments.

OTIC GANGLION.—This ganglion was discovered by Arnold. His description is as follows:—"The otic ganglion is situated immediately under the foramen ovale, on the inner side of the third division of the fifth pair, a little above the origin of the superficial temporal or auricular, at the place where the nerve sends off the deep temporal and buccal, and at the spot where the motor root of the fifth pair joins inseparably the inferior maxillary nerve. Internally, the ganglion is covered by the cartilaginous portion of the Eustachian tube and by the origin of the external peristaphyline muscle; behind it touches the middle meningeal artery. Externally it rests on the trunk of the inferior maxillary."

The ganglion is connected to the maxillary by a short communicating branch. It seems to give off the pterygoid nerve. The tympanic nerve of the glosso-pharyngeal (nerve of Jacobson) sends a filament to the otic ganglion. The filament leaves the cavity of the

tympanum by a distinct canal, before the hiatus of Fallopius, and passing forward quits the cranium by a special aperture to join the ganglion. It runs parallel with the cranial branch of the vidian, from which, however, it is quite distinct. These filaments may be considered as the roots of the ganglion.

The branches it transmits peripherally are, 1, one to the internal muscle of the malleus; 2, one to the external peristaphyline muscle; 3, a few to the auriculo-temporal nerve.

Sixth Pair of Cranial Nerves.—The nerve of the sixth pair, also called *external motor*, arises on each side from the furrow dividing the pons from the bulb. It immediately forms two fasciculi or roots, which reunite in the cavernous sinus, into which the nerve penetrates. In its passage through the sinus it crosses the vertical portion of the internal carotid artery, and here it communicates by two or three filaments with the superior cervical ganglion. At this point also it communicates with the ophthalmic branch of Willis. Finally, it penetrates into the orbit by the widest part of the sphenoidal fissure, crosses the ophthalmic, under which it is placed, and gains the inner surface of the rectus externus muscle, to which its filaments are distributed.

Nerves of the Seventh Pair.—This pair of nerves is composed of two distinct nerves; the one called the *portio dura* or *facial;* the other the *portio mollis* or *auditory.*

1. *Central extremity of the portio dura of the seventh pair.*—The facial nerve arises in the deep hollow which separates the crus of the cerebellum from the protuberance, before the auditory nerve. It emerges from the anterior part of the restiform body under the form of a fasciculated ribbon: some filaments, at first apart, soon unite with it. From the moment it becomes free it has no neurilemma.

But the real origin of the nerve is much deeper. It can be traced through the restiform body as far as the fasciculus innominatus close to the median fissure of the calamus scriptorius.

2. *Central extremity of the portio mollis or auditory.*—This nerve arises in the same fossette as the facial and behind it: it has two distinct roots; one anterior, similar to the facial; the other posterior from the floor of the fourth ventricle near the calamus scriptorius.

Portio dura or facial.—Both portions of the seventh enter the internal auditory canal; here they separate. The portio mollis is distributed to the deep ear; the portio dura enters the aqueduct of Fallopius (facial canal), from which it escapes by the foramen stylo-mastoideum, the inferior orifice of that canal.

On leaving the stylo-mastoid foramen, it passes through the parotid gland, and, after a course of five or six lines, divides into two terminal branches, called temporo-facial and cervico-facial. These, by their filaments and anastomoses, cover the temple and side of the face.

In the auditory canal they receive some filaments from the acoustic.*

On a level with the hiatus of Fallopius the facial is joined by the cranial branch of the vidian. It was Ribes who first started the idea that the vidian does not unite inseparably with the facial, but simply places itself by its side, thus travelling along until it reaches the opening in the wall of the canal by which the aqueduct communicates with the tympanum. Passing into this opening, the vidian, admitting it to be so, is now called the corda tympani. After traversing the tympanum it leaves that cavity by the fissure close to that of Glasser, and, joining the lingual branch of the fifth at an acute angle, proceeds a certain way along with that nerve, leaving it ultimately to be connected with the submaxillary ganglion.

I have made many careful dissections to test the accuracy of this view, but have never found any appearances favourable to it. On the contrary, it has always appeared to me that the vidian incorporated itself at once with the facial ; at the point of junction I have two or three times observed a bluish-coloured enlargement having a ganglionic appearance.

This opinion, however, which I have always maintained, does not disprove the idea that some filaments derived from the vidian may assist in forming the corda tympani.

Before leaving the canal of Fallopius the facial gives off the corda tympani, which enters the tympanum by a special opening, crosses that cavity, passing between the handle of the malleus and the vertical branch of the incus, leaves it by a special aperture near the fissure of Glasser, and proceeds to join the lingual branch of the inferior maxillary.

Whilst in the canal of Fallopius the facial receives a branch from the pneumo-gastric.

Having left the canal, the facial, whilst in the parotid, gives off, 1, the *posterior auricular;* and, 2, a branch to the stylo-hyoid muscle. The posterior auricular supplies the extrinsic muscles of the ear.

Terminal branches.—1. *Temporo-facial.*—This great branch of the facial crosses in its course the neck of the condyle of the lower jaw, and receives here a branch or two from the auriculo-temporal branch of the inferior maxillary. The nerve now begins to spread out into branches which form loops or arches, and from these proceed filaments which cover all the temporal and facial regions as low as a line drawn from the ear to the base of the nose.

Of these numerous branches some proceed to the integuments, but by far the greater number to the muscles of the scalp and face. Beneath the orbit they form with the sub-orbitar branch of the superior maxillary a remarkable plexus.

To enumerate the various branches of this division of the facial

* The true nature of the *intermediate filaments* connecting the two portions of the seventh has not as yet been clearly made out.

would be merely to name the muscles of the fore part of the scalp and of the upper part of the face.

2. *The cervico-maxillary.*—The other great division of the facial, on leaving the parotid, descends to the angle of the jaw, where it subdivides into three or four branches, filaments from which supply the buccinator, orbicular of the lower lip, muscles acting on this lip and on the chin. It forms a sort of plexus by anastomosing with the terminating branches of the inferior dentar.

The branches of the cervical division of the nerve supply the platysma myoides and the levator menti.

The facial nerve is unquestionably the motor nerve of most of the muscles of the face. Its anatomical distribution renders all experiments on living animals instituted to prove this fact quite unnecessary. It acts mainly on the muscles, so called, of Expression.

AUDITORY NERVE.

Portio mollis of the Seventh Pair.

The auditory nerve, usually considered as the softest of all the nerves, which I have just traced to its entrance into the internal auditory canal, enters this passage along with the facial or portio dura, forming a kind of groove for the reception of that division of the seventh pair; it divides into two cords, which remain distinct whilst in the auditory canal. These traverse the cribriform plate of the bone in the bottom of the canal, and so reach the labyrinth. Through this plate the facial passes by a single opening; the auditory by several.

Of the two cords composing the auditory nerve, one, the anterior, proceeds to the cochlea; the other, the posterior, to the vestibule and semicircular canals.

The *cochlear* branch entering the cochlea by the base is distributed to the membranous surfaces assisting in forming the spiral septum and the columella: on the spiral septum these delicate filaments anastomose with each other.

The *vestibular* branch supplies the sacculus of the vestibule and the membranous semicircular canals.

The EIGHTH PAIR of cranial nerves consists, in fact, on each side, of three nerves, probably distinct: these are—1, the glosso-pharyngeal; 2, the nervus vagus, or pneumo-gastric; 3, the spinal accessory of Willis.

Central extremity of the eighth pair.—Little is known for certain of the *central extremity* of this or of any other nerve. The glosso-pharyngeal and pneumo-gastric seem to have a common origin; they come off, like spinal nerves, by a main series of filaments from the restiform bodies, on a level with the auditory. The filaments in which the roots of the glosso-pharyngeal commence are not distinct from those of the pneumo-gastric; nor can the origins of the latter be shown to be distinct from those of the spinal accessory. It is only

after they leave the medullary tract that they show themselves as three distinct nerves.

The central extremity of the spinal accessory of Willis is in the lateral portions of the cervical part of the medulla spinalis, between the anterior and posterior roots of the cervical nerves; they vary in number and in size, but generally do not extend below the level of the fifth cervical pair; they have been seen, however, as low as the seventh—an irregularity which is the regular origin in some animals. Some of the roots of the first cervical pair join those of the accessory before leaving the canal. Placed behind the *ligamentum dentatum*, the accessory ascends to the cranium, enters by the foramen magnum, and, with the glosso-pharyngeal and the pneumo-gastric, leaves that cavity by the fore part of the foramen lacerum posterius.

First division of the eighth pair.—A. The glosso-pharyngeal.—Its name expresses its destination. Originating in the restiform body, it leaves the cranium by the foramen lacerum posterius, enclosed in a fibrous sheath derived from the dura mater, in front of the pneumo-gastric and spinal accessory, and separated from the internal jugular vein by a cartilaginous, and sometimes an osseous, lamina.

In its passage through the foramen it presents a ganglion, or ganglifform enlargement, called the petrous ganglion, or ganglion of Andersch. This ganglion lies in a little excavation of the rocky part of the temporal; *receptaculum ganglii petrosi.* From the ganglion the nerve proceeds downwards, beneath the styloid muscles, and in front of the internal carotid artery, to terminate in the mucous membrane of the tongue.

In this passage the glosso-pharyngeal gives off the following branches:—1, the branch of Jacobson; 2, a branch to join the facial; 3, one to the pneumo-gastric and spinal accessory; 4, a branch to the digastric and stylo-pharyngeal muscles; 5, carotid filaments; 6, pharyngeal branches; 7, tonsillar: the nerve itself terminates (8) in the tongue.

1. *Nerve of Jacobson.*—On the crest of the pars petrosa, which separates the fossa juglandica from the carotid canal, may be seen a small opening: this is the commencement of the canal of Jacobson. By it the nerve I now speak of enters the canal, thus penetrating into the inner wall of the cavity of the tympanum. It here divides into three branches—1, a descending one, which opens into the carotid canal; 2, two ascending. Of these the anterior opens into the groove for the cranial branch of the vidian; the posterior into another groove running parallel with that for the vidian. Arnold has described six canals branching out from the canal of Jacobson, all transmitting branches arising from the nerve of Jacobson. Be this as it may, three nervous filaments are sufficiently distinct. One joins the carotid plexus; a second joins the vidian; the third proceeds to the otic ganglion so ably described by Arnold.

The second, third, fourth, and fifth branches given off by the glosso-pharyngeal require no special description, and are readily found on dissection. The pharyngeal branches (6) assist, with branches of the

pneumo-gastric, in forming the pharyngeal plexus. Filaments from the plexus proceed evidently to the superior and middle constrictors. The tonsillar filaments (7) are very numerous; they also form a kind of plexus. Lastly, and 8th, the lingual branch, the continuation and termination of the glosso-pharyngeal itself, enters the base of the tongue, where, spreading out in a variety of directions, its numerous filaments seem to terminate exclusively in the mucous membrane of that organ.

Many experiments have been made to determine the functions of this nerve, which in man is probably a rudimentary nerve, in some, at least, of its divisions. It is in fishes that we should expect to find its full development.

Second division of the eighth pair.—B. Nervus vagus—pneumo-gastric.—The pneumo-gastric is one of the most remarkable nerves in the body.

The filaments of origin coming from the restiform body unite into seven or eight fasciculi; then into a single cord, under which form it passes through the *foramen lacerum posterius*, descending thence to the thorax and abdomen.

It leaves the cranium by the same opening with the spinal accessory, distinct from the glosso-pharyngeal. Whilst in the foramen it forms a ganglion (ganglion of the pneumo-gastric), or, at least, the body of the nerve puts on a distinct gangliform appearance. From this ganglion there proceed—1st, a filament to the petrosal ganglion; 2d, a filament to join the facial nerve.

On leaving the foramen lacerum the nervus vagus puts on a plexiform appearance, which it maintains for a considerable length. It is here that a large division of the spinal accessory joins the trunk of the vagus. To this portion of the nerve I shall presently return. It is here, also, that the vagus anastomoses, by a fine filament, with the hypo-glossal and with the glosso-pharyngeal; finally, by a filament or two, with the great sympathetic, and more especially with its superior cervical ganglion.

In the neck the pneumo-gastric descends in front of the vertebral column, in the sheath of the vessels, between, and somewhat behind, the carotid artery internally, and the internal jugular vein externally. A quantity of cellular tissue separates it from the cord of the sympathetic.* In this part of its course it gives off—1, a pharyngeal branch; 2, the superior laryngeal; 3, cardiac filaments.

1. *The pharyngeal branch.*—This nerve, like the superior laryngeal, is not unfrequently derived in whole or part from that branch of the spinal accessory which joins the nervus vagus. It passes behind the internal carotid, and furnishes filaments to assist in forming the pharyngeal plexus.

2. *The superior laryngeal*, formed, as I have described above when speaking of the pharyngeal, but larger than it, descends by the side of

* Even here the nerve has a plexiform character, still more remarkable in the horse.

the pharynx behind the internal and external carotids. It next reaches the hyo-thyroid membrane or ligament, passing immediately above the superior margin of the inferior constrictor of the pharynx, passes a certain way between the ligament and thyro-hyoid muscle, traverses the membrane, and so reaches the aryteno-epiglottic fold of mucous membrane. Here it terminates by dividing into a great number of filaments.

In its course it sends off a branch called by some the external laryngeal; this branch communicates with the superior cervical ganglion, and transmits a filament or two which join the cardiac nerves, some filaments to the inferior constrictor, and finally supplies the crico-thyroid muscle.

The anterior branches of the terminating portion of the laryngeal proceed to the epiglottis; some of these may be traced to the base of the tongue: the posterior branches are more complex; they supply—1st, the mucous membrane around the superior orifice of the larynx and the rima of the glottis; 2d, from amongst these filaments, one proceeds to the arytenoid muscle; 3d, an anastomotic branch descends between the mucous membrane and the thyro-arytenoid and crico-arytenoid muscles as far as the posterior surface of the cricoid cartilage, where it unites with the inferior laryngeal or recurrent.

3. *The cardiac filaments* which the vagus sends off in the neck vary in number and volume. Of these some join the superior cardiac nerves; others proceed directly to the cardiac plexus. One arises from the vagus a short way above the cartilage of the first rib; on the right side it passes in front of the common carotid and brachio-cephalic arteries, and then unites with the superior cardiac nerve. The left crosses the arch of the aorta, beneath which it unites with the cardiac.

In the thorax the pneumo-gastric nerves differ from each other somewhat, though not in any essential or important manner.

The right enters the chest between the subclavian vein and artery; somewhat lower it passes behind the corresponding vena innominata in the furrow which separates the trachea from the gullet. It next reaches the back part of the root of the corresponding lung, where it spreads out and seems to become larger; it here furnishes a great number of branches, some of which unite again to reconstitute, as it were, the nerve. Beneath the root of the lung the right vagus is always divided into two flattened branches, which run along the right side of the gullet, unite when near the diaphragm to pass behind the gullet, and with it to enter the abdomen.

The *left vagus* enters the thorax between the common carotid and subclavian behind the left vena innominata; then it descends behind the left bronchus, over which it spreads out to be reconstituted into one or two branches, which, passing in front of the gullet, enter the abdomen with it. Whilst in the thorax the vagus gives off the following branches:—1, The inferior laryngeal or recurrent; 2, a cardiac branch; 3, tracheal and œsophageal branches. Moreover, it forms the *pulmonary plexus*, one of the most remarkable in the body.

1. *The inferior laryngeal or recurrent* comes off from the left vagus in front of the arch of the aorta, close to the remains of the ductus arteriosus. It passes around the inferior surface or concave side of the arch of the aorta, returning into the neck by the side of the trachea to terminate ultimately in the muscles of the larynx.

On the right side the recurrent nerve winds around the subclavian artery on its way to the larnyx; on reaching the inferior margin of the inferior constrictor of the pharynx, to which it furnishes some filaments, it passes beneath the muscle behind the smaller horns of the thyroid cartilage and crico-thyroid articulation.

I have not been able satisfactorily to prove the origin of any part of this nerve from the spinal accessory, although it possibly may receive some filaments from it. Where leaving the main trunk of the vagus the filaments connecting the laryngeal to the vagus have a plexiform appearance, and some seem to arise from the peripheral portion of the nerve as well as from the central.

The recurrents send off branches called cardiac; these unite with the cardiac filaments of the sympathetic and of the nervus vagus; also branches to the gullet much more numerous on the left than on the right side; 3d, branches to the trachea; 4th, pharyngeal filaments. The terminal branches, with the exception of the anastomotic branch to the superior laryngeal, all proceed to the muscles of the larynx; namely, to the posterior crico-arytenoid, to the arytenoideus, and to the thyro-arytenoid.*

2. Of *the cardiac branches* given off by the pneumo-gastric, some proceed to the pericardium, others to the formation of the cardiac plexus.

3. *The branches to the lungs* are divided into anterior and posterior. These latter assist in forming the posterior pulmonary plexuses, one on each side. They are not quite independent of each other, being connected together by strong anastomoses. Filaments from the sympathetic join these plexuses. The plexuses are situated behind the bronchi. Of the filaments they send out, some follow the pulmonary artery; these are but few. By far the greater number accompany the bronchi to their ultimate divisions. After giving off the pulmonary branches the pneumo-gastric distributes filaments to the gullet. These are numerous.†

C. *Of the pneumo-gastric in the abdomen.*—The right pneumo-gastric enters the abdomen behind the gullet; the left in front of that tube. The *left* distributes its branches to the cul-de-sac, to the anterior surface, and to the small curvature of the stomach. Some of its filaments reach the transverse sulcus of the liver.

The *right* furnishes much fewer branches to the stomach than the left. Its largest branch joins the solar plexus, of which it forms one of the principal originating branches.

* The tracheal branches anastomose freely with the great sympathetic.

† With the main branches of the vagi descending to the abdomen, they form an œsophageal plexus.

Third division of the eighth pair.—The spinal accessory of Willis.—The origin of this nerve has been already given, together with its anatomical relations, as far as the foramen lacerum, by which it leaves the cranium. It seems, to a certain extent, to hold to the nervus vagus the same relation which the anterior roots of the spinal nerves hold to the posterior, that is, it is the motor part. But exact anatomy does not bear out all that has been said in support of this view.

As it passes through the foramen lacerum it is closely connected to the ganglionic part of the vagus, which, however, it passes over without mingling with it. Having passed through the aperture just named, it bifurcates; one branch of this bifurcation unites with the vagus, the other proceeds vertically downwards between the internal jugular vein and the occipital artery, under the digastric and stylo-hyoid muscles, next beneath the sterno-mastoid muscle, traverses this muscle, and, descending still further, reaches the deep aspect of the trapezius muscle, in which it terminates.

Whilst traversing the sterno-mastoid, it gives several filaments to that muscle; these form a sort of plexus with branches of the third cervical. The spinal had already received an anastomosing branch or two from the communication between the second and third cervical pairs. The muscular branch, which supplies the trapezius, receives, on its anterior surface, some considerable branches from the third, fourth, and fifth cervical pairs.

If we now trace the branch which the spinal accessory sends to the vagus, we shall find that a portion, at least, of this branch may be traced to the pharyngeal branch of the pneumo-gastric, which it sometimes wholly forms; frequently also a portion to the superior laryngeal;* but I have not been able successfully to trace it to the recurrent.

The NINTH PAIR of cranial nerves, or *great hypoglossal*, is the twelfth pair of Sœmmering.

Its origin is from the furrow of separation between the corpora olivaria and pyramidalia by a linear series of filaments which unite into two groups. These traverse the dura mater separately, but reunite before leaving the osseous canal, by which they escape from the cranium.

Descending vertically between the internal carotid artery and the internal jugular vein, it finally crosses in front of the pneumo-gastric. Arriving under the posterior belly of the digastric, it here changes its course, crossing in front of the internal and external carotid arteries, and, being reflected from below upwards, it reaches the inferior surface of the tongue. At the last bend of the arch it forms it is situated about two lines above the hyoid bones. Anteriorly it is in relation to

* Of the accuracy of this view I satisfied myself by repeated dissections made in Paris in 1820–21.

the hyo-glossus muscle, covered by the anterior belly of the digastric and by the stylo-hyoid: next by the submaxillary gland and mylo-hyoideus muscle.

The hyo-glossus muscle separates the nerve from the lingual artery for a certain distance.

Branches and anastomoses.—1. Filaments of communication, forming sometimes a fine plexus, unite the nerve to the eighth pair. 2. It sends or receives from the superior cervical ganglia a fine filament. 3. It receives three filaments from the nervous loop formed by the first and second cervical pairs of spinal nerves. 4. On a level with the edge of the hyo-glossus muscle it furnishes a remarkable anastomotic branch, forming a wide loop with the lingual (fifth). 5. The most remarkable of its branches is the descendens noni. This remarkable nerve, the function of which seems to be to place the muscles it supplies with branches in sympathetic relation with the tongue, of which the hypoglossal is the motor nerve, leaves the main trunk as it changes its direction, descends vertically in front of the internal carotid artery, then before the common carotid, and, curving outwards, anastomoses over the internal jugular vein with a descending branch from the cervical plexus, thus forming a wide loop or arch of a plexiform character. From the convexity of that arch so formed two branches proceed; one, the internal, to the omo-hyoideus; the other, external, subdivides into two branches, one destined for the sterno-hyoideus, the other for the sterno-thyroideus. As to the origin of the descendens noni, it may be said to come as much from the first and second cervical pairs of nerves as from the ninth cranial; dissections made many years ago led me to view the system of the descendens noni as a plexus of nerves; and such I have always described it to be. Its mode of communication superiorly with the ninth is peculiar, for the connecting filaments come more from the terminal portion of the nerve than from the central, following in fact a retrograde course. I have seen not unfrequently a second nervous loop formed inferiorly between the fourth pair of cervical nerves and the descendens noni. But all these nervous communications present many varieties. 6. The hypoglossal sends a small muscular branch to the superior part of the muscles of the sub-hyoidian region. 7. Muscular branches are detached from it to the hyo-glossus and stylo-glossus. 8. The nerve terminates by sending filaments to the genio-hyoideus, genio-glossus, and to the intrinsic muscles of the tongue. Thus the tongue receives nerves from three sources; namely, from the hypoglossal, from the lingual, and from the glosso-pharyngeal. Of these the ninth is the motor nerve; the others are connected with sensation and sympathetic action and sensation.

THE GREAT SYMPATHETIC NERVE.

Anatomists soon after the revival of literature and science became aware that there existed in man, and in vertebrate animals generally, another system of nerves, differing somewhat in their physical character, and still more so in their physiological attributes, from the system already described. They observed that the nerves, or nervous system, I am about to describe, were distributed mainly, if not wholly, to the viscera of the thorax, abdomen, and pelvis; that, generally speaking, they were limited in their distribution to the trunk, including the head; that their basis was measured by the length of the vertebral column, including, however, the cranial vertebræ; and lastly, that their connexion with the spinal marrow and encephalon was *indirect*.

As regards the *functions* of this great segment of the nervous system, it was not difficult to observe that the organs to which its nervous filaments proceed are, with certain exceptions, insensible whilst in a healthy condition; that the system shows, under experiment, neither sensibility nor irritability, and seems to be withdrawn from the cognizance of the individual. Nevertheless it was impossible to deny the importance of a system which supplies the heart, the bowels, the liver, kidneys, and other important organs, with nervous filaments, and hence the name of the Great Sympathetic was given to a system whose functions are still all but unknown.

Minute anatomy and microscopic research have of late years somewhat extended the knowledge of the anatomist in respect to this system of nerves and ganglions (for of these it is essentially composed); but before I speak of these additions to our knowledge I shall first explain the mode of dissecting and displaying the system so as to form a basis for the student's further inquiries into a department of anatomy, physiology, and pathology as yet exceedingly obscure.

Dissection.—Select for this purpose a young anatomical subject. Lay open the great splanchnic cavities cautiously but fully; retain the viscera as much as possible in their place. Meckel, if I recollect aright, commences his view of the system with the semilunar ganglion and solar plexus as the centre of the system; but although this may be the more philosophic method, it is not so practical as the method I venture to recommend, and might embarrass the student. I speak from great practical experience in these matters, and a full recollection of the extensive labours in comparative anatomy I found it necessary to embark in, before I could distinctly see the relations of this system, even anatomically, to the cerebro-spinal system.

LIMITS OF THE BASIS OF THE SYSTEM.

The *great sympathetic*, called also the system of the ganglions, system of the nerves of organic or nutritive life, vegetative system of nerves, &c., if the view be confined to the series of ganglions and their connecting filaments, which seem to form the natural basis of the

Fig. 226.*

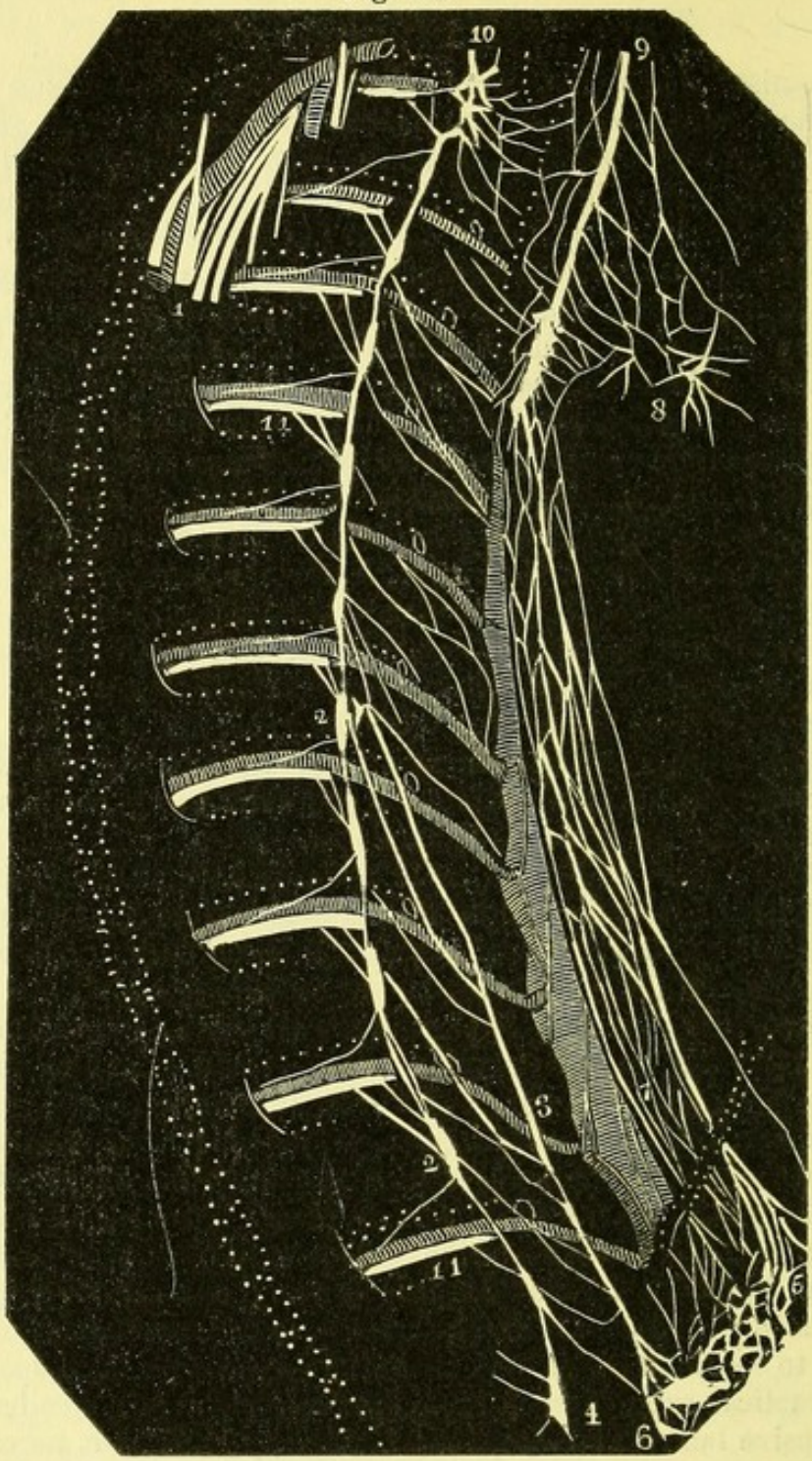

* Fig. 226.—Showing the distribution of the thoracic portion of the great sympathetic, and of the nervus vagus, whilst passing through the chest; the remarkable plexiform arrangement of the latter, and its intimate connexion with the sympathetic by means of the semilunar ganglion and solar plexus.—9, nervus vagus of the right side; 8, branches to the pulmonary plexus; 7 is placed on the lower portion of the œsophageal plexus of the nervus vagus, a little above the diaphragm; 5 is placed between the filaments it sends to the semilunar ganglion and its stomachic branches, here represented as cut short; 10, inferior cervical ganglion and first thoracic ganglion of the great sympathetic; 2, 2 point to the same system of ganglions and communicating

system, extends on each side of the vertebral column from the first cervical vertebra to the last sacral, or even the coccygeal. And this is the view I feel still disposed to adopt, admitting, however, that in all probability the *basis* of the system includes not merely the series of ganglions and their connecting filaments, which extend from the first cervical vertebra to the coccygeal, but ought, viewed philosophically, to include the series of ganglions, whatever form they may assume, which are situated anterior to the first cervical, as far at least as the cavernous sinus.

For the sake of method I shall, for the present at least, consider the two series of ganglions and their connecting filaments, already spoken of, as the basis of the sympathetic system of nerves.

Two extended cords, interrupted by ganglions, extend from the first cervical vertebra to the coccygeal. 1. All these ganglions are connected to each other by *filaments* of communication; these constitute the cords. 2. From, or to these ganglions proceed other filaments, of which some join the cerebro-spinal system of nerves, others proceed to the organs of the body. 3. Certain filaments leave the ganglions of the basis, and terminate in other ganglions situated amongst the viscera, from which *secondary ganglions*, if I may so call them, nervous filaments proceed in great numbers to the viscera.

CERVICAL PORTION OF THE GREAT SYMPATHETIC.

Commence with the *superior cervical ganglion.* This remarkable ganglion is situated in front of the second and third cervical vertebræ upon the rectus anticus muscle. From the ganglion a branch passes upwards into the carotid canal; this branch divides into two as it enters the canal, which by their interlacing form a *plexus* in the cavernous sinus, whence proceed branches to the sixth cranial pair of nerves always, and sometimes to the fifth. The same branch sends a filament to the vidian, and thus reaches the ganglion of Meckel, for both branches of the vidian are connected with the ganglion of Meckel. This is called the inferior branch of the vidian.

The cavernous plexus is situated to the inside of the carotid artery, as that vessel is about to enter the cavernous sinus. From this plexus arise filaments, which may be traced to the third pair, to the lenticular ganglion, to the fifth pair, and, finally, three which accompany the carotid artery.

From the superior cervical ganglion pass its anterior branches, communicating with the glosso-pharyngeal and pneumo-gastric nerves, and with the hypo-glossal.

cord lower down in the chest: from these ganglia may be traced the branch which each sends to or receives from the intercostal nerves. 11 is placed on one of the intercostal nerves; 0, 0, 0, 0, 0, 0, 0, 0, 0, intercostal arteries; 3, 4, greater and smaller splanchnic nerves; 6 points to the union of these nerves with the semilunar ganglion in the abdomen, beneath the diaphragm; 1, a portion of the brachial plexus. *** A double dotted line marks the position of the diaphragm.

By its external branches this ganglion communicates with the first, second, and third pairs of cervical nerves.

By its inferior, descending in the neck, behind the great vessels and the inferior thyroid artery, it communicates with

The *middle cervical ganglion*.—Its internal branches are divided into those following the branches of the external carotid artery, and five visceral branches, viz., the pharyngeal branches, the laryngeal, and the *cardiac*. The middle cervical ganglion is frequently wanting, in which case the *ramus communicans*—that is, the root or basis of the system—goes to the inferior cervical ganglion.

Haller called the middle cervical ganglion the *thyroid*, in consequence of its being generally placed in close union with the inferior thyroid artery. When this ganglion exists it communicates, of course, with the one above, and with the other below it; externally, with the third, fourth, or fifth cervical pair of nerves; internally, it gives off the middle or great cardiac nerve of Scarpa.

The *inferior cervical ganglion* is very constant, and belongs as much to the thorax as to the neck. It is placed in front of the transverse process of the seventh cervical vertebra and the head of the first rib, behind the origin of the vertebral artery. Besides the *rami communicantes* it gives off a branch following the vertebral artery; it communicates with the sixth, seventh, and eighth cervical pairs, and sometimes with the first dorsal.

Other branches pass in front of, and behind, the subclavian artery, forming a nervous ring or loop; these join, first, the *thoracic ganglion*; finally, it usually gives off the *inferior cardiac nerve*.

Before proceeding to the dissection of the thoracic portion of the sympathetic system, the dissector may follow the vertebral and the cardiac nerves. Trace the *vertebral nerve* through the canal for the vertebral artery, which it follows. M. Cruveilhier thinks that this filament connects the inferior cervical ganglion with the third, fourth, and fifth pairs of cervical nerves.

The *cardiac nerves*, *right* and *left*, arise from the cervical ganglia; they are joined by some delicate filaments from the pneumo-gastric. If traced into the thorax they will be found placed upon the origins of the pulmonary artery and aorta, there forming the *cardiac plexus*, from which proceeds the coronary plexus, which follows the course of the coronary arteries, and, after leaving these, is distributed to the muscular tissue of the heart. These nerves present remarkable varieties. The right superior cardiac nerve is usually placed behind the common carotid artery, and descends, crossing the inferior thyroid; next penetrates into the thorax behind, but sometimes in front of, the subclavian artery; it follows the course of the brachio-cephalic artery, and thus reaches the posterior surface of the arch of the aorta. Here it anastomoses with the left cardiac nerves, and then joins the cardiac plexus.

The *middle cardiac nerve* of the right side arises from the middle cervical ganglion when present, and, when absent, from the cord of the

sympathetic itself; it is often the largest of the cardiac nerves; it proceeds to join the cardiac plexus.

The *inferior right cardiac nerve* comes from the inferior cervical ganglion, accompanies the middle cardiac, and, descending with it in front of the trachea, terminates in the cardiac plexus. The left cardiac nerves differ a little in their arrangement from the right cardiac, but not in any essential points. In the cardiac plexus, which some divide into an anterior and posterior, there is generally found a ganglion or two; they are placed chiefly between the aorta and the right branch of the pulmonary artery.

The thoracic portion of the great sympathetic consists of twelve ganglia and their filaments of communication. The cord thus formed on each side of the thorax, external to the pleura, crosses, in its course, the heads of the ribs, communicating above with the last cervical ganglion, and, below, with the first lumbar. The intercostal arteries and veins pass behind the cord, and the azygos vein runs parallel to it.

The branches proceeding from this portion of the great sympathetic are external and internal. The external are generally two for each ganglion, which it receives from, or sends to, the dorso-spinal (intercostal) nerves. The *internal* branches of the second, third, fourth, and fifth of the thoracic ganglia proceed either to the walls of the aorta or to the pulmonary plexus; the *internal* branches of the sixth, seventh, eighth, ninth, tenth, eleventh, and twelfth unite to form the *splanchnic* nerves; these are usually two on each side, a large and small. The larger is formed by branches from the sixth, seventh, eighth, and ninth, but sometimes also from the fourth and fifth thoracic ganglia: these unite to form a considerable trunk, which, after descending in a sloping manner over the sides of the vertebræ, the vena azygos, and thoracic duct, passes into the lower part of the posterior mediastinum, next through the diaphragm, generally by an opening peculiar to itself, and thus reaching the abdomen joins the semilunar ganglion.

The smaller splanchnic follows pretty nearly the same course, but generally joins the renal plexus.

The semilunar ganglion and solar plexus, although placed in the abdomen, belong in an especial manner, as regards their origin, or, at least, as regards the point of connexion with the basis of the system, to the thoracic portion of the great sympathetic. The ganglia composing the plexus are placed in the middle plane of the body, around and upon the cœliac artery, above the pancreas. Both the great splanchnics proceed into its larger portion, usually called the semilunar ganglion. Its form is so irregular as to defy description.

From the solar plexus proceed, as from a centre, *plexuses* following the course of the following arteries:—Diaphragmatic; cœliac, dividing into coronary, hepatic, and splenic; superior mesenteric; inferior mesenteric. The student will do well to trace these plexuses to the organs to which they are ultimately distributed.

Lumbar Portion of the Great Sympathetic.—The lumbar ganglia are four or five on each side, placed upon the sides of the bodies of the lumbar vertebræ, and to the inner side of the psoas; they, of course, all communicate with each other, and with the last dorsal and first sacral ganglia; they have also *external* and *internal* branches.

The *external* hold the same relation to the lumbo-spinal nerves as the external branches of the thoracic ganglia do to the dorso-spinal nerves.

The internal branches assist in forming the inferior mesenteric plexus, and, moreover, constitute the aortic plexus; also the hypogastric plexus. There are two *hypogastric plexuses*, a right and left. They occupy the lateral and inferior part of the rectum and bladder in man, and of the rectum, vagina, and bladder in woman. These plexuses (hypogastric) receive filaments from several other sources, and in an especial manner from the anterior branches of the sacro-spinal nerves; from these are given off the following secondary plexuses, following the course of the arteries, viz., the hæmorrhoidal, vesical, vaginal, uterine, testicular, and ovarian.

The Sacral or Pelvic Portion of the Great Sympathetic.—This consists of a series of ganglia and their connecting filaments, placed in front of the sacral vertebræ and behind the rectum, generally four in number on each side. The system usually terminates by anastomoses between the right and left sympathetic cords, on the anterior surface of the first coccygeal vertebra: at the point of union there is usually placed a small ganglion—the *ganglion impar*. The sacral ganglia, in respect to their branches, resemble the other portions of the system,—that is, they transmit filaments of communication—1st, to the nearest spinal nerves; 2d, filaments to the adjoining organs.

ORGANS OF SENSE.

THE NOSE.

THE nose, besides being the special organ of the sense of smell, performs other functions. It forms the commencement of the respiratory tube, and hence is connected with respiration and with the voice. The function of taste seems partly also to depend on the integrity of the nasal functions; and by its muscles it assists in expressing the passions and feelings of the mind.

The organ consists,—1, of the anterior prominent part, composed of bone, cartilages, and muscles; 2, two orifices, the anterior nares; 3, the nasal fossæ; 4, two apertures called the posterior nares.

A partition (septum narium) with bony and cartilaginous walls separates the nasal fossæ from each other. Lastly, the nasal cavity or cavities communicate with others which may be called their appendages; these are the frontal, ethmoidal, sphenoidal, and maxillary sinuses. By the posterior nares they communicate directly with the pharynx.

1. The *bones* of the nose have been already described.

2. *Cartilages.*—Five on each side, namely, two larger and three smaller. The larger are called the upper and lower lateral cartilages; the smaller are named sesamoid. In addition to these there is a central piece, or cartilage of the septum.

The upper lateral cartilages are flattened and triangular; their inner margins do not touch those of the opposite side, but are connected to the margins of the cartilage of the septum. A fibrous membrane connects their other margins to the superior maxillary bone, to the nasal bones above, and to the lower lateral cartilages below.

Fig. 227.*

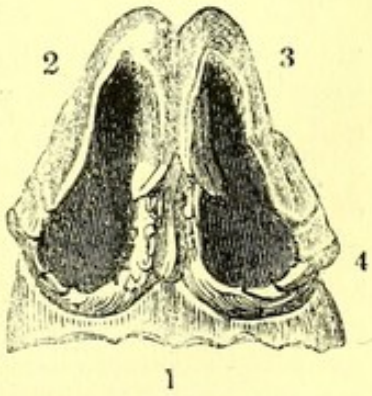

The lower lateral cartilages are each curved inwards and mesially, and thus chiefly form the apertures of the nostrils. These cartilages are connected above by a fibrous membrane to the upper lateral car-

* Fig. 227.—View of the cartilages of the nose, looking into the nostrils from below.—1, mesial line, position of the cartilaginous septum; 2, right lateral cartilage; 3, left lateral cartilage; 4, sesamoid cartilages.

tilages; externally to the superior maxillary bone, and internally to the lower and fore part of the cartilage of the septum.

The smaller or sesamoid cartilages, two or three on each side, complete the arch of the aperture of the nostrils. They are developed in the fibrous membrane connecting the lower lateral cartilage to the maxillary bone. A considerable portion of the margin of the nostrils is unsupported by any cartilage.

3. The larger muscles of the nose have been already described. The integuments of the nose abound with sebaceous follicles, and are otherwise peculiar. The short, stiff, and somewhat curved hairs, growing from the inner surface of the alæ and septum, are called vibrissæ.

The apparatus just described forms a cavity (the vestibule), small in man, large in the horse; distinct from the nasal fossæ, from which in that animal it may be shut out.*

Nasal fossæ.—These cavities, which are usually, and have been so described whilst considering the skeleton, nevertheless merit a careful examination in the recent state.

PITUITARY, MUCOUS, OR SCHNEIDERIAN MEMBRANE.

A peculiar mucous membrane lines the cavities of the nostrils throughout, extending into the sinuses, continuous with the integument at the margin of the cavity of the *vestibule*, with the mucous membrane of the pharynx and palate posteriorly, and with the conjunctiva oculi by the nasal duct and puncta lachrymalia. It varies in thickness and in vascularity. The membrane where it invests the sinuses is pale and thin, and differs greatly from that investing the walls of the fossæ and the turbinated bones. The general effect of the membrane is to diminish the size of the various cavities and apertures seen in the skeleton. Some (the spheno-palatine, anterior palatine) it closes up. The microscope shows that the membrane is protected by a layer of epithelium, which, anteriorly, is laminated. The membrane contains likewise a layer of mucous glands. Where it invests the sinuses, it shows, under the microscope, vibratile cilia.

The *blood-vessels* of the nose merit no special description. The arteries have been already enumerated in the history of the blood-vessels, and are chiefly branches from the facial, internal maxillary, and ophthalmic. The veins join the facial and ophthalmic trunks.

The *nerves* are numerous. The most important is the olfactory, or first cerebral pair. The origin, course, and ultimate distribution of these nerves have been already described.† The nerves of the septum are rather more distinct than those of the outer wall; they are no longer visible on the lower fourth of the septum. The

* In man the cartilage and muscles by which this is effected are almost vestigiary; they are most highly developed in the whale.

† See chapter on the Nervous System.

branches of the olfactory nerves have been traced to the membrane covering the lower spongy bones and to the portion investing the middle and lower meatus. For a minute history of the other nerves supplying the structure and mucous membrane of the nose, see the Chapter on Neurology.

MINUTE MUSCLES IN CONNEXION WITH THE NOSTRILS.

There are several muscles and cartilages connected with the mechanism of the human nostrils which, though merely rudimentary or vestigiary structures in man, are much more highly developed in animals lower in the scale of creation. The first of these is a muscular slip described by Santorini. This muscular slip lies beneath the levator labii superioris alæque nasi, and is connected by its lower end with the origin of the compressor nasi. It is about an inch in length, and was called by Albinus "anomalus," in consequence of being attached only to bone, and therefore having no apparent action. Santorini called it rhomboideus. This muscle seems to occupy the space of the powerful muscle which, in the Rorqual, descends from the superior maxillary, or intermaxillary bones, to be attached to the vast cartilage filling up the nostrils of the whale. In man the muscle is rudimentary, and so also is the cartilage to which, I think, it is attached, and which is represented in man by a small fibro-cartilage attached to the anterior extremity of the lower turbinated bone.

Fig. 228.*

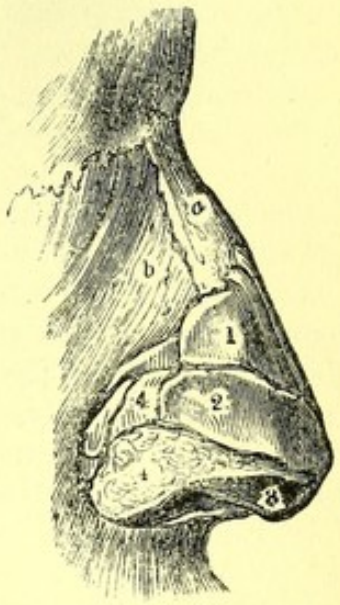

The remaining muscular fibres connected with the small cartilages and orifices of the nostrils have been lately arranged by Thiele under two heads—the dilator naris posterior and dil. naris anterior.

To display these, remove carefully the common elevator from its origin, and lay it down in connexion with the orbicularis muscle below. Cut through the compressor nasi without altogether removing it. The fibres of the *dilator posterior* may now be seen attached to the margin of the ascending process of the superior maxillary bone and the sesamoid cartilages of the alæ on one hand, and to the skin on the other. The *dilator anterior* muscle is attached to the skin and to the cartilage of the alæ.

In addition to these, I believe that there exist other muscular fibres on the inner side of the ascending process of the maxillary bone in

* Fig. 228.—Bones and cartilages of the nose, right side.—*a*, right nasal bone; *b*, ascending process of the superior maxillary bone; 1, right superior lateral cartilage; 2, lower lateral cartilage, its outer part; 3, ditto ditto, its inner part; 4, 4, sesamoid cartilages, and peculiar portion of integument completing the nostrils.

Fig. 229.*

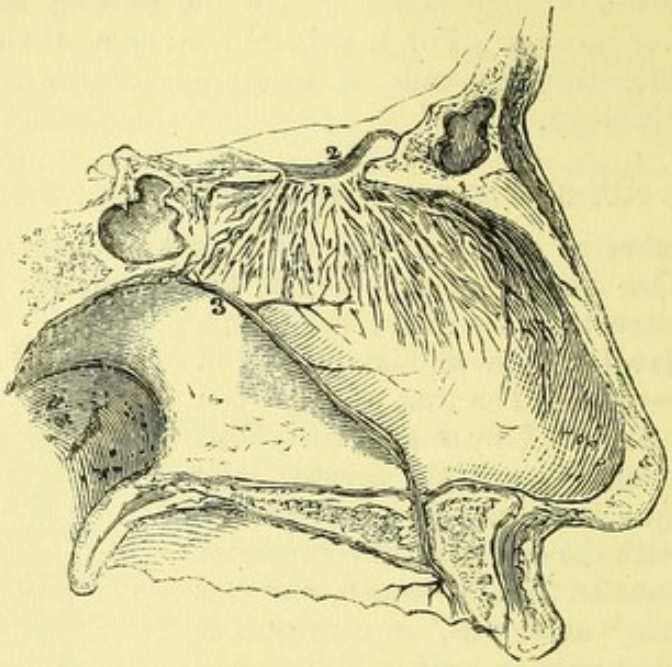

connexion with the small cartilage† just alluded to. They form a distinct muscle in the horse, and contribute to close the deep nasal cavities hermetically, and to cut off all communication with the vestibule and the deep nares. In man all these structures are rudimentary. The dilators may, I think, be traced to this cartilage.

THE TONGUE.

The extrinsic muscles of the tongue, together with its relations to the surrounding parts, and especially to the hyoid bones and larynx, have been already described. In this division of the work the tongue is viewed as the proper organ of taste, without omitting its relations to the function of deglutition, and consequently its relations, such as they are, to the organs of digestion.

Dissection.—Examine the tongue quite fresh, and when removed altogether from the body. A microscope will be required to make out the more minute structures; but a small lens of ordinary power will enable the student to take a good practical view of the organ.

The tongue assists in mastication, deglutition, and articulation. It varies in size in different persons. The base or root is backwards, the apex forwards; the base, and a great part of the lower surface, are

* Fig. 229.—Vertical section of the nostrils, to display the distribution of the olfactory nerves to that portion of the pituitary membrane investing the septum narium.—1, the nasal nerve, a branch of the first division of the fifth; 2, the olfactory, or first pair of nerves; 3, the naso-palatine, a branch of the second division of the fifth pair.

† The cartilage connected with the anterior extremity of the lower turbinated bone.

attached to other structures; the dorsum and margins, and the apex on all sides, are free.

The *attachments* of the tongue are, 1, by the general mucous membrane; 2, by the muscles already described, to other textures; 3, by the fibro-cellular tissue which unites it to the hyoid bones. On looking at the mucous membrane prior to all dissection, three folds may be observed; they are called glosso-epiglottic. The centre one is the best marked; it is not wholly formed by the mucous membrane, but is supported by a slender band of fibres of the yellow tissue, elastic and strong; these fibres, by their elasticity, give to the epiglottis its constantly vertical position, unless when pressed downwards in the act of deglutition. In some animals there exist, in the situation of this middle glosso-epiglottic fold, a pair of muscles (glosso-epiglottic), the substitute for which in man is the elastic ligament I now describe.

The three glosso-epiglottic folds give rise to two little depressions on either side the central fold.

Somewhat further out are two folds of mucous membrane connecting the tongue to the palate. These are the anterior pillars of the fauces already described, containing within them the constrictors of the fauces. By the mucous membrane the tongue is also extensively connected to the pharynx. Inferiorly and anteriorly a reflexion of the mucous membrane connects the tongue on each side with the gums; mesially this reflexion forms the *frenum*.

The free surface of the tongue, composed chiefly of the dorsum, is covered by a thin and smooth mucous membrane. This surface is not very sensitive. Below the apex, on each side the frenum, lie the lingual veins and arteries; hence the danger of rash operations there. On each side the frenum terminate the ducts of the submaxillary glands, which should be sought for and bristles passed into them; further back are the orifices of the ducts of the sublingual glands.

The upper surface of the tongue, called the *dorsum*, presents, 1, the trically. Towards line, a slight furrow dividing the tongue symme- *raphe*, or median the base the raphe leads to a depression called *foramen cœcum* by Morgagni: into this depression several mucous glands and follicles open. 2. The papillæ, found also on the apex and sides of the tongue. These papillæ, varying both in size and form, have been described as of three kinds.

1. *The large papillæ;* eight to fifteen in number, and arranged in two rows, describing the form of the letter V. They resemble inverted cones with the base turned upwards.

2. *The middle-sized papillæ* are more numerous than the last. They are small rounded eminences, scattered over the middle and fore part of the dorsum of the tongue.

3. *The smallest papillæ* (*p. minimæ*) include the conical and the filiform. They are the most numerous of all.

All these papillæ are highly vascular and sensitive: nerves proceed in abundance to them, and the nerve-tubes enter them. A squamous epithelium covers the papillary surface.

Numerous follicles and glands are found in connexion with the mucous membrane of the tongue. A group of such glands exists near the apex on the under surface: Blandin viewed them as a distinct gland.

Fig. 230.*

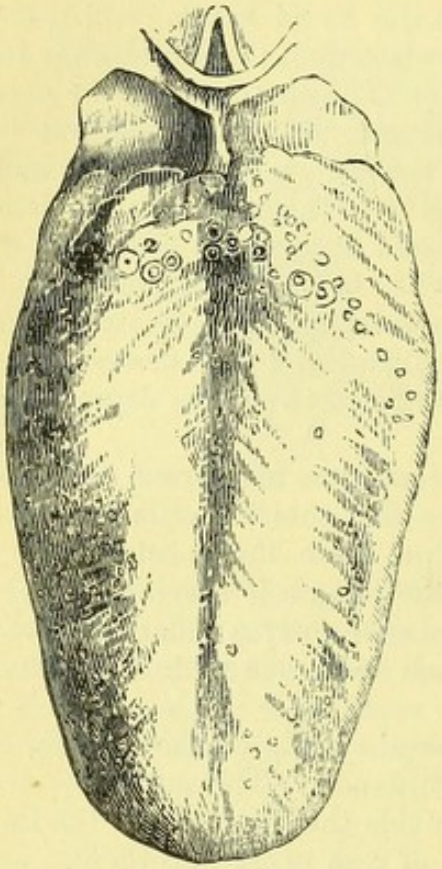

The tongue in man is essentially muscular: to prove this it is only necessary to cut it across at any point anterior to the base. The muscular fibres now alluded to are called the intrinsic muscles of the tongue, to distinguish them from the extrinsic already described. They are arranged in two principal longitudinal layers and a large mass of transverse fibres. By carefully directed incisions the course of the intrinsic fibres may readily be made out. The *vertical muscular fibres*, seen so distinctly on a transverse section of the tongue, originally described by Gerdy as a distinct muscle, are considered by Theile as merely the ascending fasciculi of the genio-glossal muscles, and the oblique bundles of the transverse intrinsic muscles.

The superficial longitudinal layer of these intrinsic muscles has been called *lingualis superficialis*. It is placed immediately beneath the mucous membrane, and runs from the apex backwards to near the hyoid bones.

The inferior or deep longitudinal layer of intrinsic fibres has been long known, having been described by Douglas and Albinus: it is the lingualis muscle, in fact, already described. It extends from the base to the apex, between the genio-glossus and hyo-glossus muscles. Some of the fibres occasionally reach the hyoid bones.

The transverse muscles (*linguales transversi*) form, with the peculiar granular fat, a considerable portion of the bulk of the tongue. The median fibrous partition, to be presently described, divides them from each other.

A vertical layer of yellow elastic tissue divides the tongue mesially and longitudinally into two parts; it is best seen by a transverse section of the tongue. This vertical layer is connected with the hyoid bone and with the fibrous structure connecting the base of the organ to the body of the hyoid. Some of these structures are vestiges of more fully developed organs in other animals.

* Fig. 230.—To show the mucous and sentient surface of the tongue.—1, foramen cœcum of Morgagni; 2, 2, the papillæ vallatæ.

The arteries of the tongue are derived from the lingual, the facial, and the ascending pharyngeal.

The nerves of the tongue are three on each side:—

1. The lingual branch of the fifth pair, called gustatory: it supplies the papillæ and mucous membrane of the fore part and apex of the tongue.

2. The lingual branch of the glosso-pharyngeal. This supplies the mucous membrane of the base and the larger papillæ.

3. The lingual, hypoglossal, or ninth pair; distributed to the muscles; it is the motor nerve of the tongue.

THE EAR.

It is usual to describe the organ of hearing as composed, on each side, of—1st, an external ear; 2d, a middle ear; 3d, a deep or internal ear.

Of these three sets of organs the deep alone is the essential part of the organ of hearing, the more external parts being mere accessories.

Of many of these various and very complex structures the functions are wholly unknown.

The EXTERNAL EAR (*auricula; pinna auriculæ*) presents the following prominences and depressions:—1. the helix; 2, the grooves of the helix; 3, the anti-helix; 4, the fossa navicularis; 5, the tragus; 6, the anti-tragus; 7, the concha; 8, the lobe of the ear. These forms are easily seen; they are peculiarly human, and, when finely and clearly defined, as in the antique ear, give to it great beauty. The lobe is found in no other animal but man.

The whole configuration is liable, however, to many deformities, which all more or less represent the condition of the ears in a fœtal state, or which represent the ears of animals lower in the scale.*

To examine these structures requires little or no dissection. When this, however, is appealed to, it will be found that the apparatus is more complex than was at first supposed. By removing the integuments cautiously the following anatomical facts may be made out:—

1. The skin of this region is remarkably fine and delicate. Its sebaceous follicles are numerous.

A cartilage forms the basis of the ear, but it does not extend into the lobe. In this cartilage there are fissures, minutely described by Santorini. Besides, this cartilage of the concha, as it is called, is continuous with that forming the cartilaginous tube, which passes towards the middle ear, and is connected by a fibrous membrane with the circumference of the osseous meatus. Thus the auditory canal is formed, extending from the cavity of the concha to the membrane of the tympanum, where the middle ear commences. Up to this point, the

* See the Manual of Artistic Anatomy.—R. KNOX.

organ, when disordered, is within the reach of surgical means; beyond that it is doubtful how far the surgeon can interfere.

The auditory canal,* thus partly osseous, partly cartilaginous, is completed by a fibrous membrane, which fills up the fissures in the cartilages composing it, and further connects it, on one hand, to the concha, and, on the other, to the temporal bone. I have seen purulent matter, formed in deep abscesses of the back of the neck, first appear externally by the meatus, having found it easier to penetrate the fibrous membrane of the tube, than to reach the surface through the strong fascia and tendinous muscles of the back of the neck. Thus *minute anatomy*, here, as elsewhere, explains pathological appearances otherwise unintelligible.

Above and behind, the fibrous membrane just described completes the auditory canal.

The *ligaments of the auricle* are—a superior, an anterior, and a posterior.

Its *extrinsic muscles* have been already described when speaking of the epicranial muscles.

The *intrinsic muscles* are rudimentary in man as compared with other animals, but they are usually quite distinct, and may be readily made out. They are—

The musculus tragicus.
,, anti-tragicus.
,, helicis major.
,, helicis minor.
,, auriculæ transversus.

If these muscles act at all, which is not impossible, their functions must be to impress minute motions on various portions of the cartilage of the concha.

The *auditory canal* is lined throughout by the integuments which cover also the membrane of the tympanum. The epidermis forms a complete sheath for the tube, as is proved by a prolonged maceration of the structures; it may then be withdrawn from the meatus, like the finger of a glove. At the upper and back part of the canal, beneath the skin, are the *ceruminous glands*, which secrete the peculiar substance called the wax of the ear—a yellowish, thick, bitter, and oily fluid, serving to protect the integumentary covering of the tube.

The arteries supplying the external ear are—the posterior auricular artery; the anterior, derived from the temporal; and a small branch from the occipital. The nerves are—the great auricular, a branch of the cervical plexus; the posterior auricular, a branch of the facial: the temporal branches of the facial supply the muscles.

The *cavity of the tympanum*, or middle ear, merits from the anatomical student a very careful examination. It may be laid open from without and from below, by removing the auditory canal and membrana tympani; or from above, by removing, with a strong scalpel, or chisel, its upper wall, which is merely the anterior part of the base of the

* See Fig. 231, next page.

pars petrosa. A fissure, or kind of suture, seen upon the cerebral aspect of the bone, between the squamous and petrous parts of the bone, points out where the removal of the bone should be effected. The outer surface of the mastoid process must be removed with the saw, or chisel and mallet: this will expose the mastoid cells. At this stage of the dissection the superior branch of the vidian may be traced into the portio dura. All this is best done if the bone, covered by all its soft parts, have been immersed for some time in an acid and spirituous liquor. Moreover, the cavity of the tympanum must be examined upon a dried preparation, from which all the soft parts have been removed by maceration; or a preparation of this kind, as well as the recent dissection, may be placed before the student, to enable him to understand the following description of the tympanum, its contents, and appendages.

Fig. 231.*

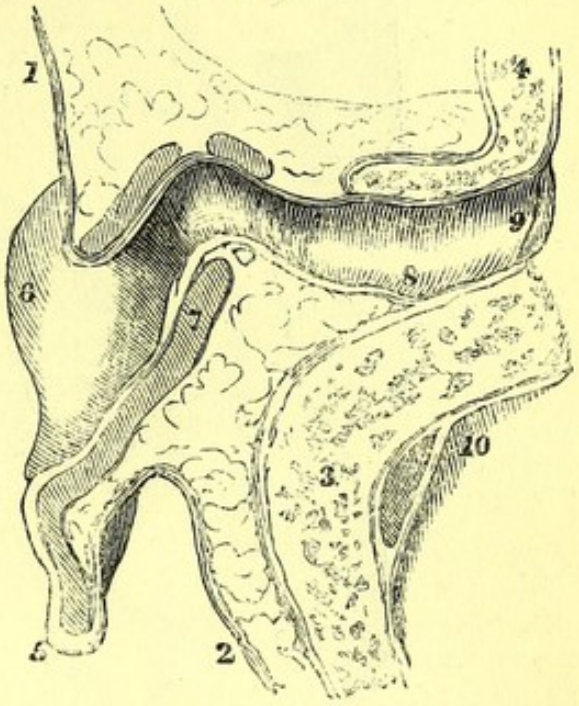

The *tympanum*, examined first on the macerated and clean bone, and afterwards with all its soft parts, is a very irregularly-shaped cavity, placed between the bottom of the external auditory canal and the labyrinth, behind the Eustachian tube, and in front of the mastoid cells. Its outer wall is formed by the membrana tympani, a complicated membrane, seemingly fibrous, and in young persons vascular. Upon the inner wall may be observed—1st, the fenestra ovalis, leading to the vestibule: this is closed by the base of the stapes; 2d, the promontory below the fenestra ovalis, marking the position of one of the scalæ of the cochlea; 3d, the fenestra rotunda: this leads from the tympanum to the inner scala of the cochlea. In the inferior wall of the tympanum may be seen the glenoid and a smaller fissure, through which pass the long process of the malleus and the corda tympani: the anterior muscle of the malleus and some blood-vessels enter here. In the posterior wall there is a canal, which leads to the mastoid cells; also an eminence called the pyramid, in which there is a small opening. The pyramid marks a cavity which contains a small muscle, the stapedius, whose tendon passes through the small opening spoken of.

* Fig. 231.—A horizontal section displaying the external auditory canal.—1, the integuments in front of the ear; 2, the integuments behind the ear; 3, mastoid process; 4, osseous part of the external auditory meatus; 5, back part of the pinna cut through; 6, the lobule; 7, cartilage of the auricula, as seen in the section; 8, external auditory meatus; 9, membrani tympani; 10, dura mater.

Fig. 232.*

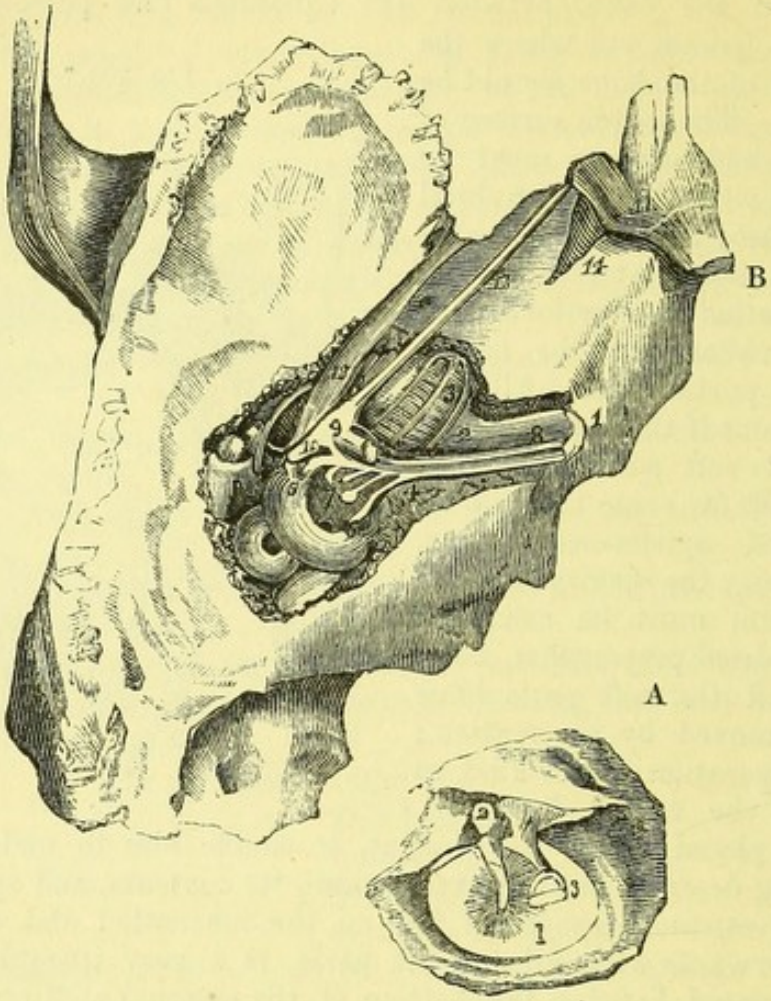

Below the pyramid is another opening, which leads into the canal of Fallopius; by this foramen the corda tympani passes into the tympanum. In the anterior wall there is the processus cochleariformis, above which is the canal for the tensor tympani muscle, and below is the Eustachian tube. By this tube, which is partly osseous, partly cartilaginous, air passes from the upper and fore part of the pharynx into the cavity of the tympanum.

The cavity of the tympanum contains a chain of small bones, *ossicula auditûs*, extending across it from the membrana tympani to the

* Fig. 232.—A. The membrani tympani, as seen on the inner side; the ossicula auditus have been left *in situ;* the base of the stapes is also seen, having been removed from the fenestra ovalis.—1, the membrana tympani; 2, the malleus; 3, the stapes; 4, the incus. B. Showing the distribution of the portio mollis.—1, situation of the meatus auditorius internus; 2, 3, 8, that portion of the portio mollis which supplies the cochlea; 8 is placed near the intermediate filaments of Wrisberg, connecting the portio mollis and portio dura: they are nearer to the fig. 2; 4, the portion of the portio mollis proceeding to the vestibule and semicircular canals; 5, filaments seen entering one of the semicircular canals; 7, distribution of the nerve to the membranous vestibule; 10, 9 are placed on the portio dura, which has been cut across: the nerve seen joining it from the front is the vidian, it is marked 13; 12, the tensor tympani muscle; 14, a small portion of the internal carotid artery; 11, the fifth pair and ganglion of Gasser.

deepest margin of the fenestra ovalis, or rather to the membranous vestibule. These are called malleus, incus, os lenticulare, and stapes. The os lenticulare is considered by many as a process of the incus. The malleus is placed vertically on the inner and upper part of the membrana tympani; it has a *head*, *neck*, *handle*, and long process described by Rau.

The incus has a body, a superior branch, and an inferior branch. The lenticular bone is articulated between the *long* branch of the incus and the head of the stapes.

This bone, the stapes, much resembles a stirrup-iron; its base is placed deep in the fenestra ovalis.

Certain muscles move these bones; according to some, they are four in number, but others admit only one, viz. the *tensor* tympani.

It arises from the petrous portion of the temporal bone, in front of the inferior orifice of the carotid canal, and in part from the Eustachian tube. It enters the tympanum by the canal already described, and is inserted into the process of the handle of the malleus.

The other muscles, the existence of which some have doubted, are, the laxator tympani, which arises from the spine of the sphenoid, and, entering the fissure of Glasser, is inserted into the summit of the process of Rau.

The *stapedius* has been already spoken of: it is very probably not muscular, but composed of the yellow elastic tissue; at least it is so in the lower animals.

A fibro-mucous membrane, liable to inflammation, ulceration, &c., invests the cavity of the tympanum: this cavity has been found filled with pus in children not more than eight or ten days old.

INTERNAL EAR OR LABYRINTH.—This dissection must be made on subjects of different ages; the fœtal age is the most favourable; and several specimens are required, as different sections must be made. To display the *vestibule* (the central portion of the labyrinth), open its upper wall, which corresponds to the superior surface of the pars petrosa, on a level with the fenestra ovalis; this opening leads directly into the vestibule. At the same time remove the superior wall of the meatus auditorius internus, in which will be found the portio mollis and portio dura. This will direct the student to the cochlea, also to the vestibule, and to the first part of the Fallopian canal (canal for the portio dura). The semicircular canals are most easily dissected in the temporal bone of the fœtus; the spongy osseous tissue surrounding them must be removed with the chisel or a strong scalpel. Of the three parts composing the labyrinth, the vestibule is towards the centre, the cochlea anteriorly, and the semicircular canals above and posteriorly.

The vestibule is composed of an osseous and a membranous vestibule. If a probe be passed into the fenestra ovalis of the tympanum, it will pass directly into the vestibule; hence this opening has been called the tympanic opening of the vestibule. This cavity is, as it

Fig. 233.*

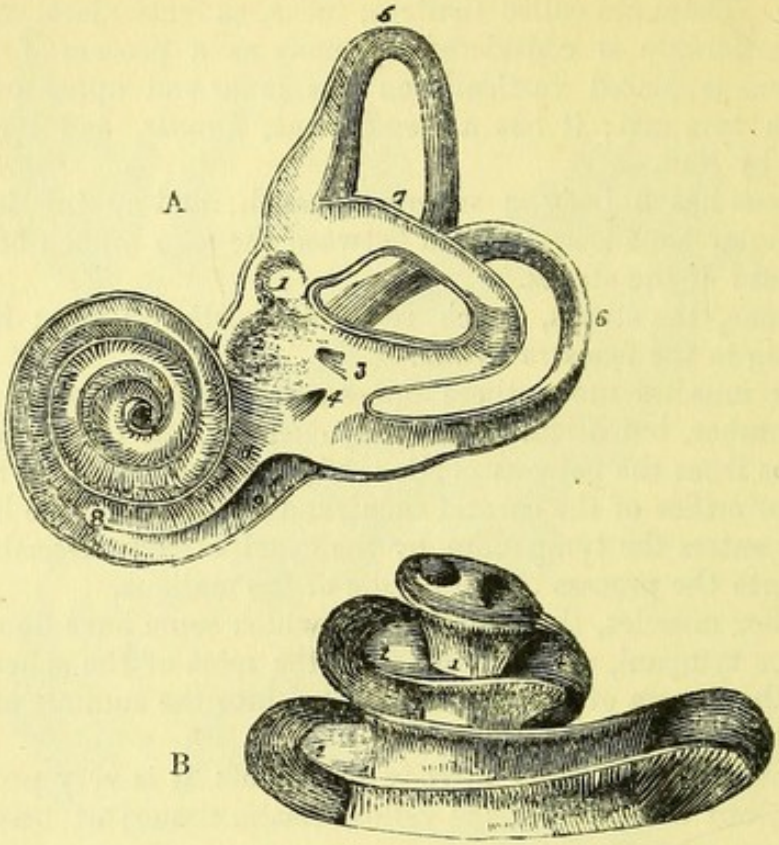

were, the centre of the internal ear; intermediate to the semicircular canals, which are external to it and somewhat behind, and to the cochlea, which is internal and in front. The openings leading into it are of two kinds, large and small; the large are, 1, the fenestra ovalis; 2, the five orifices of the semicircular canals; 3, the opening leading to the vestibular scala of the cochlea; 4, some admit an opening leading towards the upper part of the fenestra rotunda.

The small openings are, 1, that which leads to the aqueduct of the vestibule; 2, vascular openings; 3, those by which the portio mollis enters.

The osseous cavity we have just described is invested by the membranous labyrinth; this appears to have been discovered by Comparetti and Scarpa; it is full of a liquid to which M. de Blainville has given the name of auditory vitrine; besides this lymph the cavity contains two very minute cretaceous bodies, called ovalithes. In the ears of certain fishes they are large and very dense.

The membranous labyrinth is not so extensive as the osseous.

* Fig. 233.—A. A section of the labyrinth, showing its interior and inner surfaces, with the orifices leading to and from it.—1, the fovea hemi-elliptica; 2, fovea hemispherica; 3, common opening of the superior and posterior semicircular canals; 4, aperture of the aqueduct of the vestibule; 5, the superior, 6, the posterior, and 7, the external semicircular canals; 8, spiral canal of the cochlea (scala tympani); 9, entrance of the aqueduct of the cochlea; 10, lamina spiralis. B. The cochlea laid open.—1, the modiolus; 2, the lamina spiralis; 3, the tympanic scala; 4, the vestibular scala.

1, it does not seem to pass into the cochlea; and 2, it is evidently less than the osseous vestibule itself. The space thus left between the osseous vestibule and the membranous labyrinth is filled by the liquor Cotunnii.

Finally, the *membranous labyrinth* is thus composed of two parts: 1, a vestibular portion; 2, the membranous semicircular tubes.

The *osseous semicircular canals* are three in number, but they open into the vestibule by only five orifices, since two of them run together to form the *utriculus communis*. Of these canals two are vertical and one horizontal.

The superior vertical occupies the most elevated part of the labyrinth: in the fœtus it may be seen almost without preparation. By one extremity it unites with the other vertical, to form the utriculus communis.

The inferior vertical canal forms almost a complete circle.

The horizontal is the smallest. In the interior of these canals are found the membranous semicircular canals.

The *portio mollis* also penetrates into these canals.

In addition to the membranous labyrinth thus contained within the labyrinth and the semicircular canals, there are evident traces of another membrane, which serves as a periosteum to these cavities.

The *osseous cochlea* is a part difficult to describe, although its dissection, generally speaking, is one of not much difficulty. Its base rests upon the meatus auditorius internus.

We distinguish in the cochlea, 1, a compact plate forming the walls; 2, the lamina spiralis, which is a spiral septum dividing the general cavity into two others, called scalæ. This lamina spiralis proceeds from the base of the cochlea, and the neighbourhood of the fenestra rotunda to the summit, winding around a central portion or axis. The lamina spiralis is composed of two parts—an osseous and a membranous; it terminates in a process termed *hamulus* or *rostrum*. The axis or columella is the centre (*nucleus*, *modiolus*, *columella*) around which the *lamina spiralis* turns. Its surface is full of holes for the passage of the auditory nerve.

The scalæ of the cochlea are distinguished into two, a vestibular and a tympanic. The first communicates directly with the vestibule, the second with the tympanum, by means of the fenestra rotunda; when the soft parts are present, this orifice is closed by a membrane. The aqueduct of the cochlea has been already described along with the temporal bone. It seems to me to have the uses ascribed to it by Cotunni, and I venture therefore to think modern French anatomists are slightly in error in the view they take of these aqueducts.

The *auditory nerve*, or *portio mollis of the seventh pair*, passes by the meatus auditorius internus, to the cribriform plate, where it divides into two portions, an anterior and posterior. The anterior proceeds to the cochlea, passing up into its interior by the axis or columella; the posterior proceeds to the membranous vestibule and semicircular canals. How they terminate is not known with certainty.

THE EYE.

The anatomy of this organ is divided into two parts,—1, the history of certain structures called tutamina or appendages of the eye; 2, of the organ itself.

APPENDAGES OF THE EYE.

The eyebrows (*supercilia*) require no special description. A thick and rather peculiar integument, provided amply or otherwise with stiff, strong hairs of various colours, and variously disposed in different persons, constitutes the eyebrows.

The eyelids (*palpebræ*) are two in number, a superior and an inferior; these are horizontal. There is, however, a third or imperfect eyelid (the vertical eyelid or membrana nictitans), connected with the tunica conjunctiva; this will be described afterwards. In the eyelids, we have to consider their form and organization: their dissection consists merely in reflecting the layers of which they are composed, successively.

The *upper eyelid*, possessed of great mobility, descends below the transverse diameter of the eye, chiefly closing the eye. Both eyelids are convex anteriorly, and present a number of transverse wrinkles, which are particularly distinct in old age. The two eyelids are united at the extremities of the transverse diameter of the orbit, forming two angles (canthi), the inner of which is more open than the outer; this difference arises from the fibres of the orbicularis palpebrarum being inserted internally upon a tendon which does not exist at the outer angle. The free edges of both eyelids are, when closed, in contact with each other, and supported by a fibro-cartilage; that of the upper eyelid is directed downwards, while the other looks upwards. They are cut obliquely from before backwards, and are so disposed as to form, on being brought together, a narrow and triangular canal, of which the ball of the eye constitutes the posterior wall. This canal is broader internally, especially opposite the puncta lachrymalia, than externally; it serves to conduct the tears towards these orifices during sleep. The free edges of the eyelids are concave and rounded over an extent of two or three lines on the side next the nose, where they correspond to the caruncula lachrymalis. The opening between them is called fissura palpebrarum. Where they begin to be cut obliquely, there is observed a small tubercle, in which is placed the orifice of the lachrymal ducts. There, also, they change their direction, become nearly straight when the eye is open, and present, on the side next the eye, as far as the outer angle, a row of small holes which are the excretory orifices of the Meibomian glands, before which, near the skin, is a series of hairs named *ciliæ*.

The *ciliæ*, or eyelashes, are hard and solid hairs, arranged in two or three rows.

The *skin of the eyelids* is peculiar in respect of its extreme delicacy

and transparency; it is applied upon a layer of loose cellular tissue, never charged with fat, but capable of being filled with serosity with extreme facility.

The *muscular layer of the eyelids* is formed by a portion of the orbicularis palpebrarum.

The *fibrous membrane of the eyelids* exists behind the muscular layer, from which it is separated by cellular tissue; it occupies only the external part of each eyelid. In the upper it is called the ligamentum latum palpebræ superioris, and was long ago shown by Winslow to be derived from the periosteum of the frontal bone and orbit. The portion which belongs to the upper eyelid is placed between the orbicularis muscle and the expanded aponeurosis of the levator palpebræ, that of the lower eyelid is immediately applied upon the tunica conjunctiva. These two portions have their fibres mutually interlaced, from the angle of union of the tarsal cartilages to the outer angle of the orbit, and proceed thence to the corresponding part of the circumference of that cavity, as well as to the edge of the cartilages, diminishing progressively in strength and thickness, so as to be substituted internally by a lamellar tissue loaded with fat. Apertures are observed in several places of it for the passage of nerves and vessels. Moreover, the upper eyelid presents a second fibrous layer, crossing the direction of the above, constituted by the aponeurosis of its levator muscle, which attaches itself to the corresponding fibro-cartilage.

The *tarsal fibro-cartilages* are two small laminæ placed in the substance of the free edge of each eyelid, on the same level as the fibrous layer. Each of them commences at the bifurcated extremity of the tendon of the orbicularis muscle, and terminates externally, by uniting with its fellow, opposite the crossing of the two fibrous layers. They are broader in the middle than at the extremities, and differ in their form as well as size.

The *upper* is larger, about six lines broad, very contracted at the two ends; the *lower* is two lines in breadth, and presents nearly the same dimensions in its whole extent.

Their *anterior* surface is convex, and is in connexion with the orbicularis muscle; the *posterior* is concave, lined by the tunica conjunctiva, and marked with several vertical grooves, which lodge the Meibomian glands.

Their *adherent* edge gives attachment to the fibrous layer of each eyelid; but in the upper eyelid it is strongly curved, and affords insertions to the levator muscle; while in the lower it appears rectilinear.

Their *free, or ciliary edge*, is broad and thick, rounded, and slantingly cut. These two fibro-cartilages are rather thin, flexible, elastic, and of a slightly yellowish tint, but present nothing peculiar in their structure.

The *tensor tarsi muscle*, connected with these tarsal cartilages, has been already described.

The *Meibomian glands, or ciliary follicles*, are small round follicles,

lodged in particular grooves, between the tarsal cartilages and the tunica conjunctiva. They consist of a series of nearly straight tubes lined with mucous membrane, and a layer of pavement epithelium cells. They have short cœcal appendages. They are disposed, one above another, in such a manner as to represent two vertical and parallel lines of a yellowish colour, more numerous and more distinct in the upper eyelid, where there are thirty or forty, than in the lower, where there are only about twenty. They communicate with each other, and those nearest the free edge of each eyelid open externally by minute orifices disposed in one or two rows on the side next the eye, behind the ciliæ. There issues from them a sebaceous humour, which, on pressing the tarsal cartilages, may be squeezed out under the form of extremely minute cylinders.

Fig. 234.*

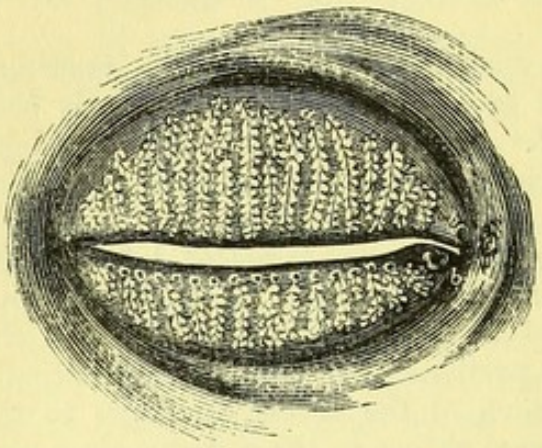

The *lachrymal glands* occupy the outer orifice of each orbit and correspond to the lachrymal fossa within the external angular process of the frontal bone. Their size varies. Above them is the periosteum of the orbit, and here they are convex; by their concave side they rest on and adapt themselves to the surface of the eyeball.

The *lachrymal gland* is composed of a number of lobules connected by cellular tissue, and separated from each other by vessels and nerves which creep in their intervals. These lobules are formed of rounded granulations of a reddish white colour, in which the last ramifications of arteries terminate, and in which the radicles of the veins commence; their more intimate structure is still entirely unknown. It is presumed that from each of them issues a small excretory canal, which, by uniting with others in its vicinity, gives rise to trunks somewhat more distinct. Anatomists who have seen and injected them, state that they are six or seven in number, and open, internally to the upper eyelid, at some distance from the outer part of the corresponding tarsal cartilage. Their orifices are seen upon the conjunctiva, where their series forms a curved line, the convexity of which is directed upwards and outwards. The capsule of the gland is fibro-cellular, and it sends partitions into its substance. The orifices of these ducts are very evident in the lower animals, as in the dog.

The *tunica conjunctiva* (*Membrana adnata*) belongs to the order of mucous membranes. It may be viewed as composed of three portions,

* Fig. 234.—*a*, the Meibomian glands as seen on the inner side; *b*, entrance to the puncta lachrymalia; *c*, caruncula lachrymalis.

a palpebral, sclerotic, and corneal; all these are quite continuous. It is thin, transparent, and lines the posterior surface of the eyelids and the fore part of the ball of the eye, but, according to Ribes, is limited to the circumference of the cornea. On the free edge of the upper eyelid it is continuous with the skin where the ciliæ arise; it then covers the edge of the fibro-cartilage, and is perforated externally by the orifices of the ciliary follicles. Internally, it introduces itself by the superior punctum lachrymale into the lachrymal duct, proceeds behind the fibro-cartilage and the aponeurosis of the levator palpebræ muscle, is reflected over the sclerotica, to gain the posterior surface of the lower eyelid, and terminates upon its free edge, where it is continuous with the skin, and dives into the inferior lachrymal punctum. On leaving the eyelids to be reflected over the eye, it forms a semicircular fold, which corresponds to the fat of the orbit. On the internal part of the ball of the eye the tunica conjunctiva forms another rather indistinct fold, named *membrana nictitans*, or vertical eyelid, because in man it seems to be the rudiment of an organ of the same name which is highly developed in certain animals. It is rendered apparent by turning the eye towards the nose. Meckel supposes that it contains a small cartilage, even in man.

The *inner surface* of the tunica conjunctiva is attached to the eyelids and ball of the eye by dense cellular tissue.

The *outer surface* is smooth, and constantly moist. When the eyelids are closed, it corresponds to itself in all points; when open, it is in part exposed to the contact of the air; it contains a number of capillary blood-vessels, especially on the eyelids. Its arteries are derived from the ophthalmic artery; it receives minute filaments from the lachrymal nerve and external nasal.

The *caruncula lachrymalis* is a small reddish tubercle, of a pyramidal form, situated in the inner angle of the eyelids, at the fore part of the ball of the eye, behind and within the puncta lachrymalia. It is a mass of small mucous crypts, *invested* by the conjunctiva, which forms anteriorly and externally to them a semilunar fold (*membrana nictitans*).

Each of the orifices of these crypts is furnished with hairs of excessive delicacy, and visible only under the microscope. The crypts receive filaments of the nasal nerve and some vascular ramifications.

Use: to retain the tears in the inner angle of the eye, and furnish a peculiar sebaceous fluid.

PUNCTA LACHRYMALIA AND LACHRYMAL DUCTS.

The puncta are small apertures, occupying the centre of a small tubercle, slightly inclined backwards, and situated at the distance of about a line and a half from the internal commissure of each eyelid, at the place where its edge changes its direction. A small mucous rim surrounds their circumference. They are placed opposite each other; that of the *lower* eyelid is directed upwards, outwards, and backwards; that of the *upper*, downwards, and also outwards and back-

wards, so that, when the eyelids are closed, they only touch each other on the side next the skin. These puncta are the external orifices of the lachrymal ducts, whose diameter is longer than the circumferences of the puncta lachrymalia themselves; it is this which makes these canals appear slightly contracted at their origin. The lachrymal ducts are distinguished into superior and inferior, according to the eyelid to which they belong.

The *superior lachrymal duct*, which is longer than the inferior, ascends at first vertically, then bends nearly at a right angle, and proceeds inwards and downwards along the inner part of the free edge of the eyelid, immediately beneath the conjunctiva.

The *inferior lachrymal duct* also at first descends nearly vertically, then directs itself inwards, ascending a little to place itself inside the superior.

Opposite the commissure of the eyelids both proceed alongside of each other, behind the tendon of the orbicularis palpebrarum, as far as the lachrymal sac, into the middle part of the outer side of which they open separately. These ducts are formed of a delicate prolongation of the conjunctiva, which is thus continuous with the mucous membrane of the lachrymal sac; they are generally wider than the puncta. The passing of bristles by these ducts into the lachrymal sac should be frequently practised by the student.

The *lachrymal sac* is a membranous bag, lodged at the inner angle of the orbit, in the channel formed by the lachrymal bone and the ascending processes of the upper maxillary bone. Its form is ovoid; its *outer side* is covered anteriorly by the skin, by the orbicularis palpebrarum, and its tendon, which divides it transversely into two portions, the *lower* being narrower and more elongated than the *upper*. *Posteriorly*, it corresponds to the caruncula lachrymalis and the conjunctiva, and furnishes some insertions to the inferior oblique muscle of the eye. Its *inner* side fills the lachrymal groove, to which it is closely attached. Its *upper* extremity is dilated and rounded, and forms a prominence above the tendon of the orbicularis palpebrarum. The *inferior* extremity is continuous with the nasal canal. In its *interior*, the sac is lined with a mucous membrane, continuous with that of the eye and nasal fossæ. It is always covered with mucus. At the *exterior*, the lachrymal sac is formed by a fibrous aponeurotic membrane, which some consider as the *reflected tendon* of the orbicularis palpebrarum. This membrane is white, dense, and strong, and fixed on all sides to the bony edge of the lachrymal groove.

Anteriorly, it is united to the tendon of the orbicularis palpebrarum and to some of its fleshy fibres, to which it gives insertion.

Nasal duct.—Dissection.—Lay open the sac from the tendo oculi downwards; and a blunt probe passed into it in the same direction will show the course of the duct. By looking into the inferior meatus of the nose the student will observe the extremity of this probe, indicating the course of the tears. The osseous part of this canal has already

Fig. 235.*

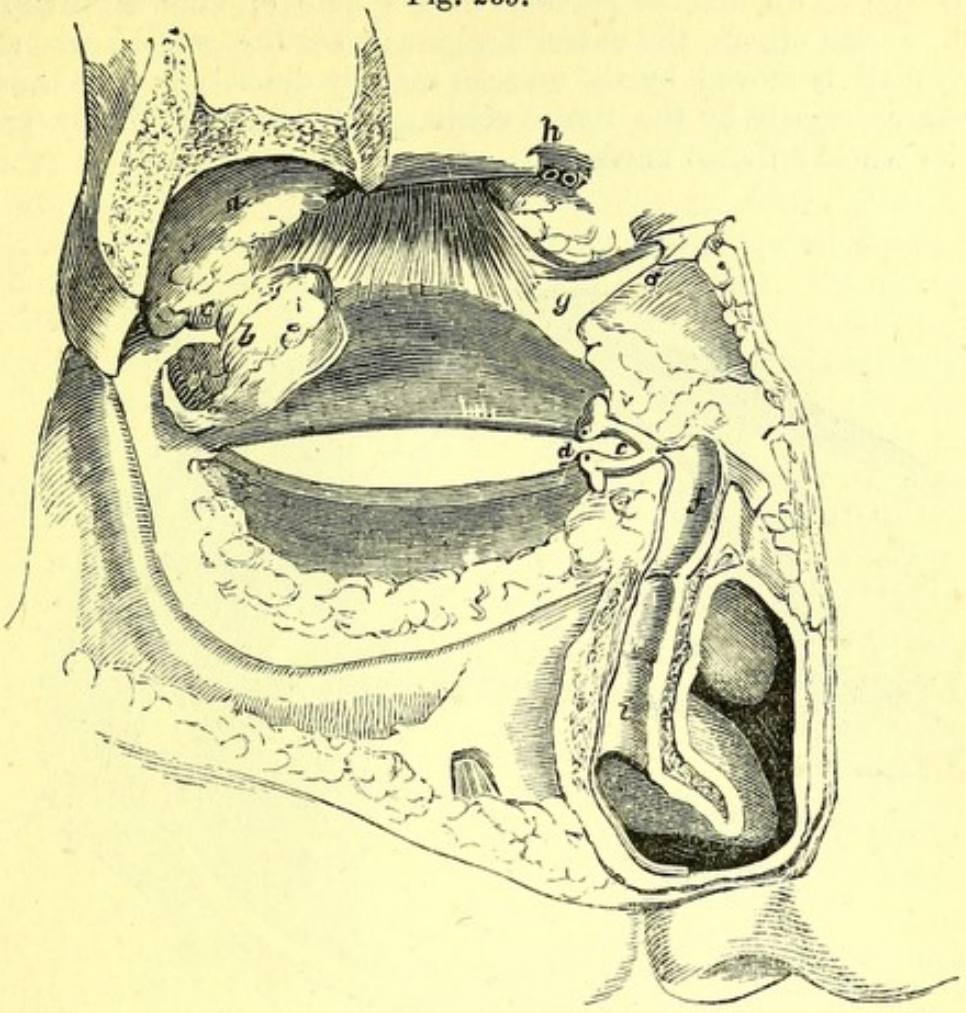

been described. It is lined by a prolongation of the mucous membrane of the lachrymal sac, which adheres feebly to the periosteum, and opens, under the inferior turbinated bone, by a contracted orifice, which is furnished with a circular fold formed by the pituitary membrane. The inferior orifice of the nasal duct may be reached from the anterior nostrils, by a firm instrument, such as a portion of brass-wire, having the curve of a common aneurism needle. It is not usual to expose the mucous membrane of the duct, or indeed any part of its course, but this may be done either by chiselling off the corresponding nasal bone, and a portion of the upper maxillary, or from within the nose by removing the anterior extremities of the inferior and middle turbinated bones.

OF THE BALL OF THE EYE.

The *ball of the eye* has not the same direction as that of the orbit, its axis being that of the other eye. Viewed in profile, it appears

* Fig. 235.—To show the lachrymal apparatus and nasal duct.—*a*, *b*, *c*, lachrymal gland and its appendage; *d*, puncta lachrymalia; *e*, lachrymal ducts; *f*, nasal duct laid open; *g*, insertion of the tendon of the superior oblique muscle after being reflected; *h*, supra-orbitar foramen; the artery, vein, and nerve have been cut across; *i*, interior of the nasal duct near its termination in the nostril.

composed of two distinct portions of a sphere of different diameters united to each other; the anterior segment has the smaller diameter. The eyeball is moved by six muscles already described; it is further covered anteriorly by the tunica conjunctiva, which probably passes over its whole anterior surface.

Fig. 236.*

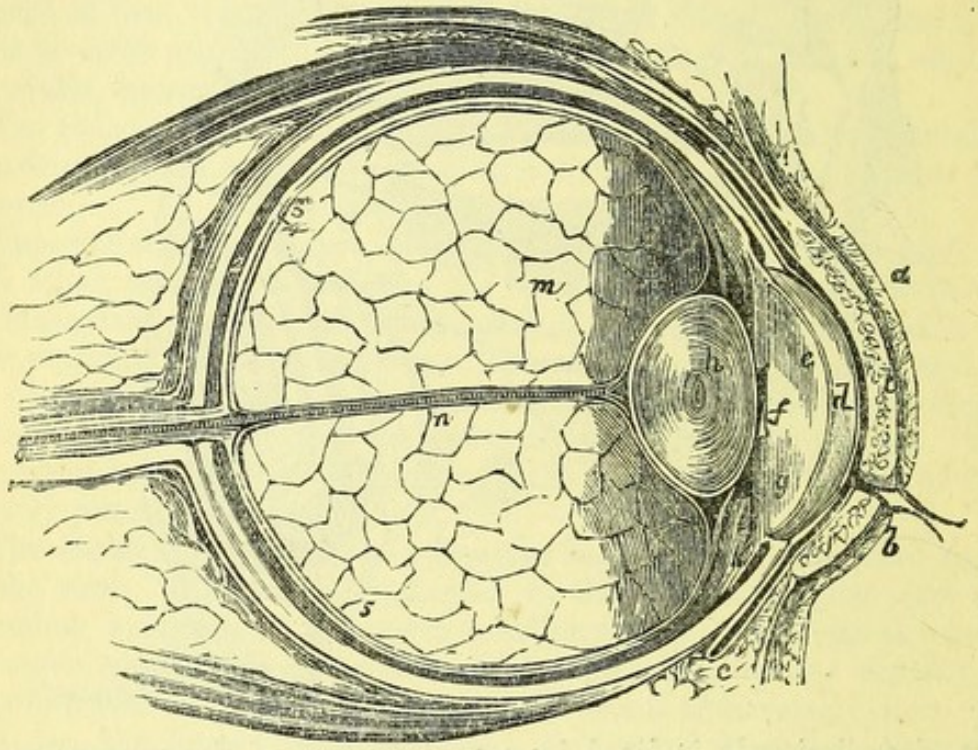

The *sclerotica* is a fibrous membrane of great strength, thinner anteriorly than posteriorly; the tendons of the recti muscles serve to add to its strength. To examine the inner surface of the tunica sclerotica, cut through the membrane cautiously with a sharp knife, and, an opening having been made into it, introduce a pair of probe-pointed scissors underneath, and cut through the sclerotic all round the eyeball, next reflect the posterior segment towards the optic nerve. This dissection exposes the greater part of the choroid, the ciliary nerves and vessels, and their passage through the sclerotic.

The *inner* surface of the sclerotica is lined by the choroid, to which it is feebly connected throughout the greater part of its extent by sheaths of cellular tissue enclosing the ciliary nerves and vessels. Behind, the

* Fig. 236.—Section of the eyeball.—*a*, the upper eyelid; *b*, Meibomian glands; *c*, point of reflexion of the tunica conjunctiva; *d*, the cornea; *e*, the anterior chamber of the aqueous humour; *f*, the pupil; *g*, the iris; *h*, the lens; 1, 2, 3, 4, 5, sclerotic, choroid, membrane of Jacob, retina, and hyaloid membrane in succession; *i*, ciliary processes of the choroid; *k*, canal of Fontana; *l*, canal of Petit; *m*, section of the vitreous humour; *n*, canal and branch of the central artery of the retina passing through the vitreous humour; *o*, the optic nerve.

sclerotica is perforated by a rounded opening for the passage of the optic nerve, the central artery of the retina and its vein.

Anteriorly the transparent cornea is strongly attached to the sclerotica. The mode of attachment differs in different animals; in man it is a simple bevelling at the expense of the inner part of the sclerotica and outer part of the cornea. The sclerotica adheres very intimately and strongly to the choroid by means of the ciliary ligament or annulus albus, which will be presently described. Before examining the choroid, ciliary nerves, &c., proceed with the examination and dissection of the *cornea*. Dissect off the cornea by pushing the probe-pointed scissors under it into the anterior chamber of the aqueous humour in front of the iris; in doing so the aqueous humour escapes, but this does not interfere with a view of any of the parts. Cut the cornea across, and take it off in two portions, tearing through at the same time the adhesion of the annulus albus to the sclerotica; or by gently detaching the annulus albus from inside the sclerotica, the cornea may be removed entire, leaving for examination the following parts, viz. the choroid and its vessels, and the ciliary nerves; the annulus albus and the iris.

The *cornea* is perfectly transparent, nearly circular, anteriorly convex, posteriorly concave, thicker than the sclerotica, and composed of six laminæ of great strength, having a serous fluid interposed. Its anterior layer is probably formed by the tunica conjunctiva; its posterior by the membrane of the aqueous humour. When the cornea is punctured, this humour escapes. It is thought to contain neither blood-vessels nor nerves. The inner layer of the cornea, whether viewed as single or double, is somewhat peculiar. It is elastic and resembles the capsule of the lens.

The *choroid* is a dark-brown membrane, soft, cellular, and extremely vascular; it is situated betwixt the sclerotica and the retina, and anteriorly is continuous with the iris, which seems to be a modification of the choroid. *Posteriorly*, the optic nerve perforates it by a number of openings; anteriorly, the annulus albus is strongly fixed to it and to the iris, and thus connects the one directly, and the other indirectly, to the sclerotica; internally, the membrane forms upon it the ciliary processes, and, being continued forwards, constitutes the layer of the iris called the uvea. The dark substance, called pigmentum nigrum, forms a coating for the choroid externally and internally; this pigment seems also enclosed, at least in some parts, by a distinct but extremely delicate membrane. The arteries of the choroid are mostly internal; the veins, called *vasa vorticosa*, are chiefly external; the division into two layers by Ruysch is artificial.

The *ligamentum ciliare*, *annulus albus*, or ciliary ligament, is a whitish or greyish ring situated between the sclerotica, the iris, and the choroid, which it connects together. Its texture is analogous to the iris; most of the ciliary nerves pass through it, but many filaments remain in it. Its uses are in some measure unknown, although it obviously serves the purpose of a ligament, and this may be one of its

uses. The true ciliary processes of the choroid correspond to its inner side, but are not in contact with it. Between the annulus, sclerotica, and cornea, is a sort of canal passing around the eye. It was first observed by Fontana, and bears his name. He considered it of no importance. The annulus albus has been viewed by some as a nervous ganglion; it is probably muscular.

The *iris* is a moveable curtain floating in the aqueous humour; the rounded opening in its centre is the pupil. It thus partially separates the *anterior* chamber of the aqueous humour from the posterior. The *pupil* varies almost every instant during the waking state, becoming smaller when the eye is exposed to a strong light, and larger as the light becomes obscure; from this has been *inferred* the muscularity of the iris. Anteriorly the iris is invested by the membrane of the aqueous humour; its second layer is the true nervous and fibrous layer, which is also coloured; the third layer is the uvea;* and the fourth the membrane of the pigmentum nigrum.† The ciliary nerves, about twenty in number, are distributed chiefly to the iris; it is also very vascular. In the fœtus the pupil is shut up by a membrane (*membrana pupillaris*) discovered by Wachendorf, and described with the greatest exactness by Dr. William Hunter. This membrane is double and vascular; it disappears generally about the seventh month of the fœtus.

Ciliary processes.—By removing a portion of the choroid and the iris, and immersing it in clear water, the *ciliary processes* may next be examined. They are vascular, spear-shaped eminences of the choroid, placed anteriorly and upon the inner side of the choroid; externally they adhere firmly to that membrane, and seem to be but processes of it; internally each of them is united, seemingly, by dovetail, but at all events most intimately with a similar number of *colourless ciliary* processes, forming appendages on the outer surface of the hyaloid membrane; these colourless ciliary processes of the hyaloid are also called the zonule of Zinn, who first spoke of them, but did not understand their mechanism. ‡

Besides this dovetailing, or intimate union of the two sets of ciliary processes, the coloured and colourless, or *choroidian* and *hyaloidian*, numerous blood-vessels pass from the one to the other. This is the reason why, in the fresh eye, these membranes adhere very intimately together, whereas, when the organ has been kept for a few days, they separate with great ease, because the *vascular* connexion has been loosened by putrefaction. This mechanism, which was first pointed out in the memoirs just referred to, has been altogether misunderstood, even by the latest writers. Taken collectively, the choroidian ciliary processes are called the *ciliary body;* anteriorly their extreme points float a little in the posterior chamber of the aqueous humour behind

* A continuation of the choroid.

† To this some add a layer of the membrane of the aqueous humour.

‡ See an account of this structure in the 'Trans. Royal Soc. of Edinburgh,' vol. x., p. 1, by Dr. Knox.

Fig. 237.*

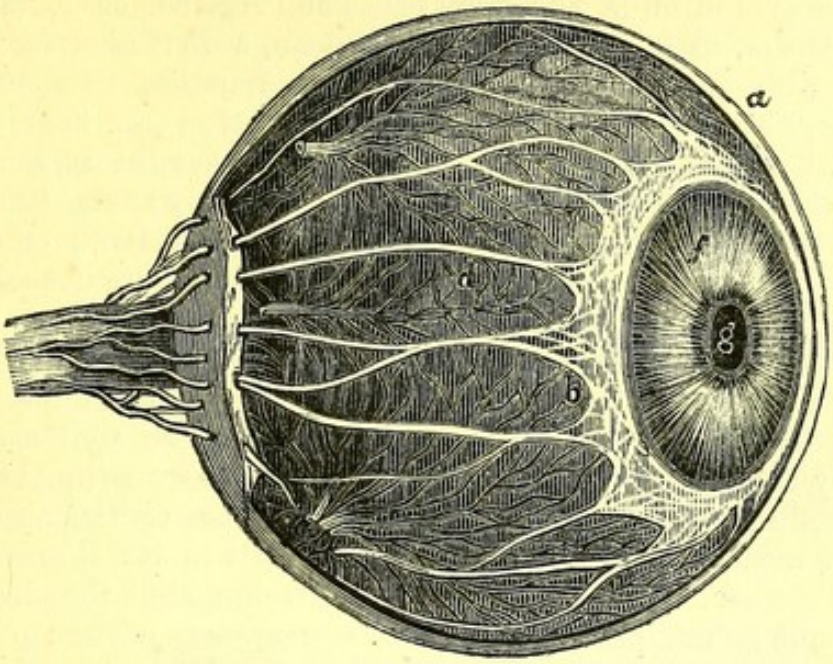

the iris. These bodies are extremely vascular, and full of pigment, which also stains the zonule of Zinn, when the choroidian ciliary processes have been forcibly torn from it.

The retina.—To expose the retina, remove the choroid, the iris, and ciliary processes, and immerse the eye in a tumbler full of clear water; the inverted glass globe is not a convenient way of examining the structure of this interesting membrane.

The retina is a soft, pulpy membrane, translucent, but of a slight greyish colour; many think that it is quite transparent during life. It extends from the termination of the optic nerve quite to the edge of the zonule of Zinn, and perhaps even further; it is composed of two layers, the inner, called *vasculosa;* the outer, *pulposa.* In compliment to Dr. Jacob, a third layer, still more external, has been added, called *serosa.* It is a delicate filamentous tissue, not demonstrable unless the preparation be made under water, but may in every instance be floated off the pulpy layer of the retina, by immersing the structure in clear water.

Central spot.—At about two lines to the outside of the junction of the optic nerve with the retina is a dark spot, with a yellow margin (limbus luteus), first discovered by Soëmmering. Here the pulpy layer of the retina is deficient, and much interest has naturally attached to the discovery, inasmuch as this spot (foramen centrale retinæ) is actually in the axis of the eyeball and of vision. It was supposed to be peculiar to man and to apes, but this was disproved, and its presence in the eyes of the chameleon and certain lizards is undoubted.† After all, the structure may merely be a rudimentary

* Fig 237.—To show the distribution of the ciliary nerves.—*a*, the sclerotica; *b*, vasa vorticosa and outer surface of the choroid; *c*, one of the chief trunks of the vasa vorticosa as they leave the choroid; *d*, *d*, ciliary nerves; *e*, annulus albus, or ciliary ligament; *f*, the iris; *g*, the pupil.

† See 'Transactions of Wern. Soc.,' vol. v., part i.

structure, of a nature analogous to the divided retina in the eyes of fishes; for the eyes of birds, and some fishes and reptiles, have, instead of a *mere foramen*, as in man and the chameleon, a *divided retina*, and occasionally, also, a *marsupium*. These peculiarities, then, in the human retina, discovered by Soëmmering, may, after all, be merely rudimentary. Microscopic observers have shown that the membrane of Jacob is composed of small columns, or rods, placed at right angles with the surface of the membrane, like the pile of velvet; on thin surfaces they resemble a mosaic pavement. Anatomists are not agreed as to the intimate structure of the nervous lamina of the retina. The vascular layer is a firm membrane, supporting the other two.

The *aqueous humour* cannot be exhibited, like the other humours of the eye, as a distinct structure, but its history may be well enough understood by the following description:—This humour is limpid and transparent, filling the two chambers, from the cornea to the anterior surface of the membrane of the lens; the iris floats in it: it amounts to five or six grains. When left to itself it putrefies, thus showing the presence of some animal particles in it. The membrane of the aqueous humour has been already spoken of. The fluid is reproduced very readily when it has been evacuated by accident, or by the surgeon. Remove the remaining structures from the interior of the eyeball. They consist of the following parts:—1, the lens, or crystalline humour, and its capsule; 2, the tunica hyaloidea and vitreous humour; 3, the zonule of Zinn; 4, the canal of Petit.

Fig. 238.*

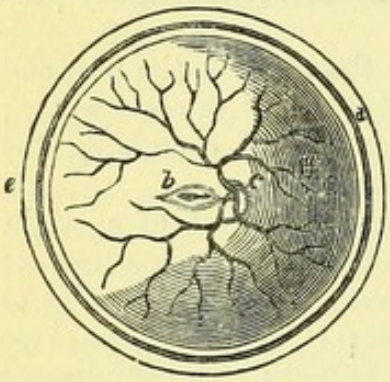

The *vitreous humour* is soft, transparent, and tremulous; it resembles melted glass, and ought to be called *vitrine*; it is a semi-solid body. Anteriorly the lens and its capsule are lodged in a depression of the vitreous humour. The membrane investing it throughout is the *membrana hyaloidea*; this membrane is intimately united to the capsule of the lens, thus connecting these humours together; anteriorly and externally its union with the choroid is equally intimate, by means of the zonule of Zinn, already explained to be a series of colourless ciliary processes, analogous to the choroidian, with which they have an intimate vascular union.

The anterior concave surface of the vitreous humour is shut in by a layer of the hyaloid membrane, which does not adhere *at this point* to the capsule of the lens.

The *canal* of Petit is formed by a splitting of the hyaloid membrane anteriorly, for a short way, into two laminæ. The outer is called the zonule of Zinn, or hyaloidian ciliary processes. The two layers unite

* Fig. 238.—Showing the foramen centrale of Soëmmering.—*a*, concave surface of the retina; *b*, foramen centrale retinæ; *c*, entrance of the optic nerve; *d*, choroid tunic; *e*, tunica sclerotica.

after a very short course, and the membrane then unites to the equatorial margin of the capsule of the lens.

The *canal*, which is irregularly swollen, may be demonstrated by opening its outer layer with sharp scissors, and blowing air into it; when thus distended it resembles the colon in miniature. It is not unfrequently partially or entirely obliterated during life. In young persons a branch of the central artery of the retina runs through the centre of the vitreous humour, to be distributed upon the posterior surface of the capsule of the lens; but this vessel is afterwards obliterated.

The *crystalline lens* is a transparent solid body enclosed in a transparent capsule. To this capsule the hyaloid membrane adheres around the equatorial margin, and perhaps passes over it. The lens has no connexion whatever with its capsule, so that, on this being punctured, it escapes very readily. In the adult the lens

Fig. 239.*

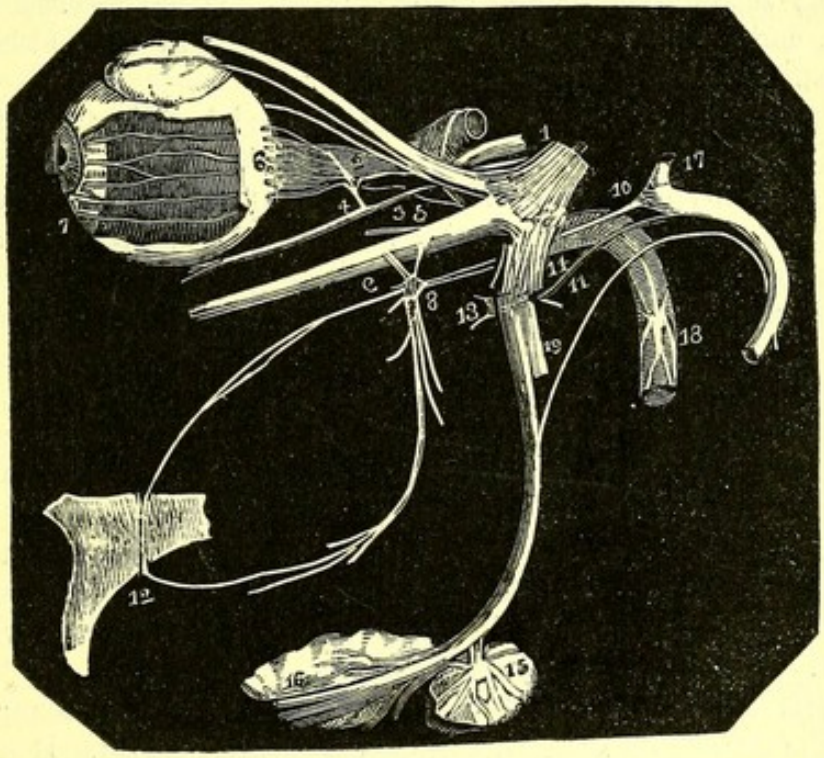

This figure, showing the distribution of the fifth pair of nerves, is placed here to show its anatomical and physiological relations to the organs of sense just described.

* Fig. 239.—1, Ganglion of Gasser; 2, ophthalmic ganglion; 3, its long root furnished by the nasal branch; 4, the large short root from a branch of the third, supplying the small oblique muscle; 5, branch from the carotid plexus of the sympathetic; 6, ciliary nerves; 7, ciliary ligament; 8, ganglion of Meckel; 9, its sensitive roots derived from the superior maxillary; 10, petrosal filament of the vidian; 11, carotid filament from the sympathetic; 12, naso-palatine ganglion; 13, otic ganglion; 14, superficial petrosal nerve of Arnold; 15, submaxillary ganglion; 16, sublingual ganglion; 17, geniculated ganglion, connected with the first turn of the facial, and giving origin to the great superficial petrosal nerve, or vidian; 18, cavernous ganglion; 19, corda tympani.

shows a central nucleus of much density, but its external layers are soft and viscous; it is composed of concentric layers of a structure but little understood. When opaque it constitutes cataract. The liquor Morgagni, interposed between the capsule of the lens and the lens itself, is thought by some to be a *post-mortem* appearance. The lens undergoes several changes in form during life, being spheroidal in the fœtus, and not quite transparent. In the adult the anterior surface is less convex than the posterior, and in old age it is flattened on both surfaces. The lens is plano-convex.

THE SKIN.

The Skin consists of two principal parts—1, the epidermis, and, 2, the corium or true skin.

1. The epidermis, or scarf-skin, belongs to the class of epithelial structures; it is insensible and non-vascular. It varies exceedingly in thickness, and the differences, as they exist even in the fœtus, cannot be the result of external causes.

It is composed of flattened cells, agglutinated together irregularly in layers. These arise in a blastema formed upon the surface of the true skin. Many of these cells contain pigment. The blackness of the skin of the negro depends entirely on the colour of the structure I now describe. It is in the cells of the deeper layers that most pigment is to be found. The deeper layers received from Malpighi the name of *rete mucosum*.

The cuticle is strictly moulded on the external surface of the *corium*; hence its deeper surface presents elevations and depressions corresponding to the exterior of the corium. As they are being separated, after macerating, fine tubular threads may be observed passing between them; they pass to, or rather from, the perspiratory apparatus of glands. Chemists describe the cuticle as being mostly composed of *keratin*, a horny substance, soluble in alkalies, insoluble in water and in alcohol. In composition it is analogous to albumen.

The *cutis vera*, or true skin, is a dense, firm membrane, placed between the cuticle and the subcutaneous cellular fascia. It is a *fibro-vascular* layer; the fibres are interlaced, and blood-vessels and nerves abound, especially in youth. Internally the corium insensibly passes into the cellular tissue; hence its absolute thickness cannot well be determined.

The free surface of the corium is beset with small eminences called papillæ, best seen on the palmar surface of the fingers. These papillæ abound with blood-vessels and nerves. On other parts of the skin the vessels form networks. Nerves are not supplied equally to all parts of the integuments.

The corium is resolvable into gelatine by boiling, and it forms leather by tanning.

NAILS AND HAIRS.

These appendages of the integuments indicate sufficiently the complexity of the structures producing them.

They belong to the system of the epidermis, and are similar in their chemical nature. They have neither vessels nor nerves, and are excrementitious.

Nails.—The part of the corium to which the nail is attached is highly vascular; it is called the matrix; it is marked with rows of papillæ; on them the nail is developed. The substance of the nail is made up of scales derived from flattened cells. In chemical composition they resemble the cuticle. The posterior part of the nail is called the root; the middle part the body; before it is the free edge; a thin semilunar part at the root is the *lunula*. The growth of the nail is a phenomenon produced by the continual reproduction and consolidation of nucleated cells at the root; these become inseparable adherent scales. As it receives new cells at the root the free edge advances, and, as it were, grows or lengthens.

Hairs.—The système pileux of Bichat. These, in so far as they interest the anatomist, may be briefly described. Each consists of a root, a stem, and a point. The stem is covered with finely imbricated scales, and these give to its edges a serrated appearance. This encloses a fibrous substance, which forms the greater part of the stem; occasionally however, it encloses another substance, called the *medulla;* the surrounding part is then called *cortical*. Modern physiologists, trusting to the accuracy of the microscopic views of Schwann, consider the fibrous portion as derived from elongated and metamorphosed cells; pigment occasionally abounds. The medulla, or pith, does not exist in all hairs; it is not commonly met with in those of the head. The bulbous enlargement at the root of the hair is received into a recess of the skin called the hair follicle; and this may pass quite through the cutis. The follicle is dilated at the bottom, and receives near its entrance the openings of several sebaceous follicles or glands. This follicle is composed of the same materials as the general integument. The cuticular hairs of the follicle are more complex than in the common integumentary surface.

The hair is a growth or extension of the epidermis; its matrix is the bottom of the follicle. This is remarkably vascular, to provide for the growth of the hair. Neither nerves nor blood-vessels pass into the substance of the hair.

Although the substance of the hair be wholly extra-vascular, it is yet organic, and subject to organic changes. It is formed, in fact, of cells, which are being continually thrown off from the matrix. At about the fourth month of intra-uterine life little black specks appear on the integument of the fœtus; these are the future hairs. The follicles appear first. The hairs of the fœtus are called lanugo; they are not destined to remain; and many are shed whilst the fœtus is in

the uterus.* The hairs, when plucked out, are reproduced, provided the follicles have not been injured. It is the same with the nails, so long as the matrix remains entire. By chemical tests it is shown that the hairs yield gelatine, and a protein compound with a large proportion of sulphur. By calcination hair gives off from 1 to $1\frac{1}{2}$ per cent. of ashes, consisting of peroxide of iron and traces of manganese, silex, chlorides of sodium and potassium, and phosphate of lime.

Glands of the skin.—1. The sebaceous. These open (each by a small duct) into the hair follicles. The gland itself is composed of sacculated recesses lined by epithelium. These recesses vary from four to twenty. They are lodged in the substance of the corium. 2. *Sudoriferous glands:* These are situated on the under surface of the corium, and even in the adipose tissue beneath. They resemble small rounded

Fig. 240.†

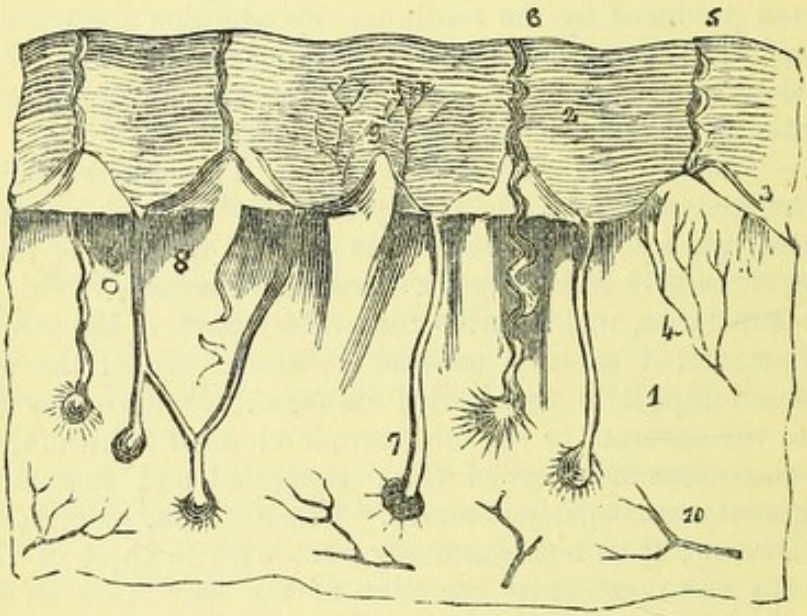

bodies, consisting each of a fine tube coiled up into a ball. The tube is viewed as the duct of the gland. It is twisted like a corkscrew as it passes through the corium and cuticle. Each gland is well supplied with a network of capillary blood-vessels.

These glands are extremely numerous. According to Krause, 2800 ducts, from these glands, open on a square inch of the palm of the hand; but they are not so numerous in other parts of the body.

* It appears to me that in some persons this fœtal system continues, to a certain extent, throughout life.

† Fig. 240.—A section of the skin showing the distribution of the sweat-glands as described by Wagner.—1, the corium; 2, 3, 9, the epidermic layers; 5, 6, twisted ducts of the sudoriferous glands; 4, 10, blood-vessels; 7, 8, sebaceous glands.

GENERAL ANATOMY.

THE genius of Bichat created "General Anatomy;" he first distinguished it clearly from the *descriptive*, which we owe also to him: the surgical followed, as a matter of course.

His first essay on general anatomy was his "Traité sur les Membranes," an immortal work, laying the basis of all his future views and discoveries. This was followed by the "Anatomie Générale," in which he surveys the body as composed of certain tissues more or less simple, more or less complex. Out of these tissues, which he also calls systems, are formed all the organs of the body.

It is not of much importance in which order these tissues are considered; the microscope has shown many of them to be more complex than they were originally supposed to be by the discoverer of general anatomy. De Blainville's view was the most philosophic: according to it, there are three great elementary tissues, out of which all the others and all the organs of the body are formed; these are, the areolar, the muscular, and the nervous. These tissues may be called primary; all the rest are secondary.

The human body, like that of every other animal, is composed of fluids and solids, the former greatly preponderating. The consideration of the fluids belongs to physiology; so also does the doctrine of the development of the tissues. Nevertheless, it may be of use to the practical student to conclude this Manual by a brief history of the development of the tissues, and of the fluids forming constituent parts of man.

I.—OF THE CELLULAR OR AREOLAR TISSUE.

During the dissection of the body it could not have escaped the attention of the student that nearly all the organs are connected to each other by a soft filamentous substance, somewhat tenacious, adherent, elastic, white, and fleecy. When drawn out, it forms cells or areolæ, and hence its names of cellular or areolar, filamentous, reticular, mucous tissue. It is generally called the cellular membrane. It receives, by reason of its connexions, the names of sub-serous, sub-mucous, superficial, profound, intermediate, investing, parenchymatous. It connects and insulates the organs, and is the most extensively diffused of all the tissues. It is continuous throughout, and this fact explains the phenomena of many diseases. The filaments composing it do not, however, form cells; they are moistened with a liquid of an unknown nature, the quantity of which seems to vary under different

circumstances; its density also varies. Examined under the microscope, it seems to be composed of fine homogeneous and transparent filaments of extreme tenuity;* these filaments never divide nor unite. It is now generally admitted that similar filaments form the chief part of the tendons, ligaments, and other white fibrous tissues. At one time it was thought that the fibres just described alone constituted the cellular tissue, but other fibres have been lately described, supposed to be identical with the yellow elastic tissue. To detect them when not apparent, acetic acid is used. The more remarkable feature in the history of these yellow fibres is their subdividing and anastomosing with each other. A few rounded and oval corpuscles are found interspersed amongst the filaments of the cellular tissue.

This tissue is almost wholly resolvable into gelatine by boiling in water. Numerous blood-vessels abound in it. Nerves and lymphatics pass through it in great numbers; but as regards the tissue itself, the filaments are insensible when cut or torn. It is said to be reproduced freely when destroyed by disease, but this statement must be received with caution. It is produced, or something like it, in many morbid growths.

1. OF THE ADIPOSE TISSUE.

Adipose or fatty matter forms an integral part of the human body in a healthy condition. It varies in quantity more than any other organic material or product. Although found in the blood and chyle, and in certain secretions, it is chiefly deposited in cells and in the cellular tissue just described. These cells or vesicles, with the fatty matter, constitute the adipose tissue.

It collects more abundantly in some situations than in others; some, as the scrotum, eyelids, &c., it altogether avoids. In youth its seat is on the deep surface of the integuments, where it forms the panniculus adiposus, so remarkable in the youth of both sexes, in the child and in the grown woman of all ages. As years creep on, the adipose tissue leaves the surface and collects in the interior. Lastly, in extreme age, as in extreme youth (the fœtus), it all but disappears.

In the bones it forms the marrow; it abounds in the omentum, and around the joints, but is never found within the cranium nor in the tissue of the lungs.

The little vesicles containing the fat are clustered into groups; they measure $\frac{1}{300}$ or $\frac{1}{600}$ of an inch in diameter. The envelope enclosing the oily matter is quite transparent.

A nucleus was observed by Schwann in the fat-cells of the embryo. This tissue is copiously supplied with blood-vessels; these, with the cellular tissue supporting them, maintain the adipose vesicles in their place, connecting them together. Lymphatics have not been observed in connexion with them, nor any nerves.

* $\frac{1}{13000}$ to $\frac{1}{23000}$ of an inch.

Fig. 241.*

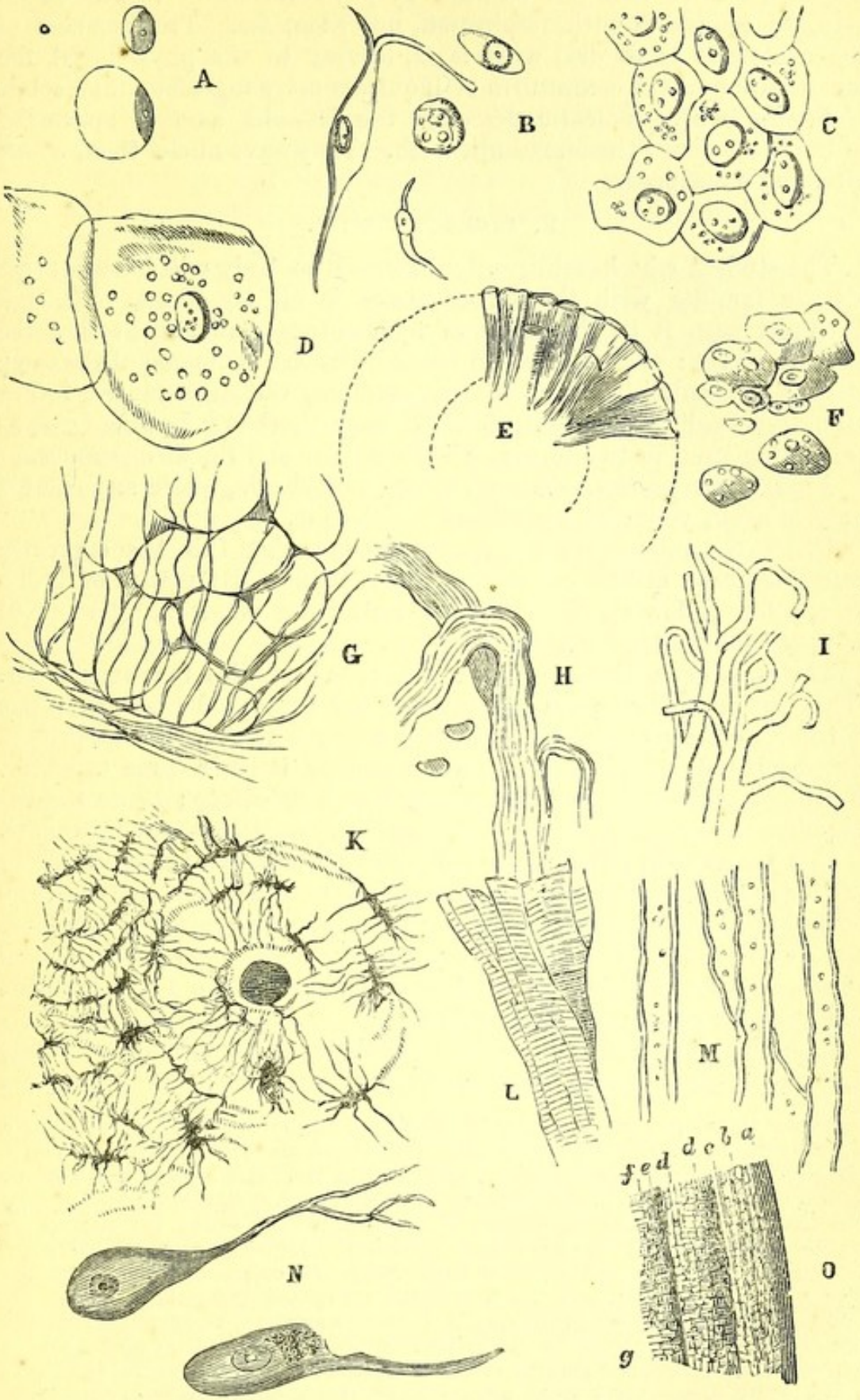

* Fig. 241.—Showing the various tissues, as seen under a microscope of high power.—A, plan of the formation of a cell and a nucleus, Schleiden; B, cells

The fat is composed chiefly of carbon and hydrogen. Many ingenious conjectures have been put forward by physiologists in respect to its uses, its connexion with respiration, nutrition, &c. The business of the anatomist is to deal with facts, leaving to the physiologist the investigation of the conjectures of inquirers more ingenious than solid.

Development.—Valentin describes the fat-cells as first appearing in the fœtus about the fourteenth week. They have nuclei then, which afterwards disappear.

2. FIBROUS TISSUE.

The student who has diligently dissected the body will have become already familiar with the fibrous tissue in all its forms. He will have met with it in the shape of ligamentous cords, connecting the bones together: the tendons and aponeuroses are composed of the same tissue; the outer layer of the pericardium, the dura mater, tunica albuginea oculi, periosteum, &c. It may therefore be considered as presenting itself in two forms—the *fascicular* and the *membranous*.

Physical properties.—Strong, tough, non-elastic, white and shining or glistening, yellowish sometimes, inextensile.

Under the microscope the filaments composing this tissue greatly resemble those of the common cellular tissue. By means of acetic acid, a few yellow elastic fibres and nuclei are detected, interspersed with the filaments of the fibrous tissue.

The two tissues then, just described, pass insensibly into each other. They agree in chemical constitution. By boiling, the fibrous tissue is resolved into gelatine; when dried it becomes translucent and brittle, but regains its physical qualities by placing it for a time in water. Nothing is more unlike a true ligament than a dried one; hence the disadvantage of consulting dried anatomical preparations of the ligaments.

In a healthy state the organs composed of this tissue are insensible; yet it is probable that they may receive some fine nervous filaments. Some have been traced to the dura mater. They are scantily supplied, also, with a few blood-vessels, yet they unite readily when torn across, as is proved by the accidental rupture of the tendo Achillis, and by numerous surgical operations.

In ununited fractures of bones it is this tissue, or something resembling it, which forms the bond of union; and it forms the basis of many tumours.

becoming developed into cellular tissue; C, fragment of epithelium from a serous membrane; D, epithelium scales from the inside of the mouth; E, transverse section of an intestinal villus, showing the form and arrangement of the columnar epithelium; F, specimen of the spheroidal epithelium; G, fat cells and filaments of the cellular tissue; H, I, the muscular fibre; I, elastic fibres of the yellow tissue; K, transverse section of the compact tissue of bone, showing a section of a Haversian canal with the corpuscles or lacunæ (as they may be viewed), and the canaliculi extending from them across the laminæ; M, arrangement of the capillary vessels amongst the muscular fibres; N, nerve-cells as described by Hannover, from the grey matter of the brain; O, plan showing the arrangement of the fibres and cells in the cortical substance of the brain; the letters from *a* to *f* show the fibres in layers; *g* points to where they come from, the central white matter intersecting the stratified white fibres of the cortical substance. The strata seen in the convolutions are arranged in white and grey layers alternately.

3. YELLOW, OR ELASTIC TISSUE.

In man this tissue forms the ligamenta flava, or subflava of the vertebræ; the vocal cords; the stylo-hyoid, thyro-hyoid, and crico-thyroid ligaments; the longitudinal bands running outside the mucous membrane of the trachea; the middle tunic of the arteries. The tissue is also found sparingly outside the mucous membrane of the gullet and rectum, and occasionally outside the serous membranes in the subserous cellular tissue, in some of the fasciæ, and in the dermoid tissue or true skin.

Its most remarkable properties are its *elasticity* and strength. In the large quadrupeds, as the horse, ox, and elephant, it mainly supports the head, forming the powerful ligamentum nuchæ, or pax-wax of the neck.

The fibres composing it, when examined under the microscope, seem transparent and follow bolder curves than the simply fibrous or cellular. Moreover they divide into branches and are reticulated. Their size is very various, from $\frac{1}{4000}$ to $\frac{1}{24000}$ of an inch in diameter. Acetic acid does not act on them. By boiling it yields an impure gelatine. Of the other blood-vessels and nerves nothing is known.

4. CARTILAGE; GRISTLE.

Elastic, admits of tension, is of great strength, opaque, but translucent when cut into thin slices; covered by a perichondrium, and does not unite when torn or divided in the living body.

The skeleton of the embryo is at first nearly cartilaginous, but the cartilages composing it do not remain in this state, but give place to bones; such cartilages are called temporary. But others, which may be viewed as *permanent*, are in reality not so; the thyroid, for example, which in extreme old age is usually converted into bone. It is a question then of time with some exceptions however, such as the cartilages of the nose and ears, which under no circumstances naturally become osseous.

Bichat called the cartilaginous surfaces of joints, cartilages of *incrustation;* the costal he called cartilages of *prolongation:* these latter often become osseous.

The perichondrium is said to be wanting in the cartilages of incrustation; this, however, is rather doubtful.

When examined in thin slices under the microscope, a cartilage seems to be composed of a matrix, homogeneous and generally transparent, and of nucleated cells disseminated throughout.

It has been much debated whether it is the synovial membrane which covers the articular cartilages or merely a fine epithelium. One thing, however, is certain, that the structure, whatever it may be, is capable of becoming exceedingly vascular when inflamed, so that blood-vessels must exist somewhere, for it is difficult to imagine that such vessels come exclusively from the subjacent osseous tissue.

The tissue is insensible in the healthy state; and in this condition

no blood-vessels have been traced into the articular cartilages, at least. Chemical processes show that cartilages contain some mineral products, chiefly the salts of soda, lime, and magnesia. But little is known of their mode of development.

When destroyed cartilages are not regenerated; the articular cartilages are much subject to atrophy or wasting. When this happens they gradually break up into fragments, finally disappear, and the bone, thus denuded of cartilage, acquires for its protection an ivory-looking texture, extending more or less deeply into the substance of the bone. The older surgeons, who did not understand the nature or object of the transformation, called it "the ivory exostosis."

In some animals, as in the first dorsal vertebra of the camel, this conversion of the bone into a substance having the density and whiteness of ivory seems to be a natural process.

5. FIBRO-CARTILAGE.

Bichat first described this peculiar tissue. It partakes of the qualities of both tissues, and hence its name. Elastic like cartilage, it is yet fibrous like ligament. It shows great strength and toughness and low vital powers, being scarcely ever found in a pathological state. Of it we find composed the interarticular fibro-cartilages of the knee and other joints; the brims or margins of articular cavities, as the glenoid, cotyloid, &c. Others merely connect bones together, and have no synovial covering; such are the intervertebral substances and symphyses of the pubes.

Sesamoid bones are developed in a cartilage which may be esteemed a modified fibro-cartilage, developed in and near the surface of tendons.

A fibro-cartilage occupies the base of the ventricles of the heart: it uniformly ossifies in the ox.

Under the microscope this tissue seems to be composed of fibres with cartilage-cells intermixed. In chemical composition it resembles ligament. In diseased conditions of the vertebræ it seems long to remain unaffected, resisting absorption much longer than bone.

6. OSSEOUS TISSUE; BONE.

No tissue has given rise to more elaborate inquiry than the osseous. The facts best ascertained may be thus briefly stated:—

In the living body bones are covered with periosteum and filled with marrow. Blood-vessels pervade them in all directions: lymphatics probably exist, and nervous filaments, which have not, however, been so clearly made out. The tissue is hard, tough, and somewhat elastic.

By calcination bone may be shown to be composed of two substances: 1, an animal part, driven off by the action of heat; 2, an osseous part, which remains and retains the original form of the bone. The animal matter thus destroyed in this simple analysis may be obtained by simply macerating the bone in acid: this dissolves the osseous portion and leaves the animal portion of the bone; the original form of the bone itself is retained; it then weighs about one-third of the original weight of the bone.

This animal substance is usually called a cartilage, which it resembles in some points, but not in others. It differs essentially from cartilage, properly so called. By boiling it may be resolved almost wholly into gelatine.

The earthy part of the bone amounts to about two-thirds the weight of the original bone, varying, however, at different periods of life, and is composed chiefly of phosphate of lime, with which there is mixed up a small quantity of carbonate of lime, fluoride of calcium, chloride of sodium, and magnesian salts.

The following is the analysis of bone by Berzelius:—

Animal matter	33·30
Phosphate of lime	51·04
Carbonate of lime	11·30
Fluoride of calcium	2·00
Magnesia, chiefly in the state of phosphate	1·16
Soda and chloride of sodium	1·20

By sawing a bone through, it is evident that the osseous tissue assumes two forms; these have been called *compact* and *cancellated*. This distinction, however, almost disappears when these tissues are examined with a glass; they are then seen to be porous everywhere, and that the difference is only in degree. They pass into one another, presenting no abrupt line of demarcation. Between the outer and inner compact tables of the cranium the cancellated structure is called *diploë*.

The cancelli are formed by delicate spicula of bone and thin lamellæ or plates; the open spaces or areolæ communicate freely with each other; they contain marrow and blood-vessels.

The compact tissue is also full of foramina, but they are small. By breaking a bone across they may be seen in great numbers; they are the openings of short longitudinal passages running in the compact substance. From Clopton Havers, who first described them, they have since been called Haversian canals. They also contain blood-vessels and marrow. They are readily seen with a common magnifying glass. A longitudinal section of the bone displays them best.

These canals of Havers are surrounded by concentric lamellæ, while this lamellated structure extends to the cancellated as well as to the compact tissue of bone. To see these requires a glass of considerable magnifying powers. It is the same also with certain vacuities, formerly called corpuscles. Running from these lacunæ are minute tubes—canaliculi. In the osseous tissue we have then, 1, areolæ; 2, Haversian canals; 3, lacunæ and canaliculi, which perhaps traverse, 4, the lamellæ, themselves composed of fibres exceedingly minute. The laminæ are superimposed. Thus the modern microscope brings the observer back to the original observations of Duhamel. Of the mode in which the osseous particles are united to the animal substance of the bone nothing is known.

The *periosteum* is a fibrous membrane covering the exterior of the bones.

It does not extend over those surfaces which are naturally encrusted with cartilage. It adheres firmly to them; sends prolongations into their substance, and transmits to them most of their blood-vessels.

The uses of the periosteum have not been fully determined. In early years it probably assists mainly in forming the bone.

The *medulla* or marrow lodged in the interior of bones is not confined to the medullary canal of the shafts of long bones.

The bones of the fœtus are at first filled with a reddish fluid like bloody serum, but firmer. The uses of the marrow are not understood, nor why; in certain birds, air should penetrate and prevail where, in mammals, there is marrow. "The bones are slow to fall into disease, and they are slow to recover."* Nevertheless, they are well supplied with blood-vessels. The veins of the cancelli are peculiar; they run separately from the arteries, and are best seen in the diploë of the bones of the cranium; the same arrangement prevails, also, in the bodies of the vertebræ.

The bones are generally admitted to have lymphatics, and fine filaments of nerves have been seen to pass into the medullary canal, along with the nourishing artery of the bone. The bones are insensible, and so also is the marrow.

The formation and growth of bone is a physiological question, which has been made the subject of the most extended inquiries. I have anxiously, and with great care, followed out the pathological part of the inquiry for many years.

In the fœtus a substance resembling cartilage precedes, generally, the deposition of earthy particles, which together constitute bone; but the bones of the skull seem to form in a membrane. When ossification takes place in membrane, as in the flat bones of the cranium, it commences by a centre, from which rays spread out in all directions. The osseous deposits resemble a network, and, from the nucleus or central point, they spread to the sutures; which, also, become ossified in old age. The precise nature of the membrane in which these bones form is not known. Soëmmering, considering that the tendency of the bones of the cranium is ultimately to unite into one, was disposed to view the membrane in which these flat bones form as essentially one.

The greater number of the bones of the skeleton form in a substance resembling cartilage, which follows very quickly the primitive soft substance preceding its formation. This substance is composed of cartilage cells, embedded in a clear matrix.

The successive appearance of the osseous centres has been already described in the descriptive part of this work.

The progress of ossification is marked by a stage at first evidently transitionary. A second follows, at the commencement of which the canals of Havers, the cancelli, and the lamellæ, begin to appear. The primary areolæ open into each other; they coalesce into larger ones, their sides being, in the mean time, thickened by new layers of bone.

* Hunter.

There are no lacunæ in the primary granular bone. How they are formed is not known; nor is it quite clear how the calcification of the fine fibres of the lamellæ proceeds. The formation of the canaliculi is equally mysterious.

It is probable that the ossification on the periosteal surface of the bone does not take place in, or is not preceded by, the formation of cartilage; still there are pathological facts which militate against this view. As the periosteum transmits nothing into the bone but blood-vessels, cellular tissue, and fibrous slips, it follows, if the above view be a correct one, that bone must be formed out of these materials.

As the bone continues to increase in length it would seem that little or no elongation takes place by interstitial deposits or growth. This was proved by the experiments of Hales, Duhamel, and John Hunter. The shaft increases in substance by depositions on its external surface, the medullary canal being enlarged by absorption from within.

7. VASCULAR TISSUE.

Under the name of *système* or *tissue vasculaire* Bichat included the various tunics of the blood-vessels, and more especially their internal tunic. Together with the lymphatic vessels they may still be viewed much in the same way.

1. *Blood-vessels.*—These comprise three sets of vessels—1, arteries; 2, veins; 3, a fine network of vessels, placed between the comparatively large ones. The vessels composing this network have been called capillaries.

The whole of the arterial blood leaves the left ventricle of the heart to be distributed throughout the system by the aorta and its branches; it returns to the right auricle of the heart by three veins—1, the vena cava superior; 2, the vena cava inferior; 3, the coronary vein of the heart itself. This is called the greater circulation of the blood. It next passes from the right auricle into the right ventricle, which propels it, by means of the pulmonary artery, through the lungs, from which organs it returns, by the pulmonary veins, to the left auricle. This is the smaller circulation.

7a. ARTERIES.

Practically speaking, an artery is composed of three tunics, the microscope, however, showing that these admit of being further subdivided: they are generally enclosed in a cellular sheath.

External tunic.—Cellular and fibrous. In the larger arteries the innermost layer of this tunic is composed of true elastic tissue.* It is this external layer which resists the action of the thread when the artery is tied.

Middle tunic, or *coat.*—Composed of distinct circular fibres, long supposed to be muscular. In the large arteries it is composed of many layers. These fibres are of a yellowish colour and highly elastic, and seem almost identical with the yellow elastic tissue already described;

* Henle.

but many class them with the unstriated muscular fibres. The tunic is slightly contractile.

Internal tunic or *coat.*—This is a fine, elastic, transparent membrane lining the interior of the arteries. To the eye it seems a single layer; under the microscope it is found to be double, and composed of —1, a scaly epithelium, which, with its basement membrane, lines its interior; 2, of a striated or perforated membrane of an unknown nature.

The tunics of the large arteries receive small blood-vessels (*vasa vasorum*). The arterial tissue is insensible. Much wild speculation has been got up by physicians respecting the nerves of the arteries; the muscularity of their walls; spasms of the extreme vessels, &c. The arteries, when cut across, do not collapse.

7 b. VEINS.

Structure.—The coats of the veins are much thinner than those of the arteries, and thus they collapse when cut across,* which does not happen to the arteries; their coats have been usually reckoned as two; a third, however, may be added to this—1, an internal tunic, resembling that of the arteries, but clearly differing in its vital properties; 2, a middle tunic, fibrous, and composed of many layers; 3, an external, close, but thin cellular coat.

The valves of the veins have been already spoken of; they are found chiefly in the superficial and deep veins of the limbs; their functions are obvious, and their structure easily examined.

7 c. CAPILLARIES.

That the blood passed from the arteries into the veins continuously was an inference assumed by Harvey, unsupported by intuitive evidence at the time. This link in the chain of evidence in respect of the circulation of the blood was supplied by Malpighi. When transparent vascular parts of living animals, as the mesentery, can be placed so as to be viewed through the microscope, the capillaries become manifest, and the blood may then be seen passing from the arteries into the veins continuously. The vessels in which this happens are sometimes so minute as not to exceed in calibre $\frac{1}{4000}$ part of an inch. The smallest are supposed to have but one coat.

The true nature of the erectile tissue has never yet been made out; it is probably of, at least, two distinct kinds.

7 d. DEVELOPMENT OF VESSELS.

New vessels are formed during life in parts not previously existing. According to Schwann and Kolliker the smaller vessels and nerves originate from nucleated cells. The cell-wall or envelope sends out slender prolongations in different directions; these meet others, and thus form a network of tubes, into which the blood at last penetrates. The whole subject belongs to physiology.

* The hepatic veins do not collapse, nor do the veins of the diploë.

7e. LYMPHATIC VESSELS AND GLANDS.

Lymphatics have not been discovered in all the organs; nevertheless they are very numerous. They seem to originate generally in networks so fine as to escape observation. From these networks single vessels emerge; these unite with others to terminate chiefly, but not wholly, in the thoracic duct. The lymphatics forming the fine networks do not seem to communicate with the veins, nor have they valves.

Structure.—The coats of the lymphatics are much thinner than those of the veins; they are provided with numerous valves. At their commencement the lymphatics are thought to have but one coat: the large have two and even three. They are elastic and extensile, and probably contractile, and are analogous to the tunics of the arteries and veins, which they resemble in structure and functions. Their tunics receive vessels and probably nerves.

Absorbent glands.—Small rounded or oval solid bodies placed in the course of the lymphatics and lacteals. The position of the greater number of them has been already described. All the lymphatics do not pass through such glands. The vessels leading to glands are called *afferent*, those leaving the glands, *efferent*.

When about to enter the gland the afferent vessels divide and subdivide minutely. The mass of the lymphatic glands seems composed of minute lymphatic vessels, some blood-vessels and cellular tissue. Thus the intimate nature of these glands has not yet been made out, nor their functions.

The thoracic duct, the terminating trunk of the absorbent system, opens into the left subclavian vein, near its junction with the internal jugular; but a short trunk also enters the right subclavian vein.

The question as to the termination of lymphatics in other veins has been much debated. My own dissections are entirely opposed to such views; neither do I believe in the termination of the lacteals in the meseraic or any other veins, directly or indirectly. The opinions of Tiedemann and Fohman respecting the opening of lacteals into the meseraic veins, based on inaccurate dissections of the seal and porpoise, were distinctly refuted by me in 1822 and 1823.

8. SEROUS MEMBRANES.

Since Bichat described these membranes and gave to the world his immortal treatise thereon, the microscope has revealed to us that they are somewhat more complex than he imagined them to be. The view taken of them at present is as follows:—

They are named from the fluid which lubricates their surface, and with one exception (the peritoneum in the female) they are shut sacs without openings. The history of each has been given in the descriptive anatomical portion of this manual.

The inner surface is smooth and polished, and bedewed with serosity. Thus the organs they invest are enabled to slide over their containing walls. The outer surface adheres closely to a great variety of struc-

tures by means of the sub-serous cellular tissue. But this also has its exception in the case of the spinal arachnoid.

These membranes are thin and transparent, and were hence called diaphanous. They are moderately extensile and elastic. The microscope shows, 1, a scaly epithelium;* 2, next to the epithelium, and supporting it, an exceedingly fine lamella of a simple and homogeneous nature; this membrane was already known to anatomists, who viewed it as a sort of delicate epidermic covering; 3, one or more layers of condensed cellular membrane, composed of bundles of white filaments mixed with elastic fibres. This is continuous with the sub-serous cellular tissue, seldom absent; and this connects the membrane to the surrounding organs.

Blood-vessels and lymphatics abound in the cellular and sub-cellular layers, but do not penetrate the peculiar layer lying upon the cellular. In a healthy state they are insensible.

The fluid which bedews these surfaces coagulates spontaneously; this must be due to the presence of fibrine.

9. SYNOVIAL MEMBRANES.

Analogous in their arrangements to the serous, they form shut sacs without any openings. They resemble them also in their intimate structure,† but differ in the nature of the fluid they secrete. This is called synovia; a viscid transparent fluid, consisting of water with 6 per cent. of albumen and a minute quantity of extractive matter and salts.

The descriptive anatomist divides the synovial membranes into—

1. The articular.
2. The vesicular.
3. The vaginal.

Fringed membranous folds exist in most synovial capsules, but chiefly in the articular; these are supposed to be concerned in the secretion of the synovia. Non-vascular secondary processes have also been described.

The vaginal synovial bursæ have been already described where most conspicuous and important; as under the annular ligaments and investing the tendons of muscles.

The vesicular bursæ have also been noticed in connexion with the system of the sub-cutaneous cellular fasciæ, to which they belong.

10. MUCOUS MEMBRANES.

These membranes, so named from the mucosities continually lubricating their surfaces, were comprehensively and philosophically viewed by Bichat. The comparative anatomist views them as an internal in-

* Said to be (Quain, p. cclxxi.) ciliated on the membrane lining the ventricles of the brain; but this is not a serous membrane: also on the part of the peritoneum, covering the fimbriated extremity of the Fallopian tubes.

† 1, A scaly epithelium; 2, a firm homogeneous membrane; 3, a dense cellular layer.

tegument, reflected from the external, that is the skin. They commence by orifices situated on the exterior of the body; the mouth and nostrils; the urethra and anus in man; the vulva and anus in woman. They form two great systems—the *gastro-pulmonary* and genito-urinary.*

The course of the mucous membrane continuously over all these surfaces has been carefully traced in the descriptive anatomy. What we have chiefly to consider here is the intimate nature of these membranes.

The mucous membranes are mostly opaque. Their tenacity and elasticity are small. The colour they have during life is due to the blood contained within the blood-vessels with which they abound. It varies much in different situations.

Structure.—When examined with a good microscope they are found to be composed, 1, of an epithelium, that is to say, an epidermic covering, essentially composed of nucleated cells and a supporting membranous matrix, or at least a coherent intercellular matter. The epithelium found here is of the sort called *columnar*, a form of epithelium covering confined to them. It extends over the ducts opening upon the mucous membranes, but not throughout their entire length.

2. Of a membrane called *corium*, as following out the analogy of these membranes with the external integuments. This is composed of a fine vascular layer of variable thickness; it is in fact the fibro-vascular layer of the mucous membrane. In this layer lymphatics abound and nervous filaments. No vessels are found in the epithelium nor in its supporting membrane.

The vessels commence in fine networks, of which some are in contact with the membrane supporting the epithelium.

The mucous membrane in some parts presents papillæ, as in the tongue: they are processes of the *corium*, containing blood-vessels and nerves, covered with the epithelium. The *villi* abound most in the intestines. They resemble the papillæ, and have with them been already described.

The alveolar recesses seen on the surface of the mucous membranes have also been described.

The structures called *tubular follicles* are minute tubes formed by recesses and inversions of the corium and the epithelial coverings. They abound in the stomach and intestines.

Saccular follicles are small cavities of a rounded shape seen on the surface of certain mucous membranes. Their nature has not yet been correctly determined. Some of these seem to open only occasionally to permit of the escape of their secretions.

Small compound glands.—These have been already alluded to when speaking of the glands of Brunn.

Nerves.—These membranes have nerves and show peculiar sensibilities according to the organ they invest.

* If the membrane lining the lactiferous ducts of the mamma be mucous, then a third system must be added.

The mucus found in abundance on the surface of these membranes is composed of, 1, epithelium particles thrown off from the membrane; 2, mucous corpuscles, of a nature not well known; 3, nucleated cells. To this must be added a substance, called by chemists *mucin*.

When destroyed by ulceration, the mucous membrane is readily regenerated, and is said even to recover its peculiar epithelium; but the tubular follicles are not reproduced. I have on many occasions examined, with common magnifying glasses, the mucous membrane of the large intestine which had suffered from dysentery. It seemed to me that the regenerated membrane was not identical or of the same nature with that which had been lost. The mucous membrane of the urethra unites readily when divided longitudinally in strictures of long standing; but the exact nature of the structures, restoring the tube to its original calibre, has not been shown. I feel disposed to doubt the regeneration of the *corium* of the intestine, in all its integrity, after it has been destroyed.

11. SECRETING GLANDS.

Besides its more legitimate application the term gland has been applied in a vague manner to a number of solid organs, with the precise functions of which anatomists are unacquainted. It is intended, in this short section, to limit the term to those bodies only which secrete.

Before the recent microscopic discoveries physiologists were divided in their opinions as to the intimate nature of the secreting glands. Some viewed them, with Malpighi, as being mainly composed of tubes closed at one end. This view received support from comparative anatomy. Others held, with Ruysch, that the parenchyma of glands was chiefly composed of vessels.

The secretion of a fluid, which is either retained in the body or ejected from it, is the function of the glands; it is analogous to nutrition; the blood furnishes the materials in both cases. Blood-vessels of the greatest tenuity approach some free surface on which the secretion takes place; but the vessels themselves do not open on the free surface. Until the discovery, by powerful microscopes, of the *nucleated cell*, nothing more was known of secretion. This new element gave further insight into its nature. Over the secreting surface a series of these cells, of a spheroidal or polyhedral figure, is spread, so as to form an epithelium; and this layer of cells rests on a membrane—the basement membrane, or membrana propria. The function of the membrane may or may not be simply mechanical; it is otherwise with the cells; they are eminently vital, though not vascular. These cells absorb the materials from the blood, and are then discharged entire, or open and suffer their contents to escape; they thus undergo continual destruction and reproduction. Their real nature is absolutely unknown. What has been said on the subject is pure hypothesis.

The cells seem capable of forming new products.

To extend the secreting surface, and to occupy as little room as possible, processes or tubes are formed, rolled up; or these tubes, or culs-de-sac, form lobules and lobes, as seen and described by Malpighi.

Lymphatics exist also in glands and nerves, but nothing is known of their mode of termination or relation to the surrounding structures. Cellular tissue, or an amorphous substance acting as a substitute for it, exists in all glands. Some have special capsules, others not. All this has been already adverted to. Their ducts open upon mucous surfaces or on the internal integuments. These ducts have also a basement membrane and epithelium. This is spheroidal at the commencement of the duct and columnar throughout the rest of its course. Outside the basement membrane is generally the mucous membrane, supported by a cellulo-fibrous layer, and sometimes by two layers of muscles; the fibres of the inner layer running longitudinally, of the outer circularly.

II. MUSCULAR TISSUE.

The muscular tissue, the second of the primitive tissues, according to De Blainville, composes the larger portion of the human body. It is essentially the instrument by which motion is performed, and is composed of fine fibres, whose characteristic is their *contractility*.

The practical anatomist finds no difficulty in dissecting and arranging the muscles; his method is mechanical and simply anatomical. With him there exists a distinction so obvious between the muscles whose fibres are collected into a well-defined mass, large or small, and those layers of fibres, obviously muscular however, which invest the mucous membranes and form a portion of the walls of hollow organs, that he never confounds the one with the other. The constrictors of the pharynx, and the muscular walls of the gullet, are to him obviously portions of two different systems of fibres.

It is when an attempt is made to classify the muscles by any physiological method, that insurmountable difficulties arise, which the discoveries of the illustrious Schwann and his great school have not been able wholly to overcome.

De Blainville, whose views were always ingenious, generally novel, and often correct, divided the muscular system into three classes of muscles. The 1st he called subcutaneous; under this head he included all the muscles usually called *voluntary*. The 2d he called submucous; and this embraced the muscular layers or tunics of the digestive tube, the urinary, uterine, and other organs and their appendages. The 3d he called subserous or deep. In this category he placed the heart.

For all practical purposes, the muscles may be divided into the voluntary and involuntary; but this by no means expresses their real character. Most of the muscles of the body act, under certain circumstances, *instinctively*, that is, against our will and without our consciousness. The intercostals and diaphragm act night and day without

our consciousness, and without our will having the slightest control over them.

Physiologists have therefore sought, in the microscopic examination of the fibres themselves, some better characteristic of the obvious differences in the muscular fibres throughout the body as regards their functions; but their laborious, not to say ingenious researches, have not led to any striking results. This may be gathered from the following brief summary of their inquiries.

The muscular fibre is well known as the food of animals. *Contractility*, or the power of shortening itself when acted on during life by certain stimuli, is its great feature. By this simple act it performs all the movements it is called on to execute, whether these be the expulsion of the urine from the bladder, the expansion of the thorax, or the transport of the body from one place to another. The division of muscles into voluntary and involuntary is based on a mistaken view of the functions of the nervous system.

The muscular fibres of the so-called voluntary muscles are collected into bundles or fasciculi, obvious to the sight; they are enclosed in cellular sheaths and so connected together. The fibres themselves are composed of groups of fibrillæ, and these can only be perceived by glasses which magnify highly. All these run parallel with each other, the fibrillæ in composing the fibre, the fibres in composing the fasciculi; and all extend from one end of the muscle to the other, unless interrupted by tendinous intersections. There is no interlacing of fasciculi. The muscle has a general sheath, often double; the fasciculi have their sheaths; so also has the fibre, and, perhaps, the fibrilla. This last does not seem derivable from the general investing cellular tissue; the same remark applies to the fibre itself.

That the texture of the muscle we now speak of varies is obvious on comparing the gluteus or deltoid with the psoas and iliacus. The length of the fasciculi is regulated by the mode of their attachment to the tendons.

The fibre itself is generally considered as being about $\frac{1}{400}$ part of an inch in diameter. They are crossed by fine dark parallel lines at short but regular intervals. This cross-striped appearance, common to all the muscles usually called *voluntary*, may be seen with a glass of moderate powers. Muscles so marked are alone found to be the nidus for the peculiar parasite (vibrio musc. hum.) infesting occasionally the human muscles; it is then a characteristic of those muscular fibres over which the will exerts a full or restricted power, and the peculiarity of the pathological condition proves them to differ from those muscular fibres, abundant in the body, not so marked.

The fibre is said to be composed of fibrillæ, that is, of still finer fibres. The fibre has a sheath, supposed not to be cellular; it has been called *sarcolemma*, in imitation of the neurolemma of the older anatomists.

The filaments or fibrillæ, on the other hand, are of a more questionable character. Under strong glasses they seem to be composed of a single row of minute particles connected together like a string of

beads. Thus we return to the vesicular theory of Cowper and the old Dutch anatomists.

From this point of the inquiry all is conjecture; hypotheses, based on optical illusions and delusions, which commenced with the second Monro, and have not yet terminated.

It has been suggested that the fibrillæ have no real existence as such in the fibre. The fibres were seen by Fontana and Prochaska.

The mode in which the muscular fibres terminate in tendons is unknown. Blood-vessels abound in muscles, but they do not enter the *fibres;* and their mode of termination is also unknown. Numerous nerves proceed to the muscles, but seem to have no direct communication with the fibres. They form loops amongst the fasciculi and fibres, but do not terminate anywhere.

INVOLUNTARY MUSCULAR FIBRES.

These form the muscular tunics of many hollow bowels; but of the heart an exception must be made, for, though strictly *involuntary*, subserous, and profound, its fibres resemble those of the ordinary voluntary muscles. The submucous muscular fibres, on the other hand, differ from these essentially in structure as well as function.

The *fibre* I now speak of *has no cross lines or markings;* they are *unstriped fibres.* When examined under the microscope they show corpuscles or nuclei interspersed. The existence of a special sheath is still doubted.

These fibres, arranged in layers, have already been described, as the muscular walls of the stomach, intestine, bladder, &c. They interlace, in some instances, and cross each other. How they terminate is not known.

The fibres of the heart present transverse striæ. They present differences from the common muscles, however, which may be readily observed without any microscope. They are of a finer texture, they interlace, and the nerves proceeding to the heart are derived from the sympathetic system of nerves.

Chemical composition of muscle.—Fibrin is the essential constituent of the muscular fibre. There is no chemical analysis of the muscular fibre, isolated from the other tissues, required to form what is called a muscle. A portion of a fresh voluntary muscle of the ox, examined by Berzelius, gave on analysis—

Water	77·17
Fibrin	15·8
Albumen, with colouring matter . . .	2·2
Alcoholic extract, with salts	1·8
Watery „ „ . . .	1·05
Phosphate of lime, with albumen . . .	0·08
	100

Development.—The muscular fibres are developed from nucleated cells, which coalesce in rows, and undergo other changes. A soft blastema precedes, in which the nuclei are formed. The cells form a tube, and within the tube the fibrillæ appear. Muscular fibre is not regenerated when once destroyed.

Of the nature of the *irritability* or *contractility* of muscles nothing is known: it seems to depend on the condition of the nerves, uniformly distributed to muscles. These systems are intimately connected with each other.

When the nerves of a limb are congenitally absent, so are the muscles.

It is probable that an oscillatory action goes on unceasingly in muscles during life, caused by the action of the nerves upon their fibres. The phenomenon is probably essentially electrical.

The stiffening of the body after death is a muscular phenomenon as yet not well explained. It indicates death.

III. THE NERVOUS TISSUE.

This is the highest organic form which matter has yet assumed. On its integrity, forms, and arrangements, depend sensibility, volition, instinct, reason, and in man, civilization.

The human brain is its highest type. Without pretending to minute accuracy, it may be said that the nervous system of man divides itself anatomically and physiologically into two distinct systems:—1. The cerebro-spinal axis and its nerves. 2. The sympathetic or extra-vertebral system, composed of ganglions and their nerves of communication and distribution. These systems are essentially distinct physiologically.

The cerebro-spinal axis, forming the centre of one of the great systems, distributes the nerves connected with it to the organs of sense and muscles of locomotion and voice: but it is not limited to these. The great nerves on which respiration and life more immediately depend, come from, or go to, the cerebro-spinal axis; the nerves supplying the diaphragm, intercostal and other muscles, continually and uninterruptedly acting without our consciousness and wholly independently of our will, all come from, or go directly to, the spinal marrow, or at least this axis. On the other hand, the sympathetic or vegetative system of nerves supplies with branches from its various ganglions the digestive tube, liver, kidneys, &c. The two systems sympathize rapidly with each other.

Albumen is the principal chemical element of brain and nervous matter: to this may be added 5 parts of fatty constituents and 80 of water.

The nervous matter examined under the microscope seems to be composed of *fibres* and *cells* or *vesicles*. The cells are not found in the nervous cords, excepting towards their periphery, in some of the organs of special sense. They exist, on the other hand, in and mainly

form the grey or cortical part of the brain and spinal marrow and ganglia; but fibres exist also there and a peculiar amorphous matter.

The fibres are said to be of two kinds—the *tubular* or *white*, and the grey or gelatinous.

The tubular fibres form the white part of the brain, spinal marrow, and nerves. They are best seen in the brains of negroes, porpoises, &c.; Spurzheim thought them more distinct in the brains of Englishmen than in those of Frenchmen. He ascribed it to the more frequent use of animal flesh as food.

The tubular fibre, if, or viewed as, a tube containing another substance, should be called a tube simply. It contains a nerve-pulp, which protrudes beyond the sheath formed by the tube when this has been torn across. An axis in the centre of this nerve-pulp, of a different character from the pulp, has been described by good observers, but it has not been fully made out.

Many of these tubes have varicose dilatations at various parts of their course; they have thence been called varicose tubes. The *tubes never anastomose or unite with each other.*

Fibres having a gelatinous appearance.—They abound in the sympathetic system of nerves, but they are also found elsewhere. They give a grey colour to the parts where they exist abundantly.

Nerve-cells or vesicles.—They are chiefly found in the grey matter of the brain and spinal cord. They consist of a fine transparent cell-membrane, containing granular matter and a nucleus also vesicular, within which are occasionally one or more nucleoli. The vesicular nucleus sometimes sends out fine prolongations; hence these are called caudate.

Such are the structural elements of the nervous system. It is needless to observe that they furnish no data whereon to found a sound physiology of that system.

In the descriptive part of this work the distribution of the grey and white matter of the brain and spinal marrow, with other minute points in the anatomy of the system, has been adverted to. It remains here to notice briefly a few minute facts which would have been misplaced in the descriptive anatomy.

The parts called *roots* of the nerves have been made the subject of repeated and most careful examinations; but these have led to no decided physiological result. They seem to be attached by one set of fibres to the white, and by another to pass into the grey matter of the spinal cord; but whether these fibres originate in the parts from which they spring or terminate, according to the view adopted, or whether they are connected at least in some instances with the caudate nuclei, is still a matter of great doubt. It is not improbable, however, that the nerve-fibre may fairly be traced to the nerve-cell: according to some the nerve-fibres begin as they end, in loops.

Rathke, the most original, perhaps, of all modern observers, classes the pituitary body with the thyroid, supra-renal glands, spleen, &c. Many grave objections might be offered to this view.

In addition to the *ganglia* already described, Remak has observed numerous minute ganglia in connexion with the nerves of the heart, lungs, and other viscera. The tubular fibres which come from the spinal marrow and enter the ganglions are not so numerous as those which leave the ganglion for the periphery. The inference therefore is, that some must originate there in ganglion nerve-cells: this view is partially supported by the direct observations of one of the most distinguished and candid observers of the present day; Rudolph Wagner traced tubular nerves to and from these ganglionic nerve-cells.

In the *spinal nerves*, the fasciculi or bundles of fibres interchange very frequently parcels of fibres with each other; this seems to have misled Bichat into an opinion that the nervous *fibres* form a network, or unite and subdivide; this idea has been completely refuted. The fibres of the cerebro-spinal nerves are mostly of the tubular kind.

A *plexus* represents on a large scale what takes place in the branches of every nerve, were they spread out and examined carefully. There is a constant interchange and commingling of fibres, but no union or dividing of the original nerve-fibre.

How the nerves terminate in the various organs has not yet been determined. They generally form loops from which no branches proceed to the organs themselves. I have verified this in as far at least as a lens of moderate power enabled me to do in the organs of most mammals; but in the electric organs of the silurus I could not perceive the loops; nor on the membranous surface of the mucous tubes which abound in the upper jaw of the shark and skate. There the nerves seemed to terminate by fibres of excessive delicacy. These inquiries were instituted in 1822, and the microscopes used were those of Dr. Brewster: the power of these instruments has been greatly increased since that period, and a re-examination might lead to very different results.

On certain branches of the nerves of the fingers and toes, and of some other organs, little knotted-looking bodies exist, in evident connexion with the nervous fibres. They were discovered by Vater, but are now called the corpuscles of Pacchini. Their real nature is wholly unknown. They seem to be enlargements of the neurolemma: the nervous fibre passes into their interior and generally terminates there; but it occasionally passes through them and proceeds onwards to another, or even to pass through the second and to terminate by joining the nerve from which it came.

Thus it may be concluded that all the nerves do not terminate in loops; that some, as the optic, end in minute fibres; but the relation of these fibres to the nervous layer of nerve-cells composing the more prominent part of the retina has not been even attempted to be displayed. In the labyrinth also, of the ear, some of the nervous fibres seem to terminate singly and not in loops.

Sympathetic ganglia and nerves. — Recent anatomical inquiries tend to confirm the opinions of Johnstone, Winslow, and the anatomists

of their time, that nerves originate in the ganglia of this system and proceed to the cerebral and spinal nerves; whilst others, also originating in them, are distributed to the viscera. It is right, however, to observe, that the integrity and uninterrupted course of the long ganglionic cord of the sympathetic seems to be as securely provided for as of the spinal marrow itself, innumerable dissections having shown me that the thoracic and abdominal portions of the cord are never interrupted, but, on the contrary, the communicating branch is further protected from the action of the diaphragm by a cellular arch.

Development.—But little is known of the development of the materials out of which this great and all-important system (the nervous) is formed; it is probably the result of a development by cells.

When cut across a nerve reunites; and it is generally admitted that the connecting fibres are true nervous fibres. The nervous fibres are then regenerated, probably by an extension from the divided ends of the nerves. Mr. Hunter was of opinion that nerves, under no circumstances, enlarge, or continue to grow, after being once fully formed; and this opinion forms the main objection to the idea, that, in the enlarged and pregnant uterus, the nerves and ganglia of the uterus partake of this increase. To me they seem to have increased somewhat under such circumstances, but how, it is impossible to say, nothing being known of the way in which nerves are originally formed.

OF THE FLUIDS.

The Epithelial Structures and the development of the Organs.

The object of the anatomist has ever been, and ever must be, to examine, with the hand and eye, unaided by magnifying glasses of any kind, the organs of the body and the textures composing them, as they appear on dissection and during life—to mark the nicest shades of difference between them, and so to recognize them under all circumstances. No other mode of examination can ever benefit the practical man.

But as a physiologist, which the anatomist, to be a good surgeon and a sound physician, must become, he naturally avails himself of the use of magnifying glasses, of chemical tests, and of all other modes of observation. Comparative anatomy furnishes much valuable aid; the philosophic or transcendental still more.

My object in the present and concluding section is to place before the readers of this manual a brief history of the fluids entering into the composition of the human body, and of the results of microscopic examinations of animal textures, from Leewenhoek to the immortal Schwann, to whom we owe the discovery of the nucleated-cell theory and nucleated cell; that plastic material, unknown in its essence, but which seems to perform all, or nearly all, the great acts of life; which

constructs, and destroys, and reconstructs, all animal and vegetable beings.

The organs of the human body, which have been the subject of the descriptive anatomy, are, though seemingly simple, with scarcely an exception, composed of several of the tissues just described.

When the analysis is pushed further it is seen that each of these tissues has a basis unlike that which appears to the naked eye; that this basis undergoes metamorphoses, which, studied and described, form the history of the development of the organs. By the aid of the microscope all this is revealed.

The *fluids* are, the blood, the chyle, and the lymph: these are compound and complex fluids. The tissues I have just described are—

Primitive.—1, The areolar; 2, the muscular; 3, the nervous.

Secondary.—1, The adipose; 2, the fibrous; 3, the yellow or elastic; 4, cartilage; 5, fibro cartilage; 6, the osseous; 7, the vascular; 8, the serous; 9, the synovial; 10, the mucous; 11, the glandular; and lastly, the dermoid, included in the descriptive anatomy.

All these systems have been already described.

In addition to the physical properties which must by this time be well known to the student, there is another which merits peculiar notice: it is that of *imbibition*.

The term was first used by Cuvier; he meant to express by it the passage of fluids through the walls of vessels into other tissues, and he explained, by its means, the nutrition of many avertebral animals.

It is probable, therefore, that even during life the animal tissues permit, within certain limits, the passage of fluids and gases through their tissues. The absorption of some, at least, of the constituent parts of the blood circulating in the uterine venous sinuses of the mother, by means of the placental tufts discovered by Wagner, is probably a phenomenon of this kind.

Chemical composition.—A detailed history of the chemical composition of animal bodies would be quite misplaced. Its elements, as shown by destructive analysis, are chiefly oxygen, hydrogen, carbon, and nitrogen; to these may be added, though in infinitely less quantities, phosphorus, sulphur, chlorine, fluorine, potassium, sodium, calcium, magnesium, iron, silica, manganese, aluminum, copper.

These do not, however, form the textures. The immediate compounds are—albumen, fibrin, casein, gelatine, chondria, extractine soluble in water, extractine soluble in alcohol, salivin, kreatin, pepsin, globulin, mucus, horny matter, pigment, hematyn, pyin, urea, uric acid, azotised biliary compound; besides these, fatty matters, sugar of milk, lactic acid, and certain principles of the bile.

Development of the tissues.—All philosophy points to the simplicity of the materials employed by Nature in the construction of her works; and this remark will be found to apply as well to the animal frame as to the globe itself.

Even in the time of Haller, physiologists were philosophic enough to

suppose that the development of the tissues proceeds from certain very simple primary elements; but it was not until of late years that this was demonstrated satisfactorily as regards both plants and animals. The demonstration of this important fact—the discovery of the primitive cell, out of which is formed not merely the various tissues of the animal body, but, in as far as is known at present, the germ of the future being itself—is due to Schwann.

In the transformation of these cells and their rapid metamorphoses would seem to reside the secret of the forms of animal and vegetable life. The process, it is true, has been more clearly made out in the vegetable kingdom; but much, also, has been done in investigating the structures of animal bodies.

Certain animal tissues in their earlier forms appear merely to be a congeries of cells. Such is cartilage.

A cell, at first, is a rounded or oval vesicle, formed of a thin, transparent, homogeneous membrane, flexible, and always of a microscopic size. It varies considerably in its dimensions. In the interior of this cell is a fluid of various consistence; and in most of them there appears, sooner or later, a smaller body called a *nucleus*.

Schleiden, who shares with Schwann the merit of these curious discoveries, calls the nucleus the cytoblast—that is, cell-germ. He ascribed to it the important function of secreting the cell itself. To this nucleus nucleoli have been added—that is, smaller dark spots within, or in connexion with the cell. Of these little or nothing is known.

But there is a something beyond the cell; it is the soft or liquid matter out of which cells are immediately produced. This has been named the *blastema*, or *cyto-blastema*.

It would seem that cells may be formed in a variety of ways; they may be formed on a nucleus, this being the usual way. The nucleus seems to be the turning-point, the generator of successive cells and of other nuclei.

The mode by reduplication has been in some measure proved by Kolliker; other modes have been described by Schwann.

Ultimately the various textures are formed by the transformation of these *cells* and of the *blastema*. They elongate, flatten, enlarge, diminish, or disappear; sometimes they grow into fibres by elongation and flattening; or ramified cells may open into each other, and so form vessels; or into the tubes thus formed other materials may be poured, and they are then transformed into nervous and muscular fibres. It has also been supposed (for there is much here which partakes of the nature of pure hypothesis) that the blastema may alone form membranes, without the intervention of cells or nuclei.

The textures, as they are constantly wasting and being destroyed, require as constant regeneration. It is the cell theory which offers some plausible explanations on this difficult subject.

The liquor sanguinis, or plasma of the blood, is presumed to be the immediate source of the nutrition of all the organs and their tissues.

It is conjectured that this exudes through the capillary vessels which carry it to the textures.

The formation and regeneration of the cuticle and epithelium are effected by a continuation of the same process. These tissues are extra-vascular. Blastema is provided by the vessels of the external and internal integumentary covering (dermis and mucous membranes); cells arise in this blastema so formed, enlarge, alter their figure and composition, and after forming, for a time, a part of the tissue, are discharged on its free surface. The same remarks apply, in part at least, to the vascular tissues of the body; the vessels merely carry the material out of which the blastema and cells are to be formed. They perform no other functions, in as far, at least, as regards the original formation and nutrition of the tissues.

Of the blood, the lymph, and the chyle, I need say nothing here; their history will be found in all physiological works. The history of the fluids of the body form no part of anatomy. As most of the facts connected with the cell theory have been derived from minute microscopic investigations into the epidermis and epithelium, I shall conclude this chapter with a brief account of this so-called cuticular tissue.

These tissues, in fact, constitute but one, though situated upon different surfaces. They have, in all cases, the same fundamental structures. It has been extended, as a cuticular tissue, to all the free surfaces of the body, and in this way made to include, 1st, the outer surface of the external integuments of the body; 2d, the inner surface of the mucous membranes; 3d, the free surface of the serous membranes; 4th, the synovial, a modification of the serous; 5th, the inner surface of the blood-vessels and lymphatics.

The tissue has neither vessels nor nerves; is devoid of sensibility; nevertheless, it is organised. It is formed by, and out of, nucleated cells, held together by a more or less coherent intercellular matter. A soft blastema exuding from the vessels of the membrane below precedes the formation of the cells. As they gradually rise to the surface they are thrown off, successive layers of them forming beneath.

The mass of cells is plastic and impressible, adapting itself to the subjacent tissue, whatever that may be.

Four different forms of this epidermic, epithelial, or cuticular tissue, have been described. They are—1, the scaly; 2, the columnar; 3, the spheroidal; 4, the ciliated.

1. The scaly, tesselated, or pavement-like epithelium, is found on the free surface of the serous membranes, the inner surface of the heart, of the blood-vessels, and absorbents. The form of this, and of the other modifications of the epithelium, will be best understood by an examination of the figures.

It would seem that this form of epithelium is not limited to the serous membranes, &c., but is found also on the skin and conjunctiva; on the membrane at the entrance of the nostrils; on the membrane of the mouth and tongue, throat, and gullet; on the vulva and vagina;

extending for a short way into the interior of the uterus; also for a short way on the surface of the urethra in both sexes; lastly, on the synovial membranes of joints.

2. The columnar epithelium is confined to mucous membranes. Its mode of shedding and renovation has not been clearly made out. It extends for a certain length along the ducts of the glands which open upon mucous surfaces; it extends, however, to the inner membrane of the gall-bladder.

3. The spheroidal, or transitional, epithelium is found chiefly on the inner surface of the mucous membrane of the urethra (with the exception of its commencement), bladder, ureters, and pelvis of the kidneys; in the excretory ducts of the mammary, perspiratory, and mucous glands.

4. The ciliated epithelium. The particles carry at their free extremities little hairlike processes, which, during life, and for some time after death, are incessantly agitated with a vibrating or lashing motion. These hairlike bodies are called cilia. The epithelium so singularly characterised occurs, 1st, on the mucous membrane of the air-passages, including parts of the nostrils, palate, Eustachian tubes, and tympanum; 2d, on the mucous membrane of the uterus and Fallopian tubes; 3d, on the parietes of the ventricles of the brain.

The dark colour of the choroid, and the colour of the negro, and other dark races of men, depends on the presence of pigment cells.

Cells less coloured exist also in the cuticle of the European.

INDEX.

Abdomen, deep fasciæ of, 289.
,, imaginary lines drawn on the surface of, for dividing it into regions, 450.
Abdominal aorta, 375.
Abdomino-pelvic Cavity, 432.
Abercrombie, Dr., weight of the brain of, 547.
Adipose tissue, 636.
Agassiz, on the sphenoid bone, 37.
Albinus, ignorant of transcendental or philosophic anatomy, 105.
Alimentary canal, illustration of, from the lower end of the gullet to the rectum, 466; development of, 471.
Allantois, urinary bladder, and urachus, 511.
Ankle-joint, 150.
Anterior and lateral regions, 251.
Aorta, the, 315, 335, 402.
,, illustration of, with the arteries arising from it, 336.
,, arteries which terminate the, 385.
,, arteries which arise from the abdominal portion of, 402.
,, arteries which spring from the arch of, 402.
,, arteries arising from the thoracic portion of, 402.
Aortic intercostal arteries, 374.
Aponeurosis, epicranial, 242.
,, temporal, 249.
Arm, surgical anatomy of the arteries and nerves in connexion with the muscles of, 181.
Arnold, the ganglion discovered by, 591.
Arteria innominata, 403.
,, nutritia tibiæ, 400.
,, profunda femoris, 405.
Arteries, the, 335, 643.
Arteries, tabular view of some minor or secondary, and their branches, 406.
,, which arise from the thoracic aorta, 373.
,, superior extremity, illustration of the distribution of, 362.
,, bronchial, 373.
Arteries, common carotid, 339.
,, common iliac, 385, 404.
,, coronary, 403.
,, inferior phrenic, 375.
,, lumbar, 384.
,, of the choroid plexus, 351.
,, plantar, coloured diagram of the course of, 400.
,, posterior mediastinal, 374.
,, renal, or emulgent, 383.
,, spermatic, 353.
,, tabular view of the principal arteries of the body, 402.
Artery, anterior tibial, 396.
,, ,, coloured diagram of the course of, 397.
,, axillary, 361; branches which it gives off in the axilla, 363.
,, basilar, 356.
,, brachial, or humeral, 364, 404.
,, cerebellar, superior and inferior, 356.
,, cerebral anterior, 352.
,, ,, posterior, 357.
,, cervical, deep, 360.
,, ,, transverse, 359.
,, circumflex iliac, 391.
,, cœliac, 376, 404.
,, common femoral, 405.
,, coronary, of the stomach, 377.
,, deep femoral, 393.
,, dorsal, of the foot, 398.
,, external carotid, 339; illustration of, 340.
,, ,, iliac, 390, 405.
,, ,, plantar, 400.
,, facial, 342, 406.
,, femoral, coloured diagram of, and its branches, 392.
,, ,, or crural, 391.
,, fibular, 405.
,, gluteal, 387.
,, hepatic, 377.
,, hypogastric, anterior branches of, 387.
,, ,, or internal iliac, 386; coloured sketch of the distribution of its branches, 387.
,, inferior mesenteric, 379, 404.

Artery, inferior mesenteric, system of the right and left colic arteries illustrated, 381.
,, inferior pharyngeal, 344.
,, intercostal superior, 359.
,, internal carotid, 348, 403.
,, ,, iliac, 387, 405.
,, ,, or common pudic, 389, 407.
,, ,, maxillary, 346, 406.
,, ,, plantar, 401.
,, ,, twig, or middle temporal, 345.
,, interosseal, 371.
,, ischiatic, 389.
,, lingual, 342, 406.
,, mammary, internal, 358.
,, mesenteric, coloured illustrations of the course of both superior and inferior, 380, 381.
,, middle cerebral, 352.
,, ,, hæmorrhoidal, 388.
,, ,, or proper capsular, 382.
,, occipital, 343.
,, œsophageal, 373.
,, ophthalmic, 349, 407.
,, popliteal, 394, 405.
,, ,, coloured diagram of the course of, 397.
,, posterior auricular, 344.
,, ,, tibial, 405.
,, pulmonary, 309, 402.
,, radial, 404.
,, ,, in the palm of the hand, 369.
,, right external carotid, 403.
,, spinal, anterior and posterior, 355.
,, splenic, 378.
,, subclavian, 353.
,, ,, and its branches, 403.
,, superficial femoral, 394, 405.
,, superior mesenteric, 378, 404.
,, ,, ,, illustration showing its course and its branches, 380.
,, superior thyroid, 406.
,, suprascapular, 360.
,, temporal, 345.
,, thyroid, superior, 341.
,, ,, inferior, 357.
,, ulnar, 370, 404.
,, ,, in the palm of the hand, 372.
,, uterine, 388.
,, vertebral, coloured illustration showing the course of, 354.
Articulations or Ligaments, 109.
Articulations in particular, 111.
,, of the bones of the superior extremities, 131.
,, of the thorax, 122.
,, of the lower extremities, 141.
Articulations, metacarpo-phalangeal, 140.
,, structures composing, 110.
,, vertebral, 111.
,, calceo-cuboid, 152.
,, diarthroses, or moveable, 109.
,, metatarso-phalangeal, 154.
,, pelvic, 127.
,, peroneo-tibial, superior, 148.
,, peroneo-tibial, middle and inferior, 149.
,, phalanges, 141.
,, radio-cubital, superior and middle, 137.
,, radio-cubital, lower, 138.
,, scapulo-clavicular, 132.
,, tarso-metatarsal, 153.
Astragalus, the, 101.
,, articulation of the scaphoid bone with, 152.
Atlas, the, 7; illustrations of upper and under surfaces of, 7.
Axis, or second cervical vertebra, 8.

Bauhin, ileo-cæcal valve of, 467.
Bertin on the inferior turbinated bone, 63.
Berzelius, examination of the fresh voluntary muscle of the ox by, 651.
Bichat, anterior metacarpo-phalangeal ligament first discovered by, 140; his opinion of the sympathetic system of nerves, 301.
Bile, excretory apparatus of, 479.
Bladder, prostate gland, and penis, illustration representing, 491.
Blumenbach on the cranium, 65; his vertical view of the facial angle, 66.
Bones, 1.
Bones of the arm, 82.
,, cranium, illustration of, 50.
,, face, 38; minute anatomy and ossification of, 48.
,, fingers, 92.
,, foot, 100.
,, hand, 88.
,, head, 59.
,, leg, 94.
,, shoulder, 78.
,, skull, 21.
,, superior extremities, 78.
Bones, carpal, articulations of, 139.
,, carpo-metacarpal, articulations of, 140.
Bone, collar, illustration of the right, 79.
,, cranial, 35.
,, cuboid, 102.
,, cuneiform, 88, 102.
Bones, cuneiform, external, articulation of, with the cuboid, 152.

Bones, cuneiform, articulations of, with each other, 153.
,, digital, ossification of, 93, 105.
Bone, ethmoid, 33.
,, ethmoid, illustrations of the lower surface and of the right side in profile, 34.
,, frontal, 31, 36.
,, ,, cerebral aspect illustrated, 31.
,, hyoid, articulations of, 118.
,, ,, illustration of, seen from the front, 66.
,, inferior maxillary, illustration of, 46.
,, ,, turbinated, illustration of, 44.
,, lachrymal, illustration of the orbitar aspect, right side, and of nasal or inner aspect, 43.
,, lachrymal, 43, 48.
,, malar or cheek, 42, 48.
,, malar, illustration of internal aspect, 43.
,, maxillary, inferior, 45.
,, ,, lower, 46.
,, ,, superior, 48.
,, metacarpal, ossification of, 93.
,, ,, articulations of, with each other, 140.
,, metacarpus, 91.
,, metatarsal, 103; ossification of, 105.
,, ,, articulations of, with each other, 153.
,, nasal, 44, 48.
,, occipital, 21, 35.
,, ,, illustrations of the external surface and cerebellar aspect of, 22.
,, os calcis, 101.
,, os hyoides, 66.
,, os innominatum, illustrations of right and left, 73.
,, os innominatum, adult, 74.
,, ,, and pelvis, 73.
,, os magnum, 89.
,, ossa innominata (nameless bones), 74.
,, os trapezoides, 89.
,, os unciforme, 90.
,, palate, right side, illustration of external aspect, and of inner or nasal aspect, 41.
,, palate, 41, 48.
,, parietal, illustration of the cerebral surface of, 27, 36.
,, pisiform, 82.
,, scaphoid, 102.
,, ,, articulation of the calcaneum and, 151.
,, ,, articulation of the astragalus with, 152.
Bone, scaphoid, articulation of, with the cuboid, 152.
,, semilunar, 88.
,, sesamoid, 93, 104.
,, sphenoid, 24, 37.
,, ,, illustrations of the cerebral and orbito-nasal aspect, 26.
,, superior maxillary, 38.
,, ,, illustration of external surface, right side, and nasal or internal aspect, 39.
,, supernumerary, 38.
,, tarsal, ossification of, 105.
,, ,, articulations of, with each other, 150.
,, temporal, 28, 36.
,, ,, illustration of right side, cerebral aspect, 28.
,, turbinated, inferior, 44, 48.
Brain, the, 537.
,, and its membranes, 523.
,, illustration of the base of, 523.
,, and spinal cord, development of, 545.
,, illustrations of, to show the interior of, 538; the anterior and inferior surface of the pons, 542; the form of the brain in the early human embryo, 564.
,, vertical section of the mesial parts of, illustrated, 543.
Brewster on the stomach, 460.
Buisson on the lungs, 321.
Bursæ, superficial, 284.

Cæcum, the, 467.
Calcaneum and astragalus, illustration of, 101.
Calcaneum, articulation of, with the scaphoid bone, 151.
Camper on the facial angle, 65; his views on the cranium mistaken, 66; on the coat of the stomach, 460.
Capillaries, 644.
Cartilages, 639; costal, 72.
Cellular fasciæ, 283.
Cellular or areolar tissue, 635.
Cerebral arachnoid, 533.
Cerebro-spinal axis, 517.
Cervical region, 161.
Cheselden, 499; on the inferior turbinated bone, 63.
Circulation, organs of, 294.
Clavicle, the, 79.
,, illustration of, 134.
Clitoris, the, 508.
Cloquet, J., includes the long and short sacro-iliac ligaments under one name, 129; adductor ossis metacarpi of, 200; his opinion on the relations of the serous membrane of the

pericardium, 303; on the supermaxillary nerve, 587.
Coccygeal vertebræ, pelvic view and back view illustrated, 13.
Coccyx, the, 13.
Cœliac axis, illustration showing the distribution of the three great branches of, 376.
Colon, the, 469.
Corpus spongiosum urethræ and glans penis, 501.
Cowper's glands, 500.
Cotunni, liquor of, 518, 519.
Cranium, coloured illustration of the sinuses at the base of the, 419, 420.
„ conformation of bones of, 49.
„ dimensions of, 57, 65.
„ illustration of the upper jaw, left side, 65.
„ illustration of the base of the skull, external, 56; viewed from within, 57.
„ inner surface of, 55.
„ muscles of, illustrated, 242.
„ supernumerary bones of, 35.
Crichton, Mr., of Dundee, 499.
Crural aponeurosis, retinacula connected with, 291.
Crural hernia, 474.
Cruveilhier, his opinion of the structure of the heart, 315; on the spinal dura mater, 519; on the medulla spinalis, 521; on the cervical ganglion and cervical nerves, 604.
Cuvier on the hyoid and styloid bones, 14; his view of the cranium, 66; his view of the facial angle, 66; his theory respecting the growth of teeth superseded by Retzius, 440; the dentition of mammals, human excepted, dicovered by, 437; on the ossification of the pulp of the teeth, 439; on the coat of the stomach, 460; his division of the urethra, 493; weight of the brain of, 547.

De Blainville on the sternum, 69; on the spinal marrow and brain, 517; on the primitive tissues of the human body, 636.
De Graaff, accuracy of his anatomical descriptions, 215; first discovers the vesicles called Graaffian, 503.
Diaphragm, the, 205; illustrated, 206.
„ muscles of, 280.
Dorsal vertebræ, illustrations of, viewed from above, below, and in profile, 10.
Dorsal vertebræ, illustrations of two of the bodies of, 124, 125.
Ductus thoracicus sinister vessel, 430; illustrated, 431.
Duodenum, the, 461.
Dura mater, coloured illustration of the sinuses of the, 418.
Dura mater, practical examination of the sinuses of, 529.
Du Verney first described the tensor tarsi muscle, 48.

Ear, the, 613.
„ deep muscles of the middle, 277.
„ external, 613.
„ extrinsic and intrinsic muscles of, 277.
„ horizontal section of, displaying the external auditory canal, 615.
„ membrana tympani of, illustrated, 616.
„ section of the labyrinth of, 618.
Ejaculatory ducts, 498.
Elbow-joint, 135; illustration of, 136.
Encephalon, 546.
Ensiform cartilage, ligament of, 123.
Eye, appendages of, 620.
„ ball of, 626.
„ ciliary nerves of, illustrated, 629.
„ crystalline lens of, illustrated, 631.
„ glands of, illustrated, 622.
„ puncta lachrymalia and ducts of, 624.
Eyeball, illustration of, 625.
„ muscles of, illustrated, 269.
„ section of, illustrated, 626.

Face, dimensions of, 59, 65.
„ inferior or palatine region of, 58.
„ lateral or zygomatic region of, 59.
„ nerves of, 552.
„ posterior or guttural region of, 58.
Fallopian tubes, 503.
Fasciæ and Aponeuroses, 283.
Fasciæ, certain deep, connected with the viscera, 287.
„ intercostal, 288.
Fascia iliaca, 290.
„ deep cervical, 287.
„ pectoral, 288.
„ superficial, 284.
„ transversalis, 289.
Female perineum, muscles of, 212; illustrated, 213.
Femur, illustrations of adult thigh-bone, anterior and posterior, 94.
Ferrein, his opinion on the circulation of the blood, 482.
Fibro-cartilage, 640.
Fibrous tissue, 638.
Fibula, the, 99.
Flexor perforans, 237.
Fluids, 655.
Fœtal circulation, 318; illustration of, 319.
Foot, right, illustrations of upper and lower surfaces of, 100.
„ dorsal region of, 232.

Foot, deep dissection of the dorsum of, illustrated, 232.
„ dissection of the sole of, illustrated, 236.
„ dorsum of the left side of, illustrated, 240.
„ first layer of muscles of the sole of, 236.
„ ligaments of the sole of, illustrated, 151.
Fossæ, nasal, 61.
„ spheno-maxillary, 64.
„ temporal, 64.
„ zygomatic, 64.
Foville on the bones of the cranium, 53.

Ganglions, system of, 601 ; illustration explanatory of the ganglion of Gasser, 631.
Genito-urinary organs, 510.
Geoffroy (St. Hilaire), his Theory of the Philosophic Anatomy of the Respiratory Organs, 318.
Gerdy on the cranium, 66 ; best explains Camper's views on the facial angle, 66.
Gimbernat, ligament of, 75.
Glisson, capsule of, 454.
Goethe on the occipital bone, 21.
Gunther, extensor coccygis muscle of, 280.

Haller, 62 ; on the inferior turbinated bone, 63 ; sub-arachnoid liquor known to, 519; his opinion of the sympathetic system of nerves, 301 ; on the cervical ganglion thyroid, 604.
Hand, ligaments of, described, 136.
Haunch, muscles of the posterior region of, illustrated, 229.
Head, minute anatomy and ossification of the bones composing the skeleton of, 35.
„ illustrations displaying the articulations of, with the vertebral column, 116, 119.
„ and neck, vertical section of, illustrated, 259.
Heart, the, 304.
„ development of, with the great blood-vessels, 317.
„ illustration of the auricles of, 316.
„ illustration of the ventral aspect of, with the back view of the same heart, 317, 318.
„ illustration to show the arrangement of the fleshy fibres of, 315 ; the superficial transverse lines, &c., 316.
„ illustration showing the position and relative size of the thymus gland in the fœtus, 328.
„ illustration of an ox's after being boiled, 315.
Heart, right and left coronary arteries of, 338.
Hip-joint, capsular ligament of, 142.
„ ileo-femoral articulation of, 141.
„ illustration of, 142.
Humerus, the, 82.
„ circumflex arteries of, 364.
„ illustrations of, anterior surface, 83.
Hunter, J., on the popliteal artery, 395 ; on the veins as absorbents, 426 ; true history of human dentition discovered by, 437 ; on the human teeth, 440.
Hunter, W., discarded the notion of the veins being absorbing vessels, 426 ; Wachendorf's discovery of the membrana pupillaris described by, 628.
Hymen, the, 509.

Ileo-cæcal valve, illustration of, 567.
Iliacus, the, 209.
Infant, skeleton of, 105 ; illustration of, 106.
Inferior extremities, lymphatic vessels, of, 429.
Ingrassias on the sphenoidal turbinated bone, &c., 61.
Inguinal and crural herniæ, 472.
„ canal, anatomy of, 472.
Inter-articular fibro cartilage, 132.
Intestine, the small, 463.

Jacobson, nerve and canal of, 595.

Kidneys, the, 483 ; illustrations of, 487.
„ and ureters, 511.
Kiernan on the circulation of the blood, 482.
Kirkringius on the liver, 482 ; ignorant of transcendental or philosophic anatomy, 105.
Knee-joint, 144.
„ vertical section of, described, 145.
„ illustration of, 147.
Kolliker, discoveries in the spleen of some animals by, 477.

Labia, the greater, 508.
Lachrymal apparatus of the eye, illustration of, 625.
Lacteals, and their glands, dissection and display of, 427.
Larynx, the, 328 ; illustrations of the larynx, trachea, and bronchi, 329, 330.
Leg, deep muscles of the posterior region of, 237.
„ muscles of the external side of the left, illustrated, 226.
„ muscles of the inner side of the left, particularised, 226.

eg, posterior and superficial region of, 234.
Leuwenhoek, the intimate structure of the teeth discovered by, 437.
Levator proprius alæ nasi posterior, 278.
Lieberkuhn on the mucous membrane of the small intestine, 464.
Ligament, annular, 137, 283.
„ (aponeuroses or retinacula), 291.
„ anterior or radiated, 125.
„ costo-transverse, posterior, 126.
„ capsular, 133.
„ coraco-acromial, 133.
„ coraco-clavicular, 132.
„ coraco-humeral, or accessory, 133.
„ costo-clavicular, 131.
„ costo-transverse, anterior, 127.
„ crucial, 146.
„ cruciform, 121.
„ glenoid, 134.
„ inter-clavicular, 131.
„ occipito-atlantal, anterior, 119.
„ occipito-atlantal, posterior, 120.
„ sterno-clavicular, anterior and posterior, 131.
Ligamentum patellæ, 145.
Liver, description of, 478.
„ structure of, 480, 481.
„ illustration to show the concave surface of, 481.
Lower jaw, illustrations of articulations of, 117, 118.
„ illustrations of muscles of, 257.
Lower limbs, aponeurosis of, 292.
Lumbar vertebra, illustrations of an upper and an inferior surface, 11.
Lumbar region, 161.
Lungs and their appendages, 320.
„ illustrations of the anterior and posterior surfaces of, 324, 325.
„ organization of, 322.
„ proper tissue of the, 322.
Lymphatics, dissection and display of, 427.
Lymphatic vessels of the inferior extremities, 429.
„ and glands, 645.

Magendie on the liquor of Cotunni, 518, 519; his opinion of openings into the fourth ventricle, 543.
Mammary glands, 514.
„ illustration of the ducts of, 515.
Martineau, Mr., 499.
Meatus urinarius and urethra, 509.
Meckel, comparisons of the vertebræ, by, 7; on the occipital, sphenoidal, and parietal bones, 36, 37; on the sternum, 69; his dimensions of the male and female pelvis, 78; on the small intestine, 463; on the remains of the vesicula umbilicalis in the fœtus, 463; his opinion that all embryos are at first of no sex, 511; on embryos, 513; his description of the nervous system, 517.
Meckel, sen., discovers the ganglion so called of Meckel, 586.
Membranes of the spinal marrow, 518.
Metacarpus, illustrations of palmar and dorsal surfaces of right hand, 91.
Monro, the second Dr., his opinion respecting the lateral ventricles of the brain, 537.
Mons veneris, 507.
Morgagni, the foramen cæcum of, 32; accuracy of his anatomical descriptions, 215; sinus of, 447; mistook the cæcum of a dog for the appendix vermiformis, 467.
Mouth and lips, 433.
Mucous membranes, 646.
Mulde, extensor coccygis muscle of, 280.
Muller, his opinion respecting Wolffian bodies, 512.
Muscles, descriptive anatomy of, 155.
Muscles, tabular view of, 277.
Muscles of the abdomen and pelvis, 202.
„ back, illustration of, 158.
„ eyelids and orbits, 278.
„ face, 278.
„ fore-arm and hand, 183.
„ head, 242.
„ head and neck, 277.
„ isthmus faucium, 263.
„ larynx, 259, 266.
„ leg and foot, 230.
„ lower extremities, 216, 281.
„ neck, 242.
„ neck, deep, 263, 279.
„ orbit, 267; illustrated, 268.
„ palate, 259, 261.
„ pelvis, 210.
„ pharynx, 259.
„ pharynx, section of, illustrated, 260.
„ left shoulder, illustrated, 178.
„ superior extremities, 173, 280.
„ superior extremity illustrated, 176.
„ trunk, 279.
Muscle, abductor minimi digiti pedis, 236, 237.
„ abductor minimi digiti, 281, 282.

Muscle, abductor pollicis, described, 196, 197, 281, 282.
„ acceleratores urinæ, 211, 280.
„ accessory, 238.
„ adductor brevis, 228, 282.
„ „ digiti, 281.
„ „ longus, 228, 282.
„ „ magnus, 228, 282.
„ „ magnus, precise form and attachments of the left side of, illustrated, 229.
„ „ minimi digiti, 198.
„ „ pollicis, 198, 241, 282.
„ anconeus, 183, 281.
„ annulus albus, 278.
„ aryteno-epiglottidei, 267, 279.
„ arytenoideus, 267, 279.
„ attollens aurem, 277.
„ attrahens aurem, 277.
„ auris, anterior, superior, and posterior, 244.
„ azygos uvulæ, 279.
„ biceps, 281.
„ „ femoris, 221.
„ „ flexor, 281.
„ „ flexor cubiti, 180.
„ brachialis flexor, 181, 281.
„ buccinator, 249, 278.
„ carpus, posterior annular ligament of, 183.
„ circumflexus palati, 279.
„ coccygeus, 214, 280.
„ complexus, 169.
„ „ major and minor, 279.
„ compressor narium, 278.
„ „ urethræ, 234.
„ constrictor isthmi faucium, 263.
„ „ pharyngis inferior, 260, 279.
„ „ pharyngis medius, 260, 279.
„ „ pharyngis superior, 261, 279.
„ „ vaginæ, 280.
„ coraco-brachialis, 180, 281.
„ corrugator supercilii, 246, 278.
„ cremaster, 280.
„ crico-arytenoidei postici, 266, 279.
„ crico-arytenoideus lateralis, 267.
„ crico-thyroideus, 266, 279.
„ crureus, 225.
„ deltoid, 173, 280.
„ depressor alæ nasi, 278.
„ „ anguli oris, 248.
„ „ labii inferioris, 278.
„ „ labii superioris, 248.
„ „ labii superioris alæque nasi, 248.
„ digastricus; biventer maxillæ, 255, 279.
„ dorsal interossei, 281, 282.
Muscle, erector clitoridis, 280.
„ erector penis, 211, 280.
„ extensor brevis communis, 232.
„ „ carpi radialis brevior, 188.
„ „ carpi radialis brevis, 281.
„ „ carpi radialis longior, 188, 281.
„ „ carpi ulnaris, 184.
„ „ coccygis, 280.
„ „ communis, 281.
„ „ communis brevis, 282.
„ „ communis digitorum, 185.
„ „ communis longus, 282.
„ „ indicis proprius, 186.
„ „ longus communis digitorum pedis, 231.
„ „ minimi digiti, 184, 281.
„ „ ossis metacarpi pollicis, 187, 281.
„ „ primi internodii pollicis, 186, 281.
„ „ proprius pollicis, 231.
„ „ proprius indicis, 281.
„ „ proprius pollicis longus, 282.
„ „ secundi internodii pollicis, 186.
„ „ secundi pollicis, 281.
„ „ ulnaris, 281.
„ external or dorsal interossei, 232.
„ flexor brevis digiti, 281, 282.
„ „ digitorum pedis, 237.
„ „ minimi digiti, illustrated, 199, 241, 282.
„ „ pollicis, 198, 281, 282.
„ „ pollicis pedis, 239.
„ flexor carpi radialis, 191, 281.
„ „ carpi ulnaris, 192, 281.
„ „ communis perforans, 282.
„ „ cruris, 221.
„ „ digitorum profundus, 194.
„ „ digitorum sublimis, 192.
„ „ longus pollicis manus, 195.
„ „ longus pollicis, 282.
„ „ longus pollicis pedis, 239.
„ „ ossis metacarpi pollicis, 196.
„ „ pollicis longus, 281.
„ „ profundus, 281.
„ „ sublimis, 281.
„ gastrocnemius, 282.
„ gemelli, superior and inferior, 221.
„ gemellus, superior and inferior, 281.
„ genio-glossus, 258.

Muscle, genio-hyoideus, 257, 279.
„ genio-hyo-glossus, 279.
„ gluteus maximus, 281.
„ „ maximus and medius, 217.
„ „ medius, 281.
„ „ minimus, 220, 281.
„ gracilis, 227, 282.
„ hyo-glossus, 258, 279.
„ iliacus, 280.
„ infracostales, 276, 280.
„ infra-spinatus, 175, 280.
„ inner pterygoid, 251.
„ intercostales externi, 274, 280.
„ „ interni, 275, 280.
„ interossei, 20[illegible].
„ inter-spinales, 280.
„ „ cervicis, 171.
„ inter-transversales, 280.
„ „ lumborum, 171.
„ inter-transversalis colli, 171.
„ iris, 278.
„ ischio-coccygeus, 214, 280.
„ latissimus colli, 252, 279.
„ „ dorsi, 160, 279.
„ laxator tympani, 277.
„ left frontal, 277.
„ „ occipital, 277.
„ levator anguli oris, 247, 278.
„ „ scapulæ, 163, 279.
„ „ ani, 213, 280.
„ „ communis, 247, 278.
„ „ glandulæ thyroideæ, 279.
„ „ labii superioris alæque nasi, 247.
„ „ labii inferioris, 248, 278.
„ „ labii proprius, 278.
„ „ menti, 248.
„ „ palati mollis, 262, 279.
„ „ palpebræ superioris, 268, 278.
„ „ proprius alæ nasi anterior, 278.
„ „ uvulæ, 262.
„ levatores costarum, 275, 280.
„ ligamentum nuchæ, 161; illustrated, 164.
„ lingualis, 258, 279.
„ longi colli, 264.
„ longissimus dorsi, 168, 279.
„ longus colli, 279.
„ lumbricales, 238.
„ male perineum, illustrated, 210.
„ masseter, 249, 278.
„ musculi accessorii, 279.
„ musculus anti-tragicus, 277.
„ „ helicis major, 277.
„ „ helicis minor, 277.
„ „ tragicus, 277.
„ „ transversus auriculæ, 277.
„ mylo-hyoideus, 256, 279.
Muscle, obliquus abdominis externus, 202, 280.
„ „ abdominis internus, 203, 280.
„ „ capitis superior and inferior, 172, 280.
„ „ inferior, 270, 278.
„ „ oculi superior, 270.
„ „ superior, 278.
„ obturator externus, 230, 281.
„ „ internus, 220, 281.
„ occipito-frontalis, 243.
„ omo-hyoideus, 254, 279.
„ opponens, 196.
„ „ minimi digiti, 200.
„ „ pollicis, 281.
„ orbicularis, 278.
„ „ palpebrarum, 245, 278.
„ palato-glossus, 279.
„ palato-pharyngeus, 263, 279.
„ palmar interossei, 281.
„ palmaris brevis, 190, 281.
„ „ longus, 281.
„ pectineus, 227, 282.
„ pectoralis major and minor, 270, 271, 272, 280.
„ peroneus brevis and longus, 233, 282.
„ „ tertius, or alter, 232.
„ peroneus alter, 282.
„ plantar interossei, 241, 282.
„ plantaris, 235, 282.
„ popliteus, 235, 282.
„ pronator teres, 190, 281.
„ pronatus quadratus, 196, 281.
„ psoas magnus, 280.
„ „ magnus and iliacus, 208.
„ „ parvus, 208, 280.
„ pterygoid, 250.
„ pterygoideus externus, 278.
„ „ internus, 250, 278.
„ pyramidales, 205, 280.
„ „ nasi, 246, 278.
„ pyriform, 220, 281.
„ quadrator femoris, 221, 281.
„ quadratus lumborum, 207, 280.
„ quadriceps extensor cruris, 224, 282.
„ rectus, 280.
„ „ abdominis, 205.
„ „ capitis anticus, major and minor, 264, 279.
„ „ capitis lateralis, 265, 171.
„ „ capitis posticus, major and minor, 172, 280.
„ „ externus, 269, 278.
„ „ femoris, 224.
„ „ inferior, 269, 278.
„ „ internus, 269, 278.
„ „ superior, 278.
„ „ oculi superior, 268.
„ retinaculum, 183.

Muscle, retinaculum tendinum musculorum, 190.
„ retrahens aurem, 277.
„ rhomboideus major and minor, 162, 279.
„ right frontal, 277.
„ „ occipital, 277,
„ risorius, 278.
„ rotatores spinæ, 280.
„ sacro-lumbalis, description of, 167, 279.
„ sartorius, 224, 282.
„ scaleni, 265.
„ scalenus anticus, 265, 279.
„ „ medius, 279.
„ „ minimus posticus, 266.
„ „ posticus, 266, 279.
„ semi-membranosus, 223, 281.
„ semi-spinalis colli, 280.
„ „ dorsi, 171, 280.
„ „ dorsi, lumbar portion of, 171.
„ „ lumborum, 280.
„ semi-tendinosus, 223, 281.
„ serratus magnus, 273, 280; illustration of, 274.
„ serratus posticus, superior, 163, 279.
„ „ inferior, 279.
„ soleus, 235, 282.
„ sphincter ani, 211, 280.
„ spinalis dorsi, 168, 280.
„ splenius, 165.
„ „ colli, 279.
„ „ capitis, 279.
„ stapedius, 277.
„ sterno-cleido-mastoideus, 253, 279.
„ sterno-hyoideus, 255, 279.
„ sterno-thyroideus, 255, 279.
„ stylo-glossus, 258, 279.
„ stylo-hyoideus, 279.
„ styloid, 257.
„ stylo-pharyngeus, 261, 279.
„ subclavius, 273, 280.
„ sub-crureus, 227.
„ subscapularis, 178, 280.
„ supinator brevis, 188, 281.
„ „ longus, 187, 281.
„ supra-spinatus, 175, 280.
„ temporalis, 278.
„ tensor fasciæ latæ, 224.
„ „ tarsi, 278, 246.
„ „ tympani, 277.
„ „ vaginæ femoris, 282.
„ teres major and minor, 177, 280.
„ thyro-arytenoidei, 267, 279.
„ thyro-epiglottideus, 279.
„ thyro-hyoideus, 255, 279.
„ tibialis anticus, 230, 282.
„ „ posticus, 239, 282.
„ transversalis abdominis, 240.
„ „ colli, 168, 279.
Muscle, transversus pedis, 241, 282.
„ „ perinei, 212, 280.
„ trapezius, 158, 279.
„ „ illustration of, 159.
„ triangularis nasi, 247.
„ „ oris, 278.
„ „ sterni, 275, 298.
„ triceps extensor, 178, 281.
„ trochlearis, 270.
„ vaginæ femoris, 224.
„ vastus externus, 225.
„ „ internus, 225.
„ zygomaticus major and minor, 247, 248, 278.
Muscular fibres, involuntary, 651.
„ tissue, 649.
Myology, 155.

Nails and hairs, 633.
Negele, obliquely oval pelvis discovered by, 108.
Nervous System, 516.
Nerves, anatomy of, summary of, 573.
„ auditory, 594.
„ brachial plexus, 553; illustration showing the position and formation of the cervical and brachial plexuses of nerves, 554.
„ cerebral pia mater, 534.
„ ciliary, of the eye, illustration to show the distribution of, 629.
„ circumflex, 564.
„ cranial, apparent origin of, 536, 592.
„ „ or encephalic, 580.
„ crural, 568.
„ cubital, illustration to show, 563.
„ dorso-spinal, 549, 565.
„ external and internal cutaneous, illustration to show, 563.
„ external cutaneous, 558.
„ „ pia mater, 534.
„ „ popliteal or femoral, 576.
„ great sympathetic, 601.
„ great sympathetic, cervical portion of, 603.
„ great sympathetic, lumbar portion of, 606.
„ great sympathetic, sacral or pelvic portion of, 606.
„ inferior maxillary, 589.
„ internal cutaneous, 557.
„ „ popliteal, or tibial, 578.
„ lumbar-plexus, terminal branches of, 568.
„ lumbo-spinal, 566.
„ lumbo-sacral plexus, illustration of, 570.
„ median, 559.

Nerves, median, illustration to show, 563.
,, medulla spinalis, 521.
,, medulla spinalis, illustration of, with medulla oblongata and pons, 521.
,, medulla spinalis, illustration to show the roots of the spinal nerves, 522.
,, medulla spinalis, development of, 547.
,, musculo-spiral, illustration to show, 563.
,, obturator, 569.
,, olfactory, 580.
,, optic, 581.
,, pathetic, 582.
,, plantar, illustration to show the distribution of, 579.
,, radial, or musculo-spiral, 562.
,, sacral, 571.
,, sacral plexus, terminating branch of, 574.
,, sacral plexus, illustration to show the distribution of the nervus tibialis, 575.
,, sciatic, illustration to show the course of, 572.
,, spinal arachnoid, 519,
,, ,, dura mater, 518.
,, ,, pia mater, 520.
,, spinal, 547-549.
,, superficial cervical, 551.
,, superior maxillary, 586.
,, trifacial, 582.
,, ulnar, 561.
Nervous tissue, 652.
Nervus vagus and great sympathetic system, illustration showing the distribution of, 602.
Nose, bones and cartilages of, illustrated, 609.
,, nerves of, particularized and illustrated, 609.
,, view of the cartilages of, 607.
Nostrils, minute muscles in connexion with, 609.
,, vertical section of, to display the distribution of the olfactory nerves, 610.
Nymphæ, 508.

Occiput, articulation of, with the axis, or second cervical vertebra, 120.
Œsophagus, the, 332.
Ophthalmic ganglion, 585.
,, nerve, 583.
Orbits, situation of, 59.
Organs of deglutition, 446.
,, digestion, 432, 433.
,, generation in the male, 494.
,, ,, female, 502.
,, ,, fœtus, 511.
Organs of insalivation, 442.
,, mastication, 436.
,, prehension, 433.
,, respiration and circulation, 294.
Organs of Sense, 607.
Organs of urine and generation in the male and female, 432, 483.
Osseous tissue, 640.
Osteology, 1.
Otic ganglion, 591.
Ovaria and Fallopian tubes, 502.

Pacchioni, glands of, 521.
Pancreas, the, 475.
Parotid gland, 442.
Patella, illustrations of outer and inner surface of, 104.
Pelvic fascia, 290.
Pelvis, the, 76.
,, deep muscles of, 212.
,, female, 77.
,, lateral section of the male, 488.
,, lateral view and section of the female, 507.
,, illustration of the true, 76.
,, section of the right side, 77.
Penis, the, 500.
Pericardium, the, 302.
Perinæal fasciæ, 291.
Peritoneum, 451.
Peroneal region, 233.
Pharynx and gullet, 446.
Pituitary, mucous, or Schneiderian membrane, 608.
Pleuræ, the, 296.
Prostate gland, 498.
Pterygoideus externus, 251.
Purkinje, on the growth of the teeth, 440.

Radius, the, 84; articulations of the ulna with, 137.
,, anterior and posterior surfaces, illustrations of, 85.
Ramus anastomoticus, 394.
Raschkow on the growth of the teeth, 440.
Rau, 499.
Rectum, the, 470.
Reiningen on the sphenoidal turbinated bone, &c., 62.
Respiration, organs of, 294.
Retzius, the intimate structure of teeth discovered by, 437.
Ribes, Mr., on the vidian and facial nerves, 593.
Ribs and their cartilages, 70.
,, illustrations of, 71, 72.
,, articulations of the cartilages of the false, with each other, 124.
,, articulations of, with the bodies of the vertebræ, 125.

Ribs, articulations of, with the transverse processes, 126.
Ruysch, F., denied the bursting of the coverings of the ovarium, 504; ignorant of transcendental or philosophic anatomy, 105; on the Malpighian corpuscles, 486.

Sacral plexus, illustration showing the terminating branches of the smaller division of the great sciatic nerve, 575.
Sacrum, illustration of its right margin, 11.
„ adult, its peculiarities and ossification, 20.
„ dorsum of, illustrated, 12.
„ pelvic or anterior surface illustrated, 12.
Salivary glands, 442.
Santorini, transverse muscle of the urethra known to, 215.
Scapula, illustrations of right scapula, posterior and costal surfaces, and viewed anteriorly, 80.
„ proper ligaments of the, 132.
„ illustration of, 134.
Scarpa, 41, 407, 499.
Schneider on the sphenoidal turbinated bone, &c., 62.
Schwann, revival of the first theory respecting teeth by, 440.
Sciatic, or sacral plexus, 571.
Scrotum, dartos, and cremaster, 494.
Secreting glands, 648.
Serous membranes, 645.
Shoulder-joint, scapulo-humeral articulation of, 133.
„ vertical section of, 135.
Shoulder, muscles of, illustrated, 174.
Skeleton, explanation of the term, 1.
„ fundamental part of, 1.
„ human, how exhibited to the student, 14.
„ number of bones of which it consists, 15.
„ male, viewed in profile, 2; in front, 5; female, 3.
„ of the infant compared with the adult, 105.
„ adult, back view, 107.
„ illustration of a portion of the base of the skull, &c., 14.
„ of the upper extremities, 82.
„ of the lower extremities, 93.
„ of the foot, 105.
„ of the torso, 67.
Skin, the, 632.
„ section to illustrate, 634.
Sœmmering, M., on the cranial nerves, 599; illustration showing the foramen centrale of, 630.
Spermatic cord, 497.
Spinal column, vertical section of, 112.
Spleen, illustration of the concave surface of, 477.
Sternum, 67; illustration of, anterior and posterior, 69.
„ articulations of the cartilages of the true ribs with, 122.
„ and collar-bone, illustration of, 124.
Stomach, the, 457.
„ and intestines, 449.
Sublingual gland, 445.
Submaxillary gland, 444.
Superficial fascia of the arm, 287.
„ of the lower extremities, 286.
Superior extremities, coloured sketch of the arteries of, 362.
Supra-renal capsules, 483.
Sutures, of those formed by the union of the cranium and face, 64.
Sweat-glands, illustration of a section of the skin, showing the distribution of, 635.
Synovial capsule, 134.
„ membranes, 645.

Teeth, 436; illustration to show the formation of a molar tooth, 437.
„ transverse and longitudinal sections, to show the form and extent of the pulp cavity, 438.
Tendons, retinacula of, connected with aponeurosis of upper extremity, 291.
Testes, spermatic cord, vas deferens, vesiculæ seminales, and ductus ejaculatorii, 496.
Testes, illustration of a vertical section of, 496.
Thiele, rotatores spinæ muscle of, 280; on the circulation of the blood, 482.
Thigh, muscles of the outer side of the left side, illustrated, 218.
„ muscles of the inner aspect of the left side, 219.
„ the left, deeper dissection of the muscles of, 222.
„ muscles of the front of, 223.
„ deep dissection of the muscles of the left side of, illustrated, 228.
„ posterior region of, 221; muscles of, illustrated, 229.
Thoracic aorta, arteries which arise from, 373.
„ duct, illustration of the formation and course of, 431.
„ extremities, coloured illustration of the superficial vein at the bend of the elbow, 421.
Thorax, the, 67.
„ examination of the cavity of, 294.

Thorax, illustrations of the articulations of, 122.
„ muscles of, 156.
„ method of opening, 295.
„ orifices of, 334.
„ superficial fascia of, 285.
„ viewed externally, 294.
Thymus gland, 327, 328.
Thyroid axis, 407.
Tibia, the, 96.
„ and fibula, right, illustrations of anterior, 98.
Toes, phalanges of, 103.
„ articulations of the phalanges of, 154.
Tongue, the, 610.
„ illustration to show the mucous and sentient surface of, 612.
„ intrinsic muscles of, 279.
Torso, illustration of the skeleton of, seen in profile, 67; front view, 68.
Trachea, the, 323.
„ and bronchi, 324.
„ and lungs, illustration of, 324, 325.
Trachelo-mastoideus, illustration of, 169.
Trapezium, the, 89.
Triangularis sterni, 280.
Trunk, arteries from the axillary portion of, 403.
„ muscles of, 155.

Ulna, the, 86.
„ articulations of the radius with, 137.
„ right, illustrations of anterior and posterior surfaces, 85.
Umbilical cord, illustration representing a portion of, 506.
Urethra, the, 493.
„ artery of the bulb of, 390.
„ muscular fibres of, 214.
„ transverse muscle of, illustrated, 215.
Urinary bladder, 483.
„ ligaments of, 490; structure of, 491.
Uterus, the, 504.
„ ovaria, and Fallopian tubes, illustration showing, 504.

Vagina, entrance of, 509.
„ the, and external organs of generation, 507.
Vaginal artery, 389.
Vascular System, the, 335.
Vascular tissue, 643.
Vas deferens, 497.
Veins, 644; systematic anatomy of, 408.
Veins of the thoracic extremities, 421.
„ of the corpora striata, 418.
Veins of the thigh, coloured illustrations showing the superficial, 411.
„ deep veins of the lower extremities, 412.
„ sketch to illustrate the superficial veins at the bend of the elbow, 421.
„ which form the hypogastric or internal iliac, 413.
Vein, axillary, 422.
„ basilic, 422.
„ capsular, 415.
„ cephalic, 421.
„ common femoral, 412.
„ common iliac, 412.
„ external iliac, 412.
„ external or short saphena, 410.
„ facial, 419.
„ „ coloured illustration of the course of, 420.
„ femoral, 412.
„ great right coronary, 409.
„ hepatic, 415.
„ inferior phrenic, 415.
„ internal jugular, 417, 420.
„ „ or long saphena, 410.
„ lateral and inferior cerebral, 418.
„ left coronary, 410.
„ „ interior thyroid, 423.
„ „ internal mammary, 423.
„ „ superior intercostal, 423.
„ lumbar, 414.
„ median, 422.
„ middle sacral, 414.
„ ophthalmic, 418.
„ popliteal, 412.
„ renal or emulgent, 414.
„ right inferior thyroid, 423.
„ „ internal mammary, 423.
„ „ superior intercostal, 423.
„ sacro-lateral, 413.
„ saphena, illustration of the short or posterior, left leg, 411.
„ saphena, coloured sketch showing the short or posterior, 411.
„ small right coronary, 410.
„ spermatic, 414.
„ splenic, 415.
„ subclavian, 421, 422.
„ superficial femoral, 412.
„ „ of the thigh, sketch of, 411.
„ superior and inferior cerebellar, 418.
„ „ cerebral, 417.
„ „ mesenteric, 415.
Vena azygos, 423; coloured illustration of the system of, 424.
Vena cava inferior, 410, 414.
„ superior, 417, 423.
Venæ innominatæ, 422.
Vena portæ, system of, 415.

Vena portarum, coloured diagram intended to show the formation of, 416.
Velum pendulum palati muscle illustrated, 262.
Ventricle, the left, 311.
„ illustration of, 311.
Vertebra, a lumbar, 4.
„ dentata, illustrations of upper and under surfaces of, 8.
„ general characters of a, 4.
„ illustration of the upper surface of a lumbar, 4.
„ proeminens, illustrations of, viewed from above, below, and in profile, 9.
„ seventh cervical, 9.
Vertebræ and vertebral column, properly so called, 16.
„ articulations of the first and second, with each other, 116, 121.
„ cervical, illustrations of their distinguishing characters, 4.
„ coccygeal, 13, 21.
„ coloured illustration of the sinuses of, 425.
„ dorsal, 10.
„ illustration of anterior common ligament of, 113.
„ lumbar, 11.
„ nomenclature of, 18.
„ ossification of the true, 18.
„ peculiar cervical, 7.
„ sacral, 11.
„ sinuses of, illustrated, 425.
Vertebral aponeurosis, the, 165.
Vertebral column, minute anatomy and ossification of, 13.
„ column, illustrations of, in front, back, and in profile, 17.
„ column, vertical and mesial section of, 20.
„ column, illustration of posterior common ligament of, 114.
„ column, illustration of, 115.
„ column, articulations of the head with, 119.
„ venous sinuses and veins of the medulla spinalis, 421.
„ veins, 422.
Vesical vein, 413.
Vesiculæ seminales, 498.
Vessels, development of, 644.
Voght, on the sphenoid bone, 37.
Vomer, the, 45, 48; illustrations of, in profile, and viewed from above, 45.

Wrist-joint, 138.
Weitbreicht, 120, 138.
Willis, communicating artery of, 351; illustration showing the circle of, 351; coloured illustrations showing the arteries of, 351; spinal accessory nerve of, 599.
Wilson, Mr., levator muscles of, 280.
Winslow, foramen of, 454.
Woman, external organs of generation in, 507.

Yellow, or elastic tissue, 638.

THE END.



LONDON: PRINTED BY W. CLOWES AND SONS, STAMFORD STREET.

52

MR. RENSHAW'S PUBLICATIONS.

THE ANATOMIST. By Henry Savage. 48mo. Price 2*s*.

THE OUTLINES OF BOTANY. By Gilbert Burnett. 250 Wood Engravings. In 8vo. Price 21*s*.

THE NERVOUS SYSTEM OF THE HUMAN BODY. By Sir Charles Bell. 16 Copper-plate Engravings. In 8vo. Price 10*s*. 6*d*.

MEMORANDA FOR EXAMINATION AT THE COLLEGE OF SURGEONS. By M. N. Bower. 32mo. sewed. Price 3*s*. 6*d*.

ON ERUPTIONS OF THE FACE, HEAD, AND HANDS. By T. H. Burgess, M.D. Coloured Plates, 8vo. Price 14*s*.

The same Work without Plates. 8vo. cloth. Price 8*s*.

ON THE EPIDEMIC FEVERS OF SIERRA LEONE. By Alexander Bryson, M.D. 12mo. cloth. Price 4*s*.

A DICTIONARY OF PRACTICAL SURGERY. By Samuel Cooper. 8vo. cloth. Price 30*s*.

ON THE MANAGEMENT AND DISEASES OF CHILDREN. By R. T. Evanson, M.D., and H. Maunsell, M.D. Fifth Edition. 8vo. cloth. Price 12*s*. 6*d*.

MEMORANDA ON THE MORE COMMON DISEASES OF THE EYE. By John Foote. 48mo. Price 1*s*.

FRORIEP ON THE APPLICATION OF ELECTRO-MAGNETISM: translated by Dr Lawrence. 8vo. cloth. Price 6*s*. 6*d*.

SYNOPSIS OF PERCUSSION AND AUSCULTATION. By R. C. Golding, M.D. 32mo. Price 1*s*.

GRAY'S SUPPLEMENT TO THE PHARMACOPŒIA. By T. Redwood. 8vo. cloth. Price 22*s*.

ELEMENTS OF THE THEORY AND PRACTICE OF MEDICINE. By G. Gregory, M.D. Sixth Edition, 8vo. cloth. Price 16*s*.

LECTURES ON THE ERUPTIVE FEVERS. By G. Gregory, M.D. 8vo. cloth. Price 7*s*. 6*d*.

ON TREATMENT OF DEAFNESS CONNECTED WITH ENLARGEMENT OF THE TONSILS. By W. Harvey. 8vo. cloth. Price 3*s*. 6*d*.

ON RHEUMATISM AND GOUT, AS AFFECTING THE HEAD AND EAR. By W. Harvey. 8vo. cloth. Price 5*s*.

HOOPER'S MEDICAL DICTIONARY. Seventh Edition. By R. Grant, M.D. 8vo. cloth. Price 30*s*.

ON THE PRINCIPLES, NATURE, AND TREATMENT OF INFLAMMATION. By J. H. James. 8vo. cloth. Price 15*s*.

A HISTORY AND DESCRIPTION OF THE VARIOUS RACES OF MAN. By R. Knox, M.D. 8vo. cloth. Price 10*s*. 6*d*.

ON INFLAMMATION OF THE VEINS. By Henry Lee. 8vo. cloth. Price 6*s*.

PRACTICAL SURGERY. By Robert Liston. 250 Wood Illustrations. 8vo. cloth. Price 22*s*.

LECTURES ON PHYSIOLOGY, ZOOLOGY, AND NATURAL HISTORY OF MAN. By W. Lawrence, F.R.S. 12 Copper-plates. 8vo. cloth. Price 6*s*.

LAENNEC ON DISEASES OF THE CHEST, AND ON AUSCULTATION. Translated by J. Forbes, M.D. 8vo. boards. Price 18*s.*

OUTLINES OF HUMAN PATHOLOGY. By Herbert Mayo, F.R.S. 8vo. cloth. Price 18*s.*

A TREATISE ON SYPHILIS. By Herbert Mayo, F.R.S. 8vo. cloth. Price 5*s.* 6*d.*

ANATOMICAL AND PHYSIOLOGICAL COMMENTARIES. By Herbert Mayo, F.R.S. 8vo. cloth. Price 5*s.*

NAEGELE ON OBSTETRIC AUSCULTATION. By C. West, M.D. 18mo. cloth. Price 3*s.*

NAEGELE ON MECHANISM OF PARTURITION. By E. Rigby, M.D. Fcap. boards. Price 5*s.*

ON INDIGESTION AND ITS CONSEQUENCES. By A. P. W. Philip, M.D. 8vo. boards. Price 6*s.* 6*d.*

ON THE LAWS OF THE VITAL FUNCTIONS. By A. P. W. Philip. 8vo. cloth. Price 12*s.*

ON THE NATURE OF SLEEP AND DEATH. By A. P. W. Philip. 8vo. boards. Price 8*s.*

ON MINUTE DOSES OF MERCURY. By A. P. W. Philip. Second Edition. 12mo. boards. Price 3*s.* 6*d.*

A TREATISE ON THE OBSCURE AFFECTIONS OF THE BRAIN. By A. P. W. Philip. 12mo. cloth. Price 4*s.*

MEMORANDA FOR YOUNG PRACTITIONERS IN MIDWIFERY. By E. Rigby, M.D. 32mo. sewed. Price 1*s.*

AN ESSAY ON UTERINE HÆMORRHAGE. By E. Rigby, M.D. 8vo. boards. Price 7*s.*

ON DYSMENORRHŒA AND OTHER UTERINE AFFECTIONS. By E. Rigby, M.D. 12mo. cloth. Price 6*s.*

HUNTER'S ANATOMICAL DESCRIPTION OF THE GRAVID UTERUS. By E. Rigby, M.D. 8vo. cloth. Price 6*s.*

A PHYSIOLOGICAL ESSAY ON THE THYMUS GLAND. By John Simon, F.R.S. 4to. cloth. Price 1*l.* 1*s.*

ON MERCURY, BLUE PILL, AND CALOMEL; THEIR USE AND ABUSE. By G. G. Sigmond, M.D. Fcap. cloth. Price 4*s.*

ON THE SOURCES OF PHYSICAL SCIENCE. By A. Smee, F.R.S. 8vo. cloth. Price 10*s.* 6*d.*

MEMORANDA ON POISONS. By T. H. Tanner, M.D. 32mo. cloth. Price 1*s.*

A TREATISE ON THE VENEREAL DISEASE AND ITS VARIETIES. By W. Wallace. Two Copper-plates. 8vo. cloth. Price 12*s.*

THE PHARMACOPÆIA OF THE ROYAL COLLEGE OF PHYSICIANS FOR 1851. Translated by a Physician. 24mo. sd. Price 2*s.* 6*d.*

ON VARICOSE VEINS AND VARICOSE ULCERS. By T. W. Nunn. Post 8vo. cloth. Price 3*s.*

ON WOUNDS AND INJURIES OF THE CHEST. By J. G. Guthrie, F.R.S. Royal 8vo. cloth. Price 4*s.* 6*d.*

RENSHAW'S
MANUAL